Merritt's Neurology

FOURTEENTH EDITION

SHOUT
SHARE
IT

Merritt's Neurology

FOURTEENTH EDITION

Elan D. Louis, MD, MS
Professor of Neurology
Linda and Mitch Hart Distinguished Chair in Neurology
Chairman, Department of Neurology
University of Texas Southwestern Medical Center
Dallas, Texas

Stephan A. Mayer, MD, FCCM, FNCS
Director of Neurocritical Care and Emergency
Neurological Services
Westchester Medical Center Health Network
Professor of Neurology and Neurosurgery
New York Medical College
Valhalla, New York

James M. Noble, MD, MS, CPH, FAAN
Associate Professor of Neurology at CUIMC
Taub Institute for Research on Alzheimer's Disease and the
Aging Brain
G.H. Sergievsky Center
Department of Neurology
Columbia University Irving Medical Center
Columbia University Vagelos College of Physicians and Surgeons
NewYork-Presbyterian Hospital
New York, New York

Wolters Kluwer

Philadelphia · Baltimore · New York · London
Buenos Aires · Hong Kong · Sydney · Tokyo

Acquisitions Editor: Chris Teja
Development Editor: Ariel S. Winter
Editorial Coordinator: Tim Rinehart
Editorial Assistant: Maribeth Wood
Marketing Manager: Kirsten Watrud
Senior Production Project Manager: Alicia Jackson
Manager, Graphic Arts and Design: Stephen Druding
Art Director, Illustration: Jennifer Clements
Senior Manufacturing Coordinator: Beth Welsh
Prepress Vendor: Absolute Service, Inc.

Fourteenth Edition

Copyright © 2022 Wolters Kluwer

Copyright © 2016 Wolters Kluwer, Copyright © 2010 Lippincott Williams & Wilkins, a Wolters Kluwer business. All rights reserved. This book is protected by copyright. No part of this book may be reproduced or transmitted in any form or by any means, including as photocopies or scanned-in or other electronic copies, or utilized by any information storage and retrieval system without written permission from the copyright owner, except for brief quotations embodied in critical articles and reviews. Materials appearing in this book prepared by individuals as part of their official duties as U.S. government employees are not covered by the above-mentioned copyright. To request permission, please contact Wolters Kluwer at Two Commerce Square, 2001 Market Street, Philadelphia, PA 19103, via email at permissions@lww.com, or via our website at shop.lww.com (products and services). 01/2021

9 8 7 6 5 4 3 2 1

Printed in Singapore

Library of Congress Cataloging-in-Publication Data

Names: Louis, Elan D., editor. | Mayer, Stephan A., editor. | Noble, James M., editor.
Title: Merritt's neurology / [edited by] Elan D. Louis, Stephan A. Mayer, James M. Noble.
Other titles: Neurology
Description: Fourteenth edition. | Philadelphia : Wolters Kluwer, [2022] | Includes bibliographical references and index.
Identifiers: LCCN 2020057250 | ISBN 9781975141226 (hardcover) | ISBN 9781975141233 (epub) | ISBN 9781975141240
Subjects: MESH: Nervous System Diseases
Classification: LCC RC346 | NLM WL 140 | DDC 616.8--dc23
LC record available at https://lccn.loc.gov/2020057250

This work is provided "as is," and the publisher disclaims any and all warranties, express or implied, including any warranties as to accuracy, comprehensiveness, or currency of the content of this work.

This work is no substitute for individual patient assessment based on health care professionals' examination of each patient and consideration of, among other things, age, weight, gender, current or prior medical conditions, medication history, laboratory data, and other factors unique to the patient. The publisher does not provide medical advice or guidance, and this work is merely a reference tool. Health care professionals, and not the publisher, are solely responsible for the use of this work including all medical judgments and for any resulting diagnosis and treatments.

Given continuous, rapid advances in medical science and health information, independent professional verification of medical diagnoses, indications, appropriate pharmaceutical selections and dosages, and treatment options should be made, and health care professionals should consult a variety of sources. When prescribing medication, health care professionals are advised to consult the product information sheet (the manufacturer's package insert) accompanying each drug to verify, among other things, conditions of use, warnings, and side effects and identify any changes in dosage schedule or contraindications, particularly if the medication to be administered is new, infrequently used, or has a narrow therapeutic range. To the maximum extent permitted under applicable law, no responsibility is assumed by the publisher for any injury and/or damage to persons or property, as a matter of products liability, negligence law or otherwise, or from any reference to or use by any person of this work.

shop.lww.com

Preface

When H. Houston Merritt first published this *Textbook of Neurology* in 1955, he was the sole author. The book became popular, and he revised it himself through the fourth edition. The body of neurologic knowledge increased and, in the fifth edition, he finally accepted contributions from colleagues. Even then, he wrote most of the book himself, and he continued to do so for the sixth edition despite serious physical disability. He died in 1979, just as the sixth edition was released for distribution.

The seventh edition, published and edited in 1984 by Lewis P. Rowland, was prepared by 70 of Merritt's former students, almost all with ties to Columbia University. Thirty of them headed neurology divisions or departments, and others had become distinguished clinicians, teachers, and investigators. That edition established Merritt's legacy as a singular leader whose career had set models for clinical investigation (when it was just beginning), clinical practice, teaching, editing books and journals, administering departments and medical schools, and commitment to national professional and voluntary health organizations.

Just as Houston Merritt did, "Bud" Rowland served as chief editor for the next five editions of the book. During that 30-year span, *Merritt's Textbook of Neurology* became firmly established as a classic the world over. At the same time, as codirector at the Neurological Institute of New York at Columbia University, Rowland trained and inspired a new generation of academic and practicing neurologists, edited the journal *Neurology* and served as an associate editor for *The New England Journal of Medicine*, and was a prolific researcher and writer in his own right, authoring hundreds of scientific articles.

In 2016, Rowland handed off the lead editing duties of the 13th edition of Merritt's textbook to Drs Elan D. Louis and Stephan A. Mayer while continuing to serve as a coeditor. The 13th edition represented a thorough modernization and substantial reboot compared to previous editions. We substantively broadened the authorship base beyond those who had trained or worked at Columbia, tapping into the best expertise across the country. More importantly, we added new focus to the mission of *Merritt's Textbook of Neurology*: While retaining its best elements and traditions, we aimed to create the essential modern neurology textbook with a global worldview.

Gone were the largely descriptive chapters and black and white photos of prior editions. The 13th edition blossomed into full color and featured a completely revamped table of contents, including an opening chapter entitled "Worldwide Epidemiology of Neurologic Disease," new chapters related to acute neurology and neurocritical care, and a new section in the front of the book entitled "Common Problems in Neurology." The 13th edition also emphasized patient management based on evidence-based guidelines, helpful diagnostic and treatment algorithms, management checklists, and practical pearls. We added for the first time numbered LEVEL 1 citations to back up all diagnostic and management recommendations based on high-quality clinical trials, evidence-based practice guidelines, or meta-analyses.

Lewis P. Rowland died in 2017 at the age of 91 years, 1 year after publication of the 13th edition. Clinical neurology continues to rapidly advance on multiple fronts, and we welcome Dr James Noble of Columbia University as a coeditor. Dr Noble, a cognitive neurologist and experienced educator, taught in clinical conferences with Dr Rowland until just weeks before his death. His inclusion builds on the longstanding tradition of *Merritt's Neurology* serving as an important tool in clinical neurology education. As students and admirers of "Bud" Rowland, we are proud to dedicate this 14th edition of *Merritt's Textbook of Neurology* to Dr Rowland. As with any dynamic book, the list of authors has continued to expand, to more than 180 authors for this 14th edition. Although many were trainees or have worked at Columbia University, we have continued to invite authors who are world-recognized leading experts. Along the same lines, we have sought to maintain Houston Merritt's literary style: direct, clear, and succinct writing; emphasis on facts rather than unsupported opinion; and ample use of illustrations and tables.

Other changes with this 14th edition of Merritt's include the continued evolution of the book's unique and colorful visual style, featuring even more algorithms, flowcharts, illustrations, and videos. The book is designed for access from tablet, phone, and computer screens with enhanced navigation, search, and annotation tools. The chief idea for our readers is to provide curated, clinically rich information at the bedside, office, and even virtual clinical session—when and where clinicians need it. The Internet is full of information, but it is difficult to sort through. Merritt's provides trusted and cohesive information from expert all in a single place.

This edition of Merritt's is fully updated and includes comprehensive revisions reflecting remarkable progress made in recent years in neurology research, including new and emerging treatments for diseases previously without effective pharmacotherapy. New material includes updates on imaging and interventional therapy for stroke, the latest approved agents for migraine, epilepsy, and multiple sclerosis and new material on neurologic care in the developing world, neuro–coronavirus disease, septic encephalopathy, and addiction medicine.

We thank all the authors for their devoted and skillful work. We also thank the many section editors for their thoughtful guidance and painstaking efforts.

This project would never have moved forward without the help of many people at Wolters Kluwer. Indeed, a full roster of people has been involved in the project, from its conception to completion. These include Chris Teja (acquisitions editor), Tim Rinehart and Ariel S. Winter (product development editors), Maribeth Wood (editorial assistant), Stephen Druding (design coordinator), Harold Medina (production project manager), and Kirsten Watrud (marketing manager). Special thanks should go to Andrea Vosburgh, who initially brought the 13th edition and the concept of a complete overhaul of the book to fruition.

In addition to Dr Lewis P. Rowland, Dr Louis also dedicates this book to his late father, Dr Sydney Louis, an academic neurologist who inspired his career in neurology—a role model as a humanist, an educator, a perceptive clinician with a keen eye for nuance and detail, and a patient-centered physician. Countless friends and colleagues with whom we have worked at The Neurological Institute of New York at Columbia University over the years deserve credit for inspiring us, most notably John Brust, E. Sander Connolly, Stanley Fahn, Matthew E. Fink, Laura Lennihan, Linda Lewis, Karen Marder, J. P. Mohr, Timothy Pedley, Robert A. Solomon, and Olajide Williams. Dr Louis would like to thank Bettina Evans, at Yale University, whose tireless efforts early on ensured that spreadsheets would be organized and authors contacted in a timely manner, and Dr David Hafler, chair of the Department of Neurology at Yale, for providing support for the project as this edition was being prepared.

Finally, we would like to personally dedicate this book to the spouses and children of all the contributors and especially to our own families. Dr Louis would like to gratefully acknowledge the wise advice and loving support of his wife, Dr Avra Louis, and that of his children, Devin, Ravi, and Kiran. The Mayer family includes Dr Elissa Fory and children, Philip, Catherine, Chloe, and Soren. Dr Noble thanks his family for support including his wife Anne and their children Josephine, Salvatore, Benicio, and Beatrice.

Section Editors

Neeraj Badjatia, MD, MS, FANA, FCCM, FNCS
Chief of Neurocritical Care, Program in Trauma
Professor and Vice Chair, Department of Neurology
University of Maryland School of Medicine
Baltimore, Maryland

Carl W. Bazil, MD, PhD
Professor
Department of Neurology
Columbia University
New York, New York

Thomas H. Brannagan III, MD
Professor of Neurology
Director, Peripheral Neuropathy Center, Department of Neurology
Columbia University, College of Physicians and Surgeons
Co-Director, EMG laboratory
NewYork-Presbyterian Hospital
New York, New York

John C. M. Brust, MD
Professor
Department of Neurology
Columbia University Vagelos College of Physicians and Surgeons
Attending
Department of Neurology
The New York Neurological Institute/NewYork-Presbyterian Hospital
New York, New York

Mitchell S. V. Elkind, MD, MS
Professor
Departments of Neurology and Epidemiology
Columbia University
Attending Neurologist
Department of Neurology
NewYork-Presbyterian Hospital
New York, New York

David A. Hafler, MD
William S. and Lois Stiles Edgerly Professor of Neurology and Chairman
Department of Neurology and Professor of Immunobiology
Yale School of Medicine
Neurologist-in-Chief
Department of Neurology
Yale New Haven Hospital
New Haven, Connecticut

Kiwon Lee, MD
Professor of Neurology
Department of Neurology
Rutgers, The State University of New Jersey
Chief of Neurology Service
Department of Neurology
Robert Wood Johnson University Hospital
New Brunswick, New Jersey

Richard B. Lipton, MD
Edwin S. Lowe Professor and Vice Chair
Department of Neurology
Albert Einstein College of Medicine
Director, Montefiore Headache Center
Department of Neurology
Albert Einstein College of Medicine/Montefiore Medical Center
Bronx, New York

Elan D. Louis, MD, MS
Professor of Neurology
Linda and Mitch Hart Distinguished Chair in Neurology
Chairman, Department of Neurology
University of Texas Southwestern Medical Center
Dallas, Texas

Arthur M. Mandel, MD, PhD
Assistant Professor of Neurology at CUIMC
Department of Neurology, Division of Child Neurology
Columbia University
Assistant Professor
Department of Neurology, Division of Child Neurology
NewYork-Presbyterian Morgan Stanley Children's Hospital
New York, New York

Karen S. Marder, MD, MPH
Sally Kerlin Professor Department of Neurology and Taub Institute on Alzheimer's Disease and the Aging Brain
Columbia University
New York, New York

Stephan A. Mayer, MD, FCCM, FNCS
Director of Neurocritical Care and Emergency Neurological Services
Westchester Medical Center Health Network
Professor of Neurology and Neurosurgery
New York Medical College
Valhalla, New York

Paul C. McCormick, MD, MPH
Herbert and Linda Gallen Professor of Neurological Surgery
Department of Neurological Surgery
Columbia University Vagelos College of Physicians and Surgeons
Director, The Spine Hospital at the Neurological Institute of New York
Department of Neurological Surgery
NewYork-Presbyterian/Columbia University Irving Medical Center
New York, New York

James M. Noble, MD, MS, CPH, FAAN
Associate Professor of Neurology at CUIMC
Taub Institute for Research on Alzheimer's Disease and the Aging Brain
G.H. Sergievsky Center
Department of Neurology
Columbia University Irving Medical Center
Columbia University Vagelos College of Physicians and Surgeons
NewYork-Presbyterian Hospital
New York, New York

Fred Rincon, MD, MSc, MBEthics
Associate Professor
Department of Critical Care and Neurotrauma
Thomas Jefferson University
Chief, Cerebrovascular Disease
Department of Critical Care and Neurotrauma
Thomas Jefferson University Hospital
Philadelphia, Pennsylvania

J. Kirk Roberts, MD
Associate Professor
Department of Neurology
Columbia University
Associate Attending
Department of Neurology
NewYork-Presbyterian Hospital
New York, New York

Karen L. Roos, MD
John and Nancy Nelson Professor of Neurology, Neurology Residency Program Director
Department of Neurology
Indiana University School of Medicine
Indianapolis, Indiana

Joel Stein, MD
Simon Baruch Professor
Department of Rehabilitation and Regenerative Medicine
Columbia University
Chief
Department of Rehabilitation Medicine
NewYork-Presbyterian Hospital
New York, New York

David H. Strauss, MD
Special Lecturer
Department of Psychiatry
Columbia University
New York, New York

Tobias Walbert, MD, MPH
Associate Professor
Department of Neurology
Wayne State University
Co-Director, Hermelin Brain Tumor Center
Department of Neurology & Neurosurgery
Henry Ford Hospital
Detroit, Michigan

Louis H. Weimer, MD
Professor of Neurology at the Columbia University Medical Center
Department of Neurology
Columbia University Vagelos College of Physicians and Surgeons
Associate Attending
Department of Neurology
NewYork-Presbyterian Hospital
New York, New York

Contributors

Sachin Agarwal, MD, MPH
Assistant Professor of Neurology
Department of Neurology
Columbia University Irving Medical Center
Assistant Professor of Neurology
Department of Neurology
NewYork-Presbyterian Hospital
New York, New York

H. Orhan Akman, PhD
Assistant Professor
Department of Neurology
Columbia University Vagelos College of Physicians and Surgeons
New York, New York

Ashhar S. Ali, DO
Clinical Assistant Professor
Department of Neurology
Wayne State University School of Medicine
Senior Staff Physician
Department of Neurology
Henry Ford Health System
Detroit, Michigan

Fawaz Al-Mufti, MD
Assistant Professor
Associate Director of Neuroendovascular Surgery Fellowship and Neurology Residency
Department of Neurology, Neurosurgery and Radiology
New York Medical College
Medical Director of Neurocritical Care
Director of Neuroendovascular Surgery and Neurological Research
Department of Neurology, Neurosurgery and Radiology
Westchester Medical Center
Valhalla, New York

Hussein Alshammari, MD
Senior Neurology Resident
Westchester Medical Center
New York Medical College
Valhalla, New York

Peter D. Angevine, MD, MPH
Associate Professor
Department of Neurological Surgery
Columbia University
NewYork-Presbyterian Hospital
New York, New York

John Ausiello, MD
Assistant Professor
Department of Medicine
Columbia University
Endocrinologist
Department of Medicine
NewYork-Presbyterian Hospital
New York, New York

Neeraj Badjatia, MD, MS, FANA, FCCM, FNCS
Chief of Neurocritical Care, Program in Trauma
Professor and Vice Chair, Department of Neurology
University of Maryland School of Medicine
Baltimore, Maryland

Jennifer M. Bain, MD, PhD
Assistant Professor
Department of Neurology, Division of Child Neurology and Department of Pediatrics
Columbia University
Departments of Neurology and Pediatrics
NewYork-Presbyterian Hospital
New York, New York

Zahid H. Bajwa, MD, FAHS
Lecturer
Department of Public Health
Tufts University School of Medicine
Boston, Massachusetts

Kelly J. Baldwin, MD, MSMEd
Assistant Professor
Department of Medicine
Tufts University School of Medicine
Boston, Massachusetts
Neuro-Infectious Disease and Neurohospitalist
Department of Neurology
Maine Medical Center
Portland, Maine

Jacob S. Ballon, MD, MPH
Associate Clinical Professor
Department of Psychiatry and Behavioral Science
Stanford University
Co-Director, INSPIRE Clinic
Department of Psychiatry and Behavioral Science
Stanford Health Care
Stanford, California

Emanuele Barca, MD, PhD
Resident
Department of Neurology
Columbia University
Resident
Department of Neurology
NewYork-Presbyterian/Columbia University Irving Medical Center
New York, New York

Megan S. Barker, PhD
Postdoctoral Research Scientist
Department of Neurology
Columbia University
New York, New York

Andrés Barrera, MD
Assistant Professor of Clinical Psychiatry
Department of Psychiatry
University of Pennsylvania
Philadelphia, Pennsylvania

Tracy T. Batchelor, MD, MPH
Miriam Sydney Joseph Professor of Neurology
Department of Neurology
Harvard Medical School
Chair
Department of Neurology
Brigham and Women's Hospital
Boston, Massachusetts

Carl W. Bazil, MD, PhD
Professor
Department of Neurology
Columbia University
New York, New York

Michelle Bell, MD
Assistant Professor
Department of Neurology
Columbia University
Adult Neurology Residency Program Director
Department of Neurology
NewYork-Presbyterian Hospital
New York, New York

Gary L. Bernardini, MD, PhD
Professor of Neurology, Vice-Chair
Department of Neurology
Weill Cornell Medical Center
Chair
Department of Neurology
NewYork-Presbyterian Queens
New York, New York

Thomas H. Brannagan III, MD
Professor of Neurology
Director, Peripheral Neuropathy Center, Department of Neurology
Columbia University, College of Physicians and Surgeons
Co-Director, EMG laboratory
NewYork-Presbyterian Hospital
New York, New York

Adam M. Brickman, PhD
Professor
Taub Institute for Research on Alzheimer's Disease and the Aging Brain
Department of Neurology
Columbia University
New York, New York

Carolyn Barley Britton, MD, MS
Professor of Neurology at CUIMC
Department of Neurology
Columbia University Vagelos College of Physicians and Surgeons
NewYork-Presbyterian/Weill Cornell Medical Center, NYP Campus
New York, New York

Jeffrey N. Bruce, MD
Professor, Vice Chairman
Department of Neurological Surgery
Columbia University
Attending
Department of Neurological Surgery
NewYork-Presbyterian Hospital
New York, New York

John C. M. Brust, MD
Professor
Department of Neurology
Columbia University Vagelos College of Physicians and Surgeons
Attending
Department of Neurology
The New York Neurological Institute/NewYork-Presbyterian Hospital
New York, New York

David Cachia, MD
Associate Professor
Department of Neurosurgery
Medical University of South Carolina
Charleston, South Carolina

Joshua Cappell, MD, PhD
Assistant Professor of Pediatrics and Neurology
Columbia University Irving Medical Center
NewYork-Presbyterian Morgan Stanley Children's Hospital
New York, New York

Jason B. Carmel, MD, PhD
Associate Professor
Department of Neurology (in Orthopedics)
Columbia University
Attending Physician
NewYork-Presbyterian Hospital
New York, New York

Alejandro S. Cazzulino
Resident (PGY-1)
Orthopaedic Surgery
University of California, San Francisco
San Francisco, California

Tiffany R. Chang, MD
Associate Professor
Department of Neurosurgery
McGovern Medical School at UTHealth
Houston, Texas

Claudia A. Chiriboga, MD, MPH
Professor of Neurology and Pediatrics at CUIMC
Department of Neurology
Columbia University
Attending Neurologist
Department of Neurology
NewYork-Presbyterian Hospital
New York, New York

Tracey A. Cho, MD
Professor
Department of Neurology
University of Iowa Carver College of Medicine
Director, Neuroimmunology Division
Department of Neurology
University of Iowa Healthcare
Iowa City, Iowa

Huimahn Alex Choi, MD
Associate Professor
Department of Neurosurgery and Neurology
UT Health McGovern Medical School
Director of Neurocritical Care
Department of Neurosurgery
Memorial Hermann Hospital
Houston, Texas

Daniel S. Chow, MD
Assistant Professor-in-Residence
Department of Radiological Sciences
Co-Director, Center for Artificial Intelligence in Diagnostic Medicine
University of California, Irvine
Irvine, California

M. Roberta Cilio, MD, PhD
Professor of Pediatric Neurology
Department of Pediatrics
Saint-Luc university Hospital, Université catholique de Louvain
Brussels, Belgium

Comana M. Cioroiu, MD
Assistant Professor of Neurology at CUIMC
Department of Neurology
Columbia University Medical Center
Attending Physician
Department of Neurology
NewYork-Presbyterian Hospital
New York, New York

Jan Claassen, MD
Associate Professor
Department of Neurology
Columbia University
Attending
Department of Neurology
NewYork-Presbyterian Hospital
New York, New York

Gary D. Clark, MD
Professor
Pediatrics-Neurology
Baylor College of Medicine
Houston, Texas

Steven P. Cohen, MD
Professor
Department of Anesthesiology, Neurology, Physical Medicine Rehabilitation and Psychiatry
Johns Hopkins & Walter Reed
Chief
Pain Medicine
Johns Hopkins Hospital
Baltimore, Maryland

Kyle J. Coleman, MD
Neuroinfectious Disease Fellow
Department of Neurology
University of Colorado
Aurora, Colorado

Iris Vanessa Marin Collazo, MD
Consultant
Department of Neurology
Mayo Clinic Hospital
Jacksonville, Florida

Stephanie Cosentino, PhD
Associate Professor of Neuropsychology
Department of Neurology
Columbia University
New York, New York

John F. Crary, MD, PhD
Professor
Department of Pathology & Neuroscience
Icahn School of Medicine
Professor
Department of Pathology
Mount Sinai Health System
New York, New York

Barry M. Czeisler, MD
Assistant Professor (Clinical)
Department of Neurology and Neurosurgery
New York University Grossman School of Medicine
Attending Neurointensivist
Department of Neurology and Neurosurgery
NYU Langone Health
New York, New York

Randy S. D'Amico, MD
Assistant Professor of Neurosurgery
Department of Neurological Surgery
Lenox Hill Hospital/Donald and Barbara Zucker School of Medicine at Hofstra
New York, New York

Katarina Dakay, DO
Endovascular Surgical Neuroradiology Fellow
Department of Neurosurgery
New York Medical College
Endovascular Surgical Neuroradiology Fellow
Department of Neurosurgery
Westchester Medical Center
Valhalla, New York

Basil T. Darras, MD
Joseph J. Volpe Professor of Neurology
Harvard Medical School
Chief
Division of Clinical Neurology
Boston Children's Hospital
Boston, Massachusetts

Darryl C. De Vivo, MD
Sidney Carter Professor of Neurology, Professor of Pediatrics
Department of Neurology and Pediatrics
Columbia University
Attending Neurologist and Pediatrician
Department of Neurology and Pediatrics
NewYork-Presbyterian Hospital
New York, New York

Anna L. Dickerman, MD
Associated Professor of Clinical Psychiatry
Department of Psychiatry
Weill Cornell Medical College
Chief, Psychiatry Consultation-Liaison Service
Department of Psychiatry
NewYork-Presbyterian Hospital/Weill Cornell Medicine
New York, New York

Salvatore DiMauro, MD
Emeritus Professor
Department of Neurology
Columbia University Vagelos College of Physicians and Surgeons
New York, New York

James J. Dowling, MD, PhD
Professor
Departments of Pediatrics and Molecular Genetics
University of Toronto
Staff Clinician and Senior Scientist
Division of Neurology and Program for Genetics and Genome Biology
Hospital for Sick Children
Toronto, Ontario, Canada

Divyanshu Dubey, MD
Assistant Professor
Department of Neurology and, Laboratory Medicine and Pathology
Mayo Clinic
Senior Associate Consultant
Department of Neurology and, Laboratory Medicine and Pathology
Mayo Clinic
Rochester, Minnesota

Mitchell S. V. Elkind, MD, MS
Professor
Departments of Neurology and Epidemiology
Columbia University
Attending Neurologist
Department of Neurology
NewYork-Presbyterian Hospital
New York, New York

Charles C. Esenwa, MD, MS
Assistant Professor
Department of Neurology
Albert Einstein College of Medicine
Medical Director, Montefiore Comprehensive Center for Stroke
Department of Neurology
Montefiore Medical Center
Bronx, New York

Stanley Fahn, MD
H. Houston Merritt Professor of Neurology
Department of Neurology
Columbia University Vagelos College of Physician and Surgeons
Attending Physician
Department of Neurology
Columbia University Irving Medical Center
New York, New York

Richard S. Finkel, MD
Professor
Department of Neurology
University of Central Florida College of Medicine
Orlando, Florida
Director, Center for Experimental Neurotherapeutics
Translational Neuroscience Program
St. Jude Children's Research Hospital
Memphis, Tennessee

Eoin P. Flanagan, MD
Associate Professor of Neurology
Consultant Neurologist
Department of Neurology
Mayo Clinic
Rochester, Minnesota

Charles L. Francoeur, MD, MSc (epid.), FRCPC
Associate Professor
Division of Critical Care, Department of Anesthesiology and Critical Care
Laval University
Intensivist
Department of Anesthesiology and Critical Care
CHU de Québec – Université Laval
Québec, Canada

Pamela U. Freda, MD
Professor of Medicine at CUIMC
Department of Medicine
Columbia University Vagelos College of Physicians and Surgeons
Assistant Attending in Medicine
Department of Medicine
NewYork-Presbyterian Hospital
New York, New York

Jennifer A. Frontera, MD
Professor
Department of Neurology
New York University Grossman School of Medicine
Attending Physician
Department of Neurology
NYU Langone Health
New York, New York

Steven J. Frucht, MD
Professor of Neurology
The Marlene and Paolo Fresco Institute for Parkinson's and Movement Disorders, Department of Neurology
New York University School of Medicine
Director
Division of Movement Disorders, The Marlene and Paolo Fresco Institute for Parkinson's and Movement Disorders, Department of Neurology
NYU Langone Health
New York, New York

Robert H. Fryer, MD, PHD
Associate Professor
Department of Neurology
Columbia University
Attending Physician
Division of Child Neurology
Children's Hospital of NY
New York, New York

Licínia Ganança, MD
Psychiatric Department, Hospital Santa Maria
University of Lisbon School of Medicine
Lisbon, Portugal

James H. Garvin, Jr, MD, PhD
Professor of Pediatrics
Department of Pediatrics
Columbia University Irving Medical Center
NewYork-Presbyterian Morgan Stanley Children's Hospital
New York, New York

Nicolas Gaspard, MD, PhD
Assistant Professor of Neurology (Adjunct)
Department of Neurology
Yale University School of Medicine
New Haven, Connecticut
Professor of Neurology and Head of the Neurology Department
Université Libre de Bruxelles - Cliniques Universitaires de Bruxelles - Hôpital Erasme
Brussels, Belgium

Michael D. Geschwind, MD, PhD, FANA, FAAN
Professor
Department of Neurology
Memory and Aging Center
University of California, San Francisco
San Francisco, California

Mark R. Gilbert, MD
Senior Investigator and Chief
Neuro-Oncology Branch
National Cancer Institute/National Institutes of Health
Bethesda, Maryland

Brian J.A. Gill, MD
Resident Physician
Department of Neurological Surgery
Columbia University Vagelos College of Physicians and Surgeons
Resident Physician
Department of Neurological Surgery
NewYork-Presbyterian/Columbia University Irving Medical Center
New York, New York

Emily J. Gilmore, MD, MS, FACNS, FNCS
Associate Professor of Neurology
Department of Neurology
Divisions of Neurocritical Care and Emergency Neurology/Epilepsy
Yale University School of Medicine
New Haven, Connecticut

Peter J. Goadsby, MD, PhD, DSc, FRACP, FRCP
Professor of Neurology
Department of Neurology
University of California, Los Angeles
Los Angeles, California

Jill S. Goldman, MPhil, MS
Professor of Genetic Counseling in Neurology
Department of Neurology
Columbia University Vagelos College of Physicians and Surgeons
New York, New York

Sylvie Goldman, PhD
Assistant Professor
Department of Neurology and G.H. Sergievsky Center Divisions of Cognitive Neuroscience and Child Neurology
Columbia University
Assistant Professor
Department of Neurology, Division of Child Neurology
NewYork-Presbyterian/Columbia University Irving Medical Center
New York, New York

Hernan D. Gonorazky, MD
Assistant Professor
The Hospital for Sick Children
Division of Neurology
Department of Pediatrics
University of Toronto
Toronto, Ontario, Canada

Paul Greene, MD
Associate Professor of Clinical Neurology
Department of Neurology
Yale School of Medicine
Attending Physician
Department of Neurology
Yale New Haven Hospital
New Haven, Connecticut

Jose Gutierrez, MD, MPH
Florence Irving Assistant Professor
Department of Neurology
Columbia University Irving Medical Center
New York, New York

Noam Y. Harel, MD, PhD
Associate Professor
Department of Neurology; Rehabilitation and Human Performance
Icahn School of Medicine at Mount Sinai
New York, New York
Staff Physician
Department of Neurology; Spinal Cord Injury
James J. Peters Veterans Affairs Medical Center
Bronx, New York

Christina J. Hayhurst, MD
Assistant Professor of Anesthesiology
Department of Anesthesiology
Program Director, Anesthesia Critical Care Medicine Fellowship
Department of Anesthesiology
Vanderbilt University Medical Center
Nashville, Tennessee

Richard A. Hickman, MBChB
Assistant Professor at CUIMC
Department of Pathology and Cell Biology
Columbia University Irving Medical Center
Assistant Attending
NewYork-Presbyterian Hospital
New York, New York

Dominique M. O. Higgins, MD, PhD
Resident
Department of Neurological Surgery
Columbia University
New York, New York

Michio Hirano, MD
Lucy G. Moses Professor
Department of Neurology
Columbia University Vagelos College of Physicians and Surgeons
Attending
Department of Neurology
NewYork-Presbyterian Hospital
New York, New York

Lawrence S. Honig, MD, PhD
Professor of Neurology
Taub Institute, G. H. Sergievsky Center, and Neurology Department
Columbia University Vagelos College of Physicians and Surgeons, Columbia University Irving Medical Center
Attending Neurologist
Department of Neurology
NewYork-Presbyterian Hospital
New York, New York

Erika Santos Horta, MD
Assistant Professor
Department of Neurology
University of Arkansas for Medical Sciences
Little Rock, Arkansas

Edward D. Huey, MD
Associate Professor
Department of Psychiatry and Neurology
Columba University
New York, New York

Christopher G. Hughes, MD, MS, FCCM
Professor of Anesthesiology
Department of Anesthesiology
Vanderbilt University Medical Center
Chief, Division of Anesthesia Critical Care Medicine Medical Director, Neuro ICU
Department of Anesthesiology
Vanderbilt University Medical Center
Nashville, Tennessee

Kevin E. Immanuel, MD
Medical Director
Department of Neurosurgery
Houston Methodist Hospital
Houston, Texas

Fabio M. Iwamoto, MD
Assistant Professor
Department of Neurology
Columbia University Medical Center
New York, New York

Joseph Jankovic, MD
Professor of Neurology
Distinguished Chair in Movement Disorders
Director, Parkinson's Disease Center and Movement Disorders Clinic
Department of Neurology
Baylor College of Medicine
Baylor St. Luke's Medical Center at the McNair Campus
Houston, Texas

Hyder A. Jinnah, MD, PhD
Professor
Department of Neurology & Human Genetics
Emory University
Atlanta, Georgia

Jasmin Jo, MD
Affiliate Associate Professor
Division of Hematology/Oncology, Department of Internal Medicine, Brody School of Medicine
East Carolina University
Physician Lead, Neuro-oncology
Division of Hematology/Oncology, Department of Internal Medicine
Vidant Medical Center
Greenville, North Carolina

Michael G. Kaiser, MD, FAANS, FACS
Sub-specialty Director of Spine Surgery
Neurosurgery
The Valley Hospital
Ridgewood, New Jersey

Thomas J. Kaley, MD
Vice Chair for Clinical Research
Neurology
Memorial Sloan Kettering Cancer Center
New York, New York

Un Jung Kang, MD
Founders Professor of Neurology
Department of Neurology, Neuroscience and Physiology
New York University Grossman School of Medicine
Attending Physician
Department of Neurology
NYU Langone Health
New York, New York

Gurmeen Kaur, MD
Assistant Professor
Department of Neurology, Neurosurgery and Radiology
New York Medical College
Attending Physician
Department of Neurology and Neurosurgery
Westchester Medical Center
Valhalla, New York

Kavneet Kaur, MD
Medical Director
Department of Neurology
Garnet Health Medical Center
Middletown, New York

Steven G. Kernie, MD
Professor of Pediatrics (in Neurology)
Department of Pediatrics
Columbia University Vagelos College of Physicians and Surgeons
Chief, Critical Care and Hospital Medicine
NewYork-Presbyterian Morgan Stanley Children's Hospital
New York, New York

Imad Khan, MD
Assistant Professor
Departments of Neurology and Neurosurgery
University of Rochester School of Medicine and Dentistry
Attending Physician
Neuromedicine Intensive Care Unit
Strong Memorial Hospital
Rochester, New York

Alexander G. Khandji, MD, FACR
Professor of Radiology in Neurological Surgery and Neurology
Department of Radiology
Columbia University
Clinical Director
Department of Radiology
NewYork-Presbyterian Hospital
New York, New York

Inna Kleyman, MD
Assistant Professor
Department of Neurology
Columbia University
Attending Physician
Department of Neurology
NewYork-Presbyterian Hospital
New York, New York

Brian B. Koo, MD
Associate Professor of Neurology
Department of Neurology
Yale University
New Haven, Connecticut

Barbara S. Koppel, MD
Clinical Professor of Neurology
Department of Neurology
New York Medical College
Valhalla, New York

Rupesh Kotecha, MD
Associate Professor
Department of Radiation Oncology
Florida International University Herbert Wertheim College of Medicine
Chief of Radiosurgery
Director of CNS Metastasis
Department of Radiation Oncology
Miami Cancer Institute, Baptist Health South Florida
Miami, Florida

Andreas H. Kramer, MD, MSc, FRCPC
Clinical Associate Professor
Departments of Critical Care Medicine & Clinical Neurosciences
University of Calgary
Calgary, Alberta, Canada

William Charles Kreisl, MD
Assistant Professor of Neurology
The Taub Institute for Research on Alzheimer's Disease and the Aging Brain
Columbia University Irving Medical Center
Attending Neurologist
Department of Neurology
NewYork-Presbyterian/Columbia University Irving Medical Center
New York, New York

Sheng-Han Kuo, MD
Assistant Professor
Department of Neurology
Columbia University
New York, New York

Shouri Lahiri, MD
Assistant Professor
Departments of Neurology, Neurosurgery, and Biomedical Sciences
Cedars-Sinai Medical Center
Interim Director, Neurocritical Care
Departments of Neurology, Neurosurgery, and Biomedical Sciences
Cedars-Sinai Medical Center
Los Angeles, California

Michael W. Lawlor, MD, PhD
Professor
Pathology
Medical College of Wisconsin
Milwaukee, Wisconsin

Matthew R. Leach, MD
Neurocritical Care Fellow
Department of Critical Care Medicine
University of Pittsburgh
Neurocritical Care Fellow
Department of Critical Care Medicine
UPMC Presbyterian Hospital
Pittsburgh, Pennsylvania

Kiwon Lee, MD
Professor of Neurology
Department of Neurology
Rutgers, The State University of New Jersey
Chief of Neurology Service
Department of Neurology
Robert Wood Johnson University Hospital
New Brunswick, New Jersey

Oren Levy, MD, PhD
Assistant Professor (Adjunct)
Department of Neurology
Columbia University Irving Medical Center
New York, New York

Peter A. LeWitt, MD, MMedSc
Professor of Neurology, and Sastry Foundation Endowed Chair in Neurology
Wayne State University School of Medicine
Detroit, Michigan

Lillian Liao, MS
Medical Student
Department of Neurosurgery
Columbia University
New York, New York

Angela Lignelli, MD
Associate Professor
Department of Radiology
Columbia University
Neuroradiology Division Chief
Department of Radiology
NewYork-Presbyterian Hospital
New York, New York

Richard B. Lipton, MD
Edwin S. Lowe Professor and Vice Chair
Department of Neurology
Albert Einstein College of Medicine
Director, Montefiore Headache Center
Department of Neurology
Albert Einstein College of Medicine/Montefiore Medical Center
Bronx, New York

Vivian P. Liu, MD
Newport Beach, California

Erin E. Longbrake, MD, PhD
Assistant Professor
Department of Neurology
Yale University
New Haven, Connecticut

Elan D. Louis, MD, MS
Professor of Neurology
Linda and Mitch Hart Distinguished Chair in Neurology
Chairman, Department of Neurology
University of Texas Southwestern Medical Center
Dallas, Texas

Hani Malone, MD
Department of Neurosurgery
Scripps Clinic
Department of Neurosurgery
Scripps Green Hospital
La Jolla, California

Arthur M. Mandel, MD, PhD
Assistant Professor of Neurology at CUIMC
Department of Neurology, Division of Child Neurology
Columbia University
Assistant Professor
Department of Neurology, Division of Child Neurology
NewYork-Presbyterian Morgan Stanley Children's Hospital
New York, New York

Christopher E. Mandigo, MD, MS
Assistant Professor of Clinical Neurosugery
Department of Neurological Surgery
Columbia University
New York, New York

Karen S. Marder, MD, MPH
Sally Kerlin Professor Department of Neurology and Taub Institute on Alzheimer's Disease and the Aging Brain
Columbia University
New York, New York

Steven Marks, MD
Section Co-Chief, Cerebrovascular Diseases
Department of Neurology
Westchester Medical Center
Valhalla, New York

Maria Martinez-Lage, MD
Assistant Professor
Department of Pathology
Harvard Medical School
Assistant Pathologist, Associate Residency Program Director
Department of Pathology
Massachusetts General Hospital
Boston, Massachusetts

Paul G. Mathew, MD, DNBPAS, FAAN, FAHS
Assistant Professor
Department of Neurology
Harvard Medical School
Headache Specialist
Department of Neurology
Brigham and Women's Hospital/Harvard Vanguard Medical Associates
Boston, Massachusetts

Stephan A. Mayer, MD, FCCM, FNCS
Director of Neurocritical Care and Emergency Neurological Services
Westchester Medical Center Health Network
Professor of Neurology and Neurosurgery
New York Medical College
Valhalla, New York

Aurélien Mazeraud, MD, PhD
Fellow
Université de Paris
Fellow
Neuroanesthesia and Neurointensive Care Unit
GHU Paris Psychiatrie et Neurosciences
Paris, France

Paul C. McCormick, MD, MPH
Herbert and Linda Gallen Professor of Neurological Surgery
Department of Neurological Surgery
Columbia University Vagelos College of Physicians and Surgeons
Director, The Spine Hospital at the Neurological Institute of New York
Department of Neurological Surgery
NewYork-Presbyterian/Columbia University Irving Medical Center
New York, New York

J. Ricardo McFaline-Figueroa, MD, PhD
Instructor in Neurology
Department of Neurology
Brigham and Women's Hospital, Harvard Medical School
Physician
Center for Neuro-Oncology
Dana-Farber Cancer Institute
Boston, Massachusetts

Andrew McKeon, MD
Professor
Departments of Laboratory Medicine and Pathology, and Neurology
College of Medicine, Mayo Clinic
Consultant
Departments of Laboratory Medicine and Pathology, and Neurology
Mayo Clinic
Rochester, Minnesota

Minesh P. Mehta, MD, FASTRO
Professor and Chair
Department of Radiation Oncology
FIU Herbert Wertheim College of Medicine
Chief and Deputy Director
Department of Radiation Oncology
Miami Cancer Institute, Baptist Health South Florida
Miami, Florida

Merrick E. Miles, MD
Assistant Professor of Anesthesiology
Department of Anesthesiology
Vanderbilt University Medical Center
Associate Medical Director, Neuro Intensive Care Unit
Department of Anesthesiology
Vanderbilt University Medical Center
Nashville, Tennessee

Heather E. Moss, MD, PhD
Associate Professor
Departments of Ophthalmology and Neurology and Neurological Sciences
Stanford University
Attending Physician
Byers Eye Institute at Stanford
Stanford Health Care
Palo Alto, California

Shibani S. Mukerji, MD, PhD
Assistant Professor
Department of Neurology
Harvard Medical School
Associate Director, Neuroinfectious Diseases Unit
Department of Neurology
Massachusetts General Hospital
Boston, Massachusetts

Philip R. Muskin, MD, MA
Professor
Department of Psychiatry
Columbia University Irving Medical Center
Senior Consultant
Consultation-Liaison Psychiatry
Columbia University Irving Medical Center
New York, New York

Lakshmi Nayak, MD
Assistant Professor
Department of Neurology
Harvard Medical School
Director, Center for CNS Lymphoma
Senior Physician, Center for Neuro-Oncology
Dana-Farber Cancer Institute
Department of Neurology
Brigham and Women's Hospital
Boston, Massachusetts

Eric Newman, MD
Neuroradiology Fellow
Department of Radiology
NewYork-Presbyterian Hospital
New York, New York

James M. Noble, MD, MS, CPH, FAAN
Associate Professor of Neurology at CUIMC
Taub Institute for Research on Alzheimer's Disease and the Aging Brain
G.H. Sergievsky Center
Department of Neurology
Columbia University Irving Medical Center
Columbia University Vagelos College of Physicians and Surgeons
NewYork-Presbyterian Hospital
New York, New York

Setareh Salehi Omran, MD
Assistant Professor of Neurology
Department of Neurology
University of Colorado School of Medicine
Aurora, Colorado

Maria A. Oquendo, MD, PhD
Professor and Chairman
Department of Psychiatry
Perelman School of Medicine, University of Pennsylvania
Chief Psychiatrist
Department of Psychiatry
University of Pennsylvania
Philadelphia, Pennsylvania

Natalie Organek, DO
Neurocritical Care
Houston Methodist
Houston, Texas

Maryam Oskoui, MD, MSc
Associate Professor
Departments of Pediatrics and Neurosciences
McGill University
Director
Division of Pediatric Neurology
McGill University Health Center
Québec, Canada

Alison M. Pack, MD, MPH
Professor
Department of Neurology
Columbia University Irving Medical Center
Attending Physician
Department of Neurology
NewYork-Presbyterian Hospital
New York, New York

Gunjan Y. Parikh, MD
Assistant Professor
Department of Neurology
University of Maryland School of Medicine
Associate Medical Director
Division of NeuroCritical Care and Emergency Neurology
University of Maryland Medical Center and R Adams Cowley Shock Trauma Center
Baltimore, Maryland

Marc C. Patterson, MD
Professor
Departments of Neurology, Pediatrics, and Medical Genetics
Mayo Clinic
Consultant
Departments of Neurology, Pediatrics, and Medical Genetics
Mayo Clinic Hospital
Rochester, Minnesota

Siddharama Pawate, MD
Associate Professor of Neurology
Department of Neurology
Vanderbilt University Medical Center
Nashville, Tennessee

Toni S. Pearson, MBBS
Associate Professor
Department of Neurology
Washington University School of Medicine
Attending Neurologist
Department of Neurology
St. Louis Children's Hospital
St. Louis, Missouri

Jonathan Perk, MD, PhD
Residency Program Director
Department of Neurology
SUNY Downstate Medical Center
Brooklyn, New York

Chiara Pisciotta, MD, PhD
Neurologist
Department of Neurology – Carver College of Medicine
University of Iowa Hospitals and Clinics
Iowa City, Iowa

Sean J. Pittock, MD
Professor of Neurology
Departments of Neurology and Laboratory Medicine and Pathology
Consultant
Departments of Neurology and Laboratory Medicine and Pathology
Mayo Clinic
Rochester, Minnesota

Prashanth S. Ramachandran, MBBS
Assistant Professor, Neurology
UCSF Weill Institute for Neurosciences
School of Medicine
San Francisco, California

Ahmad Riad Ramadan, MD
Staff Neurologist
Department of Neurology
Henry Ford Hospital
Detroit, Michigan

Ashwini K. Rao, EdD, OTR, FAOTA
Professor
Rehabilitation & Regenerative Medicine (Programs in Physical Therapy), G.H. Sergievsky Center
Columbia University
New York, New York

Alexandra S. Reynolds, MD
Assistant Professor
Departments of Neurosurgery and Neurology
Icahn School of Medicine at Mount Sinai
New York, New York

Cássia Righy, MD, PhD
Associate Researcher
Laboratory of Intensive Care Medicine
Oswaldo Cruz Foundation
Assistant Physician
Intensive Care Medicine
Paulo Niemeyer Brain's Institute
Rio de Janeiro, Brazil

Claire S. Riley, MD
Assistant Professor of Neurology
Medical Director, Columbia University Multiple Sclerosis Center
Department of Neurology
Columbia University Irving Medical Center
New York, New York

Alden Doerner Rinaldi, MD
Lecturer
Department of Internal Medicine
Harvard Medical School
Boston, Massachusetts
Staff Physician
Care Dimensions
Danvers, Massachusetts

Fred Rincon, MD, MSc, MBEthics
Associate Professor
Department of Critical Care and Neurotrauma
Thomas Jefferson University
Chief, Cerebrovascular Disease
Department of Critical Care and Neurotrauma
Thomas Jefferson University Hospital
Philadelphia, Pennsylvania

Mikael L. Rinne, MD, PhD
Instructor in Neurology
Department of Neurology
Brigham and Women's Hospital, Harvard Medical School
Physician
Center for Neuro-Oncology
Dana-Farber Cancer Institute
Boston, Massachusetts

J. Kirk Roberts, MD
Associate Professor
Department of Neurology
Columbia University
Associate Attending
Department of Neurology
NewYork-Presbyterian Hospital
New York, New York

David J. Roh, MD
Assistant Professor
Department of Neurology
Columbia University
Attending Neurointensivist
Department of Neurology
NewYork-Presbyterian/Columbia University Irving Medical Center
New York, New York

Gustavo C. Román, MD, DrHC
Professor of Neurology
Houston Neurological Institute
Weill Cornell University
New York, New York
Houston Methodist Hospital
Department of Neurology
Texas A&M
Houston, Texas

Karen L. Roos, MD
John and Nancy Nelson Professor of Neurology, Neurology Residency Program Director
Department of Neurology
Indiana University School of Medicine
Indianapolis, Indiana

Roger N. Rosenberg, MD
Zale Distinguished Chair and Professor of Neurology
Department of Neurology
University of Texas Southwestern Medical Center
Attending Neurologist
Department of Neurology
Clements University Hospital
Dallas, Texas

Sara K. Rostanski, MD
Assistant Professor of Neurology
New York University School of Medicine
Medical Director of Stroke
Bellevue Hospital Center

Tatjana Rundek, MD, PhD
Professor of Neurology, Director
Department of Neurology
University of Miami Miller School of Medicine
Miami, Florida

Dimah N. Saade, MD
Neuromuscular and Neurogenetic Disorders of Childhood Section
National Institute of Neurological Disorders and Stroke
National Institutes of Health
Bethesda, Maryland

Ned Sacktor, MD
Professor
Department of Neurology
Johns Hopkins University School of Medicine
Professor
Department of Neurology
Johns Hopkins Bayview Medical Center
Baltimore, Maryland

Daniel H. Sahlein, MD
Partner
Department of Interventional Neuroradiology
Goodman Campbell Brain and Spine
NIR Director of Stroke
Department of Neurointerventional Radiology
Ascension St. Vincent Hospital - Indianapolis
Indianapolis, Indiana

Ramandeep Sahni, MD
Associate Professor of Neurology
Department of Neurology
New York Medical College
Stroke Director
Department of Neurology
Westchester Medical Center
Valhalla, New York

Arash Salardini, MBBS
Associate Professor
Department of Neurology
UT Health San Antonio and Bigg's Institute for Alzheimer's Disease and Neurodegeneration
Associate Professor
Department of Neurology
University Hospital
San Antonio, Texas

Jacinda B. Sampson, MD, PhD
Professor
Department of Neurology
Stanford University
Palo Alto, California

Sophie Samuel, PharmD, BCPS, BCCCP
Critical Care Clinical Specialist
Department of Pharmacy
Memorial Hermann Hospital
Houston, Texas

Tristan T. Sands, MD, PhD
Assistant Professor
Department of Neurology
Columbia University
Attending
Department of Neurology
NewYork-Presbyterian Hospital
New York, New York

Deanna Saylor, MD, MHS
Assistant Professor of Neurology
Department of Neurology
Johns Hopkins University School of Medicine
Neurology Faculty
Department of Neurology
Johns Hopkins Hospital
Baltimore, Maryland

Nikolaos Scarmeas, MD, MS, PhD
Associate Professor
Department of Neurology
Columbia University
New York, New York

Sara M. Schaefer, MD, MHS
Assistant Professor of Neurology
Department of Neurology
Yale School of Medicine
Faculty
Department of Neurology
Yale New Haven Hospital
New Haven, Connecticut

Heidi Schambra, MD
Assistant Professor
Departments of Neurology and Rehabilitation Medicine
New York University Grossman School of Medicine
Division Director of Neuro-Epidemiology
Department of Neurology
NYU Langone Health
New York, New York

David Schiff, MD
Harrison Distinguished Professor
Division of Neuro-Oncology, Department of Neurology
University of Virginia
Co-Director, Neuro-Oncology Center
Division of Neuro-Oncology, Department of Neurology
University of Virginia Health System
Charlottesville, Virginia

Franklin R. Schneier, MD
Special Lecturer
Department of Psychiatry
Columbia University
Co-Director
Anxiety Disorders Clinic
New York State Psychiatric Institute
New York, New York

David B. Seder, MD
Associate Professor
Department of Medicine
Tufts University
Boston Massachusetts
Chair
Critical Care Services
Maine Medical Center
Portland, Maine

Laurent Servais, MD, PhD
Professor of Paediatric Neuromuscular Diseases
MDUK Oxford Neuromuscular Center
Department of Paediatrics
University of Oxford
Oxford, United Kingdom

Jennifer L. Sevush-Garcy, MD
Clinical Associate Professor of Neurology
Department of Neurology
New York Medical College
Valhalla, New York
Attending Neurologist
Department of Neurology
Northern Westchester Hospital
Mount Kisco, New York

Hiral Shah, MD
Assistant Professor
Department of Neurology
Columbia University
Assistant Professor
Department of Neurology
NewYork-Presbyterian Hospital
New York, New York

Vikram G. Shakkottai, MD, PhD
Associate Professor
Department of Neurology
University of Michigan
Director, Ataxia Clinic
Department of Neurology
Michigan Medicine
Ann Arbor, Michigan

Kumud Sharma, MD
Physician Fellow
Department of Neurocritical Care and Neurotrauma
Thomas Jefferson University
Physician Fellow
Department of Neurocritical Care and Neurotrauma
Thomas Jefferson University Hospital
Philadelphia, Pennsylvania

Tarek Sharshar, MD, PhD
Professor
Neuro-anesthesiology and Intensive Care Medicine
GHU-Paris Psychiatrie et Neurosciences
Université de Paris
Paris, France

Tina T. Shih, MD
Clinical Professor of Neurology
Department of Neurology, UCSF Epilepsy Center
University of California, San Francisco
Medical Director
UCSF Neurodiagnostic Lab
UCSF Medical Center
San Francisco, California

Jeffrey Shije, MD
Assistant Professor
Department of Neurology, Neuromuscular Division
University of Florida, Jacksonville
Jacksonville, Florida

Neil A. Shneider, MD, PhD
Claire Tow Associate Professor of Motor Neuron Disorders
Director, Eleanor and Lou Gehrig ALS Center
Department of Neurology
Columbia University
Attending Physician
Department of Neurology
NewYork-Presbyterian Hospital
New York, New York

Priya Shoor, MD
Attending Radiologist
Department of Radiology, Emergency Division
Columbia University Irving Medical Center
New York, New York

Michael E. Shy, MD
Professor of Neurology
Department of Neurology – Carver College of Medicine
University of Iowa
Director of the Division of Neuromuscular Medicine, Director of the Division of Neurogenetics
Department of Neurology – Carver College of Medicine
University of Iowa Hospitals and Clinics
Iowa City, Iowa

Reet Sidhu, MD
Assistant Professor of Pediatrics
Division of Pediatric Neurology
Emory University
Director, Developmental Neurology Program
Department of Pediatric Neurology
Children's Healthcare of Atlanta
Atlanta, Georgia

Harvey S. Singer, MD
Professor Emeritus
Department of Neurology
Johns Hopkins University
Staff
Department of Neurology
Kennedy Krieger Institute/Johns Hopkins Medicine
Baltimore, Maryland

Michael B. Sisti, MD, FACS
James G. McMurtry III MD Associate Professor of Neurology
Department of Neurology
Columbia University
Attending Neurosurgeon and Co-Director Center for Radiosurgery
Department of Neurosurgery
NewYork-Presbyterian Hospital
New York, New York

Robert A. Solomon, MD
Chairman Emeritus
Bennett M. Stein Professor of Neurological Surgery
Columbia University
NewYork-Presbyterian Hospital
New York, New York

Serena Spudich, MD, MA
Gilbert H. Glaser Professor and Chief, Division of Neurological Infections and Global Neurology
Department of Neurology
Yale School of Medicine
New Haven, Connecticut

Shraddha Srinivasan, MD
Assistant Professor of Neurology
Department of Neurology
Columbia University Irving Medical Center
Attending Physician
Department of Neurology
NewYork-Presbyterian Hospital
New York, New York

Joel Stein, MD
Simon Baruch Professor
Department of Rehabilitation and Regenerative Medicine
Columbia University
Chief
Department of Rehabilitation Medicine
NewYork-Presbyterian Hospital
New York, New York

Barney J. Stern, MD
Professor
Department of Neurology
Johns Hopkins University
Baltimore, Maryland

Yaakov Stern, PhD
Florence Irving Professor of Neuropsychology
Department of Neurology
Columbia University
Chief
Cognitive Neuroscience Division, Department of Neurology
Columbia University Irving Medical Center
New York, New York

Ian S. Storper, MD
Director, Otology Program
Northwell Physician Partners
Otolaryngology Lenox Hill Hospital
Department of Otolaryngology
Lenox Hill Hospital
New York, New York

T. Scott Stroup, MD, MPH
Professor
Department of Psychiatry
Columbia University
Research Psychiatrist
New York State Psychiatric Institute
New York, New York

Sally M. Sultan, MD, MS
Instructor of Pediatrics at CUIMC
Division of Pediatrics CAH, Department of Pediatrics
NewYork-Presbyterian Hospital
New York, New York

Kurenai Tanji, MD, PhD
Professor
Department of Pathology and Cell Biology
Columbia University
Attending Neuropathologist
Department of Pathology and Cell Biology
NewYork-Presbyterian Hospital
New York, New York

Claudio E. Tatsui, MD
Associate Professor
Department of Neurosurgery
UT MD Anderson Cancer Center
Houston, Texas

Boon Lead Tee, MD, MSc
Assistant Professor
Department of Neurology
University of California, San Francisco
San Francisco, California
Attending Physician
Department of Neurology
Buddhist Tzu Chi Hospital
Hualien, Taiwan

Pichet Termsarasab, MD
Consultant Neurologist
Division of Neurology, Department of Medicine
Faculty of Medicine Ramathibodi Hospital, Mahidol University
Bangkok, Thailand

Kiran T. Thakur, MD
Winifred Mercer Pitkin Assistant Professor of Neurology
Department of Neurology
Columbia University Irving Medical Center
Assistant Professor
Department of Neurology
NewYork-Presbyterian Hospital
New York, New York

Rebecca Traub, MD
Assistant Professor
Department of Neurology
University of North Carolina, Chapel Hill
Chapel Hill, North Carolina

Spyridoula Tsetsou, MD
Assistant Professor
Department of Neurosurgery
Icahn School of Medicine at Mount Sinai
New York, New York

Christina M. Ulane, MD, PhD
Assistant Professor of Neurology
Department of Neurology, Division of Neuromuscular Medicine
Columbia University Irving Medical Center/NewYork-Presbyterian Hospital
New York, New York

Julio R. Vieira, MD, MS
Assistant Professor of Neurology
Department of Neurology
Albert Einstein College of Medicine
Bronx, New York

Tobias Walbert, MD, MPH
Associate Professor
Department of Neurology
Wayne State University
Co-Director Hermelin Brain Tumor Center
Department of Neurology & Neurosurgery
Henry Ford Hospital
Detroit, Michigan

Ruth H. Walker, MB, ChB, PhD
Professor
Department of Neurology
Mount Sinai School of Medicine
New York, New York
Director, Movement Disorders Clinic
Department of Neurology
James J. Peters Veterans Affairs Medical Center
Bronx, New York

Natalie Weathered, MD, MS
Assistant Professor of Neurology
Department of Neurology
Weill Cornell Medicine
Assistant Attending of Neurology
Department of Neurology
NewYork-Presbyterian Hospital
New York, New York

Louis H. Weimer, MD
Professor of Neurology at the Columbia University Medical Center
Department of Neurology
Columbia University Vagelos College of Physicians and Surgeons
Associate Attending
Department of Neurology
NewYork-Presbyterian Hospital
New York, New York

Michael L. Weinberger, MD
Associate Professor of Anesthesiology
Columbia University Irving Medical Center
New York, New York

Brian G. Weinshenker, MD
Professor
Department of Neurology
Mayo Clinic
Consultant
Department of Neurology
Mayo Clinic
Rochester, Minnesota

Patrick Y. Wen, MD
Professor of Neurology
Harvard Medical School
Director, Center For Neuro-oncology
Medical Oncology
Dana-Farber Cancer Institute
Boston, Massachusetts

Sarah F. Wesley, MD, MPH
Assistant Professor
Department of Neurology
Yale University School of Medicine
New Haven, Connecticut

Andrew J. Westwood, MD, FRCP(Edin)
Assistant Professor
Department of Neurology
Columbia University
Attending
Department of Neurology
NewYork-Presbyterian – Columbia Campus
New York, New York

Eelco F. M. Wijdicks, MD, PhD
Professor of Neurology
Division of Neurocritical Care and Hospital Neurology
Mayo Clinic
Rochester, Minnesota

Joshua Z. Willey, MD, MS
Associate Professor
Department of Neurology
Columbia University Irving Medical Center
Attending
Department of Neurology
NewYork-Presbyterian Hospital
New York, New York

Michael R. Wilson, MD, MAS
Associate Professor
Department of Neurology
University of California, San Francisco
Attending Neurologist
Department of Neurology
University of California, San Francisco Medical Center and Zuckerberg San Francisco General Hospital
San Francisco, California

Christopher J. Winfree, MD, FAANS
Assistant Professor
Department of Neurological Surgery
Columbia University
New York, New York

Scott M. Woolf, DO
Neurology Resident
Department of Neurology
Westchester Medical Center
Chief
Department of Neurology
Westchester Medical Center
Valhalla, New York

Anne Damian Yacoub, MD
Assistant Professor
Department of Neurology
Johns Hopkins School of Medicine
Clinical Associate
Department of Neurology
Johns Hopkins Hospital
Baltimore, Maryland

Christopher Zammit, MD, FACEP
Adjunct Assistant Professor
Emergency Medicine, Neurology, and Neurosurgery
University of Rochester School of Medicine & Dentistry
Rochester, New York
Medical Director, Stroke, Neurologic Emergencies, and Neurosciences ICU
Department of Neurosciences and Critical Care
Good Samaritan Hospital, TriHealth Hospital System
Cincinnati, Ohio

Anastasia Zekeridou, MD, PhD
Assistant Professor
Department of Neurology and Laboratory Medicine and Pathology
Mayo Clinic
Rochester, Minnesota

Joseph R. Zunt, MD, MPH
Professor
Department of Neurology, Global Health, Medicine (Infectious Diseases), Epidemiology
University of Washington
Professor
Harborview Medical Center
Seattle, Washington

Contents

SECTION I

GLOBAL BURDEN OF NEUROLOGIC DISEASE 1

Section Editor: *Mitchell S. V. Elkind*

1 Worldwide Epidemiology of Neurologic Disease 1
Jennifer Sevush-Garcy and Mitchell S. V. Elkind

2 Global Delivery of Neurologic Care 9
Hiral Shah, Serena Spudich, and Kiran T. Thakur

SECTION II

APPROACH TO THE NEUROLOGIC PATIENT 15

Section Editor: *James M. Noble*

3 Neurologic History Taking, Localization, and Differential Diagnosis 15
James M. Noble

4 The Neurologic Examination 25
James M. Noble

SECTION III

COMMON PROBLEMS IN NEUROLOGY 45

Section Editor: *J. Kirk Roberts*

5 Dizziness, Vertigo, and Hearing Loss 45
J. Kirk Roberts

6 Syncope 51
Tina T. Shih

7 Seizures 57
Michelle Bell, David J. Roh, and Jan Claassen

8 Pain, Numbness, and Paresthesias 64
Comana M. Cioroiu

9 Headache and Facial Pain 70
Ashhar S. Ali and Julio R. Vieira

10 Visual Disturbances 77
Heather E. Moss

11 Delirium 88
Merrick E. Miles, Christina J. Hayhurst, and Christopher G. Hughes

12 Dementia and Memory Loss 95
Lawrence S. Honig and James M. Noble

13 Involuntary Movements 103
Sara M. Schaefer and Elan D. Louis

14 Muscle Weakness, Cramps, and Stiffness 110
Comana M. Cioroiu

15 Gait Disorders 122
Ashwini K. Rao

16 Acute Stroke: The First Hour 132
Barry M. Czeisler and Stephan A. Mayer

17 Acute Spinal Cord Syndromes 145
Natalie Weathered and Noam Y. Harel

18 Focal Mass Lesions 152
Michelle Bell, Alexander G. Khandji, and Fabio M. Iwamoto

19 Stupor and Coma 168
Jan Claassen and John C. M. Brust

20 Brain Death 179
Eelco F. M. Wijdicks

SECTION IV

DIAGNOSTIC TESTS 184

Section Editor: *James M. Noble*

21 Computed Tomography 184
Priya Shoor, Daniel S. Chow, and Angela Lignelli

22 Magnetic Resonance Imaging 189
Eric Newman and Angela Lignelli

23 Positron Emission Tomography and Single-Photon Emission Computed Tomography 203
William Charles Kreisl

24 Neurovascular Ultrasound 208
Tatjana Rundek

25 Angiography and Neuroendovascular Surgery 217
Katarina Dakay, Scott M. Woolf, Gurmeen Kaur, Daniel H. Sahlein, and Fawaz Al-Mufti

26 Electroencephalography and Evoked Potentials 230
Nicolas Gaspard and Emily J. Gilmore

27 Electromyography, Nerve Conduction Studies, and Magnetic Stimulation 243
Louis H. Weimer

28 Autonomic Testing 255
Louis H. Weimer

29 Evaluation of the Special Senses (Vision, Hearing, Smell, Vestibular System) 259
J. Kirk Roberts

30 Sleep Studies 264
Andrew J. Westwood and Carl W. Bazil

31 Neuropsychological Evaluation 271
Yaakov Stern

32 Lumbar Puncture and Cerebrospinal Fluid Analysis 277
Kiwon Lee

33 Brain, Muscle, Nerve, and Skin Biopsy 283
John F. Crary, Thomas H. Brannagan III, and Kurenai Tanji

34 Intracranial Pressure and Neurocritical Care Monitoring 288
Charles L. Francoeur and Stephan A. Mayer

35 Genetic Testing and DNA Diagnosis 297
Jill S. Goldman and Jacinda B. Sampson

SECTION V

CEREBROVASCULAR DISEASES 301
Section Editor: *Stephan A. Mayer*

36 Acute Ischemic Stroke 301
Charles C. Esenwa and Stephan A. Mayer

37 Transient Ischemic Attack 320
Setareh Salehi Omran and Jose Gutierrez

38 Hypoxic-Ischemic Encephalopathy 324
Sachin Agarwal and Alexandra S. Reynolds

39 Intracerebral Hemorrhage 332
Stephan A. Mayer and Fred Rincon

40 Subarachnoid Hemorrhage 342
Stephan A. Mayer, Gary L. Bernardini, and Robert A. Solomon

41 Cerebral Venous and Sinus Thrombosis 353
Jennifer A. Frontera and Natalie Organek

42 Vascular Malformations 361
Fawaz Al-Mufti and Stephan A. Mayer

43 Central Nervous System Vasculitis 370
Kavneet Kaur, Hussein Alshammari, Ramandeep Sahni, Steven Marks, Stephan A. Mayer, and Fawaz Al-Mufti

44 Posterior Reversible Encephalopathy Syndrome and Other Cerebrovascular Syndromes 384
Claire S. Riley, Sara K. Rostanski, and Joshua Z. Willey

45 Primary and Secondary Stroke Prevention 401
Charles C. Esenwa and Mitchell S. V. Elkind

SECTION VI

NEUROTRAUMA 413
Section Editor: *Neeraj Badjatia*

46 Concussion and Chronic Traumatic Encephalopathy 413
James M. Noble and John F. Crary

47 Traumatic Brain Injury 420
Gunjan Y. Parikh, Neeraj Badjatia, and Stephan A. Mayer

48 Traumatic Spinal Cord Injury 441
Christopher E. Mandigo, Michael G. Kaiser, and Peter D. Angevine

49 Traumatic Cranial and Peripheral Nerve Injury 451
Dominique M. O. Higgins, Lillian Liao, and Christopher J. Winfree

SECTION VII

DEMENTIA 469
Section Editor: *Karen S. Marder*

50 Mild Cognitive Impairment 469
Lawrence S. Honig, Arash Salardini, William Charles Kreisl, and James M. Noble

51 Alzheimer Disease 476
Lawrence S. Honig and James M. Noble

52 Frontotemporal Dementia 486
Edward D. Huey, Megan S. Barker, and Stephanie Cosentino

53 Lewy Body Dementias 492
Oren Levy, Richard A. Hickman, and Karen S. Marder

54 Vascular Dementia and Cognitive Impairment 500
Nikolaos Scarmeas and Adam M. Brickman

55 Prion Diseases 506
Boon Lead Tee and Michael Geschwind

SECTION VIII

HEADACHE AND PAIN SYNDROMES 521
Section Editor: *Richard B. Lipton*

56 Primary and Secondary Headache Disorders 521
Peter J. Goadsby and Richard B. Lipton

57 Facial Pain Disorders and Painful Cranial Neuralgias 538
Paul G. Mathew and Zahid H. Bajwa

58 Complex Regional Pain Syndrome 549
Steven P. Cohen, Michael L. Weinberger, and Thomas H. Brannagan III

59 Neuropathic Pain 557
Jeffrey Shije and Thomas H. Brannagan III

SECTION IX

EPILEPSY AND PAROXYSMAL DISORDERS 567
Section Editor: *Carl W. Bazil*

60 Classification of Seizures and Epilepsy 567
Shraddha Srinivasan and Carl W. Bazil

61 Management of Epilepsy 578
Carl W. Bazil and Shraddha Srinivasan

62 Ménière Syndrome, Benign Paroxysmal Positional Vertigo, and Vestibular Neuritis 597
Ian S. Storper

63 Transient Global Amnesia 602
John C. M. Brust

SECTION X

CENTRAL NERVOUS SYSTEM INFECTIONS 604
Section Editor: *Karen L. Roos*

64 Acute Bacterial Meningitis 604
Karen L. Roos

65 Brain, Spinal, and Epidural Abscess and Other Parameningeal Infections 612
Tracey A. Cho

66 Other Bacterial Central Nervous System Infections and Toxins 624
Kyle J. Coleman

67 Chronic Meningitis 640
Prashanth S. Ramachandran, Joseph R. Zunt, Kelly J. Baldwin, and Michael R. Wilson

68 Parasitic Infections 653
Gustavo C. Román

69 Viral Infections 661
Shibani S. Mukerji, Maria Martinez-Lage, and Kiran T. Thakur

70 Human Immunodeficiency Virus (HIV) and Acquired Immunodeficiency Syndrome (AIDS) 690
Arne Damian Yacoub, Deanna Saylor, Ned Sacktor, Kiran T. Thakur, Carolyn Barley Britton, and Barbara S. Koppel

SECTION XI

DEMYELINATING AND INFLAMMATORY DISEASES 711
Section Editor: *David A. Hafler*

71 Multiple Sclerosis and Related CNS Neuroimmune Diseases 711
Erin E. Longbrake and Sarah F. Wesley

72 Transverse Myelitis 736
Eoin P. Flanagan and Brian G. Weinshenker

73 Neuromyelitis Optica Spectrum Disorder 744
Iris Vanessa Marin Collazo and Brian G. Weinshenker

74 Autoimmune Encephalitis and Meningitis 755
Andrew McKeon, Divyanshu Dubey, Eoin P. Flanagan, Anastasia Zekeridou, and Sean J. Pittock

75 Neurosarcoidosis 773
Siddharama Pawate and Barney J. Stern

SECTION XII

MOVEMENT DISORDERS 778
Section Editor: *Elan D. Louis*

76 Essential Tremor 778
Elan D. Louis

77 Tics and Tourette Syndrome 784
Harvey S. Singer

78 Restless Legs Syndrome 793
Brian B. Koo

79 The Dystonias 800
Hyder A. Jinnah

80 Hemifacial Spasm 820
Paul Greene

81 Myoclonus 824
Pichet Termsarasab and Steven J. Frucht

82 Hereditary and Acquired Ataxias 831
Sheng-Han Kuo and Vikram G. Shakkottai

83 Tardive Dyskinesia and Other Neuroleptic-Induced Syndromes 849
Un Jung Kang and Stanley Fahn

84 Choreas 854
Ruth H. Walker and Joseph Jankovic

85 Huntington Disease 861
Karen S. Marder and Richard A. Hickman

86 Parkinson Disease 871
Peter LeWitt

87 Parkinson-Plus Syndromes 893
Paul Greene

SECTION XIII

NEUROMUSCULAR DISEASES 904
Section Editor: *Thomas H. Brannagan III*

88 Amyotrophic Lateral Sclerosis and Motor Neuron Diseases 904
Neil A. Shneider

89 Bell's Palsy and Cranial Neuropathies 915
Comana M. Cioroiu and Thomas H. Brannagan III

90 Mononeuropathies and Compression Neuropathies 927
Thomas H. Brannagan III

91 Acquired Peripheral Neuropathies 936
Thomas H. Brannagan III and Kurenai Tanji

92 Inherited Peripheral Neuropathies 955
Chiara Pisciotta and Michael E. Shy

93 Myasthenia Gravis and Other Disorders of the Neuromuscular Junction 963
Christina M. Ulane

94 Inflammatory and Autoimmune Myopathies 979
Rebecca Traub, Kurenai Tanji, and Christina M. Ulane

95 Critical Illness Myopathy and Neuropathy 989
Ahmad Riad Ramadan, Michio Hirano, and Louis H. Weimer

96 Endocrine and Toxic Myopathies 992
Christina M. Ulane

97 Periodic Paralysis and Other Channelopathies 998
Comana M. Cioroiu

98 Stiff Person Syndrome and Peripheral Nerve and Muscle Hyperexcitability 1004
Jonathan Perk and Christina M. Ulane

99 Metabolic and Mitochondrial Myopathies in Adults 1011
Michio Hirano, H. Orhan Akman, and Salvatore DiMauro

SECTION XIV

NEUROONCOLOGY 1019
Section Editor: *Tobias Walbert*

100 Gliomas 1019
J. Ricardo McFaline-Figueroa and Patrick Y. Wen

101 Metastatic Tumors 1034
Rupesh Kotecha and Minesh P. Mehta

102 Meningiomas 1050
Thomas J. Kaley

103 Primary Central Nervous System Lymphoma 1056
Lakshmi Nayak and Tracy T. Batchelor

104 Tumors of the Pituitary Gland 1064
Pamela U. Freda, John Ausiello, and Jeffrey N. Bruce

105 Pineal Region Tumors 1072
Jeffrey N. Bruce

106 Acoustic Neuroma and Other Skull Base Tumors 1080
Randy S. D'Amico and Michael B. Sisti

107 Spinal Tumors 1089
David Cachia, Claudio E. Tatsui, and Mark R. Gilbert

108 Paraneoplastic Syndromes 1100
Erika Santos Horta and Tobias Walbert

109 Complications of Cancer Therapy 1106
Jasmin Jo and David Schiff

SECTION XV

HYDROCEPHALUS AND CEREBRAL EDEMA 1114
Section Editor: *Fred Rincon*

110 Hydrocephalus 1114
Kumud Sharma and Fred Rincon

111 Brain Edema and Increased Intracranial Pressure 1127
Stephan A. Mayer

112 Spontaneous Intracranial Hypotension 1139
Kevin E. Immanuel, Tiffany R. Chang, and Kiwon Lee

SECTION XVI

SPINAL CORD DISORDERS 1145
Section Editor: *Paul C. McCormick*

113 Intervertebral Disk Disease and Radiculopathy 1145
Hani Malone and Peter D. Angevine

114 Cervical and Lumbar Spinal Stenosis 1153
Brian J.A. Gill and Paul C. McCormick

115 Acquired and Hereditary Myelopathies 1159
Natalie Weathered and Noam Y. Harel

SECTION XVII

AUTONOMIC AND SLEEP DISTURBANCES 1170
Section Editor: *Louis H. Weimer*

116 Autonomic Failure, Autonomic Neuropathy, and Orthostatic Intolerance 1170
Louis H. Weimer

117 Paroxysmal Sympathetic Hyperactivity After Acute Brain Injury 1178
Sophie Samuel and Huimahn Alex Choi

118 Sleep Disorders 1183
Andrew J. Westwood and Carl W. Bazil

SECTION XVIII

SYSTEMIC ORGAN FUNCTION AND THE NERVOUS SYSTEM 1195
Section Editor: *Kiwon Lee*

119 Heart-Brain Interactions 1195
Shouri Lahiri and Stephan A. Mayer

120 Sepsis-Associated Encephalopathy 1201
Aurélien Mazeraud, Cássia Righy, Stephan A. Mayer, and Tarek Sharshar

121 Respiratory Support for Neurologic Diseases 1207
David B. Seder and Stephan A. Mayer

122 Endocrine Diseases and the Brain 1215
Spyridoula Tsetsou and Alexandra S. Reynolds

123 Hematologic Diseases and the Brain 1227
Andreas H. Kramer

124 Hepatic Disease and the Brain 1245
Charles L. Francoeur and Stephan A. Mayer

125 Renal Disease, Electrolyte Disorders, and the Nervous System 1253
J. Kirk Roberts and Stephan A. Mayer

126 Gastric and Genitourinary Function and the Brain 1262
Alden Doerner Rinaldi and Charles C. Esenwa

127 Bone Diseases and the Central Nervous System 1270
Roger N. Rosenberg and Alison M. Pack

128 Malnutrition, Malabsorption, and Vitamin Deficiencies 1277
Rebecca Traub and Inna Kleyman

129 Neurologic Disease During Pregnancy 1286
Alison M. Pack

130 Neurologic Complications of Organ Transplantation 1298
Eelco F. M. Wijdicks

SECTION XIX

NEUROLOGIC TOXIDROMES 1303
Section Editor: *John C. M. Brust*

131 Alcoholism 1303
John C. M. Brust

132 Drug Intoxication and Withdrawal 1313
John C. M. Brust

133 Neurotoxicology 1319
Christopher Zammit and Stephan A. Mayer

134 Radiation Injury 1335
Matthew R. Leach and Christopher Zammit

135 Electrical and Lightning Injury 1347
Imad Khan and Christopher Zammit

136 Decompression Illness 1350
Matthew R. Leach and Christopher Zammit

SECTION XX

PEDIATRIC NEUROLOGY 1355
Section Editor: *Arthur M. Mandel*

137 Neonatal Neurology 1355
Arthur M. Mandel

138 Nervous System Formation and Malformation 1366
Gary D. Clark

139 Inherited Metabolic Diseases 1385
Marc C. Patterson

140 Chromosomal Disorders and Disorders of DNA 1410
Marc C. Patterson

141 The Floppy Infant 1417
Maryam Oskoui, Laurent Servais, and Darryl C. De Vivo

142 Disorders of Motor and Cognitive Development 1424
Jason B. Carmel, Toni S. Pearson, and Reet Sidhu

143 Autism Spectrum Disorders 1433
Sylvie Goldman and Jennifer M. Bain

144 Mitochondrial Encephalomyopathies 1441
Salvatore DiMauro, Emanuele Barca, and Michio Hirano

145 Neurocutaneous Syndromes 1456
Marc C. Patterson

146 Spinal Muscular Atrophies of Childhood 1467
Basil T. Darras, Richard S. Finkel, and Darryl C. De Vivo

147 Muscular Dystrophies and Congenital Myopathies 1474
James J. Dowling, Hernan D. Gonorazky, Dimah N. Saade, Michael W. Lawlor, and Darryl C. De Vivo

148 Seizures and Epilepsies in Neonates and Children 1502
Tristan T. Sands and M. Roberta Cilio

149 Pediatric Stroke 1515
Sally M. Sultan and Robert H. Fryer

150 Brain Tumors in Children 1528
James H. Garvin, Jr

151 Pediatric Brain Injury and Shaken Baby Syndrome 1572
Joshua Cappell and Steven G. Kernie

152 Human Immunodeficiency Virus, Fetal Alcohol Syndrome, and Drug Effects 1579
Claudia A. Chiriboga

SECTION XXI

PSYCHIATRY AND NEUROLOGY 1588
Section Editor: *David H. Strauss*

153 Psychosis 1588
Jacob S. Balion and T. Scott Stroup

154 Mood Disorders 1596
Andrés Barrera, Licínia Ganança, Alejandro S. Cazzulino, and Maria A. Oquendo

155 Anxiety Disorders, Posttraumatic Stress Disorder, and Obsessive-Compulsive Disorder 1606
Franklin R. Schneier

156 Somatic Symptom Disorders 1615
Anna L. Dickerman, Philip R. Muskin, and Vivian Liu

SECTION XXII

RECOVERY AND END-OF-LIFE CARE 1629
Section Editor: *Joel Stein*

157 Neurologic Rehabilitation 1629
Joel Stein and Heidi Schambra

158 End-of-Life and Palliative Care in Neurology 1636
Tobias Walbert, Fred Rincon, and James M. Noble

Index 1645

Videos

The following videos can be found in the companion e-book edition.

Chapter 13: Involuntary Movements

Video 13.1. Myoclonus involving the left arm.

Video 13.2. Torticollis.

Video 13.3. Chorea in two twins with Huntington disease.

Video 13.4. Facial tics.

Video 13.5. Kinetic tremor during spiral drawing in a patient with essential tremor.

Video 13.6. Akathitic movements in a patient exposed to antipsychotic drug therapy.

Video 13.7. Patient with Parkinson disease exhibits dyskinesias, especially in his legs but also in his arms.

Chapter 60: Classification of Seizures and Epilepsy

Video 60.1. Generalized tonic-clonic seizure. Abrupt vocalization with tonic posturing of both arms and legs followed by symmetric clonic jerking of all four extremities and face, followed by stertorous breathing in the postictal phase.

Video 60.2. Atonic seizure. Sudden loss of tone during activity causing head and arm drop.

Video 60.3. Automatisms in a right temporal lobe seizure. Ictal speech followed by right hand automatisms (sign of the cross with right hand, stereotyped stroking movements with right hand).

Video 60.4. Frontal lobe seizure with bizarre semiology. Bicycling movements of both legs occurring out of sleep, bizarre vocalizations, and facial grimacing followed by a very brief postictal state with rapid return to baseline mental status.

Video 60.5. Epilepsia partialis continua (EPC). Rhythmic twitching of the left face and mouth.

Chapter 61: Management of Epilepsy

Video 61.1. Psychogenic nonepileptic seizure. Waxing and waning arrhythmic and asynchronous arm and leg movements with side-to-side head movements and pelvic thrusting.

Chapter 74: Autoimmune Encephalitis and Meningitis

Video 74.1. Male patient with opsoclonus-myoclonus syndrome, immunotherapy responsive. (From Klaas JP, Ahlskog JE, Pittock SJ, et al. Adult-onset opsoclonus-myoclonus syndrome. *Arch Neurol*. 2012;69:1598-1607.)

Video 74.2. Male patient with subacute onset chorea and behavioral change. Contactin-associated protein 2 (CASPR2) autoimmunity detected, Huntington disease genetic testing negative. (From O'Toole O, Lennon VA, Ahlskog JE, et al. Autoimmune chorea in adults. *Neurology*. 2013;80[12]:1133-1144.)

Video 74.3. Male patient with faciobrachial dystonic seizures in the context of leucine-rich glioma–inactivated protein 1 (LGI1) encephalitis.

Video 74.4. Two female patients with brainstem encephalitis in the context of antineuronal nuclear antibody type 2 (ANNA-2) (anti-Ri) autoimmunity and breast adenocarcinoma. Note the eye movement abnormalities, exaggerated startle, postural instability, axial rigidity, and jaw dystonia. (From Pittock SJ, Parisi JE, McKeon A, et al. Paraneoplastic jaw dystonia and laryngospasm with antineuronal nuclear autoantibody type 2 [anti-Ri]. *Arch Neurol*. 2010;67[9]:1109-1115.)

Video 74.5. A female patient with stiff person syndrome. Note the nonreducing lumbar lordosis and stiff-legged gait.

Chapter 76: Essential Tremor

Video 76.1. A kinetic tremor is apparent as this patient with essential tremor (ET) draws a spiral.

Video 76.2. In approximately 50% of essential tremor (ET) patients, the tremor has an intentional component, worsening on finger-nose-finger maneuver as the patient approaches one or both of the two targets.

Chapter 80: Hemifacial Spasm

Video 80.1. Patient with hemifacial spasm. She has spasms of the orbicularis oculi, zygomaticus major, depressor anguli oris, and other muscles innervated by the facial nerve. Contractions in all muscles seem to be simultaneous. She has individual twitches, trains of twitches, and trains of twitches rapid enough to cause sustained partial eyelid closure and sustained pulling of the corner of the mouth. Contractions are triggered by looking up as well as many other actions controlled by the facial nerve not shown in this video. One may also see contractions of the platysma, depressors of the corner of the mouth, mentalis contractions that cross the midline), and of the upper lip.

Chapter 81: Myoclonus

Video 81.1. Myoclonus in Rasmussen encephalitis. This video demonstrates epilepsia partialis continua seen as myoclonic movements of the left orbicularis oculi with tonic contraction on the left lower face. These were much improved after intravenous immunoglobulin (IVIG) treatment.

Video 81.2. Posthypoxic myoclonus. The patient had generalized synchronous large-amplitude myoclonic jerks, more prominent with action than at rest. When standing, there was negative myoclonus of bilateral lower extremities, giving "a bouncing gait."

Video 81.3. Myoclonus-dystonia syndrome. The patient had myoclonic jerks, more prominent in proximal regions including neck, bilateral shoulders, and proximal upper extremities. Myoclonus was obvious with action including writing and pouring water from a cup but also occurred intermittently at rest.

Video 81.4. Hyperekplexia. This baby had severe exaggerated startle. Synchronous generalized myoclonic jerks of all extremities, upper greater than lower, were present even at rest and were also elicited by tapping the nose. Note that we do not recommend performing the repetitive nose tapping shown in this video. The latter part of the video shows hyperekplexia in Poll Hereford cattle. There were generalized myoclonic jerks with somesthetic stimuli.

Video 81.5. Propriospinal myoclonus. This video demonstrates reflex myoclonus, axial jerks shown as truncal flexion after being tapped with a reflex hammer. Note the relatively long latency between the taps and truncal flexion due to slow conduction via propriospinal pathways, in contrast to the short latency in cortical myoclonus due to conduction through corticospinal pathways.

Chapter 82: Hereditary and Acquired Ataxias

Video 82.1. Neurological exams of ataxia in a case of spinocerebellar ataxia type 1 (SCA1). This individual has variable stride length and walking directions. She has increased body sway in standing and also difficulty in tandem stance. While sitting, she has mild truncal sways and slurred speech while talking. She has overshoot in her finger chase exam and intention tremor in her finger-nose exam. She has slow rapid alternating movements. In the heel-shin slide exam, her heel falls off her shin several times.

Video 82.2. Gait progression in ataxia patients. An example of mild ataxia with turning difficulty in a case of spinocerebellar ataxia type 1 (SCA1) (segment 1). Another sign of mild ataxia is variable stride length and different walking directions as exemplified in a patient with POLG ataxia (segment 2). As the ataxia progresses, a slight wide-based gait develops, illustrated in a patient with spinocerebellar ataxia type 6 (SCA6) (segment 3). Finally, when ataxia becomes more severe, a marked wide-based gait becomes evident to compensate for the deficits, demonstrated in a patient with spinocerebellar ataxia type 35 (SCA35). The patient still have variable stride length and direction of walking, in addition to a wide-based gait (segment 4).

Video 82.3. Eye movement abnormalities in cerebellar ataxia. End-gaze nystagmus in POLG ataxia (segment 1). Slow saccades in spinocerebellar ataxia type 2 (SCA2) (segment 2). Hypermetric saccades in spinocerebellar ataxia type 1 (SCA1) (segment 3). Hypometric saccades in multiple system atrophy, cerebellar type (segment 4). Impaired vertical saccades with relatively preserved horizontal saccades in Niemann-Pick type C (segment 5).

Video 82.4. A spinocerebellar ataxia type 2 (SCA2) patient exhibits dysarthria, slow saccades, dysmetria in the finger-chin test, impaired rapid alternating movements, overshoot in the finger chase exam, hyporeflexia, a wide-based gait with variable walking directions.

Video 82.5. A spinocerebellar ataxia type 7 (SCA7) patient demonstrates dysarthria, impaired vision acuity, severe dysmetria on the finger-nose exam, severe overshoot on the finger chase exam, and severe dysmetria on heel-shin slides.

Video 82.6. A case of multiple system atrophy, cerebellar type shows hypomimic facial expression, bradykinesia on the hand open/close exam, hand pronation/supination exam, finger taps, and foot taps, worse on the left side than the right side. He also has overshoot in the finger chase exam, abnormal rapid alternating movements, and hyperreflexia. During walking, he has difficulty in turning, loss of left arm swing, dragging his left foot, in addition to cerebellar ataxia.

Chapter 83: Tardive Dyskinesia and Other Neuroleptic-Induced Syndromes

Video 83.1. Oculogyric crisis and drug-induced parkinsonism. A teenage girl developed drug-induced parkinsonism and oculogyric crisis on antipsychotic medication. She has intermittent involuntary eye deviation upward as well as hypomimia, bradykinesia, and tremor.

Video 83.2. Classic orobuccolingual dyskinesia and limb dyskinesia. The patient has typical orobuccolingual movements resembling chewing and swallowing as well as tongue popping and lip puckering. Oral movements cease when she talks and does not interfere with speech significantly. She also shows repetitive finger extension and flexion. The right thumb is in extended position, suggesting a dystonic component. She has similar flexion and extension movement of toes and wrist, when standing up.

Video 83.3. Tardive dystonia. The patient shows excessive eye blinking and closure (blepharospasm) as well as lower facial grimacing movement. Her eyes open better when talking than listening to examiner.

Video 83.4. Tardive akathisia. The patent has flexion and extension and rotation of ankles, which makes her look restless. She can suppress the movements partially for several seconds and describes her "need" to move.

Chapter 84: Choreas

Video 84.1. Sydenham disease. A 13-year-old boy with a 2-month history of left hemichorea and prior history of sore throat; serum antistreptolysin O (ASO) titer is greater than 600. The chorea completely resolved in 6 months.

Video 84.2. Kernicterus. An 11-year-old boy with a history of marked and prolonged neonatal jaundice, delayed developmental milestones, generalized choreoathetosis, vertical ophthalmoparesis, and deafness, typical of kernicterus.

Chapter 85: Huntington Disease

Video 85.1. Motor signs of Huntington disease.

Chapter 86: Parkinson Disease

Video 86.1. Rest tremor. The right arm tremor subsides briefly as the arm moves from resting to an outstretched position where it subsequently re-emerges. In the left arm, tremor continues from rest to kinetic and to posture-maintenance positions. No kinetic tremor is seen with the right arm during finger-to-nose maneuver, though the left arm shows some. There is jaw tremor at rest. While walking, the patient exhibits rest tremor in both arms.

Video 86.2. Typical Parkinsonian features (bradykinesia and gait disturbance). The patient exhibits mildly slurred speech and decreased facial expression with diminished blinking and a partially opened mouth. She also has mild oral dyskinesia. Rapid alternating movements are impaired bilaterally, more on the left. Finger tapping is slow, irregular, and small in amplitude; it is also more impaired on the left. The patient arises using a push against the arm rest. Her posture is mildly forward-flexed. Though she takes full strides with a normal base, her gait lacks heel strikes and there is bilateral decreased arm swing. She requires five steps to complete a 180-degree turn. In response to the pull test, she takes four steps of retropulsion before her backward fall was caught by the examiner.

Video 86.3. Levodopa-induced dyskinesia. The patient exhibits truncal, oral, and arm dyskinesia. There is also dystonic posturing of the left arm, activated by voluntary movement of the right arm. During walking, she shows excessive swinging of the left arm and oral dyskinesia is activated. The patient fails to regain balance on the pull test. Parkinsonian symptoms (left-sided rest tremor and bradykinesia) re-emerge a

few minutes after the overtly dyskinetic state (though oral dyskinesia persists).

Video 86.4. Freezing of gait. The patient freezes after reaching a destination and making a turn. While attempting to re-start walking, he develops tremulous movements in the legs. After a few seconds, he is able to resume his gait.

Chapter 87: Parkinson-Plus Syndromes

Video 87.1. Patient with mild signs and symptoms of progressive supranuclear palsy (PSP) for 2 years. Continuous, tiny square wave jerks are visible when he fixates. He has extremely limited upgaze and downgaze. He does not generate saccades when asked to look left or right. He is able to open his eyes after lid closure, but there is a delay on the left. Tongue movements are mildly slow. He has marked axial bradykinesia (slowed shoulder shrug on the right) with mild slowing of rapid succession movements of the hands or feet. His blink rate is markedly reduced, and he has a stare. He is able to rise from a chair with arms crossed, although slowly. He has a mildly broad-based, slow gait with right greater than left arm abduction ("gunslinger's walk") and decreased arm swing.

Video 87.2. Patient with more severe progressive supranuclear palsy (PSP). She has the characteristic facial dystonia of PSP producing a troubled or angry look. She has poor balance, cannot rise from a chair safely with arms crossed, and falls in all directions. She also has a mildly broad-based stance and gait. When instructed to step backward when pulled from behind, she falls backward.

Video 87.3. Patient seen initially with mild signs and symptoms of cortical-basal ganglionic degeneration (CBGD). She has dystonic posturing of the right hand with twisting, slightly jerky movements of the right forearm, wrist, and fingers. Rapid succession movements of the upper extremities are mildly slowed on the left and markedly slowed on the right. She can rise slowly from a chair using her left hand. Her gait is slow, with mildly broad-based, short stride on the left, dystonic posturing of both arm and leg on the right with even shorter stride, and no heel strike on either side. She turns en bloc, barely lifting the right foot. Two years later, she spends almost all her time in a wheelchair. She has severe dystonic posturing of the right arm and hand. She has overflow elevation of the right arm and left leg when she lifts the left. She has almost no function of the right hand or arm, requiring the left for simple actions like raising or lowering the arm. The left side is slow but significantly more functional than the right. She needs assistance to rise from a chair, and when she does, her right leg elevates and she can barely lower it to the ground and cannot support her weight with her legs alone.

Chapter 107: Spinal Tumors

Video 107.1. Gross total resection of the thoracic meningioma seen in Figure 107.6. After standard posterior thoracic laminectomy and midline opening of the dura mater is completed, microsurgical technique is used to dissect the arachnoid plane and separate the tumor from the spinal cord, nerve roots, and radiculomedullary artery and veins. Subsequently, the tumor capsule is incised, and a debulking followed by piecemeal resection is performed. After gross total resection is achieved, the dural insertion is cauterized to reduce risk of recurrence. We opted not to remove the dura given the anterior location and potential morbidity of a cerebrospinal fluid (CSF) leak.

Video 107.2. Gross total resection of an intramedullary ependymoma. After standard posterior thoracic laminectomy and midline opening of the dura mater is completed, microsurgical technique is used to perform a midline posterior myelotomy at the level of the posterior midline sulcus. The myelotomy is extended to allow complete exposure of the tumor. A plane of cleavage is developed and the dorsal and lateral border of the mass are gently separated from the surrounding spinal cord. Subsequently, the tumor is mobilized away from the ventral columns, and all feeders from the anterior spinal artery are cauterized and cut allowing en bloc resection of the ependymoma.

Chapter 119: Heart-Brain Interactions

Video 119.1. Typical takotsubo.

Video 119.2. Atypical takotsubo.

Worldwide Epidemiology of Neurologic Disease

1

Jennifer Sevush-Garcy and Mitchell S. V. Elkind

KEY POINTS

1. Assessing burden of neurologic disease requires measurement of both disease mortality and morbidity (disability, handicap, etc.).
2. The disability-adjusted life year (DALY) is a metric that combines years of life lost due to premature death and years of healthy life lost as a result of disability, weighted by the severity of the disability.
3. Neurologic disorders account for the largest proportion of DALYs of any category of disease.
4. The *double burden* of disease refers to the phenomenon whereby developing countries experience the adverse consequences of a modern lifestyle before escaping the problems of poverty, which helps to explain why countries in the middle levels of development have the highest rates of some neurologic disorders such as stroke.
5. Stroke incidence has increased in low- and middle-income countries, whereas high-income countries have experienced a 42% decrease in incidence over the past four decades.
6. Limitations in neurologic resources and variability in resource allocation to neurologic problems contribute to disparities in the global burden of neurologic disease as well as local variations within nations.

INTRODUCTION

Neurologic disorders are globally among the most important causes of human illness and mortality. Quantifying the burden of neurologic disease and its impact on populations throughout the world is challenging for several reasons, however. First, neurologic disease includes disorders that primarily affect the brain as well as diseases that affect other body systems but have prominent neurologic manifestations. Second, neurologic diseases are notable for more frequently causing disability than death. Commonly used measures of disease impact, such as hospitalization or mortality rates, may not capture the impact of nonfatal neurologic problems such as migraine or epilepsy. Third, there are often disparities in neurologic disorders caused by socioeconomic and geographic factors. Assessment and diagnosis of neurologic disease may also depend on resources available for their measurement that are not available in all environments. Despite these limitations, present estimates of the burden of neurologic disorders suggest that they have an enormous impact on human health.

THE CLASSIFICATION OF DISEASE: WHAT IS A NEUROLOGIC DISORDER?

Neurologic disorders can be broken down into two general categories: primary neurologic disorders affecting the nervous system only and secondary neurologic disorders, in which injury or dysfunction of the nervous system occurs as a result of a disease that primarily affects another organ system or in which dysfunction of the nervous system occurs along with dysfunction of several other organ systems. Examples of primary neurologic disorders include Alzheimer disease, migraine, and multiple sclerosis. Examples of secondary neurologic disorders include seizures secondary to infection with malaria, paraneoplastic syndromes associated with primary systemic cancer, and peripheral neuropathy occurring in the setting of nutritional deficiencies.

The distinction between primary and secondary neurologic disorders complicates the task of estimating global disease burden. For instance, do we classify diabetic neuropathy as a neurologic disorder or as a complication of an endocrinologic disorder? Should stroke be considered a neurologic disorder or a cardiovascular disease? Should head injury in the context of a motor vehicle accident be counted toward the burden of disease of neurologic disorders or of accidents? Various approaches have been taken to answer these questions, and in some instances, the definitions may shift depending on the purpose of the analysis. Although these distinctions may seem academic at first glance, they could have implications for public health campaigns and approaches to measuring, reporting, and acting on the relative burden of illness caused by different diseases.

ESTIMATING DISEASE BURDEN

There are several measures used to evaluate disease burden, including incidence, prevalence, morbidity, case fatality, mortality, disability, quality of life, pain, and cost. Incidence and prevalence are used to determine how common a disease is. The number of first cases of a disease over a defined time interval in a defined population determines its incidence. Prevalence measures the total number of cases, new and old, at a particular time in a defined

population. Both indices depend on the accurate and complete enumeration of cases and adequate knowledge of the underlying population at risk. Case fatality refers to the proportion of patients with a disease who die from it. Mortality refers to the overall number of deaths due to the disease in a given time period.

Mortality

Traditional approaches to estimating the impact of illness have focused on mortality because it is relatively easy to measure. The impact of some neurologic disorders may be reasonably captured by reference to their case fatality or mortality. For example, malignant brain tumors, strokes, and head injuries are often severe and may lead to death. A metric focused exclusively on mortality, however, will fail to capture the impact of many neurologic disorders that are chronic and slowly progressive, or intermittent and disabling, but that do not cause their sufferers to die. For example, multiple sclerosis is a disease process that has low mortality but inflicts a rather high level of disability on its patients; however, it is relatively rare. Alternatively, migraine is a neurologic disorder that also has low mortality but has moderate disability and is extremely common. Clearly, attempts to measure this type of disease burden require a more versatile metric than mortality alone.

Morbidity

More recent attempts to measure disease burden have therefore aimed at capturing not only mortality but also morbidity, which captures the disability, handicap, and other physical costs associated with the disease. One common approach to measuring burden of disease is to consider a time-based metric that incorporates premature mortality (the number of years of life lost due to premature death, based on an expected life span) and disability (years of healthy life lost as a result of disability weighted by the severity of the disability). The combination of both of these measures yields disability-adjusted life years (DALYs). The DALYs are a well-established metric of disease burden that measures the number of healthy years of life lost as a result of both death and disability caused by a particular disease. One DALY constitutes 1 year of healthy life lost in an ideal world in which everyone lives into old age free of any disease or disability. One advantage to using the DALY to measure disease burden is that it allows comparisons of impact across very different disease states, in effect serving as a common measure for acute severe illness (stroke, head injury, myocardial infarction) and less severe chronic illnesses (epilepsy, migraine). The DALY metric thus reflects the impact of disease on both early mortality and on disability, both of which are particularly important for assessing the overall impact of neurologic disease.

Neurologic disorders account for the largest proportion of DALYs of any category of disease, more so than cancer, heart disease, or pulmonary disease (Fig. 1.1). Neurologic disorders are also the second largest group causing global death. Among neurologic disorders, stroke, migraine, meningitis, Alzheimer disease, and epilepsy each caused more than 10 million DALYs. Within the category of neurologic disorders, the greatest proportion of DALYs is due to stroke, which represents just about half of the DALYs due to all neurologic disorders. Alzheimer disease and other dementias, together with meningitis and epilepsy, comprise another quarter of the DALYs seen with neurologic disease. Perhaps surprisingly, migraine encompasses 13.1% of DALYs among neurologic disorders, which is over 10 times that encompassed by Parkinson disease and multiple sclerosis combined, although it contributes little to the occurrence of deaths. Likewise, although epilepsy contributes to almost 5% of DALYs, it is responsible for only 1.3% of deaths. Stroke, on the other hand, which is frequently fatal, is responsible for 67.3% of deaths when compared to other neurologic disorders (Fig. 1.2).

Life Expectancy

Another increasingly used metric of the impact of neurologic disease is Health Adjusted Life Expectancy, or HALE. Life expectancy is the average number of years that a person is expected to live based on current mortality rates in the population. The HALE is life expectancy adjusted for disease and disability. This is the average number of years that person can expect to live in full health, taking into account years lived in less than full health. In order to measure HALE, a measurement is needed of both how many people a disease affects and the impact on health and function of the disease on the people who have it. Combining these two effectively creates a measure of disease-free life expectancy weighted by the severity of the disease.

Estimates from the Global Burden of Disease Study 2015, sponsored by the World Health Organization (WHO), suggested increasing life expectancy in recent years allowed more of the population to reach ages where neurologic diseases become more prevalent. In addition, there has been improvement in risk factor optimization and advances in medical care, such as secondary stroke prevention and acute stroke treatment, that impact the burden of neurologic disorders around the world.

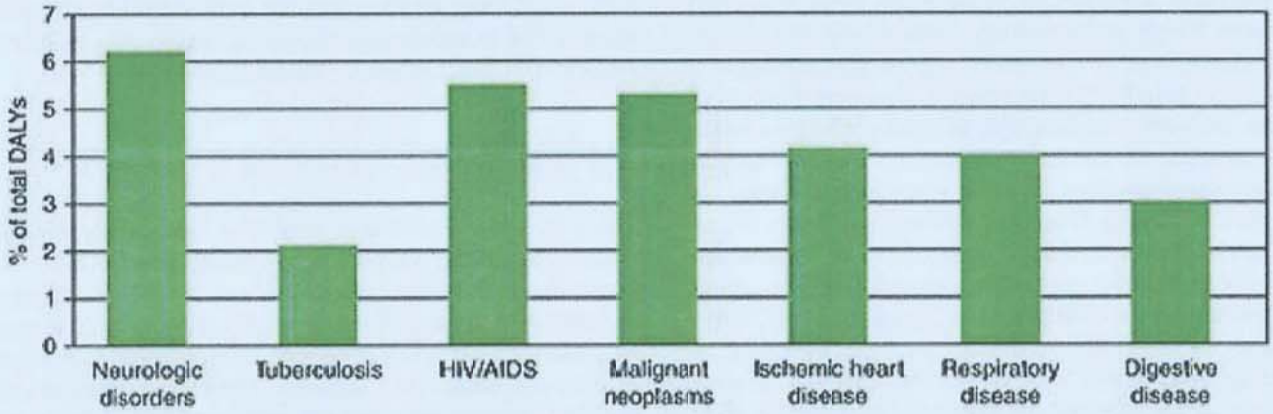

FIGURE 1.1 Percentage of total disability-adjusted life years (DALYs) for selected diseases and neurologic disorders. Abbreviation: HIV, human immunodeficiency virus.

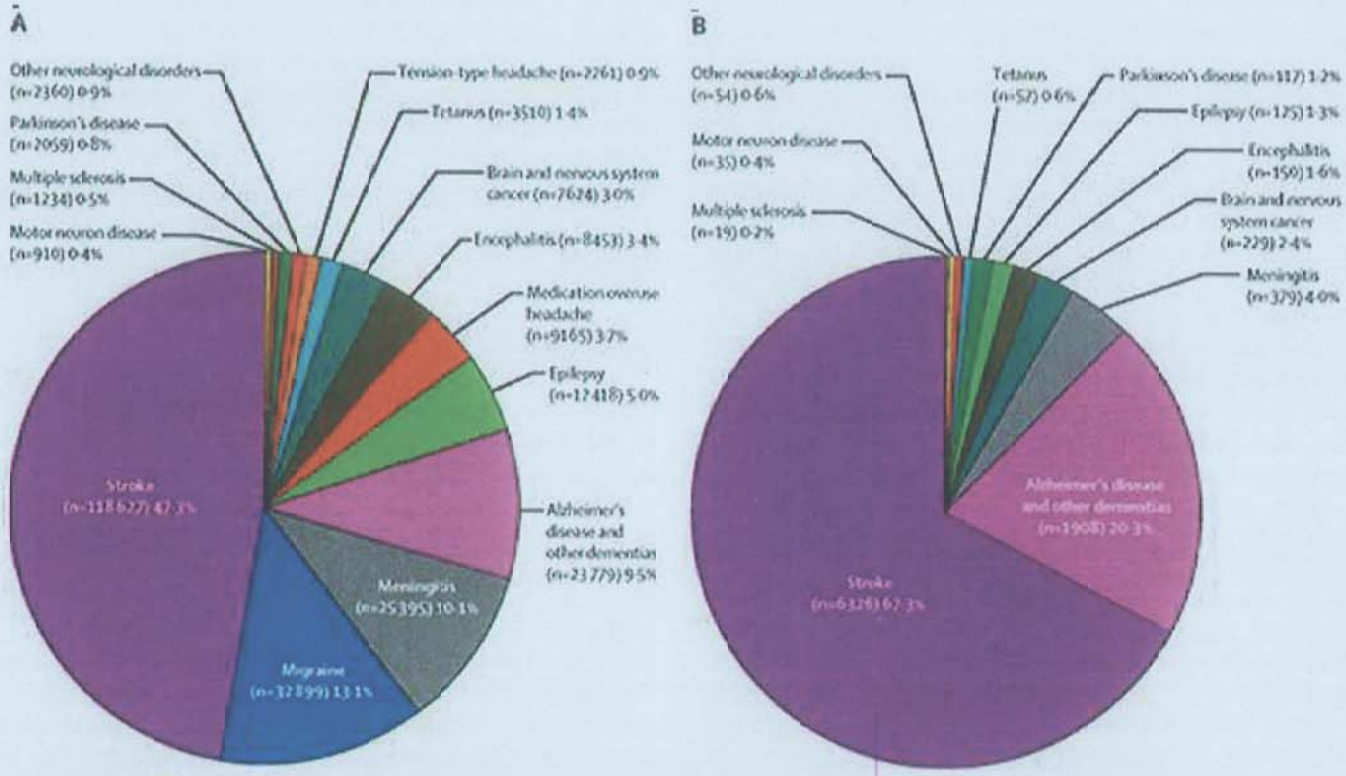

FIGURE 1.2 Contribution of various neurologic disorders to the overall burden from neurologic disorders in 2015. Estimates are for disability-adjusted life-years (A) and deaths (B). (From GBD 2015 Neurological Disorders Collaborator Group. Global, regional, and national burden of neurological disorders during 1990-2015: a systematic analysis for the Global Burden of Disease Study 2015. *Lancet Neurol.* 2017;16[11]:877-897.)

THE SHIFTING CHARACTER OF NEUROLOGIC DISEASE OVER TIME

The relative importance of different neurologic disorders over time has changed not only as a consequence of changes in population demographics and risk factors but also as a consequence of world events and scientific knowledge. For example, tremendous advances in our understanding of peripheral nerve injuries, including phantom limb pain, occurred in the 19th century during the Civil War, through the examination of amputees and injured soldiers by Silas Weir Mitchell and colleagues. Further advances in our understanding of head injuries occurred during the First World War. Early in the 20th century, neurologists also frequently encountered brain injury as a direct or indirect consequence of infections, including syphilis, tuberculosis, and viral encephalitis. For example, the Spanish flu pandemic of 1918 to 1919 gave rise to many cases of postencephalitic parkinsonism, a disorder made familiar to many through Oliver Sacks' *Awakenings*. Later in the century, as life expectancy in developed countries increased, disorders of the elderly, including stroke and neurodegenerative disorders such as Parkinson disease and Alzheimer disease, were commonly encountered. Infectious neurologic disorders resurfaced again, however, in the 1980s in the form of the human immunodeficiency virus (HIV)/AIDS epidemic, with its well-known complications of toxoplasmosis and cerebral lymphoma. Rare and initially mystifying neurologic diseases have also captured the popular imagination and generated interest beyond what would be expected from the numbers of patients affected; the spongiform encephalopathies caused by prions, such as new variant Creutzfeldt-Jakob disease (or mad cow disease), had a tremendous impact in terms of teaching us about how diseases can jump from one species to another.

THE EPIDEMIOLOGIC TRANSITION AND THE DOUBLE BURDEN OF DISEASE

The concept of the "epidemiologic transition" has been used to explain the shift in the types of diseases that often occur in countries as they pass through different stages of development. As nations industrialize and develop, the major causes of death and disability shift from a predominance of nutritional deficiencies and infectious diseases toward degenerative and chronic diseases, such as diabetes and cardiovascular disease. Investigators have described at least five stages of transition. The first stage (pestilence and famine) includes nutritional deficiencies and infection and characterizes regions such as sub-Saharan Africa and rural South Asia. In the second stage (receding pandemics), during which the pandemics of infectious disease and malnutrition recede, diseases related to hypertension, such as hemorrhagic stroke, become more common. China is an example of a region in this stage. During the third stage (degenerative and man-made diseases), life expectancy improves, but high-fat diets, sedentary lifestyles, and cigarette smoking are introduced, allowing chronic, degenerative, and "man-made" diseases, including cardiovascular disease and ischemic stroke, to become more prominent. Urban India serves as an example of a country in this stage. As countries become more industrialized, populations are also

exposed to new environmental hazards. In a study conducted in Taipei, Taiwan, urban air pollution was associated with increased numbers of emergency admissions for cerebrovascular diseases. In the fourth stage (delayed degenerative disorders), there are increased efforts to prevent, diagnose, and treat these lifestyle-related diseases, which allow for a delay in their age of onset as well as the increase in degenerative diseases affecting the elderly. Western Europe and North America are considered to be in this fourth stage of the epidemiologic transition. Finally, a fifth stage may exist (social upheaval and social regression) in which social upheaval and war break down the existing health structures, leading to a resurgence of conditions seen in the first two stages as well as to the effects of violence and accidents. Post-Soviet Russia has been suggested as an example of this fifth stage.

As countries develop, they may also fall prey to the adverse consequences of a Western lifestyle (high-fat diet, sedentary lifestyle) before they fully emerge from the problems of underdevelopment. This phenomenon has been referred to as the *double burden* of disease and explains why countries in the middle levels of development have the highest rates of many illnesses. Developing and middle-income regions such as Latin America and urban India, for example, experienced increased incidence of cardiovascular disease while simultaneously facing the lingering effects of infection and malnutrition.

Neurologic disorders are also subject to this epidemiologic staging. At any given time, different regions throughout the world may be in different stages of this transition. In particular, empirical evidence of the epidemiologic transition of stroke was nicely described in the Sino-MONICA-Beijing project. In this community-based surveillance study, investigators examined temporal trends in stroke incidence in Beijing over two decades from 1984 to 2004, a particularly rapid period of economic development in China. Four characteristics of the epidemiologic transition were observed: declining incidence of hemorrhagic stroke due to improved treatment of hypertension, reduced case fatality due to improved treatment after stroke, increased age of stroke onset, and an expanded proportion of ischemic heart disease deaths with a decreased proportion of stroke deaths in the study population. Additionally, an increase in the incidence of ischemic stroke was found, which was felt to be secondary to increased atherosclerotic risk factors.

DISPARITIES

Populations can be stratified by geography and income, and there are often disparities in neurologic disorders based on these factors. The WHO recognizes 6 geographic regions (Africa, Americas, Southeast Asia, Europe, Eastern Mediterranean, and Western Pacific) and 14 subregions, stratified according to child and adult mortality in those regions. The World Bank categorizes countries into four groups on the basis of gross national income per capita: low, lower middle, upper middle, and high income. Varying types of neurologic disorders and degrees of disease burden occur in the different regions and income groups (**Figs. 1.3** and 1.4). In 2015, the lowest DALY rates from neurologic disorders were found in high-income areas and Latin America. The highest DALY rates were found in Afghanistan, Central African Republic, Guinea-Bissau, Kiribati, and Somalia. The prevalence of stroke was highest in Eastern Europe, central Asia, Oceania, Indonesia, Myanmar, and sub-Saharan Africa. The prevalence and DALY rates for Parkinson disease were highest in high-income regions and lowest in sub-Saharan Africa and Eastern Europe. This serves as an example of the disparities found among various countries when estimating disease burden. It is notable that countries in

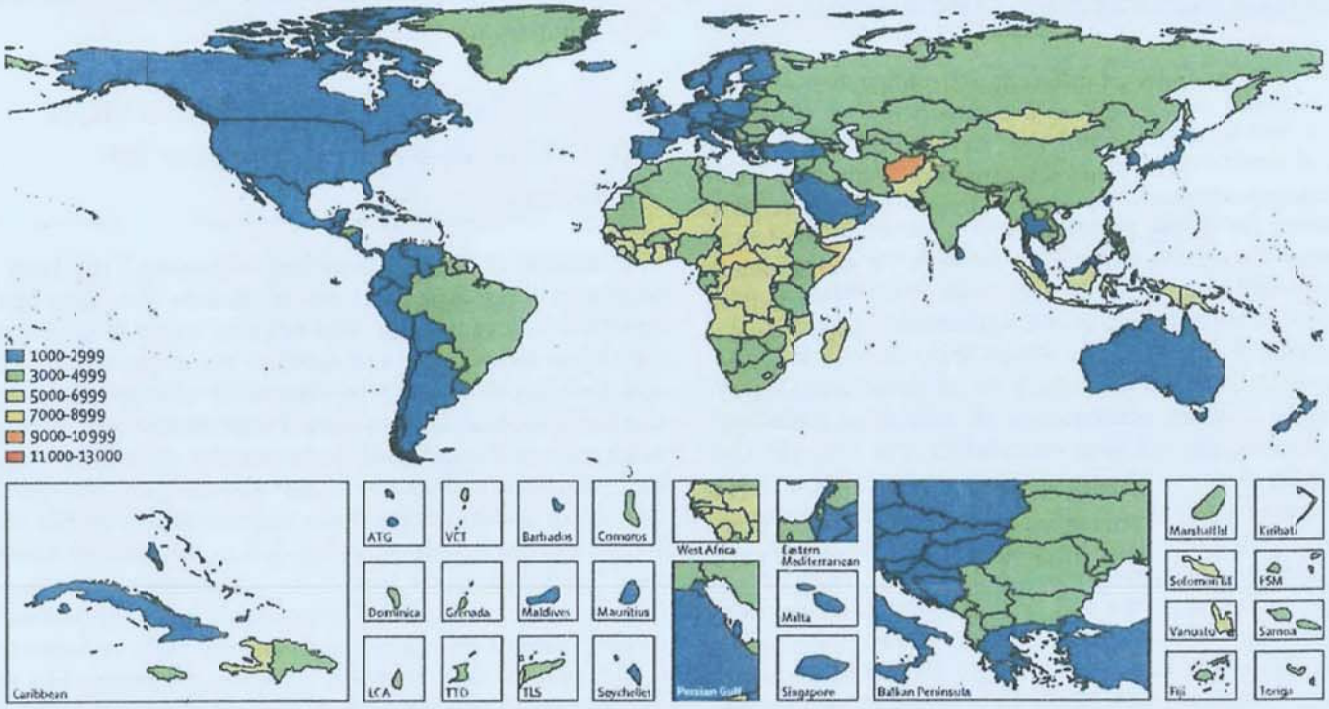

FIGURE 1.3 Age-standardized rates of disability-adjusted life-years per 100,000 people from all neurologic disorders combined in 2015. Data are for both sexes. Abbreviations: ATG, Antigua and Barbuda; FSM, Federated States of Micronesia; LCA, Saint Lucia; Marshall Isl, Marshall Islands; Solomon Isl, Solomon Islands; TLS, Timor-Leste; TTO, Trinidad and Tobago; VCT, Saint Vincent and the Grenadines. (From GBD 2015 Neurological Disorders Collaborator Group. Global, regional, and national burden of neurological disorders during 1990-2015: a systematic analysis for the Global Burden of Disease Study 2015. *Lancet Neurol.* 2017;16[11]:877-897.)

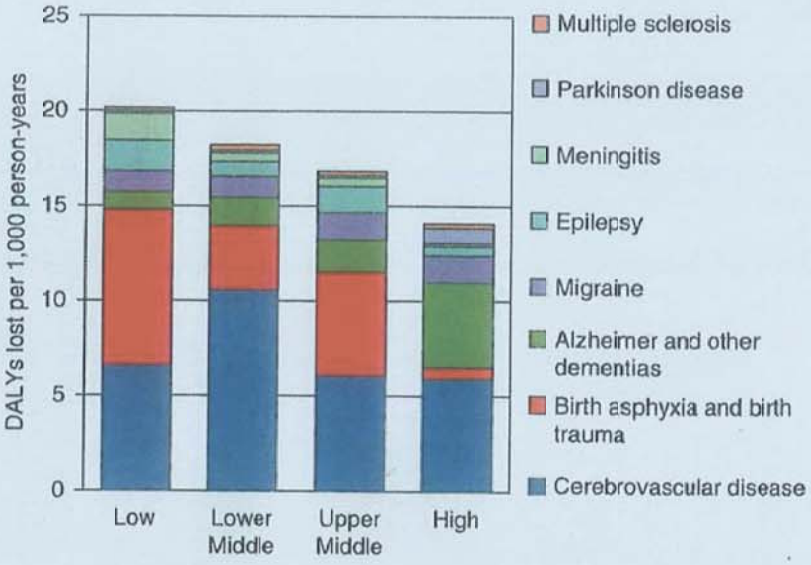

FIGURE 1.4 Burden of neurologic diseases in lost disability-adjusted life years (DALYs) per 1,000 person-years by World Bank national income level. (From Johnston SC, Hauser SL. Neurological disease on the global agenda. *Ann Neurol*. 2008;64:A11-A12.)

the WHO high mortality stratum or low-income category face major challenges from diseases associated with poverty, underdevelopment, and ineffective health care systems.

Stroke

Worldwide, stroke accounts for approximately 10% of all deaths. The highest numbers of stroke deaths occur in Northern Asia, Eastern Europe, Central Africa, and the South Pacific. Systematic reviews of population-based studies from 28 countries showed that stroke incidence has increased in low-income and middle-income countries, whereas high-income countries have experienced a 42% decrease in incidence over the past four decades. According to the original global analysis contained in the estimates from the Global Burden of Diseases, Injuries, and Risk Factors Study, stroke mortality has decreased in the past two decades, whereas global stroke burden, rated in terms of yearly stroke survivorship, related deaths, and DALYs lost, has increased with the brunt of the burden in low-income and middle-income countries. Within high-income countries, improved health services and preventative stroke care may explain the reduction in stroke incidence, mortality, and DALYs lost and the converse for low-income and middle-income regions. In areas such as sub-Saharan Africa, there are high stroke mortality rates and low rates of reduction in DALYs lost.

Stroke disparities are not limited to the developing world; in fact, global disparities are reflected within nations. In the United States, racial minorities suffer increased stroke mortality and disability rates compared to non-Hispanic whites. African Americans have the highest mortality rates due to stroke and Hispanics have a higher stroke incidence than whites. Within the United States, a geographic distribution in stroke incidence and mortality can be discerned. In the southeastern United States, within a region referred to as the *Stroke Belt*, stroke mortality and incidence rates are increased. The highest rates are found along the coast, in Georgia and the Carolinas, in a region nicknamed the *Stroke Buckle*. Variations in the race or ethnicity of people comprising the population do not appear to explain the disparities in stroke mortality and incidence that exist in the southeastern United States because African Americans in that region seem to have increased stroke risks compared to African Americans in other parts of the country. The difference may be attributable to socioeconomic factors limiting access to care, producing an increase in the prevalence of stroke risk factors. It has been noted that, at the age that Medicare becomes available to elderly Americans, African Americans have no higher in-hospital mortality than do whites and no higher incidence in stroke rates or hypertension than do Hispanics. This provides indirect evidence that it is the lack of access to care that may be responsible for some of the racial and regional disparities.

Chronic Neurological Diseases

Global disparities in neurologic disease are not limited to stroke. In a population-based survey of residents older than age 65 years in seven countries with low and middle incomes (China, India, Cuba, Dominican Republic, Venezuela, Mexico, and Peru), dementia was overwhelmingly found to be the most important independent contributor to disability for elderly people in these countries. Chronic disease disability in countries with low and middle incomes is expected to increase by 224% in the least developed regions over the next four decades. Similarly, in a cross-sectional study of elderly Chinese people living in Hong Kong, dementia, stroke, and Parkinson disease were the chronic conditions most strongly associated with severe debility.

Access to Care

Limitations in neurologic resources and variability in resource allocation to neurologic problems contribute to the disparities in the global burden of neurologic disease. In the second edition of the WHO Project Atlas launched in 2017, there were marked disparities in availability of adult neurologists, child neurologists, and neurosurgeons across regions and income strata. The European region reported the largest neurologic workforce, with a median of 9 per 100,000 population, whereas the African region reported a median of 0.1 per 100,000 (Fig. 1.5). The World Bank income groups also demonstrated similar differences, with high-income countries reporting a median of 7.1 per 100,000 people, compared with low-income countries reporting a median of 0.1 per 100,000 (Fig. 1.6). This Neurology Atlas illustrates the existence of inadequate resources for neurologic disorders in most countries and highlights the inequalities in access to neurologic care particularly present in low-income countries. This provides an example of the need for an increase in neurology services and training in lower income countries to allow for adequate care to be provided and limit the inequities.

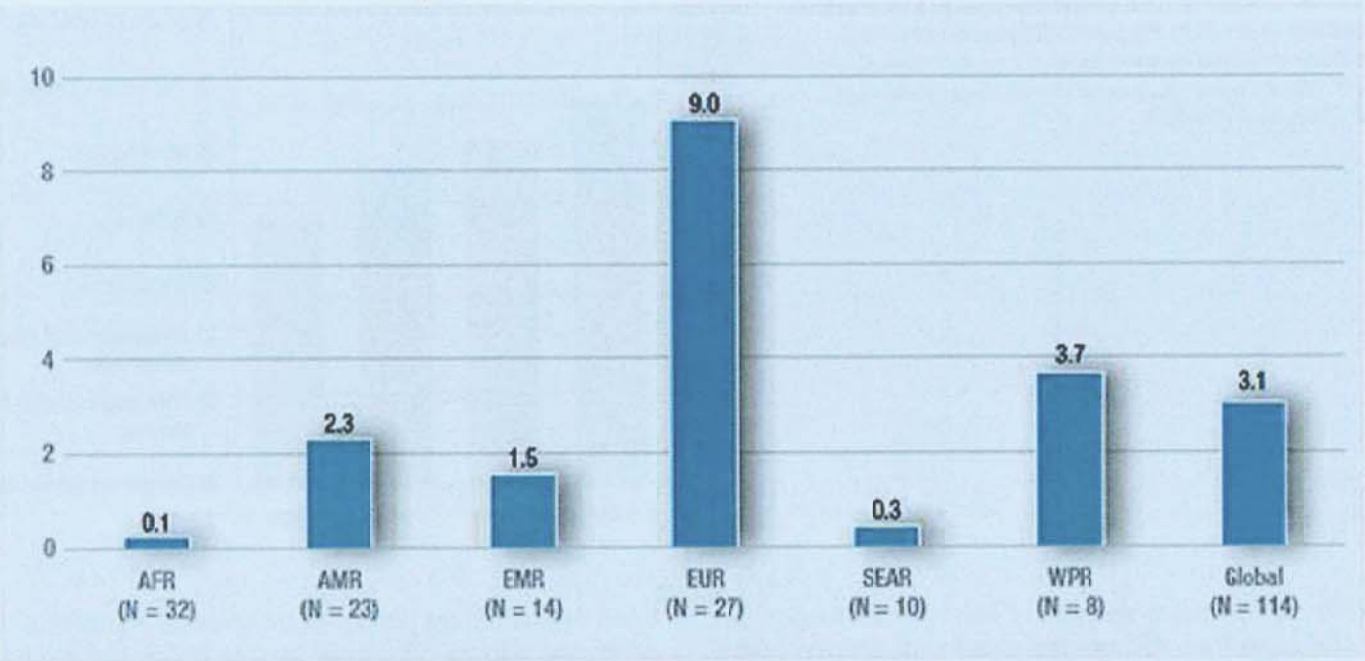

FIGURE 1.5 Median neurologic workforce per 100,000 population, by World Health Organization region. Abbreviations: AFR, African Region; AMR, American Region; EMR, Eastern Mediterranean Region; EUR, European Region; SEAR, Southeast Asian Region; WPR, Western Pacific Region. (From World Health Organization. *Atlas: Country Resources for Neurological Disorders*. 2nd ed. Geneva, Switzerland: World Health Organization; 2017: Figure 11. License: CC BY-NC-SA. 3.0 IGO.)

Variation in allocation of attention and research resources may contribute to the disparities seen in neurologic care worldwide. For example, of the 685 manuscripts published in the *Annals of Neurology* from 2005 through 2008, 91% had a corresponding author in either North America or Europe. Thus, 97% of manuscripts were produced in high-income countries where only 15% of the global population resides. Furthermore, the vast majority of clinical studies of neurologic disease describe people in high-income countries. A paradox has been observed within the pharmaceutical research realm, whereby 90% of medical research funds are spent on 10% of the world's population. Apparently, research and development expenditures for diseases of poverty, including malaria, tropical diseases, and tuberculosis, are considered more likely to provide low returns and thus are considered high risk for failure and are not pursued.

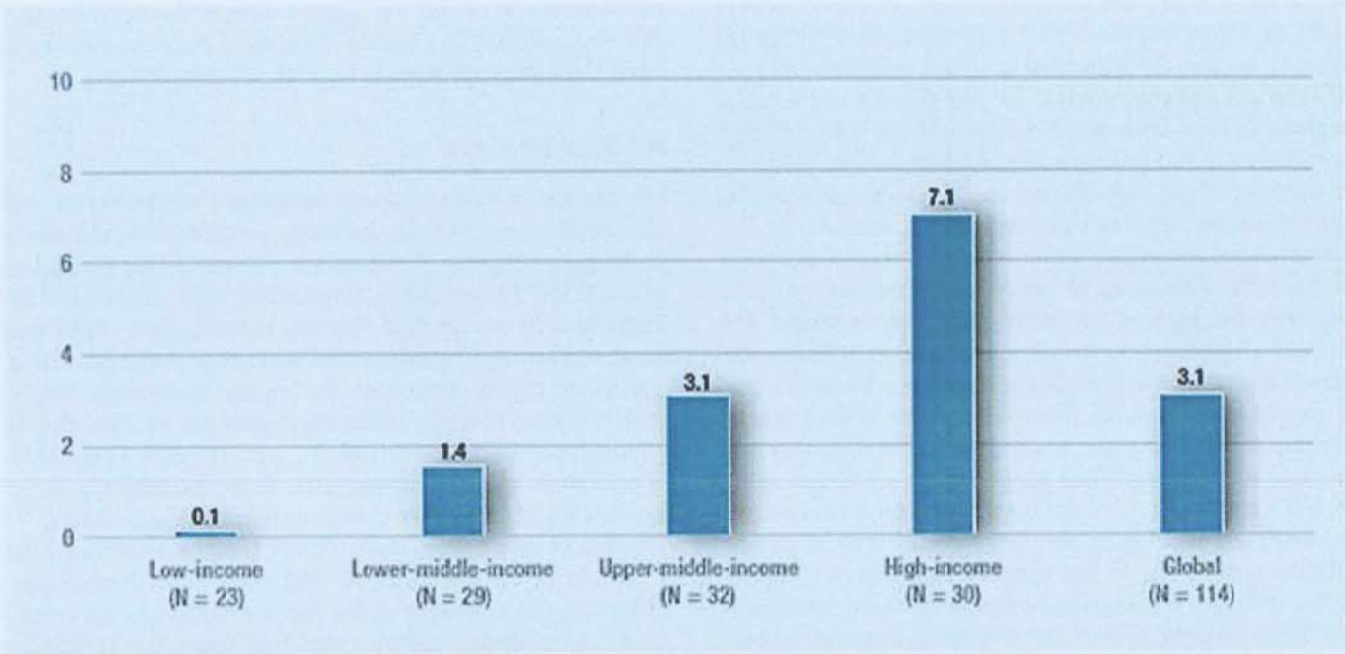

FIGURE 1.6 Median neurologic workforce per 100,000 population by World Bank income group. (From World Health Organization. *Atlas: Country Resources for Neurological Disorders*. 2nd ed. Geneva, Switzerland: World Health Organization; 2017: Figure 12. License: CC BY-NC-SA. 3.0 IGO.)

SOCIOCULTURAL DIFFERENCES IN INTERPRETATION OF DISEASE

Cultural differences in disease screening, reporting, and management may contribute to the variation in identified global neurologic disease burden. A skew in the number of neurologic diagnoses identified in developing countries, as compared to high-income countries, might be a result of neurologically afflicted patients in developing countries not coming to medical attention. In one analysis of health systems constraints in Timor-Leste, one of the poorest countries in Asia, it was found that poverty, strong beliefs in traditional medicine and healers, and low levels of education were barriers to people seeking care. Diagnostic equipment that is crucial for neurologic care, such as electroencephalography, electromyography, computed tomography, and magnetic resonance imaging, was absent. There were no manufacturers of medicine in the country, requiring importation of all necessary medicines.

In a study examining the reportable neurologic diseases in refugee camps in 19 countries within Africa, the Eastern Mediterranean, and Southeast Asia, a variety of diagnoses were revealed. Epilepsy represented more than 9 out of every 10 visits for neurologic disease in these refugee camps. The underlying causes of epilepsy in refugee camps, although unknown, were presumably similar to those for other inhabitants in the region, including perinatal injury, head trauma, cerebral malaria, and previous stroke. Within refugee camps throughout sub-Saharan Africa, the monitoring of meningitis and newer initiatives for vaccination were found to be crucial for preventing epidemic outbreaks, particularly those due to *Neisseria meningitidis*. However, there were limitations in accurate reporting in these regions, with many of the diagnoses not being verified by physicians and conditions such as meningitis being unlikely to have received cerebrospinal fluid confirmation. Regional and cultural differences in diagnosis and disease reporting can have an impact on the accurate assessment of the total global burden of neurologic disease.

Regional differences in the management of neurologic disease are also seen worldwide. Infectious disease, including meningitis, encephalitis, and cerebral malaria, is a major cause of critical neurologic illness in developing countries. Ischemic and hemorrhagic stroke, severe head injury, and epilepsy are major unaddressed causes of morbidity and mortality in many developing countries. In addition, neurologic manifestations of rabies, tetanus, eclampsia, and tuberculosis contribute to the burden of disease in these regions. The largest share of tuberculosis infection is seen in Africa and Asia where resource constraints hamper efforts to control new infections and prevent drug resistance. Infections of the nervous system by *Mycobacterium tuberculosis*, including meningitis, tuberculoma, tuberculous abscess, and nonosseous spinal tuberculoma, affect more than 10% of patients in the region. Tuberculosis is the leading cause of death in HIV-infected individuals in this population. Many low- and middle-income countries with high tuberculosis burdens have limited laboratory capacity to perform smear microscopy or run cultures for drug susceptibility testing. Unfortunately, in low-resource settings, patients often present late for medical care and are sometimes misdiagnosed and treated inappropriately, which can lead to a more severe clinical course. In some of even the least developed countries, governments fund hospitals that include intensive care unit–level care and, in addition, humanitarian efforts and military hospitals also contribute to offer some form of neurologic disease management, showing that neurocritical care can sometimes be practiced even in extremely resource-poor locations. There are, however, limitations in available resources. Many medications are not universally available. For example, although tissue plasminogen activator is a standard of care in high-income settings, developing countries still struggle with poor availability of this drug. Alternatives such as snake venom or urokinase may be employed instead despite an absence of evidence of their efficacy or optimal dose. Finally, there remains a need for attention to neurologic recovery after the illness to allow for a seamless continuum between prevention, intervention, and rehabilitation from neurologic illness.

Cultural differences worldwide are an additional contributor to the differences seen in neurologic care around the world. For example, in many countries, patients with recurrent seizure may be considered to be possessed rather than as having epilepsy. In a cross-sectional study performed in Dar es Salaam, Tanzania, it was shown that of 100 traditional healers interviewed, 30% believed that epilepsy was caused by witchcraft, whereas 19% thought epilepsy had a genetic origin that could be inherited. The traditional healers treated epilepsy with up to 60 different plants, some of which have demonstrated anticonvulsant activity. Among the Maasai population living throughout East Africa, who hold fast to their traditional and nomadic lifestyle, patients presenting with HIV/AIDS, epilepsy, and cerebral palsy are treated in remote sites using "bush medicine" within tents and working by sunlight with no electricity. In Maasai traditional medicine, herbs, roots, and bark are commonly boiled down into a soup. These examples serve as reminders that cultural differences in disease management and medication usage may vary greatly throughout the world.

There are a number of international organizations dedicated to neurologic care globally. Several member organizations within the United Nations, including the WHO, the World Bank, and the United Nations Children's Fund, have played roles in policy matters related to neurologic disease. Nongovernmental organizations provide care for people with neurologic disease in some of the least developed regions globally. Similarly, the World Federation of Neurology is an international organization of country-level neurologic societies composed of community-based and academic neurologists, who have successfully come together in the past to tackle international issues within neurologic disease.

SUMMARY

Neurologic disease has a tremendous impact on human illness and mortality globally. Despite the challenges in quantifying the burden of neurologic disease and assessing its impact on populations throughout the world, several points are clear. Neurologic diseases, whether they are primary or secondary, more frequently cause disability than death. This has been an obstacle to research employing common measures of disease impact. Additionally, disparities in incidence, diagnosis, disease management, and outcomes for patients in different geographic and socioeconomic sectors proffer a unique signature on the global burden of neurologic disease.

SUGGESTED READINGS

Anand P, Othon GC, Sakadi F, et al. Epilepsy and traditional healers in the Republic of Guinea: a mixed methods study. *Epilepsy Behav*. 2019;92:276-282.

Boehme AK, Esenwa C, Elkind MSV. Stroke risk factors, genetics, and prevention. *Circ Res*. 2017;120(3):472-495.

Brizzi K, Deki S, Tshering L, et al. Knowledge, attitudes and practices regarding epilepsy in the Kingdom of Bhutan. *Int Health*. 2016;8(4):286-291.

Chan CC, Chuang KJ, Chien LC, Chen WJ, Chang WT. Urban air pollution and emergency admissions for cerebrovascular diseases in Taipei, Taiwan. *Eur Heart J*. 2006;27:1238-1244.

Chin J, Mateen F. Central nervous system tuberculosis: challenges and advances in diagnosis and treatment. *Curr Infect Dis Rep*. 2013;15:631-635.

Chin J, Vora N. The global burden of neurologic diseases. *Neurology*. 2014;83:349-351.

Cruz-Flores S, Rabinstein A, Biller J, et al. Racial-ethnic disparities in stroke care: the American experience: a statement for healthcare professionals from the American Heart Association/American Stroke Association. *Stroke*. 2011;42:2091-2116.

Cushman M, Cantrell RA, McClure LA, et al. Estimated 10-year stroke risk by region and race in the United States: geographic and racial differences in stroke risk. *Ann Neurol*. 2008;64(5):507-513.

Feigin VL, Forouzanfar MH, Krishnamurthi R, et al. Global and regional burden of stroke during 1990-2010: findings from the Global Burden of Disease Study 2010. *Lancet*. 2014;383:245-254.

GBD 2015 Neurological Disorders Collaborator Group. Global, regional, and national burden of neurological disorders during 1990-2015: a systematic analysis for the Global Burden of Disease Study 2015. *Lancet Neurol*. 2017;16(11):877-897.

Gooch C, Pracht E, Borenstein AR. The burden of neurological disease in the United States: a summary report and call to action. *Ann Neurol*. 2017;81(4):479-484.

Gupta I, Guin P. Communicable diseases in the South-East Asia region of the World Health Organization: towards a more effective response. *Bull World Health Organ*. 2010;88(3):199-205.

Hillis JM, Berkowitz AL. Neurology training worldwide. *Semin Neurol*. 2018;38(2):135-144.

Holroyd K, Vogel A, Lynch K, et al. Neuromyelitis optica testing and treatment: availability and affordability in 60 countries. *Mult Scler Relat Disord*. 2019;33:44-50.

Johnston SC, Hauser SL. Neurological disease on the global agenda. *Ann Neurol*. 2008;64:A11-A12.

Johnston SC, Mendis S, Mathers CD. Global variation in stroke burden and mortality: estimates from monitoring, surveillance, and modelling. *Lancet Neurol*. 2009;8(4):345-354.

Mateen FJ. Multiple sclerosis in resource-limited settings: research opportunities in an unequal world. *Neurology*. 2019;93(4):176-180.

Mateen FJ. Toward minimum standards guidelines for the delivery of neurological care in complex humanitarian settings. *JAMA Neurol*. 2019;76(4):394-395.

Mateen F, Carone M, Haskew C, Spiegel P. Reportable neurologic diseases in refugee camps in 19 countries. *Neurology*. 2012;79:937-940.

Mateen F, Martins N. A health systems constraints analysis for neurologic diseases: the example of Timor-Leste. *Neurology*. 2014;82:1274-1276.

McWilliams JM, Meara E, Zaslavsky AM, Ayanian JZ. Differences in control of cardiovascular disease and diabetes by race, ethnicity, and education: U.S. trends from 1999 to 2006 and effects of Medicare coverage. *Ann Intern Med*. 2009;150(8):505-515.

Moshi MJ, Kagashe GA, Mbwambo ZH. Plants used to treat epilepsy by Tanzanian traditional healers. *J Ethnopharmacol*. 2005;97(2):327-336.

Sheikh AL. Pharmaceutical research: paradox, challenge, or dilemma? *East Mediterr Health J*. 2006;12:42-49.

Sousa RM, Ferris CP, Acosta D, et al. Contribution of chronic diseases to disability in elderly people in countries with low and middle incomes: a 10/66 Dementia Research Group population-based survey. *Lancet*. 2009;374:1821-1830.

Strong K, Mathers C, Leeder S, Beaglehole R. Preventing chronic diseases: how many lives can we save? *Lancet*. 2005;366:1578-1582.

Trimble B, Morgenstern LB. Stroke in minorities. *Neurol Clin*. 2008;26(4):1177-1190.

Woo J, Ho SC, Lau S, Lau J, Yuen YK. Prevalence of cognitive impairment and associated factors among elderly Hong Kong Chinese aged 70 years and over. *Neuroepidemiology*. 1994;13:50-58.

World Health Organization. *Atlas: Country Resources for Neurological Disorders*. 2nd ed. Geneva, Switzerland: World Health Organization; 2017.

Yusuf S, Reddy S, Ôunpuu S, Anand S. Global burden of cardiovascular diseases. Part I: general considerations, the epidemiologic transition, risk factors, and impact of urbanization. *Circulation*. 2001;104:2746-2753.

Zhao D, Liu J, Wang W, et al. Epidemiological transition of stroke in China: twenty-one-year observational study from the Sino-MONICA-Beijing Project. *Stroke*. 2008;39:1668-1674.

Zumla A, Raviglione M, Hafner R, von Reyn CF. Tuberculosis. *N Engl J Med*. 2013;358:745-755.

Global Delivery of Neurologic Care 2

Hiral Shah, Serena Spudich, and Kiran T. Thakur

KEY POINTS

1. Over 50% of the world's population cannot obtain essential health services, including basic neurologic care, and this will only continue to increase in the coming years unless significant measures are taken.
2. High-quality neurologic care is safe, accessible, affordable, effective, equitable, and with a focus on human rights.
3. Coupled with the overall limitations in access to care and treatment for many neurologic disorders in resource-limited settings, stigma often adds to the burden of disease among vulnerable populations in these regions.

GAPS IN GLOBAL ACCESS TO NEUROLOGIC CARE

Over one billion people are living with neurologic conditions globally, with more than 50 million individuals living with epilepsy and approximately 47 million with dementia. Neurologic disorders are now the leading cause of disability-adjusted life years (a measure of one lost year of healthy life) worldwide and the second leading cause of death (refer to chapter on Global Burden of Disease, Elkind et al). The global burden of neurologic disorders has increased exponentially over the past two decades, with a significant rise in noncommunicable conditions, including cerebrovascular disease, epilepsy, and dementia. The growing number of people living with neurologic disorders, particularly an aging global population, necessitates plans to enhance knowledge among health care providers in the diagnosis and management of neurologic conditions. Despite the need, current neurologic resources and services are disproportionately scarce in resource-limited settings, where much of the burden of disease exists. Major disparities exist by World Health Organization (WHO) region and World Bank income categories with regard to the neurologic workforce (Fig. 2.1). Data show a significant deficit in adult and pediatric neurologists as well as neurosurgeons. Over 50% of the world's population cannot obtain essential health services, including basic neurologic care, and this will only continue to increase in the coming years unless significant measures are taken.

Providers in many low-income countries face additional challenges given lack of resources to provide adequate care, with the poorest sectors most affected by these constraints. Clinicians, researchers, and policy makers alike should be aware of these trends and limitations to appropriately plan for services to provide comprehensive neurologic care in the future.

This chapter introduces concepts related to existing challenges and barriers to delivery of care for neurologic conditions worldwide, with a focus on the unique challenges in resource-limited settings. We present strategies and approaches for overcoming these barriers and effectively building infrastructure and capacity for care of the neurologic patient in a variety of settings. Throughout the chapter, specific examples are provided of challenges or strategies relevant to global delivery of care (see Boxes 2.1 to 2.4).

Components Required for Delivery of Neurologic Care

Optimal care delivery designed to improve the neurologic health of individuals, families, and communities should consider the local context in order to best organize resources and the health care workforce. High-quality neurologic care is safe, accessible, affordable, effective, equitable, and with a focus on human rights. Service delivery requires integration and coordination among various levels of care (primary, secondary, and tertiary) as well as among disciplines (pain, palliative care, mental health, rehabilitation, social services), where available. Information sharing via technologic advances can enhance the care process and improve quality and safety. To ensure adequate and comprehensive neurologic care, several components need to be in

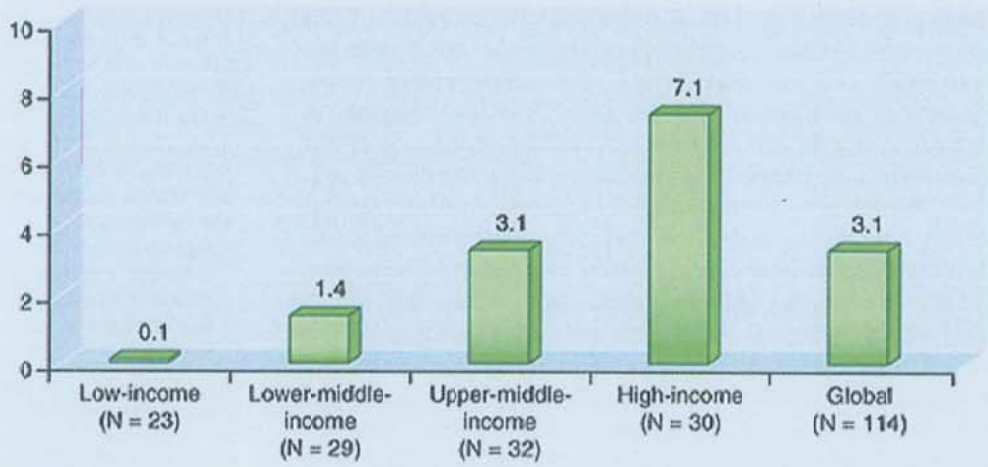

FIGURE 2.1 Median neurologic workforce per 100,000 population, by World Bank income group. (From World Health Organization. *Atlas: Country Resources for Neurological Disorders*. 2nd ed. Geneva, Switzerland: World Health Organization; 2017.)

place. Governments must support efforts for adequate health and social care services. One mechanism is universal coverage provided by governments, although often a mix of public and private funding of health services is common in low-, middle-, and high-income settings. Optimally, governmental policies and legislation should be implemented to protect vulnerable populations with neurologic disorders, such as legislation to address stigma and civil rights barriers. Leadership to champion the cause of improving health care and social supports for people living with neurologic disease, in both the public and private sectors and intersectoral collaboration of these advocates, is necessary to address the challenges the population faces.

Training of specialists in neurologic care is also essential. Country level resources often determine the level and type of training that is available and required. At the primary care level, basic training is needed in the diagnosis and management of neurologic diseases for physicians, nurses and other allied health professionals. Existing resources provided by WHO such as the WHO Mental Health Gap Action Program intervention guide and associated training materials can be adapted and implemented in the local context. At the secondary level, systems of referrals, task-shifting to train nonmedical providers in the provision of neurologic care is important. At times, this includes collaboration with local traditional healers. At the tertiary level, additional specialist training is needed, although challenges exist to addressing adequate training and retention of specialists.

Additionally, availability of adequate resources, including the health care work force, diagnostics, and medicines is critical to providing comprehensive neurologic care and is often particularly restricted where resources are limited (see in the following text). Health care costs associated with neurologic disorders place a strain on funding sources (both public and private), highlighting the importance of an appropriate financing and insurance plan.

CHALLENGES IN ADDRESSING NEUROLOGIC DISORDERS

Stigma Related to Neurologic Disorders

Stigma has been defined as "the situation of the individual who is disqualified from full social acceptance" and occurs at the individual, interpersonal, and societal level with varying consequences. Coupled with the overall limitations in access to care and treatment for many neurologic disorders in resource-limited settings, stigma often adds to the burden of disease among vulnerable populations in these regions. Stigma, however, is not a phenomenon isolated to developing regions of the world but is universally felt and experienced, particularly among people with neurologic diseases. For instance, individual stigma, or internalized stigma, refers to the individual's experience of discrimination or awareness of negative attitudes toward one's condition. This becomes an internalized stereotype that has negative consequences for the individual, including one's physical health as it affects health care-seeking habits and has significant psychiatric comorbidities, including depression and anxiety, which are correlated with poor self-esteem and social exclusion. Interpersonal stigma refers to the negative actions of others toward the individual with the condition. And, societal stigma refers to the resultant laws or policies of society that are taken toward the individual. Studies have shown that people with epilepsy who are stigmatized have a lower quality of life (as a consequence of individual and interpersonal stigma) and unequal access to health and life insurance, limited access to school and fewer employment opportunities (consequences of societal stigma). Stigma further limits disclosure of health conditions, serving as a barrier to measuring the full global burden of neurologic diseases. Stigma is often rooted in misperceptions and knowledge gaps of a disease entity. For an example, see Box 2.1.

BOX 2.1 High School Students' Knowledge and Attitudes of Epilepsy in Southern India[a]

A study was conducted to determine awareness, attitudes, and beliefs that people hold on epilepsy. The participants consisted of high school 10th graders (Kerala, Thrissur, Malappuram, and Palakkad, India). The study was performed by surveying participants with 24 yes-or-no questions and carried out by medical social workers. Although 98% of respondents had previously heard or read about epilepsy, nearly 60% classified epilepsy as a mental illness, whereas 50% believed it was a brain disorder. Additional misbeliefs were observed among the group of participants, such as believing epilepsy is a contagious condition (13.9%). Regarding attitudes about the condition, the majority believed that epilepsy posed a barrier to living a happy life (62.4%) and ability to have a normal sexual life (43.2%). In relation to measures to be taken in the event of a seizure, visiting the hospital was a common response (62.3%), yet about 24% suggested sprinkling water on the face of victims, and 60% believed in the efficacy of Ayurvedic treatment.

[a]Thapa L, Bhandari TR, Shrestha S, Poudel RS. Knowledge, beliefs, and practices on epilepsy among high school students of Central Nepal. *Epilepsy Res Treat*. 2017;2017:6705807. doi:10.1155/2017/6705807

Challenges in Health-Seeking Behavior

Studies have identified several social factors associated with poor health-seeking behavior in neurologic conditions. Some of these factors include residing in rural areas, having a lower level of education and poor literacy, and poor socioeconomic status. Other factors including physical access to services and perceived quality of service play an important role. Overall, lower health-seeking behavior is linked to worse health outcomes and increased morbidity and mortality and is a significant barrier to adequate care and treatment for neurologic conditions worldwide. See Box 2.2 for an example of factors associated

BOX 2.2 Barriers to Care for Patients With Nodding Syndrome in Northern Uganda[a]

Nodding syndrome, a cause of epileptic encephalopathy afflicting children predominantly in South Sudan, Uganda, and Tanzania, is a disorder characterized by episodic head nodding, which progresses to multiple seizures types and cognitive decline. A study performed in Northern Uganda characterized help-seeking and treatment practices for nodding syndrome among various stakeholders, including health care professionals, district leaders, and caregivers of children with nodding syndrome. Identified challenges included the following:

- Health system factors, for example, long distances to facilities, frequent unavailability of medicines, few health care providers, and long waiting times
- Contextual and societal challenges, for example, lack of money for transport and medical bills

[a]Mwaka AD, Okello ES, Abbo C, et al. Is the glass half full or half empty? A qualitative exploration on treatment practices and perceived barriers to biomedical care for patients with nodding syndrome in post-conflict northern Uganda. *BMC Res Notes*. 2015;8:386. doi:10.1186/s13104-015-1323-5

with health-seeking behavior in nodding syndrome, an epileptic encephalopathy described in Sub-Saharan Africa.

Limited Global Access to Diagnostics and Therapeutics for Neurologic Disorders

Significant disparities in the availability of diagnostics for neurologic conditions exist, both regionally and by World Bank income categories. Of the recently published WHO essential diagnostics list, only 3 of the 113 diagnostic tests pertain to neurologic disorders, which are the cerebrospinal fluid (CSF) cryptococcal antigen test for diagnosis of cryptococcal meningitis, the CSF nucleic acid amplification test for diagnosis of central nervous system tuberculosis, and CSF bacterial culture. Lack of adequate diagnostic tests (ie, serum and CSF testing, electromyography/nerve conduction study, electroencephalogram, computed tomography of the brain) may lead to less efficient use of already-scarce resources in many settings, such as medications and health care personnel. A lack of diagnostics also limits the ability to assess the epidemiology of neurologic disorders. Closing the neurodiagnostic gap requires investment in several domains, including building diagnostic infrastructure, hiring and training of staff to use and maintain equipment, training in the interpretation of diagnostic studies, increasing access to limited technologic resources via new methods such as mobile clinics, and access and integration to more cost-effective tests. There is a critical need to strategize on how to efficiently and affordably integrate diagnostics into current health care systems globally.

The availability and accessibility of treatments for neurologic disorders also shows significant disparities. Literature on the epilepsy treatment gap shows that over three-quarters of people living in resource-limited settings do not have routine access to antiepileptic medications. Lack of effective screening and approval mechanisms for new drugs as well as cost-effective purchasing mechanisms and distribution systems limits the availability of standard medications for neurologic disorders. Availability of medications may be increased through aid programs and improvements in regional purchasing and distribution systems.

Gaps in National Policies and Guidelines for Brain Health

Government and nongovernmental policies and guidelines for neurologic disorders help to delineate standards and protocols to optimize neurologic care (Box 2.3). In the latest WHO-World Federation of Neurology–led survey, 24% of countries report neurologic health policies, 41% of countries report national or subnational legislation on epilepsy, and 30% report legislation relating to people with dementia. The lack of guidelines and policies for neurologic care undermines adequate neurologic care, as these mandate adequate supply of essential diagnostic tests and medicines, standardizing training and workforce requirements, standardizing procedures for the care of brain disorders in a tiered health care system, and defining operational requirements.

Approaches and Strategies to Improve Delivery of Neurologic Care Globally

Lower income countries (LIC) and lower-middle income countries (LMIC) face the highest burden of neurologic diseases with significant resource limitations requiring novel approaches for care delivery. There are several ongoing efforts to improve neurologic care delivery globally, in both LIC and LMIC countries as well as resource-limited settings (eg, rural locations) in high-income countries. Interventions to improve care delivery can target many aspects of the continuum of care ranging from advocacy efforts, policy initiatives, health care systems strengthening, training, and capacity building to service delivery.

Collaborative Partnerships and Coordinated Action

Collaborative effort across industry, government, and nongovernmental sectors is a mechanism important to the prioritization of neurologic disorders. This effort can lead to increased investment; implementation of policies, plans, and legislation; and engagement of multisectoral stakeholders in government

BOX 2.3 World Stroke Organization Global Stroke Services Guidelines and Action Plan[a]

The Global Stroke Services Action Plan is a tool to identify essential elements in stroke care across health models with varying complexity and access to stroke services. Checklists for stroke service planning are tiered by level: minimal, essential, and advanced. This global guideline recognizes the variability of local resources when assessing requirements and developing guidelines to optimize stroke care.

Advanced stroke services	Essential stroke services	Minimal healthcare services
❑ Access to advanced diagnostic services ❑ Access to physicians with stroke expertise ❑ Access to advanced interventions in addition to tPA, such as interventional radiology and neurosurgery ❑ Access to specialist rehabilitation therapists ❑ Access to community programs for recovery after stroke ❑ Fully coordinated stroke care provided across geographically discrete regions	❑ Access to basic diagnostic services—laboratory, ECG, CT scan, ultrasound ❑ Access to nurses ❑ Access to physicians, although may not be stroke specialists ❑ Access to acute thrombolysis with tPA ❑ Access to elements of stroke unit care, including members of an interdisciplinary stroke team ❑ Access to rehabilitation services ❑ Access to stroke prevention therapies such as aspirin, lifestyle change recommendations, blood pressure management ❑ Limited coordinated stroke care provided across geographically discrete regions	❑ Variable access to healthcare workers (nurses or lay workers) ❑ Very limited access to physicians ❑ No access to diagnostic services or hospital care ❑ Limited access to the most basic lifestyle preventative advice ❑ Care provided in local communities without coordination across defined geographic regions

Abbreviations: CT, computed tomography; ECG, electrocardiogram; tPA, tissue plasminogen activator.

[a]Lindsay P, Furie KL, Davis SM, Donnan GA, Norrving B. World Stroke Organization global stroke services guidelines and action plan. *Int J Stroke*. 2014;9 (suppl A100):4-13.

and scientific agencies, professional, and advocacy organizations. At the policy level, interventions can address financing, leadership, and governance. Approaches of transitioning from vertical, disease-focused programs to horizontal, systems-focused perspectives can be employed at the primary health care level. Additional efforts can target health financing strengthening. Collaborative partnerships have led to health policy-level advocacy, improved measurement, and awareness-raising campaigns.

For example, a coordinated global response has been imperative to begin to address the challenge of dementia. In 2012, WHO published *Dementia: A Public Health Priority*, which provided an overview of the impact of dementia worldwide, with a focus on LIC and LMIC regions, where impact is high with low preparedness. This report gained support among world leaders, researchers, and stakeholders, spurring the G8 Dementia Summit that launched the Global Action Against Dementia. They agreed to 12 specific commitments and the development of a coordinated international research action plan. The Global Dementia Action Plan on the Public Health Response to Dementia 2017-2025 was launched and includes clear goals and targets for consideration by the 17th world health assembly. This work was synergistic as the WHO launched The Global Dementia Observatory, a data and knowledge exchange platform to provide a mechanism for continuous monitoring of the dementia landscape and dissemination of information. The observatory focuses on data domains of policies, service delivery along with information and research. Together, they built the Global Dementia Observatory monitoring framework (Fig. 2.2).

Another example is the Global Campaign Against Epilepsy, formed through partnerships with the WHO, International League Against Epilepsy, and the International Bureau of Epilepsy. Because of the Global Campaign Against Epilepsy, numerous community-based projects have been implemented. For further information, please see Box 2.4.

BOX 2.4 The China National Epilepsy Project[a]

In China, a large community-based project was implemented in five provinces to reduce the epilepsy treatment gap by training and educating health care providers, raising public awareness to reduce stigma, identifying prevention approaches, and integrating epilepsy care into the local health systems. Primary health care physicians were trained to diagnose and treat epilepsy. More than 2,400 people with epilepsy were treated, with 25% achieving seizure freedom and 70% with improved outcomes. The treatment gap was estimated to be reduced by half. Care-seeking behaviors increased through the implementation of awareness raising efforts with community education that epilepsy is a treatable condition. Given the positive results, the initial project was scaled up, with the establishment of The China National Epilepsy Project. The National Project has serviced 240 counties across 19 provinces where 120 million people reside in rural areas. This expansion led to treatment with antiseizure medicines of more than 110,000 people with epilepsy. The China National Epilepsy Project is exemplary of effective rural and primary health care of epilepsy.

[a]Wang W, Wu J, Dai X, et al. Global campaign against epilepsy: assessment of a demonstration project in rural China. *Bull World Health Organ.* 2008;86(12):964-969.

Improving Access to Neurologic Care: Primary Care Workforce

One mechanism to combat the shortage of specialists is to strengthen the primary care system's capacity to provide care for people with neurologic conditions. Primary care represents the gateway to medical care for many people worldwide and is thus a logical setting to first address care for people with neurologic disorders. Effective primary prevention for neurologic conditions

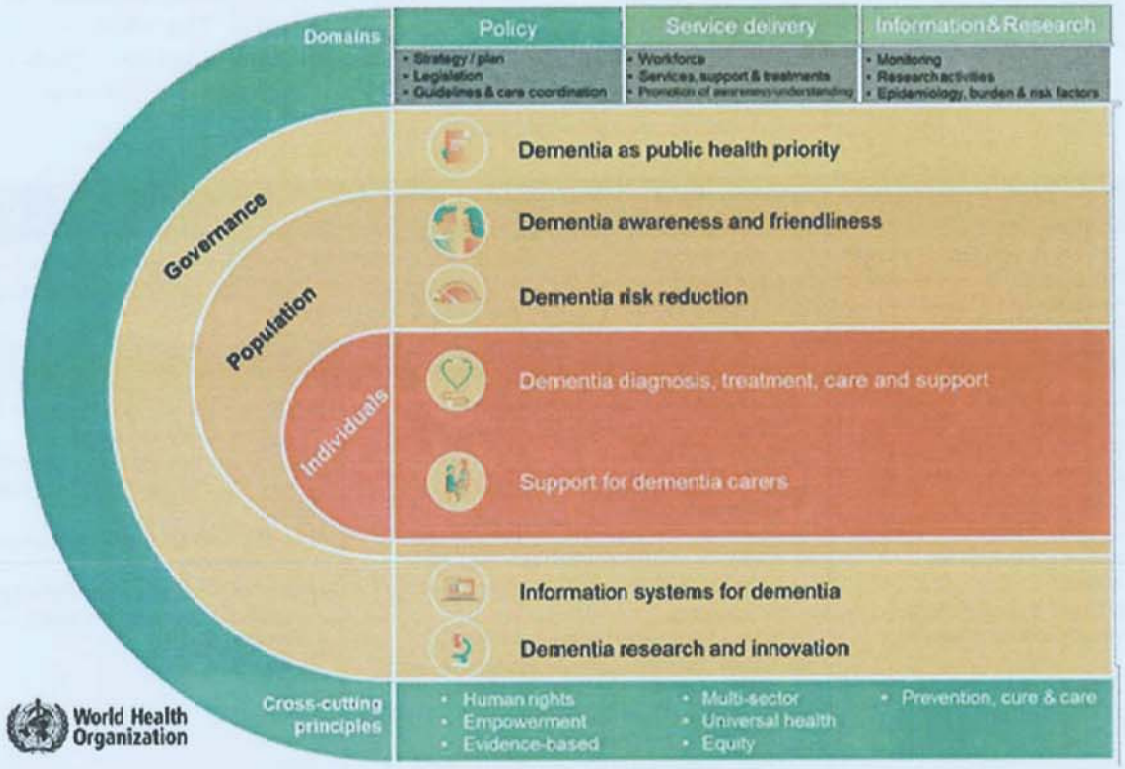

FIGURE 2.2 Global Dementia Observatory. (From World Health Organization. Some rights reserved. This work is available under the Creative Commons Attribution-NonCommercial-ShareAlike 3.0 IGO licence [CC BY-NC-SA 3.0 IGO; https://creativecommons.org/licenses/by-nc-sa/3.0/igo].)

is an essential step in curbing the burden of neurologic disorders. Neurologic care by primary health care providers is reported to be available in 91% of countries where no neurologic expertise exists, according to the WHO–World Federation of Neurology atlas, although the level of training and expertise in diagnosing and managing neurologic conditions is unknown. Utilizing the primary care workforce has been identified as one of the most feasible and cost-effective models to build neurologic care support, particularly in resource poor settings. This must be tempered with the realities of primary care practice in many regions, including a lack of training in neurology, overwhelming patient volumes, and a myriad of other challenges, which often leave primary care practitioners without the tools and resources necessary to diagnose and manage neurology patients. Careful planning to incorporate neurologic care in an already overburdened system is thus required. Complex neurologic conditions, for example, may be recognized early to avoid complications in a primary care setting and referred for early intervention to a higher level of care.

TELEMEDICINE AND INFORMATION AND COMMUNICATION TECHNOLOGY

Synchronous Approaches

Given high rates of Internet penetration and availability of mobile phones in developing countries, telemedicine and use of information and communication technology may be a viable option to allow those with neurologic conditions to gain access to the appropriate providers and specialists and overcome geographic and financial barriers to seeking care. Telemedicine and information and communication technology is an attractive and interactive method to provide diagnosis and treatment by medical providers as well as ancillary services including speech-language therapists and mental health services. Telemedicine has many advantages, reducing travel and wait times, reducing cost for health systems (eliminating some time and space constraints, reducing human resources needed to provide care), as well as improving efficiency of the providers. There remain challenges in terms of technology concerns (lack of equipment, connectivity), licensure and insurance payment mechanisms, as well as concerns about privacy and security.

Asynchronous Approaches

Telemedicine also include asynchronous approaches such as video recordings to capture function, delivery of information and skills training, as well as support systems such as online health communities. Online health communities can be a resource for knowledge exchange and improve self-management skills. Such asynchronous approaches have the advantages of being flexible, providing support at any time (even at night), person-based, client friendly, and focused on self-management and self-efficacy.

Training Approaches to Build Capacity

Another mechanism to build a cadre of neurology specialists globally is the development of training programs and centers, which are tailored to local needs and resources. Often, these programs are based at tertiary care hospitals, which serve as a referral center for complex neurologic and neurosurgical patients, allowing for concentration of expertise, diagnostics, and therapeutics. Neurologic centers of excellence can also provide leadership to establish priorities and develop regional and national planning strategies, guidelines, and policies for neurologic disorders. These programs require that trainees are retained to build further capacity to recognize and treat neurologic conditions.

Community Engagement

Perceptions of neurologic conditions such as epilepsy, cerebral palsy, and cerebrovascular disease are influenced by social and cultural factors and thus providing care that is culturally congruent is crucial. Cultural perceptions underlying neurologic conditions often serve as barriers to care, although medical personnel who work alongside communities to break down these barriers have shown increased success in reducing stigma. Engaging community members as active participants of service delivery is critical to successfully combat misperceptions. By sharing of information and engaging in active dialogue, ambiguities and stigma around prevention and treatment of neurologic conditions may be reduced.

Programs Aimed to Raise Public Awareness

One of the central goals of public awareness campaigns is to tackle stigma and discrimination. Other major goals include improving prevention strategies, enhancing access and adherence to treatment, and promoting research. Public awareness campaigns have had success when targeted and tailored with clear outcomes based on the needs of those affected with neurologic conditions. Many factors must be considered in deciding on an appropriate campaign strategy, including the ethnographic makeup of the target audience. Campaigns increasingly pull together a variety of stakeholders—including national and international health and advocacy organizations, policymakers, and patient groups—to undertake these costly and complex endeavors.

CONCLUSION

The expected increase in the number of individuals with neurologic conditions, particularly in resource-limited settings, necessitates careful, urgent planning by governments and other stakeholders to ensure adequate and accessible care. With a significant global shortage of the neurologic workforce, improving neurologic care will require innovative strategies within existing health systems. Focusing on effective primary prevention strategies and utilization of the primary care workforce will be essential, especially given the growth in the number of individuals worldwide with noncommunicable neurologic disorders. Epidemiologic and health-services research will provide evidence needed to set goals and priorities for neurologic conditions, particularly in resource-limited regions. Additional novel strategies such as telemedicine and information technology can be used for training, assessment, and care delivery.

SUGGESTED READINGS

Al-Jaddou H, Malkawi A. Prevalence, recognition and management of mental disorders in primary health care in Northern Jordan. *Acta Psychiatr Scand.* 1997;96(1):31-35.

Chin JH, Vora N. The global burden of neurologic diseases. *Neurology.* 2014;83(4):349-351.

Corrigan PW, Penn DL. Lessons from social psychology on discrediting psychiatric stigma. *Am Psychol*. 1999;54(9):765-776.

Corrigan PW, Watson A, Barr L. The self-stigma of mental illness: implications for self-esteem and self-efficacy. *J Soc Clin Psychol*. 2006;25(9):875-884.

Elliot VL, Morgan D, Kosteniuk J, Froehlich Chow A, Bayly M. Health-related stigma of noncommunicable neurological disease in rural adult populations: a scoping review. *Health Soc Care Community*. 2019;27(4):e153-e188.

GBD 2015 Neurological Disorders Collaborator Group. Global, regional, and national burden of neurological disorders during 1990-2015: a systematic analysis for the Global Burden of Disease Study 2015. *Lancet Neurol*. 2017;16(11):877-897.

Giel R, d'Arrigo Busnello E, Climent CE, et al. The classification of psychiatric disorder. A reliability study in the WHO collaborative study on strategies for extending mental health care. *Acta Psychiatr Scand*. 1981;63(1):61-74.

Giel R, Harding TW. Psychiatric priorities in developing countries. *Br J Psychiatry*. 1976;128:513-522.

Hatcher-Martin JM, Adams JL, Anderson ER, et al. Telemedicine in neurology: Telemedicine Work Group of the American Academy of Neurology update. *Neurology*. 2020;94(1):30-38.

Idro R, Opoka RO, Aanyu HT, et al. Nodding syndrome in Ugandan children—clinical features, brain imaging and complications: a case series. *BMJ Open*. 2013;3(5).

Institute of Medicine. *Neurological, Psychiatric, and Developmental Disorders: Meeting the Challenge in the Developing World*. Washington, DC: National Academy Press; 2001.

Jenkins R. Mental health and primary care-implications for policy. *Int Rev Psychiatry*. 2009;10:158-160.

Jones EE, Farina A, Hastorf A, Markus H, Miller D, Scott R. *Social Stigma: The Psychology of Marked Relationships*. New York, NY: W.H. Freeman; 1984.

Kaddumukasa M, Kaddumukasa MN, Buwembo W, et al. Epilepsy misconceptions and stigma reduction interventions in Sub-Saharan Africa, a systematic review. *Epilepsy Behav*. 2018;85:21-27.

Lacey M. Nodding disease: mystery of southern Sudan. *Lancet Neurol*. 2003;2(12):714.

Lindsay P, Furie KL, Davis SM, Donnan GA, Norrving B. World Stroke Organization global stroke services guidelines and action plan. *Int J Stroke*. 2014;9 (suppl A100):4-13.

Mehryar A, Khajavi F. Some implications of a community mental health model for developing countries. *Int J Soc Psychiatry*. 1975;21(1):45-52.

Meyer AC, Dua T, Ma J, Saxena S, Birbeck G. Global disparities in the epilepsy treatment gap: a systematic review. *Bull World Health Organ*. 2010;88(4):260-266.

Mwaka AD, Okello ES, Abbo C, et al. Is the glass half full or half empty? A qualitative exploration on treatment practices and perceived barriers to biomedical care for patients with nodding syndrome in post-conflict northern Uganda. *BMC Res Notes*. 2015;8:386.

Poungvarin N. Stroke in the developing world. *Lancet*. 1998;352(suppl 3):SIII19-SIII22.

Rao D, Choi SW, Victorson D, et al. Measuring stigma across neurological conditions: the development of the stigma scale for chronic illness (SSCI). *Qual Life Res*. 2009;18(5):585-595.

Reich MR. The global drug gap. *Science*. 2000;287(5460):1979-1981.

Rüsch N, Angermeyer MC, Corrigan PW. Mental illness stigma: concepts, consequences, and initiatives to reduce stigma. *Eur Psychiatry*. 2005;20(8):529-539.

Sartorius N, Harding TW. The WHO collaborative study on strategies for extending mental health care, I: the genesis of the study. *Am J Psychiatry*. 1983;140:1470-1473.

Sikkema KJ, Kalichman SC, Hoffmann R, Koob JJ, Kelly JA, Heckman TG. Coping strategies and emotional wellbeing among HIV-infected men and women experiencing AIDS-related bereavement. *AIDS Care*. 2000;12(5):613-624.

Sirey JA, Bruce ML, Alexopoulos GS, Perlick DA, Friedman SJ, Meyers BS. Stigma as a barrier to recovery: perceived stigma and patient-rated severity of illness as predictors of antidepressant drug adherence. *Psychiatr Serv*. 2001;52(12):1615-1620.

Waldrop G, Goetz LG, Siddiqi OK, Koralnik IJ, Shah H, Thakur KT. The World Health Organization's essential diagnostics list: diagnostics for neurologic disorders. *Neurology*. 2019;93(15):680-683.

Wang W, Wu J, Dai X, et al. Global campaign against epilepsy: assessment of a demonstration project in rural China. *Bull World Health Organ*. 2008;86(12):964-969.

Watson SI, Sahota H, Taylor CA, Chen YF, Lilford RJ. Cost-effectiveness of health care service delivery interventions in low and middle income countries: a systematic review. *Glob Health Res Policy*. 2018;3:17.

Weiner B, Perry RP, Magnusson J. An attributional analysis of reactions to stigmas. *J Pers Soc Psychol*. 1988;55(5):738-748.

Winkler AS, Friedrich K, König R, et al. The head nodding syndrome—clinical classification and possible causes. *Epilepsia*. 2008;49(12):2008-2015.

Winkler AS, Walther B, Friedrich K, et al. A longitudinal study on nodding syndrome—a new African epilepsy disorder. *Epilepsia*. 2014;55(1):86-93.

World Health Organization. *Atlas: Country Resources for Neurological Disorders*. 2nd ed. Geneva, Switzerland: World Health Organization; 2017.

World Health Organization. Dementia: a public health priority. World Health Organization Web site. https://apps.who.int/iris/handle/10665/75263. Accessed January 1, 2020.

World Health Organization. *Epilepsy: A Public Health Imperative*. Geneva, Switzerland: World Health Organization; 2019.

World Health Organization. *mhGAP Intervention Guide for Mental, Neurological and Substance Use Disorders in Non-Specialized Health Settings*. Geneva, Switzerland: World Health Organization; 2010.

World Health Organization. *Technical Report Series 564. Organization of Mental Health Services in Developing Countries. Sixteenth Report of the WHO Expert Committee on Mental Health*. Geneva, Switzerland: World Health Organization; 1975.

World Health Organization. What is health financing for universal coverage? World Health Organization Web site. https://www.who.int/health_financing/universal_coverage_definition/en/. Accessed January 1, 2020.

Neurologic History Taking, Localization, and Differential Diagnosis 3

James M. Noble

KEY POINTS

1. A high yield neurologic history requires a structured approach, framed around a solid basis of knowledge of disease localization and etiologies.
2. Organization of the neurological history is framed around common diagnoses and can't miss diagnoses, considered with frequently encountered neurologic problems.
3. Universal elements of the history, including past medical history, review of systems, and social and family histories are specifically framed to an appropriate neurologic context.
4. Diagnostic reasoning follows the synthesis of a well-rounded history and the neurologic examination and may lead to rereview of the history to clarify unexpected findings.

INTRODUCTION TO CLINICAL DIAGNOSTIC REASONING

Making a neurologic diagnosis requires a systematic approach to the patient, built on a foundational awareness of neuroanatomy and a broad range of neurologic diseases, and paths toward establishing a diagnosis in each. The history and physical examination provide essential, complementary, and readily accessible data. Together, they comprise the most meaningful information of the initial (and often subsequent) steps of clinical diagnostic reasoning, informing the diagnostic workup, and treatment plans. This chapter discusses the approach to developing a patient-specific neurologic history and should be reviewed in context with the neurologic examination (specifically covered in Chapter 4 and further in Section III: Common Problems in Neurology) and selective use of diagnostic testing (Section IV: Diagnostic Tests).

INTENTIONAL EXPLORATION OF THE PATIENT HISTORY

Fundamental to assessment of any patient presenting with a neurologic problem is development of the history specifically tailored to the patient. In neurology, this task can at first seem challenging and relates to the complexities of nervous system and a broad array of presentations of different kinds of neurologic disorders, as well as potentially subtle differences within each group of disorders. It is therefore necessary to know which diagnostic possibilities are reasonable considerations for a particular patient, best accomplished by starting with a broad approach. A strong determinant of ultimately missing a diagnosis is not considering it early on in the diagnostic search. Furthermore, overreliance on laboratory tests and technology can lead to a scattershot approach that is uninformed by clinical reasoning and appropriate differential diagnosis and most importantly prone to errors and delaying appropriate therapy.

The clinical data obtained by a careful history and physical examination are used to address four questions:

- **What anatomic structures of the nervous system are affected?** It is usually not possible to make a specific etiologic diagnosis without knowing what parts of the nervous system are affected. In addition, knowing the probable anatomic substrate restricts the etiologic possibilities. Thus, making an accurate *anatomic diagnosis* should be the first step in analyzing a neurologic disorder. Clues to identifying the anatomic sites of neurologic disorders are discussed in the following section and later in this chapter.
- **What is the nature of the neurologic disorder?** An individual patient's symptoms usually cluster into broad syndromes or categories of disease: developmental disorder, peripheral neuropathy, acute encephalopathy, progressive dementia, parkinsonian syndrome, cerebrovascular syndrome, and so on. A syndromic diagnosis assists in clarifying the nature of the disease and further focuses on possible specific causes.
- **What are the most likely etiologies for the patient's illness?** These derive from consideration of the anatomic and syndromic diagnoses in light of the tempo (rapid or slow) and course (fixed from onset, steadily progressive, or stepwise) of the illness, relevant past history and family history, and whether there is evidence of systemic involvement. The possible etiologies listed in order of probability constitute the differential diagnosis, and this in turn determines which laboratory tests need to be ordered and the urgency with which the evaluation should proceed.
- **What diagnostic possibility cannot be missed?** As much as it is important to focus on the most likely diagnosis, it is also important to effectively assess and hopefully exclude a "can't miss" diagnosis, which could lead to morbidity or mortality. Of course, sometimes, the most likely diagnosis is the most serious "can't miss" diagnosis.

An experienced clinician will likely deal with these four questions simultaneously and differing orders, patient to patient. To take an obvious example, if a patient suddenly becomes speechless

or awakens with a hemiplegia, the diagnosis of stroke is made. The location and etiology of a large and potentially fatal stroke in the territory of the dominant hemisphere's middle cerebral artery is then deduced from findings made on examination, further confirmed by neuroimaging. If there are no surprises in the imaging study (eg, demonstration of a tumor or vascular malformation), further laboratory tests might be considered to determine the precise cause of an ischemic infarct.

Identifying Localization

Aspects of the patient's history may suggest the nature of the disorder; specific symptoms, corroborated by signs on examination can suggest the site of the disorder. These are shown further in Table 3.1.

TABLE 3.1 Approach to Diagnosis Based on Localizing Features in the History

Probable Localization	Key Features in the History
Cerebral	• Seizures or focal symptoms that may be attributed to a particular area of the brain: hemiplegia, aphasia, or hemianopia are examples. • Generalized manifestations of cerebral disease are seizures, delirium, and dementia.
Brainstem disease	• Cranial nerve palsies, cerebellar signs of ataxia of gait or limbs, tremor, or dysarthria. • Crossed features (eg, contralateral face vs arm and leg weakness) • Dysarthria may be the result from incoordination in disorders of the cerebellum itself or its brainstem connections. • Cranial nerve palsies or the neuromuscular disorder of myasthenia gravis may also impair speech. • Ocular signs have special localizing value.
Basal ganglia	• Involuntary movements including tremor
Spinal cord	• Spastic gait disorder and bilateral corticospinal signs, with or without bladder symptoms • If there is neck or back pain, a compressive lesion should be suspected. • If there is no pain, demyelinating disease is likely. • The level of a spinal compressive lesion is more likely to be indicated by cutaneous sensory loss than by motor signs. • The lesion that causes spastic paraparesis may be anywhere above the lumbar segments.
Peripheral nerve disease	• Usually causes both motor and sensory symptoms (eg, weakness and loss of sensation). The weakness is likely to be more severe distally, and the sensory loss may affect only position or vibration sense. • More specific localization follows segmental or dermatomal loss of sensation.
Neuromuscular junction disorders and myopathic diseases	• Limb or cranial muscle weakness without sensory symptoms • Cramping suggests myopathic disorders but can also be reported in motor neuron and basal ganglia diseases. • Fatigability and/or facilitation of strength with repeated activity suggests a neuromuscular junction disorder.

HISTORY OF PRESENT NEUROLOGIC ILLNESS

Sources of Information

A reliable and accurate history is essential and should be obtained directly from the patient whenever possible. However, in neurologic disorders, it is often necessary to verify the patient's account or obtain additional information by speaking with relatives or close friends. Corroborating and developing the history through collateral sources is particularly important if the illness has compromised the patient's cognitive abilities, especially if memory or language is impacted.

Electronic health systems have enabled rapid discovery and communication of past history, but they have also become prone to plagiarism and riddled with diagnostic inaccuracies carried forward or diagnostic momentum carried in the wrong direction. Whenever possible, obtain information from primary sources and verify them through direct, first-hand means.

Approach to Taking the History

The manner in which questions are asked can have a strong impact on findings and impressions developed from the neurologic history LEVEL 3.[1] Whenever possible, begin with asking open-ended questions and transition to targeted questions based on the differential being formulated around the presenting problem ("chief complaint"). To avoid errors, it is important that the physician avoids leading questions and clarifies what the patient means by ambiguous terms, such as *dizziness* or *weakness*. These more focused questions are intended to refine the likelihood of disorders in the differential diagnosis. Along with confirming questions, questions should be asked to refute unlikely considerations or to explore for potentially similar syndromes or competing causes. For example, in a patient being evaluated for seizure, a series of questions exploring for potential cardiogenic cause of syncope would be necessary, given overlapping features including sudden loss of consciousness as well as observed ictal behavior. Discrepancies and inconsistencies in details obtained by different examiners are often the source of diagnostic confusion and must be resolved.

The initial approach to developing the history is principally informed and shaped by a well-rounded neurologic knowledge and broad-based experience inherent to the interviewing physician. Knowledge gaps are thought to be the primary pitfall in diagnostic reasoning errors. Experience and knowledge can enable generation of *illness scripts*, which are vignettes of prototypical cases of disease against which a clinician can judge the relative fit of the patient being interviewed. Similarly, some experienced clinicians may be able to draw on error scripts, identifying prior pitfalls in diagnostic thinking in order to refine the diagnosis. Depending on the context, inherent cognitive biases, or "cognitive dispositions to error," may further influence how clinicians synthesize a diagnosis.

Primary Components of the History

Localization

In evaluating most patients with neurologic symptoms, determining localization is the most essential component of the neurologic history. To a patient, *location* can describe where in the

body the problem is perceived or observed, in contrast to *localization*, which refers to where the problem can be placed as precisely as possible in the neuraxis. It is worthwhile spending time refining the exact location of symptoms and potential localization of the problem. Although many neurologic presentations, such as stroke will have a singular localization, ranging from small to large territory brain involvement with infarction, other neurologic disorders may have a multifocal, systemic, or diffuse presentation. Multifocal presentations must be considered in severe trauma (exploring for spinal injury concomitant to brain injury) or neurologic presentations of metastatic cancer.

Knowing the *handedness* of neurologic patients is essential in localizing many cerebral disorders, given known associations with language dominance, particularly with right handers (upward of 93% left hemispheric language dominance in right handers but closer to half left hemispheric dominance in left handers who also have overrepresentation of language codominance). Although less common in recent times, some left-handed persons may have been forced to become right handers in early life to align with cultural norms. Ambidextrous persons make clinical prediction of language dominance difficult.

Neurologic presentations with a diffuse localization but with a singular problem include neuromuscular junction disorders and myopathy. Furthermore, some neurologic disorders will suggest diffuse but not necessarily focal neurologic localization, such neurodegenerative cognitive disorders, which often present with bilateral multilobar cortical features as well as parkinsonism suggesting additional localization in the basal ganglia and other subcortical structures.

Timing, Onset, Tempo, and Duration

There are several key features of any medical neurologic or neurologic problem. The first is identifying the *timing* or important timepoints related to the presentation. Timing refers to the pace of events leading to presentation, ideally trying to find a causative or precipitating factor, or the sequence of several related symptoms, which evolve one after another or in parallel. Understanding timing is important for recent history leading to this presentation but can also be important in some neurologic diseases, which recur or progress over time. In some neurologic contexts, timing can also refer to how symptoms vary by the time of day (eg, late-day fatigue and weakness in myasthenia gravis, sundowning in Alzheimer disease, and overnight headaches in brain tumor). Another component of timing is pace of symptom *onset* or how quickly the symptoms first began. Rapid onset of limb weakness within seconds would be expected for example in stroke, and is in contrast to slowly evolving clumsiness or weakness as may be seen in brain tumor, and an evolving weakness brought on during a multiple sclerosis attack becoming more apparent over the course of hours or a day. Particular attention should be paid to the onset of symptoms, the circumstances in which they occurred, and their subsequent evolution. Have any of the symptoms resolved? Have similar or different neurologic symptoms occurred previously?

Some neurologic diseases have overlapping clinical features, with similar onset but differ in manifestations at the time of onset as well as *duration*. Key examples are of seizures, strokes, and syncope, all of which are all abrupt in onset. Syncope has the briefest duration. There are usually sensations that warn of the impending loss of consciousness. Injuries to the face more common than other areas of the head because patients often pitch forward suddenly and uncontrollably when fainting. After fainting, the patient begins to recover consciousness in a minute or so. A seizure may or may not be preceded by warning symptoms, often enough so that a patient may ease themselves to a seat or the ground/floor. The seizure may be brief or protracted and is manifested by alteration of consciousness or by repetitive movements, stereotypical behavior, or abnormal sensations. Abrasions are common in seizure, typically due to an area of the body repetitively abrading a surface during the seizure. A stroke due to cerebral ischemia or hemorrhage strikes "out of the blue" and manifests as hemiparesis or other focal brain signs. The neurologic disorder that follows brain infarction may last briefly (transient ischemic attack), be permanent, or the patient may recover partially, or completely, in days or weeks. Sometimes, it is difficult to differentiate a transient ischemic attack from the postictal hemiparesis of a focal motor seizure, especially if imaging shows no lesion, and the seizure was not witnessed. Another syndrome of abrupt onset is subarachnoid hemorrhage, in which the patient is struck by a headache that is instantaneously severe and sometimes followed by loss of consciousness.

Symptoms of less than apoplectic onset may progress for hours (intoxication, infection, or subdural hematoma), days (Guillain-Barré syndrome), or longer (most tumors of the brain or spinal cord). The acute symptoms of increased intracranial pressure or brain herniation are sometimes superimposed on the slower progression of a brain tumor. Progressive symptoms of brain tumor may be punctuated by seizures. Heritable or degenerative diseases tend to progress slowly, becoming most severe only after years of increasing disability (eg, Parkinson disease, Alzheimer disease, essential tremor).

In chronic or recurring diseases, it is important to explore for *remissions* and *exacerbations*. These are characteristic of myasthenia gravis, multiple sclerosis, and some forms of peripheral neuropathy. Bouts of myasthenia tend to last for weeks at a time; episodes in multiple sclerosis may last only days in the first attacks and then tend to increase in duration and leave more permanent residual neurologic disability. Benign paroxysmal positional vertigo will have clusters of days with attacks, often most severe in the morning, with gradual improvement in severity of symptoms day by day, interspersed with weeks to months with no symptoms. Dementia with Lewy bodies is uniquely associated with fluctuations, whereby physical abilities (eg, parkinsonian features) and/or cognitive changes (ranging from lucency to confusion) are noticeable to patients or others on a day to day (or multiple day) basis, or within a day. Some diseases become progressively worse without remissions.

Some disorders characteristically occur in bouts that usually last minutes or hours but rarely longer. Periodic paralysis, migraine headache, cluster headaches, and narcolepsy are in this category. To recognize the significance of these differences in tempo, it is necessary to have some knowledge of the clinical features of the several disorders.

Quality of Subjective Experiences

The *quality* of the neurologic symptoms is perhaps the broadest of terms and comprise a wide array of features, often describable only by the patient for changes in sensation or by a careful observer when physical problems become apparent. In the context of a presentation of sensory loss, patients may report the quality of sensory changes in a range of terms from numbness to coldness. Similarly, pain is reported variably by terms including tingling (which may instead be noxious paresthesias) to burning, gnawing, aching, stabbing, or throbbing. One important quality

of a neurologic presentation is *severity*. That is, how apparent, severe, or debilitating are the symptoms and how someone may be functionally affected in their daily life. This can range from mild to profound and has relevance in a range of presentations such as weakness, headache, and cognitive abilities impacting functional independence. Also, related to timing, an important aspect of severity is to understand how quickly and over what time frame neurologic problems evolved to its most obvious or debilitating degree (a "peak" for pain or "nadir" for neurologic deficits). Moreover, it is important to know whether the problems remained at the same level of deficit consistently or improved in some fashion, and over what time this occurred.

Alleviating and Aggravating Factors

It is also important to identify contextual factors by which neurologic problems improve or worsen, sometimes termed *alleviating* or *aggravating* factors. Sleep deprivation, medical illness such as infection, and exposure to heat can aggravate neurologic symptoms, make them more apparent, or seem to cause older problems to recur. Among neurologic problems, pain disorders are especially worth exploring for factors, which may improve symptoms, such the impact of medications, circadian patterns, stress, and diet may impact headaches. In some cases, it is worth exploring inducing or inciting factors, which may bring about neurologic symptoms. For instance, in migraine, loud sounds, bright lights, strong smells, or motion may bring initiate or worsen headache symptoms. In some patients, epilepsy, ambient strobe lights may induce seizures.

Related Symptoms

Finally, it is important to explore for other *related symptoms*, which evolve in the context of a neurologic disease presentation or other contextual factors important in describing the initial course. Related symptoms may be neurologic or nonneurologic. In the context of stroke, exploring for other stroke-like episodes in the recent past would be important to potentially identify a stuttering or recurring course. Exploring for cardiac symptoms such as tachypalpitations suggestive of undiagnosed atrial fibrillation can help narrow the search for the etiology of a large territory and thus presumed cardioembolic stroke.

It may be of diagnostic importance to ask patients how long they have been having similar symptoms. Long-standing headache is more apt to be a migraine or tension headache, but headache of recent onset is likely to imply intracranial structural disease and should never be underestimated. Similarly, a seizure or drastic personality change for days or months implies the need for computed tomography, magnetic resonance imaging, and other studies to evaluate possible brain tumor or encephalopathy. If no such lesion is found or if seizures are uncontrolled for a long time, perhaps video-electroencephalographic monitoring should be carried out to determine the best drug therapy or surgical approach.

Behaviors Only Observable by Others

A corroborative informant is often an important resource in neurologic disease with a cerebral localization, particularly for neurologic symptoms for which the patient may be unaware. Patients with epilepsy may experience lapses of time, potentially representing periods of poor awareness or alternatively memory problems related to medication side effects. If possible, subtle observable behaviors in epilepsy may suggest automatisms or perceptions of cognitive disengagement or distancing during nonmotor seizures. Also in epilepsy, observed behaviors including the sequence of events leading to more obvious motor seizures can only be provided by observation, unless it has been recorded. In dementia, much of a cognitive history may need to be provided by others knowledgeable of the history and with reliable observation; some aged spouses may face their own memory problems and may require other persons to provide reliable information. Sleep disorders are a third category, which are best disclosed through observation of snoring, dream enactment, or limb movements. Sleep is often unobserved in persons living alone or without a bed partner or may be unrecognized if a bed partner is a sound sleeper. More obvious, overnight events such as falling out of bed (also due to dream enactment) or wandering (in dementia) may only come to attention once sentinel or catastrophic events occur such as injury during the activity.

Further Shaping the History and Differential

Age of the Patient

The symptoms and signs of a stroke may be virtually identical in a 10-year-old, a 25-year-old, and a 70-year-old patient, but the diagnostic implications are vastly different for each patient. Some brain tumors are more common in children, and others are more common in adults. Progressive paraparesis is more likely to be due to spinal cord tumor in a child, whereas in an adult, it is more likely to be due to multiple sclerosis. Focal seizures are less likely to be fixed in pattern and are less likely to indicate a specific structural brain lesion in a child than in an adult. Myopathic weakness of the legs in childhood is more likely to be caused by muscular dystrophy than polymyositis; the reverse is true in patients older than 25 years. Muscular dystrophy rarely begins after age 35 years. Multiple sclerosis rarely starts after age 55 years. Functional cognitive disorders are unlikely when neurologic symptoms start after age 50 years. These ages are somewhat arbitrary, but the point is that age is a consideration in some diagnoses.

Gender Specificity

Only a few diseases are gender specific. X-linked diseases (eg, Duchenne muscular dystrophy) occur only in boys or, rarely, in girls with chromosome disorders. Among young adults, autoimmune diseases are more likely to affect women, especially systemic lupus erythematosus and myasthenia gravis, although young men are also affected in some cases. Women are exposed to the neurologic complications of pregnancy and may be at increased risk for stroke because of oral contraceptives. More men than women are exposed to activities such as sports, which involve potential repetitive head injury.

Technology as an Assistive Tool

Technologic advances in patient monitoring, including wearable devices offer continuous data, which may be used in conjunction with the history. These include heart rate and telemetry, sleep, and diabetic monitoring devices. At this point, these tools largely serve to inform risk factors potentially contributing to neurologic presentations. Additional means of engaging technology in neurologic history include more observable and objective information, such as videos, which may capture a moment of impact leading to head injury now commonplace in

organized sports. Ambulatory electroencephalography (EEG) can be used in conjunction with epilepsy histories, should an event be captured while an EEG is being worn (EEG is discussed further in Chapter 26).

Presymptomatic or Asymptomatic Genetic Variants

In recent years, one of the more transformative changes seen in medicine and neurology has been the rapid growth of genetic testing, including direct to consumer marketing, which often occurs without anticipatory guidance of a neurologist or other physician. Whole genome sequencing can also identify rare genetic sequences or variants of uncertain significance within genes associated with various neurologic diseases. Patients are increasingly presenting to offices with test results in hand, seeking understanding for their potential meaningfulness, and potential treatment options. In such cases, clinicians are tasked with looking for problems, rather than responding to a concern. This somewhat reverse approach to history taking has been a challenge for years prior to more widespread availability of genetic testing, such as patients facing a strong family history of neurologic disease but unaware of their own genetic status or even that of other family members. Internet searches undertaken by patients in advance of initial assessments can complicate matters further whereby patients learn of what potential symptoms to expect and may become fixated on these even when nonexistent. Although controlled studies of disclosure of genetic status in cognitive disorders have not suggested major differences in cognitive profiles by genetic status, some patients can become fixated on genetic test results, even when seemingly inconsequential or without known neurologic implications.

Neurologic Symptoms in Nonneurologic Disease

Unexplained neurologic symptoms are common in neurologic practice, comprising upward of one-third of outpatients seen in large academic centers. One of the essential roles of the neurologist is to not just identify neurologic disorders but to exclude patients presenting with symptoms, which could potentially be neurogenic but inevitably have a basis of explanation in another organ system, or have a functional basis (sometimes referred to as *psychogenic*). Nonetheless, these patients warrant full exploration of history as understanding the basis for interpretation by the patient and other clinicians as that of a neurologic disorder could inform complementary treatment strategies.

Problem-Based History

In addition to the framework described earlier, another helpful approach is to consider how the patient may fit into the broad framework of neurologic problems, further discussed in the following text. Perhaps unique to neurology is the relatively broad array of neurologic symptoms, which can occur, given that neurologic diseases can present and affect the entire human body and ranges in cause from molecular and microscopic peripheral disorders to space-occupying brain disease. A summary of key features and red flags for "can't miss" diagnoses are included in Table 3.2, covering common neurologic problems. This framework aims to structure the approach to the patient, particularly because the differential becomes narrowed following the initial review of the history.

PAST MEDICAL, PSYCHIATRIC, AND SURGICAL HISTORIES

It is always important to know whether there is any systemic disease in the patient's background. Common disorders, such as hypertensive vascular disease or diabetes mellitus, may be discovered for the first time when the patient is examined for neurologic symptoms. However, because they are common, these two disorders may be merely coincidental in this and other diseases. If the patient is known to have a carcinoma, especially if weight loss is present, metastatic disease is assumed to be the basis of neurologic symptoms until proven otherwise. If the patient is taking certain medications, the possibility of intoxication must be considered. Cutaneous signs may point to neurologic complications of von Recklinghausen disease or other phakomatoses or may suggest lupus erythematosus or some other systemic disease. Recent vaccinations and possible infections (including human immunodeficiency virus history and testing) are important to explore for both reactive and autoimmune disorders as well as active infection explaining the current presentation.

NEUROLOGIC REVIEW OF SYSTEMS

Although a well-rounded history should emerge following the steps described earlier, a structured and complete review of neurologic systems can help to assure that subtle neurologic symptoms are not missed. In some cases, subtle symptoms may be overlooked even though they represent a more substantial burden of disease. For example, a patient with metastatic brain cancer may present with seizure due to a small occipital metastasis, later discovered to have a much larger frontal mass causing more subtle personality change. Broadly speaking, a neurologic review of systems should include at least a cursory review of psychiatric symptoms (particularly mood changes or personality changes), cognitive symptoms (most often relatable as "memory changes"), changes in smell or taste perceptions, visual disturbances or loss (beyond just need for corrective lenses), changes in sensation anywhere in the body, speech or swallowing problems, motor symptoms (weakness, imbalance, tremor, or falls), and autonomic symptoms (light-headedness/dizziness, constipation, urination, the presence of dry eyes, sexual dysfunction). The neurologic review of systems can also be problem focused around the presumed diagnosis, such as exploring for common neurologic syndromes in patients with presumed multiple sclerosis (eg, diplopia, hemiparesis, hemisensory symptoms, mobility and gait disturbance, incontinence, and cognitive impairment), as discussed further in Table 3.2.

SOCIAL HISTORY

The "social history" has broad relevance in neurology, particularly in how it captures substantive life experiences. Important elements include educational and occupation histories (including military experience), immigration and acculturation, primary and secondary languages because these particularly can have bearing on interpretation of cognitive and neuropsychological testing. In the United States and elsewhere, life experiences tied to race and ethnicity more broadly fit into social determinants

TABLE 3.2 Neurologic Histories Based on Common Neurologic Problems

Neurologic Problem	Common Features to Explore	Concerning Features
Dizziness	• Age and symptoms at onset • Type of dizziness (vertigo, imbalance, orthostatic, poorly categorized) • Course: periodic/recurrent vs progressive • Precipitating factors including head/body movement • Frequency and intensity of events • Treatment history and response, including nonpharmacologic treatment (canalith repositioning maneuvers) • Associated features including pain and sensory changes, focal cranial weakness, vision and hearing changes, changes in alertness, autonomic features, and headache • Impact on daily activities • Profession/vocation and traumatic exposures associated with unusual positions posing risk for position vertigo or cervical dissection	• Headache • Cranial neuralgia • Focal neurologic signal • Diplopia • Progressive pulsatile tinnitus or deafness • Hoarseness or other voice/speech changes • Catastrophic vertiginous attacks leading to injury
Headache LEVEL 1[2]	• Age at onset • Headache quality (location, symptoms at onset, timing, and duration) • Frequency and intensity • Severity • Associated visual, visceral, and cognitive symptoms during the headache • Autonomic features • Hypersensitivities (light, sound, smells, scalp) • Precipitating factors (diet, sleep, stress, menstruation, head position, activities) • Medication response • Behavioral response (avoidance of noxious stimuli) • Functional impact of frequent headaches	• New-onset symptoms • Worsening/new symptoms in patient with a preexistent headache syndrome • Age >50 y • Abrupt onset • Positional features • Constitutional symptoms to suggest systemic illness • Focal neurologic features • Mental status changes
Back pain	• Onset and chronicity • Location • Quality including severity, intensity, duration, and associated features • Any patterns of radiation, weakness, and numbness • Precipitating and alleviating factors • Urination and sexual function • Strength, balance, and falls • History of immunocompromise, infection, malignancy, or suggestive constitutional symptoms • Psychological history as a possible contributor, including mood disorders, stressors including ongoing litigation, and potential secondary gain • Exploration for chronic trauma including manual occupational history	• Constitutional symptoms • Fever • Focal neurologic deficits • Progressive syndrome • Older age
Demyelinating disease	• Age at onset of first possible neurologic symptoms • Nature of onset, duration, and progression of each event • Review for current or prior common demyelinating neurologic syndromes: optic neuritis, internuclear ophthalmoplegia, hemiparesis, hemisensory syndrome, mobility and gait disturbance, incontinence, cognitive impairment. • Precipitating factors (Uhthoff and Lhermitte phenomena) • Treatment history and response including flares and prevention as well as compliance • Other autoimmune history, including undiagnosed (dermatologic, arthropathies, solid organ disease, myalgia) • Family history of autoimmune disease	• Rapid progression • Poor response to therapy • Severe burden of illness, particularly if multifocal and without tissue-based diagnosis • Systemic features
Dementia	• Explore for impact on cognitive domains (memory, visuospatial function, language, executive function, processing speed). • Duration, pace/speed, and course of changes (including progressive vs stepwise decline) • Psychiatric features (mood, sleep disturbance, psychotic symptoms, including the frequency, timing, and severity of each) • Fluctuating daily vs progressive course • Motoric changes to suggest parkinsonism (see "Movement Disorders" in this table) • Urination • Focal neurologic features • Medication history and response (particularly paradoxical response to antipsychotics) • Past history of sleep disturbance (sleep apnea), infection (syphilis or HIV), traumatic brain injury, or alcoholism • Educational, professional, vocational, and leisure history exploring for expected cognitive abilities • Psychosocial and caregiver support	• Rapid onset or progression • Focal including unilateral features • Seizures • Impaired attention to suggest delirium • Incomplete psychosocial support or observation posing immediate risk for catastrophic injury to self or others (wandering, falls, household fires, driving)

TABLE 3.2 Neurologic Histories Based on Common Neurologic Problems *(continued)*

Neurologic Problem	Common Features to Explore	Concerning Features
Movement disorders	• Age at onset and progression • Changes in handwriting, cutting food, and impairment with other dexterous movements • Slowness • Gait changes and tripping/falling hazards (slower pace, imbalance, and falls) • Tremors, fidgeting (chorea), jerking (myoclonus), and other observable adventitious movements • Voice changes • Dream enactment and other sleep disorders • Cognitive impairment • Autonomic dysfunction • Medication history and responses • Medical history for hepatic and renal disease, parathyroid disorders, diabetes, HIV, cardiac disease, and syncope • Explore for potential exposure to agricultural pesticides, heavy metals, and substance abuse. • Detailed family history for movement disorders and other neurodegenerative disorders • Identify social support network.	• Young onset • Rapid progression • Poor medication responsiveness • Gait instability and falls • Dysphagia and choking • Cognitive impairment or behavioral changes • Incomplete monitoring and support suggesting emerging risk for catastrophic injury • Constitutional symptoms, toxic exposure or recent febrile illness immediately preceding onset
Peripheral neuropathy and neuromuscular disorders	• Localization and pattern of primary features: laterality, proximal vs distal, diffuse vs focal/segmental • Age at onset • Onset, progression, and course • Recovery vs cumulative burden • Determination of presence and severity of sensory and motor symptoms • Spontaneous sensory symptom review: paresthesias, allodynia, dysesthesia, hyperalgesia, hyperpathia, spontaneous pain • Motor symptoms: weakness, speech, swallowing, diplopia, diurnal variability, influence of activity, fasciculations, cramps/pain, balance • Medical history for systemic disease: cardiac and other autonomic symptoms, recent infections, vaccinations, rash, and travel	• Constitutional symptoms • Rapidly progressive symptoms • Dysphagia or dysarthria suggesting motor neuron disease
Diseases of the spinal cord	• Onset, course, and precipitating factors • Precipitating factors, including trauma or repetitive physically demanding activities • Aggravating/alleviating factors or positions leading to motor, sensory, and pain symptoms • With pain, explore quality, radiating and radicular features, and provocative factors • Location, severity, and functional impact • Bowel, bladder, and sexual function • Perineal sensation • Medical history including malignancy, infection, immunosuppression, and recent spinal instrumentation	• Acute presentation for any disorder • Any presentation suggesting spinal cord localization • Urinary retention or loss of bowel/bladder function • Pain suggesting central spinal, cauda equina, or conus medullaris localization • Respiratory compromise suggesting diaphragmatic weakness • Autonomic dysregulation
Central nervous system tumor	• New-onset headache, seizures, cognitive decline (as reviewed in this table) • Loss of consciousness • Focal or multifocal neurologic symptoms	• New headache or unusual headaches for patient • Positional component suggesting increased intracranial pressure • Constitutional or general symptoms suggesting metastatic disease
Infections of the nervous system	• Onset, progression, and duration • Headache • Fever • Neck pain • Change in alertness • Focal neurologic deficits • Worsening or new back pain • Chronic risk factors for neurologic infection: immunosuppression, head trauma, recent ENT or neurosurgical instrumentation, sick contacts or travel to endemic areas of suspected infection, IV drug abuse, • ongoing systemic infection	• Fever • Rapid onset of symptoms • Decreased or decreasing level of alertness • Possible or obvious seizures • Hypotension

(table continues on page 22)

TABLE 3.2 Neurologic Histories Based on Common Neurologic Problems *(continued)*

Neurologic Problem	Common Features to Explore	Concerning Features
Seizures	• Age at onset • Semiology of seizures (localization/onset including "aura," progression of observable features, subtle features) • Timing, frequency, and duration of seizures • Symptoms known to be associated with various epilepsy syndromes • Associated cognitive and other neurologic disorders. • Explore for seizure mimics (headache, stroke, syncope). • Anticonvulsant medication history including responses (control, side effects, and compliance) • Precipitating factors (fever, medication, sleep deprivation, photic stimulation) • Risk factors for focal brain injury throughout a lifespan • Chronic medical problems (metabolic, psychiatric, malignant, infections) • Psychosocial impact of recurrent seizures • Family history	• New-onset seizures • Worsening seizure control with established epilepsy • Constitutional symptoms • Interictal features to suggest structural brain disease (headaches, focal symptoms, cognitive, or personality change)
Stroke	• Timing and duration, including last observed normal point in time • Contraindications to acute thrombolytic care and/or thrombectomy • Etiology and risk factors for cardioembolic, thromboembolic, small vessel, venous, inflammatory, and genetic syndromes, including compliance with therapy for known risk factors • Localization based on syndromes with known vascular territory • Stroke mimics or other neurologic features (headache, stroke, seizures, known recent history of severe hypoglycemia)	• Suggestion of large territory or posterior fossa localization, suggesting risk for immediate worsening • Rapid clinical worsening • Hemodynamic instability
Stupor and coma	• Last known normal • Potential precipitating factors or any known subtle recent symptoms • History of loss of consciousness • Constitutional symptoms • History of alcohol abuse • Family history, particularly for aneurysms, polycystic kidney disease, or connective tissue disease	• Recurrent seizures or status epilepticus • Suggestion of herniation syndrome or other indicators of critical intracranial pressure • Apnea

Abbreviations: ENT, ear, nose, and throat; HIV, human immunodeficiency virus; IV, intravenous.

of health and likely serve as surrogates for a complex and highly variable life experiences tied to income, employment, job and food security, diet, systemic racism and other sources of stress, physical health, and access to health care. Many of these factors interrelate. Often, many of these elements are challenging to discover or are not revealed in brief encounters.

Although alcohol, tobacco, and substance use/abuse are often recorded within the social history, their inclusion may be more relevant in the medical history, particularly if it has been chronically present or likely causal to various health conditions. Accurate identification of acute/recent use may be particularly relevant in neurologic patients presenting with acute cognitive disorders such as delirium, stroke, and ataxia. Some synthetic substances abused may not be detectable and require a definitively derived history.

Travel and Occupational History

A review of recent travel can be instructive for potential exposure to potentially rare or uncommon infections. It may also be the case that infections acquired while traveling are common yet uncommonly seen by the evaluating physician once the patient has returned home. Travel can also lead to preventative therapies used in advance of exposure to endemic infections, and these treatments may be associated with neurologic or psychiatric side effects. Travel can also be important in exploring for exposures to prolonged positions, such as deep vein thrombosis associated with long airline travel (and a risk factor in paradoxical stroke). Travel can also reveal subtle or unrecognized cognitive disorders, when a patient is placed in unfamiliar or confined locations, or subject to circadian disturbances leading to unexpected or severe symptoms of jetlag.

Occupational and vocational exposures as well as hobbies are important to explore given potential relevance to neurologic disorders. Toxic exposures are found in some occupations or hobbies (welders and chemists among others). Adverse ergonomics may be common with some hobbies (video gaming), occupations (computer use, manual laborers), or habituations (assumed posture while seated) and lead to a host of problems due to focal compression, including sciatica and lumbar spondylosis, fibular neuropathy, carpal tunnel syndrome, cervicalgia and cervical spinal stenosis, and ulnar neuropathy at the olecranon.

Dietary and Nutritional History

Diet and nutrition are infrequently explored in practice but can be informative in revealing nutritional deficiencies and food avoidant behaviors. Patients with developmental disorders and autism may be especially susceptible to unrecognized progressive restriction in diet and may further manifest with atypical or challenging symptoms. Persons subject to displacement, famine, or marginalization are especially susceptible to extrinsically narrowed diets due to access, due to finances, or general access food in order to satisfy caloric needs as well as a full array of micronutrients including vitamins with known neurologic micronutrient deficiency syndromes. Persons at risk for malabsorption or malnutrition including anorexia/bulimia, cystic fibrosis, ulcerative colitis/Crohn disease, and irritable bowel disease may be especially susceptible to vitamin deficiencies. Although uncommon, persons having undergone bariatric surgery may develop

micronutrient deficiencies, either due to noncompliance with vitamins taken chronically postoperatively, or other postoperative coincidental enteropathy and malabsorption syndromes. Patients with autonomic disease can have impaired gut motility and secondarily diminished appetite due to early satiety. In dementia, meals are often forgotten, and some treatments, particularly cholinesterase inhibitors, have anorexia as a potential side effect.

FAMILY HISTORY

Family history can be revealing in a broad array of neurologic diseases and should be fully explored in each patient presenting with neurologic disease. As covered further in Chapter 35, a familial basis of disease is common in nearly all neurologic disorders but may range in relevance to individual patients. Some disorders are genetically complex and common and may influence perceptions of how disease may occur. This is particularly the case with migraine and other headache disorders, which comprise upward of half of outpatient neurologic practices.

Even when perceived as negative or "noncontributory" (a nearly universally inappropriate shortcut, which should be stricken from a clinician's vocabulary) inclusion of vital status, ages of death, birth order within a sibship, and common medical problems for at least first degree family members should be recorded. For some patients, family history in remote family members may raise their concern and be the reason for presentation when asymptomatic. Some neurologic diseases or their risk factors have been historically associated exclusive with certain race-ethnic groups, but these notions are quickly becoming antiquated. This change reflects a number of factors including human globalization with interracial relationships and offspring, and earlier errors in case ascertainment when certain populations were studied without appropriate comparison to other populations. Nonetheless, there remain some neurologic diseases and founder mutations, which make them more likely in certain populations, yet not exclusive to them.

DIAGNOSTIC SYNTHESIS

As detailed in the introduction, during the course of eliciting the neurologic history, diagnostic reasoning often leads the questioning. At the conclusion of all the steps of the neurologic history, the examiner should have a fairly well-formed differential diagnosis, as well as leading considerations and a presumably brief list of "can't miss" diagnoses. At this point, reasoning has usually fairly formed into a true diagnostic synthesis, which may bear some review both internally and with the patient. The next step is most often the neurologic examination, which offers opportunities to confirm and refute this synthesis and is reviewed in the next chapter.

ACKNOWLEDGMENT

Dr. Noble acknowledges the valuable contributions of Lewis P. Rowland (deceased) and Timothy A. Pedley (retired) to prior versions of this chapter (Signs and Symptoms in Neurologic Diagnosis: Approach to the Patient).

LEVEL 1 EVIDENCE

1. Bowen JL. Educational strategies to promote clinical diagnostic reasoning. *N Engl J Med*. 2006;355(21):2217-2225.
2. Headache Classification Committee of the International Headache Society. The International Classification of Headache Disorders, 3rd edition (beta version). *Cephalalgia*. 2013;33:629-808.

SUGGESTED READINGS

Amarenco P. "Telethrombolysis:" stroke consultation by telemedicine. *Lancet Neurol*. 2008;7(9):763-765.

Aschenbrenner AJ, James BD, McDade E, et al; for Dominantly Inherited Alzheimer Network. Awareness of genetic risk in the Dominantly Inherited Alzheimer Network (DIAN). *Alzheimers Dement*. 2020;16(1):219-228.

Barohn RJ. Approach to peripheral neuropathy and neuronopathy. *Semin Neurol*. 1998;18:7-18.

Blumenfeld H. *Neuroanatomy Through Clinical Cases*. Oxford, United Kingdom: Oxford University Press; 2002.

Cho TA, Mckendall RR. Clinical approach to the syndromes of viral encephalitis, myelitis, and meningitis. *Handb Clin Neurol*. 2014;123:89-121.

Clancey WJ The epistemology of a rule-based expert system—a framework for explanation. *Artif Intell*. 1983;20:215-251.

Croskerry P. The importance of cognitive errors in diagnosis and strategies to minimize them. *Acad Med*. 2003;78(8):775-780.

DeMyer WE. *Technique of the Neurologic Examination: A Programmed Text*. 5th ed. New York, NY: McGraw-Hill; 2004.

Foreman B, Hirsch LJ. Epilepsy emergencies: diagnosis and management. *Neurol Clin*. 2012;30:11-41.

Gilliam F, Kuzniecky R, Faught E, Black L, Carpenter G, Schrodt R. Patient-validated content of epilepsy-specific quality-of-life measurement. *Epilepsia*. 1997;38:233-236.

Glymour MM, Manly JJ. Lifecourse social conditions and racial and ethnic patterns of cognitive aging. *Neuropsychol Rev*. 2008;18(3):223-254.

Green RC, Roberts JS, Cupples LA, et al; for REVEAL Study Group. Disclosure of *APOE* genotype for risk of Alzheimer's disease. *N Engl J Med*. 2009;361(3):245-254.

Hammond KW, Helbig ST, Benson CC, Brathwaite-Sketoe BM. Are electronic medical records trustworthy? Observations on copying, pasting and duplication. *AMIA Annu Symp Proc*. 2003;2003:269-273.

Hoppe C, Poepel A, Elger CE. Epilepsy: accuracy of patient seizure counts. *Arch Neurol*. 2007;64:1595-1599.

Hotson JR, Baloh RW. Acute vestibular syndrome. *N Engl J Med*. 1998;339:680-685.

Johannsen L, Smith T, Havsager AM, et al. Evaluation of patients with symptoms suggestive of chronic polyneuropathy. *J Clin Neuromusc Dis*. 2001;3:47-52.

Knecht S, Deppe M, Dräger B, et al. Language lateralization in healthy right-handers. *Brain*. 2000;123(pt 1):74-81.

Knopman DS, DeKosky ST, Cummings JL, et al. Practice parameter: diagnosis of dementia (an evidence-based review). Report of the Quality Standards Subcommittee of the American Academy of Neurology. *Neurology*. 2001;56:1143-1153.

Koes BW, van Tulder MW, Thomas S. Diagnosis and treatment of low back pain. *BMJ*. 2006;332:1430-1434.

Krieger JL, Murray F, Roberts JS, Green RC. The impact of personal genomics on risk perceptions and medical decision-making. *Nat Biotechnol*. 2016;34(9):912-918.

Loder E, Weizenbaum E, Frishberg B, Silberstein S; for American Headache Society Choosing Wisely Task Force. Choosing wisely in headache medicine: the American Headache Society's list of five things physicians and patients should question. *Headache*. 2013;53:1651-1659.

Lublin FD, Reingold SC, Cohen JA, et al. Defining the clinical course of multiple sclerosis: the 2013 revisions. *Neurology*. 2014;83:278-286.

Maizels M, Burchette R. Rapid and sensitive paradigm for screening patients with headache in primary care settings. *Headache*. 2003;43:441-450.

Noble JM, Mandel A, Patterson MC. Scurvy and rickets masked by chronic neurologic illness: revisiting "psychologic malnutrition." *Pediatrics*. 2007;119(3):e783-e790.

Norman GR, Monteiro SD, Sherbino J, Ilgen JS, Schmidt HG, Mamede S. The causes of errors in clinical reasoning: cognitive biases, knowledge deficits, and dual process thinking. *Acad Med*. 2017;92(1):23-30.

Okumura A, Watanabe K, Negoro T, et al. Epilepsies after pocket monster seizures. *Epilepsia*. 2005;46(6):980-982.

Paterson RW, Takada LT, Geschwind MD. Diagnosis and treatment of rapidly progressive dementias. *Neurol Clin Pract*. 2012;2:187-200.

Sacco RL, Kasner SE, Broderick JP, et al. An updated definition of stroke for the 21st century: a statement for healthcare professionals from the American Heart Association/American Stroke Association. *Stroke*. 2013;44:2064-2089.

Sanders DB, Guptill JT. Myasthenia gravis and Lambert-Eaton myasthenic syndrome. *Continuum (Minneap Minn)*. 2014;20(5):1413-1425.

Snijders TJ, de Leeuw FE, Klumpers UM, Kappelle LJ, van Gijn J. Prevalence and predictors of unexplained neurological symptoms in an academic neurology outpatient clinic—an observational study. *J Neurol*. 2004;251(1):66-71.

Vanstone M, Monteiro S, Colvin E, et al. Experienced physician descriptions of intuition in clinical reasoning: a typology. *Diagnosis (Berl)*. 2019;6(3):259-268.

Wang Y, Kennedy J, Caggana M, et al. Sickle cell disease incidence among newborns in New York State by maternal race/ethnicity and nativity. *Genet Med*. 2013;15(3):222-228.

The Neurologic Examination 4

James M. Noble

KEY POINTS

1. Combined with the neurologic history, the exam is a powerful tool to help shape initial steps of the diagnostic workup and tailor management.
2. An organized approach to each patient exam, informed by history and other exam findings, is an efficient way to establish localization.
3. Screening and comprehensive neurologic examinations have been proposed and should be used appropriately, tailored to the clinical context.
4. Key components include cognitive or mental status testing, followed by cranial nerve, motor, reflex, coordination, sensation, and gait exams.
5. Additional special tests and techniques are tailored to the patient's presumed diagnosis or working differential diagnosis.

INTRODUCTION

Of all the chapters presented in this book, the one most likely to remain nearly 100% relevant, if not also accurate, decades from now is that of the neurologic examination. New handheld, bedside, and other point of care tools continue to inform and will further shape the interpretation of the examination over time. Teleneurology and other virtual assessment tools have changed the way in which doctors and other clinicians engage with their patients and can be highly informative when an in-person assessment is not possible. The general utility of and approach to the neurologic examination have not substantially changed for decades and are unlikely to substantially differ over a trainee's career.

An exhaustive description of all potential tests comprising the comprehensive neurologic examination is beyond the scope of this chapter. Instead, the intent is to provide a set of guiding principles and essential techniques on which the neurologic examination can be built to support, augment, or refute findings suggested by the neurologic history. A thorough neurologic history and examination are designed to accurately localize neurologic dysfunction and develop a differential diagnosis of the most likely disease processes. The history and physical should be used in a complementary manner rather than as stand-alone devices. As detailed in Chapter 3, with the patient or family members as informants and the physician as historian, the neurologic history should be a logical, linear story told such that the history leads sensibly into the examination, without many surprises to the examiner or another physician hearing about the encounter. Furthermore, the neurologic examination may lead to a reassessment of the accuracy of the history or identifying new or additional collateral sources, particularly if memory problems are identified.

This chapter should be used in close conjunction with the guidelines for developing the neurologic history that are presented in Chapter 3. Moreover, the primary goals of this chapter regard the approach to most adult patients seen in inpatient and outpatient settings, with the exception being the critically ill neurologic patient. The approach to the stupor and coma examination is presented in Chapter 19. Key features of the infant and child neurologic examinations are covered in the Pediatric Neurology section.

Setting Goals of Examination Versus Neurologic Tests

As is the case in many professions, there are likely as many ways to accomplish an examination as there are examiners performing the examination itself. However, some approaches may be far more efficient, understandable, and sensible than others. There are numerous neurologic examination techniques known, sufficient to comprise a substantial book, let alone a single chapter.

The approach presented here is intended to demystify the reasons for and the methods by which a comprehensive neurologic examination is accomplished. Regardless of one's eventual scope of practice, neurologic or otherwise, all clinicians must have sufficient confidence, skill level, and knowledge base to begin to develop a proficient neurologic examination for each context it requires. There must be a balance between the expectation of a comprehensive examination that neurologists can accomplish, and a focused or screening neurologic examination all clinicians can perform when assessing for a potential neurologic emergency, life-threatening diagnosis, or treatable problem. Elements suggested to be included in comprehensive and screening neurologic examinations are provided in Table 4.1. Also, some elements of the neurologic examination may be expanded in specialty practices. Examples include a more involved assessment of behavior and cognition (behavioral neurology), focused assessment of movement and tremor (movement disorders), sensory and motor examinations (neuromuscular disorders), and provocative extra-ocular maneuvers (neuro-ophthalmology and sports neurology practices).

A Top-Down Approach

The manner in which the neurologic examination should be presented follows a structured approach that facilitates a complete and comprehensive neurologic examination. Anatomically and generally speaking, this follows a "top-down" approach, which begins with the mental status examination and cranial nerve examination at the top with the head, followed by the body including motor and deep tendon reflex examinations, followed

TABLE 4.1 The Neurologic Exam[a]

Comprehensive	Screening
Mental Status	
Level of alertness	Level of alertness
Language function (fluency, comprehension, repetition, and naming)	Appropriateness of responses
Memory (short- and long-term)	Orientation to date and place
Calculation	—
Visuospatial processing	—
Abstract reasoning	—
Cranial Nerves	
Vision (visual fields, visual acuity, and funduscopic examination)	Visual acuity
Pupillary light reflex	Pupillary light reflex
Eye movements	Eye movements
Facial sensation	—
Facial strength (muscles of facial expression and muscles of facial expression)	Facial strength (smile, eye closure)
Hearing	Hearing
Palatal movement	—
Speech	Speech
Neck movements (head rotation, shoulder elevation)	—
Tongue movement	—
Motor Function	
Gait (casual, on toes, on heels, and tandem gait)	Gait (casual, tandem)
Coordination (fine finger movements, rapid alternating movements, finger-to-nose, and heel-to-shin)	Coordination (fine finger movements, finger-to-nose)
Involuntary movements	Involuntary movements
Pronator drift	—
Tone (resistance to passive manipulation)	—
Bulk	—
Strength (shoulder abduction, elbow flexion/extension, wrist flexion/extension, finger flexion/extension/abduction, hip flexion/extension, knee flexion/extension, ankle dorsiflexion/plantar flexion)	Strength (shoulder abduction, elbow extension, wrist extension, finger abduction, hip flexion, knee flexion, ankle dorsiflexion)
Reflexes	
Deep tendon reflexes (biceps, triceps, brachioradialis, patellar, Achilles)	Deep tendon reflexes (biceps, patellar, Achilles)
Plantar responses	Plantar responses
Sensation	
Light touch	One modality at toes—can be light touch, pain/temperature, or proprioception
Pain or temperature	—
Proprioception	—
Vibration	—

[a]From Gelb DJ, Gunderson CH, Henry KA, et al. The neurology clerkship core curriculum. *Neurology*. 2002;58(6):849-852.

by sensory and coordination exams, and finally gait. Although it may be tempting to approach the neurologic examination in a narrow or symptom-focused manner, this method introduces the risk of unintentionally forgoing an essential element of the neurologic examination and missing a diagnosis. This approach is also designed to allow for an efficient first-pass assessment, which can be followed by more focused, detailed, and refined examination based on relevant initial findings.

Helping Your Patient Through the Neurologic Examination

Some patients undergoing their first formal neurologic examination may describe its unexpected thoroughness and that some of its elements are even strange. Perhaps related to this, some patients may unintentionally embellish the examination or even provide nonsensical physical examination responses. In such cases, it may be helpful to tell the patient very specifically what is going

to be done as well as the expected outcome or finding, particularly when a normal examination is expected based on a benign relevant history. On the other hand, it may be more worthwhile to provide no instructions to patients with functional disorders who are also prone to purposeful embellishment or feigned signs. One may also repeat some elements of the neurologic examination after describing the expected findings to the patient.

Soft Versus Hard Neurologic Examination Findings

In some cases, the examiner may be inclined to search unnecessarily for an abnormality on neurologic examination based on history provided or alternatively identify a subtle unexpected finding referred to as a "soft" neurologic sign. Common soft findings include facial asymmetries, a previously unrecognized strabismus persisting into adulthood, imperfect memory, and balance problems; these and others may worsen with advancing age without necessarily being pathologic. Slight asymmetries, particularly in the face, are commonly found during neurologic examination in normal individuals and likely do not hold much clinical relevance. Soft neurologic signs including poor motor coordination, sensory perception, and motor sequencing may occur in as much as half of all healthy individuals. Unilateral subtle motor coordination differences often reflect dominant versus nondominant side abilities. Understanding when to strongly consider a finding, simply record it, or to discard it altogether may require the judgment of a skilled examiner to cautiously interpret each finding. However, by approaching the neurologic examination with a clear sense of the likely localization based on the history, interpretation of soft signs can become less challenging. When findings are found in isolation, particularly without a clear connection to the history, it may be justifiable to recognize and record the finding but not necessarily prioritize the finding when synthesizing a diagnosis. When finding a soft sign, its relevance can often be determined by repeating the test, clarifying or asking additional history, or performing additional neurologic examination techniques to determine whether it is found in isolation or relates to others on exam.

Descriptions Versus Impressions

Whenever possible, a description of neurologic findings should be included in the examination rather than the synthesis of the findings themselves. Changes in the neurologic examination day to day can be remarkably subtle, and only a descriptive neurologic examination may reveal such changes and sometimes only in retrospect. For example, a patient may be described on a series of examinations by different examiners to be lethargic; yet, substantially different levels of stimulus are required to result in the same response from the patient, ranging from light tactile to verbal stimuli to other more rigorous stimuli applied yet inadequately described. Such a failure to accurately describe the patient, particularly in an era increasingly reliant on effective care transitions, can jeopardize true understanding of neurologic disease progression in both inpatient and outpatient practices.

Positioning the Patient (and Examiner)

Appropriately positioning the patient and the examiner is an important first step in many aspects of the neurologic examination and is described in each of the relevant sections in the following text. Positioning of the patient and the examiner is important throughout the patient encounter, including initial moments of a patient encounter when developing patient trust and rapport. At the bedside, correct position with each component of the neurologic examination is essential in both effective and efficient performance and interpretation of the neurologic examination. Positioning is most relevant not only to assessment of visual fields, funduscopy, strength, and deep tendon reflexes but also during times of potential injury during provocative or potentially risky elements of the examination to the patient, such as pull testing for assessing postural stability, or even when standing a patient affected by frailty or imbalance suggested in the history or during gross inspection. Appropriate positioning is especially important when assessing for movements, which may occur at rest. For example, rest tremor is best observed in relaxed or neutral position such as resting the hands in the lap, upright with arms flexed.

Careful Observation and Examination Interpretation

Making a judgment about the presence or absence of a neurologic finding is an essential skill to interpreting the examination. Determining or judging normative or expected responses on the neurologic examination helps to refine findings further and likely follows experience with performing examinations on many of patients, ranging in age and variety of problems, over many years. Interpreting findings may also be informed by sociodemographic factors, particularly the cognitive examination.

After gaining sufficient experience to appreciate the range of normal examination findings, ranging from funduscopy to gait to behavior, an examiner can begin to dissect a subtly abnormal neurologic examination into its principal components. Although a specific diagnosis may be hard to determine, particularly among patients with complicated history, a dissection of abnormal findings on the neurologic examination, used in conjunction with the history, can facilitate localization and diagnostic approach.

Sometimes, despite best efforts, a complete neurologic examination may not be possible. Aside from the unique context of the coma patient, patients with cognitive impairment or agitation, or other psychiatric problems may not be able to comply with many elements of the formal neurologic examination. Much can be learned by careful observation, even from afar or remotely, including behavioral interpersonal interactions; visual fields through how the patient interacts with the environment; language and speech through conversation; and limb, trunk, and facial purposeful and involuntary movements and coordination through observation of movements while taking a history.

THE PATIENT EXAMINATION

General Medical Examination

Any patient with concern for a neurologic disease should be evaluated with a comprehensive general medical examination at least once in the course of their initial neurologic assessment. However, it is typically the case that a relatively brief overview of the general medical examination will be included in any neurologic case presentation with only the elements most germane to the neurologic diagnosis presented. For example,

examination for cardiac and carotid auscultation should be performed for a patient presenting with stroke, and skin should be assessed for rash in a patient presenting with proximal myopathy.

However, each patient should have a complete and accurate description of the general impression—the essence of the strong first impression each patient may have provided to the examiner. Specific points to mention may include general appearing of wellness, nourishment, habitus, manner of dress, or other related elements. Some of these elements may be reinforced in the mental status examination.

Mental Status Examination

In contrast to other elements of the neurologic examination, the mental status examination is composed of a potentially variable set of tasks tailored to each patient. Rather than beginning with the prespecified set of neurologic examination tasks, a far preferable approach is one that aims to develop a description of the function of the cognitive domains based on a set of often interdependent tests. It is difficult, if not impossible, to find any single test that can comprise and completely describe an entire neuropsychological cognitive domain. Instead, many tests map to several cognitive domains and vice versa. Conceptually, it is well-known that cognitive functions are highly interrelated functionally and anatomically, with the principal components of interest on examination representable as Venn diagrams (Fig. 4.1). These

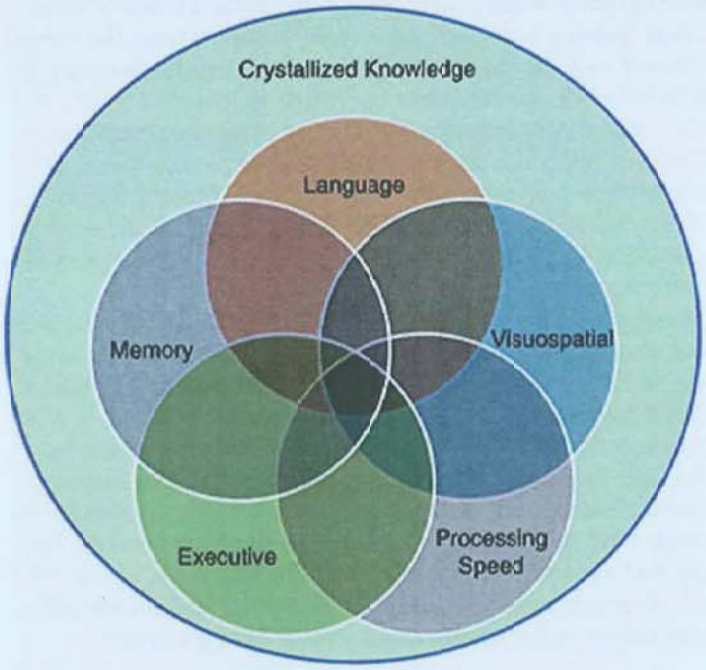

FIGURE 4.1 Conceptual framework for the mental status examination and interpretation. Each of the five principal cognitive domains (language, memory, visuospatial, processing speed, and executive function) is drawn from a series of tests comprising the mental status examination. Relative strengths and weaknesses in each domain may be inferred based on a series of related tests, which map potentially to several domains but taken together can potentially identify one or more domains of impairment. The interpretation of each abnormality must be considered within the context of each test, including normative information if known. The relative function of each domain is likely influenced by and superimposed on crystallized knowledge, which conceptually summarizes education, life experiences, and cognitive reserve.

can broadly be broken down into domains of language, memory, attention and executive function, visuospatial function, and processing speed. Predicated on each of these is that the patient has a sufficient level of consciousness in order to participate in the examination.

There are several reasons that the neurologic examination includes a standardized mental status assessment. First, any standardized cognitive screening examination will often have been developed in the context of hundreds, if not thousands, of applications and multiple social economic and cultural contexts, making its interpretation more generalizable. Second, at the level of the examiner, use of the same examination repeatedly may give the examiner greater confidence in examination skill and interpretation based on a learned experience of typical or expected responses developed over the course of giving the same test in multiple clinical contexts. Third, most standardized mental status examinations allow for a hierarchical approach to understanding someone's cognitive abilities. For instance, for a task of delayed recall, it is important to understand not only what a patient can freely recall but also what the patient may recognize either through the contextual or categorical clue given for recognition tasks or subsequently through list of forced choices. Using a sequential, hierarchical approach to assessing memory abilities allows for determination of free word retrieval (presumably a harder response) versus recognition (by choices), which are thought to be independent of registration tasks. Finally, serial assessments of an individual patient may require adjustment of examination techniques to avoid the potential effects of learning or practice.

Many caveats apply to interpreting the mental status examination and thus require understanding and how it is devised for each patient, particularly how it is tailored to each cultural context. For instance, education and lifetime cognitive abilities play a strong role in one's ability to interpret both normal and abnormal mental status examination findings. Prior to each mental status examination, developed within social history must be a clear sense of someone's educational history, literacy, and thus likely expected performance on mental status testing. When interpreting formal neuropsychological testing, two norms are considered: the person's premorbid intellectual capacity as determined by intelligence quotient and professional accomplishments as well as comparison to normative values based on peer performance matched to age, education, and potentially primary language.

It is important during the mental status examination not only to record whether or not the patient correctly answers the question but also to record the actual response itself. Much can be learned through some elements of the mental status examination, which can, to some degree, be influenced by complex factors including mood. For instance, a patient may be considered to be disoriented to time and place through simple scoring, but when review of the actual answers suggests an exactly wrong response to every single question (including nonsensical dates, often in the future), it might suggest an element of feigned or embellished neurologic examination.

Determining Alertness

The entirety of the formal mental status testing is predicated on a patient being fully awake, alert, and able to engage the examiner. Presuming this is the case, the neurologic examination as described in the following section is relevant in such a patient. Determining a depressed level of alertness is described in Chapter 19 as it relates to the examination of coma and the brainstem examination.

Language

Language is composed of seven principal components: (1) fluency, (2) prosody, (3) repetition, (4) naming, (5) comprehension, (6) reading, and (7) writing. A language examination is not complete without each of the seven elements. The pattern of dysfunction related to these seven components allows the neurologist to diagnose and classify all types of aphasia (Table 4.2).

Fluency and prosody can often be determined through development of the neurologic history before turning to formal examination. Prosody is the musical component of language, the singsong nature, and cadence that allows one to understand the nature of a stated expression. For example, prosody allows one to discern when a declarative sentence is stated versus a question. In contrast to normal prosody, aprosodic language may be identified among patients with major neuropsychiatric disorders including schizophrenia or in patients with advanced or untreated Parkinson disease. Fluency is a quality of speech pertaining to the ability of a patient to express himself or herself without hesitation or disruption spontaneously as well as during formal testing. Dysfluent speech may have hallmarks of patient frustration or an unexpected halting pattern, such as that seen in a suddenly acquired Broca area stroke, or progressively developed in a patient with the progressive nonfluent aphasia form of frontotemporal dementia. Dysfluent speech is distinct from thought blocking, which is described within the elements of psychiatric examination.

Repetition may be assessed by asking a patient to repeat a simple, understandable phrase and further tested by a longer more complex sentence if the history and examination warrant further exploration. When such a phrase cannot be repeated, repetition of single words should be attempted.

Naming also should be approached in a hierarchical manner when testing knowledge of names of presented objects and virtual pictures. Standard images/figures comprise most neurologic screening examinations but differ among each exam. Objects to be named should be ubiquitous, well-known to the patient, and have elements that offer an opportunity to test parts and not just the sum of the object. This approach may reveal difficulty in describing low-frequency relative to high-frequency words, as is often seen in disorders like Alzheimer disease. In addition, the naming examination may be tailored to the patient for objects well-known in the context of life experience or profession, such as images of a set of carpenter's tools. A number of forms of specific categorical dysnomic aphasias are known to exist, such as color dysnomia, and should be tested in the appropriate clinical context.

Comprehension is often tested as a three-step command. As with a memory task, the patient should be prompted to expect the task rather than occurring as a surprise. Numerous three-step commands have been published but should be easily understandable, contextually appropriate, and whenever possible use commonly available objects so that the same task can be repeated by a single examiner in multiple clinical contexts.

Reading testing begins with a patient reading a simple sentence aloud and offers an opportunity to test for comprehension by having the patient act on the sentence provided. Should a patient have difficulty reading a sentence (eg, "Close your eyes."), then the examiner should move on to simple phrase or a single word if the phrase cannot be read. In a similar approach, writing should begin with an instruction for the patient to write a complete sentence. If this cannot be accomplished, the patient should be asked to write a simple dictated sentence. If this is further not possible, the patient should be asked to write or sign his or her name, although this principally tests for praxis or dysgraphia. Such highly learned written tasks, and even a signature, likely localize to the nondominant frontal lobe as a procedural motor task, or engram, rather than a function of spontaneous written language.

Memory Testing

Differing definitions of working, short-, and long-term memory exist, are often used inappropriately in colloquial examination and presentations, and may have differing meanings depending on the person reviewing the examination described by others. A formal description of various forms of memory is provided in summary in Table 31.2. Working memory is generally considered to be the online or in-the-moment memory, such as what may be used when repeating a series of unrelated words or number sequence. Short-term memory involves testing a set of ideas registered with the patient and specifically queried by the examiner after a delay of several minutes. Items not freely recalled but instead recognized from a list (recognition) can be

TABLE 4.2 Types of Aphasia

Aphasia Subtype	Fluency	Comprehension	Repetition	Localization
Expressive (motor, Broca)	Effortful speech with paraphasic errors[a] and agrammatism[b]; mutism in severe cases	Normal	Impaired[c]	Frontal opercular region of inferior frontal gyrus (Broca area) in the dominant hemisphere
Receptive (sensory, Wernicke)	Fluent speech, mostly nonsensical in content; frequent paraphasic errors	Impaired	Impaired[c]	Posterior-superior temporal region (Wernicke area) in the dominant hemisphere
Global aphasia (combination of expressive and receptive)	Effortful speech with paraphasic errors[a] and agrammatism[b]; mutism in severe cases	Impaired	Impaired[c]	Both inferior frontal gyrus and posterior-superior temporal region in the dominant hemisphere
Conduction aphasia	Normal	Normal	Impaired	Due to lesions of the arcuate fasciculus connecting Broca and Wernicke areas in the dominant hemisphere

[a]*Literal (phonemic) paraphasic error*: an error made by substituting a similar-sounding word for another (ie, "pat" substituted for "cat"). *Verbal (semantic) paraphasic error*: an error made by substituting words with similar meaning (ie, "cup" for "bottle").

[b]*Agrammatism* or *telegraphic speech*: Language content of spontaneously uttered sentences is condensed, missing many filler words, such as definite articles and sometimes verbs.

[c]Normal repetition in the setting of expressive, receptive, or global aphasia denotes transcortical expressive, transcortical receptive, and transcortical mixed aphasia subtypes.

additionally informative. Long-term memory can either represent a more prolonged delay in testing responses to the task of recollection or in some other tasks may instead represent long-term general or autobiographical knowledge. It is important to document the content asked to be remembered and the duration of time until asking for retrieval of information. Recall is entirely predicated on the patient's ability to register several items to be recalled, and this begins with preparing patient for this task in a minimally distracting environment.

In its simplest form in the neurologic examination, memory testing involves having a patient remember several items in the context of an examination to be recalled several minutes later. However, it largely serves to only test verbal memory of three unrelated words and does not take into account nondominant hippocampal function such as visuospatial memory or implicit memory associated with programmed motor tasks. Certainly, this is an important element of memory testing but is just one method of assessing memory among many.

Ideally, a test of three to five unrelated words, or a brief contextually related phrase (name and address of a fictional person), should be given to a patient to register and subsequently recall. It is most important for the examiner to use a series of words that have been rigorously studied to understand their cultural and socioeconomic norms; can be understandably and simply chosen from categorical clues, which may be given to help with recognition after-the-fact (eg, "the first word was a color"); can be recognizable from a list of similar words; and is also easily memorable to the examiner who may be giving such an examination many times over the course today.

Verbal memory can also be tested through repetition and recall of a simple story. This can be particularly effective in identifying the patient with a confabulatory amnestic syndrome (ie, Korsakoff syndrome) rather than anterograde amnesia (ie, Alzheimer disease). For example, a patient may be given a brief story to recall such as "Johnny had a red tricycle. Billy liked Johnny's red tricycle and stole it one day. Billy broke Johnny's red tricycle after he took it. When Johnny found out Billy had stolen the tricycle, he got very upset." A patient with a typical amnestic disorder may respond to this task by providing a few or a restricted set of elements germane to the story with the remainder unrecalled. In contrast, a patient with a confabulatory amnestic disorder may provide the initial basic elements of the story correctly but then provide an idiosyncratic thread far beyond the initial details provided in the story. Moreover, such a patient may begin with the same thread when testing the story on a follow-up examination, only to give a remarkably different yet linear story thereafter.

Nonverbal short-term memory is thought to be localizable to the nondominant hippocampus or most typically the right side in right-handed individuals. Formal neuropsychological testing often uses complex figure copying and recall testing, but testing visuospatial memory in the office can be challenging yet is possible. For instance, one can hide three objects within a room telling the examinee each time where each object is placed, to be registered and recounted several minutes later. A hospital corridor can be used as a visuospatial memory task by having a patient and examiner pass through a specific path, to be led by the patient immediately to demonstrate registration, and again several minutes later to demonstrate recollection.

Long-term memory likely engages separate circuits, widespread across the cerebrum, and is better categorized as public or autobiographical memory rather than a true function of working or recent memory. This memory type can also be easily conflated and is dependent on knowledge of worldly events and life experiences. Testing long-term memory can be approached by using a standardized set of questions, which should be well-known to the individual, such as sequential ordering of recent presidents. However, this can be easily tailored to a patient who may lack such conventional knowledge. For example, an aging sports enthusiast can be tested for knowledge of recent sports events important to him and hierarchically working back to biographical events, which must be corroborated by an informant. A test of recent worldly events likely more reflects function of the same recent memory circuits being tested by recollecting three unrelated words, given the need to both register and recall worldly information gathered through the news.

Calculation and Other Tasks of Attention and Concentration

Typical tasks of attention and concentration relate to the ability of a patient to attend and focus any specific, often narrow, set of tasks in real time. Bedside techniques in assessing concentration include serial subtraction, spelling a five-letter common word backward, or more simply involving stating the months of the year in reverse, days of the week in reverse, or counting from 20 down to 1. The examiner should begin with the most difficult task first. Elements of these examinations are often appropriately interpreted in the context of related domains such as executive function. For instance, the ability of a patient to count down from 20 may reflect the ability to attend to the task, whereas subtracting a series of changing answers may suggest intact or impaired executive or calculation abilities. Other more practical tasks may involve simple addition and subtraction, presuming appropriate levels of literacy and numeracy. Tasks such as making monetary change may give one not only a sense of the patient's calculation abilities but also any degree of functional impairment should a clear impairment emerge. For a patient residing in a major metropolitan area, the ability to appropriately make change at a hypothetical street-side food vendor can be such an example.

Assessment of attention and concentration also occurs in the course of other cognitive tests, including memory testing when several words are registered (intending to be later recalled), following a three-step command, or drawing a complex figure. As detailed earlier, it is not the performance on a single test that draws concern but rather an overall pattern that may emerge across the sequence of several tests.

Executive Function

Executive function can be demonstrated through several types of tasks highlighting the abilities or limitations of the frontal lobe or its principal subcortical circuits. Broadly speaking, these can be thought of as tasks, which demonstrate the ability of a patient to both maintain and shift between specific tasks or concepts, as demonstrated by examinations of either language or physical/motor abilities.

Common tests of executive function involve repetition of a number series in the reverse order in which it was given, complex tasks of addition or subtraction, or sequential tasks performed by the patient in a specific order and manner. Examples of executive tasks involving the hands may be in a standard set of hand movements such as knocking ("fist"), chopping ("edge"), and slapping ("palm") the hand on a table in sequence after being instructed to register the series, also known as the *Luria sequence*.

Tests of praxis may be considered to some degree to be tests of executive function, as a demonstration of ability or limitation in fine movement of the hands or limbs based on frontal lobe function.

It is also recognized that praxis requires not just motor planning and monitoring but also visuospatial and sensory input for refinement and placement and intact language function for understanding and executing the task. With this in mind, in contrast to weakness, praxis is the ability of a patient to coordinate and perform a simple or complex set of tasks based on instruction, independent of simple motor abilities. Simple, or ideomotor, tests of praxis involve single motions with contextually independent movements such as the ability of a patient to open and close a hand either to simple instruction or to demonstration. In contrast, ideational tests of praxis instead involve a complex task often with multiple steps of a well-known or overlearned task used in daily life. Examples include demonstration of brushing one's hair, brushing teeth, or blowing out a match. More specific examples for common daily tasks include putting on a coat, known as *dressing praxis*.

Visuospatial Function

Visuospatial function is often tested through tasks, which require ability to perceive, plan, orient, and synthesize visual images. As is the case for other cognitive tests, one might typically think of as specifically testing one domain, visuospatial abilities inevitably may have a basis in other domains including frontal executive function, specifically with planning, but are also reliant on memory (how one may be familiar with the stimulus object such as a clock or cube) or language (understanding the contextual basis for an image). The simplest of drawing tasks may limit the influence of frontal executive function on the ability of a patient to draw but must be taken in consideration relative to other nonvisuospatial tasks in order to fully interpret visuospatial test findings. Examples of visuospatial tasks include drawing intersecting pentagons, a circle with a tangentially touching square, or cubes, among other figures. More complex figures used in common practice, such as a clock drawing, can be very helpful in demonstrating visuospatial function but can also reflect a number of cognitive problems including planning, memory, as well as visual field deficits and can make interpretation challenging. As is the case with language, visuospatial function may be significantly impacted by educational history, in particular simple literacy. Individuals who may not have held a writing implement rarely in their life may have difficulty with relatively simple drawing tasks.

Higher Order Cognition

Higher order cognitive functions can reflect executive functions but represent a separate set of cognitive abilities, which are more often predicated on experiential knowledge and social norms. Tests of higher order function include interpretation of proverbs or common sayings and judgment as demonstrated by patient's response to simple hypothetical situations.

Ideally, one should select a few proverbs for such tasks, which are culturally sensitive, relatively ubiquitously known, and interpretable by both the patients and the examiner in the response. Using a relatively narrow set of appropriate phrases will also give the examiner better experience in anticipating a typical response from patients. Example phrases used in proverb interpretation include "two heads are better than one," "people in glass houses should not throw stones," and "don't count your chickens before they hatch." Examples of hypothetical situations to be provided for testing judgment may include asking for patient's response to discovering an unmailed fully addressed letter, or steps taken when facing a simple public emergency. As with any test, these must be interpreted with consideration of education and culturally based normative responses.

Key Psychiatric Examination Elements

The key elements of a conventional psychiatric examination will also be germane to many patients with neurologic disease, particularly those with an acquired cognitive disorder. The patient's reported symptoms of mood are recorded as mood, whereas the examiner's interpretation of the patient's mood is better characterized as affect. These can both be matched or unmatched in the context of examination and both are important distinctions to make for later interpretation.

Thought process is an important component of the psychiatric examination and is often discovered either during or in retrospect when the examiner reflects on a simple or challenging interview. Thought processes can be characterized using the following descriptors, which also have graphical corollaries to better conceptualize how conversation transpires (Fig. 4.2). These thought processes are linear, tangential, thought insertions, thought blocking, circumstantial (too many details, meandering but with spontaneous return), circumlocutions (talking around the subject with

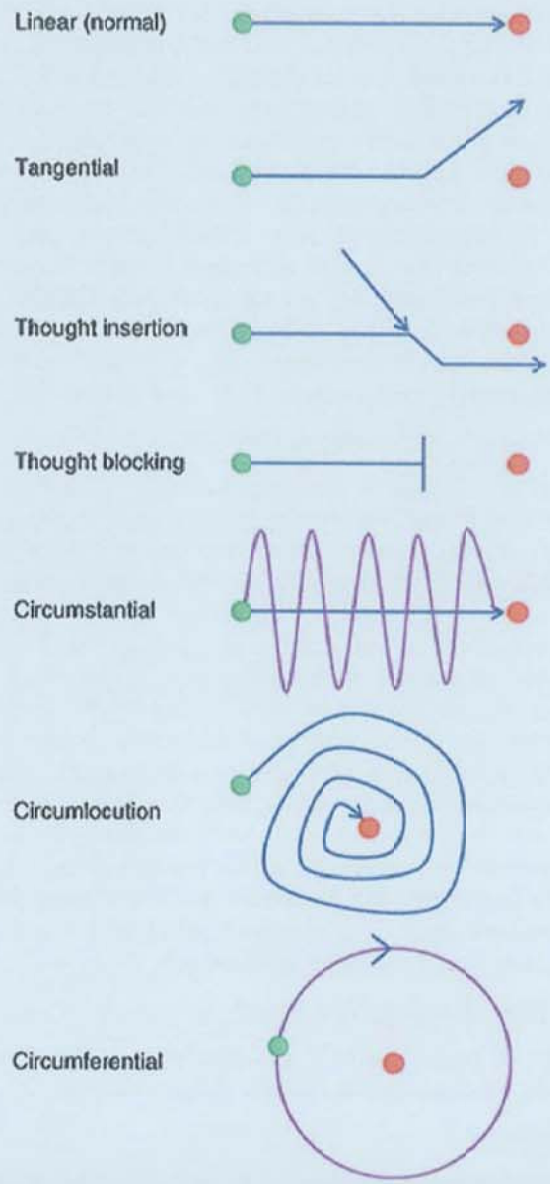

FIGURE 4.2 Graphical representations of thought processes. Starting points are indicated with a *green dot* and final points with a *red dot*. *Lines* represent direction of conversation. (Adapted with permission from Edward R. Norris, MD [written communication, October 4, 2014].)

eventual arrival), and circumferential (talking around the subject without arrival). Thought content is considered the components and characteristics, which make up thought processes and include psychotic and nonpsychotic phenomenology. Important psychotic phenomenology either identified during examination or history includes delusions (fixed false beliefs), hallucinations (idiosyncratic, spontaneously perceived visual, auditory, sensory, olfactory, or gustatory stimuli), or illusions (misperceived complex visual or auditory perceptions based on real environmental cues). Other types of abnormal thought content include ideas of reference, sense of presence, or other thought idiosyncrasies.

Cranial Nerve Examination

The cranial nerve examination is an essential component of the neurologic examination that requires skilled training and expertise to interpret appropriately. However, when approaching the examination methodically, based on its principal components, rapid interpretation of the individual and localizing findings can be accomplished.

As is the case with the remainder of the general medical and neurologic examinations, the cranial nerve examination should be described in such a manner that only the elements of examination that were performed are those recorded. For instance, one may not assess olfaction in every neurologic examination, and it is unnecessary to state when it was not done. The examiner should demonstrate the findings again in a top-down approach beginning with findings identified in an ordinal manner, presenting the cranial nerves from lowest to highest number (begin with cranial nerve I and end with cranial nerve XII). Cranial nerve function should be described in the context of the test performed rather than the nerves themselves (eg, "eye movements fully intact" rather than "cranial nerves III, IV, and VI intact").

Cranial Nerve I (Olfactory Nerve)

Assessment of olfaction is important in certain neurologic diseases including frontal lobe tumor, head trauma, and degenerative disease, among others. Testing is composed of commonly recognizable smells, which are not caustic, toxic, or excessively potent in strength. Examples of commonly used, recognizable, and available smells include coffee, vanilla, and mint. These can be stored within a neurologist's equipment bag using plastic film canisters (although these are increasingly more difficult to find) or opaque contact lenses cases (so that the patient may not see the item to be smelled in advance). To test for smell, with the patient's eyes closed, have a patient fully close one of his or her nares and ask to take a deep breath with the item to be smelled placed immediately below the nares. Formal assessments of smell including distinction of various smells and smell thresholds are available, including on scratch-off cards, but at present are principally used in research applications.

Cranial Nerve II (Optic Nerve)

Assessment of cranial nerve II includes tests of visual acuity, visual fields, funduscopy, and pupillary light reaction.

Visual Acuity

Most standard physician examination kits include a Snellen card for testing visual acuity. One of the most important steps prior to performing a visual acuity examination is to know the exact distance at which the vision is to be tested. This is typically printed on the card and varies from 16 inches (or 40cm) for near vision to 6 ft (or 2m) for far vision (as a surrogate for a standard 20-ft (or 6m) distance examination). Begin by instructing the patient to put the hypothenar eminence of his or her hand against the bridge of the nose such that the eyes completely obstructed by the palm of the hand. If the patient is simply instructed to cover his or her eye with hand, there is a tendency of using the fingers to cover the eye and therefore the possibility of peeking through these fingers in order to improve or embellish the examination findings. Related to this issue, the examiner should always hold a visual acuity card to avoid a patient's temptation to bring the card closer to the face and conflate the exam.

Visual Fields

This examination should begin with the examiner standing at an arm's distance from the patient. Testing visual fields at a farther distance may only test central vision rather than demonstrate any frank field deficits as is desired by this test. Using the instructions previously described for covering the eye, the examiner should close their ipsilateral eye when facing the patient (the examiner should close his or her own left eye while examining the patient's left eye). With arms held aloft, the examiner should attempt to assess monocular visual fields at the left and right of meridian as well as above and below the equator of each tested eye. Generally speaking, the bedside visual examination test should be used to discover quadrantanopsias, binocular visual field loss, or homonymous hemianopsias. Any smaller field deficits would be far more difficult to identify on bedside examination and may require formalized visual field testing as is done in an ophthalmologist office (Fig. 4.3).

Methods of testing visual field include counting fingers within each of these quadrants, identifying a statically held hand with a wiggling finger, or moving a hand into the field being tested. Despite their routine inclusion on examination, most bedside techniques are poorly sensitive but highly specific to identifying visual field deficits.

Funduscopy (via Direct Ophthalmoscopy)

Funduscopy is marvelously distinguished as being the only part of the neuraxis which can be directly visualized. It provides a window into many diseases, including evidence of chronic systemic disease and acute neurologic emergency. However, the funduscopic exam can be neglected out of examiner discomfort or disinterest. The quality of the remainder of the examination and

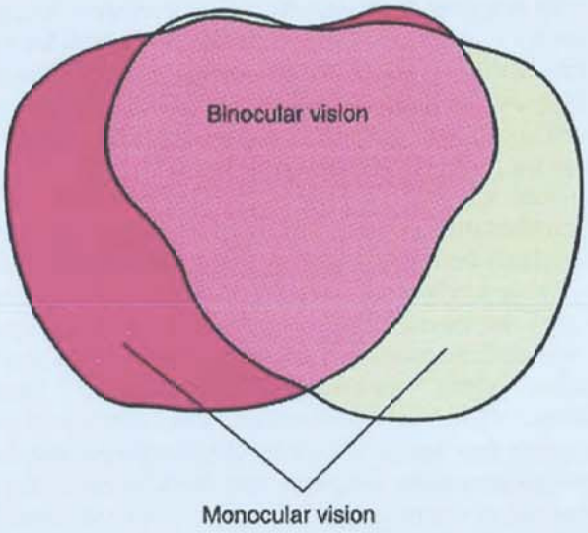

FIGURE 4.3 Visual fields. (From Bickley L. *Bates' Guide to Physical Examination and History Taking*. 11th ed. Philadelphia, PA: Wolters Kluwer Health/Lippincott Williams & Wilkins; 2013.)

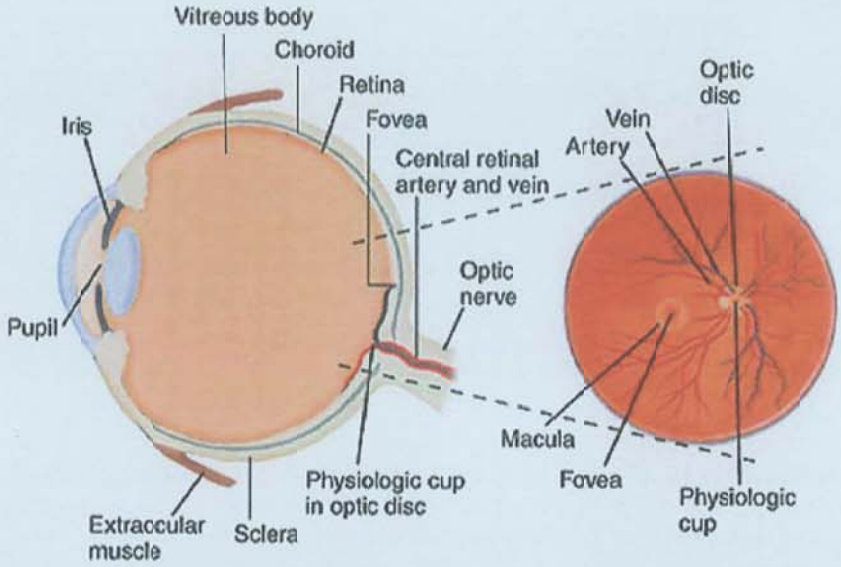

FIGURE 4.4 Funduscopic view (right eye). (From Bickley L. *Bates' Guide to Physical Examination and History Taking*. 11th ed. Philadelphia, PA: Wolters Kluwer Health/Lippincott Williams & Wilkins; 2013.)

history as performed by a referring physician, in the eyes of a consulting neurologist, may be predicated on inclusion or at least attempt of this aspect of the examination for this reason, particularly when called for by the diagnosis. Two main barriers may persist and limit the interest of a physician on performing this exam: perceived difficulty of use of the equipment and simple availability. Two forms of direct ophthalmoscopes exist for the bedside exam: conventional and panoptic. The conventional heads have the benefit of bright light for magnification, portability, and relatively ubiquitous presence of these heads in many clinics but are limited by perceived difficulty of use perhaps related to partial views of the optic disc even in optimal patients. The conventional heads are available in a normal size, as well as a smaller "micro" version, which offers even greater portability but faces the same limitations. The panoptic head offers the benefit of a wide field of view but is limited by expense and lower light intensity (which may limit visibility in patients with dense cataracts).

The essential aspects to be identified in funduscopy include characteristics of the optic nerve head including the cup, margins, and vessels as well as the immediately visualizable and relevant retinal components including the macula/fovea (Fig. 4.4). Visualizing the retina beyond the width of 2 or 3 optic disc diameters of most patients is particularly difficult by direct ophthalmoscopy.

Care should be taken to describe the color and shape of the disc as well as the cup-to-disc ratio if perceptible. A relative description of vessels can include the quantity and quality including relative diameter, or a suggestion of hypertensive change often described as "copper wiring," or "Arteriovenous (AV) nicking" when the vein appears compressed by a superimposed arteriole. Description of retinopathic changes including color variegations, vascularity, and plaques should be described. Having such an approach will leave more emergent and obvious abnormalities to the end of the focused examination and description.

Pupillary Light Response

Although listed here for the sake of organization with cranial nerve II, it is recognized that the pupillary light reflex involves both cranial nerve II and the pupillomotor circuit and fibers of cranial nerve III, which are further influenced by pupillary autonomic innervation. Two components of the pupillary response should be considered within each patient. These include the response of the ipsilateral and contralateral eyes to both direct and consensual light responses. While asking a patient to fixate on the examiner's face or another suitable target several feet away, using a light of sufficiently bright intensity, a narrowly focused beam is shown into a single eye with the examiner assessing for the ipsilateral and contralateral responses.

The swinging flashlight (Fig. 4.5) is another component of this test in which the initially examined eye is provided direct light followed by a rapid movement of light to be shown into the

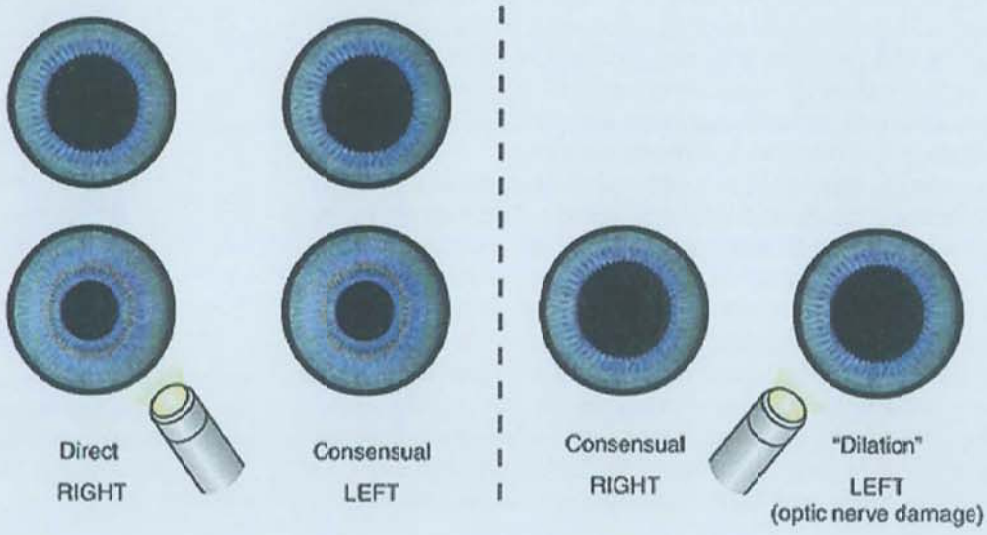

FIGURE 4.5 Swinging flashlight test. (From Bickley L. *Bates' Guide to Physical Examination and History Taking*. 11th ed. Philadelphia, PA: Wolters Kluwer Health/Lippincott Williams & Wilkins; 2013.)

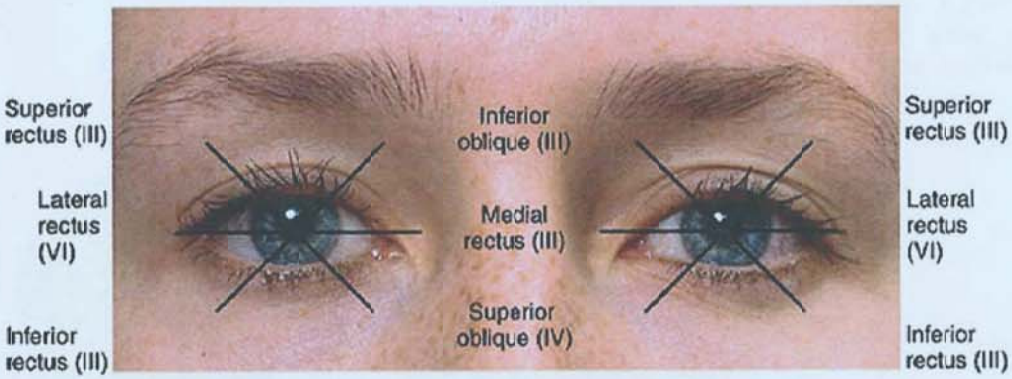

FIGURE 4.6 Extraocular movements. (From Bickley L. *Bates' Guide to Physical Examination and History Taking*. 11th ed. Philadelphia, PA: Wolters Kluwer Health/Lippincott Williams & Wilkins; 2013.)

contralateral eye followed by a movement back to the initially tested eye. The object of this examination is to identify either a lack of direct response (in the case of severe optic neuropathy) or paradoxical dilation during direct response (in less apparent cases, termed the *relative afferent pupillary defect*) as the swinging flashlight is shone back into an eye affected by an optic neuropathy.

In addition, pupillary asymmetries should be described and assessed in both a lit and a darkened environment with the use of tangential light (to assess pupillary size with minimal afferent stimulus, as may be relevant in diagnosing a Horner syndrome).

Extraocular Movements (Cranial Nerves III [Oculomotor Nerve], IV [Trochlear Nerve], and VI [Abducens Nerve])

The elements of testing extraocular movements include demonstration of limitations of excursion of either individual or consensual gaze, rapidity of saccades, preservation of smooth pursuits, and the control of multiple types of extraocular movements, both large and small excursions as well as slow and fast movements.

Prior to any testing of eye movements, the patient should be carefully examined for any spontaneous eye movements when focusing on a fixed near target placed several feet before the patient. Although this technique may demonstrate spontaneous eye movement abnormalities including so-called square wave jerks, finer perception of such movements may be identified during funduscopic examination, which magnifies subtle spontaneous eye movements otherwise missed during casual visual inspection.

To test for restriction of gaze, the patient (Fig. 4.6) should be asked to follow the finger or a similar near target at approximately an arm's length distance from the patient moving through a typical H pattern followed by assessment of near point convergence and pupillary accommodation. Care should be taken not to move through these movements too quickly; otherwise, saccadization of pursuits may occur and potentially mislead the development of the oculomotor examination.

To test for rapidity of saccadic eye movements at a similarly near distance, the patient should be asked to fixate on the examiner's nose while both hands are placed in mid position between the patient and examiner at about a shoulder width apart. With one hand wiggling (to indicate a target) and the patient staring at the examiner, the patient is instructed to look at the wiggling stimulus, followed by instructions to return to gaze back to the nose. After a series of repeated assessments, the rapidity of saccadizations as well as the ability to accurately fixate on the lateral and midline targets can be assessed using this technique. An alternating bright and dark cloth tape to stimulate optokinetic nystagmus can be an additionally helpful tool in potentially identifying lateralized saccadic eye movement deficit.

To further test for the accuracy of fixation and the ability to maintain fine, fixed, and accurate extraocular movements, the patient can be asked to additionally follow a moving target through an unpredictable series of movements in either the horizontal or vertical plane. A consistent need to provide a corrective saccade in all, or a single direction, provides a localizable deficit.

Cranial Nerve V (Trigeminal Nerve)

Principally, the trigeminal nerve serves to provide facial sensations including touch, temperature, and pinprick of the face and anterior elements of the mouth. Vibratory sensations applied to the face likely reflect neck vibratory sensory function, which is seldom if ever absent on examination and thus cannot be discerned from facial sensation. Joint position sense may only be evident in the jaw and rarely if ever demonstrably found.

As is the case for sensory testing within the torso and limbs, the goal of the sensory examination is to identify the modality of sensory deficit and thus the potential tracts and nerve fiber types involved against the pattern of sensory deficits identified on examination (Fig. 4.7). Patterns include laterality and segmentation in the face. Palpating the face (as well as within the mouth) can be useful in trying to identify trigger points in patients with suspected trigeminal neuralgia.

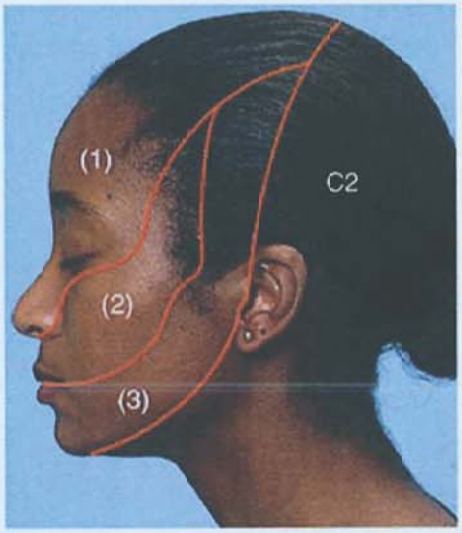

FIGURE 4.7 Dermatomes of the face and head. *(1)*, *(2)*, and *(3)* correspond to divisions of the trigeminal nerve. (From Bickley L. *Bates' Guide to Physical Examination and History Taking*. 11th ed. Philadelphia, PA: Wolters Kluwer Health/Lippincott Williams & Wilkins; 2013.)

The fifth nerve also controls the muscles of mastication including the masseter and temporalis. Demonstrating weakness of these muscles may be identified through gross testing of the jaw opening and closure but rarely identified on examination outside of severe muscular weakness. Palpation of a tender temporomandibular joint or identifying crepitus may be useful in assessing a patient with headaches; this may be done by palpating the joint while the patient opens and closes the jaw.

Cranial Nerve VII (Facial Nerve)

The goal of testing the seventh nerve is to identify specific patterns of weakness, which may be evident at rest, volitional action, or through unintentional means such as laughter. Start with simple inspection of the face, including critical appraisal during the interview. Flattened nasolabial folds will be extinguished by forced movements but may reveal low tone as a presenting sign in acute ischemic stroke or even Bell palsy. Thereafter, turn to specific movements to demonstrate either segmental or unilateral weakness of the face. Specific facial movements that should be tested include brow raising, forced eye closure including assessment of "burying the eyelashes," smiling, pursing the lips, and puffing the cheeks, to determine an upper versus lower motor neuron abnormality and thereafter which branches of the lower cranial motor nerve may be involved. Although patients may be able to demonstrate these functions on their own, assessment of force can be made by the examiner by pulling on any of the muscles being tested one side against the other.

Testing for unilateral loss of taste perception may be helpful in assessing the localization of a Bell palsy. To test for taste, take a commonly perceived recognizable flavor, such as salt or sugar, which are also conveniently typically on hand in most physician office practices or hospital-based settings. Place a small amount of this into a small cup with water and stir with a cotton-tipped applicator. With the patient's eyes closed and tongue protruded, attempt to paint the salty or sweet solution on the side of suspected facial paresis (affected and presumed ageusic side). The patient should be instructed not to draw his or her tongue into the mouth until asked whether or not he or she can taste the applied mixture. Upon demonstration or confirmation that no taste is perceived, the patient is then allowed to draw the tongue into the mouth and swirl around the fluid, and presumably, the taste will be perceived by the normal, contralateral side of the tongue.

FIGURE 4.8 Weber hearing testing for lateralization of hearing. (From Bickley L. *Bates' Guide to Physical Examination and History Taking*. 11th ed. Philadelphia, PA: Wolters Kluwer Health/Lippincott Williams & Wilkins; 2013.)

Cranial Nerve VIII (Vestibulocochlear Nerve)

The bedside examination of the cranial nerve VIII typically focuses on hearing but may include additional testing for the patient complaining of dizziness. Testing for hearing includes relatively crude screening measures to be done at the bedside beginning with perceptions of hearing grossly as simply assessed through the interview by the examiner's vocal volume required. Additional tests include using the 512 Hz (or similarly high tone) tuning fork for the Weber test for lateralized hearing loss (Fig. 4.8) and the Rinne test to identify the typical perception of air conduction being longer than bone conduction of sound (Fig. 4.9).

Additional crude hearing tests include whispering a number into the patient's ear to be then repeated by the patient, or audible hand movements including lightly rubbing the fingertips,

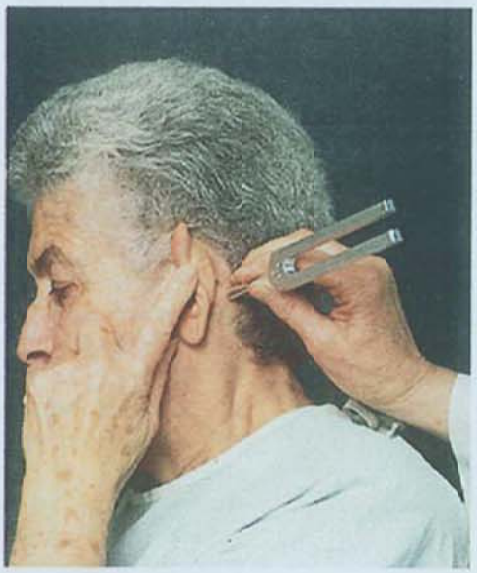

A

B

FIGURE 4.9 Rinne hearing testing for air > bone conduction. **A:** Bone conduction; once sound extinguishes. **B:** Air conduction is tested. (From Bickley L. *Bates' Guide to Physical Examination and History Taking*. 11th ed. Philadelphia, PA: Wolters Kluwer Health/Lippincott Williams & Wilkins; 2013.)

escalating to flicking the fingernail, and then snapping. Clearly, such testing cannot supplant more formal audiography. For the severely hearing impaired, history development and examination may be aided by placing the stethoscope earbuds into the patient's ears, with the examiner speaking into the diaphragm.

Vestibular testing in the dizzy patient should focus on attempting to identify central versus peripheral localizations of vertigo. Specific tests to apply to any such patient include the Dix-Hallpike maneuver and the head impulse nystagmus test (discussed later in this chapter and additionally in Chapter 5). An additional test, the Fukuda marching test, performed by having a patient march in place with eyes closed, can demonstrate a rotating station and evidence of a hypofunctioning vestibular apparatus on the side to which the patient turns. These tests in combination can help localization in disorders of dizziness and vertigo.

The Lower Cranial Nerves Involved in Speech (IX [Glossopharyngeal Nerve], X [Vagus Nerve], and XII [Hypoglossal Nerve])

Speech, or the articulation of language, can be very helpful in localizing a neurologic disorder. Table 4.3 reviews phonemes of speech and typical neurologic localization. The patient should be asked to speak each of these phonemes with particular attention paid to whether a singular or grossly abnormal speech pattern is evident.

Additional testing includes asking the patient to open his or her mouth to assess symmetry in raising the palate (Fig. 4.10), assessment of phonation for vagal nerve abnormalities, and protrusion of the tongue in one direction or another to suggest hypoglossal dysfunction.

Of note, a patient with a seventh nerve paresis may give the false impression of having an ipsilateral hypoglossal dysfunction simply because of the formation of the shape of the mouth. Thus, in patients with facial nerve weakness having tongue protrusion tested, the examiner should begin by forcibly opening the mouth in a symmetric fashion such that the tongue is allowed to exit the mouth in an unobstructed manner.

Cranial Nerve XI (Accessory Nerve)

The spinal accessory nerve has two principal functions including shoulder shrug by the trapezius muscle and head turning by the sternocleidomastoid muscles. Forcibly testing each of these movements may be of lower yield than simply observing shoulder shrug, which may demonstrate either low tone or slow or clumsy movement in a patient presenting with hemiparesis. Although frequently tested and included in neurologic examinations, head turning and shoulder shrug may only rarely be focally affected and thus infrequently provides additional information to the examination above and beyond the history and other findings on examination.

TABLE 4.3 Phonemes Tested for Patterns of Dysarthria

Phoneme	Neurologic Localization
Labial sounds: "ma," "pa"	CN VII
Pharyngeal/guttural sounds: "ga" and "ka"	CN IX, X
Lingual sounds: "la," "ta"	CN XII
Bland dysarthria (all sounds similarly involved)	Corticobulbar tracts to subcortical
Additional Speech Patterns	
Scanning or "metronomic" speech	Cerebellar
Dysphonic (hoarse) voice	CN X

Abbreviation: CN, cranial nerve.

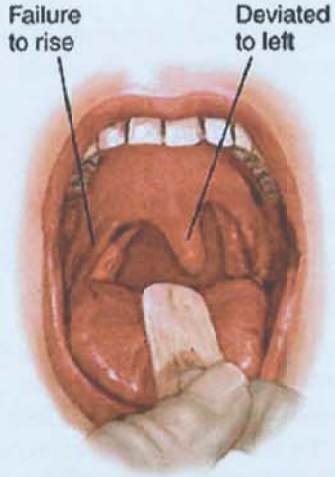

FIGURE 4.10 Examination of palate/uvula elevation to command. Weakness on the right leads to a deviation of the uvula to the left (unaffected side). (From Bickley L. *Bates' Guide to Physical Examination and History Taking*. 11th ed. Philadelphia, PA: Wolters Kluwer Health/Lippincott Williams & Wilkins; 2013.)

Motor Examination

The motor examination has several principal components, including inspection, palpation, tone, power, and drift testing and other tests for identifying subtle lateralized motor deficit.

Inspection is an essential element of the neurologic examination particularly for a patient being assessed for the first time. Relatively straightforward diagnoses are often missed by failing to place the patient into a gown. Inspection may identify focal or global patterns of atrophy, fasciculations, or rashes, which may be germane to muscular disorders. In determining the presence of fasciculations, it is often necessary to use a tangential light or observe subtle movements in the muscles affecting the overlying hair. Palpation of the muscles is indicated in a patient presenting with weakness or chronic pain, seeking to identify trigger points, but may be additionally helpful in other conditions, such as chronic low back pain in discerning musculoskeletal from neurogenic pain.

Observation and careful assessment of involuntary movements is also part of the motor examination. Tremor and involuntary movements may be identified on casual inspection or more formally during strength, tone, and coordination testing. Primary features of tremor include its relative frequency (fast vs slow), context in which it appears (with action [including specific actions if relevant], rest, posture, or multiple contexts), the consistency with which it appears during the examination (how frequently it is present), the severity of the tremor (ranging from mild to disabling), and the quality of the tremor itself (ranging from sinusoidal and monotonous to irregular and chaotic or myoclonic). Other more chaotic or less predictable movement disorders include ballism (rapid, wild, and chaotic movements), chorea (chaotic or unpredictable movements, which may give the appearance of fidgeting), athetosis (slow "snakelike" movements),

and myoclonus (rapid, brief jerks). Dystonia presents with activation of agonist and antagonist muscles and tends to present in fixed or slowly varying/moving positions, which may also be accompanied by tremor. In each involuntary movement, careful observation of regions of the body or limbs affected, intensity of movements, how often they are present during the encounter, and whether or not they are functionally debilitating, should be determined. A more in-depth description and assessment of various movement disorders is provided in Chapter 13.

Of all the components of the neurologic examination, muscle tone testing is one that requires particular attention to nuance and is learned principally through practice when working alongside a skilled examiner. Tone of the neck, arms, and legs should be assessed in all patients. Tone testing begins by the examiner moving a limb through several planes of motion simultaneously to prevent the patient from either contributing or diminishing tone in a volitional manner. Tone may be normal, increased, or decreased and may vary according to position and speed of limb movements. *Rigidity* refers to tone which is static or constantly present and to a similar degree throughout range of motion of a joint or limb. *Spasticity* refers to tone which is not constant and instead is velocity dependent; spasticity is notable for a sudden release of tension when a limb is moved quickly and/or at extremes of joint flexion/extension. In contrast, *paratonia* refers to tone which is also velocity dependent but predictably increases with increased speed of movement and decreases at lower speeds. Paratonia may also be referred to as *gegenhalten* ("holding against"). Tone may be decreased in peripheral neurologic and cerebellar disorders, as well as in acute stroke. To facilitate tone (or draw out subtle features), the patient should be instructed to perform distracting tasks, such as contralateral movements, or even a complex arithmetic question, simply to further diminish the influence of volitional control of tone.

Motor strength examination, or power testing, is among other essential elements of the motor examination. In each patient, power testing must be considered in the context of other principal motor components. The score to evaluate all motor examination findings (0-5) has been modified over time and may be idiosyncratically applied by differing examiners. The scale often leaves the neurologist to adjust findings using subtleties in the scale such as +/− symbols rather than just relying on numbers as the scale suggests. The definitions of each strength value are listed in **Table 4.4**.

TABLE 4.4 Medical Research Council Strength Assessment Scale

Strength Rating	Description
5	Full power to confrontational testing by the examiner (normal)
4	The examiner is able to overcome the strength of the patient but near full strength remains.
3	Sufficient strength to overcome gravity only
2	Flexion possible when out of the plane of gravity
1	Demonstration of muscle contraction but without any demonstrable joint movement
0	No appreciable movement

It is important to test a single muscle side to side rather than testing an entire side of the patient followed by a comparison of the strength in entire opposite side. A direct comparison of each muscle or joint side to side allows for a far more instructive examination and allows subtle asymmetries to be revealed. Correct positioning of the patient and examiner is also important to accurately interpret strength. Whenever possible, the examiner's body position should mimic the patient. Muscles being tested for strength should always be at mid position (**Fig. 4.11**) because at extremes of the joint position may convey inaccurate perception of superb strength or frank weakness. Other references are suggested as an additional guideline for testing each muscle group in a comprehensive manner, which is beyond the scope of this review.

Drift testing is an essential component of the motor examination because of its ability to detect subtle hemiparesis. *Pronator drift testing* is accomplished by having a patient either sitting or lying in bed, with hands outstretched before the patient, palms

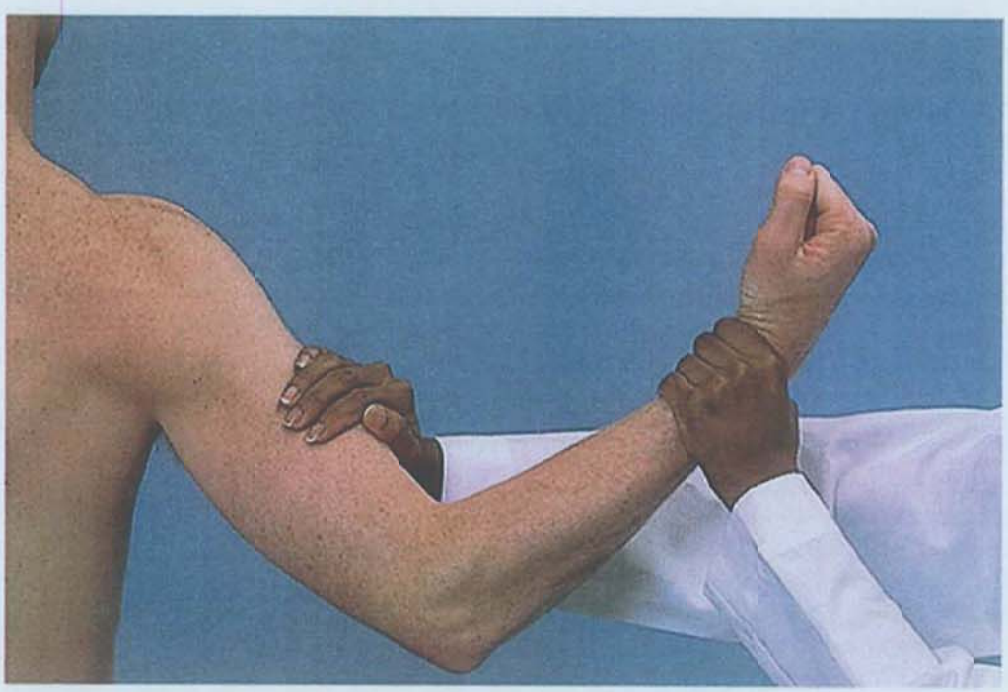

FIGURE 4.11 Testing strength. The example of biceps brachialis strength testing is provided to demonstrate the importance of (1) isolation of the muscle being tested, (2) testing force at mid position, and (3) the examiner's own arm similarly positioned to the patient. (From Bickley L. *Bates' Guide to Physical Examination and History Taking*. 11th ed. Philadelphia, PA: Wolters Kluwer Health/Lippincott Williams & Wilkins; 2013.)

facing upward. With eyes closed for approximately 10 seconds, the patient's hand position should remain static. Ordinarily, a patient should be able to maintain this forced anatomic position, rather than a relaxed or natural pronated position. During testing for pronation, an altitudinal drift may be apparent such that the hand does not pronate but moves in either an upward or downward or even a variable vertical direction. Drift testing in the foot involves bringing the leg off the bed and an approximate 30° angle and with the patient's eyes closed, maintaining that position for approximately 10 seconds. Any drift including a drop of the leg back onto the bed suggests a positive finding. Other tests that can be used to detect or confirm the presence of a subtle lateralized motor deficit include the arm roll test (in which the unaffected arm tends to "orbit" the affected, less mobile arm) and various finger tapping techniques (with velocity, dexterity, and amplitude of the finger or toe taps reduced on the affected side).

Additional components of the strength examination may also include an assessment of fatigability as may be seen with myasthenia gravis or facilitation as may be seen with the Lambert-Eaton myasthenic syndrome. Fatigability may be assessed by having a patient hold up his or her arms aloft for approximately 30 seconds and assess for fatigability when myasthenia is suspected. In contrast, facilitation may be elicited by having a patient's strength tested before and after sustained contraction (eg, sustained biceps contraction).

Coordination

The coordination examination is used to principally identify abnormalities grossly associated with ataxia and cerebellar dysfunction. Cerebellar examination techniques include assessments of appendicular and axial functions. Appendicular coordination may be demonstrated by asking the patient to extend a pointed index finger to a target provided as far away from the patient as possible, followed by touching a near target such as the nose or chin (preferable for an obviously ataxic patient given the risk for eye injury). More challenging tasks include a finger chase task, in which the patient's index finger follows as closely as possible to an examiner's brief movements with varying speed and distance. These tasks may draw out subtle corrective movements and overshooting the target. Axial coordination may be assessed using a heel-to-shin test, in which the patient places the heel of one foot against the shin of the opposite leg, with it moved vertically several times. Tests of coordination additionally include rapid movements such as finger taps (or more finely demonstrated as an index finger tapping on the thumb interphalangeal joint), rapid alternating movements (flipping the hand over, opening/closing the hand), and heel/toe tapping. These tasks are also essential in patients with suspected movement disorders. Additional coordination testing is comprised within the gait examination listed in the following section.

Gait, Station, and Body Movements

Observation of a patient's gait and station may not only be the first and importantly impressionistic examination done in the course of a visit as the patient enters from the waiting room but also the last done as part of a formal examination. Assessing primary station, or stance, is assessed without instruction and involves assessment of width of the feet and posture while spontaneously standing. Asking the patient to narrow the station, by placing the feet together, is the first step in assessing for imbalance and axial ataxia. The Romberg test is performed by having the patient stand feet together, arms outstretched, followed by eye closure once the examiner is able to determine no postural sway, which could be due to other causes such as cerebellar disease. Once eyes are closed, a tendency to sway or fall is indicative of either a defect in vestibular or proprioceptive function. Additionally, ability to maintain balance in blinded tandem station, forward and reverse tandem gait, and on a single foot have become part of standardized office-based postconcussion assessments. However, without baseline assessments, understanding normal findings for some of these and other tests of balance can prove difficult, especially in aging populations.

The gait assessment begins with watching casual gait, assessing for stride length and speed, and lateralizing findings such as a shoulder droop, asymmetric arm swing, or leg circumduction, followed by tandem gait. Specific patterns in gait may be revealed, including steppage gait (excessively flexing the hips to overcome foot drop), or a "waddling" gait (suggesting proximal leg weakness) is further described in Chapter 15. Special attention should also be given to ability to stand, quality of turns (en bloc or with appropriate, distinct steps), and passage through thresholds (doorways). The pull test, which evaluates postural stability, is performed by having the examiner stand behind the patient pulling suddenly backward on the shoulders. In a normal response, the patient makes a quick corrective step to maintain balance. An abnormal response is characteristic of parkinsonism and other diseases that affect postural stability. Toe walking assesses gastrocnemius strength as much as it does test balance, although this may be distinguished when the examiner offers a steadying hand.

Deep Tendon and Other Reflexes

As is the case for motor examination, several essential elements allow for accurate interpretation of the deep tendon reflexes. These include correct positioning of the patient and assessing reflexes for subtle asymmetry. Most neurologists have a favorite type of hammer, one that is ideally of sufficient mass to allow for a low-velocity strike to consistently test the deep tendon reflex, as opposed to a low-mass hammer requiring a high-velocity strike, and which may be more likely to injure the examiner or patient than elicit the actual response intended.

As is the case for muscle testing, other resources are suggested to identify the optimal locations in which to strike the tendon of each respective deep tendon reflex, but several principal ones are provided in Table 4.5.

Reflex testing should include biceps brachialis, brachioradialis, triceps, patellar, crossed adduction in the legs, and ankle jerks on all newly assessed patients, and recorded using a standard scale (Table 4.6). Finger flexion, thumb flexion (Hoffman reflex), and plantar scratch response ("Babinski sign" when positive) should be routinely assessed. Additional tests of the tendon reflex including jaw, shoulder, abdominal scratch, and deep abdominal reflexes may be relevant and pursued in the appropriate context.

Direct Muscle Percussion

Direct muscle percussion elicits a contraction response, which is thought to characterize the shortening of fascicles. It is most easily seen when directly striking the opponens pollicis, eliciting thumb flexion, but can be identified visually in other large muscle bodies including the biceps and gastrocnemius. The muscle

TABLE 4.5 Deep Tendon and Other Motor Reflexes[a]

Deep Tendon Reflexes		
Biceps brachialis		C5-C6
Brachioradialis	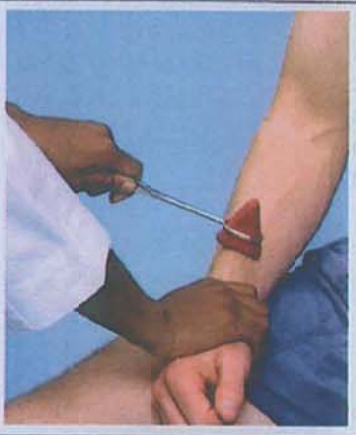	C5-C6
Triceps		C6-C7

Deep Tendon Reflexes *(continued)*		
Patellar		L2-L4
Ankle (Achilles)		S1
Cutaneous Stimulation Reflexes		
Upper abdominal reflexes		T8-T10
Lower abdominal reflexes		T10-T12
Plantar scratch		L5-S1
Anal		S2-S4

[a]Images from Bickley L. *Bates' Guide to Physical Examination and History Taking*. 11th ed. Philadelphia, PA: Wolters Kluwer Health/Lippincott Williams & Wilkins; 2013.

percussion reflex may help localize lower motor neuron disorders and will be abnormal in tetany (increased) and myotonic conditions (increased and/or sustained response with slow relaxation phase). In upper motor neuron disorders, both the deep tendon and muscle percussion reflexes are increased. In primary myopathies, both are decreased. In lower motor neuron disorders, deep tendon reflexes will be decreased, whereas muscle percussion reflexes will often elicit a contraction. Muscle percussion contraction responses may be decreased in severe, chronic neuropathic disorders with neurogenic atrophy (eg, Charcot-Marie-Tooth, and may be preserved or unchanged in myositis.

Frontal release signs, including snout (induced by tapping over the philtrum), glabellar (Myerson sign, blinking induced by tapping over the glabella and out of the patient's view), and palmomental signs (mentalis muscle movement induced by scratching the thenar eminence of the palmar surface), are commonly included in neurologic examinations but are of questionable sensitivity and specificity. Other frontal release signs include a snout and suck responses (when the inner lips or nasolabial fold are touched or stroked) as well as a grasp response (typically referring to the hand, grasping with objects or hands briefly placed in the palm, can be seen in the toes and mouth). These are not true reflexes but are instead thought to represent loss of normal cortical circuitry, which ordinarily inhibits these "primitive" adaptive responses and can be seen in a host of neurologic disorders including stroke, trauma, and degenerative disease.

Sensory Examination

Similar to guidance provided in trigeminal nerve assessment, the approach of these sensory examination is intended to identify the nerve fiber type and tract involved, as based on the tested modality. Identifying patterns of deficit are a principal goal of

TABLE 4.6 Deep Tendon Reflex Assessment Scale

4	Pathologic; with sustained clonus elicited and typically light percussion to elicit brisk reflexes
3	Usually pathologic; several beats of clonus or spread to adjacent ipsilateral muscle group or same group tested contralaterally are evident
2	Normal reflex; may have a brisk upstroke but without pathologic features
1	Hyporeflexic; contraction of the muscle as expected but insufficient force to move the joint
0	Hyporeflexic; no movement of the muscle or joint

sensory examination, including laterality, dermatomal distribution (both radicular and peripheral dermatomal patterns), possible spinal level, and determination of a distal or proximal pattern of abnormality (Fig. 4.12). Each domain should be assessed with these in mind.

Essential components of the sensory examination include assessment of light touch (using a cotton-tipped applicator or fine gauze), pinprick (using disposable implement such as a safety pin or a broken wood handle of a cotton-tipped applicator), temperature (actually heat conduction of a metal damper on a low-frequency tuning fork), vibratory sensation, and joint position sense.

One of the great challenges of the sensory examination is determining objective measures within a largely subjective examination. Of all of the modalities included, only joint position sense is truly objective nature. Patients either do not perceive (totally anesthetic), occasionally misperceive (partially anesthetic patient), or exactly misperceive (somatoform presentation) the stimulus.

Light touch, pinprick, and temperature sensations are all assessed in a relatively similar manner by asking the patient to indicate perception or intensity of the intended stimulus. An appropriate reference point may be to provide the stimulus to the cheek (for light touch, temperature, and pinprick sensation) or finger (for vibration), followed by the area being tested and

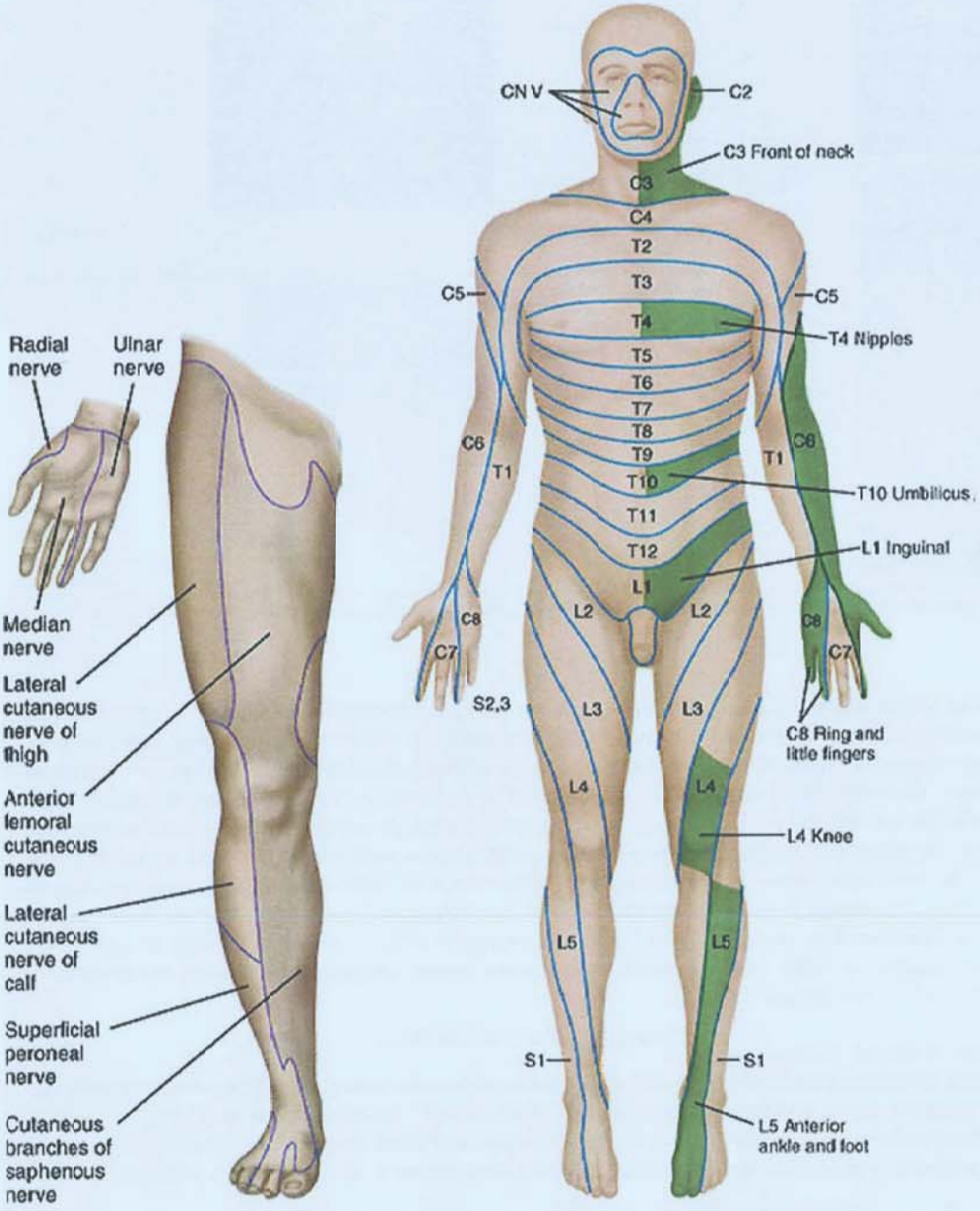

FIGURE 4.12 Dermatome maps. (From Bickley L. *Bates' Guide to Physical Examination and History Taking*. 11th ed. Philadelphia, PA: Wolters Kluwer Health/Lippincott Williams & Wilkins; 2013.)

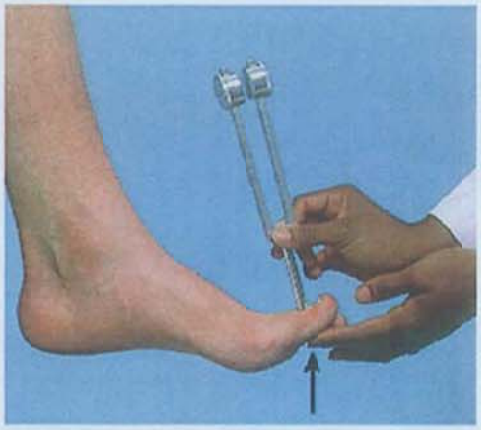

FIGURE 4.13 Vibration sensation testing. (From Bickley L. *Bates' Guide to Physical Examination and History Taking*. 11th ed. Philadelphia, PA: Wolters Kluwer Health/Lippincott Williams & Wilkins; 2013.)

FIGURE 4.14 Joint position sense testing. (From Bickley L. *Bates' Guide to Physical Examination and History Taking*. 11th ed. Philadelphia, PA: Wolters Kluwer Health/Lippincott Williams & Wilkins; 2013.)

asking the patient to assess whether they are equivalent. Although percentages of difference may be appropriate to determine the nature deficit, other familiar analogies may be more understandable, such as considerations of money ($1.00 versus 10 ¢ in lieu of percentages).

Vibration sense is crudely assessed by using a 128-Hz tuning fork struck and then with its base applied to the distal most bony prominence available on a patient's limb, such as the interphalangeal joint of the great toe or the tip of the finger (**Fig. 4.13**). The patient is then asked to assess the presence and persistence of the vibratory stimulus until it is no longer perceived, at which time it may then be applied to the more proximal limb, such as moving from the toes to the finger and asking if the stimulus is still perceived. Two control conditions are established—one within the patient as well as the examiner presuming vibratory sensory function is normal in the examiner.

Joint position sense is performed by having the examiner touch the lateral aspects of the distal interphalangeal joint and asking the patient to close his or her eyes (**Fig. 4.14**). Using the smallest excursion possible, the patient is asked to perceive the movement (either upward or downward direction). The examiner should be careful to record the responses in a patient incorrectly identifying the position change, as consistently wrong answers may suggest a feigned response. As is the case with vibratory sensory testing, assessment of the patient's sensation should begin with the most distal position and then moved proximally.

Higher order cognitive sensory testing should be included in patients with suspected cognitive impairment but can only be fully interpreted when performed in limbs/hand unaffected by primary sensory loss. These tests are myriad but commonly include assessment of graphesthesia (by drawing a number or letter on a patient's palm while eyes are closed; several training trials may be required), stereognosis (placing a single or similar objects within the palm of the patient such as paperclip/key or various familiar coins), and assessment of perception of simultaneously applied bilateral stimuli (by touching both hands after assessment of primary sensory function).

Additional Neurologic Tests for Special Conditions

Dix-Hallpike Maneuver

The Dix-Hallpike maneuver can be useful in a patient with suspected benign paroxysmal positional vertigo (BPPV; or a similar vertiginous syndrome) who is actively or very recently affected. It is often positive in patients with posterior semicircular canal BPPV, which is the semicircular canal implicated in the majority of BPPV presentations. Patients in a quiescent period will most likely be asymptomatic and have no demonstrable signs on examination. As demonstrated in the Figure 4.15, the patient begins

FIGURE 4.15 Dix-Hallpike maneuver. *1* and *2* correspond to the first and second positions of the maneuver. (From Fife TD, Iverson DJ, Lempert T, et al. Practice parameter: therapies for benign paroxysmal positional vertigo [an evidence-based review]: report of the Quality Standards Subcommittee of the American Academy of Neurology. *Neurology*. 2008;70[22]:2067-2074.)

FIGURE 4.16 Head impulse test. **A-C:** With the patient fixated on a distant target, the examiner rapidly turns the head from 15° to the right to 15° to the left, with normally maintained fixation demonstrated. Testing in the opposite direction, **D-F** illustrate a right peripheral vestibular lesion with a severe loss of right lateral semicircular canal function and no vestibulo-ocular reflex as demonstrated by loss of fixation **(E)** followed by a voluntary corrective saccade **(F)**. (From Halmagyi GM, Cremer PD. Assessment and treatment of dizziness. *J Neurol Neurosurg Psychiatry*. 2000;68[2]:129-134.)

seated with the head turned about 45 degrees in a single direction. The patient is then positioned supine with the head slightly extended (either hanging off the examination table or supported by the examiner's arm beneath the shoulder). With the patient's eyes open, looking at the examiner's face, the expected positive test will reveal a 5- to 10-second delay in onset of rotatory nystagmus and recapitulation of symptoms. These should resolve after 10 to 30 seconds. A brief vertical nystagmus phase may occur upon sitting. In most cases, the finding should be unilateral and serves as the first step of the Epley maneuver (see Chapter 5).

The Head Impulse Test

A relatively new bedside diagnostic test may be better at identifying some brainstem strokes than diffusion-weighted imaging. One component of the head impulse–nystagmus test of skew is the head impulse test. The test can only be applied and appropriately interpreted in a patient acutely symptomatic with vertigo or a suspected related disorder (ie, cerebellar dysfunction). As demonstrated in the Figure 4.16, the examiner rotates the patient's head about 30° off mid position. With the patient's gaze fixated on the examiner's face, the head is rapidly rotated to mid position. If a catch-up saccade is repeatedly identified, particularly unilaterally, a peripheral vestibular etiology is suggested but must be interpreted in the context of other neurologic examination findings because ischemic vestibular mimics do occur.

Phalen and Tinel Signs

When considering the diagnosis of carpal tunnel syndrome, in addition to inspection of the hand and assessment of weakness of the opponens pollicis, two additional tests can be helpful. The Tinel sign (Fig. 4.17A) involves percussing the course of the median nerve across the wrist, whereas the Phalen sign (Fig. 4.17B) involves keeping a sustained position of flexed wrists. Both the Phalen and Tinel signs seek to recapitulate the patient's specific neurologic syndrome and not simply discomfort.

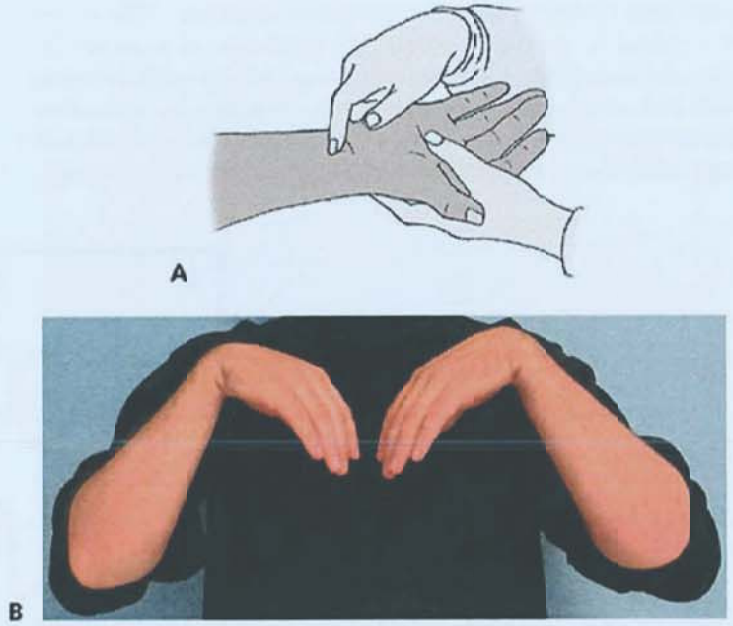

FIGURE 4.17 **A: Tinel sign.** (From Bickley L. *Bates' Guide to Physical Examination and History Taking*. 11th ed. Philadelphia, PA: Wolters Kluwer Health/Lippincott Williams & Wilkins; 2013.) **B: Phalen sign.** (Courtesy of James M. Noble, MD.)

FIGURE 4.18 Straight leg raise test. (From Bickley L. *Bates' Guide to Physical Examination and History Taking*. 11th ed. Philadelphia, PA: Wolters Kluwer Health/Lippincott Williams & Wilkins; 2013.)

A Tinel sign can also be identified anywhere a suspected focal neural compression may have occurred, such as across the olecranon or the fibular head.

Straight Leg Raise

The straight leg raise test is used in the context of diagnosing sciatica. As demonstrated in the Figure 4.18 with the patient lying down, the heel of the ipsilateral (affected) leg is raised straight off the bed by the examiner to about 30° to 45°; at its conclusion, the toe may be passively dorsiflexed.

A contralateral (crossed) straight leg raise test may be applied to the opposite leg, only if the affected leg has a positive finding; the contralateral test seeks to recapitulate the affected leg symptoms, still on the affected side. To be considered a positive sign, the patient should report the specific pain (typically lancinating) syndrome, which led to the patient to seek attention. The ipsilateral test is highly sensitive but weakly specific, whereas the contralateral test is highly specific but weakly sensitive.

Additional Spinal Reflexes (Male Patients Only)

The Cremasteric Reflex

The cremasteric reflex tests for the L1-L2 reflex arc and may be considered as a localizing test finding when considering a patient with a lower spinal cord neurologic disorder or as confirmatory reflex examination in patients exhibiting evidence of reflex abnormalities in ipsilateral limb muscle groups. The response will be absent in both central and peripheral neurologic disorders. It is performed by lightly stroking a slightly noxious tactile stimulus proximally along the inner aspect of the thigh (suggest a disposable item such as tongue depressor or hard end of a wooden swab stick). The testicle will normally rise ipsilaterally in conjunction with the applied scratch.

Bulbocavernosus Reflex

The bulbocavernosus should be applied specifically to individuals suspected of experiencing acute spinal cord injury. The test involves two potential stimuli: (1) squeezing on the glans penis or clitoris or (2) gently tugging on a Foley catheter while monitoring for anal sphincter contraction; this can be done electrophysiologically or manually. The response will be lost in acute spinal shock.

As is the case with any potentially sensitive element of physical examination, but particularly with these tests, given their involvement of examination of genitalia, inclusion of an examination chaperone, particularly one of the same gender as the patient, should be included in all such examinations.

Anal sphincter Tone

A digital examination of anal sphincter tone is an important component of a complete neurologic examination, particularly in a patient presenting with a spinal cord syndrome. Using a single-gloved, lubricated finger, and with adequate patient preparation and instruction, insert the finger to the anus such that spontaneous tone can be determined. If low tone is identified, instruct the volitionally squeeze the anus on the finger.

Tests of Malingering

Myriad tests have been proposed to potentially identify patients with embellished, feigned, or malingered signs. Of those, which have been studied to identify their sensitivity and specificity, most are imperfect. However, as detailed earlier, when findings are identified in the context of others on the neurologic examination, some of these additional tests can be useful in the appropriate context. Whenever considering applying these tests, it is most important to do so tactfully because both the act of applying and interpreting the findings takes a very skilled and advanced examiner to both appropriately perform and inform the patient of the findings with appropriate sensitivity and respect for the patient. Although some may consider these examination components potentially deceitful of the patient, they can be highly instructive, potentially avoid substantial evaluative cost and even morbidity (particularly when they may obviate invasive, unnecessary, or misleading diagnostic measures), and when appropriately disclosed, potentially highly therapeutic. The following are several techniques that can be particularly useful on examination.

Hoover Sign

This test is used to identify feigned unilateral leg weakness. Following assessment of the normal leg, with the patient lying down supine, the examiner places a hand beneath the heel of the normal leg and asks the patient to raise the opposite (presumed weak) leg. Normally, a patient attempting to raise the affected leg should depress the normal leg toward the examination surface, with the force felt by the examiner. Caution in its interpretation should be raised in the patient with evidence of dyspraxia, delayed responses, or possible paraparesis/quadriparesis.

Head Vibratory Hemianesthesia

Patients with psychogenic examinations may have hemianesthesia affecting the entire body including the face, often to all modalities tested. Vibratory sensation in the head is likely, principally or at least partially, perceived by transmitted signal to the neck and to a lesser extent the head. Several methods to identify feigned from true facial hemianesthesia using vibratory sensation have been proposed. One approach involves, with the patient's eyes open, placing a 128-Hz tuning fork centrally above the brow, visible to the patient. While keeping the base position of the fork static, tilt the fork toward the affected (anesthetic) side followed by a tilt to the normal side. Record the patient's responses. Repeat the measure, out of sequence, with the eyes closed to discern an examination discrepancy.

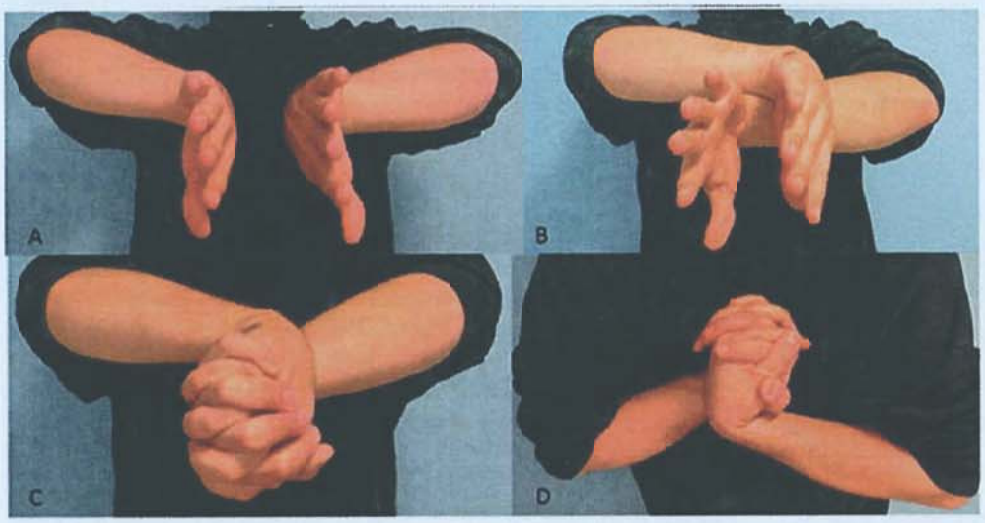

FIGURE 4.19 Bowlus and Currier test. Sequence of the Bowlus and Currier test, followed **A, B, C,** then **D.** Pinprick sensory testing is performed using a normal approach, comparing the left and right hand at baseline. When a nonphysiologic sensory examination is suspected, instruct the patient to position the hands in to that shown in **D.** Sensory testing is repeated quickly to identify discrepancies in examination. (Photos by James M. Noble, MD.)

Body Hemianesthesia

The Bowlus and Currier test (**Fig. 4.19**) can be a useful approach in distinguishing the patient with psychogenic hemianesthesia. As shown in the figures, the patient begins by pointing the thumbs down with the arms outstretched. Then, the right wrist is crossed over the left, and fingers are then interdigitated and flexed. Keeping the fingers locked together, the elbows are flexed, and the forearms supinated such that the hands are nearly at the patient's chin, thumbs pointing upward. Quickly thereafter, the examiner tests pinprick sensation on the knuckles of either hand, seeking not only for consistency but also for the rapidity with which the patient provides the answer. Substantial hesitation or inconsistency with primary sensory examination supports a feigned neurologic examination.

SUGGESTED READINGS

Abraham A, Alabdali M, Alsulaiman A, et al. The sensitivity and specificity of the neurological examination in polyneuropathy patients with clinical and electrophysiological correlations. *PLoS One*. 2017;12(3):e0171597.

Al Hussona M, Maher M, Chan D, et al. The virtual neurologic exam: instructional videos and guidance for the COVID-19 era. *Can J Neurol Sci*. 2020:1-6.

Awadallah M, Janssen F, Körber B, Breuer L, Scibor M, Handschu R. Telemedicine in general neurology: interrater reliability of clinical neurological examination via audio-visual telemedicine. *Eur Neurol*. 2018;80(5-6):289-294.

Bowlus WE, Currier RD. A test for hysterical hemianalgesia. *N Engl J Med*. 1963;269:1253-1254.

Brody IA, Rozear MP. Contraction response to muscle percussion. Physiology and clinical significance. *Arch Neurol*. 1970;23(3):259-265.

Buckley TA, Munkasy BA, Clouse BP. Sensitivity and specificity of the modified Balance Error Scoring System in concussed collegiate student athletes. *Clin J Sport Med*. 2018;28(2):174-176.

Burgess N, Maguire EA, O'Keefe J. The human hippocampus and spatial and episodic memory. *Neuron*. 2002;35(4):625-641.

Clements SD, Peters JE. Minimal brain dysfunctions in the school-age child. Diagnosis and treatment. *Arch Gen Psychiatry*. 1962;6:185-197.

Croskerry P. A universal model of diagnostic reasoning. *Acad Med*. 2009;84(8):1022-1028.

Dazzan P, Morgan KD, Chitnis X, et al. The structural brain correlates of neurological soft signs in healthy individuals. *Cereb Cortex*. 2006;16(8):1225-1231.

Devillé WL, van der Windt DA, Dzaferagi A, Bezemer PD, Bouter LM. The test of Lasègue: systematic review of the accuracy in diagnosing herniated discs. *Spine (Phila Pa 1976)*. 2000;25(9):1140-1147.

Dyck PJ, Boes CJ, Mulder D, et al. History of standard scoring, notation, and summation of neuromuscular signs. A current survey and recommendation. *J Peripher Nerv Syst*. 2005;10(2):158-173.

Ercan I, Ozdemir ST, Etoz A, et al. Facial asymmetry in young healthy subjects evaluated by statistical shape analysis. *J Anat*. 2008;213(6):663-669.

Fife TD, Iverson DJ, Lempert T, et al. Practice parameter: therapies for benign paroxysmal positional vertigo (an evidence-based review): report of the Quality Standards Subcommittee of the American Academy of Neurology. *Neurology*. 2008;70(22):2067-2074.

Gelb DJ, Gunderson CH, Henry KA, et al. The neurology clerkship core curriculum. *Neurology*. 2002;58(6):849-852.

Greer S, Chambliss L, Mackler L, Huber T. Clinical inquiries. What physical exam techniques are useful to detect malingering? *J Fam Pract*. 2005;54(8):719-722.

Halmagyi GM, Cremer PD. Assessment and treatment of dizziness. *J Neurol Neurosurg Psychiatry*. 2000;68(2):129-134.

Jarvik JG, Deyo RA. Diagnostic evaluation of low back pain with emphasis on imaging. *Ann Intern Med*. 2002;137(7):586-597.

Joseph T, Auger SD, Peress L, et al. Screening performance of abbreviated versions of the UPSIT smell test. *J Neurol*. 2019;266(8):1897-1906.

Kattah JC, Talkad AV, Wang DZ, Hsieh YH, Newman-Toker DE. HINTS to diagnose stroke in the acute vestibular syndrome: three-step bedside oculomotor examination more sensitive than early MRI diffusion-weighted imaging. *Stroke*. 2009;40(11):3504-3510.

Kerr NM, Chew SS, Eady EK, Gamble GD, Danesh-Meyer HV. Diagnostic accuracy of confrontation visual field tests. *Neurology*. 2010;74(15):1184-1190.

Liu CH, Hsu LL, Hsiao CT, et al. Core neurological examination items for neurology clerks: a modified Delphi study with a grass-roots approach. *PLoS One*. 2018;13(5):e0197463.

Monacelli AM, Cushman LA, Kavcic V, Duffy CJ. Spatial disorientation in Alzheimer's disease: the remembrance of things passed. *Neurology*. 2003;61(11):1491-1497.

Moore FG, Chalk C. The essential neurologic examination: what should medical students be taught? *Neurology*. 2009;72(23):2020-2023.

O'Brien M. *Aids to the Examination of the Peripheral Nervous System*. 5th ed. London, United Kingdom: Elsevier Health Sciences; 2010.

Oldham JR, Difabio MS, Kaminski TW, Dewolf RM, Howell DR, Buckley TA. Efficacy of tandem gait to identify impaired postural control after concussion. *Med Sci Sports Exerc*. 2018;50(6):1162-1168.

Phalen GS. The carpal-tunnel syndrome. Seventeen years' experience in diagnosis and treatment of six hundred fifty-four hands. *J Bone Joint Surg Am*. 1966;48(2):211-228.

Tinel J. The sign of "tingling" in lesions of the peripheral nerves. *Arch Neurol*. 1971;24:574-575. Originally published, in French, in: *La Presse Médicale*. 1915;23:388-389.

Dizziness, Vertigo, and Hearing Loss 5

J. Kirk Roberts

KEY POINTS

1. It is often more useful for diagnosing the cause of dizziness and vertigo to rely on associated characteristics such as triggers, duration, history of prior episodes, and associated symptoms than focusing on subjective features of the dizziness.
2. In a first attack of acute vertigo, the major diagnostic consideration is differentiating stroke from vestibular neuritis. Helpful factors include a history of vascular risk factors, HINTS testing (evaluation of head impulse test, nystagmus, and skew), and other neurologic symptoms or signs.
3. Posterior canal benign positional vertigo can be diagnosed in those with positional vertigo and a characteristic nystagmus on positioning and is often effectively treated with repositioning maneuvers.

INTRODUCTION

Dizziness is an imprecise term used to describe a variety of symptoms including but not limited to vertigo, light-headedness, faintness, giddiness, disequilibrium, confusion, etc. It affects nearly one-quarter of the general population and is a common complaint in the emergency room and in the office of the neurologist, otolaryngologist, and internist. The causes of dizziness are varied, span across medical subspecialties, and range from the relatively benign to life threatening. The evaluation of dizziness is made more difficult by the fact that the symptom is difficult for the patient to describe. A first step is an attempt to categorize dizziness into vertigo, presyncope, disequilibrium, and other or nonspecific dizziness as noted in Table 5.1.

Vertigo is an illusion of motion, either the environment or the self, most commonly rotatory but may be translational or tilting. *Presyncope* is the sensation encountered before loss of consciousness and is discussed in Chapter 6. *Dysequilibrium* is not a sensation of motion but a feeling of imbalance or unsteadiness and is discussed in Chapter 15. Other or nonspecific dizziness include those whose symptoms do not easily fit into one of the aforementioned categories or fall into more than one category. Rather than using the qualitative description of dizziness to categorize the subtype, it is often more helpful to use characteristics such as onset, duration, triggers, history of prior episodes, and associated symptoms in evaluating these patients.

VERTIGO

Neuroanatomy

Vertigo primarily results from disorders of the vestibular system, which includes the vestibular labyrinth, vestibular nerve, vestibular nuclei in the brainstem, vestibular portions of the cerebellum, connections between these structures, and only rarely higher in the cerebrum. The vestibular labyrinth, located in the temporal bones, is composed of the three orthogonally oriented semicircular canals (anterior, posterior, and lateral) and the vestibule, which contains the otolith organs, the utricle and saccule, which are also angled at approximately 90° to each other. The former responds to angular acceleration and the latter to linear acceleration including translation or tilt. When the head is rotated, endolymphatic fluid in the semicircular canals lags behind,

TABLE 5.1 Dizziness Subtypes

	Vertigo	Presyncope	Disequilibrium	Nonspecific Dizziness
Symptom description	Illusion of motion, imbalance	Going to pass out, faint	Imbalance, unsteady, symptoms not in the head	Light-headed, foggy, floating
Onset	Usually sudden	Usually sudden	Sudden to slow	Poorly defined
Duration	Seconds to hours	Seconds to minutes	Acute to chronic	Subacute to chronic
Triggers	Head motion, position change	Orthostatic maneuvers, urination, cough, dehydration	Standing or walking, not when sitting or lying	Stress, situational, nonspecific
History	None or episodes	None or episodes	Chronic	Chronic
Associated symptoms	Nausea, ear symptoms (hearing loss, tinnitus), brainstem symptoms (diplopia, slurring, numbness, weakness, incoordination, ataxia)	Graying vision, warmth, diaphoresis, nausea, palpitations, chest pain	Slurring, incoordination	Many

TABLE 5.2 Peripheral Versus Central Vertigo

	Peripheral	Central
Nausea/vomiting	Severe	Mild/moderate
Imbalance	Mild/moderate	Severe
Ear symptoms (hearing loss, tinnitus, pain)	Common	Rare
Other neurologic symptoms	Rare	Common

leading to a deflection of the gelatinous cupula within the canal, which activates or inhibits the firing of hair cells. Activation on one side is paired with inhibition in the complementary canal on the other. The otolith organs, the utricle and saccule, contain hair cells on which calcium carbonate crystals, the otoconia, rest. Translational motion or tilt (via gravity) will activate or inhibit these cells. From the vestibular labyrinth, neurons travel centrally through the vestibular portion of the eighth cranial nerve into the brainstem to the vestibular nuclei and then project on to the cerebellum, ocular motor nuclei, spinal cord, and, via some less well-understood pathways, to the cerebrum. Integration of the combinations of activations and inhibitions of the various components of the vestibular system of both ears, along with visual input and proprioceptive input, detects motion, rotation, translation, and tilt and affects eye movements and posture.

Vertigo can result from disorders of the peripheral vestibular system (labyrinth or nerve) or central vestibular system (brainstem, cerebellum, connections, and rarely, cerebrum), and this localization is the natural next step in the evaluation of vertigo. Table 5.2 lists some differentiating features.

Diagnosis

In the patient with the acute first presentation of vertigo, the most significant concern is evaluating for stroke (ischemic or hemorrhagic) and differentiating from vestibular neuritis. A history of vascular risk factors and other neurologic symptoms, headache, and complaints related to the brainstem is particularly important. However, the lack of those symptoms does not exclude an ischemic etiology. Patients presenting with isolated vertigo have a threefold increased risk of stroke compared to the general population that increases with the presence of multiple vascular risk factors. In the patient presenting with recurrent attacks of vertigo, the major differential includes benign positional paroxysmal vertigo (BPPV), Ménière syndrome, and migraines. Vertebral artery compression from neck rotation is a very rare case of episodic dizziness or vertigo.

Focused History

Loss of vestibular function affects eye movements and image stabilization, balance, and spatial orientation. In addition to vertigo, patients may feel tilted, the world jiggling while walking (oscillopsia), spatially disoriented, imbalanced, and, rarely, suffer from drop attacks, where they may feel pulled or pushed to the ground. These drop attacks, known as *Tumarkin crises*, are most commonly seen in Ménière syndrome but also may occur in other vestibular conditions.

Focused Examination

The examination of the patient with vertigo includes all components of the neurologic examination with special attention to

TABLE 5.3 Peripheral Versus Central Nystagmus

	Peripheral	Central
Appearance	Combined torsional, horizontal, and vertical Nystagmus beats away from the affected side.	Often pure vertical, horizontal, or torsional; any trajectory
Fixation	Inhibits	No effect
Gaze	Obeys Alexander law (Nystagmus increases when looking toward the side of the fast phase.)	May change direction; does not obey Alexander law

certain aspects. The ear must be examined and hearing must be tested. Examination of the eyes is particularly important. Start by observing for nystagmus in primary gaze and with eye movements in all directions. Reobserve after removing the ability to fixate by the use of Frenzel lenses, goggles with magnifying lenses that allow you to see eye movements but does not allow the patient to fixate. If Frenzel lenses are unavailable, fixation can be eliminated during ophthalmoscopic examination of one eye by covering the eye not being examined with your free hand and observing for nystagmus of the optic disc. Remember that this movement is in the opposite direction of the movement of the front of the eye. Pay attention to the type of motion (horizontal, vertical, torsional, mixed), the effect of fixation, and the effect of gaze. Pendular nystagmus is sinusoidal, whereas jerk nystagmus, the more commonly observed nystagmus, is composed of slow drift in one direction and a rapid correction back. It is caused by an imbalance in vestibular input, either peripheral or central. Characteristics of peripheral versus central jerk nystagmus are listed in Table 5.3. Jerk nystagmus is named for the direction of the fast phase and can be further categorized by its trajectory and the conditions under which it is seen. Some particular forms of nystagmus and their relevance are listed in Table 5.4.

In addition to nystagmus, unilateral peripheral vestibular dysfunction leads to a subtle skew deviation of vertical eye position with the ipsilateral eye lower in the orbit relative to the contralateral eye and conjugate torsion of the eyes to the ipsilateral side. In addition to the ocular motor findings, the patient usually has a small head roll or tilt to the affected side and a tendency to fall toward the same side. They may perceive vertical to be slightly tilted. Testing for past pointing will reveal deviation to the ipsilateral side. Tandem gait and Romberg test will be impaired but are not specific. The Fukuda step test, marching in place with the eyes closed, will show deviation toward the side of the vestibular lesion.

Head Impulse Test

The head thrust or head impulse test evaluates for loss of vestibular input from either the vestibular labyrinth or vestibular nerve to the vestibulo-ocular reflex. It is performed (Fig. 5.1) by asking the patient to focus on a target in front of him or her. The head is then rapidly rotated a small amount (approximately 15°). In normal circumstances, the eyes remain focused on the target. A vestibular lesion on the side to which the patient is being rotated will lead to a loss of fixation and the eyes will turn with the head and require a saccade to refixate. The input from the horizontal canal is most commonly tested by rotating the head in the horizontal plane. The other canals may also be tested by rotating the head

TABLE 5.4 Subtypes of Nystagmus

Jerk Nystagmus
Gaze-evoked: nystagmus at the extremes of gaze beating in the direction of gaze
Physiologic: fine nystagmus; usually fatigues **Drug/medication:** often seen with sedatives and anticonvulsants **Brainstem/cerebellar lesions:** may be sustained **Rebound nystagmus:** After looking eccentrically for approximately 1 min on return to primary gaze, there is nystagmus beating in the other direction associated with brainstem or cerebellar lesions. **Bruns nystagmus:** Slow, large-amplitude nystagmus in one direction and rapid, small-amplitude nystagmus in the other direction suggest a cerebellopontine angle lesion on the side of the slow, large-amplitude nystagmus.
Horizontal Nystagmus
Peripheral nystagmus: Nystagmus only beats in one direction, away from the affected side, obeys Alexander law, usually mixed with torsion, and inhibited by fixation. **Central nystagmus:** Nystagmus may change directions, may be purely horizontal, does not obey Alexander law, and not inhibited by fixation. **Periodic alternating nystagmus:** nystagmus alternating directions every 1-2 min associated with lesions at the cervicomedullary junction or in the cerebellum **Dissociated nystagmus:** nystagmus differing between the eyes seen with internuclear ophthalmoplegia or mimicked by myasthenia gravis
Downbeat nystagmus: Nystagmus usually increases on down and lateral gaze seen with involvement of the dorsal medulla or the cerebellar flocculus or projections associated with lesions at the cervicomedullary junction, medications (lithium, carbamazepine, phenytoin), alcohol, hypomagnesemia, thiamine deficiency, paraneoplastic syndromes, cerebellar degenerations, and other.
Upbeat nystagmus: associated with brainstem and cerebellar lesions, most commonly the medulla
Congenital nystagmus: often a mixture of jerk and pendular nystagmus
Convergence-retraction nystagmus: part of Parinaud dorsal midbrain syndrome; convergence and retraction of the eyes
Positional nystagmus: seen with specific head motions and is discussed more in the following text
Pendular Nystagmus
Acquired: seen with brainstem and cerebellar lesions
Congenital: often a mixture of jerk and pendular nystagmus
Spasmus nutans: infant onset; nystagmus is asymmetric and rapid, often associated with head nodding and head turning; usually resolves
Associated with visual loss
Seesaw nystagmus: opposite conjugate vertical and torsional movements associated with mesencephalic or parasellar lesions
Oculopalatal myoclonus: rhythmic 2-3-Hz movements seen late after lesion of Mollaret triangle
Oculomasticatory myorhythmia: rhythmic movements of eye convergence and contraction of masticatory or other muscles seen in 20% of patients with Whipple disease

along the plane of the canal in question. The head impulse test is generally normal in those with central causes of vertigo. In patients presenting with an acute vestibular syndrome, the use of the head impulse test along with the evaluation of nystagmus and the presence of skew (HINTS testing) can be used to distinguish an acute peripheral vestibular lesion from an acute central lesion such as cerebral infarct with more accuracy than magnetic resonance imaging (MRI). Dynamic visual acuity also evaluates this reflex. It is performed by testing vision while stationary and then while shaking the head at approximately 2 Hz. Most can read no more than two to four lines worse on the eye chart with normal function of at least one labyrinth.

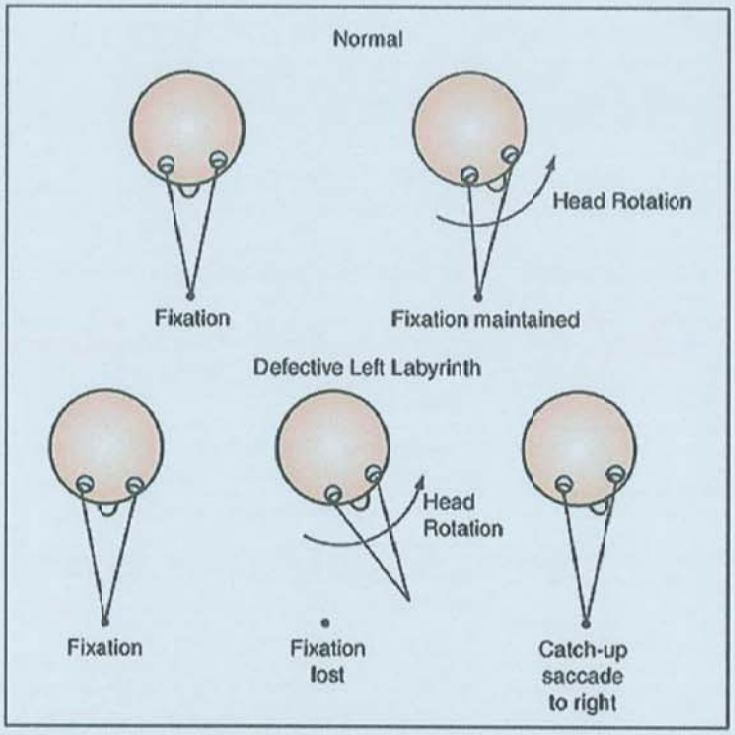

FIGURE 5.1 The head thrust test. (Modified from Barraclough K, Bronstein A. Vertigo. *BMJ*. 2009;339:b3493.)

Dix-Hallpike Maneuver

Positional maneuvers must also be performed to look for BPPV, and this is discussed in more detail in Chapter 60. In this condition, vertigo is precipitated by characteristic head motions due to otolith debris loose in the semicircular canals, most commonly the posterior canal. To evaluate, the Dix-Hallpike maneuver (see **Fig. 4.15**) is performed by having the patient sit with the head turned 45° to one side. The patient is then laid back into a supine position with the head extended 30° and is observed for nystagmus for at least 30 seconds. A positive test will result in symptoms of vertigo after a few seconds, lasting up to a minute, and the observer will see upbeating and rotatory nystagmus of the upper pole of the eye toward the ground. This response will fatigue with repeated maneuvers.

Less common horizontal canal BPPV might be revealed with horizontal nystagmus on Dix-Hallpike and is more reliably investigated with lateral head and body turns while supine. Anterior canal BPPV is quite rare. If the nystagmus is not characteristic for BPPV in terms of type, latency, and fatigability nystagmus, then a central lesion must be considered. BPPV is best treated with repositioning maneuvers designed to "roll" the otolith debris out of the affected canal.

Various causes along with characteristics of some of the causes of vertigo are listed in Tables 5.5 (peripheral) and 5.6 (central). More details may be found in other chapters.

TABLE 5.5 Causes of Peripheral Vertigo

Cause	Characteristics
BPPV	Brief, recurrent, positional nystagmus only in provoking position
Vestibular neuritis	Acute, single episode, viral prodrome
Ramsay Hunt syndrome (herpes zoster oticus)	Acute, single episode, vesicles in/near the ear, facial nerve palsy, deafness
Ménière syndrome	Recurrent, last minutes to hours, unilateral ear symptoms of fullness, hearing loss, tinnitus
Trauma	History of trauma
Perilymphatic fistula	Episodic, associated with Valsalva, loud sounds (Tullio phenomenon), history of trauma
Superior canal dehiscence	Episodic, associated with Valsalva, loud sounds
Cogan syndrome	Ménière-like syndrome with interstitial keratitis
Acoustic neuroma	Rare vertigo, more imbalance, unilateral hearing loss or tinnitus
Medications	Aminoglycoside exposure
Otitis	Evidence of otitis
Labyrinth ischemia	Presence of vascular risk factors, sudden vertigo, and hearing loss
Recurrent vestibulopathy	Recurrent attacks but without the ear symptoms to suggest Ménière syndrome

Abbreviation: BPPV, benign positional paroxysmal vertigo.

Diagnostic Testing

Diagnostic testing that is most useful in patients with vertigo includes comprehensive auditory examination to determine ear involvement especially with any complaints of hearing loss or tinnitus. Imaging is indicated when a central cause is under consideration and in other select cases. Computed tomography (CT) does not image the posterior fossa well and MRI is the imaging modality of choice. In the evaluation of superior canal dehiscence, CT better images the bony dehiscence that is the cause, although newer MRI techniques are being developed. Videonystagmography or electronystagmography is helpful if BPPV is considered, but nystagmus is not evident on clinical exam or if a unilateral vestibular lesion is suspected but not confirmed on clinical exam (see also Chapter 29). Rotational chair testing is also helpful in this circumstance and if bilateral vestibular dysfunction is suspected.

TABLE 5.6 Causes of Central Vertigo

Cause	Characteristics
Migraine-associated vertigo	Migraine history
Cerebral ischemia/hemorrhage	Vascular risk factors, other neurologic symptoms and signs, more prominent dysmetria or ataxia
Multiple sclerosis	History or presence of other neurologic symptoms or signs
Tumor	Presence of other neurologic symptoms or signs
Craniocervical junction abnormalities (Arnold-Chiari, basilar impression, etc)	Associated with headaches, neck pain, other lower cranial nerve involvement
Episodic ataxia type 2	Episodic vertigo and ataxia lasting hours to days
Cerebellar or spinocerebellar degenerations	More commonly ataxia and not vertigo
Mal de débarquement	After boat travel (or other), sensation of motion persists.

Treatment

The treatment of vertigo is primarily directed at the causes and is discussed in the appropriate chapters. Nonspecific treatments for attacks of vertigo, some off-label, include antihistamines, anticholinergics, benzodiazepines, and antiemetics for nausea and vomiting, and are listed in **Table 5.7**. Symptomatic medications should be stopped after severe symptoms remit. Vestibular rehabilitation is thought to benefit by promoting compensation, facilitating strategic substitution, limiting inactivity, and in the case of BPPV, repositioning otolith debris. There are some concerns that medications may interfere with rehabilitation.

TINNITUS

Tinnitus is the perception of sound in the head when there is no external sound present. Disability may range from none to severe. Subjective tinnitus is heard only by the patient, whereas objective tinnitus is also heard by the examiner. Tinnitus can be classified into pulsatile and nonpulsatile tinnitus, with pulsatile tinnitus usually indicating a vascular etiology. **Table 5.8** lists various causes of tinnitus.

Neuroanatomy

Most tinnitus is related to sensorineural hearing loss at the cochlear or cochlear nerve level and the tinnitus is thought to be generated in the central nervous system. Less commonly, tinnitus originates from structures in proximity to the ear, most commonly vascular structures.

Diagnosis

One should inquire about the quality of the sound, whether it is episodic or constant, whether it is pulsatile or nonpulsatile, and precipitating and alleviating factors. Pay particular attention to a history of ear disease or trauma, hearing loss, noise exposure, headaches, and conditions that predispose to atherosclerosis such as hypertension, hypercholesterolemia, diabetes mellitus, and smoking. Tinnitus that is pulsatile or humming and changes with exercise or head motion raises more concern for a vascular etiology.

Examination and Diagnostic Testing

The ear and surrounding structures must be inspected; hearing must be tested; and one should listen for bruits in the neck, over the skull, and over the eye. If a vascular etiology is suspected, further evaluation might include duplex Doppler, MRI without and with contrast, magnetic resonance angiography, CT angiography, and, in some cases, conventional angiography.

TABLE 5.7 Medications Used in the Treatment of Vertigo

	Medications	Adverse Effects
Antihistamines		
Meclizine	12.5-25 mg up to every 6 h as needed for vertigo	Drowsiness, blurred vision
Diphenhydramine	25-50 mg up to every 6 h as needed for vertigo	Drowsiness, confusion, restlessness, tachycardia, blurred vision, dryness of mucous membranes, thickened bronchial secretions, difficulty urinating, constipation
Dimenhydrinate	50-100 mg up to every 6 h as needed for vertigo or motion sickness	Drowsiness, restlessness, tachycardia, blurred vision, thickened bronchial secretions
Anticholinergics		
Scopolamine	One 1.5-mg transdermal patch every 72 h as needed for vertigo or motion sickness	Drowsiness, dizziness, confusion, agitation, blurred vision
Benzodiazepines		
Diazepam	1-5 mg up to every 8 h as needed for vertigo	Drowsiness, confusion, amnesia, tolerance, withdrawal
Lorazepam	1-2 mg up to every 8 h as needed for vertigo	Drowsiness, confusion, amnesia, tolerance, withdrawal
Alprazolam	0.25-0.5 mg up to every 6 h as needed for vertigo	Drowsiness, confusion, amnesia, tolerance, withdrawal
Clonazepam	0.25-0.5 mg up to every 8 h as needed for vertigo	Drowsiness, confusion, amnesia, tolerance, withdrawal
Antiemetics		
Prochlorperazine	5-10 mg orally up to every 6 h as needed; 25 mg rectally up to every 12 h as needed; for vertigo with nausea/vomiting	Hypotension, extrapyramidal symptoms
Metoclopramide	5-10 mg up to every 6 h as needed for vertigo with nausea/vomiting; do not use continuously for >12 wk.	Extrapyramidal symptoms including tardive dyskinesia
Ondansetron	4-mg up to every 8 h as needed for vertigo with nausea/vomiting	Constipation, dizziness, malaise, QT prolongation

Treatment

The treatment of tinnitus from vascular abnormalities or from other nonaudiologic abnormalities are usually treated by treating the underlying condition. Patients with tinnitus thought to be related to disorders of the auditory systems should be referred for complete audiologic evaluation (CAE) and otolaryngology consultation. Unfortunately, the success of treatment of this type of tinnitus is marginal. Hearing aids may benefit patients with presbycusis. Behavioral therapies may help. The success of masking devices producing low-level sounds and electrical stimulation are unproven. Medication trials have largely been disappointing.

TABLE 5.8 Causes of Tinnitus

Pulsatile Tinnitus
Arteriovenous malformations/arteriovenous fistulas
Vascular stenosis/turbulence
Paragangliomas
Increased intracranial pressure
Jugular dehiscence
Tensor tympani or stapedius muscle spasm or myoclonus
Palatal spasm or myoclonus
Eustachian tube dysfunction
Nonpulsatile Tinnitus
Sensorineural hearing loss (age, toxicity, noise exposure, etc)
Otosclerosis
Middle or inner ear trauma
Acoustic neuroma/cerebellopontine angle lesions
Temporomandibular joint dysfunction
Craniocervical junction and cervical spine disorders
Medications

HEARING LOSS

Hearing loss is common. It is typically categorized as conductive, usually from a problem in the outer or middle ear, sensorineural, usually from a problem in the inner ear or the along the eighth cranial nerve, or mixed. It can be unilateral or bilateral.

Diagnosis

The history should focus on the degree of hearing loss, time course, laterality, types of sounds affected, and precipitating factors, along with associated features such as tinnitus, vertigo, other cranial nerve abnormalities, headache, or other neurologic symptoms. Family history is important especially in those with onset at a younger age.

Outer and middle ear problems causing conductive hearing loss are listed in Table 5.9, whereas inner ear and problems along the eighth cranial nerve causing sensorineural hearing loss are listed in Table 4.10. Central nervous system causes of hearing loss are rare.

Sudden Hearing Loss

The patient with sudden sensorineural hearing loss, usually unilateral, over 1 to 3 days is a particular subcategory of hearing loss. The incidence is 5 to 27 per 100,000 people per year and is most common in the middle aged. The etiology in most cases is never identified. Autoimmune, inflammatory, infectious, and ischemic

TABLE 5.9 Causes of Conductive Hearing Loss
Outer Ear
Congenital
Cerumen
Infection
Trauma
Tumor (squamous cell carcinoma, basal cell carcinoma, melanoma, exostoses, osteoma, etc)
Foreign objects
Middle Ear
Congenital
Infection
Eustachian tube dysfunction
Tympanic membrane perforation
Otosclerosis
Trauma
Tumors (cholesteatoma, paraganglioma)

etiologies are postulated. Many report tinnitus, and some report vertigo. Urgent evaluation is warranted. A repeated history suggests Ménière or a chronic autoimmune condition. Neck pain might suggest vertebral artery dissection. The internal auditory artery is a branch of the anterior inferior cerebellar artery. Updated clinical practice guidelines are available. CAE should be performed. MRI or auditory brainstem response looking for retrocochlear pathology should be performed. Routine laboratory testing should not be performed unless clinically indicated. The use of oral glucocorticoids within 2 weeks of onset is an option and many do treat. Treatment with hyperbaric oxygen combined with steroid therapy is also an option for early treatment or for salvage therapy for those who have not responded. Salvage therapy with intratympanic steroids is recommended within 2 to 6 weeks following onset for those who have incomplete recovery. Antivirals are not routinely recommended. Prognosis is related to the severity of hearing loss at onset.

Examination

Examination must include visual inspection of the ear along with tests of hearing. Patients should be able to hear a finger rub or a whisper a few inches away from the ear. The Weber and Rinne tests provide additional information. The Weber test is performed by placing a 256-Hz tuning fork in the center of the forehead equidistant from both ears. A normal response is hearing the tuning fork similarly in both ears. A patient with a conductive hearing loss will hear the tuning fork louder in the affected ear, and a patient with sensorineural hearing loss will hear the tuning fork louder in the unaffected ear. The Rinne test is performed by placing a 512-Hz tuning fork on the mastoid bone behind the ear and asking when the sound is no longer heard. It is then moved to 1 to 2 inches from the external auditory canal. In a patient with normal hearing or sensorineural hearing loss, the sound will still be heard, as air conduction is better than bone conduction. In a patient with conductive hearing loss, bone conduction is better than air conduction. Further hearing testing includes a CAE with pure tone audiometry, speech reception thresholds and discrimination, impedance testing, and acoustic reflexes. Imaging with MRI and/or CT will depend on the clinical situation.

TABLE 5.10 Causes of Sensorineural Hearing Loss	
Congenital	Autoimmune/inflammatory
Presbycusis	Ischemic
Infection	Metabolic
Ménière syndrome	Ototoxic
Noise exposure	Structural
Trauma	

Treatment

The treatment of hearing loss is directed at the cause along with hearing amplification and cochlear implantation. The first step involves identifying appropriate candidates based on discussions about the patients' hearing difficulties and desires, the audiogram, and what hearing aids can offer. Many of those with significant hearing loss do not wear hearing aids for a variety of reasons including the financial cost, cosmetic issues, not understanding the degree of hearing loss, etc. Candidates for cochlear implants have moderate to severe hearing loss for whom hearing aids are not working well. Patients do not need to be totally deaf to be considered for cochlear implants.

SUGGESTED READINGS

Chandrasekhar SS, Tsai Do BS, Schwartz SR, et al. Clinical practice guideline: sudden hearing loss (update). *Otolaryngol Head Neck Surg*. 2019;161(suppl 1): S1-S45.

Halmagyi GM, Cremer PD. Assessment and treatment of dizziness. *J Neurol Neurosurg Psychiatry*. 2000;68:129-134.

Halmagyi GM, Curthoys IS. A clinical sign of canal paresis. *Arch Neurol*. 1988; 45(7):737-739.

Hillier SL, Hollohan V. Vestibular rehabilitation for unilateral peripheral vestibular dysfunction. *Cochrane Database Syst Rev*. 2007;(4):CD005397.

Kattah JC, Talkad AV, Wang DZ, Hsieh Y-H, Newman-Toker DE. HINTS to diagnose stroke in the acute vestibular syndrome: three-step bedside oculomotor examination more sensitive than early MRI diffusion-weighted imaging. *Stroke*. 2009;40(11):3504-3510.

Kim JS, Zee DS. Benign paroxysmal positional vertigo. *New Engl J Med*. 2014;370: 1138-1147.

Lee CC, Su Y-C, Ho HC, et al. Risk of stroke in patients hospitalized for isolated vertigo: a four-year follow-up study. *Stroke*. 2011;42:48-52.

Lee H, Yi H-A, Lee S-R, Ahn B-H, Park B-R. Drop attacks in elderly patients secondary to otologic causes with Meniere's syndrome or non-Meniere peripheral vestibulopathy. *J Neurol Sci*. 2005;232:71-76.

Neuhauser HK, Radtke A, von Brevern, Lezius F, Feldman M, Lempert T. Burden of dizziness and vertigo in the community. *Arch Intern Med*. 2008;168(19): 2118-2124.

Newman-Toker DE, Cannon LM, Stofferahn ME, Rothman RE, Hsieh Y-H, Zee DS. Imprecision in patient reports of dizziness symptom quality: a cross-sectional study conducted in an acute care setting. *Mayo Clin Proc*. 2007; 82(11):1329-1340.

Newman-Toker DE, Hsieh Y-H, Camargo CA Jr, Pelletier AJ, Butchy GT, Edlow JA. Spectrum of dizziness visits to US emergency departments: cross-sectional analysis from a nationally representative sample. *Mayo Clin Proc*. 2008;83(7):765-775.

Newman-Toker DE, Kattah JC, Alvernia JE, Wang DZ. Normal head impulse test differentiates acute cerebellar strokes from vestibular neuritis. *Neurology*. 2008;70(24, pt 2):2378-2385.

Rizk H, Agrawal Y, Barthel S, et al. Quality improvement in neurology: neurootology quality measurement set. *Neurology*. 2018;91:697-701.

Stachler RJ, Chandrasekhar SS, Archer SM, et al. Clinical practice guideline: sudden hearing loss. *Otolaryngol Head Neck Surg*. 2012;146(3 suppl):S1-S35.

Waldvogel D, Mattle HP, Sturzenegger M, Schroth G. Pulsatile tinnitus—a review of 84 patients. *J Neurol*. 1998;245(3):137-142.

Syncope 6

Tina T. Shih

KEY POINTS

1. Syncope is a transient loss of consciousness due to decreased cerebral blood flow.
2. Syncope is rapid in onset and short in duration with spontaneous, complete, and rapid recovery.
3. Distinguishing syncope from seizure requires the clinician to take a meticulous history of the event.

INTRODUCTION

Sudden alteration of consciousness is a common presenting symptom in a variety of clinical contexts, from the emergency room to the outpatient clinic. The vast majority of events can be categorized as either seizure or syncope or the proverbial "fit" versus "faint." This chapter aims to provide a practical framework to help the clinician distinguish between these two diagnoses. Syncope is defined as a transient loss of consciousness due to decreased cerebral blood flow. Seizure is defined as a transient alteration in brain function due to abnormal electrical cerebral activity. When evaluating any patient with a history of transient loss of consciousness, clinicians should take a very careful history of the event itself. The clinician would be best served spending the majority of the encounter interviewing the patient and eyewitnesses, eliciting the symptoms and signs in a step-by-step fashion in order to understand the order and tempo of the events as they unfolded. Skipping this step often results in misdiagnosis and wasted health care dollars spent on inconclusive or even misleading test results.

EPIDEMIOLOGY

Syncope is a common symptom, experienced by about half of the world's population at some point in their lifetime. Most individuals do not seek medical care. Syncope accounts for approximately 1% to 2% of emergency room visits. Vasovagal syncope is far and away the most common cause of syncope in young people and the most common cause of syncope in all age groups. Syncope due to cardiac reasons is the second most common cause. The incidence of syncope appears to increase significantly with age, doubling in individuals older than the age of 70 years as compared to younger cohorts. The causes of syncope in older populations are varied and can include vasovagal, cardiac, and orthostatic etiologies. Orthostatic hypotension is very rare in patients younger than the age of 40 years.

PATHOBIOLOGY

Syncope is defined as a transient loss of consciousness due to insufficient blood flow to the brain, resulting in a loss of postural tone. The underlying basic mechanisms resulting in decreased cerebral blood flow are *reduced cardiac output* and/or *low peripheral vascular resistance* (blood pressure). A loss of consciousness in supine individuals occurs within 6 to 8 seconds after cardiac asystole, whereas in upright individuals, tilt table recordings demonstrate loss of consciousness if systolic blood pressure drops below 60 mm Hg.

Causes of Syncope

Figure 6.1 describes the relationship between the various causes of syncope and the basic physiologic mechanisms (low cardiac output and low peripheral vascular resistance) that mediate this phenomenon.

Neurally Mediated Reflex Syncope

The most common type of syncope, accounting for over half of cases, is reflex syncope, also known as *neurocardiogenic syncope*. In this form of syncope, an external factor or set of circumstances (apprehension of pain, cough, head turning, etc) leads to bradycardia, hypotension, or a mixture of both phenomena. Reflex syncope is divided into two main categories: vasovagal syncope and carotid sinus syncope (**Table 6.1**).

Vasovagal Syncope

Vasovagal syncope, the most common type of reflex syncope, is caused by a brief loss of neurally mediated circulatory control and is generally associated with a benign prognosis. Vasovagal syncope can be subdivided into three major categories: postural, central, and situational. In the postural form of vasovagal syncope, a common patient narrative might describe a young person attending a hot and crowded school assembly or concert, standing for a long period of time and having skipped a recent meal and ingested some alcohol. In cases of centrally mediated vasovagal syncope, the trigger may involve sudden pain (commonly in the setting of venipuncture), apprehension of pain, or emotional shock immediately preceding the fainting episode. Less commonly, syncope occurs in specific situations or appears to be temporally related to specific triggers. Older men may report symptoms soon after arising from bed and emptying a distended bladder. Some young people describe recurrent syncope after exercise. Others describe syncope after coughing, laughing, or sneezing. It is not unusual for a history of vasovagal syncope to run in families. Surprisingly, despite the prevalence of this condition, the underlying pathophysiology of vasovagal syncope remains a mystery. Physiologists have yet to identify why an emotional state or coughing or prolonged standing can lead to a sudden decrease in blood pressure or why vasovagal syncope can recur frequently in some individuals, rarely in others.

Carotid Sinus Syndrome

A more unusual type of reflex syncope is carotid sinus syndrome, which occurs when normal stimulation of an unusually sensitive carotid sinus leads to hypotension and/or bradycardia. This diagnosis should be suspected in older individuals who report unexplained falls or syncope with almost no prodromal symptoms; occasionally, a history of head turning, wearing a tight-collared shirt, or

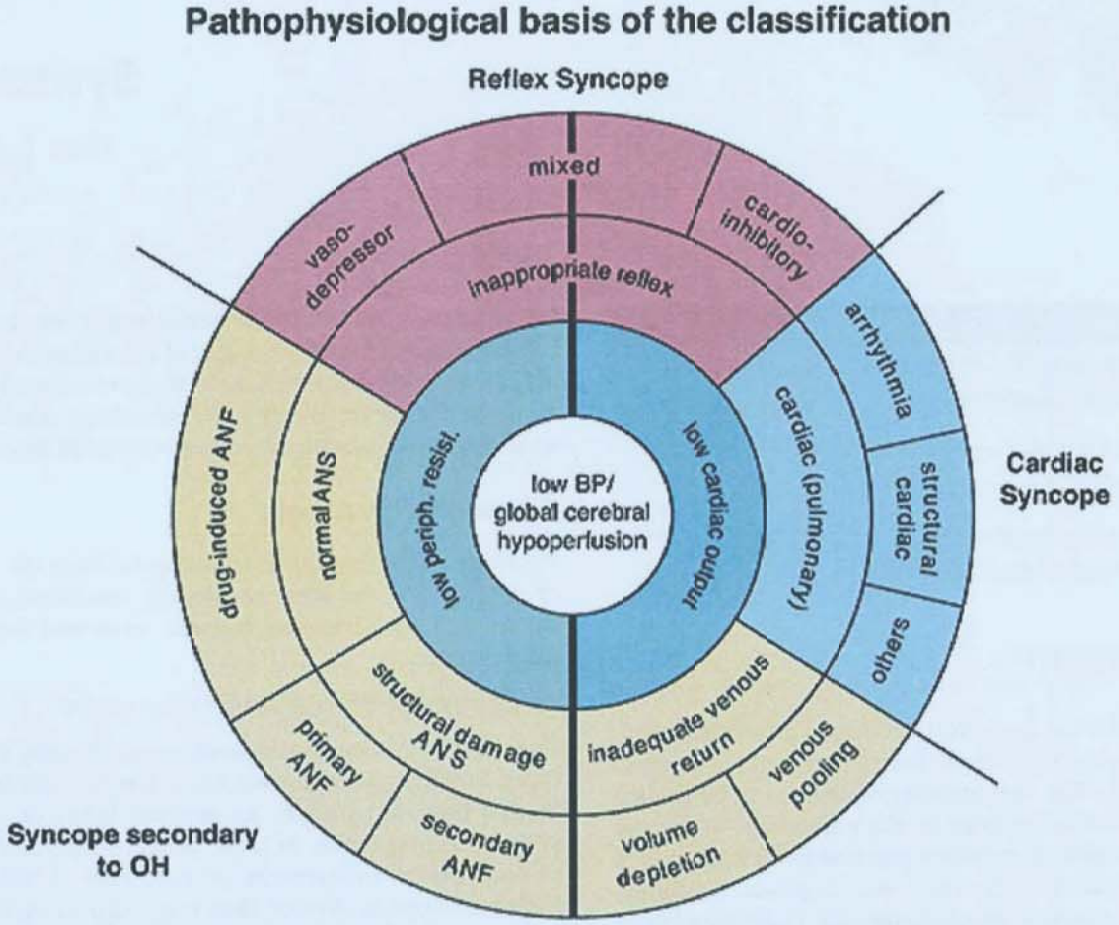

FIGURE 6.1 Pathophysiologic basis of the classification. Abbreviations: ANF, autonomic nervous failure; ANS, autonomic nervous system; BP, blood pressure; OH, orthostatic hypotension; periph. resist., peripheral resistance. (Obtained from this article Moya A, Sutton R, Ammirati F, et al. Guidelines for the diagnosis and management of syncope [version 2009]. *Eur Heart J.* 2009;30[21]:2631-2371.)

TABLE 6.1 Causes of Syncope

Neurally Mediated Reflex Syncope
• Vasovagal syncope Central (emotional stimuli) Postural (prolonged upright position) • Situational (specific triggers) • Micturition, defecation, coughing, sneezing, laughing, weight lifting, post exercising, trumpet playing
• Carotid sinus syndrome
Cardiac Syncope (Cardiovascular)
• Arrhythmias
• Structural heart disease/mechanical
Syncope due to Orthostatic Hypotension
• Autonomic failure • Multiple system atrophy, diabetes, amyloidosis, hereditary polyneuropathy
• Drug induced • Antihypertensives, diuretics, antianginal, tricyclic antidepressants, levodopa, lithium, alcohol
• Hypovolemia • Anemia, failure to thrive, malnutrition
• Postural orthostatic hypotension syndrome

shaving preceding syncope is elicited, but in general, this diagnosis is often difficult to make and is considered after extensive diagnostic testing has been inconclusive or negative.

Cardiac Syncope

The most dangerous type of syncope is cardiac syncope, when a transient loss of consciousness is caused by either cardiac arrhythmia or structural heart disease. In a large population-based study of syncope, cardiac syncope was associated with a twofold increased risk of dying, regardless of etiology, as compared to individuals without a history of syncope.

Arrhythmias are the most common cause of cardiac syncope, and both tachyarrhythmias and bradyarrhythmias have been implicated. The most common arrhythmia associated with syncope is sinus node dysfunction. Other arrhythmias include atrioventricular conduction system disease, supraventricular tachyarrhythmias, and ventricular tachyarrhythmias.

Mechanical or structural causes of cardiac syncope include prior myocardial infarction, cardiomyopathy, aortic stenosis, mitral stenosis, pericardial tamponade, myxoma, aortic dissection, and pulmonary emboli.

Because of the high morbidity associated with cardiac syncope, it is imperative to consider this diagnosis when evaluating an individual with syncope. The clinical features most predictive of cardiac syncope include age older than 60 years, male gender, known

structural heart disease, fewer events (less than three events by history), syncope while supine, and syncope during effort/exercise.

Syncope Due to Orthostatic Hypotension

Unlike individuals with vasovagal syncope (who have an intact autonomic nervous system at baseline), individuals with syncope due to orthostatic hypotension are believed to have underlying autonomic dysfunction involving sympathetic efferent pathways, preventing appropriate vasoconstriction upon standing. Therefore, when an individual with this condition rises from a supine position, he or she experiences an abnormal drop in systolic blood pressure. Patients who present with this form of syncope are usually elderly, and this condition rarely occurs in individuals younger than 40 years of age. The clinical history may reveal other symptoms upon standing, which include light-headedness/dizziness or presyncope, weakness/fatigue/lethargy, diaphoresis, vision disturbances (graying of vision, enhanced brightness, tunnel vision), muffled hearing, and/or pain in the shoulders ("coat hanger" distribution), invariably associated with an upright position.

Causes of orthostatic hypotension include the following: hypovolemia from anemia or malnutrition; medications such as antihypertensives, diuretics and tricyclic antidepressants; autonomic failure from neurodegenerative disorders such as multiple system atrophy, hereditary, toxic or paraneoplastic peripheral neuropathies and secondary neuropathies due to systemic diseases such as diabetes and amyloidosis (see Table 6.1). A rare form of orthostatic hypotension with dizziness and near syncope is postural orthostatic hypotension syndrome, a poorly understood syndrome typically seen in young women with chronic fatigue syndrome. The syndrome consists of an increase in heart rate and unstable blood pressure upon standing.

DIAGNOSIS

Differentiating Syncope From Seizure

The key to making the correct diagnosis is obtaining a detailed narrative of the event from the patient and eyewitnesses. Although many patients and witnesses will use terms such as *passing out* or *fainting* to describe either condition, it is important to delve further and elicit a second-by-second account of the patient's actual experience. An inability to obtain such a narrative severely hampers making a diagnosis, which further diagnostic testing is unlikely to resolve. The clinical hallmarks of syncope are rapid onset, short duration, and complete rapid recovery.

The most important clinical features distinguishing syncope from seizures are the following: (1) precipitating stimuli or situations, (2) prodromal symptoms before losing awareness, and (3) the postevent recovery (Table 6.2).

TABLE 6.2 Clinical Features Distinguishing Syncope From Seizure

Feature	Syncope	Seizure
Before a Spell		
Trigger (change in position, prolonged standing, emotion, Valsalva, exercise)	Common	Rare
Sweating, light-headedness, graying of vision, and/or nausea	Common	Occasional
Occurring out of sleep	Rare	Occasional
Aura (déjà vu, olfactory hallucination, unilateral symptoms)	Rare	Common
During a Spell		
Pallor	Common	Rare
Cyanosis	Rare	Common (generalized tonic-clonic seizures)
Duration of loss of consciousness	<20 s	>60 s
Movements	A few rhythmic jerking movements of the limbs, lasting <15 s	Prolonged stiffening of the limbs (tonic), transitioning to rhythmic jerking of the limbs (clonic), lasting ~1-2 min
Automatic behavior (lip smacking, picking, patting)	Occasional	Common (focal dyscognitive seizures)
Tongue biting (lateral)	Rare	Occasional
Frothing/hypersalivation/vomiting	Rare	Common
After a Spell		
Confusion/disorientation	Rare, <30 s	Common, several minutes or longer
Diffuse muscle pain	Rare, brief	Common, hours to days
Creatinine kinase elevation	Rare	Common (especially after 12-24 h)
Focal neurologic signs	Rare	Occasional
Incontinence	Rare	Occasional
Headache	Rare	Common
Amnesia for the event	Less common (sometimes seen in elderly)	Common

Clinical Features of Syncope

Syncope typically occurs when patients are upright (standing or sitting) and can be triggered by exercise, coughing, bearing down (Valsalva maneuver), venipuncture, prolonged standing, or pain. Presyncope begins with a sense of unwellness accompanied by light-headedness and nausea. Patients may feel weak and unsteady on their feet, followed by a decreased awareness or detachment from their environment. Immediately before losing consciousness, patients experience a "graying of the vision" and/or "muffling" of ambient sounds. Eyewitnesses will often note that the patients appear pale or ashen, diaphoretic, and tachypneic. Sometimes, an attack can be aborted if the patients lie down quickly or lower the head below the level of the heart. Once patients lose consciousness, they will lose tone in the muscles of their trunk and legs and they will limply collapse to the floor. On the ground, the limbs are flaccid and patients continue to appear pale and sweaty. The period of unconsciousness is generally brief, lasting only seconds up to 1 to 2 minutes. If the degree of decreased cerebral perfusion is profound enough, patients may display a few jerking movements of the limbs ("convulsive syncope"), but this is also typically very brief (lasting only a few seconds). Generally, the pulse and blood pressure quickly return to normal with the patients in the recumbent position, and they rapidly regain consciousness and quickly become oriented and aware of their surroundings. Patients will often realize that they have fainted and remember details of the event up until the moment of losing consciousness. They might experience mild fatigue or brief disorientation after the event, but this should not last more than a few minutes.

Clinical Features of Seizures

Epileptic *seizures* are defined as transient alterations in brain function due to abnormal electrocerebral activity. The clinical manifestations of seizures vary widely, depending on brain volume involvement and neuroanatomic location of electrical activation. Seizures can occur day or night, regardless of whether the patient is awake or asleep, and usually are not triggered by a precipitating stimulus or environment. Sometimes, a seizure may begin with the patients reporting an "aura" or warning. These subjective experiences might be described as a sense of déjà vu (a sense of reliving a familiar experience), a noxious smell, sudden anxiety, or tingling over one side of the body. Eyewitnesses might find the patients unresponsive to their direct questions, staring into space, or stopping what they were previously doing (behavioral arrest). Some patients exhibit oral or manual automatisms (lip smacking, chewing, rubbing of their hands, picking at their clothes). If a focal seizure then secondarily generalizes (electrical activity starting off in one area of the brain but then spreading to both hemispheres of the brain), the patients' head and eyes may suddenly and forcibly turn to one side, with stiffening of the limbs, frothing at the mouth, cyanosis of the lips, followed by rhythmic jerking of the limbs. Most secondarily generalized seizures last between 1 and 2 minutes in duration and rarely over 5 minutes in duration, but afterward, the patients may be confused and disoriented for minutes to hours. Patients may report lateral tongue biting and urinary incontinence after some seizures.

Clinical Features of Other Spells Potentially Mistaken for Syncope

Vertebrobasilar Transient Ischemic Attack

Transient ischemic attack (TIA) of the vertebrobasilar system is an extremely rare cause of brief loss of consciousness. The underlying pathophysiology is believed to be due to temporary ischemia of the brainstem reticular activating system. Almost invariably, TIAs of the vertebrobasilar system are associated with focal neurologic symptoms due to ischemia of the brainstem, cerebellum, and/or occipital lobe. Therefore, patients and family members will typically describe associated dysarthria, diplopia, dysphagia, hemianopsia, ataxia, unilateral weakness, or numbness.

Hypoglycemia

Hypoglycemia may cause feelings of light-headedness or dizziness and rarely results in a brief loss of consciousness. A more typical presentation of hypoglycemia is a slow and insidious onset of delirium that may last minutes to hours and be associated with diaphoresis, hunger, tremulousness, anxiety, and palpitations. If severe enough, hypoglycemia can progress to coma (otherwise, prolonged unresponsiveness) and/or generalized tonic-clonic seizures.

Basilar Migraine

Basilar migraine may cause confusion but rarely leads to loss of consciousness. It is associated with headache, ataxia, and positive visual phenomenon developing over minutes to hours and therefore is unlikely to be confused with syncope.

Subclavian Steal Syndrome

Subclavian steal syndrome is characterized by a reversal of blood flow in the vertebral artery, away from the brain, in order to supply blood flow to an ischemic arm. In this syndrome, exercising the affected arm leads to dizziness, vertigo, dysarthria, dysphagia, ataxia, unilateral weakness, and sometimes loss of consciousness.

Focused Physical Examination

If the clinician remains uncertain whether the diagnosis is syncope or seizure after taking the history, the physical examination is unlikely to be helpful. In cases of likely syncope, orthostatic blood pressure and auscultation of the neck and heart should be included as part of the routine physical examination and patients should have a routine 12-lead electrocardiogram (ECG).

Carotid sinus massage has been recommended in the evaluation of unexplained syncope in individuals older than age 45 years, but the procedure is generally not performed by neurologists. The generally accepted protocol for carotid sinus massage involves longitudinal massage at the region where the common carotid bifurcates, but the duration of massage should not last longer than 5 seconds and the force applied should not occlude the carotid artery. The procedure should be performed in upright and supine positions with continuous ECG and noninvasive blood pressure monitoring. The procedure should not be performed in individuals with known carotid disease, history of TIA or stroke within the last 3 months, or carotid bruit.

The *active standing test* (having the patient move from lying position to standing position) with simultaneous intermittent manual blood pressure monitoring (sphygmomanometer) may be helpful in diagnosing orthostatic hypotension. The test is considered diagnostic if there is a greater than 20 mm Hg decrease in systolic blood pressure and/or greater than 10 mm Hg decrease in diastolic blood pressure and/or decrease in systolic blood pressure <90 mm Hg within 3 minutes of standing and the patient is symptomatic. Initial orthostatic hypotension is defined as a blood pressure decrease immediately on standing of

TABLE 6.3 "Red Flags": When to Consider a Diagnosis of Cardiac Syncope

Clinical features	• Lack of clear trigger causing syncope • Absence of sweating/nausea before syncope • Syncope while supine • Palpitations at the time of syncope • Syncope with exercise/effort
Demographic features	• Older age • Family history of sudden death • Personal history of structural heart disease • Fewer events (less than three syncopal events)

greater than 40 mm Hg, whereas delayed orthostatic hypotension is described as a slow, progressive decline in systolic blood pressure while standing.

Diagnostic Tests

In rare circumstances, if the diagnosis of seizure or syncope remains unclear and the events are frequent and relatively easy to replicate, simultaneous video/electroencephalography and ECG can be performed to characterize these events.

Once the diagnosis of syncope has been established but the cause remains uncertain (unlikely reflex syncope or orthostatic hypotension), further laboratory studies to consider might include hemoglobin/hematocrit to look for anemia, chemistry panel to look for electrolyte disturbances, tilt table testing to try to reproduce neurally mediated reflex syncope, echocardiography to evaluate cardiac structure and function, and/or continuous ECG monitoring to investigate the possibility of a cardiac arrhythmia. The decision to pursue further cardiac testing (continuous ECG monitoring or echocardiography) should be strongly considered if there is any suspicion of a potential cardiac cause (Table 6.3). More systematic, protocol-based approaches attempting to stratify high-risk patients have failed to perform consistently when tested in varying patient populations, but expert consensus recommends prompt hospitalization and immediate evaluation for patients with abnormal 12-lead ECG findings, known severe cardiac disease, severe anemia, electrolyte disturbances, and/or clinical features concerning for cardiac syncope (Table 6.4). In older individuals with suspected orthostatic hypotension that is not immediately demonstrated on the active standing test, 24-hour ambulatory blood pressure monitoring should be considered, especially if postprandial or early morning blood pressure instability is a consideration.

TABLE 6.4 "Red Flags": When to Consider Prompt Hospitalization or Intensive Evaluation

Clinical features	• Severe cardiac structural dysfunction or coronary artery disease • Family history of sudden cardiac death • Syncope during exercise or while supine • Palpitations at the time of syncope
Comorbidities	• Severe anemia • Electrolyte disturbance
Abnormal ECG findings	• Bifascicular block or other intraventricular conduction block (QRS duration >120 ms) • Inadequate sinus bradycardia (<50 beats/min) in absence of negative chronotropic medication or physical training • Prolonged or short QT interval • Right bundle branch block with ST elevation in leads V_1 to V_3 (Brugada pattern) • ECG pattern suggestive of arrhythmogenic right ventricular cardiomyopathy

Abbreviation: ECG, electrocardiogram.

MANAGEMENT

For patients with vasovagal syncope and orthostatic intolerance, nonpharmacologic management strategies are most effective. Patients benefit greatly from education about the condition, identification and then avoidance of potential triggers, and learning how to perform maneuvers to abort an episode (supine posture; physical counterpressure maneuvers consist of leg crossing, arm tensing, or hand grip).

For patients with orthostatic hypotension, avoiding offending drugs (antihypertensives, diuretics, tricyclic antidepressants, and alcohol) is the first step. Sleeping with the head of the bed at 10° reduces some nocturnal hypertension and polyuria, and compression stockings should also be considered.

Management of syncope in the setting of cardiovascular disease is beyond the scope of this chapter, and patients should be referred to cardiology.

If the events are recurrent and clear triggers have not been identified, patients should be counseled about high-risk activities such as driving, operating heavy machinery, and working at unrestricted heights, and in some states, mandatory reporting is required.

OUTCOME

Prognosis and outcome measures center around two main considerations:

1. Risk of death and life-threatening events. The prognosis is largely dependent on the underlying cause. For young persons with reflex syncope and absence of any electrical or structural heart disease, the prognosis is excellent. Older individuals with orthostatic hypotension are 2 times more likely to die because of associated comorbid medical conditions. Structural and electrical heart diseases are also associated with increased mortality; the degree of risk is largely dependent on the severity of the underlying cardiac disease.
2. Syncope recurrence and physical injury. Approximately 30% of patients experience a recurrence of syncope in the following 3 years, and the recurrence risk increases with the total number of lifetime events. Risk of physical injury due to syncope appears to increase with age and absence of prodromal symptoms.

SUGGESTED READINGS

Aminoff MJ, Scheinman MM, Griffin JC, Herre JM. Electrocerebral accompaniments of syncope associated with malignant ventricular arrhythmias. *Ann Intern Med*. 1988;108(6):791-796.

Benbadis SR, Wolgamuth BR, Goren H, Brener S, Fouad-Tarazi F. Value of tongue biting in the diagnosis of seizures. *Arch Intern Med*. 1995;155(21):2346-2349.

Benditt DG, Adkisson WO. Approach to the patient with syncope. *Cardiol Clin*. 2013;31(1):9-25.

Berecki-Gisolf J, Sheldon A, Wieling W, et al. Identifying cardiac syncope based on clinical history: a literature-based model tested in four independent datasets. *PLoS One*. 2013;8(9):e75255.

Birnbaum A, Esses D, Bijur P, Wollowitz A, Gallagher EJ. Failure to validate the San Francisco Syncope Rule in an independent emergency department population. *Ann Emerg Med*. 2008;52(2):151-159.

Cornes SB, Shih T. Evaluation of the patient with spells. *Continuum (Minneap Minn)*. 2011;17(5 Neurologic Consultation in the Hospital):984-1009.

Hatoum T, Sheldon R. A practical approach to investigation of syncope. *Can J Cardiol*. 2014;30(6):671-674.

Hoefnagels WA, Padberg GW, Overweg J, van der Velde EA, Roos RA. Transient loss of consciousness: the value of the history for distinguishing seizure from syncope. *J Neurol*. 1991;238(1):39-43.

Jardine D. Vasovagal syncope: new physiologic insights. *Cardiol Clin*. 2013;31(1):75-87.

Khoo C, Chakrabarti S, Arbour L, Krahn AD. Recognizing life-threatening causes of syncope. *Cardiol Clin*. 2013;31(1):51-66.

Krediet CT, van Dijk N, Linzer M, van Lieshout JJ, Wieling W. Management of vasovagal syncope: controlling or aborting faints by leg crossing and muscle tensing. *Circulation*. 2002;106(13):1684-1689.

Lempert T, Bauer M, Schmidt D. Syncope: a videometric analysis of 56 episodes of transient cerebral hypoxia. *Ann Neurol*. 1994;36(2):233-237.

McKeon A, Vaughan C, Delanty N. Seizure versus syncope. *Lancet Neurol*. 2006;5(2):171-180.

Moya A, Sutton R, Ammirati F, et al. Guidelines for the diagnosis and management of syncope (version 2009). *Eur Heart J*. 2009;30(21):2631-2671.

Quinn J, McDermott D, Stiell I, Kohn M, Wells G. Prospective validation of the San Francisco Syncope Rule to predict patients with serious outcomes. *Ann Emerg Med*. 2006;47(5):448-454.

Seifer C. Carotid sinus syndrome. *Cardiol Clin*. 2013;31(1):111-121.

Sheldon R, Rose S, Ritchie D, et al. Historical criteria that distinguish syncope from seizures. *J Am CollCardiol*. 2002;40(1):142-148.

Soteriades ES, Evans JC, Larson MG, et al. Incidence and prognosis of syncope. *N Engl J Med*. 2002;347(12):878-885.

Sun BC, Costantino G, Barbic F, et al. Priorities for emergency department syncope research. *Ann Emerg Med*. 2014;64(6) 649-655.

Tea SH, Mansourati J, L'Heveder G, Mabin D, Blanc JJ. New insights into the pathophysiology of carotid sinus syndrome. *Circulation*. 1996;93(7):1411-1416.

van Dijk N, Quartieri F, Blanc JJ, et al. Effectiveness of physical counterpressure maneuvers in preventing vasovagal syncope: the Physical Counterpressure Manoeuvres Trial (PC-Trial). *J Am CollCardiol*. 2006;48(8):1652-1657.

7 Seizures

Michelle Bell, David J. Roh, and Jan Claassen

KEY POINTS

1. Treat early with benzodiazepines as first-line therapy; agent of choice is intravenous lorazepam.
2. Continue therapy with second-line or urgent control therapy with phenytoin/fosphenytoin or valproic acid, alternatives include levetiracetam, phenobarbital, or lacosamide.
3. Start maintenance of antiepileptic drug therapy after second-line or urgent control therapy.
4. If the patient does not return to baseline within 20 minutes after convulsions stop, suspect nonconvulsive seizures or status epilepticus.
5. Continuous electroencephalogram must be ordered to further drive therapeutic management of status epilepticus.
6. If there is evidence of prolonged seizures, intubate and escalate to continuous intravenous anesthetic antiepileptic drug agents.
7. Do not delay treatment.

INTRODUCTION

Seizures are frequently encountered in both the community and hospital setting. Epidemiologic studies in the United States have shown that 11% of the general population will have a seizure at some point in their life. There is an estimated 1 million hospital visits due to seizures per year.

On a cellular level, neurons communicate via action potentials, and a seizure is the result of excessively synchronized action potentials that are not stopped by the brain's normal inhibitory processes. On a clinical level, the International League Against Epilepsy (ILAE) defines seizures as transient clinical events due to abnormally excessive or synchronous neuronal activity in the brain. Seizures can be focal or generalized in onset and have a wide range of manifestations including cognitive, autonomic, sensory, and motor symptoms (**Fig. 7.1**).

A failure to stop isolated seizures may lead to status epilepticus (SE). Its incidence has increased in recent years with 5 to 30 cases per 100,000. SE is defined as seizures lasting more than 5 minutes, or 2 or more seizures in a 5-minute interval without a return to preseizure neurologic baseline. Historically, SE had been defined as continuous seizure activity lasting greater than 30 minutes without complete recovery. However, the minimum time elapsed to qualify for SE was shortened to 5 minutes based on the observation that isolated seizures rarely last for more than a few minutes and that irreversible brain injury can occur as early as 5 minutes of ongoing seizure activity. Furthermore, isolated seizures that are of longer duration typically do not stop spontaneously. Delaying effective recognition and treatment of SE dramatically increases the patient's morbidity and mortality.

SE constitutes a neurologic emergency requiring prompt and decisive intervention. This chapter focuses on the initial diagnostic workup and management of seizures and SE.

MANAGEMENT STRATEGY

Management is focused on controlling the seizures as quickly as possible by escalating therapy. The most common management error in the management of SE is underdosing and failure to escalate therapy in a timely fashion. An overview of the various steps in initiating and escalating therapy is shown in **Table 7.1**.

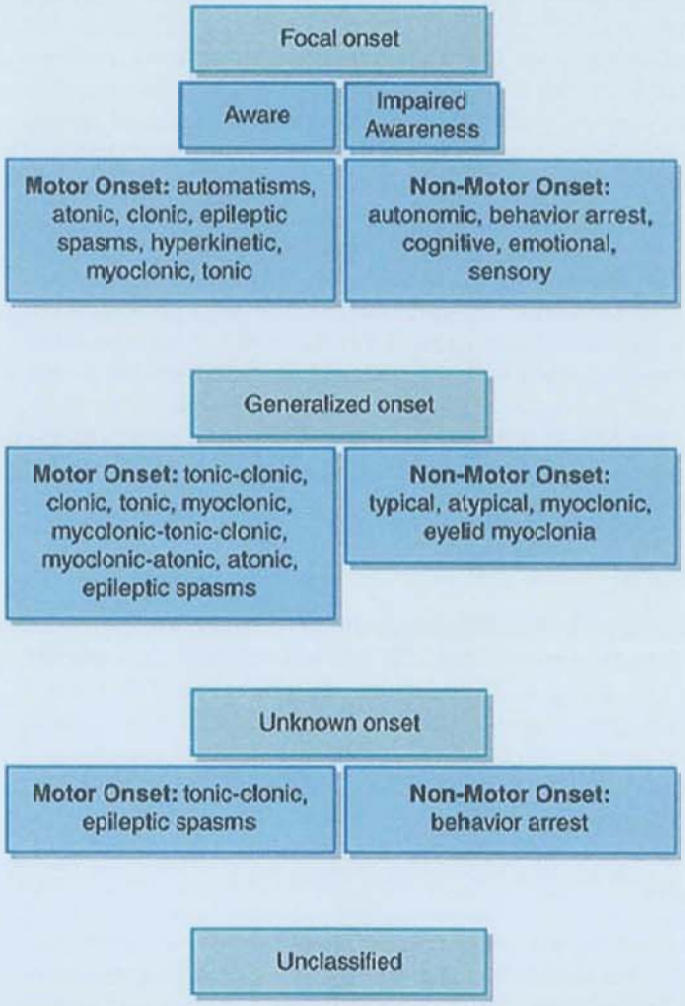

FIGURE 7.1 Classification of seizure types. (Derived from Fisher RS, Cross JH, French JA, et al. Operational classification of seizure types by the International League Against Epilepsy: position paper of the ILAE Commission for Classification and Terminology. *Epilepsia*. 2017;58[4]:522-530. doi:10.1111/epi.13670.)

TABLE 7.1 Overview of Management for Seizures and Status Epilepticus

[ ] Diagnose: by history, exam, or EEG
[ ] Airway, breathing, circulation: Assess and stabilize.
[ ] Emergent initial treatment: benzodiazepines (see **Table 7.4**)
[ ] Second-line urgent control treatment: phenytoin, valproic acid, levetiracetam, or phenobarbital (see **Table 7.5**)
[ ] Seizure workup: Look for provoking factors concurrently with other steps.
[ ] Maintain baseline AEDs: Check levels and rebolus if IV formulations exist.
[ ] If seizures persist: Obtain cEEG; intubate for refractory status epilepticus.
[ ] Refractory status epilepticus: cIV pentobarbital, propofol, midazolam, ketamine

Abbreviations: AEDs, antiepileptic drugs; cEEG, continuous electroencephalogram; cIV, continuous intravenous; IV, intravenous; SE, status epilepticus.

TABLE 7.2 History Taking for Seizures

Likelihood of This Being Seizure

- History elements concerning for:
  - Syncope: history of syncope, brief duration of the loss of consciousness, asynchronous myoclonic jerks, occurrence while standing
  - Psychogenic nonepileptic attack: occurrence in the setting of an emotional trigger, eye closure during the episode, horizontal head movement, asynchronous limb jerking, waxing and waning of symptoms in the course of one episode
  - Cateplexy: a history of narcolepsy, loss of tone without loss of consciousness, a strong emotional trigger for the episode
  - Limb-shaking transient ischemic attack: history of carotid stenosis contralateral to the movements, arrhythmic movements
  - Seizures: history of seizures, abrupt offset and onset, postepisode weakness or confusion, history of head trauma, febrile seizures, developmental delay, or family history of seizures

Provoking Factors

- In patients with a history of seizures ask about factors that can lower the seizure threshold such missed antiseizure medications and sleep deprivation.
- Query about situations that can lead to acute symptomatic seizures.

Primary Generalized or Focal Onset

- Ask if the patient had warning or an "aura."
- Ask the patient and bystanders if there were any lateralizing features before, during, or after the seizures. Specifically ask if motor symptoms were noticed first on one seizure of the body and if the weakness was noted on one side of the body after the seizure ("Todd paralysis").
- Localizing features of seizures (ie, hemifield visual aura: contralateral occipital lobe; clonic activity: contralateral motor strip; "figure-of-four": contralateral SMA; unilateral dystonic posturing: contralateral activation of basal ganglia)

Features of Status Epilepticus

- Seizure lasting more than 5 min
- If there has been a lack of return to neurologic baseline, the patient might be in convulsive status epilepticus especially if the clinical seizure preceding this unresponsiveness was >5 min.

Abbreviation: SMA, supplementary motor area.

INITIAL DIAGNOSIS

The diagnosis of a seizure is often made based on the symptoms or signs reported by the patient, bystanders, or clinicians. The symptoms/signs of a seizure are often referred to as the *semiology*. As detailed in the ILAE seizure classification, seizures can manifest as excess activity ("positive" symptoms) or lack of activity ("negative" symptoms). The positive symptoms can obvious and include rhythmic jerking or dystonic posturing, or can be subtle with symptoms of twitching, nystagmus, automatisms, and eye deviation. Negative symptoms of seizures include staring, coma, lethargy, confusion, and aphasia.

Nonconvulsive seizures are common in the critical care setting with incidences ranging from 5% to 40%. If seizures or SE are suspected based on preliminary clinical assessment, the clinician should proceed with a focused history and exam. A focused assessment will prevent delayed initiation of appropriate management, which can significantly increase the likelihood of morbidity and possibly mortality.

History

The goals of the focused history are to (1) assess the likelihood that this presentation is due to seizures, (2) ascertain whether there are any provoking factors, (3) determine if this was a primary generalized seizure or a focal seizure with or without secondary generalization, (4) localize the likely seizure focus if focal, and (5) determine if the patient is having ongoing seizure activity or SE (**Table 7.2**).

Exam

A focused general physical exam should rapidly screen the patient's clinical stability and identify life-threatening etiologies of seizures. These may include meningitis, intracranial hemorrhage, ischemic stroke, or any other type of acute intracranial mass effect. Vital signs should be monitored with particular attention to hemodynamic stability and respiratory status. Focus should be paid to the presence of fever, nuchal rigidity, and rash. These findings, if present, should raise suspicion for a central nervous system infection prompting further laboratory investigation and empiric antibiotic treatment. Skin findings can be suggestive of meningitis, but might also be indicative of an underlying neurocutaneous disease such as tuberous sclerosis (ie, ash-leaf spots or shagreen patches) or neurofibromatosis (ie, café au lait macules or neurofibromas). Such neurocutaneous diseases often cause both skin findings as well as seizures.

Observation and gross neurologic examination may detect obvious positive symptoms of seizures supporting the diagnosis. These symptoms can be obvious or subtle. Absence of obvious symptoms should not preclude the possibility of seizures. Nearly half of patients with generalized tonic clonic SE will continue to have electrographic seizures after convulsions have stopped. In these cases, the diagnosis of SE can only be made by electroencephalogram (EEG) monitoring.

Differential Diagnosis

The differential diagnosis for seizures and SE include but are not limited to movement disorders, limb-shaking transient ischemic attacks, convulsive syncope, posturing, sleep disorders, transient global amnesia, complicated migraine, and psychiatric

nonelectrographic seizure activity. The differential for nonconvulsive SE is much broader and can mimic anything that would result in impairment of consciousness ranging from toxic metabolic encephalopathy to anoxia or infections.

Causes of Seizures: Provoked Seizures, Unprovoked Seizures, and Lowered Seizure Threshold

It is important to identify any underlying cause for seizures as management will be tailored accordingly. In classifying the cause of seizures, it is important to elucidate whether the seizure was provoked. A "provoked" seizure generally occurs in the context of acute brain injury, systemic toxic—metabolic insult, illicit drug use, or medications known to lower seizure threshold (Table 7.3). The ILAE uses the term *acute symptomatic seizures* to refer to all provoked seizures and defines these as seizures that occur within the first 7 days of brain injury (eg, cerebrovascular disease, traumatic brain injury, intracranial surgery, and central nervous system infections), in the context of alcohol or drug (medication or illicit) use that is known to trigger seizures, during a febrile illness, or in the context of metabolic derangement (eg, serum glucose <36 mg/dL or >450 mg/dL associated with ketoacidosis, serum sodium <115 mg/dL, serum calcium <5.0 mg/dL, serum magnesium <0.8 mg/dL, urea nitrogen <100 mg/dL, creatinine >10.0 mg/dL).

Of note, some authors, like the ILAE, use the terms *provoked seizure* and *acute symptomatic seizure* interchangeably, whereas other authors use the term *provoked seizures* when referring to seizures secondary to toxic-metabolic insults and "acute symptomatic seizures" to describe those that occur in the context of acute brain injury. The reason for this distinction is that seizures caused by a metabolic disturbance, offending medication, or drug potentially carry a lower risk of seizure recurrence than those that occur in the context of an acute brain injury. In provoked seizures with a clearly identifiable trigger (ie, severe metabolic disturbance or offending drug), the clinical practice is to not start antiepileptic drugs (AEDs). However, with the risk of seizure recurrence after acute brain injury being between 13% and 33%, there are subsequently mixed views on the necessity of starting long-standing preventative AEDs. Some centers start AEDs in this setting acutely with the long-term plan to wean these mediations off in the outpatient setting given the potentially decreased risk of seizures over time. Ongoing studies are actively looking at the long-term risk of developing epilepsy after acute brain injury.

Unlike the low rate of recurrent late seizures seen with provoked seizures, the rates of recurrent seizures can be as high as 70% in some patients with unprovoked seizures. In patients with unprovoked seizures, it is important to identify this subset of high-risk patients and start antiepileptic treatment. This can be done by assessing for epileptiform discharges on the EEG and focal abnormalities on the magnetic resonance imaging (MRI). If either of these are present, patients meet the 2014 ILAE criteria for epilepsy and should be advised to start an AED. If the patient carries a diagnosis of epilepsy, factors that lowering the seizure threshold should be determined. Some common factors include low AED levels due to medication, noncompliance or drug interactions, recent changes in AEDs, sleep deprivation, high stress levels, menstruation, or mild to moderate systemic infection.

TABLE 7.3 Drugs That Lower Seizure Threshold

• Analgesics: narcotics (tramadol, fentanyl, meperidine)
• Antibiotics: penicillins, imipenem, cephalosporins, isoniazid, metronidazole
• Anticholinesterases
• Antidepressants: bupropion, tricyclics
• Antihistamines: diphenhydramine
• Antipsychotics: clozapine, phenothiazine
• Chemotherapy: etoposide, cisplatinum

EMERGENT MANAGEMENT

Prehospital Stabilization and Treatment

Perhaps, the most important factor in the treatment of acute seizures is the amount of time it takes to administer the initial treatment. This requires a timely recognition of seizures by bystanders and notification of emergency medical services (EMS). Prehospital EMS care with patient stabilization and medication administration is vital in early treatment of acute seizures and has been associated with improved patient outcomes. Stabilization includes initial assessment of secure airway, stable breathing, and circulation. Once stabilized, prehospital care also involves attempts at obtaining intravenous (IV) access and assessing for reversible causes of seizures such as hypoglycemia.

Following initial assessment, treatment for convulsive seizures can be given by EMS (Table 7.4). Benzodiazepines have been the AED of choice in the field and are considered first-line treatment options for seizures. IV agents have traditionally been used with lorazepam (4 mg) or diazepam (10 mg). In appropriate, targeted dosing, seizure patients that receive IV benzodiazepines have lower instances of respiratory depression/intubation than patients that have prolonged seizures without treatment. IV benzodiazepines, particularly IV lorazepam, have been found to be safe and efficacious in early prehospital

TABLE 7.4 Emergent First-Line Therapy Benzodiazepine Agents and Dosing[a]

Benzodiazepine	Route	Dosing
Lorazepam	IV	0.1 mg/kg IV (max 4 mg per dose) and can repeat at 5-10 min
Diazepam	IV	0.15 mg/kg IV (max 10 mg per dose) and can repeat in 5 min
	PR	0.2 mg/kg PR for >12 y
		0.3 mg/kg PR for 6-11 y
		0.5 mg/kg PR for 2-5 y
Midazolam	IM	0.2 mg/kg IM (max 10 mg)
	Intranasal	0.2 mg/kg intranasal
	Buccal	0.5 mg/kg buccal

Abbreviations: IM, intramuscular; IV, intravenous; max, maximum; PR, per rectum.

[a]Adapted from Brophy GM, Bell R, Claassen J, et al; for Neurocritical Care Society Status Epilepticus Guideline Writing Committee. Guidelines for the evaluation and management of status epilepticus. *Neurocrit Care*. 2012;17(1):3-23.

treatment of convulsive seizures LEVEL 7.[1] Despite its efficacy, its use has been limited due to the difficulty of obtaining IV access in a seizing patient and the challenges surrounding storage of IV lorazepam in ambulances. As a result, intramuscular (IM) midazolam (10 mg) has been increasingly used in the prehospital setting and has shown to be an effective alternative to IV lorazepam LEVEL 7.[2]

Hospital Stabilization and Treatment

Once the patient arrives to the hospital, he or she should once again be assessed for stable airway, breathing, and circulation. Supplemental oxygen can be provided. Hemodynamic monitoring should be implemented with particular attention to blood pressure, cardiac monitoring, and oxygenation. IV access, if not already established, should be obtained along with fluid resuscitation to maintain euvolemia.

Physicians should reassess glycemic status, and if there is evidence of hypoglycemia, it is important to promptly treat with Dextrose 50 in water (D50W) 50 mL IV with concurrent thiamine 100 mg IV. Handoff between EMS services and physicians should establish what treatments were given in the field, including benzodiazepine doses.

Initial first-line benzodiazepine therapy is frequently underdosed as seizure dosing is higher than most indications seen by EMS or emergency department providers. Attention should be made to provide full appropriate benzodiazepine treatment via additional doses, if not given initially. Lorazepam IV has been shown to be the preferred initial agent LEVEL 7.[3] A recommended total dose of 0.1 mg/kg (4 mg per dose) can be given. A repeat dose of 4 mg can be given after 5 to 10 minutes if needed (for a maximum total dose of 8 mg). Lorazepam should be administered at a rate up to 2 mg/min. Close attention should be taken to cardiopulmonary status during benzodiazepine administration to avoid uncontrolled hypotension or respiratory depression. Similar to the prehospital management, if there is no IV access readily available, benzodiazepines can be administered via IM, rectal, nasal, or buccal routes. Midazolam is the preferred agent for IM administration. This can be administered at 0.2 mg/kg IM for a total dose of 10 mg (see **Table 7.1**).

Initial Workup

Although emergent management is underway, concurrent diagnostic workup should be pursued (**Table 7.5**). All patients should receive serum laboratory evaluation with complete blood count, basic metabolic panel, liver function tests, and AED levels. Patients should also receive urine drug toxicology testing to evaluate for any metabolic etiologies of seizures. On admission, a noncontrast computed tomography of the brain should be performed to screen for any obvious structural etiologies of seizures.

The extended workup, to be chosen on a case-by-case basis, includes a lumbar puncture, brain MRI, and further laboratory tests (eg, paraneoplastic panel). If there is a concern for infection—the patient is febrile, there is a serum leukocytosis or nuchal rigidity on exam—then a lumbar puncture is warranted. The lumbar puncture should not delay empiric meningitis treatment if suspected. A brain MRI is often pursued if the initial noncontrast head computed tomography is negative, especially if there are focal features with the seizure, exam or on EEG. A paraneoplastic panel is often obtained in the case of new-onset refractory SE (RSE), new-onset bitemporal epilepsy, and in any presentation otherwise concerning for a paraneoplastic syndrome.

TABLE 7.5 Admission Orders for Status Epilepticus[a]

Perform immediately in ED and concurrently with emergent management and treatment

All Patients

- Glucose fingerstick
- Hemodynamic monitoring and vital signs (blood pressure, cardiac monitoring, O_2 saturation, heart rate)
- Neuro checks
- IV access
- O_2 administration (if needed)
- Head CT scan
- Serum lab test: complete blood count, basic metabolic panel, blood glucose, liver function tests, calcium (total and ionized), magnesium, troponin, antiepileptic drug levels, toxicology screen (cocaine and urine), pregnancy test (if female)
- Stat EEG

Consider Depending on Presentation

- Brain MRI
- Lumbar puncture
- Comprehensive toxicology panel: toxins that frequently cause seizures (isoniazid, tricyclic antidepressants, theophylline, sympathomimetics, organophosphates, cyclosporine)
- Serum blood work: type and screen, coagulation studies, arterial blood gas, inborn errors of metabolism, paraneoplastic workup

Abbreviations: CT, computed tomography; ED, emergency department; EEG, electroencephalogram; IV, intravenous; MRI, magnetic resonance imaging; O_2, oxygen; stat, immediately.

[a]Adapted from Brophy GM, Bell R, Claassen J, et al; for Neurocritical Care Society Status Epilepticus Guideline Writing Committee. Guidelines for the evaluation and management of status epilepticus. *Neurocrit Care*. 2012;17(1):3-23.

Indications for Hospital Admission

Typically, emergency department policy states that patients with a normal neurologic examination following a seizure can be discharged from the emergency department with outpatient follow-up. However, if the patient fails to return to baseline in 10 minutes, SE should be suspected, and admission is warranted. Failure to control convulsive seizures or persistent unexplained altered mental status requires further evaluation with a continuous EEG (cEEG). These patients with suspected SE require admission to an intensive care unit for further EEG directed treatment and hemodynamic monitoring. cEEG monitoring should be established within 1 hour of suspected SE and maintained for at least 48 hours in comatose patients to detect nonconvulsive seizures.

STATUS EPILEPTICUS

Second-Line Therapy

In patients with SE or prolonged seizures, the timely administration of second-line (or "urgent control") therapy is vital (**Fig. 7.2**). Second-line therapy administration should ideally occur concomitantly with first-line benzodiazepine therapy.

FIGURE 7.2 Status epilepticus algorithm. Abbreviations: AED, antiepileptic drug; BP, blood pressure; cEEG, continuous encephalogram; cIV, continuous intravenous; D50W, Dextrose 50 in water; ICU: intensive care unit; IM, intramuscular; IV, intravenous; O2, oxygen; RSE, refractory status epilepticus.

EMERGENT MANAGEMENT
1. Recognition and diagnosis of prolonged seizures
2. Stabilize patient: ABCs (airway, breathing, circulation). Place IV, supplemental O_2, and hemodynamic monitoring.
3. Thiamine 100 mg and D50W 50 mL IV (if hypoglycemia)
4. Lorazepam 4 mg over 2 min IV; can repeat after 5 min if still seizing; midazolam 10 mg IM or diazepam 20 mg per rectum if no IV route available
5. Monitor BP and respiratory status during treatment. If no, return to baseline:

↓

SECOND LINE THERAPY/URGENT CONTROL THERAPY
1. Fosphenytoin 20 mg/kg IV at 150 mg/min or valproic acid 40 mg/kg IV over 10 min
2. Can consider levetiracetam 1-3 g IV over 2-5 mg/kg/min
3. Start maintenance dose of loaded AEDs and order AED levels postloading.
4. Order cEEG unless patient is clearly back to baseline.
5. Can consider giving additional fosphenytoin 5-10 mg/kg IV × 1 vs valproic acid 20 mg/kg IV × 1 if no improvement or continued seizure activity. However, do not perform this at the expense of delaying more aggressive RSE treatment measures.
6. Monitor BP and respiratory status during treatment. Consider intubation if sedation or seizure compromises airway. If no improvement:

↓

REFRACTORY STATUS EPILEPTICUS
1. Intubate patient and admit to the ICU.
2. cEEG should be in place.
3. RSE cIV anesthetic agents to goal of burst suppression: See table for RSE medications.
4. Monitor hemodynamic stability and add vasopressors if needed.
5. Monitor cEEG for 24-48 h for seizure suppression and optimize maintenance AED.

Benzodiazepine therapy alone has a short duration of treatment effect and will not be effective in preventing prolonged seizures or SE. There is no need to delay the administration of second-line therapy to assess if the patient responds to first-line benzodiazepine therapy. The goal of second-line/urgent control therapy is to establish rapid therapeutic levels.

Frequently used second-line agents include phenytoin/fosphenytoin, valproic acid, phenobarbital, levetiracetam, and lacosamide. Prospective studies have not revealed a superior second-line AED agent. The Established Status Epilepticus Treatment Trial compared efficacy of phenytoin, valproic acid, and levetiracetam in generalized convulsive SE demonstrated similar efficacy with each drug; lorazepam and phenytoin (20 mg/kg) controlled seizures in 45% of patients, lorazepam and valproic acid (40 mg/kg) controlled seizures in 46% of patients, and lorazepam and levetiracetam (60 mg/kg) controlled seizures in 47% of patients LEVEL 1.[4] Due to long-standing familiarity with phenytoin's efficacy in SE, fosphenytoin/phenytoin is commonly used as the second-line therapy of choice. A 20 mg/kg IV can be given with either formulation. Fosphenytoin can be given at rate of 150 mg/min and phenytoin at 50 mg/min. Care must be taken to avoid rapid infusion because this may cause hypotension or arrhythmias. Fosphenytoin has a lower rate of cardiac toxicity and local tissue injury. Despite some institutional preference for phenytoin use, data suggests IV valproic acid is of equal efficacy and can be given at a rate of 20 to 40 mg/kg IV over 10 minutes with an option of giving an additional 20 mg/kg over 5 minutes if seizure activity continues. If levetiracetam IV is chosen, the recommended dose is 60 mg/kg with administration rate of 2 to 5 mg/kg/min IV. Most recently, lacosamide at loading doses of 50 to 400 mg has been shown to be also effective at aborting SE with overall efficacy of 57%.

After second-line or urgent control therapy is administered, AED maintenance therapy is required even if seizures are controlled. This requires giving maintenance doses of the AED that was administered IV. In spite of current guideline recommendations of utilizing second-line intermittent IV AED therapy in cases of SE, many experts advocate for more aggressive treatment of SE. Rather than treating with second-line intermittent IV AEDs, waiting for a clinical response, and reloading with these agents, many clinicians favor proceeding directly to continuous IV (cIV) infusion anesthetic agents while concomitantly using intermittent IV second-line AEDs. Studies have shown suboptimal cessation of seizure activity with the sole use of classic intermittent IV second-line agents such as phenytoin. Consequently, when possible, the aggressive escalation of treatment straight to cIV anesthetic AEDs such midazolam can be considered (see Fig. 7.2).

Refractory Status Epilepticus and Anesthetic (Third-Line) Treatment

If there is failure to control SE after the use of a benzodiazepine and second-line AED, the patient is considered to be in RSE. RSE occurs in approximately 30% of patients with SE and is associated with increased morbidity and mortality. The pathophysiology of propagation to RSE involves the internalization of γ-aminobutyric acid receptors and upregulation of excitatory *N*-methyl-D-aspartate (NMDA) receptors. Management of RSE requires rapid and aggressive escalation of care with intubation (if not already performed) and induction of coma with cIV anesthetic agents with therapeutic targets at these two receptors. It is unclear of the treatment target endpoints because some evidence suggests that RSE outcome is based on the underlying cause of

TABLE 7.6 Continuous Intravenous Anesthetic Agents for Refractory Status Epilepticus

Drug	Bolus Dose	Maintenance Dose	Side Effects
Midazolam	• 0.2 mg/kg (rate of 2 mg/min)	• 0.05-2.9 mg/kg/h	• Respiratory depression
Propofol	• 1-2 mg/kg over 3-5 min • Repeat bolus every 3-5 min until seizures stop (maximum 10 mg/kg).	• 30-100 μg/kg/min	• Hypotension • Propofol infusion syndrome (particularly at >80 μg/kg/min for >48 h)
Ketamine	• 1.5-4.5 mg/kg IV	• 2.75-5 mg/kg/h	• Hypertension and tachycardia
Pentobarbital	• 5-15 mg/kg (up to 50 mg/min)	• 1-10 mg/kg/h	• Hypotension • Ileus

Abbreviations: IV, intravenous; NMDA, *N*-methyl-D-aspartate.

RSE rather than the aggressiveness of treatment. Despite this, many experts agree that aggressive treatment tailored to EEG suppression in addition to suppression of clinical seizure activity. This suppression should be pursued with cIV agents. cEEG is vital at this point in both evaluating for seizure activity and response to therapy.

Although there is no uniform consensus on optimal RSE therapy, frequently used third-line agents include midazolam, propofol, and pentobarbital (Table 7.6). For superrefractory SE, defined as seizures that persist after 24 hours of continuous infusion anesthetic therapy, the addition of ketamine to midazolam is an increasingly popular alternative to pentobarbital. There remains a paucity of prospective comparative studies for these agents. However, retrospective analysis and limited prospective studies have given some guidance for future studies and selection of preferred RSE treatments.

Pentobarbital has been seen to have higher treatment efficacy compared to propofol and midazolam. However, longer rates of mechanical ventilation have been seen with barbiturate use due to its long half-life along with increased risk of cardiac side effects. Pentobarbital infusion is preceded by a loading dose of 5 to 15 mg/kg (up to 50 mg/min) with repeated boluses of 5 mg/kg until seizure suppression is achieved. Maintenance infusion can be started at 0.5 to 1 mg/kg/h with titration up to 10 mg/kg/h for goal of either seizure or EEG burst suppression.

Propofol is also an effective agent, but it requires careful hemodynamic monitoring. It can cause hypotension along with propofol infusion syndrome (circulatory collapse, lactic acidosis, hypertriglyceridemia, rhabdomyolysis). Propofol requires a 1 to 2 mg/kg loading dose over 3 to 5 minutes.

Repeat boluses can be given every 3 to 5 minutes until seizures stop (maximum loading dose of 10 mg/kg). Maintenance propofol dosing should be titrated to seizure or EEG burst suppression at 30 to 200 μg/kg/min. Doses of greater than 80 μg/kg/min for extended periods of time (>48 h) may place the patient at risk for propofol infusion syndrome.

Midazolam appears to have less of an effect on blood pressure in comparison to propofol or pentobarbital. However, its use is particularly prone to tachyphylaxis, and its mechanism of action is hindered by not having any effect on NMDA receptor sites. Midazolam requires a loading dose of 0.2 mg/kg at a rate of 2 mg/min. Repeat boluses of 0.2 to 0.4 mg/kg boluses every 5 minutes can be given until seizures stop with a maximum loading dose of 2 mg/kg. Maintenance infusion can be titrated for goal of seizure or EEG burst suppression at 0.05 to 2.9 mg/kg/h. However, maintenance infusion rates of as high as 2.9 mg/kg/h can be used safely with lower rates of withdrawal seizures and lower discharge mortality rates.

Ketamine is another therapeutic measure sometimes used for SE. Ketamine is an NMDA receptor antagonist, given with a loading dose of 1 to 2 mg/kg IV every 1 minute, a maintenance dose of 0.01 to 0.03 mg/kg/min cIV. It is used in caution in patients with increased intracranial pressure, traumatic brain injury, intracranial mass, hypertension, chronic congestive heart failure, tachyarrhythmias, myocardial infarction, and alcohol history. In a multicenter case series, the addition of ketamine contributed to control of RSE in 32% of patients for which it was used. Although the mortality rate was 43%, this was lower when SE was stopped within 24 hours of starting ketamine (16% vs 56%).

Add-on therapeutic hypothermia was recently studied in patients with convulsive SE, and although it was associated with a lower rate of progression to EEG confirmed SE, it was not associated with improvement in functional outcome at 90 days or a decreased progression to superrefractory SE.

There is no clear support for the length of treatment and seizure suppression with IV anesthetic agents before weaning attempts are made. However, general consensus states that patients should remain seizure free for 24 to 48 hours on cEEG monitoring. While waiting for this to occur, the patient's maintenance AED agents should be optimized to therapeutic levels. Levels can be allowed to be supratherapeutic and should be dictated based on seizure control and side effect profile. When the patient has stabilized, gradual attempts can then be made to wean off these agents. Often, this is done outside the intensive care unit (on the hospital floor) or in the outpatient setting.

ELECTROENCEPHALOGRAM MONITORING DURING STATUS EPILEPTICUS

The EEG findings during monitoring of SE are complex. One reason for this is that the EEG evolves during a given episode of SE. As described by Treiman at in "A progressive sequence of electroencephalographic changes during generalized convulsive status epilepticus," there appears to be five EEG patterns that occur sequentially during the course of generalized SE: (1) discrete seizures, (2) merging seizures with waxing and waning amplitude and frequency of EEG rhythms, (3) continuous ictal activity, (4) continuous ictal activity punctuated by low voltage "flat periods," and (5) periodic epileptiform discharges on a "flat" background. The temporal time course of these five stages varies, and there is no enough data to establish normative values, but there has been a reported case of a patient progressing through all five stages in less than 24 hours.

The second reason for the EEG complexity is that patients who have SE often later have waveforms on the "ictal-interictal continuum." These are waveforms that are not definitely seizures based on American Clinical Neurophysiology Society's Standardized Critical Care EEG Terminology criteria but have many features of seizures and are thought to represent possible ongoing underlying neuronal injury. Depending on the clinical situation, patients with these patterns are given a dose of a short-acting benzodiazepine or an AED to see if the EEG pattern and clinical exam improves.

The third reason for this complexity in the EEGs of patients with SE is that there are usually frequent to abundant epileptiform discharges. Studies have demonstrated that some of these discharges—lateralized periodic discharges, bilateral independent periodic discharges, and generalized periodic discharges—are associated with an increased incidence of seizures, particularly when there are superimposed fast activity, rhythmic activity, sharp waves, or spikes. Of note, there is evidence that periodic discharges with a frequency of greater than 2.0 Hz is associated with focal brain hypoxia. Because this is the same physiologic consequence of seizures, discharges of this frequency or greater can be clinically treated as seizures even in the absence of electrographic evidence of evolution.

Given the wealth of information that can be obtained from the EEG, placement of the EEG should not be delayed if there is a high clinical suspicion for seizures or SE.

LEVEL 1 EVIDENCE

1. Alldredge BK, Gelb AM, Isaacs SM, et al. A comparison of lorazepam, diazepam, and placebo for the treatment of out-of-hospital status epilepticus. *N Engl J Med*. 2001;345:631-637.
2. Silbergleit R, Durkalski V, Lowenstein D, et al; for NETT Investigators. Intramuscular versus intravenous therapy for prehospital status epilepticus. *N Engl J Med*. 2012;366:591-600.
3. Treiman DM, Meyers PD, Walton NY, et al. A comparison of four treatments for generalized convulsive status epilepticus. Veterans Affairs Status Epilepticus Cooperative Study Group. *N Engl J Med*. 1998;339:792-798.
4. Kapur J, Elm J, Chamberlain JM, et al; for NETT and PECARN Investigators. Randomized trial of three anticonvulsant medications for status epilepticus. *N Engl J Med*. 2019;38:2103-2113.

SUGGESTED READINGS

Alkhachroum A, Der-Nigoghossian CA, Mathews E, et al. Ketamine to treat super-refractory status epilepticus. *Neurology*. 2020;95(16):e2286-e2294.

Beghi E, Carpio A, Forsgren L, et al. Recommendation for a definition of acute symptomatic seizure. *Epilepsia*. 2010;51:671-675.

Bergey GK. Management of a first seizure. *Continuum (Minneap Minn)*. 2016; 22:38-50.

Berning S, Boesebeck F, van Baalen A, Kellinghaus C. Intravenous levetiracetam as treatment for status epilepticus. *J Neurol*. 2009;256:1634-1642.

Brophy GM, Bell R, Claassen J, et al. Guidelines for the evaluation and management of status epilepticus. *Neurocrit Care*. 2012;17:3-23.

Claassen J, Hirsch LJ, Emerson RG, Mayer SA. Treatment of refractory status epilepticus with pentobarbital, propofol, or midazolam: a systematic review. *Epilepsia*. 2002;43:146-153.

Claassen J, Mayer SA, Kowalski RG, Emerson RG, Hirsch LJ. Detection of electrographic seizures with continuous EEG monitoring in critically ill patients. *Neurology*. 2004;62:1743-1748.

Claassen J, Silbergleit R, Weingart SD, Smith WS. Emergency neurological life support: status epilepticus. *Neurocrit Care*. 2012;17(suppl 1):S73-S78.

DeLorenzo RJ, Waterhouse EJ, Towne AR, et al. Persistent nonconvulsive status epilepticus after the control of convulsive status epilepticus. *Epilepsia*. 1998;39:833-840.

Fernandez A, Lantigua H, Lesch C, et al. High-dose midazolam infusion for refractory status epilepticus. *Neurology*. 2014;82:359-365.

Fisher RS, van Emde Boas W, Blume W, et al. Epileptic seizures and epilepsy: definitions proposed by the International League Against Epilepsy (ILAE) and the International Bureau for Epilepsy (IBE). *Epilepsia*. 2005;46:470-472.

Gaspard N, Foreman B, Judd LM, et al. Intravenous ketamine for the treatment of refractory status epilepticus: a retrospective multicenter study. *Epilepsia*. 2013;54:1498-1503.

Hesdorffer DC, Benn EKT, Cascino GD, Hauser WA. Is a first acute symptomatic seizure epilepsy? Mortality and risk for recurrent seizure. *Epilepsia*. 2009;50:1102-1108.

Hirsch LJ, LaRoche SM, Gaspard N, et al. American Clinical Neurophysiology Society's Standardized Critical Care EEG Terminology: 2012 version. *J Clin Neurophysiol*. 2013;30:1-27.

Jenssen S, Gracely EJ, Sperling MR. How long do most seizures last? A systematic comparison of seizures recorded in the epilepsy monitoring unit. *Epilepsia*. 2006;47:1499-1503.

Kurtz P, Gaspard N, Wahl AS, et al. Continuous electroencephalography in a surgical intensive care unit. *Intensive Care Med*. 2014;40:228-234.

Legriel S, Lemiale V, Schenck M, et al; for HYBERNATUS Study Group. Hypothermia for neuroprotection in convulsive status epilepticus. *N Engl J Med*. 2016;375:2457-2467.

Logroscino G, Hesdorffer DC, Cascino G, Annegers JF, Hauser WA. Short-term mortality after a first episode of status epilepticus. *Epilepsia*. 1997;38: 1344-1349.

Lowenstein DH, Alldredge BK. Status epilepticus. *N Engl J Med*. 1998;338:970-976.

Mayer SA, Claassen J, Lokin J, Mendelsohn F, Dennis LJ, Fitzsimmons BF. Refractory status epilepticus: frequency, risk factors, and impact on outcome. *Arch Neurol*. 2002;59:205-210.

Misra UK, Kalita J, Patel R. Sodium valproate vs phenytoin in status epilepticus: a pilot study. *Neurology*. 2006;67:340-342.

Pallin DJ, Goldstein JN, Moussally JS, Pelletier AJ, Green AR, Camargo CA Jr. Seizure visits in US emergency departments: epidemiology and potential disparities in care. *Int J Emerg Med*. 2008;1:97-105.

Pender RA, Losey TE. A rapid course through the five electrographic stages of status epilepticus. *Epilepsia*. 2012;53:e193-e195.

Rodriguez Ruiz A, Vlachy J, Lee JW, et al; for Critical Care EEG Monitoring Research Consortium. Association of periodic and rhythmic electroencephalographic patterns with seizures in critically ill patients. *JAMA Neurol*. 2017;74:181-188.

Rossetti AO. Which anesthetic should be used in the treatment of refractory status epilepticus? *Epilepsia*. 2007;48:52-55.

Rossetti AO, Logroscino G, Bromfield EB. Refractory status epilepticus: effect of treatment aggressiveness on prognosis. *Arch Neurol*. 2005;62:1698-1702.

Rossetti AO, Milligan TA, Vulliémoz S, Michaelides C, Bertschi M, Lee JW. A randomized trial for the treatment of refractory status epilepticus. *Neurocrit Care*. 2011;14:4-10.

Strzelczyk A, Zöllner JP, Willems LM, et al. Lacosamide in status epilepticus: systematic review of current evidence. *Epilepsia*. 2017;58:933-950.

Treiman DM, Walton NY, Kendrick C. A progressive sequence of electroencephalographic changes during generalized convulsive status epilepticus. *Epilepsy Res*. 1990;5:49-60.

Vespa PM, Shrestha V, Abend N, et al. The epilepsy bioinformatics study for anti-epileptogenic therapy (EpiBioS4Rx) clinical biomarker: study design and protocol. *Neurobiol Dis*. 2019;123:110-114.

Walker M. Status epilepticus: an evidence based guide. *BMJ*. 2005;331:673-677.

Witsch J, Frey HP, Schmidt JM, et al. Electroencephalographic periodic discharges and frequency-dependent brain tissue hypoxia in acute brain injury. *JAMA Neurol*. 2017;74:301-309.

Pain, Numbness, and Paresthesias 8

Comana M. Cioroiu

KEY POINTS

1. Characterize the nature of the complaint—what does the patient mean by "numbness"? How can you characterize the pain?
2. Obtain a detailed history and examination to help localize the patient's complaints of numbness/paresthesias to a location in either the central or peripheral nervous system.
3. When examining a patient with sensory loss, look for asymmetry, a distal versus proximal gradient, and try to identify a pattern of sensory loss to guide your diagnostic impression.
4. Look out for red flags that suggest an urgent problem that needs to be addressed and treated rapidly.
5. Let your differential diagnosis guide your diagnostic testing.
6. Treatment of chronic pain and paresthesias can be complex and often requires a multidisciplinary approach.

INTRODUCTION

For the general neurologist, the evaluation of a patient with complaints of numbness can be a daunting one. Being the most subjective of neurologic complaints, numbness is often a difficult sensation for the patient to explain and often all the more difficult for the clinician to appreciate on examination and may be referable to a problem in either the central or peripheral nervous system. Numbness may also be a subjective complaint in patients with various chronic pain syndromes and certain psychiatric conditions in which cases the etiology is nonneurologic and often has no physiologic basis.

MANAGEMENT STRATEGY

As with all complaints in medicine, the first step is to obtain a detailed history. The first question should be one aimed at best characterizing the sensation (or lack thereof) described by the patient. It is important to differentiate between numbness as a *loss of sensation* as opposed to the *presence of an abnormal sensation*. At times, patients may also use the term *numbness* to describe muscle weakness, and this is important to keep in mind during one's examination.

Types of Sensory Symptoms

Numbness can occur as a result of pathology at several different parts of the neuraxis, including the cortex, brain stem, spinal cord, and peripheral nerves. *Paresthesias*, spontaneous and abnormal sensations often described as "tingling" or "pins and needles," may imply a different neurologic localization than a complete lack of sensation alone. They also may occur following a period of absent sensation as nerves begin to slowly regenerate. Certain types of sensory seizures may also present with such sensations.

Neuropathic Pain

Neuropathic pain (see Chapter 59) is a category of pain specific to that caused by nerve injury and is often described as painful paresthesias, associated with a sensation of burning or radiating pain as can be seen in cases of peripheral neuropathy or radiculopathy (Fig. 8.1). In such cases, patients may exhibit altered sensation or abnormally increased sensations—*hyperesthesia* refers to increased sensation, whereas *dysesthesia* refers to an evoked unpleasant or painful sensation by an otherwise innocuous stimulus.

An exaggerated response to stimuli that normally evoke pain is known as *hyperalgesia*, whereas an exaggerated and extreme pain response to stimuli that should not normally invoke pain is referred to as *allodynia*. These abnormal sensations can be seen with various nerve injuries, both at the central and peripheral level. Conversely, *hypoesthesia* refers to the diminished perception of pain, *anesthesia* to the inability to perceive pain, and *analgesia* to the inability to feel pain.

Neuropathic pain must be differentiated from somatic pain caused by pathology in bones, ligaments, muscles, and other soft tissues.

Complex regional pain syndrome (also known as *reflex sympathetic dystrophy*) is a chronic disease characterized by severe neuropathic pain, skin changes, and swelling in one limb. It may occur in the absence of a known nerve injury (type 1) or in the setting of known nerve injury (type 2). Diagnosis and treatment of complex regional pain syndrome is further discussed in Chapter 58.

NEUROANATOMY AND LOCALIZATION

The pattern and distribution of sensory complaints provides important clues regarding the localization of the pathology (Table 8.1). Sensory syndromes that relate to injury at different levels of the neuraxis are discussed in the following section, which also discusses the main sensory pathways of the nervous system.

Central Sensory Syndromes

Cortex

Numbness and paresthesias can result from both lesions in the central or peripheral nervous system. Higher cortical sensory functions are localized to the parietal cortex, with the primary

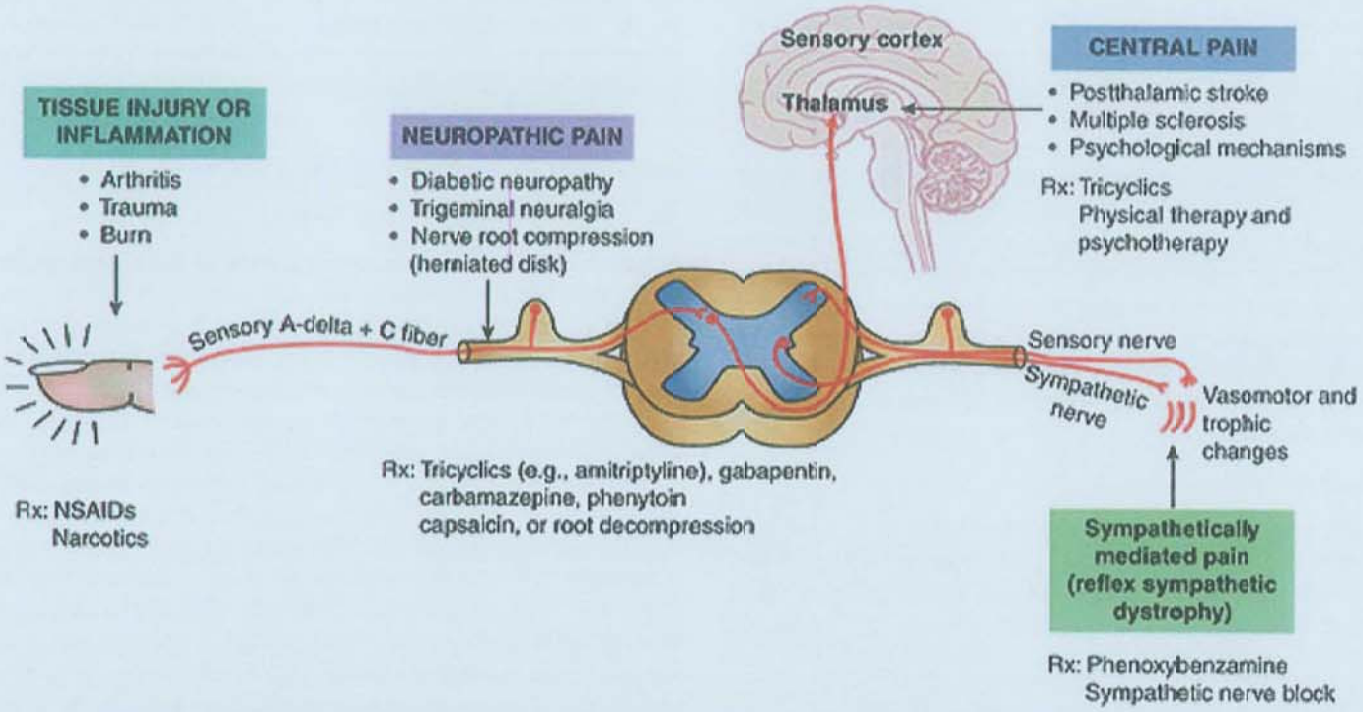

FIGURE 8.1 Sites of origin of pain within the nociceptive pathway. NSAIDs, nonsteroidal anti-inflammatory drugs. (Adapted from Marshall R, Mayer S. *On Call Neurology*. 3rd ed. Philadelphia, PA: Saunders; 2007.)

TABLE 8.1 Patterns of Sensory Loss

Localization	Sensory Pattern	Associated Findings
Cortical	• Contralateral sensory loss	• Cortical sensory loss (ie, neglect, astereognosis, agraphesthesia) • Visuospatial deficits
Brain stem	• Contralateral sensory loss of arm and leg with ipsilateral loss in face	• Cranial neuropathies (ie, ophthalmoparesis, facial weakness) • Ataxia • Contralateral weakness • Hyperreflexia
Spinal cord	• Complete transverse lesion: loss of all sensory modalities below the level of the lesion • Central cord lesion (ie, syrinx): loss of pain and temperature at and/or below the level of the lesion • Anterior cord lesion: contralateral loss of pain and temperature sensation below level of the lesion • Cord hemisection (Brown-Séquard syndrome): ipsilateral loss of vibration and joint position below the level of the lesion and contralateral loss of pain and temperature two or three segments below the level of the lesion • Cauda equina syndrome or conus medullaris syndrome: saddle anesthesia	• Contralateral or complete paralysis below the level of the lesion • Change in bladder or bowel control • Areflexia/hyporeflexia at the level of the lesion with hyperreflexia below the lesion • Dissociation between sensory modalities
Brachial plexus	• Ipsilateral sensory loss in the distribution of more than one peripheral nerve or nerve root	• Weakness in the distribution of the involved peripheral nerves or nerve roots • Areflexia • Neuropathic pain
Dorsal root ganglion	• Complete loss of sensation of all modalities in the affected dermatome	• Neuropathic pain • No weakness
Nerve root	• Loss or diminution of all sensory modalities in the affected dermatome	• Radicular pain • Weakness in the corresponding myotome • Areflexia or hyporeflexia
Peripheral nerve (also see Fig. 8.1)	• Mononeuropathy: loss or diminution of all sensory modalities in the distribution of the nerve • Polyneuropathy: distal and symmetric loss of sensation (vibration and joint position in cases of large-fiber neuropathy and pain and temperature in cases of small-fiber neuropathy) • Mononeuritis multiplex: loss of sensation in various peripheral nerves in an asymmetric fashion	• Weakness involving muscles of the corresponding peripheral nerve • Distal and symmetric weakness in cases of large fiber polyneuropathy • Autonomic findings • Neuropathic pain • Areflexia or hyporeflexia

sensory cortex being the postcentral gyrus of the parietal lobe. Lesions of the parietal lobe such as tumors or vascular insults (ie, stroke, vascular malformation, hemorrhage) may cause sensory loss and numbness and are often associated with other impaired parietal lobe functions clinically manifested by poor visuospatial skills and hemineglect. Subcortical lesions in the parietal lobe may also manifest with loss of sensation as can be seen with demyelinating plaques of multiple sclerosis. Migraine (see Chapter 56) is a condition of the central nervous system that can often be associated with sensory phenomenon both of the face and extremities, either as a migraine "aura" or associated with the pain itself. Further questioning regarding associated factors and timing will help direct one toward a differential diagnosis as discussed below.

Brain Stem

Brain stem lesions involving the trigeminal nucleus, medial lemniscus, or spinothalamic tract may also present with unilateral facial or limb numbness but are typically associated with other brain stem findings such as ophthalmoparesis, weakness, or ataxia.

Spinal Cord

Numbness resulting from spinal cord injury may correspond to a particular dermatome but may also lead to a sensory level, in which the entire body below the lesion is affected (see Chapter 17). Examples of this include cases of transverse myelitis, in which patients may present with a sensory level with complaints of numbness extending down from a particular dermatomal level. The two main central sensory pathways in the spinal cord are the *dorsal columns*, also known as the *medial lemniscus*, and the *spinothalamic tract*. Neurons carrying information related to vibration sense and proprioception travel up the cuneate and gracile fasciculus (which form the dorsal columns) in the spinal cord and synapse in their respective nuclei in the medulla, after which they decussate and form the medial lemniscus which carries these fibers to the ventral posterolateral nucleus of the thalamus before terminating in the postcentral gyrus of the parietal lobe.

Fibers carrying pain and temperature sensation form the lateral spinothalamic tract in the spinal cord and typically ascend two spinal levels in Lissauer tract in the ipsilateral cord before synapsing with a second-order sensory neuron. From there, they decussate in the anterior white commissure to the contralateral cord, and the tract then travels up the remainder of the spinal cord and brain stem and synapses again in the thalamus. Pathology of the posterior limb of the internal capsule or ventral posterolateral nucleus of the thalamus may also cause numbness, and sudden-onset isolated numbness of a limb in a patient with vascular risk factors should raise concern for a possible vascular event in these regions. Similarly, sudden-onset numbness of the face may result from a lesion in the ventral posteromedial nucleus of the thalamus.

Numbness resulting from spinal cord injury may also be accompanied by weakness and changes in bowel or bladder function. Depending on which segment of the cord is injured, patients may have preferential involvement of one tract or another and may have only certain sensory modalities affected; one classic example of this is the *Brown-Séquard syndrome*, where a spinal cord hemisection leads to ipsilateral weakness and loss of vibration and joint position sense below the level of the lesion and contralateral loss of cold and temperature sensation two or three segments below the level of the lesion (see Fig. 8.1).

Peripheral Sensory Syndromes

Nerve Roots and Dorsal Root Ganglia

Injury to the dorsal nerve root just distal to the spinal cord may cause numbness and pain in the setting of a *radiculopathy*—a patient may complain of radiating pain of an electric quality, at times associated with muscle soreness in that region. Sensory loss in a specific dermatomal distribution may be seen on exam (see Fig. 4.12), and depending on the severity of injury, there could be weakness in muscles of the corresponding myotome. The dorsal root ganglion is a group of nerve cell bodies (of first-order sensory neurons that are pseudounipolar) distal to the spinal cord carrying somatic afferents to the cord. A *sensory ganglionopathy* refers to the selective destruction or involvement of the dorsal root ganglion and clinically typically manifests as a sensory ataxia with profound deficits in proprioception, at times also with marked neuropathic pain and paresthesias. A ganglionopathy of this type may be autoimmune, paraneoplastic (specifically related to anti-Hu antibodies), toxic, or associated with a paraproteinemia or with Sjögren syndrome.

Plexuses

Processes affecting the brachial or lumbosacral plexus often present with pain as well as numbness and weakness in one limb in the distribution of more than one peripheral nerve or nerve root that tends to be more subacute in onset. *Brachial plexopathy* is the most common of these and can result from trauma, tumor infiltration, or a postinfectious autoimmune process or can often be idiopathic. Radiation resulting from treatment of certain cancers can also predispose to plexopathies in situations where the radiation is in close proximity to the plexus (ie, lumbosacral plexopathy seen after radiation for prostate cancer).

Peripheral Nerves

Neuropathic pain and numbness is a classic complaint in diseases of the peripheral nerves, such as in *polyneuropathy* (see Chapter 91). These patients will often complain of numbness and neuropathic pain that is distal and symmetric, typically starting in the feet. Polyneuropathy may preferentially affect large myelinated nerve fibers (group A fibers) carrying information related to vibration and joint position sense or small unmyelinated nerve fibers (group C fibers) transmitting pain and temperature sensation (see Fig. 8.1). Polyneuropathy can be either primarily axonal (with a predominant loss of axonal integrity) or demyelinating (due to destruction of the myelin sheath and often autoimmune in origin). Peripheral nerves may also be injured or damaged in isolation (ie, mononeuropathy as seen with carpal tunnel syndrome with medial nerve involvement) or together in cases of *mononeuritis multiplex*, classically a painful condition seen in cases of vasculitis where different peripheral nerves are affected in rapid succession. Diseases of the neuromuscular junction and muscle do not present with sensory complaints, although some patients may complain of proximal muscle pain (as with the inflammatory myopathies).

FOCUSED HISTORY

A detailed history is the best tool a clinician has in the initial evaluation of a patient with sensory complaints. First, one must try to characterize the nature of the complaint. It is helpful to determine the nature of the pain or numbness and whether the patient is referring to a complete lack of sensation or the presence of an abnormal sensation (ie, paresthesias). One must inquire as to the timing of symptom onset, because an acute or sudden onset of numbness may point more toward a vascular lesion (ie, stroke) than toward a progressive process and may require more urgent evaluation. *Red flags suggesting a more serious structural problem in a patient with primary sensory complaints include the presence of fever, muscle weakness, and bowel or bladder changes.*

Numbness and Paresthesias

When evaluating complaints of numbness or paresthesias, the *anatomic distribution* is important to determine, as this will help with localization and differential diagnosis: For instance, numbness or paresthesias localized to a specific dermatome will have different implications than numbness involving an entire limb. Sensory loss slowly progressing over both arms and sparing the legs may suggest an expanding cervical spine mass or a syrinx. One must ask about symmetry, duration of symptoms, and any alleviating or exacerbating factors. For instance, neuropathic pain due to polyneuropathy often worsens at night while patients are in bed, and radicular pain/paresthesias may be elicited with specific movements of the neck or back. In order to help formulate a differential diagnosis, it is crucial to ask about various *associated symptoms*. Numbness associated with changes in bowel or bladder habits may point toward a spinal cord lesion. Asking about any *precipitating events* such as trauma, positional changes, or a recent illness is also crucial. A recent history of viral infection associated with quickly ascending numbness should alert one to the possibility of Guillain-Barré syndrome. Asking about any recent trauma or injury may also help differentiate between an acute as opposed to a chronic nerve injury. Questions regarding gait are pertinent, as patients with polyneuropathy may complain of imbalance early in the disease course. The progression of symptoms is also of importance, as sensory symptoms moving in quick progression over a contiguous area may either be suggestive of a migrainous phenomenon or of the Jacksonian march of a partial seizure.

Pain

Acute pain is often managed very differently from chronic pain, as the former may respond well to a brief course of a particular kind of analgesic, whereas the latter may require a complex regimen of medications. *Back pain* (see Chapter 113) is one of the most common complaints in neurology, and one must differentiate between benign causes of low back pain and other more concerning causes, which may be indicative of a more serious diagnosis. An acute disk herniation is characterized by an abrupt onset often incited by lifting, Valsalva maneuver, or a sudden positional change. Lying down typically relieves this pain, whereas it is exacerbated by movement. It may be associated with radicular pain in the distribution of a particular dermatome. Chronic back pain is often challenging to treat and may require a complex therapeutic approach including medications, physical therapy, pain management, and sometimes surgical intervention.

Past Medical History

The patient's past medical history is important as well, as certain systemic illnesses may point toward an underlying etiology of the patient's symptoms. For instance, there are several conditions that may be associated with peripheral neuropathy, such as diabetes mellitus, rheumatologic diseases, or a history of cancer. A prior history of stroke of the thalamus or lateral medulla may contribute to a chronic pain syndrome (*Dejerine-Roussy syndrome*). A comprehensive list of current medications is also important to gather, as paresthesias can at times be a known side effect of certain medications (ie, paresthesias of the hands with use of topiramate). When obtaining the family history, one must be careful to inquire as to any possible neurologic diseases or any family members with a history of known neuropathy or foot deformities that may, for instance, point toward Charcot-Marie-Tooth disease. Exposure to certain substances such as heavy metals, pesticides, or chemotherapeutic agents may be implicated in those with neuropathy (some of which can be quite painful), and thus, one should ask about these possibilities when no other clear etiology can be found.

FOCUSED EXAM

The examination of a patient complaining of numbness is often challenging, as the sensory exam is the most subjective part of the neurologic exam. See Chapter 4 for a complete description of the neurologic exam.

General Medical Examination

As with all other patients, one should begin with a thorough general medical examination to look for any hints of a possible systemic disease or other findings that may be associated with the patient's complaints. For a patient with numbness or neuropathic pain, this should include an examination of the skin, assessing for rashes, hair loss, or trophic skin changes as can be seen in patients with neuropathy. Although often difficult, looking directly at the skin of the affected region may be very telling—for instance, in a patient with neuropathic pain confined to a particular dermatome, patchy erythema with grouped vesicles may be diagnostic of herpes zoster (although zoster may present without a rash, as in zoster sine herpete, or the rash may present after the onset of pain). Any patient with acute onset of numbness in which a vascular event is suspected should have a thorough cardiac evaluation and examination of the carotid arteries.

Examination of the extremities should also involve an assessment of both active and passive range of motion of affected limbs, including a *straight-leg raise test* (when indicated), which may be positive in cases of lumbosacral radiculopathy (see Fig. 4.18). A straight-leg raise is performed while having the patient lie supine as the examiner raises each leg up vertically. If the test is positive, the patient's radicular symptoms are reproduced with passive lifting of the leg (particularly the contralateral leg), as the nerve roots are stretched. *Spurling sign* is positive for cervical radiculopathy when the pain is reproduced by passively extending the neck, laterally flexing the neck toward the symptomatic side, and applying axial loading to the top of the head. *Lhermitte sign* can at times be elicited with passive flexion of the neck and is positive when the patient reports a feeling of paresthesias radiating down the arms or legs. This is caused by pressure over the posterior columns and

suggests a lesion in the posterior cervical cord as can be seen in patients with multiple sclerosis. *Tinel* and *Phalen* signs can elicit signs of median nerve compression from carpal tunnel syndrome in patients with unilateral or bilateral hand numbness (see Fig. 4.17).

Neurologic Examination

Mental Status

The majority of patients with complaints of paresthesias or neuropathic pain should have an entirely normal mental status. An abnormal finding in the patient's mental status examination points toward a cortical lesion. Higher cortical sensory function can be assessed by testing for *graphesthesia* (the ability to identify a number or letter written on the skin) and *stereognosis* (the ability to recognize an object placed in one's hand without visual or auditory stimuli). Testing for hemispatial neglect or extinction may also help identify a parietal lobe lesion.

Cranial Nerves

Similarly, a comprehensive examination of the cranial nerves can help to further localize a brain stem problem. A cranial neuropathy of any kind also suggests a central lesion as can be seen with a brain stem process or an intracranial lesion. Facial pain and neuropathies of the trigeminal nerve are discussed in detail in Chapters 57 and 89.

Motor Examination

A thorough motor examination is crucial to the evaluation of a patient with numbness and pain. In cases of chronic peripheral nerve injury, one may see atrophy of muscles in the distribution of the affected nerve. When pain is severe, a reliable determination of strength is often difficult to make. Similarly, when numbness is profound (particularly when proprioception is markedly affected), one may mistake joint position impairment for weakness. Weakness in the same distribution as numbness may point to a central lesion in the brain or spinal cord or a peripheral process in the nerve root or peripheral nerve. Distal and symmetric weakness is often most suggestive of a large-fiber polyneuropathy. Ataxia noted on finger-to-nose tests or heel-knee-shin tests may help localize a lesion to the brain stem; however, one may also find a marked sensory ataxia on coordination testing if joint position is markedly impaired.

Sensory Examination

The sensory examination is the most subjective part of the neurologic examination and often the most challenging. Several modalities can be tested and which ones are tested and how is dictated by the clinical presentation. Paresthesias that are transient and sporadic are infrequently associated with a clear loss of sensation on exam.

When examining sensation, it is helpful to keep in mind *three basic principles* (Table 8.2). Taking the time to map out a specific distribution of numbness is often diagnostic and of localizing value. For instance, in suspected spinal cord lesions, one should assess for a sensory level, which may suggest the location of the cord pathology. One can begin with an assessment of light touch sensation, for example, using the tip of a cotton swab. Pinprick sensation and temperature sensation evaluate the integrity of the spinothalamic tract and small unmyelinated nerve fibers, whereas a selective loss of vibration or joint position implies injury to the posterior columns or to the large myelinated nerve fibers as seen in polyneuropathy.

TABLE 8.2 Basic Principles of Sensory Examination

- Is the sensory loss symmetric?
- Does it follow a distal pattern?
- Does it correspond to a particular territory (ie, of one dermatome or one peripheral nerve)?

Vibration sense is determined using a 128-Hz tuning fork placed over a bony prominence, most commonly the big toe and medial malleolus of the ankle (see Fig. 4.13). Once the vibrating tuning fork is placed over the joint, one can begin to count until the patient reports no longer feeling the sensation. Alternatively, once the patient reports he or she no longer feels the vibration, the tuning fork can be placed over the examiner's metacarpophalangeal joint. Interpretation of the vibratory exam must take into account the patient's age, as vibration sense diminishes with age over time and can be absent in those older than 80 years old. Joint position is tested by moving the most distal joint passively up or down and asking the patient the direction of movement. Typically, the most subtle of movements should be detected, and if a problem is found in the most distal joint, one should move more proximally to determine the full extent of impairment. In those with severe joint position sense abnormalities, involuntary movements of the fingers may be observed with arms outstretched (*pseudoathetosis*).

Reflexes

Deep tendon reflexes are important to elicit, as they may be pathologically brisk or hyperreflexic in cases of central lesions—for instance, in spinal cord injury, reflexes may be diminished or absent at the level of the lesion but increased below the level of the lesion. In cases of peripheral neuropathies, reflexes are typically diminished or absent.

Gait and Station

A careful assessment of gait, including stance, toe walking, heel walking, and tandem gait, is also of importance, for example, as loss of balance is often a key complaint in cases of polyneuropathy. A positive Romberg test suggests impaired proprioception as can be seen with disorders of the posterior columns or with advanced large-fiber polyneuropathy.

DIAGNOSTIC EVALUATION

Following a comprehensive history and exam, one should consider appropriate diagnostic studies based on the differential diagnosis and most likely localization. Remember that when the pattern of sensory loss and history does not fit any particular diagnostic entity and the examination is entirely normal, one should consider a physical manifestation of an underlying psychiatric condition after ruling out any treatable causes.

Serologic Tests

Various tests are available to us in working up patients with neuropathic pain and numbness. Serum studies are routinely done early on in the workup and in cases of sensory loss should include electrolyte and vitamin levels (particularly vitamins B_{12}, B_6, B_1) as well as a hemoglobin A_{1c} level, as vitamin deficiencies

and diabetes are common systemic illness that often contribute to nerve damage. Depending on the clinical scenario and index of suspicion, serum testing can be expanded to include testing for human immunodeficiency virus, Lyme disease, thyroid function, hematologic malignancies, rheumatologic diseases, and various other illnesses. In any patient presentation suggestive of a peripheral polyneuropathy, a serum protein electrophoresis with immunofixation should be done to assess for a monoclonal protein. In those patients with a history of specific environmental exposures, testing can be done to evaluate for the presence of specific toxic agents such as heavy metals. Genetic causes of numbness and paresthesias exist (ie, Charcot-Marie-Tooth disease, hereditary neuropathy with liability to pressure palsies), and genetic testing should be pursued in those with a family history and the appropriate clinical phenotype.

Neuroimaging

If a central lesion is suspected, imaging studies are typically done early to evaluate for a structural lesion. Magnetic resonance imaging (MRI) (see Chapter 22) has the highest sensitivity and is the preferred imaging modality; however, a computed tomography scan can be done in patients unable to tolerate or undergo MRI testing. Spine imaging in particular can be instructive when considering a lesion at the level of the cord or the nerve root. In those patients in whom MRI is not feasible, computed tomography myelography can be used to assess for structural lesions of the spine and nerve roots. More distally, imaging of the brachial plexus is at times instructive in providing a more clear etiology in cases of plexopathy and can be used to evaluate for hemorrhage, inflammation, or infiltrative lesions.

Lumbar Puncture

Lumbar puncture (see Chapter 32) should be performed in cases of suspected inflammatory, infectious, or neoplastic processes. It is particularly helpful in cases of suspected autoimmune demyelinating neuropathies, which will show a characteristic albuminocytologic dissociation with elevated protein in the setting of a normal cell count.

Electrodiagnostic and Quantitative Sensory Testing

Nerve conduction studies and electromyography are important in helping to diagnose conditions of the peripheral nervous system and can help localize a complaint of numbness or neuropathic pain to the nerve root, plexus, or peripheral nerve (see Chapter 27). These tests have long been the standard practice in the diagnosis of neuropathy involving large nerve fibers and can characterize the severity of injury as well as distinguish between generalized and focal forms of either purely axonal or demyelinating forms of neuropathy (such as acute or chronic inflammatory demyelinating neuropathy). Nerve conduction study techniques are not sensitive in the assessment of small nerve fibers and are normal in cases of small-fiber neuropathy. More extensive quantitative sensory testing can be done in certain patients to more sensitively assess sensory dysfunction. Quantitative sensory testing uses noninvasive methods to determine the sensory threshold to various modalities including vibration, temperature, and pain and compare it to standardized normal values.

Skin and Nerve Biopsy

Given the inability of routine electrodiagnostic tests to assess for involvement of small unmyelinated cutaneous nerve fibers, a diagnosis of small-fiber neuropathy is typically made via *skin* biopsy which is done with two small punch biopsies of two different areas of skin (one proximal and one distal). *Nerve biopsy*, a more invasive test, is typically best reserved for cases involving large nerve fibers in which the diagnosis is in question and there is no known etiology (see Chapter 33). The diagnostic yield and use of nerve biopsy are best seen in cases of inflammatory, demyelinating, or infiltrative etiologies of neuropathy, with the most informative being those done on a nerve with abnormalities demonstrated on nerve conduction studies.

INITIAL MANAGEMENT

Identify Potentially Serious Conditions

Most patients with complaints of pain or paresthesias can be safely evaluated on an outpatient basis; however, exceptions certainly do exist. *Acute conditions that may lead to rapid deterioration must be identified promptly and treated as such.* For instance, a patient presenting with acute-onset lateralized numbness with vascular risk factors should be directed to the emergency room for stroke evaluation. Similarly, a patient with suspected Guillain-Barré syndrome or transverse myelitis should be evaluated rapidly and admitted to the hospital, as a delay in treatment could result in rapid deterioration and possible respiratory compromise. Inpatient hospitalization for treatment with steroids, intravenous immunoglobulin, plasmapheresis, or other immunomodulatory agents is at times necessary for these patients depending on the clinical situation.

Symptomatic Treatment

Once all diagnostic tests are completed, treatment of pain and paresthesias is twofold. The first approach is to treat the underlying etiology of the symptoms—for instance, if a structural lesion is found, surgical intervention may be appropriate, or if an autoimmune condition is diagnosed, treatment with immunomodulatory therapy is indicated. Patient with diabetes should be counseled regarding glycemic control and diet modification, those with vitamin deficiencies should be repleted, and so forth. Second, symptomatic therapy should be initiated to help with bothersome symptoms. *The treatment of neuropathic pain and paresthesias is vast and is discussed in detail in* Chapter 59. Symptomatic treatment should be multidisciplinary and include a combination of pharmacologic measures, physical therapy, and behavioral modifications. Chronic pain is often markedly challenging to treat and can be frustrating to both patients and practitioners alike.

Headache and Facial Pain 9

Ashhar S. Ali and Julio R. Vieira

KEY POINTS

1. The *International Classification of Headache Disorders*, 3rd edition, is used to differentiate the various types of headache disorders.
2. The "SNOOP" pneumonic is a useful tool to help distinguish between primary and secondary headache disorders.
3. Emergency department treatment of migraine should ideally consist of parenteral therapies, which allow for rapid and sustained relief and avoidance of opioids.
4. Craniofacial pain syndromes are rare, and secondary causes must be ruled out.

INTRODUCTION

Headache is one of the most frequent reasons for which patients seek medical attention and, when accounting for direct and indirect costs, accounts for more disability on a global scale than any other neurologic disorder. The appropriate management of headache disorders relies on (1) a careful diagnostic approach that is based on an understanding of the physiologic mechanisms of head pain and (2) symptom recognition of primary and secondary headache disorders.

GENERAL PRINCIPLES

A classification system for headache disorders has been established by the International Headache Society. The most recent version, *International Classification of Headache Disorders*, 3rd edition, divides headache disorders into *primary* headaches (in which the headache and associated features constitute the disorder itself) and *secondary* headaches (in which the headache is due to a serious underlying disorder).

The most common primary headache syndrome is tension headache, with a lifetime prevalence of around 70% to 90%. However, tension headache is rarely debilitating and is generally self-treated with over-the-counter medications. The second most common primary headache disorder is migraine, with a 1-year prevalence of 12% (17% among women and 6% among men, peaking around the fourth decade of life). Recurrent and disabling headaches in a primary care setting are most often migraine. Although life-threatening headache presents infrequently, caution is needed to ensure proper diagnosis and management.

DIAGNOSIS

History

The key to a proper diagnosis of headache is to obtain a comprehensive and precise history. Important components of the headache history include the following:

- **Onset**: abrupt versus insidious; age of onset; context in which headache began (eg, recent head or neck trauma including head/neck surgeries, systemic illness, pregnancy/postpartum)
- **Timing**: chronicity, duration, and frequency of headache attacks; time to maximal intensity; diurnal versus nocturnal
- **Quality**: sharp, dull, pressure-like, throbbing, aching, stabbing, lancinating, burning
- **Laterality**: unilateral versus bilateral; side-locked versus alternating
- **Location**: retro-orbital, frontal, temporal, occipital
- **Severity**: visual analog pain scale; disability and interference with routine activity
- **Change**: difference in pattern from prior headaches
- **Associated symptoms**: sensitivity to stimuli (eg, light, noise, smell, movement); nausea/vomiting; visual changes; numbness/tingling of the face or extremities; focal motor weakness; impairment of speech; light-headedness/vertigo; cognitive dysfunction
- **Cranial autonomic features**: lacrimation, conjunctival injection, eyelid edema, ptosis, pupillary changes; nasal congestion or rhinorrhea; aural fullness or tinnitus
- **Premonitory features**: symptoms that precede headache attacks, hours to days prior (eg, yawning, sleepiness, increased thirst, changes in bowel/bladder pattern, neck stiffness); typically a feature of migraine
- **Postdrome**: symptoms that follow headache attacks, typically lasting 1 to 2 days (eg, inability to concentrate, fatigue, mood alterations); typically a feature of migraine
- **Identifiable triggers**: menstrual cycle; skipping meals; lack of sleep or oversleeping; stress; altitude or barometric changes; positional change (lying down vs standing up); Valsalva maneuvers or physical exertion; alcohol; caffeine; cigarette smoke
- **Family history**: of primary headache disorders; cerebral aneurysm; brain tumor or malignancy

Medical and psychological history, review of systems, social history, concomitant medications, prior imaging, and laboratory testing should also be reviewed in detail, as these may suggest an underlying cause for the headache.

Physical Examination

The physical examination should include a comprehensive systemic and neurologic examination with particular attention to the following: bruits of the head or neck, temporal artery tenderness and pulsations, pericranial nerve tenderness (occipital, auriculotemporal, supraorbital, etc), pupillary size and symmetry, funduscopic examination (for evaluation of papilledema and venous pulsations), visual field testing, extraocular movements, facial sensation, cervical spine tenderness and range of motion, temporomandibular joint function, motor function, and deep tendon reflexes.

Primary Versus Secondary Headache

The first goal of diagnosis is to differentiate between a primary headache disorder, such as migraine, tension, or cluster, and a secondary headache disorder, in which headache is a symptom of an underlying illness, such as a brain tumor or malignant hypertension. There are tools available to help us distinguish between these two and are detailed in the following sections.

"Red Flags"

Symptoms that may point to a serious underlying disorder can be evaluated by the mnemonic "SNOOP" (Table 9.1). The presence of any features of SNOOP raises concern for a secondary headache and should prompt further diagnostic evaluation.

Alarming causes of secondary headache that require urgent evaluation include meningitis, intracranial hemorrhage, acute cerebral ischemia, tumor or obstructive lesion, acute angle closure glaucoma, acute sinusitis, cortical venous sinus thrombosis, cervical artery dissection, pituitary apoplexy, posterior reversible encephalopathy syndrome, and reversible cerebral vasoconstriction syndrome. Diagnostic testing, at the bare minimum, should include computed tomography (CT) or magnetic resonance imaging (MRI) of the head and selected laboratory testing. Thyroid disorders (most commonly hypothyroidism), hematologic disorders, and iatrogenic causes (such as medication side effect) may also contribute to headache in the outpatient setting and require further diagnostic evaluation.

TABLE 9.1 "Red Flags" When Evaluating Headache Symptoms[a]

Systemic	Systemic signs/symptoms: fever, night sweats, weight loss; new headache during pregnancy or postpartum; and comorbid systemic disease (eg, HIV, malignancy)
Neurologic symptoms/signs	Change in mental status; alteration of consciousness; seizure; papilledema, ataxia, focal exam findings sensation; headache induced by Valsalva maneuvers (bending, lifting, cough, sneezing)
Older	Onset after age 50 years
Onset	Abrupt, sudden, "thunderclap"
Pattern change	Change in frequency, severity, or clinical features of the attack from previous headache history; subacute worsening over days/weeks or accelerating pattern

Abbreviation: HIV, human immunodeficiency virus.
[a]Adapted from Silberstein SD, Lipton RB, Dodick D, et al. *Wolff's Headache and Other Head Pain*. 8th ed. New York, NY: Oxford University Press; 2008.

The evaluation of a patient who presents to the emergency department with a red flag is shown in Figure 9.1.

"Green Flags"

Certain clinical features support a primary headache disorder. Simple tools that can help identify migraine in a primary care setting include *ID Migraine*, a set of three questions assessing for photophobia, nausea, and disability, simplified as "PIN" (photophobia, inability to function, and nausea). If two out of the three features are present, a diagnosis of migraine is likely (with sensitivity of 84% and specificity of 76%). Another tool is the *POUND* mnemonic (Table 9.2), in which the presence of at least four out of five features can accurately predict a diagnosis of migraine.

Despite present guideline recommendations, many clinicians order testing, particularly neuroimaging, for uncomplicated primary headache disorders, such as migraine. Consequently, the American Headache Society has created the "Choosing Wisely" recommendations to address the need for neuroimaging as follows:

- Don't perform neuroimaging studies in patients with stable headaches that meet criteria for migraine.
- Don't perform CT imaging for headache when MRI is available, except in emergency settings.

PRIMARY HEADACHE DISORDERS

The primary headache disorders are discussed in Chapter 56.

SECONDARY CAUSES OF HEADACHE

Meningitis

Presence of fever, stiff neck, and Kernig and Brudzinski signs (poor sensitivity but good specificity) warrant further workup with urgent imaging (CT/MRI), followed by lumbar puncture for cerebrospinal fluid (CSF) analysis to assess for an infectious or inflammatory meningitis. If suspecting bacterial meningitis, cover with empiric antibiotics while awaiting CSF results and blood cultures.

Subarachnoid Hemorrhage and Intracranial Aneurysms

A "thunderclap headache" or "worst headache of life" can be suggestive of subarachnoid hemorrhage. Patients with this presenting symptom, which may be alongside focal neurologic symptoms or alteration in consciousness, should undergo emergent noncontrast head CT. If this is negative and subarachnoid hemorrhage is still suspected, lumbar puncture should be performed (checking for the presence of red blood cells or xanthochromia). Further workup may include an MRI of the brain and vessel imaging with either computed tomography angiogram (CTA), magnetic resonance angiogram (MRA), or a conventional angiogram.

Small unruptured intracranial aneurysms are typically asymptomatic. However, *large* unruptured intracranial aneurysms may present with focal neurologic deficits.

- A third nerve palsy suggests a possible posterior communicating artery aneurysm.
- A sixth nerve palsy can suggest a posterior fossa lesion or increased intracranial pressure.

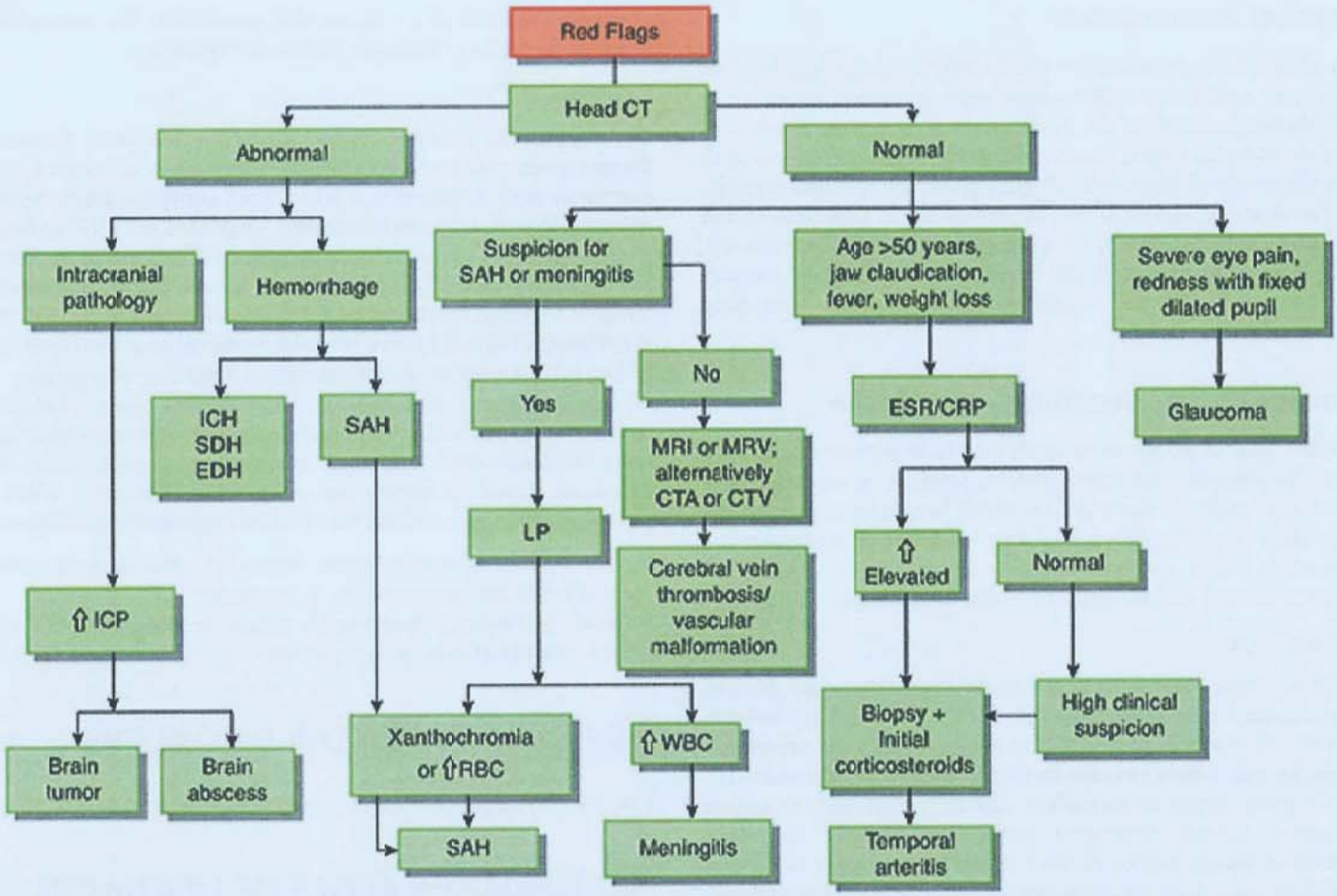

FIGURE 9.1 Evaluation of a patient with headache in the emergency room. Abbreviations: CRP, C-reactive protein; CT, computed tomography; CTA, computed tomography angiogram; CTV, computed tomography venography; EDH, extradural hemorrhage; ESR, erythrocyte sedimentation rate; ICH, intracerebral hemorrhage; ICP, intracranial pressure; LP, lumbar puncture; MRI, magnetic resonance imaging; MRV, magnetic resonance venography; RBC, red blood cell; SAH, subarachnoid hemorrhage; SDH, subdural hemorrhage; WBC, white blood cell. (Adapted from Gordon DL. Approach to the patient with acute headache. In: Biller J, ed. *Practical Neurology*. 4th ed. Philadelphia, PA: Lippincott Williams & Wilkins; 2012:194-206.)

- Bilateral leg weakness or abulia may signify an anterior communicating artery aneurysm.
- Aphasia, hemiparesis, or neglect can suggest a middle cerebral artery aneurysm.

Brain Tumor

Approximately 30% of patients diagnosed with a brain tumor report headache at presentation; however, only 1% present with headache as the *only* clinical symptom. Apart from focal neurologic deficits, clues that may suggest an intracranial lesion include sudden change in pattern of a preexisting headache disorder, worsening of headache with Valsalva maneuvers and exertion, or headache that awakens one from sleep. However, these characteristics are also commonly seen in primary headache disorders, such as migraine and cluster headache. MRI brain with and without contrast can help determine the presence or absence of a neoplasm.

TABLE 9.2 POUND Mnemonic for Identifying Migraine Headache

Pulsatile quality of headache
One-day duration (4-72 h)
Unilateral location
Nausea or vomiting
Disabling intensity

Subdural Hematoma

Headache is reported in 80% of cases of subdural hematoma and is more insidious in onset than in subarachnoid hemorrhage. Characteristics may resemble those of a brain tumor (due to mass effect). Mental status changes and gait instability are common in the elderly who are at risk for acute-on-chronic subdural bleeding (often from nonwitnessed or nonreported falls). Head CT is the initial screening test of choice. Of note, a CSF leak may present as a nontraumatic subdural hematoma, as bridging veins may rupture secondary to the decrease in CSF volume.

Cervical Artery Dissection

Headache from carotid artery dissection is typically unilateral and may be associated with ipsilateral neck pain or a Horner syndrome. Headache from vertebral artery dissection is posterolateral and, when the dissection occurs or extends intracranially, may be accompanied by meningismus. Additionally, cervical

artery dissection may present as thunderclap headache. The CTA or MRA with fat-suppressed sequences can identify cervical artery dissection. Complex presentations additionally require conventional angiography.

Cerebral Venous Sinus Thrombosis

Approximately 90% of cases present with headache (most common feature but not specific) that worsens over days; other signs include seizures, altered mental status, papilledema, and focal neurologic deficits. This condition is most common among young adult women. Diagnosis is made with CT venography, which requires iodinated contrast, or magnetic resonance venogram (MRV).

Reversible Cerebral Vasoconstriction Syndrome

This condition often presents with thunderclap or recurrent thunderclap headache, resembling subarachnoid hemorrhage. The diagnosis is established by demonstrating the absence of blood in the CSF (which would instead indicate subarachnoid hemorrhage) and the presence of diffuse cerebral arterial vasospasm (typically with noninvasive vascular imaging, although conventional angiography may be required). Ischemic stroke and intracranial hemorrhage may be present. Resolution of the syndrome over a period of weeks is expected.

Giant Cell Arteritis

New-onset headache at age 50 years or older, with associated temporal artery tenderness or decreased temporal artery pulse, should raise suspicion for giant cell arteritis (temporal arteritis). Other associated symptoms include jaw claudication, unanticipated weight loss, fatigue, night sweats, and myalgias. An erythrocyte sedimentation rate and C-reactive protein should be checked in such presentations. If one or both are elevated, or if both are normal but clinical suspicion remains high, corticosteroids should be initiated and a temporal artery biopsy should be pursued. Headache typically resolves or greatly improves within 3 days of starting high-dose corticosteroids.

Spontaneous Intracranial Hypotension

Headache is commonly orthostatic in nature, occurring in the upright position and resolving or notably improving upon lying supine. A paradoxical presentation, albeit rare, is also possible, in which case, the headache worsens when supine and improves when upright. Pain may also be worsened by Valsalva maneuvers. Neck stiffness and nausea may be present.

If intracranial hypotension is suspected, an MRI brain with and without contrast should be performed, which may reveal subdural fluid collections, pachymeningeal enhancement, engorgement of venous structures, pituitary hyperemia, and/or sagging of the brain with cerebellar tonsil displacement. If there is no clear precipitating event (such as a recent lumbar puncture), spinal MRI with heavy T2 weighting or CT myelography should be considered to identify potential sites of CSF leakage. Treatment options include bed rest, intravenous fluids and caffeine, and a blood patch even if the site of leak has not been identified. If a leak site is identified, a CT-guided therapeutic blood patch is performed. Infrequently, the site of the leak may be repaired surgically.

Idiopathic Intracranial Hypertension

Idiopathic intracranial hypertension, formerly termed *pseudotumor cerebri*, is a syndrome of elevated intracranial pressure that usually occurs in obese women of child-bearing age. Headache may share features as seen with space-occupying lesions, such as worsening with Valsalva maneuvers, wakening from sleep, and/or intractable nausea or vomiting. Other symptoms include transient visual obscurations, photopsia, horizontal diplopia, and pulsatile tinnitus. Persistently raised intracranial pressure can also trigger migraine symptoms such as photophobia or phonophobia.

The most concerning abnormal finding on examination is that of papilledema on funduscopic examination as well as the absence of spontaneous venous pulsations. Other findings include a sixth nerve palsy. Certain medications may increase the risk for developing idiopathic intracranial hypertension, such as estrogen-containing oral contraceptives, excessive intake of vitamin A or retinoic acid derivatives, and lithium.

Brain MRI and MRV should be obtained if there is concern; imaging may reveal an empty sella, flattening of the posterior globes, protrusion of optic nerve heads, optic nerve sheath swelling, tortuosity of optic nerves, or transverse venous sinus stenosis. An elevated opening pressure (greater than 25 cm H_2O) on lumbar puncture and improvement in headache following removal of CSF is diagnostic. Initial treatment is with acetazolamide 250 to 500 mg twice a day, increasing as tolerated to a daily dose of 2 to 4 g LEVEL 1.[1] Topiramate is the next treatment of choice. Patients who do not respond to medical treatment, or those with progressive visual compromise, may require intracranial pressure monitoring and subsequent intervention, such as ventriculoperitoneal shunting or optic nerve sheath fenestration. Venous sinus stenting is a new technique with reported success.

EMERGENCY DEPARTMENT EVALUATION AND MANAGEMENT

Diagnostic Evaluation

Upon presentation to the emergency department, it is necessary to evaluate for the presence of red flags—if any are present, the algorithm in **Figure 9.1** should be followed for further workup. Useful laboratory testing include the following:

- Comprehensive metabolic panel
- Complete blood count
- β-Human chorionic gonadotropin (pregnancy test)
- Erythrocyte sedimentation rate and C-reactive protein (if concern for inflammatory condition, such as giant cell arteritis)

If there is concern for intracranial or subarachnoid hemorrhage, a noncontrast head CT should be obtained emergently. A follow-up brain MRI may later be obtained for further characterization. Vascular imaging (such as with MRA/CTA, MRV/CT venography, or conventional angiography) may be considered in specific circumstances as described previously. Lumbar puncture may be necessary in certain cases.

The absence of red flags, as well as the presence of green flags, suggests a primary headache disorder.

Migraine Treatment in the Emergency Department

Goals of Treatment

It is important to first establish the patient's baseline, as a treatment goal of pain freedom may be unrealistic in someone with long-standing chronic headache. Return to baseline may be a more achievable goal. In addition to pain reduction, improvement in other bothersome symptoms (eg, nausea, photophobia, phonophobia) should also be targeted.

Parenteral Therapies

The majority of patients who present with headache in the emergency department have intractable migraine. Most have already attempted oral medications, unsuccessfully, prior to their arrival. Therefore, parenteral therapies are more likely to yield improvement.

The initial treatment regimen should consistent of intravenous fluids, even in the absence of vomiting or clinical signs of dehydration. Additionally, dopamine receptor antagonists, such as prochlorperazine 10 to 25 mg and metoclopramide 5 to 10 mg, have both antiemetic and antinociceptive properties and can be quite effective LEVEL 1.[2-5] Patients should be monitored for the development of akathisia or other extrapyramidal symptoms. Pretreatment with intravenous diphenhydramine 25 to 50 mg can help prevent these side effects. Intravenous ketorolac 30 to 60 mg should also be considered, as long as there is no history of occlusive vascular disease or kidney impairment. Intravenous magnesium may also be effective and can be administered at doses of 500 mg to 1 g. Resultant hypotension can be avoided by first administering intravenous fluids.

Intravenous valproic acid 10 to 15 mg/kg may also be considered for treatment of intractable migraine. Use of valproic acid should be avoided in pregnant women and cautiously used in women of childbearing age as well as those with liver disease or urea cycle disorders.

Headache recurrence after emergency department discharge is remarkably frequent, occurring in approximately 75% of patients within 48 hours of discharge; thus, a discharge plan is advisable as well as close outpatient follow-up. The addition of intravenous corticosteroids, such as dexamethasone 4 to 10 mg, has been shown to decrease migraine recurrence when administered in the emergency department LEVEL 1.[2,6] A tapering dose of corticosteroids may also be given at discharge.

The schematic in **Figure 9.2** is a suggested general approach to the management of the migraine patient presenting to the emergency department. However, treatment ultimately should be tailored to the patient's individual headache characteristics, associated features, and medical comorbidities.

Inpatient Admission

Patients who do not respond to repeated cycles (at least three) of the earlier often require inpatient admission. The treatment of choice for status migrainosus is intravenous dihydroergotamine. Repetitive dosing every 8 hours, or a continuous infusion, over a 3- to 5-day course, is typically effective. Contraindications include pregnancy, uncontrolled hypertension, history of occlusive vascular disease, and use of any triptan or ergot in the preceding 24 hours. Intravenous lidocaine infusion may also be considered. This will require close cardiac monitoring. Finally, occipital nerve block may provide immediate relief from migraine and should also be considered in the inpatient setting.

Opioids

Despite evidence against the effectiveness of opioids as a migraine treatment, its administration in the emergency department remains common. Conversely, effective parenteral therapies are often underused. Opioids are not as effective for acute migraine treatment as dopamine antagonists, ketorolac, and dihydroergotamine. In addition, opioids may decrease the effectiveness of migraine-specific abortive therapies (such as triptans), increase migraine relapse with recurrent emergency department visits, and may precipitate medication overuse headache with as little as one to two doses per week.

Treatment of Other Primary Headache Disorders

Apart from migraine, patients may present to the emergency department with one of the trigeminal autonomic cephalalgias, which are covered in detail in Chapter 57. The acute treatment of cluster headache includes 100% oxygen inhaled via a nonrebreather mask at a rate of 10 to 12 L per minute for 15 to 20 minutes and/or subcutaneous sumatriptan or intranasal zolmitriptan LEVEL 1.[7,8] Alternative options include dihydroergotamine 1 mg administered intramuscularly. External vagal nerve stimulation is now also a U.S. Food and Drug Administration–approved treatment LEVEL 1.[9,10]

Paroxysmal hemicrania and hemicrania continua respond exquisitely to oral indomethacin, which can be started at a dose of 25 mg 3 times daily and gradually titrated, as tolerated, to a maximum dose of 75 mg 3 times daily.

The SUNCT (short-lasting unilateral neuralgiform headache attacks with conjunctival tearing and injection) or SUNA (short-lasting unilateral neuralgiform headache attacks with cranial autonomic symptoms) that is not responsive to oral therapies (such as lamotrigine) may require a short course of intravenous lidocaine, 1 to 4 mg/min with close cardiac monitoring.

CRANIOFACIAL PAIN

The diagnosis and management of patients with craniofacial pain can be quite challenging. Presentations can vary drastically, leading to delayed diagnosis and treatment. Most patients who present with craniofacial pain will require imaging of the head and/or neck and possibly otolaryngology referral if a secondary cause is suspected.

Neuralgic Pain

Commonly, craniofacial pain presents as *neuralgias*, which are paroxysmal, fleeting, often electric shock–like painful sensations in the distribution of a particular nerve. One cause is the presence of ectatic vascular loops that compress the associated nerve (eg, trigeminal or glossopharyngeal) at the nerve root entry zone. Demyelinating lesions at the central portions of the nerve root entry zones are also causative and are more commonly seen in younger patients who are less likely to have ectatic vascular loops. Still, other causes include nerve entrapment, as is the postulated mechanism of occipital neuralgia.

Triggers

Trigger maneuvers characteristically provoke paroxysms of pain. For instance, activation by light touch over the skin of

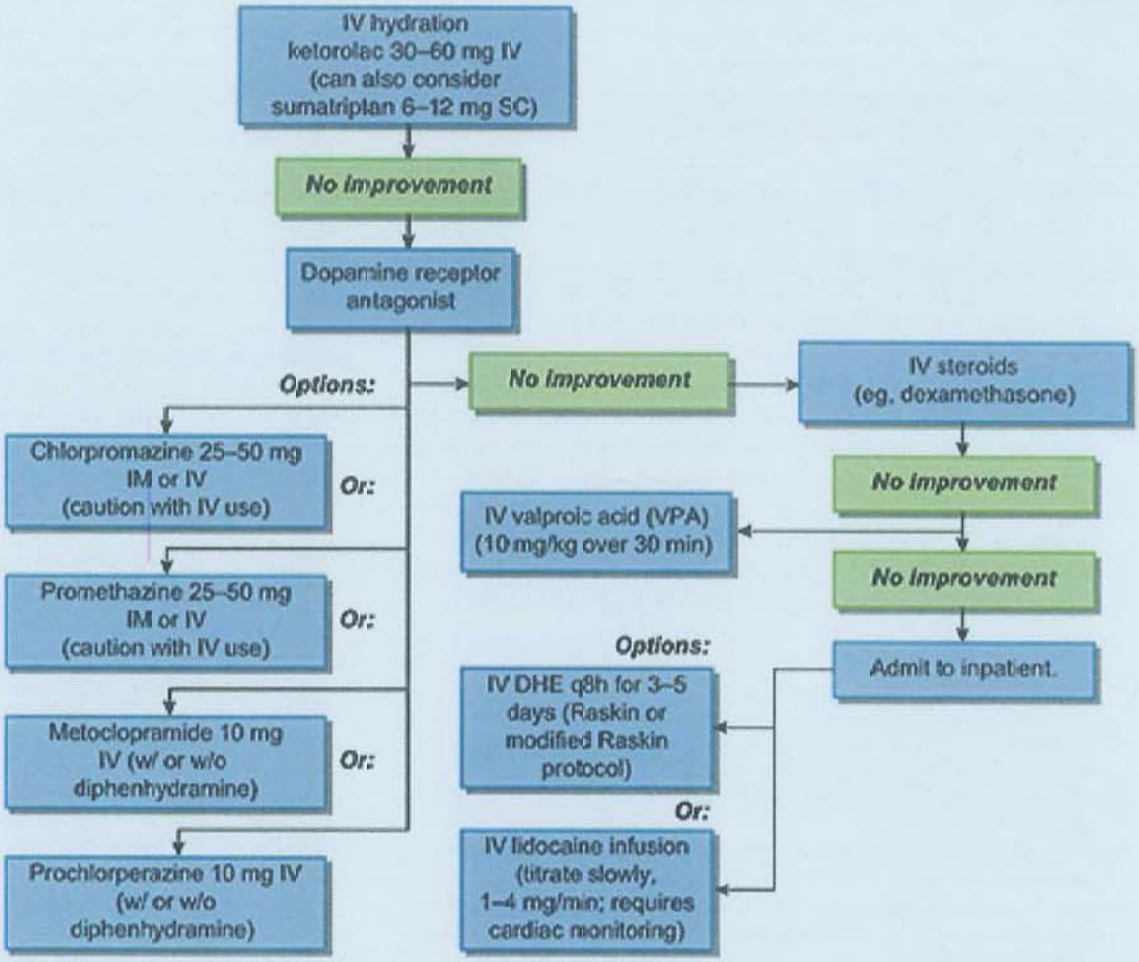

FIGURE 9.2 Treatment algorithm for the migraine patient in the emergency room. Abbreviations: DHE, dihydroergotamine; IM, intramuscular; IV, intravenous; SC, subcutaneous.

the affected trigeminal region (termed *trigger zone*) suggests trigeminal neuralgia. Pain with chewing hints toward temporomandibular joint dysfunction or giant cell arteritis (a jaw claudication), whereas swallowing is a trigger for glossopharyngeal neuralgia.

Dental Pain

Craniofacial pain may also be due to dental pathology or gingival irritation; provocation by hot or cold foods is typical. External stimuli, such as application of cold, repeatedly induce pain without a refractory period. Although neuralgic pain may also be triggered by external stimuli, a refractory period is usually present. This difference can be elicited by history and should not be missed.

Atypical Facial Pain

As with other painful conditions, some patients with craniofacial pain describe imprecise symptoms that do not conform to a stereotypic syndrome. In such cases, secondary causes should be ruled out via appropriate testing. Vague, poorly localized, continuous facial pain can be seen in secondary conditions such as nasopharyngeal carcinoma and other somatic diseases. In these cases, a burning, painful element often supervenes as deafferentation occurs, and evidence of cranial neuropathy appears. In many cases, however, a secondary etiology is not uncovered, and patients are ultimately given a diagnosis of "atypical facial pain." These patients should be followed up periodically as certain clues may arise through history and examination.

FACIAL PAIN SYNDROMES AND THE CRANIAL NEURALGIAS

Facial pain syndromes and the cranial neuralgias are further covered in Chapter 57.

LEVEL 1 EVIDENCE

1. Wall M, McDermott MP, Kieburtz KD, et al; and NORDIC Idiopathic Intracranial Hypertension Study Group Writing Committee. Effect of acetazolamide on visual function in patients with idiopathic intracranial hypertension and mild visual loss: the idiopathic intracranial hypertension treatment trial. *JAMA*. 2014;311(16):1641-1651.
2. Orr SL, Aube M, Becker WJ, et al. Canadian Headache Society systematic review and recommendations on the treatment of migraine pain in emergency settings. *Cephalalgia*. 2015;35(3):271-284.
3. Orr SL, Friedman BW, Christie S, et al. Management of adults with acute migraine in the emergency department: the American Headache Society evidence assessment of parenteral pharmacotherapies. *Headache*. 2016;56(6):911-940.
4. Colman I, Brown MD, Innes GD, Grafstein E, Roberts TE, Rowe BH. Parenteral metoclopramide for acute migraine: meta-analysis of randomised controlled trials. *BMJ*. 2004;329(7479):1369-1373.
5. Kelley NE, Tepper DE. Rescue therapy for acute migraine, part 2: neuroleptics, antihistamines, and others. *Headache*. 2012;52(2):292-306.

6. Colman I, Friedman BW, Brown MD, et al. Parenteral dexamethasone for acute severe migraine headache: meta-analysis of randomised controlled trials for preventing recurrence. *BMJ*. 2008;336(7657):1359-1361.
7. Robbins MS, Starling AJ, Pringsheim TM, Becker WJ, Schwedt TJ. Treatment of cluster headache: the American Headache Society evidence-based guidelines. *Headache*. 2016;56(7):1093-1106.
8. Francis GJ, Becker WJ, Pringsheim TM. Acute and preventive pharmacologic treatment of cluster headache. *Neurology*. 2010;75(5):463-473.
9. Goadsby PJ, de Coo IF, Silver N, et al. Non-invasive vagus nerve stimulation for the acute treatment of episodic and chronic cluster headache: a randomized, double-blind, sham-controlled ACT2 study. *Cephalalgia*. 2018;38(5):959-969.
10. Silberstein SD, Mechtler LL, Kudrow DB, et al. Non-invasive vagus nerve stimulation for the acute treatment of cluster headache: findings from the randomized, double-blind, sham-controlled ACT1 study. *Headache*. 2016;56(8):1317-1332.

SUGGESTED READINGS

Ali AS, Stillman M. What inpatient treatments do we have for acute intractable migraine? *Cleve Clin J Med*. 2018;85(7):514-516.

Ball AK, Clarke CE. Idiopathic intracranial hypertension. *Lancet Neurol*. 2006;5(5):433-442.

Bigal ME, Lipton RB. Excessive acute migraine medication use and migraine progression. *Neurology*. 2008;71(22):1821-1828.

Burstein R, Collins B, Jakubowski M. Defeating migraine pain with triptans: a race against the development of cutaneous allodynia. *Ann Neurol*. 2004;55(1):19-26.

Carolei A, Sacco S. Headache attributed to stroke, TIA, intracerebral haemorrhage, or vascular malformation. *Handb Clin Neurol*. 2010;97:517-528.

Colman I, Rothney A, Wright SC, Zilkalns B, Rowe BH. Use of narcotic analgesics in the emergency department treatment of migraine headache. *Neurology*. 2004;62(10):1695-1700.

Cousins G, Hijazze S, Van de Laar FA, Fahey T. Diagnostic accuracy of the ID Migraine: a systematic review and meta-analysis. *Headache*. 2011;51(7):1140-1148.

De Luca GC, Bartleson JD. When and how to investigate the patient with headache. *Semin Neurol*. 2010;30(2):131-144.

Detsky ME, McDonald DR, Baerlocher MO, Tomlinson GA, McCrory DC, Booth CM. Does this patient with headache have a migraine or need neuroimaging? *JAMA*. 2006;296(10):1274-1283.

Dilli E. Thunderclap headache. *Curr Neurol Neurosci Rep*. 2014;14(4):437-412.

Dodick DW. Diagnosing headache: clinical clues and clinical rules. *Adv Stud Med*. 2003;3(2):87-92.

Dodick DW. Pearls: headache. *Semin Neurol*. 2010;30(1):74-81.

Donohoe CD. The role of the physical examination in the evaluation of headache. *Med Clin North Am*. 2013;97(2):197-216.

Edlow JA, Caplan LR. Avoiding pitfalls in the diagnosis of subarachnoid hemorrhage. *N Engl J Med*. 2000;342(1):29-36.

Fiesseler FW, Kec R, Mandell M, et al. Do ED patients with migraine headaches meet internationally accepted criteria? *Am J Emerg Med*. 2002;20(7):618-623.

Friedman BW, Garber L, Yoon A, et al. Randomized trial of IV valproate vs metoclopramide vs ketorolac for acute migraine. *Neurology*. 2014;82(11):976-983.

Friedman BW, Solorzano C, Esses D, et al. Treating headache recurrence after emergency department discharge: a randomized controlled trial of naproxen versus sumatriptan. *Ann Emerg Med*. 2010;56(1):7-17.

Friedman BW, West J, Vinson DR, et al. Current management of migraine in US emergency departments: an analysis of the National Hospital Ambulatory Medical Care Survey. *Cephalalgia*. 2015;35(4):301-309.

Gelfand AA, Goadsby PJ. A neurologist's guide to acute migraine therapy in the emergency room. *Neurohospitalist*. 2012;2(2):51-59.

Gordon DL. Approach to the patient with acute headache. In: Biller J, ed. *Practical Neurology*. 4th ed. Philadelphia, PA: Lippincott Williams & Wilkins; 2012:194-206.

Grosberg BM, Friedman BW, Solomon S. Approach to the patient with headache. In: Robbins MS, Grosberg BM, Lipton RB, eds. *Headache*. Hong Kong, Hong Kong: Wiley; 2013:16-25.

Kelley NE, Tepper DE. Rescue therapy for acute migraine, part 1: triptans, dihydroergotamine, and magnesium. *Headache*. 2012;52(1):114-128.

Kelley NE, Tepper DE. Rescue therapy for acute migraine, part 2: neuroleptics, antihistamines, and others. *Headache*. 2012;52(2):292-306.

Kelley NE, Tepper DE. Rescue therapy for acute migraine, part 3: opioids, NSAIDs, steroids, and post-discharge medications. *Headache*. 2012;52(3):467-482.

Krymchantowski AV. Naproxen sodium decreases migraine recurrence when administered with sumatriptan. *Arq Neuropsiquiatr*. 2000;58(2B):428-430.

Law S, Derry S, Moore RA. Sumatriptan plus naproxen for acute migraine attacks in adults. *Cochrane Database Syst Rev*. 2013;(10):CD008541.

Leonardi M, Steiner TJ, Scher AT, Lipton RB. The global burden of migraine: measuring disability in headache disorders with WHO's Classification of Functioning, Disability and Health (ICF). *J Headache Pain*. 2005;6(6):429-440.

Lipton RB, Bigal ME, Diamond M, Freitag F, Reed ML, Stewart WF; for AMPP Advisory Group. Migraine prevalence, disease burden, and the need for preventive therapy. *Neurology*. 2007;68(5):343-349.

Lipton RB, Dodick D, Sadovsky R, et al. A self-administered screener for migraine in primary care: the ID Migraine validation study. *Neurology*. 2003;61(3):375-382.

Loder E, Weizenbaum E, Frishberg B, Silberstein S; for American Headache Society Choosing Wisely Task Force. Choosing wisely in headache medicine: the American Headache Society's list of five things physicians and patients should question. *Headache*. 2013;53(10):1651-1659.

Lynch KM, Brett F. Headaches that kill: a retrospective study of incidence, etiology and clinical features in cases of sudden death. *Cephalalgia*. 2012;32(13):972-978.

McCormack RF, Hutson A. Can computed tomography angiography of the brain replace lumbar puncture in the evaluation of acute-onset headache after a negative noncontrast cranial computed tomography scan? *Acad Emerg Med*. 2010;17(4):444-451.

Mehndiratta M, Nayak R, Garg H, Kumar M, Pandey S. Appraisal of Kernig's and Brudzinski's sign in meningitis. *Ann Indian Acad Neurol*. 2012;15(4):287-288.

Minen MT, Tanev K, Friedman BW. Evaluation and treatment of migraine in the emergency department: a review. *Headache*. 2014;54(7):1131-1145.

Miner JR, Smith SW, Moore J, Biros M. Sumatriptan for the treatment of undifferentiated primary headaches in the ED. *Am J Emerg Med*. 2007;25(1):60-64.

Mokri B. Spontaneous low pressure, low CSF volume headaches: spontaneous CSF leaks. *Headache*. 2013;53(7):1034-1053.

Murray CJL, Vos T, Lozano R, et al. Disability-adjusted life years (DALYs) for 291 diseases and injuries in 21 regions, 1990–2010: a systematic analysis for the Global Burden of Disease Study 2010. *Lancet*. 2012;380(9859):2197-2223.

Nelson S, Taylor LP. Headaches in brain tumor patients: primary or secondary? *Headache*. 2014;54(4):776-785.

Pareja JA, Álvarez M. The usual treatment of trigeminal autonomic cephalalgias. *Headache*. 2013;53(9):1401-1414.

Purdy RA, Kirby S. Headaches and brain tumors. *Neurol Clin*. 2004;22(1):39-53.

Ramirez-Lassepas M, Espinosa CE, Cicero JJ, Johnston KL, Cipolle RJ, Barber DL. Predictors of intracranial pathologic findings in patients who seek emergency care because of headache. *Arch Neurol*. 1997;54(12):1506-1509.

Robertson CE, Black DF, Swanson JW. Management of migraine headache in the emergency department. *Semin Neurol*. 2010;30(2):201-211.

Schievink WI. Spontaneous spinal cerebrospinal fluid leaks and intracranial hypotension. *JAMA*. 2006;295(19):2286-2296.

Schwedt TJ. Thunderclap headache. *Continuum (Minneap Minn)*. 2015;21(4 Headache):1058-1071.

Silberstein SD, Lipton RB, Dodick D, et al. *Wolff's Headache and Other Head Pain*. 8th ed. New York, NY: Oxford University Press; 2008.

Sobri M, Lamont AC, Alias NA, et al. Red flags in patients presenting with headache: clinical indications for neuroimaging. *Br J Radiol*. 2003;76(908):532-535.

Taylor LP. Mechanism of brain tumor headache. *Headache*. 2014;54(4):772-775.

Vinson DR. Treatment patterns of isolated benign headache in US emergency departments. *Ann Emerg Med*. 2002;39(3):215-222.

Waldman SD. Targeted headache history. *Med Clin North Am*. 2013;97(2):185-195.

Wang S-J, Fuh J-L. The "other" headaches: primary cough, exertion, sex, and primary stabbing headaches. *Curr Pain Headache Rep*. 2010;14(1):41-46.

Visual Disturbances 10

Heather E. Moss

KEY POINTS

1. Patient history is critical for differentiating ophthalmic, neurologic afferent, and neurologic efferent causes of visual symptoms.
2. Patient examination guides further localization of visual pathway disruption.
3. Ancillary structural imaging and functional testing of the visual pathway can guide diagnosis and monitoring of visual pathway disease.

INTRODUCTION

No symptom may be as disturbing or dramatic to a patient as acute vision changes. The causes span ophthalmic, neurologic, and sometimes psychiatric disease. In addition to being expert in neurologic causes, it is important for neurologists to be able to distinguish ophthalmic and psychiatric causes of visual disturbances in order to facilitate appropriate evaluation and management of the patients experiencing them.

With regard to neurologic causes of visual disturbance, they can be grouped by afferent (ie, visual perception), efferent (ie, eye movements, pupils, and eyelids), and mixed dysfunction. As with other neurologic conditions, history and physical exam findings, interpreted in the context of neuroanatomy guide localization, enable selection and interpretation of diagnostic testing and guide management.

NEUROANATOMY

Vision is perception of light. For this to occur, the eyes must be moved to and fixed on the target of interest, which is the purview of the efferent visual pathways. The light then must enter the eye, be translated into neural signals by the retina, and processed by elementary and higher level visual pathways for conscious visual perception to be experienced. Dysfunction at any point of the afferent or efferent pathways can disrupt this sensation, most commonly, and quite unhelpfully, referred to by patients as *blur*.

Afferent Visual Pathway

Light reaches the retina through the cornea, aqueous humor, lens, and vitreous before reaching the retina where it is converted to a neural signal by the photoreceptors. The cornea and lens are the optical system that focuses light on the retina. Adjustment of the native lens allows accommodation (ie, shifting depth of focus to near) (Fig. 10.1).

Neural impulses generated by the photoreceptors are processed by the intermediate retina before being transmitted to the retinal ganglion cells, which coalesce at the optic nerve head to form the optic nerve. These cells redistribute from optic nerves to optic tracts at the chiasm such that left visual fields from both eyes form the right optic tract and vice versa and extend to the lateral geniculate nucleus where they synapse. The optic radiations extend in a fan through parietal and temporal white matter to primary visual cortex in the occipital lobes, where they maintain retinotopic organization. From there, further processing occurs in the dorsal (parietal) and ventral (temporal) pathways to achieve visual spatial, movement, and recognition aspects of visual perception.

Efferent Visual Pathway

Movement of the eyes together to shift and to hold gaze is critical to the visual experience, facilitating depth perception, exploration of scenes, tracking of moving objects, and compensating for head movement. Eye movement control has both cortical and subcortical inputs with reflex control through the vestibular system and superior colliculus. Motor control is transmitted via cranial nerves III, IV, and VI to move the six extraocular muscles of each eye (Fig. 10.2).

Pupil and Eyelid Anatomy

Although often grouped with the efferent visual pathway, perhaps because of their relevance to localization, abnormalities of pupils and eyelids are more likely to impact afferent visual function. Reflex pupil diameter adjustment is important to control the amount of light entering the eye and helps to focus entering light during accommodation. The eyelid acts to clean and moisten the cornea. Dysfunction can block vision both directly and indirectly through corneal dryness.

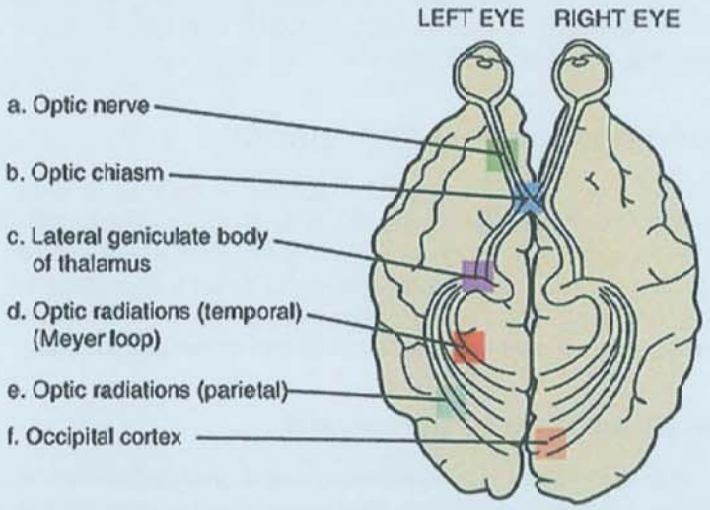

FIGURE 10.1 Major neurologic structures in the afferent visual pathway. (Adapted from Marshall R, Mayer S. *On Call Neurology*. 3rd ed. Philadelphia, PA: Saunders; 2007.)

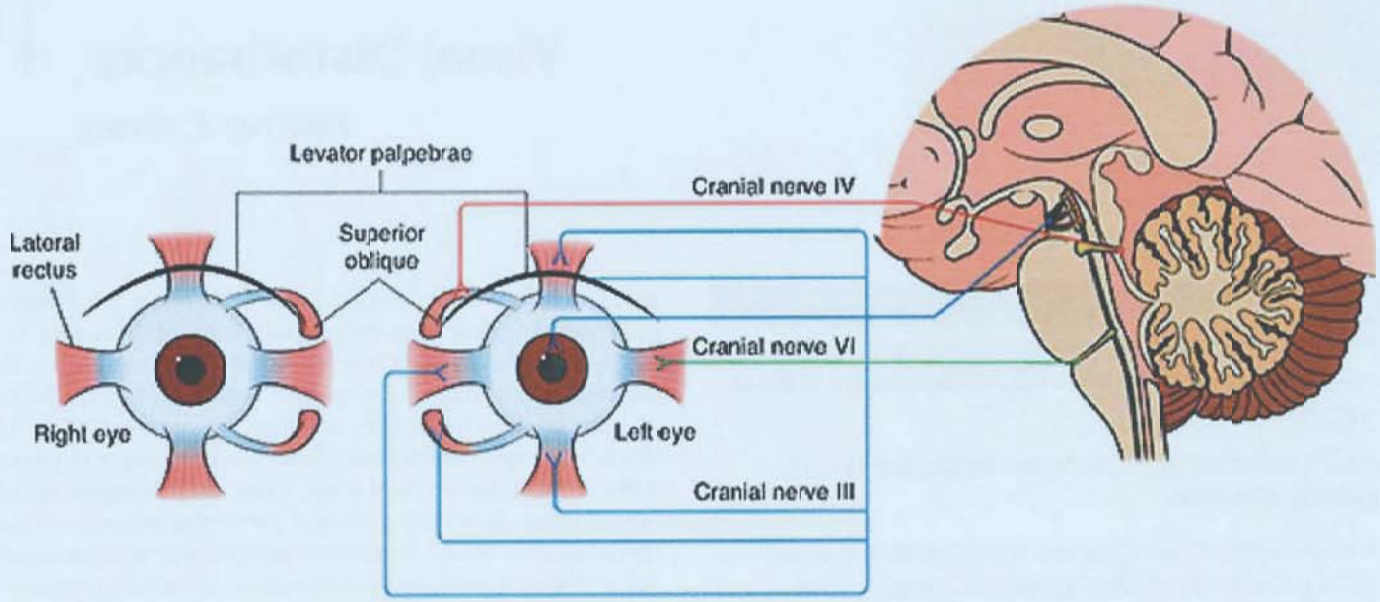

FIGURE 10.2 Innervation of major structures in the efferent visual pathway by cranial nerves III, IV, and VI.

Pupil dilation is controlled by the sympathetic system, which also controls Müller muscle, a small muscle that opens the upper and lower eyelids. Sympathetic dysfunction causes Horner syndrome with meiosis and slight upper (and often lower) lid ptosis. Pupil constriction is controlled by the parasympathetic system, which travels with cranial nerve III.

In addition to sympathetic control, eyelid position and function is governed by the orbicularis oculi, which acts to close the eye (cranial nerve VII), and the levator palpebrae, which acts to open the eye (cranial nerve III).

VISUAL SYMPTOM HISTORY

A careful history is helpful to localize visual disturbances to the part of the visual pathway they originate from (afferent/efferent) and where in this pathway (Table 10.1). Associated symptoms further guide localization. Tempo is helpful to triage between potential causes and urgency. The history is particularly important for transient symptoms, for which there may be no localizing findings on examination. The following are important clarifying points in the history.

Defining Severity of Symptoms

Blur can range from images not being sharp to inability to make out any details. Clarifying with the patient can be done by asking what they can't see or do helps to place their symptoms on this continuum. Asking about specific tasks such as reading at near, seeing at distance, and navigating can also be informative and suggest whether the problem is central or peripheral vision.

Defining Type of Symptoms

As with many neurologic symptoms, visual disturbances can be positive (simple to complex hallucinations) and/or negative (vision loss). Distorted images can occur due to optical disturbance in the light reaching the retina or from visual processing disturbance. Multiple images can occur due to optical disturbance in the eye, ocular misalignment, or a cerebral processing disturbance (palinopsia). Oscillopsia is shaking images either due to extra eye movements or inappropriate reflexive movements in response to head movement.

Defining How the Eyes Work Together

Critical to interpreting any visual symptom is understanding if it occurs only with both eyes open versus with one or both eyes individually. Symptoms due to the eyes not working together (eg, misalignment) only occur when both eyes are open. In these cases, covering either eye will eliminate the image from one eye and the symptoms due to the eyes not working together. Any symptom that persists with right and/or left eye only viewing is attributable to that eye or to the brain.

Remainder of History

The nature of symptoms, including when they occur (near vs far focus, different directions, different activities), associated symptoms in addition to the rest of the patient history, provides additional context for localization of the patient's symptom.

VISUAL PATHWAY EXAMINATION

Beyond the basic components of the neuroophthalmic examination (Table 10.2), examination of the patient with a visual symptom should be targeted based on their history. In the absence of positive exam findings to accompany a symptom, attempting to reproduce the symptom is an important part of the exam.

Central Vision

Visual Acuity

This is the vital sign of visual complaints. Pertinent parameters are which eye is tested, with or without glasses, at which distance (near or far), and what the patient can distinguish. In the absence of a calibrated chart, any visual stimulus can be used.

TABLE 10.1 Signs and Symptoms That Suggest Location in the Visual Pathway

Location of Lesion Along Visual Pathway	Signs and Symptoms
Anterior segment of the eye	• Blurred vision • Glare or halos • Foreign body sense in eye • Correction with squinting, pinhole, or glasses • Response to blinking • Visible opacities on exam
Retina	• Distortion (metamorphopsia) • Regional flashes of light in one eye • Circumscribed vision loss in one eye • Prolonged recovery from light exposure • Floaters • Night blindness • Purple, yellow, or green vision • Visible abnormality on retina exam
Optic nerve	• Regional vision loss in one eye • Decreased brightness • Decreased color saturation • Relative afferent pupillary defect • Optic nerve head abnormality on exam (cupping, pallor, or swelling)
Chiasm	• Bitemporal hemianopia • Pallor of both optic discs
Optic tract	• Homonymous hemianopia • Optic atrophy • Relative afferent pupillary defect in contralateral eye
Lateral geniculate nucleus (thalamus)	• Incongruent partial homonymous hemianopia or full homonymous hemianopia • Optic atrophy
Optic radiations	• Homonymous hemianopia • "Pie-in-the-sky" hemianopia, temporal lobe • "Pie-on-the-floor" hemianopia, parietal lobe • Optokinetic defect ipsilateral to parietal lobe lesion • Hemiparesis, aphasia, alexia, agnosia, somatosensory disturbance
Occipital lobe	• Homonymous quadrantanopia or hemianopia • Sparing central vision • Central hemianopia (scotomatous) • Preserved temporal crescent of hemianopic visual field
Oculomotor/vestibular system	• Oscillopsia • Diplopia

If large text can't be discerned, ability to count fingers, identify hand motion, or see light should be determined. If visual acuity is reduced, then testing should be repeated with pinhole to exclude an anterior ophthalmic problem as the cause. Visual acuity that is dramatically different between the two eyes suggests a problem anterior to the chiasm.

Color

Comprehensive tests of color vision are often not readily available in the clinical setting. Some information can be gained by asking the patient to compare perception of a red object between the two eyes. Difference between the eyes is a positive finding, more common in optic nerve than retinal disease. Ishihara or Hardy-Rand-Rittler color plates can be administered if available.

TABLE 10.2 Components of Neuroophthalmologic Examination

	Basic Exam	Advanced Exam
Central vision	• Visual acuity chart, corrected with glasses or pinhole	• Amsler grid to detect metamorphopsia (distortion of straight lines), which suggests retinal disease • Look for asymmetry in color perception or color desaturation (red). • Formal color testing • Electrophysiology testing
Peripheral vision	• Confrontation visual fields performed for each eye separately	• Formal perimetry such as Humphrey Visual Field testing • Electrophysiology testing
Pupils	• Record size in dark and in light. • Record response to light. • Perform swinging flashlight test to look for relative afferent pupillary defect.	• Response to near if no response to light • Dilation lag (Horner syndrome)
External exam	• Look for ptosis and proptosis. • Look for injection of conjunctiva.	• Measure eye position in orbit with Hertel exophthalmometer
Motility	• Look for restrictions in extraocular movement. • Characterize ocular misalignment.	• Measure ocular misalignment in different directions of gaze. • Characterize saccades, pursuit, nystagmus, optokinetic nystagmus
Funduscopic exam (ophthalmoscopy)	• Examine the fundus for optic nerve and retinal pathology.	• Dilated examination • Fundus photography • Optical coherence tomography imaging

Visual Distortion

The Amsler grid is a standardized grid of black lines on a white background that is useful for characterizing changes in central and near peripheral vision. The patient is asked to point out any missing or distorted lines when viewing the grid with each eye separately.

Peripheral Vision

This is the cardinal examination finding that guides neurologic localization of afferent pathway vision loss (Fig. 10.3). Single eye loss localizes anterior to the optic chiasm, bitemporal visual field loss (ie, outer field of each eye) localizes to the chiasm, and homonymous defects (ie, same field both eyes) localize to the visual pathways behind the chiasm.

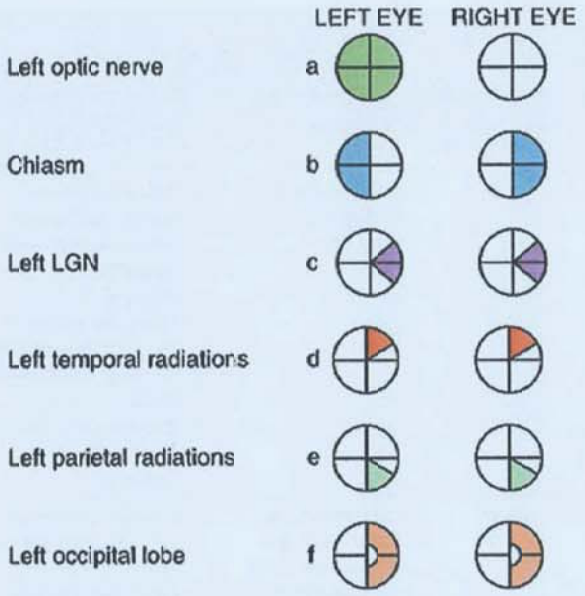

FIGURE 10.3 Visual field cuts produced by lesions at different points along the visual pathway. (*a*) Monocular blindness produced by a lesion in the left optic nerve. (*b*) Bitemporal hemianopia produced by a mass lesion at the optic chiasm. (*c*) Right segment anopia produced by a lesion in the lateral geniculate body of the left thalamus (posterior choroidal artery stroke). (*d*) Right upper quadrantanopia produced by a lesion in the left temporal optic radiation (Meyer loop). (*e*) Right lower quadrantanopia produced by a lesion in the left parietal optic radiation. (*f*) Left homonymous hemianopia produced by a lesion in the calcarine cortex of the right occipital lobe. Note that macular vision is sometimes spared in posterior cerebral artery stroke because of middle cerebral artery collateral blood flow to the occipital pole. Abbreviation: LGN, lateral geniculate nucleus. (Adapted from Marshall R, Mayer S. *On Call Neurology*. 3rd ed. Philadelphia, PA: Saunders; 2007.)

Neither lack of positive finding on bedside visual field assessment nor lack of peripheral vision complaint excludes visual field loss due to poor sensitivity. Gold standard formal visual field testing that is used in the ophthalmology clinic is more sensitive and should be pursued if diagnosis is elusive or monitoring is important.

Confrontation Visual Field Testing

The patient's ability to count the number of fingers seen in each peripheral field (superior temporal, inferior temporal, superior nasal, inferior nasal) with each eye and its variations (eg, wiggling fingers) is a component of the basic neurologic exam (Fig. 10.4). It has good specificity for localization along the afferent visual pathway but poor sensitivity.

Comparative Visual Field Testing

A simplified test of visual fields that can be easily done at the bedside is to have the patient sequentially cover each eye and describe how their symptom changes. A symptom that is exclusively in one eye is characterized by resolution when the affected eye is covered and persistence when the fellow eye is covered. This localizes anterior to the chiasm in the affected eye or optic nerve. A symptom that is in both eyes is characterized by persistence when either eye is covered. This localizes either to both eyes anterior to the chiasm, to the chiasm, or behind the chiasm. A symptom that resolves when either eye is covered suggests that there is no lesion in the afferent visual pathway and that the symptom is related to ocular misalignment.



FIGURE 10.4 Visual field technique: Sit 1 to 2 m from the patient and have the patient cover one eye completely while looking at the examiner's nose. In quick succession, flash one, two, or five fingers in all four quadrants. Then switch eyes. (Adapted from Marshall R, Mayer S. *On Call Neurology*. 3rd ed. Philadelphia, PA: Saunders; 2007.)

Ophthalmic Examination

Once visual function has been established through central and peripheral vision testing, the ophthalmic examination is a unique opportunity to visualize the causative pathology. The typical neurology clinic and emergency department are not equipped to perform the full ophthalmic exam and consultation with an ophthalmologist or skilled optometrist may be necessary to fully assess the patient.

External Exam

Eyes can appear prominent due to lid retraction or proptosis and less prominent due to ptosis or enophthalmos. Measuring the width of the palpebral fissure, the excursion of the lid margin from downgaze to upgaze to detect levator weakness and assessing for lid curtain, twitch, and fatigue are helpful for differentiating neurologic causes of ptosis, with the latter two suggesting myasthenia gravis. Neurologic causes of proptosis include cavernous sinus congestion.

Anterior Exam

Some pathologies of the cornea and lens are evident on direct ophthalmoscopy as cloudiness or yellowing. If the doctor's view to the back of the eye is poor despite good technique, that is a clue that the patient's view with the eye is also poor due to poor light transmission. Detailed examination of the front of the eye is best done using a slit lamp in the ophthalmologist's or skilled optometrist's office.

Funduscopic Exam

Most important for the neurologic exam are visualization of the optic nerve and retina. This can be difficult through an undilated pupil. Performing the exam in a dim environment and having the patient focus at distance are helpful to maximize pupil size. The optic nerve should be examined for evidence of pallor, which suggests prior injury to the optic nerve as well as edema,

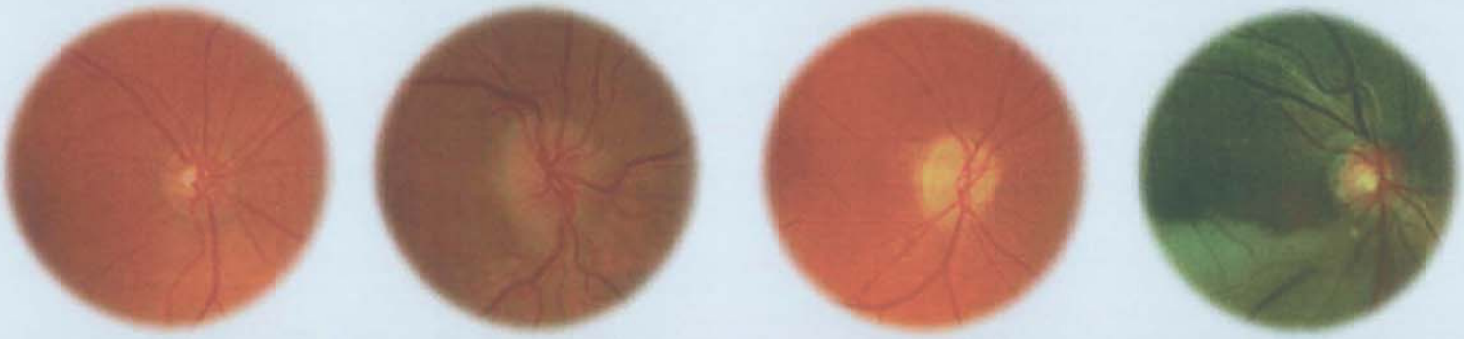

Normal or acute retrobulbar optic nerve injury | Optic nerve Head edema with blurred disc margins | Optic atrophy (chronic optic nerve injury) with pale optic nerve | Acute inferior branch retinal artery occlusion with retinal edema causing whitening

FIGURE 10.5 Key funduscopic examination findings in the neurological patient. Background color differences are attributable to patient and photographic technique.

which suggests acute injury. Blurring of the disc margins or obscuration of vessels where they cross the disc margin suggests optic nerve head edema. Retrobulbar optic nerve injury will not manifest any optic disc changes in the acute setting (Fig. 10.5).

Important retinal findings for the neurologic exam are hemorrhages and exudates, which can be seen as ophthalmic manifestations of diabetes and hypertension. Plaques in the retinal arterioles are signs of embolic disease.

Ocular Motility

Examine How the Eyes Move Individually and Together

The eyes should be examined together and separately for movement limitations. Testing of saccades (look at my pen—held to the side), smooth pursuits (follow my pen), and voluntary gaze (look to the right) should be performed with attention to whether each eye moves fully within the eye socket. Comparing between the eyes can be helpful to identify abnormalities in up, down, left, and right gaze and to identify subtle asymmetries such as adduction slowing in internuclear ophthalmoplegia (INO). If there are any limitations, evaluation of eye movements induced by reflex maneuvers (eg, vestibulo-ocular reflex using doll's eyes or caloric tests) can be helpful to localize any eye limitation to a supranuclear origin.

Examination of the extent of eye movements may be sufficient to characterize the eye movement disorder causing diplopia. However, it is important to recognize that full extraocular movements *do not* exclude a neurologic disorder causing diplopia.

Determine Eye Alignment

The goal is to define the relative alignment of the eyes (turned in = esotropia, turned out = exotropia, right eye higher = right hypertropia, left eye higher = left hypertropia) in each direction of gaze (straight ahead, up, down, left, right). This may be obvious based on inspection. If not, one important clue is to ask patients if they see double as you have them look in each direction of gaze. If they see two images, ask them if the images are horizontally, vertically, or obliquely oriented with respect to each other and if the images change in orientation/separation distance in different directions of gaze. If both the examiner and the patient are savvy observers, have the patient occlude one eye at a time to determine which image is coming from each eye. Due to the optics of the eye, the orientation of the images will be opposite to the orientation of the eyes—for example, if the right eye is higher than the left eye, the right eye image will be lower than the left eye image.

Other methods of eye alignment testing include examining the reflection of light in the pupils for relative displacement off of the center of the pupil (eg, if the light reflects of the inner iris of one eye, this suggests the eyes are relatively turned out). Alternately covering each eye while the patient fixates on an object is an easy bedside test. The examiner observes for the direction of the corrective eye movement as each eye recovers fixation.

Characterize Extra Eye Movements

Intrusive eye movements are those that interrupt gaze fixation and are assessed by having the patient attempt to maintain steady gaze in different directions. Nystagmus is characterized by rhythmic slow movements of the eyes, either with a corrective saccade (jerk nystagmus) or back to back slow movements (pendular nystagmus). Nystagmus is abnormal except for a few beats of extinguishing jerk nystagmus in lateral gazes. Peripheral vestibular nystagmus does not change direction, worsens with gaze in the direction of the fast phase, and worsens with removal of fixation. A subtle sign of INO is jerk nystagmus of the abducting eye, during lateral gaze. Nystagmoid movements include square wave jerks, which are small involuntary saccades with a latency between them, and opsoclonus, which are involuntary saccades without a latency between them.

Pupil Size and Function

Pupil size reflects the total amount of light being transmitted by both optic nerves and efferent pupillary function. There are two main pupil exam findings that are distinct from each other: anisocoria and afferent pupillary defect.

Comparing Pupils to Each Other

Pupil size should be measured under diffuse bright light and diffuse dim light. Normal pupillary function is indicated by equal size of the pupils regardless of the light exposure. Anisocoria in either bright or dim conditions reflects efferent pupillary dysfunction. In general, small pupils do not cause symptoms. Large pupils can cause light sensitivity and be associated with focusing difficulties at near.

A unilateral sympathetic lesion impairs pupil dilation with a resulting smaller pupil and anisocoria more pronounced in dim light. There is often associated mild ptosis and sometimes

ipsilateral anhidrosis (Horner syndrome). There are nonsympathetic causes of a miotic pupil including medications (eg, pilocarpine) and trauma. Cocaine, hydroxyamphetamine, and apraclonidine eye drops can guide localization of a small pupil.

A parasympathetic lesion impairs pupil constriction with a resulting larger pupil and anisocoria more pronounced in bright light. When associated with ptosis and ocular motility restrictions, this is concerning for cranial nerve III palsy. There are noncranial nerve III causes of a mydriatic pupil including medications (eg, atropine), trauma, and tonic pupil, caused by injury to the ciliary ganglion. Dilute pilocarpine can guide localization of a large pupil.

A large pupil that doesn't constrict to light but does constrict to a near stimulus is said to have light-near dissociation. This is a finding of pupil dysfunction from a tonic pupil or midbrain lesions.

Comparing Optic Nerves to Each Other Using the Pupil

The pupillary light reflex, which sets size of both pupils based on total light transmitted down both optic nerves, can be leveraged to compare the prechiasmatic visual pathways. The light is alternately shone in each eye, looking for constriction of the pupils when one eye is illuminated and dilation of the pupils when the other eye is illuminated. A subjective version of this test is to ask the patient if a standard light stimulus is perceived as equal in both eyes.

The eye with relative pupillary dilation during the swinging light test is said to have a relative afferent pupillary defect, suggestive of unilateral or asymmetric optic nerve disease, but also evident in severe retinal disease. Due to asymmetry in redistribution of ganglion cells at the chiasm, optic tract dysfunction is associated with a contralateral relative afferent pupillary defect.

Neurologic Exam

Attention should be paid to signs localizing to near the afferent and efferent visual pathways or suggesting neurologic syndromes that can involve vision loss. Of particular importance are the cranial nerves.

ANCILLARY OPHTHALMIC TESTING

Ancillary ophthalmic testing is widely available in eye care centers and increasingly available in neurology practices. It can be helpful to guide neurologic localization and for monitoring of neurologic disease.

Fundus Photography

Fundus photography techniques supplement the funduscopic examination by capturing a still or video image of the fundus. Technologic advances have made high-quality imaging possible through undilated pupils with minimal technical skill using desktop platforms. Portable platforms, including those using smartphones, are more finicky and require more technical expertise and practice to capture high-quality images. These are useful for documentation and comparison.

Optical Coherence Tomography

Optical coherence tomography (OCT) is a noninvasive imaging technique that uses near-infrared light to generate high-resolution, cross-sectional images of the optic nerve and retina (Fig. 10.6). It is in wide use in ophthalmology and optometry practices and many patients referred to a neurologist from these doctors may have had such imaging. Most relevant to neurologists is visualization of the optic nerve in three dimensions, which allows easy identification and comparison of optic nerve head edema. The analysis software also segments the images to measure the thickness of retinal layers corresponding to retinal ganglion axons around the optic nerve (peripapillary retinal nerve fiber layer (RNFL) thickness) and retinal ganglion cells in the macula (ganglion cell complex (GCC) thickness). Thickening of the RNFL can occur with optic nerve head edema. Thinning of the RNFL and/or GCC can occur with optic nerve atrophy. OCT is also helpful for visualization of retinal pathology and understanding of this, artifacts and automatic segmentation errors is important to fully interpret the images.

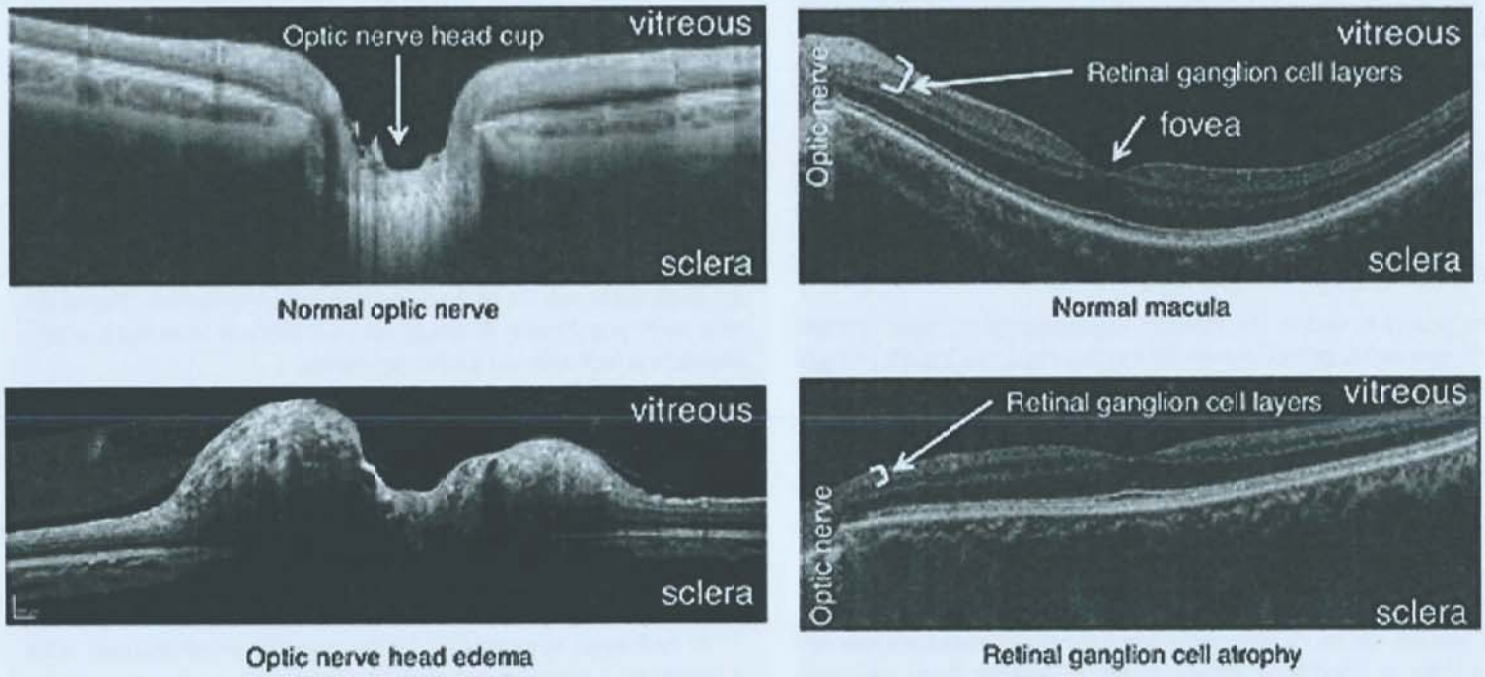

FIGURE 10.6 Optical coherence tomography findings in neurological patients.

Perimetry

Perimetry is formal assessment of peripheral vision and can be performed using a variety of devices. They share in common algorithms to map the peripheral vision in each eye individually and are often available in ophthalmology, optometry, and neuro-ophthalmology practices. Their utility lies in detecting and characterizing visual field loss that is sometimes below the level of detection on examination. It also has applications to detecting change (both progression and improvement) in vision loss not involving central vision.

Visual Electrophysiology

Visual electrophysiology can help to localize a lesion in the retina or optic nerve when no structural lesion is apparent. Visual-evoked potentials (VEP) record the occipital surface potential generated by a light stimulus in each eye and are useful for detecting decreased and slowed transmission. Full field electroretinography (ERG) is helpful for detecting abnormalities in the intermediate and outer retina and multifocal ERG is useful for detecting macular (central retinal) dysfunction. Optic nerve abnormalities can be detected on VEP as well as certain waveforms of the pattern ERG and full field ERG.

TRANSIENT VISUAL SYMPTOMS

Transient visual symptoms are the most challenging to assess because, by definition, they have resolved, and there may not be localizing findings on examination. Although much time can be spent trying to distinguish afferent from efferent and eye from brain events based on history, it is often difficult to determine conclusively. Therefore, a broad differential diagnosis must be considered with triage based can't miss diagnoses.

TABLE 10.3 Causes of Transient Unilateral or Hemifield Visual Loss

Etiology	Monocular (One Eye)	Hemianopic (One Field)	Binocular (Both Eyes)
Transient ischemic attack	x	x	
Hypotension, presyncope	x	x	x
Arterial spasm	x		
Recurrent erosions of the cornea or corneal basement membrane dystrophy	x		x
Angle closure	x		x
Optic nerve head edema	x		x
Orbital masses (causes gaze-evoked monocular visual loss)	x		
Uhthoff phenomenon	x		x
Migraine		x	
Ocular surface dryness	x		x
Seizure		x	

Transient Ischemic Attack

Transient ischemic attack (TIA) includes neurologic symptoms due to ischemia of the brain or retina or and must be included in the differential diagnosis for transient visual symptoms including monocular vision loss, homonymous visual field loss, and diplopia. In addition to common ischemic stroke causes of cardioembolic, large vessel, and small vessel, other important considerations include hypoperfusion related to vascular stenosis and vasculitis. Giant cell arteritis is of particular concern as a cause of transient visual symptoms in patients older than age 50 years especially those with systemic symptoms. Plaques in retinal vessels are clues to embolic events in the anterior circulation.

Ophthalmic Causes of Transient Visual Symptoms

Ophthalmic causes of transient visual symptoms typically affect one eye at a time, although due to their transient nature it is often difficult for patients to make this distinction. Most common is ocular surface changes, which often improve with blink or artificial tears. Retinal ischemia is emergent and addressed under TIA in the preceding text. Subacute angle closure can cause recurrent bouts of unilateral eye pain, blurry vision in that eye, and eye redness that are frequently misdiagnosed as migraine. Intraocular pressure is high during an attack, and narrowing of the angle between the iris and the cornea is evident between attacks. Arterial spasm in the ophthalmic, retinal, or choroidal circulation may result in transient monocular vision loss in otherwise healthy individuals. It is a diagnosis of exclusion based on stereotyped events and normal vascular workup.

Optic Nerve Causes of Transient Visual Symptoms

Transient ischemia of the optic nerve is included under TIA in the preceding text. Patients with optic nerve head elevation due to edema, optic nerve head drusen, or congenital malformation may experience graying out of vision associated with postural change or head movement. These are called *transient visual obscurations* and can occur even in the absence of chronic vision loss related to the elevated optic nerve. Mass lesions in the orbit can cause vision loss when eye movements either cause compression or vascular compromise to the optic nerve or retina. This is referred to as *gaze-evoked amaurosis*. Decrease in vision in one eye associated with increased body temperature is Uhthoff phenomenon and suggests demyelinating injury to the optic nerve, for example, due to past optic neuritis or optic nerve compression.

Cerebral Causes of Transient Visual Symptoms

Visual migraine aura is a stereotyped transient visual hallucination, typically with positive visual features and movement in a homonymous visual field, although patients often perceive it as being in one eye. Typically, it evolves over 20 minutes and resolves prior to a migraine headache. Epilepsy involving the visual pathways can cause stereotyped visual experiences.

Transient Diplopia

Diplopia is an all or none symptom, and thus, it is often episodic even if the lesion is persistent. In the case that it cannot be

reproduced in the office and ocular motility examination is normal, considerations include TIA, myasthenia gravis, and ocular neuromyotonia.

COMMON PATTERNS OF AFFERENT PATHWAY DISEASE

Ophthalmic

Most causes of monocular visual symptoms are due to eye disease and are readily apparent on a full ophthalmic evaluation (ie, dilated exam by an ophthalmologist). The exceptions are retrobulbar optic neuropathy and disease of the outer retinal layers, both of which can have normal slit lamp and dilated fundus examinations. Optic neuropathy is discussed in the following text. Outer retinal disease can often be visualized on OCT and can be detected using ERG.

For the neurologist, monocular diplopia is important to distinguish from binocular diplopia (ie, that resolves with covering either eye) because it is most likely due to an anterior ophthalmic cause. Central vision loss in one eye with or without distortion and without relative afferent pupillary defect suggests a retinal etiology rather than an optic nerve etiology.

Retinal arteriolar occlusion is an ophthalmic diagnosis relevant to neurology because the pathophysiology overlaps with that of ischemic stroke. It can be asymptomatic or cause partial or complete monocular vision loss depending on what arteriole is occluded.

Optic Neuropathy

The most important cause of monocular vision loss relevant to neurologists is optic neuropathy. Classically, there is either central or peripheral vision loss with associated change in color perception and relative afferent pupillary defect in unilateral cases. Bilateral optic neuropathies have less prominent relative color vision changes and relative afferent pupillary defects because these findings rely on comparison between the eyes. Optic neuropathy can also be asymptomatic, detected by optic disc swelling on clinical exam, or by ganglion cell thinning on OCT.

The differential diagnosis is broad and includes anterior (optic nerve head), intraorbital, intracanalicular, and chiasmal etiologies. Swelling of the optic nerve head identifies acute anterior optic neuropathies. Acute retrobulbar optic neuropathies may have a normal funduscopic appearance. Chronic optic neuropathies are associated with optic nerve head pallor. It takes weeks to month following retrobulbar optic nerve injury for pallor of the optic nerve head (reflecting axonal loss) to develop.

Acute Optic Neuropathies

Important considerations for monocular optic neuropathies that require rapid diagnosis or intervention include optic neuritis (particularly neuromyelitis optica spectrum, which may necessitate escalation of immunotherapy to induce remission); other inflammatory optic neuropathy (eg, sarcoidosis, which may require intravenous immunotherapy for treatment); arteritic ischemic optic neuropathy, which carries short-term risk of fellow eye involvement and stroke; acute compressive optic neuropathy (eg, pituitary apoplexy, which is associated with acute adrenal insufficiency); and fungal orbital apex syndrome.

Other optic neuropathies that present acutely include nonarteritic anterior ischemic optic neuropathy, which, by definition, has optic disc swelling in the acute phase and Leber hereditary optic neuropathy, which, although due to mitochondrial gene defect, typically presents with sequential monocular vision loss.

Progressive Optic Neuropathies

The most common optic neuropathy is glaucoma, typically managed by ophthalmologists. The most common form is primary open-angle glaucoma, which causes painless, asymmetric, bilateral, slowly progressive peripheral vision loss. It is associated with high intraocular pressure and defined by progression of optic disc cupping to accompany visual field loss.

Extrinsic lesions that compress the optic nerve are an important consideration in progressive optic neuropathies. The pattern of vision loss depends on what is compressed (optic nerve, chiasm, or tract). Common pathologies affecting the optic nerve include optic nerve sheath meningiomas, skull base meningiomas, pituitary tumors, craniopharyngiomas, and cerebral aneurysms.

Toxic or metabolic injuries to the optic nerves are typically bilateral and impact central vision. Vitamin B_{12}, folate, and copper are some of the vitamin deficiencies that can impact the optic nerves. Ethambutol, isoniazid, chloramphenicol, linezolid, and disulfiram are drugs that can cause a toxic optic neuropathy.

Dominant optic atrophy, the most common hereditary optic neuropathy, presents in childhood or adolescence with symmetric mild to moderately decreased acuity (20/25-20/200) that progresses and typically stabilizes in young adulthood.

Intrinsic optic nerve tumors include optic nerve gliomas, which are typically pilocytic astrocytomas that appear in young childhood association with neurofibromatosis type 1. They can present with bilateral visual loss, strabismus, nystagmus, optic atrophy, papilledema, hydrocephalus, and endocrine problems. Malignant optic gliomas of adulthood are rare, high-grade gliomas that progress rapidly to blindness and death.

Papilledema

Although many different acute anterior optic neuropathies can cause optic disc edema, papilledema, which is disc edema, typically bilateral, due to elevated intracranial pressure (ICP), is of particular importance because it can be a diagnostic clue to underlying secondary cause of high ICP such as brain tumor or venous sinus thrombosis. Papilledema can develop in the absence of subjective or objective vision loss and in the absence of other signs of high ICP such as headache.

In a patient that has papilledema, it is urgent to exclude secondary causes of high ICP. It is also important to characterize visual function with formal perimetry in order to identify and monitor vision loss, which can be progressive and permanent. Treatment of high ICP and, if possible, the underlying cause will reduce the risk of vision loss and possibly recover vision that has been lost.

Optic Chiasm

Pathologies impacting the optic chiasm tend to preferentially affect the crossing fibers classically causing bitemporal hemianopic

vision loss. This may not be noticed by the patient because the seeing fields in each eye complement each other. However, vision loss patterns can vary based on the anterior/posterior and lateral location of pathologies with posterior pathologies causing central visual field loss and lateral pathologies affecting one tract or optic nerve more than the other. There may be an relative afferent pupillary defect depending on the laterality of the pathology. Optic nerve pallor may develop weeks to months after axonal loss in the chiasm.

Common chiasmal pathologies are compression from pituitary tumor, meningioma, and craniopharyngioma. Gliomas can involve the chiasm as can inflammatory conditions such as optic neuritis and sarcoidosis.

Optic Tract

Lesions of the optic tract cause homonymous visual field loss in both eyes (ie, same field of both eyes) and a contralateral afferent pupillary defect. This is due to the fact that the tract contains more fibers from the contralateral than ipsilateral eye. Because the optic tract is composed of presynaptic retinal ganglion cells, chronic lesions are associated with bilateral optic nerve head pallor. Isolated visual symptoms are rare but can occur due to compression from a sellar or suprasellar process (eg, pituitary tumor or craniopharyngioma) or retinal ganglion cell pathology (eg, optic neuritis).

Lateral Geniculate Nucleus

Lesions to the lateral geniculate nucleus are associated with homonymous contralateral visual field loss in both eyes. Isolated visual symptoms are rare but can occur from either anterior circulation (anterior choroidal artery) or posterior circulation (posterior choroidal artery) strokes. Because the optic tract synapses in the geniculate body, optic atrophy may be observed several weeks after a geniculate lesion.

Optic Radiations

Dysfunction of the optic radiations is associated with visual field loss in the opposite field in both eyes (ie, homonymous hemianopias). For example, vision loss in the upper right visual field can be caused by dysfunction of the left temporal radiations (Meyer loop). Due to the distributed nature of the radiations, it is rare for injury to cause isolated visual symptoms, and it is typical to have other symptoms/signs that localize to the relevant parietal/temporal lobe. Differential diagnosis is that for parenchymal lesions of the brain including stroke, tumor, and demyelination among others.

Occipital Lobe

Similar to optic radiation dysfunction, dysfunction in an occipital lobe is associated with visual field loss in the opposite field in both eyes. Lesions to the occipital pole cause central vision loss. Posterior cerebral artery strokes typically spare the occipital poles to cause hemianopias with central (macular sparing). Unlike visual field defects localizing to the optic radiations, those from occipital lobe dysfunction are commonly isolated. The differential diagnosis is that for parenchymal lesions of the brain including stroke, tumor, and demyelination among others. Posterior cortical atrophy can cause homonymous visual field loss with only subtle findings on neuroimaging.

Midline (eg, falcine meningioma) or distributed processes (eg, reversible posterior leukoencephalopathy syndrome) can cause bilateral occipital lobe dysfunction and even blindness on a cerebral basis. In these cases, pupil reactivity is normal, and patients may be agnostic to their vision loss and confabulate (Anton syndrome).

Higher Order Visual Dysfunction

Visual processing occurring in the parietal and temporal lobes creates the visual experience. Dysfunction of these areas can lead to difficulties interpreting spatial relationships (eg, simultagnosia, palinopsia) and recognizing objects (alexia without agraphia, prosopagnosia).

COMMON PATTERNS OF EFFERENT VISUAL PATHWAY DYSFUNCTION

Disturbances of eye movement and ocular alignment result in diplopia in individuals who have good vision in both eyes and use both eyes together. This can result from ocular muscle problems, neuromuscular transmission defects, cranial neuropathies, and brainstem parenchymal lesions to cause double vision, which the patient may report as blurry vision. Damage to the central vertical and horizontal gaze pathways and vestibular systems may result in gaze palsies or nystagmus that the patient may report as visual difficulty.

Supranuclear Causes of Diplopia

INO due to lesion of the medial longitudinal fasciculus (MLF) is characterized by horizontal diplopia that is present in contralateral gaze only. Often, there is nystagmus of the abducting (normal) eye and slowed adducting saccade of the affected eye. Sometimes, this is the only finding. Adduction of the affected eye is often better during convergence because this does not use the MLF. INO localizes to the brainstem as is a common demyelinating syndrome. It can also result from small vessel stroke, sometimes, below the level of detection of diffusion weighted magnetic resonance imaging.

Skew deviation, a supranuclear disorder, is characterized by vertical diplopia with tilting of images in both eyes. Typically, it is associated with other vestibular or cerebellar symptoms and signs. Stroke and tumor are common causes.

Convergence insufficiency is trouble bringing the eyes in at near leading to horizontal diplopia when reading and is common in Parkinson disease and after concussion. Divergence insufficiency is trouble bringing the eyes apart leading to horizontal diplopia at distance. Both have similar symptoms in all directions of gaze, which distinguishes them from sixth nerve palsy and INO.

Third Nerve Palsy

A nonnuclear, third nerve palsy in isolation affects the superior rectus, inferior rectus, medical rectus, and inferior oblique (ie, all extraocular muscles except the superior rectus and lateral rectus) to cause oblique diplopia in primary gaze, vertical diplopia in up and down gaze, horizontal diplopia in contralateral gaze, and no diplopia in ipsilateral gaze. Additional localizing

signs are a larger ipsilateral pupil and ptosis. A nuclear third nerve palsy typically causes bilateral ptosis and bilateral upgaze deficits in addition to typical ipsilateral cranial nerve III signs.

Aneurysm compressing the ipsilateral third nerve is a can't miss diagnosis, which requires emergent angiographic imaging to exclude it. Uncal herniation, typically associated with altered mental status, causes pupillary dilation through third nerve compression. Skull base tumors can also cause third nerve palsy through compression. In chronic compression, there can be aberrant regeneration, which is demonstrated on exam when one third nerve action (eg lid raising), occurs when another (eg, downgaze) is attempted.

A common cause of isolated third nerve palsy in older individuals with vascular risk factors is a microvascular palsy that typically resolves in approximately 3 months. Ophthalmoplegic migraine can cause a transient third nerve palsy in children. These are diagnoses of exclusion without confirmatory diagnostic tests.

Brainstem parenchymal events such as stroke, demyelination, and tumor can cause third nerve palsy accompanying contralateral movement disorder (Benedikt syndrome), contralateral ataxia (Claude syndrome), or contralateral hemiparesis (Weber syndrome).

Fourth Nerve Palsy

A nonnuclear fourth nerve palsy in isolation affects the ipsilateral superior oblique muscle to cause vertical diplopia that is worse in down gaze, contralateral gaze, and ipsilateral head tilt. Due to the torsional action of the superior oblique, the image in the affected eye can appear tilted. Patients may adopt a compensatory head tilt. A nuclear fourth nerve palsy causes contralateral superior oblique dysfunction.

Brainstem causes of fourth nerve palsy can be accompanied by a contralateral Horner syndrome. Fascicular causes include microvascular, traumatic, and compressive. Fourth nerve palsies are a common childhood strabismus pattern that can decompensate in adulthood to cause new-onset diplopia.

Sixth Nerve Palsy

A nonnuclear sixth nerve palsy in isolation affects the lateral rectus muscle to cause horizontal diplopia in ipsilateral gaze that resolves in contralateral gaze. A nuclear sixth nerve palsy causes an ipsilateral gaze palsy (ie, affecting both eyes and therefore without diplopia).

Sixth nerve palsy is a false localizing sign of elevated ICP, for example, due to tumor, venous sinus thrombosis or meningitis, and intracranial hypotension as might occur from cerebrospinal fluid leak. As with third and fourth nerve palsies, it can be caused by microvascular disease, compression, trauma, and brainstem events.

The sixth nerve floats freely in the cavernous sinus and may be affected in isolation by disease in this region. It is affected in petrous apicitis in Gradenigo syndrome.

Multiple Cranial Neuropathies

There are a few conditions and locations where multiple ocular motor nerves can be impacted.

Wernicke encephalopathy from vitamin B_1 deficiency can affect eye movements in isolation as well as in association with ataxia, nystagmus, and encephalopathy. Empiric treatment is necessary as blood thiamine levels do not reflect body stores. Miller Fisher syndrome, associated with anti-GQ1b antibodies causes ophthalmoplegia as well as areflexia and ataxia. Imaging is typically normal.

Cavernous Sinus Syndrome

Complete or partial involvement of cranial nerves III, IV, VI, sympathetic pathways (Horner syndrome), and V1 and V2 localizes to the cavernous sinus. Any process that elevates venous pressure in the cavernous sinus can transmit this pressure to the orbit to cause significant orbital signs including proptosis and red eyes. Vision can be affected if the process extends superiorly to the optic chiasm or if blood flow to the eye is affected. A standard head computed tomography does not image this region adequately, and imaging studies protocolled for the sella or pituitary region are necessary.

Cavernous carotid fistula draining into the orbit is associated with a red, proptotic eye with ophthalmoplegia, possible vision loss, and a prominent superior ophthalmic vein on orbital imaging. Cavernous sinus thrombosis, often associated with adjacent sinus infection, can be bacterial or fungal and can progress rapidly to meningitis. Pituitary apoplexy can occur horizontally into one or both cavernous sinuses and is associated with vision loss if it extends superiorly to contact the chiasm or optic nerves. Patients are prone to acute adrenal insufficiency. Dermatologic tumors of the face can spread along sensory nerves to the cavernous sinus to impact ocular motor nerves.

Inflammation of the cavernous sinus can occur due to a variety of pathologies. Tolosa-Hunt describes the syndrome of painful ophthalmoplegia that can result from this. Because of overlap with other cavernous sinus disease including neoplasm, workup to exclude these, sometimes including biopsy, is often necessary.

Neuromuscular Junction

Neuromuscular junction disorders can affect extraocular muscles in isolation or combination. The pattern of diplopia depends on which muscles are involved and can imitate eye movement disorders from cranial nerve and supranuclear causes. If ocular misalignment does not result, the patient may not have diplopia.

Myasthenia gravis involves the eyes in a high proportion of cases and often initially presents with ocular motor symptoms of ptosis and diplopia. 30% to 50% of individuals who present with isolated ocular disease will progress to have systemic disease. Characteristic findings are variability in exam, worsening later in the day and muscular fatigability on exam.

In addition to eye movement limitations and ptosis, botulism is associated with systemic weakness, dilated pupils, and constipation. Lambert-Eaton myasthenic syndrome causes ptosis without prominent eye movement limitations.

Myopathies

Inflammation, weakness, or mass lesions of the extraocular muscles can cause eye movement limitations and misalignment if they are asymmetric. Thyroid eye disease is an inflammatory restrictive myopathy that most commonly causes esotropia, hypertropia, eyelid retraction, and proptosis.

Mitochondrial myopathies can impact the extraocular muscles in isolation (eg, chronic progressive external ophthalmoplegia) and may be detected incidentally as patients adapt to the symmetric, slow deterioration in eye movements. Identification

of pigmentary retinopathy or systemic myopathy is important so that appropriate cardiac screening can be undertaken.

AFFERENT AND EFFERENT DYSFUNCTION

Sellar Pathology

The chiasm lies above the sella, and the cavernous sinuses lie to other side. Thus, any expansion of sellar or suprasellar pathology readily impacts the afferent and or efferent visual pathways. Most of these will be subacute in onset due to slow growth of pituitary adenoma, craniopharyngioma, meningioma, or aneurysm. Acute onset of vision loss of ophthalmoplegia is concerning for pituitary apoplexy causing a pituitary tumor to suddenly expand.

Orbital Apex Syndrome

Complete or partial involvement of cranial nerves III, IV, VI, V1 and the optic nerve localizes to the orbital apex. Focal processes may not cause significant orbital signs and be very difficult to discern on imaging. The differential diagnosis is broad with most entities, for example, inflammatory lesions, tumor of foreign body, evident on neuroimaging. It is important to maintain a high suspicion for fungal infection in orbital apex syndrome cases with normal neuroimaging as this is a challenging diagnosis to confirm.

High Intracranial Pressure

High ICP can cause papilledema through compression of the optic nerve by high cerebrospinal fluid pressure in the optic nerve sheath and sixth nerve palsy due to tension on the nerve. This is a neurologic emergency both due to the possibility of high risk underlying cause and the risk of vision loss from optic neuropathy.

SUGGESTED READINGS

Bernstein EF, ed. *Amaurosis fugax*. New York, NY: Springer-Verlag; 1988.

Fisher CM. Observations of the fundus oculi in transient monocular blindness. *Neurology*. 1959;9:333-347.

Gerling J, Meyer JH, Kommerell G. Visual field defects in optic neuritis and anterior ischemic optic neuropathy: distinctive features. *Graefes Arch Clin Exp Ophthalmol*. 1998;236:188-192.

Glaser JS. Topical diagnosis: prechiasmal pathways. In: Glaser JS, ed. *Neuro-Ophthalmology*. Philadelphia, PA: Lippincott Williams & Wilkins; 1999: 95-198.

Harrington DO. The character of visual field defects in temporal and occipital lobe lesions, localizing value of congruity and incongruity in incomplete homonymous hemianopia. *Trans Am Ophthalmol Soc*. 1961;59:333-369.

Horton JC, Hoyt WF. The representation of the visual field in human striate cortex. A revision of the classic Holmes map. *Arch Ophthalmol*. 1991;109:816-824.

Hoyt WF. Ocular symptoms and signs. In: Wylie EJ, Ehrenfeld WK, eds. *Extracranial Occlusive Cerebrovascular Disease: Diagnosis and Management*. Philadelphia, PA: WB Saunders; 1970:64-95.

Hoyt WF, Beeston D. *The Ocular Fundus in Neurologic Disease: A Diagnostic Manual and Stereo Atlas*. St Louis, MO: CV Mosby; 1966.

Kedar S, Zhang X, Lynn MJ, Newman NJ, Biousse V. Congruency in homonymous hemianopia. *Am J Ophthalmol*. 2007;143:772-780.

Kline LB, Hoyt WF. The Tolosa-Hunt syndrome. *J Neurol Neurosurg Psychiatry*. 2001;71:577-582.

Leigh RJ, Zee DS. *The Neurology of Eye Movements*. New York, NY: Oxford University Press; 2015.

Lepore FE. The preserved temporal crescent: the clinical implications of an "endangered" finding. *Neurology*. 2001;57:1918-1921.

Liu GT, Volpe NJ, Galetta SL, eds. *Neuro-ophthalmology: Diagnosis and Management*. Elsevier; 3rd edition. 2018.

Miller NR, Newman NJ, eds. *Walsh & Hoyt's Clinical Neuro-Ophthalmology*. Philadelphia, PA: Lippincott Williams & Wilkins; 2005.

Scott GI. *Traquair's Clinical Perimetry*. London, United Kingdom: Henry Kimpton; 1957.

Skarf B, Glaser JS, Trick GL, et al. Neuro-ophthalmologic examination: the visual sensory system. In Glaser JS, ed. *Neuro-Ophthalmology*. Philadelphia, PA: Lippincott Williams & Wilkins; 1999:7-50.

Smith JL. Homonymous hemianopia. A review of one hundred cases. *Am J Ophthalmol*. 1962;54:616-623.

Thompson HS, Corbett JJ, Cox TA. How to measure the relative afferent pupillary defect. *Survey Ophthalmol*. 1981;23:39-42.

Zhang X, Kedar S, Lynn MJ, Newman NJ, Biousse V. Homonymous hemianopias: clinical-anatomic correlations in 904 cases. *Neurology*. 2006;66:906-910.

Delirium 11

Merrick E. Miles, Christina J. Hayhurst, and Christopher G. Hughes

KEY POINTS

1. Delirium is common among hospitalized patients, occurring in up to 50% of patients after stroke and 80% of patients with critical illness.
2. Development of delirium increases hospital length of stay and is associated with long-term cognitive impairment, disability, and mortality.
3. Prevention is paramount in the fight against delirium.
4. Treatment is focused on correcting causes and improving environmental factors. Pharmacologic therapy may be undertaken for symptom management.
5. Medications should be used judiciously due to uncertainty about their efficacy and their potential effect on patient's sensorium.

INTRODUCTION

Delirium is a clinical syndrome characterized by fluctuations in mental status caused by acute cerebral dysfunction. Patients present with inattention, disorganized thinking, disorientation, and/or altered levels of consciousness. Other symptoms associated with delirium include sleep disturbances, abnormal psychomotor activity, hallucinations, and emotional disturbances such as fear, depression, or anxiety. Patients may experience symptomatology that is hyperactive or hypoactive or fluctuate between both (mixed delirium). Although hyperactive delirium is more dramatic, hypoactive delirium is more common and much more underdiagnosed.

Development of delirium while in the intensive care unit (ICU) has been associated with increased cost, ICU length of stay, hospital length of stay, higher readmission rates, and long-term cognitive dysfunction. This risk is independent of preexisting comorbid conditions, severity of concurrent illness, and age. Additionally, duration of delirium has been shown to increase the relative risk of death by 10% per day of delirium.

Delirium is common among hospitalized patients. Upon admission, approximately 11% to 25% of elderly patients are delirious, and an additional 30% or so will go on to develop delirium. Delirium is even more frequent among critically ill patients; it is estimated that up to 80% of patients in the ICU experience an episode of delirium. Given the implications of an episode of delirium on patient outcomes, prevention and treatment is of utmost importance.

CAUSES OF DELIRIUM

The underlying mechanism of delirium or acute brain dysfunction has many proposed pathways. Systemic inflammation, cholinergic deficiency, and disturbances in other neurotransmitters such as serotonin and norepinephrine have been implicated in the development of delirium.

Risk factors for delirium can be characterized into patient factors, current illness factors, and iatrogenic causes, as outlined in Table 11.1. Baseline patient factors that have been associated with development of delirium include preexisting dementia, history of stroke, advanced age, frailty, and cardiopulmonary comorbid disease. Thus, patients with lower cognitive and physical reserve possess decreased capacity to maintain normal brain functioning in response to the acute stress of injury and hospitalization.

Clinicians are able to modify several risk factors for delirium by improving sleep hygiene and sedative regimens and avoiding medications that might trigger delirium. For instance, benzodiazepines, steroids, and anticholinergics are independent risk factors for development of delirium. Analgesic regimens, specifically opiates, do not have a clearly defined relationship with development of delirium. In fact, inadequate pain control is a risk factor for development of delirium, but data regarding the specific effects of opioids on delirium are inconsistent (although meperidine and morphine appear to confer increased risk). It appears that adequate pain control might be beneficial in protection against delirium, but use of opiates for sedation might place patients at risk for development of delirium.

EPIDEMIOLOGY

Delirium is common among all patient populations. In the surgical patient population, rates of delirium directly postoperatively can reach 45%, whereas those admitted to the hospital have rates between 32% and 50%. In the critically ill population, rates range from 30% to 50%, with those requiring mechanical ventilation reaching rates up to 80% of patients. After stroke, incidence of

TABLE 11.1 Clinical Risk Factors for Delirium

Patient Factors	Acute Illness	Iatrogenic Causes
Baseline cognitive impairment	High severity of illness	Deep versus light sedation
Advanced age	Hypoxemia	Sleep disturbances
Ischemic heart disease or congestive heart failure	Electrolyte disturbances	Anticholinergic medications
Frailty	Sepsis	Opiates (meperidine, morphine)
Prior stroke	Poor pain control	Mechanical ventilation
Depression	Atrial fibrillation	Steroids
Alcohol and drug abuse	Anemia	Benzodiazepines

delirium has been reported to range from 20% to 50%, depending on the age of the cohort studied and the type of stroke.

Older patients have a higher risk of delirium than their younger cohorts, which is reflected in the fact that 30% of those admitted to the hospital will experience delirium. In older cancer patients, 50% to 60% will experience delirium during their hospitalization. In patients aged 70 years and older who have undergone spine surgery, up to 40.5% developed delirium, which was associated with higher hospital charges. In the palliative care setting, 50% of patients experience delirium, and those at the end stage of life experience rates up to 85%.

PATHOBIOLOGY

The pathobiology of delirium is a continuously evolving field with current ongoing research. Currently primarily implicated in the pathophysiology of delirium is inflammation, endothelial dysfunction, blood-brain barrier breakdown, and neurotransmitter imbalance. These changes lead to neuroinflammatory processes, microglial activation, neuronal injury, and neuronal death in the central nervous system. Markers of these processes have been associated with acute brain dysfunction across a variety of patient populations.

Acetylcholine has also been associated with delirium, with elevated levels in the serum and decreased levels in the cerebrospinal fluid found in delirious patients. Importantly, acetylcholine helps to decrease the inflammatory cytokines released, and with its cerebrospinal fluid deficiency, this action is inhibited. Norepinephrine elevation has been associated with hyperactive delirium, and one study showed that patients receiving dopamine infusion were more likely to develop delirium. The serotonin precursor, tryptophan, found in elevated levels is associated with delirium.

Neuroanatomic changes that include brain atrophy and white matter changes have been witnessed in patients with delirium. Atrophy and white matter changes continue to persist even after hospital discharge and may be the cause of long-term cognitive impairment in these patients.

DIAGNOSIS

The gold standard in diagnosis of delirium is evaluation by psychiatrist using the criteria for delirium as outlined in the *Diagnostic and Statistical Manual of Mental Disorders*. However, this in-depth psychiatric evaluation is at times unavailable, or unnecessary, and evaluation can be done using the following guidance. Importantly, diagnosis of delirium should prompt a thorough investigation into the potential etiology of the acute brain dysfunction or encephalopathy that includes detailed history and physical exam findings.

Focused History

Causes of delirium such as drug ingestion, alcohol or drug withdrawal, metabolic derangements, and infection should be sought. Because features of delirium such as confusion or inattention may be present, history may be difficult to obtain from the patient. Assistance from staff or family members may be necessary. In addition, baseline cognitive and functional status of the patient should be obtained because this can help differentiate between dementia and delirium.

Focused Exam

Focal neurologic findings that could point to seizure activity or stroke should be sought. Physical exam should also look for possible sources of infection (eg, pneumonia or urinary tract infection) as the cause of the patient's acute change in mental status. In addition, physical exam findings suggestive of drug exposure may be useful. For example, anticholinergic exposure would reveal increased temperature, flushed dry skin, tachycardia, and pupillary dilation on exam.

Initial Laboratory Workup

In addition to a history and physical exam, other causes of changes in mental status should be sought. An electrolyte panel, blood count, and liver and thyroid function tests should be obtained. Additionally, infectious causes should be ruled out with appropriate testing such as chest radiograph, urinalysis, and culture data. Hypoxemia and hypercarbia should also be excluded as causes of confusion, which may require arterial blood gas analysis.

Arousal Level

A patient's level of arousal and content of consciousness need to be examined to evaluate for delirium. The first step is determining the patient's level of arousal through the use of Glasgow Coma Scale or a sedation scale. The Richmond Agitation-Sedation Scale (Table 11.2) and the Riker Sedation-Agitation Scale are commonly

TABLE 11.2 Richmond Agitation-Sedation Scale

Score	Term	Description
+4	Combative	Overly combative, violent, immediate danger to staff
+3	Very agitated	Pulls or removes tube(s) or catheter(s); aggressive
+2	Agitated	Frequent or nonpurposeful movements, fights ventilator
+1	Restless	Anxious but movements not aggressive/vigorous
0	Alert and calm	
−1	Drowsy	Not fully alert but has sustained awakening (eye opening/eye contact) to voice >10 s
−2	Light sedation	Briefly awakens with eye contact to voice (<10 s)
−3	Moderate sedation	Movement or eye opening to voice (but no eye contact)
−4	Deep sedation	No response to voice but movement or eye opening to physical stimulation
−5	Unarousable	No response to voice or physical stimulation

TABLE 11.3 Confusion Assessment Method

Diagnosis of delirium requires the presence of *both* features A and B and the presence of *either* feature C or D.

A. Acute onset or fluctuating course	Is there evidence of an acute change in mental status from baseline? Does the abnormal behavior: • Fluctuate over time? • Come and go? • Increase/decrease in severity?
B. Inattention	Does the patient: • Have difficulty focusing? • Become easily distracted? • Have difficulty keeping track of what is said?
C. Disorganized thinking	Is the patient's thinking: • Disorganized? • Incoherent?
D. Altered level of consciousness	Is the patient: • Alert (normal)? • Vigilant (hyperalert)? • Lethargic (drowsy but arousable)? • Stuporous (difficult to arouse)? • Comatose (unarousable)?

used tools that can be used to assess level of arousal, including in patients on mechanical ventilation. If the patient is determined to be unresponsive, then he or she is in a comatose state and cannot be assessed for delirium. Thus, assessment for delirium cannot occur if the patient has Richmond Agitation-Sedation Scale −4 to −5 or Riker Sedation-Agitation Scale of 1 to 2. If the patient is responsive to verbal stimuli, then delirium can be assessed using tools such as the Confusion Assessment Method (CAM), the Confusion Assessment Method for the ICU (CAM-ICU), or the Intensive Care Delirium Screening Checklist (ICDSC).

Delirium Assessment

Diagnosis of delirium relies on determination from the history and physical that the condition is an acute change in the patients' status. In patients who are not mechanically ventilated, the CAM (Table 11.3) can be used for diagnosis. The CAM assesses the patient for the key features of delirium such as an acute onset, fluctuating course, and inattention. It then assesses the patient for other symptomatology of delirium such as disorganized thinking or altered level of consciousness.

In critically ill or mechanically ventilated patients, the CAM-ICU (Table 11.4) and ICDSC (Table 11.5) have been validated. The CAM-ICU assesses the same four features as the CAM in an abbreviated manner more applicable to patients with critical illness: acute change or fluctuation in mental status, inattention, disorganized thinking, and an altered level of consciousness. The ICDSC uses eight diagnostic features; the diagnosis of delirium requires four or more features to be present.

Delirium is a heterogeneous syndrome of brain dysfunction and rarely presents as a single clinical entity. Pure hyperactive delirium is less common despite being the foremost perception of delirium to most clinicians. Patients with hyperactive delirium display prominent agitated motor behaviors such as pulling at lines/catheters and physically or verbally assaulting staff. In contrast, most patients are either hypoactive or have a mixed subtype. Hypoactive delirium is characterized by slow patient movements, decreased speed of cognition, and decreased alertness. It has been associated with worse outcomes compared to hyperactive delirium; however, patients are often overlooked because they are not displaying disruptive behavior. The mixed subtype is characterized by having both hyper- and hypoactive delirium within a 24-hour period.

TABLE 11.4 Confusion Assessment Method for the Intensive Care Unit (CAM-ICU)

Feature A plus B and either C or D present = CAM-ICU positive.

A. Acute onset or fluctuating course	• Is the patient different than his or her baseline? *or* • Has the patient had any fluctuation in mental status in the past 24 h?
B. Inattention	• Letters attention test: Say to the patient, "I am going to read to you a series of 10 letters. Whenever you hear the letter 'A,' indicate by squeezing my hand." SAVEAHAART or CASABLANCA or ABADABADAAY Errors are counted when patient fails to squeeze on the letter "A" and when patient squeezes on any letter other than "A." If greater than two errors, patient has inattention.
C. Altered level of consciousness	• Present if the RASS score is anything other than alert and calm or RASS 0.
D. Disorganized thinking	• Ask patient yes/no questions: 1. Will a stone float on water? 2. Are there fish in the sea? 3. Does 1 lb weigh more than 2 lb? Errors are counted when the patient incorrectly answers a question. • Have the patient follow commands: Say to patient "Hold this many fingers up." (Show two fingers to patient.) Have him or her repeat with the other hand using a different number of fingers. An error is counted if patient is unable to complete the entire command. If patient makes greater than one error, then he or she is positive for this feature.

Abbreviation: RASS, Richmond Agitation-Sedation Scale.

TABLE 11.5 Intensive Care Delirium Screening Checklist

1. Altered level of consciousness	
A. Exaggerated response to normal stimulation	RASS +1 to +4
B. Normal wakefulness	RASS 0
C. Response to mild/moderate stimulation	RASS −1 to −3
D. Response only to intense stimulation	RASS −4
E. No response	RASS −5
Assessment is terminated if patient is a RASS −4 or RASS −5.	
2. Inattention	
A. Difficulty in following commands	
B. Easily distracted by external stimuli	
C. Difficulty in shifting focus	
One point if any are present	
3. Disorientation	
Patient not oriented to person, place, or time	
One point if any are present	
4. Hallucinations or delusions	
A. Equivocal evidence of hallucinations or behavior due to hallucinations	
B. Delusions	
One point if any are present	
5. Psychomotor agitation or retardation	
A. Hyperactivity requiring the use of addition sedatives or restraints	
B. Hypoactivity or psychomotor slowing	
One point if any are present	
6. Inappropriate speech or mood	
A. Inappropriate, disorganized, or incoherent speech	
B. Inappropriate mood	
One point if any are present	
7. Sleep/wake cycle disturbance	
A. Sleeping <4 h per night	
B. Waking frequently at night	
C. Sleeping >4 h during the day	
One point if any are present	
8. Symptom fluctuation	
Fluctuation of any of the above items over the previous 24 h	
Total score is based on adding items up from 1 to 8. A score >4 is concerning for delirium.	

Abbreviation: RASS, Richmond Agitation-Sedation Scale.

Diagnosis of Delirium After Neurologic Injury

Diagnosing delirium in the neurologically injured patient remains an important part of care for this patient population. Those that are diagnosed with delirium have longer lengths of stay in the ICU and hospital, and this diagnosis has also been associated with worse functional independence and cognition.

When evaluating patients with neurologic injury, it should always be noted that mental status changes and positive delirium screening tests can also be contributed to underlying pathology and should be evaluated appropriately before assigning the diagnosis of delirium. A screening too is also best operationalized by comparing the patient's postinjury baseline status with subsequent neurologic exams and assessments.

Diagnosis of delirium in this patient population requires the ability to differentiate delirium from mental status changes from the underlying disease process. The CAM-ICU has been validated in neurocritically ill patients by comparing it to the *Diagnostic and Statistical Manual of Mental Disorders*, 4th edition, criteria for delirium. The CAM-ICU proved to be 76% sensitive and 98% specific for the diagnosis of delirium after stroke. The positive predictive value was 91%. In patients with traumatic brain injury, the CAM-ICU proved to be 62% sensitive, 74% specific, and had a positive predictive value of 63%.

Electroencephalogram Findings in Delirium

The fluctuating state of awareness in delirium is accompanied by changes in the electroencephalogram. Changes in level of attention parallel the slowing of background electroencephalogram rhythms. There may be deceleration or complete loss of posterior background rhythm, global slowing, and intermittent rhythmic delta activity especially in the frontal regions. Triphasic waves may be present when metabolic encephalopathy is a contributing factor.

Delirium Versus Dementia: A Diagnostic Challenge

It is estimated that 4.5 million older Americans have Alzheimer disease. As the population continues to age, this number will continue to increase. The prevalence of delirium in hospitalized patients with coexisting Alzheimer disease is estimated at 60% to 89% of patients, and delirium in patients with preexisting dementia has been associated with long-term cognitive decline that persists for at least 5 years after discharge from the hospital. Diagnosis of delirium in patients with underlying dementia can be difficult; symptoms of delirium can be attributed to the underlying cognitive dysfunction and overlooked as new symptomatology. Trials for validating delirium assessment tools have either excluded or included few patients with underlying dementia; however, based on the available evidence, the CAM and CAM-ICU are currently considered the best available tools.

MANAGEMENT

Delirium is an urgent medical condition, and prompt review of possible causes or inciting factors should be performed. Underlying causes such as pain, metabolic derangements, infection, and hypoxemia should be sought and treated. Prevention and treatment consist of two broad categories: *pharmacologic symptom management* and *environmental optimization*. Prevention is of paramount importance and should be always a consideration in the care plan of a patient.

Once delirium sets in, the initial step in management is to ensure patient and staff safety. If the patient is exhibiting signs of hyperactive delirium and is trying to remove medically necessary devices, pharmacologic management is likely needed. If pain is an inciting cause, analgesic therapy with opioids or nonsteroidal anti-inflammatory drugs should be used as the first line of therapy. Symptomatic treatment is usually with dexmedetomidine or an antipsychotic medication such as haloperidol, olanzapine, or quetiapine (**Table 11.6**). Benzodiazepines can often exacerbate delirium symptoms and should be avoided unless the cause is alcohol withdrawal or if there is a component of severe anxiety. Despite common use among clinicians, no drug

TABLE 11.6 Medications Used to Control Delirium Symptoms

Drug	Dose
Dexmedetomidine (Precedex)	0.2-1.4 μg/kg/min IV infusion
Haloperidol (Haldol)	1-10 mg IV q4-6h
Olanzapine (Zyprexa)	5-10 mg by mouth q8h
Quetiapine (Seroquel)	25-400 mg q8-12h

Abbreviation: IV, intravenous.

has been approved by the U.S. Food and Drug Administration for prevention or treatment of delirium. Furthermore, although some smaller studies have found benefit, there is paucity of large randomized controlled trials that support the use of medications for the treatment of delirium. In general, agents that tend to be used to prevent or treat delirium affect the sensorium and have significant side effects. For example, antipsychotic agents can cause sedation, respiratory depression, prolonged QT intervals, and neuroleptic malignant syndrome.

Pharmacologic Prevention

First-line pharmacologic therapy for delirium prevention in the ICU consists mostly of appropriate sedation regimens. Sedative regimens that focus on targeted arousal levels and light sedation have positively affected the rates of delirium, and exposure to sedative medications and deeper levels of sedation have been associated with increased risk of delirium. The increased sedation intensity was also associated with higher mortality. Sedation should therefore be titrated to the minimal required amount to keep the patient comfortable and safe but awake.

The use of dexmedetomidine for sedation during mechanical ventilation has improved delirium outcomes in randomized controlled trials when compared to lorazepam, midazolam, propofol, and morphine. The Maximizing Efficacy of Targeted Sedation and Reducing Neurological Dysfunction trial compared lorazepam and dexmedetomidine for sedation in critically ill patients, and patients who received dexmedetomidine for sedation had more days free of delirium LEVEL 1.[1] The Safety and Efficacy of Dexmedetomidine Compared with Midazolam trial showed that patients sedated with dexmedetomidine achieved adequate levels of sedation while experiencing less episodes of delirium and shorter time to extubation LEVEL 1.[2] Dexmedetomidine for sedation after surgery versus propofol has shown decreased risk of delirium development and duration of delirium in patients receiving dexmedetomidine. However, a recent study compared patients undergoing mechanical ventilation in the ICU sedated with dexmedetomidine versus those receiving usual care (propofol, midazolam, or other sedatives). This study's primary outcome was all-cause mortality at 90 days, which showed no difference between the two groups. As a secondary cause, the study found no difference in the days spent without coma or delirium LEVEL 2.[3] This unblinded study was confounded by deeper levels of sedation, additional sedative use in 70% of the dexmedetomidine group, and delirium reduction was only a secondary outcome. Overall, studies support the use of dexmedetomidine for sedation to prevent delirium in mechanically ventilated ICU patients.

Prophylactic dexmedetomidine (compared to dexmedetomidine infusion for sedation) has been studied as a method to prevent delirium. Studies have shown this to be beneficial in older patients admitted to the surgical ICU after noncardiac surgery and as nocturnal administration in critically ill patients. Other studies, however, have not found benefit with prophylactic dexmedetomidine in older patients undergoing major noncardiac or cardiac surgery. The role of prophylactic dexmedetomidine after neurologic injury is unclear.

There are several randomized controlled trials examining the efficacy of antipsychotics for prevention of delirium, including haloperidol, olanzapine, and risperidone. For the most part, these studies have been small with low-study quality and have produced inconsistent results. Meta-analyses of antipsychotics for delirium prevention found no benefit. The more recent and larger prophylactic haloperidol use for delirium in ICU patients with a high risk for delirium (REDUCE) trial showed that prophylactic haloperidol versus placebo starting within 24 hours of ICU admission did not change the incidence of delirium, length of stay, or mortality LEVEL 3.[4]

Anti-inflammatory agents, including steroids and statins, have been of interest given the potential role of inflammation in delirium. Several large studies have not shown a benefit of steroid administration with regard to reducing delirium. Statin therapy while in the ICU has been shown in two studies to be associated with lower overall risk of delirium. Also, increasing duration of statin discontinuation in chronic statin users increased the odds of developing delirium, potentially from a rebound pro-inflammatory state from statin discontinuation. Randomized controlled trials of statin versus placebo, however, have not shown a decreased risk of delirium. Although cholinergic depletion is thought to play a role in delirium development, acetylcholinesterase inhibitors such as rivastigmine and donepezil have had disappointing results with regard to delirium.

Pharmacologic Therapy

Pharmacologic agents for the treatment of delirium should be restricted to the patient who has failed prevention strategies and who is a risk to self or others. The most popular pharmacologic treatments are antipsychotic medications (eg, haloperidol, olanzapine, quetiapine) and dexmedetomidine.

When haloperidol was compared to olanzapine for delirium treatment, there was no difference in length of delirium. In a small study of patients who required intravenous haloperidol, subjects were randomized to receive placebo versus quetiapine in addition to the haloperidol. The quetiapine group had a faster resolution of the first episode of delirium. Another small study of low-dose bedtime quetiapine in patients with delirium found a reduction in delirium severity. The largest and best study to date on antipsychotics for the treatment of delirium—Modifying the Incidence of Delirium United States study—found no difference between haloperidol, ziprasidone, and placebo with regard to delirium, mortality, length of stay, and additional outcomes LEVEL 2.[5]

A randomized controlled trial compared dexmedetomidine to placebo in patients with critical illness that had otherwise resolved but for whom weaning from mechanical ventilation was prevented by hyperactive delirium. Patients treated with dexmedetomidine had increased ventilator-free hours and faster resolution of their delirium symptoms. A nonrandomized study

examined the effectiveness of dexmedetomidine versus haloperidol as a rescue therapy for nonintubated ICU patients with hyperactive delirium. Patients receiving dexmedetomidine had faster resolution of delirium, less oversedation, and a shorter ICU length of stay without increased incidence of hemodynamic side effects. The overall failure rate of haloperidol was 43%, demonstrating the limited efficacy of antipsychotic agents in the treatment of delirium.

Environmental Optimization

Nonpharmacologic interventions have been shown to be beneficial in patients with delirium, and improving the environmental factors remains the first-line intervention for delirium prevention and treatment. These treatments include sleep hygiene and patient reorientation. A study in medical patients reduced the incidence of delirium by 40% by focusing on regulation of environmental factors LEVEL 1.[6] These factors included appropriate and early removal of catheters/restraints, nonpharmacologic sleep protocols, early mobilization, providing regular stimulating activities, and attention to hydration. Patients should have continuity of caregivers and be provided eyeglasses or hearing aids as needed to provide cognitive stimulation. In a randomized trial of early physical and occupational therapy in critically ill patients, patients in the early mobilization group had greater return to functional status at hospital discharge and shorter duration of delirium LEVEL 1.[7] Therapy typically progresses from passive range of motion to active range of motion, exercise in bed, sitting, standing, and walking depending on a patient's neurologic deficits, sedation level, and physical abilities. Sleep hygiene is important to the prevention of delirium because fragmented sleep has been associated with increased rates of delirium. A decrease in the incidence of ICU delirium has been demonstrated when sleep disruptions are minimized and normal circadian rhythms are promoted. Nonpharmacologic sleep aids should be used when capable and alternative sleep medications used only when necessary. In the ICU, bundles involving frequent assessment and control of pain, awakening and breathing trial coordination, light sedation, minimizing benzodiazepine use, delirium monitoring and management, early mobility, and family involvement (ie, the ABCDEF bundle) have been advocated to improve outcomes associated with delirium. Studies of the ABCDEF bundle across multiple hospitals have found that increased bundle compliance was associated with improved survival and increased the number of days alive without delirium or coma.

CONCLUSION

Delirium commonly occurs in hospitalized patients and is independently associated with worse outcomes. Early recognition of delirium may be achieved through active use of screening tools such as the CAM or CAM-ICU. Treatment should focus on nonpharmacologic therapy such as improvement in the patient's sleep/wake cycle, early mobility, removal of unnecessary lines/catheters, and frequent stimulating activities (Table 11.7). Pharmacologic therapy should be used when patient behavior places themselves or staff at risk. These therapies should be used judiciously because they have unproven efficacy and alter patient sensorium.

TABLE 11.7 Management Strategies for Delirium

- Ensure patient and staff safety. Pharmacologic management may be required in patients whose agitation may harm themselves or others.
- Rule out emergent causes of mental status change such as hypoxia, hypercarbia, drug withdrawal, seizures, cerebral edema, and new/worsening stroke.
- Perform focused history and physical exam including assessment of arousal level.
- Assess delirium with tools such as the confusion assessment method or confusion assessment method for the intensive care unit.
- Removal of catheters/restraints; promote sleep; perform early mobilization; glasses and hearing aids; eliminate unnecessary alarms and stimuli; medication review.
- Light sedation strategies with avoidance of benzodiazepines
- Establish a calm, reassuring environment and promote human contact, especially with loved ones.

LEVEL 1 EVIDENCE

1. Pandharipande PP, Pun BT, Herr DL, et al. Effect of sedation with dexmedetomidine vs lorazepam on acute brain dysfunction in mechanically ventilated patients: the MENDS randomized controlled trial. *JAMA*. 2007;298(22):2644-2553.
2. Riker RR, Shehabi Y, Bokesch PM, et al. Dexmedetomidine vs midazolam for sedation of critically ill patients: a randomized trial. *JAMA*. 2009;301(5):489-499.
3. Shehabi Y, Howe BD, Bellomo R, et al. Early sedation with dexmedetomidine in critically ill patients. *N Engl J Med*. 2019;380:2506-2517. doi:10.1056/NEJMoa1904710.
4. van den Boogaard M, Slooter AJC, Brüggemann RJM, et al. Effect of haloperidol on survival among critically ill adults with a high risk of delirium: the REDUCE randomized clinical trial. *JAMA*. 2018;319:680-690.
5. Girard TD, Exline MC, Carson SS, et al. Haloperidol and ziprasidone for treatment of delirium in critical illness. *N Engl J Med*. 2018;379:2506-2516.
6. Inouye SK, Bogardus ST Jr, Charpentier PA, et al. A multicomponent intervention to prevent delirium in hospitalized older patients. *N Engl J Med*. 1999;340(9):669-676.
7. Schweickert WD, Pohlman MC, Pohlman AS, et al. Early physical and occupational therapy in mechanically ventilated, critically ill patients: a randomised controlled trial. *Lancet*. 2009;373(9678):1874-1882.

SUGGESTED READINGS

Bergeron N, Dubois MJ, Dumont M, Dial S, Skrobik Y. Intensive care delirium screening checklist: evaluation of a new screening tool. *Intensive Care Med*. 2001;27(5):859-864.

Carrasco G, Baeza N, Cabré L, et al. Dexmedetomidine for the treatment of hyperactive delirium refractory to haloperidol in nonintubated ICU patients a nonrandomized controlled trial. *Crit Care Med*. 2016;44:1295-1306.

Dahl MH, Rønning OM, Thommessen B. Delirium in acute stroke—prevalence and risk factors. *Acta Neurol Scand Suppl*. 2010;(190):39-43.

Devlin JW, Roberts RJ, Fong JJ, et al. Efficacy and safety of quetiapine in critically ill patients with delirium: a prospective, multicenter, randomized, double-blind, placebo-controlled pilot study. *Crit Care Med*. 2010;38(2):419-427.

Devlin J, Skrobik Y, Gélinas C, et al. Clinical practice guidelines for the prevention and management of pain, agitation/sedation, delirium, immobility, and sleep disruption in adult patients in the ICU. *Crit Care Med*. 2018;46:e825-e873.

Djaiani G, Silverton N, Fedorko L, et al. Dexmedetomidine versus propofol sedation reduces delirium after cardiac surgery: a randomized controlled trial. *Anesthesiology*. 2016;124:362-368.

Dubois MJ, Bergeron N, Dumont M, Dial S, Skrobik Y. Delirium in an intensive care unit: a study of risk factors. *Intensive Care Med*. 2001;27(8):1297-1304.

Ely EW, Inouye SK, Bernard GR, et al. Delirium in mechanically ventilated patients: validity and reliability of the confusion assessment method for the intensive care unit (CAM-ICU). *JAMA*. 2001;286(21):2703-2710.

Fick DM, Agostini JV, Inouye SK. Delirium superimposed on dementia: a systematic review. *J Am Geriatr Soc*. 2002;50(10):1723-1732.

Flannery AH, Oyler DR, Weinhouse GL. The impact of interventions to improve sleep on delirium in the ICU: a systematic review and research framework. *Crit Care Med*. 2016;44(12):2231-2240.

Gross AL, Jones RN, Habtemariam DA, et al. Delirium and long-term cognitive trajectory among persons with dementia. *Arch Intern Med*. 2012;172(17):1324-1331.

Gunther ML, Morandi A, Krauskopf E, et al. The association between brain volumes, delirium duration, and cognitive outcomes in intensive care unit survivors: the VISIONS cohort magnetic resonance imaging study. *Crit Care Med*. 2012;40(7):2022-2032.

Gustafson Y, Olsson T, Erikkson S, Asplund K, Bucht G. Acute confusional states (delirium) in stroke patients. *Cerebrovasc Dis*. 1991;1:257-264.

Inouye SK, van Dyck CH, Alessi CA, Balkin S, Siegal AP, Horwitz RI. Clarifying confusion: the confusion assessmen: method. A new method for detection of delirium. *Ann Intern Med*. 1990;113(12):941-948.

Jacobson S, Jerrier H. EEG in delirium. *Semin Clin Neuropsychiatry*. 2000;5:86-92.

Mitasova A, Kostalova M, Bednarik J, et al. Poststroke delirium incidence and outcomes: validation of the Confusion Assessment Method for the Intensive Care Unit (CAM-ICU). *Crit Care Med*. 2012;40(2):484-490.

Morandi A, McCurley J, Vasilevskis E, et al. Tools to detect delirium superimposed on dementia: a systematic review. *J Am Geriatr Soc*. 2012;60(11):2005-2013.

Morandi A, Rogers BP, Gunther ML, et al. The relationship between delirium duration, white matter integrity, and cognitive impairment in intensive care unit survivors as determined by diffusion tensor imaging: the VISIONS prospective cohort magnetic resonance imaging study. *Crit Care Med*. 2012;40(7):2182-2189.

Neufeld KJ, Yue J, Robinson TN, Inouye SK, Needham DM. Antipsychotic medication for prevention and treatment of delirium in hospitalized adults: a systematic review and meta-analysis. *J Am Geriatr Soc*. 2016;64:705-714.

Page VJ, Casarin A, Ely EW, et al. Evaluation of early administration of simvastatin in the prevention and treatment of delirium in critically ill patients undergoing mechanical ventilation (MoDUS): a randomised, double-blind, placebo-controlled trial. *Lancet Respir Med*. 2017;5:727-737.

Page VJ, Ely EW, Gates S, et al. Effect of intravenous haloperidol on the duration of delirium and coma in critically ill patients (Hope-ICU): a randomised, double-blind, placebo-controlled trial. *Lancet Respir Med*. 2013;1(7):515-523.

Pandharipande PP, Girard TD, Jackson JC, et al. Long-term cognitive impairment after critical illness. *N Engl J Med*. 2013;369(14):1306-1316.

Patel MB, Bednarik J, Lee P, et al. Delirium monitoring in neurocritically ill patients: a systematic review. *Crit Care Med*. 2018;46(11):1832-1841.

Pisani MA, Kong SY, Kasl SV, Murphy TE, Araujo KL, Van Ness PH. Days of delirium are associated with 1-year mortality in an older intensive care unit population. *Am J Respir Crit Care Med*. 2009;180(11):1092-1097.

Pun BT, Balas MC, Barnes-Daly MA, et al. Caring for critically ill patients with the ABCDEF bundle: results of the ICU Liberation Collaborative in over 15,000 adults. *Crit Care Med*. 2019;47:3-14.

Reade MC, Eastwood GM, Bellomo R. Effect of dexmedetomidine added to standard care on ventilator-free time in patients with agitated delirium: a randomized clinical trial. *JAMA*. 2016;315:1460-1468.

Sampson EL, Raven PR, Ndhlovu PN, et al. A randomized, double-blind, placebo-controlled trial of donepezil hydrochloride (Aricept) for reducing the incidence of postoperative delirium after elective total hip replacement. *Int J Geriatr Psychiatry*. 2007;22(4):343-349.

Shehabi Y, Bellomo R, Kadiman S, et al. Sedation intensity in the first 48 hours of mechanical ventilation and 180-day mortality: a multinational prospective longitudinal cohort study. *Crit Care Med*. 2018;46:850-859.

Stephens RJ, Dettmer MR, Roberts BW, et al. Practice patterns and outcomes associated with early sedation depth in mechanically ventilated patients: a systematic review and meta-analysis. *Crit Care Med*. 2018;46:471-479.

Skrobik YK, Bergeron N, Dumont M, Gottfried SB. Olanzapine vs haloperidol: treating delirium in a critical care setting. *Intensive Care Med*. 2004;30:444-449.

Tahir TA, Eeles E, Karapareddy V, et al. A randomized controlled trial of quetiapine versus placebo in the treatment of delirium. *J Psychosom Res*. 2010;69:485-490.

van Eijk MM, Roes KC, Honing ML, et al. Effect of rivastigmine as an adjunct to usual care with haloperidol on duration of delirium and mortality in critically ill patients: a multicentre, double-blind, placebo-controlled randomised trial. *Lancet*. 2010;376:1829-1837.

Dementia and Memory Loss 12

Lawrence S. Honig and James M. Noble

KEY POINTS

1. A range of cognitive changes including normal cognitive aging, delirium, depression, and mild cognitive impairment/dementia may prompt an evaluation for memory loss.
2. The clinical history, often informed by a care partner, and neurologic exam are essential to formulating an appropriate differential diagnosis.
3. A workup includes laboratory tests and structural neuroimaging to rule out treatable and reversible causes of cognitive impairment.
4. Increasingly, fluid and imaging biomarker-based assessments have enabled more specific dementia diagnoses.

INTRODUCTION

Dementia is characterized by intellectual deterioration, with concomitant decline in independence and daily social or occupational functions.

With different dementia disorders, various cognitive domains may predominantly affect including memory, orientation, abstraction, learning ability, visuospatial perception, language functions, constructional praxis, and higher executive functions such as planning, organizing, and sequencing activities. By past convention, now loosened, a diagnosis of dementia required significant impairment of at least two cognitive domains.

In the *Diagnostic and Statistical Manual of Mental Disorders* (*DSM*) versions I through IV-TR, there was a requirement that at least one of the affected cognitive domains be memory. This requirement, designed originally for Alzheimer disease (see Chapter 51), has been dropped in the most recent *DSM-5* with recognition of various dementias that do not initially or primarily involve memory, for example, frontotemporal dementia (see Chapter 52).

Dementia is diagnosed only when there is some significant decline in ability to function at home or at work. Dementia may be distinguished from mild cognitive impairment (MCI; see Chapter 50) in the requirement of significant impairment of independence in everyday activities such as occupational, social, or self-maintenance activities. The patient with MCI may have cognitive impairment in one or more domains, but this dysfunction is insufficient to cause functional impairment. For this reason, detailed analysis of the patient's need for help from others for simple activities of daily living (eg, toileting, food preparation, shopping, housework) is crucial.

Terminology and Classification

In the most recent *DSM-5*, the American Psychiatric Association has eliminated the term *dementia* in favor of major neurocognitive disorder. However, the distinction between dementia and MCI remains because it pertains to functional status. The *DSM-5* formulation is of "major" and "minor" neurocognitive disorders, depending on the degree of functional impairment. The major neurocognitive disorders are what were termed *dementias*, and the minor neurocognitive disorders represent types of MCI that may be precursors to dementias (see Chapter 50). The new *DSM-5* criteria permit both major and minor neurocognitive disorders to involve impairment with even a single domain but keep the distinction as to presence or absence of functional impairment. Despite the revised terminology of the *DSM-5*, the use of the terms *dementia* and *MCI* persisted in both neurologic care, lay audiences, and research.

Dementia can be classified in various ways. From the standpoint of clinical utility, dementia can be defined based on several features as a means to determine the differential diagnosis. These features include speed of progression, age of onset, and whether or not a reversible cause can be identified. The prior terminology of presenile (ie, young at onset) or senile (ie, old at onset) is no longer used because each of the dementing disorders can have first symptoms arise over a wide range of age at onset. However, age can be helpful in some cases of early-onset dementia (younger than 60 years of age) with a similar autosomal dominant family history given strong associations with several highly penetrant genes. Another dichotomous categorization of dementia proposed separating disorders into those of genetic origin and others of "sporadic" nature. However, this also has proven to be of minimal use because most dementia disorders may occur in either inherited (familial) forms or sporadic varieties, and some sporadic cases actually have a genetic basis. Dividing dementias into those with principally cortical or subcortical features, or into those with or without motor signs, has not proven useful for diagnosis, prognosis, or treatment and management. Thus, the most useful categorization of dementias is now based on the pathoetiologic basis of disease (Table 12.1). With clinicopathologic correlation, it is now usually possible to provide a specific diagnosis during life with 75% to 85% accuracy. It is important to recognize that even with an excellent clinical history and examination and auxiliary testing, clinical diagnosis of the dementia pathoetiology will not have perfect sensitivity or specificity.

Some patients have subjective complaints of cognitive disturbance, which is objectively verifiable but insufficient in either severity or functional disturbance or activities of daily life to meet criteria for dementia. In these cases, a diagnosis of MCI may be made, with specification of the involved cognitive domains (memory, language, visuospatial, executive, or attention). A large proportion of persons with MCI will develop some form of dementia within 5 to 7 years, with an annual rate of conversion of MCI to dementia as high as 10% to 15%.

Dementia Versus Mild Cognitive Impairment

Attempts have been made to better define cognitive changes associated with aging, and varying sets of criteria have produced multiple terms, including such terms as *age-associated memory*

TABLE 12.1 Dementias Categorized by Pathoetiologic Basis

Primary Neurodegenerative Disorders
Alzheimer disease (AD)
Lewy body disorders
Dementia with Lewy bodies (DLB)
Parkinson disease dementia (PDD)
Frontotemporal dementias (FTD)
Behavioral variant frontotemporal dementia (bvFTD)
Progressive nonfluent aphasia (PNFA)
Frontotemporal dementia with motor neuron disease (FTD-ALS, FTD-MND)
Progressive supranuclear palsy (PSP)
Corticobasal degeneration (CBD)
Huntington disease (HD)
Wilson disease (WD)
Creutzfeldt-Jakob disease (CJD) and other prion diseases
Hippocampal sclerosis
Limbic-predominant age-related TDP-43 encephalopathy (LATE)
Chronic traumatic encephalopathy (CTE)
Others: British familial dementia, HDLS, others
Vascular dementias: multi-infarct dementia, Binswanger disease, CADASIL
Immune-mediated encephalitides: NMDARAE, VGKCAE, others
Demyelinating dementias: multiple sclerosis, adreno- and metachromatic leukodystrophies
Inflammatory dementias: CNS vasculitides, Behçet syndrome, systemic lupus
Infectious dementias: neurosyphilis, neuroborreliosis, HIV dementia, others
Neoplastic dementias: tumors, carcinomatous meningitis, paraneoplastic syndromes
Metabolic or endocrine dementias: B_{12} or rarer vitamin deficiencies, hypothyroidism
Structural dementias: hydrocephalus, brain trauma

Abbreviations: CADASIL, cerebral autosomal dominant arteriopathy with subcortical infarcts and leukoencephalopathy; CNS, central nervous system; FTD-ALS, frontotemporal dementia with amyotrophic lateral sclerosis; HDLS, hereditary diffuse leukoencephalopathy with spheroids; HIV, human immunodeficiency virus; NMDARAE, *N*-methyl-D-aspartate receptor antibody encephalitis; VGKCAE, voltage-gated potassium channel antibody encephalitis.

impairment, *age-related cognitive change*, and *questionable dementia*, among others. The most widely used term for cognitive change insufficient to meet criteria for dementia is *mild cognitive impairment* or, in the most recent psychiatric lexicon (*DSM-5*), *minor neurocognitive disorder* (see Chapter 50). Criteria for MCI include subjective cognitive complaints and objective cognitive dysfunction but preserved general cognitive function and activities of daily living. Follow-up examinations of individuals with MCI indicate that some, but not all, develop dementia over time.

Dementia Versus Delirium

As further reviewed in Chapter 11, delirium presents acutely or subacutely and is a state of mental confusion that, unlike dementia, is primarily characterized by inattention to the immediate environment. Dementia is insidious in onset, evolves over months to years with normal consciousness and progressively worsens, whereas delirium is acute in onset, evolving in days to weeks, with fluctuations in consciousness. Both dementia and delirium may involve anxiety, hallucinations, illusions, delusions, and dysautonomia. Delirium is often a consequence of diffuse systemic or cerebral insults, including pain, infections, intoxications, or withdrawal from medications or drugs of abuse, metabolic disorders including hepatic or renal dysfunction, hypoxemia, or other medical or neurologic diseases. It is not possible to diagnose dementia with certainty in the presence of delirium. Delirium in elderly hospitalized patients very often has an underlying substrate of a baseline dementing illness that becomes apparent once the delirium has resolved.

Several features help differentiate dementia from delirium. Attention is not usually impaired in patients with dementia, although it is almost always altered in delirium. Increased or decreased motor activity is inherent in delirium but absent usually in dementia. If the cause is identified, delirium itself can be reversed (although not necessarily an underlying dementia process), although most forms of dementia progressively worsen.

Dementia Versus Depression

Differentiating dementia from depression can sometimes be difficult. Depression (see Chapter 154) may be an early manifestation of Alzheimer disease. In depression, memory loss typically declines as the mood worsens. The onset of memory problems may be more abrupt than usually occurs in dementia and is mild, fluctuating, and nonprogressive. Neuropsychological test results may reflect variability or effort in performance and greater difficulties with learning, concentration, and attention, rather than true memory deficits such as seen with Alzheimer disease.

EPIDEMIOLOGY

Dementia increases in prevalence with age. Although uncommon in younger persons, with a prevalence of 1% by age 60 years, dementia becomes dramatically more common thereafter, with a prevalence of 50% or greater at age 90 years and older. In autopsy studies of individuals with dementia, about 70% to 80% of brains show pathologically definite Alzheimer disease (see **Table 12.2**). About half of these have concomitant pathology, with evidence of Lewy body involvement or cerebrovascular infarctions. Thus, only one-third of autopsy brains have "pure" Alzheimer disease.

PATHOBIOLOGY

Dementing disorders are best etiologically classified as endocrine, metabolic, cerebrovascular, inflammatory, infectious, structural, or neurodegenerative (see **Table 12.1**). The last category is characterized by absence of the prior-listed etiologies.

Neurodegenerative Dementias

In the United States, the most common causes of dementia of the elderly are neurodegenerative. These include Alzheimer disease, Lewy body dementia, frontotemporal dementia, and Creutzfeldt-Jakob disease (CJD).

TABLE 12.2 Prevalent Causes of Dementia in the Elderly

Alzheimer disease[a]	65%-85%
Lewy body disorders[b]	15%-30%
Frontotemporal dementias	5%-10%
Vascular dementias[c]	2%-10%
Other dementias	5%-10%

[a]Note that Lewy bodies may also be present in 20%-40% of cases.
[b]Note that concomitant Alzheimer disease is present in 55%-90% of cases.
[c]Note that infarcts are noted in ~35% of cases of dementia.

Alzheimer Disease

Alzheimer disease (see Chapter 51), with prominent memory and language impairment, is the most frequent form of dementia, accounting in the elderly for about 80% of the total number of patients in autopsy, clinical, or population-based series (Table 12.2). Structurally, it is marked by temporal and parietal degeneration. Molecularly, it is characterized as an "amyloidopathy" because the most specific hallmark is abnormal deposits of β-amyloid in plaques, in addition to the less specific hyperphosphorylated tau protein evident in neurofibrillary tangles. Recently described is limbic-predominant age-related TAR DNA-binding protein 43 (TDP-43) encephalopathy (LATE), in older adults, with or without coexisting hippocampal sclerosis pathology. Phenotypically LATE patients may appear clinically very similar to late-onset Alzheimer patients, although LATE tends to primarily involve the amygdala, hippocampus, and middle frontal gyrus and usually has a very slow course. Given that patients are older, copathology including Alzheimer changes are often present.

Lewy Body Dementia

Lewy body dementia is the second most frequent cause of dementia in the elderly (see Chapter 53), characterized clinically by parkinsonism, hallucinations, fluctuations in level of consciousness, and REM sleep behaviors. Pathologically, the presence of Lewy bodies with molecular composition principally alpha-synuclein has led to the term *synucleinopathy*.

Frontotemporal Dementias

Frontotemporal dementias represent a molecularly heterogeneous group of degenerative disorders marked by frontal and temporal degeneration (see Chapter 52). Frontotemporal degeneration often presents with onset of symptoms at younger ages, in the 50s, and accounts for 5% to 10% of cases. Manifestations typically consist of either frontal-type behavioral disturbances (eg, disinhibition, apathy, social impropriety, obsessions) or language disturbances. The molecular pathologies of this group of disorders can be broadly divided into those involving tau and those involving TDP-43 protein, with less common involvement of FUS, CHMP3, or VCP proteins. Pathologic entities including Pick disease, progressive supranuclear palsy (PSP), corticobasal degeneration (CBD), tangle dominant dementia, and argyrophilic grain disease are marked by prominent tau abnormalities and all now termed *tauopathies*. Motor neuron disease with dementia (amyotrophic lateral sclerosis dementia), some progressive aphasic disorders, and some behavioral variant frontotemporal dementias are TDP-43 proteinopathies.

Less Common Neurodegenerative Dementias

Other degenerative dementias include Wilson disease (see Chapter 139), a genetic disorder marked by copper deposition in the basal ganglia, dementia, and tremor, and Huntington disease (see Chapter 85), a genetic disorder marked by bicaudate atrophy, clinical dementia, chorea, and gait disorder. Even less frequent neurodegenerative dementing disorders include CJD (see Chapter 56), British familial dementia, neuroaxonal dystrophy, certain spinocerebellar ataxias, fragile X tremor ataxia syndrome, and others.

Vascular Dementia

Cerebrovascular disease was once considered to be a major cause of dementia of the elderly but is now recognized to be the principle cause of dementia in less than 5% of cases in the United States. Syndromes of strategic infarct dementia, multiple infarct dementia, severe ischemic white matter disease (Binswanger disease or subcortical arteriosclerotic dementia), and hemorrhagic brain disease may all cause dementia (see Chapter 54). Acute stroke is a common cause of cognitive impairment but does not present as a gradually progressive dementing illness; instead, cognitive deficits follow in the aftermath of acute focal neurologic deficits or may take a stepwise course with discrete episodes of impairment and disability.

Structural Causes of Dementia

The most common structural causes of dementia are chronic subdural hematoma (see Chapter 47), hydrocephalus (see Chapter 110), and brain tumors (Section 14). Both diagnoses are established, in part, by neuroimaging, such as computed tomography or magnetic resonance imaging (MRI), although imaging itself is not sufficient to determine the role of hydrocephalus in dementia. Subdural hematoma typically presents as progressive deterioration in cognition and gait over days to weeks. Headache and lateralized focal deficits may or may not be present. Hydrocephalus represents a relative increase in cerebrospinal fluid (CSF) in the cranial vault, causing compressive dysfunction of descending cortical pathways and cortex itself. The symptoms classically involve gait disorder, urinary incontinence, and dementia. Risk factors for hydrocephalus include prior history of intracranial hemorrhage, head injury, or meningitis, although these may not be known. Radiologically, distinguishing ventricular enlargement due to hydrocephalus from ventricular enlargement due to brain atrophy (hydrocephalus ex vacuo) can be challenging.

Metabolic Causes of Dementia

Metabolic causes of dementia include cobalamin (vitamin B_{12}) deficiency, hypothyroidism, hypercalcemic disorders, and rarer vitamin or endocrine deficiencies. Toxic disorders can include inhalant, mercury, or manganese poisoning. Inherited metabolic disorders that may lead to dementia in adults include Wilson disease, the adult form of ceroid lipofuscinosis (Kufs disease), cerebrotendinous xanthomatosis, metachromatic leukodystrophy, adrenoleukodystrophy, and mitochondrial disorders such as MELAS (mitochondrial encephalomyopathy, lactic acidosis, and stroke-like episodes). Transient reversible memory loss may occur from acute medical illness, drug intoxications (most notably benzodiazepines), or from the poorly understood syndrome of *transient global amnesia* (see Chapter 64). This disorder typically occurs in older persons and consists of an acute circumscribed

period of time in which no new memories are acquired, with complete anterograde amnesia. Patients typically repetitively ask questions about their current situation.

Infectious Causes of Dementia

Infectious causes of dementia are less common in the developed world and mostly more frequent in the younger population. CJD, which results from prion protein infiltration of the brain resulting in a spongiform encephalopathy (see Chapter 56), is the most notorious potentially infectious cause of dementia, although it is only transmissible by direct exposure to diseased nervous system tissue. Viral disorders include human immunodeficiency virus (HIV)-associated dementia or herpesvirus family disorders (herpes simplex virus, varicella-zoster virus, cytomegalovirus, Epstein-Barr virus, human herpesvirus 6). Bacterial disorders include spirochetal disorders neurosyphilis and neuroborreliosis (Lyme disease) and atypical bacterial infections (tuberculosis). Fungal infections include meningitides owing to infection with *Cryptococcus*, *Coccidioides*, histoplasmosis, or others.

Dementia From Endocrine Dysfunction

Undiagnosed hypothyroidism is the most common endocrine abnormality that can present as dementia. Other endocrine disturbances that can cause dementia include Addison or Cushing disease, repeated episodes of hypoglycemia in diabetics, hyperparathyroidism associated with hypercalcemia, and hyperthyroidism (see Chapter 122). Hashimoto encephalopathy is a rare autoimmune encephalitis that occurs in conjunction with autoantibodies to thyroid proteins (see Chapter 74).

Inflammatory Causes of Dementia

Rapidly progressive dementia can be caused by the immune-mediated encephalitides (see Chapter 74), some of which are paraneoplastic disorders.

DIAGNOSIS

Focused History and Differential Diagnosis

The first symptoms of dementia often include occasional forgetfulness, misplacing objects, and word-finding difficulties (Table 12.3). With aging, a decline in memory may be observed, and thus sometimes, the distinction between cognitive decline in old age and early dementia may be difficult. By definition, dementia is associated with progressive decline in functioning and thus is distinguished from a static encephalopathy such as mental retardation or congenital syndromes. Important exclusionary criteria for dementia include syndromes that are better explained by delirium (see Chapter 11) or by a primary psychiatric disorder such as major affective disorder or schizophrenia.

Questions to Ask

Evaluation of complaints of cognitive dysfunction, whether described by the affected person or by a family member or caregiver, are first elicited by obtaining a thorough history. Particular attention should be paid as to which symptoms predominated at onset. Symptoms of memory loss (whether short term or long term), language usage (word-finding problems or decreased fluency, comprehension, or naming), praxis (dressing, use of utensils, or use of mechanical devices such as telephone or remote electronic controls), executive function (disorganization), insight (such as failure to recognize symptoms), dyscalculia, or behavioral dysfunction (agitation, disinhibition, depression, obsessions, delusions, or hallucinations) should be elicited. Symptoms of motor or gait impairment, adventitious movements, autonomic involvement (hypotension, urinary or bowel dysfunction), or sleep disturbance (evidence of rapid eye movement sleep behavior disorder, fractured sleep, and sleep apnea) should also be elicited.

TABLE 12.3 Ten Warning Signs of Alzheimer Disease[a]

1. Memory loss that affects job skills
2. Difficulty performing familiar tasks
3. Problems with language
4. Disorientation to time and place
5. Poor or decreased judgment
6. Problems with abstract thinking
7. Misplacing things
8. Changes in mood or personality
9. Problems with directions or spatial relations
10. Loss of initiative

[a]Adapted from the Alzheimer's Association. 10 early signs and symptoms of Alzheimer's. Alzheimer's Association Web site. https://www.alz.org/alzheimers-dementia/10_signs. Accessed October 15, 2020.

Focused Examination

Mental Status Examination

The mental status evaluation is an essential part of every neurologic examination but particularly so in the evaluation of patients with cognitive symptoms. Much of the evaluation is predicated on an attentive and communicative patient. Thus, the evaluation starts with determination of level of consciousness, alertness, and attention and proceeds to basic ascertainment of expressive and receptive language. If these are not intact, the evaluation is necessarily difficult and limited. A broad overview of the mental status examination is covered in Chapter 4. General assessments include the following:

- Awareness and consciousness
- Verbal behavior including appropriateness
- Motor behavior including agitation or picking movements
- Mood and emotional state

More specific cognitive assessments include the following:

- Orientation to time (hour, day, date, month, year, season) and place (institution, address, floor, city, state)
- Concentration (eg, spelling a five-letter word in reverse, counting backward by serial 7s, reciting the months of the year in reverse)
- Detailed language testing (expressive speech; aural and reading comprehension of one-, two-, or three-step commands; naming of solid objects or drawings; repetition of easy or difficult [prepositional] phrases; reading comprehension; ability to write a sentence)
- Registration or immediate recall (of three or five objects or words)

- Short-term memory or delayed recall after 3 to 10 minutes of three or five objects or words
- Long-term memory or fund of knowledge (names of current and prior elected officials, birthdates of family members, items of history)
- Visuospatial constructive abilities (copying simple shapes)
- Arithmetic calculations (mentally summing the values of coins, simple one- or two-digit additions or subtractions)
- Abstract reasoning (defining similarities, interpreting proverbs)
- Motor sequencing and praxis (sequential movements and motor commands)

Bedside Standardized Cognitive Testing

Two widely used brief standardized cognitive assessments are the Mini-Mental State Examination (MMSE) and the Montreal Cognitive Assessment (MoCA). These tests were introduced as standard measures of cognitive function for both research and clinical purposes. They are short, requiring less than 10 minutes, relatively easy to administer, and result in scores of 0 (failing all items) to 30 points (perfect score).

It is important to emphasize that the MMSE and MoCA, like all brief mental status exams, are not perfectly sensitive or specific for dementia. These tests are sensitive to cultural and language factors and level of education. Well-educated patients may suffer from dementia and nonetheless score a "perfect" 30 points on these 30-point scales, whereas poorly educated patients may score much lower and yet be nondemented. Therefore, the MMSE or MoCA should be used as screening instruments, but they do not replace a detailed history and examination or full neuropsychological testing (see Chapter 31).

General Neurologic Examination

The general neurologic examination is useful in the evaluation of the patient with dementia because certain signs (Table 12.4) may make a diagnosis of Alzheimer unlikely and may point to another causative etiology. For example, focal findings of hemiparesis may suggest a vascular component or, in cases of hemineglect, the degenerative disorder CBD. Prominent visual dysfunction may suggest posterior cortical atrophy, usually a variant of Alzheimer disease. Paralysis of supranuclear gaze with preserved brainstem reflexes may suggest PSP or CBD. Symmetric parkinsonism could support Lewy body dementia, PSP, or CBD. Lower motor neuron signs, such as fasciculations and atrophy, may suggest frontotemporal dementia with motor neuron disease. Primitive reflexes, although often checked, are commonly seen in dementia of any cause but also can be seen in normal aging.

Diagnostic Testing

The American Academy of Neurology in 2001 developed the evidence-based practice parameters for evaluation of the diagnosis and cause of dementia. These parameters have been entirely revolutionized by the development of modern neuroimaging, biomarkers, and genetic tests. A workgroup formed by the National Institute on Aging in conjunction with the Alzheimer's Association published in 2011, revised recommendations on diagnostic criteria, which are included in Table 12.5.

Neuropsychological Testing

Detailed neuropsychological testing (see Chapter 31) may be performed to augment the clinical mental status examination by assessing severity and regional pattern of cognitive impairment through use of standardized tests with normative values. This can be very helpful not only in differential diagnosis but also in monitoring disease progression.

Memory impairment can be parsed into immediate or working memory, short-term memory, and remote memory. Working memory is typically unaffected in early Alzheimer disease but often significantly affected in depression and subcortical dementias such as Parkinson disease dementia. In contradistinction, short-term recall is severely and early affected in Alzheimer disease and its precursor, amnestic MCI. Remote or long-term memory is affected later in the disease course of Alzheimer disease but may be relatively preserved even late in the course of some of the other dementias.

Language impairments can be assessed. Naming difficulties, common in Alzheimer disease, are less common in subcortical dementias. Verbal fluency for categories (semantic verbal fluency) is much more severely affected in disorders of the temporal lobes, such as Alzheimer disease, compared to verbal fluency for letters (phonemic verbal fluency), which is more affected in disorders of the frontal lobes, such as frontotemporal dementia.

Visuospatial impairments can be assessed. Typically, visuoperceptive impairment is marked in Alzheimer disease, whereas disorganization is more prominent in frontotemporal dementias. Micropraxia (drawing very small shapes) is common in the Lewy body disorders.

TABLE 12.4 Neurologic Signs and Symptoms Atypical for Alzheimer Disease

Sign or Symptom	Possible Significance
Dominant nonmemory features (eg, language, praxis, visuospatial dysfunction)	Frontotemporal degenerations, posterior cortical atrophy
Prominent behavioral, personality, psychotic symptoms	Frontotemporal degenerations, Lewy body dementia
Early parkinsonism (eg, resting tremor, bradykinesia, cogwheeling)	Lewy body dementia, progressive supranuclear palsy (no rest tremor), corticobasal degeneration, hydrocephalus
Urinary incontinence	Hydrocephalus
REM sleep behavior disorder	Parkinson disease dementia, Lewy body dementia
Seizures	Immune-mediated or infectious encephalitides
Myoclonus	Creutzfeldt-Jakob disease
Frequent falls	Progressive supranuclear palsy
Early unexplained gait abnormalities	Lewy body dementia, progressive supranuclear palsy, corticobasal degeneration, hydrocephalus
Early prominence of bulbar/brainstem signs	Progressive supranuclear palsy
Unexplained motor or reflex asymmetries	Vascular dementia, corticobasal degeneration
Unexplained (early) UMN signs (eg, Babinski sign)	Frontotemporal degeneration with motor neuron disease
Unexplained LMN signs (eg, fasciculations)	Frontotemporal degeneration with motor neuron disease

Abbreviations: LMN, lower motor neuron; REM, rapid eye movement; UMN, upper motor neuron.

TABLE 12.5 Practice Parameters for Diagnosis of Dementia[a]

Clinical Evaluation
History from patient and an informant
Cognitive assessment—mental status examination
Neuropsychological testing (when above is insufficient for confident diagnosis)
Routine Testing
Complete blood cell count
Serum chemistry—electrolytes, glucose
Serum BUN, creatinine, liver function tests
Serum TSH and B_{12} level
Serologic tests for syphilis and HIV (optional—depending on risk)
Biomarkers
Measures of brain atrophy, infarction, and structural changes
Brain MRI
Measures of neurodegeneration or neuronal injury
CSF total tau measurement
FDG-PET
MRI regional volumes and grey matter thickness
Measures of β-amyloid
CSF β-amyloid measurement
PET amyloid imaging
Measures of neurofibrillary tangles
CSF phospho-tau measurement
PET tau imaging
Measure of dopaminergic dysfunction
Ioflupane SPECT scan
Genetic tests (depending on age, family history, and clinical presentation)
AD mutations: PS1, PS2, APP
FTD mutations: tau, C9orf, progranulin
Prion protein mutations
Other mutations

Abbreviations: AD, Alzheimer disease; APP, amyloid precursor protein; BUN, blood urea nitrogen; C9orf, Chromosome 9 Open Reading Fram; CSF, cerebrospinal fluid; FDG, ^{18}F-fluorodeoxyglucose; FTD, frontotemporal dementia; HIV, human immunodeficiency virus; MRI, magnetic resonance imaging; PET, positron emission tomography; PS1, presenilin 1; PS2, presenilin 2; SPECT, single photon emission computed tomography; TSH, thyroid function tests.

[a]This table is based on first practice guidelines published by American Academy of Neurology (2001), more recent National Institute on Aging-Alzheimer's Association Workgroup recommendations (2011), and other practice guidelines.

Laboratory Blood Testing

Recommendations for auxiliary testing generally include basic laboratory tests (blood chemistry and cell counts) and, more specifically, laboratory testing for vitamin B_{12} deficiency (with homocysteine and methylmalonate ordered if B_{12} is borderline or low) and thyroid deficiency (thyroid-stimulating hormone [TSH], with free T4 ordered if TSH is out of normal range). The American Academy of Neurology guidelines specify B_{12}, TSH, and structural imaging (generally MRI) to exclude contributory disorders to cognitive symptoms, which might be otherwise unrecognized LEVEL 7.[1] Serologic tests for exposure to syphilis (Venereal Disease Research Laboratory and fluorescent treponemal antibody-absorption test), Lyme disease (screening enzyme immunoassay, with confirmatory Western blots), or HIV (HIV-1/HIV-2 antibody and antigen) may be of value.

Laboratory Cerebrospinal Fluid Testing

Analysis of CSF obtained through lumbar puncture (see Chapter 32) is increasingly used in diagnosis of cognitive dysfunction. CSF provides information in two broad categories: (1) In an exclusionary fashion, it may be used to be certain that various infectious or inflammatory etiologies of dementia discussed earlier are not present, and (2) in an inclusionary fashion, it may provide information with regard to neurodegenerative diseases, such as Alzheimer disease or CJD, through use of protein biomarkers (see Chapter 32). Presence of abnormal numbers of leukocytes, taking into account any blood contamination, is typically indicative of an inflammatory or infectious process. Biomarkers including β-amyloid-42, total tau, phosphotau, and 14-3-3 protein are established as of use in the diagnosis of Alzheimer disease and CJD. In Alzheimer disease, typically β-amyloid-42 is lower than normal, total tau is higher than normal, and phosphotau is higher than normal. These changes are often the earliest biomarker of Alzheimer disease and may be evident prior to clinical symptoms and prior to structural and functional neuroimaging changes seen by MRI or positron emission tomography (PET) scans. Currently, these biomarkers are being increasingly used not only for their diagnostic value but also to potentially provide surrogate indices of dementia severity and progress. For CJD, typically both total tau and 14-3-3 are highly elevated. CSF biomarkers not only may yield improvements in the differential diagnostic process but also allow better assessment of change during investigational therapies designed to affect disease symptoms or modify the disease process (Table 12.6).

Neurophysiologic Testing

Electroencephalogram testing can be useful in two contexts: (1) It may assist in the assessment of the possibility of subclinical paroxysmal disorders being responsible for abnormal mental status and (2) it may be of use in cases where it is less clear whether a primary psychiatric or neurologic diagnosis explains the clinical presentation. Epileptiform activity may be particularly prominent in the immune-mediated encephalitides or other

TABLE 12.6 Dementias Categorized by Protein Pathologies

β-Amyloidopathy	AD
α-Synucleinopathy	Lewy body disorders (DLB), PDD
Tauopathy	Frontotemporal dementia: Pick disease, PSP, CBD (Note that AD has secondary tau pathology.)
TDP-43 proteinopathy	Frontotemporal dementia (FTD-U), ALS with dementia
Prionopathy	Creutzfeldt-Jakob disease, sporadic/familial fatal insomnia, GSS, vCJD

Abbreviations: AD, Alzheimer disease; ALS, amyotrophic lateral sclerosis; CBD, corticobasal degeneration; DLB, dementia with Lewy bodies; FTD-U, FTD with ubiquitinated inclusions; GSS, Gerstmann-Sträussler-Scheinker disease; PDD, Parkinson disease dementia; PSP, progressive supranuclear palsy; TDP-43, TAR DNA-binding protein 43; vCJD, variant Creutzfeldt-Jakob disease.

rapidly progressive dementias such as rabies or herpes simplex encephalitis. In disorders that are purely psychiatric, frequently background EEG rhythm may be normal, whereas conversely neurologic disorders may be accompanied by focal or generalized background slowing.

Electromyography provides an assessment of the lower motor neurons, which can be helpful in ascertaining the presence of frontotemporal dementia with motor neuron disease. Sensory nerve studies may be helpful in rarer disorders such as metachromatic leukodystrophy.

Neuroimaging

Conventional Computed Tomography and Magnetic Resonance

Structural neuroimaging can be useful in both exclusionary and inclusionary fashions with respect to neurodegenerative dementias. Discovery of significant vascular injury, inflammatory lesions, contrast-enhancing processes, or tumors may be decisive in ruling out degenerative processes and indicating some infectious, inflammatory, or neoplastic process. However, even in cases of "radiologically normal" scans, structural features such as parietal atrophy or temporal atrophy may be indicative of an Alzheimer process. Specialized imaging such as gradient echo (or susceptibility weighted imaging) sequences can reveal microhemorrhages, which when multiple may be suggestive of amyloid angiopathy, cerebral autosomal dominant arteriopathy with subcortical infarcts and leukoencephalopathy, or hypertensive cerebrovascular injury. Other specialized sequences such as diffusion-weighted imaging may show strong evidence of prion disease. CJD typically results in diffusion-weighted hyperintensities in cortical regions confined to the gray matter cortical ribbon and also to the deep gray nuclei, including thalami, caudate, and lenticular nuclei.

Biomarker Imaging

Nuclear medicine imaging provides useful information in cases of suspected dementia. Single-photon emission computed tomography imaging (see Chapter 23) using technetium 99m–hexamethyl propylene amine oxime (HMPAO) or technetium 99m–ethyl cysteine dimer allows imaging of brain perfusion. These tests, as well as ^{18}O-PET, which also images brain blood perfusion, and more frequently used ^{18}F-fluorodeoxyglucose PET imaging (see Chapter 23), which images the closely linked feature of brain glucose metabolism, can be of value in displaying topographic patterns of brain dysfunction. These patterns can be relatively disease-specific. Typically, Alzheimer disease shows a pattern of biparietal and bitemporal hypoperfusion, or hypometabolism, that may be more or less asymmetric. There is sparing of the primary cortices including sensory, motor, and visual regions, as well as the deep gray nuclei. Lewy body disease shows a similar pattern but often with less prominent temporal involvement and much more parietal and occipital involvement, often involving the visual cortices. Frontotemporal dementias typically involve frontal and/or anterior temporal regions, sometimes quite asymmetrically, with preservation of parietal and other posterior regions. Most recently, the expanding field of molecular imaging has provided more specific imaging biomarker tools for neurodegenerative disorders. Assistance with diagnosis of Lewy body disorders may be provided, albeit with less than excellent sensitivity or specificity, through dopamine transporter imaging, such as iodine 123–joflupane single-photon emission computed tomography. The use of amyloid imaging, including ^{18}F-florbetapir, ^{18}F-florbetaben, and ^{18}F-flutemetamol, has allowed in vivo assessment in humans of fibrillar β-amyloid, indicating an Alzheimer process. Currently, this testing has high sensitivity but low specificity because many clinically unaffected individuals older than age 65 years may show evidence of amyloid deposition as determined by binding of these radiopharmaceutical tracers imaged using PET. However, additional molecular imaging tools such as the tracer ^{18}F flortaucipir specific for the tau protein aggregated in neurofibrillary tangles provide additional in-vivo diagnostic clarity and permit monitoring of progression of Alzheimer disease.

TREATMENT

For many forms of dementia, treatments are symptomatic and palliative. Recent advances suggest that disease modifying treatments, at least for Alzheimer's disease, are on the horizon. Some causes of dementia, such as vascular dementia, reducing the risk of recurrent stroke, and thus subsequent cognitive decline due to worsening stroke burden, may be possible through routine measures including targeted risk reduction of vascular risk factors. Treatments for specific conditions including depression, metabolic abnormalities, and autoimmune causes of dementia are directed at the underlying problem and are reviewed in their respective treatments. For all patients, particularly those with neurodegenerative causes of dementia, treatments are prioritized and directed to the primary symptoms impacting day to day life, through both pharmacologic and nonpharmacologic strategies aiming to help both the patient and the family unit through disease transitions. Further descriptions of treatment for neurodegenerative dementias are described in their respective chapters.

OUTCOME

Outcomes of various forms of dementia are highly variable patient to patient even within specific diagnostic categories, particularly neurodegenerative dementias. Factors determining longevity and mortality include comorbidities at the time of onset, support infrastructure, and patient-centered goals of care. Although uncommon, reversible causes of dementia may not have an appreciable impact on mortality and presumably will not recur if the underlying factor (ie, cobalamin deficiency, hypothyroidism, depression, or autoimmune causes, among others) are effectively treated.

LEVEL 1 EVIDENCE

1. Knopman DS, DeKosky ST, Cummings JL, et al. Practice parameter: diagnosis of dementia (an evidence-based review). Report of the Quality Standards Subcommittee of the American Academy of Neurology. *Neurology*. 2001;56(9):1143-1153.

SUGGESTED READINGS

Boyle PA, Yu L, Wilson RS, Leurgans SE, Schneider JA, Bennett DA. Person-specific contribution of neuropathologies to cognitive loss in old age. *Ann Neurol*. 2018;83(1):74-83. doi:10.1002/ana.25123.

Downing LJ, Caprio TV, Lyness JM. Geriatric psychiatry review: differential diagnosis and treatment of the 3 D's—delirium, dementia, and depression. *Curr Psychiatry Rep*. 2013;15:365.

Farlow JL, Foroud T. The genetics of dementia. *Semin Neurol*. 2013;33:417-422.
Folstein MF, Folstein SE, McHugh PR. "Mini-mental state": a practical method for grading the cognitive state of patients for the clinician. *J Psychiatr Res*. 1975;12:189-198.
Fong TG, Tulebaev SR, Inouye SK. Delirium in elderly adults: diagnosis, prevention and treatment. *Nat Rev Neurol*. 2009;5:210-220.
Frisoni GB, Bocchetta M, Chételat G, et al. Imaging markers for Alzheimer disease: which vs how. *Neurology*. 2013;81:487-500.
Hyman BT, Phelps CH, Beach TG, et al. National Institute on Aging-Alzheimer's Association guidelines for the neuropathologic assessment of Alzheimer's disease. *Alzheimers Dement*. 2012;8:1-13.
Jack CR Jr, Barrio JR, Kepe V. Cerebral amyloid PET imaging in Alzheimer's disease. *Acta Neuropathol*. 2013;126:643-657.
Karch CM, Goate AM. Alzheimer's disease risk genes and mechanisms of disease pathogenesis. *Biol Psychiatry*. 2015;77(1):43-51.
Maldonado JR. Neuropathogenesis of delirium: review of current etiologic theories and common pathways. *Am J Geriatr Psychiatry*. 2013;21:1190-1222.
McKhann GM, Knopman DS, Chertkow H, et al. The diagnosis of dementia due to Alzheimer's disease: recommendations from the National Institute on Aging-Alzheimer's Association workgroups on diagnostic guidelines for Alzheimer's disease. *Alzheimers Dement*. 2011;7:263-259.
Nasreddine ZS, Phillips NA, Bédirian V, et al. The Montreal Cognitive Assessment, MoCA: a brief screening tool for mild cognitive impairment. *J Am Geriatr Soc*. 2005;53:695-699.
Nelson PT, Dickson DW, Trojanowski JQ, et al. Limbic-predominant age-related TDP-43 encephalopathy (LATE): consensus working group report. *Brain*. 2019;142(6):1503-1527.
Petersen RC. Clinical practice. Mild cognitive impairment. *N Engl J Med*. 2011;364:2227-2234.
Riedl L, Mackenzie IR, Förstl H, Kurz A, Diehl-Schmid J. Frontotemporal lobar degeneration: current perspectives. *Neuropsychiatr Dis Treat*. 2014;10:297-310.
Sonnen JA, Postupna N, Larson EB, et al. Pathologic correlates of dementia in individuals with Lewy body disease. *Brain Pathol*. 2010;20:654-659.
Warren JD, Rohrer JD, Rossor MN. Clinical review. Frontotemporal dementia. *BMJ*. 2013;347:f4827.
Wardlaw JM, Smith C, Dichgans M. Small vessel disease: mechanisms and clinical implications. *Lancet Neurol*. 2019;18(7):684-696.

Involuntary Movements 13

Sara M. Schaefer and Elan D. Louis

KEY POINTS

1. A careful history is key when a patient presents with involuntary movements, including the determination of duration, involved body part, exacerbating and relieving factors, and associated symptoms.
2. The movement disorders examination relies on attention to detail, prolonged observation of the patient in various configurations, and integrating the history and examination to perform tailored maneuvers.
3. Involuntary movements should first be described using basic terms (eg, *rhythmic*) to identify the correct phenomenology (eg, tremor) and guide the practitioner toward the appropriate diagnosis (eg, essential tremor).
4. Movement disorders may arise from anywhere in the neuraxis.
5. Treatment of movement disorders involves identifying and treating the underlying etiology, as applicable. Symptomatic treatment should be tailored to what is bothering the patient rather than what is observable on examination.
6. There are several movement disorders emergencies that require quick and accurate diagnosis because immediate intervention is critical to reduce associated morbidity and mortality.

INTRODUCTION

Approaching abnormal involuntary movements is a multidimensional process that relies first on a careful history and a detailed examination.

FOCUSED HISTORY

The neurologic history is an important first step in arriving at the correct diagnosis (Table 13.1). It is important to ask the patient about the location of the movements. Some patients may feel the movements in body parts that are not visibly shaking. The periodicity of the movements is an important historical clue, as some movement disorders are by definition paroxysmal (eg, paroxysmal dyskinesias, episodic ataxias, paroxysmal hypnogenic dyskinesias, or transient dyskinesias of infants). The items that exacerbate and/or relieve the movements may point toward a particular diagnosis, such as exercise in paroxysmal kinesigenic dyskinesias or a sensory trick in dystonia. The conditions during which the movements occur (eg, at rest or with movement) are also of importance in tremor classification, and accompanying feelings of restlessness, urges to move, ability to suppress the movements, and relief after the movement are important features to consider when diagnosing tics, akathisia, and restless legs syndrome. The provider should assess for any associated features such as vocalizations that may accompany the movements, as may be seen in tics or hyperekplexia or pain or pulling sensation that may indicate abnormal muscle contraction/spasm as seen in dystonia. Family history is also vital to collect, and it may be instructive to examine additional family members; several movement disorders display Mendelian genetic inheritance (eg, Huntington chorea), whereas others tend to run in families (eg, essential tremor). It is important to obtain a list of current

TABLE 13.1 Questions to Ask the Patient Who Presents With Involuntary Movements

Question	Relevant Involuntary Movement
Where (ie, in what body regions) are the movements?	All
Are the movements periodic?	Paroxysmal movement disorders
Does anything (eg, movement, startle) trigger or exacerbate the movements?	Paroxysmal movement disorders, hyperekplexia, dystonia
Is there a sensory trick (a place they can touch to lessen the movement)?	Dystonia
Do movements occur at rest or with action?	All
Is the patient feeling restless?	Tics, akathisia, restless legs syndrome
Is there an urge to move?	Akathisia, tics, restless legs syndrome
Is the patient able to suppress the movements?	Akathisia, restless legs syndrome
Does the movement produce a feeling of relief?	Tics, akathisia, restless legs syndrome
Are there accompanying vocalizations?	Tics, hyperekplexia
Is there pain/discomfort in the region where the movements are occurring?	Dystonia (especially cervical dystonia)
Is there a pulling feeling in the muscles?	Dystonia (especially cervical dystonia)
Is there a family history?	Paroxysmal movement disorders, dystonia, tremor, tics, hyperekplexia, chorea, ataxia
What are the current medications?	All
What were the past medications (eg, dopamine blockers)?	Tardive movements

medications (as these may be producing, exacerbating, or partially suppressing movements) as well as medication exposures in the past (especially medications with dopamine blockade).

FOCUSED EXAMINATION

Visual inspection of the patient with a thorough and careful neurologic examination is of central importance when assigning a movement disorders diagnosis. The neurologic examination is the most important tool for the diagnosis of involuntary movements. To begin with, it is important to spend time observing the patient and visualizing the movements. Tell the patient that you are going to watch their movements and then sit in front of them and observe. Patients may sometimes be self-conscious and may try to inhibit their involuntary movements, particularly if these movements are embarrassing. If this is the case, then ask the patient to just let their body "do what it wants to do . . . don't try to stop it." After the observation, it is important to ask the patient to perform certain maneuvers designed to bring out the movement (eg, writing may bring out a tremor, heel-to-shin maneuver may bring out asynergia, and walking may bring out a dystonic foot movement). A careful history can inform tailored examination techniques; for example, if a patient reports that a certain maneuver brings out or alleviates the movement, one can incorporate it into the examination. Some movements may be quite elaborate, and the examiner may need to observe for quite some time before being able to detect a consistent pattern or before being able to fully encapsulate and describe the phenomenology.

DESCRIPTION OF INVOLUNTARY MOVEMENTS

When examining a patient, the examiner must first decide whether the abnormal movement is hyperkinetic or hypokinetic. *Hyperkinetic* refers to movements in excess of normal, whereas *hypokinetic* is a paucity of movement.

Hypokinetic movements may be slow (*bradykinesia*), small (*hypokinesia*), or absent (*akinesia*). Although these terms have specific meanings, as noted earlier, they are often used interchangeably; in practice, *bradykinesia* is often used as an umbrella term that encompasses all of these entities. Paucity of movement due to weakness (such as from a stroke) is not included in the hypokinetic definition. The most ubiquitous movement disorders that are characterized by hypokinetic movements are parkinsonisms, which—along with resting tremor, rigidity, and postural instability—are partially defined by bradykinesia/akinesia. Bradykinesia may manifest during numerous aspects of a patient's examination; these include ambulation (eg, decreased stride length and arm swing), phonation (eg, hypophonia), writing (eg, micrographia), repetitive movements (eg, slow finger taps), and spontaneous gesturing (eg, global bradykinesia). The blink rate may be slow, and the face may be poorly expressive (hypomimia). In parkinsonism, not only are the movements slow and small, but the examiner often sees a decrement of speed and amplitude over time. This phenomenon may be seen with repetitive movements such as finger or toe tapping or even during handwriting and spiral drawing (the letter amplitude gets smaller as the patient writes or the lines get closer together as the patient draws the spiral). Furthermore, hesitation and freezing phenomena (ie, delays and interruptions of movement) are frequent features of parkinsonian states.

The inverse of hypokinetic movements is hyperkinetic movements. Just as hypokinetic movements do not include those related to weakness, hyperkinetic movements do not include those related to convulsions, neuromuscular dysfunction (fasciculations), or reflex clonus—these are abnormal involuntary movements that are categorized elsewhere due to their etiologies. When describing a hyperkinetic movement, one should start with basic descriptors (eg, oscillatory, flowing) to determine the correct phenomenology (eg, tremor, chorea) and reach the appropriate diagnosis (eg, essential tremor, Huntington disease) (**Fig. 13.1**).

Several categories of descriptors may be used: level of voluntariness, rhythmicity, pattern (stereotyped vs. nonstereotyped), and texture (ie, look and feel of the movement) (**Fig. 13.2**). The essence of each phenomenologic diagnosis may originate from some or all of these categories. Tremor, for example, is an involuntary, rhythmic, oscillatory movement. See **Table 13.2** for explanations of each of these terms.

TYPES OF HYPERKINETIC PHENOMENOLOGIES

There are a number of abnormal hyperkinetic phenomenologies (**Table 13.3**), and each of these are described further in the following text.

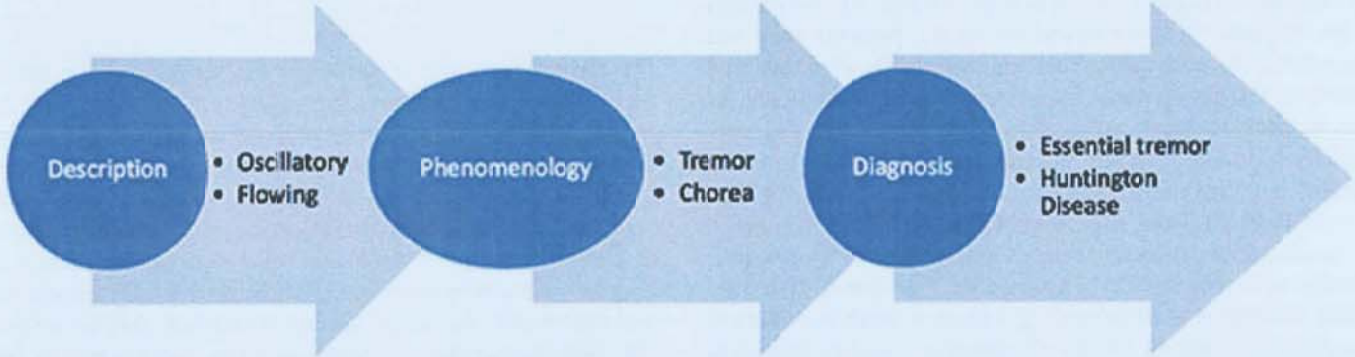

FIGURE 13.1 Flow diagram of the process of evaluating an involuntary movement, from description to diagnosis.



FIGURE 13.2 Descriptive terms for involuntary movements by category.

Myoclonus

Myoclonus (see Chapter 81) refers to a fast (less than 100 ms), involuntary, jerky movement that may arise from sudden muscle contractions (ie, positive myoclonus) (▶ Video 13.1) or sudden interruption of ongoing muscle contractions with resultant postural lapses (ie, negative myoclonus or asterixis). In asterixis, when the hands are examined extended in front of the patient with the wrists maximally extended, the brief flapping of the outstretched arms is due to transient relaxation of the muscles that maintain posture of those extremities. Asterixis is usually due to metabolic abnormalities.

Myoclonus can appear when the affected body part is at rest, but it may also occur when it is performing a voluntary motor act (ie, "action myoclonus"). Myoclonic jerks are usually arrhythmic but can also be rhythmic (such as in *myorhythmia*).

Dystonia

Dystonia (see Chapter 79) is an involuntary movement of sustained muscle contraction that frequently causes twisting or abnormal postures. The spasms may affect the neck muscles (*cervical dystonia*) (▶ Video 13.2), periocular muscles (*blepharospasm*), facial muscles (*Meige syndrome*), vocal cords (*spasmodic dysphonia*), or limb muscles (eg, *writer's cramp*). At the muscular level, dystonia is characterized by sustained cocontractions of agonist and antagonist muscles simultaneously, resulting in muscles combatting each other and the generally slow development of an abnormal posture. Voluntary movements may be opposed by contractions of muscles that are inappropriate to the task (*action dystonia*).

Several additional features may be present, including (1) an increase of these involuntary contractions when voluntary movement in other body parts is attempted ("overflow"); (2) interruptions of these involuntary, sustained contractions with jerky oscillatory movements that appear tremor-like (*dystonic tremor*); (3) the presence of a "sensory trick" or *geste antagoniste*, which is when the dystonic movements can be diminished by tactile or proprioceptive inputs, such as lightly touching the involved or an adjacent body part (eg, touching the chin in cervical dystonia); and (4) the emergence of the dystonic movements only during certain actions such as writing or playing a musical instrument (*task specificity*). Inexperienced clinicians might assume that some of these features point to a psychogenic origin of the symptoms, but in reality, the presence of these features is classic for organic dystonia.

TABLE 13.2 Explanation of Descriptive Terms for Involuntary Movements by Category

Category	Descriptive Term	Explanation	Example Phenomenology
Voluntariness	Voluntary	Completely within the control of the patient	Lifting a cup to drink
	Semivoluntary	Partially within the control of the patient; may be suppressed if even temporarily; may be associated with an uncontrollable urge to move and relief after movement	Akathisia
	Involuntary	Completely outside of the patient's control; insuppressible	Myoclonus
Rhythmicity	Rhythmic	Occurring at a regular frequency	Tremor
	Arrhythmic	Occurring at an irregular frequency	Dystonia
Pattern	Stereotyped	Patterned and somewhat predictable	Tics
	Nonstereotyped	Unpatterned and unpredictable	Chorea
Texture	Oscillatory	Consisting of alternating agonist and antagonist muscle activity rotating around a central plane or axis	Tremor
	Jerky	Brief and unilaterally directed	Myoclonus
	Flowing	Appearing to continuously move from one body part to another	Chorea
	Sustained	Consisting of prolonged muscle contractions	Dystonia
	Ballistic	Large amplitude	Ballism

TABLE 13.3 List of Hyperkinetic Phenomenologies With Descriptive Terms

Phenomenology	Descriptors
Myoclonus	Involuntary, jerky
Dystonia	Involuntary, sustained
Chorea	Involuntary, nonstereotyped, flowing
Athetosis	Involuntary, nonstereotyped, flowing
Ballism	Involuntary, nonstereotyped, ballistic
Tics	Semivoluntary, stereotyped
Stereotypies	Semivoluntary, stereotyped
Tremor	Involuntary, rhythmic, oscillatory
Akathisia	Semivoluntary, stereotyped or nonstereotyped, flowing

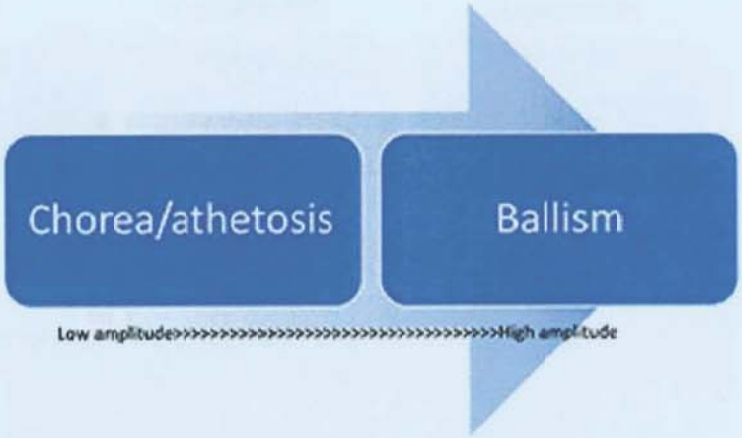
Chorea/athetosis
Ballism
Low amplitude>>>

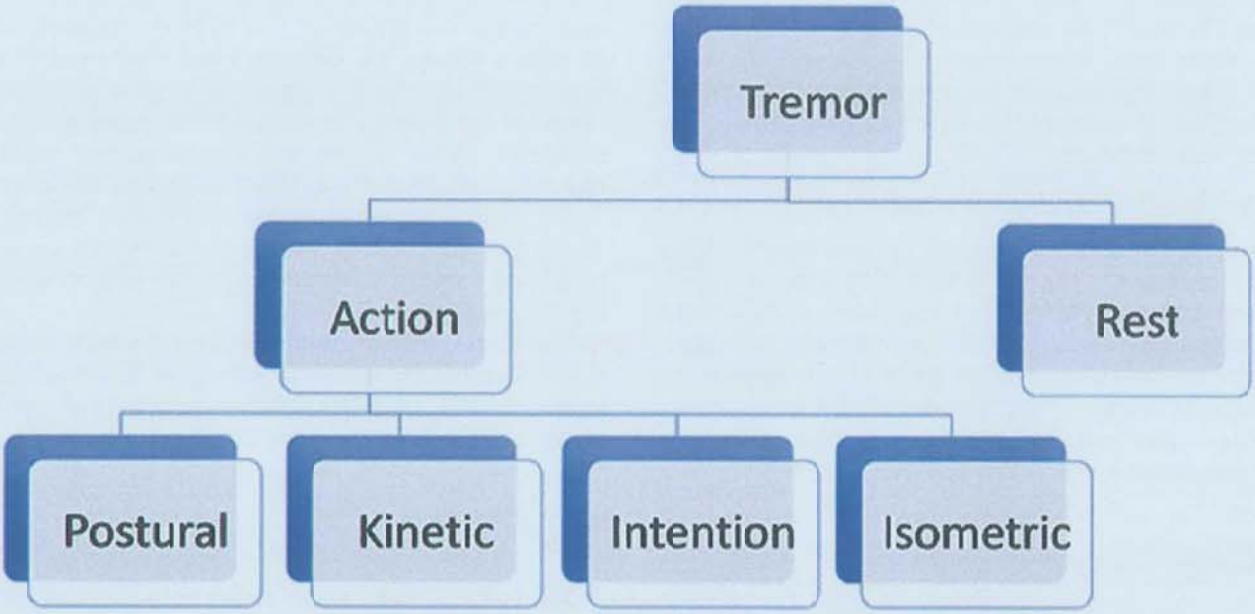

FIGURE 13.5 Flowsheet of types of tremor.

whether the tremor is present during different conditions: when the affected body part is at rest (rest tremor), as in parkinsonian disorders, or when the affected body part is being used (action tremor) (Fig. 13.5). There are several types of action tremor: (1) postural tremor—present when an antigravity posture is maintained (eg, with arms outstretched in front of the body or with elbows flexed with arms in a winged position), as in essential tremor and Wilson disease (see Chapters 76 and 139); (2) kinetic tremor—occurring when action is undertaken (eg, writing or pouring water from a cup) (▶ Video 13.5), as in essential tremor; (3) intention tremor—present when approaching a target (eg, during finger-to-nose maneuver), as in diseases involving the cerebellum such as ataxias and essential tremor (see Chapters 76 and 82); and (4) isometric tremor—occurring with sustained muscle contraction against a stationary object (eg, when making a fist or carrying a shopping bag).

Akathisia

Akathisia is a semivoluntary, stereotyped or nonstereotyped, flowing movement. Much like in tics—which are also semivoluntary—patients with akathisia report an urge to move, manifesting as an inner feeling of profound restlessness (▶ Video 13.6). Movements may be stereotyped, such as rocking or pacing, or nonstereotyped, appearing simply as jitteriness or restlessness. Akathisia is most commonly seen as a side effect of medications with dopamine-blocking properties (eg, antipsychotics, antiemetics), either as acute akathisia or tardive akathisia (after prolonged treatment), the latter of which often accompanies tardive dyskinesia. Stimulants may also induce akathisia. In addition to that induced by medications, pathologic akathisia may be seen in the encephalopathies of confusional states, in some dementias, and in Parkinson disease. Picking at the bedclothes (ie, carphology) is a manifestation of akathitic movements in patients who are bedridden. Akathitic movements may also be a reaction to stress, anxiety, boredom, or impatience, such as when a person shakes his or her leg up and down while seated in a chair; these may then be termed *physiologic akathisia*.

Other Hyperkinetic Movements With Variable Phenomenologic Features

Dyskinesias

Dyskinesias are abnormal involuntary movements that do not cleanly fit into a phenomenologic category (▶ Video 13.7). Commonly, dyskinesias are related to medication side effects, such as in levodopa-induced dyskinesia or tardive dyskinesia (see Chapter 83) secondary to dopamine-blocking agents. Dyskinesias may consist of a combination of phenomenologies or may appear similar to a particular phenomenology but differ in an essential way. For example, tardive dyskinesias are often referred to as *choreiform* in that they are involuntary, flowing movements but are commonly more stereotyped than what is characteristic of chorea and can include dystonic features.

Asynergia and Ataxia

Like dyskinesias, *asynergia* or *dyssynergia* do not cleanly categorize into a hyperkinetic phenomenology; rather, they are related to abnormal regulation of voluntary movements, resulting in incoordination. This may manifest as *dysmetria* or *limb ataxia*, such as may be observed in finger-nose-finger or heel-to-shin testing, wherein the limb misses the target with alternating overshooting and undershooting. There may be an associated *intention* (or terminal) *tremor*. *Dysdiadochokinesia*, the breakup and irregularity that occurs when the limb is attempting to carry out rapid alternating movements, is another example of *asynergia*. *Ataxia* of gait is typified by unsteadiness on walking with a wide base, the body swaying, and a difficulty with tandem walking (heel-to-toe walking).

Asynergic disorders may be episodic, static, or progressive. Hypotonia may be present on examination. Such disorders result from cerebellar diseases (see Chapter 82) or lesions involving the pathways to or from the cerebellum.

Hyperekplexia

Hyperekplexia (exaggerated startle) consists of dramatic, complex motor responses to sudden tactile or auditory stimuli. The reaction can consist of a blink; facial contortion; abduction of

the arms; and flexion of the neck, trunk, and arms. Sometimes, instead of movements, the body becomes stiff and immobile. When it is severe, the patient's movements must be curtailed because a sudden attack may lead to injury from falling. The etiology may be hereditary or sporadic.

Functional Involuntary Movements

Functional or psychogenic involuntary movements are highly variable, manifesting as shaking, fixed postures, bizarre gaits, paroxysmal disorders, or other phenomena (**Table 13.4**). Careful evaluation of the phenomenology for inconsistency, incongruity, prolonged fixed postures, deliberate slowness, suggestibility, distractibility, entrainment, false (give-way) weakness, nonanatomic sensory impairment, and marked fatigue and exhaustion from the movements suggest the diagnosis.

NEUROANATOMY

Most involuntary movements are the result of central nervous system disorders and, more specifically, lesions involving the basal ganglia or cerebellum. For example, the motor features of Parkinson disease are related to a lesion in the substantia nigra pars compacta, chorea is related to disorders of the caudate nucleus but sometimes involving other structures, and ballism is most often related to lesions of the subthalamic nucleus. Ataxia and intention tremor are related to lesions of the cerebellum. Despite central nervous system predominance in movement disorders pathophysiology, abnormal movements attributed to a peripheral etiology do also occur (eg, hemifacial spasm, painful legs–moving toes, jumpy stump).

The neural site of origin of myoclonus spans central and peripheral localizations, including the cerebral cortex (cortical myoclonus), brain stem (reticular reflex myoclonus), spinal cord (propriospinal myoclonus), or peripheral nerve (eg, hemifacial spasm).

TABLE 13.4 Red Flags for Functional/Psychogenic Movements

Finding	Explanation
Inconsistency	Movements that change quality (eg, change in direction or frequency)
Combination of several hyperkinesias that do not ordinarily occur together	Unusual combinations of movements that do not typically co-occur in organic disease
Fixed postures	Postures that are sustained for prolonged periods of time
Deliberate slowness	Practiced slowness that resolves when the patient is unaware that they are still being observed
Effortfulness	Patient demonstrates extraordinary effort during tasks that should not be affected (cognitive tasks, tasks with unaffected body parts).
Suggestibility	The movement is reproduced when the examiner performs a maneuver that he or she suggests will acutely bring on the movement.
Distractibility	The movement stops when the examiner draws the patient's attention away from the affected body part to perform a task that requires considerable effort and concentration.
Entrainment (in tremor disorders)	Tremor frequency changes to match the frequency of tapping with the opposite limb.
Give-way weakness	During strength testing, the patient initially provides resistance against the examiner's force but then suddenly "gives way" and provides no further muscular resistance.
Nonanatomic sensory impairment	Sensory deficits that do not follow anatomic patterns/boundaries
Marked fatigue and exhaustion	By history, the amount of fatigue is out of proportion to the severity of the movements.

DIAGNOSIS

The first step in diagnosing a movement disorder is to recognize the movement phenomenology itself, and this is based primarily on keen and unhurried observation. Once the specific movement or movement types are identified, one may consider the various etiologies that can result in that/those type(s) of movements. In some instances, electromyogram may be helpful by determining the rate, rhythmicity, and synchrony of involuntary movements as well as the duration of individual contractions. The duration of an individual contraction may distinguish specific types of involuntary movements; for instance, differentiating an organic myoclonic jerk from a psychogenic one. Motor control physiology laboratories typically perform this service. Additional blood work as well as brain imaging may aid in the diagnosis, although these should not be used as a substitute for clinical observation.

Functional/psychogenic movements are subconscious and thus involuntary, in contrast to malingering. A common mistake is to label an abnormal movement not previously encountered by the physician as functional. Experience of seeing a large number of movement disorders brings knowledge that helps in distinguishing functional versus organic movements. Functional disorders are not simply diagnoses of exclusion, but rather the diagnosis is made based on positive findings on history and examination as outlined in **Table 13.4**.

TREATMENT

The initial management of involuntary movements is the triaging into those that require acute treatment versus those that do not. There are a small number of movement disorders that must be dealt with acutely, including acute dystonic reactions, neuroleptic malignant syndrome, and the paralytic form of Sydenham chorea (**Table 13.5**). A number of emergent situations may arise in the treatment of patients with involuntary movements, including acute psychosis in patients with Parkinson disease and dystonic storm (see **Table 13.5**). The initial management of the remaining patients depends very much on the stage and severity of the disease; in many instances, a realistic goal of therapy is to lessen the frequency, severity, and functional impact of movements rather than to aim for complete cessation. Many patients may not require treatment; it is important to ascertain impact of the abnormal movement on the patient's quality of life to determine if treatment is necessary.

Videos can be found in the companion e-book edition. For a full list of video legends, please see the front matter.

TABLE 13.5 Movement Disorders Emergencies

Entity	Comments	Acute Management
Dystonic storm	Continuous dystonic spasms	• Admission to ICU • Monitor fluids and electrolytes. • Treat rhabdomyolysis. • Treat with anticholinergic agents (diphenhydramine), baclofen, and benzodiazepines (lorazepam). • Sedation, airway protection, and paralysis may be necessary.
Hemiballismus	Continuous violent flailing, lateralized arm and leg movements seen with injury to the subthalamic nucleus	• May require intubation, sedation, and paralysis in the most severe cases
Acute psychosis in patients with Parkinson disease	Generally due to medication effects	• Acute hospitalization may be necessary. • Reduce and/or withdraw medication. • Treat with antipsychotic agents (ideally with low dopamine blockade).
Parkinsonian hyperpyrexia	May occur in a variety of settings including abrupt medication withdrawal, infection	• Admission to ICU • Monitor fluids and electrolytes. • Carbidopa/levodopa, dantrolene, or steroids may be beneficial.
Stridor in patients with multiple system atrophy	More often at night and may result in respiratory arrest	• Nasal continuous positive airway pressure mask • Botulinum toxin injections to the thyroarytenoid muscles • Tracheostomy
Neuroleptic malignant syndrome	Due to drugs with dopamine-blocking activity	• Admission to ICU • Withdrawal of offending medication • Treat with bromocriptine, amantadine, dantrolene, or lorazepam.
Acute dystonic reaction	Due to drugs with dopamine-blocking activity	• Withdraw offending drug. • Treat with IV diphenhydramine.
Oculogyric crisis	Due to drugs with dopamine-blocking activity	• Withdraw or lower dose of offending drug. • Treat with IV diphenhydramine.
Paralytic form of Sydenham chorea	A severe hypotonic state with paralysis	• Treatment with IV steroids

Abbreviations: ICU, intensive care unit; IV, intravenous.

SUGGESTED READINGS

Albanese A, Bhatia K, Bressman SB, et al. Phenomenology and classification of dystonia: a consensus update. *Mov Disord*. 2013;28(7):863-873.

Ashizawa T, Xia G. Ataxia. *Continuum (Minneap Minn)*. 2016;22(4 Movement Disorders):1208-1226.

Bakker MJ, van Dijk JG, van den Maagdenberg AM, Tijssen MA. Startle syndromes. *Lancet Neurol*. 2006;5(6):513-524.

Barbey A, Aybek S. Functional movement disorders. *Curr Opin Neurol*. 2017;30(4):427-434.

Bhatia KP, Bain P, Bajaj N, et al. Consensus statement on the classification of tremors from the Task Force on Tremor of the International Parkinson and Movement Disorder Society. *Mov Disord*. 2018;33(1):75-87.

Bogan RK, Cheray JA. Restless legs syndrome: a review of diagnosis and management in primary care. *Postgrad Med*. 2013;125(3):99-111.

Elias WJ, Shah BB. Tremor. *JAMA*. 2014;311(9):948-954.

Espay AJ, Chen R. Myoclonus. *Continuum (Minneap Minn)*. 2013;19(5 Movement Disorders):1264-1286.

Fahn S, Jankovic J, Hallett M. *Principles and Practice of Movement Disorders*. 2nd ed. Philadelphia, PA: Elsevier Saunders; 2011.

Frucht SJ. Treatment of movement disorder emergencies. *Neurotherapeutics*. 2014;11(1):208-212.

Ghosh D, Rajan PV, Erenberg G. A comparative study of primary and secondary stereotypies. *J Child Neurol*. 2013;28(12):1562-1568.

Hallett M. Electrodiagnosis in movement disorders. In: Levin KH, Lüders HO, eds. *Comprehensive Clinical Neurophysiology*. Philadelphia, PA: WB Saunders; 2000:281-294.

Jankovic J, Kurlan R. Tourette syndrome: evolving concepts. *Mov Disord*. 2011;26(6):1149-1156.

Klockgether T. The clinical diagnosis of autosomal dominant spinocerebellar ataxias. *Cerebellum*. 2008;7(2):101-105.

Louis ED. Diagnosis and management of tremor. *Continuum (Minneap Minn)*. 2016;22(4 Movement Disorders):1143-1158.

Martino D, Hedderly T. Tics and stereotypies: a comparative clinical review. *Parkinsonism Relat Disord*. 2019;59:117-124.

Mestre TA. Chorea. *Continuum (Minneap Minn)*. 2016;22(4 Movement Disorders):1186-1207.

Morgante F, Edwards MJ, Espay AJ. Psychogenic movement disorders. *Continuum (Minneap Minn)*. 2013;19(5 Movement Disorders):1383-1396.

Ondo WG. Restless legs syndrome. *Neurol Clin*. 2009;27(3):779-799.

Pringsheim T, Okun MS, Muller-Vahl K, et al. Practice guideline recommendations summary: treatment of tics in people with Tourette syndrome and chronic tic disorders. *Neurology*. 2019;91(19):896-906.

Reich SG. Painful legs and moving toes. *Handb Clin Neurol*. 2011;100:375-383.

Roper LS, Saifee TA, Parees I, et al. How to use the entrainment test in the diagnosis of functional tremor. *Pract Neurol*. 2013;13(6):396-398.

Sanger TD, Chen D, Fehlings DL, et al. Definition and classification of hyperkinetic movements in childhood. *Mov Disord*. 2010;25(11):1538-1549.

Schaefer SM, Rostami R, Greer DM. Movement disorders in the intensive care unit. *Semin Neurol*. 2016;36(6):607-614.

Shanker V, Bressman SB. Diagnosis and management of dystonia. *Continuum (Minneap Minn)*. 2016;22(4 Movement Disorders):1227-1245.

Singer HS. Motor stereotypies. *Semin Pediatr Neurol*. 2009;16(2):77-81.

Sternberg EJ, Alcalay RN, Levy OA, et al. Postural and intention tremors: a detailed clinical study of essential tremor vs. Parkinson's disease. *Front Neurol*. 2013;4:51.

Walker RH. Differential diagnosis of chorea. *Curr Neurol Neurosci Rep*. 2011;11(4):385-395.

14 Muscle Weakness, Cramps, and Stiffness

Comana M. Cioroiu

KEY POINTS

1. Complaints of true muscle weakness must be distinguished from similar subjective symptoms caused by problems outside of the nervous system.
2. Pathology within the extrapyramidal system (ie, basal ganglia and cerebellum) may cause symptoms of stiffness, clumsiness, or imbalance that may be experienced by the patient as weakness.
3. A detailed history and neurologic exam is crucial to establishing the etiology of the patient's weakness and helps localize it to a particular portion of the central or peripheral nervous system.
4. "Red flag" features such as a rapidly progressive or sudden weakness or associated features such as shortness of breath or incontinence warrant a much more expedited workup.
5. It is important to identify patients in need of prompt evaluation where the most important tests to be ordered often include pulmonary function tests and a formal swallowing evaluation.
6. Pattern recognition is key in localization of a complaint to a particular part (or parts) of the nervous system.
7. Testing should be ordered following a detailed history and examination suggesting the appropriate localization and may include imaging, laboratory studies, and electrodiagnostic tests among others.

INTRODUCTION

Weakness is one of the most common complaints in all of neurology; hence, both the scope of the term and its differential diagnosis is broad. A patient may have weakness due to a lesion anywhere in the central or peripheral nervous system from the motor cortex to the muscle itself. Often, patients will use the term *weakness* to describe various functionally limiting symptoms unrelated to loss of strength as with the bradykinesia seen in parkinsonism or the clumsiness experienced with cerebellar ataxia. The concept of weakness is particularly challenging to differentiate from an overall sense of fatigue or asthenia, which is a common complaint in patients with psychiatric (ie, depression) or systemic diseases such as cancer.

It is not at all uncommon for patients to present to the neurologist with a feeling of poorly described generalized weakness, which can be attributed to various nonneurologic etiologies with no specific neurologic cause. The charge of the neurologist in this situation is to focus on the backbone of our specialty: Obtain a comprehensive history and perform a detailed neurologic examination to determine if the patient's complaints are caused by a problem within the nervous system.

MANAGEMENT STRATEGY

Asking the patient about the specific functional consequences of his or her weakness (ie, trouble climbing stairs, buttoning buttons, opening jars) may help distinguish generalized weakness due to fatigue from weakness with an underlying localizable neurologic cause. Both the history and examination should help the clinician localize the problem to a specific region of the central or peripheral nervous system and give clues to possible etiologies. Symptoms concurrent and associated with the weakness are helpful in formulating a diagnostic impression. Complaints of muscle pain, cramping, or stiffness may invoke a myopathy, whereas numbness or tingling suggests a peripheral neuropathy or central nervous system lesion.

Specific "red flags" in the history or examination may provide important clues and prompt one to institute more acute treatment (Table 14.1). Once a comprehensive differential diagnosis is made, testing is done to confirm or exclude a specific disorder and may include but not be limited to serum studies, imaging, and electrodiagnostic testing. Many weak patients are encountered in the office setting; however, acute weakness may present in the hospital as well and often warrants a more prompt evaluation and rapid institution of therapy (Table 14.2).

NEUROANATOMY AND LOCALIZATION OF WEAKNESS

Weakness can be localized to various regions within the neuraxis, from the cortex to the muscle itself, and can be thought of as originating within either the central or peripheral nervous system.

TABLE 14.1 Red Flags in the Evaluation of Weakness

- Weakness that becomes severe over a few days or less
- Dyspnea
- Inability to raise the head against gravity
- Bulbar symptoms (eg, difficulty chewing, talking, and swallowing)
- Loss of ambulation
- Changes in bowel or bladder function

TABLE 14.2 Key Steps in the Diagnosis and Management of Weakness

- Characterize the weakness in terms of tempo, variability, distribution, and associated symptoms.
- Perform a detailed neurologic examination to help localize the weakness within the neuraxis.
- Determine if there are predominantly upper or lower motor neuron findings.
- Look out for red flags (see Table 14.1).
- Order appropriate tests depending on most likely localization and differential diagnosis.
- Beware of diagnoses or signs prompting acute intervention (ie, Guillain-Barré syndrome, mononeuritis multiplex, or myasthenia gravis).

The central, or pyramidal, motor system is composed of the motor cortex, corticospinal tract, and the various other tracts that modify and interact with it (ie, the rubrospinal and tectospinal tracts). Weakness related to a central process affecting the corticospinal tract or pyramidal system is typically thought to produce a clinical syndrome of upper motor neuron weakness manifested by spastic tone, hyperreflexia, and pathologic reflexes (ie, Babinski response).

Weakness due to pathology in the peripheral nervous system characteristically produces a pattern of peripheral lower motor neuron weakness consisting of hyporeflexia, muscle atrophy and wasting, reduced tone, and in some cases, spontaneous muscle activity such as fasciculations. The peripheral motor system is typically considered to include the motor neuron within the anterior horn of the spinal cord (or brain stem for cranial nerves), the peripheral nerve, neuromuscular junction, and muscle distal to it. Both the history and neurologic exam will help localize the problem to a particular part of the neuraxis and thus guide one's differential diagnosis and treatment plan.

Central (Upper Motor Neuron) Weakness

The corticospinal tract or pyramidal system can be damaged anywhere along its tract from the cortex through the corona radiata to the posterior limb of the internal capsule and down to the brain stem via the cerebral peduncles of the midbrain to the medulla and spinal cord. The highest possible lesion is in the primary motor cortex of the brain, where the largest of the pyramidal cells (Betz cells) lie in layer 5 of the cortex. Responsibility for planning and preparation of movement lies within the supplementary and premotor cortices, which regulate the motor action. The actions of the corticospinal tract are further modulated by the cerebellum as well as the basal ganglia and its tracts, which is also known as the *extrapyramidal system*. Pathology within this system can lead to either a paucity or an exaggeration of movement, and the functional impairment experienced by the patient can be frequently described as weakness.

The neurologic examination and history can point toward a diagnosis localized within either the cerebellar or extrapyramidal system (such as Parkinson disease) and can include such findings as ataxia, bradykinesia (paucity and slowness of movement), tremor, and postural instability. In many cases, the key to localization is "pattern-matching"—actively looking for a pattern or constellation of findings that point to a specific cause of weakness (Table 14.3).

Cortical Lesions

A variety of diseases can affect the corticospinal tract from large strokes or hemorrhages to tumors and infections. Cortical lesions cause a characteristic pattern of weakness, where one limb is typically preferentially affected due to the distribution of motor representation in the homunculus of the primary motor cortex. For instance, infarcts affecting the middle cerebral artery territory will preferentially affect the arm and face more so than the leg. Often, there are other associated cortical signs such as aphasia or neglect, and patients may also present with headaches or seizures. Cortical weakness can also result from etiologies such as atypical migraine or postictal Todd paralysis; these diagnoses should be considered in the appropriate clinical setting.

Subcortical Lesions

Subcortical lesions, such as those in the internal capsule, will present with more complete unilateral weakness that may or may not spare the face. Demyelinating diseases such as multiple sclerosis (MS) are often implicated in subcortical weakness, although various other etiologies such as infarct or tumor are possible as well. Weakness attributed to a brain stem lesion can present with unilateral weakness of an arm and leg, and the face may be involved as well. There are usually associated symptoms attributable to cranial nerve dysfunction such as diplopia and facial numbness or hemiataxia due to involvement of cerebellar tracts within the brain stem.

Spinal Cord Lesions

After decussating in the pyramids of the medulla, the lateral corticospinal tract is formed within the spinal cord where it travels ipsilateral to the innervated side of the body, lying anterior to the posterior columns and medial to the posterior spinocerebellar tract. Of note, about 10% of fibers in the corticospinal tract do not decussate and travel down into the cord to form the anterior or ventral corticospinal tract. Patients with weakness related

TABLE 14.3 Common Etiologies of Weakness Depending on Time Course

Acute (Seconds to Minutes)	Subacute (Minutes to Hours)	Chronic (Months to Years)
• Infarction • Hemorrhage • Periodic paralysis • Complicated migraine • Trauma • Postictal Todd paralysis • Conversion disorder	• Demyelinating CNS disease (ie, MS) • Toxic ingestion • Plexopathy • Acute demyelinating neuropathy (Guillain-Barré syndrome) • Metabolic disturbances • Neuromuscular junction disease • Infection • Mononeuritis multiplex	• Neoplasm • Neuromuscular junction disorder • Axonal polyneuropathy • Structural lesion (ie, herniated disk) • Motor neuron disease • Myopathy

Abbreviations: CNS, central nervous system; MS, multiple sclerosis.

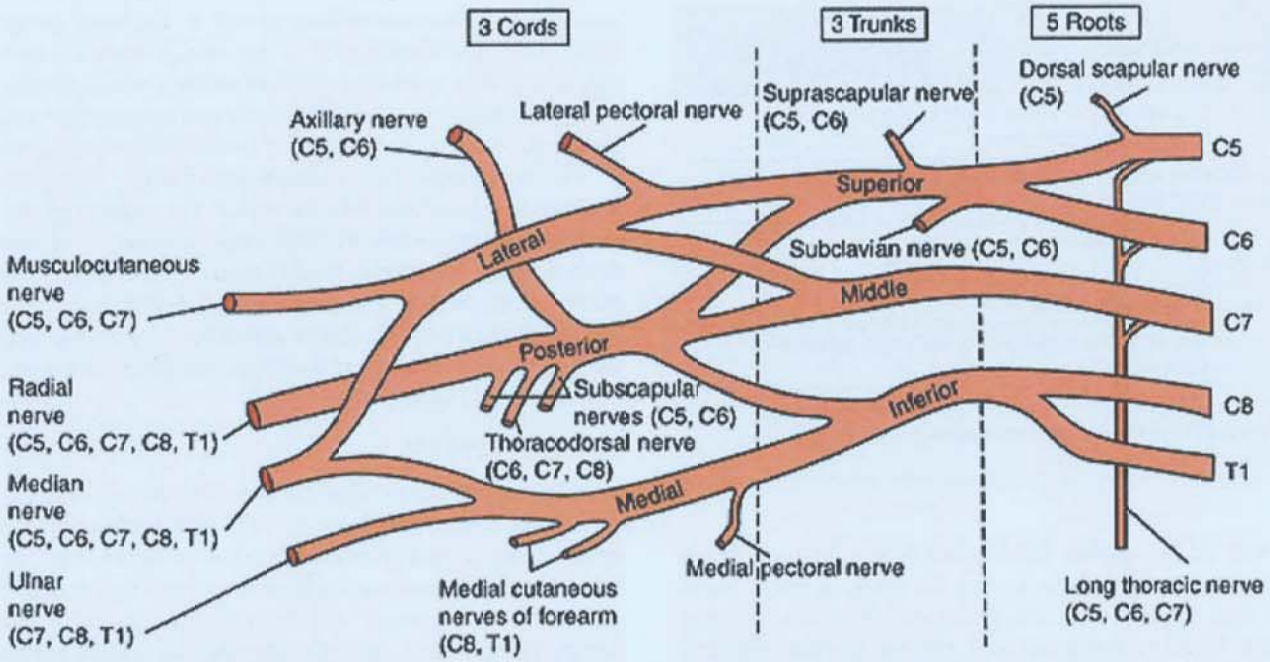

FIGURE 14.1 Brachial plexus. (Adapted from Marshall R, Mayer S. *On Call Neurology*. 3rd ed. Philadelphia, PA: Saunders; 2007.)

to spinal cord pathology will typically present with both motor and sensory complaints, which can be bilateral or localized to one limb. Pain may be present or absent, and its description will vary depending on the cause of weakness. For instance, it may be described as stiffness related to myelopathy, Lhermitte sign (shock-like sensations with back flexion), or diffuse back pain. There may be disturbances in bowel or bladder function requiring prompt evaluation for cord compression.

Peripheral (Lower Motor Neuron) Weakness

Upper motor neurons that form the corticospinal tracts synapse with both interneurons and lower motor neurons within the anterior horn of the spinal cord. The motor unit is defined as one α-motor neuron within the anterior horn (or brain stem when related to cranial nerves) and all of the muscle fibers it innervates. Pathology within the anterior horn itself may present with a combination of both upper and lower motor neuron signs as seen in amyotrophic lateral sclerosis and often includes concomitant bulbar weakness. Patients with weakness localized to the anterior horn will often present with asymmetric weakness, which begins in the bulbar region or within one limb and then progresses segmentally over time. Pain related to muscle cramps and stiffness is a common complaint.

The lower motor neuron exits the spinal cord to form the ventral motor portion of the spinal nerve root, after which it meets the dorsal sensory nerve root past the dorsal root ganglion to form the peripheral nerve. At this location, the dorsal nerve root is commonly susceptible to compression by vertebral disk herniation, and patients may present with radiating pain or sensory loss corresponding to a particular *dermatome*. A *myotome* is defined as the group of muscles innervated by one single nerve root. Most muscles are supplied by two or more nerve roots, and thus a single root lesion rarely causes marked weakness due to this overlap within myotomes.

Brachial Plexus

Prior to separating into specific peripheral nerves, the motor and sensory fibers together form a network called a *plexus*, of which there are two (brachial and lumbosacral). The brachial plexus consists of nerve roots from C5 to T1, whereas the lumbosacral plexus consists of those from L1 to S3. The brachial plexus is composed of three trunks (upper, middle, lower) dividing into two divisions (anterior and posterior), which then form three cords (medial, lateral, posterior) ultimately subdividing and ending in terminal peripheral nerves (Fig. 14.1). Different peripheral nerves come off the brachial plexus at different levels; some, such as the phrenic nerve, exit immediately off the nerve roots, whereas others form the terminal branches of the plexus. These terminal nerves may be pure motor, pure sensory, or mixed.

Lumbosacral Plexus

The lumbosacral plexus is arranged somewhat differently, with various nerve roots coming together to form large nerves that then continue to differentiate into terminal branches or peripheral nerves. For instance, nerve roots from L4 to S3 come together to form the sciatic nerve, which later then subdivides into the fibular and tibial nerves. Weakness localized to the plexus typically presents with acute or subacute pain in one limb and is most commonly traumatic but can also result from other various etiologies such as infectious, structural, and inflammatory causes. Weakness is localized to one limb, often in the distribution of various nerves. There may be associated sensory complaints, but the sensory examination is frequently normal.

Peripheral Nerves

Terminal or peripheral nerves may be affected in isolation (mononeuropathy) or together in a uniform or multifocal pattern. Mononeuropathies are most commonly due to compression, and symptoms and exam findings are restricted to the distribution of one nerve distal to the injury. Polyneuropathies have a broad

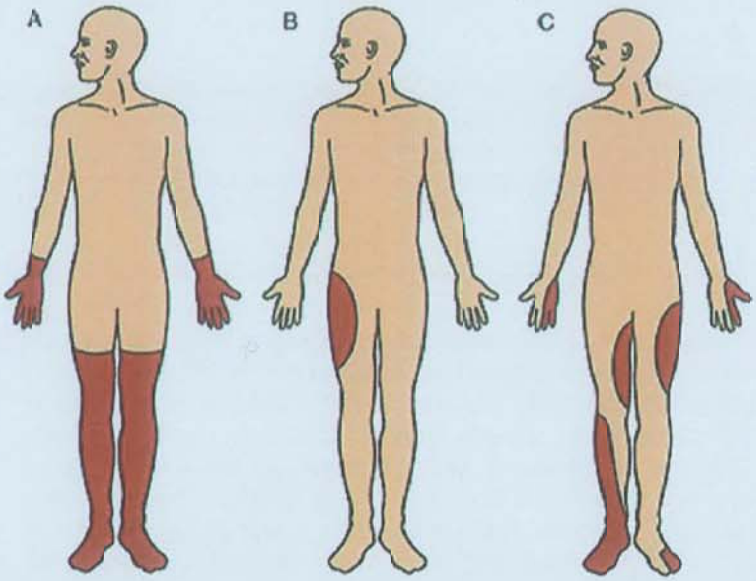

FIGURE 14.2 Patterns of sensory loss in patients with neuropathy. A: Polyneuropathy: diffuse stocking-glove pattern. B: Mononeuropathy: focal involvement corresponding to a single peripheral nerve. C: Mononeuritis multiplex: pattern of multiple, asymmetric regions of sensory loss corresponding to multiple peripheral nerves. (Adapted from Marshall R, Mayer S. *On Call Neurology*. 3rd ed. Philadelphia, PA: Saunders; 2007.)

differential and can be subdivided into those caused by demyelination and those with predominant axonal involvement.

Demyelinating neuropathies typically also involve the nerve roots and can be referred to as *radiculoneuropathies*. They tend to have a motor greater than sensory predominance, present with more generalized or multifocal rather than length-dependent weakness, and areflexia is typical on examination. Cranial nerves may be affected as well.

Axonal polyneuropathies are usually length-dependent, affect sensory greater than motor function, and spare cranial nerves. The differential for such a polyneuropathy is vast and includes metabolic, infectious, and systemic causes among others. Diabetic neuropathy is by far the most common etiology of length-dependent axonal polyneuropathy.

At times, different peripheral nerves can be affected in an asymmetric and patchy fashion (Fig. 14.2). Such a syndrome of multiple mononeuropathies (also frequently referred to as *mononeuritis multiplex*) is often the result of ischemic injury to different peripheral nerves and present with acute and painful weakness and sensory loss. In these instances, it is crucial to rule out an underlying vasculitis because management must be prompt to avoid further irreversible injury.

Neuromuscular Junction

Each peripheral nerve ultimately terminates at the motor endplate of the muscle it supplies, where it forms the neuromuscular junction. At this point, calcium influx into the terminal portion of the neuron leads to binding of acetylcholine-containing vesicles to the neuronal membrane and release of acetylcholine into the postsynaptic space. The acetylcholine-release site is known as the *active zone* and is the location of both calcium influx via voltage-gated calcium channels and acetylcholine release. Binding of acetylcholine to its corresponding postsynaptic receptors at the motor endplate leads to opening of sodium channels and consequent depolarization of the muscle membrane and an endplate potential. The summation of several endplate potentials is ultimately what leads to a discrete muscle fiber potential and subsequent muscle contraction.

Weakness localized to the neuromuscular junction (see Chapter 93) often presents with proximal and bulbar weakness, which fluctuates with activity and time of day. Autoantibodies may be directed toward components of the presynaptic membrane (ie, toward the voltage-gated calcium channel in Lambert-Eaton myasthenic syndrome) or the postsynaptic membrane (ie, myasthenia gravis, where antibodies are formed against acetylcholine receptors). The muscle fiber action potential causes depolarization of the internal portion of the muscle fiber and leads to activation of calcium channels in the sarcoplasmic reticulum of the myocyte leading to calcium release. Calcium then binds to troponin C on the actin filaments of the myofibril, thereby unbinding tropomyosin from the filament, allowing the binding of myosin. The binding of adenosine triphosphate to myosin then allows unbinding and release of actin, thereby leading to muscle relaxation.

Myopathy

Muscle weakness due to pathology within the muscle itself is frequently proximal, symmetric, and progressive. There can be associated facial weakness and weakness of eye movements (such as in mitochondrial myopathies). Myalgias are common, and the sensory examination should be normal. Etiologies are variable and can include inflammatory, congenital, and metabolic causes.

FOCUSED HISTORY

Demographics and Past Medical History

Knowledge of the patient's age and prior medical history is crucial because various etiologies are more or less likely depending on the age of the patient. A left hemiparesis presenting in a young woman is more likely to be attributable to an MS flare than a stroke, and the opposite is true in an 87-year-old man with hypertension.

One must be careful to obtain a complete list of medications the patient is taking because certain exposures may provide diagnostic clues (ie, statin myopathy). The social history is important to obtain, particularly with respect to toxic exposures and travel because both toxic ingestion (ie, alcohol, lead) and various infectious agents may lead to weakness of either central or peripheral origin. A detailed family history is required in cases of suspected hereditary disorders and a pedigree is often helpful. Thus, the age and complete medical, social, and family history of a patient will help formulate an appropriate differential diagnosis based on likelihood and help dictate management.

Tempo of Weakness

One of the key questions one must ask is the time of onset and whether the weakness is acute, subacute, or chronically progressive (see Table 14.3). Focal weakness that begins abruptly (ie, over seconds to minutes) is most concerning for a vascular event such as a hemorrhage or infarct, and these patients must be emergently assessed and evaluated. Subacute onset of weakness has a broader differential and may be due to demyelinating disease such as MS, a mass lesion, or an acute demyelinating neuropathy, among others. Weakness that evolves chronically

over months to years is suggestive of a neurodegenerative disease such as motor neuron disease, peripheral neuropathy, myopathy, or a slowly progressive structural lesion. *The tempo of the course of symptoms dictates the urgency with which the patient should be evaluated and managed.*

Variability of Weakness

Another crucial component of a detailed neurologic history includes asking about the nature of the weakness and whether it is transient, fluctuating, or permanent. Transient weakness that fluctuates with the time of day or with exertion may point toward a neuromuscular junction disorder, MS flare, or a channelopathy (ie, periodic paralysis).

Distribution of Weakness

The distribution and symmetry of weakness is equally important to characterize when formulating a plan for localization and likely etiology. Weakness affecting one arm and leg on the same side is referred to as *hemiparesis*. If the arm and leg are affected on opposite sides, this is known as *crossed hemiparesis*. If the weakness involves only one limb, this is called *monoparesis*, whereas weakness of both legs is known as *paraparesis*. The term *plegia* in the same context refers to complete paralysis.

Certain patterns of weakness give clues regarding localization. Predominantly upper motor neuron weakness of one limb, with or without facial involvement, suggests a cortical lesion in the central nervous system such as a stroke or MS. Given the distribution of the motor homunculus, incomplete upper motor neuron weakness in one limb suggests a lesion in the cortex, whereas complete hemiplegia involving the face is more likely to be localized to subcortical structures or the brain stem. If certain muscles within one limb (corresponding to a particular myotome or peripheral nerve) are preferentially affected, this may indicate a problem in the peripheral nervous system such as a radiculopathy or mononeuropathy. Generalized weakness can involve all four limbs and be related to a process within the spinal cord (ie, cervical myelopathy), peripheral nerve (ie, polyneuropathy), neuromuscular junction, or muscle.

Further characterizing the pattern as being *distal* or *proximal* is also helpful. For instance, generalized weakness that is symmetric and distal is commonly related to a polyneuropathy, whereas proximal weakness is more likely referable to a problem in the neuromuscular junction or muscle.

Sensory Symptoms

Asking about associated symptoms is crucial to determining not only proper localization but also in assisting with thinking of possible etiologies (Table 14.4). One must ask about associated sensory symptoms because this could point toward a neuropathy, plexopathy, or spinal cord lesion. Sensory disturbances can have a positive quality (tingling, paresthesias, pain) or a negative quality (numbness or loss of sensation). A specific sensory level is indicative of pathology within the spinal cord and should be looked for in the appropriate setting.

Cognitive complaints or language symptoms will always be most suspicious of a cortical process, and weakness in this instance may involve the face and typically affect one limb more than another.

Pain

Pain can be encountered in the setting of neuromuscular weakness but must be differentiated from the diffuse myalgias that can be related to an underlying systemic medical illness or psychiatric disease. Often, this distinction is difficult to make because complaints can be nearly identical. Patients with neuropathy often present with burning pain, which is distal and symmetric, and those with radiculopathy or plexopathy may complain of radiating neck, arm, or shoulder pain. Hand pain is a common manifestation of carpal tunnel syndrome, which may eventually progress to hand weakness and clumsiness. Mononeuritis multiplex due to nerve infarcts in the setting of vasculitis can present with acute pain in a variable distribution. Plexopathy is often heralded by acute to subacute pain in the affected limb prior to weakness or sensory complaints. Weakness in the setting of a slowly progressive brain or spinal cord mass may present associated with headaches or back pain.

Stiffness and Cramps

Muscle stiffness is commonly encountered in upper motor neuron lesions causing spasticity and can be seen in both weakness due to cortical, subcortical, and brain stem lesions as well as with myelopathy in spinal cord syndromes. *Cramps* (a localized muscle spasm or persistent contraction) are more of a lower motor neuron/muscle phenomenon and are encountered frequently in various peripheral syndromes. It is seen as a frequent manifestation of motor neuron disease, where patients may complain of frequent cramps and intermittent debilitating muscle spasms. Those with polyneuropathy may often also have cramping or stiffness that is more constant and less paroxysmal.

Various primary muscle diseases include cramps as a primary symptom, and often, the distinction must be made between cramps and more diffuse myalgias. Myopathies characterized by *myotonia* (prolonged muscle contraction after voluntary contraction or percussion) such as myotonic dystrophy and certain channelopathies commonly present with cramps as an initial symptom. Metabolic and certain mitochondrial myopathies often also may present with intermittent cramps. *Stiff person syndrome* (see Chapter 98) is an autoimmune disorder characterized by painful muscle spasms caused by diffuse or localized body stiffness usually in the absence of weakness.

Visual and Speech Disturbances

If visual complaints are present, it is necessary to characterize them well. A visual field cut or gaze preference may point to a cortical problem, whereas ptosis or diplopia could be a manifestation of a neuromuscular junction disorder or a myopathy.

Trouble with speech in the form of dysarthria must first be differentiated from a language disturbance. The presence of dysarthria may point toward bulbar weakness of various etiologies. A cortical, subcortical, or brain stem lesion may affect tongue fibers; motor neuron disease may present with or lead to bulbar involvement; and similarly, a neuromuscular junction or muscle disorder may involve trouble with speech and swallowing. A complaint of dysarthria should always prompt one to inquire about swallowing difficulties because this may have important management and prognostic implications.

TABLE 14.4 Symptoms Associated With Various Weakness Syndromes

	Cortex	Brain Stem	Spinal Cord	Motor Neuron	Nerve Root or Plexus	Peripheral Nerve	Neuromuscular Junction	Muscle
Sensory loss	May be in the same distribution of weakness (ie, stroke, MS plaque)	May be in the same distribution of weakness	Corresponds to level of weakness, usually with sensory level	*Absent*	Can be in a dermatomal or peripheral nerve distribution	May be in the distribution of one nerve or many nerves (ie, distal stocking-glove distribution)	*Absent*	*Absent*
Cognitive or language deficits	Present	*Absent*	*Absent*	*Absent* (Advanced ALS can be associated with cognitive deficits.)	*Absent*	*Absent*	*Absent*	*Absent*
Pain	Headache may be present.	Headache may be present.	Localized or diffuse back pain	*Absent*	Radicular pain or diffuse pain with plexopathy in the affected limb	Burning or paresthesias (ie, polyneuropathy), acute pain (ie, mononeuritis multiplex)	*Absent*	Myalgias, proximal greater than distal
Cramps or stiffness	Spasticity	Spasticity	Spasticity	Both cramps and stiffness are common.	*Absent*	Both cramps and stiffness with both polyneuropathy and certain mononeuropathies	*Absent*	Cramps common in • Myotonic dystrophy • Channelopathies • Metabolic myopathies • Mitochondrial myopathies • Stiff person syndrome
Visual changes	Involvement of frontal eye fields or hemianopsia	Diplopia or nystagmus	*Absent*	*Absent*	*Absent*	Ophthalmoparesis or diplopia can be seen in GBS or Miller-Fisher syndrome.	Diplopia or ptosis occurs with myasthenia gravis.	Diplopia as can be seen in mitochondrial myopathies, among others.
Speech or swallowing difficulties	Due to tongue/facial weakness	Due to tongue/facial weakness	*Absent*	Bulbar involvement in motor neuron disease	*Absent*	Can be seen in demyelinating neuropathies with cranial nerve involvement	Nasal speech, dysphagia in myasthenia gravis	Due to both pharyngeal and tongue weakness
Respiratory compromise	Occurs with large infarcts or hemorrhages	Occurs with infarcts or hemorrhages	Can be present with high cervical lesions	Bulbar involvement in motor neuron disease	Phrenic involvement in plexopathies	Can be seen in demyelinating neuropathies with bulbar and phrenic nerve involvement	Bulbar involvement in both pre- and postsynaptic neuromuscular junction disorders	Can be present in certain myopathies (ie, amyloid, distal myopathy with early respiratory failure)
Cardiac symptoms	*Absent*	*Absent*	*Absent*	*Absent*	*Absent*	*Absent*	*Absent*	Cardiomyopathy can be associated with various myopathies (ie, myotonic dystrophy, Duchenne or Becker myopathy).
Urinary disturbances	Incontinence with paracentral frontal lesions	*Absent*	Urinary incontinence with cord compression	*Absent*	*Absent*	*Absent*	*Absent*	Myoglobinuria with certain myopathies (ie, McArdle disease)

Abbreviations: ALS, amyotrophic lateral sclerosis; GBS, Guillain-Barré syndrome; MS, multiple sclerosis.

Respiratory Symptoms

Asking about respiratory involvement is also essential in patients presenting with weakness whether localized or general. Large cortical and brain stem lesions may rapidly lead to respiratory failure when acute. Disorders of the motor neuron, neuromuscular junction, and muscle may often be complicated by respiratory insufficiency, which may present as shortness of breath, early morning headaches, or daytime fatigue. Acute inflammatory demyelinating polyneuropathy at times may lead to diaphragmatic weakness and subsequent respiratory failure, and thus, respiratory function must be carefully monitored in these patients.

Autonomic Disturbances

Urinary complaints (most often incontinence or frequency) are most commonly seen with upper motor neuron lesions, such as those involving the paracentral frontal lobe or spinal cord. A complaint of dark-colored urine may indicate the presence of myoglobinuria indicative of muscle breakdown suggesting a primary muscle disease such as McArdle disease. One should ask about autonomic involvement as well (ie, symptoms of orthostasis, dry mouth or eyes) because this may play an important role in certain neuropathies. Finally, symptoms suggesting cardiac involvement such as syncope, chest pain, and shortness of breath with activity may be worrisome for a concurrent cardiomyopathy as can be seen with certain myopathies (ie, Duchenne or Becker muscular dystrophy).

FOCUSED EXAM

A focused and goal-directed neurologic exam is critical to the evaluation of a patient with weakness. Ideally, this should be done with the patient undressed and in a gown. Acquisition of both supine and standing heart rate and blood pressure, when appropriate, is useful to assess for orthostatic changes suggestive of autonomic nervous system involvement.

Mental Status

Testing of mental status is important, particularly in cases of weakness due to cortical and subcortical processes (ie, stroke, neoplasm) because this may further assist in localization. Weakness due to a peripheral nervous system disorder should be accompanied by preserved cognitive and language function.

Cranial Nerves

In testing cranial nerves, particular attention should be paid to examination of the eyes starting with their appearance at rest. One should make note of the presence or absence of ptosis, skew, or other asymmetry at rest. Both central and peripheral processes may lead to pupillary involvement with or without ophthalmoparesis.

A careful assessment of extraocular movements is essential because they can be abnormal in states affecting supranuclear, nuclear, and peripheral cranial nerve function (ie, brain stem processes) as well as in diseases of the neuromuscular junction (ie, myasthenia gravis) and muscle (ie, mitochondrial myopathies).

Facial strength is examined both by assessment of asymmetry at rest (ie, a flattened nasolabial fold) as well as by having the patient activate various muscles. Ask the patient to forcefully close his or her eyes and subsequently try to pry them open to assess strength of eye closure. Patients with facial weakness are typically unable to bury their eyelashes with forced eye closure, and eyes are easily pried open. To assess strength in the lower face, ask the patient to purse his or her lips together or whistle. Asymmetric facial weakness sparing the forehead implicates an upper motor neuron facial nerve lesion, whereas facial weakness involving the entire half of the face suggests a peripheral seventh cranial nerve lesion. Symmetric weakness of the facial muscles most typically implies a lesion of the neuromuscular junction or muscle but can rarely also be seen in certain demyelinating neuropathies and in motor neuron disease with bulbar involvement.

Tongue weakness can be evaluated by looking for deviation with tongue protrusion and by having the patient push the tongue against the inner cheek with the examiner's resistance. The tongue should also be carefully inspected for the presence of atrophy and fasciculations as can be seen with motor neuron disease. Pharyngeal weakness should also be assessed by having the patient make guttural sounds and checking for the presence of an intact gag reflex.

Motor Examination

Inspection

The motor examination should always begin with inspection and observation. It is in this part of the examination that one makes the distinction between weakness due to upper motor neuron dysfunction (most commonly related to a process localized to the corticospinal tract) versus lower motor neuron disease localized to the peripheral nervous system. One should look for muscle atrophy and wasting, both in large proximal muscles as well as in the smaller distal muscles such as the intrinsic hand muscles (ie, first dorsal interosseous) in which subtle atrophy can often be more frequently appreciated.

Adventitious Movements

Abnormal movements such as *fasciculations*, *myokymia*, and *tremor* should be sought in various muscles. The presence of atrophy and fasciculations are indicative of lower motor neuron dysfunction as can be seen with motor neuron disease or chronic mono- or polyneuropathies. Myokymia can be seen not only in limb muscles but also in the face, where it typically is suggestive of a brain stem lesion such as an MS plaque. The back should also be inspected for both atrophy (ie, scapular winging) as well as fasciculations.

Tone

Increased tone in the arms can manifest as either rigidity (resistance that is consistent and present throughout the full range of motion) related to basal ganglia dysfunction or spasticity (resistance that is velocity dependent) related to corticospinal tract disease and upper motor neuron dysfunction. When testing tone in the arms, it is often helpful to have the patient open and close the opposite hand, which may accentuate mildly increased tone. Examining tone in the legs is often best done in the supine position where the knees are grasped and quickly pulled up. An unintentional lifting of the heels off the bed is indicative of increased tone in the legs, whereas the heels will naturally slide up the bed in the setting of normal tone.

The motor exam is also an appropriate time to check for the presence or absence of *myotonia* when clinically suspected. One approach is to test for grip myotonia by having the patient squeeze the examiner's hand for 10 seconds and then asking the

patient to quickly let go. In the presence of myotonia, the patient will be unable to relax his/her grip quickly. Similarly, one can check for percussion myotonia by tapping on a muscle—those with myotonia will demonstrate subsequent prolonged muscle contraction (typically, the abductor pollicis brevis is used, but the tongue can be checked as well).

Power

Assessment of strength can be done both by objectively examining different muscle groups and by observation. The first step in examination of strength is often testing of *pronator drift* where the arms are outstretched with the palms up and the patient's eyes closed. Those with subtle or overt hemiparesis due to an upper motor neuron lesion will exhibit pronation and a downward drift. Testing of *rapid finger taps* and *arm rolling* may also demonstrate subtle weakness in the setting of a mild hemiparesis. Particularly in cases of suspected peripheral causes of weakness, a detailed examination of various muscle groups is necessary. One must remember to test strength of neck flexion and extension because this may have important implications particularly in motor neuron disease, neuromuscular junction disorders, and myopathies. Strength of neck flexion is often correlated with respiratory insufficiency due to respiratory muscle weakness and is important to check in all cases of motor neuron disease, neuromuscular junction disease, myopathy, and acute inflammatory demyelinating polyneuropathy.

Objective testing of muscle power is traditionally based on the Medical Research Council scale from 0 to 5, with 5 representing full strength and 0 being complete absence of muscle movement. A score of 1 implies a discernable muscle twitch without movement of a full muscle. A score of 2 indicates movement in the same plane of gravity, whereas movement against gravity but not resistance is a score of 3. A score of 4 represents active movement against resistance and can be further assigned a "+" or a "−" when appropriate to make a more subtle distinction between variations in resistance.

When testing power, each muscle should be tested in a position in which it is at its maximal mechanical advantage—for instance, finger abduction should be tested with the wrist in the neutral position and not flexed. At times, weakness may be too subtle to detect with formal testing of power. It is helpful at times to ask the patient to perform certain functional movements, which may be impaired in cases of subtle weakness. For instance, someone with full strength on testing of power may have trouble standing up from a squatted position or hopping on one foot. A recognition and identification of a specific pattern of weakness is important because different diseases will manifest with different patterns of weakness. For instance, weakness in one limb following a specific myotome may point toward a root or plexus problem, whereas symmetric proximal weakness may suggest either a neuromuscular junction or muscle disorder. Knowledge of the innervation and action of various muscle groups are essential in localization of weakness due to a peripheral cause because the pattern of muscle involvement may point one toward a particular localization and diagnosis (Table 14.5).

Sensory Examination

Evaluation of sensory loss is often challenging because it is the most subjective and thus least reliable portion of the neurologic exam. The best approach is to use the sensory exam to confirm what is clinically suspected. Look for particular patterns of sensory loss to complement the clinical picture, such as sensory loss in a dermatomal pattern consistent with a mononeuropathy or in a distal and symmetric pattern consistent with a polyneuropathy. Testing of different modalities is often helpful in discerning specific spinal cord syndromes (ie, Brown-Séquard syndrome) and in distinguishing a large- from a small-fiber neuropathy.

Reflexes

The absence of reflexes or hypoactive reflexes point toward a lower motor neuron lesion in the peripheral nervous system, whereas pathologically hyperactive reflexes, particularly when in the presence of a Babinski sign or Hoffmann sign, are indicative of an upper motor neuron lesion and corticospinal tract localization. Examination of reflexes may be an important diagnostic clue; for instance, complete loss of reflexes in the setting of subacute weakness should prompt one to quickly consider a diagnosis of acute inflammatory demyelinating neuropathy.

Coordination

Tests of coordination such as finger-to-nose testing are often impaired in the setting of weakness, and the distinction should be made accordingly to avoid confusing subtle weakness for cerebellar or sensory ataxia.

Gait

Examination of gait is often critical because the scissoring, spastic gait of myelopathy will look appreciably different from the waddling gait of myopathy with proximal leg weakness. When assessing gait, one can also notice subtle steppage related to a footdrop or circumduction in the setting of a hemiparesis. It is important to differentiate gait disturbance due to weakness from that related to basal ganglia dysfunction as seen with a shuffling, stooped parkinsonian gait or cerebellar disease where a wide-based ataxic gait is the predominant manifestation. More subtle gait testing involving heel, toe, and tandem gait is often sometimes necessary to further complement the rest of the examination and help elucidate the problem.

DIAGNOSIS AND INITIAL TREATMENT

Once one has formed a differential diagnosis based on likelihood of a particular diagnosis (Table 14.6), various tests can be ordered to further confirm or refute one's diagnostic impression. The urgency of certain tests will depend on the clinical context and circumstances. Patients seen in an emergency room or inpatient setting with acute complaints will often require a more prompt evaluation, and tests can be performed on a more urgent basis. Most patients in the office can be managed with tests ordered on an outpatient basis. However, at times, patients can be seen in the outpatient setting that need urgent evaluation, and it is crucial for the clinician to make this distinction following a detailed history and examination.

Recognition of Emergent Situations

A patient presenting to the office with subacute ascending weakness and areflexia should be promptly admitted to the hospital for evaluation and treatment of probable Guillain-Barré syndrome. Similarly, those with chronic weakness and known diagnoses may present with progressive symptoms requiring hospitalization and more urgent management. For instance, a myasthenic presenting

TABLE 14.5 Common Muscle Groups, Actions, and Innervation[a]

Muscle	Peripheral Nerve	Nerve Root	Action
A. Muscles of the Back, Shoulder, and Neck			
Sternocleidomastoid	Spinal accessory	CN XI, C2, C3	Contralateral rotation of the head
Trapezius	Spinal accessory	CN XI, C3, C4	Shoulder elevation
Diaphragm	Phrenic	C3, C4, C5	Inspiration
Serratus anterior	Long thoracic	C5, C6, C7	Protraction and stabilization of scapula
Rhomboid	Dorsal scapular	C4, C5	Abduction and elevation of scapula
Levator scapulae	Dorsal scapular	C4, C5	Elevation of scapula
Supraspinatus	Suprascapular	C5, C6	Abduction of arm to 90 degrees
Infraspinatus	Suprascapular	C5, C6	Lateral arm rotation
Deltoid	Axillary	C5, C6	Abduction of arm past 30 degrees
Teres minor	Axillary	C4, C5	Medial arm rotation
Teres major	Subscapular	C5, C6, C7	Medical rotation and adduction of arm
Latissimus dorsi	Thoracodorsal	C6, C7, C8	Adduction of arm
B. Muscles of the Arm and Hand			
Biceps brachii	Musculocutaneous	C5, C6	Forearm flexion with arm supinated
Brachialis	Musculocutaneous	C5, C6	Forearm flexion with arm pronated
Triceps brachii	Radial	C6, C7, C8	Forearm extension
Brachioradialis	Radial	C6, C7	Forearm flexion with arm supinated to 90 degrees
Extensor carpi radialis	Radial	C6, C7	Hand extension
Supinator	Radial	C6, C7	Forearm supination
Extensor digitorum	Radial (PIN)	C7, C8	Extension of hand and digits two to five
Extensor carpi ulnaris	Radial (PIN)	C7, C8	Hand extension toward ulna
Abductor pollicis longus	Radial (PIN)	C7, C8	Thumb abduction
Extensor pollicis longus and brevis	Radial (PIN)	C7, C8	Thumb extension
Extensor indicis	Radial (PIN)	C7, C8	Index finger extension
Flexor carpi ulnaris	Ulnar	C7, C8, T1	Ulnar hand flexion
Flexor digitorum profundus	Ulnar	C8, T1	Flexion of distal phalanx of digits four and five
Adductor pollicis	Ulnar	C8, T1	Thumb adduction
Abductor digiti minimi	Ulnar	C8, T1	Abduction of fifth digit
Interossei	Ulnar	C8, T1	Finger abduction or adduction
Lumbricals three and four	Ulnar	C8	Flexion of proximal phalanx and extension of distal phalanx of digits four and five
Flexor carpi radialis	Median	C6, C7	Radial hand flexion
Pronator teres	Median	C6, C7	Forearm pronation
Flexor digitorum superficialis	Median	C7, C8, T1	Flexion of the middle phalanx of digits two to five
Abductor pollicis brevis	Median	C8, T1	Abduction of thumb at the metacarpal joint
Flexor pollicis brevis	Median	C8, T1	Flexion of thumb at the metacarpal joint
Opponens pollicis	Median	C8, T1	Thumb opposition
Lumbricals one and two	Median	C8, T1	Flexion of proximal phalanx and extension of distal phalanx of digits two and three
Flexor digitorum profundus	Median (AIN)	C7, C8	Flexion of distal phalanx of digits two and three
Flexor pollicis longus	Median (AIN)	C7, C8	Flexion of distal phalanx of the thumb
Pronator quadratus	Median (AIN)	C8, T1	Forearm pronation

(table continues on page 119)

TABLE 14.5 Common Muscle Groups, Actions, and Innervation[a] *(continued)*

Muscle	Peripheral Nerve	Nerve Root	Action
C. Muscles of the Hip, Leg, and Foot			
Iliopsoas	Femoral and nerve roots	L1, L2, L3	Hip flexion
Sartorius	Femoral	L2, L3	Hip flexion and lateral thigh rotation
Quadriceps femoris	Femoral	L2, L3, L4	Knee extension
Adductor longus, brevis, magnus	Obturator	L2, L3, L4	Thigh adduction
Gracilis	Obturator	L2, L3, L4	Thigh adduction
Obturator externus	Obturator	L3, L4	Thigh adduction and lateral rotation
Gluteus medius and minimus	Superior gluteal	L4, L5, S1	Thigh abduction and medial rotation
Tensor fasciae latae	Superior gluteal	L4, L5	Thigh abduction
Gluteus maximus	Inferior gluteal	L5, S1, S2	Hip extension
Biceps femoris (long head)	Sciatic	L5, S1, S2	Knee flexion
Biceps femoris (short head)	Sciatic (fibular)	L5, S1, S2	Knee flexion
Semitendinosus	Sciatic	L5, S1, S2	Knee flexion
Semimembranosus	Sciatic	L5, S1, S2	Knee flexion
Tibialis anterior	Fibular	L4, L5	Foot dorsiflexion
Extensor digitorum longus	Fibular	L5, S1	Extension of toes two to five
Extensor hallucis longus	Fibular	L5, S1	Great toe extension
Extensor digitorum brevis	Fibular	L5, S1	Toe extension
Fibularis longus and brevis	Fibular	L5, S1	Foot eversion
Tibialis posterior	Tibial	L5, S1	Foot inversion and plantarflexion
Flexor digitorum longus	Tibial	S2, S3	Flexion of toes two to four
Flexor hallucis longus	Tibial	S1, S2	Flexion of great toe
Gastrocnemius	Tibial	S1, S2	Foot plantarflexion
Soleus	Tibial	S1	Foot plantarflexion
Muscles of perineum	Pudendal	S2, S3, S4	Contraction of pelvic floor muscles

Abbreviations: AIN, anterior interosseous nerve; CN, cranial nerve; PIN, posterior interosseous nerve.
[a]The nerve roots in boldface are the dominant roots involved in that particular muscle's innervation.

with new-onset shortness of breath and dysphagia needs hospitalization for respiratory monitoring and treatment for likely crisis. It is important to identify patients in need of prompt evaluation where the most important tests to be ordered often include pulmonary function tests and a formal swallowing evaluation.

Laboratory Testing

Various tests are available in the evaluation of muscle weakness. Serum studies are important to exclude various metabolic, infectious, inflammatory, or autoimmune conditions. The extent of testing depends on the differential diagnosis. For instance, the workup for causes of axonal polyneuropathy is very broad and can include tests from vitamin levels to heavy metal testing. In cases of suspected neuromuscular junction disease, appropriate antibody testing is necessary, and a creatine kinase should be checked in patients with suspected myopathy.

Genetic tests are now available for those with a family history or other evidence to suggest a congenital or genetic etiology. Imaging is often first line for patients with central causes of weakness.

Imaging Studies

For patients with predominantly upper motor neuron signs and cortical involvement, a computed tomography (CT) scan (see Chapter 21) or magnetic resonance imaging (MRI) (see Chapter 22) of the brain is indicated. Brain imaging is indicated for anyone with a history and exam that localizes to the cortex, subcortex, or brain stem.

In cases of suspected spinal cord pathology, an MRI of the spinal cord is indicated. The exam will guide which particular part of the cord to image because it can be either cervical or thoracic. In some instances, imaging of the lumbosacral spine may also be needed to evaluate the cauda equina and nerve roots. Imaging can also be done of the brachial or lumbosacral plexus, and this is often instructive in cases of plexopathy where trauma, structural lesions, or neoplastic infiltration are suspected. A contrast MRI of the plexus can at times be abnormal in cases of idiopathic brachial neuritis. In patients who cannot tolerate MRI, a CT scan can be helpful to exclude structural and neoplastic processes. A CT myelography is still performed at times in those who cannot undergo MRI and can provide more detailed imaging of the nerve roots than a CT scan alone.

Lumbar Puncture

A lumbar puncture (see Chapter 32) is important to consider in various cases of both central and peripheral weakness. For instance, a patient with a suspected inflammatory, autoimmune, infectious, or neoplastic etiology will typically warrant examination

TABLE 14.6 Common Causes of Weakness

Cortical, Subcortical, or Brain Stem
• Infarct
• Hemorrhage
• Trauma
• Tumor
• Infection (eg, abscess)
• Vascular malformation
• Complicated migraine
• Postical Todd paralysis
• Demyelinating disease
◦ MS
◦ ADEM
◦ PML
Spinal Cord
• Structural (eg, disk herniation, syringomyelia)
• Tumor
• Demyelinating disease (eg, transverse myelitis or NMO)
• Infection (eg, zoster, HIV, HTLV-1)
• Vascular malformation
• Nutritional (eg, B_{12} deficiency)
• Spinal cord infarction
• Inflammatory (eg, lupus, sarcoid)
• Toxic (eg, nitrous oxide)
Motor Neuron/Anterior Horn
• Amyotrophic lateral sclerosis
• Primary lateral sclerosis
• Progressive muscular atrophy
• Monomelic amyotrophy
• Spinal muscular atrophy
• Policmyelitis
• Kennedy disease
Nerve Root
• Structural
◦ Herniated disk
◦ Spondylosis
• Infection
◦ CMV polyradiculopathy
◦ Lyme

Nerve Root *(continued)*
• Malignancy
◦ Tumor invasion
◦ Leptomeningeal metastasis
• Infarction
• Inflammatory
◦ Sarcoidosis
Plexus
• Trauma
• Structural
◦ Thoracic outlet syndrome
• Idiopathic brachial neuritis (Parsonage-Turner syndrome)
• Radiation plexopathy
• Tumor infiltration
• Diabetic amyotrophy
Peripheral Nerve
• Mononeuropathy
◦ Entrapment
• Carpal tunnel syndrome
• Ulnar nerve entrapment at the elbow
• Fibular nerve entrapment at the fibular head
• Mononeuritis multiplex
◦ Vasculitis
• Polyneuropathy
◦ Demyelinating
• Acquired
◦ AIDP (Guillain-Barré syndrome)
◦ CIDP
• Congenital
◦ CMT
◦ Axonal
• Associated with systemic disease (diabetes, monoclonal gammopathy, amyloid)
• Infectious (HIV, Lyme)
• Nutritious (vitamin deficiency such as B_{12}, B_6, B_1)
• Toxic (chemotherapy, alcohol, nitrous oxide, arsenic)
• Autoimmune (anti-MAG, anti-sulfatide)
• Hereditary (CMT2)

(table continues on page 121)

TABLE 14.6 Common Causes of Weakness *(continued)*

Neuromuscular Junction	Muscle *(continued)*
• Myasthenia gravis	• Endocrine myopathies
• Lambert-Eaton myasthenic syndrome	◦ Hyper- or hypothyroidism
• Botulism	◦ Diabetes
• Congenital myasthenia	• Mitochondrial myopathies
Muscle	◦ MELAS
• Electrolyte imbalance	◦ Leigh disease
◦ Hyper-/hypokalemia	◦ Progressive external ophthalmoplegia
◦ Hypophosphatemia	• Toxic myopathies
◦ Hypercalcemia	◦ Statin
• Metabolic myopathies	◦ Steroid
◦ Glycogen storage diseases	• Inflammatory myopathies
◦ Disorders of lipid metabolism	◦ Dermatomyositis
• Muscular dystrophies	◦ Polymyositis
◦ Dystrophinopathy (eg, Duchenne/Becker)	◦ Inclusion body myositis
◦ Limb girdle muscular dystrophy	◦ Infectious myositis (eg, trichinosis)
◦ Myotonic dystrophy	• Periodic paralysis
◦ Myotonic dystrophy	• Amyloid myopathy
• Congenital myopathies	• Critical illness myopathy

Abbreviations: ADEM, acute disseminated encephalomyelitis; AIDP, acute inflammatory demyelinating polyneuropathy; CIDP, chronic inflammatory demyelinating polyneuropathy; CMT, Charcot-Marie-Tooth; CMT2, Charcot-Marie-Tooth type 2; CMV, cytomegalovirus; HIV; human immunodeficiency virus; HTLV-1, human T-lymphotropic virus 1; MAG, myelin-associated glycoprotein; MELAS, mitochondrial encephalomyopathy, lactic acidosis, and stroke-like episodes; MS, multiple sclerosis; NMO, neuromyelitis optica; PML, progressive multifocal leukoencephalopathy.

of the cerebrospinal fluid looking for cells, abnormal protein, and the presence of various other antibodies and cells, which may be diagnostic. It is particularly useful in the diagnosis of Guillain-Barré syndrome where one typically sees a cytoalbuminologic dissociation with elevated protein in the absence of cells.

Electrodiagnostic Testing

Electrodiagnostic testing (see Chapter 26) is important in the evaluation of weakness due to a peripheral cause. Classically, electrodiagnostic testing consisting of nerve conduction studies and electromyography (EMG) have been the standard practice in the diagnosis of several diseases of the peripheral nervous system. These studies are useful for several reasons. First, they can help to localize the problem to the peripheral nerve and exclude other etiologies such as a primary muscle disease, a plexopathy, or a mononeuropathy. Second, it is of crucial importance in helping to distinguish between generalized and focal forms of either purely axonal or demyelinating forms of neuropathy (such as acute or chronic inflammatory demyelinating neuropathy), which may show evidence of markedly slowed conduction velocity or conduction block. Nerve conduction studies and EMG also help assess the severity of the nerve injury partially in demonstrating whether there is resultant denervation of muscle.

Repetitive stimulation testing can be done to evaluate for neuromuscular junction diseases, which may show evidence of electrodecrement or increment. Single-fiber EMG can be done in certain instances because it is the most sensitive (although not specific) test for neuromuscular junction disorders. In cases of motor neuron disease, EMG is necessary to demonstrate diffuse active and chronic denervation of several muscles in various distributions. An EMG is often abnormal in primary muscle diseases and may show evidence of myopathic changes with or without muscle inflammation.

Muscle or Nerve Biopsy

In situations where testing is inconclusive, biopsies can be performed on most tissues in an attempt to make a definitive diagnosis (see Chapter 33). This may include biopsy of brain tissue, the meninges, muscle, or nerve. Given the invasive nature of biopsy, this is typically not performed unless there is a clear need and the benefits of the procedure outweigh the risks.

ACKNOWLEDGMENT

The author would like to acknowledge the work of Dr. Lewis Rowland, who worked on this chapter in the previous edition.

SUGGESTED READINGS

Blumenfeld H. *Neuroanatomy Through Clinical Cases*. 2nd ed. Sunderland, MA: Sinauer Associates; 2010.

Haerer AF, DeJong RN. *DeJong's the Neurologic Examination*. Philadelphia, PA: Lippincott; 1992.

Gait Disorders 15

Ashwini K. Rao

KEY POINTS

1. Gait is a complex task that involves a number of neural networks. It is important to understand the characteristics of gait and the neural control of gait.
2. Disorders of gait are very common in aging and neurologic disorders. Among neurologic disorders, gait impairments are most commonly seen in sensory ataxia, Parkinson disease, hemiparesis, cerebellar ataxia, and frontal cognitive disorders.
3. Falls are a common sequela of gait and balance impairments. It is important to understand the factors (intrinsic and extrinsic) that may influence fall risk.
4. When assessing gait disorders, it is extremely important to obtain a detailed history, medications prescribed, and timeline of onset before conducting standardized assessment of gait and balance.
5. Assessment of gait can be focused by asking a series of questions regarding gait symmetry, pain, bony deformity, step length, step height, support base, pelvic rotation, and joint coordination.

INTRODUCTION

In humans, locomotion enables us to travel greater distances and interact with novel and complex environments. The evolution of bipedal locomotion facilitated the development of complex manipulation skills. The capacity for independent gait is crucial for function: For instance, the loss of independent ambulation is a predictor of the need for long-term care in a number of age-related neurologic disorders. In addition to independent gait, achieving a requisite speed is also important for independent mobility in the community. For example, in people who have suffered a stroke, speed of 0.85 m/s is predictive of the ability to independently ambulate in the community.

The purpose of this chapter is to briefly describe the gait cycle, the neural pathways underlying gait, methods for clinical assessment of gait, and the most commonly seen disorders of gait. Finally, we present the risk factors and assessment of falls in the elderly.

INTRODUCTION TO THE GAIT CYCLE

The gait cycle consists of repetitive sequential movements of the limbs that help propel the body forward along a predetermined line of progression. The gait cycle is defined by foot contact with the ground and extends from the heel strike of one lower limb to the subsequent heel strike of the same limb (Fig. 15.1). We define two phases within each gait cycle: a stance phase, which consists of approximately 60% of the gait cycle, and a swing phase, which consists of approximately 40% of the gait cycle. Stance phase begins with heel strike and ends with toe off and consists of three events—foot flat, midstance, and heel off. The function of the stance phase is to accept the weight of the body on to the supporting (stance) limb. At the beginning of stance (from heel strike to foot flat on the right side) and at the end of stance (from heel off to toe off on the right), both feet are on the ground simultaneously. The period of double

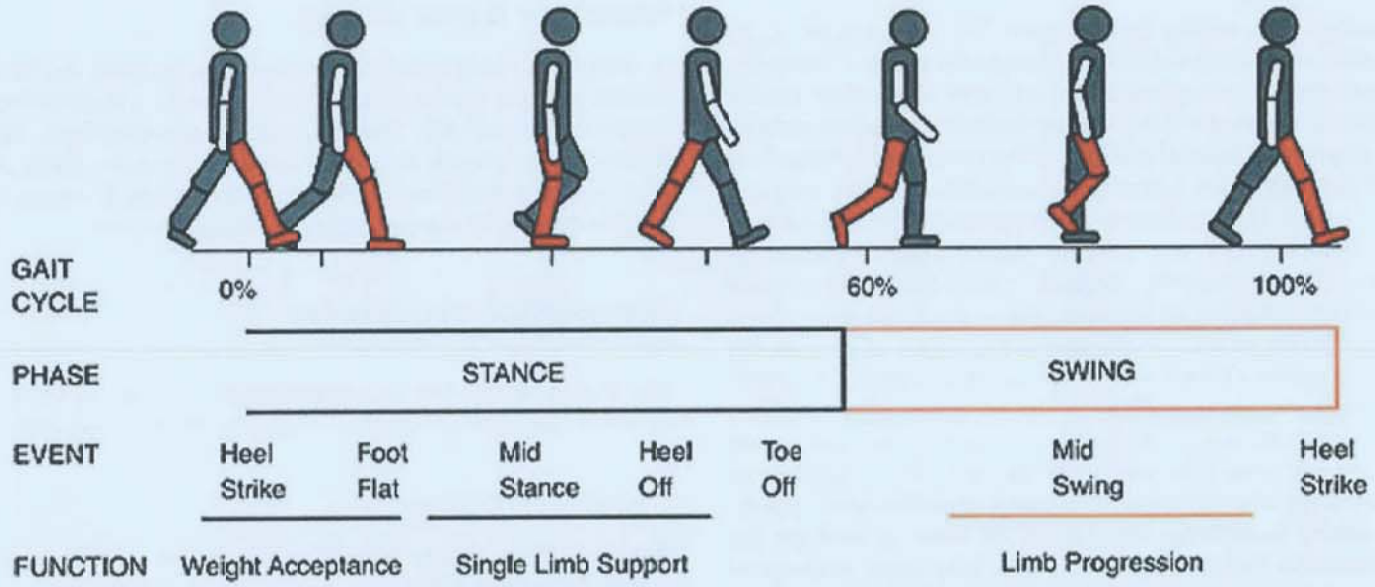

FIGURE 15.1 The gait cycle. The position of the right leg *(shaded red)* shows major events within the gait cycle during stance and swing phases.

TABLE 15.1 Definition of Clinical Gait Measures

Gait Measure	Definition
Speed	Distance covered in unit time (eg, meters per second)
Cadence	Step frequency—number of steps in a given time (steps per minute)
Step length	Distance (measured in meters along the line of progression) between successive heel strikes of the lower limbs
Stride length	Distance (measured in meters along the line of progression) between successive heel strikes of the same limb
Step width	Distance (measured in meters perpendicular to the line of progression) between successive heel strikes of the lower limbs
Step height	Vertical clearance of the foot from the floor during swing
Step symmetry	Ratio of step length on the right and left sides
Step continuity	Ratio of step time on the right and left sides
Foot angle	Angle formed by the long axis of the foot with the line of progression
Walking path	Direction of the line of progression

support comprises approximately 20% of the gait cycle. During midstance, body weight is supported by one limb (single limb support). During a typical gait cycle, the lower limbs move in a symmetric alternating movement with a phase lag of 0.5 (indicating that when one limb initiates swing, the opposite limb is in the middle of stance phase).

The swing phase of a limb begins with toe off and ends with heel strike. The events within the swing phase (foot clearance and midswing) serve to allow the foot to clear the floor as it propels the body forward in preparation for the subsequent step. The events within the gait cycle described earlier pertain to walking at a comfortable preferred speed. As speed of gait increases, the percentage of time spent in double support decreases. During running, there is no double support phase. Gait can be described quantitatively with respect to its spatial and temporal features. Gait measures that can be assessed in the clinical setting are described in Table 15.1 and Figure 15.2.

NEURAL CONTROL OF GAIT

Gait is a complex task that requires the coordinated activity of several brain circuits. Even walking in an uncluttered environment at a preferred speed (considered an easy task) elicits activity in higher cortical regions. The following description briefly discusses the role of different neural circuits in controlling gait. Readers interested in additional details are referred to excellent recent reviews in the Suggested Readings list.



FIGURE 15.2 Spatial characteristics of gait. Spatial gait variables defined by foot placement along the line of progression.

In order to successfully initiate and control gait, the nervous system needs to perform the following tasks:

- Maintain balance against the force of gravity under static (eg, during stance) and dynamic conditions (eg, during walking). Maintenance of balance under dynamic conditions includes predictive and reactive control of destabilizing forces that are either generated internally (eg, destabilizing forces generated by movement of the arms) or externally (eg, destabilizing forces generated by bumping into another person).
- Coordinate movements of the lower limbs to propel the body forward.
- Help navigate complex environments, which may include stationary obstacles (eg, furniture) and moving obstacles (eg, people walking).
- Perform concurrent tasks with walking, such as talking, listening, or manipulating objects (eg, mobile phone).

Most of the experimental work in understanding the neural control of gait has come from experiments with quadruped and biped animals. These experiments suggest that distinct neural circuits perform specific functions. Cortical circuits (including premotor and motor areas, parietal and occipital areas) are involved with activation and guidance. Reciprocal circuits between the cortex-basal ganglia and cortex-cerebellum are involved with regulation of gait (including postural tone, balance, and coordination of limb movement). Finally, brainstem and spinal cord circuits are involved with the execution of gait (including gait initiation, step frequency, reciprocal movements of the lower limbs). A simplified diagram of the neural structures involved in control of gait is presented in Figure 15.3 and functions of brain structures are summarized in Table 15.2.

Activation and Visual Guidance of Gait

Gait can be activated either by a volitional process under the control of cerebral cortical circuits or by emotional cues (fight or flight reaction) under the control of limbic circuits. Volitional guidance of gait requires precise visual information about the environment, which is processed in the visual areas of the occipital cortex. The posterior parietal cortex receives information from the visual cortex and project to the motor areas in the frontal cortex. An important function of the posterior parietal cortex is to construct maps of

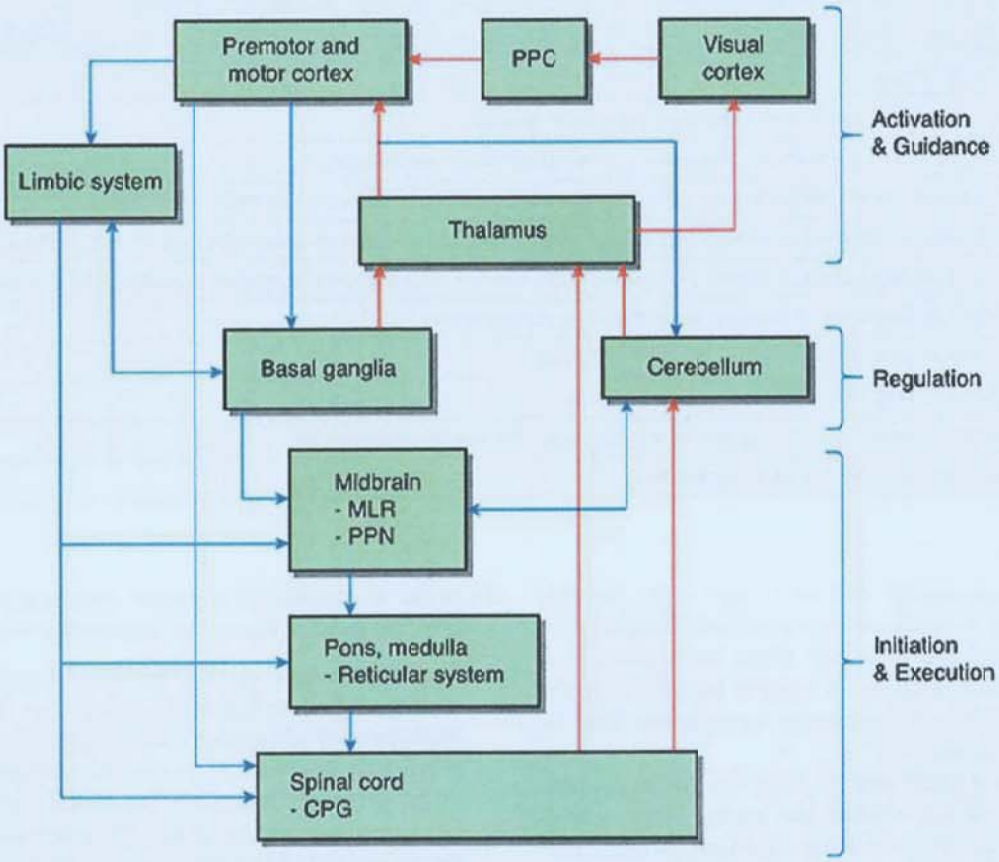

FIGURE 15.3 Neural control of gait. Schematic illustration of neural structures involved in the control of gait. Efferent connections are shown in *blue arrows* and afferent connections in *red arrows*. Abbreviations: CPG, central pattern generator; MLR, midbrain locomotor region; PPC, posterior parietal cortex; PPN, pedunculopontine nucleus.

space, which are very important for visual guidance of locomotion. The premotor areas, in particular the supplementary motor area, are important for postural control during gait. The motor cortex projects to interneurons and motor neurons in the spinal cord and is important in the control of limb movements during gait.

TABLE 15.2 Neural Control of Gait

Region	Area	Function
Cortex	Motor areas	Volitional activation
		Visual guidance
	Limbic system	Emotional activation
Subcortical	Basal ganglia	Inhibition of postural tone
		Regulate rhythmic aspects of gait
	Cerebellum	Balance
		Limb coordination
		Adaptation
Brainstem	MLR	Initiation of locomotor pattern
	PPN	Postural muscle tone
Spinal cord	Interneurons	Control locomotor pattern

Abbreviations: MLR, midbrain locomotor region; PPN, pedunculopontine nucleus.

Regulation of Gait

The basal ganglia and cerebellum have a major influence on motor output even though they do not directly project to the motor neurons in the spinal cord. The basal ganglia input nuclei, in particular the putamen, receive inputs from the premotor and motor cortex. The output nuclei of the basal ganglia (globus pallidus internal segment and substantia nigra pars reticulata) project back to the premotor and motor cortex via the thalamus. These projections are thought to be important for regulating movement amplitude and speed. In addition, the basal ganglia send inhibitory projections to the midbrain locomotor region (MLR) and the pedunculopontine nucleus (PPN). The projection from the basal ganglia to the MLR is responsible for regulating the rhythmic aspects of gait. When there is damage to these projections, as seen in Parkinson disease and Huntington disease, rhythmic control of gait is impaired. The projection from the basal ganglia to the PPN is responsible for regulating muscle tone. Damage to these projections leads to disorders of postural muscle tone, as seen in Parkinson disease.

The cerebellum receives a tremendous amount of afferent information from the limbs and vestibular apparatus. In addition, projections from the cerebral cortex to the cerebellum provide information regarding the upcoming movement. The output of the cerebellum is directed to the motor areas of the

cerebral cortex, midbrain (MLR and PPN), and brainstem (vestibular and reticular nuclei). A major function of the cerebellum is to evaluate disparities between intended movement and actual movement (based on feedback). The cerebellum is important for regulating balance and limb coordination during gait and for providing adaptability to novel conditions based on trial and error learning.

Execution of Gait

Two areas in the brainstem are important for initiating and executing locomotion—the MLR and the PPN. The MLR receives inputs from the cerebral cortex, limbic system, basal ganglia, and cerebellum. A primary function of the MLR is activation of spinal cord circuitry to initiate gait. Inputs from the motor areas and the limbic system to MLR provide the neural substrate for activation of gait based on volitional (motor areas) and emotional (limbic system) cues. The PPN also receives inputs from the motor areas of the cerebral cortex, limbic system, basal ganglia, and cerebellum. The PPN inhibits spinal interneurons and motor neurons. A major function of the PPN is to modulate muscle tone during stance and gait. The spinal cord circuitry includes networks of interneurons (central pattern generators) and motor neurons that innervate skeletal muscles. There are two sets of interneurons, termed *half centers*, that project to flexor and extensor motor neurons. The half centers mutually inhibit each other and are responsible for producing the basic locomotor pattern. Although the half centers do not require sensory input to generate the basic locomotor pattern, their activity can be modulated by sensory input from the limbs. For example, signals from proprioceptors of the hip flexors may be used to signal the end of stance phase. In addition, skin afferents from the limbs are important for adjusting stepping movements in the presence of obstacles. Thus, the function of the spinal cord is to execute the rhythmic movement pattern of gait.

EPIDEMIOLOGY OF GAIT DISORDERS

Although it is widely accepted that gait disorders are commonly seen with advancing age and neurologic disorders, their prevalence and incidence are not well understood. The challenge in examining prevalence and incidence is that defining abnormal gait is difficult, partly due to the high variability of typical gait and partly because of unclear standards for classification of gait disorders. For people older than the age of 60 years, about 32% to 36% have gait disorders, of which 16% to 24% are due to neurologic disorders. Among people older than the age of 85 years, approximately 55% report gait impairments. The prevalence of gait disorders is much higher (60%) in people hospitalized with neurologic disorders. The incidence (new cases of gait disorders) of gait disorders due to neurologic disorders is approximately 10% per year.

Among neurologic causes of gait disorders, the most common are sensory ataxia, Parkinson disease, hemiparetic, cerebellar ataxia, and frontal cognitive disorders. Gait impairments can have devastating consequences including falls and injury. Approximately, one-third of community-dwelling individuals older than the age of 65 years fall. Injuries related to falls increase with age. An unfortunate consequence of falls is that individuals often reduce their mobility in order to prevent falls and related incidents. However, reduced mobility further increases risk for falls by reducing muscle strength and worsening balance. In addition, gait disorders increase the risk of institutionalization and death.

FALLS IN THE ELDERLY

Falls are defined as "unexpected events in which a person comes to rest on the floor, ground, or supporting surface." Falls are considered an inevitable consequence of aging and may result in serious adverse events in older adults. Approximately one-third of community-dwelling people older than the age of 65 years fall each year. The number of falls is much higher for older people living in nursing homes: approximately 1.5 falls per bed per year. The high incidence of falls coupled with the susceptibility to injury (because of comorbidities and age-related physiologic changes) leads to adverse events in the elderly. Falls may result in injuries such as abrasions, bruising, lacerations, and sprains. It is important to note that falls resulting in minor injuries may be underreported by patients. A careful ascertainment of history of falls is very important in clinical practice. About 10% of falls result in fractures, the type of fracture depending on the nature of the fall. Forward or backward falls on outstretched hands result in wrist fractures, falls to the side result in hip fractures, and falls resulting in impact to the head may result in head injury and loss of consciousness. Backward falls on the buttocks result in lower rates of fractures, although fractures of the vertebrae can occur.

Falls account for two-thirds of accidental deaths. The other negative consequences of falls include increased fear of falls and reduced mobility. This results in a negative spiral: Reduced mobility leads to reduction in muscle strength, flexibility and postural stability, and gait impairments, all of which, in turn, increase the risk for additional falls. Falls have a significant negative impact on the quality of life of elders.

Risk factors for falls can be classified as intrinsic or extrinsic. Intrinsic factors include age, muscle strength, gait and balance impairments, and neurologic or cognitive disorder. Extrinsic factors include medications, environmental hazards, and type of activity (based on hazard). The greatest risk factors for falls are previous history of falls, muscle weakness, imbalance, reduced walking speed, use of walking aids, vertigo, sedentariness, and number of medications used (polypharmacy). It is important to note that a number of these factors, such as weakness, gait and balance impairments, use of walking aids, and medications are modifiable factors. Often, patients report near falls, defined as a "loss of balance that would have resulted in a fall if sufficient recovery mechanisms (movement of the trunk or arms, change in stride length or velocity) were not activated." Near falls often precede falls and are more frequent than falls. Clinical assessment of falls should include information on near fall events. More information on fall assessment appears in the following section. Physical exercise (under the supervision of a physical or occupational therapist) is effective in reducing the frequency of falls and preventing future falls. In addition, home hazard assessment and

reduction (under the supervision of occupational therapists) reduces the frequency of fallers and the number of falls. Clinicians should consult physical and occupational therapists, as needed.

CLINICAL ASSESSMENT OF STANCE, GAIT, AND FALLS

Assessment should include a detailed medical history and clinical exam, which consists of two parts: clinical observation and standardized assessment. A summary of the clinical assessment procedures is provided in Table 15.3.

History

It is important to document the history of acute and chronic medical problems, history of near falls and falls, history of problems with balance and gait, and level of physical activity. Ask the patient about the most recent fall and ascertain the circumstances around the fall, including what the patient was doing, what caused the fall, where the fall occurred, environmental hazards that may have caused the fall, and the consequence of the fall.

It is also important to ask about the timeline of onset of gait impairments because the timeline may provide clues to diagnosis. For instance, if the onset of gait disorder is acute (minutes to hours), it may signal an infarction, hemorrhage, or head trauma. If the onset of gait disorder is between hours to days, it may be due to disorders such as multiple sclerosis, Guillain-Barré syndrome, or tumor. Gait disorders that begin over weeks to months may indicate presence of degenerative disorders of the basal ganglia or cerebellum, hydrocephalus, or chronic infections. If the gait disorder is present episodically, it may be due to multiple sclerosis or transient ischemic attack. Examples of conditions with gait disorders and the timeline of onset is shown in Figure 15.4.

Medications

Note the list of prescribed medications and if any medications and/or dosages have been recently modified.

Physical Examination

Physical examination should include an assessment of musculoskeletal function and footwear. Neurologic examination should include tests of cognitive function (using an assessment such as the Montreal Cognitive Assessment), muscle strength, reflexes, sensation, coordination, and presence of involuntary movements.

Balance and Gait Assessment

The examination begins with observation of a patient in a quiet stance. Clinicians should observe the patient from the front, back, and side. Determine if head is flexed, translated forward or backward, or tilted to one side. It is important to note if the shoulders are level or positioned asymmetrically. Examine if shoulders are hunched (rotated) forward. Note the position of the trunk to determine if it is kyphotic (rounded) as seen in

TABLE 15.3 Clinical Assessment

History	Falls and near falls Level of physical activity Complaints of gait and balance
Medications	Prescribed medications Change in medication or dosage
Most recent fall incident	1. What was the patient doing? (standing, walking, turning, bending, reaching for objects, transfers, climbing on step-stool or ladder, recreational activity) 2. What caused the fall? (dizziness, loss of balance, weakness, dual-task performance, slip/trip, fatigue, bumped into object) 3. Where did the fall occur? (indoor level surface, indoor uneven surface, outdoor level surface, outdoor uneven surface) 4. Did environmental hazard cause fall? (icy or wet surface, clutter, rugs/carpet, darkness, moving objects) 5. What was the result of the fall? (minor injury, major injury)
Physical examination	Cognitive function (eg, Montreal Cognitive Assessment) Musculoskeletal examination (range of motion, joint pain, swelling) Footwear (sandals, flip-flops, sneakers)
Neurologic examination	Muscle strength Reflexes Sensation Presence of involuntary movements Coordination
Balance and gait assessment	Clinical observation and standardized assessments. Please see **Table 15.4.**
Environmental assessment	Presence of safety grab bars Clutter and presence of area rugs or carpets Adequacy of lighting Height of chairs Surfaces (uneven, incline, stairs) Use of walking aids (cane, walker)

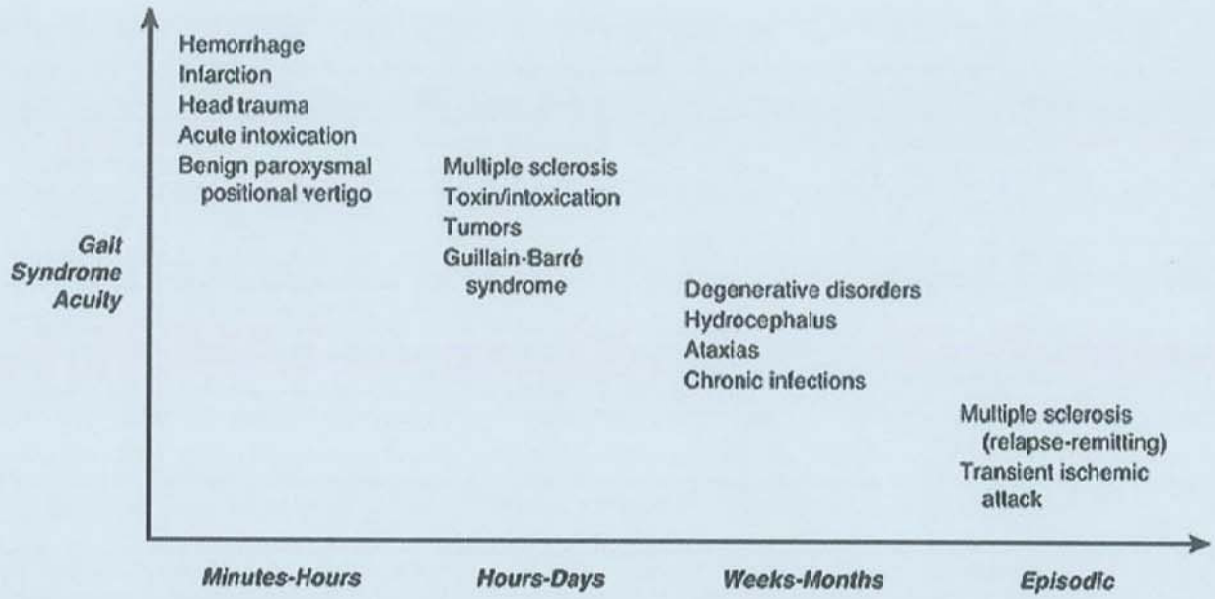

FIGURE 15.4 Timeline of onset of gait disorders. Schematic illustration of disorders gait syndrome acuity, and the timeline of onset (x-axis).

disorders of aging or lordotic (hyperextended). Examine if trunk is tilted to one side because this may be an indication of pain, diminished sensory feedback, or impaired vestibular system.

Upper Extremities

Healthy people tend to maintain their arms next to the trunk with slight internal rotation at the shoulder and extension at the elbows. Observe if the arm is maintained in a flexed and internally rotated posture (as is often the case in people with stroke) and if involuntary movements are present (such as writhing choreic movements in Huntington disease or resting hand tremor seen in Parkinson disease). Also note if the hand is maintained in a fixed posture because this may be a sign of dystonia.

Lower Extremities

Healthy people stand with the pelvis in a neutral position and lower limbs extended with the feet pointing straight ahead. Note if the hip and knee joints are maintained in flexion, as is sometimes seen in people with muscle tightness or weakness.

Assessment of Gait

Ensure that there is adequate space (length of 7-10 m) to conduct a comprehensive gait assessment. Observe the patient from the front, back, and sides. Note the position of the head and trunk during gait, presence or absence of arm swing, and instability during walking and turning.

- *Standard walk*: Ask the patient to walk at their comfortable pace. Observe position of the head and trunk, walking path, and length and symmetry of steps. Note presence of instability during gait.
- *Turns*: Ask the patient to turn and observe the number of steps taken to turn. Note presence of instability during turns.
- *Narrow doorway*: Ask the patient to walk through a narrow doorway. This test is provocative for freezing of gait. Note presence of freezing.
- *Tandem walk*: Ask the patient to walk heel to toe for 10 steps. Note whether the patient can perform the task without support and the number of steps taken away from a straight line.
- *Dual-task walk*: Ask the patient to walk at his or her comfortable speed while performing a secondary motor or cognitive task. Typical secondary motor tasks include carrying a cup of water or carrying a tray with a cup on it. Several secondary cognitive tasks have been employed and include the following:
  - Count backward: Give the patient a number and ask him or her to count backward by 3 (serial 3) or by 7 (serial 7). Note that performance on the serial 7 task is dependent on level of education and may be too difficult for several patients.
  - Verbal fluency: Ask the patient to generate words that begin with a certain letter (such as "d") or words that belong to a category (eg, animals).
  - Walking while talking: Ask the patient a question (such as "What did you have for breakfast today?")

In addition to clinical observation, several standardized assessments of mobility, balance, and fall risk are available, summarized in Table 15.4.

The assessment of gait can be focused by asking the following questions, which will assist in classifying the gait disorder.

1. Is the gait symmetrical?
   A. If asymmetrical, then assess whether there is pain.
      i. If pain is present → antalgic
      ii. If no pain is present, assess if there is bony deformity.
         a. If bony deformity present → orthopedic gait disorder
         b. If no bony deformity is seen → hemiplegic gait
   B. If gait is symmetrical, then move to next step.
2. Are steps short?
   A. If steps are short, examine posture.
      i. If posture stooped and no arm swing → parkinsonian gait

TABLE 15.4 Standardized Assessments of Mobility, Balance, and Fall Risk

Assessment	Details	Clinical Indication
Timed up and go	Time taken to get up from a seated position, walk 3 m, turn around, walk back, and take a seat	Increased fall risk in the following: 1. Community-dwelling elderly: >13.5 s 2. Parkinson disease: >11.5 s 3. Stroke: >14 s
Tinetti performance-oriented mobility assessment	Balance scale consists of nine items that assess balance in sitting, standing, transitions, and turning.	Total score is 28. Score >25 indicates low fall risk, score between 19 and 24 indicates medium fall risk, and scores <19 indicate high fall risk.
Berg Balance Scale	Measures performance on 14 functional tests of sitting and standing balance, transfers, turning, etc.	Total score is 56. Scores <45 indicative of increased fall risk.
Dynamic Gait Index	Measures ability to walk a distance of 6.1 m (20 ft) under external demands (such as head turns)	Total score is 24. Score <19 indicative of fall risk.
Walking while talking	Examines whether patients are able to walk while reciting the alphabet (simple) or every alternate alphabet (complex)	Community-dwelling elderly: >20 s for simple task; >30 s for complex task indicative of falls.
10-m walk	Patient is asked to walk a distance of 10 m at either a self-selected comfortable speed or fast speed. Time taken to cover middle 6-m distance is measured to eliminate the effect of acceleration and deceleration.	Household ambulator = speed <0.4 m/s Limited community ambulator = speed between 0.4 and 0.8 m/s Community ambulator = speed >0.8 m/s
Tandem walk	Measures ability to walk 10 steps tandem (heel to toe) walk	<2 completed steps indicative of fall risk
6-min walk test	Measures the distance walked in a period of 6 min along a 30-m long walkway	Distance <400 m indicates lack of aerobic capacity.

   ii. If posture is upright, and arm swing normal → Marche à petit pas
   B. If steps are normal, examine support base.
3. Is support base normal?
   A. If support base is narrow with crossing over → scissor gait
   B. If support base is wide, then examine step height.
      i. If step height is normal → cerebellar ataxic gait
      ii. If step height is high → sensory ataxic gait
   C. If support base is normal, examine step height.
      i. High step height → bilateral foot drop
      ii. If step height is normal, examine pelvic rotation.
4. Does the pelvis rotate?
   A. If pelvis rotation seen → waddling gait
   B. If pelvis rotation normal, examine joint coordination.
5. Is joint movement of lower limbs coordinated?
   A. Uncoordinated joint movements → apraxia
   B. If joint movements are coordinated, examine overall quality of gait.
6. Are gait impairments unusual and inconsistent from one trial to the next?
   A. If yes → psychogenic/functional gait

CLASSIFICATION OF GAIT DISORDERS

In neurologic disorders, gait is classified as disordered based on comparison with healthy subjects, for whom normative values through the course of aging are available. However, given the large variability of what is considered "normal" gait, caution must be used in order to describe gait patterns as impaired. Table 15.5 highlights gait impairments that are clinically evident in neurologic disorders. Several classifications have been proposed for gait disorders including anatomic, hierarchical (eg, low, mid, and high level), etiologic (eg, degenerative), or phenomenologic (eg, antalgic gait). Anatomic classification describes gait disorders based on brain pathology (eg, cerebellar gait). Hierarchical classification differentiates gait disorders into three categories based on the level of pathology (eg, low level, midlevel, and high level). Gait disorders due to peripheral sensory (eg, sensory ataxic) or motor disorders (eg, spinal muscular atrophy) are classified as low-level disorders. Disorders that occur as a result of pathology in the motor system, including motor cortical areas, basal ganglia, and cerebellum, are classified as midlevel disorders. Finally, gait disorders that result from the interaction of cognitive (frontal cortex) and motor systems (eg, Alzheimer disease) are classified as high-level disorders. Finally, classification of gait disorders by phenomenology takes into account etiology and clinical features. In this chapter, gait disorders are classified by hierarchy and pathophysiology, which more closely reflects clinical practice. The table also separates phenomena that may be observed throughout gait observation (continuous) from those that are unpredictable (episodic). According to this classification, continuous phenomena reflect the underlying pathology and compensatory mechanisms, whereas episodic phenomena are those that the patient cannot adapt to because of their unpredictability.

TABLE 15.5 Disorders of Gait

Disorder	Continuous Phenomena (Speed, Support Base, Arm Swing, Symmetry, Path)	Episodic Phenomena (Freezing of Gait, Gait Initiation, Falls)
High-Level Gait Disorders		
Alzheimer disease Gait disorder occurs late in the disease.	Slow gait speed Short step length Increased time in double support Increased variability, particularly when performing cognitive dual task	Increased risk for falls
Mild cognitive impairment (MCI)	Slow gait speed Short step length Increased time in double support Gait variability higher in amnestic MCI but not in nonamnestic MCI Poor limb coordination (foot tapping) compared with controls	Increased risk for falls and fear of falls
Vascular dementia Gait disorder occurs early in the disease.	Slow gait speed Short step length Wide support base Rigidity	Freezing of gait Imbalance and falls seen
Normal pressure hydrocephalus Gait disorder seen early in the disease in conjunction with cognitive impairment and urinary incontinence	Slow gait speed Short step length Wide support base and outward rotation of foot (may be compensation for poor balance) Asymmetric steps Low step height (shuffling steps)	Increased risk for falls
Dementia with Lewy bodies Gait impairments seen in conjunction with visual hallucinations	Slow gait speed Reduced arm swing Flexed trunk posture Rigidity	Increased risk for falls
Frontotemporal dementia Gait impairments seen in the presence of behavioral disturbances (impulsivity, disinhibition)	Slow gait speed Involuntary trunk movements Postural instability	Increased risk for falls
Psychogenic (functional) gait disorder Gait impairments seen in the presence of psychiatric disorders such as anxiety, depression, or personality disorder	Gait impairments not consistent from one assessment to the next, may have sudden onset, very severe impairments at onset, and spontaneous remissions. Astasia-abasia Knee buckling during stance Wide support base and short step length (waddling) Excessive retropulsion	Tremor and dystonia seen, although may not be observed when the patient is distracted
Midlevel Gait Disorders		
Hemiparesis	Slow gait speed Asymmetric stepping Swing phase—impaired lower limb moves in circumduction; hip hiking seen (Trendelenburg sign) Ankle may be maintained in plantar flexion and inversion leading to loss of heel strike at the beginning of stance. Stance phase—knee joint may hyperextend. Reduced arm swing on impaired side and reduced trunk rotation During dual-task gait, impairments worsen.	Increased risk for falls
Head trauma	Slow gait speed in the acute phase; resolves with time Increased time in double support may be seen Increased imbalance during tandem stance and gait Impairments more prominent during dual-task gait	Increased fall risk in the acute phase
Paraparesis	Slow gait speed Low cadence Low step height Circumduction may be seen. Decreased support base (scissoring gait) seen in patients with spasticity	Increased risk for falls due to weakness and imbalance
Parkinson disease Gait impairments seen in the presence of tremor, rigidity, and postural instability	Slow gait speed Very short step length Poor foot clearance during swing (which leads to shuffling gait) Increased temporal variability Postural instability and impaired balance seen (missteps during tandem gait) Stooped posture Limited or no arm swing During dual-task gait, Parkinson disease patients pay greater attention to secondary cognitive task as opposed to gait leading to greater gait impairments (posture second strategy).	Freezing of gait Difficulty initiating gait Increased fear of falls and increased risk for falls as disease progresses

TABLE 15.5 Disorders of Gait *(continued)*

Disorder	Continuous Phenomena (Speed, Support Base, Arm Swing, Symmetry, Path)	Episodic Phenomena (Freezing of Gait, Gait Initiation, Falls)
Midlevel Gait Disorders		
Multiple system atrophy Gait impairments seen in the presence of autonomic dysfunction and urinary incontinence	May present like Parkinson disease (slow speed, short step length) May present like cerebellar ataxia (gait ataxia—increased support base, path deviation, postural instability, impaired balance—missteps during tandem gait)	Increased risk for falls as disease progresses
Progressive supranuclear palsy	Postural instability Wide support base Rigid support base and low vertical displacement of the pelvis during gait Slow gait speed Difficulty turning (turn en bloc)	High risk for falls, increased fear of falls
Huntington disease	Slow gait speed Decreased step length Reduced cadence Increased time in double support Asymmetric step length Inconsistent step time Gait impairments worsen during secondary dual task. Chorea of limbs or trunk may increase instability. Dystonic posturing of ankle, trunk, neck or arm during gait	Increased fear of falls and greater number of falls as disease progresses
Essential tremor	Slow gait speed Reduced cadence Increased time in double support Asymmetric step length Wide support base Increased temporal variability Prominent balance impairment (missteps during tandem gait)	Increased fear of falls and greater number of falls
Cerebellar ataxia	Inconsistent step time Asymmetric step length Short step length and low step height Wide support base Increased temporal variability Increased postural sway Greater missteps during tandem gait	High risk for falls, increased fear of falls
Low-Level Gait Disorders		
1. Peripheral sensory disorders (peripheral neuropathy, posterior *column* disorder, vestibular and visual deficit)		
Sensory ataxic gait	Wide support base Postural instability increased when standing with eyes closed Increased step height Short step length Foot slap at beginning of stance phase Patients tend to look at their feet while walking.	Increased risk for falls when not using vision
2. Peripheral *motor* disorders		
Antalgic gait	Decreased weight bearing on painful limb leading to shorter stance phase Short stride length Reduced range of motion in affected joint(s) Trendelenburg sign may be seen due to pain at the hip joint.	
Spinal muscular atrophy	Slow gait speed Decreased step length Reduced cadence Wide support base Trendelenburg sign Impairments worsen with fatigue during continuous walking.	Increased risk for falls
Duchenne muscular dystrophy	Lordotic posture and anterior pelvic tilt Waddling gait (short step length, wide support base) Knee hyperextension during stance Ankle plantar flexion during swing Gait pattern does not change with continuous walking.	Increased risk for falls

SUGGESTED READINGS

Alexander NB, Goldberg A. Gait disorders: search for multiple causes. *Cleve Clin J Med*. 2005;72:586, 589-590, 592-584 passim.

Allali G, Verghese J. Management of gait changes and fall risk in MCI and dementia. *Curr Treat Options Neurol*. 2017;19(9):29.

Al-Yahya E, Dawes H, Smith L, Dennis A, Howells K, Cockburn J. Cognitive motor interference while walking: a systematic review and meta-analysis. *Neurosci Biobehav Rev*. 2011;35:715-728.

Bahureksa L, Najafi B, Saleh A, et al. The impact of mild cognitive impairment on gait and balance: a systematic review and meta-analysis of studies using instrumented assessment. *Gerontology*. 2017;63(1):67-83.

Beauchet O, Annweiler C, Callisaya ML, et al. Poor gait performance and prediction of dementia: results from a meta-analysis. *J Am Med Dir Assoc*. 2016;17(6):482-490.

Belghali M, Chastan N, Cignetti F, Davenne D, Decker LM. Loss of gait control assessed by cognitive-motor dual-tasks: pros and cons in detecting people at risk of developing Alzheimer's and Parkinson's diseases. *Geroscience*. 2017;39(3):305-329.

Berg KO, Wood-Dauphinee SL, Williams JI, Maki B. Measuring balance in the elderly: validation of an instrument. *Can J Public Health*. 1992;83(suppl 2):S7-S11.

Bilney B, Morris ME, Churchyard A, Chiu E, Georgiou-Karistianis N. Evidence for a disorder of locomotor timing in Huntington's disease. *Mov Disord*. 2005;20:51-57.

Bohannon RW. Comfortable and maximum walking speed of adults aged 20–79 years: reference values and determinants. *Age Ageing*. 1997;26:15-19.

Bugalho P, Alves L, Miguel R. Gait dysfunction in Parkinson's disease and normal pressure hydrocephalus: a comparative study. *J Neural Transm (Vienna)*. 2013;120:1201-1207.

Cohen JA, Verghese J, Zwerling JL. Cognition and gait in older people. *Maturitas*. 2016;93:73-77.

Cruz-Jimenez M. Normal changes in gait and mobility problems in the elderly. *Phys Med Rehabil Clin N Am*. 2017;28(4):713-725.

Delval A, Krystkowiak P, Delliaux M, et al. Role of attentional resources on gait performance in Huntington's disease. *Mov Disord*. 2008;23:684-689.

Fino PC, Parrington L, Pitt W, et al. Detecting gait abnormalities after concussion or mild traumatic brain injury: a systematic review of single-task, dual-task, and complex gait. *Gait Posture*. 2018;62:157-166.

Giladi N, Horak FB, Hausdorff JM. Classification of gait disturbances: distinguishing between continuous and episodic changes. *Mov Disord*. 2013;28:1469-1473.

Hallett M, Weiner WJ, Kompoliti K. Psychogenic movement disorders. *Parkinsonism Relat Disord*. 2012;18(suppl 1):S155-S157.

Hollman JH, McDade EM, Petersen RC. Normative spatiotemporal gait parameters in older adults. *Gait Posture*. 2011;34:111-118.

Koenraadt KL, Roelofsen EGJ, Duysens J, Keijsers NLW. Cortical control of normal gait and precision stepping: an fNIRS study. *Neuroimage*. 2014;85(pt 1):415-422.

Martin LG, Freedman VA, Schoeni RF, Andreski PM. Trends in disability and related chronic conditions among people ages fifty to sixty-four. *Health Aff (Millwood)*. 2010;29:725-731.

Mc Ardle R, Morris R, Wilson J, Galna B, Thomas AJ, Rochester L. What can quantitative gait analysis tell us about dementia and its subtypes? A structured review. *J Alzheimers Dis*. 2017;60(4):1295-1312.

Miyoshi N, Kazui H, Ogino A, et al. Association between cognitive impairment and gait disturbance in patients with idiopathic normal pressure hydrocephalus. *Dement Geriatr Cogn Disord*. 2005;20(2-3):71-76.

Montes J, Blumenschine M, Dunaway S, et al. Weakness and fatigue in diverse neuromuscular diseases. *J Child Neurol*. 2013;28:1277-1283.

Montes J, Dunaway S, Montgomery MJ, et al. Fatigue leads to gait changes in spinal muscular atrophy. *Muscle Nerve*. 2011;43:485-488.

Moretti R, Torre P, Antonello RM, Esposito F, Bellini G. Gait and equilibrium in subcortical vascular dementia. *Curr Gerontol Geriatr Res*. 2011;2011:263507.

Morton SM, Bastian AJ. Mechanisms of cerebellar gait ataxia. *Cerebellum*. 2007;6:79-86.

Nonnekes J, Goselink RJM, Růžička E, Fasano A, Nutt JG, Bloem BR. Neurological disorders of gait, balance and posture: a sign-based approach. *Nat Rev Neurol*. 2018;14(3):183-189.

Osoba MY, Rao AK, Agrawal SK, Lalwani AK. Balance and gait in the elderly: a contemporary review. *Laryngoscope Investig Otolaryngol*. 2019;4(1):143-153.

Park SH. Tools for assessing fall risk in the elderly: a systematic review and meta-analysis. *Aging Clin Exp Res*. 2018;30(1):1-16.

Peterson DS, Horak FB. Neural control of walking in people with parkinsonism. *Physiology (Bethesda)*. 2016;31(2):95-107.

Pijnenburg YA, Gillissen F, Jonker C, Scheltens P. Initial complaints in frontotemporal lobar degeneration. *Dement Geriatr Cogn Disord*. 2004;17:302-306.

Plummer-D'Amato P, Altmann LJ, Saracino D, Fox E, Behrman AL, Marsiske M. Interactions between cognitive tasks and gait after stroke: a dual task study. *Gait Posture*. 2008;27:683-688.

Podsiadlo D, Richardson S. The timed "Up & Go": a test of basic functional mobility for frail elderly persons. *J Am Geriatr Soc*. 1991;39:142-148.

Rao AK. Wearable sensor technology to measure physical activity (PA) in the elderly. *Curr Geri Rep*. 2019;8:55-66.

Rao AK, Louis ED. Ataxic gait in essential tremor: a disease-associated feature? *Tremor Other Hyperkinet Mov (N Y)*. 2019; 9:10.7916/d8-28jq-8t52.

Rao AK, Muratori L, Louis ED, Moskowitz CB, Marder KS. Spectrum of gait impairments in presymptomatic and symptomatic Huntington's disease. *Mov Disord*. 2008;23:1100-1107.

Rochester L, Galna B, Lord S, Burn D. The nature of dual-task interference during gait in incident Parkinson's disease. *Neuroscience*. 2014;265:83-94.

Sheridan PL, Hausdorff JM. The role of higher-level cognitive function in gait: executive dysfunction contributes to fall risk in Alzheimer's disease. *Dement Geriatr Cogn Disord*. 2007;24:125-137.

Silva de Lima AL, Evers LJW, Hahn T, et al. Freezing of gait and fall detection in Parkinson's disease using wearable sensors: a systematic review. *J Neurol*. 2017;264(8):1642-1654.

Snijders AH, van de Warrenburg BP, Giladi N, Bloem BR. Neurological gait disorders in elderly people: clinical approach and classification. *Lancet Neurol*. 2007;6:63-74.

Stevens V, Goodman K, Rough K, Kraft GH. Gait impairment and optimizing mobility in multiple sclerosis. *Phys Med Rehabil Clin N Am*. 2013;24(4):573-592.

Stolze H, Klebe S, Petersen G, et al. Typical features of cerebellar ataxic gait. *J Neurol Neurosurg Psychiatry*. 2002;73:310-312.

Takakusaki K. Neurophysiology of gait: from the spinal cord to the frontal lobe. *Mov Disord*. 2013;28:1483-1491.

Thach WT, Bastian AJ. Role of the cerebellum in the control and adaptation of gait in health and disease. *Prog Brain Res*. 2004;143:353-366.

Tinetti ME, Speechley M, Ginter SF. Risk factors for falls among elderly persons living in the community. *N Engl J Med*. 1988;319:1701-1707.

Tilley E, McLoughlin J, Koblar SA, et al. Effectiveness of allied health therapy in the symptomatic management of progressive supranuclear palsy: a systematic review. *JBI Database System Rev Implement Rep*. 2016;14(6):148-195.

Tricco AC, Thomas SM, Veroniki AA, et al. Comparisons of interventions for preventing falls in older adults: a systematic review and meta-analysis. *JAMA*. 2017;318(17):1687-1699.

Verghese J, Robbins M, Holtzer R, et al. Gait dysfunction in mild cognitive impairment syndromes. *J Am Geriatr Soc*. 2008;56:1244-1251.

Wheelock VL, Tempkin T, Marder K, et al. Predictors of nursing home placement in Huntington disease. *Neurology*. 2003;60:998-1001.

Wonsetler EC, Bowden MG. A systematic review of mechanisms of gait speed change post-stroke. Part 1: spatiotemporal parameters and asymmetry ratios. *Top Stroke Rehabil*. 2017;24(6):435-446.

Wonsetler EC, Bowden MG. A systematic review of mechanisms of gait speed change post-stroke. Part 2: exercise capacity, muscle activation, kinetics, and kinematics. *Top Stroke Rehabil*. 2017;24(5):394-403.

Acute Stroke: The First Hour 16

Barry M. Czeisler and Stephan A. Mayer

KEY POINTS

1. Emergency head imaging combining noncontrast computed tomography (CT) with CT angiography is rapidly becoming the standard first-line imaging protocol for all patients presenting with potential stroke within 24 hours of last known well.
2. When intracerebral hemorrhage is identified, the primary management goals are to identify and reverse anticoagulation, control systolic blood pressure to 130 to 150 mm Hg, and assess for possible neurosurgical intervention.
3. Intravenous thrombolysis should be given to all eligible patients with acute ischemic stroke presenting within 4.5 hours of onset. Many previously recognized contraindications to thrombolysis are now considered relative.
4. If CT angiography identifies a large vessel occlusion, mechanical thrombectomy is the treatment of choice. For patients presenting within 6 to 24 hours, CT perfusion demonstrating a significant penumbra is key to identify eligibility for mechanical thrombectomy.

INTRODUCTION

Sudden focal neurologic deficits can result from a variety of causes, the most frequent and concerning of which is acute stroke. The two most common forms of stroke, both of which cause sudden onset of focal neurologic deficits without antecedent symptoms, are acute ischemic stroke (AIS) and intracerebral hemorrhage (ICH). Both conditions are neurologic emergencies. The symptoms of AIS and ICH (**Table 16.1**) have significant overlap necessitating imaging studies to distinguish the two conditions.

Emergency management of AIS is focused on attaining vascular reperfusion as soon as possible with the administration of intravenous tissue plasminogen activator (IV tPA) for thrombolysis, endovascular thrombectomy, or both. Time is critical, as it has been estimated that 1.9 million neurons die each minute prior to reperfusion. Every 15-minute reduction in onset-to-treatment time translates into a meaningful reduction in the risk of long-term disability at 3 months. In the case of ICH, emergency care is focused on blood pressure (BP) control, reversal of anticoagulation, and management of intracranial pressure (ICP).

This chapter focuses on the emergency management of the patient presenting with an acute focal neurologic deficit. Subsequent management after the first hour is discussed in Chapter 36 for AIS and in Chapter 39 for ICH.

TABLE 16.1 Symptoms and Signs of Acute Stroke

Facial asymmetry
Lateralized limb weakness or clumsiness
Lateralized numbness or paresthesias
Slurred or confused speech
Visual disturbances (diplopia or difficulty seeing)
Dizziness or vertigo
Gait instability
Headache
Alterations in level of consciousness

PHASE 1: INITIAL MANAGEMENT AND IMAGING

Due to the importance of early intervention in stroke, the emphasis of emergency department (ED) evaluation should not be on identifying subtle, unusual, or interesting neurologic signs but on the following five simple priorities. These tasks are ideally performed in parallel by four different personnel immediately upon patient arrival (eg, the ED attending, resident, nurse, and stroke neurologist):

1. Assess level of consciousness and ensure adequate airway, breathing, and circulation.
2. Obtain the history with precise attention to the specific time of onset (or time last known to be at neurological baseline) of symptoms along with a list of current medications.
3. Establish large-bore (preferably 18 gauge) intravenous access and obtain admission labs.
4. Perform a National Institutes of Health Stroke Scale examination.
5. Obtain head computed tomography (CT) imaging as soon as possible.

Modern emergency stroke management is evolving toward a paradigm that resembles trauma resuscitation. The initial goal is to minimize door-to-CT time because subsequent management is entirely dependent on the results of the initial imaging. For AIS, the conventional goal is to obtain CT within 20 minutes and to start tPA infusion within 45 minutes of arrival to the ED (Fig. 16.1). Currently, 75% of U.S. hospitals have a mean tPA door-to-needle time of less than 60 minutes despite nationwide efforts to streamline and expedite care.

New acute stroke care delivery models emphasizing parallel processing and lean management principles that exclude unnecessary steps have been shown to significantly reduce door-to-needle time for AIS. In the Helsinki model, physicians have proven the feasibility of safely administering IV tPA within 20 minutes of hospital arrival. In this paradigm, prehospital

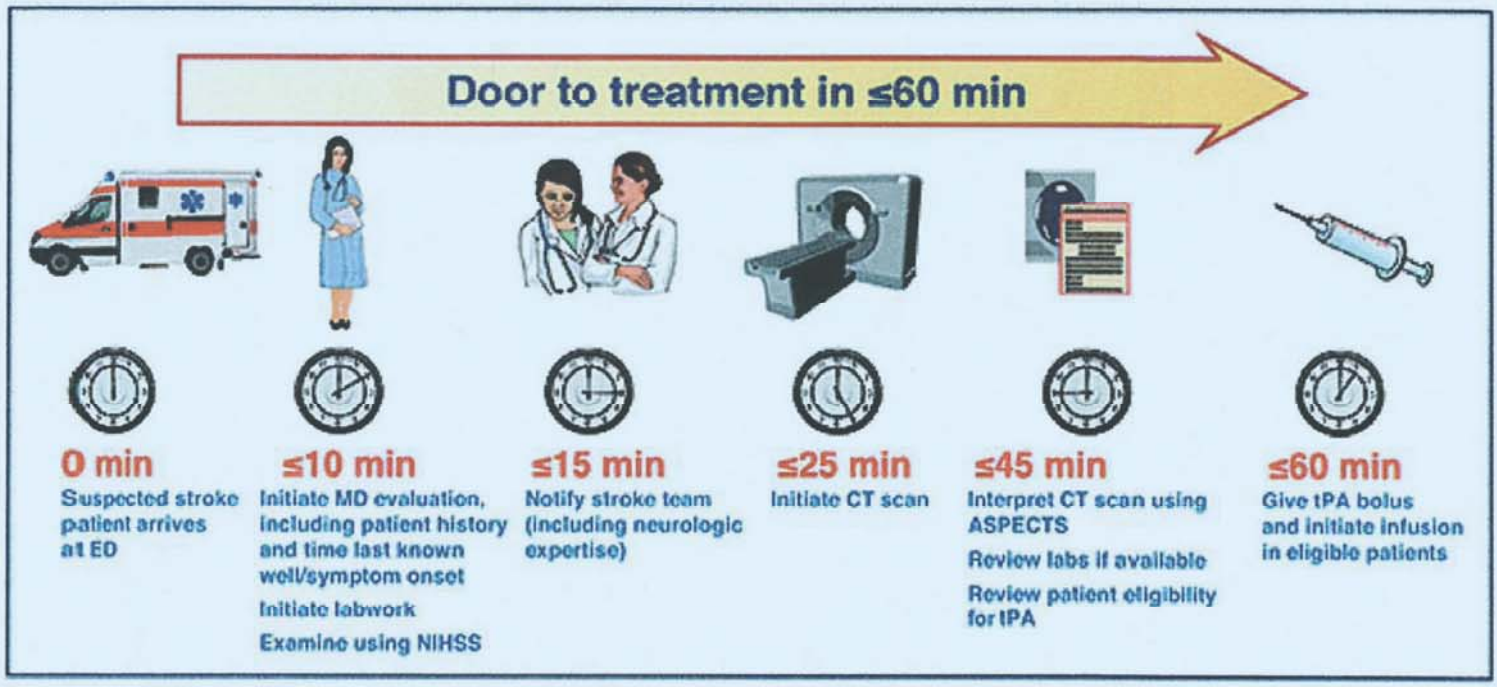

FIGURE 16.1 National Institute of Neurological Disorders and Stroke timeline targets for attaining an intravenous tissue plasminogen activator door-to-needle time of 60 minutes or less. Abbreviations: ASPECTS, Alberta Stroke Program Early CT Score; CT, computed tomography; ED, emergency department; MD, doctor of medicine; NIHSS, National Institutes of Health Stroke Scale; tPA, tissue plasminogen activator.

notification by ambulance triggers the stroke code, which then leads to the following:

1. Notification of the stroke team and ED staff, which assembles to meet the patient at the CT scanner
2. Transmitting the mobile phone number of any first responders or eyewitnesses to the stroke team to facilitate obtaining the history
3. Establishing a medical record number and hospital chart prior to arrival
4. Preordering the CT scan
5. Notification of pharmacy so that tPA or an anticoagulation reversing agent can be provided as soon as possible after the CT scan

Given the complexity of coordinated personnel, resources, preparation, and teamwork that is required, most municipalities triage acute stroke patients directly to hospitals that are designated as primary stroke centers. After the initial resuscitation is completed, if the patient is unusually complex or critically ill, consideration should be given to transferring the patient to the nearest comprehensive stroke center.

Initial Survey and Vital Signs Prior to Computed Tomography

Level of Consciousness

Intracerebral hemorrhage with mass effect as well as ischemic strokes of the brainstem, thalami, or large cortical regions can cause impairment in mental status. Depressed level of consciousness may in turn lead to aspiration of oropharyngeal contents or ineffective respirations due to upper airway obstruction, either of which may necessitate endotracheal intubation prior to further evaluation and management.

Blood Pressure

Hypertension occurs commonly as a nonspecific response to cerebral injury and can be present in both AIS and ICH. Elevated BP is a strong indicator that the patient is actually having a stroke as opposed to a stroke mimic. Early BP elevation may be advantageous in AIS, allowing for increased cerebral perfusion to the *ischemic penumbra*, areas of marginally perfused brain. Aggressive BP reduction within the first few hours of AIS onset can lead to worsening of the neurologic deficit and therefore should be avoided.

The BP should only be lowered prior to noncontrast CT if the systolic BP is higher than 220 mm Hg, diastolic BP is higher than 120 mm Hg LEVEL 2,[1] or it is suspected that hypertension is leading to acute end-organ damage (eg, acute myocardial infarction, aortic dissection, or cardiogenic pulmonary edema). If BP is lowered, a systolic BP of 180 mm Hg is a reasonable target. The preferred agents and their dosages for emergency BP control in acute stroke are shown in **Table 39.3**. Blood pressure goals are reevaluated after CT imaging has established the etiology of the symptoms and, for AIS, once decisions are made regarding reperfusion therapy.

Heart Rate

Atrial fibrillation (AF) with rapid ventricular response, the most common significant arrhythmia in patients with acute stroke, or other tachyarrhythmias can occur on presentation and may necessitate stabilization prior to obtaining CT. Diltiazem 10 mg IV or metoprolol 5 mg IV are commonly used initial therapies for AF with rapid ventricular response in this setting. A cardiac monitor should be placed if there is any concern about heart rate or if the patient reports chest pain or palpitations. Routine electrocardiography should be obtained in acute stroke patients but is only required prior to CT if there is significant dysrhythmia or if an acute coronary syndrome is suspected.

Respirations and Breathing

Obvious respiratory distress should trigger placement of an oxygen saturation monitor and oxygen via nasal cannula, targeting an oxygen saturation greater than or equal to 94%. A decision then needs to be made about whether to proceed directly to CT or to defer until adequate airway and ventilation can be assured. Patients with severe dyspnea or significantly impaired level of consciousness (stupor or coma) should be intubated prior to CT scan because failure to control the airway can lead to respiratory arrest or severe aspiration.

Temperature

In general, it is not necessary to measure body temperature prior to CT in a patient with acute stroke unless meningitis is suspected.

Initial History

If eyewitnesses are available, obtain a collateral history from them to corroborate the patient's account. Whenever possible, confirm the patient's history with emergency medical system personnel, and ask prehospital providers to provide mobile phone numbers of eyewitnesses who might not be immediately present in the ED. Be sure to inquire about the following points.

1. ***Exactly when did the stroke symptoms first begin?***
   If the onset of symptoms cannot be reported by the patient and were not witnessed, ask when the patient was last known well. For those who present on waking from sleep, the physician must determine whether the symptoms were present immediately upon awakening or shortly thereafter after a brief period of normalcy. If they truly awoke with the symptoms, the last known well time may be the time when they went to sleep the prior evening but often will be a time that they awoke transiently in the middle of the night.
2. ***What were the initial symptoms?***
   A maximal deficit at onset in a fully alert patient supports cerebral infarction and suggests embolism in particular. Ask specifically if the patient's deficits have worsened or fluctuated since onset. Early headache, vomiting, or change in level of consciousness supports ICH. Inquire specifically about lateralized weakness, numbness, or other classic symptoms of acute stroke (see **Table 16.1**).
3. ***Was any seizure activity observed?***
   Postictal deficits from seizures can mimic stroke. Seizures manifesting as focal motor convulsions or generalized tonic-clonic activity can also occur at the onset of ICH or AIS, but this is unusual.
4. ***What is the patient's medical history and neurologic baseline?***
   Assess for stroke risk factors such as hypertension, diabetes mellitus, dyslipidemia, cigarette smoking, AF, carotid stenosis, and prior transient ischemic attacks or strokes. A patient presenting with worsening of an existing or previously resolved neurologic deficit may have recrudescence of their prior deficits due to systemic derangements such as fever, hypoglycemia, or hypoxia (**Table 16.2**).
5. ***What medications is the patient taking?***
   Ask particularly about anticoagulants or antiplatelet agents. Use of these agents not only predisposes to ICH but can also limit therapeutic options in the setting of ischemic stroke.

Establish Intravenous Access and Draw Admission Labs

Ideally, two peripheral IVs should be placed, at least one of which should be 18 gauge to facilitate advanced imaging studies (ie, CT angiography or CTA) if necessary. Routine admission labs should be drawn including complete blood count, serum chemistries, prothrombin time/partial thromboplastin time/international normalized ratio (INR), troponin I, and other tests as indicated (eg, liver function tests, toxicology screen). Point-of-care finger stick blood glucose level should also be obtained.

National Institutes of Health Stroke Scale Examination

The National Institutes of Health Stroke Scale (**Table 16.3**) is a simple algorithm for quantifying the severity of neurologic deficits in patients with acute stroke. Eleven items are tested, and a score is generated on a scale ranging from 0 (no deficit) to 42 (comatose and quadriplegic). In expert hands, the test takes only several minutes to administer. Scores higher than 20 in patients with AIS imply a high risk of large territory infarction and a very poor prognosis if reperfusion is not attained. Once the history and examination are completed, the lesion should be able to be localized clinically.

Perform Head Computed Tomography Imaging

Noncontrast head CT (NCHCT) is by far the most readily available test for differentiation of AIS and ICH and the only one that must absolutely be obtained prior to administering thrombolytic therapy for AIS. The ability to obtain timely CT scans is greatly improved by having the CT scanner located within the ED. To minimize any delays in treatment, the patient should ideally be taken directly from the ambulance to the CT scanner with coordinated evaluation and intervention performed just outside the CT suite or on the CT table.

Studies show that obtaining CT imaging is the rate-limiting step in acute stroke management, so optimization of door-to-CT times should be of high priority. *The main differential diagnosis in acute stroke is infarction versus hemorrhage*. All further management decisions will depend on making this distinction.

More recently, CTA has proved to be indispensable for diagnosing large vessel occlusions (LVO), which respond best to endovascular mechanical thrombectomy. To minimize delays in the diagnosis and treatment of LVO, many stroke systems are combining NCHCT with CTA as the initial imaging protocol for all stroke codes. CT perfusion is also often performed to assess tissue viability and potential candidacy for thrombectomy when an LVO is identified 6 to 24 hours from last known well.

Analysis for Hemorrhage

Blood is hyperdense (bright) and easily identifiable on NCHCT (**Fig. 16.2A**). Intracerebral hemorrhage appears as a discrete focus of blood that displaces the surrounding brain parenchyma. Intracerebral hemorrhage volume, a strong predictor of 30-day mortality and functional outcome, can be quickly measured using the ABC / 2 method (see **Fig. 39.3**). Two diameters (A + B), measured at right angles on the slice that corresponds to the epicenter of the hemorrhage, are measured in centimeters. The third diameter perpendicular to that plane (C) is measured by multiplying the number of slices on which the bleed is apparent by each slice thickness (usually 5 mm, expressed 0.5 cm).

TABLE 16.2 Differential Diagnosis of Acute Neurologic Deficits

Diagnosis	Clinical Characteristics
Stroke	
Ischemic stroke	• Deficits that are maximal at onset suggest embolism. • Sometimes preceded by transient ischemic attacks • Headache is uncommon. • BP often elevated
Intraparenchymal hemorrhage	• Often presents with headache and/or nausea and vomiting • Deficit commonly worsens over minutes to hours as hemorrhage expands. • Loss of consciousness at onset is rare. • BP often extremely elevated
Subarachnoid hemorrhage	• Typically presents with sudden "thunderclap headache" • Often associated with transient loss of consciousness • Focal symptoms are unusual.
Stroke Mimics	
Seizure with postictal deficit	• Occurs in aftermath of focal motor activity or an unwitnessed seizure • Deficits gradually improve and resolve over minutes to hours after onset. • Can be differentiated from ischemic stroke with DWI MRI • EEG may show corresponding epileptiform activity.
Migraine with aura	• Typical patient has a history of migraine and prior similar events. • Can present with weakness, aphasia, neglect, visual changes, and/or sensory loss • Symptoms may precede, be concurrent with, or follow a typical migraine headache. • Typically occurs in younger patients with no stroke risk factors
Recrudescence of a prior focal deficit	• Sudden worsening of old stroke symptoms (does not cause new symptoms) • Triggered by fever, hypoxia, hypoglycemia, hyponatremia, or other metabolic disturbances • Focal deficits are typically accompanied by features of encephalopathy.
Stroke Mimics *(continued)*	
Subdural hematoma	• May not have a clear history of recent trauma in elderly patients with acute-on-chronic bleeding • Typically presents with focal deficits or subacute confusion and gait disturbance in an elderly patient • Headache is common but not universal.
Brain tumor or abscess	• Usually has a subacute to chronic presentation but can suddenly worsen due to associated seizure or bleeding into the tumor • Often with symptoms of headache, especially when recumbent
Multiple sclerosis or other demyelinating disease	• Usually has a more subacute presentation but can mimic acute stroke at times • Often has history of prior deficits in varying locations • Can be differentiated from ischemic stroke with DWI MRI • Affects younger patients with no stroke risk factors
Peripheral (labyrinthine) vertigo	• Can mimic an infarct in the brainstem or cerebellum causing acute vertigo • Can be differentiated from ischemic stroke with careful examination (horizontal head impulse test, characterization of nystagmus, and cover-uncover test[a]) in most but not all cases • Definitive exclusion of ischemic stroke requires DWI MRI, although DWI can also miss small brainstem infarcts.
Hypertensive encephalopathy (posterior reversible encephalopathy syndrome)	• Most commonly presents with altered mental status, headache, vision changes, or seizures • Usually does not cause unilateral symptoms • BP usually elevated • Can occur in younger patients with no stroke risk factors
Conversion disorder	• A diagnosis of exclusion • Detailed neurologic exam sometimes reveals inconsistencies suggesting a nonphysiologic cause of symptoms. • Positive signs of misdirected effort may be elicited (eg, Hoover sign).

Abbreviations: BP, blood pressure; DWI, diffusion-weighted imaging; EEG, electroencephalogram; MRI, magnetic resonance imaging.
[a]See Chapter 5 for details of the Head Impulse Nystagmus Test of Skew (HINTS) examination for differentiating central from peripheral vertigo.

The product of these three diameters is divided by two as a simplification of the equation for the volume of an ellipsoid. Patients with ICH volumes of less than 30 mL have potential for a good prognosis and have a small risk of early deterioration, whereas those with ICH volumes between 30 and 70 mL are at higher risk for early deterioration due to mass effect. Patients with hemorrhages greater than 70 mL were traditionally considered to be uniformly lethal, although survival with reasonable recovery can be attained in this group with emergency surgery, such as hemorrhage evacuation or hemicraniectomy.

Whenever ICH is present, be sure to check for the following radiographic findings:

- *Subarachnoid hemorrhage* (Fig. 16.2B) in association with ICH suggests a ruptured aneurysm and requires angiography.
- *Intraventricular hemorrhage* (Fig. 16.2C) in association with ventricular enlargement requires neurosurgical evaluation for possible emergent ventriculostomy.
- *Fluid/fluid levels* within a hematoma (Fig. 16.2D) result from separation of red blood cells and plasma and are indicative of a coagulopathy.
- *Edema, mass effect, and midline shift* usually lead to delayed neurologic deterioration when associated with a large hemorrhage (>30 mL). Perihematomal edema takes several hours to develop after ICH and is therefore not usually seen on initial head CT. An abnormally large or an irregular amount of edema associated with hemorrhage on initial presentation may suggest hemorrhagic conversion of infarcted tissue, bleeding associated with neoplasm, or venous infarction from dural sinus thrombosis.

Analysis for Ischemic Stroke

Infarction does not cause consistent changes on CT within 6 hours of stroke onset. Infarction is suspected when a patient presenting with sudden onset of neurologic deficits has a normal CT scan. Over a period of approximately 6 hours, regions of

TABLE 16.3 The National Institutes of Health Stroke Scale[a]

1a. Level of consciousness (LOC):
0 = Alert; keenly responsive
1 = Not alert but arousable by minor stimulation to obey, answer, or respond
2 = Not alert; requires repeated stimulation to attend or is obtunded and requires strong or painful stimulation to make movements (not stereotyped)
3 = Responds only with reflex motor or autonomic effects or totally unresponsive, flaccid, and areflexic
1b. LOC questions: The patient is asked the month and his or her age.
0 = Answers both questions correctly
1 = Answers one question correctly
2 = Answers neither question correctly
1c. LOC commands: The patient is asked to open and close the eyes and then to grip and release the nonparetic hand.
0 = Performs both tasks correctly
1 = Performs one task correctly
2 = Performs neither task correctly
2. Best gaze: horizontal eye movements
0 = Normal
1 = Partial gaze palsy; gaze is abnormal in one or both eyes.
2 = Forced deviation or total gaze paresis not overcome by the oculocephalic maneuver
3. Visual loss:
0 = No visual loss
1 = Partial hemianopia
2 = Complete hemianopia
3 = Bilateral hemianopia (blind including cortical blindness)
4. Facial palsy:
0 = Normal symmetric movements
1 = Minor paralysis (flattened nasolabial fold, asymmetry on smiling)
2 = Partial paralysis (total or near-total paralysis of lower face)
3 = Complete paralysis of one or both sides (absence of facial movement in the upper and lower face)
5. Motor arm: The limb is elevated for 10 s, scored separately for left and right.
0 = No drift; limb holds 90° (or 45°) for full 10 s.
1 = Drift; limb holds 90° (or 45°) but drifts down before full 10 s; does not hit bed or other support
2 = Some effort against gravity; limb cannot get to or maintain (if cued) 90° (or 45°), drifts down to bed, but has some effort against gravity.
3 = No effort against gravity; limb falls.
4 = No movement
6. Motor leg: The limb is elevated for 5 s, scored separately for left and right.
0 = No drift; leg holds 30° position for full 5 s.
1 = Drift; leg falls by the end of the 5-s period but does not hit bed.
2 = Some effort against gravity; leg falls to bed by 5 s but has some effort against gravity.
3 = No effort against gravity; leg falls to bed immediately.
4 = No movement
7. Limb ataxia:
0 = Absent
1 = Present in one limb
2 = Present in two limbs
8. Sensory:
0 = Normal; no sensory loss
1 = Mild to moderate sensory loss; patient feels pinprick is less sharp or is dull on the affected side; or there is a loss of superficial pain with pinprick, but patient is aware of being touched.
2 = Severe to total sensory loss; patient is not aware of being touched in the face, arm, and leg.
9. Best language:
0 = No aphasia; normal
1 = Mild to moderate aphasia
2 = Severe aphasia; all communication is through fragmentary expression.
3 = Mute, global aphasia; no usable speech or auditory comprehension
10. Dysarthria:
0 = Normal
1 = Mild to moderate dysarthria; patient slurs at least some words and, at worst, can be understood with some difficulty.
2 = Severe dysarthria; patient's speech is so slurred as to be unintelligible in the absence of or out of proportion to aphasia.
11. Extinction and inattention:
0 = No abnormality
1 = Visual, tactile, auditory, spatial, or personal inattention or extinction to bilateral simultaneous stimulation in one of the sensory modalities
2 = Profound hemi-inattention or extinction to more than one modality; does not recognize own hand or orients to only one side of space

[a]Total score ranges from 0 (normal) to 42 (comatose and quadriplegic). For informational purpose only. Accurate and reliable scoring of the National Institutes of Health Stroke Scale requires strict adherence to a standardized testing protocol. Refer to https://www.ninds.nih.gov/sites/default/files/nih_stroke_scale_508c.pdf for complete instructions on how to conduct and score the test and for smartphone applications than can assist in performance and scoring.

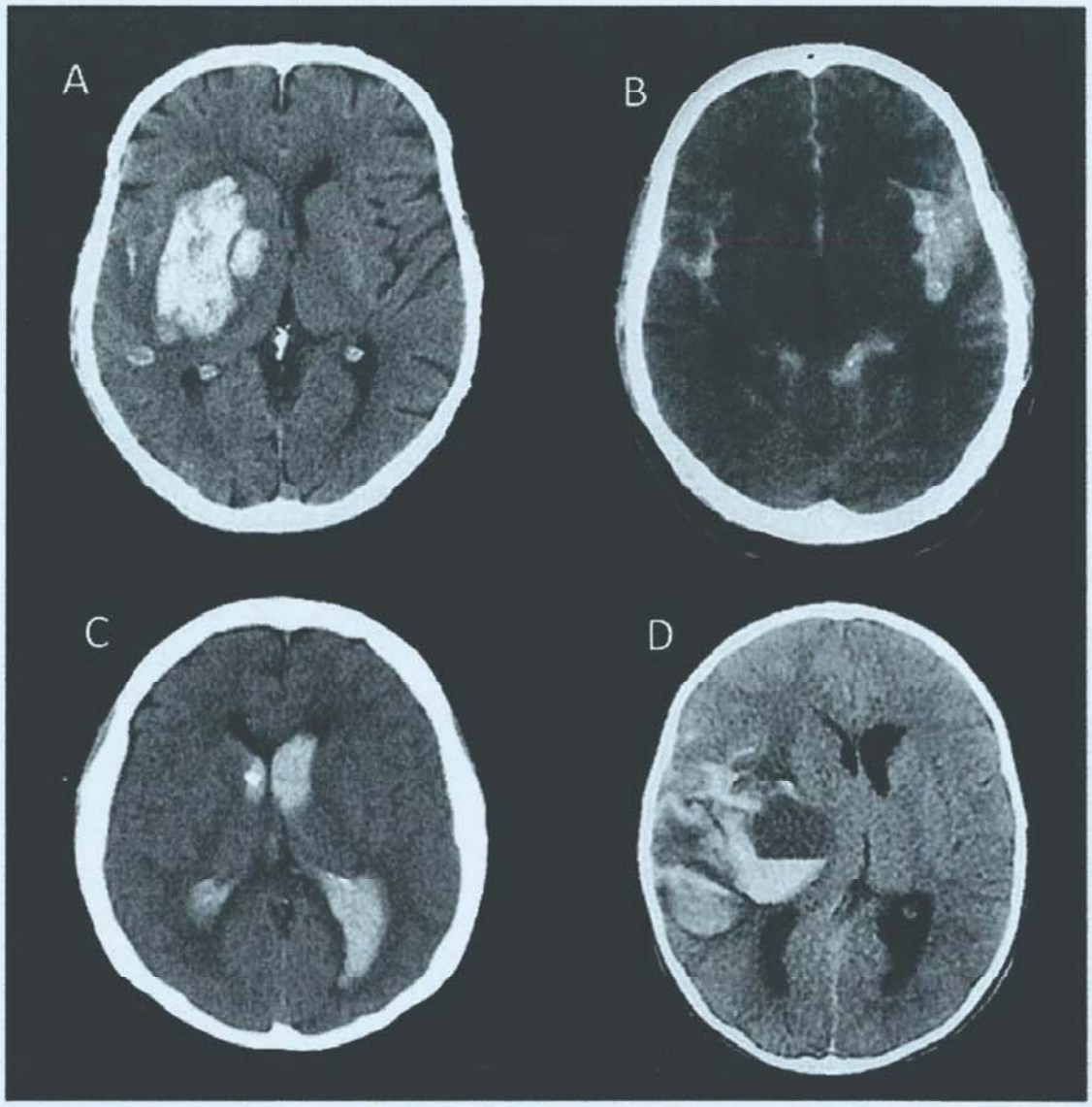

FIGURE 16.2 Computed tomography scans of brain hemorrhage. **A:** Intracerebral hemorrhage. **B:** Subarachnoid hemorrhage. **C:** Intraventricular hemorrhage. **D:** Acute intracerebral hemorrhage with fluid/fluid level indicative of a coagulopathy.

ischemia will gradually develop into an area of hypodensity as the tissue infarcts. The presence of a large hypodensity on NCHCT in an AIS patient should prompt reevaluation and careful scrutiny of the reported time of onset.

The Alberta Stroke Programme Early CT Score (ASPECTS) was developed to quantify the extent of infarction on initial CT imaging for middle cerebral artery (MCA) infarction (Fig. 16.3). Loss of differentiation between gray and white matter in the cortex and deep structures such as the caudate, putamen, or globus pallidus results from early ischemic injury and portends eventual progression to irreversible infarction (Fig. 16.4). The score is composed of seven cortical regions and three subcortical regions of the MCA territory totaling 10 points for a normal study from which 1 point is subtracted for each area of visualized infarct. This score has high interrater reliability and serves to quantify infarction, predict outcome, and stratify patients regarding the potential benefit of reperfusion therapies.

Acute thrombus in a proximal vessel such as the MCA ("dense MCA sign") or basilar artery can create a hyperdense appearance to the vessel on NCHCT. The presence of a hyperdense vessel may have clinical use in the acute setting because it helps to confirm the diagnosis of LVO and may lead clinicians to mobilize neurointerventional teams for endovascular mechanical thrombectomy.

PHASE 2: POSTCOMPUTED TOMOGRAPHY EMERGENCY MANAGEMENT

Intracerebral Hemorrhage

The following management guidelines apply specifically to spontaneous ICH. Refer to Chapter 40 for management of *subarachnoid hemorrhage* and Chapter 47 for management of *traumatic brain injury*.

Diagnose and Reverse Coagulopathy and Platelet Dysfunction

The presence of blood on CT mandates that a prothrombin time /INR, partial thromboplastin time, and platelet count are sent as

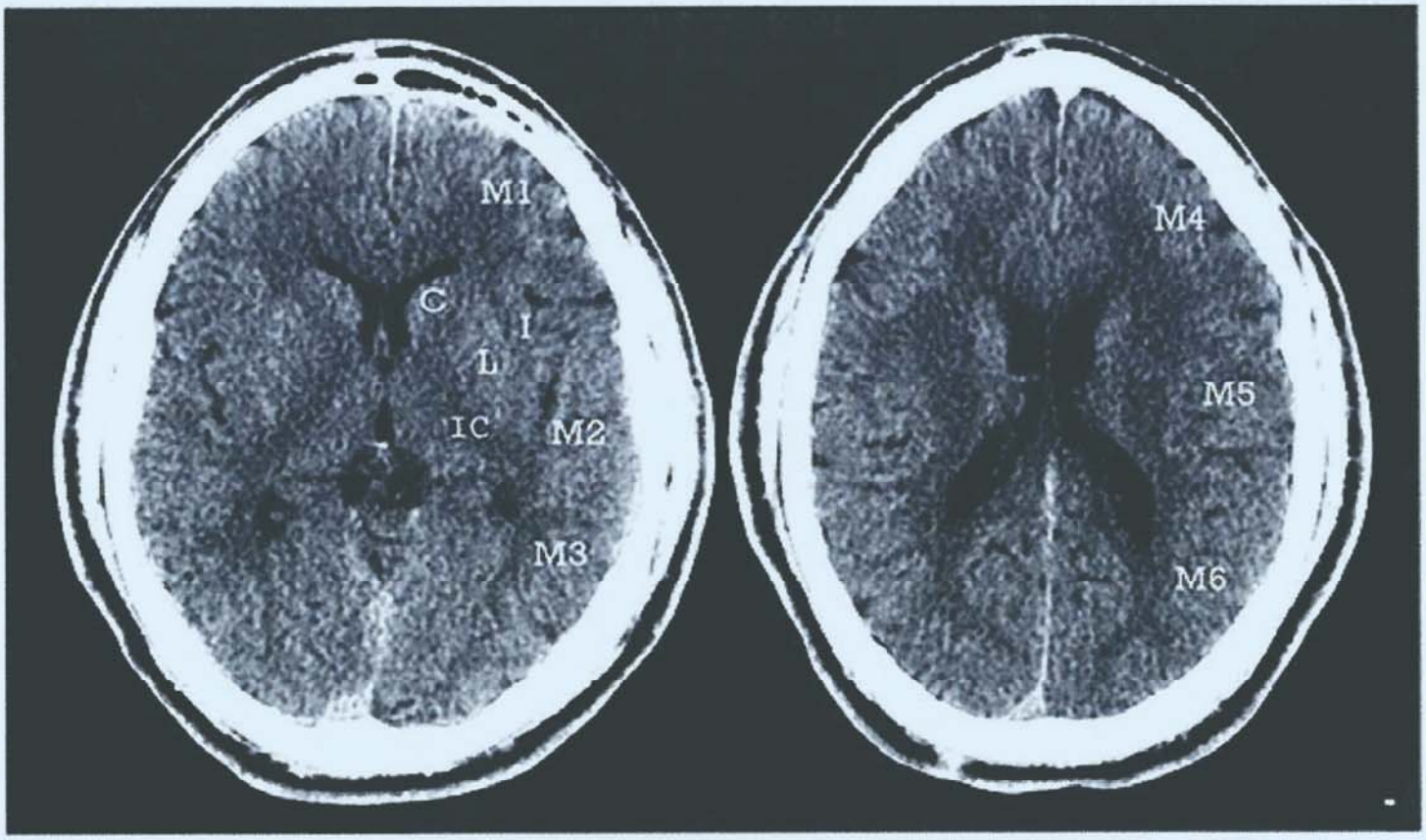

FIGURE 16.3 Anatomic regions evaluated in the Alberta Stroke Programme Early CT Score. A score of 10 indicates no evidence of early ischemic change from which 1 point is subtracted for each region of infarction. Patients with scores below 7 are at high risk for hemorrhagic transformation if given intravenous tissue plasminogen activator. Abbreviations: C, caudate; I, insula; IC, internal capsule; L, lentiform nucleus; M, middle cerebral artery territories 1 through 6.

FIGURE 16.4 Early cerebral infarction with loss of gray-white definition and sulcal effacement. (*Arrows* indicate anterior and posterior borders of the involved territory of the middle cerebral artery.)

STAT tests to confirm normal values as soon as possible. Next, confirm whether or not the patient is taking any anticoagulants that do not significantly affect these values (eg, dabigatran, rivaroxaban, apixaban, low molecular weight heparins). Also, inquire about antiplatelet agents (eg, aspirin, clopidogrel, ticagrelor, dipyridamole, prasugrel). A basic metabolic panel is also useful to show evidence of uremia, which can cause a qualitative platelet defect.

Suggested protocols for the reversal of different forms of anticoagulation or platelet dysfunction are shown in **Table 16.4**. *If there is a clear history of current use, steps to reverse anticoagulation or restore platelet function should be considered urgently to minimize the risk of hemorrhagic expansion* LEVEL 1.[2] In patients with vitamin K antagonist–associated ICH, successful reversal of the INR to less than 1.5 combined with control of systolic BP is associated with a reduced risk of hematoma enlargement.

Reversal of platelet dysfunction in patients with acute ICH is controversial and data are limited. Desmopressin is often used with meager evidence to support its use. One recent trial reported that platelet transfusions are not helpful, and possibly harmful, in ICH patients on antiplatelet agents LEVEL 1.[3] Platelet transfusion certainly remains reasonable in ICH patients with thrombocytopenia (<50,000/μL).

Control Severe Hypertension

In contrast to the AIS patient, continued hypertension may harm the ICH patient by causing expansion of the hemorrhage and worsened perihematomal edema. Two randomized trials of BP goals in the setting of ICH have yielded somewhat contradictory results. Lowering systolic BP to less than 150 mm Hg appears to

TABLE 16.4 Strategies for Reversal of Anticoagulation or Platelet Dysfunction in Acute Intracerebral Hemorrhage

Agent	Treatment Strategy	Comments
Warfarin (vitamin K antagonist that results in reduced synthesis of factors II, VII, IX, and X)	Administer vitamin K 10 mg IV over 30 min *and* Four-factor PCC 25-50 U/kg IV *or* FFP 2-4 200 mL units IV	If available, PCC is preferable, as it results in a substantially quicker time to INR reversal than FFP using a much smaller volume of infusion. The goal should be to lower the INR to <1.5.
Dabigatran (direct thrombin inhibitor)	Give activated charcoal if the medication was ingested within the past 2 h *and* Administer idarucizumab 5 g IV *or* Consider emergent hemodialysis	Idarucizumab specifically normalizes coagulation parameters in patients on dabigatran but has not yet been studied in a trial to prove benefit in clinical outcomes. There is limited data to support other therapies, but four-factor PCC or factor VIIa can be considered.
Rivaroxaban, apixaban, edoxaban, fondaparinux (Xa inhibitors)	Consider andexanet alfa in either low dose (400 mg IV then 4 mg/min IV infusion) or high dose (800 mg IV then 8 mg/min IV infusion) for 120 min *or* Consider a four-factor PCC 25-50 U/kg IV	Andexanet alfa specifically normalizes coagulation parameters associated with Xa inhibitors but has not yet been studied in a trial to prove benefit in clinical outcomes. It is approved for reversal of rivaroxaban and apixaban. <8 h since last dose: • Apixaban up to 5 mg: low-dose andexanet • Apixaban >5 mg: high-dose andexanet • Rivaroxaban up to 10 mg: low-dose andexanet • Rivaroxaban >10 mg: high-dose andexanet >8 h since last dose: low-dose andexanet There is limited data for the benefit of PCC for reversal of Xa inhibitors.
UFH	For IV bolus UFH given <1 h ago, administer 1 mg of protamine sulfate for every 100 units of UFH. If UFH was given 1-2 h ago, give 1 mg of protamine sulfate for every 200 units of UFH. If UFH was given >2 h ago, give 1 mg of protamine sulfate for every 400 units of UFH.	For patients receiving an IV infusion of UFH, administer protamine sulfate 1 mg for every 100 units given in the past 2 h.
Enoxaparin, dalteparin (LMWH)	If LMWH was given <8 h ago, give 1 mg of protamine sulfate per 100 anti-Xa units of LMWH. If LMWH was given 8-24 h ago, give 1 mg of protamine sulfate per 200 anti-Xa units of LMWH. If bleeding continues, an additional dose of 0.5 mg per 100 anti-Xa units can be administered.	Enoxaparin has 100 anti-Xa U/mg, whereas dalteparin has 156 anti-Xa U/mg.
Antiplatelet agents, platelet abnormalities (ie, uremia), or thrombocytopenia	*Give* DDAVP 0.3 μg/kg IV over 30 min. *Consider* 1 unit of single-donor platelets (or 6 units of pooled platelets) in ICH patients with uremia, thrombocytopenia, or in those undergoing neurosurgical intervention. *Avoid* platelet transfusion in nonoperative ICH.[a]	Limited data is available to support these interventions. For thrombocytopenia, transfuse platelets to goal of >50,000/μL.

Abbreviations: DDAVP, desmopressin acetate; FFP, fresh frozen plasma; ICH, intracerebral hemorrhage; INR, international normalized ratio; IV, intravenous/intravenously; LMWH, low molecular weight heparin; PCC, prothrombin complex concentrate; UFH, unfractionated heparin.

[a]Trial data suggests no benefit of platelet transfusion to reverse the effects of anti-platelet agents in patients with ICH, and platelet transfusion in this setting may be associated with harm LEVEL 1.[3] It might be reasonable to consider platelet transfusion in patients with planned neurosurgical intervention to minimize intraoperative bleeding.

be potentially beneficial, but lowering systolic BP further to less than 120 mm Hg may be associated with worsened renal injury without any additional benefit LEVEL 1.[4,5] Therefore, a goal of 130 to 150 mm Hg may be most appropriate. Nicardipine or clevidipine infusion is preferable because of their reliable dose-response characteristics and quick onset and offset times. If these short-acting agents are unavailable, labetalol can be administered initially as IV pushes followed by an infusion (see Table 39.3). Nitrates such as sodium nitroprusside should be avoided due to their potential to cause cerebral vasodilation and elevated ICP.

Treat Elevated Intracranial Pressure or Symptomatic Mass Effect

If the NCHCT shows significant mass effect (midline shift, effacement of the basal cisterns, or both) and the patient has depressed level of consciousness, empiric treatment of ICP should be initiated. Hyperventilation causes vasoconstriction that will lower cerebral blood volume and thus lower ICP. It should be used transiently as a bridge to further intervention in intubated patients who show signs of transtentorial herniation (ie, dilated pupil). In general, a PCO_2 level of 30 is targeted. If the patient is intubated and agitated or coughing, sedation should be considered. Bolus osmotherapy with mannitol 1 to 1.5 g/kg IV can be easily administered through a peripheral IV. Alternatively, 30 mL of 23.4% hypertonic saline can be given, but this requires central venous access. Steroids should not be administered because they have been shown to be ineffective for management of cerebral edema after ICH LEVEL 1[6] and may increase the risk of infectious complications (see also Chapter 34).

Consider External Ventricular Drain Placement or Placement of an Intracranial Pressure Monitor

Obstructive hydrocephalus typically develops in ICH patients who also have a significant amount of intraventricular hemorrhage.

Any new enlargement of the temporal horns of the lateral ventricles on NCHCT in a patient with altered level of consciousness should prompt consideration of external ventricular drain placement for management of hydrocephalus and control of ICP. Without diversion of cerebrospinal fluid, patients with acute hydrocephalus can deteriorate rapidly. If significant mass effect is present in a patient who is ineligible for surgical evacuation, a parenchymal ICP monitor may be considered to allow for optimization of ICP management (see Chapter 34).

Consider Emergent Surgical Hematoma Evacuation

For cerebellar hemorrhage with associated clinical deterioration, brainstem compression, or hydrocephalus, suboccipital surgical decompression with or without hematoma evacuation is recommended LEVEL 1.[2] For supratentorial hemorrhage, however, there is far less consensus. The Surgical Trial in Intracerebral Hemorrhage was unable to show definitive benefit for craniotomy with evacuation of supratentorial ICH within 72 hours of onset compared with best medical therapy LEVEL 1.[7,8] Most likely, the incision in cerebral cortex required to surgically evacuate deeper hemorrhage leads to further neurologic injury that negates any benefit. Despite these results, there is some suggestion that patients with active deterioration due to mass effect may still benefit from surgical evacuation, as these patients were not randomized into the trials. New minimally invasive strategies for hemorrhage evacuation have been developed, such as endoscopic aspiration, although the benefit of these techniques has not yet been proven in clinical trials. Hemicraniectomy is also used at times as a salvage procedure but is similarly of unproven benefit in this setting. Nevertheless, all of these surgical options should be considered on a case-by-case basis, especially in cases where the clinical assessment is that the patient is unlikely to survive without surgery and could otherwise possibly achieve a good clinical outcome.

Consider Anticonvulsant Therapy

Hemorrhage can cause cortical irritation and the development of seizure activity. If clinical seizures occur or electrographic seizures are noted on electroencephalogram, patients should be given an IV antiepileptic medication such as levetiracetam 60 mg/kg (loading dose for active seizures) followed by a maintenance dose of 1 g every 12 hours. Prophylactic treatment with anticonvulsants has not been shown to be beneficial and, in some cases, may be associated with harm, and thus routine use of prophylactic anticonvulsants should be avoided LEVEL 1.[2]

Consider Advanced Imaging

Intracerebral hemorrhage is most commonly due to hypertension when it occurs in the putamen, globus pallidus, caudate, thalamus, pons, or cerebellum. Cortical ICH occurs more frequently in the elderly and usually results from *amyloid angiopathy*, the deposition of amyloid into the arterial wall. However, ICH may also be caused by aneurysms (if adjacent to the subarachnoid space), arteriovenous malformations, dural arteriovenous fistulas, cavernous malformations, tumors, hemorrhagic conversion of infarcted tissue, or other less common etiologies. Young patients, those with atypical CT findings, and those without a history of hypertension or anticoagulant use should undergo further imaging studies to evaluate for an underlying lesion. Imaging options include CTA, magnetic resonance imaging (MRI)/magnetic resonance angiography, or catheter angiography. CT angiography can be performed on the CT table immediately after NCHCT identifies ICH, provided the patient remains stable and does not urgently require any additional treatments.

Disposition

Due to high risks of neurologic deterioration and development of medical complications, most patients with acute ICH should be admitted to an intensive care unit for further evaluation and management.

Acute Ischemic Stroke

For patients presenting with an acute neurologic deficit who show no signs of hemorrhage on noncontrast CT, the presumptive diagnosis is ischemic stroke and the primary goal is to provide eligible patients with reperfusion therapy as soon as possible.

In the setting of acute cerebrovascular occlusion, there will usually be an area of the brain with very poor blood flow where the neurons die quickly, which is often called the *ischemic core*. Surrounding this area, however, is the *ischemic penumbra*, which can be small or large depending on collateral blood flow patterns in individual patients. This region has cells that are usually electrically quiescent because they shut down their electrical signaling to conserve energy in the face of impaired oxygen and glucose delivery due to vascular occlusion. The neurons in this region, unlike in the ischemic core, are still alive at presentation but will gradually die as time passes. As such, the goal of all reperfusion therapies is timely reperfusion to the ischemic penumbra, to prevent cell death in this area, and thereby ultimately improve the patient's neurologic function and outcome.

Thrombolysis with IV tPA and endovascular treatments both lose efficacy as acute ischemia progresses to infarction. Optimization of each step of acute stroke management is required to ensure timely therapies. In the world's best stroke centers, thrombolysis with IV tPA can be administered within 20 minutes after ED arrival, and endovascular thrombectomy can be initiated within 60 minutes.

Indications for Intravenous Tissue Plasminogen Activator

With the completion of the National Institute of Neurological Disorders and Stroke trial in 1995, administration of IV tPA (specifically alteplase) became the standard of care for acute reperfusion therapy in AIS within 3 hours of symptom onset LEVEL 1.[9] Thrombolysis with alteplase increases the chances of a good recovery at 3 months after infarction from approximately 26% to 39% corresponding to a number needed to treat of 8 with no effect on mortality. Unfortunately, alteplase also carries a 6% risk of symptomatic hemorrhagic conversion, most commonly in patients given alteplase at later time points relative to symptom onset or in those with extensive signs of early ischemic change as evidenced by an ASPECTS lower than 7. Despite this increase in hemorrhage, however, there was no difference in mortality and ultimate outcomes were improved in the alteplase group.

In 2008, the European Cooperative Acute Stroke Study III trial confirmed the safety and efficacy of IV alteplase up to 4.5 hours after symptom onset in a subgroup of patients who were younger than 80 years of age. The benefit of alteplase in this subset is less than those treated within 3 hours. Patients given alteplase within the 3.0- to 4.5-hour window also have increased rates of hemorrhagic conversion and worsened mortality compared with patients given tPA within 3 hours of onset LEVEL 1.[10]

Speed of attaining reperfusion is by far the most important determinant of the efficacy of tPA. The number needed to treat

to achieve one functionally independent patient after ischemic stroke increases from as little as 5 for patients treated within 90 minutes of onset to 15 when alteplase is given within the 3.0- to 4.5-hour window. For unselected patients who present beyond 4.5 hours from onset, IV alteplase is not of proven benefit and may cause harm because the risk of hemorrhagic conversion increases LEVEL 1.[11] It has recently been shown that patients with an unknown time of onset who undergo urgent MRI showing diffusion-weighted imaging (DWI) hyperintensity but no fluid-attenuated inversion recovery hyperintensity (suggesting recent onset) can benefit from IV tPA administration LEVEL 1,[12] but urgent MRI is not currently available at most centers, which limits its utility. CT perfusion imaging is more widely available, and patients 4.5 to 9 hours after stroke onset with a large penumbra demonstrated on CT perfusion imaging may still benefit from IV tPA LEVEL 1[13] but the benefit of thrombolysis in this setting is more modest, and further evidence is needed to support its widespread use.

Contraindications to Tissue Plasminogen Activator Administration

The 1995 National Institute of Neurological Disorders and Stroke trial used strict exclusion criteria derived from expert opinion at the time, which were subsequently translated into contraindications for tPA administration. However, these rigorous contraindications may not necessarily define the full population of patients who might benefit from tPA. Table 16.5 shows the relative strength of various contraindications to tPA therapy. These updated recommendations largely reflect case series, cohort studies, and 25 years of clinical experience since the original approval of alteplase. It is crucial to use sound clinical judgment when giving tPA in the setting of a relative contraindication and to fully explain how this may alter the risks of therapy relative to the expected benefit. The most commonly encountered exclusions are discussed in the following sections.

TABLE 16.5 Strength of Evidence for Contraindications to Tissue Plasminogen Activator Therapy[a]

Clinical Scenario	Strength of Contraindication
CT evidence of hemorrhage	Absolute
Completed infarct signs involving >1/3 of the MCA territory	Absolute
Time of symptom onset unknown	Absolute
History of coagulopathy or anticoagulant use or documented elevation of INR (>1.7) or aPTT (>1.5 × control)	Relative, strong
Thrombocytopenia (platelet count <100,000 μL)	Relative, strong
SBP >185 mm Hg or DBP >110 mm Hg[b]	Relative, moderate
Major surgery or serious trauma within preceding 14 d	Relative, moderate
Glucose <50 or >400 mg/dL[b]	Relative, moderate
Pregnancy	Relative, moderate
Stroke or serious head trauma within preceding 3 mo	Relative, weak
Seizure at onset of stroke	Relative, weak
Rapidly improving or minor symptoms (eg, pure sensory, minimal weakness)	Relative, weak
Gastrointestinal, urinary tract, or other significant bleeding within preceding 21 d	Relative, weak
Significant MI within past 4 wk or symptoms of post-MI pericarditis	Relative, weak
Arterial puncture at a noncompressible site within preceding 7 d	Relative, weak
Lumbar puncture within preceding 7 d	Relative, weak

Abbreviations: aPTT, activated partial thromboplastin time; CT, computed tomography; DBP, diastolic blood pressure; INR, international normalized ratio; MCA, middle cerebral artery; MI, myocardial infarction; SBP, systolic blood pressure.

[a]This information is intended to serve only as a guideline. Successful and safe use of intravenous tissue plasminogen activator (tPA) has been reported despite the presence of one or more of these complications. Decisions regarding the risks and benefits of tPA should be individualized.

[b]Blood pressure and glucose can be urgently corrected and then tPA can be administered.

Early Infarct Signs

Early ischemic changes on imaging are clearly associated with higher rates of hemorrhagic conversion. Early ischemic changes should not exclude patients from thrombolysis if the extent of these changes is small (ASPECTS of 7-9).

Improving or Mild Symptoms

Although as many as 30% of AIS patients are not administered tPA due to rapidly improving or minor stroke syndromes, 25% of these patients still have poor functional outcomes or death after stroke. The AIS patients with minor or resolving deficits may still benefit from thrombolysis and should be considered on a case-by-case basis.

Blood Pressure Higher Than or Equal to 185/110 mm Hg

Severe hypertension is thought to increase the risk of hemorrhagic transformation after thrombolysis, although good evidence of cause and effect is scant. It is reasonable to rapidly control BP to lower than 185/110 mm Hg and start tPA while continued efforts are made to maintain target BP with a continuous infusion agent such as nicardipine or clevidipine (see Table 39.3).

Seizure at Onset

Seizures at onset are unusual in AIS and raise the strong possibility that the patient may have a postictal rather than ischemic deficit. Nevertheless, tPA is safe in patients with seizures at onset, and it is reasonable to give tPA if the index of suspicion for AIS is high.

Warfarin With International Normalized Ratio Greater Than 1.7

A history of liver failure or warfarin use in patients with AIS mandates a STAT INR. Otherwise, there is no need to check coagulation routinely prior to giving tPA, as the prevalence of unexpected coagulopathy is very low in this population. There is conflicting evidence as to whether tPA is associated with an increased risk of hemorrhagic transformation when the INR is either below or mildly above 1.7 among patients taking warfarin.

Abnormal Blood Glucose

Elevated blood glucose has been associated with a decreased likelihood of neurologic improvement, decreased rates of recanalization, and a higher risk of hemorrhagic conversion after thrombolysis for AIS. Treatment of hyperglycemia has not yet

been shown to modify outcome, but it nevertheless is prudent to control blood glucose within a tight normal range when administering tPA. Both hyper- and hypoglycemia raises the possibility of a stroke mimic due to "unmasking" of a prior focal deficit.

Old Age

Although those older than age 80 years do not benefit as much from thrombolysis, patients given tPA still show improved outcomes compared with those in whom tPA is withheld. Thrombolysis with IV tPA should not be withheld from elderly patients without other contraindications.

Tissue Plasminogen Activator and Stroke Mimics

The prevalence of potential AIS that proves to be a stroke mimic is as high as 20% to 25% in some regions, most of which represent seizure, complicated migraine, or conversion disorder. MRI, which can more definitively differentiate stroke from mimics, leads to delays that reduce the efficacy of tPA in improving neurologic outcomes. Fortunately, several studies show that tPA administration to stroke mimics is not associated with ICH or other complications. A rate of treating stroke mimics with thrombolysis of up to 15% is considered acceptable in most active stroke centers.

Dosage of Intravenous Tissue Plasminogen Activator

Alteplase is supplied in powder form and must be reconstituted with sterile water prior to administration. For eligible patients, 0.9 mg/kg of IV alteplase is administered up to a maximum dose of 90 mg with the initial 10% given as an IV push and the remainder infused over 1 hour.

Post–Tissue Plasminogen Activator Blood Pressure Management

The BP should be strictly maintained at lower than 180/105 mm Hg for at least 24 hours after tPA is administered to minimize the risk of hemorrhagic conversion. Because the half-life of tPA is extremely short, a radial arterial line can be safely placed for BP monitoring 1 hour after discontinuation of the infusion because direct pressure can be effectively applied if bleeding occurs at this location. Intravenous short-acting drip antihypertensive agents that can be easily titrated are optimal to definitively achieve this goal and to avoid large swings in BP.

Aspirin

Patients who do not receive IV tPA should be given aspirin 81 to 325 mg as soon as possible. For those who receive IV tPA, aspirin administration should be delayed for 24 hours after tPA infusion to prevent hemorrhagic conversion and then started thereafter. Early aspirin administration after AIS has been shown to decrease the risk of early recurrent stroke, death, and dependency at 1 year, although the number needed to treat is approximately 100 LEVEL 1.[14,15]

Role of Endovascular Therapy

An important limitation of IV tPA is that it fails to recanalize the occluded vessel in 40% of cases. When larger clots occlude the major large intracranial vessels—the proximal MCA, internal carotid artery terminus, or basilar artery—recanalization rates are even worse and outcomes remain poor despite IV tPA administration. If an LVO is present, endovascular intervention to extract the clot from the vessel using a suction or retrievable stent device can then be attempted (see Chapter 25 for details). In 2015, several trials, including Multicenter Randomized Clinical Trial of Endovascular Treatment for Acute Ischemic Stroke in the Netherlands LEVEL 1,[16] Endovascular Treatment for Small Core and Anterior Circulation Proximal Occlusion with Emphasis on Minimizing CT to Recanalization Times LEVEL 1,[17] and three additional trials (see **Table 35.5**), showed that endovascular intervention can dramatically improve functional outcome, whether or not patients received adjunctive IV tPA. Such benefit has been shown in trials to occur with endovascular intervention performed up 6 hours or more from stroke onset.

FIGURE 16.5 Computed tomography angiogram maximum intensity projection image (coronal view) demonstrating total occlusion of the left M1 segment of the middle cerebral artery.

In order to effectively select patients for endovascular therapy, acute vessel imaging is required, usually done with CTA (**Fig. 16.5**). Many stroke centers have established protocols in which tPA therapy is initiated in the CT scanner immediately after the noncontrast CT is obtained. This allows the team to proceed directly with a CT angiogram without delaying tPA administration. Even more recently, some hospitals and health care systems have adopted a "CTA-for-All" policy, in which all patients triggering a stroke code within 24 hours of last known well automatically get an NCHCT and CTA as the initial imaging study, regardless of the baseline National Institutes of Health Stroke Scale score. The rationale for this is to expedite the diagnosis of LVO in all potentially treatable patients, including those with wake-up strokes or late presentation. In these protocols, routine documentation of a normal serum creatinine level is waived owing to the urgency of the situation and the low risk of serious contrast-induced nephropathy (<1%). Demonstration of LVO then triggers an interventional "secondary page" that mobilizes the interventional team with the goal of beating a 60-minute "picture-to-puncture" time interval.

For patients presenting beyond 6 hours from onset, more advanced imaging can help determine potential eligibility for

endovascular therapies. Using CT perfusion with software calculating the volume of core infarction and penumbra to assess eligible patients, the Endovascular Therapy Following Imaging Evaluation for Ischemic Stroke trial showed a significant benefit with thrombectomy performed out to 16 hours after last known well in those with a core infarct volume less than 70 mL, a ratio of penumbral tissue to core infarct volume of 1.8 or more, and an absolute volume of penumbra of 15 mL or more LEVEL 2.[18] Similarly, using DWI-MRI or CT perfusion (CTP) to measure core infarction and clinical assessment to indirectly measure the ratio of penumbra to core infarction, the DWI or CTP Assessment with Clinical Mismatch in the Triage of Wake-Up and Late Presenting Strokes Undergoing Neurointervention with Trevo trial showed benefit of mechanical thrombectomy in selected patients as far out as 24 hours after onset LEVEL 2.[19] Thus, these therapies have the potential to improve patient outcomes far beyond the traditional 4.5-hour time window for IV tPA.

Patients may sometimes be agitated and always require some form of anesthesia during the thrombectomy procedure, which can be as brief as 20 minutes or take over 2 hours. The two main anesthetic techniques, intubation with general (deep) anesthesia or conscious sedation (also known as *monitored anesthesia care*), yield similar long-term results. Perhaps the most important aspect of periprocedural care is to avoid excessive drops in BP.

Even if mechanical thrombectomy is not being pursued, vessel and perfusion imaging may clarify or confirm sites of cervical vessel occlusion, guide BP management, affect disposition, and establish prognosis. Therefore, CTA can be useful in many cases.

Disposition

Ischemic stroke patients should be transferred to a stroke unit or a neuro-ICU whenever possible depending on the clinical scenario, including active comorbidities and the immediate risk of neurologic deterioration.

LEVEL 1 EVIDENCE

1. Powers WJ, Rabinstein AA, Ackerson T, et al. 2018 Guidelines for the early management of patients with acute ischemic stroke: a guideline for healthcare professionals from the American Heart Association/American Stroke Association. *Stroke*. 2018;49(3):e46-e110.
2. Hemphill JC III, Greenberg SM, Anderson CS, et al. Guidelines for the management of spontaneous intracerebral hemorrhage: a guideline for healthcare professionals from the American Heart Association/American Stroke Association. *Stroke*. 2015;46(7):2032-2060.
3. Baharoglu MI, Cordonnier C, Salman RAS, et al. Platelet transfusion versus standard care after acute stroke due to spontaneous cerebral haemorrhage associated with antiplatelet therapy (PATCH): a randomised, open-label, phase 3 trial. *Lancet*. 2016;387(10038):2605-2613.
4. Qureshi AI, Palesch YY, Barsan WG, et al. Intensive blood-pressure lowering in patients with acute cerebral hemorrhage. *N Engl J Med*. 2016;375:1033-1043.
5. Anderson CS, Heeley E, Huang Y, et al. Rapid blood-pressure lowering in patients with acute intracerebral hemorrhage. *N Engl J Med*. 2013;368(25):2355-2365.
6. Poungvarin N, Bhoopat W, Viriyavejakul A, et al. Effects of dexamethasone in primary supratentorial intracerebral hemorrhage. *N Engl J Med*. 1987;316(20):1229-1233.
7. Mendelow AD, Gregson BA, Rowan EN, Murray GD, Gholkar A, Mitchell PM. Early surgery versus initial conservative treatment in patients with spontaneous supratentorial lobar intracerebral haematomas (STICH II): a randomised trial. *Lancet*. 2013;382(9890):397-408.
8. Mendelow AD, Gregson BA, Fernandes HM, et al. Early surgery versus initial conservative treatment in patients with spontaneous supratentorial intracerebral haematomas in the International Surgical Trial in Intracerebral Haemorrhage (STICH): a randomised trial. *Lancet*. 2005;365(9457):387-397.
9. The National Institute of Neurological Disorders and Stroke rt-PA Stroke Study Group. Tissue plasminogen activator for acute ischemic stroke. *N Engl J Med*. 1995;333(24):1581-1587.
10. Hacke W, Kaste M, Bluhmki E, et al. Thrombolysis with alteplase 3 to 4.5 hours after acute ischemic stroke. *N Engl J Med*. 2008;359(13):1317-1329.
11. Sandercock P, Wardlaw JM, Lindley RI, et al; for IST-3 Collaborative Group. The benefits and harms of intravenous thrombolysis with recombinant tissue plasminogen activator within 6 h of acute ischaemic stroke (the third International Stroke Trial [IST-3]): a randomised controlled trial. *Lancet*. 2012;379(9834):2352-2363.
12. Thomalla G, Simonsen CZ, Boutitie F, et al; for WAKE-UP Investigators. MRI-guided thrombolysis for stroke with unknown time of onset. *N Engl J Med*. 2018;379(7):611-622.
13. Ma H, Campbell BCV, Parsons MW, et al. Thrombolysis guided by perfusion imaging up to 9 hours after onset of stroke. *N Engl J Med*. 2019;380(19):1795-1803.
14. International Stroke Trial Collaborative Group. The International Stroke Trial (IST): a randomised trial of aspirin, subcutaneous heparin, both, or neither among 19435 patients with acute ischaemic stroke. *Lancet*. 1997;349(9065):1569-1581.
15. Chinese Acute Stroke Trial Collaborative Group. CAST: randomised placebo-controlled trial of early aspirin use in 20,000 patients with acute ischaemic stroke. *Lancet*. 1997;349(9066):1641-1649.
16. Berkhemer OA, Fransen PSS, Beumer D, et al. A randomized trial of intraarterial treatment for acute ischemic stroke. *N Engl J Med*. 2015;372(1):11-20.
17. Goyal M, Demchuk AM, Menon BK, et al; for ESCAPE Trial Investigators. Randomized assessment of rapid endovascular treatment of ischemic stroke. *N Engl J Med*. 2015;372(11):1019-1030.
18. Albers GW, Marks MP, Kemp S, et al. Thrombectomy for stroke at 6 to 16 hours with selection by perfusion imaging. *N Engl J Med*. 2018;378(8):708-718.
19. Nogueira RG, Jadhav AP, Haussen DC, et al; for DAWN Trial Investigators. Thrombectomy 6 to 24 hours after stroke with a mismatch between deficit and infarct. *N Engl J Med*. 2018;378(1):11-21.

SUGGESTED READINGS

Barber PA, Demchuk AM, Zhang J, Buchan AM. Validity and reliability of a quantitative computed tomography score in predicting outcome of hyperacute stroke before thrombolytic therapy. ASPECTS Study Group. Alberta Stroke Programme Early CT Score. *Lancet*. 2000;355(9216):1670-1674.

Brinjikji W, Demchuk AM, Murad MH, et al. Neurons over nephrons: systematic review and meta-analysis of contrast-induced nephropathy in patients with acute stroke. *Stroke*. 2017;48(7):1862-1868.

Chernyshev OY, Martin-Schild S, Albright KC, et al. Safety of tPA in stroke mimics and neuroimaging-negative cerebral ischemia. *Neurology*. 2010;74(17):1340-1345.

Cocho D, Belvís R, Martí-Fàbregas J, et al. Reasons for exclusion from thrombolytic therapy following acute ischemic stroke. *Neurology*. 2005;64(4):719-720.

De Herdt V, Dumont F, Hénon H, et al. Early seizures in intracerebral hemorrhage: incidence, associated factors, and outcome. *Neurology*. 2011;77(20):1794-1800.

Demaerschalk BM, Kleindorfer DO, Adeoye OM, et al. Scientific rationale for the inclusion and exclusion criteria for intravenous alteplase in acute ischemic stroke: a statement for healthcare professionals from the American Heart Association/American Stroke Association. *Stroke*. 2016;47:581-641.

Ford AL, Williams JA, Spencer M, et al. Reducing door-to-needle times using Toyota's lean manufacturing principles and value stream analysis. *Stroke*. 2012;43(12):3395-3398.

Ford GA, Ahmed N, Azevedo E, et al. Intravenous alteplase for stroke in those older than 80 years old. *Stroke*. 2010;41(11):2568-2574.

Frontera JA, Lewin JJ III, Rabinstein AA, et al. Guideline for reversal of antithrombotics in intracranial hemorrhage: a statement for healthcare professionals from the Neurocritical Care Society and Society of Critical Care Medicine. *Neurocrit Care*. 2016;24(1):6-46.

Heldner MR, Zubler C, Mattle HP, et al. National Institutes of Health stroke scale score and vessel occlusion in 2152 patients with acute ischemic stroke. *Stroke*. 2013;44(4):1153-1157.

Hemphill JC III, Bonovich DC, Besmertis L, Manley GT, Johnston SC. The ICH score: a simple, reliable grading scale for intracerebral hemorrhage. *Stroke*. 2001;32(4):891-897.

Ilyas A, Chen CJ, Ding D, et al. Endovascular mechanical thrombectomy for acute ischemic stroke under general anesthesia versus conscious sedation: a systematic review and meta-analysis. *World Neurosurg*. 2018;112:e355-e367.

Kuramatsu JB, Gerner ST, Schellinger PD, et al. Anticoagulant reversal, blood pressure levels, and anticoagulant resumption in patients with anticoagulation-related intracerebral hemorrhage. *JAMA*. 2015;313:824-836.

Lees KR, Bluhmki E, von Kummer R, et al. Time to treatment with intravenous alteplase and outcome in stroke: an updated pooled analysis of ECASS, ATLANTIS, NINDS, and EPITHET trials. *Lancet*. 2010;375(9727):1695-1703.

Lindsberg PJ, Häppölä O, Kallela M, Valanne L, Kuisma M, Kaste M. Door to thrombolysis: ER reorganization and reduced delays to acute stroke treatment. *Neurology*. 2006;67(2):334-336.

Mayer SA, Viarasilpa T, Panyavachiraporn N, et al. CTA-for-All: impact of emergency computed tomographic angiography for all patients with stroke presenting within 24 hours of onset. *Stroke*. 2020;51(1):331-334.

Meretoja A, Strbian D, Mustanoja S, Tatlisumak T, Lindsberg PJ, Kaste M. Reducing in-hospital delay to 20 minutes in stroke thrombolysis. *Neurology*. 2012;79(4):306-313.

Meretoja A, Weir L, Ugalde M, et al. Helsinki model cut stroke thrombolysis delays to 25 minutes in Melbourne in only 4 months. *Neurology*. 2013;81(12):1071-1076.

Prabhakaran S, Naidech AM. Ischemic brain injury after intracerebral hemorrhage: a critical review. *Stroke*. 2012;43(8):2258-2263.

Riedel CH, Zimmermann P, Jensen-Kondering U, Stingele R, Deuschl G, Jansen O. The importance of size: successful recanalization by intravenous thrombolysis in acute anterior stroke depends on thrombus length. *Stroke*. 2011;42(6):1775-1777.

Rost NS, Masrur S, Pervez MA, Viswanathan A, Schwamm LH. Unsuspected coagulopathy rarely prevents IV thrombolysis in acute ischemic stroke. *Neurology*. 2009;73(23):1957-1962.

Smith EE, Fonarow GC, Reeves MJ, et al. Outcomes in mild or rapidly improving stroke not treated with intravenous recombinant tissue-type plasminogen activator: findings from Get With The Guidelines-Stroke. *Stroke*. 2011;42(11):3110-3115.

Tsivgoulis G, Alexandrov AV, Chang J, et al. Safety and outcomes of intravenous thrombolysis in stroke mimics: a 6-year, single-care center study and a pooled analysis of reported series. *Stroke*. 2011;42(6):1771-1774.

Vespa PM, Martin N, Zuccarello M, Awad I, Hanley DF. Surgical trials in intracerebral hemorrhage. *Stroke*. 2013;44(6, suppl 1):S79-S82.

Acute Spinal Cord Syndromes 17

Natalie Weathered and Noam Y. Harel

KEY POINTS

1. The majority of cases of acute nontraumatic spinal cord syndromes (transverse myelitis) are caused by inflammation. Up to 30% of cases remain idiopathic despite extensive testing.
2. Features of the history, including time course and risk factors, are key to refining the etiology.
3. Spinal cord magnetic resonance imaging with and without contrast and lumbar puncture are critical tests that may inform diagnosis and guide treatment.
4. Be wary of neurogenic spinal shock, which may lead to systemic hypotension and worsened cord perfusion.

INTRODUCTION

Patients presenting with acute spinal cord syndromes represent true neurologic emergencies. Pathologic damage to the cord is usually incomplete. Therefore, time is cord: There is opportunity to salvage (and peril of losing) vital cord tissue and function over the ensuing minutes and hours after presentation. Minimizing secondary damage can make the difference between a patient retaining independent daily function or requiring 24-hour care. This chapter deals largely with nontraumatic myelopathy. See Chapter 48 for more on traumatic spinal cord injury (SCI).

Transverse myelitis is the term applied to most forms of acute nontraumatic myelopathy. However, this term is a description rather than a diagnosis. A broad range of underlying etiologies may be responsible. The clinician must first localize and then differentiate the type of damage in order to initiate the most effective interventions. Thorough workup reduces the percentage of transverse myelitis cases that remains idiopathic to roughly 30%.

EPIDEMIOLOGY

Approximately 17,000 new cases of acute traumatic SCI occur in the United States annually, with around 300,000 individuals living with SCI in the United States. Motor vehicle accidents and falls are the leading causes. The epidemiology of nontraumatic acute SCI is harder to measure. Extrapolated estimates from Canada and Australia suggest an incidence of approximately 22,000 and prevalence of about 400,000 individuals with nontraumatic SCI in the United States.

PATHOBIOLOGY

Spinal Cord Anatomy

To aid with localization, recall that the caudal spinal cord segments do not align with the vertebrae bearing the same names. Be wary of patients with "T12" or "L2" spine injuries—patients with traumatic or compressive myelopathy are often labeled by *vertebral* level of injury rather than cord *segmental* level of injury. The spinal cord ends around L1, with the roots of the cauda equina below that vertebral level (Fig. 17.1). An L2 vertebral injury will therefore result in damage to the cauda equina, not the cord per se.

Motor System

Most corticospinal projections decussate in the caudal medulla to form the lateral corticospinal tract (CST) (Fig. 17.2) Roughly 5% of corticospinal projections run ipsilaterally in the anterior CST. Other descending tracts involved in motor function, generally of more axial and proximal limb muscles, include the rubrospinal tract (just ventral to the lateral CST) and the tecto-, vestibulo-, and reticulospinal tracts (just lateral to the anterior CST). Because they are more diffusely branched, fibers of these non-CST motor tracts tend to show higher degrees of sparing after SCI and can mediate significant restoration of function.

Sensory System

Fibers of the spinothalamic tract travel rostrally within Lissauer's tract for one to two spinal segments before synapsing within the dorsal horn and crossing to the contralateral anterolateral system. Therefore, a focal process causing unilateral disruption of this pathway will result in loss of pain and temperature sensation on the opposite side beginning one to two segments below the lesion. Most fibers mediating proprioception, vibratory sensation, and two-point discrimination travel within the ipsilateral dorsal columns to the gracilis and cuneatus nuclei of the lower medulla, although some proprioceptive signals ascend via the dorsal and ventral spinocerebellar tracts.

Autonomic System

Parasympathetic preganglionic neurons are found within four brainstem nuclei (cranial nerves III, VII, IX, and X) of which only the vagus nerve contributes to autonomic control below the head. Parasympathetic preganglionic neurons also reside in cord segments S2-4. Notably, even subtle lesions affecting the spinal cord above the S2 level can disrupt bladder inhibitory circuits, resulting in urinary urgency and frequency. Sympathetic preganglionic neurons are located within the intermediolateral nucleus of the thoracic and upper lumbar cord. Sympathetic circuits arising from the upper thoracic levels (T1-5) increase heart rate and

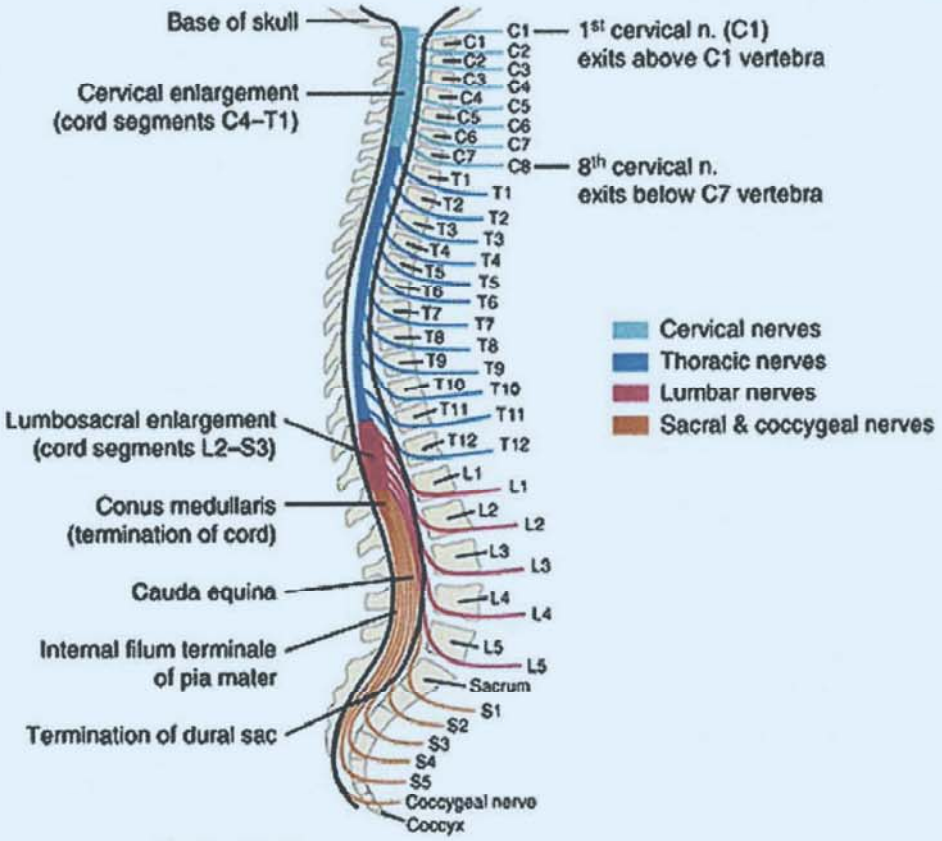

FIGURE 17.1 Relation of spinal nerve roots to vertebrae.

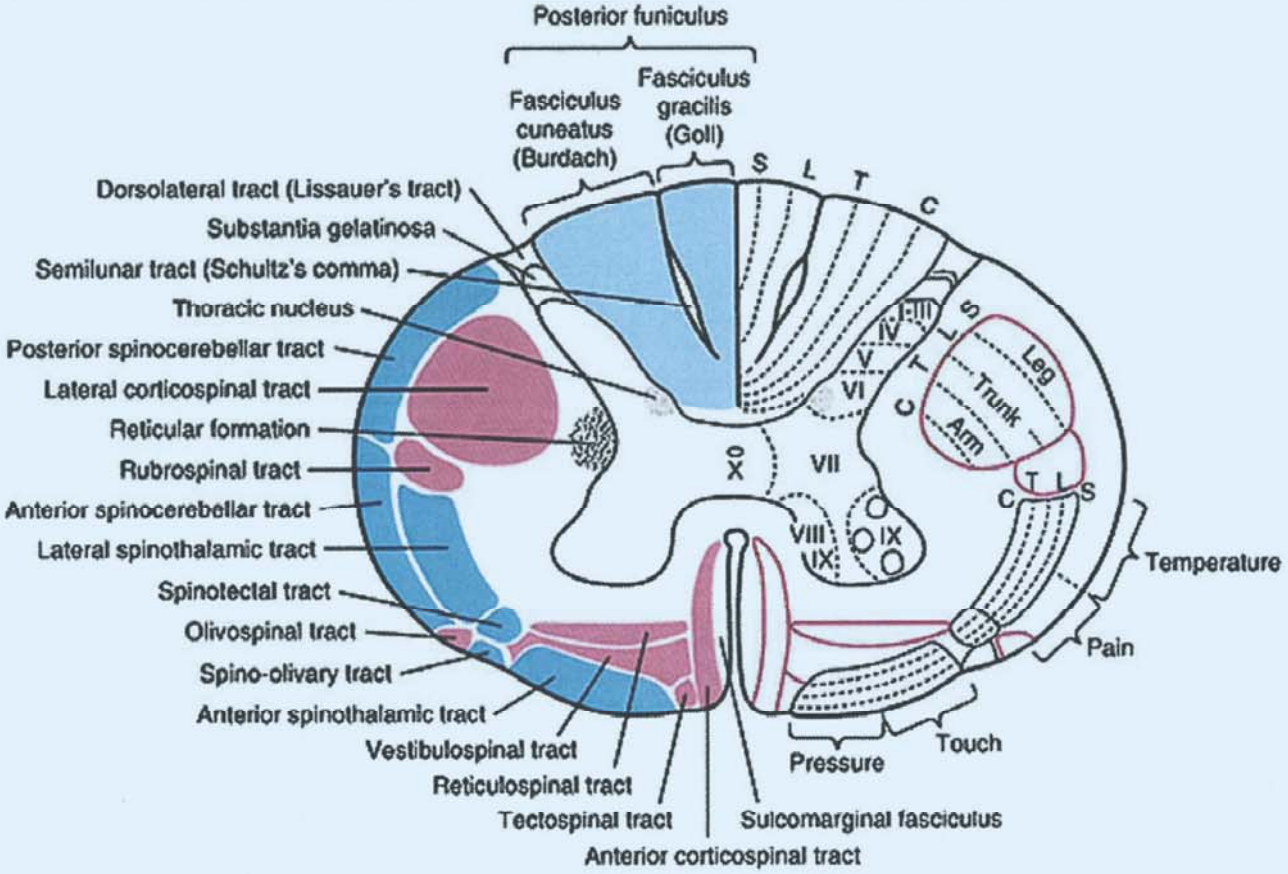

FIGURE 17.2 Anatomy of the spinal cord (cross-section). Tract lamination: C, cervical segments; L, lumbar segments; S, sacral segments; T, thoracic segments. (From Brazis PW, Masdeu JC, Biller J. *Localization in Clinical Neurology*. 5th ed. Philadelphia, PA: Lippincott Williams & Wilkins; 2007.)

contractility, whereas sympathetic circuits from T5-12 increase vasoconstriction in the splanchnic bed and lower extremities. In individuals with cord lesions at or above the T6 level, unregulated splanchnic vasoconstriction can increase systemic blood pressure to dangerous, even lethal levels, in the phenomenon of autonomic dysreflexia.

Vascular Anatomy

The anterior spinal artery and two posterior spinal arteries run longitudinally along the spinal cord. Branches of the single anterior spinal artery are responsible for two-thirds of the cord's cross-sectional area, whereas branches of the two posterior arteries serve a combined one-third of the cord's area. Therefore, the anterior portion of the cord is more susceptible to ischemia (Fig. 17.3).

The spinal arteries are fed by segmental radicular arteries, which are notoriously variable between individuals. The artery of Adamkiewicz is one of the largest radicular arteries, most commonly arising from the 9th to 12th intercostal arteries on the left. This artery is vulnerable to occlusion by aortic aneurysms and aortic repair procedures, resulting in a high rate of catastrophic cord ischemia and paraplegia. Rostral to the artery of Adamkiewicz, there is a relative paucity of collateral blood flow, making the midthoracic region particularly susceptible to ischemia from systemic hypotension.

Syndromic Pathology

Inflammation

Inflammatory myelopathy is the most common form of acute transverse myelitis. A wide range of etiologies may be responsible, ranging from neurologic manifestations of systemic autoimmune disease to primarily neuroautoimmune attack to parainfectious cross-reactions. Antibody-, complement-, and/or cell-mediated immune attack may occur against cell surface or intracellular antigens within neurons or glial cells. Autoantigens may be innocent bystanders that happen to mimic microbial antigens, leading to cross-reaction with an immune system honed to fight infection. Autopsy series have revealed monocytic, lymphocytic, and microglial infiltration into parenchyma and perivascular spaces. In most cases, damage is more prominent in white matter, with demyelination and axonal injury predominating over gray matter or neuronal inflammation.

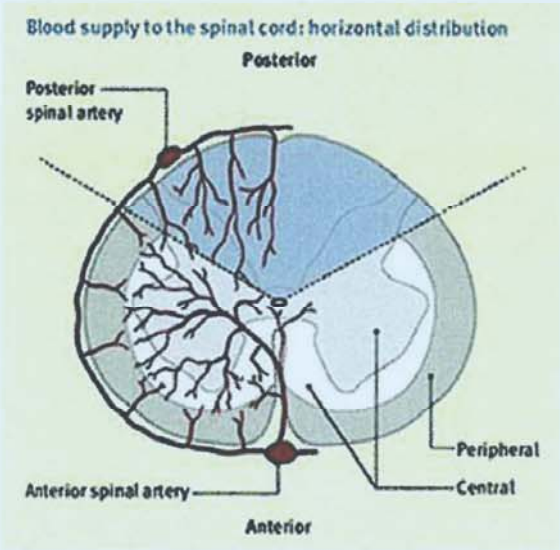

FIGURE 17.3 The vascular supply of the spinal cord. (From Brazis PW, Masdeu JC, Biller J. *Localization in Clinical Neurology*. 5th ed. Philadelphia, PA: Lippincott Williams & Wilkins; 2007.)

Ischemia

As mentioned earlier, the anterior two-thirds of the cord, especially at thoracic levels, is highly susceptible to ischemia. The *anterior spinal artery syndrome* comprises acute bilateral weakness and pain/temperature sensory loss, usually associated with loss of bowel and bladder control. Hypotension may occur through a spinal shock-like syndrome, which further exacerbates ongoing cord ischemia.

Infection

Although only a small percentage of systemic viral infections invade the cord parenchyma, the results may be permanent damage and paralysis. Enteroviruses such as polio and enterovirus D68 and flaviviruses such as West Nile virus directly target anterior horn cells (lower motor neurons), leading to acute flaccid paralysis with little to no chronic motor recovery. Herpesviruses more often affect dorsal horn (sensory neurons) and white matter, resulting in recurring lifelong flares of neuralgic pain. Bacterial infections of the spine usually cause epidural abscesses that result in myelopathy via compression (see below).

Compression

In contrast to inflammatory pathology, compression often damages segmental gray matter more than white matter. This is especially true in the cervical cord, where compression often presents as a "central cord syndrome": The upper extremities show flaccid weakness and sensory loss to pain and temperature, whereas the legs show milder spastic paresis, with bladder urgency. Acute traumatic compression is covered in Chapter 48. Acute nontraumatic compression usually occurs through epidural neoplasm, abscess, or hematoma. Almost all epidural neoplasms are metastatic to the vertebral bodies rather than the epidural space per se. Therefore, symptoms usually present with progressively severe pain (arising from periosteal irritation), followed by compression of anterior aspects of the cord, with prominent weakness and pain/temperature loss. Breast, lung, prostate, kidney, and colon cancers are the most common primary sources. Abscesses originate either through local trauma/disruption or hematogenously in patients with systemic infection. Key demographics include illicit parenteral drug users with endocarditis and patients with mechanical heart valves after dental procedures. Spinal epidural hematomas most often occur via trauma (including iatrogenic trauma), especially in patients on anticoagulants or with underlying coagulopathy. In contrast to epidural metastases, abscesses and hematomas usually compress the cord posteriorly.

DIAGNOSIS

A patient bought to the emergency department with bilateral leg paralysis after a motor vehicle accident does not require extensive deliberation over the differential diagnosis (see Chapter 48). However, acute cord syndromes can occur under many different circumstances, ranging from mechanical to vascular, infectious, inflammatory, neoplastic, and toxic etiologies (Table 17.1). A careful history regarding remote or recent trauma, other systemic symptoms, or toxic habits may help narrow your differential.

TABLE 17.1 Differential Diagnosis for Acute Spinal Syndromes

Compressive/Mechanical	**Infectious**
Trauma	Viral gray matter/acute flaccid paralysis
Disk herniation/subluxation	Poliovirus
Epidural abscess	Enterovirus
Epidural hematoma	Coxsackieviruses A and B
Epidural neoplasm/metastasis	West Nile virus
Vertebral compression fracture	Japanese encephalitis
Vascular	Tick-borne encephalitis
Stroke	Viral white matter/ longitudinal myelitis
Dural arteriovenous fistula	Herpes simplex virus
Arteriovenous malformation	Varicella-zoster virus
Cavernous malformation	Cytomegalovirus
Inflammatory	Epstein-Barr virus
Multiple sclerosis	Influenza
Neuromyelitis optica	Bacterial
Transverse myelitis	*Mycoplasma pneumoniae*
Acute disseminated encephalomyelitis	Syphilis
Sarcoidosis	Tuberculosis
Paraneoplastic	Lyme
Systemic lupus erythematosus	Fungal
Antiphospholipid antibody syndrome	*Cryptococcus neoformans*
Sjögren syndrome	*Coccidioides immitis*
Mixed connective tissue disease	*Blastomyces dermatitidis*
Behçet disease	*Histoplasma capsulatum*
Toxic/Metabolic	*Candida* species
Heroin	*Aspergillus* species
Konzo	Zygomycetes
Arachnoiditis after angiographic/myelographic contrast agents	Parasitic
Methotrexate toxicity	*Schistosoma* species
Cytarabine toxicity	*Toxoplasma gondii*
Amphotericin B toxicity	*Taenia solium* (cysticercosis)
Neoplasm	

Determining the rate of symptom progression proves critical, as patients whose symptoms reach maximal involvement within minutes are more likely to have a mechanical or vascular cause rather than an infectious, inflammatory, or neoplastic cause.

Focused History

Patients with acute spinal cord dysfunction are at risk for catastrophic cardiac and respiratory complications. Therefore, before taking the history, one must quickly assess airway, breathing, and circulation (ABCs). Once these ABCs (and cervical spine) are stabilized, key questions can determine etiology and localization before any physical or radiologic examination.

Etiology

- What is the *time course*? Although spinal cord ischemia does not usually present as suddenly as cerebral ischemia, patients reach a functional nadir within 4 to 12 hours, whereas patients with inflammatory or infectious myelopathies usually take 4 to 21 days to reach a nadir.
- Was there a gradual change in *gait* (stiffness, fatiguability) or bladder (urgency, nocturia) function in the weeks or months prior to presentation? That would point to a slowly encroaching mass (neoplastic or mechanodegenerative).
- Is there a history of *trauma*? Be wary of vertebral compression fracture after otherwise innocuous falls in patients with osteoporosis or occult vertebral metastasis.
- Was there any recent *surgery* that may have led to global hypotension or local cord ischemia? Aortic aneurysm procedures are notorious for causing the latter.
- Is there any known history of *cancer* or recent unexplained weight loss? Vertebral or epidural metastasis may be the presenting symptom of cancer in up to 20% of patients.
- Is the patient *immunocompromised* or are any recent *infectious symptoms* such as fevers, chills, or cough present? Back pain and fever in an intravenous drug abuser should raise red flags for possible epidural abscess. In 30% to 60% of idiopathic transverse myelitis cases, an antecedent respiratory, gastrointestinal, or systemic illness exists.
- Any *visual* symptoms? Concurrent acute nontraumatic myelopathy and optic neuritis suggest neuromyelitis optica (NMO).
- Is there a history of *coagulopathy*, *nutritional deficiency*, *environmental exposures*, or anything else that could guide the investigation?

Localization

- What is the distribution of any *weakness*? Thoracic and lumbar cord syndromes cause weakness in the lower extremities (paraparesis), whereas cervical syndromes affect all four limbs (tetraparesis).
- What is the distribution of any *numbness or paresthesias*? As with weakness, sensory findings are usually bilateral, although when a lesion is mostly on one side of the cord, there may be relative sparing of vibration and proprioception contralaterally and sparing of pain and temperature sensation ipsilateral to the lesion (Brown-Séquard syndrome). Description of a band or belt-like sensation around the trunk raises strong suspicion for a thoracic cord syndrome.
- Is there any *pain* present? Is it local to the back (worrisome for epidural metastasis or abscess), or does it follow a segmental distribution that might help localize the lesion?
- Is there any evidence of *bowel or bladder dysfunction*? Quite often, subtle changes in bladder function such as increased frequency and urgency (especially at night, when it is termed *nocturia*) may occur days, weeks, or even months prior to what otherwise presents as an acute cord syndrome. Conversely, lesions affecting the lumbosacral cord may present with bladder hypotonia, leading to retention, overflow incontinence, and frequent urinary tract infection.

Focused Exam

General Exam

Cardiovascular

Lesions at or above T6 place the patient at risk of unbalanced sympathetic-parasympathetic drive. Therefore, these patients may present with neurogenic shock: hypotension, bradycardia, or other cardiac arrhythmias including asystole. These patients are also at risk for autonomic dysreflexia: episodes of extreme hypertension (due to excessive sympathetic vasoconstriction of the splanchnic vessel bed) associated with symptoms such as diaphoresis, piloerection, facial flushing, and headache (all due to parasympathetic-mediated vasodilation above the lesion). These episodes most often have an identifiable trigger such as bladder or bowel irritation.

Pulmonary

Any lesion between the C3-5 levels may affect phrenic motoneurons. Thoracic lesions may affect accessory muscles of inspiration. The astute examiner must observe for excess work of breathing and auscultate for diminished breath sounds.

Temperature

Fever in the context of acute myelopathy may point to epidural abscess. Look for risk factors for immunocompromise and signs of parenteral drug abuse such as "track marks"; inspect sites of recent surgery.

Genitourinary and Gastrointestinal

Acutely, bladder and bowel tone may be decreased, leading to urinary retention and severe constipation. Therefore, the rectal exam and checking the postvoid residual are required.

Neurologic Exam

See **Table 17.2** for a summary of typical findings associated with specific syndromes.

Strength and Reflexes

CST damage results in upper motor neuron weakness: Below the lesion, one observes spasticity and hyperreflexia (often but not always including an extensor response to noxious plantar stimulation). Ventral horn involvement results in lower motor neuron weakness *at* the lesion levels with decreased or flaccid tone and hyporeflexia. Atrophy takes weeks or longer to develop. Note that cervical injuries often demonstrate *both* types of weakness—lower motor neuron weakness *at* the cervical level and upper motor neuron weakness *below* the lesion (due to damage of the passing CSTs). Additionally, a period of *spinal shock* lasting up to several days may result in the patient presenting with flaccid tone and diffuse hyporeflexia regardless of upper or lower motor neuron involvement. This is more common in traumatic SCI (see Chapter 48). Key muscle groups useful for localizing spinal levels include elbow flexors (C5), wrist extensors (C6), elbow extensors (C7), intrinsic hand muscles (C8-T1), hip flexors (L2), knee extensors (L3), ankle dorsiflexors (L4), and ankle plantarflexors (S1).

Sensory

A sensory "level," with sharply demarcated sensory loss below the level of the lesion, may be seen, especially in thoracic lesions. Depending on the distribution of the lesion in the anteroposterior and mediolateral axes, different combinations of bilateral, ipsilateral, and contralateral sensory loss may be observed, such as loss of vibration and proprioception (dorsal columns) and/or loss of pain and temperature (anterolateral system). Useful dermatomal landmarks include the nipple line (T4) and navel line (T10).

Imaging

Urgent magnetic resonance imaging (MRI) with T2-weighted imaging is required for the workup of acute myelopathy unless the patient has an absolute contraindication to MRI. In cases where MRI is not feasible, the best option for imaging compressive lesions of the cord is computed tomography myelography, which involves injecting contrast dye into the subarachnoid space. Gadolinium contrast MRI sequences should always be performed unless the patient's renal function is compromised because enhancement represents a critical element in the diagnostic workup. In patients presenting with leg weakness, hypertonia, and hyperreflexia, the clinician should avoid the common mistake of imaging the lumbosacral cord. This upper motor neuron presentation strongly argues for a thoracic, not a lumbosacral lesion. Regardless, total spinal cord survey may be warranted in many situations, such as to assess for multiple lesions or diffuse meningeal involvement. Unfortunately, MRI alone does not usually provide a definitive diagnosis. Diffusion-weighted imaging, which is highly sensitive for cerebral ischemia, has relatively poor resolution and sensitivity for cord ischemia.

Laboratory Evaluation

A lumbar puncture should almost always be performed for the workup of acute myelopathy. Cerebrospinal fluid (CSF) and serum tests to consider are listed in **Table 17.3**. In addition to the basic CSF laboratory tests of glucose, protein, and cell count, oligoclonal band assessment and an immunoglobulin G index

TABLE 17.2 Classic Spinal Cord Syndromes

Syndrome	Typical Causes	Clinical Characteristics
Central cord syndrome (syringomyelia)	Underlying cervical spondylosis with hyperextension injury; damage relatively greater to gray than white matter	Weakness in upper extremities > lower extremities; may have neurogenic bladder dysfunction and varying degrees of sensory loss at or below the lesion (often in a "cape-like" distribution)
Brown-Séquard syndrome	Penetrating trauma (many nonpenetrating injuries show partial asymmetric syndromes)	Ipsilateral motor and vibration/proprioception loss below the lesion, contralateral pain/temperature loss two levels below the lesion
Anterior cord syndrome	Hypotensive event leading to infarct within the midthoracic region, or hyperflexion injury leading to compression of the anterior spinal artery	Bilateral loss of motor, pain/temperature sensation below the lesion with preservation of vibration/proprioception/two-point discrimination
Posterior cord syndrome	Vitamin B_{12} deficiency, multiple sclerosis, vascular malformations, atlantoaxial subluxation	Bilateral loss of vibration/proprioception/two-point discrimination with preservation of motor, pain/temperature sensation below the lesion
Cauda equina syndrome	Disk herniation, tumor	Asymmetric lower extremity weakness, patchy impaired sensation to all modalities, loss of deep tendon reflexes as well as bulbocavernosus reflex and anal wink, often with low back and radicular pain
Conus medullaris syndrome	Disk herniation, trauma, tumor	Symmetrical sacral > lumbar weakness (may have normal leg strength), saddle anesthesia, bowel/bladder dysfunction

TABLE 17.3 Laboratory Evaluation for Acute Spinal Cord Syndromes

Source	Laboratory Test
Lumbar puncture	Cell count with differential Glucose Total protein Gram stain and culture HSV 1 and 2 PCR VZV PCR VZV IgG/IgM EBV PCR Enterovirus PCR VDRL Oligoclonal band profile (needs matching serum sample) IgG index Angiotensin-converting enzyme (ACE)
Serum	Aquaporin-4 antibody ACE ANA dsDNA antibodies Anti-Smith antibodies Anti-Ro/SSA antibodies Anti-La/SSB antibodies Anti-RNP antibodies Anti-slc-70 antibodies RPR Paraneoplastic

Abbreviations: ANA, antinuclear antibodies; EBV, Epstein-Barr virus; HSV, herpes simplex virus; IgG, immunoglobulin G; IgM, immunoglobulin M; PCR, polymerase chain reaction; RPR, rapid plasma regain; VDRL, Venereal Disease Research Laboratory; VZV, varicella-zoster virus.

are usually indicated—this requires parallel CSF and serum collection to infer the relative synthesis rate of new antibodies within the CSF compartment.

Of the basic CSF lab tests, pleocytosis is common in infection, NMO, acute disseminated encephalomyelitis (ADEM), and sarcoidosis. In NMO, neutrophils and eosinophils predominate, whereas in ADEM and sarcoid, the profile is usually lymphocytic. Supernumerary oligoclonal bands are present in 85% of multiple sclerosis CSF samples and only rarely in ADEM and NMO.

MANAGEMENT

Initial Stabilization

Spinal Stabilization

As part of the "ABCs" of emergency medicine, any acute traumatic spinal cord presentation should be immediately stabilized with a rigid cervical collar in the emergency department if not already applied in the field. Please see Chapter 48 for more on the management of acute spinal trauma.

Intensive Care Unit Admission

Intensive care, within a neurologic intensive care unit if available, is preferred in any patient who has cardiovascular or pulmonary symptoms or who has rapid progression of neurologic symptoms.

Pulmonary Management

Patients with cervical lesions should be monitored for respiratory compromise even if intubation is not immediately needed. Hypercarbia often precedes hypoxia, so abnormalities are often present on arterial blood gas before they become evident on pulse oximetry.

Cardiovascular Management

Spinal shock may result in decreased sympathetic outflow, leading to neurogenic hypotension, bradycardia, and arrhythmia. Therefore, patients should be closely followed using telemetry and frequent or continuous blood pressure monitoring. Fluid resuscitation and vasopressors should be used as needed to keep mean arterial pressure at least 85 mm Hg or spinal cord perfusion pressure at least 60-65 mm Hg (level 3 evidence) to prevent exacerbation of cord dysfunction from systemic hypoperfusion. This is especially critical in the setting of suspected cord ischemia.

Etiology-Specific Treatment

Inflammation

In the acute setting, parenteral glucocorticoids always play a major role in treating inflammatory myelopathy. Regimens range from dexamethasone at doses ranging 4 to 10 mg every 4 hours to methylprednisolone 1,000 mg/d. When patients do not respond to glucocorticoids, or when presentation of inflammatory myelitis is especially severe, other immunomodulating interventions such as plasma exchange, intravenous immunoglobulin, cyclophosphamide, or rituximab are frequently initiated. There are no level 1 guidelines or standards of care.

Ischemia

As mentioned earlier, blood pressure support (mean arterial pressure >85 mm Hg) is critical for maintaining cord perfusion. In some cases, placement of a lumbar drain to lower CSF pressure and improve spinal cord perfusion pressure can be considered. If vascular imaging studies can localize a thrombus, malformation, or dissection causing the ischemia, then catheter-based intervention may be possible. A role for intravenous or intra-arterial tissue plasminogen activator has been proposed, but no controlled studies have been performed.

Infection

For bacterial abscesses, empiric antibiotics should be administered urgently, followed by percutaneous drainage or surgical resection, and a specific antibiotic regimen once cultures and sensitivity are determined. For viral parenchymal infections, options are unfortunately sparse. Aside from acyclovir and valacyclovir for varicella zoster myelitis, treatment for most viral infections consists of supportive care. Multiple modes of immunomodulatory treatment, such as intravenous immunoglobulin, plasma exchange, interferons, and others, have been used to theoretically counter parainfectious inflammation, but no clear benefit has been demonstrated.

Compression

As noted earlier, time is cord. Once a compressive etiology is confirmed, whether the cause is neoplastic, structural, infectious, or hematoma, definitive treatment involves direct decompression via resection or drainage. Not surprisingly, the prognosis for ambulation depends on preintervention ambulatory status and time between symptom onset and intervention.

OUTCOME

It is critical to recall that most spinal syndromes are anatomically incomplete. Even when patients demonstrate complete loss of motor and sensory function below a lesion during the acute period, there is almost always a degree of spared tissue traversing the lesion. Assuming further damage is halted, there is a realistic chance at regaining function. Based on data from traumatic SCI, patients with complete sensorimotor loss during the acute period have a greater than 3% chance at regaining antigravity strength in paralyzed muscles at 1 year. Likewise, those with complete motor but incomplete sensory deficits acutely have a nearly 25% chance at regaining antigravity strength.

Patients with ischemic myelopathy likely have similar odds of recovery as trauma patients—most who present with severe sensorimotor paralysis remain paralyzed, but functional recovery is by no means miraculous. Unfortunately, even though early radiation and surgical decompression can maintain or restore ambulatory status in patients with metastatic compressive myelopathy, their average life span after presentation is only 6 months.

For patients with acute transverse myelitis without abnormalities on brain MRI, recurrence may occur in ~25% to 30% of cases. If brain abnormalities are present at the time of initial presentation, between 60% and 90% of patients will eventually progress to a formal diagnosis of multiple sclerosis. For patients with nonrecurrent inflammatory myelitis, roughly a third make full recoveries, a third have moderate long-term disability, and a third have severe long-term disability.

SUGGESTED READINGS

Alexander M, Biering-Sorensen F, Bodner D, et al. International standards to document remaining autonomic function after spinal cord injury. *Spinal Cord*. 2009;47(1):36-43.

Angeli CA, Edgerton VR, Gerasimenko YP, Harkema SJ. Altering spinal cord excitability enables voluntary movements after chronic complete paralysis in humans. *Brain*. 2014;137(pt 5):1394-1409.

Becker D, McDonald JW III. Approaches to repairing the damaged spinal cord: overview. *Handb Clin Neurol*. 2012;109:445-461.

Casha S, Christie S. A systematic review of intensive cardiopulmonary management after spinal cord injury. *J Neurotrauma*. 2011;28(8):1479-1495.

Consortium for Spinal Cord Medicine. Early acute management in adults with spinal cord injury: a clinical practice guideline for health-care professionals. *J Spinal Cord Med*. 2008;31(4):403-479.

Cree B. Acute inflammatory myelopathies. *Handb Clin Neurol*. 2014;122:613-667.

Dhall SS, Hadley MN, Aarabi B, et al. Deep venous thrombosis and thromboembolism in patients with cervical spinal cord injuries. *Neurosurgery*. 2013;72(suppl 2):244-254.

Dhall SS, Hadley MN, Aarabi B, et al. Nutritional support after spinal cord injury. *Neurosurgery*. 2013;72(suppl 2):255-259.

Dididze M, Green BA, Dietrich WD, Vanni S, Wang MY, Levi AD. Systemic hypothermia in acute cervical spinal cord injury: a case-controlled study. *Spinal Cord*. 2013;51(5):395-400.

Fink JK. Hereditary myelopathies. *Continuum (N Y)*. 2008;14(3):58-73.

Flanagan EP, Lennon VA, Pittock SJ. Autoimmune myelopathies. *Continuum (Minneap Minn)*. 2011;17(4):776-799.

Flanagan EP, McKeon A, Lennon VA, et al. Paraneoplastic isolated myelopathy: clinical course and neuroimaging clues. *Neurology*. 2011;76:2089-2095.

Francis K. Physiology and management of bladder and bowel continence following spinal cord injury. *Ostomy Wound Manage*. 2007;53(12):18-27.

Furlan JC, Fehlings MG. Cardiovascular complications after acute spinal cord injury: pathophysiology, diagnosis and management. *Neurosurg Focus*. 2008;25(5):E13.

Gajofatto A, Monaco S, Fiorini M, et al. Assessment of outcome predictors in first-episode acute myelitis: a retrospective study of 53 cases. *Arch Neurol*. 2010;67(6):724-730.

Gorman PH, Qadri SFA, Rao-Patel A. Prophylactic inferior vena cava (IVC) filter placement may increase the relative risk of deep venous thrombosis after acute spinal cord. *J Trauma*. 2009;66(3):707-712.

Hadley MN, Walters BC, Aarabi B, et al. Clinical assessment following acute cervical spinal cord injury. *Neurosurgery*. 2013;72(suppl 2):40-53.

Hansebout RR, Hansebout CR. Local cooling for traumatic spinal cord injury: outcomes in 20 patients and review of the literature. *J Neurosurg Spine*. 2014;20(5):550-561.

Ho EL. Infectious etiologies of myelopathy. *Semin Neurol*. 2012;32(2):154-160.

Hurlbert RJ, Hadley MN, Walters BC, et al. Pharmacological therapy for acute spinal cord injury. *Neurosurgery*. 2013;72(suppl 2):93-105.

Kakulas BA. The clinical neuropathology of spinal cord injury: a guide to the future. *Paraplegia*. 1987;25(3):212-216.

Ko H-Y, Ditunno JF Jr, Graziani V, Little JW. The pattern of reflex recovery during spinal shock. *Spinal Cord*. 1999;37(6):402-409.

Koch M, Sepp D, Prothmann S, Poppert H, Seifert CL. Systemic thrombolysis in anterior spinal artery syndrome: what has to be considered? *J Thromb Thrombolysis*. 2016;41(3):511-513.

Kumar N. Metabolic and toxic myelopathies. *Semin Neurol*. 2012;32(2):123-136.

Kwon B, Sekhon L, Fehlings M. Emerging repair, regeneration, and translational research advances for spinal cord injury. *Spine*. 2010;35(21 suppl):S263-S270.

Lemons VR, Wagner FC. Respiratory complications after cervical spinal cord injury. *Spine*. 1994;19(20):2315-2320.

Liu Y-H, Hu Y-C, Yang X-G, et al. Prognostic factors of ambulatory status for patients with metastatic spinal cord compression: a systematic review and meta-analysis. *World Neurosurg*. 2018;116:e278-e290.

Maas JW Jr. Inherited myelopathies. *Semin Neurol*. 2012;32(2):114-122.

McKinley W, Santos K, Meade M, Brooke K. Incidence and outcomes of spinal cord injury clinical syndromes. *J Spinal Cord Med*. 2007;30(3):215-224.

Mihai C, Jubelt B. Infectious myelitis. *Curr Neurol Neurosci Rep*. 2012;12(6):633-641.

Moftakhar P, Hetts SW, Ko NU. Vascular myelopathies. *Semin Neurol*. 2012;32(2):146-153.

Nagpal S, Clarke JL. Neoplastic myelopathy. *Semin Neurol*. 2012;32(2):137-145.

National Spinal Cord Injury Statistical Center. *Spinal Cord Injury Facts and Figures at a Glance*. Birmingham, AL: University of Alabama at Birmingham; 2019.

New PW, Simmonds F, Stevermuer T. A population-based study comparing traumatic spinal cord injury and non-traumatic spinal cord injury using a national rehabilitation database. *Spinal Cord*. 2011;49(3):397-403.

Noonan VK, Fingas M, Farry A, et al. Incidence and prevalence of spinal cord injury in Canada: a national perspective. *Neuroepidemiology*. 2012;38(4):219-226.

Ramer L, Ramer M, Bradbury E. Restoring function after spinal cord injury: towards clinical translation of experimental strategies. *Lancet Neurol*. 2014;13(12):1241-1256.

Ryken TC, Hurlbert RJ, Hadley MN, et al. The acute cardiopulmonary management of patients with cervical spinal cord injuries. *Neurosurgery*. 2013;72(suppl 2):84-92.

Squair JW, Bélanger LM, Tsang A, et al. Empirical targets for acute hemodynamic management of individuals with spinal cord injury. *Neurology*. 2019;93(12):E1205-E1211.

Theodore N, Hadley MN, Aarabi B, et al. Prehospital cervical spinal immobilization after trauma. *Neurosurgery*. 2013;72(suppl 2):22-34.

Transverse Myelitis Consortium Working Group. Proposed diagnostic criteria and nosology of acute transverse myelitis. *Neurology*. 2002;59(4):499-505.

West TW, Hess C, Cree BA. Acute transverse myelitis: demyelinating, inflammatory and infectious myelopathies. *Semin Neurol*. 2012;32(2):97-113.

Winslow C, Rozovsky J. Effect of spinal cord injury on the respiratory system. *Am J Phys Med Rehabil*. 2003;82(10):803-814.

Yoshioka K, Niinuma H, Ehara S, Nakajima T, Nakamura M, Kawazoe K. MR angiography and CT angiography of the artery of Adamkiewicz: state of the art. *Radiographics*. 2006;26(suppl 1):S63-S73.

Focal Mass Lesions 18

Michelle Bell, Alexander G. Khandji, and Fabio M. Iwamoto

KEY POINTS

1. Elevated intracranial pressure is a neurologic emergency, and immediate measures (ie, bed elevation and bolus osmotherapy) should taken to reduce the intracranial pressure.
2. Brain focal masses are typically caused by cancers (primary or metastatic), infections (abscess or cerebritis), or other inflammatory processes.
3. Magnetic resonance imaging of the brain with and without contrast is always recommended in evaluation of focal mass lesions unless there is a medical contraindication (eg, pacemaker).
4. If imaging demonstrates significant swelling and impending herniation, patient should receive steroids followed by open biopsy and decompression.
5. In patients with AIDS, toxoplasmosis and primary central nervous system lymphoma are the most common etiologies.

INTRODUCTION

The differential diagnosis of an undifferentiated focal brain mass lesion is broad and the clinical presentation quite variable. This chapter discusses the major etiologic categories of focal brain mass lesions—namely, tumors, abscesses, and other inflammatory lesions—and present an algorithm for implementing empiric management in stable patients while a definitive diagnosis is pursued.

EMERGENT MANAGEMENT OF SYMPTOMATIC INTRACRANIAL MASS EFFECT

The first step in management of a focal mass lesion is to assess for increased intracranial pressure (ICP) and signs of herniation in patients with radiographic signs of mass effect and midline shift.

Common symptoms and signs of increased ICP include headache, vomiting, depressed level of consciousness, papilledema, abducens nerve palsies, and systolic hypertension with or without bradycardia (Cushing reflex). As mass effect worsens, in addition to the expected contralateral hemiparesis, patients develop motor signs *ipsilateral* to the lesion as a result of lateral and rotation displacement of both corticospinal tracts. Common signs include stiffening, hyperreflexia, and extensor plantar responses. With further brain tissue displacement, transtentorial herniation leads to ipsilateral third nerve palsy ("blown pupil").

If the clinical assessment is concerning for elevated ICP, it is imperative to take immediate measures to reduce it. First-line interventions include head elevation to 30 degrees LEVEL 4[1] and bolus osmotherapy with either 20% mannitol 1 g/kg intravenous (IV) or 30 mL of 23.4% hypertonic saline if there is central venous access LEVEL 4.[2,3] If level of consciousness is depressed with inability to maintain and protect the airway, the patient should be intubated and hyperventilated to $PaCO_2$ of 30 mm Hg while awaiting definitive treatment (see Chapter 111 for further details) LEVEL 4.[4]

If there is no evidence of increased ICP, further management should be determined by the clinician's assessment of the most likely underlying cause of the mass lesion. This chapter discusses the diagnostic evaluation of undifferentiated mass lesions and the initial steps in management depending on the suspected diagnosis.

CAUSES OF FOCAL BRAIN LESIONS

Figure 18.1 shows common causes of focal lesions of the brain not consistent with stroke or trauma based on location.

Brain Tumors

Tumors account for the majority of focal brain mass lesions. In adults, *metastatic tumors* account for approximately 50% of symptomatic brain tumors (**Fig. 18.2**). The most common primary tumor to metastasize to the brain is lung cancer. Approximately 50% to 60% of brain metastasis originate from lung cancer, with 25% to 40% being of non–small cell lung cancer origin and 5% to 15% being of small cell lung cancer origin. About 20% of lung cancer brain metastases are found at the time of initial diagnosis. The next most common sources of brain metastases are breast cancers (15%-30%), melanoma (10%), renal cancer (5%), and gastrointestinal cancers (5%) (see Chapter 101).

Approximately 70,000 primary brain tumors are diagnosed each year. The most common form of primary brain tumor found in adults are *meningiomas* (35%). These dural-based masses enhance densely with gadolinium on magnetic resonance imaging (MRI) (**Fig. 18.3**) and are easy to identify prior to surgery due to their highly characteristic appearance (see Chapter 102). *Gliomas* are the second most common form of primary tumor accounting for 30% of all brain tumors (see Chapter 101). Glioblastoma multiforme is the most common form of glioma and account for 80% of all malignant brain tumors (**Fig. 18.4**). Anaplastic astrocytoma and oligodendrogliomas (**Fig. 18.5**) are lower grade tumors that show less prominent enhancement and no necrosis. Less common adult primary brain tumors, in order of frequency, are pituitary adenomas (**Fig. 18.6** and Chapter 104), nerve sheath tumors such as acoustic neuromas (see Chapter 106), and

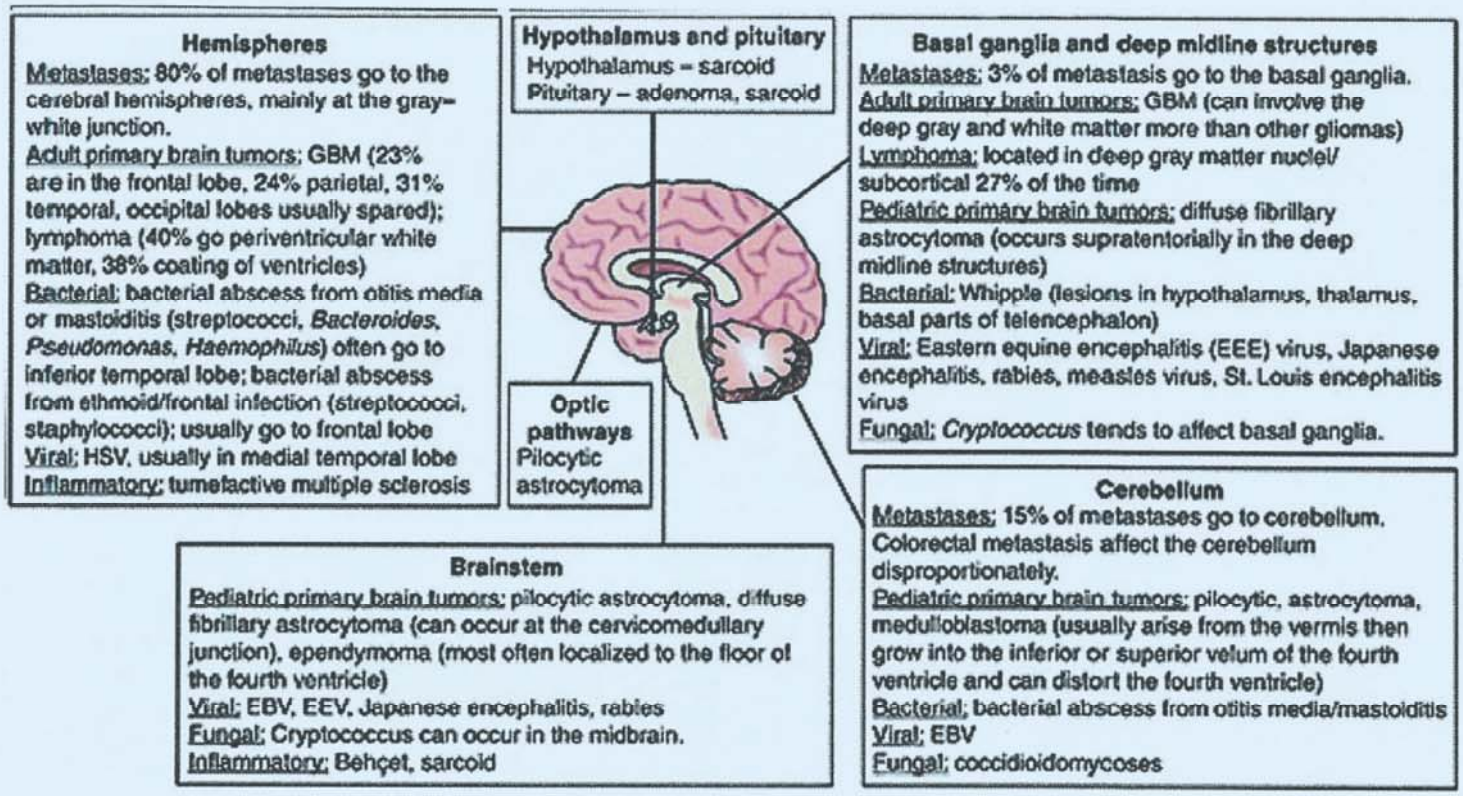

FIGURE 18.1 Common causes of focal lesions in the brain based on location. Abbreviations: EBV, Epstein-Barr virus; GBM, glioblastoma; HSV, herpes simplex virus.

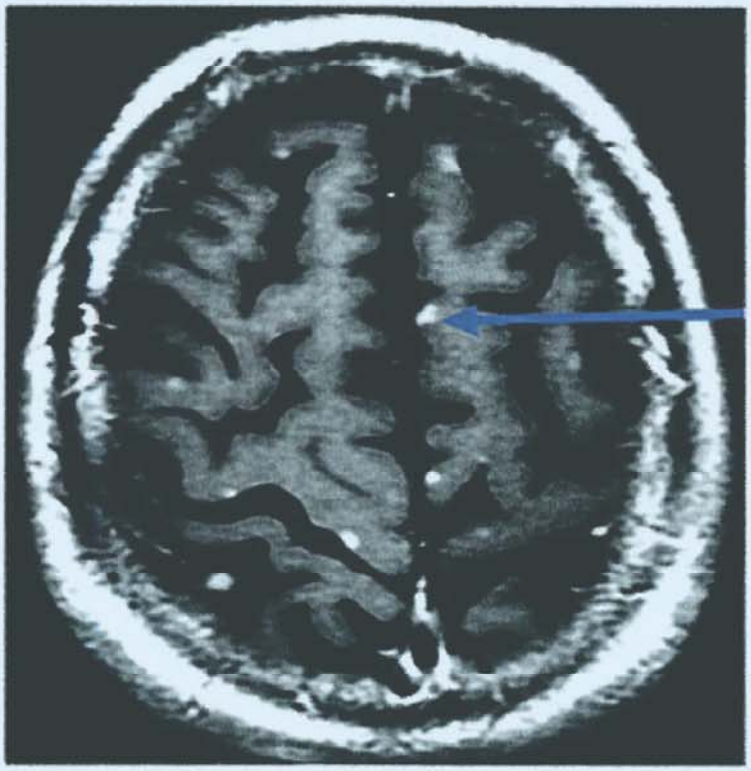

FIGURE 18.2 Metastatic small cell lung cancer. T1 magnetic resonance imaging of the brain shows multiple small enhancing metastatic nodules.

primary central nervous system lymphomas (PCNSLs) (Fig. 18.7 and Chapter 103). Table 18.1 outlines typical clinical features, imaging findings, and suggested ancillary testing in adult patients with suspected brain neoplasm.

In children, the most common primary brain tumors are gliomas (40%) including pilocytic astrocytoma (Fig. 18.8), embryonal tumors (15%) including medulloblastoma (Fig. 18.9), and ependymoma (~5%). Table 18.2 outlines typical clinical features, imaging findings, and suggested ancillary testing in children with suspected brain neoplasm (see also Chapter 150).

Cerebritis and Abscesses

Approximately 1,500 cases of brain abscess occur annually in the United States with an incidence of 0.3 to 1.3 cases per 100,000 of the population annually. Brain abscess (see Chapter 65) is most commonly caused by bacterial infection (Fig. 18.10), most commonly streptococci and staphylococci. Focal brain infection resulting in cerebritis or abscess can also be caused by *fungi* (Table 18.3). Among fungal infections, aspergillosis (Fig. 18.11), cryptococcosis (Fig. 18.12), candida, mucormycosis, and nocardia are most common in immunosuppressed patients. *Blastomyces*, histoplasmosis, and *Coccidioides* are most common in immunocompetent patients. The most common *parasitic* organisms that causes brain abscess are by far toxoplasmosis (Fig. 18.13) and cysticercosis (Fig. 18.14), although *Strongyloides* and *Entamoeba histolytica* are also common causes (see Chapter 68). *Tuberculosis* forms solid tuberculomas; after the caseous core liquefies, the tuberculoma becomes a tuberculous abscess (see Chapter 67). *Syphilis* can form gummas, cysticercosis can cause an inflammatory mass lesion when the cyst degenerates and dies, and

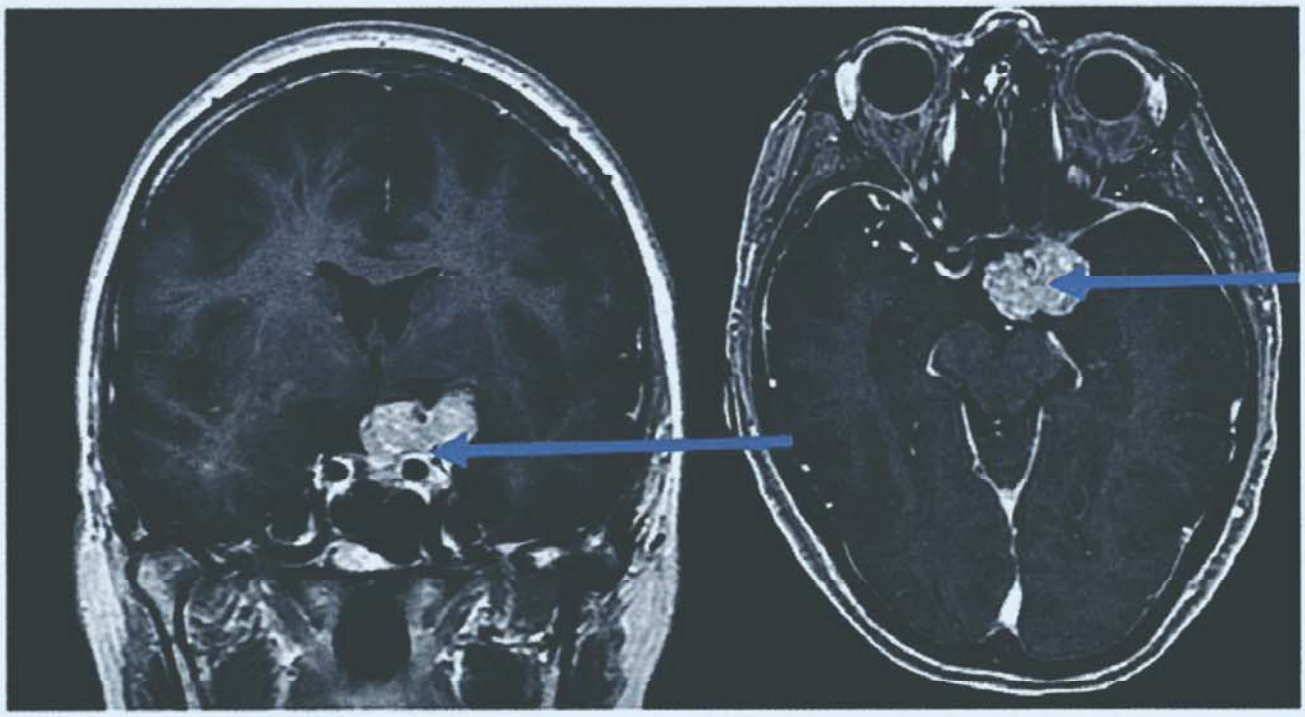

FIGURE 18.3 Large parasagittal olfactory groove meningioma strongly enhancing after contrast. Note the small cleft of cerebrospinal fluid noted along the left margin of the lesion (coronal image, A).

FIGURE 18.4 Glioblastoma multiforme. T1 magnetic resonance imaging shows central necrosis and ring enhancement with a nodular component extending into the center of the lesion.

viruses such as *herpes simplex 1* (see Chapter 69) can cause encephalitis complicated by acute swelling and inflammation of the affected temporal lobes (Fig. 18.15).

Other Inflammatory Lesions

Occasionally, noninfectious inflammatory processes can also cause mass lesions (Table 18.4). Most notoriously, *multiple sclerosis* (see Chapter 71) can form a large demyelinating mass lesion known as *Marburg variant* or *tumefactive multiple sclerosis* (Fig. 18.16). *Sarcoidosis* (see Chapter 75) can also present as an inflammatory intraparenchymal mass lesion. *Radiation necrosis* can present as a space-occupying mass lesion months to decades after prior radiation treatment (see Chapter 109).

FOCUSED HISTORY

Demographics

Age is an important factor for narrowing the differential diagnosis particularly for brain tumors. Children develop a very different set of brain tumors than do adults. Ependymoma affects the youngest children (high incidence among infants, toddlers, and preschoolers), followed by medulloblastoma and pilocytic astrocytoma (peak incidence between 5 and 10 y of age), oligodendroglioma (incidence peak at 40 y of age), anaplastic astrocytoma (incidence peak at 50 y of age), and glioblastoma (incidence peak at 65 y of age). The average age at diagnosis for pituitary adenomas and meningiomas straddle several decades, with pituitary adenomas primarily being diagnosed between age 20 and 50 years and meningiomas between age 40 and 60 years. Pituitary adenoma and meningiomas occur more commonly in women.

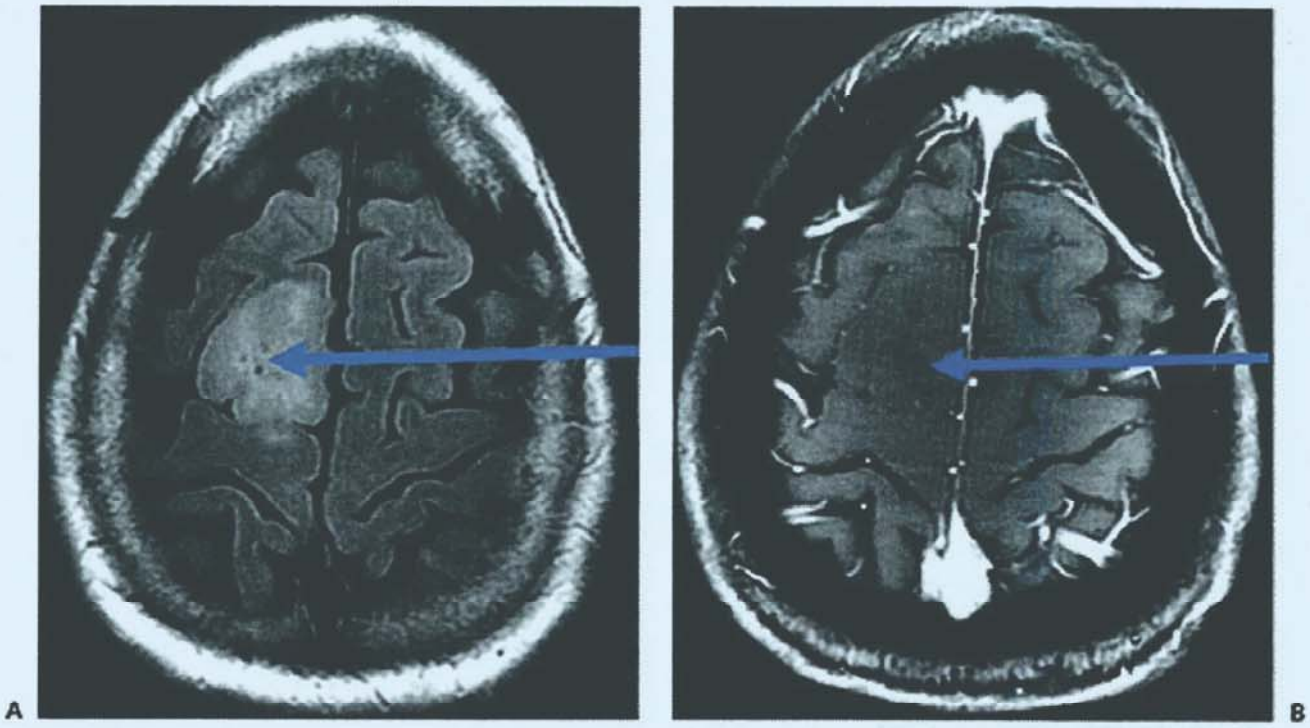

FIGURE 18.5 Fluid-attenuated inversion recovery **(A)** and T1 gadolinium-enhanced magnetic resonance **(B)** of a right frontal oligodendroglioma showing very little contrast enhancement and very little surrounding edema.

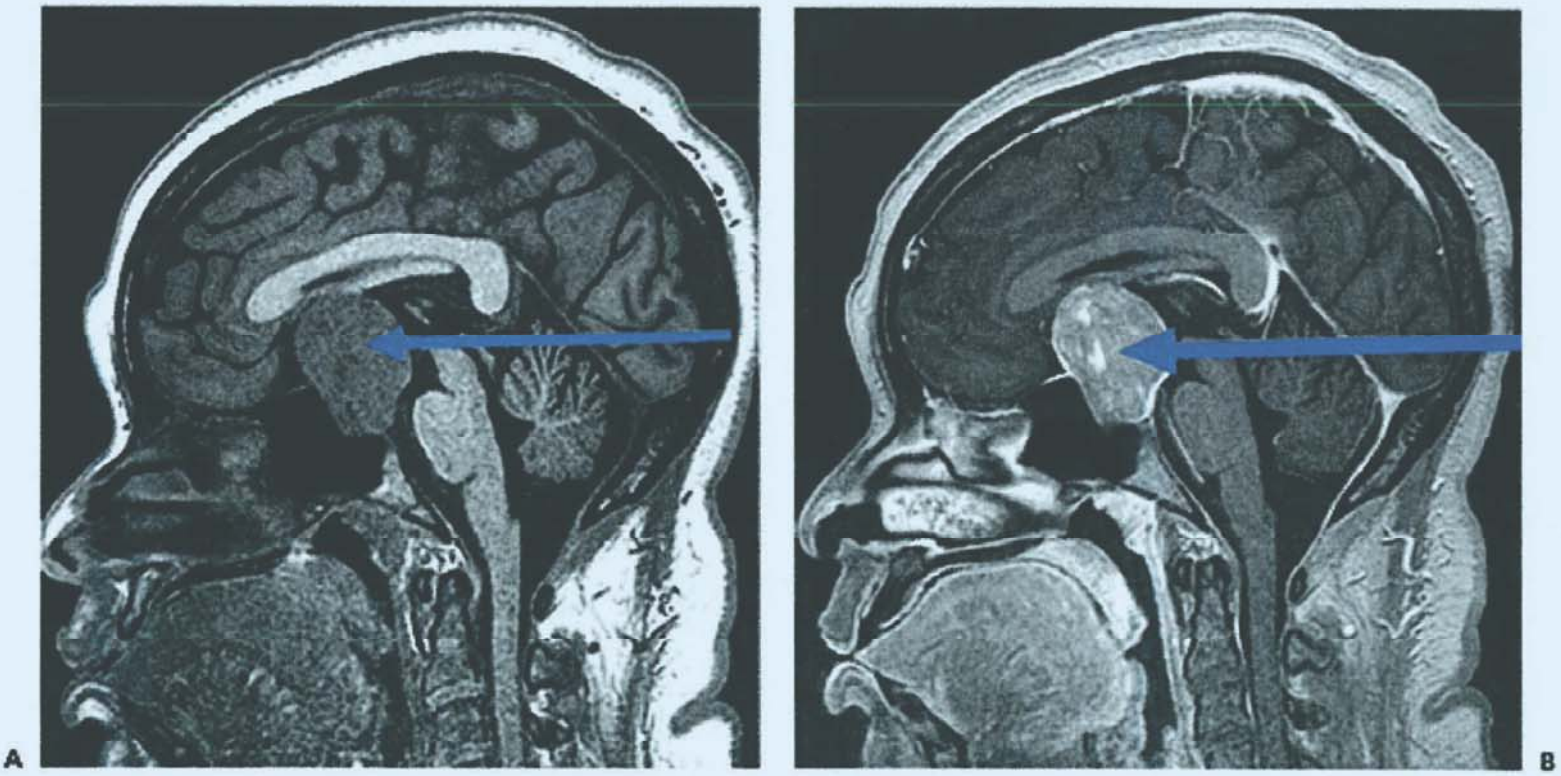

FIGURE 18.6 Pituitary macroadenoma. **A:** Hypointense on T1. **B:** Enhancing postcontrast.

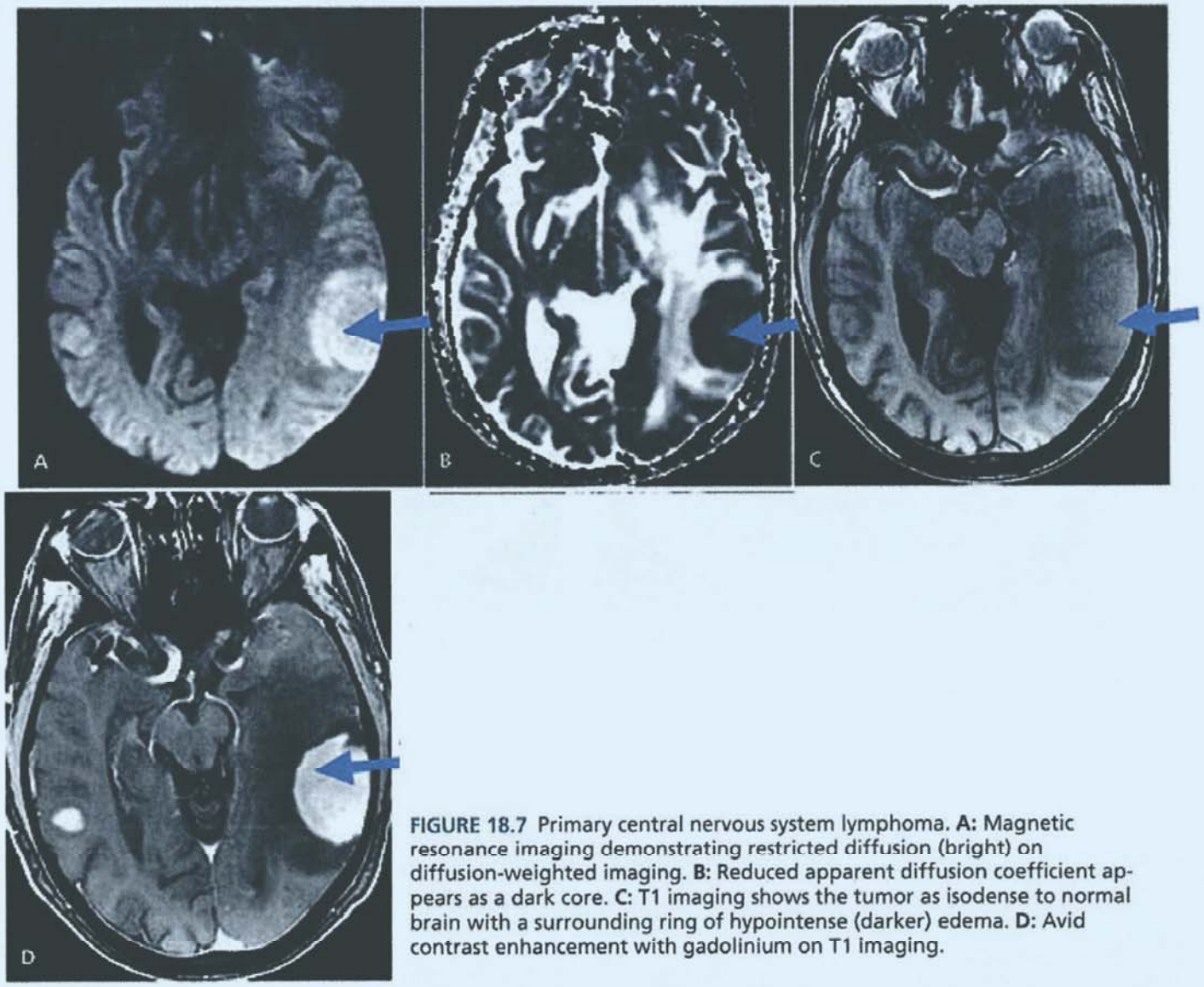

FIGURE 18.7 Primary central nervous system lymphoma. **A:** Magnetic resonance imaging demonstrating restricted diffusion (bright) on diffusion-weighted imaging. **B:** Reduced apparent diffusion coefficient appears as a dark core. **C:** T1 imaging shows the tumor as isodense to normal brain with a surrounding ring of hypointense (darker) edema. **D:** Avid contrast enhancement with gadolinium on T1 imaging.

Time Course

Symptoms associated with abscesses tend to develop acutely to subacutely (with bacterial infections presenting more acutely and fungal infections more subacutely), whereas tumors present more subacutely to chronically based on their grade (for instance, glioblastoma tends to have a more subacute presentation as compared to meningiomas, which tend to have a more chronic presentations).

Past Medical History

It is essential to learn whether there was a past history of cancer and/or a history of immunosuppression. In patients with a history of systemic cancer, certain details are helpful in determining the likelihood that brain mass is a metastatic tumor. Small cell lung cancer metastasizes to the brain in about 50% of instances as opposed to 7% in cases of non–small cell lung cancer. In patients with prior breast cancer, HER2+/ER− status portends a higher likelihood of metastasis to the brain. The same applies for melanoma patients with head/neck/oral lesions and colorectal cancer patients with left-sided cancers. Regarding immunosuppression, a history of human immunodeficiency virus (HIV) is a major risk factor for PCNSL and toxoplasma infection (see Chapter 70), whereas neutropenia and steroid use is a major risk factor for aspergillosis, candida, mucormycosis, and nocardia infections.

Other important history elements include the following:

- A prior distant (usually 5-30 y prior) history of irradiation, which increases the long-term risk of meningiomas and malignant glioma
- A recent history of radiation treatment, which can lead to radiation necrosis
- A history of systemic sarcoidosis, which increases the likelihood that a brain mass is due to neurosarcoidosis
- Prior diagnoses of amenorrhea, galactorrhea, erectile dysfunction, infertility, or hyperthyroidism, which can be seen in pituitary adenomas

Social History

The social history portion of the interview may reveal HIV risk factors and/or risk factors for systemic cancers such as smoking history. Additionally, the patient's travel history may be helpful, particularly for identifying potential fungal and helminthic infections (see **Table 18.1**).

TABLE 18.1 Common Adult Brain Tumors

	Clinical Pearls	Imaging Features	CSF Studies and Systemic Workup
Metastatic tumors (in order of frequency)	Lung • Small cell lung cancer eventually metastasized to the brain in up to 50% of cases. Breast • HER2+/ER− receptor status portends a higher likelihood of metastasis to the brain. Melanoma • Head, neck, and primary oral lesions have a higher rate of metastasis. Renal • In up to 10% of patients, a new metastasis later develops in patients who were thought to have been cured of their primary tumor. Colorectal • Left-sided cancers are more likely to metastasize to the lung and brain, whereas right-sided tumors usually go to liver.	• Eighty percent of brain metastases occur in the cerebral hemispheres, 15% in the cerebellum, and 5% in the basal ganglia. • Metastases tend to localize to the gray-white junction location and the border zone between two major arterial distributions. • Brain metastases are multiple, approximately 50% of cases. • FLAIR imaging tends to reveal a large amount of associated vasogenic edema. • Magnetic resonance spectroscopy shows low NAA and creatine levels and elevated choline levels reflecting cell membrane and myelin turnover. • Gradient echo or SWI may demonstrate hemosiderin deposits in cancers that tend to hemorrhage (eg, melanoma, choriocarcinoma, renal cell, and thyroid cancer). Melanoma tends to be hyperdense on CT scan even in the absence of hemorrhage. On MRI, melanoma is hyperintense on T1 and hypointense on T2. • Colorectal metastases involve the cerebellum disproportionately.	More than 60% of patients with brain metastases will have a mass demonstrated on chest imaging that is either due to a primary lung cancer or lung metastases from a primary tumor elsewhere. Tests to consider when brain metastases are suspected: • Mammogram • Skin exam • Whole-body CT • Whole-body FDG-PET
Meningoma	• 35% of all primary brain tumors • 67% of cases occur in women. • Peak incidence, age 40-60 y	Dural based with dense, homogeneous enhancement • Isointense to hypointense on T1 • Isointense to hyperintense on T2 Anatomic predilection in order of frequency • Parasagittal • Convexity • Sphenoid ridge • Cerebellopontine angle • Olfactory groove Can elicit a bony reaction leading to hyperostosis of the overlying calvarium Calcification occurs in approximately 20% of cases.	None

Gliomas	• 30% of all primary brain tumors
	• Average age of diagnosis:
	  • Glioblastoma: 65 y
	  • Anaplastic astrocytoma: 50 y
	  • Oligodendroglioma: 40 y
	  • Anaplastic astrocytoma usually evolves from a lower grade astrocytoma.
		GBM
		• Causes extensive edema in the deep white matter
		• Enhances with gadolinium
		• Central areas of necrosis restrict on DWI (bright)
		• May have satellite lesions
		• Tumor often crosses the corpus callosum and anterior commissure.
		• Magnetic resonance spectroscopy: Cho/NAA ratio >2.2 is thought to be high grade.
		Anaplastic astrocytoma
		• Some contrast enhancement but no necrosis
		Oligodendroglioma
		• 40%-80% rate of calcification
		• Enhances in 50%-70%
		• Hemorrhage or cyst formation occurs in 20%.
		• Usually, there is little edema.
			Order lower extremity Doppler in patients with GBM. Ultimately, up to 25% of these patients suffer from venous thromboembolism during the first year of diagnosis.

Pituitary adenoma	10% of all primary brain tumors Classified as secretory (75%) and nonsecretory (25%) Prolactinoma • Amenorrhea • Galactorrhea • Gynecomastia • Erectile dysfunction or impotence • Infertility • Decrease in body hair	• Tends to be hypodense on CT • Microadenomas are generally hypointense on T1 and variable intensity on T2. • Adenomas do not enhance as much, and enhance later, than normal pituitary tissue. Dynamic contrast-enhanced MRI scans are best of delineate adenomas. • Macroadenoma are adenomas >10 mm. They have a propensity for hemorrhage and infarction (pituitary apoplexy).	Pituitary hormone panel • Prolactin • FSH • LH • Serum and 24-h urine cortisol levels • TSH and T_3/T_4 levels • Growth hormone Formal visual field testing and ophthalmologic evaluation are critical.

TABLE 18.1 Common Adult Brain Tumors *(continued)*

	Clinical Pearls	Imaging Features	CSF Studies and Systemic Workup
	Growth hormone–producing tumor • Gigantism • Acromegaly ACTH-producing tumors • Cushing syndrome TSH-producing tumors: • Primary hyperthyroidism	• Differential diagnosis • Rathke cyst: hyperintense on T1 and does not enhance • Craniopharyngioma: has cystic lesions and calcifications	Serum prolactin >200 μg/L with an adenoma >10 mm in size is diagnostic of a prolactinoma.
PCNSL	• Causes <5% of all primary brain tumors • Immunocompromised state (eg, HIV, transplant) is a major risk factor. • Among immunocompetent patients, the mean age of onset is 60 y and there is a slight male predominance.	Tends to be hypodense on CT MRI features • T1 hypointense and T2 hyperintense • DWI shows diffusion restriction (bright). Anatomic predilection • Periventricular white matter in 40% • Coating of ventricles in 40% • Deep gray matter nuclei/subcortical in 30% • Unusual multifocal distribution of tumor can occur. Diffusely enhancing in the immunocompetent patients; necrotic center can occur in immunocompromised patients. Spread across corpus callosum is suggestive of PCNSL. Masses tend to be <2 cm in patients with AIDS and >2 cm in non-AIDS patients.	Slit lamp examination reveals intraocular involvement in 15% of patients.

Abbreviations: ACTH, adrenocorticotropic hormone; Cho, choline; CSF, cerebrospinal fluid; CT, computed tomography; DWI, diffusion-weighted imaging; GBM, glioblastoma; FDG-PET, ^{18}F-fluorodeoxyglucose positron emission tomography; FLAIR, fluid-attenuated inversion recovery; FSH, follicle-stimulating hormone; HER2, human epidermal growth factor receptor 2; ER, estrogen receptor; HIV, human immunodeficiency virus; LH, luteinizing hormone; MRI, magnetic resonance imaging; NAA, *N*-acetylaspartate; PCNSL, primary central nervous system lymphoma; SWI, susceptibility-weighted imaging; T_3, triiodothyronine; T_4, thyroxine; TSH, thyroid-stimulating hormone.

TABLE 18.2 Common Pediatric Brain Tumors

	Clinical Pearls	Imaging Features	CSF Studies and Systemic Workup
Gliomas • Grade 1: pilocytic astrocytoma (see **Fig. 18.7**) • Grade 2: diffuse fibrillary astrocytoma	Two main types in children • Pilocytic astrocytoma • Diffuse fibrillary astrocytoma	• Pilocytic astrocytoma is predominately located in the cerebellum, optic pathways, and the dorsal brainstem. • Well circumscribed with a cystic component and an enhancing mural nodule • Diffuse fibrillary astrocytoma occurs more often supratentorially in deep midline structures and at the cervicomedullary junction. • Hypointense on T1 and hyperintense on T2 with varying degrees of enhancement	None
Medulloblastoma	Peak incidence is approximately between 5 and 10 y of age. Occurs in boys twice as often as girls	• Accounts for 50% of cerebellar tumors in children • Usually arise from the vermis then grow into the inferior or superior velum of the fourth ventricle • As opposed to ependymoma, medulloblastoma distorts the fourth ventricle. • Well circumscribed and hyperdense on CT. Up to 20% have calcification or cystic changes. • MRI often has diffusion restriction on DWI. Medulloblastoma tends to enhance to a moderate degree.	None
Ependymoma	Among pediatric patients, peak incidence among infants, toddlers, and preschoolers Another peak of incidence occurs in adults.	• Intracranial in 90% of pediatric patients (more often spinal in adults); most often localized to the floor of the fourth ventricle • Hypodense to isodense on CT • Calcification in up to 50%, cystic changes in 15%. Mild enhancement is the rule.	Spinal MRI is mandatory if cranial ependymoma is suspected. Spinal drop metastasis occurs in 5% of cases.

Abbreviations: CSF, cerebrospinal fluid; CT, computed tomography; DWI, diffusion-weighted imaging; MRI, magnetic resonance imaging.

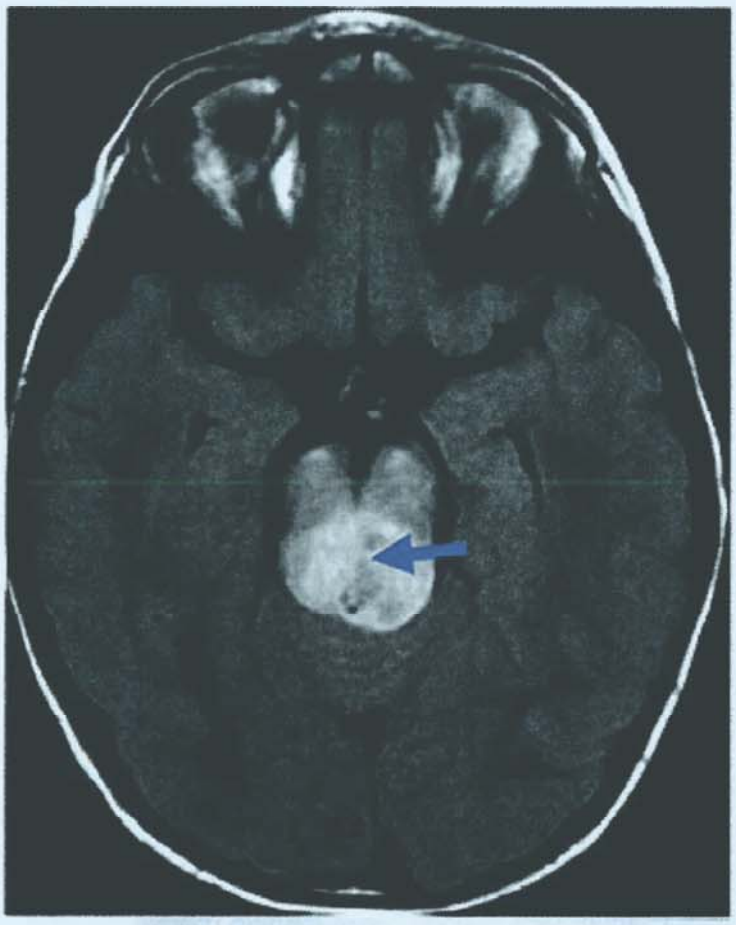

FIGURE 18.8 Pilocytic astrocytoma with high signal intensity on fluid-attenuated inversion recovery imaging invading the midbrain.

Review of Systems

In the neurologic review of systems, a history of episodic changes in neurologic status may indicate either an epileptic seizure or an ICP plateau wave. Plateau waves are thought to be the result of a sudden increase in cerebral blood volume because of a sudden decrease in cerebral vascular resistance. Patients who have diminished blood flow absorption, either from an intracranial mass or leptomeningeal disease, are more likely to develop plateau waves than patients with normal cerebrospinal fluid (CSF) absorption.

Another important point of query should focus on prior episodes of focal neurologic deficits lasting days in distributions characteristic of multiple sclerosis attacks, such as unilateral vision loss, bilateral leg paresthesias, unilateral arm weakness/paresthesia, or double vision. This can point to tumefactive multiple sclerosis as the causative etiology.

Symptoms of subacute to chronic weight loss can point to an occult malignancy and when combined with fever and night sweats may indicate either a central nervous system lymphoma or tuberculosis, given the clinical context. History of galactorrhea or gynecomastia can raise concern for pituitary adenoma (see Chapter 104).

FOCUSED EXAM

In patients with focal mass lesions of the brain, the most important role of the exam is to assess for increased ICP and herniation. A pale optic disc, red desaturation, partial internuclear ophthalmoplegia, and increased leg reflexes with normal arm reflexes can all be indications of prior multiple sclerosis demyelinating episodes.

The next most important elements of the exam are found in the general exam. Patients with undetermined focal mass lesions require a careful lung, breast, skin, and gastrointestinal exam to assess for lumps or masses suggestive of malignancy.

The breast exam is also helpful to assess for gynecomastia, which can occur with pituitary adenoma. Skin examination may also be helpful to look for herpes simplex rashes, melanoma, Kaposi sarcoma, or peripheral manifestations of bacterial endocarditis such as Janeway lesions (nontender, small erythematous macular lesions on the palms or soles only a few millimeters in diameter that are indicative of infective endocarditis).

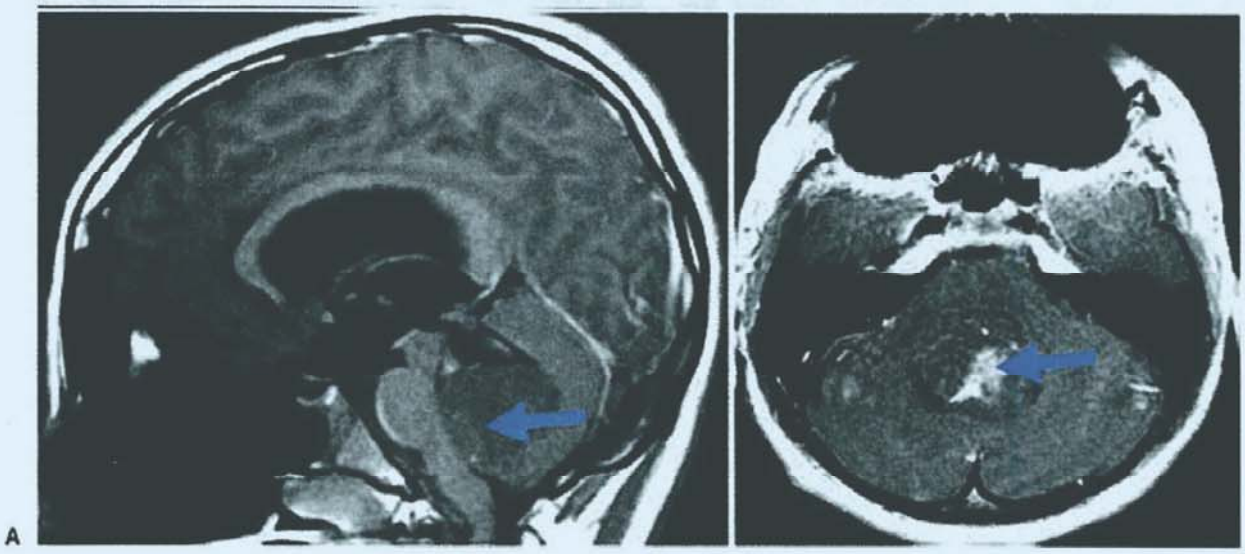

FIGURE 18.9 Medulloblastoma with distortion of the fourth ventricle and secondary hydrocephalus. **A:** Hypointense on T1. **B:** Nodular partial gadolinium enhancement within the tumor.

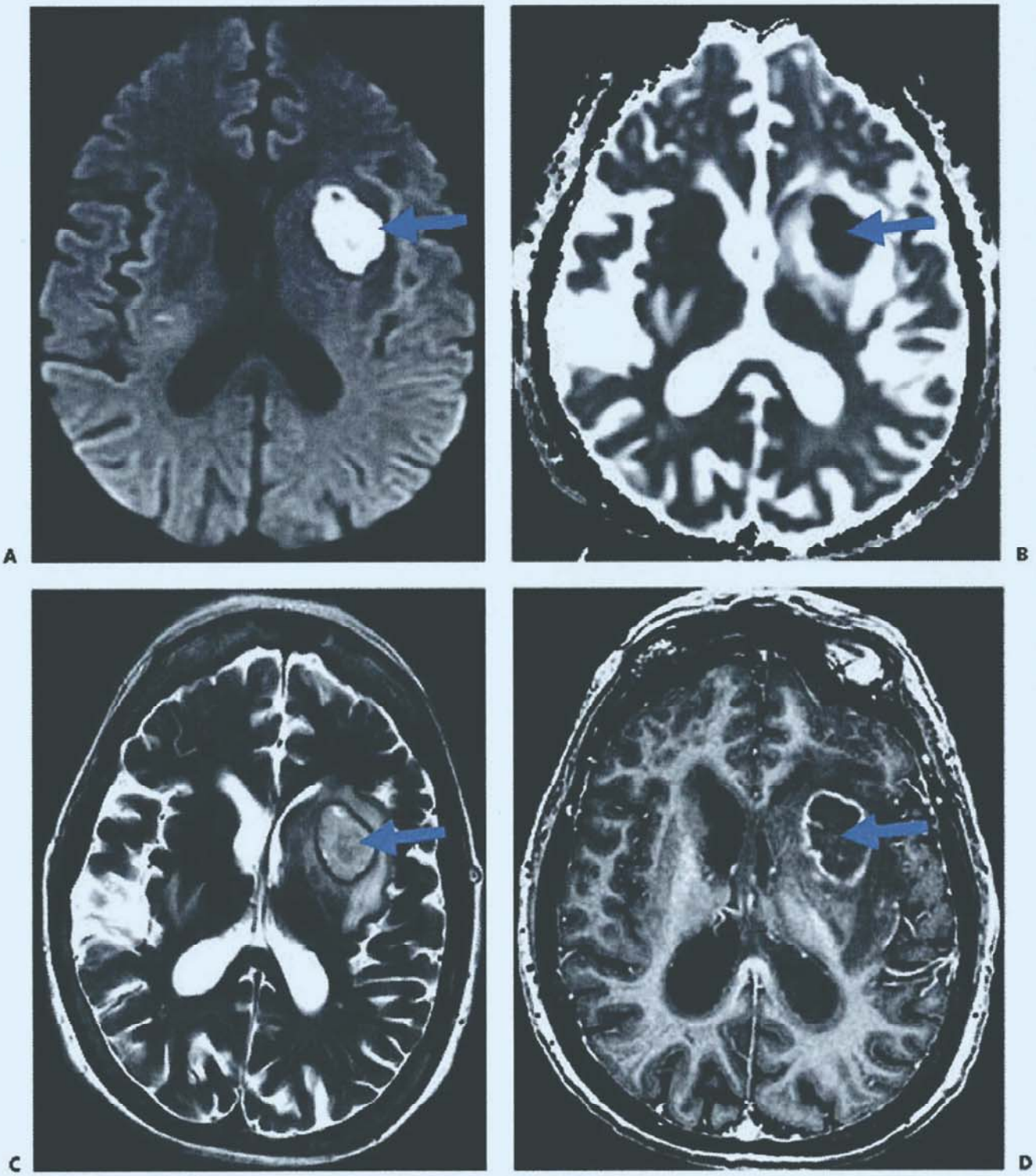

FIGURE 18.10 Left basal ganglia abscess. Bright on diffusion-weighted imaging **(A)** with restricted apparent diffusion coefficient **(B)** which appears dark, consistent with central necrosis. T2 images show hyperintense core and a hypointense ring **(C)** and postcontrast T1 image shows sharply demarcated thin rim enhancement postcontrast **(D)**.

TABLE 18.3 Common Infectious Etiologies of Mass Lesions

	Clinical Pearls	Imaging Features	CSF Studies and Systemic Workup

Bacterial abscess	Most abscesses in immunocompetent individuals are bacterial.
	Only 50% of patients have fever on initial presentation.
		• Characterized on T2 imaging as hyperintense core and hypointense ring, both of which restrict on DWI.
		• Ring enhancement with contrast imaging
		• MRS features
		  • Pyogenic aerobic abscess: Amino acids, lactate, and lipid are elevated.
		  • Pyogenic anaerobic abscess: Succinate and acetate are elevated.
		  • TB: Only lipid is elevated.
			• Blood cultures
			• Transesophageal echocardiography to detect a valvular vegetation
			• LP may reveal concurrent meningitis.

Tuberculoma	When the caseous core of the tuberculoma liquefies, a tuberculous abscess results.	CT appearance • Solid-enhancing, ring-enhancing, or mixed lesions • Occasionally, there is the "target sign," which is pathognomonic of TB: central calcification surrounded by a hypodense area with peripheral ring enhancement. MRI appearance • DWI: no abnormalities or can be bright with restriction like a bacterial abscess • T1: isointense in gray matter with a hyperintense ring • T2: noncaseating: hyperintense with nodular enhancement; caseating: iso-/hypointense with ring enhancement	• Tuberculin skin test is positive in up to 85% of patients. • Chest CT suggests pulmonary TB in 50%-80% of patients.
Gummatous neurosyphilis	Histology reveals that the central portion of the mass is necrotic material, and the peripheral region is infiltrated with plasma cells.	• CNS gummas can arise from the meningeal surfaces and extend directly into the brain or may arise directly from the parenchyma. • Presents as a ring-enhancing mass lesion	• Serum RPR and FTA-ABS • CSF VDRL
Viral encephalitis	HSV-1 only rarely causes a typical vesicular skin eruption in the setting of meningitis.	• DWI sequences on MRI are most sensitive for detecting tissue injury from encephalitis. • Herpes encephalitis can cause significant swelling and mass effect of the temporal lobes, mimicking tumor.	• CSF shows lymphocytic pleocytosis with normal or decreased glucose but can be normal.
Fungal	Immunocompromised • Aspergillosis • Cryptococcosis • Candida • Mucormycosis • Nocardia Immunocompetent • *Blastomyces* • *Histoplasma* • *Coccidioides*	• DWI shows restricted diffusion in the wall of a fungal abscess. Typically, the core does not show restriction (unlike in a bacterial abscess). • MRS can show increased trehalose, amino acids, and lactate. • Anatomic predilations • *Cryptococcus*: predominately in midbrain and basal ganglia • Coccidioidomycosis: predilection for the cerebellum • Mucormycosis: rim of soft-tissue thickness along the walls of the paranasal sinus. In some cases, bony destruction is present. • Nocardial: enhancing capsule containing multiple loculations • Aspergillosis: Aggressive forms manifest as meningoencephalitis; less aggressive forms manifest as solitary abscess or isolated granulomas.	• CSF shows lymphocytic predominance, although neutrophils may predominate early in the course. • Histoplasmosis causes CSF mononuclear pleocytosis. • *Coccidioides* may cause CSF eosinophilia.

(table continues on page 162)

TABLE 18.3 Common Infectious Etiologies of Mass Lesions *(continued)*

	Clinical Pearls	Imaging Features	CSF Studies and Systemic Workup
Helminthic infection	Travel history • Coenurosis cerebralis: sheep-raising areas North America/Europe/South America/Africa • Cysticercosis: endemic in Latin America, sub-Saharan Africa, and some regions of Asia • *Echinococcus granulosus*: reported in the Americas as well as Mediterranean countries • *Ascaris*: endemic in North America. Hosts are raccoons. • *Paragonimus*: Asia and South Pacific Islands • *Schistosoma japonicum*: Southeast Asia • *Spirometra*: Southeast Asia and the Americas • *Toxocara*: worldwide • *Trichinella*: worldwide • *Strongyloides*: Latin America, Caribbean, Africa, Asia	Cyst-forming • Coenurosis • Cysticercosis • *Echinococcus granulosus* Granuloma-forming • *Ascaris* • *Paragonimus* • *Schistosoma japonicum* • *Spirometra* • *Toxocara* • *Trichinella* Abscess • *Strongyloides*	CSF shows lymphocytic predominance except: • *Trichinella*, which demonstrates eosinophilic pleocytosis • *Strongyloides*, which demonstrates a neutrophilic pleocytosis
Protozoal infections	Immunosuppressed • *Acanthamoeba*: transmitted via swimming in freshwater pools • Toxoplasmosis: transmitted via food or congenitally • *Entamoeba histolytica* is associated with liver abscess.	Granulomatous encephalitis • *Acanthamoeba* • Toxoplasmosis Brain abscess • *Entamoeba histolytica*	• *Acanthamoeba* • CSF protein and glucose usually normal • Toxoplasmosis • The presence of IgG antibodies indicates prior exposure to the parasites and potential for reactivation.

Abbreviations: CNS, central nervous system; CSF, cerebrospinal fluid; CT, computed tomography; DWI, diffusion-weighted imaging; FTA-ABS, fluorescent treponemal antibody absorption; LP, lumbar puncture; HSV-1, herpes simplex virus 1; IgG, immunoglobulin G; MRI, magnetic resonance imaging; MRS, magnetic resonance spectroscopy; RPR, rapid plasma reagin; TB, tuberculosis; VDRL, Venereal Disease Research Laboratory.

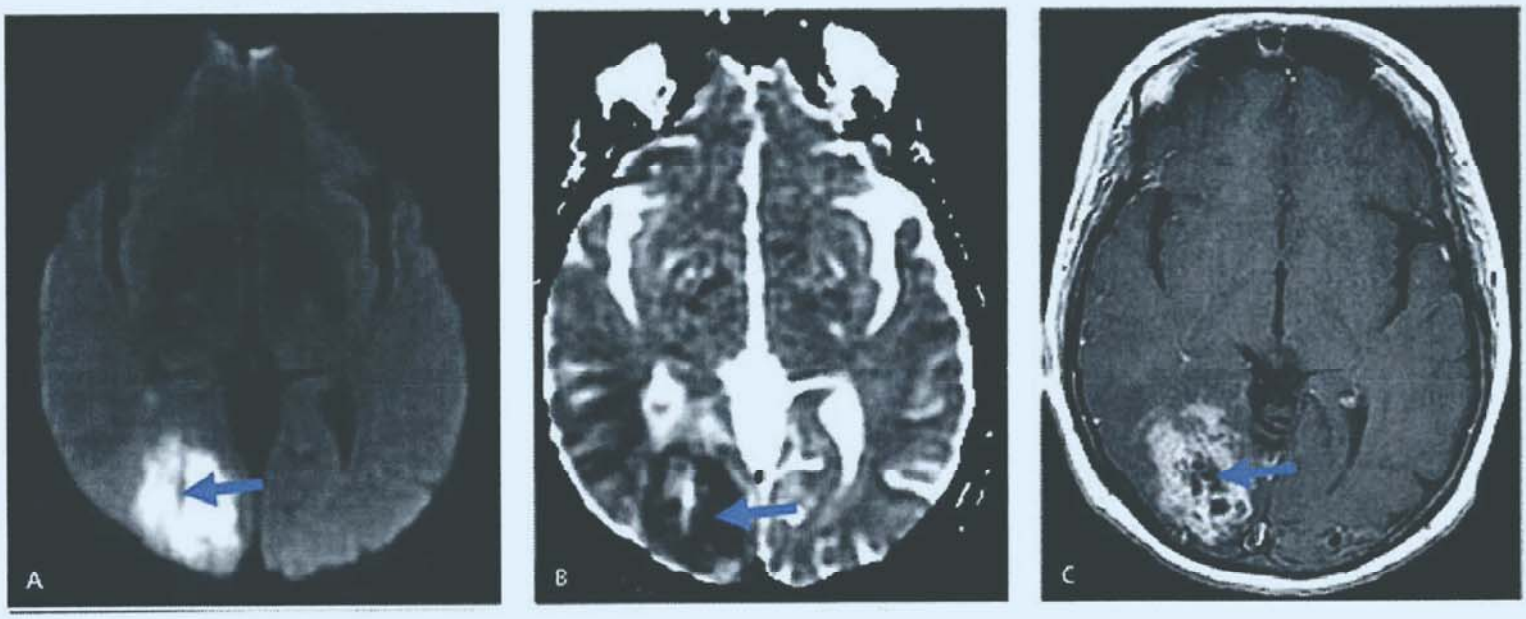

FIGURE 18.11 Focal *Aspergillus* infection with little edema or mass effect. **A:** Bright on diffusion-weighted imaging with restriction. **B:** Dark on apparent diffusion coefficient suggesting necrosis. **C:** Heterogeneous coarse irregular enhancement on T1 with gadolinium.

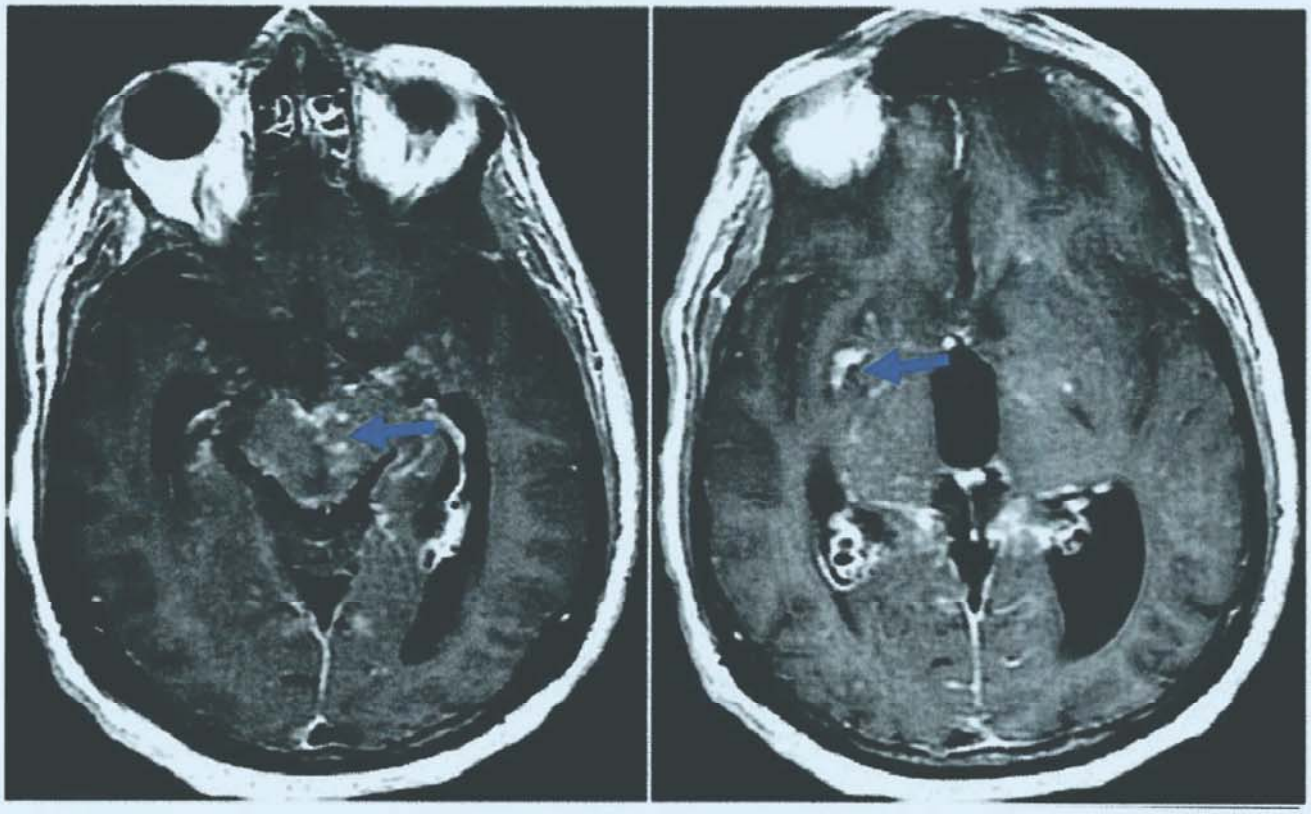

FIGURE 18.12 Cryptococcal meningitis with hydrocephalus and small punctate areas of enhancement in the midbrain **(A)** and basal ganglia **(B)** on T1-enhanced imaging.

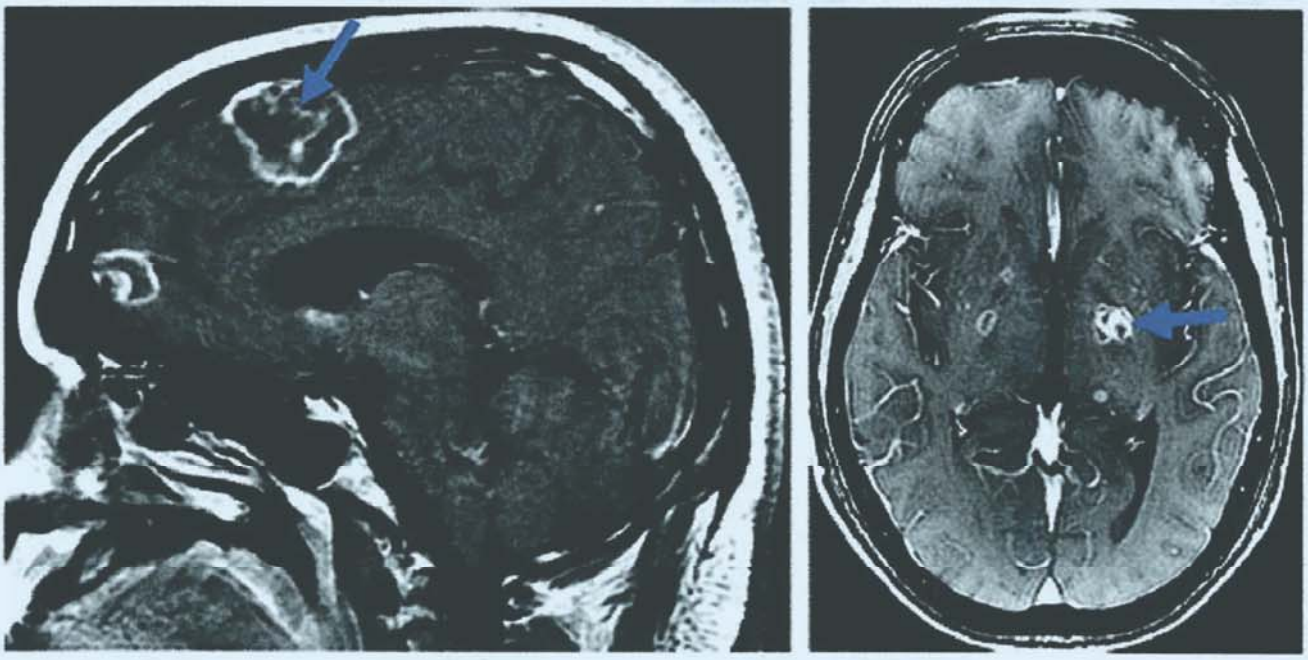

FIGURE 18.13 Toxoplasmosis. Multiple ring-enhancing lesions in the cortex **(A)** and basal ganglia **(B)** on T1 imaging with gadolinium.

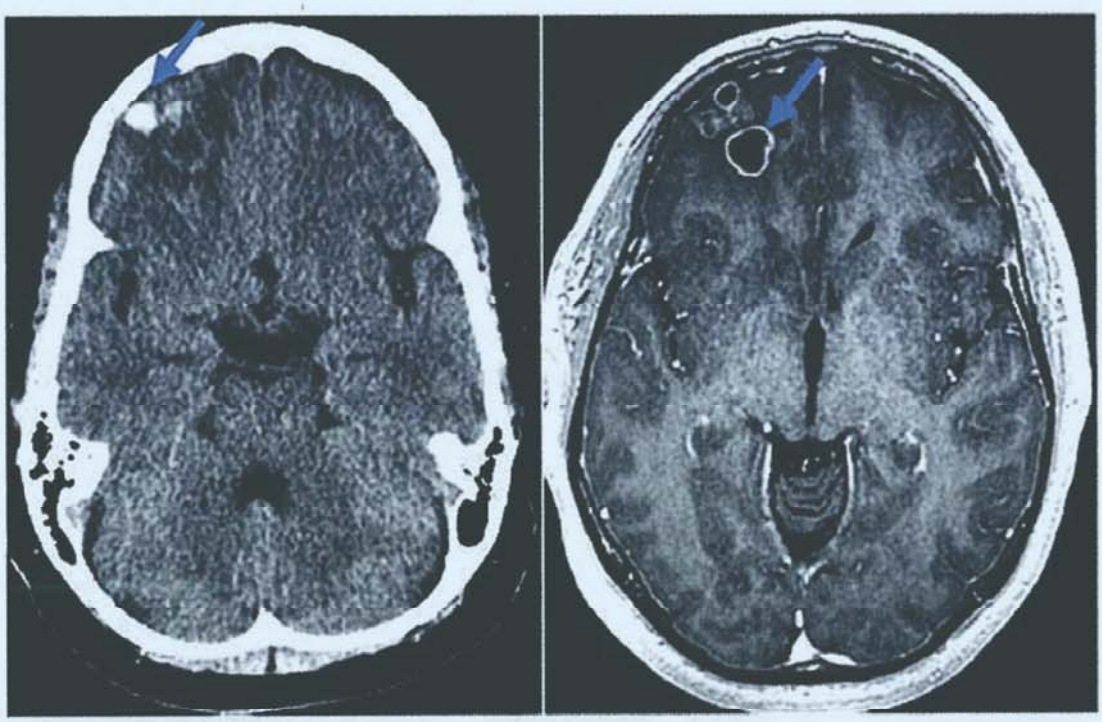

FIGURE 18.14 Cysticercosis. **A:** Partially calcified right frontal lesion with a 1-cm ringlike lesion on noncontrast computed tomography. **B:** Multiple cortical ring-enhancing cystic lesions in T1 gadolinium-enhanced imaging.

FIGURE 18.15 Herpes simplex virus 1 encephalitis. Fluid attenuated inversion recovery image showing characteristic edema and swelling of right medial temporal lobe.

DIAGNOSIS

The diagnostic cornerstones for brain masses are imaging, lumbar puncture, and biopsy.

Imaging

Usually, a computed tomography (CT) scan (see Chapter 21) is the first radiographic study performed when a patient presents with a new neurologic symptom. Most focal brain lesions from tumor or abscess tend to be hypodense on CT. Admixture of heterogenous hyperdense signal usually represents hemorrhage into a tumor (typically glioblastoma multiforme) or less commonly an abscess. A homogenous hyperdense pattern can result from melanoma, medulloblastoma, or meningioma. Calcification, usually punctate, occurs in 40% of ependymomas, 20% of meningiomas, and 10% of medulloblastomas. Tuberculomas have a pathognomic "target sign" resulting from central calcification surrounded by a hypodense area with peripheral ring enhancement with IV contrast.

Although the CT scan can sometimes be helpful, an MRI (see Chapter 22) is always recommended unless there is a contraindication (eg, pacemaker). The important MRI sequences are diffusion-weighted imaging, fluid-attenuated inversion recovery (FLAIR), susceptibility-weighted imaging, T1 precontrast, and T1 postcontrast. Important imaging features are reviewed in Table 18.1.

Magnetic resonance spectroscopy is sometimes pursued, although its use is limited. Primary brain tumors are classically thought of as having an increased choline/*N*-acetylaspartate ratio (with ratio >2 suggestive of a high-grade tumor). In high-grade brain tumors, the surrounding FLAIR hyperintensity is thought to represent infiltrative tumor and also has an elevated

TABLE 18.4 Select Inflammatory Causes of Focal Brain Lesions

	Clinical Pearls	Imaging Features	CSF Studies and Systemic Workup
Sarcoidosis	• Sarcoidosis primarily occurs in the third and fourth decade. • Five percent of cases of systemic sarcoid have neurologic involvement.	• Intraparenchymal sarcoid masses may or may not enhance. • Nodules may be calcified, have an increased density, or be isodense and can occur throughout the brain parenchyma. • Nodular meningeal enhancement is common. • The nodules are not usually associated with edema. • Sarcoid nodules do not cavitate as frequently as tuberculosis.	• Chest CT • Gallium scan • Lacrimal gland biopsy • CSF and serum ACE activity
Whipple disease	• Mean age of onset is around 50 y. • Men are more commonly affected (80%). • In about 5% of the cases, the presentation is solely neurologic. In other cases, the small bowel is involved. • Granuloma formation is a delayed hypersensitivity to Whipple disease.	• The lesions are in the gray matter, in the basal part of the telencephalon, the hypothalamus, and the thalamus.	• *Tropheryma whippelii* PCR • Small bowel biopsy
Behçet disease	• Most common in the countries around the eastern shores of the Mediterranean, the Middle East, and Eastern Asia • Mean age of onset of neurologic symptoms is about 30 y of age. • Triad of recurrent genital ulcerations, skin or eye lesions, and meningitis	• Predilection for brainstem • Enhancement may occur as a ring or nodule.	• May also present as cortical vein thrombosis or isolated increased intracranial pressure
Tumefactive multiple sclerosis	• Mean age of onset is approximately 35 y of age. • The female-to-male prevalence is 1.2:1. • May have had previous neurologic symptoms isolated in space and time supportive of multiple sclerosis as a diagnosis	• Demyelinating lesion ≥2 cm in size • Incomplete ring enhancement open on the gray matter side of the lesion • Does not restrict on DWI • Magnetic resonance perfusion normal	• C-spine MRI

Abbreviations: ACE, angiotensin-converting enzyme; CSF, cerebrospinal fluid; CT, computed tomography; DWI, diffusion-weighted imaging; MRI, magnetic resonance imaging; PCR, polymerase chain reaction.

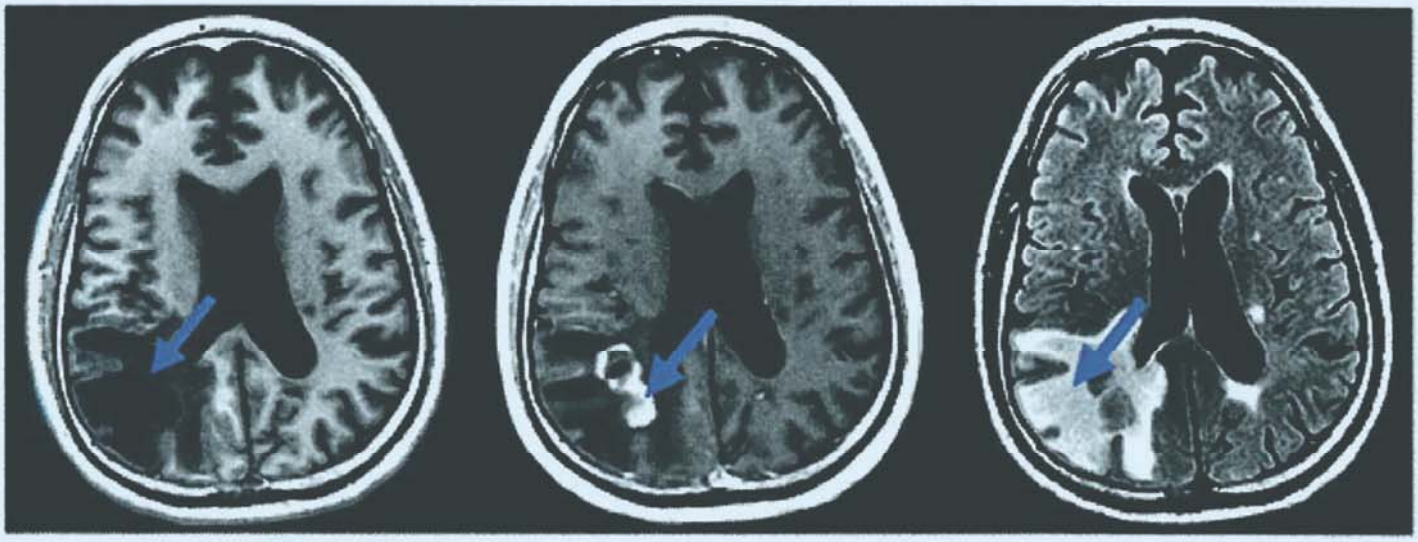

A,B C

FIGURE 18.16 Tumefactive multiple sclerosis. **A:** T1 image showing an intense hypodensity in the right parietal lobe. **B:** Gadolinium enhancement of the T1 image shows nodular ring enhancement in the core of the lesion, indicating acute inflammation and demyelination. **C:** Fluid attenuation inversion recovery image showing vasogenic edema infiltrating the surrounding cortex. Note also the periventrivcular lesions in the left hemisphere.

choline/*N*-acetylaspartate ratio, whereas in metastatic tumor, this surrounding FLAIR hyperintensity is thought to represent vasogenic edema and therefore has a low choline level. Additionally, lactate is thought to be very elevated in infections, although it can also be elevated in necrotic tumors, making the distinction somewhat difficult.

Brain positron emission tomography (PET) scans (see Chapter 23) can be helpful in distinguishing between radiation necrosis and recurrent tumor in that radiation necrosis is hypometabolic and recurrent tumor is hypermetabolic. The PET scan would also demonstrate increased metabolism in a high-grade tumor as opposed to a low-grade tumor. PET scans, however, have poor spatial resolution and are not useful for lesions smaller than 1 cm.

Whole-body CT scanning should be pursued whenever metastatic disease is being entertained.

Lumbar Puncture and Biopsy

Lumbar puncture (see Chapter 32) is an essential part of the neurologic examination in patients with intracranial mass lesions. CSF examination can reveal an infectious organism or the presence of malignant cells by cytology when central nervous system lymphoma, germ cell tumors, or carcinomatous meningitis is suspected.

For most primary brain tumors, however, lumbar puncture is not diagnostic, and when there is evidence of impending herniation, it is also not safe. CSF in the setting of cerebral abscess formation is often nondiagnostic. An important exception is in patients with HIV/AIDS who often can be infected with multiple opportunistic infections. In the case of encephalitis, whether viral, parasitic, or fungal, lumbar puncture is essential for establishing the diagnosis. Lumbar puncture is also routinely performed for the diagnosis of inflammatory masses resulting from sarcoidosis or multiple sclerosis.

The diagnostic method of choice for suspected malignancy or abscess is tissue biopsy or CT-guided drainage and culture, respectively (see Chapter 33). Eventually, the majority of patients with suspected brain tumor are diagnosed by pathologic examination of surgically resected tissue as the result of a diagnostic biopsy or as part of a partial debulking or gross total resection of the lesion.

INITIAL MANAGEMENT

If imaging reveals significant vasogenic edema, corticosteroids can be used to prevent further neurologic injury in the case of impending herniation or for symptomatic relief if the cause is felt to be tumor or abscess LEVEL 3.[5] Most often, the corticosteroid regimen is dexamethasone 10 mg IV as an initial dose followed by 4 to 6 mg every 6 hours LEVEL 2.[6] Use of steroids should be avoided when PCNSL is a main consideration because steroids can significantly lead to loss of the main histologic findings if the lesion is biopsied LEVEL 3.[7]

One situation in which lymphoma should be seriously considered is the case of the AIDS patient (CD4 <100/μL). In this case, the two most common etiologies of enhancing focal mass lesions are toxoplasmosis and PCNSL. **Figure 18.17** outlines an algorithm for managing to diagnosis, and **Table 18.5**

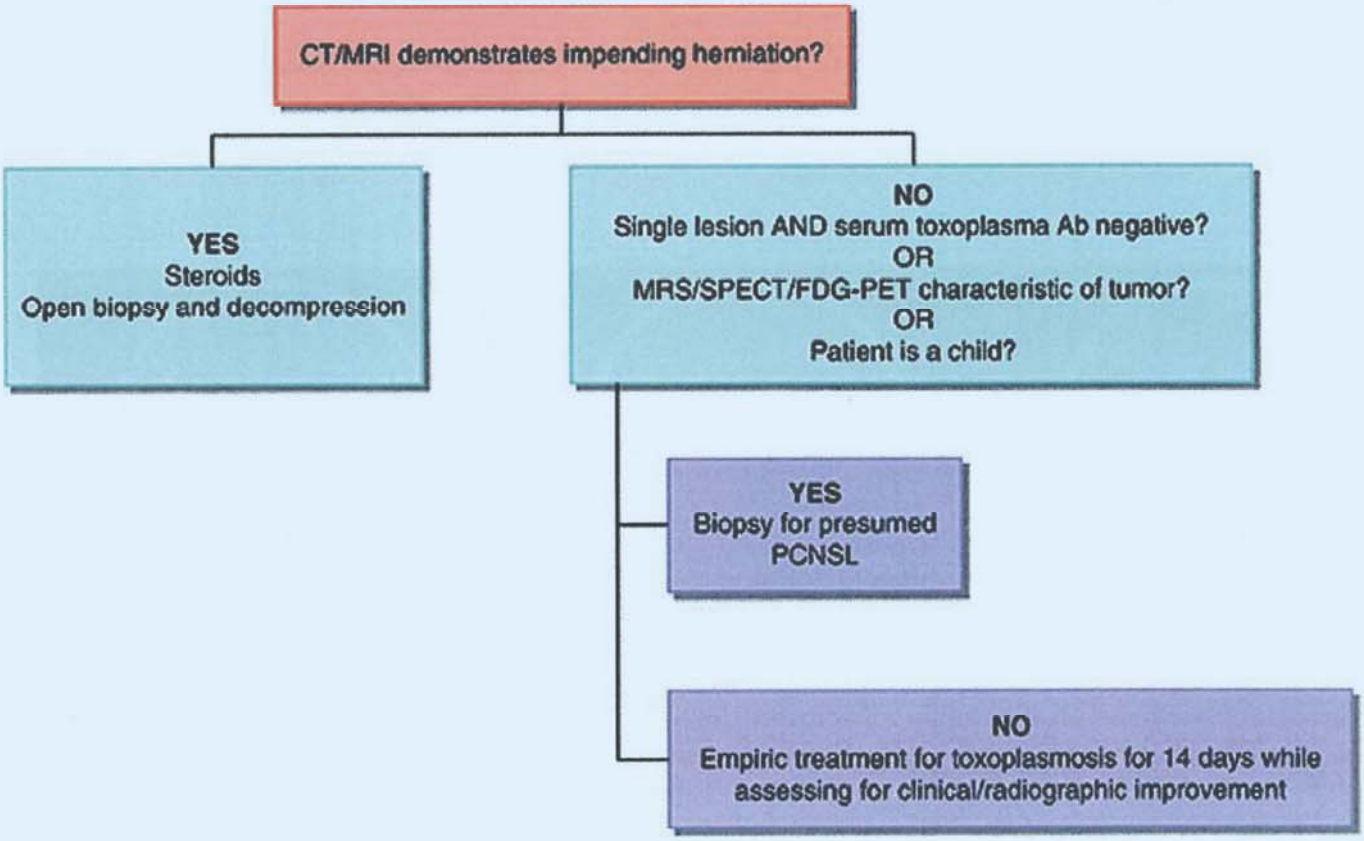

FIGURE 18.17 Algorithm for diagnosis and management of enhancing mass lesions in an AIDS patient. Abbreviations: CT, computed tomography; FDG-PET, ^{18}F-fluorodeoxyglucose positron emission tomography; MRI, magnetic resonance imaging; MRS, magnetic resonance spectroscopy; PCNSL, primary central nervous system lymphoma; SPECT, single-photon emission computed tomography.

TABLE 18.5 Imaging Differences Between Lymphoma and Toxoplasmosis

Lymphoma	Toxoplasmosis
Periventricular propensity	Basal ganglia propensity
Hypodense on T2/FLAIR	Hyperdense on T2/FLAIR
Single or multiple lesions	Lesions more numerous and smaller than lymphoma lesions
Does not tend to bleed except after steroids	May bleed pretreatment
Thallium spectroscopy and MR perfusion demonstrate increased uptake.	Thallium spectroscopy and MR perfusion demonstrate decreased uptake.
MR spectroscopy shows moderately elevated lactate and lipid and markedly elevated choline.	MR spectroscopy shows markedly elevated lactate and lipid.

Abbreviations: FLAIR, fluid-attenuated inversion recovery; MR, magnetic resonance.

outlines the imaging differences between lymphoma and toxoplasmosis. The standard approach is to withhold steroids unless absolutely necessary and proceed directly to biopsy in patients at high risk for PCNSL and otherwise to proceed with empiric therapy for toxoplasmosis. Therapy for toxoplasma encephalitis is oral pyrimethamine (adults: an initial loading dose of 50-200 mg followed by 25-50 mg/d; children: 2 mg/kg/d administered in divided doses every 12 h for 1-3 d, then 1 mg/kg daily or as divided doses every 12 h to a maximum of 25 mg/d) and sulfadiazine (adults: 6-8 g/d divided into four equal doses; children: 120 mg/kg/d in divided doses every 6 h in doses not to exceed the adult dose). Individuals allergic to sulfadiazine may be desensitized to sulfadiazine or alternatively treated with clindamycin 2,400 mg/d in three equal doses LEVEL 1.[8] Other treatment alternatives include atovaquone or azithromycin. In conjunction with the antitoxoplasmosis agents, folinic acid (5-10 mg/d) is concurrently administered to diminish bone marrow suppression. Regression of the lesion on follow-up magnetic resonance or CT confirms the diagnosis of toxoplasmosis. The total duration of therapy is at least 6 weeks and longer if the clinical response is incomplete at that time.

Another question that frequently arises in patients with new-onset mass lesions is whether to initiate antiepileptic treatment. Generally, unless the patient has had a seizure, antiepileptic treatment is not recommended LEVEL 1.[9,10] If the patient has significant increase in ICP with impending herniation, it is reasonable to initiate antiepileptic treatment even without a clinical history of a seizure. The thought in this circumstance is that by causing an increased cerebral metabolic demand, a seizure can lead to further increase in ICP and herniation.

LEVEL 1 EVIDENCE

1. Feldman Z, Kanter MJ, Robertson CS, et al. Effect of head elevation on intracranial pressure, cerebral perfusion pressure, and cerebral blood flow in head-injured patients. *J Neurosurg*. 1992;76(2):207-211.
2. Battison C, Andrews PJ, Graham C, Petty T. Randomized, controlled trial on the effect of a 20% mannitol solution and a 7.5% saline/6% dextran solution on increased intracranial pressure after brain injury. *Crit Care Med*. 2005;33(1):196-202.
3. Francony G, Fauvage B, Falcon D, et al. Equimolar doses of mannitol and hypertonic saline in the treatment of increased intracranial pressure. *Crit Care Med*. 2008;36(3):795-800.
4. Rangel-Castilla L, Gopinath S, Robertson CS. Management of intracranial hypertension. *Neurol Clin*. 2008;26(2):521-541.
5. Alberti E, Hartmann A, Schütz HJ, Schreckenberger F. The effect of large doses of dexamethasone on the cerebrospinal fluid pressure in patients with supratentorial tumors. *J Neurol*. 1978;217(3):173.
6. Koehler PJ. Use of corticosteroids in neuro-oncology. *Anticancer Drugs*. 1995;6(1):19-33.
7. Önder E, Arıkök AT, Önder S, et al. Corticosteroid pre-treated primary CNS lymphoma: a detailed analysis of stereotactic biopsy findings and consideration of interobserver variability. *Int J Clin Exp Pathol*. 2015;8(7):7798-7808.
8. Katlama C, De Wit S, O'Doherty E, Van Glabeke M, Clumeck N. Pyrimethamine-clindamycin vs. pyrimethamine-sulfadiazine as acute and long-term therapy for toxoplasmic encephalitis in patients with AIDS. *Clin Infect Dis*. 1996;22(2):268-275.
9. Sirven JI, Wingerchuk DM, Drazkowski JF, Lyons MK, Zimmerman RS. Seizure prophylaxis in patients with brain tumors: a meta-analysis. *Mayo Clin Proc*. 2004;79:1489-1494.
10. Kong X, Guan J, Yang Y, Li Y, Ma W, Wang R. A meta-analysis: do prophylactic antiepileptic drugs in patients with brain tumors decrease the incidence of seizures? *Clin Neurol Neurosurg*. 2015;134:98-103.

SUGGESTED READINGS

American Academy of Neurology. Evaluation and management of intracranial mass lesions in AIDS: report of the Quality Standards Subcommittee of the American Academy of Neurology. *Neurology*. 1998;50(1):21-26.

Beckham J, Tyler K. Neuro-intensive care of patients with acute CNS infections. *Neurotherapeutics*. 2012;9(1):124-138.

Kennecke H, Yerushalmi R, Woods R, et al. Metastatic behavior of breast cancer subtypes. *J Clin Oncol*. 2010;28(20):3271-3277.

Prasad G, Haas-Kogan D. Radiation-induced gliomas. *Expert Rev Neurother*. 2009;9(10):1511-1517.

Roser F, Rosahl SK, Samii M. Single cerebral metastasis 3 and 19 years after primary renal cell carcinoma: case report and review of the literature. *J Neurol Neurosurg Psychiatry*. 2002;72(2):257-258.

Schuette W. Treatment of brain metastases from lung cancer: chemotherapy. *Lung Cancer*. 2004;45(suppl 2):S253-S257.

Tan WS, Ho KS, Eu KW. Brain metastases in colorectal cancers. *World J Surg*. 2009;33(4):817-821.

19 Stupor and Coma

Jan Claassen and John C. M. Brust

KEY POINTS

1. Disorders of consciousness include abnormal arousal and awareness
2. Clinically disorders of consciousness are classified into coma, vegetative state/unresponsive wakefulness syndrome, and minimally conscious state
3. Classic herniation syndromes can be identified based on clinical examination
4. Impaired consciousness results from supra and infratentorial structural lesions, and metabolic or diffuse brain injury
5. Recovery from coma involves a variety of mechanisms that result in restored excitatory neurotransmission across long corticocortical, thalamocortical and thalamostriatal connections

INTRODUCTION

"Normal human consciousness consists of a serially, time-ordered, organized, restricted, and reflective awareness of self and the environment. Moreover, it is an experience of graded complexity and quantity." Schiff and Plum, *J Clin Neurophys*, 2000.

Philosophical and religious frameworks may influence definitions of consciousness. Consciousness is classically defined as awareness of self and the environment and requires both arousal (ie, wakefulness) and cognitive content (ie, thoughts and perceptions).

Coma is a state of unconsciousness that differs from sleep in that it represents a neurologic deficit and is not readily reversed. Brain metabolism is normal in sleep, and brain electrical activity progresses thorough organized stages of synchronized activity on electroencephalography (EEG). In coma, brain metabolism is abnormally reduced, and EEG activity progressively slows and becomes attenuated, with loss of normal reactivity to sensory stimuli.

DEFINITIONS

Coma is clinically defined by the neurologic examination, especially responses to external stimuli. Terms such as *lethargy*, *obtundation*, *stupor*, and *coma* usually depend on the patient's response to normal verbal stimuli, shouting, shaking, or pain. Some of these terms such as obtundation are not rigidly defined, and it is useful to record both the response and the stimulus that elicited it. Occasionally, the true level of consciousness may be difficult or impossible to determine due to coexisting behavioral disturbances (ie, catatonia in severe depression) or neurologic deficits (ie, akinesia plus aphasia) that blunt responses to stimuli.

The chronicity of the impaired mental status differentiates acute disorders of consciousness such as stupor and coma from their long-term correlates: the chronic disorders of consciousness known as *unresponsive wakefulness syndrome* (UWS) or *vegetative state* (VS) and minimally conscious state (MCS). UWS/VS is characterized by arousal (ie, eyes open) without awareness (ie, lack of the ability to follow verbal commands).

MCS differs from VS in that the patient demonstrates low-level awareness (eg, visual pursuit or inconsistent command following) with the presence or absence of language function distinguishing between MCS plus and minus, respectively. Cognitive motor dissociation represents a state in which task specific brain activity can be detected using functional magnetic resonance imaging (MRI) or EEG in behaviorally unresponsive patients.

Induced states of altered consciousness such as those seen during general anesthesia or with sedation in the intensive care unit (ICU) share some similarities with coma induced by brain injury and may confound the assessment of comatose patients. Sedatives are frequently required in critically ill patients to facilitate ventilator management or to manage pain or agitation. *Accurate neurologic assessments of the level of consciousness in the ICU are challenging in the context of these confounders, and sedation can not safely be interrupted in all patients (ie, risk of elevated intracranial pressure* [ICP]). For this reason, short-acting continuous infusion agents such as propofol, midazolam, or fentanyl are preferred, and novel ways of assessing consciousness such as EEG are investigated.

Confusional state and *delirium* are terms that refer to a state of inattentiveness, altered cognitive content, and sometimes hyperactivity, rather than to a decreased level of arousal; these states may be seen in the context of emergence from coma.

NEUROANATOMY

Widespread areas spanning the brainstem (particularly the reticular activating system), basal ganglia (particularly central thalamic nuclei that diffusely project with striatopallidal modulation), and the cortex are fundamental to support a conscious state. Location for classic structural brain lesions associated with stupor and coma have been derived from lesion studies and more recently confirmed and expanded based on structural and functional brain imaging studies such as diffusion tensor and resting state MRI (Fig. 19.1).

MANAGEMENT STRATEGY

A suggested algorithm for the initial management of new-onset coma is shown in Figure 19.2.

Initial Resuscitation

Initial management of the comatose patient should always focus on the airway, breathing, and circulation. Assuring a patent airway, securing adequate ventilation, and restoring or

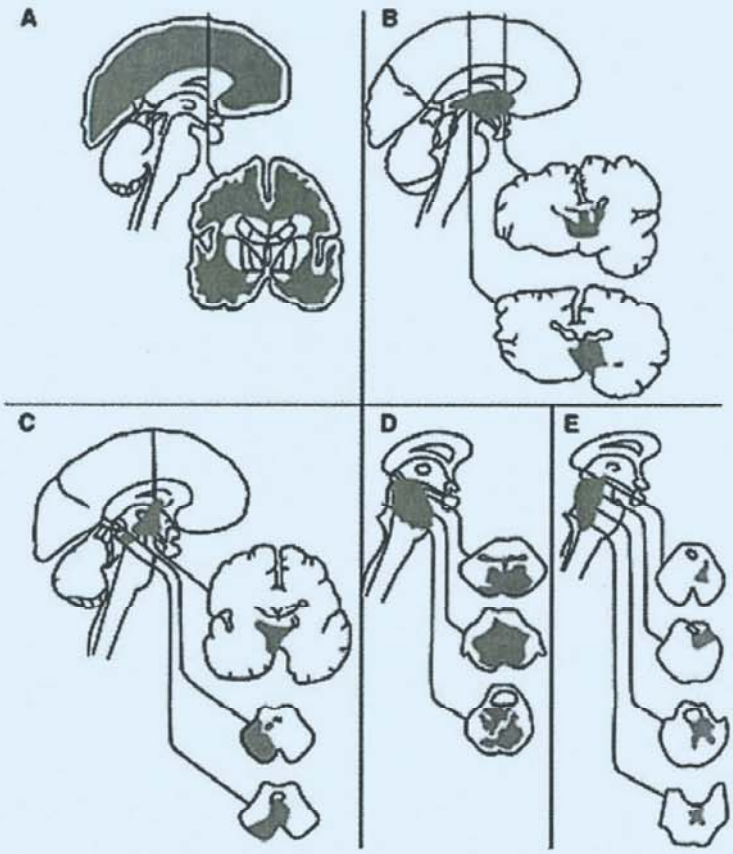

FIGURE 19.1 Anatomy of coma. Classic brain lesions that cause coma include those located diffuse bihemispheric **(A)**, diencephalic **(B)**, paramedian caudal midbrain and caudal diencephalic **(C)**, high pontine and lower midbrain paramedian tegmental regions **(D)**, and pontine **(E)**. (From Posner JB, Saper CB, Schiff ND, Claassen J. *Plum and Posner's Diagnosis and Treatment of Stupor and Coma*. 5th ed. New York, NY: Oxford University Press; 2019.)

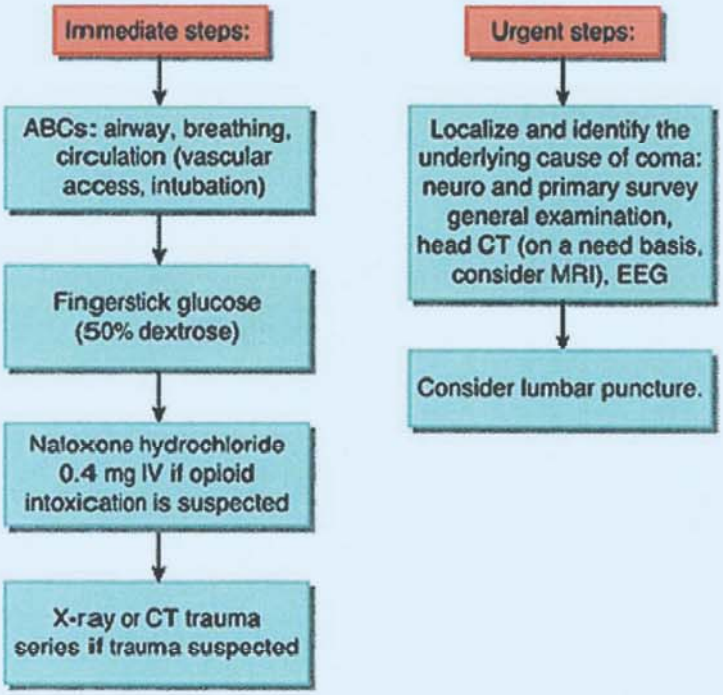

FIGURE 19.2 Management algorithm for new-onset coma. Abbreviations: CT, computed tomography; EEG, electroencephalography; IV, intravenous; MRI, magnetic resonance imaging.

maintaining circulation should take precedence as it does with any critically ill patient. Vascular access needs to be obtained as soon as possible and may include central venous access and large-bore peripheral access. Detection and treatment of immediately life-threatening systemic conditions may include stopping a hemorrhage; supporting the circulation by administration of fluids, blood products, or pressors; intubation when necessary (eg, to prevent aspiration in a patient who is vomiting); and obtaining an electrocardiogram to detect dangerous arrhythmias. Fingerstick glucose should be obtained immediately and if in doubt, 50% dextrose should be given intravenously with parenteral thiamine. (Administering glucose alone to a thiamine-deficient patient can precipitate Wernicke-Korsakoff syndrome.) When opioid overdose is a possibility, naloxone hydrochloride (Narcan) 0.4 mg intravenous is given. If trauma is suspected, damage to internal organs and cervical fracture should be assumed until radiographs determine otherwise, and emergency ultrasound scanning (ie, focused assessment with sonography for trauma) or other imaging has ruled out major internal bleeding or organ injury.

History and General Physical Examination

The next step is to localize and identify the underlying cause of coma. A history is obtained from whoever accompanies the patient, including emergency medical service providers. **Table 19.1** lists a number of practical pearls to look for that can aid in the diagnosis of nontraumatic coma. Order an emergent EEG to evaluate for nonconvulsive seizures or status epilepticus if even minor involuntary facial or extremity twitching is observed or the imaging and laboratory studies do not conclusively identify the impairment of consciousness.

Focused Neurologic Examination

In their classic monograph, Plum and Posner divided the causes of coma into supra- and infratentorial structural lesions and diffuse or metabolic diseases. By concentrating on motor responses to stimuli, respiratory patterns, pupils, and eye movements, the clinician can usually localize the cause and identify the category of coma. This is helpful to guide the immediate approach to the patient because the majority of patients have nonstructural causes of coma. However, immediate computed tomography (CT) imaging should not be delayed because immediate surgical interventions may be lifesaving in patients with structural lesions, such as the placement of an external ventricular drainage catheter in patients with hydrocephalus.

Motor Responses

The patient is observed to assess respiration, limb position, and spontaneous movements. Myoclonus or seizures may be subtle (eg, twitching of one or two fingers or the corner of the mouth). More florid movements, such as facial grimacing, jaw gyrations, tongue protrusion, or complex repetitive limb movements, may defy ready interpretation. Asymmetric movements or postures may signify either focal seizures or hemiparesis.

Assessment of motor tone is crucial in the examination of coma. Asymmetry of muscle tone suggests a structural lesion, but it is not always clear which side is abnormal. *Gegenhalten*, or *paratonia*, is variable resistance to passive movement that often increases with the velocity of the movement; it is attributed to diffuse forebrain dysfunction and is often accompanied by a grasp reflex. *Rigidity* is present throughout the entire range of

TABLE 19.1 Practical Pearls in the Physical Examination of the Comatose Patient

System	Positive Finding
Body temperature	• Fever (implies infection or heatstroke) • Hypothermia (cold exposure, sepsis, cardiac arrest, hypothyroidism, hypoglycemia)
Peripheral pulses	• Asymmetry of pulses suggests dissecting aortic aneurysm.
Head and scalp	• External signs of trauma (eg, mastoid ecchymoses consistent with Battle sign) • Ears and nose are examined for blood or CSF.
Skin, nails, and mucous membranes	• Pallor • Cherry redness (carbon monoxide poisoning) • Cyanosis • Jaundice • Sweating • Uremic frost • Myxedema (dry, flaky, cool skin) • Petechiae • Dehydration • Decubiti • Signs of trauma
Breath	• Acetone • Alcohol • Fetor hepaticus
Optic fundi	• Papilledema (suggests elevated ICP), hypertensive or diabetic retinopathy, retinal ischemia • Roth spots (suggests endocarditis) • Subhyaloid hemorrhages (suggests subarachnoid hemorrhage)
Neck	• Resistance to passive neck flexion but not to turning suggests meningitis, subarachnoid hemorrhage, or foramen magnum herniation. • Resistance to manipulation in all directions suggests bone or joint disease, including fracture.
Urinary or fecal incontinence	• May signify an unwitnessed seizure, especially in patients who subsequently awaken

Abbreviations: CSF, cerebrospinal fluid; ICP, intracranial pressure.

movement, is often seen in combination with cogwheeling, and usually indicates basal ganglia dysfunction (eg, parkinsonism) or symptomatic hydrocephalus. *Spasticity* has a characteristic "catch" midway through passive movement and indicates corticospinal pathway dysfunction. Acute transtentorial herniation often produces exaggerated lower extremity spasticity and clonus.

Motor responses to stimuli may be appropriate, inappropriate, or absent. Even when patients are not fully awake, they may be roused to follow simple commands. Some patients who respond only to noxious stimuli (eg, pressure on the sternum or supraorbital bone; pinching the neck or limbs; or squeezing muscle, tendon, or nail beds) may make voluntary avoidance responses. The terms *decorticate* and *decerebrate* posturing are physiologic misnomers but refer to stereotyped hypertonic flexion or extension in response to noxious stimuli (Fig. 19.3). In *decorticate rigidity*, the arms are flexed, adducted, and internally rotated, and the legs are extended; in *decerebrate rigidity*, the arms and legs are all extended. These postures are most often associated with cerebral hemisphere disease, including hypoxic-ischemic or metabolic encephalopathy, but may follow upper brainstem lesions or transtentorial herniation as well (see later section for a discussion of herniation syndromes). Flexor posturing generally implies a more rostral lesion and has a better prognosis than extensor posturing, but the pattern of response may vary with different stimuli, or there may be flexion of one arm and extension of the other. When these postures seem to occur spontaneously, there may be an unrecognized stimulus (eg, airway obstruction or bladder distention). With continuing rostrocaudal deterioration, there may be extension of the arms and flexion of the legs until, with lower brainstem destruction, there is flaccid unresponsiveness. However, lack of motor response to any stimulus should always raise the possibility of limb paralysis caused by cervical trauma, Guillain-Barré neuropathy, or the locked-in state.

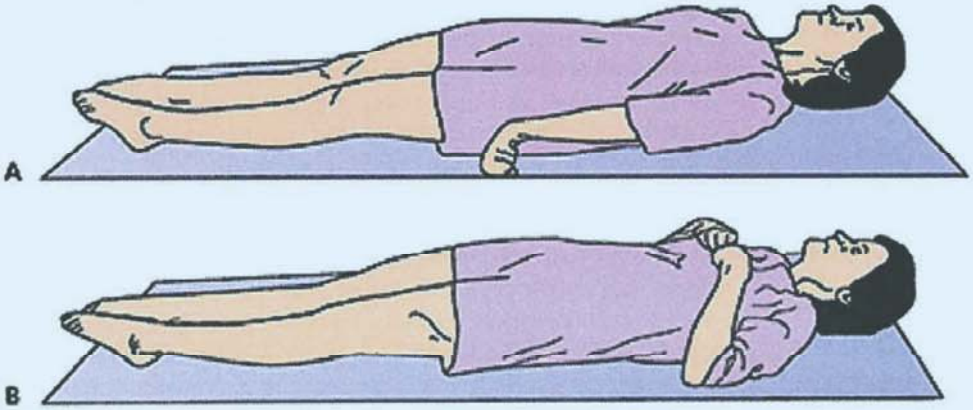

FIGURE 19.3 Decerebrate or extensor posturing **(A)** and decorticate or flexor posting **(B)**.

Respiration

In Cheyne-Stokes respiration (CSR), periods of hyperventilation and apnea alternate in a crescendo-decrescendo fashion. The hyperpneic phase is usually longer than the apneic, so arterial gases tend to show respiratory alkalosis. CSR occurs with bilateral cerebral disease or metabolic encephalopathy. It usually signifies that the patient is not in imminent danger. Long-cycle CSR, with brief periods of apnea occurring every 1 to 2 minutes, is a stable breathing pattern and does not imply impending respiratory arrest. Conversely, "short-cycle CSR" (*cluster breathing*) with less smooth waxing and waning is often an ominous sign of a posterior fossa lesion or dangerously elevated ICP.

Sustained hyperventilation is usually due to metabolic acidosis, pulmonary congestion, hepatic encephalopathy, or during acute herniation (see Fig. 19.3). Rarely, it is the result of a lesion in the rostral brainstem. *Apneustic breathing*, consisting of long inspiratory pauses, is seen with pontine lesions, especially infarction; it occurs infrequently with metabolic coma or transtentorial herniation.

Respiration having a variably irregular rate and amplitude (*ataxic breathing*) indicates medullary damage and may progress to apnea, which also occurs abruptly in acute posterior fossa lesions. Loss of automatic respiration with preserved voluntary breathing (*Ondine curse*) occurs with medullary lesions; as the patient becomes less alert, apnea may be fatal. Other ominous respiratory signs are end-expiratory pushing (eg, coughing) and "fish-mouthing" (ie, lower jaw depression with inspiration). Stertorous breathing (ie, inspiratory noise) is a sign of airway obstruction.

Pupils

Pupillary abnormalities in coma may reflect an imbalance between input from the parasympathetic and sympathetic nervous systems or lesions of both. Although many people have slight pupillary inequality, anisocoria should be considered pathologic in a comatose patient. Retinal or optic nerve damage does not cause anisocoria, even though there is an afferent pupillary defect. Parasympathetic lesions (eg, oculomotor nerve compression in uncal herniation or after rupture of an internal carotid artery aneurysm) cause pupillary enlargement and, ultimately, full dilation with loss of reactivity to light. Sympathetic lesions, either intraparenchymal (eg, hypothalamic injury or lateral medullary infarction) or extraparenchymal (eg, invasion of the superior cervical ganglion by lung cancer), cause Horner syndrome with miosis. With involvement of both systems (eg, midbrain destruction), one or both pupils are in midposition and are unreactive. Small but reactive pupils following pontine hemorrhage are the result of damage to descending intra-axial sympathetic pathways.

With few exceptions, metabolic disease does not cause unequal or unreactive pupils. Fixed, dilated pupils after diffuse anoxia-ischemia denote a bad prognosis. Anticholinergic drugs, including glutethimide, amitriptyline, and antiparkinsonian agents, abolish pupillary reactivity. Hypothermia and severe barbiturate intoxication may cause not only fixed pupils but also a reversible picture that mimics brain death. Bilateral or unilateral pupillary dilation and nonreactivity may accompany (or briefly follow) a seizure. In opiate overdose, miosis may be so severe that a very bright light and a magnifying glass are necessary to detect reactivity. Some pupillary abnormalities are local in origin (eg, trauma or synechiae).

Eyelids and Eye Movements

Spontaneous blinking may occur with or without purposeful limb movements. Eyes that are conjugately deviated away from hemiparetic limbs indicate a destructive cerebral lesion on the side toward which the eyes are directed. Eyes turned toward paretic limbs may indicate a pontine lesion, an adversive seizure, or the wrong-way gaze paresis of thalamic hemorrhage. Eyes that are dysconjugate while at rest may indicate paresis of individual muscles, internuclear ophthalmoplegia, or preexisting tropia or phoria.

When the brainstem is intact, the eyes may rove irregularly from side to side with a slow, smooth velocity; jerky movements suggest saccades and relative wakefulness. Repetitive smooth excursions of the eyes first to one side and then to the other, with 2- to 3-second pauses in each direction (*periodic alternating* or *ping-pong gaze*), may follow bilateral cerebral infarction or cerebellar hemorrhage with an intact brainstem.

If cervical injury has been ruled out, oculocephalic testing (the *doll's eyes maneuver*) is performed by passively turning the head from side to side; with an intact reflex arc (vestibular system → brainstem → eye muscles), the eyes move conjugately in the opposite direction (Fig. 19.4). A more vigorous stimulus is produced by irrigating each ear with 30 to 60 mL of ice water. A normal, awake person with head elevated at 30 degrees has nystagmus with the fast component in the direction opposite the ear stimulated, but a comatose patient with an intact reflex arc has deviation of the eyes toward the stimulus, usually for several minutes. Simultaneous bilateral irrigation causes vertical deviation, upward after warm water and downward after cold water.

Oculocephalic or caloric testing may reveal intact eye movements, gaze palsy, individual muscle paresis, internuclear ophthalmoplegia, or no response. Cerebral gaze paresis may often be overcome by these maneuvers, but brainstem gaze palsies are usually fixed. Complete ophthalmoplegia may follow

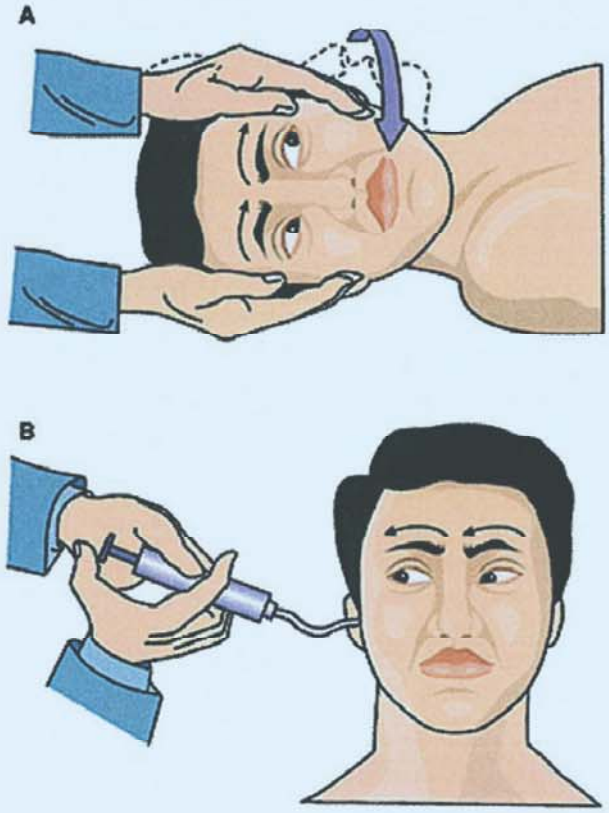

FIGURE 19.4 **A:** Doll's eye maneuver (oculocephalic reflex): With intact brainstem (cranial nerves III through VIII), the eyes remain relatively stationary and move opposite to the direction of head turning. **B:** Cold caloric test (oculovestibular reflex): With intact brainstem, cold water in the auditory canal results in tonic conjugate eye deviation toward the cold ear.

either extensive brainstem damage or metabolic coma, but except for barbiturate or phenytoin poisoning, eye movements are preserved early in metabolic encephalopathy. Unexplained disconjugate eyes indicate a brainstem or cranial nerve lesion (including abducens palsy due to increased ICP).

Downward deviation of the eyes occurs with lesions in the thalamus or midbrain pretectum and may be accompanied by pupils that do not react to light (*Parinaud syndrome*). Downward eye deviation also occurs in metabolic coma, especially in barbiturate poisoning and after a seizure. Skew deviation, or vertical divergence, follows lesions of the cerebellum or brainstem, especially the pontine tegmentum.

Retraction and convergence nystagmus may be seen with midbrain lesions, but spontaneous nystagmus is rare in coma. *Ocular bobbing* (ie, conjugate brisk downward movements from the primary position) usually follows destructive lesions of the pontine tegmentum (when lateral eye movements are lost). Preservation of voluntary vertical eye movements with loss of lateral eye movements and quadriplegia is consistent with *locked-in syndrome*. Unilateral bobbing (ie, nystagmoid jerking) signifies pontine disease.

DIAGNOSTIC TESTS

CT or MRI should be promptly performed whenever coma is unexplained. Unless meningitis is suspected, imaging should precede lumbar puncture. If imaging is not readily available, a spinal tap is cautiously performed with a 20- or 22-gauge needle. If imaging reveals frank, transtentorial, or foramen magnum herniation, the comparative risks of performing a lumbar puncture or of treating for meningitis without cerebrospinal fluid confirmation must be weighed individually for each patient.

Other emergency laboratory studies include serum levels of glucose, sodium, calcium, and blood urea nitrogen or creatinine; determination of arterial pH and partial pressures of oxygen and carbon dioxide; and blood or urine toxicology testing (including testing serum levels of sedative drugs and ethanol). Blood and cerebrospinal fluid should be cultured and liver function studies and other serum electrolyte levels determined. The use of coagulation studies and other metabolic tests is based on the index of suspicion.

The EEG may distinguish coma from psychic unresponsiveness or complete locked-in state. In metabolic coma, the EEG is typically abnormal, and early in the course, it may be a more sensitive indicator of abnormality than the clinical state of the patient. The EEG may also reveal asymmetries or evidence of clinically unsuspected seizure activity. Patients without clinical seizures can demonstrate repetitive electrographic seizures or continuous spike-and-wave activity; conversely, patients with subtle motor manifestations of seizures sometimes display only diffuse electrographic slowing. Distinguishing true status epilepticus from myoclonus (common after anoxic-ischemic brain damage) is often difficult, both clinically and electrographically; if any doubt exists, anticonvulsant therapy should be instituted.

COMA PRESENTATIONS AND TREATMENT

Many structural and nonstructural pathologies can result in impaired consciousness, necessitating a structured diagnostic approach with a broad differential. For rapid efficient communication between providers, generalizable scales such as the Full Outline of UnResponsiveness score may be helpful (**Fig. 19.5**). A more commonly used alternative is the Glasgow Coma Scale (**Table 19.2**). The most accurate scale to quantify consciousness and predict recovery is the Coma Recovery Scale-Revised, which allows reliable diagnosis of the prognostically significant MCS.

Coma From Supratentorial Herniation Syndromes

Coma may result from bilateral cerebral damage or from sudden large unilateral lesions that functionally disrupt the contralateral hemisphere (*diaschisis*). Herniation syndromes result from mass lesions that shift the brain out of its normal position. CT studies indicate that with acute hemisphere masses, early depression of consciousness correlates more with lateral brain displacement than with downward transtentorial herniation. The different types of herniation syndromes are described in (**Table 19.3**). It is important to keep in mind that different herniation syndromes can occur in a sequence or combination. For instance, an expanding hemispheric mass lesion resulting in lateral brain displacement may initially produce subfalcine herniation, followed by uncal herniation as a combination of downward and lateral displacement ensues.

Subfalcine herniation results from lateral displacement of the brain from mass lesions that are positioned rostrally in the cranial vault, at the level of the lateral ventricles or above (**Fig. 19.6**). *Transtentorial herniation* can result from lateralized (uncal) or bilateral (central) downward displacement. In *uncal herniation*, brainstem signs are initially lateralized. Typically, there is early compression of the oculomotor nerve by the inferomedial temporal lobe with ipsilateral pupillary enlargement. Alertness may not be altered until the pupil is dilated, at which point there may be an acceleration of signs, with unilaterally and then bilaterally fixed pupils and oculomotor palsy, hyperventilation or ataxic breathing, and progressive unresponsiveness. Typically, a lateralized motor deficit progresses to symmetric and bilateral flexor and then extensor posturing because the most caudal level of injury progresses to the upper brainstem. During the downward course of transtentorial herniation, there may be hemiparesis ipsilateral or oculomotor nerve compression contralateral to the cerebral lesion, which can be attributed to compression of the contralateral midbrain peduncle against the tentorial edge (*Kernohan notch*). Aqueduct obstruction and posterior cerebral artery compression may further raise supratentorial pressure. If the process is not halted, there is progression to deep coma, apnea, bilaterally unreactive pupils, ophthalmoplegia, and eventually, circulatory collapse, and brain death.

In *central transtentorial herniation* (as in thalamic hemorrhage), consciousness is rapidly impaired, and abnormalities of brainstem reflexes progress in rostrocaudal fashion. Pupils initially are of normal or small diameter and react to light, lateral eye movements and corneal reflexes are preserved, and bilateral spasticity progresses to flexor posturing. This stage is referred to as *diencephalic syndrome* because the level of injury is localized to the level of the thalamus. As herniation progresses, the pupils become fixed in midposition (midbrain pupils); this is followed by loss of pontine level brainstem reflexes (corneal and oculocephalic) and sometimes by pinpoint unreactive pupils (pontine pupils). Eventually, only medullary function remains (gag and cough), and after these are abolished brain death ensues.

The major lesions causing transtentorial herniation are traumatic (eg, epidural, subdural, or intraparenchymal hemorrhage), vascular (eg, ischemic or hemorrhagic), infectious (eg, abscess or granuloma,

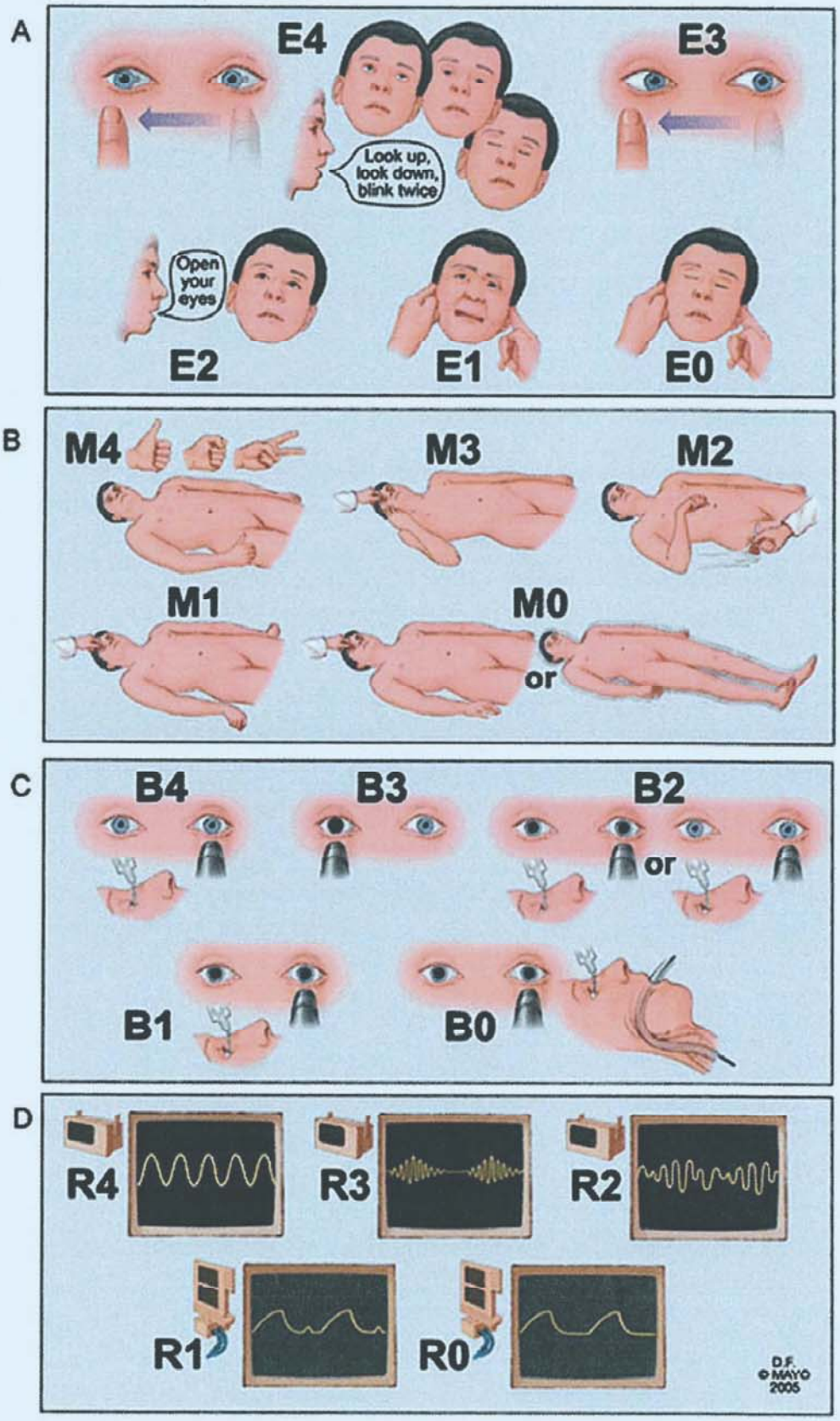

FIGURE 19.5 **A:** Eye response. *E4*, eyelids open or opened, tracking, or blinking to command; *E3*, eyelids open but not tracking; *E2*, eyelids closed but open to loud voice; *E1*, eyelids closed but open to pain; *E0*, eyelids remain closed with pain. **B:** Motor response. *M4*, thumbs-up, fist, or peace sign; *M3*, localizing to pain; *M2*, flexion respónse to pain; *M1*, extension response to pain; *M0*, no response to pain or generalized myoclonus status. **C:** Brainstem reflexes. *B4*, pupil and corneal reflexes present; *B3*, one pupil wide and fixed; *B2*, pupil or corneal reflexes absent; *B1*, pupil and corneal reflexes absent; *B0*, absent pupil, corneal, and cough reflex. **D:** Respiration pattern. *R4*, not intubated, regular breathing pattern; *R3*, not intubated, Cheyne-Stokes breathing pattern; *R2*, not intubated, irregular breathing; *R1*, breathes above ventilatory rate; *R0*, breathes at ventilator rate or apnea. (From Wijdicks EFM, Bamlet WR, Maramattom BV, Manno EM, McClelland RL. Validation of a new coma scale: the FOUR score. *Ann Neurol*. 2005;58[4]:585-593.)

TABLE 19.2 Glasgow Coma Scale[a,b]

Eye opening	Spontaneous	4
	To voice	3
	To pain	2
	None	1
Best motor response	Obeys commands	6
	Localizes to pain	5
	Withdraws to pain	4
	Flexor posturing	3
	Extensor posturing	2
	None	1
Best verbal response	Conversant and oriented	5
	Conversant and disoriented	4
	Inappropriate words	3
	Incomprehensible sounds	2
	None	1
Total score		3-15

[a]Although a total score can be calculated, proper notation of the Glasgow Coma Scale involves delimitation of the three subscores. For instance, e3 m5 v3 applies to a patient who opens eyes to voice, localizes to pain, and is capable of uttering words but not sentences.
[b]From Teasdale G, Jennett B. Assessment of coma and impaired consciousness. A practical scale. *Lancet*. 1974;2(7872):81-84.

including lesions associated with AIDS), and neoplastic (primary or metastatic). CT or MRI locates and often defines the lesion.

Coma From Infratentorial Structural Lesions

Infratentorial structural lesions may compress or directly destroy the brainstem. Such lesions may also cause brain herniation either transtentorially upward (with midbrain compression) or downward through the foramen magnum, with distortion of the medulla by the cerebellar tonsils. Abrupt tonsillar herniation causes apnea and circulatory collapse; coma is then secondary, for the medullary reticular formation has little direct role in arousal. In coma, *primary infratentorial structural lesions* are suggested by bilateral weakness or sensory loss, crossed cranial nerve and long-tract signs, miosis, loss of lateral gaze with preserved vertical eye movements, dysconjugate gaze, ophthalmoplegia, short-cycle CSR, and apneustic or ataxic breathing. The clinical picture of pontine hemorrhage (ie, sudden coma, pinpoint but reactive pupils, and no eye movement) is characteristic, but if the sequence of signs in a comatose patient is unknown, it may not be possible to tell whether the process began supratentorially or infratentorially without the use of imaging. Infrequent brainstem causes of coma include multiple sclerosis and central pontine myelinolysis.

TABLE 19.3 Herniation Syndromes

Types	Mechanism of Herniation/Complications
Subfalcine	• Mechanism: lateral shifting displacement of the brain by a compartmentalized hemispheric mass lesion at the level of the ventricles or above • Classic causes: malignant MCA infarction, acute subdural or epidural hematoma • Imaging: midline shift with ipsilateral widening of the perimesencephalic cisterns • Clinical: contralateral hemiparesis progressing to bilateral motor posturing and coma, with late ipsilateral CN III palsy due to stretching of the oculomotor nerve • Complications: delayed ipsilateral ACA pericallosal infarction due to compression against the falx
Central transtentorial	• Mechanism: downward displacement of the brain by a bilateral supratentorial mass lesion, with craniocaudal pressure on diencephalon with downward displacement • Classic causes: massive bilateral intraventricular hemorrhage leading to acute obstructive hydrocephalus, massive global cerebral edema • Imaging: bilateral loss of the perimesencephalic cisterns and downward displacement of the midbrain tectum into the posterior fossa • Clinical: early Parinaud syndrome (loss of upgaze and convergence, retraction nystagmus) followed by rostrocaudal loss of brainstem reflexes associated with progression from decorticate to decerebrate posturing • Complications: stretching of small penetrating vessels leading to diencephalic and brainstem infarction, sometimes pituitary damage • Less common dorsal pressure leading to Parinaud syndrome (limitation of upward eye movements, usually with impairment of pupillary light reflex and difficulty with convergence)
Uncal transtentorial	• Mechanism: displacement of medial temporal lobe over free tentorial edge by a temporal lobe mass lesion or during the late stages of lateral and downward herniation • Classic causes: intracerebral mass lesions, for example, intracerebral hematoma, subdural hematoma, brain tumor • Imaging: prominent medial displacement of the uncus into the tentorial notch • Clinical: early ipsilateral dilated pupil due to CN III compression and ipsilateral or contralateral hemiparesis/posturing • Complications: trapping of the contralateral lateral ventricle due to compression of the third ventricle and aqueduct; compression of posterior cerebral arteries with resultant infarction
Tonsillar	• Mechanisms: displacement of cerebellar tonsils into the foramen magnum → compression of medulla and fourth ventricle • Classic cause: acute cerebellar ICH or rapidly expanding tumor • Imaging: herniation of cerebellar tonsils into the foramen magnum at level of the medulla • Clinical: impaired respiratory and cardiac function, neck stiffness, flaccid paralysis, and coma • Complications: secondary obstructive hydrocephalus due to obstruction of the fourth ventricle
Upward herniation	• Mechanisms: displacement of superior cerebellar vermis upward leading to compression of dorsal mesencephalon, blood vessels, and aqueduct • Classic cause: acute cerebellar ICH or rapidly expanding tumor • Imaging: cerebellar mass lesion with effacement of quadrigeminal cistern and upward displacement of midbrain tectum • Clinical: impaired consciousness, loss of pupillary and oculocephalic reflexes • Complications: secondary obstructive hydrocephalus due to obstruction of the cerebral aqueduct

Abbreviations: ACA, anterior cerebral artery; CN, cranial nerve; ICH, intracranial hemorrhage; MCA, middle cerebral artery.

FIGURE 19.6 Herniation syndromes.

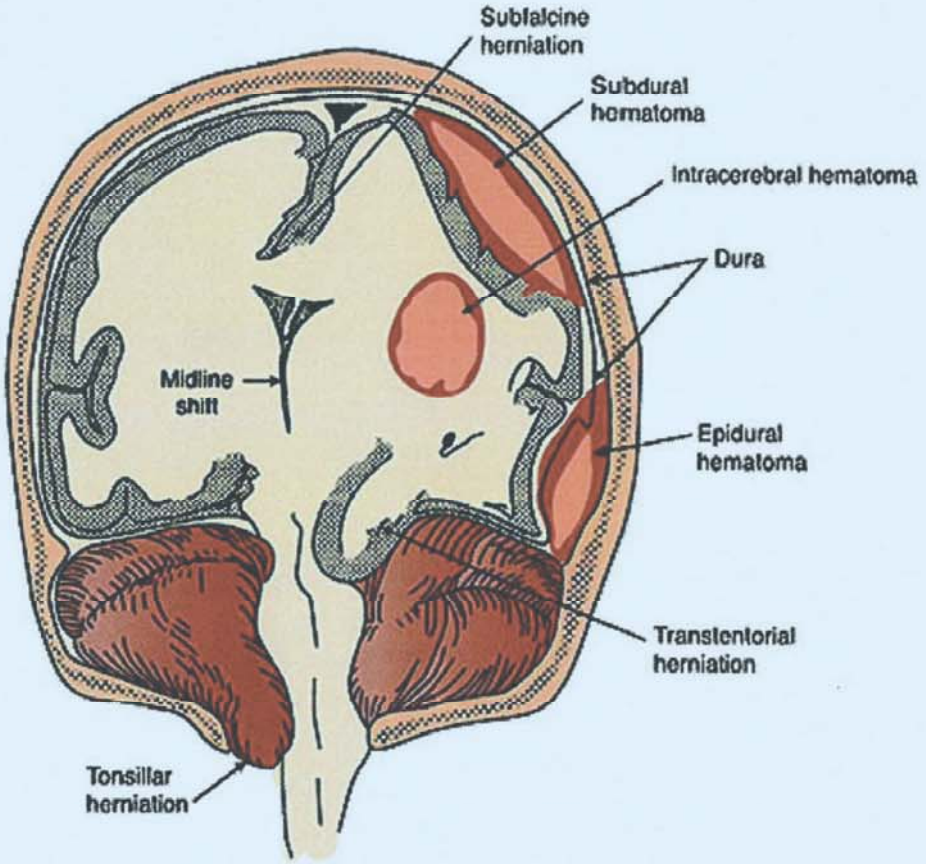

Coma From Metabolic or Diffuse Brain Disease

In metabolic, diffuse, or multifocal encephalopathy, cognitive and respiratory abnormalities occur early; there is often tremor, asterixis, or multifocal myoclonus. Gegenhalten, frontal release signs (eg, snout, suck, or grasp), and flexor or extensor posturing may occur. Except in anoxia-ischemia and anticholinergic intoxication, the pupils remain reactive. The eyes may be deviated downward, but the presence of sustained lateral deviation or disconjugate eyes argues against the diagnosis of a metabolic disturbance. Metabolic disease, however, may cause both focal seizures and lateralizing neurologic signs, often shifting but sometimes persisting (as in hypoglycemia and hyperglycemia).

Arterial blood gas determinations are especially useful in diagnosing metabolic coma. Of the diseases listed in **Table 19.4**, psychogenic hyperventilation is more likely to cause delirium than stupor but may coexist with hysterical coma. Cognitive change associated with metabolic alkalosis is usually mild. Metabolic and diffuse brain diseases causing coma are numerous, but the diversity is not overwhelming. Most entities listed in **Table 19.5** are described in other chapters.

HYSTERIA AND CATATONIA

Hysterical (conversion) unresponsiveness is rare. Clinically indistinguishable from malingering, it is usually associated with closed eyes, eupnea or tachypnea, and normal pupils. The eyelids may resist passive opening and, when released, may close abruptly rather than with smooth descent; lightly stroking the eyelashes causes lid fluttering. The eyes do not slowly rove but move with saccadic jerks, and ice water caloric testing causes nystagmus rather than sustained deviation. The limbs usually offer no resistance to passive movement, yet demonstrate normal tone. Unless organic disease or drug effect is also present, the EEG pattern is one of normal wakefulness.

Catatonia is a behavioral disturbance characterized by wakeful unresponsiveness with minimal or no spontaneous purposeful behavior or speech. It is most commonly associated with depression, schizophrenia, toxic psychosis, or other brain diseases. There may be akinetic mutism, grimacing, rigidity, posturing, catalepsy, or excitement. Respirations are normal or rapid, pupils are large but reactive, and eye movements are normal. The EEG is usually normal.

LOCKED-IN SYNDROME

Infarction, hemorrhage, or rarely, central pontine myelinolysis may destroy the basis pontis, producing total paralysis of the lower cranial nerve and limb muscles, with preserved alertness and respiration. At first glance, the patient appears unresponsive, but examination reveals voluntary vertical eye movements, including blinking. (Even with facial paralysis, inhibition of the levator palpebrae may produce partial eye closure.) Communication is possible with the use of purposeful blinking or eye movements to indicate "yes," "no," or in response to letters.

VEGETATIVE STATE AND MINIMALLY CONSCIOUS STATE

Persistent impairment of consciousness in the postacute hospitalization phase is categorized into MCS and UWS, also known as *vegetative state*. Patients with UWS have sleep-wake cycles,

TABLE 19.4 Causes of Abnormal Ventilation in Unresponsive Patients[a]

Hyperventilation
Metabolic acidosis
Anion gap
Diabetic ketoacidosis[b]
Diabetic hyperosmolar coma[a]
Lactic acidosis
Uremia[b]
Alcoholic ketoacidosis
Acidic poisons (ethylene glycol, methyl alcohol, paraldehyde)[b]
No anion gap
Diarrhea
Pancreatic drainage
Carbonic anhydrase inhibitors
NH_4Cl ingestion
Renal tubular acidosis
Ureteroenterostomy
Respiratory alkalosis
Hepatic failure[b]
Sepsis[b]
Pneumonia
Anxiety (hyperventilation syndrome)
Mixed acid-base disorders (metabolic acidosis and respiratory alkalosis)
Salicylism
Sepsis[b]
Hepatic failure[b]
Hypoventilation
Respiratory acidosis
Acute (uncompensated)
Sedative drugs[b]
Brainstem injury
Neuromuscular disorders
Chest injury
Acute pulmonary disease
Chronic pulmonary disease
Metabolic alkalosis
Vomiting or gastric drainage
Diuretic therapy
Adrenal steroid excess (Cushing syndrome)
Primary aldosteronism
Bartter syndrome

Abbreviation: NH_4Cl, ammonium chloride.
[a]From Posner JB, Saper CB, Schiff ND, Claassen J. *Plum and Posner's Diagnosis and Treatment of Stupor and Coma*. 5th ed. New York, NY: Oxford University Press; 2019.
[b]Common causes of stupor or coma.

TABLE 19.5 Diffuse Brain Diseases or Metabolic Disorders That Cause Coma

The internal milieu: an overview of cerebral metabolism and the environment necessary to maintain normal neuronal function
• Cerebral blood flow, oxygen, and glucose utilization • Ionic environment in the brain and cortical spreading depolarization • Synaptic environment in the brain and seizures
Disorders of the internal milieu: lack of substrate
• Cerebral hypoxia and ischemia • Hyperoxia • Hypoglycemia • Cofactor deficiency • Mitochondrial disorders
Disorders of the internal milieu: ionic and osmotic environment
• Hyponatremia • Hypernatremia • Hypercalcemia • Hypocalcemia • Metabolic acidosis (disorders of systemic acid-base balance) • Hyperglycemic hyperosmolar state
Disorders of the internal milieu: hormonal and temperature
• Hypothyroidism • Hyperthyroidism • Adrenal gland • Hypothermia • Hyperthermia
Disorders of the internal milieu: electrical environment
• Seizure disorders • Cortical spreading depression
Disorders of the internal milieu: abnormal CSF pressure or constituents
• Intracranial hypertension • Intracranial hypotension • Subarachnoid hemorrhage • Acute bacterial meningitis • Chronic bacterial or fungal meningitis • Viral meningitis versus encephalitis • Acute viral encephalitis • Carcinomatous meningitis
Disorders of endogenous toxins
• Hypercarbia • Hepatic encephalopathy • Renal failure • Pancreatic encephalopathy • Systemic septic encephalopathy • Autoimmune disorders: specific antibodies
Disorders of exogenous toxins
• Sedative/hypnotic drugs and anesthetics ($GABA_A$ receptor enhancers) • Endogenous benzodiazepines • Ethanol intoxication and ethanol withdrawal • Ketamine, phencyclidine (NMDA receptor antagonist drugs) • Antidepressants • Neuroleptics • Opioids • Intoxication with antipyretic/analgesic medications • Intoxication with drugs of abuse • Intoxication with drugs causing metabolic acidosis

Abbreviations: CSF, cerebrospinal fluid; GABAA, γ-aminobutyric acid type A; NMDA, *N*-methyl-D-aspartate.

TABLE 19.6 Criteria for Determination of Unresponsive Wakefulness State (Also Known as *Vegetative State*)

1. No evidence of awareness of self or surroundings. Reflex or spontaneous eye opening may occur.
2. No meaningful and consistent communication between examiner and patient, auditory or written. Target stimuli not usually followed visually but sometimes visual tracking present; no emotional response to verbal stimuli
3. No comprehensible speech or mouthing of words
4. Smiling, frowning, or crying inconsistently related to any apparent stimulus
5. Sleep-wake cycles present
6. Brainstem and spinal reflexes variable, eg, preservation of sucking, rooting, chewing, swallowing, pupillary reactivity to light, oculocephalic responses, and grasp or tendon reflexes
7. No voluntary movements or behavior, no matter how rudimentary; no motor activity suggesting learned behavior; no mimicry. Withdrawal or posturing can occur with noxious stimuli.
8. Usually intact BP control and cardiorespiratory function; incontinence of bladder and bowel

Abbreviation: BP, blood pressure.

intact cardiorespiratory function, and primitive responses to stimuli but without evidence of inner or outer awareness present for at least 1 month (Table 19.6). In contrast, patients with MCS intermittently show signs of low-level awareness with or without intact language function. These may include eye tracking and visual smooth pursuit for the former and inconsistent command following for the latter. Identifying this state is important because it may represent a transitory state on the road to recovery.

Likewise, both in the chronic as well as acute disorders of consciousness context task-based EEG or functional MRI allows detection of volitional brain activation in behaviorally unresponsive patients. This brain activation may include only the primary or association cortices suggesting different levels of complexity in the brain response. Detection of this state, called *cognitive motor dissociation*, early after brain injury is associated with later behavioral recovery and functional outcomes.

Predicting recovery of consciousness and long-term functional outcomes is challenging early after the injury, as outlined above. Electrophysiologic and imaging assessments of the brain at rest (ie, resting state MRI or EEG, positron emission tomography) and in response to sensory stimulation (ie, local global paradigms a type of late evoked potentials) are emerging as potential additions to the clinical examination. Particularly promising are motor command responses detected by functional MRI or EEG.

Patients who survive coma usually show varying degrees of recovery within 2 to 4 weeks; those who enter UWS may recover further, even fully. Increasingly, data indicate that much of our formerly pessimistic assumptions regarding outcome of comatose patients are likely based on self-fulfilling prophecies and biases. Approximately three of four unconscious patients with acute brain injury die from withdrawal of care. This is concerning because our ability to accurately predict long-term outcomes in these patients is extremely poor. In the Multi-Society Task Force study, patients remaining in the UWS 3 months after traumatic brain injury were associated with a 35% rate of recovery of consciousness at 1 year, and 16% of these patients recovered independent function by 1 year after injury. The majority (>80%) of patients remaining in MCS at 3 to 6 months after injury will improve, some eventually demonstrating no disability. Patients with traumatic brain injury tend to have better recovery compared to those with anoxic-ischemic injury. Much research is currently directed toward identifying predictors of who will recover to which state at what time. Amantadine hydrochloride 100 mg 3 times a day has been shown to accelerate the pace of functional recovery among patients with UWS and MCS after severe traumatic brain injury LEVEL 1.[1] Also under study are the use of the pharmacologic interventions (eg, zolpidem) and thalamic stimulation.

BRAIN DEATH

Unlike the disorders of consciousness discussed above including the UWS/VS in which the brainstem and possibly other areas of the brain are intact, the term *brain death* refers to a state in which the cerebrum and the brainstem are both permanently destroyed. The only spontaneous activity is cardiovascular; apnea persists in the presence of hypercarbia sufficient for respiratory drive, and the only reflexes present are those mediated by the spinal cord. In adults, brain death rarely lasts more than a few days and is always followed by circulatory collapse despite persistence on a ventilator. In the United States, brain death is equated with legal death. When criteria are met, artificial ventilation and blood pressure support are appropriately discontinued, regardless of whether or not organ harvesting is intended. Detailed information on how to diagnose and manage brain death in the ICU is provided in Chapter 20.

FUTURE DIRECTIONS

Functional imaging and EEG provides biomarkers to study interventions to support the recovery of consciousness. Likely, these will need to be targeted based on individual phenotypes of the underlying brain injury.

LEVEL 1 EVIDENCE

1.* Giacino JT, Whyte J, Bagiella E, et al. Placebo-controlled trial of amantadine for severe traumatic brain injury. *N Engl J Med.* 2012;366(9):819-826.

SUGGESTED READINGS

Brown EN, Lydic R, Schiff ND. General anesthesia, sleep, and coma. *N Engl J Med.* 2010;363:2638-2650. doi:10.1056/NEJMra0808281.

Childs NL, Mercer WN. Brief report: late improvement in consciousness after post-traumatic vegetative state. *N Engl J Med.* 1996;334:24-25.

Claassen J, Doyle K, Matory A, et al. Detection of brain activation in unresponsive patients with acute brain injury. *N Engl J Med.* 2019;380:2497-2505. doi:10.1056/NEJMoa1812757.

Claassen J, Velazquez A, Meyers E, et al. Bedside quantitative electroencephalography improves assessment of consciousness in comatose subarachnoid hemorrhage patients. *Ann Neurol.* 2016;80:541-553. doi:10.1002/ana.24752.

Curley WH, Forgacs PB, Voss HU, Conte MM, Schiff ND. Characterization of EEG signals revealing covert cognition in the injured brain. *Brain.* 2018;141:1404-1421. doi:10.1093/brain/awy070.

Edlow BL, Chatelle C, Spencer CA, et al. Early detection of consciousness in patients with acute severe traumatic brain injury. *Brain.* 2017;140:2399-2414.

Fischer DB, Boes AD, Demertzi A, et al. A human brain network derived from coma-causing brainstem lesions. *Neurology.* 2016;87:2427-2434. doi:10.1212/WNL.0000000000003404.

Fox MD. Mapping symptoms to brain networks with the human connectome. *N Engl J Med*. 2018;379:2237-2245. doi:10.1056/NEJMra1706158.

Giacino JT, Kalmar K, Whyte J. The JFK Coma Recovery Scale-Revised: measurement characteristics and diagnostic utility. *Arch Phys Med Rehabil*. 2004;85:2020-2029. doi:10.1016/j.apmr.2004.02.033.

Giacino JT, Katz DI, Schiff ND, et al. Practice guideline update recommendations summary: disorders of consciousness: report of the Guideline Development, Dissemination, and Implementation Subcommittee of the American Academy of Neurology; the American Congress of Rehabilitation Medicine; and the National Institute on Disability, Independent Living, and Rehabilitation Research. *Arch Phys Med Rehabil*. 2018;99:1699-1709. doi:10.1016/j.apmr.2018.07.001.

Goudreau JL, Wijdicks EFM, Emery SF. Complications during apnea testing in the determination of brain death: predisposing factors. *Neurology*. 2000;55:1045-1048.

Kondziella D, Friberg CK, Frokjaer VG, Fabricius M, Møller K. Preserved consciousness in vegetative and minimal conscious states: systematic review and meta-analysis. *J Neurol Neurosurg Psychiatry*. 2016;87:485-492. doi:10.1136/jnnp-2015-310958.

Michelson DJ, Ashwal S. Evaluation of coma and brain death. *Semin Pediatr Neurol*. 2004;11(2):105-118.

Owen AM, Coleman MR, Boly M, Davis MH, Laureys S, Pickard JD. Detecting awareness in the vegetative state. *Science*. 2006;313:1402.

Posner JB, Saper CB, Schiff ND, Claassen J. *Plum and Posner's Diagnosis and Treatment of Stupor and Coma*. 5th ed. New York, NY: Oxford University Press; 2019.

Saper CB, Scammell TE, Lu J. Hypothalamic regulation of sleep and circadian rhythms. *Nature*. 2005;437(7063):1257-1263.

Saposnik G, Bueri JA, Mauriño J, Saizar R, Garretto NS. Spontaneous and reflex movements in brain death. *Neurology*. 2000;54:221-223.

Schiff ND. Recovery of consciousness after brain injury: a mesocircuit hypothesis. *Trends Neurosci*. 2010;33(1):1-9.

Schiff ND, Giacino JT, Kalmar K, et al. Behavioural improvements with thalamic stimulation after severe traumatic brain injury. *Nature*. 2007;448(7153):600-603.

Sitt JD, King JR, El Karoui I, et al. Large scale screening of neural signatures of consciousness in patients in a vegetative or minimally conscious state. *Brain*. 2014;137(pt 8):2258-2270.

Teasdale G, Jennett B. Assessment of coma and impaired consciousness. A practical scale. *Lancet*. 1974;2(7872):81-84.

Thibaut A, Schiff N, Giacino J, Laureys S, Gosseries O. Therapeutic interventions in patients with prolonged disorders of consciousness. *Lancet Neurol*. 2019;18:600-614. doi:10.1016/S1474-4422(19)30031-6.

Velly L, Perlbarg V, Boulier T, et al. Use of brain diffusion tensor imaging for the prediction of long-term neurological outcomes in patients after cardiac arrest: a multicentre, international, prospective, observational, cohort study. *Lancet Neurol*. 2018;17:317-326. doi:10.1016/S1474-4422(18)30027-9.

Wijdicks EFM, Bamlet WR, Maramattom BV, Manno EM, McClelland RL. Validation of a new coma scale: the FOUR score. *Ann Neurol*. 2005;58(4):585-593.

Brain Death 20

Eelco F. M. Wijdicks

KEY POINTS

1. Brain death determination is a clinical assessment.
2. A number of preconditions are required.
3. Apnea test is a safe procedure when guidelines are followed.
4. Brain death often results in organ donation.

INTRODUCTION

Brain death is used to describe an apneic patient with not only irreversible coma from a massive brain injury but also loss of all brainstem reflexes and often uncontrolled diuresis and hypotension from loss of vascular tone. Nothing else should explain this condition, and characteristically, it is due to an acute catastrophic bihemispheric and diencephalic injury that has progressed to total brainstem injury. Brain death remains uncommon because such progression would require not only involvement of both hemispheres of the brain but also loss of brainstem function. Typically, this clinical situation would be an acute massive hemispheric lesion (eg, cerebral hemorrhage) compressing and sequentially damaging the mesencephalon, pons, and medulla oblongata (Fig. 20.1). The brainstem is very resilient to injury, and it would take a substantial shift (from mass effect) or poor perfusion (from basilar artery occlusion or massively increased intracranial pressure) for it to get permanently damaged. This core neurologic principle—the brainstem to be the last brain structure to go out of function—is the most important attribute to our understanding of brain death. Once brainstem function is lost, breathing stops first and the heart soon thereafter. If in the acute phase the patient can be intubated, placed on a mechanical ventilator, sufficiently oxygenated, fluid resuscitated, and vasopressors and vasopressin added, this agonal sequence can potentially be halted for some time.

Once an untreatable catastrophic neurologic structural injury has been proven and the brainstem reflexes have disappeared, recovery does not occur, and there is no known effective medical or surgical intervention. The clinical diagnosis involves testing of absent motor responses, loss of all brainstem reflexes, and observation of apnea after a carbon dioxide challenge in a patient temporarily detached from the ventilator. Irreversibility is not determined by observation over time but determined by these findings.

Brain death determination requires a skill set but is relatively straightforward. Physicians should work through a set of criteria and not be swayed by supposedly quicker options.

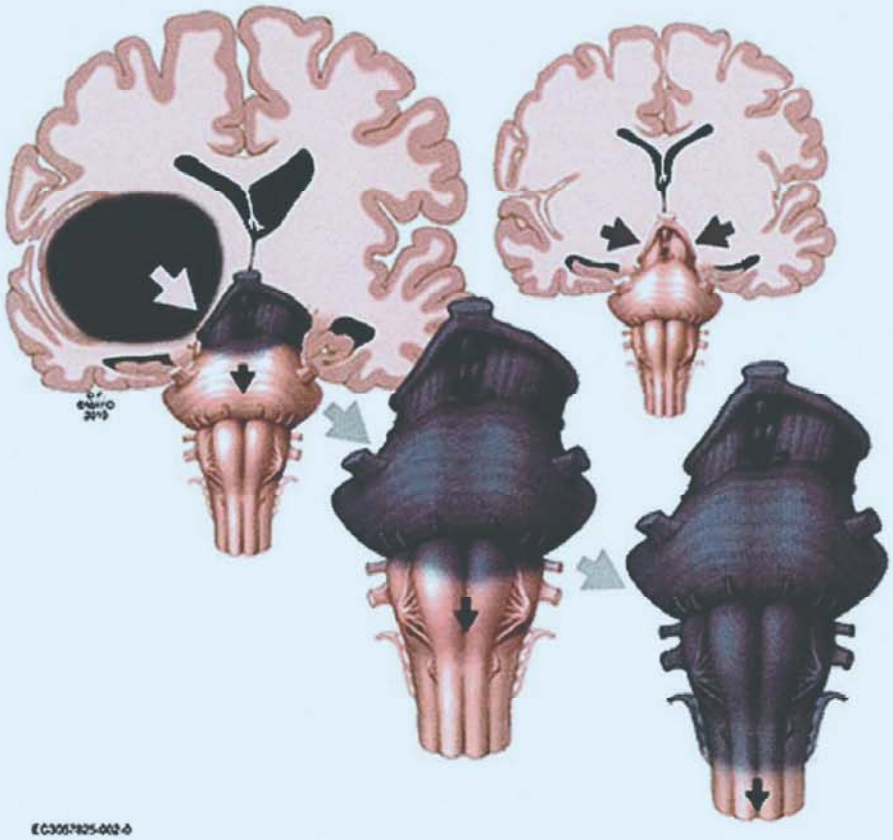

FIGURE 20.1 Supratentorial lesions (mass, cerebral edema) leading to rostrocaudal damage of the brainstem and eventually to brain death. *Arrows* point at direction of tissue compression and loss of function. (Courtesy of the Mayo Foundation for Medical Education and Research.)

The fundamental medical principle is that brain death is death, and organ and tissue donation must be a priority. This chapter provides ways on how to proceed with this evaluation and how to prevent common pitfalls.

THE CLINICAL DIAGNOSIS OF BRAIN DEATH

Declaring a patient brain dead can be considered in a comatose patient with a major destructive brain injury, loss of at least three brainstem reflexes, and no evidence of a breathing effort. A more formal assessment, however, may only proceed when the patient worsens even more, when all medical or neurosurgical interventions are futile, and when there are no confounding factors or alternative explanations. The clinical examination starts when a patient with a massive acute brain injury has no motor response to pain, fails to grimace to pain, has absent brainstem reflexes, and does not trigger the ventilator. Commonly, the patient has become hypotensive and polyuric from diabetes insipidus and has been placed on vasopressors. Using this starting point, many patients will fulfill the criteria of brain death after detailed neurologic examination. With any other (earlier) starting point, there is a greater chance that there will be retained brainstem function and even spontaneous breathing when the patient is briefly disconnected.

Determine the Cause of Brain Death

Brain death evaluation involves several sequential steps (Table 20.1). First, there is nothing more important than to be very certain that all possible confounding factors have been excluded. This implies there can be no lingering effects of prior sedation, other confounding medications, or prior use of illegal drugs or alcohol. A reasonable guideline is to calculate 5 to 7 times the drug's elimination half-life in hours and allow that time to pass before clinical examination is performed. Examples of long elimination half-life drugs are phenobarbital (100 h), diazepam (40 h), amitriptyline (24 h), primidone (20 h), and lorazepam (15 h). A commonly used short-acting benzodiazepine is midazolam, but the elimination may still take 3 hours. Prior use of therapeutic hypothermia may substantially slow down the metabolism of medications such as lorazepam and fentanyl used to support the procedure. Substantial alcohol levels should be excluded, but alcohol content below the legal alcohol limit for driving (blood alcohol content 0.08%) is acceptable to determine brain death. Absence of neuromuscular blockade (defined by the presence of four twitches with a train of four with maximal ulnar nerve stimulation) should be demonstrated but is likely if the patient has tendon reflexes (or breathes). Furthermore, absence of severe electrolyte, acid-base, or endocrine disturbances (defined by marked acidosis or any substantial deviation from the normal values) should be documented. A core temperature greater than 32°C must be present, but preferably, there should be near normothermia (36°C-37°C), which can be achieved with a warming blanket—assuming the patient is not a victim of environmental severe hypothermia. Systolic blood pressure should be greater than 90 mm Hg because pupil size and light reflex can fully disappear with lower values. Only after these confounders have been addressed should a more formal examination proceed.

TABLE 20.1 Checklist for Establishing Brain Death

Prerequisites (ALL MUST BE CHECKED)
☐ Coma, irreversible and cause known
☐ Neuroimaging explains coma
☐ Sedative drug effect absent *(if indicated, order a toxicology screen)*
☐ No residual effect of paralytic drug *(if indicated, use peripheral nerve stimulator)*
☐ Absence of severe acid-base, electrolyte, or endocrine abnormality
☐ Normal or near normal temperature *(core temperature ≥36°C)*
☐ Systolic blood pressure ≥100 mm Hg
☐ No spontaneous respirations
Examination (ALL MUST BE CHECKED)
☐ Pupils non-reactive to bright light *(typically mid-position at 5-7 mm)*
☐ Corneal reflexes absent *(use both saline jet and tissue touch)*
☐ Eyes immobile, oculocephalic reflexes absent *(tested only if C-spine integrity ensured)*
☐ Oculovestibular reflexes absent *(50 cc of ice water in each ear sequentially)*
☐ No facial movement to noxious stimuli at supraorbital nerve or temporomandibular joint compression *(absent snout and rooting reflexes in neonates)*
☐ Gag reflex absent *(gloved index finger to posterior pharynx)*
☐ Cough reflex absent to tracheal suctioning *(at least 2 passes)*
☐ No motor response to noxious stimuli in all 4 limbs *(triple flexion response is most common spinal-mediated reflex)*
Apnea Testing (ALL MUST BE CHECKED)
☐ Patient is hemodynamically stable *(systolic blood pressure ≥ 100 mm Hg)*
☐ Ventilator adjusted to normocapnia *($PaCO_2$ 35-45 mm Hg)*
☐ Patient pre-oxygenated with 100% oxygen for 10 minutes *(PaO_2 ≥ 200 mm Hg)*
☐ Patient maintains oxygenation with a PEEP of 5 cm H_2O *(if not, consider recruitment maneuver)*
☐ Disconnect ventilator
☐ Provide oxygen via an insufflation catheter to the level of the carina at 6 liters/min or attach T-piece with CPAP valve @ 10-20 cm H_2O and resuscitation bag
☐ Spontaneous respirations absent
☐ Arterial blood gas drawn at 8-10 minutes, patient reconnected to ventilator
☐ $PaCO_2$ ≥ 60 mm Hg, or 20 mm Hg rise from normal baseline value or Apnea test aborted and confirmatory ancillary test *(EEG or cerebral blood flow study)*
Documentation
• Time of death *(use time of final blood gas result or use time of completion of ancillary test)*

Imaging Confirmation of Brain Death

Next, the computed tomography (CT) scan should be carefully reviewed and expectedly demonstrate massive brain destruction. Abnormalities may include a large mass with brain tissue shift, multiple hemorrhagic lesions, or diffuse cerebral edema with obliteration of basal cisterns. The CT scan can be initially normal

if the patient has been imaged very early after cardiopulmonary arrest. However, in the patients with anoxic-ischemic encephalopathy who eventually fulfill these criteria, brain edema or marked hypodensities in thalami, caudate nuclei, and basal ganglia are typically seen on a repeat CT scan. A normal CT should under no circumstances be acceptable. In some cases of cardiac arrest, a magnetic resonance imaging can be helpful to demonstrate the full extent of ischemic tissue damage compatible with brain death.

Clinical Examination

The main components of neurologic examination and technique of the apnea test in a patient suspected of brain death are summarized in **Table 20.1**.

Cranial Nerves

Clinical examination can proceed after these aforementioned hurdles have been cleared. The examination begins with evaluation of pupillary responses. Pupils should be midposition (4-6 mm) and unresponsive to light. A magnifying glass or handheld pupillometer can be helpful, in particular, when there is an uncertainty about the reactivity of pupils. One should be aware that atropine used during cardiopulmonary resuscitation may cause pupillary dilation, but intravenous drugs do not change reactivity. The corneal reflex is tested with squirting water on the cornea or by touching with a tissue and no blink response should be seen. (Subtle blink responses may be only a movement of eyelashes.) Oculocephalic reflexes ("doll's eyes") should be absent bilaterally (fast turning of the head to both sides should not produce any ocular movement). The oculovestibular response ("cold calorics") should be absent. The head should be elevated 30°. Approximately 50 mL of ice water is then infused in the external auditory canal. No eye movement should be observed for 2 minutes. The examination then proceeds with evaluation of gag and cough reflexes, both of which should be absent. Gag reflex could be tested by a movement of the endotracheal tube but is far more reliable with sticking a gloved finger of the examiner deep in the back of the throat moving the uvula. Cough reflex should be tested by deep bronchial suctioning and with at least two passes.

Motor Responses to Pain

The comatose patient should be unresponsive to verbal or painful stimuli. Standard noxious stimuli include compression of the supraorbital nerves, forceful nail bed pressure, and bilateral temporomandibular joint compression. Eye opening to noxious stimuli should be absent. No motor response should be observed. Some motor responses may be preserved, and the challenge is to label them as "spinal responses." They may occur with neck flexion and nail bed compression but are absent with supraorbital nerve compression. These responses are not classifiable as decorticate or extensor responses because that would imply an intact subcortical circuitry. These responses are uncommon—and far less common than claimed in the literature—but include triple flexion responses, finger flexion or extension, head turning, and slow arm lifting. These movements do, on occasion, cause concern for the family members (and later even transplant surgeons) and have to be properly explained and documented in the medical record.

Apnea Testing

Finally, absent breathing is proven with a formal apnea test. The apnea test is best performed under controlled circumstances and with disconnection of the mechanical ventilator. The ventilator may spuriously indicate a breathing drive of the patient, and this phenomenon—caused by minimal pressure or volume changes in the breathing circuit—is quite commonly not recognized. There is a real concern that some patients with "retained breathing drive" may have been excluded from formal testing, or worse, a prolonged waiting time for the respiratory drive to "disappear" may have led to premature cardiac arrest in a potential organ donor.

The apnea test is a complex testing procedure. The apnea test cannot proceed if preconditions are not met and the patient is not prepared (preoxygenation, reducing positive end-expiratory pressure to 5 cm of H_2O and drawing a baseline blood gas). Once ready, the patient is disconnected from the ventilator while an oxygen source is provided with an oxygen flow catheter placed at the level of the carina. The oxygenation diffusion method is very safe method with few aborted tests and in our experience less than 2 %. Demonstration of apnea with a rise in P_{CO_2} to 60 mm Hg or 20 mm Hg about a normal baseline value after completion of the brainstem reflexes defines brain death and death of the patient (the time of the second blood gas is best used as the official time of death).

Ancillary Tests to Confirm the Diagnosis of Brain Death

Technical tests to support the clinical diagnosis of brain death have been developed and may demonstrate absent blood flow to the brain or absent electrical activity of the cortex (**Table 20.2**). These tests have considerable inaccuracy and should not replace, in any way, a clinical assessment. Interpretation of these tests, when results are not obvious, remains difficult, and results of multiple tests may not be matching. Elevating an ancillary test to a diagnostic test may lead to errors in brain death determination. Ancillary tests are used in less than 5% of patients diagnosed with brain death and are better generally avoided. These tests have mostly been used when there is an inability to perform an apnea test (due to poor oxygenation of the patient, hemodynamic instability, or evidence of prior chronic carbon dioxide retention). Some countries in the world legally require performing these tests, but in the United States, there is no such requirement. Once the patient is declared brain dead and time of death is documented in the medical record, decisions can be

TABLE 20.2 Tests Commonly Used for the Confirmation of Brain Death

1. **Electroencephalography (EEG):** Confirmation of neocortical death can be documented by at least 30 min of electrocerebral silence using a 16-channel instrument with increased gain settings, according to guidelines developed by the American Electroencephalographic Society. If any brain wave is present, the diagnosis of brain death cannot be made. The EEG confirmation of brain death is also not valid in patients exposed to sedatives or toxins because they can directly suppress the brain electrical activity.
2. **Digital subtraction or CT angiography:** Complete absence of intracranial blood flow above the level of the proximal internal carotid and vertebral arteries confirms the diagnosis of brain death.
3. **Radioisotope cerebral imaging:** The complete absence of cerebral perfusion can also be established using radionuclide angiography or single-photon emission computed tomography (SPECT).
4. **Transcranial Doppler ultrasonography:** A velocity profile showing systolic spikes with absent or reversed diastolic flow is consistent with the cessation of cerebral blood flow and brain death.

Abbreviation: CT, computed tomography.

made without further hesitation and should first involve notification of organ donation agencies. Refusal of organ donation (in estimated 30% of cases) will lead to withdrawal of support.

BRAIN DEATH IN CHILDREN

Brain death in children was recently revisited by a multidisciplinary task force. Most concerns regarding interpretation of neurologic examination are in neonates several months old, and the advanced skills of a neonatologist are needed to obtain reliable findings. Examination of a child in an incubator remains limited, and neurologists should be aware of incompletely developed brain function and motor response. The new pediatric guideline suggests a 24-hour interval between examinations by two physicians in neonates and children from 37-week gestation to the end of the first month. However, in children aged 1 month or older, the pediatric guidelines still impose two examinations 12 hours apart by two different attending physicians. Two examinations in children are different from adults, but the need for such a distinction is highly questionable. The guideline also recommends that physicians be competent to perform examinations in infants and neonates but speculatively suggest that these examinations be performed by pediatric intensivists and neonatologists, pediatric neurologists and neurosurgeons, pediatric trauma surgeons, and pediatric anesthesiologists with critical care training.

COMMON DIAGNOSTIC CHALLENGES AND PITFALLS

The examination and later communication with distraught family members require experience. There are situations that can easily create unease and uncertainty. Some common mistakes are shown in **Table 20.3**. Most pitfalls relate to premature assessment of the patient and suggesting the patient might be brain dead when there has not been a formal evaluation.

Targeted temperature management has become a common treatment of comatose patients following cardiopulmonary resuscitation. However, the category of patients who fulfill brain death after cardiopulmonary resuscitation more often are hemodynamically unstable, and many of them die from irreversible cardiac shock before brain death can be determined. The clinical examination of brain death may be difficult to complete due to persistent hypotension and use of multiple vasopressors. The apnea test may also be compromised due to the presence of significant pulmonary edema from cardiac failure. How to assess these patients after prior use of therapeutic hypothermia and use of sedative drugs and recovering from shock liver or acute renal failure remains unclear, and it may be prudent not to proceed with a brain death examination at all. Targeted temperature management in a patient with an infusion of fentanyl or midazolam—certainly both—will seriously confound neurologic examination. There is no precise way to calibrate the effect of confounders, particularly because metabolic effects persist after rewarming, especially for drugs with long half-lives.

The most important challenge for physicians is to perform a complete examination in patients with primary lesion in the brainstem. More often than not, physicians will find patients with a primary brainstem lesion or a compressed brainstem from a cerebellar lesion that do not fulfill all criteria of brain death and may even benefit from aggressive intervention (ventriculostomy or suboccipital craniotomy). A destructive primary brainstem lesion is as irreversible lesion as the one that involves the hemispheres and brainstem, and it is therefore unnecessary to perform an ancillary test. These tests often will show preserved blood flow when the intracranial pressure has not increased to extreme values, and early electroencephalography may show nonreactive alpha or spindle coma patterns.

Ancillary testing demonstrating complete intracranial circulatory arrest by catheter or CT angiography or a radionuclide brain perfusion study remains very problematic if used to confirm brain death in the setting of confounding medications, hypothermia, or metabolic disarray.

TABLE 20.3 Common Misjudgments in the Diagnosis of Brain Death

• Incomplete testing
• Examination in a patient with confounders (mostly recently administered medication, drug, and alcohol use)
• Use of cerebral blood flow study as a diagnostic test
• Misinterpretation of ancillary test
• Misinterpretation of "spinal reflexes"
• Premature discussion with family about brain death and organ donation

INTENSIVE CARE UNIT MANAGEMENT OF THE POTENTIAL ORGAN DONOR

Brain death eventually leads to severe homeostatic derangements and cardiac arrest despite mechanical ventilation and aggressive life support measures. This inexorable progression toward multisystem organ failure creates a challenge in managing the potential organ donor, in whom the goal is to maintain and optimize organ viability for transplantation. However, in some patients, acute neurogenic pulmonary edema and stress cardiomyopathy can subside in 24 to 48 hours and provides the opportunity for organ donation.

Most patients become hypotensive due to sudden loss of resting sympathetic tone and require intravenous pressors at the time brain death occurs, and soon thereafter, they develop diabetes insipidus (because antidiuretic hormone secretion ceases). *Arginine vasopressin* is the first-line therapy for hypotension in brain death because it works effectively and also because it guards against central diabetes insipidus, which also occurs in the majority of brain dead patients. Adrenergic vasopressors such as norepinephrine or dopamine can also be added, but their usefulness can be limited by tachyarrhythmias, severe peripheral vasoconstriction, or aggravation of sympathetically mediated myocardial injury. In some cases, continued hypotension will respond to thyroid and glucocorticoid hormone replacement, indicating a relative deficiency of these hormones. Management of the organ donor in the United States is fully directed by the organ donation agency.

ETHICAL ISSUES

Some physicians and ethicists have repudiated the infallibility of terminal cardiac arrest, questioning irreversibility and even the definition of death. With improving intensive care unit technology and, certainly, with the introduction of multiple vasopressors, terminal cardiac arrest—albeit expected—may not occur quickly anymore. Isolated reports of prolonged somatic support of brain-death patients may have religious, cultural, legal, and pecuniary motives but remain conspicuously unexamined at these later stages, and it is likely many, if not most, did not fulfill the 2010 American Academy of Neurology criteria. Prolonged care followed by cesarean section has been provided in rare circumstances such in brain death in advanced pregnancy. Providing support until delivery is rarely successful if the brain death mother has no viable fetus. More recently, neurologists have been confronted with families intervening with neurologic testing, which includes an apnea test. When families deny brain death as a definition of death, legal counsel is required.

CONCLUSIONS

Brain death examination requires expertise and follows a stepwise protocol. It is an obvious enough fact that the diagnosis of brain death is complex due to its clinical testing, in determination of confounding factors, and in the interpretation of ancillary tests. The responsibilities of neurologists are substantial also because it eventually involves organ transplantation.

SUGGESTED READINGS

Ashwal S, Schneider S. Brain death in children: part I. *Pediatr Neurol*. 1987; 3(1):5-11.

Ashwal S, Schneider S. Brain death in children: part II. *Pediatr Neurol*. 1987; 3(2):69-77.

Braksick SA, Robinson CP, Gronseth GS, Hocker S, Wijdicks EFM, Rabinstein AA. Variability in reported physician practices for brain death determination. *Neurology*. 2019;92(9):e888-e894.

Bueri JA, Saposnik G, Mauriño J, Saizar R, Garretto NS. Lazarus' sign in brain death. *Mov Disord*. 2000;15(3):583-586.

Daneshmand A, Rabinstein AA, Wijdicks EFM. The apnea test in brain death determination using oxygen diffusion method remains safe. *Neurology*. 2019; 92(8):386-387.

Martí-Fàbregas J, López-Navidad A, Caballero F, Otermin P. Decerebrate-like posturing with mechanical ventilation in brain death. *Neurology*. 2000;54(1): 224-227.

Nakagawa TA, Ashwal S, Mathur M, et al. Guidelines for the determination of brain death in infants and children: an update of the 1987 Task Force recommendations. *Crit Care Med*. 2011;39(9):2139-2155.

Saposnik G, Bueri JA, Mauriño J, Saizar R, Garretto NS. Spontaneous and reflex movements in brain death. *Neurology*. 2000;54(1):221-223.

Shemie SD, Pollack MM, Morioka M, Bonner S. Diagnosis of brain death in children. *Lancet Neurol*. 2007;6(1):87-92.

Webb AC, Samuels OB. Reversible brain death after cardiopulmonary arrest and induced hypothermia. *Crit Care Med*. 2011;39(6):1538-1542.

Wijdicks EFM. *Brain Death*. 3rd ed. New York, NY: Oxford University Press; 2017.

Wijdicks EFM. Critical synopsis and key questions in brain death determination. *Intensive Care Med*. 2019;45(3):306-309.

Wijdicks EFM. The case against confirmatory tests for determining brain death in adults. *Neurology*. 2010;75(1):77-83.

Wijdicks EFM, Rabinstein AA, Manno EM, Atkinson JD. Pronouncing brain death: contemporary practice and safety of the apnea test. *Neurology*. 2008;71(16):1240-1244.

Yee AH, Mandrekar J, Rabinstein AA, Wijdicks EFM. Predictors of apnea test failure during brain death determination. *Neurocrit Care*. 2010;12(3):352-355.

Computed Tomography 21

Priya Shoor, Daniel S. Chow, and Angela Lignelli

KEY POINTS

1. Noncontrast head computed tomography (CT) is the most appropriate first-line imaging in the evaluation of a patient with unexplained acute neurologic deficit suggesting a brain or brainstem localization.
2. CT head can rapidly identify processes demonstrating intracranial mass effect, midline shift, and increased intracranial pressure.
3. Low-osmolar contrast enhanced CT is useful for the evaluation of pathology that involves the breakdown of the blood-brain barrier such as primary tumor, metastatic lesions, infections, and inflammatory conditions.
4. Identification of subarachnoid hemorrhage on a noncontrast head CT warrants further evaluation with vessel imaging including CT angiography, magnetic resonance angiography, and/or conventional angiography.
5. In acute stroke, CT angiography should be performed as a first-line test in addition to noncontrast head CT in order to diagnose large vessel occlusion (LVO), which can be treated with thrombectomy.
6. CT perfusion provides quantitative color maps of cerebral blood volume and flow, cerebral mean transit time, and time to peak and may be used to quickly differentiate ischemic core from penumbra and identify candidates for thrombectomy in the 6-24 hour time window.

INTRODUCTION

This chapter provides a framework for understanding the basic principles of x-ray (roentgenogram) production and computed tomography (CT) image formation along with appropriate window and level parameters for evaluation of intracranial pathologies. In addition, the common indications for CT are discussed along with precautions and recommendations related to CT usage and iodinated contrast. Advanced CT modalities including CT perfusion and CT angiogram are given special consideration.

Description

CT is based on image reconstruction from sets of quantitative x-ray measurements through the head. A beam of x-rays serves as the source of photon energy, which is received by a detector. Although the exact physics of x-ray production is beyond the scope of this chapter, this section tries to simplify the basic principles of x-ray production important for image formation. Briefly, x-ray beams are generated when electrons, produced in the cathode of the tube unit, strike the anode target. The potential difference across the tube is measured as peak kilovoltage. Thus, increasing the peak kilovoltage increases the energy of x-rays produced, which will increase penetration of the beam during image production but decrease contrast (and vice versa). Imaging intravenous (IV) or oral contrast in CT imaging is based on the differential attenuation of the x-ray beam through various tissues. As the electron density of the tissue increases, the attenuation increases (giving a "whiter" image). Therefore, the bony calvarium appears "white" compared to soft tissue and air because of its greater attenuation.

Modern CT scanners use highly collimated x-ray beams, which are rotated over many different angles to obtain a differential absorption pattern across various rays through a slice of a patient's body. A circular scanner gantry houses the x-ray source and detectors; the plane of the circle can be tilted to perform scans at a range of angles from axial to coronal, depending on head position and scanner specifications. The x-ray source rotates around the patient's head, and the x-ray attenuation through the section plane is measured in compartments called *voxels*. A voxel is a volume element similar to a picture element, or pixel, with the added dimension of section thickness to create an image volume component. Through projection reconstruction, the computer creates or builds the image from more than 800,000 measurements per image plane and assigns a number to each voxel according to its x-ray attenuation (which is proportional to tissue electron density averaged over the volume of the voxel). These values are termed *Hounsfield units* (**Table 21.1**) in honor of Nobel Prize winner Sir Godfrey Hounsfield who first developed CT technology in 1973.

CT of the head differentiates cerebrospinal fluid and brain as well as white matter and cortical gray matter, delineates the

TABLE 21.1 Hounsfield Units for Common Structures

Structure	HU
Air (blackest)	−1,000
Fat	−100 to −50
Water	0
Cerebrospinal fluid	0-15
White matter	20-30
Gray matter	35-45
Acute hemorrhage[a]	45-65
Bone (whitest)	>500

[a]In patients with anemia or iron deficiency, Hounsfield unit (HU) values for hemorrhage may be lower.

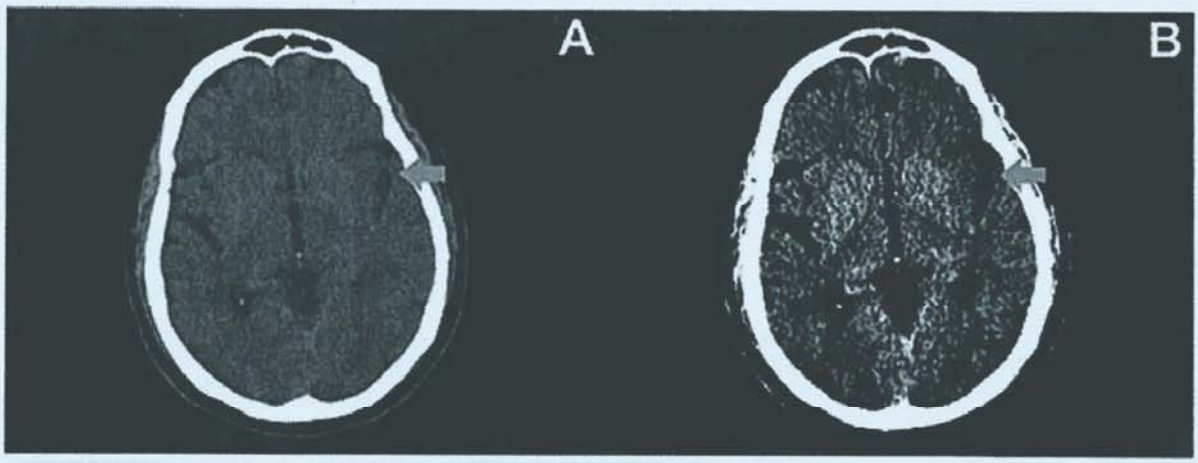

FIGURE 21.1 Noncontrast computed tomography of the head with standard brain **(A)** and narrow stroke **(B)** windows in a patient with acute right-sided weakness. Stroke windows reveal loss at the left insular ribbon *(arrows)*, which was not clearly visualized on conventional windows.

deep gray nuclei from the internal capsule, and images the skull and skull base in detail. Noncontrast computed tomography (NCCT) of the brain is especially useful for identifying acute hemorrhage, which is easily and reliably visualized as higher density than normal brain or cerebrospinal fluid. Typically, intracranial arteries are not well delineated on standard NCCT. Iodinated water-soluble contrast agents, which have high x-ray density, when administered intravenously enhance differences in tissue density, demonstrate vasculature and vascular pathology, and detect areas of blood-brain barrier breakdown.

A major limitation of CT has been imaging the posterior fossa, where linear artifacts appear because bone selectively attenuates the low-energy components of the x-ray beam; the resulting "beam hardening" creates dense or lucent streaks that project across the brainstem and may obscure underlying lesions in the brainstem and cerebellum. However, new detector technology and image-processing algorithms have reduced this artifact in the latest CT scanners, improved spatial resolution, and reduced the radiation dose. Current CT technology allows scan time per section ("slice") to be shortened to less than 1 second to minimize motion artifact. Multisection helical CT can acquire contiguous thin sections to produce three-dimensional (3D) data sets of an entire body part, such as the neck or head. Rapidly, repeated acquisitions can be used to acquire dynamic computed tomography angiography (CTA) and computed tomography perfusion (CTP) studies, which is discussed later in this chapter.

Windows and Levels

Although CT imaging can display 4,096 shades of gray, the human eye can only visualize between 16 and 32 shades of gray, which is well beyond human perception. "Windowing" allows users to narrow the range of shades of gray, which in turn adjusts the contrast scale. Two factors that can be adjusted by the user are the window width (W) and the window level (L). The W determines the range of shades of gray that can be displayed. Therefore, "narrowing the window" would increase the contrast of the image. The L determines the center of the W. By convention, users can decrease the W by dragging the mouse from right to left, increasing the contrast. The L can be decreased by dragging the mouse from top to down on monitors.

Although the default "brain window" (80 W 40 L) is suitable for assessing a wide range of pathologies, there are several other important windows for neuroimaging to assess for subtle abnormalities. For example, evaluation of parenchymal hypodensity as a marker for early infarct in stroke patients may be improved by using narrow windows (35 W 35 L) (**Fig. 21.1**). Additionally, subdural hemorrhages are often located at the convexities adjacent to bone and may be difficult to identify due to beam hardening and volume averaging. Using wider windows may assist in countering these limitations (**Fig. 21.2**). Lastly, bone windows (2,000 W 210 L) are

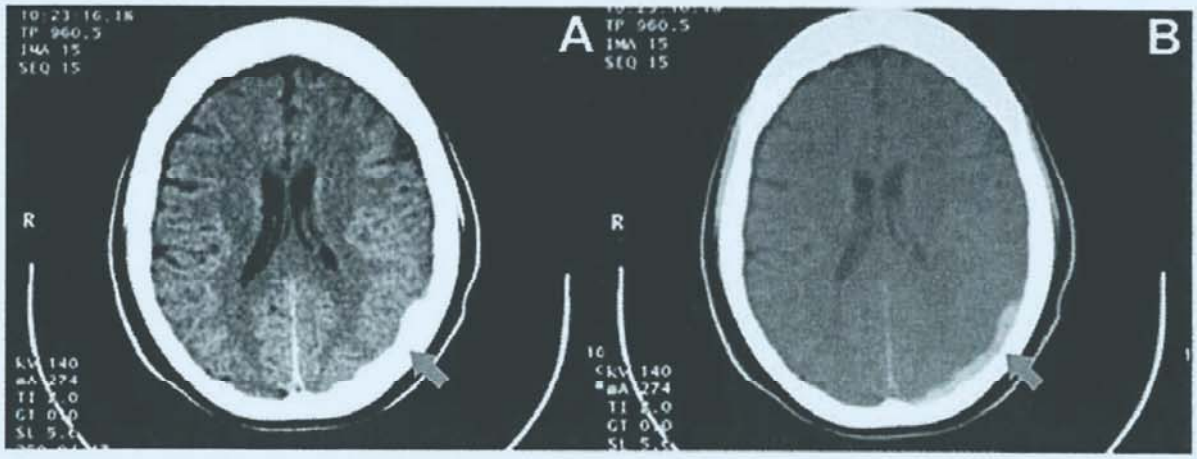

FIGURE 21.2 Noncontrast computed tomography of the head with standard brain **(A)** and wider subdural windows **(B)** in a patient after fall. Subdural windows reveal a subdural hematoma at the left parietal convexity *(arrows)*, which is not clearly visualized on conventional windows.

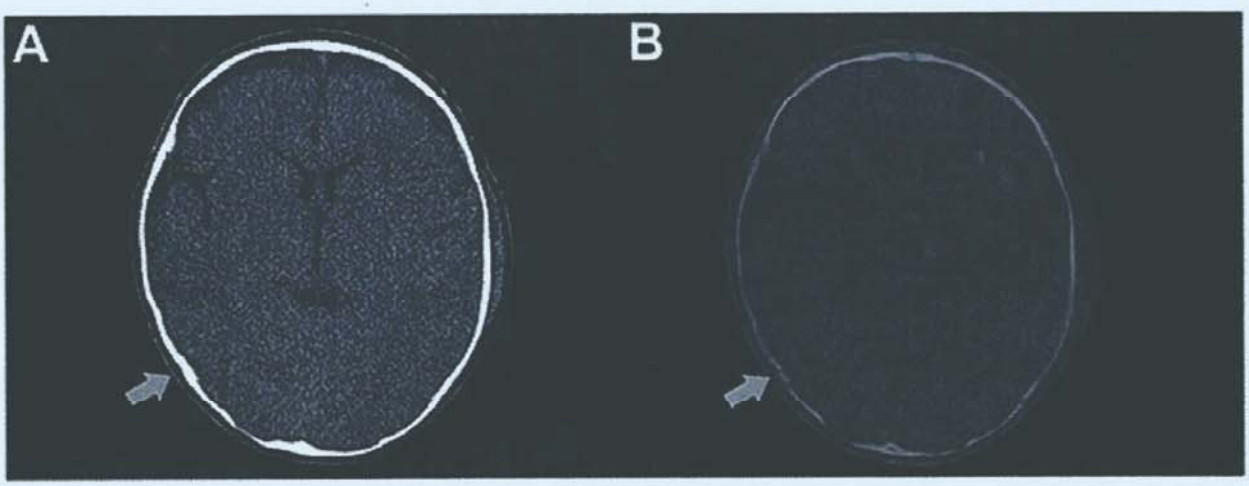

FIGURE 21.3 Noncontrast computed tomography of the head with standard brain **(A)** and bone **(B)** windows in a pediatric patient after fall. Bone windows reveal a nondisplaced hairline fracture of the right temporal bone, which is not visualized on conventional brain windows.

formed with wide ranges and centered above soft tissues and are best for evaluating for subtle nondisplaced calvarial fractures (Fig. 21.3).

ROLE OF COMPUTED TOMOGRAPHY

For reasons of cost, speed, and availability, CT remains widely used for screening in the acute evaluation of trauma, stroke, and infections (Table 21.2). CT is widely accepted as the more reliable method for detection of acute brain parenchymal or extra-axial hemorrhage, especially subarachnoid hemorrhage. It is particularly useful for patients who are neurologically or medically unstable, uncooperative, or claustrophobic as well as for patients with pacemakers or other metallic implants that may be contraindications for magnetic resonance imaging (MRI). The principle drawback of CT is its use of ionizing radiation, which is discussed at the end of this chapter. Although there are numerous indications for obtaining a CT examination of the central nervous system, this section briefly focuses on the appropriate use of CT in common clinical scenarios.

Head Trauma

An NCCT is the most appropriate first study for evaluation of acute head trauma. In patients with moderate or high risk for intracranial injury, there is consensus that postinjury NCCT is useful in excluding intracerebral hematoma, midline shift, or increased intracranial pressure. Additionally, NCCT is also very sensitive for identification of acute trauma in patients with minor head injury with the following risk factors: headache, vomiting, drug/alcohol intoxication, age older than 60 years, short-term memory deficit, physical findings of supraclavicular trauma, and/or seizure. CT's advantage for evaluation of traumatic injury includes its sensitivity for acute hemorrhage, fractures, and mass effect. CT is limited by its relative insensitivity to lesions adjacent to bony surfaces (ie, at the greater sphenoid wing) due to streak artifact. Additionally, diffuse axonal injury may go undetected.

TABLE 21.2 Common Indications for Emergency Computed Tomography Examination

Acute or chronic focal neurologic deficit
Head or facial trauma
Headache
Change in mental status
New-onset seizure

Headache

Routine screening head CT is generally not warranted in patients with chronic headaches in the absence of focal neurologic symptoms, change in headache pattern, or history of seizure activity. Several studies have confirmed the low yield of neuroimaging in individuals with isolated headaches and have reported a 0.4% yield for treatable lesions. However, neuroimaging is likely to be of greater yield for particular patient populations. For example, patients with cancer, immunocompromised status, or other systemic illness are more likely to have a "positive" scan. Imaging may also offer greater yield in headaches associated with trauma, abrupt or worsening headache, headache radiating to the neck or suspected meningitis, positional headache, or temporal headaches in older patients. Regarding suspected meningitis, CT imaging is often performed prior to lumbar puncture to assess for elevated intracranial pressure.

Subarachnoid Hemorrhage

NCCT imaging remains the most appropriate choice of imaging for patients with suspected subarachnoid hemorrhage, and failure of obtaining a head CT accounts for 73% of misdiagnosis. Patients diagnosed with subarachnoid hemorrhage require imaging of the cerebral vasculature, which may include CTA, magnetic resonance angiography, or direct catheter angiography. CTA has gained popularity and is frequently used for its noninvasiveness and sensitivity and specificity comparable to that of cerebral angiography.

Stroke

Initial workup for patients with suspected acute stroke is an NCCT in patients who are candidates for IV tissue plasminogen activator in order to differentiate between hemorrhagic and ischemic infarcts. NCCT remains the standard of care imaging

modality for exclusion of intracranial hemorrhage. In considering patients for endovascular therapies, the American Society of Neuroradiology, American College of Radiology, and Society of NeuroInterventional Surgery have recommended that appropriate imaging options include NCCT followed by digital subtraction angiography, or NCCT with CTA and perfusion CT, or MRI (with perfusion) and magnetic resonance angiography. Although NCCT has relatively low sensitivity to early ischemic injury compared to magnetic resonance diffusion imaging, it is not recommended that these findings be used to withhold IV tissue plasminogen activator treatment. With regard to CTP and CTA, its use has gained increased popularity in acute stroke evaluation and is discussed in the subsequent section.

COMPUTED TOMOGRAPHY PERFUSION AND ANGIOGRAPHY

Spiral CT increases scanning speed and image acquisition to less than 1 second per section and allows large-volume acquisitions that can be used for 3D presentation of anatomic information. Advances in CT technology have widened the extent of coverage per scan rotation from 2 cm (32 slices) to 4 cm (64 slices) and most recently to 16 cm (320 slices), which allows a set of images of the entire head to be obtained in a few rotations as the patient moves through the scanner or in as little as a single subsecond scan rotation in a stationary patient using the widest detector array. Rapidly repeating the scan acquisitions at 2 or 3 times per second during a bolus of IV contrast produces a set of "dynamic" images through a volume of tissue as wide as the detector array. This approach, with the widest detector array on a cone beam computed tomography, can be used to produce whole-brain "real-time" four-dimensional images of blood flow through the intracranial vessels (CTA) combined with "functional" images of brain parenchymal blood flow (CTP) in a total time of 1 minute, with a single IV contrast bolus injection.

CTA allows vascular imaging with IV contrast agents. Without contrast, intracranial vessels are not well seen on CT, unless abnormally large or dense—as with a thrombus. As previously described, modern CT scanners allow for rapid imaging, which permits noninvasive arterial phase imaging. Advantages of CTA over catheter angiography include more widely available technology; less specialized skill requirements; and no risk of dissection, stroke, or pseudoaneurysm at groin site. A limitation of CTA is the time-consuming processing required to edit out bone and calcium and to generate 3D surface renderings, although this has improved with the availability of specialized software that partially automates this process. *Maximum intensity projection* reformations or 3D renderings with surface shading can be used to display vascular anatomy and abnormalities such as stenosis or aneurysm with either of these approaches.

CT perfusion allows quantitative measures of cerebral blood volume (CBV), cerebral mean transit time (MTT), time to peak, and cerebral blood flow (CBF). These parametric maps can be easily generated at a work station, following the IV bolus administration of contrast. Perfusion imaging measurements can be used as a quick screening method in assessment of acute cerebral ischemia in major vascular territories and for differentiating between infarct and penumbra, with results comparable to MRI perfusion. Specifically, the infarct core, that is, region of irreversible injury, has been described as prolonged MTT, decreased CBV, and decreased CBF. The ischemic penumbra, potentially salvageable tissue, is described as prolonged MTT and time to peak with normal or increased CBV and resultant mildly reduced CBF, thought to reflect compensatory vasodilatation. The combination of NCCT, CTA, and CTP allows CT imaging to provide a complete evaluation of acute stroke.

IODINATED CONTRAST ADMINISTRATION

Contrast-enhanced CT is used to detect lesions that involve breakdown of the blood–brain barrier, such as brain or spinal tumors, infections, and inflammatory conditions. Contrast-enhanced CT is often used to rule out cerebral metastases. However, it is less sensitive than gadolinium-enhanced MRI, which is also better for detection of primary intracranial tumors and infections. IV CT contrast agents are based on iodine, and the older agents are classified as high-osmolar contrast media. Newer, nonionic agents, classified as low-osmolar contrast media, are less allergenic, and they cause less morbidity than do high-osmolar contrast media. The majority of patients receiving IV iodinated contrast media will have suffer no ill effects. With use of low-osmolar contrast media, the overall incidence of reactions is between 0.2% and 0.7% with severe and life-threatening reactions occurring between 0.01% and 0.02%.

With regard to the risk factors, history of prior contrast reaction is associated with a 5 times greater likelihood of a subsequent contrast reaction. Other risk factors include history of anaphylaxis, atopy, asthma, and significant cardiac disease. Of note, history of shellfish allergy is no longer considered a risk factor for contrast administration. In patients at increased risk for allergic reaction, several premedication strategies have been proposed by the American College of Radiology (Table 21.3).

Another important consideration for iodine-based IV contrast agents is contrast-induced nephrotoxicity (CIN), which is defined as an acute deterioration in renal function following IV iodinated contrast administration in the absence of other nephrotoxic event. However, the majority of the prior literature studying the incidence of CIN has failed to include a control

TABLE 21.3 Premedication Strategies for Patients With Known Risk Factors to Intravenous Iodinated Contrast Agents[a]

Elective	Prednisone: 50 mg orally at 13 h, 7 h, and 1 h before contrast injection *or* Methylprednisolone: 32 mg orally 12 h and 2 h before contrast injection *plus* Diphenhydramine: 50 mg IV, IM, or orally 1 h before contrast
Emergent	In decreasing order of desirability: Methylprednisolone sodium succinate: 40 mg *or* Hydrocortisone sodium succinate: 200 mg IV every 4 h until contrast injection *plus* Diphenhydramine: 50 mg IV 1 h prior to contrast injection

Abbreviations: IM, intramuscular; IV, intravenous.
[a]Data from the American College of Radiology. *ACR Manual on Contrast Media, Version 9.* Reston, VA: American College of Radiology, ACT Committee on Drugs and Contrast Media; 2013.

TABLE 21.4 Premedication Strategies for Patients at Risk for Contrast-Induced Nephropathy

1. A 3-mL/kg bolus 1 h prior to procedure followed by 1 mL/kg/h for 6 h postprocedure
2. N-acetylcysteine 600 mg orally or IV 12 h preprocedure, followed by 600 mg every 12 h orally or IV postprocedure × three doses

Abbreviation: IV, intravenous.

group. In one study with a control group by Newhouse et al involving 30,000 patients at a single institution, half of the control group (patients who did not receive contrast medium) displayed a change in serum creatinine of at least 25% and a change of 0.4 mg/dL in 40%. This study concluded that had some of these patients received IV iodinated contrast, a creatinine rise would have been attributed to it, rather than to physiologic variation. Nonetheless, it is important to recognize risk factors described for CIN, which includes preexisting renal insufficiency.

There is no universally agreed on threshold of serum creatinine elevation (or degree of renal dysfunction) to contraindicate intravascular iodinated contrast administration. With regard to prevention against CIN in patients receiving contrast, studies suggest that adequate hydration is beneficial. Although an accepted ideal infusion rate has yet to be established, isotonic fluids are preferred (ie, lactated Ringer or 0.9% normal saline). Protocols using sodium bicarbonate solution infusion or N-acetylcysteine exist for reducing the risk of CIN (Table 21.4). These are safe and reasonable therapeutic options when IV contrast is required for patients with chronic renal insufficiency, although their efficacy is not established.

SUGGESTED READINGS

Adams HP Jr, del Zoppo G, Alberts MJ, et al. Guidelines for the early management of adults with ischemic stroke: a guideline from the American Heart Association/American Stroke Association Stroke Council, Clinical Cardiology Council, Cardiovascular Radiology and Intervention Council, and the Atherosclerotic Peripheral Vascular Disease and Quality of Care Outcomes in Research Interdisciplinary Working Groups: the American Academy of Neurology affirms the value of this guideline as an educational tool for neurologists. *Stroke*. 2007;38:1655-1711. doi:10.1161/STROKEAHA.107.181486.

Campbell BC, Christensen S, Levi CR, et al. Cerebral blood flow is the optimal CT perfusion parameter for assessing infarct core. *Stroke*. 2011;42:3435-3440. doi:10.1161/STROKEAHA.111.618355.

Gilbert JW, Johnson KM, Larkin GL, Moore CL. Atraumatic headache in US emergency departments: recent trends in CT/MRI utilisation and factors associated with severe intracranial pathology. *Emerg Med J*. 2012;29:576-581. doi:10.1136/emermed-2011-200088.

Haydel MJ, Preston CA, Mills TJ, Luber S, Blaudeau E, DeBlieux PM. Indications for computed tomography in patients with minor head injury. *N Engl J Med*. 2000;343:100-105. doi:10.1056/NEJM200007133430204.

Jayaraman MV, Mayo-Smith WW, Tung GA, et al. Detection of intracranial aneurysms: multi-detector row CT angiography compared with DSA. *Radiology*. 2004;230:510-518. doi:10.1148/radiol.2302021465.

Kowalski RG, Claassen J, Kreiter KT, et al. Initial misdiagnosis and outcome after subarachnoid hemorrhage. *JAMA*. 2004;291:866-869. doi:10.1001/jama.291.7.866.

Lee B, Newberg A. Neuroimaging in traumatic brain imaging. *NeuroRx*. 2005;2:372-383. doi:10.1602/neurorx.2.2.372.

Newhouse JH, Kho D, Rao QA, Starren J. Frequency of serum creatinine changes in the absence of iodinated contrast material: implications for studies of contrast nephrotoxicity. *AJR Am J Roentgenol*. 2008;191:376-382. doi:10.2214/AJR.07.3280.

Reinus WR, Erickson KK, Wippold FJ II. Unenhanced emergency cranial CT: optimizing patient selection with univariate and multivariate analyses. *Radiology*. 1993;186:763-768. doi:10.1148/radiology.186.3.8430185.

Sandrini G, Friberg L, Coppola G, et al. Neurophysiological tests and neuroimaging procedures in non-acute headache (2nd edition). *Eur J Neurol*. 2011;18:373-381. doi:10.1111/j.1468-1331.2010.03212.x.

Sempere AP, Porta-Etessam J, Medrano V, et al. Neuroimaging in the evaluation of patients with non-acute headache. *Cephalalgia*. 2005;25:30-35. doi:10.1111/j.1468-2982.2004.00798.x.

Stiell IG, Wells GA, Vandemheen K, et al. The Canadian CT Head Rule for patients with minor head injury. *Lancet*. 2001;357:1391-1396.

Suarez JI, Tarr RW, Selman WR. Aneurysmal subarachnoid hemorrhage. *N Engl J Med*. 2006;354:387-396. doi:10.1056/NEJMra052732.

Wardlaw JM, Mielke O. Early signs of brain infarction at CT: observer reliability and outcome after thrombolytic treatment—systematic review. *Radiology*. 2005;235:444-453. doi:10.1148/radiol.2352040262.

Wintermark M, Flanders AE, Velthuis B, et al. Perfusion-CT assessment of infarct core and penumbra: receiver operating characteristic curve analysis in 130 patients suspected of acute hemispheric stroke. *Stroke*. 2006;37:979-985. doi:10.1161/01.STR.0000209238.61459.39.

Wintermark M, Sanelli PC, Albers GW, et al. Imaging recommendations for acute stroke and transient ischemic attack patients: a joint statement by the American Society of Neuroradiology, the American College of Radiology, and the Society of NeuroInterventional Surgery. *AJNR Am J Neuroradiol*. 2013;34:E117-E127. doi:10.3174/ajnr.A3690.

Magnetic Resonance Imaging 22

Eric Newman and Angela Lignelli

KEY POINTS

1. Magnetic resonance imaging (MRI) is a high-resolution structural imaging modality with a broad application of clinical uses.
2. MRI is based on nuclear spin spectroscopy of water protons and does not involve ionizing radiation.
3. T1 sequences are useful in identifying structural neuroanatomy, contrast enhancement sequences, and acute hemorrhage.
4. T2-related sequences, including fluid-attenuated inversion recovery, are useful in a broad array of pathologic processes, especially evaluation of white matter diseases.
5. Diffusion-weighted imaging is especially helpful in acute ischemic stroke but may be abnormal in other metabolic, infectious, neoplastic, and neurodegenerative processes.
6. Susceptibility-weighted imaging identifies calcification or iron content and also has a broad array of clinical applications.
7. Vascular MRI, including angiography and venography, is most useful in the workup and localization of stroke.
8. Magnetic resonance spectroscopy is useful in differentiating some structural and metabolic changes, through identification of abnormal energy storage and anaerobic metabolism as well as cell membrane and myelin content.
9. Diffusion tensor imaging uses directional dependence of diffusion of water to assess the integrity of white matter tracts.
10. Functional MRI uses hemodynamic coupling of cerebral activation to indirectly infer cerebral activation and is primarily used for preoperative surgical planning and research.

INTRODUCTION

Magnetic resonance imaging (MRI) is a noninvasive medical imaging technique. The images created by MRI often appear similar to gross-anatomic specimens. The major strength of MRI is the ability to distinguish different soft tissues and identify pathologic abnormalities. It is indispensable to modern neurologic practice for diagnosis, confirmation, and characterization of neurologic conditions as well as for monitoring response to therapy. Although MRI signal abnormalities can be very sensitive to pathologic processes, in isolation, the findings may lack specificity, requiring thorough integration of clinical information. The main weaknesses of MRI are cost, inherent low signal to noise necessitating high magnetic fields as well as lengthy exam times, and distortion of images by artifacts. The MRI scanner consists of a bore that is generally small and constricting, creating anxiety or claustrophobia in many patients. In addition, implanted devices can be ferromagnetic and therefore contraindicated for MRI imaging, for example, some pacemakers. As in all radiologic procedures, contrast agents should be administered when the benefit of improved diagnostic accuracy outweighs their generally low risk. In the following paragraphs, the physics of MRI and technical considerations are discussed. In addition, the application of basic imaging sequences and advanced imaging methods are reviewed.

PHYSICS OF MAGNETIC RESONANCE IMAGING

MRI is based on Fourier transform nuclear spin spectroscopy of water protons. Clinical imaging is performed on the nuclear spin of water protons because water is abundant in biologic tissues and protons have relatively greater sensitivity in a magnetic resonance than other nuclei.

In the classical description relevant for clinical imaging, MRI can be understood by considering the spin properties of protons to be equivalent to small magnetic dipoles that align in a magnetic field. In the quantum mechanical description of proton magnetic resonance, individual proton spins exist as a combination (superposition) of two quantized energy states, transitions between which can be manipulated using radiofrequency pulses and delays. The very large number of water protons leads to behavior of biologic tissues in the magnetic field that can be thought of as net magnetization. This longitudinal magnetization can be *tipped* from the aligned state by a radiofrequency excitation pulse. The change in angle from the original aligned state is called the *flip angle*. Once in the transverse plane, the magnetization begins to rotate (precess) around the magnetic field at a specific resonant frequency called the *Larmor frequency* (~43 MHz per tesla for protons). This precessional motion in turn generates a time-varying voltage in a receiver coil. The specific resonance frequency depends on the nucleus being imaged, its local environment, and the magnetic field strength.

Relaxation of the signal back to equilibrium is described by the T1 and T2 exponential time constants. Relaxation of magnetization is not a spontaneous process but rather a phenomenon that is due to underlying molecular motion and molecular interactions. The BPP theory of relaxation named after Bloembergen, Purcell, and Pound has proven accurate and permits calculation of relaxation times from first principles. The two principal relaxation mechanisms are termed *T1* and *T2 processes*, which are relevant to clinical imaging and approximately depend on the

molecular tumbling rate or rather the rotational diffusion of individual molecules. The T1 time constant describes the recovery of longitudinal magnetization back to the equilibrium aligned state (after a time T1 ~63% of the magnetization has realigned). The T2 time constant describes the decay of magnetization in the transverse plane (after a time T2 ~63% of the magnetization has decayed).

Image Creation

MRI creates images by applying linear spatial magnetic field gradients so that different parts of the human body resonate at different frequencies. One dimension can be sampled directly (called the *frequency dimension*), whereas other dimensions can be sampled indirectly (called *phase dimensions*). By combining multiple gradient directions, two-dimensional or three-dimensional images can be constructed.

The MRI signal is composed of time-dependent damped sinusoids and requires Fourier transform to convert it to a power spectrum that is the image. The term *k-space* is used to refer to the time-dependent data. This is sometimes a source of confusion because the Fourier transform is very similar to its own inverse, and acquisition of time-dependent MRI data in k-space is essentially equivalent to acquisition of different frequency components of the image. For this reason, it is often noted that the center of the k-space image determines image contrast (low-frequency components), whereas the edges of the k-space image determine detail in the image (high-frequency components).

Since the first live human images were obtained in the late 1970s, the field has drastically expanded to include a wide variety of clinical applications. The sequence of radiofrequency pulses, gradient pulses, and intervening time delays used to prepare magnetization and the methods of sampling k-space are referred to as the *pulse sequence*. Different pulse sequences are also tailored for specific applications. The two basic sequences are gradient echo and spin echo techniques, upon which additional sequences can be derived. Gradient echo sequences refocus magnetization following a radiofrequency pulse using a field gradient, whereas spin echo sequences refocus magnetization using a radiofrequency inversion (180-degree) pulse. Spin echo sequences are generally less susceptible to artifacts because artifacts are also inverted by the refocusing pulse and subsequently cancel out.

CLINICAL MAGNETIC RESONANCE IMAGING SYSTEMS

Clinical imaging systems are rated by the strength of the main magnetic field, referred to the as the B_0 *field*, measured in tesla (1 T = 10,000 gauss ~15,000-40,000 the earth's magnetic field). The majority of clinical imaging systems use field strengths of 1.5 or 3 T. The term *high field* in the context of clinical imaging refers to magnet systems operating at 7 to 9 T. High-field systems have clear benefits in terms of improved anatomic resolution and increased signal to noise but are more prone to artifacts and require more radiofrequency power (higher specific absorption rate). Higher field magnets are typically closed-bore, meaning that they are shaped like long tube or cylinder. A variety of open-bore magnets is also commercially available. These magnets are more accommodating to variations in patient body habitus and typically create a less claustrophobic environment. Completely open-bore magnets operate at lower field strengths than closed-bore systems, with resultant lower resolution that may compromise clinical diagnosis.

Multiple components of the magnetic imaging system influence the ultimate sensitivity in detecting the magnetic resonance signal and generating a distortion-free image. One important physical factor that is changed between different applications is the radiofrequency coil. A variety of receive and transmit/receive coils are available for specific applications to the brain, head, neck, and spine. These include bird cage–type coils for imaging the brain, surface coils, multichannel, and parallel imaging coils, all of which have different trade-offs in terms of size of allowed imaging volume as well as sensitivity and speed of imaging.

MAGNETIC RESONANCE IMAGING SAFETY

The main safety considerations in MRI include the powerful main magnetic field, rapidly changing magnetic field gradients, deposition of radiofrequency power, sound pressure levels, and safety concerns related to contrast agents. The powerful magnetic field produced by an MRI scanner is a major safety consideration because objects can become dangerous projectiles when placed in the field. Moreover, non–MRI-compatible implanted devices or metallic foreign bodies pose a danger because of local tissue-heating effects and movement of the object in respect to critical structures. Commonly encountered devices in clinical practice include implanted cardiac devices (eg, cardiac pacemakers) as well as others such as infusion pumps, cochlear implants, and a variety of surgical implants such as some aneurysm clips. Recently, MRI-compatible cardiac devices have been devised and new MRI-compatible implanted surgical devices are being developed. However, precaution needs to be taken with every implanted device to ensure MRI compatibility and patient safety. Before the patient is even brought near the magnetic field, which is never turned off, a thorough safety check by appropriately trained medical personnel must be performed.

Once inside the MRI scanner, some patients may experience a variety of physical effects in addition to the possibility of claustrophobia. Federal limits on the main magnetic field strength imposed by the U.S. Food and Drug Administration are 8 T for adults and 4 T for neonates. Fields greater than these limits may pose a risk. Limits are also placed on the speed of the rapidly switching magnetic field gradients in MRI due to the possibility of neural or cardiac depolarization resulting in pain, auras, or possibly cardiac arrhythmias. Regulatory limits are also placed on the rate of energy deposition by radiofrequency pulses (eg, similar to limits placed on cell phones). This limit is referred to as the *specific absorption rate* and meant to prevent heating damage of body tissues.

Gadolinium chelates are commonly used contrast agents in MRI because of the local relaxivity effects that lead to T1 shortening and resultant bright signal on T1-weighted images. Other contrast agents including manganese-based contrast agents and superparamagnetic iron oxides are currently less common in clinical practice. The risk of contrast administration in the context of MRI includes contrast reactions that may be life-threatening. The deposition of gadolinium in tissues and resulting fibrosis, commonly known as *nephrogenic systemic fibrosis*, has been reported in patients with significantly reduced renal function necessitating appropriate screening.

BASIC SEQUENCES

For the purpose of clinical imaging, there are many sources of image contrast. Dynamic processes on the molecular level such as flow-related and diffusion effects and a variety of relaxation mechanisms are responsible for the power of MRI to generate contrast between different biologic tissues.

The basic sequences that are weighted for specific sources of image contrast are as follows:

- T1-weighted
- T2-weighted
- Fluid-attenuated inversion recovery (FLAIR) T2-weighted
- Diffusion-weighted
- Susceptibility-weighted
- Post–contrast-enhanced images

T1-Weighted and T2-Weighted Imaging

The two core sequences in magnetic resonance are T1-weighted and T2-weighted sequences, which individually emphasize either the T1 or the T2 relaxation time of tissues. *T1-weighted* imaging emphasizes *short T1* relaxation times as bright signal; tissues composed of spins with long T1 relaxation times will appear relatively lower signal intensity (dark) on T1-weighted images. The main clinical use of T1 imaging is to display brain and spinal cord anatomy. However, T1-weighted images are also useful to evaluate for subacute hemorrhage, lipids, paramagnetic metals, or proteinaceous composition of lesions, which all shorten the T1 relaxation time and appear bright on T1-weighted images. T1-weighted images also serve as the baseline comparison to contrast-enhanced images. T1-weighting can be accomplished by either decreasing the *repetition time* (TR) between successive excitations thus preventing magnetization from fully relaxing to equilibrium or by changing phase of successive radiofrequency pulses thus causing destructive inference (referred to as *spoiled gradient echo*).

The main clinical use of T2 imaging is to display brain and spinal cord pathology, as evidenced by increased tissue water content. *T2-weighted* images emphasize *long T2* relaxation times as a bright signal. Tissues composed of spins with short T2 relaxation times will appear dark on T2-weighted images. However, susceptibility effects resulting in local field inhomogeneities also decrease the T2 time (this type of effect is sometimes referred to as *T2**). T2 weighting can be accomplished by increasing the time the magnetization spends in the transverse plane, or *time to echo* (TE), prior to acquisition. Different from both T1-weighted and T2-weighted images, proton-density weighted images are obtained with a short TE to minimize relaxation losses and long repetition time to allow more magnetization to recover between successive excitations.

FLAIR is the preferred sequence for demonstrating subtle brain pathology. FLAIR images are obtained by preparing magnetization with a radiofrequency inversion pulse, which inverts the equilibrium alignment. As the magnetization relaxes back to the aligned state with the T1 time constant, it temporarily becomes negligible as it crosses zero and timing detection at this time can essentially null signal from spins with a specific T1. Although FLAIR sequences can be T1- or T2-weighted, in common clinical parlance, the FLAIR method refers to FLAIR T2-weighted images. The main advantage of FLAIR images is sensitivity to detect a broad array of pathologic processes and is specifically useful for the evaluation of white matter diseases in the brain. The archetypal example is multiple sclerosis (MS), which is characterized by periventricular white matter lesions, radially oriented to the bodies of the lateral ventricles (requiring both axial and sagittal FLAIR sequences for complete assessment) (**Fig. 22.1**; see **Fig. 22.6**).

Individual tissues have characteristic appearance on T1-weighted, T2-weighted, and FLAIR images. For example, cerebrospinal fluid (CSF) has a relatively long T1 and long T2 relaxation time and thus appears dark on T1-weighted images and bright on T2-weighted images (**Fig. 22.2A,B**). CSF appears dark on FLAIR images because these images are specifically calibrated to suppress CSF or "free" water (**Fig. 22.2C**). White matter in the adult is fully myelinated and appears slightly bright on T1-weighted images and dark on T2-weighted images (see **Fig. 22.2A,B**). Gray matter is brighter than white matter on T2-weighted images, whereas the reverse is true for T1-weighted images. Parenchymal hemorrhage can have a variety of appearances on T1- and T2-weighted images based on its components. In the brain, hemorrhage evolves predictably and its appearance can be used to infer its age. T2 prolongation (bright on T2-weighted images) correlates with hyperacute hemorrhage and late subacute hemorrhage, whereas T1 shortening (bright on T1-weighted images) correlates with early and late subacute hemorrhage. These characteristic appearances are summarized in **Table 22.1**.

Quantification of T1 and T2 Times

T1 and T2 relaxation time constants can be quantified to provide information of dynamic properties on a molecular level. Relaxation can also be measured during the application of a continuous radiofrequency pulse; in this case, the relaxation time constants are referred to as *T1-rho* and *T2-rho* (rho referring to a rotating reference frame used in the theoretical description). Magnetization transfer imaging as well as chemical exchange saturation transfer imaging are additional methods that rely on using a radiofrequency pulse to attenuate magnetization. These emerging methods are currently confined to the research setting but hold promise for future clinical applications.

Diffusion-Weighted Imaging

Diffusion-weighted imaging (DWI) is invaluable for the detection of early ischemic brain injury (**Fig. 22.3**). Like T1 and T2 processes, DWI creates image contrast by exploiting dynamic molecular properties, specifically translational diffusion, by applying multidirection diffusion sensitizing field gradients. In clinical practice, DWI is typically performed for water, although applications to other molecules have been reported. The "effect" of the diffusion gradient sequence is often quantified using a b-value. For adults, a b-value = 1,000 s/mm^2 is typically used, whereas b-value = 1,500 s/mm^2 is sometimes preferred in pediatric cases. In routine clinical practice, DWI is typically detected using an echo planar imaging (EPI) technique due to the speed of imaging. EPI is a gradient echo technique that can acquire the entirety of k-space within one excitation by interweaving frequency and phase dimensions.

Diffusion imaging is considered a quantitative technique, permitting the calculation of an apparent diffusion coefficient (ADC), which measures the extent to which the diffusivity of water is restricted from free diffusion, presumably due to structural barriers such as cell membranes or association of water with larger molecules that have lower diffusion coefficients. The most useful

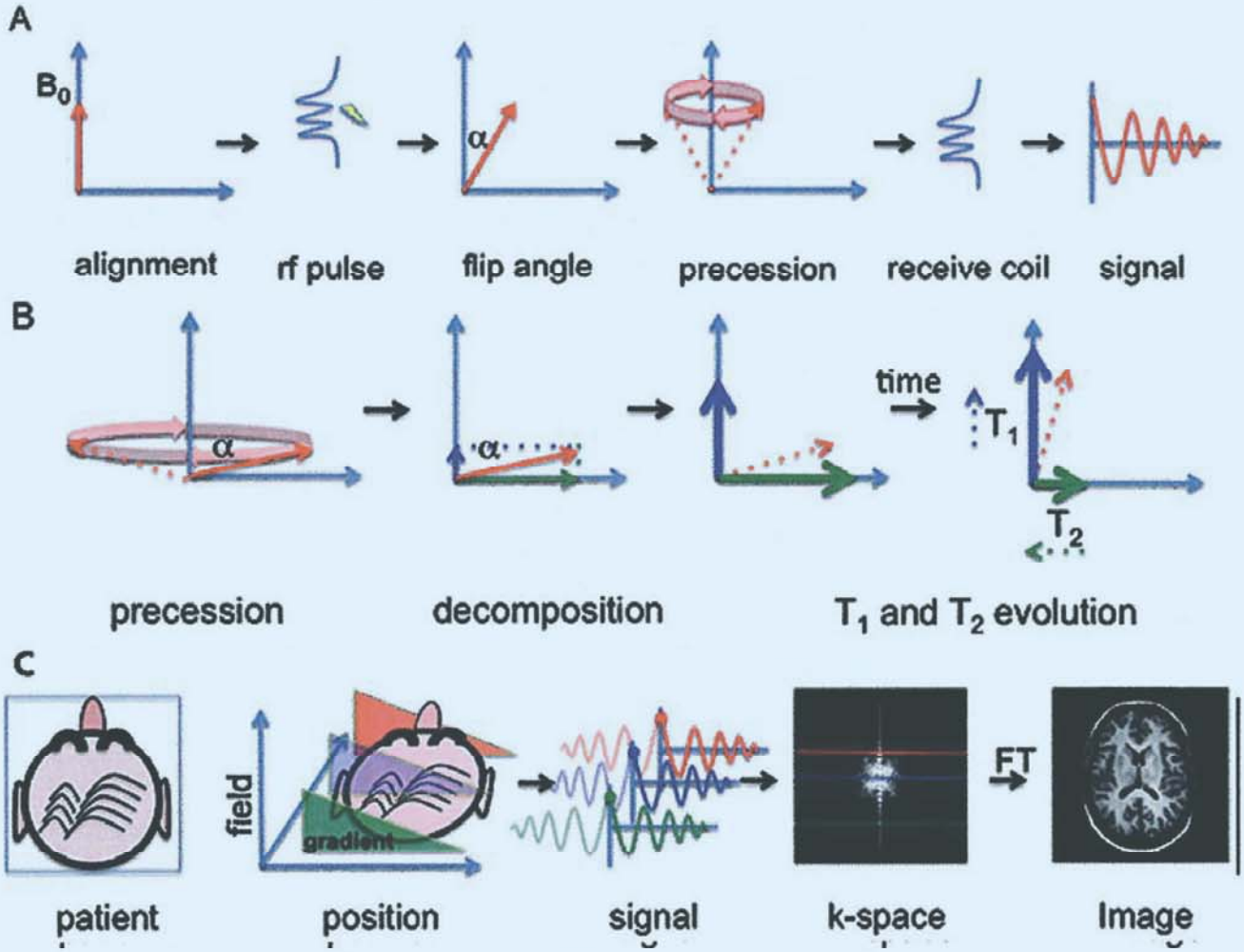

FIGURE 22.1 Schematic representation of magnetic resonance. **A:** Magnetization *(red arrow)* aligns along the main magnetic field (B_0). A radiofrequency (*rf*) pulse generated by a transmit coil tips the magnetization from the aligned state by a flip angle (α). The magnetization precesses around the main magnetic field. The precessional motion results in a time-varying voltage in a radiofrequency receive coil, which is recorded as the magnetic resonance signal. **B:** While the magnetization precesses around the magnetic field, the decay of magnetization can be described by two separate exponential time constants. The magnetization vector can be decomposed into a longitudinal component parallel to the main magnetic field and a transverse component orthogonal to the main magnetic field. The T1 time describes the relaxation of magnetization back to the equilibrium-aligned state. The T2 time constant describes the decay of transverse magnetization. **C:** Images are created in magnetic resonance by applying multiple field gradients, which positionally encode the magnetic resonance signal. In this schematic of a patient's head, directly acquiring signal from each gradient direction allows encoding of the frequency dimension. Applying an additional increasing orthogonal gradient with every frequency encoding gradient allows encoding of the phase dimension. The signal from one gradient direction thus corresponds to one line of k-space. Once all of the lines of k-space are filled, a Fourier transform (FT) is used to make an image representation.

application of DWI is in acute stroke imaging (see Fig. 22.3A). This occurs most frequently in the setting of cellular bioenergetic failure and cytotoxic brain edema due to cerebral hypoxia/ischemia. Acute and early subacute infarcts display restricted diffusion and are easily detected as bright regions on DWI. Differentiation of acute infarcts from late subacute infarcts, both of which can appear bright on DWI (known colloquially as *T2 shine through*), can be accomplished by examination concurrent ADC image. Acute to early subacute infarcts truly demonstrate restricted diffusion and appear dark on the ADC image (see Fig. 22.3B). Subacute to chronic infarcts are bright on DWI due to T2 shine through and appear isointense to bright on the ADC image.

Other conditions including uncontrolled status epilepticus and prion diseases (eg, Creutzfeldt-Jacob disease) may demonstrate increased cortical DWI signal. Restricted diffusion can also be observed in hemorrhage and for tissues/neoplasms with high cellular density in the case of active inflammation and within the center of abscesses. DWI is specifically useful in the evaluation of brain tumors, where foci of restricted diffusion raise suspicion for an aggressive hypercellular tumor component, which may predate contrast enhancement.

Gradient-Recalled Echo and Susceptibility-Weighted Imaging

The primary clinical use of gradient-recalled echo (GRE) or susceptibility-weighted imaging (SWI) is sensitivity to the presence of small amounts of hemorrhage. SWI or GRE images

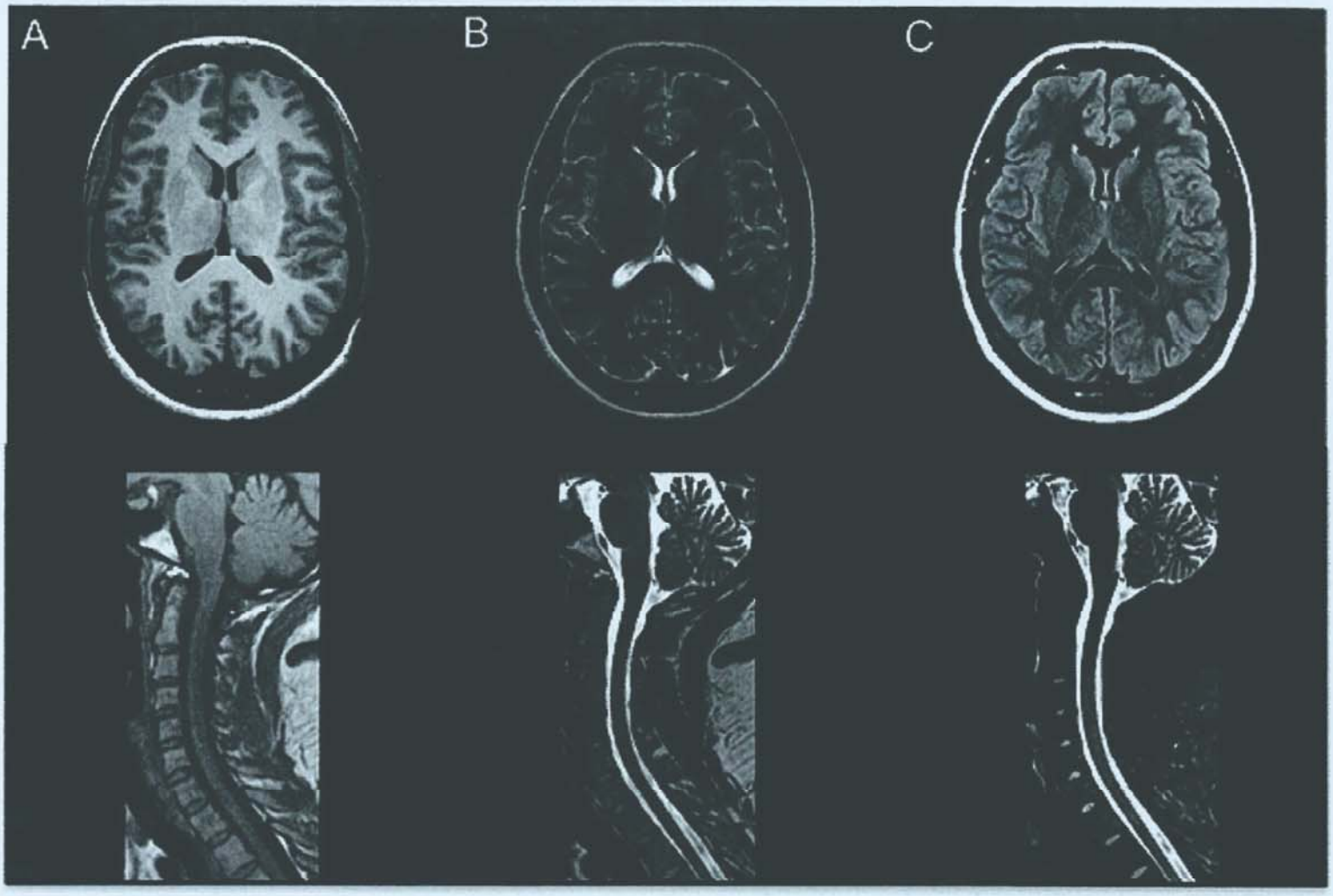

FIGURE 22.2 Normal T1-weighted, T2-weighted, fluid-attenuated inversion recovery (FLAIR), and inversion recovery (IR) images. **A:** Normal T1-weighted images of the brain and cervical spine. White matter is bright and gray matter is dark. Cerebrospinal fluid (CSF) signal is dark. **B:** Normal T2-weighted images of the brain and cervical spine. Gray matter is bright, and white matter is dark. CSF signal is bright. **C:** Normal FLAIR image of the brain and IR image of the cervical spine. On the FLAIR image, CSF signal is suppressed and appears dark; white matter is dark and gray matter is bright similar to a T2-weighted image. On the IR image of the cervical spine, fat is suppressed and there is increased contrast in the spinal cord.

TABLE 22.1 Usual Appearance of Normal Structures on T1-Weighted, T2-Weighted, FLAIR, DWI/ADC, and GRE or SWI Images

	T1-Weighted	T2-Weighted	FLAIR	DWI/ADC	GRE or SWI
CSF	Dark	Bright	Dark	Dark/bright	Bright
White matter or gray matter brighter	White matter brighter	Gray matter brighter	Gray matter brighter	Gray matter brighter/ white matter brighter	Variable
Acute infarct	Dark	Bright	Bright	Bright/dark	Variable
Hemorrhage	Bright if early or late subacute	Bright if hyperacute or late subacute	Variable	Variable	Dark
Edema	Dark	Bright	Bright	Variable/bright	Isointense

Abbreviations: ADC, apparent diffusion coefficient; CSF, cerebrospinal fluid; DWI, diffusion-weighted imaging; FLAIR, fluid-attenuated inversion recovery; GRE, gradient-recalled echo; SWI, susceptibility-weighted imaging.

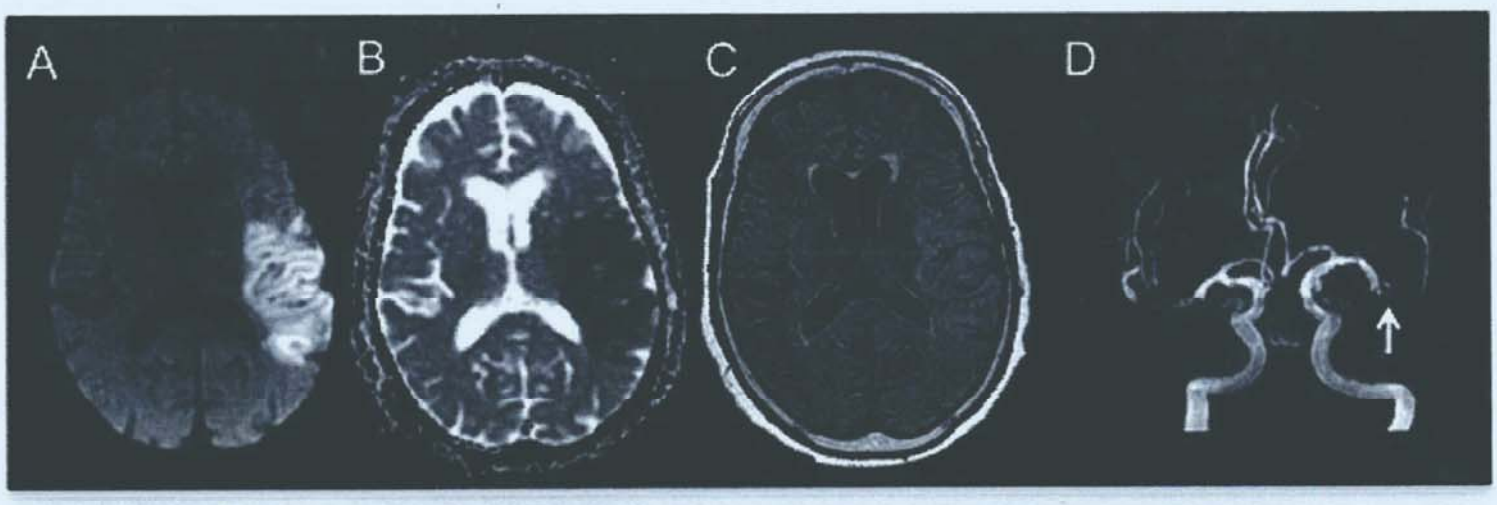

FIGURE 22.3 Acute left middle cerebral artery (MCA) infarct. **A:** The diffusion-weighted imaging image shows bright signal in the left MCA territory. **B:** The corresponding apparent diffusion coefficient image shows dark signal confirming an acute or early subacute infarct. **C:** The corresponding fluid-attenuated inversion recovery image shows mild associated increased signal compatible with edema. **D:** Magnetic resonance angiography of the circle of Willis shows absent flow-related enhancement of the left distal M1 MCA segment *(arrow)* compatible with occlusion. Irregularity is also noted of the contralateral right M1 segment.

generate image contrast from differences in underlying magnetic susceptibility. Differences in susceptibility are interpreted to represent underlying paramagnetic or diamagnetic species and have important implications for characterizing tissue components such as calcification or iron content. SWI are slightly different from GRE images in that they depict intracranial vessels and are considered more sensitive than conventional GRE. Methods to quantify susceptibility are called *quantitative susceptibility mapping*. In the research setting, quantitative methods have applications in more accurate dating of hemorrhage, quantifying contrast agent enhancement, and in the evaluation for neurodegenerative disease associated with heavy metal deposition.

Gadolinium Contrast Enhancement

The use of intravenous paramagnetic contrast agents, typically gadolinium chelates, is invaluable in MRI. Enhancement is defined as increased T1 shortening following administration of contrast, and the concept is further developed in the context of magnetic resonance perfusion imaging. The presence of contrast enhancement in the brain parenchyma signifies a breakdown of the blood-brain barrier and has important implications for characterizing lesions from brain tumors and metastases to infectious and inflammatory etiologies (see Fig. 22.3D).

Several structures in the brain lack a blood-brain barrier such as the pineal gland and pituitary gland and normally enhance. Vascular enhancement is variable. Vessels are typically bright on *spoiled gradient echo*–type T1 postcontrast images but have a variable appearance on spin echo T1-type images, depending on flow rate and other imaging parameters. In the spine, enhancement can be observed in the epidural veins as well as the soft tissues. Dedicated magnetic resonance angiographic images may be necessary to characterize some vascular malformations, and conventional catheter angiography may be necessary to evaluate subtle vascular malformations.

In some situations, contrast-enhanced imaging may not be appropriate. Examples include contraindications to contrast such as prior severe allergic reactions or renal failure. In the setting of possible or prior allergic reaction, premedication with a standard steroid algorithm is necessary if the benefit of contrast to make a diagnosis outweighs the risks. Many imaging protocols such as for the evaluation of infarct, hypertensive hemorrhage, or acute spinal cord compression do not typically require postcontrast imaging. In the setting of an evolving infarct or parenchymal hemorrhage, contrast enhancement is sometimes seen and may in fact present a diagnostic dilemma in the absence of adequate clinical history.

Magnetic Resonance Angiography and Magnetic Resonance Venography

Vascular structures in the head and neck can be imaged noninvasively using MRI without the use of intravenous contrast agents as well as with contrast. Primary clinical applications include evaluating for stenosis, thrombosis, dissection, and aneurysm in the vascular structures of the head or neck. The *time-of-flight* (TOF) method relies on vascular flow to bring *fresh* unrelaxed spins into the imaging volume. As a result, vessels that contain flowing spins appear bright and are easily delineated. The *phase contrast* or *velocity encoding* method detects phase changes of spins moving through a gradient. *Contrast-enhanced magnetic resonance angiography* (MRA) methods rely on the T1 shortening effects of gadolinium chelates, which are directly injected intravenously. Appropriate timing of a bolus of contrast and imaging can provide individual arterial and venous phases.

In the neck, MRA is commonly used to assess the patency of the carotid and vertebral systems, although ultrasound (US) and neck computed tomography angiography (CTA) may be used as well. Specific protocols used at individual imaging facilities depend on the resources available and the pretest probability for abnormalities in the specific patient population. The American College of Radiology Appropriateness Criteria give equally high recommendations for carotid US, CTA, and MRA for screening in the setting of a physical exam finding, such as a carotid bruit.

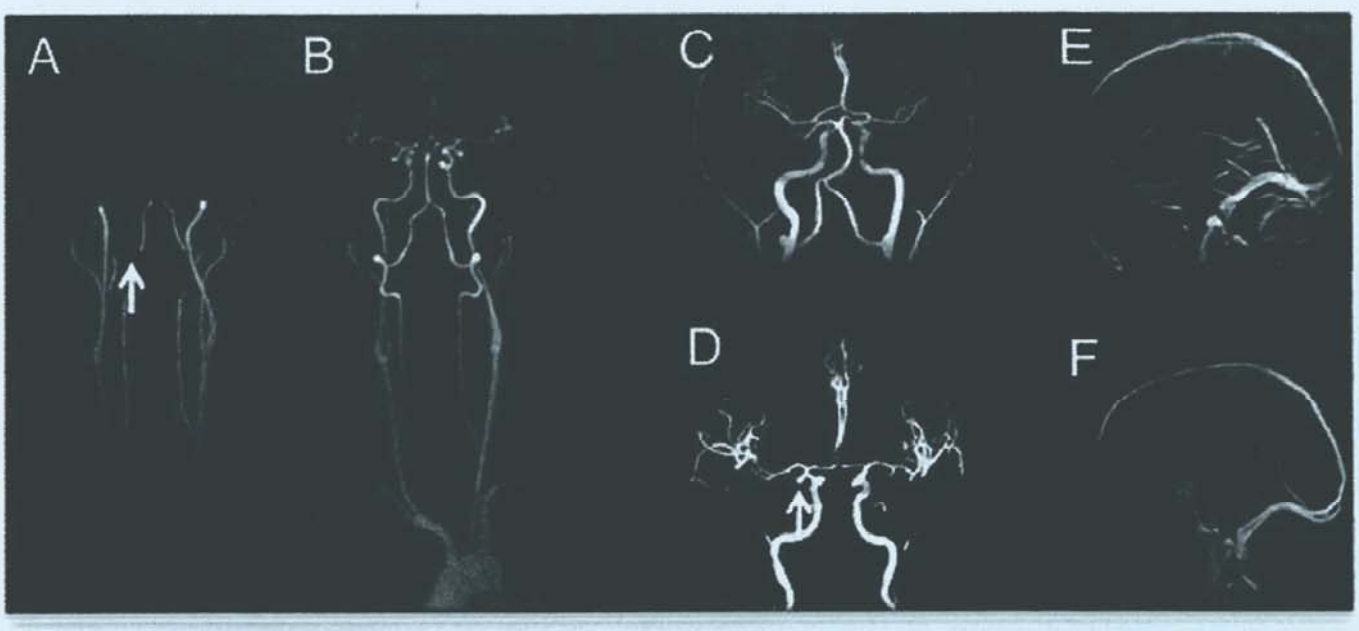

FIGURE 22.4 Magnetic resonance angiography (MRA) and magnetic resonance venography. **A:** MRA of the neck delineates the carotid and vertebral arteries. Note the in-plane flow artifact *(arrow)* in the V3 segments of the vertebral artery. **B:** Contrast-enhanced MRA arterial phase shows resolution of flow artifacts. **C:** Normal MRA of intracranial vessels. **D:** MRA depicts a right supraclinoid carotid artery aneurysm *(arrow)*. **E:** Three-dimensional time-of-flight magnetic resonance venography depicts the dural venous sinuses. **F:** Velocity-encoded magnetic resonance venography of the dural venous sinuses.

However, in the setting of focal neurologic deficit, MRA and CTA are preferred over US.

Noncontrast MRA of neck, using two-dimensional and three-dimensional TOF methods may be sufficient to exclude hemodynamically significant carotid stenosis. One limitation of noninvasive TOF techniques, however, is turbulent or slow flow, which can lead to loss of signal and overestimate the degree of stenosis, leading to false-positive results. This is specifically true in the carotid bulb or the V3 vertebral artery segments, which are sensitive to flow artifacts (**Fig. 22.4A,B**). Contrast-enhanced MRA is considered the most sensitive noninvasive imaging method for the diagnosis of 70% to 99% internal carotid artery stenosis with meta-analytic estimates of sensitivity equal to 85% (95% CI, 69%-93%) and specificity equal to 85% (76%-92%). Furthermore, in cases of carotid or vertebral arterial dissection, subtle luminal changes may be better evaluated with additional T1-weighted or proton-density weighted fat-saturated images in addition to contrast-enhanced methods.

In the intracranial circulation, TOF MRA methods are well suited to evaluate for vessel patency and aneurysm formation (**Fig. 22.4C,D**). In the setting of screening for aneurysm, for example, when there is a positive family history, the American College of Radiology Appropriateness Criteria gives slightly higher recommendations to the use of CTA over MRA given the higher resolution of CTA and absence of flow artifacts.

The use of contrast-enhanced MRA methods is preferred when evaluating aneurysms following intervention, such as coiling or stenting or when evaluating cerebrovascular malformations. Time-resolved contrast-enhanced methods (in which successive acquisitions can provide multiple arterial and venous phases) in the head and neck are typically applied when the temporal profile of enhancement is important. Examples include differentiating low- from high-flow vascular malformations or slow flow from complete occlusion.

Magnetic resonance venography is used clinically to evaluate for patency of the dural venous sinuses in the setting of venous sinus stenosis or thrombosis. 2D TOF (**Fig. 22.4E**) and velocity encoding techniques (**Fig. 22.4F**) are typically employed. Time-resolved postcontrast methods are useful, however, when an abnormality is identified to differentiate flow artifacts or partial stenosis/occlusion from complete occlusion.

Outside of the head and neck, MRA can be applied to the spine to evaluate for vascular malformations. Lastly, although MRA and magnetic resonance venography are useful techniques, some subtle vascular malformations may only be identified on conventional catheter angiography, and this must be considered if there is the need to completely exclude an underlying vascular malformation.

MAGNETIC RESONANCE IMAGING ARTIFACTS

MRI is subject to a multitude of artifacts, which in general refers to image representations that are distortions of the true underlying anatomy. Artifacts can both introduce nonexistent structures or obscure anatomy. Artifacts can originate from any of the multiple steps in signal generation, acquisition, and processing in addition to the underlying properties of biologic tissues and patient cooperation.

Some of the most commonly encountered artifacts arise from motion, either due to voluntary or involuntary patient motion (**Fig. 22.5A**) or biologic flow phenomena such as in vascular structures or pulsation of CSF (**Fig. 22.5B**). Flow phenomena lead to either increased or decreased signal within vascular structures, similar to effects exploited in noncontrast TOF MRA. Patient motion or pulsating structures such as vessels result in ghosting-type artifacts in clinical images (**Fig. 22.5C**).

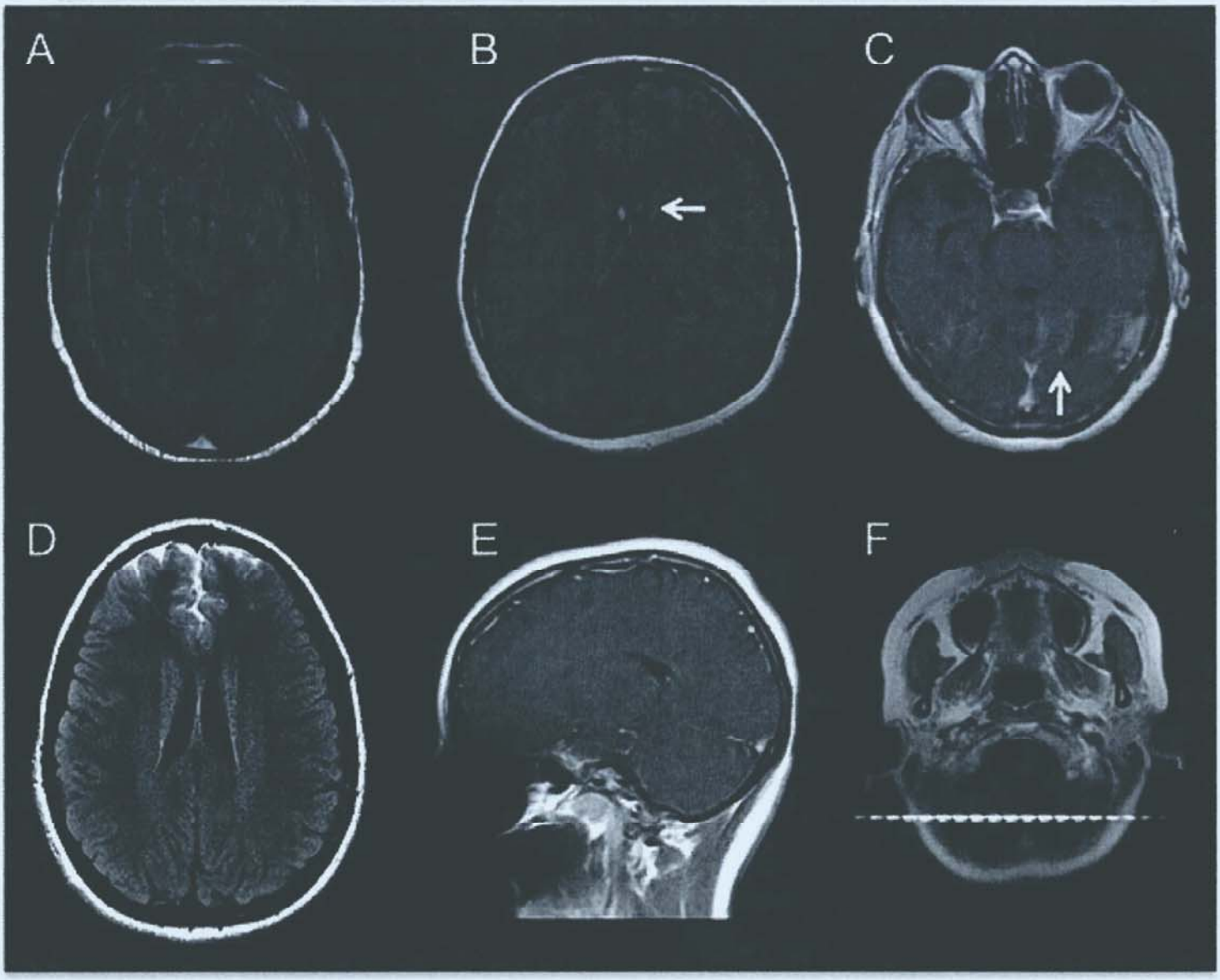

FIGURE 22.5 Magnetic resonance imaging artifacts. **A:** Motion artifact results in ghosting on a fluid-attenuated inversion recovery image. **B:** Flow artifact due to cerebrospinal fluid pulsations in the lateral ventricles *(arrow)*. **C:** Ghosting artifact due to pulsatile flow in the transverse sinuses *(arrow)*. **D:** Susceptibility artifact leads to increased signal in the frontal region due to failure of cerebrospinal fluid suppression. **E:** Corresponding susceptibility artifact due to dental hardware is shown on a T1-weighted image. **F:** Zipper artifact due to stray radiofrequency interference.

Ghosting artifacts also arise in EPI (called *N/2 ghosts*) due to distortions between successive echoes.

Susceptibility artifacts arise when there are distortions of the local magnetic field. This can be due to air-tissue interfaces or implanted metallic material. These artifacts are commonly encountered in the setting of dental hardware (such as fillings or braces), aneurysm clips, or spine fusion hardware. Usually, these artifacts lead to loss of signal in adjacent structures, but they may also result in increased signal, for example, in FLAIR imaging (Fig. 22.5D,E).

Aliasing artifacts are common when the field of view in the phase encoding dimension is too small; structures outside the field wrap within the image. It is important to note that these artifacts can arise from any phase encode direction.

Stray radiofrequency interference leads to so-called zipper artifacts (Fig. 22.5F). For this reason, MRI rooms are electrically shielded and must be operated with the door closed. Many additional artifacts are described in MRI, related to chemical shift effects, coil, and radiofrequency inhomogeneity.

CLINICAL MAGNETIC RESONANCE IMAGING

MRI attains significantly higher contrast between different biologic tissues compared to other cross-sectional imaging techniques such as computed tomography (CT) or US. For this

reason, MRI is considered the most precise and sensitive imaging modality for detecting CNS tissue pathology. Appropriateness criteria for MRI, CT, and other imaging modalities in various neurological conditions have been developed by the American College of Radiology. These are regularly updated and available at www.acr.org/Quality-Safety/Appropriateness-Criteria.

Approaches to imaging use in several common clinical scenarios—infarction, white matter disease and transverse myelitis (TM), and brain and intradural spinal cord tumors, are discussed in the following sections. Discussed throughout this text are suggested and typical uses of neuroimaging in the workup of a wide range of neurological diseases.

Cerebrovascular Disease

MRI has revolutionized stoke imaging. Acute infarcts are bright on DWI and display restricted diffusion on ADC images (see **Fig. 22.3**). Mass effect and vasogenic or cytotoxic edema can be evaluated on associated T2-weighted or FLAIR images. The presence of hemorrhage can be identified on SWI or GRE images. The size of the infarct can be quantified and the specific vascular territories involved can be delineated. Various scoring scales may be used to determine prognosis or indicate treatment based on imaging. Concurrently, performed vascular imaging can show causative vascular disease, such as stenosis, thrombosis, or dissection.

The approach to stroke imaging begins with close inspection of the DWI for increased diffusion-weighted signal relative to the background of normal structures. Once a lesion is identified, evaluation of the ADC image can confirm an acute or early subacute infarct, which is dark relative to background. Evaluation of the SWI or GRE images is used to look for evidence of hemorrhage or hemorrhagic conversion. It is important not to confuse hemorrhage with an acute infarct, both of which may show restricted diffusion. Additional sequences including T2 and FLAIR images are used to evaluate for mass effect, cytotoxic, and vasogenic edema. Some authors suggest that inspection of the concurrent FLAIR images may differentiate between acute and subacute infarcts when clinical information is incomplete or unavailable.

The specific structures involved in stroke and multiplicity of infarcts help to differentiate individual vascular territories from embolic-type infarcts and diffuse ischemia/hypoxia. Stroke imaging typically is performed in conjunction with vascular imaging such as MRA or CTA of the head and neck with attention specifically focused on determining if vascular occlusion is responsible for the infarct (see **Fig. 22.3D**). Perfusion imaging in stroke is sometimes performed to determine the size of the territory at risk and guide intervention. Spinal cord infarct may also be evaluated using the DWI sequence.

White Matter Disease

Abnormalities in the white matter are best identified on FLAIR images. The differential diagnosis of white matter disease includes demyelinating and dysmyelinating etiologies, vasculitic and vasospastic processes, infection and inflammatory processes, toxic/metabolic etiologies, edema, trauma, seizures, as well as neoplasm and hypoxic/ischemic processes including arterial and venous infarcts. Characterizing these processes and narrowing the differential diagnosis require concurrent integration of clinical information and a complete set of MRI sequences.

As an example, we discuss an approach to MS, an archetypal disease process with imaging abnormalities on brain and spine MRI (**Fig. 22.6**). The approach to MS begins with thorough

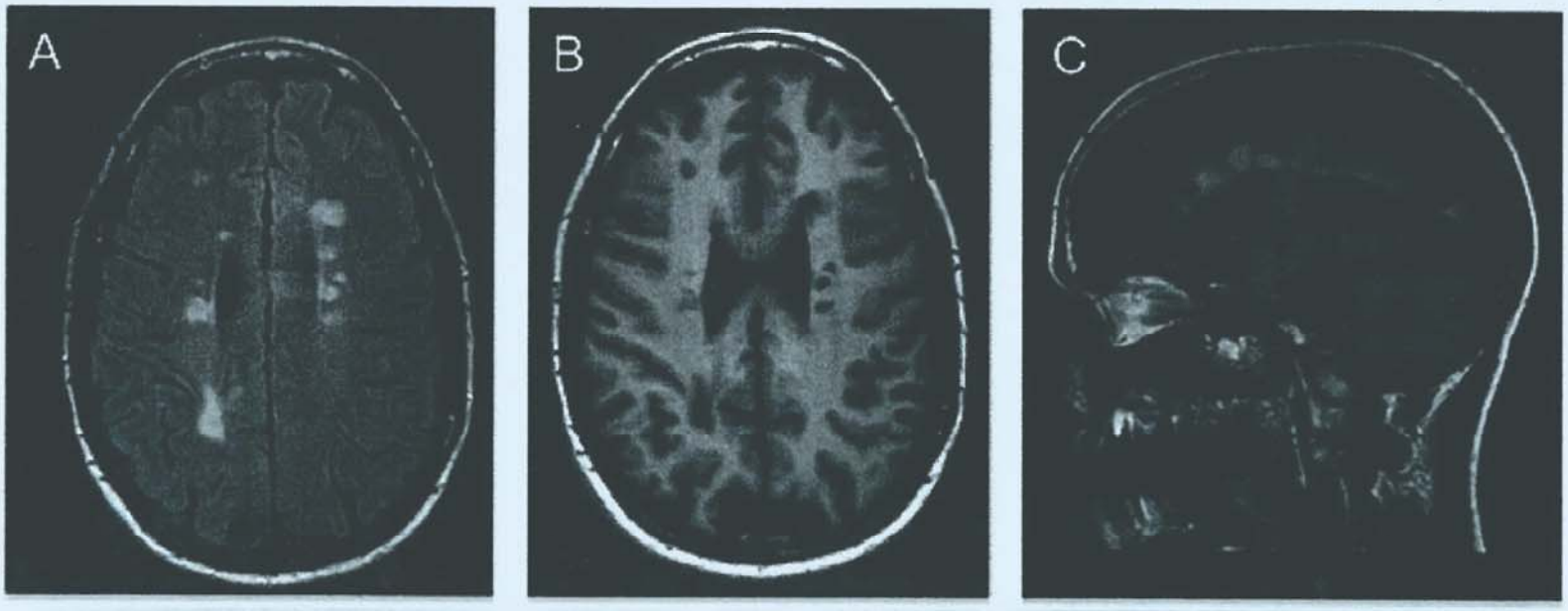

FIGURE 22.6 Multiple sclerosis. A: Characteristic white matter lesions of multiple sclerosis depicted on an axial fluid-attenuated inversion recovery image. **B:** Low signal intensity of the lesions on T1-weighted images suggests chronic lesions. **C:** Sagittal fluid-attenuated inversion recovery image depicts the radial orientation of white matter lesions characteristic of multiple sclerosis.

inspection of the FLAIR images for abnormal signal specifically involving the white matter. Supratentorially, lesions are typically identified in the periventricular, deep, and subcortical/juxtacortical white matter and corpus callosum, as well sometimes the basal ganglia, although cortical disease burden in MS is not well delineated on FLAIR imaging. Sagittal FLAIR images are invaluable for confirming subtle lesions on axially acquired sequences and for evaluating the corpus callosum. T2-weighted images are preferred for the evaluation of white matter lesions in the brainstem and cerebellar white matter due to artifacts in the posterior fossa on FLAIR images. After lesions are identified, their acuity is estimated based on associated diffusion abnormality and contrast enhancement, both of which would suggest acute demyelinating lesions. Finally, because MS patients undergoing treatment may be immunosuppressed, it is important to evaluate for superimposed infection such as progressive multifocal encephalopathy.

In the spine, the approach to MS concentrates on using T2-weighted images and IR T2-weighted images. IR T2-weighted images are similar to FLAIR images in that they also employ an inversion pulse; however, they are timed not to suppress CSF signal but rather to increase the conspicuity of lesions and suppress signal from fat. In contradistinction to the brain, spinal cord white matter is located peripherally to the central gray matter. Therefore, MS lesions within the spinal cord tend to be peripherally located (best seen on axial images) and span less than two vertebral body segments (on sagittal images). They are most frequently located within the cervical cord. As in the brain, the presence of contrast enhancement is used to identify acute lesions. It is important to remember that patient symptoms may not be due to demyelinating lesions in the spinal cord but rather to degenerative changes, such as disk herniations.

Brain and Spinal Cord Tumors

Tumors are defined by the presence of mass effect, where normal structures are displaced or infiltrated and display abnormal signal characteristics including postcontrast enhancement. Despite common belief, contrast enhancement does not always correlate with World Health Organization tumor grade. For example, both grade I pilocytic astrocytoma and grade IV glioblastoma typically display postcontrast enhancement. On the other hand, grade III anaplastic astrocytoma may not display contrast enhancement. FLAIR imaging is indispensable in brain tumor imaging because FLAIR imaging demonstrates nonenhancing tumor components but also associated mass effect and edema (Fig. 22.7). One of the main problems in evaluating brain tumors is distinguishing tumor recurrence (progression) from posttreatment changes (pseudoprogression). For this reason, tumor imaging typically entails advanced MRI methods such as magnetic resonance perfusion imaging and magnetic resonance spectroscopy (MRS), in addition to correlation with other modalities such as nuclear medicine ^{18}F-fluorodeoxyglucose positron emission tomography or thallium single-photon emission computed tomography.

The approach to assessment of brain tumors begins with localization of the lesion in the intra-axial or extra-axial space. Subsequent evaluation of mass effect and definition of the mass on T1-weighted, T2-weighted, FLAIR, or postcontrast images is performed. The adjacent parenchyma is evaluated for associated edema or infiltration. Diffusion-weighted images are used to evaluate associated ischemic changes or hypercellular components of the tumor. SWI or GRE images are used to evaluate for associated hemorrhage or calcifications. Given the heterogeneity of brain tumors, the location, appearance, signal characteristics, enhancement, or comparison to prior studies are all integrated to arrive at a differential diagnosis.

Similar to brain tumors, assessment of intradural spinal cord tumors begins with localization of the lesion in the intramedullary (intrinsic to the spinal cord) or extramedullary space (extrinsic to the spinal cord). Intradural, intramedullary lesions are generally T2 hyperintense with expansion of the cord and characteristically enhance. The primary differential diagnosis for intradural intramedullary lesion includes ependymoma or astrocytoma. Ependymomas arise from the central canal ependymal cells and thus tend to occur centrally within the cord and cause symmetric diffuse cord expansion. They are more common in adults and commonly involve the cervical and/or thoracic cord.

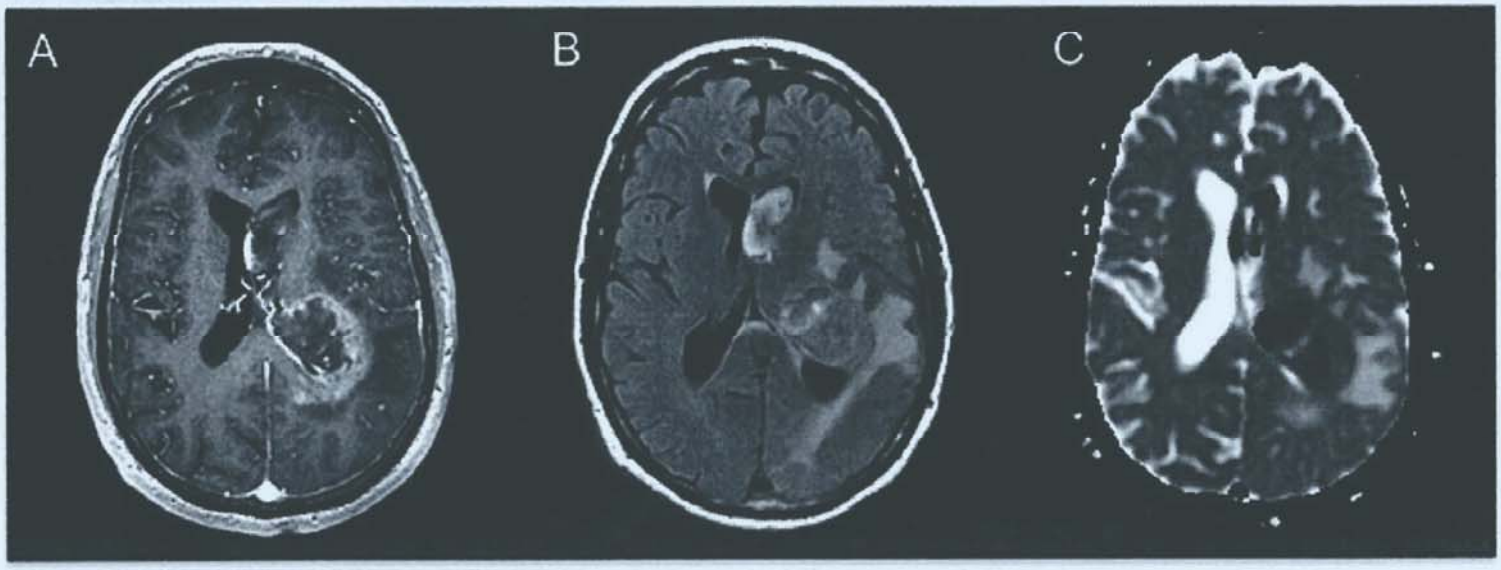

FIGURE 22.7 Glioblastoma. **A:** Post–contrast-enhanced image shows a large enhancing mass with central necrosis. **B:** Fluid-attenuated inversion recovery image depicts the associated white matter abnormality compatible with a combination of edema and nonenhancing tumor. **C:** Apparent diffusion coefficient image shows restricted diffusion in components of the tumor suggestive of increased cellular density.

Spinal astrocytomas are more common in young adults and children and occur slightly more commonly in the thoracic than cervical cord. Astrocytomas arise from the cord parenchyma and therefore are typically eccentric or exophytic with patchy enhancement as opposed to ependymomas, which often demonstrate avid focal enhancement with hemorrhage and/or peritumoral cysts. The primary differential diagnosis for intradural extramedullary lesion includes meningioma versus peripheral nerve sheath tumor (schwannoma or neurofibroma).

Transverse Myelitis

TM is characterized by hyperintense T2 signal within the spinal cord. The differential diagnosis includes demyelinating process such as MS, tumor such as astrocytoma, vascular ischemia/cord infarct, or postinfectious/inflammatory etiology such as acute disseminated encephalomyelitis. The differential diagnosis of TM can be further narrowed by the clinical history, laboratory and lumbar puncture results, and imaging appearance. On sagittal imaging, if the T2 signal abnormality typically extends at least three vertebral body segments, it is termed *longitudinally extensive TM*, which is characteristic of demyelination secondary to neuromyelitis optica. Neuromyelitis optica is diagnosed by the major criteria of longitudinally extensive TM and optic neuritis without evidence of sarcoid, vasculitis, lupus, or Sjögren syndrome. Additionally, the cross-sectional region of involvement within the cord on axial imaging is evaluated when refining the differential diagnosis.

ADVANCED MAGNETIC RESONANCE IMAGING METHODS

Functional Magnetic Resonance Imaging

Functional magnetic resonance imaging (fMRI) refers to the use of magnetic resonance for the localization of cerebral activation. The most commonly employed technique takes advantage of hemodynamic coupling of cerebral activation to indirectly infer cerebral activation. The blood oxygen level–dependent contrast mechanism results from a relative increase in the concentration of oxyhemoglobin (a paramagnetic species) compared to deoxyhemoglobin (a diamagnetic species) in response to cerebral activation. This change can be detected using rapid MRI sequences typically employing gradient echo sequences sensitive to T2* contrast, allowing cerebral activation to be imaged in the brain. Some authors have proposed using DWI to map cerebral activation but this is not common.

fMRI can be performed in conjunction with specific task paradigms (Fig. 22.8A,B). This type of fMRI has current clinical applications for mapping the cortical location of known cognitive and motor functional units and has specific use in presurgical and pretherapeutic planning. Examples include mapping the primary motor and visual cortices or localizing language activation areas.

In the research setting, the technique has been applied to monitor a variety of psychiatric disorders. When acquired without a specific task paradigm, the technique is referred to as *resting state fMRI*, which maps connectivity features of the so-called default-mode network.

Diffusion Tensor Imaging

Diffusion tensor imaging (DTI) is a technique that can quantify the directional dependence of diffusion of water. Clinically, DTI is most commonly applied to assess the integrity of white matter tracts (Fig. 22.8C). Normal white matter tracts are densely packed, which creates an anisotropic environment. Diffusion perpendicular to white matter tracts is relatively hindered compared to diffusion parallel to white matter tracts. Therefore, measuring the direction of greatest diffusion will estimate the dominant orientation of white matter tracts. Measuring multiple directions of diffusion can subsequently be used to define a diffusion tensor. The diffusion tensor information can then be postprocessed to generate images with white matter tracts.

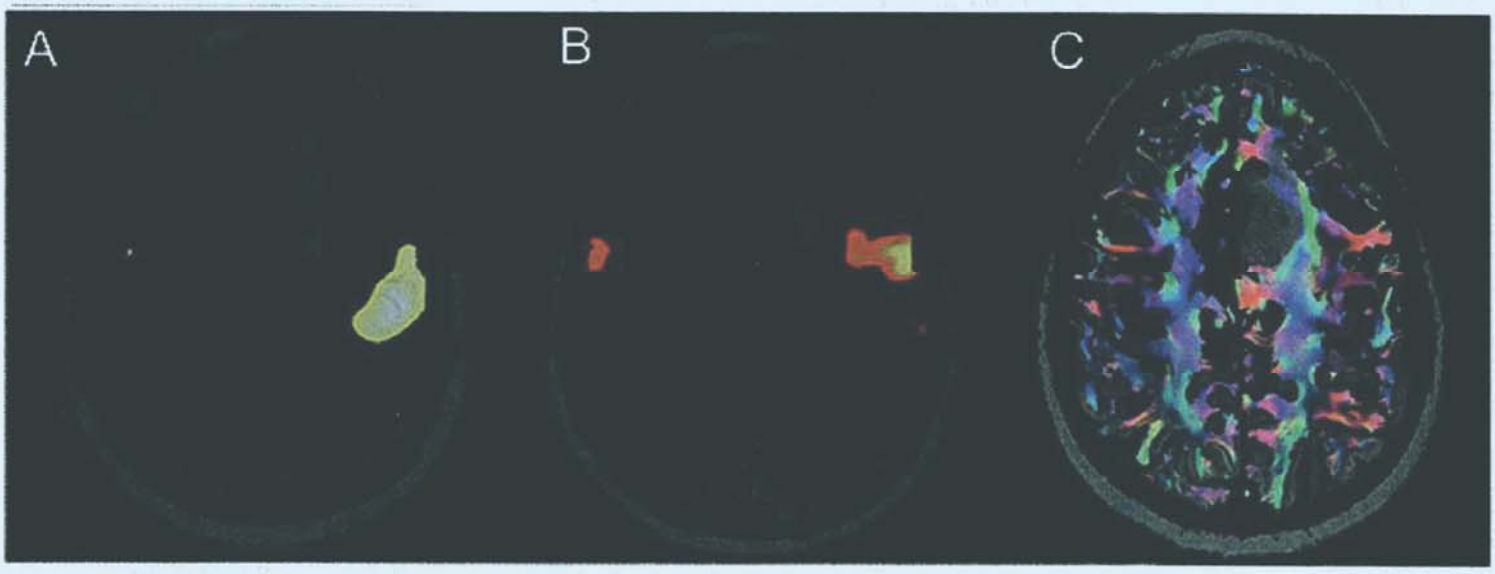

FIGURE 22.8 Functional magnetic resonance imaging (fMRI) and diffusion tensor imaging. **A:** Preoperative fMRI showing activation of primary motor cortex during a motor task in a patient with a left frontal neoplasm. **B:** Preoperative fMRI showing activation of left frontal language processing area during a verb generation task. **C:** Fiber tracking performed based on diffusion tensor data showing displacement of the left frontal tracts by the left frontal mass.

More advanced approaches, such as Q-ball and diffusion spectrum imaging, provide a more general description of diffusion and have improved performance in resolving crossing white matter fibers. The current clinical application of DTI is definition of white matter tracts in presurgical and pretherapeutic planning. A multitude of applications of DTI to variety of neurologic conditions including stroke, MS, dementia, and traumatic brain injury primarily reside in the research setting. In part, this is due to lack of standardization of acquisition and postprocessing techniques as well as data lacking on clinical use, heterogeneity of findings across a population, and effect on patient outcomes.

Magnetic Resonance Spectroscopy

MRS is considered an advanced imaging technique within MRI, although it is an integral part in the formation of anatomic magnetic resonance images. In the absence of an applied field gradient, different nuclei can be resolved by their chemical shift. MRS in clinical practice typically refers to spatially selective acquisition (single or multiple voxel) of proton spectra, where care has been taken to suppress the dominant water resonance, thus increasing sensitivity for the resonances of small molecules. In the brain, the most commonly observed resonances belong to *N*-acetylaspartate (2.0 ppm—interpreted to signify normal neuronal tissue), creatine (3.0 ppm—interpreted to signify energy stores), choline (3.2 ppm—interpreted to signify components of the cell membrane and myelin), and lactate (doublet at 1.3 ppm—interpreted to signify anaerobic metabolism) (**Fig. 22.9**). The lactate doublet resonance corresponding to the lactate methyl protons is inverted at an echo time of 144 ms compared to 288 ms due to J-coupling effects with the lactate methine proton.

Additional metabolites such as inositol/myoinositol (interpreted as a marker of astrocytes and astrogliosis seen in MS lesions), glutamate/glutamine, and several amino acids such as alanine (described in meningiomas) and glycine can also be observed. The relative amplitude of the resonance peaks reflects the relative concentrations of metabolites; however, it should be noted that in general, relaxation effects may alter resonance amplitudes, highlighting attention to the TE. In general, more metabolites are seen with a shorter TE. In routine clinical practice, spectroscopy is often used as a problem-solving technique, for example, in an attempt to differentiate tumor recurrence from posttreatment effects (higher choline-to-creatine ratios tend to be observed with recurrent brain tumors than radiation necrosis; **Fig. 22.10C**) or to evaluate for inborn errors of metabolism such as mitochondrial disorders and leukodystrophies (the presence of a lactate peak may signify a mitochondrial disorder such as mitochondrial encephalomyelopathy, lactic acidosis, and stroke). MRS has also been used to directly observe 2-hydroxyglutarate, a metabolite that accumulates in isocitrate dehydrogenase mutant glioblastoma tumors, and thus constitutes a biomarker for isocitrate dehydrogenase status in glioma.

Magnetic Resonance Perfusion Imaging

Magnetic resonance perfusion is a method of quantifying blood flow through biologic tissues. The method is usually applied to the brain but has been extended to other parts of the body including the spine. The relevant measures include measurement of cerebral blood volume, cerebral blood flow, and mean transit time.

This is achieved in MRI using a *first-pass* or *bolus*-tracking method that records the signal reduction that occurs when rapidly repeated images are acquired during the first passage of an intravascular bolus of paramagnetic contrast, usually a gadolinium chelate. The images produced are called *perfusion-weighted images* or *dynamic susceptibility contrast images*. Gradient echo images with EPI-type detection are usually used because they provide the ability to image very rapidly to track the contrast bolus.

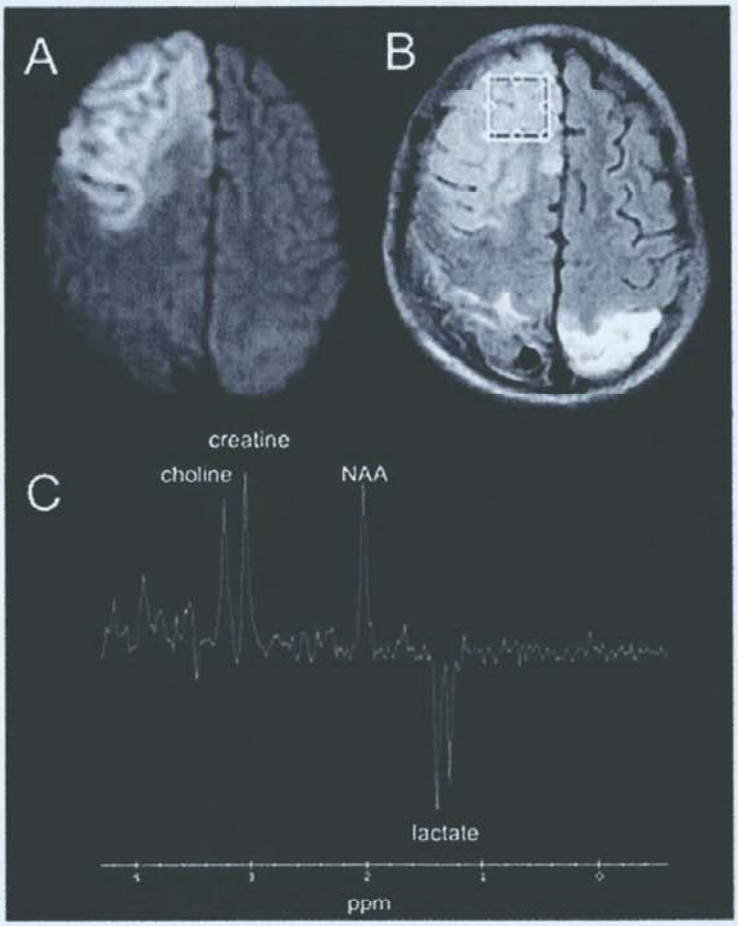

FIGURE 22.9 Magnetic resonance imaging spectroscopy. **A:** Diffusion-weighted imaging shows an acute infarct in the right superior frontal lobe. **B:** Voxel *(square)* is placed in the right superior frontal image on the corresponding fluid-attenuated inversion recovery image. **C:** Magnetic resonance spectroscopy performed at an echo time of 144 ms shows choline, creatine, and *N*-acetylaspartate (NAA) resonances with relative decrease of the NAA resonance. An inverted lactate doublet is present compatible with anaerobic metabolism in the setting of an infarct.

The time course of the signal change during the passage of the bolus can be used to obtain the cerebral blood volume (CBV), mean transit time (MTT), and their ratio, the cerebral blood flow (CBF = CBV / MTT). Because of the technical difficulty in measuring the arterial input function of the contrast bolus, perfusion maps are semiquantitative and are best interpreted as relative rather than absolute perfusion values (relative cerebral blood volume [rCBV], relative mean transit time [rMTT], and relative cerebral blood flow [rCBF]). If the arterial input function is known, then a measure of permeability of the extravascular-extracellular space known as *k-trans* can be calculated. Algorithms exist in clinical practice for quantifying the permeability of tissues to contrast (called *leakage*) from modeling of the perfusion time course without knowledge of the exact arterial input function.

Magnetic resonance perfusion can be performed without contrast with the arterial spin labeling (ASL) method. Similar to

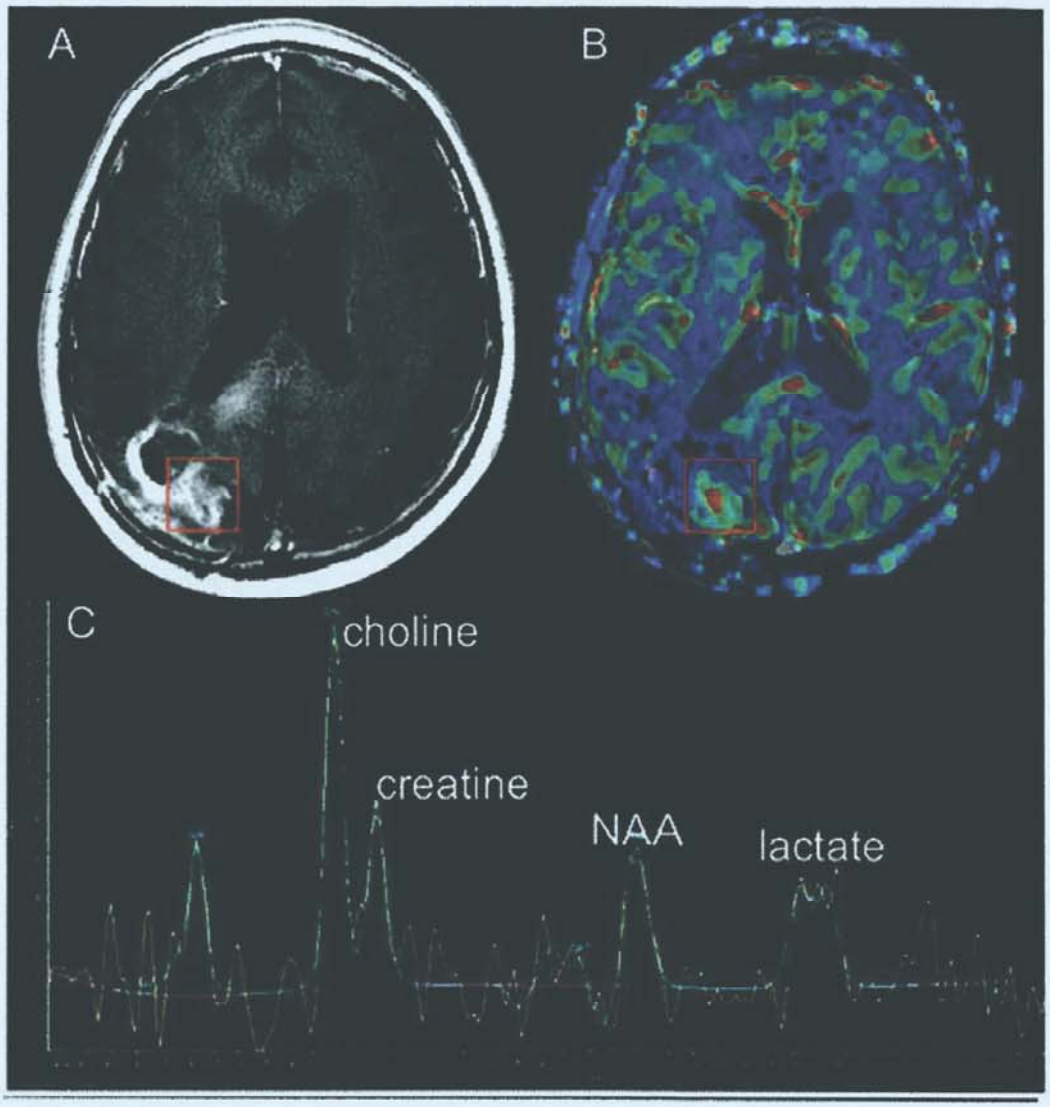

FIGURE 22.10 Magnetic resonance perfusion imaging and magnetic resonance spectroscopy in recurrent high-grade glioma. **A:** Post–contrast-enhanced image showing abnormal enhancement *(red square)* in the posterior right parietal region. **B:** Magnetic resonance perfusion image shows a focus of increased relative cerebral blood volume *(red square)* suggestive of recurrent tumor. **C:** Magnetic resonance spectroscopy at a time to echo of 288 ms shows elevated choline and decreased *N*-acetylaspartate resonances suggestive of recurrent tumor. A lactate doublet is present.

TOF MRA, the ASL method depends on inflow of spins through vessels. ASL may provide more quantitative information without the need for arterial input functions but is less widely available than contrast bolus tracking methods.

Clinical applications of magnetic resonance perfusion include cerebrovascular disease. In cases of stroke or vasospasm, measures of perfusion delay, such as MTT, are sensitive indicators of small reductions in cerebral perfusion that can delineate relatively hypoperfused vascular territories. In this way, magnetic resonance perfusion is similar to CT perfusion methods but can be performed without ionizing radiation and permits direct correlation with other magnetic resonance images. Outside of cerebrovascular disease imaging, clinical applications of magnetic resonance perfusion include brain tumors and metastases. These applications focus on assessment of CBV, which correlates with histologic tumor grade and characterizes response to treatment of the tumor (Fig. 22.10A,B).

EMERGING MAGNETIC RESONANCE IMAGING METHODS

Recent advances in MRI aim to drastically improve the resolution of images and speed of imaging as well as to significantly extend clinical applications. The emergence of high field (>7 T) imaging systems promises improvements in signal to noise and image resolution as well as functional imaging. Similarly, improvements in imaging speed have been a constant focus since the inception of MRI. Recent advances rely on undersampling and subsequent reconstruction using nonlinear methods. One of the most popular of such methods called *compressed sensing* holds promise for implementing near real-time imaging, especially when combined with methods to improve signal to noise.

Although magnetic resonance is a very powerful technique to study structure and dynamic processes on a molecular level, its application to biologic systems is primarily limited by its inherent low signal to noise. As a result, low-concentration molecules involved in metabolism and other cellular functions are essentially inaccessible by conventional techniques. This limitation is primarily evident in MRS, where multidimensional experiments could in theory characterize a multitude of metabolites, provided there was sufficient signal to noise. The goal of emerging methods called *hyperpolarization* (HP) is to increase nuclear spin polarization and thus drastically increase signal to noise. A primary application of HP-MRI is the study of in vivo transient interactions through HP of small metabolites suited to probing varied processes such as metabolism and oxidative stress or as agents of perfusion. HP-MRI is a promising technique for combining the intrinsic biologic tissue contrast, temporal and

chemical shift resolution, as well as sensitivity to dynamic processes of magnetic resonance with molecular imaging.

Perhaps the most important advancement in clinical imaging comes from contemporary advances in information technology and quantitative image-processing methods. The availability of electronic medical records and digitally archived images has permitted the correlation of imaging features with molecular pathology and development of a new field of *radiogenomics*. This field is predicated on correlation of quantitative image analysis features with molecular markers and information pertaining to patient diagnosis, prognosis, and treatment response available within the electronic medical record. This revolution in medicine embraces the heterogeneity of pathologic processes and individual responses in the patient population and seeks to tailor therapeutics for maximal efficacy.

SUGGESTED READINGS

Acosta-Cabronero J, Williams GB, Cardenas-Blanco A, Arnold RJ, Lupson V, Nestor PJ. In vivo quantitative susceptibility mapping (QSM) in Alzheimer's disease. *PLoS One*. 2013;8(11):e81093.

American College of Radiology. ACR Appropriateness Criteria®. American College of Radiology Web site. http://www.acr.org/Quality-Safety/Appropriateness-Criteria. Accessed January 1, 2015.

Andronesi OC, Kim GS, Gerstner E, et al. Detection of 2-hydroxyglutarate in IDH-mutated glioma patients by in vivo spectral-editing and 2D correlation magnetic resonance spectroscopy. *Sci Transl Med*. 2012;4(116):116ra4.

Chappell FM, Wardlaw JM, Young GR, et al. Carotid artery stenosis: accuracy of noninvasive tests—individual patient data meta-analysis. *Radiology*. 2009;251(2):493-502.

Chatterjee S, Chatterjee U. Intramedullary tumors in children. *J Pediatr Neurosci*. 2011;6(suppl 1):S86-S90.

De Coene B, Hajnal JV, Gatehouse P, et al. MR of the brain using fluid-attenuated inversion recovery (FLAIR) pulse sequences. *AJNR Am J Neuroradiol*. 1992;13(6):1555-1564.

Deoni SC. Quantitative relaxometry of the brain. *Top Magn Reson Imaging*. 2010;21(2):101-113.

de Rochefort L, Brown R, Prince MR, Wang Y. Quantitative MR susceptibility mapping using piece-wise constant regularized inversion of the magnetic field. *Magn Reson Med*. 2008;60(4):1003-1009.

Duong TQ, Yacoub E, Adriany G, Hu X, Ugurbil K, Kim SG. Microvascular BOLD contribution at 4 and 7 T in the human brain: gradient-echo and spin-echo fMRI with suppression of blood effects. *Magn Reson Med*. 2003;49(6):1019-1027.

Fox MD, Snyder AZ, Vincent JL, Corbetta M, Van Essen DC, Raichle ME. The human brain is intrinsically organized into dynamic, anticorrelated functional networks. *Proc Natl Acad Sci U S A*. 2005;102(27):9673-9678.

Geurts JJ, Bö L, Pouwels PJ, Castelijns JA, Polman CH, Barkhof F. Cortical lesions in multiple sclerosis: combined postmortem MR imaging and histopathology. *AJNR Am J Neuroradiol*. 2005;26(3):572-577.

Goh C, Desmond PM, Phal PM. MRI in transverse myelitis. *J Magn Reson Imaging*. 2014;40:1267-1279.

Goldman M. *Quantum Description of High-Resolution NMR in Liquids*. Oxford, United Kingdom: Clarendon Press; 1988.

Gupta A, Young RJ, Karimi S, et al. Isolated diffusion restriction precedes the development of enhancing tumor in a subset of patients with glioblastoma. *AJNR Am J Neuroradiol*. 2011;32(7):1301-1306.

Haacke EM, Cheng NY, House MJ, et al. Imaging iron stores in the brain using magnetic resonance imaging. *Magn Reson Imaging*. 2005;23(1):1-25.

Hajnal JV, Bryant DJ, Kasuboski L, et al. Use of fluid attenuated inversion recovery (FLAIR) pulse sequences in MRI of the brain. *J Comput Assist Tomogr*. 1992;16(6):841-844.

Kaunzner UW, Gauthier SA. MRI in the assessment and monitoring of multiple sclerosis: an update on best practice. *Ther Adv Neurol Disord*. 2017;10(6):247-261.

Keshari KR, Wilson DM. Chemistry and biochemistry of 13C hyperpolarized magnetic resonance using dynamic nuclear polarization. *Chem Soc Rev*. 2014;43(5):1627-1659.

Krings T, Reinges MH, Erberich S, et al. Functional MRI for presurgical planning: problems, artefacts, and solution strategies. *J Neurol Neurosurg Psychiatry*. 2001;70(6):749-760.

Kuo PH, Kanal E, Abu-Alfa AK, Cowper SE. Gadolinium-based MR contrast agents and nephrogenic systemic fibrosis. *Radiology*. 2007;242(3):647-649.

Lansberg MG, Thijs VN, O'Brien MW, et al. Evolution of apparent diffusion coefficient, diffusion-weighted, and T2-weighted signal intensity of acute stroke. *AJNR Am J Neuroradiol*. 2001;22(4):637-644.

Le Bihan D, Urayama S, Aso T, Hanakawa T, Fukuyama H. Direct and fast detection of neuronal activation in the human brain with diffusion MRI. *Proc Natl Acad Sci U S A*. 2006;103(21):8263-8268.

Levitt MH. *Spin Dynamics: Basis of Nuclear Magnetic Resonance*. 2nd ed. Chichester, United Kingdom: Wiley; 2008.

Linfante I, Llinas RH, Caplan LR, Warach S. MRI features of intracerebral hemorrhage within 2 hours from symptom onset. *Stroke*. 1999;30(11):2263-2267.

Lustig M, Donoho D, Pauly JM. Sparse MRI: the application of compressed sensing for rapid MR imaging. *Magn Reson Med*. 2007;58(6):1182-1195.

Mader I, Rauer S, Gall P, Klose U. (1)H MR spectroscopy of inflammation, infection and ischemia of the brain. *Eur J Radiol*. 2008;67(2):250-257.

McRobbie DW, Moore EA, Graves MJ, et al. *MRI From Picture to Proton*. 2nd ed. Cambridge, United Kingdom: Cambridge University Press; 2006.

Mitterschiffthaler MT, Ettinger U, Mehta MA, Mataix-Cols D, Williams SCR. Applications of functional magnetic resonance imaging in psychiatry. *J Magn Reson Imaging*. 2006;23(6):851-861.

Mohajeri Moghaddam S, Bhatt AA. Location, length, and enhancement: systematic approach to differentiating intramedullary spinal cord lesions. *Insights Imaging*. 2018;9:511-526.

Ogawa S, Tank DW, Menon R, et al. Intrinsic signal changes accompanying sensory stimulation: functional brain mapping with magnetic resonance imaging. *Proc Natl Acad Sci U S A*. 1992;89(13):5951-5955.

Parizel P, Makkat S, Van Miert E, Van Goethem JW, van den Hauwe L, De Schepper AM. Intracranial hemorrhage: principles of CT and MRI interpretation. *Eur Radiol*. 2001;11(9):1770-1783.

Prince MR, Grist TM, Debatin JF. *3D Contrast MR Angiography*. Berlin, Germany: Springer-Verlag; 2002.

Prince MR, Zhang HL, Roditi GH, Leiner T, Kucharczyk W. Risk factors for NSF: a literature review. *J Magn Reson Imaging*. 2009;30(6):1298-1308.

Sorensen AG, Buonanno FS, Gonzalez RG, et al. Hyperacute stroke: evaluation with combined multisection diffusion-weighted and hemodynamically weighted echo-planar MR imaging. *Radiology*. 1996;199(2):391-401.

Thomalla G, Cheng B, Ebinger M, et al. DWI-FLAIR mismatch for the identification of patients with acute ischaemic stroke within 4-5 h of symptom onset (PRE-FLAIR): a multicentre observational study. *Lancet Neurol*. 2011;10(11):978-986.

Warach S, Chien D, Li W, Ronthal M, Edelman RR. Fast magnetic resonance diffusion-weighted imaging of acute human stroke. *Neurology*. 1992;42(9):1717-1723.

Watts R, Andrews T, Hipko S, Gonyea JV, Filippi CG. In vivo whole-brain T1-rho mapping across adulthood: normative values and age dependence. *J Magn Reson Imaging*. 2014;40(2):376-382.

Zhuo J, Gullapalli RP. AAPM/RSNA physics tutorial for residents: MR artifacts, safety, and quality control. *Radiographics*. 2006;26(1):275-297.

23 Positron Emission Tomography and Single-Photon Emission Computed Tomography

William Charles Kreisl

KEY POINTS

1. Positron emission tomography (PET) and single-photon emission computed tomography (SPECT) imaging use radionuclide decay to measure a specific biologic target or phenomenon.
2. [^{18}F]Fluorodeoxyglucose PET and perfusion SPECT may be useful in staging brain tumors, identifying seizure foci in epilepsy patients, and identifying patterns of neurodegeneration in dementia patients.
3. Ioflupane ^{123}I SPECT may be useful in distinguishing parkinsonism from essential tremor.
4. Amyloid and tau PET imaging may be used in select patients to aid in diagnosis of dementia.

INTRODUCTION

Molecular imaging is used in the clinical practice of nuclear medicine and in medical research to better understand the biochemical processes that underlie human disease. Two examples of molecular imaging are positron emission tomography (PET) and single-photon emission computed tomography (SPECT). In both PET and SPECT, patients are administered a radioactive compound with a pharmacokinetic behavior that targets a molecular pathway related to the pathology of a certain disease.

PET and SPECT allow highly sensitive and selective measurement of specific biologic changes in the human body. Agents are administered in amounts too small to cause pharmacologic effects ("trace" doses) so as to avoid perturbation of the biochemical pathway being studied. Many radioactive compounds used in PET and SPECT reversibly bind to a target protein via ligand-receptor kinetics. In these cases, the radioactive ligand is referred to as a *radioligand*. However, some radioactive compounds used for PET or SPECT do not bind a target protein. For example, oxygen-15 water ([^{15}O]H_2O) is used to measure perfusion because the uptake of this compound reflects the flow of blood into a given tissue. A [^{15}O]H_2O PET scan therefore does not measure the binding of water to any receptor but rather it traces the flow of blood to different tissues (**Fig. 23.1**). In this case, the term *radiotracer* is more appropriate. A broader term that applies to all compounds used with PET or SPECT is *radiopharmaceutical*, reflecting that the radioactive compounds used in molecular imaging are given the same regulatory considerations as drugs.

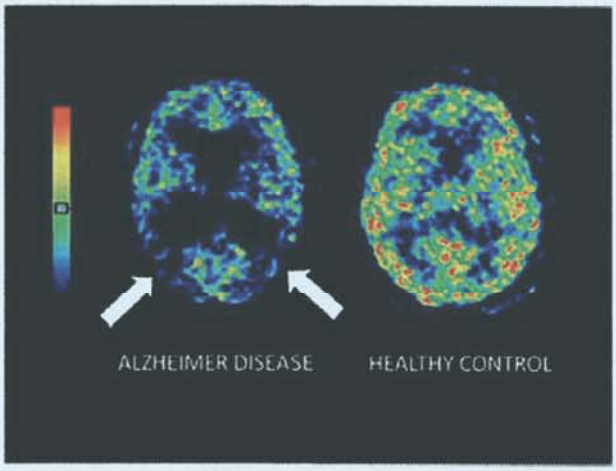

FIGURE 23.1 Example of [^{15}O]H_2O perfusion scan. The patient with Alzheimer disease has lower cerebral perfusion in the parietal cortex bilaterally *(arrows)* than the age-matched cognitively normal control subject. (Image courtesy of Robert Innis and William Charles Kreisl, Molecular Imaging Branch, National Institute of Mental Health.)

BASIC PRINCIPLES

Both PET and SPECT employ the physical phenomenon of radioactive decay, which occurs in radionuclides that are unstable due to incompatible number of protons and neutrons or excess energy.

In PET imaging, radionuclides are proton rich and, as a result, undergo decay and emission of a positron. An example of a radionuclide is carbon-11 (^{11}C), which has six protons and five neutrons. Unstable due to the greater number of protons than neutrons, ^{11}C undergoes a decay event in which a proton is converted to a neutron and the nucleus emits a positron and a neutrino. The positron will then zigzag around the vicinity of the decay event, losing energy as it collides with electrons of neighboring atoms, until it comes almost to rest and combines with an electron. Because a positron and electron are of equal mass but opposite charge, this event results in an annihilation encounter, with two 511-keV gamma rays (photons) emitted at about 180 degrees from each other. Other examples of positron-emitting radionuclides used for PET are fluorine-18 (^{18}F), oxygen-15 (^{15}O), and nitrogen-13 (^{13}N).

In SPECT imaging, radionuclides exist in a metastable state and decay from their excited state to ground state, resulting in emission of a single photon. The gamma-emitting radionuclides technetium 99m (^{99m}Tc) and iodine-123 (^{123}I) are commonly used for SPECT.

RADIOPHARMACEUTICALS AND SELECTION OF RADIONUCLIDES

Radionuclides are combined with a pharmaceutical through a series of synthetic steps to create a radiopharmaceutical. Radiopharmaceuticals are administered either intravenously or orally, and once in the biologic system, they interact with different molecules based on the kinetic properties of the pharmaceutical to which the radionuclide is attached. The radionuclide will then undergo nuclear decay as described earlier, ultimately resulting in the emission of two photons in the case of PET and a single photon in the case of SPECT. The radiation exposure to the patient is a function of the radionuclide used and the amount of radiopharmaceutical administered. Radionuclides with longer half-lives (eg, ^{18}F, $t_{1/2}$ = 110 min) result in larger exposure than those with shorter half-lives (eg, ^{11}C, $t_{1/2}$ = 20.5 min). However, the advantage of radiopharmaceuticals with long half-lives is that they may be synthesized offsite and delivered to medical facilities, providing greater availability for clinical use. Use of radiopharmaceuticals with short half-lives is limited to facilities capable of onsite synthesis.

DETECTION, ACQUISITION, AND DISPLAY OF SIGNAL

When radiopharmaceutical decay events occur inside a PET or SPECT scanner, crystals in a scintillation detector absorb the photons and then emit pulses of light that are then amplified, sorted, and registered as a count. The sum of these counts creates a tomographic map of all the decay events that occur within the view of the scanner. The result is an image that represents the different densities of radioactivity throughout the tissues captured by the scanner. The basis of PET and SPECT imaging is that the majority of decay events occur in proximity to where the radiopharmaceutical is acting on the molecular target of interest. The sensitivity of PET and SPECT is a function of the fraction of emitted photons that contribute to the total image. In PET, coincidence detection of the pair of photons that are emitted per decay event allows greater efficiency than in SPECT, which captures only the single photons that approach the detector at certain angles. Therefore, PET is generally more sensitive than SPECT and is more frequently used for quantitative imaging, although absolute quantitation has been reliably attained with SPECT.

The PET and SPECT images reflect only the amount of radioactivity detected by the scanner. The scanner cannot distinguish between sources of radioactivity (which radionuclide or which radiopharmaceutical was administered). Therefore, sufficient time (at least six half-lives of the radionuclide) must pass between consecutive scans on the same subject; otherwise, the second scan will be contaminated from residual signal from the first. In addition, once injected, radiopharmaceuticals are broken down by enzymes in the liver and other tissues (including brain in some instances) leading to the generation of radiolabeled metabolites. If these metabolites are generated in the brain or cross from the blood into the brain, they will contribute to the total signal in the resulting images, potentially confounding accurate quantification. For this reason, using radiopharmaceuticals that do not generate radiometabolites that cross the blood-brain barrier is beneficial. Another problem is cross-selectivity and nonspecific binding. If a radiopharmaceutical binds more than one receptor in the brain, the resulting image will overestimate the density of the intended target. As radiopharmaceuticals must be lipophilic to cross the blood-brain barrier, they often bind nonspecifically to lipids throughout the brain. Both specific binding to the target protein and nonspecific binding contribute to the signal seen on the resulting image. However, only the specific binding component represents the density of the target protein. Therefore, a high ratio of specific to nonspecific binding is favorable for reliable PET and SPECT measurements.

CLINICAL APPLICATIONS

The radiopharmaceuticals in **Table 23.1** are currently approved by the U.S. Food and Drug Administration (FDA) for indications in clinical neurology.

The sensitivity of PET and SPECT is ideal for measuring spe-

TABLE 23.1 Neurologic Applications of PET and SPECT Imaging

PET Radioligand	Molecular Target/Mechanism Studied	Clinical Indication
[^{18}F]Fluorodeoxyglucose (FDG)	Glucose metabolism	• Tumor staging and evaluation • Epilepsy • Distinguishing Alzheimer disease from frontotemporal dementia
[^{18}F]florbetapir (*Amyvid*) [^{18}F]flutemetamol (*Vizamyl*) [^{18}F]florbetaben (*Neuraceq*)	Fibrillar amyloid plaques	Diagnosis of Alzheimer disease
[^{18}F]flortaucipir (*Tauvid*)	Paired helical filament tau	Estimate the density and distribution of aggregated tau neurofibrillary tangles in adult patients with cognitive impairment who are being evaluated for Alzheimer disease.
SPECT Radioligand	**Target**	**Clinical Indication**
Ioflupane ^{123}I (DaTscan)	Dopamine transporter	Distinguishing neurodegenerative parkinsonism from essential tremor
[^{99m}Tc]HMPAO (*Neurolite*) [^{99m}Tc]ECD (*Ceretec*)	Cerebral perfusion	• Stroke • Epilepsy • Dementia

Abbreviations: ^{99m}Tc, technetium 99m; ECD, ethyl cysteinate dimer; FDG, fluorodeoxyglucose; HMPAO, hexamethyl-propylene amine oxime; PET, positron emission tomography; SPECT, single-photon emission computed tomography.

cific biochemical changes in the brain. However, the expense of molecular imaging limits its cost-effectiveness in clinical practice. This is particularly true when diagnoses can be made with reasonable confidence using other techniques or when the results of molecular imaging are unlikely to alter management of the patient. Therefore, PET and SPECT imaging have a limited role in clinical neurology. However, as new disease-modifying therapies for neurologic disorders become available, molecular imaging may provide a critical role in predicting and monitoring treatment response.

Glucose Imaging

[^{18}F]Fluorodeoxyglucose (FDG) is structurally identical to D-glucose except for the substitution of ^{18}F for a hydroxyl group at the 2′ position. Like glucose, FDG is taken up by cells using the glucose transporter and phosphorylated by hexokinase in the first step of glycolysis. Once phosphorylated, FDG becomes charged and therefore trapped in the cell. Lacking a 2′ hydroxyl group, [^{18}F]FDG-6-phosphate cannot undergo further metabolism. The concentration of FDG in cells therefore reflects the metabolic activity, both in taking up FDG via active transport and its phosphorylation during glycolysis.

Positron Emission Tomography Using [^{18}F]Fluorodeoxyglucose in Epilepsy

Although the most widely used PET radiopharmaceutical for clinical applications, FDG is only approved by the FDA for cancer staging and evaluation, measuring myocardial viability in patients with coronary artery disease, and detecting seizure foci in epilepsy patients. In the case of epilepsy, during a seizure, the cells at the focus of epileptic activity will have greater metabolic demand and take up more FDG than surrounding cells. Therefore, focal increase in FDG-PET signal can identify epileptic foci if the scan is performed during a seizure. Between seizures, the epileptic focus often has lower metabolic demand than normal brain tissue, as repeated seizures are associated with decrement in baseline function. Therefore, interictal FDG-PET may show an area of hypometabolism (reduced FDG uptake) in the seizure foci. These findings may aid the neurosurgeon in planning surgical excision for treatment of refractory epilepsy.

Positron Emission Tomography Using [^{18}F]Fluorodeoxyglucose in Dementia

The FDG-PET is often used off-label to assist in diagnosis of dementia, particularly when attempting to distinguish Alzheimer disease from frontotemporal dementia (Fig. 23.2). Patients with Alzheimer disease typically show a signature pattern of FDG hypometabolism in the temporal and parietal cortices bilaterally. Patients with frontotemporal dementia, in contrast, show early hypometabolism in the prefrontal cortex, particularly in behavioral variant frontotemporal dementia. These differing patterns of hypometabolism may aid the clinician in making the correct diagnosis, particularly when both behavioral and memory symptoms are present in the same patient. Although not FDA approved for this purpose, the Centers for Medicare & Medicaid Services provides reimbursement for FDG-PET when used for this indication.

Dopamine Imaging

Ioflupane ^{123}I (DaTscan) is a SPECT radiopharmaceutical that binds to presynaptic dopamine transporters (Fig. 23.3). Ioflupane ^{123}I is approved to aid clinicians in distinguishing tremor caused by neurodegenerative parkinsonian syndromes from that caused by essential tremor. In the former, loss of dopaminergic neurons that originate in the substantia nigra will result in fewer presynaptic dopamine transporters in the striatum. Patients with neurodegenerative parkinsonian syndrome will have reduced striatal signal on DaTscan, whereas a patient with essential tremor will have normal signal. DaTscan is commonly used off-label to help distinguish dementia with Lewy bodies from Alzheimer disease.

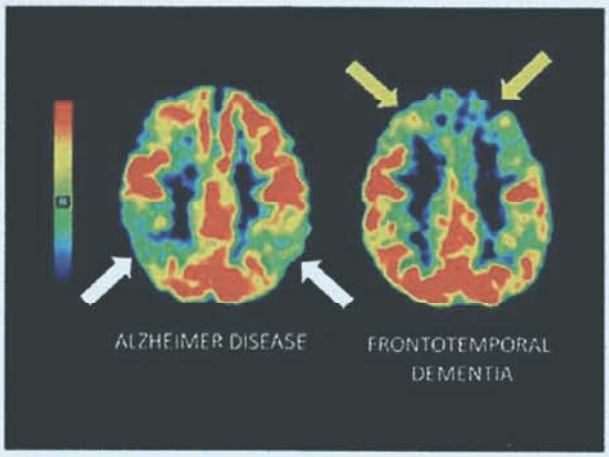

FIGURE 23.2 Using [^{18}F]fluorodeoxyglucose-positron emission tomography to distinguish Alzheimer disease from frontotemporal dementia. The Alzheimer disease patient on the left shows biparietal hypometabolism *(white arrows)*, whereas the frontotemporal dementia patient on the right shows bifrontal hypometabolism *(yellow arrows)*. (Image courtesy of Robert Innis and William Charles Kreisl, Molecular Imaging Branch, National Institute of Mental Health.)

Perfusion Imaging

[^{99m}Tc]-hexamethyl-propylene amine oxime (Neurolite) and [^{99m}Tc] ethyl cysteinate dimer (Ceretec) are SPECT radiopharmaceuticals approved as adjunct in detecting areas of abnormal cerebral perfusion in patients who have had a stroke. These SPECT

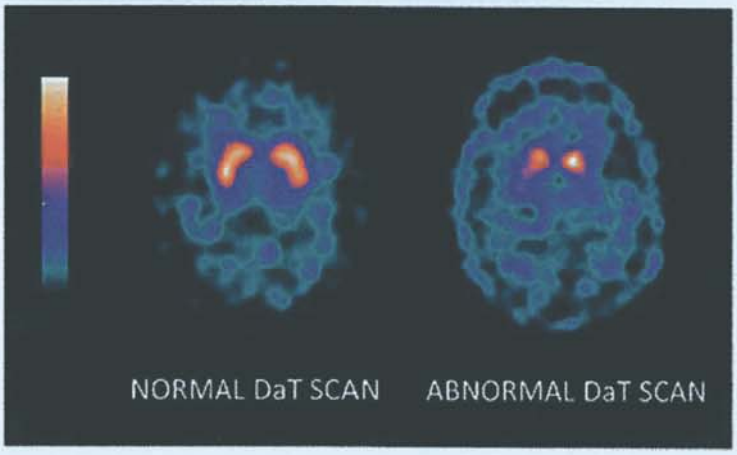

FIGURE 23.3 Left: a normal Ioflupane ^{123}I (DaTscan) single-photon emission computed tomography (SPECT) scan. The SPECT signal is concentrated in the striatum bilaterally, reflecting normal density of presynaptic dopamine transporters and intact nigrostriatal dopaminergic innervation. **Right:** an abnormal DaTscan showing reduced tracer uptake in striatum bilaterally, worse on the right side of the brain. This abnormal scan represents reduced density of presynaptic dopamine transporters due to nigrostriatal neurodegeneration.

scans are often performed after vasodilatory challenge with acetazolamide to measure cerebrovascular reserve. The SPECT perfusion imaging can also be used to identify ictal foci in patients with seizures or status epilepticus. Because reduced blood flow typically localizes to neurodegeneration, perfusion SPECT may also be used to distinguish different types of dementia.

Amyloid Imaging

Several PET radiopharmaceuticals that label the β-amyloid plaques found in Alzheimer disease have been developed (Fig. 23.4). These compounds bind to amyloid in neuritic plaques more strongly than diffuse plaques and do not label soluble amyloid at all. As studies suggest that amyloid plaque deposition occurs years prior to symptom onset, amyloid PET may be of particular use in early diagnosis of Alzheimer disease to distinguish mild cognitive impairment caused by Alzheimer disease versus that caused by other entities. Because non-Alzheimer diagnoses such as cerebral amyloid angiopathy and dementia with Lewy bodies may be associated with amyloid deposition in brain, and up to one-third of older cognitively normal adults have incidental amyloid positivity on PET, a positive amyloid scan should not be taken as proof positive of an Alzheimer disease diagnosis. However, a negative scan is considered inconsistent with the known neuropathology of Alzheimer disease. The amyloid-detecting radiopharmaceutical [^{11}C]-Pittsburgh compound B has been widely used in Alzheimer disease research; however, the short half-life of ^{11}C makes its clinical use impractical. [^{18}F]Florbetapir (Amyvid), [^{18}F]flutemetamol (Vizamyl), and [^{18}F]florbetaben (Neuraceq) have longer half-lives and have been approved by the FDA to assist clinicians in the diagnosis of Alzheimer disease. In 2013, the Centers for Medicare & Medicaid Services decided not to provide coverage for amyloid PET imaging for diagnosis of Alzheimer disease, except for patients participating in certain studies under Coverage with Evidence Development program. The first such study (Imaging Dementia—Evidence for Amyloid Scanning), which included 11,409 Medicare beneficiaries with mild cognitive impairment or dementia, showed that use of amyloid PET resulted in change of management (eg, initiation of discontinuation of cholinesterase inhibitor therapy) in approximately 60% of patients. Use of amyloid PET was associated with change in clinical diagnosis from Alzheimer disease to non-Alzheimer disease in 25% of patients and from non-Alzheimer disease to Alzheimer disease in 10.5% of patients.

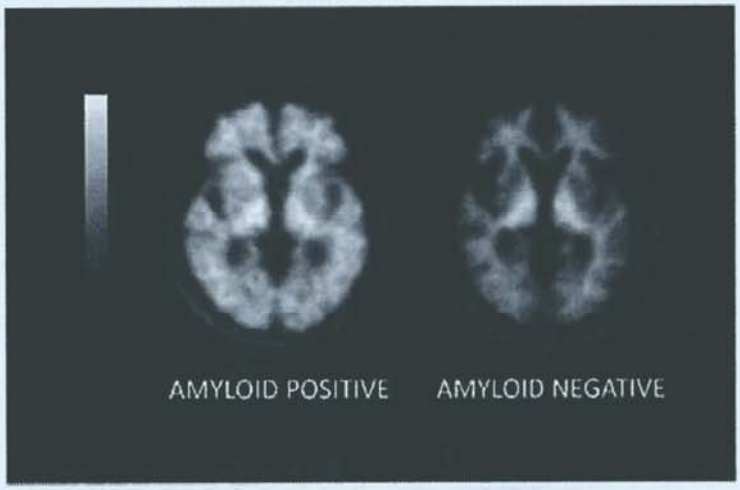

FIGURE 23.4 Example of amyloid positron emission tomography (PET) imaging. Two patients meeting clinical criteria for dementia underwent PET imaging with [^{18}F]florbetaben (Neuraceq). The image on the **left** shows radioligand binding in amyloid plaque–rich cortical areas, whereas the image on the **right** shows PET signal limited to nonspecific binding in white matter. These results suggest that the patient on the left has dementia due to underlying Alzheimer disease, whereas the patient on the right has dementia due to another cause.

To guide clinicians on when to order an amyloid PET scan on a patient, Appropriate Use Criteria have been proposed. In general, it was agreed on that amyloid PET imaging should be reserved for patients with cognitive complaints and objective evidence of impairment on testing, when the diagnosis is uncertain but Alzheimer disease is a diagnostic consideration. In addition, the result of the amyloid PET scan should be expected to change management, either in the decision to order additional diagnostic tests or in the decision to start or stop medications such as cholinesterase inhibitors. Persistent and unexplained mild cognitive impairment, atypical (eg, nonamnestic) presentation, etiologically mixed presentation, and dementia in an unusually young patient (less than 65 y of age) are examples when amyloid PET may be appropriate. Amyloid PET imaging in place of genetic testing for suspected autosomal dominant mutation carriers, in cognitively normal individuals, and for nonmedical use (eg, insurance coverage) are examples of inappropriate use. Clinical interpretation of amyloid PET imaging use a binary "positive" or "negative" designation. Therefore, amyloid PET imaging should not be used to determine dementia severity.

Tau Imaging

PET radiopharmaceuticals that bind to the paired helical filament tau that makes up the neurofibrillary tangles found in Alzheimer disease have recently been developed (Fig. 23.5). As of publication, one such radiopharmaceutical, [^{18}F]flortaucipir (*Tauvid*) has been approved in the United States to estimate the density and distribution of aggregated tau neurofibrillary tangles in adult patients with cognitive impairment who are being evaluated for Alzheimer disease. Other tau radiopharmaceuticals currently under research development include [^{18}F]MK-6240, [^{18}F]PI-2620, [^{18}F]APN-1607, [^{18}F]GTP1, and [^{18}F]RO948.

RADIOPHARMACEUTICALS CURRENTLY IN DEVELOPMENT WITH POTENTIAL FOR CLINICAL USE

Synaptic Density Imaging

Synaptic dysfunction or loss of synapses and the resultant aberrant signaling is implicated in several neurologic disorders including Alzheimer disease and epilepsy as well as schizophrenia and other psychiatric diseases. The synaptic vesicle glycoprotein 2A (SV2A), as the name implies, is a synaptic vesicle protein that mediates neurotransmitter release. The antiepileptic action of levetiracetam is thought to be due at least in part to its binding to SV2A. A growing number of radiopharmaceuticals, including [^{11}C]UCB-J and [^{18}F]SDM-8, is currently under development to measure SV2A density in vivo. These radiopharmaceuticals may have broad clinical applicability, particularly in psychiatric diseases that lack established biomarkers.

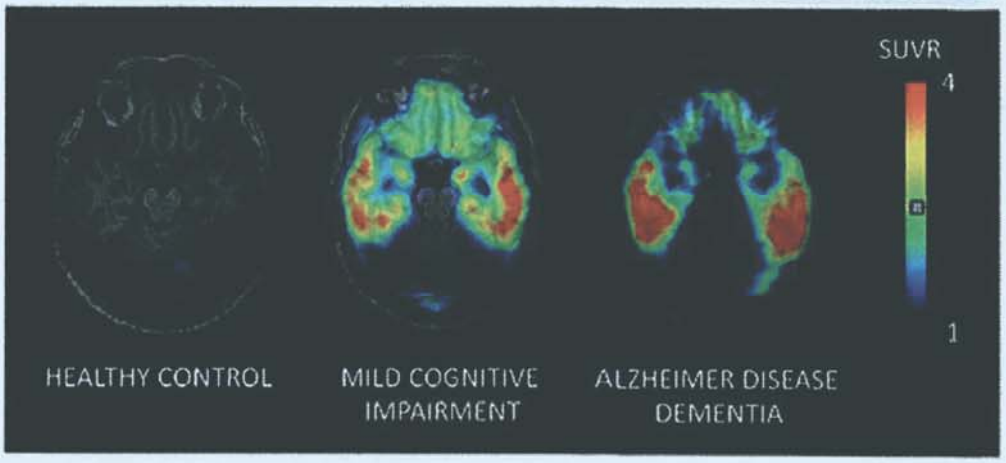

FIGURE 23.5 Example of tau positron emission tomography imaging. [^{18}F]MK-6240, which binds to paired helical filament tau tangles, shows no appreciable signal in a cognitively normal individual **(left)**. However, radioligand binding is evident in a patient with mild cognitive impairment, particularly in medial and lateral temporal cortices **(center)**. [^{18}F]MK-6240 signal is even more intense in the patient with Alzheimer disease dementia **(right)**.

SUGGESTED READINGS

Abi-Dargham A, Gandelman M, Zoghbi SS, et al. Reproducibility of SPECT measurement of benzodiazepine receptors in human brain with iodine-123-iomazenil. *J Nucl Med*. 1995;36(2):167-175.

Accorsi R. Brain single-photon emission CT physics principles. *AJNR Am J Neuroradiol*. 2008;29(7):1247-1256.

Benamer HTS, Patterson J, Grosset DG, et al. Accurate differentiation of parkinsonism and essential tremor using visual assessment of [^{123}I]-FP-CIT SPECT imaging: the [^{123}I]-FP-CIT study group. *Mov Disord*. 2000;15(3):503-510.

Blennow K, Hampel H, Zetterberg H. Biomarkers in amyloid-β immunotherapy trials in Alzheimer's disease. *Neuropsychopharmacology*. 2014;39(1):189-201.

Finnema SJ, Nabulsi NB, Mercier J, et al. Kinetic evaluation and test-retest reproducibility of [^{11}C]UCB-J, a novel radioligand for positron emission tomography imaging of synaptic vesicle glycoprotein 2A in humans. *J Cereb Blood Flow Metab*. 2018;38(11):2041-2052.

Fox PT, Mintun MA, Raichle ME, Herscovitch P. A noninvasive approach to quantitative functional brain mapping with H2 (15)O and positron emission tomography. *J Cereb Blood Flow Metab*. 1984;4(3):329-333.

Friedland RP, Budinger TF, Ganz E, et al. Regional cerebral metabolic alterations in dementia of the Alzheimer type: positron emission tomography with [18F]fluorodeoxyglucose. *J Comput Assist Tomogr*. 1983;7(4):590-598.

Gomperts SN, Locascio JJ, Marquie M, et al. Brain amyloid and cognition in Lewy body diseases. *Mov Disord*. 2012;27(8):965-973.

Grimmer T, Diehl J, Drzezga A, Förstl H, Kurz A. Region-specific decline of cerebral glucose metabolism in patients with frontotemporal dementia: a prospective 18F-FDG-PET study. *Dement Geriatr Cogn Disord*. 2004;18(1):32-36.

Innis RB, Cunningham VJ, Delforge J, et al. Consensus nomenclature for in vivo imaging of reversibly binding radioligands. *J Cereb Blood Flow Metab*. 2007;27(9):1533-1539.

Jack CR Jr, Knopman DS, Jagust WJ, et al. Tracking pathophysiological processes in Alzheimer's disease: an updated hypothetical model of dynamic biomarkers. *Lancet Neurol*. 2013;12(2):207-216.

Johnson KA, Minoshima S, Bohnen NI, et al. Appropriate use criteria for amyloid PET: a report of the Amyloid Imaging Task Force, the Society of Nuclear Medicine and Molecular Imaging, and the Alzheimer's Association. *Alzheimers Dement*. 2013;9(1):e-1-e-16.

Juni JE, Waxman AD, Devous MD Sr, et al. Procedure guideline for brain perfusion SPECT using ^{99m}Tc radiopharmaceuticals 3.0. *J Nucl Med Technol*. 2009;37(3):191-195.

Li S, Cai Z, Wu X, et al. Synthesis and in vivo evaluation of a novel PET radiotracer for imaging of synaptic vesicle glycoprotein 2A (SV2A) in nonhuman primates. *ACS Chem Neurosci*. 2019;10(3):1544-1554.

Lohith TG, Bennacef I, Vandenberghe R, et al. Brain imaging of Alzheimer dementia patients and elderly controls with ^{18}F-MK-6240, a PET tracer targeting neurofibrillary tangles. *J Nucl Med*. 2019;60(1):107-114.

Ly JV, Donnan GA, Villemagne VL, et al. 11C-PIB binding is increased in patients with cerebral amyloid angiopathy-related hemorrhage. *Neurology*. 2010;74(6):487-493.

Mazziotta JC, Engel J Jr. The use and impact of positron computed tomography scanning in epilepsy. *Epilepsia*. 1984;25(suppl 2):S86-S104.

Mueller A, Bullich S, Barret O, et al. Tau PET imaging with ^{18}F-PI-2620 in patients with Alzheimer's disease and healthy controls: a first-in-human study [published online ahead of print November 11, 2019]. *J Nucl Med*. doi:10.2967/jnumed.119.236224.

Owen DR, Matthews PM. Imaging brain microglial activation using positron emission tomography and translocator protein-specific radioligands. *Int Rev Neurobiol*. 2011;101:19-39.

Pike KE, Ellis KA, Villemagne VL, et al. Cognition and beta-amyloid in preclinical Alzheimer's disease: data from the AIBL study. *Neuropsychologia*. 2011;49(9):2384-2390.

Rabinovici GD, Gatsonis C, Apgar C, et al. Association of amyloid positron emission tomography with subsequent change in clinical management among Medicare beneficiaries with mild cognitive impairment or dementia. *JAMA*. 2019;321(13):1286-1294.

Rowe CC, Villemagne VL. Amyloid imaging with PET in early Alzheimer disease diagnosis. *Med Clin North Am*. 2013;97(3):377-398.

Saha GB, ed. In: *Basics of PET Imaging: Physics, Chemistry, and Regulations*. 2nd ed. New York, NY: Springer; 2010:1-14.

Schöll M, Lockhart SN, Schonhaut DR, et al. PET imaging of tau deposition in the aging human brain. *Neuron*. 2016;89(5):971-982.

Sokoloff L, Reivich M, Kennedy C, et al. The [14C]deoxyglucose method for the measurement of local cerebral glucose utilization: theory, procedure, and normal values in the conscious and anesthetized albino rat. *J Neurochem*. 1977;28(5):897-916.

Zanotti-Fregonara P, Lammertsma AA, Innis RB. Suggested pathway to assess radiation safety of ^{18}F-labeled PET tracers for first-in-human studies. *Eur J Nucl Med Mol Imaging*. 2013;40(11):1781-1783.

Zoghbi SS, Liow JS, Yasuno F, et al. 11C-loperamide and its N-desmethyl radiometabolite are avid substrates for brain permeability-glycoprotein efflux. *J Nucl Med*. 2008;49(4):649-656.

Neurovascular Ultrasound 24

Tatjana Rundek

KEY POINTS

1. Neurovascular ultrasound is a noninvasive methodology that uniquely provides real-time information on neurovascular structure and function.
2. Major neurovascular imaging technologies (extracranial duplex ultrasound and transcranial Doppler) have been widely validated, indispensable technologies in stroke centers, and clinically indicated in stroke and other cerebrovascular and cardiovascular conditions.

INTRODUCTION

Neurovascular ultrasound is imaging technology that uses ultrasound to image structure and examine the function of the brain vasculature. Neurovascular ultrasound includes two major ultrasound imaging technologies: extracranial ultrasound (duplex ultrasound or color Doppler) and transcranial ultrasound (transcranial Doppler [TCD]). Together, these techniques provide a real-time, noninvasive, and comprehensive evaluation of the major brain-supplying arteries. Besides, these imaging technologies are repeatable and portable and therefore can be performed at bedside, emergency rooms, or at any other patient care settings. Extracranial Doppler and TCD have become an integral part of the evaluation of patients with cerebrovascular disease or in asymptomatic individuals at an increased risk of vascular disease. These technologies are also an integral part of primary and comprehensive stroke centers. The most established clinical situations for the use of neurovascular ultrasound include the early detection and characterization of extracranial and intracranial atherosclerosis and occlusive disease; the evaluation of cerebral hemodynamic consequences of proximal arterial occlusive disease; monitoring of response to treatment of acute or chronic occlusive atherosclerotic disease; the time course and reversibility of cerebral vasospasm after subarachnoid hemorrhage; the detection of cerebral emboli in patients with cardiac, aortic, and carotid disease; and selection of sickle cell patients for blood transfusion as an effective imaging technology in primary stroke prevention. Neurovascular ultrasound is often used to complement other neuroimaging technologies such as magnetic resonance angiography and computed tomography angiography (CTA). All of these neuroimaging techniques provide concordant results when performed in accredited laboratories. If discrepancies arise, conventional two-dimensional angiography may be indicated and in most institutions only if an immediate interventional revascularization procedure is considered.

EXTRACRANIAL ULTRASOUND (DUPLEX ULTRASOUND OR COLOR DOPPLER)

Extracranial ultrasound is the noninvasive method of screening the extracranial carotid and vertebral arteries (VAs) for an atherosclerotic disease and detecting and monitoring structural and hemodynamic changes in existing extracranial atherosclerotic or other inflammatory or noninflammatory vascular diseases. Extracranial ultrasound is the technology with the lowest risk and cost. It provides real-time imaging of anatomy, physiology (hemodynamics), and pathophysiology of the extracranial circulation. Extracranial ultrasound is used in the risk stratification of patients with symptomatic or latent cerebrovascular disease as well as in asymptomatic patients to detect the presence of carotid stenosis and to evaluate other carotid artery phenotypes, including carotid plaque size, plaque echomorphology, intima-media thickness (IMT), and carotid stiffness. It is an ideal technology to frequently follow the existing extracranial vascular disease and monitor the status of the vasculature after interventional therapies such as carotid stenting or endarterectomy.

Imaging modes of extracranial ultrasound include the *brightness* or *B mode*, *color* or *C mode*, *Doppler* or *D mode*, *power mode* or *P mode*, and *motion* or *M mode* (Table 24.1). An ultrasound system that combines the B and D modes is called *duplex ultrasound*, and if B, C, and D modes are combined, it is called *triplex* or

TABLE 24.1 Ultrasound Imaging Modalities

Ultrasound Modality (Mode)	Abbreviation	Mode Display
Brightness mode	B mode	Echoes are displayed in various levels of gray.
Color mode	C mode	The Doppler signal of blood flow velocities is displayed in color.
Doppler mode	D mode	Shift in echoes is obtained from the moving blood particles and displayed as a Doppler spectrum of blood flow velocities.
Power mode	P mode	The Doppler signal of blood flow is displayed independent of the angle of insonation and is therefore magnified.
Motion mode	M mode	Motion of interfaces is recorded along the depth axis.

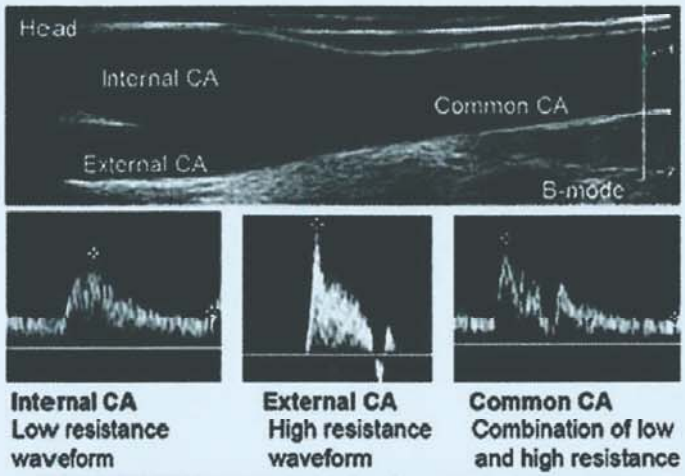

FIGURE 24.1 Normal appearance of carotid arteries on B mode and classic carotid artery (CA) waveforms on D mode.

color Doppler. All current ultrasound systems are equipped with a combination of all of these imaging modes.

Normal carotid arteries appear straight with bifurcation oriented toward the head (Fig. 24.1), without any pathologic processes in the arterial lumen (black) or in arterial wall (white) on B-mode imaging, and with classic arterial waveforms with blood flow directions toward the head on D-mode.

Carotid Ultrasound Criteria for Detection of Carotid Stenosis

Carotid stenosis is traditionally defined as stenosis greater than 50% by carotid ultrasound criteria. The most important ultrasound measures in assessing carotid stenosis are peak systolic velocity, end-diastolic velocity, and velocity ratios. These are applied in prestenotic, stenotic, and poststenotic regions. The degree of stenosis is also assessed visually and measured from grayscale ultrasound images and cross-checked with color Doppler imaging, which can guide Doppler velocity determination in order to select the most critical part of stenosis for Doppler velocity examination. The examples of carotid ultrasound criteria for the degree of carotid stenosis are widely available. The Society of Radiologists in Ultrasound has published multidisciplinary consensus on diagnostic criteria to grade the internal carotid artery (ICA) stenosis using Duplex ultrasound (Table 24.2) LEVEL 2.[1] These criteria can be used as a template for new vascular laboratories as well as to validate individual laboratory criteria for the estimation of carotid stenosis (Fig. 24.2). Because of variability in Doppler velocity measurements and standards, there are discrepant criteria for Doppler parameters of carotid stenosis. Each carotid ultrasound laboratory must, therefore, develop and validate its own criteria to grade carotid stenosis. These parameters must be validated with other imaging modalities and/or surgical findings and an ongoing quality control program must be implemented.

Assessment of Carotid Artery After Carotid Endarterectomy and Stenting

Carotid imaging shows changes in the carotid artery wall after successful carotid surgery or stenting. Special attention needs to be paid to the evaluation of the arterial wall changes at the edges of carotid reconstruction where incomplete plaque removal, intimal flap or step, and residual stenosis can be detected. In addition, Doppler velocities may show values above normal through the reconstructed part of the artery likely due to flow remodeling or increased stiffness in the stented segments. If peak systolic velocities at maximal narrowing in the reconstructed artery are greater than 150 cm/s and the peak systolic ratio between stenotic and prestenotic (or prestented) segment is greater than 2, then significant restenosis likely occurred (Fig. 24.3).

Sensitivity and Specificity of Duplex Ultrasound in Detecting Carotid Stenosis

Extracranial ultrasound is accurate and reliable in detecting carotid stenosis. The positive predictive value (PPV) of carotid ultrasound as compared to conventional angiography is 82% to 97%. In a large meta-analysis of 17 studies comparing carotid ultrasound with carotid angiography, carotid ultrasound had a pooled sensitivity of 86% (95% confidence interval [CI], 84%-89%) and a pooled specificity of 87% (95% CI, 84%-90%) for carotid stenosis LEVEL 2.[2] For diagnosis of occlusion, carotid ultrasound had a sensitivity of 96% (95% CI, 94%-100%). Although there can be considerable variation in the accuracy of duplex scanning among laboratories, accreditation programs such as Intersocietal Accreditation Commission set standards for performance and accuracy of vascular testing using most current validated and published data.

TABLE 24.2 The Society of Radiologists in Ultrasound Multidisciplinary Consensus Criteria for Carotid Stenosis[a]

Degree of Stenosis	ICA PSV (cm/s)	Plaque	ICA/CCA PSV ratio	ICA EDV (cm/s)
Normal	<125	None	<2	<40
<50%	<125	<50% diameter reduction	<2	<40
50%-69%	125-230	≥50% diameter reduction	2.0-4.0	40-100
70% to near occlusion	>230	≥50% diameter reduction	>4	>100
Near occlusion	High, low, or undetectable	Visible, detectable lumen	Variable	Variable
Occlusion	Undetectable	Visible, no detectable lumen	Not applicable	Not applicable

Abbreviations: CCA, common carotid artery; EDV, end-diastolic velocity; ICA, internal carotid artery; PSV, peak systolic velocity.
[a]Data from Grant EG, Benson CB, Moneta GL, et al. Carotid artery stenosis: gray-scale and Doppler US diagnosis—Society of Radiologists in Ultrasound Consensus Conference. *Radiology*. 2003;229(2):340-346.

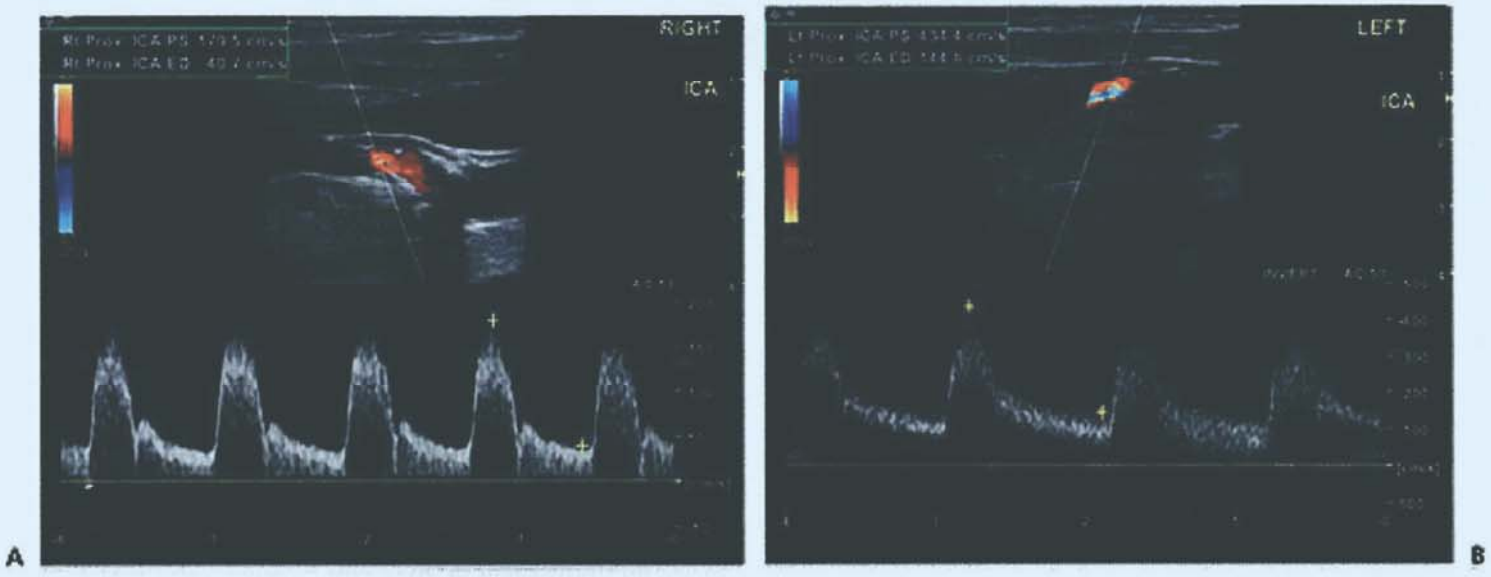

FIGURE 24.2 Two color Doppler carotid artery studies, each showing different degree of the extracranial internal carotid stenosis. The studies show B-mode (brightness mode) ultrasound image (grayscale) of the internal carotid artery (ICA) with corresponding atherosclerotic plaque, C mode (color mode) with color-coded blood flow velocity in the chosen volume sample (*the selected box in the image*), and D mode (Doppler mode) with the blood flow waveforms representing the velocity profile calculated from the Doppler shift (waveforms shown with velocity in cm/s) in each picture from the chosen volume sample (represented by the *diagonal line* within the color-selected box). The peak systolic and end-diastolic velocities are marked with the *yellow calipers* in both pictures and used for the assessment of the degree of carotid stenosis. Two examples of varying degrees of ICA stenosis are presented. **A:** An ICA stenosis of 40% to 60%, with peak systolic velocity of 179.5 cm/s and end-diastolic velocity of 40.7 cm/s (or 50%-70% stenosis using the Society of Radiologists in Ultrasound Multidisciplinary Consensus Criteria LEVEL 1[1]). **B:** An ICA stenosis of 60% to 80% (or >70% using the Society of Radiologists in Ultrasound consensus), with peak systolic velocity of 434.4 cm/s and end-diastolic velocity of 144.8 cm/s and moderate turbulent blood flow.

FIGURE 24.3 Carotid in-stent stenosis. Color Doppler of the common carotid artery and the internal carotid artery shows stent placed in both arteries. The lumen in the proximal internal carotid artery is reduced. The peak systolic and end-diastolic velocities are marked with the *yellow calipers* in spectral image and used for the assessment of in-stent stenosis. In the narrowing segment, peak systolic velocity was 218.9 cm/s and end-diastolic velocity 51.1 cm/s, which indicates in-stent stenosis greater than 50%.

Carotid Ultrasound of Carotid Plaque Size, Morphology, and Carotid Intima-Media Thickness

Carotid ultrasound provides information on plaque size (regardless of the degree of stenosis) and plaque echomorphology and arterial wall thickness or carotid IMT (Fig. 24.4). The *presence of small nonstenotic carotid plaque* on ultrasound is an independent predictor of future stroke and other cardiovascular disease independent of the degree of stenosis, although it is related to the degree of carotid stenosis.

Detection of *plaque ulceration* by ultrasound imaging is limited except in contrast-enhanced carotid imaging, which is primarily limited to research settings. However, plaque *surface irregularity* is easy to detect on carotid ultrasound and was shown to be associated with an increased risk of stroke. Ultrasound may help characterize plaque using a qualitative scoring system (echolucent or echodense; homogenous or heterogeneous plaque) as well as by the quantitative, computer-assisted echodensity parameters such as the *grayscale median index* that was shown to be clinically relevant in the prediction of stroke. *Echolucent carotid plaque* (soft, with predominately lipid content) has been associated with an increased risk of first-ever stroke or myocardial infarction in asymptomatic individuals as well as with restenosis and more recurrent events after carotid stenting. *Echodense carotid plaque* (calcified) is in general considered to be of a good prognostic feature based on the lower rates of stroke. Recent studies,

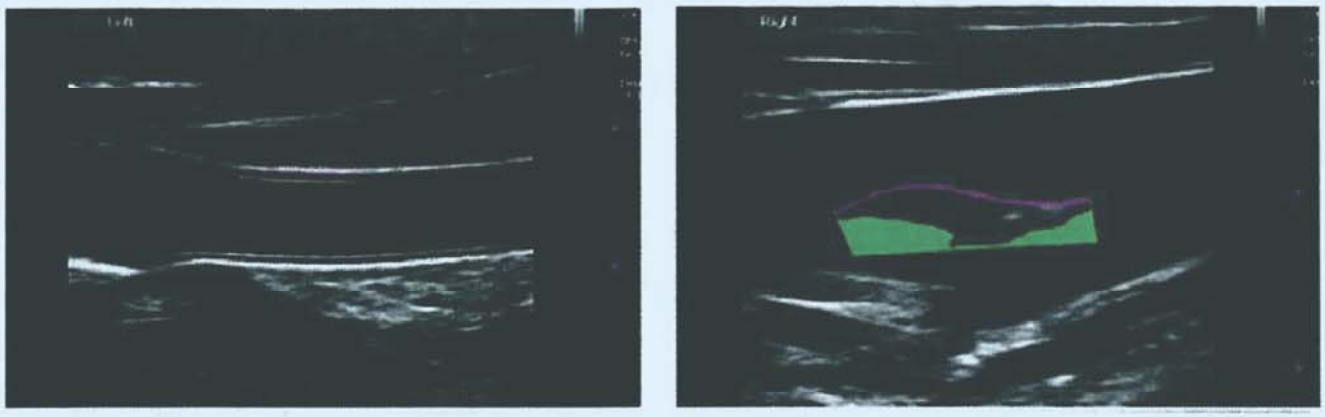

FIGURE 24.4 Two color Doppler carotid artery studies, each showing B-mode (brightness mode) ultrasound image (grayscale). Figure on the **left** shows carotid intima-media thickness (IMT) automated measurements using edge-detection algorithm *(colored lines)* in the common carotid artery near wall (the mean IMT 0.756 mm, which is considered within normal range for adults). Figure on the **right** shows a large carotid plaque in the carotid bifurcation extending to the internal carotid artery that is measured by the automated edge-detection algorithm (plaque is outlined by the *colored line* and *green area* and measures 50.28 mm^2, indicating moderate to severe atherosclerosis).

however, have shown opposite results with an increased risk of stroke. Similar observation was reported for coronary calcium score. This presumably paradoxical effect of plaque calcification may be explained by the fact that echodense plaque is not a cause of stroke but rather a marker of presence of an "active" plaque in other vascular beds, which then can explain its association with increased vascular risk.

Carotid IMT is a measure of subclinical atherosclerosis shown to be associated with an increased risk of stroke and other cardiovascular disease. It has been used extensively as an outcome measure in numerous clinical trials testing the effect of lipid, blood pressure, and glucose-lowering medications. It has been associated with traditional vascular risk factors across different age groups, including in children and young adults. The American Society of Echocardiography and Society for Vascular Medicine have supported the use of carotid IMT in vascular risk stratification in moderate-risk individuals and outlined the recommendations for the IMT protocols LEVEL 2.[3]

Duplex Ultrasound of the Vertebral Arteries

The ultrasound evaluation of the VAs is similar to that of the carotid arteries. Examination of the VA is, however, limited by its anatomy because VA, unlike the carotid, cannot be traced continuously when it passes within the transverse processes of cervical vertebrae. Therefore, ultrasound examination of the extracranial VA is reliable only at the origin, intervertebral segments, and at the atlas loop portion. Color Doppler and power Doppler are particularly useful in assessing the caliber of VAs. Use of other diagnostic technologies (magnetic resonance angiography, CTA, and even conventional angiography) is often recommended in symptomatic patients with suspected VA stenosis on duplex ultrasound.

Multiparametric Extracranial Ultrasound

Newer techniques like contrast-enhanced ultrasound, tissue elastography, and three-dimensional (3D) ultrasound have been recently introduced as multiparametric ultrasound technologies for research. These novel technologies have expanded the fundamental role of ultrasound in clinical assessments as well but only in advanced laboratories. Contrast-enhanced ultrasound vascular imaging uses intravenous ultrasound contrast agents (gas-filled microbubbles), which serve as intravascular reflectors of ultrasound waves. The potential clinical use of contrast-enhanced ultrasound has been proposed in different vascular beds including the carotid arteries. It is particularly useful in the situations of poor visualization of high-grade carotid stenosis or suspected occlusion, complex carotid plaque imaging, and evaluation of plaques with suspected ulcerations. It also provides a noninvasive method for the assessment of the vasa vasorum and the vascularization of the atherosclerotic plaque neovascularization, possibly helping in the risk stratification of patients with high risk of plaque rupture. The use of targeted microbubbles further enhances the diagnostic capabilities of vascular ultrasound by detecting specific molecular processes important in the pathophysiology of atherosclerosis. Similarly, tissue-elastography and 3D carotid ultrasonography detect vulnerable carotid plaque (plaques prone for rupture and embolization) with more precision. The current ultrasound systems are equipped with these novel ultrasound imaging modalities, and their research advances may be soon incorporated into clinical practice. However, these techniques are currently not optimized for clinical use as there are no standards for performing and evaluating the results obtained by these new technologies. Although the adoption of multiparametric ultrasound into clinical practice could help in better prediction of stroke risk, it is not routinely used in clinical practice.

Indications for Extracranial Ultrasound Examination

The guidelines for noninvasive vascular testing and indications for vascular ultrasound has been proposed by the American Society of Echocardiography and the Society for Vascular Medicine and adopted by other professional organizations, Centers

for Medicare & Medicaid Services, and private insurers LEVEL 3.[4] *Indications for carotid artery ultrasound* include the following:

- Evaluation of patients with cerebral ischemia, stroke, or transient ischemic attack
- New or worsening hemispheric neurologic symptoms (eg, unilateral motor or sensory deficit, speech impairment, or amaurosis fugax)
- Hollenhorst plaque visualized on retinal examination
- Evaluation of patients with a cervical bruit
- Evaluation of pulsatile mass in the neck
- Evaluation of blunt neck trauma
- Preoperative evaluation of patients undergoing major cardiovascular or other major surgical procedures, including cardiac, liver, and kidney transplant
- Drop attacks or syncope (rare indications primarily seen in vertebrobasilar insufficiency or bilateral carotid artery disease)
- Syncope of uncertain cause after initial cardiovascular evaluation
- Light-headedness or impaired vision in the setting of upper extremity exertion
- Suspected symptomatic vertebrobasilar occlusive disease in the symptomatic patient (eg, vertigo, ataxia, diplopia, dysphagia, dysarthria)
- Vasculitis involving extracranial arteries
- Follow-up of patients with known carotid artery disease
- Evaluation of postoperative patients following carotid endarterectomy or carotid stenting (surveillance after carotid artery intervention)
- Evaluation of suspected subclavian-vertebral steal phenomenon
- Evaluation of suspected carotid or VA dissection

INTRACRANIAL ULTRASOUND (TRANSCRANIAL DOPPLER)

Transcranial Doppler (TCD) is a noninvasive ultrasound technology that provides real-time information on blood flow velocity and blood flow direction in large intracranial arteries. Using a probe with great tissue-penetration properties, it is possible to insonate the major vessels of the circle of Willis, the distal intracranial segments of the VAs, and much of the length of the basilar artery (BA). Most TCD devices have a color-coded B mode and power Doppler display. The TCD provides only spectrum analysis of blood flow velocities, whereas transcranial color duplex imaging provides spectrum analysis as well as color-coded imaging of the intracranial vessels and visualization in power Doppler. Transcranial power motion Doppler is the technology that continuously displays flow intensity and direction of blood flow over 6 cm of intracranial space. Its advantage is in easier insonation, which allows inexperienced individuals to learn technique faster. Any of these TCD technologies produce the spectral signal that estimates of the cerebral hemodynamic status and the degree of arterial stenosis.

Arteries of the circle of Willis are insonated through temporal, orbital, suboccipital (foramen magnum), and submandibular acoustic "windows." In about 10% to 20% of individuals, the intracranial arteries cannot be assessed due to poor acoustic windows due to thick bones. This is particularly the case in elderly and postmenopausal women. The measures used include distance from the probe, direction of flow (toward or away from the probe), flow velocities, waveform characteristics

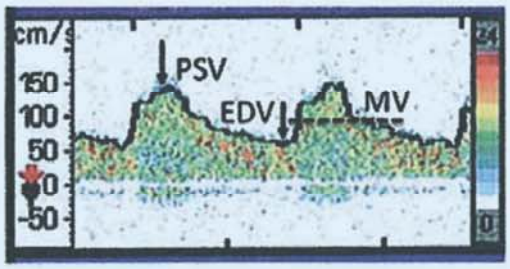

$$\text{Pulsatility Index (PI)} = \frac{PSV - EDV}{MV}$$

$$\text{Resistance Index (RI)} = \frac{PSV - EDV}{PSV}$$

FIGURE 24.5 A sample of normal waveform in the middle cerebral artery with the algorithms for calculation of pulsatility index and resistance index. Abbreviations: EDV, end-diastolic velocity; MV, mean velocity; PSV, peak systolic velocity.

(low-resistance and high-resistance pulsatile waveform), and derived blood flow indices including pulsatility index and resistance index (Fig. 24.5).

Indications for Transcranial Doppler Ultrasound

The American Institute of Ultrasound in Medicine has published practice guidelines LEVEL 3,[5] for the performance of TCD for adults and children. The *TCD indications in adults* include the following:

- Detection and follow-up of stenosis or occlusion in a major intracranial artery in the circle of Willis and vertebrobasilar system and monitoring of thrombolytic therapy in acute stroke
- Detection of cerebral vasculopathy
- Detection and monitoring of vasospasm in patients with subarachnoid hemorrhage
- Evaluation of collateral pathways of intracranial blood flow, including after intervention
- Detection of circulating cerebral microemboli
- Detection of right-to-left shunts
- Assessment of cerebral vasomotor reactivity (CVR)
- As an adjunct in the confirmation of the clinical diagnosis of brain death
- Intraoperative and periprocedural monitoring to detect cerebral embolization, thrombosis, hypoperfusion, and hyperperfusion
- Evaluation of sickle cell disease to determine the stroke risk
- Assessment of arteriovenous malformations (AVMs)
- Detection and follow-up of intracranial aneurysms
- Evaluation of positional vertigo or syncope

Additional *TCD applications in children* include the following:

- Assessment of intracranial pressure and hydrocephalus
- Assessment of hypoxic ischemic encephalopathy
- Assessment of dural venous sinus patency

In the American Academy of Neurology report LEVEL 1,[6] the highest level of evidence was given to the use of TCD for the screening of children aged 2 to 16 years with sickle cell disease for stroke risk (type A, class I) and the detection and monitoring of angiographic vasospasm after spontaneous subarachnoid hemorrhage (type A, class I-II) (Table 24.3).

TABLE 24.3 Recommendations and Level of Evidence for the Use of Transcranial Doppler by the American Academy of Neurology Therapeutics and Technology Assessment Subcommittee[a,b]

Setting/Disease/Condition	Rating of Recommendation/Level of Evidence
Sickle cell disease	Type A, class I
Detection and monitoring of angiographic vasospasm	Type A, class I-II
Detection of cerebral circulatory arrest/brain death	Type A, class II
Intracranial steno-occlusive disease	Type B, class II-III
Vasomotor reactivity testing	Type B, class II-III
Monitoring carotid endarterectomy	Type B, class II-III
Cerebral microembolism detection	Type B, class II-IV
Monitoring cerebral thrombolysis	Type B, class II-III
Monitoring coronary artery bypass graft surgeries	Type B-C, class II-III
Right-to-left cardiac shunts	Type A, class II
Intracranial occlusive disease	Type B, class II-IV

[a]Type A, established as useful/predictive recommendation; type B, probably useful/predictive; type C, possibly useful/predictive; class I, evidence provided by prospective study in broad spectrum of persons with suspected condition, using a "gold standard" to define cases, where test is applied in blinded evaluation, and enabling assessment of appropriate tests of diagnostic accuracy; class II, evidence provided by prospective study in narrow spectrum of persons with suspected condition or well-designed retrospective study of broad spectrum of persons with suspected condition (by gold standard) compared with broad spectrum of controls where test is applied in blinded evaluation and enabling assessment of appropriate tests of diagnostic accuracy; class III, evidence provided by retrospective study where either persons with established condition or controls are of narrow spectrum and where test is applied in blinded evaluation; class IV, any design where test is not applied in blinded fashion or evidence provided by expert opinion or descriptive case series.
[b]From Sloan MA, Alexandrov AV, Tegeler CH, et al. Assessment: transcranial Doppler ultrasonography: report of the Therapeutics and Technology Assessment Subcommittee of the American Academy of Neurology. *Neurology*. 2004;62(9):1468-1481.

Sickle Cell Disease

The TCD is an important tool for the selection of children with sickle cell disease in need of blood transfusion and who should stay on blood transfusion to sustain the benefit for prevention of stroke. In the Stroke Prevention Trial in Sickle Cell Anemia, TCD detection of time-averaged maximum mean flow velocity (MFV) of 200 cm/s on two separate examinations in middle cerebral artery (MCA) or terminal ICA was used to determine the need for blood transfusion that resulted in 90% relative risk reduction of first-ever stroke. Moreover, long-term follow-up results from the Stroke Prevention Trial in Sickle Cell Anemia indicated that persistent elevation in TCD velocities in these patients is indicative of ongoing increased risk of stroke.

Intracranial Stenosis and Occlusion

Stenosis of greater than 50% lumen narrowing can reliably be detected by TCD in arterial segments with anatomically favorable insonation angles, particularly in the M1 segment of the MCA. Significant narrowing of intracranial arteries results in focal increases in flow velocities, turbulent flow, and increased waveform pulsatility at the level of stenosis. Compensatory collateral flow from uncompromised vessels to deprived areas may result in flow reversal and augmentation of flow. Because some patients have suboptimal temporal windows, failure to obtain a waveform reading does not imply vessel occlusion unless a prior study had demonstrated vessel patency. An intracranial stenosis of the major intracranial arteries should be suspected when the normal hierarchy of the flow velocities is disrupted. The flow in the MCA should be greater than in the anterior cerebral artery, where blood flow velocities should be greater than in the posterior cerebral artery or BA and VA. The difference in these disrupted MFV should be greater than 20%. According to the Stroke Outcomes and Neuroimaging of Intracranial Atherosclerosis criteria LEVEL 3,[7] the TCD MFV cutoff for more than 50% stenosis for MCA is greater than 100 cm/s and for VA and BA is greater than 80 cm/s (**Fig. 24.6**).

Sensitivity and Specificity of Transcranial Doppler in Detecting Intracranial Stenosis

The TCD can reliably detect stenosis in M1 segment of MCA, ICA syphon and terminal ICA, terminal VA, proximal BA, and P1 segment of posterior cerebral artery. The sensitivity of TCD for stenosis in these segments is 85% to 90%, and specificity is 90% to 95%. The PPV is 85% and negative predictive value is 98%, with lower accuracy values for posterior circulation. In the Stroke Outcomes and Neuroimaging of Intracranial Atherosclerosis trial LEVEL 3,[7] the accuracy of TCD in detection of intracranial steno-occlusive disease was superior to CTA or digital subtraction angiography for ruling out than ruling in stenosis (having a higher negative predictive value than PPV) for all intracranial arterial segments.

Detection of Arteriovenous Malformations

The AVMs are direct communications between the arterial and venous systems, without an intervening capillary bed. No resistance vessels exist to impede or regulate flow, and therefore, flow measurements from feeding vessels typically demonstrate elevated velocities and low-resistance waveforms. Because of the large volume of flow that traverses an AVM, flow patterns may also be altered in vessels not directly connected to the AVM, resulting in altered waveform recordings. The TCD is sensitive for the detection of medium- to large-sized AVMs. Transcranial color duplex imaging may be very useful in evaluation of AVMs

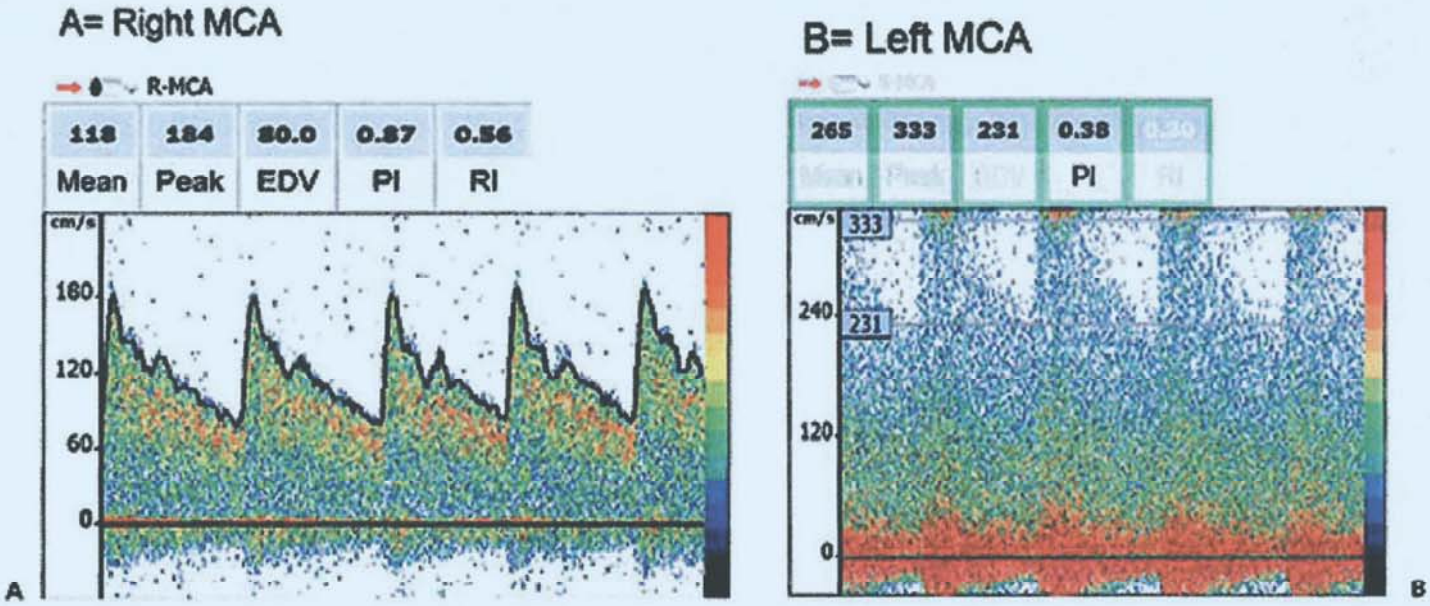

FIGURE 24.6 Example of transcranial Doppler study of the both middle cerebral arteries (MCA) in patients with left MCA stenosis. The spectral velocities are obtained at the depth of 50 cm from both sides of the head overlying the temporal bone. The blood flow velocity profile of the Doppler shift is calculated from the blood in the MCA flowing toward the probe (*the red arrow on the left side of both images directed toward the probe*). The image on the left **(A)** represents the normal spectral flow with peak systolic velocity of 184 cm/s and end-diastolic velocity of about 80 cm/s in a young individual. The image on the right **(B)** represents the high-grade MCA stenosis with systolic blood flow velocity over 333 cm/s and end-diastolic blood flow velocity of 231 cm/s and marked turbulent flow.

as it may provide more information about anatomic characteristics of AVMs than regular TCD.

Vasospasm in Subarachnoid Hemorrhage

The TCD has become a standard procedure for the detection, quantification, and monitoring of arterial vasospasm after subarachnoid hemorrhage or head trauma. Most clinically important spasm occurs in the proximal cerebral vessels, which are accessible to TCD insonation. The TCD monitoring, however, is limited in identifying vasospasm in distal cerebral arteries. The TCD flow velocity criteria appear to be most reliable for detecting angiographic MCA and BA vasospasm. Mean MCA velocities greater than 120 cm/s are indicative of moderate vasospasm, whereas velocities greater than 200 cm/s show severe vasospasm. A Lindegaard ratio (MFV MCA/ICA) greater than 3 is suggestive of vasospasm, whereas a ratio of 6 or greater reliably predicts the presence of clinically significant angiographic vasospasm. In addition, a sudden rise in MCA MFV by greater than 65 cm/s or by 20% increase is suggestive of vasospasm. The TCD is most useful in monitoring the temporal course of vasospasm to help guide the timing of additional diagnostic procedures and therapeutic angiographic interventions.

Cerebral Microemboli Detection

The TCD can detect microemboli or high-intensity transient signal in real time. Cerebral microemboli account for up to 70% of all ischemic strokes. Most of cerebral emboli originate from carotid atherosclerosis and cardiac sources including atrial fibrillation, prosthetic heart valves, right-to-left cardiac shunt (patent foramen ovale), aortic arch atheroma, vertebral disease, and stenosis in other intracranial arteries. Criteria for microemboli are established by the consensus committee at the Ninth International Cerebral Hemodynamic Symposium LEVEL 3,[8] which defines microembolus as a TCD signal with (1) random occurrence during the cardiac cycle, (2) brief duration (embolic signals should be transient lasting <300 ms), (3) high intensity (at least 3 dB higher than the background blood flow signal), (4) primarily unidirectional signal within the Doppler spectrum, and is (5) accompanied by an audible component ("snap," "chirp," or "pop").

Cerebral Vasomotor Reactivity Testing

The TCD can be used to assess cerebral hemodynamic reserve. When arterial perfusion is compromised, distal regulating arterioles dilate to allow more flow and to prevent cerebral ischemia. However, when perfusion is severely impaired, the arterioles are maximally dilated and CVR decreases or disappears, indicating a state of exhausted cerebrovascular reserve or "misery" perfusion. Impaired CVR may predict impending ischemia in patients with extracranial or intracranial artery stenosis or occlusion. The CVR testing include the breath holding index, blood pressure changes, or the carbon dioxide inhalation test. Impaired CVR has been found in various conditions, including severe carotid artery stenosis, stroke, sleep apnea, and congestive heart failure. The CVR is not a direct measure of cerebral autoregulation, but newer methods that include correlations between flow velocities and spontaneous fluctuations in blood pressure have been developed to assess cerebral autoregulation (dynamic cerebral autoregulation [dCA]). The TCD in combination with continuous blood pressure measurement is a technology that offers evaluation of cerebral autoregulation that is particularly

impaired in patients with stroke. However, there are no standards for TCD-dCA methodology, and therefore, the use of TCD-dCA is currently not used in clinical practice.

Sonothrombolysis

The TCD may be hold some promise in care as an adjunct therapy to intravenous thrombolysis after acute MCA occlusion. However, it is still under research and not yet used in clinical practice. Application of *intravascular low-intensity ultrasound* at the site of occlusion may enhance the outcome after ischemic stroke even without the administration of tissue plasminogen activator (tPA). Also, augmentation of tPA-associated thrombolysis with standard diagnostic TCD monitoring has been safe and associated with a higher arterial recanalization rate. Cochrane Stroke Group reported that sonothrombolysis was likely to reduce death or dependency and patients who received any form of sonothrombolysis had more than twofold higher likelihood of achieving complete arterial recanalization than thrombolysis alone. In addition, gaseous microspheres, initially developed as ultrasound contrast agents, can further increase the effectiveness of tPA. A microsphere dose-escalation study showed sustained complete recanalization rates of 67% in patients receiving TCD monitoring with perflutren lipid microspheres compared to controls receiving tPA alone with no increase in hemorrhage rate. Sonothrombolysis using TCD with the administration of microspheres may further improve thrombolytic effect in acute stroke management in the future.

Limitations of Transcranial Doppler

The TCD is highly operator dependent. It requires technical skills, detailed 3D knowledge of cerebrovascular anatomy and its variations, and global understanding of brain hemodynamics. The use of TCD is also limited by the 10% to 20% rate of inability to perform TCD due to inadequate acoustic windows, which is prevalent in elderly. This is related to thickness and porosity of the bone, which causes attenuation of the ultrasound energy transmission. The TCD examination is also limited to the large cerebral basal arteries, and it cannot directly examine a status of local cerebral blood flow. The proper performance of TCD and interpretation of TCD finding require specialized training and hands-on skills, which is not often available during traditional medical training. These limitations of TCD are the main reason for its underutilization, and most of them can be overcome by vascular laboratory accreditation and proper training and certification of sonographers and interpreting physicians.

SUMMARY

Extracranial and transcranial Doppler are clinically established noninvasive imaging neuroimaging modalities. Their value, however, has been constantly assessed and their validity evaluated. As new neurovascular laboratories are established, it is important that these new laboratories establish their normative values using guidelines provided in this brief neurosonology fundamentals and other established guidelines in the literature. These imaging modalities are now integral part of most stroke units. However, they are still infrequent in community hospitals and outpatient settings and therefore less accessible outside larger medical centers.

LEVEL 1 EVIDENCE

1. Grant EG, Benson CB, Moneta GL, et al. Carotid artery stenosis: gray-scale and Doppler US diagnosis—Society of Radiologists in Ultrasound Consensus Conference. *Radiology*. 2003;229(2):340-346.
2. Wardlav JM, Chappell FM, Best JJ, Wartolowska K, Berry E; for the NHS Research and Development Health Technology Assessment Carotid Stenosis Imaging Group. Non-invasive imaging compared with intra-arterial angiography in the diagnosis of symptomatic carotid stenosis: a meta-analysis. *Lancet*. 2006;367(9521):1503-1512.
3. Stein JH, Korcarz CE, Hurst RT, et al; for the American Society of Echocardiography Carotid Intima-Media Thickness Task Force. Use of carotid ultrasound to identify subclinical vascular disease and evaluate cardiovascular disease risk: a consensus statement from the American Society of Echocardiography Carotid Intima-Media Thickness Task Force. Endorsed by the Society for Vascular Medicine. *J Am Soc Echocardiogr*. 2008;21(2):93-111.
4. Gerhard-Herman M, Gardin JM, Jaff M, Mohler E, Roman M, Naqvi TZ. Guidelines for noninvasive vascular laboratory testing: a report from the American Society of Echocardiography and the Society for Vascular Medicine and Biology. *Vasc Med*. 2006;11(3):183-200.
5. American College of Radiology, Society for Pediatric Radiology, Society of Radiologists in Ultrasound. AIUM practice guideline for the performance of a transcranial Doppler ultrasound examination for adults and children. *J Ultrasound Med*. 2012;31(9):1489-1500.
6. Sloan MA, Alexandrov AV, Tegeler CH, et al. Assessment: transcranial Doppler ultrasonography: report of the Therapeutics and Technology Assessment Subcommittee of the American Academy of Neurology. *Neurology*. 2004;62(9):1468-1481.
7. Feldmann E, Wilterdink JL, Kosinski A, et al. The Stroke Outcomes and Neuroimaging of Intracranial Atherosclerosis (SONIA) trial. *Neurology*. 2007;68(24):2099-2106.
8. Consensus Committee of the Ninth International Cerebral Hemodynamic Symposium. Basic identification criteria of Doppler microembolic signals. *Stroke*. 1995;26(2):1123.

SUGGESTED READINGS

Aaslid R, Lindegaard KF. Cerebral hemodynamics. In: Aaslid R, ed. *Transcranial Doppler Sonography*. New York, NY: Springer; 1986:60-85.

Alexandrov AV. Ultrasound enhanced thrombolysis for stroke. *Int J Stroke*. 2006;1(1):26-29.

Alexandrov AV, Sloan MA, Tegeler CH, et al; for the American Society of Neuroimaging Practice Guidelines Committee. Practice standards for transcranial Doppler (TCD) ultrasound. Part II. Clinical indications and expected outcomes. *J Neuroimaging*. 2012;22(3):215-224.

Alsulaimani S, Gardener H, Elkind MS, Cheung K, Sacco RL, Rundek T. Elevated homocysteine and carotid plaque area and densitometry in the Northern Manhattan Study. *Stroke*. 2013;44(2):457-461.

Beach KW, Leotta DF, Zierler RE. Carotid Doppler velocity measurements and anatomic stenosis: correlation is futile. *Vasc Endovascular Surg*. 2012;46(6):466-474.

Brant-Zawadzki M, Heiserman JE. The roles of MR angiography, CT angiography, and sonography in vascular imaging of the head and neck. *Am J Neuroradiol*. 1997;18(10):1820-1825.

Brown OW, Bendick PJ, Bove PG, et al. Reliability of extracranial carotid artery duplex ultrasound scanning: value of vascular laboratory accreditation. *J Vasc Surg*. 2004;39(2):366-371.

De Bray JM, Baud JM, Dauzat M. Consensus concerning the morphology and the risk of carotid plaques. *Cerebrovasc Dis*. 1996;7:289-296.

Frontera JA, Rundek T, Schmidt JM, et al. Cerebrovascular reactivity and vasospasm after subarachnoid hemorrhage: a pilot study. *Neurology*. 2006;66(5): 727-729.

Garami Z, Alexandrov AV. Neurosonology. *Neurol Clin*. 2009;27(1):89-108.

Garami ZF, Bismuth J, Charlton-Ouw KM, Davies MG, Peden EK, Lumsden AB. Feasibility of simultaneous pre- and postfilter transcranial Doppler monitoring during carotid artery stenting. *J Vasc Surg*. 2009;49(2):340-345.

Hartmann A, Mast H, Thompson JL, Sia RM, Mohr JP. Transcranial Doppler waveform blunting in severe extracranial carotid artery stenosis. *Cerebrovasc Dis*. 2000;10(1):33-38.

Helton KJ, Adams RJ, Kesler KL, et al. Magnetic resonance imaging/angiography and transcranial Doppler velocities in sickle cell anemia: results from the SWiTCH trial. *Blood*. 2014;124(6):891-898.

Johnsen SH, Mathiesen EB, Joakimsen O, et al. Carotid atherosclerosis is a stronger predictor of myocardial infarction in women than in men: a 6-year follow-up study of 6226 persons: the Tromsø Study. *Stroke*. 2007;38(11): 2873-2880.

Kolkert JL, Meerwaldt R, Loonstra J, et al. Relation between B-mode gray-scale median and clinical features of carotid stenosis vulnerability. *Ann Vasc Surg*. 2014;28(2):404-410.

Komotar RJ, Zacharia BE, Valhora R, Mocco J, Connolly ES Jr. Advances in vasospasm treatment and prevention. *J Neurol Sci*. 2007;261(1-2):134-142.

Lennihan L, Petty GW, Fink ME, Solomon RA, Mohr JP. Transcranial Doppler detection of anterior cerebral artery vasospasm. *J Neurol Neurosurg Psychiatry*. 1993;56(8):906-909.

Marshall RS, Rundek T, Sproule D, et al. Monitoring of cerebral vasodilatory capacity with transcranial Doppler carbon dioxide inhalation in patients with severe carotid artery disease. *Stroke*. 2003;34(4):945-949.

Mast H, Mohr JP, Thompson JL, et al. Transcranial Doppler ultrasonography in cerebral arteriovenous malformations. Diagnostic sensitivity and association of flow velocity with spontaneous hemorrhage and focal neurological deficit. *Stroke*. 1995;26(6):1024-1027.

Molina CA, Barreto AD, Tsivgoulis G, et al. Transcranial ultrasound in clinical sonothrombolysis (TUCSON) trial. *Ann Neurol*. 2009;66(1):28-38.

Moussa I, Rundek T, Mohr JP, eds. *Risk Stratification and Management of Patients With Asymptomatic Carotid Artery Disease*. New York, NY: Taylor & Francis; 2007:95-105.

Moussouttas M, Trocio S, Rundek T. Vascular ultrasound: carotid and transcranial Doppler imaging. In: Orloff L, ed. *Head and Neck Ultrasound*. San Diego, CA: Plural Publishing; 2008:257-290.

Nederkoorn PJ, Brown MM. Optimal cut-off criteria for duplex ultrasound for the diagnosis of restenosis in stented carotid arteries: review and protocol for a diagnostic study. *BMC Neurol*. 2009;9:36.

Nussel F, Wegmuller H, Huber P. Comparison of magnetic resonance angiography, magnetic resonance imaging and conventional angiography in cerebral arteriovenous malformation. *Neuroradiology*. 1991;33:56-61.

Ortega-Gutierrez S, Petersen N, Masurkar A, et al. Reliability, asymmetry, and age influence on dynamic cerebral autoregulation measured by spontaneous fluctuations of blood pressure and cerebral blood flow velocities in healthy individuals. *J Neuroimaging*. 2014;24(4):379-386.

Prabhakaran S, Rundek T, Ramas R, et al. Carotid plaque surface irregularity predicts ischemic stroke: the Northern Manhattan Study. *Stroke*. 2006;37(11): 2696-2701.

Prabhakaran S, Singh R, Zhou X, Ramas R, Sacco RL, Rundek T. Presence of calcified carotid plaque predicts vascular events: the Northern Manhattan Study. *Atherosclerosis*. 2007;195(1):e197-e201.

Rundek T. Beyond percent stenosis: carotid plaque surface irregularity and risk of stroke. *Int J Stroke*. 2007;2(3):169-171.

Rundek T, Arif H, Boden-Albala B, Elkind MS, Paik MC, Sacco RL. Carotid plaque, a subclinical precursor of vascular events: the Northern Manhattan Study. *Neurology*. 2008;70(14):1200-1207.

Rundek T, Spence JD. Ultrasonographic measure of carotid plaque burden. *JACC Cardiovasc Imaging*. 2013;6(1):129-130.

Saqqur M, Tsivgoulis G, Molina CA, et al. Symptomatic intracerebral hemorrhage and recanalization after IV rt-PA: a multicenter study. *Neurology*. 2008;71(17):1304-1312.

Staub D, Partovi S, Imfeld S, et al. Novel applications of contrast-enhanced ultrasound imaging in vascular medicine. *Vasa*. 2013;42(1):17-31.

Touboul P-J, Hennerici MG, Meairs S, et al. Mannheim carotid intima-media thickness and plaque consensus (2004-2006-2011). An update on behalf of the advisory board of the 3rd, 4th and 5th watching the risk symposia, at the 13th, 15th and 20th European Stroke Conferences, Mannheim, Germany, 2004, Brussels, Belgium, 2006, and Hamburg, Germany, 2011. *Cerebrovasc Dis*. 2012;34(4):290-296.

Zivanović Z, Alexandrov AV, Jesić A, Slankamenac P. Sonothrombolysis: is the story (t)old or just the beginning. *Med Pregl*. 2014;67(1-2):17-23.

25 Angiography and Neuroendovascular Surgery

Katarina Dakay, Scott M. Woolf, Gurmeen Kaur, Daniel H. Sahlein, and Fawaz Al-Mufti

KEY POINTS

1. Neuroendovascular surgery allows for diagnosis and treatment of cerebral aneurysms, arteriovenous malformations, acute ischemic stroke with large vessel occlusion, atherosclerotic lesions, and venous abnormalities.
2. The most common complication of diagnostic cerebral angiogram is access site hematoma.
3. Several randomized controlled trials have demonstrated the benefit of mechanical thrombectomy in patients with acute ischemic stroke caused by large vessel occlusion who meet certain clinical and imaging criteria.
4. Current techniques for endovascular treatment of acute ischemic stroke with large vessel occlusion include mechanical thrombectomy, direct clot aspiration, intra-arterial lytics, and combination methods.
5. Strategies for endovascular treatment of cerebral aneurysms include coiling, stent-assisted coiling, flow-diverting stents, neck reconstruction device plus coiling, and more recently the intrasaccular Woven EndoBridge device.
6. Areas of active research and development in the neurointerventional field include the use of intracranial stenting for intracranial atherosclerosis, venous sinus stenting for idiopathic intracranial hypertension, middle meningeal artery embolization for chronic subdural hematoma, neuroendovascular delivery of chemotherapeutic agents, and expanding the indications for mechanical thrombectomy, among others.

INTRODUCTION

Neuroendovascular surgery (NES) is a subspecialty that uses endovascular access, most often peripheral, to gain entry to the vasculature of the brain and spinal cord in order to visualize and treat a wide array of neurologic conditions. Neuroendovascular surgeons diagnose and manage many different disease processes, including acute ischemic stroke, carotid artery stenosis, cerebral aneurysms, and arteriovenous malformations (AVMs), among others.

The foundation of NES is cerebral angiography, which can be used as a purely diagnostic test or as a means of access for an interventional procedure. Significant advantages of neurointerventional procedures are their minimally invasive nature compared to open surgery, the ability to navigate deep structures, which would be challenging or impossible to safely access with conventional surgical techniques, and the utility of angiography to simultaneously visualize and treat lesions with exquisite detail.

NES is a subspecialty that comprises aspects of neurosurgery, radiology, and neurology; it is also sometimes referred to as *endovascular surgical neuroradiology*, *interventional neurology*, or *endovascular neurosurgery*. These multiple terms illustrate the unique diversity of the neurointerventional workforce, a specialty in which neurosurgeons, neurologists, and radiologists are eligible for training. The unique perspectives brought by each field have ushered the subspecialty into an era of rapid growth and expansion, as neurointerventional devices continue to improve and evolve, and conditions such as basilar tip aneurysms previously thought to be inaccessible for treatment are now able to be secured. Although the first diagnostic angiography was performed nearly a century ago, it is primarily within the last two decades that technologic advances and new research have allowed NES to expand into its current state as a major diagnostic and therapeutic technique. This chapter discusses the history of neurointervention, important procedural considerations and complications, conditions in which neuroendovascular treatment is used, and, finally, areas of active research and development within the neurointerventional field.

HISTORY

The first diagnostic cerebral angiogram performed on a living patient was by Portuguese neurologist Egaz Moniz in 1927; Moniz had previously experimented with injecting contrast into cadavers and dogs. Prior to the successful angiogram in 1927, Moniz had previously attempted angiography with a more potent contrast medium, 70% strontium bromide, which caused a transient Horner syndrome in two patients and death of one patient due to stroke. It was because of this that Moniz temporarily abandoned the procedure before adapting his technique to use 25% sodium iodide. Later, Thorotrast, a thorium dioxide–based contrast media, was used; however, it was abandoned after it was found to have a high incidence of delayed carcinogenesis. Over the subsequent decades, the contrast solutions were refined, increasing the safety of neuroangiographic procedures; a shift from high-osmolality, ionic contrast media such as meglumine to lower risk, low-osmolality nonionic media such as iohexol (Omnipaque) has improved the tolerability and safety of contrast administration.

In the early era of angiography, procedures were performed with direct carotid puncture, a method which had a high risk of complications. In the 1940s, physicians began to use peripheral access in order to gain access to the intracranial vessels. The first angiography of the aorta by femoral access was performed by Farinas in 1941, and in fact, the first radial angiography in which the vertebral artery was examined was performed in 1947

by Radner. In the 1960s, femoral access for carotid and vertebral angiography became commonplace. Prior to the era of computerized tomography, one of the major indications for cerebral angiography was to visualize tumors, in which the location of the tumor could be surmised by visualizing which vessels were displaced and in which direction. Initially, only extracranial arteries were accessible; however, in the 1960s, the first experimental usage of flexible catheters to enter the intracranial circulation was reported. In the 1970s, Serbinenko developed a nondetachable balloon used to obliterate carotid-cavernous fistulae; it was also during this decade that the liquid embolic agent cyanoacrylate was developed by Zanetti and Sherman.

In 1991, neuroendovascular therapy underwent a significant breakthrough with the invention of Guglielmi detachable coils, a platinum-based electrolytically detachable coil, which could be deployed into a cerebral aneurysm, causing thrombosis within the aneurysm dome due to interaction between the positively charged coil and negatively charged fibrinogen, leukocytes, erythrocytes, and platelets. During the 1990s, coil technology continued to be refined with three-dimensional coils and coils formed with a bioactive coating. In the late 1990s, endovascular therapy for acute stroke treatment also began with the study of intra-arterial urokinase in the Prolyse in Acute Cerebral Thromboembolism (PROACT)-I and PROACT-II trials, which showed the potential for benefit of endovascular therapy in acute ischemic stroke; however, these trials were followed by negative trials such as the Randomized Controlled Trial on Intra-arterial Versus Intravenous Thrombolysis in Acute Ischemic Stroke (SYNTHESIS) and Mechanical Retrieval and Recanalization of Stroke Clots using Embolectomy (MR-RESCUE) trials. These negative results dampened enthusiasm for endovascular stroke treatment until 2014, when several randomized controlled trials demonstrated the benefit of mechanical thrombectomy in carefully selected patients with anterior circulation large vessel occlusion.

In the early 2000s, flow diversion with an endoluminal stent, the Pipeline Embolization Device, was developed for treatment of aneurysms with features that rendered them untreatable by coiling. Further developments during this timeframe included the refinement of stent retrievers for mechanical thrombectomy, the increasing utilization of perfusion-based imaging for patient selection in stroke care, and the development of new liquid embolic agents, such as *n*-butyl cyanoacrylate ("glue") and Onyx.

The neurointerventional field continues to evolve and expand; topics of ongoing active research and development are described at the conclusion of the chapter.

PROCEDURAL OUTLINE AND CONSIDERATIONS

Preprocedural Considerations

Preprocedural considerations include those applicable to any preoperative evaluation and those specific to the neuroendovascular realm. The indication for the study should be assessed; common indications for angiography include the evaluation and treatment of a known or suspected cerebral aneurysm or AVM, evaluation or treatment of extracranial or intracranial stenosis, emergent treatment of acute ischemic stroke caused by large vessel occlusion, and arteriovenous fistulas. Less commonly encountered but significant other conditions in which angiography is often employed include evaluation of moyamoya disease, fibromuscular dysplasia, suspected central nervous system vasculitis, and reversible cerebral vasoconstriction syndrome. Noninvasive alternatives to angiography should be considered, particularly in cases where angiography is being employed strictly as a diagnostic tool; for example, recent literature suggests that the diagnosis of reversible cerebral vasoconstriction syndrome can often be made based on clinical features and noninvasive vessel imaging.

A thorough history and physical should be obtained from the patient, with careful attention to the neurologic examination to identify any baseline neurologic abnormalities. Additionally, assessment of the Mallampati scale and palpation of distal pulses is important in the preoperative patient.

It is paramount to review any prior angiographic studies because findings such as carotid stenosis or a heavily calcified aortic arch have implications on the risk of catheterization and may guide either alternate diagnostic modalities or the placement of the catheter. Likewise, any available noninvasive imaging of the aortic arch or cerebral vasculature of interest, such as computed tomography or magnetic resonance angiogram, should be reviewed. Allergies, particularly to antiplatelets, heparin, or contrast media, should be meticulously noted. Clinicians should be aware of any prior adverse reactions to anesthesia in the past as well as any concomitant medical conditions such as obstructive sleep apnea and renal or hepatic insufficiency that may contribute to an increased risk of anesthetic complications. Any history of groin complications should be considered seriously because this may influence decision to either use the contralateral side or a different vessel. Clinicians should note the patient's medication list, with careful attention to antiplatelet or anticoagulant regimen, as well as metformin, which is often held in the perioperative period because of the risk of lactic acidosis should contrast nephropathy develop.

Procedure

Cerebral angiography is performed by obtaining peripheral access, typically femoral or radial, and using a guidewire inserted within a hollow catheter to engage the aortic arch and then select the precerebral and cerebral vessels. Figure 25.1 demonstrates the basic equipment required to perform an angiogram. Although the femoral artery has traditionally been the site of access, recent studies show that the radial artery can be cannulated with a high success rate of up to 99.3% in experienced operators with no major complications in one case series, and randomized controlled trial data extrapolated from coronary angiography suggests that radial access is associated with reduced all-cause mortality and groin access complications LEVEL 1.[1] This has resulted in the European Society of Cardiology recommending radial access site as the preferred access site for patients with non-ST segment myocardial infarction undergoing invasive revascularization. Advantages over radial access include patient's preference, a shorter observation period for outpatient procedures, and the ability to sit up immediately after the procedure. Challenges of radial access include a learning curve prior to acclimation in clinicians new to the technique, the current limitations in adapting catheter equipment designed for the femoral artery to radial access particularly in interventional cases, and radial artery vasospasm; however, intra-arterial spasm can be treated with an antispasmodic cocktail of verapamil and nitroglycerin.

Angiography can be performed in the awake patient with conscious sedation or under generalized endotracheal anesthesia, depending on the patient's preferences and cooperation, the

FIGURE 25.1 Basic equipment required for a diagnostic angiogram including heparinized saline flush lines, syringes for contrast and saline hand injection, micropuncture kit, sterile drape, sterile gauze, and bowls to hydrate the hydrophilic guidewires while not in use.

procedure being performed, and the potential need for neuromuscular paralysis for particular interventions in which even small movements could be treacherous. Although the particular technical nuances of each neurointerventional procedure are beyond the scope of this chapter, the general steps involved in a diagnostic cerebral angiogram are explained in the following text.

First, the patient is positioned on the angiography table; the method of access is determined and either the femoral or radial artery should be palpated and identified. The area is then sterilized with chlorhexidine or a similar agent, and a sterile drape is placed over the patient. The head should be secured, often with a headrest and/or tape. Either anatomic landmarks, fluoroscopy, sonographic guidance, or a combination of these methods is used to verify the access site. Topical anesthesia with lidocaine is employed in the consciously sedated patient. Sonographic guidance allows the examiner to directly visualize the artery being cannulated; one meta-analysis showed that the use of ultrasound guidance for percutaneous coronary intervention decreased the rate of inadvertent venipuncture and bleeding events.

Once the puncture needle has been inserted and there is blood return, an introducer wire is placed through the needle and advanced into the vessel; this is done under fluoroscopic guidance to confirm that the puncture is arterial. The needle is removed and a dilator is inserted over the wire and then replaced with an introducer sheath, which is then connected to a continuous heparinized saline flush. Intravenous heparin is often given during the procedure, with monitoring of activated clotting time levels being crucial particularly with longer procedural times such as interventional cases.

The diagnostic catheter, preflushed with heparinized saline and with a guidewire inserted, is then inserted into the sheath and advanced under fluoroscopic guidance into the thoracic aorta. The wire is then removed, and the catheter is flushed with heparinized saline to remove any bubbles, clots, or debris. The catheter is then placed on either continuous saline flush or maintained on a meticulous hand-flush regimen for the duration of the study. The guidewire is replaced into the catheter, and the operator leads with the wire in order to traverse the great vessels and select the appropriate vessel for study; contrast is "puffed" into the catheter to visualize the outline of the vessel. Imaging techniques such as "roadmapping" allow for the superimposition of a live fluoroscopic image onto a stored subtraction image to assist the operator in confirming catheter location. The biplane is then adjusted to obtain standardized views of the vessels being catheterized; contrast is injected through the catheter as images are captured. Figure 25.2 demonstrates standard anteroposterior and lateral views of the right internal carotid artery, and Figure 25.3 demonstrates standard views of the vertebral artery. In particular conditions such as aneurysm or AVMs, three-dimensional spin imaging is employed using a power injector to inject contrast through the catheter parked in the vessel of interest, as the C-arm of the biplane rotates around the patient's head, capturing a series of images that are then compiled into a three-dimensional reconstruction.

Once all necessary images have been captured, the catheter is pulled back under fluoroscopic guidance; in most cases, a femoral arteriogram is captured to evaluate the placement of the sheath. The decision of whether to hold pressure or place a closure device is then made; either a wire is inserted to exchange the sheath for a closure device or the sheath is simply removed under manual pressure, which is held for a variable period of time depending on the size of the catheter and patient-specific characteristics such as anticoagulation use. Both femoral and dorsalis pedis pulses are palpated and monitored both immediately and for several hours after the study. A sterile dressing should be placed over the puncture site once hemostasis is confirmed.

Postprocedural Care

Meticulous attention should be paid to the access site and distal pulses; the extremity in which arterial access was obtained should be immobilized for a period of several hours depending on the size of the sheath and the method of closure. Blood pressure parameters

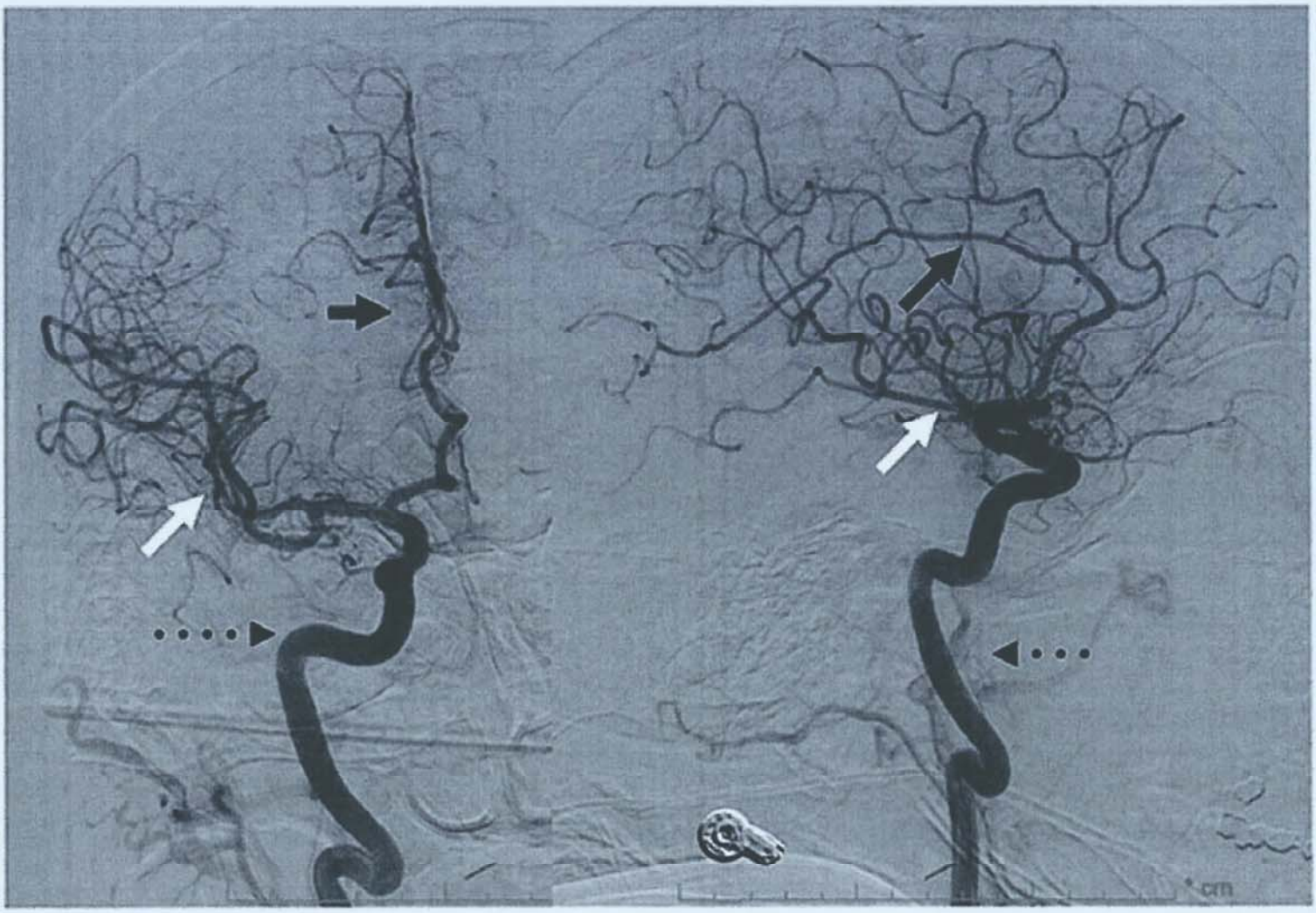

FIGURE 25.2 Anteroposterior **(left)** and lateral **(right)** views of a normal right internal carotid angiogram showing the internal carotid artery *(dotted arrows)*, middle cerebral artery *(white arrows)*, and anterior cerebral artery *(black arrows)*.

should be stipulated particularly in cases where interventions were performed; an arterial line for continuous blood pressure measurements may be necessary in some cases. Neurologic status should be monitored, and any changes in the neurologic exam should prompt consideration of appropriate neuroimaging. Appropriate antiplatelet regimen should be maintained in cases in which an intravascular stent was placed. It is crucial that the clinician be aware of both general angiographic complications and procedure- and condition-specific considerations; procedure-specific complications are outlined in the sections to follow.

COMPLICATIONS OF ANGIOGRAPHY

Complications of angiography include access site complications, perioperative stroke or transient ischemic attack, and complications related to contrast such as allergy or contrast-induced nephropathy (CIN). A retrospective study of over 19,000 diagnostic cerebral angiograms found that access site hematoma was the most common overall complication, occurring in 4.2% of patients; the rate of neurologic complications was 2.6%, and the rate of permanent neurologic disability from perioperative stroke was 0.14%.

Access Site Complications

Potential groin site complications include femoral artery dissection from subintimal passage of guidewire or malpositioned closure device; retroperitoneal hematoma from suprainguinal puncture; arterial pseudoaneurysm; and, rarely, acute lower extremity limb ischemia from arterial spasm, dissection, embolization of atherosclerotic plaque, or closure device. Retroperitoneal hematoma can cause hemodynamic instability; monitoring of vitals, hemoglobin and hematocrit, and visible hematoma expansion should be performed. Repletion of blood products may be necessary, and a type and screen and large-bore intravenous access are crucial; small hematomas may be treated conservatively, whereas larger hematomas often require surgical evacuation. Lower limb ischemia should warrant an emergent vascular surgery consultation, with consideration of anticoagulation and evaluation for emergent revascularization.

Contrast Allergy

Contrast allergy is seen in a minority of patients; if angiography is required, patients with a contrast allergy can be premedicated with a combination of antihistamines and steroids; if an acute

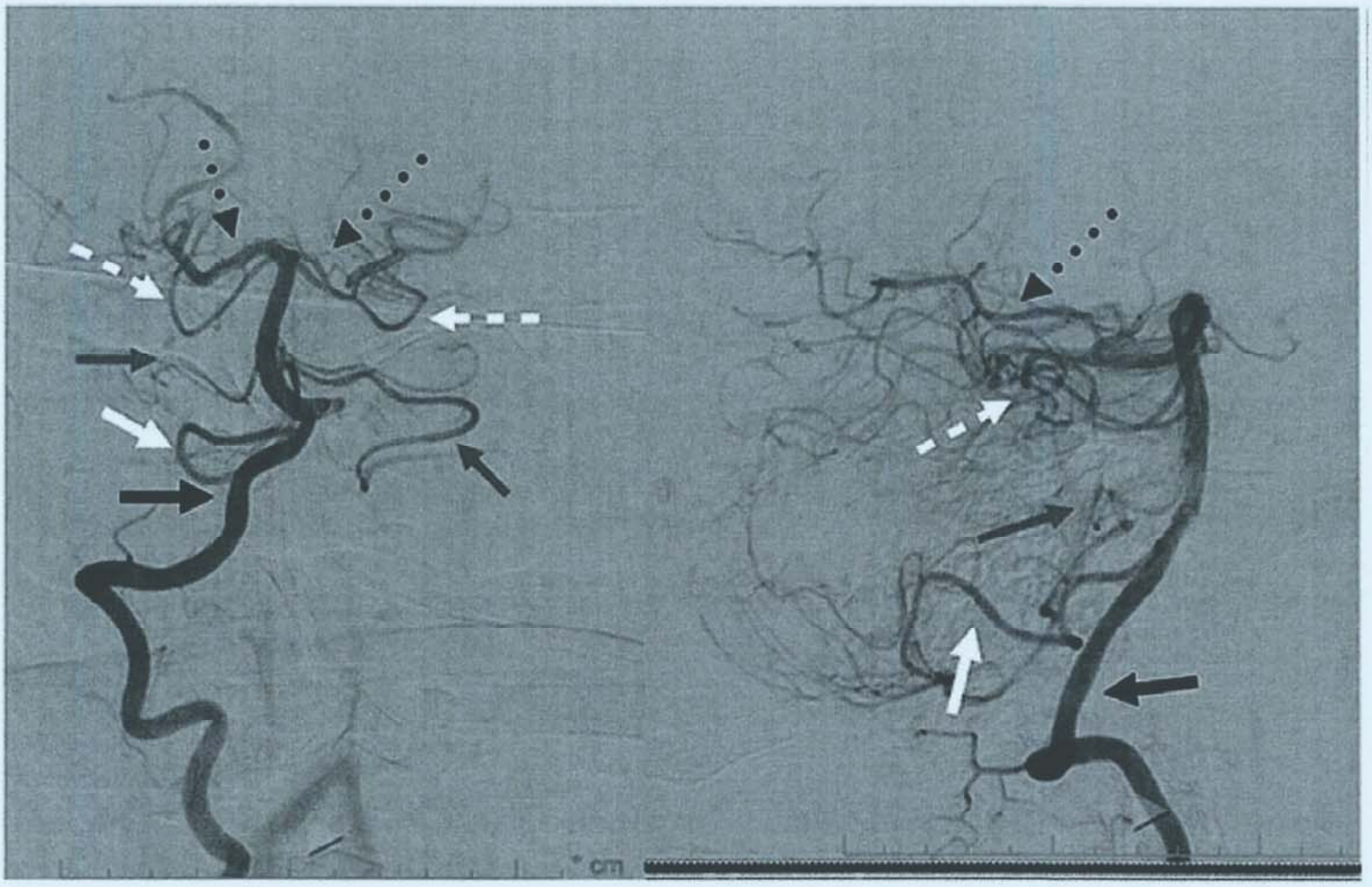

FIGURE 25.3 Anteroposterior **(left)** and lateral **(right)** views of a normal right vertebral artery angiogram demonstrating distal vertebral artery *(black solid arrows)*, posterior inferior cerebellar artery *(white solid arrows)*, anterior inferior cerebellar artery *(gray arrows)*, superior cerebellar artery *(white dotted arrows)*, and posterior cerebral artery *(black dotted arrows)*.

anaphylactoid reaction occurs with contrast exposure, administration of epinephrine is recommended. The American College of Radiology has outlined commonly encountered contrast reactions and proposed treatment algorithms.

Contrast-Induced Nephropathy

The rate of CIN from catheter-based angiography ranges from 0.5% to 6.0% in the published literature depending on the patient population and the definition of CIN employed; risk factors for CIN include preexisting diabetes mellitus and advanced age. Strategies recommended to reduce the risk of CIN include pre- and postoperative hydration, holding blood pressure medications and avoiding perioperative hypotension, and limiting contrast administration to the minimum necessary to obtain the required angiographic runs.

Neurologic Complications

Neurologic complications are the most feared consequence of diagnostic cerebral angiography; however, fortunately with the advent of technologic advances, the reported complication rate is as low as 0% to 2.3% for reversible neurologic deficits and 0% to 5% for permanent neurologic deficits. Older age and preexisting cardiovascular disease have been identified as risk factors for neurologic complications. However, these rates are reported for diagnostic angiograms only; the rate of complications with interventional procedures varies based on the clinical condition and technique being employed.

SELECTED CONDITIONS DIAGNOSED AND TREATED WITH NEUROINTERVENTIONAL PROCEDURES

Cerebral Aneurysms

Diagnosis and management of cerebral aneurysms is a common indication for endovascular treatment. Broadly, aneurysms can be categorized on their ultrastructural features such as their size, morphology, and location; however, the most significant distinction is between unruptured aneurysms and those which have ruptured and caused subarachnoid hemorrhage (SAH); both clinical scenarios are discussed in brief in the following text.

Unruptured Aneurysms

Unruptured aneurysms are present in approximately 3.4% of the population; often, these are discovered incidentally on neuroimaging performed for other indications. Risk factors for having a

cerebral aneurysm include family history of aneurysm in two or more first-degree relatives, smoking, hypertension, increasing age, and presence of certain disorders such as polycystic kidney disease or collagen vascular diseases. The International Study of Unruptured Intracranial Aneurysms was a large prospective study of patients with unruptured aneurysms dichotomized into two groups: those with a prior history of SAH from a separate aneurysm and those with no history of SAH; in patients with no history of SAH, the rupture rate for small aneurysms less than 10 mm in diameter was 0.05% per year. Factors associated with rupture risk in the group without prior history of SAH included posterior circulation or posterior communicating artery location and size; in the patients with a history of SAH, the rupture risk was 0.5% per year, 11 times higher than in the first group. Several risk scores have been proposed to assess the risk of SAH in unruptured intracranial aneurysms; these include the Population, Hypertension, Age, Size, Earlier subarachnoid hemorrhage, Site (PHASES) score, which is a composite of several of the risk factors noted earlier, and the Unruptured Intracranial Aneurysm score, which is based on location, size, current smoking, and age at diagnosis. A common challenge faced by neurointerventionalists is whether to treat these incidentally discovered aneurysms. The decision on whether to treat or observe unruptured intracranial aneurysms, and how often to follow with serial imaging, is at this time based on observational studies, patient's preference, and clinician's assessment of aneurysm- and patient-specific risk factors.

Surgical Versus Endovascular Treatment

The two major strategies for aneurysm treatment are surgical clipping and endovascular treatment; the latter is colloquially often referred to in the literature as *coiling*, although it is noteworthy that there are now several endovascular treatment strategies beyond coiling. Each treatment modality has its advantages. Endovascular treatment has been shown to be associated with a lower procedure-related morbidity and mortality but a higher rate of recurrence than surgical clipping.

The International Subarachnoid Aneurysm Trial was a prospective, randomized, multicenter trial of 2,143 patients comparing the safety and efficacy of endovascular coiling versus microsurgical clipping for ruptured cerebral aneurysms and found that for small- to moderate-sized anterior circulation aneurysms, there was a lower rate of death or dependency in the coiling group (24%) versus the clipping group (31%) LEVEL 1.[2,3] The Barrow Ruptured Aneurysm Trial showed similar findings in a smaller cohort of 471 patients; 34% of patients in the clipping arm versus 23% in the coil arm experienced death or dependency. The main disadvantage of the endovascular arm was that 33% of patients crossed over to surgical treatment LEVEL 1.[4]

Currently, the American Heart Association does not categorically recommend one treatment over the other but states that both clipping and coiling should be performed at high-volume centers accustomed to such treatment.

Overview of Endovascular Treatment Strategies for Aneurysms

Many endovascular strategies exist for treating aneurysms; most have only risen to prominence within the last decade. Each method has its own advantages and downsides; in some cases, aneurysm morphology may not allow for coiling but may be favorable for flow diversion. Aneurysm size, neck-to-dome ratio and other morphologic features, location, and proximity to other vessels all factor into the neurointerventionalist's decision on how to best secure an aneurysm.

Coiling

Although attempts at coiling aneurysms began several decades ago, coiling in earnest began in 1991 when Guido Guglielmi collaborated with the University of California Los Angeles to invent the prototypical coils used in practice today, termed *Guglielmi detachable coils*. These platinum-based detachable coils could be introduced through a catheter and then deployed into the aneurysm sac by electrolytic detachment; their positive charge attracts the negative charge of platelets, red blood cells, and white blood cells leading to thrombosis. The initial coil should provide a "frame" for additional coils; there are in fact framing coils designed precisely for this purpose. Subsequently, successive coils are deployed into the aneurysm until there is moderate resistance against further coil addition or until there is radiographic obliteration of the sac. Risks of coiling include aneurysm rupture, coil prolapse, and thrombosis of normal parent vessels.

Stent-Assisted Coiling and Balloon-Assisted Coiling

In some cases, aneurysm neck anatomy makes placement of coils challenging without prolapsing into the parent vessel. In these cases, an adjunctive technique with either a temporarily inflatable balloon or a permanent intravascular stent can help provide support and a scaffold on which coils can be placed in a satisfactory configuration. Balloon-assisted coiling involves temporary inflation of an intravascular balloon to cause flow arrest and allow for placement of coils without prolapse. Following coil placement, the balloon is deflated and removed and the coils are left in place. Stent-assisted coiling involves placing an intravascular stent designed for this purpose such as the Enterprise stent or LVIS Jr. stent and then deploying coils through the wall of the stent into the aneurysm sac. The main disadvantage of stent-assisted coiling is the requirement of dual antiplatelet therapy; however, pooled data from several studies has shown stent-assisted coiling to result in higher aneurysm obliteration rates as compared to balloon-assisted coiling. Complications of stent-assisted coiling are similar to those for coiling alone, with the added concern of in-stent thrombosis.

Flow Diversion

Flow-diverting stents are stents designed to promote flow stagnation within the aneurysm; in contrast to stents used for stent-assisted coiling, the metal coverage of flow-diverting stents is higher and the porosity is lower. Similar to stents used for stent-assisted coiling, use of a flow-diverting stent mandates dual antiplatelet therapy for a period of at least several months due to the risk of stent thrombosis. Typically, flow-diverting stents are employed for wide-neck or giant aneurysms in which coiling would not suffice. The Pipeline Embolization Device is the prototypical flow-diverting stent; it was studied in the Pipeline for Uncoilable or Failed Aneurysms study, in which a 73% occlusion rate was found as well as a 5.6% rate of major stroke or neurologic death. Similarly, the Surpass device, a more recently released flow-diverting stent, was studied in unruptured aneurysms deemed untreatable by coiling and found to have a 2.5% risk of SAH, 2.5% risk of intracerebral hemorrhage, and 3.7% risk of ischemic stroke with a 75% complete occlusion rate on follow-up angiogram. Risks inherent to flow-diverting stents include the risk of acute stent thrombosis, hemorrhagic complications due to antiplatelet use, and intimal hyperplasia within the body of the stent leading to stenosis of the vessel. An additional consideration of flow diversion is that aneurysm occlusion

is often delayed as compared to other methods such as coiling. Nevertheless, flow diversion has become an indispensable tool in the neurointerventionalist's arsenal for treating aneurysms that are not amenable to other methods.

Woven EndoBridge Intrasaccular Device

The Woven EndoBridge (WEB) device is a recent and novel endosaccular flow-diverting device, which is an ellipsoid device that is deployed into wide-neck aneurysms. The device is compressed within the microcatheter and is expanded into its final shape and detached electrothermically once the neurointerventionalist obtains satisfactory placement. European registry data from the WEB Clinical Assessement of Intrasaccular Aneurysm Therapy-2 (WEBCAST-2) study demonstrated a 1.8% risk of intraoperative rupture and an 8.0% retreatment rate with 80% of patients achieving successful aneurysm occlusion. Thromboembolic complications are a risk of WEB treatment, with incidence ranging from 4.7% to 15.6% depending on the series. Postoperative antiplatelet use varies between centers with wide heterogeneity, although in most cases, either aspirin or aspirin plus clopidogrel is administered for a variable length of time.

Intraluminal Support Device (PulseRider)

The PulseRider device is an intraluminal support device for wide-neck bifurcation aneurysms such as basilar tip aneurysms; it is an alternative to Y-stenting, where two crossing stents are placed to give support for coils to be placed in the sac of a bifurcation aneurysm. Six-month occlusion rates range from 87% to 100% depending on the series. A small prospective trial of 34 patients who underwent treatment with this device found procedural complications in 3 patients: one intraoperative rupture, one femoral artery dissection, and one thromboembolic event. At 6-month follow-up, 3 patients had neurologic events: one mild diplopia, one with coil-mass effect requiring subsequent stenting, and one occipital stroke after dual antiplatelet was interrupted for a procedure. Nevertheless, this device has a unique niche for treating challenging basilar tip aneurysms.

Subarachnoid Hemorrhage

Angiography is useful in making the diagnosis of cerebral aneurysm, potentially securing the aneurysm to decrease the risk of rerupture as well as treating symptomatic vasospasm due to SAH. As discussed earlier, previous studies (International Subarachnoid Aneurysm Trial and the Barrow Ruptured Aneurysm Trial) have found a lower risk of death and dependency in the endovascular as compared to clipping group, but there remains the potential for need for subsequent surgery or aneurysm recurrence.

A meta-analysis of five randomized controlled trials of clipping versus coiling in ruptured aneurysms found similar results, with not only a higher rate of poor outcome in the surgical cohort but also a higher rate of complete aneurysm occlusion.

Considerations when treating a ruptured aneurysm with endovascular treatment include the potential need for antiplatelet therapy; flow-diverting stent placement mandates dual antiplatelet therapy, which may be a concern in a patient who has experienced a recent SAH. Flow diversion also leads to delayed aneurysm thrombosis, raising concerns about leaving an aneurysm functionally unsecured until endothelialization takes place. A meta-analysis of flow diversion in ruptured aneurysms found a favorable clinical outcome in 81% of patients with SAH treated with flow diversion, a 5% risk of aneurysm rerupture with two-thirds of cases occurring within the first 24 hours, and a 12% risk of overall complications. The WEB device has also successfully been used to treat ruptured aneurysms, although experience is limited with this relatively new device compared to other methods. **Figure 25.4** demonstrates the breadth of techniques available for treating aneurysms endovascularly.

Vasospasm is a common complication of SAH, thought to be due to spasmogenic blood products causing dysregulation of the blood vessels; it occurs in 30% to 40% of patients with SAH. Currently accepted medical treatments for vasospasm include nimodipine for prophylaxis and hypertensive euvolemia as medical therapy. However, these are often not sufficient, and elevating blood pressure with vasopressors has potential cardiac side effects. Intra-arterial calcium channel blockers are often employed into vessels with symptomatic vasospasm; one retrospective study has shown that aggressive endovascular treatment of vasospasm with lower thresholds to treat is associated with a lower risk of delayed cerebral ischemia and a higher likelihood of favorable outcome as compared to more conservative management. Nimodipine is commonly employed for this purpose.

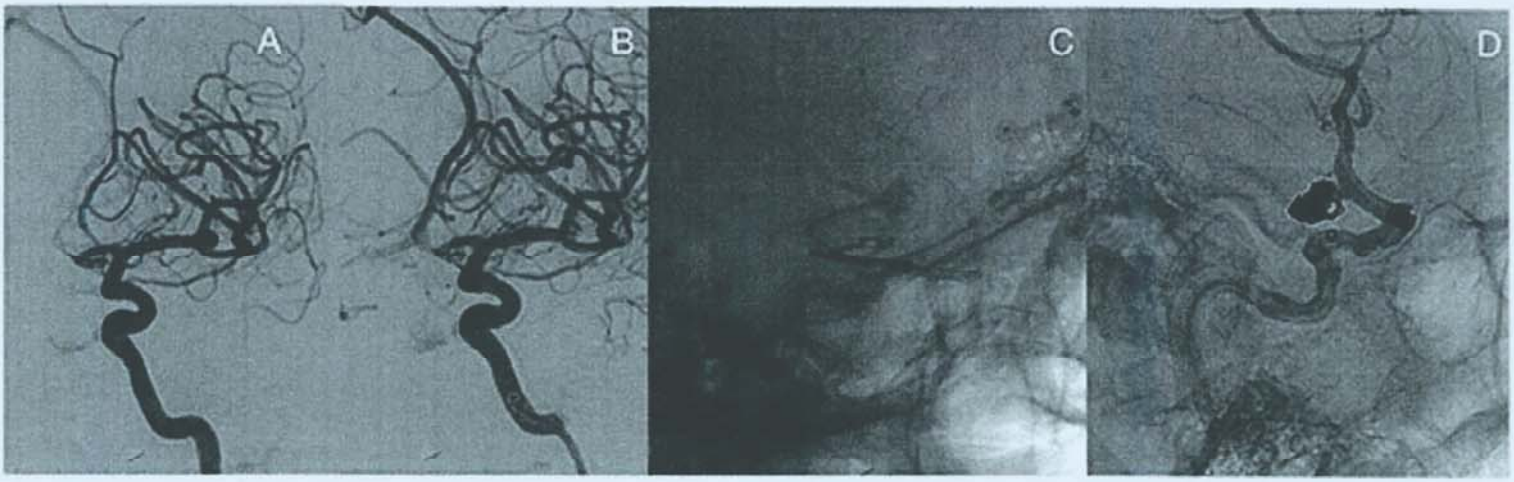

FIGURE 25.4 Endovascular aneurysm treatment. Middle cerebral artery bifurcation aneurysm **(A)** treated with coiling **(B)**. **C:** Middle cerebral artery bifurcation aneurysm treated with a Woven EndoBridge device. **D:** Previously ruptured posterior communicating aneurysm, previously coiled with recurrence, was treated with a flow-diverting stent.

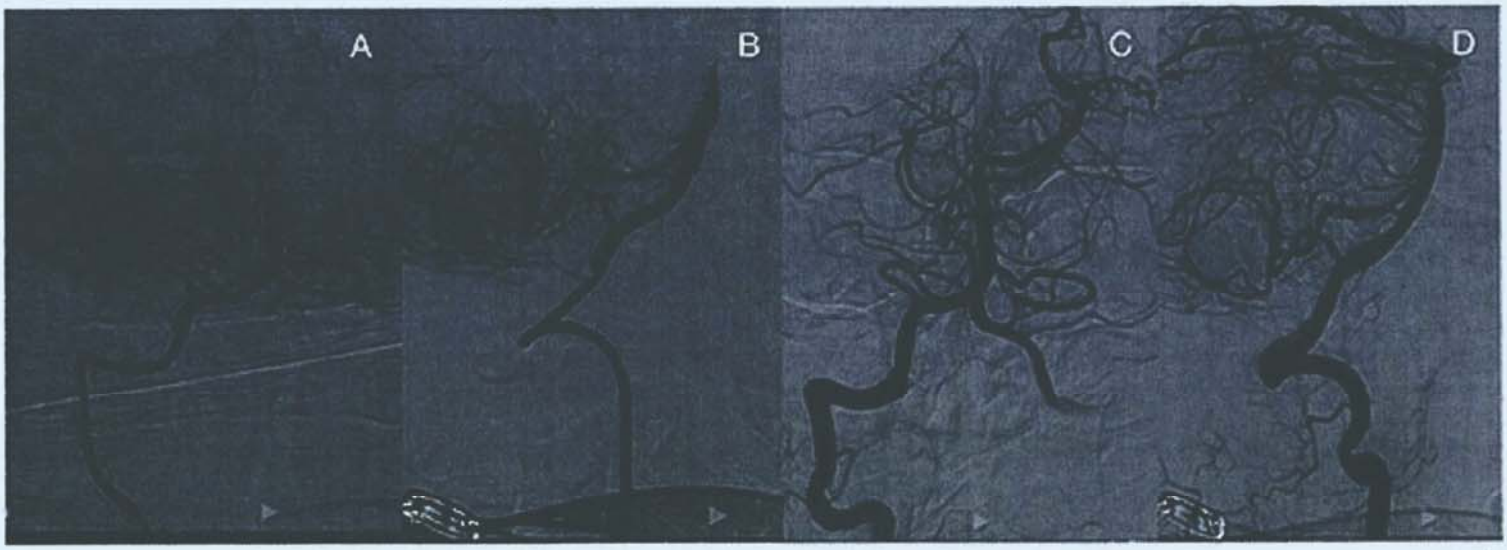

FIGURE 25.5 Mechanical thrombectomy of a basilar occlusion. Preintervention, a midbasilar occlusion is present on both anteroposterior **(A)** and lateral **(B)** images. **C,D:** After two passes, there is thrombolysis in cerebral infarction (TICI 3) recanalization. The patient has a fetal right posterior cerebral artery.

Acute Ischemic Stroke

Stroke remains the leading cause of disability and the second leading cause of death worldwide. The last two decades have seen a revolution in acute stroke therapy with the advent of alteplase and mechanical thrombectomy. In 1995, the National Institute of Neurological Diseases and Stroke (NINDS) trial showed that treatment with intravenous tissue plasminogen activator within 3 hours of the onset of ischemic stroke improved clinical outcome at 3 months LEVEL 1.[5] This window was extended to 4.5 hours based on the European Cooperative Acute Stroke Study (ECASS) trial.

In 2015, the Multicenter Randomized Clinical Trial of Endovascular Treatment for Acute Ischemic Stroke in the Netherlands reported significant improvement in 3-month outcome with no effect on mortality when tissue plasminogen activator followed by endovascular therapy was compared to endovascular therapy alone (33% vs 19% with good outcome) for strokes presenting within 6 hours of onset LEVEL 1.[6] This was a new revolution in acute stroke therapy and was followed by other similar trials. The Highly Effective Reperfusion Evaluated in Multiple Endovascular Stroke Trials collaboration was formed by the trial investigators of Endovascular Treatment for Small Core and Proximal Occlusion Ischemic Stroke, Extending the Time for Thrombolysis in Emergency Neurological Deficits—Intra-Arterial, Multicenter Randomized Clinical Trial of Endovascular Treatment for Acute Ischemic Stroke in the Netherlands, Pragmatic Ischaemic Stroke Thrombectomy Evaluation, Endovascular Revascularization With Solitaire Device Versus Best Medical Therapy in Anterior Circulation Stroke Within 8 Hours, Solitaire With the Intention for Thrombectomy as Primary Endovascular Treatment Trial, and Trial and Cost Effectiveness Evaluation of Intra-arterial Thrombectomy in Acute Ischemic Stroke. The Highly Effective Reperfusion Evaluated in Multiple Endovascular Stroke Trials meta-analysis has conclusively demonstrated the efficacy of mechanical thrombectomy in acute stroke treatment. The number needed to treat with endovascular thrombectomy to reduce disability by at least one level on modified Rankin Scale for one patient is 2.6.

The year 2018 saw another major revolution and change of guidelines for stroke treatment with extension of the stroke thrombectomy window to 24 hours in selected patients based on perfusion imaging scans as was seen in the DWI or CTP Assessment With Clinical Mismatch in the Triage of Wake Up and Late Presenting Strokes Undergoing Neurointervention With Trevo (DAWN) and EnDovascular ThErapy Following Imaging EvalUation for ISchemic StrokE 3 (DEFUSE 3) trials LEVEL 1.[7,8] **Figure 25.5** demonstrates an example of a large vessel occlusion of the basilar artery successfully treated with mechanical thrombectomy.

This pragmatic shift in treatment of acute strokes is attributed to careful patient selection as well as the advent of new technologies for clot extraction including stent retrievers, advanced aspiration systems, and balloon guide catheter systems.

Extracranial Carotid Artery Disease

Cervical internal carotid artery stenosis is an important cause of stroke; currently, revascularization is indicated in patients who have symptoms referable to the carotid artery who have 70% to 99% stenosis and considered in patients with 50% to 70% stenosis who have an acceptable operative risk of less than 6%. This benefit of revascularization for symptomatic carotid stenosis was shown by the North American Symptomatic Carotid Endarterectomy Trial and the pooled data from North American Symptomatic Carotid Endarterectomy Trial, Veterans Affairs trial, and European Carotid Surgery Trial LEVEL 1.[9,10] Asymptomatic carotid stenosis is treated on an individualized basis depending on operative risk; typically, carotid stenosis of more than 80% may be considered for treatment if the surgical risk is less than 3%. Carotid revascularization can occur via carotid endarterectomy (CEA) or via endovascular stent placement; each method has its relative advantages and disadvantages. CEA is associated with a higher cardiac risk relative to stenting; it also may be technically challenging in patients with a high carotid bifurcation (above the mandible) due to difficulty accessing the diseased segment. On the other hand, stent placement requires obligatory dual antiplatelet for a period of several months, which may have bearing on patients with a history of systemic bleeding or who may require other operations within the months following the stent placement. Stent placement is

also associated with a higher risk of ipsilateral stroke within the first 30 days. Patients older than 70 years benefit from CEA over carotid angioplasty and stenting due to a higher risk of perioperative stroke with stenting. However, in patients with high surgical risk or those with radiation necrosis or a history of prior CEA with restenosis, stent may be a preferred option.

Arteriovenous Malformations

AVMs are congenital anomalous vascular structures consisting of direct arterial-venous communications without an intervening capillary bed; they consist of a nidus that allows for high-flow arteriovenous shunting and are supplied by one or more feeding arteries and exhibit early drainage into surrounding venous structures. The most common presentation of AVM is intracerebral hemorrhage, accounting for over half of all presentations; however, seizures are the presenting symptom in about one-third of patients. The risk of hemorrhage is approximately 3% per year; however, this risk varies widely based on clinical and structural features of the AVM. Risk factors for hemorrhage include exclusively deep venous drainage, prior episodes of bleeding, intranidal aneurysm, history of prior hemorrhage, and presence of a single draining vein. **Figure 25.6** demonstrates an example of an AVM. Treatment of unruptured AVMs is controversial; A Randomized Trial of Unruptured Brain Arteriovenous Malformations found that medical management was associated with a lower risk of stroke and death than interventional treatment. However, there were issues with A Randomized Trial of Unruptured Brain Arteriovenous Malformations including a high crossover rate, relatively short follow-up period of only 33 months, and heterogeneity regarding type of intervention and individual risk factors associated with complications.

The Spetzler-Martin grading scale is the most widely used classification for grading AVMs and accounts for size, deep venous drainage, and location in eloquent cortex; it predicts outcomes after surgical excision. The scale ranges from 1 to 5, with lower scores indicating lower risk; 1 point is assigned for deep venous drainage, 1 point for the involvement of eloquent cortex, and the other points are assigned based on size (1 point for nidus <3 cm, 2 points for nidus 3-6 cm, and 3 points for nidus >6 cm). There are several strategies for managing AVMs including conservative management, microsurgical excision, stereotactic radiosurgery, and endovascular embolization. For low-grade AVMs, surgery alone may suffice; however, for higher grade lesions, a multidisciplinary staged approach is often employed. Endovascular embolization can be performed with a goal of complete cure, as an adjunctive treatment to preoperatively shrink the AVM prior to stereotactic radiosurgery or open microsurgery, or as a palliative treatment for inoperable AVMs to relieve hypoperfusion caused by arterial steal, when the AVM nidus shunts blood away from normal tissue. Endovascular embolization is performed most commonly by injecting liquid embolic agents into the AVM to occlude its arterial supply. Commonly used agents include Onyx (ethylene-vinyl copolymer, dimethyl sulfoxide, tantalum) and *n*-butyl cyanoacrylate (glue); embolic particles are also sometimes used as well as detachable coils. Caution is required to prevent inadvertently embolizing normal proximal arterial branches or obstructing normal venous outflow leading to venous infarct and hemorrhage; additionally, care must be taken to avoid precipitation of liquid embolic in the catheter, which can make it challenging or impossible to remove. One large retrospective study found a rate of 1.6% for permanent disabling neurologic complications, and 2.6% for permanent nondisabling neurologic complications.

Dural Arteriovenous Fistulas

Cranial or spinal dural arteriovenous fistulas (DAVFs) are acquired pathologic shunts between dural arteries and dural venous sinuses. The pathogenesis of DAVFs is unknown, although multiple associations have been described including anomalies of venous system, venous thrombosis, head trauma, transcranial surgery, association with pregnancy, delivery and menopause, increased systemic thrombotic activity, cortical vein thrombosis, role of hormonal changes (use of oral contraceptive and pregnancy) causing increased angiogenesis, tumors (meningiomas obstruct dural venous outflow), general surgery, otitis, and sinusitis. Signs and symptoms include pulse-synchronous tinnitus and exophthalmos, cranial nerve deficits, cognitive impairment, venous infarction, intracranial hemorrhage, and even death depending on fistula location, duration of disease, and venous drainage pattern. DAVFs are dynamic lesions that may either spontaneously regress or progress. For this reason, close clinical and radiologic monitoring is critical. Treatment should be pursued for all lesions with cortical venous drainage or intolerable symptoms. First-line management of DAVFs is endovascular

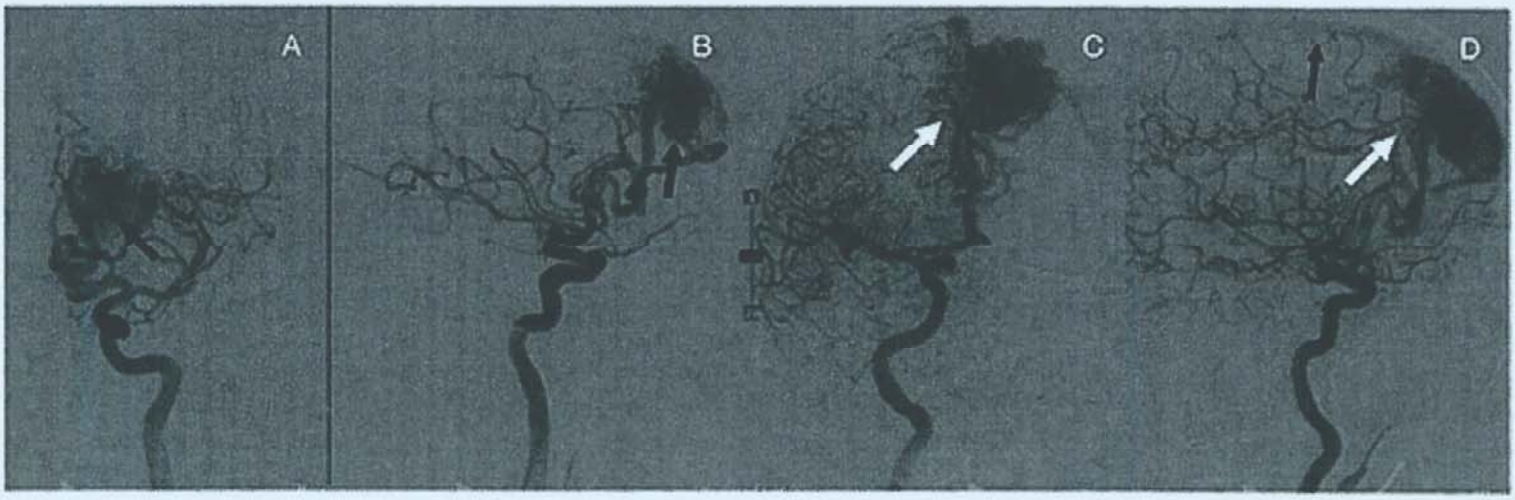

FIGURE 25.6 An arteriovenous malformation of the left frontal lobe (Spetzler-Martin grade IV) with arterial supply from left anterior cerebral artery **(A,B)** *(black arrows)* and right anterior cerebral artery **(C,D)** *(white arrows)*. **D:** Early venous drainage is noted into the superior sagittal sinus *(black arrow)*.

embolization via the transarterial route, transvenous route, or a combination of both. Transarterial embolization is typically performed with a liquid embolic agent such as *n*-butyl cyanoacrylate or Onyx. Transvenous embolization is performed by retrograde catheterization of the involved dural sinus or cortical vein followed by deposition of coils and/or liquid embolic material at the site of inflow of the arteriovenous shunt. Transvenous embolization has been shown to have a high likelihood of cure and is often used to treat transverse/sigmoid sinus and cavernous sinus DAVFs. Detachable coils are deployed to form a scaffolding, after which pushable fibered coils, which are more thrombogenic and much less expensive, can then be added to achieve complete occlusion of the venous segment.

Other Diagnostic Uses

Diagnostic cerebral angiography can also be employed as a purely diagnostic tool; it is useful in classifying the severity of moyamoya disease and both arteritic and nonarteritic vasculopathies such as fibromuscular dysplasia or vasculitis. It is often used in the diagnosis of reversible cerebral vasoconstriction syndrome, although this indication is beginning to be supplanted by noninvasive imaging in some cases. Vessel wall imaging with high-resolution magnetic resonance imaging has emerged as an area of ongoing research in visualizing luminal properties noninvasively; at this time, the comparative utility relative to angiogram is unknown, but it is likely to become more widely used particularly in imaging atherosclerosis and suspected vasculitis. Angiography is also important in the preoperative evaluation of patients undergoing ablative surgery for epilepsy or tumor resection; the Wada test involves intra-arterial injection of a barbiturate to evaluate hemisphere dominance for language. In some centers, however, functional magnetic resonance imaging is becoming a preferred modality for this purpose.

EMERGING CONSIDERATIONS

Chronic Subdural Hematoma

Chronic subdural hematoma is a challenging condition to manage particularly in the elderly population; often, these patients require antiplatelet or anticoagulation for concomitant cardiac conditions, and this complicates management. Surgery is a commonly accepted treatment, but some series have reported recurrence rates of 8% to 15% in some modern series. It is theorized that in chronic subdural hematoma, abnormal "neomembranes" develop after liquefaction of the subdural hematoma, causing collagen synthesis and fibroblast deposition; these neomembranes are supplied via branches of the middle meningeal artery. Obliterating the blood supply by endovascular embolization of middle meningeal artery branches has been shown to successfully resolve the chronic subdural hematoma; a recent meta-analysis of 15 studies demonstrated a low recurrence rate of 3.6% in patients undergoing middle meningeal artery embolization. Operative techniques vary between neurointerventionalists; however, the general premise involves first selectively catheterizing the external carotid artery ipsilateral to the subdural hematoma and ensuring that no "dangerous anastomoses" exist between the external carotid artery and internal carotid artery and vertebral artery. This is crucial because inadvertent spread of embolic particles from the middle meningeal artery branches into branches of the ophthalmic, ascending pharyngeal, or other branches can lead to neurologic deficits. Once a safe embolic trajectory is ascertained, a combination of coils and embolic particles, or particles in isolation, is injected into the middle meningeal artery until successful embolization has been achieved.

Idiopathic Intracranial Hypertension

Idiopathic intracranial hypertension (IIH), also known as *pseudotumor cerebri*, is a condition in which intracranial pressure is elevated in the absence of a mass lesion; risk factors include obesity, female sex, and certain medications. IIH can cause tinnitus, headaches, and both transient and permanent vision loss. Treatment strategies include topiramate or acetazolamide, weight loss, optic nerve sheath fenestration, and ventriculoperitoneal shunting; additionally, transverse sinus stenting is another potential strategy for managing IIH. In a series of 143 patients treated with transverse sinus stenting, the authors reported a 6% rate of combined major and minor procedural complications, an 88% rate of headache improvement, and an 87% rate of visual symptom improvement. Meta-analysis of 20 articles and 474 patients who underwent venous sinus stenting found over 90% improvement in papilledema, 90% improvement in pulsatile tinnitus, and a major complication rate defined as subdural hematoma or SAH of 1.9%. All patients who had an intracranial hemorrhage made a full recovery. A small prospective study of 13 patients also reported high success rates with transverse sinus stenting in terms of headache improvement, reduction in visual symptoms, and resolution of pulsatile tinnitus. The current data suggests that transverse sinus stenting can be beneficial in selected patients with IIH.

Intracranial Stenting

Intracranial atherosclerosis is a common cause of stroke; it is particularly prevalent in Asians, accounting for up to 30% to 50% of strokes in this population. It is known that greater than 80% stenosis in the symptomatic vessel correlates with a high risk of recurrent stroke; thus, revascularization with stenting has been studied in several trials. Two randomized controlled trials have studied the utility of intracranial stenting in patients with symptomatic intracranial atherosclerosis; the Stenting and Aggressive Medical Management for Preventing Recurrent Stroke in Intracranial Stenosis (SAMMPRIS) found that medical management was associated with a lower risk of stroke and death than endovascular treatment. Likewise, the Vitesse Intracranial Stent Study for Ischemic Stroke Therapy found higher rates of stroke and death in the procedural group compared to the medical arm; however, the study was stopped prior to target enrollment after the results of SAMMPRIS were published. However, it is notable that these studies were undertaken with earlier generation stents, which may have had higher complication rates than newer technology. Case series with newer stents such as the Enterprise stent have reported complication rates as low as 1.5% with one SAH in a series of 68 patients. Additionally, both SAMMPRIS and Vitesse Intracranial Stent Study for Ischemic Stroke Therapy excluded patients with ongoing progressive neurologic symptoms. It is this latter group of patients, whom are experiencing ongoing and progressive ischemic events, that may arguably be the most likely to benefit from a stent. Submaximal angioplasty has been proposed as an

alternative to stenting with several published case series but has not been studied as extensively as stenting. Further studies in a carefully selected patient population with modern devices are necessary to evaluate the potential benefit of stenting in intracranial atherosclerosis; until then, stenting of the intracranial arteries is generally reserved as a rescue measure for patients with severe, progressive neurologic deficits refractory to maximal medical therapy.

Tumors

Microcatheters have allowed for superselective catheterization of intracranial vessels; this ability has allowed for the use of neuroendovascular therapy in the treatment of intracranial tumors. There are two major methods of treating intracranial tumors endovascularly: embolization of the blood supply of the tumor and infusion of intra-arterial chemotherapy into the vascular supply of the tumor. In patients undergoing arterial embolization, a Japanese registry data of over 40,000 patients found a procedural complication risk of 3.7%; meningioma accounted for the vast majority of tumors in this study. Superselective intra-arterial infusion of chemotherapy is an area of active research, and feasibility has been demonstrated in several small series, although further research is needed on this topic.

SUMMARY

Neuroendovascular treatments have evolved into a rapidly expanding field with the previous sections covering the most common applications. There are many additional procedures that fall under the realm of neuroendovascular therapy, which are beyond the scope of this chapter; examples include petrosal sinus sampling, sphenopalatine artery embolization for epistaxis, treatment of congenital vein of Galen malformations, carotid-cavernous fistulas, kyphoplasty, and vertebroplasty, among others. As technology continues to improve, the limitations of vessel caliber become less of an issue; aneurysms, which could previously not be accessed are now candidates for endovascular treatment, and strokes caused by distal middle cerebral artery branch occlusions are now being regularly treated at some centers. The myriad of treatments discussed in this chapter illustrates the broad scope and applications of endovascular neuroradiology.

LEVEL 1 EVIDENCE

1. Valgimigli M, Gagnor A, Calabró P, et al. Radial versus femoral access in patients with acute coronary syndromes undergoing invasive management: a randomised multicentre trial. *Lancet*. 2015;385:2465-2476.
2. Molyneux A, Kerr R, Stratton I, et al. International Subarachnoid Aneurysm Trial (ISAT) of neurosurgical clipping versus endovascular coiling in 2143 patients with ruptured intracranial aneurysms: a randomised trial. *Lancet*. 2002;360:1267-1274.
3. Molyneux AJ, Kerr RS, Birks J, et al. Risk of recurrent subarachnoid haemorrhage, death, or dependence and standardised mortality ratios after clipping or coiling of an intracranial aneurysm in the International Subarachnoid Aneurysm Trial (ISAT): long-term follow-up. *Lancet Neurol*. 2009;8:427-433.
4. McDougall CG, Spetzler RF, Zabramski JM, et al. The Barrow Ruptured Aneurysm trial. *J Neurosurg*. 2012;116:135-144.
5. National Institute of Neurological and Stroke rt-PA Stroke Study Group. Tissue plasminogen activator for acute ischemic stroke. *N Engl J Med*. 1995;333(24):1581-1587.
6. Berkhemer OA, Fransen PS, Beumer D, et al. A randomized trial of intraarterial treatment for acute ischemic stroke. *N Engl J Med*. 2015;372(1):11-20.
7. Albers GW, Marks MP, Kemp S, et al. Thrombectomy for stroke at 6 to 16 hours with selection by perfusion imaging. *N Engl J Med*. 2018;378(8):708-718.
8. Nogueira RG, Jadhav AP, Haussen DC, et al. Thrombectomy 6 to 24 ours after stroke with a mismatch between deficit and infarct. *N Engl J Med*. 2018;378(1):11-21.
9. Rothwell PM, Eliasziw M, Gutnikov SA, et al. Analysis of pooled data from the randomised controlled trials of endarterectomy for symptomatic carotid stenosis. *Lancet*. 2003;361(9352):107-116.
10. Henderson RD, Eliasziw M, Fox J, Rothwell PM, Barnett HJ. Angiographically defined collateral circulation and risk of stroke in patients with severe carotid artery stenosis. North American Symptomatic Carotid Endarterectomy Trial (NASCET) Group. *Stroke*. 2000;31(1):128-132.

SUGGESTED READINGS

Albers GW, Marks MP, Kemp S, et al. Thrombectomy for stroke at 6 to 16 hours with selection by perfusion imaging. *N Engl J Med*. 2018;378(8):708-718.

American College of Radiology Committee on Drugs and Contrast Media. *ACR Manual on Contrast Media*. American College of Radiology Web site. Retrieved from https://www.acr.org/-/media/ACR/Files/Clinical-Resources/Contrast_Media.pdf. Accessed August 1, 2019.

Antunes JL. Egas Moniz and cerebral angiography. *J Neurosurg*. 1974;40(4):427-432.

Ban SP, Hwang G, Byoun HS, et al. Middle meningeal artery embolization for chronic subdural hematoma. *Radiology*. 2018;286(3):992-999.

Becske T, Kallmes DF, Saatci I, et al. Pipeline for uncoilable or failed aneurysms: results from a multicenter clinical trial. *Radiology*. 2013;267(3):858-868.

Berenstein A, Song JK, Niimi Y. Personal accounts of the evolution of endovascular neurosurgery. *Neurosurgery*. 2006;59(5, suppl 3):S15-S21.

Berkhemer OA, Fransen PS, Beumer D, et al. A randomized trial of intraarterial treatment for acute ischemic stroke. *N Engl J Med*. 2015;372(1):11-20.

Bink A, Berkefeld J, Kraus L, Senft C, Ziemann U, du Mesnil de Rochemont R. Long-term outcome in patients treated for benign dural arteriovenous fistulas of the posterior fossa. *Neuroradiology*. 2011;53(7):493-500.

Chimowitz MI, Lynn MJ, Derdeyn CP, et al. Stenting versus aggressive medical therapy for intracranial arterial stenosis. *N Engl J Med*. 2011;365(11):993-1003.

Ciccone A, Abraha I, Santilli I. Glycoprotein IIb-IIIa inhibitors for acute ischaemic stroke. *Cochrane Database Syst Rev*. 2006;(4):CD005208.

Citron SJ, Wallace RC, Lewis CA, et al. Quality improvement guidelines for adult diagnostic neuroangiography. Cooperative study between ASITN, ASNR, and SIR. *J Vasc Interv Radiol*. 2003;14(9, pt 2):S257-S262.

Cole JW. Largeartery atherosclerotic occlusive disease. *Continuum (Minneap Minn)*. 2017;23(1, Cerebrovascular Disease):133-157.

del Zoppo GJ, Higashida RT, Furlan AJ, Pessin MS, Rowley HA, Gent M. PROACT: a phase II randomized trial of recombinant pro-urokinase by direct arterial delivery in acute middle cerebral artery stroke. PROACT Investigators. Prolyse in Acute Cerebral Thromboembolism. *Stroke*. 1998;29(1):4-11.

Ding YH, Lewis DA, Kadirvel R, Dai D, Kallmes DF. The Woven EndoBridge: a new aneurysm occlusion device. *AJNR Am J Neuroradiol*. 2011;32(3):607-611.

Dinkin MJ, Patsalides A. Venoussinus stenting for idiopathic intracranial hypertension: where are we now? *Neurol Clin*. 2017;35(1):59-81.

Ducruet AF, Grobelny BT, Zacharia BE, et al. The surgical management of chronic subdural hematoma. *Neurosurg Rev*. 2012;35(2):155-169.

Dumont TM, Sonig A, Mokin M, et al. Submaximal angioplasty for symptomatic intracranial atherosclerosis: a prospective phase I study. *J Neurosurg*. 2016;125(4):964-971.

Fiorella D, Woo HH, Albuquerque FC, Nelson PK. Definitive reconstruction of circumferential, fusiform intracranial aneurysms with the pipeline embolization device. *Neurosurgery*. 2008;62(5):1115-1120.

Furlan A, Higashida R, Wechsler L, et al. Intra-arterial prourokinase for acute ischemic stroke. The PROACT II study: a randomized controlled trial. Prolyse in Acute Cerebral Thromboembolism. *JAMA*. 1999;282(21):2003-2011.

Goyal M, Menon BK, van Zwam WH, et al. Endovascular thrombectomy after large-vessel ischaemic stroke: a meta-analysis of individual patient data from five randomised trials. *Lancet*. 2016;387(10029):1723-1731.

Greving JP, Wermer MJ, Brown RD Jr, et al. Development of the PHASES score for prediction of risk of rupture of intracranial aneurysms: a pooled analysis of six prospective cohort studies. *Lancet Neurol*. 2014;13(1):59-66.

Guglielmi G, Viñuela F, Dion J, Duckwiler G. Electrothrombosis of saccular aneurysms via endovascular approach. Part 2: preliminary clinical experience. *J Neurosurg*. 1991;75(1):8-14.

Gupta A, Periakaruppan A. Intracranial dural arteriovenous fistulas: a review. *Indian J Radiol Imaging*. 2009;19(1):43-48.

Hacke W, Kaste M, Bluhmki E, et al. Thrombolysis with alteplase 3 to 4.5 hours after acute ischemic stroke. *N Engl J Med*. 2008;359(13):1317-1329.

Halbach VV, Higashida RT, Hieshima GB, Mehringer CM, Hardin CW. Transvenous embolization of dural fistulas involving the transverse and sigmoid sinuses. *AJNR Am J Neuroradiol*. 1989;10(2):385-392.

Henderson RD, Eliasziw M, Fox AJ, Rothwell PM, Barnett HJ. Angiographically defined collateral circulation and risk of stroke in patients with severe carotid artery stenosis. North American Symptomatic Carotid Endarterectomy Trial (NASCET) Group. *Stroke*. 2000;31(1):128-132.

Holmstedt CA, Turan TN, Chimowitz MI. Atherosclerotic intracranial arterial stenosis: risk factors, diagnosis, and treatment. *Lancet Neurol*. 2013;12(11):1106-1114.

International Study of Unruptured Intracranial Aneurysms Investigators. Unruptured intracranial aneurysms—risk of rupture and risks of surgical intervention. *N Engl J Med*. 1998;339(24):1725-1733.

Jabbarli R, Pierscianek D, Rölz R, et al. Endovascular treatment of cerebral vasospasm after subarachnoid hemorrhage: more is more. *Neurology*. 2019;93(5):e458-e466.

Jayaraman MV, Marcellus ML, Hamilton S, et al. Neurologic complications of arteriovenous malformation embolization using liquid embolic agents. *AJNR Am J Neuroradiol*. 2008;29(2):242-246.

Jia ZY, Shi HB, Miyachi S, et al. Development of new endovascular devices for aneurysm treatment. *J Stroke*. 2018;20(1):46-56.

Joo C, Park E, Min JW, Kang H, Yoo DS, Jung HJ. Contrast media-induced nephropathy in patients with unruptured cerebral aneurysm after coiling endovascular treatment. *World Neurosurg*. 2019;121:e39-e44.

Jovin TG, Nogueira RG. Thrombectomy 6 to 24 hours after stroke. *N Engl J Med*. 2018;378(12):1161-1162.

Juvela S. Treatment scoring of unruptured intracranial aneurysms. *Stroke*. 2019;50(9):2344-2350.

Kaufmann TJ, Huston J III, Mandrekar JN, Schleck CD, Thielen KR, Kallmes DF. Complications of diagnostic cerebral angiography: evaluation of 19,826 consecutive patients. *Radiology*. 2007;243(3):812-819.

Kernan WN, Ovbiagele B, Black HR, et al. Guidelines for the prevention of stroke in patients with stroke and transient ischemic attack: a guideline for healthcare professionals from the American Heart Association/American Stroke Association. *Stroke*. 2014;45(7):2160-2236.

Kidwell CS, Jahan R, Gornbein J, et al. A trial of imaging selection and endovascular treatment for ischemic stroke. *N Engl J Med*. 2013;368(10):914-923.

Kim J, Male S, Jagadeesan BD, Streib C, Tummala RP. Safety of cerebral angiography and neuroendovascular therapy in patients with chronic kidney disease. *Neuroradiology*. 2018;60(5):529-533.

Kim YS, Lim SH, Oh KW, et al. The advantage of high-resolution MRI in evaluating basilar plaques: a comparison study with MRA. *Atherosclerosis*. 2012;224(2):411-416.

Li K, Barras CD, Chandra RV, et al. A review on the management of cerebral vasospasm following aneurysmal subarachnoid haemorrhage. *World Neurosurg*. 2019;126:513-527.

Madaelil TP, Moran CJ, Cross DT III, Kansagra AP. Flow diversion in ruptured intracranial aneurysms: a meta-analysis. *AJNR Am J Neuroradiol*. 2017;38(3):590-595.

Marquis-Gravel G, Tremblay-Gravel M, Lévesque J, et al. Ultrasound guidance versus anatomical landmark approach for femoral artery access in coronary angiography: a randomized controlled trial and a meta-analysis. *J Interv Cardiol*. 2018;31(4):496-503.

Massot-Tarrús A, White K, Mirsattari SM. Comparing the Wada test and functional MRI for the presurgical evaluation of memory in temporal lobe epilepsy. *Curr Neurol Neurosci Rep*. 2019;19(6):31.

McDougall CG, Spetzler RF, Zabramski JM, et al. The Barrow Ruptured Aneurysm trial. *J Neurosurg*. 2012;116(1):135-144.

Molyneux A, Kerr R, Stratton I, et al. International Subarachnoid Aneurysm Trial (ISAT) of neurosurgical clipping versus endovascular coiling in 2143 patients with ruptured intracranial aneurysms: a randomised trial. *Lancet*. 2002;360(9342):1267-1274.

Morris P. *Practical Neuroangiography*. 2nd ed. Philadelphia, PA: Lippincott Williams & Wilkins; 2007.

Muskens IS, Senders JT, Dasenbrock HH, Smith TR, Broekman ML. The Woven EndoBridge device for treatment of intracranial aneurysms: a systematic review. *World Neurosurg*. 2017;98:809.e1-817.e1.

National Institute of Neurological Disorders and Stroke rt-PA Stroke Study Group. Tissue plasminogen activator for acute ischemic stroke. *N Engl J Med*. 1995;333(24):1581-1587.

Nicholson P, Brinjikji W, Radovanovic I, et al. Venous sinus stenting for idiopathic intracranial hypertension: a systematic review and meta-analysis. *J Neurointerv Surg*. 2019;11(4):380-385.

Obusez EC, Hui F, Hajj-Ali RA, et al. High-resolution MRI vessel wall imaging: spatial and temporal patterns of reversible cerebral vasoconstriction syndrome and central nervous system vasculitis. *AJNR Am J Neuroradiol*. 2014;35(8):1527-1532.

Osborn A. *Introduction to Cerebral Angiography*. Philadelphia, PA: Lippincott Williams & Wilkins; 1980.

Peschillo S, Miscusi M, Missori P. Endovascular superselective treatment of brain tumors: a new endovascular era? A quick review. *J Neurointerv Surg*. 2015;7(3):222-224.

Pierot L, Gubucz I, Buhk JH, et al. Safety and efficacy of aneurysm treatment with the web: results of the WEBCAST 2 study. *AJNR Am J Neuroradiol*. 2017;38(6):1151-1155.

Puffer RC, Mustafa W, Lanzino G. Venous sinus stenting for idiopathic intracranial hypertension: a review of the literature. *J Neurointerv Surg*. 2013;5(5):483-486.

Qureshi AI, Georgiadis AL. *Textbook of Interventional Neurology*. Cambridge, United Kingdom: Cambridge University Press; 2011.

Rajah G, Narayanan S, Rangel-Castilla L. Update on flow diverters for the endovascular management of cerebral aneurysms. *Neurosurg Focus*. 2017;42(6):E2.

Rasuli P, Hammond DI. Metformin and contrast media: where is the conflict? *Can Assoc Radiol J*. 1998;49(3):161-166.

Rocha EA, Topcuoglu MA, Silva GS, Singhal AB. $RCVS_2$ score and diagnostic approach for reversible cerebral vasoconstriction syndrome. *Neurology*. 2019;92(7):e639-e647.

Roffi M, Patrono C, Collet JP, et al. 2015 ESC Guidelines for the management of acute coronary syndromes in patients presenting without persistent ST-segment elevation: Task Force for the Management of Acute Coronary Syndromes in Patients Presenting without Persistent ST-Segment Elevation of the European Society of Cardiology (ESC). *Eur Heart J*. 2016;37(3):267-315.

Rothwell PM, Eliasziw M, Gutnikov SA, et al. Analysis of pooled data from the randomised controlled trials of endarterectomy for symptomatic carotid stenosis. *Lancet*. 2003;361(9352):107-116.

Salik AE, Selcuk HH, Zalov H, Kilinc F, Cirak M, Kara B. Medium-term results of undersized angioplasty and stenting for symptomatic high-grade intracranial atherosclerotic stenosis with Enterprise. *Interv Neuroradiol*. 2019;25(5):484-490

Santos-Ditto RA, Santos-Franco JA, Pinos-Gavilanes MW, Mora-Benítez H, Saavedra T, Martínez-Gonzáles V. Management of chronic subdural hematoma with twist-drill craniostomy. Report of 213 patients [in Spanish]. *Gac Med Mex*. 2007;143(3):203-208.

Shao B, Wang J, Chen Y, et al. Clipping versus coiling for ruptured intracranial aneurysms: a meta-analysis of randomized controlled trials. *World Neurosurg*. 2019;127:e353-e365.

Sharma J, Nanda A, Jung RS, Mehta S, Pooria J, Hsu DP. Risk of contrast-induced nephropathy in patients undergoing endovascular treatment of acute ischemic stroke. *J Neurointerv Surg*. 2013;5(6):543-545.

Slaby J. Groin complications during neuroendovascular procedures. In: Khatri R, Rodriguez GJ, Raymond J, Qureshi AI, eds. *Complications of Neuroendovascular Procedures and Bailout Techniques*. Cambridge, United Kingdom: Cambridge University Press; 2016:1-9.

Smith WS, Furlan AJ. Brief history of endovascular acute ischemic stroke treatment. *Stroke*. 2016;47(2):e23-e26.

Snelling BM, Sur S, Shah SS, et al. Transradial cerebral angiography: techniques and outcomes. *J Neurointerv Surg*. 2018;10(9):874-881.

Solomon RA, Connolly ES Jr. Arteriovenous malformations of the brain. *N Engl J Med*. 2017;377(5):498.

Spetzler RF, Martin NA. A proposed grading system for arteriovenous malformations. *J Neurosurg*. 1986;65(4):476-483.

Spiotta AM, Derdeyn CP, Tateshima S, et al. Results of the ANSWER trial using the PulseRider for the treatment of broad-necked, bifurcation aneurysms. *Neurosurgery*. 2017;81(1):56-65.

Stapf C, Mast H, Sciacca RR, et al. Predictors of hemorrhage in patients with untreated brain arteriovenous malformation. *Neurology*. 2006;66(9):1350-1355.

Sugiu K, Hishikawa T, Murai S, et al. Treatment outcome of intracranial tumor embolization in Japan: Japanese Registry of NeuroEndovascular Therapy 3 (JR-NET3). *Neurol Med Chir (Tokyo)*. 2019;59(2):41-47.

Texakalidis P, Chaitidis N, Giannopoulos S, et al. Carotid revascularization in older adults: a systematic review and meta-analysis. *World Neurosurg*. 2019;126:656.e1-663.e1.

Texakalidis P, Giannopoulos S, Karasavvidis T, Rangel-Castilla L, Rivet DJ, Reavey-Cantwell J. Mechanical thrombectomy in acute ischemic stroke: a meta-analysis of stent retrievers vs direct aspiration vs a combined approach. *Neurosurgery*. 2020;86(4):464-477.

Thompson BG, Brown RD Jr, Amin-Hanjani S, et al. Guidelines for the management of patients with unruptured intracranial aneurysms: a guideline for healthcare professionals from the American Heart Association/American Stroke Association. *Stroke*. 2015;46(8):2368-2400.

Valgimigli M, Gagnor A, Calabró P, et al. Radial versus femoral access in patients with acute coronary syndromes undergoing invasive management: a randomised multicentre trial. *Lancet*. 2015;385(9986):2465-2476.

van Rooij WJ, Peluso JP, Bechan RS, Sluzewski M. WEB treatment of ruptured intracranial aneurysms. *AJNR Am J Neuroradiol*. 2016;37(9):1679-1683.

Wakhloo AK, Lylyk P, de Vries J, et al. Surpass flow diverter in the treatment of intracranial aneurysms: a prospective multicenter study. *AJNR Am J Neuroradiol*. 2015;36(1):98-107.

Wang F, Chen X, Wang Y, et al. Stent-assisted coiling and balloon-assisted coiling in the management of intracranial aneurysms: a systematic review & meta-analysis. *J Neurol Sci*. 2016;364:160-166.

Waqas M, Vakharia K, Weimer PV, Hashmi E, Davies JM, Siddiqui AH. Safety and effectiveness of embolization for chronic subdural hematoma: systematic review and case series. *World Neurosurg*. 2019;126:228-236.

Waters MF, Hoh BL, Lynn MJ, et al. Factors associated with recurrent ischemic stroke in the medical group of the SAMMPRIS trial. *JAMA Neurol*. 2016;73(3):308-315.

Willinsky RA, Taylor SM, TerBrugge K, Farb RI, Tomlinson G, Montanera W. Neurologic complications of cerebral angiography: prospective analysis of 2,899 procedures and review of the literature. *Radiology*. 2003;227(2):522-528.

Xu K, Ji T, Li C, Yu J. Current status of endovascular treatment for dural arteriovenous fistulae in the anterior cranial fossa: a systematic literature review. *Int J Med Sci*. 2019;16(2):203-211.

Yang Q, Tong X, Schieb L, et al. Vital signs: recent trends in stroke death rates—United States, 2000-2015. *MMWR Morb Mortal Wkly Rep*. 2017;66(35):933-939.

You W, Zhu Y, Wang Y, et al. Prevalence of and risk factors for recurrence of chronic subdural hematoma. *Acta Neurochir (Wien)*. 2018;160(5):893-899.

Zaidat OO, Fitzsimmons BF, Woodward BK, et al. Effect of a balloon-expandable intracranial stent vs medical therapy on risk of stroke in patients with symptomatic intracranial stenosis: the VISSIT randomized clinical trial. *JAMA*. 2015;313(12):1240-1248.

26 Electroencephalography and Evoked Potentials

Nicolas Gaspard and Emily J. Gilmore

KEY POINTS

1. Electroencephalography (EEG) is a widely used tool that allows for the functional assessment of the central nervous system integrity.
2. EEG is the single most important ancillary test for the diagnosis of epilepsy and the characterization of patient's spells.
3. EEG identifies which patients with acute confusion or obtundation suffer from nonconvulsive seizures and provides prognostic value after traumatic and anoxic brain injuries.
4. Evoked potentials are an extension of the neurologic examination by providing objective confirmation of a lesion that may have been suggested by ambiguous or subtle signs or symptoms.
5. Magnetoencephalography, as a complement to EEG, noninvasively localizes epileptic foci in patients with drug-refractory epilepsy and presurgical functional mapping of eloquent cortical areas.

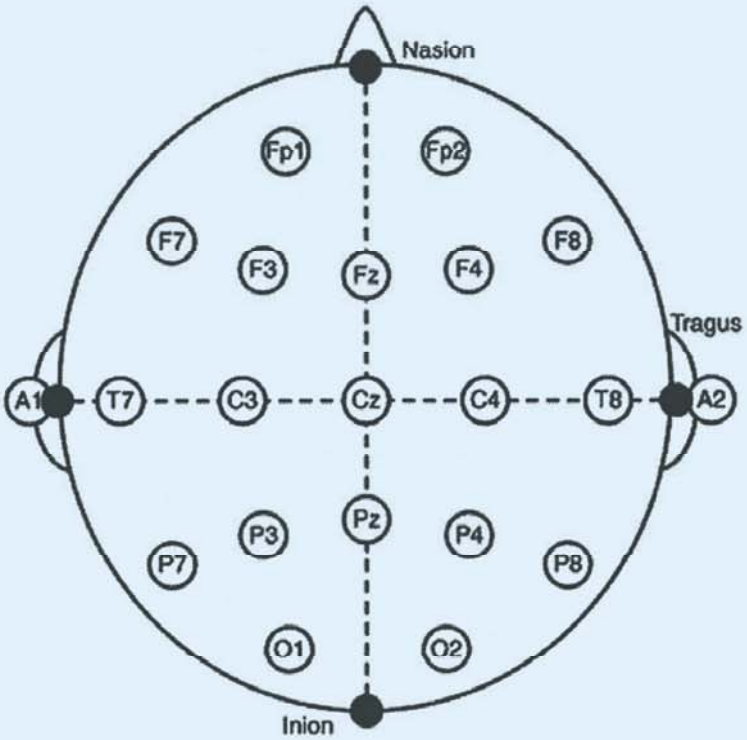

FIGURE 26.1 The International 10-20 system. The International 10-20 system is a conventional method used to place scalp electrodes for electroencephalography recordings. Electrodes bear labels referring to their anatomic locations in relationship to cortical areas (T for temporal, Fp for frontopolar, F for frontal, C for central, P for parietal, and O for occipital). Even and odd numbers refer to right and left hemispheric locations, respectively, whereas Z is used to denote midline electrodes. Inter-electrode distances are calculated as 10% or 20% of the total anterior-posterior or right-left distance of the skull along specific lines *(dotted lines)*. These lines are drawn between anatomic landmarks, such as the nasion, the inion, and the tragus. Ear electrodes (A1 and A2) are located on the earlobes or behind the ears on the mastoid bones. Additional electrodes are usually placed to record eye movements (electrooculogram) and electrocardiogram.

ELECTROENCEPHALOGRAPHY

Introduction

Electroencephalography (EEG), evoked potentials (EPs), and magnetoencephalography (MEG) measure the electromagnetic activity generated by neural structures. They allow for the functional assessment of the central nervous system and are often complimentary to imaging studies. Electrophysiologic studies are especially important to the differential diagnosis when neurologic disorders are unaccompanied by detectable alterations in brain morphology. This chapter is an overview of the current capabilities and limitations of these techniques in clinical practice. There are numerous published guidelines, many of which are publically available and beyond the scope of this chapter. See references for further details.

Normal Electroencephalography

The EEG measures electrical potentials resulting from the summation of the postsynaptic activity of cortical neurons. Although generated by cortical cells, these potentials are influenced by ascending projections from subcortical structures such in the thalamus and upper brainstem. Most commonly, the EEG is recorded with electrodes placed on the scalp, following a conventional method based on anatomic landmark called the *International 10-20 system* (Fig. 26.1). The scalp EEG presents a very low resolution view of electrical activity of the brain that favors contributions from the lateral convexities due to attenuation and blurring from overlying tissue layers.

The EEG varies greatly with the state of arousal. The main feature of the normal EEG during wakefulness in adults is the posterior dominant rhythm, also called *alpha rhythm*. This rhythm consists in an 8 to 13 cycle per second (cps) sinusoidal activity that is best observed over the parietal and occipital regions bilaterally (Fig. 26.2). In a relaxed individual, the alpha rhythm manifests with eye closure and attenuates with alerting or eye opening. Faster activity, in the 14 to 30 cps range, called *beta activity*, can be observed in health individuals during wakefulness, usually

FIGURE 26.2 Normal electroencephalography in an awake 37-year-old man. The posterior dominant rhythm *(dashed lines)* is in the alpha frequency range, is symmetrical, and attenuates with eye opening.

in the frontocentral regions. It can also be seen with a broader distribution during drowsiness (Fig. 26.3) and is enhanced in individuals taking benzodiazepines or barbiturates.

EEG interpretation and reporting should attempt to follow well-defined terminology.

Sleep is divided in four stages on the basis of EEG, eye movements, and muscle activity. Stage N1, or drowsiness, is characterized by the disappearance of the posterior dominant rhythm, which is replaced by low-voltage slower activity. Sharp waves maximal at the vertex, called *vertex sharp waves*, also occur. Stage N2 is defined not only by the presence of sleep spindles (12-14 cps sinusoidal activity that is maximal over the central regions) but also features vertex sharp waves, K complexes (large amplitude diphasic slow waves usually brought up by auditory stimulation and often occurring in close temporal proximity to a spindle [Fig. 26.4]), and positive occipital sharp transients of sleep (surface-positive check mark–like waveforms occurring singly or in trains in the occipital regions). Slow waves of sleep (0.5-1 cps) progressively occupy most of the recording during stage N3. During rapid eye movement (REM) sleep, the EEG resembles the EEG of drowsiness, but REM and general atonia are present. In adults, REM occurs about 90 minutes after sleep onset and thus is not usually seen on routine studies.

EEG activity undergoes major changes with age. In neonates, these changes occur on a nearly daily basis, and knowledge of the conceptional age is required for proper interpretation. Sleep-wake cycles can be identified on the basis of characteristic EEG patterns that are beyond the scope of this chapter. A posterior dominant rhythm that is reactive to eye opening becomes visible in most children by 4 months of age. With increasing age, the frequency of the posterior dominant rhythm progressively increases, reaching 6 cps in most children at 1 year and 8 cps in most children at 4 years. Sleep spindles appear at 2 months but do not become synchronous in most children until the age of 2 years. Normal delta activity persists during wakefulness through childhood, adolescence, and early adulthood but becomes progressively less prominent and more intermittent and restricted to the posterior regions (*posterior slow wave of youth*).

Abnormal Electroencephalography

Epilepsy

The EEG is the most single important ancillary test for the diagnosis of epilepsy. Epileptiform discharges include spikes (<70 ms), polyspikes, sharp waves (70-200 ms), spike-and-slow-wave complexes, and sharp-and-slow-wave complexes. Other nonspecific findings in epilepsy include focal polymorphic slowing and intermittent rhythmic delta activity.

Not only can the presence of epileptiform discharges (EDs) confirm a clinical suspicion of epilepsy, but the localization and type of discharge also helps to identify the diagnosis of a specific syndrome (Table 26.1). A proper syndromic classification is paramount to ensure adequate management because different syndromes may call for different treatments. It should be noted that EDs may occasionally be absent in a minority of patients who have epilepsy. The first routine EEG obtained after an inaugural seizure demonstrates EDs in approximately 30% to 50% of cases. This proportion increases to a maximum of 80% to 90% after the third routine EEG, and subsequent EEGs do not raise this proportion further. Longer recordings, sleep recordings, and so-called activation procedures, such as hyperventilation, intermittent photic stimulation, and sleep deprivation can be performed to increase the sensitivity of the EEG.

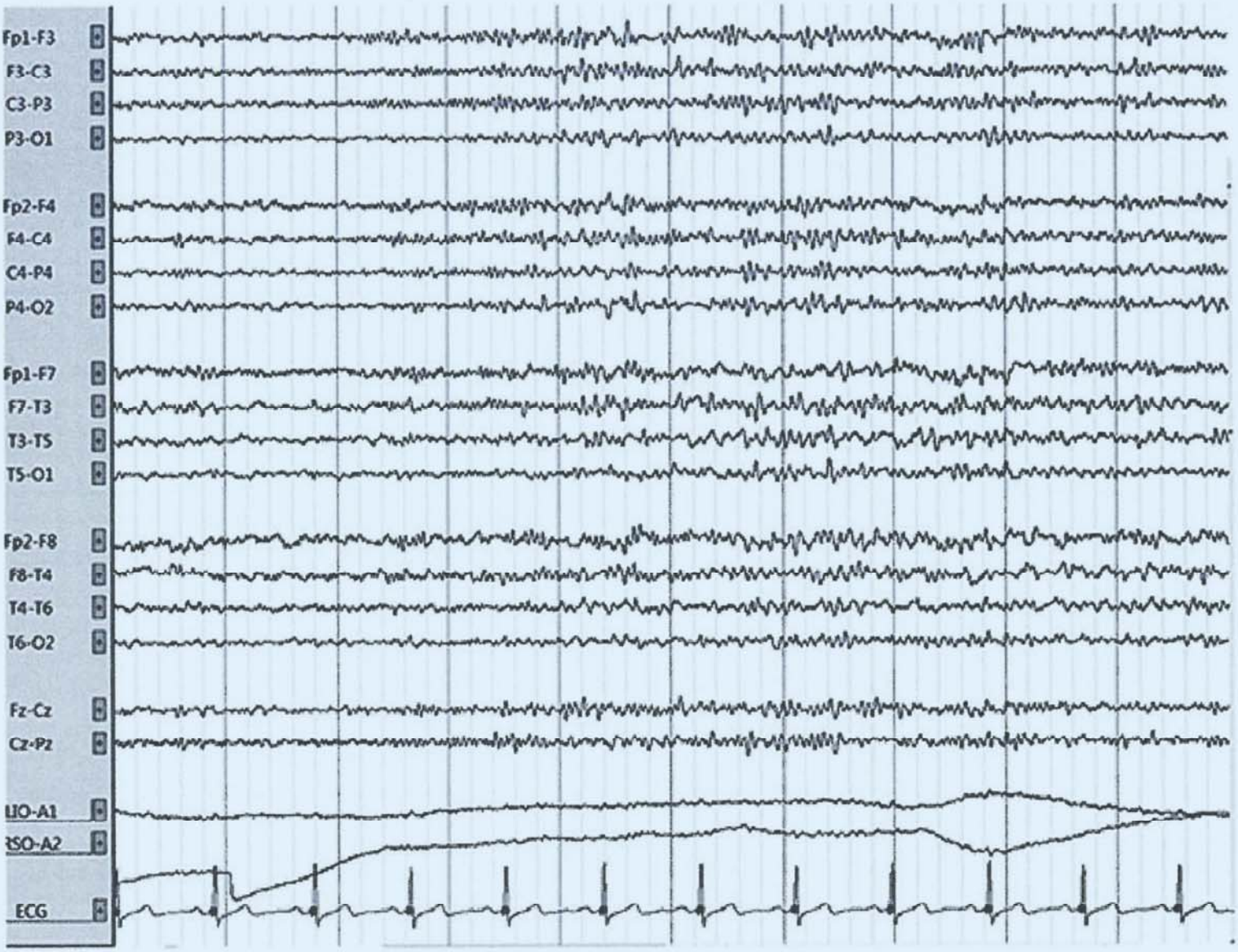

FIGURE 26.3 Normal electroencephalography in a 42-year-old man during drowsiness. Beta activity with a broad distribution.

Conversely, EDs are seen in 1% to 2% of EEGs of individuals without a history of epilepsy. This proportion is higher in children and in siblings of patients with epilepsy.

In addition to diagnosis, EEG results also help with the management of epilepsy. A finding of interictal EDs after a single seizure increases the likelihood of seizure recurrence and therefore influences the decision about whether to treat with antiepileptic drugs. Similarly, the presence of interictal EDs increases the likelihood of seizure recurrence when consideration is being given to discontinuing antiepileptic drugs after a period of seizure control. Finally, in the setting of convulsive status epilepticus, EEG can be extremely helpful in determining whether individuals with prolonged postictal cognitive impairment (usually >30 min) are experiencing electrographic seizures (up to 50%) or nonconvulsive status epilepticus (up to 14%).

Finally, so-called benign epileptiform variants should not be confused for *bona fide* EDs. These variants are physiologic activity with a somewhat sharp morphology that may resemble spikes or sharp waves but can be readily dismissed after careful inspection. This distinction is important because it is not uncommon to encounter patients who carry a diagnosis of medically refractory epilepsy but turn out to have nonepileptic spells and in whom a normal variant has been mislabeled as an ED.

Focal Brain Lesion or Dysfunction

With the advances of brain imaging, the usefulness of EEG for the diagnosis of focal brain injury has significantly decreased. However, EEG remains the only way to assess the epileptogenic potential of a cerebral lesion. The hallmark of focal brain injury is the presence of localized nonrhythmic delta (1-4 cps) or theta (5-7 cps) activity, referred to as *focal polymorphic slowing* (**Fig. 26.5**). As a rule of thumb, delta activity is associated with more destructive lesions than theta activity. *Focal attenuation of fast activity*, the absence of normal alpha or beta (14-30 cps) activity over a region of the scalp indicates focal cortical injury. Both focal slowing and attenuation can be seen in the absence of a focal lesion (**Fig. 26.6**). In this case, they represent the presence of focal cerebral dysfunction as a result of a postictal state or, rarely, migraine. *Lateralized periodic discharges* (LPDs; also referred to as *periodic lateralized epileptiform discharges*) usually indicate the presence of an acute destructive lesion with a high epileptogenic potential, usually stroke, neoplasm, or encephalitis because up to 85% of patients will experience

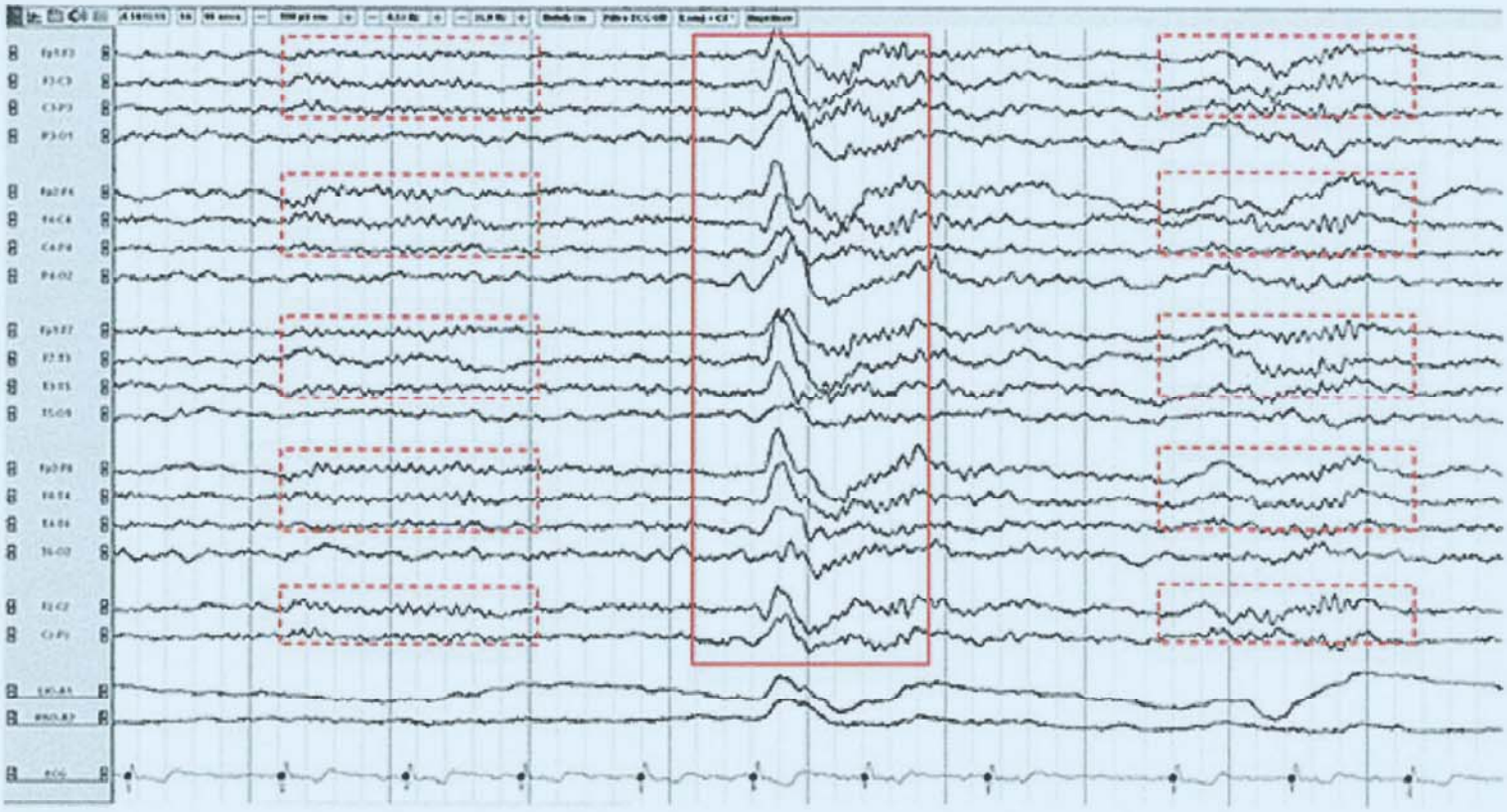

FIGURE 26.4 Normal electroencephalography in a 25-year-old man during stage N2 sleep. Sleep spindles *(dashed boxes)* and K complex *(solid box)*.

seizures during the acute phase of their illness (Fig. 26.7). They can occasionally be seen in the aftermath of a seizure in patients with chronic epilepsy or with a remote brain injury. Rarely, LPDs are associated with clinical manifestations (time-locked contralateral myoclonus, visual hallucinations, etc.).

Diffuse Brain Dysfunction or Injury

Toxic, metabolic, diffuse hypoxic-ischemic, and other global insults to the brain result in generalized nonspecific EEG changes. Mild encephalopathy is characterized by slowing of the posterior dominant rhythm and a generalized excess of polymorphic theta activity. With more pronounced brain dysfunction, the posterior dominant rhythm is lost and replaced by a mixture of theta and delta activity. These changes are described as *generalized polymorphic slowing*. In more severe cases, cerebral activity consists mostly of delta activity, which may become monotonous. At this point, *reactivity to external stimulation* (noise, noxious stimuli) may be lost. In the most severe forms of encephalopathy, there is attenuation (<20 μV) or even suppression (<2 μV) of all cerebral activity. A *suppression-burst pattern* in which periods of suppression alternate with bursts of high amplitude activity can also be seen in severe cases (Fig. 26.8). *Generalized rhythmic delta activity*

TABLE 26.1 Electroencephalography (EEG) Features of Major Epileptic Syndromes

Syndrome	EEG Features
Ohtahara syndrome	Suppression-burst pattern during sleep and wakefulness
Early myoclonic encephalopathy	Suppression-burst pattern during sleep
West syndrome	Hypsarrhythmia (highly disorganized background with arrhythmic and asynchronous high-amplitude slow waves and multifocal spikes)
Lennox-Gastaut syndrome	Slow (<2.5 cps) generalized spike-and-wave complexes Generalized paroxysmal fast activity Slowed background
Benign idiopathic focal epilepsy of childhood	Focal (often bilateral independent or multifocal) sharp waves or spikes Normal background
Childhood absence epilepsy	≥3 cps generalized spike-and-wave complexes Normal background
Juvenile myoclonic epilepsy	≥3 cps (often up to 6 cps) generalized spike-and-wave and polyspike-and-wave complexes Normal background
Localization-related epilepsy	Focal spikes, sharp waves, or spike-and-wave complexes Sometimes focal polymorphic or rhythmic slow activity

FIGURE 26.5 Diffuse slowing in a 72-year-old woman with sepsis. The posterior dominant rhythm is not visible. The background consists of admixed theta and delta activity.

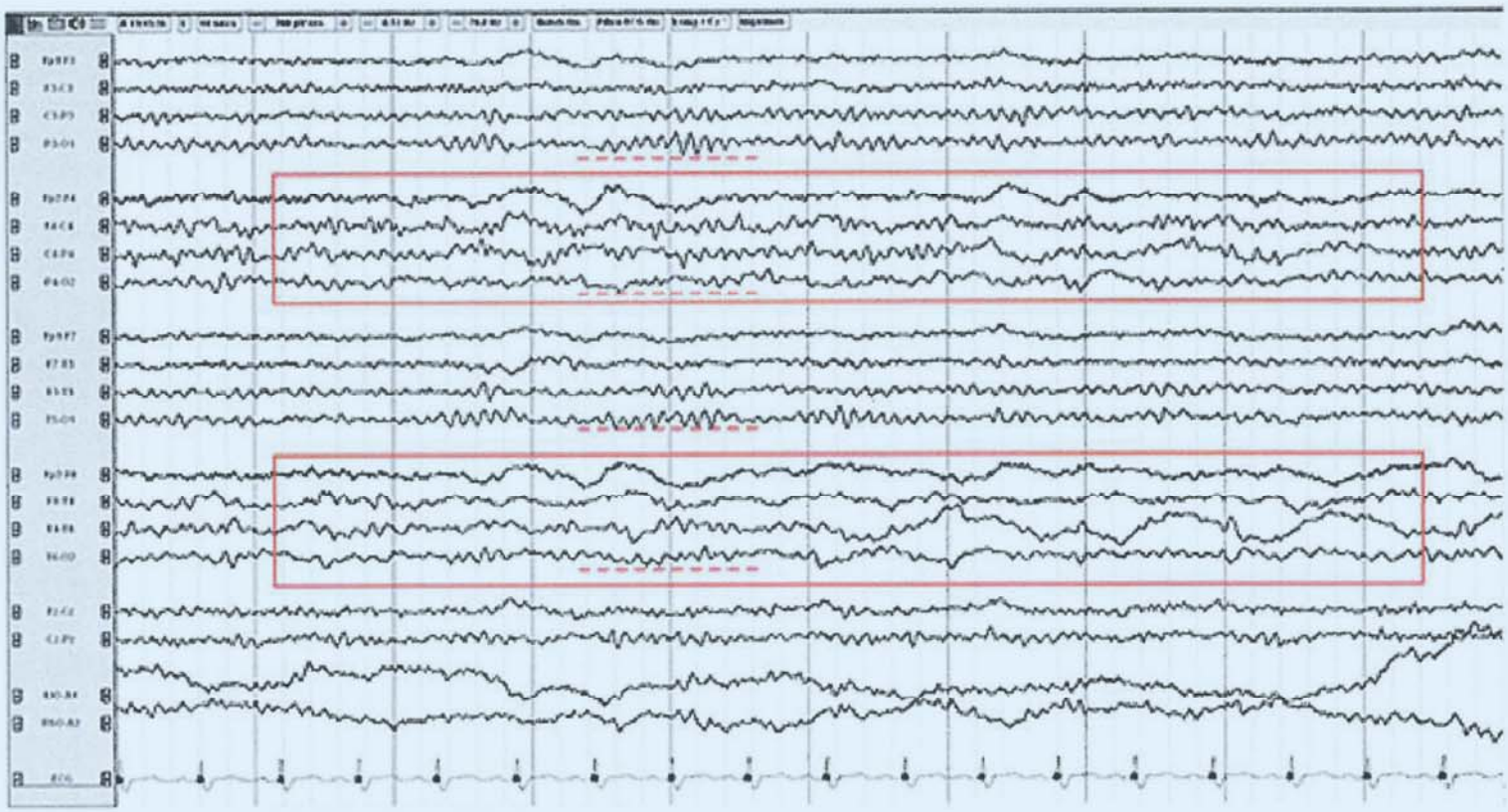

FIGURE 26.6 Focal slow (polymorphic delta) activity *(boxes)* with attenuation of the posterior dominant rhythm *(dashed lines)* over the right hemisphere in a 64-year-old woman with a glioblastoma multiforme.

FIGURE 26.7 Left hemispheric lateralized periodic discharges *(boxes)* at approximately one per second in a 52-year-old man with herpes encephalitis.

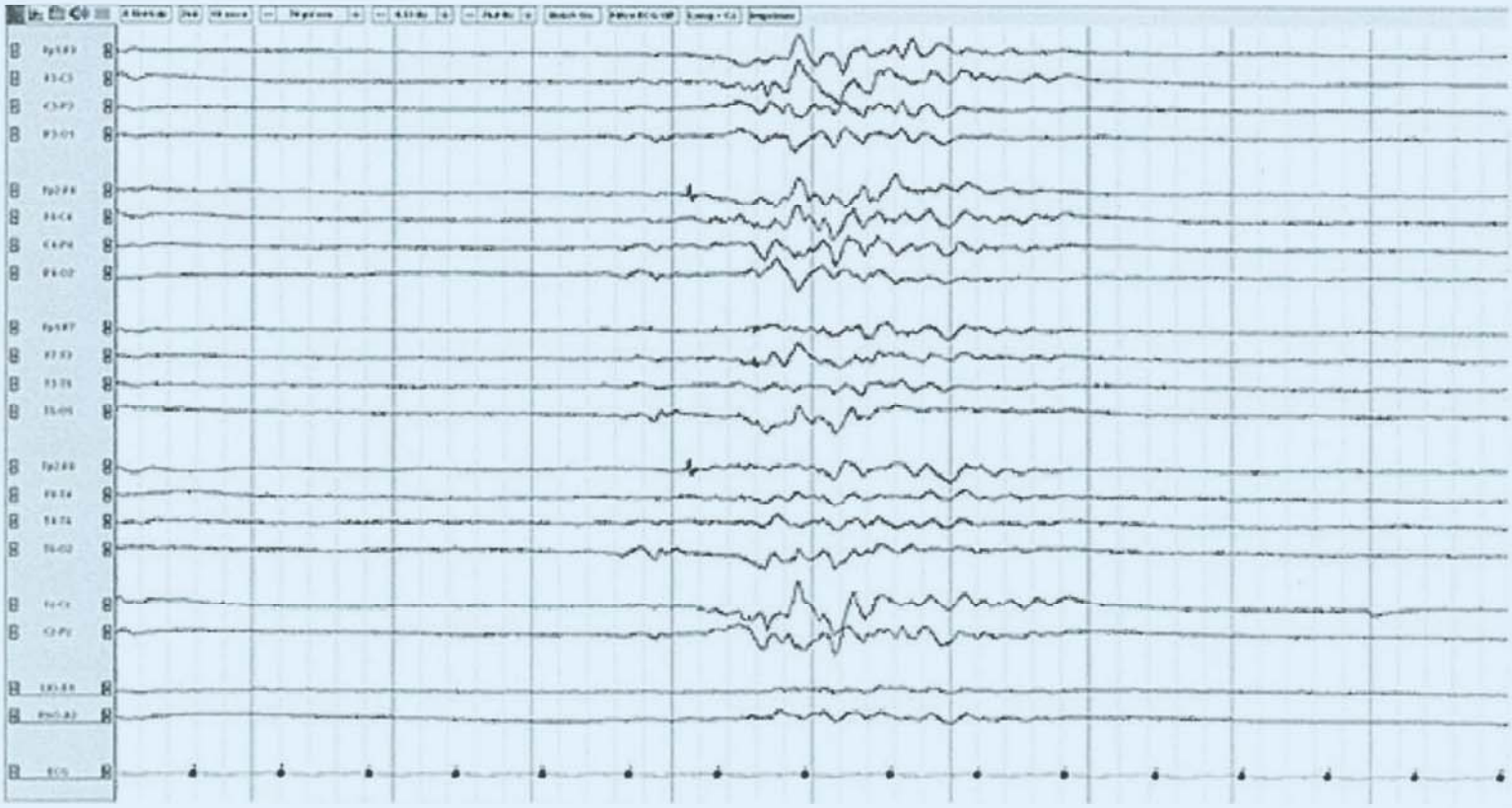

FIGURE 26.8 Suppression-burst pattern following cardiac arrest in a 54-year-old man. Periods of suppression are interrupted by bursts of sharply contoured delta and theta activity.

FIGURE 26.9 Generalized periodic discharges with triphasic morphology (triphasic waves) at 1.5 per second in a 35-year-old man with acute liver failure. Each discharge consists of three phases: (1) a small-amplitude negative sharp wave followed by (2) prominent positive sharp wave and (3) a negative slow wave.

(often frontal and intermittent) is another nonspecific finding of encephalopathy, although it can be seen with lesions in the frontal lobes. *Generalized periodic discharges* (GPDs) are repetitive waveforms that occur either at periodic or quasiperiodic intervals of 0.5 to 3 cps. They can be encountered in any type of encephalopathy, at a moderate to severe stage, and are associated with an increased risk of seizures. *Triphasic waves* are a subtype of GPDs with a typical morphology (**Fig. 26.9**). They were initially thought to be specific of hepatic encephalopathy. They can in fact be seen in most metabolic or toxic encephalopathies and even during or after status epilepticus. A major role of the EEG in patients with acute confusion or obtundation is to identify those who suffer from nonconvulsive status epilepticus.

Neurodegenerative disorders affecting the cortex and subcortical structures can be associated with similar nonspecific findings, albeit most often mild (ie, slowing of the posterior dominant rhythm, diffuse excess of theta activity, and frontal and intermittent rhythmic delta activity).

Occasionally, the EEG discloses patterns that point toward a specific diagnosis. In Creutzfeldt-Jakob disease, severe disruption of the background and periodic discharges (LPDs or more commonly GPDs) occur, always within 3 months after the onset. Huntington disease is associated with a progressive attenuation of cerebral activity. At least 50% of patients with anti–*N*-methyl-D-aspartate receptor encephalitis show a typical pattern of rhythmic delta activity overridden by beta activity, which has been termed *extreme delta brush* due to its resemblance to normal delta brushes of neonates.

Long-term Monitoring

Epilepsy Monitoring Unit

Long-term EEG monitoring, simultaneously with audio and video recording, can be performed in dedicated epilepsy monitoring units to not only capture interictal epileptiform activity but also characterize patients' typical spells. These recordings are useful to clarify the nature of spells of uncertain etiology and assist in the determination of seizure type and epilepsy syndrome (**Figs. 26.10** and **26.11**). The EEG shows typical changes in all patients during generalized or focal impaired awareness seizures (previously referred to as *complex partial seizures*) but can remain normal during focal awareness seizures (previously referred to as *simple partial seizures*). In patients with medically refractory epilepsy, long-term monitoring provides invaluable electroclinical correlations that will contribute to the assessment of potential candidates for resective surgery. If the results of monitoring with scalp EEG and other ancillary tests (magnetic resonance imaging, positron emission tomography scan with ^{18}F-fluorodeoxyglucose, etc.) are inconclusive, patients may benefit from invasive EEG, either with cortical electrodes (electrocorticography [ECoG]) or with depth electrodes implanted stereotactically (stereo-EEG). These invasive studies offer better spatial resolution and can identify a seizure focus that was not detected or well circumscribed with scalp EEG. Invasive recordings also allow the investigation of EEG activities in frequency bands that are outside the conventional bands (0.5-30 cps), which can be reliably studied with scalp EEG. These activities include infraslow activity

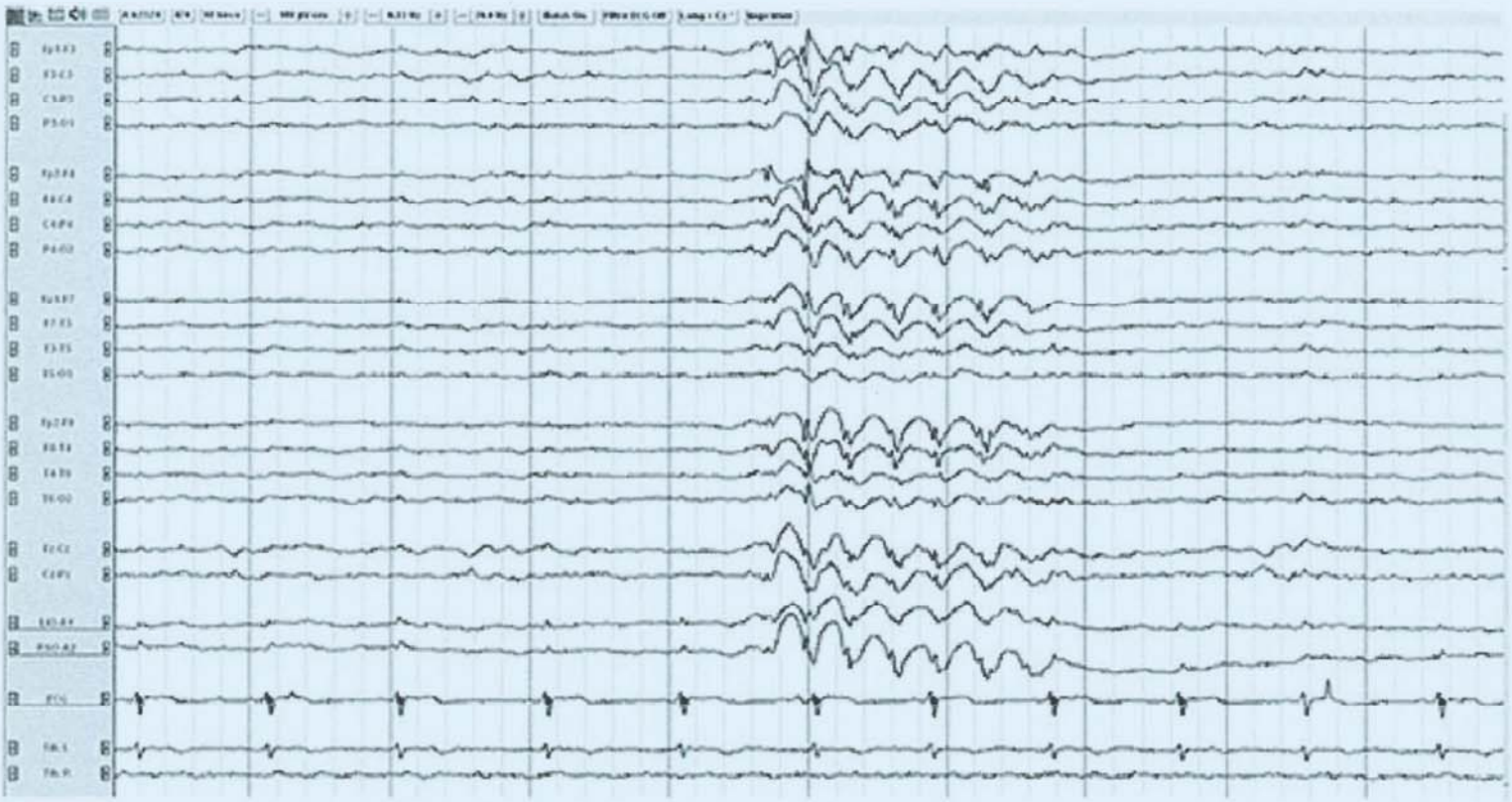

FIGURE 26.10 Three-cycle-per-second generalized spike-and-wave complexes in a 6-year-old girl with childhood absence epilepsy.

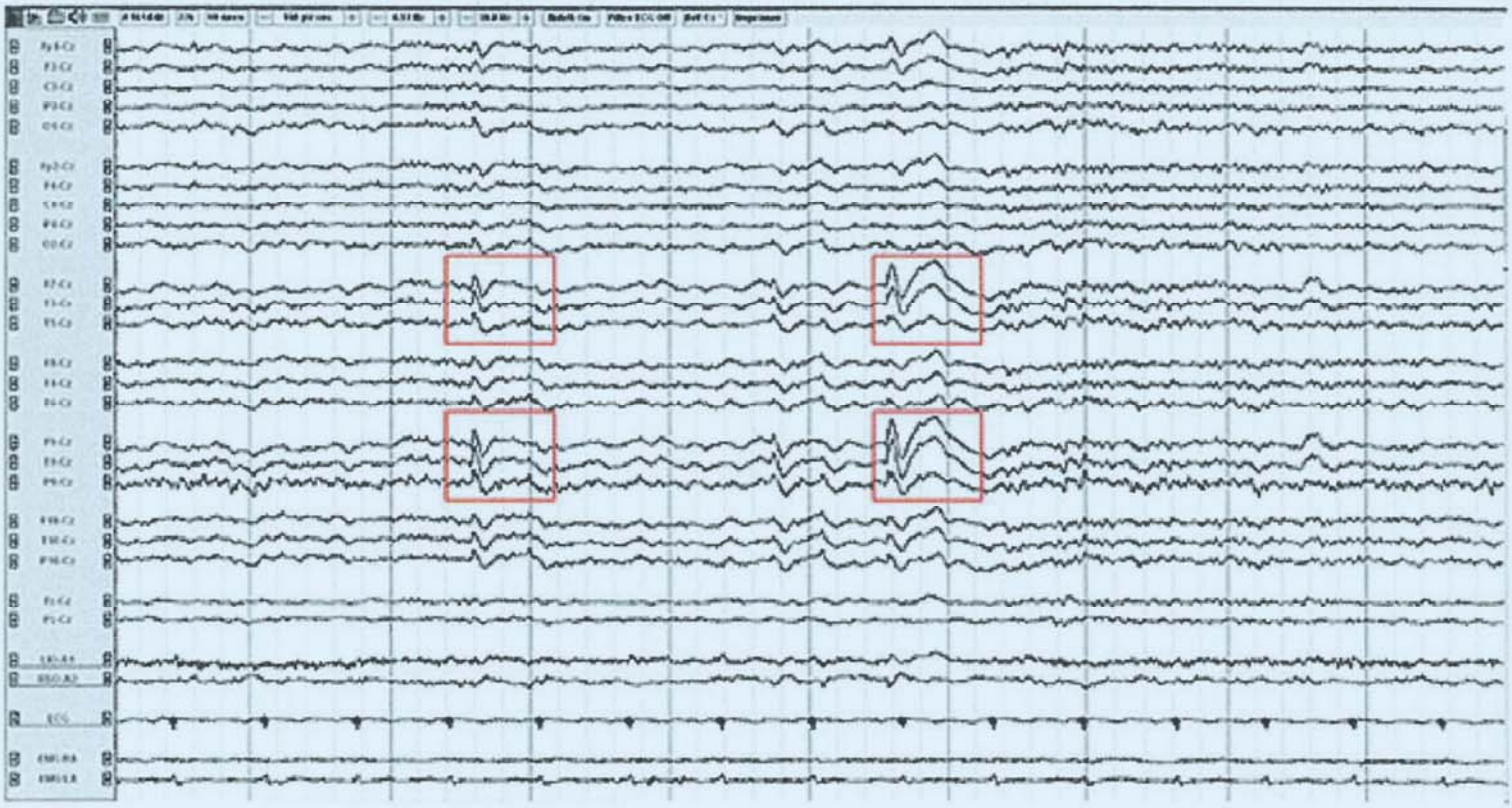

FIGURE 26.11 Left temporal spike-and-wave discharges in a 32-year-old man with mesial temporal lobe sclerosis and epilepsy. The discharges *(boxes)* are maximal over the left anterior inferior temporal region (F7, T3, F9, and T9).

(<0.5 cps) and high-frequency oscillations (ripples [80-250 cps], fast ripples [250-500 cps]; and very high-frequency oscillations [500-2,000 cps]). Studies in the past decade have shown that both infraslow activity and high-frequency oscillations provide useful information for the localization of the seizure focus. Finally, invasive studies permit the delineation of functional cortical areas through electrical cortical stimulation mapping.

Intraoperative Neuromonitoring

Given the exquisite sensitivity of cortical neurons to ischemia, the EEG can detect reduction in cortical perfusion at an early and reversible stage. This can be advantageously used to monitor for cerebral ischemia secondary to carotid clamping during carotid endarterectomy. EEG monitoring may identify those patients who would benefit from the use of a vascular shunt during the procedure in order to restore adequate perfusion. Conversely, shunts, which have an associated risk of complications, can be avoided in those patients in whom the EEG remains normal. EEG monitoring has also been advocated during cardiac and aortic surgery, but its use in this indication has been limited to selected academic centers.

ECoG can be used during awake neurosurgery to map functional cortical areas and to delineate the critical limits of a resection. Intraoperative ECoG recordings can also be used to identify epileptogenic regions for resection.

Critical Care Electroencephalography Monitoring

Continuous EEG monitoring is increasingly used in the critical care setting LEVEL I.[1] These prolonged recordings are currently indicated to detect and monitor treatment of nonconvulsive seizures, clarify the nature of abnormal motor activity, and monitor brain function during drug-induced coma.

Between 15% and 20% of critically ill patients develop seizures during their acute illness. Half of them will develop status epilepticus. Risk factors include acute brain injury, a chronic seizure disorder, younger age, sepsis, and severe alteration of consciousness (ie, stupor and coma). Up to 90% of these seizures are nonconvulsive and will be missed if EEG monitoring is not performed. There is mounting evidence that nonconvulsive seizures have detrimental metabolic and hemodynamic effect and contribute to secondary brain injury and poorer outcome. A monitoring period of 24 hours is required to detect 90% of these seizures. A longer period is required in comatose patients and in patients with LPDs. A 60-minute EEG will miss half of the patients who have seizures. Episodes of abnormal spontaneous motor activity do not always correspond to seizures. Nonepileptic myoclonus, tremor, clonus, and rigors are frequent among acutely ill patients. Continuous EEG monitoring will help clarify the nonepileptic nature of these episodes and avoid the unnecessary and potentially harmful prescription of antiepileptic drugs. Deep sedation with high-dose barbiturates is sometimes performed to control refractory intracranial hypertension. In this indication, the EEG is used to monitor sedation, with the aim of maintaining a suppression-burst pattern.

EEG abnormalities have prognostic values after traumatic and anoxic brain injury. Malignant patterns of suppression-burst, suppression, and low-voltage unreactive widespread delta activity are almost invariably associated with poor outcome. Other possible applications of EEG monitoring include early detection of delayed cerebral ischemia after aneurysmal subarachnoid hemorrhage.

In addition to seizures, cortical spreading depolarizations are increasingly recognized phenomena in acute brain injury and are associated with outcome, particularly in traumatic brain injury. Animal and human studies have demonstrated that cortical spreading depolarizations contribute to secondary brain injury in traumatic brain injury, expansion of ischemic stroke, and both early brain injury and delayed cerebral ischemia after subarachnoid hemorrhage.

EVOKED POTENTIALS

Introduction

EPs are potentials generated by the nervous system in response to stimuli.

Somatosensory, auditory, and visual pathways can be investigated using simple sensorial stimulation and recording from neural structures, whereas motor pathways are explored by transcranial magnetic stimulation of the motor cortex and recording of muscle response. EPs have a low signal-to-noise ratio, being of much lower amplitude than spontaneous activity, and require the averaging of a large number of responses to be identified.

Clinically, EPs are functional tests, which can be viewed as an extension of the neurologic examination. They can provide objective confirmation of the existence of a lesion that may have been suggested by ambiguous or subtle signs or symptoms. Additionally, they can also reveal dysfunction of sensory pathways that is not clinically apparent. Finally, they have the capacity to localize a suspected lesion.

EPs are composed of a stereotyped sequence of waveforms that are labelled by their polarity (negative [N] or positive [P]) and their peak latency from the time of stimulation (expressed in milliseconds). Dysfunction of sensory or motor pathways due to disease or injury leads to increased waveform latency, whereas complete interruption of conduction or destruction of the neural generators results in the absence of waveforms.

Somatosensory-Evoked Potentials

Somatosensory-evoked potentials (SSEPs) are elicited by light electrical stimulation of peripheral nerves and reflect sequential activation of structures along the afferent sensory pathways, principally the dorsal column lemniscal system. Upon stimulation of the median nerve, the following responses are clinically useful: First, the N9 (Erb's point potential), representing the afferent volley entering the brachial plexus; the N13, generated by postsynaptic activity in the gray matter of the spinal cord; the P14, generated by the caudal medial lemniscus in the lower brainstem; the N18, generated by the rostral brainstem; and, finally, the N20, reflecting the activation of the somatosensory cortex. Similar responses can be recorded upon stimulation of the posterior tibial nerves from which the following responses are clinically useful: First, the lumbar potential (LP)/N22, recorded from the T12 spinal process, represents the afferent volley entering the dorsal roots and dorsal root entry zone; the N34, recorded at the cervical spine, is thought to represent the brainstem or perhaps thalamus; P37/P38, referred to as *the scalp potentials*, reflect activation of the somatosensory cortex (**Fig. 26.12**).

SSEPs are altered by most conditions affecting the somatosensory pathways, including stroke, tumors, traumatic injury, and demyelinating disorders. They are abnormal in 50% to 60% of patients with multiple sclerosis, even in the absence of clinical signs or symptoms.

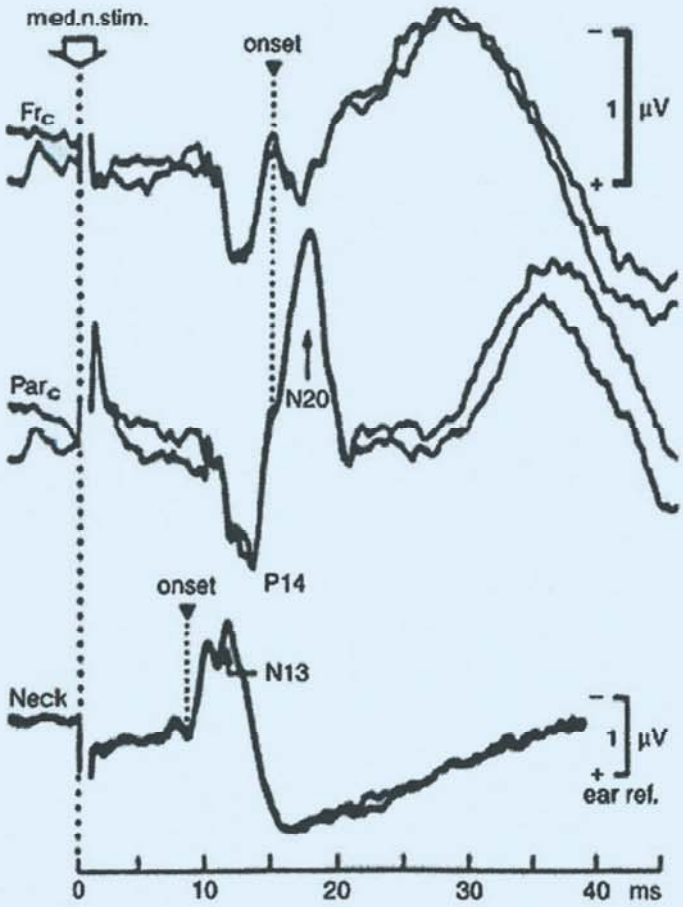

FIGURE 26.12 Technique for obtaining either upper or lower extremity somatosensory-evoked potential (SSEP) and normal SSEPs obtained by stimulation of the median nerve at the wrist. Abbreviations: ear ref, ear reference; Fr_C, frontal contralateral; Par_C, parietal contralateral.

SSEPs are increasingly used for prognostication in comatose patients after anoxic or traumatic brain injury. The absence of N20 after the rewarming period is almost invariably associated with a poor outcome (Fig. 26.13).

SSEPs are also commonly used to monitor the integrity of the spinal cord during high-risk neurosurgical, orthopedic, and vascular interventions. They are also increasingly used to monitor the integrity of the brain function during high-risk cardiovascular surgery because loss of the N20 indicates early ischemia at a reversible stage.

Visual-Evoked Potentials

Visual-evoked potentials (VEPs) are obtained by stimulation with an alternating checkerboard pattern of black and white squares (ie, white squares change to black and vice versa at a regular frequency). This stimulation with pattern reversal produces an occipital positive response with a mean latency of 100 milliseconds (P100). VEPs are performed for each eye individually. Because fibers from the temporal side of the retina decussate at the optic chiasm, an abnormal P100 after stimulation of one eye implies the presence of a prechiasmatic lesion, affecting the retina or the optic nerve on the side of the stimulation. An abnormal P100 upon stimulation of both eyes may be caused either by bilateral prechiasmatic and/or retrochiasmatic lesions. Unilateral retrochiasmatic lesions usually do not significantly alter the P100. Acute optic neuritis is initially accompanied by an attenuation of the P100 (Fig. 26.14). In the postacute phase, although the P100 may return to almost normal amplitude, it is significantly delayed. Abnormal VEPs are found in up to 70% of patients with multiple sclerosis, even in the absence of a history of optic neuritis. These findings are nonspecific and can also be seen in other conditions, including demyelinating disorders (acute disseminated encephalomyelitis, anti–neuromyelitis optica spectrum), ischemic optic neuropathy, compression of the optic nerve, cataracts, glaucoma, toxic and metabolic optic neuropathy, degenerative disorders, and retinal disease. In the setting where a patient reports visual loss, a normal VEP strongly favors a psychogenic disorder (ie, hysteria or malingering).

Brainstem Auditory–Evoked Responses

Brainstem auditory–evoked potentials (BAEPs) consist of five waveforms, labelled I to V, of which waves I, III, and V are the most important from a clinical point of view. The nature of the generators of the responses is largely unclear but it is believed that wave I is generated by the peripheral portion of the acoustic nerve, whereas waves III and V are probably generated in the brainstem by the superior olivary complex and the inferior colliculus, respectively.

BAEPs are abnormal in most cases of tumors of the cerebellopontine angle, such as acoustic neuroma. Abnormalities include delay or absence of all waves after wave I and absence of all waves (Fig. 26.15).

BAEPs are also sensitive to lesions affecting the auditory pathways in the brainstem. They are almost always abnormal in

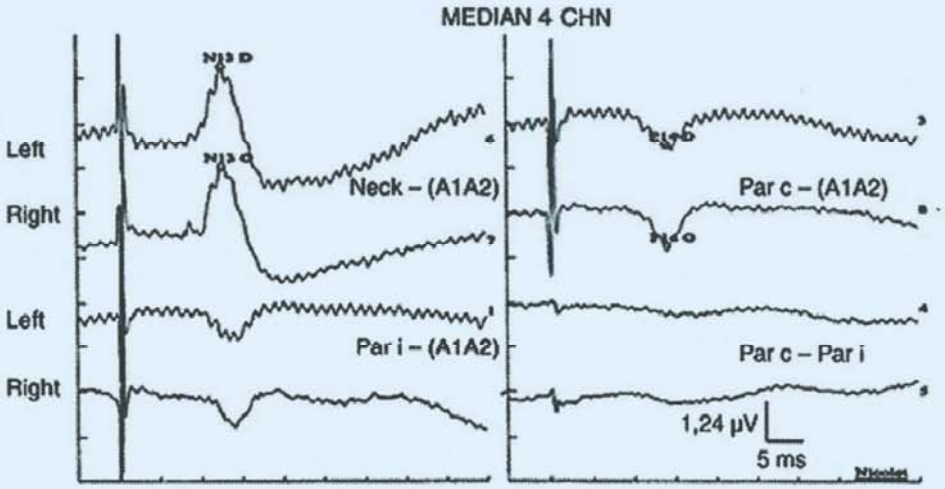

FIGURE 26.13 Somatosensory-evoked potentials obtained by stimulation of the median nerves at the wrist in a patient with postanoxic brain injury. N13 and P14 potentials, generated in the brainstem, are identified. N20 potentials, generated in the cortex, are not identified, indicating a poor prognosis. Abbreviations: CHN, channels; Par_C, parietal contralteral; Parl, parietal ipsilateral. (Courtesy of Nicolas Mavroudakis, MD, PhD.)

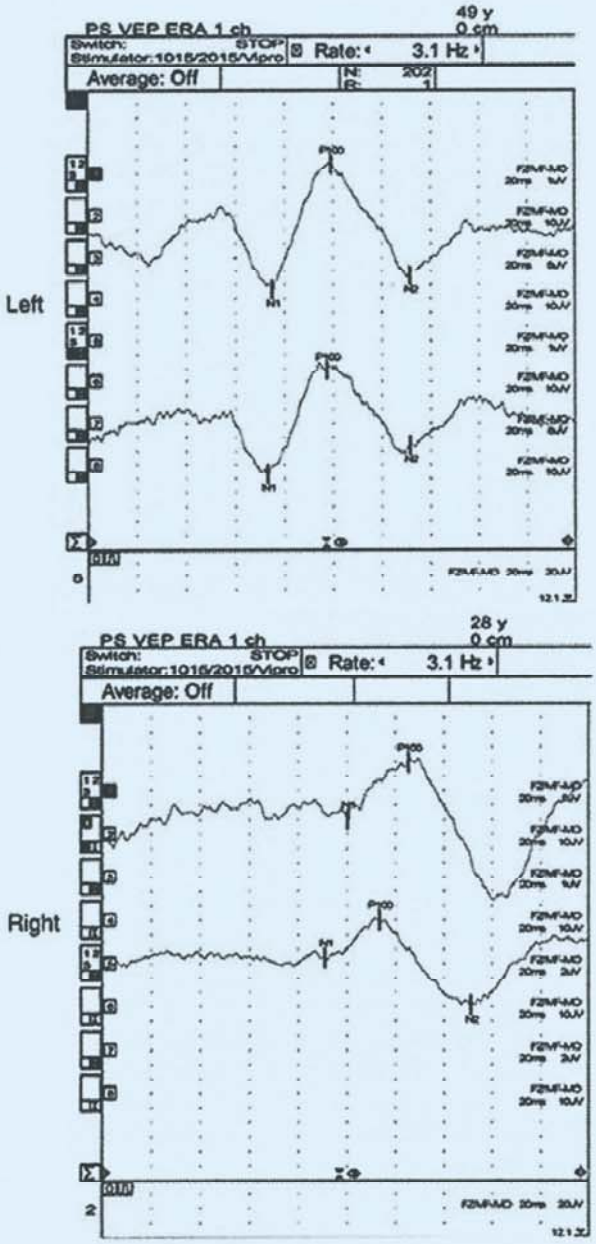

FIGURE 26.14 Visual-evoked potentials in patient with probable multiple sclerosis. The P100 after stimulation of the left eye is normal, whereas there is a significant delay after stimulation of the right eye. (Courtesy of Nicolas Mavroudakis, MD, PhD.)

the case of intrinsic tumors of the brainstem. They are preserved when the auditory pathways are spared because may occur in vascular lesions of the pontine tegmentum causing a locked-in syndrome. BAEPs abnormalities are frequent in patients with multiple sclerosis and in other demyelinating conditions.

In comatose patients, BAEPs are normal when the cause is metabolic or toxic. They are abnormal when the brainstem is directly affected between the midbrain and the lower pons by a primary infratentorial lesion or by herniation due to a supratentorial mass. The absence of all waves subsequent to wave I carries a poor prognosis, whereas the presence of wave V is associated with good outcome. BAEPS are relatively insensitive to sedative drugs, including anesthetic doses of barbiturates. They can be used as a confirmatory test of brain death, even in the presence of doses of barbiturates that induce an isoelectric EEG. Absence of all waves or the sole persistence of wave I indicates brain death.

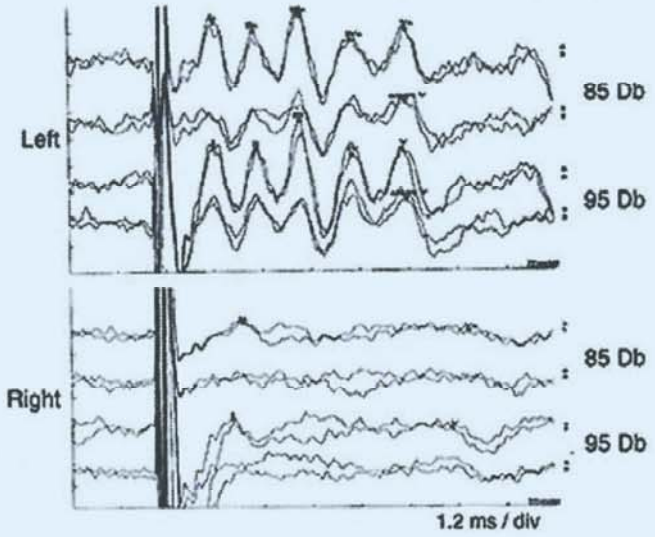

FIGURE 26.15 Brainstem auditory–evoked potentials in a patient with a meningioma in the right pontocerebellar angle. With left stimulation, waves I to V are identified and have a normal latency. With right stimulation, only wave I (generated in the peripheral acoustic nerve) is identified; subsequent waves generated in the brainstem are not visible, indicating impairment of auditory pathways in the right pons and/or midbrain. (Courtesy of Nicolas Mavroudakis, MD, PhD.)

Motor-Evoked Potentials

Motor-evoked potentials assess the integrity of motor pathways. They are elicited by transcranial magnetic stimulation of the primary motor cortex. Muscle compound potentials are recorded and the latency of response can be measured. Stimulation can also be delivered at the spinal cord level allowing for calculation of central conduction time by subtracting the latency after spinal cord stimulation from the latency after cortical stimulation (Fig. 26.16). MEPs are increasingly used in association with SSEPs to monitor spinal cord integrity during surgery.

MAGNETOENCEPHALOGRAPHY

MEG allows the noninvasive measure of magnetic fields generated by the electrical activity of cortical neurons. Magnetoencephalographic recordings rely on the technology of superconducting quantum interference device, which need to be constantly cooled by liquid helium at −270°C (−452°F) in a cryogenic vessel. Because external magnetic noise is several orders of magnitude larger than neuromagnetic fields, a shielded room is required. MEG is usually combined with magnetic resonance imaging volumetric scans to provide accurate localization of the sources of the magnetic fields, a process called *magnetic source imaging*. Contrary to scalp EEG that records activity from radially oriented electric dipoles, MEG records activity from tangential dipoles because magnetic fields are orthogonal to the electric activity by which they are generated. MEG is, thus, able to investigate regions that are poorly accessible to scalp EEG recordings, such as the insula and opercular cortex, and, in general, provides information that is complementary to EEG.

The current clinical applications of MEG are noninvasive localization of epileptic foci in patients with drug-refractory epilepsy and presurgical functional mapping of eloquent cortical areas.

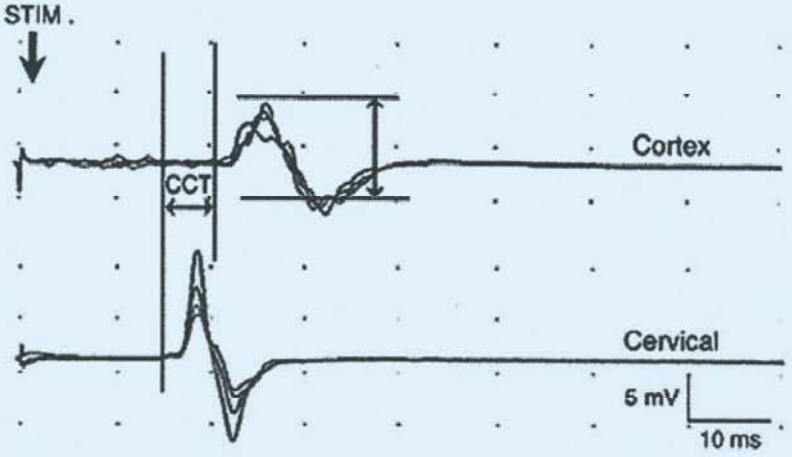

FIGURE 26.16 Motor-evoked potentials by transcranial magnetic stimulation of the motor cortex and by stimulation of the cervical spinal cord. The response is recorded with surface electromyogram electrodes over the first dorsal interosseous. The delay between the two responses is the central conduction time in the corticospinal tract. Abbreviations: CCT, central conduction time; STIM, stimulation. (Courtesy of Nicolas Mavroudakis, MD, PhD.)

The American Clinical MEG Society and the International Federation of Clinical Neurophysiology have published practical guidelines for clinical MEG.

LEVEL 1 EVIDENCE

1. Herman ST, Abend NS, Bleck TP, et al. Consensus statement on continuous EEG in critically ill adults and children, part I: indications. *J Clin Neurophysiol*. 2015;32(2):87-95.

SUGGESTED READINGS

Ajmone-Marsan C. Electroencephalographic studies in seizure disorders: additional considerations. *J Clin Neurophysiol*. 1984;1:143-157.

American Clinical Neurophysiology Society. Guidelines in electroencephalography and evoked potentials. *J Clin Neurophysiol*. 2006;23:125-179.

Bagić AI, Knowlton RC, Rose DF, Ebersole JS; for ACMEGS Clinical Practice Guideline (CPG) Committee. American Clinical Magnetoencephalography Society Clinical Practice Guideline 1: recording and analysis of spontaneous cerebral activity. *J Clin Neurophysiol*. 2011;28(4):348-354.

Burgess RC, Funke ME, Bowyer SM, Lewine JD, Kirsch HE, Bagić AI; for ACMEGS Clinical Practice Guideline (CPG) Committee. American Clinical Magnetoencephalography Society Clinical Practice Guideline 2: presurgical functional brain mapping using magnetic evoked fields. *J Clin Neurophysiol*. 2011;28(4):355-361.

Buzsáki G, Draguhn A. Neuronal oscillations in cortical networks. *Science*. 2004;304:1926-1929.

Chiappa KH. *Evoked Potentials in Clinical Medicine*. 3rd ed. Philadelphia, PA: Lippincott-Raven; 1997.

Chong DJ, Hirsch LJ. Which EEG patterns warrant treatment in the critically ill? Reviewing the evidence for treatment of periodic epileptiform discharges and related patterns. *J Clin Neurophysiol*. 2005;22:79-91.

Claassen J, Jetté N, Chum F, et al. Electrographic seizures and periodic discharges after intracerebral hemorrhage. *Neurology*. 2007;69:1356-1365.

Claassen J, Mayer SA, Kowalski RG, Emerson RG, Hirsch LJ. Detection of electrographic seizures with continuous EEG monitoring in critically ill patients. *Neurology*. 2004;62(10):1743-1748.

Claassen J, Taccone FS, Horn P, et al. Recommendations on the use of EEG monitoring in critically ill patients: consensus statement from the neurointensive care section of the ESICM. *Intensive Care Med*. 2013;39(8):1337-1351.

Claassen J, Vespa P; and The Participants in the International Multi-disciplinary Consensus Conference on Multimodality Monitoring. Electrophysiologic monitoring in acute brain injury. *Neurocrit Care*. 2014;21(suppl 2):S129-S47.

Cruccu G, Aminoff MJ, Curio G, et al. Recommendations for the clinical use of somatosensory-evoked potentials. *Clin Neurophysiol*. 2008;119(8):1705-1719.

DeLorenzo RJ, Waterhouse EJ, Towne AR, et al. Persistent nonconvulsive status epilepticus after the control of convulsive status epilepticus. *Epilepsia*. 1998;39:833-840.

Dreier JP, Fabricius M, Ayata C, et al. Recording, analysis, and interpretation of spreading depolarizations in neurointensive care: review and recommendations of the COSBID research group. *J Cereb Blood Flow Metab*. 2017;37(5):1595-1625.

Emerson RG, Pedley TA. Intraoperative monitoring. In: Ebersole JS, Pedley TA, eds. *Current Practice of Clinical Electroencephalography*. 3rd ed. New York, NY: Lippincott Williams and Williams; 2003:936-954.

Epstein CE. Visual evoked potentials. In: Levin KH, Lueders HO, eds. *Comprehensive Clinical Neurophysiology*. Philadelphia, PA: WB Saunders; 2000:507-524.

Fisch BJ, Klass DW. The diagnostic specificity of triphasic wave patterns. *Electroencephalogr Clin Neurophysiol*. 1988;70:1-8.

Foreman B, Claassen J, Abou Khaled K, et al. Generalized periodic discharges in the critically ill: a case-control study of 200 patients. *Neurology*. 2012;79(19):1951-1960.

Friedman D, Claassen J, Hirsch LJ. Continuous electroencephalogram monitoring in the intensive care unit. *Anesth Analg*. 2009;109(2):506-523.

Gaspard N, Hirsch LJ. Pitfalls in ictal EEG interpretation: critical care and intracranial recordings. *Neurology*. 2013;80(1 suppl 1):S26-S42.

Gaspard N, Manganas L, Rampal N, Petroff AC, Hirsch LJ. Similarity of lateralized rhythmic delta activity to periodic lateralized epileptiform discharges in critically ill patients. *JAMA Neurol*. 2013;70(10):1288-1295.

Guérit JM, Amantini A, Amodio P, et al. Consensus on the use of neurophysiological tests in the intensive care unit (ICU): electroencephalogram (EEG), evoked potentials (EP), and electroneuromyography (ENMG). *Neurophysiol Clin*. 2009;39(2):71-83.

Hallett M. Transcranial magnetic stimulation and the human brain. *Nature*. 2000;406:147-150.

Hari R, Baillet S, Barnes G, et al. IFCN-endorsed practical guidelines for clinical magnetoencephalography (MEG). *Clin Neurophysiol*. 2018;129(8):1720-1747.

Hartings JA, Shuttleworth CW, Kirov SA, et al. The continuum of spreading depolarizations in acute cortical lesion development: examining Leão's legacy. *J Cereb Blood Flow Metab*. 2017;37(5):1571-1594.

Herman ST, Abend NS, Bleck TP, et al. Consensus statement on continuous EEG in critically ill adults and children, part II: personnel, technical specifications and clinical practice. *J Clin Neurophysiol*. 2015;32(2):96-108.

Hirsch LJ. Classification of EEG patterns in patients with impaired consciousness. *Epilepsia*. 2011;52 suppl 8:21-24.

Hirsch LJ, Claassen J, Mayer SA, Emerson RG. Stimulus-induced rhythmic, periodic, or ictal discharges (SIRPIDS): a common EEG phenomenon in the critically ill. *Epilepsia*. 2004;45(2):109-123.

Hirsch LJ, LaRoche SM, Gaspard N, et al. American Clinical Neurophysiology Society's Standardized Critical Care EEG Terminology: 2012 version. *J Clin Neurophysiol*. 2013;30(1):1-27.

Kane N, Acharya J, Beniczky S, et al. A revised glossary of terms most commonly used by clinical electroencephalographers and updated proposal for the report format of the EEG findings. Revision 2017. *Clin Neurophysiol Pract*. 2017;2:170-185.

Kellaway P. Orderly approach to visual analysis characteristics of the normal EEG of adults and children. In: Ebersole JS, Pedley TA, eds. *Current Practice of Clinical Electroencephalography*. 3rd ed. New York, NY: Lippincott Williams & Wilkins; 2003:100-159.

Lai CW, Gragasin ME. Electroencephalography in herpes simplex encephalitis. *J Clin Neurophysiol*. 1988;5:87-103.

Lee S, Issa NP, Rose S, et al. DC shifts, high frequency oscillations, ripples and fast ripples in relation to the seizure onset zone. *Seizure*. 2020;77:52-58.

Lerman P. Benign partial epilepsy with centro-temporal spikes. In: Roger J, Bureau M, Dravet C, et al, eds. *Epilepsy Syndromes in Infancy, Childhood, and Adolescence*. 2nd ed. London, United Kingdom: John Libbey; 1992:189-200.

Levy SR, Chiappa KH, Burke CJ, Young RR. Early evolution and incidence of electroencephalographic abnormalities in Creutzfeldt-Jakob disease. *J Clin Neurophysiol*. 1986;3:1-21.

Lueders HO, Terada K. Auditory evoked potentials. In: Levin KH, Lueders HO, eds. *Comprehensive Clinical Neurophysiology*. Philadelphia, PA: WB Saunders; 2000:525-541.

Mendiratta A, Emerson RG. Transcranial electrical MEP with muscle recording. In: Nuwer MR, ed. *Intraoperative Monitoring of Neural Function*. Amsterdam, Netherlands: Elsevier B.V.; 2008:275-288. *Handbook of Clinical Neurophysiology*; vol 8.

Noachtar S, Rémi J. The role of EEG in epilepsy: a critical review. *Epilepsy Behav*. 2009;15(1):22-33.

Novotny EJ Jr. The role of clinical neurophysiology in the management of epilepsy. *J Clin Neurophysiol*. 1998;15:96-108.

Nuwer MR, Emerson RG, Galloway G, et al. Evidence-based guideline update: intraoperative spinal monitoring with somatosensory and transcranial electrical motor evoked potentials: report of the Therapeutics and Technology Assessment Subcommittee of the American Academy of Neurology and the American Clinical Neurophysiology Society. *Neurology*. 2012;78(8):585-589.

Oddo M, Carrera E, Claassen J, Mayer SA, Hirsch LJ. Continuous electroencephalography in the medical intensive care unit. *Crit Care Med*. 2009;37(6):2051-2056.

Pedley TA, Mendiratta A, Walczak TS. Seizures and epilepsy. In: Ebersole JS, Pedley TA, eds. *Current Practice of Clinical Electroencephalography*. 3rd ed. New York, NY: Lippincott Williams & Wilkins; 2003:506-587.

Pohlmann-Eden B, Hoch DB, Cochius JI, Chiappa KH. Periodic lateralized epileptiform discharges—a critical review. *J Clin Neurophysiol*. 1996;13:519-530.

Reeves AL, Westmoreland BE, Klass DW. Clinical accompaniments of the burst-suppression EEG pattern. *J Clin Neurophysiol*. 1997;14:150-153.

Salinsky M, Kanter R, Dasheiff RM. Effectiveness of multiple EEGs in supporting the diagnosis of epilepsy: an operational curve. *Epilepsia*. 1987;28:331-334.

Scheffer IE, Berkovic S, Capovilla G, et al. ILAE classification of the epilepsies: position paper of the ILAE Commission for Classification and Terminology. *Epilepsia*. 2017;58(4):512-521.

Scheuer ML. Continuous EEG monitoring in the intensive care unit. *Epilepsia*. 2002;43 suppl 3:114-127.

Sutter R, Kaplan PW. Clinical and electroencephalographic correlates of acute encephalopathy. *J Clin Neurophysiol*. 2013;30(5):443-453.

Tatum WO IV, Husain AM, Benbadis SR, et al. Normal adult EEG and patterns of uncertain significance. *J Clin Neurophysiol*. 2006;23(3):194-207.

Zifkin BG, Cracco RQ. An orderly approach to the abnormal EEG. In: Ebersole JS, Pedley TA, eds. *Current Practice of Clinical Electroencephalography*. 3rd ed. New York, NY: Lippincott Williams & Wilkins; 2003:288-302.

27 Electromyography, Nerve Conduction Studies, and Magnetic Stimulation

Louis H. Weimer

KEY POINTS

1. Electrodiagnostic studies can assess many motor and sensory nerves and the majority of skeletal muscles, but each study must be tailored to the clinical condition in question.
2. Nerve conduction studies separately test sensory and motor fibers and may demonstrate axonal loss, focal processes and compression, or generalized demyelination.
3. Needle electromyography studies can distinguish neurogenic from myopathic weakness.
4. Studies are often an extension of the neurologic exam and not a predetermined protocol.
5. Many technical factors or challenges must be avoided in order to have reliable data and conclusions.
6. Testing is often considered neuromuscular physiology, which is complementary to anatomic imaging tests, for example, magnetic resonance imaging, computed tomography, and ultrasound.
7. Specialized techniques are employed in certain situations, such as repetitive nerve stimulation, single-fiber electromyography, and transcortical magnetic stimulation.
8. Transcortical magnetic stimulation is an emerging treatment as well as testing modality.

INTRODUCTION

Advances in electronics enabled clinical assessment of peripheral nerve and muscle physiology in the mid-20th century, spawning the neurologic specialty of clinical neurophysiology. Electrodiagnostic signals are now mostly digitized and increasingly computerized. Studies remain indispensable for the proper diagnosis and management of patients with neuromuscular disease. Despite technologic improvements, a basic understanding of the principles, potential errors, and disease-specific effects are essential for meaningful interpretation and conclusions. Notably, these techniques provide physiologic information in contrast and complementary to the primarily anatomic information provided by various imaging technologies. This chapter provides a brief overview of nerve conduction studies (NCS), needle electromyography (EMG), neuromuscular junction assessment, and central motor function techniques.

NERVE CONDUCTION STUDIES

Sensory and Motor Nerve Conduction Studies

The NCS measure the speed and strength of an electrical impulse conducted along a peripheral nerve. Typically, the impulse is generated using a bipolar stimulator placed on the skin surface over the anatomic course of the tested nerve. The intensity and duration of this transcutaneous stimulus is gradually increased until all available axons within that nerve are depolarized, sparking an action potential that travels down the nerve to the recording site. For *sensory NCS*, the recording electrodes are placed on the skin surface overlying the nerve (usually over a pure sensory branch) at some distance from the stimulation site (**Fig. 27.1**).

When an action potential passes under these bipolar recording electrodes, a *sensory nerve action potential* (SNAP) waveform is recorded and displayed (**Fig. 27.2**). The SNAP is produced by large Ia sensory axons and not small-diameter A or C fibers.

Motor NCS are performed similarly, except that the recording electrodes are placed over the motor endplate region of an innervated muscle, rather than over the nerve itself (**Fig. 27.3**).

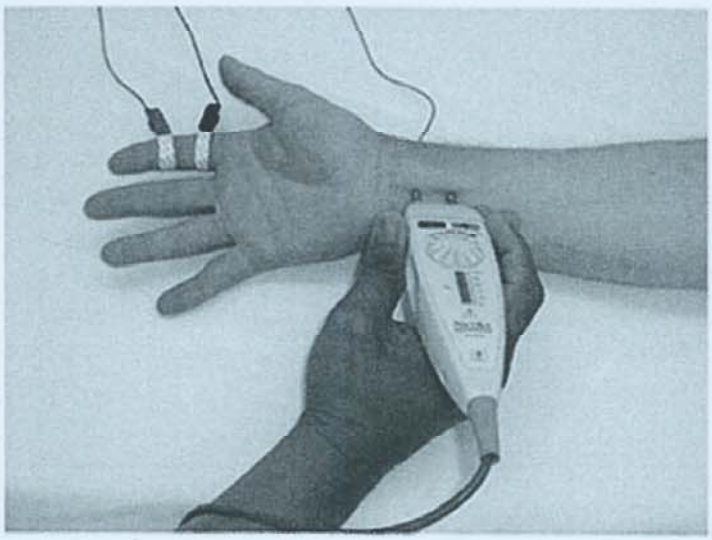

FIGURE 27.1 Setup for sensory nerve conduction studies. A bipolar stimulator is placed over the median nerve at the wrist, and self-adhesive recording electrodes are placed over the median sensory branches over the index finger, ensuring that only sensory nerve responses are recorded. A self-adhesive ground electrode is placed over the dorsum of the hand.

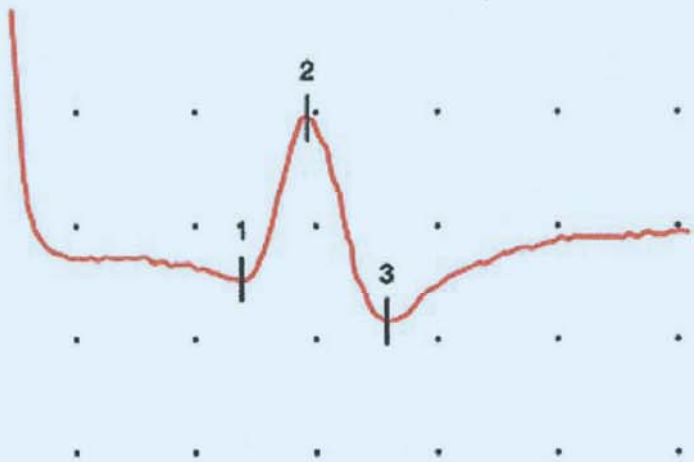

FIGURE 27.2 Sensory nerve action potential recorded using the setup depicted in **Fig. 27.1**. The horizontal space between two dots, or graticules (one division), is assigned a specific value (the time base shown is 1 ms per division) to enable time measurements. Vertical divisions are also assigned a specific value to enable measurement of stimulus strength (the gain or sensitivity; 10 μV per division as shown). The time between the stimulus artifact and the waveform peak (the sensory peak latency) is 2.75 milliseconds, and the peak-to-peak waveform amplitude is 13.2 μV, within the normal range. Onset latency is needed to calculate a conduction velocity.

For motor NCS, the action potential passes down the nerve, triggers acetylcholine release at the neuromuscular junction, and produces muscle membrane depolarization. The recording electrodes capture the electrical potential generated by depolarization of the innervated muscle, subsequently generating a waveform known as the *compound motor action potential* (CMAP) (Fig. 27.4). Care must be taken to maximally but not excessively stimulate nerve axons at each stimulation site. Multiple other technical considerations can impede quality NCS and must be controlled as much as feasible, including standardized procedures, temperature maintenance, accurate electrode placement and measurement, interference avoidance, detection of anatomic anomalies, and stimulation of unintended nerves.

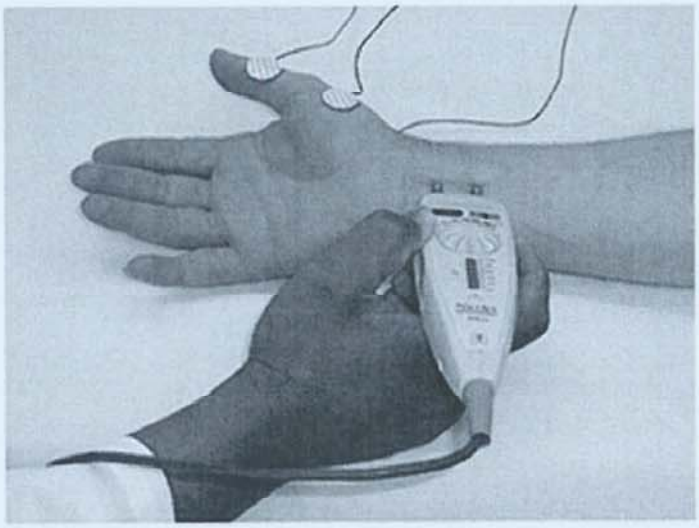

FIGURE 27.3 Setup for motor nerve conduction studies. The bipolar stimulator is placed over the median nerve at the wrist, and recording electrodes are placed over the median-innervated abductor pollicis brevis. The resultant muscle depolarization produces the recorded waveform. Note that sensitivities are in the millivolt, rather than microvolt, range.

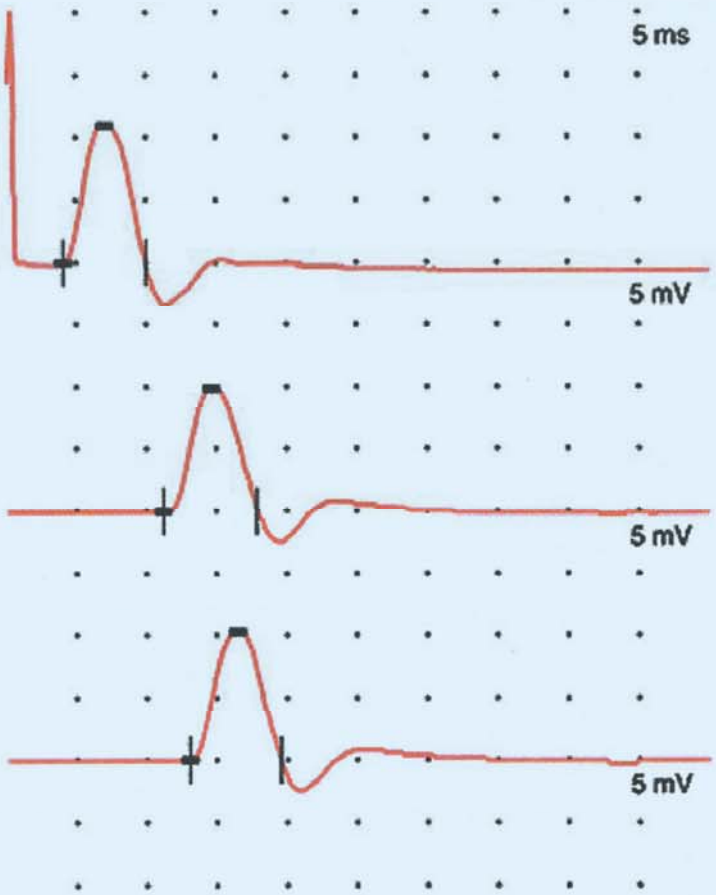

FIGURE 27.4 A compound motor action potential. These three responses were recorded from the extensor digitorum brevis muscle of the foot following stimulation of the peroneal nerve at three different sites: the ankle (**top waveform**), just below the fibular head (**middle waveform**), and above the knee (**bottom waveform**). The recording sensitivity was 5 mV per division, and the sweep speed was 5 milliseconds per division. Onset latencies are 4.0, 11.1, and 13 milliseconds, respectively, predictably increasing as the distance between the stimulating and recording electrodes increases. Subtracting one onset latency from another yields the time for the impulse to travel from one stimulation point to the other. The measured distance is divided by this value to produce the segmental conduction velocity in meters per second. The amplitude is measured from baseline to peak.

Although modern equipment is computerized with digital processing and storage to capture and analyze the data, the waveform display owes its origins to the cathode ray oscilloscope. By convention, the x-axis of the tracing is the time base (or sweep speed) in milliseconds, whereas the y-axis measures the impulse strength. The waveform *amplitude*, measured either in microvolts (sensory waveforms) or millivolts (motor waveforms), reflects the summated number of responsive nerve axons. The time difference between the stimulus and the waveform onset, one of several measures of nerve speed, is the *distal latency*. Using this value and the measured distance between the stimulating and recording points, a *nerve conduction velocity* may be calculated for sensory nerves (m/s). Some prefer to measure the latency to the sensory waveform peak instead of the onset and to compare this

value to controls (*peak latency*). Similarly, the *distal motor latency* is measured from the stimulation point to the waveform onset and compared to control values; some laboratories use a standard distance from the stimulation point and the muscle to improve reliability. Because of the non–nerve-related components of the motor system including the neuromuscular junction and muscle membrane depolarization, motor NCS require additional stimulation sites to calculate conduction velocity. A waveform from a second, typically more proximal, stimulation site is captured and the time difference between the two waveforms is measured. This step subtracts out the time for the nonnerve factors and assesses only the motor nerve axon components. The distance between the two sites (mm) divided by the time difference (ms) provides the *conduction velocity* of that segment (m/s). Additional segments may be added by stimulating further sites along the nerve course. Accuracy is reduced, however, if the stimulation points are too close together. A difference of 10 cm is typical except for special circumstance, such as short-segment studies across the elbow in the assessment of ulnar neuropathy. Another consideration is the accessibility of the nerve to surface stimulation.

It is important to measure and control limb temperature; cold limbs influence many electrodiagnostic measures. The most significant effect is on conduction velocity, with a conduction velocity fall on average of 2 m/s/°C and latency increase of approximately 0.2 ms/°C below ideal, typically 32°C.

Because muscle tissue is much more electrically potent than nerve fibers, the CMAP is approximately three orders of magnitude larger than the SNAP, and its amplitude is measured in millivolts rather than microvolts. Otherwise, latency and amplitude measures are similar to the SNAP.

Both latency and conduction velocity depend on an intact, myelinated nerve; myelin and the saltatory conduction it fosters are essential for rapid action potential propagation. In contrast, the waveform amplitude depends primarily on the number of functioning axons within the nerve. Significant slowing of conduction velocity or prolongation of latency usually implies demyelinating injury, whereas loss of amplitude usually correlates with axonal loss or dysfunction. However, axonal loss also may mildly slow conduction velocity by eliminating the fastest conducting axons. When demyelination is severe enough, a complete block of transmission in most axons can occur; demyelination results in a loss of local current and an insufficient charge to activate the next node of Ranvier. The NCS may be used to demonstrate the conduction block. In this situation, recordings made from nerve stimulation above the site of injury produce waveforms with a much lower amplitude and area than recordings made from stimulation below the site of demyelination of the same nerve. When severe enough, this loss of waveform amplitude due to block of impulse transmission in a group of axons at a single site is known as a *conduction block* and is an important diagnostic feature of acquired demyelinating neuropathies (Fig. 27.5). If some, but not all, fibers show reduced conduction velocity without a conduction block, the increased range of velocities may produce *temporal dispersion*, a broadened waveform that demonstrates increased waveform duration but a lesser reduction in waveform area. Despite the fact that certain accessible nerves dominate most NCS, techniques are described for most recognized peripheral nerves; studies for uncommon procedures are performed on the basis of clinical necessity.

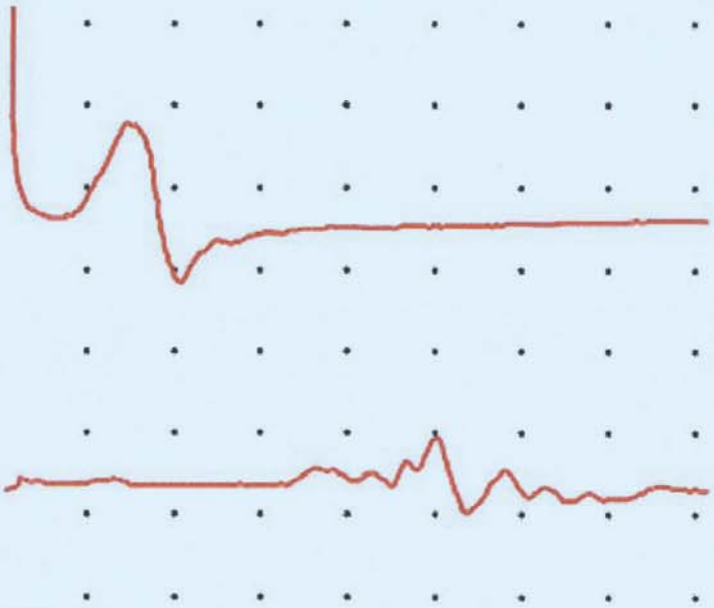

FIGURE 27.5 Conduction block with temporal dispersion. Two compound motor action potentials recorded from the abductor hallucis muscle of the foot following stimulation of the tibial nerve at the ankle and the knee (**top** and **bottom**, respectively) in a patient with demyelinating neuropathy. The sensitivity was 1 μV per division, and the sweep speed was 5 milliseconds per division. When stimulation is moved from the ankle to the knee, the recorded waveform decreases in amplitude (from 1.1-0.5 mV, a 54% decline), its duration lengthens, and its morphology becomes irregular and complex. These findings suggest significant demyelination of the nerve segment between the stimulation sites, with partial conduction block. An increased range of axonal conduction times between different axons, caused by differential involvement, produces increased waveform duration as the distance between stimulation and recording sites increases (*temporal dispersion*). A 30% increase is considered to be significant in motor axons.

Late Responses

Routine NCS are limited to accessible segments in the proximal and distal arms and legs. Nerve roots are not easily stimulated, and *long-latency reflex* tests are typically used to assess these most proximal segments. When a stimulus is delivered to the distal nerve, action potentials are propagated both proximally and distally. The impulse traveling up the motor axons (in a direction opposite to the normal flow or *antidromic*) eventually reaches the anterior horn cells. The anterior horn cells then generate a second nonsynaptic action potential that travels back down the axon into the muscle (in the direction paralleling the normal flow or *orthodromic*), where it is recorded as a much smaller waveform known as the *F wave*, named because it was originally recorded foot muscles (Fig. 27.6).

The time required for this round trip up and down the motor nerve is measured as *the F-wave minimal latency*. Although pathology at any point along the nerve may prolong the F-wave latency, if normal function of the distal nerve is documented by motor NCS in the more distal nerve sites, F-wave prolongation must be the result of slowing in the proximal segment.

A different long-latency response, *the H reflex* (named after Hoffmann, who first described it in 1918), may be elicited in

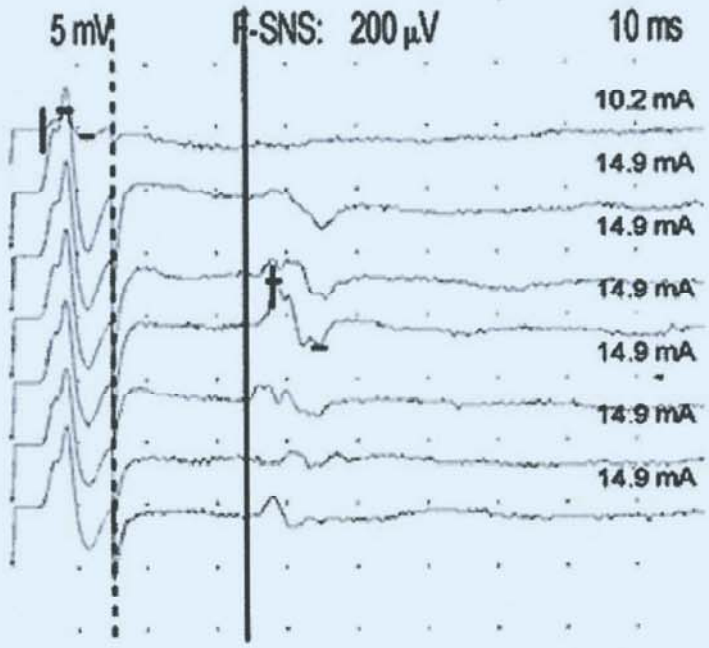

FIGURE 27.6 A series of F waves recorded from the thenar eminence following repeated median nerve stimulations in a patient with cervical radiculopathy. The screen is split with lower sensitivity (5 mV per division) to the left of the *dotted line* to show the full compound motor action potentials generated by distal stimulation and higher sensitivity (200 µV per division) to the right to allow visualization of the much smaller F-wave responses. The sweep speed is 10 milliseconds per division. The *dark vertical line* marks the latency of the earliest F-wave potential in the group (minimal F latency).

the legs by electrical stimulation of the type Ia sensory nerve afferents in the tibial nerve at the knee while recording over the soleus muscle. (The type Ia sensory fiber [also called the *primary afferent fiber*] is a component of the muscle spindle that monitors stretch velocity.) The contraction resulting from soleus activation is analogous to the monosynaptic stretch reflex pathway elicited by testing the tendon reflex. Thus, the H reflex is the electrical equivalent of the ankle jerk reflex and aids primarily in the assessment of S1 nerve root disease and involvement of sensory fibers. In adults, the H reflex is not normally found in other muscles except for the flexor carpi radialis. F waves are present in nearly all nerves. By analyzing motor and sensory nerve conductions and long-latency responses in multiple nerves, the nature of a given neuronal injury (axonal, demyelinating, or both) and its geographic distribution may be identified, aiding in the diagnosis of neuronopathy, radiculopathy, plexopathy, mononeuropathy, and polyneuropathy.

Other Specialized Reflex Tests

Numerous other reflex tests are described and uncommonly performed. The *blink reflex* is one exception. This relatively simple-to-perform test assesses both trigeminal and facial nerve pathways. Recording electrodes are placed on the orbicularis oculi bilaterally, and the supraorbital nerve is stimulated. An ipsilateral R1 response is seen on the stimulated side only. A later R2 complex response is seen bilaterally. Differing patterns are evident in trigeminal or facial neuropathy and central pontine or medullary disease.

NEEDLE ELECTROMYOGRAPHY

Basic Concepts

Complementary to NCS is assessment of clinically relevant muscles using needle EMG. A sterile, disposable, needle recording electrode is placed directly into the selected muscle, which is then activated by voluntary contraction at differing levels of effort. Anterior horn cell action potentials propagate impulses to the end of multiple axonal branches and initiate neuromuscular junction transmission, thereby activating individual muscle fibers; normally every muscle fiber innervated by a motor neuron fires following a nerve action potential. A single motor axon with all of its multiple branches and innervated muscle fibers is known as a *motor unit*. The strength of a muscle contraction is determined primarily by the number of activated motor units and motor unit firing rates. The recording characteristics of the EMG needle enable live recording and analysis of individual and aggregate motor unit waveforms. Two types of electrode are most commonly used. *Monopolar electrodes* are flexible, solid stainless-steel needles coated with inert material so that only the bare tip can record activity. The reference point is typically a surface electrode on the skin. *Concentric electrodes* are a rigid stainless-steel cannula that includes a specialized central wire. The activity is recorded from the wire and referenced to the cannula. Monopolar needles record from a larger territory, which is slightly better for spontaneous activity discussed later. Concentric electrodes record from a smaller area and are better for motor unit analysis also discussed later. Some consider monopolar electrodes to be less painful, but the difference is minimal when ultrasharp disposable electrodes are used. Either electrode is acceptable for use.

Insertional and Spontaneous Activity

During the needle EMG examination, three major categories are assessed: *spontaneous activity*, *motor unit configuration*, and *motor unit recruitment*, including the *interference pattern*. Different areas of the muscle are explored to ensure a representative sample and to detect focal changes. Insertional activity is the brief burst of electrical activity provoked by the EMG needle as it moves through the muscle, generating a cluster of transient high-frequency spikes lasting from 50 milliseconds to a few hundred milliseconds. In some disorders, the insertional activity is consistently prolonged or reduced with each movement of the needle, but the distinction is often subjective and not considered by most to be diagnostic. Once needle movement has ceased, no other electrical activity should normally appear as long as the muscle remains at rest. Reduced insertional activity is present in muscle replaced by nonexcitable tissue, such as fat or connective tissue.

Muscle fibers that have lost innervation through motor axon injury or muscle degeneration or muscle necrosis may undergo spontaneous depolarization, generating brief spikes (*fibrillations*) and *positive sharp waves* in the resting muscle; sharp waves usually fire in a regular pattern with a frequency of 0.5 to 15 Hz (Fig. 27.7). This activity is generated by individual myocytes. Waveforms similar to fibrillations normally occur at the muscle endplate region and must be distinguished; *endplate spikes* also fire at fast semirhythmic rates. Also recorded at the endplate region is *endplate noise*, a disturbance of the baseline that correlates with miniature endplate potentials.



FIGURE 27.7 Spontaneous activity in a resting muscle. This tracing was recorded from the triceps muscle of a patient with cervical radiculopathy. A positive sharp wave, named for its sharp initial positive (downward) deflection, is seen on the **left**. On the **right**, a smaller triphasic fibrillation is seen. These potentials are markers of active denervation and result from the random, spontaneous depolarization of denervated single muscle fibers.

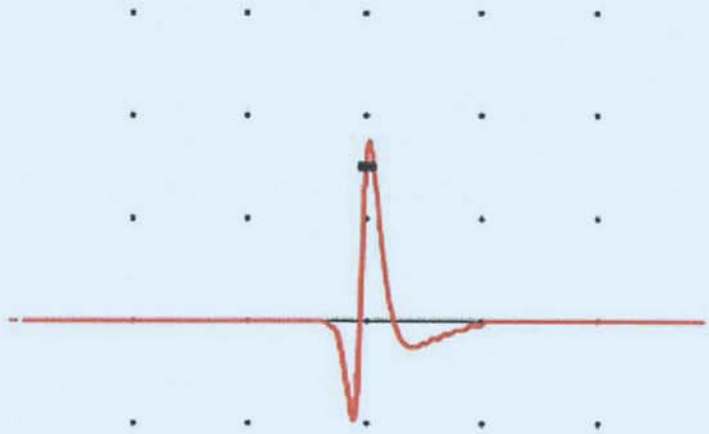

FIGURE 27.8 A normal MUP. This waveform was recorded from the biceps muscle with a concentric needle electrode as the first potential recruited during minimal voluntary contraction in a normal subject. Sweep speed was 10 milliseconds per division, and sensitivity was 500 μV per division. This waveform has an amplitude of 1.4 mV, a duration of 12.5 milliseconds, and a simple morphology with three turns.

Abnormal spontaneous activity is the hallmark of denervating axonal injury at any point from the anterior horn cell to the nerve terminal (eg, radiculopathy, plexopathy, axonal polyneuropathy, mononeuropathy) but is also prominent in inflammatory myopathies, such as polymyositis or dermatomyositis because of isolation of section of muscle from the endplate region producing functional denervation. Lesser degrees of spontaneous activity may be observed in other myopathies with muscle fiber necrosis (eg, myotonic dystrophy, Duchenne or limb-girdle muscular dystrophy) and in some toxic, metabolic, and infectious myopathies (eg, myoglobinuria [rhabdomyolysis] or viral myositis). Spontaneous activity typically begins to initially occur at 10 to 14 days after denervation but is more evident 3 to 4 weeks after onset and may persist for a protracted time unless that muscle fiber is reinnervated. Cold muscle temperature will reduce evident spontaneous activity.

Other aberrant involuntary discharges may appear with certain neurogenic or myopathic disorders. *Fasciculations* are isolated spontaneous discharges of whole or partial motor units and are prominent in motor neuron disease, benign fasciculation syndrome, and disorders of nerve excitability. Fasciculations may be visible as a muscle twitch, EMG needle sudden movement, or recordable discharge. *Complex repetitive discharges* are relatively nonspecific, machine-like phenomena more common in chronic neurogenic conditions. These discharges are very regular and start and stop abruptly. The origin is considered to a stable circuit created between several adjacent muscle fibers. *Myotonic discharges* are distinctive discharges that resemble a revving motor. This finding has limited associations, including myotonic dystrophy and myotonia congenita; however, acquired conditions can also demonstrate these findings. Waxing and waning frequency and amplitude are characteristic. *Myokymic discharges* are repetitive, grouped, nerve-generated discharges (doublets or multiplets) and occur commonly in the facial muscles from diverse cause but are uncommon in the limbs. Limb myokymic discharges suggest radiation injury, timber rattlesnake venom, or certain channelopathies. The origin is nerve components. Most rare are the very rapid *neuromyotonic discharges*, characteristic of Isaac syndrome or other forms of motor unit hyperactivity.

Motor Unit Configuration

Assessment of the waveform generated by motor unit activation (*the motor unit potential* or MUP) yields important information (Fig. 27.8). The MUP parameters include waveform duration, amplitude, and morphology (number of turns or baseline crossings). Motor unit characteristics are best assessed by capturing MUPs with the aid of a trigger and delay line so that the waveform can be frozen and assessed. The duration is measured from the point where the waveform deviates from the baseline to the point where a stable baseline returns following the waveform. The amplitude is typically measured from the largest waveform-positive and waveform-negative peaks. *Polyphasic* waveforms have five or more phases, determined by the number of times the waveform crosses the baseline plus one. Waveform turns or phase reversals are considered as well. The MUPs that contain more than seven or more turns are considered by some to be *complex MUPs*. Both polyphasic and complex MUPs are indicators of desynchronization seen in all forms of chronic neuromuscular disease that affects neurogenic or myogenic components. Small percentages of these potentials are evident in normal muscle as well, typically less than 12%. Some MUPs include a small additional time-locked component following a return to baseline—a *satellite potential*. Because a muscle may contain hundreds of motor units, the EMG examination must include a representative sample of motor units collected at varying levels of voluntary contraction.

Diseases of the motor nerve and muscle alter these motor unit parameters in characteristic ways. When motor axons fail, the associated muscle fibers lose their innervation. However, branches from surviving motor axons in the same nerve may reinnervate these denervated muscle fibers in a process called *collateral reinnervation*. Over the course of several months, this compensatory repair process gradually expands both the total number of muscle fibers innervated by surviving motor units as well as the geographic territory spanned within the muscle. Reinnervated motor units produce abnormally enlarged MUPs of long duration, high amplitude, and increased complexity, which are markers of chronic neurogenic injury (Fig. 27.9).

In contrast, myopathies destroy or inactivate some muscle fibers in most or all of the motor units within a muscle, thereby reducing both the number and distribution of fibers within each unit, producing abnormally small MUPs of short duration, low amplitude, and increased complexity (Fig. 27.10).

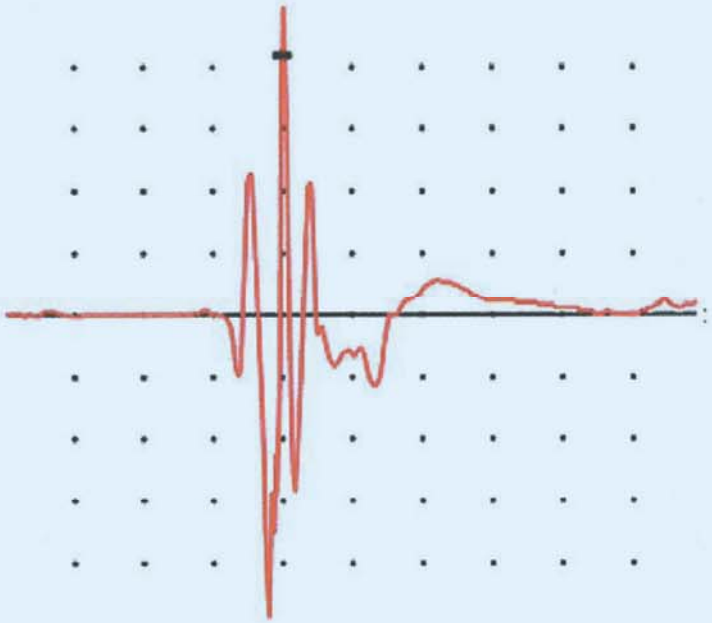

FIGURE 27.9 A neurogenic MUP. This waveform was recorded during voluntary activation of the gastrocnemius muscle with a concentric needle electrode in a patient with a distal diabetic neuropathy. Sweep speed was 5 milliseconds per division, and sensitivity was 1 mV per division. This waveform has a high amplitude of 10 mV and a significantly increased duration of 29 milliseconds and is highly complex, with more than 10 turns. This motor unit likely innervated a number of muscle fibers denervated from loss of other motor axons, producing the characteristic MUP changes in neurogenic conditions.

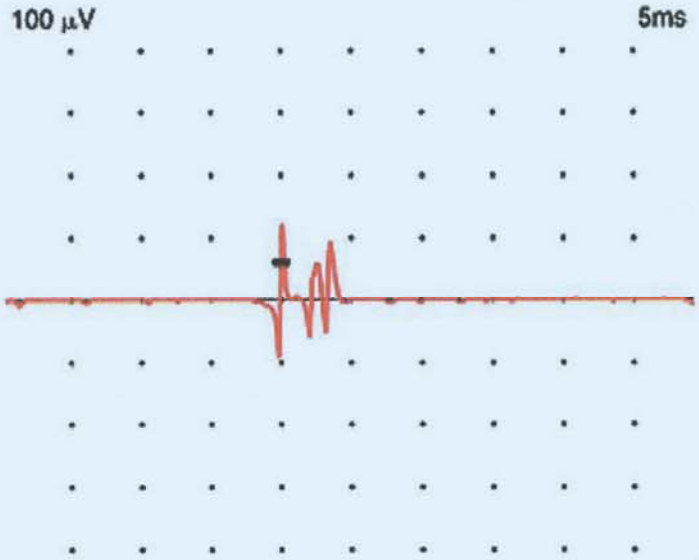

FIGURE 27.10 A myopathic MUP. This waveform was recorded during voluntary activation of the vastus lateralis muscle with a concentric needle electrode in a patient with polymyositis. Sweep speed was 5 milliseconds per division, and sensitivity was 100 μV per division. This waveform has a low amplitude of 210 μV and a short duration of 7 milliseconds and is complex with eight turns. As individual muscle fibers within a motor unit drop out during myopathic injury, the electric potential generated shrinks proportionately, resulting in decreased MUP amplitude and duration and increasingly complex morphology from reduced synchronization.

In normal individuals as well as patients with neuropathic or myopathic disorders, there is a wide range of sizes of individual MUPs. The size of the motor neuron, motor axon, and corresponding motor unit specifies the available strength, maximal firing rate, and fatigue resistance of that unit. In addition, different muscles may have divergent average motor unit size depending on the muscular function. For example, an extraocular muscle may have relatively few muscle fibers per motor unit to deliver small precise movements in contrast to a proximal hip girdle muscle where high fatigue resistance predominates. Thus, the characteristics of a small number of MUPs are insufficient for a definitive diagnosis. Determining the mean duration of 20 MUPs is one reliable way to separate neuropathic from myopathic disorders. Normal values, generated in Copenhagen, for the mean durations of most muscles in each decade of life were published in 1975 and remain widely used. However, qualitative MUP assessment invokes the same process by assessing a number of different MUPs without quantitative measurement. This assessment requires experience with the process and specific muscle undergoing testing.

Disorders of the neuromuscular junction, as in myasthenia gravis, may also prevent activation of enough fibers, owing to cumulative neuromuscular junction blockade, to produce myopathic-appearing MUPs. Following severe nerve injury, the earliest phases of reinnervation and the latest phases of denervation during neurogenic atrophy may also produce short-duration motor units (*nascent units*) when the initial few muscle fibers are reinnervated.

Recruitment and Interference Patterns

Needle EMG also enables assessment of motor unit recruitment patterns. As a muscle begins to contract at the lowest force levels, the first recruited motor unit begins to fire repeatedly at a specific frequency, usually at a minimum of 4 to 5 Hz. As demand for more strength increases, the firing frequency of the motor unit increases until a second motor unit is recruited. The specific firing frequency of the first recruited motor unit at the moment the second motor unit appears is *the recruitment frequency*. Abnormally high recruitment frequencies appear as motor units are lost, forcing surviving units to fire at faster and faster rates before additional units appear because of reduced numbers of motor units available for recruitment. In contrast, because most motor units are smaller and weaker, owing to loss of muscle fibers, lower recruitment frequencies are seen in myopathies (*early recruitment*). Consequently, multiple motor units must be activated earlier than in normal subjects to generate the same levels of force. Following damage to upper motor neuron pathways, recruitment is disordered, and motor units may fire at a slower than needed rate despite true maximal voluntary effort, as disrupted descending impulses improperly modulate firing frequency. The *firing ratio* is calculated by dividing the firing frequency (firing rate of the fastest firing MUP) over the number of different MUPs activated. This ratio is typically around five. In other words, if the fastest MUP fires at 15 Hz, one expects to see three total firing MUPs. Neurogenic processes increase this ratio.

The *interference pattern* is the overlapping pattern generated by the simultaneous activation of large numbers of MUPs during maximal contraction; the spike density and the amplitude of the summated response (*envelope amplitude*) are assessed. This response typically appears as a dense band of competing waveform activity at slow sweep speeds, which normally obscures the baseline tracing (Fig. 27.11).

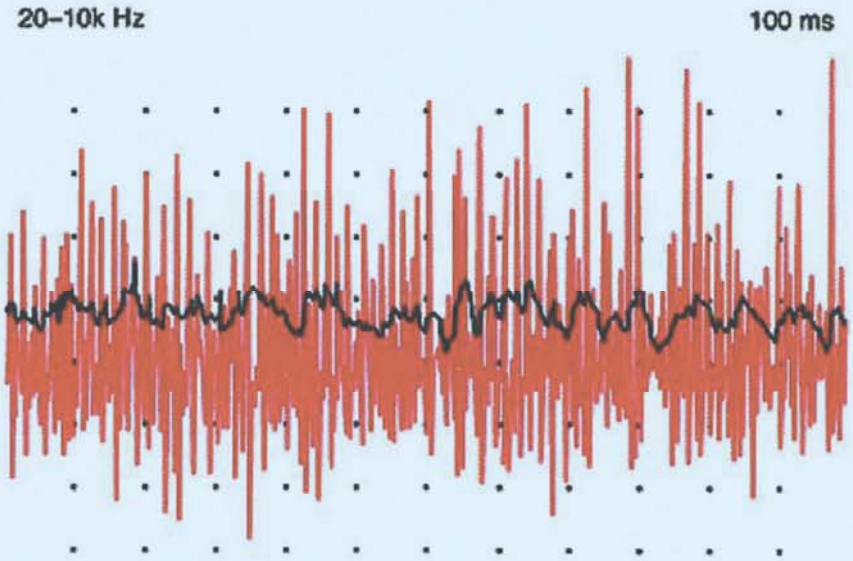

FIGURE 27.11 A normal interference pattern. This dense, overlapping group of MUP waveforms was recorded with a concentric needle electrode from the biceps muscle during maximal voluntary contraction in a normal subject. The pattern represents the simultaneous activation of all the functional motor units within that muscle. The sweep speed was 100 milliseconds per division, and the sensitivity was 1 mV per division.

Normal recruitment from low to intermediate to full contraction should produce a full interference pattern with a conical onset, as amplitudes increase progressively with the recruitment of larger and larger motor units to generate increasing force. *Incomplete or reduced interference patterns* (despite maximal contraction) are seen in advanced denervating disorders as more and more motor units drop out, ultimately leaving a *picket-fence* pattern, termed *discrete recruitment* (Fig. 27.12).

Maximal voluntary effort must be elicited before interference patterns are accurately assessed because poor volitional effort also produces an incomplete pattern; weakness due to central motor neuron injury may also result in reduced recruitment. In contrast, full *interference patterns, despite weakness*, occur with myopathic disorders. A full pattern appears almost immediately with minimal effort, owing to the large numbers of weakened motor units that are required to generate low levels of force. This pattern also has low envelope amplitude because the size of the constituent MUPs is reduced. Advanced methods that attempt to minimize the effects of voluntary effort (cloud analysis) are available on most machines but are not routinely applied, partly from limited normative data.

NERVE CONDUCTION STUDIES AND ELECTROMYOGRAPHY APPLICATIONS

A wide range of neuromuscular and central disorders may benefit from electrodiagnosis. Many specific applications are discussed in other sections dedicated to specific conditions. Some common examples include focal mononeuropathy, multifocal neuropathy, axonal and demyelinating polyneuropathy, motor neuronopathy,

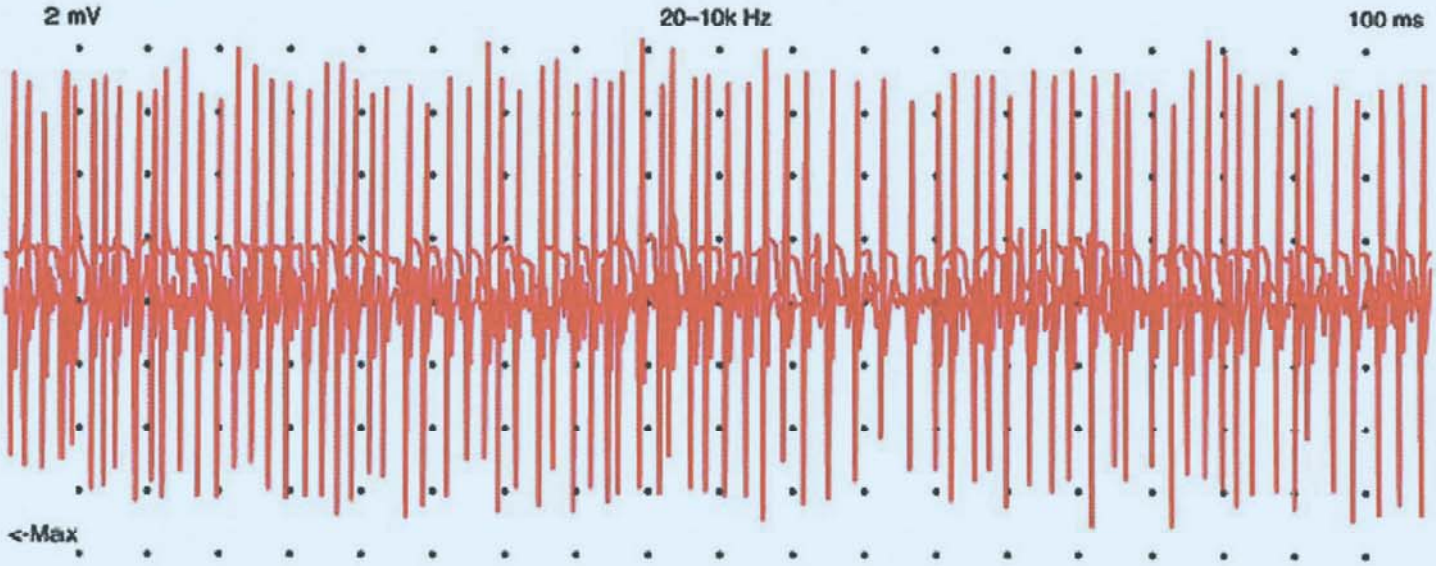

FIGURE 27.12 A reduced interference pattern. This pattern of MUP waveforms was recorded with a concentric needle electrode from the biceps muscle of a patient with amyotrophic lateral sclerosis during maximal voluntary contraction. The sweep speed was 100 milliseconds per division and the sensitivity was 2 mV per division. Instead of the normal, dense band of overlapping MUPs observed in the normal subject (see **Fig. 27.11**), a "picket-fence" pattern (*discrete recruitment*) representing the activation of only one rapid firing motor unit emerges because so many motor units have been lost. The MUP amplitude of the most prominent surviving unit is increased (8-10 mV), consistent with collateral reinnervation.

myopathy, myositis, and radiculopathy. A proper electrodiagnostic medicine consultation relies on a targeted clinical assessment so that the study design is focused on the clinical problem at hand and includes assessment of sufficient but not excessive numbers of clinically relevant nerves and muscles. Small-diameter fibers may be assessed by other means, most commonly skin biopsy for determination of epidermal nerve fiber density. Nerves are amenable to ultrasonography; however, this technology is currently considered to be a supplemental adjunct to electrodiagnostic methods described. A guideline found Level A evidence for use of ultrasound in the diagnosis of suspected carpal tunnel syndrome. Magnetic resonance imaging (MRI) of nerve is increasing sophisticated with higher power magnetic fields and improved protocols (MRI neurography). However, imaging of nerve and muscle is also adjunct information that typically identifies potential sites of nerve swelling and muscle signal changes that do not provide information on the disease type or process. Additionally, the MRI sequences and expertise are not widely available. The MRI can identify atrophic muscles. Practice parameters and diagnostic criteria exist for some common conditions, including but not limited to carpal tunnel syndrome, ulnar neuropathy, amyotrophic lateral sclerosis (ALS), chronic inflammatory demyelinating polyneuropathy, polyneuropathy, and others. In nearly all cases, both sensory and motor NCS and needle EMG are performed. Timely reporting of results is required that includes numeric data described earlier and written interpretation of the normality of obtained values. A diagnostic conclusion based on the data acquired is expected. In some cases, guidance on disease severity, time course, and prognosis is possible.

TESTS OF NEUROMUSCULAR TRANSMISSION

Repetitive Nerve Stimulation

Repetitive nerve stimulation (RNS) studies assess neuromuscular transmission using a standard motor nerve conduction setup (see "Nerve Conduction Studies" section) to deliver a series of supramaximal stimulations to a motor nerve at a specific frequency while recording each generated CMAP. A CMAP trains of 4 to 10 waveforms are usually recorded at rates from 2 to 3 Hz (low-frequency stimulation). By convention, the waveforms within each train are displayed horizontally on the same baseline from left to right (Fig. 27.13).

Trains are then evaluated either for decreases in consecutive CMAP size (as assessed by area and amplitude, from the first to a later potential, typically the fourth or fifth, and expressed as percentage decrement) or for increases in size (usually expressed in percentage increments). Most protocols include one baseline train, followed by a brief period of voluntary exercise without stimulation, and then followed by one immediate, postexercise train and several more trains at intervals over the next 1 to 5 minutes. The role of exercise is explained in the following text. For high-frequency stimulation studies, either transcutaneous stimulation at rates of 20 to 50 Hz, or maximal voluntary contraction itself, which provides painless activation of the nerve at similar rates, is used. However, high-frequency RNS studies are quite painful and very infrequently used in clinical practice; scenarios almost exclusively are for presynaptic disorders such as Lambert-Eaton myasthenic syndrome (LEMS), organophosphate poisoning, or botulism (as described later in the chapter and in Chapter 142)



FIGURE 27.13 Repetitive nerve stimulation. A train of 10 compound motor action potentials (CMAPs) recorded from the thenar eminence following repetitive nerve stimulation of the median nerve at a frequency of 3 Hz, arrayed in the order of stimulation (**left** to **right**). Each individual CMAP is normal, and no significant change in CMAP amplitude or area is observed during repetitive stimulation.

Postsynaptic Neuromuscular Junction Dysfunction

Patients with postsynaptic neuromuscular junction dysfunction, most commonly caused by myasthenia gravis, may demonstrate decremental responses following low-frequency stimulation. During normal neuromuscular junction transmission, depolarization of the motor axon induces acetylcholine release from the nerve terminal; the transmitter diffuses across the synaptic cleft to activate a group of acetylcholine receptors on the muscle fiber, each of which generates a local depolarization. These summated depolarizations ultimately reach threshold and generate a muscle action potential, which then initiates muscle fiber contraction. Declining release of acetylcholine normally occurs with stimulation at low frequencies; however, because postsynaptic acetylcholine receptors are abundant, these declines do not affect neuromuscular transmission, ensuring adequate muscle fiber depolarization despite the lower levels of acetylcholine released (*safety margin*). However, in myasthenia and some rare genetic postsynaptic disorders, the decline in acetylcholine release becomes critical because there are fewer functional acetylcholine receptors. The result is failure of neuromuscular transmission at multiple neuromuscular junctions with continued stimulation. As increasing numbers of muscle fibers drop out with successive stimulation, the size of the overall summated CMAP also decreases (Fig. 27.14). Rare hereditary disorders of neuromuscular

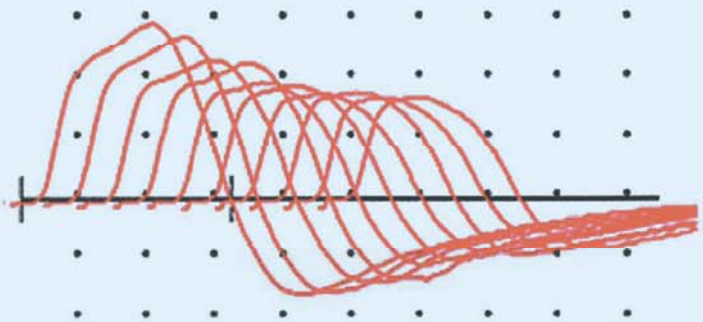

FIGURE 27.14 Decrement during repetitive nerve stimulation (RNS). Progressive decreases in the size of compound motor action potentials were recorded from the thenar eminence during a train of RNS at 3 Hz in a patient with myasthenia gravis. Losses in both amplitude and area of 40% to 50% appeared during RNS, owing to transmission failure at increasing numbers of neuromuscular junctions.

junction physiology (congenital myasthenia) cause differing effects on this test depending on the affected component.

Additionally, the size (amplitude or area) of a single CMAP immediately after brief exercise, in myasthenia, may increase by 10% to 50% or more compared to the baseline (preexercise) CMAP. This phenomenon, known as *postexercise facilitation* or *posttetanic potentiation*, is attributed to a temporary increase in acetylcholine release after a brief maximal contraction because of transiently heightened presynaptic calcium influx. Postexercise facilitation is assessed by comparing the first CMAP in the first train acquired immediately after exercise to the amplitude of the first CMAP in the preexercise train. In addition to postexercise facilitation of CMAP amplitude, any decrement in the baseline train may transiently improve immediately after exercise (*decrement repair*). However, after this transient repair, decrement typically worsens in trains recorded over the next 3 to 4 minutes, often dipping below baseline (*postactivation exhaustion*) as reserve acetylcholine levels are exhausted. Decrement ultimately returns to preexercise levels within 10 minutes. The decrement is typically greater in proximal and bulbar muscles but is simpler and more reliably performed in distal muscles. Cold temperature will blunt and warmer temperature will enhance the degree of decremental response.

Presynaptic Neuromuscular Junction Dysfunction

In the presynaptic LEMS and some cases of botulism, the CMAP amplitude may be reduced on routine NCS, and low-frequency RNS produces decrement similar to that seen in postsynaptic dysfunction. Both the low-baseline CMAP and the decrement seen on low-frequency stimulation are the result of the combination of normal decline in acetylcholine release at low rates of stimulation superimposed on the diminished release of acetylcholine resulting from antibody blockade of the presynaptic voltage-gated calcium channel (LEMS) or disruption of the mechanisms of acetylcholine release (botulism). High-frequency RNS, in contrast, characteristically leads to CMAP increment (facilitation) over 1 to 2 seconds, usually exceeding 100%. The pain of high-frequency stimulation may be avoided by having the patient voluntarily contract the muscle with maximum force for 10 to 20 seconds, after which a second single CMAP is immediately obtained; this "exercise test" shows postexercise facilitation comparable in magnitude to the increment observed after high-frequency stimulation.

Single-Fiber Electromyography

Another test of the neuromuscular junction is single-fiber electromyography (SFEMG). A specialized reusable electrode or small concentric disposable electrode is used that records single muscle fiber potentials. When an axon is selectively stimulated and a single muscle fiber action potential is measured (*stimulated SFEMG*), the interval between stimulus and response varies with each stimulus. This normal variation results from the fluctuating time required for electrochemical transmission across the junction and is quantitated as *jitter*. *Volitional SFEMG* recordings are more commonly performed and measure jitter by assessing the differences between two voluntarily activated muscle fibers from the same motor unit. With neuromuscular dysfunction, jitter increases, and, in severe cases, complete block of neuromuscular transmission may be documented. An SFEMG is the single most sensitive assay of neuromuscular junction dysfunction in myasthenia gravis, having a sensitivity of greater than 95% when applied to a clinically affected muscle (Fig. 27.15A,B).

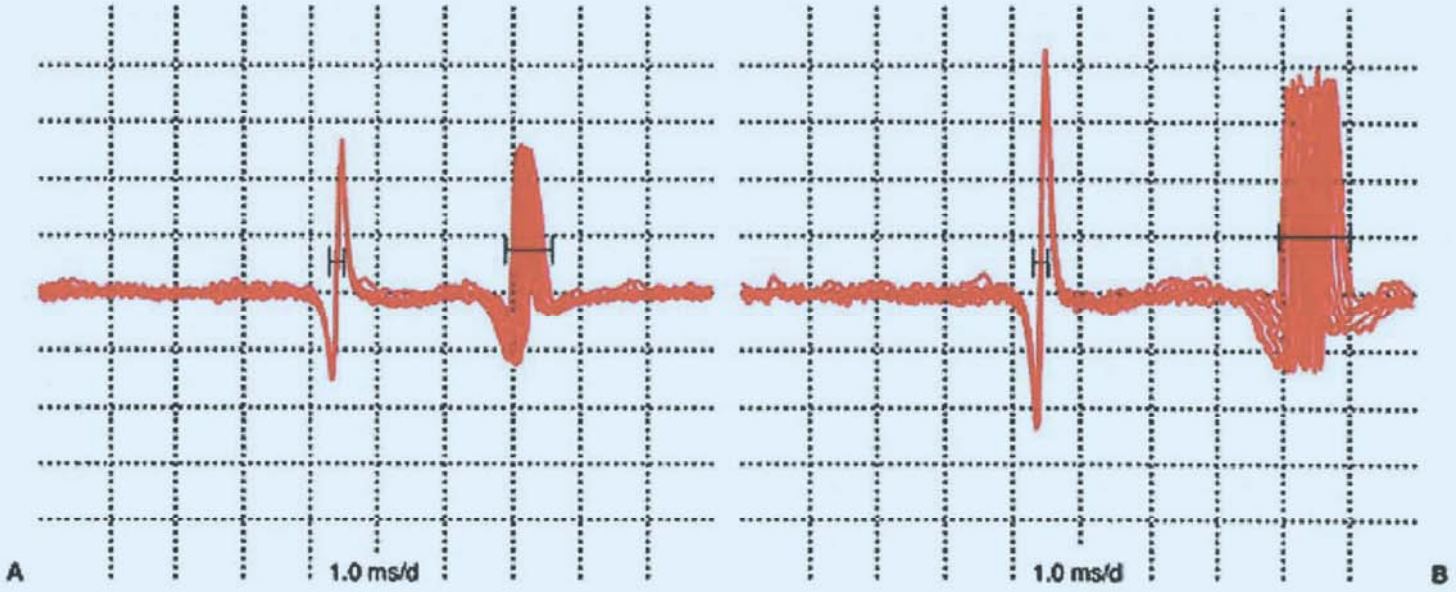

FIGURE 27.15 **A:** Single-fiber electromyography in a normal subject. In this tracing, 50 to 100 consecutive discharges generated by two single muscle fibers from the same motor unit during voluntary activation of the frontalis muscle are superimposed. The tracings are arrayed so that the first (*left*) potential is fixed with each discharge. Consequently, the variability in the time between the firing of the first (*left*) and second (*right*) potential with each discharge (the interpotential interval) is illustrated solely as variation of the second waveform. This effect, quantitated as *jitter*, is due to the variable time required for neuromuscular transmission to produce an action potential from discharge to discharge. **B:** Single-fiber electromyography in a patient with myasthenia gravis during volitional activation of the frontalis muscle using the same recording methods described in **A**. This tracing illustrates increased variability in neuromuscular transmission and clearly differs from that of the normal subject above. The jitter in this fiber pair is 160 microseconds, well above the normal upper limit.

Although SFEMG is highly sensitive, it is not specific and may be abnormal in any condition causing damage to nerve or muscle that produces reinnervation. Consequently, it is essential to perform other electrodiagnostic methods and a careful clinical assessment before considering SFEMG. An SFEMG is most useful for confirming neuromuscular junction dysfunction in suspected myasthenia gravis when other tests are equivocal or negative and other conditions that produce muscle weakness are assessed (see **Fig. 27.11**). Because of the limitations of reusable SFEMG electrodes that require cleaning, sharpening, and sterilization, use of high gauge disposable concentric needles is increasingly popular. These electrodes, however, record a large territory and may underestimate jitter; true single-fiber recordings are more difficult. Use of a higher low frequency filter (1 kHz) and a lower normal range are advised.

TRANSCRANIAL MAGNETIC STIMULATION

Transcranial magnetic stimulation (TMS) evokes compound motor potentials through noninvasive stimulation of the cortex. The TMS is an important method for studying the conductivity and excitability of the corticospinal system, abnormal cortical circuitry in neurologic diseases, and the reorganization of sensorimotor and visual systems after peripheral and central lesions. Electromagnetic induction may stimulate neural tissue. The TMS is accomplished through the generation of high-intensity current (5-10 kA) and discharged as a quick pulse through wire coils placed on the surface of the head. The coils induce a magnetic flux of short duration (100-200 μs) and high intensity (1-2 T). The magnetic fields, in turn, induce electrical current in the underlying cerebral cortex. The TMS delivery devices are embedded in a nonconductive plastic or rubber material and typically fashioned into figure eight, butterfly, or flat or concave circular shapes and applied near the part of the brain under study. The various shapes and sizes are designed to distribute or focus the induced magnetic fields. Round coils generate more diffuse magnetic fields and figure eight coils produce a narrower region of neural activation.

Stimulus intensity is expressed as a function of either the motor threshold or the percentage of machine output. The TMS is less painful than transcranial electrical stimulation, which causes uncomfortable shocks in the underlying skin and muscle. Unlike transcranial electrical stimulation, which directly excites cortical long tracts, the induced electrical fields of TMS preferentially stimulate neural elements oriented parallel to the surface of the brain (ie, primarily interneurons). The TMS pulses are associated with benign acoustic clicks and mild scalp or facial muscle activation. A momentary sense of disorientation at maximal stimulation may be felt. However, there are virtually no clinical cognitive or sensory effects at low intensities of TMS stimulation. Waveform recordings are usually obtained from a contralateral distal limb muscle, the motor-evoked potential (MEP).

A TMS may be delivered as a single pulse, in paired pulses, or as repetitive trains of stimulation (repetitive transcranial magnetic stimulation [rTMS]). Paired pulse and rTMS are powerful in studying human brain function, transiently stimulating or inhibiting different brain areas in awake and behaving subjects. Effects of rTMS on cortical excitability and inhibition outlast (for minutes to hours) the stimulation itself, a characteristic that could lead to therapeutic applications. Clinical trials have been conducted primarily not only in depression but also in Parkinson disease, epilepsy, obsessive-compulsive disorders, and schizophrenia.

Single-Pulse Transcranial Magnetic Stimulation

Following a single TMS, the MEP latency and amplitude measure the integrity of pathways and membrane excitability characteristics of the upper motor neuron. Central motor conduction time is calculated by subtracting the peripheral MEP latency (ie, cervical or lumbosacral proximal roots to distal limb muscles) from the total conduction latency (ie, TMS to MEP onset of the same muscle) and is obtained with a single, maximal TMS over the primary motor cortex (**Fig. 27.16**).

Prolongation of the central motor conduction time may originate with the loss of large myelinated motor axons subsequent to degeneration, and the test assesses upper motor neuron (UMN) dysfunction. Central motor conduction time, as well as other TMS measures, is helpful in diagnosing and following progression in patients with upper motor neuron diseases, such as ALS. However, central motor conduction time may be of limited value when large-diameter axons remain normal or in diseases where long-tract integrity is known to be normal, such as Parkinson disease.

As a measure of UMN functional integrity, TMS may detect abnormalities when there are no clinical UMN signs. The TMS may reveal subtle subclinical UMN dysfunction and help clarify the diagnosis of ALS, as well as the relationship between ALS and its variants, including progressive muscular atrophy where there may be subclinical UMN changes.

The MEP amplitudes and latencies are influenced by multiple factors, including configuration and placement of the TMS coil, stimulus intensity, presence of conditioning pulses, muscle facilitation, and degree of phase cancellation. Suprasegmental modulation of MEPs may be inferred in several ways, including demonstration of relatively unchanged F-wave properties under the same stimulus conditions. Motor threshold is defined as the lowest stimulus intensity that evokes MEPs of 50 μV in amplitude in 5 of 10 trials. Stimulus intensity is expressed as a percentage of the TMS device's maximum output. The MEP amplitude is usually measured peak to peak, increases with stimulus intensity, and plateaus at 80% of the amplitude of the wave produced by peripheral stimulation.

Voluntary muscle activation during TMS lowers the motor threshold and increases the MEP amplitude and is associated with shorter latency. This facilitation may result from an increased number and synchronization of descending impulses from the motor cortex or from reafferent facilitation at the spinal level. Recruitment is measured by plotting a stimulus-response curve of stimulus intensity versus MEP amplitude. The slope of this curve is normally increased by facilitation as well as by maneuvers that enlarge cortical representation of muscles, such as highly skilled, fine motor actions. Temporal summation may also follow repeated delivery of stimuli. In the first minutes following rTMS trains at low frequency (1 Hz), the amplitude of single-pulse MEP decreases. Conversely, high-frequency (>10 Hz) stimulation increases the response; these patterns resemble long-term depression and facilitation.

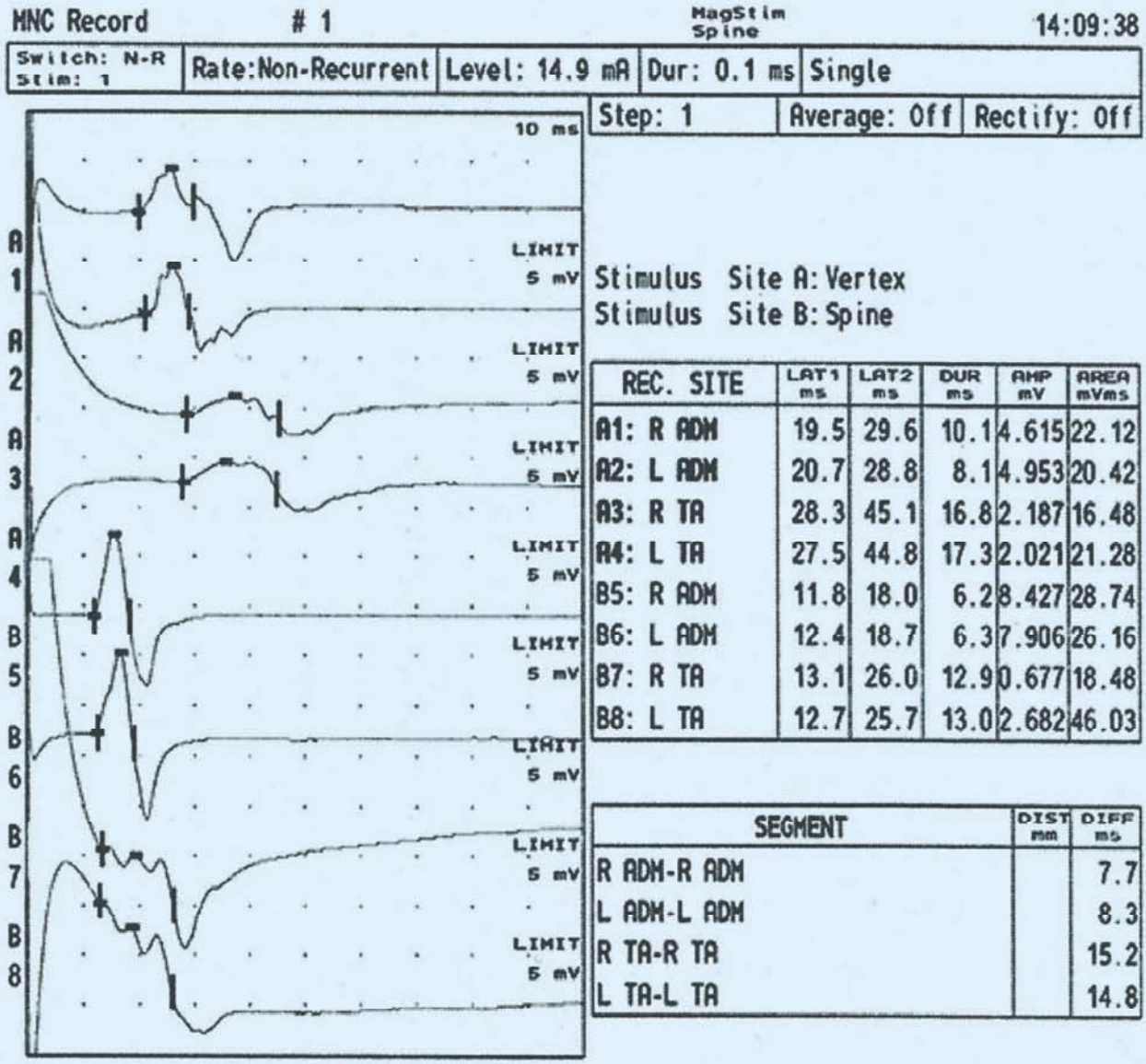

FIGURE 27.16 Transcranial magnetic stimulation in a normal subject. These tracings show the motor-evoked responses recorded from the right and left abductor digiti minimi (ADM) muscle of the hand and the right and left tibialis anterior (TA) muscles, following stimulation of the cerebral cortex with the stimulator placed over the vertex of the skull (traces *A1* to *A4*) and following stimulation of the spine; cervical stimulation for the ADM and lumbosacral stimulation for the TA is shown in traces *B5* to *B8*. Latencies, in milliseconds, from stimulation to the onset of the waveform recorded from the muscle are shown in the *first column* (*LAT1*). Central-conduction latency (ie, time from cortex to spinal segment) is calculated by subtracting the peripheral-conduction latency (ie, time from spine to muscle) from the total conduction latency (ie, time from cortex to muscle) and is shown in SEGMENT table, final column (DIFF).

Silent Period

The cortical or central silent period is measured from an actively contracting muscle, representing suppression of voluntary EMG activity for up to 300 milliseconds after a single TMS. The cortical silent period is an important method of assessing inhibitory mechanisms in neurologic disease. The silent period typically follows a MEP but may be induced by subthreshold stimuli that do not produce a MEP. This *negative effect* is mechanistically distinct from the positive effect seen in MEP induction. Although the origin of the initial segments of the cortical silent period are controversial, the latter part of the silent period is modulated by central mechanisms.

Repetitive Transcranial Magnetic Stimulation

Technical advances allow rTMS output from just under 1 Hz to pulse trains up to 50 Hz. The rTMS at frequencies greater than 20 Hz increases cerebral blood flow and neuronal excitability, whereas low-frequency rTMS (1-2 Hz) has the opposite effect. The therapeutic potential of TMS is of interest as a painless and relatively safe alternative to electroshock therapy. The TMS is a treatment option in treatment refractory depression and is under study for pain syndromes including migraine, stroke recovery, obesity, refractory schizophrenia, and other neurologic and psychiatric disorders.

ACKNOWLEDGMENTS

The author acknowledges significant contributions from authors of earlier editions of this section, especially Dale J. Lange, MD, Thomas H. Brannagan, MD, Clifton Gooch, MD, and Seth Pullman, MD.

SUGGESTED READINGS

Nerve Conduction Studies and Electromyography

American Association of Neuromuscular & Electrodiagnostic Medicine. *AANEM Glossary of Terms in Neuromuscular and Electrodiagnostic Medicine*. 3rd ed. Rochester, MN: American Association of Neuromuscular & Electrodiagnostic Medicine; 2015.

Buchthal F. Electromyography in the evaluation of muscle diseases. *Neurol Clin*. 1985;3:573-598.

Chen S, Andary M, Buschbacher R, et al. Electrodiagnostic reference values for upper and lower limb nerve conduction studies in adult populations. *Muscle Nerve*. 2016;54:371-377.

Cornblath DR, Sumner AJ, Daube J, et al. Conduction block in clinical practice. *Muscle Nerve*. 1991;14:869-871.

Dillingham T, Chen S, Andary M, et al. Establishing high-quality reference values for nerve conduction studies: a report from the normative data task force of the American Association of Neuromuscular & Electrodiagnostic Medicine. *Muscle Nerve*. 2016;54(3):366-370.

Falck B, Stålberg E. Motor nerve conduction studies: measurement principles and interpretation of findings. *J Clin Neurophysiol*. 1995;12:254-279.

Gooch CL, Weimer LH. The electrodiagnosis of neuropathy: basic principles and common pitfalls. *Neurol Clin*. 2007;25:1-28.

Gutmann L. Pearls and pitfalls in the use of electromyography and nerve conduction studies. *Semin Neurol*. 2003;23:77-82.

Jones LK Jr. Nerve conduction studies: basic concepts and patterns of abnormalities. *Neurol Clin*. 2012;30(2):405-427.

Kimura J. *Electrodiagnosis in Diseases of Nerve and Muscle: Principles and Practice*. 4th ed. New York, NY: Oxford University Press; 2013.

Oh J. *Clinical Electromyography, Nerve Conduction Studies*. 3rd ed. Philadelphia, PA: Lippincott Williams & Wilkins; 2003.

Olney RK, Lewis RA, Putnam TD, Campellone JV Jr. Consensus criteria for the diagnosis of multifocal motor neuropathy. *Muscle Nerve*. 2003;27(1):117-121.

Preston DC, Shapiro BE. *Electromyography and Neuromuscular Disorders: Clinical-Electrophysiologic Correlations*. 3rd ed. London, United Kingdom: Elsevier Saunders; 2013.

Ross MA. Electrodiagnosis of peripheral neuropathy. *Neurol Clin*. 2012;30(2):529-549.

Wilbourn AJ. Sensory nerve conduction studies. *J Clin Neurophysiol*. 1994;11(6):584-601.

Tests of Neuromuscular Transmission

American Association of Electrodiagnostic Medicine Quality Assurance Committee. Literature review of the usefulness of repetitive nerve stimulation and single fiber EMG in the electrodiagnostic evaluation of patients with suspected myasthenia gravis or Lambert-Eaton myasthenic syndrome. *Muscle Nerve*. 2001;24(9):1239-1247.

Drachman DB. Myasthenia gravis. *N Engl J Med*. 1994;330:1797-1810.

Howard JF Jr. Electrodiagnosis of disorders of neuromuscular transmission. *Phys Med Rehabil Clin N Am*. 2013;24(1):169-192.

Oh SJ. *Electromyography: Neuromuscular Transmission Studies*. Baltimore, MD: Lippincott Williams & Wilkins; 1988.

Sanders DB. Clinical neurophysiology of disorders of the neuromuscular junction. *J Clin Neurophysiol*. 1993;10:167-180.

Sanders DB, Stålberg EV. AAEM minimonograph #25: single-fiber electromyography. *Muscle Nerve*. 1996;19:1069-1083.

Tim RW, Sanders DB. Repetitive nerve stimulation studies in the Lambert-Eaton myasthenic syndrome. *Muscle Nerve*. 1994;17:995-1001.

Transcortical Magnetic Stimulation

Barker AT, Jalinous R, Freeston IL. Non-invasive magnetic stimulation of human motor cortex. *Lancet*. 1985;1:1106-1107.

Eisen AA, Shtybel W. AAEM minimonograph #35: clinical experience with transcranial magnetic stimulation. *Muscle Nerve*. 1990;13:995-1011.

Hallett M. Transcranial magnetic stimulation: a tool for mapping the central nervous system. *Electroencephalogr Clin Neurophysiol Suppl*. 1996;46:43-51.

Kobayashi M, Pascual-Leone A. Transcranial magnetic stimulation in neurology. *Lancet Neurol*. 2003;2:145-156.

Mitsumoto H, Ulug AM, Pullman SL, et al. Quantitative objective markers for upper and lower motor neuron dysfunction in ALS. *Neurology*. 2007;68:1402-1410.

Rossini PM, Rossi S. Transcranial magnetic stimulation: diagnostic, therapeutic, and research potential. *Neurology*. 2007;68:484-488.

Turner R, Bowser R, Bruijn L, et al. Mechanisms, models and biomarkers in amyotrophic lateral sclerosis. *Amyotroph Lateral Scler Frontotemporal Degener*. 2013;14(suppl 1):19-32.

Wassermann EM, Lisanby SH. Therapeutic application of repetitive transcranial magnetic stimulation: a review. *Clin Neurophysiol*. 2001;112:1367-1377.

Autonomic Testing 28

Louis H. Weimer

KEY POINTS

1. Clinical autonomic testing assess responses of reflex loops instead of direct nerve measures.
2. Testing most commonly measures heart rate variability, blood pressure responses to adrenergic challenges, and sudomotor (sweating) responses.
3. Consensus agreement advised testing a variety of measures.
4. Additional organ-specific testing is often by nonneurology specialists.

INTRODUCTION

Recognition of disorders producing autonomic dysfunction continues to increase the demand for noninvasive clinical testing in order to validate clinical diagnoses. Because autonomic systems affect virtually all organ systems, symptoms produced are multiple and varied, often affecting functions not considered by neurologists. Because many autonomic complaints can appear to be nonspecific, objective assessment is desirable in many instances. Laboratories testing autonomic function are generally available in part due to reliable noninvasive techniques. Formal accredited training opportunities in this neurologic specialty are limited but are available and increasing.

Unlike other systems, autonomic function is not directly assessed. Instead, responses of complex overlapping reflex loops are measured after controlled perturbations, most commonly heart rate (HR), blood pressure (BP), and sweating. Techniques to evaluate autonomic function are numerous and continue to be devised, but only a limited number are considered to be suitable for routine clinical application (**Table 28.1**). Tests of cardiovagal, adrenergic, and sudomotor function are most commonly performed and are recognized, standard clinical measures. Consensus recommends use of a standardized testing battery in a controlled setting. Bedside screening tests complement a clinical evaluation; some techniques can be performed with limited equipment such as an electrocardiography or electromyography machine. The primary testing goal is to identify autonomic failure and to assess and quantify disease severity. In some cases, determining the systems involved, such as parasympathetic, sympathetic, or panautonomic, can refine diagnostic possibilities. In most instances, localization to central, preganglionic, or postganglionic dysfunction is not possible. The effects of medications, environmental conditions, dehydration, and acute illness should be minimized during testing. Selected commonly performed tests are briefly discussed in this chapter.

SELECTED TESTS

Heart Rate Variability

Measures of HR variability are simple to record and are sensitive indicators of parasympathetic function. Cyclic deep breathing at 6 breaths per minute is the best validated stimulus; both afferent and efferent pathways are vagally mediated and blunted by anticholinergic agents. Most commonly, beat-to-beat HR is recorded, and R-R intervals or sequential HR data are measured, and the resultant enhanced sinus arrhythmia is analyzed with one of numerous methods; the test is currently the best cardiovagal measure available. Age-segregated normative ranges are well described. Other parasympathetic cardiovagal tests include measures of HR variability during rest, coughing, diving reflex, standing, squatting, and active lying down. The HR response to Valsalva maneuver (VM) is discussed later. Spectral and frequency HR analysis is an important research tool that has not been adequately validated for routine clinical application, although commercial automated testing devices using these methods are employed typically by nonneurologists and cardiologists.

Sympathetic Measures

The VM is a reliable and reproducible method that provides information for both parasympathetic and sympathetic function if beat-to-beat HR and BP data are recorded. Devices that noninvasively record continuous BP are typically used; multiple machines are commercially available. The subject blows into a closed tube at 40 mm Hg for 15 seconds while HR and BP are recorded. Isolated Valsalva ratio (VR) HR recording requires minimal equipment, but more information is gathered with less chance of misinterpretation if continual BP is recorded. The VM BP waveform is divided into four distinct phases (I-IV). Phases I and III signify nonspecific transmitted pressure and release from the maneuver, which initially causes cardiac output and BP to drop, providing the test stimulus. Normally, peripheral vasoconstriction and increased HR produce partial or full reversal of the BP decline, marking early (BP drop) and late (BP recovery) phase II. After Valsalva ends, the BP slowly overshoots and later returns to baseline (phase IV overshoot). Adrenergic insufficiency causes phase II to progressively deepen or fail to correct. Phase IV may fail to overshoot. Phase II recovery is likely mediated by α-adrenergic stimulation and phase IV by β-adrenergic supported by pharmacologic studies. The HR normally increases during the Valsalva period and then overshoots below baseline values.

The VR is calculated by dividing the R-R interval of the HR nadir over the HR peak. Normative values are well established and decline with age. The baroreflex index is also measurable

TABLE 28.1 Selected Tests of Autonomic Function

Cardiovagal
Well established
HR variability to cyclic deep breathing
HR response to the VM (VR)
HR response to standing (30:15 ratio)
Other
Diving reflex/cold face test
HR variability at rest
HR response to cough
Spectral analysis of HR signals (frequency domain)
Transfer function analysis (nonlinear dynamics)
Adrenergic
Well established
BP response to the VM (phase IV and late phase II)
BP response to orthostatic stress
• Head-up tilt
• Standing
Other
Sustained handgrip test
Squat test
BP response to alternate stressors
• Lower body negative pressure
• Neck suction
• Lying down
• Liquid meal
Plasma catecholamine levels (supine/standing)
Microneurography
Mental stress tests
Cold pressor test
Spectral and transfer function BP analysis
Sudomotor
Well established
Sympathetic skin response
Quantitative sudomotor axon reflex test
Thermoregulatory sweat test
Silastic sweat imprint testing
Skin biopsy for sweat gland innervation
Sudoscan
Additional or investigational methods
Pharmacologic challenges
Vasomotor testing
Pupillary testing (pharmacologic)
Pupillometry, pupillography
Urodynamics/cystometrogram with bethanechol
GI motility studies
GI manometry
Salivary testing/Schirmer test
Penile plethysmography, papaverine injection
Neuroendocrine tests
Neurogenic flare test
Quantitative direct and indirect test of sudomotor function
Cardiac PET scanning

Abbreviations: BP, blood pressure; GI, gastrointestinal; HR, heart rate; PET, positron emission tomography; VM, Valsalva maneuver; VR, Valsalva ratio.

and correlates well with traditional invasive methods. The HR response is affected by both atropine and β-blockade. The isolated HR response can be measured on most current electromyography devices. Abnormalities are evident in a high percentage of patients with autonomic failure and significant autonomic neuropathy; the BP findings are more sensitive than tilt studies, which are described later. Abnormalities also correlate with the severity of diabetic autonomic neuropathy and diabetes disease duration. Patients with orthostatic intolerance or the *postural orthostatic tachycardia syndrome* may show excessive phase II decline and insufficient recovery but additionally markedly enhanced phase IV overshoot and a high VR.

Standing and the 30:15 Ratio

Standing initiates a coordinated sequence of reflexes to maintain BP and therefore cerebral perfusion. Simple HR and BP responses to standing are important bedside markers of autonomic integrity, but further information is gained by laboratory testing. Most labs, however, use passive tilting. Responses are best measured after a supine rest period of 15 to 30 minutes, but shorter periods suffice. Baseline values are recorded, and readings are taken at least every minute for 2 to 5 minutes. Leg muscle contraction necessary for active standing triggers an exercise reflex that transiently reduces BP that can mimic orthostatic hypotension. Pressure normally returns to baseline levels within 1 to 2 minutes but can be delayed for 3 to 15 minutes in patients with mild orthostatic intolerance. This phenomenon is why standing BP measures must be delayed. The 30:15 ratio, the R-R interval ratio of the HR nadir around beat 30 after standing divided by the HR peak near beat 15, is reduced by inadequate parasympathetic function. A BP decrease of 20 mm Hg systolic or 10 mm Hg diastolic within 3 minutes is considered significant; triggered symptoms are also noted. The recognition of delayed or slowly declining BP has been noted that can be missed by shorter measurement periods. Fifteen percent of cases in one series had BP declines between 3 and 10 minutes after head-up tilt, and nearly 40% occurred after 10 minutes suggesting milder adrenergic insufficiency than patients with more acute declines.

Tilt Table Studies

Orthostatic challenge with passive upright tilting is the standard method used in most laboratories. Tilting employs slightly different physiologic mechanisms to active standing; however, testing is more easily controllable, enables reproducible tilting angles, simplifies BP monitoring at heart level, and is easier for patients with neurologic impairment. Neurogenic orthostatic hypotension from autonomic failure or HR changes characteristic of primary orthostatic intolerance are generally evident within

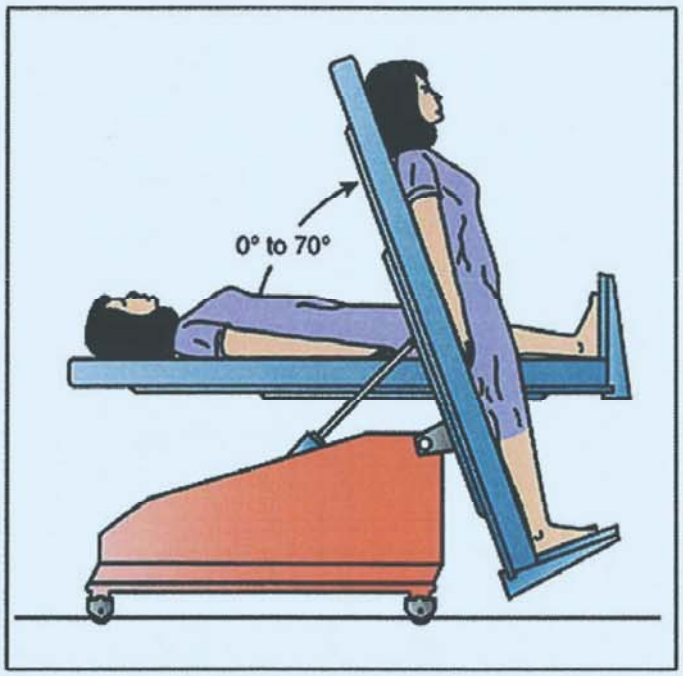

the first 5 to 15 minutes of tilting. In contrast, prolonged studies are often needed to trigger reflex or vasovagal syncope, which are further delayed or require pharmacologic challenge. Tilt angles range from 60 to 90 degrees depending on the laboratory (**Fig. 28.1**). Electrocardiography recordings are continuously monitored, and serial BP measurements are recorded with a manual cuff with an automated sphygmomanometer or ideally with continuous BP monitoring. Additional systems can be simultaneously monitored in special circumstances such as electroencephalography, transcranial Doppler, or noninvasive cardiac impedance plethysmography. The BP measurement point is maintained at heart level. Orthostatic hypotension, however, is a sign and not a disease; diagnosis of central autonomic disorders or autonomic neuropathy also depends on clinical assessment and other autonomic tests (see Chapter 116). Similar to active standing, a systolic BP decline of 20 mm Hg is considered to be abnormal, but most centers require at least a 30 mm Hg drop. Although drops of this magnitude may be asymptomatic, ideally, the patient's typical symptoms are reproduced during testing. Diastolic BP declines of 10 mm Hg are significant.

Patients with autonomic failure often have impaired HR response despite orthostatic hypotension. In contrast, orthostatic intolerance (postural orthostatic tachycardia syndrome) patients have excessive HR increases commonly defined as a 30-beat-per-minute increase usually with a rate exceeding 120 beats per minute and induced symptoms. Asymptomatic orthostatic hypotension is prevalent, especially in elderly patients. Confirmation of benign, recurrent vasovagal syncope, which comprises the majority of unexplained recurrent syncopal cases, is the most frequent use of cardiologic tilt table testing. Unexplained noncardiac syncope is increasingly recognized in older patients, including reflex or situational triggers, carotid sinus hypersensitivity, and acute events with subclinical autonomic failure.

Multiple other techniques that test adrenergic responses have been devised but are considered archaic or research methods because of lower sensitivity or reliability. Orthostatic stress can be enhanced by lower body negative-pressure chambers but primarily only in research applications. The *sustained handgrip test* is performed by continual handgrip at 30% of maximal strength, which normally elevates diastolic BP by at least 10 to 15 mm Hg within 3 to 5 minutes; some normal controls, however, have minimal BP elevation. *Mental stress* is an older method to elevate BP that has unclear use. The *cold pressor test* is another long-standing means to elevate BP that is surprisingly still performed. The subject immerses a hand into ice water for 3 to 5 minutes and BP increases similar to the handgrip test are produced. Measurement of supine and standing *plasma norepinephrine* and other catecholamine levels is a somewhat useful but relatively insensitive marker of adrenergic function. In this circumstance, supine pressure levels characteristically are low and fail to increase adequately with upright tilting. Levels increase poorly with both central and peripheral causes of autonomic failure and rise excessively in pheochromocytoma and some forms of orthostatic intolerance. Nearly unrecordable norepinephrine and epinephrine and increased dopamine levels are characteristic of dopamine β-hydroxylase deficiency. *Microneurography* directly records sympathetic nerve traffic; insertion of a tungsten microelectrode directly into a nerve fascicle enables recording bursts of muscle or skin sympathetic impulses. This powerful technique has important research applications but has limited clinical use and requires considerable expertise and specialized equipment.

Tests of Sudomotor Function

Heat and cold intolerance are prevalent symptoms. Thermal homeostasis is a complex process that relies on both sweating and vasomotor control for heat elimination and shivering and nonshivering mechanisms for heat production and conservation. Disorders producing excessive sweating, with or without neurologic dysfunction, are generally treated by other specialties, usually dermatologists. Vasomotor assessment is possible using laser Doppler techniques but is not highly reliable; however, measurement of sweat gland activity and assessment of sweat gland innervation are commonly performed methods. Reproducible and generally accepted tests are discussed in this chapter.

The *quantitative sudomotor axon reflex test* records chemically induced dynamic sweat output. The test basis is an axon reflex induced by chemically stimulating muscarinic eccrine sweat gland receptors with iontophoresed acetylcholine. This activation induces an antidromic response up a cholinergic axon and induces an orthodromic signal down to a different and isolated group of sweat glands. The sweat produced in this isolated chamber is measured over time. Denervated sweat glands fail to function. Testing requires specialized but commercially available equipment, is reproducible, and correlates variably with epidermal nerve fiber density skin biopsy analysis as a measure of small-diameter nerve integrity. Many, but not most, centers have the necessary equipment. The *thermoregulatory sweat test* assesses sweat output over the anterior body surface in response to a thermal stimulus. This approach uses a physiologic stimulus (core temperature increase) and simultaneously assesses wide areas of skin. An indicator dye, usually alizarin red and not iodine, is applied. The subject is heated to a predetermined degree in a temperature-controlled chamber, and the color change is recorded. Abnormal patterns are readily apparent, but normal variant patterns can complicate interpretation. The test has limited availability. *Sweat imprint techniques* are additional sudomotor testing methods that rely on inducing sweat using heat or cholinergic agents and recording the resultant output on a recording medium; a special quick-hardening silastic media is

typical. Availability of this method is limited. The *sympathetic skin response* is a simple to record and widely available technique well known for over a hundred years. The response, however, is a highly complex multisynaptic reflex with sudomotor activity as the final efferent arm. Both sweat glands and surrounding skin tissue provide the response generators. Interest stems primarily from the simplicity of recording and lack of need for specialized equipment. Multiple protocols are used with various methods. Electrical shock is the most common stimulus; other triggers include startle, cough, deep inspiration, and magnetic stimulation. Responses are best recorded over the palm and sole, ideally all four limbs simultaneously. The evoked amplitude is the most sensitive indicator but is variable and habituates with repeated trials. The range of reported normal values is correspondingly wide; no uniform methods or consensus normative values are accepted. Numerous pitfalls hamper meaningful sympathetic skin response interpretation, so the test is not recommended in isolation. Anticholinergic medications dampen responses. Sensory deficits such as sensory neuropathy may blunt the noxious effect of electrical, but not respiratory, stimuli. Anxiety and distractions can produce unprovoked responses.

In addition to epidermal nerve fiber density determination, some skin biopsy samples include sweat glands. The innervating nerves can be stained with PGP9.5 identically to small sensory nerve fibers. New methods to estimate the density of innervation in these complex structures were devised and are commercially employed and available. Measures reliably distinguish patients with diabetic neuropathy from controls. Reduced sweat gland innervation also correlated with thermoregulatory sweat test measures in one cohort of 10 patients. Other techniques to measure or image small nerve fibers are evolving. *Sudoscan* is a newer, emerging, and U.S. Food and Drug Administration–approved technology that measures electrochemical skin conductance that is proposed to correlate with the number of functional sweat glands. Various comparison studies suggest that results correlate with skin biopsy, autonomic symptom and testing quantitative scores, and other measures of small-fiber and autonomic neuropathy.

Other Organ/System-Specific Tests

Multiple other systems are testable. Some measures are less reliable, difficult to perform, require special expertise, or need further evaluation. Some are performed by specialists in other fields, such as pupillography, gastrointestinal motility and manometry studies, cystometry and urodynamic studies, and sexual dysfunction testing.

USE IN CLINICAL PRACTICE

Current autonomic testing batteries have multiple well-validated, sensitive, and noninvasive tests available that can help confirm, quantify, and characterize clinical autonomic disorders. A multispecialty consensus panel in 2009 recommended that there is level B evidence of autonomic testing to be considered as part of a neuropathy evaluation, especially in the setting of suspected autonomic involvement and there is level C evidence for testing patients with purely sensory neuropathy. Autonomic testing is also potentially useful in the assessment of parkinsonian syndromes, multiple system atrophy, acute and chronic autonomic neuropathy, atypical syncope, and other disorders with suspected autonomic insufficiency or autonomic dysregulation. Multiple clinical syndromes can benefit from testing to guide symptomatic and disease-specific therapy and to aid with diagnosis and management.

SUGGESTED READINGS

Assessment: clinical autonomic testing report of the Therapeutics and Technology Assessment Subcommittee of the American Academy of Neurology. *Neurology*. 1996;46:873-880.

Consensus statement on the definition of orthostatic hypotension, pure autonomic failure, and multiple system atrophy. The Consensus Committee of the American Autonomic Society and the American Academy of Neurology. *Neurology*. 1996;46:1470.

England JD, Gronseth GS, Franklin G, et al. Practice parameter: evaluation of distal symmetric polyneuropathy: role of autonomic testing, nerve biopsy, and skin biopsy (an evidence-based review). Report of the American Academy of Neurology, American Association of Neuromuscular and Electrodiagnostic Medicine, and American Academy of Physical Medicine and Rehabilitation. *Neurology*. 2009;72(2):177-184.

Ewing DJ. Which battery of cardiovascular autonomic function tests? *Diabetologia*. 1990;33:180-181.

Gibbons CH, Freeman R. Delayed orthostatic hypotension: a frequent cause of orthostatic intolerance. *Neurology*. 2006;67:28-32.

Gibbons CH, Illigens BM, Wang N, Freeman R. Quantification of sweat gland innervation: a clinical-pathologic correlation. *Neurology*. 2009;72(17):1479-1486.

Illigens BMW, Gibbons CH. Autonomic testing, methods and techniques. *Handb Clin Neurol*. 2019;160:419-433.

Jones PK, Gibbons CH. The role of autonomic testing in syncope. *Auton Neurosci*. 2014;184:40-45.

Kimpinski K, Iodice V, Burton DD, et al. The role of autonomic testing in the differentiation of Parkinson's disease from multiple system atrophy. *J Neurol Sci*. 2012;317(1-2):92-96.

Loavenbruck A, Wendelschaefer-Crabbe G, Sandroni P, Kennedy WR. Quantification of sweat gland volume and innervation in neuropathy: correlation with thermoregulatory sweat testing. *Muscle Nerve*. 2014;50(4):528-534.

Low PA, Caskey PE, Tuck RR, Fealey RD, Dyck PJ. Quantitative sudomotor axon reflex test in normal and neuropathic subjects. *Ann Neurol*. 1983;14:573-580.

Low PA, Denq JC, Opfer-Gehrking TL, Dyck PJ, O'Brien PC, Slezak JM. Effect of age and gender on sudomotor and cardiovagal function and blood pressure response to tilt in normal subjects. *Muscle Nerve*. 1997;20:1561-1568.

Low VA, Sandroni P, Fealey RD, Low PA. Detection of small-fiber neuropathy by sudomotor testing. *Muscle Nerve*. 2006;34(1):57-61.

Report and recommendations of the San Antonio Conference on Diabetic Neuropathy. Consensus statement. *Diabetes*. 1988;37:1000-1004.

Smith AG, Lessard M, Reyna S, Doudova M, Singleton JR. The diagnostic utility of Sudoscan for distal symmetric peripheral neuropathy. *J Diabetes Complications*. 2014;28(4):511-516.

Stewart JD, Low PA, Fealey RD. Distal small fiber neuropathy: results of tests of sweating and autonomic cardiovascular reflexes. *Muscle Nerve*. 1992;15:661-665.

Vogel ER, Sandroni P, Low PA. Blood pressure recovery from Valsalva maneuver in patients with autonomic failure. *Neurology*. 2005;65(10):1533-1537.

Weimer LH. Autonomic testing: common techniques and clinical applications. *Neurologist*. 2010;16(4):215-222.

29 Evaluation of the Special Senses (Vision, Hearing, Smell, Vestibular System)

J. Kirk Roberts

KEY POINTS

1. Diagnostic testing supplements the history and physical examination and is available for all the special senses.
2. Vision testing includes assessment of acuity, color, visual fields, and retinal anatomy and function.
3. Hearing assessments include audiogram and brainstem auditory-evoked potentials.
4. Smell assessments include both informal and formal testing for detection of individual smells as well as smell thresholds.
5. Vestibular function is assessed by electronystagmography/videonystagmography, rotary chair, vestibular-evoked myogenic potentials, and computerized dynamic posturography, along with gait analysis.
6. The sensitivity, accuracy, and limitations of the various diagnostic tests must be understood to properly determine when appropriate to order them as well as in interpretation.

INTRODUCTION

As with all neurologic complaints, diagnosis begins with a proper history and physical examination.

Appropriate testing supplements the examination and provides more refined measures of neurologic function and impairment. The neurologist may order or request testing that is performed by another physician or a technician in another specialty, or the neurologist may supervise, interpret, or perform the test. In either circumstance, the neurologist should understand the test and its appropriate use. This section reviews some commonly performed vision, hearing, smell, taste, and vestibular tests.

VISION TESTING

Visual Acuity

Visual acuity measures central or foveal vision. Testing usually involves reading letters of different sizes but may involve identifying other symbols. The Snellen chart, which uses letters, and the E chart, which uses the letter E in various orientations, are commonly used tests (Fig. 29.1). Testing is typically done at a distance, to approximate infinity, often 20 ft, and the smallest row read accurately is the visual acuity. If distance vision cannot be performed, then near vision may be tested at a distance of 15.7 inches. For those with such poor vision that the largest letter on the eye chart cannot be read, acuity can be recorded, in order of worsening vision by counting fingers, hand motion, and finally light perception or no light perception. So-called normal vision using the foot as the unit of measurement is defined as 20/20 and means the person can see detail at 20 ft that a person with normal eyesight would see at 20 ft. Thus, a person with 20/40 vision can see at 20 ft what a person with normal vision would see at 40 ft. In the metric system, normal visual acuity is reported as 6/6 (meters), and in the decimal system, normal eyesight is reported as 1.00. However, many have vision that is better than 20/20. Moreover, distance vision and near vision acuity may differ because of hyperopia, myopia, or presbyopia. Specialized testing has been developed to evaluate visual acuity in infants, preverbal children, and others who cannot identify the letters or symbols.

Color Vision

Color vision testing is most commonly evaluated with Ishihara plates, many of which have been adapted to handheld devices. This test consists of a series of plates with colored dots with a pattern of different colored dots forming a number or a shape. This test was originally designed to test for congenital disease, which is

FIGURE 29.1 Snellen chart.

most commonly red-green color deficiency. There are other tests of color vision that include blue-yellow testing. Congenital color vision deficiency is not rare and is more common in men than women. Acquired color vision deficiencies typically, although not strictly, divide into loss of red-green vision in optic nerve disorders and blue-yellow vision in retinal or macular disorders.

Visual-Evoked Potentials

Visual-evoked potentials (VEPs), also known as *visual-evoked responses*, are recorded by measuring brain electrical activity over the occipital lobe in response to repetitive visual stimulation (see Chapter 26). Typically, the P100 wave is the most useful response, and its latency and amplitude are measured. Responses, including latency and amplitude, are measured for each eye, with latency prolongation having the most clinical significance. Ocular, retinal, and visual pathway dysfunction may affect the VEP responses. For the neurologist, the VEP is most commonly used in the evaluation of optic neuritis, where there is a prolonged latency from one eye and/or an elevated interocular latency, as long as ocular and retinal pathology has been excluded.

Electroretinogram

The flash electroretinogram tests retinal function and is not affected by damage more central, such as in the optic nerve.

Visual Fields

Visual field testing is commonly performed in the neurologist's office using finger motion and finger counting (see Chapter 4). More formal testing such as Goldman kinetic perimetry uses a test light of various sizes and intensities, which is moved from the periphery to the center of the vision and thus establishes a boundary of visual detection for each level of stimulus. Most visual field testing is now automated (eg, Humphrey) with lights of varying intensities and sizes appearing in different areas of the visual field while the patient's eye is focused on a specific spot (Fig. 29.2). Although the ophthalmologist uses visual fields to monitor a variety of eye conditions, the neurologist is generally monitoring them in patients with occipital lesions or pituitary lesions with pressure on the optic nerve or chiasm.

Optical Coherence Tomography

Optical coherence tomography is a recently developed test that uses light scattering to produce cross-sectional images of the retina with a resolution that allows evaluation of the different layers. It has had increasing adoption in ophthalmologic practices, where it is used in early detection and monitoring of macular degeneration and glaucoma, among other applications (Fig. 29.3). It has been used in neurologic contexts to measure the retinal nerve fiber layer, which reflects the state of the optic nerve. It is reduced, for example, in patients with multiple sclerosis with optic neuritis. Research applications are being explored in a host of neurologic disorders in hopes of identifying biomarkers of potential use in diagnosis or prognostication.

Adaptive Optics

High-resolution retinal imaging is possible with adaptive optics. These systems compensate for optical faults with a wavefront sensor, deformable mirror, and control system and has been used with retinal cameras, optical coherence tomography, and scanning laser ophthalmoscopes. Highly detailed retinal imaging can offer near cellular level detail.



FIGURE 29.2 Computerized automated visual field report showing a right homonymous hemianopia.

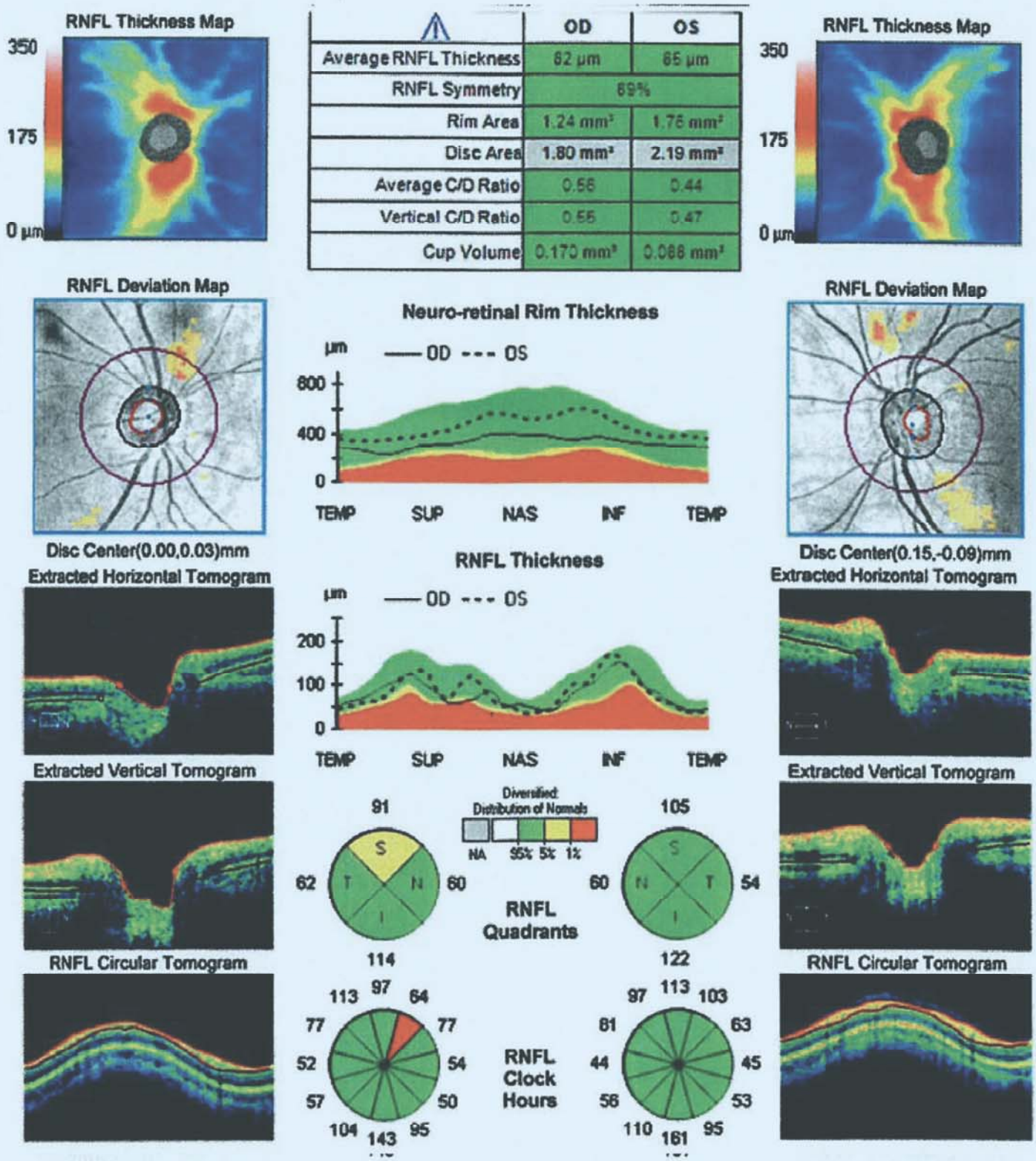

FIGURE 29.3 Optical coherence tomography, focusing on retinal nerve fiber layer (RNFL) of an asymptomatic patient presenting to an ophthalmologist for visual health screening. Retinal fields: INF, inferior; NAS, nasal; OD, right eye; OS, left eye; SUP, superior; TEMP, temporal. Images at left are the right retina; images on right are the left retina. This person has less than 1% retinal fiber layer thickness in the right eye in the superior quadrant, more specifically corresponding to about 1 to 2 o'clock. The thickness of other retinal layers are not described but can be separately determined using OCT.

HEARING TESTING

Audiogram

The audiogram or pure tone testing plots the threshold of hearing in decibels (dB) with standardized frequencies, typically from 125 to 8 kHz. Normal hearing is typically better than 15 dB. Each ear is tested, and both air and bone conduction hearing may be tested. Speech audiometry evaluates how softly someone is able hear words and to understand them. Impedance audiometry includes tympanometry, which measures the changes in acoustic impedance with changes in air pressure and basically measures the compliance of the eardrum.

Brainstem Auditory-Evoked Potentials

Brainstem auditory-evoked potentials, also known as *brainstem auditory-evoked responses* or *auditory brainstem responses*, are the auditory equivalent of the VEP (see Chapter 26). In this test, the patient listens to auditory clicks, and electrical responses are generated at specific anatomic points along the auditory pathway: wave I at the cochlear nerve, wave III at the superior olivary nucleus, and wave V at the inferior colliculi. Brainstem auditory-evoked potentials were typically used in the diagnosis of multiple sclerosis and in the evaluation for an acoustic neuroma, but magnetic resonance imaging has largely supplanted this testing. Electrocochleography is another evoked potential measuring the electrical response of the cochlea to sound. It is used to aid in the diagnosis of Ménière syndrome and in perilymph fistula, although its use is controversial. Otoacoustic emissions measure sounds produced by the ear and are useful in that, if present, indicate a relatively normal functioning cochlea with at least near-normal hearing. However, they are not that helpful in determining the cause of hearing loss.

Smell and Taste Testing

Informal bedside testing of smell can be done with nonirritative substances such as coffee or vanilla. Similarly, bedside testing of taste can be done with a salt or sugar solution. Several formal tests are available to evaluate smell and taste, although are more frequently used in research than in clinical practice. One test, the University of Pennsylvania Smell Identification Test consists of 40 microencapsulated odorants in "scratch and sniff" strips. Others are available, which may additionally allow for discretion of smell intensity thresholds as well as individual smells. Relatedly, kits are available to test taste.

VESTIBULAR SYSTEM

Electronystagmography/ Videonystagmography

Electronystagmography (ENG), which uses electrodes to record eye movements, has largely been supplanted in clinical practice by videonystagmography, in which goggles with infrared cameras are used to track eye motion (Fig. 29.4). The test can be divided into three components: ocular motor testing, tests for spontaneous and positional nystagmus, and caloric testing. Ocular motor testing measures several parameters of saccadic motion (the rapid movement of an eye between fixation points) including velocity, accuracy, and latency; smooth pursuit gain

FIGURE 29.4 Videonystagmography.

(the accuracy of following a moving object); and optokinetic nystagmus (the accuracy of following a moving object and the rapid return of the eyes to the original position). The second part includes an evaluation for spontaneous nystagmus with and without fixation. Positional testing includes the Dix-Hallpike maneuver (see Chapter 5) and lateral head and body turn looking for nystagmus associated with canalolithiasis or cupulolithiasis in the posterior, lateral, or anterior canal. Lastly, bithermal caloric testing with both cool and warm stimuli applied to each ear, is completed to evaluate the response of the vestibular system. Conventionally, water irrigation is used, but more and more are using air because of the ease of performing. The vestibular system generates the slow phase, and the velocity of the slow phase is measured in degrees per second, and the responses between the two ears are compared. More specifically, Jongkees formula is used to calculate a relative vestibular reduction by subtracting the sum of the left cool and left warm response from the sum of the right cool and right warm response and then dividing by the sum of all four responses. More than 20% to 25% asymmetry is considered abnormal. Bilateral dysfunction can be suggested by markedly reduced responses (sum total responses <20° per second), but this might also be due to anatomic or technical issues. The use of air, which is potentially less stimulating than water, is of particular concern in this setting. ENG is most helpful at identifying certain peripheral causes of vertigo including benign paroxysmal positional vertigo where there is an abnormal Dix-Hallpike maneuver and unilateral vestibular neuritis where caloric testing is asymmetric. Testing is often normal in central cause of vertigo, but there may be abnormalities in ocular motor testing.

Rotary Chair

Rotary chair testing adds additional certainty to vestibular testing particularly if the ENG is inconclusive and most importantly if bilateral vestibular dysfunction might be present. The rotary chair may also be useful if mechanical obstruction of the ear canal impedes ENG bithermal caloric testing. As it sounds, in this test, a patient is rotated while eye movements are recorded. The chair is moved either sinusoidally or with step changes in velocity, and eye movements are recorded for gain, phase, and

symmetry. Responses to optokinetic stimulation and a test of visual fixation suppression are also measured. In a patient with bilateral vestibular dysfunction, for example, gain is reduced, and there is a phase lead. Although patients with unilateral vestibular dysfunction may also show abnormalities of gain and phase, rotary chair testing is not sensitive to the side of the dysfunction.

VIDEO HEAD IMPULSE TESTING

Head impulse testing is commonly performed at the bedside, where the patient is asked to focus on the examiner's nose and the examiner quickly rotates the head a small amount and looks for a "lag" where the eyes do not stay focused on the nose, but rather travel with the head and there is a late saccade to refixate on the nose. This identifies a peripheral vestibular hypofunction. Video head impulse testing systems using lightweight goggles have now been developed to further quantify and identify vestibular hypofunction, perhaps increasing the sensitivity and accuracy over that of standard bedside testing.

Vestibular-Evoked Myogenic Potentials

Vestibular-evoked myogenic potentials (VEMPs) are a relatively less commonly used test meant to evaluate the saccule and the inferior vestibular nerve. In this test, the response of the sternocleidomastoid to auditory stimuli is recorded. Of note, hearing does not seem necessary for VEMPs. In general, VEMPs are considered abnormal if there is a significant asymmetry or if they are low or absent. In addition, thresholds to generate VEMPs may be abnormally low in patients with perilymphatic fistula or superior canal dehiscence. Some have reported that VEMPs are low or have a higher threshold in Ménière syndrome, but their use in diagnosing this disorder is questionable. Similar responses may also be seen in muscles other than the sternocleidomastoid, such as the eye muscles.

Computerized Dynamic Posturography

Computerized dynamic posturography attempts to quantify balance disorders. In this test, the patient stands on a horizontal platform, which can translate or incline, along with measuring the forces exerted by the patient's feet, and can also alter the visual surround. Testing systems that do not include all of the mentioned are less useful. A common testing protocol includes the sensory organization test, which includes six subtests. The subtests grow progressively more difficult by altering the conditions including eyes open or closed, flat or tilted floor, and vertical or tilted visual surround. Computerized dynamic posturography is not necessarily abnormal in those with vestibular disorders and is therefore complementary to vestibular testing.

Gait Analysis

Gait testing can be formally analyzed through objective metrics, but may be limited to use in specialized centers or research programs, and is discussed further in Chapter 15.

SUGGESTED READINGS

Baloh RW, Jacobson KM, Enrietto JA, Corona S, Honrubia V. Balance disorders in older persons: quantification with posturography. *Otolaryngol Head Neck Surg*. 1998;119(1):89-92.

Bouffard MA, Prasad S. Advances in neuro-ophthalmic imaging. *Semin Neurol*. 2017;37(5):566-579.

Chandrasekha SS, Tsai Do BS, Schwartz SR, et al. Clinical practice guideline: sudden hearing loss (update). *Otolaryngol Head Neck Surg*. 2019;161(suppl 1): S1-S45.

Desmond AL. *Vestibular Function: Evaluation and Treatment*. New York, NY: Thieme; 2004.

Fife TD, Colebatch JG, Kerber KA, et al. Practice guideline: cervical and ocular vestibular evoked myogenic potential testing: report of the Guideline Development, Dissemination, and Implementation Subcommittee of the American Academy of Neurology. *Neurology*. 2017;89: 2288-2296.

Fife TD, Tusa RJ, Furman JM, et al. Assessment: vestibular testing techniques in adults and children: report of the Therapeutics and Technology Assessment Subcommittee of the American Academy of Neurology. *Neurology*. 2000;55:1431-1441.

Handelsman JA, Shepard NT. Electronystagmography and videonystagmography. In: Goebel JA, ed. *Practical Management of the Dizzy Patient*. 2nd ed. Philadelphia, PA: Lippincott Williams & Wilkins; 2008: 117-135.

Handelsman JA, Shepard NT. Rotational chair testing. In: Goebel JA, ed. *Practical Management of the Dizzy Patient*. 2nd ed. Philadelphia, PA: Lippincott Williams & Wilkins; 2008:137-152.

Leigh RJ, Zee DS. *The Neurology of Eye Movements*. 4th ed. Oxford, United Kingdom: Oxford University Press; 2006.

Nashner LM. Computerized dynamic posturography. In: Goebel JA, ed. *Practical Management of the Dizzy Patient*. 2nd ed. Philadelphia, PA: Lippincott Williams & Wilkins; 2008:153-182.

Rizk H, Agrawal Y, Barthel S, et al. Quality improvement in neurology: neurootology quality measurement set. *Neurology*. 2018;91:697-701.

Skarf B, Glaser JS, Trick GL, et al. Neuro-ophthalmologic examination: the visual sensory system. In: Glaser JS, ed. *Neuro-ophthalmology*. 3rd ed. Philadelphia, PA: Lippincott Williams & Wilkins; 1999:7-49.

Sweetow RW, Sabes J. Audiologic testing. In: Lalwani AK, ed. *Current Diagnosis & Treatment in Otolaryngology—Head & Neck Surgery*. 3rd ed. New York, NY: McGraw-Hill; 2012:617-625.

Valente M. Audiometric tests. In: Goebel JA, ed. *Practical Management of the Dizzy Patient*. 2nd ed. Philadelphia, PA: Lippincott Williams & Wilkins; 2008:183-201.

Wicki CA, Hanson JVM, Schippling S. Optical coherence tomography as a means to characterize visual pathway involvement in multiple sclerosis. *Curr Opin Neurol*. 2018;31(5):662-668.

Welgampola MS, Taylor RL, Halmagyi GM. Video head impulse testing. *Adv Otorhinolaryngol*. 2019;82:56-66.

Wylęgała A. Principles of OCTA and applications in clinical neurology. *Curr Neurol Neurosci Rep*. 2018;18(12):96.

Sleep Studies 30

Andrew J. Westwood and Carl W. Bazil

KEY POINTS

1. A sleep diary is a simple method to obtain information about an individual's sleep over several weeks, particularly in evaluation of circadian disorders and insomnia and to rule out insufficient sleep.
2. Polysomnography is the gold standard diagnostic test of most sleep disorders.
3. Home sleep apnea testing is a convenient screening test for individuals suspected of having obstructive sleep apnea.
4. When narcolepsy is suspected, a polysomnogram followed by multiple sleep latency test should be ordered. A mean sleep latency of less than 8 minutes and two or more sleep-onset rapid eye movement periods is supportive of the diagnosis.

INTRODUCTION

The National Institutes of Health estimates that 50 to 70 million Americans are affected by sleep problems (see Chapter 118). Sleep deprivation and disorders have been linked not only to chronic medical diseases such as obesity, stroke, and diabetes but also to mental health issues and to an increased risk of accidents, particularly motor vehicle accidents. Lack of sleep is not a trivial concern, and increasingly, this is becoming identified by providers and the public.

Validated questionnaires and sleep logs (including those now available as smartphone applications) provide detailed, albeit subjective, information about sleep that can be combined with objective testing to direct appropriate treatment and management of sleep concerns.

INDICATIONS FOR DIAGNOSTIC SLEEP TESTING

The polysomnogram (PSG) is the most common test ordered; however, with changes in medical insurance, many screening home sleep apnea tests are performed prior to this. As well as the overnight PSG, other procedures include the multiple sleep latency test (MSLT), a measure of the ability to fall asleep during the day and maintenance of wakefulness test (MWT), a measure of the ability to stay awake during the day. Additionally, actigraphy—using movement as a surrogate for sleep—can provide useful information about sleep patterns over days to weeks. Each of these will be discussed in detail in the following text.

Polysomnography should be considered for those whose sleep is chronically interrupted, terminates early, or is prolonged in duration. It is not typically useful in those with difficulty initiating sleep unless the individual has not responded well to standard treatments.

Obstructive sleep apnea (compromise of the upper air resulting in disrupted respiration during sleep) is the most common reason for testing due to its high prevalence and ability to mimic other sleep disorders. Symptoms of obstructive sleep apnea may include snoring, frequent nocturia, sensation of choking, or inability to breathe as well as excessive daytime sleepiness, morning headaches, and impaired vigilance in the daytime. Less common symptoms include dream enactment, automatic sleep behaviors, nocturnal limb movements, and nightmares. Signs to suggest sleep apnea include obesity, retrognathia, a crowded oropharynx, and floppy eyelids. Obstructive sleep apnea is common in neuromuscular disorders, cerebrovascular disease, and cognitive disorders. Central sleep apnea (dysregulated respiratory drive in the brain resulting in disrupted respiration during sleep) can be due to Arnold-Chiari malformation, cerebrovascular disease, and cardiomyopathy, for example.

In individuals where prolonged sleep or unexplained excessive daytime sleepiness occurs, the PSG is followed by the MSLT. A very short sleep latency and presence of rapid eye movement (REM) in two or more naps is highly suggestive of narcolepsy. However, recent evidence suggests the repeatability of this test is poor and remains an area of research to provide alternative approaches.

Parasomnias may sometimes be diagnosed entirely by history and without testing, but due to the possible confusion between them, association with other sleep disorders such as obstructive sleep apnea, and mimickers such as nocturnal seizures, polysomnography is often advisable. Parasomnias include night terrors, rhythmic movement disorder, sleepwalking (especially in adults), and REM behavior disorder. When nocturnal seizures are in the differential, polysomnography should be performed with simultaneous video electroencephalography (EEG).

Polysomnography

The (in-laboratory) PSG is the gold standard diagnostic test of most sleep disorders (**Table 30.1**). Clinical polysomnography consists of the simultaneous recording of multiple physiologic variables, allowing objective documentation of sleep state and for evaluation of common sleep disorders. Practitioners will routinely use a minimum of four EEG channels, covering the occipital and central regions required for scoring of sleep, but most will use more. Electrooculography (EOG); mentalis electromyography (EMG); surface EMG of the anterior tibial muscles for detection of leg movements in sleep; electrocardiography; and measurement of nasal and oral airflow, respiratory effort, and oxygen saturation as well as audio and video recording are also standard. Additional variables analyzed may include carbon dioxide monitoring and esophageal manometry.

TABLE 30.1 Indications for Polysomnography[a]

• Diagnosis of sleep-related breathing disorders
• PAP titrations for sleep-related breathing disorders
• Preoperative evaluation prior to upper airway surgery for snoring or obstructive sleep apnea
• Follow-up after good clinical response to oral appliance treatment
• Follow-up after surgical treatment
• Recurrence of symptoms despite initial response to surgical or dental treatments
• Follow-up in patients with substantial weight loss after PAP initiation
• Follow-up in patients with substantial weight gain after PAP initiation
• Insufficient response to PAP therapy despite a good initial response
• Patients with systolic or diastolic heart failure with sleep complaints despite optimal cardiac treatments
• Patients with neuromuscular disorders and sleep complaints despite optimal sleep hygiene
• Narcolepsy (followed by MSLT)
• Periodic limb movement disorder
• Uncertainty of restless legs syndrome

Abbreviations: MSLT, multiple sleep latency test; PAP, positive airway pressure.

[a]Based on Kushida CA, Littner MR, Morgenthaler T, et al. Practice parameters for the indications for polysomnography and related procedures: an update for 2005. *Sleep*. 2005;28(4):499-521.

The recordings are analyzed at 30-second intervals or epochs. Each epoch is evaluated based on muscle tone, electrooculography, and EEG to determine sleep stage or wakefulness. Each epoch is also evaluated for abnormalities in respiratory flow/pressure, oxygen saturation, heart rate, and leg movements (Fig. 30.1). The American Academy of Sleep Medicine provides guidance on scoring for sleep stage and respiratory disturbances (apneas, hypopneas, respiratory-related arousals) as well as limb movements. Once each epoch has been analyzed, a convenient way to display this significant amount of data is the hypnogram. This can show the macroarchitecture over the course of the entire night and can be modified to provide additional information such as timings of respiratory disturbances and body position.

Patients should ideally fill out sleep logs for at least 1 week prior to the test. Medications and napping on the day of the study should be noted, and it is often helpful to have the patient's impression of his or her sleep during the study. It is common for an individual to sleep more supine in the study than at home and should be considered in the clinical implications of the result.

Evoking Parasomnias

Parasomnias such as sleepwalking and sleep terrors typically arise from slow-wave sleep (stage N3). They may not occur on a nightly basis. In order to increase the yield of recording such events, a patient may sometimes be asked to restrict his or her sleep the night prior in order to provoke a rebound of slow-wave sleep. There are some data that deliberate external stimuli, such as sound, during slow-wave sleep may also cause provocation of the events.

Evaluating Rapid Eye Movement Behavior Disorder

Recording of dream enactment behavior during REM sleep (Fig. 30.2) is helpful, however not required, to support a diagnosis of REM behavior disorder. One of the cardinal features of this disorder is the lack of atonia during REM sleep. Atonia is usually identified in the chin lead; however, it may be present in one or more limb leads. Some practitioners may apply additional leads to all four extremities in cases where REM behavior disorder is a concern. It is important to note that melatonin can suppress the atonia and should be stopped prior to the study.

Home Sleep Apnea Test

Obstructive sleep apnea is a prevalent condition within the general population. In those with no significant comorbidities such as neuromuscular weakness, heart failure, seizure disorder, or morbid obesity, a simplified version of the in-laboratory PSG may be warranted. There are many devices available that may monitor only three variables (typically oxygen saturation, pulse, and air flow) or provide a more thorough evaluation including electrocardiography and extrapolated EEG using one or two electrodes. The benefits of the test are typically in cost saving as well as being beneficial for individuals who may not sleep well in unfamiliar environment. As portable testing typically does not allow reliable sleep scoring and excludes video and limb EMG, it is not indicated for evaluation of suspected parasomnias, REM behavior disorder, or periodic limb movement disorder. However, this testing is becoming increasingly required prior to performing in-laboratory polysomnography from insurance companies despite these reservations.

The home sleep apnea test can be a useful screening tool for obstructive sleep apnea but lacks sensitivity, as it yields limited data in many cases, relying on the individual to set up and adjust the equipment. In-laboratory polysomnography may be required if the study remains unrevealing or if the apnea-hypopnea index is borderline.

Multiple Sleep Latency Test

Patients with excessive daytime sleepiness may be evaluated by the MSLT, a series of five nap opportunities (sometimes four or six) with sleep recordings at 2-hour intervals throughout the day. "Normal" sleep for that individual is recommended for 7 days prior to the test, and any medications that can disrupt sleep architecture, particularly antidepressants, should ideally be discontinued 2 weeks prior to the study. Polysomnography should be performed the night prior to testing so that prior sleep is documented. If significant obstructive sleep apnea is noted on polysomnography, the MSLT is typically not performed. A minimum of 6 hours of sleep should occur during polysomnography to reliably proceed with an MSLT.

Sleep onset is defined as the first epoch of nonwakefulness. The nap is terminated 15 minutes after sleep onset. If no sleep occurs, each recording session is terminated after 20 minutes. The sleep latency (the time it takes to fall asleep) is determined for each nap and provides an objective measure of daytime sleepiness. If no REM sleep occurs in four naps, the test may be terminated. Similarly, if REM occurs in at least two of four naps, testing could be terminated early. If, however, REM has occurred in only one of four naps, the patient is generally given the fifth nap in order to determine whether narcolepsy is likely.

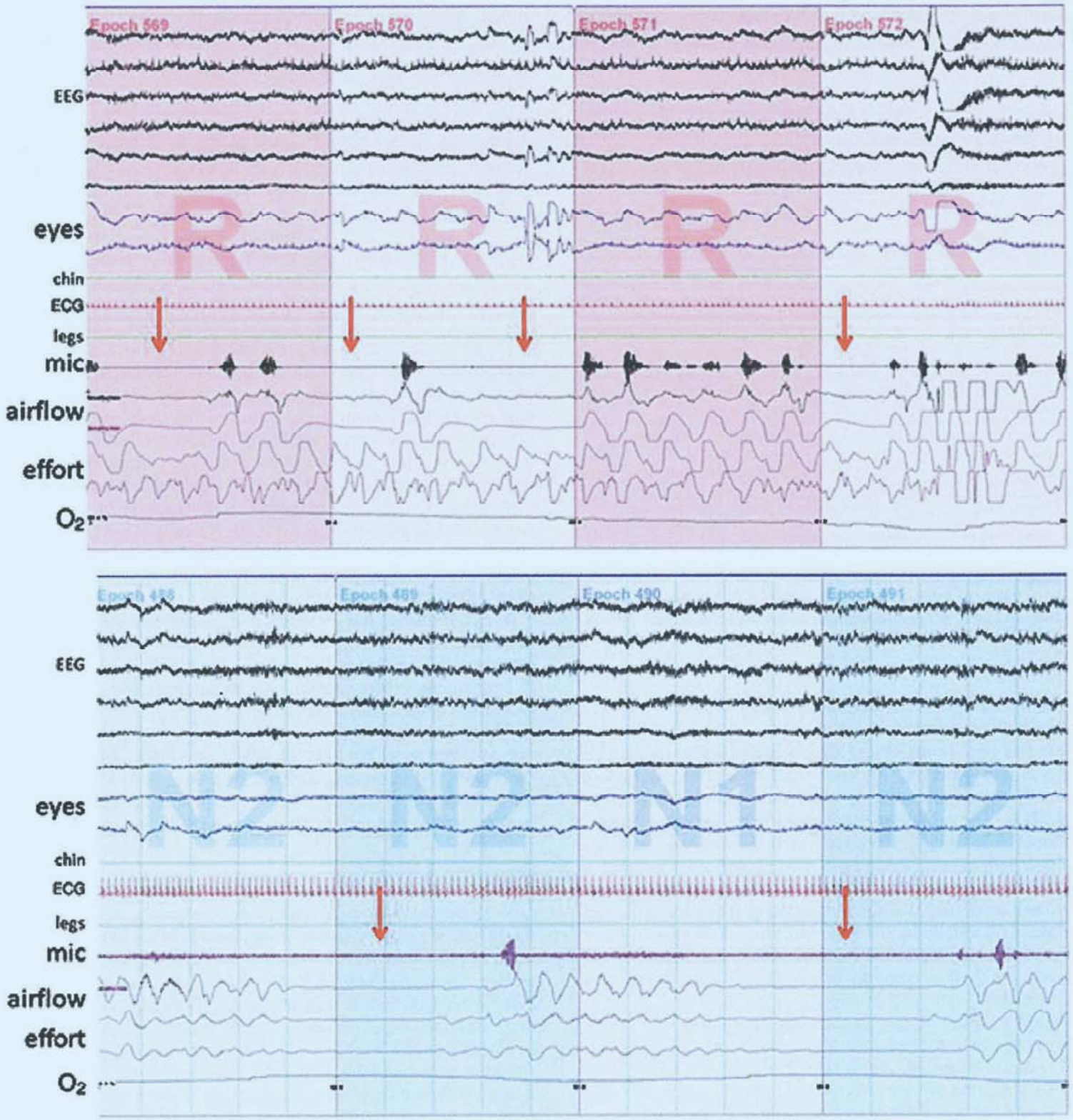

FIGURE 30.1 **A:** A 4-minute recording of stage R (rapid eye movement sleep) showing cessation of airflow with continued abdominal and chest movements during apneic pauses illustrated by the *red arrows*. Note the snoring ceases with airflow and oxygen saturation declines. This is consistent with obstructive sleep apnea. **B:** A 4-minute recording of N1 and N2 (nonrapid eye movement sleep) showing cessation of airflow and abdominal and chest movements illustrated by the *red arrows*. This is consistent with central sleep apnea. Abbreviations: ECG, echocardiography; EEG, electroencephalography; O_2, oxygen.

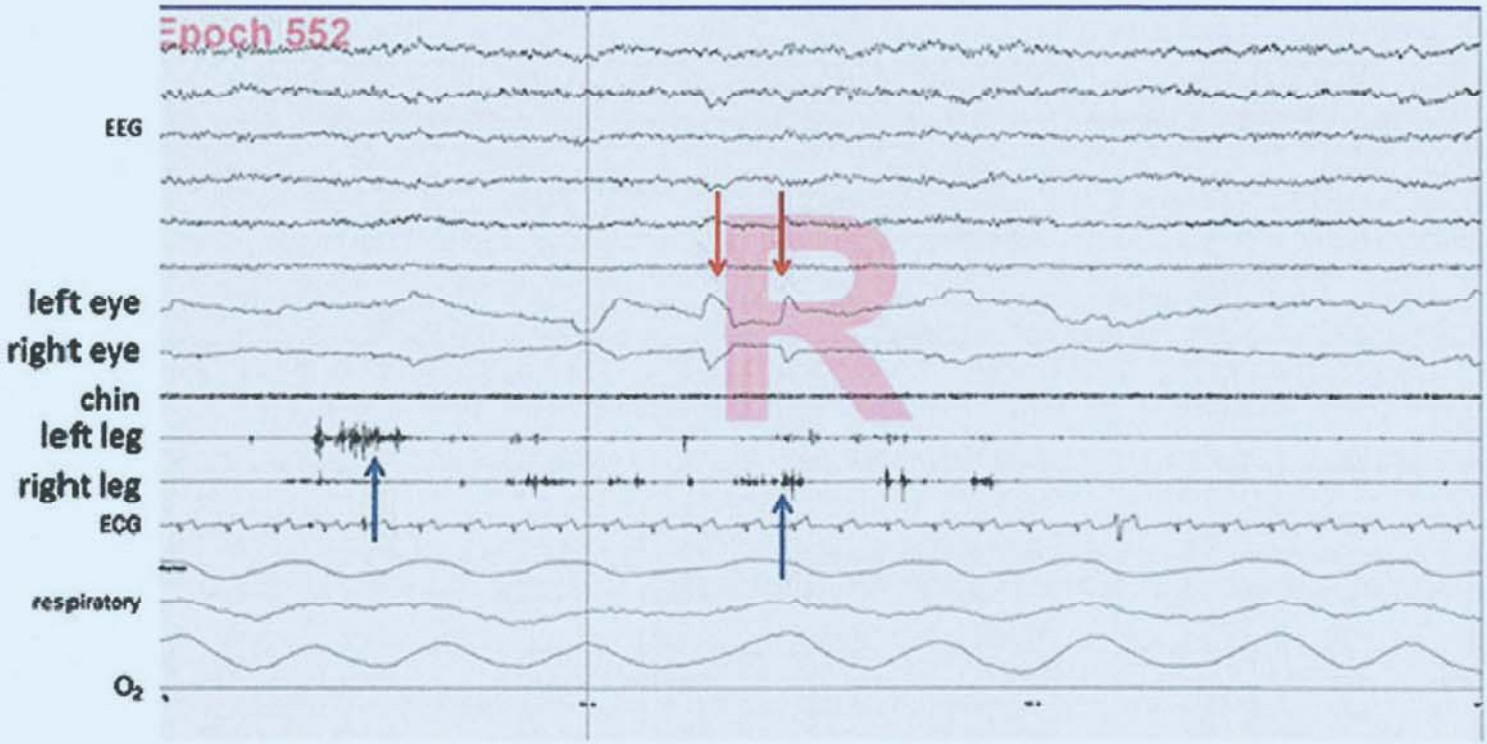

FIGURE 30.2 Single epoch of phasic R sleep (*red arrows* indicate rapid eye movements) with movements of both the left and right legs *(blue arrows)*. Abbreviations: ECG, echocardiography; EEG, electroencephalography; O_2, oxygen.

Sleep latency over the course of the naps is averaged (20 min is used as time onset if the patient does not fall asleep). Additionally, any REM periods are counted; REM within 15 minutes is considered abnormal. These are described as sleep-onset rapid eye movement periods (SOREMPs). If an SOREMP is obtained in the prior night polysomnography, this can also be taken into consideration.

The main indication of this study is to support the diagnosis of narcolepsy. Individuals with narcolepsy tend to have mean sleep latencies of 3 ± 3 minutes. However, 16% of normal individuals will have a sleep latency of less than 5 minutes. Patients with narcolepsy typically have a mean sleep latency of less than 8 minutes and demonstrate at least two naps with sleep-onset REM. Although there is significant overlap of the mean sleep latencies of normal individuals and those who complain of excessive sleepiness, normal is considered to be a mean sleep latency of greater than 10 minutes.

The SOREMPs can also be seen as a result of obstructive sleep apnea, sleep deprivation, drug(s) withdrawal, or narcolepsy; in these cases, only one is typically seen in an MSLT. Two SOREMPs have 78% sensitivity and 93% specificity for narcolepsy. Notably, no large systematically collected repository of normative MSLT data is known to exist, and normal values for individuals younger than 6 years of age have not been established. If the individual has an SOREMP during the overnight PSG, this also counts toward the total number obtained on the MSLT.

Maintenance of Wakefulness Test

The MWT measures the time a patient is able to remain awake in a low-light environment during four 40-minute (sometimes 20-min) attempts. The patient is instructed to remain awake in a semirecumbent position, without any stimulating behaviors. The test may provide more information about the patient's ability to sustain wakefulness, but the validity of test results to real-life experience is unclear. It is sometimes used to evaluate driving performance in individuals who may be at high risk for daytime sleepiness.

Sleep onset is defined as three epochs (90 s) of continuous stage 1 sleep or one epoch of any other stage of sleep. A total of 97.5% of normal sleepers stay awake for an average of 8 minutes or more during the MWT. Falling asleep in an average of less than 8 minutes during the test would be considered abnormal. Results show that from 40% to 59% of people with normal sleep stay awake for the entire 40 minutes of all four trials.

EVALUATION OF CIRCADIAN RHYTHM DISTURBANCES

As well as the intrinsic characteristic of a person's sleep, extrinsic factors placed on the timing of the sleep-wake cycle may disrupt the ability of an individual to sleep when necessary. Several variants have been described including the delayed and advanced sleep phase syndromes, shift work disorder, and jet lag disorder. Non–24-hour sleep syndrome, in which the internal clock is free running, is the most severe of these but is quite rare. Diagnosis may be made simply through history taking and documentation with a sleep diary; however, patient recall of sleep patterns over time may be limited. Actigraphy can be helpful to objectively document sleep patterns.

Actigraphy

The essence of actigraphy is based on the concept that movement is limited during sleep. A device typically worn on the nondominant wrist monitors movement over a specific duration of time, typically up to 2 weeks, and is typically correlated to a diary of activity (Fig. 30.3). The parameters on some devices can be used to assess specifics such as the frequency of limb movements that occur during sleep. Studies that compare actigraphy to sleep with polysomnography show that it is a reasonable, although not perfect, surrogate measurement for sleep. It is clearly not practical (or necessary) to do formal polysomnography for weeks at a time to determine sleep patterns.

Many commercially available applications now use the principle of actigraphy to allow patients to track their sleep. Actigraphy applications using smartphone accelerometers have limited use, as most require movement of the bed rather than the person, and are not well correlated with actual sleep. In contrast, other linked accelerometry devices may be worn on the body (typically the arm); these are likely reasonably similar to actigraphy and have potential to be viewed by the clinician to help with diagnosis and to monitor treatment progress.

Biomarkers of Circadian Rhythm

Several variables are used to evaluate the sleep-wake rhythm, principally for research purposes and to a lesser extent in clinical practice. Melatonin or its metabolites can be measured in the urine, blood, or saliva. Melatonin secretion begins in the evening hours and peak overnight. During the daytime hours, levels are barely detectable. Dim light melatonin onset (DLMO) is the point at which melatonin levels reach 2 pg/mL in plasma or 4 pg/mL in the saliva. It can also be measured as the mean of three daytime samples plus two standard deviations of these three daytime samples. It typically occurs 2 hours before bedtime provided that lighting is dim. The DLMO is considered the standard measure of circadian pattern. For example, a patient with delayed sleep phase phenomenon would have very late DLMO (3 to 5 AM). A patient with shift work sleep disorder would continue to show DLMO during the typical work shift.

Core body temperature usually peaks in the late afternoon. Sleep typically occurs on the downward slope and ends about 2 hours following the nadir. Loss of normal core body temperature rhythm can be diagnosed with continuous temperature monitoring, but this is not a convenient method for determining circadian pattern clinically.

SUBJECTIVE REPORTING OF SLEEP

In addition to reports of sleep complaints, a patient can keep a log of his or her sleep-wake cycle over time (Fig. 30.4). This can be used in combination with actigraphy, particularly when evaluating for paradoxical insomnia. It can also be used to visually evaluate potential sleep-wake disorders as well as help to ensure

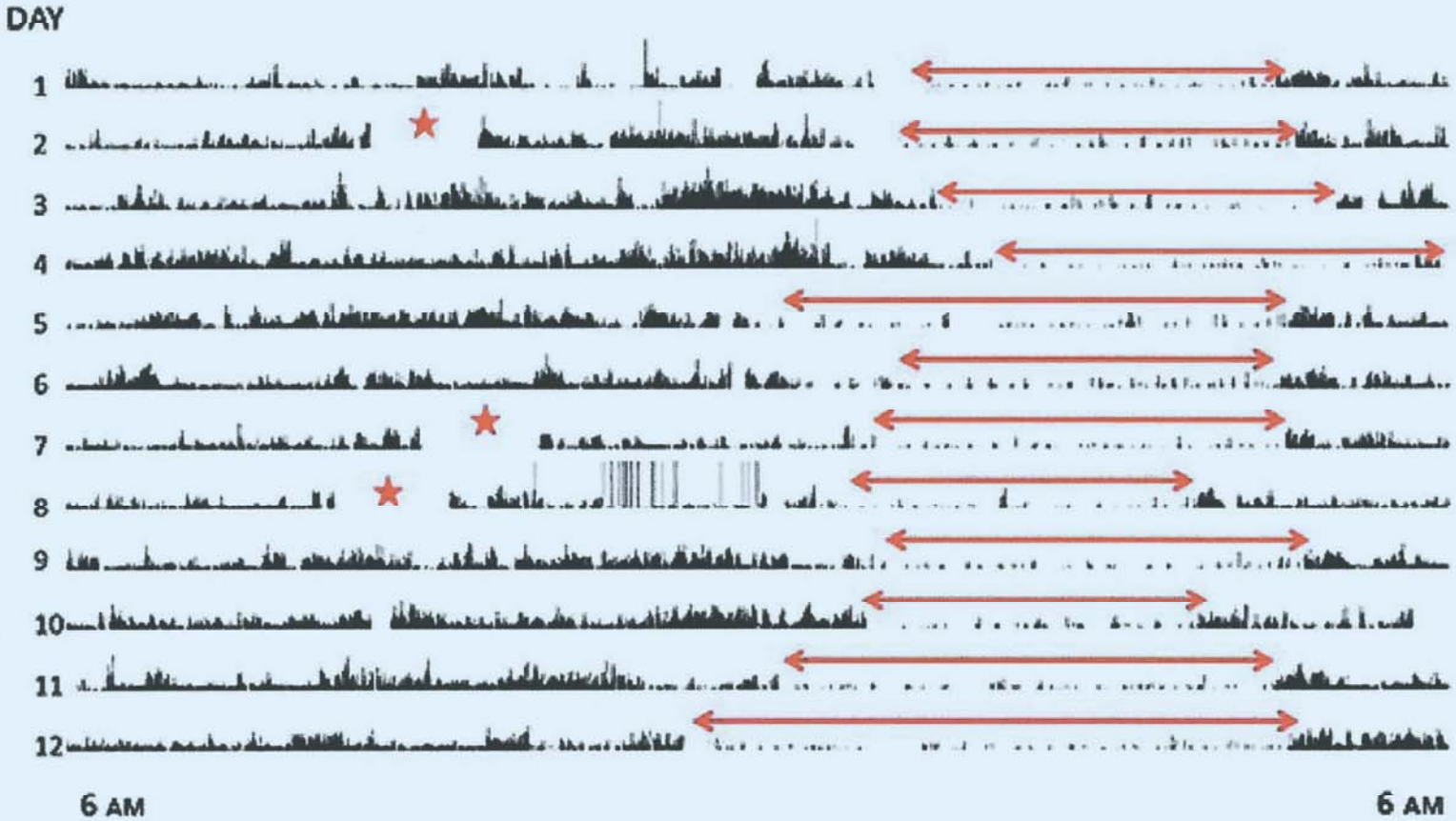

FIGURE 30.3 Actogram of activity for 12 days. Each day is plotted on a row, and quantity of movement is indicated by *black*. This is typically correlated with a log by the individual. Periods with limited movement likely correlate with sleep *(red arrows)*. Periods of absolute lack of movement *(red stars)* suggest removal of the watch.

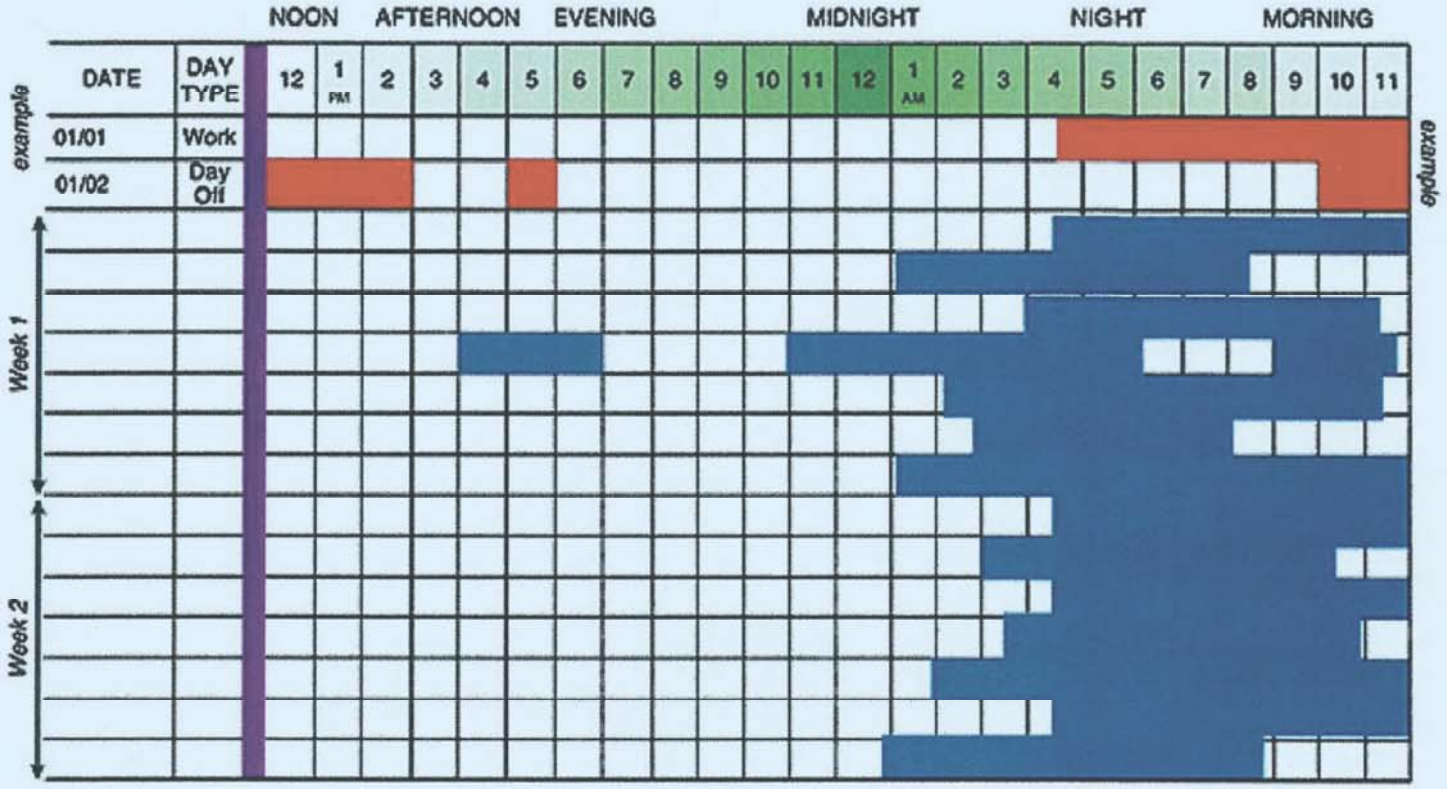

FIGURE 30.4 Sleep diary. The individual is asked to shade the boxes indicating the estimated sleep. Here, the individual has a delayed sleep phase syndrome typically not sleeping until 2 AM or later. Note that on the day of a nap in the afternoon, the individual remains awake during the typical hours of sleep. Further information could be added such as time of medication, times of caffeine intake or exercise, and time getting into and out of bed.

the patient is getting sufficient sleep prior to polysomnography, which may otherwise alter sleep architecture.

Many questionnaires related to sleep exist, with most particularly focusing on obstructive sleep apnea or snoring, whereas others may evaluate the quality of sleep, degree of sleepiness, or the inability to sleep. A frequently used questionnaire in many practices is the Epworth Sleepiness Scale. Rating eight situations on a scale of 0 to 3 for severity of sleepiness results in a possible total of 24. A level of 10 or more typically indicates excessive sleepiness. Persons with narcolepsy may have scores around 16, although this is varied between individuals. Not only is it used for diagnostic purposes but can also be quickly and easily used to monitor efficacy of treatment. It is important to know that the Epworth shows very limited correlation with the objective sleepiness seen on MSLT. Patients with severe sleepiness due to obstructive sleep apnea, for example, may be observed to fall asleep in the waiting room but score normally on the Epworth. This supports that patients are often unaware or in denial of their own sleepiness; nevertheless, the Epworth can be useful in documenting a patient's perception of his or her drowsiness.

Other questionnaires are typically used as a screening tool for potential sleep disorders. There are over 14 questionnaires that exist for the evaluation of sleep-disordered breathing. Although many can help increase the sensitivity for sleep apnea, the diagnosis can only be made through the use of polysomnography. There are also at least five available questionnaires to evaluate for REM sleep behavior disorder but ultimately, a PSG determines the diagnosis and excluded mimickers such as periodic limb movement disorder or obstructive sleep apnea.

INDICATIONS FOR LABORATORY TESTING

Narcolepsy

In rare circumstances or for research purposes, laboratory tests may be useful to confirm a suspicion of narcolepsy. In individuals who have narcolepsy type 1 (associated with cataplexy), a lumbar puncture can be performed. Cerebrospinal fluid levels of hypocretin-1 of less than 110 ng/mL are diagnostic with 87% sensitivity and 99% specificity for narcolepsy type 1. The majority of patients with idiopathic hypersomnia and narcolepsy type 2 have normal cerebrospinal fluid hypocretin-1 levels. Genetic testing can also be helpful in some circumstances. The allele HLA-DQB1*0602 is present in over 90% of individuals with narcolepsy type 1, 56% of type 2 narcolepsy, and 52% of individuals with idiopathic hypersomnia. However, it is found in between 12% and 35% of healthy individuals.

Restless Legs Syndrome

Restless legs syndrome (RLS) is a clinical diagnosis based on an urge to move limbs (not necessarily legs or a leg) that is typically worse in the evening or inactivity that is temporarily relieved by movement and not due to position, cramps, or pain (see Chapter 78). Secondary causes may include anemia, uremia, thyroid dysfunction, or venous disease. Of particular note is that a ferritin level of less than 50 μg/L, sometimes 75 μg/L despite being considered to be within the normal range, is treated with exogenous iron supplementation. A morning fasting ferritin is

recommended due to diurnal fluctuations. Single nucleotide polymorphisms in some genes have been associated with an increased risk of RLS; however, these are not diagnostic. For example, variants in the gene *BTBD9* can be seen in 75% of individuals with RLS but also in 65% of those who have never had the syndrome.

IMAGING

Imaging is not routinely performed as part of a workup for sleep disturbances. However, rare presentations of narcolepsy have resulted from strokes or demyelinating lesions in the brainstem. Hypoperfusion in the thalami of individuals with Kleine-Levin syndrome during symptomatic periods can be seen on single-photon emission computed tomography or positron emission tomography imaging. Brain imaging should be considered in any individual with respiratory arrests not typical of obstructive sleep apnea or that occur during wakefulness. In a subset of individuals with congenital central hypoventilation syndrome—respiratory arrests during sleep, typically seen in childhood as a result of inborn failure of autonomic control of breathing—there is a higher incidence of neural crest tumors such as neuroblastomas.

SUGGESTED READINGS

Berry RB, Brooks R, Gamaldo CE, et al; for the American Academy of Sleep Medicine. *The AASM Manual for the Scoring of Sleep and Associated Events: Rules, Terminology and Technical Specifications. Version 2.6.* Westchester, IL: American Academy of Sleep Medicine; 2020.

Brown EN, Czeisler CA. The statistical analysis of circadian phase and amplitude in constant-routine core-temperature data. *J Biol Rhythms.* 1992;7(3):177-202.

Buysse DJ, Reynolds CF III, Monk TH, Berman SR, Kupfer DJ. The Pittsburgh Sleep Quality Index: a new instrument for psychiatric practice and research. *Psychiatry Res.* 1989;28(2):193-213.

Carskadon MA, Dement WC, Mitler MM, Roth T, Westbrook PR, Keenan S. Guidelines for the multiple sleep latency test (MSLT): a standard measure of sleepiness. *Sleep.* 1986;9(4):519-524.

Collop NA, Anderson WM, Boehlecke B, et al. Clinical guidelines for the use of unattended portable monitors in the diagnosis of obstructive sleep apnea in adult patients. Portable Monitoring Task Force of the American Academy of Sleep Medicine. *J Clin Sleep Med.* 2007;3(7):737-747.

Doghramji K, Mitler MM, Sangal RB, et al. A normative study of the maintenance of wakefulness test (MWT). *Electroencephalogr Clin Neurophysiol.* 1997;103(5):554-562.

Fedson AC, Pack AI, Gislason T. Frequently used sleep questionnaires in epidemiological and genetic research for obstructive sleep apnea: a review. *Sleep Med Rev.* 2012;16(6):529-537.

Hertenstein E, Gabryelska A, Spiegelhalder K, et al. Reference data for polysomnography-measured and subjective sleep in healthy adults. *J Clin Sleep Med.* 2018;14(4):523-532.

Huang Y-S, Guilleminault C, Kao P-F, Liu F-Y. SPECT findings in the Kleine-Levin syndrome. *Sleep.* 2005;28(8):955-960.

Johns MW. A new method for measuring daytime sleepiness: the Epworth Sleepiness Scale. *Sleep.* 1991;14(6):540-545.

Johns MW. Sensitivity and specificity of the multiple sleep latency test (MSLT), the maintenance of wakefulness test and the Epworth Sleepiness Scale: failure of the MSLT as a gold standard. *J Sleep Res.* 2000;9(1):5-11.

Kapur VK, Auckley DH, Chowdhuri S, et al. Clinical practice guideline for diagnostic testing for adult obstructive sleep apnea: an American Academy of Sleep Medicine clinical practice guideline. *J Clin Sleep Med.* 2017;13(3):479-504.

Kushida CA, Littner MR, Morgenthaler T, et al. Practice parameters for the indications for polysomnography and related procedures: an update for 2005. *Sleep.* 2005;28(4):499-521.

Lewy AJ, Bauer VK, Ahmed S, et al. The human phase response curve (PRC) to melatonin is about 12 hours out of phase with the PRC to light. *Chronobiol Int.* 1998;15(1):71-83.

Littner MR, Kushida C, Wise M, et al. Practice parameters for clinical use of the multiple sleep latency test and the maintenance of wakefulness test. *Sleep.* 2005;28(1):113-121.

Mignot E, Lammers GJ, Ripley B, et al. The role of cerebrospinal fluid hypocretin measurement in the diagnosis of narcolepsy and other hypersomnias. *Arch Neurol.* 2002;59(10):1553-1562.

Morgenthaler TI, Lee-Chiong T, Alessi C, et al. Practice parameters for the clinical evaluation and treatment of circadian rhythm sleep disorders. An American Academy of Sleep Medicine report. *Sleep.* 2007;30(11):1445-1459.

Patil SP, Ayappa IA, Caples SM, et al. Treatment of adult obstructive sleep apnea with positive airway pressure: an American Academy of Sleep Medicine clinical practice guideline. *J Clin Sleep Med.* 2019;15(2):335-343.

Pilon M, Montplaisir J, Zadra A. Precipitating factors of somnambulism: impact of sleep deprivation and forced arousals. *Neurology.* 2008;70(24):2284-2290.

Roehrs T, Roth T. Multiple sleep latency test: technical aspects and normal values. *J Clin Neurophysiol.* 1992;9(1):63-67.

Smith MT, McCrae CS, Cheung J, et al. Use of actigraphy for the evaluation of sleep disorders and circadian rhythm sleep-wake disorders: an American Academy of Sleep Medicine clinical practice guideline. *J Clin Sleep Med.* 2018;14(7):1231-1237.

Stiasny-Kolster K, Mayer G, Schäfer S, et al. The REM sleep behavior disorder screening questionnaire—a new diagnostic instrument. *Mov Disord.* 2007;22(16):2386-2393.

Trotti LM, Staab BA, Rye DB. Test-retest reliability of the multiple sleep latency test in narcolepsy without cataplexy and idiopathic hypersomnia. *J Clin Sleep Med.* 2013;9(8):789-795.

Neuropsychological Evaluation 31

Yaakov Stern

KEY POINTS

1. Neuropsychological evaluation is important for differential diagnosis as well as for characterizing the cognitive status.
2. Most tests are designed to evaluate specific cognitive functions.
3. Mental status tests can be used for quicker screening.
4. Careful characterization of the referral question will help yield more useful information.

Neuropsychological testing can assist in the diagnosis of dementia, in evaluating or quantifying cognition and behavior in development, brain diseases, and clinical treatment. It is also incorporated into research that evaluates cognitive functions in healthy and diseased individuals.

STRATEGY OF NEUROPSYCHOLOGICAL TESTING

Conditions that affect the brain often cause cognitive, motor, or behavioral impairment that can be detected by appropriately designed tests. Defective performance on a test and certain patterns of test performance may suggest specific pathology. Alternatively, patients with known brain changes may be assessed to determine how the damaged brain areas affect specific cognitive functions. Before relating test performance to brain dysfunction, however, other factors that affect test performance must be considered.

Typically, test performance is compared with normative values derived from populations similar to the patient in age, education, socioeconomic background, and other variables. Scores significantly below the mean expected values imply impaired performance. Performance sometimes can be evaluated by assumptions about what might be expected from the average person (eg, repeating simple sentences or simple learning and remembering).

Unfortunately, comparable data may not exist for the patient being tested. This problem is common in the elderly and those with language and cultural differences. This situation may be addressed by collecting local, normal characteristics that are more descriptive of the local clinical population or by evaluating the cognitive areas that remain intact. In this way, the patient guides the clinician in terms of the level of performance that should be expected in possibly affected domains. Other factors that also influence test performance include the patient's current mood, anxiety, depression or other psychiatric disorders, medication, and the patient's motivation to participate fully.

Patterns of performance, such as strengths in some cognitive domains and weaknesses in others, have been associated with specific conditions, based on empiric observation and knowledge of the brain pathology associated with those conditions. Observation of these patterns may aid in diagnosis.

TEST SELECTION

Neuropsychological tests in an assessment battery come from many sources. Some were developed for academic purposes (eg, intelligence tests), and others for experimental psychology. The typical clinical battery consists of a series of standard tests that have been proved useful and are selected for the referral issue. These tests should have established reliability and validity. A trade-off exists between the breadth of application and ease of interpretation, available from standard batteries, and the ability to pinpoint specific or subtle deficits, offered by more experimental tasks that are useful in research but have not yet been standardized.

Most tests are intended to measure performance in specific cognitive or motor domains, such as memory, spatial ability, language function, or motor agility. These domains may be subdivided (eg, memory may be considered verbal or nonverbal; immediate, short term, long term, or remote; semantic or episodic; public or autobiographic; or implicit or explicit). However, no matter how focused a test is, multiple cognitive processes are likely to be invoked. An ostensibly simple task, such as the Wechsler Adult Intelligence Scale (WAIS) Coding subtest (previously called *Digit Symbol Coding*), which uses a table of nine digit-symbol pairs to fill in the proper symbols for a series of numbers, assesses learning and memory, visuospatial abilities, motor abilities, attention, and speeded performance. In addition, tests may be failed for more than one reason: Patients may draw poorly because they may not appreciate spatial relationships, because they plan the construction process poorly, or because they are distractible or lack motivation. Thus, relying solely on test scores may lead to spurious conclusions.

TESTS USED IN A NEUROPSYCHOLOGICAL EVALUATION

Intellectual Ability

Typically, a test such as the fourth edition of WAIS (WAIS-IV) or the fourth edition of the Wechsler Intelligence Scale for Children is used to assess the present level of intellectual function for adults and children, respectively. These tests yield a global IQ score and index scores that are standardized, so that 100 is the mean expected value at any age (with a standard deviation of 15).

The WAIS-IV consists of 10 core and 5 supplemental subtests (Table 31.1). The 10 core subtests comprise the full-scale IQ. In previous WAIS versions, verbal and performance IQ estimates were calculated. In contrast, the WAIS-IV emphasizes a

TABLE 31.1 Subtests of the Wechsler Adult Intelligence Scale Fourth Edition Arranged by the Four Index Groups[a]

Verbal Comprehension	**Verbal Concept Formation, Verbal Reasoning, Knowledge Acquired From Environment**
Similarities	Derive relevant superordinate category or similarity for word pairs; abstract verbal reasoning
Vocabulary	Name pictures and define words; often used to assess "premorbid" level of ability
Information	Answer questions that address a broad range of general knowledge topics; ability to acquire, retain, and retrieve general factual knowledge
(Comprehension)	Answer questions based on understanding of general principles and social situations
Perceptual Reasoning	**Perceptual and Fluid Reasoning, Spatial Processing, Visual Motor Integration**
Block Design	Arrange blocks with red, white, and half-red and half-white sides to form 14 designs; spatial perception, visual abstract processing, and problem solving
Matrix Reasoning	Identify the picture that completes a pattern using pattern completion, classification, analogy, or serial reasoning; classic measure of fluid intelligence
Visual Puzzles	View a completed puzzle and select three response options that, when combined, reconstruct the puzzle; visual perception and organization, nonverbal reasoning
(Picture Completion)	Determine the missing feature in pictures; visual perception
(Figure Weights)	View a scale with missing weight(s) and select the response option that keeps the scale balanced; quantitative and analogical reasoning
Working Memory	**Attention, Concentration, Mental Control, Reasoning**
Digit Span	Standardized assessment of digits forward and backward. In addition, hear a sequence of numbers and recall the numbers in ascending order; attention, concentration, mental control
Arithmetic	Verbal arithmetic problems; mental manipulation, concentration, attention, short- and long-term memory, numerical reasoning ability
(Letter-Number Sequencing)	Listen to a combination of numbers and letters and recall first the numbers in ascending order and then the letters in alphabetical order; sequential processing, mental manipulation, attention, concentration, memory span, short-term auditory memory
Processing Speed	**Ability to Quickly and Correctly Scan, Sequence, and Discriminate Simple Visual Information, Short-Term Visual Memory, Attention, Visual-Motor Coordination**
Symbol Search	Scan a search group and indicate whether one of the symbols in the target group matches; processing speed, visual discrimination
Coding	Using a key, copy symbols that are paired with numbers; processing speed, short-term visual memory
(Cancellation)	Scan a structured arrangement of shapes and mark target shapes; processing speed, visual selective attention

[a]Supplementary subtests are indicated by parentheses. Comments describe the subtests and identify some select cognitive features that they tap.

set of index scores, based on groups of subtests, each assessing a broad, separate class of cognitive abilities. These include Verbal Comprehension, Perceptual Reasoning, Working Memory, and Processing Speed. The WAIS-IV also adds a General Ability Index, which consists of selected subtests from the Verbal Comprehension and the Perceptual Reasoning subtests. The intention of this index score is to assess cognitive abilities that are not as susceptible to changes in processing speed and working memory. For the individual subtests, scaled scores range from 1 to 19, with a mean of 10 and a standard deviation of 3; the average range for subtest scaled scores is from 7 to 13.

The overall IQ and index scores supply summary information about the level of general intelligence and broad ability categories. The neuropsychologist is often more interested in the "scatter" of subtest scores, which indicates strengths and weaknesses. The subtests are often better considered as separate tests, each assessing specific areas of cognitive function. There are many other tests of general intelligence, including some that are nonverbal.

Global cognitive function can also be evaluated at the bedside using a simple abbreviated cognitive screening test such as the Mini-Mental State Examination of the Montreal Cognitive Assessment (Fig. 31.1). These tests take approximately 15 minutes to perform, and yield a total score below which dementia should be considered.

Memory

The subclassifications of memory have evolved from clinical observation and experimentation; most are important to the assessment (Table 31.2).

For example, preservation of remote memories, despite the inability to store and recall new information, is the hallmark of specific amnestic disorders. Other subclassifications are used to evaluate different clinical syndromes.

Processing Speed

Processing speed is defined as either the amount of time it takes to process a set amount of information or the amount of information that can be processed within a certain amount of time. In the WAIS-IV, it is assessed with the Coding and Symbol Search subtests. Another commonly used test is pattern comparison, where two patterns are presented and the test taker must decide as quickly as possible if they are the same or different.

Perception

Neuropsychologists may provide a standardized version of neurologists' perceptual tasks: double (simultaneous) stimulation

MONTREAL COGNITIVE ASSESSMENT (MOCA)
Version 7.1 Original Version

VISUOSPATIAL / EXECUTIVE

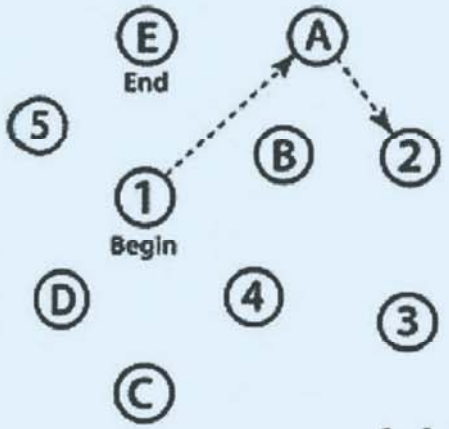

[ ]

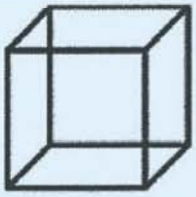

Copy cube [ ]

Draw CLOCK (Ten past eleven) (3 points)

[ ] Contour [ ] Numbers [ ] Hands

POINTS __/5

NAMING

[ ]

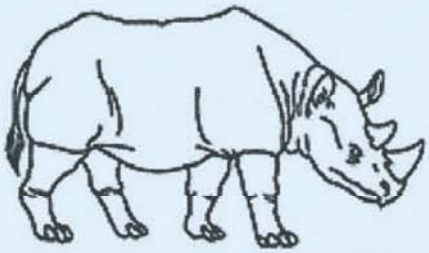

[ ]

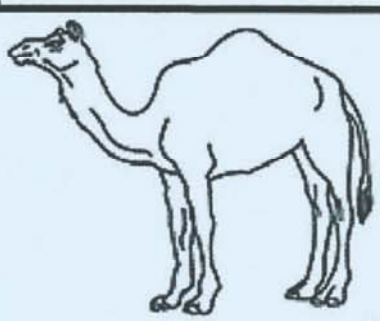

[ ]

__/3

MEMORY Read list of words, subject must repeat them. Do 2 trials, even if 1st trial is successful. Do a recall after 5 minutes.

	FACE	VELVET	CHURCH	DAISY	RED
1st trial					
2nd trial					

No points

ATTENTION Read list of digits (1 digit/ sec.).

Subject has to repeat them in the forward order [ ] 2 1 8 5 4

Subject has to repeat them in the backward order [ ] 7 4 2

__/2

Read list of letters. The subject must tap with his hand at each letter A. No points if ≥ 2 errors

[ ] F B A C M N A A J K L B A F A K D E A A A J A M O F A A B

__/1

Serial 7 subtraction starting at 100 [ ] 93 [ ] 86 [ ] 79 [ ] 72 [ ] 65

4 or 5 correct subtractions: **3 pts**, 2 or 3 correct: **2 pts**, 1 correct: **1 pt**, 0 correct: **0 pt**

__/3

LANGUAGE Repeat : I only know that John is the one to help today. [ ]

The cat always hid under the couch when dogs were in the room. [ ]

__/2

Fluency / Name maximum number of words in one minute that begin with the letter F [ ] _____ (N ≥ 11 words)

__/1

ABSTRACTION Similarity between e.g. banana - orange = fruit [ ] train – bicycle [ ] watch - ruler

__/2

DELAYED RECALL

	FACE	VELVET	CHURCH	DAISY	RED
Has to recall words WITH NO CUE	[ ]	[ ]	[ ]	[ ]	[ ]
Category cue					
Multiple choice cue					

Points for UNCUED recall only

Optional

__/5

ORIENTATION [ ] Date [ ] Month [ ] Year [ ] Day [ ] Place [ ] City

__/6

© Z.Nasreddine MD www.mocatest.org Normal ≥26 / 30

TOTAL __/30

Add 1 point if ≤ 12 yr edu

FIGURE 31.1 The Montreal Cognitive Assessment (MoCA).

TABLE 31.2 Typical Subclassifications of Memory Addressed by Neuropsychologic

Verbal and nonverbal	Memory for material that is or is not verbally encoded
Immediate, short term	Length of time between exposure to material and recall. The length of time has implications for how long term and remote the memory may be stored and retrieved.
Semantic and episodic	Memory for encodable knowledge, such as vocabulary or facts about the world, as opposed to memory for events
Public and autobiographic	Memory for public, commonly known events vs events that occurred in one's own life
Implicit and explicit	Memory tested on tasks that do not require conscious, explicit recollection of recent exposures (such as motor skills, procedural skills, classical conditioning, or priming) vs tasks that demand explicit recall of prior information (such as recall or recognition tasks)
Working	Similar to what in the past has been called short-term memory, working memory provides a buffer for briefly holding on to information, such as a telephone number or the name of a newly met person. It is also important for tasks that require mental manipulation of information, such as multistep arithmetic problems. For many theorists, working memory also has a more important role at the work space where recalled information is actually used, manipulated, and related to other information, allowing complex cognitive processes such as comprehension, learning, and reasoning to take place.

in touch, hearing, or sight; stereognosis; graphesthesia; spatial perception; or auditory discrimination.

Some tasks tap basic perceptual abilities. For example, the Benton Judgment of Line Orientation test assesses a person's ability to match the angle and orientation of lines.

Construction

Construction, typically assessed by drawing or assembly tasks, requires both accurate spatial perception and an organized motor response. The Block Design subtest of the WAIS-IV is examples of assembly tasks. In the Rey-Osterrieth Complex Figure, the patient is asked to copy a figure that contains many details embedded within an organizing framework. In addition to the scores these tests yield, the clinician attends to the patient's construction performance to determine factors that may underlie poor performance (eg, a disorganized impulsive strategy may be more related to anterior brain lesions, whereas difficulty aligning angles may arise from parietal lobe injury).

Language

"Mapping" of different aphasic disorders to specific brain structures was one of the early accomplishments of behavioral neurology. In neuropsychological assessment, this model is often followed. Individual tests of comprehension, fluency, repetition, and naming are used to assess spoken or written language. Fluency refers to the ability to use one or more strategies that maximize the production of responses while avoiding response repetition. Two types of verbal fluency tasks are phonemic: letter fluency, where the patient is given a fixed period of time to name as many words as possible that begin with a specific letter, and semantic, where the task is to name as many words as possible in a specific category.

More extensive batteries are available, such as the Boston Diagnostic Aphasia battery. Language deficits typically indicate dominant hemisphere pathology, although specific patterns of language difficulties are also evident in various forms of dementia, including the primary progressive aphasias.

Executive Function

The ability to plan, sequence, monitor, and inhibit behavior has been called *executive function*. These functions, often linked to the prefrontal cortex, rely on and organize other intact cognitive functions that are required components for performance. Several schemes for classifying executive functions: For example, Miyake et al (2000) identified three separable functions in a meta-analytic study: mental set shifting, information updating and monitoring, and inhibition of prepotent responses. Here, I summarize several task classifications typically included under the umbrella of executive function. Others, not described here, include planning, insight, and social cognition and behavior.

Working Memory

Working memory describes the ability to hold several pieces of information in the mind for a short period of time and manipulate them. For example, the Letter-Number Sequencing subtest of the WAIS-IV requires patients to listen to a series of randomly ordered letters and numbers and then state first the numbers in numerical order and letters in alphabetical order.

Inhibition

One test of inhibition is the Stroop Color-Word Test. The patient is given a series of color names printed in contrasting ink colors (eg, the word *blue* printed in red ink) and is asked to name the color of the ink. The response set must be maintained while the subject suppresses the alternate (and more standard) inclination to read words without regard to the color of the print.

Set Shifting

Set shifting tasks require the testee to shift attention between one task and another or to alternate strategies. One commonly used task is the Wisconsin Card Sorting Test, which uses symbols that may be sorted by color, number, or shape. Based only on feedback about whether each card was or was not correctly placed, the subject must infer an initial sort rule. At intervals, the sort rule is changed without the subject's knowledge; subjects must switch based only on their own observation that the current rule is no longer effective. Other set shifting tasks use explicit use a fixed set of rules that do not change, such as the Trail Making Test.

Motor and Praxis

Tests of motor strength, such as grip strength, and of motor speed and agility, such as assessing speed and peg placement, establish lateral dominance and focal point of impairment. In some diseases, such as the dementia of AIDS, reduced motor agility is

part of the diagnosis. Tasks such as the grooved pegboard assess manual dexterity and sensorimotor integration. They can identify lateralized brain damage since both hands are tested. The grooved pegboard task contains 25 holes with randomly positioned slots and pegs, which have a key along one side. Pegs must be rotated to match the hole before they can be inserted. The patient is asked to insert the pegs into the holes as rapidly as possible.

Higher order motor tasks, such as double alternating movements or triple sequences, are used to assess motor sequencing or programming, as opposed to pure strength or speed.

Attention

The ability to sustain attention is often tested by cancellation tasks, in which the patient must detect and mark targets embedded in distractors, or by computerized continuous performance tests, which measure accuracy, response time, and variability in response time as a function of time on task. Continuous performance tests assess sustained attention over relatively long time intervals (10-20 min) and are frequently used in the assessment of attention deficit disorder. Mental tracking tasks such as Digit Span Forward may also be included in this category.

Concept Formation and Reasoning

Brain damage is often associated with concrete reasoning. Tests of concept formation include verbal tasks, such as proverb interpretation, and nonverbal tasks, where underlying concepts must be extracted from visual displays. Tests of abstract reasoning include the Similarities subtest of the WAIS-IV, where the subject must explain how two words are alike. The quality of the response is judged. A general classification response that is pertinent to both words receives a higher score than a specific property or function that is relevant to both.

Perceptual reasoning can be assessed with tasks such as matrix reasoning. This task usually involves a series of figures in which there is a discernible pattern, with one figure in the series left blank. The patient is asked to choose, from an array of possibilities, what figure would complete the series or pattern.

Personality and Emotional Status

Mood may affect test performance. At minimum, the neuropsychologist notes the psychiatric history and probes for current psychiatric symptoms. Standardized mood rating scales are also available. Many neurophysiologists use standardized personality scales to aid in diagnosis and test interpretation.

CLINICAL OBSERVATION

Along with the formal scores, the intake interview and testing period afford an extensive period to observe the patient under controlled conditions. These clinical observations are valuable for diagnosis. Formal test scores capture only certain aspects of performance. The patient's problem-solving approach or the nature of the errors made may be telling. Also important in timed tasks is determining whether the patient may complete them with additional time or is actually incapable of solving them. Another important dimension of assessment is the patient's ability to learn and follow directions for the many tests.

More subtle aspects of behavior include responses or coping abilities when confronted with difficult tasks, the ability to remain socially appropriate as the session progresses, and the subjects' appreciation of their own capacities.

MENTAL STATUS TESTING

Several brief mental status tests have been developed for rapid screening for cognitive impairment. These are often used in the clinician's office, or in studies tracking progression of cognitive change. One of the most ubiquitous is the Mini-Mental State Evaluation (MMSE). This is a 30-point questionnaire that examines orientation; registration of three items for recall, attention, and calculation (serial sevens, or spell WORLD backward); delayed recall; language (repetition, naming, writing a sentence, following simple oral and written commands); and construction (intersecting pentagons).

The Montreal Cognitive Assessment was introduced in 2005. It is also a brief, 30-question test but contains some more diverse items than the MMSE, including tests of executive function, abstraction, and verbal fluency. The immediate and delayed recall task contains five items, compared to the three on the MMSE, and the learning phase of the memory task is standardized into two trials.

The Montreal Cognitive Assessment may be more sensitive than the MMSE to cognitive changes in non–Alzheimer disease dementias because of its inclusion of the additional cognitive domains.

DIAGNOSIS-SPECIFIC ISSUES

Neuropsychological testing is useful for the diagnosis of some conditions and is a tool for evaluating or quantifying the effects of disease on cognition and behavior. The tests may assess the beneficial or adverse effects of drug therapy, radiation, or surgery. Serial evaluations give quantitative results that may change with time. In temporal lobectomy for intractable epilepsy, tests that help identify the location of dysfunction are required in presurgical evaluation to minimize the possibility of adverse effects. Specific referral issues are summarized in the following paragraphs.

Dementia

Testing may detect early dementing changes and discriminate them from "normal" performance. It also helps to obtain information contributing to differential diagnosis, either between dementia and nondementing illness, such as depression versus dementia, or between alternate forms of dementia (eg, Alzheimer disease, dementia with Lewy bodies, or vascular dementia). Test results may also confirm or quantify disease progression and measure efficacy of clinical interventions.

Other Brain Disease

The effects on cognitive function of stroke, cancer, head trauma, Parkinson disease, Huntington disease, multiple sclerosis, brain infection, or other conditions may be investigated. Testing may be prompted by the patient's complaints. The evaluation helps to clarify the cause or extent of the condition.

Epilepsy

Testing is part of the presurgical evaluation to determine whether cognitive deficits are consistent with EEG and possibly magnetic resonance imaging evidence of focal dysfunction. Additionally, test results, together with knowledge of the proposed surgery, can be used to predict risk of postoperative cognitive decline or the probability of postoperative improvement. Nonsurgical patients are frequently assessed to address memory, attention, and mood issues associated with epilepsy and antiepileptic medications.

Deep Brain Stimulation

Neuropsychological evaluation prior to deep brain stimulation can identify existing impairments in cognitive function. Lower cognitive function in general can be predictive of poorer cognitive outcome. Also, based on implant location, specific deficits may be associated with greater risk of a poor cognitive outcome. Postsurgical evaluation is important for detecting potential adverse effects.

Toxic Exposure

Testing may evaluate the consequences of toxic or potentially toxic exposures, either on an individual basis or for particular exposed groups (eg, factory workers). Exposures may include metals, solvents, pesticides, alcohol and drugs, or any other compounds that may affect the brain.

Medication

The potential effect of medications on the central nervous system may be evaluated in therapeutic trials or clinical practice. For example, in trials of agents used to treat Alzheimer disease, neuropsychological tests are typically primary measures of drug efficacy. In clinical practice, adverse or therapeutic effects of newly introduced medications may be evaluated.

Psychiatric Disorders

Testing may help in the differential diagnosis of psychiatric and neurologic disorders, especially affective disorders and schizophrenia. It may also assess cognition and areas of competence in patients with these conditions. For example, individuals with schizophrenia can have impairments in attention, executive functions, episodic memory, certain aspects of working memory performance, and processing speed, with relatively spared language functions, perceptual processes, and nondeclarative memory.

Learning Disability

Testing may evaluate learning disabilities and the residuals of these disabilities in later life. Behavioral disorders, attention deficit disorder, autism, dyslexia, and learning problems are common referral issues. The evaluation can evaluate the specific functions that are often involved in learning disabilities, such as auditory-linguistic abilities, visual abilities, memory, processing speed, cognitive efficiency, and reasoning. In addition, it can assess functions that might enhance or detract from overall performance, such as attention or motor and sensory abilities.

EXPECTATIONS FROM A NEUROPSYCHOLOGICAL EVALUATION

The minimum that a neuropsychological evaluation yields is an extensive investigation of the abilities of the patient. In these cases, although the studies do not lead to a definite diagnosis, they help determine the patient's capacities, establish a baseline from which to track the future, and advise the patient and family.

Sometimes, the evaluation suggests that additional diagnostic tests would be useful. For example, if a patient's pattern of performance deviates substantially from that typically expected at the current stage of dementia, a vascular contribution may be considered. Similarly, evaluation may suggest the value of psychiatric consultation or more intensive electroencephalographic recordings.

Many times, the neuropsychologist may offer a tentative diagnosis or discuss the possible diagnoses compatible with the test findings. Neuropsychological evaluation may not yield a diagnosis without appropriate clinical and historical information. In the context of multidisciplinary testing, however, it may provide evidence to confirm or refute a specific diagnosis. In this case, testing might best be considered an additional source of information to be used by the clinician for diagnosis in conjunction with the neurologic examination and laboratory tests.

HOW TO REFER

The more information the examiner has at the start, the more directly the issues may be addressed. For example, if the magnetic resonance imaging has revealed a particular lesion, tests may be tailored specifically to better understand the lesion. The examination is not an exploration of the ability to detect a lesion but is rather a contribution to understanding the implications of the lesion. Similarly, the more explicit the referral question, the more likely the evaluation may yield useful information. Besides providing the relevant history, a useful referral describes the problem to be assessed. This is often a statement of the differential diagnosis being entertained. Alternately, the neurologist or the family may simply want to document the current condition or explore some specific aspect of performance, such as language.

SUGGESTED READINGS

Lezak MD, Howieson DB, Bigler ED, Tranel D. *Neuropsychological Assessment*. 5th ed. New York, NY: Oxford University Press; 2012.

Miyake A, Friedman NP, Emerson MJ, Witzki AH, Howerter A, Wager TD. The unity and diversity of executive functions and their contributions to complex "frontal lobe" tasks: a latent variable analysis. *Cogn Psychol*. 2000;41(1):49-100.

Salmon DP, Bondi MW. Neuropsychological assessment of dementia. *Annu Rev Psychol*. 2009;60:257-282.

Vliet EC, Manly J, Tang MX, Marder K, Bell K, Stern Y. The neuropsychological profiles of mild Alzheimer's disease and questionable dementia as compared to age-related cognitive decline. *J Int Neuropsychol Soc*. 2003:9(5):720-732.

Wechsler D. *Wechsler Adult Intelligence Scale*. 4th ed. San Antonio, TX: The Psychological Corp; 2008.

Wechsler D. *Wechsler Intelligence Scale for Children*. 5th ed. Bloomington, MN: Pearson; 2014.

32 Lumbar Puncture and Cerebrospinal Fluid Analysis

Kiwon Lee

KEY POINTS

1. Lumbar puncture is essential in assessing patients with potential central nervous system infection, and it is important to remember typical cerebrospinal fluid profiles in common diseases.
2. One needs to understand the limitations of the cerebrospinal fluid analysis caused by confounders such as traumatic tap and concurrent acute inflammatory processes such as aneurysmal subarachnoid hemorrhage (eg, red blood cell:white blood cell ratios).

INTRODUCTION

Accessing the cerebrospinal fluid (CSF) compartment—typically via lumbar puncture (LP)—is one of the key skills every neurologist should have. Proper analysis of CSF findings may result in a diagnosis (even if the neurologic examination and neuroimaging have not); furthermore, LP and the removal of CSF may be therapeutic in certain cases. This chapter reviews step by step the technique of the LP, including advances in the procedure (eg, ultrasound guidance); in addition, we outline here a guide for the interpretation of CSF findings in various neurologic disorders ranging from infectious to demyelinating to neoplastic. A new section on precaution for patients with hemicraniectomy has been added for this edition.

LUMBAR PUNCTURE

Techniques

Careful positioning of the patient is often the key to performing a successful LP. Patients may be placed in either a lateral recumbent position with the spine flexed—head bowed, knees bent, and drawn up into the torso, for example, the "fetal position" (Fig. 32.1). Alternatively, patients may sit upright with the neck and back flexed forward (typically resting on a table). The lateral recumbent position should be used if an opening pressure is needed. As the conus medullaris ends at the level of the L1 and L2 interspace in 94% of adults, this level should be avoided during LP. Instead, the L3-L4, L4-L5, and L5-S1 interspaces are appropriate for needle puncture. These interspaces can be identified via palpation of bony landmarks. The line joining the superior aspect of the iliac crests posteriorly (the intercristal line) identifies the L4 spinous process or L3 and L4 interspace.

The interspace for needle insertion should be marked, and the skin overlying the LP site should be sterilized and draped using standard aseptic technique. Local anesthetic—usually 1% lidocaine—is then applied; the 25-gauge needle should be used to raise a skin wheal at the LP site and the longer, 20-gauge needle should then be used to infiltrate the deeper layers. The spinal needle (with stylet in) is then inserted through the skin wheal into the interspinous space. Ideally, needle insertion should be midline, orthogonal to the plane of the back. To reduce the risk of post-LP headache, the bevel should be parallel to the longitudinal fibers of the dura; if the patient is in the lateral recumbent position, the bevel should face up, and if the patient is sitting upright, the bevel should face to one side. Theoretically, this allows dural fibers to be separated rather than cut. The spinal needle is then advanced slowly at a slightly cephalad angle (directed toward the umbilicus) in order to follow the contour of the spinous processes. The needle passes through the supraspinous ligament and the ligamentum flavum, perhaps resulting in a "pop" when the dura is pierced and the subarachnoid space is entered. The stylet should then be removed, and CSF should readily appear at the needle hub if in the subarachnoid space. If instead CSF does not flow, the stylet should be replaced and the needle advanced or withdrawn incrementally, with frequent removal of the stylet, until CSF is obtained or bone encountered.

Ultrasound Guidance

Ultrasound visualization of landmarks may significantly improve the rate of LP success. This is particularly true in certain patient populations where palpation of landmarks may be challenging—neonates, pregnant women, obese patients, and patients with generalized edema, for example. One large meta-analysis of 14 studies and 1,334 patients revealed a significant reduction in the risk of failed or traumatic LPs and epidural catheterizations with the use of ultrasound guidance.

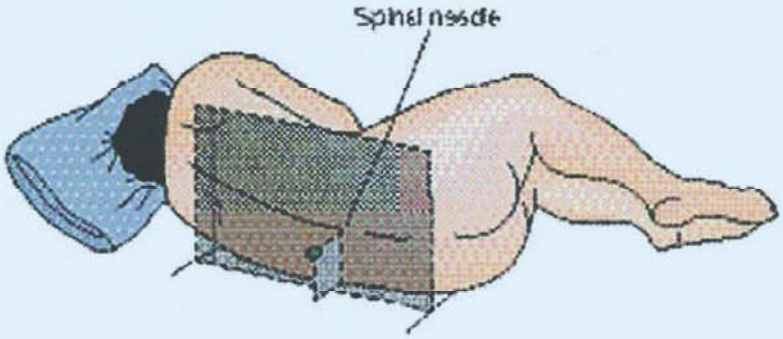

FIGURE 32.1 Proper positioning for lumbar puncture. Position the patient's back at the edge of the bed with the head flexed and the legs curled up in the fetal position. Place a pillow under the head. Hips are parallel to each other and perpendicular to the bed. The spinal needle should be parallel to the bed. (Adapted from Marshall R, Mayer S. *On Call Neurology*. 3rd ed. Philadelphia, PA: Saunders; 2007.)

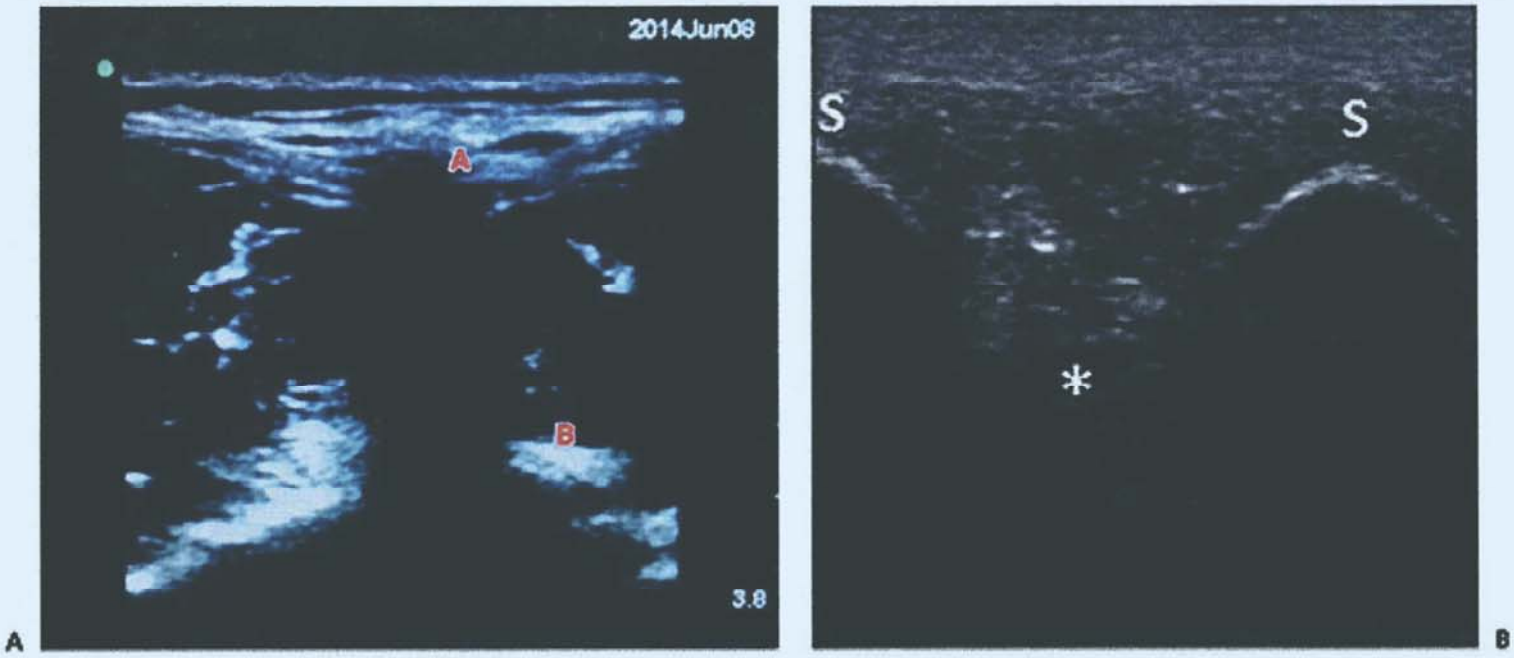

FIGURE 32.2 Ultrasound-guided lumbar puncture. **A:** Transverse view. The anechoic shadow below *A* represents the spinous process—the midline; *B* localizes the transverse process. **B:** Longitudinal view. The interspace *(asterisk)* is located between the two crescentic-shaped, hyperechoic spinous processes (*S*).

To perform an ultrasound-guided LP, the linear probe (higher resolution of superficial structures) should be used. The first view that should be obtained is the transverse view—the goal of this view is to determine an accurate anatomic midline by identification of the spinous process (Fig. 32.2A). To obtain this view, the probe is placed perpendicularly to the long axis of the spine. The spinous process will appear as a hyperechoic white convex rim with an anechoic shadow (or the anechoic shadow itself can simply be used if the rim is not identified). The midline should be marked and the longitudinal view should then be obtained (using the midline as a reference). The goal of the longitudinal view is to determine the spinal interspace—where the spinal needle will be inserted. To obtain this view, the transducer should be rotated into the sagittal/longitudinal plane with the probe marker pointing cephalad. Identify the hyperechoic spinous process again and then adjust the probe cephalad and caudal in order to center the probe/image between two contiguous, crescentic-shaped spinous processes; the interspace will be the hypoechoic gray gap in between (Fig. 32.2B). This interspace should also be marked. Remove the probe and extend the transverse/longitudinal markings until they intersect; this intersection represents the ideal position for the spinal needle to be inserted.

CEREBROSPINAL FLUID ANALYSIS

Cerebrospinal Fluid Pleocytosis

Basic analysis of the CSF begins with red blood cell (RBC) and white blood cell (WBC).analysis and measurements of protein and glucose, although an extensive variety of additional tests can also be ordered (Table 32.1). The normal WBC count of CSF ranges from 0 to 5 lymphocytes or monocytes per cubic millimeter. Rarely, a single polymorphonuclear (PMN) cell may be identified from a large volume tap; the presence of two or greater PMNs, although, should be considered abnormal. A myriad of neurologic

TABLE 32.1 Cerebrospinal Fluid Tests

Common tests
• Cell counts and differentials
• Protein and glucose levels
• Gram stain and culture
Less common tests
• VDRL test
• India ink test (for *Cryptococcus neoformans*)
• Wet smear (for fungi and amebae)
• Stain and culture for AFB (for tuberculosis)
• Cryptococcal antigen titers
• pH and lactate levels (abnormal in MELAS)
• Oligoclonal bands (abnormal in multiple sclerosis)
• IgG index (intrathecal IgG production)
• IgG and IgM antibody titers (for viral infections, compare to serum)
• Lyme disease antibody titers (compare with serum titers) and Western blot
• Latex agglutination bacterial antigen tests (for pneumococcus, meningococcus, and *Haemophilus influenzae*)
• Viral isolation studies
• Cytology (requires fixation in formalin)
• Polymerase chain reaction for Lyme disease, tuberculosis, and causes of viral encephalitis including SARS-CoV-2
• CSF ACE activity (abnormal with tuberculosis or sarcoidosis)
• 13-9-9 protein and RT-QuIC (elevated in Creutzfeldt-Jacob disease)

Abbreviations: ACE, angiotensin-converting enzyme; AFB, acid-fast bacilli; CSF, cerebrospinal fluid; IgG, immunoglobulin G; IgM, immunoglobulin M; MELAS, mitochondrial encephalomyopathy, lactic acidosis, and stroke; RT-QuIC, real-time quaking-induced conversion; SARS-CoV-2, severe acute respiratory syndrome due to novel coronavirus; VDRL, Venereal Disease Research Laboratory.

disorders can result in a CSF pleocytosis, ranging from acutely life-threatening (bacterial meningitis) to entirely chronic (as can be seen in patients with HIV). A common neurologic disorder such as seizure may cause mild pleocytosis (0-12 white blood cells).

Assessing the magnitude of pleocytosis along with the relative predominance of neutrophils to lymphocytes is often key, as is the clinical history—specifically whether the neurologic symptoms are acute or chronic in nature. For instance, a patient presenting with acute encephalopathy and a neutrophil-predominant CSF pleocytosis should be presumed to have bacterial meningitis (and promptly treated as such). In general, patients with acute bacterial meningitis have a CSF WBC count of several thousand (although the range may be from hundreds to >60,000). Furthermore, a CSF sample with greater than 33% neutrophils, a protein concentration of greater than 100 mg/dL, and a glucose level of less than 50% of the serum glucose level is strongly suggestive of bacterial meningitis. Exceptions include bacterial meningitis due to *Listeria* (often with a lymphocytic rather than neutrophilic pleocytosis), early viral or atypical (fungal/mycobacterial) infections that may initially recruit neutrophils into the CSF, neuroinvasive disease due to West Nile virus, and neuroinflammatory disorders (neuro-Behçet, Sweet syndrome).

In an acutely ill patient with a lymphocytic CSF pleocytosis, viral meningoencephalitis is often the cause. The WBC count generally ranges from 10 to 1,000 cells/mm^3 and is composed primarily of mononuclear cells. The cornerstone of etiologic diagnosis is the detection of viral nucleic acid sequences in the CSF via polymerase chain reaction (PCR). In cases of suspected viral meningoencephalitis, CSF PCRs for the enteroviruses along with the herpesviruses (herpes simplex virus 1 and 2, cytomegalovirus, varicella-zoster virus, Epstein-Barr virus [EBV], and in immunocompromised patients, human herpesvirus-6) should be sent, along with serologic testing for HIV. Serologic testing for several additional viruses can be considered (West Nile virus, St. Louis encephalitis virus, Eastern equine encephalitis virus, Venezuelan equine encephalitis virus, and La Crosse virus).

In patients with chronic neurologic symptoms and a lymphocytic CSF pleocytosis, an atypical infection such as fungal, tuberculous, or spirochetal should be considered. Etiologic diagnosis can be made via these CSF studies: India ink staining, fungal cultures, assays for cryptococcal antigen or histoplasma antigen, and *Coccidioides* complement fixation antibodies; acid-fast bacilli smear and culture, PCR for *Mycobacterium tuberculosis*; Venereal Disease Research Laboratory in conjunction with serum testing for syphilis; and antibodies against *Borrelia burgdorferi*. A chronic lymphocytic CSF pleocytosis may also be caused by various noninfectious disorders, including neoplasm (central nervous system [CNS] lymphoma, leptomeningeal carcinomatosis), paraneoplastic encephalitides, autoimmune/demyelinating disorders (CNS vasculitis, neurosarcoidosis, neuromyelitis optica [NMO], multiple sclerosis [MS]), and even medications or toxins (nonsteroidal anti-inflammatory drugs, sulfa drugs, intravenous immunoglobulin [Ig], carbamazepine). The clinical history along with neuroimaging is often vital for the diagnostic interpretation of a chronic lymphocytic CSF pleocytosis. Clinicians should also remember that there are three scenarios by which chronic hydrocephalus may occur: fungal, tuberculous, and partially treated other bacterial meningitis.

In December 2019, severe acute respiratory syndrome due to novel strain of corona virus has spread to numerous countries worldwide, leading to a pandemic. Reports have been variable with respect to the CSF profiles of infected hosts. For patients with positive nasal or saliva test for severe acute respiratory syndrome due to novel strain of coronavirus, the CSF analysis may or may not show any virus on real-time PCR test, making it difficult to assess or confirm CNS involvement. Due to its natural tendency for prothrombotic state, patients may suffer from pure meningoencephalitis or both arterial or venous thrombotic complications.

The CSF findings in the various meningitides are summarized here in Table 32.2.

There are two frequently encountered caveats to the interpretation of a CSF pleocytosis—the first being CSF obtained from a traumatic LP and the second being CSF obtained from an external ventricular drain (EVD). Inadvertent needle trauma to a capillary or venule during LP will introduce additional WBCs from the peripheral blood into the CSF, increasing the total number of WBCs. A useful rule of thumb if a traumatic LP is suspected is to subtract 1 WBC for every 500 to 1,000 RBCs present in the CSF. In other words, a WBC to RBC ratio of 1:500 to 1,000 is compatible with traumatic tap rather than infectious etiology.

TABLE 32.2 Cerebrospinal Fluid Findings in Various Meningitides

Type	Leukocytes (mm^3)	Protein (mg/dL)	Glucose (mg/dL)
Acute bacterial	>1,000 although ranges from several hundred to >60,000; PMNs predominate.	100-500, occasionally >1,000	5-40; typically a CSF-to-serum glucose ratio of <0.33
Viral	5-1,000; lymphocytes predominate (although early in the disease course, PMNs may predominate).	Frequently normal or slightly elevated; generally <100	Normal (although rarely reduced in cases of LCMV, CMV, paramyxoviruses, HSV)
Tuberculous	25-100; rarely >500; lymphocytes predominate (although early in the disease course, PMNs may predominate).	Elevated; 100-200	Low; <45 in 75% of cases
Cryptococcal	0-800; lymphocytes predominate.	20-500	Often reduced; average 30
Syphilitic	Average 500; primarily lymphocytes	100	Generally normal although may be mildly reduced
Sarcoid	0 to <100	Slight to moderate elevation	May be reduced in 18%-50% of patients
Leptomeningeal carcinomatosis	0 to several hundred; cytology may reveal malignant cells.	Elevated	Low in 40%-75% of cases

Abbreviations: CMV, cytomegalovirus; CSF, cerebrospinal fluid; HSV, herpes simplex virus; LCMV, lymphocytic choriomeningitis virus; PMNs, polymorphonuclear cells.

Alternatively, the following formula can be used, especially in patients with an abnormal peripheral WBC count:

$$WBC\ (CSF) = \frac{WBC\ (blood) \times RBC\ (CSF)}{RBC\ (blood)}$$

In the neurocritical care unit, patients may have an EVD inserted into the lateral ventricle to aid in CSF diversion or to monitor intracranial pressure. CSF can be easily sampled through this drain and is often sampled to exclude nosocomial meningitis/ventriculitis associated with the drain itself. Whether a truly pathologic pleocytosis (eg, one due to meningitis/ventriculitis) is present in EVD-sampled CSF can be challenging to ascertain; patients who have EVDs inserted for CSF diversion may have high RBC counts in the ventricular system (eg, those with subarachnoid hemorrhage or intracerebral hemorrhage) and the aforementioned corrections for RBCs are not entirely valid for EVD CSF samples. Furthermore, patients with large volumes of blood in the subarachnoid or ventricular compartments often develop an inflammatory response with an elevation in the WBC count in ventricular CSF. To aid with the diagnosis of meningitis/ventriculitis in patients with EVDs, the cell index, in conjunction with CSF Gram stain and culture, can be used. The cell index is calculated as follows:

$$Cell\ index = \frac{WBC\ (CSF) \div RBC\ (CSF)}{WBC\ (blood) \div RBC\ (blood)}$$

A cell index of 1 is (by definition) normal. And although there is no explicit cutoff for an "abnormal" cell index, a significant rise in the cell index from 1 day to the next may signal the presence of infection. It is important to understand that CSF pleocytosis alone is not sufficient to make the diagnosis of EVD infection or ventriculitis because blood products have been introduced to the subarachnoid and ventricular space. The concept of so called, "chemical meningitis" refers to inflammatory CSF pleocytosis rather than true infectious process. In order to avoid false-positive EVD infection claims, it is prudent to collect daily CSF profiles and track the *trend*, rather than one-time absolute value, of WBC to RBC ratio as well as other parameters such as CSF glucose levels and culture data.

Hypoglycorrhachia

A reduced CSF glucose level may be caused by impaired glucose transport into the CSF (eg, due to severe disruption of the blood-brain barrier and its glucose transporter, GLUT1) or as a result of increased glucose use within the CNS. There are a handful of pathologies that typically result in an abnormally low CSF glucose and as such, hypoglycorrhachia can be a very helpful diagnostic clue. In general, a CSF glucose of 45 to 80 mg/dL is considered normal, although this is dependent on a fairly normal range of serum glucose (70-120 mg/dL). Of greater usefulness is the CSF-to-serum glucose ratio because this is relatively constant through a wide range of serum glucose levels. The normal CSF-to-serum glucose ratio is 0.6 to 0.8; a ratio less than 0.5 is abnormal and should prompt urgent evaluation.

The principal causes of a reduced CSF-to-serum glucose ratio are listed in Table 32.3. Several infectious meningitides—bacterial, fungal, tuberculous, and spirochetal—are often heralded by hypoglycorrhachia. For instance, in one study of adults with bacterial meningitis, 70% had CSF glucose concentrations of less than 50 mg/dL. The CSF-to-serum glucose ratio in patients with bacterial meningitis is generally less than 0.33; a ratio of less than 0.23 in patients with acute meningitis had a positive predictive value of 99% for a bacterial etiology.

TABLE 32.3 Causes of Hypoglycorrhachia

Bacterial meningitis
CNS lymphoma
Fungal meningitis
Leptomeningeal carcinomatosis
Meningitis due to spirochetes (syphilis, Lyme)
Neurosarcoidosis
Tuberculous meningitis

Abbreviation: CNS, central nervous system.

Fungal meningitis is also associated with low CSF glucose—generally 20 to 40 mg/dL in one-half to two-thirds of patients. *M tuberculosis* meningitis characteristically depresses the CSF glucose; in one study of CSF culture-positive patients, the mean admission CSF glucose level was 23 mg/dL. Hypoglycorrhachia has also been reported in patients with Lyme disease and syphilitic meningitis, although the reduction in CSF glucose is often modest compared to cases of bacterial meningitis. The CSF glucose level in patients with viral meningitis is classically normal; that being said, rare cases of viral meningitis due to cytomegalovirus, paramyxoviruses, and lymphocytic choriomeningitis virus have been associated with low CSF glucose.

Other causes of hypoglycorrhachia include CNS lymphoma (approximately 10% of patients), leptomeningeal carcinomatosis (40% of patients), neurosarcoidosis (18% of patients), and lupus cerebritis/vasculitis (8% of patients). Patients with aneurysmal subarachnoid hemorrhage may have transient reductions in their CSF glucose (usually 4-8 d postictal). And finally, hypoglycorrhachia has been reported in patients who have received intrathecal injections of corticosteroids. Low levels of CSF glucose alone are not sufficient to make the diagnosis of ventriculitis or meningitis.

Cerebrospinal Fluid Findings in Inflammatory and Demyelinating Disorders

Although a detailed description of the CSF findings across the gamut of autoimmune and demyelinating neurologic disorders is beyond the scope of this chapter, there are certain CSF generalizations we can refer to. For instance, a mild lymphocytic pleocytosis and modest elevation in protein is frequently encountered in these patients. Approximately, one-third of patients with MS, optic neuritis, transverse myelitis, and even acute disseminated encephalomyelitis will have a mild lymphocytic pleocytosis. A greater proportion of patients with neurosarcoidosis and NMO will have a lymphocytic pleocytosis, and in the proper clinical context, a CSF pleocytosis of greater than 50 WBC/mm^3 or greater than 5 PMNs/mm^3 is strongly supportive of a diagnosis of NMO.

Even if the CSF cell count and protein are normal, evidence of an active intrathecal humoral immune response is often fundamental to the diagnosis of a neuroinflammatory disorder. During CNS inflammation, CSF IgG content may preferentially increase above serum levels, reflecting intrathecal synthesis. A routinely

TABLE 32.4 Cerebrospinal Fluid Cytology Yield

Type of CNS Malignancy	Percentage of Patients With Positive Cytology	Notes
Malignant glioma	7-66 (more than one sample)	
Parenchymal metastatic lesions	2-10	
Primary CNS lymphoma	16-26 (single sample)	Flow cytometry = higher yields EBV PCR as an adjunct in HIV+
Leptomeningeal carcinomatosis	47-92	41-71 with one sample; increasing yields with repeat sampling

Abbreviations: CNS, central nervous system; EBV, Epstein-Barr virus; PCR, polymerase chain reaction.

used estimate of intrathecal IgG synthesis is the IgG index, calculated as follows:

$$IgG\ index = \frac{IgG\ (CSF) \div IgG\ (serum)}{albumin\ (CSF) \div albumin\ (serum)}$$

An IgG index greater than 0.70 to 0.75 is often considered elevated (although parameters range depending on the clinical laboratory processing the sample). As an adjunct to the IgG index, the detection of unique oligoclonal bands (OCBs) within the CSF—distinct from those found in the serum—provides qualitative evidence of intrathecal Ig production. If two or more distinct CSF bands (bands absent from a corresponding serum sample) are detected, OCBs are considered to be positive. In MS patients, for instance, approximately 90% will have either an elevated IgG index or two or greater OCBs in the CSF, and these CSF findings may even precede a diagnosis of MS based on clinical history (or radiology) alone.

Cerebrospinal Fluid Cytology

Diagnosis of a CNS malignancy via CSF cytology is highly specific and relatively noninvasive (eg, compared to biopsy)—unfortunately, the sensitivity of CSF cytology ranges from low to moderate. Several factors may alter the yield of CSF cytology, including the site sampled (lumbar vs cisterna magna), the volume of CSF collected, the number of specimens examined, tumor location/grade, and the extent of leptomeningeal disease. The sensitivity of CSF cytology across CNS malignancies is outlined in Table 32.4. In general, repeated sampling will increase the yield of CSF cytology; for instance, in patients with leptomeningeal carcinomatosis, 41% to 71% will have a positive cytopathology on the first CSF sample, whereas 79% to 92% will have a positive cytology with repeated sampling. These findings form the basis for the recommendation that three large-volume (ideally >20 mL; >10 mL at the very least) LPs should be analyzed for malignant cells in patients with presumed leptomeningeal disease. Furthermore, CSF samples should be promptly delivered to the cytopathology laboratory for processing as autolysis begins within 1 to 2 hours of sample collection. In cases where primary CNS lymphoma is suspected, several additional CSF studies may aid in diagnosis. Immunophenotyping the CSF via flow cytometry can considerably increase the diagnostic yield by differentiating monoclonal B lymphocyte populations from reactive polyclonal lymphocytes even if the sample is relatively hypocellular. And in patients with HIV, CNS lymphoma is strongly associated with transformation of malignant cells by EBV; as such, EBV PCR in CSF has a high sensitivity and specificity for the diagnosis of CNS lymphoma in this particular patient population.

Precaution for Patients With Hemicraniectomy

For patients with malignant edema due to middle cerebral artery infarction and severe traumatic brain injury, hemicraniectomy can be life-saving. When patients who have history of hemicraniectomy waiting for cranioplasty (ie, still missing bone flap) present with altered mental status, it is important for clinicians to understand that unnecessary LP might lead to paradoxical herniation; atmospheric pressure may cause sunken sink syndrome to get worse and cause altered mental status, seizures, contralateral hemisensory or motor deficits and even coma.

Therefore, it is prudent to only proceed with LP when signs and symptoms of meningitis (fever, leukocytosis, somnolence, etc) are present rather than simply doing LP just to complete the workup or because of depressed alertness alone. When paradoxical herniation occurs due to LP in a patient with hemicraniectomy, one must keep the patient in Trendelenburg position, provide IV hydration and proceed with cranioplasty unless contraindicated.

SUGGESTED READINGS

Boon JM, Abrahams PH, Meiring JH, Welch T. Lumbar puncture: anatomical review of a clinical skill. *Clin Anat*. 2004;17:544-553.

Cascella C, Nausheen S, Cunha BA. A differential diagnosis of drug-induced aseptic meningitis. *Infect Med*. 2008;25:331-334.

Chakraverty R, Pynsent P, Isaacs K. Which spinal levels are identified by palpation of the iliac crests and the posterior superior iliac spines? *J Anat*. 2007;210(2):232-236.

Cinque P, Brytting M, Vago L, et al. Epstein-Barr virus DNA in cerebrospinal fluid from patients with AIDS-related primary lymphoma of the central nervous system. *Lancet*. 1993;342:398-401.

Conly JM, Ronald AR. Cerebrospinal fluid as a diagnostic body fluid. *Am J Med*. 1983;75(1B):102-108.

Dougherty JM, Roth RM. Cerebral spinal fluid. *Emerg Med Clin North Am*. 1986;4:281-297.

Ellul MA, Benjamin L, Singh B, et al. Neurological associations of COVID-19. *Lancet Neurol*. 2020;19(9):767-783.

Fishman RA. *Cerebrospinal Fluid in Diseases of the Nervous System*. 2nd ed. Philadelphia, PA: WB Saunders; 1992.

Hegde U, Filie A, Little RF, et al. High incidence of occult leptomeningeal disease detected by flow cytometry in newly diagnosed aggressive B-cell lymphomas at risk for central nervous system involvement: the role of flow cytometry versus cytology. *Blood*. 2005;105:496-502.

Hussein AS, Shafran SD. Acute bacterial meningitis in adults. A 12-year review. *Medicine (Baltimore)*. 2000;79:360-368.

Irani DN. *Cerebrospinal Fluid in Clinical Practice*. Philadelphia, PA: Saunders Elsevier; 2009.

Kaplan JG, DeSouza TG, Farkash A, et al. Leptomeningeal metastases: comparison of clinical features and laboratory data of solid tumors, lymphomas and leukemias. *J Neurooncol*. 1990;9:225-229.

Kilpatrick ME, Girgis NI, Yassin MW, Abu el Ella AA. Tuberculous meningitis—clinical and laboratory review of 100 patients. *J Hyg (Lond)*. 1986;96:231-238.

Lee K. *The NeuroICU Book*. 2nd ed. New York, NY: McGraw-Hill Medical; 2018.

McLean BN, Luxton RW, Thompson EJ. A study of immunoglobulin G in the cerebrospinal fluid of 1007 patients with suspected neurological disease using isoelectric focusing and the log IgG-index. A comparison and diagnostic applications. *Brain*. 1990;113(pt 5):1269-1289.

Moriguchi T, Harii N, Goto J, et al. A first case of meningitis/encephalitis associated with SARS-Coronavirus-2. *Int J Infect Dis*. 2020;94:55-58.

Noble VE, Bret NA, Sutingco N. Ultrasound for procedural guidance: lumbar puncture. In: Noble VE, Nelson BP, Sutingco AN, eds. *Manual of Emergency and Critical Care Ultrasound*. New York, NY: Cambridge University Press; 2007:319-322.

Pfausler B, Beer R, Engelhardt K, Kemmler G, Mohsenipour I, Schmutzhard E. Cell index—a new parameter for the early diagnosis of ventriculostomy (external ventricular drainage)-related ventriculitis in patients with intraventricular hemorrhage? *Acta Neurochir (Wien)*. 2004;146:477-481.

Roos KL. Lumbar puncture. *Semin Neurol*. 2003;23:105-114.

Shaikh F, Brzezinski J, Alexander S, et al. Ultrasound imaging for lumbar punctures and epidural catheterisations: systematic review and meta-analysis. *BMJ*. 2013;346:f1720.

Spanos A, Harrell FE Jr, Durack DT. Differential diagnosis of acute meningitis. An analysis of the predictive value of initial observations. *JAMA*. 1989;262:2700-2707.

Thomson RB Jr, Bertram H. Laboratory diagnosis of central nervous system infections. *Infect Dis Clin North Am*. 2001;15:1047-1071.

Tunkel AR, Glaser CA, Bloch KC, et al. The management of encephalitis: clinical practice guidelines by the Infectious Diseases Society of America. *Clin Infect Dis*. 2008;47:303-327.

Wingerchuk DM, Lennon VA, Pittock SJ, Lucchinetti CF, Weinshenker BG. Revised diagnostic criteria for neuromyelitis optica. *Neurology*. 2006;66:1485-1489.

Brain, Muscle, Nerve, and Skin Biopsy 33

John F. Crary, Thomas H. Brannagan III, and Kurenai Tanji

KEY POINTS

1. Morphologic categorization on the microscopic level of the disease by brain, muscle, and/or nerve biopsy, in conjunction with careful clinical and laboratory data assessment, remains relevant for diagnosis.
2. In the era of next generation gene sequencing, roles of tissue assessment through brain and neuromuscular biopsies are widening from conventional tissue diagnosis to assessment of specific genetic abnormalities, treatment effects, and clinical course and prognosis.
3. Less invasive skin biopsy is useful to assess the epidermal sensory nerve density and the autonomic innervation for a wide variety of systemic, or neurological diseases including neurodegenerative conditions such as α-synucleinopathy.

INTRODUCTION

Despite major advances in other diagnostic modalities, obtaining a tissue-based diagnosis through a biopsy of brain, muscle, or nerve remains an immensely powerful tool. Modern molecular and genetic techniques are increasingly being applied to biopsy specimens, greatly increasing their utility. Although widespread deployment of next-generation DNA and RNA sequencing technology has obviated the need for biopsy in some settings, these modern ancillary studies have not supplanted classical histomorphologic analysis. Biopsies are always performed in the context of an interdisciplinary team, which can include neurologists, internists, neuroradiologists, neurosurgeons, neurooncologists, and neuropathologists. To ensure appropriate assessment of the biopsy, a high level of communication between providers is of the utmost importance. Any potential benefits associated with having a tissue-based diagnosis must be balanced against the risks associated with the procedure. Brain biopsy is standard of care for brain tumors and has a high degree of utility in many other settings. Modern surgical techniques have helped to minimize complications and the probability of obtaining a nondiagnostic biopsy. In many contexts, the benefits of establishing a diagnosis and optimal treatment plan may outweigh the risks. Brain biopsy should always be a last resort, reserved for clinical settings where all other approaches have been exhausted. In this chapter, we provide an overview of the critical issues associated with the brain, muscle, and nerve biopsy. We also discuss the use of skin biopsies for epidermal nerve fiber density analysis.

BRAIN BIOPSY

Indications

Certain general considerations must be weighed before referring a patient for a brain biopsy. General risks associated with brain biopsy are similar to those associated with any surgical procedure, including deep vein thrombosis, postoperative hemorrhage, infection, etc. Patients on anticoagulant treatment might need to make adjustments given the risk of postoperative intracranial hemorrhage. Other complications include stroke, seizures, and cerebrospinal fluid (CSF) leak (fistula). Given the risks, it is generally accepted that all other diagnostic modalities must be exhausted before proceeding to brain biopsy.

An essential consideration prior to biopsy is determining the likelihood that the answer will lead to a change in patient management. Should, for example, the expected diagnoses have similar or no disease-modifying treatments, then the decision to proceed to a biopsy should be questioned. Furthermore, there is often a window of opportunity for the biopsy to be useful clinically. If the patient has deteriorated beyond the point to which a reasonable recovery in function can be anticipated, the biopsy might also be of limited value. Furthermore, the ability of the neuropathologist to recognize diagnostic features in the tissue is highest during the active phase of a disease. Once the pathology has run its course, secondary changes in the tissue can predominate and increase the likelihood of a nondiagnostic biopsy. Treatment effects, such as brain irradiation or steroids, may also mask diagnostic changes. For example, in a patient with a possible diagnosis of central nervous system (CNS) lymphoma, the use of systemic steroids should be deferred unless essential in the context of clinical care (ie, as a component of treating brain herniation) because treatment can make the biopsy nondiagnostic. Thus, it is essential that empiric treatments be used judiciously should a patient be a candidate for brain biopsy.

Brain biopsies have a prominent place in the treatment and management of CNS neoplasms. For mass lesions, partial brain resection and/or biopsy may be performed, depending on the functional importance of the region that contains the lesion. For malignant brain tumors, resections have the additional advantage of being both diagnostic and therapeutic in the form of debulking. Watchful waiting might be considered for benign brain tumors. Certain brain tumors in vital regions of the brain, such as brainstem gliomas, or eloquent cortical regions might not be amenable to a full resection, but guided stereotactic biopsy might be performed in some cases.

Brain biopsies are generally not required for most CNS infections because other forms of diagnosis are often definitive. For example, viral, bacterial, and fungal organisms can be identified with CSF sampling. In ambiguous contexts, a brain biopsy might be performed. Such biopsies are often of highest clinical use when two pathogenic processes with contradictory treatments are under consideration, for example, infectious versus autoimmune. Immunocompromised patients also provide a special setting where a broad differential diagnosis might trigger consideration of a brain biopsy.

In the case of age-related neurodegenerative disorders, brain biopsy is rarely performed. However, a biopsy may be considered in the setting of a rapidly progressive dementia, when there is

a reasonable chance that a treatable cause might be uncovered, which cannot be diagnosed by other means. Recent advances have led to the ability to diagnose specific autoimmune encephalitis through the detection of CSF autoantibodies. Moreover, CSF biomarkers and positron emission tomography scans have shown increasing use in diagnosing Alzheimer disease and prion disease. These advances have altered referral patterns, perhaps decreasing the total number of subjects undergoing brain biopsy for rapidly progressive dementia but increasing the diagnostic yield.

Brain biopsy is not indicated for ischemic stroke, but brain tissue may be sampled in the setting of hemorrhagic stroke to assess the vasculature for cerebral amyloid angiopathy. Vascular abnormalities may be resected surgically, and histopathologic analysis of such lesions is useful for differentiating arteriovenous malformations, cavernomas, and other lesions.

Brain Biopsy Requires an Interdisciplinary Approach

Brain biopsies are always performed in the context of an interdisciplinary team. The neurologist plays a critical role in clinical workup and referring patients to biopsy only when all other diagnostic modalities have been exhausted. Next, the neurologist will work closely with both the neuroradiologist and neurosurgeon to identify a radiographically evident lesion that is amenable to biopsy. Although "blind" biopsies of the nondominant (usually right) frontal cortex are often performed, targeting a specific lesion will most often provide the most informative results. If a biopsy is indicated, an open biopsy consisting of 1 cm^3 full-thickness specimen that contains gray matter, leptomeninges, and subcortical white matter is considered optimal. However, if the lesion is located within a vital or eloquent brain region, stereotactic core biopsies, sometimes measuring just a few millimeters, can provide diagnostic material.

During surgery, neurosurgeons often call on the neuropathologist to perform a *frozen section*. These intraoperative consultations are a means to rapidly obtain some diagnostic information and involve quickly freezing tissue, cutting on a cryostat, rapid hematoxylin and eosin (H&E) staining, and a preliminary diagnostic read by the pathologist. Although these tissue sections are of only limited diagnostic value, given the severe tissue freezing artifacts that develop (ie, interstitial and intracytoplasmic distortion from ice crystal formation), the assessment of the tissue architecture and cellularity provided can often place lesions in broad categories and may be helpful to guide intraoperative surgical decision making. Another use of the frozen section is confirming the presence of lesional tissue within the biopsy. Even with image-guided biopsies, small lesions may not be adequately represented. Performing a frozen section allows the team to sample additional tissues if necessary and greatly decreases the likelihood of a nondiagnostic biopsy. Critically, the preliminary diagnostic impression obtained through a frozen section must be interpreted with caution because it is not uncommon for revision following additional sampling and ancillary studies.

Neuropathologic Interpretation of the Brain Biopsy

Classical histopathologic examination by a neuropathologist remains the foundation of brain biopsy interpretation. Tissue sections from formalin-fixed brain are mounted on glass slides, stained with H&E for screening purposes, and examined microscopically. The H&E stain allows for visualization of the cytoarchitecture and all the cellular types in the brain, including neurons and glia. Other "special" stains are in routine use, including variations of the Bielschowsky silver stain, which is excellent for visualizing neuronal processes. Connective tissue stains such as trichrome, reticulin, or van Gieson are particularly useful for assessing vascular pathology. Congo red and thioflavin are useful for visualizing amyloid. Gram, Gömöri methenamine silver, and the Ziehl-Neelsen (acid-fast bacilli) stains are routinely used for microorganisms. While most pathology laboratories continue to rely on glass slides for their workflow, some have begun the transition to digital whole slide images. Once this happens more broadly, it is anticipated that we will begin to see more widespread deployment of machine learning algorithms (ie, computer vision) being applied in neuropathology, which will greatly increase the precision of many histologic tests.

Various ancillary studies are routinely used in neuropathology. Immunohistochemical stains, which rely on specific antisera to mark pathologic changes, are commonly employed in various contexts, particularly in the setting of neoplasms, where alterations can be detected with both diagnostic and prognostic relevance. Most molecular tests can be performed in fixed tissues, and it is no longer necessary to set aside frozen tissue for this purpose prior to processing. Should an infectious etiology be a consideration, tissue cultures are ideally performed using swabs of the surgical site, but fragments of fresh tissue can be submitted after surgery provided that it has not been fixed or contaminated. If lymphoma is a consideration, flow cytometry on fresh brain tissue can be performed to characterize the neoplastic population, but CNS lymphoma is most often of the diffuse large B-cell type, and these fragile cells generally do not perform well. Alternatively, neoplastic cells may be grown in culture for cytogenetic analysis. Electron microscopy is generally of only very limited use in the setting of brain biopsies. Next-generation DNA sequencing has become standard of care for most brain tumors for subclassification and targeted treatments, with IDH1/2 mutations, alongside ATRX loss and 1p/19q loss forming the foundation of the diffuse glioma classification scheme in the 2016 World Health Organization Classification of Tumors of the Central Nervous System. Also, next-generation sequencing can detect very low levels of pathogen DNA/RNA and may become more widely deployed in the future for this use.

MUSCLE BIOPSY

A muscle biopsy may be warranted when neurologic examination, laboratory tests, and electrophysiologic studies suggest a neuromuscular disease. Microscopic examination can help to distinguish between neurogenic and myogenic disorders and can also provide assistance in subclassifying myopathies and in rendering a specific diagnosis. With the advent of new genetic techniques including selective candidate gene sequencing, high-throughput sequencing of specialized gene panels, whole exome, and even whole genome sequencing, several genetic myopathies are diagnosed without invasive muscle biopsy. However, prior to embarking on exhaustive and often costly genetic investigations, a muscle biopsy chosen by thorough history taking and careful neurologic examination may provide an important aid in identifying the most likely cause of the disease that could be treatable. For example, the presence of widespread inflammation suggests

an acquired inflammatory myopathy as distinguished from other acquired or hereditary myopathies such as muscular dystrophy. Vasculitis and amyloidosis are often associated with a neuropathy, but both disorders may also be identified in muscle. Even with genetic investigations, morphologic categorization remains essential in some cases, especially when genetic abnormalities of unknown significance might complicate a diagnostic odyssey.

The decision to perform a muscle biopsy should also include noninvasive tools including blood test (eg, electrolytes, glucose, thyroid-stimulating hormone, vitamin D, creatine kinase [CK], and autoimmune screen), electrodiagnostic studies, and other laboratory tests. Imaging studies, such as magnetic resonance imaging (MRI), have been increasingly incorporated into the evaluation of muscle diseases. When combined with a biopsy, MRI can provide preoperative information about the muscle and adjacent structures (eg, fascia and subcutaneous tissue). In some cases, the MRI may disclose a characteristic pathologic involvement of muscle groups, which may lead directly to a genetic test and obviate the need for a biopsy.

The best muscles for biopsy are those moderately affected by the disease. MRI may be helpful in selecting a muscle that is most likely to provide diagnostic findings histologically. Severely atrophic muscles, prior injection, or electromyography examination sites, or previously traumatized muscles must be avoided. Patients with myoglobinuria or rhabdomyolysis should have the biopsy performed 6 to 8 weeks following the episode to allow muscle to recover from myonecrosis because extensive and active myonecrosis/regeneration on biopsy may obscure the underlying pathology. The most commonly investigated muscles are the deltoid, biceps, and vastus lateralis, when proximal weakness predominates. In patients with distal weakness, the anterior tibialis or gastrocnemius can be chosen depending on anterior or posterior predominance in weakness or atrophy. The clinical history should be available to the pathologist who examines the biopsy, to apply optimal histologic, histochemical, immunohistochemical, or electron microscopic techniques, to detect the important pathology in the tissue.

Technically, an accurate *morphologic diagnosis* requires formalin-fixed tissue to be processed for routine histology, rapidly and properly frozen tissue for histochemical and immunohistochemical preparations, and glutaraldehyde-fixed tissue for possible electron microscopic examination. Preserving a separate piece of snap frozen muscle is helpful for potential biochemical enzymatic assay(s) of glycogenolytic and glycolytic pathways; lipid metabolism; or mitochondrial respiration, electrophoresis for the protein expression study of muscle proteins, or genetic study.

When the routine histology of muscle demonstrates large or small groups of atrophic fibers, it is most suggestive of a *neurogenic disorder*. In contrast, *myopathic features* include a significantly increased fiber size, an increased number of internally nucleated fibers, necrotic and/or regenerating fibers, and abnormal intracytoplasmic storage material or inclusions. In chronic myopathies, notable endomysial fibrosis is often present. Inflammatory myopathies tend to display widespread, often multifocal, inflammatory infiltrates in the endomysium and/or perimysium. Recognizing certain immunocytologic and/or distribution patterns of inflammation may help subclassify the disease. The diagnosis of vasculitis, infectious or noninfectious granulomatous diseases, and amyloidosis can be established by routine histologic evaluation.

Histochemical staining techniques applied on cryosections help classify the fiber types (eg, myosin adenosine triphosphatase) and delineate cytologic abnormalities. A neurogenic disease can demonstrate fiber-type grouping and/or target/targetoid fibers, best demonstrated by myosin adenosine triphosphatase and nicotinamide adenine dinucleotide tetrazolium reductase, respectively. In certain myopathies, fiber-type predominance (eg, type 1 predominance in congenital myopathy) or selective fiber atrophy (eg, type 2 myofiber atrophy in steroid myopathy, critical illness myopathy, and collagen vascular disease) may occur. A variety of cytologic abnormality associated with myopathies, such as cores, nemaline (rods), tubular aggregates, caps, hyaline bodies, reduced bodies, cytoplasmic bodies, cytoplasmic mass, significantly increased mitochondria (ragged red fibers), excessive intracytoplasmic glycogen or lipid, and increased lysosomal reactivity with or without fiber vacuolation, are best characterized by proper histochemical preparations. Certain enzymatic deficiencies in metabolic myopathy can be histochemically demonstrated. These include myophosphorylase deficiency (glycogenosis type V), phosphofructokinase deficiency (type VII), myoadenylate deaminase deficiency, and cytochrome *c* oxidase (respiratory chain complex IV) deficiency (mitochondrial myopathy).

In the next-generation sequencing era, immunohistochemical staining using the antibodies against certain proteins may still offer an informative guide to select candidate gene(s) to be molecularly investigated. Genetic defects of dystrophin, sarcoglycan proteins, dysferlin, caveolin 3, emerin, merosin (α_2-laminin), collagen VI, carbohydrate side chain of α-dystroglycan, and others can be reliably tested in the tissue. When a muscular dystrophy demonstrates on biopsy morphologically indistinguishable abnormalities from those of other acquired myopathies, immunohistologic staining may help establish the cause of the disease. Furthermore, immunohistochemical detection of a specific protein deficiency may find the cause of otherwise nonspecific clinical symptoms in patients without typical dystrophic muscle weakness, such as persistent CK elevation (so-called benign hyperCKemia), myoglobulinuria/rhabdomyolysis, myalgia, or cramp. The other advantage of immunohistochemical staining is found in the analysis of inflammatory myopathies. The immunohistochemical detection of inflammatory markers (eg, major histocompatibility complex class I and II antigens, membrane attack complex) and immunocytologic typing of lymphocytic infiltrates may aid subclassification of immune-mediated inflammatory myopathies such as dermatomyositis, polymyositis, immune-mediated necrotizing myopathy, and inclusion body myositis.

In summary, to promptly establish an accurate and clinically meaningful diagnosis for patients with muscle disorders posing diagnostic challenges, it is essential to wisely minimize the number of investigations that could be extremely costly, especially under the increasing availability of commercial testing. Although next-generation sequencing methods face their own challenges including consent and interpretation of the sequenced data, traditional diagnostic methods such as muscle biopsy remain important tools in narrowing the differential diagnosis, in subclassifying the disease in a certain entity of disorders, in assessing the severity of disease, and in aiding the genetic alteration(s) of unknown significance to be properly interpreted.

NERVE BIOPSY

Nerve biopsy is indicated in patients with peripheral neuropathy when additional information about the etiology and severity of the disorder is needed. Although the options for biopsy sites are limited and the indications have generally decreased in the last

20 years, mostly due to increasing availability of molecular diagnostic testing for hereditary peripheral neuropathies and partly to various serologic autoantibody detection for dysimmune peripheral neuropathies, certain specific disorders require tissue diagnosis or characterization. These may include vasculitis; sarcoid neuropathy; amyloidosis; leprous neuropathy; chronic inflammatory demyelinating polyneuropathy, especially cases with clinically and/or electrophysiologically atypical and/or asymmetric presentation; neuropathy associated with monoclonal gammopathy; toxic neuropathy; storage disorders; and other systemic disorders with peripheral nervous system involvement. Several CNS diseases, for instance, metachromatic leukodystrophy, adrenoleukodystrophy, Krabbe disease, Lafora disease, neuronal lipofuscinosis, and other lysosomal storage diseases, may clinically involve the peripheral nerve. Nerve biopsy may also be helpful in identifying sporadic cases of genetically defined neuropathy or be required in the follow-up of patients with genetically diagnosed neuropathy with unusual clinical presentations. In children, the pathologically characteristic features in nerve may establish the diagnosis of giant axonal neuropathy and neuroaxonal dystrophy.

The sural nerve is the most widely studied nerve in health and disease and is generally recommended for biopsy. Motor nerve biopsy could be carried out for rare specific aims such as distinguishing motor neuropathies from motor neuron diseases. If mononeuritis multiplex clinically spares the sural nerve, another cutaneous nerve can be selected. For example, in most patients with suspected vasculitic neuropathy, a combined superficial fibular (peroneal) nerve/fibularis (peroneus) brevis muscle biopsy through a single incision on the lateral aspect of the leg is the most efficient and cost-effective procedure. For a comprehensive morphologic diagnosis, the removed nerve specimen is conventionally divided into three parts: buffered formalin-fixed for paraffin-embedded sections; buffered glutaraldehyde-fixed for epoxy resin sections, teasing fiber analysis, and electron microscopic assessment; and frozen for potential immunofluorescent study.

The routine histology of nerves demonstrates diagnostic features of vasculopathy (vasculitis, arteriolosclerosis, embolus, intravascular malignancy, etc), amyloid deposition, sarcoidosis, inflammation, infiltration of nerve by hematologic neoplasia, leprosy, giant axon neuropathy, and polyglucosan body disease. The hematologic neoplasia invading the nerve may be distinguished from reactive processes using immunocytologic lymphocytic markers. Immunoglobulin light-chain deposition secondary to plasma cell dyscrasia can be identifiable by in situ hybridization or by immunofluorescence study for kappa and lambda light chains. If a sizable amyloid deposit is histologically detected, the tissue may be useful for amyloid typing by mass spectroscopy. In general, however, most neuropathies do not show distinctive or specific morphologic findings in paraffin sections and usually require examination of semithin epoxy resin sections that are significantly thinner than paraffin sections, offering a better resolution of histology. Combined with observation of the teased myelinated fibers, axonopathy can be distinguished from demyelinating neuropathy. *Axonopathy* is recognized by marked depletion of nerve fibers associated with endoneurial fibrosis, with or without myelin debris or axonal regeneration. Teased fibers may exhibit prominent wallerian degeneration of myelinated fibers in an active phase of the disease. These axonopathic features can be seen in vasculitic neuropathy, toxic (iatrogenic) neuropathies, alcoholic neuropathy, amyloid neuropathy, and various neuropathies associated with metabolic disease, nutritional defect, and infectious disease. Segmental demyelination and remyelination, recognized in section as thinly myelinated fibers or onion bulb (concentric layers of Schwann cell processes) formation, are often the result of *primary demyelinating disorders* (eg, immune-mediated and inherited). The teasing fiber analysis may further illustrate myelin changes such as excessive myelin wrinkling and folding and tomacula formation (irregular thickening of myelin within internodes), and the semiquantitative analysis of those myelin alterations may be informative in identifying the presence of pathologic demyelinating condition because a low degree of myelin irregularity can be physiologically associated with aging.

Electron microscopic examination is useful to further delineate the pathology of axons, myelin, Schwann cells, or interstitial tissue (eg, accumulation of neurofilaments, organelles, or protein aggregation in axon; widened, uncompacted, or irregularly folded myelin lamellae; various intracellular inclusions or deposits) and is essential for the assessment of unmyelinated fibers.

For various autoimmune polyneuropathies, many serum autoantibodies directed against peripheral nerve glycoconjugate antigens have been identified as putative targets to date, and the direct *immunofluorescent study* using nerve frozen sections could be used to demonstrate possible immunoglobulin and compliment deposits within the myelin sheath. For example, intense and widespread deposits of the C3 component of complement and immunoglobulin M along the myelin sheath could help distinguish neuropathy associated with immunoglobulin M paraproteinemia from a morphologically or clinically resembling chronic inflammatory demyelinating polyneuropathy.

In summary, in the new genetic era, conventional nerve biopsy can still offer clinically useful information, when it is wisely chosen. However, it is noted that in various neuropathies with a multifocal nature or with proximal involvement such as plexuses and roots, findings in the nerve biopsy may not be representative of primary pathology taking place at other sites of the nerve and that the diagnostic usefulness of nerve biopsy must be assessed on a case-by-case basis.

SKIN BIOPSY

Skin biopsy is primarily used to evaluate cutaneous sensory and autonomic nerves, and clinically, it has been widely used as a useful diagnostic tool for acquired and hereditary small-fiber neuropathy by the quantification of *intraepidermal nerve fiber density* (IENFD). The clinical course of certain systemic autoimmune diseases including celiac disease, Sjögren syndrome, and certain channelopathies may be complicated by small-fiber symptoms. Skin biopsy has also been used in detection of other neuropathies such as small fiber–predominant polyneuropathy and distal symmetric neuropathy. Given the minimally invasive nature, it enables multiple sampling from different biopsy sites (eg, proximal and distal sites in a same limb of the patient) for distinguishing non–length-dependent neuropathies (eg, ganglionopathies, multifocal involvement of nerve) from the length-dependent and for comparison or monitoring patients over the clinical course. For IENFD analysis, epidermal axons are immunohistochemically visualized in the tissue sections, commonly using the antibody against a panaxonal marker, PGP9.5 (an ubiquitin hydrolase: a major protein of nerve cells including axons and dendrites), and are counted in a given length of the epidermis. The quantitative analysis of nerve fibers requires normative values, and in patients with small-fiber neuropathy,

the IENFD tends to be significantly low. Morphologic abnormalities in the epidermal axons (eg, short length, small diameters, swelling, and complicated branching patterns) may precede the actual dropout of the epidermal axons. The limitations of skin biopsy include the following: (1) Skin biopsy rarely provide the specific differentiation of pathogenic mechanism/cause of the disease, and (2) except in a clinical trial setting, the observation of skin biopsy rarely changes clinical management especially in diseases where the cause of neuropathy is already known. Skin biopsy can be used also for evaluation of patients with autonomic disorders such as diabetes, impaired glucose tolerance, chemotherapy-induced autonomic neuropathy, and connective tissue disorders. Furthermore, autonomic dysfunctions in neurodegenerative disorders could be assessed by semiquantification of the autonomic innervation to sweat glands or arrector pili muscle. In particular, recent studies of α-synuclein intraneural deposition in sudomotor and pili motor nerve have demonstrated high specificity with variable sensitivity, raising the possibility that the analysis of α-synuclein in relatively noninvasive skin biopsy could serve as a possible biomarker of synucleinopathy including Parkinson disease for a prompt and effective treatment by early detection of the disease at prodromal stages. However, reliability and correlation with neuropathy/autonomic function scores have been debatable in variable published methods that have not been as yet optimized and standardized, and availability of normative values is limited.

In summary, skin biopsy is a unique minimally invasive biopsy technique, and the quantification of IENFD remains a reliable diagnostic tool for small-fiber neuropathy, with high diagnostic specificity and relatively good sensitivity, which cannot be readily detected by nerve conduction study. Indications of skin biopsy are expanding, with potential use as biomarkers of certain neurologic diseases for effective treatment and management of neurologic diseases involving small nerve fibers.

SUGGESTED READINGS

Brain Biopsy

Love S, Perry A, Ironside J, Budka H. *Greenfield's Neuropathology*. 9th ed. London, United Kingdom: Hodder Arnold; 2015.

Perry A, Brat DJ. *Practical Surgical Neuropathology: A Diagnostic Approach*. 2nd ed. Philadelphia, PA: Churchill Livingstone/Elsevier; 2017.

Muscle Biopsy

Banwell BL, Gomez MR, Daube JR, et al. General approaches to neuromuscular diseases. In: Engel AG, Franzini-Armstrong C, eds. *Myology*. 3rd ed. New York, NY: McGraw-Hill; 2004:599-958.

Dubowits V, Sewry CA. The procedure of muscle biopsy. In: Dubowits V, Sewry CA, eds. *Muscle Biopsy*. 3rd ed. London, United Kingdom: Elsevier Saunders; 2007:3-20.

Malfatti E, Romero NB. Disease of the skeletal muscle. In: Kovacs GG, Alafuzoff I, eds. *Handbook of Clinical Neurology*. Vol 145. London, United Kingdom: Elsevier B.V.; 2018:429-451.

Tanji K, Hays AP. Muscle biopsy. In: Aminoff MJ, Daroff RB, eds. *Encyclopedia of the Neurological Sciences*. Vol 3. 2nd ed. Oxford, United Kingdom: Academic Press; 2014:174-178.

Nerve Biopsy

Dyck PL, Dyck PJB, Engelstad J. Role of pathology study of peripheral nerve. In: Dyck PL, Thomas PK, eds. *Peripheral Neuropathy*. 4th ed. Philadelphia, PA: Elsevier Saunders; 2005:733-754.

Mendell JR, Erdem S, Agamanolis DP. The role of peripheral nerve and skin biopsies. In: Mendell JR, ed. *Diagnosis and Management of Peripheral Nerve Disorders*. Oxford, United Kingdom: Oxford University Press; 2001:90-125.

Gorson KC, Herrmann DN, Thiagarajan R, et al. Non-length dependent small fibre neuropathy/ganglionopathy. *J Neurol Neurosurg Psychiatry*. 2008;79:163-169.

Vallat JM, Vital A, Magy L, Martin-Negrier ML, Vital C. An update on nerve biopsy. *J Neuropathol Exp Neurol*. 2009;68(8):833-844.

Skin Biopsy

Devigili G, Tugnoli V, Penza P, et al. The diagnostic criteria for small fibre neuropathy: from symptoms to neuropathology. *Brain*. 2008;131(pt 7): 1912-1925.

England JD, Gronseth GS, Franklin G, et al. Evaluation of distal symmetric polyneuropathy: the role of autonomic testing, nerve biopsy, and skin biopsy (an evidence-based review). *Muscle Nerve*. 2009;39:106-115.

Gibbons CH, Illigens BM, Wang N, Freeman R. Quantification of sweat gland innervation: a clinical-pathologic correlation. *Neurology*. 2009;72: 1479-1486

McArthur JC, Stocks EA, Hauer P, Cornblath DR, Griffin JW. Epidermal nerve fiber density: normative reference range and diagnostic efficiency. *Arch Neurol*. 1998;55:1513-1520.

Myers MI, Peltier AC. Uses of skin biopsy for sensory and autonomic nerve assessment. *Curr Neurol Neurosci Rep*. 2013;13:323.

Kim JY, Illigens BMW, McCormick MP, Wang N, Gibbons CH. Alpha-synuclein in skin nerve fibers as a biomarker for alpha-synucleinopathies. *J Clin Neurol*. 2019;15(2):135-142.

Siepmann T, Penzlin AI, Illigens BMW, Reichmann H. Should skin biopsies be performed in patients suspected of having Parkinson's disease? *Parkinsons Dis*. 2017;2017:6064974.

34 Intracranial Pressure and Neurocritical Care Monitoring

Charles L. Francoeur and Stephan A. Mayer

KEY POINTS

1. Intracranial pressure monitoring is indicated in comatose patients (noncommand following) who have evidence of abnormal intracranial mass effect on computed tomography and a prognosis that merits aggressive intervention.
2. External ventricular drains can be used to treat intracranial hypertension via cerebrospinal fluid drainage and are also capable of measuring intracranial pressure.
3. Continuous electroencephalography monitoring can detect nonconvulsive seizures or status epilepticus in 10% to 30% of comatose intensive care unit patients.

INTRODUCTION

Monitoring plays a fundamental role in the daily practice of neurocritical care. Bedside neuromonitoring supplements clinical evaluation and imaging with the underlying goal of detecting physiologic derangements before neurologic deterioration and irreversible damage occurs. This chapter introduces continuous bedside neuromonitoring modalities that are in use in the most advanced neurocritical care units around the world. Although no study has tested whether "multimodality" monitoring improves outcomes, these advanced systems allow for recognition of real-time pathologic events that we were unable to identify just a few years ago and provide new insights into the complex pathophysiology of severe brain injury.

INTRACRANIAL PRESSURE AND CEREBRAL PERFUSION PRESSURE MONITORING

Physiologic Principles

Intracranial Pressure

The rigid skull is filled with incompressible content, namely brain (1,400 mL), cerebrospinal fluid (CSF) (150 mL), and blood (75 mL). In normal state, with blood outflow being equal to blood inflow, CSF absorption equals CSF production (~20 mL/h) and intracranial pressure (ICP) lies between 5 and 15 mm Hg in the supine position (8-20 cm H_2O).

As described in the Monro-Kellie model, if any one of those compartments increases in volume, as in the case of obstructive hydrocephalus, or a new mass lesion is added (a subdural hematoma for example), buffering mechanisms are called upon. The first adaptive process is egress of CSF in the spinal canal, provided there is no obstruction to flow. The second step is shifting of blood from the capacitance vessels (veins) out of the intracranial compartment. Once these buffering mechanisms are exhausted, intracranial compliance is reduced and ICP quickly rises (Fig. 34.1).

Secondary neurologic injury occurs with ICP over 20 mm Hg, and elevated ICP above this threshold after traumatic brain injury (TBI) or subarachnoid hemorrhage (SAH) correlates with increased mortality. Initially, cerebral blood flow (CBF) is reduced, causing ischemia, a problem exacerbated by loss of cerebral autoregulation. At this point, level of consciousness may decrease. The most dramatic clinical signs related to ICP elevation, such as an unreactive "blown" pupil and motor posturing, are produced by ICP gradients within the cranial vault, which lead to brain tissue shifting and herniation. In these cases, initial regional CBF reduction will be compounded by vascular compression in later stages of herniation, inducing secondary territorial infarcts of the anterior or posterior cerebral artery.

Numerous ICP treatment thresholds have been proposed in the literature, ranging from 15 to 35 mm Hg, including in the latest Brain Trauma Foundation guidelines, which suggest maintaining ICP below 22 mm Hg. The relationship of ICP to outcome is complex. Although the evidence suggests a clear relationship with mortality, most studies have found only a weak or no association between intracranial hypertension and morbidity. We also know from multimodal monitoring that some patients with mildly elevated ICP show no dysfunction of brain energy metabolism and that the reverse is also true (ie, patients with normal ICP values can have highly dysfunctional energy metabolism).

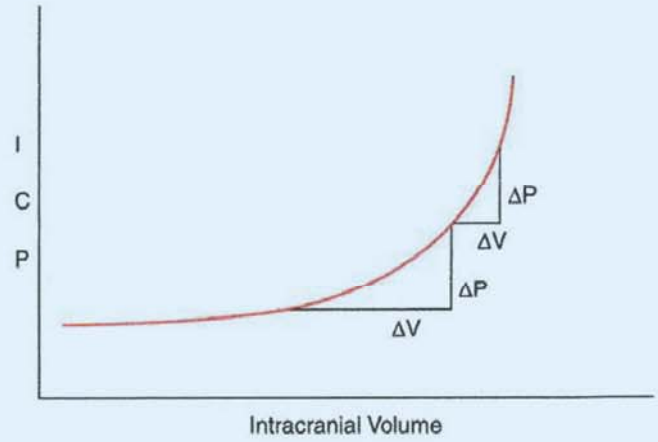

FIGURE 34.1 Compliance is the change in pressure per change in unit of volume ($\Delta P/\Delta V$). Once compensatory mechanisms are overwhelmed, compliance dramatically decreases, meaning that with a smaller increment in intracranial volume, a much more dramatic increase in pressure develops. Abbreviation: ICP, intracranial pressure.

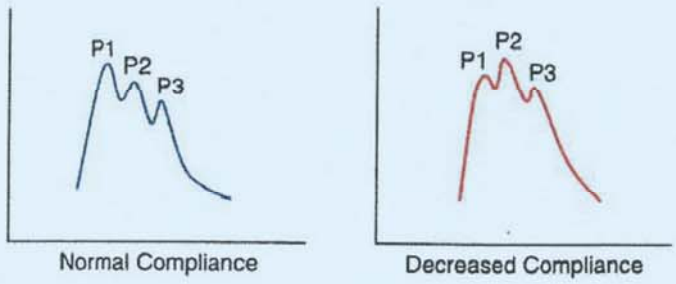

FIGURE 34.2 Intracranial pressure waveform. *P1*, the percussive wave, comes from arterial transmission through the choroid plexus. *P2*, the tidal wave, reflects brain tissue elastance. As it rises, so does *P2*. When *P2* exceeds *P1*, it has an excellent sensitivity to predict incoming increase in intracranial pressure. The third and final wave (*P3*) is secondary to aortic valve closure, a corollary of the arterial dicrotic notch.

The underlying concept behind brain multimodality monitoring is to move away from generalized treatment thresholds and toward individualized ICP treatment thresholds that may vary over time and with clinical context.

Waveforms

Mean ICP is a time average of the ICP waveform. The latter consists of three components, in order of frequency: (1) the pulse pressure waveforms, (2) the respiratory waveforms (0.1-0.3 Hz) associated with the respiratory cycle, and (3) the slow vasogenic waveforms (eg, "Lundberg A and B waves"). The pulse pressure waveform presents deflections that correspond to transient increases in cerebral blood volume with each systole that are divided into three waves (**Fig. 34.2**): an initial percussion wave, which occurs at the start of systole and under normal conditions is of greatest amplitude (called *P1*); a secondary tidal wave then occurs, which reflects brain recoil or elastance (*P2*); followed by a third dicrotic wave created by closure of the aortic valve at the start of diastole (*P3*). In states of reduced intracranial compliance, the pulse pressure amplitude typically increases and P2 component exceeds P1 in the waveform display, as the "shock" of systolic inflow becomes less absorbable.

Slow vasogenic waveforms are not only less specific but also present typical patterns in cases of low cerebral compliance, where pathologic waveforms may occur. Lundberg A waves (or plateau waves) are prolonged periods (5-20 min) of sharp rise in ICP (>20 mm Hg) (**Fig. 34.3**). They are caused by sustained vasodilation and abruptly occur when either cerebral perfusion pressure (CPP) or intracranial compliance is low (see **Fig. 111.4**). Severe plateau waves preceding the onset of brain death can last for hours and reach levels as high as 50 to 100 mm Hg. Lundberg B waves are shorter duration (<10 min), clustered and cyclic (0.01-0.05 Hz), low-amplitude elevations (<20 mm Hg) that indicate that intracranial compliance is compromised, although they are sometimes observed in nonpathologic states.

Cerebral Perfusion Pressure and Pressure Reactivity

Arterial blood carries oxygen and glucose, which are necessary for neuronal function and survival. CPP, defined as the difference between mean arterial pressure (MAP) and ICP, is the main determinant of CBF.

$$CPP = MAP - ICP$$

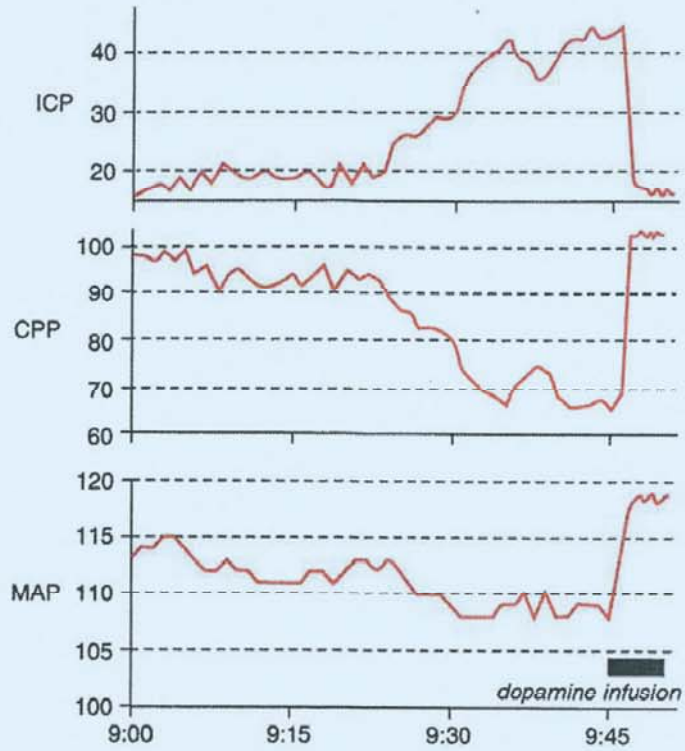

FIGURE 34.3 Lundberg A (plateau) wave, with characteristic "mirror" reduction in cerebral perfusion pressure (CPP). The plateau wave is terminated by an infusion of dopamine, which leads to an elevation in mean arterial pressure and reversal of the brain's vasodilated state. Abbreviations: ICP, intracranial pressure; MAP, mean arterial pressure.

Adequate comprehension of CPP physiology requires an understanding of cerebrovascular pressure reactivity, which is the intrinsic capacity of the cerebral vasculature to adapt to changing pressure and maintain constant CBF by varying the caliber of its resistance vessels at the precapillary level. In healthy individuals, this mechanism allows for a stable level of CBF across a wide range of MAP (40-160 mm Hg). In pathologic states, however, autoregulation often fails and CBF becomes pressure passive, putting the brain at risk for both ischemia or hyperemia. Cerebral autoregulation can also be affected by extrinsic factors such as pH, temperature, and drugs.

Accurate measurement of CPP requires the same zero reference point for both arterial blood pressure and ICP, that is, using the tragus of the ear as the external landmark. Head elevation with the zero reference point at the tragus for ICP and at heart level for MAP induces a significant overestimation (up to >10 mm Hg) of CPP, which can put the brain at risk for hypoperfusion and ischemia.

The usually accepted critical autoregulatory threshold exposing patients to risk of cerebral ischemia is below 50 mm Hg (**Fig. 34.4**). Optimal CPP values are, however, more elusive. Recommended targets are usually between 60 and 70 mm Hg, based on low-quality evidence. It is plausible that optimal values vary both across individuals, pathologies, and within a patient's clinical evolution. Some experts advocate different treatment approaches, and hence different targets, according to the presence or absence of an intact pressure reactivity.

Pressure Reactivity Indices

The potential benefit associated with monitoring pressure autoregulation is to individualize and thereby optimize CPP. A surrogate measure of pressure autoregulation is the correlation

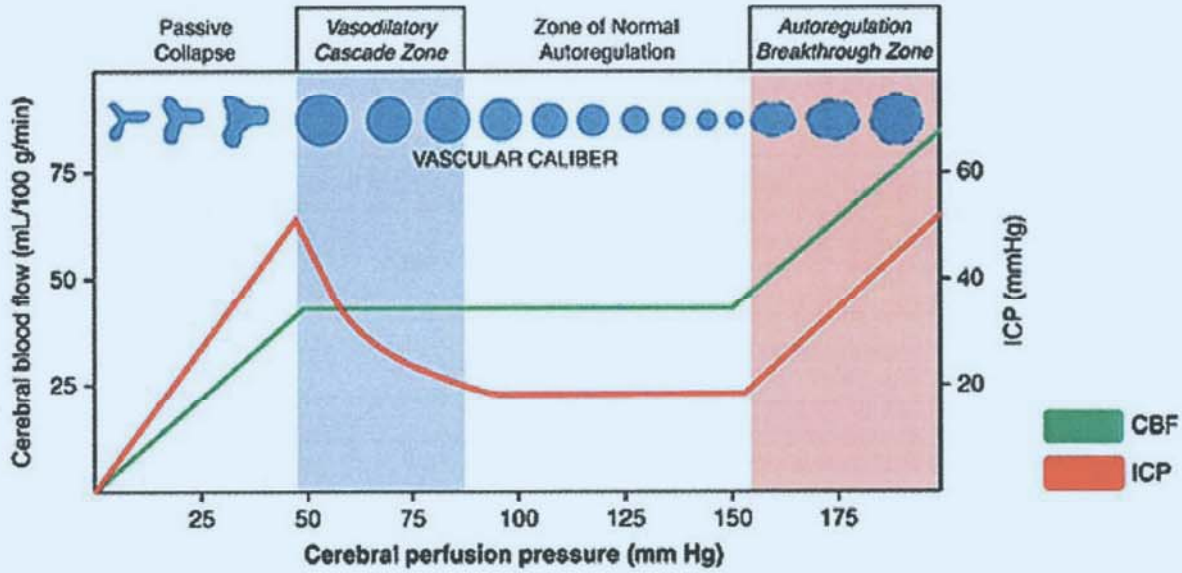

FIGURE 34.4 Autoregulation allows for a constant cerebral blood flow in the face of changing cerebral perfusion pressure (CPP) by varying vascular caliber *(red line)*. Over the limit of around 150 mm Hg of CPP in a healthy brain, there is endothelial injury and blood-brain barrier disruption with luxury perfusion and edema formation. Under 50 mm Hg of CPP, vasodilatation is maximal and cerebral blood flow (CBF) becomes directly proportional to CPP with great risks of hypoperfusion. Both hyperemia and reactive vasodilation can increase intracranial pressure (ICP) when intracranial compliance is reduced *(green line)*. With vasodilatory cascade physiology (*shaded blue*), vasodilation in response to low CPP drives up cerebral blood volume ICP. With perfusion pressure breakthrough physiology *(shaded orange)*, vasodilation from hydrostatic forces increases cerebral blood volume and ICP.

between MAP and ICP because they are physiologically interconnected. Many methods have been described to assess this relationship. An example of static measurements is with the manipulation of mean arterial pressure (MAP), commonly following the administration of drugs, such as a bolus of norepinephrine. If pressure reactivity is intact, a significant MAP rise will be accompanied by a decreased ICP due to vasoconstriction. If autoregulation is failing, a rise in MAP will cause an increase in ICP due to pressure-passive vasodilation. The most studied and best validated method to assess autoregulation is a continuous real-time measurement coined PRx (pressure reactivity index). It is calculated using high-frequency sampling (50 Hz) of the MAP and ICP to create a moving correlation coefficient from 30 consecutive 10-second averages of the MAP and ICP waveforms. The linear correlation coefficient points produces a PRx value between −1.0 and +1.0. Where negative or close to zero, autoregulation is intact. A positive value, however, implies a failing autoregulation. PRx can then be plotted against CPP, which under normal conditions shows a U-shaped curve. Published data support the concept of targeting CPP at the point where PRx is most negative and autoregulation is most intact (CPP_{opt}; **Fig. 34.5**). To obtain such a continuous, validated, high-resolution and real-time index, one must use specialized software such as Intensive Care Monitoring (ICM+; University of Cambridge, England, United Kingdom) or a similar alternative

External Ventricular Drainage

Since the landmark study published by Lundberg in 1960, external ventricular drainage (EVD) has been the gold standard for ICP monitoring. It consists of a catheter blindly inserted into the lateral ventricle and connected via fluid-filled tubing to an external pressure transducer. The insertion is usually on the nondominant side just anterior to the coronal suture roughly in the midpupillary line approximately 6 cm deep, although other approaches are described. The fluid-filled system relays the pulsatile waveform to a transducer, which is then converted to a digital signal. The ICP number displayed at the bedside represents the mean pressure. The hydrostatic reference point is the foramen of Monro, which is estimated using the external acoustic meatus or the tragus.

EVD placement has the advantage of allowing therapeutic CSF drainage, making it the monitoring of choice in case of

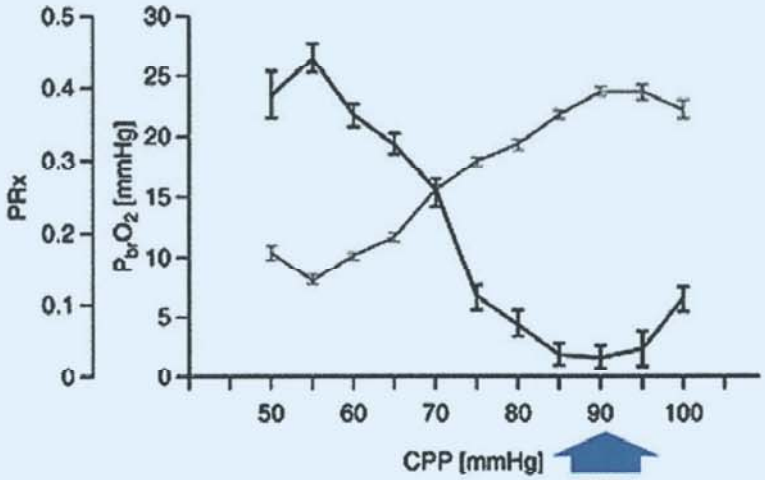

FIGURE 34.5 Pressure reactivity index (PRx, *black line*) and brain tissue oxygen tension ($PbtO_2$, *gray line*) as a function of cerebral perfusion pressure (CPP) in a patient with poor-grade subarachnoid hemorrhage. *Arrow* denotes the point of optimal autoregulation (CPP_{opt}) at 90 mm Hg, corresponding to the lowest values of PRx. Note that this also corresponds to the highest levels of $PbtO_2$ and that $PbtO_2$ values fall progressively as CPP drops from 90 to 55 mm Hg.

elevated ICP secondary to hydrocephalus. Depending on the indication, height of the EVD drip chamber is kept from 0 to 20 cm above the tragus, with lower levels causing a higher hourly CSF drainage rate. With a conventional EVD system, either ICP can be monitored with the system clamped or CSF can be drained but not both at the same time. Some EVD systems are equipped with a fiber-optic pressure transducer at the tip, which allows for simultaneous pressure monitoring and CSF drainage.

The main complications of EVD placements are bleeding and infection. Clinically significant (requiring intervention) bleeding rates are 1% or less, but the risk of infection (ventriculitis) ranges from 5% to 15%. As for any other invasive devices, aseptic insertion technique, limited manipulations, avoidance of routine CSF sampling, and quick removal are the best ways to keep infectious complications to a minimum.

Safe discontinuation of an EVD is accomplished by performing a 24-hour clamp trial. If the ICP remains below 20 mm Hg, the patient remains stable, and a follow-up computed tomography (CT) shows no interval ventricular enlargement, the EVD can be safely removed.

Intraparenchymal Intracranial Pressure Monitors

Intraparenchymal devices are now the most commonly used method of ICP monitoring, and they are as reliable and accurate as EVD. In most systems, a fiber-optic or strain gauge pressure transducer is located at the catheter tip, which is inserted 1 to 3 cm into the cerebral parenchyma. Although often placed on the nondominant side, insertion should be ipsilateral to the lesion aiming for the brain parenchyma most at risk for secondary injury. The risk of insertional bleeding with a parenchymal ICP monitor is lower than that of an EVD, and the risk of infection is negligible. Displacement or breakage is the most commonly observed technical complication. Although drift (ie, loss of accuracy over monitoring time) is well described with strain gauge devices, it is rare with fiber-optic ones. The main challenge in interpretation stems from the basic assumption that the ICP read at one point properly reflects the average pressure throughout the intracranial system.

Indications for Intracranial Pressure Monitoring

As a general rule, indications for the placement of an EVD or ICP monitor are as follows:

1. The patient is comatose (generally Glasgow Coma Scale score ≤8).
2. Brain imaging indicates that the patient is at risk for elevated ICP due to the presence of significant intracranial mass effect.
3. Aggressive intensive care unit (ICU) care is warranted.

The Brain Trauma Foundation issued updated recommendations in 2015 regarding indications for ICP monitoring of severe TBI patients (Table 34.1). Other considerations include when clinical exam is likely to be lost for a moderate to a long period of time, especially if associated with physiologic derangement, for example, during major surgery or a difficult to ventilate acute respiratory distress syndrome patient. Obstructive hydrocephalus is also a clear indication for EVD insertion. Recent guidelines from the International Multidisciplinary Consensus Conference on Multimodality issued recommendations for ICP monitoring in non-TBI patients (Table 34.2). Examples given in the consensus include intracerebral and SAH, massive ischemic stroke, meningitis, hypoxic-ischemic injury, and fulminant hepatic failure. Any pathology complicated by elevated ICP might benefit of such monitoring when clinical exam is not trustworthy because it allows optimization of cerebral hemodynamics through CPP manipulation, aggressive ICP treatment, as well as detection of new catastrophic events.

TABLE 34.1 Indications for Intracranial Pressure Monitoring in TBI Patients[a]

Level of Evidence	Indication
Level I and II A	There is insufficient evidence to support a level I or II A recommendation for this topic.
Level II B	Management of severe TBI patients using information from ICP monitoring is recommended to reduce in-hospital and 2-wk postinjury mortality.

Abbreviations: ICP, intracranial pressure; TBI, traumatic brain injury.
[a]From Carney N, Totten AM, O'Reilly C, et al. *Guidelines for the Management of Severe Traumatic Brain Injury*. 4th ed. New York, NY: Brain Trauma Foundation; 2016.

BRAIN OXYGENATION MONITORING

Physiologic Principles

The human brain, composing 2% of our body weight, consumes 20% of total body oxygen. Approximately, 90% of the energy is used by neurons mainly for synaptic activity and to preserve ionic gradients. The energy substrate is high-energy adenosine triphosphate (ATP) produced from glucose through aerobic metabolism. In the absence of continuous oxygen delivery, ATP production ceases within seconds. Osmotic gradients are lost, edema sets in, intracellular calcium rises, and early apoptotic mechanisms are triggered. Specific monitoring allows for early detection and reversal of brain hypoxia in the neuro-ICU. Two invasive bedside techniques are described: *brain tissue oxygen partial pressure* ($PbtO_2$) and *jugular venous oxygen saturation* ($SjvO_2$) monitoring.

Both $SjvO_2$ and $PbtO_2$ are dependent on CBF, arterial oxygen content, and the cerebral metabolic rate of oxygen consumption

TABLE 34.2 Indications for Intracranial Pressure Monitoring in Non-TBI Patients

Level of Evidence	Indication
Moderate	Patients at high risk or those with clinical or radiologic evidence of acute symptomatic hydrocephalus
Low	SAH, ICH, and other non-TBI conditions in patients at risk for elevated ICP based on clinical and/or imaging features
Low	All poor-grade SAH patients with consideration for multimodality monitoring
Low	Patients who undergo hemicraniectomy in the setting of cerebral edema

Abbreviations: ICH, intracerebral hemorrhage; ICP, intracranial pressure; SAH, subarachnoid hemorrhage; TBI, traumatic brain injury.

($CMRO_2$). $AVDO_2$, the arteriovenous difference in oxygen content, can be simplified as $SaO_2 - SjvO_2$ because other parameters, such as hemoglobin, remain constant during cerebral transit.

$$CMRO_2 = CBF \times AVDO_2, \text{ where } AVDO_2 \approx SaO_2 - SjvO_2$$

Low $PbtO_2$ values are often seen in severe neurologic injuries despite normal ICP and CPP values. Imaging cannot reliably predict brain tissue hypoxia because some episodes result from cellular distress and increased oxygen demand related to seizures, shivering, or other hypermetabolic states.

Available data strongly suggest an independent association of the burden of brain tissue hypoxia with poor outcome both in TBI and SAH patients. Taken together, these findings underline the rationale for incorporating invasive brain oxygenation monitoring as a management option for life-threatening brain injury. Use of either $SjvO_2$ or $PbtO_2$ monitoring is recommended for patients at risk for cerebral ischemia according to the latest International Multidisciplinary Consensus Conference on Multimodality Monitoring.

Jugular Venous Oxygen Saturation Monitoring

This technique employs continuous oximetry in the jugular bulb to analyze oxygen content of cerebral venous drainage. The six major cranial sinuses, running between the dura mater and the cranial periosteum, end up forming the left and right internal jugular veins (IJV). The IJV starts with the jugular bulb, a small dilation at the jugular foramen, into which the cerebral hemispheres, the cerebellum, and the brainstem drain. Venous blood from extracranial sources make up less than 5% of net blood flow in the jugular bulb. Sampling necessitates retrograde placement of a catheter in the IJV up to the bulb. The tip of the catheter, verified with a lateral or anteroposterior x-ray, should lie at the level of the mastoid bone above the lower border of C1.

Normal $SjvO_2$ values range between 55% and 75%. Low values suggest insufficient oxygen delivery to the brain to meet metabolic needs, which may reflect either high cerebral oxygen consumption, low CBF, or both. Values under 45% are associated with cellular dysfunction. One limitation of $SjvO_2$ is that it reflects global oxygenation; regional ischemia can be missed. It has been estimated that 13% of the brain volume must be ischemic to impact on $SjvO_2$. Another technical point is that improper catheter placement will mean a greater contamination by extracranial blood reducing sensitivity to detect brain hypoxia. $SjvO_2$ values above 75% suggest either hyperemia from loss of autoregulation resulting in excessive cerebral vasodilation or low oxygen consumption.

Brain Tissue Oxygen Pressure Monitoring

The most commonly used technologies for $PbtO_2$ measurement today are based on use of a Clark electrode (Licox) and oxygen quenching methods using a microchip at the catheter tip (Raumedic). The Clark electrode has two metallic electrodes surrounded by electrolytes and a membrane. Oxygen from the interstitial space diffuses through the membrane and is reduced at the cathode, which changes the voltage difference between the two electrodes. The more oxygen, the more the voltage change measured. The oxygen quenching method uses a lanthanide polymeric matrix that luminesces at different wavelengths based on regional oxygen tension. A fiber-optic cable detects these wavelengths and transmits a continuous output signal.

TABLE 34.3 Brain Tissue Oxygen Partial Pressure Thresholds (Clark Electrode Technology)

$PbtO_2$ Value (mm Hg)	Interpretation
>50	Hyperemia or inability to extract O_2
25-50	Normal
<20	Hypoxia
<10	Severe hypoxia

Abbreviations: O_2, oxygen; $PbtO_2$, brain tissue oxygen partial pressure.

The tip of the probe should be located in the white matter, where normal $PbtO_2$ levels range from 25 to 50 mm Hg (Table 34.3). A postinsertion CT scan is mandatory to confirm positioning and interpret readings because placement in hemorrhagic or infarcted tissue results in uninterpretable readings near zero. An equilibration period of 60 minutes is expected, and an oxygen challenge (5 min 100% fraction of inspired oxygen) is performed daily to make sure of the proper monitor functioning: It should lead to a threefold $PbtO_2$ increase, provided CBF is adequate.

The volume of brain tissue sampled with this focal form of monitoring ranges from 15 to 20 mm^3. As with ICP monitoring, the area of probe insertion should be carefully considered; areas most at risk for secondary injury are the best target. An example would be in the vascular territory of the ruptured aneurysm, which is at highest risk for developing delayed cerebral ischemia (DCI).

$PbtO_2$ measured with different technologies are not interchangeable, and the most cited values come from data obtained with Clark electrode technology (see Table 34.3). Values with the oxygen quenching systems tend to run higher.

$PbtO_2$ monitoring is an adjunct to ICP monitoring in comatose patients. A low $PbtO_2$ can help detect a new critical event, such as vasospasm after SAH or a seizure. A reassuring value, on the contrary, may be an argument for permissive ICP management. $PbtO_2$ changes are a way to evaluate the patient's response to DCI treatment with hemodynamic augmentation therapy. It can also be used to carefully titrate aggressive hyperventilation therapy or to detect a detrimental ventilation strategy. Some observational studies suggest that combining ICP/CPP and $PbtO_2$-based management leads to better outcomes in TBI or SAH patients. A recent pilot clinical trial gave an interesting signal that PbO_2-based management of severe TBI patients is both feasible and might lead to better outcomes than ICP-only management. A phase III trial testing this hypothesis (BOOST-3) is now underway.

Near-Infrared Spectroscopy

Cerebral oximetry monitoring systems allow continuous, real-time, noninvasive measurement of regional cortical oxygen saturation, a reflection of the balance between oxygen delivery and utilization that has been shown to correlate well with jugular venous bulb saturation and brain tissue oxygen pressure. Based on near-infrared spectroscopy, it relies on multiple wavelengths in the near-infrared range (ie, 680-900 nm) to discriminate between the unique absorption spectra of oxyhemoglobin and deoxyhemoglobin. Sensors with an integrated light source and photodetector are applied to each side of the forehead and the cerebral tissue sampling volume is estimated to be 1.5 mL.

Unfortunately, there is a lack of standardization between commercially available near-infrared spectroscopy devices, and significant differences exist in how they respond to changes in oxygen saturation. Clinical studies suggest that it is reliable in detecting perioperative cerebral oxygen desaturation events, especially in cardiac surgery. Although promising in the ICU environment and in the neurocritical care population, data is still limited. Threshold regional cortical saturation values associated with poor outcomes or that should trigger intervention are poorly defined, although <50% is probably a reasonable limit to detect serious events.

CEREBRAL BLOOD FLOW MONITORING

Physiologic Principles

Adequate CBF is critical to proper function and survival of neurons, and hence, avoidance of hypoperfusion is essential to limit secondary injury (see Fig. 34.4). Precise regulation of CBF at a constant level involves numerous overlapping mechanisms globally named autoregulation, of which pressure reactivity described earlier is a component, and which also includes reactivity to arterial oxygen and carbon dioxide (CO_2), neurovascular coupling, and autonomic control.

The cerebral vessels are highly sensitive to variations in the P_{CO_2}, a feature unique to cerebrovasculature. However, a long-standing question has been whether Pa_{CO_2} or pH is the main driver of autoregulation. It appears that vessel caliber is mediated by extracellular pH levels, with lower pH (acidosis) values leading to dilation and higher pH (alkalosis) to constriction. However, CO_2 molecules diffuse readily across the cerebral blood-brain barrier, inducing changes in pH, which is not the case of intravascular buffers such as bicarbonate. The point is that alterations in alveolar gas exchange elicit immediate changes in CBF, but they are short-lived (approximately 6 h) as a changes in CSF and extracellular bicarbonate concentration and correction of extracellular pH by glial cells will ensue. From a clinical standpoint, hyperventilation will reduce CBF significantly enough to aggravate ischemia in an already injured brain, and hypoventilation can augment cerebral blood volume significantly enough to worsen existing intracranial hypertension.

Hypoxia will reduce cerebrovascular smooth muscle tone and increase CBF when the arterial content of oxygen reaches a threshold at the steep portion of the oxyhemoglobin dissociation curve (<80% arterial saturation of oxygen or, a Pa_{O_2} of 50 mm Hg) (see Chapter 111). Neurovascular coupling is another broad mechanism of autoregulation allowing local cerebral metabolism to be tightly associated to local brain perfusion. Autonomic regulation also appears to play a significant role in regulating CBF. All these mechanisms are redundant and synergistic with various interactions. For example, loss of pressure reactivity doesn't preclude sensitivity to changes in pH. Significant hypotension, however, may abolish cerebrovascular reactivity to CO_2.

Continuous Cerebral Blood Flow Monitoring

These examples stress the importance of direct and valid CBF monitoring to detect hypoperfusion before it leads to irreversible ischemia and while it is still amenable to treatment. Modern imaging techniques such as positron emission tomography and CT perfusion allow detailed information about cerebral hemodynamics to be obtained but are unable to provide continuous data for clinical monitoring at the bedside.

Thermal Diffusion Flowmetry

Thermal diffusion flowmetry is an invasive technique that allows continuous quantitative measurement of regional cerebral blood flow (rCBF) measured in mL/100 g/min. The probe is inserted 25 mm into the brain and comprises a thermistor at the tip and a temperature sensor a few millimeters proximal. Tiny temperature fluctuations are produced by transiently heating the thermistor tip; according to the Fick principle, the resulting change in temperature at the proximal sensor is inversely related to CBF.

Real-time dynamic rCBF data have been correlated with xenon CT perfusion studies and Pbt_{O_2} monitoring. Studies relating rCBF to outcomes are limited. Because the probe is located in the subcortical white matter, 15 mL/100 g/min is a reasonable threshold for defining critical hypoperfusion. Low CBF values alone, however, do not necessarily imply active ischemia because low CBF can also be coupled to a low rate of cerebral metabolism. Concurrent Pbt_{O_2} or Sjv_{O_2} monitoring is helpful in differentiating low CBF states.

One of the main limitations of thermal diffusion flowmetry is its focal nature; the data is highly dependent on the probe's location. Other technical limitation is the 5-minute recalibrations that occur every 30 minutes during which monitoring is unavailable. Infectious and bleeding complications are well under 1%.

CEREBRAL MICRODIALYSIS

Physiologic Principles

Key elements to the pathophysiology of brain injury and ischemia that can be monitored include (1) energy substrates (glucose), (2) brain glucose metabolism products (lactate, pyruvate), (3) excitatory neurotransmitters (glutamate), and (4) products of cell membrane degeneration (glycerol). Brain energetic function relies on glucose metabolism to pyruvate, which then enters the Krebs cycle to produce a total of 38 moles of ATP per mole of glucose. This process is contingent on oxygen availability. Hypoxia will lead to anaerobic metabolism, where pyruvate is metabolized into lactate, a much less efficient energy-producing pathway with a yield of only 2 moles of ATP per mole of glucose. Lactate can be used as a source of energy production by neurons when glucose is unavailable. If the entire glycolysis process is accelerated, for example, in the presence of catecholamines or fever, both pyruvate and lactate will be elevated. If hypoxemia is present, only lactate will increase, as pyruvate is anaerobically consumed with lactate as an end product. This is the logic behind the use of lactate-to-pyruvate ratio (LPR) to detect anaerobic metabolism, an important physiologic marker of ischemia (Fig. 34.6).

Another important mechanism of neuronal injury is excitotoxicity. Glutamate is the main excitatory amino acid, and levels are kept low by astrocytes responsible for converting glutamate back to glutamine. This is an energy-dependent process and metabolic failure will lead to elevated glutamate levels. This will mediate excessive intracellular calcium influx and neuronal damage.

When cellular metabolism fails, one of the final common pathways is loss of cellular integrity and membrane degradation.

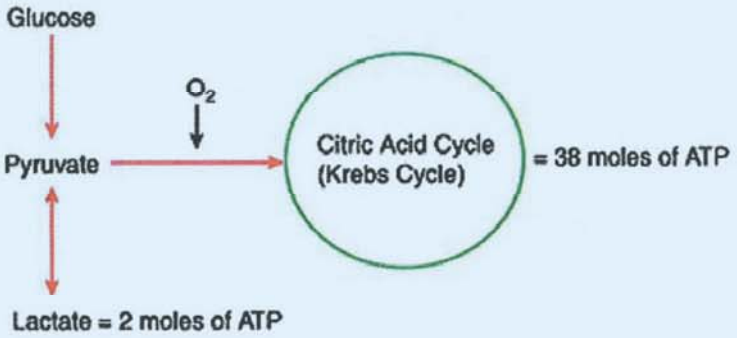

FIGURE 34.6 Efficient adenosine triphosphate (ATP) production from glucose necessitates oxygen (O_2). Without O_2 or if the cells are unable to use it, the pathway shifts to lactate production.

Release of phospholipids ensues, which are converted to free fatty acids and glycerol. This makes glycerol a marker of advanced cellular damage.

Microdialysis Monitoring

Microdialysis allows bedside semicontinuous analysis of the chemical composition of the brain interstitial fluid. The probe is a 0.6-mm double-lumen catheter with a semipermeable membrane that permits free diffusion of water and solutes down their concentration gradient. Isotonic fluid is perfused at a constant rate of 0.3 μL/min and the perfusate is collected and analyzed hourly. The probe is usually 2 cm deep, close to white matter.

The commercially available biomarkers for clinical use are lactate, pyruvate, glucose, glycerol, and glutamate (**Table 34.4**). One of the most clinically useful indices is the LPR. Values over 20 to 25 correlates with worse outcomes in TBI and SAH patients, and a ratio over 40 is used to define "metabolic distress." LPR elevation can be further defined as a type I or II depending on trends in pyruvate levels. Type I LPR elevation is present when pyruvate is decreased with a marked increase in lactate; it is attributed to a lack of oxygen. In type II, pyruvate is normal or elevated indicating mitochondrial failure and a normal supply of metabolic substrates.

Low brain glucose levels (normally 1-2 mmol/L) are also related to outcome in SAH and TBI patients, especially when less than 0.50 mmol/L. An LPR ratio greater than 40 combined with a brain interstitial glucose level less than 0.5 mmol/L is termed *metabolic crisis* and is associated with poor outcomes and a high risk of death among comatose patients. Active glucose transport across the blood-brain barrier into the central nervous system is impaired after severe brain injury, which may further compromise brain energetic function. Low levels of brain glucose associated with metabolic crisis despite normal CBF has been reported with blood glucose levels in the normal range

TABLE 34.4 Threshold Values in Brain Interstitial Tissue of Selected Biomarkers Associated With Worse Outcome

Biomarker	Threshold Values
Glucose (mmol/L)	<0.7 or >2.6
Lactate (mmol/L)	>4
Pyruvate (μmol/L)	<70
LPR	>40
Glutamate (mmol/L)	>20

Abbreviation: LPR, lactate-to-pyruvate ratio.

Clinical Use

A useful aspect of microdialysis monitoring is that derangements can precede impending deterioration, including elevated ICP in TBI patients or delayed neurologic injury in SAH patients. Severe derangements can be used to trigger emergent decompressive neurosurgical intervention, induction of hypothermia, or angiography to reverse ongoing ischemia. It is also potentially useful for helping to minimize the risk of critical brain tissue hypoglycemia when continuous insulin infusion is used to control stress hyperglycemia, to define the optimal individualized CPP thresholds, or to improve oxygen delivery either through ventilation strategies or blood transfusions.

CONTINUOUS ELECTROENCEPHALOGRAPHY

Technical advances and the era of digitization have made continuous electroencephalography (cEEG) monitoring an essential tool in neurocritical care. Specific uses include detection of seizures, titration of therapy for status epilepticus, monitoring for DCI in SAH patients, titration of sedation in refractory intracranial hypertension, and coma prognostication. Refer to Chapter 26 for a detailed discussion of basic electroencephalography (EEG) physiology and interpretation. Listed in the following sections are some of the recommended indications for EEG monitoring in the ICU setting (**Table 34.5**).

Seizure Detection

One of the main goals of cEEG is seizure detection. Ten percent to 30% of comatose patients have nonconvulsive seizures or nonconvulsive status epilepticus (NCSE) when monitored with cEEG depending on the primary diagnosis, and the vast majority are clinically undetectable (**Table 34.6**). Nonconvulsive seizures can directly produce depressed levels of consciousness and are associated with poor outcomes after all forms of severe acute brain injury.

TABLE 34.5 Indications for Continuous Electroencephalography in the Intensive Care Unit According to the Neurocritical Care Society and the European Society of Intensive Care Medicine

- All patients with ABI and unexplained and persistent altered consciousness
- All patients having suffered a seizure that are not back to their functional baseline 60 min after receiving AED
- During therapeutic hypothermia and within 24 h of rewarming in all comatose patients after cardiac arrest
- All comatose ICU patients without ABI but with unexplained impairment of mental status or unexplained neurologic deficits, particularly in those with severe sepsis or renal/hepatic failure
- In comatose SAH patients, in whom neurologic examination is unreliable, to detect DCI

Abbreviations: ABI, acute brain injury; AED, antiepileptic drug; DCI, delayed cerebral ischemia; ICU, intensive care unit; SAH, subarachnoid hemorrhage.

TABLE 34.6 Yield of Continuous Electroencephalography for Detecting Nonconvulsive Seizures or Status Epilepticus in Selected Conditions

Condition	Yield
Coma after termination of convulsive status epilepticus	48%
Lobar intracerebral hemorrhage	36%
Encephalitis or meningitis	36%
Cardiac arrest	22%
Traumatic brain injury	22%
Poor-grade SAH	18%
Septic encephalopathy	16%

Abbreviation: SAH, subarachnoid hemorrhage.

In TBI patients, nonconvulsive seizures are associated with elevated ICP, metabolic crisis, and long-term hippocampal atrophy.

Duration of monitoring is an important factor in the ability to detect seizures: A 30-minute spot EEG has approximately one-third the sensitivity of a 24-hour cEEG study. A minimum of 48 hours of cEEG monitoring is required to attain greater than 90% sensitivity for detecting nonconvulsive seizures or NCSE.

Surface cEEG in comatose patients often detects periodic or rhythmic patterns that appear to be highly epileptiform but fail to meet conventional diagnostic criteria for electrographic seizures. The term *ictal-interictal continuum* has been used to describe these patterns, which typically create vexing diagnostic and treatment dilemmas. Intracortical (or depth) EEG monitoring is an invasive form of focal electrical brain monitoring that can be used in addition to multimodality monitoring of CBF and $PbtO_2$ to determine whether these ictal-interictal patterns are truly ictal or not. Intracortical EEG has 2 to 3 times the sensitivity of surface EEG for detecting electrographic seizures in comatose patients.

Titration of Therapy for Status Epilepticus

cEEG is essential for guiding therapy for refractory status epilepticus (see Chapter 7). Delays in efficient treatment of status epilepticus lead to less therapeutic success and higher mortality. Almost 50% of patients presenting with convulsive status epilepticus who fail to recover consciousness after initial therapy continue to have evidence of nonconvulsive seizures or NCSE. Failure to urgently detect and treat these seizures leads to prolonged coma and increasing refractoriness to therapy. The EEG target of continuous infusion treatments for NCSE (ie, midazolam, propofol, ketamine, or pentobarbital) can range from simple elimination of ictal discharges to induction of burst suppression depending on the clinical scenario.

Monitoring for Delayed Cerebral Ischemia After Subarachnoid Hemorrhage

EEG is very sensitive to brain physiology, and changes in the EEG pattern are a promising way to detect DCI after SAH. Reduction in alpha variability and the alpha-to-delta ratio has been found to signal the imminent onset of DCI. Most interestingly, those changes can precede the onset of clinical symptoms by 1 to 2 days and might allow therapy titration with the surrogate objective of reversing the EEG anomaly.

Coma Outcome

Trends in the background EEG over several days of monitoring has prognostic value in coma. After cardiac arrest, improvement of the background from near isoelectric attenuation to burst suppression to a continuous pattern of diffuse slowing implies improving brain function and a more hopeful prognosis. Absence of a posterior dominant (ie, alpha) rhythm or reactivity of the background EEG to painful stimuli are poor prognostic signs; recovery of these findings implies a better chance of recovery. Comatose patients with electrographic seizures or generalized periodic epileptiform discharges have a worse prognosis than those with lateralized periodic epileptiform discharges, who in turn have a worse prognosis than those with no epileptiform activity. The presence of normal sleep architecture implies an extremely good likelihood of eventual recovery of consciousness.

Limitations of Continuous Electroencephalography

The main limitations of cEEG monitoring are technical and logistic. The recordings are subject to multiple artifacts from eye movement and other electrostatic forces. The continuous recordings constitute an incredible amount of data to be interpreted, and conclusions can vary from one reader to another. Automated systems are being developed, but raw cEEG remains a cost and labor-intensive modality requiring expert technical and medical staff. Advances in digital EEG now allow time-frequency analysis to be applied to raw signals to quantify EEG changes over time. It includes total EEG power; alpha, theta, or delta power; alpha power variability index; and alpha or theta/delta power ratios. For example, alpha/delta power ratio combines the decrease in fast activity and the increase in delta rhythm due to a CBF reduction. Tools such as color density spectral array might allow continuous, bedside, simpler visualization allowing nonexperts, including ICU nurses, to recognize significant events. Further research is still needed to validate practical approaches that can be applied to the general neuro-ICU population by nonneurophysiologists.

MULTIMODALITY MONITORING DATA ACQUISITION AND ANALYSIS

Since the advent of ICP monitoring, the number of monitored physiologic parameters in neurocritical care has grown faster than our ability to integrate it to a meaningful clinical management plan without special tools that allow us to store, review, and analyze the data. In addition to the brain-specific measurements discussed in this chapter, clinicians must take into account systemic physiologic variables such as heart rate, blood pressure, temperature, and end-tidal CO_2. The amount of data to integrate can be overwhelming.

The primary goal of ICU multimodality monitoring is to act as an alarm system to detect harmful physiologic processes before they lead to irreversible damage. A secondary goal is to allow neurointensivists to optimize the physiologic environment to prevent secondary injury from occurring altogether. In order to do so, modern ICUs will be increasingly grounded within an informatics infrastructure that allows for real-time synchronized data acquisition, storage, and analysis. Raw data must be processed to differentiate signals from noise and to eliminate artifacts.

Complex analysis systems are being developed to allow for automated event detection and to minimize unnecessary alarms. Information displays must be optimized to avoid information overload and assist in clinical decision making. All of this implies a greater role for informatics and artificial intelligence in neurocritical care units in the future. A stand-alone data acquisition system is commercially available at present (Moberg Research Inc, Ambler, PA), and two systems exist for data display and analysis (ICU Pilot, M Dialysis, Stockholm, Sweden; ICM+, University of Cambridge, Cambridge, United Kingdom).

SUGGESTED READINGS

Carney N, Totten AM, O'Reilly C, et al. *Guidelines for the Management of Severe Traumatic Brain Injury*. 4th ed. New York, NY: Brain Trauma Foundation; 2016.

Carteron L, Bouzat P, Oddo M. Cerebral microdialysis monitoring to improve individualized neurointensive care therapy: an update of recent clinical data. *Front Neurol*. 2017;8:601.

Claassen J, Taccone FS, Horn P, Holtkamp M, Stocchetti N, Oddo M. Recommendations on the use of EEG monitoring in critically ill patients: consensus statement from the neurointensive care section of the ESICM. *Intensive Care Med*. 2013;39(8):1337-1351.

Copplestone S, Welbourne J. A narrative review of the clinical application of pressure reactiviy indices in the neurocritical care unit. *Br J Neurosurg*. 2018;32(1):4-12.

Le Roux P, Menon DK, Citerio G, et al. Consensus summary statement of the International Multidisciplinary Consensus Conference on Multimodality Monitoring in Neurocritical Care. *Neurocrit Care*. 2014;21:1-26.

Perez-Barcena J, Llompart-Pou JA, O'Phelan KH. Intracranial pressure monitoring and management of intracranial hypertension. *Crit Care Clin*. 2014;30(4):735-750.

Sivaganesan A, Manley GT, Huang MC. Informatics for neurocritical care: challenges and opportunities. *Neurocrit Care*. 2014;20(1):132-141.

Smith M. Multimodality neuromonitoring in adult traumatic brain injury: a narrative review. *Anesthesiology*. 2018;128:401-415.

Sutter R, Stevens RD, Kaplan PW. Continuous electroencephalographic monitoring in critically ill patients: indications, limitations, and strategies. *Crit Care Med*. 2013;41(4):1124-1132.

Willie CK, Tzeng YC, Fisher JA, Ainslie PN. Integrative regulation of human brain blood flow. *J Physiol*. 2014;592(pt 5):841-859.

Genetic Testing and DNA Diagnosis 35

Jill S. Goldman and Jacinda B. Sampson

KEY POINTS

1. A thorough family history is an essential first step for determining the likelihood of a neurogenetic disease, but a lack of family history does not rule out a genetic diagnosis.
2. Genetic counseling is an important part of testing, including anticipatory guidance.
3. Penetrance, phenotypic variability, and anticipation are important factors in both planning for and interpretation of genetic test results.
4. Testing strategies can vary by disease, available test modalities, and patient-centered factors.

INTRODUCTION

Enormous advances in genetic technology are changing what we know about the molecular mechanisms and causes of neurologic disease. As a result, genetic testing is becoming more common and, at the same time, more complicated. The need for both clinicians and patients to understand the various types of genetic tests and the implication of genetic results is greater than ever. This chapter reviews the process of genetic counseling, the genetic mechanisms that influence the appropriate choice of different types of genetic tests, and the interpretation of genetic results.

THE PROCESS OF GENETIC COUNSELING

Obtaining the Family History

A review of family history and drawing of a pedigree are the essential first steps for determining the likelihood of a neurogenetic disease. A carefully constructed pedigree can guide the differential diagnosis by indicating whether any family history exists and, if it does, the possible mode of inheritance. At least a three-generation family history should be obtained, which includes ethnicity, age of onset of symptoms, age and cause of death, diagnoses determined by genetic testing, and known history of consanguinity. Targeted family history questions can help to narrow the differential diagnosis. As an example, consider the patient with ataxia: A family history that includes mental retardation or premature ovarian failure would suggest a diagnosis of fragile X–associated tremor ataxia syndrome. Similarly, for a patient with amyotrophic lateral sclerosis and a family history of dementia, a likely cause is a hexanucleotide expansion in *C9orf72*. An Ashkenazi Jewish background in the presence of Parkinson disease could indicate an *LRRK2* or *GBA* mutation and, in the presence of dystonia, a *Tor1A* deletion (Table 35.1).

A lack of family history, however, does not rule out a genetic diagnosis. A negative family history may be due to lack of information, early death, autosomal recessive inheritance, undisclosed adoption, false paternity, or de novo mutations (mutations that first appeared in the patient).

The Genetic Counseling Discussion

The process of genetic counseling and testing differs, depending on whether the patient is being seen for diagnostic testing or for predictive testing. Regardless, enough time should be given to genetic counseling to provide the patient/family with the understanding of the implications of testing and the various types of test results. Clinicians may refer to the National Society of Genetic Counselors (http://www.nsgc.org) if they wish to locate a genetic counselor in their area. In general, patients should be encouraged to attend all counseling sessions with a support person who can help them interpret the information, support them through the process, and act as a contributor to the patient's history.

In the course of genetic counseling for diagnostic testing, the nature and genetics of the disorder, the implications of a positive result for other family members, the benefits, risks, and limitations of testing and an emotional impact of testing should always be discussed (**Table 35.2**).

Pretest counseling for predictive genetic testing is an opportunity for anticipatory guidance. Patients should be asked how they would feel both over the short term and long term upon receiving a positive or negative result. They should consider how a positive or negative result would impact their life decisions including relationships, school or work choices, financial decisions, and reproductive choices. Many patients may need referrals for psychological counseling to help them work through the decision to test. In fact, the Huntington disease genetic testing protocol, which is used by many centers for predictive testing for fatal, untreatable neurogenetic conditions, advocates for a psychiatric assessment of all patients prior to predictive testing (**Table 35.3**).

As with counseling for diagnostic genetic testing, the benefits, risks, and limitations of testing should be covered. In general, predictive testing should not be performed without confirmation of a genetic diagnosis (and known mutation) in another family member. Without a known mutation in the family, a negative result may falsely reassure the individual, or a discovery of a variant of unknown significance will be inconclusive without other informative cases in the family.

Whenever possible, genetic results should be given in person, especially when they are predictive. While delivering the results, the clinician should review the meaning of the test result for the patient and family members, assess the psychological state of the patient and refer for psychological counseling as necessary, determine a plan of action, and give information about appropriate disease associations and support groups. When a positive result has been given, the clinician should follow up with the patient/family following the posttest session.

TABLE 35.1 Family History Questions for Differential Diagnosis of Neurogenetic Disorders

Disorder	Specific Questions: "Has any family member ever had . . ."
Dementia	Dementia
	Memory problems or other cognitive problems
	Language or speech problems
	Personality or behavioral change
	Mental illness including depression
	Any other neurologic disease such as Parkinson disease, ALS
	Movement or gait disorder
	Strokes
	Migraines
	Seizures
Neuromuscular disease	Gait or walking problems
	Weakness
	Heart failure or pacemaker
	Developmental delay
	Learning disabilities
	Dementia or cognitive impairment
	Language or speech problems
	Personality or behavioral change
	Psychiatric illness including depression
	Vision problems, including early-onset cataracts
	Infertility
	Diabetes
Movement disorders	Dementia or cognitive impairment
	Learning disabilities or intellectual disability
	Language or speech problems
	Personality or behavioral change
	Mental illness including depression suicide
	Gait or walking problems
	Weakness
	Vision problems
	Infertility
	Tremor
	Seizures
	Writer's cramp or cramps in other muscles
Movement disorders *(continued)*	Abnormal posture
	Tics or other abnormal movements
	Alcoholism
	Clumsiness
	Immune deficiency
	Cancer
	Heart problems
	Hearing loss
Neuropathies	Walking problems
	Numbness, tingling, or pain in limbs
	Clumsiness
	Difficulty fitting shoes
Neurocutaneous disorders	Birthmarks or spots on skin
	Seizures
	Hearing problems
	Vision problems
	Tumors or growths that were removed
	Bumps on skin
	Scoliosis
	Intellectual disability or learning disabilities
	Heart problems, arrhythmias
	Kidney problems
	Stroke
	Cancer or tumors of brain, spinal cord, or peripheral nerve
Epilepsy	Seizures, infantile spasms
	Periods of staring or seeming vacant
	Headaches
	Vision problems
	Learning disabilities, autism, or autism spectrum disorders
Amyotrophic lateral sclerosis	Progressive weakness
	Speech or swallowing problems
	Gait or walking problems, wheelchair requirement
	Dementia

Abbreviation: ALS, amyotrophic lateral sclerosis.

GENETIC PHENOMENOLOGY

The genetics of neurologic disease is complicated by an array of genetic mechanisms. When considering a genetic etiology, all of these phenomena warrant attention and discussion with patients.

Incomplete and Age-Dependent Penetrance

Penetrance is the likelihood that an individual carrying a pathogenic mutation will develop the disorder caused by that gene. Incomplete penetrance can be found in many autosomal dominant conditions. Examples of incomplete penetrance include *DYT1* early-onset dystonia (about 30% of carriers develop symptoms) and *LRRK2*-related Parkinson disease (age-dependent penetrance increasing during the life span to less than 30%). Penetrance sometimes correlates with certain mutations within the gene but may also be influenced by other largely unknown genetic or environmental factors. In some disorders such as myoclonus-dystonia (ε-sarcoglycan or *SGCE*), the sex of the transmitting parent determines penetrance (most symptomatic individuals have inherited the mutation from their father).

TABLE 35.2 Genetic Counseling Discussion Points

Disorder symptoms and course
Genetics of the disease
• Gene/genes
• Modes of inheritance
• Penetrance
• Degree of variability in symptom expression
Implication of genetic testing for family members
• Recurrence risk for children
• Risk for siblings
• Carrier status of parents
Benefits of genetic testing
• Diagnosis
• Clinical trial candidacy
• Management, if applicable
• Ability to make reproductive choices, including preimplantation genetic diagnosis
• More information for life planning
• End of uncertainty
Risks of genetic testing
• Possible insurance discrimination (life, long-term care, and disability insurances), particularly for presymptomatic individuals

• Emotional impact
  ◦ For diagnostic testing—confirmation of risk to children
  ◦ For predictive testing—knowledge that one will (may) develop disorder

Limitations of genetic testing
• May not discover the genetic cause
• Variants of unknown significance
• For predictive testing: inability to predict age of onset, severity, or exact symptomology, incomplete penetrance (if applicable)
• The need to identify a mutation in an affected family member prior to predictive testing
Communication of test result
• Will the genetic result be shared with family or others? If so, how and when?
• Right of relative not to know—encourage family discussion before results are in.

Phenotypic Variability

Neurogenetic disorders can have remarkable inter- and intrafamilial variability in severity of symptoms, type of symptoms, age of onset, and disease course. Consider spinal muscular atrophy (SMA), which can occur in infancy and if untreated is a severe and rapidly fatal condition (SMA type 1) to onset in childhood (SMA type 2) to onset in adolescence or adulthood (SMA type 4) due to the influence of the modifier gene, *SMN2*. Hexanucleotide repeat expansions in the gene *C9orf72* can cause frontotemporal degeneration, amyotrophic lateral sclerosis, or both. Additional phenotypes that have been reported with this gene include ataxia, parkinsonism, Alzheimer-like dementia, and psychosis. *DYT1* can cause severe childhood dystonia with contractures, adult-onset writer's cramp, or no symptoms at all.

TABLE 35.3 Huntington Disease Protocol for Predictive Genetic Testing[a]

1. Telephone screen: demographics, family history, motivation for testing, review of protocol, anticipatory guidance
2. Pretest counseling session with support person
3. Psychiatric assessment
4. Neurologic evaluation
5. Informed consent and blood draw
6. In person posttest result and counseling session with support person
7. Follow-up phone call

[a]From International Huntington Association, World Federation of Neurology Research Group on Huntington's Chorea. Guidelines for the molecular genetics predictive test in Huntington's disease. *Neurology*. 1994;44(8):1533-1536.

Some genotype/phenotype correlations exist, as with the D178N mutation in *PRNP*, which, when present on the same chromosome with the polymorphism codon 129M, causes fatal familial insomnia but, when with 129V, causes Creutzfeldt-Jakob disease. Another example is dystrophinopathy, where in-frame deletions are more likely to result in the milder Becker muscular dystrophy phenotype, and out-of-frame deletions result the more severe Duchenne muscular dystrophy phenotype, but there are frequent exceptions to the reading frame rule. At other times, unknown factors seem to influence gene expression.

Polynucleotide Repeat Expansion and Anticipation

Many examples of polynucleotide repeat disorders are found in neurogenetic disease. These include Huntington disease, many of the spinocerebellar ataxias, fragile X–associated tremor ataxia syndrome, and the myotonic dystrophies. Age of onset for these diseases is inversely correlated with the number of repeats; however, this correlation is insufficient to be used to predict the age of onset. Expansion of the allele size occurs during gamete formation so that the repeat number can increase, and therefore, age of onset can decrease with successive generations. This phenomenon is called *anticipation*. Contractions occasionally occur. Depending on the disorder, expansion is more common when being inherited from one parent over the other. For Huntington disease, spinocerebellar ataxias, and fragile X–associated tremor ataxia syndrome, expansion usually occurs in the father. In myotonic dystrophy type 1, large expansions more often occur in the mother and can result in a congenital form of the disease. Additionally, these conditions have ranges of repeats whereby the carrier is asymptomatic or will have a very late onset but can transmit an expansion to their children. Thus, a negative family history for these disorders is not uncommon.

Genetic Heterogeneity

Many neurogenetic diseases are multigenic. Presently, over 25 loci for dystonia and over 50 loci for hereditary spastic paraparesis have been reported. Testing for such conditions can be expensive and problematic. Although certain types of gene panels may be appropriate, the ordering clinician has to evaluate which genes are being tested and how. For some of the genes, such as *Parkin*, when sequencing does not reveal a mutation, duplication/deletion testing should be ordered.

Pleiotropy

Many genes causing neurologic conditions can cause problems in other systems as well. Examples of pleiotropy include hearing loss in fascioscapulohumeral muscular dystrophy and cataracts in myotonic dystrophy. For this reason, targeted questions about associated symptoms can help to clarify an otherwise negative family history.

Phenocopies

Neurologic conditions such as Alzheimer and Parkinson diseases represent some of the most common conditions in the population. Finding a genetic etiology for one of these diseases in one family member does not necessitate that another family member has the mutation, especially with an older onset.

TYPES OF GENETIC TESTS

Many options now exist for genetic testing of neurologic disease. Determining the most appropriate test is essential because they do not all analyze the same types of mutations. The ordering physician may want to consult with a geneticist, genetic counselor, or laboratory director before testing to ensure that they are ordering the correct test and that the test has clinical use. The cost of testing, and whether it will be covered by insurance, is another factor to consider. The types of genetic tests and their appropriate use are described in the following section.

Microarray

Microarray detects large deletions and duplications by detecting the relative signal of markers (single nucleotide polymorphisms) spaced through the genome; loss of a copy by a deletion results in a decreased signal; a duplication results in increased signal at that locus. Microarray does not detect single nucleotide point mutations or does it define the exact breakpoints of a deletion or duplication, only that it is present between the normal and changed copy number single nucleotide polymorphism. Microarray cannot pick up balanced translocations that can be seen on karyotypes but can pick up unbalanced ones. Insertions or deletions smaller than the spacing between microarray markers can be detected using a multiple ligation polymerase assay with polymerase chain reaction (PCR) primers designed to bind to an exon in question; if both primers can bind, they are ligated and amplified by PCR. If one primer is not able to bind its target sequence due to a deletion, no signal will be detected for the primer pair for that exon.

Testing for Polynucleotide Repeat Disorders

Small repeat sizes can be directly sequenced after PCR. Larger ones may require southern blot testing, where genomic DNA is cut with restriction enzymes around the repeat motif and separated on a gel. At larger sizes, polynucleotide repeat disorders may appear to be a smear rather than a single band—this reflects a range of repeat sizes called *somatic mosaicism*.

Sanger Sequencing

Primers are designed to bracket the sequence of interest, allowing PCR amplification followed by sequencing, an excellent way of detecting missense mutations or small deletions or duplications falling within the bracketing primers.

Next-Generation Sequencing (Next-Gen)

Genomic DNA is fragmented into small pieces, which are then sequenced and aligned by comparison to the reference human genome. This next generation sequencing technique (NextGen) is excellent at detecting point mutations and small insertions/deletions but may not detect larger insertions or deletions, cannot detect polynucleotide repeats, and can have difficulty aligning highly homologous sequences or detecting areas with high guanine-cytosine content. It can be used for designing panels of genes using a reagent to capture those sequences of interest. It can also be used for the whole exome sequencing (WES) or the whole genome sequencing (WGS).

A limitation of next-gen large panels and WES/WGS is that the more genes that are sequenced, the greater chance of discovering one or more variants of unknown significance (VUS). If a VUS is discovered, testing parents or other affected and unaffected relatives may be helpful establishing if the VUS is significant. A trio analysis of the patient and parents, or patient and 2 relatives, can be ordered for WES/WGS testing. Other VUS deleteriousness prediction tools used to interpret VUS significance include allelic frequency (is the variant present in population databases), effect of the VUS on amino acid sequence or splicing, and evolutionary conservation at that locus.

TESTING STRATEGY

More than one type of test may be available for a disorder, and more than one gene may cause a disorder. A panel may be useful by including other genetic disorders on the differential, avoiding serial testing. A single gene or panel may be less expensive, with a faster turnaround time, than exome or genome sequencing.

Pretest counseling is vitally important for genetic testing because most laboratories require informed consent. Patients and families should be counseled about the cost of testing, time until results, probability of finding a mutation, and limitations of a selected test. Counseling should also include information on whether insurance will cover the costs and their financial responsibility, whether the chosen test is the end of the diagnostic odyssey or if there may be more testing in their future and how a confirmation of genetic diagnosis may affect their prognosis, their medical care, and their family. It is important to allow sufficient time for these discussions and questions.

SUGGESTED READINGS

Bennett RL. The family medical history. *Prim Care*. 2004;31(3):479-495, vii-viii.

Foo JN, Liu J, Tan EK. Next-generation sequencing diagnostics for neurological diseases/disorders: from a clinical perspective. *Hum Genet*. 2013;132(7):721-734.

International Huntington Association, World Federation of Neurology Research Group on Huntington's Chorea. Guidelines for the molecular genetics predictive test in Huntington's disease. *Neurology*. 1994;44(8):1533-1536.

Klein C. Genetics in dystonia. *Parkinsonism Relat Disord*. 2014;20(suppl 1):S137-S142.

Korf BR, Rehm HL. New approaches to molecular diagnosis. *JAMA*. 2013;309(14):1511-1521.

Singleton AB, Farrer MJ, Bonifati V. The genetics of Parkinson's disease: progress and therapeutic implications. *Mov Disord*. 2013;28(1):14-23.

Acute Ischemic Stroke 36

Charles C. Esenwa and Stephan A. Mayer

KEY POINTS

1. Acute ischemic stroke is defined by critical loss of blood flow with resultant cerebral, spinal cord, or retinal infarction within a specific vascular territory.
2. Core infarct is surrounded by an area of potentially salvageable tissue, called the *penumbra*, in which cerebral blood flow is sufficient to temporarily support cell survival but insufficient to maintain normal function.
3. Intravenous thrombolysis as far out as 4.5 hours after symptom onset or last known well time is standard first-line therapy for all eligible patients.
4. Mechanical thrombectomy using retrievable stent devices decreases long-term disability in all patients with large-vessel occlusion presenting within 6 hours.
5. Thrombectomy can also benefit large-vessel occlusion patients 6 to 24 hours from last known well if a substantial amount of salvageable penumbral tissue is identified on computed tomography perfusion imaging.
6. Standardized management in a dedicated stroke or neurointensive care unit reduces stroke-related morbidity and mortality.
7. Decompressive hemicraniectomy is a powerful life-saving intervention for patients with completed middle cerebral artery or cerebellar infarction.

INTRODUCTION

Ischemic stroke is defined as an episode of neurologic dysfunction caused by vascular stenosis, spasm, or occlusion leading to focal cerebral, spinal cord, or retinal infarction within a specific vascular territory. With the development of acute reperfusion therapies, streamlined algorithms for management of acute ischemic stroke (AIS) are necessary for effective treatment. Management revolves around the processes of (1) early diagnosis, including early stroke recognition and notification of emergency medical services (EMS); (2) rapid clinical and radiologic assessment; (3) early administration of intravenous (IV) thrombolytic therapy; (4) performing advanced catheter-based mechanical thrombectomy in appropriate patients with large-vessel occlusion (LVO); and (5) specialized poststroke management in either a stroke unit or neurologic intensive care unit (ICU).

Epidemiology

An estimated 650,000 AIS occur each year in the United States alone. The most significant individual risk factors for ischemic stroke include hypertension, diabetes mellitus, cigarette smoking, poor nutrition, physical inactivity, cardiac dysrhythmia, alcohol consumption, and obesity. Other causes of AIS include paradoxical embolism through a parent foramen ovale (PFO), cervical dissection, inflammatory or infectious vasculitis, genetic or congenital vasculopathy (eg, carotid web), and systemic hypercoagulable states. In-hospital mortality after AIS is relatively rare, occurring in approximately 5% of cases, and is associated with increasing age, stroke severity, history of atrial fibrillation, previous stroke, carotid stenosis, diabetes mellitus, and history of coronary artery disease. Functional disability and morbidity from poststroke complications occur much more commonly, affecting the majority of patients. As a result, only half of AIS patients are discharged home, whereas the remainder requires further care in skilled nursing facilities, rehabilitation, or palliative care centers.

Pathobiology

Despite making up only 2% of total body weight, the brain consumes 20% of the body's total energy and relies on a constant supply of glucose and oxygen to maintain function and structural integrity. Each minute, nearly 1 L of blood is supplied to the brain through the carotid arteries and, to a lesser extent, the vertebrobasilar system. To ensure a constant cerebral blood flow (CBF) across a range of blood pressures and metabolic states, cerebral vessels constrict or dilate in response to changes in the concentration of carbon dioxide, oxygen, and vessel wall shear stress related to velocity of blood flow. The primary mediator of vasodilation is nitric oxide, which acts to relax the circumferential smooth muscle cells in the tunica media. In normal brain, researchers have described a feed-forward mechanism in which neurovascular coupling is achieved through neuronal innervation of astrocytes, pericytes, and endothelial cells. In this scenario, neurons respond to increased metabolic activity by directly modulating local arteriolar and capillary vasoactivity. It has been shown that endothelial and smooth muscle cells then propagate vasodilation along the neighboring vascular matrix through spreading hyperpolarization and a resultant myogenic response.

CEREBRAL BLOOD FLOW REDUCTION

When cerebral perfusion pressure falls below approximately 60 mm Hg due to either systemic hypotension or local arterial blockage, autoregulatory vasodilation cannot compensate leading

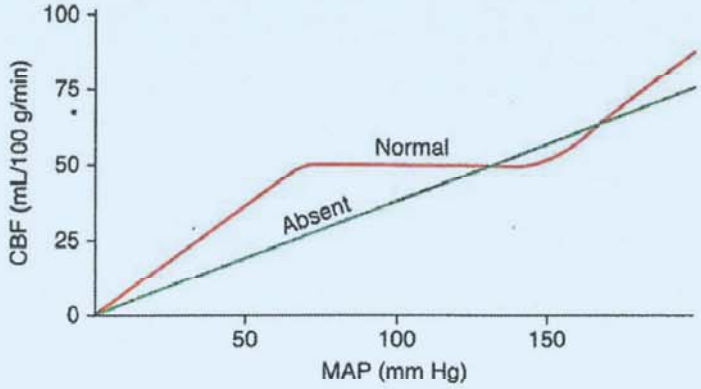

FIGURE 36.1 Cerebral autoregulation. With autoregulation intact (*red line*), cerebral blood flow (CBF) begins to fall below a normal range of 60 mL/100 g/min and hits a critical ischemic level of approximately 20 mL/100 g/min. When autoregulation is impaired or absent (*green line*), CBF can fall to critical levels when mean arterial pressure (MAP) is as high as 50 mm Hg.

to decreased CBF from its normal range of 50 to 60 mL/100 g/min (Fig 36.1). When CBF falls below 30 mL/100 g/min, regional exchange of nutrients and oxygen fails within the neurovascular unit (endothelial cell, surrounding pericytes, basement membrane, perivascular astrocytes, and adjoining neurons), resulting in pathologic depolarization of neurons and glia and suppression of the normal electrical activity as evidenced by slowing and attenuation of the electroencephalographic background (Fig 36.2). Sustained severe hypoperfusion, with CBF levels falling below 20 mL/100 g/min, triggers a cascade of ischemic injury that can lead to irreversible neuronal necrosis and cerebral infarction.

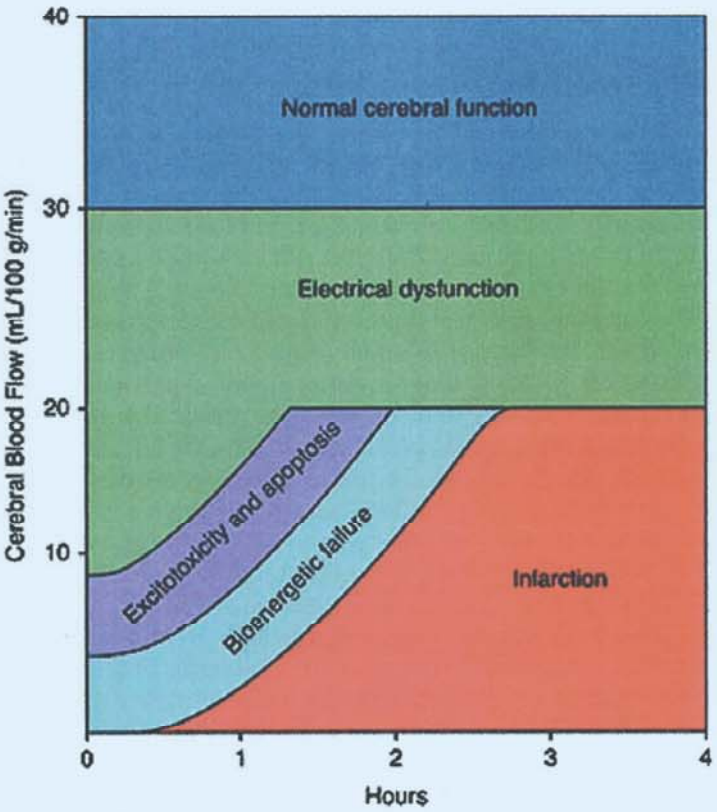

FIGURE 36.2 Progression of ischemic tissue to infarction over time as a function of cerebral blood flow (CBF). A CBF level below 20 mL/100 g/min is the level below which tissue progresses through a phase of reversible ischemic injury to infarction. Lower CBF produces more intense ischemia and faster progression to infarction.

Infarct Core and Penumbra

With decreases in CBF below 20 mL/100 g/min, assuming a normal rate of neuronal metabolism, brain tissue progresses from a state of reversible electrical dysfunction to a "penumbral" state of excitotoxic damage and programmed cell death (apoptosis). *Penumbra* is an ancient Latin term that refers to the shadow that advances across the land in advance of the complete darkness of a solar eclipse. In modern stroke therapy, penumbral tissue is brain tissue in the shadow of death.

Failure of the sodium/potassium transmembrane adenosine triphosphate pump occurs first, causing neurons and glia to depolarize. Widespread depolarization causes uncontrolled release of excitatory neurotransmitters such as glutamate, which in turn leads to an intracellular influx of calcium and sodium. Once the phase of excitotoxicity and apoptosis has set in, a phase of bioenergetic failure occurs with ionic pump dysfunction and loss of normal transmembrane sodium and calcium gradients.

In the infarct core, where the bioenergetic failure is greatest, these massive electrolyte shifts cause water to passively follow its osmotic gradient resulting in cellular swelling and eventual lysis. The resultant edema, termed *cytotoxic edema* as it results from intracellular swelling, manifests within minutes of the initial insult and can be detected with magnetic resonance imaging (MRI) as hyperintensity on diffusion-weighted imaging (DWI) sequences.

The core of the infarct is surrounded by an area of relative hypoperfusion, the ischemic penumbra, in which CBF is sufficient to temporarily support cell survival but insufficient to maintain normal cellular function indefinitely (Fig 36.3). Penumbral tissue may be salvageable if adequate perfusion to the territory can be restored in a timely fashion, which is the basis for all AIS reperfusion therapies. Penumbral tissue, however, is inherently unstable and commonly will progress to completed infarction over time, making *time to reperfusion* the most important therapeutic factor for improving neurologic outcome and preventing disability and mortality after AIS.

Completed Infarction

It is estimated from human and experimental studies that the time from vessel occlusion to fully completed infarction in most cases ranges from 3 to 6 hours. Once the tissue becomes necrotic and infarcted, it is easily visible on both computed tomography (CT) and fluid-attenuated inversion recovery MRI scans. The CBF is maintained at near-normal levels up to the margin of a completed infarct where it rapidly drops to undetectable levels as long as the affected vessel remains occluded. Over the next several days, the infarct progressively swells. Ischemic cells that progress to frank infarction release various proinflammatory cytokines and proteases that disrupt the architecture and function of the neurovascular unit, increasing permeability of the blood-brain barrier. Apoptosis is triggered through the function of various inflammatory processes, including the receptor/ligand combination of the CD95 receptor and tumor necrosis factor–related apoptosis-inducing ligand and mitochondrial membrane release of cytochrome *c* oxidase, both of which lead to activation of the intrinsic programmed cell death cascade and delayed cell death. This delayed neurologic injury could in theory be prevented with neuroprotective agents, although none has proven to be of use in clinical trials.

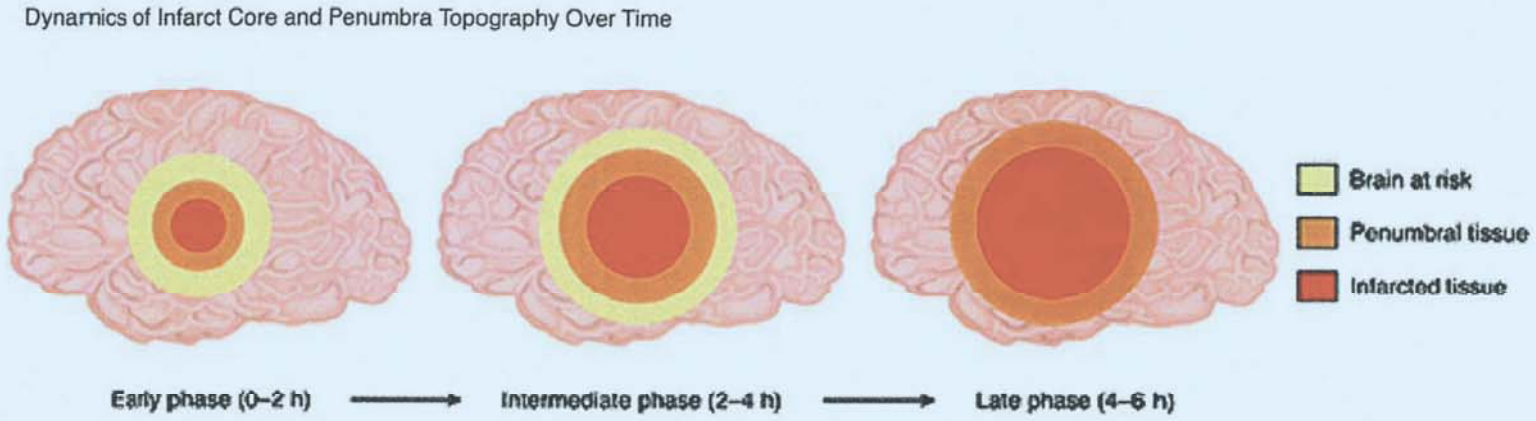

FIGURE 36.3 Dynamics of infarct core and penumbra topography over time in focal ischemia. In the earliest minutes to hours, only a portion of the total brain territory at risk is ischemic as a small core of infarct begins to form. Between 2 and 4 hours, the penumbra moves peripherally in a dynamic fashion around a progressively infarct core and collateral failure may lower CBF in some of the outermost regions of the territory at risk to ischemic levels. Beyond 4 hours, the penumbra evolves into a relatively thin rim of ischemic tissue around a large core of infarcted tissue making reperfusion less effective, as amount of salvageable tissue dwindles and the risk of hemorrhagic infarction increases.

The parenchymal inflammatory response results from upregulation of endothelial cell leukocyte adhesion receptors that cause leukocyte adhesion and transmigration into the affected tissue and is responsible for the prolonged process of tissue inflammation and remodeling after an infarct is completed, as the swelling resolves and the involved regions convert to gliotic scar tissue.

ETIOLOGY OF ISCHEMIC STROKE

The microscopic process of acute cerebral infarction is preceded by macrovascular occlusion of the territory in question. Accurate classification of AIS etiology is important to understand poststroke prognosis, quantify the risk of recurrence, and guide strategies for secondary stroke prevention. Although imperfect, the Trial of Organon in Acute Stroke Treatment classification criteria is the most widely accepted ischemic stroke classification system and includes the following five subtypes: large artery atherosclerosis (15%-40%), cardioembolic (15%-30%), small-vessel occlusion or "lacunar" (15%-30%), cryptogenic (up to 40%), and "other" cause (<5%) (Fig. 36.4).

Large Artery Atherosclerosis

Atherosclerotic plaque may develop at any point along the extracranial or intracranial arterial tree but is usually seen at vessel-branch points where turbulent flow occurs, most commonly at the common carotid bifurcation, vertebral artery origin, vertebrobasilar junction, or the origin of the middle or anterior cerebral arteries. Atherosclerotic plaque causes ischemic stroke by one of two mechanisms: hypoperfusion across a region of critical stenosis or, more commonly, plaque rupture leading to thrombus formation and subsequent distal embolization of thrombus or plaque fragments.

Artery-to-artery embolism occurs when fragments of atherosclerotic plaque or fresh thrombus formed on top of the plaque embolize to occlude a distal vessel. Plaques with a lipid-rich necrotic core and thin fibrous cap pose a risk of spontaneous rupture and activation of the coagulation cascade leading to superimposed thrombus formation. Biomechanical forces induced by turbulent blood flow along this irregular portion of vessel can act to destabilize the cholesterol plaque or dislodge a superimposed thrombus. When this happens, the thrombus may rapidly dissolve causing the clinical symptoms to be fleeting or absent, or it may persistently occlude a distal vessel leading to lasting symptoms of AIS.

Clinically, ischemia from large-artery atherosclerosis is difficult to distinguish from stroke originating from the heart (cardioembolic stroke). Favoring the former are repeated transient ischemic attacks or completed infarcts within the same vascular territory, the best example of which is repeated episodes of painless *transient monocular blindness* related to ipsilateral carotid artery atherosclerosis. This condition, known as *amaurosis fugax*,

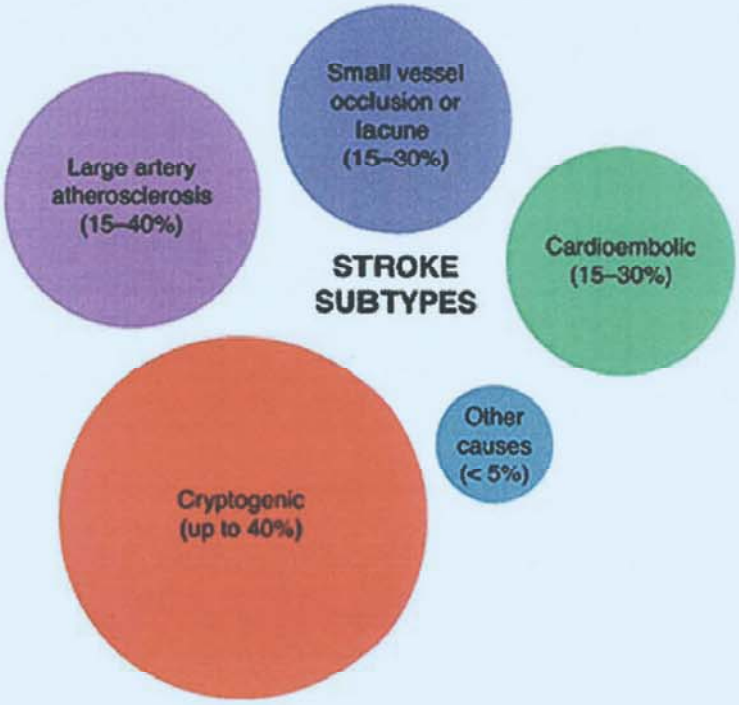

FIGURE 36.4 Stroke subtypes. This figure shows the Trial of Org 10172 in Acute Stroke Treatment classification criteria for ischemic stroke and the estimated relative distribution of stroke within each category.

results from cholesterol embolism from the carotid plaque causing occlusion of the central retinal artery or one of its branches. When the lumen of the carotid artery is nearly occluded, transient attacks can also be due to retinal hypoperfusion, clinically manifesting as vision loss with exposure to bright light. Similarly, repeated episodes of vertigo, diplopia, hemiparesis, hemianesthesia, gait unsteadiness, and even loss of consciousness can be a sign of high-grade vertebral or basilar artery stenosis.

Cardioembolic Stroke

Cardioembolic stroke includes all strokes caused by a cardiac source of thromboembolism. Most commonly, cardioembolism occurs from thrombus formed in the left atrial appendage of the heart in patients with atrial fibrillation, but cardioembolism can also result from a diseased native or prosthetic heart valve or ventricular wall thrombus resulting from recent myocardial infarction or severe dilated cardiomyopathy. Cardioembolic strokes can also result from neoplastic causes, such as atrial myxoma or marantic endocarditis, or infectious causes such as infectious endocarditis. Radiologically, scattered strokes at the gray-white matter junction that occur in both hemispheres, or in both the anterior and posterior circulation, are most commonly cardioembolic in origin. However, strokes that appear in association with proximal LVOs or that appear most consistent with small-vessel infarction can also be seen after cardioembolism.

Small-Vessel Infarction

Lacunar strokes from small-vessel occlusion are clinically defined by five general subtypes: (1) pure motor hemiparesis, (2) pure sensory syndrome, (3) mixed sensorimotor syndrome, (4) ataxic hemiparesis, and (5) clumsy-hand dysarthria, although various other manifestations can occur depending on the territory of the vessel involved. These strokes result from blockage of small perforating arteries arising from the middle cerebral artery (MCA) (lenticulostriate), the posterior cerebral or posterior communicating arteries (tuberothalamic, paramedian, posterior choroidal, inferolateral), and basilar artery (pontine perforators). These vessels are prone to segmental arterial wall disorganization and fibrosis, a process known as *lipohyalinosis*, and microatheroma formation. Over time, the arterial wall thickens and the vessel lumen is compromised causing a region of acute ischemia that is usually smaller than 1.5 cm in diameter. Hypertension is the greatest risk factor, although diabetes, age, and smoking may contribute as well. Lacunar infarction occurs most commonly in the basal ganglia, thalamus, internal capsule, corona radiata, and pons. Imaging helps distinguish lacunar stroke from other types of stroke by their subcortical location and relatively small size.

Undetermined Cause of Stroke

The etiology of up to 40% of strokes remains *cryptogenic*, or undetermined, even after extensive laboratory and radiologic investigation. The majority of cryptogenic strokes are territorial and appear to be embolic, despite the absence of atrial fibrillation, carotid or proximal large vessel disease, intracardiac thrombus, or other causes, in which case the term *embolic stroke of unknown source* is frequently used. Many embolic stroke of unknown source patients in fact have undiagnosed paroxysmal atrial fibrillation with studies showing that 10% to 20% of "cryptogenic" stroke patients are found to have occult atrial fibrillation on prolonged ambulatory cardiac monitoring. Although PFO and atrial septal defect are also associated with cryptogenic stroke, PFO closure should only be considered in patients younger than age 60 years with presumed paradoxical embolism and in whom no other identifiable stroke etiology could be established. The presence of an atrial septal aneurysm or large interatrial shunt makes it more likely that the cause of stroke is PFO related. Five large randomized controlled trials have evaluated the efficacy of PFO closure comparing it to medical therapy alone, in the setting of cryptogenic stroke. A meta-analysis including 3,440 patients found PFO closure to be associated with a 0.96% absolute reduction in recurrent stroke (1.04% vs 2.00% per 100 patient-years), compared to medical therapy alone. This relatively minor but statistically significant benefit of stroke reduction is partly offset by the risk of atrial fibrillation with PFO closure, which occurred between 1.8% and 6.6%, depending on the closure device and trial in question LEVEL 1.[1]

Other Causes of Stroke

The "other" causes of stroke category makes up less than 5% of AIS, and it is defined by a specific disease process that is shown to have a temporal relationship or association to the stroke. In addition, diagnostic investigation should not reveal any other more common mechanism. Examples include stroke due to hematologic disorders (eg, hypercoagulability, sickle cell anemia), infectious or inflammatory disease, intrinsic disease of the arterial wall (ie, vasculopathy), vessel dissection, genetic disorders, or iatrogenic causes. Coronavirus disease 2019 can cause a chronic inflammatory and hypercoagulable state and has been associated with large vessel embolic stroke in 0.5% to 1% of cases.

CLINICAL MANIFESTATIONS

Ischemic strokes can be defined clinically by the nature of the associated neurologic deficit with signs and symptoms fitting into defined syndromes representing specific vascular territories (Fig. 36.5). Knowledge of the following major stroke syndromes

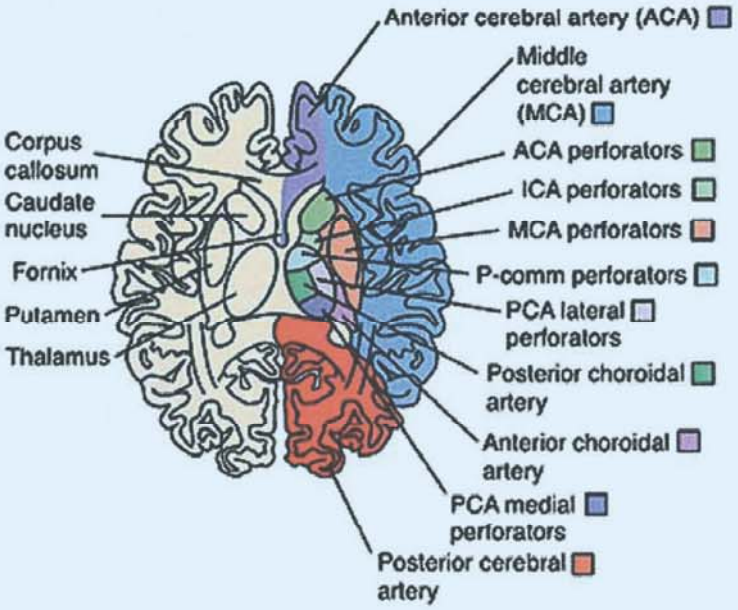

FIGURE 36.5 Cerebral vascular supply. ICA, internal carotid artery; PCA, posterior cerebral artery.

TABLE 36.1 Syndromes of Cerebral Infarction

Arterial Distribution	Subdivision	Syndrome
Middle cerebral	Main trunk	Variable combination of hemiplegia, hemianesthesia, gaze deviation/preference, hemianopia and global aphasia (dominant hemisphere), or profound multimodal hemineglect (nondominant hemisphere)
	Upper division	Variable combination of hemiparesis, hemianesthesia, gaze deviation, and expressive (Broca) aphasia (dominant hemisphere) or hemineglect (nondominant)
	Lower division	Variable combination of hemianopia or quadrantanopia, mild or absent hemiparesis, receptive (Wernicke) aphasia (dominant hemisphere), or hemineglect and behavior disorder (nondominant)
	Perforating branches	Contralateral hemiparesis occasionally seen in combination with ataxia or dysarthria
Internal carotid		Can be asymptomatic or cause any of the following: ipsilateral monocular blindness, transient limb shaking, or a combination of middle cerebral and anterior cerebral artery syndromes
Anterior cerebral		Variable combination of hemiparesis and sensory loss of the contralateral leg more than the arm, transcortical motor aphasia (dominant hemisphere), motor neglect (nondominant hemisphere), impaired responsiveness ("abulia"), gait apraxia, ideomotor apraxia, or tactile anomia (nondominant hemisphere)
Posterior cerebral	Main trunk	Variable combination of hemianopia or quadrantanopia, alexia, color anomia, inability to perceive parts of an objects as a whole ("simultanagnosia"), face blindness ("prosopagnosia"), amnesia, agitated delirium (especially when bilateral), or cerebral blindness (with bilateral injury)
	Perforating branches	*Thalamus*: pure sensory stroke that may leave a residual pain syndrome ("thalamic pain syndrome"), ataxia, aphasia (dominant), hemineglect (nondominant), visual field deficits, memory loss, or behavioral disturbances *Subthalamic nucleus*: hemiballism *Midbrain*: various eye movement abnormalities, depressed level of arousal, hemianesthesia, hemiparesis, hemiataxia, hemiparkinsonism

can oftentimes accurately predict the territory of infarction and specific vessel involved (Table 36.1). Exceptions arise when there is underlying preexisting central nervous system injury, presence of collateral circulation, or variations in the vascular or brain anatomy that can produce atypical or unexpected clinical presentations.

Middle Cerebral Artery Infarction

Infarction of the MCA produces clinical syndromes that depend on the extent of the infarct and the side and level of vessel occlusion. Proximal, or branch MCA occlusion, can affect both the deep and the cortical hemispheric structures or deep structures only when there is robust collateral vascularization supplying the cortex. Isolated ischemia of the deep cerebral structures—mainly the internal capsule, basal ganglia, and corona radiata—occurs due to blockage of the lenticulostriate artery origins causing contralateral hemiparesis and possibly hemisensory loss that often is indistinguishable from a lacunar syndrome. Larger deep infarcts ("striatocapsular infarction") that affect cortical connections to the thalamus and optic radiations can cause the cortical syndromes of hemineglect, aphasia, and homonymous hemianopia or quadrantanopia.

Cortical ischemia in the MCA territory is encountered in isolation when vessel occlusion is localized to the superior or inferior MCA divisions (the number and location of these branch arteries can vary). Damage to either hemispheric cortex can cause contralateral limb weakness, contralateral sensory loss, astereognosia (inability to identify objects using touch), agraphesthesia (inability to recognize writing traced on the skin), diminished two-point discrimination, contralateral visual field deficits, and gaze deviation toward the damaged side. Ideational apraxia (inability to understand the purpose of an object or manipulate it) follows left-sided or bilateral hemispheric damage.

Syndromes resulting from a dominant (usually left) hemispheric lesion include aphasia (language dysfunction), bilateral ideomotor apraxia (inability to perform learned motor tasks), and buccolingual apraxia (inability to voluntarily direct mouth and tongue movements). The type and severity of aphasia depends on the location and size of the infarct. A superior MCA branch occlusion will affect the anterior perisylvian cortex and specifically the inferior frontal gyrus to produce Broca (expressive) aphasia that is characterized by decreased or absent word fluency and inability to write but with preserved comprehension. When aphasia is expressive or global, hemiparesis is also usually present and severe. Inferior branch MCA occlusion, affecting the posterior perisylvian cortex and specifically the superior temporal gyrus and temporoparietal junction, produces Wernicke (receptive) aphasia, which is characterized by preserved fluency and prosody but incomprehensible content; semantic and phonemic paraphasic errors; impaired comprehension; and inability to read, name, or repeat. Receptive aphasia is often associated with a homonymous hemianopia or quadrantanopia, but hemiparesis can be mild or even absent. Gerstmann syndrome (left-right confusion, finger agnosia, acalculia, and agraphia), or an incomplete version of this tetrad, follows infarction of the dominant angular gyrus.

Infarction of the nondominant (usually right) parietal lobe produces contralateral hemispatial neglect or an inattention to sensory inputs or motor outputs to the contralateral half of the environment or body. Specific findings include sensory or visual neglect (that can involve the entire contralateral visual field or be specific to various objects), anosognosia (lack of awareness of neurologic deficits), asomatognosia (inability to recognize one's limb on the affected side), and allochiria (spatial transposition

resulting in the patient attending to the ipsilateral hemispace when presented with a stimulus on the neglected contralateral side). Constructional apraxia (inability to assemble or draw objects) may result from damage to either hemisphere but is more obvious in nondominant hemispheric lesions. Although speech content or the propositional aspect of speech is preserved, a nondominant hemispheric lesion may cause deficits in the pragmatics, or sociolinguistic aspects of speech, involving tone and inferred intent.

Anterior Cerebral Artery Infarction

Anterior cerebral artery (ACA) infarction most commonly causes contralateral leg hemiparesis and/or hemisensory loss, although many other features may also be seen. Similar to watershed infarcts, ACA territory infarcts can cause transcortical aphasia of the motor type. *Motor neglect*, or a disinclination to use the contralateral limb despite the absence of weakness, is often encountered and is due to dysfunction of the prefrontal supplementary motor cortex. Bilateral ACA infarction often results in executive dysfunction with motor inertia and *abulia* (paucity of spontaneous behaviors) or even *akinetic mutism* (awake unresponsiveness). *Gait apraxia*, although typical of bilateral lesions, can also result from unilateral strokes. *Alien hand syndrome* (unwilled motor activity) or hemiballism of the contralateral arm can result from injury to the anterior corpus callosum or medial frontal cortex. *Utilization* and *imitation behavior* are neurobehavioral syndromes that can occur with unilateral prefrontal infarcts. With utilization behavior, the patient automatically and impulsively grabs objects that appear within visual field and are within reach. Imitation behavior is automatic and involuntary imitation of the examiner's movements.

Occlusion of the recurrent artery of Heubner, a large perforating artery arising from the proximal ACA, leads to infarction of the head of the caudate, anterior internal capsule, and anterior putamen. Common clinical features include dysarthria, motor perseveration, contralateral hemiparesis, abulia, and incontinence.

Internal Carotid Artery Infarction

Acute carotid occlusion causes acute hemispheric hypoperfusion that, in the absence of a patent circle of Willis, can manifest as seizure, contralateral limb shaking, or holohemispheric infarction of both the ACA and MCA territories. Occasionally, and especially in the presence of a robust circle of Willis, occlusion of the internal carotid artery (ICA) spares the ACA and produces a clinical scenario indistinguishable from branch MCA infarction. If collateral flow across the posterior communicating artery, anterior communicating artery, or pial arteries is adequate, the occlusion can be clinically silent or only affect smaller susceptible areas. By contrast, ICA occlusion with poor collateral or a distal ICA "T occlusion" can lead to catastrophic holohemispheric infarction with sparing of only the posterior cerebral artery (PCA) territory (thalamus and medial temporal and occipital lobes).

Border Zone Infarction

Border zone (or watershed) territories occur at the boundaries between the anterior, middle, and posterior cerebral arteries and are susceptible to ischemia in severe carotid artery stenosis or occlusion, or global hypoperfusion. *Superficial border zone infarction* occurs high along the convexity of the corona radiata between the deep and cortical structures anteriorly between the ACA and MCA territories or posteriorly between the MCA and PCA territories (**Fig. 36.6**). This pattern of infarction occurs when collateral flow is able to supply the majority of the involved territories but is unable to "meet" between territories. Resulting symptoms form a combination of weakness, hemisensory loss, and cortical signs. Transcortical aphasia of the expressive or receptive type with relatively preserved ability to repeat is also common. The ACA-MCA watershed infarcts primarily cause arm weakness because the affected region corresponds anatomically with neurons in the motor strip that innervate the upper extremities. When bilateral, as occurs with cardiac arrest, ACA-MCA watershed infarctions result in *man-in-the-barrel syndrome* characterized by proximal bilateral arm and leg weakness with relative preservation of facial and distal extremity strength.

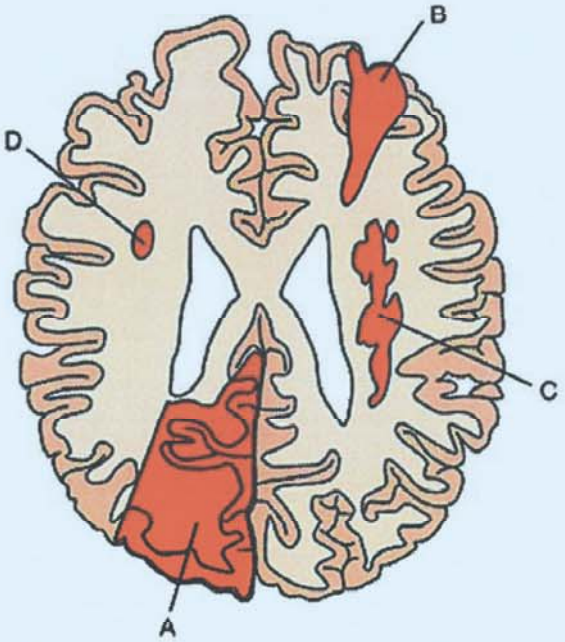

FIGURE 36.6 Schematic representation of different topographic patterns of cerebral infarction. (*A*) Territorial infarction (from posterior cerebral artery occlusion). (*B*) Watershed border-zone infarction (between the territories of the anterior cerebral artery and the middle cerebral artery). (*C*) Internal border zone infarction (deep middle cerebral artery territory). (*D*) Lacunar infarction (lenticulostriate-penetrating artery occlusion). (Adapted from Marshall R, Mayer S. *On Call Neurology*. 3rd ed. Philadelphia: Saunders; 2007.)

Internal border zone infarction (see **Fig. 36.6**) can occur with total ICA occlusion or with large MCA branch occlusions. Noncollateralized deep-penetrating arteries that descend from the cortex to the lateral wall of the ventricles represent the most hemodynamically vulnerable "distal field" in this scenario. The result is a pattern of multiple small deep infarcts involving the deep white matter of the corona radiata and centrum semiovale.

Anterior Choroidal Artery Infarction

The anterior choroidal artery is the last branch of the ICA originating just proximal to the ACA-MCA bifurcation. It traverses posteriorly to supply a number of structures, including the internal capsule, lateral thalamus, and the lateral geniculate body or optic radiations. Thus, occlusion of the anterior choroidal

artery results in the classic syndrome of contralateral hemiparesis, hemianesthesia, and homonymous hemianopia. Occasionally, cortical symptoms such as aphasia or hemineglect can result from disruption of thalamocortical white matter tracts.

Posterior Cerebral Artery

Occlusion of the PCA will cause infarction of the occipital and inferior temporal lobes. The usual presentation is sudden onset of a contralateral homonymous hemianopia. Bilateral occipital lobe lesions can cause *Anton syndrome* (cortical blindness unrecognized by the patient). *Charles Bonnet syndrome*, or release visual hallucinations, can also be seen in cortical blindness from bilateral occipital lobe injury. *Balint syndrome* is seen in bilateral parietooccipital junction infarcts and is characterized by simultanagnosia (inability to perceive parts of an object as a whole), oculomotor apraxia (incoordination of gaze), and optic ataxia (poor hand coordination using visual guidance). Hemineglect, although uncommon with occipital lesions, can be seen when the injury extends to the parietal lobe. Left PCA infarcts that involve either the deep white matter of the temporoparietal junction or the splenium of the corpus callosum may cause alexia without agraphia, a type of disconnection syndrome between the nondominant occipital cortex and the language-processing area in the dominant parietotemporal cortex. Inferomedial temporal lobe infarction may cause agitated delirium or global amnesia.

Proximal PCA infarction affecting the thalamic perforating arteries will lead to infarction of the thalamus or midbrain. If the ventral posterior nucleus of the thalamus is preferentially affected, the patient will have contralateral hemianesthesia. Hyperpathia may subsequently develop in a condition called the *Dejerine-Roussy* or *thalamic pain syndrome*. As the thalamus serves as a relay to the cortex, thalamic infarction can also cause a variety of atypical symptoms such as ataxia, aphasia (dominant), hemineglect (nondominant), visual field deficits, memory loss, or behavioral disturbances.

Lethargy or coma can result if the reticular activating system in the midbrain or thalami is affected and will often be accompanied by oculomotor abnormalities. Alterations in consciousness are especially common in the presence of an anatomically variant artery, termed the *artery of Percheron*, which supplies the bilateral medial thalami and rostral midbrain from a single vessel originating from a unilateral PCA. Midbrain lesions, when posterior, cause Parinaud syndrome characterized by sustained conjugate downgaze, upgaze paralysis, convergence-retraction nystagmus, lid retraction or Collier sign, and pupillary light-near dissociation.

Vertebrobasilar Territory Infarction

The basilar artery is the main conduit to supply the PCA arteries, and basilar thrombosis can manifest with a combination of medullary, pontine, midbrain, and posterior cortical signs. Basilar thrombosis leading to infarction of the anterior pons bilaterally causes "locked-in" syndrome: complete bilateral face, arm, and leg paralysis with isolated preservation of vertical eye movements and preservation of consciousness. Infarcts resulting from small-vessel thrombosis of the pontine-perforating arteries cause a combination of cranial nerve dysfunction, long tract signs, reflexive posturing or hyperreflexia, sensory loss, and/or cerebellar findings. Small anterior pontine strokes can also produce lacunar syndromes without cranial nerve deficits that are clinically indistinguishable from anterior circulation lacunes. Oculomotor or gaze palsies, including internuclear ophthalmoplegia and skew deviation, or nystagmus, are also common. *Top of the basilar* syndrome refers to occlusion of bilateral distal basilar and proximal PCA thalamic- and midbrain-penetrating arteries from embolism. The result is a pattern of bilateral small-vessel infarcts involving the midbrain and thalami with asymmetric ophthalmoparesis, horizontal and vertical gaze abnormalities, skew deviation, changes in level of consciousness, and variable bilateral motor and sensory deficits.

Infarction of the lateral medulla occurs when the posterior inferior cerebellar artery or a branch of the vertebral artery is affected. What results is a lateral medullary or *Wallenberg syndrome*, which is characterized by vertigo, ipsilateral ataxia, loss of pain and temperature sense in the ipsilateral face and the contralateral arm and leg, dysphagia, and ipsilateral oculosympathetic syndrome (*Horner syndrome*). Other brainstem infarct syndromes are described in **Table 36.2**.

DIAGNOSIS

Symptom Recognition

Delay in prehospital recognition of stroke symptoms is the greatest barrier to prompt treatment and a major factor in explaining why less than 10% of patients with AIS receive fibrinolytic therapy. Despite the established benefit of timely assessment and the potential for neurologic recovery with early treatment, only approximately 20% of patients present within 2 hours of symptom onset and approximately 25% within the therapeutic window of 4.5 hours. Limited insight and lack of community-level awareness to the time-sensitive nature of treatment are partly to blame, with studies suggesting that only 5% of people in an urban population have knowledge of at least three stroke symptoms. The mnemonic FAST (face, arm, speech, time to call 911) has been disseminated using multiple community education efforts, in order to raise awareness about stroke symptoms and the urgent nature of seeking medical care. Public education efforts play a critical role in increasing the proportion of patients who present within the therapeutic time window.

Once EMS is activated, first responders must quickly and accurately characterize the symptoms of a stroke. Prehospital stroke scales (**Table 36.3**) should be used to assist in the screening and rapid triage process LEVEL 2.[2] The most widely used are the Cincinnati Prehospital Stroke Scale; the Los Angeles Motor Scale; the Face, Arm, Speech Test; and the Rapid Arterial oCclusion Evaluation scales. All allow for the rapid identification of hemiparesis, speech disturbances, and other signs of focal neurologic deficit and can be performed in a matter of minutes. With the advent of mechanical thrombectomy for treating qualifying patients with LVO, early screening and identification of patients with LVO is an integral part of any regional stroke systems of care protocol. Similar to ST-elevation myocardial infarction pathways, a positive LVO screen allows for high-likelihood patients be rerouted to thrombectomy-capable centers by EMS or be transferred emergently from one hospital to another capable of providing advanced reperfusion therapies. In many instances, regional stroke systems are dependent on real-time image sharing and 24/7 remote audiovisual communication capabilities provided by a trained neurologist LEVEL 2.[2] A study by McTaggart

TABLE 36.2 Syndromes of Brainstem Infarction[a]

Syndrome		Artery Affected	Structure Involved	Manifestations
Medial syndromes	Medulla	Paramedian branches of basilar artery	Emerging fibers of 12th nerve	Ipsilateral paralysis of tongue
			Corticospinal tract	Contralateral limb paresis/paralysis
			Medial lemniscus	Contralateral hemianesthesia
	Inferior pons	Paramedian branches of basilar artery	Pontine gaze center, near or in nucleus of sixth nerve	Paralysis of gaze to side of lesion
			Emerging fibers of sixth nerve	Ipsilateral abduction paralysis
			Corticospinal tract	Contralateral limb paresis/paralysis
	Superior pons	Paramedian branches of basilar artery	Medial longitudinal fasciculus	Internuclear ophthalmoplegia
Lateral syndromes	Medulla	Posterior inferior cerebellar artery or vertebral artery branches	Emerging fibers of 9th and 10th nerves	Dysphagia, hoarseness, ipsilateral paralysis of vocal cord; ipsilateral loss of pharyngeal reflex
			Vestibular nuclei	Vertigo, nystagmus
			Descending tract and nucleus of fifth nerve	Ipsilateral facial analgesia
			Solitary nucleus and tract	Taste loss on ipsilateral half of tongue posteriorly
			Spinothalamic tract	Contralateral sensory loss
			Hypothalamospinal tract	Ipsilateral oculosympathetic dysfunction ("Horner syndrome")
	Inferior pons	Anterior inferior cerebellar artery	Emerging fibers of seventh nerve	Ipsilateral facial paralysis
			Solitary nucleus and tract	Taste loss on ipsilateral half of tongue anteriorly
			Cochlear nuclei	Hearing loss, tinnitus
			Spinothalamic tract	Contralateral sensory loss
	Mid-pons	Anterior inferior cerebellar artery and circumferential branches of basilar	Motor nucleus of fifth nerve	Ipsilateral jaw weakness
			Emerging sensory fibers of fifth nerve	Ipsilateral facial numbness

[a]Modified from Rowland LP. Clinical syndromes of the spinal cord and brain stem. In: Kandel ER, Schwartz JH, Jessell T, eds. *Principles of Neural Science*. 3rd ed. New York, NY: Elsevier; 1991:711-730.

et al found that implementation of a standardized LVO screening and transfer protocol, and the capability for cloud-based image sharing, led to significant improvements in treatment times and decreased long-term disability for patients transferred from 1 of 14 primary stroke centers to a comprehensive stroke center l. Rapid stroke and LVO assessments should be followed by activation of the acute stroke chain of care. This increases the use of intravenous tissue plasminogen activator (IV tPA) and decreases time to medical and catheter-based treatments LEVEL 1.[2]

TABLE 36.3 Prehospital Stroke Scales

Cincinnati Prehospital Stroke Scale/FAST	Yes	No
Facial droop?	☐	☐
Arm drift?	☐	☐
Speech abnormal?	☐	☐

POSITIVE SCREEN if any questions are positive.

	Points		
Los Angeles Motor Scale	0	1	2
Facial strength	Normal	Droop	—
Arms outstretched	Normal	Drifts down	Falls rapidly
Grip strength	Normal	Weak grip	No grip

POSITIVE SCREEN for stroke with high likelihood of large-vessel occlusion for a score of 2 or more.

Initial Hospital Evaluation

The American Heart Association and American Stroke Association guidelines recommend that all patients suspected of having an acute stroke or LVO be brought to a stroke-certified or thrombectomy-capable center to ensure a standardized level of care LEVEL 1.[2] Upon arrival to the emergency department, the patient must undergo rapid clinical and diagnostic evaluation in preparation for potential treatment. Initial history should be directed at defining the deficit and specific time of onset or last known time when the patient was seen normal. The clinician must then perform a rapid neurologic assessment using the National Institutes of Health Stroke Scale (NIHSS). The NIHSS (see Table 16.3) ranges from 0 to 42 with higher scores signifying greater neurologic deficit. Emergent imaging is then used to look for intracranial hemorrhage. If exam findings are suggestive, advanced vascular imaging is needed to diagnose LVO. Hospitals that provide both medical and interventional treatment for ischemic stroke often employ a streamlined process to deal with this complex diagnostic pathway in a time-sensitive manner. An LVO screening using Los Angeles Motor Scale or an NIHSS cutoff

Imaging

Computed Tomography

Noncontrast head computed tomography (NCHCT) is widely available, rapid, and extremely sensitive for detecting acute blood products. Its value in distinguishing cerebral hemorrhage from presumed ischemia has made obtaining an NCHCT a vital and necessary step in the assessment of acute stroke. Early CT findings in AIS include loss of gray-white differentiation (seen first in the insular cortex), obscuration of gray matter in the basal ganglia, and acute thrombus visualized in the proximal MCA, also known as the *dense MCA* sign (Fig. 36.7A). However, CT findings in AIS are not reliably seen until after 6 hours from stroke onset; thus, normal imaging in the setting of a clinical stroke syndrome suggests an ischemic etiology. The Alberta Stroke Program Early CT Score can be helpful in quantifying signs of acute ischemia on NCHCT (see Fig. 16.3). The Alberta Stroke Program Early CT Score and NIHSS scores can help predict functional outcome and response to treatment.

Magnetic Resonance Imaging

Although CT is the most sensitive imaging modality for acute hemorrhagic stroke, MRI, and specifically DWI, is the most sensitive modality for detecting ischemic stroke within the first 6 hours of

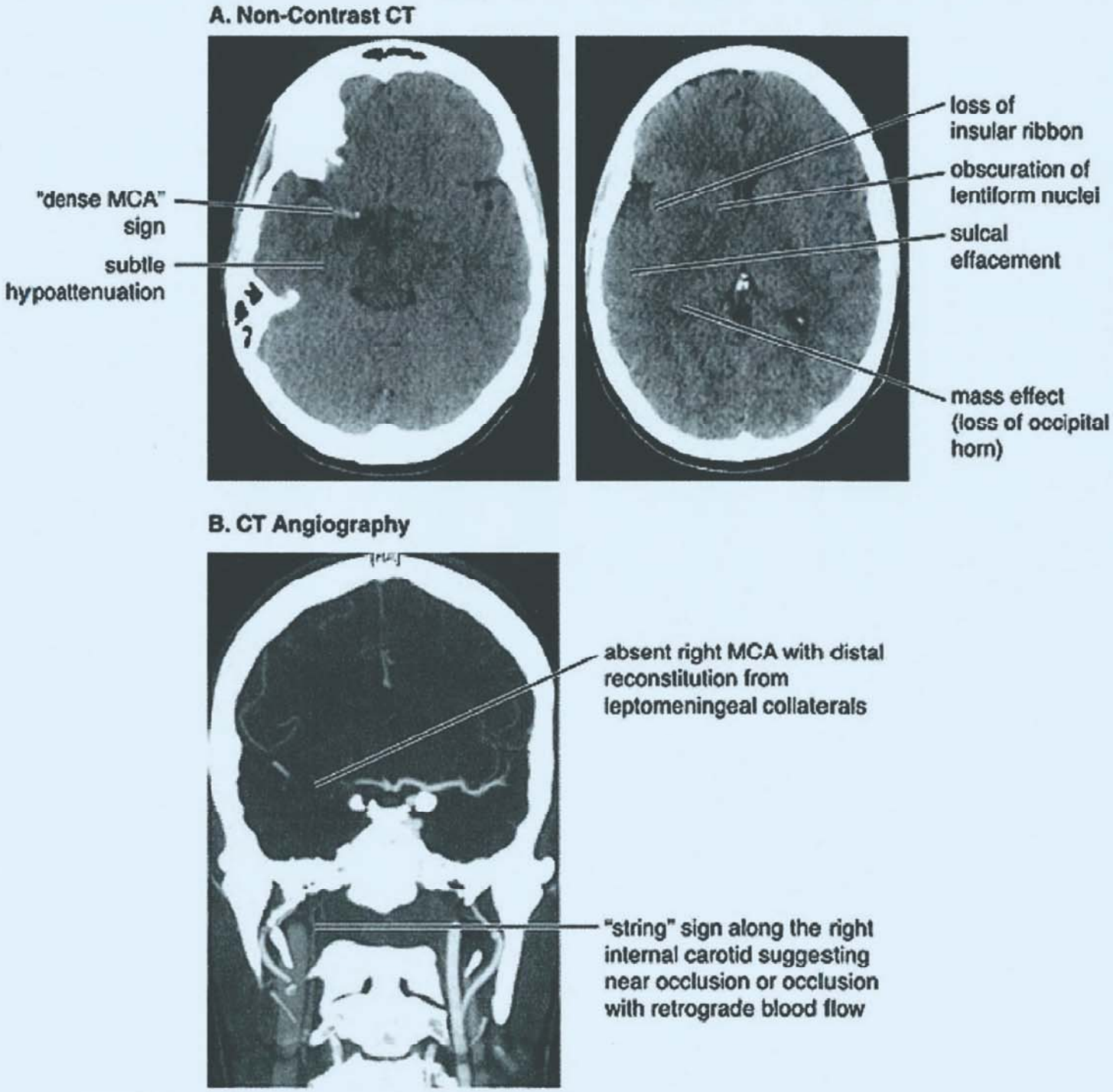

FIGURE 36.7 Acute ischemic stroke imaging. This figure shows the stepwise imaging approach for a patient presenting with acute onset of left-sided weakness and right gaze deviation. The initial noncontrast head computed tomography (CT) **(A)** shows early infarct signs in the right hemisphere. CT angiography **(B)** shows an absent right internal carotid artery and right middle cerebral artery (MCA). (continued)

C. CT Perfusion

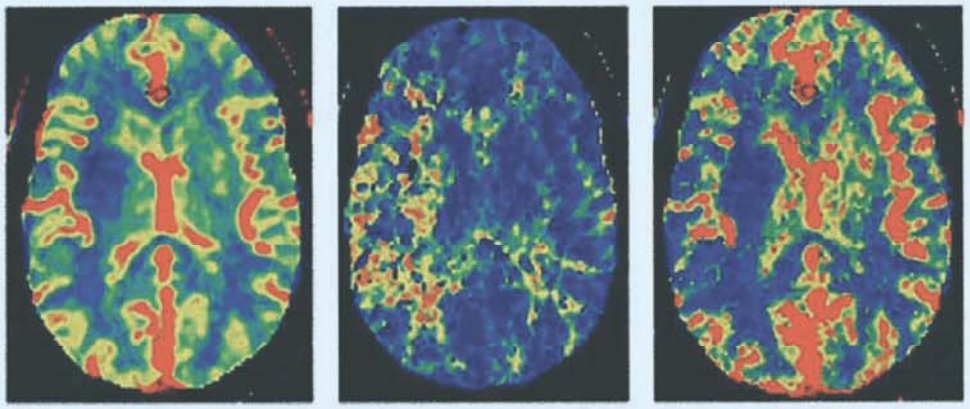

Cerebral blood volume (CBV) – decreased in the deep right MCA territory

Mean transit time (MTT): prolonged in the entire right MCA territory

Cerebral blood flow (CBF): Decreased in a large portion of the right MCA territory

D. MRI

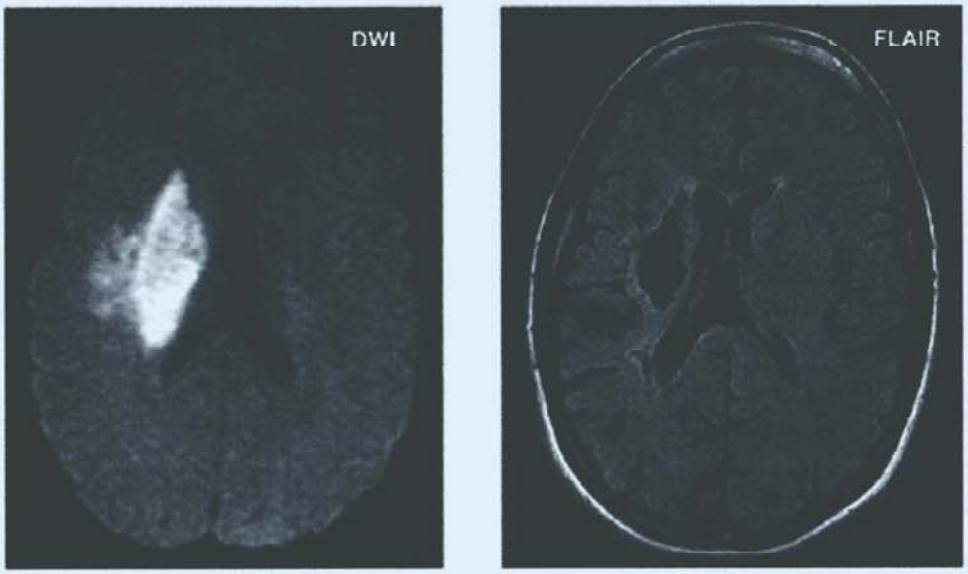

Diffusion-weighted imaging (DWI): hyperintensity in the deep right MCA territory signifying acute infarct

Fluid-attenuated inversion recovery (FLAIR): 1-y follow-up showing chronic infarct in the deep structures with relative preservation of the cortex

FIGURE 36.7 *(continued)* CT perfusion (C) shows an area of core infarct defined by a low cerebral blood volume, prolonged mean transit time, and decreased cerebral blood flow surrounded by a widespread area of tissue at risk defined by relatively stable cerebral blood volume, prolonged mean transit time, and decreased cerebral blood flow. On magnetic resonance imaging (MRI), the diffusion-weighted imaging sequence in the acute setting and the fluid-attenuated inversion recovery sequence 1 year later (D) confirmed that only the presumed core area had infarcted and not the hemisphere as a whole, probably due to good leptomeningeal collaterals.

onset (Fig. 36.7D). Despite its superior sensitivity, however, the use of MRI in the acute management of AIS is limited due to its relative unavailability in most emergency departments and the prolonged time necessary for image acquisition. Despite its superior sensitivity, small infarcts and those in the posterior circulation may not be seen on DWI, especially in the early hours after infarction. Although these issues limit its utility in the acute setting, obtaining an MRI after treatment decisions are made can be helpful in confirming the presence of ischemic stroke, identifying the specific stroke location, and helping to diagnose the stroke etiology.

Vascular Imaging

Computed tomography angiography (CTA) allows for acute evaluation of the cervical and cerebral vessels by opacifying the vasculature with IV contrast delineating any irregularities, stenoses, or occlusions (Fig. 36.7B). Magnetic resonance angiography detects flow within blood vessels allowing for visualization of vasculature and any "flow voids" that occur within them but, similar to MRI, is limited by the time necessary for image acquisition. Special MRI techniques such as vessel wall imaging and arterial spin labeling can show details of the vessel wall and flow dynamics within the vessel, but their role in the clinical setting remains investigational. Ultrasound evaluation of the carotid arteries or the proximal intracranial vasculature can provide information about the direction of blood flow and define sites of arterial stenosis or occlusion. Although vessel imaging is not recommended for all cases of AIS, its use in select patients may help in planning for interventional therapies.

Perfusion Imaging

A computed tomography perfusion (CTP) study can be performed along with CTA measuring the time to arrival and volume of contrast arriving in various areas of the brain by repeatedly scanning during a timed IV contrast injection (Fig. 36.7C). The opposite

hemisphere is used for comparison, and images are created to show relative amounts of CBF, cerebral blood volume (CBV), and mean transit time of contrast. Perfusion imaging may help differentiate the penumbra from core infarct. The penumbra retains cerebrovascular autoregulation and experiences vasodilation and recruitment of collateral vessels in response to relative hypoperfusion. It is defined by a low CBF and prolonged mean transit time with a compensatory increase in CBV caused by vasodilation. The ischemic core, in contrast, loses its physiologic ability to autoregulate and therefore has blood shunted away from it creating a relative deficit in CBV. If the penumbra further destabilizes, autoregulation fails and the area with low CBV expands.

Magnetic resonance perfusion imaging is similar to CTP and can distinguish infarcted from at-risk tissue by comparing perfusion imaging to DWI sequences, but it is more time-consuming than CTP. Perfusion imaging, in some cases automated volumetric assessment of core infarct and penumbra, is becoming standard practice in advanced stroke care centers. The CTP is particularly helpful in patients who are outside of the traditional time-based treatment window or in whom a timeline cannot be established, as in wake-up stroke LEVEL 3.[2]

ACUTE TREATMENT

Estimations based on mathematical modeling suggest that 1.9 million neurons and 14 billion synapses are lost for every minute of ischemia. Stroke expansion is usually complete within 4 to 6 hours of onset, at which point potentially salvageable areas of penumbra become irreversibly infarcted. Emergency treatment with IV tissue plasminogen activator (tPA) is the fundamental medical therapy used to achieve reperfusion. Benefit directly correlates with time to treatment with a linear relationship between shorter onset-to-needle time and improved 3-month functional outcome. Benefit levels off after 4.5 hours and the risk of hemorrhagic transformation begins to exceed the benefit of salvaging penumbral tissue at risk. Rapid onset-to-treatment time will always remain the most important factor in the treatment of AIS.

Intravenous Thrombolysis

The only currently U.S. Food and Drug Administration–approved medical treatment for AIS is IV tPA. As onset-to-treatment time increases, the effectiveness of tPA diminishes and the risk of hemorrhage increases. Optimal treatment involves the administration of tPA as quickly as possible up to 3 hours from symptom onset for most patients and 4.5 hours in a select group of patients LEVEL 2.[3,4] The original 3-hour time window is largely based on the National Institute of Neurological Disorders and Stroke (NINDS) trial from 1995, which showed that administration of IV tPA within 3 hours of symptom onset led to an improved clinical outcome at 3 months with a 13% absolute increase in good functional recovery compared to placebo despite an approximate 6% absolute risk increase in symptomatic intracerebral hemorrhage (ICH) with IV tPA. This translates to a number needed to treat of eight patients to achieve good recovery in one patient who would have otherwise had a poor outcome.

A pooled analysis of the Alteplase Thrombolysis for Acute Noninterventional Therapy in Ischemic Stroke, European Cooperative Acute Stroke Study (ECASS) I and II, and NINDS trials showed that administration of tPA up to 4.5 hours after symptom onset appeared beneficial, which prompted the ECASS III trial. The ECASS III excluded patients older than age 80 years, those with an NIHSS score higher than 25, those with a history of diabetes and prior ischemic stroke, and those on anticoagulation regardless of international normalized ratio (INR) values. An IV tPA administration within the 3- to 4.5-hour range, was associated with higher chance of favorable long-term outcome when compared to the placebo group, albeit to a milder degree than that in the original NINDS trial. The American Heart Association and American Stroke Association therefore recommend the use of IV tPA up to 4.5 hours after ischemic stroke symptom onset in patients younger than 80 years of age who are not on anticoagulation and do not have both comorbid diabetes and history of stroke LEVEL 3.[3,4] A practical protocol and checklist for IV tPA use is provided in Chapter 16.

Contraindications to Intravenous Thrombolysis

Contraindications for IV tPA are based on the inclusion criteria used in the original NINDS trial. However, these rigorous contraindications may not necessarily define the full population of patients who might benefit from tPA. **Table 16.5** shows the relative strength of various contraindications to tPA therapy based on published experience since the original NINDS trials.

Weak to Moderate Relative Contraindications

Minor symptoms, a rapidly resolving deficit, seizures, and hypo- or hyperglycemia at presentation are examples of relative contraindications. Despite these initial relative exclusions, most patients with minor or resolving deficits should in fact be considered for IV tPA treatment, as a subanalysis of the NINDS trial confirmed the benefit of tPA administration in this population. Seizure at time of presentation is also considered by most experts to be a relative rather than an absolute contraindication. The main concern here is treating a stroke mimic, although data suggest that the rate of hemorrhagic complications in stroke mimics treated with IV tPA is very low. Onset seizures are rare in AIS but do not increase the risk of hemorrhagic conversion per se. Blood glucose should be measured and corrected in all patients because hypo- or hyperglycemia can lead to neurologic deficits mimicking acute stroke, and hyperglycemia has been associated with an increased risk of hemorrhagic conversion after thrombolysis. Nonetheless, it may be reasonable to give IV tPA if the index of suspicion for a true stroke is high and glucose levels can be readily normalized during and after the treatment period.

Blood pressure higher than 185/110 mm Hg is a moderate relative contraindication to treatment. In most cases, blood pressure can be quickly controlled with a continuous IV infusion of nicardipine, labetalol or clevidipine, and IV tPA given once blood pressure is successfully lowered.

Absolute to Strong Relative Contraindications

The presence of cerebral hemorrhage on initial head CT, early infarction already involving greater than one-third of the MCA territory, or treatment beyond the 4.5-hour time window are absolute contraindications to IV thrombolysis (see **Table 16.5**). Active treatment with warfarin and an INR greater than 1.7 is also an absolute contraindication. Thrombocytopenia (platelet count less than 100,000) is a strong relative contraindication to IV tPA; in the proper circumstances, it may be reasonable to treat as long as a relative increment in hemorrhagic conversion is recognized and accepted. The use of direct oral anticoagulants, including dabigatran, rivaroxaban, apixaban, and edoxaban, are

more problematic because they do not produce reliable changes in prothrombin time (PT)/INR or partial thromboplastin time, and other assays are not readily available. The current consensus is to avoid using IV tPA and seek intra-arterial (IA) reperfusion strategies in patients who have taken a novel oral anticoagulant within 48 hours of presentation. It is important to note that tPA should never be delayed while waiting for a platelet count or INR in a patient with no suspicion of having a coagulation disturbance by history. Studies have shown that the risk of encountering clinically significant thrombocytopenia or coagulopathy in tPA candidates in whom the history did not suggest a possible abnormality was only 0.2% to 0.3%.

As many as one-third of dissection patients can present with acute neurologic symptoms from ischemic stroke. Suspected aortic dissection is an absolute contraindication to thrombolysis, as IV tPA can worsen the dissection and prove fatal. Patients with characteristic chest or back pain should therefore be screened with urgent CTA of the chest to rule out aortic dissection prior to further consideration of thrombolysis.

Complications of Thrombolysis

Hemorrhagic Conversion

Hemorrhagic conversion of the infarcted tissue bed is a known complication after stroke, and risk is significantly increased in patients treated with IV tPA. Hemorrhagic conversion is classified as hemorrhagic infarction or parenchymal hematoma (PH) depending on radiologic characteristics. Hemorrhagic infarction is defined by hemorrhagic petechiae within the stroke bed and is not associated with a worsened outcome, whereas PH is defined by blood occupying either less than 30% of the stroke bed with mild space-occupying effect (PH1) or over 30% with significant mass effect (PH2). Only PH2 is as associated with an increase in mortality. Hemorrhagic conversion usually manifests with headache, nausea, vomiting, worsened neurologic deficit, and/or altered level of consciousness. Risk factors for hemorrhagic conversion after thrombolysis include advanced age, increased onset-to-treatment time, higher NIHSS (stroke severity), hyperglycemia, and hypertension before or after tPA administration. The SEDAN score (Table 36.4) is a validated tool that can help to identify IV tPA candidates with greater than the expected 3% risk of symptomatic hemorrhagic conversion.

TABLE 36.4 The SEDAN Score for Predicting Risk of Hemorrhagic Conversion With Intravenous Tissue Plasminogen Activator[a,b]

Sugar (blood glucose level)	
• 145-216 mg/dL	+1
• >216 mg/dL	+2
Early infarct signs	+1
Dense MCA (or other vessel) sign on admission CT	+1
Age older than 75 yr	+1
NIHSS >9 points	+1
TOTAL	0-6

Abbreviations: CT, computed tomography; MCA, middle cerebral artery; NIHSS, National Institutes of Health Stroke Scale.

[a]Total scores range from 0 to 6. The approximate risk of symptomatic hemorrhagic conversion for a score of 0, 1, 2, 3, 4, or 5+, respectively, are 1%, 3%, 6%, 10%, 20%, and 30%.

[b]From Strbian D, Engelter S, Michel P, et al. Symptomatic intracranial hemorrhage after stroke thrombolysis: the SEDAN score. *Ann Neurol.* 2012;71:634-641.

Angioedema

A tPA-associated angioedema and/or anaphylaxis occurs in 1% to 5% of cases usually beginning 30 to 120 minutes after tPA infusion. Patients taking angiotensin-converting enzyme inhibitors are at higher risk, but all patients receiving tPA should be monitored closely for signs of angioedema and airway compromise. Should angioedema occur, administration of steroids, antihistamines, and/or epinephrine can be considered depending on severity and comorbidities.

Endovascular Therapies

Successful recanalization after LVO is associated with improved prognosis, and early reperfusion has been consistently shown to result in better long-term functional outcome than later reperfusion. Unfortunately, IV tPA leads to recanalization less than 50% of the time in LVO on average, with smaller and more distal clots responding more favorably compared with the large proximal clots that cause massive infarcts. One study using transcranial Doppler after IV tPA found recanalization rates for distal MCA, proximal MCA, and distal ICA locations to be 44%, 29%, and 10%, respectively. Recanalization after tPA is also dependent on clot length, with lower rates of recanalization seen for clots greater than 8 mm in length. Due to the relatively low recanalization rates seen with IV tPA in large proximal vascular occlusions, intra-arterial thrombolysis with tPA (IA tPA), mechanical thrombectomy, and sonothrombolysis with high-frequency ultrasound have all been proposed as viable adjuncts to tPA in LVO. Of these, only mechanical thrombectomy has proven unequivocally effective for use in the clinical setting.

Intra-arterial Thrombolysis

The first endovascular therapy developed for treatment of ischemic stroke was IA delivery of thrombolytics beginning in the 1990s. Initial studies showed favorable recanalization rates, which prompted the Prolyse in Acute Cerebral Thromboembolism (PROACT) II trial. In this study, 180 patients with proximal MCA occlusion within 6 hours of symptoms onset were randomized to IA prourokinase plus IV heparin versus IV heparin alone. Recanalization rates were 66% in the study group compared to 18% in the control group. Although mortality was similar in both, good functional outcome at 3 months was seen in 40% of the endovascular therapy group compared to 25% in the placebo group despite a higher rate of symptomatic ICH in the prourokinase group (10% vs 2%). Mechanical thrombectomy devices have proven to be more effective at achieving recanalization than IA tPA, although IA thrombolysis continues to be used in adjunct to these newer devices.

Mechanical Thrombectomy

The Merci device was the first cerebral clot extraction device approved for use in acute LVO. Initial small and uncontrolled studies of this corkscrew-like device demonstrated recanalization in 40% to 60% of patients, with recanalization rates improving to 70% when thrombectomy was combined with IA tPA. The second available device was Penumbra, a suction device that showed recanalization rates of up to 80% within 8 hours of stroke in the Penumbra Pivotal Stroke Trial. The newest and most effective clot extraction devices are the intrathrombus retrievable stent

devices. The Trevo and Solitaire intrathrombus "*stentriever*" devices were individually tested head-to-head with the Merci device and showed significantly higher rates of recanalization.

Corkscrew and Suction Devices

Despite evidence showing increased recanalization rates with use of endovascular techniques of mechanical thrombectomy and or administration of IA tPA, the first randomized controlled trials evaluating the efficacy of endovascular therapies for improving neurologic outcome after AIS were not published until 2013. The Interventional Management of Stroke III (IMS III) trial randomized patients who had already received IV tPA within 3 hours of stroke onset to additional endovascular therapy beginning within 5 hours of onset versus no additional treatment (IV tPA alone). The study did not show a benefit in functional outcomes at 3 months for tPA plus adjunctive endovascular therapy administered within 5 hours of stroke onset compared to tPA administration alone. The Local Versus Systemic Thrombolysis for Acute Ischemic Stroke (SYNTHESIS) trial randomized patients within 4.5 hours of stroke onset to IV tPA alone or within 6 hours of onset to endovascular intervention alone. Good functional recovery at 3 months was seen in 35% of the IV tPA group compared to 30% in the endovascular intervention group. The Mechanical Retrieval and Recanalization of Stroke Clots Using Embolectomy (MR-RESCUE), published concurrently with IMS III and SYNTHESIS, also failed to show benefit of endovascular intervention compared to IV tPA in patients with perfusion deficits determined by MRI or CTP imaging.

The negative results in these trials prompted questions regarding optimal timing of therapy, patient selection, and the role of thrombectomy devices. In IMS III, for example, the mean time from stroke onset to start of endovascular therapy was longer than 4 hours and although not reported, time to recanalization likely exceeded the 4.5 hours that is accepted as beneficial for IV thrombolysis. Similarly, in SYNTHESIS, the endovascular group received intervention 1 hour later than the group receiving IV tPA, and in MR-RESCUE, the mean time from stroke onset to groin puncture was greater than 6 hours. The IMS III and SYNTHESIS also did not confirm LVO prior to intervention, and consequently, nearly 25% of patients in IMS III randomized to the intervention group did not actually receive any intervention. For SYNTHESIS, if no LVO was seen on angiography, IA tPA was infused into the suspected vascular territory based on clinical exam, which is not likely to be an effective therapy. Finally, and perhaps most importantly, the newest retrievable stent devices were used infrequently as they were not yet available when the trials began, making it more difficult to achieve high rates of recanalization. Only 30% to 40% of patients in the intervention groups in IMS III and MR-RESCUE attained greater than 50% recanalization in affected territory compared with expected recanalization rates of 60% to 80% with the stent retriever devices.

Stentriever Technology

In 2014, a well-designed randomized trial—Multicenter Randomized Clinical Trial of Endovascular Treatment for Acute Ischemic Stroke in the Netherlands—employed more accurate patient selection measures than IMS III and SYNTHESIS and, unlike these two trials, used retrievable stent thrombectomy devices. The proportion of patients with minimal or no disability at 90 days was 33% in those treated with IA therapy and tPA compared to 19% with tPA alone: a number needed to treat of seven patients to prevent one outcome of moderate or severe disability (Table 36.5).[5] There was no effect on mortality. Mean time from stroke onset to IV tPA was 1 hour and 15 minutes and

TABLE 36.5 Recent Trials of Intra-arterial Therapy for Acute Ischemic Stroke LEVEL 1

Trial	N	Imaging Selection[a]	NIHSS	Time Window for IAT	TICI 2B-3 for IAT Group	mRS 0-2 (%)				Mortality (%)		
						IAT[b]	Control	NNT	OR [95% CI]	IAT	Control	OR [95% CI]
MR CLEAN[5]	500	LVO	≥2	≤6 h	59%	33%	19%	7	2.1 [1.4-3.4]	21%	22%	NS
EXTEND-IA[6]	70	LVO and favorable CT perfusion	None	≤6 h	86%	71%	40%	3	4.2 [1.4-12]	9%	20%	NS
ESCAPE[7]	315	LVO and favorable collaterals on multiphase CTA	≥6	≤12 h	72%	53%	29%	4	1.7 [1.3-2.2]	10%	19%	0.5 [0.3-0.8]
REVASCAT[8]	206	LVO	≥6	≤8 h	66%	44%	28%	6	2.0 [1.1-3.5]	18%	15%	NS
SWIFT PRIME[9]	196	LVO and favorable CT perfusion	10-30	≤6 h	83%	60%	35%	4	1.7 [1.2-2.3]	9%	12%	NS
THRACE[10]	414	LVO (including basilar)	10-25	≤5 h	NA	53%	42%	8	1.6 [1.1-2.3]	13%	12%	NS
THERAPY[11,c]	108	LVO with clot length >8 mm on NCHCT	≥8	≤4.5 h	NA	38%	30%	NS	NS	12%	24%	NS

Abbreviations: CI, confidence interval; CT, computed tomography; CTA, CT angiography; IAT, intra-arterial therapy; LVO, large-vessel occlusion; mRS, modified Rankin scale; NA, not available; NCHCT, noncontrast head CT; NIHSS, National Institutes of Health Stroke Scale; NNT, number needed to treat; NS, nonsignificant; OR, odds ratio; TICI, Thrombolysis in Cerebral Infarction score.

[a]All studies except for THERAPY used CTA for confirmation of LVO.

[b]Treatment arms were IAT +/− intravenous tissue plasminogen activator (if eligible) versus best medical management except for EXTEND-IA and SWIFT PRIME, which required intravenous tissue plasminogen activator in the interventional group.

[c]THERAPY trial terminated early due to other positive trials (planned enrollment of 692 patients) and was therefore underpowered to show significant results for this outcome.

to groin puncture was 4 hours and 20 minutes. Follow-up CTA showed no residual LVO in 75% of the IA + tPA group and 33% of the tPA-only group.

In the spring of 2015, the Endovascular Treatment for Small Core and Anterior Circulation Proximal Occlusion with Emphasis on Minimizing CT to Recanalization Times, SWIFT PRIME, and four additional randomized controlled trials comparing mechanical thrombectomy to tPA alone reported superior outcomes with IA treatment (see **Table 36.5**) LEVEL 1.[6-10] The HERMES collaboration, a pooled analysis of nearly 1,300 patients from five modern thrombectomy trials, showed that mechanical thrombectomy was associated with a 14% absolute increase in patients achieving an excellent functional outcomes and independence at 3 months compared to the control group. Benefit was maintained in patients older than age 80 years and those who were treated beyond 5 hours LEVEL 1.[12] The benefits of mechanical thrombectomy in the extended time window—beyond 6 hours and as far out as 24 hours—were realized in 2018 with the DAWN and DEFUSE-3 trials LEVEL 1.[13,14] trials. Both employed advanced perfusion imaging to select for and treat patients with LVO and a significant core to penumbra mismatch. For this carefully selected subset of patients, there was a powerful treatment effect, similar to that in the traditional treatment window thrombectomy trials. The preponderance of evidence supporting endovascular therapy has resulted in national recommendations for endovascular treatment as (1) an adjunctive treatment in patients with documented LVO of onset less than 6 hours who have already received IV tPA, (2) the sole treatment for patient with LVO of less than 6 hours who have contraindications for IV tPA or are out of the 4.5-hour time window for IV tPA, or (3) the sole treatment for patients with LVO who are found to have a favorable advanced imaging profile in the 6- to 24-hour window LEVEL 1.[2,5-12] A favorable perfusion profile is a direct function of an individual's cerebral collateral circulation. Those with a complete circle of Willis, and robust leptomeningeal and extra- to intra-cranial collaterals, are more likely to maintain a slowly expanding core infarct to penumbra ratio. Good collaterals are therefore the hallmark of a good response to treatment in the extended time window and the basis for a "*tissue-based*" rather than the traditional "*time-based*" clock (Fig. 36.8).

Complications

Like IV tPA, endovascular therapy carries an increased risk of symptomatic ICH that varies depending on the technique used and timing of intervention. Although earlier IA thrombolysis studies like PROACT II reported a rate of 10%, recent studies report rates of symptomatic ICH of around 6%. Asymptomatic hemorrhage is much more common and may even signify adequate reperfusion within the ischemic territory. Other complications of endovascular therapy include thrombus fragmentation with distal embolization, device malfunction, groin hematoma, and the rare vessel rupture.

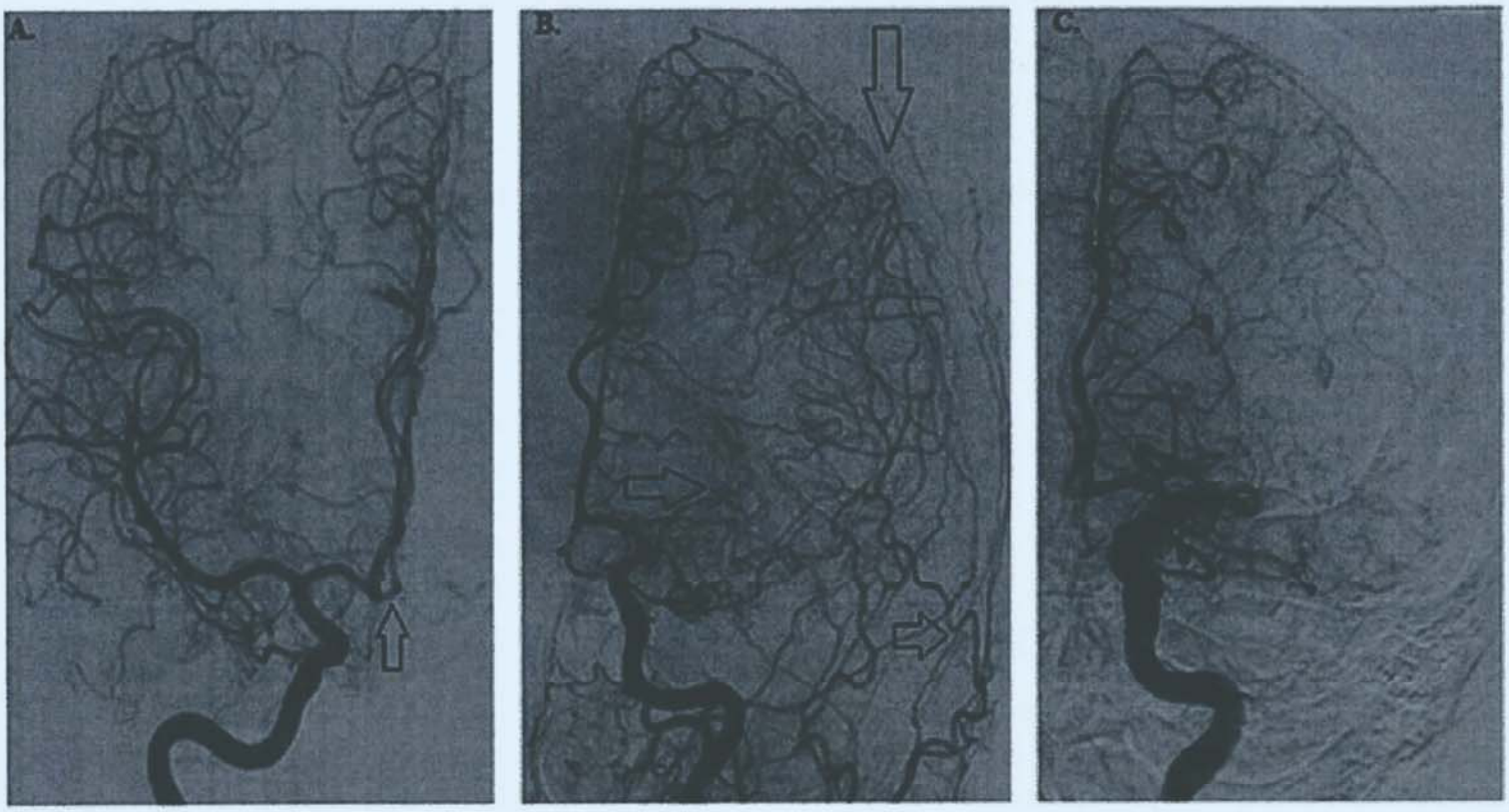

FIGURE 36.8 Cerebral collateral circulation. **A:** Panel shows a normal carotid bifurcation and hemispheric circulation. The *arrow* shows a patent anterior communicating artery, a component of a complete circle of Willis. **B:** Panel shows a proximal right middle cerebral artery (MCA) occlusion with of robust leptomeningeal *(top arrow)*, extra- to intracranial *(bottom arrow)* and deep perforating *(middle arrow)* collaterals all of which provide sufficient perfusion to the MCA territory. This patient had no deficits at the time of the encounter. **C:** Panel shows a mid-MCA occlusion with lack of robust collaterals, consistent with hemispheric hypoperfusion and resultant progression of ischemia to infarct. This patient presented with severe deficits.

CRITICAL CARE IN STROKE

Intensive care of stroke depends on a team approach and adherence to protocols that support best practices. Closed ICUs that provide around-the-clock availability of neurointensivists are important because this model has been shown to reduce costs, improve outcomes, and decrease hospital length of stay. These benefits may be the result of (1) organizational improvements, including the development of urgent interhospital transfer systems; (2) the uniform institution of best medical practices; (3) improved access to specialized neuroimaging, monitoring, and therapeutic techniques; and (4) the creation of physician and nursing care teams with special expertise in caring for neurologic patients. The use of checklists (Table 36.6) has been shown to improve outcome in stroke units and neurocritical care units.

A systematized and multidisciplinary approach to poststroke management initiated in a specialized stroke unit or neuro-ICU has been shown to minimize common complications after stroke and should be used whenever possible LEVEL 1.[2] Aside from the prevention of poststroke complications, evaluation for stroke etiology and management aimed at limiting stroke recurrence should ensue in the period immediately following AIS. For details, refer to Chapter 45: Primary and secondary stroke prevention.

Clinical Syndromes

Malignant Middle Cerebral Artery Infarction

Large hemispheric or *malignant MCA* infarction is a massive stroke that occurs as a result of ICA or proximal MCA occlusion resulting in cerebral edema that leads to herniation and death in 40% to 80% of patients without treatment. Malignant MCA infarction is essentially a hemispheric compartment syndrome, in which swelling and increased local tissue pressure leads to extension of the ischemic territory, herniation, and compressive injury of the brainstem. Patients with acute infarction involving over half of the MCA territory are at risk, whereas 95% of those with infarction affecting more than two-thirds of the MCA territory will progress to herniation. Imaging, including CT and MRI, can be used as early as 6 hours after infarction to predict malignant evolution. These patients should be managed in a neuro-ICU to allow for prompt detection of early neurologic deterioration and treatment of cerebral edema if it occurs. Monitoring of intracranial pressure is not useful because the swelling is focal, and patients can herniate from cerebral edema without developing a rise in intracranial pressure. The definitive treatment to prevent herniation and mortality is hemicraniectomy, but bolus osmotherapy with hypertonic saline and mannitol is effective temporizing measure. Therapeutic hypothermia has been tested as a treatment for malignant cerebral edema but has not been shown to improve outcome. In most patients, medical therapies should be used as a bridge to decompressive surgery and not as stand-alone therapy.

Three trials for decompressive hemicraniectomy in malignant MCA infarction have been performed, although all were underpowered to show efficacy. As they used similar inclusion criteria, a prespecified combined analysis of these trials was performed and showed an absolute risk reduction of 51% for death or severe disability and a 23% absolute increase in the proportion of patients who were alive and able to walk independently at 6 months compared with conservative medical management. These results corresponded to a number needed to treat of two patients to prevent one death and four patients to turn what would have been one death to a patient living with a moderate level of functional disability but still able to walk independently. As a result, hemicraniectomy is recommended for the treatment of malignant MCA infarction in patients younger than 60 years of age when the procedure is in line with the wishes of the patient or the patient's family LEVEL 1.[15] None of the three trials included patients older than age 60 years. A subsequent study, the Decompressive Surgery for the Treatment of Malignant Infarction of the Middle Cerebral Artery II trial, showed a mortality reduction from 70% to 33% in patients aged 61 to 82 years, but with worsened neurologic outcomes compared to younger patients LEVEL 3.[16] There was not a significant increase in the survivors with mild or moderate disability, as nearly all of the survivors were bedbound or unable to walk independently. This expected prognosis along with the premorbid functional status should be taken into account and discussed with family members prior to making any treatment decisions.

TABLE 36.6 Stroke Unit Checklist

☐ BP goal <180/105 mm Hg for 24 h if IV tPA was given
☐ BP goal <220/120 mm Hg if no IV tPA was used
☐ Serial monitoring of vital signs
☐ Serial monitoring of neurologic deficits
☐ Dysphagia screen
☐ Aspirin (by mouth or rectal)[a]
☐ Enoxaparin 40 mg SC daily (heparin 5,000 units 3 times a day if renal dysfunction)[a]
☐ Place sequential compression device.
☐ High-dose statin
☐ Neurovascular work-up: carotid and intracranial Doppler ultrasounds, CTA or MRA
☐ Cardiac workup: ECG, serial troponins, telemetry, echocardiogram
☐ Screen: hemoglobin A_{1c}, lipid panel, toxicology, urinalysis
☐ Remove Foley.

Abbreviations: BP, blood pressure; CTA, computed tomography angiography; ECG, electrocardiogram; IV tPA, intravenous tissue plasminogen activator; MRA, magnetic resonance angiography; SC, subcutaneous.
[a]Contraindicated in the first 24 hours after thrombolysis.

Cerebellar Infarction

Cerebellar infarction represents approximately 3% of total ischemic strokes. In cases of a large cerebellar infarction, cytotoxic edema in the limited compartment of the posterior fossa can lead to brainstem compression, hydrocephalus from obstruction of the fourth ventricle, and tonsillar or upward herniation. The peak period of deterioration is 72 hours, although patients may deteriorate earlier or as many as 10 days after the ischemic insult. Signs of worsening edema include drowsiness, gaze disturbance, hemiparesis, and hyperreflexia. The onset of these clinical signs is often insidious, and coma can develop rapidly without intervention, necessitating that all patient with large cerebellar infarction be closely monitored in an intensive care setting. In cases where brainstem compression or hydrocephalus appears, posterior fossa craniectomy is highly effective at preventing mortality and allowing for good functional outcome, although randomized trials have not been performed. Management with

an external ventricular drain or excision of the infarcted tissue can also effectively alleviate compression but carries the risk of upward herniation by lowering the supratentorial pressure. Thus, decompressive surgery should be the initial intervention considered in most cases.

Basilar Artery Occlusion

Basilar artery occlusion carries a mortality of up to 90% without treatment. Those who survive are often left with significant functional deficits ranging from ataxia or weakness to *locked-in* syndrome. Given its poor natural history, aggressive attempts at reperfusion, even beyond the accepted range of therapy for ischemic stroke in other locations, are often considered. Although IV tPA within 4.5 hours remains the only proven treatment option, anecdotal data show potential benefit of IA thrombolysis or mechanical thrombectomy as long as 24 hours after stroke onset. For patients with mild to moderate symptoms, IV tPA and close monitoring may be sufficient. However, for those who present with severe symptoms, IV tPA, IA tPA, and/or mechanical thrombectomy are all appropriate considerations.

Cervical Artery Dissection

Carotid and vertebral artery dissections are uncommon etiologies of stroke causing only 2% of all cases. However, they account for a much higher proportion of AIS in young patients causing 10% to 25% of all strokes in this population. The most common risk factor is cervical twisting or trauma, but presentations can be spontaneous or resulting from an underlying arteriopathy such as fibromuscular dysplasia, Marfan syndrome, or Ehlers-Danlos syndrome type IV. Clinical presentations of internal carotid dissection include facial pain, headache, neck pain, an incomplete oculosympathetic syndrome (Horner syndrome with preserved sweat response), and contralateral stroke symptoms, such as hemiparesis or aphasia. When strokes occur, they most often result from artery-to-artery embolism but can also occur in a watershed territory from arterial narrowing or occlusion of the dissected vessel.

The Cervical Artery Dissection in Stroke Study is the only randomized trial comparing management options in acute cervical artery dissection. Like several meta-analyses, it showed no difference in mortality or stroke occurrence in patients treated with antiplatelet agents versus those treated with anticoagulation. Nevertheless, anticoagulation is often used in patients with evidence of a free-floating thrombus within the lumen of the vessel, or in those with recurrent events despite treatment with antiplatelet agents. In contrast, patients with large infarcts or intracranial extension of their dissection should be treated with antiplatelet agents due to an increased risk of bleeding with anticoagulation.

Complications of Stroke

Neurologic Deterioration

Neurologic deterioration occurs in up to 40% of patients in the first 24 hours after AIS and is associated with a history of diabetes, high blood glucose concentrations, stroke severity, and early signs of edema on imaging. Although most forms of deterioration are due to progressive extension of the infarct core into surrounding penumbra, the causes of neurologic worsening are diverse and often require further investigation. All patients should undergo general and neurologic examination to determine the nature and extent of clinical change. Vital signs are important, especially because fever can cause deterioration and changes in blood pressure in either direction can have deleterious effects.

If neurologic worsening directly coincides with relative hypotension, trials of increasing cerebral perfusion can be used to confirm the presence of a blood pressure–dependent deficit. Administration of IV fluids, positioning the patient in the Trendelenburg position, or infusion of a vasopressor such as phenylephrine (starting at 20 μg/min, titrated upward to raise blood pressure by 20%) can be trialed followed by a repeat neurologic examination. If there is clinical improvement correlating to a higher mean arterial pressure, a blood pressure goal can be maintained using vasopressor agents administered under close observation in an intensive care setting. Vascular and perfusion imaging with CT or MRI may be useful at this point to evaluate for high-grade vascular stenosis and downstream perfusion/infarction mismatch.

Patients with large infarcts are more likely to develop hemorrhagic conversion, which, when symptomatic, usually presents with relatively abrupt changes in clinical signs and may be accompanied by symptoms of headache, nausea, and vomiting. Noncontrast head CT is used to evaluate for signs of hemorrhage. If a hemorrhage with associated mass effect is found, the clinician should reverse any form of anticoagulation or antiplatelet therapy (see **Table 16.4**).

If preliminary evaluations with examination, vital signs, and imaging do not reveal an etiology for neurologic worsening with depressed level of consciousness, electroencephalogram may be considered to evaluate for nonconvulsive seizure activity. Early seizures after AIS occur in approximately 5% of cases and are more common in cortical infarcts but can also occur after subcortical strokes. Although primary seizure prophylaxis is not recommended, treatment with antiepileptic agents is warranted after a seizure has occurred.

Hypertension

A *U-shaped* relationship exists between blood pressure on admission and clinical outcome, with both extremes conferring a poor outcome. The optimal blood pressure goal in AIS remains undefined. However, studies have consistently found that an acute fall in blood pressure, specifically a systolic decrease of higher than 20 mm Hg, is associated with poor functional outcome and increased mortality. Hypotension should be avoided in the acute phase of stroke, and any attempts at lowering blood pressure should be done slowly.

Current practice for those who have not received thrombolytic therapy is to allow permissive hypertension of up to 220/120 mm Hg for 24 to 48 hours, after which point antihypertensive therapy is started and slowly titrated to an extended goal toward normotension. This upper limit should be adjusted accordingly for patients with heart failure, valvular heart disease, or coronary artery disease in order to prevent any cardiac injury or complications. Similarly, in patients with hemorrhagic conversion or brain edema, blood pressure targets should be individualized at lower levels. A strict blood pressure goal of lower than 180/105 mm Hg should be maintained for 24 hours in those treated with IV tPA or mechanical thrombectomy in order to limit secondary ICH LEVEL 1.[2]

Infectious Complications

Aspiration Pneumonia

Dysphagia occurs in nearly 40% of stroke patients and is associated with a significant increase in the incidence of pneumonia. Of all the medical complications after stroke, pneumonia carries the

highest proportion of attributable risk for mortality. All stroke patients should undergo an early dysphagia screen using an objective test, such as a simple bedside water swallow test. Comprehensive evaluation by a speech-language pathologist followed by barium esophagography or videofluoroscopy may be necessary. Early recognition of dysphagia can lead to prevention techniques and therapies, such as maintaining patients in a sitting position after feeding and providing oral care, which may reduce morbidity and mortality associated with aspiration-related pneumonia. When necessary, a nasogastric or nasoduodenal feeding tube should be placed for nutritional support and medication administration. If prolonged dysphagia is expected, a percutaneous endoscopic gastrostomy allows for extended nutritional support.

Urinary Tract Infection

Urinary tract infection occurs in 10% to 15% of stroke-related hospitalizations and is associated with worsened neurologic and functional outcomes. Risk factors for urinary tract infection include increasing age, female sex, poststroke disability, urinary retention, and, most importantly, urinary catheterization. Avoiding urinary catheterization and early removal of urinary catheters reduces the risk of catheter-associated urinary tract infections.

Venous Thromboembolism

Patients with stroke are at high risk for developing deep vein thrombosis (DVT) due to hemiparesis and immobility. Studies done in the absence of pharmacologic DVT prophylaxis suggest that DVT occurs in as many as 40% to 50% of hemiplegic patients within 2 weeks of stroke onset. The associated risk of pulmonary embolism is 15% in untreated patients, which can lead to early death following AIS.

Although unfractionated heparin has been proven effective for DVT prophylaxis, the Prevention of VTE After Acute Ischemic Stroke with Low-Molecular Weight Heparinoid Enoxaparin trial showed that enoxaparin 40 mg daily was more effective at preventing DVT than unfractionated heparin administered twice daily. Pneumatic sequential compression devices are also effective when used independently and provide an added benefit when used in addition to pharmacologic DVT prophylaxis. Early mobilization is also effective in preventing DVT and provides added benefits in functional recovery. Current guidelines recommend pharmacologic DVT prophylaxis in all stroke patients, unless there is a substantial risk of bleeding that would outweigh the potential benefits, in which case nonpharmacologic options should be employed LEVEL 2.[17] Pharmacologic DVT prophylaxis should also be held for 24 hours after tPA administration.

STROKE OUTCOMES

Outcome after stroke is defined as the level of functional impairment or death months to years after the insult. Stroke is now the fifth leading cause of death in the United States and the leading cause of disability among adults. Accurately predicting a patient's outcome can aid in deciding the best management approach and help establish appropriate expectations for quality of life. Using retrospective data from various cohorts, a number of prediction models have been established to predict long-term stroke outcomes at the time of the acute stroke. Stroke severity, which can be assessed with the NIHSS, and patient age have consistently proven predictive of outcome. Specific exam features that have been cited include upper extremity paralysis and inability to walk independently. Others frequently cited factors include infarct volume, fever, diabetes, and congestive heart failure (Table 36.7). Outcome after ischemic stroke can be improved by care in a dedicated stroke unit, using a systematic approach to minimizing preventable medical complications, and instituting early rehabilitation.

TABLE 36.7 Risk Factors for Death or Poor Functional Outcome After Ischemic Stroke

• Patient age
• Female gender
• Prestroke functional baseline
• NIHSS
• Infarct volume
• Diabetes mellitus
• Fever
• Heart failure

Abbreviation: NIHSS, National Institutes of Health Stroke Scale.

LEVEL 1 EVIDENCE

1. Mojadidi MK, Zaman MO, Elgendy IY, et al. Cryptogenic stroke and patent foramen ovale. *J Am Coll Cardiol.* 2018;71(9):1035-1043.
2. Powers WJ, Rabinstein AA, Ackerson T, et al. 2018 Guidelines for the early management of patients with acute ischemic stroke: a guideline for healthcare professionals from the American Heart Association/American Stroke Association. *Stroke.* 2018;49(3):e46-e110 .
3. National Institute of Neurological Disorders and Stroke rt-PA Stroke Study Group. Tissue plasminogen activator for acute ischemic stroke. *N Engl J Med.* 1995;333(24):1581-1587.
4. Del Zoppo GJ, Saver JL, Jauch EC, Adams HP Jr; for American Heart Association Stroke Council. Expansion of the time window for treatment of acute ischemic stroke with intravenous tissue plasminogen activator: a science advisory from the American Heart Association/American Stroke Association. *Stroke.* 2009;40(8):2945-2948.
5. Berkhemer OA, Fransen PS, Beumer D, et al. A randomized trial of intraarterial treatment for acute ischemic stroke. *N Engl J Med.* 2015;372(1):11-20.
6. Campbell BCV, Mitchell PJ, Kleinig TJ, et al. Endovascular therapy for ischemic stroke with perfusion-imaging selection. *N Engl J Med.* 2015;372(11):1009-1018.
7. Goyal M, Demchuk AM, Menon BK, et al. Randomized assessment of rapid endovascular treatment of ischemic stroke. *N Engl J Med.* 2015;372(11):1019-1030.
8. Jovin TG, Chamorro A, Cobo E, et al. Thrombectomy within 8 hours after symptom onset in ischemic stroke. *N Engl J Med.* 2015;372:2296-2306.
9. Saver JL, Goyal M, Bonafe A, et al. Stent-retriever thrombectomy after intravenous t-PA vs. t-PA alone in stroke. *N Engl J Med.* 2015;372(24):2285-2295.
10. Bracard S, Ducrocq X, Mas JL, Soudant M, Oppenheim C, Moulin T, Guillemin F; for THRACE Investigators. Mechanical thrombectomy after intravenous alteplase versus alteplase alone after stroke (THRACE): a randomised controlled trial. *Lancet Neurol.* 2016;15(11):1138-1147.

11. Mocco J, Zaidat OO, von Kummer R, et al; for THERAPY Trial Investigators. Aspiration thrombectomy after intravenous alteplase versus intravenous alteplase alone. *Stroke*. 2016;47(9):2331-2338.
12. Goyal M, Menon BK, van Zwam WH, et al. Endovascular thrombectomy after large-vessel ischaemic stroke: a meta-analysis of individual patient data from five randomised trials. *Lancet*. 2016;387(10029):1723-1731.
13. Nogueira RG, Jadhav AP, Haussen DC, et al; for DAWN Trial Investigators. Thrombectomy 6 to 24 hours after stroke with a mismatch between deficit and infarct. *N Engl J Med*. 2018;378(1):11-21.
14. Albers GW, Marks MP, Kemp S, et al; for DEFUSE 3 Investigators. Thrombectomy for stroke at 6 to 16 hours with selection by perfusion imaging. *N Engl J Med*. 2018;378(8):708-718.
15. Vahedi K, Hofmeijer J, Juettler E, et al; for DECIMAL, DESTINY, and HAMLET Investigators. Early decompressive surgery in malignant infarction of the middle cerebral artery: a pooled analysis of three randomised controlled trials. *Lancet Neurol*. 2007;6:215-222.
16. Jüttler E, Unterberg A, Woitzik J, et al; for DESTINY II Investigators. Hemicraniectomy in older patients with extensive middle-cerebral artery stroke. *N Engl J Med*. 2014;370:1091-1100.
17. Qaseem A, Chou R, Humphrey LL, Starkey M, Shekelle P; and Clinical Guidelines Committee of the American College of Physicians. Venous thromboembolism prophylaxis in hospitalized patients: a clinical practice guideline from the American College of Physicians. *Ann Intern Med*. 2011;155(9):625-632.

SUGGESTED READINGS

Adams HP Jr, Bendixen BH, Kappelle LJ, et al. Classification of subtype of acute ischemic stroke. Definitions for use in a multicenter clinical trial. TOAST. Trial of Org 10172 in Acute Stroke Treatment. *Stroke*. 1993;24(1):35-41.

Ahmed N, Wahlgren N, Brainin M, et al. Relationship of blood pressure, antihypertensive therapy, and outcome in ischemic stroke treated with intravenous thrombolysis: retrospective analysis from Safe Implementation of Thrombolysis in Stroke-International Stroke Thrombolysis Register (SITS-ISTR). *Stroke*. 2009;40(7):2442-2449.

Aslanyan S, Weir CJ, Diener HC, Kaste M, Lees KR. Pneumonia and urinary tract infection after acute ischaemic stroke: a tertiary analysis of the GAIN International trial. *Eur J Neurol*. 2004;11(1):49-53.

Ay H, Furie KL, Singhal A, Smith SW, Sorensen AG, Koroshetz WJ. An evidence-based causative classification system for acute ischemic stroke. *Ann Neurol*. 2005;58(5):688-697.

Barlinn K, Tsivgoulis G, Barreto AD, et al. Outcomes following sonothrombolysis in severe acute ischemic stroke: subgroup analysis of the CLOTBUST trial. *Int J Stroke*. 2014;9(8):1006-1010.

Benninger DH, Georgiadis D, Kremer C, Studer A, Nedeltchev K, Baumgartner RW. Mechanism of ischemic infarct in spontaneous carotid dissection. *Stroke*. 2004;35(2):482-485.

Bernhardt J; and AVERT Trialist Collaboration. Early mobilization testing in patients with acute stroke. *Chest*. 2012;141(6):1641-1642.

Bhatia R, Hill MD, Shobha N, et al. Low rates of acute recanalization with intravenous recombinant tissue plasminogen activator in ischemic stroke: real-world experience and a call for action. *Stroke*. 2010;41(10):2254-2258.

Bose A, Henkes H, Alfke K, et al. The penumbra system: a mechanical device for the treatment of acute stroke due to thromboembolism. *AJNR Am J Neuroradiol*. 2008;29(7):1409-1413.

Broderick JP, Palesch YY, Demchuk AM, et al. Endovascular therapy after intravenous t-PA versus t-PA alone for stroke. *N Engl J Med*. 2013;368(10):893-903.

Castaño C, Dorado L, Guerrero C, et al. Mechanical thrombectomy with the Solitaire AB device in large artery occlusions of the anterior circulation: a pilot study. *Stroke*. 2010;41(8):1836-1840.

Castillo J, Leira R, García MM, Serena J, Blanco M, Dávalos A. Blood pressure decrease during the acute phase of ischemic stroke is associated with brain injury and poor stroke outcome. *Stroke*. 2004;35(2):520-526.

Chan DK, Cordato D, O'Rourke F, et al. Comprehensive stroke units: a review of comparative evidence and experience. *Int J Stroke*. 2013;8(4):260-264.

Christensen LM, Krieger DW, Højberg S, et al. Paroxysmal atrial fibrillation occurs often in cryptogenic ischaemic stroke. Final results from the SURPRISE study. *Eur J Neurol*. 2014;21(6):884-889.

Ciccone A, Valvassori L, Nichelatti M, et al; for SYNTHESIS Expansion Investigators. Endovascular treatment for acute ischemic stroke. *N Engl J Med*. 2013;368(10):904-913.

del Zoppo GJ, Higashida RT, Furlan AJ, Pessin MS, Rowley HA, Gent M. PROACT: a phase II randomized trial of recombinant pro-urokinase by direct arterial delivery in acute middle cerebral artery stroke. PROACT Investigators. Prolyse in Acute Cerebral Thromboembolism. *Stroke*. 1998;29(1):4-11.

Dennis M, Sandercock P, Reid J, Graham C, Forbes J, Murray G; for CLOTS (Clots in Legs Or sTockings after Stroke) Trials Collaboration. Effectiveness of intermittent pneumatic compression in reduction of risk of deep vein thrombosis in patients who have had a stroke (CLOTS 3): a multicentre randomised controlled trial. *Lancet*. 2013;382(9891):516-524.

Divani A, Andalib S, Di Napoli M, et al. Coronavirus disease 2019 and stroke: clinical manifestations and pathophysiological insights. *J Stroke Cerebrovasc Dis*. 2020;29(8):104941.

Dundar Y, Hill R, Dickson R, Walley T. Comparative efficacy of thrombolytics in acute myocardial infarction: a systematic review. *QJM*. 2003;96(2):103-113.

Dzialowski I, Hill MD, Coutts SB, et al. Extent of early ischemic changes on computed tomography (CT) before thrombolysis: prognostic value of the Alberta Stroke Program Early CT Score in ECASS II. *Stroke*. 2006;37(4):973-978. doi:10.1161/01.STR.0000206215.62441.56.

Edlow JA, Newman-Toker DE, Savitz SI. Diagnosis and initial management of cerebellar infarction. *Lancet Neurol*. 2008;7(10):951-964.

Engelter ST, Brandt T, Debette S, et al. Antiplatelets versus anticoagulation in cervical artery dissection. *Stroke*. 2007;38(9):2605-2611.

Fiorelli M, Bastianello S, von Kummer R, et al. Hemorrhagic transformation within 36 hours of a cerebral infarct: relationships with early clinical deterioration and 3-month outcome in the European Cooperative Acute Stroke Study I (ECASS I) cohort. *Stroke*. 1999;30(11):2280-2284.

Fisher CM. Concerning recurrent transient cerebral ischemic attacks. *Can Med Assoc J*. 1962;86:1091-1099.

Fonarow GC, Smith EE, Saver JL, et al. Improving door-to-needle times in acute ischemic stroke: the design and rationale for the American Heart Association/American Stroke Association's Target: stroke initiative. *Stroke*. 2011;42(10):2983-2989.

Furlan A, Higashida R, Wechsler L, et al. Intra-arterial prourokinase for acute ischemic stroke. The PROACT II study: a randomized controlled trial. Prolyse in Acute Cerebral Thromboembolism. *JAMA*. 1999;282(21):2003-2011.

Gaul C, Dietrich W, Friedrich I, Sirch J, Erbguth FJ. Neurological symptoms in type A aortic dissections. *Stroke*. 2007;38(2):292-297.

Go AS, Mozaffarian D, Roger VL, et al. Heart disease and stroke statistics—2014 update: a report from the American Heart Association. *Circulation*. 2014;129(3):e28-e292.

Hacke W, Donnan G, Fieschi C, et al. Association of outcome with early stroke treatment: pooled analysis of ATLANTIS, ECASS, and NINDS rt-PA stroke trials. *Lancet*. 2004;363(9411):768-774.

Hacke W, Kaste M, Bluhmki E, et al. Thrombolysis with alteplase 3 to 4.5 hours after acute ischemic stroke. *N Engl J Med*. 2008;359(13):1317-1329.

Harrigan MR, Leonardo J, Gibbons KJ, Guterman LR, Hopkins LN. CT perfusion cerebral blood flow imaging in neurological critical care. *Neurocrit Care*. 2005;2(3):352-366.

Hemmen TM, Meyer BC, McClean TL, Lyden PD. Identification of nonischemic stroke mimics among 411 code strokes at the University of California, San Diego, Stroke Center. *J Stroke Cerebrovasc Dis*. 2008;17(1):23-25.

Heuschmann PU, Kolominsky-Rabas PL, Misselwitz B, et al. Predictors of in-hospital mortality and attributable risks of death after ischemic stroke: the German Stroke Registers Study Group. *Arch Intern Med*. 2004;164(16):1761-1768.

Hill MD, Lye T, Moss H, et al. Hemi-orolingual angioedema and ACE inhibition after alteplase treatment of stroke. *Neurology*. 2003;60(9):1525-1527.

Iadecola C. The neurovascular unit coming of age: a journey through neurovascular coupling in health and disease. *Neuron*. 2017;96(1):17-42.

Ihle-Hansen H, Thommessen B, Wyller TB, Engedal K, Fure B. Risk factors for and incidence of subtypes of ischemic stroke. *Funct Neurol*. 2012;27(1):35-40.

Ingeman A, Andersen G, Hundborg HH, Svendsen ML, Johnsen SP. In-hospital medical complications, length of stay, and mortality among stroke unit patients. *Stroke*. 2011;42(11):3214-3218.

Jauss M, Krieger D, Hornig C, Schramm J, Busse O. Surgical and medical management of patients with massive cerebellar infarctions: results of the German-Austrian Cerebellar Infarction Study. *J Neurol*. 1999;246(4):257-264.

Johnston SC, Mendis S, Mathers CD. Global variation in stroke burden and mortality: estimates from monitoring, surveillance, and modelling. *Lancet Neurol*. 2009;8(4):345-354.

Kamran SI, Downey D, Ruff RL. Pneumatic sequential compression reduces the risk of deep vein thrombosis in stroke patients. *Neurology*. 1998;50(6):1683-1688.

Kase CS, Albers GW, Bladin C, et al. Neurological outcomes in patients with ischemic stroke receiving enoxaparin or heparin for venous thromboembolism prophylaxis: subanalysis of the Prevention of VTE after Acute Ischemic Stroke with LMWH (PREVAIL) study. *Stroke*. 2009;40(11):3532-3540.

Katzan IL, Cebul RD, Husak SH, Dawson NV, Baker DW. The effect of pneumonia on mortality among patients hospitalized for acute stroke. *Neurology*. 2003;60(4):620-625.

Kidwell CS, Jahan R, Gornbein J, et al. A trial of imaging selection and endovascular treatment for ischemic stroke. *N Engl J Med*. 2013;368(10):914-923.

Kidwell CS, Starkman S, Eckstein M, Weens K, Saver JL. Identifying stroke in the field. Prospective validation of the Los Angeles Prehospital Stroke Screen (LAPSS). *Stroke*. 2000;31(1):71-76.

Koennecke HC, Belz W, Berfelde D, et al. Factors influencing in-hospital mortality and morbidity in patients treated on a stroke unit. *Neurology*. 2011;77(10):965-972.

Kothari RU, Pancioli A, Liu T, Brott T, Broderick J. Cincinnati Prehospital Stroke Scale: reproducibility and validity. *Ann Emerg Med*. 1999;33(4):373-378.

Krieger DW, Demchuk AM, Kasner SE, Jauss M, Hantson L. Early clinical and radiological predictors of fatal brain swelling in ischemic stroke. *Stroke*. 1999;30(2):287-292.

Latchaw RE, Alberts MJ, Lev MH, et al. Recommendations for imaging of acute ischemic stroke: a scientific statement from the American Heart Association. *Stroke*. 2009;40(11):3646-3678.

Lees KR, Bluhmki E, von Kummer R, et al. Time to treatment with intravenous alteplase and outcome in stroke: an updated pooled analysis of ECASS, ATLANTIS, NINDS, and EPITHET trials. *Lancet*. 2010;375(9727):1695-1703.

Leonardi-Bee J, Bath PM, Phillips SJ, Sanderstock PAG; and IST Collaborative Group. Blood pressure and clinical outcomes in the International Stroke Trial. *Stroke*. 2002;33(5):1315-1320.

Lucas C, Moulin T, Deplanque D, Tatu L, Chavot D. Stroke patterns of internal carotid artery dissection in 40 patients. *Stroke*. 1998;29(12):2646-2648.

Lyrer P, Engelter S. Antithrombotic drugs for carotid artery dissection. *Cochrane Database Syst Rev*. 2010;(10):CD000255.

McTaggart RA, Yaghi S, Cutting SM, et al. Association of a primary stroke center protocol for suspected stroke by large-vessel occlusion with efficiency of care and patient outcomes. *JAMA Neurol*. 2017;74(7):793-800.

Moser DK, Kimble LP, Alberts MJ, et al. Reducing delay in seeking treatment by patients with acute coronary syndrome and stroke: a scientific statement from the American Heart Association Council on Cardiovascular Nursing and Stroke Council. *J Cardiovasc Nurs*. 2007;22(4):326-343.

Mullins ME, Schaefer PW, Sorensen AG, et al. CT and conventional and diffusion-weighted MR imaging in acute stroke: study in 691 patients at presentation to the emergency department. *Radiology*. 2002;224(2):353-360.

Nogueira RG, Lutsep HL, Gupta R, et al. Trevo versus Merci retrievers for thrombectomy revascularisation of large vessel occlusions in acute ischaemic stroke (TREVO 2): a randomised trial. *Lancet*. 2012;380(9849):1231-1240.

Potter J, Mistri A, Brodie F, et al. Controlling hypertension and hypotension immediately post stroke (CHHIPS)—a randomised controlled trial. *Health Technol Assess*. 2009;13(9):iii, ix-xi, 1-73.

Riedel CH, Zimmermann P, Jensen-Kondering U, Stingele R, Deuschl G, Jansen O. The importance of size: successful recanalization by intravenous thrombolysis in acute anterior stroke depends on thrombus length. *Stroke*. 2011;42(6):1775-1777.

Saqqur M, Uchino K, Demchuk AM, et al. Site of arterial occlusion identified by transcranial Doppler predicts the response to intravenous thrombolysis for stroke. *Stroke*. 2007;38(3):948-954.

Saver JL. Time is brain—quantified. *Stroke*. 2006;37(1):263-266.

Saver JL, Fonarow GC, Smith EE, et al. Time to treatment with intravenous tissue plasminogen activator and outcome from acute ischemic stroke. *JAMA*. 2013;309(23):2480-2488.

Saver JL, Jahan R, Levy EI, et al. SOLITAIRE™ with the intention for thrombectomy (SWIFT) trial: design of a randomized, controlled, multicenter study comparing the SOLITAIRE™ Flow Restoration device and the MERCI Retriever in acute ischaemic stroke. *Int J Stroke*. 2014;9(5):658-668.

Schievink WI. Spontaneous dissection of the carotid and vertebral arteries. *N Engl J Med*. 2001;344(12):898-906.

Schneider AT, Pancioli AM, Khoury JC, et al. Trends in community knowledge of the warning signs and risk factors for stroke. *JAMA*. 2003;289(3):343-346.

Schonewille WJ, Wijman CA, Michel P, et al. Treatment and outcomes of acute basilar artery occlusion in the Basilar Artery International Cooperation Study (BASICS): a prospective registry study. *Lancet Neurol*. 2009;8(8):724-730.

Silver B, Lu M, Morris DC, Mitsias PD, Lewandowski C, Chopp M. Blood pressure declines and less favorable outcomes in the NINDS tPA stroke study. *J Neurol Sci*. 2008;271(1-2):61-67.

Singer OC, Humpich MC, Fiehler J, et al. Risk for symptomatic intracerebral hemorrhage after thrombolysis assessed by diffusion-weighted magnetic resonance imaging. *Ann Neurol*. 2008;63(1):52-60.

Smith WS, Sung G, Saver J, et al. Mechanical thrombectomy for acute ischemic stroke: final results of the Multi MERCI trial. *Stroke*. 2008;39(4):1205-1212.

Sussman E, Kellner C, McDowell M, et al. Endovascular thrombectomy following acute ischemic stroke: a single-center case series and critical review of the literature. *Brain Sci*. 2013;3(2):521-539.

The Publications Committee for the Trial of ORG 10172 in Acute Stroke Treatment Investigators. Low molecular weight heparinoid, ORG 10172 (danaparoid), and outcome after acute ischemic stroke: a randomized controlled trial. *JAMA*. 1998;279(16):1265-1272.

Tong D, Reeves MJ, Hernandez AF, et al. Times from symptom onset to hospital arrival in the Get with the Guidelines—Stroke Program 2002 to 2009: temporal trends and implications. *Stroke*. 2012;43(7):1912-1917.

Tsivgoulis G, Frey JL, Flaster M, et al. Pre-tissue plasminogen activator blood pressure levels and risk of symptomatic intracerebral hemorrhage. *Stroke*. 2009;40(11):3631-3634.

Vaduganathan M, Qamar A, Gupta A, et al. Patent foramen ovale closure for secondary prevention of cryptogenic stroke: updated meta-analysis of randomized clinical trials. *Am J Med*. 2018;131(5):575-577.

Weil AG, Rahme R, Moumdjian R, Bouthillier A, Bojanowski MW. Quality of life following hemicraniectomy for malignant MCA territory infarction. *Can J Neurol Sci*. 2011;38(3):434-438.

Wessels T, Wessels C, Ellsiepen A, et al. Contribution of diffusion-weighted imaging in determination of stroke etiology. *AJNR Am J Neuroradiol*. 2006;27(1):35-39.

Wilson RD. Mortality and cost of pneumonia after stroke for different risk groups. *J Stroke Cerebrovasc Dis*. 2012;21(1):61-67.

Transient Ischemic Attack 37

Setareh Salehi Omran and Jose Gutierrez

KEY POINTS

1. Transient ischemic attack (TIA) is a transient episode of neurologic impairment caused by focal cerebral or retinal ischemia without any permanent infarction.
2. Authentic TIAs are associated with a high risk of subsequent stroke within the acute period. The stroke risk in the first 2 days after a TIA is around 5%.
3. The best validated tool for assessing the short-term risk of ischemic stroke after TIA is the $ABCD^2$ score. The score relies on patient factors, presenting features, and duration of symptoms. A higher score is associated with a greater risk of subsequent stroke.
4. Immediate evaluation and management of TIAs may reduce the risk of a subsequent stroke. Evaluation includes urgent brain and neurovascular imaging, identification of vascular risk factors, and cardiac work up. TIA treatment is similar to ischemic stroke management and is based on the identified etiology.

INTRODUCTION

A transient ischemic attack (TIA) is an episode of neurologic impairment caused by focal cerebral or retinal ischemia without any permanent infarction. Although classically defined as less than 24 hours in duration, studies have challenged the time-based definition of TIA by illustrating that most TIAs are brief and less than 1 hour in duration. In fact, attacks typically last for only a few minutes to an hour. Despite the short period of ischemia, there is still a risk of permanent tissue infarction, with nearly half of all TIAs causing visible infarction on brain imaging. This has led to a shift from a time-based to a tissue-based definition of TIA, with TIA consisting of neurologic impairment in the absence of any imaging findings of infarction.

Although often referred to as a *ministroke*, a TIA may have ominous implications. TIA patients are at an increased risk for a subsequent ischemic stroke within the short and long term. Urgent recognition, evaluation, and treatment can aid in reducing the risk of future ischemic events in this population.

EPIDEMIOLOGY

Around 240,000 TIAs occur each year in the United States, with an incidence ranging from 68 to 83 per 100 000 residents. Around 2% of the U.S. population has experienced a TIA. Ethnic and sex differences exist in the incidence of TIAs, with men and blacks more commonly affected than women and whites.

PATHOBIOLOGY

TIAs can occur through several different mechanisms. The three main mechanisms are embolic, lacunar or small-artery disease, and low-flow TIAs. TIAs caused by embolism—from the heart, aorta, or proximal large-vessel atherosclerotic plaque or dissection—last longer because the embolus transiently occludes a distal arterial branch before spontaneously dissolving. Small-artery TIAs result from lipohyalinosis and arteriolosclerosis of penetrating arteries, such as the lenticulostriate branches of the middle cerebral artery, or penetrators of the vertebral and basilar arteries. TIAs can be caused by low flow distal to a severe carotid or vertebrobasilar stenosis; such TIAs are typically brief and stereotyped, presenting with repeated episodes of the same syndrome.

Less common mechanisms include intracranial or extracranial arterial dissection causing a low-flow state or distal embolism; vasospasm-related TIA from subarachnoid hemorrhage or reversible cerebral vasoconstrictive syndrome; hyperviscosity syndromes (polycythemia, sickle cell anemia, thrombocythemia); cerebral venous thrombosis; bacterial endocarditis; and temporal arteritis. Permanent small-artery occlusion with evidence of a small infarct on magnetic resonance (MR) diffusion-weighted imaging (DWI) can result in a transient deficit lasting up to 24 hours before resolving ("cerebral infarction with transient symptoms").

DIAGNOSIS

Symptoms vary depending on the pathophysiologic mechanism and the involved arterial territory. Embolic TIAs can occur from artery-to-artery embolism, cardioembolism, or an undetermined embolic source and can affect the anterior or posterior circulation. Anterior circulation embolic TIAs can affect the parenchyma or retinal arteries. Central retinal artery—a branch of the ophthalmic artery and ultimately the internal carotid artery—involvement causes transient monocular blindness, otherwise known as *amaurosis fugax*. Amaurosis fugax presents as blurring or darkening of vision in one eye, peaking within a few seconds (sometimes as if a curtain had descended) and usually clearing within minutes. In some patients, embolic particles (Hollenhorst plaques) are seen in retinal artery branches; in others, spasm of the central retinal artery and its branches is observed. Apart from transient monocular blindness, anterior circulation TIAs can also affect the parenchyma and produce varying combinations of limb weakness and sensory loss, aphasia, hemineglect, and homonymous hemianopia. Posterior circulation TIAs cause symptoms referable to the occipital cortex (visual field loss or cortical blindness), brainstem (cranial nerve and long-tract symptoms, sometimes crossed or bilateral), or cerebellum (ataxia, gait instability).

Lacunar or small-artery TIAs result from stenosis of one of the penetrating arteries of the middle cerebral artery, basilar artery, vertebral artery, or the circle of Willis. These TIAs produce "lacunar syndromes" such as pure hemiparesis or pure hemisensory loss. Lacunar or small-artery TIAs can consist of brief, stereotyped clinical symptoms. A particularly concerning presentation of lacunar TIAs is the *capsular warning syndrome*, which consists of multiple brief attacks of motor impairment resulting from hemodynamic changes in diseased small lenticulostriate or basilar penetrating arteries. Capsular warning syndromes have been shown to progress to early subsequent lacunar infarction in 42% of cases.

Low-flow TIAs can result from severe stenosis of a large artery, such as the proximal internal carotid artery, proximal middle cerebral artery, or vertebrobasilar junction. Unlike embolic TIAs, low-flow TIAs usually last minutes in duration and are often recurrent, with episodes occurring as frequently as a few times a day to several times in a year. The episodes can be stereotyped due to repetitive ischemia to the brain area supplied by the artery distal to the stenosis. Indeed, recurrent TIAs of the same type are more likely to be the result of perfusion failure due to critical narrowing or occlusion of the involved artery than from embolism. Common symptoms of low-flow TIAs from significant internal carotid artery or middle cerebral artery stenosis include recurrent episodes of contralateral hemiparesis or hemisensory loss, neglect, and aphasia. Low-flow TIAs from vertebrobasilar stenosis can cause a myriad of symptoms including dizziness, diplopia, dysarthria, and bilateral or unilateral leg and arm weakness or numbness. TIAs of this hemodynamic type may occur only during upright posture or during transient hypotension or cardiac arrhythmia.

TIAs can also manifest with clinical symptoms that mimic seizures and movement abnormalities, such as paroxysmal dyskinesias, tremors, ataxia, limb dystonia, and myoclonic jerking. Similarly, critical carotid artery stenosis or occlusion can cause low-flow TIAs that resemble seizure-like episodes. These "limb-shaking TIAs" consist of coarse irregular shaking of an arm or leg lasting seconds to a minute that can be precipitated by a change in posture. Additionally, episodes that resemble "drop attacks" may be seen in people with an anatomic variant consisting of both anterior cerebral arteries supplied by a single, severely stenotic internal carotid artery.

Subclavian steal syndrome can also produce transient neurologic deficits resulting from vertebrobasilar ischemia. In the subclavian steal syndrome, stenosis of the subclavian or innominate artery proximal to the origin of the vertebral artery leads to diversion of anterograde flow via the contralateral vertebral artery retrograde down the ipsilateral vertebral artery distal to the occlusion, depriving the basilar artery of blood flow. Subclavian steal syndrome can cause brainstem, cerebellar, or even cerebral symptoms, often manifested during exertion and sometimes accompanied by symptoms of arm claudication.

The diagnosis of TIA may be difficult to ascertain and is based mostly on the clinical features of the event. Since most patients present after symptom resolution, a detailed clinical history must be obtained to determine if the pattern of involvement is consistent with an ischemic insult. Typical TIAs are characterized by transient neurologic events that localize to a single vascular territory within the brain. However, many patients present with more ambiguous symptoms, such as staggering or drop attacks; dizziness, lightheadedness, or syncope; vertigo; fleeting diplopia; transient amnesia; atypical visual disturbance in one or both eyes such as flashes, distortions, or tunnel vision; a heavy sensation or "tiredness" in one or more limbs; and fixed or transient paresthesias of limbs or midline structures (eg, tongue numbness). Although these atypical symptoms are more commonly due to other causes, TIAs should be on the differential, particularly in patients presenting with brainstem symptoms. In evaluating such cases, a wide differential diagnosis of TIA needs to be considered, including migraine, cardiac arrhythmia, seizures, hypoglycemia, compressive neuropathy, conversion, and neurosis.

Although TIAs are defined in terms of their clinical reversibility and are presumed to signify ischemia too brief or incomplete to cause infarction, imaging demonstrates appropriately located infarcts in around half of cases. DWI-detected abnormalities are especially likely when symptoms last more than an hour, and those lasting longer than 3 hours show infarcts in 70% of cases. Symptom duration of more than an hour, aphasia, and motor deficits have each independently been associated with increased likelihood of DWI-detected abnormalities. Of the three symptoms, patients with a DWI-detected abnormality were almost 10 times more likely to have symptom duration of more than an hour and 16 times more likely to have experienced transient motor deficits. Some investigators therefore believe that the definition of TIA should be changed from a clinical description to a tissue-based definition, with TIAs indicating brief episodes—typically less than 1 hour—without imaging evidence of acute infarction (either on computed tomography or on magnetic resonance imaging). This is supported by evidence that neurologic deficits reemerged after giving intravenous midazolam to TIA patients whose initial deficits had resolved within 24 hours and who did not have evidence of infarction on DWI, suggesting that TIA may cause a structural lesion.

MANAGEMENT

TIAs require urgent evaluation because early implementation of secondary stroke prevention strategies following a TIA can lead to 80% reduction in future risk of stroke LEVEL 1.[1] When evaluating a TIA, a detailed clinical history and diagnostic workup is obtained to determine the exact TIA mechanism. The initial evaluation typically includes urgent brain and neurovascular imaging, identification of vascular risk factors, and cardiac evaluation (Table 37.1) LEVEL 1.[1] The secondary stroke prevention strategies depend on the stroke etiology and include revascularization for symptomatic carotid artery stenosis, anticoagulation for atrial fibrillation, management of hypertension, initiation of an antiplatelet agent and a statin, and lifestyle modifications LEVEL 1.[2]

All patients with a TIA should be on an antithrombotic agent, whether it is an anticoagulant for atrial fibrillation or an antiplatelet. Recently published data supports the short-term use of dual antiplatelet therapy for stroke prevention after a TIA LEVEL 1.[3,4] The largest international randomized controlled trial showed that a combination of aspirin and clopidogrel for 90 days after a TIA or a minor ischemic stroke was associated with a lower risk of recurrent major ischemic events but a higher risk of major hemorrhage than aspirin alone. The benefit of dual antiplatelet therapy was greatest immediately after the TIA, whereas the risk of hemorrhage increased over time. Current secondary stroke prevention guidelines state that treatment with dual antiplatelet therapy within 24 hours from event can be beneficial for secondary stroke prevention up to 90 days from

TABLE 37.1 Diagnostic Tests for the Evaluation of Transient Ischemic Attack

In most patients
Brain imaging
Noncontrast CT head
MRI brain
Neurovascular evaluation
Doppler (carotid duplex ultrasonography, transcranial Doppler)
CT angiography
Magnetic resonance angiography
Cardiac evaluation
Electrocardiogram
Transthoracic echocardiography
Blood tests
Complete blood count, complete metabolic panel
Partial thromboplastin time, prothrombin time
Fasting blood glucose or hemoglobin A_{1c}
Fasting lipid panel
In selected patients
Portable cardiac rhythm monitoring (Holter or event-loop monitoring)
Transesophageal echocardiography
Erythrocyte sedimentation rate (rule out giant cell arteritis)
Toxicology screen
Hypercoagulability workup

Abbreviations: CT, computed tomography; MRI, magnetic resonance imaging.

symptom onset. Patients with TIA of atherosclerotic origin are also recommended to be on high-intensity statin therapy, such as atorvastatin 80 mg LEVEL 1.[5] Further treatment strategies are identical to secondary prevention in patients diagnosed with acute ischemic stroke and are discussed in Chapter 36.

The decision to admit TIA cases or treat as an outpatient depends on several factors. Patients who are at high risk for subsequent stroke and those that cannot undergo the emergent workup within 48 hours of symptoms may be admitted for inpatient management.

OUTCOME

TIAs are associated with a high risk of subsequent stroke. In 1,707 patients presenting with TIA to an emergency department, 10% had a stroke within the next 90 days, and in half, the stroke occurred within the first 48 hours of the TIA. Retinal TIAs had about half this rate of stroke (5% within 90 d). In four European studies combining 2,416 patients who presented with ischemic stroke, 15% to 26% of ischemic strokes were preceded by a TIA and 43% of TIAs occurred within 7 days of the stroke.

Methods that can reliably assist with acute stroke risk assessment after a TIA can aid in patient triage. The best validated tool for assessing the short-term risk of ischemic stroke after TIA is the $ABCD^2$ score. $ABCD^2$ score relies on patient factors, presenting features, and duration of symptoms to assign a score of 0 to 7 (Table 37.2). The score determines the 2-day risk of stroke as either high (score 6-7), moderate (score 4-5), or low risk (score 0-3). Additionally, a higher score implies a higher 90-day risk of stroke. This highly validated scoring system is recommended for use in determining early stroke risk by the national guidelines.

Accumulating evidence suggests that the presence of an acute infarct on computed tomography or magnetic resonance imaging after a TIA is associated with a higher risk of early subsequent stroke. This was shown in a large multicenter study of early risk

TABLE 37.2 The $ABCD^2$ score

Age	
60 y or older	1 point
Younger than 60 y	0 points
Blood pressure when first assessed after TIA presentation	
Systolic ≥140 mm Hg or diastolic ≥90 mm Hg	1 point
Systolic <140 mm Hg and diastolic <90 mm Hg	0 points
Clinical features	
Unilateral weakness	2 points
Isolated speech disturbance	1 point
Other	0 points
Duration of TIA symptoms	
≥60 min	2 points
10-59 min	1 point
<10 min	0 points
Diabetes	
Present	1 point
Absent	0 points

Abbreviation: TIA, transient ischemic attack.

of recurrent stroke after TIA using $ABCD^2$ score, subcategorized as tissue-positive or tissue-negative on imaging, where the risk of recurrent stroke rates at 7 days were significantly higher in patients with DWI-positive compared to DWI-negative TIAs (Table 37.3). Attempts to increase the predictive value of the $ABCD^2$ score have been proposed, with additional scale items including the presence of more than one TIA ($ABCD^3$), DWI-positive image, or the presence of greater than 50% carotid stenosis ($ABCD^3$-I) or intracranial arterial stenosis ($ABCD^3$-I[c/i]). Each of these scores adds a small degree of incremental predictive value compared to the original $ABCD^2$ score at the expense of simplicity. For clinical use and ease of communication, we recommend use of the standard $ABCD^2$ score while recognizing that multiple TIA events, cerebral infarction with transient symptoms, or evidence of significant extracranial or intracranial stenosis further increases the 90-day stroke risk.

Crescendo TIAs—two or more attacks within 24 hours—should be considered a medical emergency. Particularly concerning is the *capsular warning syndrome* and its high risk of subsequent lacunar infarction. Asymptomatic coronary artery

TABLE 37.3 7- and 90-d Stroke Risk Based on $ABCD^2$ Score in Patients With and Without Infarction on Brain Imaging[a]

	7-d Stroke Risk		90-d Stroke Risk	
$ABCD^2$ Score	With Infarction	Without Infarction	With Infarction	Without Infarction
≤1	0%	0%	0%	1%
2	2%	0%	4%	0%
3	3%	1%	4%	2%
4	5%	1%	8%	2%
5	13%	2%	17%	3%
≥6	15%	3%	19%	6%

[a]Data from Giles MF, Albers GW, Amarenco P, et al. Early stroke risk and $ABCD^2$ score performance in tissue- vs time-defined TIA: a multicenter study. *Neurology*. 2011;77(13):1222-1228.

disease is especially common in patients with carotid stenosis and should be checked for. The overall risk of stroke, myocardial infarction, and vascular death remains high for at least 10 to 15 years in patients with a history of TIA.

LEVEL 1 EVIDENCE

1. Easton JD, Saver JL, Albers GW, et al; for Interdisciplinary Council on Peripheral Vascular Disease. Definition and evaluation of transient ischemic attack: a scientific statement for healthcare professionals from the American Heart Association/American Stroke Association Stroke Council; Council on Cardiovascular Surgery and Anesthesia; Council on Cardiovascular Radiology and Intervention; Council on Cardiovascular Nursing; and the Interdisciplinary Council on Peripheral Vascular Disease. The American Academy of Neurology affirms the value of this statement as an educational tool for neurologists. *Stroke*. 2009;40(6):2276-2293.
2. Kernan WN, Ovbiagele B, Black HR, et al. Guidelines for the prevention of stroke in patients with stroke and transient ischemic attack: a guideline for healthcare professionals from the American Heart Association/American Stroke Association. *Stroke*. 2014;45(7):2160-2236.
3. Johnston SC, Easton JD, Farrant M, et al. Clopidogrel and aspirin in acute ischemic stroke and high-risk TIA. *N Engl J Med*. 2018;379(3):215-225.
4. Wang Y, Wang Y, Zhao X, et al. Clopidogrel with aspirin in acute minor stroke or transient ischemic attack. *N Engl J Med*. 2013;369(1):11-19.
5. Amarenco P, Bogousslavsky J, Callahan A III, et al. High-dose atorvastatin after stroke or transient ischemic attack. *N Engl J Med*. 2006;355(6):549-559.

SUGGESTED READINGS

Brown RD Jr, Petty GW, O'Fallon WM, Wiebers DO, Whisnant JP. Incidence of transient ischemic attack in Rochester, Minnesota, 1985-1989. *Stroke*. 1998;29(10):2109-2113.

Clark TG, Murphy MF, Rothwell PM. Long term risks of stroke, myocardial infarction, and vascular death in "low risk" patients with a non-recent transient ischaemic attack. *J Neurol Neurosurg Psychiatry*. 2003;74(5):577-580.

Coutts SB, Modi J, Patel SK, Demchuk AM, Goyal M, Hill MD. CT/CT angiography and MRI findings predict recurrent stroke after transient ischemic attack and minor stroke: results of the prospective CATCH study. *Stroke*. 2012;43(4):1013-1017.

Crisostomo RA, Garcia MM, Tong DC. Detection of diffusion-weighted MRI abnormalities in patients with transient ischemic attack: correlation with clinical characteristics. *Stroke*. 2003;34(4):932-937.

Donnan GA, O'Malley HM, Quang L, Hurley S, Bladin PF. The capsular warning syndrome: pathogenesis and clinical features. *Neurology*. 1993;43(5):957-962.

Gerstner E, Liberato B, Wright CB. Bi-hemispheric anterior cerebral artery with drop attacks and limb shaking TIAs. *Neurology*. 2005;65(1):174.

Giles MF, Albers GW, Amarenco P, et al. Early stroke risk and ABCD2 score performance in tissue- vs time-defined TIA: a multicenter study. *Neurology*. 2011;77(13):1222-1228.

Johnston SC, Fayad PB, Gorelick PB, et al. Prevalence and knowledge of transient ischemic attack among US adults. *Neurology*. 2003;60(9):1429-1434.

Johnston SC, Gress DR, Browner WS, Sidney S. Short-term prognosis after emergency department diagnosis of TIA. *JAMA*. 2000;284(22):2901-2906.

Johnston SC, Rothwell PM, Nguyen-Huynh MN, et al. Validation and refinement of scores to predict very early stroke risk after transient ischaemic attack. *Lancet*. 2007;369(9558):283-292.

Johnston SC, Sidney S, Bernstein AL, Gress DR. A comparison of risk factors for recurrent TIA and stroke in patients diagnosed with TIA. *Neurology*. 2003;60(2):280-285.

Kidwell CS, Alger JR, Di Salle F, et al. Diffusion MRI in patients with transient ischemic attacks. *Stroke*. 1999;30(6):1174-1180.

Kimura K, Minematsu K, Yasaka M, Wada K, Yamaguchi T. The duration of symptoms in transient ischemic attack. *Neurology*. 1999;52(5):976-980.

Kiyohara T, Kamouchi M, Kumai Y, et al. ABCD3 and ABCD3-I scores are superior to ABCD2 score in the prediction of short- and long-term risks of stroke after transient ischemic attack. *Stroke*. 2014;45(2):418-425.

Kleindorfer D, Panagos P, Pancioli A, et al. Incidence and short-term prognosis of transient ischemic attack in a population-based study. *Stroke*. 2005;36(4):720-723.

Klempen NL, Janardhan V, Schwartz RB, Stieg PE. Shaking limb transient ischemic attacks: unusual presentation of carotid artery occlusive disease: report of two cases. *Neurosurgery*. 2002;51(2):483-487.

Lavallée PC, Meseguer E, Abboud H, et al. A transient ischaemic attack clinic with round-the-clock access (SOS-TIA): feasibility and effects. *Lancet Neurol*. 2007;6(11):953-960.

Lazar RM, Fitzsimmons BF, Marshall RS, Mohr JP, Berman MF. Midazolam challenge reinduces neurological deficits after transient ischemic attack. *Stroke*. 2003;34(3):794-796.

Levy DE. How transient are transient ischemic attacks? *Neurology*. 1988;38(5):674-677.

Merwick A, Albers GW, Amarenco P, et al. Addition of brain and carotid imaging to the $ABCD^2$ score to identify patients at early risk of stroke after transient ischaemic attack: a multicentre observational study. *Lancet Neurol*. 2010;9(11):1060-1069.

Paul NL, Simoni M, Rothwell PM. Transient isolated brainstem symptoms preceding posterior circulation stroke: a population-based study. *Lancet Neurol*. 2013;12(1):65-71.

Rothwell PM, Warlow CP. Timing of TIAs preceding stroke: time window for prevention is very short. *Neurology*. 2005;64(5):817-820.

Rovira A, Rovira-Gols A, Pedraza S, Grivé E, Molina C, Alvarez-Sabín J. Diffusion-weighted MR imaging in the acute phase of transient ischemic attacks. *AJNR Am J Neuroradiol*. 2002;23(1):77-83.

Shah KH, Kleckner K, Edlow JA. Short-term prognosis of stroke among patients diagnosed in the emergency department with a transient ischemic attack. *Ann Emerg Med*. 2008;51(3):316-323.

Wu CM, McLaughlin K, Lorenzetti DL, Hill MD, Manns BJ, Ghali WA. Early risk of stroke after transient ischemic attack: a systematic review and meta-analysis. *Arch Intern Med*. 2007;167(22):2417-2422.

Hypoxic-Ischemic Encephalopathy 38

Sachin Agarwal and Alexandra S. Reynolds

KEY POINTS

1. Comatose adult survivors of cardiac arrest should undergo therapeutic hypothermia between 32°C and 36°C for shockable rhythms with out-of-hospital cardiac arrest, nonshockable rhythms, and in-hospital cardiac arrest.
2. Studies involving cellular, animal, and human models suggest that therapeutic hypothermia has the potential to mitigate reperfusion-related secondary injury after cardiac arrest.
3. Delayed and multimodal neuroprognostication schemes are highly recommended.
4. Both sedation and therapeutic hypothermia alone and in combination have been shown to affect neuroprognostic markers of cardiac arrest to varying degrees.
5. Survivors of cardiac arrest experience long-term "extra-cardiac sequelae," that is, cognitive, functional, and psychosocial deficits.

INTRODUCTION

Hypoxic-ischemic encephalopathy (HIE) is a term used to describe cerebral dysfunction after a global insult to the brain. Mechanisms of such damage include prolonged interruption of blood flow and/or oxygen, most commonly after cardiac arrest.

EPIDEMIOLOGY

Approximately 630,000 cardiac arrests occur in the United States per year with an overall 14% survival to discharge. Despite an increased survival from all-rhythm cardiac arrest, the mortality is at least 50% in those who have survived to the hospital admission, and overall disease-specific mortality is around 90%. Brain injury alone is the primary cause in 68% of patients. Among all out-of-hospital cardiac arrest patients between 2000 and 2006, patients who found in asystolic arrest had the worst outcomes (1% survival to discharge and 0.5% 30-d survival), whereas those with shockable initial rhythm (ventricular fibrillation or pulseless ventricular tachycardia) had the best outcomes (15%-20% survival to discharge). Those with pulseless electrical activity fell somewhere in the middle (5%-8% survival to discharge). Utstein bystander patients (witnessed by a bystander with an initial shockable rhythm and received some bystander intervention [cardiopulmonary resuscitation and/or automated external defibrillator application]) could have a survival rate as high as 38.2%. In general, the faster the return of spontaneous circulation, the better the outcome.

These numbers do not capture the neurologic morbidity associated with cardiac arrest. Those who survive may still have significant neurologic and psychosocial deficits including cognitive dysfunction such as memory problems, difficulty with activities of daily living, and a large group of cardiac arrest survivors will experience personality changes, depression, anxiety, and post-traumatic stress disorder. Furthermore, a proportion of patients will ultimately remain in minimally conscious or persistent vegetative states. The true proportions are unknown because of high rates of withdrawal of care in patients who remain comatose after a cardiac arrest leading to a "self-fulfilling prophecy."

PATHOBIOLOGY: CAUSES OF HYPOXIC-ISCHEMIC ENCEPHALOPATHY

Cardiac Arrest

Cardiopulmonary arrest is a complex process that causes diffuse damage to the brain. The initial mechanisms of damage include hypoxemia and hypoperfusion due to circulatory arrest. However, as the cardiac arrest progresses, damage is caused by resultant hypoglycemia, acidosis, and toxin accumulation (see following text). The model of cardiac arrest resuscitation involves three time-sensitive ischemic-reperfusion phases, including electrical, circulatory, and metabolic. Although rapid reperfusion is needed after ischemia, it can also paradoxically contribute to tissue injury and destruction. Various mechanisms of cell death, including necrosis, apoptosis, and autophagy-associated cell death, have been implicated. Tissue necrosis results in swelling, and this is exacerbated by rebound hyperemia from reperfusion as well as progression of the inflammatory cascade. On a molecular level, reintroduction of glucose causes formation of nitric oxide and oxygen free radicals that can induce DNA damage and consumption of NAD+ leading to a second round of cell death. Studies involving cellular, animal, and human models suggest that therapeutic hypothermia (TH) has the potential to mitigate these deleterious processes (**Table 38.1**) even after a period of ischemia. Models where hypothermia was initiated before reperfusion have resulted in the most cellular protection.

Prolonged Hypotension

Hypotension results in preferential injury to parts of the central nervous system that lie in between vascular distributions. Areas supplied by narrowed arteries are also at risk for hypoperfusion in low-flow states like carotid stenosis or in heart failure with low cardiac output. Low cerebral blood flow results in patchy ischemic infarctions. Watershed areas in the brain affected by hypotension include the cortical border zones between the anterior cerebral and middle cerebral arteries and middle cerebral and posterior

TABLE 38.1 Mechanisms of Neuroprotection With Therapeutic Hypothermia

Metabolic	Decreased cerebral metabolism (6%-10%/°C below 38°C) Inhibition of mitochondrial injury and dysfunction Decreased production of toxic metabolites and free radicals
Neuroinflammatory	Decreased generation of inflammatory proteins Decreased release of glutamate and decreased neuroexcitotoxicity
Vascular	Decreased vascular permeability and edema Decreased cerebral thermo-pooling, reducing local hyperthermia
Cellular	Decreased ion pump dysfunction and decreased intracellular calcium influx Decreased cell membrane leakage and cytotoxic edema Decreased apoptosis and proteolysis
Other	Decreased spreading depression-type depolarizations Suppression of epileptic activity Decreased coagulation activation with formation of fewer microthrombi

cerebral arteries or internal border zone areas in the periventricular white matter or the deep structures supplied by the recurrent artery of Heubner and the anterior choroidal and lenticulostriate arteries. In the spinal cord, the anterior portion of the midthoracic distribution is considered to be the watershed region; however, one study showed disproportionate damage to the lumbosacral spinal cord after prolonged hypotension and/or cardiac arrest.

Hypoxia

Pure hypoxic hypoxia can occur in the absence of circulatory breakdown, in the case of aspiration, hanging/strangulation, or drowning. Hypoxic damage to the brain occurs solely due to decreased partial pressure of blood oxygen and results in a lesser degree of injury than combined hypoxic-ischemia. However, prolonged hypoxia will progress to cardiac arrest. Once oxygen supply to the brain is interrupted, adenosine triphosphate stores only last for minutes. After energy-dependent membrane ion transport starts to fail, damaged cells release excitotoxic glutamate, intracellular calcium begins to accumulate and activates proteases and phospholipases, and damage is propagated via inflammatory cascades. Intracellular influx of calcium in surrounding areas leads to diffuse cell death. The areas particularly susceptible to hypoxic damage are hippocampal CA1 neurons, thalami, cerebellar Purkinje cells, and cortical pyramidal cells in layers 3, 5, and 6. Among the cortical areas, perirolandic areas are most vulnerable because of the high concentration of *N*-methyl-D-aspartate receptors. White matter injury also occurs because of damage to oligodendroglial cells.

Carbon Monoxide Poisoning

Carbon monoxide (CO) primarily exerts harmful effects to the brain by causing hypoxemia in a so-called anemic-histotoxic hypoxia. As in hypoxic hypoxia, preservation of circulation portends a lesser damage to the brain. The CO preferentially binds to heme proteins and displaces bound oxygen because of its greater affinity for hemoglobin. The CO thus limits oxygen-carrying capacity of blood and impairs mitochondrial function of the tissues attempting to use oxygen, resulting in a hypoxic and acidotic state. Ultimately, CO poisoning causes intravascular and intracellular oxidative stress, inflammation, and apoptosis. The cortical laminae and basal ganglia are particularly prone to damage. Additional reports of delayed demyelination in the centrum semiovale have been published. In severe cases, cardiac toxicity can occur resulting in hypotensive brain injury as well.

Cyanide Poisoning

Cyanide poisoning causes metabolic failure by inhibiting oxidative phosphorylation. It results in direct metabolic damage to the brain but ultimately causes mixed injury due to early cardiac failure. Cyanide impairs oxidative phosphorylation by inhibiting the mitochondrial cytochrome oxidase a_3 complex. Mitochondria are unable to produce adenosine triphosphate and increased glycolysis occurs, quickly resulting in a metabolic acidosis as pyruvate is reduced to lactate. Coronary artery vasoconstriction occurs, and cardiac output decreases suddenly, causing hypotension and cardiac shock. The brain is damaged not only from this hypotension but also from metabolic failure on a cellular level.

Profound Hypoglycemia

Glucose is the primary source of energy for the brain in both adults and infants, and prolonged or repeated hypoglycemic episodes can therefore cause significant injury to the brain. Concurrent hypoglycemia also exacerbates the damage caused by hypoxemia. Brain damage usually occurs once serum glucose levels fall below 20 mg/dL. Mechanisms of cell death with hypoglycemia are similar to hypoxia, including excitotoxic glutamate and aspartate release and involvement of *N*-methyl-D-aspartate receptors. More recent studies have shown that activation of poly(ADP-ribose) polymerase 1, release of zinc from nerve terminals, and activation of calcium-dependent protease calpain also contribute to neuronal death. Furthermore, depolarization of the mitochondrial membrane leads to apoptosis. The parts of the brain most sensitive to low-glucose levels are the hippocampus (CA1, CA3, and dentate gyrus), caudate, putamen, and insular cortex.

CLINICAL FEATURES

The clinical manifestations of HIE can range from mild changes in cognition to coma. Damage to the hippocampus can result in memory deficits. Damage to the basal ganglia can present as a variety of movement disorders. Thalamic damage can result in a wide variety of symptoms from sensory changes to dementia or coma. Damage to the Purkinje cells results in cerebellar dysfunction. Cortical damage can result in inattentiveness, executive dysfunction, or aphasia. Because of the resistance of the deep gray matter of the brainstem to anoxic injury compared with the neocortex, HIE often results in coma with preservation of brainstem reflexes. However, brain death can occur with prolonged hypoxic-ischemic injury.

Watershed injury in the brain can manifest as proximal greater than distal extremity weakness and ultimately spasticity ("man-in-a-barrel syndrome"). Watershed injury to the spinal cord results in an "anterior cord syndrome" or Beck syndrome, including motor paralysis below the level of the lesion, loss of pain and temperature but intact proprioception and vibratory sensation, and loss of bowel and/or bladder control.

Lance-Adams syndrome, or posthypoxic action myoclonus, can occur several days after recovery from hypoxic injury to the brain.

The rare syndrome of delayed posthypoxic leukoencephalopathy (DPHL) following seemingly full recovery from a comatose state can occur days to weeks after the initial insult. The onset is usually insidious and can manifest as personality changes, irritability, inattentiveness, confusion, and memory problems. This can progress to include extrapyramidal motor symptoms and, in some cases, eventually coma or death. Those patients who survive stabilize to one of two ultimate syndromes: either parkinsonism with hallucinations or odd behaviors or akinetic mutism. A DPHL may occur as a result of any cause of HIE mentioned earlier but is most often seen in cases of acute CO poisoning or opioid overdose. The main histopathologic patterns seen in this syndrome are demyelination in the centrum semiovale and necrosis of the cortical laminae and basal ganglia, which correlate with brain magnetic resonance imaging (MRI) features. Severity and persistence of DPHL sequelae have been correlated to the presence and persistence of low signal intensity on the apparent diffusion coefficient (ADC) map on cranial MRI.

DIAGNOSIS

Imaging

A *computed tomography head* is usually normal immediately after hypoxic-ischemic insult. In severe injury, there can be evidence of loss of the gray-white junction within hours (Fig. 38.1A). After 24 to 48 hours, linear hyperdensities outlining the cortex develop, corresponding to laminar necrosis of the cortex. After days, the "reversal sign" develops where cerebral white matter appears hyperdense than cortical gray matter. Pseudosubarachnoid hemorrhage can also occur when the falx cerebri and tentorium cerebelli appear hyperdense as compared to the adjacent injured parenchyma (Fig. 38.1B).

An *MRI brain* is the earliest way to visualize damage, as early cytotoxic edema can be visualized on diffusion-weighted imaging (DWI) and can be quantified using the ADC (Fig. 38.1C-G). Importantly, DWI and ADC changes may not be apparent early on, and thus, early imaging may underestimate the injury burden. Moreover, there may be attenuation of ADC values for every 1°C decrease in body temperature. The DWI sequences can pseudonormalize by 7 days, but T2 hyperintensities on fluid-attenuated inversion recovery sequences develop after the first week. The damage is most often symmetric and corresponds in location to the neuronal subtypes that are preferentially damaged (see "Pathobiology: Causes of Hypoxic-Ischemic Encephalopathy" section). With time, focal laminar necrosis can be seen due to deposition of blood products (see Fig. 38.1E). In one small study, changes occurring over time within the same patient were analyzed. The location of the injury shifts with time from the initial hypoxic-ischemic event, starting in the cerebellum and

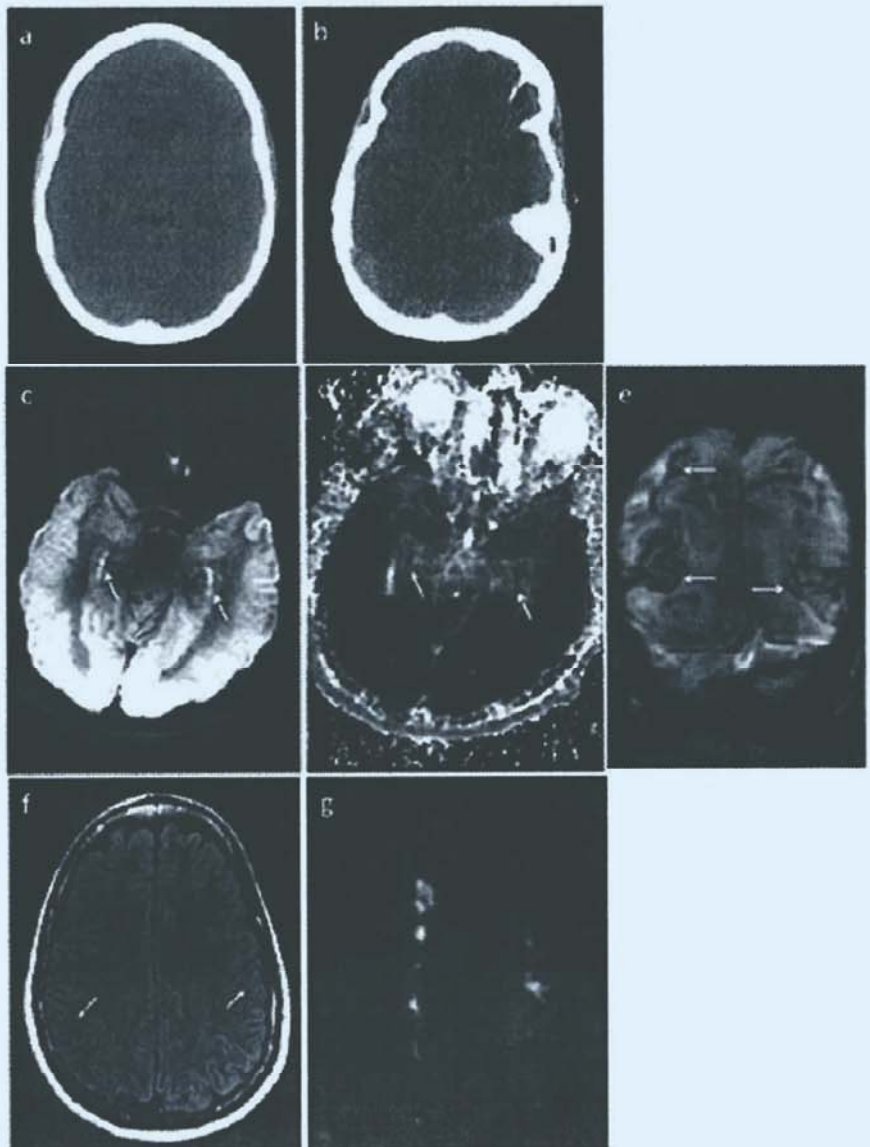

FIGURE 38.1 Imaging findings after hypoxic-ischemic encephalopathy. Computed tomography scan done 12 hours **(A)** and 10 days **(B)** after a near-drowning episode. **A:** There is diffuse loss of gray-white matter differentiation and severe global cerebral edema. There are bilateral, but right greater than left, hypodensities of the basal ganglia. **B:** The diffusely attenuated white and gray matter result in a pseudosubarachnoid hemorrhage appearance of the relatively hyperdense dura. Diffusion-weighted imaging **(C)** and apparent diffusion coefficient **(D)** sequences of a magnetic resonance imaging done 2 days after a primary respiratory arrest showing restricted diffusion in the bilateral hippocampi *(arrows)* and diffusely throughout the cortex. **E:** Susceptibility-weighted imaging sequence in coronal section done 7 days after a pulseless electrical activity arrest showing areas of laminar necrosis in the posterior parietal lobes *(arrows)*. **F:** Fluid-attenuated inversion recovery sequence 10 days after cardiopulmonary arrest only showing mild swelling and indistinctness of the gray-white junction in the bilateral parietal lobes *(arrows)*. **G:** Diffusion-weighted imaging sequence of a magnetic resonance imaging done 11 days after a pulseless electrical activity arrest resulting from a type A aortic dissection. There are scattered foci of restricted diffusion along the anterior cerebral and middle cerebral arteries and middle cerebral and posterior cerebral arteries border zones, more prominent on the right, consistent with watershed infarct.

basal ganglia in days 1 and 2, moving to the cortex around days 3 to 5, and involving subcortical white matter on days 6 to 12. Pronounced hippocampal abnormalities on DWI—the so-called bright hippocampus sign—has been associated with extremely poor outcomes (see Fig. 38.1C,D). In the case of DPHL, MRI findings are pathognomonic, with diffuse T2 hyperintensities predominantly in the dorsal frontal and parietal lobes. Whether hypothermia has any effect on resting state neural networks, fractional anisotropy on diffusion tensor imaging or any metabolites measured via magnetic resonance spectroscopy is unknown.

Somatosensory-Evoked Potentials

A noninvasive way to evaluate the functioning of the somatosensory system in a comatose patient is by performing evoked potentials. There are multiple types of evoked potentials including auditory and visual; however, somatosensory-evoked potentials (SSEPs) are most commonly used after a hypoxic-ischemic event or cardiac arrest. The SSEPs are done by providing a transcutaneous electrical stimulation along a peripheral nerve, most commonly the median nerve. The impulse is then tracked as it travels up the peripheral nerve to the elbow (N5), Erb point in the brachial plexus (N9), the posterior column of the midcervical cord (N13), and ultimately to the contralateral primary sensory cortex (N20). In cases of significant cortical damage, the N20 can be absent (Fig. 38.2).

Electroencephalography

The 2006 American Academy of Neurology practice parameters emphasized the importance of identifying electrographic seizures and burst suppression for prognostication, but minimal data was available at that time. In last few years, there have been many studies describing the evolution of electroencephalography (EEG) during hypothermia and after rewarming. The occurrence of seizures more in the first 24 hours, that is, during hypothermia phase, was to be an unexpected observation. Therefore, many experts recommend early and prolonged EEG monitoring. Most studies have confirmed an incidence of seizures in 25% of patients, and status epilepticus at any point during the hospital course is thought to be a bad prognostic indicator. However, patients have achieved good outcomes after seizures were detected and treated aggressively. The most common finding on EEG is generalized periodic discharges that are also known to be a precursor of seizures and thus poor outcomes, but more systematic evaluation of different patterns needs to be done. The EEG background features like continuity and reactivity have also been shown to be predictive of outcomes, that is, persistence of continuous background and EEG reactivity in first few days of the event is associated with good recovery. Because sedation is known to affect the EEG background and in the absence of any studies assessing its effect on reactivity, the most recent international consensus for EEG reactivity reporting recommended that information on analgesics and sedatives be reported when testing EEG reactivity in cardiac arrest patients. Further research in this area is warranted, and eventually, inclusion of appropriate, well-studied EEG patterns should be a part of multimodal prognostication paradigm.

TREATMENT

General Concepts

Intracranial pressure (ICP) can increase after cardiac arrest both because of reflex hyperemia postcardiac arrest and because of global cerebral edema in cases of significant global injury. High ICP and low cerebral perfusion pressures are associated with poor outcomes. The ICP also increases with seizure activity.

Hyperoxia is correlated with worse outcomes in humans. Each 100 mm Hg increase in Pa_{O_2} above the normal level of 100 mm Hg is associated with 24% increased risk of mortality. Unnecessary increases in the fraction of inspired oxygen should

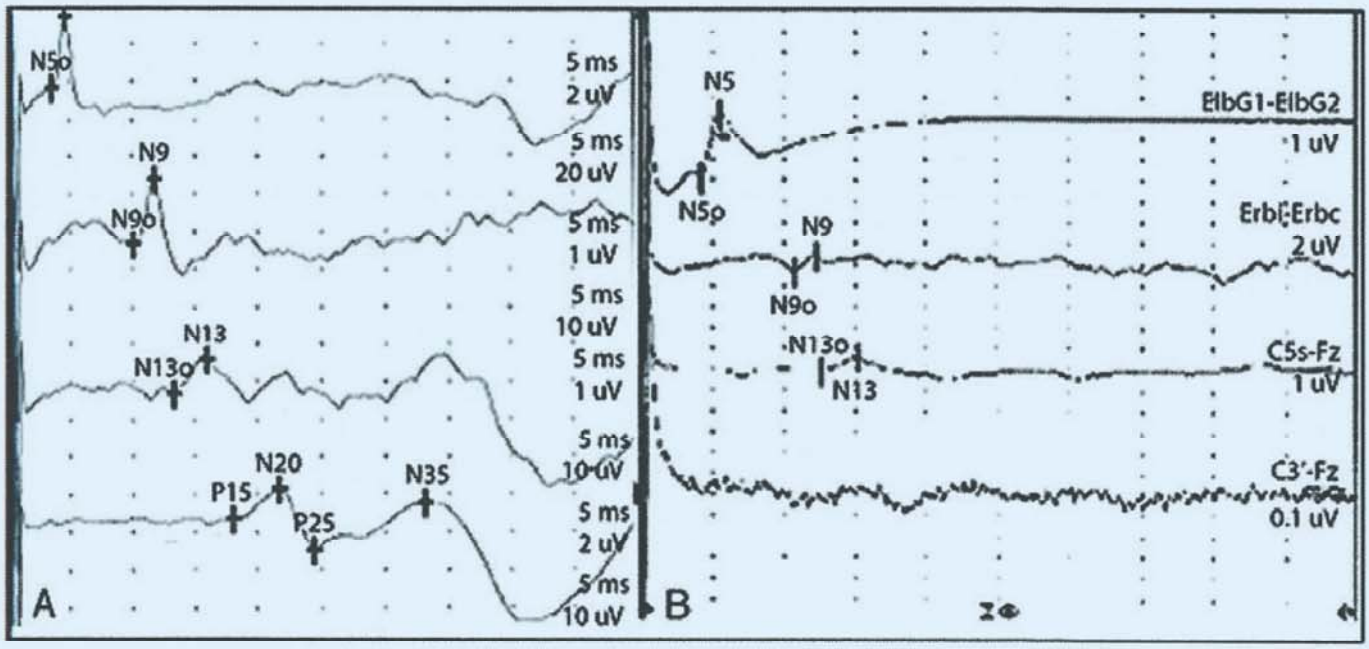

FIGURE 38.2 Median nerve somatosensory-evoked potentials. **A:** The normal somatosensory-evoked potential tracing including the N5 waveform at the elbow, N9 at Erb point, N13 at the cervical cord, and N20 at the contralateral sensory cortex. **B:** An absent N20 after hypoxic-ischemic injury from cardiac arrest. (Chiota NA, Freeman WD, Barrett KM. Hypoxic-ischemic brain injury and prognosis after cardiac arrest. *Continuum [Minneap Minn]*. 2011;17[5 Neurologic Consultation in the Hospital]:1094-1118.)

be avoided. The goal for $PaCO_2$ should be on the higher end of normocapnia, as lower ends of the threshold are associated with decreased cerebral blood flow.

Seizures

With cortical damage comes the potential for development of complex, evolving epileptiform discharges and/or seizures. Early detection and treatment of seizures is paramount to prevent further brain damage. Myoclonic status epilepticus, characterized as a poor prognostic marker in pre-TH era, has been questioned by more recent small studies and case reports. The definition involved spontaneous, unrelenting, generalized, multifocal myoclonus involving face, limbs, and axial musculature, but no EEG correlate was needed for the diagnosis. An EEG monitoring with a trial of paralytic to remove muscle artifact, if necessary, should be attempted, and if the patient is found to be in electrographic status epilepticus, they should be treated aggressively.

Therapeutic Hypothermia

Beginning in the 1950s, cardiothoracic surgeons used moderate hypothermia (28°C-32°C) during cardiac surgery to prevent brain ischemia. The idea of cooling after unexpected cardiac arrest and subsequent resuscitation, however, was not seriously pursued until the early 1990s, when animal studies became popular. In 2002, two randomized controlled trials were published suggesting that patients in cardiac arrest with an initial rhythm of ventricular fibrillation who remained comatose after return of spontaneous circulation had better outcomes after mild TH to 32°C to 33°C for 12 to 24 hours LEVEL 1.[1,2] Recent study showed that there is no benefit to cooling to 33°C when compared to 36°C LEVEL 1.[3] Recent data confirmed the benefit of moderate TH in patients with coma who had been resuscitated from cardiac arrest with nonshockable rhythm. The 2015 American Heart Association guideline recommends that comatose adult survivors of cardiac arrest undergo TH between 32°C and 36°C LEVEL 1[4] for shockable rhythms with out-of-hospital cardiac arrest, nonshockable rhythms, and in-hospital cardiac arrest LEVEL 1.[4] A TH is neuroprotective in many ways (see **Table 38.1**). The hypothermia protocol is complex (**Table 38.2**) and requires close monitoring for shivering via the Bedside Shivering Assessment Scale (**Table 38.3**). Sometimes, EEG can detect microshivering that is not palpable on the neck or thorax. Shivering must be treated aggressively, as it increases metabolic demand, raises the patient's core temperature, causes tachycardia, and increases ICP.

TABLE 38.2 Hypothermia Checklist

Contraindications
Absolute contraindications:
• Refractory bleeding at a noncompressible site or uncontrollable bleeding
• Severe and recurrent symptomatic bradycardia requiring pacing or continuous medial therapy
Relative contraindications (consider cooling to 36°C instead of 33°C):
• Acute multisystem organ failure due to prolonged arrest
• Hemodynamic instability requiring more than two vasopressors and/or recurrent cardiac arrests
• Concurrent meningitis
• Severe systemic infection and/or sepsis
• Significant trauma with high risk of internal bleeding
• Severe baseline neurologic or medical disorders
• Pregnancy or postpartum patient
• Head trauma with intracranial bleeding
Induction of Hypothermia
• Immediate initiation of cooling with ice packs, infusion of cold saline, and cooling blanket (protecting the skin from direct contact)
• Use of one of the following methods: superficial cooling pads or intravascular temperature modulation devices
• Administration of one-time paralytic dose for expediting cooling
• Central temperature monitoring with bladder or esophageal probe
• Maintain temperature for 24 h after initiation of hypothermia.

Shivering
• cEEG to detect microshivering
• Goal Bedside Shivering Assessment Scale ≤1
• Acetaminophen 650 every 4 h standing
• Buspar 30 mg orally every 8 h standing
• Meperidine 25 mg IV every 6 h as needed shivering
• Bair hugger set at 43°C for skin counterwarming
• If shivering refractory, can start Mg drip at 0.5-1 g/h with goal Mg level 3-4 mEq/L
• If shivering still refractory, can add fentanyl, propofol, or dexmedetomidine drips
• If shivering remains refractory to sedation, start neuromuscular blockade (must be on sedation) with vecuronium 0.1 mg/kg IV every hour or rocuronium or cisatracurium drips.
Seizures and Myoclonus
• Continuous EEG to identify seizures
• Treat seizures aggressively with phenytoin, valproic acid, levetiracetam, or benzodiazepines.
• Noncortical myoclonus (ie, Lance-Adams syndrome) has no effect on outcome but can be treated for comfort with levetiracetam, valproic acid, gabapentin, or benzodiazepines.
Rewarming to Normothermia
• Rewarm at 0.1°C-0.2°C/h to a goal of 38°C.
• Shivering is most common during rewarming and should be treated aggressively.
Other Monitoring
• Electrolytes should be monitored and repleted to a goal of K = 3.0 mEq/L, as overrepletion can result in hyperkalemia during rewarming.
• Platelets should be transfused for goal >20,000 or >50,000 if active bleeding.

Abbreviations: cEEG, continuous electroencephalography; EEG, electroencephalography; IV, intravenous; K, potassium; Mg, magnesium.

TABLE 38.3 Bedside Shivering Assessment Scale

Score	Severity	Location of Shivering
0	None	None detected on palpation of masseter, neck, and chest muscles
1	Mild	Shivering localized to neck and thorax only
2	Moderate	Shivering involves gross movement of the arms and trunk.
3	Severe	Shivering involves gross movement of the arms, legs, and trunk.

OUTCOME

In 2006, the American Academy of Neurology published guidelines for prognostication in comatose survivors of cardiac arrest after an exhaustive review of the literature (Fig. 38.3). Features that nearly guaranteed poor outcome were early clinical (not electrographic) myoclonic status epilepticus, absent N20 responses on SSEPs in the first 72 hours after arrest, absent corneal or pupillary reflexes or extensor or absent motor response to pain at 72 hours, and serum neuron-specific enolase greater than 33 μg/L. Subsequent studies looking at routine use of hypothermia in comatose patients postcardiac arrest have revealed an unacceptably high false-positive rate of almost every feature (see Fig. 38.3). These findings have prompted further studies on prognostic factors that may be valid for use in the posthypothermia era. In 2014, the European Resuscitation Council's advisory statement on outcome prediction recommended delaying neuroprognostication beyond 72 hours if residual effects of sedation or paralysis are suspected (see Table 38.4 for suggested neuroprognostication checklist after cardiac arrest).

Other biomarkers being studied as predictors of clinical outcome include brain-specific markers such as S100-B and microRNAs, inflammatory markers including C-reactive protein and the interleukins, and neurohormonal markers such as copeptin. Serum neurofilament light chain has shown promise as a predictor of poor

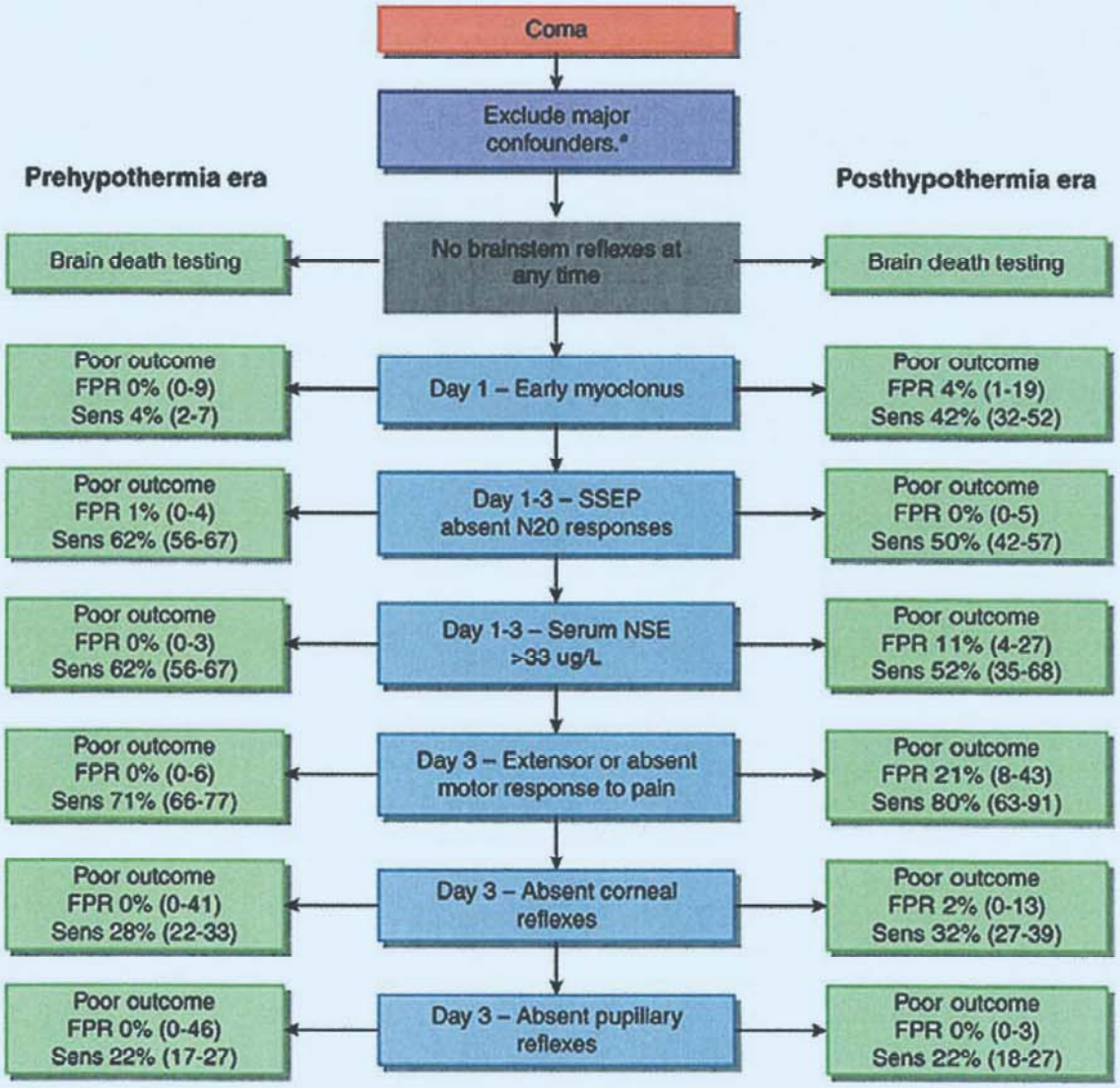

FIGURE 38.3 Prognostication algorithm in comatose survivors of cardiac arrest. On the *left* appear false-positive rate (FPR) and sensitivity of each feature in the prehypothermia era, on the *right* in the posthypothermia era. For posthypothermia era, in cases of multiple studies, the data from the study with the largest number of subjects were used. Abbreviations: NSE, neuron-specific enolase; Sens, sensitivity; SSEP, somatosensory-evoked potential. [a]Major confounders at the time of examination include hypothermia, sedatives/hypnotics, and paralytics. (Adapted from Wijdicks EF, Hijdra A, Young GB, et al. Practice parameter: prediction of outcome in comatose survivors after cardiopulmonary resuscitation [an evidence-based review]: report of the Quality Standards Subcommittee of the American Academy of Neurology. *Neurology*. 2006;67:203-210.)

TABLE 38.4 Recommended Postcardiac Arrest Prognostication Checklist After Therapeutic Hypothermia

First 24 h:
- ☐ Neurologic exam with brainstem reflexes and best motor response
- ☐ NSE daily on days 1-3
- ☐ Noncontrast head CT
- ☐ Connect to continuous EEG and assess reactivity and seizures.
- ☐ Characterize myoclonus (A. spontaneous, stimulus-induced or stimulus-worsened; B. whole body, segmental [one limb] or multifocal; C. if multifocal, synchronous or nonsynchronous; D. stereotyped or nonstereotyped).
- ☐ Document sedatives and paralytics at onset of myoclonus.

Preferred timing of neurologic prognostication is beyond 72 h of postrewarming AND cessation of sedation

5 d postarrest:
- ☐ Order SSEPs; minimize sedation.
- ☐ MRI brain without contrast days 5-7 postarrest or head CT if MRI not feasible

7 d postarrest:
- ☐ Exclude confounders (2.5 half-lives of sedatives, paralytics, metabolic derangements, etc).
- ☐ Brainstem exam and best motor response
- ☐ Follow-up EEG reports (reactivity, seizures, and background patterns)

Abbreviations: CT, computed tomography; EEG, electroencephalography; MRI, magnetic resonance imaging; NSE, neuron-specific enolase; SSEPs, somatosensory-evoked potentials.

outcome compared to neurologic exam or electrophysiologic assessments with comparable specificity. The role of imaging in prognostication is also being studied. In particular, MRI has been studied in an attempt to quantify extent of cerebral damage on ADC. Ultimately, there may be a combination of biomarker and imaging data that may aid in prognostication when the patient's outcome is otherwise indeterminate based on clinical exam, neuron-specific enolase, and SSEP.

It is important to keep in mind the so-called self-fulfilling prophecy that occurs in clinical practice and is a limitation in many studies on outcome after cardiac arrest. There is always a temptation to prognosticate earlier and earlier due to scarcity of resources, anxious families, and astronomical health care costs. Additionally, results of tests that may not accurately predict outcome in the post-TH era can influence clinician decision making. These tests are studied as predictors of outcome but often directly affect the clinician's decision making and counseling to families—thereby confounding any study of outcome. Moving forward, outcome measures need to be changed from survival to degree of neuropsychosocial impairment in survivors.

LEVEL 1 EVIDENCE

1. Hypothermia After Cardiac Arrest Study Group. Mild therapeutic hypothermia to improve the neurologic outcome after cardiac arrest. *N Engl J Med*. 2002;346:549-556.
2. Bernard SA, Gray TW, Buist MD, et al. Treatment of comatose survivors of out-of-hospital cardiac arrest with induced hypothermia. *N Engl J Med*. 2002;346:557-563.
3. Nielsen N, Wetterslev J, Cronberg T, et al. Targeted temperature management at 33°C versus 36°C after cardiac arrest. *N Engl J Med*. 2013;369:2197-2206.
4. Callaway CW, Donnino MW, Fink EL, et al. Part 8: post-cardiac arrest care: 2015 American Heart Association guidelines update for cardiopulmonary resuscitation and emergency cardiovascular care. *Circulation*. 2015;132(18)(suppl 2):S465-S482.

SUGGESTED READINGS

Admiraal MM, van Rootselaar AF, Horn J. International consensus on EEG reactivity testing after cardiac arrest: towards standardization. *Resuscitation*. 2018;131:36-41.

Adrie C, Adib-Conquy M, Laurent I, et al. Successful cardiopulmonary resuscitation after cardiac arrest as a "sepsis-like" syndrome. *Circulation*. 2002;106:562-568.

Arbelaez A, Castillo M, Mukherji SK. Diffusion-weighted MR imaging of global cerebral anoxia. *AJNR Am J Neuroradiol*. 1999;20:999-1007.

Bettermann K, Patel S. Neurologic complications of carbon monoxide intoxication. In: Biller J, Ferro JM, eds. *Neurologic Aspects of Systemic Disease, Part II*. Amsterdam, Netherlands: Elsevier; 2014:971-979. *Handbook of Clinical Neurology*; vol 120.

Bouwes A, Binnekade JM, Kuiper MA, et al. Prognosis of coma after therapeutic hypothermia: a prospective cohort study. *Ann Neurol*. 2012;71:206-212.

Daubin C, Quentin C, Allouche S, et al. Serum neuron-specific enolase as predictor of outcome in comatose cardiac-arrest survivors: a prospective cohort study. *BMC Cardiovasc Disord*. 2011;11:48.

Duggal N, Lach B. Selective vulnerability of the lumbosacral spinal cord after cardiac arrest and hypotension. *Stroke*. 2002;33:116-121.

Els T, Kassubek J, Kubalek R, Klisch J. Diffusion-weighted MRI during early global cerebral hypoxia: a predictor for clinical outcome? *Acta Neurol Scand*. 2004;110:361-367.

Fugate JE, Wijdicks EF, Mandrekar J, et al. Predictors of neurologic outcome in hypothermia after cardiac arrest. *Ann Neurol*. 2010;68:907-914.

Go AS, Mozaffarian D, Roger VL, et al. Heart disease and stroke statistics—2014 update: a report from the American Heart Association. *Circulation*. 2014;129:e28-e292.

Greer DM, Rosenthal ES, Wu O. Neuroprognostication of hypoxic-ischaemic coma in the therapeutic hypothermia era. *Nat Rev Neurol*. 2014;10:190-203.

Greer D, Scripko P, Bartscher J, et al. Clinical MRI interpretation for outcome prediction in cardiac arrest. *Neurocrit Care*. 2012;17:240-244.

Jarnum H, Knutsson L, Rundgren M, et al. Diffusion and perfusion MRI of the brain in comatose patients treated with mild hypothermia after cardiac arrest: a prospective observational study. *Resuscitation*. 2009;80:425-430.

Kamps MJ, Horn J, Oddo M, et al. Prognostication of neurologic outcome in cardiac arrest patients after mild therapeutic hypothermia: a meta-analysis of the current literature. *Intensive Care Med*. 2013;39:1671-1682.

Kilgannon JH, Jones AE, Parrillo JE, et al. Relationship between supranormal oxygen tension and outcome after resuscitation from cardiac arrest. *Circulation*. 2011;123:2717-2722.

Kim F, Nichol G, Maynard C, et al. Effect of prehospital induction of mild hypothermia on survival and neurological status among adults with cardiac arrest: a randomized clinical trial. *JAMA*. 2014;311:45-52.

Kim J, Choi BS, Kim K, et al. Prognostic performance of diffusion-weighted MRI combined with NSE in comatose cardiac arrest survivors treated with mild hypothermia. *Neurocrit Care*. 2012;17:412-420.

Languren G, Montiel T, Julio-Amilpas A, Massieu L. Neuronal damage and cognitive impairment associated with hypoglycemia: an integrated view. *Neurochem Int*. 2013;63:331-343.

Lascarrou J-B, Merdji H, Le Gouge A, et al. Targeted temperature management for cardiac arrest with nonshockable rhythm. *N Engl J Med*. 2019;381(24):2327-2337.

Muttikkal TJ, Wintermark M. MRI patterns of global hypoxic-ischemic injury in adults. *J Neuroradiol*. 2013;40:164-171.

Oksanen T, Tiainen M, Skrifvars MB, et al. Predictive power of serum NSE and OHCA score regarding 6-month neurologic outcome after out-of-hospital ventricular fibrillation and therapeutic hypothermia. *Resuscitation*. 2009;80:165-170.

Polderman KH. Mechanisms of action, physiological effects, and complications of hypothermia. *Crit Care Med*. 2009;37(suppl 7):S186-S202.

Pynnönen L, Falkenbach P, Kamarainen A, Lonnrot K, Yli-Hankala A, Tenhunen J. Therapeutic hypothermia after cardiac arrest—cerebral perfusion and metabolism during upper and lower threshold normocapnia. *Resuscitation*. 2011;82:1174-1179.

Rossetti AO, Oddo M, Logroscino G, Laplan PW. Prognostication after cardiac arrest and hypothermia: a prospective study. *Ann Neurol*. 2010;67:301-307.

Rossetti AO, Urbano LA, Delodder F, Kaplan PW, Oddo M. Prognostic value of continuous EEG monitoring during therapeutic hypothermia after cardiac arrest. *Crit Care*. 2010;14:R173.

Rundgren M, Karlsson T, Nielsen N, Cronberg T, Johnsson P, Friberg H. Neuron specific enolase and S-100B as predictors of outcome after cardiac arrest and induced hypothermia. *Resuscitation*. 2009;80:784-789.

Samaniego EA, Mlynash M, Caulfield AF, Eyngorn I, Wijman CAC. Sedation confounds outcome prediction in cardiac arrest survivors treated with hypothermia. *Neurocrit Care*. 2011;15:113-119.

Sandroni C, Cariou A, Cavallaro F, et al. Prognostication in comatose survivors of cardiac arrest: an advisory statement from the European Resuscitation Council and the European Society of Intensive Care Medicine. *Intensive Care Med*. 2014;40(12):1816-1831.

Satran R. Spinal cord infarction. *Stroke*. 1988;19:529-532.

Shprecher D, Mehta L. The syndrome of delayed post-hypoxic leukoencephalopathy. *NeuroRehabilitation*. 2010;26:65-72.

Singhal AB, Topcuoglu MA, Koroshetz WJ. Diffusion MRI in three types of anoxic encephalopathy. *J Neurol Sci*. 2002;196:37-40.

Steffen IG, Hasper D, Ploner CJ, et al. Mild therapeutic hypothermia alters neuron specific enolase as an outcome predictor after resuscitation: 97 prospective hypothermia patients compared to 133 historical non-hypothermia patients. *Crit Care*. 2010;14:R69.

Weaver LK. Clinical practice. Carbon monoxide poisoning. *N Engl J Med*. 2009;360:1217-1225.

Weisfeldt ML, Becker LB. Resuscitation after cardiac arrest: a 3-phase time-sensitive model. *JAMA*. 2002;288:3035-3038.

Wijman CA, Mlynash M, Caulfield AF, et al. Prognostic value of brain diffusion-weighted imaging after cardiac arrest. *Ann Neurol*. 2009;65:394-402.

Wu O, Sorensen AG, Benner T, Singhal AB, Furie KL, Greer DM. Comatose patients with cardiac arrest: predicting clinical outcome with diffusion-weighted MR imaging. *Radiology*. 2009;252:173-181.

Intracerebral Hemorrhage 39

Stephan A. Mayer and Fred Rincon

KEY POINTS

1. Intracerebral hemorrhage (ICH) remains the most devastating and most untreatable form of stroke.
2. The most important modifiable risk factor for ICH is chronic hypertension.
3. Oral anticoagulants are a significant cause of ICH, accounting for approximately 15% of cases.
4. Mainstays of ICH management include emergent blood pressure control, correction of coagulopathy, and treatment of mass effect from cerebral edema.
5. Risk factors for poor outcome after ICH include advanced age, hematoma volume, coma, infratentorial location, and the presence of intraventricular hemorrhage.

INTRODUCTION

Intracerebral hemorrhage (ICH) is defined as the acute spontaneous bleeding into the brain parenchyma (**Fig. 39.1**). Primary ICH results from microscopic small artery degeneration in the brain, caused either by chronic, poorly controlled hypertension (80% of cases), or cerebral amyloid angiopathy (CAA; 20% of cases). Secondary ICH refers to intraparenchymal bleeding from a diagnosable anatomic vascular lesion or coagulopathy (**Table 39.1**).

EPIDEMIOLOGY

The overall incidence of ICH is estimated to be 12 to 15 cases per 100,000 per year. As the least treatable and most devastating form of stroke, ICH is a leading cause of mortality, morbidity, and disability in the United States and worldwide, accounting for 10% to 30% of all stroke hospital admissions. Many ICH patients require long-term health care, and only 20% of patients regain functional independence. About 40% to 80% of ICH patients die within the first 30 days, and half of all deaths occur within the first 48 hours.

RISK FACTORS

Hypertension and older age are the strongest predictors of incident ICH. Studies have shown that noncompliance with antihypertensive medications increases the risk of ICH, and control of blood pressure (BP) has been shown to reduce this risk. Chronic hypertension causes a small-vessel vasculopathy characterized by fragmentation, degeneration, and the eventual rupture of small penetrating vessels within the brain termed *lipohyalinosis*. Commonly affected structures include the basal ganglia and thalamus (50%), lobar regions (33%), and brainstem and cerebellum (17%). On pathologic examination, the pattern of small-vessel damage is characterized by (1) degeneration of medial smooth muscle cells; (2) small miliary aneurysms associated with thrombosis

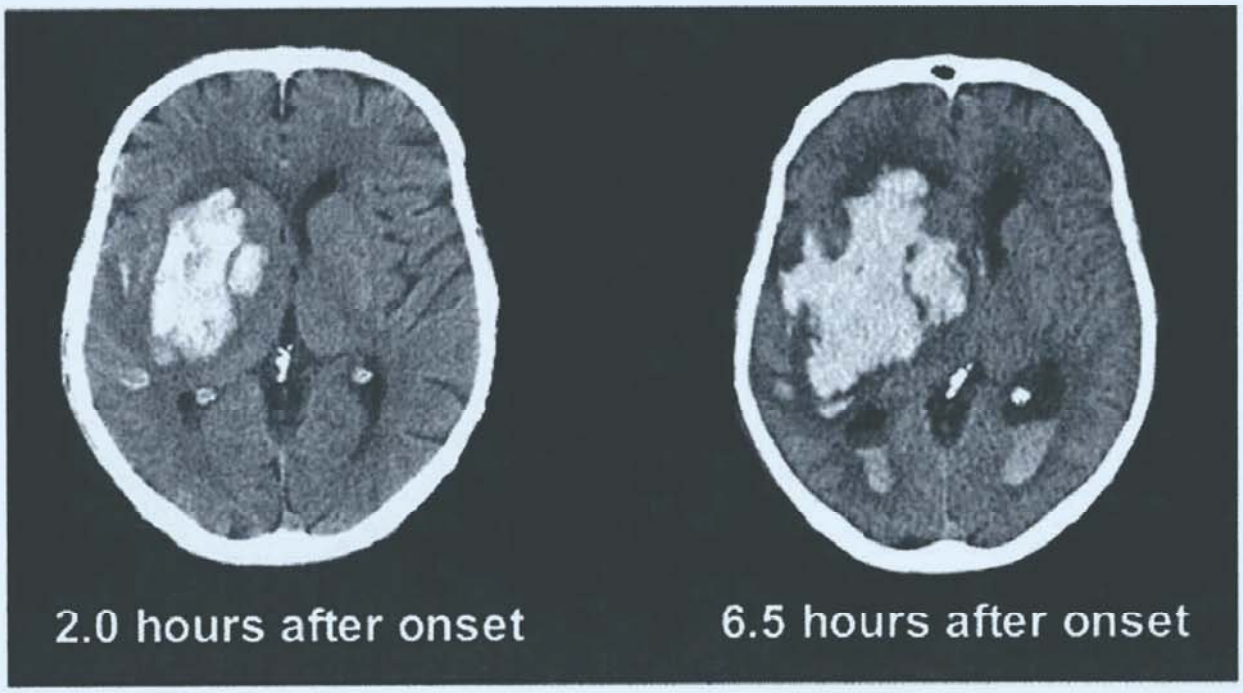

FIGURE 39.1 Basal ganglia intracerebral hemorrhage with hematoma followed by expansion and intraventricular hemorrhage.

TABLE 39.1 Etiologic Factors for Intracerebral Hemorrhage

Risk Factors for Primary Intracerebral Hemorrhage
Demographic
Age
Black race/ethnicity
Vascular Risk Factors
Chronic hypertension (small-vessel disease)
Alcohol
Smoking
Low low-density lipoprotein cholesterol
Vascular Pathology
Amyloid angiopathy (including hereditary forms)
Risk Factors for Secondary Intracerebral Hemorrhage
Brain Infarction
Hemorrhagic transformation of subacute ischemic lesion
Cerebral venous/sinus thrombosis
Preexisting Vascular Lesions
Cavernous angioma
Arteriovenous malformation
Malignancies
Brain tumor
Cerebral metastasis
Inflammatory
Vasculitis
Endocarditis (mycotic aneurysm)
Hematologic
Coagulopathy
Thrombocytopenia
Iatrogenic
Anticoagulants
Fibrinolysis
Toxic
Cocaine
Amphetamines

and microhemorrhages; (3) accumulation of nonfatty debris; and (4) hyalinization of the intima, preferentially at bifurcation points and distal portions of the vessel. It is unclear why some patients develop deep brain infarcts and others develop hemorrhages, but some have implicated the sudden rupture of microaneurysms, also known as *Charcot-Bouchard microaneurysms*, as the basis for ICH. Other nonmodifiable risk factors for ICH include male gender and African American or Japanese race/ethnicity.

Because cholesterol has a key role in the structural formation of cell membranes, low-density lipoprotein cholesterol levels have been implicated as a risk factor for primary ICH, although there is controversy regarding this association, as the results from observational studies and prospective randomized trials of cholesterol reduction have yielded conflicting results.

Heavy alcohol intake has been implicated as a risk factor for ICH in several studies. In theory, alcohol may affect platelet

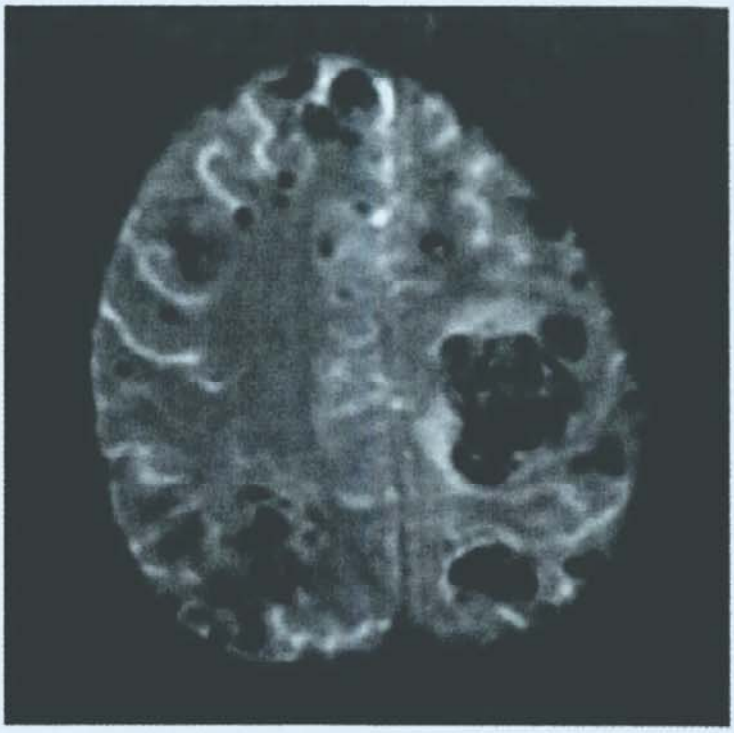

FIGURE 39.2 Gradient echo magnetic resonance imaging sequence showing multiple chronic cortical microbleeds, diagnostic of amyloid angiopathy.

function and coagulation physiology and enhance vascular fragility.

The CAA is an important risk factor for ICH in the elderly (Fig. 39.2). The CAA is characterized by the deposition of β-amyloid protein in small- to medium-sized blood vessels of the brain and leptomeninges, which may undergo fibrinoid necrosis. It can occur as a sporadic disorder, in association with Alzheimer disease, or with certain familial syndromes (apolipoprotein E2 and E4 allele). Traditionally, CAA has generally been diagnosed by postmortem examination. In certain circumstances, CAA can be ascertained in life by examination of a drained hematoma and/or brain biopsy. The Boston CAA criteria (Table 39.2) is a validated criterion that uses both clinical and radiologic variables for the diagnosis of CAA.

Brain tumors, use of sympathomimetic drugs, coagulopathies, cavernomas, and arteriovenous malformations can also cause brain hemorrhages. Further differential diagnoses of underlying pathologies are summarized in Table 39.1. Although treatment with anticoagulants or fibrinolytic agents entails a higher risk of hemorrhage with increasing doses, the role of aspirin intake in this context is controversial. The detection of microbleeds in gradient echo magnetic resonance imaging (MRI) implies that aspirin is a risk factor for hemorrhage in patients on anticoagulant therapy; MRI evidence of microbleeds should prompt reconsideration of the indications for anticoagulation.

PATHOBIOLOGY

Abrupt arterial rupture leads to rapid accumulation of blood within the brain parenchyma and increase in local tissue pressure followed by the abrupt onset of shearing forces and physical destruction. In addition to the relative mass effect, the hematoma itself induces three early pathophysiologic changes in the surrounding brain tissue: (1) neuronal and glial cell death

TABLE 39.2 Boston Criteria for Diagnosis of Cerebral Amyloid Angiopathy (CAA)-Related Hemorrhage

1. Definite CAA
A. Full postmortem examination demonstrating
i. Lobar, cortical, or corticobasal hemorrhage
ii. Severe CAA with vasculopathy
iii. Absence of other diagnostic lesion
2. Probable CAA with supporting pathology
B. Clinical data and pathologic tissue (evacuated hematoma or cortical biopsy) demonstrating
i. Lobar, cortical, or corticosubcortical hemorrhage
ii. Some degree of CAA in specimen
iii. Absence of other diagnostic lesion
3. Probable CAA
C. Clinical data and MRI or CT demonstrating
i. Multiple hemorrhages restricted to lobar, cortical, or corticosubcortical regions (cerebellar hemorrhage allowed)
ii. Age ≥55 years
iii. Absence of other cause of hemorrhage
4. Possible CAA
D. Clinical data and MRI or CT demonstrating
i. Single lobar, cortical, or corticosubcortical hemorrhage
ii. Age ≥55 years
iii. Absence of other cause of hemorrhage

Abbreviations: CT, computed tomography; MRI, magnetic resonance imaging.

due to apoptosis and inflammation, (2) vasogenic edema, and (3) breakdown of the blood-brain barrier.

Hematoma expansion is an important cause of early neurologic deterioration, and ICH volume is a powerful predictor of outcome after primary ICH. An expanding hematoma may result from persistent bleeding and/or rebleeding from a single arteriolar rupture. Some studies have reported evidence of ICH growth from bleeding into an ischemic penumbra zone surrounding the hematoma, but studies have not confirmed the existence of ischemia in the hypoperfused area in the periphery of the hematoma. Because ischemia does not explain the changes and degree of neurologic dysfunction that occurs after the hemorrhage, neurotoxic and inflammatory mechanisms have more recently been implicated in the pathogenesis of perihemorrhagic tissue damage.

Perihematomal edema may be produced by local and systemic inflammatory mediators that enhance tissue damage either directly or indirectly by the activation of leukocytes, generation of prostaglandins and leukotrienes, and activation of the complement. Intracerebral blood is in part directly responsible for the formation of local edema after ICH.

CLINICAL MANIFESTATIONS

Because most spontaneous hemorrhages arise from tiny vessels, the accumulation of a hematoma takes time and explains the smooth onset of the clinical syndrome over minutes or hours. The progressive course, frequent vomiting, and headache are major points that help to differentiate hemorrhage from infarction.

The *putamen* is the site most frequently affected. When the expanding hematoma involves the adjacent internal capsule, there is a contralateral hemiparesis, usually with hemianesthesia and hemianopia and, in large hematomas, aphasia or impaired awareness of the disorder. However, small self-limiting hematomas close to the capsular region may occasionally mimic lacunar syndromes featuring pure motor or sensory deficits. When the hemorrhage arises in the *thalamus*, hemianesthesia precedes the hemiparesis. Once contralateral motor, sensory, and visual field signs are established, the main points that distinguish the two sites are (1) conjugate horizontal ocular deviation in putaminal hemorrhage and (2) impaired upward gaze in thalamic hemorrhage. *Pontine* hemorrhage usually plunges the patient into coma with quadriparesis and grossly dysconjugate ocular motility disorders, although small hemorrhages may mimic syndromes of infarction. Primary spontaneous hemorrhages within the *mesencephalon* or the *medulla* remain objects of debate and are rare curiosities. When they occur, the anatomic involvement is usually secondary to hemorrhage originating in neighboring diencephalic, cerebellar, or pontine regions. In the *cerebral lobes*, there is an as-yet-unexplained predilection for hemorrhages to occur within the posterior two-thirds of the brain. When they affect one or more cerebral lobes, the syndrome is difficult to distinguish, clinically, from infarction because progressive evolution and vomiting are much less frequent in infarction; also, lobar white matter hematomas often result from arteriovenous malformations, amyloid angiopathy, tumors, or other causes that only uncommonly affect the basal ganglia, thalamus, and pons.

Cerebellar hemorrhage warrants separate description because the mode of onset differs from that of cerebral hemorrhage and because it often necessitates surgical evacuation. The syndrome usually begins abruptly with vomiting and severe ataxia (which usually prevents standing and walking); it is occasionally accompanied by dysarthria, adjacent cranial nerve (mostly sixth and seventh) affection, and paralysis of conjugate lateral gaze to one side, findings that may mislead clinicians into thinking the disease is primarily in the brainstem. However, a cerebellar origin is suggested by the lack of changes in the level of consciousness and lack of focal weakness or sensory loss.

Enlargement of the mass does not change the clinical picture until there is enough brainstem compression to precipitate coma, at which point it is too late for surgical evacuation of the hemorrhage to reverse the disorder. This small margin of time between an alert state and an irreversible coma makes it imperative to consider the diagnosis in all patients with this clinical syndrome and is a reason to have patients who present in the emergency room with vomiting of undetermined origin attempt to stand and walk.

DIAGNOSIS

Nonenhanced computed tomography (CT) scan of the brain is the method of choice to evaluate the presence of ICH (see Fig. 39.1). The CT scan evaluates the size and location of the hematoma, extension into the ventricular system, degree of surrounding edema, and anatomic disruption. Hematoma volume, a powerful predictor of 30-day mortality, can be easily calculated from CT scan images by use of the ABC / 2 method, which involves multiplying the diameter of the hematoma in three dimensions and dividing by 2 (Fig. 39.3). The CT angiography may reveal secondary ICH due to an aneurysm or arteriovenous malformation, or active contrast extravasation into the clot ("spot sign"), which implies an increased risk of early hematoma growth when identified soon after the onset of symptoms. The MRI techniques such as gradient echo are highly sensitive for the diagnosis of ICH as well (see Fig. 39.2). The MRI in patients with atypical ICH patterns on CT may disclose a cause of secondary ICH (ie, tumor, arteriovenous malformation, or hemorrhagic infarction up to 20% of cases). Conventional diagnostic cerebral angiography should be reserved for patients in whom secondary causes of ICH are suspected (see Table 39.1). Findings on CT

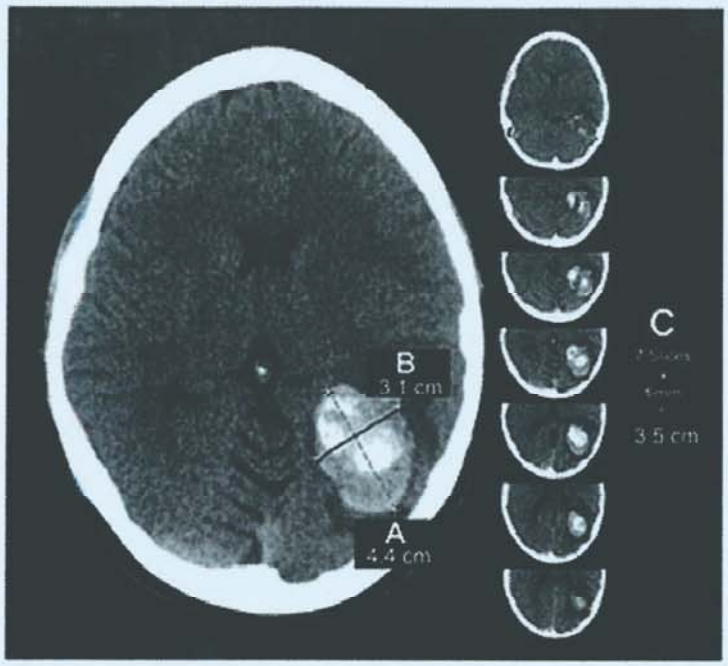

FIGURE 39.3 Intracerebral hemorrhage volume measurement. *A*, largest hemorrhage axial diameter; *B*, largest axial diameter perpendicular to A on same slice; *C*, vertical hemorrhage diameter (number of slices with hemorrhage multiplied by slice thickness). For this example, ABC / 2 = (4.4 cm × 3.1 cm × 3.5 cm) / 2 = 23.9 cm³. (From Beslow LA, Ichord RN, Kasner SE, et al. ABC/XYZ estimates intracerebral hemorrhage volume as a percent of total brain volume in children. *Stroke*. 2010;41[4]:691-694, with permission.)

scan or MRI that should prompt angiographic study include the presence of subarachnoid hemorrhage, intraventricular hemorrhage (IVH), underlying calcification, or lobar hemorrhage in nonhypertensive younger patients. Diagnostic catheter angiography should be strongly considered in all patients with primary IVH and younger nonhypertensive patients with lobar ICH.

MEDICAL MANAGEMENT

Prehospital care of ICH follows similar guidelines as for other types of stroke, where the objective is to provide rapid access to medical facilities capable of dealing with stroke patients. The increasing use of mobile stroke units will increase the diagnosis of ICH during the prehospital stage. The BP control, reversal of anticoagulation, and initiation of seizure prophylaxis may start before admission to the emergency department (ED). Clinical trials are planned to evaluate hemostatic therapies such as recombinant factor VIIa (rFVIIa) given within 2 hours of onset for noncoagulopathic ICH in mobile stroke units.

In the ED, ICH patients should be triaged rapidly with CT scans to access stroke units or intensive care units (ICUs). Observation in an ICU or a similar setting is strongly recommended for at least the first 24 hours because the risk of neurologic deterioration is highest during this period and because the majority of patients with brainstem or cerebellar hemorrhage have depressed level of consciousness requiring ventilatory support. A protocolized checklist for care in the ICU is recommended to ensure standardization of best practices (Table 39.3).

TABLE 39.3 Medical Management Checklist for Acute Intracerebral Hemorrhage

Blood pressure	• Maintain systolic arterial pressure between 130 and 150 mm Hg with continuous infusion labetalol, nicardipine, or clevidipine. • If stuporous or comatose, measure ICP and maintain CPP >70 mm Hg.

Reversal of anticoagulation	• For elevated INR: vitamin K 10 mg IV and 4F-PCC
	  • INR 2-<4: 25 U/kg; not to exceed 2,500 units
	  • INR 4-6: 35 U/kg; not to exceed 3,500 units
	  • INR >6: 50 U/kg; not to exceed 5,000 units
	• For dabigatran: idarucizumab 2.5 g IV over 5 min times two doses (total 5 g)
	• For apixaban or rivaroxaban: andexanet alfa IV
	  Low dose = 400 mg bolus + 480 mg over 120 min
	  High dose = 800 mg bolus + 960 mg over 120 min
	  <8 h of ingestion
	  Rivaroxaban <10 mg low dose; >10 mg or unknown high dose
	  Apixaban <5 mg low dose; >5 mg or unknown high dose
	  >8 h of ingestion, use low dose
	• For heparin or LMWH: protamine sulfate 10-50 mg slow IV (1 mg reverses approximately 100 units of heparin)
	• For thrombocytopenia (platelet <100,000/μL) or platelet dysfunction: desmopressin 0.3 μg/kg IV and/or transfuse 1 unit of platelets (single-donor apheresis)

Intracranial hypertension	• Elevate head of bed to 30°. • Analgosedation with propofol, fentanyl, midazolam or dexmedetomidine to a quiet, motionless state • Fever control, acetaminophen, advanced cooling methods • Mannitol 1.0-1.5 g IV and hypertonic saline 23% 30 mL IV over 30 min • Hyperventilate to Pco_2 of 30 mm Hg for <30 min.
Fluids and nutrition	• Normal (0.9%) saline at 1.0 mL/kg/h • Begin enteral feeding via nasoduodenal tube within 24 h.
Seizure prophylaxis	• For coma with intracranial hypertension or acute seizures: fosphenytoin (15-20 mg/kg) followed by 300 mg IV daily or levetiracetam 1,000 mg twice a day for 7 d
Physiologic homeostasis	• Treat fever aggressively. • Insulin drip to maintain glucose 150-180 mg/dL
Deep venous prophylaxis	• Intermittent compression devices upon admission • Start heparin or LMWH 48 h post-ICH.

Abbreviations: CPP, cerebral perfusion pressure; 4F-PCC, four-factor prothrombin complex concentrate containing factors II, VII, IX, and X; ICH, intracerebral hemorrhage; ICP, intracranial pressure; INR, international normalized ratio; IV, intravenously; LMWH, low molecular weight heparin.

Hemostasis and Emergency Reversal of Anticoagulation

The aim of hemostasis is to stop ongoing bleeding and to identify patients for specific reversal strategies who may have received antithrombotic therapies.

Hemostatic Therapy for Noncoagulopathic Intracerebral Hemorrhage

Observational studies indicate that in patients with normal coagulation active bleeding occurs in nearly 40% of patients within the first 2 to 3 hours of symptom onset. The strongest determinant of the risk of continued bleeding is the interval from onset to baseline CT, with shorter intervals implying greater risk. Other features that imply an increased risk of hemorrhage expansion within this early time window include larger baseline hematoma volume, concurrent antiplatelet therapy, greater irregularity of clot contour and density, and presence of contrast extravasation within the hematoma on CT angiography ("spot sign").

Two agents, rFVIIa and tranexamic acid, have been tested in clinical trials in noncoagulopathic ICH patients. Despite the presence of a mild-to-moderate hemostatic effect with these agents (3.8 mL less bleeding with rFVIIa and 1.2 mL less bleeding with tranexamic acid), neither produced significant improvement in outcome at 3 months LEVEL 1.[1,2] More recently, two smaller trials of rFVIIa in ICH patients with a positive spot sign on CT angiography treated as late as 6 hours failed to produce a clinical benefit. To this end, new trials are planned to determine whether rFVIIa can arrest active bleeding and improve outcomes when given within 2 hours of symptom onset.

Reversal Agents for Anticoagulation-Related Intracerebral Hemorrhage

Hemostatic abnormalities in patients with acute ICH should be corrected as rapidly as possible. Patients at risk include those on oral anticoagulants (OACs) for several indications, antiplatelet agents, and congenital or acquired factor or platelet deficiencies. The incidence of ICH related to OACs has increased over the last decade. Vitamin K antagonists are the most commonly prescribed OACs, but newer direct oral anticoagulant (DOAC) agents that inhibit thrombin or factor Xa such as dabigatran, rivaroxaban, and apixaban are increasingly being offered on the basis of superior safety data. As a general measure, activated charcoal 1 g/kg is a treatment option for patients with ICH who have ingested warfarin or a DOAC orally within the last 2 hours.

Warfarin

Patients with ICH receiving warfarin should be reversed immediately with a four-factor prothrombin complex concentrate at a dose of 25 to 50 U/kg depending on the baseline international normalized ratio (INR) (see **Table 39.3**) and vitamin K 10 mg intravenously LEVEL 1.[3,4] Four-factor prothrombin complex concentrates contain the vitamin K–dependent coagulation factors II, VII, IX, and X; normalize the INR more rapidly than fresh frozen plasma; and can be given in much smaller volumes much more rapidly. The rates of hematoma expansion and death are significantly lower in anticoagulated ICH patients achieving correction of INR to <1.3 and systolic blood pressure (SBP) to <160 mm Hg within 4 hours of hospital admission. Treatment should never be delayed in order to check coagulation tests when a patient has acute ICH and a stated history of OAC use.

Dabigatran

For the newer DOACs, specific reversal agents are now U.S. Food and Drug Administration approved in the United States. For ICH related to the direct thrombin inhibitor dabigatran, the monoclonal antibody idarucizumab should be administered intravenously at a dose of 5 g divided into two doses (see **Table 39.3**) LEVEL 1.[5]

Factor Xa Inhibitors

For rivaroxaban, apixaban, edoxaban, and other factor Xa inhibitors, andexanet alfa is an inactive form of factor Xa designed to temporarily bind with high affinity to circulating factor Xa inhibitors in a 1:1 ratio, inhibiting their action. Treatment should be given immediately and dosing depends on the dose of the agent (see **Table 39.3**) LEVEL 1.[6]

Unfractionated and Low Molecular Weight Heparin

Patients with ICH who have been anticoagulated with unfractionated or low molecular weight heparin should be reversed with protamine sulfate. As a general rule, 1 mg of protamine should be given for each 100 mg of unfractionated heparin or 100 units of low molecular weight heparin received within the past 2 hours (see **Table 39.3**).

Antiplatelet Agents

The ICH patients with any form of platelet dysfunction, including renal disease, exposure to antiplatelet agents, or an acquired or hereditary platelet disorder (eg, mechanical circulatory support or von Willebrand disease) can be treated with a single dose of desmopressin 0.3 μg/kg intravenously. It is reasonable to transfuse platelets (6 units of pooled whole blood or 1 unit of single-donor apheresis platelets) to ICH patients who are thrombocytopenic (<50,000/μL). One recent trial reported that platelet transfusions are not helpful, and possibly harmful, in ICH patients on antiplatelet agents LEVEL 1.[7]

Blood Pressure Control

Acute hypertension is common in stroke patients upon arrival to the ED. Acute ICH often leads to extreme arterial hypertension, which has been associated with hematoma expansion, neurologic deterioration, and poor outcome. Excessive reduction in BP after ICH in the setting of impaired autoregulation can theoretically result in exacerbation of ischemic injury, whereas lack of BP control can theoretically exacerbate early hematoma growth and cerebral edema. Single-center studies and a systematic review have reported an increased risk of deterioration, death, or dependency with extremely high or low admission BP after ICH.

Blood Pressure Targets

Two phase 3 clinical trials, INTERACT-2 and ATACH-2, compared standard permissive management (goal SBP <180 mm Hg vs more aggressive BP reduction goal SBP <140 mm Hg). In INTERACT-2, lowering the SBP to <140 mm Hg within 6 hours of onset was not associated with improved functional outcome when the modified Rankin scale was analyzed in a dichotomized fashion as the primary endpoint LEVEL 1.[8] However, when outcome was studied using shift analysis, which measures differences across the entire range of outcomes, a slightly more favorable result was achieved with the <140 mm Hg target. However, this effect was not confirmed in the ATACH-2 study, which was stopped prematurely for futility after an interim analysis of 1,000 patients LEVEL 1.[9] Moreover, ATACH-2 demonstrated

that lowering of SBP <140 mm Hg was associated with higher proportion in serious adverse events, especially renal complications, particularly if SBP fell below 120 mm Hg. Neither trial demonstrated a substantial effect on hematoma expansion. In summary, it appears that the intensive SBP lowering to a range no lower than 130 to 150 mm Hg after ICH is reasonably safe and might be associated with a slight benefit if overshoot is avoided.

Once in the ICU, current American Heart Association guidelines suggest that intracranial pressure (ICP) monitoring should be used in patients with large hematomas and depressed level of consciousness to ensure that cerebral perfusion pressure (CPP) is maintained above 60 mm Hg. A more recent study of 18 comatose ICH patients using brain multimodality monitoring showed that CPP levels less than 80 mm Hg were associated with an increased risk of critical brain tissue hypoxia, which was in turn associated with increased mortality.

Antihypertensive Agents

Given the need to precisely control BP levels in the setting of impaired autoregulation, use of fast-acting continuous infusion agents with intra-arterial monitoring is recommended. Preferred agents are β-blockers (intravenous labetalol) and calcium channel blockers (nicardipine and clevidipine) (Table 39.4). Use of nitroprusside has drawbacks because this agent is associated with higher rate of medical complications and may exacerbate cerebral edema and ICP. Clevidipine, an ultrashort-acting, dihydropyridine L-type calcium channel blocker with rapid onset and offset of action, has also recently been approved for the reduction of BP. Comparative studies have demonstrated that clevidipine is as safe and effective as nitroglycerin, sodium nitroprusside, or nicardipine for reducing BP but has greater ability to maintain a given target range. Oral and sublingual agents are not preferred because of the need for immediate and precise BP control. Although no prospective study has addressed the timing of conversion from intravenous to oral antihypertensive management, this process can generally be started between 24 and 72 hours as long as the patient's critical condition has been stabilized.

Cerebral Edema and Intracranial Pressure

Large-volume ICH carries the risk of developing cerebral edema (Chapter 111) and elevated ICP. Brain swelling can progress for many days after the onset of ICH but most often drives neurologic deterioration within the first 72 hours in patients with hemorrhages exceeding 30 mL in volume. The presence of IVH further increases ICP and the risk of mortality. This effect is primarily related to the development of obstructive hydrocephalus and alterations of normal cerebrospinal fluid flow dynamics. Patients with large-volume ICH, intracranial mass effect, and coma may benefit from ICP monitoring, although this intervention has not been proven to benefit outcomes after ICH.

Management of cerebral edema should be guided by measurement of ICP with an external ventricular drain or parenchymal monitor, with efforts directed at maintaining ICP less than 20 mm Hg and CPP greater than 70 mm Hg. Therapy should be directed by an algorithm that includes head elevation, fever control, analgosedation, CPP optimization, bolus osmotherapy, controlled hyperventilation, and, as a last resort, salvage hemicraniectomy in selected younger patients (see Chapter 111 for a detailed protocol).

TABLE 39.4 Parenteral Vasoactive Agents in Neurologic Emergencies: Preferred Antihypertensives (Listed in Order of Preference)[a]

Drug	Mechanism	Dose	Onset	Duration	Adverse Effects and Cautions	Comments
Clevidipine	L-type CCB (dihydropyridine)	1-2 mg/h infusion	2-4 min	5-15 min	Reflex tachycardia, hypertriglyceridemia. Cautions: soybean allergy	Mean interval 4-6 min to target BP
Nicardipine	L-type CCB (dihydropyridine)	5-15 mg/h infusion	5-10 min	30 min to 4 h	Reflex tachycardia, headache, flushing, local phlebitis; caution in AS and LV failure	Fast acting and easy to titrate
Labetalol	α_1, β_1, β_2 antagonist	20-80 mg bolus every 10 min, up to max 300 mg; then 0.5-2 mg/min infusion	5-10 min	3-6 h	Bradycardia, heart block, bronchospasm, orthostatic hypotension, worsened LV failure	ICH patients may be refractory to beta blockade
Hydralazine	Arterial vasodilator	5-40 mg IV bolus every 6 hours	15 min	5-30 min	Reflex tachycardia, drug-induced lupus syndrome	Use as 2nd or 3rd line therapy
Enalaprilat	ACE inhibitor	0.625 mg test dose then 1.25-5 mg every 6 h	15-30 min	6-12 h	Variable response, precipitous fall in BP in high-renin states	Use as 2nd or 3rd line therapy
Nitroprusside[b]	Nitrovasodilator (arterial and venous)	0.25-10 μg/kg/min infusion	Immediate	1-4 min	Thiocyanate and cyanide intoxication, unreliable response with excessive BP reduction, ICP elevation	Should not be used as 1st line therapy

Abbreviations: ACE, angiotensin-converting enzyme; AS, aortic stenosis; BP, blood pressure; CCB, calcium channel blocker; COPD, chronic obstructive pulmonary disease; HTN, hypertension; ICP, intracranial pressure; LV, left ventricle; MI, myocardial infarction.

[a]Data from Rose JC, Mayer SA. Optimizing blood pressure in neurological emergencies. *Neurocrit Care*. 2004;1(3):287-299.

[b]Nitroprusside is becoming less favored for use in neurologic emergencies (see text).

Because controlled ventilation, sedation, and CPP targets are usually maintained in the background over the long term, bolus osmotherapy with either 1.0 to 1.5 g/kg of 20% mannitol or 0.5 to 2.0 mL/kg of 23.4% hypertonic saline are the main weapons at the clinician's disposal for actively herniation or ICP. The effectiveness of 23.4% saline solution over 10% saline and mannitol during imminent transtentorial herniation has been demonstrated in a canine model of ICH, but for the most part, both solutions can be considered equivalent, with a peak ICP-lowering effect at 30 minutes. Apart from a negative trial of glycerol given within 48 hours of ICH onset, no prospective randomized control trials have compared the effectiveness of the different osmotic agents available for the management of increased ICP in ICH. Effectiveness of hyperosmolar therapy for control of ICP depends on rapid institution of therapy and achieving higher differences in baseline osmolarity. Corticosteroids such as dexamethasone do not improve the outcome of ICH and are not indicated for the treatment of cerebral edema associated with ICH LEVEL 2.[10]

Seizures

Twelve percent of ICH patients experience convulsive seizures during their hospitalization; the risk is increased with lobar location. Seizure activity in ICH patients should aggressively be diagnosed and treated. Patients with ICH may benefit from prophylactic antiepileptic therapy (antiepileptic drugs [AEDs]), but no randomized trial has addressed the use of AEDs in the setting of ICH so current guidelines do not endorse the use of AEDs for ICH patients without seizures. Continuous electroencephalographic monitoring is recommended in all comatose patients in order to detect convulsive seizures or status epilepticus. Even with anticonvulsant therapy, continuous electroencephalographic monitoring reveals electrographic seizure activity in 20% of comatose patients. It is unclear whether midazolam infusion or other aggressive measures to eliminate these seizures can improve outcome. If seizures have not occurred, anticonvulsants should be discontinued at discharge because they can hamper neurologic recovery during rehabilitation.

Medical Support

For patients requiring ventilatory support, maintain normoxia and normocapnia, avoid routine hyperoxygenation, and prevent ventilator-associated infections. Additional measures in the stroke unit or ICU include evaluation and assessment of speech and swallowing for nutritional support, maintenance of normoglycemia (goal <180 mg/dL), gastrointestinal prophylaxis for intubated patients, and deep venous thrombosis prophylaxis, which can be safely started 48 hours after ICH onset. Early enteral feeding should be initiated via a nasoduodenal feeding tube within inpatients who lack the capacity to swallow to combat malnutrition and muscle wasting. Though the relationship between fever, cerebral edema and poor outcome after ICH has been established in observational studies, no prospective data is currently available to evaluate the impact of active fever prophylaxis. Trials evaluating this treatment strategy are underway. Until further evidence becomes available, fever should be actively treated with antipyretics and advanced cooling methods if needed.

SURGICAL MANAGEMENT

The most urgent treatment consideration for ICH is often whether to proceed emergently with surgical evacuation or external ventricular drain placement. Owing to the irreversible nature of secondary brain injury related to herniation and ICP, results are always better when definitive measures to reverse these processes are performed as soon as possible. Delayed surgical intervention triggered by clinical deterioration must always be tempered by realization that an earlier procedure would have been the better plan.

Ventricular Drainage

An external ventricular drain is indicated in all stuporous or comatose patients with IVH and ventricular enlargement in whom aggressive support is indicated. This lifesaving procedure, which can be performed at the bedside, decompresses the intracranial vault and arrests the process of downward brainstem herniation by allowing drainage of bloody cerebrospinal fluid into a drainage receptacle. Connecting the drainage system to a pressure transducer also allows measurement of ICP and monitoring of CPP.

Intraventricular thrombolysis with tissue plasminogen activator (1 mg every 8 h over a maximum of 4 d) has been given to promote clot lysis and possibly improve neurologic outcome by reducing obstructive hydrocephalus and hemorrhage-related neurotoxicity. The CLEAR-III study found that at 6 months, this treatment reduces mortality but increases the proportion of survivors dependent with poor functional outcome, resulting in no net benefit in terms of survival with good outcome LEVEL 2.[11] For this reason, intraventricular thrombolysis remains a therapeutic option but is not considered standard of care.

Craniotomy

Apart from cases suffering cerebellar hemorrhage, any decision on whether, how, and when to intervene neurosurgically after ICH is subject to intense debate and awaits further data from ongoing prospective trials. To date, all clinical trials have failed to show a superiority of hematoma evacuation over medical therapy for supratentorial ICH in both patients with hematoma >2 cm in diameter and Glasgow Coma Scale score ≥5 (STICH-I) or in conscious patients with superficial lobar ICH 10 to 100 mL without IVH (STICH-II) LEVEL 2.[12,13] However, these trials did not enroll patients if the investigator felt that emergency surgery was clearly a lifesaving intervention, leading to inclusion bias. Many experts feel that urgent craniotomy can improve the outcome of younger patients with large lobar hemorrhages and a deteriorating course due to mass effect (Fig. 39.4).

In contrast to supratentorial ICH, it is widely accepted that patients with cerebellar hemorrhages exceeding 3 cm in diameter benefit from emergent surgical evacuation. Abrupt and dramatic deterioration to coma can occur within the first 24 hours of onset in these patients. For this reason, it is generally unwise to defer surgery in these patients until further clinical deterioration occurs.

Minimally Invasive Surgery

As emergent craniotomy has been unable to improve neurologic outcome after ICH, the role of other surgical techniques such as minimally invasive surgery has garnered interest over the last decade, and good anecdotal results have been reported (Fig. 39.5).

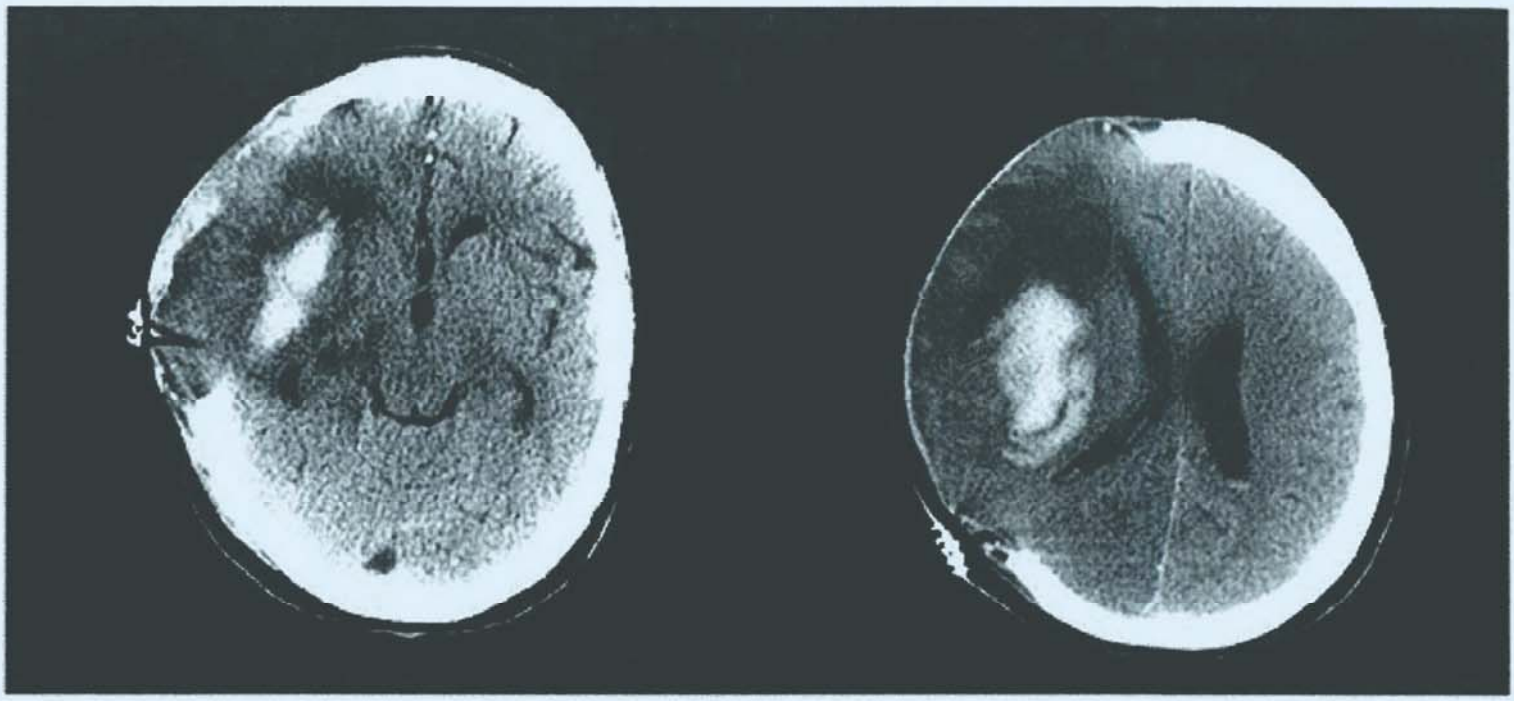

FIGURE 39.4 Lifesaving hemicraniectomy in a patient with lobar intracerebral hemorrhage considered otherwise lethal.

The advantages of minimally invasive surgery over conventional craniotomy include reduced operative time, the possibility of performance under local anesthesia, and reduced surgical trauma to the brain. However, in the recent MISTIE III trial, catheter-directed clot aspiration assisted with thrombolysis (tissue plasminogen activator 1 mg every 8 h) failed to improve functional outcomes LEVEL 2.[14] Further trials evaluating a variety of endoscopic suction devices are planned or underway.

SECONDARY PREVENTION

The risk of recurrent ICH is 2% per year in patients with chronic hypertension, and in those patients with diastolic BP higher than 90 mm Hg, the rate of recurrence is as high as 10% per year. The BP reduction significantly decreases the risk of ICH and other forms of stroke and is unequivocally the most effective method for primary and secondary prevention of ICH. In the Perindopril Protection Against Recurrent Stroke Study trial, a BP regimen of perindopril, an angiotensin-converting enzyme inhibitor, was found to be more effective than placebo for preventing recurrent stroke among both hypertensive and nonhypertensive individuals following incident stroke or transient ischemic attack LEVEL 2.[15]

Prior studies have demonstrated that all survivors of lobar ICH and some patients with deep hemispheric ICH who have a history of atrial fibrillation should not be offered long-term anticoagulation therapy due to the high risk of recurrent hemorrhage. Conversely, patients with a high risk of thromboembolic events and low recurrent risk of ICH may benefit from long-term anticoagulation therapy. Cerebral microbleeds, a phenotype of small vessel

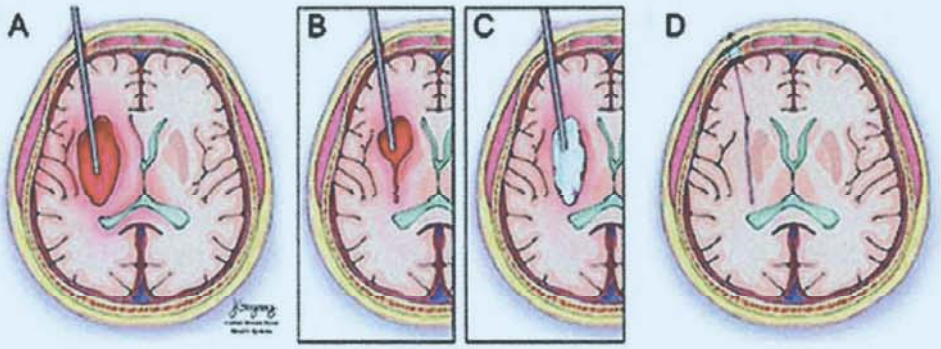

FIGURE 39.5 Schematic representation of the Stereotactic Intracerebral Hemorrhage Underwater Blood Aspiration technique for minimally invasive endoscopic intracerebral hemorrhage evacuation. **A:** The endoscope sheath is inserted 1.5 cm from the distal wall of the hematoma under stereotactic guidance. **B:** Blood is aspirated until the brain closes in around the end of the sheath at which point it is retracted 1 to 2 cm. **C:** When the sheath retracts to the proximal wall of the hematoma cavity, saline is infused through the sheath, inflating the hematoma cavity. **D:** After evacuation, the sheath is removed, and burr hole ultrasound followed by DynaCT are performed to confirm adequate removal. (From Kellner CP, Chartrain AG, Nistal DA, et al. The Stereotactic Intracerebral Hemorrhage Underwater Blood Aspiration [SCUBA] technique for minimally invasive endoscopic intracerebral hemorrhage evacuation. *J NeuroIntervent Surg*. 2018;10[8]:771-776, with permission.)

disease that can be detected on susceptibility weighted or gradient echo MRI, are biomarkers that imply an even particularly high risk of recurrent ICH. This form of imaging may be useful in evaluating the risk and benefits of long-term anticoagulation in ICH survivors with atrial fibrillation or venous thromboembolic disease.

PROGNOSIS

The mortality of ICH is 35% to 50% at 30 days and 47% at 1 year. Factors that consistently predict mortality or adverse outcomes in ICH have been studied extensively. Independent predictors for 30-day and 1-year mortality include Glasgow Coma Scale and/or depressed level of consciousness, age, ICH volume, presence of IVH, and infratentorial origin. A simple clinical grading scale, the *ICH Score* (**Table 39.5**), permits calculation of mortality, allowing use of uniform terms and enhancing communication between physicians. The mortality rates for scores of 0, 1, 2, 3, 4, and 5 are 0%, 13%, 26%, 72%, 97%, and 100%, respectively. Additional factors associated with high mortality after ICH include the presence of subarachnoid hemorrhage, wide pulse pressure, history of coronary artery disease, and hyperthermia. Factors associated with good outcomes include a low National Institutes of Health Stroke Scale score and low temperature on admission.

Except in the most severe cases, caution is warranted when communicating a hopeless prognosis before aggressive efforts have been made to resuscitate victims of ICH. It has become increasingly evident that physicians tend to underestimate the chances of a good outcome and that many poor outcomes result from self-fulfilling prophesies of doom. Mortality after ICH is reduced in patients cared for in a specialty neurologic ICU. This is presumably the result of adherence to best medical practices, early transition to rehabilitation, and being cared for by a team or health care professionals who take an active interest in promoting survival and recovery.

TABLE 39.5 Determination of the Intracerebral Hemorrhage (ICH) Score[a]

Component	Score Points
Glasgow Coma Scale Score	
3-4	2
5-12	1
13-15	0
ICH Volume (cm^3)	
≥30	1
<30	0
Intraventricular Hemorrhage	
Yes	1
No	0
Infratentorial ICH	
Yes	1
No	0
Age (y)	
≥80	1
<80	0

[a]From Hemphill JC III, Bonovich DC, Besmertis L, Manley GT, Johnston SC. The ICH score: a simple, reliable grading scale for intracerebral hemorrhage. Stroke. 2001;32(4):891-897.

LEVEL 1 EVIDENCE

1. Mayer SA, Brun NC, Begtrup K, et al. Efficacy and safety of recombinant activated factor VII for acute intracerebral hemorrhage. *New Engl J Med*. 2008;358(20):2127-2137.
2. Sprigg N, Flaherty K, Appleton JP, et al. Tranexamic acid for hyperacute primary IntraCerebral Haemorrhage (TICH-2): an international randomised, placebo-controlled, phase 3 superiority trial. *Lancet*. 2018;391(10135):2107-2115.
3. Sarode R, Milling TJ, Refaai MA, et al. Efficacy and safety of a 4-factor prothrombin complex concentrate in patients on vitamin K antagonists presenting with major bleeding: a randomized, plasma-controlled, phase IIIb study. *Circulation*. 2013;128:1234-1243.
4. Steiner T, Poli S, Griebe M, et al. Fresh frozen plasma versus prothrombin complex concentrate in patients with intracranial haemorrhage related to vitamin K antagonists (INCH): a randomised trial. *Lancet Neurol*. 2016;15(6):566-573.
5. Pollack CV, Reilly PA, van Ryn J, et al. Idarucizumab for dabigatran reversal—full cohort analysis. *N Engl J Med*. 2017;377(5):431-441.
6. Connolly S, Crowther M, Eikelboom J, et al. Full study report of andexanet alfa for bleeding associated with factor Xa inhibitors. *N Engl J Med*. 2019;380:1326-1335.
7. Baharoglu MI, Cordonnier C, Salman RA, et al. Platelet transfusion versus standard care after acute stroke due to spontaneous cerebral haemorrhage associated with antiplatelet therapy (PATCH): a randomised, open-label, phase 3 trial. *Lancet*. 2016;387(10038):2605-2613.
8. Anderson CS, Heeley E, Huang Y, et al. Rapid blood-pressure lowering in patients with acute intracerebral hemorrhage. *N Engl J Med*. 2013;368(25):2355-2365.
9. Qureshi A, Palesch Y, Barsan W, et al. Intensive blood-pressure lowering in patients with acute cerebral hemorrhage. *N Engl J Med*. 2016;375:1033-1043.
10. Poungvarin N, Bhoopat W, Viriyavejakul A, et al. Effects of dexamethasone in primary supratentorial intracerebral hemorrhage. *N Engl J Med*. 1987;316(20):1229-1233.
11. Hanley D, Lane K, McBee N, et al. Thrombolytic removal of intraventricular haemorrhage in treatment of severe stroke: results of the randomised, multicentre, multiregion, placebo-controlled CLEAR III trial. *Lancet*. 2017;389(10069):603-611.
12. Mendelow AD, Gregson BA, Fernandes HM, et al. Early surgery versus initial conservative treatment in patients with spontaneous supratentorial intracerebral haematomas in the International Surgical Trial in Intracerebral Haemorrhage (STICH): a randomised trial. *Lancet*. 2005;365(9457):387-397.
13. Mendelow AD, Gregson BA, Rowan EN, Murray GD, Gholkar A, Mitchell PM; for the STICH II Investigators. Early surgery versus initial conservative treatment in patients with spontaneous supratentorial lobar intracerebral haematomas (STICH II): a randomised trial. *Lancet*. 2013;382(9890):397-408.
14. Hanley DF, Thompson RE, Rosenblum M, et al. Efficacy and safety of minimally invasive surgery with thrombolysis in intracerebral haemorrhage evacuation (MISTIE III): a randomised, controlled, open-label, blinded endpoint phase 3 trial. *Lancet*. 2019;393(10175):1021-1032.
15. PROGRESS Collaborative Group. Randomised trial of a perindopril-based blood-pressure-lowering regimen among 6105 individuals with previous stroke or transient ischaemic attack. *Lancet*. 2001;358(9287):1033-1041.

SUGGESTED READINGS

Becker KJ, Baxter AB, Bybee HM, Tirschwell DL, Abouelsaad T, Cohen WA. Extravasation of radiographic contrast is an independent predictor of death in primary intracerebral hemorrhage. *Stroke*. 1999;30(10):2025-2032.

Brott T, Broderick J, Kothari R, et al. Early hemorrhage growth in patients with intracerebral hemorrhage. *Stroke*. 1997;28(1):1-5.

Diringer MN, Edwards DF. Admission to a neurologic/neurosurgical intensive care unit is associated with reduced mortality rate after intracerebral hemorrhage. *Crit Care Med*. 2001;29(3):635-640.

Felberg RA, Grotta JC, Shirzadi AL, et al. Cell death in experimental intracerebral hemorrhage: the "black hole" model of hemorrhagic damage. *Ann Neurol*. 2002;51(4):517-524.

Goldstein JN, Fazen LE, Snider R, et al. Contrast extravasation on CT angiography predicts hematoma expansion in intracerebral hemorrhage. *Neurology*. 2007;68(12):889-894.

Greenberg SM. Cerebral amyloid angiopathy: prospects for clinical diagnosis and treatment. *Neurology*. 1998;51(3):690-694.

Hemphill JC III, Bonovich DC, Besmertis L, Manley GT, Johnston SC. The ICH score: a simple, reliable grading scale for intracerebral hemorrhage. *Stroke*. 2001;32(4):891-897.

Inaji M, Tomita H, Tone O, Tamaki M, Suzuki R, Ohno K. Chronological changes of perihematomal edema of human intracerebral hematoma. *Acta Neurochir Suppl*. 2003;86:445-448.

Knudsen K, Rosand J, Karluk D, Greenberg SM. Clinical diagnosis of cerebral amyloid angiopathy: validation of the Boston criteria. *Neurology*. 2001;56(4):537-539.

Kothari RU, Brott T, Broderick JP, et al. The ABCs of measuring intracerebral hemorrhage volumes. *Stroke*. 1996;27(8):1304-1305.

Ma C, Gurol M, Huang Z, et al. Low-density lipoprotein cholesterol and risk of intracerebral hemorrhage. *Neurology*. 2019;93(5):e445-e457.

Mayer SA, Kurtz P, Wyman A, et al. Clinical practices, complications, and mortality in neurological patients with acute severe hypertension: the Studying the Treatment of Acute hyperTension registry. *Crit Care Med*. 2011;39(10):2330-2336.

Mayer SA, Sacco RL, Shi T, Mohr JP. Neurologic deterioration in noncomatose patients with supratentorial intracerebral hemorrhage. *Neurology*. 1994;44(8):1379-1384.

Morgenstern LB, Hemphill JC III, Anderson C, et al; for the American Heart Association Stroke Council and Council on Cardiovascular Nursing. Guidelines for the management of spontaneous intracerebral hemorrhage: a guideline for healthcare professionals from the American Heart Association/American Stroke Association. *Stroke*. 2010;41(9):2108-2129.

Naidech AM, Maas MB, Levasseur-Franklin KE, et al. Desmopressin improves platelet activity in acute intracerebral hemorrhage. *Stroke*. 2014;45(8):2451-2453.

Ott KH, Kase CS, Ojemann RG, Morh JP. Cerebellar hemorrhage: diagnosis and treatment. A review of 56 cases. *Arch Neurol*. 1974;31(3):160-167.

Parry-Jones AR, Sammut-Powell C, Paroutoglou K, et al. An intracerebral hemorrhage care bundle is associated with lower case fatality. *Ann Neurol*. 2019;86(4):495-503.

Qureshi AI, Suri MF, Ringer AJ, Guterman LR, Hopkins LN. Regional intraparenchymal pressure differences in experimental intracerebral hemorrhage: effect of hypertonic saline. *Crit Care Med*. 2002;30(2):435-441.

Rincon F, Lyden P, Mayer S. Relationship between temperature, hematoma growth, and functional outcome after intracerebral hemorrhage. *Neurocrit Care*. 2012;18(1):45-53.

Rincon F, Mayer SA. The epidemiology of intracerebral hemorrhage in the United States from 1979 to 2008. *Neurocrit Care*. 2013;19(1):95-102.

Vespa PM, O'Phelan K, Shah M, et al. Acute seizures after intracerebral hemorrhage: a factor in progressive midline shift and outcome. *Neurology*. 2003;60(9):1441-1446.

Wijman CA, Venkatasubramanian C, Bruins S, Fischbein N, Schwartz N. Utility of early MRI in the diagnosis and management of acute spontaneous intracerebral hemorrhage. *Cerebrovasc Dis*. 2010;30(5):456-463.

Wilson D, Ambler G, Shakeshaft C, et al. Cerebral microbleeds and intracranial haemorrhage risk in patients anticoagulated for atrial fibrillation after acute ischaemic stroke or transient ischaemic attack (CROMIS-2): a multicentre observational cohort study. *Lancet Neurol*. 2018;17(6):539-547.

Zazulia AR, Diringer MN, Videen TO, et al. Hypoperfusion without ischemia surrounding acute intracerebral hemorrhage. *J Cereb Blood Flow Metab*. 2001;21(7):804-810.

Ziff O, Banerjee G, Ambler G, Werring D. Statins and the risk of intracerebral haemorrhage in patients with stroke: systematic review and meta-analysis. *J Neurol Neurosurg Psychiatry*. 2019;90(1):75-83.

Subarachnoid Hemorrhage 40

Stephan A. Mayer, Gary L. Bernardini, and Robert A. Solomon

KEY POINTS

1. The cardinal symptom of subarachnoid hemorrhage (SAH) is "the worst headache of my life."
2. In 85% of cases, SAH is caused by rupture of an identifiable saccular "berry" aneurysm.
3. Left untreated, the risk of aneurysm rebleeding is 20% after 2 weeks and 30% after 1 month.
4. Endovascular coiling has been shown to be safer than open surgical clipping in good-grade patients with anterior circulation aneurysms.
5. Approximately 70% of SAH patients develop delayed arterial vasospasm, resulting in delayed cerebral ischemia in 20% to 30%.
6. The calcium channel blocker nimodipine reduces the risk of delayed cerebral ischemia from vasospasm.
7. Hemodynamic augmentation and intra-arterial vasodilators are mainstays of rescue therapy for symptomatic vasospasm.

INTRODUCTION

Subarachnoid hemorrhage (SAH) accounts for 5% of all strokes; it affects nearly 30,000 people each year in the United States, with an annual incidence of 1 per 10,000. Saccular (or berry) aneurysms at the base of the brain cause 80% of all cases of SAH. Nonaneurysmal causes of SAH are listed in **Table 40.1**.

TABLE 40.1 Nonaneurysmal Causes of Subarachnoid Hemorrhage (SAH)

• Trauma
• Idiopathic perimesencephalic SAH
• Arteriovenous malformation
• Intracranial arterial dissection
• Cocaine and amphetamine use
• Mycotic aneurysm
• Pituitary apoplexy
• Moyamoya disease
• Central nervous system vasculitis
• Sickle cell disease
• Coagulation disorders
• Primary or metastatic neoplasm

SAH most frequently occurs between ages 40 and 60 years, and women are affected more often than men.

SAH due to the rupture of an intracranial aneurysm is a devastating event; approximately 12% of patients die before receiving medical attention, and another 20% die after admission to the hospital. Of the two-thirds of patients who survive, approximately one-half remain permanently disabled, primarily due to neurocognitive deficits and depression. Advances in neurosurgery and intensive care, including an emphasis on early aneurysm clipping and aggressive therapy for vasospasm, have led to improved survival over the last three decades, with a reduction in overall case fatality from approximately 50% to 20% in high-volume centers.

PATHOLOGY AND EPIDEMIOLOGY OF INTRACRANIAL ANEURYSMS

Saccular aneurysms most often occur at the circle of Willis or its major branches, especially at bifurcations. They arise where the arterial elastic lamina and tunica media are defective and tend to enlarge with age. The typical aneurysm wall is composed only of intima and adventitia and can become paper thin. Many aneurysms, particularly those that rupture, are irregular and multilobulated, and larger aneurysms may be partially or completely filled with an organized clot, which occasionally is calcified. The point of rupture is usually through the dome of the aneurysm.

Eighty-five percent to 90% of intracranial aneurysms are located in the anterior circulation, with the three most common sites being the anterior communicating artery complex (approximately 40%), the junction of the posterior communicating and internal carotid artery (approximately 30%), and the middle cerebral artery at the first major branch point in the sylvian fissure (approximately 20%). Posterior circulation aneurysms most often occur at the apex of the basilar artery or at the junction of the vertebral and posteroinferior cerebellar artery. Saccular aneurysms of the distal cerebral arterial tree are rare. Nearly 20% of patients have two or more aneurysms; many of these are "mirror" aneurysms on the same vessel but on the contralateral side.

Intracranial aneurysms are uncommon in children but occur with a frequency of 2% in adults, suggesting that approximately 2 to 3 million Americans have an aneurysm. However, more than 90% of these are small (<10 mm) and remain asymptomatic throughout life. The annual risk of rupture of an asymptomatic intracranial aneurysm is approximately 0.7%. Important risk factors for the initial rupture of an aneurysm include increasing size, prior SAH from a separate aneurysm, and basilar apex and posterior communicating artery location (**Table 40.2**). The most powerful of these risk factors is size: For example, internal carotid artery aneurysms less than 7 mm in diameter bleed at a

TABLE 40.2 Five-Year Cumulative Hemorrhage Rates of Unruptured Aneurysms According to Size and Location[a]

	<7 mm				
	No Prior SAH	Prior SAH[b]	8-12 mm	13-25 mm	≥25 mm
Cavernous carotid artery (N = 210)	0	0	0	3.0%	6.4%
ACA, MCA, ICA (not intracavernous) (N = 1,037)	0	1.5%	2.6%	14.5%	40%
Posterior circulation or P-comm (N = 445)	2.5%	3.4%	14.5%	18.4%	50%

Abbreviations: ACA, anterior communicating or anterior cerebral artery; ICA, internal carotid artery; MCA, middle cerebral artery; P-comm, posterior communicating artery; SAH, subarachnoid hemorrhage.

[a]From Wiebers DO, Whisnant JP, Huston J III, et al; for International Study of Unruptured Intracranial Aneurysms Investigators. Unruptured intracranial aneurysms: natural history, clinical outcome, and risks of surgical and endovascular treatment. *Lancet*. 2003;362:103-110.

[b]Refers to prior subarachnoid hemorrhage from a separate intracranial aneurysm.

rate of approximately 0.1% per year, compared to an annual rate of 8% for those greater than 25 mm in size. Other risk factors for aneurysm rupture in approximate order of importance include cigarette smoking, aneurysm-related headache or cranial nerve compression, heavy alcohol use, a family history of SAH, female sex (especially when postmenopausal), multiple aneurysms, hypertension, and exposure to cocaine or other sympathomimetic agents. In deciding whether to treat an unruptured intracranial aneurysm, the risks associated with repair should always be balanced against the patient's estimated lifetime risk of hemorrhage without repair.

The prevalence of aneurysms increases with age and is higher in patients with atherosclerosis, a family history of intracranial aneurysm, or autosomal dominant polycystic kidney disease. Intracranial aneurysms have also been associated with Ehlers-Danlos syndrome, Marfan syndrome, pseudoxanthoma elasticum, coarctation of the aorta, and sickle cell disease. Screening for unruptured intracranial aneurysms with computed tomography (CT) or magnetic resonance angiography is indicated in patients with polycystic kidney disease and in family members who have two or more first-degree relatives with intracranial aneurysms; testing is positive in 5% to 10% of these individuals.

CLINICAL FEATURES

SAH usually commences with an explosive "thunderclap" headache followed by stiff neck. The pain is often described as "the worst headache of my life." The headache is usually generalized, but focal pain may refer to the site of aneurysmal rupture (eg, periorbital pain related to an ophthalmic artery aneurysm). Commonly associated symptoms include loss of consciousness, nausea and vomiting, back or leg pain, and photophobia. In patients who lose consciousness, tonic posturing may occur and may be difficult to differentiate from a seizure. Although aneurysmal rupture often occurs during periods of exercise or physical stress, SAH can occur at any time, including sleep.

Approximately 20% of patients give a history of suspicious symptoms days or weeks earlier, including headache, stiff neck, nausea and vomiting, syncope, or disturbed vision. These prodromal symptoms are often due to minor leaking of blood from the aneurysm and are therefore referred to as "warning leaks" or "sentinel headaches." Initial misdiagnosis of SAH occurs in approximately 15% of patients, and those with the mildest symptoms are at greatest risk. Approximately 40% of misdiagnosed patients experience subsequent neurologic deterioration due to rebleeding, hydrocephalus, or vasospasm before reaching medical attention, with increased morbidity and mortality.

Stiff neck and the Kernig sign are hallmarks of SAH. However, these signs are not invariably present, and confusion and low back pain are sometimes more prominent than headache. Preretinal or subhyaloid hemorrhages—large, smooth-bordered, and on the retinal surface—occur in up to 25% of patients and are practically pathognomonic of SAH.

The most important determinant of outcome after SAH is the patient's neurologic condition on arrival at the hospital. Alterations in mental status are the most common abnormality; some patients remain alert and lucid; others are confused, delirious, amnestic, lethargic, stuporous, or comatose. The modified Hunt and Hess grading scale serves as a means for risk stratification for SAH based on the first neurologic examination (Table 40.3). Patients classified as grade I or II SAH have a relatively very good prognosis (<5% mortality), grades III and IV carry an intermediate prognosis (10%-15% mortality), and grade V patients have a poor prognosis (50%-70% mortality). Focal neurologic signs occur in a minority of patients but may point to the site of bleeding; hemiparesis or aphasia suggests a middle cerebral artery aneurysm, and paraparesis or abulia suggests an aneurysm of the proximal anterior cerebral artery. These focal signs are sometimes due to a large hematoma, which may require emergency evacuation.

TABLE 40.3 Mortality According to the Hunt-Hess Grading Scale for Aneurysmal Subarachnoid Hemorrhage[a]

		Hospital Mortality (%)	
Grade	Clinical Findings	1968	2012
I	Asymptomatic or mild headache	11	3
II	Moderate to severe headache or oculomotor palsy	26	3
III	Confused, drowsy, or mild focal signs	37	9
IV	Stupor (localizes to pain)	71	24
V	Coma (posturing or no motor response to pain)	100	70
TOTAL		35	20

[a]Data are from 275 patients reported by Hunt and Hess in 1968 and 1,200 patients treated at Columbia University Medical Center between 1996 and 2012.

FIGURE 40.1 Two computed tomography images of subarachnoid hemorrhage (SAH). **A:** Diffuse, thick SAH is seen in the anterior interhemispheric and bilateral sylvian fissures and the quadrigeminal cistern. A left middle cerebral artery aneurysm was identified. **B:** Perimesencephalic SAH; only a small focus of blood in the interpeduncular cistern is identified. No aneurysm was identified.

About 15% of patients with spontaneous nontraumatic SAH have no identifiable aneurysm on angiography. In about half of these cases, CT reveals blood confined to the perimesencephalic cisterns, with the center of bleeding adjacent to the midbrain and pons (Fig. 40.1). Patients with "perimesencephalic" SAH always have normal findings on neurologic examination and a benign clinical course; rebleeding and symptomatic vasospasm or hydrocephalus almost never occur. The source of hemorrhage in these patients is presumably venous. In patients with extensive and diffuse SAH and a negative angiogram, the bleeding source is presumably a "blister" aneurysm.

Symptoms and signs of an unruptured intracranial aneurysm may result from compression of adjacent neural structures or thromboembolism. These aneurysms are often, but not always, large or giant (>25 mm). Aneurysms of the posterior communicating artery frequently compress the oculomotor nerve (almost always affecting the pupil). Aneurysms of the intracavernous segment of the internal carotid artery may damage the third, fourth, fifth, or sixth cranial nerves, and their rupture can lead to formation of a carotid-cavernous fistula. Less often, large aneurysms compress the cortex or brainstem, causing focal neurologic signs or seizures. Thrombosis within the aneurysmal sac occasionally sends emboli to the artery's distal territory, causing transient ischemic attacks or infarction. In the absence of SAH, some patients experience sudden, severe headache without nuchal rigidity, perhaps related to aneurysmal enlargement, thrombosis, or meningeal irritation; these symptoms can clear with aneurysm clipping.

DIAGNOSIS

Computed Tomography

CT should be the first diagnostic study for establishing the diagnosis of SAH because it is readily available and interpretation is straightforward. When SAH is misdiagnosed, the most common error is failure to obtain a CT scan. CT most commonly demonstrates diffuse blood in the basal cisterns (see Fig. 40.1); with more severe hemorrhages, blood extends into the sylvian and interhemispheral fissures, ventricular system, and over the convexities. The distribution of blood can provide important clues regarding the location of the ruptured aneurysm. CT may also demonstrate a focal intraparenchymal or subdural hemorrhage, ventricular enlargement, a large thrombosed aneurysm, or infarction due to vasospasm. The sensitivity of CT for SAH is 90% to 95% within 24 hours, 80% at 3 days, and 50% at 1 week. Accordingly, a normal CT never rules out SAH, and a lumbar puncture should always be performed in patients with suspected SAH and negative CT. Magnetic resonance imaging (MRI) can also be used to make the initial diagnosis of SAH or can be used to detect a completely thrombosed aneurysm if the initial angiogram is negative. The Ottawa SAH Rule (Table. 40.4) includes six clinical features that collectively have 100% sensitivity for CT or lumbar puncture documented SAH among patients presenting with acute headache peaking within 1 hour of onset. If all six features are absent, SAH is effectively ruled out and imaging is not needed.

TABLE 40.4 The Ottowa Subarachnoid Hemorrhage Rule for Acute Headache

Investigation to rule out SAH (CT followed by LP) required if any one of the following are present
- Symptom of neck pain or stiffness
- Age > 40 yr
- Witnessed loss of consciousness
- Onset during exertion
- Thunderclap headache (peak pain instantly)
- Limited neck flexion upon exam

If all of the above are absent, SAH has effectively been ruled out.

Lumbar Puncture

The cerebrospinal fluid (CSF) is usually grossly bloody. SAH can be differentiated from a traumatic tap by a xanthochromic (yellow-tinged) appearance of the supernatant fluid after centrifugation. However, xanthochromia may take up to 12 hours to appear. The CSF pressure is nearly always high and the protein elevated. Initially, the proportion of CSF leukocytes to erythrocytes is that of peripheral blood, with a usual ratio of 1:700; after several days, a reactive pleocytosis and low glucose levels may arise from a sterile chemical meningitis caused by the blood. Red blood cells and xanthochromia disappear in about 2 weeks, unless hemorrhage recurs.

Angiography

Cerebral angiography is the definitive diagnostic procedure for detecting intracranial aneurysms and defining their anatomy (Fig. 40.2). Although the increasing availability and image quality of CT and magnetic resonance angiography has allowed some centers to use these tests to make the initial diagnosis, a four-vessel (bilateral internal carotid and vertebral artery injections) angiogram is mandatory when those tests are negative. Moreover, angiography performed during coiling or after surgical clipping is generally advisable to evaluate the adequacy of aneurysmal repair and to screen for smaller secondary aneurysms that may be missed by CT or magnetic resonance angiography. Vasospasm, local thrombosis, or poor technique can lead to a false-negative angiogram. For this reason, patients with

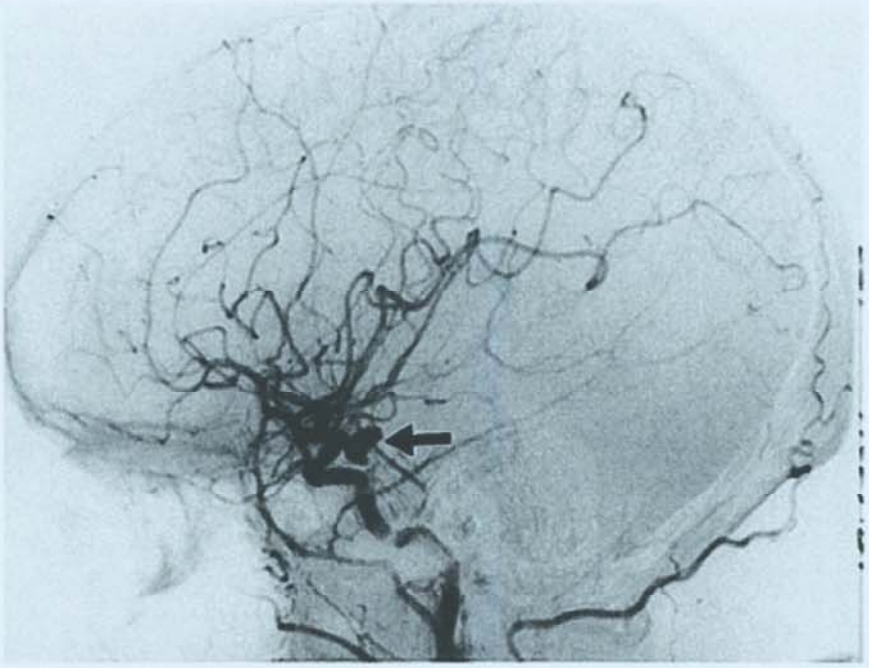

FIGURE 40.2 Lateral view of a left common carotid angiogram demonstrates a bilobed aneurysm of the left internal carotid artery *(arrow)* at the level of the posterior communicating artery. (Courtesy of Dr. S. Chan.)

a negative angiogram at first should have a follow-up study 1 to 2 weeks later; an aneurysm will be demonstrated in about 5% of these cases. The exception to this rule is found in patients with "perimesencephalic" SAH who usually do not require follow-up angiography.

Laboratory Testing

In addition to routine admission laboratory tests, care should be taken to check a prothrombin time/partial thromboplastin time to diagnose a coagulopathy, an electrocardiogram and serum troponin level to diagnose sympathetically mediated cardiac injury, and a chest X-ray to diagnose neurogenic pulmonary edema or aspiration pneumonitis. Patients with electrocardiogram abnormalities (typically peaked T-waves with QTc segment prolongation) or troponin elevation should have an echocardiogram performed.

COMPLICATIONS OF ANEURYSMAL SUBARACHNOID HEMORRHAGE

Rebleeding

Aneurysmal rebleeding is a dreaded complication of SAH. The risk of rebleeding is highest within the first 24 hours after the initial aneurysmal rupture (4%) and remains elevated (approximately 1%-2% per day) for the next 4 weeks (Fig. 40.3). The cumulative risk of rebleeding in untreated patients is 20% at 2 weeks, 30% at 1 month, and 40% at 6 months. After the first 6 months, the risk of rebleeding is 2% to 4% annually. Poor clinical grade and larger aneurysm size are the strongest risk factors for in-hospital rebleeding. The prognosis of patients who rebleed is poor; approximately 50% die immediately, and another 30% die from subsequent complications. Although rebleeding is often attributed to uncontrolled hypertension, elevated blood pressure has not been convincingly linked to an increased risk of aneurysm rebleeding. Endogenous fibrinolysis of clot around the rupture point of the aneurysm may be a more important causative mechanism.

Vasospasm

Delayed cerebral ischemia (DCI) from vasospasm accounts for a large proportion of morbidity and mortality after SAH. Progressive arterial narrowing develops after SAH in approximately 70% of patients, but delayed ischemic deficits develop in only 20% to 30%. The process begins 3 to 5 days after the hemorrhage, becomes maximal at 5 to 14 days, and gradually resolves over 2 to 4 weeks. Accordingly, deterioration attributable to vasospasm never occurs before the third day after SAH and occurs with peak frequency between 5 and 7 days (see Fig. 40.3). There is a strong relationship between the amount of cisternal blood seen on initial CT and the risk for development of symptomatic ischemia; for uncertain reasons, the presence

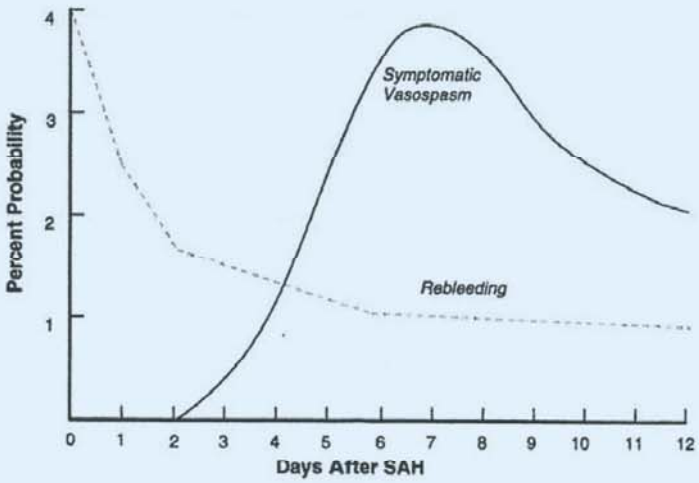

FIGURE 40.3 The daily percentage probability for the development of symptomatic vasospasm *(solid line)* or rebleeding *(dashed line)* after subarachnoid hemorrhage. Day 0 denotes day of onset of subarachnoid hemorrhage.

TABLE 40.5 Modified Fisher Computed Tomography Rating Scale for the Prediction of Symptomatic Vasospasm[a]

Grade	Criteria	Percentage of Affected Patients	Frequency of Delayed Cerebral Ischemia	Frequency of Infarction
0	No SAH or IVH	5%	0%	0%
1	Minimal/thin SAH, no biventricular IVH	30%	12%	6%
2	Minimal/thin SAH, *with* biventricular IVH	5%	21%	14 %
3	Thick SAH,[b] no biventricular IVH	43%	19%	12%
4	Thick SAH,[b] *with* biventricular IVH	17%	40%	28%
	All patients	100%	20%	12%

Abbreviations: IVH, intraventricular hemorrhage; SAH, subarachnoid hemorrhage.
[a]From Claassen J, Bernardini GL, Kreiter K, et al. Effect of cisternal and ventricular blood on risk of delayed cerebral ischemia after subarachnoid hemorrhage: the Fisher scale revisited. *Stroke*. 2001;32:2012-2020.
[b]Thick SAH is defined as completely filling at least one cistern or fissure.

of large amounts of blood in the lateral ventricles adds to this risk (Table 40.5). Symptomatic vasospasm usually involves a decrease in level of consciousness, hemiparesis, or both, and the process is usually most severe in the immediate vicinity of the aneurysm. In more severe cases, the symptoms develop earlier after aneurysm rupture, and multiple vascular territories are involved.

Although thick subarachnoid blood is the principal precipitating factor, the precise cause of arterial narrowing after SAH is poorly understood. Vasospasm is not simply due to vascular smooth muscle contraction, and changes in vessel caliber develop slowly over several days. Inflammatory arteriopathic changes are seen in the vessel wall, including subintimal edema and infiltration of leukocytes. The prevailing view is that substances released from the blood clot interact with the vessel wall to cause inflammatory arterial spasm. Putative mediators with intrinsic vasoconstrictive properties include oxyhemoglobin, hydroperoxides and leukotrienes, free radicals, prostaglandins, thromboxane A2, serotonin, endothelin, platelet-derived growth factor, and other inflammatory mediators. Cortical spreading depolarization may further contribute to DCI after SAH by creating prolonged neuronal depolarization in conjunction with a paradoxical reduction in local cerebral blood flow.

Hydrocephalus

Acute symptomatic hydrocephalus occurs in 15% to 20% of patients with SAH and is primarily related to the volume of intraventricular and subarachnoid blood. In mild cases, hydrocephalus causes lethargy, psychomotor slowing, and impaired short-term memory. Additional findings may include limitation of upward gaze, sixth cranial nerve palsies, and lower extremity hyperreflexia. In more severe cases, acute obstructive hydrocephalus leads to elevated intracranial pressure and stupor or coma. Progressive brainstem herniation eventually results from continued CSF production unless a ventricular catheter is inserted.

Delayed hydrocephalus may develop 3 to 21 days after SAH. The clinical syndrome is that of normal pressure hydrocephalus, with failure to fully recover and prominent symptoms of dementia, gait disturbance, and urinary incontinence. The clinical response to ventriculoperitoneal shunting is usually excellent. Overall, 20% of SAH survivors require shunting for chronic hydrocephalus.

Global Cerebral Edema and Early Brain Injury

CT often demonstrates a characteristic form of global brain edema after poor-grade SAH (Fig. 40.4). This finding is most common in patients who experience loss of consciousness at the onset of bleeding, suggesting a transient episode of intracranial circulatory arrest with subsequent reperfusion injury to the brain. Global cerebral edema after SAH has been linked to an increased risk of mortality, disability, and cognitive dysfunction among survivors. MRI performed within 72 hours shows a distinctive pattern of symmetric ischemic injury in 70% of Hunt-Hess grade IV or V patients, most often involving the anterior

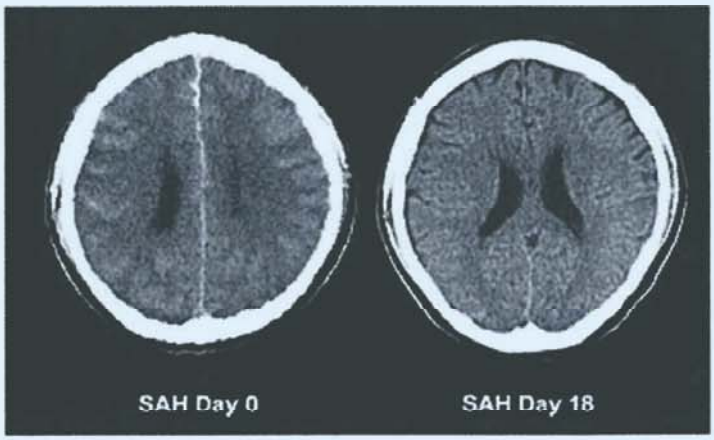

FIGURE 40.4 Global edema on the admission computed tomography scan (subarachnoid hemorrhage [SAH] day 0) in a 55-year-old man with a Hunt-Hess grade V SAH from a left anterior communicating artery aneurysm, which was clipped. Note the complete effacement of all convexity sulci and presence of "fingerlike" extensions of white matter lucencies to the cortical surface. A follow-up scan on SAH day 18 showed complete normalization of the CT findings. (From Claassen J, Carhuapoma JR, Kreiter KT, et al. Global cerebral edema after subarachnoid hemorrhage: frequency, predictors, and impact on outcome. *Stroke*. 2002;33:1225-1232.)

cerebral artery territories, a process termed *early brain injury*. The relative contribution of acute ischemia, reperfusion injury, microvascular dysfunction, inflammation, and spreading depolarization in early brain injury remains poorly understood.

Seizures

Clinically obvious tonic-clonic seizures occur in 5% of SAH patients during hospitalization and in another 10% in the first year after discharge. Seizures after SAH are related primarily to focal pathology, including large subarachnoid clots, subdural hematoma, or cerebral infarction. Ictal events at the onset of bleeding do not portend an increased risk of late seizures. With continuous electroencephalographic monitoring, nonconvulsive seizures or status epilepticus can be detected in up to 20% of poor-grade patients and has become increasingly recognized as a cause of otherwise unexplained clinical deterioration after SAH, with ominous implications for prognosis.

Fluid and Electrolyte Disturbances

Hyponatremia and intravascular volume contraction frequently occur after SAH and reflect homeostatic derangements that favor excessive free-water retention and sodium loss. Hyponatremia occurs in 5% to 30% of patients after SAH and is usually related to inappropriate secretion of antidiuretic hormone and free-water retention. This process may be further exacerbated by excessive natriuresis that occurs after SAH ("cerebral salt wasting"), related to elevations of atrial natriuretic factor and the glomerular filtration rate. Whereas hyponatremia after SAH is usually asymptomatic, untreated sodium losses resulting in intravascular volume contraction can increase the risk of DCI in the presence of vasospasm. To minimize the development of hypovolemia and hyponatremia after SAH, patients should be given large volumes of isotonic crystalloid, with restriction of other potential sources of free water.

Neurogenic Cardiac and Pulmonary Disturbances

Severe SAH is typically associated with a surge in catecholamine levels and sympathetic tone, which in turn can lead to neurogenic cardiac dysfunction, neurogenic pulmonary edema, or both (see Chapter 119). Transient electrocardiographic abnormalities occur in 50% to 100% of SAH patients but usually do not produce symptoms. In 5% to 10% of poor-grade patients, however, cardiac enzyme release and a reversible form of neurogenic "stunned myocardium" can occur. Cardiac troponin elevation always occurs, but the extent of these elevations is usually smaller than expected compared to ischemic acute coronary syndromes. Hypotension, hypoxia, and reduction of cardiac output may occur acutely, leading to impaired cerebral perfusion in the face of increased intracranial pressure or vasospasm. Neurogenic pulmonary edema, characterized by increased permeability of the pulmonary vasculature, may occur in isolation or in combination with neurogenic cardiac injury.

Fever

Fever, the most common medical complication of SAH, develops in 80% of patients at some time and may result from infection or "central" fever. Poor-grade patients with intraventricular blood often experience sustained fever that can lead to worsening of level of consciousness and exacerbation of ischemic injury caused by vasospasm. For these reasons, aggressive fever control in SAH patients with surface or intravascular cooling systems are recommended.

Anemia

SAH leads to a contraction of red blood cell mass. Combined with phlebotomy and volume resuscitation, all patients become progressively anemic during the first 10 days after SAH, and 20% to 40% require blood transfusions. Anemia has been linked to poor outcome after SAH, but it remains unclear if this is a cause or consequence of disease severity. With symptomatic vasospasm, even mild anemia (serum hemoglobin <10 mg/dL) can cause reduced oxygen delivery to ischemic brain tissue and should be avoided.

TREATMENT

The initial goal of treatment is to prevent rebleeding by excluding the aneurysmal sac from the intracranial circulation while preserving the parent artery and its branches. Once the aneurysm has been secured, the focus shifts toward monitoring and treating vasospasm and other secondary medical complications of SAH. This is best performed in an intensive care unit.

Emergency Management

The diagnosis of SAH is almost always made in the emergency department. Management at this juncture should focus on (1) minimizing ongoing brain injury in poor-grade patients with mental status changes and (2) reducing the risk of aneurysm rebleeding prior to an effective repair procedure. In Hunt-Hess grades IV and V patients, the immediate concern is ensuring adequate perfusion and oxygenation of the brain. Patients with impaired ability to protect the airway should be intubated, supplemental oxygen should be given as needed, and hypotension should be treated aggressively with fluids and vasopressors to maintain a mean arterial pressure of 90 mm Hg. Stuporous or comatose patients with extensive SAH or intraventricular blood on CT should be empirically treated for intracranial hypertension with 1.0 g/kg of 20% mannitol prior to placement of an external ventricular drain. Medical interventions that may reduce the risk of acute aneurysm rebleeding include control of arterial hypertension (systolic blood pressure <160 mm Hg), intravenous (IV) loading with an antifibrinolytic agent (epsilon aminocaproic acid 4 g followed by 1 g/h until 4 h prior to angiography, for a maximum of 72 h after SAH onset) LEVEL 1,[1] and administration of an anticonvulsant to minimize the risk of acute seizure activity (a loading dose of levetiracetam 2 g IV or phenytoin 20 mg/kg IV is most commonly used).

Surgical Management

In the 1980s, neurosurgeons began to abandon the traditional practice of delaying surgery until several weeks after aneurysmal rupture, in favor of early clipping within 48 to 72 hours. This change in practice became feasible with safer microsurgical techniques. Nonetheless, surgery still remains hazardous, with a 5% to 10% risk of major morbidity or mortality in most cases;

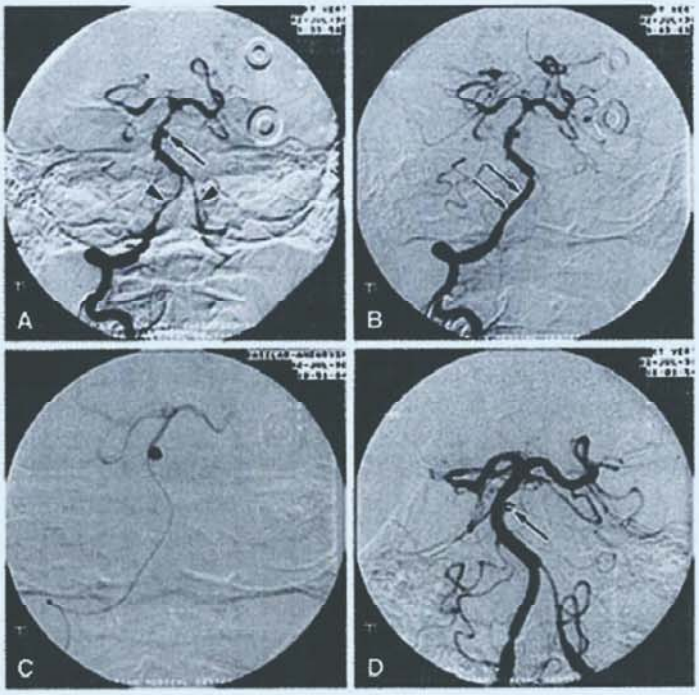

FIGURE 40.5 **A:** Cerebral angiogram demonstrates a left-pointing, 3-mm, midbasilar aneurysm *(arrow)* and vasospasm of both vertebral arteries *(arrowhead)*, the distal basilar artery, and the proximal right posterior cerebral artery. **B:** Significant increase in luminal diameter of the right vertebral artery after balloon angioplasty *(arrows)*. **C:** Microcatheter positioned at the neck of the midbasilar aneurysm. **D:** Midbasilar aneurysm *(arrow)* with no residual filling after packing with a single platinum detachable coil. (Courtesy of Dr. Huang Duong.)

smaller aneurysms have a lower risk of procedural complications than larger aneurysms. Besides preventing early rebleeding, early surgery also permits aggressive treatment of vasospasm with hypertensive hypervolemic therapy, which can be dangerous with an unprotected aneurysm. Although early surgery was at one time reserved for patients in good clinical condition (Hunt-Hess grades I to III), this approach has been extended to all but the most moribund patients. The advent of endovascular coil embolization has been a major advance because it is a treatment option for high-risk patients who are not good candidates for early surgery.

The management of asymptomatic unruptured aneurysms is controversial. Most neurosurgeons recommend surgery for aneurysms larger than 5 mm, as long as the hoped-for benefit of surgery (reduced lifetime risk of bleeding) outweighs the risks. In good hands, the risk of major morbidity or mortality from clipping of an unruptured aneurysm is 2% to 5%; the risk is highest for large aneurysms and for aneurysms of the basilar artery.

Endovascular Therapy

Endovascular coil embolization, introduced in the early 1990s, is a safe and effective alternative to surgical clipping for treating ruptured intracranial aneurysms. Endovascular packing of aneurysms (Fig. 40.5) with soft, thrombogenic detachable platinum coils leads to nearly complete obliteration of smaller aneurysms (<12 mm in diameter) in 80% to 90% of cases, with an acceptable complication rate of approximately 9% (see Chapter 25). The long-term risk of postprocedural rebleeding is minimal after successful clipping or coiling, and there is fairly compelling evidence that the less invasive coiling procedure is safer. In the International Subarachnoid Aneurysm Trial, 2,143, SAH patients with predominantly small (<10 mm) anterior circulation aneurysms were randomly assigned to clip or coil therapy. Those treated with coils were 23% less likely to be dead or disabled 1 year later (Fig. 40.6) LEVEL 1.[2] Reasons for the observed improvement in outcome with coils are unclear but may include lower risk of perioperative rebleeding, reduced physical manipulation of the brain, less delayed ischemia from vasospasm, or other unidentified factors.

Aneurysms with wide necks are less amenable to coil embolization because it is harder for the aneurysmal sac to contain the coil. With wide neck saccular aneurysms, it is sometimes necessary to place a stent in the parent vessel across the aneurysm neck and deploy coils through the stent (stent-assisted coiling). For shallow "blister" aneurysms, or very large aneurysms that involve a substantial portion of the circumference of the parent artery, a dense flow-diverting (Pipeline) stent can be placed across the diseased arterial segment, with excellent angiographic results. Data on the long-term efficacy of these advanced endovascular techniques are lacking.

The main disadvantage of endovascular treatment is the requirement for periodic reevaluation to ensure durable occlusion of the aneurysm. Approximately 5% of coiled patients develop recurrent dilations at the neck of the original aneurysm and that requires repeat coil embolization or delayed surgical clipping.

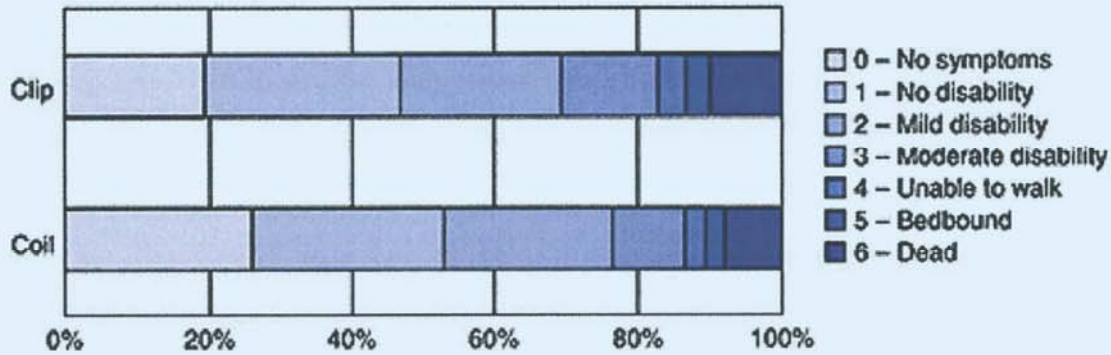

FIGURE 40.6 Distribution of modified Rankin Scale (mRS) outcome scores in the International Subarachnoid Aneurysm Treatment Trial, which compared surgical clipping to endovascular coiling as the primary treatment for subarachnoid hemorrhage due to ruptured intracranial aneurysm. The results showed that 190 of 801 (23.7%) patients allocated to coil treatment were dependent or dead at 1 year (mRS 3-6), compared with 243 of 793 (30.6%) allocated neurosurgical clipping ($P = .0019$).

TABLE 40.6 Critical Care Management Protocol for Acute Subarachnoid Hemorrhage (SAH)[a]

Blood pressure	• Control elevated blood pressure during the preoperative phase (systolic blood pressure <160 mm Hg) with IV labetalol, nicardipine, or clevidipine to prevent rebleeding.
Rebleeding prophylaxis	• Epsilon aminocaproic acid 4 g IV upon diagnosis followed by 1 g/h until aneurysm repair, for a maximum of up to 72 h after ictus
IV hydration	• Normal (0.9%) saline or a balanced isotonic solution (ie, Plasma-Lyte) at 1.0-1.5 mL/kg/h
Laboratory testing	• Periodically check complete blood count and electrolytes. • Obtain serial ECGs and check admission cardiac troponin I (cTI) to evaluate for cardiac injury; perform echocardiography in patients with abnormal ECG findings or cTI elevation.
Seizure prophylaxis	• Fosphenytoin (15-20 mg/kg) or levetiracetam 2 g IV; discontinue on postop day 1 unless patient has seized, is poor grade, or has focal cortical pathology or is otherwise unstable.
Vasospasm prophylaxis	• Nimodipine 60 mg orally every 4 h until day SAH 21 or discharge
Physiologic homeostasis	• Cooling blankets to maintain temperature ≤37.5°C • Insulin drip to maintain glucose 120-180 mg/dL • Transfuse to maintain hemoglobin >7.0 g/dL (in the absence or active cerebral or cardiac ischemia).
Ventricular drainage	• Emergent EVD placement in all stuporous/comatose patients (Hunt-Hess grade IV/V) as well as lethargic patients with hydrocephalus • Begin trials of clamping external ventricular drain and monitoring ICP on day 3 after placement. • Perform ventriculoperitoneal shunting during subacute phase of illness in patients with persistent cognitive dysfunction and ventriculomegaly.
Vasospasm diagnosis	• Transcranial Doppler sonography every 1-2 d until the 10th day after SAH • CT angiography on days 4-8 after SAH if high risk
Therapy for symptomatic vasospasm	• Place patient in Trendelenburg (head-down) position. • Infuse 500 mL 5% albumin or 1 L of 0.9% saline over 30 min. • If the deficit persists, raise the systolic BP with phenylephrine or norepinephrine until the deficit resolves (target 180-220 mm Hg). • If refractory, monitor cardiac output and add dobutamine or milrinone to maintain cardiac index ≥4.0 L/min/m^2. • Transfuse to maintain hemoglobin >10.0 g/dL. • Emergency angiogram for intra-arterial verapamil or cerebral angioplasty unless the patient responds well to the above measures

Abbreviations: CT, computed tomography; ECG, electrocardiogram; EVD, external ventricular drain; ICP, intracranial pressure; IV, intravenous.
[a]Adapted from Komotar R, Schmidt JM, Starke RM, et al. Resuscitation and critical care of poor grade subarachnoid hemorrhage. *Neurosurgery*. 2009;64(3):407-410.

Intensive Care Management

A suggested algorithm for the postoperative management of SAH is outlined in **Table 40.6**. All patients with SAH should be monitored in an intensive care unit, where neurologic examinations can be performed frequently. Blood pressure control can be liberalized once the aneurysm has been repaired and brain perfusion becomes the dominant consideration. Anticonvulsants are discontinued on the first postoperative day in good-grade patients who have not had a seizure; anticonvulsant prophylaxis is continued for approximately 1 week in poor-grade patients.

Most centers advocate the use of aggressive fluid resuscitation with isotonic crystalloid (with or without additional colloids) to prevent volume contraction, although this has not been proven to reduce the risk of symptomatic ischemia from vasospasm. Patients should receive isotonic fluid resuscitation (ie, 1 mL/kg/h of 0.9% saline) to maintain a euvolemic state guided by total fluid balance, central venous pressure, and other measures of volume status. The calcium channel blocker nimodipine reduced the frequency of delayed ischemic deterioration by about 30% in several clinical trials; this effect was attributed to reduction of calcium entry into ischemic neurons or by improvement in microcollateral flow because no effect on angiographic spasm was demonstrated LEVEL 1.[3]

Externalized ventricular drains are used to treat obstructive hydrocephalus in patients who are stuporous or comatose, but these devices carry a risk of infection (up to 10% overall) and therefore should be removed once intracranial pressure is stable during a 24-hour clamping trial.

Transcranial Doppler ultrasonography is widely used to diagnose vasospasm of the larger cerebral arteries after SAH. Accelerated blood flow velocities, which occur as flow is maintained through narrowed arteries, have a sensitivity and specificity of 90% for angiographic vasospasm of the proximal middle cerebral artery, but they are less sensitive for detecting spasm of the anterior cerebral or basilar arteries. Increased transcranial Doppler velocity does not imply increased likelihood of developing ischemia from vasospasm. For this reason, a CT perfusion scan is obtained between SAH days 4 and 8 to determine whether cerebral blood flow is regionally compromised.

Treatment of acute symptomatic vasospasm relies on increasing blood volume, blood pressure, and cardiac output in an attempt to improve cerebral blood flow through arteries that have lost the capacity to autoregulate. Hypertensive-hypervolemic-hemodilution ("triple-H therapy") of this type involves administration of isotonic crystalloid solutions to maintain central venous pressure greater than 10 mm Hg and pressors such as norepinephrine or phenylephrine to elevate systolic blood pressure to levels as high as 180 to 220 mm Hg. Hemoglobin levels of about 10 mg/dL are optimal for oxygen delivery, balancing the increase in cerebral blood flow that results from anemia and the increase in blood oxygen content that comes with higher

hemoglobin levels. In refractory poor-grade patients (Hunt-Hess grade IV and V), early goal-directed fluid therapy using transpulmonary thermodilution monitoring to maintain the cardiac index above 3 $L/min^1/m^2$ has been shown to reduce the risk of DCI and improve outcome compared to standard management LEVEL 2.[4] Hemodynamic augmentation results in clinical improvement in about 70% of patients. Rescue therapy with intra-arterial vasodilators (verapamil, nicardipine, or milrinone) or cerebral angioplasty can lead to dramatic improvement in patients with severe deficits that are refractory to hemodynamic augmentation (see **Fig. 40.4**).

Vasospasm can lead to clinically "silent" brain infarction in poor-grade patients who are stuporous or comatose and require sedation to assist in mechanical ventilation. To detect ischemia at its earliest stages, many centers rely on continuous electroencephalogaphic and invasive monitoring of brain tissue oxygen and cerebral blood flow to provide real-time information about the adequacy of cerebral perfusion and autoregulatory capacity (see also Chapter 34). Trends indicating a reduction in brain perfusion generally trigger a trial of induced hypertension or urgent referral for angiography.

OUTCOME

Approximately 20% of SAH patients treated at high-volume centers do not survive to discharge. In contrast to older patients indicating that delayed ischemia from vasospasm is the major cause of death and disability after SAH, most mortality today is related to the acute effects of hemorrhage in poor-grade patients (**Fig. 40.7**). Important risk factors for mortality or poor functional recovery after SAH include poor clinical grade, advanced age, large aneurysm size, aneurysm rebleeding, cerebral infarction from vasospasm, and global cerebral edema. Medical complications such as fever, hyperglycemia, and anemia have also been linked to poor outcome.

In contrast to the focal neurologic deficits that typically follow ischemic stroke, survivors of SAH are disabled primarily by cognitive impairment. Neuropsychological testing reveals long-term problems in memory, concentration, psychomotor speed, visuospatial skills, or executive function in 60% to 80% of SAH patients. Depression and anxiety are also common. These disturbances do not lead to the outward appearance of disability but can affect work, relationships, and quality of life; about 50% of SAH patients do not return to their previous level of employment. Cognitive and physical rehabilitation are essential for maximizing recovery in severely affected patients.

OTHER KINDS OF MACROSCOPIC ANEURYSMS

Fusiform or Dolichoectatic Aneurysms

These circumferential vessel dilations usually involve the carotid, basilar, or vertebral arteries. Atherosclerosis probably plays a role in their formation, but a developmental defect of the wall may be present in some. Fusiform aneurysms seldom become occluded with thrombus and rarely rupture. If bleeding occurs, treatment often requires proximal vessel occlusion.

Mycotic Aneurysm

Mycotic aneurysms are caused by septic emboli, which are most often formed by bacterial endocarditis (see Chapter 64). They are usually only a few millimeters in size and tend to occur on distal branches of pial vessels, especially those of the middle cerebral artery. Mycotic aneurysms have been reported in up to 10% of endocarditis patients, but arteriography is not routinely performed, and the incidence is probably underestimated. Pyogenic segmental arteritis from septic emboli in the

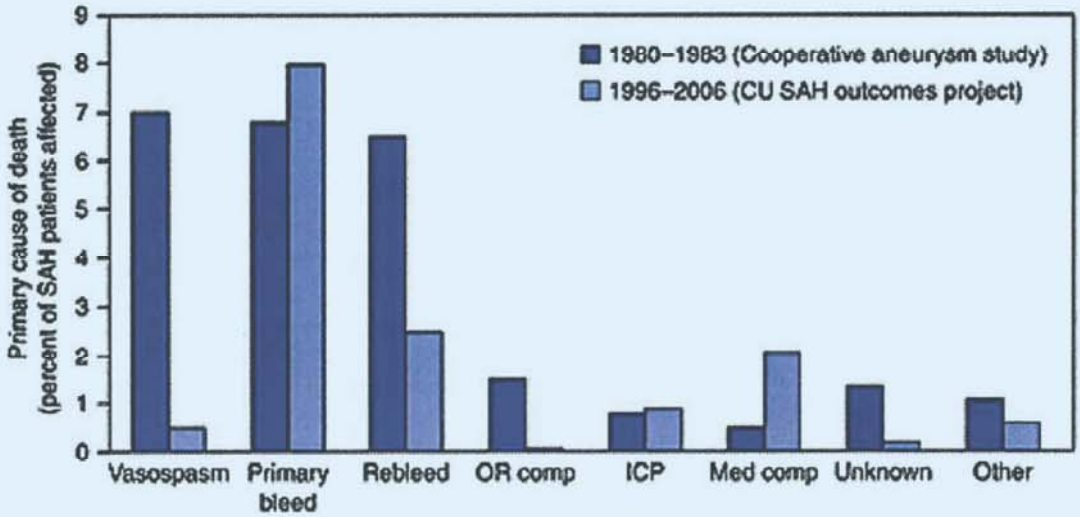

FIGURE 40.7 Mortality after subarachnoid hemorrhage (SAH) according to the primary cause of death or neurologic devastation leading to withdrawal of support. Data are from 3,521 patients enrolled in the Cooperative Aneurysm Study between 1980 and 1983 and 1,019 patients enrolled in the Columbia University Outcomes Project between 1996 and 2006. Numbers represent the percentage of all subarachnoid hemorrhage patients who died as a direct consequence of the listed variable. Abbreviations: ICP, intracranial pressure; OR, operating room. (From Komotar R, Schmidt JM, Starke RM, et al. Resuscitation and critical care of poor-grade subarachnoid hemorrhage. *Neurosurgery*. 2009;64[3]:397-410.)

absence of frank aneurysm formation can also lead to intracranial hemorrhage. Because rupture is fatal in 80% of patients with mycotic aneurysms, cerebral arteriography should be performed when endocarditis is accompanied by suspicious headaches, stiff neck, seizure, focal neurologic symptoms, or CSF pleocytosis. Although mycotic aneurysms occasionally disappear radiographically with antimicrobial therapy, the outcome cannot be predicted, and the aneurysm should be treated surgically as soon as possible.

Pseudoaneurysm

Dissection of an intracranial vessel, which usually results from trauma, can lead to extension of blood from the false lumen through the entire vessel wall. The extravasated blood is contained by either a thin layer of adventitia or the surrounding tissues and does not have a true aneurysmal wall; hence, the designation *pseudoaneurysm*. If a vessel traversing the subarachnoid space is affected, SAH can result. Treatment may require endovascular or surgical vessel occlusion or trapping, or angioplasty and stenting of the involved segment.

Vascular (Arteriovenous) Malformations

Vascular malformations account for less than 5% of all cases of SAH. Intracranial and spinal vascular malformations can be classified into five main types: (1) arteriovenous malformations (AVMs), which are high-flow and most often symptomatic; (2) dural arteriovenous fistulas (dAVF); (3) cavernous malformations; (4) capillary telangiectasias; and (5) venous malformations.

AVMs are a conglomerate of abnormal arteries and veins with intervening gliotic brain tissue; they resemble a "bag of worms." dAVFs are direct arterial to venous shunts that form in the walls of a dural sinus, that over time result in local venous hypertension and congestion.

SAH from brain vascular malformations is almost exclusively related to rupture of an AVM or dAVF. Many cases of SAH related to an AVM are caused by a feeding artery or intranidal saccular aneurysm, the former of which can be treated by clip or coil occlusion. SAH related to dAVF results from rupture of a vein in the subarachnoid space that has been subjected to arterialized flow. Dural and spinal cord AVMs and dAVFs should be kept in mind in patients with angiogram negative SAH. MRI of the head and neck can sometimes detect these malformations, especially if small or thrombosed. For more details on brain vascular malformations refer to Chapter 42.

LEVEL 1 EVIDENCE

1. Hillman J, Fridriksson S, Nilsson O, Yu Z, Saveland H, Jakobsson KE. Immediate administration of tranexamic acid and reduced incidence of early rebleeding after aneurysmal subarachnoid hemorrhage: a prospective randomized study. *J Neurosurg*. 2002;97:771-778.
2. Molyneux AJ, Kerr RS, Yu LM, et al. International Subarachnoid Aneurysm Trial (ISAT) of neurosurgical clipping versus endovascular coiling in 2143 patients with ruptured intracranial aneurysms: a randomised comparison of effects on survival, dependency, seizures, rebleeding, subgroups, and aneurysm occlusion. *Lancet*. 2005;366:809-817.
3. Feigin VL, Rinkel GJ, Algra A, Vermeulen M, van Gijn J. Calcium antagonists in patients with aneurysmal subarachnoid hemorrhage: a systematic review. *Neurology*. 1998;50:876-883.
4. Mutoh T, Kazumata K, Terasaka S, Taki Y, Suzuki A, Ishikawa T. Early intensive versus minimally invasive approach to postoperative hemodynamic management after subarachnoid hemorrhage. *Stroke*. 2014;45;1280-1284.

SUGGESTED READINGS

Broderick JP, Brott TG, Duldner JE, Tomsick T, Leach A. Initial and recurrent bleeding are the major causes of death following subarachnoid hemorrhage. *Stroke*. 1994;25:1342-1347.

Brust JCM, Dickinson PCT, Hughes JEO, Holtman RN. The diagnosis and treatment of cerebral mycotic aneurysms. *Ann Neurol*. 1990;27:238-246.

Cahill WJ, Calvert JH, Zhang JH. Mechanisms of early brain injury after subarachnoid hemorrhage. *J Cereb Blood Flow Metab*. 2006;26(11):1341-1353.

Claassen J, Bernardini GL, Kreiter K, et al. Effect of cisternal and ventricular blood on risk of delayed cerebral ischemia after subarachnoid hemorrhage: the Fisher scale revisited. *Stroke*. 2001;32:2012-2020.

Connolly ES Jr, Rabinstein AA, Carhuapoma JR, et al. Guidelines for the management of aneurysmal subarachnoid hemorrhage: a guideline for healthcare professionals from the American Heart Association/American Stroke Association. *Stroke*. 2012:43:1711-1737.

Crowley RW, Medel R, Dumont AS, et al. Angiographic vasospasm is strongly correlated with cerebral infarction after subarachnoid hemorrhage. *Stroke*. 2011;42:919-923.

Diringer MN, Bleck TP, Claude Hemphill J III, et al. Critical care management of patients following aneurysmal subarachnoid hemorrhage: recommendations from the Neurocritical Care Society's Multidisciplinary Consensus Conference. *Neurocrit Care*. 2011;15:211-240.

Fisher CM, Kistler JP, Davis JM. Relation of cerebral vasospasm to subarachnoid hemorrhage visualized by computerized tomographic scanning. *Neurosurgery*. 1980;6:1-9.

Francoeur CL, Mayer SA. Management of delayed cerebral ischemia after subarachnoid hemorrhage. *Critical Care*. 2016;20(1):277.

Hayman EG, Wessell A, Gerzanich V, Sheth KN, Simard JM. Mechanisms of global cerebral edema formation in aneurysmal subarachnoid hemorrhage. *Neurocrit Care*. 2017;26(2):301-310.

Hop JW, Rinkel GJE, Algra A, van Gijn J. Case-fatality rates and functional outcome after subarachnoid hemorrhage: a systematic review. *Stroke*. 1997;28:660-664.

Juvela S, Porras M, Heiskanen O. Natural history of unruptured intracranial aneurysms: a long-term follow-up study. *J Neurosurg*. 1993;79:174-182.

Komotar R, Schmidt JM, Starke RM, et al. Resuscitation and critical care of poor grade subarachnoid hemorrhage. *Neurosurgery*. 2009;64:397-411.

Kowalski RG, Claassen J, Kreiter KT, et al. Initial misdiagnosis and outcome after subarachnoid hemorrhage. *JAMA*. 2004;291:866-869.

Lantigua H, Ortega-Gutierrez S, Schmidt JM, et al. Subarachnoid hemorrhage: who dies, and why? *Critical Care*. 2015;19:309-318.

Longstreth WT Jr, Nelson LM, Koepsell TD, van Belle G. Clinical course of spontaneous subarachnoid hemorrhage: a population-based study in King County, Washington. *Neurology*. 1993;43:712-718.

Mayer SA, Fink ME, Homma S, et al. Cardiac injury associated with neurogenic pulmonary edema following subarachnoid hemorrhage. *Neurology*. 1994;44:815-820.

Perry JJ, Stiell IG, Sivilotti ML, et al. Clinical decision rules to rule out subarachnoid hemorrhage for acute headache. *JAMA*. 2013;310:1248-1255.

Rinkel GJE, Djibuti M, Algra A, van Gijn J. Prevalence and risk of rupture of intracranial aneurysms: a systematic review. *Stroke*. 1998;29:251-256.

Schmidt JM, Ko SB, Helbok R, et al. Cerebral perfusion pressure thresholds for brain tissue hypoxia and metabolic crisis after poor-grade subarachnoid hemorrhage. *Stroke*. 2011;42(5):1351-1356.

Suarez JI, Tarr RW, Selman WR. Aneurysmal subarachnoid hemorrhage. *N Engl J Med*. 2006;354:387-496.

Venkatraman A, Khawaja AM, Gupta S, et al. Intra-arterial vasodilators for vasospasm following aneurysmal subarachnoid hemorrhage: a meta-analysis. *J Neurointerv Surg*. 2018;10:380-387.

Vergouwen MD, Ilodigwe D, Macdonald RL. Cerebral infarction after subarachnoid hemorrhage contributes to poor outcome by vasospasm-dependent and -independent effects. *Stroke*. 2011;42(4):924-929.

Viñuela F, Duckwiler G, Mawad M. Guglielmi detachable coil embolization of acute intracranial aneurysm: perioperative anatomical and clinical outcome in 403 patients. *J Neurosurg*. 1997;86:475-482.

Wartenberg KE, Schmidt JM, Claassen J, et al. Medical complications after subarachnoid hemorrhage: frequency and impact on outcome. *Crit Care Med*. 2006;34:617-623.

Wiebers DO, Whisnant JP, Huston J III, et al; for International Study of Unruptured Intracranial Aneurysms Investigators. Unruptured intracranial aneurysms: natural history, clinical outcome, and risks of surgical and endovascular treatment. *Lancet*. 2003;362:103-110.

Woitzik J, Dreier JP, Hecht N, et al. Delayed cerebral ischemia and spreading depolarization in absence of angiographic vasospasm after subarachnoid hemorrhage. *J Cereb Blood Flow Metab*. 2012;32:203-212.

Zaroff JG, Leong J, Kim H, et al. Cardiovascular predictors of long-term outcomes after non-traumatic subarachnoid hemorrhage. *Neurocrit Care*. 2012;17(3):374-381.

41 Cerebral Venous and Sinus Thrombosis

Jennifer A. Frontera and Natalie Organek

KEY POINTS

1. Patients with cerebral venous thrombosis (CVT) can have a variety of clinical presentations including headache, focal neurologic deficits, seizure, abnormal mental status, and coma.
2. A CVT is a neurologic emergency with time-dependent treatments.
3. The diagnosis of CVT is confirmed radiographically. Computed tomography and magnetic resonance venograms are the most commonly used imaging tools.
4. The mainstay of CVT treatment is anticoagulation, even in the context of CVT-related intraparenchymal hemorrhage
5. Enoxaparin is likely a superior to unfractionated heparin for anticoagulation.
6. Patients who worsen despite adequate anticoagulation may be candidates for endovascular intervention including thrombectomy and intrasinus thrombolysis.

INTRODUCTION

Cerebral venous thrombosis (CVT) is thrombosis of the venous channels that drain blood from the brain (Fig. 41.1). The CVT includes both cerebral sinus thrombosis and cortical vein thrombosis. Often, it is associated with other conditions causing thrombi, but not infrequently, its cause remains unknown. The CVT commonly presents with isolated headache but also must be kept on the differential for causes of cerebral ischemia, hemorrhage, and even coma. The CVT image findings may be subtle but are important because overlooking them can have catastrophic consequences. Treatment recommendations for CVT had been controversial for many years, although anticoagulation remains the mainstay of treatment and endovascular therapies are becoming more common. Overall, the outcome for CVT is positive; if it is treated early, recurrence rates are low.

EPIDEMIOLOGY

The CVT is an uncommon disorder affecting a variable patient population. The CVT in adults is thought to affect about 5 to

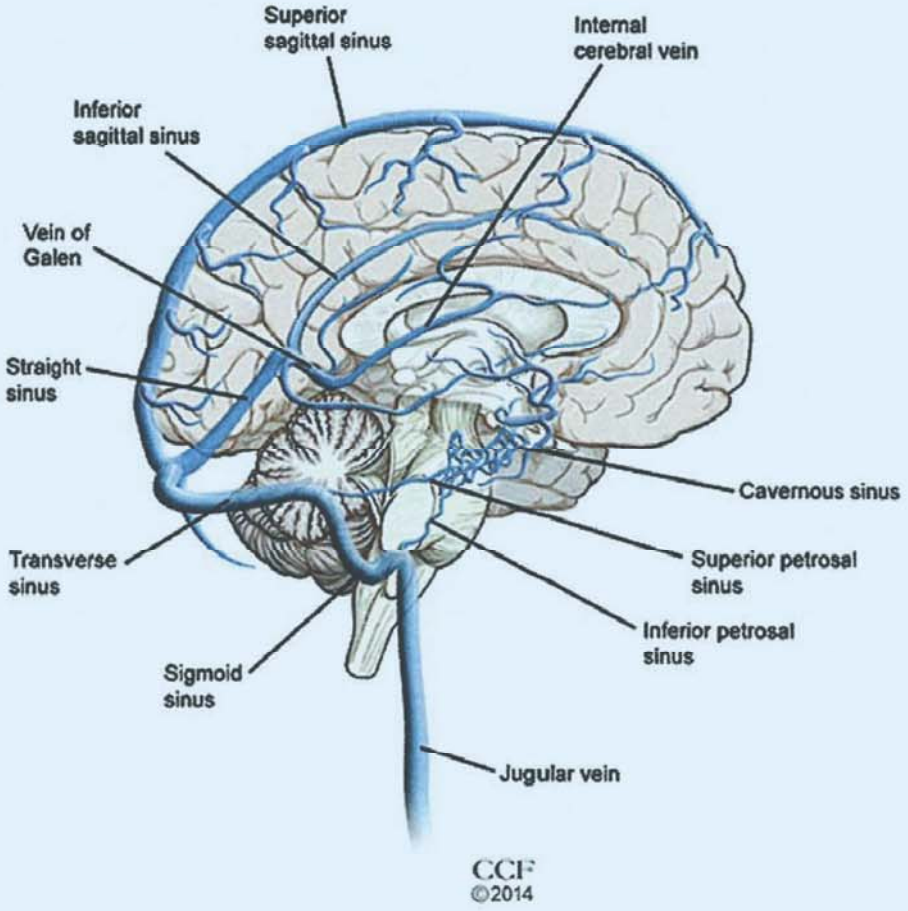

FIGURE 41.1 Cerebral venous anatomy. (Reprinted with permission, Cleveland Clinic Center for Medical Art & Photography © 2014-2015. All Rights Reserved.)

15.7 people per 1 million every year. Most accounts estimate that CVT represents slightly less than 1% of all strokes. The International Study on Cerebral Vein and Dural Sinus Thrombosis (ISCVT), the largest multicenter collaboration of consecutively enrolled symptomatic CVT patients older than 15 years with imaging confirmation, collected data on 624 patients from 24 countries and 89 centers and found the following epidemiologic data for CVT: median age was 37 years (age range 16-86 y), and 74% of enrollees were female. These data are in keeping with the general belief that, although it can affect any age or sex, in the adult population, CVT is largely a disorder of young to middle-aged females. The preponderance of women affected may be related to hormonal risks associated with oral contraceptives, pregnancy, and puerperium.

The Canadian Pediatric Ischemic Stroke Registry (CPISR) is one of the largest pediatric CVT registries and involved 16 pediatric tertiary care centers in Canada collecting data on 160 consecutive cases of radiologically confirmed CVT in children 0 to 18 years old. These data demonstrated an incidence of pediatric CVT to be about 6.7 per 1 million people. Among the 160 children enrolled, 54% were younger than 1 year old (with 43% younger than 1 mo of age) and 54% were male. This follows the general understanding that the pediatric CVT population largely involves very young children, and the female preponderance seen in adult CVT is not present in pediatric CVT populations.

PATHOBIOLOGY

The CVT has been attributed to numerous causes, yet even after extensive workup, almost 30% of CVT diagnoses remain idiopathic. The ISCVT found that thrombophilia (34.1%) and oral contraception (54%, overall data corrected for females of childbearing age) accounted for a significant portion of the causes of CVT. Other important causes of CVT were puerperium (14%, overall data corrected for females of childbearing age) and pregnancy (6%, overall data corrected for females of childbearing age). Additionally, infection (especially of the ear, sinus, mouth, face, and neck) contributed to 12% of CVT cases in their data set, and malignancy (within and outside of the central nervous system, both solid tumor and hematologic) was found to have caused 7% of CVT in the ISCVT population. Regarding genetic causes, Marjot et al performed a meta-analysis of 26 studies. This included 1,183 CVT patients, explored six genes, and demonstrated a statistically significant association between CVT and two genes: factor V Leiden (odds ratio = 2.40; 95% confidence interval, 1.75-3.30; $P < .00001$) and prothrombin gene mutation (odds ratio = 5.48; 95% confidence interval, 3.88-7.74; $P < .00001$). Finally, more than 44% of subjects were found to have more than one cause of CVT, an important fact to remember when exploring causes of CVT in hopes of preventing reoccurrence. **Table 41.1** summarizes common causes of CVT.

In contrast to adult data, the most common cause of CVT in children is infection. In the CPISR data, acute infection was most commonly found in neonates (children younger than 1 mo; 84%). Perinatal complications (51%) and dehydration (30%) were also common causes of CVT in the neonatal population. In older children (older than 1 mo but younger than 18 y), chronic illness was the most common risk factor, especially connective tissue disorders (23%), hematologic disease (20%), and cancer (13%). Similar to the adult data, the CPISR data found prothrombotic states to be an important cause of CVT in neonates (20%) and children (54%).

TABLE 41.1 Common Causes of Cerebral Sinus Thrombosis

Drugs	Oral contraceptives (especially in combination with tobacco, obesity, and/or prothrombotic disease), hormone replacement therapy, fertility medications, asparaginase chemotherapy, tamoxifen, steroids, androgens
Hematologic diseases	Polycythemia, thrombocythemia, paroxysmal nocturnal hemoglobinuria
Hypercoagulable state	Protein C, S, or antithrombin III deficiency; factor V Leiden mutation; prothrombin gene mutation; antiphospholipid syndrome (lupus anticoagulant/anticardiolipin antibody); nephrotic syndrome; hyperhomocysteinemia
Infections	Encephalitis; cerebritis; meningitis; mastoiditis; otitis; sinusitis; infections of the mouth, face, and neck
Inflammatory diseases	Vasculitis, lupus, Wegener granulomatosis, polyarteritis nodosa, inflammatory bowel disease, Behçet disease, thromboangiitis obliterans, sarcoidosis
Malignancy	CNS tumors with invasion of the venous sinus, hematologic cancers, myeloproliferative syndromes, nasopharyngeal cancers, meningioma, head and neck tumors, hypercoagulable state due to malignancy
Obstetric	Pregnancy and puerperium
Trauma (including iatrogenic)	Head injury, lumbar puncture, neurosurgical procedures
Cerebrovascular abnormalities	Dural arteriovenous fistula

Abbreviation: CNS, central nervous system.
Adapted from Frontera J, ed. *Decision Making in Neurocritical Care.* New York, NY: Thieme; 2009.

CLINICAL FEATURES

The variable clinical presentation is one of the challenges of CVT. The two main mechanisms by which CVT causes symptoms are (1) obstruction of venous drainage leading to increased venous pressure, disruption of the blood brain barrier, vasogenic edema, and ischemic or hemorrhagic stroke; and (2) elevated venous pressure resulting in reduced resorption of cerebral spinal fluid by arachnoid granulations with consequent hydrocephalus and/or elevated intracranial pressure (ICP). Increased cerebral blood volume due to reduced venous drainage will also contribute to elevated ICP.

Diffuse progressive headache over hours to days is the most common presentation in patients with CVT, although thunderclap and migrainous-type headache have also been described. Importantly, isolated headache without other neurologic findings or signs of elevated ICP occurred in 25% of confirmed CVT in the ISCVT cohort. It is important to consider that persistent headache following lumbar puncture could be CVT because, rarely, spinal fluid drainage can precipitate CVT.

When CVT does cause an increase in ICP, patients commonly present with the following neurologic signs: papilledema, diplopia (most commonly due to sixth nerve palsy), headache which worsens with recumbency, nausea/vomiting, and encephalopathy. Because symptoms of idiopathic intracranial hypertension

often mimic those of CVT, it is critical to evaluate for CVT when idiopathic intracranial hypertension is suspected.

In addition to signs of increased ICP, focal neurologic deficits following cerebral ischemia or hemorrhage are also important clinical presentations in patients with CVT. Indeed, 30% to 40% of CVT patients present with intracerebral hemorrhage. The actual signs of the focal brain injury are attributed to the site of venous ischemia and are therefore variable but include focal weakness, sensory changes, visual field deficits, and aphasias. Further confounding this picture in CVT, the superior sagittal sinus, the most commonly involved cerebral venous structure in CVT, drains both cerebral hemispheres and therefore when thrombosed can cause bilateral deficits complicating neurologic localization. A small yet clinically important subset of CVT patients are those with deep CVT. A CVT affecting the basal ganglia or thalamus is commonly bilateral and can lead to venous ischemia or hemorrhages. A CVT affecting the deep parts of the brain tends to be more severe and quickly results in profound deficits including altered mental status and coma.

Seizures may also occur in the context of CVT. In ISCVT, seizures occurred in 39% of patients. In children, seizures have been reported in 44% of CVT patients.

The cavernous sinuses are a unique set of cerebral sinuses. They are deep bilateral structures at the base of the cerebrum that house the internal carotid artery, ophthalmic vein, branches of the sphenoid, and superficial middle cerebral veins as well as cranial nerves III, IV, V1, V2, and VI. Venous thromboses affecting the cavernous sinuses are associated with palsies affecting these cranial nerves leading to diplopia and ophthalmoparesis as well as pain, ptosis, chemosis, and proptosis. Increased intraocular pressure due to poor venous drainage can lead to papilledema and loss of visual acuity. Fever, periorbial edema, and sensory loss in cranial nerves V1 and V2 distributions may occur. Most cavernous sinus thromboses are related to infection, typically due to *Staphylococcus aureus*, although *Streptococcus pneumoniae*, gram-negative rods, anaerobes, and occasionally fungal infections may be culprits. Venous drainage from the facial veins and pterygoid plexus via the superior and inferior ophthalmic veins provide a route for the spread of facial infections to the cavernous sinus, which is highly trabeculated and can act as a repository for bacteria. Sphenoid and ethmoid sinus infections can also lead to septic thrombosis of the cavernous sinus. Otitis media, dental, and mastoid infections can rarely be associated with cavernous vein thrombosis. Noninfectious causes of cavernous sinus thrombosis include Tolosa-Hunt syndrome (granulomatous inflammation of the cavernous sinus and superior orbital vein), Cogan syndrome (polyarteritis nodosa with CVT), trauma, meningioma, and nasopharyngeal tumor. Spread of symptoms to the contralateral eye via the intracavernous sinuses may occur within 24 to 48 hours of the initial presentation and is pathognomonic for cavernous sinus thrombosis.

Septic lateral sinus thrombosis can occur in the context of mastoiditis and typically involves the sigmoid sinus with extension to the transverse sinus and jugular vein. Secondary hydrocephalus can occur if the dominant transverse sinus is involved because the final common pathway of cerebral spinal fluid resorption from the arachnoid granulations is through the sagittal sinus, sigmoid sinus, and jugular vein. Fluent aphasia may be a presenting feature of left-sided (or dominant) lateral sinus thrombosis. Multiple cranial neuropathies and/or pulsatile tinnitus can be presenting features of lateral sinus and/or jugular vein thrombosis. Gradenigo syndrome is a triad of otitis media, sixth nerve palsy, and temporal/retroorbital pain and is highly suggestive of lateral sinus thrombosis. The most common organisms involved in lateral sinus thrombosis are *Proteus* species, *S aureus*, *Escherichia coli*, *Pseudomonas*, and anaerobic species.

TABLE 41.2 Common Cerebral Venous Thrombosis Syndromes

CVT Location	Symptoms
Superior sagittal sinus	Large vein, symptoms depend on location affected Motor deficits (can be bilateral due to central location) Psychiatric symptoms (when affecting the frontal lobes) Seizures due to cortical location
Transverse sinus	Aphasias when they affect areas of speech
Cerebral cortical vein	Deficit varies depending on location of CVT. Seizures due to cortical location
Deep venous system	Change in mental status Coma Bilateral deficits due to central location
Cavernous sinus	Palsies affecting cranial nerves III, IV, V1, V2, or VI Orbital pain, chemosis, proptosis, papilledema, decreased visual acuity

Abbreviation: CVT, cerebral venous thrombosis.
Adapted from Frontera J, ed. *Decision Making in Neurocritical Care*. New York, NY: Thieme; 2009.

Table 41.2 summarizes common syndromes associated with CVT.

Clinical presentation for CVT in children is similar to adults except in neonates where seizure is more common. In the CPISR database, 71% of neonates (children younger than 1 mo old) with CVT had seizure attributed to CVT, in contrast to only 48% of nonneonate CPISR children and 44% of CVT patients older than 15 years.

DIAGNOSIS

The CVT is a pathology known for its infrequent as well as variable clinical presentation both of which can complicate diagnosis. Delays in diagnosis of CVT are not uncommon; therefore, a high level of suspicion must be maintained in the proper clinical context. Diagnosing CVT begins with a thorough patient history and physical examination. Elements discovered in these investigations help to determine the necessary laboratory and radiologic evaluation.

The key to diagnosis in CVT is direct imaging of the cerebral venous system. Both computed tomography venography (CTV) and magnetic resonance venography (MRV) have been studied in CVT; they have been found to be equivalent imaging techniques in CVT. Figure 41.2A demonstrates CVT in the torcula on T2 magnetic resonance imaging (MRI) and in the left transverse sinus on MRV (Fig. 41.2B, *white arrows*). Figure 41.3 shows an MRV with a complete filling defect of the superior sagittal sinus from the origin to the torcula. Drawbacks associated with CTV include radiation exposure, contrast allergy, and limited use in renal failure. The MRV is limited in patients with pacemakers and requires significant time that is typically unavailable in urgent neurologic evaluations. Distinguishing thrombosis

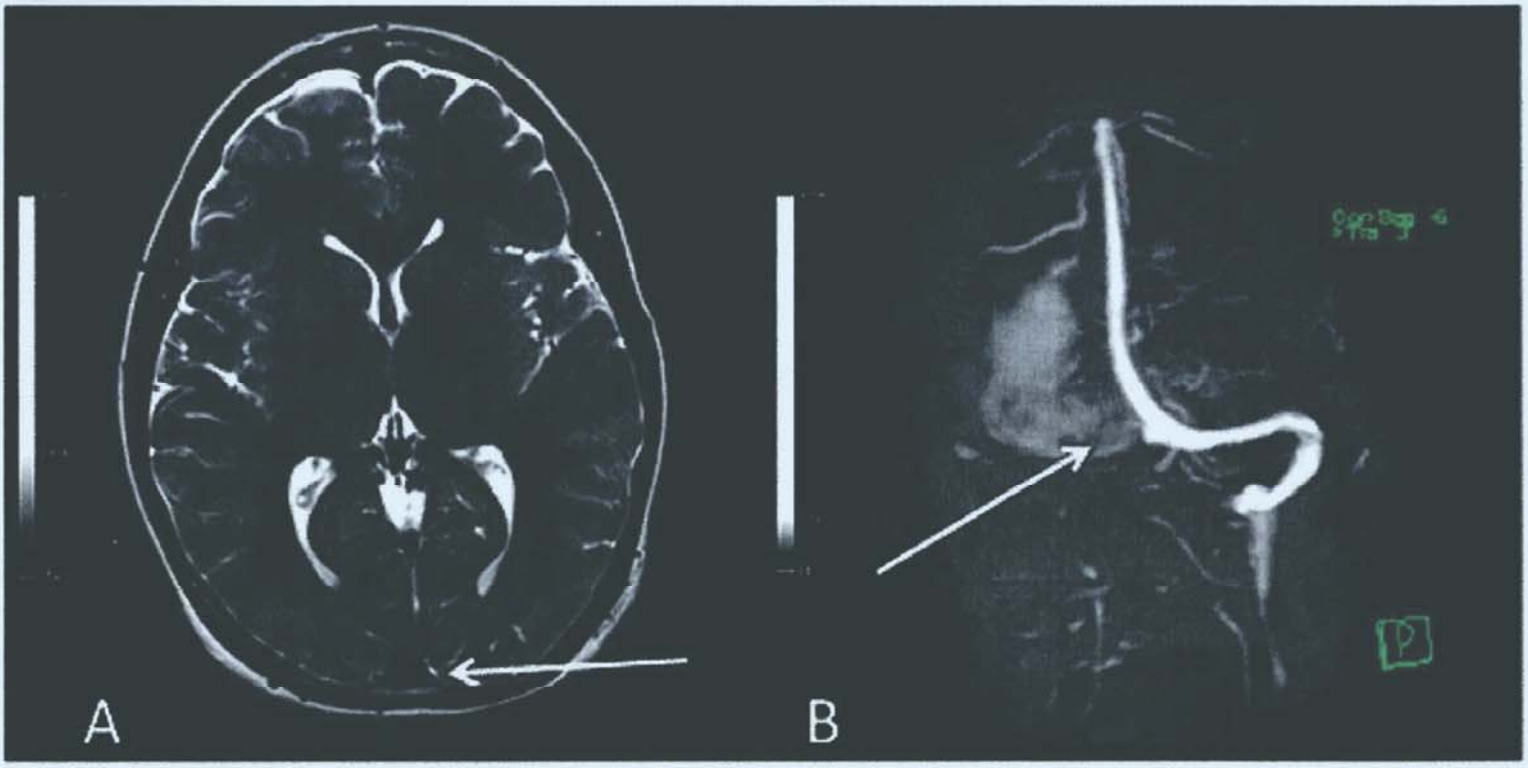

FIGURE 41.2 Axial T2 magnetic resonance imaging **(A)** and coronal magnetic resonance venography **(B)** demonstrating a thrombus at the torcula (*white arrow* in **A**) and at the transverse sinus (*white arrow* in **B**).

from venous hypoplasia (particularly of the transverse sinus) or venous arachnoid granulations can complicate interpretation of MRV and CTV imaging. Parenchymal MRI sequences can be useful in making this distinction (**Table 41.3**) and is particularly useful for diagnosing cavernous sinus thrombosis.

FIGURE 41.3 Sagittal time of flight magnetic resonance venography demonstrating complete filling defect of the superior sagittal sinus from the origin to the torcula in a woman with a history of fertility injections, oral contraceptive use, tobacco use, and leiomyoma. There is also a filling defect in the midtransverse sinus *(white arrow)*. Note the prominent cortical venous drainage that has developed to compensate *(small black arrows)*.

Conventional digital subtraction angiography was the gold standard for the diagnosis of CVT for many years, although, for the most part, it is currently reserved for inconclusive CTV or MRV imaging or when endovascular intervention is required. In patients with persistent symptoms or those with previously diagnosed CVT and a change in symptoms, repeat imaging should be considered to evaluate for new CVT as well as propagation of known thrombus. Digital subtraction angiography may be particularly useful for suspected cortical vein thrombosis, where MRV and CTV resolution is limited. **Figure 41.4A** shows a digital subtraction angiogram with partial superior sagittal sinus thrombosis and proliferation of cortical venous drainage as well as prominent deep venous drainage. A follow-up MRV 1 month after endovascular treatment shows a patent superior sagittal sinus (**Fig. 41.4B**).

In 2011, the American Heart Association (AHA) and the American Stroke Association (ASA) created the statement for health care professional on the diagnosis and management of CVT LEVEL 1,[1] which reviewed, among other topics, invasive and noninvasive CVT diagnostic imaging modalities. In the AHA/ASA review, noncontrast CT of the brain was the most common imaging modality for patients with new neurologic symptoms.

TABLE 41.3 Using Magnetic Resonance Imaging to Age Cerebral Blood

Phase	Time	T1	T2	Hemoglobin
Acute	1-3 d	Isodense	Dark	Deoxyhemoglobin
Early subacute	3-7 d	Bright	Dark	Methemoglobin
Late subacute	7-14 d	Bright	Bright	Methemoglobin
Chronic	>14 d	Dark	Dark	Hemosiderin

Adapted from Frontera J, ed. *Decision Making in Neurocritical Care.* New York, NY: Thieme; 2009.

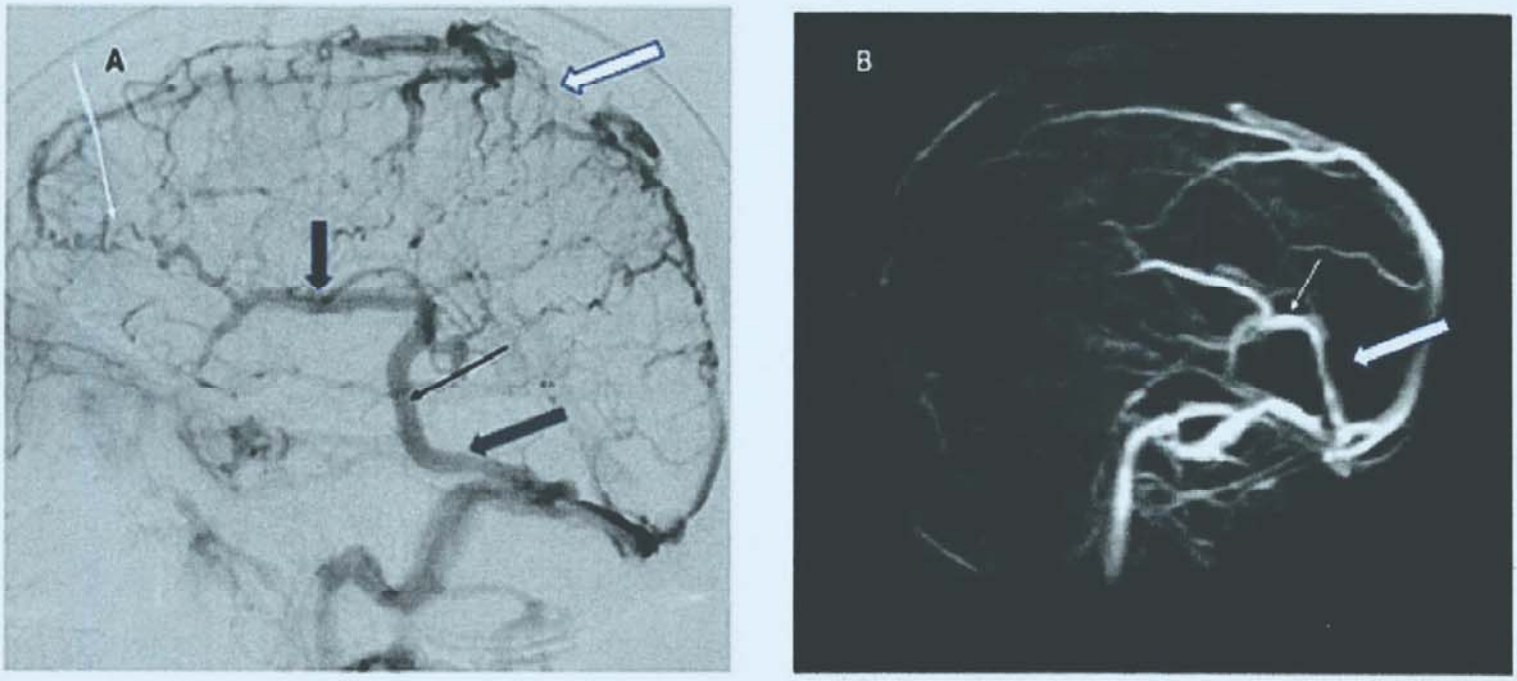

FIGURE 41.4 Sagittal digital subtraction angiography **(A)** and magnetic resonance venography **(B)** in a patient with partial sagittal sinus thrombosis (*thick white arrow*, **A**). Note the compensatory hypertrophied and corkscrew cortical venous drainage (*thin white arrow*, **A**) and prominent deep venous drainage (internal cerebral vein, *thick black arrow* in **A**; vein of Galen, *thin black arrow* in **A**; and straight sinus, *thick gray arrow* in **A**). One month following endovascular thrombectomy and intrasinus tPA infusion, the magnetic resonance venography **(B)** demonstrates a patent superior sagittal sinus. The internal cerebral vein (*thick black arrow* in **B**), vein of Galen (*thin white arrow* in **B**), and straight sinus (*thick white arrow* in **B**) are still easily visualized. Abbreviation: tPA, recombinant tissue plasminogen activator.

Noncontrast head CT is often unremarkable but may demonstrate subtle signs suggestive of the CVT, namely, hyperdensities in the cerebral veins. This finding is present in only about one-third of patients. The most well-known noncontrast head CT finding in CVT is the dense triangle found in the posterior sagittal sinus called the *filled delta sign*. There is often a delay in visualization of this sign for days, but once present, it typically persists for weeks, which make it likely to be most helpful with late presentation of CVT. The noncontrast head CT in Figure 41.5 demonstrates a hyperdense clot in the left transverse sinus (*white arrow*). More often, noncontrast head CT demonstrates nonspecific indirect signs of CVT including CT hypodensities and a decrease in ventricular size both associated with parenchymal edema. Nonenhanced head CT is also helpful in demonstrating cerebral venous infarctions or intracerebral hemorrhage, which characteristically are in vascular distributions inconsistent with more common arterial disease. Perhaps most importantly, noncontrast CT is helpful in ruling out other causes for the clinical presentation. In CVT, contrast-enhanced CT may demonstrate the "empty delta sign" wherein the thrombus creates a filling defect in the cerebral venous system and, therefore, becomes "empty." The overall accuracy of head CT and CTV in combination is 90% to 100%. Finally, as with most cerebrovascular disease, MRI of the brain can be helpful in demonstrating earlier signs of venous infarct associated with CVT.

A CVT laboratory workup is focused on determining the cause and should include basic labs as well as an evaluation for hypercoagulability. Anticoagulation can affect the outcome of the hypercoagulable labs, and therefore, these should be examined prior to initiating anticoagulation treatment for CVT. Table 41.4 lists laboratory workup for CVT.

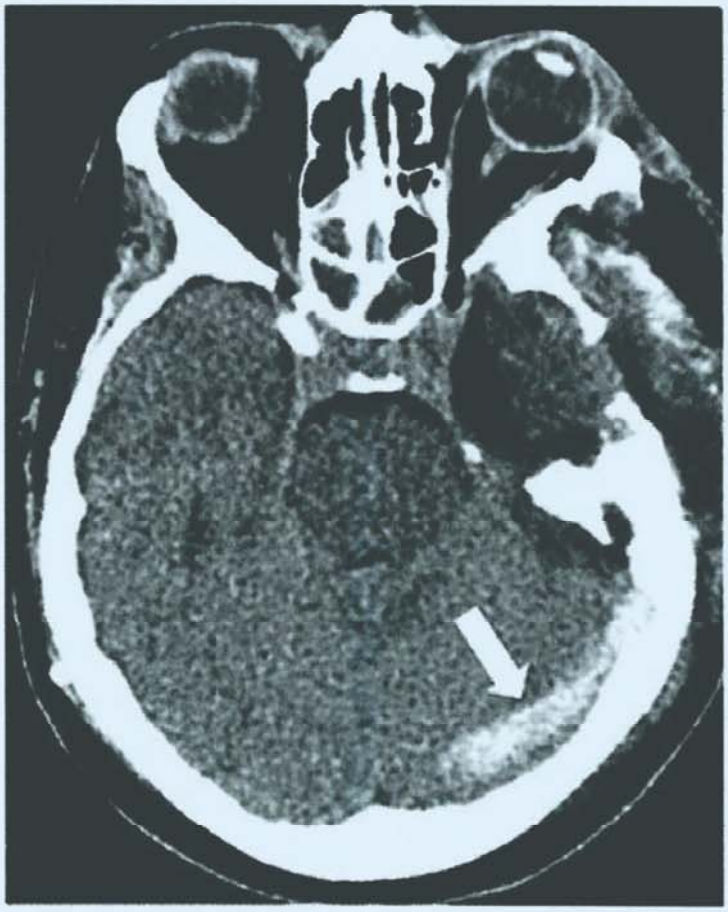

FIGURE 41.5 Noncontrast head computed tomography demonstrates a left transverse sinus thrombosis *(white arrow)*.

TABLE 41.4 Laboratory Workup for Cerebral Venous Thrombosis (CVT)

Basic labs	CBC, chemistry, liver function testing, antinuclear antibody, D-dimer (elevated levels support the diagnosis, but normal levels do not exclude CVT)
Hypercoagulable workup (test prior to starting anticoagulation)	PT/INR, aPTT, homocysteine, methylmalonic acid, MTHFR gene mutation, factor V Leiden mutation, prothrombin gene mutation, antiphospholipid and anticardiolipin antibodies, lupus anticoagulant, protein C and S levels and activity, antithrombin III levels, factor VIII level, fibrinogen, B2 glycoprotein
Specific testing (patient specific)	Urine protein (if nephrotic syndrome is suspected)

Abbreviations: aPTT, activated partial thromboplastin time; CBC, complete blood count; INR, international normalized ratio; PT, prothrombin time.

D-dimer has been explored as a possible diagnostic marker for CVT, but high pretest probability remains paramount. Meng et al performed a prospective study of confirmed CVT in 94.1% of patients who had elevated D-dimer and during the acute phase, the sensitivity and specificity of predicting CVT with D-dimer were 94.1% and 97.5%. Similarly, in a meta-analysis of 1,134 CVT cases by Dentali et al, D-dimer was found to have a mean sensitivity of 93.9% and mean specificity of 89.7%. The AHA/ASA CVT statement LEVEL 2[1] reviewed sensitivity and specificity of a number of studies exploring D-dimer and CVT and suggests D-dimer may be helpful in those with very low suspicion of CVT but cannot be used to preclude further evaluation in patients in whom there is a strong clinical suspicion.

Diagnosis of CVT in children is similar to adults in that, most importantly, although CVT is rare and has a nonspecific presentation, it must not be left off a comprehensive differential in children with appropriate neurologic symptoms. As described earlier, this may be especially challenging in neonates who more commonly present with seizure but have otherwise nonspecific presentation. In general, CVT imaging is very similar in children and adults, but neonatal physiologic differences must be considered. The hypointensity of the immature unmyelinated brain as well as the hyperintensity of physiologic polycythemia associated with neonates can mimic the "delta sign" and is therefore known as the *pseudodelta sign*. This CVT mimic in neonates is easily clarified with administration of contrast material. Additionally, in neonates, transfontanellar ultrasound has been explored for CVT diagnosis but was generally found unreliable especially in nonocclusive thrombus and therefore has limited use in neonatal CVT without confirmation with other imaging modalities.

MANAGEMENT

The CVT treatment is typically trimodal: The mainstay of treatment is (1) anticoagulation, (2) treatment of the underlying etiology when appropriate (ie, antimicrobial for cases involving infection), and (3) symptomatic treatment (headache management, addressing increased ICP). In patients who present with seizure, antiepileptic drugs (AEDs) are indicated. Endovascular therapies should be considered in patients who fail anticoagulation or have extensive symptomatic CVT.

Anticoagulation Therapy

Anticoagulation is essential for preventing CVT propagation and to prevent systemic thrombosis in those with underlying hypercoagulable states. Einhäupl et al studied 20 patients with CVT (confirmed on imaging) who were randomized to intravenous unfractionated heparin (UFH) versus placebo. The study was stopped prematurely due to the obvious benefit of treatment with anticoagulation. Additionally, this group documented two intracerebral hemorrhages, both in the placebo group (none among the anticoagulation treatment group). Subsequently, in a study by de Bruijn et al LEVEL 2,[2] 59 patients with CVT were randomized to low molecular weight heparin (LMWH) versus placebo. The placebo group was more likely to have a poor outcome compared with the treatment group, and no intracerebral hemorrhages occurred in either group. The 2011 AHA/ASA guidelines for CVT recommend initial anticoagulation with UFH or weight-based LMWH in full doses followed by vitamin K antagonists regardless of the presence of intracerebral hemorrhage LEVEL 1.[1] In 2012, the American College of Chest Physicians formally recommended initial treatment for CVT with either dose-adjusted heparin or LMWH followed by oral anticoagulation for 3 to 6 months for most patients and lifelong anticoagulation for CVT patients with permanent risk factors for recurrent events LEVEL 1.[3] Similarly, the 2014 AHA/ASA guidelines for prevention of stroke LEVEL 1[4] and the 2017 European Stroke Organization guidelines both recommend acute anticoagulation regardless of the presence of intracerebral hemorrhage. The 2017 European Stroke Organization guidelines recommend using LMWH over UFH LEVEL 1.[5] It is important to note that anticoagulation *should be administered for CVT even in the context of intracranial hemorrhage*.

An LMWH may be preferred over UFH in patients who do not require urgent surgical intervention. The ISCVT investigators compared the outcomes of CVT patients treated with UFH and LMWH and found a better efficacy and safety for LMWH. Additionally, a randomized controlled trial of 66 CVT patients also explored treatment with UFH and LMWH and found LMWH to have a significantly lower mortality in CVT compared to UFH LEVEL 1.[6] Finally, women of childbearing age with CVT present a unique challenge. In women with a history of CVT, oral contraceptives should generally be avoided, and in pregnant women with a history of CVT, prophylaxis with LMWH during future pregnancies and in the postpartum period may be reasonable LEVEL 1.[7] Anticoagulation is generally continued for 3 to 6 months in provoked CVT and 6 to 12 months in unprovoked CVT using warfarin but may be continued longer in patients with long-term risk factors including thrombophilia. There is little data regarding the use of direct oral anticoagulants for long-term anticoagulation in CVT, although off-label use has been increasing.

Endovascular Therapy

The data for endovascular invasive therapy, including direct endovascular thrombolysis and thrombectomy, to this point has not proven to provide greater benefit than anticoagulation alone. The thrombolysis or anticoagulation for cerebral venous thrombosis (TO-ACT) LEVEL 1[8] randomized controlled trial of anticoagulation versus endovascular intervention in high-risk CVT patients was stopped early for futility. However, in patients with CVT who clinically deteriorate while on anticoagulation and in those who have an absolute contraindication to anticoagulation (such as hemodynamically significant hemorrhage or allergy to

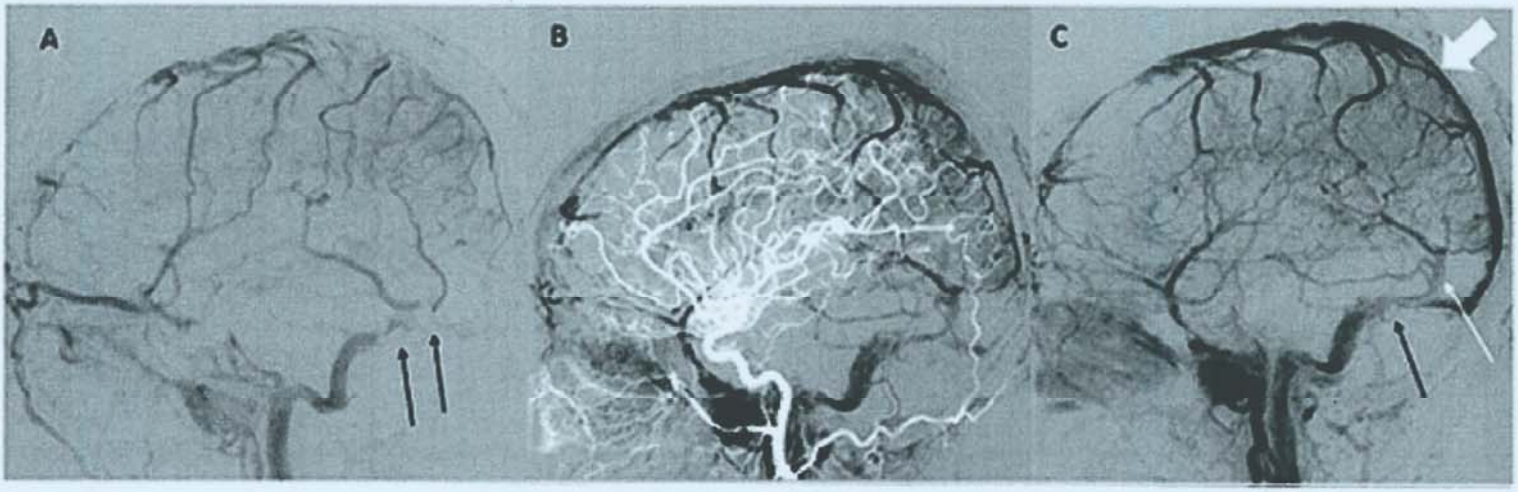

FIGURE 41.6 **A:** Sagittal digital subtraction angiography demonstrates complete occlusion of the superior sagittal sinus from the origin to the torcula. Note clots present in the transverse and straight sinuses (*black arrows* in **A**). **B:** An overlay of normal arterial angiography *(white)* and the venous drainage pattern with diffuse cerebral venous thrombosis in the same patient. **C:** Improved venous flow following endovascular thrombectomy with recanalization of the superior sagittal sinus and torcula (*large white arrow* in **C**). There is improved flow in the straight sinus (*small white arrow* in **C**); however, some irregularity remains at the transverse-sigmoid sinus junction (*small black arrow* in **C**).

anticoagulation agents), endovascular intervention may be considered. Options for endovascular treatment include local infusion of recombinant tissue plasminogen activator as well as mechanical thrombolysis using balloons and rheolytic catheters. A systematic review of 42 studies with 185 patients reported a good outcome in 84% of CVT patients who underwent a variety of endovascular therapies including balloon angioplasty, clot retrieval, and thrombolysis with a 95% recanalization rate. However, worsened intracerebral hemorrhage occurred in 10% and mortality rates were 12%. Figure 41.6 shows the digital subtraction angiogram of a patient with extensive superior sagittal sinus thrombosis from the origin to the torcula. The patient remained symptomatic despite anticoagulation and underwent endovascular thrombectomy with recanalization of the superior sagittal sinus and torcula (panel C). In light of the recent advances in endovascular therapy, open surgical treatment for CVT is limited mostly to those patients with large cerebral venous infarcts who develop clinical and radiologic signs of herniation and may benefit from decompressive hemicraniectomy or minimally invasive clot removal.

Treatment of Comorbid Conditions

In patients with symptomatic intracranial hypertension, efforts to lower ICP should be considered. Elevation of the head of the bed with the head midline to promote venous drainage, osmotic therapy, and management of hypermetabolic states (shivering, fever, seizure, agitation) should be considered as part of routine intracranial hypertension management.

In patients with seizure related to CVT, AEDs should be administered LEVEL 7[1]; however, prophylactic AED use is not advised. The optimum duration of treatment with AEDs in CVT patients with seizure remains unknown.

In cases of septic thrombosis (eg, septic cavernous sinus thrombosis), antibiotics are a mainstay of treatment. Typical treatment regimens should cover *S aureus* and include vancomycin, ceftriaxone, or cefepime (if *Pseudomonas* is suspected). Anaerobic coverage for dental or sinus infections should include metronidazole. There is no evidence supporting the use of glucocorticoids for septic cerebral sinus thrombosis.

Treatment of Cerebral Venous Thrombosis in Children

There is a dearth of data regarding treatment of CVT in children; treatment guidelines are largely extrapolated from adult data. The AHA/ASA LEVEL 7[1] current recommendations for treating CVT in children older than 1 month of age align with adult recommendations for treatment with anticoagulation even in the context of intracerebral hemorrhage. Treatment recommendations for children younger than 1 month of age remain controversial and variable. Neonates should be treated with anticoagulation for 6 weeks to 3 months with close imaging follow-up to assess for recanalization with low threshold for stopping anticoagulation at 6 weeks if the venous system recanalizes LEVEL 7.[1] The AED recommendations in children (and neonates) are similar to that of adults.

OUTCOME

Overall, the outcome for most patients with CVT is positive, but there remains an important minority in whom the disease causes significant morbidity and mortality. According to ISCVT data, about 87% of CVT patients had complete recovery, but about 8% had significant morbidity with an additional mortality rate of about 5%. Similarly, Borhani Haghighi et al investigated a national cohort of almost 3,500 CVT patients had a mortality rate of 4.39%. Certain characteristics have been found to be associated with poor outcome in CVT including male gender, age older than 37 years, those with significant neurologic deficit and coma, as well as those who develop seizure. In the acute phase of CVT, brain herniation attributed to CVT remains the most common cause of death; in the late stages, mortality associated with

CVT is mostly related to the underlying cause of the thrombosis. Rates of CVT recurrence range from 2% to 4%. Recanalization rates in patients treated with anticoagulation are as high as 85% based on a meta-analysis of retrospective studies.

In childhood, CVT coma has been shown to predict mortality, but overall, few studies have followed children for more than 2 years after CVT. In the CPISR data (with only over 2 y of follow-up), approximately 75% of neonates and approximately 50% of nonneonates were neurologically normal.

LEVEL 1 EVIDENCE

1. Saposnik G, Barinagarrementeria F, Brown RD Jr, et al. Diagnosis and management of cerebral venous thrombosis: a statement for healthcare professionals from the American Heart Association/American Stroke Association. *Stroke*. 2011;42(4): 1158-1192.
2. de Bruijn SF, Stam J. Randomized, placebo-controlled trial of anticoagulant treatment with low-molecular-weight heparin for cerebral sinus thrombosis. *Stroke*. 1999;30(3): 484-488.
3. Lansberg MG, O'Donnell MJ, Khatri P, et al. Antithrombotic and thrombolytic therapy for ischemic stroke: antithrombotic therapy and prevention of thrombosis, 9th ed: American College of Chest Physicians evidence-based clinical practice guidelines. *Chest*. 2012;141(2 suppl): e601S-e636S.
4. Kernan WN, Ovbiagele B, Black HR, et al. Guidelines for the prevention of stroke in patients with stroke and transient ischemic attack: a guideline for healthcare professionals from the American Heart Association/American Stroke Association. *Stroke*. 2014;45(7):2160-2236.
5. Ferro JM, Bousser MG, Canhão P, et al. European Stroke Organization guideline for the diagnosis and treatment of cerebral venous thrombosis—endorsed by the European Academy of Neurology. *Eur J Neurol*. 2017;24(10):1203-1213.
6. Misra UK, Kalita J, Chandra S, Kumar B, Bansal V. Low molecular weight heparin versus unfractionated heparin in cerebral venous sinus thrombosis: a randomized controlled trial. *Eur J Neurol*. 2012;19(7):1030-1036.
7. Bushnell C, McCullough LD, Awad IA, et al. Guidelines for the prevention of stroke in women: a statement for healthcare professionals from the American Heart Association/American Stroke Association. *Stroke*. 2014;45(5): 1545-1588.
8. Coutinho JM, Zuurbier SM, Bousser MG, et al. Effect of endovascular treatment with medical management vs standard care on severe cerebral venous thrombosis: the TO-ACT randomized clinical trial. *JAMA Neurol*. 2020;77(8): 966-973.

SUGGESTED READINGS

Aguiar de Sousa D, Lucas Neto L, Canhão P, Ferro JM. Recanalization in cerebral venous thrombosis. *Stroke*. 2018;49(8):1828-1835.

Borhani Haghighi A, Edgell RC, Cruz-Flores S, et al. Mortality of cerebral venous-sinus thrombosis in a large national sample. *Stroke*. 2012;43(1):262-264.

Bousser MG, Ferro JM. Cerebral venous thrombosis: an update. *Lancet Neurol*. 2007;6(2):162-170.

Canhão P, Falcão F, Ferro JM. Thrombolytics for cerebral sinus thrombosis: a systematic review. *Cerebrovasc Dis*. 2003;15(3):159-166.

Canhão P, Ferro JM, Lindgren AG, et al. Causes and predictors of death in cerebral venous thrombosis. *Stroke*. 2005;36(8):1720-1725.

Coutinho JM, Ferro JM, Canhão P, Barinagarrementeria F, Bousser MG, Stam J. Unfractionated or low-molecular weight heparin for the treatment of cerebral venous thrombosis. *Stroke*. 2010;41(11):2575-2580.

Coutinho JM, Ferro JM, Zuubier SM, et al. Thrombolysis or anticoagulation for cerebral venous thrombosis: rationale and design of the TO-ACT trial. *Int J Stroke*. 2013;8(2):135-140.

Dentali F, Squizzato A, Marchesi C, Bonzini M, Ferro JM, Ageno W. D-dimer testing in the diagnosis of cerebral vein thrombosis: a systematic review and a meta-analysis of the literature. *J Thromb Haemost*. 2012;10(4):582-589.

Devasagayam S, Wyatt B, Leyden J, Kleinig T. Cerebral venous sinus thrombosis incidence is higher than previously thought: a retrospective population-based study. *Stroke*. 2016;47(9):2180-2182.

deVeber G, Andrew M, Adams C, et al. Cerebral sinovenous thrombosis in children. *N Engl J Med*. 2001;345(6):417-423.

Einhäupl K, Bousser MG, de Bruijn SF, et al. EFNS guideline on the treatment of cerebral venous and sinus thrombosis. *Eur J Neurol*. 2006;13(6):553-559.

Einhäupl KM, Villringer A, Meister W, et al. Heparin treatment in sinus venous thrombosis. *Lancet*. 1991;338(8767):597-600.

Ferro JM, Canhão P, Stam J, Bousser MG. Prognosis of cerebral vein and dural sinus thrombosis: results of the International Study on Cerebral Vein and Dural Sinus Thrombosis (ISCVT). *Stroke*. 2004;35(3):664-670.

Girot M, Ferro JM, Canhão P, et al. Predictors of outcome in patients with cerebral venous thrombosis and intracerebral hemorrhage. *Stroke*. 2007;38(2): 337-342.

Lee EJ. The empty delta sign. *Radiology*. 2002;224(3):788-789.

Linn J, Ertl-Wagner B, Seelos KC, et al. Diagnostic value of multidetector-row CT angiography in the evaluation of thrombosis of the cerebral venous sinuses. *AJNR Am J Neuroradiol*. 2007;28(5):946-952.

Marjot T, Yadav S, Hasan N, Bentley P, Sharma P. Genes associated with adult cerebral venous thrombosis. *Stroke*. 2011;42(4):913-918.

Martinelli I, Bucciarelli P, Passamonti SM, Battaglioli T, Previtali E, Mannucci PM. Long-term evaluation of the risk of recurrence after cerebral sinus-venous thrombosis. *Circulation*. 2010;121(25):2740-2746.

Meng R, Wang X, Hussain M, et al. Evaluation of plasma D-dimer plus fibrinogen in predicting acute CVST. *Int J Stroke*. 2014;9(2):166-173.

Siddiqui FM, Dandapat S, Banerjee C, et al. Mechanical thrombectomy in cerebral venous thrombosis: systematic review of 185 cases. *Stroke*. 2015;46(5): 1263-1268.

Wasay M, Bakshi R, Bobustuc G, et al. Cerebral venous thrombosis: analysis of a multicenter cohort from the United States. *J Stroke Cerebrovasc Dis*. 2008;17(2):49-54.

Wasay M, Dai AI, Ansari M, Shaikh Z, Roach ES. Cerebral venous sinus thrombosis in children: a multicenter cohort from the United States. *J Child Neurol*. 2008;23(1):26-31.

Yang JY, Chan AK, Callen DJ, Paes BA. Neonatal cerebral sinovenous thrombosis: sifting the evidence for a diagnostic plan and treatment strategy. *Pediatrics*. 2010;126(3):e693-e700.

Vascular Malformations 42

Fawaz Al-Mufti and Stephan A. Mayer

KEY POINTS

1. Arteriovenous malformations (AVMs) are congenital high-flow arteriovenous shunts, which can rupture.
2. Because bleeding often originates from the venous side, AVM hemorrhages are typically less severe than hypertensive intracerebral hemorrhage.
3. The most important risk factors for AVM hemorrhage are a previous bleeding event, small size, deep location, a single draining vein, and the presence of a feeding artery aneurysm.
4. Treatment of AVMs can be accomplished with surgical excision, arterial embolization, focused radiosurgery, or a combination of these modalities.
5. Dural arteriovenous fistulas are usually acquired lesions in which meningeal arteries connect directly to veins on the wall of a dural venous sinus.
6. Caverous malformations are small (<1 cm) low flow vascular anomalies. They are characterized by "target" lesions on MRI and are not visualized by angiography.

INTRODUCTION

This chapter deals with a heterogeneous group of central nervous system vascular lesions, including true vascular malformations such as arteriovenous malformations (AVMs) and cavernous malformations, acquired arteriovenous fistulas, vascular neoplasms, and other rare vascular disorders.

ARTERIOVENOUS VASCULAR MALFORMATIONS

AVMs are the most common of these rare disorders. They are thought to be congenital, arising in the prenatal period, but do not present clinically until middle life. Although many remain static anomalies, others enlarge in size and proliferate in vascular complexity, driven by incompletely understood pathophysiologic forces.

Epidemiology

AVMs are rare, occurring with a prevalence of 18 per 100,000, and a new AVM is discovered in approximately 1.5 per 100,000 individuals per year. Every year, about 1 out of every 100 people with an AVM will experience a hemorrhage. AVM symptoms tend to occur early in life; two-thirds of AVMs become symptomatic before age 40 years. Among pregnant women with an AVM, the annual bleeding risk is increased from 1.3% to 5.7%.

Pathobiology

Most AVMs are thought to be sporadic congenital developmental vascular lesions arising in the prenatal period. Well-documented reports of de novo brain AVM formation indicate that in some cases, AVMs can form later in life. A few are caused by brain contusions, which enlarge from normal tiny arteriovenous shunts. In genetic studies, specific polymorphisms of the NOTCH4 gene, which controls the normal development of vessels and proper arteriovenous specification, have been linked to AVM formation and rupture. Abnormalities of vascular endothelial growth factor and transforming growth factor (TGF)-β are also implicated in the creation of AVMs.

Whether congenital or acquired, AVMs are anatomically limited to the brain, spinal cord, or dura. Those embedded in the brain are most common, and 90% of these are supratentorial. The angioarchitecture of brain AVMs involves direct arterial to venous connections without an intervening capillary network. This vascular tangle, also referred to as the *vascular nidus*, resides within gliotic brain and is comprised of irregularly sized thin walled vascular channels lacking the expected media of arteries. The location and size of AVMs varies widely. Some are limited to the surface of a cerebral hemisphere, are fed by a single small artery and drain into a single small vein. At the opposite extreme, others form a huge wedge from the brain surface through the white matter to the ventricular wall (schizencephalic AVM); some are so large they can occupy a large portion of one hemisphere. A few lie in the subcortical white matter, whereas others are others located within the deep structures (eg, basal ganglia or thalamus), brainstem, or spinal cord. Those on the brain surface lying in the border zone between the major cerebral arteries typically have a higher incidence of seizures but a lower hemorrhage rate than those deeper in the brain. Collateral flow from the adjacent dura may occur. Rarely, feeding arteries can stenose or occlude over time; for them moyamoya type changes can appear with collateral small vessel recruitment due to proximal feeding artery stenosis or occlusion. Those that penetrate to the ventricular wall often draw blood supply from the deep vasculature that normally supplies the basal ganglia. Venous drainage may be into superficial or the deep venous systems, and draining veins may be slightly or enormously distended due to high pressure and flow. AVMs are typically solitary; multiple AVMs occur in approximately 5% of cases.

Clinical Features

AVMs present most often with bleeding, less often with headaches or seizures, and occasionally with progressive gait disturbance, focal neurologic deficit, or cognitive decline. Abnormal flow dynamics leading to edema and gliosis and "steal" phenomena, resulting in ischemia of surrounding tissues, have been postulated to cause nonhemorrhagic clinical features. Although the notion "steal" of blood flow was easily inferred by the disproportionate

flood of contrast into large AVMs on angiography, more recent studies of regional cerebral blood flow have found no evidence of ischemia in tissues adjacent to AVMs, prompting a challenge to the notion of cerebral steal as a cause of focal symptoms.

The most feared complication of AVMs by far is hemorrhage. Approximately 50% of AVMs present with hemorrhage, and AVMs are the most common cause of spontaneous cerebral hemorrhage in children. When hemorrhage occurs, it affects the following regions: intracerebral (30%), intraventricular (30%), subarachnoid (15%), and various combinations (25%). Although it might be assumed that physical exertion can trigger a hemorrhage, no such correlation has been found. The hemorrhage usually arises within the nidus and, when limited in volume, displaces adjacent healthy brain with varying degrees of symptoms and signs. Compared with hypertensive intracerebral hemorrhage, the morbidity of AVM hemorrhage is much less devastating, which may be due to the fact that may AVM hemorrhages originate from rupture of venous draining vessels. For AVMs that drain to the ventricular wall, bleeding may originate from the venous aspect of the malformation and extend mainly into the ventricle, which presents as intraventricular hemorrhage with hydrocephalus and only minor injury to adjacent brain structures. Larger hemorrhages escape the nidus and dissect into healthy brain tissue like any primary brain hematoma.

Arteries feeding the AVM nidus may develop flow-related aneurysms, which may bleed separately, typically causing subarachnoid hemorrhage (SAH) syndromes. AVMs with a high-flow arteriovenous communication are frequently associated with venous varices and inflow or outflow aneurysms, which are found in 20% to 25% of cases. Feeding artery aneurysms can be a source of bleeding in patients with brain AVMs and are thought to worsen their prognosis. AVMs are the second most identifiable cause of SAH after brain aneurysms, accounting for 5% of all cases of SAH.

The annual hemorrhage risk of an unruptured AVM ranges from 1% to 2%. Death from the first hemorrhage ranges between 5% and 20%, depending primarily on the size of the hemorrhage and the presence of ventricular extension. When hemorrhage occurs, some destabilization of the fistula occurs, and it can set the stage for recurrent hemorrhage. Once a bleeding event has occurred, an AVM is more than 5 times more likely to bleed again during the first year, with an annual risk of hemorrhage ranging from 4% to 5%. Besides prior hemorrhage, important risk factors for bleeding from an AVM include deep location, small size, a single draining vein, an associated feeding artery aneurysm, and pregnancy.

Unruptured AVMs are associated with seizures in 8% of cases, and this risk increases to 20% following a hemorrhage. Seizures are primarily seen when the AVM is cortically located, large, with superficial venous drainage. Overall, approximately 25% of AVMs present with seizures as the initial symptom.

AVMs are sometimes associated with headaches. No distinctive features separate either the seizures or the types of headache (including migraine) from non-AVM causes. Although an attractive clinical maxim, recurrent headaches of the same side have not proved predictive of an AVM. The diagnostic yield of detecting an AVM in patients presenting with headache alone is extremely low (0.2%).

Diagnosis

The diagnosis of AVM can be made by magnetic resonance imaging (MRI) with high reliability, which characteristically demonstrates "flow voids" (Fig. 42.1). MRI also demonstrates the

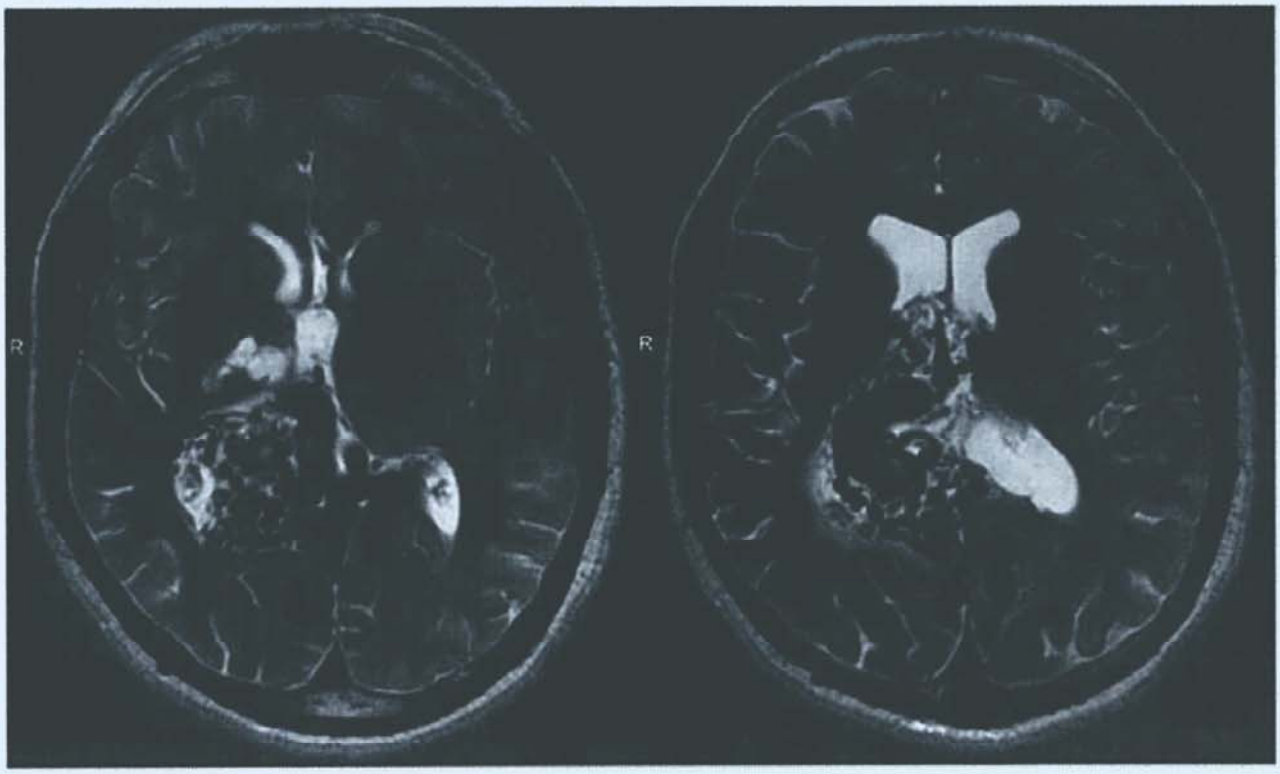

FIGURE 42.1 T2-weighted magnetic resonance images of a 36-year-old patient with a large deeply situated right parietooccipital arteriovenous malformation manifesting as a large cluster of dark serpiginous flow voids. The patient had a history of two prior hemorrhage events and had been symptomatic with left hemiparesis and dysarthria at the time of the magnetic resonance imaging.

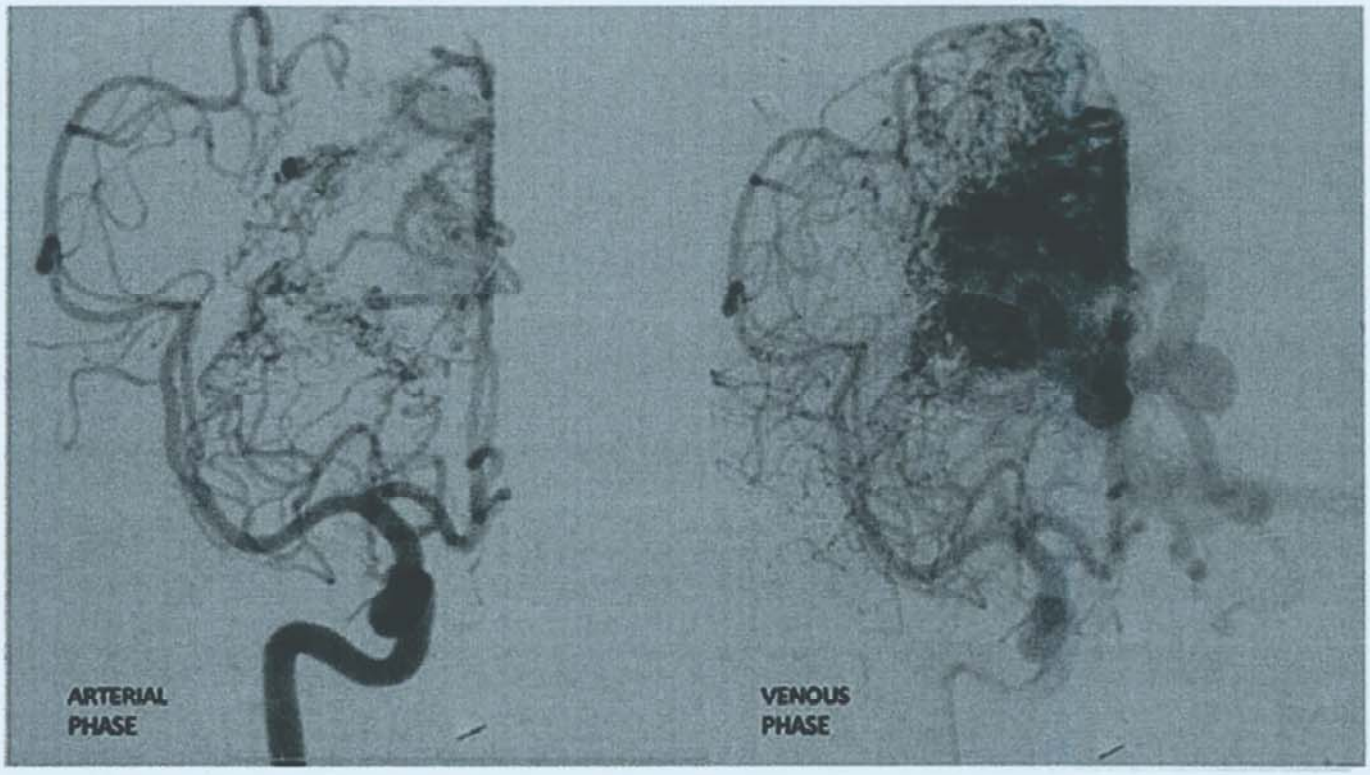

FIGURE 42.2 Anteroposterior view from arterial **(left)** and venous **(right)** phase of right internal carotid arteriogram of the same patient in **Figure 42.1** shows arterial supply from right middle cerebral artery including ascending lenticulostriate, the anterior cerebral artery, and the posterior cerebral artery. Venous drainage is both superficial and deep, with the deep drainage converging on a large complex of veins draining into the posterior superior sagittal sinus.

feeding and draining vessels, the nidus, and its relationship to surrounding tissue. A computed tomography (CT) scan is considered less helpful unless the AVM is calcified. The gold standard diagnostic test is a cerebral angiogram (Fig. 42.2; see also Chapter 25), which most accurately delineates the vascular supply and venous drainage pattern, and can identify high-risk features. A cerebral angiogram should be performed in patients who have clinical symptoms, a history of hemorrhage, or when surgery is being contemplated. In the case of conservatively managed AVMs, surveillance MRI can help analyze changes in the size of the AVM, and identify hemosiderin staining consistent with recent bleeding. Dural and cervical spinal cord AVM should be kept in mind in patients with radiographically unexplained SAH, requiring examination of the external carotid arterial supply and cervical vertebral arteries.

Treatment

Treatment depends on the location of the AVM and the age and condition of the patient. Direct microsurgical resection, endovascular glue embolization, and directed-beam radiation therapy with a linear accelerator or Gamma Knife are the main treatment modalities.

Unruptured Arteriovenous Malformations

With the advent of MRI, asymptomatic AVMs or those presenting only with headaches or seizures have become increasingly prevalent. The increasing discovery of these conditions before bleeding occurs long posed a management dilemma—whether to take the risk of eradicating the lesion, embedded as it is in brain, or await the natural history of hemorrhage, hoping that if it occurs, it will not much damage the adjacent tissues. The A Randomized trial of Unruptured Brain AVMs (ARUBA) indicates that unless hemorrhage occurs, delaying definitive therapy may be safer than proceeding with attempts to remove or eradicate an unruptured AVM. The trial randomized 226 patients with an unruptured AVM to medical management alone or to interventional therapy (any combination of surgery, embolization, or radiosurgery). After 5 years of follow-up, the rate of symptomatic stroke or death was 3.4 per 100 patient years (15 of 110 patients) with conservative management compared to 12.3 per 100 patient years (41 of 116) with invasive management (hazard ratio, 0.31; 95% confidence interval, 0.17-0.56) LEVEL 1.[1,2] Most of the excess morbidity in the interventional arm resulted from procedural complications.

The real-world applicability of lessons learned from the ARUBA has been challenged. Criticism of the trial has focused on the heterogeneity of the patient population, lack of standardization of the treatment arm, and a higher than expected complication rate with treatment. Available evidence indicates unruptured brain AVM intervention rates have not changed in the United States since the publication of ARUBA in 2013.

Vein of Galen malformations are a special AVM associated with the deep venous system, often with marked aneurysmal dilatation of the vein of Galen region. The arterial supply may be complex and difficult to occlude by intravascular or surgical techniques. Most present in neonates or young children. Arteriovenous shunting leads to cardiac failure and compression of the midbrain, which causes hydrocephalus. The currently accepted treatment of these lesions is embolization, occasionally followed by surgery.

Ruptured Arteriovenous Malformations

The Spetzler-Martin grading scale is used to stratify the risk of death or major complications from surgery (Table 42.1). Individualized decision making for intervention is complex and relies on clinical expertise, the specifics of the anatomy of the AVM, and the wishes of the patient. Surgery remains the most effective means of eradicating AVMs. For larger or more complex lesions, adjunct intravascular occlusive therapy using liquid embolics such as n-butyl cyanoacrylate can obliterate some AVM feeders, shrinking the malformation before surgery or radiation. In 15% to 25% of cases, glue embolization alone can result in complete angiographic obliteration of smaller AVMs. For deeply lying lesions not suitable for embolization or surgery, focused beam radiotherapy (radiosurgery) with a linear accelerator or Gamma Knife is an alternative therapy. Radiosurgery is most suitable for smaller (<3 cm) AVMs that are deeply situated and within eloquent brain tissue, making surgical resection more dangerous. Radiosurgery alone leads to complete obliteration of the AVM in approximately 65%, with permanent symptomatic radiation necrosis occurring of 2% to 4% and a subsequent annual AVM bleeding rate of 1.4%.

Complete eradication of an AVM using any combination of these techniques is documented with loss of any evidence of early venous filling during the arterial phase of angiography. Despite complete eradication documented by angiogram, a small number of lesions recur. At 1 year, the rate of AVM recurrence after complete surgical removal is approximately 3% in adults and 9% in children.

Outcome

Former estimates of morbidity and mortality from AVM hemorrhage have been revised downward. Widely cited annual rates of 4% per year documented in some publications applied predominantly in those with large, complex AVMs who have bled in the past and whose AVM was deemed too daunting for attempted removal. For 49% of those presenting with first hemorrhage at a large referral institution, their morbidity documented by the modified Rankin scale was 1 (no significant disability) and showed significantly better outcomes that those with primary brain hemorrhage not from AVM. Hemorrhages arising from venous aspect of the AVM into the ventricle may present with a spectacular-appearing hemohydrocephalus but experience a satisfactory outcome.

TABLE 42.1 Spetzler-Martin Grading Scale

	Grade
Size of Nidus	
Small (<3 cm)	1
Medium (3-6 cm)	2
Large (>6 cm)	3
Eloquence of Adjacent Brain	
Noneloquent	0
Eloquent[a]	1
Venous Drainage	
Superficial only	0
Deep	1

[a]Scores are used only to estimate the risk of surgical arteriovenous malformation resection. Scores range from 1 to 5. Score of 1 denotes low risk of surgical morbidity (approximately 5%). Arteriovenous malformations with a score of 5 are considered inoperable, with a surgical risk approaching 50% or more.

DURAL ARTERIOVENOUS FISTULAS

A dural arteriovenous fistula (dAVF) is an arteriovenous shunt located in the dural wall of the venous sinus or expanded layer of the dura mater. These shunts linking an arterial source directly to a dural sinus arise from a combination of factors: some traumatic, others from venous thrombosis, and some for reasons still not understood. They account for some 10% to 15% of intracranial vascular malformations.

Pathobiology

Thrombosis of a large vein or sinus may be the most common cause of dAVFs, occurring in more than half of cases. Current understanding is that the venous thrombosis creates a high enough resistance to normal arterial flow as to force creation of new pathways. Closed head injury with trauma to the brain surface or local spontaneous venous sinus thrombosis appears to recruit or enlarge the existing 90 μm arteriovenous shunts known to exist in the walls of the venous sinuses. The middle meningeal and other meningeal arteries are the most common sources of inflow, and the resulting fistula may be single or multiple. In some cases, the arterial inputs converge on a "shunted pouch," a bulging tubular or elliptic vascular structure that protrudes from a dural sinus. Once having developed, these fistulas presumably lose their capacity for autoregulation and progressively enlarge, recruiting arterial inflow and creating arterialized high-pressure flow in adjacent veins. The sites most affected are the transverse sigmoid sinus, tentorial, and anterior cranial fossa (including the cavernous sinus) and less often the spinal system or foramen magnum.

Clinical Features

dAVFs can reverse the blood flow of neighboring superficial and deep venous structures, including the dural sinuses and cortical and deep medullary veins, resulting in brain venous hypertension. Current classifications cite three types of dAVFs based on the type of venous drainage, presence of cortical venous reflux, and the number of fistulae. The Borden classification system (Table 42.2) assigns higher risk to the presence of retrograde cortical venous drainage and the development of local venous hypertension. Type I dAVFs, which drain anterograde into normal veins, usually have more benign clinical behavior. Type II and III dAVFs exhibit retrograde venous drainage into cortical veins in the subarachnoid space, which usually results from local thrombosis and occlusion of the adjacent dural venous sinuses. Type II and III dAVFs have a more aggressive natural history, with an increased risk of hemorrhage or of a nonhemorrhagic neurologic deficit. In one study, type II dAVFs were found to have aggressive behavior in 40% and type III in 80% of cases.

Hemorrhage is the presenting symptom of dAVF in 20%. Many other patients present with unusual syndromes of local brain edema, among them complex aphasia and visual disturbances.

TABLE 42.2 Borden Classification System for Dural Arteriovenous Fistulas[a]

Type I
• Drainage into meningeal veins, spinal epidural veins, or a dural venous sinus
• Normal anterograde flow in both the draining veins and other veins draining into the system
Type II
• Drainage into meningeal veins, spinal epidural veins, or a dural venous sinus
• Retrograde flow into the normal subarachnoid cortical veins
Type III
• Direct drainage into a dilated subarachnoid cortical veins or into an isolated segment of the venous sinus (which results from a thrombosis on either side of the dural sinus segment)
• Associated with local venous hypertension

[a]According to this classification, these lesions are further subclassified in type a (single-connection) or type b (multiple-connection) fistulas.

For fistulas affecting the cavernous sinus, the clinical spectrum is broad: A link to the venous system from a small arterial source may create diagnostic problems suggesting myasthenia gravis or ocular myopathy, less dramatic than the rapidly developing bulging erythematous eye in carotid-cavernous sinus fistula that was created by trauma.

Diagnosis

dAVFs are notoriously difficult to diagnose with a high degree of reliability by CT or magnetic resonance. For this reason, digital subtraction angiography is the gold standard for making the diagnosis. When diagnosed by angiogram (Fig. 42.3), there is usually early venous filling via the fistula into enlarged venous structures, with or without associated local venous sinus thrombosis. Those branches having access to a patent vein or sinus (meningeal and other dural arteries) can be dilated and convoluted to a degree seen in AVMs.

Management and Outcome

Treatment is by surgery or by transarterial or transvenous endovascular methods. The goal of treatment is complete obliteration of the fistula, correction of the venous shunting, and reversal of any cortical venous reflux. One of the most definitive means of treating dAVFs is to clip or embolize (using coils or liquid glue via the transvenous approach) a shunted pouch connecting the arterial inputs to a dural venous sinus. In a recent meta-analysis, surgery (sometimes preceded by embolization) was found to be associated with significantly lower odds of treatment failure and later recurrence compared to endovascular therapy alone. Neurologic improvement was also significantly higher after surgery compared with embolization alone. No difference in complication rates was observed between the two approaches. Persistence in efforts is often required, and repeated angiographic follow-up is mandatory because 10% to 15% of dAVFs recur even after

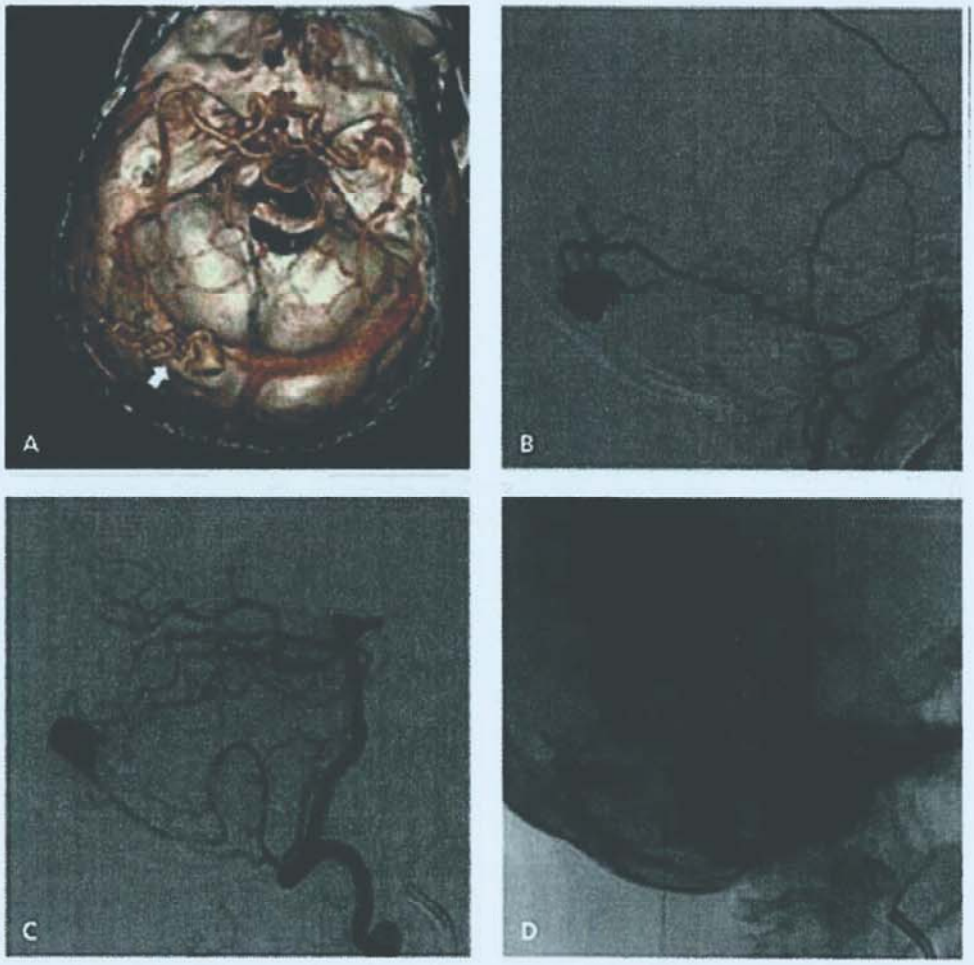

FIGURE 42.3 Images of a patient with a dural arteriovenous fistula (dAVF) involving the left transverse sinus. **A:** Three-dimensional computed tomography angiogram (view from top down) shows dilated veins on the left transverse sinus *(arrow)*. **B:** Angiogram of the left external carotid artery shows the dAVF; posterior division of the middle meningeal was the main feeding artery, and cortical venous reflux was observed. **C:** Angiogram of the vertebral artery showed that the posterior meningeal artery was also a feeding artery. **D:** The dAVF was embolized via the posterior division of the middle meningeal artery. (Reproduced with permission from Kirsch M, Liebig T, Kühne D, Henkes H. Endovascular management of dural arteriovenous fistulas of the transverse and sigmoid sinus in 150 patients. *Neuroradiology*. 2009;51:477-483.)

an angiographic cure. Interestingly, some reports document spontaneous regression of dAVF, and partial embolization can also lead to spontaneous resolution of the fistula later on. In one study of 150 transverse or sigmoid sinus dAVFs, the immediate angiographic cure rate after endovascular therapy was 54%. At follow-up, 88% of patients with some residual shunting after the treatment showed complete occlusion later on.

CAVERNOUS MALFORMATIONS

Cerebral cavernous malformations (CCMs) are also known as cavernomas, cavernous hemangiomas, and cavernous angiomas. Cavernous malformations are low flow, highly focal vascular anomalies; most of them are less than 1 cm in size. They may occur anywhere in the brain.

Pathobiology

The lesion is histologically characterized by grossly dilated vascular spaces (known as *caverns*) lined by a single layer of endothelium, lacking mature vessel wall angioarchitecture, and manifesting features of chronic hemorrhage in adjacent neuroglial parenchyma (Fig. 42.4). The gross appearance of the lesion has been likened to a mulberry.

In its sporadic form, CCMs occur as a solitary hemorrhagic vascular lesion, or as clustered lesions associated with a developmental venous anomaly. Multiple lesions—some numbering in the many dozens—have been documented in families. In its autosomal dominant familial form CCM caused by a heterozygous germline loss-of-function mutation in one of three genes—*CCM1/KRIT1*, *CCM2/Malcavernin*, and *CCM3/PDCD10*—that causes multifocal lesions throughout the brain and spinal cord. A founder mutation (Q455x) involving *KRIT1* and an associated preserved haplotype accounts for clustering of familial CCM disease in Hispanic Americans of Mexican descent and a common deletion in the *CCM2/Malcavernin* accounts for clustering among Ashkenazi Jews.

Diagnosis

The individual vessels and even the cluster are too small and low flow to be seen on angiogram and are rarely documented by CT scan but are easily seen on MRI (Fig. 42.5), thanks to the hemosiderin-iron composition from the slow flow through the lesion or from asymptomatic hemorrhages. The typical target lesions appear as rings and result from repeated microhemorrhages. Gradient recalled echo acquired (T2*) sequences reveal the "blooming" effect of hemosiderin, increasing the sensitivity of detection of CCMs. Although they may be mistaken for a vascular tumor on imaging, there is no displacement of the surrounding structure.

Clinical Features

Approximately two-thirds of cavernous malformations are diagnosed when patients with symptoms of hemorrhage, seizures, headaches, or vague neurologic symptoms occur. Symptoms tend

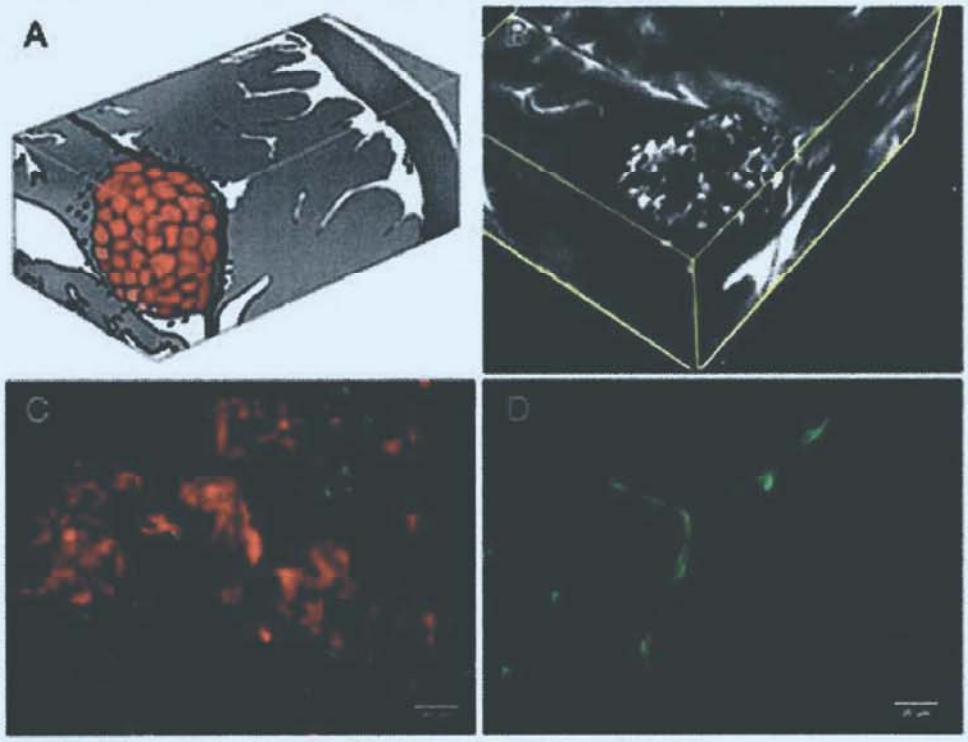

FIGURE 42.4 **A:** Artist's rendition of the mulberry-like cerebral cavernous malformation. **B:** Three-dimensional magnetic resonance imaging slab of a human lesion, T2 acquisition at 3 Tesla, highlighting the characteristic "popcorn appearance" of a CCM with a hemosiderin ring. **C:** Confocal immunofluorescence photomicrograph with staining (CD31, *green*) of endothelial cells lining the lesion's vascular spaces (caverns). Red blood cells (*red*) fill the caverns and extravasate beyond the "leaky" endothelium. **D:** Comparative image of normal brain capillaries. (Reproduced with permission from Awad IA, Polster SP. Cavernous angiomas: deconstructing a neurosurgical disease. *J Neurosurg*. 2019;131[1]:1-13.)

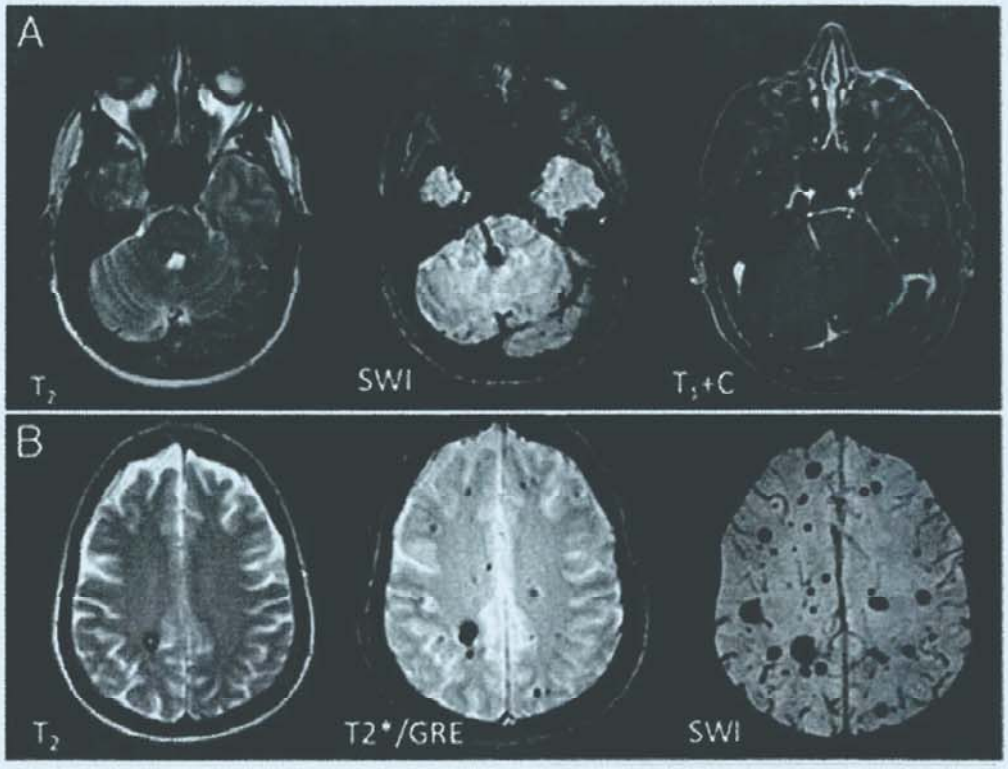

FIGURE 42.5 Magnetic resonance imaging features of cavernous malformations. **A:** Magnetic resonance imaging features of a solitary CCM at the floor of the fourth ventricle, clustered around a developmental venous malformation traversing the pons. **B:** Autosomal dominant familial multifocal CCMs, including punctate lesions on susceptibility weighted imaging (SWI), which are not seen on conventional (T2 and gradient recalled echo [GRE] weighted) sequences. (Reproduced with permission form Awad IA, Polster SP. Cavernous angiomas: deconstructing a neurosurgical disease. *J Neurosurg*. 2019;131[1]:1-13.)

to develop between the second and fifth decade of life. The risk of hemorrhage is 6% annually in patients who have already experienced a bleeding event, and the risk gradually goes down with time. The median interval from primary to a repeat hemorrhage is 8 months. The incidence of symptomatic hemorrhage or rehemorrhage is higher in brainstem lesions. The risk of bleeding in patients presenting with symptoms unrelated to hemorrhage is 2% annually. Of the one-third of patients who present with an incidentally discovered cavernous malformation, the bleeding risk is only 0.08% per year. However, once a symptomatic hemorrhage has occurred, the annual risk of a subsequent episode of bleeding is dramatically increased—at least 10-fold by most estimates. This elevated risk is greatest soon after a hemorrhage but persists thereafter, with a 5-year risk estimated at 40%. The risk of symptomatic rebleeding is higher with brainstem lesions, although this may reflect enhanced sensitivity due to the eloquence of these structures.

The bleeding events themselves tend to be low impact, compatible with gradual breakdown of the malformation and "oozing" of blood over period of hours, in contrast with the violent bleeding events that can occur with rupture of a lenticulostriate artery in the setting of hypertensive intracerebral hemorrhage (see Chapter 39). The clinical effects of hemorrhage are accordingly usually limited, often causing no or minimal symptoms. Serious deficits are generally restricted to patients with malformations in the brainstem.

Management

If hemorrhage has occurred and the lesion is readily accessible, surgery is usually recommended. Case series generally report low rates of surgical morbidity and mortality for supratentorial CCMs but much higher rates for brainstem lesions. Surgical complication rates, however, clearly exceed the low risks from hemorrhage in lesions that have never bled. Hence, surgical excision of asymptomatic lesions, particularly those lying deep or in brainstem locations, are almost never justified. On the other hand, the risk-benefit ratio with surgery appears to be beneficial when compared to the risk of recurrent hemorrhage from CCMs that have already bled. Stereotactic radiosurgery has been suggested as an alternative treatment for symptomatic CCMs located in eloquent areas, with most series identifying a decline in the hemorrhage rate more than 2 years after stereotactic radiosurgery treatment

VENOUS MALFORMATIONS

Venous malformations (also deep venous anomalies) have no apparent arterial supply. They are not an AVM, they are simply anomalous veins that form from normal arterial vessels and capillary beds (see Fig. 42.5, panel A). They may cause headaches, seizures, or, rarely, hemorrhage, but the vast majority are asymptomatic. They generally lie in the deep white matter and portions of the brainstem and cerebellum and often have spiderlike venous branches into the adjacent parenchyma (so-called caput medusa). They are easily recognized on MRI because of their contrast enhancement. Because they are so often asymptomatic and also serve as the venous draining system for the adjacent brain, they are not amenable to obliteration by occlusion of the arterial supply or surgical resection. They generally follow a benign course.

TELANGIECTASIAS

Telangiectasias are collections of engorged capillaries or cavernous spaces separated by relatively normal brain tissue. They are usually small and poorly circumscribed. Although found in any portion of the central nervous system, they have a propensity for the cerebral white matter. In the Rendu-Osler-Weber syndrome, brain telangiectasias are associated with similar lesions of the skin (mucous membranes, respiratory, gastrointestinal, and genitourinary tracts). Those occurring in the lung may provide a path for septic material for brain abscess formation. The fistulas are usually tiny, and some are not demonstrated despite angiography. Major hemorrhage is rare. Interest in genetic mapping for the remarkable variety of telangiectasias has increased greatly and may well lead to a total reclassification of these lesions separate from the classical clinical description.

Sturge-Weber Disease

The main features of this rare disorder, also known as *Krabbe-Weber-Dimitri disease*, are localized atrophy and calcification of the cerebral cortex associated with capillary and venous malformations. Any portion of the cerebral cortex may be affected by the atrophic process, but the occipital and parietal regions are most commonly involved. Usually, also present is an ipsilateral port-wine–colored facial nevus, usually in the distribution of the first division of the trigeminal nerve. Included among the clinical features may be angiomatous malformations in the meninges, ipsilateral exophthalmos, glaucoma, buphthalmos, angiomas of the retina, optic atrophy, and dilated vessels in the sclera.

In the atrophic cortical areas, there is a loss of nerve cells and axons and a proliferation of the fibrous glia. The small vessels are thickened and calcified, particularly in the second and third cortical layers. Small calcium deposits are also present in the cerebral substance, and rarely, there are large calcified nodules. When an angioma is present, it is limited to the meninges overlying the area of shrunken cortex. Although the combination of a port-wine facial nevus and localized cortical atrophy may exist without clinical symptoms, convulsive seizures are usually present from infancy. Developmental delay, glaucoma, contralateral hemiplegia, and hemianopia are also present in most cases.

Sturge-Weber disease can be diagnosed without difficulty from the clinical syndrome. The presence of the cortical lesion can be demonstrated in most cases by the appearance of characteristic shadows in the radiographs. The treatment of Sturge-Weber disease is essentially symptomatic. Anticonvulsive drugs are given for the seizures. Radiation therapy has been recommended, but there is no evidence that it is of any benefit.

Sinus Pericranii

The disorder is a combination of thin-walled vascular spaces interconnected by numerous anastomoses that protrude from the skull and communicate with the superior longitudinal sinus. The malformation is usually evident in infancy, soft and compressible; it increases in size when the venous pressure in the head is raised by coughing, straining, or lowering the head. It may enlarge slowly over a period of years. The external protuberance may be seen at any portion of the midline of the skull, including the occiput, but is most often found in the midportion of the forehead. Imaging shows a defect of the underlying bone, through which the lesion communicates with the longitudinal sinus.

VASCULAR TUMORS

These three forms of neoplastic lesions may be variations of the same tumor. Histologically, they are indistinguishable but share similar clinical features.

Hemangioblastomas

Hemangioblastomas are composed of primitive vascular elements and are rare, accounting for 1% to 2% of all intracranial neoplasms. They occur at all ages, but young and middle-aged adults are more frequently afflicted. In children, they are almost as common in the posterior fossa as are meningiomas. Symptoms are generally present for approximately a year before the diagnosis is made. Male incidence predominates. Von Hippel-Lindau disease is defined by the coexistence of hemangioblastoma and multiple angiomatoses of the retina, cysts of the kidney and pancreas, and, occasionally, renal cell carcinomas, and capillary nevi of the skin. There is a familial incidence in 20% of cases. Only 10% to 20% of the hemangioblastomas, however, are associated with the systemic signs known as the *Lindau syndrome*. All gradations of clinical expression between the full syndrome and incomplete manifestations may be seen in the same family. Associated with these disorders are pheochromocytoma, syringomyelia, and polycythemia (which disappear after resection of the neoplasm but returns with recurrence).

Hemangioblastomas occur predominantly in the cerebellum and are often associated with large cysts that are surrounded by a glial wall containing yellow proteinaceous fluid, the result of secretion, and hemorrhage from the tumor. It resembles the cyst and mural nodule of the cystic cerebellar astrocytoma but has a distinctive vascular appearance on an angiogram. They may be multiple, in which case difficulty in achieving a cure or total removal of the lesion may be encountered. They have no dural attachment.

Hemangioblastoma can also occur in the spinal cord or in the medulla in the area postrema. They rarely occur in the supratentorial area, where they may be confused with angioblastic meningiomas.

Clinical features of the hemangioblastoma of the cerebellum are symptoms typical of any cerebellar mass, such as headache, papilledema, and ataxia. When the tumor is multiple, lesions may involve the brainstem and upper cervical cord as well. Spinal cord hemangioblastomas are often associated with syrinx formation. Hemangioblastoma of the cerebellum can be diagnosed without difficulty with MRI and magnetic resonance angiography. The diagnosis is even more certain when the tumor is associated with angiomas of the retina and polycythemia. Treatment is surgical, with evacuation of the cyst and removal of the mural nodule; 85% of all patients who undergo this treatment are alive and well 5 to 20 years after surgery. There is a high incidence of recurrence, however, if the tumor is partially removed or is associated with multiple tumors.

Angioblastic Meningioma and Hemangiopericytoma

Angioblastic meningioma is grossly identical to other meningiomas but has a significant dural attachment and is located either above or below the tentorium. Hemangiopericytoma originates in other areas of the body, presumably from blood vessel elements.

LEVEL 1 EVIDENCE

1. Mohr JP, Parides MK, Stapf C, et al; for International ARUBA Investigators. Medical management with or without interventional therapy for unruptured brain arteriovenous malformations (ARUBA): a multicentre, non-blinded, randomised trial. *Lancet*. 2014;383:614-621.
2. Mohr JP, Overbey JR, Hartmann A, et al; for ARUBA Coinvestigators. Medical management with interventional therapy versus medical management alone for unruptured brain arteriovenous malformations (ARUBA): final follow-up of a multicentre, non-blinded, randomised controlled trial. *Lancet Neurol*. 2020;19(7):573-581.

SUGGESTED READINGS

Ampie L, Choy W, Lamano JB, et al. Safety and outcomes of preoperative embolization of intracranial hemangioblastomas: a systematic review. *Clin Neurol Neurosurg*. 2016;150:143-151.

Awad IA, Polster SP. Cavernous angiomas: deconstructing a neurosurgical disease. *J Neurosurg*. 2019;131(1):1-13.

Borden JA, Wu JK, Shucart WA. A proposed classification for spinal and cranial dural arteriovenous fistulous malformations and implications for treatment. *J Neurosurg*. 1995;82(2):166-179.

Brancati F, Valente EM, Tadini G, et al. Autosomal dominant hereditary benign telangiectasia maps to the *CMC1* locus for capillary malformation on chromosome 5q14. *J Med Genet*. 2003;40:849-853.

Cagnazzo F, Brinjikji W, Lanzino G. Arterial aneurysms associated with arteriovenous malformations of the brain: classification, incidence, risk of hemorrhage, and treatment—a systematic review. *Acta Neurochir (Wien)*. 2016;158:2095-2104.

Choi JH, Mast H, Sciacca RR, et al. Clinical outcome after first and recurrent hemorrhage in patients with untreated brain arteriovenous malformation. *Stroke*. 2006;37(5):1243-1247.

De la Torre AJ, Luat AF, Juhász C, et al. A multidisciplinary consensus for clinical care and research needs for Sturge-Weber syndrome. *Pediatr Neurol*. 2018;84:11-20.

Derdeyn CP, Zipfel GJ, Albuquerque FC, et al; for American Heart Association Stroke Council. Management of brain arteriovenous malformations: a scientific statement for healthcare professionals from the American Heart Association/American Stroke Association. *Stroke*. 2017;48(8):e200-e224.

Elsenousi A, Aletich VA, Alaraj A. Neurological outcomes and cure rates of embolization of brain arteriovenous malformations with n-butyl cyanoacrylate or Onyx: a meta-analysis. *J Neurointerv Surg*. 2016;8(3):265-272.

Flemming KD. Clinical management of cavernous malformations. *Curr Cardiol Rep*. 2017;19(12):122.

Flemming KD, Link MJ, Christianson TJH, Brown RD Jr. Prospective hemorrhage risk of intracerebral cavernous malformations. *Neurology*. 2012;78:632-636.

Goldberg J, Raabe A, Bervini D. Natural history of brain arteriovenous malformations: systematic review. *J Neurosurg Sci*. 2018;62(4):437-443.

Goyal A, Cesare J, Lu VM, et al. Outcomes following surgical versus endovascular treatment of spinal dural arteriovenous fistula: a systematic review and meta-analysis. *J Neurol Neurosurg Psychiatry*. 2019;90(10):1139-1146.

Gross BA, Du R. Hemorrhage from cerebral cavernous malformations: a systematic pooled analysis. *J Neurosurg*. 2017;126(4):1079-1087.

Hacein-Bey L, Konstas AA, Pile-Spellman J. Natural history, current concepts, classification, factors impacting endovascular therapy, and pathophysiology of cerebral and spinal dural arteriovenous fistula. *Clin Neurol Neurosurg*. 2014;121:64-75.

Hou K, Xu K, Chen X, Ji T, Guo Y, Yu J. Targeted endovascular treatment for ruptured brain arteriovenous malformations [published online ahead of print November 13, 2019]. *Neurosurg Rev*. doi:10.1007/s10143-019-01205-1.

Kasasbeh AS, Kalaria A, Comi AM, Lo W, Lin DD. Atypical intracerebral developmental venous anomalies in Sturge-Weber syndrome: a case series and review of literature. *Pediatr Neurol*. 2020;104:54-61.

Kim J. Introduction to cerebral cavernous malformation: a brief review. *BMB Rep*. 2016;49(5):255-262.

Kirsch M, Liebig T, Kühne D, Henkes H. Endovascular management of dural arteriovenous fistulas of the transverse and sigmoid sinus in 150 patients. *Neuroradiology*. 2009;51:477-483.

Lang M, Moore NZ, Rasmussen PA, Bain MD. Treatment outcomes of a randomized trial of unruptured brain arteriovenous malformation-eligible unruptured brain arteriovenous malformation patients. *Neurosurgery*. 2018;83(3):548-555.

Lyne SB, Girard R, Koskimäki J, et al. Biomarkers of cavernous angioma with symptomatic hemorrhage. *JCI Insight*. 2019;4(12):e128577.

Magro E, Gentric JC, Darsaut TE, Ziegler D, Bojanowski MW, Raymond J. Responses to ARUBA: a systematic review and critical analysis for the design of future arteriovenous malformation trials. *J Neurosurg*. 2017;126(2):486-494.

Marks MP, Marcellus ML, Santarelli J, et al. Embolization followed by radiosurgery for the treatment of brain arteriovenous malformations (AVMs). *World Neurosurg*. 2017;99:471-476.

Mohr JP, Overbey JR, von Kummer R, et al; for International ARUBA Investigators. Functional impairments for outcomes in a randomized trial of unruptured brain AVMs. *Neurology*. 2017;89(14):1499-1506.

Naff NJ, Wemmer J, Hoenig-Rigamonti K, et al. A longitudinal study patients of venous malformations: documentation of a negligible risk and benign natural history. *Neurology*. 1998;50:1709-1714.

Neumann HP, Lips CJ, Hsia YE, Zbar B. Von Hippel-Lindau syndrome. *Brain Pathol*. 1995;5:181-193.

Pezeshkpour P, Dmytriw AA, Phan K, et al. Treatment strategies and related outcomes for brain arteriovenous malformations in children: a systematic review and meta-analysis. *AJR Am J Roentgenol*. 2020;215(2):472-487.

Poorthuis M, Samarasekera N, Kontoh K, et al. Comparative studies of the diagnosis and treatment of cerebral cavernous malformations in adults: systematic review. *Acta Neurochir (Wien)*. 2013;155:643-649.

Porras JL, Yang W, Philadelphia E, et al. Hemorrhage risk of brain arteriovenous malformations during pregnancy and puerperium in a North American cohort. *Stroke*. 2017;48(6):1507-1513.

Rammos SK, Gardenghi B, Bortolotti C, Cloft HJ, Lanzino G. Aneurysms associated with brain arteriovenous malformations. *AJNR Am J Neuroradiol*. 2016;37(11):1966-1971.

Reynolds AS, Chen ML, Merkler AE, et al. Effect of a randomized trial of unruptured brain arteriovenous malformation on interventional treatment rates for unruptured arteriovenous malformations. *Cerebrovasc Dis*. 2019;47(5-6):299-302.

Reynolds MR, Lanzino G, Zipfel GJ. Intracranial dural arteriovenous fistulae. *Stroke*. 2017;48(5):1424-1431.

Russell D, Peck T, Ding D, et al. Stereotactic radiosurgery alone or combined with embolization for brain arteriovenous malformations: a systematic review and meta-analysis. *J Neurosurg*. 2018;128(5):1338-1348.

Sahlein DH, Mora P, Becske T, et al. Features predictive of brain arteriovenous malformation hemorrhage: extrapolation to a physiologic model. *Stroke*. 2014;45(7):1964-1970.

Sheu M, Fauteux G, Chang H, Taylor W, Stopa E, Robinson-Bostom L. Sinus pericranii: dermatologic considerations and literature review. *J Am Acad Dermatol*. 2002;46(6):934-941.

Sorenson TJ, Brinjikji W, Bortolotti C, Kaufmann G, Lanzino G. Recurrent brain arteriovenous malformations (AVMs): a systematic review. *World Neurosurg*. 2018;116:e856-e866.

Spetzler RF, Martin NA. A proposed grading system for arteriovenous malformations. *J Neurosurg*. 1986;65(4):476-483.

Tang SC, Jeng JS, Liu HM, Yip PK. Diffuse capillary telangiectasia of the brain manifested as a slowly progressive course. *Cerebrovasc Dis*. 2003;15:140-142.

Taslimi S, Modabbernia A, Amin-Hanjani S, Barker FG II, Macdonald RL. Natural history of cavernous malformation: systematic review and meta-analysis of 25 studies. *Neurology*. 2016;86(21):1984-1991.

Winkler EA, Lu AY, Raygor KP, et al. Defective vascular signaling & prospective therapeutic targets in brain arteriovenous malformations. *Neurochem Int*. 2019;126:126-138.

Wu EM, El Ahmadieh TY, McDougall CM, et al. Embolization of brain arteriovenous malformations with intent to cure: a systematic review. *J Neurosurg*. 2019;132(2):388-399.

Xu K, Yang X, Li C, Yu J. Current status of endovascular treatment for dural arteriovenous fistula of the transverse-sigmoid sinus: a literature review. *Int J Med Sci*. 2018;15(14):1600-1610.

Central Nervous System Vasculitis 43

Kavneet Kaur, Hussein Alshammari, Ramandeep Sahni, Steven Marks, Stephan A. Mayer, and Fawaz Al-Mufti

KEY POINTS

1. The gold standard for diagnosis of primary angiitis of the central nervous system (PACNS) is tissue biopsy.
2. Systemic vasculitis is more common than primary central nervous system vasculitis.
3. For the majority of systemic vasculitis, treatment with glucocorticoids and cyclophosphamide for induction therapy and maintenance therapy with azathioprine have improved outcome and mortality rates.
4. Clinical suspicion of giant cell arteritis should prompt early initiation of high-dose steroids without waiting for biopsy to delay treatment.
5. Polyarteritis nodosa is associated with hepatitis B virus but association with hepatitis C virus, cytomegalovirus, and parvovirus B19 has been reported.
6. Catheter angiography findings of reversible cerebral vasoconstriction syndrome are indistinguishable from PACNS and is the most common mimicker of PACNS.
7. Reversible cerebral vasoconstriction syndrome is self-limited and more benign than PACNS.

INTRODUCTION

Vasculitis affecting the central nervous system (CNS) or peripheral nervous system often presents major diagnostic and therapeutic challenges for physicians because of its variable clinical manifestations and the lack of specific diagnostic tests other than biopsy. The CNS vasculitis comprises a heterogeneous group of inflammatory diseases that affect leptomeningeal and parenchymal blood vessels of the brain with different but frequently overlapping clinical and pathologic manifestations.

The histopathologic changes of CNS vasculitis essentially consist of an inflammatory infiltrate within the vessel wall associated with necrosis, vessel occlusion and infarction, and occasionally hemorrhage. The cases of CNS vasculitis are protean: It may occur as an idiopathic primary autoimmune process or within the context of systemic to autoimmune disease, as a reaction to an infection such as varicella-zoster or a neurodegenerative process such as amyloid angiopathy, after drug exposure (eg, cocaine), as a manifestation of radiation exposure, and in the setting of malignancy. Although the precise pathogenesis often remains obscure, in all cases, the immune system plays a central role, and immunosuppressive agents are the cornerstones of treatment.

There are several different classifications for CNS vasculitis. Some classifications are based on the size of the affected vessels (small, medium, large), whereas other classifications are based on histologic features (eg, granulomatous, lymphomatous, or leukocytoclastic inflammation) or immunologic markers (eg, the association with antineutrophil cytoplasmic antibodies [ANCAs] with some forms of vasculitis). The CNS vasculitis can also be further broadly classified into primary and secondary vasculitis depending on whether the process is confined to the CNS or is part of a systemic illness.

In 2012, the International Chapel Hill Consensus Conference proposed a revised nomenclature system that groups different vasculitides by taking in consideration multiple factors including size of vessels and whether the vasculitis involves a single organ or is part of a more systemic condition (Table 43.1 and Fig. 43.1).

PRIMARY ANGIITIS OF THE CENTRAL NERVOUS SYSTEM

Primary angiitis of the central nervous system (PACNS) is associated with select inflammation and destruction of small- and medium-sized arteries of the brain parenchyma, spinal cord, and leptomeninges, resulting in symptoms and signs of CNS dysfunction. The term *angiitis* is synonymous with vasculitis and refers to involvement of blood vessels on both the arterial and venous sides of the circulation. The PACNS is also frequently referred to as *primary central nervous system vasculitis*.

Epidemiology

The annual incidence rate of PACNS is 2.4 cases per 1 million person-years. The disease affects patients of all ages, peaking at 50 years of age, with a 2:1 male predominance.

Pathobiology

The etiology and pathogenesis of PACNS is unknown. Infectious agents such as herpes zoster virus, West Nile virus, and varicella-zoster virus have been proposed as possible causes or triggers.

Three main histopathologic patterns are generally seen: granulomatous, lymphocytic, and necrotizing vasculitis. In lymphocytic PACNS, immunohistochemical staining reveals predominant infiltration by memory T cells in and around small cerebral vessels, signifying an antigen-specific immune response occurring in the wall of cerebral arteries.

Clinical Features

Due to diffuse involvement of the CNS, the clinical manifestations are variable and nonspecific, with a clinical course rang-

TABLE 43.1 Vasculitis Syndromes: 2012 International Chapel Hill Consensus Conference[a]

Syndromes	Pathologies
3.1 Large-Vessel Vasculitis	
3.1.1 Giant cell (temporal) arteritis	Granulomatous arteritis of aorta and its major branches; predilection for extracranial branches of carotid artery; often involves temporal artery; patients older than 50 years with polymyalgia rheumatica
3.1.2 Takayasu arteritis	Granulomatous arteritis of aorta and major branches; patients younger than age 50 years
3.2 Medium-Sized Vessel Vasculitis	
3.2.1 Polyarteritis nodosa	Necrotizing inflammation of medium- or small-sized arteries; no glomerulonephritis or vasculitis of arterioles, capillaries, venules
3.2.2 Kawasaki disease	Arteritis of large, medium-sized, small arteries plus mucocutaneous-lymph node syndrome; coronary arteries often involved; aorta and veins may be involved; usually in children
3.3 Small-Vessel Vasculitis	
3.3.1 Granulomatosis with polyangiitis (Wegener granulomatosis)	Granulomatous inflammation including respiratory tract and necrotizing vasculitis of small to medium vessels (capillaries, venules, arterioles, arteries); necrotizing glomerulonephritis common
3.3.2 Eosinophilic granulomatosis with polyangiitis (Churg-Strauss syndrome)	Eosinophil-rich granulomatous inflammation of respiratory tract and necrotizing vasculitis of small- to medium-sized vessels; with asthma and eosinophilia
3.3.3 Microscopic polyangiitis	Necrotizing vasculitis with few or no immune deposits; affects small vessels (capillaries, venules, arterioles); may involve small- and medium-sized arteries; common features: necrotizing glomerulonephritis and involvement of pulmonary capillaries
3.3.4 IgA vasculitis (Henoch-Schönlein purpura)	Vasculitis with IgA-dominant immune deposits on small vessels (capillaries, venules, arterioles); affects skin, gut, and glomeruli plus arthritis or arthralgia
3.3.5 Cryoglobulinemic vasculitis	Vasculitis with immune deposits on small vessels (capillaries, venules, arterioles); cryoglobulins in serum; skin and glomeruli often involved
3.4 Variable-Vessel Vasculitis	
3.4.1 Behçet disease	Vasculitis that can affect arteries or veins accompanied by cutaneous, ocular, articular, gastrointestinal, and/or central nervous system inflammatory lesions
3.4.2 Cogan syndrome	Arteritis (affecting small, medium, or large arteries), aortitis, aortic aneurysms, and aortic and mitral valvulitis accompanied by ocular inflammatory lesions, including interstitial keratitis, uveitis, and episcleritis, and inner ear disease, including sensorineural hearing loss and vestibular dysfunction
3.4.3 Vasculitis associated with systemic disease	Vasculitis that is associated with and may be secondary to (caused by) a systemic disease (eg, rheumatoid vasculitis, lupus vasculitis)
3.4.4 Vasculitis associated with probable etiology	Vasculitis that is associated with a probable specific etiology (eg, hydralazine-associated microscopic polyangiitis, hepatitis B virus–associated vasculitis, hepatitis C virus–associated cryoglobulinemic vasculitis)

Abbreviation: IgA, immunoglobulin A.
[a]Modified from Jennette JC, Falk RJ, Bacon PA, et al. 2012 revised International Chapel Hill Consensus Conference nomenclature of vasculitides. *Arthritis Rheum.* 2013;65(1):1–11.

ing from hyperacute to stepwise to chronic and insidious. Mental obtundation and decreased cognition are the most frequent clinical presentations, usually evolving subacutely as a progressive encephalopathy. Other symptoms may include headaches, seizures, and focal neurologic deficits due to ischemic stroke or cerebral hemorrhage. Signs and symptoms of systemic vasculitis, such as peripheral neuropathy, fever, weight loss, or rash, are by definition lacking in PACNS.

Diagnosis

On the basis of clinical experience and evidence from published work, Calabrese and Mallek proposed a set of criteria for the diagnosis of PACNS; the diagnosis is established when all three of the following criteria are met (Table 43.2).

Laboratory Findings

There is no specific laboratory diagnostic test for PACNS, although routine laboratory testing, serologic evaluations, lumbar puncture results, neuroimaging studies, cerebral angiography, and brain biopsy may all have roles in the evaluation (Table 43.3). Acute phase reactants such as the erythrocyte sedimentation rate (ESR) and C-reactive protein (CRP) are normal or slightly elevated in PACNS; elevated levels should raise suspicion of systemic involvement by either an infectious, malignant, or inflammatory process. Both serologic testing and analyses of the cerebrospinal fluid (CSF) are important for excluding secondary causes of CNS dysfunction that may mimic PACNS. Nonspecific abnormalities, primarily leukocyte and protein elevations, are seen on CSF analysis in 80% to 90% of patients with pathologically documented disease.

Imaging

Magnetic resonance imaging (MRI) typically shows multifocal small-vessel infarcts and hemorrhages of varying age (Fig. 43.2). These vascular lesions often involve structures that are not typically involved in conventional cerebrovascular disease, such as the corpus callosum. In some cases, large-vessel infarcts, convexity subarachnoid hemorrhage, or small foci of gadolinium

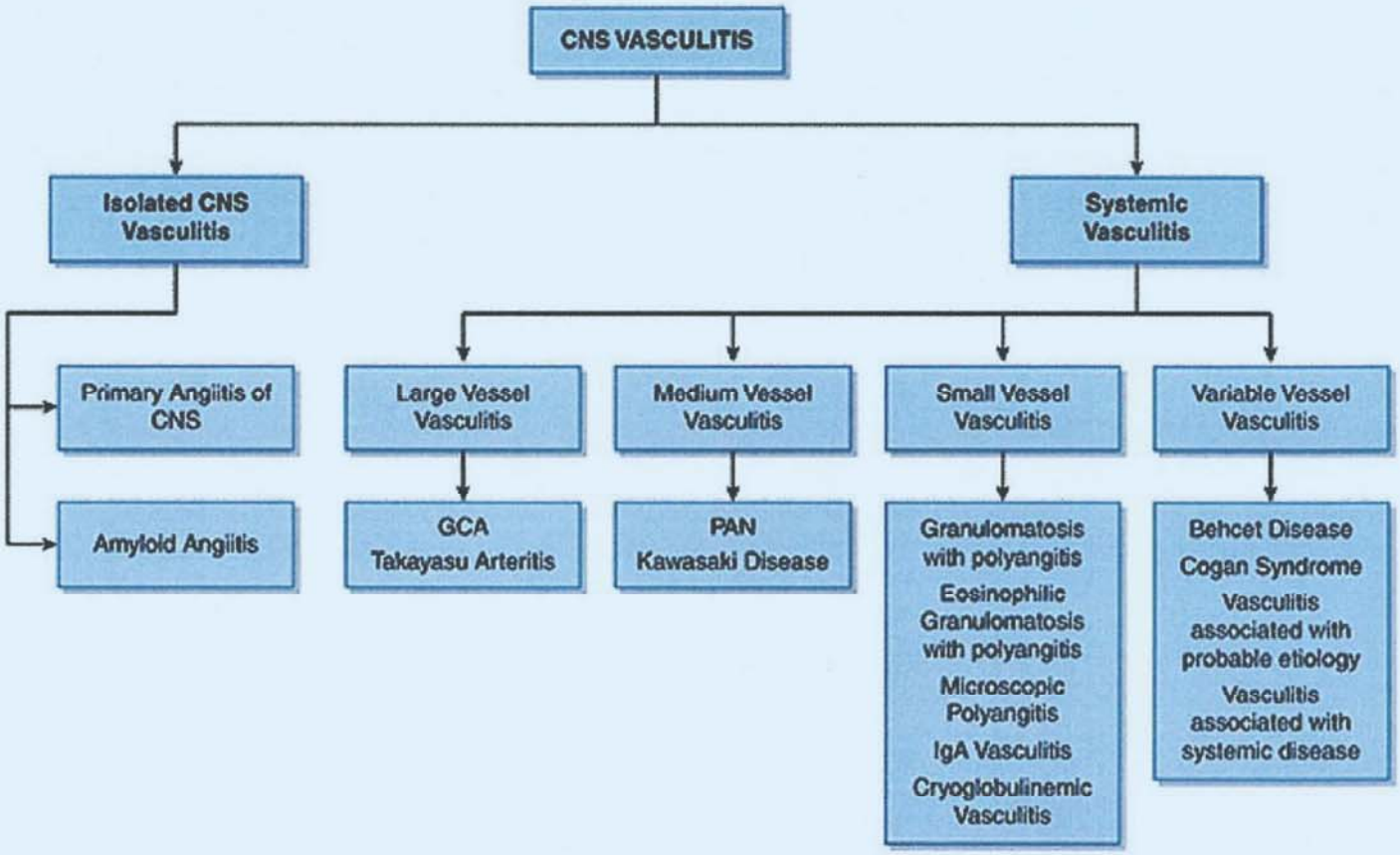

FIGURE 43.1 Classification of CNS vascultis, which takes into account primary CNS versus systemic involvement and the size of the involved vessels.

enhancement can occur. It is extremely rare for PACNS to cause advanced disease with severe symptoms with a normal MRI.

The gold standard for the detection of vascular abnormalities is tissue biopsy. In PACNS, cerebral angiography may show multiple segmental areas of ectasia, dilation or stenosis referred to as *beading*: circumferential or eccentric vessel irregularities with sharp cutoffs, delayed arterial emptying, small arteriovenous anastomotic channels, and rarely, microaneurysms (Fig. 43.3). The main condition that PACNS must be differentiated from a patient with beading on diagnostic angiography is reversible cerebral vasoconstriction syndrome (RCVS), a much more benign condition discussed later in this chapter (see also Chapter 44). About 4% of patients with primary CNS vasculitis present with a solitary tumorlike mass lesion due to brain tissue inflammation. Given the poor resolution of computed tomography and magnetic resonance angiography for distal medium and small blood vessels, these tests have limited specificity for diagnosing PACNS.

Arteries with diameter below 0.4 mm, arterioles, and capillaries are beyond the resolution of conventional angiography, and because PACNS often involves small blood vessels, the sensitivity of angiography in biopsy-proven PACNS cases is only 60%. Thus, a negative angiogram cannot exclude the diagnosis of PACNS. Furthermore, cerebral angiography has limited specificity because not infrequently, patients with angiographic findings interpreted as being positive for vasculitis are not found to have vasculitic changes at brain biopsy. It should be noted that normal biopsy specimens may reflect sample error due to the patchy distribution of inflammation. The false-negative rate of an initial biopsy is 25%; in some cases, two or more biopsies are necessary to establish the diagnosis. The yield of biopsy is improved with larger tissue blocks (ie, 1 cm^3) with inclusion of the overlying meninges and when areas affected with enhancement on MRI are targeted.

TABLE 43.2 Diagnostic Criteria for Primary Angiitis of the Central Nervous System

- History or clinical findings of an acquired neurologic deficit of unknown origin after a thorough initial basic assessment
- Cerebral angiography reveals classic features of vasculitis, or a CNS biopsy sample shows vasculitis.
- There is no evidence of systemic vasculitis or any other disorder to which the angiographic or pathologic features can be attributed to.

Abbreviation: CNS, central nervous system.

Management

No randomized clinical trials of medical management for PACNS exist. First-line therapy usually starts with glucocorticoids. Fulminant PACNS in hospitalized patients usually starts with empiric intravenous *methylprednisolone*, 15 mg/kg/d for 3 to 5 days, followed by *prednisone*, 1 mg/kg/d to a maximum of 100 mg/d. Less severe disease in outpatients can be started on *prednisone* alone. Glucocorticoids should be continued at the initial dose for 4 to 6 weeks after which a slow taper should be initiated.

Patients with biopsy-confirmed granulomatous variant PACNS should be started on a combination of glucocorticoids and *cyclophosphamide*. *Cyclophosphamide* is given in order to induce remission in either a daily oral regimen (1.5-2 mg/kg/d) or a monthly intravenous regimen (600-750 mg/m^2, infused once a month). After induction of remission, typically in 3 to 6 months, *cyclophosphamide* therapy is switched to maintenance therapy with other agents such as mycophenolate mofetil or azathioprine.

TABLE 43.3 Suggested Laboratory Testing for Central Nervous System Vasculitis

Complete blood count with differential
Serum urea nitrogen and creatinine
Serum aspartate and alanine aminotransferases
ESR and C-reactive protein
Urinalysis
CSF Studies
Cell count (mild to moderate CSF pleocytosis expected)
CSF protein (elevated to 1,034 mg/dL reported) CSF glucose (usually normal)
Oligoclonal bands
Gram stain and cultures
Cytology and flow cytometry to rule-out malignancy
PCR and IgG, IgM directed at infectious sources (below)
Specialized Laboratory Testing
Antinuclear antibodies
Rheumatoid factor
Antibodies to the Ro/SSA, La/SSB, Sm, and RNP antigens
Antibodies to double-stranded DNA
Antineutrophil cytoplasmic antibodies (ANCA)
Serum C3 and C4
Serum cryoglobulins
Serum and urine protein electrophoresis with immune electrophoresis
Quantitative immunoglobulin levels (IgG, IgM, IgA)
Infectious Etiologies (In Appropriate Circumstances as Indicated)
Bacterial—*Mycoplasma* PCR and serology, antistreptolysin O test, syphilis serology, Mantoux skin test
Viral—serology for hepatitis B and C, parvovirus B19, HIV, herpes simplex virus, Epstein-Barr virus, cytomegalovirus, varicella
Fungal culture (*Aspergillus*, *Coccidioides*, and *Histoplasma* species)
Parasite: serum anticysticercal antibodies demonstrated by immunoblot assay and CSF ELISA for detection of anticysticercal antibodies or cysticercal antigens
Thrombophilia Investigations
Prolonged activated partial thromboplastin time, which does not correct with mixing
Screening for lupus anticoagulant
Anticardiolipin antibody by ELISA
Anti-β_2-microglobulin-1 antibody by ELISA

Abbreviations: CSF, cerebrospinal fluid; ELISA, enzyme-linked immunosorbent assay; ESR, erythrocyte sedimentation rate; HIV, human immunodeficiency virus; IgA, immunoglobulin A; IgG, immunoglobulin G; IgM, immunoglobulin M; PCR, polymerase chain reaction; RNP, ribonucleoprotein; Ro/SSA, Anti-Sjögren's-syndrome-related antigen A (also called anti-Ro); Sm, Smith.

FIGURE 43.2 Fluid-attenuated inversion recovery magnetic resonance imaging showing multifocal infarcts in a patient with biopsy-proven primary angiitis of the central nervous system.

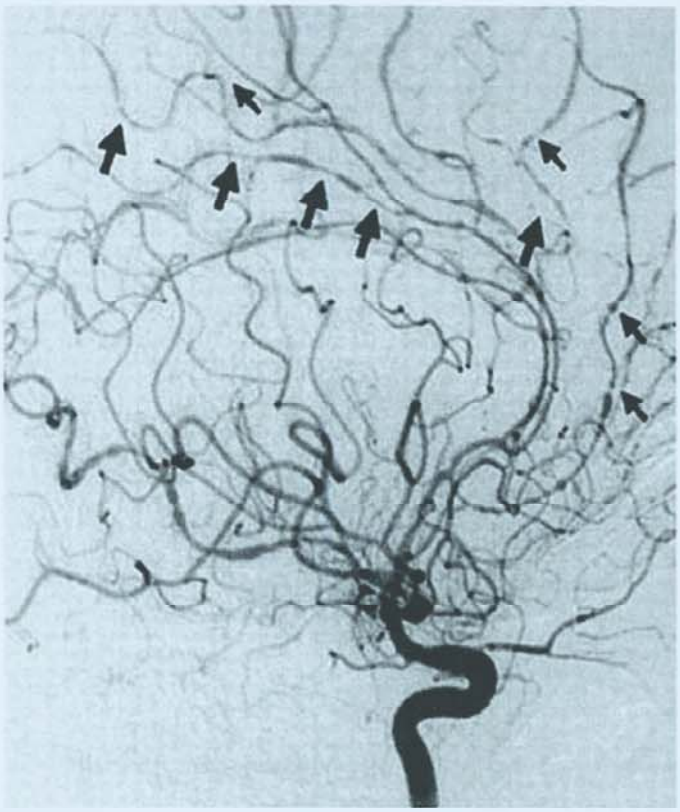

FIGURE 43.3 Typical angiographic findings in a patient with central nervous system vasculitis. *Arrows* point to areas of alternating stenosis and ectasia. (From Hajj-Ali RA, Ghamande S, Calabrese LH, Arroliga AC. Central nervous system vasculitis in the intensive care unit. *Crit Care Clin*. 2002;18:897-914.)

In patients with lymphocytic variant PACNS or those in whom the diagnosis is performed by cerebral angiogram and not confirmed by biopsy, an initial glucocorticoid treatment is only followed by *cyclophosphamide* if the neurologic decline is progressive. As a general rule, chemotherapeutic immunosuppressant therapy should only be given to patients with biopsy-proven PACNS.

Treatment response is monitored by periodic reassessment of symptoms and neuroimaging abnormalities. A follow-up MRI

should be obtained 4 to 6 weeks after beginning treatment, then every 3 to 6 months throughout therapy, and subsequently according to the evolution of the disease to assess for progression of the disease.

Outcome

Earlier descriptions characterized PACNS as a fatal disease, and most cases were diagnosed at autopsy. With better understanding of the disease and with aggressive immunosuppression, more favorable outcomes and improving mortality rate have been reported. Recent reports indicate that the short-term mortality rate is 10% and that 20% suffer severe functional impairment. Mild cognitive deficits and reduced energy level remain common among those with a good functional recovery. Approximately 30% of patients experience a relapse of the disease after going into remission, which requires reescalation of immunosuppression.

AMYLOID β–RELATED ANGIITIS

Amyloid β–related angiitis (ABRA) is a rare form of CNS vasculitis in which perivascular β–amyloid is thought to act as a trigger for inflammation mediated by $CD68^+$ 1macrophages and $CD3^+$ T lymphocytes. The condition develops in patients with symptomatic or asymptomatic amyloid angiopathy (see Chapter 39), which presents as dementia, gait disorder, and progressive brain hemorrhages (both microbleeds and parenchymal intracerebral hemorrhage). Patients with amyloid β–related angiitis often exhibit altered mental status and respond to immunosuppressive treatment. Common CSF findings include an elevated protein and a lymphocytic pleocytosis. The MRI often demonstrates T2 hyperintense lesions extending through the cortical white matter and often gray matter, suggestive of breakdown of the blood-brain barrier and a reversible leukoencephalopathy. Cerebral angiography shows beading in a minority of patients, perhaps due to involvement of exclusively medium- and small-sized vessels. In every case on brain biopsy, microglia, macrophages, and T cells surround amyloid-laden vessels. After initiating anti-inflammatory treatment consisting of *steroids* followed by *cyclophosphamide* for a duration ranging from 2 weeks to several months, a majority of patients with amyloid β–related angiitis show improvement. However, some patients relapse, and other patients do not improve or progressively decline.

CENTRAL NERVOUS SYSTEM VASCULITIS ASSOCIATED WITH SYSTEMIC VASCULITIS

Large-Vessel Vasculitis

Giant Cell (Temporal) Arteritis

Giant cell arteritis (GCA), also known as *temporal arteritis* because of its predilection for superficial temporal artery involvement, is a large-vessel granulomatous vasculitis. The disease usually affects the aorta or its major branches, with a predilection for the branches of the cervical internal and external carotid arteries and the vertebral arteries. The intracranial vessels are generally spared. The GCA is often linked with polymyalgia rheumatica in terms of its systemic manifestations, ESR elevation, and response to steroid therapy.

Epidemiology

The GCA has an annual incidence that is highest among white individuals, ranging between 10 and 20 cases per 100,000 among persons older than 50 years of age. The incidence is markedly lower in persons of Asian or African descent in the range of 1 case per 100,000. Although GCA almost never occurs before age 50 years, the incidence increases thereafter, reaching its peak incidence between the ages of 70 and 80 years.

Pathobiology

Although the etiology of GCA is unknown, there appears to be an interplay between increasing age, a genetic predisposition, and infectious triggers that involves both the cellular and humoral immune system, resulting in an acute vascular inflammatory state. Current literature regarding the molecular basis of GCA suggests that activated dendritic cells, residing in the vessel wall, play an important role in the pathophysiology by initiating the pathogenic cascade, recruiting T cells and macrophages to form granulomatous infiltrates.

GCA is a panarteritis, including all the arterial layers. Thrombosis may develop at sites of active inflammation. Fibrosis, scarring, and narrowing or occlusion of the arteries develops secondary to the inflammation, tissue injury, and repair process.

Clinical Manifestations

GCA is classically characterized by a combination of five features:

- Age older than 50 years
- A localized new-onset headache
- Tenderness over the temporal artery
- An elevated ESR (>50 mm/h)

Biopsy revealing a necrotizing arteritis with a predominance of mononuclear cells or a granulomatous process with multinucleated giant cells is classically characterized by a combination of five features:

1. Age older than 50 years
2. A localized new-onset headache
3. Tenderness over the temporal artery
4. An elevated ESR (>50 mm/h)
5. Biopsy revealing a necrotizing arteritis with a predominance of mononuclear cells or a granulomatous process with multinucleated giant cells

The presence of three of the above five criteria is associated with 94% sensitivity and 91% specificity for the diagnosis of GCA. The GCA typically presents with a constellation of constitutional symptoms, headache and tenderness over the temporal artery, jaw claudication, visual symptoms, and symptoms of polymyalgia rheumatica (diffuse myalgias and body aches). Because intracranial vascular involvement is rare in GCA, transient ischemic attacks (TIAs) and stroke are usually secondary to embolism or flow failure related to cervical vertebral or internal carotid lesions.

Neurologic manifestations arise in approximately 30% of patients, with more than half being peripheral neuropathies, followed by one-third with TIA or stroke, one-third with ophthalmologic symptoms, and one-fifth with neuro-otologic syndromes. Ophthalmologic symptoms can include transient monocular blindness (ie, retinal TIA or amaurosis fugax) due to

internal carotid artery stenosis or sustained unilateral visual loss due to anterior ischemic optic neuropathy or occlusion of the central retinal artery (see Chapter 10).

Diagnosis

Tests to rule out CNS vasculitis should be performed as delineated in **Table 43.3**. The classic diagnostic screening test is an ESR, which is elevated in nearly all patients. The CRP levels are also elevated, and CRP tends to correlate more than ESR with GCA disease activity. Interleukin-6 levels have been used to evaluate disease progression, although this is investigational at this point.

Temporal artery biopsy, evidencing vasculitis with predominance of mononuclear cell infiltration or granulomatous inflammation, usually with multinucleated giant cells, is the gold standard for the diagnosis of GCA. A negative initial temporal artery biopsy may be present and occurs in up to 40% of patients with suspected of GCA. This may be due to sampling error due to skip lesions, biopsy, or attainment of too small a specimen (<2 cm). In the presence of a high index of suspicion, a contralateral biopsy should be performed if the first biopsy is negative. If bilateral temporal artery biopsies are negative, alternate artery biopsy sites should be considered.

Management

Treatment recommendations for GCA are based on clinical experience rather than the results of randomized controlled trials with most cases being managed effectively with glucocorticoid monotherapy. Induction therapy with *prednisone* at a dose of 1 mg/kg of body weight per day (maximum of 60 mg/d) is initiated in patients who lack symptoms or signs of ischemic organ damage (eg, visual loss).

Patients with signs and symptoms suggestive of compromised blood flow to the eyes or the CNS should be managed with *methylprednisolone* at a dose of 1,000 mg/d for 3 consecutive days to more rapidly induce immunosuppression. This is then followed by oral therapy with 1 mg/kg of body weight per day (maximum of 60 mg/d) as recommended earlier for uncomplicated GCA. Once tissue necrosis occurs (eg, optic nerve ischemia with blindness for several hours), it is irreversible.

Treatment initiation for suspected GCA with neurologic involvement should never be delayed until the biopsy is obtained because resolution of the inflammation occurs slowly after the start of treatment, and a confirmed pathologic diagnosis can take several weeks or even months to attain.

Despite lack of prospective trials, anecdotal reports suggest some beneficial effects with glucocorticoid-sparing therapies such as *methotrexate*, *cyclophosphamide*, and *tocilizumab* (interleukin-6 receptor antagonist). These therapies may be considered in patients at highest risk for experiencing glucocorticoid-related side effects.

Once clinical signs have subsided and laboratory values have normalized, steroids can be tapered by 10 mg/kg every 2 to 4 weeks, with a substantial slowing of the taper to 1 mg decrements per month once the daily dose of 10 mg is reached. Expert consensus also recommends the addition of *acetylsalicylic* acid (75-50 mg/d) to reduce the risk of ischemic complications such as visual loss, TIAs, or stroke.

Outcome

GCA tends to run a self-limited course over several months to several years. Rapid clinical improvement following the initiation of treatment is typical. The glucocorticoid dose can eventually be reduced or discontinued with the average duration of treatment being 2 to 3 years. Fatalities are rare.

Takayasu Vasculitis

Also, known as *pulseless disease*. This large vessel vasculitis is a chronic granulomatous inflammatory process in which neurologic involvement is not very common but has been reported. It usually affects middle-aged women of Asian descent. Usually, it affects large vessels commonly aorta and its major branches including the subclavian, carotids, and vertebral arteries. Neurologic manifestations are secondary to vessel occlusion, stenosis, dilatation, or aneurysm formation that may lead to TIA, stroke, and hypertensive encephalopathy. Treatment is usually with glucocorticoids.

Medium-Vessel Vasculitis

Polyarteritis Nodosa

Polyarteritis nodosa (PAN) is a systemic necrotizing small- and medium-sized arteritis sparing the arterioles, capillaries, and venules. The ANCAs are typically negative in PAN; this is important in differentiating it from ANCA-associated vasculitis, which can present almost indistinguishably, both clinically and pathologically.

Epidemiology

PAN is a rare disease occurring in two per million people, with about 25% of cases involving the CNS. Men and women are affected equally. The disease may occur at any age, but the peak incidence is in the fourth to sixth decades of life. With the advent of hepatitis B vaccination, the incidence of hepatitis B virus (HBV)-associated PAN is declining.

Pathobiology

The etiology of PAN remains unknown; immune complex deposition, antigen-specific T-cell–mediated immune responses and reactions to bacterial or viral infection have been postulated. Hepatitis B has been identified as one of the most common triggers for a subset of PAN; this form of arteritis may be monophasic with a good prognosis. The PAN has also been reported with hepatitis C virus (HCV), cytomegalovirus, human immunodeficiency virus, and parvovirus B19.

Vascular inflammatory lesions in PAN are segmental and predominate in branching points of small- and medium-sized arteries. Small vessels, including arterioles, capillaries, and venules, are characteristically spared, as are large vessels (the aorta and its major branches). Consequently, glomerulonephritis is not part of the spectrum of PAN. Vessel inflammation starts in the adventitia and vasa vasorum may subsequently progress to include the entire arterial wall, resulting in fibrinoid necrosis. At bifurcations and branch points, multiple small aneurysms can form, and at later stages, angiogenesis becomes apparent. As these lesions progress, they may rupture or occlude the vessel, resulting in hemorrhage or infarction. Vessel biopsies typically show acute necrotizing lesions intermixed with more chronic fibrotic or healing changes, representing different stages of the inflammatory process.

Clinical Manifestations

The ubiquitous nature of PAN allows for the diverse clinical manifestations, ranging from more chronic, insidious symptoms to acute, life-threatening complications. Nonspecific constitutional manifestations are common early in the course.

Peripheral neuropathy, in the form of mononeuritis multiplex or diffuse sensorimotor peripheral neuropathy, is the most common neurologic disorder. Involvement of the CNS occurs in fewer than 10% of patients with PAN. The CNS manifestations range from headache, retinopathy, and encephalopathy with seizures and cognitive decline to cerebral infarction and intracerebral hemorrhage due to involvement of medium-sized vessels. Other symptoms may arise from affection of the cranial nerves or the spinal cord.

Cutaneous hemorrhages, tender erythematous eruptions, subcutaneous nodules, and necrotic ulcers may appear on the trunk or limbs. Variable degrees of renal insufficiency and hypertension may develop secondary to tissue infarction and hematoma formation secondary to rupture of renal microaneurysms. Furthermore, gastrointestinal, hepatic, testicular, or cardiac symptoms may develop.

Diagnosis

The diagnosis of PAN should be considered in all patients with an obscure febrile illness marked by systemic symptoms and chronic peripheral neuropathy. According to the American College of Rheumatology 1990 consensus criteria for the classification of PAN, the diagnosis is 82% sensitive and 87% specific in a patient with systemic vasculitis if there are more than 3 of the following 10 criteria: weight loss (≥4 kg), livedo reticularis, testicular pain or tenderness, myalgia, mononeuritis multiplex or other polyneuropathy, hypertension, azotemia, HBV antibody, angiographic occlusion of visceral arteries, or biopsy evidence of granulocytes in vessel wall.

Laboratory

The diagnosis can often be established by biopsy of sural nerve, muscle, or testicle. A high index of suspicion is crucial to diagnose PAN. Basic laboratory tests, liver function studies, and hepatitis (HBV and HCV) serologies help rule out potential etiologies and ascertain the extent of organs affected and their degree of involvement. Acute-phase proteins are typically elevated. There is a leukocytosis with inconstant eosinophilia. Additional specialized autoimmune laboratory testing is valuable in narrowing the differential diagnosis (see **Table 43.3**). The presence of myeloperoxidase (MPO) ANCA or proteinase 3 (PR3) ANCA antibodies strongly argues against PAN and in favor of one of the ANCA-associated vasculitides.

Management

There is no specific therapy. Treatment varies according to the severity of the disease state ranging from high doses of corticosteroids in milder disease forms to a combination of corticosteroids and immunosuppressive drugs (*azathioprine*, *methotrexate*, or *cyclophosphamide*). Patients with mild PAN and evidence of infection with HBV or HCV should receive antivirals, whereas those with severe hepatitis virus–associated PAN, short-term treatment corticosteroids, and plasma exchange maybe considered until antiviral therapy becomes effective. Plasma exchange may have a role in the acute management of HBV-associated PAN.

Outcome

Untreated PAN is associated with a poor prognosis. The French Vasculitis Study Group described the 1- and 5-year relapse rates for patients with non–HBV-associated PAN as 9.2% and 24%, respectively; the relapse rates for HBV-associated PAN were lower. Most deaths occur within 18 months of disease onset primarily due to renal failure and mesenteric, cardiac, or cerebral infarctions.

Kawasaki Disease

Kawasaki disease, also known as *Kawasaki syndrome*, previously called mucocutaneous lymph node syndrome, is one of the most common vasculitides of childhood. The affected patient population is children younger than 5 years old, but Kawasaki disease also occurs rarely in adults. Higher prevalence is seen in Japan. Clinical manifestations include long-standing fever, sore throat, diarrhea, lymphadenopathy, genital rash, red eyes, lips, palm, or soles. Complications include coronary artery vasculitis (50%) and CNS involvement (30%). Neurologic manifestations vary and can include cerebral hypoperfusion, stroke, subdural effusion, seizures, and coma. Unless it is contraindicated, all published guidelines include aspirin with intravenous immunoglobulin as initial treatment of Kawasaki disease.

Small-Vessel Vasculitis

The Antineutrophil Cytoplasmic Antibody–Positive Vasculitides

The ANCA vasculitis is a group of necrotizing small-vessel vasculitides predominantly affecting small vessels (ie, capillaries, venules, arterioles, and small arteries). The ANCA antibodies (usually immunoglobulin G) react against antigens in the cytoplasm of neutrophil granulocytes. Specific subtypes of ANCA are based on immunofluorescence patterns and target antigens. Cytoplasmic antineutrophil cytoplasmic antibody is directed specifically at PR3. Perinuclear antineutrophil cytoplasmic antibody antigens include MPO and bacterial permeability increasing factor.

The ANCA-associated vasculitides include the following:

1. Granulomatosis with polyangiitis (formerly known as *Wegener granulomatosis*)
2. Microscopic polyangiitis (MPA)
3. Eosinophilic granulomatosis with polyangiitis (formerly *Churg-Strauss syndrome*)
4. Renal-limited vasculitis
5. Drug-induced vasculitis

All are associated with ANCAs and a focal necrotizing, often crescentic, pauci-immune glomerulonephritis. The presence or absence of ANCA antibodies does not indicate presence or absence of disease. The ANCA is highly correlated with the conditions described in the following sections, but not all patients with the condition test positive for the antibody. The association of ANCA positivity and disease activity remains controversial; however, the reappearance of ANCA after treatment can indicate a relapse.

Granulomatosis With Polyangiitis

Introduction

The hallmarks of granulomatosis with polyangiitis (GPA), formerly known as *Wegener granulomatosis*, are necrotizing granulomatous inflammation involving the upper and lower respiratory tract, necrotizing glomerulonephritis, and systemic necrotizing vasculitis affecting predominantly small to medium vessels (eg, capillaries, venules, arterioles, arteries, and veins).

Epidemiology

The annual incidence of GPA is 5 to 10 cases per million population equally affecting males and females between the ages of 65 and 70 years. The GPA affects Caucasians more than Asians, Africans, and the Afro-Caribbean and African American populations.

Pathobiology

The immunopathobiology of GPA is complex and involves the generation of ANCA against PR3 in approximately 50% to 80% of GPA patients and against MPO in approximately 10% to 18% of GPA patients. The GPA is believed to develop following exposure to infectious (bacterial, mycobacterial, fungal, or viral infections of the upper respiratory tract), environmental, chemical, toxic, or pharmacologic triggers in genetically predisposed individuals who lack tolerance to ANCA self-antigens.

Clinical Manifestations

Prodromal symptoms may last for weeks to months with constitutional symptoms including fever, migratory arthralgias, malaise, anorexia, and weight loss. The GPA has a predilection for the respiratory system and kidneys. According to criteria of the American Academy of Rheumatology, the diagnosis can be made if there are two of the following four criteria:

1. Oral ulcers or purulent bloody nasal discharge
2. Abnormal chest film showing nodules, fixed infiltrates, or cavities
3. Microscopic hematuria
4. Biopsy evidence of granulomatous inflammation in the wall of an artery or perivascular tissue

As with other vasculitic syndromes, GPA affects the peripheral nervous system in the form of a sensorimotor peripheral neuropathy (mononeuritis multiplex) more than the CNS. The CNS is affected in less than 10% of patients. In such cases, intracranial granuloma may arise following direct invasion from the nasal cavity and in turn involvement of the basal cranial nerves. Additionally, aseptic meningeal necrotizing granulomas, encephalopathy, or vasculitis with secondary stroke or venous sinus thrombosis may occur.

Diagnosis

Approximately 90% of patients are ANCA positive and 10% of patients are ANCA negative. The definitive diagnosis is made by biopsy of an affected organ (generally skin, kidney, or lung).

In patients with neurologic manifestations, involvement of the dura with pachymeningitis may be detected on MRI after contrast administration. Because the caliber of the affected vessels may be beyond the spatial resolution of digital subtraction angiography, radiologic confirmation of CNS vasculitis in Wegener granulomatosis is rare. Nerve biopsies may show arteritis in patients with polyneuropathy and no signs of systemic disease.

Management

Patients should be treated empirically if the clinical suspicion for ANCA vasculitis is high, and a tissue diagnosis cannot be obtained in a timely manner. Therapy of GPA has two components: induction of remission and maintenance using immunosuppressive therapy. Patients with mild disease lacking active glomerulonephritis and organ-threatening or life-threatening manifestations may be treated with a regimen of glucocorticoids in combination with *methotrexate*. Patients with moderate to severe disease who are at imminent risk for organ damage or who have life-threatening manifestations should receive a regimen consisting of glucocorticoids in combination with either *cyclophosphamide* (oral or intravenous) or *rituximab*. Plasma exchange is reserved for patients with GPA or MPA who have one or more of the following: pulmonary hemorrhage, a positive antiglomerular basement membrane antibody, a serum creatinine more than 5.7 mg/dL, and/or requiring dialysis.

Outcome

Long-term survival with GPA is improved with immunosuppression, and the natural history of this disease has transformed from being an imminently life-threatening condition to a chronic condition prone to relapse throughout life. Left untreated, approximately 90% of patients will experience severe morbidity or mortality within 2 years. Even with aggressive treatment, GPA continues to be associated with morbidity due to chronic renal, pulmonary, or CNS failure, which affects 12% to 25% of patients within 10 years. Death is generally due to irreversible organ dysfunction and progressive renal failure.

Eosinophilic Granulomatosis With Polyangiitis

Introduction

Eosinophilic granulomatosis with polyangiitis (EGPA), previously known as *Churg-Strauss syndrome*, is a multisystem disorder due to small-vessel vasculitis characterized by eosinophil-rich and necrotizing granulomatous inflammation often involving the respiratory tract and necrotizing vasculitis predominantly affecting small to medium blood vessels. Asthma and peripheral blood eosinophilia are other prominent features. Mononeuritis multiplex is the most common form of neurologic involvement.

Epidemiology

The exact incidence and prevalence of EGPA is unknown but it is rare: Estimates are in the range of 10 to 13 cases per million population. The mean age at diagnosis is 48 years without clear gender predominance. There is a higher incidence among asthmatics.

Pathobiology

EGPA is classified among the ANCA-positive vasculitides with several characteristics pointing to an immunologic etiology, which include the presence of elevated T_H1 and T_H2 lymphocyte function, increased eosinophil recruitment, decreased eosinophil apoptosis, and altered humoral immunity in the form of hypergammaglobulinemia and rheumatoid factor positivity. Genetic factors appear to play a role in the pathogenesis as implicated by the association with human leukocyte antigen class and certain interleukin-10 polymorphisms. Histopathologically, EGPA was originally described as a pathologic triad consisting of (1) necrotizing giant cell vasculitis, (2) eosinophilic tissue infiltration, and (3) extravascular necrotizing granuloma formation, but these characteristics rarely coexist in any one patient. Nerve biopsy may demonstrate epineural necrotizing vasculitis with accompanying eosinophil and lymphocyte infiltrates.

Clinical Manifestations

The American Academy of Rheumatology established six criteria for the diagnosis of EGPA in patients with documented vasculitis. These included the presence of (1) asthma, (2) eosinophilia, (3) a mononeuropathy or polyneuropathy, (4) migratory transient pulmonary opacities detected radiographically, (5) paranasal sinus abnormalities, and (6) biopsy containing a blood vessel showing eosinophil infiltrates in extravascular areas. The presence of four or more of these criteria had a sensitivity of 85% and a specificity of 99% for EGPA.

A peripheral neuropathy, usually mononeuritis multiplex, associated with severe neuropathic pain is seen in up to 75% of patients; other neurologic manifestations may include subarachnoid and intracerebral parenchymal hemorrhage and cerebral infarction, but these are rare.

Diagnosis

A high index of suspicion is necessary for the diagnosis of EGPA. Tests to rule out CNS vasculitis should be performed (see Table 43.3). Most patients with EGPA have peripheral blood eosinophilia, although this may be obscured by use of systemic glucocorticoids to control asthma. The ANCAs are noted in 40% to 60% of EGPA patients with the majority being MPO ANCA. Typical findings on chest high-resolution computed tomography include patchy parenchymal consolidation or ground-glass opacification; nodules may also be noted.

Management

Systemic glucocorticoids are the cornerstone in EGPA therapy and are usually continued for 6 to 12 weeks and then gradually tapered. *Prednisone* 60 mg daily is a typical starting dose. Patients with severe disease with CNS or cardiac involvement require induction with *cyclophosphamide* in combination with systemic glucocorticoid therapy. Induction is followed by a transition to maintenance therapy with azathioprine or methotrexate and leflunomide to induce disease remission over 12 to 18 months; longer courses are necessary for patients with multiple relapses.

Outcome

With the use of systemic glucocorticoids and immunomodulatory medication, the prognosis of EGPA has improved dramatically from a 50% mortality rate among untreated patients within 3 months of onset to a 70% to 90% 5-year survival rate with aggressive therapy. Death usually occurs secondary to cardiac failure, myocardial infarction, renal failure, cerebral hemorrhage, gastrointestinal bleeding, or status asthmaticus.

Microscopic Polyangiitis

Introduction

In MPA, a necrotizing vasculitis with few or no immune deposits predominantly affects small vessels (ie, capillaries, venules, or arterioles) throughout the body. Necrotizing glomerulonephritis is very common, pulmonary capillaritis is common, and neurologic involvement occurs in about half of cases. Granulomatous inflammation is absent.

Epidemiology

The exact incidence and prevalence of MPA are unknown, although the incidence has been estimated to be in the range of six cases per million population affecting men slightly more than women, with an age range of 60 to 65 years.

Pathobiology

As with GPA, the immunopathobiology of MPA is complex; there is increasing evidence that MPA is an autoimmune disease, with ANCA antibodies positive in 95% of cases. The pathophysiology involves the generation of ANCA against MPO in approximately 70% and against PR3 in 30% of MPA patients. The ANCA, directed against MPO and PR3, activates neutrophils to produce reactive oxygen species and release lytic enzymes causing the detachment and destruction of endothelial cells contributing to the pathophysiology.

Clinical Manifestations

As with all other systemic vasculitides, multiple organs are affected with MPA, primarily the kidneys in 90% of cases and less frequently the lungs. Renal involvement is manifested by microscopic hematuria and rapidly progressive glomerulonephritis; 10% progress to end-stage renal disease requiring renal replacement therapy. Pulmonary manifestations range from dyspnea, cough, and hemoptysis to pulmonary hemorrhages, secondary to pulmonary capillaritis, which can be life-threatening. In contrast to GPA, MPA lacks granulomatous inflammation and involvement of the upper respiratory tract. The nervous system is involved in 50% of cases, with polyneuropathy or mononeuritis multiplex being the most common manifestation. Cerebral vasculitis resulting in tissue ischemia, hemorrhage, encephalopathy, and generalized or focal seizures can also occur.

Diagnosis

Tests to rule out CNS vasculitis should be performed as delineated in Table 43.3. Microscopic hematuria with cellular casts in the urine in addition to proteinuria may be demonstrated on urinalysis. An important diagnostic test is the presence of perinuclear antineutrophil cytoplasmic antibody against with MPO or PR3. In patients with neuropathy, an electromyogram may reveal a sensorimotor peripheral neuropathy.

Management and Outcome

The treatment and outcome of MPA is generally the same as that for GPA, as described earlier.

Immunoglobulin A Vasculitis Henoch-Schönlein Purpura

Immunoglobulin A vasculitis (IgA vasculitis, IgAV; formerly called Henoch-Schönlein purpura) involves skin, joints, kidneys, and gastrointestinal tract. Single reports and case series document neurologic manifestations due to small vessel vasculitis in children with IgAV (Henoch-Schönlein purpura) including headaches, seizures, encephalopathy (both hypertensive encephalopathy and posterior reversible encephalopathy syndrome), focal neurologic deficits, ataxia, intracerebral hemorrhage, and central and peripheral neuropathy. The IgAV is usually a self-limiting disease. Pulse corticosteroid therapy is widely used as the first-line treatment and has proven to be effective in most patients

Cryoglobulinemic Vasculitis

Cryoglobulinemic vasculitis is characterized pathologically by deposition of cryoglobulins and complement in small-vessel lumens and walls leading to vessel inflammation. The clinical and pathologic manifestations of cryoglobulinemic vasculitis overlap with those of other systemic vasculitides. The peripheral nervous system is often involved in patients with mixed cryoglobulinemia, whereas there are only few reports of CNS involvement.

Variable-Vessel Vasculitis

Behçet Syndrome

Introduction

Behçet syndrome is a chronic, multisystem vessel vasculitis that has no predilection to the type or size of vessel. Neurologic involvement occurs in about one in five patients.

Epidemiology

Behçet syndrome is most common in the Middle East and Eastern Asia with prevalence ranges from 13.5 to 35 per 100,000. In North American and Northern European countries, the prevalence is from 1 to 7 per 100,000. There is no gender predilection; the disease typically affects young adults 20 to 40 years of age.

Pathobiology

The exact cause is unknown, but there is increasing evidence that an underlying immune-mediated vasculitis underlies the mucocutaneous lesions. Although vasculitic changes may not be demonstrated in all lesions, the classic finding is a necrotizing leukocytoclastic obliterative perivasculitis with fibrinoid necrosis of postcapillary venules. Venous thrombosis with lymphocytic infiltration of capillaries, veins, and arteries of all sizes may also be visible. It has been reported that those with active Behçet syndrome have elevated serum levels of several proinflammatory cytokines, perhaps as a result of an aberrant immune reaction due to infectious or environmental pathogens. Numerous reports have found a strong genetic predisposition to develop Behçet disease among those with the HLA-B51 major histocompatibility complex subtype.

Clinical Manifestations

Behçet syndrome is characterized by uveitis and recurrent oral and genital aphthous ulcers. Other manifestations include ocular, cutaneous, joint, gastrointestinal, or CNS inflammatory lesions. Small-vessel vasculitis, thromboangiitis, vessel thrombosis, arteritis, and arterial aneurysms may occur. The CNS involvement is present in 20% of patients and can be subdivided into parenchymal (inflammation of the CNS tissue) or nonparenchymal (vascular neuro-Behçet).

Parenchymal disease may be due to lesions in the corticospinal tract, periventricular white matter, basal ganglia, brainstem, and spinal cord. Clinical presentations are often subacute and manifestations may include headache, behavior changes, encephalopathy, acute meningeal syndromes, hemiparesis, hemisensory loss, seizures, cranial neuropathies, cerebellar dysfunction, alterations in mental status, and optic neuropathy. Spinal cord lesions may occur in isolation. Vascular manifestations may include diffuse vasculitis, venous sinus thrombosis, and uncommonly stroke due to arterial thrombosis, dissection, or aneurysm. In contrast to other systemic vasculitides, peripheral neuropathy is not commonly seen in Behçet syndrome.

Diagnosis

Due to the lack of a specific diagnostic laboratory test, the diagnosis is made based on clinical criteria. The Behçet International Study Group criteria and the International Criteria for Behçet's Disease both require the presence of recurrent oral ulcers in addition to a constellation of recurrent genital ulcers, eye lesions (anterior or posterior uveitis or retinal vasculitis), or skin lesions (including erythema nodosum, pseudovasculitis, papulopustular lesions, or acneiform nodules consistent with Behçet). The International Criteria for Behçet's Disease also adds the presence of vascular lesions (superficial phlebitis, deep vein thrombosis, arterial thrombosis, or aneurysm formation) to the diagnostic criteria. Nonspecific markers of inflammation such as proinflammatory cytokines, circulating immune complexes, C reactive protein, and the ESR may be elevated.

Management

Treatment is dependent on the severity of the disease and the organ systems involved. Glucocorticoids or other immunosuppressive agents should be considered for treatment of erythema nodosum and pyoderma gangrenosum. Posterior uveitis and neurologic involvement requires prompt treatment with both high-dose glucocorticoids and a second immunosuppressive agent (*azathioprine*, *tumor necrosis factor α inhibitors*, *cyclosporine*, *interferon α*, *cyclophosphamide*, and *methotrexate*).

Outcome

Behçet syndrome typically has a relapsing and remitting course. Delay in diagnosis and treatment increases morbidity and mortality. The greatest morbidity and mortality comes from neurologic, ocular, and large-vessel arterial or venous disease. Mucocutaneous, articular, and ocular diseases are often at their worst in the early years of disease; CNS and large-vessel involvement tends to develop later in the disease course. Patients with parenchymal CNS involvement have a worse outcome than patients with nonparenchymal vascular involvement, with more frequent recurrent disease, disability, and premature death.

Cogan Syndrome

Cogan syndrome is a rare autoimmune systemic vasculitis characterized by nonsyphilitic interstitial keratitis and audiovestibular symptoms that resemble Meniere disease (sudden onset of tinnitus, nausea and vertigo, accompanied by gradual hearing loss), and neurologic involvement has been described in literature based on biopsy results.

Cogan syndrome is a rare disease, which primarily affects young adults but can affect children also, the age of onset ranging from 3 to 50 years have been published. The average age of disease onset is second decade. There are fewer than 250 reported cases in literature, and it is mostly described in Caucasian patients of both sexes.

In 1980, Haynes and coauthors proposed the classification of Cogan syndrome as "typical" Cogan syndrome and "atypical" Cogan syndrome (chronic and recurrent conjunctivitis, scleritis, uveitis, optic disc edema, and retinal vasculitis).

The diagnosis should be suspected when patients present with ocular abnormalities along with audiovestibular symptoms. Clinically, vasculitis has been reported to affect the skin, kidneys, distal coronary arteries, CNS, and muscles. Autopsies have revealed vasculitis in the dura, brain parenchyma, gastrointestinal system, kidneys, spleen, aorta, and the coronary arteries. Pathologic examinations of the proximal portion of the aorta in patients with Cogan syndrome have shown generalized dilatation and narrowing of the coronary arteries in the region of the aortic valve. No serologic marker for the disease has been found, so it is a diagnosis of exclusion.

Corticosteroids are the first line of treatment and can aid in the recovery of hearing if they are administered early in the disease course. In some cases, immunosuppressive drugs have proven to be effective. The most recent therapeutic options are tumor necrosis factor α blockers.

Patients without systemic involvement have a good prognosis with average life expectancy, whereas patients with serous vasculitis have an increased risk of death due to complications.

Vasculitis Associated With Systemic Disease

CNS Vasculitis in Rheumatoid Arthritis

CNS involvement in rheumatoid arthritis is not common. The most frequent neurologic manifestations of rheumatoid arthritis are peripheral neuropathy and cervical spinal cord compression due to subluxation of the cervical vertebrae. Cerebral rheumatoid

vasculitis is an uncommon complication, which is associated with high morbidity.

The rate of occurrence of cerebral vasculitis in patients with rheumatoid arthritis is 1% to 8%. Neurologic involvement includes atlantoaxial subluxation, polymyositis, mononeuritis multiplex, peripheral neuropathy, rheumatoid nodules in the central or peripheral nervous system, and rheumatoid vasculitis causing stroke and/or neuropathy.

It has been described traditionally in seropositive patients with long-standing, active and erosive rheumatoid arthritis, with subcutaneous nodules and extra-articular manifestations. Catheter angiogram and biopsy is the gold standard for diagnosis.

Glucocorticoids are used in the treatment of CNS rheumatoid vasculitis. Several alternatives such as azathioprine, intravenous immunoglobulins, and cyclophosphamide are available for patients with corticosteroid-resistant or contraindicated vasculitis. Prognosis is generally poor.

CNS Nervous System Vasculitis in Systemic Lupus Erythematosus

CNS vasculitis secondary to systemic lupus erythematosus (SLE) is a rare diagnosis. The exact pathogenesis of the vasculopathy and the vasculitis is not known, and it is possible that the entity constitutes multiple overlapping pathomechanisms. Certain autoantibodies associated with ischemic and inflammatory pathways may be involved in the pathogenesis.

In SLE, neurologic damage can be a result of direct antibody-mediated tissue damage or damage to the vessels supplying the tissues (cerebral vasculitis). However, there is little histologic support for lupus cerebritis. Vasculopathy on the other hand is seen often in SLE.

MISCELLANEOUS CAUSES AND MIMICS OF CENTRAL NERVOUS SYSTEM VASCULITIS

Reversible Cerebral Vasoconstriction Syndrome

Formerly known as *Call-Fleming syndrome*, RCVS is a monophasic self-limited acute cerebral vasoconstriction syndrome (see Chapter 44 for a full discussion). Patients typically present with headache and may develop minor neurologic deficits related to vasogenic edema or small infarcts, seizures, or convexity subarachnoid hemorrhage. Classic beading is seen on digital subtraction angiography that can be indistinguishable from PACNS. The important differences between RCVS and PACNS are that the former syndrome tends to be much more benign and self-limited. Misdiagnosis of RCVS as PACNS (Table 43.4) and treatment with immunosuppressive agents is not warranted because the condition results from myogenic arterial spasm rather than an autoimmune process causing intramural vessel inflammation. Apart from use of calcium channel blockers such as oral nimodipine 60 mg every 4 hours, treatment is supportive and spontaneous recovery over several weeks is the rule.

Intravascular Large Cell Lymphoma

Intravascular large B-cell lymphoma (IVLBCL) is a rare type of non-Hodgkin lymphoma classified by the World Health Organization as an extranodal diffuse large B-cell lymphoma (LBCL) characterized by the selective growth of neoplastic lymphocytes

TABLE 43.4 Differentiating Primary Angiitis of the Central Nervous System and Reversible Cerebral Vasoconstriction Syndrome

	PACNS	RCVS
Gender predominance and mean age at onset	Male, 50 y	Female, 40 y
Onset and clinical presentation	Insidious with subacute to chronic onset of headache with focal and nonfocal deficit	Acute onset of thunderclap headache with or without neurologic deficit
Clinical course	Chronic, relapsing	Remission within 1 mo, monophasic
Headache	Progressive, dull aching	Severe, throbbing, often thunderclap
CSF findings	Abnormal lymphocytic pleocytosis and elevated protein levels	Normal to near normal
Diagnosis	Leptomeningeal and brain parenchymal tissue biopsy necessary	No biopsy indicated
Common neuroimaging findings	Ischemic, high-intensity T2/FLAIR lesions abnormal MRI scans in 100 % of cases	Ischemic, edema, convexity subarachnoid hemorrhage, ICH normal MRI images in 20% of cases
Vascular findings	Normal in one-third of cases. Diffuse abnormalities are often indistinguishable from RCVS; irregular and asymmetric arterial stenoses or multiple occlusions are more suggestive of PCNSV; abnormalities might be irreversible.	Abnormal in all cases; strings of beads appearance of cerebral arteries; abnormalities reversible within 6-12 wk
Histologic findings	Vasculitic changes	Normal
Drug treatment	Glucocorticoids with or without cytotoxic agents	Nimodipine; no glucocorticoids
Immunosuppressive therapy	Essential	Not indicated
Prognosis	Improved with immunosuppressive therapy	Excellent

Abbreviations: CSF, cerebrospinal fluid; FLAIR, fluid-attenuated inversion recovery; ICH, intracranial hemorrhage; MRI, magnetic resonance imaging; PACNS, primary angiitis of the central nervous system; PCNSV, primary central nervous system vasculitis; RCVS, reversible cerebral vasoconstriction syndrome.

within blood vessel lumina of small vessels, particularly capillaries and venules. This type of lymphoma has also been described as *intravascular lymphomatosis*, *angiotropic large cell lymphoma*, and *malignant lymphangioendotheliomatosis*. The IVLBCL is not a form of vasculitis per se but is often included in the differential diagnosis of PACNS because it can cause a rapidly progressive pattern of widespread brain infarction in a patient without risk factors for cerebrovascular disease.

Epidemiology

The incidence of IVLBCL is unknown; the median age at diagnosis is in the sixth to seventh decades with no gender predilection.

Pathobiology

The diagnosis of IVLBCL is made by demonstrating large lymphoid cells with high mitotic activity within small to medium blood vessels.

Clinical Manifestations

The clinical presentation is varied and often includes symptoms related to organ dysfunction caused by occlusion of small blood vessels. Constitutional symptoms are seen in 55% to 85% of patients. The IVLBCL is considered a disseminated disease at diagnosis frequently manifesting with CNS and cutaneous symptoms in Western countries or with hemophagocytic syndromes in Asian countries. Rapidly progressive, recurrent ischemic strokes and peripheral neuropathies are frequently seen. The CNS symptoms may include progression from lethargy to coma, focal neurologic deficits, seizures, or central hyperventilation. Neurologic symptoms are less commonly seen in patients of Asian descent who frequently present with involvement of the bone marrow, spleen, and liver.

Diagnosis

A wide range of laboratory abnormalities may be seen, ranging from elevated lactate dehydrogenase, β_2-microglobulin, and ESR levels to abnormal liver, renal, or thyroid function tests; anemia; thrombocytopenia; and hypoalbuminemia. The CSF analysis only rarely demonstrates malignant cells, but CSF cytology and flow cytometry should be obtained. The IVLBCL is not typically associated with an obvious extravascular tumor mass, adenopathy, or detectable circulating lymphoma cells in the peripheral blood.

Brain biopsy or deep skin biopsy including the subcutaneous tissues is necessary to confirm the diagnosis. The bone marrow, lymph nodes, peripheral blood, and CSF are often uninvolved. Cerebral MRI findings include infarctions when occlusions occur in small arteries, patchy foci of white matter hyperintensities when the pathology involves the capillaries, mass-like lesions, and thickening of the meningeal vessels with meningeal or focal parenchymal enhancement.

Treatment and Outcome

Accurate and timely diagnosis of IVLBCL is still a problematic issue, and many cases are diagnosed at autopsy. However, in recent years, the heightened awareness of IVLBCL with appropriate investigations has resulted in more patients being diagnosed during life. Treatment of patients with IVLBCL includes a combination of *cyclophosphamide*, *doxorubicin*, *vincristine*, and *prednisone* with *rituximab*, a recombinant anti-CD20 monoclonal antibody (R-CHOP). The addition of *rituximab* has been shown to improve progression-free 2-year survival from 27% to 56%.

Infectious Central Nervous System Vasculitis

Infection is a well-recognized cause of CNS vasculopathy that can mimic autoimmune PACNS. The spectrum of infections that can cause segmental vascular inflammation of the cerebral arteries ranges includes viruses (eg, varicella-zoster virus or hepatitis C; see Chapter 69), bacterial meningitis or endocarditis (see Chapter 64); chronic meningitis due to tuberculosis, spirochete infection (eg, neurosyphillis), or fungal infection (eg, *Aspergillus*, *Cryptococcus*; see Chapter 67); rickettsial infection (eg, Rocky Mountain spotted fever; see Chapter 66); and parasites (see Chapter 68). In most cases, the process is believed to be due to direct invasion and proliferation of pathogens in vessel walls with resultant inflammation, although some may develop as a result of an autoimmune response initiated by exposure to a pathogen (eg, cryoglobulinemic vasculitis in the setting of HCV infection).

Varicella-zoster virus is a frequent cause of viral CNS vasculitis affecting large vessels in immunocompetent hosts while causing a more extensive protracted disease in immunocompromised individuals by affecting small vessels. Hepatitis C has been associated with small-vessel vasculitis related to mixed cryoglobulinemia, which accounts for the majority of cases, or a small- to medium-vessel vasculitis similar to PAN.

Bacterial cerebral vasculitis usually starts as purulent infection at the base of the brain progressing to inflammatory cell infiltration of vessel walls, with subsequent septic thrombosis and thrombophlebitis manifesting clinically as ischemic stroke and hemorrhages. Syphilitic vasculitis usually occurs as part of tertiary syphilis and occurs for 10% to 40% of untreated cases. Diffuse syphilitic vasculitis preferentially involves the cortical arteries and veins, whereas the gummatous vasculitis usually affects proximal middle cerebral artery branches. Classic angiographic findings include narrowing of the proximal portions of the cerebral arteries with distal beading due to alternating segmental stenoses and dilatations.

The CNS tuberculosis is frequently associated with segmental infectious vasculitis, secondary aneurysm formation, and thromboses causing infarctions of the basal ganglia, cerebral cortex, brainstem, and cerebellum in patients with CNS tuberculosis.

Drug-Induced Central Nervous System Vasculitis

Although the exact incidence and pathobiology is unknown, there is ample evidence that some illicit and therapeutic drugs can result in either a self-limited or more protracted form of cerebral vasculitis. The pathogenesis is likely multifactorial. Drugs with sympathomimetic activity (*amphetamines*, *cocaine*, *phenylpropanolamine*) have been frequently implicated in causing biopsy-proven inflammatory cerebral vasculitis as well as ischemic stroke precipitated by noninflammatory cerebral vasoconstriction.

The clinical diagnosis is one of exclusion based on the temporal relationship between the administration of the offending drugs and clinically evident vasculitis. Management is generally supportive in addition to removal of the instigating agent, which alone is often sufficient to induce prompt resolution of clinical manifestations. There is little data to guide management of severe cases where there is vital organ involvement.

Fibromuscular Dysplasia

Fibromuscular dysplasia (FMD) involves small- and medium-sized arteries. It is a noninflammatory, nonatherosclerotic angiopathy that occurs most commonly in women. FMD can mimic vasculitis angiographically but is usually asymptomatic and rarely has a severe clinical course. The most common clinical manifestation of FMD is dissection due to vessel wall degeneration. Isolated cases of FMD have been reported mimicking the following conditions: PAN, Ehlers-Danlos syndrome, Alport syndrome, pheochromocytoma, Marfan syndrome, and Takayasu arteritis. The etiology of FMD remains unknown. The major sites affected are renal, cerebral, carotid, visceral, iliac, subclavian, brachial, and popliteal arteries. The diagnosis of FMD is made by histopathology and/or angiography.

Characteristic findings on angiography are described as "string of pearls" or beads on a string appearance. Treatment may include revascularization in certain circumstances.

SUGGESTED READINGS

Al-Araji A, Kidd DP. Neuro-Behçet's disease: epidemiology, clinical characteristics, and management. *Lancet Neurol*. 2009;8(2):192-204.

Al-Shagahin H, Al-Hamaidah A. Cogan's syndrome in a Jordanian patient: a case report. *Alexandria J Med*. 2014;50:377-380.

Alves NR, Magalhães CM, Almeida R, Santos RC, Gandolfi L, Pratesi R. Prospective study of Kawasaki disease complications: review of 115 cases. *Rev Assoc Med Bras*. 2011;57(3):295-300.

Benamour S, Naji T, Alaoui FZ, El-Kabli H, El-Aidouni S. Neurological involvement in Behcet's disease. 154 cases from a cohort of 925 patients and review of the literature [in French]. *Rev Neurol (Paris)*. 2006;162(11):1084-1090.

Bonaguri C, Orsoni J, Russo A, et al. Cogan's syndrome: anti-Hsp70 antibodies are a serological marker in the typical form. *Isr Med Assoc J*. 2014;16:285-288.

Booth AD, Almond MK, Burns A, et al. Outcome of ANCA-associated renal vasculitis: a 5-year retrospective study. *Am J Kidney Dis*. 2003;41(4):776-784.

Byram K, Hajj-Ali RA, Calabrese L. CNS vasculitis: an approach to differential diagnosis and management. *Curr Rheumatol Rep*. 2018;20(7):37.

Caballol Pons N, Montalà N, Valverde J, Brell M, Ferrer I, Martínez-Yélamos S. Isolated cerebral vasculitis associated with rheumatoid arthritis. *Joint Bone Spine*. 2010;77:361-363. doi:10.1016/j.jbspin.2010.02.030.

Cacoub P, Saadoun D, Limal N, Léger JM, Maisonobe T. Hepatitis C virus infection and mixed cryoglobulinaemia vasculitis: a review of neurological complications. *AIDS*. 2005;19(suppl 3):S128-S134.

Calabrese LH, Duna GF, Lie JT. Vasculitis in the central nervous system. *Arthritis Rheum*. 1997;40(7):1189-1201.

Calabrese LH, Mallek JA. Primary angiitis of the central nervous system. Report of 8 new cases, review of the literature, and proposal for diagnostic criteria. *Medicine (Baltimore)*. 1988;67:20-39.

Calvetti O, Biousse V. *Cogan's Syndrome—Uncommon Causes of Stroke*. Cambridge, United Kingdom: Cambridge University Press; 2008:259-262.

Chan KH, Cheung RT, Lee R, Mak W, Ho SL. Cerebral infarcts complicating tuberculous meningitis. *Cerebrovasc Dis*. 2005;19(6):391-395.

Chen M, Kallenberg CG. ANCA-associated vasculitides—advances in pathogenesis and treatment. *Nat Rev Rheumatol*. 2010;6(11):653-664.

Cundiff J, Kansal S. Cogan's syndrome: a cause of progressive hearing deafness. *Am J Otolaryngol*. 2006;27:68-70.

Deng F, Lu L, Zhang Q, Hu B, Wang SJ, Huang N. Henoch-Schönlein purpura in childhood: treatment and prognosis. Analysis of 425 cases over a 5-year period. *Clin Rheumatol*. 2010;29:369-374.

Falk RJ, Jennette JC. ANCA small-vessel vasculitis. *J Am Soc Nephrol*. 1997;8(2):314-322.

Ferreri AJ, Dognini GP, Govi S, et al. Can rituximab change the usually dismal prognosis of patients with intravascular large B-cell lymphoma? *J Clin Oncol*. 2008;26(31):5134-5137.

Finkielman JD, Lee AS, Hummel AM, et al. ANCA are detectable in nearly all patients with active severe Wegener's granulomatosis. *Am J Med*. 2007;120(7):643.e9-643.e14.

Garg A. Vascular brain pathologies. *Neuroimaging Clin N Am*. 2011;21(4):897-926.

Garzoni L, Vanoni F, Rizzi M, et al. Nervous system dysfunction in Henoch-Schonlein syndrome: systematic review of the literature. *Rheumatology (Oxford)*. 2009;48:1524-1529.

Gayraud M, Guillevin L, le Toumelin P, et al. Long-term followup of polyarteritis nodosa, microscopic polyangiitis, and Churg-Strauss syndrome: analysis of four prospective trials including 278 patients. *Arthritis Rheum*. 2001;44(3):666-675.

Guillevin L, Cohen P, Gayraud M, et al. Churg-Strauss syndrome. Clinical study and long-term follow-up of 96 patients. *Medicine (Baltimore)*. 1999;78(1):26-37.

Guillevin L, Durand-Gasselin B, Cevallos R, et al. Microscopic polyangiitis: clinical and laboratory findings in eighty-five patients. *Arthritis Rheum*. 1999;42(3):421-430.

Han S, Rehman HU, Jayaratne PS, Carty JE. Microscopic polyangiitis complicated by cerebral haemorrhage. *Rheumatol Int*. 2006;26(11):1057-1060.

Haynes BF, Kaiser-Kupfer MI, Mason P, Fauci AS. Cogan syndrome: studies in thirteen patients, long-term follow-up, and a review of the literature. *Medicine (Baltimore)*. 1980;59:426-441.

Huang X, Lu T, Guo Z, Wei L, Chen S, Qiu W, Lu Z. Susceptibility-weighted imaging in the differential diagnosis of autoimmune central nervous system vasculitis and multiple sclerosis. *Mult Scler Relat Disord*. 2019;33:70-74.

Hunder GG, Bloch DA, Michel BA, et al. The American College of Rheumatology 1990 criteria for the classification of giant cell arteritis. *Arthritis Rheum*. 1990;33(8):1122-1128.

International Study Group for Behcet's Disease. Criteria for diagnosis of Behçet's disease. International Study Group for Behçet's Disease. *Lancet*. 1990;335(8697):1078-1080.

Ito Y, Suzuki K, Yamazaki T, Yoshizawa T, Ohkoshi N, Matsumura A. ANCA-associated vasculitis (AAV) causing bilateral cerebral infarction and subsequent intracerebral hemorrhage without renal and respiratory dysfunction. *J Neurol Sci*. 2006;240(1-2):99-101.

Jennette JC, Falk RJ, Bacon PA, et al. 2012 revised International Chapel Hill Consensus Conference nomenclature of vasculitides. *Arthritis Rheum*. 2013;65(1):1-11.

Kalra S, Silman A, Akman-Demir G, et al. Diagnosis and management of neuro-Behçet's disease: international consensus recommendations. *J Neurol*. 2014;261(9):1662-1676.

Kelley RE. CNS vasculitis. *Front Biosci*. 2004;9:946-955.

Kobayashi T, Saji T, Otani T, et al. Efficacy of immunoglobulin plus prednisolone for prevention of coronary artery abnormalities in severe Kawasaki disease (RAISE study): a randomised, open-label, blinded-endpoints trial. *Lancet*. 2012;379(9826):1613-1620.

Leavitt RY, Fauci AS, Bloch DA, et al. The American College of Rheumatology 1990 criteria for the classification of Wegener's granulomatosis. *Arthritis Rheum*. 1990;33(8):1101-1107.

Lhote F, Cohen P, Guillevin L. Polyarteritis nodosa, microscopic polyangiitis and Churg-Strauss syndrome. *Lupus*. 1998;7(4):238-258.

Lie JT. Primary (granulomatous) angiitis of the central nervous system: a clinicopathologic analysis of 15 new cases and a review of the literature. *Hum Pathol*. 1992;23:164-171.

Mahr A, Moosig F, Neumann T, et al. Eosinophilic granulomatosis with polyangiitis (Churg-Strauss): evolutions in classification, etiopathogenesis, assessment and management. *Curr Opin Rheumatol*. 2014;26(1):16-23.

McVerry F, McCluskey G, McCarron P, Muir KW, McCarron MO. Diagnostic test results in primary CNS vasculitis: a systematic review of published cases. *Neurol Clin Pract*. 2017;7(3):256-265.

Miller DV, Salvarani C, Hunder GG, et al. Biopsy findings in primary angiitis of the central nervous system. *Am J Surg Pathol*. 2009;33(1):35-43.

Moosig F, Bremer JP, Hellmich B, et al. A vasculitis centre based management strategy leads to improved outcome in eosinophilic granulomatosis and polyangiitis (Churg-Strauss, EGPA): monocentric experiences in 150 patients. *Ann Rheum Dis*. 2013;72(6):1011-1017.

Morrow PL, McQuillen JB. Cerebral vasculitis associated with cocaine abuse. *J Forensic Sci*. 1993;38(3):732-738.

Mouthon L, Dunogue B, Guillevin L. Diagnosis and classification of eosinophilic granulomatosis with polyangiitis (formerly named Churg-Strauss syndrome). *J Autoimmun*. 2014;48-49:99-103.

Mukhtyar C, Guillevin L, Cid MC, et al. EULAR recommendations for the management of primary small and medium vessel vasculitis. *Ann Rheum Dis*. 2009;68(3):310-317.

Pagnoux C, Cohen P, Guillevin L. Vasculitides secondary to infections. *Clin Exp Rheumatol*. 2006;24(2 suppl 41):S71-S81.

Pagnoux C, Hajj-Ali RA. Pharmacological approaches to CNS vasculitis: where are we at now? *Expert Rev Clin Pharmacol*. 2016;9(1):109-116.

Pagnoux C, Seror R, Henegar C, et al. Clinical features and outcomes in 348 patients with polyarteritis nodosa: a systematic retrospective study of patients diagnosed between 1963 and 2005 and entered into the French Vasculitis Study Group Database. *Arthritis Rheum*. 2010;62(2):616-626.

Papandony MC, Brady SRE, Aw T-J. Vasculitis or fibromuscular dysplasia? *Med J Aust*. 2015;202(2):100-101. doi:10.5694/mja14.00224.

Pezzini A, Gulletta M, Pinelli L, et al. Meningovascular syphilis: a vascular syndrome with typical features? *Cerebrovasc Dis*. 2001;11(4):352-353.

Ponzoni M, Ferreri AJ, Campo E, et al. Definition, diagnosis, and management of intravascular large B-cell lymphoma: proposals and perspectives from an international consensus meeting. *J Clin Oncol*. 2007;25(21):3168-3173.

Pozzi M, Roccatagliata D, Sterzi R. Drug abuse and intracranial hemorrhage. *Neurol Sci*. 2008;29(suppl 2):S269-S270.

Provenzale JM, Allen NB. Neuroradiologic findings in polyarteritis nodosa. *AJNR Am J Neuroradiol*. 1996;17(6):1119-1126.

Saadoun D, Terrier B, Semoun O, et al. Hepatitis C virus-associated polyarteritis nodosa. *Arthritis Care Res (Hoboken)*. 2011;63(3):427-435.

Salvarani C, Brown RD Jr, Calamia KT, et al. Primary central nervous system vasculitis: analysis of 101 patients. *Ann Neurol*. 2007;62(5):442-451.

Salvarani C, Brown RD Jr, Calamia KT, et al. Primary central nervous system vasculitis: comparison of patients with and without cerebral amyloid angiopathy. *Rheumatology (Oxford)*. 2008;47(11):1671-1677.

Salvarani C, Brown RD Jr, Hunder GG. Adult primary central nervous system vasculitis. *Lancet*. 2012;380(9843):767-777.

Samson M, Puéchal X, Devilliers H, et al. Long-term outcomes of 118 patients with eosinophilic granulomatosis with polyangiitis (Churg-Strauss syndrome) enrolled in two prospective trials. *J Autoimmun*. 2013;43:60-69.

Siva A, Saip S. The spectrum of nervous system involvement in Behçet's syndrome and its differential diagnosis. *J Neurol*. 2009;256(4):513-529.

Tamargo RJ, Connolly ES Jr, McKhann GM, et al. Clinicopathological review: primary angiitis of the central nervous system in association with cerebral amyloid angiopathy. *Neurosurgery*. 2003;53(1):136-143.

Watts RA, Mooney J, Lane SE, Scott DG. Rheumatoid vasculitis: becoming extinct? *Rheumatology (Oxford)*. 2004;43:920-923. doi:10.1093/rheumatology/keh210.

Watts RA, Mooney J, Skinner J, Scott DG, Macgregor AJ. The contrasting epidemiology of granulomatosis with polyangiitis (Wegener's) and microscopic polyangiitis. *Rheumatology (Oxford)*. 2012;51(5):926-931.

Weiss PF. Pediatric vasculitis. *Pediatr Clin North Am*. 2012;59:407-423.

Weyand CM, Goronzy JJ. Clinical practice. Giant-cell arteritis and polymyalgia rheumatica. *N Engl J Med*. 2014;371(1):50-57.

Weyand CM, Goronzy JJ. Immune mechanisms in medium and large-vessel vasculitis. *Nat Rev Rheumatol*. 2013;9(12):731-740.

Williams RL, Meltzer CC, Smirniotopoulos JG, Fukui MB, Inman M. Cerebral MR imaging in intravascular lymphomatosis. *AJNR Am J Neuroradiol*. 1998;19(3):427-431.

Wolf J, Bergner R, Mutallib S, Buggle F, Grau AJ. Neurologic complications of Churg-Strauss syndrome—a prospective monocentric study. *Eur J Neurol*. 2010;17(4):582-588.

Yamamoto A, Kikuchi Y, Homma K, O'uchi T, Furui S. Characteristics of intravascular large B-cell lymphoma on cerebral MR imaging. *AJNR Am J Neuroradiol*. 2012;33(2):292-296.

Younger DS. Vasculitis of the nervous system. *Curr Opin Neurol*. 2004;17(3):317-336.

Younger DS, Coyle PK. Central nervous system vasculitis due to infection. *Neurol Clin*. 2019;37(2):441-463.

44 Posterior Reversible Encephalopathy Syndrome and Other Cerebrovascular Syndromes

Claire S. Riley, Sara K. Rostanski, and Joshua Z. Willey

POSTERIOR REVERSIBLE ENCEPHALOPATHY SYNDROME

KEY POINTS

1. Posterior reversible encephalopathy syndrome results from failure of autoregulation leading to hyperperfusion with cerebral dysfunction.
2. A large majority of patient with posterior reversible encephalopathy syndrome will also have cerebral vasospasm and there is substantial overlap with reversible cerebral vasoconstriction syndrome (RCVS).
3. The pattern of edema is posterior predominant but can affect multiple structures and the changes can become permanent leading to cerebral infarction.
4. Treatment includes reversal of the underlying cause and supportive care.

Introduction

The posterior reversible encephalopathy syndrome (PRES) has been evolving as a clinical entity for at least two decades with significant confusion as to what the syndrome is. Several terms have now been used interchangeably to define PRES, including *reversible posterior leukoencephalopathy syndrome*, although the terminology itself is not specific given the syndrome is not always posterior and not always reversible. The PRES is now recognized as a syndrome defined by clinical and radiologic features with multiple different etiologies but which shares several common features with the reversible cerebral vasoconstriction syndrome (RCVS).

Epidemiology

Limited data exist to describe the epidemiology of this condition. The literature has mostly been centered around case reports and case series.

Pathobiology

Disorders leading to PRES have in common cerebral injury due to failure of cerebral autoregulation leading to hyperperfusion, or an excessive vascular reactivity in cerebral arterioles. The hallmark clinical entities that most often cause PRES are hypertensive encephalopathy and eclampsia (see Chapter 129). A focal process that shares some features of this condition is cerebral hyperperfusion syndrome occurring after carotid revascularization, although in this entity the radiologic features tend to be limited to one hemisphere. In patients with chronic hemodynamic failure, distal arterioles tend to dilate to reduce cerebral vascular resistance; in clinical scenarios of a sudden increase in cerebral blood flow (CBF), these maximally dilated cerebral arteries may not be able to adapt further to changes in CBF, leading to cerebral edema and hemorrhage. In addition to impaired autoregulation in the face of hypertension and hyperperfusion, in many cases, PRES is also associated with abnormal capillary permeability in the brain and large-vessel proximal vasoconstriction detectable by angiography. Up to 87% of patients with PRES have diffuse vasoconstriction if studied with angiography, hence, PRES and RCVS (discussed later) often overlap and are felt in many cases to share a common pathogenesis. It is notable that many patients with RCVS will not develop PRES and that patients with PRES may not have RCVS. In PRES, there is vasogenic edema that preferentially affects the posterior hemispheres of the brain and the white matter more than the gray matter. Interspersed in this picture are scattered microinfarcts and microhemorrhages. The most severe cases can manifest as massive global cerebral edema with transtentorial herniation or larger infarcts or hemorrhages.

Clinical Features

The clinical syndrome associated with PRES is dependent on the underlying cause, although regardless of underlying etiology, common clinical symptoms include headache, seizures, loss of visual acuity including blindness, nonlocalizing confusion, and somnolence (Table 44.1). The neurologic examination will not reveal localizing findings on the mental status, although cases

TABLE 44.1 Approximate Frequency of Clinical Features of Posterior Reversible Encephalopathy Syndrome

Clinical Feature	Frequency
Hypertension	80%
Consciousness impairment	75%
Seizures	70%
Headaches	40%
Visual abnormalities	30%
Nausea and vomiting	20%

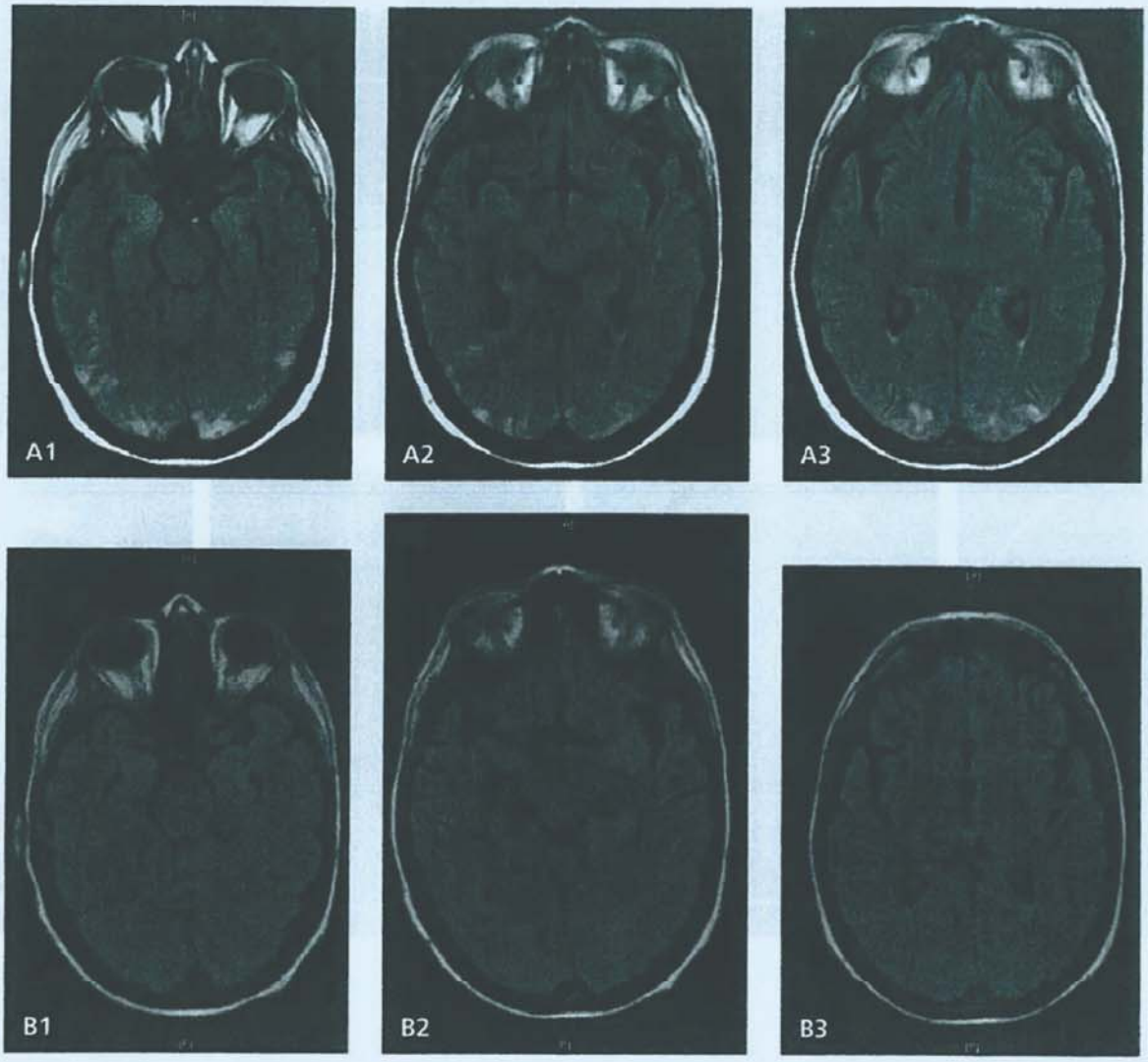

FIGURE 44.1 Magnetic resonance fluid-attenuated inversion recovery image of posterior reversible encephalopathy syndrome on admission **(A)** and 2 weeks after stopping inciting medication **(B)**.

of cortical blindness and Balint syndrome may occur due to involvement of the occipital lobes (Fig. 44.1). Other described findings include visual field cuts, loss of visual acuity, papilledema, and mild hemiparesis. More prominent bulbar and cerebellar symptoms have been described in case series where the pathology is restricted to the brainstem (Fig. 44.2). A larger variety of clinical syndromes, which can be localized anywhere in the cerebral hemisphere, occurs in the context of severe cases with cerebral infarction or hemorrhage.

Diagnosis

Neuroimaging is essential in the diagnosis of this condition, with magnetic resonance imaging (MRI) providing greater clinical information than computed tomography (CT). The "classical" description in this condition is white matter hyperintensities seen on fluid-attenuated inversion recovery (FLAIR) sequences representing vasogenic edema (see Chapter 22). The FLAIR changes have a predilection to occipital lobes and adjacent posterior temporal and parietal regions and are not typically associated with cerebral microhemorrhages, infarction, or involvement of gray matter structures. A hallmark of this condition is that these clinical findings improve with treatment of the underlying condition, along with the cerebral vasogenic edema. Common underlying predisposing conditions include hypertensive emergency/malignant hypertension, eclampsia, and medication toxicity (notably FK-506 in prevention of transplant organ rejection). Table 44.2 describes a variety of underlying etiologies for PRES.

The differential diagnosis of PRES includes conditions, which have a predilection for causing bilateral involvement of the hemispheres, particularly the white matter, or that affect watershed regions between the major vascular territories. These include progressive multifocal leukoencephalopathy, encephalitis, vasculitis, and watershed infarction from cardiac arrest, among others.

Management

Management of PRES begins with a careful review of medications and discontinuation of any potential inciting agent. Management of other PRES-associated causes and complications, such as hypertension, respiratory failure, and seizures will often require the intensive care unit. Control of hypertensive emergency, if present, is an important part of the symptomatic management. The aim is not to normalize the blood pressure but rather to decrease the mean arterial pressure by 10% to 20% within the first 1 hour, followed over the next 23 hours of a reduction by 5% to 10%; by 24 hours, a typical target is less than 160/110 mmHg

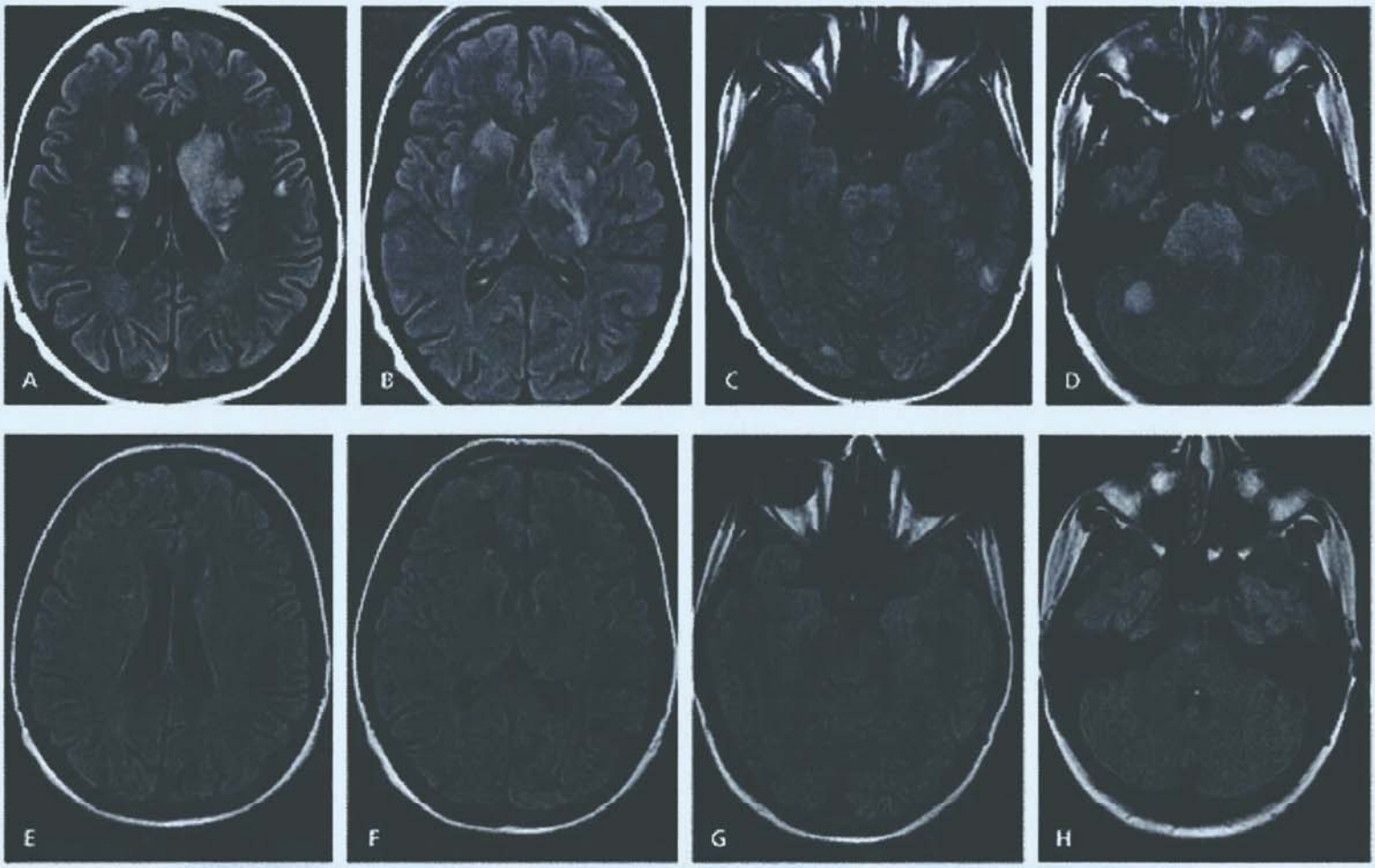

FIGURE 44.2 Fluid-attenuated inversion recovery images of posterior reversible encephalopathy syndrome presenting with prominent brainstem involvement **(A-D)**. Nine days later, the lesions had significantly resolved **(E-H)**.

TABLE 44.2 Etiologies of Posterior Reversible Encephalopathy Syndrome

Malignant hypertension	**Biologic agents**
Eclampsia	• Erythropoietin (in end-stage renal disease)
Immunosuppressants	• Immunomodulatory cytokines (interferon-α, interleukin-2)
• Tacrolimus (FK-506)	• Monoclonal antibodies (rituximab, infliximab)
• Cyclosporine A	• Antiangiogenic agents (bevacizumab)
• Mycophenolate mofetil	• Antilymphocyte globulin
Autoimmune disease	• IVIG
• Systemic lupus erythematosus	**Sepsis**
• Polyarteritis nodosa	**Blood transfusion**
• Wegener granulomatosis	**Other agents**
• Systemic sclerosis	• Antiretroviral agents
Chemotherapy drugs	• Linezolid
• Cytarabine	• Cocaine
• Gemcitabine	• Ephedra
• Methotrexate	• IV contrast agents
• Cisplatin	• Carbamazepine
• Carboplatin	

Abbreviations: IV, intravenous; IVIG, intravenous immunoglobulin.

but not significantly lower due to the risk of hypotension. More rapid blood pressure reduction can promote ischemia due to loss of cerebral autoregulation and in more chronically hypertensive patients a shift of the autoregulatory curve. Continuous infusion of intravenous antihypertensive agents is preferred to allow for precise blood pressure control with the most commonly used agents being labetalol or nicardipine; nitrates should be avoided due to the potential venous dilation leading to an increase in intracranial pressure.

Antiepileptic treatment should be initiated on an emergency basis for treatment of clinical or electrographic seizures or status epilepticus. In patients who do not have a neurologic examination that can be readily tracked, continuous electroencephalogram (EEG) is indicated given the high prevalence of nonconvulsive seizures. The management of convulsive and electrographic status epilepticus is covered elsewhere.

Patients with PRES due to eclampsia should also be started on magnesium infusion (1-2 g/h targeting a serum magnesium level of 2.0-3.5 to 4 mmol/L) LEVEL 7.[1] Magnesium infusion is also recommended for any PRES patient with hypomagnesemia.

Outcome

There are few studies describing outcomes among patients who have had PRES. A good outcome is expected in patients who have not sustained cerebral infarction as demonstrated on diffusion weighted imaging, whereas recurrence is rare if the offending agent is removed. Whether patients without structural injury require long-term antiepileptics has not been well established. Most PRES patients are continued on antiepileptics for 6 months, and the risk of future epilepsy is risk stratified based on imaging and EEG.

REVERSIBLE CEREBRAL VASOCONSTRICTION SYNDROME

KEY POINTS

1. RCVS is a common cause of thunderclap headache associated with convexity subarachnoid hemorrhage.
2. Cerebral vasospasm with cerebral infarction may be delayed for up to 2 weeks after the onset of the subarachnoid hemorrhage and is associated with elevated velocities on transcranial Doppler.
3. Treatment of RCVS involved removing the offending medication, and on a case by case basis, intra-arterial or oral verapamil and oral nimodipine; steroids may be harmful.

Introduction

In 2007, the term *reversible cerebral vasoconstriction syndrome* was proposed to encompass several previously described cerebral vascular disorders that mimicked vasculitis: Call-Fleming syndrome, thunderclap headache–associated vasoconstriction, postpartum angiopathy, migraine angiitis, and cerebral vasospasm caused by serotonergic and sympathomimetic drugs.

The RCVS is characterized by a monophasic course of diffuse segmental constriction of cerebral arteries that typically resolved within 3 months. Although the angiographic findings may be similar to primary angiitis of the central nervous system (PACNS) and other vasculitides, RCVS is not associated with inflammation in the cerebral arteries and therefore does not require immunosuppression (or antimicrobials for infectious vasculitis). The cerebrospinal fluid (CSF) does not tend to show the same inflammatory profile as vasculitis, and the clinical course tends to be benign despite similar imaging characteristics.

Epidemiology

Due to the lack of epidemiologic studies, the true incidence of RCVS has not been estimated, although there has been an increased awareness in the neurologic community leading to potentially reported increased rates reflecting ascertainment bias. Overall, RCVS remains a rare complication of all the potential inciting factors with the exception of preeclampsia and eclampsia associated RCVS. Interestingly, it is likely that many of the cases reported previously in the literature as PACNS actually reflected RCVS.

Pathobiology

Other than vasoconstriction and potentially disrupted cerebral autoregulation, there is no known unifying pathologic mechanism that underlies RCVS. An aberrant sympathetic response of cerebral vasculature is one of the preferred hypotheses resulting in an unpredictable and short-lived failure of normal regulation of cerebral arterial tone. This leads to segmental vasoconstriction and vasodilatation in small cerebral vessels, often triggering thunderclap headaches often due to cortical subarachnoid hemorrhage (SAH) or stretching of arterial walls.

The RCVS appears to be triggered by a wide variety of pharmacologic and physical stimuli (**Table 44.3**). Different precipitating factors, including vasoconstrictive drug exposure (serotonergic or adrenergic agents), recreational drugs, and postpartum state are associated with RCVS in around 50% of cases. Head injuries and neurosurgical interventions have also been associated with RCVS.

The PRES occurs in a substantial proportion of patients with RCVS. Hence, a shared pathophysiology between these two overlapping syndromes is highly probable. Severe forms of RCVS are likely to lead to PRES.

Clinical Features

In over 80% of cases, patients present with a sudden onset of single or recurrent thunderclap headaches, oftentimes associated with cortical SAH, which distinguishes RCVS from aneurysmal SAH. Focal neurologic deficits may occur during the original presentation due to cerebral infarction or intracerebral hemorrhage. In patients with isolated cerebral arterial vasoconstriction, cerebral infarction may occur up to 2 weeks after the initial thunderclap headache leading to delayed focal neurologic symptoms. Headaches in RCVS may persist for several weeks after the initial presentation.

Diagnosis

Diagnostic criteria have been proposed for RCVS that encompass clinical, radiographic, and CSF findings. An important aspect of the diagnosis is a comprehensive history of all medications, recreational drugs, and supplements as they can be common triggers for RCVS. Because RCVS can mimic PACNS, differentiation is crucial because management is extremely different (**Table 44.4**). Basic hematologic

TABLE 44.3 Precipitants of Reversible Cerebral Vasoconstriction Syndrome[a]

Vasoactive drugs	Illicit drugs: cocaine, amphetamines, LSD, MDMA (also known as *ecstasy*) Antidepressants: selective serotonin reuptake inhibitors, serotonin-norepinephrine reuptake inhibitors α-Sympathomimetic agents: phenylpropanolamine, pseudoephedrine, ephedrine Other: triptans, ergot alkaloid derivatives, ginseng
Catecholamine-secreting tumors	Pheochromocytoma Bronchial carcinoid tumor
Immunosuppressants or blood products	Intravenous immunoglobulin Tacrolimus Cyclophosphamide Erythropoietin α-Interferon Red blood cell transfusion
Metabolic abnormalities	Hypercalcemia Porphyria Phenytoin intoxication Binge drinking
Neurologic pathologies	Traumatic brain injury Neurosurgical interventions, for example, postcarotid endarterectomy Subdural spinal hematoma Cerebral venous thrombosis CSF hypotension Autonomic dysreflexia/paroxysmal sympathetic hyperactivity
Pregnancy and puerperium	Usually peripartum or postpartum Associated with eclampsia or preeclampsia

Abbreviations: CSF, cerebrospinal fluid; LSD, lysergic acid diethylamide; MDMA, 3,4-methylenedioxymethamphetamine.
[a]Modified from Ducros A. Reversible cerebral vasoconstriction syndrome. *Lancet Neurol*. 2012;11(10):906-917.

and metabolic tests, including erythrocyte sedimentation rate and liver and renal function tests, are typically normal in RCVS. Tests to rule out CNS vasculitis should be performed as delineated in Table 42.3 as well as urine toxicology screens.

A normal CSF profile is typical, although mild abnormalities in the CSF can be present when subarachnoid or intracerebral hemorrhages exist. If the white blood cell count exceeds 10 cells/μL or the protein concentration exceeds 80 mg/dL, analysis of CSF should be repeated after a few weeks to ensure that these abnormalities have normalized. In patients with a typical clinical and radiographic presentation and a well-identified trigger, a lumbar puncture can be postponed.

A significant proportion of patients may have normal parenchymal imaging (either CT or MRI) despite vasoconstriction seen on vascular imaging. Common findings include convexity SAH, intracerebral hemorrhage, and cerebral infarcts.

Digital subtraction angiography is the most sensitive method for demonstrating multifocal segmental vessel constriction, particularly in smaller and distal arteries (Fig. 44.3). Arterial imaging with computed tomography angiogram or magnetic resonance angiogram (MRA) can demonstrate medium- to large-sized arterial vasoconstriction and can be sufficient in cases with typical clinical and parenchymal imaging features without requiring digital subtraction angiography. Findings on angiography may be dynamic, with repeat scans demonstrating resolution of some abnormalities and new vasoconstriction of others. Initial angiography might

TABLE 44.4 Summary of Critical Elements for the Diagnosis of Reversible Cerebral Vasoconstriction Syndrome[a]

A.	Transfemoral angiography or indirect computed tomography angiography or magnetic resonance angiography documenting multifocal segmental cerebral artery vasoconstriction
B.	No evidence for aneurysmal subarachnoid hemorrhage
C.	Normal or near-normal cerebrospinal fluid analysis (protein level <80 mg/dL, leukocytes <10-15/mm^3, and normal glucose level)
D.	Severe, acute headaches with or without additional neurologic signs or symptoms
E.	Monophasic course without new symptoms more than 1 mo after clinical onset
F.	Reversibility of angiographic abnormalities within 12 wk after onset. If death occurs before the follow-up studies are completed, autopsy rules out such conditions as vasculitis, intracranial atherosclerosis, and aneurysmal subarachnoid hemorrhage, which can also manifest with headache and stroke.

[a]Adapted from the International Headache Society criteria for acute reversible cerebral angiopathy and the criteria proposed in 2007 by Calabrese. Headache Classification Subcommittee of the International Headache Society. The international classification of headache disorders. 2nd ed. *Cephalalgia*. 2004;24(suppl 1):1-160; Ducros A. Reversible cerebral vasoconstriction syndrome. *Lancet Neurol*. 2012;11(10):906-917.

be normal if performed very early in the course of the disease, whereas in latter stages, an infusion of intra-arterial verapamil could help determine if vasospasm is present. The onset of headache and cortical SAH may precede the development of vasospasm on vascular imaging. Elevated flow velocities can be demonstrated on transcranial Doppler (TCD) after the initial presentation and may predict risk of subsequent cerebral infarction.

Management

Treatment of RCVS is largely supportive and no specific agents have been examined in the randomized clinical trials. Several agents purported to relieve vasoconstriction have been used in

FIGURE 44.3 Multifocal beading of the cerebral vasculature, characteristic of reversible cerebral vasoconstriction syndrome. (From Neil WP, Dechant V, Urtecho J. Pearls & oy-sters: reversible cerebral vasoconstriction syndrome precipitated by ascent to high altitude. *Neurology*. 2011;76:e7-e9.)

RCVS and reported in case series including *nimodipine*, *verapamil*, and *magnesium sulfate*, although none have clearly reduced the risk of cerebral infarction. Steroids on the other hand do not reduce the risk of RCVS-associated infarction and may actually increase the risk of neurologic complications. Management focuses on discontinuation or avoidance of precipitating agents, blood pressure control, antiepileptic drugs for seizure control, and management of headaches with similar agents used for status migrainosus (except for vasoactive medications such as triptans or dihydroergotamine [D.H.E. 45]). Intra-arterial vasodilators and balloon angioplasty have been used in severe cases with unclear efficacy. Frequent neurologic monitoring is indicated for detecting vasoconstriction-associated cerebral infarction, and although the duration has not been well established, most cerebral infarcts will occur in the first 2 weeks and can be predicted by elevated velocities on TCD.

Outcome

The RCVS is generally considered a monophasic, self-limiting condition with a good long-term prognosis. Headaches usually resolve within 3 weeks, and neurologic complications are rare after 2 weeks. The angiographic and parenchymal findings typically resolve within 3 months. Less than 5% of patients develop fulminant disease with multiple strokes and global cerebral edema. The vast majority of patients make a complete functional recovery. The case fatality rate is less than 1%.

FIBROMUSCULAR DYSPLASIA

KEY POINTS

1. Fibromuscular dysplasia (FMD) is a noninflammatory, nonatherosclerotic arteriopathy of medium-sized vessels of unknown cause.
2. The cervicocranial carotid and vertebral arteries are the most common extrarenal site of FMD.
3. The characteristic radiographic appearance of FMD vessels is a "string of beads" reflective of alternating areas of constriction and dilation.
4. Intracranial aneurysms and cervical dissections are the most common manifestations of symptomatic cervicocranial FMD.

Introduction

Fibromuscular dysplasia (FMD) is a noninflammatory, nonatherosclerotic arteriopathy of medium-sized vessels of unknown cause. Although it can affect any vascular bed, the renal and cervicocranial carotid and vertebral arteries are most commonly involved.

Epidemiology

Cervicocranial FMD is a rare condition, with one autopsy study citing an overall prevalence of 0.02%. Rates for renovascular FMD are higher, with prevalence estimates of up to 4% shown in several studies. In confirmed FMD cases, renal involvement is generally seen in up to 65% of cases, with cerebrovascular involvement in 25% to 30% of cases. In a series of 1,100 FMD patients, women were twice as frequently affected as men with Caucasians disproportionately affected. The mean age of diagnosis in patients with cerebrovascular involvement is 50 years, older than for renovascular involvement. Approximately 10% of cases are felt to be familial. Diagnosis is frequently delayed, with up to 9 years elapsing from initial symptoms to diagnosis.

Pathobiology

There are three types of FMD, characterized by arterial layer of involvement: intimal fibroplasia, medial dysplasia, and adventitial fibroplasia. Intimal fibroplasia occurs in up to 10% of cases and results from accumulation of abnormal subendothelial mesenchymal cells, which project into the vessel lumen. This commonly results in areas of smooth, focal stenosis or long tubular stenosis. Adventitial fibroplasia, where the fibrous adventitia is replaced by collagen, is very rare.

Medial dysplasia is the most common, with three distinct subtypes recognized: medial fibroplasia, perimedial fibroplasia, and medial hyperplasia. Medial fibroplasia is the most common and accounts for up to 80% of cases.

The main histologic hallmark is disruption of smooth muscle cells, which are replaced by fibroblasts and collagen. There is frequently secondary disruption of the internal elastic lamina, which may lead to aneurysm formation. The alternating areas of medial disruption give rise to the commonly seen "string of beads" radiographic appearance, where areas of stenosis are admixed with dilated areas that are of larger caliber than the original vessel. Perimedial fibroplasia results from abnormal collagen deposition between the media and adventitia, leading to areas of stenosis with preserved internal elastic lamina. Radiographic appearance may be similar to medial fibroplasia, but the "beads" are of smaller diameter than the original vessel.

Although the etiology is unknown, FMD is associated with a variety of diseases including α_1-antitrypsin deficiency, Marfan syndrome, and Alport syndrome.

Clinical Features

Cervicocranial FMD is frequently an incidental finding and rates of neurologic symptoms vary. Neurologic complications mainly arise due to ischemic or hemorrhagic symptoms that result from stenosis, thrombosis, dissection, or aneurysmal formation. Carotid-cavernous fistulas have also been described. Severe stenosis can cause distal hypoperfusion. Thrombotic occlusion of a stenotic vessel or distal embolism can lead to hemispheric ischemic symptoms. An SAH can result from intracranial aneurysm rupture. Spontaneous cervical dissection can also occur, and headache, dizziness, carotidynia, pulsatile tinnitus, and Horner syndrome are all symptoms commonly seen with cervicocranial FMD. Dissection may be more common in Asian populations, whereas "carotid webs" are an increasingly recognized form of intimal FMD in African Americans. Carotid bulb diaphragms also known as *carotid webs* are an atypical form of FMD. The web represents an area of intimal hyperplasia, and it is more commonly seen in African Americans. Thrombus formation at the site of the web is a cause of stroke.

Diagnosis

The gold standard for diagnosis remains catheter-based angiography. Noninvasive imaging modalities such as Doppler ultrasound and MRA may also detect FMD, but because lesions most commonly occur in the middle to distal carotid artery near

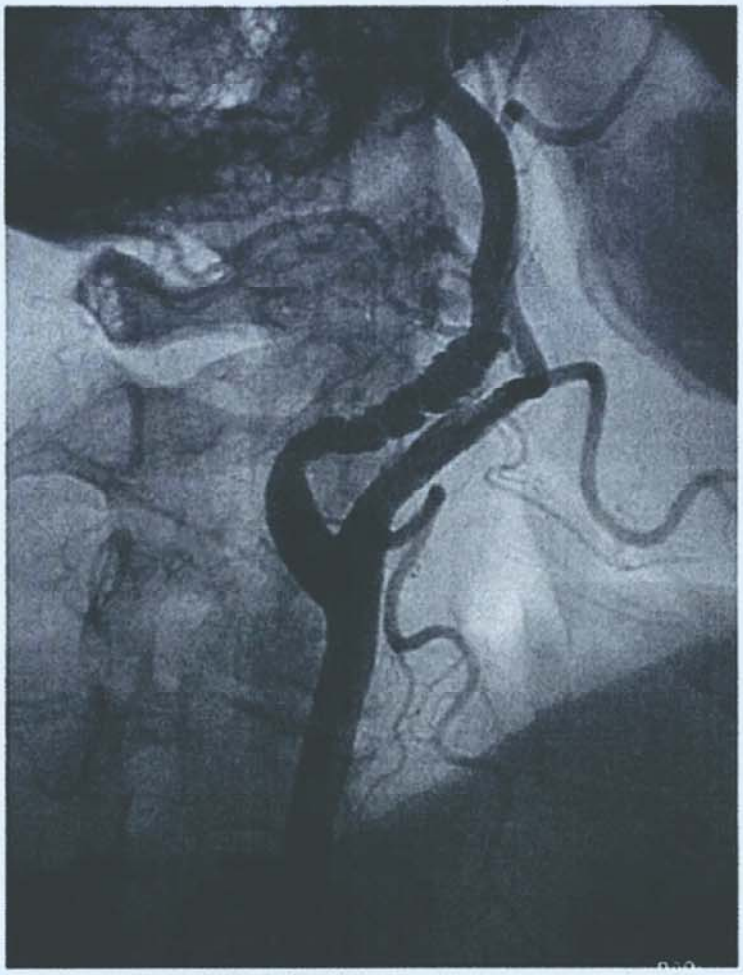

FIGURE 44.4 Angiogram of fibromuscular dysplasia in a 43-year-old female patient with multiple transient ischemic attacks. Note the multiple saccular dilatations of the internal carotid artery between the first and second cervical vertebrae.

C1-C2, adequate visualization with Doppler may be limited. Based on the underlying histology, a string of beads appearance due to medial fibroplasia is most commonly seen. Aneurysmal dilatation and areas of smooth tubular stenosis may also be present (Fig. 44.4). When cervicocranial disease is discovered, intracranial vessels should be imaged to evaluate for aneurysms and renal vessels for renovascular disease that may predispose to hypertension. The main differential diagnoses to consider are vasculitis and atherosclerotic disease.

Management

No trial data exist to guide treatment. Antiplatelet therapy is generally used when FMD is diagnosed to prevent thrombotic complications, although some practitioners institute therapy only when symptoms occur. In cases of dissection, a short course of antiplatelet therapy is often used. When intracranial aneurysms are present, treatment is based on size.

Outcome

Although outcome data is limited to case series, in general, the course of cervicocranial FMD is fairly benign. Many patients who are asymptomatic at the time of diagnosis remain so at follow-up several years later. The main cause of long-term morbidity is related to extracranial manifestations.

MOYAMOYA DISEASE

KEY POINTS

1. Moyamoya disease is a chronic, progressive steno-occlusive arteriopathy of unclear etiology.
2. The distal supraclinoid internal carotid artery and/or proximal anterior and middle cerebral arteries are most commonly affected.
3. Ischemia due to hemodynamic failure is the most common presentation of moyamoya disease in children and most adults.
4. Intracerebral hemorrhage occurs in some adult patients and is most common in Asia.
5. Both indirect and direct revascularization can be used to prevent ischemic strokes and hemorrhage.

Introduction

Moyamoya disease (MMD) is a chronic, progressive steno-occlusive arteriopathy of unclear etiology that affects the distal supraclinoid internal carotid artery (ICA) and/or proximal anterior and middle cerebral arteries. Chronic occlusive disease is believed to result in ischemia with subsequent neovascular proliferation of small, fragile, collateral vessels at the base of the brain. It is the hazy, fluffy angiographic appearance of this fine collateral network from which the name derives, as moyamoya means "puff of smoke" in Japanese. An essential distinction is between MMD and moyamoya syndrome, where the latter refers to vessel stenosis and subsequent collateralization owing to a clearly identifiable underlying provoking condition (see Table 44.5 for causes of secondary moyamoya syndrome). The following discussion

TABLE 44.5 Secondary Causes of Moyamoya Disease (Moyamoya Syndrome) and Mimics[a]

Genetic disorders	Sickle cell disease
	Trisomy 21
	Pseudoxanthoma elasticum
	Glycogen storage disease type 1a
	Fabry disease
	Neurofibromatosis 1
	Polycystic kidney disease
	Tissue plasminogen activator deficiency
Central nervous system infections	Epstein bar infection
	Tuberculosis
Inflammatory diseases	Eosinophilic angiitis
	Kawasaki
	Sjögren
	Lupus
Postradiation vasculopathy	
Fibromuscular dysplasia	

[a]Adapted from Scott MR, Smith ER. Moyamoya disease and moyamoya syndrome. *N Engl J Med*. 2009;360:1226-1237.

focuses on idiopathic/primary MMD, although management may be similar regardless of underlying etiology.

Epidemiology

Worldwide incidence and prevalence data is limited. The MMD was initially described in Japan, and incidence is generally felt to be highest in East Asia. Overall, worldwide incidence appears to be rising, although epidemiologic studies are limited by differences in data collection methods. Ascertainment bias due to increased disease awareness is also possible. Literature originating from East Asia reports incidence rates of 0.54 per 100,000 to 2.3 per 100,000 depending on the country, with higher rates reported in later reports and generally a higher female preponderance. There are far fewer North American and European epidemiologic studies, although the incidence tends to be lower than in East Asia with still a female predominance. A large case series from the Mayo clinic showed higher rates of moyamoya syndrome among women of European descent compared to others, starting in the fourth decade of life and with a significant prevalence of autoimmune diseases (notably Graves and Hashimoto disease and type 1 diabetes mellitus). A bimodal distribution of age of onset is generally demonstrated with a pediatric and adult presentation in Asia, and a predominant adult presentation (after excluding sickle cell disease) MMD is the most common cause of pediatric stroke in Asia. Clustering of MMD within families has been recognized, with rates as high as 15% in studies from Japan, consistent with an autosomal dominant trait with incomplete penetrance. Genetic heterogeneity is demonstrated by at least four documented linked loci; one site is located at 17q25.3, but no culprit gene has been identified.

Pathobiology

The etiology of MMD remains unknown. Histopathologic studies have shown the stenotic vessels to have a severely thickened intima, primarily driven by smooth muscle proliferation, with luminal thrombosis and duplication and tortuosity of the internal elastic lamina frequently demonstrated on autopsy specimens. Signs of vascular inflammation are distinctly absent. Moyamoya vessels, the medium-sized dilated vessels originating from the distal ICA or proximal circle of Willis vessels, form complex networks, which anastomose with distal anterior cerebral artery and/or middle cerebral artery (MCA), with small, fragile, dilated vessels that penetrate the base of the brain. Pathologic evaluation has shown these dilated vessels to either have a very thin wall, prone to microaneurysm formation, or to be thick-walled with significant luminal stenosis and thrombosis.

Based on identification of a familial predisposition of 15% in Asia, recent genetic linkage studies identified the first susceptibility gene for MMD: RNF213 on chromosome 17, with the p.R4810K mutation demonstrating a high prevalence among East Asians. Although the exact etiologic role in MMD remains unknown, RNF213 is known to mediate vascular development in zebrafish, and its role in MMD is under active investigation. Interestingly, the p.R4810K mutation has not been found in European origin populations.

Clinical Features

The main clinical manifestations relate to ischemia in the territory of the stenotic vessel, most often due to hemodynamic flow failure (rather than artery-to-artery embolus) or hemorrhage from the fragile neovascular lenticulostriate vessels. Both intracerebral and SAH can occur. Among adults, hemorrhage is more common in Asia and rarer in North American and European cohorts; hemorrhage is infrequent in pediatric cases. Intracerebral hemorrhage is most common in deep locations and supratentorially and adjacent to dilated penetrating vessels. This is presumably due to either rupture of microaneurysms or simply rupture of the fragile vessel wall in the setting of persistent hemodynamic stress. An SAH may occur due to saccular aneurysm rupture at the circle of Willis frequently affecting the posterior circulation (most commonly the basilar bifurcation) because it is placed under increased stress given its role in providing collateral blood flow. Convexity SAH has also been observed in the setting of dilated pial collaterals, which are subsequently more prone to rupture.

Ischemia is the most common presentation in children and in adults in most studies. Ischemic symptoms are frequently hemispheric, with either a transient or fixed deficit depending on duration of ischemia and are attributable to hemodynamic failure. Some patients may develop ischemic symptoms exclusively in deep hemispheric structures with relative sparing of cortical function. Cerebral infarction due to embolism or in situ thrombosis of a stenotic vessel is uncommon. In children, symptoms have been described as provoked by maneuvers that lead to hyperventilation and thus vasoconstriction, such as crying or inflating a balloon. Exercise-induced symptoms are another possible manifestation of chronic hemodynamic failure.

Other common manifestations of MMD include refractory migraine-like headache, thought to be due to dilation of meningeal and leptomeningeal vessels with subsequent activation of dural nociceptive receptors as well as seizures. Some patients, particularly pediatric, present primarily with cognitive or psychiatric symptoms from hypoperfusion, most commonly when bilateral frontal lobes are involved. Cognitive profiles of children with MMD reveal lower intelligence quotients independently of the incidence of stroke.

Diagnosis

Diagnosis rests on angiographic demonstration of stenosis or occlusion of the bilateral supraclinoid ICAs and/or proximal anterior cerebral artery/MCAs with resulting proliferation of a small, fine network of collateral vessels originating just distal to the site of stenosis. The determination of MMD versus syndrome is incumbent upon exclusion of underlying conditions, which could predispose to the arterial narrowing including large vessel vasculitis or atherosclerosis. Recently, diagnostic guidelines have acknowledged that MRI and MRA can be used in lieu of conventional angiography if bilateral distal ICA stenoses on MRA are accompanied by abnormal vascular networks within the basal ganglia, frequently described as two or more flow voids (Fig. 44.5). In children, if the collateralization is present unilaterally but bilateral ICAs are stenotic, the condition is considered "definite" MMD, but when adults present with unilateral features, they are termed *probable moyamoya disease*. In some case series, up to 50% of patients will start with unilateral involvement, although in fact, many unilateral cases at 5 years of follow-up will demonstrate bilateral involvement. Posterior circulation involvement may be present in up to 10% of patients.

Disease severity on angiography is graded using the Suzuki classification, a scheme with six phases denoting increasing disease progression (Table 44.6). The MMD can progress to any stage without further progression; only a minority of patients progress to stage 6.

In addition to angiographic severity, assessment of hemodynamic status may provide further insight into the clinical severity

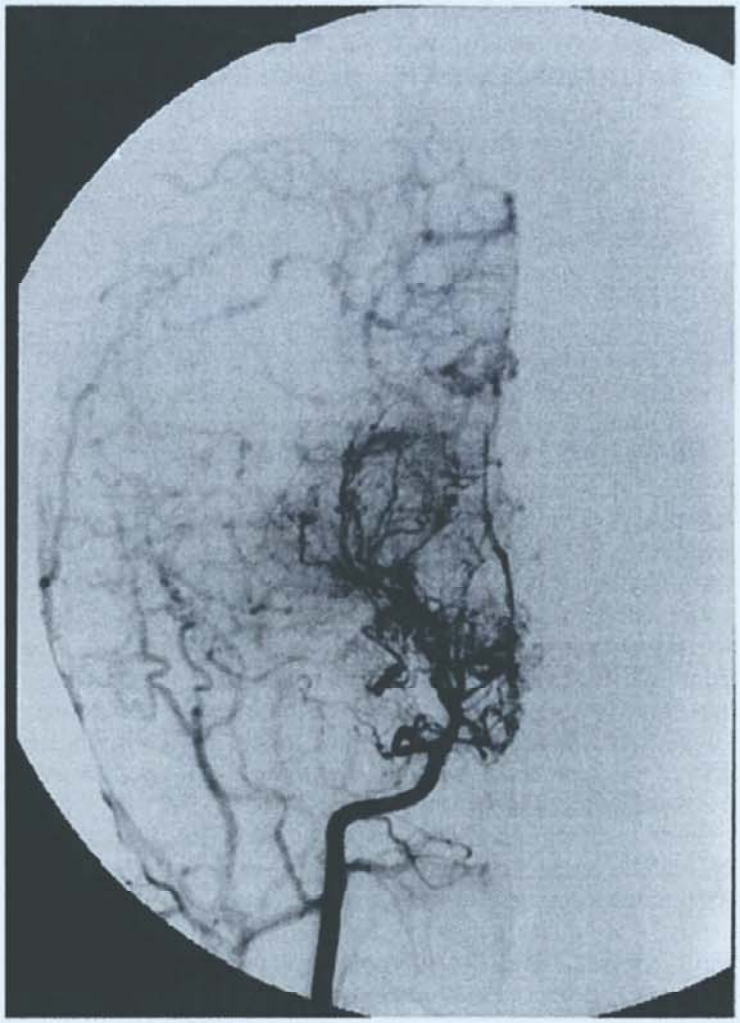

FIGURE 44.5 Internal carotid artery angiogram demonstrating moyamoya disease. (From Yamauchi T, Tada M, Houkin K, et al. Linkage of familial moyamoya disease [spontaneous occlusion of the circle of Willis] to chromosome 147q25. *Stroke*. 2000;31:930-935, with permission.)

of MMD in those patients without stroke. Proposed imaging methods include single-photon emission CT (see Chapter 23), CT perfusion (see Chapter 21), and magnetic resonance perfusion. The CT perfusion/magnetic resonance perfusion also allows assessment of vascular reserve by allowing evaluation of cerebral blood volume: As the severity of stenosis progresses, the distal arteries vasodilate, producing an increase in cerebral blood volume. Single-photon emission CT can also be used to assess vascular reserve by measuring changes in CBF before and after administration of acetazolamide, a carbonic anhydrase inhibitor that induces a transient metabolic acidosis in the brain, resulting in vasodilation. Failure to augment CBF in an area of reduced perfusion after acetazolamide implies that the distal vascular territory is already maximally dilated and hence at greater risk for progression to infarction. TCD ultrasonography (see Chapter 24) can also measure cerebrovascular reserve by comparing flow velocities before and after induced hypercapnia after inhalation of 5% carbon dioxide via face mask. Failure to augment CBF velocity by 5% implies a state of maximal vasodilation and greater risk. Many centers will use degree of impaired vascular reserve to both risk stratify patients prior to surgery who have not had stroke. Novel measures of CBF, including arterial spin labeling and blood oxygen level–dependent MRI, have been proposed for measuring CBF but are not widely available.

TABLE 44.6 Suzuki Scale for Severity of Moyamoya Disease[a]

	Suzuki Stage	Angiographic Description
1	Narrowing of distal carotid	No other angiographic abnormalities aside from carotid narrowing
2	Initiation of the moyamoya	First signs of fine collateral networks become apparent.
3	Intensification of the moyamoya	Collaterals become more pronounced; MCA and ACA may start to become obscured.
4	Minimization of the moyamoya	First signs of ECA collaterals are apparent; moyamoya collaterals start to thin.
5	Reduction of the moyamoya	Moyamoya collaterals further regress; carotid occlusion progresses proximally.
6	Disappearance of the moyamoya	Only intracranial blood flow is via collaterals from the ECA; no angiographic evidence of distal carotid or moyamoya collaterals at the base of the brain

Abbreviations: ACA, anterior cerebral artery; ECA, external carotid artery; MCA, middle cerebral artery.

[a]Adapted from Suzuki J, Takaku A. Cerebrovascular "moyamoya" disease. Disease showing abnormal net-like vessels in base of brain. *Arch Neurol*. 1969;20:288-299.

Management

There are no randomized clinical trials to guide management in MMD patients who are asymptomatic or present with ischemic symptoms. The Japan Adult Moyamoya trial, randomized patients who presented with intracerebral hemorrhage to surgery versus conservative management within 1 year of presentation. The recurrent hemorrhage rate was 11.9% in the surgical group compared with 31.6% in the conservative group (an annualized risk of 2.7% vs 7.6% per year; $P = .04$) LEVEL 2[2]; patients with a posterior predominant pattern of moyamoya-like vessels had the maximal benefits of bypass surgery.

Among patients with ischemic symptoms, treatment recommendations are based on case series and expert opinion. The goal of surgical approaches is to augment CBF, thereby hoping to reduce the risk of ischemic stroke and the strain on dilated deep moyamoya-type vessels, which may be prone to hemorrhage. Bypass surgery is generally performed in patients who have had ischemic symptoms, whereas the management of asymptomatic patients is generally based on risk stratification using imaging to quantify CBF or vascular reserve. There are multiple revascularization strategies, generally divided into direct and indirect approaches. No randomized controlled trials have directly compared these techniques, although the direct approach was used in the Japan Adult Moyamoya trial.

The direct approach is an anastomosis between the intracranial and extracranial circulation, which is most commonly achieved by connecting the superficial temporal artery to a branch of the MCA on the cortical surface. With this procedure, revascularization is immediate. Downsides include an increased risk of perioperative stroke or hemorrhage and the frequent occurrence (up to 25% in some studies) of the cerebral hyperperfusion syndrome, owing to the immediate revascularization in the setting of altered hemodynamics. The main symptoms of this syndrome include hemorrhage, seizures, and focal neurologic deficits from vasogenic cerebral edema.

There are several indirect approaches possible, although only encephaloduroarteriosynangiosis is widely used. In the encephaloduroarteriosynangiosis procedure, the superficial

temporal artery (most commonly), is placed on the cortical surface through a dural defect, sometimes with removal of intervening arachnoid (a modification termed *pial synangiosis*). Both of these techniques rely on the induced angiogenesis that naturally occurs between the underlying ischemic cortex and the apposed tissue or vessel. A third procedure is burr hole placement (with stripping of the underlying dura) in the vicinity of ischemic cortex, whereby scalp vessels grow through the burr holes to form collaterals with vessels on the cortical surface. The main complication from the indirect bypass is that augmentation of CBF may take more than 6 weeks to occur. Indirect bypass is more commonly performed in children due in part to direct bypass being more technically challenging. Many centers use a direct and indirect combined approach in adults. The optimal approach in adults is often dictated by donor vessel morphology and characteristics, surgical expertise, and patient preference.

Medical management of MMD has not been formally evaluated in clinical trials, although aspirin 81 mg is commonly prescribed in patients with ischemic symptoms. Anticoagulation is generally avoided given the attendant increased risk of hemorrhage on the setting of fragile vessels.

Outcome

Adults are generally felt to display less progression of proximal occlusion than children with lower recurrent stroke rates. Much of the data on progression in adults is from Japan, where a 5-year rate of progression of proximal stenosis as high as 20% has been shown in the affected vessel. Other studies have shown recurrent ipsilateral stroke rates over 5 years to be as high 65% in the absence of surgery. Female sex is generally the main identified risk factor for disease progression. Even in asymptomatic patients, disease activity is apparent, as seen from a Japanese study where 20% of asymptomatic patients had imaging evidence of infarction, whereas 40% had evidence of impaired cerebral hemodynamics. The annual rate of stroke in this asymptomatic population was 3.2%.

BINSWANGER DISEASE

KEY POINTS

1. Binswanger Disease, also known as ischemic leukoencephalopathy, is a form of incomplete white matter infarction due to small vessel disease.
2. Clinical features include dementia with frontal lobe dysfunction, parkinsonism, and gait disorder.

Introduction

Binswanger disease (BD) refers to a progressive subcortical dementia with white matter degeneration of small-vessel etiology also known as *subcortical arteriosclerotic leukoencephalopathy*. It is not a well-defined disease entity, and in fact, the clinical picture in BD is similar to the subcortical dementia seen in other small-vessel angiopathies, for example, cerebral autosomal dominant arteriopathy with subcortical infarcts and leukoencephalopathy (CADASIL), which is discussed later in this chapter. In general, the term *Binswanger disease* is appropriately used when subcortical dementia is present in the setting of vascular risk factors with evidence of extensive deep and periventricular ischemic leukoencephalopathy on neuroimaging without an alternative explanatory cause.

Epidemiology

The BD can be considered a subset of vascular dementia (VaD) (see Chapter 54). Given the extensive overlap between cerebrovascular disease and Alzheimer disease and other dementing pathologies, clinical diagnosis of "pure" VaD is fraught with challenges and prevalence estimates are highly variable. Estimating the true prevalence of BD within the context of VaD subtypes is therefore challenging. Although exact numbers are not known, BD in its classical form likely accounts for a small portion of these "pure" VaD cases.

Pathobiology

The general pathologic picture is one of roughly symmetric degeneration of central white matter with myelin pallor and multiple lacunes. The term *incomplete white matter infarction* has been used to describe the pathology of BD. The degree of demyelination is heterogeneous with some areas demonstrating extensive demyelination and gliosis admixed with relatively normal-appearing white matter. Axonal loss is variable, there is no inflammatory cell infiltrate, and cortical atrophy is minimal, if not wholly absent. Although the arcuate fibers and anterior commissure are usually spared, central white matter from the periventricular region to the centrum semiovale, extending from frontal to occipital lobes, is involved to varying degrees. In addition to frequent lacunes, other hallmarks include dilated perivascular spaces, so-called état criblé, and moderately enlarged lateral and third ventricles. The vascular hallmarks are small, penetrating vessels with hyalinized, thickened walls with focal fibrinoid necrosis, notably without occlusion. Generally, there is some degree of atherosclerosis in large, proximal intracerebral arteries. Interestingly, perfusion studies have shown the areas of white matter hyperintensities to have lower CBF, suggesting chronic hypoperfusion and ischemic damage due to the small-vessel changes may be the pathophysiologic mechanism of the white matter degeneration.

Clinical Features

The clinical manifestations of BD owe mainly to the disruption of white matter tracts interconnecting primary processing areas of the brain, theorized in particular to those specifically subserving the frontal cortices. Main signs include those that tend to localize to the frontal lobe, including slowed information processing, memory disturbances, and visuospatial deficits and executive dysfunction; the latter includes impaired initiation, planning, and goal-directed activity. Behavioral disturbances are frequent. Varying degrees of pyramidal and extrapyramidal dysfunction may be present in addition to pseudobulbar signs, parkinsonism, and gait abnormalities. Focal neurologic deficits may be present at the onset or during the disease course, owing to acute lacunar infarction.

Diagnosis

No consensus guidelines exist for the diagnosis for BD. In general, the diagnosis is made when subcortical dementia is found in the presence of vascular risk factors, notably hypertension, with neuroimaging evidence of white matter disease. Other causes of leukoencephalopathy such as acute disseminated encephalomyelitis (ADEM) or progressive multifocal leukoencephalopathy must be absent. In general, patients with a known small-vessel

arteriopathy and associated dementia, such as CADASIL, are not considered under the umbrella term of BD.

The white matter degeneration is best seen on MRI but is also present on CT where confluent, symmetric hypodense areas throughout the central white matter are apparent. On MRI, areas of white matter degeneration appear bright on T2 (white matter hyperintensities) and are best seen on FLAIR sequences where CSF is suppressed. The lesions are generally large and rather than being isolated to the immediate periventricular region, extend throughout the corona radiata and centrum semiovale. Scattered lacunes are frequently seen, both throughout the white and deep gray matter.

Management

Given most patients with BD have evidence of lacunar infarcts, treatment is directed at secondary stroke prevention, that is, modification of vascular risk factors and introduction of antiplatelets and statins. Control of hypertension is essential, in addition to aggressive diabetes management and smoking cessation. There is no evidence that hypertension control leads to reversal of white matter changes. Supportive care for patients with severe cognitive impairment is often necessary.

Outcome

In one series of clinicopathologically confirmed cases, clinical course took one of three patterns: gradual progression punctuated by acute focal deficits, gradual worsening not punctuated by acute focal deficits, and multiple acute focal deficits without progression.

SUSAC SYNDROME

KEY POINTS

1. Susac syndrome is an autoimmune microangiopathic endotheliopathy.
2. Encephalopathy, branch retinal artery occlusion, and hearing loss represent the clinical triad of Susac syndrome.
3. Characteristic radiographic findings include small white matter lesions in the cerebral hemispheres with prominent corpus callosal involvement. Callosal lesions are centrally located and frequently have a "snowball appearance."
4. Treatment is directed at immunosuppression.

Introduction

Susac syndrome comprises a triad of encephalopathy, branch retinal artery occlusion (BRAO), and hearing loss. It is thought to be an autoimmune microangiopathic endotheliopathy that affects brain, retina, and cochlea. The disease, which was first described in 1977 by John O. Susac after he encountered two young women with personality changes, including paranoia and hostile behavior, hearing loss, and visual disturbances, is also termed *retinocochleocerebral vasculopathy* and can be frequently misdiagnosed initially as multiple sclerosis (MS) or ADEM.

Epidemiology

Susac syndrome typically begins in the third or fourth decade but may occur during childhood or after age 70 years. There is 3:1 female predominance but no racial predilection. The true incidence and prevalence of the disease are unknown. Fewer than 1,000 cases have been reported but diagnostic confusion abounds and the condition is likely underdiagnosed.

Pathobiology

Susac syndrome is thought to be an immune-mediated endotheliopathy of unknown etiology. Antiendothelial cell antibodies either play a pathogenic role or arise from endothelial damage caused by other immune mechanisms. Histopathologic examination of brain biopsy samples usually reveals microinfarcts in the cerebral cortex and white matter. Areas of demyelination along with axonal and neuronal damage are also seen. Pauci-inflammatory endothelial cell injury in small arterioles, capillaries, and venules is observed.

Muscle biopsy in patients with Susac syndrome shows abnormal endothelial cells, some swollen to the point of occluding small arterioles. Muscle inflammation is subclinical, unlike dermatomyositis, although the pathology is virtually identical, including endothelial cell degeneration and necrosis as well as thickening, reduplication, and lamellation of the basement membrane.

Clinical Features

Encephalopathy may be manifested by psychiatric symptoms, confusion, memory loss, or simply dulling of cognitive function. The BRAO, which may occur before, during, or after the encephalopathy, may cause a scotoma or photopsia. Migrainous headaches often precede other symptoms, and the association with visual symptoms may be misleading. Hearing loss may be difficult to assess, depending on the degree of encephalopathy. It frequently affects the lower tones first, which implies microinfarction of the cochlear apex, a particularly territory. The speed and severity of hearing loss varies from profound and precipitous, with loss of hearing in one ear and the other days to weeks thereafter, to slow and insidious or fluctuating as in Ménière disease. Hearing loss may be accompanied by nausea, vertigo, tinnitus, or gait ataxia.

Diagnosis

Diagnosis requires a high index of suspicion because it is uncommon for the entire clinical triad to be present at the time of the first encounter with a physician. Furthermore, encephalopathic patients may not complain of hearing loss or visual problems. Brain MRI, dilated funduscopic examination, and retinal fluorescein angiography are the most useful diagnostic tests.

Brain MRI reveals multiple small (typically 1-7 mm) white matter lesions in the cerebral hemispheres. The corpus callosum is involved in 88% to 100% of patients (Fig. 44.6). The callosal lesions that occur with acute encephalopathy are centrally located and have a "snowball" appearance. Basal ganglia, thalamic, brainstem, cerebellar, and gadolinium-enhancing lesions are common. Leptomeningeal enhancement is occasionally observed. Arteriography is typically normal because the affected arterioles are too small to be seen in angiography.

FIGURE 44.6 Susac syndrome findings on magnetic resonance imaging. **A:** Axial fluid-attenuated inversion recovery image shows nonspecific lesions in the cerebral hemispheres. Sagittal fluid-attenuated inversion recovery **(B)** and T1-weighted **(C)** images show the characteristic central "snowball lesions" and "punched out holes," respectively.

Although the MRI findings may lead to an incorrect diagnosis of MS or ADEM, the morphology and central location of the acute callosal lesions and their evolution into hypointense holes on T1-weighted imaging are characteristic findings in Susac syndrome and atypical of MS lesions, which are smaller and involve the callosal-septal interface.

Dilated funduscopic examination and retinal fluorescein angiography may reveal retinal infarcts and BRAO (**Fig. 44.7**). Audiometry may detect sensorineural hearing loss. Examination of the CSF during the acute encephalopathy typically reveals a mild lymphocytic pleocytosis. The protein content is often more than 100 mg/dL, an uncommon finding in MS. However, the occasional presence of oligoclonal bands or an elevated immunoglobulin G index may lead to further diagnostic confusion.

Management

There have been no controlled therapeutic trials in Susac syndrome, but many different approaches have been explored. Treatment recommendations are largely based on case series. Although the disease often enters spontaneous remission, treatment is recommended to try to prevent irreversible disability.

Prednisone monotherapy, pulses of methylprednisolone, or a combination of corticosteroids and intravenous immunoglobulin appears to be beneficial in some patients. More severe cases may respond to *cyclophosphamide* or *mycophenolate* mofetil. Plasma exchange has been used in refractory cases. The use of *rituximab* in dermatomyositis, a humorally mediated autoimmune vasculopathy that shares immunopathogenic features with Susac syndrome, has increased the use of B-cell depletion as a treatment strategy for Susac syndrome. Low-dose aspirin therapy is often added in attempt to forestall microinfarcts. Although aggressive treatment is often indicated, the disease is often self-limited and may remit spontaneously after several years, so tapering of immunotherapy should be attempted judiciously.

Outcome

Three major clinical courses have been described: monocyclic, polycyclic, and chronic continuous. Most patients with symptomatic encephalopathy follow a monocyclic course in which the disease remits spontaneously after 1 to 2 years and does not return. The polycyclic course includes variable periods of remission separating disease activity and may persist for many years.

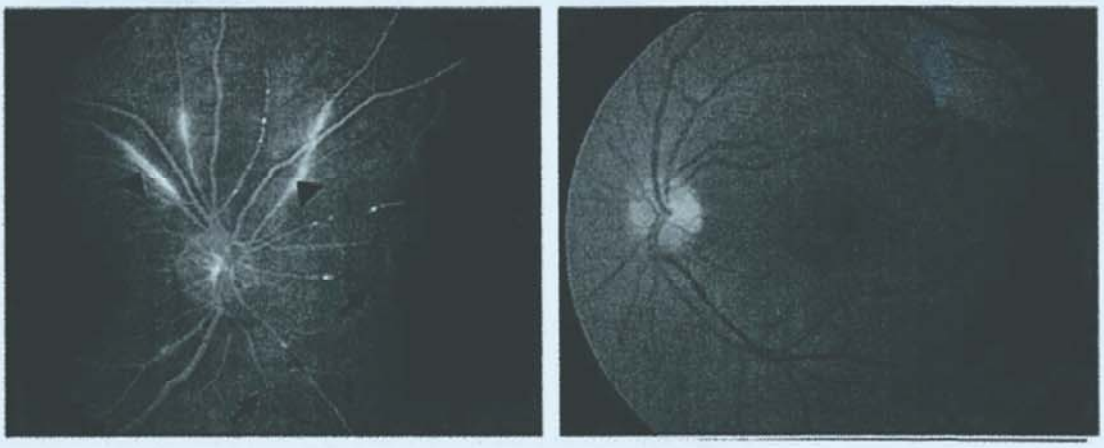

FIGURE 44.7 **Left:** Retinal abnormalities in Susac syndrome demonstrating hyperfluorescence of the arteriolar walls *(arrowheads)*. **Right:** Retinography of the left eye shows retinal infarct *(arrow)*. (Images courtesy of Zachary Grinspan, MD.)

The chronic continuous syndrome shows variations in severity of symptoms but no clear remissions, even though a slow remission may eventually occur. Case reviews suggest that those with prominent encephalopathy are more likely to have a monocyclic course, whereas those with BRAO and hearing loss may be more likely to develop prolonged polycyclic disease.

The disease usually lasts 2 to 4 years with the chronic continuous course being the least common form of the illness. Although 50% of patients are able to lead a basically normal life, most are left with varying degrees of bilateral hearing loss, and 35% to 50% have residual cognitive dysfunction, which prevents some from returning to work. Asymptomatic visual field defects are much more common than symptomatic visual loss. Treatment with immunosuppressive chemotherapy may result in infertility.

SNEDDON SYNDROME

KEY POINTS

1. Sneddon syndrome is the combination of livedo reticularis and ischemic stroke.
2. Sneddon syndrome can occur in the presence of antiphospholipid antibodies, but many cases are seronegative.

Introduction

Sneddon syndrome refers to the dyad of livedo reticularis (LR), a lacy erythematous or purplish rash on the anterior legs, and ischemic stroke (Fig. 44.8). The exact underlying pathophysiology remains unknown and whether this entity is distinct from, or lies on a spectrum with, the antiphospholipid antibody syndrome remains to be clarified.

Epidemiology

Two forms of Sneddon syndrome are generally recognized: those associated with the presence of antiphospholipid antibodies and those that are not (seronegative cases). This is a rare disease, with the overall annual incidence estimated at 4 per million and with women predominantly affected. In general, first clinical stroke is evident by the mid-40s.

Pathobiology

Two forms of LR are recognized: "physiologic" LR or cutis marmorata, which occurs in the setting of cold temperatures and disappears when the affected limb is warmed, and "secondary" LR due to an underlying condition. In Sneddon syndrome, subcutaneous arteriolar occlusion leads to decreased oxygenation of venous blood that causes LR, generally present over a large area. The trunk and limbs are usually involved, with the violaceous rings appearing irregular and broken.

Pathologic series of skin biopsy specimens of seronegative Sneddon syndrome patients have shown that it is the small- to medium-sized arteries at the dermis–subcutaneous border that are affected. These vessels undergo four stages of involvement. Initially, there is endothelial disruption and lymphocyte infiltration, which is followed by partial vascular occlusion by stimulated monocytes that trap erythrocytes and fibrin, associated with a perivascular lymphohistiocytic infiltrate. Later stages are characterized by reorganization of this plug associated with subendothelial proliferation of smooth muscle cells and resolution of the perivascular infiltrate. The final stage is characterized by proliferation of fibroblasts and collagen, where completely occluded, shrunken vessels are apparent without inflammatory infiltrate. Following the discovery of an initial inflammatory vasculopathy, the presence of antiendothelial antibodies has been found in up to 35% of patients; whether they play a pathophysiologic role remains uncertain.

Unlike skin vessels, pathologic studies of cerebral vessels are limited. Stroke most commonly affects the cortex and subcortical white matter, with some series showing frequent small, multifocal ischemic lesions within the deep white matter, a nonspecific finding that is seen in many disorders affecting small arteries.

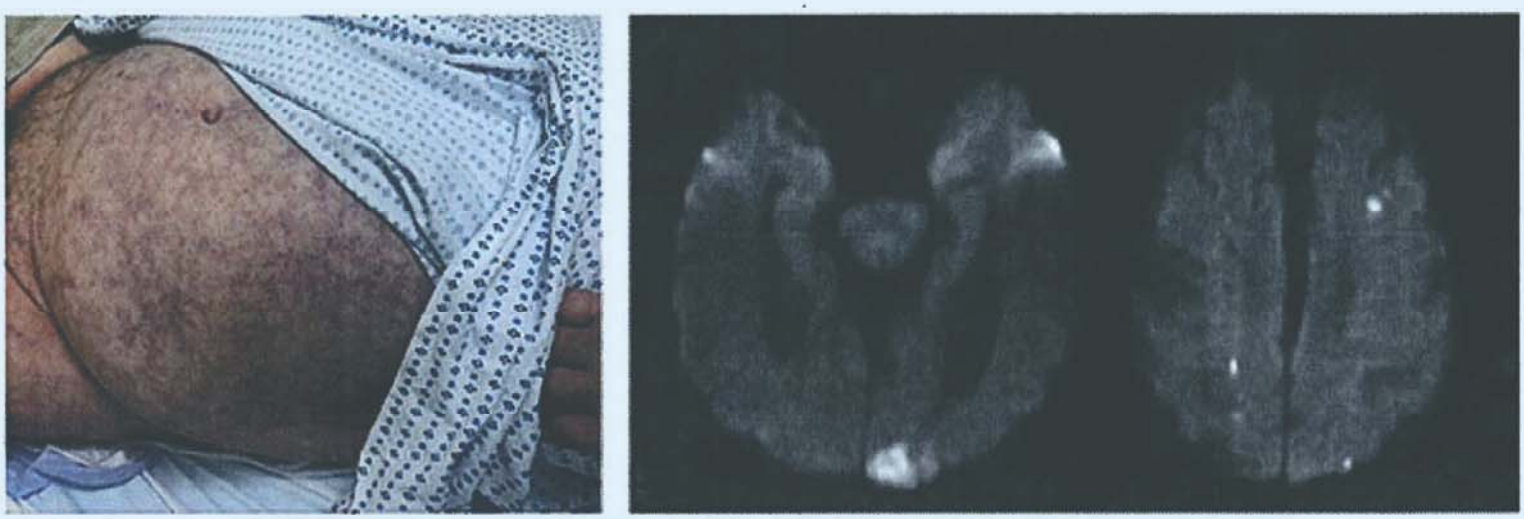

FIGURE 44.8 A 62-year-old man with Sneddon Syndrome. He presented with one week of progressive confusion culminating in a fall. On exam he was delirious but non-focal and could only state his name. Brain diffusion weighted imaging **(left)** revealed an acute left posterior cerebral artery infarct and multiple other small infarcts throughout both hemispheres. The day after the MRI extensive livedo reticularis **(right)** developed on his abdomen and lower extremities. (Images courtesy Dr. Stephan A. Mayer.)

Clinical Features

In general, the first manifestations are frequently nonspecific neurologic symptoms such as dizziness and headache. These are followed by LR, which in most cases is followed by stroke, although the two can present simultaneously. On average, symptoms evolve over 9 years. Patients seronegative for antiphospholipid antibodies generally have a wider area of LR and are less likely to have seizures compared to patients with antiphospholipid antibodies. Seropositive patients are more likely to have thrombocytopenia, in keeping with coexistent SLE and other autoimmune disease. Studies showing differences between seronegative and positive patients are however inconsistent.

Multiple MRI patterns in patients have been described including cortical-subcortical infarcts, FLAIR lesions in the deep periventricular white matter, and scattered punctate subcortical T2 hyperintensities. Although the majority of lesions are supratentorial, infratentorial and basal ganglia lesions are less frequent. None of these imaging findings are specific.

Some studies have also shown an increased incidence of hypertension and cardiac valvular abnormalities (thickening and calcification) in keeping with comorbid autoimmune disease.

Diagnosis

Diagnosis is made by the presence of skin biopsy–confirmed LR with the aforementioned pathologic features in the presence of focal neurologic deficit and imaging-confirmed cerebral infarction. Other conditions associated with LR should be ruled out, namely systemic lupus erythematosus (SLE) and polyarteritis nodosa. The presence of antiphospholipid antibodies is not essential for the diagnosis, as up to 60% of cases are considered seronegative.

Management

Seronegative patients are generally treated with antiplatelet agents such as aspirin 325 mg daily, whereas seropositive patients are anticoagulated with warfarin (target international normalized ratio between 2.0 and 3.0), along with current antiphospholipid syndrome (APS) guidelines. Immunosuppressive regimens may be used for coexistent autoimmune disease.

Outcome

Given its low incidence, large longitudinal studies are lacking, which make accurate predictions about outcome challenging.

MARANTIC ENDOCARDITIS

KEY POINTS

1. Nonbacterial thrombotic endocarditis or marantic endocarditis refers to sterile valvular vegetations.
2. Nonbacterial thrombotic endocarditis is most commonly seen in malignancy and systemic lupus erythematosus.
3. Ischemic stroke from vegetation embolization is the most common manifestation.
4. Treatment is generally with anticoagulation; rarely valve surgery is needed.

Introduction

Nonbacterial thrombotic endocarditis (NBTE) refers to sterile valvular vegetations made up of fibrin and platelets, which are found in association with many underlying conditions. Perhaps the most prominent association is with malignancy, where NBTE is termed *marantic* (or "wasted") *endocarditis*, and SLE, where the verrucous vegetations are termed *Libman-Sacks endocarditis* (LSE). The NBTE can also be found in primary APS and is increasingly recognized in a host of other systemic illnesses including sepsis, advanced AIDS, cirrhosis, and extensive burns. It has been hypothesized that hypercoagulability is a common link.

Epidemiology

The most common underlying tumors include mucin-producing adenocarcinomas of the colon, pancreas, ovary, and lung in addition to hematologic malignancies. Autopsy studies have put the incidence of NBTE in the general population at 1% with studies of SLE patients showing rates upward of 30% and as high as 19% among cancer patients, although other series indicate lower rates among cancer patients. Specific features of SLE that predispose to LSE have not been consistent with some studies showing an increased risk in the presence of antiphospholipid antibodies, whereas others have not confirmed this association.

Pathobiology

Despite the underlying cause, the pathology is generally the same: superficial bland vegetations affixed to a valve with preserved underlying architecture. The vegetations generally consist of a fibrin core with aggregated platelets, without any demonstrable evidence of infectious organisms or inflammatory reaction. Vegetations are generally found on left-sided valves, with the mitral valve most commonly affected. Vegetations have a predilection for the atrial side of the mitral valve and ventricular side of the aortic valve and are generally at the contact margins of the valve leaflets, perhaps due to the highest turbulence of blood at these locations with resulting microtrauma to the underlying valve. An underlying immune-mediated destructive process has also been hypothesized in addition to an underlying hypercoagulable state. The NBTE vegetations span a range of sizes, from submillimeter to over 1 cm, with the lesions generally consisting of single or multiple mobile verrucae. It is thought that the lack of inflammatory reaction and attendant cellular organization makes these lesions particularly friable.

Although the underlying valve architecture is generally preserved in NBTE, one large echocardiographic study did find that a majority of patients had some degree of valvular dysfunction, most commonly regurgitation. Mitral and aortic valves were also diffusely thickened, demonstrating frequent calcification of the mitral valve annulus and chordae.

Clinical Features

Although NBTE rarely causes hemodynamically significant valvular dysfunction, the consequence of importance is systemic embolism, of which stroke is the most clinically apparent. In fact, it has been estimated that up to one-third of patients with NBTE have evidence of thromboembolic ischemic stroke, with rates as high as 55% noted in autopsy studies of cancer patients and between 10% and 20% in patients with SLE. Studies on the brain MRI findings of NBTE patients show that the majority of cases have evidence of

numerous small- and medium-sized infarcts in multiple vascular territories. This was in contrast to infective endocarditis patients, where infarcts along with microhemorrhages or hemorrhages (parenchymal and subarachnoid) are seen.

Diagnosis

Because the lesions are generally smaller and not associated with underlying valvular dysfunction, cardiac murmurs are infrequent. Identifying NBTE is often more difficult than infective endocarditis and requires a high index of clinical suspicion, such as multiple infarcts in the setting of systemic malignancy or autoimmune disease in the absence of other explanations. Transesophageal echocardiography (TEE) is often needed, as the small size makes transthoracic echocardiography evaluation insensitive. Indeed, one series demonstrated over twice the diagnostic yield of TEE compared with transthoracic echocardiography in cancer patients with NBTE; TEE may nonetheless show no clear vegetations and NBTE may only be present on autopsy. TCD with microembolic signal detection over 30 minutes many demonstrate evidence of high-intensity transients consistent with microembolic, but the yield remains unknown. Diagnosis rests on excluding an underlying infection; thus, serial blood cultures in addition to a thorough systemic infectious evaluation is necessary. The distinction from culture-negative infective endocarditis may be particularly challenging because patients with malignancy and autoimmune disease often present with fever. In general, it is reasonable to consider NBTE in embolic stroke of unknown source patients with embolic-appearing infarcts when there is a concern for an underlying malignancy or rheumatologic disease.

Management

Although no trial data exists on treatment for NBTE, anticoagulation is generally recommended in those with marantic endocarditis and evidence of thromboembolic stroke. Heparinoids are preferred to warfarin given the superiority of the former in preventing venous thromboembolism in cancer patients. When NBTE is identified in patients with primary or secondary APS with evidence of stroke, anticoagulation with warfarin is generally recommended per APS treatment guidelines. The case of SLE with LSE is less clear, and in general, antiplatelet agents are recommended if there is no evidence of thromboembolism, with anticoagulation considered if strokes occur. No data exists on improvement in LSE lesions with immunologic therapy.

An additional concern is the potential for NBTE lesions to get secondarily infected; thus, antibiotic prophylaxis may be warranted in certain situations, for example, prior to high-risk dental procedures or surgery. Although rare, in severe cases with multiple strokes refractory to anticoagulation, surgical mitral valve replacement has been used.

Outcome

The outcome of NBTE generally depends on the underlying disease process. Echocardiography-based studies of patients with LSE have shown that during follow-up between 1 and 5 years, vegetations persisted, regressed, or appeared, making the course highly unpredictable. In marantic endocarditis, prognosis often depends on the underlying malignancy, with anticoagulation somewhat effective in preventing recurrent stroke, although refractory cases have been reported.

CEREBRAL AUTOSOMAL DOMINANT ARTERIOPATHY WITH SUBCORTICAL INFARCTS AND LEUKOENCEPHALOPATHY

KEY POINTS

1. Cerebral autosomal dominant arteriopathy with subcortical infarcts and leukoencephalopathy (CADASIL) is autosomal dominant and presents with multiple strokes despite adequate medical therapy in the subcortical region.
2. Progressive cognitive impairment is seen in CADASIL even without clinically overt infarcts.
3. Characteristic imaging includes fluid-attenuated inversion recovery hyperintensities in the external capsule and anterior temporal lobe, cortical atrophy, and multiple cerebral microbleeds.
4. Commercially available CADASIL tests cover the most frequent mutations but do not capture several de novo or founder mutations and whole-exome or whole-genome testing may be needed.

Introduction

The CADASIL is one of the few single-gene disorders that causes stroke. The median age of the first stroke is 50 years, although the strokes may occur as early as 19 years of age. Common stroke risk factors, such as hypertension and diabetes mellitus, are conspicuously absent. The MRI findings include a widespread leukoencephalopathy, and the findings are virtually pathognomonic when involvement of the anterior temporal lobes and external capsule is seen. Subcortical cerebral microbleeds are also commonly present. A phenotypic variant of CADASIL has been identified by familial clustering of hemiplegic migraine and labeled CADASILM ("M" for migraine.)

Epidemiology

Minimum prevalence has been estimated at 1.98/100,000 adults from a population-based study in Scotland. Due to underdiagnosis, this is likely an underestimate of the true prevalence.

Pathobiology

The CADASIL is a protein elimination failure angiopathy, similar to amyloid angiopathy (see Chapter 39). The genetic defect is a mutation on chromosome 19p, in the *NOTCH3* gene, a highly conserved gene regulating development. The protein is a transmembrane receptor involved in intercellular communication, and it is found on vascular smooth muscle cells. The mechanism by which the smooth muscle cell pathology leads to vasculopathy and stroke remains uncertain, but it does not appear to be a thrombotic disorder.

Clinical Features

Patients present with multiple subcortical infarcts, progressive dementia, and gait disorder. Migraine headaches especially with aura are common. Psychiatric manifestations such as depression and psychosis are frequently seen.

Diagnosis

Diagnosis is made by genetic testing, which can detect 70% of the clustering mutations causing the disease, or skin biopsy, in which the presence of granular osmiophilic material between smooth muscle cells and the basement membrane or immunostaining for the Notch3 protein is seen.

Management

Apart from antiplatelet therapy with aspirin, clopidogrel, or a similar agent, there is no known treatment. Control of blood pressure when comorbid hypertension is present and smoking cessation are essential to prevent additional subcortical injury. Genetic counseling about disease risk for offspring is an essential component of care.

Outcome

The mean survival time is 20 years from onset of symptoms.

LEVEL 1 EVIDENCE

1. Altman D, Carroli G, Duley L, et al; for Magpie Trial Collaborative Group. Do women with pre-eclampsia, and their babies, benefit from magnesium sulphate? The Magpie Trial: a randomised placebo-controlled trial. *Lancet*. 2002;359:1877-1890.
2. Miyamoto S, Yoshimoto T, Hashimoto N, et al. Effects of extracranial-intracranial bypass for patients with hemorrhagic moyamoya disease: results of the Japan Adult Moyamoya Trial. *Stroke*. 2014;45(5):1415-1421.

SUGGESTED READINGS

Posterior Reversible Encephalopathy Syndrome

Bartynski WS, Boardman JF, Zeigler ZR, Shadduck RK, Lister J. Posterior reversible encephalopathy syndrome in infection, sepsis, and shock. *AJNR Am J Neuroradiol*. 2006;27(10):2179-2190.

Casey SO, Sampaio RC, Michel E, Truwit CL. Posterior reversible encephalopathy syndrome: utility of fluid-attenuated inversion recovery MR imaging in the detection of cortical and subcortical lesions. *AJNR Am J Neuroradiol*. 2000;21(7):1199-1206.

Fugate JE, Claassen DO, Cloft HJ, Kallmes DF, Kozak OS, Rabinstein AA. Posterior reversible encephalopathy syndrome: associated clinical and radiologic findings. *Mayo Clin Proc*. 2010;85(5):427-432.

Fugate JE, Rabinstein AA. Posterior reversible encephalopathy syndrome: clinical and radiological manifestations, pathophysiology, and outstanding questions. *Lancet Neurol*. 2015;14(9):914-925.

Hinchey J, Chaves C, Appignani B, et al. A reversible posterior leukoencephalopathy syndrome. *N Engl J Med*. 1996;334(8):494-500.

Liman TG, Bohner G, Heuschmann PU, Endres M, Siebert E. The clinical and radiological spectrum of posterior reversible encephalopathy syndrome: the retrospective Berlin PRES study. *J Neurol*. 2012;259(1):155-164.

Peixoto AJ. Acute severe hypertension. *N Engl J Med*. 2019;381(19):1843-1852.

Staykov D, Schwab S. Posterior reversible encephalopathy syndrome. *J Intensive Care Med*. 2012;27(1):11-24.

Reversible Cerebral Vasoconstriction Syndrome

Calabrese LH, Dodick DW, Schwedt TJ, Singhal AB. Narrative review: reversible cerebral vasoconstriction syndromes. *Ann Intern Med*. 2007;146:34-44.

Chen SP, Fuh JL, Chang FC, Lirng JF, Shia BC, Wang SJ. Transcranial color Doppler study for reversible cerebral vasoconstriction syndromes. *Ann Neurol*. 2008;63(6):751-757.

Chen SP, Fuh JL, Wang SJ, et al. Magnetic resonance angiography in reversible cerebral vasoconstriction syndromes. *Ann Neurol*. 2010;67(5):648-656.

Ducros A, Boukobza M, Porcher R, et al. The clinical and radiological spectrum of reversible cerebral vasoconstriction syndrome. A prospective series of 67 patients. *Brain*. 2007;130(pt 12):3091-3101.

Rocha EA, Topcuoglu MA, Silva GS, Singhal AB. RCVS2 score and diagnostic approach for reversible cerebral vasoconstriction syndrome. *Neurology*. 2019;92(7):e639-e647.

Fibromuscular Dysplasia

Corrin LS, Sandok BA, Houser OW. Cerebral ischemic events in patients with carotid artery fibromuscular dysplasia. *Arch Neurol*. 1981;38(10):616-618.

Mettinger KL. Fibromuscular dysplasia and the brain. II. Current concept of the disease. *Stroke*. 1982;13:53-58.

Olin JW, Gornick HL, Bacharach JM, et al. Fibromuscular dysplasia: state of the science and critical unanswered questions: a scientific statement from the American Heart Association. *Circulation*. 2014;129:1048-1078.

Schievink WI, Björnsson J. Fibromuscular dysplasia of the internal carotid artery: a clinicopathological study. *Clin Neuropathol*. 1996;15:2-6.

Slovut DP, Olin JW. Fibromuscular dysplasia. *Curr Treat Options Cardiovasc Med*. 2005;7:159-169.

Slovut DP, Olin JW. Fibromuscular dysplasia. *N Engl J Med*. 2004;350(18):1862-1871.

Touzé E, Southerland AM, Boulanger M, et al. Fibromuscular dysplasia and its neurologic manifestations: a systematic review. *JAMA Neurol*. 2019;76(2):217-226.

Moyamoya Disease

Ahn IM, Park D, Hann HJ, Kim KH, Kim HJ, Ahn HS. Incidence, prevalence, and survival of moyamoya disease in Korea: a nationwide, population-based study. *Stroke*. 2014;45:1090-1095.

Fukui M. Guidelines for the diagnosis and treatment of spontaneous occlusion of the circle of Willis ('moyamoya' disease). Research Committee on Spontaneous Occlusion of the Circle of Willis (Moyamoya Disease) of the Ministry of Health and Welfare, Japan. *Clin Neurol Neurosurg*. 1997;99(suppl 2):S238-S240.

Hervé D, Ibos-Augé N, Calvière L, et al. Predictors of clinical or cerebral lesion progression in adult moyamoya angiopathy. *Neurology*. 2019;93(4):e388-e397.

Kim SK, Cho BK, Phi JH, et al. Pediatric moyamoya disease: an analysis of 410 consecutive cases. *Ann Neurol*. 2010;68:92-101.

Kleinloog R, Regli L, Rinkel GJE, Klijn CJM. Regional differences in incidence and patient characteristics of moyamoya disease: a systematic review. *J Neurol Neurosurg Psychiatry*. 2012;83:531-536.

Kuroda S, Hashimoto N, Yoshimoto T, Iwasaki Y. Radiological findings, clinical course, and outcome in asymptomatic moyamoya disease: results of multicenter survey in Japan. *Stroke*. 2007;38(5):1430-1435.

Kuroda S, Houkin K. Moyamoya disease: current concepts and future perspectives. *Lancet Neurol*. 2008;7:1056-1066.

Liu W, Morito D, Takashima S, et al. Identification of RNF213 as a susceptibility gene for moyamoya disease and its possible role in vascular development. *PLoS One*. 2011;6:e22542.

Miyamoto S, Yoshimoto T, Hashimoto N, et al. Effects of extracranial-intracranial bypass for patients with hemorrhagic moyamoya disease: results of the Japan Adult Moyamoya Trial. *Stroke*. 2014;45:1415-1421.

Scott MR, Smith ER. Moyamoya disease and moyamoya syndrome. *N Engl J Med*. 2009;360:1226-1237.

Starke RM, Komotar RJ, Connolly ES. Optimal surgical treatment for moyamoya disease in adults: direct versus indirect bypass. *Neurosurg Focus*. 2009;26:E8.

Suzuki J, Takaku A. Cerebrovascular "moyamoya" disease. Disease showing abnormal net-like vessels in base of brain. *Arch Neurol*. 1969;20:288-299.

Binswanger Disease

Babikian V, Ropper AH. Binswanger's disease: a review. *Stroke*. 1987;18:2-12.

Caplan LR, Gomes JA. Binswanger disease—an update. *J Neurol Sci*. 2010;299(1-2):9-10.

Farkas E, de Vos RA, Donka G, Steur ENJ, Mihály A, Luiten PGM. Age-related microvascular degeneration in the human cerebral periventricular white matter. *Acta Neuropathol*. 2006;111:150-157.

Fisher CM. Binswanger's encephalopathy: a review. *J Neurol*. 1989;236:65-79.

Fitzpatrick AL, Kuller LH, Lopez OL, Kawas CH, Jagust W. Survival following dementia onset: Alzheimer's disease and vascular dementia. *J Neurol Sci*. 2005;229-230:43-49.

Jellinger KA. Pathology and pathogenesis of vascular cognitive impairment—a critical update. *Front Aging Neurosci*. 2013;5:17.

Susac Syndrome

Aubart-Cohen F, Klein I, Alexandra JF, et al. Long-term outcome in Susac syndrome. *Medicine (Baltimore)*. 2007;86:93-102.

García-Carrasco M, Mendoza-Pinto C, Cervera R. Diagnosis and classification of Susac syndrome. *Autoimmun Rev*. 2014;13(4-5):347-350.

Kleffner I, Dörr J, Ringelstein M, et al. Diagnostic criteria for Susac syndrome. *J Neurol Neurosurg Psychiatry*. 2016;87(12):1287-1295.

Law LY, Riminton DS, Nguyen M, et al. The spectrum of immune-mediated and inflammatory lesions of the brainstem: clues to diagnosis. *Neurology*. 2019;93(9):390-405.

Magro CM, Poe JC, Lubow M, Susac JO. Susac syndrome: an organ-specific autoimmune endotheliopathy syndrome associated with anti-endothelial cell antibodies. *Am J Clin Pathol*. 2011;136(6):903-912.

Martinet N, Fardeau C, Adam R, et al. Fluorescein and indocyanine green angiographies in Susac syndrome. *Retina*. 2007;27(9):1238-1242.

Mateen FJ, Zubkov AY, Muralidharan R, et al. Susac syndrome: clinical characteristics and treatment in 29 new cases. *Eur J Neurol*. 2012;19(6):800-811.

Rennebohm RM, Susac JO. Treatment of Susac's syndrome. *J Neurol Sci*. 2007;257:215-220.

Susac JO, Hardman JM, Selhorst JB. Microangiopathy of the brain and retina. *Neurology*. 1979;29:313-316.

Susac JO, Murtagh FR, Egan RA, et al. MRI findings in Susac's syndrome. *Neurology*. 2003;61:1783-1787.

Sneddon Syndrome

Boesch SM, Plörer AL, Auer AJ, et al. The natural course of Sneddon syndrome: clinical and magnetic resonance imaging findings in a prospective six year observation study. *J Neurol Neurosurg Psychiatry*. 2003;74:542-544.

Francès C, Le Tonquèze M, Salohzin KV, et al. Prevalence of anti-endothelial cell antibodies in patients with Sneddon's syndrome. *J Am Acad Dermatol*. 1995;33(1):64-68.

Francès C, Piette JC. The mystery of Sneddon syndrome: relationship with antiphospholipid syndrome and systemic lupus erythematosus. *J Autoimmun*. 2000;15(2):139-143.

Samanta D, Cobb S, Arya K. Sneddon syndrome: a comprehensive overview. *J Stroke Cerebrovasc Dis*. 2019;28(8):2098-2108.

Sneddon IB. Cerebro-vascular lesions and livedo reticularis. *Br J Dermatol*. 1965;77(4):180-185.

Wohlrab J, Francès C, Sullivan KE. Strange symptoms in Sneddon's syndrome. *Clin Immunol*. 2006;119:13-15.

Marantic Endocarditis

Dutta T, Karas MG, Segal AZ, Kizer JR. Yield of transesophageal echocardiography for nonbacterial thrombotic endocarditis and other cardiac sources of embolism in cancer patients with cerebral ischemia. *Am J Cardiol*. 2006;97(6):894-898.

Greaves M, Cohen H, MacHin SJ, Mackie I. Guidelines on the investigation and management of the antiphospholipid syndrome. *Br J Haematol*. 2000;109(4):704-715.

Katsouli A, Massad MG. Current issues in the diagnosis and management of blood culture-negative infective and non-infective endocarditis. *Ann Thorac Surg*. 2013;95(4):1467-1474.

Lee A, Levine MN, Baker RI, et al. Low-molecular-weight heparin versus a coumarin for the prevention of recurrent venous thromboembolism in patients with cancer. *New Engl J Med*. 2003;349:146-153.

Merkler AE, Navi BB, Singer S, et al. Diagnostic yield of echocardiography in cancer patients with ischemic stroke. *J Neurooncol*. 2015;123(1):115-121.

Moustafa S, Patton DJ, Balon Y, Kidd WT, Alvarez N. Mitral valve surgery for marantic endocarditis and multiple cerebral embolisation. *Heart Lung Circ*. 2013;7(22):545-547.

Navi BB, Iadecola C. Ischemic stroke in cancer patients: a review of an underappreciated pathology. *Ann Neurol*. 2018;83(5):873-883.

Reisner SA, Brenner B, Haim N, Edoute Y, Markiewicz W. Echocardiography in nonbacterial thrombotic endocarditis: from autopsy to clinical entity. *J Am Soc Echocardiogr*. 2000;13:876-881.

Roldan CA, Shively BK, Crawford MH. An echocardiographic study of valvular heart disease associated with systemic lupus erythematosus. *N Engl J Med*. 1996;335:1424-1430.

Singhal AB, Topcuoglu MA, Buonanno FS. Acute ischemic stroke patterns in infective and nonbacterial thrombotic endocarditis: a diffusion-weighted magnetic resonance imaging study. *Stroke*. 2002;33:1267-1273.

CADASIL

Carare RO, Hawkes CA, Jeffrey M, Kalaria RN, Weller RO. Review: cerebral amyloid angiopathy, prion angiopathy, CADASIL and the spectrum of protein elimination failure angiopathies (PEFA) in neurodegenerative disease with a focus on therapy. *Neuropathol Appl Neurobiol*. 2013;39(6):593-611.

Ciolli LF, Pescini E, Salvadori A, et al. Influence of vascular risk factors and neuropsychological profile on functional performances in CADASIL: results from the MIcrovascular LEukoencephalopathy Study (MILES). *Eur J Neurol*. 2014;21(1):65-71.

Joutel A. Pathogenesis of CADASIL. *Bioessays*. 2011;33(1):73-80.

Jouvent E, Duering M, Chabriat H. Cerebral autosomal dominant arteriopathy with subcortical infarcts and leukoencephalopathy: lessons from neuroimaging. *Stroke*. 2020;51(1):21-28.

Pescini F, Nannucci S, Bertaccini B, et al. The Cerebral Autosomal-Dominant Arteriopathy With Subcortical Infarcts and Leukoencephalopathy (CADASIL) scale: a screening tool to select patients for NOTCH3 gene analysis. *Stroke*. 2012;43(11):2871-2876.

45 Primary and Secondary Stroke Prevention

Charles C. Esenwa and Mitchell S. V. Elkind

KEY POINTS

1. Primordial stroke prevention measures target community-level stroke risk factors and aim to improve population-level cardiovascular health through broad healthy living campaigns.
2. In general, the most important individualized risk factor for stroke is hypertension, which accounts for at least one-third of all strokes.
3. After an ischemic stroke has occurred, the goal is to minimize disability and prevent recurrent events using an approach that is specific to the stroke subtype and personalized risk factors.
4. The stroke subtypes of large artery atherosclerosis, cardiogenic, and small-vessel disease require differing prevention strategies.
5. Anticoagulation is the main stroke prevention strategy in patients with atrial fibrillation.
6. Carotid endarterectomy or carotid artery stenting is recommended for patients with ischemic stroke in the territory of a severely stenotic internal carotid artery.
7. Patients with all ischemic stroke subtypes require a multipronged approach aimed at controlling modifiable stroke risk factors such as hypertension, diabetes mellitus, hypercholesterolemia, and tobacco use.

INTRODUCTION

Prevention of stroke can be divided into three types: (1) primordial prevention, which focuses on improving community-wide health behaviors, such as diet, exercise, and smoking; (2) primary prevention, which attempts to mitigate an individual's stroke risk factors; and (3) secondary prevention, which targets risk of stroke recurrence in those who have already suffered a stroke or transient ischemic attack (TIA).

Risk factors are generally classified as either nonmodifiable or modifiable. Nonmodifiable risk factors, although they cannot be altered, remain important in quantifying a patient's future risk of stroke. Examples include age, sex, family history, ethnicity, and race. Modifiable risk factors allow for intervention to decrease future risk of stroke.

Primordial prevention deals with population-level strategies aimed at reducing the development of cardiovascular disease and specifically stroke. Primary and secondary prevention measures should be individualized and require a careful history and tailored diagnostic evaluation to stratify stroke risk and guide the appropriate prevention strategy. Both focus on improving the individual's risk factor profile, and secondary prevention methods further depend on the stroke mechanism. For ischemic stroke, these mechanisms include atherothrombotic, small-vessel (or "lacunar"), cardioembolic, stroke due an unknown or yet to be determined etiology (or "cryptogenic"), and, finally, "other," a category that captures rare and unusual stroke types. Multiple randomized controlled trials have been conducted over the past half-century evaluating optimal stroke prevention strategies, especially for atherothrombotic and cardioembolic stroke subtypes.

Hemorrhagic strokes account for 15% to 20% of all strokes and are further divided into subarachnoid hemorrhage (SAH) and intracerebral hemorrhage (ICH). Causes of SAH include trauma, berry or congenital aneurysms, and, less often, arteriovenous malformations. The ICH is most commonly caused by hypertension and cerebral amyloid angiopathy (CAA). Appropriate classification of a stroke and its etiology aids the clinician in determining the most effective prevention strategy.

PRIMORDIAL STROKE PREVENTION

The INTERSTROKE case-control study among 22 countries determined that 10 risk factors accounted for nearly 90% of strokes. Listed in order of significance, they are as follows: hypertension, cardiac disease, current smoking, waist-to-hip ratio, poor diet, sedentary lifestyle, excessive alcohol intake, diabetes mellitus, depression, and psychosocial stress. The highest burden of stroke in the United States falls in the so-called "stroke belt" located in the southeast, where high prevalence of diabetes, hypertension, obesity, and a number of social determinants of cardiovascular health cluster together to increase stroke incidence and related mortality. Population level prevention of stroke in such areas relies on improving cardiovascular health through campaigns aimed at increasing stroke awareness, improving diet and physical activity, and limiting exposure to tobacco products.

Diet

The Mediterranean diet may protect against cardiovascular disease, including stroke. It is characterized by high intake of fruits, vegetables, and legumes; olive oil as the principal source of fat; moderate consumption of fish and poultry, with minimal intake of red meat and dairy; and an option of mild to moderate consumption of red wine, mostly with meals. Compared to a low-fat diet, this complex combination of nutrients decreased 5-year stroke risk by approximately 30% in a prospective study. In general, any diet aimed at promoting cardiovascular health,

such as the Mediterranean diet or the Dietary Approach to Stop Hypertension diet, revolves around the central notions of a high intake of plant-based nutrients, low-salt intake, and a curbing of saturated fats and simple sugars.

Smoking

Tobacco use is strongly discouraged, and among smokers, cessation of smoking leads to a reduction in stroke risk to levels similar to nonsmokers by 5 years. It is still unclear how much e-cigarettes, or "vaping," affects stroke risk, but early data suggests an increased risk of stroke in e-cigarette users; risk is even higher in those who use both e-cigarettes and conventional cigarettes compared to never users.

Exercise

Physical activity is associated with a reduced risk of stroke, and importantly, several studies provide evidence that only a moderate level of activity is required, and so physical activity should be encouraged even among the elderly. A sedentary lifestyle, in combination with consumption of simple carbohydrates, has contributed to one-third of Americans becoming obese and to even more becoming overweight. Obesity is an independent risk factor for stroke, even after adjusting for physical activity and diet. Obesity is comorbid with diabetes, hypertension, and heart disease.

PRIMARY STROKE PREVENTION

Like primordial stroke prevention, primary stroke prevention aims to limit the risk of first-time stroke, but instead of addressing large groups of people, the health care provider focuses on each individual separately. Specific targets for intervention are a person's major modifiable risk factors, including hypertension, diabetes mellitus, hypercholesterolemia, and atrial fibrillation (AF). Several randomized trials have demonstrated the benefits of specific interventions to prevent a first stroke among patients with certain stroke risk factors (**Table 45.1**).

Hypertension

Blood pressure is the most important contributor to stroke incidence, increasing the risk of stroke in a linear fashion. High blood pressure accounts for at least 35% of all strokes. β-Blockers, thiazide diuretics, angiotensin-converting enzyme inhibitors (ACEIs), angiotensin II receptor blockers (ARBs), and calcium channel blockers are the most widely studied agents in stroke prevention. Although calcium channel blockers may provide the greatest neurovascular protection, they are also associated with an increased risk of heart failure. The general consensus is that protection against stroke depends on the level of blood pressure control rather than on the specific class of medication used. Blood pressure reductions of 10 mm Hg systolic or 5 mm Hg diastolic have been shown to reduce risk of first-time stroke by more than 40% LEVEL 1.[1] In the United States, efforts targeting hypertension have contributed to the steady decline in stroke incidence and stroke-related mortality in the last half-century.

The effects of adequate blood pressure management may be more robust in those with diabetes mellitus. The ACEIs and ARBs are recommended because they have been proven renoprotective and also effective in reducing cardiovascular events and specifically stroke in those with diabetes mellitus. Intensive blood pressure management has also proven effective in those over 75 years of age. The Randomized Trial of Intensive versus Standard Blood Pressure Control (SPRINT) trial demonstrated that intensive blood pressure management (defined as systolic blood pressure less than 120 mm Hg) led to a significantly lower incidence of the composite cardiovascular outcome that included stroke, compared to standard blood pressure goals. It is therefore widely accepted that lifelong blood pressure management holds central importance in the primary prevention of stroke.

TABLE 45.1 Evidence-Based Primary Stroke Prevention

Risk Factor	Treatment
Hypertension	Antihypertensive
Myocardial infarction	HMG-CoA reductase inhibitor
Hyperlipidemia	HMG-CoA reductase inhibitor
Atrial fibrillation	Warfarin or oral anticoagulants
DM/vascular disease	ACE inhibitor
Asymptomatic carotid stenosis (60%-99%)	Consider carotid endarterectomy.
"High-risk" populations	HMG-CoA reductase inhibitor

Abbreviations: ACE, angiotensin-converting enzyme; DM, diabetes mellitus; HMG-CoA, hydroxymethylglutaryl-coenzyme A.

Diabetes Mellitus

Epidemiologic studies show a positive relationship between hyperglycemia and stroke incidence, but aggressive management of hyperglycemia may actually be harmful. In the Action to Control Cardiovascular Risk in Diabetes study, investigators compared intensive glucose-lowering therapy with a goal glycated hemoglobin level below 6% to a glycated hemoglobin goal of 7% to 7.9%. They found no difference in stroke incidence, with a slight, but statistically significant, increase in overall mortality in the group undergoing tight control. Similarly, postprandial hyperglycemia and glycemic variability have both been associated with increased cardiovascular disease burden in epidemiologic studies, but prospective studies have not shown any benefit. Current recommendations are for a glycated hemoglobin goal of less than 7% LEVEL 1.[2]

The presence of diabetes also has ramifications for the management of other risk factors, specifically low-density lipoprotein (LDL) cholesterol. Diabetes is considered a cardiovascular disease equivalent, and those 40 to 75 years of age with diabetes should be placed on a hydroxymethylglutaryl-coenzyme A (HMG-CoA) reductase inhibitor or statin, unless there is a contraindication LEVEL 1.[3]

Hypercholesterolemia

Large studies, such as the Multiple Risk Factor Intervention Trial that included over 350,000 men, have shown a positive association between death from ischemic stroke and increased cholesterol levels. There has also been evidence of a relationship between hemorrhagic strokes and low cholesterol levels. In line with the Multiple Risk Factor Intervention Trial data, trials using HMG-CoA reductase inhibitors among cardiac and other high vascular disease risk patients have demonstrated benefits in terms of stroke risk reduction, in addition to the effects on cardiac event rates. The effect on stroke risk is more modest, however, probably reflecting the fact that stroke is more heterogeneous than heart

disease and less strongly linked to elevated cholesterol levels.

In the Heart Protection Study, a randomized, multicenter, placebo-controlled trial of simvastatin therapy, there was a 25% risk reduction for stroke (from 5.7% to 4.3%; $P < .0001$), without an increase in risk of hemorrhagic stroke over a 5-year period. Importantly, these benefits remained in those with LDL less than 100 mg/dL.

Evidence suggests that the optimal way to think about cholesterol goals within the context of primary stroke prevention is to consider the individual's long-term absolute risk of combined cardiovascular events. The Pooled Cohort Risk Assessment Equations was developed by the American College of Cardiology and American Heart Association using data from several large epidemiologic studies to predict a 10-year risk of cardiovascular events and identify appropriate candidates for statin therapy. Those with a high risk of cardiovascular events (considered to be at least 7.5% over 10 y) should be placed on cholesterol-lowering therapy, independent of specific risk factors. Other high-risk groups that should receive statin therapy are individuals with an LDL greater than 190 mg/dL and those aged 40 to 75 years with comorbid diabetes mellitus LEVEL 1.[3]

Proprotein convertase subtilisin-kexin type 9 (PCSK9) inhibitors are a novel class of drugs whose therapeutic class effect is through promoting the degradation of LDL receptors, thereby decreasing LDL levels far beyond that of statins alone. The Evolocumab and Clinical Outcomes in Patients with Cardiovascular Disease (FOURIER) trial enrolled nearly 30,000 participants with an elevated LDL who were already on a statin and found a modest but statistically significant absolute risk reduction of ischemic stroke (0.4%), over a 2-year period. Hemorrhagic stroke was not affected. Alirocumab was also shown to have a similar effect on stroke risk in a more recent trial of high–cardiovascular risk patients with elevated LDL levels despite statin therapy. A major limitation to using PCSK9 inhibitors is cost. The PCSK9 inhibitors can therefore be considered in very high–cardiovascular risk patients with elevated LDL levels despite otherwise maximal lifestyle and medical management LEVEL 1.[3]

Atrial Fibrillation

Cardioembolic stroke accounts for approximately 15% to 30% of all ischemic strokes. Compared to stroke related to small-vessel disease and large-vessel atherosclerosis, it is associated with a longer hospital stay, greater levels of residual disability, and higher rates of stroke-related mortality. The AF is the most common cause of cardioembolic stroke. Anticoagulation is effective in preventing both incident and recurrent strokes in patients with AF LEVEL 1.[4] Warfarin, a vitamin K antagonist associated with a 60% to 70% relative risk reduction in stroke, was formerly the only available oral anticoagulant for long-term use, but several anticoagulants that directly inhibit factor Xa and thrombin are now available, with more still in the development phase. Large randomized clinical trials have compared warfarin to these direct-acting oral anticoagulants (DOACs, including dabigatran, apixaban, rivaroxaban, and edoxaban) and have shown similar or slightly better efficacy with the newer agents. Some of the trials also indicate a lowered risk of intracranial hemorrhage with little need for serum monitoring. Additionally, left atrial appendage closure devices are an alternative to long-term drug therapy, particularly among patients at increased risk for hemorrhagic complications. In the Stroke Prevention in Atrial Fibrillation study, anticoagulation reduced stroke recurrence substantially, even in patients older than 75 years.

Risk of stroke is associated with the following risk factors: age older than 65 years, female sex, previous embolization, sustained hypertension, congestive heart failure, peripheral vascular disease, and diabetes mellitus. With a history of embolization alone or a combination of any other two risk factors, the stroke incidence is nearly 3% per year and increases to 18% when all risk factors are present. In patients with nonvalvular AF, and a low hemorrhagic risk, anticoagulation is typically recommended if the personalized annual stroke risk is approximately 3% or greater LEVEL 1.[4]

Carotid Stenosis

Another major source of preventable cerebral infarction is large-vessel atherosclerotic disease and, specifically, internal carotid artery stenosis. In asymptomatic patients with greater than 60% carotid stenosis and low perioperative risk, carotid endarterectomy (CEA) should be considered with the expectation that approximately 20 procedures must be performed to prevent one stroke over a 5-year period. Men are more likely to benefit than women, which along with the patient-specific perioperative risk, helps the clinician decide whether or not to recommend surgery. However, modern-day medical therapy with potent lipid-lowering medications and novel blood pressure agents has changed since the original carotid revascularization trials were performed. The Carotid Revascularization and Medical Management for Asymptomatic Carotid Stenosis Study, an ongoing multicenter clinical trial, hopes to provide definitive evidence regarding the best treatment in patients with asymptomatic high-grade stenosis. Although CEA is the gold standard, carotid artery stenting (CAS) is another viable alternative; it is also being studied in the Carotid Revascularization and Medical Management for Asymptomatic Carotid Stenosis Study and may be employed if the anatomy is unfavorable to surgical intervention. There is no benefit of either procedure in patients with less than 50% stenosis or in chronic carotid occlusion.

SECONDARY STROKE PREVENTION

Once a stroke or TIA has occurred, the goals of the clinician are to minimize long-term disability and direct management to prevent another stroke. Secondary stroke prevention measures do not alter progression of the initial stroke, but research has shown that initiating preventive therapy in the acute setting after stroke has an immediate impact on the recurrence risk and further increases the likelihood of preventive therapy being in place in the long term (**Fig. 45.1**).

Stroke Mechanism and Evaluation

Therapies aimed at limiting risk of recurrence depend in large part on the mechanism of the stroke, its severity, and the individualized modifiable risk factor profile. Because the risk of a repeat stroke is highest in the first 2 weeks after the initial event, a comprehensive evaluation must be employed as soon as possible to determine stroke mechanism and quantify the underlying risk factors. The importance of a good history and physical examination cannot be overstated and should be followed by hypothesis-driven diagnostic testing.

Neuroimaging

Magnetic resonance imaging of the brain visualizes acute ischemic injury and can aid in determining the mechanism. Although lacunar strokes, or deep punctate infarcts within the white matter

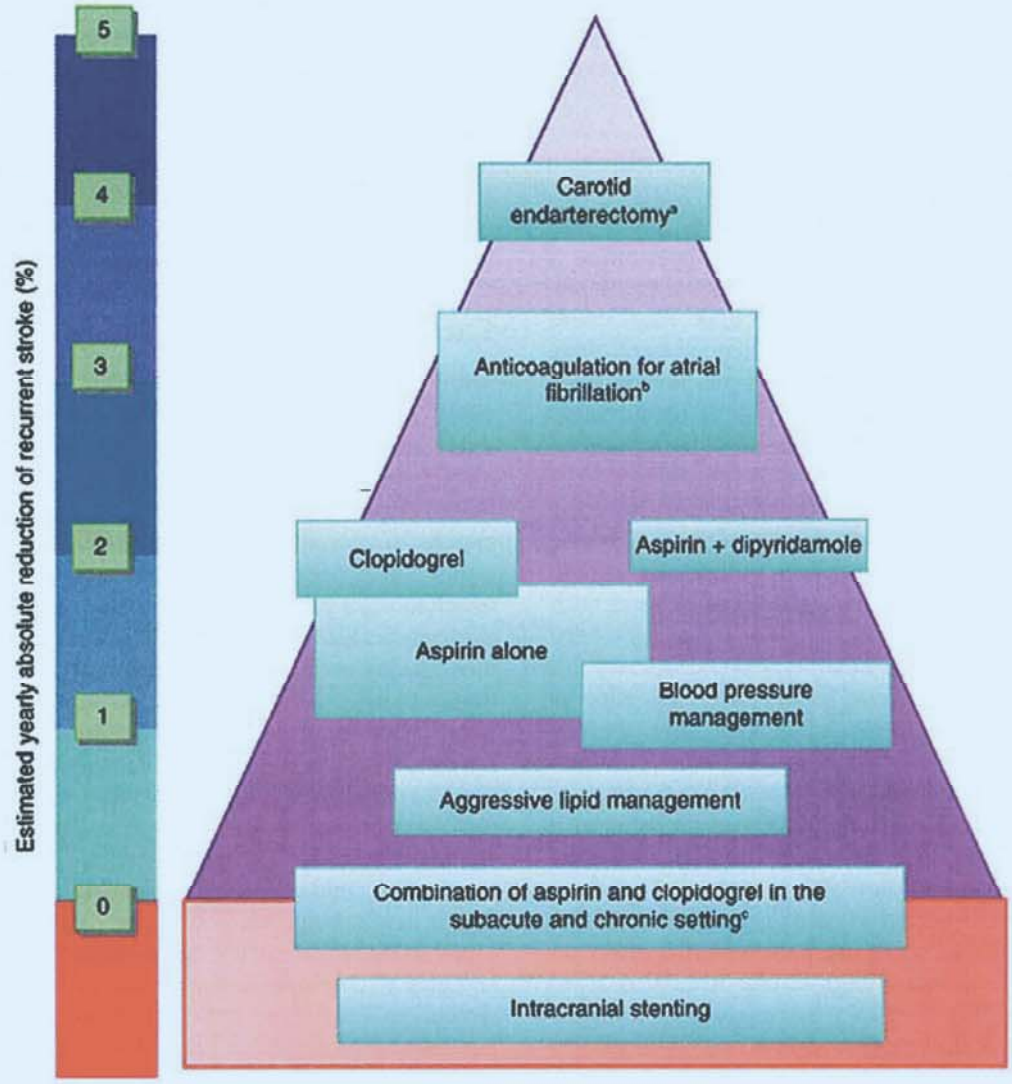

FIGURE 45.1 Effect of secondary stroke prevention measures on stroke recurrence. Estimated absolute risk reductions in stroke of various secondary stroke prevention therapies compared to placebo or in some cases, standard management. [a]Refers to symptomatic carotid stenosis of 70% to 99%. [b]Warfarin or direct oral anticoagulants. [c]Compared to single antiplatelet agent and not including dual antiplatelet therapy initiated in the acute setting after stroke.

predominantly occur from small-vessel disease, for example, large superficial wedge-shaped infarcts or multifocal infarcts are more consistent with embolism. Extracranial vessel imaging is a crucial step in the diagnostic algorithm, whereas intracranial vessel imaging in the form of magnetic resonance angiography or computed tomography angiography may be useful to identify intracranial stenosis. The gold standard for carotid imaging is digital subtraction angiography, but it is impractical for screening purposes. Carotid Doppler has therefore become the main screening test for carotid atherosclerosis, whereas the widespread availability of magnetic resonance angiography and computed tomography angiography provides alternatives to be used at the clinician's discretion and, if needed, to confirm the findings on ultrasound.

Cardiac Evaluations

Transthoracic echocardiography is used to assess structural cardiac abnormalities that predispose to cardioembolism. In cases with a high pretest probability of embolism, transesophageal echocardiography can be used to better visualize the left atrium and cardiac valves, looking for intra-atrial thrombus, cardiac myxoma, or valvular vegetations. A second arm of the cardiac evaluation assesses the cardiac rhythm for evidence of AF. Electrocardiography and cardiac telemetry are used in screening, whereas prolonged monitoring for several weeks to months, and even years in some cases, can be very helpful in capturing occult AF.

Blood Work and Other Laboratory Testing

Measuring LDL, high-density lipoprotein, hemoglobin A_{1c}, and—in appropriate or otherwise unexplained cases—erythrocyte sedimentation rate; C-reactive protein; rapid plasma reagin; or hypercoagulability testing allows for proper management and prevention of recurrent stroke. Rarely, given the right clinical context, a patient may require evaluation for underlying genetic, infectious, or inflammatory disorders. Examples include cerebral autosomal dominant arteriopathy with subcortical infarcts and leukoencephalopathy, Fabry disease, varicella zoster virus cerebral vasculopathy, human immunodeficiency virus vasculopathy, syphilitic arteritis, and cerebral involvement of any one of the systemic inflammatory vasculitides. Evaluation for these

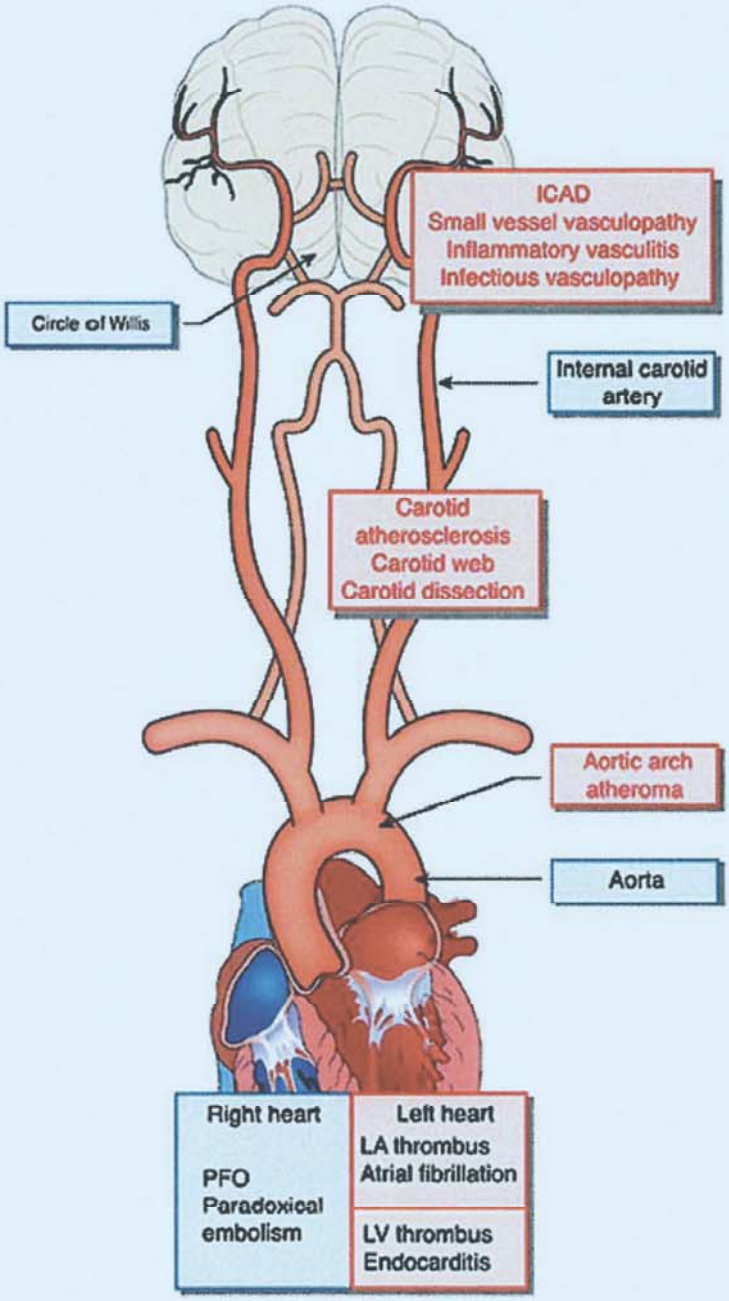

FIGURE 45.2 Common vascular mechanisms of ischemic stroke. Abbreviations: ICAD, intracranial atherosclerotic disease; LA, left atrial; LV, left ventricle; PFO, patent foramen ovale.

more uncommon disorders is typically achieved through a combination of specialized serum or genetic tests, advanced imaging, and cerebrospinal fluid analysis (Fig. 45.2).

Prevention Early After Transient Ischemic Attack and Stroke

It is important to recognize that TIAs call for the same urgency in evaluation as proven strokes. Johnston et al showed that the risk of stroke after TIA is about 5% in the first 2 days and 10% within 90 days. Further, 1 in 20 individuals will suffer a fatal or disabling stroke within 90 days after TIA. Trials have shown that urgent evaluation and directed management of TIA or minor stroke dramatically decreases the recurrence rate of stroke.

Early interventions aimed at stroke prevention revolve around mitigating high-risk situations, such as moderate- to high-grade carotid stenosis and AF. Dual antiplatelet therapy in the realm of stroke prevention has been reserved for preventing recurrent events in patients presenting with high-risk TIA or minor stroke. The Clopidogrel in High-Risk Patients With Acute Non-disabling Cerebrovascular Events (CHANCE) trial found that a 21-day course of dual antiplatelet therapy with aspirin and clopidogrel among Chinese patients with TIA and minor stroke, given within 24 hours of symptom onset, lowered the 3-month stroke recurrence rate. The more recent Clopidogrel and Aspirin in Acute Ischemic Stroke and High-Risk TIA (POINT) trial confirmed the findings from CHANCE, making a short course of aspirin and clopidogrel in the early period after stroke a recommended treatment for patients with high-risk TIA or minor stroke. Initiating therapy outside of the 24-hour window, maintaining treatment for longer than 3 months, or treating patients with moderate to severe stroke limits benefit and increases the risk of harm, mostly in the form of major hemorrhage. Short-term heparin is not effective in preventing stroke recurrence compared to aspirin, according to the International Stroke Trial, which enrolled nearly 20,000 ischemic stroke patients; similar findings were seen in the Chinese Acute Stroke Trial with nearly the same number of patients.

Antiplatelet Therapy

All patients with ischemic stroke without a definite indication for anticoagulation or dual antiplatelet therapy, and in whom no contraindication is present, should receive long-term single antiplatelet therapy. Aspirin monotherapy, the combination of aspirin with extended-release dipyridamole or clopidogrel are all acceptable options for initial therapy in the secondary prevention of noncardioembolic stroke LEVEL 2.[5]

Mechanism of Action and Dosing

The action of aspirin is to irreversibly acetylate and inhibit platelet cyclooxygenase-1, which stops synthesis of the powerful platelet aggregant thromboxane A2. Lower doses of aspirin have the advantage of minimizing inhibition of endothelial cell production of prostacyclin (PGI2), the powerful platelet antiaggregant. The concept of a balance between thromboxane A2 and PGI2 in the normal circulation without aggregate formation won Sir John Vane a Nobel Prize. Dipyridamole acts in conjunction with aspirin by increasing adenosine and PGI2, two potent antiaggregants. The optimum daily dose of aspirin remains somewhat controversial, but doses as low as 30 mg daily appear effective and have less side effects, such as gastrointestinal bleeding. The U.S. Food and Drug Administration currently recommends doses between 50 and 325 mg daily for stroke prevention.

Clopidogrel, a thienopyridine derivative, blocks platelet activation and aggregation by irreversibly inhibiting the P2Y12 ADP receptor. It is increasingly being used for secondary stroke prevention. Cilostazol is a phosphodiesterase 3 inhibitor used in peripheral arterial disease that has proven to reduce recurrence of stroke in Asian populations but is less well studied and therefore not widely used in stroke prevention in the United States. In general, the risk of adverse events with standard antiplatelet agents is very low, but a few points need to be considered: (1) Treating with the combination of aspirin and dipyridamole

requires twice-daily dosing and is complicated by a high rate of secondary headache and gastrointestinal symptoms, thus reducing patient compliance; (2) higher doses of aspirin increase bleeding risk without providing clinical benefit; (3) clopidogrel can cause diarrhea, thrombocytopenia, rash, and, in very rare circumstances, thrombotic thrombocytopenic purpura; and (4) patient variability in the cytochrome P450 2C19 gene may impair metabolism to the active clopidogrel metabolite, effectively decreasing response to clopidogrel.

Impact on Outcomes

As a group, antiplatelets offer an absolute risk reduction of 2% in annual vascular events (myocardial infarction, stroke, and death), with a 0.1% to 0.2% increase in major extracranial hemorrhages (number needed to harm is 500-1,000 to cause one major extracranial hemorrhage). There may also be a modest benefit of clopidogrel, or aspirin with dipyridamole, over aspirin alone for prevention of recurrent strokes, according to some meta-analyses. Aspirin with dipyridamole compared to aspirin alone produced an approximate annual absolute risk reduction of 1% in two large clinical trials. On the other hand, clopidogrel and the combination of aspirin with dipyridamole produced nearly identical results in one study. Choice of antiplatelet depends on the setting, comorbidities, and access to health care, but aspirin is the most widely studied and least expensive medication, making it ideal for large-scale use especially in developing countries where the number treated is usually determined by the cost of therapy. Clopidogrel and aspirin with dipyridamole are reasonable alternatives as first-line therapy or second-line therapy in those who have suffered a stroke while on aspirin.

Dual Antiplatelet Therapy

More recently, dual antiplatelet therapy with clopidogrel and aspirin, compared to aspirin alone, has been investigated in secondary prevention after lacunar stroke in the Secondary Prevention of Small Subcortical Strokes (SPS3) trial. There was no evidence of a reduction in risk of stroke recurrence, despite an increase in risk of bleeding and mortality, among those treated with dual antiplatelet therapy. There are several reasons that may account for the difference in results between the CHANCE and POINT trials described earlier and SPS3: (1) CHANCE and POINT provided antiplatelet therapy within 24 hours of stroke onset; (2) CHANCE and POINT also included patients with mild stroke and TIA, isolating a group with low risk of hemorrhagic conversion; and (3) they studied the use of dual antiplatelet agents for a short period of time followed by a single antiplatelet agent, whereas SPS3 enrolled patients within 6 months of stroke onset and used dual antiplatelet therapy for the duration of the trial. The majority of the benefit from dual antiplatelet therapy occurs within the first week of treatment, whereas treatment with dual antiplatelets beyond 3 months of stroke onset increases risk without added benefit. This immediate reduction in recurrent vascular events is a phenomenon echoed in trials that studied dual antiplatelet agents within 24 hours of cardiac ischemia.

Anticoagulation

Anticoagulation with warfarin is indicated in patients with definite cardioembolic sources of stroke, such as mechanical valves or left ventricular thrombus. In patients with nonvalvular AF, anticoagulation with warfarin or a DOAC (described earlier) is indicated.

Carotid Endarterectomy, Angioplasty, and Stenting

In good surgical candidates, the treatment of choice for stroke and TIA caused by carotid stenosis of equal to, or greater than, 70% of the vessel diameter is CEA by a skilled surgeon with an acceptable complication rate (<5%) combined with optimal medical management, as demonstrated by three prospective studies: the North American Symptomatic Carotid Endarterectomy Trial, the European Carotid Surgery Trial, and the U.S. Veterans Affairs Cooperative Study on CEA LEVEL 3.[5] The first published case of successful CEA was performed by DeBakey in 1954, but it was not until 1991 that these studies confirmed its benefits. In those with high-grade carotid stenosis, CEA yields a number needed to treat of 16 to prevent one stroke over a 1-year period. There is also a benefit, albeit more modest, of CEA in symptomatic patients with moderate carotid stenosis (50%-69%). Post hoc analysis has also demonstrated that the greatest value of CEA is within 2 weeks of the event, and contemporary literature argues for intervention as soon as is medically possible.

More recently, CAS has been compared to CEA in three large trials: Stent-Protected Angioplasty Versus Carotid Endarterectomy, the International Carotid Stenting Study, and the Carotid Revascularization Endarterectomy versus Stenting Trial. Results have been consistent in showing a slight increase in periprocedural stroke (30 d) with CAS compared to CEA. In Stent-Protected Angioplasty Versus Carotid Endarterectomy and Carotid Revascularization Endarterectomy versus Stenting Trial, combined adverse outcomes over a 2-year period were similar, whereas International Carotid Stenting Study showed that CEA was superior in combined outcomes both in the acute and long-term settings. Although CEA remains the treatment of choice for symptomatic high-grade carotid stenosis, CAS is an alternative that can be employed in high-risk surgical patients or those with unsuitable anatomy. Transcarotid arterial revascularization is a stenting approach that uses direct carotid puncture and blood flow reversal, thereby providing distal embolization protection. It is increasingly being used in a subset of patients with lesions that are otherwise difficult to access.

There have been a number of trials looking at strategies for preventing stroke from intracranial stenotic lesions that are not readily accessible to surgeons. Stroke distal to a 50% to 99% vascular stenosis carries an estimated recurrence rate of 15% in the first year. In the Warfarin and Aspirin for Symptomatic Intracranial Stenosis trial, investigators studied aspirin versus warfarin in patients with symptomatic intracranial stenosis 50% to 99%. The study was stopped because of a high rate of adverse events in the warfarin group, leading researchers to conclude that warfarin provides no benefit over aspirin in patients with intracranial stenosis. Despite the negative primary result, the study provided the important finding that risk was highest in patients with greater than 70% stenosis, a group that had a 25% stroke recurrence rate in the first year. The subsequent Stenting versus Aggressive Medical Therapy of Intracranial Atherosclerotic Stenosis trial thus targeted patients with recent stroke and high-grade intracranial stenosis (>70%), comparing percutaneous transluminal angioplasty and stenting with best medical management with aggressive risk factor control. Both groups received dual antiplatelet therapy with aspirin and clopidogrel for 3 months. There was also aggressive management of risk factors including hypertension, lipids, diabetes, and tobacco use. The primary end point of recurrent stroke or death was reached in 20% of the stenting group as opposed to 12% in the medical

management group. Interestingly, the medical group had a lower than expected stroke recurrence rate compared to the 25% risk predicted by the Warfarin and Aspirin for Symptomatic Intracranial Stenosis study. The results suggested that aggressive medical therapy is superior to intervention for high-grade intracranial stenosis with currently available technology.

Cardiac Abnormalities

Treatment of cardiogenic emboli depends on the offending pathology. Infected prosthetic valves need replacement, and emboli from a benign tumor called myxoma require surgical removal of the tumor (**Table 45.2**). The role of anticoagulation among patients with possible paradoxical embolism through a patent foramen ovale (PFO) depends on the presence of an identified venous thrombus. In those without another identified stroke etiology or venous thrombosis, the closure of a PFO using transcardiac devices can reduce secondary stroke based on results of several large prospective trials comparing closure to medical therapy. Although initial trials did not show benefit of PFO closure when compared to medical therapy alone, follow-up trials that limited enrollment criteria to relatively young patients (younger than 60 y) with recent cryptogenic stroke and absence of extracranial or intracranial atherosclerotic disease found a modest benefit in stroke prevention with PFO closure compared to antiplatelets alone. A meta-analysis by Ntaios et al published in 2018 combined the results of five trials (n = 3,627 patients). It showed that PFO closure using a percutaneous transcatheter approach led to a 2.1% absolute risk reduction of stroke over the course of 3.7 years (number of patients needed to treat to prevent one stroke per year approximately 170). Patient preference, future need for anticoagulation, and procedural complications including AF must all be considered before recommending PFO closure.

To aid in decision making regarding PFO closure, clinicians may apply the Risk of Paradoxical Embolism scoring system, in which the attributable risk of stroke from a PFO increases when a patient is young; has a cryptogenic embolic-appearing infarct; and lacks the common stroke risk factors of hypertension, diabetes mellitus, cigarette smoking, and previous stroke (**Table 45.3**).

TABLE 45.2 Cardioembolic Sources of Stroke

High Risk	Low Risk/Unknown Risk
Atrial fibrillation	Cardiomyopathy
Mechanical prosthetic valve	Aortic arch atheroma
Recent myocardial infarction	Patent foramen ovale
Left ventricular thrombus	Atrial septal aneurysm
Rheumatic heart disease	Mitral valve strands
Marantic endocarditis	
Atrial myxoma	
Infective endocarditis	

TABLE 45.3 Risk of Paradoxical Embolism (RoPE) Score Used to Predict Attributable Risk of Stroke From Patent Foramen Ovale[a]

RoPE Score			Example Stroke Patients, Both of Whom Have Patent Foramen Ovale Identified on Their Echocardiography	
Age at time of index event:	Points		20-y-old healthy video gamer with no past history other than smoking and acute onset of aphasia and small left frontal opercular infarction	75-y-old woman with a history of diabetes and hypertension and acute onset left hemiparesis, with acute right internal capsule infarction and multifocal chronic small-vessel disease
18-29 y	5			
30-39 y	4			
40-49 y	3			
50-59 y	2			
60-69 y	1			
>70 y	0			
Age points			5	0
	No	Yes		
No history of hypertension	0	1	1	0
No history of diabetes	0	1	1	0
No history of stroke or TIA	0	1	1	1
No history of smoking	0	1	0	1
Peripheral (superficial, cortical) infarct on CT or MRI	0	1	1	0
Total RoPE score			9	2
Approximate likelihood stroke attributable to patent foramen ovale (attributable fraction)			88%	0%
Approximate risk of stroke recurrence over 2 y			20%	2%

Abbreviations: CT, computed tomography; MRI, magnetic resonance imaging; TIA, transient ischemic attack.

[a]Adapted from Kent DM, Ruthazer R, Weimar C, et al. An index to identify stroke-related vs incidental patent foramen ovale in cryptogenic stroke. *Neurology*. 2013;81(7):619-625.

Aortic arch atheromatous plaque is another condition associated with increased risk of stroke, with retrospective case-control studies consistently showing an association. Complex plaques, defined by a protruding component greater than 4 mm, presence of a mobile component, or intraplaque ulceration, are deemed high risk for embolization. Despite the known association, a causal relationship between aortic arch atheroma and stroke has never been proven, mirroring the uncertainty in therapeutic recommendations. There is no clear evidence to support use of anticoagulation, even in complex plaques. Statins are recommended because of their potential to remodel and cause regression in atheromatous plaques, along with standard antiplatelet therapy for secondary stroke prevention.

MODIFIABLE RISK FACTOR MANAGEMENT

Hypertension

Recent studies have provided evidence for increased use of antihypertensive agents in patients with stroke and TIA. Despite evidence of the efficacy of blood pressure reduction in reducing risk of a first stroke, concerns about lowering blood pressure in patients with existing cerebrovascular disease remained due to the theoretical possibility that in patients with arterial disease of cerebral vessels, a reduction in blood pressure could worsen perfusion and precipitate clinical events or affect cognition.

Much has been made of the potential benefits of ACEIs or ARBs in stroke prevention. This has been an attractive hypothesis, but the data does not provide an entirely convincing picture regarding the privileged position of ACEIs and ARBs among antihypertensive agents, particularly after stroke. Although patients with diabetes should probably receive these medications for prevention of progression of renal disease, it is not clear that this therapy dramatically reduces the incidence of stroke beyond what would be expected from reducing the blood pressure to a similar degree using other agents. The Perindopril Protection Against Recurrent Stroke Study (PROGRESS) trial was designed and conducted in large part to address these concerns. The PROGRESS was a randomized, double-blind, placebo-controlled trial of antihypertensive therapy among 6,105 patients with a history of hemorrhagic or ischemic stroke or TIA. Patients were enrolled independent of hypertension status, and 52% were nonhypertensive—considered to be systolic blood pressure 160 mm Hg or lower and diastolic blood pressure 90 mm Hg or lower—the blood pressure thresholds in use at the time the study started. Active treatment used the ACEI perindopril, with or without the thiazide diuretic indapamide. Active therapy led to a mean blood pressure reduction of 9/4 mm Hg compared with placebo, with a statistically significant 28% relative risk reduction in recurrent stroke or an absolute risk reduction of 4%. Of particular interest, the benefit of combination therapy was of a similar magnitude among hypertensive and nonhypertensive patients. There was also greater benefit for those with initial hemorrhagic stroke (relative risk reduction 49%) than for those with ischemic stroke (relative risk reduction 26%), likely reflecting the even stronger association of blood pressure with hemorrhagic stroke risk. The PROGRESS has therefore been interpreted as indicating a benefit for blood pressure reduction among patients with cerebrovascular disease, independent of a history of hypertension.

The SPS3 study, aside from studying the effect of dual antiplatelet therapy, also examined the role of strict versus standard blood pressure management (systolic <130 vs 130-149 mm Hg) on the outcome of stroke recurrence among patients with small-vessel (lacunar) strokes. It showed a trend toward benefit in stroke recurrence in the lower blood pressure group (hazard ratio 0.81, 95% confidence interval 0.64-1.03). Current guidelines recommend blood pressure lowering based on individualized targets, but it is reasonable to use a systolic blood pressure goal of less than 140 mm Hg and diastolic less than 90 mm Hg LEVEL 1.[6] Reducing daily salt intake to 2 g, engaging in regular physical activity, and losing weight in overweight or obese patients may also have substantial benefits on blood pressure levels, apart from use of pharmacologic therapy.

Hyperlipidemia

Hyperlipidemia is another important modifiable risk factor for vascular disease, although its relationship to stroke is less clear than that for heart disease. The Stroke Prevention by Aggressive Reduction of Cholesterol Levels trial provides direct evidence of the benefit of statin therapy in secondary prevention of stroke among patients presenting with stroke or TIA. The Stroke Prevention by Aggressive Reduction of Cholesterol Levels trial enrolled 4,731 patients with stroke or TIA within the previous 6 months, and at least 30 days, after stroke. Patients were required to have baseline LDL cholesterol levels between 100 and 190 mg/dL. Those with AF, cardioembolism, and SAH were excluded, and patients were randomized to atorvastatin 80 mg daily or to placebo. Over a median duration of follow-up of nearly 5 years, atorvastatin reduced the risk of recurrent stroke from 13.1% to 11.2%. Effects on other cardiovascular outcomes were slightly greater, but there was no effect on overall mortality.

Because lipids are not thought to contribute greatly to stroke risk, some of this benefit may derive from the anti-inflammatory or other effects of statins. Other putative mechanisms through which statins may exert their effects include effects on blood flow and vascular endothelial function, inflammation, free radical scavenging, hemostasis, and others.

Statins are the mainstay in lipid reduction therapy, and aggressive lipid-lowering treatment should be employed after a stroke or TIA LEVEL 1.[3] As discussed in the section on primary stroke prevention, PCSK9 inhibitors should be considered in patients with a history of stroke whose LDL levels remain elevated despite aggressive statin therapy and efforts to maximize lifestyle related factors.

Diabetes Mellitus

Although glycemic control has been shown to reduce risks of microvascular complications, the benefit in reducing macrovascular complications, such as stroke, is less certain. In one trial, tight glycemic control of a prospective cohort of newly diagnosed diabetics was not found to significantly reduce stroke risk. Nonetheless, among sufferers of stroke who have concomitant diabetes, diet and exercise, oral hypoglycemic drugs, and insulin are recommended to obtain appropriate glycemic control.

Lifestyle Modification

Behavioral risk factors may be most difficult to control, but physicians should endeavor to educate patients about their importance. Smoking is addictive, and cessation may necessitate

psychological counseling and medical aids, such as nicotine patches or varenicline. Physical activity should be encouraged, as a sedentary lifestyle is associated with elevations in blood pressure and stroke risk. Alcohol consumption in excess of two drinks daily should be discouraged, although there is evidence that moderate alcohol consumption may have protective effects against stroke risk. However, proof that control of these risk factors reduces stroke risk is difficult to obtain from randomized trials. Patient education regarding behavioral risk factor control is extremely important and is similar for both primary and secondary stroke prevention LEVEL 7.[4,5]

HEMORRHAGIC STROKE

Intracerebral Hemorrhage

The ICH accounts for approximately 10% to 15% of all strokes in the United States and carries a 1-year mortality close to 60%. Other than hypertension, spontaneous ICH can be caused by CAA or angiitis, anticoagulation therapy, vascular malformations, brain tumors, cavernous angiomas, aneurysms, cerebral vein thrombosis, illicit drugs or alcohol abuse, pathologic coagulopathy, infectious or inflammatory arteritis, and genetic vasculopathies. Massive ICH of more than 60 mL in volume is often lethal if surgical evacuation is not performed because vital structures are irreversibly damaged, whereas smaller hemorrhages may be treated with supportive care. Given the dismal 1-year prognosis even with small- to moderate-sized hemorrhage, primary prevention of ICH is of the upmost importance.

Hypertension

As with ischemic stroke, first-time ICH can in many cases be avoided through identification and management of specific risk factors. Hypertension is the most important modifiable risk factor and doubles the risk of first-time spontaneous ICH. Blood pressure control lowers the risk of ICH recurrence by nearly 50%. Annual recurrence is 2% of those with a deep location and as high as 4% of those with a lobar localization. The higher risk of recurrence with lobar hemorrhage likely represents the occurrence of CAA.

Cerebral Amyloid Angiopathy

The CAA is not yet modifiable. The CAA-associated microhemorrhages and microinfarcts are much more common than clinically evident bleeds. The biggest risk factors for recurrent CAA-associated hemorrhages are age, the number of microbleeds present at baseline, and the presence of the apolipoprotein E E2 or E4 alleles. Amyloid-depleting therapy is currently not approved for clinical use, limiting attempts at secondary prevention.

The PROGRESS trial, discussed earlier, studied a subset of patients with recurrent ICH and determined that blood pressure lowering by systolic/diastolic of 9/4 mm Hg decreased risk of cumulative ICH by 50%, and by over 70% in those with presumed CAA, establishing the viability of a traditional risk prevention approach in those with CAA-related hemorrhage. Many studies reported an association of HMG-CoA reductase inhibitors with an increased risk of ICH, but that concern was ultimately refuted by a large meta-analysis that included over 40 trials with nearly 250,000 individuals. Nonetheless, there is no benefit for statins in the prevention of ICH, although they may be used in those with previous ICH who have other indications, such as cardiovascular disease or ischemic stroke.

Issues Related to Risk of Hemorrhage

Anticoagulation-Associated Hemorrhage

The rates of major hemorrhage were compared among the DOACs and warfarin in a meta-analysis among 102,607 patients. The risk of major hemorrhage was about 28% lower among those on DOACs, and the risk of ICH was about 50% lower; there was no difference in risk of gastrointestinal bleeding. The incidence of ICH was 0.51% in the DOAC group and 1.08% in the warfarin group. Despite the relatively small absolute risk of ICH, chronic oral anticoagulation may be contraindicated if there are patient-specific factors, such as previous major hemorrhage, that may significantly increase the risk of future hemorrhage.

Management of Atrial Fibrillation in Patients at High Risk for Intracerebral Hemorrhage

Patients with a history of symptomatic hemorrhage thought to be related to CAA carry a relative contraindication for chronic anticoagulation. An alternative for such patients is left atrial appendage closure. Closing the atrial appendage was first theorized as a way to prevent AF-related thromboembolism, as an estimated 90% of thromboembolic material originates in the atrial appendage in patients with nonrheumatic AF. The two ways to achieve atrial appendage closure and make it functionally obsolete are through surgical ligation or through a catheter approach using the WATCHMAN device. The catheter-based approach involves venous catheterization and atrial septal puncture before insertion and deployment of the closure device in the atrial appendage. Randomized controlled trials comparing these devices to warfarin found them to be noninferior in efficacy. Pericardial effusion, periprocedural stroke, and device embolization accounted for the major early complications, whereas device thrombosis and resultant stroke can develop months after implantation. Left atrial appendage closure can therefore be considered in patients who have had a major bleed or carry an increased risk of ICH (**Fig. 45.3**).

Hemorrhage Related to Anticoagulation

Due to ease in administration and limited need for regular monitoring, physicians routinely recommend DOACs over warfarin for the prevention of thromboembolism in patients with nonvalvular AF. In the event of major hemorrhage, such as intracerebral bleeding, warfarin is effectively reversed by fresh frozen plasma or multifactor prothrombin complex concentrate. The development of antidotes for DOACS is an area of intense research. Idarucizumab is a monoclonal antibody against dabigatran and is currently U.S. Food and Drug Administration approved for reversal of dabigatran-related major hemorrhage. For factor Xa inhibitors, andexanet alfa—a modified recombinant inactive form of human factor Xa—has been shown to rapidly and effectively reduce levels of anticoagulant activity and thus decrease hemorrhage burden.

Arteriovenous Malformations

Bleeding from arteriovenous malformations (AVMs) is the most common cause of ICH in those younger than 45 years of age. The Medical Management with or without Interventional Therapy for Unruptured Brain Arteriovenous Malformations (ARUBA) trial

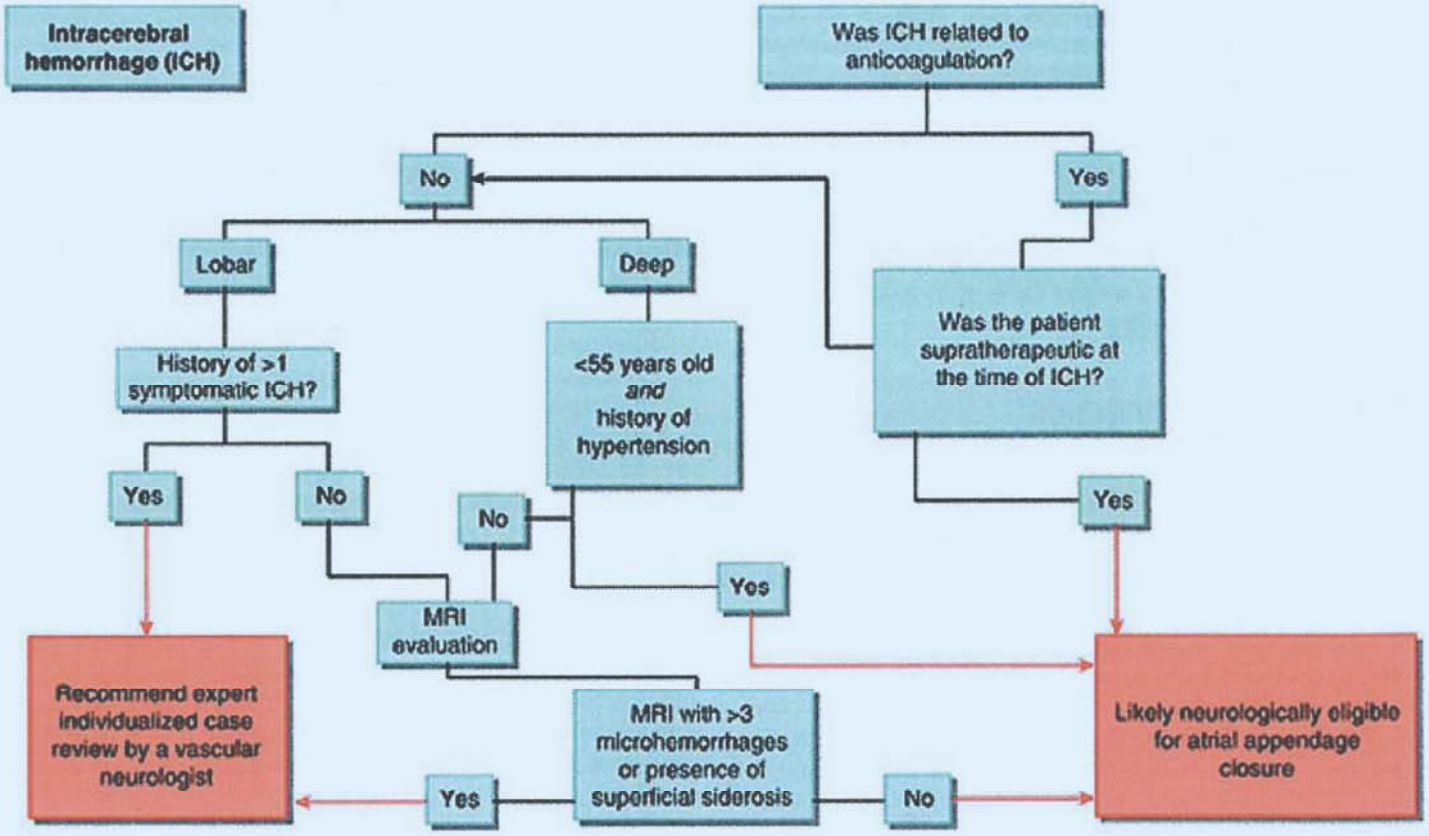

*This algorithm only takes into account patients with primary intracerebral hemorrage. Patients with secondary causes, such as from vascular malformation, should be considered separately.

FIGURE 45.3 Determining the need for atrial appendage closure. For patients with atrial fibrillation, atrial appendage closure should be considered when the risk of future intracerebral or major systemic hemorrhage is deemed insufficiently high, establishing a relative contraindication to anticoagulation. Individuals at very high risk for recurrent intracerebral hemorrhage (ICH) may not be candidates for atrial appendage closure, given the requirement among some practitioners for a concomitant short course of anticoagulation after the procedure. Abbreviation: MRI, magnetic resonance imaging.

evaluated interventional therapy versus medical therapy alone as management of previously unruptured AVMs. The study was stopped early because those in the medical therapy group had a lower risk of stroke or death compared to the intervention group. It is therefore prudent to manage unruptured AVMs conservatively. Heterogeneity of the lesions makes generalization to all AVMs difficult, however, and individual clinician and surgeon experience may also be considered. The AVMs that have ruptured are more likely to rebleed, and surgery, embolization, or stereotactic radiotherapy may be considered when anatomically feasible.

Aneurysmal Subarachnoid Hemorrhage

Extirpation of an aneurysm is the definitive therapy for aneurysms causing SAH and may be accomplished surgically or with balloons, coils, or embolic material deposited in the aneurysm. Prevention of aneurysmal rupture among patients with asymptomatic lesions, however, depends on the natural history of the aneurysm and risk of intervention. The International Study of Unruptured Intracranial Aneurysms defined annual risk of aneurysmal rupture by site and size of the aneurysm in question. The PHASES score was established in 2014 using a pooled analysis of six prospective trials, including over 8,000 individuals, to further help predict risk of aneurysmal rupture. It recognizes seven factors (hypertension, age, history of SAH, anatomic location, size, and geographical location of residence) as predictors of aneurysmal rupture that, when combined into a single score, could more accurately quantify future risk of rupture and help determine the need for intervention. The risk of rupture must be weighed against the risks of the intervention, which are determined by the patient's comorbidities and the historical periprocedural risk of the institution.

STROKE REHABILITATION

A team approach for stroke rehabilitation, starting from a stroke recovery unit with experienced physiatrists and physical, occupational and speech therapists, has proven beneficial for the optimum recovery of patients. This approach is particularly helpful in averting various complications from strokes, such as infections, contractures, and decubitus ulcers, and in maximizing independence for patients with hemiplegia/paresis by teaching them to transfer effectively from bed to wheelchair. Activities of daily living may be optimized for personal hygiene, dressing, and feeding as well. Speech and occupational therapists further help patients improve their skills needed in communication and performance of activities of daily living.

Depression is a frequent accompaniment of stroke, partially as a reaction to physical disability but also because there is altered brain chemistry, which may respond well to selective serotonin reuptake inhibitors and tricyclic antidepressants. One randomized trial found that escitalopram administered prophylactically to stroke patients was effective in preventing the development of depression. A Cochrane review of selective serotonin reuptake inhibitors in the poststroke setting showed them efficacious in improving not only depression but also stroke-related dependence as well as disability. Further studies will be needed to determine whether there is a benefit to prophylactic treatment of depression compared to treatment initiated at the time of diagnosis.

LEVEL 1 EVIDENCE

1. Law MR, Morris JK, Wald NJ. Use of blood pressure lowering drugs in the prevention of cardiovascular disease: meta-analysis of 147 randomised trials in the context of expectations from prospective epidemiological studies. *BMJ*. 2009;338:b1665.
2. American Diabetes Association. 10. Cardiovascular disease and risk management: *Standards of Medical Care in Diabetes—2019*. *Diabetes Care*. 2019;42(suppl 1):S103-S123.
3. Grundy SM, Stone NJ, Bailey AL, et al. 2018 AHA/ACC/AACVPR/AAPA/ABC/ACPM/ADA/AGS/APhA/ASPC/NLA/PCNA Guideline on the management of blood cholesterol: a report of the American College of Cardiology/American Heart Association Task Force on Clinical Practice Guidelines. *J Am Coll Cardiol*. 2019;73(24):e285-e350.
4. Meschia JF, Bushnell C, Boden-Albala B, et al. Guidelines for the primary prevention of stroke: a statement for healthcare professionals from the American Heart Association/American Stroke Association. *Stroke*. 2014;45(12):3754-832.
5. Kernan WN, Ovbiagele B, Black HR, et al. Guidelines for the prevention of stroke in patients with stroke and transient ischemic attack: a guideline for healthcare professionals from the American Heart Association/American Stroke Association. *Stroke*. 2014;45(7):2160-2236.
6. James PA, Oparil S, Carter BL, et al. 2014 Evidence-based guideline for the management of high blood pressure in adults: report from the panel members appointed to the Eighth Joint National Committee (JNC 8). *JAMA*. 2014;311(5):507-520.

SUGGESTED READINGS

Amarenco P, Bogousslavsky J, Callahan A III, et al. High-dose atorvastatin after stroke or transient ischemic attack. *N Engl J Med*. 2006;355(6):549-559.

Arima H, Tzourio C, Anderson C, et al. Effects of perindopril-based lowering of blood pressure on intracerebral hemorrhage related to amyloid angiopathy: the PROGRESS trial. *Stroke*. 2010;41(2):394-396.

Bailey RD, Hart RG, Benavente O, Pearce LA. Recurrent brain hemorrhage is more frequent than ischemic stroke after intracranial hemorrhage. *Neurology*. 2001;56(6):773-777.

Boden-Albala B, Cammack S, Chong J, et al. Diabetes, fasting glucose levels, and risk of ischemic stroke and vascular events: findings from the Northern Manhattan Study (NOMAS). *Diabetes Care*. 2008;31(6):1132-1137.

Burnett AE, Mahan CE, Vazquez SR, Oertel LB, Garcia DA, Ansell J. Guidance for the practical management of the direct oral anticoagulants (DOACs) in VTE treatment. *J Thromb Thrombolysis*. 2016;41(1):206-232.

Chimowitz MI, Lynn MJ, Howlett-Smith H, et al. Comparison of warfarin and aspirin for symptomatic intracranial arterial stenosis. *N Engl J Med*. 2005;352(13):1305-1316.

Connolly SJ, Ezekowitz MD, Yusuf S, et al for RE-LY Steering Committee and Investigators. Dabigatran versus warfarin in patients with atrial fibrillation. *N Engl J Med*. 2009;361(12):1139-1151.

DeBakey ME. Successful carotid endarterectomy for cerebrovascular insufficiency. Nineteen-year follow-up. *JAMA*. 1975;233(10):1083-1085.

Derdeyn CP, Chimowitz MI, Lynn MJ, et al. Aggressive medical treatment with or without stenting in high-risk patients with intracranial artery stenosis (SAMMPRIS): the final results of a randomised trial. *Lancet*. 2014;383(9914):333-341.

Eckstein HH, Ringleb P, Allenberg JR, et al. Results of the Stent-Protected Angioplasty versus Carotid Endarterectomy (SPACE) study to treat symptomatic stenoses at 2 years: a multinational, prospective, randomised trial. *Lancet Neurol*. 2008;7(10):893-902.

Ederle J, Dobson J, Featherstone RL, et al. Carotid artery stenting compared with endarterectomy in patients with symptomatic carotid stenosis (International Carotid Stenting Study): an interim analysis of a randomised controlled trial. *Lancet*. 2010;375(9719):985-997.

Elkind MS. Implications of stroke prevention trials: treatment of global risk. *Neurology*. 2005;65(1):17-21.

Elkind MS, Sacco RL, Macarthur RB, et al. High-dose lovastatin for acute ischemic stroke: results of the phase I dose escalation Neuroprotection with Statin Therapy for Acute Recovery Trial (NeuSTART). *Cerebrovasc Dis*. 2009;28(3):266-275.

Estruch R, Ros E, Martínez-González MA. Mediterranean diet for primary prevention of cardiovascular disease. *N Engl J Med*. 2013;369(7):676-677.

Granger CB, Alexander JH, McMurray JJ, et al. Apixaban versus warfarin in patients with atrial fibrillation. *N Engl J Med*. 2011;365(11):981-992.

Greving JP, Wermer MJ, Brown RD Jr, et al. Development of the PHASES score for prediction of risk of rupture of intracranial aneurysms: a pooled analysis of six prospective cohort studies. *Lancet Neurol*. 2014;13(1):59-66.

Hackam DG, Woodward M, Newby LK, et al. Statins and intracerebral hemorrhage: collaborative systematic review and meta-analysis. *Circulation*. 2011;124(20):2233-2242.

Halkes PH, van Gijn J, Kappelle LJ, Koudstaal PJ, Algra A. Medium intensity oral anticoagulants versus aspirin after cerebral ischaemia of arterial origin (ESPRIT): a randomised controlled trial. *Lancet Neurol*. 2007;6(2):115-124.

Iso H, Jacobs DR Jr, Wentworth D, Neaton JD, Cohen JD. Serum cholesterol levels and six-year mortality from stroke in 350,977 men screened for the multiple risk factor intervention trial. *N Engl J Med*. 1989;320(14):904-910.

Johnston SC, Gress DR, Browner WS, Sidney S. Short-term prognosis after emergency department diagnosis of TIA. *JAMA*. 2000;284(22):2901-2906.

Kent DM, Ruthazer R, Weimar C, et al. An index to identify stroke-related vs incidental patent foramen ovale in cryptogenic stroke. *Neurology*. 2013;81(7):619-625.

Lackland DT, Roccella EJ, Deutsch AF, et al. Factors influencing the decline in stroke mortality: a statement from the American Heart Association/American Stroke Association. *Stroke*. 2014;45(1):315-353.

LaRosa JC, Grundy SM, Waters DD, et al. Intensive lipid lowering with atorvastatin in patients with stable coronary disease. *N Engl J Med*. 2005;352(14):1425-1435.

Lavallée PC, Meseguer E, Abboud H, et al. A transient ischaemic attack clinic with round-the-clock access (SOS-TIA): feasibility and effects. *Lancet Neurol*. 2007;6(11):953-960.

Luengo-Fernandez R, Gray AM, Rothwell PM. Effect of urgent treatment for transient ischaemic attack and minor stroke on disability and hospital costs (EXPRESS study): a prospective population-based sequential comparison. *Lancet Neurol*. 2009;8(3):235-243.

Mantese VA, Timaran CH, Chiu D, Begg RJ, Brott TG; for CREST Investigators. The Carotid Revascularization Endarterectomy versus Stenting Trial (CREST): stenting versus carotid endarterectomy for carotid disease. *Stroke*. 2010;41(10 suppl):S31-S34.

Meier B, Frank B, Wahl A, Diener HC. Secondary stroke prevention: patent foramen ovale, aortic plaque, and carotid stenosis. *Eur Heart J*. 2012;33(6):705-713, 713a, 713b.

Mohr JP, Parides MK, Stapf C, et al. Medical management with or without interventional therapy for unruptured brain arteriovenous malformations (ARUBA): a multicentre, non-blinded, randomised trial. *Lancet*. 2014;383(9917):614-621.

Mohr JP, Thompson JL, Lazar RM, et al. A comparison of warfarin and aspirin for the prevention of recurrent ischemic stroke. *N Engl J Med*. 2001;345(20):1444-1451.

Ntaios G, Papavasileiou V, Sagris D, et al. Closure of patent foramen ovale versus medical therapy in patients with cryptogenic stroke or transient ischemic attack: updated systematic review and meta-analysis. *Stroke*. 2018;49(2):412-418.

Patel MR, Mahaffey KW, Garg J, et al. Rivaroxaban versus warfarin in nonvalvular atrial fibrillation. *N Engl J Med*. 2011;365(10):883-891.

PROGRESS Collaborative Group. Randomised trial of a perindopril-based blood-pressure-lowering regimen among 6,105 individuals with previous stroke or transient ischaemic attack. *Lancet*. 2001;358(9287):1033-1041. doi:10.1016/S0140-6736(01)06178-5.

Reddy VY, Doshi SK, Kar S, et al. 5-Year outcomes after left atrial appendage closure: from the PREVAIL and PROTECT AF trials. *J Am Coll Cardiol*. 2017;70(24):2964-2975.

Rengifo-Moreno P, Palacios IF, Junpaparp P, Witzke CF, Morris DL, Romero-Corral A. Patent foramen ovale transcatheter closure vs. medical therapy on recurrent vascular events: a systematic review and meta-analysis of randomized controlled trials. *Eur Heart J*. 2013;34(43):3342-3352.

Ridker PM, Cook NR, Lee I-M, et al. A randomized trial of low-dose aspirin in the primary prevention of cardiovascular disease in women. *N Engl J Med*. 2005;352(13):1293-1304.

Robinson RG, Jorge RE, Moser DJ, et al. Escitalopram and problem-solving therapy for prevention of poststroke depression: a randomized controlled trial. *JAMA*. 2008;299(20):2391-2400.

Sacco RL, Chong JY, Prabhakaran S, Elkind MSV. Experimental treatments for acute ischaemic stroke. *Lancet*. 2007;369(9558):331-341.

Sacco RL, Diener HC, Yusuf S, et al. Aspirin and extended-release dipyridamole versus clopidogrel for recurrent stroke. *N Engl J Med*. 2008;359(12):1238-1251.

Standl E, Schnell O, Ceriello A. Postprandial hyperglycemia and glycemic variability: should we care? *Diabetes Care*. 2011;34(suppl 2):S120-S127.

Viswanathan A, Greenberg SM. Cerebral amyloid angiopathy in the elderly. *Ann Neurol*. 2011;70(6):871-880.

Wang Y, Wang Y, Zhao X, et al. Clopidogrel with aspirin in acute minor stroke or transient ischemic attack. *N Engl J Med*. 2013;369(1):11-19.

Wiebers DO, Whisnant JP, Huston J III, et al. Unruptured intracranial aneurysms: natural history, clinical outcome, and risks of surgical and endovascular treatment. *Lancet*. 2003;362(9378):103-110.

Wolf SL, Winstein CJ, Miller JP, et al. Effect of constraint-induced movement therapy on upper extremity function 3 to 9 months after stroke: the EXCITE randomized clinical trial. *JAMA*. 2006;296(17):2095-2104.

Wright JT Jr, Williamson JD, Whelton PK, et al. A randomized trial of intensive versus standard blood-pressure control. *N Engl J Med*. 2015;373(22):2103-2116.

Concussion and Chronic Traumatic Encephalopathy 46

James M. Noble and John F. Crary

KEY POINTS

1. Concussion is a mild traumatic brain injury defined by transient neurologic signs and symptoms, with or without loss of consciousness.
2. Concussion is highly visible in youth and young adult contact and collision sports but occurs more often in nonsports contexts and across the age span.
3. Concussion is further distinguished from other forms of traumatic brain injury by having no evidence of brain injury on standard neuroimaging.
4. Ongoing efforts are working toward a biomarker-based diagnostic and prognostic assessments, but at present, concussion remains a clinical diagnosis.
5. Chronic traumatic encephalopathy is a pathologic entity of uncertain frequency, which occurs almost exclusively in persons with multiple recognized traumatic brain injuries or a history of longitudinal exposure to activities at risk for frequent head contact and injury.
6. The diagnostic hallmark of chronic traumatic encephalopathy is accumulation of abnormal hyperphosphorylated tau in a distinct neuroanatomic distribution, which differentiates it from other neurodegenerative diseases and aging.
7. Traumatic encephalopathy syndrome is a proposed clinical correlate for chronic traumatic encephalopathy, recognizing features including cognitive and behavioral changes, parkinsonism, and motor neuron disease.

CONCUSSION

Introduction

Concussion is a mild traumatic brain injury (TBI) that has been recognized for centuries as an entity in accidents, battle, and sport. The visibility of higher profile cases of recurrent concussion in contact sports and growing concern for potential long-term impacts of concussion have brought it to the fore in recent years. These concerns have particularly focused on potentially vulnerable youths and developing brains. Significant inroads have been made over the past 15 years into understanding the pathobiology of near- and long-term consequences of single and repeat concussion and its epidemiology particularly in sports. Major challenges in the field include the need for improved accuracy of diagnosis in real-time, biomarker-based assessments to better determine objective metrics of recovery, and personalized risk assessment for recurrent injury.

Definition

Concussion is a mild TBI defined by a typically transient appearance of neurologic signs and symptoms, including headache, dizziness, imbalance, tiredness and fatigue, light and sound sensitivity, concentration difficulties, and memory impairment (often described as a brain "fog"), sleep disturbance, or mood disorder, following either a direct or an indirect rapid movement in the brain causing extreme rotational or translational brain acceleration or deceleration injury. Loss of consciousness at the time of impact is not required to make a diagnosis of concussion. Additional symptoms of the time of impact may include transient visual disturbances or spontaneous visual hallucinations, commonly described to "seeing stars." A related term, *subconcussive brain injury*, is also a mild TBI, often with the same underlying cause or etiology of concussive injury, but without any signs or symptoms.

Concussion can occur by any traumatic etiology including falls from a sufficient height, motor vehicle accidents, nonpenetrating blast injuries in the field of combat, domestic violence, or other physical traumatic events. *Sport-related concussion* (SRC) is defined as a concussion that occurs coincidentally during the play of a contact sport with a high risk of concussion (ie, American football, soccer [European football], hockey, lacrosse, basketball, wrestling, and rugby, among others) or during combat sports, which are distinguished by having the specific goal of inducing a concussion in the opponent (boxing, mixed martial arts, and related sports). Regardless of the etiology of concussion, the symptoms are largely indistinguishable but may have differing psychosocial factors associated with recovery.

In contrast to other more advanced forms of TBI, concussion lacks defining neuroradiologic features such as hemorrhage or other obvious abnormalities on conventional neuroimaging such as computed tomography (CT) or magnetic resonance imaging (MRI). Although imaging biomarkers including high-field MRI sequences such as diffusion tensor imaging and functional MRI, fluid-based biomarkers and electroencephalogram approaches are currently under study, none is presently used

in part of standard of care practice for the diagnosis of concussion or subconcussive injuries. Given substantial differences in these MRI sequences between individuals, the comparison of an individual against normative values has substantial limitations and thus currently limits the use of diffusion tensor imaging and functional MRI principally to research rather than clinical practice.

Epidemiology

The substantial degree of heterogeneity in TBI has made determining its epidemiology difficult. No two injuries are alike, person to person, or even within a single individual with multiple concussions. Other differences in each injury include mechanism of injury, forces applied to and head kinematics of the injured person, the location of injury, the context in which the injury occurred, as well as the likelihood of reporting symptoms. The lifetime incidence of single and repeat concussion is not well-known but is thought to occur in several million individuals annually in the United States alone. The epidemiology follows a trimodal pattern over lifetime with peaks in the first few months of life, followed by adolescence, and followed by a third peak in the elderly. Contributions to concussion etiology among the very young and very old likely principally relate to accidental falls, whereas concussions in adolescents is related to risk-taking behaviors involving driving, exposure to violence, as well as exposure to increasingly competitive athletics.

Although SRC comprises only a small fraction of all concussions, SRC offers the opportunity for more clearly establishing its epidemiology, symptomatology, and recovery timelines given relatively contained systems in place for monitoring athletes, particularly at the collegiate level. The annual incidence of SRC is at least 300,000 in the United States alone, although this is likely an underestimate given poor recognition by affected players. The epidemiology of recurrent concussion is not well described but is thought to happen in a small proportion of players previously affected by SRC who may be at subsequent greater risk. Factors leading to recurrent concussion are not well-known and may relate to ongoing exposure to sports at high risk for contact and collision.

Pathobiology

Given that concussion patients generally have no evidence of structural brain injury using conventional neuroimaging with MRI or CT, concussion has historically been considered a physiologic alteration, but this has become a matter of some debate. Concussion may reflect substantial physiologic disturbance with significant microstructural axonal disruption, which remains difficult to detect but nonetheless occurs. These injuries may be widespread or alternatively relatively focal but involving pathways with major widespread clinical implications. Experimental models suggest metabolic changes including elevated tissue lactate, which peaks over the course of several days followed by gradual recovery of cerebral blood flow within the affected tissues, with most demonstrable changes resolving by 7 to 10 days. In response to rotational or translational shear physical stress, animal histopathologic models of concussion demonstrate disruption of the viscoelastic properties of axons with rare disruption or lysis of axons themselves (**Fig. 46.1**).

When considering an individual experiencing a single concussion, injury thresholds required to cause concussion are not well understood but are thought to occur following at least 60 g of linear acceleration or at least 2,000 to 4,000 rad/s^2 rotational acceleration; these forces are seldom if ever experienced in the course of normal daily life outside of recognized physically traumatic events experienced by the affected individuals. At present, risks for concussion occurrence, severity, and recurrence are not well understood but suggest prior TBI raises the risk of subsequent concussion. The highly variable nature of concussion expression and recovery raises the possibility of an unrecognized gene-environment risk profile.

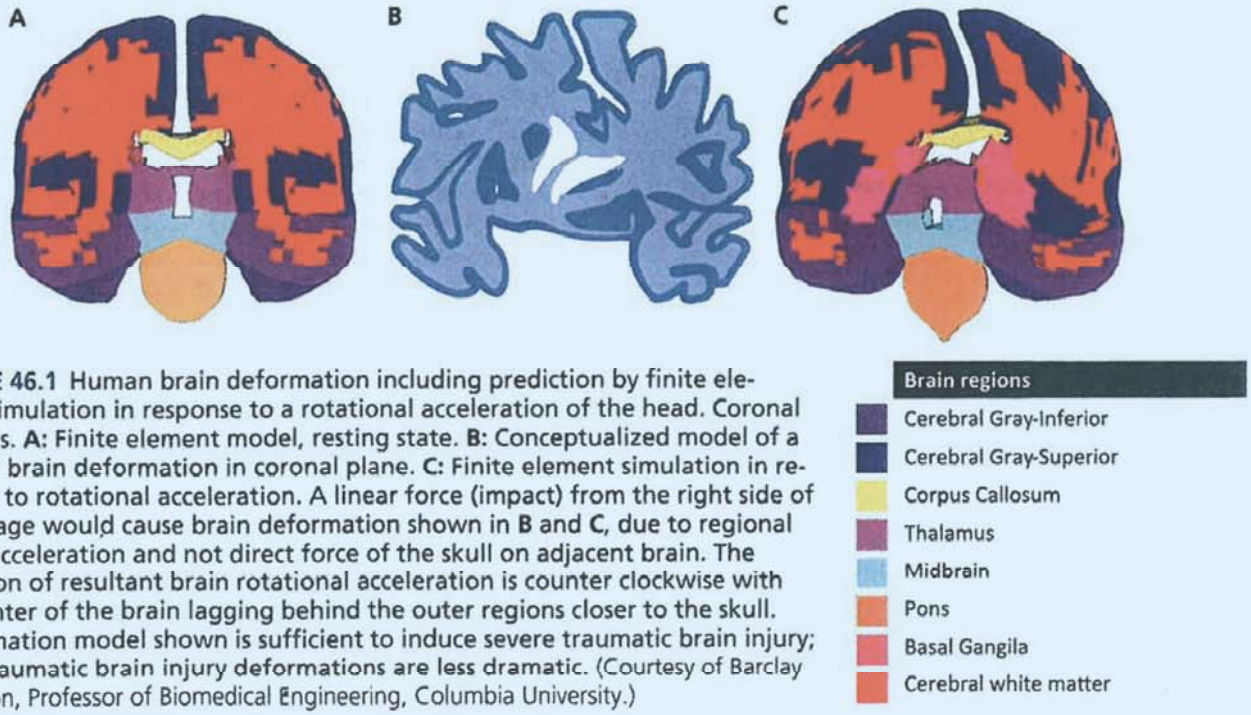

FIGURE 46.1 Human brain deformation including prediction by finite element simulation in response to a rotational acceleration of the head. Coronal sections. **A:** Finite element model, resting state. **B:** Conceptualized model of a human brain deformation in coronal plane. **C:** Finite element simulation in response to rotational acceleration. A linear force (impact) from the right side of the image would cause brain deformation shown in **B** and **C**, due to regional brain acceleration and not direct force of the skull on adjacent brain. The direction of resultant brain rotational acceleration is counter clockwise with the center of the brain lagging behind the outer regions closer to the skull. Deformation model shown is sufficient to induce severe traumatic brain injury; mild traumatic brain injury deformations are less dramatic. (Courtesy of Barclay Morrison, Professor of Biomedical Engineering, Columbia University.)

Diagnosis

Concussion experienced in nonsports contexts, such as motor vehicle accidents or other causes of trauma, is often diagnosed at the time that the individual is brought to attention for other matters related to bodily or head trauma. Although many concussion screening rubrics have been proposed, fundamentally, the diagnosis is based on a clinician's suspicion that concussion has occurred based on neurologic symptoms and that a more serious form of TBI has not occurred. In concussion, there should be no significant focal neurologic findings on examination. Any localizing or lateralizing signs or symptoms should prompt a clinician to consider neuroimaging, such as CT if the patient is suspected of having urgently declining neurologic condition or MRI if the patient is being assessed in a nonurgent setting or experiencing unexpectedly prolonged recovery of signs or symptoms following injury.

A number of devices and tools have been suggested to comprise concussion monitoring strategies, including questionnaires, complemented by a range of tests from simple reaction time to automated neuropsychological testing to more formal/conventional neuropsychological testing. Aside from symptom inventories and cognitive screening, initial and subsequent clinical exams following concussion should specifically focus on balance and eye movements. Balance assessments can include conventional assessments of gait and station, but more sensitive tests including tandem station and single foot stance may be further revealing of subtle balance problems. Moreover these can be tracked in the office and by the patient over time to monitor recovery. Extraocular movement abnormalities may include spontaneous or provoked nystagmus, saccadization of pursuits and overshoot of distal targets, impaired convergence, and impaired suppression of the vestibulo-ocular response. These can often be identified on clinical examination; formal assessment of extraocular movements may be useful in subtle or refractory cases, especially if misalignment is suspected. Accompanying TBI may be other sequelae of the same injury mechanism, including benign paroxysmal positional vertigo, whiplash injury, and focal traumatic cranial neuropathies.

In the special case of SRC, in recent years, a more conservative approach to care has involved youth, collegiate, and professional sports. Broadly speaking, aims have shifted toward early recognition of injury (including on the field or sideline), removal from play when concussion has been suspected, and no return to play until medically cleared. Legal statutes dictate this approach in youth sports in all 50 states, and conference/league policies now take a similar approach in collegiate and professional levels. Once the athlete has been removed from play, the approach to diagnosis is similar to that of other persons with concussion, although some tools have been developed specifically for sports. Current consensus guidelines advocate the use of a standardized screening assessment, such as the Sideline Concussion Assessment Tool (fifth version) in the context of game play, but the validity of this and other screening tools in clinical contexts remain uncertain, and a comprehensive neurologic assessment should be pursued whenever concussion is suspected.

With the exception of formal neuropsychological testing, which has a significant disadvantage as a screening tool given its cost and time required, most if not all, other tests in this field were developed as tools to assist in sideline assessments by nonmedical staff, with the intention of screening to limit the risk of prematurely returning a player to contact sport. Thus, they must be interpreted with some caution and cannot supplant formal neurologic evaluation, which may capture subtleties not otherwise recognized on these screening assessments. Moreover, some screening assessments are considered normal within a relatively large range of values, are prone to baseline errors and retest bias, and may have limited generalizability beyond a relatively small reference population of youth and young adult athletes. Finally, most tests used in serial concussion monitoring programs are susceptible to "gaming" or "sandbagging" by a player eager to return to play, with baseline assessments purposefully performed poorly such that postconcussion assessments may not substantially differ.

Management

At present, there are no rigorously studied or U.S. Food and Drug Administration–approved medical therapies or physical therapy treatments, which have been clearly proven to hasten recovery following a single concussion or improve lingering postconcussion symptoms. Empiric approaches to concussion treatment among non-SRC are based on approaches developed for SRC recovery. For SRC, guidelines recommend at least 24 hours removal from contact sport following any suspected concussion. Thereafter, players experience a graduated, patient-centered return-to-play protocol beginning with slow introduction of aerobic, followed by anaerobic exercise leading into full contact drills. In the past, "cocoon therapy," or prolonged rest and removal from any potentially cognitively or physically engaging scenarios, was suggested but is now thought to not only not work but may even delay recovery or make patients worse. Instead, symptom-limited engagement in physical, cognitive, and social activities should be resumed as early as possible and in a graduated manner. Recovery from concussion of any kind typically takes place over the course of at least a week following a suspected concussion, predicated on a player not reexperiencing symptoms of concussion as each threshold of activity is gradually approached. In the case of an athlete, only when a player is symptom-free and off all medications potentially providing a clinical advantage or benefit (including those used for pain relief) is the player considered to have recovered from a concussion.

Although much attention has historically been paid to reengaging an athlete in their sport, return to academic activity in student-athletes is of high priority. The process of engaging the injured student, their school, and parents in academic and other scholarly activities involves a multimodal treatment approach referred to as *return to learn*. Youth athletes should have completed their return to learn process with full recovery before cleared to return to sports at high risk for contact/collision or other high-risk activities. At each point of contact with a young individual having experienced concussion, clinicians should attempt to assess the player's current level of stamina for athletic and/or cognitively stimulating activities as well as potentially aggravating symptoms such as screen time in the course of computer or cellular telephone use typically used in social and academic settings. These guidelines provide a tool to monitor progress and encourage the individual to be an active participant in the recovery. Approaches to patients affected by concussion in nonsport contexts should follow similar threshold-based, gradual, patient-centered approaches to return to work, social, and professional life. Psychological support, at the same time as supporting physiologic recovery from concussion, can be a

key element of treatment in both children and adults, who may perceive that they are falling behind in their personal, social, and academic goals. Engaging the patient, family, school, or work may be helpful in setting shared expectations of recovery and support of the individual along the course of recovery.

Retirement from sport or a risky behavior associated with recurrent concussions in an individual may be considered in some scenarios; in the context of SRC, this concept is called *medical retirement* or *medical disqualification from sport*. Such a discussion is done in a highly individualized and often challenging manner, balancing factors of patient and family motivation, potential scholarship, or other fiscal incentive to continue playing against an uncertain and highly variable neurologic prognosis. However, this may be an appropriate decision among players who demonstrate progressively lower thresholds of injury required to express concussion; progressively longer neurologic recovery periods following successive concussions; and declining scholarly, neuropsychological, or athletic performance.

Outcome

The natural history of a single uncomplicated concussion is not well understood. Based on SRC studies of high school and collegiate athletes involved in contact sports, approximately 80% to 90% of all persons with single uncomplicated concussions will fully recover within several days to 2 weeks. In the short term, approximately 10% to 20% of individuals with concussion will have a prolonged recovery—longer than 1 to 2 weeks and occasionally up to several months. Symptoms lingering beyond this time frame raise the possibility of a preexistent or superimposed neuropsychological condition including a mood disorder or premorbid migraine headaches. Some studies have suggested that recurrent concussions portend to a more prolonged recovery, with decreasing threshold of injury in some being associated with subsequent concussion.

Following head trauma of any kind, including concussion, patients may be more likely to express migraine headaches, mood disorders, or benign paroxysmal positional vertigo, given the likely contribution of the impact to canalithiasis. At present, no evidence exists to treat these individuals any differently than would a patient be treated with these diagnoses as primary or nontraumatic disorders. However, some patients experiencing several lingering symptoms or syndromes may be best served by using therapies, which offer treatment impact in multiple modalities through a relatively simple regimen. Some evidence of nonsport mild TBI suggests that social, interpersonal, and professional repercussions of TBI may be more apparent in the long term even after objective cognitive deficits have resolved. Those engaging in early care and support may be able to address emerging behavioral and interpersonal issues, which can begin to emerge around the time of objective neurologic recovery but before full return to social, academic, and professional routines.

The long-term risks and outcomes associated with single uncomplicated concussion are not well-known, and large epidemiologic studies have found inconsistent relationships in clinical and pathologic outcomes. Studies of apolipoprotein E4 are limited but have not identified differences in concussion risk or recovery based on carrier status. Although single uncomplicated concussion is considered a mild TBI, recurrent concussions have been associated with significantly increased likelihood of developing major neuropsychiatric disorders associated with aging, including depression, dementia, Parkinson disease, amyotrophic lateral sclerosis, and erratic psychosocial behaviors including drug abuse and suicide, thus significantly impacting the quality of life of many affected individuals and their families.

One reason for the mandatory removal from play for a suspected concussion and graduated return to play thereafter is based on concern for a rare yet clearly defined neurologic syndrome called *second impact syndrome*. The disease has been identified exclusively among individuals who have returned to sports or had a second concussion prior to complete recovery from the first concussion, even if the two events are separated by days. The pathophysiology of second impact syndrome is not well understood but appears to involve severe, aggressive, and often medically refractory focal or whole brain edema following the second concussion.

CHRONIC TRAUMATIC ENCEPHALOPATHY

Introduction

Chronic traumatic encephalopathy is a term used to describe the long-term neurodegenerative pathology that arises following repetitive concussions (ie, mild TBI). Chronic traumatic encephalopathy (CTE) was initially termed *punch drunk* and later *dementia pugilistica* in light of its long-established association with boxing. The CTE can arise in any individual with repetitive concussive or subconcussive injuries (eg, victims of domestic violence and autistic patients with head-banging behavior), but athletes who have participated in contact and/or combat sports have received the most attention. Military veterans represent another at-risk population that has been increasingly studied. Furthermore, some veterans with a clinical diagnosis of posttraumatic stress disorder have been found to have CTE at autopsy, suggesting a potential overlap between these conditions. The diagnostic hallmark is accumulation of abnormal hyperphosphorylated tau protein in a distinct neuroanatomic distribution that clearly differentiates it from other neurodegenerative diseases and aging.

Epidemiology

The epidemiology of CTE is not well established given the lack for formalized diagnostic clinical criteria, some similarities with other sporadic neurodegenerative diseases. Some pathologic studies suggest coexpression of CTE with other pathologies, including Alzheimer disease, Lewy body diseases, and cerebral amyloid angiopathy, is common, and TBI exposure may make these other copathologies more severe. As is the case in degenerative cognitive disorders, clinical features may incompletely track with pathologic findings, including presence and severity of CTE and related pathologies. This is even so in known high-risk combat sports such as boxing where to date, only case series have been published, followed by more recent series involving participants in contact sports such as football, hockey, baseball, and soccer as well as combat military veterans. Case reports also exist among domestic violence victims. A recent case series of professional football players from a highly selected population of families and individuals concerned about major neurobehavioral

changes identified CTE in the vast majority of subjects. Despite potential for bias, for all known professional American football brain autopsies among the published 110 cases published as of 2017 coincided with approximately 1,300 known deaths over the same time frame. Thus, a minimum of 8.5% had neuropathologic-defined CTE at death. An expanded autopsy cohort suggested a dose dependence between years of professional football and both CTE risk and severity. Several young football players with neuropathologically defined early-stage CTE, who died for unrelated causes, have had no recognizable neurologic or psychiatric symptoms. However, a growing concern is that it may have substantial clinical sequelae when advanced neuropathologic changes are present. To date, the disease has not been recognized in the absence of head trauma, although the threshold of risk (how much and how severe injury is required to cause CTE) remains uncertain. Also, whether a single TBI can trigger CTE is not known.

Pathobiology

The pathogenesis of CTE is currently under investigation. Physical trauma is thought to lead to mechanical stress in the acute setting, shearing cellular structures (eg, axons, dendrites, synaptic connections, glial processes, and blood vessels), resulting in cognitive impairment, or postconcussive syndrome. Associated molecular changes with acute trauma include elevation of amyloid precursor protein and other proteins. Repetitive injury may progress to neurodegeneration, sometimes many years later. Gross brain changes are nonspecific but include brain atrophy and a cavum septum pellucidum. Microscopically, CTE patients exhibit marked accumulation of abnormal aggregates containing hyperphosphorylated forms of the microtubule-associated protein tau. Tau pathology is present in neurons and glia, leading to some diagnostic confusion at autopsy, especially in older patients who may have comorbid primary age-related tauopathy or aging-related tau astrogliopathy. Importantly, the pattern of tau pathology in CTE is distinct, with accentuation in mechanically vulnerable brain regions, including the neocortical sulcal depths and perivascular regions, which is pathognomonic (Fig. 46.2). The CTE as a sole pathology may be more likely discovered among younger persons with a history of recurrent TBI exposure. As many as 85% of CTE patients also exhibit accumulation of 43 kDa TAR DNA–binding protein, the primary disease protein in amyotrophic lateral sclerosis. Amyloid plaques that are characteristic of Alzheimer disease and α-synuclein–positive inclusions of Parkinson disease can also be observed. Additional findings are diverse, including subcortical axonal varicosities and axonal loss.

Diagnosis

The proposed clinical correlate of CTE has been termed *traumatic encephalopathy syndrome* (TES) and is associated with a spectrum of personality and behavioral changes, depression, increased suicidal behavior, memory loss, and cognitive dysfunction. The clinical spectrum of TES is broad, and the full extent of the symptomatology awaits larger autopsy series, but recent research suggests that TES has two clinical variants. The first is a *behavioral/mood variant* with features that develop at a younger age. The other is a *cognitive variant* that arises at an older age. Movement disorders, including parkinsonism, are also common. Proposed criteria for TES are provided in **Table 46.1**.

Furthermore, it is not uncommon to observe motor neuron disease in CTE patients; this had been referred to as *chronic traumatic encephalomyelopathy*, but this term has fallen out of favor. Dementia, parkinsonism, and motor neuron disease can occur singly or collectively in a single patient. Cognitive decline may be similar clinically to Alzheimer disease or frontotemporal dementia and the approach to the patient presenting with TES should involve the diagnostic approach taken in diagnosing other neurodegenerative disorders. A TES can serve as an alternative explanation to atypical presentations of neurodegenerative cognitive disorders but remains a diagnosis of exclusion at present. Most CTE cases are thought to progress over decades. Manifestations of neurologic decline typically begin years after cessation of exposure to high-risk sports or recognized head injury, although some athletes have quit after developing chronic cognitive problems in the context of ongoing competitive play. Whether these changes signal active clinical manifestations of CTE is of great debate because no validated in vivo biomarkers currently exist.

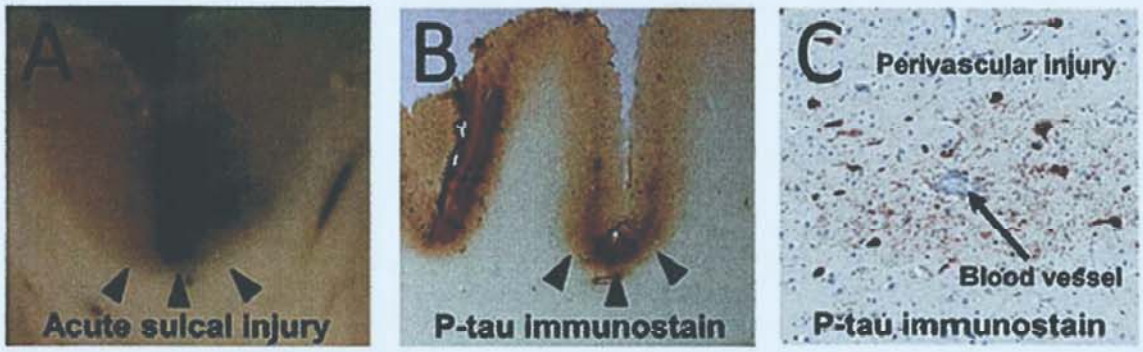

FIGURE 46.2. Regional vulnerability following traumatic brain injury. **A:** Contusions can be demonstrated grossly in the depths of the neocortical sulci after acute traumatic brain injury *(arrowheads)*. **B:** Immunohistochemistry using antisera that specifically target abnormal hyperphosphorylated tau (p-tau) reveals a predilection for the neocortical sulci *(arrowheads)* in a retired professional football player with chronic traumatic encephalopathy. **C:** Photomicrograph of a brain section from the cortex of a patient with chronic traumatic encephalopathy showing p-tau immunostain-positive neurons *(brown)* surrounding a blood vessel *(arrow)*. The section is counterstained with hematoxylin *(blue)*. (**B** courtesy of Dr. Ann McKee, Boston University.)

TABLE 46.1 Diagnostic Criteria for Traumatic Encephalopathy Syndrome[a]

Required Features	Supportive Features
Persistence of symptoms for longer than 2 y	Emotional dysregulation including depression, anxiety, agitation, aggression, paranoid ideation, deterioration of interpersonal relationships, and suicidality
Absence of another neurologic disorder that is more likely to account for all the clinical features	Behavioral change including violence, poor impulse control, socially inappropriate behavior, avolition, apathy, change in personality, and comorbid substance abuse
History of head trauma exposure, typically associated with history of concussion, although may be limited to subconcussive trauma Head trauma exposure is repetitive in nature Progressive course Delayed symptom onset Self-report or observer report of cognitive dysfunction, typically affecting more than one domain, confirmed with objective cognitive decline documented by results of formal neuropsychological testing	Motor disturbance including bradykinesia, tremor, rigidity, gait instability, dysarthria, dysphagia, ataxia, and gaze disturbance
Criteria for Diagnosis	
Possible TES: requires history of head trauma exposure, persistence of symptoms for longer than 2 y, no other neurologic disorder that is more likely to account for all the clinical features, progressive course, and at least one supportive feature.	
Probable TES: meets the criteria of possible TES plus history of traumatic impact exposure that is repetitive in nature, delayed symptom onset, cognitive decline, and at least one supportive feature.	
Unlikely TES would not meet minimum diagnostic criteria for possible TES and may include individuals in whom another neurodegenerative disease or psychiatric disorder is likely.	

Abbreviation: TES, traumatic encephalopathy syndrome.
[a]Adapted from Reams N, Eckner JT, Almeida AA, et al. A clinical approach to the diagnosis of traumatic encephalopathy syndrome: a review. *JAMA Neurol.* 2016;73(6):743-749.

Management

The care of patients with a history TBI and possible or probable TES should involve an individualized care plan, tailored toward supporting the specific cognitive, behavioral, motoric, and functional challenges faced by the patient and their caregivers. No specific therapies are available for the treatment of TES once symptoms develop. Prevention measures include harm reduction strategies related to both TBI and other adverse outcomes.

Outcome

Several longitudinal clinical studies of high-risk athletes are underway, including professional and amateur American football and international soccer players. Based on mortality studies, it is suggested that exposure to professional American football or international soccer is associated with higher rate of death due to dementia or amyotrophic lateral sclerosis, and possibly Parkinson disease, relative to the causes of death among controls or the general population. Notably, these athletes experience lower mortality rates overall and have lower rates of death due to cardiovascular disease or cancer. The natural history of TES and CTE remains uncertain.

In American football, a cumulative head impact index has been proposed to identify thresholds of lifetime exposure to recurrent head impacts and possible inflection points increasing the risk of behavioral and cognitive outcomes as well as biomarker-based changes in later adulthood. Suicide has emerged as a cause of death among several former elite athletes, including in a period prior to recently increased CTE awareness, yet its epidemiology is not well understood. Although high-risk sports may portend to slightly higher risk of suicide in college athletes during the period of activity, studies of American football have suggested lower risks of suicide than the general U.S. population, perhaps related complex factors associated with playing professional sport.

Finally, given the distinctly known and highly preventable risk factor of head injury leading to concussion and presumably CTE in combat sports and perhaps also in contact sports, a substantial ethical and moral dilemma is raised by this spectrum of disease. Although many professional groups, including neurologists, have advocated for banning boxing, most likely public interest in these sports will persist. Historical accounts suggest an increased risk of death during time periods when sports like these are banned yet persist in an underground or unsanctioned manner without the involvement of neurologists or colleagues in supervision or consultation. At present, there are no personalized models of neurologic risks of high-risk sports yet the appetite of the general public for such sports remains high. Neurologists have an important role in shaping public knowledge of combat and high-risk contact sports, navigating the understanding and uncertainty of near- and long-term risks for the individual athlete and supporting the inherent benefits of exercise and athleticism.

SUGGESTED READINGS

Adams JW, Alvarez VE, Mez J, et al. Lewy body pathology and chronic traumatic encephalopathy associated with contact sports. *J Neuropathol Exp Neurol*. 2018;77(9):757-768.

Alosco ML, Kasimis AB, Stamm JM, et al. Age of first exposure to American football and long-term neuropsychiatric and cognitive outcomes. *Transl Psychiatry*. 2017;7(9):e1236.

Alosco ML, Mez J, Tripodis Y, et al. Age of first exposure to tackle football and chronic traumatic encephalopathy. *Ann Neurol*. 2018;83(5):886-901.

Arbogast KB, Curry AE, Pfeiffer MR, et al. Point of health care entry for youth with concussion within a large pediatric care network. *JAMA Pediatr*. 2016;170(7):e160294.

Asken BM, Bauer RM, DeKosky ST, et al. Concussion BASICS III: serum biomarker changes following sport-related concussion. *Neurology*. 2018;91(23): e2133-e2143.

Baker DR, Kulick ER, Boehme AK, Noble JM. Effects of the New York State Concussion Management and Awareness Act ("Lystedt Law") on concussion-related emergency health care utilization among adolescents, 2005-2015. *Am J Sports Med*. 2018;46(2):396-401.

Baker JG, Willer BS, Dwyer MG, Leddy JJ. A preliminary investigation of cognitive intolerance and neuroimaging among adolescents returning to school after concussion. *Brain Inj*. 2020;34(6):818-827.

Bari S, Svaldi DO, Jang I, et al. Dependence on subconcussive impacts of brain metabolism in collision sport athletes: an MR spectroscopic study. *Brain Imaging Behav*. 2019;13(3):735-749.

Breedlove EL, Robinson M, Talavage TM, et al. Biomechanical correlates of symptomatic and asymptomatic neurophysiological impairment in high school football. *J Biomech*. 2012;45(7):1265-1272.

Bruns J Jr, Hauser WA. The epidemiology of traumatic brain injury: a review. *Epilepsia*. 2003;44(suppl 10):2-10.

Cantu RC. The role of the neurologist in concussions: when to tell your patient to stop. *JAMA Neurol*. 2013;70(12):1481-1482.

Centers for Disease Control and Prevention. Nonfatal traumatic brain injuries related to sports and recreation activities among persons aged ≤19 years—United States, 2001-2009. *MMWR Morb Mortal Wkly Rep*. 2011;60(39):1337-1342.

Corsellis JA, Bruton CJ, Freeman-Browne D. The aftermath of boxing. *Psychol Med*. 1973;3(3):270-303.

Cubon VA, Murugavel M, Holmes KW, Dettwiler A. Preliminary evidence from a prospective DTI study suggests a posterior-to-anterior pattern of recovery in college athletes with sports-related concussion. *Brain Behav*. 2018;8(12):e01165.

Davis-Hayes C, Baker DR, Bottiglieri TS, et al. Medical retirement from sport after concussions: a practical guide for a difficult discussion. *Neurol Clin Pract*. 2018;8(1):40-47.

Echemendia RJ, Meeuwisse W, McCrory P, et al. The Sport Concussion Assessment Tool 5th Edition (SCAT5): background and rationale. *Br J Sports Med*. 2017;51(11):848-850.

Garcia GP, Lavieri MS, Jiang R, et al. A data-driven approach to unlikely, possible, probable, and definite acute concussion assessment. *J Neurotrauma*. 2019;36(10):1571-1583.

Gavett BE, Stern RA, McKee AC. Chronic traumatic encephalopathy: a potential late effect of sport-related concussive and subconcussive head trauma. *Clin Sports Med*. 2011;30(1):179-xi.

Giza CC, Hovda DA. The neurometabolic cascade of concussion. *J Athl Train*. 2001;36(3):228-235.

Giza CC, Kutcher JS, Ashwal S, et al. Summary of evidence-based guideline update: evaluation and management of concussion in sports: report of the Guideline Development Subcommittee of the American Academy of Neurology. *Neurology*. 2013;80(24):2250-2257.

Goldfinger MH, Ling H, Tilley BS, et al. The aftermath of boxing revisited: identifying chronic traumatic encephalopathy pathology in the original Corsellis boxer series. *Acta Neuropathol*. 2018;136(6):973-974.

Guskiewicz KM, Register-Mihalik J, McCrory P, et al. Evidence-based approach to revising the SCAT2: introducing the SCAT3. *Br J Sports Med*. 2013;47(5):289-293.

Halstead ME, McAvoy K, Devore CD, et al. Returning to learning following a concussion. *Pediatrics*. 2013;132(5):948-957.

Harmon KG, Clugston JR, Dec K, et al. American Medical Society for Sports Medicine position statement on concussion in sport. *Br J Sports Med*. 2019;53(4):213-225.

Holbourn AHS. Mechanics of head injuries. *Lancet*. 1943;242(6267):438-441.

Institute of Medicine, National Research Council. *Sports-Related Concussions in Youth: Improving the Science, Changing the Culture*. Washington, DC: The National Academies Press; 2013.

Lehman EJ, Hein MJ, Baron SL, Gersic CM. Neurodegenerative causes of death among retired National Football League players. *Neurology*. 2012;79(19):1970-1974.

Mackay DF, Russell ER, Stewart K, MacLean JA, Pell JP, Stewart W. Neurodegenerative disease mortality among former professional soccer players. *N Engl J Med*. 2019;381(19):1801-1808.

Martland HS. Punch drunk. *JAMA*. 1928;91(15):1103-1107.

Martland HS, Beling CC. Traumatic cerebral hemorrhage. *Arch NeurPsych*. 1929;22(5):1001-1023.

Mayeux R, Ottman R, Maestre G, et al. Synergistic effects of traumatic head injury and apolipoprotein-epsilon 4 in patients with Alzheimer's disease. *Neurology*. 1995;45(3, pt 1):555-557.

McCrory P, Meeuwisse W, Dvořák J, et al. Consensus statement on concussion in sport–the 5th International Conference on Concussion in Sport held in Berlin, October 2016. *Br J Sports Med*. 2017;51(11):838-847.

McKee AC, Stern RA, Nowinski CJ, et al. The spectrum of disease in chronic traumatic encephalopathy. *Brain*. 2013;136(pt 1):43-64.

McLendon LA, Kralik SF, Grayson PA, Golomb MR. The controversial second impact syndrome: a review of the literature. *Pediatr Neurol*. 2016;62:9-17.

Mez J, Daneshvar DH, Abdolmohammadi B, et al. Duration of American football play and chronic traumatic encephalopathy. *Ann Neurol*. 2020;87(1): 116-131.

Mez J, Daneshvar DH, Kiernan PT, et al. Clinicopathological evaluation of chronic traumatic encephalopathy in players of American football. *JAMA*. 2017;318(4):360-370.

Moeller JJ, Tu B, Bazil CW. Quantitative and qualitative analysis of ambulatory electroencephalography during mild traumatic brain injury. *Arch Neurol*. 2011;68(12):1595-1598.

Montenigro PH, Alosco ML, Martin BM, et al. Cumulative head impact exposure predicts later-life depression, apathy, executive dysfunction, and cognitive impairment in former high school and college football players. *J Neurotrauma*. 2017;34(2):328-340.

Murugavel M, Cubon V, Putukian M, et al. A longitudinal diffusion tensor imaging study assessing white matter fiber tracts after sports-related concussion. *J Neurotrauma*. 2014;31(22):1860-1871.

Neidecker J, Sethi NK, Taylor R, et al. Concussion management in combat sports: consensus statement from the Association of Ringside Physicians. *Br J Sports Med*. 2019;53(6):328-333.

Nelson LD, Temkin NR, Dikmen S, et al. Recovery after mild traumatic brain injury in patients presenting to US level I trauma centers: a Transforming Research and Clinical Knowledge in Traumatic Brain Injury (TRACK-TBI) study. *JAMA Neurol*. 2019;76(9):1049-1059.

Noble JM, Hesdorffer DC. Sport-related concussions: a review of epidemiology, challenges in diagnosis, and potential risk factors. *Neuropsychol Rev*. 2013;23(4):273-284.

Puzo C, Labriola C, Sugarman MA, et al. Independent effects of white matter hyperintensities on cognitive, neuropsychiatric, and functional decline: a longitudinal investigation using the National Alzheimer's Coordinating Center Uniform Data Set. *Alzheimers Res Ther*. 2019;11(1):64.

Reams N, Eckner JT, Almeida AA, et al. A clinical approach to the diagnosis of traumatic encephalopathy syndrome: a review. *JAMA Neurol*. 2016;73(6):743-749.

Rigg JL, Mooney SR. Concussions and the military: issues specific to service members. *PM R*. 2011;3(10 suppl 2):S380-S386.

Rowson S, Duma SM, Beckwith JG, et al. Rotational head kinematics in football impacts: an injury risk function for concussion. *Ann Biomed Eng*. 2012;40(1):1-13.

Shahim P, Tegner Y, Wilson DH, et al. Blood biomarkers for brain injury in concussed professional ice hockey players. *JAMA Neurol*. 2014;71(5):684-692.

Standring OJ, Friedberg J, Tripodis Y, et al. Contact sport participation and chronic traumatic encephalopathy are associated with altered severity and distribution of cerebral amyloid angiopathy. *Acta Neuropathol*. 2019;138(3):401-413.

Stern RA, Adler CH, Chen K, et al. Tau positron-emission tomography in former National Football League players. *N Engl J Med*. 2019;380(18):1716-1725.

Sugarman MA, McKee AC, Stein TD, et al. Failure to detect an association between self-reported traumatic brain injury and Alzheimer's disease neuropathology and dementia. *Alzheimers Dement*. 2019;15(5):686-698.

Tagge CA, Fisher AM, Minaeva OV, et al. Concussion, microvascular injury, and early tauopathy in young athletes after impact head injury and an impact concussion mouse model. *Brain*. 2018;141(2):422-458.

Weinstein E, Turner M, Kuzma BB, Feuer H. Second impact syndrome in football: new imaging and insights into a rare and devastating condition. *J Neurosurg Pediatr*. 2013;11(3):331-334.

Wilde EA, Hunter JV, Li X, et al. Chronic effects of boxing: diffusion tensor imaging and cognitive findings. *J Neurotrauma*. 2016;33(7):672-680.

Zhang L, Yang KH, King AL. A proposed injury threshold for mild traumatic brain injury. *J Biomech Eng*. 2004;126(2):226-236.

Traumatic Brain Injury 47

Gunjan Y. Parikh, Neeraj Badjatia, and Stephan A. Mayer

KEY POINTS

1. Traumatic brain injury (TBI) is a heterogeneous group of pathologic disorders that can be categorized by mechanism of injury, clinical severity, radiologic appearance, pathology, or anatomic distribution.
2. TBI endophenotypes other than axonal injury include vascular injury and an exaggerated inflammatory response.
3. The epidemiology of TBI is trimodal with accidents and falls occurring in early and late life and accidents associated with road travel and risk-taking activities most common in early and mid-adulthood.
4. Coordinated systems of care are crucial for optimal TBI management, but inconsistencies in implementation occur in all phases along the chain of trauma care.
5. In TBI, patient-centered treatment strategies may not always align with generalized guidelines, which encompass a wide range of injury type and severity.
6. TBI is a chronic, progressive health condition. Secondary injury continues to occur for days to weeks after primary insult secondary to innate host response to injury.
7. Functional outcomes after TBI can show improvement or deterioration up to two decades after injury, and rates of all-cause mortality remain elevated for many years.
8. TBI is an important modifiable risk factor for epilepsy, stroke, and late-life neurodegenerative disease.

EPIDEMIOLOGY

Traumatic brain injury (TBI) is a modern scourge of industrialized society. It is a major cause of death, especially in young adults, and a major cause of disability. The costs in human misery and dollars are exceeded by few other conditions.

More than 2.8 million patients with head injuries are seen annually in U.S. emergency rooms, and 10% of these patients are admitted to a hospital. In general, total combined rates for TBI-related emergency department (ED) visits, hospitalizations, and deaths have increased over the past decade. Almost 10% of all deaths in the United States are caused by injury, and about half of the traumatic deaths involve the brain. In the United States, a head injury occurs every 7 seconds and a death every 5 minutes. About 200,000 people are killed or permanently disabled annually as a result. Worldwide, more than 50 million people have a TBI each year, and it is estimated that half the world's population will sustain one or more TBI over their lifetime. A disproportionate burden of disability and death occurs in low-income and middle-income countries. It has been estimated that TBI costs the global economy more than $400 billion annually.

Brain injuries occur at all ages, but the peak is in young adults between the ages of 15 and 24 years. Head injury is the leading cause of death among people younger than the age of 24 years. Men are affected 3 or 4 times as often as women. The major causes of brain injury differ in different parts of the United States; in all areas, motor vehicle accidents are prominent, and in metropolitan areas, personal violence is prevalent. There is, however, a trend toward an increase of mortality rates from TBI among populations aged older than 65 years over the past decade. It is anticipated that this trend will continue as the overall population ages. Among older adults, the most prevalent mechanism of injury is falls, and TBIs occur more commonly in women.

PATHOBIOLOGY

Skull Fractures

Skull fractures may be divided into linear, depressed, or comminuted types. If the scalp is lacerated over the fracture, it is considered an open or *compound fracture*. Skull fractures are important markers of a possibly serious injury but rarely cause problems by themselves; prognosis depends more on the nature and severity of injury to the brain than on the severity of injury to the skull.

About 80% of fractures are linear. They occur most commonly in the temporoparietal region, where the skull is thinnest. Detection of a linear fracture often raises the suspicion of serious brain injury, but computed tomography (CT) in most patients is otherwise normal. Nondisplaced, linear skull fractures generally do not require surgery and can be managed conservatively.

In *depressed* fracture of the skull, one or more fragments of bone are displaced inward, compressing the underlying brain. In comminuted fracture, there are multiple, shattered bone fragments, which may or may not be displaced. In 85% of cases, depressed fractures are open (or "compound") and liable to become infected or leak cerebrospinal fluid (CSF). Even when closed, most depressed or comminuted fractures require surgical exploration for debridement, elevation of bone fragments, and repair of dural lacerations. The underlying brain is injured in many cases. In some patients, depressed skull fractures are associated with tearing, compression, or thrombosis of underlying venous dural sinuses.

Basilar skull fractures may be linear, depressed, or comminuted. They are frequently missed by standard skull x-rays and are best identified by CT bone windows. There may be associated cranial nerve injury or a dural tear adjacent to the fracture site, which may lead to delayed meningitis if bacteria enter the subarachnoid space.

Signs that lead the physician to suspect a fracture of the petrous portion of the temporal bone include hemotympanum or tympanic perforation, hearing loss, CSF otorrhea, peripheral facial nerve weakness, or ecchymosis of the scalp overlying the mastoid process (Battle sign). Anosmia, bilateral periorbital ecchymosis, and CSF rhinorrhea suggest possible fracture of the sphenoid, frontal, or ethmoid bones.

Cerebral Concussion and Axonal-Shearing Injury

Concussion is defined as a mild TBI without obvious structural abnormality identified on standard neuroimaging. Loss of consciousness may occur at the moment of impact in about 10% to 15% of concussion and is thought to be caused by acceleration-deceleration movements of the head, which result in the stretching and, in some cases, shearing of axons. Persons with concussion may be completely unconscious or remain awake but appear dazed; most recover within seconds or minutes, rather than hours, and some have retrograde or anterograde amnesia surrounding the event. Concussion is reviewed in further detail in Chapter 46.

The mechanism by which concussion leads to loss of consciousness is believed to be transient functional disruption of the reticular activating system caused by rotational forces on the upper brainstem. Experimentally, sudden and violent head rotation may produce concussion without impact to the head. Most patients with concussion have normal CT or magnetic resonance imaging (MRI) findings because concussion results from physiologic, rather than structural, injury to the brain. Only 5% of patients who have sustained a concussion and are otherwise intact have an intracranial hemorrhage on CT, although this figure may be biased toward persons presenting to EDs. In some series of adolescent sports-related concussion, detection of intracranial hemorrhage may be less than 1 in 1,000.

The term *diffuse axonal injury* (DAI) is applied to traumatic coma lasting more than 6 hours. In these cases, when no other cause of coma is identified by CT or MRI, it is presumed that widespread microscopic and macroscopic axonal-shearing injury has occurred. Coma of 6 to 24 hours duration is deemed mild DAI; coma lasting more than 24 hours is considered moderate or severe DAI, depending on the absence or presence of brainstem signs, such as decorticate or decerebrate posturing (**Table 47.1**).

Autonomic dysfunction (eg, hypertension, hyperhidrosis, hyperpyrexia) is common in patients with acute severe DAI and may reflect brainstem or hypothalamic injury. Patients may remain unconscious for days, months, or years, and those who recover may be left with severe cognitive and motor impairment, including spasticity and ataxia. DAI is considered the single most important cause of persistent disability after traumatic brain damage.

Axonal shearing injury tends to be most severe in specific brain regions that are anatomically predisposed to maximal stress from rotational forces. Macroscopic tissue tears, best visualized by MRI, tend to occur in midline structures, including the dorsolateral midbrain and pons, posterior corpus callosum, parasagittal white matter, periventricular regions, and internal capsule. Microscopic damage occurs more diffusely, as manifested by axonal retraction bulbs throughout the white matter of the cerebral hemispheres. TBI endophenotypes other than axonal injury include vascular injury and an exaggerated inflammatory response (**Fig. 47.1**). Prolonged loss of consciousness from DAI tends to be associated with bilateral, asymmetric, focal lesions of the dorsal tegmentum of the pons and midbrain, a region densely populated with brainstem nuclei of the ascending arousal network that are critical to consciousness (**Fig. 47.2**). Small hemorrhages, known as *traumatic microbleeds*, are sometimes associated with focal-shearing lesions (see **Fig. 47.1**; **Fig. 47.3**).

Axonal shearing is thought to initiate a dynamic sequence of pathologic events that evolve over days to weeks. Initially, injury causes physical transection of some neurons and internal axonal damage to many others. In both cases, the process of axoplasmic transport continues, and materials flow from the cell body to the site of damage. These materials accumulate and may lead to secondary axonal transection, with formation of a "retraction ball" from 12 hours to several days after the injury. Membrane channels may open to admit toxic levels of calcium. If the patient survives, MRI may demonstrate chronic atrophy of involved white matter tracts (wallerian degeneration) and gliosis.

TABLE 47.1 Clinical Characteristics and Outcome of Rotational Brain Injury[a]

	Concussion			Diffuse Axonal Injury		
	Grade 1	Grade 2	Grade 3	Mild	Moderate	Severe
Loss of consciousness	None	<5 min	>5 min	6-24 h	>24 h	Days to weeks
Memory deficit and amnesia	Minutes	Hours	Days	Days to weeks	Weeks	Months
Motor posturing	None	None	None	Rare	Occasionally	Present
Chronic motor deficits	None	None	None	None	Mild-to-moderate	Severe
MRI shearing lesions	None	None	None	None	Few and variable	Multiple and extensive
Outcome at 3 mo (%)						
Good recovery	100	95	90	80	70	20
Moderate deficit	0	5	5	20	20	25
Severe deficit	0	0	5	0	15	15
Vegetative	0	0	0	0	0	5
Death	0	0	0	0	5	35

[a]Data from Gennarelli TA. Cerebral concussion and diffuse brain injuries. In: Cooper PR, ed. *Head Injury*, 3rd ed. New York, NY: Williams & Wilkins; 1993:140; Iverson GL, Gardner AJ, Terry DP, et al. Predictors of clinical recovery from concussion: a systematic review. *Br J Sports Med*. 2017;51(12):941-948; Humble SS, Wilson LD, Wang L, et al. Prognosis of diffuse axonal injury with traumatic brain injury. *J Trauma Acute Care Surg*. 2018;85(1):155-159.

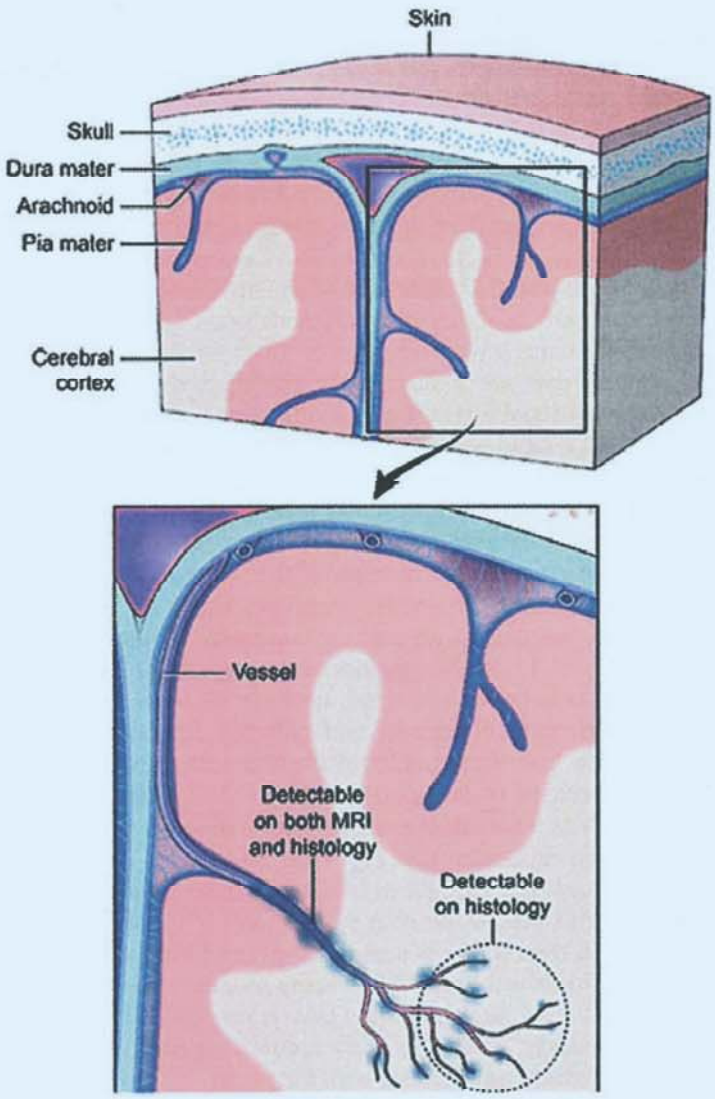

FIGURE 47.1 Traumatic vascular injury. Traditionally, traumatic microbleeds have been described as markers for diffuse axonal injury, not as a form of traumatic vascular injury. However, magnetic resonance imaging (MRI) and three-dimensional histology identified an underlying pathology of traumatic microbleeds to be an injury to not just a single vessel but injury that extends to a vascular network. Injury to a large blood vessel causes iron deposition that is detectable on in vivo and ex vivo MRI (at 3T and 7T). Smaller vessels that form a broader vascular network with the larger vessels are missed in these magnetic resonance images. High-resolution three-dimensional histology of iron deposits in macrophages identified more extensive vascular injury involving smaller vessels that connect to the larger injured vessel detected on MRI. The schematic above illustrates a model of this vascular injury pattern and potential levels of detection with MRI and histologic approaches. (From Griffin AD, Turtzo LC, Parikh GY, et al. Traumatic microbleeds suggest vascular injury and predict disability in traumatic brain injury. *Brain*. 2019;142[11]:3550-3564.)

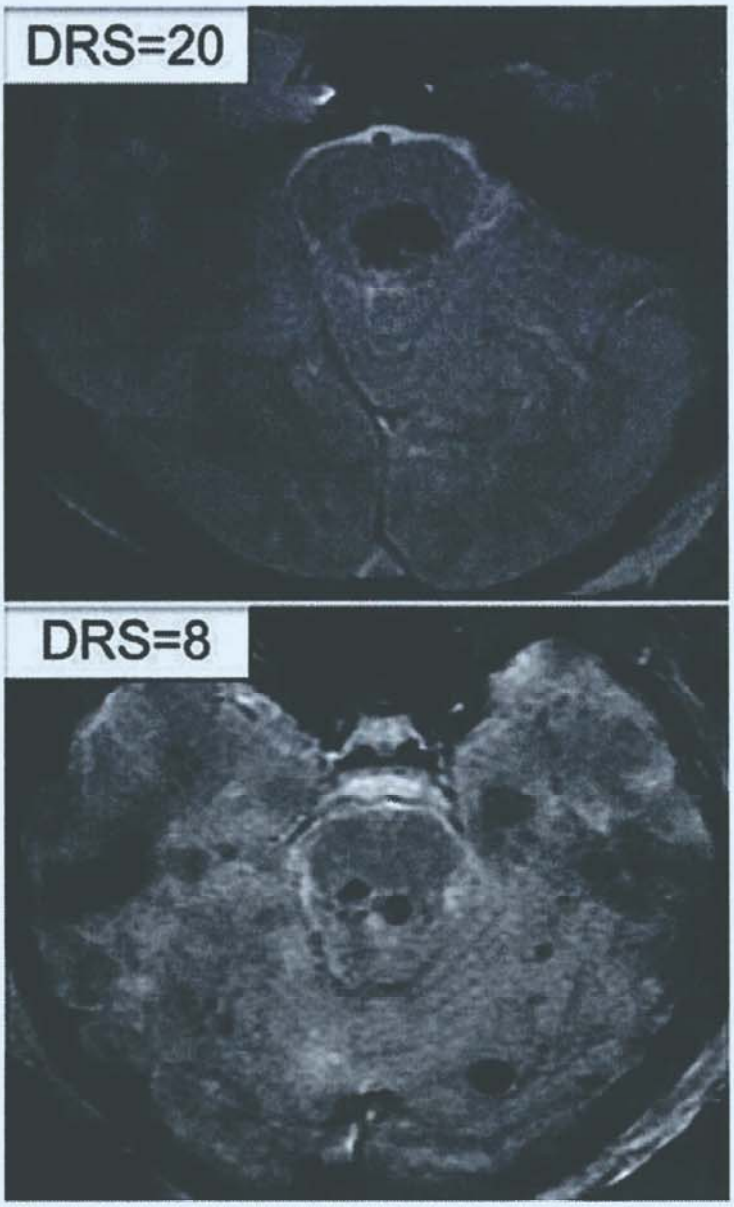

FIGURE 47.2 Revisiting grade 3 diffuse axonal injury: Not all brainstem microbleeds are prognostically equal. Brainstem traumatic microbleeds (TMBs) detected by T2* gradient-recalled echo magnetic resonance imaging. A patient with a large cluster of hypointense lesions, representing TMBs, in the dorsal pons is shown in the **top panel**. A patient with two smaller ovoid TMBs in the dorsal pons is shown in the **bottom panel**. The patient whose gradient-recalled echo scan is shown in the **top panel** had a poor outcome, as evidenced by a high disability rating scale (DRS) score of 20. The patient in the **bottom panel** had a better outcome, with a DRS score of 8, indicating less functional disability. Notably, both patients had a total of four dorsal brainstem TMBs, but the patients had different burdens of injury within the ascending arousal network nuclei (104 vs 20 mm^3), which may explain the divergence in functional outcomes. (From Izzy S, Mazwi NL, Martinez S, et al. Revisiting grade 3 diffuse axonal injury: not all brainstem microbleeds are prognostically equal. *Neurocrit Care*. 2017;27[2]:199-207.)

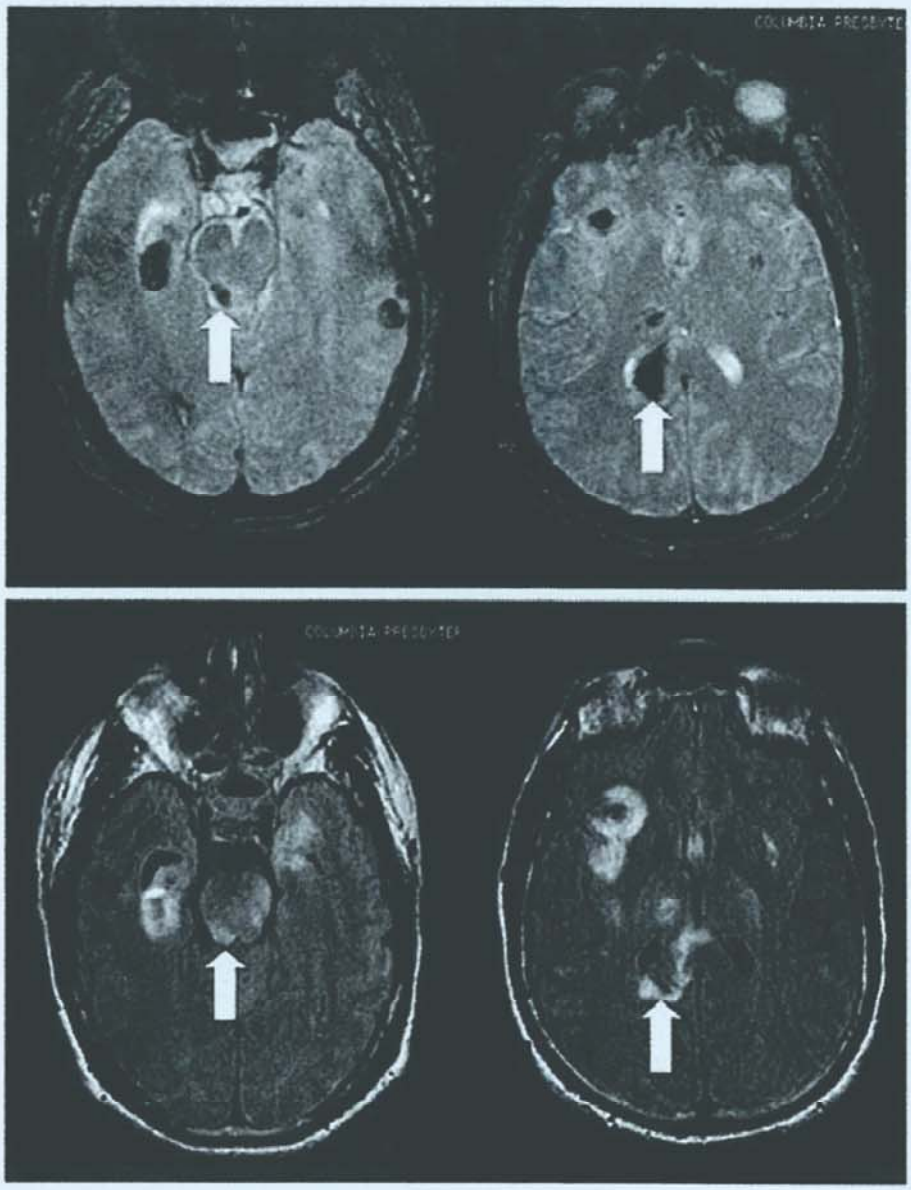

FIGURE 47.3 Focal magnetic resonance imaging findings characteristic of diffuse axonal-shearing injury after neurotrauma. **Top:** Gradient echo images demonstrating hemorrhagic lesions (traumatic microbleeds) of the right dorsolateral midbrain and splenium of the corpus callosum. **Bottom:** Fluid-attenuated inversion recovery images showing edema in these regions.

Brain Swelling and Cerebral Edema

Brain swelling after head injury is a poorly understood phenomenon that may result from several different mechanisms. Posttraumatic brain swelling may result from *cerebral edema* (eg, an increase in the content of extravascular brain water), an increase in cerebral blood volume (CBV) resulting from abnormal vasodilatation, or both. Cerebral edema may be further classified as cytotoxic, vasogenic, or interstitial (see Chapter 111). The swelling may be diffuse or focal, adjacent to a parenchymal or extradural hemorrhage, or related to contusion or infarction.

Brain swelling may follow any type of head injury. Curiously, the magnitude of swelling does not always correlate well with the severity of injury. In some cases, particularly in young people, severe diffuse brain swelling that may be fatal occurs minutes to hours after a minor concussion. Abnormal dilation of the cerebral blood vessels is thought to lead to increased CBV, hyperperfusion, and increased vascular permeability, resulting in secondary leakage of plasma and vasogenic cerebral edema. Cerebral blood flow studies indicate that after an initial period of hypoperfusion within the first 24 hours, hyperemia occurs in nearly all patients 1 to 3 days after severe head injury, followed less commonly by arterial vasospasm between days 4 and 7. Severe brain swelling may be related to local endothelial and microcirculatory dysfunction or from damage to cerebral vasomotor regulatory centers in the brainstem.

Parenchymal Contusion and Hemorrhage

Cerebral *contusions* are focal parenchymal hemorrhages that result from scraping and bruising of the brain as it moves across the inner surface of the skull. The inferior frontal and temporal lobes, where brain tissue comes in contact with irregular protuberances at the base of the skull, are the most common sites of traumatic contusion (Fig. 47.4). Linear tears of the meninges or cerebral tissue, usually a result of cuts from the sharp edges of depressed skull fragments, are called *lacerations*.

Hemorrhagic contusions may occur at the site of a skull fracture but more often occur without a fracture and with the overlying pia and arachnoid left intact. In most patients, contusions are small and multiple. With lateral forces, contusions may occur at the site of the blow to the head (coup lesions) or at the opposite pole as the brain impacts on the inner table of the skull

FIGURE 47.4 Traumatic contusions. Axial noncontrast view demonstrates areas of contusion with small focal hemorrhages involving the lower poles of the left frontal and temporal lobes adjacent to the rough cranial vault. (Courtesy of Drs. S. K. Hilal, J. A. Bello, and T. L. Chi.)

FIGURE 47.5 Traumatic intracerebral hemorrhage, frontal lobe. Axial noncontrast computed tomography demonstrates left frontal lobe density (hemorrhage), surrounding lucency (edema), and mass effect (sulcal and ventricular effacement). (Courtesy of Drs. S. K. Hilal and J. A. Bello.)

(contrecoup lesions). Contusions frequently enlarge over 12 to 24 hours, especially in the setting of coagulopathy. In some cases, contusions appear in delayed fashion 1 or more days after injury.

When rotational forces lead to tearing of small- or medium-sized vessels within the parenchyma, an intracerebral *hematoma* may occur (Fig. 47.5). Hematomas are focal collections of blood clots that displace the brain, in contrast to contusions, which resemble bruised and bloodied brain tissue (Fig. 47.6). Most parenchymal hematomas are located in the deep white matter, in contrast to contusions, which tend to be cortical.

If there is no DAI, brain swelling, or secondary hemorrhage, recovery from one or more small contusions may be excellent. Healed contusions are often found at autopsy of people with no clinical evidence of permanent brain damage. Large, parenchymal hematomas with mass effect may require surgical evacuation.

Contusions are often managed conservatively unless they lead to significant symptomatic mass effect because they often consist of hemorrhagic or ecchymotic (but potentially viable) brain tissue.

Subdural Hematoma

Subdural hematomas usually arise from a venous source, with blood filling the potential space between the dural and arachnoid membranes. In most cases, the bleeding is caused by movements of the brain within the skull that leads to stretching and tearing of "bridging" veins that drain from the surface of the brain to the dural sinuses.

Most subdural hematomas are located over the lateral cerebral convexities, but subdural blood may also collect along the medial surface of the hemisphere, between the tentorium and occipital lobe, between the temporal lobe and the base of the skull, or in the posterior fossa. CT usually reveals a high-density, crescentic collection across the entire hemispheric convexity (Fig. 47.7).

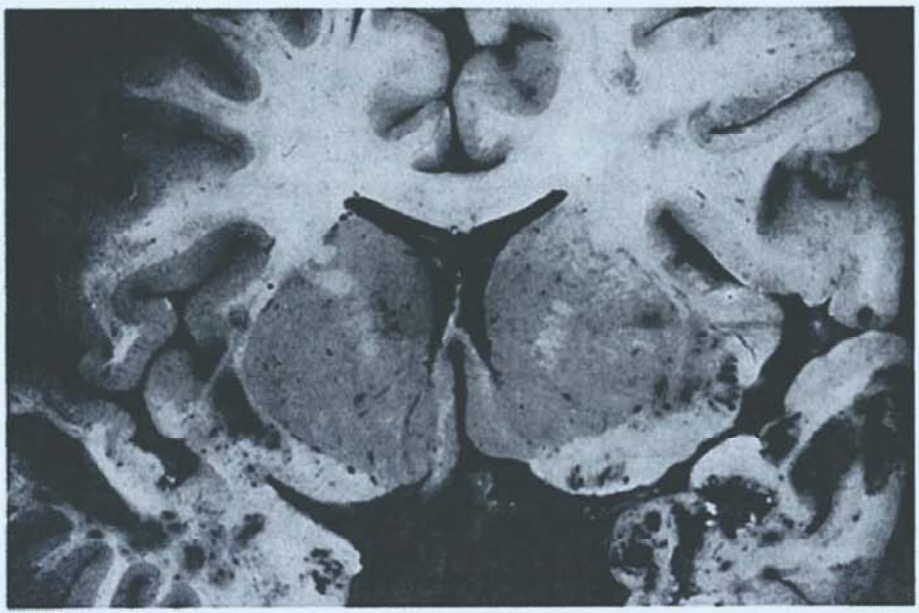

FIGURE 47.6 Pathologic specimen demonstrating traumatic contusions in the temporal lobes.

FIGURE 47.7 Acute subdural hematoma. Noncontrast axial computed tomography demonstrates a hyperdense, crescent-shaped, extra-axial collection showing mass effect (sulcal and ventricular effacement) and midline shift from left to right. (Courtesy of Drs. J. A. Bello and S. K. Hilal.)

Elderly or alcoholic patients with cerebral atrophy are particularly prone to subdural bleeding; in these patients, large hematomas may result from trivial impact or even from pure acceleration-deceleration injuries, such as whiplash. Coagulopathy, including the use of oral anticoagulants, is another important risk factor for subdural hematoma and is associated with increased mortality.

Acute subdural hematomas, by definition, are symptomatic within 72 hours of injury, but most patients have neurologic symptoms from the moment of impact. They may occur after any type of head injury but seem to be less common after vehicular trauma and relatively more common after falls or assaults. Half of all patients with an acute subdural hematoma lose consciousness at the time of injury; 25% are in coma when they arrive at the hospital, and half of those who awaken lose consciousness for a second time after a "lucid interval" of minutes to hours as the subdural hematoma grows in size. Hemiparesis and pupillary abnormalities are the most common focal neurologic signs, each occurring in one-half to two-thirds of patients. The usual picture is ipsilateral pupillary dilation and contralateral hemiparesis. However, so-called false localizing signs are common with acute subdural hematoma because uncal herniation may lead to compression of the contralateral cerebral peduncle or third cranial nerve against the tentorial edge (*Kernohan notch*).

Chronic subdural hematomas become symptomatic after 21 days. They are more likely to occur in patients after age 50 years. In 25% to 50% of cases, there is no recognized episode of head injury. Risk factors for chronic subdural hematomas include cerebral atrophy, alcoholism, bleeding disorders or use of anticoagulant medication, and overdrainage of a ventriculoperitoneal shunt.

In many cases of chronic subdural hematoma, bleeding results from trivial trauma, and symptoms are minimal because the brain accommodates the gradual buildup of mass effect. After 1 week, fibroblasts on the inner surface of the dura form a thick outer membrane; after 2 weeks, a thin inner membrane develops, resulting in encapsulation of the clot, which eventually liquefies into a *hygroma*. Enlargement of the hematoma may then result from recurrent bleeding (acute-on-chronic subdural hematoma) or because of osmotic effects related to a high-protein content of the fluid. Symptoms may be restricted to altered mental status, a syndrome sometimes mistaken for dementia. CT typically shows an isodense or hypodense, crescent-shaped mass that deforms the surface of the brain, and the membranes may enhance with intravenous (IV) contrast (Fig. 47.8).

Symptomatic acute and chronic subdural hematomas with significant mass effect should be evacuated. Surgical evacuation of the thick, clotted blood that constitutes an acute subdural

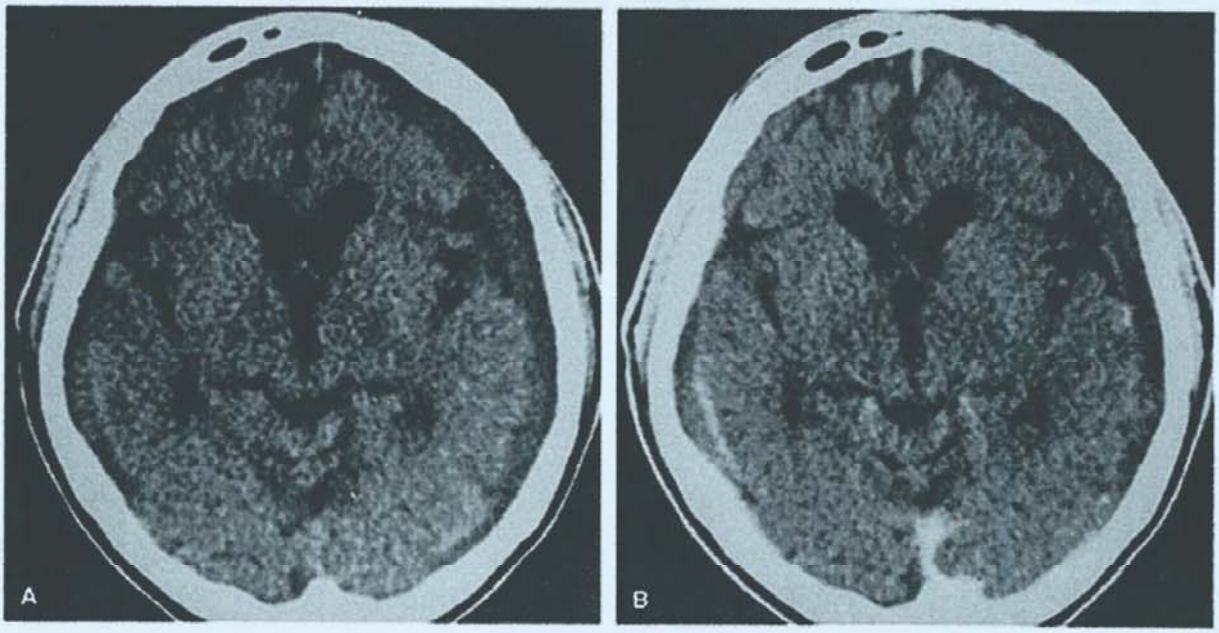

FIGURE 47.8 Bilateral chronic subdural hematoma. **A:** Noncontrast axial computed tomography shows bilateral isodense extra-axial collections, larger on the left. **B:** These are better demonstrated on the postcontrast scan, in which enhancing membranes, typical of the subacute phase, may be seen. (Courtesy of Drs. J. A. Bello and S. K. Hilal.)

hematoma usually requires a large-window craniotomy. Outcome after surgical evacuation depends primarily on the severity of the initial deficit and the interval from injury to surgery. Liquefied chronic subdural hematomas are usually evacuated with drainage of the collections via a series of burr holes. Reoperations for acute and chronic subdural hematomas are required in about 15% of cases. Steroids have no role in the conservative management of smaller, minimally symptomatic, subdural hematomas.

Epidural Hematoma

Epidural hematoma is a rare complication of head injury. It occurs in less than 1% of all cases but is found in 5% to 15% of autopsy series, attesting to the potential seriousness of this complication.

Bleeding into the epidural space is generally caused by a tear in the wall of one of the meningeal arteries, usually the middle meningeal artery, but in 15% of patients, the bleeding arises from a dural sinus. Seventy-five percent of patients are associated with a skull fracture. The dura is separated from the skull by the extravasated blood, and the size of the clot increases until the ruptured vessel is compressed or occluded by the hematoma.

Most epidural hematomas are located over the convexity of the hemisphere in the middle cranial fossa, but occasionally, hemorrhages may be confined to the anterior fossa, possibly as a result of tearing of anterior meningeal arteries. Extradural hemorrhage in the posterior fossa may occur when the torcular herophili is torn. In most cases, the hematoma is ipsilateral to the site of impact.

Epidural hematoma is primarily a problem of young adults; it is rarely seen in the elderly because the dura becomes increasingly adherent to the skull with advanced age. The clinical course, in one-third of patients, proceeds from an immediate loss of consciousness caused by concussion to a lucid interval (representing a brief recovery from the concussion itself) and then to a relapse into coma, with hemiplegia as the epidural hematoma expands. The ipsilateral pupil loses reactivity to light because the third cranial nerve is stretched as the midbrain is displaced contralaterally. Later, it becomes fixed and dilated as the third nerve is compressed by the hippocampal gyrus as it herniates over the free edge of the tentorium.

As with acute subdural hematomas, false localizing signs may occur. The presence of cerebellar signs, nuchal rigidity, and drowsiness, together with a fracture of the occipital bone, should prompt suspicion of a clot in the posterior fossa.

Epidural blood takes on a bulging convex pattern on CT (Fig. 47.9) because the collection is limited by firm attachments from the dura to the cranial sutures. Progression to herniation and death may occur rapidly because the bleeding is arterial. The mortality rate approaches 100% in untreated patients and ranges from 5% to 30% in treated patients. As the interval between injury and surgical intervention decreases, survival improves. If there is little coexisting brain damage, functional recovery may be excellent.

Traumatic Subarachnoid Hemorrhage

Some extravasation of blood into the subarachnoid spaces is to be expected in any patient with head injury. In most cases, subarachnoid blood is detected only by CSF examination and is of little clinical importance. With more serious injuries, when larger vessels traversing the subarachnoid space are torn, focal or diffuse *subarachnoid hemorrhage* may be detected by CT. In most cases, traumatic subarachnoid hemorrhage is distributed over the convexities. By contrast, spontaneous aneurysmal rupture results in bleeding into the basal cisterns. Although the presence of a large amount of subarachnoid blood is a poor prognostic sign, delayed complications of aneurysmal subarachnoid hemorrhage, such as hydrocephalus and ischemia from vasospasm, are unusual after traumatic subarachnoid hemorrhage.

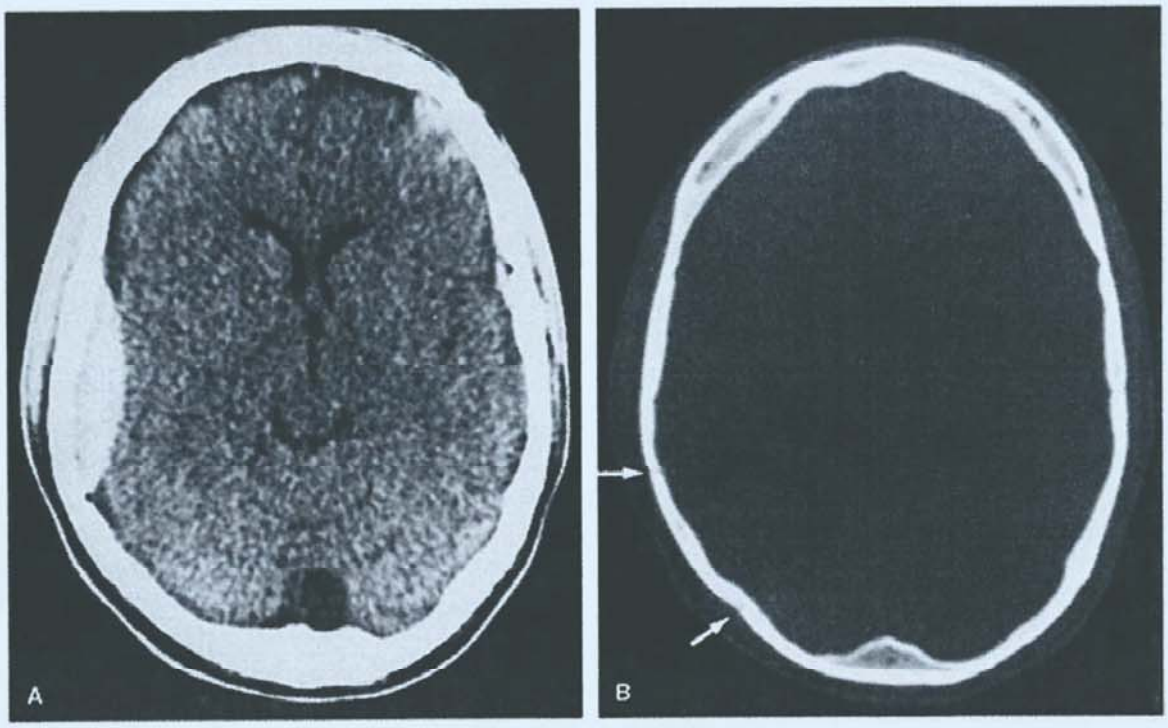

FIGURE 47.9 **A:** Epidural hematoma is evident on computed tomography. **B:** Computed tomography with bone windows shows two adjacent fractures *(arrows)*; the anterior fracture is at the site of the groove for the middle meningeal artery.

INITIAL ASSESSMENT AND STABILIZATION

On admission to the emergency room, resuscitation measures, history taking, and examination should begin simultaneously. The immediate goals of management are to assess and stabilize the airway, breathing, circulation, and disability. The immediate goals of the initial neurologic assessment are to (1) perform a rapid screening neurologic examination; (2) classify the severity of the head injury as low, moderate, or high risk; (3) stabilize and rule out a fracture of the cervical spine; (4) begin empiric treatment for increased intracranial pressure (ICP) if it is suspected; and (5) perform an emergency CT scan of the head and neck to rule out bony fractures or intracranial bleeding. Careful screening at this time is also required to identify significant extracranial injuries.

Cardiopulmonary Resuscitation

Hypoxia and *hypotension* have a devastating effect on head-injured patients. If the patient is hypoxic (arterial oxygen saturation level <90%), in respiratory distress, or comatose and unable to protect his or her airway, endotracheal intubation should be performed urgently to be certain that the spine is immobilized during the procedure. Two doses of peri-intubation cefuroxime (1.5 g) may reduce the risk of subsequent pneumonia. Minute ventilation should initially be set to maintain a tidal volume of 6 mL/kg and rate of 8 to 12 breaths per minute, with the goal of maintaining the P_{CO_2} between 30 and 40 mm Hg. The fraction of inspired oxygen can be quickly reduced from 100% to 40% as long as oxygen saturation levels are above 95%. Prophylactic aggressive hyperventilation (P_{CO_2} <25 mm Hg) during the acute stage of injury may cause excessive vasoconstriction and aggravation of ischemic injury and is contraindicated.

Hypotension (systolic blood pressure [BP] <90 mm Hg) should be corrected with large-volume IV infusions of isotonic fluids such as normal saline or lactated Ringer solution (10-40 mL/kg) and blood transfusions or vasopressors as needed. Systolic BP during the stabilization phase should be maintained above 90 mm Hg to ensure adequate cerebral blood flow. If the patient is hypotensive, bleeding into the abdomen, thorax, retroperitoneal space, or tissues surrounding a long-bone fracture should be excluded by CT. Hypotension may also reflect *spinal shock* related to a coexisting spinal cord injury (see Chapter 48). Hypertension associated with wide pulse pressure and bradycardia (Cushing reflex) may reflect increased ICP or focal brainstem injury.

Initial Neurologic Assessment and Stabilization

A baseline neurologic evaluation should be performed immediately while airway, respiration, and circulation are assessed. Injuries may be ranked as low, moderate, or high risk according to risk factors and a rapid initial neurologic assessment (Table 47.2). The skull should be palpated for fractures, hematomas, and lacerations. A step-off or palpable bony shelf is presumed to be a depressed skull fracture. A hard neck collar should be in place for all patients with any history of concussion, whiplash, or trauma above the level of the clavicles.

TABLE 47.2 Risk Stratification of Patients With Head Injury[a]

Risk Category	Characteristics
Mild	• Normal neurologic examination • No concussion • No drug or alcohol intoxication • May complain of headache and dizziness • May have scalp abrasion, laceration, or hematoma • Absence of moderate or severe injury criteria
Moderate	• Glasgow Coma Scale score of 9-14 (confused, lethargic, stuporous) • Concussion • Posttraumatic amnesia • Vomiting • Seizure • Signs of possible basilar or depressed skull fracture of serious facial injury • Alcohol or drug intoxication • Unreliable or no history of injury • Age <2 y, >65 y
Severe	• Glasgow Coma Scale score of 3-8 (comatose) • Progressive decline in level of consciousness ("talked and deteriorated") • Focal neurologic signs • Penetrating skull injury or palpable depressed skull fracture

[a]Adapted from Masters SJ, McClean PM, Arcarese JS, et al. Skull x-ray examinations after head trauma. Recommendations by a multidisciplinary panel and validation study. *N Engl J Med*. 1987;316(2):84-91.

TABLE 47.3 Glasgow Coma Scale[a]

Activity/Response	Score[b]
Eye opening	
Spontaneous	4
To voice	3
To pain	2
None	1
Best motor response	
Obeys commands	6
Localizes to pain	5
Withdraws to pain	4
Flexor posturing	3
Extensor posturing	2
None	1
Best verbal response	
Conversant and oriented	5
Conversant and disoriented	4
Inappropriate words	3
Incomprehensible sounds	2
None	1

[a]From Teasdale G, Jennett B. Assessment of coma and impaired consciousness. A practical scale. *Lancet*. 1974;2:81-84.
[b]Total score = sum of the score for each of the three components.

TABLE 47.4 Estimated Mortality Based on Various Features of Head Injury[a]

	Mortality (%)[b]
Glasgow Coma Scale score	
15	<1
11-14	3
8-10	15
6-7	20
4-5	50
3	80
Age (y), among comatose patients	
16-35	30
36-45	40
46-55	50
56 or older	80
CT abnormalities, among comatose patients	
None	10
Intracranial pathology without diffuse swelling or midline shift	15
Intracranial pathology with diffuse swelling (cisterns compressed or absent)	35
Intracranial pathology with midline shift (>5 mm)	55
Intracranial pressure, among comatose patients	
<20 mm Hg	15
>20 mm Hg, reducible	45
>20 mm Hg, not reducible	90
Pathologic entity	
Epidural hematoma	5-15
Gunshot wound	55
Acute subdural hematoma	
Simple	20-25
Complicated	40-75
Bilateral	75-100

Abbreviation: CT, computed tomography.
[a]From Greenberg J, Brawanaki A. Cranial trauma. In: Hacke W, ed. *Neurocritical Care*. New York, NY: Springer; 1994:705; Vollmer DG, Torner JC, Jane LA, et al. Age and outcome following traumatic coma: why do older patient's fare worse? *J Neurosurg*. 1991;75(suppl 1):S37-S49; Marshall LF, Gautille T, Klauber MR, et al. The outcome of severe closed head injury. *J Neurosurg*. 1991;75(suppl 1):S28-S36; Miller JD, Becker DP, Ward JD, Sullivan HG, Adams WE, Rosner MJ. Significance of intracranial hypertension in severe head injury. *J Neurosurg*. 1977;47:503-516.
[b]Percentages are adapted from several sources and have been rounded. Data are based on historical cohort studies and may not reflect current outcomes with aggressive surgical and critical care management.

The Glasgow Coma Scale (GCS; **Table 47.3**) is based on eye opening and the patient's best verbal and motor responses; these three individual scores should be recorded separately. The GCS is widely used as a semiquantitative clinical measure of the severity of brain injury; it also provides a guide to prognosis (**Table 47.4**). Patients who are comatose (GCS score ≤8), or who show clinical signs of herniation, require emergency interventions to reduce ICP, including 30° of head elevation, hyperventilation to a target $PaCO_2$ of 30 mm Hg, and 20% mannitol solution at a dose of 0.5 to 1.0 g/kg via rapid IV infusion (**Table 47.5**).

TABLE 47.5 Emergency Measures for Intracranial Pressure Reduction in an Unmonitored Patient With Clinical Signs of Herniation[a]

1. Elevate head of bed 15-30°.
2. Normal saline (0.9%) at 80-100 mL/h (Avoid hypotonic fluids.)
3. Intubate and hyperventilate (target P_{CO_2} = 28-32 mm Hg).
4. Mannitol 20% 1-1.5 g/kg via rapid IV infusion
5. Foley catheter
6. Neurosurgical consultation

Abbreviation: IV, intravenous.
[a]From Mayer SA, Chong J. Critical care management of increased intracranial pressure. *J Intensive Care Med*. 2002;17:55-67.

History

The circumstances of the accident and the clinical condition of the patient before admission to the emergency room should be ascertained from records of the emergency medical services, the patient (if possible), and eyewitnesses. The force and location of head impact should be determined as precisely as possible. Specific inquiry should be made about concussion; because patients are amnesic during the concussion, only an eyewitness may accurately gauge the duration of loss of consciousness.

Patients who have "talked and deteriorated" should be assumed to have an expanding intracranial hematoma until proven otherwise. Reports of headache, nausea, vomiting, confusion, or seizure activity must be noted. A medical history, including medications and drug and alcohol use, should be obtained. Recent drug and alcohol use occurs in many trauma patients.

Radiography and Imaging

CT is the emergency imaging method of choice for head injury. CT is more informative than standard skull radiographic films for detecting skull or neck fractures and provides unsurpassed sensitivity for detecting intracranial blood. In general, all patients with a head injury should have CT, except for those who are classified as low risk (eg, without concussion; with no neurologic abnormalities on examination; and with no evidence or suspicion of a skull fracture, alcohol or drug intoxication, or other moderate-risk criteria) (see **Table 47.2**).

In GCS 13 to 15, adult patients presenting to the ED after blunt head trauma with at least one of the following—witnessed loss of consciousness, amnesia, or mental status changes—**the Canadian CT Head Rule** is a well-validated clinical support tool. This decision aide safely rules out the presence of clinically significant intracranial injuries that would require hospital admission for observation and/or neurosurgical intervention, without the need for CT imaging. Applying the Canadian CT Head Rule may allow physicians to safely reduce head CT imaging after minor blunt head trauma by approximately 30%.

Canadian CT Head Rule	
High-Risk Criteria	**Medium-Risk Criteria**
Glasgow Coma Scale <15 at 2 h postinjury	Retrograde amnesia to the event ≥30 min
Suspected open or depressed skull fracture	"Dangerous" mechanism? (pedestrian struck by motor vehicle, occupant ejected from motor vehicle, or fall from >3 ft or >5 stairs)
Any sign of basilar skull fracture?	
≥2 episodes of vomiting	
Age ≥65 y	

Alternatively, in GCS 15 (neurologically normal) adult trauma patients with witnessed loss of consciousness, the **New Orleans Head CT Rule** can help determine which blunt head trauma patients can be discharged home from the ED without undergoing a CT head or admission for further clinical observation.

New Orleans/Charity Head Trauma/Injury Rule
Headache
Emesis
Age >60 years
Drug or alcohol intoxication
Convulsion
Trauma visible above the clavicles
Short-term memory deficits

Use mnemonic "Head CTs" to remember the seven criteria. Absence of all seven criteria suggests that it is safe to discharge the patient without as head CT scan.

CT images of the head should be assessed for evidence of the presence of epidural or subdural hematoma, subarachnoid or intraventricular blood, parenchymal contusions and hemorrhages, cerebral edema, and gliding contusions related to DAI. With bone window settings, fractures, sinus opacification, and pneumocephalus may be identified.

Axial CT images of the entire cervical spine should also be obtained in all patients. If traumatic arterial dissection is possible, CT angiography of the head and neck is indicated

MRI is better for detecting subtle injury to the brain, particularly for focal (noncontusional) hemorrhagic lesions related to DAI and traumatic axonal injury (TAI) but is generally not used for emergency evaluations unless it is rapidly and readily available. Recovery of functional independence is possible in patients with brainstem TAI; however, its radiologic classification is typically performed using the histopathologic model proposed by JH Adams, in which all brainstem lesions are grouped into a single prognostic category of "grade 3 DAI." This classification system fails to consider the prognostic importance of lesions in specific brainstem regions, such as dorsal pons and dorsal midbrain, which contain arousal (ie, wakefulness) nuclei that are critical to recovery of consciousness (see Fig 47.2).

Secondary Neurologic Evaluation

On arrival at the intensive care unit (ICU), more detailed physical and neurologic examinations should be performed (the "secondary survey"). The patient should again be examined for external signs of trauma to the neck, chest, back, abdomen, and limbs. A bloody discharge from the nose or ear may indicate leakage of CSF; bloody CSF may be differentiated from blood by a positive halo test (ie, a halo of CSF forms around the blood when dropped on a white cloth sheet). If there is no admixture of blood, CSF may be distinguished from nasal secretions because the CSF glucose concentration is 30 mg/dL or more, whereas lacrimal secretions and nasal mucus usually contain less than 5 mg/dL glucose.

After determining the patient's level of consciousness (eg, alert, lethargic, stuporous, or comatose), a focused mental status examination should be performed if the patient is conversant. Particular attention should be paid to attention capabilities, concentration (eg, counting backward from 20 to 1 or reciting the months in reverse), orientation, and memory, including assessment for retrograde and anterograde amnesia.

Eye movements, pupillary size and shape, and reactivity to light should be noted. A sluggishly reactive or dilated pupil suggests transtentorial herniation with compression of the third cranial nerve. A midposition, poorly reactive, and irregular pupil may result from injury to the oculomotor nucleus in the midbrain tegmentum. Nystagmus often follows a concussion. In comatose patients, the oculocephalic and oculovestibular reflexes should be tested (see Chapter 19).

Motor examination should focus on identifying asymmetric weakness or posturing. Spontaneous movements should be assessed for preferential use of the limbs on one side. If the patient is not fully cooperative, lateralized weakness may be detected by assessment of an asymmetry in tone or tendon reflexes or by the presence of an arm drift, preferential localizing response to sternal rub, or extensor plantar reflex. Noxious stimuli, such as pinching the medial arm or applying nail bed pressure, may reveal subtle motor posturing in a limb that otherwise moves purposefully. *Decorticate posturing* (ie, flexion of arms, extension of legs) results from injury to the corticospinal pathways at the level of the diencephalon or upper midbrain. *Decerebrate posturing* (ie, extension of legs and arms) implies injury to the motor pathways at the level of the lower midbrain, pons, or medulla.

Gait is particularly important to check in low-risk patients who are treated and scheduled for release without CT. Balance and equilibrium, tested by tandem heel-to-toe walking, are frequently impaired after a concussion.

MANAGEMENT

Admission to the Hospital

Low-risk Group

Low-risk patients who meet all criteria described in **Table 47.2**, generally, may be discharged from the emergency room without CT, so long as a responsible person is available to observe the patient for the next 24 hours. In general, these are patients who did not sustain a concussion and have normal findings on neurologic examination. Patients are given a checklist of symptoms (eg, headache, vomiting, confusion) and instructed to return immediately to the emergency room if any occur.

Moderate-risk Group

Among patients who have had a concussion, a normal GCS score of 15 (eg, alert, fully oriented, and following commands) and

TABLE 47.6 Criteria for Hospital Admission After Head Injury

• Intracranial blood or fracture identified on head CT
• Confusion, agitation, or depressed level of consciousness
• Focal neurologic signs or symptoms
• Posttraumatic seizure
• Alcohol or drug intoxication
• Significant comorbid medical illness
• Lack of a reliable home environment for observation

Abbreviation: CT, computed tomography.

normal CT eliminate the need for hospital admission. These patients may be discharged to home for observation with a warning card, even in the presence of headache, nausea, vomiting, dizziness, or retrograde amnesia, because the risk of a significant intracranial lesion developing thereafter is minimal. Criteria for hospital admission for patients with head injury are listed in **Table 47.6**.

Patients with mild to moderate neurologic deficits (generally corresponding to GCS scores of 9-14) and CT findings that do not require neurosurgical intervention should be admitted to an intermediate care unit or ICU for observation. Follow-up CT at 24 hours is often helpful to check for progression of bleeding.

High-risk Group

All patients with a serious head injury are admitted to the hospital. An early neurosurgical consultation is crucial because once the patient has been stabilized, assessed, and imaged, the immediate consideration is whether emergency surgery is indicated. If the decision is made to operate, surgery should proceed immediately because delays only increase the likelihood of further brain damage during the waiting period. Medical management of severe-injury patients should take place in an ICU. Although little may be done about the brain damage that occurs on impact, ICU care may play a major role in reducing secondary brain injury that develops over hours or days.

Surgical Intervention

Simple wounds of the scalp should be thoroughly cleaned and sutured. Compound fractures of the skull should be completely debrided. Operative treatment of compound fractures should be performed as soon as possible but may be delayed for 24 hours until the patient is transported to a hospital equipped for this purpose or until the patient is hemodynamically stable. Elevation of small, depressed fractures need not be performed immediately, but the depressed fragments should be elevated before the patient is discharged from the hospital, particularly if the inner table of the skull is involved.

The treatment of massive acute subdural, epidural, or parenchymal hematomas with mass effect is *craniotomy* and surgical removal of the clot. Results from a large randomized clinical trial indicate that decompressive *craniectomy*—removal of a large unilateral or bifrontal portion of the skull—is not indicated emergently LEVEL I.[1,2] The bleeding point should be identified and either ligated or clipped. The operative results depend to a great extent on the degree of associated brain damage. In the absence of coexisting brain injury, remarkable improvement may occur after evacuation of a subdural or epidural hematoma, with disappearance of the hemiplegia or other focal neurologic signs.

Burr-hole or *twist-drill* evacuation is insufficient for acute, large, subdural, and epidural hematomas, but for liquefied, chronic, subdural hematomas, it is associated with better outcomes than craniotomy. A plastic catheter (eg, Jackson-Pratt drain) is usually placed in the subdural space for several days until the drainage subsides.

Intracranial Pressure Management

As a general rule, an ICP monitor should be placed in all head-injured patients who are comatose (ie, GCS score of 8) after resuscitation. Intracranial hypertension occurs in more than 50% of comatose patients with CT evidence of mass effect from intracranial hemorrhage or cerebral edema and in 10% to 15% of patients with normal imaging. A ventricular catheter or fiberoptic parenchymal monitor may be used. Ventriculostomy has the advantage of allowing CSF drainage to reduce ICP but has a high risk of infection (approximately 12%). The risk of infection or hemorrhage is substantially lower with parenchymal ICP monitors (approximately 1%-2%).

Normal ICP is less than 15 mm Hg, or 20 cm water. Cerebral perfusion pressure (CPP) is routinely monitored in conjunction with ICP because it is an important determinant of cerebral blood flow; CPP is defined as mean arterial BP minus ICP. The goal of ICP management after head injury is to maintain ICP less than 20 mm Hg and CPP greater than 60 mm Hg. The magnitude and duration of derangements beyond these targets is highly correlated with poor outcome after severe TBI.

Treatment of elevated ICP is most successful when a preestablished protocol is used. Treatment of elevated ICP is most successful when a preestablished protocol is used. The Seattle International Severe Traumatic Brain Injury Consensus Conference (SIBICC) stepwise management protocol for treating ICP elevations in monitored ICU patients is shown in **Figure 47.10**.

An acute, severe increase in ICP always prompts a repeat CT to assess the need for a definitive neurosurgical procedure. If the patient is agitated or appears to be fighting the ventilator, a short-acting IV sedative agent, such as propofol, or analgesic, such as fentanyl, should be given alone or in combination to attain a quiet, motionless state. Thereafter, if CPP is less than 60 mm Hg, vasopressors may lead to reduction of ICP by decreasing cerebral vasodilation that occurs in response to inadequate perfusion. Alternately, if CPP exceeds 120 mm Hg, BP reduction with IV labetalol or nicardipine may sometimes lead to a parallel decrease of ICP. The relationship between extremes of CPP and ICP in states of reduced intracranial compliance is shown in **Figure 47.11**.

Mannitol and hypertonic saline are used only after all surgical options have been exhausted and sedation and CPP optimization fail to normalize ICP. Mannitol, an osmotic diuretic, lowers ICP via its cerebral dehydrating effects. The initial dose of mannitol 20% solution is 0.5 to 1.0 g/kg, followed by doses of 0.25 to 1.0 g/kg as needed. Further doses should be given individually based on ICP measurements rather than on a standing basis. Mannitol boluses may also be used to reverse acute herniation syndromes (ie, a blown pupil) resulting from compartmental mass effect and ICP gradients. The effect of mannitol is maximal when given rapidly; ICP reduction occurs within 10 to 20 minutes and may last for 2 to 6 hours. Serum osmolality should be monitored closely and the osmolar gap calculated by subtracting the measured osmolality from the calculated osmolality. Should the osmolar gap

Tier Zero (Basic Severe TBI Care - Not ICP Dependent)

Expected Interventions:

- Admission to ICU
- Endotracheal intubation and mechanical ventilation
- Serial evaluations of neurologic status and pupillary reactivity
- Elevate HOB 30°C-45°C
- Analgesia to manage signs of pain (not ICP directed)
- Sedation to prevent agitation, ventilator asynchrony, etc. (not ICP directed)
- Temperature management to prevent fever
  - *Measure core temperature*
  - *Treat core temperature above 38°C*
- Consider antiseizure medications for 1 wk only (in the absence of an indication to continue)
- Maintain CPP initially ≥60 mm Hg
- Maintain Hb >7 g/dL
- Avoid hyponatremia
- Optimize venous return from head (eg, keeping head midline, ensure cervical collars are not too tight)
- Arterial line continuous blood pressure monitoring
- Maintain SpO_2 ≥94%

Recommended Interventions:

- Insertion of a central line
- End-tidal CO_2 monitoring

Tier 1

- Maintain CPP 60-70 mm Hg
- Increase analgesia to lower ICP
- Increase sedation to lower ICP
- Maintain $Paco_2$ at low end of normal (35-38 mm Hg/4.7-5.1 kPA)
- Mannitol by intermittent bolus *(0.25-1.0 g/kg)*
- Hypertonic saline by intermittent bolus[a]
- CSF drainage if EVD *in situ*
- Consider placement of EVD to drain CSF if parenchymal probe used initially
- Consider anti-seizure prophylaxis for 1 week only (unless indication to continue)
- Consider EEG monitoring

Principles for Using Tiers:

- When possible, use lowest tier treatment
- There is no rank order within a tier
- It is not necessary to use all modalities in a lower tier before moving to the next tier
- If considered advantageous, tier can be skipped when advancing treatment

Tier 2

- Mild hypocapnia range (32-35 mm Hg/4.3-4.6 kPa)
- Neuromuscular paralysis in adequately sedated patients if efficacious[b]
- **Perform MAP Challenge to assess cerebral autoregulation and guide MAP and CPP goals in individual patients[c]**
  - *Should be performed under direct supervision of a physician who can assess response and ensure safety*
  - *No other therapeutic adjustments (ie, sedation) should be performed during the MAP Challenge*
  - *Initiate or titrate a vasopressor or inotrope to increase MAP by 10 mm Hg for not more than 20 minutes*
  - *Monitor and record key parameters (MAP, CPP, ICP, and $PbtO_2$) before during and after the challenge*
  - *Adjust vasopressor/inotrope dose based on study findings*
- Raise CPP with fluid boluses, vasopressors and/or inotropes to lower ICP when autoregulation is intact

- Reexamine the patient and consider repeat CT to reevaluate intracranial pathology
- Reconsider surgical options for potentially surgical lessions
- Consider extracranial causes of ICP elevation
- Review that basic physiologic parameters are in desired range (eg, CPP, blood gas values)
- Consider consultation with higher level of care if applicable for your health care system

Tier 3

- Pentobarbital or thiopentone coma titrated to ICP control if efficacious[d]
- Secondary decompressive craniectomy
- Mild hypothermia (35°C-36°C) using active cooling measures

FIGURE 47.10 Interventions fundamental to the intensive care of severe traumatic brain injury patients. [a]We recommend using sodium and osmolality limits of 155 and 320 mEq/L, respectively, as administration limits for both mannitol and hypertonic saline. [b]We recommend a trial dose of neuromuscular paralysis and only proceeding to a continuous infusion when efficacy is demonstrated. [c]Rosenthal G, Sanchez-Mejia RO, Phan N, Hemphill JC III, Martin C, Manley GT. Incorporating a parenchymal thermal diffusion cerebral blood flow probe in bedside assessment of cerebral autoregulation and vasoreactivity in patients with severe traumatic brain injury. *J Neurosurg*. 2011;114:62-70. [d]Barbiturate administration should only be continued when a beneficial effect on intracranial pressure (ICP) is demonstrated. Abbreviations: CO_2, carbon dioxide; CPP, cerebral perfusion pressure; CSF, cerebrospinal fluid; CT, computed tomography; EEG, electroencephalogram; EVD, external ventricular drain; Hb, hemoglobin; HOB, head of bed; ICU, intensive care unit; MAP, mean arterial pressure; $PbtO_2$, continuous brain tissue oxygen; SpO_2, oxygen saturation. (Adapted from SIBIC Severe TBI Guidelines.)

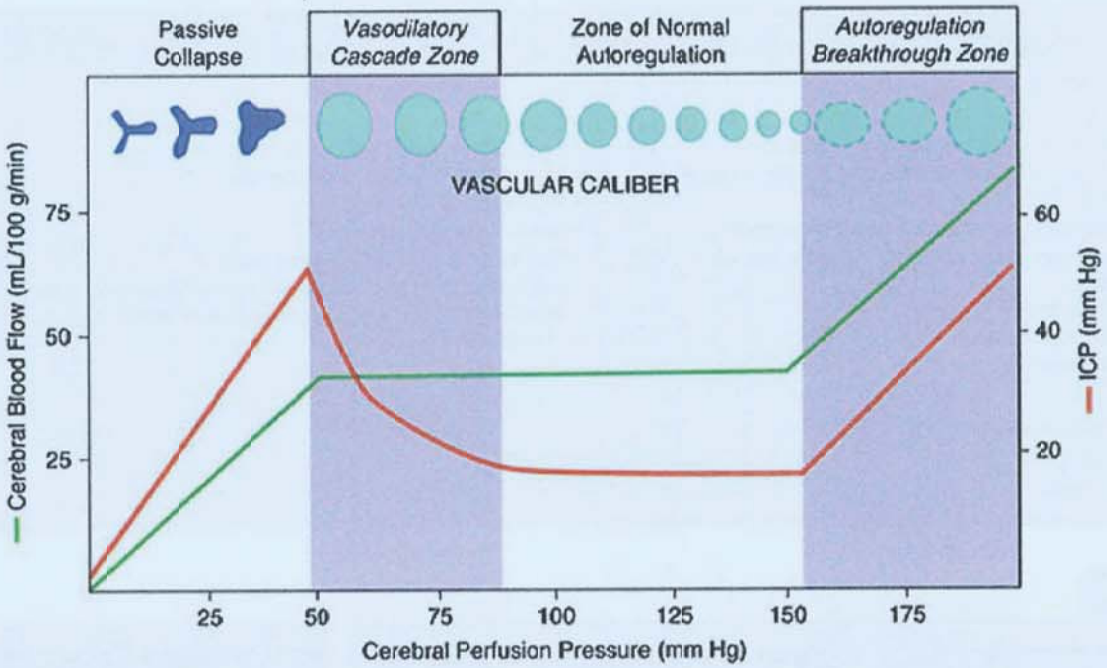

FIGURE 47.11 Relationship between extremes of cerebral perfusion pressure (CPP) and increased intracranial pressure (ICP) in states of reduced intracranial compliance. In the vasodilatory cascade zone, CPP insufficiency and intact pressure autoregulation leads to reflex cerebral vasodilation and increased ICP; the treatment is to raise CPP. In the autoregulation breakthrough zone, pressure and volume overload, which overwhelms the brain's capacity to autoregulate, leads to increased cerebral blood volume and ICP; the treatment is to lower CPP. (Adapted from Rose JA, Mayer SA. Optimizing blood pressure in neurological emergencies. *Neurocrit Care*. 2004;1:287-299, with permission.)

increase to greater than 15 mOsm/L, then there is a greater likelihood of mannitol leading to renal failure. Urinary losses should be compensated for with IV normal saline to avoid secondary hypovolemia. Assessment of intravascular volume status with a combination of invasive monitoring and ultrasound is generally recommended. More recently, hypertonic saline in the form of a 3% sodium chloride/acetate continuous infusion, or 10% or 23.4% sodium chloride as an alternative to mannitol bolus therapy, has been advocated for the treatment of intracranial hypertension and herniation syndromes. Studies evaluating equiosmolar doses of mannitol and hypertonic saline indicate that in most cases, hypertonic saline is at least equivalent, if not superior, to mannitol for lowering ICP in terms of the rapidity, extent, and duration of ICP reduction. The exception is in the prehospital setting where empiric administration with hypertonic saline failed to improve outcomes after TBI LEVEL 1.[3] As a general rule in the critical care setting, hypertonic saline is generally preferred in patients who are hypotensive or hypovolemic, whereas mannitol is preferable for patients who are volume overloaded or who have congestive heart failure.

Hyperventilation lowers ICP by inducing cerebral alkalosis and reflex vasoconstriction, with a concomitant reduction of CBV. Hyperventilation to P_{CO_2} levels of 28 to 32 mm Hg may lower ICP within minutes, although the effect gradually diminishes over as little as 1 to 3 hours, as acid-base buffering mechanisms correct the alkalosis within the CNS. Additionally, prophylactic hyperventilation has been shown to lead to detrimental outcomes LEVEL 1,[4] and overly aggressive hyperventilation to P_{CO_2} levels less than 26 mm Hg may potentially exacerbate cerebral ischemia and, in general, should be avoided unless jugular venous oxygen saturation or brain tissue oxygen monitoring is available to ensure that cerebral hypoxia does not occur.

High-dose barbiturate therapy with pentobarbital given in doses equivalent to those used for general anesthesia (5-20 mg/kg as a loading dose, followed by 1-4 mg/kg/h) effectively lowers ICP in most patients who are refractory to the steps outlined earlier. It can be dosed as either a continuous infusion or given as bolus injection as needed for ICP control (50-200 mg every 15 min). The effect of pentobarbital is multifactorial but most likely stems from a coupled reduction in cerebral metabolism, blood flow, and blood volume. Pentobarbital may cause profound hypotension and usually requires the use of vasopressors to maintain CPP of at least 60 mm Hg. The other major side effect of pentobarbital is prolonged immobilization and ventilator dependence, which increases the risk of nosocomial infection and exposure to other iatrogenic complications. In a clinical trial, the prophylactic use of pentobarbital was associated with poor outcome, and its use currently is reserved for cases of refractory raised ICP LEVEL 1.[5]

Mild to moderate systemic hypothermia (33°C) has been shown to reduce ICP in patients with refractory intracranial hypertension. The application of hypothermia is complex and requires a management protocol that emphasizes the use of agents such as meperidine, fentanyl, or dexmedetomidine and neuromuscular blocking agents, if necessary, to prevent shivering that increases cerebral and metabolic stress and fights the cooling process. The routine application of mild to moderate hypothermia within 8 hours of TBI, as a form of neuroprotection, or as an early-stage ICP therapy was tested in several large clinical trials and was shown not to be of benefit LEVEL 1.[6-9] For this reason, its use should be limited to the management of refractory intracranial hypertension.

Intensive Care Unit Management of Severe Head Injury

Patients with severe head injuries are best treated in an ICU (see Fig 47.10). In some hospitals, patients with head injuries are treated in a special neurologic or neurosurgical ICU. A time-coded flow sheet is helpful to allow for meticulous, continuous updating of the patient's clinical, neurologic, and physiologic status that supports crisp management decisions balancing both the increasing risk of treatment-related complications as well as potential benefits of escalation from one tier to the next (Fig 47.12).

Serial Neurologic Evaluation

The patient should be examined repeatedly to evaluate level of consciousness and the presence or absence of signs of injury to the brain or cranial nerves. Variations in level of consciousness, reflected by changes in the GCS score or the appearance of hemiplegia or other focal neurologic signs, should prompt repeat CT.

Airway and Ventilation

In general, patients who are unable to protect their airways because of depressed levels of consciousness should be intubated with an endotracheal tube. Routine hyperventilation is not recommended; in the absence of increased ICP, ventilatory parameters should be set to maintain P_{CO_2} at 30 to 40 mm Hg and P_{O_2} at 90 to 100 mm Hg.

Blood Pressure Management

If the patient shows signs of hemodynamic instability, a radial artery catheter should be placed to monitor BP. Because cerebral blood flow autoregulation is frequently impaired in acute head injury, mean BP (or CPP if ICP is being monitored) must be carefully regulated to avoid hypotension that may lead to cerebral ischemia or hypertension that may exacerbate cerebral edema. Continuous infusion, short-acting vasopressors (eg, phenylephrine and norepinephrine), and antihypertensive agents (eg, labetalol and nicardipine) are preferable because of their abilities to stabilize BP within a narrow therapeutic range. Sodium nitroprusside should be avoided because it may dilate cerebral vessels and raise ICP.

Fluid Management

Only isotonic fluids, such as 0.9% (ie, normal) saline or plasmalyte solution, should be administered to head-injured patients because the extra free water in half-normal saline or 5% dextrose in water may exacerbate cerebral edema. Hypertonic saline (ie, 3% sodium chloride/acetate solution) with a target osmolality of 300 to 320 mOsm/L may be used as an alternative in patients with significant brain edema and may reduce the number of ICP elevations, at the risk of causing fluid overload and pulmonary edema if volume status and oxygenation are not carefully monitored. Central venous pressure monitoring is helpful to guide fluid management in hypotensive or hypovolemic patients. Negative fluid balance is associated with poor outcome after TBI and should be avoided.

Nutrition

Severe head injury leads to a generalized hypermetabolic and catabolic response, with caloric requirements that are 50% to 100% higher than normal. Enteral feedings via a nasogastric or nasoduodenal tube should be instituted as soon as possible (eg, usually after 24-48 h). Early enteral feeding on day 1 after injury is generally well tolerated and has been shown to improve outcome compared

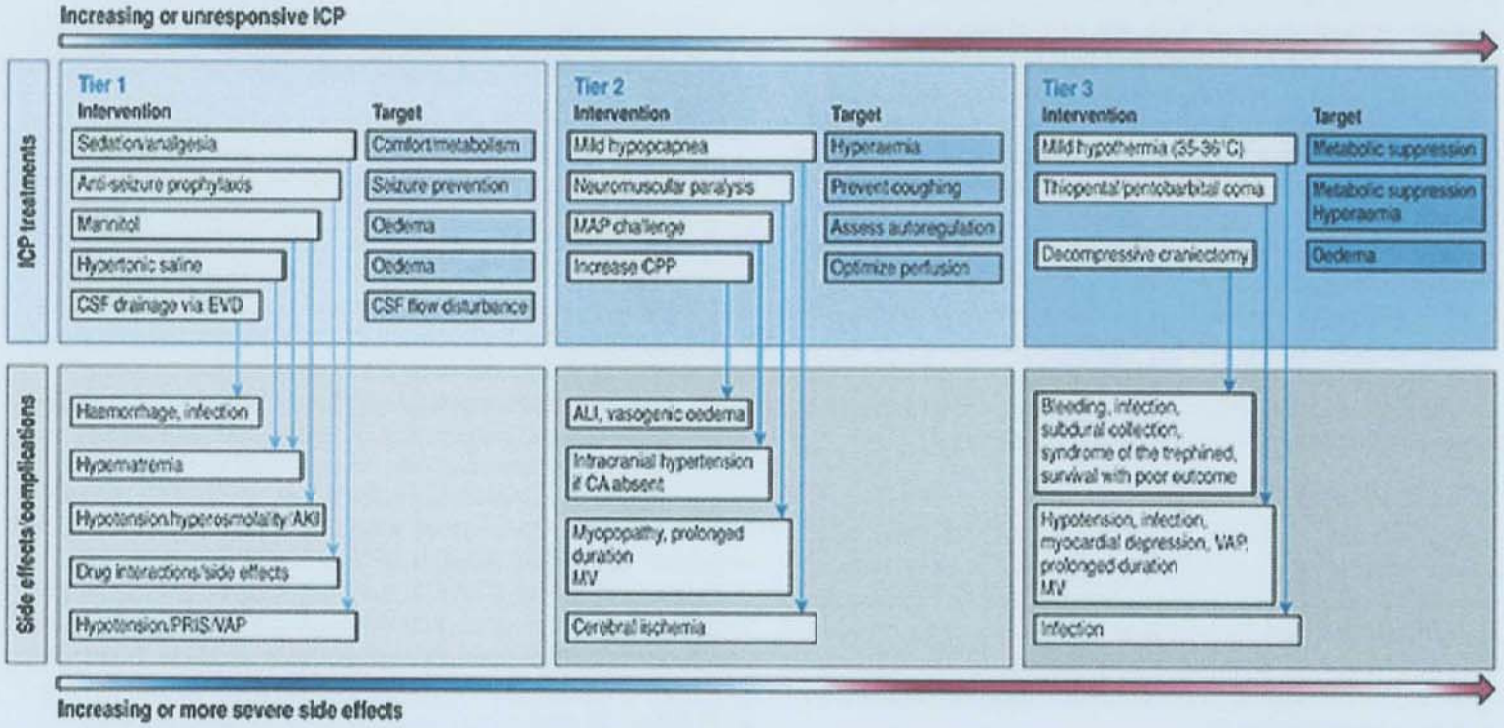

FIGURE 47.12 Tiered treatment of intracranial hypertension in adult traumatic brain injury. Clinicians must always consider both the increasing risk of treatment-related complications with as well as potential benefits of escalation from one tier to the next. Tier-3 treatments are associated with the most severe complications. Abbreviations: AKI, acute kidney injury; ALI, ; CA, cerebral autoregulation; CPP, cerebral perfusion pressure; CSF, cerebrospinal fluid; EVD, external ventricular drain; ICP, intracranial pressure; MAP, mean arterial pressure; MV, mechanical ventilation; PRIS, propofol infusion syndrome; VAP, ventilator-associated pneumonia. (Adapted from SIBIC Severe TBI Guidelines and Smith M, Maas AIR. An algorithm for patients with intracranial pressure monitoring: filling the gap between evidence and practice. *Intensive Care Med.* 2019;45:1819-1821.)

with delayed feeding. Parenteral nutrition carries significant risks, primarily those of infection and electrolyte derangements, and should be used only if enteral feeding may not be tolerated.

Analgosedation

Patients may be agitated or delirious, which may lead to self-injury, forcible removal of monitoring devices, systemic and cerebral hypermetabolism, and increased ICP. Intubated patients may be sedated using a continuous IV infusion of a rapid-acting sedative agent, such as propofol, fentanyl, or remifentanil, that may be turned off periodically to allow neurologic assessments. Pain control should always be the first consideration when using analgosedation. Daily interruption of sedation in mechanically intubated patients allows for improved sensitivity to changes in neurologic status, more appropriate titration of sedation, and reduced duration of mechanical ventilation. Nonintubated patients with delirium may be treated with haloperidol 2 to 10 mg every 4 hours as needed, quetiapine 25 to 50 mg orally every 6 to 8 hours, or a similar agent.

Temperature Management

Fever (>38.3°C) is common after TBI and may be the result of infection or of central fever. Even small temperature elevations may exacerbate TBI and ischemic brain injury and should be aggressively treated. Newer cooling devices using adhesive cooling pads or intravascular heat-exchange catheters are superior to standard water-circulating cooling blankets for maintaining normothermia in comatose brain-injured patients.

Anticonvulsants

Phenytoin or fosphenytoin (15-20 mg/kg loading dose, then 300 mg/d) reduced the frequency of early (ie, first week) post-traumatic seizures from 14% to 4% in a clinical trial of patients with intracranial hemorrhage but did not prevent later seizures LEVEL 1.[10] IV valproic acid or levetiracetam is an acceptable alternative for patients with phenytoin allergy. If the patient has not had a seizure, prophylactic anticonvulsants should be discontinued after 7 days. Anticonvulsant serum levels of head-injured patients should be monitored closely because subtherapeutic levels frequently result from drug hypermetabolism, particularly in younger men. Nonconvulsive seizures and status epilepticus, which are diagnosable only with continuous electroencephalogram monitoring, occur in over 10% to 20% of comatose TBI patients, are associated with poor outcome and generally warrant aggressive treatment with continuous infusion midazolam or similar agents.

Intensive Insulin Therapy

Continuous insulin infusion therapy to control blood glucose to between 100 and 180 mg/dL in hyperglycemic patients reduces mortality in critically ill surgical patients and is increasingly being adopted as a practice option in the ICU management of severe TBI. Meticulous attention, including hourly blood glucose monitoring, must be paid to avoid excessive hypoglycemia with continuous insulin infusion.

Steroids

Glucocorticoids have been used to treat cerebral edema for years but have not been shown to favorably alter outcomes or lower ICP in head-injured patients. A large randomized controlled trial demonstrated an increased rate of death in patients given high-dose steroids during the first week after TBI LEVEL 1.[11] This was probably attributable to increased risk of infection, hyperglycemia, or other complications. For these reasons, dexamethasone and other steroids are absolutely contraindicated for use in patients with head injury.

Deep Vein Thrombosis Prophylaxis

Patients with head injury who are immobilized are at high risk for deep vein thrombosis in the legs and pulmonary thromboembolism. Pneumatic compression boots should be used routinely to protect against this risk, and patients should also be given subcutaneous heparin 5,000 units every 8 hours or enoxaparin 40 mg daily. Low-dose anticoagulants to prevent thromboembolic disease can safely be added within 48 hours after injury, even in the presence of intracranial hemorrhage, so long as hematoma expansion is not noted on serial imaging.

Gastric Stress Ulcer Prophylaxis

Patients on mechanical ventilation or with coagulopathy are at increased risk for gastric stress ulceration and should receive pantoprazole 40 mg daily IV, famotidine 20 mg IV every 12 hours, or sucralfate 1 g orally every 6 hours.

Antibiotics

The routine use of prophylactic antibiotics in patients with open skull injuries is controversial, and opinions are sharply divided. Prophylactic antibiotics with gram-positive activity, such as oxacillin, are often used to reduce the risk of meningitis in patients with CSF otorrhea, rhinorrhea, or intracranial air; however, these agents may increase the risk of infection with more virulent or resistant organisms. A single dose of an antibiotic with activity against gram-positive bacteria such as oxacillin or cefazolin should be administered immediately prior to the insertion of an intracranial monitor.

ACUTE COMPLICATIONS OF HEAD INJURY

Cerebrospinal Fluid Fistula

CSF fistulas result from tearing of the dura and arachnoid membranes. They occur in 3% of patients with closed head injury and in 5% to 10% of those with basilar skull fractures. They are usually associated with fractures of the ethmoid, sphenoid, or orbital plate of the frontal bone.

CT may demonstrate pneumocephalus (air in the subarachnoid space). Clinical manifestations include obvious leakage of CSF from a scalp laceration, the nose, or the ear. CSF leakage ceases after head elevation alone for a few days in 85% of cases. If it persists, the insertion of a lumbar drain may lower CSF pressure, reduce flow through the fistula, and hasten spontaneous closure of the dural tear. Patients with dural leaks are at increased risk for meningitis, and although the use of prophylactic antibiotics is controversial, most physicians use them. Persistent CSF otorrhea or rhinorrhea for more than 2 weeks calls for surgical repair, as does recurrent meningitis. If there is a leak and the site of the fracture is not evident, a metrizamide CT study is the diagnostic method of choice.

Carotid-Cavernous Fistula

Carotid-cavernous fistulae are characterized by the clinical triad of pulsating exophthalmos, ocular chemosis, and orbital bruit. They

result from traumatic laceration of the internal carotid artery as it passes through the cavernous sinus; approximately 20% of cases are nontraumatic, and most of these are related to spontaneous rupture of an intracavernous internal carotid artery aneurysm. Other symptoms may include distended orbital and periorbital veins and paralysis of the cranial nerves (eg, III, IV, V, and VI) that pass through or within the wall of the cavernous sinus.

Traumatic carotid-cavernous fistulae may develop immediately or within days after injury. Angiography is required to confirm the diagnosis (see Fig. 47.9). Endovascular treatment, with a balloon placed through the defect in the arterial wall into the venous side of the fistula, is the most effective means of repair and may prevent permanent visual loss caused by venous retinal infarction if performed as soon as possible after injury.

Traumatic Arterial Dissection and Vascular Injuries

Traumatic injuries may be associated with dissections of the extracranial or intracranial internal carotid or vertebral arteries, which may lead to thrombosis at the site of the intimal flap and stroke resulting from distal thromboembolism. The gold standard for diagnosis is conventional angiography, but CT and magnetic resonance angiography are often used to screen for arterial dissections. Anticoagulation with unfractionated heparin is the primary strategy to prevent intravascular thrombosis and thromboembolism. However, anticoagulation poses risks when there is evident intracranial hemorrhage or coexisting intracranial dissection with pseudoaneurysm formation. Treatment decisions must be individualized.

Basilar skull fractures are sometimes associated with thrombosis of adjacent dural sinuses; the sphenoid and transverse sinuses are most commonly involved. Symptoms are related to increased ICP or associated venous infarction. The diagnosis is established by angiography or magnetic resonance venography, and anticoagulation is the treatment of choice (see Chapter 44).

In patients with large epidural or subdural hematomas and subfalcine herniation, secondary cerebral infarction may sometimes result from compression of the ipsilateral anterior cerebral artery against the falx or posterior cerebral artery against the tentorium. Urgent neurosurgical decompression to prevent these infarcts is the only effective management strategy.

Cranial Nerve Injury

Injury to the cranial nerves can occur with basilar skull fractures (see Chapter 49). The facial nerve is the most commonly injured nerve in these cases, complicating 0.3% to 5% of all head injuries. Occasionally, the paralysis may not develop until several days after the injury. Partial or complete recovery of function is the rule with traumatic injuries to the cranial nerves, with the exception of injury to the first or second cranial nerve.

Infections

Infections within the intracranial cavity after head injury may be extradural (eg, osteomyelitis), subdural (eg, empyema), subarachnoid (eg, meningitis), or intracerebral (eg, abscess). These infections usually develop in the first few weeks after injury but may be delayed. Diagnosis is suggested by CT or MRI and confirmed by culture of the infected tissue. Treatment includes surgical debridement and administration of antibiotics.

Meningitis may follow any type of open fracture associated with tearing of the dura, including compound skull fractures, penetrating missile injury, or linear fractures that extend into the nasal sinuses or the middle ear. Meningitis occurs in as few as 2% and as many as 22% of patients with basilar skull fractures. Cases of meningitis that develop within a few days after injury are almost always caused by pneumococcus or other gram-positive bacteria, but any pathogenic organism may be the cause. Diagnosis depends on the CSF findings after lumbar puncture. The principles of treatment are those recommended for meningitis in general (see Chapter 64). The presence of a persistent CSF fistula with rhinorrhea or otorrhea favors the recurrence of meningitis; as many as seven or eight attacks have been reported. Treatment in such cases may require surgical closure of the fistula.

OUTCOMES

Outcomes that may be expected after head injury are often matters of great concern, particularly in those with serious injuries. *Depth of coma*, *CT findings*, and *age* of the patient are the variables most predictive of late outcome. Other factors of prognostic importance include the absence of pupillary responses, hypotension or hypoxemia on admission, specific patterns of injury noted on admission CT scan, persistently elevated ICP, hyperthermia, and critically reduced (<10 mm Hg) brain tissue oxygen levels. Functional outcomes from severe TBI have improved markedly over the past 20 years, although mortality remains constant at approximately 30%.

Severity of coma may be quantified using the admission GCS score (see Table 47.3), which has substantial prognostic value. Historically, patients scoring 3 or 4 (deep coma) have an 85% chance of dying or remaining vegetative, whereas these outcomes occur in only 5% to 10% of patients scoring 12 or more. In general, elderly patients do very poorly. In one series of comatose patients older than 65 years of age, only 10% survived, and only 4% regained functional independence. However, many older adults with TBI respond well to aggressive management and rehabilitation, suggesting that chronologic age and TBI severity alone are inadequate prognostic markers. TBI prognostic models do not perform optimally in this population. Death may result from progression to brain death or refractory medical complications but most often is the consequence of decisions to limit life support because poor functional recovery is anticipated. It is increasingly recognized, however, that caregivers tend to underestimate capacity for recovery from severe brain injury, and some fatal outcomes may be the result of self-fulfilling prophecy. Attempts to make a firm prognosis in severe head injuries, especially in the early stages, are hazardous because the outcome depends on so many variables. Behaviors that presage later recovery (ie, ability to communicate, verbalize intelligibly, follow commands, recognize familiar stimuli, and use common objects) may not emerge within the ICU phase (Figs. 47.13 and 47.14). The 2018 disorders of consciousness (DoC) ascending arousal network practice guidelines recommend that when clinicians are discussing prognosis with caregivers of patients with DoC who are within 28 days of injury, they must avoid statements that suggest that these patients have a universally poor prognosis. Some indices, however, are valuable as prognostic indicators (see Table 47.4).

In general, the prospects of recovery from trauma-induced coma are better than recovery from coma by other causes. Fifty percent of adults and 60% of children who experience trauma-

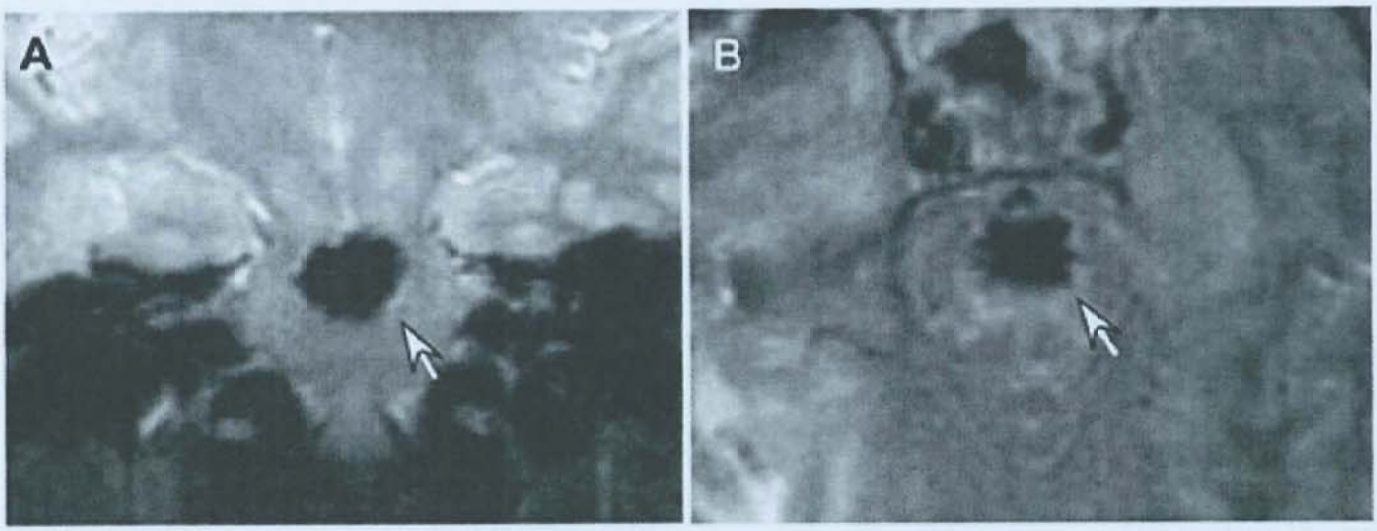

FIGURE 47.13 A case of good recovery following cerebral herniation with Duret hemorrhage following severe traumatic brain injury. Three months postinjury, the patient had mild left upper extremity weakness, was able to stand independently, and could walk with minimal assistance. Cognition was intact and she could verbalize in short sentences. Coronal multiplanar gradient echo imaging sequence **(A)** and axial fluid-attenuated inversion recovery sequence **(B)** demonstrating blood in the pons *(arrows)*. (From Stiver SI, Gean AD, Manley GT. Survival with good outcome after cerebral herniation and Duret hemorrhage caused by traumatic brain injury. *J Neurosurg*. 2009;110(6):1242-1246.)

induced coma for 30 days will recover consciousness within 1 year compared with 15% of patients in coma from nontraumatic causes. Recovery of consciousness is operationally defined as the ability to follow verbal commands convincingly and consistently. *Unresponsive wakefulness*, rather than the former used term *persistent vegetative state*, refers to a state of eyes open coma with no external signs of consciousness. The *minimally conscious state* refers to a transitional state between coma and full consciousness. Patients exhibit the capacity to understand and obey commands and make some purposeful behaviors but otherwise demonstrate a paucity of spontaneous thought and activity. Rehabilitation inpatients with prolonged DoC after head trauma are systematically assessed using a validated neurobehavioral assessment measure, the Coma Recovery Scale-Revised, ranging from 0 to 23, with higher scores indicating a higher level of function. The Coma Recovery Scale-Revised tracks the frequency of recovery of six behaviors that represent precursors of functional independence. A linear relationship exists between the number of behaviors recovered and degree of disability (Disability Rating Scale score) at follow-up.

Cognitive impairment is by far the most common and disabling problem among survivors of head injury. During the acute phase, disorientation and agitation are particularly common.

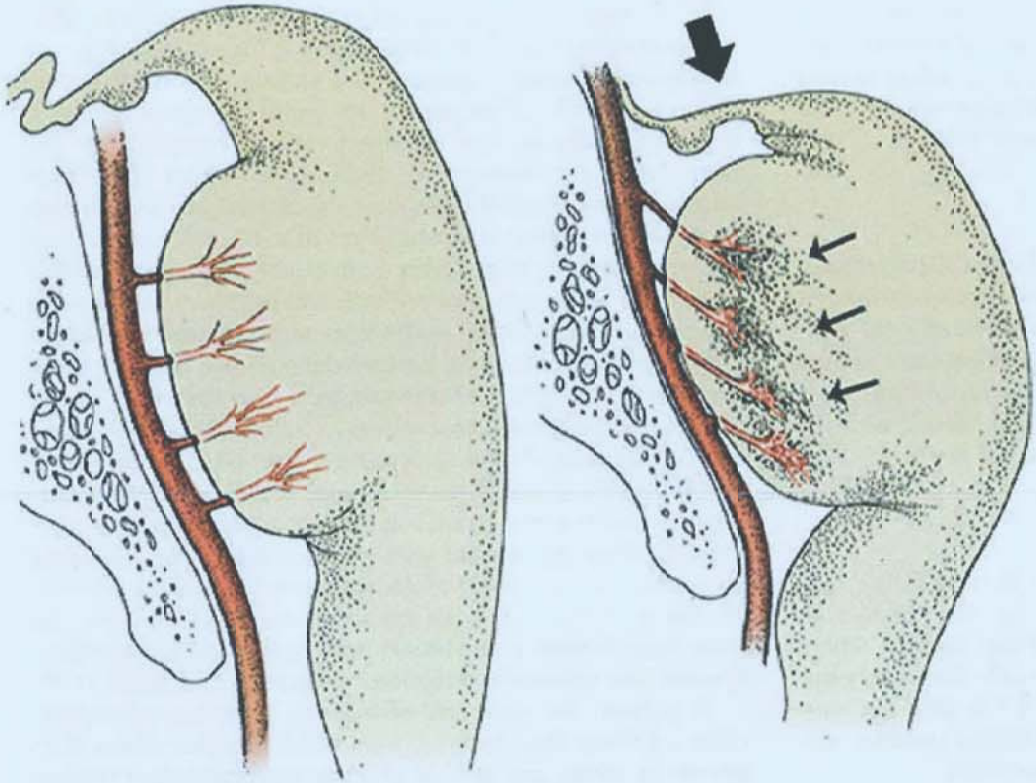

FIGURE 47.14 Sagittal schematic views of the basilar artery and brainstem before **(left)** and after **(right)** cerebral herniation. In a normal brainstem, the basilar perforating arteries penetrate the pons in a perpendicular fashion. With downward herniation *(large arrow)*, the basilar artery remains fixed by the circle of Willis and the caudal shift of the pons results in stretching and rupture of small pontine perforating vessels, which leads to a Duret hemorrhage *(arrows)*. (From Gean AD. *Imaging of Head Trauma*. Philadelphia, PA: Raven Press; 1994:214, Fig. 10. Previously modified with permission from Wolters Kluwer.)

In addition to cognitive and motor deficits, headache, dizziness, vomiting, or vertigo may be present in the immediate posttraumatic period. These symptoms usually disappear in a few weeks but may persist for months. Common chronic cognitive problems include impaired short- and long-term memory, attention, and concentration; slowing of psychomotor speed and mental processing; and changes in personality. There may be loss of memory for the events that occurred in the immediate period after recovery of consciousness (ie, *posttraumatic amnesia*) and a similar amnesia for the events immediately preceding the injury (ie, *retraumatic amnesia*). These periods of amnesia may encompass days, weeks, or years. Depression occurs in up to 40% of TBI survivors during the first year of recovery and is highly amenable to medical therapy. With time, there is usually considerable improvement in the signs and symptoms of brain damage, but permanent sequelae are common. Even at the milder range of TBI, patients presenting to U.S. level 1 trauma centers report persistent, injury-related life difficulties at 1 year postinjury, suggesting the need for more systematic outpatient follow-up of patients with mild traumatic brain injury (mTBI) to provide treatments and reduce risk of chronic problems after mTBI.

Early cognitive, physical, and occupational therapy is an important part of optimizing recovery after TBI. Physical therapy, including range-of-motion exercises to prevent limb contractures, may begin even while patients are still in the ICU. Once the patients are stabilized, they can be transferred to an acute or subacute rehabilitation facility. Whether cognitive rehabilitative measures truly improve neuropsychological outcome remains to be established.

In a study of patients with moderate or severe injuries, only 46% returned to work 2 years later, and most of those who did return to work did not go back to their original work. Only 18% were financially independent, inducing considerable stress on the family. Vocational training may play a key role in helping patients reintegrate into the workforce.

Postconcussion Syndrome

About 40% of patients who have sustained minor or severe injuries to the head complain of dizziness, fatigue, insomnia, irritability, restlessness, and inability to concentrate. Often, there is overlap with mood disorders, including anxiety and depression, migraines, or other premorbid neuropsychiatric conditions. This group of symptoms, which may be present for only a few weeks or may persist for years, is known as *postconcussion syndrome* (see also Chapter 46).

Postconcussion syndrome is somewhat misleadingly named because affected individuals need not have suffered loss of consciousness. There are no criteria to define the role of either physiologic or psychological factors in the etiology of postconcussion syndrome. Patients may be severely disabled yet have normal findings on neurologic examination and no magnetic resonance evidence of brain injury. The correlation between the severity of the original injury and the severity and duration of later symptoms is poor. For instance, the incidence of postconcussion syndrome is not related to the duration of retrograde amnesia, coma, or posttraumatic amnesia. In some patients, symptoms may be related to the brain damage; in others, they seem to be entirely psychogenic. In practice, it is often difficult to sort out the complicated origins of this disorder.

Posttraumatic symptoms may develop in patients who had previously shown normal adjustment but are more likely to occur in patients who had psychiatric symptoms before the injury. Factors such as domestic or financial difficulties, unrewarding occupations, and the desire to obtain compensation, financial or otherwise, tend to produce and may prolong the symptoms once they have developed.

The prognosis of the postconcussion syndrome is uncertain. In general, progressive improvement may be expected. The duration of symptoms is not related to the severity of the injury. In some patients with only mild injuries, symptoms continue for long periods, whereas patients with severe injuries may have only mild or transient symptoms. By and large, however, it is a matter of 2 to 6 months before the headache and dizziness, and the more definite mental changes, show much improvement. Treatment for postconcussion syndrome is based on psychotherapy, cognitive and occupational therapy, vocational rehabilitation, and treatment with antidepressant or antianxiety agents. However, the Transforming Research and Clinical Knowledge in Traumatic Brain Injury (TRACK-TBI) study revealed that a large proportion of patients with mTBI do not receive any follow-up care during the first 3 months after injury even when they experience ongoing postconcussive symptoms or have an abnormal head CT.

Seizures and Posttraumatic Epilepsy

Posttraumatic seizures may be immediate (ie, within 24 hours), early (ie, within the first week), or late (ie, occurring after the first week).

The exact incidence of seizures after head injury is unknown, but figures in the literature vary from 2.5% to 40%. As a rule, the more severe the injury, the greater the likelihood that seizures will develop. The overall incidence of seizures is about 25% in those with brain contusion or hematoma and as high as 50% in those with penetrating head injury.

Immediate seizures are infrequent; they are risk factors for further early seizures but not for late seizures. Early seizures occur in 3% to 14% of patients with head injury who are admitted to the hospital. Risk factors include depressed skull fracture, penetrating head injury, intracranial hemorrhage (ie, epidural, subdural, or intraparenchymal), prolonged unconsciousness (ie, >24 h), coma, and immediate seizures; the risk of early seizures in patients with any of these risk factors is 20% to 30%. Children are more likely to develop early posttraumatic seizures than are adults. Patients who experience early seizures remain at risk for late seizures and should be maintained on anticonvulsants after discharge from the hospital.

The overall incidence of late seizures (eg, posttraumatic epilepsy) after closed-head injury is 5%, but the risk is as high as 30% among patients with intracranial hemorrhage or a depressed skull fracture and 50% among patients who have experienced early seizures. About 60% of patients experience their initial seizures during the first year, but the risk of seizures remains increased for up to 15 years after a severe head injury. Because 25% of patients have only a single late seizure, many practitioners begin anticonvulsants only after a second seizure occurs. Therapy of posttraumatic epilepsy is discussed further in Chapter 60.

Posttraumatic Movement Disorders

Movement disorders are rare sequelae of head injury. Action tremor is most common, although its pathogenesis remains obscure. Cerebellar ataxia, rubral tremor, and palatal myoclonus have been described in patients with focal shearing injuries of the

superior cerebellar peduncle, midbrain, and dentato-rubro-olivary triangle, respectively. Parkinsonism and other basal ganglia syndromes have been reported after a single episode of head trauma.

PEDIATRIC TRAUMA BRAIN INJURY

Injuries are the leading cause of death in children, and brain injury is the most common cause of pediatric traumatic death (see also Chapter 151, Pediatric Brain Injury and Shaken Baby Syndrome). Motor vehicle accidents account for the largest number of severe injuries in children, but children are also prone to unique forms of injury, such as birth injury and child abuse. Children are more likely than adults to experience brain swelling and seizures after head injury and, in general, make better recoveries than do adults.

The new Brain Trauma Foundation guidelines for the management of pediatric severe TBI include an algorithm for first- and second-tier therapies. These guidelines emphasize the importance of maintaining CPP between 40 and 50 mm Hg while providing treatments to keep ICP <20 mm Hg. The treatment algorithm prioritizes the avoidance of hypoxia, hypocarbia, and circulatory compromise during stabilization; does not recommend prophylactic hypothermia; recommends seizure prophylaxis and ICP monitoring; and promotes hyperosmolar therapy with hypertonic saline and CSF removal via an external ventricular drain as initial steps to treat elevated ICP. The guidelines also address brain tissue oxygenation monitoring and advanced therapies for refractory intracranial hypertension.

MISSILE-RELATED CEREBRAL BLAST INJURY

Historically, penetrating military missile and blast injuries to the brain have led to a uniformly fatal outcome. With improvements in body armor and helmet construction, however, a previously unrecognized syndrome of cerebral *blast injury* has been described in soldiers injured in the United States–Iraq conflict. The syndrome is produced by explosive devices that propel a blast wave and a shower of metallic fragments. In addition to producing concussion, DAI, and the typically encountered forms of acute intracranial bleeding, cerebral blast injury is manifest as massive brain swelling and diffuse arterial vasospasm that begins within several days and resolves on average of 2 weeks after the injury. The syndrome is attributed to diffuse high-frequency shock wave–mediated tissue injury at the time of impact. Hemicraniectomy is often used as a lifesaving procedure because standard measures to reduce brain edema and control ICP often fail despite absence of data regarding its efficacy. Arterial vasospasm, which can result in delayed cerebral infarction, can be treated successfully with balloon angioplasty.

LEVEL 1 EVIDENCE

1. Cooper DJ, Rosenfeld JV, Murray L, et al; for DECRA Trial Investigators and Australian and New Zealand Intensive Care Society Clinical Trials Group. Decompressive craniectomy in diffuse traumatic brain injury. *N Engl J Med*. 2011;364(16):1493-1502.
2. Hutchinson PJ, Kolias AG, Timofeev IS, et al. Trial of decompressive craniectomy for traumatic intracranial hypertension. *N Eng J Med*. 2016;375(12):1119-1130.
3. Muizelaar JP, Marmarou A, Ward JD, et al. Adverse effects of prolonged hyperventilation in patients with severe head injury: a randomized clinical trial. *J Neurosurg*. 1991;75(5):731-739.
4. Cooper DJ, Myles PS, McDermott FT, et al; for HTS Study Investigators. Prehospital hypertonic saline resuscitation of patients with hypotension and severe traumatic brain injury: a randomized controlled trial. *JAMA*. 2004;291(11):1350-1357.
5. Ward JD, Becker DP, Miller JD, et al. Failure of prophylactic barbiturate coma in the treatment of severe head injury. *J Neurosurg*. 1985;62(3):383-388.
6. Clifton GL, Miller ER, Choi SC, et al. Lack of effect of induction of hypothermia after acute brain injury. *N Eng J Med*. 2001;344(8):556-563.
7. Clifton GL, Valadka A, Zygun D, et al. Very early hypothermia induction in patients with severe brain injury (the National Acute Brain Injury Study: Hypothermia II): a randomised trial. *Lancet Neurol*. 2011;10(2):131-139.
8. Cooper DJ, Nichol AD, Bailey M, et al. Effect of early sustained prophylactic hypothermia on neurologic outcomes among patients with severe traumatic brain injury: the POLAR randomized clinical trial. *JAMA*. 2018;320(21):2211-2220.
9. Andrews PJ, Sinclair HL, Rodriguez A, et al. Hypothermia for intracranial hypertension after traumatic brain injury. *N Eng J Med*. 2015;373(25):2403-2412.
10. Temkin NR, Dikmen SS, Wilensky AJ, Keihm J, Chabal S, Winn HR. A randomized, double-blind study of phenytoin for the prevention of post-traumatic seizures. *N Engl J Med*. 1990;323(8):497-502.
11. Roberts I, Yates D, Sandercock P, et al. Effect of intravenous corticosteroids on death within 14 days in 10008 adults with clinically significant head injury (MRC CRASH trial): randomised placebo-controlled trial. *Lancet*. 2004;364(9442):1321-1328.

SUGGESTED READINGS

Head Injury, General Considerations

Adams JH, Graham DI, Gennarelli TA, Maxwell WL. Diffuse axonal injury in non-missile head injury. *J Neurol Neurosurg Psychiatry*. 1991;54:481-483.

Armonda RA, Bell RS, Vo AH, et al. Wartime traumatic cerebral vasospasm: recent review of combat casualties. *Neurosurgery*. 2006;59(6):1215-1225.

Bratton SL, Chesnut RM, Ghajar J, et al. Guidelines for the management of severe traumatic brain injury. XIV. Hyperventilation. *J Neurotrauma*. 2007;24(suppl 1):S87-S90.

Cruz J, Minoja G, Okuchi K, Facco E. Successful use of the new high-dose mannitol treatment in patients with Glasgow Coma Scale scores of 3 and bilateral abnormal pupillary widening: a randomized trial. *J Neurosurg*. 2004;100:376-383.

Diringer MN, Zazulia AR. Osmotic therapy: fact and fiction. *Neurocrit Care*. 2004;1(2):219-233.

Eisenberg HM, Frankowski RF, Contant CF, Marshall LF, Walker MD. High-dose barbiturate control of elevated intracranial pressure in patients with severe head injury. *J Neurosurg*. 1988;69:15-23.

Ghajar J. Traumatic brain injury. *Lancet*. 2000;356:923-929.

Graham DI, Ford I, Adams JH, et al. Ischaemic brain damage is still common in fatal non-missile head injury. *J Neurol Neurosurg Psychiatry*. 1989;52:346-350.

Ibanez J, Arikan F, Pedraza S, et al. Reliability of clinical guidelines in the detection of patients at risk following mild head injury: results of a prospective study. *J Neurosurg*. 2004;100(5):825-834.

Jane JA, Anderson DK, Torner JC, Young W. *Central Nervous System Trauma Status Report—1991*. New York, NY: Mary Ann Liebert, 1992.

Lingsma H, Yue JK, Maas A, Steyerberg EW, Manley GT. Outcome prediction after mild and complicated mild traumatic brain injury: external validation of existing models and identification of new predictors using the TRACK-TBI pilot study. *J Neurotrauma*. 2015;32(2):83-94.

Marshall LF, Marshall SB, Klauber MR, et al. A new classification of head injury based on computerized tomography. *J Neurosurg*. 1991;75(suppl 1): S14-S20.

Martin NA, Patwardhan RV, Alexander MJ, et al. Characterization of cerebral hemodynamic phases following severe head trauma: hypoperfusion, hyperemia, and vasospasm. *J Neurosurg*. 1997;87:9-19.

Mayer SA, Chong J. Critical care management of increased intracranial pressure. *J Intensive Care Med*. 2002;17:55-67.

Merritt HH. Head injury. *War Med*. 1943;4:61-82.

Oertel M, Kelly DF, McArthur D, et al. Progressive hemorrhage after head trauma: predictors and consequences of the evolving injury. *J Neurosurg*. 2002;96:109-116.

Pearl GS. Traumatic neuropathology. *Clin Lab Med*. 1998;18:39-64.

Smith M. Monitoring intracranial pressure in traumatic brain injury. *Anesth Analg*. 2008;106(1):240-248.

Stiell IG, Wells GA, Vandemheen K, et al. The Canadian CT Head Rule for patients with minor head injury. *Lancet*. 2001;357:1391-1396.

Symonds C. Concussion and its sequelae. *Lancet*. 1962;1:1-5.

Tawil I, Stein DM, Mirvis SE, Scalea TM. Posttraumatic cerebral infarction: incidence, outcome, and risk factors. *J Trauma*. 2008;64(4):849-853.

Taylor SJ, Fettes SB, Jewkes C, Nelson RJ. Prospective, randomized, controlled trial to determine the effect of early enhanced enteral nutrition on clinical outcome in mechanically ventilated patients suffering head injury. *Crit Care Med*. 1999;27:2525-2531.

Teasdale G, Jennett B. Assessment of coma and impaired consciousness. A practical scale. *Lancet*. 1974;2:81-83.

Teasdale GM, Murray G, Anderson E, et al. Risks of acute traumatic intracranial haematoma in children and adults: implications for managing head injuries. *BMJ*. 1990;300:363-367.

Valadka AB, Robertson CS. Surgery of cerebral trauma and associated critical care. *Neurosurgery*. 2007;61(1 suppl):203-220.

Vespa PM, Nuwer MR, Nenov V, et al. Increased incidence and impact of nonconvulsive and convulsive seizures after traumatic brain injury as detected by continuous electroencephalographic monitoring. *J Neurosurg*. 1999;91:750-760.

Vialet R, Albanèse J, Thomachot L, et al. Isovolume hypertonic solutes (sodium chloride or mannitol) in the treatment of refractory posttraumatic intracranial hypertension: 2 mL/kg 7.5% saline is more effective than 2 mL/kg 20% mannitol. *Crit Care Med*. 2003;31:1683-1687.

Johnson VE, Stewart W, Weber MT, Cullen DK, Siman R, Smith DH. SNTF immunostaining reveals previously undetected axonal pathology in traumatic brain injury. *Acta Neuropathol*. 2016;131(1):115-135.

Loane DJ, Faden AI. Traumatic meningeal injury and repair mechanisms. *Nat Immunol*. 2018;19(5):431-432.

Griffin AD, Turtzo LC, Parikh GY, et al. Traumatic microbleeds suggest vascular injury and predict disability in traumatic brain injury. *Brain*. 2019; 142(11):3550-3564.

Veenith TV, Carter EL, Geeraerts T, et al. Pathophysiologic mechanisms of cerebral ischemia and diffusion hypoxia in traumatic brain injury. *JAMA Neurol*. 2016;73(5):542-550.

Kurland D, Hong C, Aarabi B, Gerzanich V, Simard JM. Hemorrhagic progression of a contusion after traumatic brain injury: a review. *J Neurotrauma*. 2012;29(1):19-31.

Plog BA, Dashnaw ML, Hitomi E, et al. Biomarkers of traumatic injury are transported from brain to blood via the glymphatic system. *J Neurosci*. 2015;35(2):518-526.

Burda JE, Bernstein AM, Sofroniew MV. Astrocyte roles in traumatic brain injury. *Exp Neurol*. 2016;275(pt 3):305-315.

Russo MV, McGavern DB. Inflammatory neuroprotection following traumatic brain injury. *Science*. 2016;353(6301):783-785.

Simon DW, McGeachy MJ, Bayir H, Clark RS, Loane DJ, Kochanek PM. The far-reaching scope of neuroinflammation after traumatic brain injury. *Nat Rev Neurol*. 2017;13(3):171.

Jassam YN, Izzy S, Whalen M, McGavern DB, El Khoury J. Neuroimmunology of traumatic brain injury; time for a paradigm shift. *Neuron*. 2017;95(6): 1246-1265.

Stocchetti N, Carbonara M, Citerio G, et al. Severe traumatic brain injury: targeted management in the intensive care unit. *Lancet Neurol*. 2017;16(6): 452-464.

Okonkwo DO, Shutter LA, Moore C, et al. Brain tissue oxygen monitoring and management in severe traumatic brain injury (BOOST-II): a phase II randomized trial. *Crit Care Med*. 2017;45(11):1907-1914.

Imaging

Haydel MJ, Preston CA, Mills TJ, Luber S, Blaudeau E, DeBlieux PM. Indications for computed tomography in patients with minor head injury. *N Eng J Med*. 2000;343(2):100-105.

Izzy S, Mazwi NL, Martinez S, et al. Revisiting grade 3 diffuse axonal injury: not all brainstem microbleeds are prognostically equal. *Neurocrit Care*. 2017;27(2):199-207.

Kuppermann N, Holmes JF, Dayan PS, et al. Identification of children at very low risk of clinically-important brain injuries after head trauma: a prospective cohort study. *Lancet*. 2009;374(9696):1160-1170.

Schonfeld D, Bressan S, Da Dalt L, Henien MN, Winnett JA, Nigrovic LE. Pediatric Emergency Care Applied Research Network head injury clinical prediction rules are reliable in practice. *Arch Dis Child*. 2014;99(5):427-431.

Stiell IG, Clement CM, Rowe BH, et al. Comparison of the Canadian CT Head Rule and the New Orleans Criteria in patients with minor head injury. *JAMA*. 2005;294(12):1511-1518.

Stiell IG, Wells GA, Vandemheen K, et al. The Canadian CT Head Rule for patients with minor head injury. *Lancet*. 2001;357(9266):1391-1396.

Thelin EP, Nelson DW, Vehviläinen J, et al. Evaluation of novel computerized tomography scoring systems in human traumatic brain injury: an observational, multicenter study. *PLoS Med*. 2017;14(8):e1002368.

Epidural Hematoma

Borzone M, Rivano C, Altomonte M, Baldini M. Acute traumatic posterior fossa haematomas. *Acta Neurochir*. 1995;135:32-37.

Bricolo AP, Pasut LM. Extradural hematoma: toward zero mortality. A prospective study. *Neurosurgery*. 1984;14:8-12.

Bullock R, Smith RM, van Dellen JR. Nonoperative management of extradural hematoma. *Neurosurgery*. 1985;16:602-606.

Dhellemmes P, Lejeune JP, Christiaens JL, Combelles G. Traumatic extradural hematomas in infancy and childhood. Experience with 144 cases. *J Neurosurg*. 1985;62:861-865.

Lobato RD, Rivas JJ, Cordobes F, et al. Acute epidural hematoma: an analysis of factors influencing the outcome of patients undergoing surgery in coma. *J Neurosurg*. 1988;68(1):48-57.

Subdural Hematoma

Bender MB. Recovery from subdural hematoma without surgery. *J Mt Sinai Hosp N Y*. 1960;26:52-58.

Bershad EM, Farhadi S, Suri MF, et al. Coagulopathy and inhospital deaths in patients with acute subdural hematoma. *J Neurosurg*. 2008;109:664-669.

Lee KS. The pathogenesis and clinical significance of traumatic subdural hygroma. *Brain Inj*. 1998;12:595-603.

Liu W, Bakker NA, Groen RJ. Chronic subdural hematoma: a systematic review and meta-analysis of surgical procedures. *J Neurosurg*. 2014;121(3): 665-673.

Munro D, Merritt HH. Surgical pathology of subdural hematoma. *Arch Neurol Psychiatry*. 1936;35:64-78.

Munro PT, Smith RD, Parke TR. Effect of patients' age on management of acute intracranial haematoma: prospective national study. *BMJ*. 2002;325:1001.

Rohde V, Graf G, Hassler W. Complications of burr-hole craniostomy and closed-system drainage for chronic subdural hematomas: a retrospective analysis of 376 patients. *Neurosurg Rev*. 2002;25:89-94.

Weigel R, Schmiedek P, Krauss JK. Outcome of contemporary surgery for chronic subdural haematoma: evidence based review. *J Neurol Neurosurg Psychiatry*. 2003;74:937-943.

Complications of Head Injury

Bell RB, Dierks EJ, Homer L, Potter BE. Management of cerebrospinal fluid leak associated with craniomaxillofacial trauma. *J Oral Maxillofac Surg*. 2004;62(6):676-684.

Chesnut RM. Intracranial pressure monitoring: headstone or a new head start. The BEST TRIP trial in perspective. *Intensive Care Med*. 2013;39(4):771-774.

D'Ambrosio R, Perucca E. Epilepsy after head injury. *Curr Opin Neurol*. 2004; 17(6):731-735.

Davis JM, Zimmerman RA. Injury of the carotid and vertebral arteries. *Neuroradiology*. 1983;25:55-69.

Dott NM. Carotid-cavernous arteriovenous fistula. *Clin Neurosurg*. 1969;16:17-21.

Friedman AP, Merritt HH. Damage to cranial nerves resulting from head injury. *Bull Los Angel Neurol Soc*. 1944;9:135-139.

Hemphill JC III, Gress DR, Halbach VV. Endovascular therapy of traumatic injuries of the intracranial cerebral arteries. *Crit Care Clin*. 1999;15:811-829.

Klisch J, Huppertz HJ, Spetzger U, Hetzel A, Seeger W, Schumacher M. Transvenous treatment of carotid cavernous and dural arteriovenous fistulae: results for 31 patients and review of the literature. *Neurosurgery*. 2003;53(4):836-856.

Luo CB, Teng MM, Yen DH, Chang FC, Lirng JF, Chang CY. Endovascular embolization of recurrent traumatic carotid-cavernous fistulas managed previously with detachable balloons. *J Trauma*. 2004;56(6):1214-1220.

Morgan MK, Besser M, Johnston I, Chaseling R. Intracranial carotid artery injury in closed head trauma. *J Neurosurg*. 1987;66:192-197.

Scott BL, Jancovic J. Delayed-onset progressive movement disorders after static brain lesions. *Neurology*. 1996;46:68-74.

Stocchetti N, Maas AIR. Traumatic intracranial hypertension. *N Engl J Med*. 2014;370:2121-2130.

Vespa PM, Shrestha V, Abend N, et al. The epilepsy bioinformatics study for anti-epileptogenic therapy (EpiBioS4Rx) clinical biomarker: study design and protocol. *Neurobiol Dis*. 2019;123:110-114.

Yuh EL, Hawryluk GW, Manley GT. Imaging concussion: a review. *Neurosurgery*. 2014;75(suppl 4):S50-S63.

Pediatric Trauma

Adelson PD, Kochanek PM. Head injury in children. *J Child Neurol*. 1998;13:2-15.

Carbaugh SF. Understanding shaken baby syndrome. *Adv Neonatal Care*. 2004;4(2):105-114.

Duhaime AC, Christian CW, Rorke LB, Zimmerman RA. Nonaccidental head injury in infants—the "shaken-baby syndrome." *N Engl J Med*. 1998;338:1822-1829.

Kochanek PM, Tasker RC, Bell MJ, et al. Management of pediatric severe traumatic brain injury: 2019 consensus and guidelines-based algorithm for first and second tier therapies. *Pediatr Crit Care Med*. 2019;20(3):269-279.

Schutzman SA, Barnes P, Duhaime AC, et al. Evaluation and management of children younger than two years old with apparently minor head trauma: proposed guidelines. *Pediatrics*. 2001;107:983-993.

Squier W. Shaken baby syndrome: the quest for evidence. *Dev Med Child Neurol*. 2008;50(1):10-14.

Ward JD. Pediatric issues in head trauma. *New Horiz*. 1995;3:539-545.

Outcome

Anderson VA, Morse SA, Catroppa C, Haritou F, Rosenfeld JV. Thirty month outcome from early childhood head injury: a prospective analysis of neurobehavioural recovery. *Brain*. 2004;127(pt 12):2608-2620.

Annegers JF, Grabow JD, Groover RV, Laws ER Jr, Elveback LR, Kurland LT. Seizures after head trauma: a population study. *Neurology*. 1980;30(7, pt 1):683-689.

Brooke OG. Delayed effects of head injuries in children. *Br Med J (Clin Res Ed)*. 1988;296:948.

Cifu DX, Kreutzer JS, Marwitz JH, Rosenthal M, Englander J, High W. Functional outcomes of older adults with traumatic brain injury: a prospective, multicenter analysis. *Arch Phys Med Rehabil*. 1996;77:883-888.

Cole JH, Leech R, Sharp DJ; for Alzheimer's Disease Neuroimaging Initiative. Prediction of brain age suggests accelerated atrophy after traumatic brain injury. *Ann Neurol*. 2015;77(4):571-581.

Dennis M, Levin HS. New perspectives on cognitive and behavioral outcome after childhood closed head injury. *Dev Neuropsychol*. 2004;25(1-2):1-3.

Englander J, Bushnik T, Duong TT, et al. Analyzing risk factors for late posttraumatic seizures: a prospective, multicenter investigation. *Arch Phys Med Rehabil*. 2003;84:365-373.

Gardner RC, Dams-O'Connor K, Morrissey MR, Manley GT. Geriatric traumatic brain injury: epidemiology, outcomes, knowledge gaps, and future directions. *J Neurotrauma*. 2018;35(7):889-906.

Giacino JT, Sherer M, Christoforou A, et al. Behavioral recovery and early decision making in patients with prolonged disturbance in consciousness after traumatic brain injury. *J Neurotrauma*. 2020;37(2):357-365.

Gordon E, von Holst H, Rudehill A. Outcome of head injury in 2298 patients treated in a single clinic during a 21-year period. *J Neurosurg Anesthesiol*. 1995;7:235-247.

Grima N, Ponsford J, Rajaratnam SM, Mansfield D, Pase MP. Sleep disturbances in traumatic brain injury: a meta-analysis. *J Clin Sleep Med*. 2016;12(3):419-428.

Imbach LL, Büchele F, Valko PO, et al. Sleep-wake disorders persist 18 months after traumatic brain injury but remain underrecognized. *Neurology*. 2016;86(21):1945-1949.

Jiang JY, Gao GY, Li WP, Yu MK, Zhu C. Early indicators of prognosis in 846 cases of severe traumatic brain injury. *J Neurotrauma*. 2002;19(7):869-874.

Klonoff H, Clark C, Klonoff PS. Long-term outcome of head injuries: a 23 year follow up study of children with head injuries. *J Neurol Neurosurg Psychiatry*. 1993;56:410-415.

Levin HS, Amparo E, Eisenberg HM, et al. Magnetic resonance imaging and computerized tomography in relation to the neurobehavioral sequelae of mild and moderate head injuries. *J Neurosurg*. 1987;66:706-713.

Levin HS, Gary HS Jr, Eisenberg MM, et al. Neurobehavioral outcome 1 year after severe head injury. Experience of the Traumatic Coma Data Bank. *J Neurosurg*. 1990;73:699-709.

Lishman WA. Physiogenesis and psychogenesis in the "postconcussional" syndrome. *Br J Psychiatry*. 1988;153:460.

Macciocchi SN, Barth JT, Littlefield LM. Outcome after mild head injury. *Clin Sports Med*. 1998;17:27-36.

Nelson LD, Temkin NR, Dikmen S, et al. Recovery after mild traumatic brain injury in patients presenting to US level I trauma centers: a Transforming Research and Clinical Knowledge in Traumatic Brain Injury (TRACK-TBI) study. *JAMA Neurol*. 2019;76(9):1049-1059.

Pohlmann-Eden B, Bruckmeir J. Predictors and dynamics of posttraumatic epilepsy. *Acta Neurol Scand*. 1997;95:257-262.

Rovlias A, Kotsou S. Classification and regression tree for prediction of outcome after severe head injury using simple clinical and laboratory variables. *J Neurotrauma*. 2004;21(7):886-893.

Sakas DE, Bullock MR, Teasdale GM. One-year outcome following craniotomy for traumatic hematoma in patients with fixed dilated pupils. *J Neurosurg*. 1995;82:961-965.

Seabury SA, Gaudette É, Goldman DP, et al. Assessment of follow-up care after emergency department presentation for mild traumatic brain injury and concussion: results from the TRACK-TBI study. *JAMA Netw Open*. 2018;1(1):e180210.

Silverberg N, Gardner AJ, Brubacher J, Panenka WJ, Li JJ, Iverson GL. Systematic review of multivariable prognostic models for mild traumatic brain injury. *J Neurotrauma*. 2015;32(8):517-526.

Temkin NR, Holubkov R, Machamer JE, Winn HR, Dikmen SS. Classification and regression trees (CART) for prediction of function at 1 year following head trauma. *J Neurosurg*. 1995;82:764-771.

Wickwire EM, Schnyer DM, Germain A, et al. Sleep, sleep disorders, and circadian health following mild traumatic brain injury in adults: review and research agenda. *J Neurotrauma*. 2018;35(22):2615-2631.

Traumatic Spinal Cord Injury 48

Christopher E. Mandigo, Michael G. Kaiser, and Peter D. Angevine

KEY POINTS

1. About 12,000 new cases of traumatic spinal cord injury (SCI) occur annually in the United States
2. Any patient with suspected SCI should be immobilized with a hard cervical collar or a rigid head-strap with backboard until definitive imaging can take place
3. The complete absence of any sign of fracture or misalignment of the bony structures on neck CT indicates a less than 0.1% chance of the patient harboring a clinically significant unstable cervical spine injury
4. The ASIA impairment scale grades the severity of SCI from A (complete loss of motor and sensory loss below the level of injury) to E (normal).
5. Current guidelines do not recommend administration of methylpredisolone or other steroids for traumatic SCI.
6. Current guidelines recommend maintenance of mean arterial pressure at a minimum value of 85 to 90 mm Hg for the first 7 days after injury to optimize spinal cord perfusion.

INTRODUCTION

Traumatic spinal cord injury (SCI) is a sudden event with possibly catastrophic effects that may create a medical, financial, and social burden for the individual and society. Adequate management of these patients requires knowledge of SCI, including epidemiology and pathophysiology, acute and chronic medical complications, and long-term rehabilitation and social needs.

ETIOLOGY AND EPIDEMIOLOGY

Epidemiologic data can guide the use of resources for treating and preventing SCI. The best source of this information for the United States is the National Spinal Cord Injury Database, which has been collecting information from facilities that have participated in the Model Spinal Cord Injury System since 1973. This database includes data from an estimated 13% of new SCI cases each year and has information on over 25,000 people with SCI. SCI occurs in the United States in approximately 40 per 1 million people per year, which results in about 12,000 new cases annually. This figure does not include injuries that result in fatality before hospital arrival, which may double the number of injuries. Currently, 225,000 to 300,000 people are living with SCI.

SCI primarily affects young adults aged between 16 and 30 years, but the average is increasing. The average age in the 1970s was 28.7 years; in the period 2005-2008, it was 39.5 years. The median age is 27 years, and 65% of SCI patients are younger than 35 years. The highest incidence occurs between ages 20 and 24 years. The most significant changes between the 1970s and 2005-2008 have occurred at the extremes of age. The proportion of patients older than 65 years has increased from 5% to 11%, and the proportion of children from birth to 15 years has decreased from 6% to 2%. The increasing age could arise from data collection bias, improved survival of older patients in the acute period of SCI, or in age-specific incidence rates. That is, the larger population of elderly patients requires special consideration for medical, surgical, and rehabilitative care.

Seventy-eight percent of SCI patients are male. Among those injured after 2000, 63% were White, 23% were African American, 12% were Hispanic, and 2% were from other racial or ethnic groups.

Motor vehicle accidents account for approximately 40% of cases, a figure that has been increasing in developing countries due to increases in motorized transportation, poor infrastructure, and regulatory challenges. Falls account for 30% of all cases and have been increasing in developed countries due to aging of the population. Work-related injury (10%), sports (7%), and violence, typically gunshot wounds (15%), account for most of the remaining causes of SCI. Most injuries occur on the weekends and during the summer months.

Since 2000, the most frequent neurologic category at discharge is incomplete tetraplegia (34%), followed by complete paraplegia (23%), complete tetraplegia (18%), and incomplete paraplegia (19%). Less than 1% of persons experienced complete neurologic recovery by hospital discharge. The average length of hospital stay for a patient with SCI was 15 days in 2005, and the length of rehabilitation stay was 36 days. As one might expect, length of stay for patients with neurologically complete injuries is significantly longer. The life expectancy for patients with SCI is significantly less than those for uninjured people. Mortality rates are significantly higher during the first year after injury than during subsequent years. As shown in Table 48.1, adapted from the National Spinal Cord Injury Database Web site, life expectancy rates for SCI are directly related to the severity of injury.

There are profound sociologic and economic effects from SCI. About 57% of people with SCI were employed at the time of their injury. Ten years after injury, only 32% of persons with paraplegia and 24% with tetraplegia are employed. About 80% to 90% of patients with SCI are eventually discharged to a private residence, and only 6% are discharged to nursing homes. The rest are discharged to hospitals, group living situations, or other destinations. Most SCI patients (53%) are single at the time of injury, and those who are married, or become married, are slightly more likely to become divorced than uninjured individuals. The average yearly and lifetime costs of SCI patients are

TABLE 48.1 Life Expectancy After Spinal Cord Injury[a]

		For Persons Who Survive the First 24 h					For Persons Surviving at Least 1 y Postinjury				
Age at Injury (y)	No SCI	Motor Functional at Any Level	Para	Low Tetra (C5-C8)	High Tetra (C1-C4)	Ventilator Dependent at Any Level	Motor Functional at Any Level	Para	Low Tetra (C5-C8)	High Tetra (C1-C4)	Ventilator Dependent at Any Level
20	58	53	45	40	36	17	53	46	41	37	24
40	40	34	28	23	20	7	35	28	24	21	11
60	22	18	13	10	8	2	18	13	10	9	3

SCI, spinal cord injury; para, paraplehia; tetra, tetraplegia.
[a]Life expectancy in years based on age and injury severity.

directly related to the severity and level of injury. For example, a patient with high tetraplegia (injury at C1-C4) is estimated to have expenses totaling $775,000 in the first year and $140,000 for each subsequent year. A 25-year-old with a C1-C4 injury will have a lifetime expense of $3 million, and a 50-year-old will have an expense of $1.8 million. A patient with low tetraplegia (injury at C5-C8) will have expenses of $500,000 in the first year and about $55,000 for each subsequent year. Paraplegics and incomplete motor injuries cost from $225,000 to $300,000 for the first year and $15,000 to $30,000 for each subsequent year. These numbers do not reflect the additional indirect costs that relate to unemployment and loss in productivity, which average another $60,000 per year per patient.

Nontraumatic SCI affects a large number of people and can result from a number of etiologies (see Chapter 115). These include multiple sclerosis, neoplastic diseases, vascular disease, inflammatory disease, infections, and degenerative spinal stenosis. This population of patients more commonly presents with incomplete lesions and over a subacute or chronic period. The extent of injury at presentation, the response to treatment, and the prognosis of the underlying disease process will guide medical therapy and the ultimate rehabilitation goals.

MECHANISM OF INJURY

It is generally accepted that acute SCI is a two-step process that involves primary and secondary mechanisms. The primary mechanism results from the initial mechanical injury due to local deformation and energy transformation, whereas the secondary mechanisms encompass a cascade of biochemical and cellular processes that are initiated by the primary process and cause ongoing cellular damage and death.

Primary SCI is most commonly a combination of the initial impact as well as subsequent persisting compression. The most frequent primary mechanism of SCI is impact of bone and ligament against the spinal cord from high translational forces, such as that generated by flexion, extension, axial rotation, or vertebral compression. These motions may result in a variety of vertebral column injuries, which can be identified through imaging studies such as plain radiographs, computed tomography (CT) scans, or magnetic resonance imaging (MRI) scans. The spinal cord may consequently be compressed, stretched, or crushed by fracture or dislocations, burst fractures of the vertebral body, or acutely ruptured intervertebral disks. Injury can result from only the initial impact without ongoing compression. These may occur from severe ligamentous injuries in which the spinal column dislocates and then spontaneously reduces or when there is preexisting cervical spondylosis or spinal stenosis. In this circumstance, a trivial injury may cause major neurologic damage even without obvious fracture or dislocation after the event.

Similarly, SCI from sharp bone fragments or stabbing or missile injuries can produce a mixture of spinal cord laceration, concussion, contusion, and/or compression. Direct injuries, like indirect injuries, may be partial or complete in their destruction of the cord.

An understanding of the mechanism of injury and the radiographic findings can provide insight into the biomechanical stability of the vertebral column after SCI. For example, flexion injuries, particularly in the cervical and thoracic regions, may cause anterior compression fractures of vertebral bodies and unilateral or bilateral facet joint dislocation, which can cause spinal cord compression and spinal instability. Severe axial loading can cause complete fracture of the vertebral body with displacement of bony fragments and disk material into the spinal canal and SCI. Any combination of forces may occur in a single case. Understanding the mechanism of injury permits a more complete assessment of the underlying cord injury and the instability of the spinal column.

Secondary mechanisms that result from biochemical cascades that occur after the initial event are a source of ongoing SCI and neurologic deterioration. These cause damage to neural tissue on the cellular level and include the pathologic effects of microvascular changes, excitatory amino acids, cell membrane destabilization, free radicals, inflammatory mediators, and neuroglia apoptosis.

PATHOBIOLOGY

Gross Pathology

The pathology of SCI has been divided into four relatively simple groups based on gross findings: solid cord injury, contusion/cavity, laceration, and massive compression. Solid cord injury refers to a cord that grossly appears normal without evidence of softening, discoloration, or cavity formation. However, damage to the cord can be clearly seen on histologic examination. Contusion or cavity injuries have no breach or disruption in the surface anatomy, and there are no dural adhesions. Areas of hemorrhage and necrosis (eventually evolving into cysts) are readily identified in the cord parenchyma. In many instances, these lesions taper rostrally and caudally in a cone-like fashion along the ventral regions of the posterior columns. Lacerations result in clear-cut disruption of the surface anatomy. This type of injury is most often caused by penetrating missiles or sharp

fragments of bone. The lesions are characterized by a break in the glia limitans, with damage to the underlying cord parenchyma. The epicenter of the injury generally shows minimal to no evidence of cavity formation; rather, the lesion is dominated by the deposition of a variable amount of collagenous connective tissue that, in most cases, is adherent to the overlying meninges. With massive compression injury, the cord is macerated or pulpified to a varying degree. This lesion is often accompanied by severe vertebral body fractures or dislocations. In many instances, the epicenter of this lesion is replaced by connective tissue scar and fragments of nerve roots. The tissue response is similar to that seen with laceration injuries where extensive fibrous scarring occurs over time.

There are additional anatomic characteristics of SCI worth noting. The lesion may be surprisingly small and may involve no more than a single spinal cord segment. There may be multiple lesions, especially with gunshot wounds. It is also rare to observe a complete transection of the spinal cord; on close examination, there is almost always a small amount of residual tissue traversing the cord.

Histopathology

The histologic changes in SCI can be divided into immediate, acute, intermediate, and late phases.

Immediate Phase (Initial 1-2 H)

The immediate event, presumably arising from the primary injury, consists of the actual mechanical disruption of tissue that occurs at the time of injury, such as tears, compression, and distortions. Vascular changes are commonly found and are characterized by vasodilatation, congestion (hyperemia), and petechial hemorrhages. In many cases, however, no abnormalities are observed during this early time period, particularly in the absence of a massive compression or laceration injury. This lack of pathologic changes in the early period reflects the observation that the pathology of SCI is also due to secondary phenomena, which include progressive edema, ischemia, hemorrhage, inflammation, hyperthermia, as well as calcium-, free radical-, nitric oxide- and glutamate-mediated cell injury.

Acute Phase (Hours to 1-2 D)

Vascular changes, edema, hemorrhage, inflammation, and neuronal and myelin changes characterize this phase. Edema may be vasogenic or cytotoxic. Vasogenic edema is leakage of plasma fluid into the extracellular space from breakdown of the blood-brain barrier. Cytotoxic edema results from intracellular swelling after cell death. Edema from either mechanism may result in pressure-induced ischemia caused by diminished blood flow to the injured region. Edema is seen from 3 hours to 3 days after injury. In addition to creating pressure effects, cell swelling may also alter astroglial functions.

Injury to vessels may lead to hemorrhage, which occurs primarily in the gray matter following contusion injury. Hemorrhages are primarily due to rupture of postcapillary venules or sulcal arterioles, either from mechanical disruption by the trauma or from intravascular coagulation leading to venous stasis and distention.

The inflammatory response that follows early after injury is a complex process involving vascular changes, cellular responses, and chemical mediators. There is a mild influx of neutrophils within 1 day, a peak at 2 days, and most are gone by 3 days. It is likely that the neutrophilic response is neurotoxic in nature, as these cells normally act to eradicate infection through the release of free radicals.

Neurons are very vulnerable to injury following SCI. Most neurons die from necrosis, but neuronal apoptosis also has been observed. Acute injury is characterized by axonal swelling, manifested as retraction balls or spheroids. Myelin breakdown occurs early following SCI. It is characterized initially by swelling of myelin sheaths and ultimately by its fragmentation and phagocytosis by macrophages. The loss of myelin occurs with the destructive process and is almost always associated with axonal pathology. Oligodendrocytes, like neurons, are exquisitely sensitive to SCI and undergo necrosis and apoptosis. It is likely that the death of oligodendrocytes contributes significantly to the process of wallerian degeneration.

Intermediate Phase (Days to Weeks)

Over the ensuing days and weeks, there are prominent glial responses with the elimination of necrotic debris, the beginning of astroglial scarring, the resolution of edema, the revascularization of tissue, and restoration of the blood-brain barrier.

Late Phase (Weeks to Months/Years)

The later phases of SCI are characterized by wallerian degeneration, astroglial and mesenchymal scar formation, development of cysts and syrinx, and schwannosis.

Wallerian degeneration is the anterograde disintegration of axons and their myelin sheaths that have been transected following injury. It is characterized by distorted and fragmented myelin sheaths with absent or malformed axons. An astroglial "scar," which comprises tightly interwoven astrocyte processes and extracellular matrix, eventually replaces the destroyed myelinated axon. Wallerian degeneration is a protracted process and may take more than a year to complete. The spinal cord may also be replaced by fibrous connective tissue and collagen. This occurs particularly after lacerating-type injuries and is stimulated by violation of the glia limitans. This abnormal healing coupled with astroglial scarring are thought to create physical and biochemical barriers to axonal migration and spinal cord healing.

Another late finding is the formation of cysts and syrinxes, which may be single, multiple, or multiloculated. Cysts and syrinxes are surrounded by an astrogliotic wall and represent the final "healing" phase of the necrotic process. These cavities are filled with extracellular fluid and commonly contain residual macrophages, small bands of connective tissue, and blood vessels. These cavities typically do not create a clinical problem, except that they do not provide a good substrate for regeneration.

Schwannosis is an aberrant intra- and extramedullary proliferation of Schwann cells with associated axons. It is similar, if not identical, to traumatic neuromas that occur in injured peripheral nerves. Varying amounts of spinal cord tissue may be replaced by schwannosis. The Schwann cells are introduced into the spinal cord after penetrating injuries. The incidence of schwannosis in human SCI is very high and directly correlates with time after injury, suggesting an ongoing mechanism. Its clinical significance is unclear. The prolific schwannosis may be a physical barrier to spinal cord healing. The aberrant axons that are part of this process may have untoward physiologic consequences and potentially contribute to pain, spasticity, and other abnormal responses observed in the chronically injured patient with SCI.

In general, the morphologic responses in human SCI are stereotyped and follow discernible patterns. Early glial (astrocytic and microglial) responses may greatly influence the outcome of SCI.

DIAGNOSIS, NEUROLOGIC ASSESSMENT, AND CLASSIFICATION

Clinical Evaluation

The diagnosis and initial management in patients with SCI often are intertwined, as a large percentage of patients present acutely, often with multisystem trauma, and require rapid assessment and medical intervention.

Prehospital trauma protocols are critical to prevent further injury to the spinal cord, particularly by modifying factors that contribute to secondary spinal cord damage. *Any patient with suspected SCI should be immobilized with a hard cervical collar and/or a rigid head-strap/backboard until definitive neurosurgical assessment can take place.* Treatment of hypoxia and hypotension, proper monitoring of vital signs, and transfer to an appropriate trauma center will affect ultimate outcomes positively.

On arrival to the trauma center, a rapid assessment should be undertaken to assess the status of the airway, respiratory, and circulatory systems. In addition, a cursory assessment of the neurologic status ("disability") and removal of all clothing with attention to possible injuries missed on the primary survey ("exposure") are now included in the initial steps of trauma protocols. Clinical signs of shock and hypoxia require immediate attention and appropriate therapy.

Specific diagnosis of SCI requires a more comprehensive neurologic exam as outlined later in the text with the steps necessary to determine the exact spinal cord impairment. Concomitant with the physical exam, complete and accurate imaging studies of the spinal column are necessary if SCI is suspected. These can enhance the accuracy of diagnosis and determine the extent of spinal column injury, especially in a comatose, confused, or uncooperative patient. Imaging studies are not necessary when patients are awake, are alert and cooperative without evidence of intoxication, do not have evidence of neurologic injury, and have no pain or tenderness along the spine to palpation and no associated injuries distracting from the general evaluation.

Imaging Studies

Risk Stratification

Trauma patients typically arrive with neck collars. Some patients are clearly at high risk, whereas other can be cleared clinically in the emergency department or intensive care unit without imaging. The cervical collar and spinal precautions should remain in place, and cervical spine imaging is clearly necessary; when clear symptoms, neck pain, or distracting conditions exist, clinical conditions are met (Table 48.2). National Emergency X-Radiography Utilization Study criteria (Table 48.3) address the question of who does not require imaging after presenting with head or neck trauma. *A patient who meets all five National Emergency X-Radiography Utilization Study criteria is deemed to have a low probability of injury to the cervical spine and can be cleared clinically without imaging because the risk of significant injury is miniscule* LEVEL 2.[1] The Canadian C-Spine Rule offers even slightly better sensitivity and specificity for identifying low-risk patients but is a bit more complicated to use.

TABLE 48.2 High-Risk Criteria for Patients Who Clearly Need C-Spine Imaging

- Altered mental status (Glasgow Coma Scale <15)
- Neurologic deficit (ie, limb weakness or paralysis, numbness, tingling)
- Distracting injuries present
- Neck pain or tenderness present
- Decreased range of motion of the cervical spine

Cervical X-Rays

Anteroposterior (AP) and lateral x-rays can be taken of the appropriate spinal region as directed by the clinical evaluation. AP and lateral x-rays of the cervical spine, visualizing the superior part of the first thoracic vertebral body, and open-mouth, odontoid radiographic views can form part of the initial radiologic survey. However, due to its ease of use and superior sensitivity, most centers go directly to cervical spine CT as the initial imaging study of choice. When CT scanning is available, plain x-rays contribute no additional information and need not be obtained.

Upright flexion and extension films, when appropriate, are useful for assessing biomechanical instability due to ligamentous injury. In suspected thoracic and lumbar injuries, AP, lateral, oblique, upright, and dynamic (flexion/extension) views may be necessary. Indications for thoracolumbar x-rays include falls greater than 6 ft, expulsion from motor vehicles, complaints of back pain, associated injuries, and altered mental status with an unknown mechanism of injury.

Cervical Computed Tomography

High-resolution CT scanning (see Chapter 21) with sagittal and coronal reconstruction is the best procedure for evaluating uncertain findings seen on x-rays as well as for detecting bone pathology (Fig. 48.1). The study should be performed from the occiput to T1 with three-dimensional sagittal and coronal reformats. Three-dimensional reconstructions allow for visualization in the coronal, sagittal, and axial planes and provide superior injury detection compared with plain x-ray. The main limitation of CT rests in its relative inability to detect changes in soft tissues including the spinal cord and ligamentous structures.

Whether it is safe to remove a neck collar in a comatose or obtunded patient with a normal neck CT has long remained a

TABLE 48.3 National Emergency X-Radiography Utilization Study Criteria for Low-Risk Patients Who Do Not Require Imaging After Head or Neck Injury[a]

1. No tenderness at the posterior midline of the cervical spine
2. No focal neurologic deficit
3. Normal level of alertness
4. No evidence of intoxication
5. No clinically apparent, painful injury that might distract the patient from the pain of a cervical spine injury

[a]In these patients, the neck collar can be removed and the patient cleared clinically after demonstrating full range of motion with no neck pain or point tenderness.

FIGURE 48.1 Type 2 acute dens fracture (*blue arrow* and *green arrow*) on sagittal T1- **(left)** and T2-weighted **(center)** magnetic resonance imaging and a computed tomography sagittal reconstruction *(red arrow)* **(right)**. (Images courtesy of Dr. Alexander Khandji.)

vexing clinical conundrum. In the past, it was felt that it was necessary to obtain a cervical MRI within 72 hours in order to rule out possible ligamentous injury, which appears as swelling or thickening of the interspinal ligaments. More recent data indicate that in obtunded or intubated patients, the use of modern CT alone is sufficient to exclude unstable cervical spine injuries. The complete absence of any sign of fracture or misalignment of the bony structures indicates a less than 0.1% chance of the patient harboring a clinically significant unstable cervical spine injury LEVEL 3.[2]

MRI (see Chapter 22) is the best technique for imaging the spinal cord itself. Specific indications for MRI scanning include a neurologic deficit with normal x-rays, lack of correlation between a neurologic deficit and x-ray findings, deterioration following closed reduction, and failed attempts at closed reduction. Multiplanar, high-resolution MRI with T1-weighted and gradient echo or T2-weighted imaging is the most specific and sensitive technique for assessing soft-tissue paraspinal lesions, disk herniation, spinal cord hemorrhage, spinal cord edema, and intra- or extradural hemorrhage (**Fig. 48.2**). The ability to adequately monitor the critically injured must be a priority when MRI is considered. If MRI is not available or possible, CT myelography is the current best alternative.

Neurologic Assessment and Classification

The most widely accepted, standardized method of classifying SCI is the *International Standards for Neurological and Functional Classification of Spinal Cord Injury* published jointly by the American Spinal Injury Association (ASIA) and the International Medical Society of Paraplegia. It is more commonly known as the ASIA Impairment Scale. This is an excellent guide for clinical evaluation and neurologic assessment and allows uniform comparisons among clinicians and researchers.

The ASIA Impairment Scale is scored from A to E and is detailed in **Table 48.4**. The steps to classify injury severity in a patient with SCI are described in **Table 48.5**. There are some terms that require clear definitions for categorizing impairments within the ASIA scoring system. The motor level is the most caudal key muscle group that is graded 3 out of 5 or greater, with the segments cephalad to that level graded normal strength (5 out of 5). The sensory level is the most caudal dermatome to have normal light touch and pinprick sensation on both sides. The neurologic level of injury is the most caudal level at which both motor and sensory modalities are intact. A complete injury is the absence of motor and sensory function in the lowest sacral segments. An incomplete injury has preservation of motor or sensory function below the neurologic level of injury that includes the lowest sacral segments. A zone of partial preservation describes all segments below the neurologic level of injury that have preserved motor or sensory findings; this is used only in complete injuries.

A subset of SCIs has been grouped by their specific clinical features into six clinical syndromes: Brown-Séquard, central cord, anterior cord, posterior cord, conus medullaris, and cauda equina.

Brown-Séquard Syndrome

This syndrome is characterized anatomically by a hemicord injury with ipsilateral proprioceptive and motor loss and contralateral pain and temperature sensation loss below the level of the lesion. The pattern of neurologic deficits observed in Brown-Séquard injuries result from the local spinal cord anatomy. Pain and temperature fibers cross to the opposite side of the spinal cord at the level of nerve root entry, whereas the proprioception and motor fibers decussate at the level of the brainstem. Brown-Séquard accounts for 1% to 5% of all traumatic SCIs. The most common presentation is the Brown-Séquard plus syndrome, which refers to

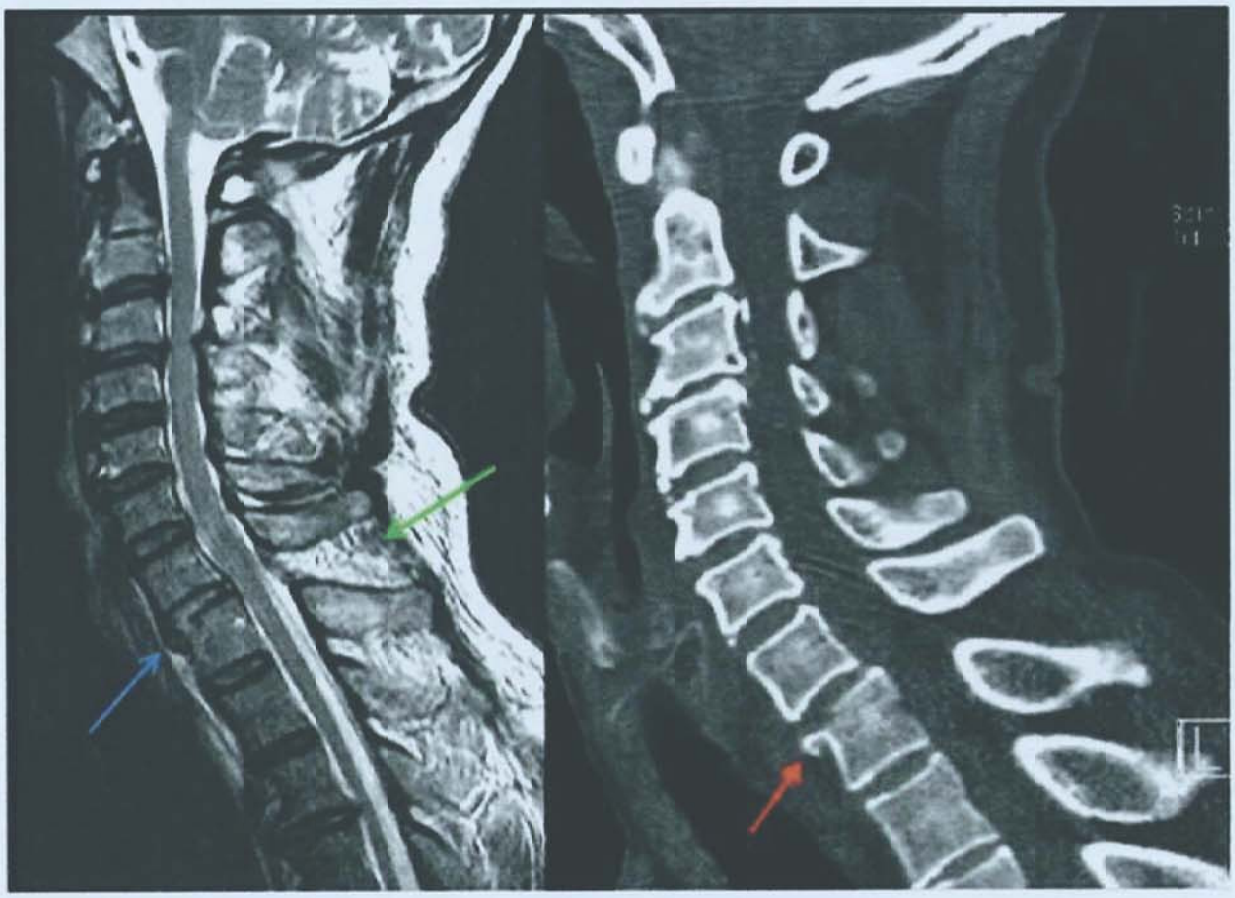

FIGURE 48.2 Left: Non–fat-saturated T2 image showing anterior subluxation of C7 on T1 (with anterior teardrop fracture of T1 *blue arrow*) and widened interspinous space C7-T1 posteriorly *(green arrow)*. **Right:** Sagittal computed tomography reconstruction demonstrating anterior teardrop fracture of T1 *(red arrow)*. (Images courtesy of Dr. Alexander Khandji.)

a relative ipsilateral hemiplegia with a relative contralateral hemianalgesia. Although Brown-Séquard traditionally has been associated with stab or missile injuries, a variety of etiologies may cause this syndrome. Brown-Séquard has the best prognosis for ambulation of the SCI clinical syndromes, as 75% to 90% of patients ambulate independently in long-term follow-up.

Central Cord Syndrome

This lesion is characterized by disproportionately more motor impairment of the upper than the lower extremities, bladder dysfunction, and varying degrees of sensory loss below the level of the lesion. The most common presentation occurs in older patients with preexisting cervical spondylosis who experience hyperextension injuries of the cervical spine. Cord compression occurs between osteophyte-disk complexes anteriorly and infolded ligamenta flava posteriorly. Studies have reported falls as the most common etiology, followed by motor vehicle accidents. Recent evidence from clinical pathologic studies using MRI scans has demonstrated that this clinical pattern likely results from injury to the corticospinal tract in the cervical spine, which affects

TABLE 48.4 American Spinal Injury Association Impairment Scale

A	Complete	No sensory or motor function preserved in the lowest sacral segments (S4/S5)
B	Sensory incomplete	Sensory but no motor function preserved below the neurologic level, including the sacral segments
C	Motor incomplete	Motor function is preserved below the neurologic level, and more than half of the key muscles below the level have a grade <3, and there is some sacral sensory and/or motor sparing.
D	Motor incomplete	Motor function is preserved below the neurologic level, and more than half of the key muscles below the level have a grade ≥3, and there is some sacral sensory and/or motor sparing.
E	Normal	Sensory and motor functions are normal. There can be reflex abnormalities.

TABLE 48.5 Physical Examination Steps for Classifying Spinal Cord Injury

1. Perform sensory examination in 28 dermatomes bilaterally for pinprick and light touch, including the S4/S5 dermatome, and test for anal sensation.
2. Determine sensory level (right and left).
3. Perform motor examination in the 10 key muscle groups, including anal contraction.
4. Determine motor level (right and left).
5. Determine neurologic level of injury.
6. Classify injury as complete or incomplete.
7. Categorize ASIA Impairment Scale (A-E).
8. Determine zone of partial preservation if ASIA A.

Abbreviation: ASIA, American Spinal Injury Association.

the distal, more than proximal, limb musculature and not the specific somatotopic representation within the corticospinal tract. It is considered the most common of the SCI syndromes, accounting for approximately 9% of all traumatic SCIs. Central cord syndrome generally has a favorable prognosis for functional recovery, especially in younger patients with good hand function, evidence of early motor recovery, and absence of lower extremity impairment.

Anterior Cord Syndrome

This syndrome results from a lesion that affects the anterior two-thirds of the spinal cord with preservation of the posterior columns. It is characterized by complete paralysis and loss of pain and temperature sensation below the level of the lesion, accompanied by preservation of touch and proprioception. It occurs in 3% of all traumatic SCIs. It can result from flexion injuries, direct damage from bony fragments or disk compression, or secondary to occlusion of the anterior spinal artery. This syndrome carries a poor prognosis for functional improvement.

Posterior Cord Syndrome

This is the least common of the clinical syndromes and has an incidence of less than 1%. It is a lesion of the posterior columns with resultant loss of touch and proprioception below the level of injury and preservation of pain and temperature sensation and motor strength. It can be caused by hyperextension, posterior spinal artery occlusion, or nontraumatic etiologies such as tumors or vitamin B_{12} deficiency.

Conus Medullaris and Cauda Equina Syndromes

Conus medullaris syndrome is an injury of the caudal spinal cord (conus) and its associated sacral nerve roots within the spinal canal. The conus typically sits at the level between the first and second lumbar vertebrae. This condition is characterized by a combination of upper and lower motor neuron signs. Findings include saddle anesthesia, areflexic bladder and bowel, and variable degrees of lower extremity weakness and sensory loss.

Cauda equina syndrome results from an injury to the lumbosacral nerve roots within the neural canal below the conus medullaris and presents with saddle anesthesia, bladder and bowel dysfunction, and variable lower extremity involvement. The difference from the conus medullaris syndrome is the absence of upper motor neuron signs, and it is usually characterized by asymmetric lower extremity weakness and reflex changes. It is believed to have a better prognosis for neurologic recovery than SCI because nerve roots have the ability to regenerate. Important predictors for favorable outcome from cauda equina are early diagnosis and surgical decompression.

ACUTE MEDICAL MANAGEMENT

The acute management of patients with SCI is primarily directed at medical stabilization to prevent secondary injury and to permit the accurate clinical and radiographic diagnosis of spinal cord and column pathology. The specifics of initial management have been detailed to some degree in the earlier section covering diagnosis of SCI, as the acute management and evaluation of SCI are intertwined.

General Trauma Care

In general, patients should be managed at a trauma center, preferably level 1, with SCI experience. If an appropriate trauma center is not immediately available, transfer to a trauma center as soon as possible is advocated. Emergency medical services in urban areas should preferentially take patients to level 1 centers, potentially bypassing nearer hospitals. Level 1 centers are required to have in-house neurosurgical consultation for rapid evaluation. The patient should be immobilized with a cervical collar and backboard/headstrap as soon as possible. The backboard can be removed after radiographic studies are completed and interpreted. The cervical collar should be maintained until the cervical spine has been clinically and/or radiographically cleared. Neurosurgical evaluation should happen as soon as possible; neural element decompression and spinal stabilization within 24 hours may improve neurologic recovery in patients with deficits and spinal cord compression, but the clinical data are inadequate to advocate this as a standard of care. It is important to note that there has been no demonstrated increased risk of neurologic deterioration from early surgery.

Steroids

High-dose methylprednisolone has long been considered a potential neuroprotective agent in SCI, with the potential of reducing tissue injury by inhibiting lipid peroxidase and free radical production. Methylprednisolone therapy was evaluated in 487 SCI patients in the National Acute Spinal Cord Injury Study II (NASCIS II) trial in 1990. Patients were given a bolus of 30 mg/kg of methylprednisolone over 15 minutes, followed by a 5.4-mg/kg infusion over 23 hours. The authors reported a mean improvement of 5 points in motor score (total possible score = 50) and 4 points in sensory scores (total possible score = 58) for patients treated with methylprednisolone compared to controls at 6 months, but only if they received the drug within 8 hours of injury. Although NASCIS II was initially reported as a positive trial, reanalysis has showed that the strength of the evidence generated is weakened by omission of data from publication, the arbitrary assignment of an 8-hour therapeutic window, the inconsistency of reported benefit, and the absence of functional outcome measures. Accordingly, the beneficial results of NASCIS II have been downgraded to class III medical evidence. Due to a trend toward more serious complications associated with steroid use, current guidelines do not recommend administration of methylprednisolone for the treatment of acute SCI LEVEL 3.[3]

Autonomic Dysfunction and Blood Pressure Management

Autonomic dysfunction with hypotension can occur acutely in SCI, especially in patients with cervical injuries. Autonomic dysfunction may result from a variety of reasons including the following: spinal shock, neurogenic shock, hypovolemia, bradycardia, sepsis, and cardiogenic shock. Hypotension is a common contributor to secondary neurologic injury and should be avoided; its treatment can involve careful volume resuscitation, vasopressors, and diagnostic maneuvers such as an arterial line, a central venous catheter, and noninvasive continuous cardiac output assessment. *Current SCI guidelines recommend maintenance of mean arterial pressure at a minimum value of 85 to 90 mm Hg for the first 7 days after injury.* This has limited supporting clinical data, but hypotension clearly should be avoided. Occasionally, intravenous (IV) atropine sulfate may be necessary to counter unopposed parasympathetic activity. Vasomotor paralysis may also cause loss of thermal control and lead to poikilothermy,

which usually may be treated by the appropriate use of warming blankets. Acute cervical SCI is also associated with a risk of cardiac arrhythmia due to excess vagal tone as well as complicating hypoxia, hypotension, and fluid and electrolyte imbalances.

Critical Care

After complete medical stabilization, neurologic assessment, and spinal column stabilization and/or bracing within the initial 24 to 48 hours, attention is paid to the prevention of common medical problems in patients with acute SCI. Prophylactic treatment for deep venous thrombosis should begin no later than 72 hours after SCI. The first-line therapy is subcutaneous injection of low molecular weight heparin (enoxaparin 40 mg subcutaneously every day), and second-line therapy is subcutaneous injection of unfractionated heparin (5,000 U subcutaneously two or three times a day). In patients with contraindications to anticoagulation, an inferior vena cava filter should be placed to prevent pulmonary embolism. Lower extremity sequential compression devices should also be employed when feasible. Stress ulceration should be prevented with proton pump inhibitors or H_2 blockers with a minimum of 4 weeks of therapy after SCI. Nutritional support, via feeding tubes or parenteral nutrition if appropriate, is suggested to begin with 72 hours after SCI. Pressure ulcers of the occiput, sacrum, and heels should be prevented through manual or automatic turning every 2 hours without lateral sliding to prevent sacral shearing. Rehabilitation maneuvers should begin as soon as possible and should include passive and active range-of-motion (ROM) activities, bowel and bladder programs (eg, chronic intermittent catheterizations), pulmonary programs (mechanical ventilation, manually assisted cough), and dysphagia evaluations.

Surgical Treatment

After control of the acute medical issues and accurate neurologic and radiographic diagnosis of SCI, attention is directed toward treating instability of the vertebral column and neural element compression, if present. This is directed by neurosurgical or orthopedic caregivers. There are currently no standards and no evidence-based guidelines regarding the role and method of decompression in acute SCI. In a recent prospective randomized trial, decompression of cervical spinal cord injuries within 24 hours of injury was found to be safe and associated with improved neurologic outcome at 6 months follow-up when compared to more delayed surgical intervention LEVEL 2.[4] Multiple observational cohort studies have confirmed that emergency decompressive surgery performed within 24 hours for incomplete injuries (ASIA B, C, and D) results in improved motor recovery and reduced hospital length of stay. The management of cervical, thoracic, and lumbar spine and spinal cord injuries depends mainly on the particular injury but also on a surgeon's personal experience and practice norms in his or her center. The options include closed reduction via traction and open surgical procedures. The overall goals are to decompress the spinal cord and nerve roots, to restore the spinal alignment, and to prevent progressive deformity.

Cervical spine fracture or dislocations may be treated with closed reduction through the use of traction. Thoracic and lumbar fractures cannot be corrected with this treatment. Traction uses skull tongs or the headpiece of a halo attached to a system to apply rostral force, usually with rope, a pulley, and weights. An initial weight of 5 to 15 lb is applied, and a lateral x-ray is obtained. Weight can be increased at 5-lb increments, and a neurologic exam and lateral x-ray should be obtained after each adjustment. The maximum weight applied relates to the level of injury. A general rule of 3 to 5 lb per vertebral level is used. We suggest that after 35 lb is applied, patients be observed for at least an hour with repeat cervical spine x-rays before the weight is cautiously increased further. Muscle relaxants and analgesics may help facilitate reduction.

Cervical spine surgery is indicated for injuries that are not amenable or do not respond to closed reduction. These include unstable cervical fractures and cord compression with an incomplete neurologic deficit. Patients without neurologic deficits are often treated nonoperatively with bracing unless there is evidence of instability. Some penetrating injuries may require surgical exploration to ensure that there are no foreign bodies imbedded in the tissue and also to clean the wound to prevent infection.

Thoracolumbar injuries do not lend themselves to external traction, and accordingly, surgical repair is typically achieved through open reduction followed by stabilization. There are a variety of anterior and posterior approaches that employ metallic implants such as interbody cages, pedicle screws, laminar wires or hooks, and connecting rods.

In clinical studies, surgery has little effect on the neurologic outcome of the primary injury. When cord compression is evident, or the initial neurologic deficit progresses, immediate decompression (ie, 1-2 h after injury) may halt or reverse the process. There are no set rules for determining appropriate selection of early or late surgical intervention. Individual patient factors and clinical judgment continue to direct the surgical timing in each case.

CHRONIC MEDICAL MANAGEMENT

Chronic medical therapy is directed at preventing and treating the common, and often severe, medical complications of SCI. SCI produces a wide variety of changes in systemic physiology that can lead to a number of complications, which rival the impact of neurologic deficits on function and quality of life. In the National Spinal Cord Injury database, rehospitalizations occurred in 55% of patients in the first year after SCI and continued at a stable rate of about 37% per year over the next 20 years. Factors contributing to the risk of rehospitalization included increased age and severity of SCI. Genitourinary problems, respiratory complications, and pressure ulcers were the most common reasons for hospitalization. As mentioned earlier, life expectancy is reduced among patients with SCI. The mortality rates are highest during the first year. Higher injury levels, more severe injury, and older age correlate with higher mortality. The most common causes of death are respiratory diseases and cardiovascular events.

Pain

Pain is a serious consequence of SCI. Approximately 80% of patients reported pain at all times during the first year after injury. Neuropathic pain related to SCI increases over time, whereas musculoskeletal pain decreases slightly, with both still being present in 60% of patients at 1 year. Early (1 mo) sensory hypersensitivity (particularly cold-evoked dysesthesia) is a predictor of the development of below-level, but not at-level, SCI pain at 1 year.

Management of pain should focus on the avoidance of chronic opioid abuse, judicious use of nonsteroidal anti-inflammatory agents for chronic musculoskeletal pain, and appropriate agents for treatment of central neuropathic pain (see Chapter 59).

Autonomic Dysreflexia

Injuries above T6 may be complicated by autonomic dysreflexia, which results from the loss of coordinated autonomic responses to physiologic stimuli. Uninhibited or exaggerated sympathetic responses to noxious stimuli can lead to extreme hypertension through vasoconstriction. The parasympathetic system will respond with vasodilation and bradycardia above the level of the lesion, but it is not sufficient to correct the elevated blood pressure (BP). SCIs below T6 do not produce dramatic effects as the intact splanchnic innervation allows for compensatory dilatation of the splanchnic vascular bed.

Typical stimuli producing autonomic dysreflexia include bladder distention, bowel impaction, pressure sores, bone fractures, or occult visceral disturbances.

Common clinical manifestations are hypertension, bradycardia, headache, and sweating. Attacks have a range of severity from asymptomatic hypertension to hypertensive crisis with possible cardiac arrest from bradycardia and intracranial hemorrhage. The severity of attacks correlates with the severity of the SCI. The management of acute autonomic dysreflexia involves monitoring BP, removing tight-fitting garments, and searching for sources of noxious stimuli, including bladder distension and fecal impaction. Reduction of elevated BP can be achieved with sitting the patient upright and with rapid-acting antihypertensives with short half-lives. Sublingual or oral nitrates and IV β-blockers, calcium channel blockers, or angiotensin-converting enzyme inhibitors are often used. Recognition and avoidance of inciting stimuli are important in preventing attacks.

Orthostatic hypotension can also affect patients with SCI. Treatment involves the implementation of temporary maneuvers, such as gradual position changes, compression stockings, and abdominal binders, until the body adapts to the loss of peripheral tone. Medical therapy, if necessary, can include salt tablets to increase blood volume, α-adrenergic agonists, such as midodrine, or mineralocorticoid supplements, such as fludrocortisone.

Coronary Artery Disease

Coronary artery disease (CAD) is a prominent complication of SCI with long-term survivors. Patients with SCI are more likely to acquire CAD risk factors than the average population secondary to loss of muscle mass, inactivity, and increased body fat. CAD is 3 to 10 times more likely in patients with chronic SCI, and SCI patients have higher mortality rates with CAD-related events. This is partly explained by abnormal presentations that occur in patients with lesions higher than T5 and the higher likelihood of episodic autonomic dysreflexia.

Pulmonary Disease

Cervical and high thoracic SCI will affect respiration. The severity of respiratory failure and need for assisted ventilation is directly related to the level and severity of SCI. Patients have impaired cough strength and difficulty mobilizing lung secretions and are at increased risk for pneumonia, especially during the first year following injury (see also Chapter 121). Prevention of pneumonia includes chest physiotherapy and pneumococcal vaccination. Deep venous thrombosis and pulmonary embolism are common early complications of SCI. Prophylactic use of low molecular weight heparin is the treatment of choice for most patients with SCI; treatment should be continued for at least 3 months after SCI, after which the risk appears to approximate that of the general population.

Genitourinary Complications

SCI produces bladder dysfunction, often referred to as the *neurogenic bladder* (see also Chapter 126). Other complications can result from this, including infections, vesicoureteral reflux, renal failure, and nephrocalculi. Urologic evaluation with regular follow-up is recommended for patients after SCI. Genitourinary complications may not produce symptoms and, if untreated, can have serious consequences. The frequency and specific testing involved (serum creatinine, cystoscopy, urodynamic studies, renal ultrasound) are not well defined but depend in part on the nature of the patient's urologic problems and other risk factors.

After SCI, the sensation for bladder fullness as well as motor control of bladder and sphincter function can be impaired. Depending on the timing, the level, and the severity of injury, one of several types of bladder dysfunction can occur. These include bladder hyperactivity with reflexive bladder emptying, sphincter hyperactivity with impaired emptying of the bladder, detrusor-sphincter dyssynergia leading to uncoordinated bladder contractions, bladder flaccidity with urinary retention, and overflow incontinence.

Clean intermittent catheterization programs achieve the goal of preserving renal function while eliminating urine at regular and socially acceptable times. This avoids high bladder pressures, retention, incontinence, and infection. This should be initiated as early as possible after SCI. Catheterization is performed approximately every 4 hours and is adjusted as necessary. Often, patients have a fluid intake restriction of 2 L to prevent bladder overdistention. After ruling out an infection and adjusting the frequency of clean intermittent catheterization and fluid intake, medications targeting the sympathetic and parasympathetic receptors are employed depending on the specific bladder condition.

Urinary tract infections are common in SCI and are the most frequent source of septicemia in SCI patients. Asymptomatic urinary tract infections are not generally treated, and prophylactic antibiotics are not used for prevention.

Sexual dysfunction has a high prevalence in SCI; dysfunction in males can exceed 75% and is related to the severity of injury. There are a variety of treatment options for men with SCI, which include medicines for erectile dysfunction and surgically implanted prosthetics. Sexual responses in women may also be impaired after SCI, but ovulation and fertility are generally unaffected. Pregnancy with SCI is considered high risk because of the high rate of complications secondary to infections and autonomic dysreflexia.

Gastrointestinal Dysfunction

Bowel dysfunction is very common after SCI and can significantly affect quality of life. There are no evidence-based recommendations for clinical management of this problem. A structured bowel regimen employing a regular diet, 2 to 3 L of fluid per day, 30 g of fiber, and chemical and mechanical stimulation is often employed to achieve predictable bowel evacuation to avoid fecal incontinence and impaction.

Abnormal Bone Metabolism

Osteoporosis can affect the bones below the level of SCI, most likely secondary to disuse, and may predispose to fractures. Bone resorption in the first few months after SCI can lead to symptomatic hypercalcemia. Treatment can involve the use of hydration with IV fluids, loop diuretics, and IV bisphosphonate therapy.

Heterotopic ossification, the deposition of bone within the soft tissue around peripheral joints, can also occur in SCI. This occurs in up to half of SCI patients but is symptomatic, as evidenced by pain and inflammation in the affected joints, in 10% to 20% of patients. Treatment involves passive ROM exercise, oral bisphosphonates, nonsteroidal anti-inflammatory drugs, and, in some cases, delayed surgery.

Spasticity

Problematic spasticity requiring treatment occurs in approximately 35% of SCI patients during the first year of recovery. Patients with incomplete ASIA C injuries appear to be at highest risk. Spasticity results from the disruption of the descending inhibitory pathways with a concomitant increase in the excitability of spinal reflexes and resting muscle tone. Spasticity can negatively affect quality of life through pain, decreased mobility, muscle spasms, and ultimately contractures. Prevention of contractures involves proper positioning, passive ROM exercises, appropriate splinting, and treatment of spasticity. However, the increased tone can also make some activities easier, such as standing and transfers. Treatment can include physical therapy, passive ROM exercises, oral medications (baclofen, tizanidine, valium, etc), and surgical interventions (intrathecal baclofen pumps, rhizotomies, etc).

Psychiatric Complications

Psychiatric disorders associated with SCI include depression, suicide, and drug addiction. Approximately a third of patients with SCI will be depressed within the first year after SCI; this is not closely associated with severity of injury. Suicide occurs at a rate 4 to 5 times higher in patients with SCI and is the leading cause of death in patients with SCI younger than the age of 55 years. Patients should be regularly screened for symptoms of depression, and symptoms should be treated immediately.

CONCLUSION

SCI remains a difficult medical, social, and financial problem. A more clear understanding of the pathophysiology and resultant medical complications has resulted in improved long-term survival and functional status. However, the unsolved problem of SCI repair remains. It is worth remembering that the best treatment is prevention. Nationwide educational programs should be concerned with combating the causes of SCI: motor vehicle safety, water and occupational safety, eliminating drunk driving, adhering to speed limits, and mandatory use of seatbelts and other protective gear.

LEVEL 1 EVIDENCE

1. Hoffman JR, Mower WR, Wolfson AB, Todd KH, Zucker MI. Validity of a set of clinical criteria to rule out injury to the cervical spine in patients with blunt trauma. *N Engl J Med.* 2000;343:94-99.
2. Panczykowski DM, Tomycz ND, Okonkwo DO. Comparative effectiveness of using computed tomography alone to exclude cervical spine injuries in obtunded or intubated patients: meta-analysis of 14,327 patients with blunt trauma. *J Neurosurg.* 2011;115:541-549.
3. Hurlburt RJ, Hadley MN, Walters BC, et al. Pharmacological therapy for acute spinal cord injury. *Neurosurgery.* 2013;72:93-105.
4. Fehlings MG, Vaccaro A, Wilson JR, et al. Early versus delayed decompression for traumatic cervical spinal cord injury: results of the Surgical Timing in Acute Spinal Cord Injury Study (STASCIS). *PLoS One.* 2012;7(2):e32037. doi:10.1371/journal.pone.0032037.

SUGGESTED READINGS

Ahuja CS, Wilson JR, Nori S, et al. Traumatic spinal cord injury. *Nat Rev Dis Primers.* 2017;3(1):17018.

Bracken MB. Methylprednisolone and spinal cord injury. *J Neurosurg.* 2002;96:140-141.

Dvorak MF, Noonan VK, Fallah N, et al. The influence of time from injury to surgery on motor recovery and length of hospital stay in acute traumatic spinal cord injury: an observational Canadian cohort study. *J Neurotrauma.* 2015;32(9):645-654.

Finnerup NB, Norrbrink C, Trok K, et al. Phenotypes and predictors of pain following traumatic spinal cord injury: a prospective study. *J Pain.* 2014;15(1):40-48.

Holtz KA, Lipson R, Noonan VK, Kwon BK, Mills PB. Prevalence and effect of problematic spasticity after traumatic spinal cord injury. *Arch Phys Med Rehab.* 2017;98(6):1132-1138.

Inoue T, Manley GT, Patel N, Whetstone WD. Medical and surgical management after spinal cord injury: vasopressor usage, early surgerys, and complications. *J Neurotrauma.* 2014;31:284-291.

Jackson AB, Dijkers M, Devivo MJ, Poczatek RB. A demographic profile of new traumatic spinal cord injuries: change and stability over 30 years. *Arch Phys Med Rehabil.* 2004;85:1740-1748.

Kong CY, Hosseini AM, Belanger LM, et al. A prospective evaluation of hemodynamic management in acute spinal cord injury patients. *Spinal Cord.* 2013;51:466-471.

Liu J-M, Long X-H, Zhou Y, Peng H-W, Liu Z-L, Huang S-H. Is urgent decompression superior to delayed surgery for traumatic spinal cord injury? A meta-analysis. *World Neurosurg.* 2016;87:124-131.

Maynard FM Jr, Bracken MB, Creasey G, et al. International standards for neurological and functional classification of spinal cord injury. American Spinal Injury Association. *Spinal Cord.* 1997;35:266-274.

McKinley W, Santos K, Meade M, Brooke K. Incidence and outcomes of spinal cord injury clinical syndromes. *J Spinal Cord Med.* 2007;30:215-224.

Stiell IG, Clement C, McKnight RD, et al. The Canadian C-spine rule versus the NEXUS low-risk criteria in patients with trauma. *N Engl J Med.* 2003;349:2510-2158.

49 Traumatic Cranial and Peripheral Nerve Injury

Dominique M. O. Higgins, Lillian Liao, and Christopher J. Winfree

KEY POINTS

1. The olfactory nerve, facial nerve, and cranial nerves responsible for ocular movement are the most likely to be associated with head trauma.
2. Peripheral nerve injuries can be classified into three main categories: neuropraxia, axonotmesis, and neurotmesis.
3. Electrodiagnostic evaluations are critical for establishing the severity, location, and prognosis of peripheral nerve lesions.
4. Generally, for peripheral nerve injuries, acute surgical intervention should be avoided.
5. Spontaneous recovery should be looked for initially if there is no evidence of sharp nerve transection or acute nerve compression
6. Depending on the mechanism of injury, functional connectivity can be achieved surgically by scar tissue removal, reapproximation, or placement of interposition grafts.

INTRODUCTION

Traumatic injury to peripheral nerves is associated with significant disability and decreased quality of life. In this chapter, we discuss the classification, pathophysiology, evaluation, and treatment of peripheral nerve injuries as well as the clinical manifestations of common peripheral and cranial nerve lesions. Understanding of the principles described in this chapter, by clinicians, is important for timely diagnosis and treatment of these common clinical entities.

It has been estimated that approximately 3% to 10% of all patients presenting to a Level 1 trauma center present with injury to a peripheral nerve. Motor vehicle accidents are most commonly cited as the leading cause, whereas industrial accidents, recreational vehicle use, falls, gunshot, and stab wounds as well as iatrogenic injuries also contribute. The potential economic and social impact of these injuries is compounded by the fact that they occur most commonly within the productive age range, with highest incidence reported between 20 and 40 years of age. Males are affected more often than females, and injury to the nerves of the upper extremity occur more commonly than do those to the nerves of the lower extremity. Peripheral nerve injuries are also commonly comorbid with traumatic injury to the brain, which can result in delayed diagnosis and intervention.

Anatomy and Physiology

Evaluation of traumatic peripheral nerve injury requires understanding of nerve structure. Peripheral nerves consist of a mixture of myelinated and unmyelinated, somatic and autonomic, nerve fibers. Each fiber is surrounded by an endoneurial sheath, which provides some tensile strength. Multiple fibers, of various types, are grouped together into fascicles and surrounded by the perineurium, a specialized structure composed of perineurial cells and collagen that serves to maintain homeostasis of the endoneurial fluid that surrounds individual fibers. This perineurial sheath provides most of the tensile strength and elasticity of the nerve and provides a diffusion barrier that resists and maintains intrafascicular pressure. Multiple fasciculi, in turn, are embedded in a connective tissue matrix called the *epineurium*, which protects the nerve from compression. The most superficial layer of the epineurium condenses to form an external epineural sheath, which gives the nerve a cord-like appearance on gross examination.

Both within and between nerve fibers, the number, size, and organization of fascicles varies significantly. As fascicles branch, split, and rejoin continuously along their course, sections through the nerve may alternatively reveal plexiform and cable-like structure, which has implications for both clinical presentation of nerve injuries as well as surgical repair and functional regeneration. Furthermore, variability in internal organization is partially responsible for observed differences in the prevalence of particular nerve injuries. That is, peripheral nerves with a higher proportion of epineural tissue to fasciculi may be more resistant to compression injuries, whereas peripheral nerves with greater numbers of fasciculi have greater tensile strength.

Mechanisms of Injury

Traumatic nerve injuries may be acute or chronic and iatrogenic or idiopathic. They result from the application of kinetic energy to a nerve, which is transformed into damaging compressive or tensile forces. Chronic traumatic nerve injuries most often result from anatomic nerve entrapment leading to well-described clinical entities, such as carpal tunnel syndrome. These chronic syndromes, requiring unique medical and surgical treatment approaches, are discussed more thoroughly in other chapters.

Acute traumatic nerve injuries occur, most commonly, from traction/stretch, compression, contusion, laceration, or ischemia. Injury is derived primarily from direct application of mechanical forces and secondarily from vascular compromise. Multiple mechanisms of injury may be present, particularly when the lesion occurs during a catastrophic event, such as a motor vehicle accident. Identifying the type of insult incurred, when possible, is important for treatment planning because various types of forces result in different patterns of injury.

TABLE 49.1 Seddon's Nerve Injury Classifications and Prognosis

Class	Pathology	Mechanism	Treatment	Prognosis	Time Course
Neurapraxia	Demyelination	Compression Ischemia	Medical Physical therapy	Excellent	Hours to 3 mo
Axonotmesis	Axonal disruption Distal degeneration Epineurium intact	Crush Stretch Percussion	Variable: may require surgery	Variable: good to poor	Weeks to years
Neurotmesis	Complete loss of continuity Transection Distal degeneration	Sharp injuries Traction	Surgical: end-to-end neurorrhaphy, grafting, or neurotization	Poor/nil without repair	Months to years with surgery No spontaneous recovery

Injury Classification

Two major classifications systems are used most commonly to describe peripheral nerve injuries. The injury categories defined by these systems each have unique diagnostic characteristics, prognoses, and therapeutic approaches.

The classification system used most commonly in clinical settings was proposed by Seddon in 1942. Seddon's system divides injuries into three main categories delineated by the extent of disruption to the structure of the nerve. The three categories are *neurapraxia*, *axonotmesis*, and *neurotmesis* (**Table 49.1**).

Neurapraxia is the least severe of the three injury types. It most commonly is caused by a mild insult resulting in focal demyelination with no associated axonal degeneration. It is characterized by transient focal conduction block across the lesion. The axon distal to the site of injury remains intact, and the nerve remains in continuity. Clinically, this class of injury may manifest as weakness or sensory loss in the anatomic distribution of the affected nerve. Prognosis for this type of injury is excellent, with spontaneous recovery occurring within hours to, in the most severe cases, a few months. No specific therapeutic intervention is required.

Axonotmesis occurs most commonly during crush, stretch, or percussive injuries, such as gunshot wounds where injury is most commonly caused by indirect heat and shock wave from the bullet rather than transection. These injuries result in irreversible damage to axonal elements including the myelin sheath, leading to distal degeneration. Supporting structures such as the epineurium, perineurium, and, at times, the endoneurium remain intact.

Prognosis for axonotmetic injuries depends on several factors. These factors include the degree of disruption of the internal structure of the nerve as well as distance from the end organ and the particular characteristics of the injured nerve. Spontaneous recovery is possible after axonotmetic injury, but the time course is considerably greater than that of neurapraxic lesions. Recovery is more commonly partial than complete.

Neurotmesis is defined by complete loss of continuity of the nerve. All connective tissue layers, the axon, and the myelin sheath are irreversibly damaged. Surgical intervention is required because no spontaneous recovery is possible. The timing of surgery is dependent on the mechanism of injury because blunt injuries continue to evolve through an inflammatory process over a period of weeks. Prognosis after surgery is variable but is generally poorer than that of spontaneous recovery.

A second important peripheral nerve injury classification system was proposed by Sunderland in 1951 (**Table 49.2**). Expanding on the work of Seddon, he described five classes of nerve injury, with class I describing neurapraxic lesions and class V equivalent to neurotmesis. For classes II to IV, Sunderland subdivided axonotmesis into three levels, of increasing severity and worsening prognosis, based on the extent of internal disruption, from axon only in class II to endoneurial sheath in class III and perineurium in class IV. Although this additional level of detail is helpful in a research setting, the clinical use is more limited because all classes II to IV will require the same initial therapeutic approach. Nevertheless, this classification scheme highlights the importance of internal nerve structure for spontaneous recovery and functional regeneration.

TABLE 49.2 Sunderland's Classification of Peripheral Nerve Injuries

Class	Pathology	Mechanism	Treatment	Prognosis	Time Course
I	Demyelination	Compression Ischemia	Medical Physical therapy	Excellent	Hours to 3 mo
II	Axonal disruption Distal degeneration	Crush Stretch Percussion	Variable	Good	Months to years
III	II + endoneurial disruption	Crush Stretch Percussion	Variable	Moderate	Months to years
IV	III + perineurial disruption	Crush Stretch Percussion Traction	Variable	Poor without repair	Months to years
V	Complete transection	Sharp injury Traction	Surgery	Poor/nil without repair	Months to years with surgery No spontaneous recovery

Repair and Regeneration

Characteristic pathologic changes in the nerve occur as a result of traumatic insult. In the mildest form, demyelination is observed at the injury site. When trauma results in axonal disruption, the distal nerve undergoes a process of degeneration that extends to the end organ. The duration of the degenerative process is dependent on the distance of the injury from the end organ. Morphologic and functional changes also take place within the proximal stump adjacent to the injury site.

In the initial period immediately following injury, acute axonal degeneration, extending approximately 300 mm proximally and distally from the lesion site, is triggered by an influx of extracellular calcium. On electron microscopy, vacuoles resembling autophagosomes accumulate in the axon ends. Swelling and disruption of neurofilaments is observed.

These immediate changes are followed by fragmentation and phagocytosis of the myelin sheath. Within 2 days, whorls of myelin debris and small lipid droplets may be observed within the Schwann cells. Circulating macrophages are recruited and enter the distal stump. Loss of axonal contact and the presence of macrophages stimulate Schwann cell proliferation and dedifferentiation. These dedifferentiated Schwann cells line up along the basal lamina to form bands of Büngner, which will act as guides to regenerating nerve axons.

Reinnervation occurs via two main mechanisms: collateral axonal sprouting from uninjured axons and axonal regeneration, which occurs spontaneously from the proximal stump following degeneration. Collateral sprouting is an early mechanism of functional motor recovery. It occurs with incomplete lesions, in which some of the axons remain intact. New axonal outgrowths are noted to arise from both nearby nodes and terminal branches. These fine axonal extensions travel along the remaining nerve structures to provide partial reinnervation to nearby motor targets. Generally, collateral sprouting is not sufficient to restore full power to the muscle but may be responsible for some early functional recovery.

Axonal regeneration is the primary mechanism by which reinnervation occurs, following distal degeneration, in axonotmetic and neurotmetic lesions. Regeneration begins from the proximal stump and extends along intact basal lamina toward the end organ at a variable rate of approximately 1 to 2 mm/d. Once the target organ has been reached, a process of maturation occurs to reestablish functional connections. The appearance of clinical evidence of reinnervation reflects both the distance from injury site to the end organ and the maturation process. Rate of regeneration appears to be slower for transected lesions than for crush injuries.

Successful regeneration and functional recovery rely on a number of factors. Inflammation and scar tissue provide major barriers to axonal growth. Gap lengths that are too long result in disorganized and highly tortuous axonal paths, which may coalesce within scar tissue to form a nonfunctional and potentially painful bulb referred to as a *neuroma*.

Even when regeneration does occur successfully, functional recovery is not guaranteed. Regenerating sprouts must be able to form mature connections with appropriate motor or sensory targets in order for recovery to occur. In highly mixed nerves, with an approximately equal amount of sensory and motor fibers, some regenerating motor fibers may be lost to sensory targets or vice versa. Nerves that contain one predominant modality generally have a better prognosis for functional recovery.

Finally, sensory targets maintain viability for a much longer period of time than does muscle tissue. Within 12 to 18 months, fibrotic changes take place in denervated muscle that makes successful reinnervation unlikely. Sensory targets, on the other hand, maintain viability for up to 2 to 3 years. Therefore, patients may continue to experience recovery of sensation well beyond the period of motor recovery.

CLINICAL FEATURES

The clinical manifestation of traumatic peripheral nerve injury depends on the mode, location, and extent of the injury sustained. Signs and symptoms reflect both the location and severity of the lesion as well as the composition of the injured nerve. Injury to a nerve that consists predominantly of motor fibers will manifest as weakness or paralysis and atrophy in the corresponding myotomal distribution. Injury to a predominantly sensory nerve, on the other hand, will present with sensory alteration or loss in the corresponding dermatomes. Autonomic and trophic function may also be affected resulting in decreased sweating, hair loss, and skin changes in the affected region. Partial lesions and faulty regeneration may result in the development of difficult to treat pain, often described as "pins and needles," stabbing or burning in character. For some patients, a debilitating symptom complex called *complex regional pain syndrome II*, also referred to as *causalgia*, may develop, which is characterized by allodynia, autonomic dysregulation, and maladaptive neuroplastic changes in central nervous system response to and processing of pain signals. This syndrome often does not respond well to conventional pain management strategies.

Some common associations are seen between various injury mechanisms and specific peripheral nerves. Awareness by clinicians, of these associations, may contribute to the earlier identification and treatment of potentially disabling injuries. Some of these common associations and their clinical presentations are discussed in the following section.

Cranial Nerve Lesions

Acute injury to cranial nerves often accompanies trauma to the head and neck. Significant injury may occur even with mild head trauma. One study by Coello and colleagues that evaluated cranial nerve function in 16,440 mild head trauma patients, defined by a Glasgow Coma Scale score of 14 or 15 at the time of presentation, over a period of 6 years, found a prevalence of associated cranial nerve injury of 0.3%, with the olfactory nerve being the most commonly affected, followed by the facial nerves and the nerves responsible for ocular movement. Injury to the lower cranial nerves (IX-XII) was noted to occur less frequently as a consequence of head trauma but to be more closely associated with iatrogenic injury during various medical and surgical interventions. The prevalence, location, and type of cranial nerve injuries observed most frequently result from the specific anatomic vulnerabilities of the affected nerve (**Table 49.3**).

Cranial Nerve I: The Olfactory Nerve

The olfactory nerve, responsible for our ability to detect and distinguish smells, is one of the most commonly cited cranial nerves to be injured as a result of head trauma. Olfactory dysfunction has been reported to occur in up to 4% to 7% of all cases of head trauma. Injury may occur at multiple sites along

TABLE 49.3 Cranial Nerve Injury, Mechanisms, and Presentation

Cranial Nerve	Type of Injury	Mechanism of Injury	Clinical Presentation
I: Olfactory	Head trauma from acceleration-deceleration forces (eg, MVAs)	Shearing of olfactory nerve ligaments crossing cribriform plate Contusion of olfactory bulb against frontal bone Damage of cortical olfactory tract by edema, hemorrhage, or ischemic injury of orbitofrontal and temporal lobes	Anosmia Parosmia Impaired perception of taste
II: Optic	Direct Indirect Complication of facial fracture repair for maxillofacial trauma	Anatomic disruption of nerve fibers by fracture fragments, penetrating trauma, or hematoma within nerve sheath Transmission of forces to optic canal during blunt head trauma Direct intraoperative nerve injury, retinal vascular occlusion from orbital edema, increased intraorbital pressure in optic canal	Visual acuity impairment
III: Oculomotor	Compressive • Expanding hematoma • Uncal herniation • Aneurysm of posterior communicating artery aneurysm Ischemic	Compression of parasympathetic fibers running along outside of nerve	Pupillary constriction deficit (mydriasis) more likely first Motor deficit more likely first • "Down and out" eye deviation • Ptosis • Loss of pupillary constriction to light but not accommodation
IV: Trochlear	Dorsal midbrain hemorrhage Complication of dental anesthesia during upper molar surgery (rare)	Direct injury to the trochlear nerve or its brainstem nucleus.	Inclining head toward unaffected eye (unable to move eye medially and inferiorly) Other oculomotor and neurologic deficits
VI: Abducens	Cranial base fracture, clival epidural hematoma Cervical hyperextension, atlanto-occipital dislocation, hyperflexion	Downward displacement against petrous ridge at turning point to enter into Dorello canal	Severe double vision Medial deviation of affected eye
V: Trigeminal	Iatrogenic • Dental/cranial trauma • Supraglottic airway devices	Compression of lingual nerve	Temporary loss of sensation and taste in anterior tongue (resolves within 6-9 wk)
VII: Facial	Intracranial lesion Lesion in facial canal of temporal bone Extracranial lesion	Direct injury to the facial nerve.	Impaired movement of facial muscles, taste from anterior two-thirds of tongue, salivation, lacrimation, hyperacusis (less common) Lacrimation may be spared Motor deficits
IX: Glossopharyngeal	Trauma	Fracture at jugular foramen where IX, X, and XI exit (rarely isolated)	Diminished taste in posterior one-third of tongue Loss of gag reflex on side of lesion
X: Vagus	Injury to pharyngeal branches Injury to superior/recurrent laryngeal branches	Fracture at jugular foramen where IX, X, and XI exit (rarely isolated).	Dysphagia Dysarthria Palate on affected side low at rest Deviation of uvula toward unaffected side with phonation
XI: Spinal Accessory	Trauma Iatrogenic • Lymph node biopsy • Internal jugular central venous line placement • Carotid endarterectomy	Fracture at jugular foramen where IX, X, and XI exit (rarely isolated) Extracranial lesion as nerve passes through posterior triangle of neck	Atrophy of upper trapezius Inability to shrug affected shoulder Impairment in head rotation to contralateral side Scapular winging at rest (worsened by abduction)
XII: Hypoglossal	Iatrogenic • Carotid endarterectomy • Endotracheal intubation • Supraglottic airway device Trauma	Fracture of occipital condyle	Dysarthria Deviation of tongue toward side of lesion

Abbreviation: MVA, motor vehicle accident.

the olfactory pathway. It is most often associated with acceleration-deceleration forces, such as those generated during motor vehicle accidents. Common injury sites include the olfactory nerve filaments as they cross the cribriform plate and are subject to shearing forces; the olfactory bulb, which may be contused against the frontal bone; and the cortical olfactory tracts, which may be damaged by edema, hemorrhage, or ischemic injury of the orbitofrontal and temporal lobes. *Anosmia*, the complete loss of odor detection, is the most common clinical finding, but *parosmia*, a decrease in olfaction acuity, is also observed, particularly with injury to the temporal lobe. The perception of taste, which is reliant on olfaction, is also commonly impaired in patients with injury to the olfactory nerve, and it is this symptom for treatment of which most patients present.

Despite the relative frequency with which injury to the olfactory nerve occurs following head trauma, deficits are rarely identified in the acute period. This may be because of the fact that trauma patients present with multiple injuries of varying severity and immediacy that require disproportionate allocation of resources. Nevertheless, loss of olfaction may have significant impact on quality of life, resulting in diminishment of enjoyment of food and other sensual experiences reliant on smell; loss of employment, when dependent on the sense of smell or taste; and decreased ability to detect environmental cues that may signal danger, such as the odor of volatile gas or fire. Awareness by clinicians of the association of head trauma with cranial nerve I dysfunction is important for early detection and diagnosis.

Cranial Nerve II: The Optic Nerve

Traumatic optic neuropathy, which may result in complete or partial loss of visual acuity in the affected eye, has been reported to occur in 1.4% to 5% of head trauma cases. Injury may be *direct*, resulting from anatomic disruption of nerve fibers by fracture fragments, penetrating trauma, or hematoma within the nerve sheath, or *indirect*, reflecting the transmission of forces to the optic canal during blunt head trauma. Early decompressive surgery may be required to prevent irreversible vision loss.

Additionally, injury to the optic nerve is recognized as a potential complication of facial fracture repair in patients with maxillofacial trauma, with a reported incidence of 0.3%. Mechanisms include direct intraoperative nerve injury, retinal vascular occlusion from orbital edema, and increased intraorbital pressure in the optic canal resulting in indirect injury to the nerve. This complication is most often reported after surgical intervention of the orbital floor, and ischemia is the most common final pathway leading to injury.

Unlike skeletal tissues, the optic nerve and retinal tissues are extremely sensitive to hypoxia and pressure, with irreversible ischemic damage occurring within 60 minutes to 2 hours. Because of this sensitivity, prompt identification of even subtle changes in visual acuity by the clinician is essential to provide potentially vision-sparing interventions in a timely manner.

Cranial Nerve III, IV, VI: The Oculomotor, Trochlear, and Abducens Nerves

Together, the oculomotor, trochlear, and abducens nerves innervate the muscles responsible for ocular movements. Damage to these nerves is a common complication of closed head injury. It may result in diplopia, impairments in eye movement, and ocular deviation. Injury to the nerves may occur at the nuclei in the brainstem, as the nerve exits the brainstem, and at the point where it pierces the dura mater. The site of injury reflects both the injury mechanism and the anatomic characteristics of the nerve. One or all of the nerves for oculomotor control may be affected, and clinical presentation will vary accordingly.

Cranial nerve III, the oculomotor nerve, innervates many of the muscles responsible for eye movement, including the medial rectus, superior rectus, inferior rectus, inferior oblique, levator palpebrae superior, and the pupillary constrictor. Additionally, the oculomotor nerve carries parasympathetic fibers to the eye. Complete lesion of this nerve results in a "down and out" deviation of the eye, ptosis, dilation of the pupil, and loss of pupillary constriction to light but not accommodation. Partial lesions may result in any combination of these findings, depending on the specific nerve fibers affected. Because the parasympathetic fibers run along the outside of the nerve, compressive lesions, such as an expanding hematoma or progressive uncal herniation secondary to intracranial hemorrhage or edema, tend to present with pupillary changes first, which may progress to oculomotor palsy with increasing pressure. Aneurysms of the posterior communicating artery may also compress the third cranial nerve and should be considered when evaluating a patient with oculomotor nerve palsy. Injuries that cause third nerve ischemia, on the other hand, are more likely to affect the motor fibers before disrupting the parasympathetic components. This distinction may help the clinician to identify the etiology of idiopathic third nerve palsy.

The trochlear nerve provides innervation to the superior oblique muscle. Lesion of this nerve results in an inability to move the eye medially and inferiorly. The resulting diplopia may be resolved by inclining the head toward the unaffected eye. Trochlear nerve palsies occurring in isolation have been observed following dorsal midbrain hemorrhage and as a complication of dental anesthesia during upper molar surgery but are extremely rare. Generally, injury to the fourth cranial nerve is accompanied by other oculomotor and neurologic deficits.

The abducens nerve innervates the lateral rectus muscle, which is responsible for abduction of the eye. Injury to this nerve results in severe double vision in almost all gaze directions and medial deviation. Traumatic injury to the sixth cranial nerve has been associated with cranial base fracture and the development of clival epidural hematoma as well as cervical hyperextension, atlanto-occipital dislocation, and hyperflexion. The sixth cranial nerve vulnerability to injury is thought to be a result of its long and delicate intracranial source. After exiting the pons, it ascends vertically within the subarachnoid space for 15 mm before piercing the dura mater. From there, the nerve travels over the ridge of the petrous bone and changes directions abruptly at a 120° angle to enter Dorello canal, which is a triangular space defined by the apex of the petrous bone the posterior clinoidal process, and Gruber ligament, a thickened portion of the dura mater that connects the two. The nerve is tethered by the dura on either side of the canal. From Dorello canal, the nerve passes through the cavernous sinus and the superior orbital fissure to reach the lateral rectus muscle. Traumatic injury to the abducens nerve is thought to occur most commonly by downward displacement against the petrous ridge at the point at which it turns to enter the canal.

Cranial Nerve V: The Trigeminal Nerve

The trigeminal nerve supplies sensation to the face through three major peripheral branches: the ophthalmic (V1), maxillary (V2), and mandibular (V3) nerves. V1 and V2 are purely sensory, whereas V3 also carries motor fibers to the muscles

of mastication. VI is also responsible for the corneal reflex. Traumatic injury to the branches of the trigeminal nerve is uncommon but may result from dental, surgical, or cranial trauma. Several cases of damage by supraglottic airway devices to the lingual nerve have been reported. This nerve, which is a branch of the mandibular division, is joined by the chorda tympani from cranial nerve VII and provides sensation to the anterior two-thirds of the tongue. Compression of this branch by the device results in temporary loss of sensation and taste (from the gustatory fibers of cranial nerve VII) in the anterior tongue, which, although potentially upsetting to the patient, generally resolves spontaneously within 6 to 9 weeks. The patient experiencing these symptoms postoperatively should be reassured regarding chance of recovery.

Cranial Nerve VII: The Facial Nerve

The facial nerve provides most of the motor innervation for the muscles of expression in the face. It also, via the nervus intermedius, relays afferent taste sensation from the anterior two-thirds of the tongue and carries sympathetic fibers to the lacrimal and salivary glands. Depending on the location of the injury, motor, autonomic, and gustatory deficits may be seen. Lesions of the intracranial portion of the nerve near the origin or close to the geniculate ganglion by the internal acoustic meatus may affect all three components, whereas those in the facial canal of the temporal bone between the geniculate ganglion and the origin of the chorda tympani near the stylomastoid foramen may spare lacrimation. Lesions occurring after the stylomastoid process in the extracranial portion of the nerve result primarily in motor deficits. Symptoms may be mild to severe depending on the severity of injury.

Injury to the facial nerve may present as complete paralysis of the facial muscles, with flattening of the facial folds around the nose, lips, and forehead; widening of palpebral fissures; and incomplete closure of the eyelid on the affected side, which can result in corneal scarring from desiccation, particularly if the injury also affects lacrimation. Decreased salivation and loss of taste in the anterior two-thirds of the tongue may also be present if the chorda tympani is affected. Less commonly, patients with seventh nerve injuries may experience sensitivity to loud sounds, or hyperacusis, as the facial nerve supplies motor input to the stapedius muscle, which has a dampening effect on the tympanic membrane. During regeneration, *synkinesis* may develop, which is the movement of unrelated facial muscles during attempts at isolated muscle movements, such as lip twitch with blinking, if aberrant reinnervation occurs. Importantly, lesions of the peripheral facial nerve can be distinguished from central motor pathway lesions by assessing involvement of the forehead. Central lesions spare forehead motion due to bilateral representation in the central nervous system, whereas peripheral lesions do not.

Traumatic injury to the facial nerve may result from temporal bone fracture, penetrating injuries such as knife or gunshot wounds, iatrogenic injury during resection of acoustic neuromas and other cerebellopontine angle lesions, or in the neonate at the time of delivery by the application of forceps. The superficial peripheral branches are particularly vulnerable to injury. Studies suggest that approximately 7% to 10% of temporal bone fractures result in facial nerve dysfunction. Trauma to the temporal bone may result in both an initial direct injury to the nerve followed by a secondary ischemic injury because edema causes increased pressure in the fallopian canal containing the nerve. Decompressive surgery may be necessary to prevent progression of injury and should be undertaken as early as possible. Likewise, penetrating injuries most often result in nerve transection and early surgical exploration is desirable. Surgical approach is dependent on the location of the injury.

Cranial Nerve IX: The Glossopharyngeal Nerve

Trauma to cranial nerves IX, X, XI, and XII is most often iatrogenic. The glossopharyngeal nerve carries both sensory and motor fibers. The sensory fibers transmit information from the upper part of the pharynx and taste from the posterior one-third of the tongue. The motor component innervates the constrictor muscles of the pharynx and the stylopharyngeus as well as secretory glands in the pharyngeal mucosa. Traumatic injury to the nerve occurs most commonly with fractures through the jugular foramen where it exits the skull together with the vagus and accessory nerves. Lesions resulting from trauma are rarely isolated and occur most commonly with injuries of the X and XI cranial nerves. Clinically, glossopharyngeal dysfunction presents with diminished taste in the posterior one-third of the tongue and loss of gag reflex on the side of the lesion. The presence of dysphagia or dysarthria may signal concomitant injury to the vagus nerve because these symptoms are rarely present in isolated glossopharyngeal injuries.

Cranial Nerve X: The Vagus Nerve

The vagus nerve provides motor, sensory, and autonomic innervation to a wide variety of targets. Motor fibers originating in the nucleus ambiguous in the brainstem innervate the somatic muscles of the pharynx and larynx, which coordinate the initial phase of swallowing. Autonomic fibers from the dorsal motor nucleus provide innervation to the heart, lungs, esophagus, and stomach. Sensory fibers from the upper gastrointestinal tract and oropharynx travel within the vagus nerve to the spinal nucleus, and sensation from the thoracic and abdominal organs is transmitted to the tractus solitarius. Dysarthria and dysphagia may occur with injury, and the palate on the affected side will be low at rest. Deviation of the uvula toward the unaffected side with phonation may be observed as the unopposed contralateral muscles contract.

Individual branches of the vagus nerve may be injured during surgical intervention on the head and neck. Careful physical examination aids injury localization because clinical presentation varies with site of lesion. Injury to the pharyngeal branches of the vagus nerve will present with dysphagia, which may be mild or severe. The superior laryngeal nerve, which carries sensory fibers from the larynx and provides motor innervation to the cricothyroid muscle, will present with anesthesia of the larynx and paralysis of the cricothyroid muscle. Injury to the recurrent laryngeal nerve leads to vocal cord paralysis, resulting in hoarseness and dysphonia. The voice may sound breathy or harsh during speech production. Bilateral injury results in complete vocal cord paralysis, which can be distinguished by the presence of dyspnea, inspiratory stridor, and an inability to phonate, *aphonia*. Lesions of the pharyngeal and superior laryngeal nerves may also produce vocal abnormalities, resulting in a voice that is weak and easily fatigable.

Cranial Nerve XI: The Spinal Accessory Nerve

The spinal accessory nerve, unlike the other cranial nerves, originates from the C2, C3, and C4 in the upper cervical spinal cord. It enters the skull through the foramen magnum and then

travels back out through the jugular foramen with cranial nerves IX and X. Like the glossopharyngeal and vagus nerves, the spinal accessory nerve may be damaged by trauma that results in fracture through the jugular foramen. Iatrogenic injury has also been observed during lymph node biopsy, internal jugular central venous line placement, and carotid endarterectomy. In these instances, injury generally occurs extracranially as the nerve passes through the posterior triangle in the neck.

The spinal accessory nerve carries motor fibers to the sternocleidomastoid muscle and the upper portion of the trapezius. Lesions of this nerve result in atrophy of the upper trapezius, inability to shrug the affected shoulder, and impairment in rotation of head to the contralateral side. Winging of the scapula at rest, which is worsened by abduction, may be present. The scapular winging that results from upper trapezius weakness may be distinguished from that associated with long thoracic nerve injury and anterior serratus weakness by the position of the scapula at rest. When the anterior serratus is affected, winging will be minimal at rest and increase with force applied to the outstretched arm when held out in front of the body.

Cranial Nerve XII: The Hypoglossal Nerve

The hypoglossal nerve originates from the medulla and exits the skull through the hypoglossal foramen in the posterior fossa. It carries motor fibers to the muscles of the tongue and is particularly important for articulation. Injury to this nerve produces dysarthria and atrophy with deviation of the tongue on protrusion toward the side of the lesion due to the action of the unopposed contralateral muscles. Trauma to the hypoglossal nerve has been reported with many surgical interventions including carotid endarterectomy, endotracheal intubation, and supraglottic airway device usage. Cranial nerve XII compression during head turning has also been observed to result from medially oriented, elongated styloid processes with associated ossification of the stylohyoid ligament. During acute head trauma, hypoglossal nerve injury may be associated with fracture of the occipital condyle. Presence of a 12th nerve palsy after trauma should prompt a magnetic resonance imaging of the cervical spine to assess spinal stability. Urgent decompression may be necessary to prevent irreversible injury to the spinal cord.

UPPER EXTREMITY NERVE LESIONS

The peripheral nerves of the upper extremity are vulnerable to traumatic injury by compression and stretch, lacerating and penetrating wounds, fracture and dislocation of nearby bones and joints, and ischemic and iatrogenic insults of various etiologies. Trauma, resulting in injury, may be either acute or chronic. Carpal tunnel syndrome and cubital tunnel syndrome are two examples of chronic entrapment syndromes, in which the application of chronic traumatic compressive forces result in impaired nerve function. These and other common entrapment syndromes are discussed in detail in subsequent chapters. This section focuses on common acute upper extremity traumatic peripheral nerve injuries and their mechanisms.

Brachial Plexus Injuries

Injury to the brachial plexus, which supplies much of the motor, sensory, and vasomotor innervation of the upper limb and shoulder, can be severely disabling, particularly as traumatic injury to the brachial plexus tends to occur most frequently within the productive age groups. Recovery is often incomplete, resulting in lasting disability, which may negatively affect quality of life. The superficial location, large size, and position between two highly mobile structures (the neck and the arm) make the brachial plexus vulnerable to traumatic injury. Although brachial plexopathies are discussed in greater detail elsewhere in this book, it is important for the clinician to be aware of common traumatic mechanisms and presentations of brachial plexus injury (Table 49.4).

The brachial plexus, which travels from the spinal cord to the axilla, is derived from the nerve roots of C5-T1. It is progressively

TABLE 49.4 Brachial Plexus Injuries, Mechanisms, and Presentation

Injury Classification	Mechanism of Injury	Clinical Presentation
Supraclavicular: *roots, trunks*	High-velocity injuries (eg, MVAs)	Motor and sensory loss in associated myotomes and dermatomes
Infraclavicular: *trunks, terminal nerves*	Penetrating injuries	Terminal branch deficits

Upper: C5-C6	Closed traction (Shoulder is forcibly separated from head.)
	• Contact sports
	• Prolonged operational positioning with contralateral rotation of head or upper extremity abduction greater than 90°
	• Excessive traction to plexus during delivery
		Erb palsy
		• Weakness/paralysis of deltoid, biceps, brachioradialis, pectoralis major, supraspinatus, infraspinatus, subscapularis, teres major
		• Loss of biceps reflex
		• Hypesthesia in lateral arm and forearm
		• "Waiter's tip" position:
		  • Internal rotation of arm
		  • Extension and pronation of forearm
		  • Flexion of wrist and fingers

Lower: C8-T1	Thoracic surgery requiring median sternotomy Cervical rib and band syndrome Obstetrical trauma Pancoast tumor	Klumpke palsy • Isolated hand paralysis • Ipsilateral Horner syndrome • Hypesthesia in medial arm and forearm and ulnar side of hand • Atrophy of intrinsic hand muscles • Loss of triceps reflex

Abbreviation: MVA, motor vehicle accident.

divided into five roots, three trunks (upper, middle, lower), six divisions (three anterior, three posterior), three cords (lateral, posterior, and medial), and several terminal branches, which provide motor, sensory, and sympathetic innervation to the upper limb. C5 and C6 contain the largest number of motor fibers, whereas C7 and T1 contain the least. C7 contains the largest amount of sensory fibers followed in descending order by C6, C8, T1, and C5. These relative sensory and motor distributions have implications for both injury presentation and chance of spontaneous functional recovery because nerves with greater proportion of either sensory or motor fibers have a greater likelihood of having regenerating axons make appropriate end-organ connections, as compared to mixed nerves.

Injury to the plexus occurs commonly with stretch from extreme positioning associated with falls, direct lacerating or penetrating trauma, dislocation of the shoulder, traction during birth, and stretch or compression during surgical positioning. Injury may be classified as *supraclavicular* (affecting roots and trunks), *retroclavicular* (divisions), or *infraclavicular* (trunks and terminal nerves), with the deficit pattern reflecting the site of injury. Supraclavicular lesions result in motor and sensory loss in myotomal and dermatomal distributions associated with the affected roots, whereas infraclavicular injuries tend to have deficits limited to the territories of the terminal branches. Infraclavicular injuries are more commonly seen with penetrating injuries, whereas high-velocity injuries, as occur with motor vehicle accidents, are more likely to result in closed traction supraclavicular injury patterns.

Additionally, injuries may be classified as *upper* (C5-C6), *lower* (C8-T1), or *panplexal* (C5-T1), with implications for both presentation and prognosis. The presence of Horner syndrome or involvement of proximal branches such as the dorsal scapular, which provides motor innervation to the rhomboids, or latissimus dorsi dysfunction due to long thoracic nerve injury, indicates a proximal injury and carries a poorer prognosis. Dysautonomic features, such as vasomotor abnormalities or skin changes, may be observed in the affected limb. Severe pain in an anesthetic limb may be suggestive of root avulsion, in which the nerve roots are torn from their attachment to the spinal cord by the force of the injury. Avulsion generally requires a different surgical approach than more distal nerve injuries and may carry a worse prognosis. In acute trauma, the position of the arm at time of impact, as well as the associated injuries, may provide clues to the clinician about possible plexus injuries.

The upper plexus is the most common site of injury. Injury to this region results from closed traction, which occurs when the shoulder is forcibly separated from the head. This injury pattern is common in contact sports as well as postoperatively as a result of prolonged positioning with contralateral rotation of the head or upper extremity abduction greater than 90°. It may also result from the application of excessive traction to the plexus during delivery and is referred to as *Erb palsy* (C5-C6) or *Erb palsy plus* (C5-C7), depending on the roots involved. Weakness or paralysis of the deltoid, biceps, brachioradialis, pectoralis major, supraspinatus, infraspinatus, subscapularis, and teres major results in the classic "waiter's tip" position, with internal rotation of the arm, extension and pronation of the forearm, and flexion of the wrists and fingers. The biceps reflex is absent and sensory loss incomplete, with hypesthesia on the outer surface of the arm and forearm. Contracture may result if passive range-of-motion exercises are not undertaken early. Prognosis for upper plexus injuries associated with birth trauma is generally very good, with 90% chance of spontaneous recovery reported most often in the literature, although controversy remains regarding the optimal timing of surgical intervention in these patients. Generally, the watchful waiting period of 3 to 6 months in adults with closed nerve injuries may be extended to 9 or more months in children, depending on the clinical circumstances.

Traumatic lower plexopathies, affecting C8-T1 nerve roots, are less common than upper plexus injuries but have been associated with thoracic surgery requiring median sternotomy, cervical rib and band syndrome, obstetrical trauma, and the presence of a Pancoast tumor by compression or direct tumor invasion. The resulting syndrome is referred to as *Klumpke palsy*. It presents with isolated hand paralysis and ipsilateral Horner syndrome. This clinical presentation mimics that of a combined median and ulnar lesion. Sensory loss is observed on the medial arm and forearm and the ulnar side of the hand. Atrophy of the intrinsic hand muscles occurs. The anatomic particularities of the C8 and T1 nerve roots make the lower plexus more susceptible to avulsion than the upper and middle plexus. The greater vulnerability to avulsion results in a poorer prognosis for lower plexus injuries.

Isolated middle plexus injury, affecting nerve root C7 or the middle trunk, is the least common form of traumatic brachial plexopathy. These lesions cause paralysis in a primarily radial distribution with sparing of the brachioradialis. Due to extensive dual innervation, sensory loss is minimal and may be limited hypesthesia over the dorsal surface of the hand and forearm.

A complete lesion of the brachial plexus results in a flail arm with or without ipsilateral Horner syndrome. Complete plexus injuries carry the worst prognosis and extensive surgical intervention may be required to restore function and alleviate pain.

Proximal Nerve Injuries

The *long thoracic nerve* is a purely motor nerve that arises from the ventral rami of C5-C7. It provides motor innervation to the serratus anterior muscle, which stabilizes, protracts, and upwardly rotates the scapula to abduct the arm over the head. Weakness or paralysis of this nerve results in winging of the scapula, which is particularly notable during abduction and forward flexion. Very little winging is observed at rest, which distinguishes long thoracic palsy from injury to the spinal accessory nerve. Abduction between 90° and 180° may be limited.

Injury to this nerve is most commonly seen in the context of more profound brachial plexus injuries. Iatrogenic injury has been associated with first rib resection and radical mastectomy. Isolated long thoracic injuries in the absence of a clear-cut mechanism are rare, and Parsonage-Turner syndrome should be considered as an alternative diagnosis in these cases.

The *suprascapular nerve* branches from the upper trunk and is derived of fibers mostly from C5. It provides motor innervation to the supraspinatus and the infraspinatus muscles as well as sensory and sympathetic innervation to two-thirds of the shoulder capsule, the glenohumeral, and the acromioclavicular joints. Weakness of the supraspinatus muscle results in difficulty in initiating shoulder abduction, particularly through the first 15° to 30°, after which the deltoid takes over. The infraspinatus externally rotates the shoulder, and weakness may be observed with external rotation as a result of suprascapular nerve injury. Isolated injury is rare with shoulder trauma, although

chronic trauma from entrapment by the suprascapular ligament has been reported. Compression by tumors and ganglion cysts may also occur.

Median Nerve

The median nerve derives from the C6-T1 nerve roots. In the forearm, it provides motor innervation to the pronator teres, the flexor carpi radialis, palmaris longus, and flexor digitorum superficialis muscles before branching into the purely motor anterior interosseous nerve and the main branch. The main branch passes through the carpal tunnel and then gives off the recurrent motor branch to the abductor pollicis brevis and the opponens brevis. It terminates in the palm where it supplies innervation to lumbricals I and II. The median nerve is therefore involved with pronation of the forearm, wrist flexion, thumb, index and middle finger flexion, and opposition of the thumb.

Additionally, the median nerve provides sensation to the radial palm, ventral thumb, index, middle fingers, and the radial half of the ring finger. The dorsal surfaces of the distal phalanx of the thumb, along with the terminal phalanges of the index and middle fingers, are also supplied by the median nerve.

Injury to the median nerve may occur at multiple points along its course as a result of trauma. Median nerve palsy has been associated with stabbing injuries to the brachial plexus, crush injury from prolonged crutch or tourniquet usage, fracture of the distal humerus, anterior shoulder dislocation, and Colles fracture of the wrist, although chronic trauma due to entrapment is the most common median nerve injury observed clinically. The nerve may become entrapped within the carpal tunnel or between the heads of the pronator teres in the forearm. Chronic entrapment within the carpal tunnel results in pain and sensory loss in the distal median distribution with wasting and weakness of the thenar muscles and lumbricals I and II. Direct traumatic injury to the median nerve has also been reported secondary to poorly placed steroid injections for treatment of carpal tunnel syndrome. Histologic examination in several cases revealed the presence of white crystals with the median nerve sheath suggesting that aberrant injection directly into the nerve was the likely mechanism of injury. Carpal tunnel syndrome is discussed more thoroughly in subsequent chapters.

Radial Nerve

The radial nerve arises from the posterior cord and contains elements from C5 to T1 nerve roots. It is composed of primarily motor fibers and provides innervation to the wrist, forearm, and finger extensors. It passes through the axilla to supply the triceps and then winds around the posterior humerus, descending in the spiral groove. The nerve innervates the brachioradialis and extensor carpi radialis longus muscles before branching into the superficial radial nerve, which carries sensory information from the dorsoradial aspect of the distal forearm and the dorsal surface of the hand and the posterior interosseous nerve, which supplies motor innervation to the remaining forearm, wrist, and finger extensors as well as the supinator.

The clinical presentation of traumatic injury to the radial nerve will vary with the level at which the injury occurs. Several common injury mechanisms have been identified that are associated with lesions at various levels. Injury to the nerve in the axilla, resulting from the use of crutches that are too long, causes extensor weakness and numbness in the radial distribution described earlier. Midshaft humeral fracture or external compression, referred to commonly as *Saturday night palsy* when it occurs after a particularly heavy night's sleep on an extended arm, causes weakness of forearm and wrist extensors with wrist drop and weakness of finger extensors. Elbow extension is preserved.

Iatrogenic trauma to the radial nerve has also been reported in the literature to have occurred with peripheral venous cannulation and arterial monitoring at the wrist, blood pressure cuffs at the midhumeral shaft, and rarely, with vaccine administration in the upper arm. Prognosis is generally good due to the predominant motor component of the radial nerve limiting motor/sensory cross-reinnervation and synergy between radial nerve–innervated muscles.

Ulnar Nerve

The ulnar nerve is a terminal branch of the medial cord of the plexus and contains fibers from C8 to T1 nerve roots. It descends between the biceps and triceps before moving posteriorly to pass behind the medial epicondyle and through the cubital tunnel to the forearm. It provides motor fibers to the flexor carpi ulnaris and flexor digitorum profundus II before passing through Guyon canal into the hand. The ulnar nerve terminates as a superficial sensory branch, which supplies the palmar and dorsal sides of the ulnar part of the hand and the palmar and dorsal surfaces of the little finger and the medial half of the ring finger. A deep motor branch supplies the abductor, opponens, and flexor digiti minimi medially and the adductor pollicis and the medial half of the flexor pollicis brevis laterally. It is responsible for many of the fine motor manipulations of the hand, and injury can be quite disabling.

The superficial course of the ulnar nerve behind the medial epicondyle makes this nerve vulnerable to injury by external compression. Ulnar nerve palsy is one of the most commonly reported postoperative peripheral nerve complications and may result from poor positioning, from insufficient padding around the elbow, or from external pressure by surgical instruments and personnel. Entrapment of the ulnar nerve may also occur at the elbow in the ulnar groove, distal to the elbow as it traverses the cubital tunnel, or within Guyon canal at the wrist. Several cases of ulnar nerve palsy at the wrist have been reported to result from ganglion cysts within Guyon canal, leading to weakness and atrophy of the intrinsic muscles of the hand. Injury to the ulnar nerve may also be seen with articular fractures of the distal humerus. Prolonged denervation may result in clawing of the little and ring finger, and atrophy of hypothenar and interosseous muscles.

The likelihood of functional recovery after traumatic injury is lower for the ulnar nerve than for either the median or the radial nerve. This inequity is attributed to the ulnar nerve's innervation of muscles responsible for fine movement in the hand, which require greater specificity in reinnervation to regain useful function.

Axillary Nerve

The axillary nerve arises as a terminal branch of the posterior cord with fibers originating from C5 to C6 nerve roots. The axillary nerve crosses anterior to the subscapularis before entering the quadrilateral space and dividing into two main trunks. The posterior branch supplies motor innervation to the teres minor

and posterior deltoid before terminating as the superior lateral brachial cutaneous nerve, whereas the anterior branch travels within the deltoid muscle providing motor innervation to the middle and anterior deltoid muscle.

Traumatic injury to the nerve is associated with glenohumeral dislocation, proximal humeral fracture, and direct blow to the deltoid muscle, as can occur during sports events. Compression can also occur within the quadrilateral space, resulting in deltoid muscle weakness and diffuse pain over the posterior shoulder. Compression is thought to be secondary to the development of abnormal fibrous bands and hypertrophy of the muscles forming the boundaries of the anatomic space. The axillary nerve is vulnerable to iatrogenic injury during surgery involving the shoulder and glenohumeral joint, including shoulder arthroscopy during portal placement. Clinically, injury to the axillary nerve may present with weakness of shoulder abduction and paresthesia over the lateral arm. Prognosis for axillary nerve injury is generally good, although it varies with injury mechanism and severity.

LOWER EXTREMITY NERVE LESIONS

Lumbosacral Plexus

The nerve supply to the pelvis and lower limbs originates from the lumbosacral plexus. Functionally and anatomically, the lumbosacral plexus can be divided into two major divisions, the lumbar and sacral plexuses (Table 49.5).

The lumbar plexus is formed within the psoas major muscle and is derived from the nerve roots of L2-L4. The lumbar plexus gives rise to the *femoral nerve*, which passes along the lateral border of the psoas major, under the inguinal ligament, to the anterior leg where it supplies motor innervation to the

TABLE 49.5 Lower Extremity Injuries, Mechanisms, and Presentation

Nerve	Mechanism of Injury	Clinical Presentation
Obturator	Compression from expanding pelvic masses (hematomas, tumors, abscesses) Labor	Abnormal gait due to adductor weakness Impaired internal/external rotation of thigh
Iliohypogastric/ Ilioinguinal	Iatrogenic complications of surgery • Aberrant suture/staple placement • Development of neuroma • Entrapment in fibrous adhesions	Anesthesia/paresthesia over a small strip of skin Pain
Lateral femoral cutaneous	Compression of anterior branch due to the following: • Tight-fitting belt/pants • Lumbar hyperlordosis from pregnancy • Prolonged maintenance of lithotomy position during surgery • Extreme hip flexion during vaginal delivery	Meralgia paresthetica • Dysesthesia and hypesthesia along lateral thigh
Femoral	Compression within pelvis (tumors, abscesses, enlarged lymph nodes) Spontaneous hematoma within iliacus or retroperitoneal space	Weakness of iliopsoas Paralysis of quadriceps femoris Hypesthesia over anteromedial leg (saphenous nerve distribution) Loss of patellar reflex Flexed, abducted, externally rotated leg Gait abnormality (especially walking on an incline)
Sciatic	In the buttocks: • Injection injury • Hip fracture/dislocation • Hip arthroplasty • Fall-related contusion • Gunshot wounds • Laceration • Compression from prolonged immobilization In thigh: • Gunshot wounds • Stretch injury associated with femoral shaft fracture • Laceration in posterior thigh In all locations, injury to common peroneal division is more common than injury of tibial division.	Weakness of knee flexion Paralysis of all movements of ankles and toes Loss of ankle reflex Foot drop on affected side Circular swinging motion of hip during leg advancement to compensate for loss of ankle dorsiflexion Hypesthesia over outer leg, shin, instep, dorsal surface of toes Sciatica (suggests compression at level of L5-S1 roots)
Common peroneal	Compression from prolonged leg crossing, squatting, or lateral decubitus position	Foot drop Weakness in ankle eversion Inability to extend toes Hypesthesia over outer leg, shin, instep, dorsal surface of toes
Tibial	Contusion with fracture, laceration, and gunshot wounds Tarsal tunnel syndrome	Paralysis of plantarflexion, inversion of foot, and flexion and abduction of toes Hypesthesia over plantar foot Loss of plantar reflex Burning/paresthesia/anesthesia over tarsal tunnel behind medial malleolus with radiation to plantar foot, heel, and arch

pectineus, sartorius, rectus femoris, vastus lateralis, vastus intermedius, and vastus medialis muscles. The femoral nerve then terminates as the saphenous nerve, providing sensation to the medial lower leg.

The *obturator nerve* also arises from the anterior branches of L2, L3, and L4. It passes through the obturator canal in the pelvis and gives off anterior branches that supply the adductors. It also may provide sensation to the inner thigh and knee, although cutaneous innervation in this area is highly variable.

A number of smaller sensory nerves also arise from the lumbar plexus. These nerves include the *iliohypogastric*, the *ilioinguinal*, the *genitofemoral*, and the *lateral femoral cutaneous nerves*. Lesions of these nerves are discussed individually in the following text, but traumatic injury is most often iatrogenic or anatomic, and rarely the result of acute trauma.

The sacral plexus is formed from the nerve roots of L5, S1, and S2 with variable contribution from L4. The sacral plexus supplies motor innervation to the gluteus minimus, gluteus medius, and tensor fascia lata via the *superior gluteal nerve*, which contains fibers from L4 to S1, whereas the *inferior gluteal nerve*, derived from L5 to S1, supplies the gluteus maximus.

The *sciatic nerve* forms from the posterior divisions of L4-S1. It exits the pelvis through the greater sciatic foramen and through the piriformis muscle, which can act as a site of compression when hypertrophied. The sciatic nerve travels down the posterior leg as two anatomically approximated but functionally distinct components: the lateral peroneal portion and the medial tibial portion. In the posterior thigh, the lateral peroneal portion of the sciatic nerve provides motor innervation to the short head of the biceps femoris, whereas the medial tibial division supplies the long head of the biceps femoris, the semitendinosus, and the semimembranosus. The lateral position of the peroneal portion increases its vulnerability to injury, particularly from penetrating and concussive forces. At the level of the posterior knee, the sciatic nerve divides into the common peroneal and tibial nerves.

Traumatic injury to the lumbosacral plexus is uncommon, although injury has been observed to occur secondary to gynecologic surgery and normal labor due to compression by fetal presenting part or instrumentation used in vaginal delivery. Hematoma, abscess, and tumor may all present with lumbosacral plexopathy. Clinical presentation varies with the site and severity of injury, although damage to the plexus may be distinguished from more peripheral injury if dysfunction of the anal sphincter is present.

Obturator Nerve

Traumatic injury of the obturator nerve is uncommon; compression may result from expanding pelvic masses such as hematomas, tumors, abscesses, or from compression by the presenting part of the fetus during labor. Clinically, injury to the obturator nerve manifests as abnormal gait due to adductor weakness. Internal and external rotation of the thigh may also be affected.

Iliohypogastric Nerve

The iliohypogastric nerve is derived from the upper portion of the lumbar plexus. It provides sensation to the upper buttocks and the lower abdomen as well as supplying some motor innervation to the internal oblique and transversus abdominis muscle. Traumatic injury to this nerve is most commonly reported as an iatrogenic complication of surgery. Aberrant suture or staple placement, development of painful neuroma, or entrapment of the nerve in fibrous adhesions can cause anesthesia, paresthesias, and pain that is refractory to most conventional pain management strategies. Entrapment in mesh used for hernia repair has also been reported. In cases of nerve injury uncomplicated by pain, lesion to this nerve may produce minimal deficits with anesthesia over a small strip of skin as the primary manifestation.

Ilioinguinal Nerve

The ilioinguinal nerve provides sensation to the pubic region, the upper inner thigh, and the external genitalia. Injury to the ilioinguinal nerve often accompanies injury to the iliohypogastric nerves and is associated with similar traumatic mechanisms.

Genitofemoral Nerve

The genitofemoral nerve is a sensory nerve that derives from the L2 nerve root. It provides sensation to the scrotum and a portion of the inner thigh. Traumatic injury of this nerve is rare.

Lateral Femoral Cutaneous Nerve

The lateral femoral cutaneous nerve is derived from nerve fibers between L2 and L3. This sensory nerve travels beneath the fascia of the iliacus and emerges at the anterior superior iliac spine. It divides into two branches: a posterior branch, which provides sensation to the external buttock, and an anterior branch, which provides sensation to the outer lateral thigh. A syndrome called *meralgia paresthetica*, which consists of dysesthesia and sensory loss along the lateral thigh, occurs with compression of the anterior branch. Compression may result as a consequence of tight-fitting belts and pants, lumbar hyperlordosis resulting from pregnancy, prolonged maintenance of the lithotomy position during surgery, or extreme hip flexion during vaginal delivery. Hypertrophy of the iliopsoas, as can occur with dancers who repeatedly maintain the leg in greater than 90° of flexion, has also been reported as a cause of lateral cutaneous femoral neuropathy.

Femoral Nerve

Traumatic injury to the femoral nerve is less common than injury to the sciatic, common peroneal, or tibial nerves, although injury may result from femur and pubic ramus fractures. More commonly, injury to the femoral nerve is derived from compression within the pelvis by tumor, abscesses, and other space-occupying lesions such as enlarged lymph nodes. Spontaneous hematoma within the iliacus or retroperitoneal space, associated classically with hemophilia and more recently with the use of anticoagulation medication, has also been described in the literature as a cause of femoral neuropathy. In hemophiliacs, it has been shown that bleeding into the iliacus muscle, which occupies a nondistensible space between the pelvic bone and the iliac fascia, raises the pressure within the compartment, compressing the femoral nerve as it travels between the iliacus and psoas muscles. A second mechanism has also been proposed based on more recent anatomic studies, which suggests that blood within the iliac fascia traps the femoral nerve at the point at which it

passes beneath the inguinal ligament. In this model, hemorrhagic dissection down to the level of the inguinal ligament is necessary for compression to occur and may explain why femoral neuropathy generally presents in isolation.

Injury to the femoral nerve results in weakness of the iliopsoas, paralysis of the quadriceps femoris, and hypesthesia over the anteromedial leg in the distribution of the saphenous nerve. Patellar reflex is lost and the leg is often held in flexed, abducted, and externally rotated position. Severe abnormalities in gait may be observed, particularly when attempting to walk on an incline or upstairs because both hip flexion and knee extension are affected.

Sciatic Nerve

Lesions of the sciatic nerve comprise the largest subset of lower extremity traumatic injuries. At the level of the buttocks, injection injury is the most common cause of traumatic nerve lesion with hip fracture/dislocation; hip arthroplasty; fall-related contusion; gunshot wounds; laceration, such as from a boat propeller; and compression from prolonged immobilization following in descending order. In the thigh, gunshot wounds, followed by stretch injury associated with femoral shaft fracture, and laceration in the posterior thigh were the most common mechanisms of traumatic injury. In all locations, injury to the common peroneal division of the sciatic nerve occurs more frequently than injury of the tibial division. This is hypothesized to be the result of the lateral position of the peroneal division.

Complete lesion of the sciatic nerve is rare. Clinically, it presents as weakness of knee flexion as well as complete paralysis of all movements of the ankles and toes. Ankle reflex is lost and foot drop is observed on the affected side. Also, gait is characterized by a circular swinging motion of the hip during leg advancement because patients attempt to compensate for the loss of ankle dorsiflexion. Sensation is altered on the outer surface of the lower leg, over the toes, and on the instep and sole of the foot. *Sciatica*, or pain extending from the low back to the toes following the course of the nerves that is associated with foot drop and weakness in ankle eversion, suggests compression at the level of the L5-S1 nerve roots and should warrant imaging evaluation of the lumbar spine.

Common Peroneal Nerve

The common peroneal nerve is particularly vulnerable to traumatic injury. Its anatomic course around the fibular head makes it susceptible to stretch, contusion, and compression forces around the knee as well as to laceration resulting from fibular fracture. Compressive trauma may occur with leg crossing, squatting, or prolonged lateral decubitus position with insufficient padding while sleeping, unconscious, or anesthetized. Injury to the common peroneal nerve results in footdrop and weakness in ankle eversion. Patients may be unable to extend the toes. Depending on the level of injury, sensory loss may occur over the outer leg, shin, instep, and dorsal surface of the four small toes.

Injuries to the common peroneal nerve carry a worse prognosis than do injuries to other nerves of the lower leg. This is thought to be due to a number of factors including the distance from target end organs, the mixed nature of the nerve, the risk for more severe injury associated with the nerve's lateral location, and the characteristics of the target muscles, which require coordinated input for effective contraction. Distal injuries tend to have a better chance of recovery than do their proximal counterparts.

Tibial Nerve

Injury to the tibial nerve occurs significantly less frequently than injury to the common peroneal, and it carries a much better prognosis. Contusion with fracture, laceration, and gunshot wounds are the most common mechanisms of traumatic injury. Because the tibial nerve provides motor innervation to the gastrocnemius and soleus, complete lesion of the nerve leads to paralysis of plantarflexion and inversion of the foot as well as flexion and abduction of the toes. Sensory loss occurs over the plantar aspect of the foot and plantar reflex is lost.

A syndrome of chronic trauma by entrapment, called *tarsal tunnel* syndrome, has also been described as occurring within the flexor retinaculum in proximity to the medial malleolus. This syndrome produces a variable pain over the tarsal tunnel behind the medial malleolus with radiation to the plantar aspect of the foot, heel, and arch, which may be described as burning, tingling, or numbness. Discomfort is often exacerbated by prolonged weight-bearing activity and may be present at night. Bifurcation of the tibial nerve into the medial and lateral plantar nerves proximal to the tunnel is thought to be an anatomically predisposing factor for the development of the syndrome.

Prognosis after tibial nerve injury is favorable compared to that of the common peroneal nerve. This is attributed to several factors intrinsic to the nerve including a greater connective tissue to fascicle ratio, with increased shock-absorbing capabilities; a singular fixation point, which provides more elasticity and protection from stretch; a better blood supply to minimize secondary ischemic damage; and closer proximity to end-organ targets. Additionally, functional recovery is aided by the size and biomechanical characteristics of the gastrocnemius and soleus muscles, which require relatively little innervation for contraction to be effective.

DIAGNOSIS

The initial diagnosis of traumatic nerve injury is clinical; it relies primarily on a thorough physical examination and the identification of a history that is suggestive of acute or chronic trauma. The mechanism of trauma, along with the presence of injuries to other structures, such as skeletal fractures or lacerations that are commonly associated with injury to peripheral nerves, may help focus the clinician's initial examination on those areas most likely to be effected, although a full cranial and peripheral nerve examination should be undertaken whenever possible. Evaluation may be complicated by injuries that require immediate lifesaving therapeutic intervention as well as by alterations in level of consciousness in a multi-injury trauma patient.

Once a peripheral nerve injury has been identified by clinical evaluation, additional information should be sought regarding pathophysiology and extent of the injury because these factors will influence the timing and type of treatment provided. Several laboratory and imaging tools are available to aid in classification, including electrodiagnostic studies, ultrasound,

magnetic resonance imaging, magnetic resonance neurography, and somatosensory-evoked potentials.

Electrodiagnostic Findings in Peripheral Nerve Injury

Electrodiagnostic evaluation, consisting primarily of electromyography (EMG) and nerve conduction studies, is critical for establishing the severity, location, and prognosis of peripheral nerve lesions. Properly timed examination seeks to answer four important questions: (1) localization of the injury, (2) pathophysiology, (3) severity of resultant dysfunction, and (4) progress of reinnervation and likelihood of spontaneous recovery. More detailed information regarding the administration and general characteristics of these tests is provided in other chapters. In this section, we focus on the electrophysiologic characteristics associated with each of Seddon's nerve injury types and their impact on surgical planning.

Neurapraxia

Neurapraxic lesions are characterized by focal conduction block at the site of the lesion with no loss of conduction in the distal segment. The injury, which is usually the result of direct compression or ischemia, results in focal demyelination with no associated axonal loss. On nerve conduction studies, this is reflected by maintenance of the compound muscle action potential (CMAP) and sensory nerve action potential (SNAP) on stimulation distal to the lesion site when recording from distal nerve targets. When stimulation is applied proximal to the lesion, CMAP recordings might show loss of amplitude, slowing of conduction velocity, and change in morphology. SNAP will demonstrate a similar pattern, although interpretation of SNAPs is somewhat more complicated because amplitude is also affected by distance between the stimulating and recording electrodes. Abnormalities are expected to resolve with remyelination, although some conduction slowing may persist permanently because remyelination results in shorter and thinner internodes than previously present, with slightly decreased conduction capability.

Needle EMG of neurapraxic lesions is characterized by loss of motor unit action potentials (MUAPs) that are under voluntary control and abnormal patterns of motor unit recruitment. In incomplete lesions in which some proportion of axons are blocked, rendering some motor units ineffective, remaining unaffected motor units must increase the rate of firing to generate the same amount of force. On EMG, this abnormal recruitment results in a decreased number of MUAPs of normal morphology, amplitude, and duration, firing rapidly. No MUAPs will be observed with complete neurapraxic lesions. Resolution of these findings will occur with remyelination.

Axonotmesis

In axonotmesis, unlike neurapraxia, injury to the nerve produces complete or partial axonal disruption, resulting in progressive degeneration of the distal stump. The time to completion of the degenerative process depends on the length of the distal stump, as well as on fiber composition, but is generally completed within 10 to 14 days. The time required to complete this process is reflected in the evolution of the electrodiagnostic picture, and studies carried out in the acute traumatic period will not adequately distinguish neurapraxic from axonotmetic and neurotmetic lesions.

Generally, on nerve conduction studies, upon completion of the degenerative process, CMAP and SNAP, distal to the injury, will show a decrease in amplitude that is proportional to the degree of axonal loss. Motor fibers degenerate more quickly, with completion experimentally determined to occur around 5 to 8 days, and complete loss of amplitude observed around 9 days. Sensory fibers require more time, and complete loss is generally observed at day 11. Comparison of CMAP amplitude in the injured limb may be made to that of the unaffected side to approximate the degree of axonal loss. Comparison of distal to proximal CMAP amplitude within the affected limb may estimate the amount of demyelination present.

Needle EMG provides a measure of end-organ denervation. Fibrillation potentials and sharp waves are markers of denervation resulting from axonal degeneration in complete lesions. Their appearance distinguishes neurapraxic lesions from axonotmesis and neurotmesis, although the timing of their appearance is dependent on the distance from the injury site. Proximal muscles may begin to show fibrillation potentials at 10 to 14 days, whereas distal muscles may require 3 to 4 weeks. Incomplete lesions will show firing patterns similar to that of neurapraxia.

As regeneration progresses, motor units will remodel. Surviving MUAPs will become increasingly complex and "nascent units" will develop. Nascent units are characteristically of small amplitude, polyphasic, and with a rapid firing rate. These early MUAPs will develop into fully reinnervated units, which exhibit large amplitude, increased duration, and polyphasia, indicating increased motor unit territory. Evidence of such reinnervation, from local sources, may appear as early as 3 weeks, indicating the possibility of spontaneous recovery, although generally axonal reinnervation requires 3 to 4 months before adequate assessment can be made. Serial examinations may be used to follow the progress of reinnervation. If no evidence of regeneration is found within 3 to 6 months, surgical exploration may be appropriate.

Neurotmesis

Neurotmetic lesions are by definition complete lesions, resulting from transection of all structural nerve elements. Initial electrodiagnostic studies will follow the same pattern of progressive degeneration as occurs in axonotmesis. Unlike axonotmesis, no evidence of reinnervation will be apparent on follow-up examinations because fully transected nerves are not capable of undergoing functional spontaneous regeneration. Surgical intervention with grafting or tension-free reapproximation is required.

Timing of Studies

Some debate exists regarding the optimal timing of electrodiagnostic evaluations. Conventional teaching is that initial evaluation should be performed no earlier than 3 weeks to allow for degeneration to be completed. Immediate evaluation, within 7 days of the injury, on the other hand, has been proposed as a potentially valuable tool both in lesion localization and to determine whether a lesion is complete or incomplete. Detection of conduction block precisely identifies the location of the injury, which may be particularly helpful in the setting of extensive or anatomically distorting trauma. Incomplete lesions

carry a better prognosis and are less likely to need early surgical intervention.

In general, the timing of studies should reflect the clinical setting and questions to be answered, with the following guidelines applicable: (1) Studies performed within 1 week provide information regarding completeness of lesion and location; (2) at 1 to 2 weeks, neurapraxia can be separated from axonotmesis and neurotmesis; (3) evaluation at 3 weeks provides the most information regarding lesion type and prognosis; and (4) by 3 to 4 months evidence of reinnervation should be present.

Role in Surgical Planning

EMG is also an important tool for surgical planning. In thinking about nerve repair and functional recovery, consideration must be given to the time required for regenerating axons to reach the target tissues and establish mature connections. This thought is particularly important for motor recovery because irreversible changes are observed to occur in muscle within 12 to 18 months, rendering innervation after that point ineffectual. Regeneration, after either grafting or direct anastomosis, occurs at a rate of approximately 1 inch per month. Surgery must be timed to allow for the appropriate period of regeneration to occur. EMG assists in this planning by monitoring the progression of reinnervation. By measuring the distance from the injury site to the most proximal muscle and calculating the time needed for reinnervation to occur based on regeneration rate, EMG evaluation can be planned to assess for spontaneous recovery within a timeframe that would still facilitate successful surgical intervention. Surgery may provide some benefit when performed outside the ideal window because sensory targets remain viable for up to 2 to 3 years and reestablishment of protective sensation may be achieved.

TREATMENT

The timing and technique of surgical intervention is dependent on the mechanism and characteristics of the nerve injury. Injuries may be classified as either open or closed, depending on the status of the associated cutaneous tissue (Figs. 49.1 and 49.2).

Closed peripheral nerve injuries occur most commonly as a result of stretching, contusion, or compression and are more likely to be in continuity. Transection is rare, and neurapraxic and axonotmetic injuries predominate. Lesions of this sort rarely require immediate surgical intervention and should be managed conservatively for a period of at least 3 months to allow for spontaneous recovery.

Open injuries, which result from lacerations, are more frequently associated with neurotmetic lesions and may require early surgery. In general, prognosis for functional recovery is better if spontaneous regeneration is able to occur. Therefore, open injuries with a nerve in continuity may be treated conservatively, with medical management, early mobilization and physical therapy, and serial electrodiagnostic studies to monitor progress. If no evidence of reinnervation is found within 3 months, surgical exploration may be appropriate. On the other hand, for open injuries with evidence of nerve transection, early surgical exploration is preferred. The timing and extent of the surgery will differ according to the mechanism of injury.

Sharp injury to a nerve, as is seen most commonly with knife or scalpel wounds, results in clean transection with minimal trauma to adjacent nerve tissue and no inflammation. Sharp injuries should be repaired promptly, ideally within the first 3 days after injury, and are usually able to be directly reapproximated with tension-free suture. Prognosis is generally good in these cases.

Blunt transections that are often associated with boat propeller accidents have significant inflammation and damage to

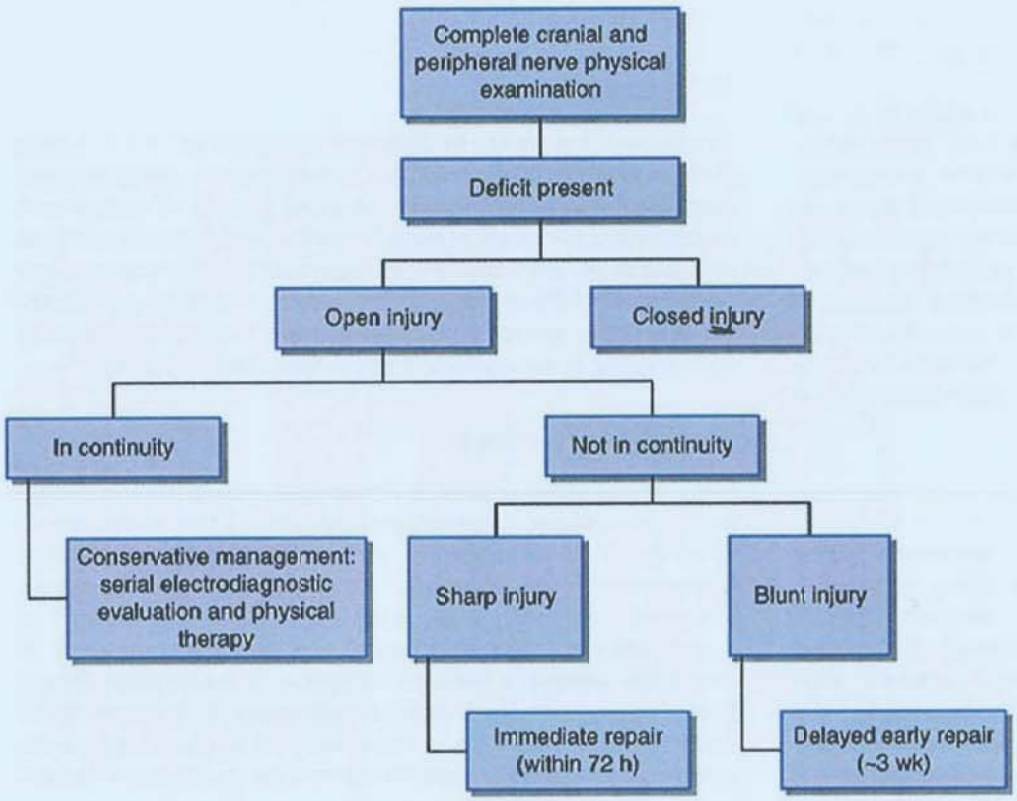

FIGURE 49.1 Initial evaluation of open nerve injury.

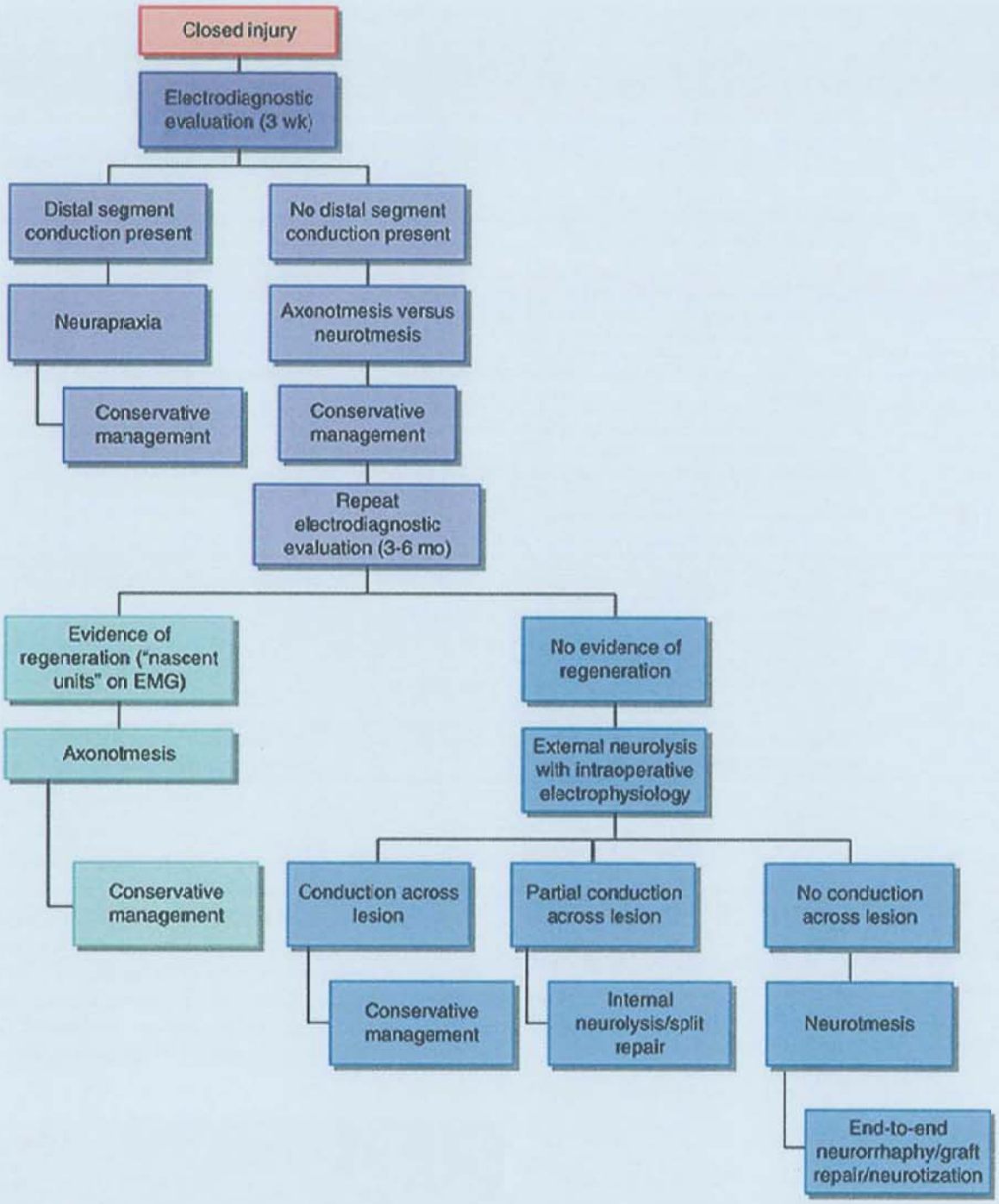

FIGURE 49.2 Closed nerve injury management. Abbreviation: EMG, electromyography.

surrounding tissues. Inflammatory changes in the blunt ends continue to evolve over a period of 3 weeks, and surgical repair should be delayed. Ongoing inflammation can disrupt the repair. Direct reapproximation is less likely to be successfully performed because the contused areas must be trimmed back to the point of healthy tissue, lengthening the gap. Nerve grafting may be necessary. Prognosis is poorer after grafting than direct neurorrhaphy, but good functional recovery may still be achieved.

Nerve injuries sustained as a result of gunshot wounds require special consideration. Most lesions caused by gunshot wounds are the result of indirect heat and shock waves generated by the bullet, rather than transection. As continuity is usually preserved, spontaneous recovery may be achieved. Furthermore, damage to surrounding tissues may limit the success of early repairs. Therefore, surgical exploration and repair should be delayed for 3 to 4 months postinjury.

Indications for Early Operative Management

Early operative management may be indicated in certain settings. As discussed earlier, sharp transections, in which transected ends are not significantly contused, benefit from surgery performed within 3 days. Progressive nerve deficit suggests the presence of associated vascular injury or abnormality. Evidence of an expanding hematoma, pseudoaneurysm, or other compressive lesion should prompt early surgical intervention to alleviate compression.

TABLE 49.6 Surgical Repair Options

Surgical Technique	Description	Indications
External neurolysis	Dissection and mobilization of nerve from surrounding tissue	Positive response to electric stimulus—external neurolysis may be sufficient Negative response to electric stimulus—resection and repair may be warranted
Internal neurolysis	Dissection and removal of individual nerve fascicles for evaluation and scar tissue removal	Incomplete lesions associated with pain refractory to conventional medical therapy Performed as part of split repair
Split repair	Testing individual fascicles, preserving conducting fascicles, and resecting/repairing nonconducting fascicles with end-to-end neurorrhaphy or with grafts	Conductive heterogeneity around circumference of a nerve as indicated by electrophysiologic examination
End-to-end neurorrhaphy	Reapproximation and suturing together of transected nerve ends	Repairing sharp transections
Graft repair	Sural, antebrachial cutaneous, or superficial sensory radial nerve is harvested from patient. Damaged nerve tissue is removed from lesion site proximally and distally until normal fascicular structure is identified. Groups of fascicles are separated and small-caliber donor nerve graphs are sutured to healthy nerve tissue.	Nerve gaps that are too long to be repaired via end-to-end neurorrhaphy (blunt transections)
Nerve transfer (neurotization, nerve crossing, heterotopic nerve suture)	Proximal end of recipient nerve is sutured to an epineural window of the intact donor nerve. For example: • Transfer of ulnar nerve to motor branch of biceps or intercostal nerves to musculocutaneous nerve to restore elbow flexion • Transfer of spinal accessory nerve to suprascapular nerve to restore shoulder abduction	Avulsive injuries of brachial plexus
Tendon transfer	Transfer of entire functioning muscle, with its innervation, to replace actions of one that is paralyzed	Final option for restoring function and stability for patients presenting late for treatment

Surgical Techniques

The goal of surgical repair is to restore functional connectivity across the site of lesion and to alleviate neural pain. This may be accomplished by the removal of scar tissue, reapproximation and direct suturing of transected nerve ends, or through the interposition of graft material. The type and extent of surgical intervention is dependent on lesion characteristics (Table 49.6).

Neurolysis

The term *neurolysis* refers to the exposure of a peripheral nerve and dissection free of surrounding tissues. External or internal neurolysis may be performed.

External neurolysis is the first step of all surgical peripheral nerve interventions. During this step, the nerve is freed from surrounding tissue and mobilized (Fig. 49.3). Thickened and scarred areas of the endoneurium are removed as the surgeon progresses from normal to abnormal tissue, distal and proximal to the lesion. Careful dissection seeks to minimize disruption to vasculature that could slow healing or cause secondary injury.

For lesions in continuity, upon completion of external neurolysis, intraoperative stimulation and electrophysiologic recording is employed to assess functional connectivity. An electric stimulus is applied proximal to the lesion, and response is recorded distally (Fig. 49.4). If a measurable response is present in the distal segment, external neurolysis may be sufficient to relieve pain and support healing. If no response is noted, resection and repair may be warranted. Performing external neurolysis prior to intraoperative electrophysiologic evaluation allows more accurate placement of electrodes.

Internal neurolysis refers to the dissection and mobilization of individual nerve fascicles for evaluation and scar tissue removal. It is indicated for use with incomplete lesions that are associated with pain refractory to conventional medical therapy. Removal of scar tissue from around individual fascicles may help alleviate neuropathic pain, but dissection within the nerve

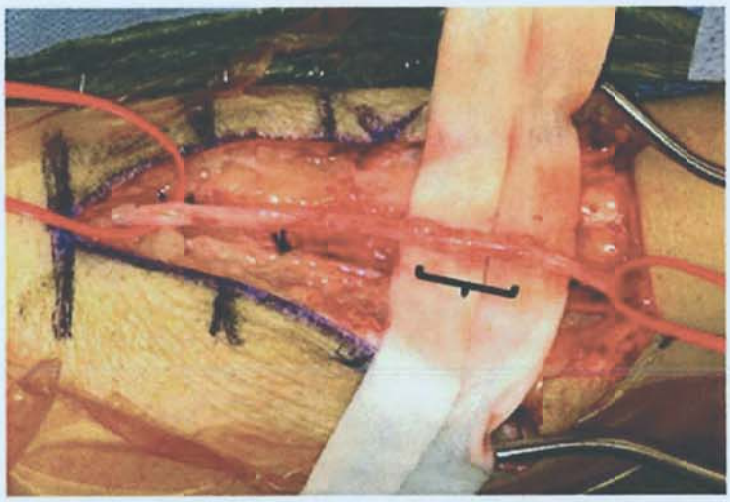

FIGURE 49.3 Intraoperative photo demonstrating a sural nerve injury that occurred during an Achilles tendon repair. External neurolysis across the injured segment reveals a traumatic neuroma marked by the *black bracket*. The nerve is in continuity.

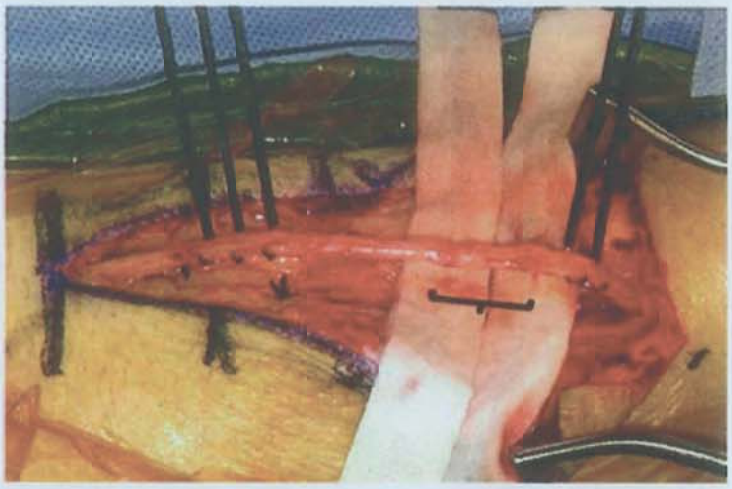

FIGURE 49.4 Intraoperative photo demonstrating a sural nerve neuroma-in-continuity marked with the *black bracket*. Intraoperative nerve action potential recording using the hook electrodes reveal no conduction across the injured segment. Therefore, the neuroma is excised, and a conduit repair is performed.

sheath has the potential to damage regenerating axons. Internal neurolysis is also performed as part of a split repair, described in the following text. Internal neurolysis is also used to relieve compression of the nerve from intrinsic scarring, as found in hourglass constrictions.

Split Repair

Split repair is an operative technique that is used when electrophysiologic examination reveals conductive heterogeneity around the circumference of a nerve. After internal neurolysis is completed, individual fascicles (or groups of fascicles) can be tested and preserved if conductance across the lesion is achieved. Those fascicles that do not conduct will undergo resection and repair with either direct end-to-end neurorrhaphy or with grafts. The benefit of the split repair technique is that it allows uninjured fascicles to undergo spontaneous regeneration, which generally is more successful than either direct suturing or graft interposition.

End-to-End Neurorrhaphy

End-to-end neurorrhaphy refers to the reapproximation and suturing together of transected nerve ends. It is commonly used to repair sharp transections and generally carries a better prognosis than grafting. The use of this technique is limited by the size of the gap created after resection of injured tissue. Excessive tension at the suture line can increase scar formation and impede functional recovery. External neurolysis and mobilization of the nerve stumps may help to decrease the gap length. Transposition of some nerves, such as the ulnar nerve at the elbow, may also provide more length. Groups of fascicles may be individually reapproximated and sutured to help minimize formation of neuroma and maximize chance of regeneration. Because the composition of fascicles changes every 1 to 2 mm, various techniques have been developed to try to match fascicles by predominant component, motor or sensory, to improve the chance of proper end-organ target reinnervation.

Graft Repair

For nerve gaps that are too long to be directly sutured without excessive tension, nerve graft repair is indicated. Longer gap lengths are commonly seen as a result of blunt transections, which damage tissue surrounding the lesion, and moderate to long complete lesions in continuity, which require resection. Although autografts are used most commonly today, cadaveric nerve grafts and specialized hollow tubes have also been used to restore continuity of the nerve.

For this procedure, the sural, antebrachial cutaneous, or superficial sensory radial nerve is harvested from the patient. Damaged nerve tissue is removed from the lesion site proximally and distally until normal fascicular structure is identified. Groups of fascicles are carefully separated and small-caliber donor nerve graphs are sutured to the healthy nerve tissue. The ends of the grafts are "fish-mouthed" or spread to increase the surface area. Good results can be achieved with this technique, although controversy exists regarding the maximum length for which grafts are successful. An inverse relationship has been observed between graft length and prognosis.

Nerve Transfer

Nerve transfer is an additional option for restoring function to an injured limb, particularly when the nerve lesion cannot be repaired by the techniques described earlier. This technique, which is also referred to as *neurotization*, is used most commonly to treat injuries of the brachial plexus. In this surgical technique, an uninjured nerve is used as a substitute for one that is no longer working. Transfers may be single or dual, in which either one or two nerve transfers are used to restore function. Nerves may be coapted end-to-end or end-to-side in which the proximal end of the recipient nerve is sutured to an epineural window in the intact, donor nerve. Generally, end-to-end direct neurorrhaphy is preferred.

The most commonly used procedure for restoration of elbow flexion was described by Oberlin and colleagues in 1994. During the Oberlin procedure, one or two fascicles from the ulnar nerve branch are transferred directly to the motor branch of the biceps. Intraoperative stimulation may be employed to identify fascicles of the ulnar nerve that innervate the flexor carpi ulnaris to minimize resulting deficit. Direct transfer of the ulnar fascicles to the biceps motor branch reduces sensory/motor cross-reinnervation by limiting aberrant motor reinnervation of the sensory territory of the lateral antebrachial cutaneous nerve. A second common procedure used to reestablish elbow flexion is transfer of a group of intercostal nerves to the musculocutaneous nerve. This transfer may be used when the Oberlin procedure is not available. Because the intercostal nerve is not a native elbow flexor, a period of retraining, which can extend from 12 to 24 months, may be necessary to restore function.

Similar procedures are used to restore shoulder abduction and external rotation, which are important for shoulder stability. The most commonly used procedure to restore shoulder abduction is the transfer of the spinal accessory nerve to the suprascapular nerve. In this procedure, distal fascicles of the spinal accessory nerve are directly sutured to the suprascapular nerve, which provides motor innervation to the supraspinatus. Superior branches of the spinal accessory nerve, which innervate the trapezius, are left intact to preserve function. An additional strategy to restore shoulder abduction is transfer of the triceps

branch of the radial nerve to the axillary nerve, which innervates the deltoid. Nerve branches of the long, medial, or lateral head of the triceps may be used. This procedure may be combined with spinal accessory transfer to maximize chance of functional recovery. In all cases, the choice of intervention derives from the needs and functional status of the individual patient.

Tendon Transfer

A final option for restoring some function and stability for patients who present for late treatment, when successful reinnervation is less likely, is tendon transfer. Tendon transfer consists of the transfer of an entire functioning muscle, with its innervation, to replace the actions of one that is paralyzed and thereby restore some motion across a joint. Tendon transfers are generally the last resort before fusion options are considered.

OUTCOMES

Functional restoration is dependent on both injury and patient-specific factors. Age, mechanism and type of injury, location, and timing of intervention all influence the final outcome. The interaction of these complex clinical characteristics makes prognostication difficult.

In general, neurapraxic lesions have the best prognosis with functional recovery apparent within weeks to a few months. Axonotmetic injuries recover more slowly, requiring several months for regeneration to occur. Neurotmetic lesions carry the worse prognosis with chance of recovery closely related to timing and type of surgical intervention. These lesions will not recover spontaneously. Sensory restoration can continue for a period of up to 3 years, whereas muscle targets are no longer viable after 12 to 18 months. Spontaneous recovery always carries a better prognosis than surgical reapproximation, and clinical recovery may be followed for up to 3 years.

SUGGESTED READINGS

Ali ZS, Bakar D, Li YR, et al. Utility of delayed surgical repair of neonatal brachial plexus palsy. *J Neurosurg Pediatr*. 2014;13(4):462-470.

Antoniadis G, Kretschmer T, Pedro M, König RW, Heinen CPG, Richter H-P. Iatrogenic nerve injuries: prevalence, diagnosis and treatment. *Dtsch Arztebl Int*. 2014;111(16):273-279.

Bodine-Fowler SC, Allsing S, Botte MJ. Time course of muscle atrophy and recovery following a phenol-induced nerve block. *Muscle Nerve*. 1996;19:497-504.

Brecknell JE, Fawcett JW. Axonal regeneration. *Biol Rev Camb Philos Soc*. 1996;71:227-255.

Brown M, Holland R, Hopkins W. Motor nerve sprouting. *Annu Rev Neurosci*. 1981;4:17-42.

Burnett MG, Zager EL. Pathophysiology of peripheral nerve injury: a brief review. *Neurosurg Focus*. 2004;16(5):E1.

Chaudhry V, Cornblath DR. Wallerian degeneration in human nerves: serial electrophysiological studies. *Muscle Nerve*. 1992;15:687-693.

Coello AF, Canals AG, Gonzalez JM, Martín JJ. Cranial nerve injury after minor head trauma. *J Neurosurg*. 2010;113(3):547-555.

Dejerine-Klumpke A. The classic: Klumpke's paralysis 1859–1927. *Clin Orthop Relat Res*. 1999;368:3-4.

Dorfman LJ. Quantitative clinical electrophysiology in the evaluation of nerve injury and regeneration. *Muscle Nerve*. 1990;13:822-828.

Dubuisson AS, Kline DG. Brachial plexus injury: a survey of 100 consecutive cases from a single service. *Neurosurgery*. 2002;51(3):673-683.

Elhassan B, Bishop A, Shin A, Spinner R. Shoulder tendon transfer options for adult patients with brachial plexus injury. *J Hand Surg*. 2010;35(7):1211-1219.

Giuffre JL, Kakar S, Bishop AT, Spinner RJ, Shin AY. Current concepts of the treatment of adult brachial plexus injuries. *J Hand Surg Am*. 2010;35(4):678-688.

Gunasekera SM, Wijesekara RL, Sesath HG. Proximal axonal changes after peripheral nerve injury in man. *Muscle Nerve*. 2011;43(3):425-431.

Guth L. Neuromuscular function after regeneration of interrupted nerve fibers into partially denervated muscle. *Exp Neurol*. 1962;6:129-141.

Irgit KS, Cush G. Tendon transfers for peroneal nerve injuries in the multiple ligament injured knee. *J Knee Surg*. 2012;25(4):327-333.

Kim DH, Cho YJ, Tiel RL, Kline DG. Outcomes of surgery in 1019 brachial plexus lesions treated at Louisiana State University Health Sciences Center. *J Neurosurg*. 2003;98(5):1005-1016.

Kim DH, Moronic JA, Tiel RL, Kline DG. Mechanisms of injury in operative brachial plexus lesions. *Neurosurg Focus*. 2004;16(5):E2.

Kline DG. Surgical repair of peripheral nerve injury. *Muscle Nerve*. 1990;13:843-852.

Kline DG, Kim D, Midha R, Harsh C, Tiel R. Management and results of sciatic nerve injuries: a 24-year experience. *J Neurosurg*. 1998;89:13-23.

Lee SK, Wolfe SW. Nerve transfers for the upper extremity: new horizons in nerve reconstruction. *J Am Acad Orthop Surg*. 2012;20(8):506-517.

Murovic JA. Lower-extremity peripheral nerve injuries: a Louisiana State University Health Sciences Center Literature Review with comparison of the operative outcomes of 806 Louisiana State University Health Sciences Center sciatic, common peroneal, and tibial nerve lesions. *Neurosurgery*. 2009;65(suppl 4):A18-A23.

Murovic JA. Upper-extremity peripheral nerve injuries: a Louisiana State University Health Sciences Center literature review with comparison of the operative outcomes of 1837 Louisiana State University Health Sciences Center median, radial, and ulnar nerve lesions. *Neurosurgery*. 2008;65(suppl 4):A11-A17.

Navarro X, Vivó M, Valero-Cabré A. Neural plasticity after peripheral nerve injury and regeneration. *Prog Neurobiol*. 2007;82:163-201.

Seddon H. A classification of nerve injuries. *Br Med J*. 1942;2(4260):237-239.

Seiler JG III, Desai MJ, Payne SH. Tendon transfers for radial, median, and ulnar nerve palsy. *J Am Acad Orthop Surg*. 2013;21(11):675-684.

Stewart JD. Peripheral nerve fascicles: anatomy and clinical relevance. *Muscle Nerve*. 2003;28:525-541.

Sunderland S. A classification of peripheral nerve injuries producing loss of function. *Brain*. 1951;74(4):491-516.

Sunderland S. The anatomy and physiology of nerve injury. *Muscle Nerve*. 1990;13:771-784.

Winfree CJ, Kline DG. Intraoperative positioning nerve injuries. *Surg Neurol*. 2005;63:5-18.

Wong CA. Nerve injuries after neuraxial anaesthesia and their medicolegal implications. *Best Pract Res Clin Obstet Gynaecol*. 2010;24:367-381.

Yang LJ, Chang KW, Chung KC. A systematic review of nerve transfer and nerve repair for the treatment of adult upper brachial plexus injury. *Neurosurgery*. 2012;71(2):417-429.

Mild Cognitive Impairment 50

Lawrence S. Honig, Arash Salardini, William Charles Kreisl, and James M. Noble

KEY POINTS

1. Mild cognitive impairment (MCI) is a cognitive state that falls between normal aging and dementia.
2. MCI subtypes are defined by which cognitive domains are affected: amnestic MCI and nonamnestic MCI.
3. Individuals with MCI, particularly amnestic MCI, are at increased risk for progressing to dementia, most often Alzheimer disease.
4. The evaluation of MCI should proceed similarly to the evaluation of the patient with dementia.
5. Diagnostic testing in MCI consists of testing to exclude reversible causes of cognitive impairment and identify domains most affected.
6. Imaging and cerebrospinal fluid studies can be used to determine the likelihood that a patient with MCI will progress to Alzheimer disease or other neurodegenerative diseases.
7. There are no currently approved treatments for MCI.

INTRODUCTION

Cognitive complaints are common in the aging population. In many cases, history and examination reveal significant impairment in more than one cognitive domain and concomitant functional decline—and in these cases, the findings provide for a diagnosis of dementia (see Chapter 12). However, in many other cases, there may be involvement of just one cognitive domain and/or lack of any clear functional decline, and diagnosis of dementia may not be warranted. An "intermediate state," representing neither dementia proper nor normality, clearly exists in the gradually progressive transition from normal brain health to dementia. Over time, several terms were developed to categorize such a transitional state as a diagnostic entity, even if representative of an early stage of a degenerative brain disease. In the 20th century, a variety of nonspecific terms were invoked to describe this intermediate state, including *pure amnestic disorder*, *age-related memory impairment*, *age-associated memory impairment*, *questionable dementia*, *cognitive impairment no dementia*, and *prodromal dementia*. Originally, such terms were predicated on the idea that cognitive changes were perhaps to be expected as part of aging. With the increased understanding of the biologic underpinnings of cognitive disorders, this view became less tenable. Thus for individuals with impairment not meeting dementia criteria, the term *mild cognitive impairment* (MCI) was coined.

The original clinical definition of MCI was memory-based and required a subjective memory complaint, a documented objective deficit in memory, overall normal general cognitive function, and a lack of "significant" functional impairment precluding a diagnosis of dementia. This was codified by the American Academy of Neurology in 2001. The definition of MCI has been broadened to domains other than memory to reflect non–Alzheimer dementias (Table 50.1). These other types of MCI include single domain amnestic MCI, amnestic multidomain MCI, nonamnestic single domain MCI, and nonamnestic multidomain MCI (Table 50.2). Research approaches have further refined the continuum of MCI itself into earlier and later stages based on objective neuropsychological test performance, the earliest stage of which is termed *subjective cognitive decline* when identified by patient self-report. This chapter discusses MCI reflecting this spectrum of potential stages including subjective cognitive decline.

TABLE 50.1 Broad Definition of Mild Cognitive Impairment

Core Criteria	Examples
Subjective (self-reported or informant-reported) cognitive complaint	• Forgetfulness about events, appointments, or items of information • Forgetfulness regarding date or time • Misplacing or "losing" objects • Word-finding problems, such as "forgetting words" • Spatial disorientation, such as becoming lost
Objective evidence of cognitive dysfunction on testing	• Decreased performance on standardized testing of cognitive domains, including memory, language, visuospatial, attentional, or executive functions or skills[a]
Preservation of functional activities	• Essentially normal function in living activities[b]
Absence of diagnosis of dementia	• Diagnosis of dementia is exclusionary.[c]

[a]Various cutoffs have been used for the objective tests, including 1.5 standard deviations below age- and sex-adjusted norms on one or more tests within a particular cognitive domain.

[b]Functional preservation is the most problematic of the three core inclusionary features because function may depend on living situation and demands.

[c]Diagnosis of mild cognitive impairment and dementia are mutually exclusionary, but diagnosis of dementia is not independent from the criteria in the table.

TABLE 50.2 Classification of Types of Mild Cognitive Impairment (MCI)[a]

MCI Type	Domains Affected	Possible Prodromal Disease
Amnestic single domain	Memory alone	Alzheimer disease
Amnestic multidomain	Memory PLUS one or more other domain: language, attention, executive, or visuospatial dysfunction	Alzheimer disease, dementia with Lewy bodies
Nonamnestic single domain	Language, attention, executive, or visuospatial dysfunction	Frontotemporal dementia, Lewy body dementia (including dementia with Lewy bodies and Parkinson disease dementia), vascular dementia, posterior cortical atrophy, hydrocephalus
Nonamnestic multidomain	Memory not affected but more than one domain affected: language, attention, executive, or visuospatial dysfunction	Frontotemporal dementia, Lewy body dementia, vascular dementia, posterior cortical atrophy, hydrocephalus

[a]Different types of MCI, left-most column, may ultimately more likely represent, as shown in right-most column, prodromal states of different dementia disorders.

MCI has also been codified by the committees of the American Psychiatric Association in 2013. The formulation of the diagnostic criteria of *Diagnostic and Statistical Manual of Mental Disorders*, 5th edition, recognizes that for each dementing disorder, there must be a state in which the impairment does not reach the level of dementia. Thus, each dementing disorder is categorized as a "major neurocognitive disorder" or "minor neurocognitive disorder." For example, Alzheimer dementia is "major," whereas amnestic MCI is "minor." As noted in Chapter 12, the use of the terms "dementia" and "MCI" are likely to persist in both neurologic and lay parlances.

In summary, *MCI* is a diagnostic term referring to a cognitively impaired state of less extent or severity than a dementia. MCI is generally, but not always, an early symptomatic state of a neurodegenerative process. As reviewed in Chapters 12 and 51, Alzheimer disease is the most common underlying cause of dementia and is the likely outcome for most amnestic MCI patients. Biomarkers have allowed segmentation of the relatively slow neurodegenerative process of Alzheimer disease into different diagnostic phases. The National Institute on Aging and Alzheimer's Association workgroup in 2011 divided the Alzheimer neurodegenerative spectrum into three phases: "preclinical" disease in which persons are asymptomatic but have biomarker evidence of an early Alzheimer process, a "symptomatic predementia phase" synonymous with MCI, and then the actual symptomatic dementia phase of Alzheimer disease (**Table 50.3** and **Fig. 50.1**). Thus as best demonstrated in Alzheimer disease, the definition of MCI continues to evolve and increasingly incorporates biomarker-based evidence with clinical finding.

EPIDEMIOLOGY

Both incidence and prevalence of MCI increase with age. Prevalence estimates vary widely depending on the exact definition of MCI. Subjective memory or other cognitive complaints (eg, word finding) that are elicited upon interview are extremely common in the elderly, although they depend on the population examined; in the United States, there is a prevalence of about 80% in persons older than age 70 years. However, most such persons will not have MCI when using objective neuropsychological testing measures. A relatively small fraction of persons with subjective memory or cognitive complaints present for neurologic or medical attention. Many persons with MCI are unaware of their deficits and this impacts care-seeking behavior by themselves or care partners. Of those who do present for medical evaluation, yet do not have diagnosable dementia, a high proportion (as many as 85%) will indeed meet MCI criteria, and most of these will be amnestic MCI. Once identified, a large proportion of amnestic MCI cases ultimately develop dementia, mostly due to Alzheimer disease. This is to be expected given the relative prevalences of underlying dementia disorders (see **Table 50.2**).

MCI, defined as reasonably preserved function but combined subjective memory or cognitive change and objective memory or cognitive impairment (see **Table 50.1**), is not as common as subjective memory complaints. The prevalence and incidence rates of MCI depend on the population assessed, including age, education, and cultural milieu, and the exact diagnostic criteria. In persons older than age 60 years, prevalence estimates for overall MCI have varied from as low as 1% to 5% to as high

TABLE 50.3 Stages of Alzheimer Disease[a]

Stage of Alzheimer Disease	Cognitive Signs and Symptoms	Functional Impairment	Biomarker Status
No disease	None	None	Negative
Presymptomatic disease (preclinical Alzheimer)	None	None	Positive
Symptomatic predementia (mild cognitive impairment)	Single or multidomain	Not significant	Positive
Symptomatic dementia (Alzheimer disease)	Multiple domains	Definite impairment	Positive

[a]This formulation is the result of the National Institute on Aging and Alzheimer's Association workgroups, as published in 2011. Biomarkers include structural magnetic resonance imaging (regional hippocampal atrophy), positron emission tomography metabolic imaging (bitemporoparietal hypometabolism), positron emission tomography amyloid imaging (evidence of amyloid), and cerebrospinal fluid (low β-amyloid 42, high tau, and high phospho-tau).

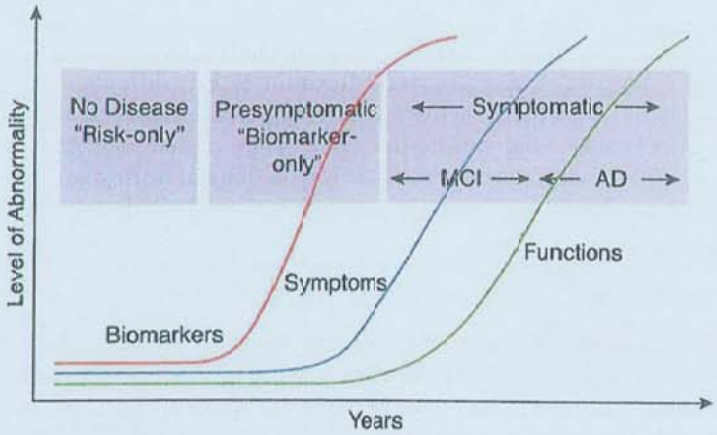

FIGURE 50.1 Mild cognitive impairment (MCI) on the spectrum of neurodegeneration. The figure shows schematic increases over time in brain biomarkers (red line), symptoms (blue line), and functional deficits (green line). For Alzheimer disease (AD), biomarkers include (1) evidence for fibrillar β-amyloid accumulation in the brain through florbetapir, florbetaben, or flutemetamol imaging or because of low cerebrospinal fluid β-amyloid 42 and (2) evidence of neurodegeneration indicated by decreased hippocampal volume, decreased gray matter gyral thickness, or increased tau and/or phospho-tau in the cerebrospinal fluid. Symptoms would include memory, language, visuospatial, or executive dysfunction confirmed on neuropsychological testing. A disease-free (*at-risk*) period is followed by an asymptomatic but biomarker-positive period (*presymptomatic*), followed by a *symptomatic* period. This latter period consists of an intermediate, earlier time period marked by cognitive symptoms without significant effect on function (*MCI*) and a later time period in which cognitive symptoms are more evident and there is concomitant functional impairment (*dementia*).

as 30% to 40%. Studies of populations older than age 75 years in North America and Europe suggest a convergent estimate of prevalence of about 20%, most of which is amnestic MCI or amnestic multidomain MCI. Incidence rates of overall MCI vary in different reports from as low as 10 to as high as 200 cases per 1,000 person-years, depending on exact age range of elderly, the population studied, the numbers of years followed, and the exact criteria applied.

Risk factors for MCI appear to be the same as the risk factors for dementia conditions, notably Alzheimer disease (see Chapter 51). Age is the dominant risk factor. Gender has not proven to be a risk factor when controlling for age. Lower education has generally been found to be a risk factor, as sometimes has ethnicity, medical illnesses including cardiovascular disease, and genetic factors, including apolipoprotein E (APOE) ε4 allele. If a case of MCI ultimately progresses to a particular dementia, then retrospectively, it is found that the risk factors for that form of MCI were those for the dementia disorder. However, for the MCI patients who improve over 1 to 3 years, or stay stable, and do not progress to dementia, the major risk factors, in retrospect, are often psychiatric illnesses, including depression and anxiety, and reversible medical conditions.

Overall, adults aged 50 to 60 years or younger without a family history of early-onset dementia, presenting with subjective memory complaints, with or without objective confirmation, are more likely to have an underlying psychiatric basis to their dysfunction than are elderly persons. This is likely due to the fact that early dementia is less common in young and middle aged adults, anxiety and depression as primary psychiatric disorders are common in young and middle aged adults, and anxiety and depression rarely present de novo in the elderly.

PATHOBIOLOGY

The pathobiology of MCI is that of the disorders for which it is a precursor state. Thus, if MCI is an early form of Alzheimer disease, then Alzheimer pathology is the substrate. Correspondingly, if the MCI is a precursor to frontotemporal dementia (FTD), then the pathology is that of FTD. Thus the condition, as presently defined, is not a homogeneous clinicopathologic entity. The reader is referred to Chapter 12 on the dementias and the individual chapters covering specific causes of dementia later in this section.

DIAGNOSIS

The early and primary MCI consensus criteria have been shaped around the fact that MCI most often is prodromal for Alzheimer disease, reflecting the epidemiology of dementia. These criteria are detailed in this chapter's "Introduction" section and shown in Tables 50.1 to 50.3 and Fig. 50.1. More recently, there have been efforts to develop MCI criteria potentially predicting other neurodegenerative diseases, including dementia with Lewy bodies, Parkinson disease dementia, FTD, and vascular cognitive impairment. It is estimated that a quarter to one-half of patients with Parkinson disease have MCI, is most associated with the akinetic rigid phenotype of PD, and is found more often in older individuals. The cognitive domains that are affected and the quantitative cutoffs are not yet formalized but generally identify impaired attention/executive function and memory impairment. In dementia with Lewy bodies (DLB; further reviewed in Chapter 53), the second most common neurodegenerative dementia, there are now three recognized prodromal stages, including an MCI presentation, which may be similar to the Parkinson disease MCI phenotype but with more profound impairments identified in those perhaps reflecting early fluctuations seen later in DLB. Psychiatric onset of DLB is a third form, in which patients may present with late-onset major depressive disorder or psychoses seen in more apparent later stages of DLB; some patients with this presentation may present with severe symptoms requiring hospitalization. Parkinsonian features may be an additional diagnostic clue but may be difficult to discern from medication side effects for those patients treated with antipsychotics. Other DLB features including rapid eye movement sleep behavior disorder can occur in isolation, sometimes years before other cognitive or behavioral features and can be seen in other synucleinopathies or disorders with brainstem pathology.

The earliest stages of MCI in FTD are largely based on well-characterized family studies with known deterministic genes and reflect minor syndromic deficits of later stage presentations, including executive/attention deficits and language impairment. A cerebrovascular basis of MCI may be invoked if a patient has demonstrable evidence of large- or small-vessel strokes in the absence of other clinical or biomarker-based evidence of alternative neurodegenerative disease.

Several other terms potentially relatable to MCI have emerged but have not been as broadly adopted as the MCI framework.

Motoric cognitive risk syndrome describes patients with slow walking speed and subjective cognitive complaints. The underlying neuropathologic changes have not been described and its use may be limited to serving as a screening construct in geriatric primary care settings. *Mild behavioral impairment* formalizes what is may be described by care partners as a "personality change" and encompasses changes in motivation, affective regulation, social appropriateness, impulse control, or thought/perceptual content, which may be seen in FTD or frontal manifestations of other neurodegenerative diseases including Alzheimer disease. More detail is provided on the clinical presentations of FTD and Alzheimer disease, including behavioral features, later in this section.

Clinical Features

MCI manifestations are subjective and objective cognitive impairment (see Table 50.1), but each of the cardinal aspects of MCI has interpretative leeway. Generally, a diagnosis of MCI requires a "consistent" symptomatology not single disturbing events. Corroboration of a patient's symptoms by a knowledgeable informant also increases likelihood that the symptoms represent abnormal cognition. Assessment of objective memory and cognitive impairment depends on the exact domains (memory, language, attention, executive, and visuospatial function), the tests used for each domain, and the criteria for abnormality. Different standards have been used, including 1, 1.5, or 2 standard deviations below the normative mean, without formal consensus or agreement on which of these is most appropriate.

Assuming the unequivocal presence of subjective and objective cognitive changes, often the most diagnostically difficult criteria to assess is that of relative preservation of function. Particularly in the elderly, depending on their spousal or family support and on their residential environment, the patient may not be expected or in the habit of performing routine functions commonly performed earlier in life. Bills may be prearranged, meals may be preprepared, and travel may be circumscribed or always accompanied. In these settings, it is often difficult to assess what is evidence of significant functional decline. Even persons engaged in their occupation may have a narrow range of responsibilities and well-learned skills in their occupational field that makes decline in function inevident.

Diagnostic Testing

The diagnostic workup in MCI typically takes on two parallel paths, including laboratory- and imaging-based workup and neuropsychological testing through either screening tools and comprehensive assessment when possible. Laboratory and imaging studies have two potential roles. The first role is to exclude nonneurodegenerative medical conditions not evident on the clinical examination that might be responsible for the cognitive impairment and might be reversible with known therapies. The second reason is to discern biomarkers whether in cerebrospinal fluid or on brain imaging that might be of value in assessing the prognosis of the MCI state and whether it is more or less likely to progress to a dementing disorder.

Neuropsychological Testing

Neuropsychological testing may have even greater use in the case of suspected MCI than in dementia. Psychometric test results can be helpful in establishing the extent of cognitive impairment, the domains affected, and the degree to which there is impairment, in comparison to a normative sample of others with comparable age, sex, and education. Subtle differences can often be important in formulating regional involvement and thus diagnosis and can be lost later in the course of cognitive decline including dementia. Neuropsychological testing strongly informs the diagnosis of MCI and also provides a baseline for subsequent evaluations.

Laboratory Testing and Neuroimaging

Laboratory exclusionary tests are the same as those used in the workup of Alzheimer disease and other dementias (see Chapters 12 and 51) and include blood laboratory testing to assess the presence of renal or hepatic dysfunction; vitamin B_{12} deficiency; thyroid deficiency; and in some cases, infectious diseases such as Lyme disease, syphilis, or human immunodeficiency virus infection. Routine neuroimaging using magnetic resonance imaging (MRI) is often reasonable to exclude structural disorders representing infections, tumors, traumatic, hydrocephalic, or vascular injuries and may also provide information on pattern of brain atrophy indicative of an underlying process (see the following text). A noncontrast computed tomography of the brain is often sufficient to exclude these concerns if an MRI is not possible or practical. Electroencephalography or other neurophysiologic measures are rarely needed, unless there is the suggestion of some episodic nature to the symptoms suggesting the possibility of complex partial seizures. Electroencephalography is typically normal or shows nonspecific mild temporal slowing or diffuse background rhythm slowing. Cerebrospinal fluid testing is optional. Like MRI, it may rarely reveal the unlikely presence of an unsuspected contributory condition that might have its own specific therapeutic approach. Such disorders include central nervous system inflammatory, infectious, or neoplastic disorders, including neurosyphilis, neurosarcoidosis, or meningeal carcinomatosis.

Biomarker-Based Assessments

To determine the etiology of MCI and assist with prognostication, a number of tests have been shown to be of value in assessing the likelihood of progression of cognitive symptoms of MCI to dementia (Table 50.4). These tests include structural neuroimaging, molecular neuroimaging, and examination of cerebrospinal fluid biomarkers and genetic biomarkers. Although predictive, they are primarily used in research studies focused on MCI, are not currently supported by most insurances, but may have relevance to clinical practice should disease-modifying therapies become available.

The biomarker-based assessments are largely shaped around Alzheimer-based biomarkers because some of the other neurodegenerative disorders lack a suggestive profile other than the absence of suggestive incipient Alzheimer disease biomarker profile. Taken together, they are used similarly to a research diagnostic construct used in Alzheimer disease, which intends to identify the combinations of three principal biomarker-based hallmarks of Alzheimer disease: evidence of β-amyloid deposition ("A" through amyloid positron emission tomography [PET] or cerebrospinal fluid Aβ42), tau biomarker ("T" via cerebrospinal fluid phospho tau or tau PET), and neurodegeneration or neuronal injury ("N," through fluorodeoxyglucose-PET, structural MRI, or cerebrospinal fluid total tau). As detailed in Chapter 51, there is a very strong association with Alzheimer disease when all three are evident, or when two including amyloid

TABLE 50.4 Biomarkers Useful in Prognostication for Mild Cognitive Impairment[a]

Biomarker	Result	Prognostic Implications
Brain MRI	Focal decreased hippocampal volume, parietal gyral atrophy, or cortical thinning	Likely AD
Fluorodeoxyglucose PET imaging	Bitemporoparietal hypometabolism Frontal or anterior temporal hypometabolism Occipital hypometabolism	Likely AD Suggestive of FTD Suggestive of PCA or DLB
Florbetapir, florbetaben, or flutemetamol PET imaging	Positive signal for fibrillar amyloid	Suggestive of AD with or without involvement of DLB
Ioflupane SPECT imaging (DAT)	Decreased unilateral or bilateral striatal uptake	Suggestive of DLB
Cerebrospinal fluid biomarker analysis	Low β-amyloid 42 High phospho-tau	Suggestive of AD
Apolipoprotein E genotyping	ε4 Allele present	Suggestive of underlying AD

Abbreviations: AD, Alzheimer disease; DAT, dopamine transporter single photon emission computerized tomography; DLB, dementia with Lewy bodies; FTD, frontotemporal dementia; MRI, magnetic resonance imaging; PCA, posterior cortical atrophy; PET, positron emission tomography; SPECT, single-photon emission computed tomography.

[a]The above assessments are useful in research-based studies of MCI and are anticipated to have broader clinical implications should disease-modifying therapies become available.

are evident, and less so with other combinations. Cautious use of these biomarkers is warranted in MCI and subjective cognitive impairment, in which these tools are presently intended to shape a differential diagnosis and not inform a presymptomatic clinical diagnosis. This approach is expected to be increasingly informative as the field remains collectively hopeful for disease-modifying therapies for neurodegenerative diseases.

In MCI, structural MRI may show patterns of cerebral atrophy, which can be suggestive of the presence of a particular neurodegenerative disorder. Early Alzheimer disease is marked by temporal lobe and parietal lobe gyral atrophy and cortical thinning. Studies show that temporal lobe atrophy is associated with a greater risk of progression of memory symptoms and development of Alzheimer dementia. FTD is more often marked by asymmetric or symmetric frontal and anterior temporal atrophy (see Chapter 52). Molecular neuroimaging using PET imaging tracers for amyloid such as florbetapir, florbetaben, or flutemetamol may show the early deposition of fibrillar β-amyloid indicative of the presence of neuritic plaques. Positive amyloid imaging is a strong risk for progression of MCI to dementia due to Alzheimer disease, and negative amyloid imaging makes it less likely to predict Alzheimer disease, although various cutoffs for imaging have been used. Most recently, flortaucipir, a PET imaging tracer for neurofibrillary tau, has been approved for use to estimate the density and distribution of aggregated tau neurofibrillary tangles in persons with cognitive impairment being evaluated for Alzheimer disease; its sensitivity and specificity were based primarily on persons with advanced disease. Cerebrospinal fluid biomarkers, particularly, the presence of low β-amyloid 42 but also likely the presence of high tau and phospho-tau, are associated with MCI progression to Alzheimer disease. Biomarkers for MCI due to DLB reflect those for dementia due to DLB and include reduced dopamine transporter uptake in the basal ganglia as seen on DAT–single-photon emission computed tomography or fluorodeoxyglucose-PET, polysomnogram evidence of rapid eye movement sleep without atonia, and abnormalities on myocardial scintigraphy (using the cardiac tracer metaiodobenzylguanidine, MIBG). Genetic testing for *APOE* genotype is not recommended in the workup of MCI regardless of suspected underlying diagnosis. As detailed in subsequent chapters in this section, the genetics of dementias are distinct and complex, and persons diagnosed MCI with a family history of dementia may benefit from genetic counseling with or without eventual testing (genetic counseling is further discuss in Chapter 35). The combinations of these factors in which multiple markers indicate the same incipient disease process are likely of even greater prognostic value, although correspondingly, the presence of discordant biomarkers makes prognostication of progression less clear.

TREATMENT

Because many cases of MCI, particularly amnestic MCI, develop into Alzheimer disease over time, a number of investigations have examined whether any of the four commonly used disease-specific treatments available for Alzheimer disease are of any benefit in either improving cognition or delaying the time period to conversion to dementia. The three cholinesterase inhibitors donepezil, galantamine, and rivastigmine have all been the subjects of trials in MCI. Only donepezil (10 mg/d) showed some mild evidence LEVEL 1[1] of efficacy in delaying progression to a diagnosis of Alzheimer disease (sometimes termed *conversion*). Galantamine trials showed a small degree of increased mortality in drug treatment compared to placebo, but it is suspected that this was a statistical finding, not necessarily indicative of an injurious effect of this drug in MCI. The sole approved noncholinesterase inhibitor Alzheimer medication memantine has been tried in MCI and mild Alzheimer disease and has been found to be inefficacious.

Disease-modifying treatments are not yet available for MCI, Alzheimer disease, or other neurodegenerative dementias. The wide presumption is that if a medication is shown to slow the progression of neurodegenerative disease, then that treatment given at the MCI stage would be even more useful than treatment of more advanced states beginning with mild dementia. Furthermore, even it is presumed that if a drug worked equally effectively at different stages of the disease, slowing progressive disease earlier would be more beneficial than slowing it later. Thus, increasingly prospective investigational therapies for Alzheimer disease are also being tested in subject populations with MCI. Imaging biomarkers for β-amyloid and tau, cerebrospinal fluid biomarkers for β-amyloid, tau, phospho-tau, synuclein,

and others and genetic markers including APOE genotype may be useful in predicting which persons with MCI are most likely to be in the early phases of Alzheimer disease. However, a biomarker-based approach to guiding treatment is principally used in research paradigms and is not standard clinical practice.

MCI also frequently involves concurrent anxiety or depression. In some cases, as mentioned earlier, the primary etiology of the MCI state may be depression. Thus, for any individual with anxiety or depression, consideration should be given to treatment of the psychiatric symptoms with antidepressants, most commonly selective serotonin reuptake inhibitors such as fluoxetine, sertraline, paroxetine, citalopram, or escitalopram.

In the period immediately following the diagnosis of MCI, patients and families are highly motivated to seek more information on MCI and dementia. This period presents a good opportunity for education, providing anticipatory support, referral into research studies, and discussing advance care planning (discussed further in Chapter 158). Although there is much interest in preventative strategies to address conversion from MCI to more obvious dementia, epidemiologic associations with potentially protective adulthood habits (eg, diet, exercise, and cognitive leisure) have not translated into clear evidence of protective cognitive benefit in randomized trials of nonpharmacologic interventions focused on diet, exercise, and cognitively engaging activities. Potentially modifiable cardiovascular and stroke risk factors should be addressed, given associations between these and cognitive decline regardless of presumed underlying neuropathology of MCI.

OUTCOMES

MCI is not a pathologically specific diagnosis, so the epidemiology of progression to dementia is most relevant to anticipating outcomes. It is clear that the majority of persons meeting criteria for MCI do progress to dementia over a period of 5 to 10 years. Both the rate of such progression and the particular dementia to which there is progression vary, in part depending on severity and in part depending on the type of MCI. Overall, amnestic MCI and amnestic multidomain MCI both most frequently progress to Alzheimer disease, and community-based studies estimate rates of progression to dementia between 5% and 20% per year. Some other less common forms of MCI, such as single-domain visuospatial MCI, may upon progression best fit the clinical syndromic diagnosis of posterior cortical atrophy, which, however, usually still reflects underlying Alzheimer disease pathology. Over the course of a few years, some persons with MCI remain relatively stable or even improve, although this course is more common in nonamnestic forms. Even persons who "revert" from MCI to normal cognition are at higher future risk of dementia. However, some persons remain stable with a diagnosis of MCI for many years, and the underlying basis of their dysfunction is unclear, as is their ultimate prognosis.

LEVEL 1 EVIDENCE

1. Lu PH, Edland SD, Teng E, Tingus K, Petersen RC, Cummings JL; for Alzheimer's Disease Cooperative Study Group. Donepezil delays progression to AD in MCI subjects with depressive symptoms. *Neurology*. 2009;72:2115-2121.

SUGGESTED READINGS

Adams JW, Alosco ML, Mez J, et al. Association of probable REM sleep behavior disorder with pathology and years of contact sports play in chronic traumatic encephalopathy [published online ahead of print September 17, 2020]. *Acta Neuropathol*. doi:10.1007/s00401-020-02206-x.

Albert MS, DeKosky ST, Dickson D, et al. The diagnosis of mild cognitive impairment due to Alzheimer's disease: recommendations from the National Institute on Aging-Alzheimer's Association workgroups on diagnostic guidelines for Alzheimer's disease. *Alzheimers Dement*. 2011;7:270-279.

American Psychiatric Association. *Diagnostic and Statistical Manual of Mental Disorders (DSM-5®)*. 5th ed. Washington, DC: American Psychiatric Association; 2013.

Albert M, Soldan A, Gottesman R, et al. Cognitive changes preceding clinical symptom onset of mild cognitive impairment and relationship to *ApoE* genotype. *Curr Alzheimer Res*. 2014;11:773-784.

Blazer DG, Yaffe K, Liverman CT. *Cognitive Aging: Progress in Understanding and Opportunities for Action*. Washington, DC: National Academies Press; 2015.

Bondi MW, Edmonds EC, Jak AJ, et al. Neuropsychological criteria for mild cognitive impairment improves diagnostic precision, biomarker associations, and progression rates. *J Alzheimers Dis*. 2014;42:275-289.

Clem MA, Holliday RP, Pandya S, Hynan LS, Lacritz LH, Woon FL. Predictors that a diagnosis of mild cognitive impairment will remain stable 3 years later. *Cogn Behav Neurol*. 2017;30(1):8-15.

Delrieu J, Piau A, Caillaud C, Voisin T, Vellas B. Managing cognitive dysfunction through the continuum of Alzheimer's disease: role of pharmacotherapy. *CNS Drugs*. 2011;25:213-226.

Dukart J, Mueller K, Villringer A, et al; for Alzheimer's Disease Neuroimaging Initiative. Relationship between imaging biomarkers, age, progression and symptom severity in Alzheimer's disease. *Neuroimage Clin*. 2013;3:84-94.

Farlow MR. Treatment of mild cognitive impairment (MCI). *Curr Alzheimer Res*. 2009;6:362-367.

Ferman TJ, Smith GE, Kantarci K, et al. Nonamnestic mild cognitive impairment progresses to dementia with Lewy bodies. *Neurology*. 2013;81:2032-2038.

Fleisher AS, Chen K, Liu X, et al. Using positron emission tomography and florbetapir F18 to image cortical amyloid in patients with mild cognitive impairment or dementia due to Alzheimer disease. *Arch Neurol*. 2011;68:1404-1411.

Ismail Z, Agüera-Ortiz L, Brodaty H, et al. The Mild Behavioral Impairment Checklist (MBI-C): a rating scale for neuropsychiatric symptoms in predementia populations. *J Alzheimers Dis*. 2017;56(3):929-938.

Jack CR Jr, Albert MS, Knopman DS, et al. Introduction to the recommendations from the National Institute on Aging-Alzheimer's Association workgroups on diagnostic guidelines for Alzheimer's disease. *Alzheimers Dement*. 2011;7:257-262.

Jack CR Jr, Bennett DA, Blennow K, et al. NIA-AA research framework: toward a biological definition of Alzheimer's disease. *Alzheimers Dement*. 2018;14(4):535-562.

Jack CR Jr, Wiste HJ, Therneau TM, et al. Associations of amyloid, tau, and neurodegeneration biomarker profiles with rates of memory decline among individuals without dementia. *JAMA*. 2019;321(23):2316-2325.

Jessen F, Amariglio RE, Buckley RF, et al. The characterisation of subjective cognitive decline. *Lancet Neurol*. 2020;19(3):271-278.

Jessen F, Amariglio RE, van Boxtel M, et al; and Subjective Cognitive Decline Initiative Working Group. A conceptual framework for research on subjective cognitive decline in preclinical Alzheimer's disease. *Alzheimers Dement*. 2014;10(6):844-852.

Jessen F, Wolfsgruber S, Wiese B, et al. AD dementia risk in late MCI, in early MCI, and in subjective memory impairment. *Alzheimers Dement*. 2014;10(1):76-83.

Jiskoot LC, Panman JL, van Asseldonk L, et al. Longitudinal cognitive biomarkers predicting symptom onset in presymptomatic frontotemporal dementia. *J Neurol*. 2018;265(6):1381-1392.

Karow DS, McEvoy LK, Fennema-Notestine C, et al; and Alzheimer's Disease Neuroimaging Initiative. Relative capability of MR imaging and FDG PET to depict changes associated with prodromal and early Alzheimer disease. *Radiology*. 2010;256:932-942.

Kemppainen NM, Scheinin NM, Koivunen J, et al. Five-year follow-up of 11C-PIB uptake in Alzheimer's disease and MCI. *Eur J Nucl Med Mol Imaging*. 2014;41:283-289.

Knopman DS, Petersen RC. Mild cognitive impairment and mild dementia: a clinical perspective. *Mayo Clin Proc*. 2014;89:1452-1459.

Koepsell TD, Monsell SE. Reversion from mild cognitive impairment to normal or near-normal cognition: risk factors and prognosis. *Neurology*. 2012;79(15):1591-1598

Landau SM, Harvey D, Madison CM, et al; for Alzheimer's Disease Neuroimaging Initiative. Comparing predictors of conversion and decline in mild cognitive impairment. *Neurology*. 2010;75:230-238.

Li J-Q, Tan L, Wang H-F, et al. Risk factors for predicting progression from mild cognitive impairment to Alzheimer's disease: a systematic review and meta-analysis of cohort studies. *J Neurol Neurosurg Psychiatry*. 2016;87(5):476-484.

Lim YY, Maruff P, Pietrzak RH, et al; for AIBL Research Group. Effect of amyloid on memory and non-memory decline from preclinical to clinical Alzheimer's disease. *Brain*. 2014;137(pt 1):221-231.

Litvan I, Goldman JG, Tröster AI, et al. Diagnostic criteria for mild cognitive impairment in Parkinson's disease: Movement Disorder Society Task Force guidelines. *Mov Disord*. 2012;27(3):349-356.

Livingston G, Huntley J, Sommerlad A, et al. Dementia prevention, intervention, and care: 2020 report of the Lancet Commission. *Lancet*. 2020;396(10248):413-446.

Mattsson N, Tosun D, Insel PS, et al; for Alzheimer's Disease Neuroimaging Initiative. Association of brain amyloid-β with cerebral perfusion and structure in Alzheimer's disease and mild cognitive impairment. *Brain*. 2014;137:1550-1561.

McKhann GM, Knopman DS, Chertkow H, et al. The diagnosis of dementia due to Alzheimer's disease: recommendations from the National Institute on Aging-Alzheimer's Association workgroups on diagnostic guidelines for Alzheimer's disease. *Alzheimers Dement*. 2011;7:263-269.

McKeith IG, Ferman TJ, Thomas AJ, et al; for prodromal DLB Diagnostic Study Group. Research criteria for the diagnosis of prodromal dementia with Lewy bodies. *Neurology*. 2020;94(17):743-755.

Ngandu T, Lehtisalo J, Solomon A, et al. A 2 year multidomain intervention of diet, exercise, cognitive training, and vascular risk monitoring versus control to prevent cognitive decline in at-risk elderly people (FINGER): a randomised controlled trial. *Lancet*. 2015;385(9984):2255-2263.

Pagani M, Dessi B, Morbelli S, et al. MCI patients declining and not-declining at mid-term follow-up: FDG-PET findings. *Curr Alzheimer Res*. 2010;7:287-294.

Petersen RC, Aisen P, Boeve BF, et al. Mild cognitive impairment due to Alzheimer disease in the community. *Ann Neurol*. 2013;74:199-208.

Petersen RC, Caracciolo B, Brayne C, Gauthier S, Jelic V, Fratiglioni L. Mild cognitive impairment: a concept in evolution. *J Intern Med*. 2014;275:214-228.

Petersen RC, Lopez O, Armstrong MJ, et al. Practice guideline update summary: mild cognitive impairment. *Neurology*. 2018;90(3):126-135.

Petersen RC, Smith GE, Waring SC, Ivnik RJ, Tangalos EG, Kokmen E. Mild cognitive impairment: clinical characterization and outcome. *Arch Neurol*. 1999;56:303-308.

Prestia A, Caroli A, van der Flier WM, et al. Prediction of dementia in MCI patients based on core diagnostic markers for Alzheimer disease. *Neurology*. 2013;80:1048-1056.

Roberts R, Knopman DS. Classification and epidemiology of MCI. *Clin Geriatr Med*. 2013;29:753-772.

Roberts RO, Knopman DS, Mielke MM, et al. Higher risk of progression to dementia in mild cognitive impairment cases who revert to normal. *Neurology*. 2014;82:317-325.

Rowe CC, Bourgeat P, Ellis KA, et al. Predicting Alzheimer disease with β-amyloid imaging: results from the Australian imaging, biomarkers, and lifestyle study of ageing. *Ann Neurol*. 2013;74:905-913.

Sachdev P, Kalaria R, O'Brien J, et al. Diagnostic criteria for vascular cognitive disorders: a VASCOG statement. *Alzheimer Dis Assoc Disord*. 2014;28(3):206-218.

Salardini A. Interpretation of biomarker data in diagnosis of primary dementias. *Semin Neurol*. 2019;39(2):200-212.

Slot RER, Sikkes SAM, Berkhof J, et al. Subjective cognitive decline and rates of incident Alzheimer's disease and non-Alzheimer's disease dementia. *Alzheimers Dement*. 2019;15(3):465-476.

Smith E. Vascular cognitive impairment. *Contin Lifelong Learn Neurol*. 2016;22(2, Dementia):490-509.

Sperling RA, Aisen PS, Beckett LA, et al. Toward defining the preclinical stages of Alzheimer's disease: recommendations from the National Institute on Aging-Alzheimer's Association workgroups on diagnostic guidelines for Alzheimer's disease. *Alzheimers Dement*. 2011;7:280-292.

Tricco AC, Soobiah C, Berliner S, et al. Efficacy and safety of cognitive enhancers for patients with mild cognitive impairment: a systematic review and meta-analysis. *CMAJ*. 2013;185:1393-1401.

van de Pol LA, Korf ES, van der Flier WM, et al. Magnetic resonance imaging predictors of cognition in mild cognitive impairment. *Arch Neurol*. 2007;64:1023-1028.

Verghese J, Wang C, Lipton RB, Holtzer R. Motoric cognitive risk syndrome and the risk of dementia. *J Gerontol A Biol Sci Med Sci*. 2013;68(4):412-418.

Wang X, Huang W, Su L, et al. Neuroimaging advances regarding subjective cognitive decline in preclinical Alzheimer's disease. *Mol Neurodegener*. 2020;15(1):55.

Ward A, Arrighi HM, Michels S, Cedarbaum JM. Mild cognitive impairment: disparity of incidence and prevalence estimates. *Alzheimers Dement*. 2012;8:14-21.

Wolfsgruber S, Kleineidam L, Guski J, et al; for DELCODE Study Group. Minor neuropsychological deficits in patients with subjective cognitive decline. *Neurology*. 2020;95(9):e1134-e1143.

Alzheimer Disease 51

Lawrence S. Honig and James M. Noble

KEY POINTS

1. Alzheimer disease (AD) is the most common neurodegenerative dementia and is the underlying cause of memory loss in most cases of dementia.
2. AD neuropathologic changes, including amyloid and tau deposition, are thought to cause symptoms when directly impacting cortical structures or related networks.
3. Other symptoms of AD include impairments in language, visuospatial, executive, and motoric abilities, alone or in combination, with or without concomitant amnesia.
4. Workup for AD includes exploring for reversible causes of dementia, through clinical evaluations coupled with laboratory and imaging based assessments.
5. Fluid and imaging based biomarkers of amyloid and tau burden are available for use in forming a specific AD diagnosis and may have a role in prognostication and monitoring.
6. Current treatment options are palliative and provide symptomatic relief through central cholinesterase inhibition and the *N*-methyl-D-aspartate antagonist memantine.
7. Additional pharmacotherapies target behavioral and psychotic features, which may be faced by some but not all patients affected by AD.

INTRODUCTION

The most common dementia is Alzheimer disease. The disease was first named by Emil Kraepelin in 1910, after Alois Alzheimer, who in 1906 had described the clinical features and pathologic manifestations of dementia in a 51-year-old woman. For some decades, Alzheimer disease was considered a presenile form of dementia, affecting individuals with symptoms beginning before age 65 years. But the mid-20th century brought the understanding that the same clinical, pathologic, ultrastructural, and biochemical features of presenile Alzheimer disease are shared by those with the more common "senile" (older than age 65 y) dementia. The disease is commonly sporadic, although susceptibility relates to a variety of genetic and potentially modifiable risk factors, which are further impacted by age. Uncommonly, the disease has an autosomal dominant inheritance pattern, particularly in younger persons.

EPIDEMIOLOGY

Alzheimer disease is a chronic disease of aging, and both the incidence and prevalence of disease increase with age. Prevalence estimates reveal that fewer than 1% of persons younger than age 65 years are clinically affected, but about 5% are affected at age 65 to 75 years, about 20% at age 75 to 85 years, and likely over 50% at age 85 years and older. The increasing prevalence with age is because the age-specific incidence, or the number of new cases arising over a specific period of time, rises steeply from less than 1% per year before age 65 years to about 6% per year for individuals aged 85 years and older. The average duration of symptoms from first noticeable symptoms until death is typically from 10 to 20 or more years. More recent community-based studies suggest that incidence has decreased slightly in later birth cohorts, but prevalence has remained static, likely reflecting longer disease duration and, in part, changes in care patterns.

It is presumed that both a mix of factors, considered potentially modifiable or nonmodifiable, or classified as environmental and genetic factors are involved in the risk of the disease, all of which are influenced by age. However, extensive investigations of environmental risk factors have not been as consistently linked with neuropathologic changes. Late-life depression is associated with Alzheimer disease, although the direction of causality is unclear—it is likely that depressive symptoms are often early manifestations of this dementing disorder. Similarly, hearing loss and poor oral health have been epidemiologically associated with dementia, but their potential pathophysiologic links remain uncertain. Traumatic head injury has been associated with increased risk of Alzheimer like symptoms, but neuropathologically show a mix of distinct taupathic changes, Alzheimer pathology, as well as Lewy bodies, with these copathologies being increasingly common in older populations. Likewise, diabetes and cardiovascular and cerebrovascular disorders have been associated with increased risk of dementia, but these may be due to additive ischemic injury to the brain, rather than a true increase in Alzheimer disease. Some other midlife and late-life potentially modifiable risk factors including healthy diet, regular exercise, and adequate sleep have been epidemiologically associated with lower incidence of Alzheimer disease, but late-life lifestyle intervention trials have not translated into either prevention or slowing of cognitive decline. Studies of identical twins show that they are not necessarily concordantly affected, so almost certainly there are some factors other than classic genetic ones. However, the main risk factors for development of Alzheimer disease, each small in and of itself, appear to be the members of a growing long list of genetic variations (**Fig. 51.1**).

Genetic Basis of Alzheimer Disease

Most Alzheimer disease is "sporadic" rather than a Mendelian dominant or recessive condition. However, a small proportion of the total number of persons with Alzheimer disease (<0.5%) have disease that is transmitted as an autosomal dominant identified monogenic familial disorder, commonly, but not always, with onset before age 65 years. Mutations in

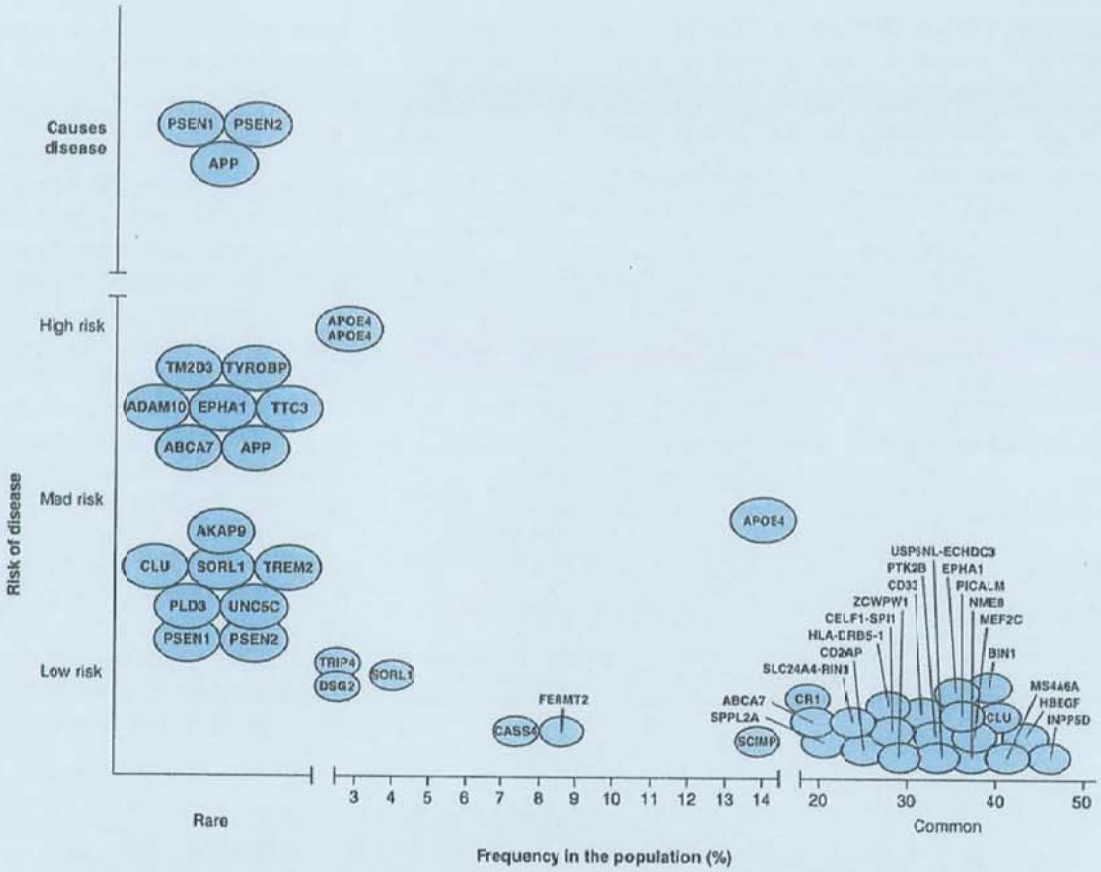

FIGURE 51.1 Genetic markers of Alzheimer disease. As shown by allelic frequency in the population (x-axis) as well as penetrance (y-axis). PSEN1, PSEN2, and APP are genes for which mutations can lead to autosomal dominant inherited Alzheimer disease, although a particular mutation in APP can also be protective against Alzheimer disease. APOE, SORL1, and the other genes listed all have been shown to have allelic variation that affects risk of Alzheimer disease. (Figure created by Alan Renton, PhD, and provided courtesy of Alison Goate, D.Phil, Icahn School of Medicine at Mount Sinai, New York, NY.)

three genes, the amyloid precursor protein (APP) gene on chromosome 21, the presenilin 1 (*PSEN1*) gene on chromosome 14, and the presenilin 2 (*PSEN2*) gene on chromosome 1, result in such autosomal dominant forms of the disease beginning as early as the third decade of life, with essentially complete penetrance (see **Fig. 51.1**). In addition, trisomy 21, or Down syndrome, results in near certainty of Alzheimer disease pathology by age 50 years and in symptoms of the disease in those who survive long enough. Finally, there is a protective variant in APP (the "Icelandic" allele, A673T), which is highly correlated with protection from Alzheimer disease. There are at least 217 described different variants in *PSEN1*, and its pathogenic variants lead to the most common form of familial early-onset Alzheimer disease. Pathogenic variants in these three genes account for as many as half of the familial forms of early-onset Alzheimer disease, may be considered deterministic because of nearly complete correspondence between the genotype and phenotype, and seem to lead to increased production of amyloid-β (Aβ) or specifically the $A\beta_{42}$ peptide.

There is a higher risk of Alzheimer disease in first-degree relatives of persons with Alzheimer disease. Siblings of patients have about two- to threefold the expected lifetime risk of developing the disease. Monozygotic twins have significantly higher concordance of Alzheimer disease than do dizygotic twins. Some of the genetic risk relates to the ε4 polymorphism of the apolipoprotein E (*APOE*) gene on chromosome 19, which shows a strong association with onset of Alzheimer disease in the age range of 60 to 80 years. The ε4 polymorphism of *APOE* is a normally occurring variant of the gene present in about one-third of the unaffected American population but present in about two-thirds of those with late-onset Alzheimer disease. APOE has been called a *susceptibility* gene because possession of the ε4 allele, a polymorphism, does not always lead to Alzheimer disease. One APOE ε4 allele is associated with about a 2- to 3-fold increased risk, whereas having two copies is associated with a 5- to 10-fold increased risk. Overall, the population attributable risk associated with APOE ε4 is approximately 20%, making it one of the most important risk factors for the disease. However, it is also recognized that these risks may dramatically differ by race-ethnicity for reasons not entirely understood.

A large number of gene variants have now been identified that each conveys a smaller risk of Alzheimer disease than that of APOE ε4 (see **Fig. 51.1**). Several dozen such genes are currently identified including some involved in lipid biology, intracellular processing, or endosomal pathways, and others involved in inflammation or the immune response, cell migration, cytoskeleton, axonal transport, and microglial cell function. Other genes will likely be identified adding to the already complex genetic architecture of this disease.

PATHOBIOLOGY

Alzheimer disease pathology is marked by two specific neuropathologic features (**Table 51.1** and **Fig. 51.2**): extracellular amyloid plaques molecularly consisting in large part of a fibrillar aggregation of the 40 and 42 amino acid peptides $A\beta_{40}$ and $A\beta_{42}$ and intracellular neurofibrillary tangles, which consist of paired helical filamentous polymers of hyperphosphorylated tau protein. Although these specific features permit pathologic diagnosis of Alzheimer disease, it is likely that the symptoms of the disease relate primarily to extensive synaptic losses and

TABLE 51.1 Pathologic Hallmarks of Alzheimer Disease[a]

Macroscopic/Regional	Clinical Implications
Hippocampal atrophy	Memory impairment
Parietotemporal atrophy	Dysnomia/visuospatial impairment
Nucleus basalis cell loss	Attentional impairment
Microscopic	**Molecular Concomitant**
Neuritic plaques	$A\beta_{42}$ and $A\beta_{40}$ fibrillar aggregates with associated neuritic changes
Diffuse plaques	$A\beta_{42}$ and $A\beta_{40}$ fibrillar aggregates
Neurofibrillary tangles	Paired helical filamentous aggregates of phosphorylated tau protein
Synaptic loss	Not known—but accompanied by decreases in various neurotransmitters
Neuronal loss	Not known
Granulovacuolar degeneration	Intraneuronal vesicular changes

[a]List of pathologic hallmarks of Alzheimer disease, including macroscopic/regional changes and microscopic changes and their clinical and molecular correlates.

later to frank neuronal losses. Much of the earliest brunt of this injury is borne by the entorhinal region of the medial temporal lobe.

The senile neuritic plaques are spherical microscopic lesions with a core of extracellular Aβ infiltrated and surrounded by abnormal nerve fibers (neurites). The $A\beta_{40}$ and $A\beta_{42}$ peptides are derived from the APP, a transmembrane protein present in most tissues. A region of the APP resides within an intramembranous domain of intracellular organelles in neurons, and several proteolytic enzyme activities, known as *secretases*, are responsible for cleavage of the protein. When cleaved by α-secretase, a soluble peptide derivative of amyloid is formed. However, when the APP is cleaved by β-secretase, and subsequently by γ-secretase, the peptides $A\beta_{40}$ and $A\beta_{42}$ are generated. These Aβ peptide monomers aggregate, forming oligomers, and ultimately large polymers, a process that can be demonstrated in vitro and presumably results in the amyloid plaques observed histologically. It is thus not surprising that the three autosomal dominant genes for Alzheimer disease are the APP gene itself and the PSEN1 and PSEN2 genes, which contribute to γ-secretase activity. Although there is little doubt as to a pathologic role of APP products, it is not clear which products might be most re-

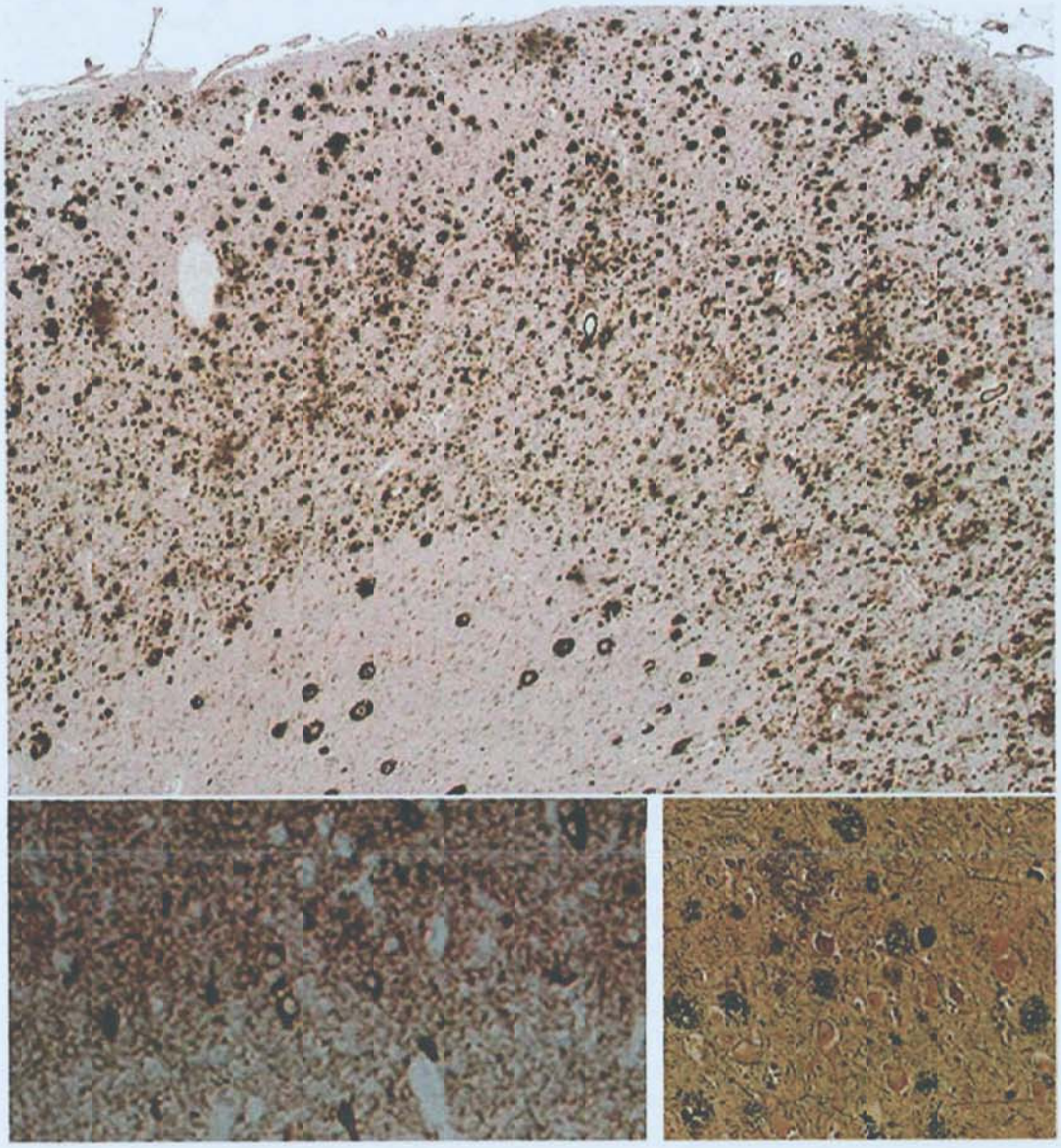

FIGURE 51.2 Top panel shows a cortical brain section immunohistochemically stained with antibody to β-amyloid. There are extensive stained extracellular deposits, which include plaques and also blood vessel staining in the white matter (amyloid angiopathy). **Bottom left panel** shows section stained with antibody specific for phosphorylated tau protein, and the intracellular stained deposits are neurofibrillary tangles. **Bottom right panel** shows a histochemical stained section (silver stained with the Bielschowsky method), visualizing both plaques and tangles.

sponsible for presumed neurotoxicity and synaptic losses: monomers, oligomers, polymers, or even other more soluble fragments. In addition to the parenchymal deposition of amyloid in Alzheimer disease, there is in nearly all cases amyloid angiopathy, which is amyloid deposition around meningeal and cerebral vessels. This condition is of varying severity and import in different patients but is accompanied by a propensity for hemorrhages, which may be microscopic, although visible on susceptibility-weighted magnetic resonance imaging (MRI), or macroscopic, with medium or large lobar hemorrhages. In a small proportion of patients, acute localized or diffuse brain edema may occur, now known as amyloid-related imaging abnormality (ARIA), including ARIA with "vasogenic edema" and/or sulcal effusion/exudate (ARIA-E), and ARIA with microhemorrhages and/or superficial hemosiderosis (ARIA-H) either spontaneously or after delivery of investigational antiamyloid therapies.

Neurofibrillary tangles are fibrillary intracytoplasmic structures within the neurons. Electron microscopy shows paired helical filaments of the microtubule-associated protein, known as *tau protein*. Normally, tau is a protein responsible in part for the axonal cytoskeleton, participating in microtubule assembly. In Alzheimer disease, hyperphosphorylated tau aggregates form, which are recognized in the electron microscope as twisted paired helical filaments and recognized in the light microscope as neurofibrillary tangles. Neurofibrillary tangles are not specific to Alzheimer disease, but in this disease, they occur first in the hippocampal formation and later are seen throughout the cerebral cortex. This apparent topographic spread of tangles has been codified as a staging system by Braak and Braak, including involvement of entorhinal (stages 1 and 2), hippocampal (stages 3 and 4), and neocortical (stages 5 and 6) regions. Tangles seem to increase in severity and extent with disease progression. This is more evident than is the case for amyloid plaques, which are often present even before symptoms and do not appear to correlate so highly with disease severity in autopsy tissues. Recent human in vivo imaging evidence suggests that amyloid deposition does indeed increase with disease, but it may "saturate" earlier than the formation of tangles. The relative injurious basis of these two hallmark pathologies is still not clear.

An important but nonspecific pathologic feature of Alzheimer disease is widespread, regionally specific losses of synapses and ultimately losses of neurons. Synaptic losses are accompanied by a wide variety of neurotransmitter deficits. These include particular decline in cholinergic terminals in the hippocampus and cortex, which apparently owes to early and prominent degenerative involvement of the nucleus basalis of Meynert, whose large cholinergic neurons project widely. It is this cholinergic deficit that informs the basis for symptomatic treatment of Alzheimer disease with drugs that increase cholinergic tone. Alzheimer disease is also variably marked by granulovacuolar degeneration of hippocampal pyramidal cells, which is a poorly understood pathologic feature, amyloid deposition in blood vessels, and glial changes. Finally, it is common in Alzheimer to have coexistent pathologies and pathologic case series support copathologies make dementia symptoms more likely at an earlier age or more apparent. Copathologies include intracytoplasmic inclusions of α-synuclein known as *Lewy bodies* or *Lewy neurites*. Lewy bodies are discussed in Chapters 53 and 86 because they represent pathologic hallmarks of Parkinson spectrum disease. They are present in as many as 35% of Alzheimer disease brains and even present in brains of persons with early-onset autosomal dominant Alzheimer disease, for example, due to PSEN1 mutations. Vascular lesions, in addition to amyloid angiopathy (discussed earlier), are another common coexistent pathology, occurring in 30% to 50% brains of persons with Alzheimer disease. These include microinfarcts, microhemorrhages, and lacunar or large-artery infarcts. It is likely that, when present, Lewy body pathology and vascular pathologies contribute to the phenotype in Alzheimer disease, leading to the term *mixed dementia*. However, most studies show that the burden of plaques and tangles is best correlated with the progressive dementia in Alzheimer disease. Other frequent copathologies with Alzheimer disease include TAR DNA-binding protein 43 (TDP-43) and aging-related tau astrogliopathy. Some of these copathologies may also occur in isolation and present with clinical symptoms potentially suggesting Alzheimer disease, including limbic predominant age-related TDP-43 encephalopathy (LATE). Another related pathology of aging is that of isolated neurofibrillary tangles, termed *primary age-related tauopathy* (ARTAG), which likely occurs on a continuum of cognitive aging. The placement of primary age-related tauopathy (PART) in relation to neuropathologic and clinical Alzheimer disease remains a formulation in process.

DIAGNOSIS

The first organized criteria for clinical diagnosis of Alzheimer disease were established in 1984 by a joint effort of the National Institute of Neurological and Communicative Disorders and Stroke and the Alzheimer's Association (previously known as *the Alzheimer's Disease and Related Disorders Association*). These criteria, the National Institute of Neurological and Communicative Disorders and Stroke-Alzheimer's Disease and Related Disorders Association criteria, consisted of three levels of clinical certainty: definite, reserved only for autopsy-confirmed cases, probable, and possible. The criteria included a history of progressive deterioration in cognitive ability, not explicable by other known disorders, involving memory and at least one other cognitive domain, and causing some significant disturbance of functioning in the patient. These criteria were endorsed by the American Academy of Neurology in 2001, with the additional provision of preferred laboratory tests, such as computed tomography (CT) or MRI, and optional laboratory tests, such as serologic testing for syphilis. However, over time, it became clear that these criteria were inadequate due to the requirements for memory involvement, functional disturbance, and the lack of reference to more modern and specific biologic imaging and fluid marker tests, referred to in the following text. New sets of criteria have been developed by consensus sponsored by the National Institute on Aging and the Alzheimer's Association, and these National Institute on Aging-Alzheimer's Association criteria provide for preclinical diagnosis, early symptomatic diagnosis without functional impairment (see Chapter 50), and presymptomatic diagnosis. An additional construct has attempted to establish clinical trajectories relative to various combinations of three principal biomarker-based hallmarks of Alzheimer disease: evidence of β-amyloid deposition ("A" through amyloid positron emission tomography [PET] or cerebrospinal fluid [CSF] $A\beta_{42}$), tau biomarker ("T" via CSF phosphorylated tau, or tau PET); and neurodegeneration or neuronal injury ("N," through ^{18}F-fluorodeoxyglucose PET, structural MRI, or CSF total tau),

suggesting a strong association with Alzheimer disease when all three are evident, or when two including amyloid are evident, and less so with other combinations.

Clinical Features

The signs and symptoms of Alzheimer disease present and evolve variably, with the most common early signs being subjectively and objectively impaired memory (see Chapter 12). Overall, there is slow progressive cognitive impairment, eventually affecting many cognitive domains.

Cognitive impairment is the hallmark of Alzheimer disease. Memory impairment is the most common presenting symptom, present in over 90% of affected patients. The difficulty with memory is most prominent for newly acquired information, so-called short-term memory, whereas immediate, or "working" memory, is typically unaffected. "Long-term memory" for remote events is relatively unimpaired in the early phases of the illness but ultimately is also severely affected. As the disease progresses, impairments in language and visuospatial function typically become more prominent (Fig. 51.3) as well as impairments in abstract reasoning and executive function or decision making. The increasing impairment in language and visuospatial function may be particularly evident on serial office testing (see Fig. 51.3). In some, language dysfunction may be the earliest feature, and one form of primary progressive aphasia, the "logopenic" variant primary progressive aphasia, is often due to Alzheimer disease. In these patients, word-finding difficulty, circumlocutions, and impaired repetition are commonly present; primary progressive aphasia is discussed further in Chapter 52. In other persons, visuospatial impairment, which may progress to the extent of complete cortical blindness, may be the presenting symptom of Alzheimer disease, and this syndrome is termed *posterior cortical atrophy*. Alzheimer disease can also present as a corticobasal syndrome (CBS), with prominent features of limb apraxia, myoclonus, gait disturbance, and cortical sensory loss. The CBS in Alzheimer disease is less likely than corticobasal degeneration in frontotemporal dementia to have alien limb phenomenon; language problems may also present earlier in Alzheimer disease-CBS than in amnestic Alzheimer presentations.

Behavioral dysfunction is present at some point in the course of most patients with Alzheimer disease. The most common symptoms are not only depressive, principally with apathy, but also irritability, agitation, insomnia, hypersomnia, decreased or increased food intake, dependency, disinhibition, and repetitive or compulsive activities. These symptoms, in some cases, likely relate to neuroanatomic changes but, in other cases, may represent reactive changes to cognitive incapacities. The most common psychotic symptoms in Alzheimer include periods of agitation when patients become convinced of their delusions. Auditory or visual hallucinations may occur in Alzheimer disease but should prompt consideration of an

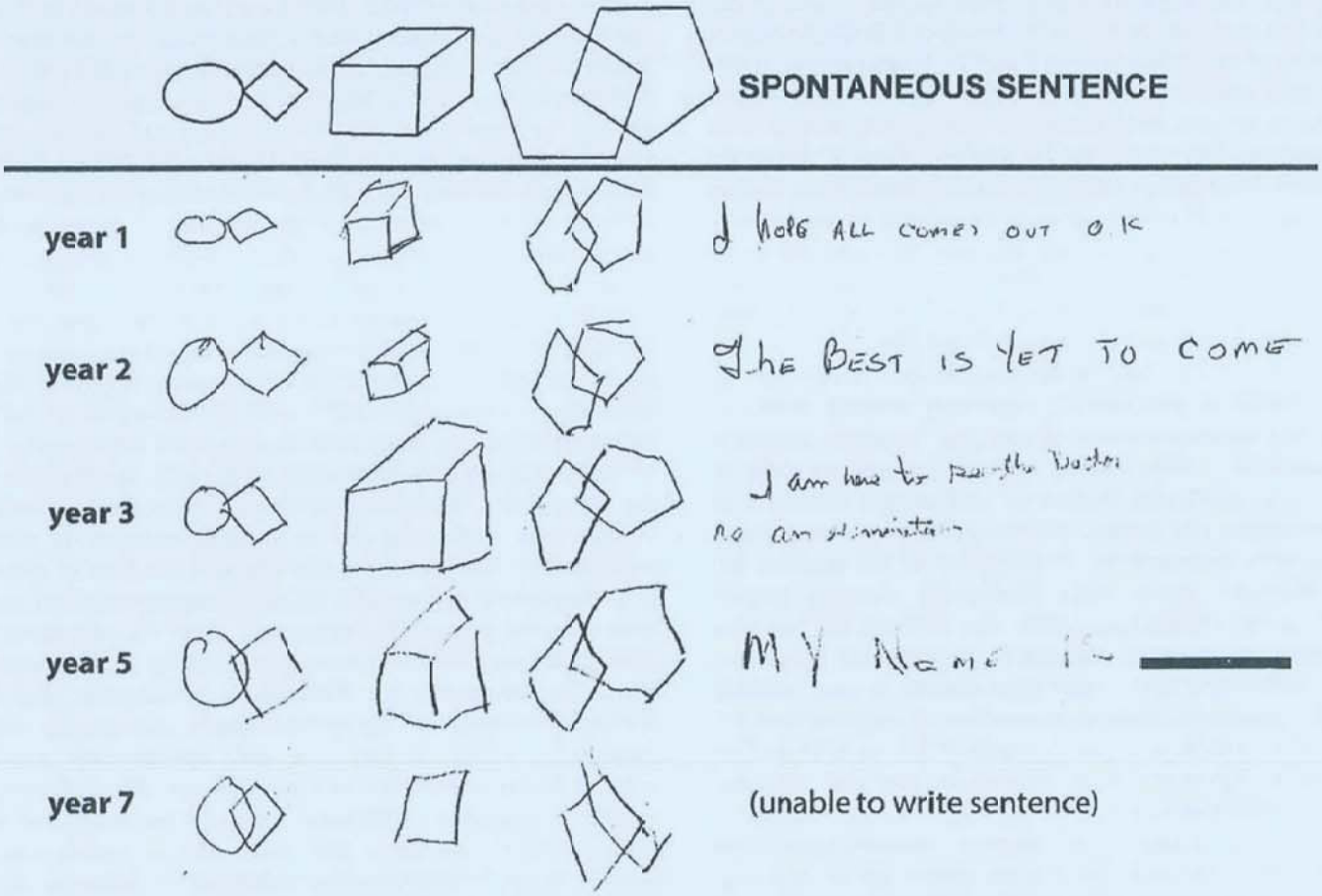

FIGURE 51.3 Mental status testing in a patient with memory problems, for whom a diagnosis of Alzheimer disease was made in year 1. Over a 7-year period, the drawings show increasing impairment in constructional praxis—the ability to copy figures. **Top row** shows example provided to the patient, and subsequent rows are the patient's performance initially and in succeeding years. The patient was also asked each visit to write a full sentence of his or her choice. There is increasing difficulty with both penmanship and content.

alternative explanation or a copathology. Delusions frequently have paranoid ideation regarding theft or infidelity and also may involve misidentification of place or person; they are much more common than hallucinations. The presence of detailed visual hallucinations, in the absence of concomitant primary visual system disease, should be a clue as to involvement of Lewy body dementia (see Chapter 53) as primary (diffuse Lewy body disease) or contributing (Lewy body variant of Alzheimer disease) dementia disorders.

Functional decline results from both cognitive and behavioral features. Loss of employment, financial difficulties, marital or other family dysfunction, driving difficulties, and difficulties learning new technologies such as automobile controls, home entertainment device remote controls, computers, or home security systems are frequent.

Examination of the patient with Alzheimer disease typically reveals only impairments in mental state. The remainder of the neurologic examination is usually normal, especially in the mild to moderate stages. In the later stages of the disease, parkinsonian signs, including rigidity, bradykinesia, shuffling gait, and postural change, are not uncommon. These features may in some cases be solely a consequence of Alzheimer disease but in other cases may relate to concomitant involvement of Lewy body dementia (see Chapter 53). Primary motor and sensory functions are typically spared. Early symptoms of seizures or falling, or early signs of cortical motor or sensory dysfunction, cranial or motor neuropathies, or cerebellar dysfunction, should all strongly raise the possibility of some other form of dementia (see Chapter 12).

Diagnostic Testing

Neuropsychological Testing

Neuropsychological testing is useful in establishing the extent of cognitive impairment in terms of domains affected and in terms of degree of affectation compared to persons of comparable age, sex, and education (normative results). Examination of test results in comparison to persons of a similar group allows for better assessment than results on an absolute basis because of the general wide variation in performance on these tests, which relate in large part to education (see Chapter 31). Such testing can also be very useful in following progression of disease, particularly in early stage disease, to distinguish trajectories from normal aging or when depression is present.

Laboratory Testing and Neuroimaging

Routine laboratory examinations of blood, urine, and CSF are unremarkable in Alzheimer disease. Electroencephalography and other neurophysiologic measures are nonspecific, revealing background rhythm slowing or other changes not diagnostic of any particular brain condition. Likewise, routine imaging by CT or MRI does not reveal gross structural abnormalities other than atrophy, particularly early in the course of the disease. Later in the disease, significant cortical and subcortical atrophy, although not entirely specific, is typically observed (Fig. 51.4). Often in Alzheimer disease, a regional pattern atrophy involving temporal, parietal, and to a lesser extent frontal regions, can be apparent, often represents earliest and most involved neuropathologic Alzheimer changes can be seen. However, many pathologically proven cases do not show consistent patterns. Regional cortical

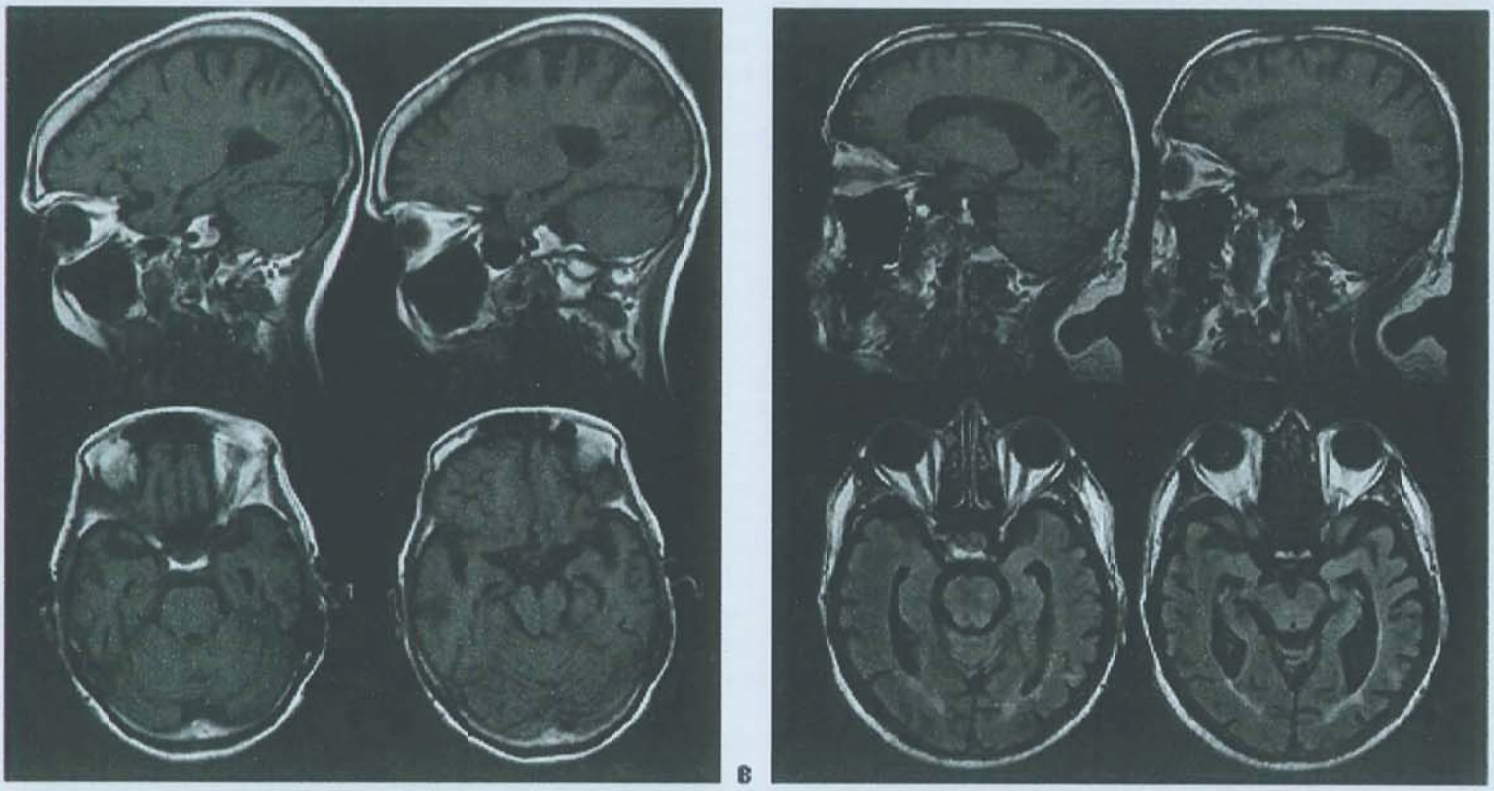

FIGURE 51.4 Magnetic resonance imaging T1-weighted structural images from two patients (**A** and **B**) with Alzheimer disease, including in each patient selected sagittal (**top rows**) and axial (**bottom rows**) images. **A** shows a pattern of atrophy most prominent in parietal regions. **B** shows a pattern of atrophy more prominent in temporal regions.

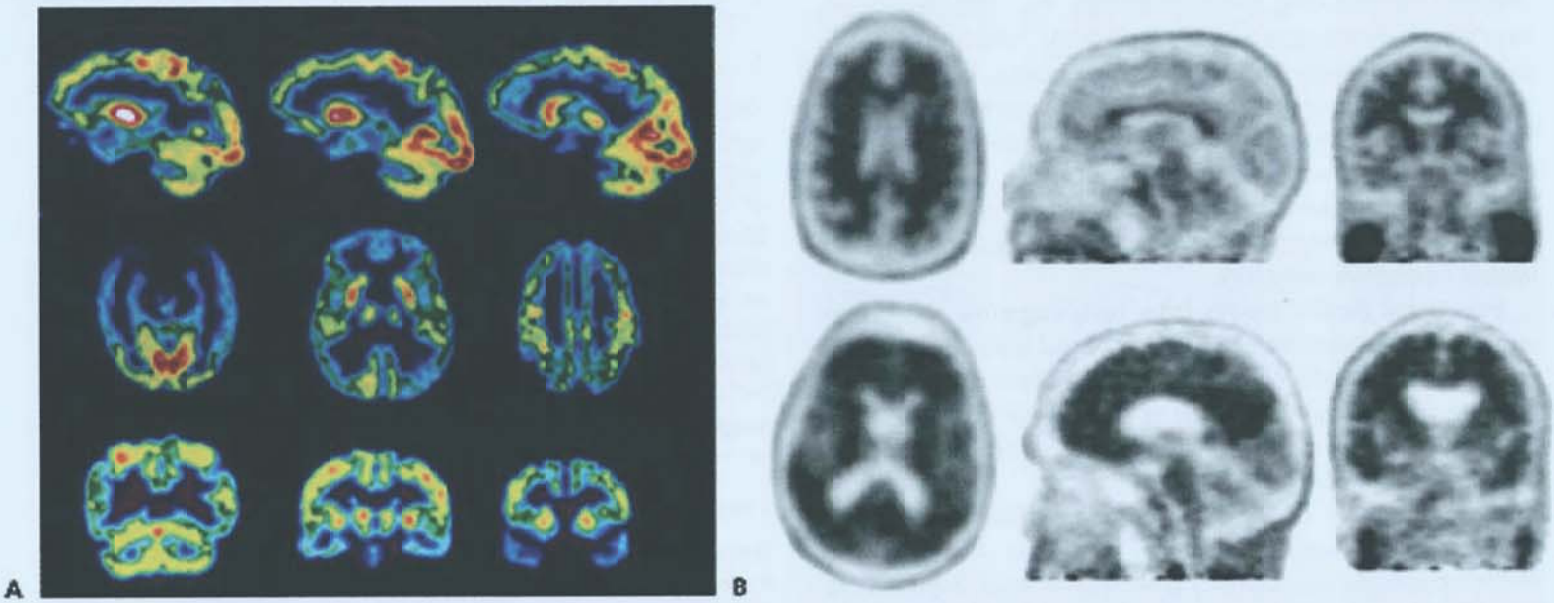

FIGURE 51.5 **A** shows images from a single patient who underwent an ^{18}F-fluorodeoxyglucose positron emission tomography scan. **Top row** shows sagittal sections, **middle row** axial sections, and **bottom row** coronal sections. The images demonstrate decreased brain metabolic activity in bilateral parietal, temporal, and to a lesser extent frontal regions. Note that in this color coding scheme, "cooler" colors such as *green* and *blue* are lower activity, and "hotter" colors such as *yellow*, *red*, and *white* are higher activity. **B** shows ^{18}F-florbetapir positron emission tomography scan in two individuals, with a *black* and *white* image display scheme, in which blacker represents higher uptake of florbetapir. Each row shows an example of an axial, sagittal, and coronal brain imaging slice. The **top row** is of a normal control individual who shows cerebral uptake of the radioligand only in the white matter. The **bottom row** shows the images of patient with Alzheimer disease, who shows extensive gray matter uptake of the radioligand throughout cerebral cortex including frontal, temporal, and parietal regions and basal ganglia.

thinning is also identifiable on MRIs but is limited to research settings at present.

Most importantly, it has become clear that both CSF and functional brain imaging, often when used together along with structural imaging, can serve as relatively sensitive and specific markers of Alzheimer disease (as covered here in subsequent "Biomarker-Based Assessments" section, Fig. 51.5, as well as Chapter 12) and can be of use in the differential diagnosis of this disorder.

Genetic tests are generally not recommended for diagnosis of Alzheimer disease. However, selected testing may be useful in the diagnosis in families with the rare early-onset autosomal dominant forms of Alzheimer disease. For sporadic or familial late-onset Alzheimer disease, the $\varepsilon 4$ polymorphism of the *APOE* gene is associated with a higher risk of the disease, but because at least one-third of persons with Alzheimer have no $\varepsilon 4$ alleles, and because some persons with even two $\varepsilon 4$ alleles are symptom free even in their 10th decade of life, the test does not provide sufficient sensitivity or specificity to be used for diagnosis and is not recommended.

Biomarker-Based Assessments

Measurements of CSF proteins (see Chapter 32) are established to be of use in the diagnosis of Alzheimer disease. Typically in Alzheimer disease, $A\beta_{42}$ is decreased in concentration, perhaps related in part to deposition of amyloid in the brain. Total tau protein is typically elevated, relating presumably to neurodegeneration and loss of axonal integrity. Phosphorylated tau is also elevated and more specific for Alzheimer disease because in this disorder, the tau protein is abnormally phosphorylated. Combined measures of the concentrations of these three biomarkers results in sensitivity and specificity each in the range of 90%. Of note, it is clear that changes in $A\beta_{42}$, tau, and phosphorylated tau can precede clinical symptoms and diagnosis of disease by up to 15 years. Blood analytes in serum or plasma have particular appeal as a noninvasive means of potentially establishing an Alzheimer disease diagnosis and monitoring progression or response to therapy. Plasma $A\beta_{40}$ and $A\beta_{42}$ measures are now commercially available in some areas. Some metrics of specific plasma phosphorylated tau isoforms have been especially predictive of cognitive decline in research settings and may be on the horizon for eventual clinical applications.

Brain imaging has become important in diagnosis of Alzheimer disease, can aid in early detection of disease, and may be helpful in research studies following treatment of the disease. Brain imaging includes "structural" imaging, "functional" imaging, and "molecular" imaging. Structural imaging techniques including CT and MRI are used to exclude other causes of dementia, such as tumors or strokes. However, in Alzheimer disease, structural imaging typically reveals dilatation of the lateral ventricles and widening of the cortical sulci, particularly in temporal and parietal regions (see Fig. 51.4). Such cortical atrophy is not specific for Alzheimer disease because it can be seen in some older individuals who function normally by clinical and neuropsychological testing. MRI approaches have been developed to measure precise volumetric changes in the brain, and these can be useful in differentiating Alzheimer disease from frontotemporal dementia and have been used in monitoring therapies with investigational drugs (see Chapter 22). Functional brain imaging techniques include single-photon emission

computed tomography (SPECT), PET, and functional magnetic resonance imaging (fMRI) (see Chapters 22 and 23). Although using different technologies, functional imaging techniques hold in common a sensitivity to brain metabolism—either glucose uptake in the case of ^{18}F-fluorodeoxyglucose PET or the closely correlated blood flow measures examined by technetium 99m hexamethyl-propylene-aminoxime-SPECT or fMRI. Studies using PET or SPECT reveal a characteristic pattern of hypometabolism and hypoperfusion in the mesial temporal and posterior parietal lobes, with preservation of function of the deep gray nuclei and the primary sensory and motor cortices (see **Fig. 51.5A**). With the superior spatial resolution afforded by fMRI, studies have begun to map patterns of dysfunction in smaller brain subregions of the medial temporal lobe, the general area where the disease is thought to begin. Within the hippocampal formation, high-resolution fMRI has shown that, in contrast to the early stages of Alzheimer disease that target the entorhinal cortex, normal aging involves the dentate gyrus, a neighboring hippocampal subregion. Finally, the most recent development in brain imaging is being able to detect the molecular features of Alzheimer disease: amyloid-containing plaques and neurofibrillary tangles. The first such molecular imaging reagent for detecting neuritic plaques in vivo was "Pittsburgh compound B" (whose chemical formulation is ^{11}C-6-OH-benzothazole-1), but there are currently three approved ^{18}F-labeled reagents: florbetapir, florbetaben, and flutemetamol, all of which have been shown through clinical and autopsy studies to show cortical binding of radioligand in Alzheimer disease (see **Fig. 51.5B**). The absence of cortical binding is inconsistent with Alzheimer disease. However, as might be expected for a disease that starts with small amounts of asymptomatic $A\beta_{42}$ deposition, a substantial fraction of clinically normal elders (eg, about 25% of those older than age 65 y, with increasing proportions in older age groups) do have some binding, consistent with the possibility that they may later develop Alzheimer disease. Most recently, an ^{18}F-labeled reagent flortaucipir for neurofibrillary tau is approved for use based on a high sensitivity and modest specificity for the presence of Alzheimer tau changes. In the United States, presently, amyloid and tau imaging have limited application because they are not supported by most if not all health insurance programs. Additional investigational radioligands for tau, inflammatory signal, and as well as SPECT and PET radiopharmaceutical reagents to examine dopaminergic systems, promise a greater armamentarium of advanced molecular imaging biomarkers that may assist in early diagnosis and assessment of disease.

MANAGEMENT

Therapies for Alzheimer disease are currently symptomatic and palliative, because there are no proven disease-modifying treatments, although some appear to be on the horizon. Nonspecific treatments for secondary symptoms of Alzheimer disease can be useful. These include treatment of depressive symptomatology with antidepressants including selective serotonin reuptake inhibitors. Likewise, treatment of psychotic symptoms such delusions and hallucinations as well as agitation and irritability can be managed with judicious use of antipsychotic medications. Side effects of these medications can be limiting, including drug-induced parkinsonism. Neuroleptics have, in some studies but not others, been associated with small increases in mortality from various causes. Anxiolytics such as benzodiazepines may also be used but are generally avoided due to adverse effects on cognition. Despite potential risks, pharmacologic treatment of behavioral symptoms with neuroleptics can be of major help to patients and their caregivers.

TABLE 51.2 Treatments of Alzheimer Disease[a]

Medication	Dosages	Presumed Mechanism
Donepezil hydrochloride	5-10 mg/d PR or 23 mg/d ER oral	Cholinesterase inhibition
Galantamine hydrobromide	8-24 mg/d PR or ER oral	Cholinesterase inhibition
Rivastigmine tartrate	3-12 mg/d oral or 4.5-13.3 mg/d transdermal	Cholinesterase inhibition
Memantine hydrochloride	5-20 mg/d PR or 7-28 mg/d ER oral	NMDA receptor inhibition

Abbreviations: ER, extended release; NMDA, *N*-methyl-D-aspartate; PR, prompt release.

[a]List of medications approved by the U.S. Food and Drug Administration specifically for Alzheimer disease. Donepezil and rivastigmine are labeled for use in mild, moderate, and severe disease; galantamine is labeled for use in mild and moderate disease; memantine is labeled for use only in moderate and severe disease. Donepezil and memantine are also marketed as combination therapies.

There are five disease-specific treatments available for Alzheimer at this time. These five medications are symptomatic and do not appear to modify disease course but have received U.S. Food and Drug Administration approval for specific treatment of the disease (**Table 51.2**) on the basis of level 1 randomized placebo-controlled trials. Four of these are cholinesterase inhibitors, which effectively increase synaptic levels of brain acetylcholine through inhibition of synaptic acetylcholinesterase, which normally hydrolyzes acetylcholine released from the presynaptic neuron into the synaptic cleft. Tacrine was the first such drug LEVEL 3,[1] but it is no longer in common use due to 4 times daily dosing and hepatotoxicity; it has only limited availability internationally at this point. The three cholinesterase inhibitors currently in common use are donepezil LEVEL 1,[2-4] rivastigmine LEVEL 1,[5] and galantamine LEVEL 1.[6] The evidence is that these three have similar mild efficacy in improving cognition and may also cause small improvements in behavior and function in patients with mild, moderate, or severe Alzheimer disease (see "Level 1 Evidence" in the following section). One other drug, memantine, has been approved for treatment only of moderate to severe Alzheimer disease, for which there is level 1 evidence LEVEL 1,[7,8] whereas such evidence is lacking for mild disease. Memantine is an activity-dependent *N*-methyl-D-aspartate receptor antagonist and provides an independent modest benefit in cognition, behavior, and function in persons with moderate to severe disease. This benefit occurs in both settings of monotherapy LEVEL 1[7] and concomitant therapy with cholinesterase inhibitors LEVEL 1[8] in such patients.

Disease-modifying treatments are not yet available. However, the increasing understanding of Alzheimer disease as a disorder characterized by accumulation of β-amyloid, and tau aggregates has given rise to a significant number of experimental drugs that have been studied or are currently under investigation. Current approaches to potentially ameliorating the course of Alzheimer disease include monoclonal antibodies or active immunizations designed to clear amyloid protein from the brain, β-secretase inhibitors designed to decrease intracerebral generation of β-amyloid, and other therapies proposed

to deter tau aggregation or neuronal dysfunction. As noted in the chapter on mild cognitive impairment (see Chapter 50) and earlier in this chapter, although there is much interest in Alzheimer's preventative strategies, epidemiologic associations with potentially protective adulthood habits (eg, diet, exercise, and cognitive leisure) have not translated into prevention or slowing cognitive decline in randomized trials. From a broader neurologic perspective, it remains important in patients with Alzheimer disease that medical diseases are addressed, such as appropriate management of hypertension and diabetes, in an effort to appropriately reduce the risk of stroke and related complications. Standard advice regarding nutrition and physical activity may portend to better general health and control of cardiovascular risk factors in aging patients independent of potential impact on Alzheimer disease.

OUTCOME

When persons live long enough with disease, the continuous process of Alzheimer changes results in complete incapacity, and ultimately death, from conditions associated with and complications of severe cognitive dysfunction and immobility. As the disease progresses, supportive care measures become increasingly important for both patient and caregiver, often focused on maintaining some progressively smaller modicum of independence while avoiding catastrophic injury. Complications of falls, other accidents, and hospitalizations can dramatically accelerate subsequent clinical decline and impairment. The final chapter of this book (see Chapter 158) extensively covers many end-of-life care decisions in advance of and including supportive and hospice care, which come to dominate the terminal period of Alzheimer disease. The overall course from first symptoms to death is often as long as 20 years. Typically, diagnosis is not made until the disease is well established clinically, but on a molecular basis in CSF or neuroimaging, it can now be identified years prior to first symptoms. Although it is common for clinical disease to progress at different rates person to person, it is unlikely that there is truly any "plateau" or temporary cessation of neuropathologic progression. The field remains hopeful that one of the many approaches in development, nearly all of which are focused on developing disease modifying therapy, will substantially slow or prevent decline in Alzheimer disease.

LEVEL 1 EVIDENCE

1. Davis KL, Thal LJ, Gamzu ER, et al. A double-blind, placebo-controlled multicenter study of tacrine for Alzheimer's disease. The Tacrine Collaborative Study Group. *N Engl J Med*. 1992;327:1253-1259.
2. Rogers SL, Friedhoff LT. The efficacy and safety of donepezil in patients with Alzheimer's disease: results of a US multicentre, randomized, double-blind, placebo-controlled trial. The Donepezil Study Group. *Dementia*. 1996;7:293-303.
3. Rogers SL, Doody RS, Mohs RC, Friedhoff LT. Donepezil improves cognition and global function in Alzheimer disease: a 15-week, double-blind, placebo-controlled study. Donepezil Study Group. *Arch Intern Med*. 1998;158:1021-1031.
4. Winblad B, Engedal K, Soininen H, et al; for Donepezil Nordic Study Group. A 1-year, randomized, placebo-controlled study of donepezil in patients with mild to moderate AD. *Neurology*. 2001;57:489-495.
5. Rösler M, Anand R, Cicin-Sain A, et al. Efficacy and safety of rivastigmine in patients with Alzheimer's disease: international randomised controlled trial. *BMJ*. 1999;318:633-638.
6. Wilkinson D, Murray J. Galantamine: a randomized, double-blind, dose comparison in patients with Alzheimer's disease. *Int J Geriatr Psychiatry*. 2001;16:852-857.
7. Reisberg B, Doody R, Stöffler A, Schmitt F, Ferris S, Möbius HJ; for Memantine Study Group. Memantine in moderate-to-severe Alzheimer's disease. *N Engl J Med*. 2003;348:1333-1341.
8. Tariot PN, Farlow MR, Grossberg GT, Graham SM, McDonald S, Gergel I; for Memantine Study Group. Memantine treatment in patients with moderate to severe Alzheimer disease already receiving donepezil: a randomized controlled trial. *JAMA*. 2004;291:317-324.

SUGGESTED READINGS

Albert MS, DeKosky ST, Dickson D, et al. The diagnosis of mild cognitive impairment due to Alzheimer's disease: recommendations from the National Institute on Aging-Alzheimer's Association workgroups on diagnostic guidelines for Alzheimer's disease. *Alzheimers Dement*. 2011;7:270-279.

Arboleda-Velasquez JF, Lopera F, O'Hare M, et al. Resistance to autosomal dominant Alzheimer's disease in an *APOE3*-Christchurch homozygote: a case report. *Nat Med*. 2019;25(11):1680-1683.

Ashton NJ, Hye A, Rajkumar AP, et al. An update on blood-based biomarkers for non-Alzheimer neurodegenerative disorders. *Nat Rev Neurol*. 2020;16(5):265-284.

Barthélemy NR, Li Y, Joseph-Mathurin N, et al; and Dominantly Inherited Alzheimer Network. A soluble phosphorylated tau signature links tau, amyloid and the evolution of stages of dominantly inherited Alzheimer's disease. *Nat Med*. 2020;26(3):398-407.

Besser LM, Teylan MA, Nelson PT. Limbic predominant age-related TDP-43 encephalopathy (LATE): clinical and neuropathological associations. *J Neuropathol Exp Neurol*. 2020;79(3):305-313.

Boyle PA, Yu L, Leurgans SE, et al. Attributable risk of Alzheimer's dementia attributed to age-related neuropathologies. *Ann Neurol*. 2019;85(1):114-124.

Boyle PA, Yu L, Wilson RS, Leurgans SE, Schneider JA, Bennett DA. Person-specific contribution of neuropathologies to cognitive loss in old age. *Ann Neurol*. 2018;83(1):74-83.

Carrillo MC, Rowe CC, Szoeke C, et al; for NIA/Alzheimer Association and International Working Group. Research and standardization in Alzheimer's trials: reaching international consensus. *Alzheimers Dement*. 2013;9:160-168.

Crary JF, Trojanowski JQ, Schneider JA, et al. Primary age-related tauopathy (PART): a common pathology associated with human aging. *Acta Neuropathol*. 2014;128(6):755-766.

Cummings J, Lee G, Ritter A, Sabbagh M, Zhong K. Alzheimer's disease drug development pipeline: 2020. *Alzheimers Dement (N Y)*. 2020;6(1):e12050.

Farina N, Isaac MG, Clark AR, Rusted J, Tabet N. Vitamin E for Alzheimer's dementia and mild cognitive impairment. *Cochrane Database Syst Rev*. 2012;(11):CD002854.

Fleisher AS, Pontecorvo MJ, Devous MD Sr, et al; for A16 Study Investigators. Positron emission tomography imaging with [^{18}F]flortaucipir and postmortem assessment of Alzheimer disease neuropathologic changes. *JAMA Neurol*. 2020;77(7):829-839.

Frisoni GB, Bocchetta M, Chételat G, et al; for ISTAART's NeuroImaging Professional Interest Area. Imaging markers for Alzheimer disease: which vs how. *Neurology*. 2013;81:487-500.

Grøntvedt GR, Lauridsen C, Berge G, et al. The amyloid, tau, and neurodegeneration (A/T/N) classification applied to a clinical research cohort with long-term follow-up. *J Alzheimers Dis*. 2020;74(3):829-837.

Hardy J, Bogdanovic N, Winblad B, et al. Pathways to Alzheimer's disease. *J Intern Med*. 2014;275:296-303.

Hickman RA, Flowers XE, Wisniewski T. Primary age-related tauopathy (PART): addressing the spectrum of neuronal tauopathic changes in the aging brain. *Curr Neurol Neurosci Rep*. 2020;20(9):39.

Hill DL, Schwarz AJ, Isaac M, et al. Coalition Against Major Diseases/European Medicines Agency biomarker qualification of hippocampal volume for enrichment of clinical trials in predementia stages of Alzheimer's disease. *Alzheimers Dement*. 2014;10:421-429.

Hyman BT, Phelps CH, Beach TG, et al. National Institute on Aging-Alzheimer's Association guidelines for the neuropathologic assessment of Alzheimer's disease. *Alzheimers Dement*. 2012;8:1-13.

Jack CR Jr, Barrio JR, Kepe V. Cerebral amyloid PET imaging in Alzheimer's disease. *Acta Neuropathol*. 2013;126:643-657.

Jack CR Jr, Bennett DA, Blennow K, et al. A/T/N: an unbiased descriptive classification scheme for Alzheimer disease biomarkers. *Neurology*. 2016; 87(5):539-547.

Jack CR Jr, Holtzman DM. Biomarker modeling of Alzheimer's disease. *Neuron*. 2013;80:1347-1358.

Jonsson T, Atwal JK, Steinberg S, et al. A mutation in APP protects against Alzheimer's disease and age-related cognitive decline. *Nature*. 2012;488:96-99.

Kantarci K. Molecular imaging of Alzheimer disease pathology. *AJNR Am J Neuroradiol*. 2014;35:S12-S17.

Karch CM, Goate AM. Alzheimer's disease risk genes and mechanisms of disease pathogenesis. *Biol Psychiatry*. 2015;77(1):43-51.

Klunk WE. Amyloid imaging as a biomarker for cerebral β-amyloidosis and risk prediction for Alzheimer dementia. *Neurobiol Aging*. 2011;32(suppl 1):S20-S36.

Kongpakwattana K, Sawangjit R, Tawankanjanachot I, Bell JS, Hilmer SN, Chaiyakunapruk N. Pharmacological treatments for alleviating agitation in dementia: a systematic review and network meta-analysis. *Br J Clin Pharmacol*. 2018;84(7):1445-1456.

Kovacs GG, Ferrer I, Grinberg LT, et al. Aging-related tau astrogliopathy (ARTAG): harmonized evaluation strategy. *Acta Neuropathol*. 2015;131(1):87-102.

Lannfelt L, Relkin NR, Siemers ER. Amyloid-β-directed immunotherapy for Alzheimer's disease. *J Intern Med*. 2014;275:284-295.

Lyketsos CG, Carrillo MC, Ryan JM, et al. Neuropsychiatric symptoms in Alzheimer's disease. *Alzheimers Dement*. 2011;7:532-539.

Maurer K, Volk S, Gerbaldo H. Auguste D and Alzheimer's disease. *Lancet*. 1997;349(9064):1546-1549.

Mayeux R, Stern Y. Epidemiology of Alzheimer disease. *Cold Spring Harb Perspect Med*. 2012;2:a006239.

McDade E, Wang G, Gordon BA, et al; for Dominantly Inherited Alzheimer Network. Longitudinal cognitive and biomarker changes in dominantly inherited Alzheimer disease. *Neurology*. 2018;91(14):e1295-e1306.

McKhann G, Drachman D, Folstein M, Katzman R, Price D, Stadlan EM. Clinical diagnosis of Alzheimer's disease: report of the NINCDS-ADRDA Work Group under the auspices of Department of Health and Human Services Task Force on Alzheimer's Disease. *Neurology*. 1984;34:939-944.

McKhann GM, Knopman DS, Chertkow H, et al. The diagnosis of dementia due to Alzheimer's disease: recommendations from the National Institute on Aging-Alzheimer's Association workgroups on diagnostic guidelines for Alzheimer's disease. *Alzheimers Dement*. 2011;7:263-269.

Morris JC, Blennow K, Froelich L, et al. Harmonized diagnostic criteria for Alzheimer's disease: recommendations. *J Intern Med*. 2014;275:204-213.

Mukadam N, Sommerlad A, Huntley J, Livingston G. Population attributable fractions for risk factors for dementia in low-income and middle-income countries: an analysis using cross-sectional survey data. *Lancet Glob Health*. 2019;7(5):e596-e603.

Nelson PT, Alafuzoff I, Bigio EH, et al. Correlation of Alzheimer disease neuropathologic changes with cognitive status: a review of the literature. *J Neuropathol Exp Neurol*. 2012;71:362-381.

Nelson PT, Dickson DW, Trojanowski JQ, et al. Limbic-predominant age-related TDP-43 encephalopathy (LATE): consensus working group report. *Brain*. 2019;142(6):1503-1527.

Noble JM, Scarmeas N. Application of PET imaging to diagnosis of Alzheimer's disease and mild cognitive impairment. *Int Rev Neurobiol*. 2009;84: 133-149.

Noble JM, Schupf N, Manly JJ, Andrews H, Tang MX, Mayeux R. Secular trends in the incidence of dementia in a multi-ethnic community. *J Alzheimers Dis*. 2017;60(3):1065-1075.

Nolan A, De Paula Franca Resende E, Petersen C, et al. Astrocytic tau deposition is frequent in typical and atypical Alzheimer disease presentations. *J Neuropathol Exp Neurol*. 2019;78(12):1112-1123.

Palmqvist S, Janelidze S, Quiroz YT, et al. Discriminative accuracy of plasma phospho-tau217 for Alzheimer disease vs other neurodegenerative disorders. *JAMA*. 2020;324(8):772-781.

Power MC, Mormino E, Soldan A, et al. Combined neuropathological pathways account for age-related risk of dementia. *Ann Neurol*. 2018;84(1):10-22.

Reitz C, Mayeux R. Alzheimer disease: epidemiology, diagnostic criteria, risk factors and biomarkers. *Biochem Pharmacol*. 2014;88:640-651.

Rupp C, Beyreuther K, Maurer K, Kins S. A presenilin 1 mutation in the first case of Alzheimer's disease: revisited. *Alzheimers Dement*. 2014;10(6): 869-872.

Sakae N, Josephs KA, Litvan I, et al. Clinicopathologic subtype of Alzheimer's disease presenting as corticobasal syndrome. *Alzheimers Dement*. 2019;15(9): 1218-1228.

Simrén J, Ashton NJ, Blennow K, Zetterberg H. An update on fluid biomarkers for neurodegenerative diseases: recent success and challenges ahead. *Curr Opin Neurobiol*. 2020;61:29-39.

Small SA. Imaging Alzheimer's disease. *Curr Neurol Neurosci Rep*. 2003;3: 385-392.

Sperling RA, Aisen PS, Beckett LA, et al. Toward defining the preclinical stages of Alzheimer's disease: recommendations from the National Institute on Aging-Alzheimer's Association workgroups on diagnostic guidelines for Alzheimer's disease. *Alzheimers Dement*. 2011;7:280-292.

Steinerman JR, Honig LS. Laboratory biomarkers in Alzheimer disease. *Curr Neurol Neurosci Rep*. 2007;7:381-387.

Vellas B, Carrillo MC, Sampaio C, et al; for EU/US/CTAD Task Force Members. Designing drug trials for Alzheimer's disease: what we have learned from the release of the phase III antibody trials: a report from the EU/US/CTAD Task Force. *Alzheimers Dement*. 2013;9:438-444.

Verghese PB, Castellano JM, Holtzman DM. Apolipoprotein E in Alzheimer's disease and other neurological disorders. *Lancet Neurol*. 2011;10:241-252.

Weintraub S, Wicklund AH, Salmon DP. The neuropsychological profile of Alzheimer disease. *Cold Spring Harb Perspect Med*. 2012;2:a006171.

Wisniewski T, Goñi F. Immunotherapy for Alzheimer's disease. *Biochem Pharmacol*. 2014;88:499-507.

Frontotemporal Dementia 52

Edward D. Huey, Megan S. Barker, and Stephanie Cosentino

KEY POINTS

1. Frontotemporal dementia (FTD) most commonly presents as a disorder of behavior and executive function (behavioral variant).
2. FTD can also manifest as a disorder of language (primary progressive aphasia).
3. Primary progressive aphasia can be further classified into nonfluent, semantic, and logopenic variants.
4. FTD is associated with cortical volume loss in frontal and anterior temporal lobes with relative sparing of posterior parietal and occipital cortex.
5. The three major genetic causes of FTD are mutations in the *MAPT*, *C9orf72*, and *GRN* genes.

INTRODUCTION

Frontotemporal dementia (FTD) is the most common clinical presentation of frontotemporal lobar degeneration (FTLD). FTLD is clinically and pathologically heterogeneous and also includes corticobasal degeneration (CBD), progressive supranuclear palsy (PSP), Pick disease, and amyotrophic lateral sclerosis (ALS) as well as several rare FTLD-related tauopathies (eg, argyrophilic grain disease, multiple system tauopathy with dementia). The term *FTLD* generally denotes pathologic diagnosis, whereas FTD describes a clinical spectrum. Two main FTD phenotypes are seen. One form is primarily a disorder of behavior and executive function (behavioral variant FTD [bvFTD]), and the second, less frequent form is primarily a disorder of language, termed *primary progressive aphasia* (PPA) and defined by predominant language impairment for at least 2 years. Classifications of PPA include nonfluent variant/agrammatic (nfvPPA), semantic variant (svPPA), and logopenic variant (lvPPA). Cases of "mixed" PPA have also been reported. Combinations of behavioral and language symptoms that do not fit clearly into defined clinical subtypes reflect overlapping distributions of neuropathology in prefrontal and anterior temporal regions and can be present at disease onset but typically become more frequent with advancing disease severity.

EPIDEMIOLOGY

Overall, FTD (including both behavioral and language phenotypes) is the fourth most common dementia (behind Alzheimer disease [AD], vascular dementia, and dementia with Lewy bodies), affecting 1% to 16% of all people with dementia. FTD is the most common dementia prior to age 60 years and approaches the prevalence of AD prior to age 65 years. Approximately, 60% of cases occur in individuals aged 45 to 64 years, while individuals aged 65 years and older comprise 20% to 25% of all cases. Although we do not yet have definitive epidemiologic studies, the estimated point prevalence of FTD in individuals younger than 65 years, based on studies primarily including Caucasians in North America and Europe, is 7 to 30/100,000. Of these, 20% to 40% demonstrate some aspect of PPA. Most studies implicate an equal distribution by gender, although there are reports that bvFTD and svPPA are more common in males, whereas nfvPPA is more common in females. It is currently unknown how the prevalence of FTD differs across ethic groups. When interpreting prevalence estimates, it is important to note that lvPPA was only added as a third PPA classification in 2011 and is most commonly associated with AD rather than FTLD pathology. Prior to 2011, studies categorized cases of PPA into semantic and nonfluent variants, or as "fluent" versus "nonfluent," and these binary categories captured cases that would go on to be reclassified as lvPPA. Therefore, the majority of studies reporting on the prevalence of FTD likely include cases of lvPPA in their estimates.

PATHOBIOLOGY

Gross frontal and temporal lobe atrophy is usually evident in FTLD (a pathologic diagnosis, not necessarily corresponding to a clinical diagnosis of FTD) patients at autopsy, with histopathology revealing neuronal loss and gliosis affecting superficial cortical lamina of these same cortical regions, along with absence of the typical pathologic findings of AD (except in the case of lvPPA). FTLD encompasses several different pathologies, including neuronal inclusions containing TAR DNA-binding protein 43 (TDP-43), tau isoforms, and fused in sarcoma/translocated in liposarcoma (FUS/TLS) protein. Some individuals will have clinical and/or pathologic evidence of ALS. ALS is most commonly associated with bvFTD but can co-occur with any of the clinical presentations of FTD (eg, PPA). As demonstrated in Figure 52.1, several gene mutations associated with FTLD result in specific neuropathologies and sometimes specific clinical presentations. Therefore, the clinician can infer the neuropathology based on some (eg, when ALS is present in the context of bvFTD), but not other (eg, lvPPA), clinical presentations.

Fewer than half of all bvFTD patients will demonstrate prominent tau aggregates, whereas approximately half of bvFTD patients will stain for ubiquitin, a nonspecific marker of cell death. However, the breakdown of pathologies across clinical subtypes differs. For example, while FTLD-tau is the most common pathology in bvFTD and nfvPPA phenotypes, TDP-43 pathology is the most common pathology in svPPA.

A major FTLD subtype associated with tau aggregates is Pick disease. First described by Alois Alzheimer, Pick disease is characterized by argyrophilic cytoplasmic tau inclusions (Pick bodies) and swollen neurons (Pick cells). Ubiquitin-positive cases of FTLD were recently discovered to be characterized by inclusions composed of aggregates of TDP-43 and more rarely

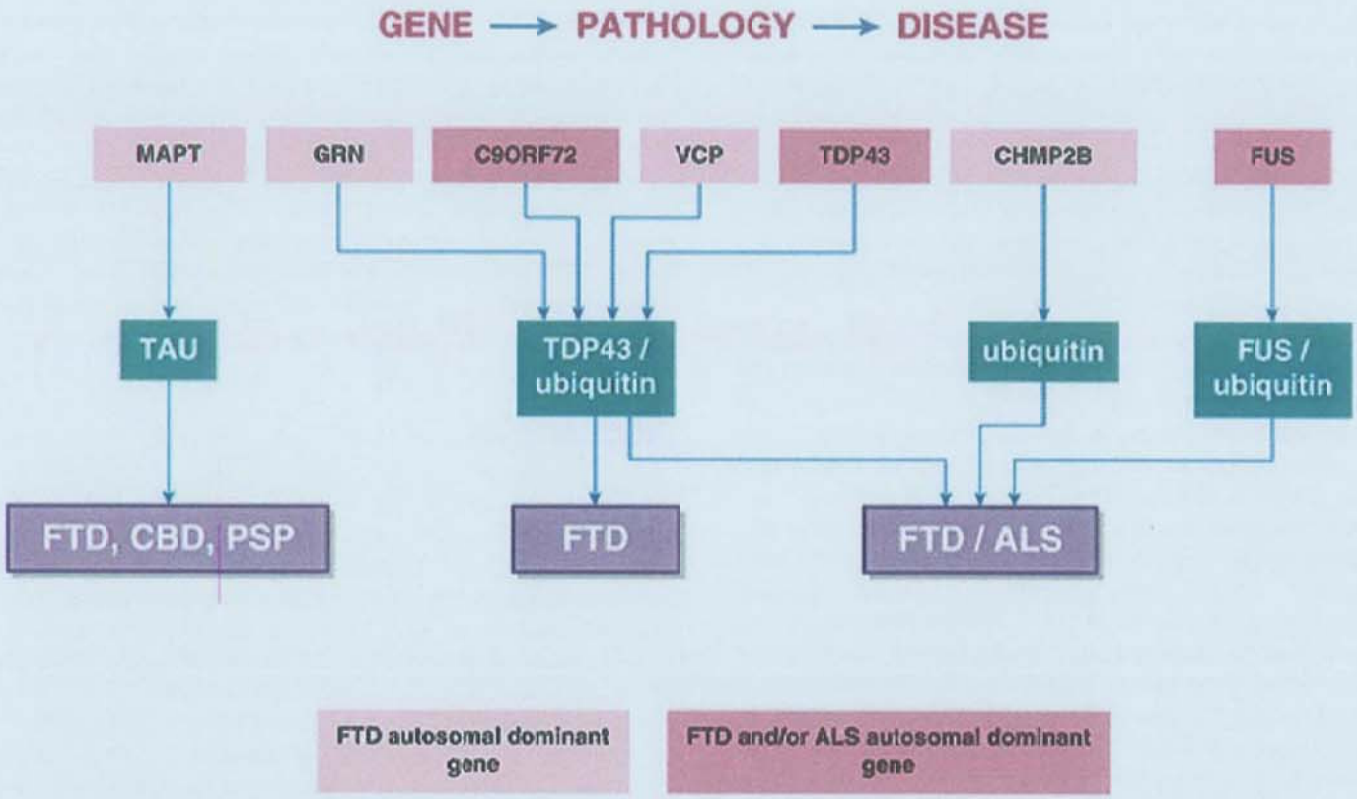

FIGURE 52.1 Association between pathologic, genetic, and clinical variants of frontotemporal dementia (FTD). Abbreviations: ALS, amyotrophic lateral sclerosis; CBD, corticobasal degeneration; PSP, progressive supranuclear palsy.

FUS. The clinical presentation of FTD-ALS is associated with TDP-43–positive FTLD (see Fig. 52.1).

GENETICS

An estimated 40% to 50% of cases of FTD are familial, but only 10% to 15% follow a clear autosomal dominant pattern. Mutations in three genes account for the great majority of cases of FTD with an identified genetic cause (see Fig. 52.1). The most common genetic cause of both FTD and ALS appears to be the hexanucleotide repeat expansion in *C9orf72* on chromosome 9. The phenotype associated with *C9orf72* expansions can be FTD, ALS, or combined FTD-ALS. This expansion accounts for approximately 35% to 40% of familial ALS, 6% of sporadic ALS, 25% of familial FTD (with or without ALS), 5% of sporadic FTD, and up to 88% of familial patients with both FTD and ALS.

The two other known major genetic causes of FTD are mutations in the *MAPT* (tau) and *GRN* genes. Like *C9orf72*, *MAPT* and *GRN* mutations are autosomal dominant with high penetrance. Tau binds to microtubules, and it exists in isoforms of three and four microtubule-binding domains generated by alternate splicing of exon 10. Deposition of three-repeat tau is associated with Pick disease, whereas four-repeat tau is associated with CBD and PSP. *GRN* is an oncogene that codes for the protein granulin, which is a growth factor involved in wound healing. Reduced levels of granulin are associated with FTD, but elevated levels of granulin are associated with certain tumors including teratomas and breast, esophageal, and liver cancers. This is similar to another FTD/oncogene, *FUS*, in which elevated levels are associated with sarcoma, but reduced levels are associated with FTD. Rare other genetic causes of FTD or FTD-ALS include mutations in valosin-containing protein (*VCP*), *TARDBP*, *TBK1*, *UBQLN2*, *CCNF*, *SQSTM1*, *CHCHD10*, *OPTN*, *TIA1*, and *CHMP2B*. Clinical genetic testing can be considered with the guidance of a genetic counselor. Until recently, it was generally thought that an FTD patient should have a first-degree relative with FTD or a related illness, such as ALS, to be offered clinical genetic testing. However, genetic testing of cases of FTD or FTD-ALS without a family history should be considered. Clinical presentation and pathology in family members can guide genetic testing; for example, whether to test only for known mutations or to sequence the entire gene that is associated with FTD, or even perform whole exome or whole genome sequencing.

CLINICAL MANIFESTATIONS

Behavioral Variant

The ventral prefrontal cortex is usually implicated in bvFTD and appears to play an important role in social cognition and behavior. Alteration in personality and behavior, reflecting impaired judgment of social norms, is a hallmark feature of bvFTD. Patients display a loss of social graces, generally characterized by decreased empathy, diminished reactions to emotional events, excessive familiarity with strangers or acquaintances, inappropriate jocularity, and a general lack of self-consciousness. Distractibility, impulsivity, and apathy are also components of bvFTD. Such symptoms may be subtle at onset. Patients may also present with stereotyped behaviors, involving movement, language, or more complex behaviors. Increased appetite and

hyperphagia, particularly for sweets, and hyperorality can also occur. Patients with bvFTD frequently demonstrate reduced awareness of or lack of concern for their symptoms. The apathetic and amotivational aspect of bvFTD may initially be mistaken for depressed mood; however, it is relatively rare for patients with bvFTD to endorse feelings of sadness or hopelessness. In fact, recent work found a lower prevalence of major depressive disorder among prodromal *MAPT* carriers destined to develop bvFTD and an elevated prevalence of atypical depression (eg, irritability, agitation) as compared to familial controls.

With regard to cognitive function, changes in behavior and social cognition are often observed at the earliest stages of the disease and even in prodromal in *MAPT* carriers. Formal neuropsychological testing most commonly reveals executive dysfunction and changes in language with preserved visuospatial functions. Language deficits in bvFTD tend to be subtle and not qualify as aphasia; for example, patients might exhibit poor narrative organization, tangential speech, and reduced spontaneous speech output. However, early semantic (eg, naming) problems have been reported in prodromal *MAPT* carriers (sometimes considered a "mixed" behavioral-semantic phenotype), and language presentations in bvFTD can be highly variable. Performance on measures of memory is also quite variable. The most recent diagnostic criteria for bvFTD (2011) allow for inclusion of individuals with atypical cognitive presentations such as those with severe amnesia or spatial disorientation. Finally, it is possible that objectively measured cognition can be within normal limits in patients with bvFTD despite marked behavioral changes in everyday life, or alternatively, performance may be globally impaired secondary to apathy, inattention, or stimulus-bound responding.

Primary Progressive Aphasia

The three PPA phenotypes broadly map onto disruption of different components of the language network, with nfvPPA reflecting left frontal perisylvian involvement, svPPA implicating the anterior temporal lobes, and lvPPA associated with left posterior temporoparietal compromise. nfvPPA patients generally demonstrate reduced speech output that is both effortful and dysgrammatic. Such symptoms may be preceded by anomia (problems with naming), subtle deficits in sentence construction, as well as apraxia of speech (ie, impaired motor planning and sequencing of the movements required for correct speech production). Comprehension is generally preserved, although patients may have difficulty decoding syntactically complex phrases. In contrast, svPPA is a fluent aphasia, with normal prosody and tempo, but patients have progressive loss of semantic knowledge (ie, understanding and recognizing the meaning of words and/or objects). Anomia and single-word comprehension deficits are the core diagnostic criteria. Surface dyslexia, the phonologic decoding or "regularization" of irregularly spelled words (eg, "*sue*" for *sew*), is also a feature of svPPA, reflecting loss of item-specific knowledge. Patients with svPPA are also described to present with fixations on and/or frequent questions about the meaning of a word (eg, "What is a comb?"). Behavioral changes are also typical of svPPA, including obsessive-compulsiveness and socioemotional changes characterized by indifference and lack of warmth particularly with differential right hemisphere involvement. There is evidence that the behavioral syndrome associated with svPPA overlaps with, but differs in some ways from, the behavioral symptoms in bvFTD. Another sign of compromise to right anterior temporal regions is prosopagnosia (inability to recognize faces). Finally, lvPPA is characterized by slow but generally grammatically correct spontaneous speech with frequent word finding pauses, difficulty naming, phonologic paraphasias (ie, use of an incorrect word that is phonologically related to or sounds like the intended word) as well as sentence repetition errors. Repetition errors are generally seen for sentences of increasing length and complexity rather than for single words or simple phrases and appear to reflect limited auditory short-term memory capacity. lvPPA is most often associated with AD pathology, reflecting FTD pathology in less than one-third of cases. There is some evidence that low episodic memory scores are predictive of AD pathology in lvPPA, but this is not always the case.

DIAGNOSIS

The diagnostic probability of FTD is heightened in those younger than 65 years and in those with an autosomal dominant pattern of inheritance. Rapidly developing knowledge regarding the phenotypes associated with FTD resulted in revisions to the diagnostic criteria in 2011. The new bvFTD criteria allow for heterogeneous presentation of disease as well as levels of diagnostic certainty (ie, possible, probable, definite), and the most recent PPA criteria (2011) include lvPPA as a third variant. In one neuropathologic case series, addition of the lvPPA diagnostic category resulted in reclassification of approximately half of cases that had been previously diagnosed as nfvPPA and improved separation of FTLD versus AD pathology.

The diagnostic workup for FTD relies heavily on cognitive and behavioral assessment. Formal neuropsychological testing can identify subtle language or executive dysfunction that aid in the differential diagnosis of FTD from other dementias, such as AD, as well as in the characterization of the FTD phenotype. In particular, nonverbal abilities such as spatial processing and nonverbal memory are usually relatively well preserved on formal testing of FTD patients. Regarding the cognitive profile of FTD versus AD, a common differential diagnosis, visuospatial functions are generally well preserved in FTD but poor in AD. The integrity of memory storage, measured through recognition testing and proportion of information retained after a delay, has traditionally served as a critical variable for differentiating FTD from AD. However, it is increasingly recognized that poor performance on these metrics is not uncommon in FTD. Moreover, the retrieval of information from memory may be equally impaired in both groups. With regard to PPA, language assessments can be tailored toward identifying the specific deficits that characterize the three variants, although mixed presentations are common and cases are often not clear cut.

In addition to the primary behavioral and language phenotypes described earlier, patients with FTD may present with or develop other neurologic signs; therefore, it is essential to perform a detailed neurologic examination in all suspected cases. Approximately 10% to 15% of patients with FTD exhibit signs of motor neuron disease consistent with ALS, and 20% to 30% of all patients with FTD display parkinsonism at some point. The presence of parkinsonian and other motor signs (eg, gait disturbance, limb rigidity, apraxia, dystonia) may suggest a diagnosis of CBD or PSP. Some patients will also present with psychosis, most frequently in the context of *C9orf72* or *GRN* mutations.

Magnetic resonance imaging in FTD often reveals cortical volume loss in the frontal and anterior temporal lobes with relative sparing of posterior parietal and occipital cortices (Figs. 52.2 and 52.3). Functional neuroimaging

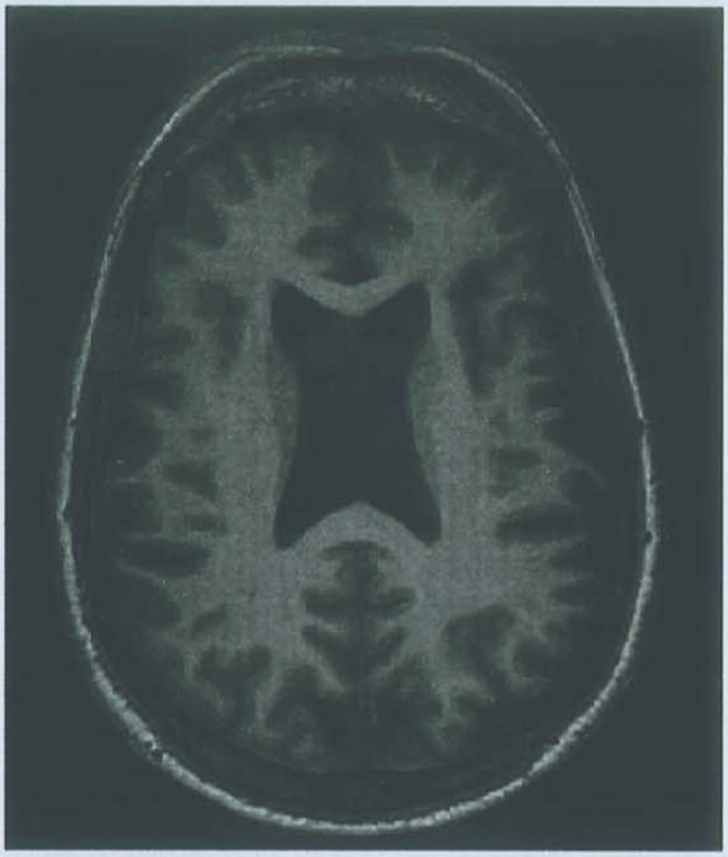

FIGURE 52.2 Magnetic resonance imaging demonstrating frontal atrophy in a patient with behavioral variant frontotemporal dementia.

FIGURE 52.3 Sagittal brain magnetic resonance image of the patient shown in **Figure 51.3.**

(^{18}F-fluorodeoxyglucose positron emission tomography or technetium 99m hexamethylpropyleneamine oxime single-photon emission computed tomography) often reveals frontotemporal hypometabolism (Fig. 52.4). nfvPPA is associated with left-sided frontal perisylvian involvement and svPPA with anterior temporal involvement. Recent developments in tau-specific PET tracers may prove useful in diagnosing FTD in the future. Cerebrospinal fluid (CSF) findings include normal cell count and protein. CSF phosphorylated tau (p-tau)/total tau (t-tau) and Aβ42 levels have not demonstrated sufficiently reliable differences from controls to use as a diagnostic test for FTD. However, these protein levels can be useful in distinguishing FTD from AD, as patients with AD will usually show elevated levels of t-tau and p-tau and reduced levels of Aβ42 in CSF compared to controls and patients with FTLD. The combination of imaging and CSF biomarkers can greatly increase diagnostic accuracy. These tests can also be helpful in determining the neuropathologic process associated with certain clinical presentations such as lvPPA. The development of motor symptoms can elucidate the underlying pathology with symptoms of corticobasal syndrome (eg, apraxia, cortical sensory deficits, parkinsonism, dystonia) or PSP (decreased balance, vertical gaze palsy, axial rigidity) associated with underlying tau pathology and symptoms of ALS associated with underlying TDP-43 pathology. It is important to note that the differential diagnoses for FTD may include both neurodegenerative and psychiatric disorders.

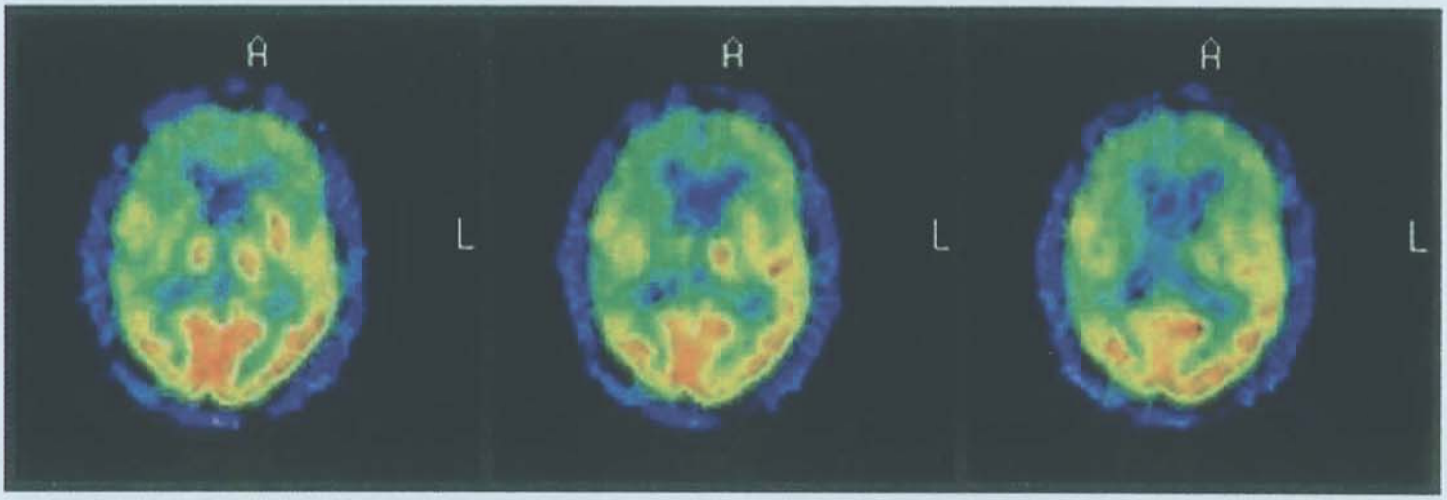

FIGURE 52.4 Positron emission tomography scan showing moderate and severe reductions in glucose utilization affecting cortical areas of the frontal, temporal, and parietal lobes. Cooler colors represent reduced glucose utilization.

MANAGEMENT

Currently, we do not have medications that have been shown to be disease-modifying therapies for FTD. Cholinesterase inhibitors do not appear to help (level 2 studies), although there is a rationale for treating lvPPA with cholinesterase inhibitors as it usually indicates underlying pathologic AD. Serotonergic antidepressants show some efficacy reducing certain behavioral symptoms including agitation and repetitive behaviors in level 1 and 2 studies LEVEL 2.[1] Atypical antipsychotic medications are also often used to attempt to reduce behavioral symptoms in FTD. Cognitive deficits and apathy generally do not improve with medication treatment. Memantine has not demonstrated efficacy for the treatment of the cognitive symptoms of FTD LEVEL 1.[2]

Management of FTD relies in large part on nonpharmacologic interventions. Foremost of these is patient and family education. At diagnosis, patients and families will want to know what to expect in the years to come. Genetic counselors can be useful for education about genetic testing. Referral to local support groups and to nationwide organizations can be helpful. A symptom diary can be a useful tool to track symptoms, especially behavioral symptoms, as the disease progresses, and to see the effects of therapeutic interventions as they are introduced. Environmental modifications, including locking doors and removing visible food, can be helpful for wandering behavior and hyperphagia. Providing only small portions on plates can also be useful in managing hyperphagia. Wander bracelets can improve safety and can be equipped with tracking systems such as GPS to help in finding the patient. Calendars and consistent routines can provide structure and predictability for the patient and may help in managing executive problems. Safety measures should be put in place (eg, locks on drawers/cabinets) for dangerous items, such as firearms or knives, due to impulsive behavior and poor judgment. Physicians should continually assess if the level of assistance provided to the caregiver is sufficient. Physicians should also consider whether the patient is able to continue driving or remain at work. The behavioral symptoms of bvFTD can put family members of patients at risk for physical injury or sexually inappropriate behavior toward minors. Children are often at greater risk for exposure to behavioral symptoms in FTD than in other types of dementia because the patients are frequently younger, more likely to have young children at home, and more mobile. These behaviors will likely necessitate placement out of the home. In the later stages of the illness, palliative care and hospice referrals can be helpful in managing symptoms.

OUTCOME

Knowledge on the natural history of FTD is limited to epidemiologic studies drawn from dementia specialty centers. The median time from first symptom onset to death ranges from 9.5 years for bvFTD (approximate range 3-16 y), to 8 years for nfvPPA (approximate range 3-12 y), to 12 years for svPPA (approximate range 6-18 y). Comorbid ALS shortens life span, with median survival of 3 years from symptom onset, although outliers with unusually long survival have been reported. Tau mutations are generally associated with a slower disease progression. The ways in which people die from FTD are similar to other types of dementia and include infection, often related to decreased mobility, aspiration, or incontinence, and decreased oral intake of food and water leading to dehydration and malnutrition.

LEVEL 1 EVIDENCE

1. Huey ED, Putnam KT, Grafman J. A systematic review of neurotransmitter deficits and treatments in frontotemporal dementia. *Neurology*. 2006;66:17-22.
2. Boxer AL, Knopman DS, Kaufer DI, et al. Memantine in patients with frontotemporal lobar degeneration: a multicentre, randomised, double-blind, placebo-controlled trial. *Lancet Neurol*. 2013;12:149-156.

SUGGESTED READINGS

Chare L, Hodges JR, Leyton CE, et al. New criteria for frontotemporal dementia syndromes: clinical and pathological diagnostic implications. *J Neurol Neurosurg Psychiatry*. 2014;85(8):865-870.

Davies RR, Kipps CM, Mitchell J, Kril JJ, Halliday GM, Hodges JR. Progression in frontotemporal dementia: identifying a benign behavioral variant by magnetic resonance imaging. *Arch Neurol*. 2006;63:1627-1631.

DeJesus-Hernandez M, Mackenzie IR, Boeve BF, et al. Expanded GGGGCC hexanucleotide repeat in non-coding region of *C9ORF72* causes chromosome 9p-linked frontotemporal dementia and amyotrophic lateral sclerosis. *Neuron*. 2011;72:245-256.

Goldman JS. New approaches to genetic counseling and testing for Alzheimer's disease and frontotemporal degeneration. *Curr Neurol Neurosci Rep*. 2012;12:502-510.

Gorno-Tempini ML, Brambati SM, Ginex V, et al. The logopenic/phonological variant of primary progressive aphasia. *Neurology*. 2008;71:1227-1234.

Gorno-Tempini ML, Hillis AE, Weintraub S, et al. Classification of primary progressive aphasia and its variants. *Neurology*. 2011;75:1006-1014.

Greaves CV, Rohrer JD. An update on genetic frontotemporal dementia. *J Neurol*. 2019;266:2075-2086.

Harciarek M, Cosentino S. Language, executive function and social cognition in the diagnosis of frontotemporal dementia syndromes. *Int Rev Psychiatry*. 2013;25:178-196.

Hogan DB, Jetté N, Fiest KM, et al. The prevalence and incidence of frontotemporal dementia: a systematic review. *Can J Neurol Sci*. 2016;43(suppl 1):S96-S109.

Hornberger M, Piguet O, Kipps C, Hodges JR. Executive function in progressive and nonprogressive behavioral variant frontotemporal dementia. *Neurology*. 2008;71:1481-1488.

Hornberger M, Shelley BP, Kipps CM, Piguet O, Hodges JR. Can progressive and non-progressive behavioural variant frontotemporal dementia be distinguished at presentation? *J Neurol Neurosurg Psychiatry*. 2009;30:591-593.

Kansal K, Mareddy M, Sloane KL, et al. Survival in frontotemporal dementia phenotypes: a meta-analysis. *Dement Geriatr Cogn Disord*. 2016;41:109-122.

Khan BK, Yokoyama JS, Takada LT, et al. Atypical, slowly progressive behavioral variant frontotemporal dementia associated with *C9ORF72* hexanucleotide expansion. *J Neurol Neurosurg Psychiatry*. 2012;83:358-364.

Knopman DS, Roberts RO. Estimating the number of persons with frontotemporal lobar degeneration in the US population. *J Mol Neurosci*. 2011;45:330-335.

Manoochehri M, Huey ED. Diagnosis and management of behavioral issues in frontotemporal dementia. *Curr Neurol Neurosci Rep*. 2012;12:528-536.

Onyike CU, Diehl-Schmid J. The epidemiology of frontotemporal dementia. *Int Rev Psychiatry*. 2013;25:130-137.

Park HK, Chung SJ. New perspective of parkinsonism in frontotemporal lobar degeneration. *J Mov Disord*. 2013;6:1-8.

Rascovsky K, Hodges JR, Knopman D, et al. Sensitivity of revised diagnostic criteria for the behavioural variant of frontotemporal dementia. *Brain*. 2011;134:2456-2477.

Renton AE, Majounie E, Waite A, et al. A hexanucleotide repeat expansion in *C9ORF72* is the cause of chromosome 9p21-linked ALS-FTD. *Neuron*. 2011;72:257-268.

Rosen HJ, Allison SC, Ogar JM, et al. Behavioral features in semantic dementia vs other forms of progressive aphasias. *Neurology*. 2006;67:1752-1756.

Seeley WW, Bauer AM, Miller BL, et al. The natural history of temporal variant frontotemporal dementia. *Neurology*. 2005;64:1384-1390.

Shinagawa S, Nakajima S, Plitman E, et al. Psychosis in frontotemporal dementia. *J Alzheimers Dis*. 2014;42:485-499.

Snowden JS, Thompson JC, Neary D. Knowledge of famous faces and names in semantic dementia. *Brain*. 2004;127(pt 4):860-872.

Thompson SA, Patterson K, Hodges JR. Left/right asymmetry of atrophy in semantic dementia: behavioral-cognitive implications. *Neurology*. 2003;61:1196-1203.

Van Blitterswijk M, DeJesus-Hernandez M, Rademakers R. How do C9ORF72 repeat expansions cause amyotrophic lateral sclerosis and frontotemporal dementia: can we learn from other noncoding repeat expansion disorders? *Curr Opin Neurol*. 2012;25:689-700.

Lewy Body Dementias 53

Oren Levy, Richard A. Hickman, and Karen S. Marder

KEY POINTS

1. Neocortical Lewy bodies, containing α-synuclein, are the defining pathologic finding in dementia with Lewy bodies.
2. Core clinical features of dementia with Lewy bodies include visual hallucinations, fluctuations in cognition, rapid eye movement sleep behavior disorder, and parkinsonism.
3. Abnormal dopamine transporter imaging provides strong evidence supporting a diagnosis of dementia with Lewy bodies.
4. Acetylcholinesterase inhibitors improve multiple cognitive and psychiatric features of dementia with Lewy bodies.

INTRODUCTION

Lewy body dementias (LBDs) refer to a group of dementias with prominent motor parkinsonism and α-synuclein pathology. The nomenclature in this area is confusing and warrants clarification. The LBD is a broad designation that includes two main disease entities: dementia with Lewy bodies (DLB) and Parkinson disease dementia (PDD). Indeed, part of the confusion arises from underlying uncertainty in the field about whether DLB and PDD are distinct disorders or represent different presentations of the same disease. Early dementia characterizes DLB, whereas PDD is used to describe dementia occurring later in the course of well-established Parkinson disease (PD). The "1-year rule" is a consensus guideline to distinguish the two: When cognitive impairments precede or appear within 1 year of the motor signs, DLB is diagnosed; the term *PDD* is used when dementia occurs more than 1 year after the onset of parkinsonism. This chapter focuses primarily on DLB.

EPIDEMIOLOGY

The DLB is considered to be a common cause of dementia, with an estimated worldwide population prevalence of 4.2% to 7.5% and incidence of 3.8% in those newly diagnosed with dementia. However, neuropathologic studies indicate that DLB comprises 15% to 20% of autopsied dementia cases. Although autopsy studies are typically small and prone to selection bias, they highlight the likelihood that the actual prevalence and incidence rates of DLB may be higher due to the difficulty of diagnosing DLB clinically. In larger studies, the average age at diagnosis is in the mid-70s. Men are likely more susceptible to DLB and have a worse prognosis than women.

PATHOBIOLOGY

Neuropathology

Common pathologic findings of DLB are summarized in Table 53.1 and illustrated in Figure 53.1. Lewy body (LB) pathology, particularly in the cortex, is the most important factor in the development of LBDs (Fig. 53.1A,C). The LB are the only essential feature in the pathologic diagnosis of DLB; other features are apparent in most but not all cases.

Lewy Bodies

The LB are eosinophilic intracytoplasmic neuronal inclusion bodies and are found in both the subcortical regions and brainstem as well as in the cortex in DLB (Fig. 53.1A). Brainstem LB occur in the substantia nigra and locus coeruleus. The term *cortical Lewy body* refers to less well-defined spherical inclusions seen in cortical neurons (Fig. 53.1B). Identification of cortical LB may be complicated by the presence of severe Alzheimer changes in some individuals and the paucity of cortical LB in some DLB cases.

Lewy Neurites

Lewy neurites are neurofilament abnormalities and a distinctive part of LB pathology in which proteins cluster into diffuse aggregates (Fig. 53.1C). They occur in the hippocampus (CA2/3 region), amygdala, nucleus basalis of Meynert, dorsal vagal nucleus, and other brainstem nuclei.

Alzheimer Pathology

Most cases of DLB demonstrate comorbid Alzheimer disease (AD) pathology including amyloid plaques and neurofibrillary tangles. Plaque types in DLB are classified as either diffuse/immature plaques with τ-positive neurites or diffuse/immature plaques with

TABLE 53.1 Pathologic Features Associated With Dementia With Lewy Bodies

Essential for diagnosis of DLB
- Lewy bodies

Associated but not essential for diagnosis of DLB
- Lewy-related neurites
- Plaques (all morphologic types)
- Neurofibrillary tangles
- Regional neuronal loss, especially in the brainstem (including the substantia nigra and the locus coeruleus) and the nucleus basalis of Meynert
- Microvacuolation (spongiform changes) and synapse loss
- Reduced concentrations of choline acetyltransferase (ChAT) in neocortex

Abbreviation: DLB, dementia with Lewy bodies.

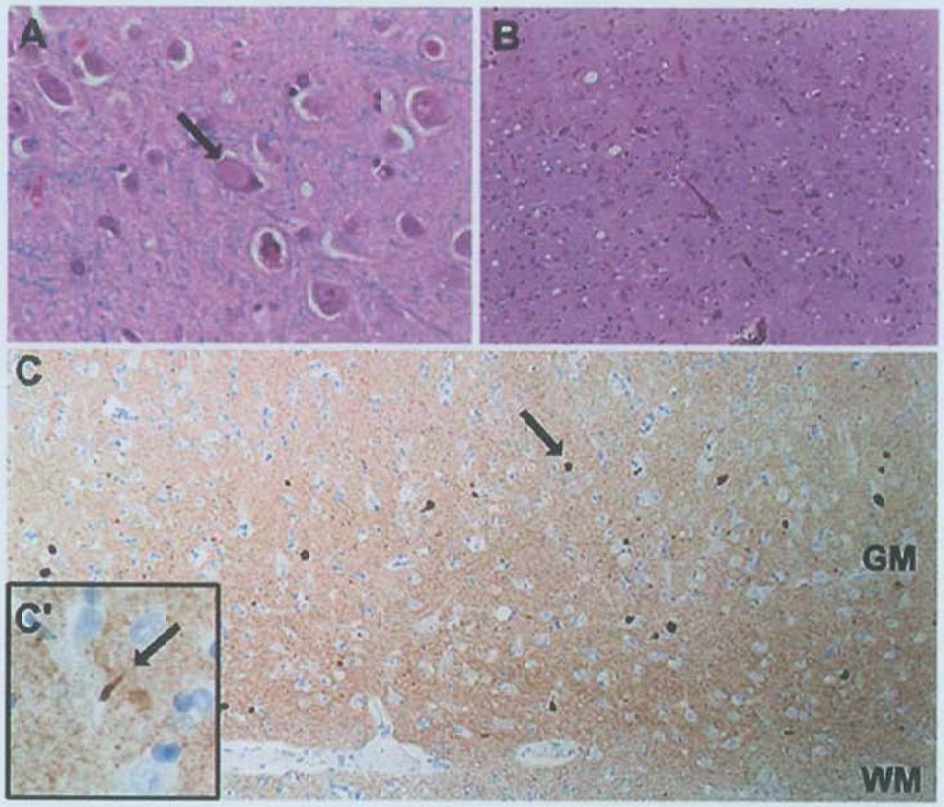

FIGURE 53.1 Neuropathologic features of dementia with Lewy bodies (DLB). A: Photomicrograph of a cortical Lewy body (LB) within a diseased neuron of a patient with DLB (layer V, precuneus, original magnification: 630×). The LB within the cortex lack the characteristic halo around the circumference of the inclusion, which is in contrast to brainstem LB. B: Photomicrograph of DLB showing spongiform change that is histologically reminiscent of Creutzfeldt Jakob disease (layers V-VI, anterior temporal pole, original magnification: 100×). C: Immunohistochemical stain against α-synuclein labels widespread LB within the infragranular layers of the cortex (layers V-VI, occipitotemporal gyrus, original magnification: 100×). C': A Lewy neurite within the cortex is labeled by an α-synuclein immunostain. Abbreviations: GM, gray matter; WM, white matter.

τ-negative, ubiquitin positive neurites. Biochemical studies have shown that α-synuclein deposition promotes the intracellular aggregation of τ- and β-amyloid in cell models, providing a potential mechanism that contributes to the frequent co-occurrence of AD pathology.

Spongiform Change/Microvacuolation

This is a feature of some DLB cases and occurs mainly in temporal cortex. It may relate to the severity of the disease. These spongiform changes are similar to those seen in Creutzfeldt-Jakob and prion-related diseases. Although there is considerable interest in the "prion hypothesis" of α-synuclein aggregation and spread, there is currently no evidence that DLB is a transmissible disorder.

Distinction Between Dementia With Lewy Bodies and Parkinson Disease Dementia

Although there are many histologic similarities between DLB and PDD, subtle morphologic differences between the two diseases are becoming apparent through neuropathologic studies. First and foremost, neuronal loss in the substantia nigra may be more extensive in PDD than in DLB. There are now reports of a greater amyloid burden and neuritic plaque score in DLB than in PDD and that there tends to be a greater α-synuclein burden within the temporal and parietal cortices in DLB. An increased amyloid burden has also been suggested within the caudate nucleus and putamen in DLB than in PDD. Further investigation is needed to draw out the pathologic differences in the spectrum of DLB and PDD.

Neurotransmitter Systems

The exact mechanisms leading to dementia in DLB are unknown. However, there is an association between structural neuropathologic findings in DLB, dopamine depletion and noradrenergic, serotonergic and cholinergic dysfunction. The LB have a predilection for the substantia nigra, and DLB is characterized by dopaminergic changes in the striatum and frontal cortex, leading to parkinsonism. In addition to motor control, dopamine is involved in a range of nonmotor behaviors such as cognition, motivation, sleep, and mood. The cholinergic nucleus basalis is another susceptible region, leading to widespread and severe cortical cholinergic deficits. Lewy pathology may also affect brainstem nuclei such as the locus coeruleus, which receives noradrenergic activation, and the serotonergic raphe nuclei. All of these areas are known to be involved in modulation of cognitive and psychiatric symptoms.

Genetic Risk Factors

The majority of genetic studies in DLB have used a candidate gene approach and have relied on clinically diagnosed DLB. The first genome-wide association study was performed in 2017 in 1,743 cases of DLB (1,324 pathologically proven). The heritability of DLB has been calculated to be 36%, similar to PD. The DLB has been shown to be genetically correlated to both AD and PD, but there is consensus that there are yet to be identified unique genes associated with DLB. Three genes have been consistently associated with DLB: *APOE*, *SNCA*, and *GBA1*.

APOE

The most consistent risk factor for DLB (as well as PDD) is *APOE* ε4. Although the association of *APOE* ε4 and DLB was thought to be mediated by the presence of AD-related neuropathology, it has been shown to be a risk factor even among cases of "pure" DLB with minimal AD pathology. In a series of 652 autopsy confirmed LBD and 660 controls, *APOE* ε4 was associated with risk of diffuse LBD regardless of the degree of AD pathology. Furthermore, the presence of *APOE* ε4 was associated with the severity of LB pathology independent of AD pathology.

SNCA

The *SNCA* gene encodes the α-synuclein protein, which aggregates in neurons to form LB. Point mutations in *SNCA* (p. Ala53Thr and p. Glu46Lys) as well as locus multiplications (three and four copies of *SNCA*) have been associated with familial cases of parkinsonism and dementia with DLB phenotypes. There are different single-nucleotide polymorphism within the *SNCA* gene associated with the risk of PD and DLB. Pathogenic changes in the *SNCA* gene may increase the probability of the protein to aggregate. In addition, changes in *SNCA* expression levels and distribution are also likely to affect disease risk and phenotype (ie, PD vs DLB).

GBA1

Several individual studies and an international multicenter collaborative study have demonstrated that patients with PD who carried mutations for the lysosomal enzyme glucocerebrosidase (*GBA1*) have a higher incidence of PD-mild cognitive impairment (MCI) and PDD. Other multicenter autopsy studies have demonstrated that subjects with DLB were more than 8 times more likely to carry a *GBA1* mutation than were controls. Further analyses indicate that *GBA1* mutations are also significantly associated with earlier age at onset and death in DLB. Although mechanisms underlying *GBA1*-associated parkinsonism and dementia are still not completely understood, accumulating evidence suggests that impairment of the aging lysosome, enhanced by deficient or mutant glucocerebrosidase, can affect α-synuclein degradation.

CLINICAL MANIFESTATIONS

Cognitive Impairment

The diagnosis of DLB presupposes the presence of dementia, that is, cognitive decline sufficient to interfere with function and/or activities of daily living. Early signs of cognitive impairment in patients with DLB include executive dysfunction, visuospatial impairment, and deficits in verbal memory. Executive dysfunction is a hallmark feature of DLB and includes impairment in set shifting, attention, and planning. Memory deficits in DLB are to be related to retrieval of learned information, which is improved by cuing.

The Mini-Mental State Exam (MMSE) is less sensitive to the earliest cognitive changes in DLB due to its reliance on memory and language performance and its weakness in assessment of executive dysfunction. Alternative generic tests such as Dementia Rating Scale and Montreal Cognitive Assessment and PD-specific scales such as Parkinson Disease-Cognitive Rating Scale have shown higher sensitivity in PD and have been recommended for use in LBDs. Because of the frequent comorbidity of depression in DLB, screening for depression as an alternative cause or a contributor to cognitive impairment is recommended. Medications should be carefully reviewed, especially those with potential cognitive side effects, such as anticholinergic agents.

Psychiatric Symptoms

Detailed visual hallucinations (McKeith core clinical criterion) frequently occur in DLB. There is often overlap between visual hallucinations and other disorders of visual perception, including illusions, misidentification syndromes, and visual agnosias. Auditory, tactile, or gustatory hallucinations may also occur but are less common (McKeith supportive clinical criterion). In addition, complex and elaborate delusional beliefs can be seen early in the disease course (McKeith supportive clinical criterion). Several drugs used in the treatment of PD, including anticholinergic agents, dopaminergic agents, and amantadine can exacerbate psychotic symptoms. Depression, anxiety, and apathy (McKeith supportive clinical criteria) commonly occur in DLB and are closely associated with cognitive decline.

Parkinsonism

The core features of parkinsonism include rigidity, bradykinesia, and resting tremor. As a core clinical feature of DLB, only one of these three are required (as opposed to PD, where at least two are required). Resting tremor and asymmetry of symptoms are less common in DLB than in PD, especially in older individuals. Other common parkinsonian signs are hypophonic speech, masked facies, stooped posture, and shuffling gait.

During the neurologic examination, a careful search for extrapyramidal features should be performed, even when the patient does not endorse motor symptoms. The use of a standardized assessment, such as the Movement Disorder Society-United Parkinson's Disease Rating Scale, for parkinsonian features may be particularly useful for research purposes.

Sleep Disorders

The RBD (McKeith core clinical feature) is a highly specific marker of synucleinopathies, particularly DLB. The RBD often precedes, sometimes by decades, the onset of cognitive and motor symptoms (see "Prodromal Dementia With Lewy Bodies" section in the following text). Selective serotonin reuptake inhibitors diminish the diagnostic utility of RBD because these agents can cause RBD behaviors. In addition to RBD, other sleep disturbances commonly found in DLB include daytime hypersomnolence (McKeith supportive clinical criterion) and insomnia.

Autonomic Dysfunction

Dysautonomia is common early in the course of DLB and can even occur prior to the onset of cognitive or motor symptoms. Frequent manifestations include orthostatic hypotension, syncope, constipation, and urinary incontinence (McKeith supportive clinical criteria) as well as urinary retention and erectile dysfunction. These symptoms are sometimes severe enough to lead to diagnostic consideration of multiple system atrophy (MSA).

Fluctuating Attention and Concentration

Significant fluctuations in cognition are one of core clinical features of DLB. Patients may show episodic deficits in cognition that alternate with periods of normal or near-normal performance. Fluctuations may include both rapid (lasting minutes or hours) as well as slower (weekly or monthly) variations in alertness. As a result, changes in mental status and behavior may be seen within a single clinical interview as well as between consecutive examinations. Caregivers are the most reliable source of information regarding the presence of fluctuations.

DIAGNOSIS

Updated diagnostic criteria for DLB were recently put forth by the fourth report of the DLB consortium (Table 53.2) LEVEL 3.[1] Significant changes compared to the third report include elevation of rapid eye movement sleep behavior disorder (RBD) as a core clinical feature; lowering of neuroleptic sensitivity from a core to a supportive clinical feature; and creation of a biomarker category of criteria, with abnormal dopamine transporter imaging, cardiac sympathetic deinnervation, and polysomnographic demonstration of RBD as findings that can contribute to a diagnosis of probable DLB. The supportive clinical and biomarker features do not factor into the classification of probable or possible DLB but may prove useful to clinicians in bolstering a diagnosis of DLB.

The relative timing of the cognitive and motor symptoms is an important factor in diagnosing DLB. As stated earlier, the "1-year rule" posits that DLB is diagnosed when dementia predates or begins within 1 year of the onset of motor parkinsonian symptoms; if dementia starts more than 1 year after parkinsonism, then the diagnosis is PDD. This admittedly arbitrary cutoff, established by the first consensus DLB criteria, has been controversial, and some groups have advocated for its elimination. However, the revised McKeith guidelines supported its continued use.

The neuropathologic accuracy of these revised criteria has yet to be determined. The prior core criteria have high specificity but lower sensitivity (range 0%-85%, mean approximately 40%). In particular, the consensus criteria are more predictive for the rarer "pure" form of DLB rather than the more common findings of mixed DLB and AD pathology.

TABLE 53.2 Diagnostic Criteria for Dementia With Lewy Bodies[a]

Clinical Features	
Core	**Supportive**
• Fluctuations • Recurrent visual hallucinations, usually well-formed • REM sleep behavior disorder • Parkinsonism • At least one of bradykinesia, rigidity, or resting tremor	• Neuroleptic sensitivity • Postural instability, frequent falls • Recurrent syncope/transient unresponsiveness • Dysautonomia (constipation, orthostatic hypotension, urinary incontinence) • Hypersomnia • Hyposmia • Nonvisual hallucinations • Delusions • Apathy, depression, anxiety
Biomarkers	
Indicative	**Supportive**
• Abnormal DaTscan • Abnormal cardiac MIBG scan • Polysomnography showing REM sleep without atonia	• Lack of medial temporal atrophy on CT/MRI • Generalized reduced functional brain activity with reduced occipital activity (SPECT/PET) • Cingulate island sign • Posterior slowing on EEG
Diagnosis	
Probable DLB can be diagnosed when: • Two or more core clinical features are present. • One core clinical feature and one (or more) indicative biomarkers are present.	
Possible DLB can be diagnosed when: • One core clinical feature is present. • One (or more) indicative biomarker is present (without core clinical features).	

Abbreviations: CT, computed tomography; DLB, dementia with Lewy bodies; EEG, electroencephalography; MIBG, metaiodobenzylguanidine; MRI, magnetic resonance imaging; PET, positron emission tomography; REM, rapid eye movement; SPECT, single-photon emission computed tomography.

[a]From McKeith IG, Boeve BF, Dickson DW, et al. Diagnosis and management of dementia with Lewy bodies: fourth consensus report of the DLB consortium. *Neurology*. 2017;89:88-100.

Prodromal Dementia With Lewy Bodies

Although a formal diagnosis of DLB requires the presence of dementia, there is great interest in identifying DLB patients at earlier stages of disease. Several studies have found that patients with nonamnestic MCI are more likely to develop DLB than AD. Cognitive symptoms predominate in this phenotype of prodromal DLB, but other patterns of prodromal DLB have been identified. These include prominent delirium and late-onset psychiatric disease, particularly psychosis and affective disorder. However, there are currently no formal criteria for prodromal DLB.

Another group at high risk for developing DLB are those with "idiopathic" RBD. The rate of conversion to a neurodegenerative synucleinopathy is very high, approaching 80% after 10 years of follow up. Of these, approximately half develop DLB, half develop PD, and a small percentage develop MSA. Even in those that develop PD, the presence of RBD confers an increased risk of developing cognitive impairment.

Diagnostic Testing and Evaluation

Laboratory workup is advised to exclude other potentially reversible causes of symptoms including infection, metabolic derangement, vitamin B_{12} deficiency or thyroid disease. Ancillary evaluations may include neuropsychological testing, neuroimaging, and cerebrospinal fluid (CSF) analysis.

Neuropsychological Testing

To most thoroughly assess for associated cognitive changes in DLB, formal neuropsychological testing is recommended. Although patients with DLB were more likely to have visuospatial and attentional deficits, AD patients were more likely to have significant impairment on memory testing, particularly memory encoding; the presence of prominent deficits on tests of executive function and problem solving, such as the Wisconsin Card Sorting Test, the Trail Making Test, and verbal fluency for categories and letters, may be useful clinical diagnostic indicators of DLB, as may pronounced impairment on tests of visuospatial performance such as block design, clock drawing, or figure copy tests. With the progression of dementia, the selectivity of this pattern for DLB versus AD may be lost. As a result, making an accurate differential diagnosis during the later stages of dementia using clinical presentation and neuropsychological testing alone becomes increasingly difficult because the cognitive deficits demonstrated in advanced DLB frequently overlap with those seen in AD. For such patients, functional neuroimaging may assist in diagnosis.

Neuroimaging

Structural Brain Imaging

Magnetic resonance imaging (MRI) of the brain without contrast or computed tomography if MRI cannot be done, should be obtained on patients without recent brain imaging to assess for

alternative structural abnormalities that may be contributing to or causing patients' complaints, including localized neoplasms, infections, strokes, or diffuse subcortical cerebrovascular disease. However, computed tomography or MRI as isolated studies has limited diagnostic utility. Generalized atrophy and white matter hyperintensities are nonspecific findings in dementia, and MRI may play a limited role in differentiating between types of dementia. Several studies indicate that coronal sections through the hippocampi usually show a greater degree of hippocampal atrophy in AD compared with DLB (McKeith supportive biomarker criterion). Despite the changes in the occipital lobe on functional imaging as described in the following text, regional occipital atrophy is generally not observed on MRI in DLB.

Dopamine Transporter Imaging

Ioflupane iodine 123 dopamine transporter single-photon emission computed tomography (SPECT) imaging (DaTscan) demonstrates reduced striatal dopaminergic activity in DLB (**Fig. 53.2A**). These findings are also seen in PD and atypical parkinsonisms but not in AD. A study in 326 patients with dementia reported a sensitivity of 78% and a specificity of 90% for DLB versus AD using DaTscan LEVEL 2.[2] A small study in autopsy-confirmed cases supports this robust discrimination. These results underlie the addition of abnormal dopamine transporter imaging as an indicative biomarker in the diagnosis of probable DLB.

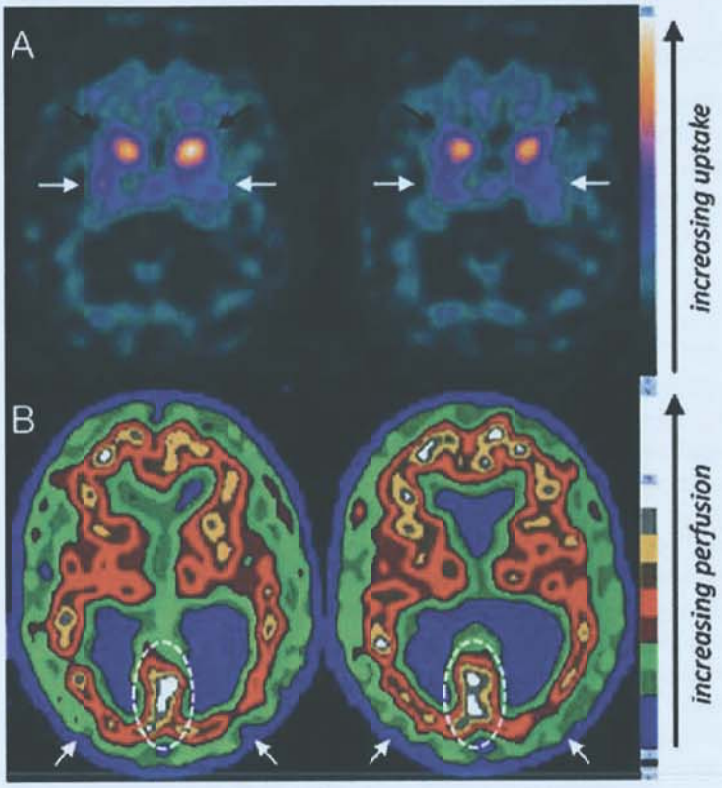

FIGURE 53.2 Neuroimaging features of dementia with Lewy bodies (DLB). Characteristic neuroimaging findings in DLB, taken from a patient with pathologically confirmed DLB. **A:** DaTscan with adjacent axial sections showing nearly absent uptake in the putamen *(white arrows)* with relatively intact uptake in the caudate *(black arrows)*. **B:** Single-photon emission computed tomography scan showing cingulate island sign. The perfusion is reduced in the bilateral occipital cortices *(white arrows)*, with relative preservation in the cingulate cortex *(encircled with white dashed line)*. (Images courtesy of Lawrence Honig.)

Functional Brain Imaging

The DLB patients show decreased perfusion (technetium 99m labeled hexamethylpropylene amine oxime, ^{99m}Tc-HMPAO-SPECT) and metabolism (fluorodeoxyglucose positron emission tomography) in the lateral frontal, temporoparietal, and occipital lobes. The occipital lobe findings have potential diagnostic utility in distinguishing DLB from AD, with a sensitivity and specificity for SPECT of 65% and 87% and for PET of 90% and 80% (McKeith supportive biomarker criterion). The related cingulate island sign (**Fig. 53.2B**), showing preservation of posterior cingulate function relative to the occipital cortex, also shows promise in distinguishing DLB from AD, and may be useful in earlier, MCI-level stages of disease (McKeith supportive biomarker criterion).

Amyloid Imaging

The high frequency of concomitant AD pathology in DLB has prompted investigations in amyloid imaging. According to a recent meta-analysis, about 57% of DLB patients demonstrate positive amyloid imaging findings. By comparison, 35% of PDD patients have abnormal amyloid imaging. The anatomic pattern of amyloid tracer binding in DLB (and PDD) is very similar to that seen in AD, with preferential binding in the frontal lobes, posterior cingulate and precuneus, temporoparietal region and striatum.

Cerebrospinal Fluid Analysis

The CSF analysis can assist in the diagnosis of DLB. In particular, differentiating between AD and DLB can be aided by analysis of "AD biomarkers"—total τ, 181-phosphorylated τ (P-τ), and β-amyloid 1-42. The typical AD profile of elevated P-τ and reduced Abeta1-42 (often expressed as ATI, or Abeta1-42/tau index) is very sensitive for AD changes. Therefore, the absence of these changes can support a diagnosis of DLB in the correct clinical context. However, the specificity of the AD CSF profile is not as strong; this is likely to be especially so in the case of DLB, where (as discussed earlier) coexisting AD pathology is common. Indeed, one large series found that 22% of clinically diagnosed DLB patients had an AD CSF profile. Interestingly, only 9% of PDD subjects had an AD profile. One weakness of studies on CSF biomarkers in this area is the lack of data in pathologically confirmed cases.

A promising area is the analysis of markers of Lewy pathology in CSF. Many (although not all) studies have shown reduced levels of CSF total α-synuclein in DLB. The utility of this measure in distinguishing between DLB and AD is still unclear. Furthermore, other measures of aSyn that are more closely linked to Lewy pathology, such phosphorylated species, for example, phospho S-129 α-synuclein, or oligomeric α-synuclein, may prove more useful.

Autonomic Testing

Autonomic studies may be useful in distinguishing between DLB and AD. In particular, reduced cardiac sympathetic innervation, assessed by cardiac iodine 123 metaiodobenzylguanidine uptake, is an indicative biomarker criterion in the new McKeith guidelines. (It should be noted that cardiac metaiodobenzylguanidine scans are not approved for use in the evaluation of dementia in the United States.) Other assessments, such as tilt table testing and abnormal skin reflexes on sudomotor testing, may also be useful.

Differential Diagnosis

Alternative diagnostic considerations include AD (with coexisting parkinsonism or prominent psychiatric features), vascular dementia, and atypical parkinsonisms.

Although subtle extrapyramidal signs may be present in early stages of AD, notable parkinsonism typically does not develop until late-stage AD. The early appearance of cortical dysfunction, such as aphasia, or profound early memory loss usually suggests the presence of AD. Given that the pathologic changes of AD and DLB often occur together, it can be particularly difficult to clinically differentiate these diagnoses, particularly in later stages. In these cases, functional neuroimaging (eg, dopamine transporter imaging, amyloid imaging) may provide some indication of the underlying pathologic process(es).

Vascular disease may manifest as infarctions in multiple vascular territories or as microvascular/small vessel ischemic changes affecting periventricular and subcortical white matter, basal ganglia, and brainstem. These vascular changes can produce dementia and parkinsonism, which classically affects gait (lower body parkinsonism). A history of vascular risk factors, abrupt onset of symptoms with stepwise progression over time, focal neurologic signs, and evidence of diffuse vascular disease on neuroimaging suggest this alternate diagnosis.

The atypical parkinsonisms—progressive supranuclear palsy, MSA, and corticobasal degeneration—can sometimes present similarly to DLB. For example, MSA can cause RBD and dysautonomia, and progressive supranuclear palsy can present with early cognitive changes and postural instability. Other less common entities that may be included in the differential include depression, medication effects, prion disease, and delirium caused by metabolic or systemic disorders.

TREATMENT

The treatment of patients with DLB is clinically challenging and limited to symptomatic management. Because medications may be poorly tolerated, patient and caregiver education regarding risks, benefits, and limitations of treatment is important.

Cognitive Symptoms

The first step in the treatment of cognitive decline in patients with any DLB should be elimination of medications with detrimental cognitive effects, especially anticholinergic medications.

The rationale for the use of cholinesterase inhibitors is based on the widespread and severe cortical cholinergic deficits present in LBDs as well as their U.S. Food and Drug Administration (FDA) approval in AD. The cholinesterase inhibitor rivastigmine (4.6-13.3 mg/d by transdermal patch or 6-12 mg/d orally) is FDA approved for the symptomatic treatment of cognitive impairment in PDD LEVEL 1.[3] Although not FDA approved for the treatment of DLB, the use of rivastigmine is supported by meta-analysis as well as positive results in one double-blind randomized clinical trial. Importantly, rivastigmine treated participants improved on measures of apathy and anxiety and had fewer delusions and hallucinations. A phase 2 exploratory trial of donepezil (n = 140) showed it to be safe and well tolerated and showed improvement in both cognition and behavior. A phase 3 trial of donepezil (n = 120) did not yield positive results in the coprimary endpoints (MMSE and neuropsychiatric inventory [NPI-2]); however, the 10-mg dose showed significant improvement in MMSE. Donepezil was approved for treatment of DLB in Japan in 2014. There have been case reports of worsening cognitive function, rapid eye movement sleep disorder, or parkinsonism with cholinesterase inhibitors, so patients should be followed carefully while using these drugs. These medications also carry risk of gastrointestinal side effects including nausea, vomiting, or diarrhea, although risk appears to be minimized through transdermal delivery. If cholinesterase inhibitors are discontinued, they should be tapered as opposed to abruptly stopped in order to minimize risk of sudden cognitive and behavioral worsening. Overall, the use of cholinesterase inhibitors (specifically rivastigmine and donepezil) as first-line treatment of both cognitive and neuropsychiatric symptoms is recommended by the revised McKeith consensus criteria.

Animal models of parkinsonism demonstrate glutamatergic overactivity in the striatum, and memantine, an *N*-methyl-D-aspartate receptor antagonist, has been FDA approved for moderate to severe AD. Studies of the effects of memantine (10 mg orally twice per day) have been inconsistent. The two largest randomized controlled trials combined both PDD and DLB. The first (n = 72 combined; 32 with DLB) showed improvement in clinical global impression of change in the DLB group only over 24 weeks. The second trial of memantine (N = 199, with 75 DLB) demonstrated improvement in NPI-2 only in the DLB group. Neither study showed improvement in cognition. Other studies have noted that memantine may worsen delusions and hallucinations in patients with DLB.

Several clinical trials are testing novel approaches to the treatment of cognitive deficits in LBDs. Selective targeting of serotonin receptor subtypes is a promising approach for cognitive dysfunction. However, recent failed trials have included targeted antagonism of serotonin 5-HT6 and/or serotonin 5-HT2A (5-HT2A), inhibition of phosphodiesterase 9, D1 receptor activation, glutamatergic inhibition, and stabilization of glucocerebrosidase. Several nonpharmacologic interventions are also promising. A small trial of bilateral deep brain stimulation of the nucleus basalis of Meynert in patients with PDD is underway. In patients with PD-MCI, noninvasive stimulation, with either repetitive transcranial magnetic stimulation or transcranial direct current stimulation, led to improvement in cognitive measures. Finally, exercise in nondemented PD patients improved working memory and attention.

Motor Symptoms

Parkinsonian motor symptoms in DLB are treated similarly because they are in PD. Generally speaking, patients with DLB appear to be less responsive to dopaminergic therapy than those with PD or PDD. Patients with DLB may be particularly susceptible to the neuropsychiatric side effects of dopaminergic medications, which may limit dosage level or require concomitant use of antipsychotic agents. Levodopa likely provides the best risk-benefit profile in DLB patients. Most adjunctive medications (eg, monoamine oxidase-B inhibitors, catechol-O-methyltransferase inhibitors) do not provide enough motor benefit to warrant their potential side effects. In particular, anticholinergic agents and amantadine frequently worsen cognitive impairment and psychosis and should be used with caution. Similarly, dopamine agonists should also be avoided due to potential for worsening psychosis and sedation. Patients with DLB are generally excluded from consideration for deep brain stimulation therapy due to poor outcome. Interestingly, zonisamide, an anticonvulsant that also inhibits release of glutamate, was studied as adjunctive treatment along with levodopa in DLB patients in a phase 2 trial. After 12 weeks, the higher dose (50 mg) led to a

modest motor benefit, without worsening cognitive or psychiatric symptoms.

Often overlooked are nonpharmacologic measures that can play an important role in the management of motor symptoms. Given patients' risk of falls and fluctuations in alertness, clinicians should encourage caregivers, with assistance from ancillary services, to take preventative steps to improve safety in the home environment. Multidisciplinary care, incorporating physical, occupational, and speech therapy, can provide significant improvement in several areas of motor function.

Psychosis

Passive observation of visual hallucinations and delusions can be considered if these symptoms are not causing significant disruption. Elimination or reduction of medications, especially anticholinergics that can exacerbate psychosis should be attempted first. Consideration should also be given to lowering the dosage of dopaminergic medications if possible.

If treatment is needed, typical and most atypical antipsychotics should be avoided in DLB patients because they are particularly sensitive to dopamine receptor blockers. It is estimated that almost 60% of patients with DLB may exhibit exaggerated extrapyramidal signs, sedation, immobility, or neuroleptic malignant syndrome with fever, generalized rigidity, and muscle breakdown following exposure to neuroleptics. Among the atypical antipsychotic agents, clozapine has the best established utility, although most of the studies have been performed in PDD patients LEVEL 1 .[4] Clozapine has an extremely low risk of exacerbating parkinsonism; however, it has a risk of agranulocytosis and requires close monitoring of white blood cell count. Low-dose quetiapine (25-100 mg) is considered effective (despite negative results from a single placebo-controlled trial in DLB). Common side effects include sedation and orthostatic hypotension; furthermore, patients and caregivers must be educated about its association with increased risk of cardiac morbidity, mortality, and stroke in elderly patients with dementia. Finally, as discussed earlier, cholinesterase inhibitors improve psychotic symptoms in patients with LBD patients and can be considered as a first-line approach.

Pimavanserin, a selective 5-HT2A inverse agonist, was approved in the United States for treating hallucinations and delusions in PD psychosis. It has not been studied in PDD or DLB; in fact, patients with dementia were excluded from the pivotal phase 3 trial in PD psychosis. Interestingly, post hoc analysis of this study found that patients with poorer cognitive function (MMSE 21-24) benefited equally from pimavanserin as compared with subjects with MMSE >24. There is an ongoing study of pimavanserin in psychosis associated with all-cause dementia.

Other Features

Additional common features of DLB include mood and sleep disorders as well as dysautonomia. These disorders are covered separately in Chapter 86 and are briefly covered here in the context of DLB. Evidence is lacking regarding the treatment of many of these conditions in DLB, and recommendations are often adapted from PD and other neurodegenerative cognitive disorders including AD.

Mood Disorders

Monoamine reuptake inhibitors—including selective serotonin reuptake inhibitors and serotonin-norepinephrine reuptake inhibitors—may be effective in treating anxiety and depression in patients with DLB. However, more research needs to be performed on the safety of these medications in these patient populations. There have been no randomized controlled trials in DLB for depression or anxiety. Electroconvulsive therapy has been successfully used to treat depression, but electroconvulsive therapy is infrequently used in dementia out of concern for worsening cognitive impairment related to treatment. Moreover, most studies have explored its use in early stage dementia. Benzodiazepines should be avoided (except for RBD), especially for long-term use, because of the potential for worsening confusion, gait disorder, and paradoxical agitation. Tricyclic antidepressants should be avoided due to their anticholinergic effects. Finally, psychotherapy may also be effective, especially in milder patients.

Sleep

Insomnia is a common problem in LBD. Usually, patients have trouble with sleep maintenance, rather than initiation. Proper sleep hygiene is important in optimizing the sleep-wake cycle. Maintaining a daily routine, exposure to natural light during the daytime hours, eliminating daytime naps, and elimination of late-day caffeine consumption are important recommendations. If pharmacologic treatment is needed, several options are available, including (starting with the most benign) melatonin, mirtazapine, trazodone. Sedatives, such as zolpidem, should be used with extreme caution because they can exacerbate neuropsychiatric symptoms. The antipsychotic quetiapine can also be used given its soporific effects, but should be used with caution, related to its adverse effect profile described earlier (see "Psychosis" section).

The RBD, if present, often does not require treatment if it is infrequent and does not lead to injury. Clonazepam (0.25-1 mg orally before bed) or melatonin (3 mg orally before bed) can be used to effectively treat symptoms. Nonpharmacologic treatments may include separate bed for partner, the placement of the mattress on the floor, or placing the mattress against the wall in conjunction with a bedrail on the opposite site, padding the corners of nearby furniture, removing potentially dangerous objects from the bedroom, and bed alarms alerting others if the patient has no bed partner.

Dysautonomia

Nonpharmacologic treatment of orthostatic hypotension includes use of compression stockings, ensuring adequate hydration, use of salt tablets. Pharmacologic options include fludrocortisone, pyridostigmine, midodrine, and droxidopa, either alone or in combination. Constipation can often be successfully addressed with dietary changes and adequate hydration. Nonprescription options, such as docusate sodium, senna, or polyethylene glycol, are also effective.

Lifestyle

It is important to discuss management of finances and medications with patients and caregivers. Cognitive impairment and parkinsonism associated with DLB place patients at higher risk for driving impairment. A formal driving evaluation should be considered in patients with DLB who wish to continue driving.

Future Directions

No clinical trials published to date have investigated disease-modifying agents in DLB. Future clinical trial investigations in DLB may include stimulation of endogenous neurotrophic factors, reduction of α-synuclein aggregation, immune-modulating therapies, and inflammatory inhibitors.

OUTCOME

There is no cure or disease-modifying therapy for DLB. Psychotic symptoms, particularly visual hallucinations, persist over time. Parkinsonism also worsens over time, especially in patients for whom this is an early symptom. Relative to AD, DLB has a more aggressive course. A recent meta-analysis found that survival time in DLB was 4.1 years from diagnosis, versus 5.7 years for AD. Other studies have found that patients with DLB progress to institutionalization earlier than patients with other types of dementia, perhaps due to earlier development of parkinsonism and daytime somnolence. Survival after nursing home placement is significantly impacted by the presence of depression and parkinsonism, including rigidity and gait abnormalities.

LEVEL 1 EVIDENCE

1. McKeith IG, Boeve BF, Dickson DW, et al. Diagnosis and management of dementia with Lewy bodies: fourth consensus report of the DLB consortium. *Neurology*. 2017;89:88-100.
2. McKeith I, O'Brien J, Walker Z, et al. Sensitivity and specificity of dopamine transporter imaging with 123I-FP-CIT SPECT in dementia with Lewy bodies: a phase III, multicentre study. *Lancet Neurol*. 2007;6:305-313.
3. Maidment I, Fox C, Boustani M. Cholinesterase inhibitors for Parkinson's disease dementia. *Cochrane Database Syst Rev*. 2006;(1):CD004747.
4. Parkinson Study Group. Low-dose clozapine for the treatment of drug-induced psychosis in Parkinson's disease. *N Engl J Med*. 1999;340:757-763.

SUGGESTED READINGS

Aarsland D, Ballard C, Walker Z, et al. Memantine in patients with Parkinson's disease dementia or dementia with Lewy bodies: a double-blind, placebo-controlled, multicentre trial. *Lancet Neurol*. 2009;8:613-618.

Aarsland D, Brønnick K, Ehrt U, et al. Neuropsychiatric symptoms in patients with Parkinson's disease and dementia: frequency, profile and associated care giver stress. *J Neurol Neurosurg Psychiatry*. 2007;78:36-42.

Aarsland D, Perry R, Larsen JP, et al. Neuroleptic sensitivity in Parkinson's disease and parkinsonian dementias. *J Clin Psychiatry*. 2005;66:633-637.

Aarsland D, Rongve A, Nore SP, et al. Frequency and case identification of dementia with Lewy bodies using the revised consensus criteria. *Dement Geriatr Cogn Disord*. 2008;26:445-452.

Ballard C, Holmes C, McKeith I, et al. Psychiatric morbidity in dementia with Lewy bodies: a prospective clinical and neuropathological comparative study with Alzheimer's disease. *Am J Psychiatry*. 1999;156:1039-1045.

Beyer MK, Larsen JP, Aarsland D. Gray matter atrophy in Parkinson disease with dementia and dementia with Lewy bodies. *Neurology*. 2007;69:747-754.

Boeve BF, Dickson DW, Duda JE, et al. Arguing against the proposed definition changes of PD. *Mov Disord*. 2016;31:1619-1622.

Boot BP, McDade EM, McGinnis SM, Boeve BF. Treatment of dementia with Lewy bodies. *Curr Treat Options Neurol*. 2013;15:738-764.

Dalrymple-Alford JC, MacAskill MR, Nakas CT, et al. The MoCA: well-suited screen for cognitive impairment in Parkinson disease. *Neurology*. 2010;75:1717-1725.

Dickson DW, Heckman MG, Murray ME, et al. *APOE* 4 is associated with severity of Lewy body pathology independent of Alzheimer pathology. *Neurology*. 2018;91:e1182-e1195.

Emre M, Tsolaki M, Bonuccelli U, et al. Memantine for patients with Parkinson's disease dementia or dementia with Lewy bodies: a randomised, double-blind, placebo-controlled trial. *Lancet Neurol*. 2010;9:969-977.

Ferman TJ, Boeve BF, Smith GE, et al. Inclusion of RBD improves the diagnostic classification of dementia with Lewy bodies. *Neurology*. 2011;77:875-882.

Ferman TJ, Smith GE, Kantarci K, et al. Nonamnestic mild cognitive impairment progresses to dementia with Lewy bodies. *Neurology*. 2013;81:2032-2038.

Guerreiro R, Ross OA, Kun-Rodrigues C, et al. Investigating the genetic architecture of dementia with Lewy bodies: a two-stage genome-wide association study. *Lancet Neurol*. 2018;17:64-74.

Ikeda M, Mori E, Matsuo K, Nakagawa M, Kosaka K. Donepezil for dementia with Lewy bodies: a randomized, placebo-controlled, confirmatory phase III trial. *Alzheimers Res Ther*. 2015;7:4.

Kantarci K, Ferman TJ, Boeve BF, et al. Focal atrophy on MRI and neuropathologic classification of dementia with Lewy bodies. *Neurology*. 2012;79:553-560.

Klatka LA, Louis ED, Schiffer RB. Psychiatric features in diffuse Lewy body disease: a clinicopathologic study using Alzheimer's disease and Parkinson's disease comparison groups. *Neurology*. 1996;47:1148-1152.

Lippa CF, Duda JE, Grossman M, et al. DLB and PDD boundary issues: diagnosis, treatment, molecular pathology, and biomarkers. *Neurology*. 2007;68:812-819.

Lobotesis K, Fenwick JD, Phipps A, et al. Occipital hypoperfusion on SPECT in dementia with Lewy bodies but not AD. *Neurology*. 2001;56:643-649.

McKeith I, Taylor J-P, Thomas A, Donaghy P, Kane J. Revisiting DLB diagnosis: a consideration of prodromal DLB and of the diagnostic overlap with Alzheimer disease. *J Geriatr Psychiatry Neurol*. 2016;29:249-253.

Minoshima S, Foster NL, Sima AA, et al. Alzheimer's disease versus dementia with Lewy bodies: cerebral metabolic distinction with autopsy confirmation. *Ann Neurol*. 2001;50:358-365.

Mishima A, Nihashi T, Ando Y, et al. Biomarkers differentiating dementia with Lewy bodies from other dementias: a meta-analysis. *J Alzheimers Dis*. 2016;50:161-174.

Mori E, Ikeda M, Kosaka K; for Donepezil-DLB Study Investigators. Donepezil for dementia with Lewy bodies: a randomized, placebo-controlled trial. *Ann Neurol*. 2012;72:41-52.

Murata M, Odawara T, Hasegawa K, et al. Adjunct zonisamide to levodopa for DLB parkinsonism: a randomized double-blind phase 2 study. *Neurology*. 2018;90:e664-e672.

O'Brien JT, McKeith IG, Walker Z, et al. Diagnostic accuracy of 123I-FP-CIT SPECT in possible dementia with Lewy bodies. *Br J Psychiatry*. 2009;194:34-39.

Oda H, Ishii K, Terashima A, et al. Myocardial scintigraphy may predict the conversion to probable dementia with Lewy bodies. *Neurology*. 2013;81:1741-1745.

Postuma RB, Berg D, Stern M, et al. Abolishing the 1-year rule: how much evidence will be enough? *Mov Disord*. 2016;31:1623-1627.

Postuma RB, Gagnon J-F, Bertrand J-A, Génier Marchand D, Montplaisir JY. Parkinson risk in idiopathic REM sleep behavior disorder: preparing for neuroprotective trials. *Neurology*. 2015;84:1104-1113.

Sadiq D, Whitfield T, Lee L, Stevens T, Costafreda S, Walker Z. Prodromal dementia with Lewy bodies and prodromal Alzheimer's disease: a comparison of the cognitive and clinical profiles. *J Alzheimers Dis*. 2017;58:463-470.

Stern Y, Marder K, Tang MX, Mayeux R. Antecedent clinical features associated with dementia in Parkinson's disease. *Neurology*. 1993;43:1690-1692.

Stinton C, McKeith I, Taylor J-P, et al. Pharmacological management of Lewy body dementia: a systematic review and meta-analysis. *Am J Psychiatry*. 2015;172:731-742.

Taylor JP, McKeith IG, Burn DJ, et al. New evidence on the management of Lewy body dementia. *Lancet Neurol*. 2020;19(2):157-169.

Vendette M, Gagnon JF, Décary A, et al. REM sleep behavior disorder predicts cognitive impairment in Parkinson disease without dementia. *Neurology*. 2007;69:1843-1849.

Wang H-F, Yu J-T, Tang S-W, et al. Efficacy and safety of cholinesterase inhibitors and memantine in cognitive impairment in Parkinson's disease, Parkinson's disease dementia, and dementia with Lewy bodies: systematic review with meta-analysis and trial sequential analysis. *J Neurol Neurosurg Psychiatr*. 2015;86:135-143.

Yoshita M, Taki J, Yokoyama K, et al. Value of 123I-MIBG radioactivity in the differential diagnosis of DLB from AD. *Neurology*. 2006;66:1850-1854.

54 Vascular Dementia and Cognitive Impairment

Nikolaos Scarmeas and Adam M. Brickman

KEY POINTS

1. Vascular dementia is characterized by cognitive dysfunction with accompanying functional decline caused by either ischemic or hemorrhagic cerebrovascular disease, or sequelae of hypoperfusion, hypotension, or hypoxia.
2. Cerebrovascular disease can contribute to dementia syndromes even if not the primary biologic etiology of dementia, or can be the primary cause of dementia.
3. A diagnosis of vascular dementia requires (1) clinically and radiologically ascertained strokes, (2) dementia, and (3) a clear temporal (presumably causal) relationship between stroke(s) and dementia.
4. As many as 15% to 20% of patients with acute ischemic stroke older than age 60 years have dementia at the time of the stroke, and 5% per year develop dementia thereafter.
5. The majority of older adults with dementia harbor mixed Alzheimer and vascular neuropathologic changes.
6. Patients with vascular dementia often experience a stepwise cognitive decline resulting from additional cerebrovascular events.
7. Primary prevention of stroke via control of related risk factors may reduce vascular dementia rates.

INTRODUCTION

During much of the 20th century, it was assumed that most dementia of the elderly was vascular in origin, an assumption challenged during the last few decades after the recognition of the importance of Alzheimer pathologic changes. Nevertheless, interest in the role of cerebrovascular disease on cognition and function reemerged particularly not only due to wider use of modern neuroimaging techniques but also due to accumulation of more knowledge on the impact of small-vessel cerebrovascular pathology. The traditional concepts that blood vessel blockage and leakage are primary causes of cognitive impairment through their impact on neuronal cell loss is being gradually enriched by deeper understanding of the role of the neurovascular unit, which includes the interaction of endothelial cells and pericytes with astrocytes, oligodendrocytes, and microglia (**Fig. 54.1**). Overall, the clinical importance of vascular abnormalities in cognitive performance has been a focus of increased attention.

Brain injury caused by ischemic or hemorrhagic lesions, ischemic white matter disease, and sequelae of hypotension or hypoxia, can undoubtedly contribute to cognitive impairment. Vascular dementia can be characterized generally as cognitive dysfunction attributable to vascular brain injury that affects functional abilities, such as instrumental and basic activities of daily living. It can result from a variety of mechanisms (**Table 54.1** and **Figs. 54.2** to **54.3**).

Although several diagnostic schemes for vascular dementia have been proposed, there is no current consensus. Available clinical criteria have been somewhat controversial and many have not been adequately validated, have been inconsistently applied, and lack satisfactorily high sensitivity and specificity. *Overall, as a practical rule, a diagnosis of vascular dementia requires (1) clinically (symptoms-signs) and radiologically confirmed strokes, (2) dementia, and (3) a clear temporal relationship between stroke(s) and dementia.* Cerebrovascular disease is itself heterogeneous, with a variety of pathophysiologic mechanisms and clinical manifestations and correspondingly, vascular dementia manifests as a heterogeneous clinical syndrome.

Cerebrovascular disease can cause cognitive impairment in the absence of dementia. There is also a growing appreciation that most cases of dementia are characterized by mixed pathologies, including cerebrovascular disease in addition to neurodegenerative, and that cerebrovascular disease can contribute to cognitive dysfunction even if it is not considered the primary cause of dementia. Because of these factors, the term *vascular cognitive impairment* was introduced to recognize the continuum of the contributions of cerebrovascular disease—across multiple subtypes—to cognitive functioning, which ranges from subtle effects on cognition, to a secondary or comorbid contributor to dementia, to the primary etiology of dementia. Cerebrovascular disease can be focal or distributed across multiple brain systems; the cognitive manifestations of vascular cognitive impairment is equally heterogeneous.

EPIDEMIOLOGY

As many as 15% to 20% of patients with acute ischemic stroke older than age 60 years have dementia at the time of the stroke, and 5% per year develop dementia thereafter. On a clinical basis, vascular dementia has been long considered the second (after Alzheimer disease) or third (after Alzheimer and dementia with Lewy bodies) most frequent cause of dementia. Considering data from pathologic series and related clinical-pathologic correlations highlights the complexity of the issue, particularly because most cases of dementia are of mixed etiology. Although most elderly patients with dementia have Alzheimer type pathologic changes (70%-80%), the vast majority of them have coexisting

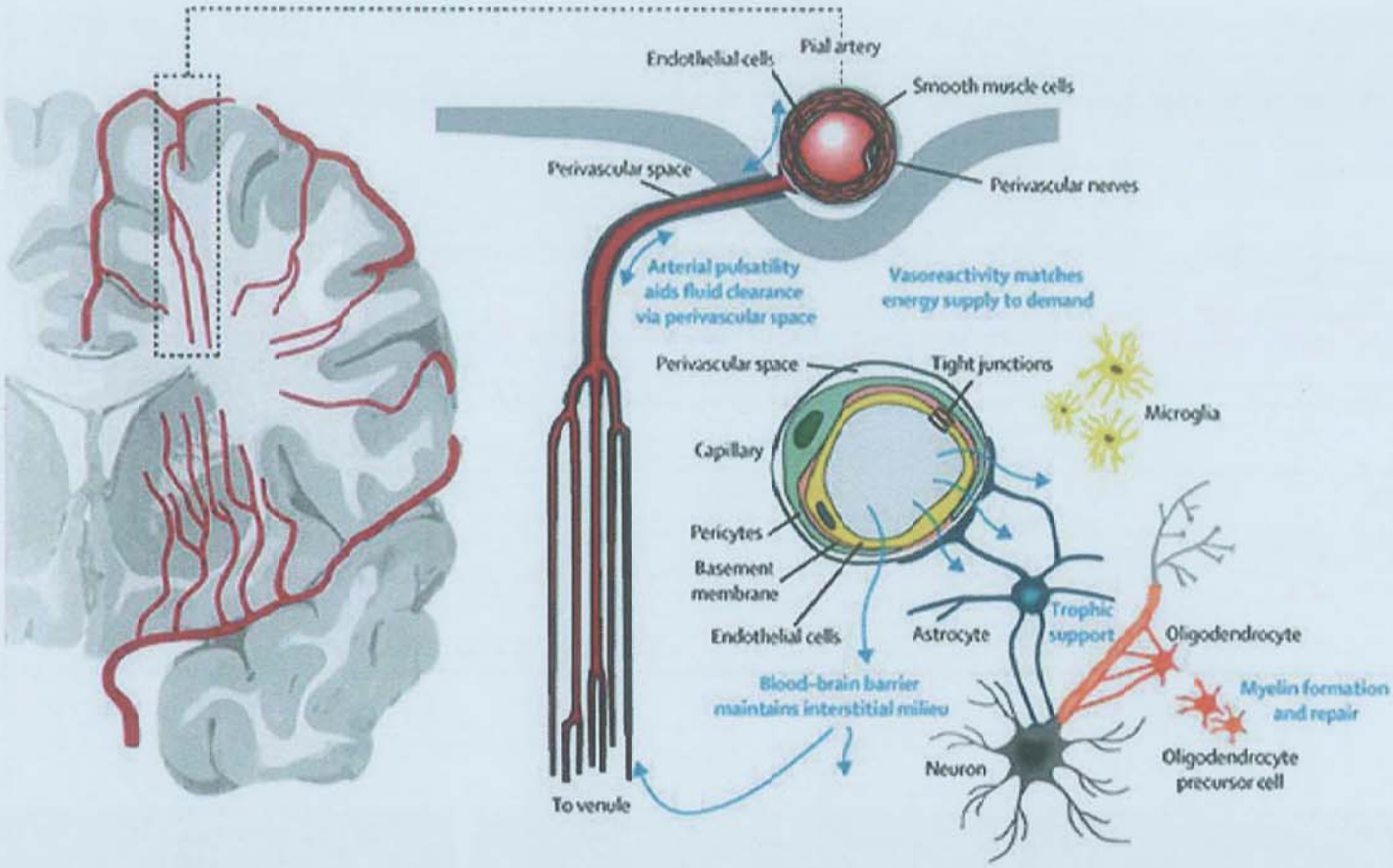

FIGURE 54.1 Key constituents of the neurovascular unit and possible entry points for disease mechanisms in cerebral small-vessel disease. Arterioles penetrate the brain and branch into capillaries. They are each surrounded by a perivascular space that is connected to the cerebrospinal fluid. Capillary endothelial cells, including their connecting tight junctions, a specialized basement membrane, pericytes, and astrocyte end-feet collectively form the blood-brain barrier. The blood-brain barrier is essential for maintaining the interstitial milieu. Astrocytes maintain the interstitial fluid balance, provide energy to neurons, and relay signals between neurons and other cells to the vasculature to adapt blood flow to energy demand. Oligodendrocytes form and repair myelin around axons to which they also provide metabolic and trophic support. At the cellular level, endothelial cell dysfunction and blood-brain barrier dysfunction increase interstitial fluid and proteins, disrupt astrocyte end-feet, which impairs interstitial fluid exchange, block oligodendrocyte precursor cell maturation, which impairs myelination and repair and energy support to axons, and impede normal astrocyte function, decreasing neuronal energy supply. Several of the cellular and functional constituents of the vasculo-glio-neuronal unit (ie, endothelial cells, pericytes, astrocytes, oligodendrocytes, neurons, and the extracellular matrix) represent possible entry points for disease mechanisms in small-vessel disease. (Obtained from Wardlaw JM, Smith C, Dichgans M. Small vessel disease: mechanisms and clinical implications. *Lancet Neurol.* 2019;18(7):684-696.)

cerebrovascular disease, whereas fewer than 30% have "pure," Alzheimer-only, pathology. Similarly, most older adults have some degree of small-vessel cerebrovascular pathology, but a large amount of small-vessel dysfunction may be necessary to be the sole cause of dementia. Dementia due to infarcts solely without significant pathologic contributions of Alzheimer or Lewy body pathology is strikingly uncommon, with estimated rates between 2% and 10% of dementia cases.

Ethnic and geographic variability of vascular cognitive impairment and dementia rates have been reported. Vascular dementia prevalence in developing countries seems to be low, whereas rates seem to be relatively higher in many Latin American and Asian countries, including China. Adding to the argument of higher contribution rates of vascular cognitive impairment as contributory to dementia but perhaps less frequently the sole cause is the fact that most pathologic studies consider only larger infarcts, whereas microinfarcts are extremely common and diffuse in the brain, although the clinical importance of such microinfarcts is not fully established. Finally, many white matter abnormalities visualized on brain magnetic resonance imaging are often undetectable by standard neuropathologic examinations performed upon autopsy, suggesting limited sensitivity of neuropathology for detection of cerebrovascular damage.

PATHOBIOLOGY

Overall, strokes themselves and factors that predispose to cerebrovascular disease are considered risk factors for vascular dementia and vascular cognitive impairment. Predisposing conditions for cerebral infarcts or hemorrhages are numerous and should be included in patients' workups (see Chapter 45, Primary and Secondary Stroke Prevention). Patients with vascular dementia are usually old and may suffer from cardiovascular

TABLE 54.1 Proposed Types of Vascular Dementia Based on Localization and Pathophysiologic Mechanism

Vascular Dementia Subtype	Comments/Additional Information for Each Subtype, Including Localization, Mechanisms, etc
Critically located (strategic "single") infarcts	Bilateral frontal infarctions from anterior cerebral artery occlusions Bilateral thalamic infarction from posterior cerebral artery occlusions Inferior medial temporal lobe infarcts Middle cerebral artery occlusions leading to frontal/parietal infarcts, etc
Multiple ischemic infarcts affecting large vessels	Not necessarily in critical locations but leading to significant parenchymal volume loss
Small-vessel disease	Multiple lacunar infarcts in the basal ganglia Multiple lacunar infarcts in subcortical or periventricular white matter leading to a more widespread, patchy pattern often described as leukoaraiosis in brain imaging studies—previously called *Binswager disease*
Hemorrhagic infarcts	Intraparenchymal hemorrhages due to chronic vascular damage from hypertension Amyloid angiopathy Intracerebral or subdural hematomas or subarachnoid hemorrhage
Hypoperfusion	Due to internal carotid artery stenosis; due to (or sometimes in combination with) systemic causes such as heart failure, hypotension, bypass surgery, cardiac arrest, medications, or other systemic conditions
Other mechanisms	Combinations of the above Cerebral autosomal dominant arteriopathy with subcortical infarcts and leukoencephalopathy (CADASIL), an autosomal dominant form of cerebrovascular dementia (and also migraines and psychiatric symptoms) related to mutations in the *NOTCH3* gene on chromosome 19 Mitochondrial encephalomyopathy with lactic acidosis and stroke-like episodes (MELAS)

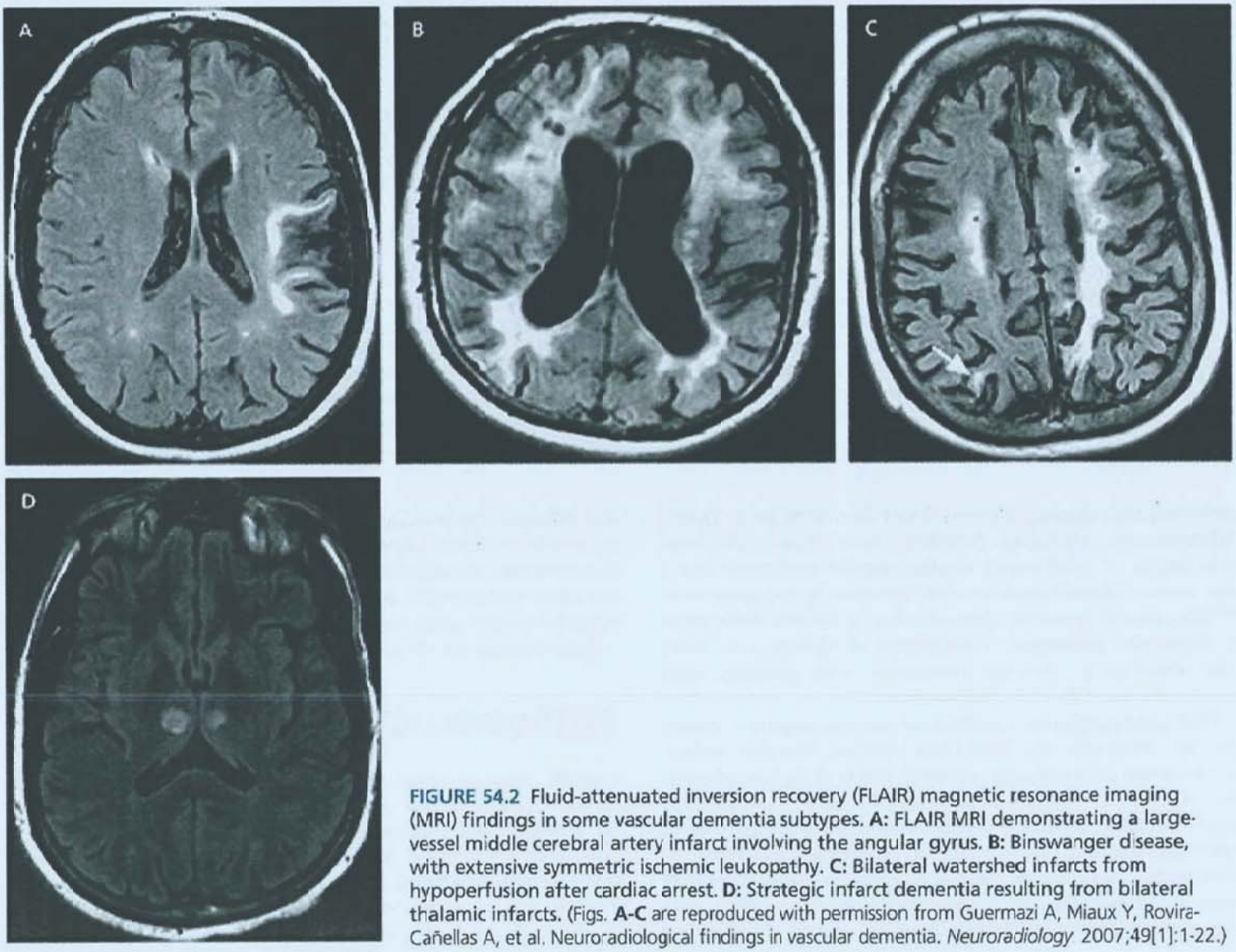

FIGURE 54.2 Fluid-attenuated inversion recovery (FLAIR) magnetic resonance imaging (MRI) findings in some vascular dementia subtypes. **A:** FLAIR MRI demonstrating a large-vessel middle cerebral artery infarct involving the angular gyrus. **B:** Binswanger disease, with extensive symmetric ischemic leukopathy. **C:** Bilateral watershed infarcts from hypoperfusion after cardiac arrest. **D:** Strategic infarct dementia resulting from bilateral thalamic infarcts. (Figs. **A-C** are reproduced with permission from Guermazi A, Miaux Y, Rovira-Cañellas A, et al. Neuroradiological findings in vascular dementia. *Neuroradiology* 2007;49[1]:1-22.)

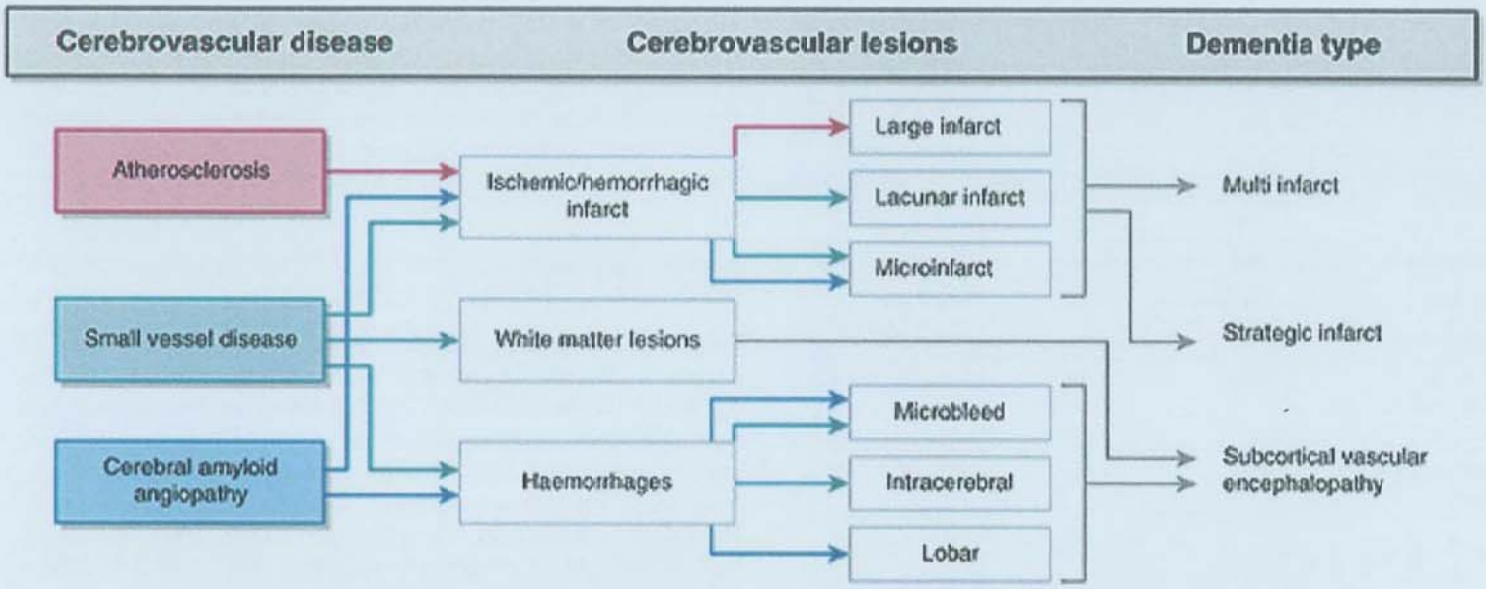

FIGURE 54.3 Schematic diagram illustrating the three most commonly observed cerebrovascular diseases and their resulting cerebrovascular lesions that may lead to specific types of vascular dementia. (Obtained from McAleese KE, Alafuzoff I, Charidimou A, et al. Post-mortem assessment in vascular dementia: advances and aspirations. *BMC Med*. 2016;14[1]:129.)

disease, including heart attacks, cardiac arrhythmias, and congestive heart failure, or from diabetes, hypertension, and dyslipidemia, with eventual damage in many organs. Cerebral amyloid angiopathy is among the most common causes of hemorrhagic lesions that are typically in lobar regions; small hemorrhagic lesions in subcortical areas are more commonly attributable to hypertensive vasculopathy. Cerebral amyloid angiopathy is characterized by amyloid β peptide deposits within small to medium-sized blood vessels of the brain and leptomeninges. It can present with or without coexisting Alzheimer disease neuropathologic changes. Beyond genetic susceptibility to strokes, rare genetic causes of vascular dementia include cerebral autosomal dominant arteriopathy with subcortical infarcts and leukoencephalopathy (CADASIL) and mitochondrial encephalomyopathy with lactic acidosis and stroke-like episodes.

Whether Alzheimer type pathologic changes induce cerebrovascular damage or whether cerebrovascular disease promote Alzheimer neuropathology is not settled. Overall, there is a complex interaction among stroke, vascular risk factors, and Alzheimer disease, although the exact nature of this interaction remains unknown.

DIAGNOSIS

In contrast to mild cognitive impairment or dementia due to underlying Alzheimer disease that predominantly affects memory, vascular cognitive impairment, and vascular dementia may have more variable effects on cognitive domains (with or without memory). The symptoms and signs of vascular dementia or vascular cognitive impairment may include difficulty with acquiring and remembering new information, impaired reasoning, judgment and handling of complex tasks, deficits in visual spatial abilities, problems with language function (comprehension, expression, etc), and changes in personality or behavior. The exact mix of the above abilities depends on cerebral localization of vascular damage or the brain systems affected by cerebrovascular disease. If for example, the temporal lobe neural circuits responsible for memory function are less affected, amnesic deficits, a key feature in Alzheimer disease, may be less prominent in vascular dementia. Focal noncognitive deficits related to vascular dementia causing strokes may also coexist.

A more "cortical" syndrome with clear stepwise deterioration including focal motor or sensory symptoms and signs, aphasia, neglect, abulia, apraxia, agnosia, amnesia, etc, resulting from repeated distinct strokes may be present. However, vascular dementia often presents as a more "subcortical" syndrome that is characterized by apathy, inertia, bradyphrenia, deficits in attention and concentration, executive dysfunction (problems with organization, planning, and strategy), often abnormal gait (which may mimic apraxic or magnetic gait or that of lower body parkinsonism), urinary urgency or incontinence, depression, as well as emotional incontinence ("pseudobulbar affect"), including inappropriate crying or laughing.

In general, in the differential diagnosis from Alzheimer disease, features that would favor the diagnosis of vascular dementia would include an abrupt onset of dementia temporally related to a cerebral infarct, a stepwise deterioration, and a fluctuating course. There are no diagnostic tests specific for vascular dementia.

Clinical presence of stroke documented by either history (symptoms) or neurologic examination (residual signs), although not entirely required, enhances specificity of vascular dementia diagnosis.

Presence of infarcts in brain imaging studies is a requirement for a diagnosis of vascular dementia. Their nature (hemorrhagic, ischemic), size (small, large), number (one strategic, many), or location (cortical, subcortical, different brain structures) can widely vary (Fig. 54.2). Widespread, confluent white matter disease or hyperintensities, often referred to leukoaraiosis, can be a prominent feature and may be an indicator of vascular cognitive impairment even in the absence of frank infarct.

Evaluation to define a specific stroke subtype and etiology should be included in a diagnostic workup. In nonadvanced stages, cognitive deficits should be documented with neuropsychological evaluation, but their nature is also nonspecific because

TABLE 54.2 Medications Commonly Prescribed for Vascular Dementia

Medication — Active Substance	Route	Targeted Maximum Daily Dose	Frequency of Administration
Donepezil	Oral	10 mg	Once a day
Rivastigmine	Oral	12 mg	6 mg twice a day
Rivastigmine	Transdermal	13.3 mg	Once a day
Galantamine	Oral	24 mg	Once a day
Memantine (immediate release)	Oral	20 mg	10 mg twice a day
Memantine (extended release)	Oral	28 mg	Once a day

they depend on stroke localization that may vary from patient to patient. However, deficits in frontal function, including difficulties with attention-concentration, slow speed of processing, difficulties with initiation, and executive dysfunction may be prominent. Particularly, in subcortical forms of vascular dementia, amnestic deficits may be characterized by difficulties in free recall of information with relative improvement in recognition (ie, when aided with various strategy cues).

MANAGEMENT

Prevention and Treatment of Stroke

Primary prevention of stroke treatment, treatment of recent stroke, and prevention of recurrent stroke are central to vascular dementia rates, course, and prognosis. Smoking cessation, control/treatment of hypertension, diabetes, dyslipidemia, obesity, asymptomatic carotid endarterectomy, etc are examples of preventive strategies. Similarly, antiplatelets, anticoagulants, and symptomatic carotid endarterectomy are examples of stroke recurrence prevention approaches. Stroke treatment and stroke preventative strategies are discussed in more detail in Chapters 36 and 45.

Cognitive and Behavioral Symptoms

The efficacy of cholinesterase inhibitors and memantine, approved therapies for Alzheimer dementia have not been extensively studied in populations where dementia is considered to be only due to vascular origin. At the same time, efficacy of these medications—medication classes has been demonstrated in patients with mixed Alzheimer dementia and stroke/vascular dementia LEVEL 1.[1-11] Given that such mixed dementia is quite common and that it is clinically often difficult to rule out concomitant Alzheimer pathologic changes in patients diagnosed with vascular dementia, it stands to reason to offer cholinesterase inhibitors and memantine therapy to such patients. Initiation with one of the three approved cholinesterase inhibitors, subsequently followed by addition of memantine is the common practice. The doses commonly prescribed and corresponding titration schedules toward the maximum dose (occurring during the course of weeks/months depending on the particular medication) are those used for Alzheimer dementia, the primary indication for such treatments (Table 54.2). The treatment approaches to behavioral and neuropsychiatric symptoms of dementia are similar to those taken in Alzheimer disease and related dementias as discussed elsewhere in this section.

OUTCOME

Prognosis in vascular dementia is more variable than that of Alzheimer disease because it is largely dependent on coexisting strokes. Providing effective modification of cerebrovascular disease risk factors occurs, none or only a limited number of future strokes may occur, and the cognitive deficits can remain relatively static for protracted periods or until death. For other vascular dementia patients who continue to suffer from additional cerebral infarcts, a progressive cognitive decline and dementia deterioration is usually noted.

LEVEL 1 EVIDENCE

1. Black S, Román GC, Geldmacher DS, et al. Efficacy and tolerability of donepezil in vascular dementia: positive results of a 24-week, multicenter, international, randomized, placebo-controlled clinical trial. *Stroke*. 2003;34:2323-2330.
2. Wilkinson D, Doody R, Helme R, et al. Donepezil in vascular dementia: a randomized, placebo-controlled study. *Neurology*. 2003;61:479-486.
3. Erkinjuntti T, Kurz A, Gauthier S, Bullock R, Lilienfeld S, Damaraju CV. Efficacy of galantamine in probable vascular dementia and Alzheimer's disease combined with cerebrovascular disease: a randomised trial. *Lancet*. 2002;359:1283-1290.
4. Auchus AP, Brashear HR, Salloway S, Korczyn AD, De Deyn PP, Gassmann-Mayer C. Galantamine treatment of vascular dementia: a randomized trial. *Neurology*. 2007;69:448-458.
5. Orgogozo JM, Rigaud AS, Stöffler A, Möbius HJ, Forette F. Efficacy and safety of memantine in patients with mild to moderate vascular dementia: a randomized, placebo-controlled trial (MMM 300). *Stroke*. 2002;33:1834-1839.
6. Wilcock G, Möbius HJ, Stöffler A. A double-blind, placebo-controlled multicentre study of memantine in mild to moderate vascular dementia (MMM500). *Int Clin Psychopharmacology*. 2002;17:297-305.
7. Kumar V, Anand R, Messina J, Hartman R, Veach J. An efficacy and safety analysis of Exelon in Alzheimer's disease patients with concurrent vascular risk factors. *Eur J Neurol*. 2000;7:159-169.
8. Román GC, Wilkinson DG, Doody RS, Black SE, Salloway SP, Schindler RJ. Donepezil in vascular dementia: combined analysis of two large-scale clinical trials. *Dement Geriatr Cogn Disord*. 2005;20(6):338-344.
9. Malouf R, Birks J. Donepezil for vascular cognitive impairment. *Cochrane Database Syst Rev*. 2004;(1):CD004395.
10. Moretti R, Torre P, Antonello RM, Cazzato G, Bava A. Rivastigmine in subcortical vascular dementia: a randomized, controlled, open 12-month study in 208 patients. *Am J Alzheimers Dis Other Demen*. 2003;18(5):265-272.
11. Birks J, Craig D. Galantamine for vascular cognitive impairment. *Cochrane Database Syst Rev*. 2006;(4):CD004746.

SUGGESTED READINGS

Breteler MM. Vascular risk factors for Alzheimer's disease: an epidemiologic perspective. *Neurobiol Aging*. 2000;21(2):153-160.

Chui HC, Mack W, Jackson JE, et al. Clinical criteria for the diagnosis of vascular dementia: a multicenter study of comparability and interrater reliability. *Arch Neurol*. 2000;57(2):191-196.

Chui HC, Zheng L, Reed BR, Vinters HV, Mack WJ. Vascular risk factors and Alzheimer's disease: are these risk factors for plaques and tangles or for concomitant vascular pathology that increases the likelihood of dementia? An evidence-based review. *Alzheimers Res Ther*. 2012;4(1):1.

Erkinjuntti T. Subcortical vascular dementia. *Cerebrovasc Dis*. 2002;13(suppl 2):58-60.

Gold G, Giannakopoulos P, Montes-Paixao Júnior C, et al. Sensitivity and specificity of newly proposed clinical criteria for possible vascular dementia. *Neurology*. 1997;49(3):690-694.

Guermazi A, Miaux Y, Rovira-Cañellas A, et al. Neuroradiological findings in vascular dementia. *Neuroradiology*. 2007;49[1]:1-22.]

Hachinski V, Iadecola C, Petersen RC, et al. National Institute of Neurological Disorders and Stroke-Canadian Stroke Network vascular cognitive impairment harmonization standards. *Stroke*. 2006;37(9):2220-2241.

Hachinski VC, Lassen NA, Marshall J. Multi-infarct dementia. A cause of mental deterioration in the elderly. *Lancet*. 1974;2(7874):207-210.

Jellinger KA. The pathology of ischemic-vascular dementia: an update. *J Neurol Sci*. 2002;203-204:153-157.

Kalaria RN, Ballard C. Overlap between pathology of Alzheimer disease and vascular dementia. *Alzheimer Dis Assoc Disord*. 1999;13(suppl 3):S115-S123.

Kalaria RN, Maestre GE, Arizaga R, et al. Alzheimer's disease and vascular dementia in developing countries: prevalence, management, and risk factors. *Lancet Neurol*. 2008;7(9):812-826.

Kalmijn S, Foley D, White L, et al. Metabolic cardiovascular syndrome and risk of dementia in Japanese-American elderly men. The Honolulu-Asia Aging Study. *Arterioscler Thromb Vasc Biol*. 2000;20(10):2255-2260.

Kapasi A, DeCarli C, Schneider JA. Impact of multiple pathologies on the threshold for clinically overt dementia. *Acta Neuropathol*. 2017;134(2):171-186.

Kavirajan H, Schneider LS. Efficacy and adverse effects of cholinesterase inhibitors and memantine in vascular dementia: a meta-analysis of randomised controlled trials. *Lancet Neurol*. 2007;6(9):782-792.

Langa KM, Foster NL, Larson EB. Mixed dementia: emerging concepts and therapeutic implications. *JAMA*. 2004;292(23):2901-2908.

Launer LJ, Hughes TM, White LR. Microinfarcts, brain atrophy, and cognitive function: the HAAS autopsy study. *Ann Neurol*. 2011;70(5):774-780.

Libon DJ, Heilman KM. Assessing the impact of vascular disease in demented and nondemented patients. *Stroke*. 2008;39(3):783-784.

Lobo A, Launer LJ, Fratiglioni L, et al. Prevalence of dementia and major subtypes in Europe: a collaborative study of population-based cohorts. Neurologic Diseases in the Elderly Research Group. *Neurology*. 2000;54(11 suppl 5):S4-S9.

Lopez OL, Kuller LH, Becker JT. Diagnosis, risk factors, and treatment of vascular dementia. *Curr Neurol Neurosci Rep*. 2004;4(5):358-367.

Lopez OL, Kuller LH, Becker JT, et al. Classification of vascular dementia in the Cardiovascular Health Study Cognition Study. *Neurology*. 2005;64(9):1539-1547.

Marchant NL, Reed BR, Sanossian N, et al. The aging brain and cognition: contribution of vascular injury and Aβ to mild cognitive dysfunction. *JAMA Neurol*. 2013;70(4):488-495.

McAleese KE, Alafuzoff I, Charidimou A, et al. Post-mortem assessment in vascular dementia: advances and aspirations. *BMC Med*. 2016;14(1):129.

Moorhouse P, Rockwood K. Vascular cognitive impairment: current concepts and clinical developments. *Lancet Neurol*. 2008;7(3):246-255.

O'Brien JT, Erkinjuntti T, Reisberg B, et al. Vascular cognitive impairment. *Lancet Neurol*. 2003;2(2):89-98.

Reed BR, Marchant NL, Jagust WL, et al. Coronary risk correlates with cerebral amyloid deposition. *Neurobiol Aging*. 2012;33(9):1979-1987.

Reed BR, Mungas DM, Kramer JH, et al. Profiles of neuropsychological impairment in autopsy-defined Alzheimer's disease and cerebrovascular disease. *Brain*. 2007;130(pt 3):731-739.

Regier DA, Kuhl EA, Kupfer DJ. The DSM-5: classification and criteria changes. *World Psychiatry*. 2013;12(2):92-98.

Román GC. Vascular dementia: distinguishing characteristics, treatment, and prevention. *J Am Geriatr Soc*. 2003;51(5 suppl dementia):S296-S304.

Román GC, Sachdev P, Royall DR, et al. Vascular cognitive disorder: a new diagnostic category updating vascular cognitive impairment and vascular dementia. *J Neurol Sci*. 2004;226(1-2):81-87.

Román GC, Tatemichi TK, Erkinjuntti T, et al. Vascular dementia: diagnostic criteria for research studies. Report of the NINDS-AIREN International Workshop. *Neurology*. 1993;43(2):250-260.

Sonnen JA, Larson EB, Crane PK, et al. Pathological correlates of dementia in a longitudinal, population-based sample of aging. *Ann Neurol*. 2007;62(4):406-413.

Tomlinson BE, Blessed G, Roth M. Observations on the brains of demented old people. *J Neurol Sci*. 1970;11(3):205-242.

Troncoso JC, Zonderman AB, Resnick SM, Crain B, Pletnikova O, O'Brien RJ. Effect of infarcts on dementia in the Baltimore Longitudinal Study of Aging. *Ann Neurol*. 2008;64(2):168-176.

van der Flier WM, Skoog I, Schneider JA, et al. Vascular cognitive impairment. *Nat Rev Dis Primers*. 2018;4:18003.

Viswanathan A, Greenberg SM. Cerebral amyloid angiopathy in the elderly. *Ann Neurol*. 2011;70(6):871-880.

Wardlaw JM, Smith C, Dichgans M. Small vessel disease: mechanisms and clinical implications. *Lancet Neurol*. 2019;18(7):684-696.

Weslover MB, Bianchi MT, Yang C, Schneider JA, Greenberg SM. Estimating cerebral microinfarct burden from autopsy samples. *Neurology*. 2013;80(15):1365-1369.

Wetterling T, Kanitz RD, Borgis KJ. Comparison of different diagnostic criteria for vascular dementia (ADDTC, DSM-IV, ICD-10, NINDS-AIREN). *Stroke*. 1996;27(1):30-36.

Zheng L, Mack WJ, Chui HC, et al. Coronary artery disease is associated with cognitive decline independent of changes on magnetic resonance imaging in cognitively normal elderly adults. *J Am Geriatr Soc*. 2012;60(3):499-504.

Prion Diseases 55

Boon Lead Tee and Michael Geschwind

KEY POINTS

1. Prion diseases are a group of neurodegenerative disorders caused by misfolding of the prion-related protein into the pathologic form commonly known as *prions*.
2. Human prion diseases can occur in three ways: sporadic (most common), genetic mutations in the prion protein gene, and acquired cases (rare).
3. Sporadic Creutzfeldt-Jakob disease (CJD) typically begins in the seventh decade with rapid onset and progression of several cognitive, motor, and behavioral changes; visual disturbances and constitutional symptoms also are common.
4. Many of the cerebrospinal fluid biomarkers used for sporadic CJD diagnosis reflect rapid brain cell injury and are not as specific as real-time quaking-induced conversion assay.
5. Brain magnetic resonance imaging changes in sporadic CJD include cortical gyral and/or deep nuclei hyperintensities on fluid-attenuated inversion recovery and especially diffusion-weighted imaging sequences.
6. A negative family history does not exclude the possibility of a genetic prion disease.
7. Most prion protein gene missense mutations have near 100% penetrance.
8. Genetic testing panels for autosomal dominant dementias and/or next-generation sequencing may miss less common prion protein octapeptide insertions and other insertions/deletions.

INTRODUCTION

Prion diseases represent a group of fatal and transmissible neurodegenerative disorders. They are caused by the conversion of the prion-related protein (PrP^C, in which C stands for the normal cellular form of the protein) into the misfolded pathologic form of PrP commonly known as *prions* or PrP^{Sc} (Sc stands for scrapie, the prion disease of sheep and goats). The term *prion* stemmed from the term *proteinaceous infectious particle*. Prions were discovered by Stanley B. Prusiner in 1982 who was subsequently awarded the Nobel Prize in Physiology or Medicine in 1997. Prior to this, prion diseases were thought to be caused by "slow viruses" with long incubation period between exposure and disease onset. The ground-breaking discovery of the prion protein, and its mechanism for causing disease by misfolding, expanded the scientific understandings of infectious diseases that traditionally regarded the presence of nucleic acids (ie, DNA or RNA) as mandatory in infectious agents. Studies have not only proven that the prion protein is necessary for the development of prion diseases, but researchers also have identified the self-templating and self-propagating nature of prions, with the latter being a common feature of other neurodegenerative diseases. The discovery of the human prion protein gene, *PRNP*, that encodes human PrP and that mutations in *PRNP* lead to genetic prion disease (gPrD) further strengthened the prion hypothesis.

History and Nomenclature

The first prion disease was described more than 150 years ago in animals, sheep and goats, and was named scrapie because the infected animals developed itching and scraped themselves against objects for relief. As a result, the pathologic form of prion protein often is referred to as PrP^{Sc}. Other terms also are used in the literature to refer to prions, such as PrP^{Res}, in which Res refers to the transmissible core of prions that is resistant to protease digestion. The resemblance of the animal prion disease scrapie to the acquired human prion disease Kuru, and with sporadic human prion disease (sporadic Creutzfeldt-Jakob disease or sCJD), was first highlighted in 1959. At the time, all were thought to be caused by a "slow virus." In 1920, the German neurologist Hans Gerhard Creutzfeldt reported a 23-year-old woman with spastic paraparesis, status epilepticus, dystonia, and cerebellar ataxia. Between 1921 and 1923, another German neurologist, Alfons Maria Jakob, described five cases that he thought were similar to Creutzfeldt's case. In retrospect, Jakob's cases were clinically different from Creutzfeldt's case, and in review of the clinical presentation and pathology, Creutzfeldt's case was not prion disease and only two, or possibly three, of Jakob's cases had what we would now consider prion disease clinically and/or pathologically. For decades, the disease was called *Jakob disease*, *Creutzfeldt disease*, or *Jakob-Creutzfeldt disease* or *syndrome*. In the 1960s, however, a prominent researcher in the field, Clarence J. Gibbs, began to use the term *CJD* because he liked having the initials closer to his own. Thus, some researchers consider that the most accurate terminology for human prion disease should be Jakob disease or possibly Jakob-Creutzfeldt disease. The abbreviation for Jakob-Creutzfeldt disease, however, has caused some clinicians to confuse it with the John Cunningham (JC) virus that causes progressive multifocal leukoencephalopathy. For this reason and because the term *CJD* has become so common, we use this ubiquitous, albeit historically inaccurate, terminology in this chapter.

Prior to the discovery of the prion, prion diseases were referred to as *transmissible spongiform encephalopathies* (TSEs) given the transmissibility of the diseases and the spongiform pattern (actually vacuolation) commonly found on neuropathology. In view that some prion diseases have not been shown to be transmissible and not all prion diseases show spongiform pathologic changes, the term *TSE* is somewhat antiquated, and therefore we do not use it as a general term to describe prion diseases in this chapter.

TABLE 55.1 Prion Disease Classification

Category	Name of Disorder or Syndrome	Abbreviation	Subtypes/Comments
Sporadic	Sporadic Creutzfeldt-Jakob disease	sCJD	At least six different subtypes or "molecular classification" based on *PRNP* codon 129 polymorphism and prion typing
	Sporadic fatal insomnia	sFI	The MM2thalamic subtype of sCJD, which clinically presents similarly to FFI
	Variable protease-sensitive prionopathy	VPSPr	Very rare sporadic disease with most of PrP^{Sc} being sensitive to protease digestion; fewer than 20 cases reported
Genetic	Familial CJD	fCJD	More than 20 missense mutations and some OPRIs
	Gerstmann-Sträussler-Scheinker syndrome	GSS	More than a dozen missense mutations and some OPRIs
	Fatal familial insomnia	FFI	Due to a single *PRNP* missense mutation, D178N, usually with codon 129M
	Octapeptide repeat insertions	OPRIs	Named based on the number of OPRIs; typically depending on size of OPRI, can present as fCJD, GSS, or along the spectrum of the two.
	Stop codon mutations	—	Highly variable, atypical clinical features for most PrDs, and pathology findings reveal brain amyloid plaques and/or prion amyloid angiopathy.
Acquired	Variant CJD	vCJD	From consumption of bovine spongiform encephalopathy or exposure to vCJD prions in blood
	Kuru	Kuru	—
	Iatrogenic CJD	iCJD	Human pituitary hormones, dura mater grafts and corneal transplants, reused depth electrodes

Abbreviations: PrDs, prion diseases; PrP^{Sc}, scrapie isoform of the prion protein.

Human prion diseases can occur in three ways: sporadic (spontaneous), genetic (familial, inherited), and acquired (transmitted, infectious) (Table 55.1). Approximately 85% of human prion diseases cases occur spontaneously, 15% are genetic (due to autosomal dominant mutations in *PRNP*), and fewer than 1% are acquired cases. The sporadic form of prion disease is referred to as *sCJD* because it is believed to occur through the spontaneous misfolding of normal form of the prion protein, PrP^{C}, into the pathologic misfolded form, PrP^{Sc}. Based on their clinical and pathologic features, gPrDs have been historically categorized into three different forms: familial CJD (fCJD), Gerstmann-Sträussler-Scheinker disease (GSS), and fatal familial insomnia (FFI). This classification, however, is antiquated because it developed prior to the discovery of *PRNP* and thus fails to encompass the variability within certain mutations as well as the clinical and pathologic phenotypes of some *PRNP* mutations, such as stop codons and octapeptide repeat insertions (OPRIs). Despite being the least common form of human prion diseases, the acquired forms of CJD (including Kuru, variant CJD [vCJD], and iatrogenic CJD [iCJD]) have received much attention due to their inadvertent transmission from animals to humans and from human to human. Human prion diseases generally are considered as the prototypical rapidly progressive dementia (RPD), although not all forms, particularly of some genetic mutations, progress rapidly.

PATHOBIOLOGY

Prion Protein Properties

Both PrP^{C} and PrP^{Sc} share identical amino acid sequences (with the exception of gPrDs) but differ in their three-dimensional conformational structures. PrP^{C} is comprised predominantly of α-helical structure, whereas PrP^{Sc} is comprised primarily of β-sheet structure that is likely stacked in a solenoid manner. Proteins rich in β-sheet structure are usually found to be highly resistant to proteolysis and thermodynamically stable. PrP^{Sc} also possesses a self-templating property in which PrP^{Sc} can act as a template and convert PrP^{C} into the misfolded conformation, PrP^{Sc}, when they come into contact with each other; this conversion process becomes exponential. Furthermore, different strains of PrP^{Sc} exist that vary in terms of their biologic and physicochemical properties. Such strain diversity partially explains the variabilities in tissue tropism, host affinity, and clinical presentations of different prion diseases.

Animal studies have shown that the presence of PrP^{C} is compulsory for prion pathogenicity; $PrP^{-/-}$ (knockout) transgenic mice can neither be infected with prions nor replicate prions in their tissues. When $PrP^{-/-}$ transgenic mice are transplanted with neuronal tissue expressing PrP^{C} and the mice are infected with prions, only this explanted tissue has PrP^{Sc} accumulation, whereas the host brain tissue remains devoid of PrP^{Sc}.

Prion Protein Functions

The human prion protein gene, *PRNP*, is located on the short arm of chromosome 20 and is highly evolutionarily conserved. Its normal form protein, PrP^{C}, is speculated to be related to neuronal development and function, although the exact functions remain largely unknown. Scientists have attempted to investigate the functions of PrP^{C} by analyzing the phenotypes of mice with their prion protein gene, *PRNP*, knocked out. Unfortunately, numerous reported traits were found not to be reproducible in *PRNP* knockout mice of different genetic backgrounds. This raised concerns that some of the reported traits were caused by the Mendelian segregations of *PRNP*-flanking genes in mice with mixed genetic background. Thus, studying the phenotypes

of *PRNP* knockout mice with pure genetic background may better represent PrP^C protein functions. *PRNP* knockout mice with pure genetic background have been found to develop chronic demyelinating peripheral neuropathy, altered circadian rhythm, and altered synaptic plasticity. Such findings suggest that PrP^C protein may play a role in sustaining myelin integrity, maintaining circadian rhythm, and facilitating synaptic plasticity. Furthermore, if *PRNP* is only knocked out after mice have fully developed, mice remain largely phenotypically normal, suggesting that PrP^C may be more essential during development.

Prion Protein Pathogenicity

Prion disease is generally believed to be more of a gain of function than a loss of function disease primarily for two reasons: (1) Homozygous or hemizygous *PRNP* knockout mice (the latter with half the level of PrP^C) remain largely asymptomatic, and (2) prion protein expression level is directly associated with the rate of disease progression in mice models. Some studies suggest that the pathogenicity of prion protein may be associated with its proteolytic processing. Mice in a high-stress environment seem to favor the β-cleavage over α-cleavage proteolytic processing, which generates membrane-bound C terminal protein (C2) that possess a amyloidogenic core that may in turn facilitate prion aggregation. Furthermore, the glycosylphosphatidylinositol anchor that attaches PrP^C onto the cell membrane may be involved in the pathophysiology of prion protein. Evidence supporting this is that transgenic mice which encode PrP^C without its glycosylphosphatidylinositol anchor have been reported to be clinical asymptomatic despite having PrP^{Sc} plaque deposition in the brain or shown to have late-onset neurologic symptoms with GSS-like pathology.

SPORADIC CREUTZFELDT-JAKOB DISEASE

Epidemiology

In most countries with adequate surveillance, the annual incidence of sCJD is estimated to range between 1 and 1.5 per 1 million population, with a slight growth over the past two decades likely contributed by the improvement of diagnostic methods and the rapidly growing aging population. The estimated median age of onset for sCJD is 60 to 67 years old, although with high variability, ranging between 12 and 95 years old. Young-onset sCJD (20s-40s) and onset after the age of 80 years are uncommon. Some studies suggest that sCJD cases with a younger age of onset tend to have longer survival and often present with noncognitive symptoms, including mood disorder, behavioral change, or sleep illnesses. The mean and median survival of sCJD is estimated to be 8 ± 11 months and 4.5 to 6 months (range, 1-130), respectively.

Clinical Presentation

Patients can present with a wide range of symptoms including cognitive impairment, behavioral changes, movement disorders, visual disturbances, and constitutional symptoms. Because of the varied presentations, sCJD often is called *the great mimicker*. A common early presentation is cognitive impairment, which may manifest as confusion, disorientation, memory decline, attention deficits, executive dysfunction, aphasia, and/or other higher cortical deficits. In a retrospective record review of 230 pathologically confirmed CJD cases, nearly all (96%) exhibited cognitive decline during their clinical course. Motor symptoms often include extrapyramidal symptoms (eg, bradykinesia, dystonia, tremor), cerebellar symptoms (eg, gait, or less commonly, limb ataxia), myoclonus, and/or pyramidal symptoms. Myoclonus can be spontaneous or startle provoked and may occur early in the classic sCJD variant (see next paragraph) or later in the disease course in some nonclassic forms. Extrapyramidal symptoms often include tremor (usually postural or with action), bradykinesia, cogwheeling, and/or movements. Pyramidal signs typically occur later in the disease course and typically include hyperreflexia or spasticity, but (in our experience) focal weakness is very rare. Typical behavioral symptoms seen in sCJD individuals include irritability, anxiety, depression, and, less commonly, psychosis. Other commonly reported clinical presentations or prodromes include constitutional symptoms (fatigue, malaise, headache, dry cough, light-headedness, vertigo, urinary incontinence, and sleep disturbance), visual symptoms (blurred or double vision and cortical blindness), and, less commonly, sensory symptoms (numbness, tingling, and/or pain).

Based on the initial presenting and predominant symptoms, sCJD has been classified into different clinical variants or presentations: classic (RPD, early and prominent myoclonus, often with a typical electroencephalogram [EEG] with periodic sharp wave complexes [PSWCs]), cognitive, Heidenhain (early and prominent visual symptoms), affective (early, prominent mood disorders), and Brownell-Oppenheimer (early, prominent ataxia) variants. In one of our own studies, with about 100 serial sCJD cases, the first clinical manifestations were cognitive in 40%, cerebellar, constitutional or behavioral in 20% for each, and extrapyramidal or pyramidal, visual or sensory symptoms in 10% or fewer of cases for each. In addition to having different initial presentations, these sCJD variants may differ in their clinical course, EEG, and brain magnetic resonance imaging (MRI) findings (see Diagnosis section). Classic and visual variants tend to be more rapidly progressive with a shorter disease course, whereas in one study the affective variant had the longest disease survival and younger age of onset compared to other variants. Conversely, the Oppenheimer-Brownell (ataxic) variant has an older age of onset and rarely exhibits PSWCs on EEG. Regardless of the sCJD variants, most sCJD cases will develop akinetic mutism (no purposeful movement and not speaking) at the end stage of the disease, with aspiration pneumonia being the most common direct cause of death.

Classic neuropathologic findings for sCJD include PrP^{Sc} deposition, vacuolation (formerly known as *spongiform changes*), neuronal loss without inflammation, and gliosis (proliferation of astrocytes) (Fig. 55.1). Pathologists have increasingly favored the term *vacuolation* over *spongiform changes* because the small cavities seen in the superficial cortical layers are fluid-filled vesicles formed in distal dendrites and not air-filled holes. Table 55.1 summarizes the clinical characteristics of several human prion diseases.

Molecular Classification

In addition to clinical phenotypes, sCJD has traditionally been subdivided into six "molecular" subtypes based on: (1) the genetic polymorphism at codon 129 in *PRNP* and (2) the prion type, the latter of which is determined by the molecular weight of PrP^{Sc} fragments after protease digestion. Type 1 prions are

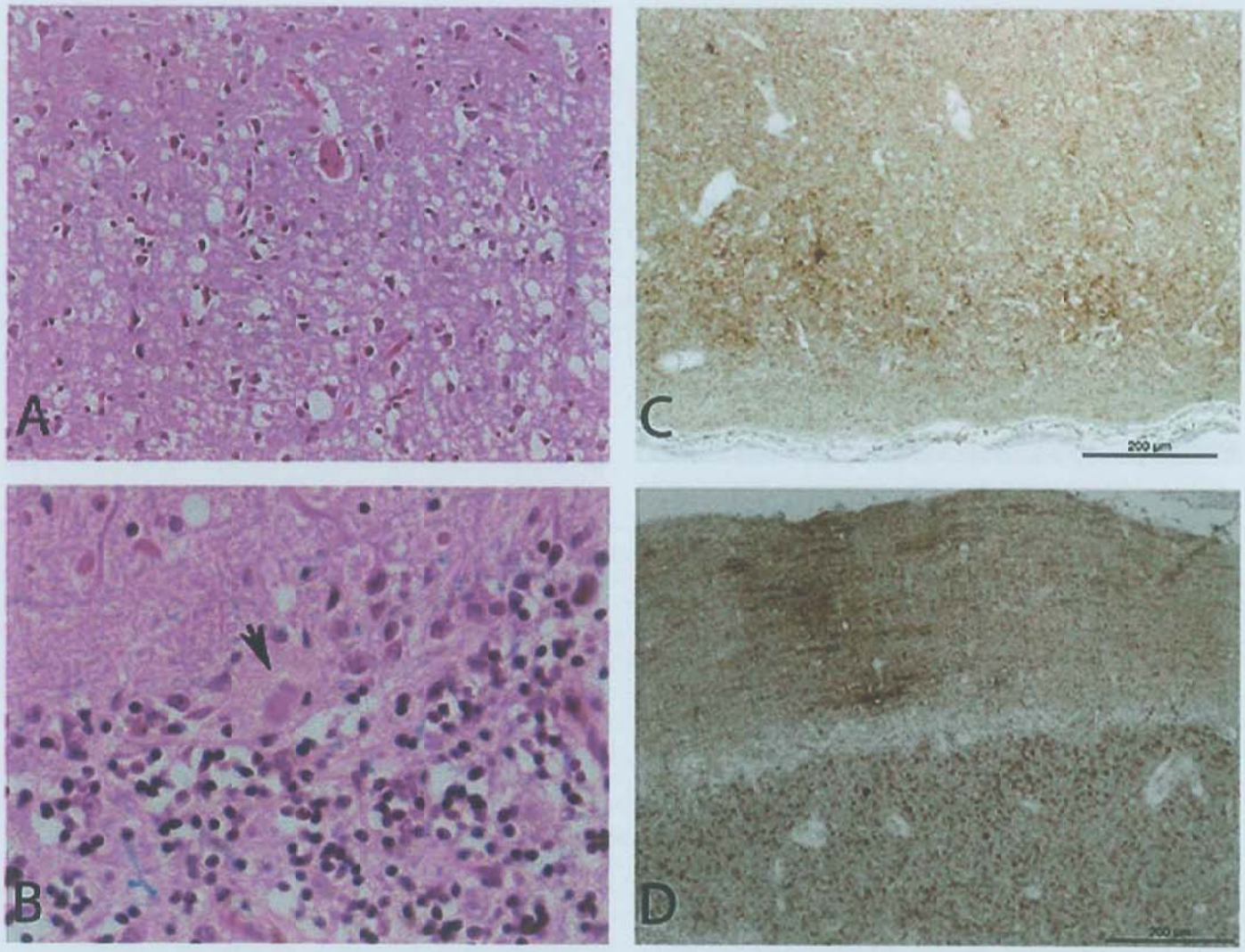

FIGURE 55.1 **A** and **B** show stained histologic sections of frontal cortex and cerebellar cortex, respectively, stained with hematoxylin, eosin, and Luxol fast blue. **C** and **D** show immunohistochemically stained sections of frontal cortex and cerebellar cortex, respectively, stained with monoclonal antibody 3F4, specific for PrP^{res} (also called PrP^{Sc}). **A** and **C** are oriented with white matter up and pial surface downward. **A** shows prominent vacuolation of the gray matter more than the white matter, typical of prion-related spongiform change. **C** shows brown staining of granular deposits of abnormal prion protein, variably aggregated but more prominent in gray matter than white matter. **B** and **D** are oriented with cerebellar molecular layer up and granular cell layer downward. **B** shows minimal spongiform change but a prominent Kuru plaque *(arrow)*. **D** shows brown staining of granular deposits of abnormal prion protein in the molecular layer. (**A** and **B** courtesy of Dr. Jean Paul Vonsattel, Columbia University; **C** and **D** courtesy of Dr. Pierluigi Gambetti, Case Western Reserve University.)

21 kilodaltons (KDa) and type 2 are 19 KDa. By combining the codon 129 polymorphism and prion type, sCJD cases historically have been classified into six molecular subtypes: MM1, MV1, VV1, VV2, MV2, and MM2. As MM1 and MV1 share many similar clinicopathologically features, some large studies group them together as a single subtype, although they can have differences from each other, such as on MRI. The MM1/MV1 subtype is the most common accounting for about 70% of sCJD, with about 67.5 % being MM1 and 2.5% being MV1. The MM1/MV1 subtype typically presents as classic sCJD, with RPD, ataxia and myoclonus; a large minority of cases can have prominent visual or unilateral motor symptoms. It has the shortest disease duration with a median of about 4 months. The VV2 subtype is the second most common, comprising about 16% of sCJD cases. It generally manifests as the Brownell-Oppenheimer variant (ataxia) with late dementia and slightly longer medial duration of about 6 months and usually does not have a typical EEG. The MV2 subtype is third most common and represents about 9% of sCJD; similar to VV2 it usually presents with ataxia and does not have a typical EEG but has early progressive dementia and a longer median duration of 12 to 17 months. This subtype has been further divided and includes a large subset with focal amyloid "Kuru" plaques in the cerebellum and is referred to as the *Kuru plaque variant* or MV2K. The MM2 subtype is often subdivided into a cortical and a thalamic form, MM2-C and MM2-T, respectively, each representing approximately 2% of sCJD cases; both have median durations of about 12.5 to 15 months and usually do not have typical EEGs. MM2-C typically presents with progressive cognitive dysfunction and neuropathologically has confluent vacuoles in cortical layers, whereas MM2-T clinically often (but not always) resembles familial fatal insomnia with early insomnia and dysautonomia, followed by psychomotor hyperactivity, ataxia, and dementia at the later stage of the disease. This MM2-T form is also referred to as sporadic fatal insomnia

(sFI). Neuropathologically, MM2-T usually shows PrP^{Sc} deposition, but with very prominent gliosis and neuronal loss confined mainly to the thalamus and inferior olives, but little vacuolation (which probably explains why the MRI usually does not show restricted diffusion). VV1 is the rarest subtype (approximately 1%) with much younger, by about 15 to 20 years, median age of onset (39-47 y old) and a long disease duration of approximately 11 to 15 months, a large minority of sCJD cases have both type 1 and type 2 PrP^{Sc}. As the clinicopathologic phenotype appears to depend on the relative proportion of the two prion types, this supports the PrP^{Sc} type playing some role in determining the sCJD phenotype. Similarly, the codon 129 plays a large role in disease survival, with heterozygosity, MV, being associated with slower progression, independent of prion typing.

Diagnosis

Diagnostic criteria for sCJD have been modified several times due to improved diagnostic tests and increased understanding of the early presentations of the disease. Most sCJD criteria have three levels of diagnostic certainty: definite, probable, and possible (**Table 55.2**). Definite sCJD diagnosis requires evidence of PrP^{Sc} protein in infected tissue, either via immunohistochemistry or Western blot. Possible criteria generally are based on a constellation of symptoms alone, whereas probable criteria require symptoms plus a positive supportive diagnostic test (ie, EEG, MRI, and/or cerebrospinal fluid [CSF]). **Table 55.2** shows four commonly used diagnostic criteria for probable sCJD. Clinical features generally require a progressive dementia and include myoclonus, visual and/or cerebellar features, pyramidal or extrapyramidal features, and/or akinetic mutism. University of California, San Francisco (UCSF) criteria have added higher cortical dysfunction (ie, aphasia, apraxia, alien limb, neglect, etc) and separate out visual and cerebellar findings because in our experience, they do not necessarily co-occur and have very different anatomy. Biomarker tests for probable sCJD criteria include typical EEG (PSWCs), certain brain MRI findings (discussed in detail later), elevated CSF 14-3-3 protein (hereon referred to as "14-3-3") or a positive real-time quaking-induced conversion assay (RT-QuIC) from CSF or other tissue.

The most common EEG finding in sCJD is PSWCs, characterized by periodic sharp biphasic or triphasic waves, occurring about once every second (Fig. 55.2). Some large studies show only about 58% to 64% of sCJD cases have PSWCs during their disease course, and these findings usually present at late stage of the disease, with occurrence varying greatly based on the molecular classification (MM1: 73%, MV1: 53%, MV2/VV2/VV1: 12%-18%). Furthermore, PSWCs can be found in other neurologic illnesses, some which may share clinical features with sCJD, including Alzheimer disease, Lewy body disease, vascular dementia, hypoxic encephalopathies, progressive multifocal leukoencephalopathy, Hashimoto encephalopathy, and autoimmune-associated encephalopathy. Although this fact somewhat limits EEG's role in sCJD diagnosis by itself, by using criteria symptoms and other diagnostic tests (see the following paragraphs on CSF and MRI) may further increase diagnostic certainty for sCJD.

Numerous CSF proteins that reflect rapid brain cell injury have been proposed as sCJD diagnostic biomarkers, including 14-3-3, total tau, neuron-specific enolase (NSE), and the astrocytic protein S100β (S100β). The 14-3-3 was among the first proposed diagnostic biomarkers for sCJD and can be measured via Western blot or enzyme-linked immunosorbent assay. Due to the heterogeneity of the control groups and the different quantifying methods/protocols adopted, the sensitivity and specificity of these CSF biomarkers varies considerably among different publications and cohorts. Although, 14-3-3 is considered by many experts to be highly predictive of sCJD when there is a classic presentation LEVEL 1[1] but has limited value in atypical cases or less common subtypes its diagnostic utility remains an issue of controversy among CJD experts, however. In our own UCSF cohort of several hundred cases of RPD, 14-3-3 shows low sensitivity (approximately 55%) and specificity (approximately 70%-75%) for prion disease. Over time, the specificity of 14-3-3 has clearly been shown to be rather poor in large studies. One possible reason for the higher sensitivity for the 14-3-3 reported in studies from national prion surveillance centers, is that some centers have used it to screen for patients with CJD, thus sCJD patients with positive 14-3-3 are more likely to be referred to these national prion surveillance centers. For unclear reasons, European centers have often found higher diagnostic accuracy with 14-3-3 than North American centers. Nevertheless, an increasing number of studies have consistently shown several other CSF nonspecific biomarkers, such as total tau and NSE, to have better diagnostic sensitivity and/or specificity than 14-3-3. Among other non–prion-specific CSF biomarkers such as total tau, NSE, and S100β, several studies have indicated that CSF total tau as well as the ratio between phosphorylated tau to total tau have higher predictability in identifying sCJD. These CSF diagnostic markers, however, have much lower sensitivity and specificity for other forms of prion disease, such as vCJD and gPrDs. CSF neurofilament light chain (NfL) appears to have relatively high sensitivity for CJD but extremely low specificity because it is elevated in many neurodegenerative and related neurologic disorders. Several studies have also studied serum NfL and tau concentration as potential serum biomarkers and found them to be potential indicators for the severity and/or prognosis of prion diseases.

In contrast to previous biomarkers that reflect rapid neuronal injury, a relatively new test, RT-QuIC, detects PrP^{Sc} itself. This method allows detection of very small quantities of PrP^{Sc} that might be present in a sample (eg, CSF) by amplifying it. The sample to be tested to determine if it contains PrP^{Sc} is pipetted onto a microwell plate containing PrP^{C} substrate. When the plate is shaken, if any PrP^{Sc} is present in a well, this promotes conversion of the PrP^{C} substrate into PrP^{Sc}. PrP^{Sc} eventually forms amyloid fibrils, which bind thioflavin T that is added to the mixture, thereby emitting a fluorescent signal to reflect the presence of PrP^{Sc}. Multiple tissues have been investigated using RT-QuIC, including brain tissue, CSF, nasal mucosa, skin, and eye tissues (retina, optic nerve, extraocular muscle, choroid, lens, vitreous, and sclera). Depending on the study, the substrate used and assay conditions, RT-QuIC sensitivity and specificity generally ranges between 77% to 97% and 98% to 100%, respectively. Thus, RT-QuIC is regarded as useful minimally to mildly invasive ante mortem test to confirm a sCJD diagnosis in the proper clinical context LEVEL 1,[2] but certainly negative results do not exclude the disease.

Brain MRI as a diagnostic tool for sCJD has evolved considerably over the past three decades. The first identified MRI characteristics were increased signal intensity in basal ganglia on T2-weighted scans. Later, cortical gyral hyperintensities, commonly referred to as *cortical ribboning*, on fluid-attenuated inversion recovery (FLAIR) and DWI MRI sequences were noted to be more sensitive indicators for sCJD. These MRI abnormalities,

TABLE 55.2 Diagnostic Criteria for Sporadic, Genetic, Variant, and Iatrogenic Creutzfeldt-Jakob Disease[a]

	Sporadic CJD	Genetic CJD	Variant CJD	Iatrogenic CJD
Definite	Progressive neurologic syndrome **AND** Neuropathologically **OR** Immunocytochemically **OR** Biochemically confirmed	• Definite TSE **AND** • Definite or probable TSE in first-degree relative **OR** • Pathogenic *PRNP* mutation[b]	Progressive neuropsychiatric disorder **AND** Neuropathologic confirmed[c]	Definite CJD with a recognized iatrogenic risk factor[d]
Probable	Rapidly progressive cognitive impairment with two of the following: • Myoclonus • Visual or cerebellar disturbance • Pyramidal or extrapyramidal signs • Akinetic mutism **AND** • Typical EEG[e] **OR** • Typical MRI[f] **OR** • Elevated CSF 14-3-3 **OR** Progressive neurologic syndrome with a positive RT-QuIC in CSF or other tissues	Progressive neuropsychiatric disorder **AND** • Definite or probable TSE in first-degree relative **OR** • Pathogenic *PRNP* mutation[b]	• Progressive neuropsychiatric disorder • Duration of illness >6 mo • Routine investigations do not suggest an alternative diagnosis • No history of potential iatrogenic exposure • No evidence of a familial form of TSE **AND** Four of the following: • Early psychiatric features[g] • Persistent painful sensory symptoms[h] • Ataxia • Myoclonus or chorea or dystonia • Dementia **AND** Positive tonsil biopsy **OR** EEG does not show the typical appearance of sporadic CJD in the early stages of illness.[e] **AND** Bilateral pulvinar high signal on MRI scan	• Progressive predominant cerebellar syndrome in human pituitary hormone recipients **OR** • Probable CJD with a recognized iatrogenic risk factor[d]
Possible	Rapidly progressive cognitive impairment with two of the following: • Myoclonus • Visual or cerebellar disturbance • Pyramidal or extrapyramidal signs • Akinetic mutism **AND** Disease duration <2 y		• Progressive neuropsychiatric disorder • Duration of illness >6 mo • Routine investigations do not suggest an alternative diagnosis. • No history of potential iatrogenic exposure • No evidence of a familial form of TSE **AND** Four of the following: • Early psychiatric features[g] • Persistent painful sensory symptoms[h] • Ataxia • Myoclonus or chorea or dystonia • Dementia **AND** EEG does not show the typical appearance of sporadic CJD in the early stages of illness.[e]	• Possible CJD with a recognized risk factor[d]

Abbreviations: CJD, Creutzfeldt-Jakob disease; CSF, cerebrospinal fluid; EEG, electroencephalogram; MRI, magnetic resonance imaging; RT-QuIC, real-time quaking-induced conversion assay; TSE, transmissible spongiform encephalopathy.

[a]Criteria are borrowed (with slight modifications) with permission from UK National Creutzfeldt-Jakob Disease Research & Surveillance Unit. Diagnostic criteria for human prion disease. National CJD Research & Surveillance Unit Web site. https://www.cjd.ed.ac.uk/diagnostic-criteria. Updated January 2017. Accessed August 28, 2019.

[b]Pathogenic *PRNP* mutations include P102L, P105L, A117V, G131V, F198S, D202N, Q212P, Q217R, M232T, 192 bpi, D178N-129V, V180I, V180I + M232R, T183A, T188A, E196K, E200K, V203I, R208H, V210I, E211Q, M232R, 96 bpi, 120 bpi, 144 bpi, 168 bpi, 48 bpdel, D178N-129M, Y145s, H187R, 216 bpi, I138M, G142S, Q160S, T188K, M232R, 24 bpi, 48 bpi, and 48 bpi + nucleotide substitution in other octapeptides.

[c]Spongiform change and extensive prion protein deposition with florid plaques throughout the cerebrum and cerebellum.

[d]Treatment with human pituitary growth hormone, human pituitary gonadotrophin or human dura mater graft, corneal graft in which the corneal donor has been classified as definite or probable human prion disease, or exposure to neurosurgical instruments previously used in a case of definite or probable human prion disease.

[e]Typical EEG: periodic sharp waves complexes.

[f]Typical MRI for European Consortium 2017 criteria: High signal abnormalities in caudate nuclei and putamen or at least two cortical regions (temporal-parietal-occipital but not frontal, cingulate, insular, or hippocampal) either on diffusion-weighted imaging or fluid-attenuated inversion recovery MRI. Note: The authors of this chapter consider the University of California, San Francisco (UCSF) sporadic CJD MRI criteria (Staffaroni et al., 2017) to be far more sensitive and specific than the European Consortium MRI criteria (Zerr et al., 2009).

[g]Depression, anxiety, apathy, withdrawal, delusions.

[h]Includes frank pain and/or dysesthesias.

[i]Tonsil biopsy is not recommended routinely nor in cases with EEG appearances typical of sporadic CJD but may be useful in suspect cases in which the clinical features are compatible with variant CJD and MRI does not show bilateral pulvinar high signal.

FIGURE 55.2 Electroencephalogram tracings show pseudoperiodic generalized paroxysmal discharges. The electroencephalogram montage shows generalized paroxysmal discharges with a sharp, often triphasic, morphology that occur in a nearly periodic fashion of about one per second. Amplitude is somewhat greater in the frontal regions.

however, are much more evident on DWI than on T2 or even FLAIR sequences (Fig. 55.3). Such DWI hyperintensities in sCJD are due to restricted diffusion (of water molecule flow likely due to vacuolation), and thus there is usually corresponding decreased signal intensity on apparent diffusion coefficient (ADC) map sequences. It is important to confirm on MRI that this DWI hyperintensity has corresponding ADC hypointensity because some brain regions, particularly areas with air-brain interface, are artefactually hyperintense on DWI or T2 and not true restricted diffusion. The pattern and sensitivity of MRI findings varies considerably among the six sCJD molecular subtypes (Fig. 55.4). For instance, VV1 often does not have basal ganglia hyperintensity on T2 or DWI, whereas more than 50% of VV1, MM2, and MV1 subtypes have cortical ribboning, and thalamic hyperintensity is found more commonly (approximately 45%) in VV2 and MV2 but in less than 10% of MM1 and VV1 and in about 20% to 35% of MV1 and MM2 subtypes. The diagnostic accuracy of MRI in sCJD may be affected by the MRI acquisition sequences used and the radiologists' experience. Obtaining higher b values, such as b2000, rather than the typical b1000, on DWI and ADC map reduces air-brain artifacts and allows improved detection of cortical ribboning from background. As knowledge of MRI features of sCJD has improved, MRI criteria have also been modified to improve diagnostic accuracy. The UCSF 2017 sCJD MRI criteria (see Staffaroni et al., 2017) emphasize the importance of diffusion over T2 and FLAIR sequences because abnormal signal usually is more evident on diffusion sequences. Furthermore, with optimal acquisition protocols (eg, b2000 DWI, ADC and exponential ADC images acquired in multiple directions), brain regions previously considered to have a lot of artefact—such as frontal and insular cortices, cingulate gyrus, and anterior temporal lobes—now can be incorporated as regions of interest in sCJD MRI criteria (see **Table 55.2**). In general, the sensitivity and specificity of brain MRI for sCJD range from 91% to 96% LEVEL 2.[3]

GENETIC PRION DISEASE

Unlike most "infectious" disease, 10% to 15% of prion diseases are of genetic etiology and caused by mutations in *PRNP* (see **Table 55.2**). To date, there are more than 60 *PRNP* variants reported, with the majority being missense mutations; all are autosomal dominant inheritance pattern and most are highly penetrant. Some variants initially purported to be pathogenic, however, are frequent enough in the normal population that they are likely either risk factors, very low penetrance pathogenic variants (ie, mutations) or even nonpathogenic. Worldwide, about 85% of gPrDs are caused by five missense *PRNP* mutations: E200K, V210I, V180I, P102L, and D178N. In one large European study, nearly half of the gPrD cases (47%) identified had a negative family history, although with wide variations among the major mutations (E200K, 49.1%; V201I, 12.3%; FFI, 88%). Two primary reasons for these negative family histories are likely misdiagnoses of previous cases in the family (such as Alzheimer or Parkinson disease) or that the disease was hidden from family members or branches of a family, both of which

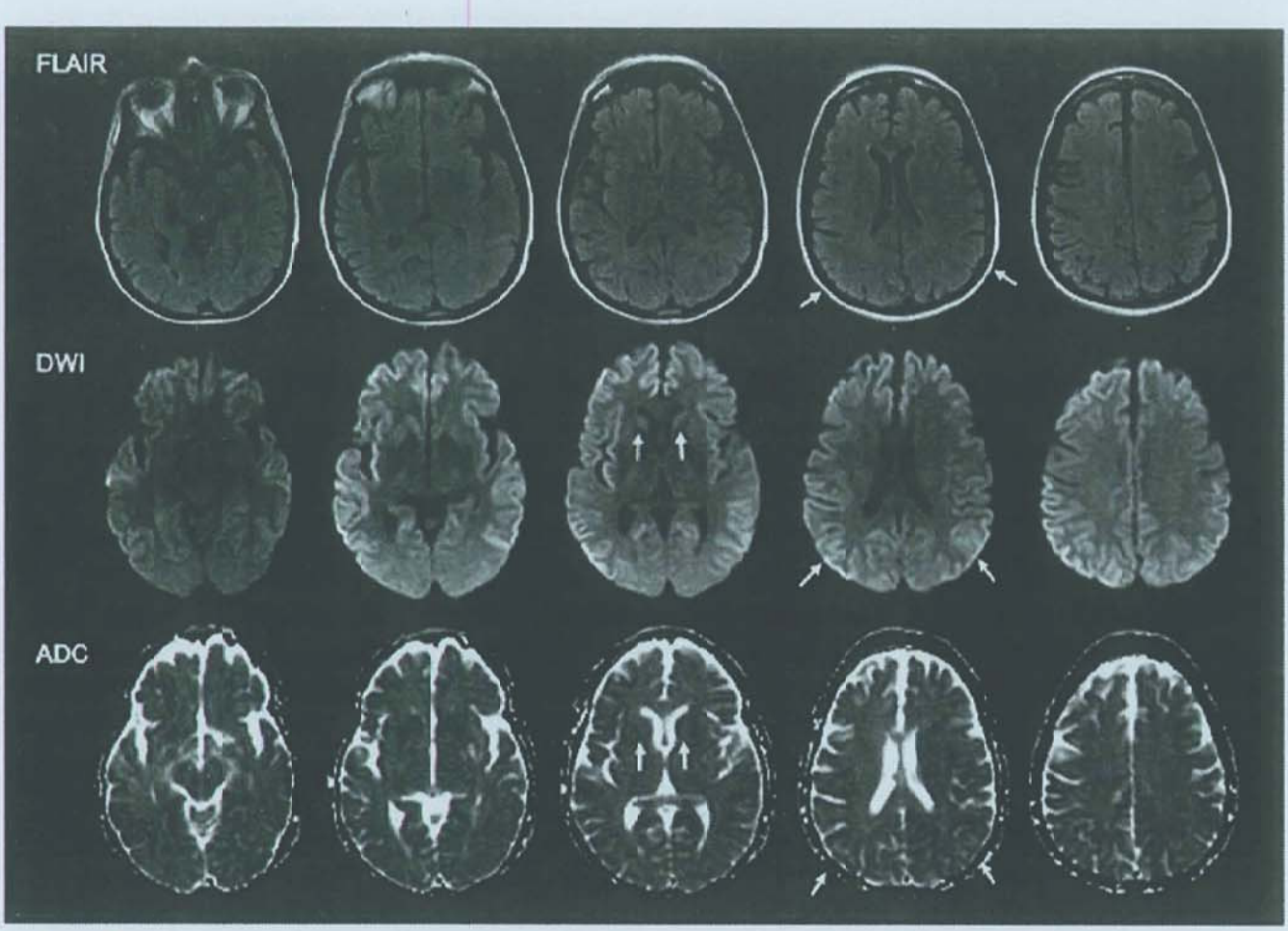

FIGURE 55.3 The image depicts the brain magnetic resonance imaging of a sporadic Creutzfeldt-Jakob disease patient in three different imaging sequences: fluid-attenuated inversion recovery (FLAIR), diffusion-weighted imaging (DWI), and apparent diffusion coefficient (ADC). Diffuse cortical gyral hyperintensities *(angled arrows)* (*"cortical ribboning"*) are shown on FLAIR and DWI sequences, most prominent over the bilateral frontoparietal lobes and caudate nuclei (*arrows* at bilateral parietal and caudate nuclei). Corresponding hypointensity is present on ADC sequences *(arrows)*. These findings show that these imaging abnormalites are due to restricted diffusion of water molecules and are the typical imaging findings in the vast majority of sporadic Creutzfeldt-Jakob disease cases.

are quite common. With some mutations, such as V210I, V180I and others, family histories might have been missed because the *PRNP* mutation was not fully penetrant. In rare cases, the mutation may have been de novo. It is for this reason that we prefer not to use the term *inherited prion disease* but rather gPrD.

The original classification of familial prion diseases into fCJD, GSS, and FFI was based on clinicopathologic features and before the discovery of *PRNP*. This historical classification system is inadequate based on our current understanding of the genetic origin of familial prion disease and the variety of *PRNP* mutations that can cause prion disease. For example, several *PRNP* mutations, such as OPRIs and stop codons do not fit neatly into any of the three historical classification groups. Similar to many genetic forms of other neurodegenerative diseases, the genotype and phenotype are not fully correlated in gPrDs; thus, the clinical presentations can vary considerably within the same pathogenic variant or even within the same family, which makes classification based on clinical-pathogenic features problematic. Because of the common use of the historical clinicopathologic classification of gPrDs—fCJD, GSS and FFI—we use these terms in our discussion of gPrDs but also discuss mutations based on other features, such as the variant location, and discuss OPRI and stop codon mutations separately (see Table 55.1). We briefly review gPrDs in the following sections, but more comprehensive reviews are listed in the "Suggested Readings" section.

Familial Creutzfeldt-Jakob Disease

For most *PRNP* mutations that are classified as fCJD, patients generally present similarly to sCJD clinically and pathologically, other than having a younger age of onset (approximately 7 y younger). There are more than 20 *PRNP* missense variants reported including but not limited to P105T, G114V, R148H, D178N (codon 129 cis V), V180I, T183A, T188A, T188K, T188R, T193I, K194E, E196A, E196K, E200K, E200G, V203I, R208H, V210I, E211Q, I215V, A224V, M232R, and P238S, although a few of these are of unclear pathogenic significance (eg, M232R) or have very low penetrance (eg, V180I, V210I). *PRNP* missense mutations, OPRIs with four (or possibly fewer) 24-base pair (octapeptide) repeats and a two octapeptide deletion usually manifest as fCJD. OPRIs are discussed in more detail in the following text. The E200K mutation is the most common *PRNP* pathogenic variant worldwide. Although resembling sCJD clinically, some individuals with E200K mutation have been reported to develop symptoms atypical for sCJD. Such symptoms include pruritus, demyelinating

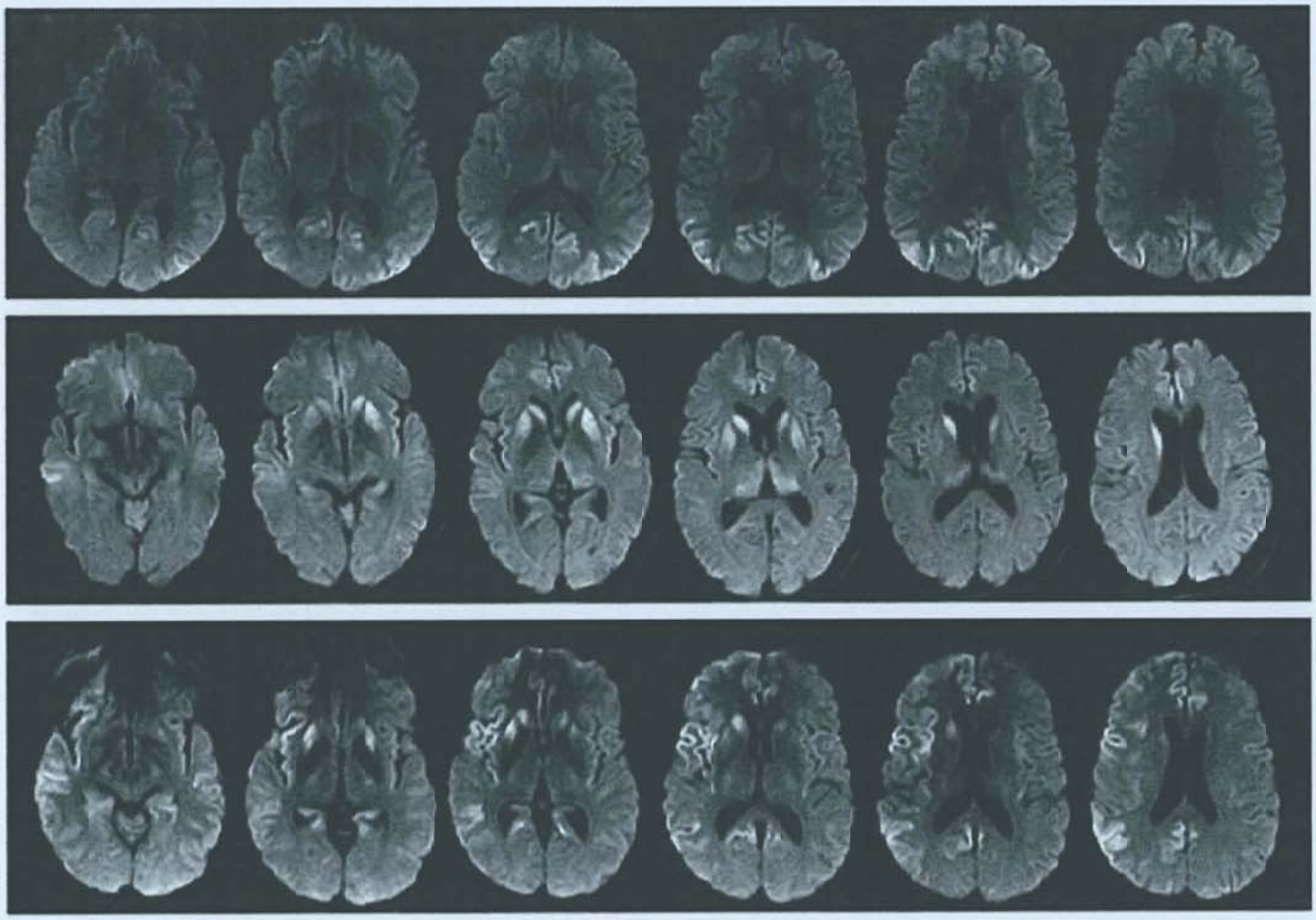

FIGURE 55.4 Each row shows an axial diffusion-weighted imaging MRI (DWI) sequence of a different patient with definite sporadic Creutzfeldt-Jakob disease (sCJD). These rows show the variable involvement of cortex and deep nuclei (striatum and/or thalami) in sCJD. For the patient whose MRI is shown on the **top row**, prominent cortical ribbon hyperintensity can be seen in the parieto-occipital cortex bilaterally, but there is no clear signal abnormality in the deep nuclei. In the patient's MRI shown in the **middle row**, there is prominent abnormal hyperintensity in the striatum and thalami bilaterally but much less cortical ribboning (bilateral anterior cingulate and left inferior lateral temporal). In the **bottom row**, the patient's images show hyperintense abnormalities in the striatum and cortex, as well as the insula and hippocampal tails or posterior parahippocampal gyri.

peripheral neuropathy, and supranuclear gaze palsy, and there may be a higher prevalence of headache and seizure when compared to sCJD. There is also some data suggesting certain E200K cases, particularly those from Western and Eastern Europe, can be distinguished from sCJD by the presence of pathologic inclusions. Patients with the D178N mutation with valine at the cis codon 129 generally present as sCJD phenotype, whereas those with cis methionine at codon 129 typically manifest as FFI, showing a strong effect of the codon 129 polymorphism on the clinicopathologic presentation. The relationship of D178N and the codon 129 polymorphism, however, is by no means invariable—some cases with cis 129 valine present as FFI, and some with cis 129 methionine present as CJD. FFI is discussed in more detail in the following text. In contrast to E200K, D178N, and many other pathogenic variants that have high penetrance approaching 100%, the V210I, V180I, and M232R *PRNP* variants have much lower penetrance, estimated to be around 10%, 1%, and 0.1%, respectively. Most V180I cases tend to progress slower with a mean disease duration of about 25 months. Among M232R cases of prion disease, about three-quarters of cases have a relatively rapidly progressive course (disease duration, 12.5 ± 10.9 mo) and have type 1 PrP^{Sc} with synaptic-type depositions. The remaining 25% of cases have a much slower disease course (disease duration, 49.9 ± 53.8 mo) and more often have type 2 PrP^{Sc} with perivacuolar depositions and spongiform changes. Most M232R and V180I cases have been identified in Japan.

Gerstmann-Sträussler-Scheinker Disease

The eponymous name GSS was first introduced in 1980 in honor of some of the authors that first reported the disease in an Austrian family. GSS typically presents with slow progressive cerebellar ataxia with gait disturbance (72%), accompanied by cognitive impairments (82%), psychiatric symptoms (21%), speech and swallowing problems, parkinsonism (36%), and myoclonus (15%) at the later stage of the disease. The age of symptom onset is usually in one's 50s, but can range widely, between the second and the seventh decades. Although disease duration in GSS is quite variable, in general, survival ranges from a few years to a decade or more, much longer than most other prion diseases. Some GSS cases, however, can present with RPD with survival of 1 year or less. The majority of the GSS cases have a positive family history (69%-100%) with autosomal dominant inheritance and penetrance estimated to approach 100%. More than 19 *PRNP* missense mutations (including but not limited to P84S, P102L, P105L, P105S, P105T, A117V, G131V, S132I,

A133V, R136S, V176G, H187R, F198S, D202N, E211D, Q212P, Q217R, Y218N, and M232T), several stop codon mutations (Y145X, Q160X, Y163X, Y226X, and Q227X), and OPRI variants have been linked to a GSS phenotype, with P102L being the most common *PRNP* mutation causing GSS worldwide, and also the first *PRNP* mutation identified. Neuropathologic features of GSS includes PrP^{Sc}-amyloid plaques (ie, prion proteins aggregate and form large uni- or multicentric amyloid plaques that deposit the cerebellum and cerebral cortices), PrP^{Sc}-related amyloid angiopathy (ie, PrP^{Sc}-immunoreactive amyloid depositions within the cerebral vessels wall), and vacuolation (ie, spongiform changes). Given the neuropathologic findings of PrP^{Sc}-amyloid plaques and the dominant inheritance pattern, GSS is sometimes referred as *dominantly inherited PrP cerebral amyloidosis*. Most biomarkers used for diagnosis of sCJD are less sensitive in GSS. The EuroCJD study conducted by the European Creutzfeldt-Jakob Disease Surveillance Network reported that only 50% patients with GSS had elevated CSF 14-3-3, fewer than 10% had PSWCs on EEG and only about 30% showed MRI findings typically found in sCJD (**Fig. 55.5**). Because of its somewhat slowly progressive clinical presentation and often negative ancillary tests for prion disease, GSS is often mistaken for other neurodegenerative conditions, such as multiple system atrophy, spinocerebellar ataxias, idiopathic Parkinson disease, Alzheimer disease, or Huntington disease, unless *PRNP* analysis is performed. GSS can even be missed pathologically, as the PrP^{Sc}-amyloid plaques are sometimes mistaken for amyloid-β if specific immunohistochemistry for abeta-amyloid and PrP are not used. In view of the PrP^{Sc}-amyloid plaque deposition in GSS, researchers are investigating the feasibility of using amyloid-binding positron emission tomography (PET) tracers such as 2-(1-(6-[(2-[^{18}F] fluoroethyl) (methyl) amino]-2-naphthyl)ethylidene) malononitrile ([^{18}F]FDDNP) to diagnose GSS.

Fatal Familial Insomnia

FFI classically presents with somewhat insidious onset over months of progressive insomnia and dysautonomia with the latter including symptoms such as tachycardia, hyperpyrexia, fluctuating blood pressure, episodic hyperventilation, hyperhidrosis, sexual dysfunction, and/or urinary incontinence. This is usually followed by truncal and appendicular ataxia, brainstem signs (gaze and swallowing abnormalities), with profound confusion and cognitive problems appearing later in the course. For those with insomnia, vivid dreams can be common during limited sleep. Cognitive symptoms often manifest as slow processing speed, decreased attention, and impairment in short-term memory that eventually progresses to a state of delirium. As noted in earlier discussion, persons with FFI usually have *PRNP* D187N missense variant with cis-methionine codon 129

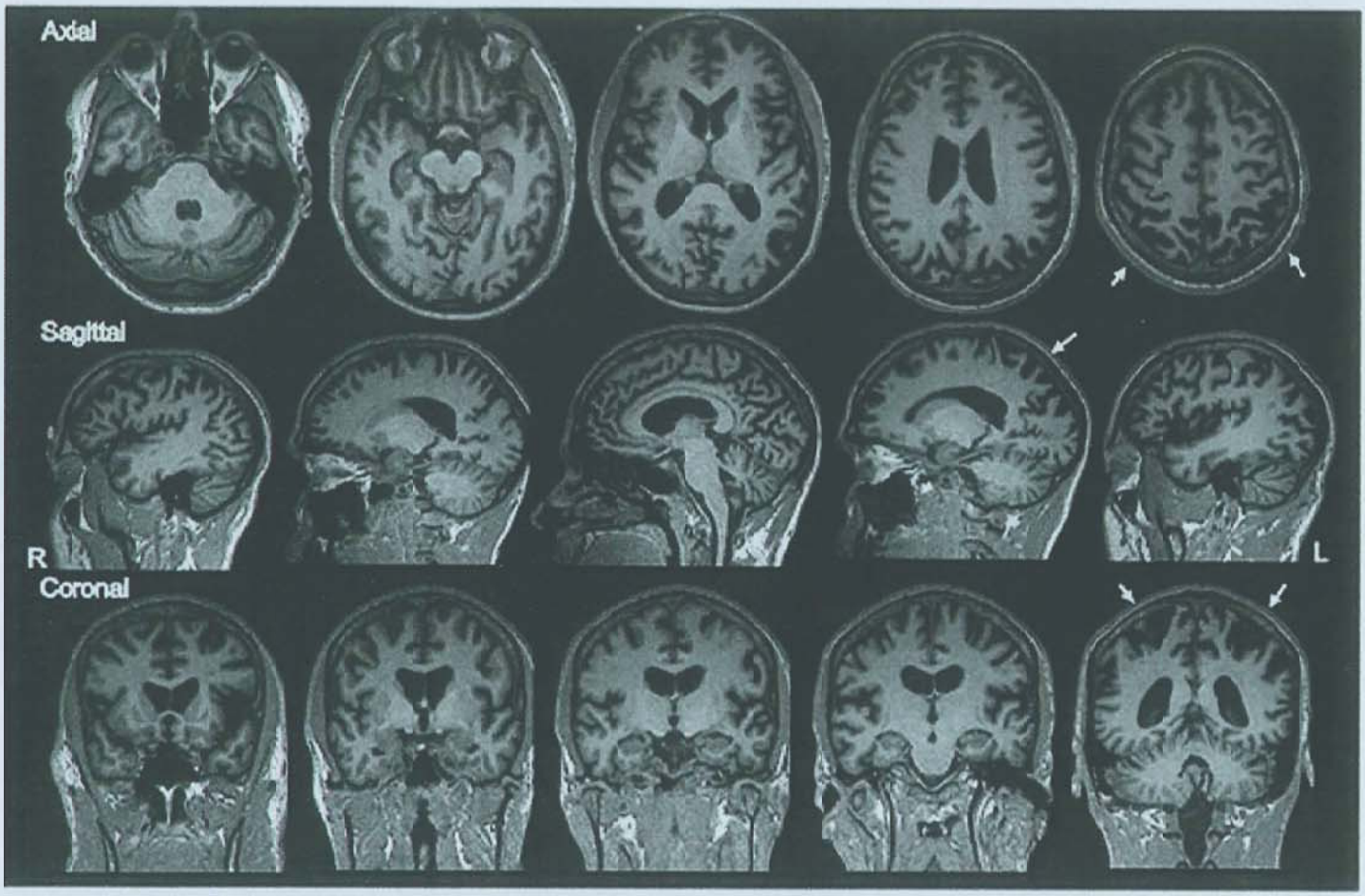

FIGURE 55.5 The image shown here is the T1 sequence brain magnetic resonance imaging of a 46-year-old patient who presented with a Gerstmann-Sträussler-Scheinker clinical phenotype, and further genetic testing revealed a six octapeptide repeat insertion *PRNP* mutation. Note that the MRI reveals diffuse brain atrophy, most evident over the bilateral parietal *(arrows)* and frontal lobes, as well as to a lesser extent the superior cerebellum. No abnormal cortical or subcortical hyperintensity was found on fluid-attenuated inversion recovery and diffusion-weighted imaging sequences, nor was there any restricted diffusion commonly foiund in sCJD.

(D178N-129M), but some D178N-129M cases present as sCJD, and some D178N-129V cases present as FFI. Even within the same family, different presentations can occur. FFI (D178N-129M) has been reported in about 30 families worldwide, with a mean age at symptom onset of about 52 years (range, approximately 20-76 y), and an average disease duration of 13.5 months (range, 4-40 mo). Some studies note that individuals with D178N-129M, who are heterozygous (MV) at codon 129 (ie, trans V), have longer disease durations (mean, approximately 23 mo) compared to individuals who are codon 129 MM (mean, approximately 11 mo), suggesting an effect of the trans codon 129 polymorphism in this disease as well. Whereas brain MRI is often unremarkable, fluorodeoxyglucose (FDG)-PET imaging frequently displays marked thalamic, and sometimes cingulate, hypometabolism, which may be present even prior to disease onset. Neuropathologically, individuals with FFI typically exhibit marked neuronal loss and atrophy in the anterior ventral and dorsomedial thalamic nuclei and the inferior olivary nucleus. Frequently, there is also cerebellar Purkinje cell loss which is frequently associated with fusiform axonal swelling in the granule cell layer called axonol "torpedoes."

Octapeptide Repeat Insertions

The N-terminal of the normal prion protein consists of a nonapeptide (Pro-Gln-Gly-Gly-Gly-Gly-Trp-Gly-Gln), named R1, followed by four octapeptide (24-base pair) repeats, named R2-R2-R3-R4, each with the same amino acid sequence (Pro-His-Gly-Gly-Gly-Trp-Gly-Gln) but R3 and R4 differ slightly from each other and R2 at two nucleotides. Thus, a normal variant of the tandem repeats is termed *R1-R2-R2-R3-R4* and is referred to as the *octapeptide repeat region of PRNP*, which is a copper-binding region of the protein. Perhaps due to unequal crossover during recombination process or faulty replication process, deletion of two octapeptide repeats or insertion of four or more octapeptide repeats in *PRNP* gene have been associated with gPrDs. The 1-OPRI variant is considered to be nonpathogenic. Although two and three OPRIs have been reported as pathogenic in a few reports, their pathogenicity is an issue of debate, and many consider them to be nonpathogenic variants based on their frequencies in the general population and/or that when identified in more than one family member with dementia, only one family member clearly had prion disease (clinically or pathologically) and the prion disease resembled sCJD. OPRIs have been shown to produce protease-resistant aggregation-prone PrP^{C} protein, thus predisposing the formation of PrP^{Sc}. The clinical and pathologic phenotype of OPRIs has been reported to be somewhat correlated with the number of octapeptide repeats. Most individuals with four OPRIs manifests as sCJD with shorter disease course, and there is a question as to whether 4-OPRI is a low penetrance pathogenic variant or requires another polymorphism for it to be deleterious. OPRIs of five or more have more clearly been shown to be pathogenic, however. Individuals with five to seven OPRIs have heterogenous clinical phenotypes and often have long clinical courses of several years, with age of onset varying from 20s to 80s, although most commonly 20s to 40s, and pathology usually shows elongated PrP^{Sc} deposits. Patients with eight or more OPRIs tend to have clinical and pathological overlap with GSS, although there is great clinicopathologic variability. One 8-OPRI family was reported to have a Huntington disease–like presentation and considered to be a Huntington disease phenocopy. The only 12-OPRI family reported has a frontotemporal dementia–like presentation and is also a tauopathy on pathology and on tau-PET imaging.

In our experience, many commercial laboratory standard dementia gene panels, particularly those using next-generation sequencing, can miss expansions or deletions in *PRNP*. Thus, if a result is negative, but gPrD is still suspected, we would recommend that a blood sample be sent to a laboratory that does Sanger sequencing of *PRNP* or uses other methods that are sensitive for detection of deletions and expansions.

ACQUIRED PRION DISEASE

Acquired prion diseases are "transmitted" forms of prion diseases and include three different prion disease types: Kuru, iCJD, and vCJD. Kuru was the first known acquired prion diseases, identified in the Fore people of Papua New Guinea (see Table 55.1). It was transmitted among the Fore people thru the endocannibalism of deceased relatives as a mourning ritual. As woman and children more often consumed the brain and viscera, including nervous system tissue, they were more at risk for consuming prions and contracting the disease than the adult men. The term *Kuru* means "to shake or tremble" in Fore language, as the disease typically presents as slow progressive cerebellar ataxia, sometimes accompanied by tremor, chorea and athetoid movements. The incidence of Kuru greatly diminished when missionaries stopped the endocannibalism rituals in the 1950s. Kuru is essentially extinct, except very rare new cases in persons born before the cessation of endocannibalism, showing the incubation period can be as long as 50 years, especially in individuals whom are heterozygous, MV, at *PRNP* codon 129. Interestingly, a very clever study examining the genetics of females who lived in the region of Kuru and survived the epidemic identified a *PRNP* polymorphism at codon 127 that appears to be protective against prion disease. Furthermore, mice with this polymorphism appear to be resistant to prion disease. Understanding of the mechanism of this polymorphism might help lead to therapies for prion diseases. As Kuru is essentially extinct, the remainder of this section mainly focuses on vCJD and iCJD.

Variant Creutzfeldt-Jakob Disease

vCJD was first described in 1995 and soon after raised much public concern when it was linked to the bovine spongiform encephalopathy (BSE) epidemic. Compelling evidence support that the majority of vCJD cases were exposed to the disease through the inadvertent consumption of meat and offal contaminated with BSE, commonly known as *mad cow disease*. It is believed that BSE emerged because of the practice of feeding cattle the body parts of sheep that were contaminated by scrapie. As of January 2020, about 229 vCJD cases have been officially reported worldwide, with 178 of the cases diagnosed in United Kingdom, 28 in France, 5 in Spain, 4 each in United States and Ireland, 3 each in Italy and Netherlands, 2 each in Portugal and Canada, and 1 each in Taiwan, Japan, and Saudi Arabia. Several cases, particularly those outside of the United Kingdom and France, were likely exposed in a different country than where they were diagnosed. Through the strong implementation of import control and feeding regulations, the incidence of vCJD has drastically decreased since the year 2000 and to our knowledge, no new cases has been officially reported from 2017 through at least the end of 2019.

vCJD typically manifests initially with psychiatric symptoms such as depression, anxiety, irritability, and apathy. This usually is followed by persistent painful paresthesias, cognitive impairment, cerebellar ataxia, and/or motor symptoms such as

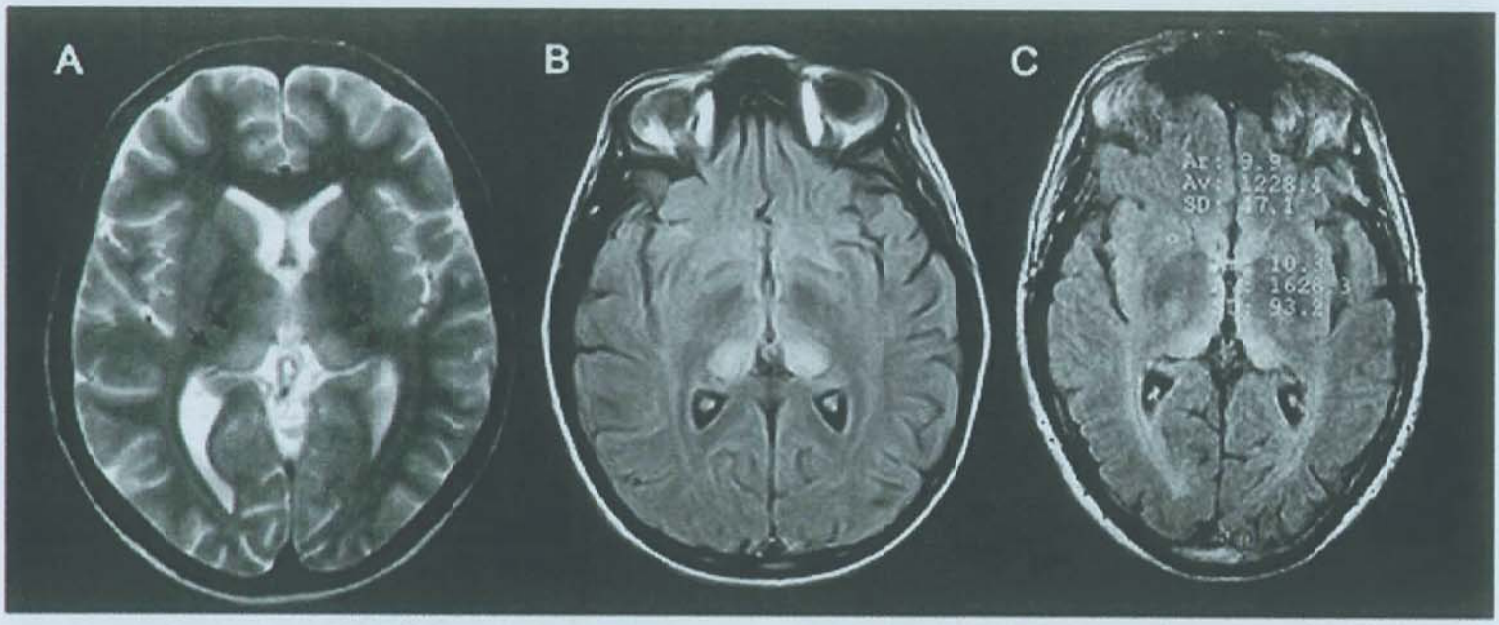

FIGURE 55.6 Brain magnetic resonance imaging of a patient with variant Creutzfeldt-Jakob disease case. **A:** Note that on the T2-weighted imaging, there are hyperintensities in the bilateral pulvinar nuclei *(black arrows)* and to a lesser degree in the bilateral caudate and putamen. The pulvinar being more hyperintense than the anterior putaman is referred to as the *pulvinar sign*. **B:** Corresponding pulvinar hyperintensities are also noted on the proton-density weighted images. **C:** Signal intensity quantification of the pulvinar relative to the anterior putamen on fluid-attenuated inversion recovery images. The pulvinar signal intensity is 25% higher when compared with the putamen area, which is consistent with the pulvinar sign. (Images borrowed with permission from Collie DA, Sellar RJ, Zeidler M, Colchester CF, Knight R, Will RG. MRI of Creuztfeldt-Jakob disease: imaging features and recommended MRI protocol. *Clin Radiol*. 2001;56[9]:726-739.)

myoclonus, chorea, or dystonia. In contrast to most prion diseases, vCJD generally affects younger pateints, with median age of symptom onset around 26.5 years (range, 12-74 y). vCJD is considered to have longer disease duration compared to sCJD, averaging around 14.5 months. Unlike sCJD in which PSWCs on EEG are eventually found in about two-thirds of cases, EEG in vCJD rarely shows these specific abnormalities and even then, only at the end stage of the disease. Brain MRI in vCJD usually shows involvement of the thalamus. This, however, is not unique to vCJD; the pulvinar sign in which pulvinar hyperintensity is brighter than the anterior putamen or other basal ganglia, particularly on T2-weighted proton-density sequences (probably also on DWI as well) has at least 79%, and probably much higher, sensitivity for vCJD and relatively high specificity for vCJD versus other prion diseases (Fig. 55.6). T2-weighted hyperintensities of the medial dorsal thalamus and pulvinar, making the so-called hockey stick sign, or double hockey-stick if bilateral, can be seen in vCJD as well, but is less specific than the pulvinar sign, and such thalamic hyperintensities can be found in other prion and nonprion disorders. As with other prion diseases, in long-lived cases, these MRI hyperintensities on T2-weighted or DWI MRIs may eventually disappear, usually where there is significant atrophy.

In vCJD, PrP^{Sc} can be detected not only in the nervous system but also in the lymphoreticular system, including lymph nodes, tonsils, spleen, and appendix. PrP^{Sc} fibrillary protein aggregates around groups of vacuoles and form flower-like (florid) plaque appearance, the pathognomonic neuropathologic hallmark of vCJD. PrP^{Sc} from vCJD also has a distinct profile on Western blot, differentiating it from most other prion diseases. Given the peripheral distribution of PrP^{Sc} in vCJD cases, sampling the tonsillar tissue to detect the presence of PrP^{Sc} has been included as one of the diagnostic criteria for probable vCJD. Some research studies have shown that PrP^{Sc} can be detected in the urine and in blood in vCJD, but these tests are not available clinically. Similar to sCJD, the diagnosis of vCJD is divided into definite, probable, and possible categories based on the level of diagnostic certainty (see **Table 55.2**). Unlike other prion diseases, vCJD has been proven to be transmissible by blood, even from blood of preasymptomatic patients (who carry vCJD prions in their blood). Interestingly, the three receipients of vCJD-contaminated blood who ultimately developed clinical vCJD were MM-homozygotes at codon 129 in *PRNP*, whereas the two recipients who died of other causes but at autopsy were found to have vCJD prions outside their nervous system were heterozygous for MV. Furthermore, to date, all reported vCJD cases have been homozygous for MM at codon 129, with the rare exception of one (or possibly two) being MV, suggesting that individuals with the codon 129 MM polymorphism may be more susceptible to vCJD. Two large-scale studies in the United Kingdom found that 1 in 2,000 to 1 in 4,000 of stored appendix tissue samples were positive for PrP^{Sc}, raising safety concerns of the blood products provided by the residents for vCJD-affected countries.

Iatrogenic Creutzfeldt-Jakob Disease

iCJD occurred because cases of prion disease were undiagnosed prior to undergoing certain medical procedures, and routine sterilization methods in medical practice had not been (and some still currently are not) targeted toward inactivating prions. This has led to human-to-human transmission of prions through a few medical procedures. iCJD was first reported in 1974, and as of

around 2016, 492 cases worldwide have been reported. This includes cases that received cadaveric human pituitary hormones (growth hormone and gonadotrophic hormone), dura mater graft transplants, corneal transplants, or whom were operated on inadvertently with prion-contaminated neurosurgical instruments or EEG stereotactic depth electrodes (see Table 55.2).

Approximately 238 cases of human growth hormone associated iCJD had been reported worldwide as of 2016. Individuals with growth hormone associated iCJD tend to have long incubation periods (mean, 17 y, ranging from 5 to 24 y). Most cases have *PRNP* codon 129 MM genotype. Typically, patients with iCJD present with cerebellar motor symptoms and with cognitive impairment occurring at the late stage of the disease. In United States, there have been no reports of iCJD cases whom received growth hormone after the year 1977, which is the year when a highly selective column chromatography step was introduced into the purification protocol for human growth factors. It is possible and even likely that there will be future cases presenting after long incubation periods from remote exposures.

The first case of dura mater graft associated iCJD was reported in 1987, and there were roughly 238 cases officially reported worldwide as of 2016, with 60% of the reported cases occurring in Japan. Most contaminated dura mater graft were batches of a product called *Lyodura*, manufactured by a German company B. Braun Melsungen AG, which combines dura mater from many human cadavers; unfortunately, some of the donors at the time of dura mater removal were not realized to have prion disease. Lyodura was used worldwide, although most widely in Japan where it was used for a wide variety of medical procedures. The mean incubation period for dura mater graft–associated iCJD is about 12 years (ranging from 1.3 to 30 y). Two-thirds of the dura mater graft–associated iCJD cases present as sCJD clinically, with rapid progression of cognitive, cerebellar, and visual symptoms, often with PSWCs on EEG and no PrP^{Sc} plaques in the brain. The remaining one-third of cases are more slowly progressive, have PrP^{Sc} plaques in the brain and rarely show PSWCs on EEG. Some evidence suggests that the slower dura mater iCJD subgroup were infected by dura matter from VV2 or MV2 sCJD patients and the more common subgroup from MM1/MV1 sCJD dura mater.

There are at least four reports of possible neurosurgical instruments transmitted iCJD cases: three in the United Kingdom and one in France. The time interval between cranial surgery to symptoms onset range between 1.4 and 2.2 years. The identification of these cases is challenging given that they clinically resemble sCJD, and the source cases were not easy to trace. Other reported transmission routes include corneal transplant, EEG depth electrodes, and blood transfusion (from persons who later developed vCJD with some recipients later developing vCJD). The World Health Organization has guidelines on best practices for decontaminating prions from medical and surgical equipment.

MANAGEMENT AND OUTCOMES

Symptomatic Treatments

To date, there are no curative or disease modifying treatments available for any form of prion disease. There are various nonpharmacologic management strategies and pharmacologic treatments to alleviate some of the symptoms commonly seen in persons suffering from prion disease. In general, nonpharmacologic management is recommended prior to starting pharmacologic treatments, unless intervention is urgently required. Given that human prion evolve quickly over their course, medication lists should be assessed periodically to optimize management of symptoms and to avoid overmedication. Table 55.3 lists some supportive and symptomatic treatments for various common symptoms in prion disease.

Any medicines mentioned in this chapter need to be used cautiously to avoid or reduce side effects. Nutrition and feeding are important aspects to manage in prion disease because almost all patients with prion disease will ultimately die from aspiration pneumonia. Swallowing assessments are recommended at baseline and/or when patients exhibit speech difficulties, choking signs, or decreased food/fluid intake. If feeding is complicated by motor difficulty, depending on the symptoms ergonomic utensils may facilitate self-feeding. To encourage adequate food intake, frequent reminders on meal schedule and being flexible on diet preferences can be considered. Oral hygiene care such as using a child's toothbrush, washcloth, or swab may lower the risk of aspiration pneumonia and maintain comfort care. When dysphagia is present, adding thickener to liquids, chopping up food into small pieces, and giving small amounts at a time can decrease choking episodes. We generally recommend against feeding tubes, which can extend survival in prion disease but usually do not improve quality of life and may worsen it by extending suffering of patients and families. As prion diseases often impact cognitive function early in the disease course, advance care planning while patients are still cognitively competent is important.

Investigational Treatments

There are no effective treatments or cures to stop or reverse the disease course for human prion disease. Several medications have been tried, but none has been successful. Of the four medications have formally tested in human prion disease, only three were tested in appropriate randomized, controlled trials (oral flupirtine, oral quinacrine, oral doxycycline, and intrathecal pentosan polysulfate [PPS]), and none showed improved survival. Flupirtine was tested in a small randomized, controlled trial of 28 patients with CJD in Germany and showed some mild brief improvement in cognition but showed no benefit in survival. The antimalarial quinacrine inhibited conversion of PrP^{C} into PrP^{Sc} in vitro, but observational studies in the United Kingdom and France and a randomized, double-blinded, placebo-controlled trial in the United States showed no improved survival. Doxycycline showed potential effect in vitro and in small animal models but revealed no benefit in survival or other outcomes in a randomized, controlled trial of symptomatic prion disease. Nevertheless, it is being studied in an ongoing clinical trial in presymptomatic FFI mutation carriers in a large Italian family to see if it can delay the average age of onset compared to historical controls. PPS showed promise in some animal models, even when given after symptom onset, but needs to be administered intraventricularly because it does not cross the blood-brain barrier. It is controversial as to whether PPS had any benefit in human case reports or observational studies. It might have shown some reduction of PrP^{Sc} or other expected pathology. In vCJD, it may have prolonged duration of disease in some cases but did not result in symptomatic improvement. As of 2020, there is an experimental treatment being given to qualified patients with symptomatic prion disease using an experimental monoclonal antibody, PRN100, against the prion protein through the United Kingdom National Health Service at the Medical Research Council in London, United Kingdom for (eg, sCJD) that is

TABLE 55.3 Nonpharmacologic and Pharmacologic Managements of Human Prion Disease

	Nonpharmacologic	Pharmacologic (Off-label)
Myoclonus	• Minimizing environmental auditory and tactile stimuli • Limiting number of visitors • Keep bed in a quiet area.	• Benzodiazepine (eg, clonazepam) • Antiepileptic medications (eg, levetiracetam, valproic acid)
Pain/dysesthesia	• Identify and manage source of pain.	• Nonneuropathic pain: acetaminophen, opioids, other • Neuropathic pain: antiepileptic (eg, pregabalin, gabapentin, eslicarbazepine, carbamazepine) and serotonin-noradrenaline reuptake inhibitors (SNRIs; eg, duloxetine). Beware of central nervous system depression.
Psychosis/agitation/irritability	• Risk assessment and care resource evaluation • Identifying and removing precipitating factors • Art, soft music, and aroma therapy	• Selective serotonin reuptake inhibitors (SSRIs; eg, escitalopram and citalopram), trazodone, neuroleptics (eg, quetiapine), benzodiazepines. Beware of extrapyramidal side effects from neuroleptics.
Depression/anxiety	• Counseling • Art, music therapy	• SSRIs (eg, escitalopram and citalopram), SNRIs, mirtazapine, benzodiazepines
Dysphagia/malnutrition	• Periodic swallowing and body weight assessment • Ergonomic utensils • Oral hygiene care • Liquid thickener, chopped or pureed food, small meals • Diet adjusted to patient's preferences • Authors recommend avoiding feeding tubes in late stages with clear prion diagnosis.	• Glycopyrrolate or similar agents to decrease salivation if aspirating on saliva
Nausea/vomiting	• Adjust feeding amount and content. • Elevate bed. • Oral hygiene care	• Antiemetics, including serotonin 5-HT_3 receptor antagonists (eg, ondansetron) and prochlorperazine (caution for extrapyramidal side effects)
Insomnia	• Sleep hygiene • Regimented daily routine	• Melatonin, trazodone, mirtazapine, and quetiapine (latter mostly if agitation also an issue). Stronger agents might be needed for sporadic fatal insomnia or fatal familial insomnia.
Incontinence	• Regular bathroom schedules • Diapers • Condom catheter	• Consider various bladder agents, ideally those that are less anticholinergic.
Seizures	• Confirm seizures and not myoclonus.	• Antiepileptic agents, benzodiazepines
Visuospatial impairment/hemineglect	• Decrease the visuospatial complexity of environment. • Objects requiring attention presented at unaffected side or by moving around	

only open for U.K. citizens. As of October 2019, the sixth and final patient was treated, four of the patients had already died, and data was being analyzed to determine whether to move forward.

One of the more exciting developments in the treatment of neurologic and nonneurologic disorders has been the use of antisense oligonucleotides (ASOs) to block translation of messenger RNA and hence reduce production of specific proteins. ASOs are now in clinical practice for the treatment of at least three neurologic disorders, spinomuscular atrophy, Duchenne muscular dystrophy, and familial amyloid polyneuropathy and in phase 1 to 3 trials for several more disorders. There is some data to suggest that partial reduction of PrP^C should be safe in humans. Knockout mice for *PRNP* live a normal lifespan with only minor abnormalities detected. A few adults identified as *PRNP* hemizygous appear to be healthy. *PRNP* knockout mice are resistant to prions, and when mice hemizygous for *PRNP* (which have half the level of PrP^C) are inoculated with prions they have significantly increased survival. Thus, lowering of PrP^C levels may be a disease-modifying treatment for human prion disease, particularly if given prior to symptom onset, such as in carriers of *PRNP* mutations or persons exposed to prions. A recent study with ASOs targeted to reduce PrP^C (delivered via intracerebroventricular injection) in prion-infected wild-type mice showed prolonged survival when administered prophylactically prior to prion inoculation or even after infection but prior to symptom onset. ASOs may be effective in human prion diseases, particularly if used prophylactically. Such studies in humans are currently being planned. The coming decade should be an exciting one for improved understanding and treatment of human prion disease.

LEVEL 1 EVIDENCE

1. Muayqil T, Gronseth G, Camicioli R. Evidence-based guideline: diagnostic accuracy of CSF 14-3-3 protein in sporadic Creutzfeldt-Jakob disease: report of the guideline development subcommittee of the American Academy of Neurology. *Neurology*. 2012;79(14):1499-1506.
2. Hermann P, Laux M, Glatzel M, et al. Validation and utilization of amended diagnostic criteria in Creutzfeldt-Jakob disease surveillance. *Neurology*. 2018;91(4):e331-e338.
3. Staffaroni AM, Elahi FM, McDermott D, et al. Neuroimaging in dementia. *Semin Neurol*. 2017;37(5):510-537.

SUGGESTED READINGS

Bongianni M, Orrù C, Groveman BR, et al. Diagnosis of human prion disease using real-time quaking-induced conversion testing of olfactory mucosa and cerebrospinal fluid samples. *JAMA Neurol*. 2017;74(2):155-162.

Brown P, Cathala F, Castaigne P, Gajdusek DC. Creutzfeldt-Jakob disease: clinical analysis of a consecutive series of 230 neuropathologically verified cases. *Ann Neurol*. 1986;20(5):597-602.

Brown P, Gibbs CJ Jr, Rodgers-Johnson P, et al. Human spongiform encephalopathy: the National Institutes of Health Series of 300 cases of experimentally transmitted disease. *Ann Neurol*. 1994;35(5):513-529.

Carswell C, Thompson A, Lukic A, et al. MRI findings are often missed in the diagnosis of Creutzfeldt-Jakob disease. *BMC Neurol*. 2012;12:153.

Collie DA, Summers DM, Sellar RJ, et al. Diagnosing variant Creutzfeldt-Jakob disease with the pulvinar sign: MR imaging findings in 86 neuropathologically confirmed cases. *AJNR Am J Neuroradiol*. 2003;24(8):1560-1569.

Collins SJ, Sanchez-Juan P, Masters CL, et al. Determinants of diagnostic investigation sensitivities across the clinical spectrum of sporadic Creutzfeldt-Jakob disease. *Brain*. 2006;129(pt 9):2278-2287.

Coulthart MB, Jansen GH, Olsen E, et al. Diagnostic accuracy of cerebrospinal fluid protein markers for sporadic Creutzfeldt-Jakob disease in Canada: a 6-year prospective study. *BMC Neurol*. 2011;11:133.

Forner SA, Takada L, Bettcher BM, et al. Comparing CSF biomarkers and brain MRI in the diagnosis of sporadic Creutzfeldt-Jakob disease. *Neurol Clin Pract*. 2015;5(2):116-125.

Foutz A, Appleby BS, Hamlin C, et al. Diagnostic and prognostic value of human prion detection in cerebrospinal fluid. *Ann Neurol*. 2017;81(1):79-92.

Geschwind MD. Prion diseases. *Continuum (Minneap Minn)*. 2015;21(6):1612-1638.

Geschwind MD. Rapidly progressive dementia. *Continuum (Minneap Minn)*. 2016;22(2):510-537.

Ghetti B, Piccardo P, Zanusso G. Dominantly inherited prion protein cerebral amyloidoses–a Modern View of Gerstmann–Sträussler–Scheinker. In: Pocchiari M, Manson J, eds. *Handbook of Clinical Neurology*. Ottawa, Ontario, Canada: Elsevier; 2018:243-269.

Haïk S, Marcon G, Mallet A, et al. Doxycycline in Creutzfeldt-Jakob disease: a phase 2, randomised, double-blind, placebo-controlled trial. *Lancet Neurol*. 2014;13(2):150-158.

Kim MO, Takada LT, Wong K, Forner SA, Geschwind MD. Genetic PrP prion diseases. *Cold Spring Harb Perspect Biol*. 2018;10:a033134.

Kovács GG, Puopolo M, Ladogana A, et al. Genetic prion disease: the EuroCJD experience. *Hum Genet*. 2005;118(2):166-174.

Krasnianski A, Bartl M, Sanchez Juan PJ, et al. Fatal familial insomnia: clinical features and early identification. *Ann Neurol*. 2008;63(5):658-661.

Meissner B, Kallenberg K, Sanchez-Juan P, et al. MRI lesion profiles in sporadic Creutzfeldt-Jakob disease. *Neurology*. 2009;72(23):1994-2001.

Minikel EV, Vallabh SM, Lek M, et al. Quantifying prion disease penetrance using large population control cohorts. *Sci Transl Med*. 2016;8:322:322ra9.

Parchi P, Giese A, Capellari S, et al. Classification of sporadic Creutzfeldt-Jakob disease based on molecular and phenotypic analysis of 300 subjects. *Ann Neurol*. 1999;46(2):224-233.

Prusiner SB. Cell biology. A unifying role for prions in neurodegenerative diseases. *Science*. 2012;336(6088):1511-1513.

Prusiner SB. Prions. *Proc Natl Acad Sci U S A*. 1998;95(23):13363-13383.

Puoti G, Bizzi A, Forloni G, Safar JG, Tagliavini F, Gambetti P. Sporadic human prion diseases: molecular insights and diagnosis. *Lancet Neurol*. 2012;11(7):618-628.

Rabinovici GD, Wang PN, Levin J, et al. First symptom in sporadic Creutzfeldt-Jakob disease. *Neurology*. 2006;66(2):286-287.

Raymond GJ, Zhao HT, Race B, et al. Antisense oligonucleotides extend survival of prion-infected mice. *JCI Insight*. 2019;5:e131175.

Staffaroni AM, Elahi FM, McDermott D, et al. Neuroimaging in dementia. *Semin Neurol*. 2017;37(5):510-537.

Thompson AGB, Mead SH. Review: fluid biomarkers in the human prion diseases. *Mol Cell Neurosci*. 2019;97:81-92.

Vitali P, Maccagnano E, Caverzasi E, et al. Diffusion-weighted MRI hyperintensity patterns differentiate CJD from other rapid dementias. *Neurology*. 2011;76(20):1711-1719.

World Health Organization. *Global Surveillance, Diagnosis and Therapy of Human Transmissible Spongiform Encephalopathies: Report of a WHO Consultation, Geneva, Switzerland 9-11 February 1998*. Geneva, Switzerland: World Health Organization; 1998.

World Health Organization. *WHO Infection Control Guidelines for Transmissible Spongiform Encephalopathies: Report of a WHO Consultation, Geneva, Switzerland, 23-26 March 1999*. Geneva, Switzerland: World Health Organization; 1999.

Will RG, Ironside JW. Sporadic and infectious human prion diseases. *Cold Spring Harb Perspect Med*. 2017;7(1):a024364.

Zerr I, Kallenberg K, Summers DM, et al. Updated clinical diagnostic criteria for sporadic Creutzfeldt-Jakob disease. *Brain*. 2009;132(pt 10):2659-2668.

Primary and Secondary Headache Disorders 56

Peter J. Goadsby and Richard B. Lipton

KEY POINTS

1. Headache disorders, whether primary or secondary, share second-order trigeminocervical neurons as a final common sensory pathway, which can lead to symptom overlap. A careful history and examination is needed to differentiate them.
2. Secondary headache can herald a life-threating vascular or infectious condition, but are more commonly a manifestation of benign disorders such has a viral infection, the flu, a hangover, or mild head injury.
3. Migraine is the most common disabling primary headache and the most likely to be seen in the office practice of neurologists.
4. Trigeminal autonomic cephalalgias, particularly cluster headache, present with extremely severe, lateralized pain and associated symptoms needing rapid diagnosis and management.
5. Recent advances in the therapies of primary headache disorders, such as pathway specific treatments and neuromodulation approaches, are enriching disease understanding and making practice increasingly rewarding for patient and doctor.

ANATOMY AND PHYSIOLOGY OF HEADACHE

Headache is one of the most common clinical symptoms evaluated by neurologists and has a broad differential diagnosis. The successful management of both primary and secondary headache disorders requires an understanding of the relevant neuroanatomy and underlying physiology.

Pain in many settings is adaptive. It typically occurs when peripheral nociceptors are stimulated by factors such as tissue injury or visceral distension. In these settings, pain perception is a normal physiologic response mediated by a healthy nervous system. However, pain can also occur from damage, or inappropriate activation of pain-producing pathways of the peripheral or central nervous system. Headache may result from either, or both, of these mechanisms depending on the setting. The cranial pain-generating structures include the scalp, the falx cerebri, the dural sinuses, and the proximal segments of the large pial arteries. The majority of the brain parenchyma, ventricular ependyma, choroid plexus, and pial veins are not thought to be capable of producing pain.

The key structures involved in primary headache disorders include (Fig. 56.1)

- The large intracranial vessels, dura mater, and the peripheral terminals of the trigeminal nerve that innervate these structures
- The caudal portion of the trigeminal nucleus, which extends into the dorsal horns of the upper cervical spinal cord and receives input from the trigeminal nerve as well as the first and second cervical nerve roots: the trigeminocervical complex
- Rostral pain-processing regions, such as the ventroposteromedial thalamus and the cortex
- Pain modulatory systems in the brain that modulate input from trigeminal nociceptors at all levels of the pain-processing pathways and influence vegetative functions, such as hypothalamus and brainstem structures

The innervation of the large intracranial vessels and dura mater by the trigeminal nerve is referred to as the *trigeminovascular system*. Cranial autonomic symptoms, such as *lacrimation*, *conjunctival injection*, *nasal congestion*, *rhinorrhea*, *periorbital swelling*, *aural fullness*, and *ptosis*, are prominent in the trigeminal autonomic cephalalgias (TACs) and may also be seen in migraine. These autonomic symptoms result from activation of cranial parasympathetic pathways; functional imaging studies also suggest that vascular changes in migraine and cluster headache, when present, are driven by these cranial autonomic systems. When mistaken as evidence of sinus infection or inflammation, these symptoms may result in misdiagnosis and inappropriate management. Migraine and other primary headache syndromes are not primarily "vascular headaches" as was once thought; these disorders do not reliably demonstrate vascular changes, and treatment outcomes cannot be predicted by vascular effects. Migraine is fundamentally a brain disorder and should be understood and treated as such.

CLINICAL EVALUATION OF HEADACHE DISORDERS

The differential diagnosis of a new-onset, severe headache is quite different from that of a chronic, recurrent headache. There is a greater likelihood of finding a potentially serious underlying cause in a patient with new-onset and severe headache

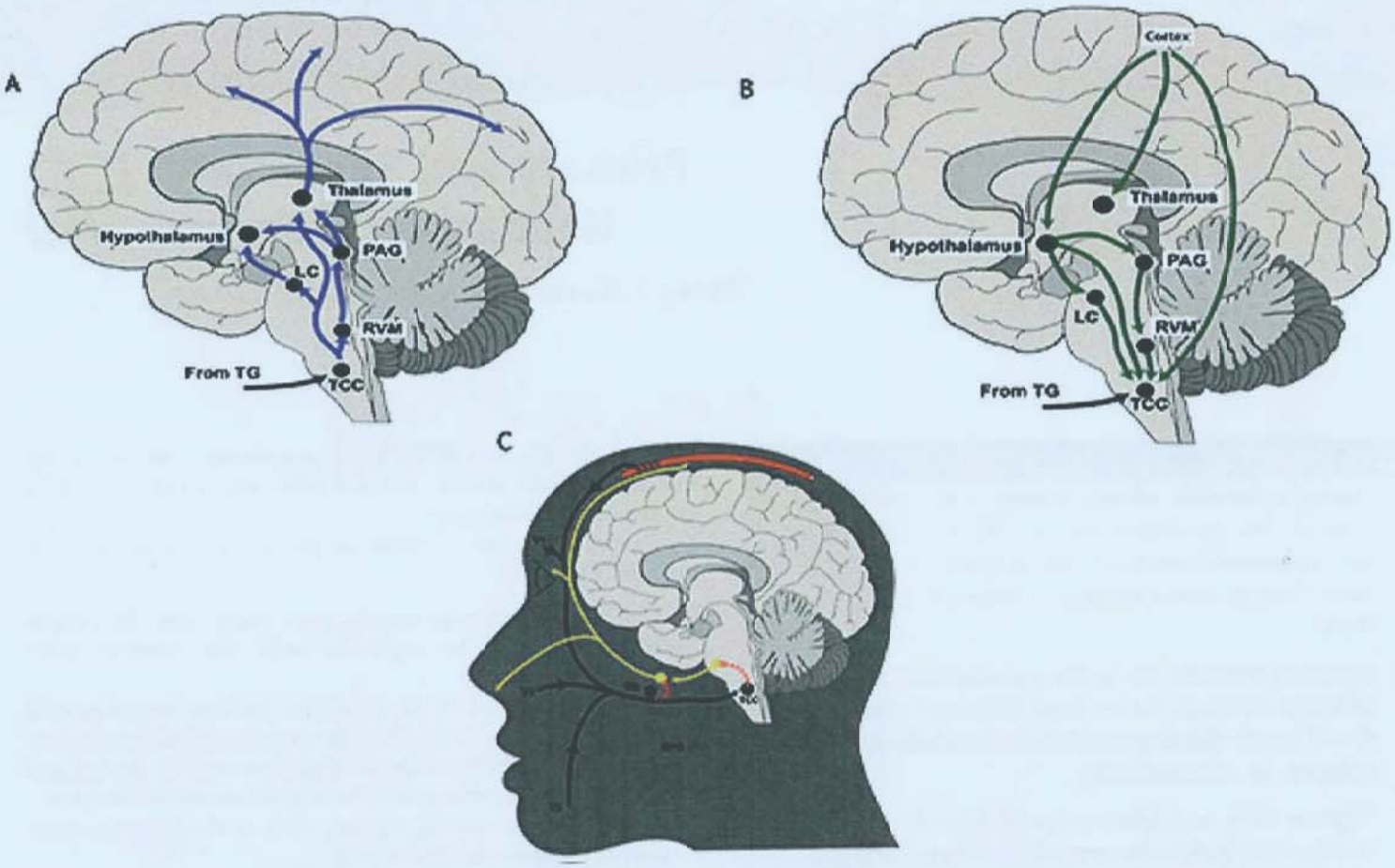

FIGURE 56.1 Pathophysiology of migraine. Peripheral sensory inputs are conveyed via trigeminal afferents arising in the trigeminal ganglion (TG) to the trigeminocervical complex (TCC) that represents the main interface for trigeminal pain processing between the peripheral and central nervous systems. Projection neurons then ascend in the quintothalamic tract decussating in the brainstem, synapsing on thalamocortical relay neurons in multiple thalamic nuclei. Collateral ascending projections also target several nuclei, including the rostral ventromedial medulla (RVM), locus coeruleus (LC), periaqueductal grey (PAG), and hypothalamus. **A:** Thalamocortical relay neurons then convey the sensory information to multiple cortical regions. This trigeminal pain processing network receives descending modulatory inputs at several levels. **B:** At the level of the TCC, direct projections from multiple cortical regions and indirect projections via the hypothalamus, PAG, RVM, and LC exert potent modulatory effects on neuronal firing. **C:** The TCC receives its peripheral sensory inputs from primary afferents innervating the intracranial and extracranial structures of all three dermatomes of the head (mandibular [V3], maxillary [V2], and ophthalmic [V1]) as well as convergent inputs from the posterior dura and cervical dermatomes. In addition to the ascending trigeminothalamic projections from the TCC, a trigeminal-autonomic reflex exists between the trigeminal sensory afferents and the superior salivatory nucleus (SSN) that regulates parasympathetic outflow to the face via the sphenopalatine ganglion (SPG). The *dashed lines* represent the potential interfaces between the trigeminal and parasympathetic arms of the trigeminal-autonomic reflex that remain to be fully characterized. (*After* Goadsby PJ, Holland PR. An update: pathophysiology of migraine. *Neurol Clin*. 2019;37:651-671.)

than in a patient with similar headaches that have recurred over years. Life-threatening headache is relatively uncommon, but vigilance is required in order to recognize and appropriately treat such patients. Serious causes to be considered include meningitis, subarachnoid hemorrhage, epidural or subdural hematoma, glaucoma, tumor, and purulent sinusitis. A classification system for headache disorders has been established by the International Headache Society—the International Classification of Headache Disorders, now in its third edition. The most recent version divides the disorders into *primary headaches*, in which the headache and associated features constitute the disorder itself, and *secondary headaches*, in which the headache results from exogenous causes.

SECONDARY HEADACHE

Chapter 9 presents an approach for identifying secondary headaches based on the identification of red flags, warning signals that suggest secondary headache. Figure 9.1 provides an algorithm for excluding secondary headache as a prelude to diagnosing primary headache disorders. Table 9.1 provides a list of red flags and the secondary headache disorders associated with those red flags. Table 9.2 summarizes worrisome clinical presentations and associated diagnostic possibilities. Although identifying secondary headaches is crucial, the vast majority of patients presenting with severe recurrent headache have a benign cause. The management of secondary headache focuses on diagnosis

and treatment of the underlying cause. In the following text we highlight a few important causes of secondary headache:

- **Meningitis:** Acute, severe headache with fever and stiff neck suggests meningitis (see Chapter 64). Often, there is significant worsening of pain with eye movement. Lumbar puncture is necessary for diagnosis. Meningitis can be easily mistaken for migraine in that the cardinal symptoms of pounding headache, photophobia, nausea, and vomiting are frequently present, perhaps reflecting an underlying biology in some of these cases.
- **Subarachnoid hemorrhage:** Acute, severe headache with stiff neck but without fever suggests subarachnoid hemorrhage (see Chapter 40). A ruptured aneurysm, arteriovenous malformation, or intraparenchymal hemorrhage may also present with headache alone. In rare cases (particularly if the hemorrhage is small or below the foramen magnum), head computed tomography can be normal. Thus, lumbar puncture may be required for definitive diagnosis of a subarachnoid hemorrhage.
- **Brain tumor:** Brain tumor is a rare cause of headache and even less commonly a cause of severe pain. The head pain is generally nondescript—an intermittent deep, dull ache of moderate intensity, which may worsen with exertion or change in position and may be associated with nausea and vomiting. Such symptoms are caused by migraine far more often than from brain tumor. The headache of brain tumor awakens patients from sleep in about 10% of cases. Vomiting that precedes the development of headache by weeks is highly characteristic of posterior fossa brain tumors. Head pain triggered by Valsalva maneuvers such as bending, lifting, or coughing can be due to a posterior fossa mass. De novo headache in a patient with known malignancy may suggest cerebral metastases and/or carcinomatous meningitis.
- **Giant cell arteritis (temporal arteritis):** Giant cell arteritis is an inflammatory disorder of arteries that frequently involves the extracranial carotid circulation. The average age of onset is 70 years, and women account for 65% of cases. About half of patients with untreated temporal arteritis develop blindness due to involvement of the ophthalmic artery and its branches, specifically the short posterior ciliary arteries. Because treatment with glucocorticoids is effective in preventing this complication, prompt recognition of the disorder is important. Headache is the dominant symptom and often appears in association with malaise and myalgias. Head pain may be unilateral or bilateral and is located temporally in 50% of patients but may involve any and all aspects of the cranium. The quality is almost always described as dull and boring, with superimposed episodic stabbing pains and exquisite scalp tenderness. Patients often describe a superficial origin of their headache (external to the skull rather than originating deep within the head as in migraine). Headache is usually worse at night and often aggravated by exposure to cold. Additional findings may include reddened, tender nodules or red streaking of the skin overlying the temporal arteries and tenderness of the temporal or, less commonly, the occipital arteries. The management of temporal arteritis is further discussed in Chapter 43.
- **Glaucoma:** Glaucoma may present with a prostrating headache of sudden onset associated with nausea and vomiting. The headache often starts with severe eye pain. On physical examination, the eye is often red with a fixed, moderately dilated pupil. Patients may report seeing halos around brightly illuminated objects. Angle closure glaucoma requires prompt treatment.

PRIMARY HEADACHE DISORDERS

Primary headache disorders involve headache and associated features occurring in the absence of exogenous etiologies. The most common categories of primary headache are migraine, tension-type headache (TTH), and the TACs, notably cluster headache; the complete list is in **Table 56.1**. Each of these categories includes multiple related disorders, which may differ in prognosis and response to treatment. Chapter 9 presents an approach to primary headaches based on syndromes defined by attack frequency (<15 headache days per month and ≥15 headache days per month) and attack duration (<4 h and ≥4 h per attack). This syndromic approach defines four syndromes each with its own differential diagnosis. In the syndromic approach, episodic migraine falls into the episodic long duration group and chronic migraine falls into the chronic long duration group. In this chapter, we present primary headache disorders in groups defined by the International Classification of Headache Disorders, 3rd edition.

MIGRAINE

Epidemiology

Migraine is the most common disabling headache and ranks second on the list of world's most disabling disorders as measured by disability adjusted life years. Migraine afflicts 12% to 15 % of the population, more than 1 billion people globally. It is 3 times more common in women than in men and most common between the ages of 25 and 55 years. Migraine is characterized by recurring episodes of headache pain and associated neurologic dysfunction, manifested as sensitivity to sensory stimuli (light, sound, smell, or movement); nausea and vomiting often accompany the headache.

The migraine brain is particularly sensitive to environmental and sensory stimuli; migraine-prone patients do not habituate easily to sensory input. Headache can be initiated or amplified by various triggers, including bright lights, sounds, smells, or other afferent stimulation; hunger; stress or the letdown from stress; physical exertion; stormy weather, altitude, or barometric pressure changes; hormonal fluctuations during menses; lack of or excess sleep; and alcohol or other chemicals, such as nitrates. Identifying a patient's susceptibility to specific triggers, and sign-posting symptoms occurring in the premonitory phase, can be useful in advising lifestyle adjustments as part of the treatment plan.

Pathophysiology

The sensory sensitivity that is characteristic of migraine is due, in part, to dysfunction of monoaminergic sensory control systems located in the brainstem and diencephalon. Activation of cells in the trigeminal nucleus results in the release of vasoactive neuropeptides, particularly calcitonin gene–related peptide (CGRP), at vascular terminations of the trigeminal nerve and within the trigeminal nucleus. Centrally, second-order trigeminal neurons cross the midline and project to ventrobasal and posterior nuclei of the thalamus for further processing. There are additional projections to the periaqueductal gray, parabrachial nucleus, and hypothalamus, from which reciprocal descending systems have established

TABLE 56.1 Primary Headache Disorders[a]

Migraine	■ *Migraine without aura* ■ *Migraine with aura* • Migraine with typical aura • Typical aura with headache • Typical aura without headache • Migraine with brainstem aura • Hemiplegic migraine • Familial hemiplegic migraine (FHM) • Familial hemiplegic migraine type 1 • Familial hemiplegic migraine type 2 • Familial hemiplegic migraine type 3 • Sporadic hemiplegic migraine • Retinal migraine ■ *Chronic migraine* ■ *Complications of migraine* • Status migrainosus • Persistent aura without infarction • Migrainous infarction • Migraine aura-triggered seizure ■ *Probable migraine* • Probable migraine without aura • Probable migraine with aura ■ *Episodic syndromes that may be associated with migraine* • Recurrent gastrointestinal disturbance • Cyclical vomiting syndrome • Abdominal migraine • Benign paroxysmal vertigo • Benign paroxysmal torticollis
Tension-type headache	■ *Infrequent episodic tension-type headache* ■ *Frequent episodic tension-type headache* ■ *Chronic tension-type headache*
Trigeminal autonomic cephalalgias	■ *Cluster headache* • Episodic cluster headache • Chronic cluster headache ■ *Paroxysmal hemicrania* • Episodic paroxysmal hemicrania • Chronic paroxysmal hemicrania ■ *Short-lasting unilateral neuralgiform headache attacks* • Short-lasting unilateral neuralgiform headache attacks with conjunctival injection and tearing (SUNCT) • Short-lasting unilateral neuralgiform headache attacks with cranial autonomic symptoms (SUNA) ■ *Hemicrania continua*
Other primary headache disorders	■ *Primary cough headache* ■ *Primary exercise headache* ■ *Primary headache associated with sexual activity* ■ *Primary thunderclap headache* ■ *Cold-stimulus headache* • Headache attributed to external application of a cold stimulus • Headache attributed to ingestion or inhalation of a cold stimulus ■ *External-pressure headache* • External-compression headache • External-traction headache ■ *Primary stabbing headache* ■ *Nummular headache* ■ *Hypnic headache* ■ *New daily persistent headache (NDPH)*

[a]Modified from International Headache Society. Headache Classification Committee of the International Headache Society (IHS). The International Classification of Headache Disorders, 3rd edition. *Cephalalgia*. 2018;38:1-211.

antinociceptive effects. Other brainstem regions likely to be involved in descending modulation of trigeminal pain include the nucleus locus coeruleus in the pons and the rostroventromedial medulla.

Pharmacologic and other data implicate the involvement of the neurotransmitter 5-hydroxytryptamine (5-HT or serotonin) in migraine. The *triptans*, a widely used class of acute treatments, were designed to selectively stimulate subpopulations of 5-HT receptors; at least 14 different 5-HT receptors have been identified in humans. The triptans are potent 5-HT_{1B} and 5-HT_{1D} receptor agonists, and some are active at the 5-HT_{1F} receptor. Specific agonists of the 5-HT_{1F} receptor are called *ditans*. Triptans arrest nerve signaling in the nociceptive pathways of the trigeminovascular system, at least in the trigeminal nucleus caudalis and trigeminal sensory thalamus, through 5-HT_{1D} effects, and cause cranial vasoconstriction through 5-HT_{1B} effects. *Ditans*, specifically lasmiditan, are for the treatment of acute migraine, acting only at neuronal targets and do not cause vasoconstriction. An interesting range of neural targets is now being actively pursed for the acute and preventive management of migraine.

Data also support a role for dopamine in the pathophysiology of migraine. The majority of migraine symptoms can be induced by dopaminergic stimulation. Moreover, there is dopamine receptor hypersensitivity in migraineurs, as demonstrated by the induction of yawning, nausea, vomiting, hypotension, and other symptoms of a migraine attack by dopaminergic agonists at doses that do not affect nonmigraineurs. Dopamine receptor antagonists are effective therapeutic agents in migraine, especially when given parenterally or concurrently with other antimigraine agents. Importantly, hypothalamic activation, anterior to that seen in cluster headache, has now been shown in the premonitory phase of migraine using functional imaging and this may hold a key to understanding some part of the role of dopamine in the disorder.

Migraine genes have been identified by studying families with familial hemiplegic migraine (FHM) and reveal involvement of ion channels, suggesting that alterations in membrane excitability can predispose to migraine. Mutations involving the $Ca_v2.1$ (P/Q)-type voltage-gated calcium channel *CACNA1A* gene are now known to cause FHM-1; this mutation is responsible for about 50% of cases of FHM. Mutations in the Na^+-K^+ adenosine triphosphatase *ATP1A2* gene, designated FHM-2, are responsible for about 20% of FHM. Mutations in the neuronal voltage-gated sodium channel *SCN1A* cause FHM-3. Genome-wide association studies have identified at least 38 genomic loci that influence migraine risk, with a polygenic basis for the inheritance seeming most likely for the majority of patients.

Diagnosis and Clinical Features

Diagnostic criteria for migraine headache are summarized in Table 56.2. Migraine has several forms that are distinguished by the presence or absence of aura (migraine with and without aura) or by the number of monthly headache days (episodic migraine and chronic migraine) (see Table 56.1). The migraine aura is characterized by focal neurologic symptoms that evolve slowly and often involve a mix of positive and negative features. Visual aura is most common and may include positive features such as flashing lights or zigzag lines that move across the visual field, as well as negative features, such as a graying out of vision

TABLE 56.2 Simplified Diagnostic Criteria for Migraine[a]

Repeated attacks of headache lasting 4-72 h in patients with a normal physical examination, no other reasonable cause for the headache, and

At Least Two of the Following Features	Plus at Least One of the Following Features
Unilateral pain	Nausea/vomiting
Throbbing pain	Photophobia and phonophobia
Aggravation by movement	
Moderate or severe intensity	

[a]Adapted from Headache Classification Committee of the International Headache Society (IHS). The International Classification of Headache Disorders, 3rd edition. *Cephalalgia*. 2018;38:1-211.

(a scotoma). For sensory aura, the positive features include tingling and the negative features include numbness. Other aura types are described in the following text. Aura is reported in only 20% to 25% of patients with migraine. Visual aura should be distinguished from visual snow syndrome, which presents with pan-field continuous movement of uncountable dots. Visual snow does not have the evolution or the mix of positive and negative features that typify migraine aura. Patients with migraine-like headache at least 8 days per month and headache on at least 15 days per month are considered to have chronic migraine. Most patients with disabling headache likely have migraine, as opposed to TTH, which is the most common primary headache disorder (discussed later in this chapter).

Migraine aura has a range of manifestations other than the visual and sensory aura described above. Vertigo can be prominent; it has been estimated that one-third of patients referred for vertigo or dizziness have a primary diagnosis of migraine. Migraine aura can have prominent brainstem symptoms (such as diplopia, ataxia, altered consciousness, dysarthria, tinnitus, and vertigo), and the terms *basilar artery* and *basilar-type migraine* have now been replaced by *migraine with brainstem aura* (see **Table 56.1**). In hemiplegic migraine, the aura may have motor manifestations; in FHM, there is autosomal dominant transmission related to a number of genetic variants discussed above. Patients with acephalgic migraine (typical aura without headache) experience recurrent neurologic symptoms, frequently with nausea or vomiting, but with little or no headache.

Treatment of Migraine

Once a diagnosis of migraine has been established, it is important to assess the extent of a patient's disease and level of functional impairment. The Migraine Disability Assessment Score is a well-validated, easy-to-use tool. A headache diary also helps assess disability as well as the frequency of abortive medication use. Patient education is an important aspect of migraine management. It is useful for patients to understand that migraine is an inherited vulnerability for head pain and associated neurologic symptoms and that although the disorder cannot be "cured," migraine can be modified and managed by lifestyle adjustments and medications. Furthermore, patients should be reassured that migraine is generally not associated with serious or life-threatening illnesses. In patients who have migraine with aura, there is an increased risk of stroke, myocardial infarction, and all-cause cardiovascular mortality, although the absolute risk of these events is low.

Trigger and Lifestyle Approaches to Management

Migraineurs may benefit by identifying and avoiding specific headache triggers. A regulated lifestyle is important, including a healthy diet (with a regular eating schedule), exercise, routinized sleep patterns, avoidance of excess caffeine and alcohol, and minimizing acute changes in stress levels (such as through biofeedback, meditation, or yoga). Lifestyle modifications that are effective in reducing headache frequency should be maintained on a routine basis because these provide a simple, cost-effective approach to migraine management. If these measures fail to prevent an attack, abortive pharmacologic measures are then needed.

Acute Therapies

Table 56.3 summarizes the commonly used approaches for acute treatment of migraine, which include the nonsteroidal anti-inflammatory drugs (NSAIDs), 5-$HT_{1B/1D}$ receptor agonists (triptans), dihydroergotamine, selective 5-HT_{1F} receptor agonists (ditans), CGRP receptor antagonists (gepants), and dopamine receptor antagonists and neuromodulation devices [LEVEL 2].[1-29] Selecting the optimal regimen for an individual patient depends on several factors, the most important of which is the severity of the attack. Mild migraine attacks can usually be managed by oral agents, with an average efficacy rate of 50% to 70%. Severe migraine attacks may require intranasal or parenteral treatments for faster onset. In general, an adequate dose of the selected medication should be used as soon as possible after the onset of an attack. If additional medication is required within 1 hour due to persistence or recurrence of symptoms, the initial dose should be increased or a different class of rescue therapy should be taken. Migraine therapy must be individualized; a standardized approach for all patients is not feasible. Furthermore, a treatment regimen may need to be frequently revised until a successful plan is reached that provides rapid, complete, and consistent relief with minimal side effects (**Table 56.4**).

Nonsteroidal Anti-inflammatory Drugs

NSAIDs can significantly reduce the severity and duration of a migraine attack and are most effective when taken early in the attack. However, these agents alone may not completely abort a moderate or severe migraine attack. The combination of aspirin and metoclopramide has been shown to be comparable to a single dose of oral sumatriptan. Important side effects of NSAIDs include dyspepsia and gastrointestinal irritation as well as potential cardiovascular and renal effects (particularly with frequent or long-term use).

5-Hydroxytryptamine$_{1B/1D}$ Receptor Agonists (Triptans) and Ergots

Stimulation of 5-$HT_{1B/1D}$ receptors can abort an acute migraine attack. Ergotamine and dihydroergotamine are nonselective receptor agonists, whereas the triptans are selective 5-$HT_{1B/1D}$ receptor agonists. A variety of triptans, 5-$HT_{1B/1D}$ receptor agonists—almotriptan, eletriptan, frovatriptan, naratriptan, rizatriptan, sumatriptan, and zolmitriptan—are available for the acute treatment of migraine. Each drug in the triptan class has similar pharmacologic properties yet varies slightly in terms of clinical efficacy. Rizatriptan and eletriptan are the most likely to be efficacious. Sumatriptan and zolmitriptan have similar rates of efficacy as well as time to onset, with an advantage of having different routes of administration. Almotriptan has a similar

TABLE 56.3 Acute Treatment of Migraine Attacks[a]

Drug	Trade Name	Dosage
NSAIDs		
Naproxen[b]	Aleve, Anaprox, generic	220-550 mg orally twice a day
Ibuprofen[b]	Advil, Motrin, Nuprin, generic	400-800 mg orally q6-8h
Acetylsalicylic acid[b]	Aspirin, generic	500-1,000 mg orally twice a day
Tolfenamic acid	Clotam Rapid	200 mg orally; may repeat × 1 after 1-2 h
Diclofenac potassium[b]	Cambia, generic	50 mg orally with water
Compound Analgesics		
Acetaminophen, aspirin, caffeine[b]	Excedrin Migraine	Two tablets or caplets q6h (max 8 per day)
Migraine Specific: Triptans: 5-$HT_{1B/1D}$ Receptor Agonists		
Oral		
Naratriptan[b]	Amerge, generic	2.5-mg tablet at onset; may repeat once after 4 h
Rizatriptan[b]	Maxalt, generic Maxalt-MLT	5- to 10-mg tablet at onset; may repeat after 2 h (max 30 mg/d)
Sumatriptan[b]	Imitrex, generic	50- to 100-mg tablet at onset; may repeat after 2 h (max 200 mg/d)
Frovatriptan[b]	Frova	2.5-mg tablet at onset; may repeat after 2 h (max 5 mg/d)
Almotriptan[b]	Axert	6.25- to 12.5-mg tablet at onset; may repeat after 2 h (max 25 mg/d)
Eletriptan[b]	Relpax	20- to 40-mg mg tablet at onset (max 80 mg/d)
Zolmitriptan[b]	Zomig, generic Zomig Rapimelt	2.5- to 5-mg tablet at onset; may repeat after 2 h (max 10 mg/d)
Nasal		
Dihydroergotamine[b]	Migranal nasal spray	Prior to nasal spray, the pump must be primed four times; one spray (0.5 mg) is administered, followed in 15 min by a second spray.
Sumatriptan[b]	Imitrex nasal spray	5- to 20-mg intranasal spray as four sprays of 5 mg or a single 20-mg spray (may repeat once after 2 h, not to exceed a dose of 40 mg/d)
Zolmitriptan[b]	Zomig	2.5- to 5-mg intranasal spray as one spray (may repeat once after 2 h, not to exceed a dose of 10 mg/d)
Parenteral		
Dihydroergotamine[b]	D.H.E. 45	1 mg IV, IM, or SC at onset and q1h (max 3 mg/d, 6 mg/wk)
Sumatriptan[b]	Imitrex injection, generic Alsuma Sumavel DosePro	6 mg SC at onset (may repeat once after 1 h for max of two doses in 24 h)
Ditans: 5-HT_{1F} Receptor Agonists		
Lasmiditan	Reyvow	50, 100, or 200 mg taken orally
Gepants: CGRP Receptor Antagonists		
Rimegepant	Nurtec	75 mg taken orally
Ubrogepant	Ubrelvy	50 or 100 mg taken orally
Dopamine Receptor Antagonist		
Oral		
Metoclopramide	Reglan,[c] generic[c]	5-10 mg/d
Prochlorperazine	Compazine,[c] generic[c]	1-25 mg/d
Promethazine	Phenergan,[c] generic[c]	25-50 mg/d
Chlorpromazine	Thorazine,[c] generic[c]	25-50 mg/d
Parenteral		
Metoclopramide[b]	Reglan,[c] generic	10 mg IV
Prochlorperazine[b]	Compazine,[c] generic[c]	10 mg IV
Chlorpromazine[b]	Thorazine,[c] generic[c]	12.5-25 mg IM or IV (0.1 mg/kg IV at 2 mg/min)
Promethazine	Phenergan,[c] generic[c]	12.5-25 mg IM or IV (slow)

(table continues on page 527)

TABLE 56.3 Acute Treatment of Migraine Attacks[a] *(continued)*

Drug	Trade Name	Dosage
Neuromodulation		
Transcutaneous supraorbital nerve stimulation	Cefaly	Stimulate for 60 min.
sTMS	sTMS mini	Three pulses repeated if no initial response
Noninvasive vagus nerve stimulation	Gammacore	1-2 120 s stimuli to affected side
Remote electrical neuromodulation	Nerivio Migra	45-min stimulation on the upper arm

Abbreviations: 5-HT, 5-hydroxytryptamine; CGRP, calcitonin gene–related peptide; IM, intramuscular; IV, intravenous; NSAIDs, nonsteroidal anti-inflammatory drugs; SC, subcutaneous; sTMS, single pulse transcranial magnetic stimulation.
[a]Antiemetics (eg, domperidone 10 mg or ondansetron 4 or 8 mg) or prokinetics (eg, metoclopramide 10 mg) are sometimes useful adjuncts.
[b]Supported by level 1 evidence.
[c]Not all drugs are specifically indicated by the U.S. Food and Drug Administration for migraine. Local regulations and guidelines should be consulted.

rate of efficacy to sumatriptan but is better tolerated, whereas frovatriptan and naratriptan are somewhat slower in onset yet have milder side effect profiles. Clinical efficacy appears to be related more to the t_{max} (time to peak plasma level) than to the potency, half-life, or bioavailability. This observation is consistent with various studies indicating that faster acting analgesics are more effective than slower acting agents.

TABLE 56.4 Clinical Stratification of Acute Specific Migraine Treatments

Clinical Situation	Treatment Options
Failed NSAIDs/simple analgesics	**First tier** Sumatriptan 50-100 mg orally Almotriptan 12.5 mg orally Rizatriptan 10 mg orally Eletriptan 40 mg orally Zolmitriptan 5 mg orally **Slower effect/better tolerability** Naratriptan 2.5 mg orally Frovatriptan 2.5 mg orally **Newer alternatives** Lasmiditan Rimegepant Ubrogepant
Early nausea or difficulty taking tablets	Zolmitriptan 5 mg nasal spray Sumatriptan 20 mg nasal spray Rizatriptan 10 mg MLT wafer Zolmitriptan 5 mg ZMT Rapimelt
Early vomiting	Zolmitriptan 5 mg nasal spray Sumatriptan 6 mg SC
Headache recurrence	Naratriptan 2.5 mg orally Almotriptan 12.5 mg orally Eletriptan 40 mg orally Frovatriptan Rimegepant Ubrogepant
Tolerating acute treatments poorly due to side effects	Naratriptan 2.5 mg orally Almotriptan 12.5 mg orally Lasmiditan Rimegepant Ubrogepant
Menstrual-associated headache	Frovatriptan 2.5 mg with Naprosyn 500 mg around menses
Rapidly developing symptoms	Zolmitriptan 5 mg nasal spray Sumatriptan 6 mg SC Dihydroergotamine 1 mg IM

Abbreviations: IM, intramuscular; NSAIDs, nonsteroidal anti-inflammatory drugs; SC, subcutaneous.

Unfortunately, monotherapy with oral triptan therapy does not yield rapid, consistent, and complete relief of migraine in all patients. Triptans may not be effective in migraine with aura unless taken after completion of the aura and initiation of the headache; recurrence of headache is another limitation of triptan use. Evidence from randomized controlled trials demonstrates that coadministration of a longer acting NSAID (such as naproxen 500 mg) with sumatriptan will augment the initial effect of sumatriptan and, importantly, reduce rates of headache recurrence. Side effects of triptans include nausea, chest tightness, dizziness, asthenia, and flushing. 5-$HT_{1B/1D}$ receptor agonists are contraindicated in individuals with a history of cardiovascular or cerebrovascular disease. In addition, there are precautions in labeling for individuals with multiple cardiovascular risk factors. In practice, rates of vascular events following triptan administration have been very low.

Nasal formulations of dihydroergotamine, zolmitriptan, or sumatriptan can, particularly with the addition of a permeation enhancer, be useful in patients requiring a nonoral route of administration (eg, due to nausea/vomiting). Intranasal administration can result in substantial blood levels within 30 to 60 minutes. Although nasal sprays in theory might provide faster and more effective relief than oral formulations, their reported efficacy is only 50% to 60%. Studies with a new inhalational formulation of dihydroergotamine indicate that its absorption problems can be overcome to produce rapid onset of action with good tolerability. Orally dissolving formulations of rizatriptan and zolmitriptan are convenient because no water is needed and may be less likely to induce nausea.

Sumatriptan and dihydroergotamine are also available in injection formulations. Sumatriptan 4 to 6 mg subcutaneously (SC) is effective in approximately 50% to 80% of patients. Peak plasma levels of dihydroergotamine are achieved 3 minutes after intravenous dosing, 30 minutes after intramuscular dosing, and 45 minutes after SC dosing. If an attack has not already reached peak, SC or intramuscular administration of 1-mg dihydroergotamine can be effective in about 80% to 90% of patients.

Dopamine Receptor Antagonists

Oral dopamine receptor antagonists can be considered as adjunctive acute migraine treatments. Drug absorption is impaired during migraine due to reduced gastrointestinal motility (even in the absence of nausea) and is related to the severity of the attack rather than duration. Therefore, when oral NSAIDs and/or triptans fail, the addition of an oral dopamine receptor antagonist (such as metoclopramide 10 mg) should be considered

to enhance gastric absorption as well as to decrease nausea/vomiting. Certain dopamine blockers such as metoclopramide, and some phenothiazine drugs (such as promethazine, prochlorperazine, or chlorpromazine), can also independently improve headache pain, particularly when given parenterally, although akathisia, sedation, and orthostatic hypotension may limit use.

Ditans: 5-HT_{1F} Receptor Agonists

Ditans are centrally penetrant, neurally active acute treatments of migraine with no vasoconstrictor lability. One is currently available, lasmiditan, which was more effective than placebo at 2 hours in rendering patients pain free and most bothersome symptom free when administered orally. Dizziness occurs in about 15% of patients, and it is advised that patients do not drive for 8 hours after taking the medicine. Because ditans do not cause vasoconstriction, they offer an effective and safe option in patients with vascular contraindications to triptans.

Gepants: Calcitonin Gene–Related Peptide Receptor Antagonists

Gepants are orally active small molecule CGRP receptor antagonists available for the acute treatment. Both ubrogepant and rimegepant were more effective than placebo at 2 hours in rendering patients pain free and most bothersome symptom free. Ubrogepant is available in 50 or 100 mg tablets. Rimegepant is being marketed as a 75-mg orally dissolving tablet. Both drugs are extremely well tolerated with only mild side effects in less than 5% of patients. Apart from avoiding ubrogepant with strong CYP3A4 inhibitors, they are easy to use and effective medicines. Broadly, acute gepants will likely be most useful in patients who do not respond to or cannot tolerate triptans, and in patients with cardiovascular contraindications to triptans. Because oral gepants are being developed as preventive treatments (see in the following text), and because frequent use of rimegepant as an acute treatment is associated with a reduction in monthly migraine days, it is hoped that this class, unlike the triptans and combination analgesics, will not cause medication overuse. A nasal spray formulation of a gepant, vazegepant, is in development.

Other Medications for Acute Migraine

Opioids are modestly effective in the acute treatment of migraine and are commonly administered in the emergency room. Such agents can "help" in the sense that the pain of migraine is eliminated or reduced. However, this regimen is suboptimal for patients with recurrent headache. Opioids do not treat the underlying headache pathophysiology; rather, they act to alter the sensation of pain, and there is evidence that they can render other migraine medications (such as triptans) less effective. Moreover, frequent opioid use can result in medication overuse headache as well as physical dependence or addiction; opioid craving and/or withdrawal can in turn worsen migraine. Therefore, it is recommended that opioid use in migraine be restricted to patients with severe, but infrequent, headaches that are unresponsive to other pharmacologic approaches or who have contraindications to other treatments.

Butalbital-containing compounds are also frequently given for acute migraine treatment. Although these medications may provide analgesic relief, there is a high potential for dependence and the development of medication overuse headache (also known as *rebound headache*), which is a state of refractory daily or near-daily headache. This condition is likely not a separate headache entity but a reaction of the migraine patient to a particular medicine. Butalbital-containing medications have been banned in some countries and, although still available in the United States, should be avoided.

Neuromodulation Approaches to Acute Therapy

Transcutaneous supraorbital nerve stimulation, single pulse transcranial magnetic stimulation (sTMS), noninvasive vagus nerve stimulation, and remote electrical neuromodulation have all been shown to have some benefit in the acute treatment of migraine. In females considering pregnancy, sTMS is particularly attractive given what is known about the low birth risks with magnetic resonance imaging (MRI).

Preventive Treatments for Migraine

Patients who experience an increasing frequency of migraine attacks, or attacks that are poorly responsive to acute medications, warrant preventive therapy. In general, preventive treatments should be considered for patients with four or more migraine days a month; however, the decision of when to start a preventive agent may also depend on the severity and duration of attacks, response to acute therapy, and patient preference. Many preventive medications have significant side effects, and the therapeutic dose can vary significantly among individual patients. The mechanism of action of these drugs is not entirely known; it is likely that they modify the brain sensitivity that underlies migraine. For oral preventive medications, patients are usually started on a low dose, which is gradually titrated up to a reasonable target dose. Oral preventive medication must be taken daily, and there is usually a lag of 2 to 12 weeks before benefits occur.

Commonly used preventive medications for migraine are listed by class in **Table 56.5** LEVEL 7.[30-65] The oral drugs that have been approved by the U.S. Food and Drug Administration for the preventive treatment of migraine include two β-blockers (propranolol, timolol) and two anti-epilepsy drugs (sodium valproate and topiramate). In addition, a number of other drugs appear to display preventive efficacy. This includes amitriptyline, nortriptyline, candesartan, flunarizine, phenelzine, gabapentin, and cyproheptadine. Onabotulinum toxin type A has been shown to be effective in placebo-controlled studies for the prevention of chronic migraine but not of episodic migraine. The probability of success with any one of these medications is approximately 50%.

Once effective stabilization is achieved, the drug is continued for approximately 6 to 12 months and then slowly tapered to assess whether continuation is needed. Many patients are able to wean off prophylactic medications successfully, with fewer and milder attacks for long periods. This may suggest that treatment alters the natural history of disease, although there are other possibilities. The newest edition to therapeutic options for migraine prevention target the CGRP pathway.

Monoclonal Antibodies

Given the role of CGRP in migraine pathophysiology, monoclonal antibodies have been developed to either the CGRP peptide (eptinezumab, fremanezumab and galcanezumab), or to the canonical CGRP receptor (erenumab). These medicines are each effective in the preventive treatment of migraine. Patients with episodic migraine, 4 to 14 days a month, or chronic migraine, ≥15 days a month, have reduced migraine frequency with these medicines versus placebo. They are given either monthly SC, or quarterly, SC or intravenously. They are well tolerated and, in prospective randomized placebo controlled trials, are effective in patients who have failed up to four preventives.

Monoclonal antibodies, as a group, are recommended for patients who do not respond to, or who cannot tolerate oral generic

TABLE 56.5 Preventive Treatments in Migraine[a]

Drug	Dose	Selected Side Effects
β-Blockers		Fatigue, postural symptoms, bradycardia, depression, nightmares
Propranolol[b]	40-120 mg twice a day	Caution in patients with asthma
Metoprolol[b]	25-100 mg twice a day	—
Timolol[b]	5-10 mg twice a day	—
Atenolol	25-100 mg every day	—
Nadolol	40-240 mg divided twice or 3 times a day	—
Anticonvulsants		
Topiramate[b]	25-200 mg/d	Paresthesias, cognitive impairment, weight loss, nausea, fatigue, glaucoma, and metabolic acidosis; caution with nephrolithiasis
Valproate[b]	400-600 mg twice a day	Drowsiness, weight gain, hair loss, tremor, hematologic or liver abnormalities, fetal abnormalities
Gabapentin	900-3,600 mg every day	Dizziness, sedation, weight gain
Antidepressants		
Amitriptyline	10-100 mg at night	Drowsiness, dry mouth, constipation, blurred vision, postural hypotension, weight gain
Nortriptyline	10-100 mg at night	***Note:*** Some patients may only need a total dose of 10 mg, although generally, 1-1.5 mg/kg body weight is required.
Doxepin	10-75 mg at night	Sedation, dry mouth, weight gain
Venlafaxine[b]	75-150 mg every day	Nausea, insomnia, dizziness, fatigue, nervousness
Serotonergic Drugs		
Pizotifen[c]	0.5-2 mg every day	Weight gain, drowsiness
CGRP Pathway Monoclonal Antibodies		
Eptinezumab (Vyepti)	100 or 300 mg IV quarterly	—
Erenumab (Aimovig)	70 or 140 mg SC monthly	—
Fremanezumab (Ajovy)	225 mg SC monthly or 675 mg SC quarterly	—
Galcanezumab (Emgality)	240 mg SC loading dose then 120 mg SC monthly	—
Neuromodulation		
sTMS	sTMS mini	2-8 pulses 2 to 3 times daily
Transcutaneous supraorbital nerve stimulation	Cefaly	Stimulate 20 min daily
Other Classes		
Flunarizine[c] (calcium channel blocker)	5-15 mg every day	Drowsiness, weight gain, depression, parkinsonism
Candesartan (ARB inhibitor)	16 mg every day	Dizziness, hypotension
Onabotulinum toxin type A[b] (Botox)	155 units divided in 31 sites (PREEMPT protocol)	Loss of brow furrow, ptosis, pain at injection sites, neck stiffness
Complementary Agents		
Petasites (butterbur)[b]	75 mg twice a day	Stomach upset
Riboflavin (vitamin B_2)	400 mg every day	Urine discoloration
Magnesium	500-600 mg every day	Increased bowel motility
Feverfew (MIG-99)	6.25 mg 3 times a day	Stomach upset, nausea

Abbreviations: ARB, angiotensin II receptor blocker; CGRP, calcitonin gene–related peptide; IV, intravenous; PREEMPT, Phase III Research Evaluating Migraine Prophylaxis Therapy protocol; sTMS, single pulse transcranial magnetic stimulation.

[a]Commonly used preventives are listed with typical doses and common side effects. Not all listed medicines are approved by the U.S. Food and Drug Administration; local regulations and guidelines should be consulted.

[b]Supported by level 1 evidence.

[c]Not available in the United States.

preventive medications. They have a number of advantages over oral generic preventive medications. First, dose titration is not necessary; the initial dose is often the optimal dose. Secondly, therapeutic benefits develop relatively rapidly with statistically significant reduction in migraine days in the first week following administration. Full benefits sometimes develop more slowly, over several months. Thirdly, these agents are very well tolerated relative to oral preventives; and finally, with infrequent dosing, adherence is easier than with the daily oral generics.

Gepants as Preventives

Given the success of CGRP pathway monoclonal antibodies, and the outcome of an initial clinical trial with a gepant, these medicines are being developed as preventives. Two are in clinical development: atogepant with two positive phase 3 studies and rimegepant, currently under study.

Neuromodulation Approaches to Prevention

Neuromodulation with transcutaneous supraorbital nerve stimulation or sTMS have been shown to be effective in the preventive treatment of migraine. They are safe and extremely well tolerated approaches, particularly for patients in the reproductive years or who have had significant side effects with pharmacologic preventives.

TENSION-TYPE HEADACHE

Clinical Features

TTH is the most common primary headache disorder, although patients rarely present to the clinic due to the low level of associated disability. TTH is characterized by bilateral tight, band-like head discomfort of mild to moderate severity. The pain usually progresses slowly, fluctuates in severity, and may persist more or less continuously for many days. The headache may be episodic or chronic (present on 15 or more days per month). Unlike migraine, TTH is otherwise featureless and lacks accompanying features such as nausea, vomiting, photophobia, phonophobia, osmophobia, throbbing, and aggravation with movement.

Pathophysiology

The pathophysiology of TTH is incompletely understood. It seems likely that TTH is due to a primary disorder of central nervous system pain modulation alone, unlike migraine, which involves a more generalized disturbance of sensory modulation. Data suggest a genetic contribution to TTH, although this may not be a valid finding, as these studies likely included many migraine patients. The name *tension-type headache* implies that pain is a product of *nervous tension*; however, there is no clear evidence for tension as an etiology. Muscle contraction has been considered to be a feature that distinguishes TTH from migraine, but there appear to be no differences in electromyogram activity between the two headache types.

Treatment

The pain of TTH usually responds to simple analgesics such as acetaminophen, aspirin, or other NSAIDs. Behavioral approaches including relaxation can also be effective. Clinical studies have demonstrated that triptans in pure TTH are not helpful, although triptans are effective in TTH when the patient also has migraine. For chronic TTH, amitriptyline (10-100 mg/d) is the only proven treatment; other tricyclics, selective serotonin reuptake inhibitors, and the benzodiazepines have not been shown to be effective. There is no evidence for the efficacy of acupuncture. Placebo-controlled trials of onabotulinum toxin type A in chronic TTH have been negative.

TRIGEMINAL AUTONOMIC CEPHALALGIAS

The TACs describe a group of primary headaches including cluster headache, paroxysmal hemicrania (PH), short-lasting unilateral neuralgiform headache attacks with conjunctival injection and tearing (SUNCT)/short-lasting unilateral neuralgiform headache attacks with cranial autonomic symptoms (SUNA), and hemicrania continua (HC) (see Table 56.1). The TACs are characterized by relatively short-lasting attacks of head pain in the first division of the trigeminal nerve (hence trigeminal in the name) associated with cranial autonomic symptoms, such as lacrimation, conjunctival injection, or nasal congestion (Table 56.6). Pain is usually severe and may occur more than once a day. Because of the associated nasal congestion or rhinorrhea, patients are often misdiagnosed with "sinus headache" and treated with decongestants, which are ineffective. The key feature of this class of headaches is the lateralized nature of symptoms (eg, side-locked head pain and ipsilateral cranial autonomic features).

TACs must be differentiated from short-lasting headaches that do not have prominent cranial autonomic syndromes, notably trigeminal neuralgia (TN), primary stabbing headache, and hypnic headache. The cycling pattern and length, frequency, and timing of attacks are useful in classifying patients. Patients with TACs should undergo pituitary imaging and pituitary function tests because there is an excess of TAC presentations in patients with pituitary tumor–related headache.

Cluster Headache

Clinical Features

Cluster headache is a rare primary headache syndrome with a population frequency of approximately 0.1%, affecting men more than women at a gender prevalence ratio of 3:1. The pain is deep, usually retro-orbital, often excruciating in intensity, nonfluctuating, and explosive in quality. A core feature of cluster headache is periodicity. At least one of the daily attacks of pain recurs at about the same hour each day for the duration of a cluster bout. Onset is nocturnal in about 50% of patients. The typical cluster headache patient has daily bouts of one or two attacks of relatively short-duration unilateral pain for 8 to 10 weeks a year; this is usually followed by a pain-free interval that averages a little less than 1 year. Cluster headache is characterized as chronic when attacks persist over for at least a year with less than 3 month of sustained remission without treatment. Patients with cluster headache tend to be restless during attacks and may pace, rock, or rub their head for relief; some may even become aggressive during attacks. This is in sharp contrast to patients with migraine who prefer to remain motionless during attacks.

Pathophysiology

Cluster headache is likely to be a disorder involving central pacemaker neurons in the posterior hypothalamic region, thus

TABLE 56.6 Clinical Features of the Trigeminal Autonomic Cephalalgias

	Cluster Headache	Paroxysmal Hemicrania	SUNCT/SUNA
Gender pain	M > F	F = M	F ~ M
Type	Stabbing, boring	Throbbing, boring, stabbing	Burning, stabbing, sharp
Severity	Excruciating	Excruciating	Severe to excruciating
Site	Orbit, temple	Orbit, temple	Periorbital
Attack frequency	1/alternate day to 8/d	1-20/d (>5/d for more than half the time)	3-200/d
Duration of attack	15-180 min	2-30 min	5-240 s
Autonomic features	Yes	Yes	Yes (prominent conjunctival injection and lacrimation)[a]
Migrainous features[b]	Yes	Yes	Yes
Alcohol trigger	Yes	No	No
Cutaneous triggers	No	No	Yes
Indomethacin effect	—	Yes[c]	—
Abortive treatment	Sumatriptan injection or nasal spray Zolmitriptan nasal spray Oxygen Noninvasive vagus nerve stimulation	No effective treatment	Lidocaine (IV)
Preventive treatment	Verapamil Lithium Galcanezumab	Indomethacin	Lamotrigine Topiramate Gabapentin

Abbreviations: F, female; IV, intravenous; M, male; SUNA, short-lasting unilateral neuralgiform headache attacks with cranial autonomic features; SUNCT, short-lasting unilateral neuralgiform headache attacks with conjunctival injection and tearing.
[a]If conjunctival injection and tearing not present, consider SUNA.
[b]Nausea, photophobia, or phonophobia; photophobia and phonophobia are typically unilateral on the side of the pain and seen in patients with a personal or family history of migraine.
[c]Indicates complete response to indomethacin.

accounting for its periodicity. Other hallmark features of cluster headache include the ipsilateral symptoms of cranial parasympathetic autonomic activation: conjunctival injection or lacrimation, rhinorrhea or nasal congestion, or cranial sympathetic dysfunction such as ptosis. The sympathetic deficit is peripheral and likely due to parasympathetic activation with injury to ascending sympathetic fibers surrounding a dilated carotid artery as it passes into the cranial cavity. When present, photophobia and phonophobia are far more likely to be unilateral and on the same side of the pain, rather than bilateral, as is seen in migraine. This phenomenon of unilateral photophobia/phonophobia is characteristic of TACs.

Treatment

As with migraine, there are both abortive (acute) medications and preventive therapies that can be used during a cluster bout LEVEL 2.[66-81]

Abortive Treatment

Cluster headache attacks peak rapidly, and thus, a treatment with quick onset is required. Many patients with acute cluster headache respond very well to oxygen inhalation. This should be given as 100% oxygen at 10 to 12 L/min for 15 to 20 minutes at the onset of the attack. Sumatriptan 6 mg SC is rapid in onset and will usually shorten an attack to 10 to 15 minutes; there is no evidence of tachyphylaxis. Sumatriptan (20 mg) and zolmitriptan (5 mg) nasal sprays are also both effective in acute cluster headache. Oral sumatriptan is not effective for either prevention or acute treatment of cluster headache. Noninvasive vagus nerve stimulation is effective in the treatment of attacks in episodic cluster headache, compared to sham, at 15 minutes, although not useful for attacks in patients with chronic cluster headache.

Preventive Treatments

Table 56.7 summarizes commonly used treatments for the prevention of cluster headache. The choice of a preventive treatment in cluster headache depends in part on the length of the bout. Patients with long bouts or those with chronic cluster headache

TABLE 56.7 Preventive Management of Cluster Headache

Short-Term Prevention	Long-Term Prevention
Episodic Cluster Headache	Episodic Cluster Headache and Prolonged Chronic Cluster Headache
Prednisone 1 mg/kg up to 60 mg every day, tapering over 21 d	Verapamil 160-960 mg/d *(immediate-release formulation, divided twice or 3 times a day)*
Verapamil 160-960 mg/d	Lithium 400-800 mg/d
Greater occipital nerve injection[a]	Topiramate[b] 100-400 mg/d
	Gabapentin[b] 1,200-3,600 mg/d
	Melatonin[b] 9-12 mg/d
Galcanezumab 300 mg SC monthly	Non-invasive vagus nerve stimulation

[a]Supported by level 1 evidence.
[b]Unproven but of potential benefit.

require medicines that are safe when taken for long periods. For patients with relatively short bouts, limited courses of oral glucocorticoids can be very useful. A 10-day course of prednisone, beginning at 60 mg daily for 7 days and followed by a rapid taper, can also help to interrupt the cycle. An alternative with controlled trial evidence is greater occipital nerve injection with a corticosteroid and a local anesthetic. Lithium (400-800 mg/d) appears to be particularly useful for the chronic form of the disorder. Noninvasive vagus nerve stimulation is effective compared to standard of care in the preventive treatment of chronic cluster headache. Melatonin and topiramate are used in the preventive treatment of cluster headache, although the evidence base is limited.

Many experts favor verapamil as the first-line preventive treatment for patients with chronic cluster headache or prolonged bouts. Although verapamil compares favorably with lithium in practice, some patients require verapamil doses far in excess of those administered for cardiac disorders. The initial dose range is 40 to 80 mg twice daily; effective doses may be as high as 960 mg/d. Side effects include constipation and lower extremity edema. Of greater concern is the cardiovascular safety of verapamil, particularly at high doses. Verapamil can induce heart block by slowing conduction in the atrioventricular node and thus requires close monitoring of the PR interval with serial electrocardiograms (ECGs). Approximately 20% of patients treated with verapamil develop ECG abnormalities, which can occur at doses as low as 240 mg/d; these abnormalities can worsen over time in patients on stable doses. A baseline ECG is recommended for all patients. The ECG is then repeated 10 days after a dose change in those patients whose dose is being increased above 240 mg daily. Dose increases are usually made in 80-mg increments. Patients on long-term verapamil should have ECG monitoring every 6 months.

Galcanezumab, a monoclonal antibody to CGRP, has been shown to be effective compared to placebo in reducing attacks in patients with episodic cluster headache. It did not have a demonstrable effect in chronic cluster headache.

Neurostimulation Therapy

When medical therapies fail in chronic cluster headache, neurostimulation strategies can be considered. There are two sham-controlled positive studies with sphenopalatine ganglion stimulation in the preventive treatment of chronic cluster headache. There is open-label experience with occipital nerve stimulation. Deep brain stimulation of the region of the posterior hypothalamic gray matter has proven successful in a substantial proportion of patients in open label use, although with its morbidity and possible mortality, and a negative controlled trial, it is not recommended prior to less invasive approaches.

Paroxysmal Hemicrania

PH is characterized by unilateral, severe, short-lasting attacks (2-45 min) of head pain that are frequent (more than five times per day). Like cluster headache, the pain tends to be retroorbital but also may be experienced in other regions of the head and is associated with ipsilateral cranial autonomic phenomena such as lacrimation and nasal congestion. However, unlike cluster headache, which predominantly affects males, the male-to-female ratio in PH is close to 1:1. Episodic PH is characterized by periods of remission, whereas the nonremitting form is termed *chronic PH*. PH is marked by an excellent response to indomethacin (25-75 mg three times a day), which can completely suppress attacks often within a few days of initiating the required dose. Although therapy may be complicated by indomethacin-induced gastrointestinal side effects, currently, there are no consistently effective alternatives. Noninvasive vagus nerve stimulation is useful in half of patients with PH. Topiramate (50-300 mg/d) has been reported to be helpful in some cases, as has piroxicam (20-40 mg/d), although not to the same extent as indomethacin. Verapamil, an effective treatment for cluster headache, does not appear to be useful for PH. In occasional patients, PH can coexist with TN (PH-tic syndrome); similar to cluster-tic syndrome, each component may require separate treatment.

Secondary PH has been reported from lesions in the region of the sella turcica, including arteriovenous malformation, cavernous sinus meningioma, pituitary pathology, and epidermoid tumors. Secondary PH is more likely if the patient requires high doses (>200 mg/d) of indomethacin. In patients with apparent bilateral PH, raised cerebrospinal fluid (CSF) pressure should be suspected. It is important to note that indomethacin reduces CSF pressure. When a diagnosis of PH is considered, as with other TACs, MRI is indicated to exclude a pituitary lesion.

SUNCT/SUNA

Clinical Features

SUNCT is a rare primary headache syndrome characterized by severe, unilateral orbital or temporal pain that is stabbing or throbbing in quality. Diagnosis requires at least 20 attacks, lasting for 5 to 240 seconds; ipsilateral conjunctival injection, and lacrimation should be present. In some patients, conjunctival injection or lacrimation is missing, and the diagnosis of SUNA can be made.

The pain of SUNCT/SUNA is unilateral and may be located anywhere in the head. Three basic patterns can be seen: *single stabs*, which are usually short lived; *groups of stabs*; or a longer attack consisting of many stabs between which the pain does not completely resolve, thus yielding a "*sawtooth*" *pattern* with attacks lasting many minutes. Each pattern may be seen in the context of an underlying continuous head pain. Characteristics that lead to a suspected diagnosis of SUNCT are the cutaneous (or other) triggerability of attacks, a lack of refractory period to triggering between attacks (to distinguish it from TN), and the lack of a response to indomethacin (to distinguish it from PH). Apart from trigeminal sensory disturbance, the neurologic examination is normal in primary SUNCT.

The diagnosis of SUNCT is often confused with TN particularly in first-division TN (as discussed in Chapter 57). Minimal or no cranial autonomic symptoms and a clear refractory period to triggering indicate a diagnosis of TN. Secondary SUNCT can be seen with posterior fossa or pituitary lesions. All patients with SUNCT/SUNA should be evaluated with pituitary function tests and a brain MRI with pituitary views.

Treatment

Abortive therapy is not practical in SUNCT/SUNA because the attacks are of such short duration. The main goal of treatment is long-term prevention to minimize disability. The most effective prophylactic medication is lamotrigine at doses of 200 to 400 mg/d. Topiramate (50-300 mg/d) and gabapentin (800-2,700 mg/d) may also be effective. Carbamazepine (400-600 mg/d) has been reported by some to be moderately helpful. Surgical approaches such as microvascular decompression or destructive trigeminal procedures are seldom useful and often cause long-term complications such as permanent numbness and anesthesia doloroso. Greater occipital nerve blocks may yield limited benefit in some patients. Occipital nerve stimulation is

probably helpful in a subgroup of patients with SUNCT/SUNA. For intractable cases, short-term prevention with intravenous lidocaine, which can arrest symptoms rapidly, can be useful.

Hemicrania Continua

The essential features of HC are moderate and continuous unilateral pain with superimposed exacerbations of severe pain, which may be associated with cranial autonomic features and photophobia/phonophobia on the affected side. The age of onset reported in the literature ranges from 11 to 58 years; women are affected twice as often as men. The cause is unknown, although as with other TAC syndromes, pituitary pathology has been associated with HC.

As with PH, definitive treatment is indomethacin (25-75 mg three times a day); other NSAIDs appear to be of little or no benefit. Indomethacin should be initiated at 25 mg orally three times a day and then increased to 50 mg three times a day if no effect, and further to 75 mg three times a day if needed. Up to 2 weeks at the maximal dose may be necessary to assess whether a dose has a useful effect. Noninvasive vagus nerve stimulation is useful in more than half of patients with HC. Topiramate can be helpful in some patients, as can greater occipital nerve blocks. Occipital nerve stimulation probably has a role in patients with HC who are unable to tolerate indomethacin.

OTHER PRIMARY HEADACHES

Primary Cough Headache

Primary cough headache is a generalized headache that begins suddenly, lasts for several minutes, sometimes up to a few hours, and is precipitated by Valsalva maneuver, with coughing the best known; it is preventable by avoiding coughing or other precipitating events, which can include sneezing, straining, laughing, or stooping. In all patients with this syndrome, serious etiologies must be excluded before a diagnosis of "benign" primary cough headache can be established (as discussed earlier in this chapter and also in Chapter 9). Benign cough headache can resemble benign exertional headache (in the following text), but patients with the former condition are typically older. Remarkably, Valsalva maneuver, in the context of sexual activity during orgasm in patients with primary cough headache, is generally not painful. This distinction is generally a sign of benignity.

Indomethacin 25 to 50 mg two to three times daily is the treatment of choice. Some patients with cough headache obtain complete cessation of their attacks with lumbar puncture; this is a simple option when compared to prolonged use of indomethacin, and it is effective in about one-third of patients. The mechanism of this response is unclear.

Primary Exertional Headache

Primary exertional headache (PEH) has features resembling both cough headache and migraine. It may be precipitated by any form of exercise and often has the pulsatile quality of migraine. The pain, which can last from 5 minutes to 24 hours, is bilateral and throbbing at onset; migrainous features may develop in patients susceptible to migraine. When seen, it tends to be shorter in adolescents. PEH can be prevented by avoiding excessive exertion, particularly in hot weather or at high altitude. As with primary cough headache, exertion in the context of sexual activity generally does not trigger headache in patients with PEH.

The mechanism of PEH is unclear. Acute venous distension may account for the acute onset of headache with straining and breath holding. As with primary cough headache, serious underlying conditions must be excluded. Pain from angina may be referred to the head, probably by central connections of vagal afferents, and may present as exertional headache (cardiac cephalgia) upon exercising. Other potential causes include pheochromocytoma, intracranial lesions, and carotid artery stenosis.

Treatment for benign PEH includes indomethacin (25-150 mg/d) and modification of one's exercise regimen. Propranolol may also provide prophylactic benefit. Indomethacin (50 mg), frovatriptan (2.5 mg), ergotamine (1 mg orally), or dihydroergotamine (2 mg intranasally) taken 30 to 45 minutes before exercise can be helpful as prophylaxis.

Primary Headache Associated With Sexual Activity

The pain of primary sex headache usually begins as a dull, bilateral headache that suddenly becomes intense at orgasm. The headache can be prevented or eased by ceasing sexual activity before orgasm. Two types of sex headache are reported: a dull ache in the head and neck that intensifies as sexual excitement increases and a sudden, severe, explosive headache occurring at orgasm. A postural headache developing after coitus can be a presentation of low CSF pressure. Headaches developing at the time of orgasm are not always benign; 5% to 12% of cases of subarachnoid hemorrhage are precipitated by sexual intercourse. Sex headache is reported by men more often than women and may occur at any time during the years of sexual activity. It may develop on several occasions in succession and then disappear, even without an obvious change in sexual activity. In patients who stop sexual activity when headache is first noticed, the pain may subside within a period of 5 minutes to 2 hours. In about half of patients, sex headache will self-remit within 6 months. Comorbid migraine is more likely in this population.

Treatment includes reassurance (once serious causes have been excluded) and advising patients to cease sexual activity if a "warning" headache develops. If the headache occurs regularly, propranolol can be used for prevention (40-200 mg/d) or alternatively diltiazem (60 mg three times a day). Frovatriptan (2.5 mg), ergotamine (1 mg), or indomethacin (25-50 mg) taken about 30 to 45 minutes prior to sexual activity can also be helpful.

Cold-Stimulus Headache

Headache may be triggered in isolation, in the absence of other headache disorders, by external application, or ingestion of a cold stimulus. External cold-stimulus headache is generalized, develops when exposed to cold, and resolves when the stimulus is removed. Ingestion of a cold substance results in a short-lasting frontal or temporal pain. This has been called *ice-cream headache*. Naproxen can be taken premptively to treat cold stimulus headache.

External Pressure Headache

Headache can arise from compression or traction of pericranial structures, for example, as can be experienced with a long ponytail. It is relieved by eliminating the traction or compression.

Primary Stabbing Headache

Primary stabbing headache is characterized by stab-like pains in the head or, rarely, the face, lasting from one to many seconds or minutes and occurring as a single stab or a series of stabs, absence of associated cranial autonomic features, absence of cutaneous triggering of attacks, and a pattern of recurrence at irregular intervals (hours to days). The pains have been variously described as *ice pick pains* or *jabs and jolts* and are more common in patients with other primary headaches, such as migraine and the TACs. If pain is frequent, indomethacin (25-50 mg two or three times a day) can be used for prevention. It is considered in the literature that the perceived trajectory of the stabs may differentiate another syndrome, epicrania fugax; this has no apparent treatment implication.

Nummular Headache

The pain in nummular headache is localized to a round or elliptical focus that is fixed in place, ranging in size from 1 to 6 cm and may be continuous or intermittent. In rare cases, it may be multifocal. Nummular headache is usually continuous with exacerbations, although can be episodic. There may be focal sensory disturbances, such as allodynia or hypesthesia. The pathophysiology is unknown, although a focal neuropathic disorder has been suggested. In the authors' experience, the presentation is best treated by detailing the entire phenotype and treating the underlying primary headache disorder. Local dermatologic or bony lesions must be excluded by examination and investigation. Treatment includes tricyclics, such as amitriptyline, or anticonvulsants, such as topiramate, valproate, or gabapentin. The condition is considered difficult to treat, although this is complex in relationship to any underlying headache disorder.

Hypnic Headache

Hypnic headache is marked by occurrence after a few hours following sleep onset. The headache lasts from 15 to 30 minutes and is typically generalized and moderate in severity, although can also be unilateral and throbbing. Photophobia or phonophobia and nausea are usually absent. Attacks can occur up to three times throughout the night, and daytime naps can also precipitate head pain. Most patients are female, and the onset is usually after age of 60 years. The major secondary consideration in this headache type is poorly controlled hypertension; 24-hour blood pressure monitoring is recommended in such cases.

Patients with hypnic headache usually respond to lithium carbonate (200-600 mg nightly). For those intolerant of lithium, verapamil (160 mg) or indomethacin (25-75 mg) may be tried. One to two cups of coffee or oral caffeine (60-100 mg) at bedtime may be effective in approximately one-third of patients. Case reports suggest that melatonin and flunarizine (5 mg nightly) can also be helpful.

New Daily Persistent Headache

New daily persistent headache (NDPH) is a clinically distinct syndrome, characterized by daily headache from onset for at least 3 months. The patient with NDPH can clearly recall the exact date and moment of onset. The headache usually begins abruptly, although onset may be more gradual in some cases; evolution over 3 days has been proposed as the upper limit for this syndrome. Antecedent illness (such as an upper respiratory infection or viral prodrome) has been reported in about one-third of patients with NDPH in one series. However, often there is no remarkable triggering event. The first priority is to distinguish between a primary and a secondary cause of this syndrome. Subarachnoid hemorrhage is the most serious of the secondary causes and must be excluded either by history or appropriate investigation. Other causes include chronic meningitis as well as abnormalities of CSF pressure (see Chapter 9).

Primary NDPH can be of the migrainous type or can appear featureless, appearing as new-onset TTH. Migrainous features are common and include unilateral headache and throbbing pain; nausea, photophobia, and/or phonophobia occur in about half of patients. Some patients have a previous history of episodic migraine. Treatment of migrainous-type primary NDPH consists of using standard migraine preventive therapies (see earlier discussion). Featureless NDPH tends to be refractory to treatment—although conventional headache preventive therapies (such as tricyclic antidepressants and anticonvulsants) can be offered, most are ineffective.

Posttraumatic Headache

A traumatic event can trigger a headache process that lasts for many months or years after the event. The term *trauma* is used here very broadly: Headache can develop following an injury to the head (including after neurosurgical; dental; or ear, nose, and throat procedures), but it can also develop after an infectious episode such as with viral meningitis or a flu-like illness. The underlying theme appears to be that a traumatic event involving the pain-producing meninges can trigger a headache process that lasts for many years. Complaints of dizziness, vertigo, and impaired memory can accompany the headache. Symptoms may remit after several weeks or persist for months and even years after the injury. Typically, the neurologic examination is normal and computed tomography or MRI studies are unrevealing. However, serious underlying causes must be ruled out, such as chronic subdural hematoma, subarachnoid hemorrhage, and carotid dissection. The headache is best treated by characterizing the phenotype with many patients having migrainous headaches that can be treated with suitable preventives.

LEVEL 1 EVIDENCE

1. Silberstein SD. Practice parameter: evidence-based guidelines for migraine headache (an evidence-based review): report of the Quality Standards Subcommittee of the American Academy of Neurology. *Neurology*. 2000;55:754-763.
2. Kloster R, Nestvold K, Vilming ST. A double-blind study of ibuprofen versus placebo in the treatment of acute migraine attacks. *Cephalalgia*. 1992;12(3):169-171.
3. Johnson ES, Ratcliffe DM, Wilkinson M. Naproxen sodium in the treatment of migraine. *Cephalalgia*. 1985;5(1):5-10.
4. Lipton RB, Grosberg B, Singer RP, et al. Efficacy and tolerability of a new powdered formulation of diclofenac potassium for oral solution for the acute treatment of migraine: results from the International Migraine Pain Assessment Clinical Trial (IMPACT). *Cephalalgia*. 2010;30:1336-1345.
5. Tokola RA, Kangasniemi P, Neuvonen PJ, Tokola O. Tolfenamic acid, metoclopramide, caffeine and their combinations in the treatment of migraine attacks. *Cephalalgia*. 1984;4(4):253-263.

6. Lipton RB, Stewart WF, Ryan RE Jr, Saper J, Silberstein S, Sheftell F. Efficacy and safety of acetaminophen, aspirin, and caffeine in alleviating migraine headache pain: three double-blind, randomized, placebo-controlled trials. *Arch Neurol*. 1998;55:210-217.
7. Thorlund K, Mills EJ, Wu P, et al. Comparative efficacy of triptans for the abortive treatment of migraine: a multiple treatment comparison meta-analysis. *Cephalalgia*. 2014;34:258-267.
8. Ferrari MD, Roon KI, Lipton RB, Goadsby PJ. Oral triptans (serotonin 5-$HT_{1B/1D}$ agonists) in acute migraine treatment: a meta-analysis of 53 trials. *Lancet*. 2001;358:1668-1675.
9. Tfelt-Hansen P, De Vries P, Saxena PR. Triptans in migraine: a comparative review of pharmacology, pharmacokinetics and efficacy of triptans in migraine. *Drugs*. 2000;6:1259-1287.
10. Silberstein SD, Elkind AH, Schreiber C, Keywood C. A randomized trial of frovatriptan for the intermittent prevention of menstrual migraine. *Neurology*. 2004;63(2):261-269.
11. Brandes JL, Poole A, Kallela M, et al. Short-term frovatriptan for the prevention of difficult-to-treat menstrual migraine attacks. *Cephalalgia*. 2009;29:1133-1148.
12. Brandes JL, Kudrow D, Stark SR, et al. Sumatriptan-naproxen for acute treatment of migraine: a randomized trial. *JAMA*. 2007;297:1443-1454.
13. Dihydroergotamine Nasal Spray Multicenter Investigators. Efficacy, safety, and tolerability of dihydroergotamine nasal spray as monotherapy in the treatment of acute migraine. *Headache*. 1995;35:177-184.
14. Callaham M, Raskin N. A controlled study of dihydroergotamine in the treatment of acute migraine headache. *Headache*. 1986;26:168-171.
15. Winner P, Ricalde O, Le Force B, Saper J, Margul B. A double-blind study of subcutaneous dihydroergotamine vs subcutaneous sumatriptan in the treatment of acute migraine. *Arch Neurol*. 1996;53:180-184.
16. Kuca B, Silberstein SD, Wietecha L, Berg PH, Dozier G, Lipton RB; for COL MIG-301 Study Group. Lasmiditan is an effective acute treatment for migraine: a phase 3 randomized study. *Neurology*. 2018;91:e2222-e2232.
17. Goadsby PJ, Wietecha LA, Dennehy EB, et al. Phase 3 randomized, placebo-controlled, double-blind study of lasmiditan for acute treatment of migraine. *Brain*. 2019;142:1894-1904.
18. Dodick DW, Lipton RB, Ailani J, et al. Ubrogepant for the treatment of migraine. *N Engl J Med*. 2019;381:2230-2241.
19. Lipton RB, Dodick DW, Ailani J, et al. Effect of ubrogepant vs placebo on pain and the most bothersome associated symptom in the acute treatment of migraine: the ACHIEVE II randomized clinical trial. *JAMA*. 2019;322(19):1887-1898.
20. Croop R, Goadsby PJ, Stock DA, et al. Efficacy, safety, and tolerability of rimegepant orally disintegrating tablet for the acute treatment of migraine: a randomised, phase 3, double-blind, placebo-controlled trial. *Lancet*. 2019;394:737-745.
21. Chou DE, Yugrakh MS, Winegarner D, Rowe V, Kuruvilla D, Schoenen J. Acute migraine therapy with external trigeminal neurostimulation (ACME): a randomized controlled trial. *Cephalalgia*. 2019;39:3-14.
22. Lipton RB, Croop R, Stock EG, et al. Rimegepant, an oral caclitonin gene-related peptide receptor antagonist, for migraine. *N Engl J Med*. 2019;381:142-149.
23. Colman I, Brown MD, Innes GD, Grafstein E, Roberts TE, Rowe BH. Parenteral metoclopramide for acute migraine: meta-analysis of randomised controlled trials. *BMJ*. 2004;329:1369-1373.
24. Kelly AM, Walcynski T, Gunn B. The relative efficacy of phenothiazines for the treatment of acute migraine: a meta-analysis. *Headache*. 2009;49(9):1324-1332.
25. Bigal ME, Bordini CA, Speciali JG. Intravenous chlorpromazine in the emergency department treatment of migraines: a randomized controlled trial. *J Emerg Med*. 2002;23(2):141-148.
26. Chou DE, Gross GJ, Casadei CH, Yugrakh MS. External trigeminal nerve stimulation for the acute treatment of migraine: open-label trial on safety and efficacy. *Neuromodulation*. 2017;20(7):678-683.
27. Lipton RB, Dodick DW, Silberstein SD, et al. Single-pulse transcranial magnetic stimulation for acute treatment of migraine with aura: a randomised, double-blind, parallel-group, sham-controlled trial. *Lancet Neurol*. 2010;9:373-380.
28. Tassorelli C, Grazzi L, de Tommaso M, et al. Noninvasive vagus nerve stimulation as acute therapy for migraine: the randomized PRESTO study. *Neurology*. 2018;91:e364-e373.
29. Yarnitsky D, Volokh L, Ironi A, et al. Nonpainful remote electrical stimulation alleviates episodic migraine pain. *Neurology*. 2017;88(13):1250-1255.
30. Silberstein SD, Holland S, Freitag F, Dodick DW, Argoff C, Ashman E. Evidence-based guideline update: pharmacologic treatment for episodic migraine prevention in adults: report of the Quality Standards Subcommittee of the American Academy of Neurology and the American Headache Society. *Neurology*. 2012;78:1337-1345.
31. Holland S, Silberstein SD, Freitag F, Dodick DW, Argoff C, Ashman E. Evidence-based guideline update: NSAIDs and other complementary treatments for episodic migraine prevention in adults: report of the Quality Standards Subcommittee of the American Academy of Neurology and the American Headache Society. *Neurology*. 2012;78:1346-1353.
32. Borgesen SE, Nielsen JL, Moller CE. Prophylactic treatment of migraine with propranolol. A clinical trial. *Acta Neurol Scand*. 1974;50(5):651-656.
33. Forssman B, Henriksson KG, Johannsson V, Lindvall L, Lundin H. Propranolol for migraine prophylaxis. *Headache*. 1976;16(5):238-245.
34. Pradalier A, Serratrice G, Collard M, et al. Long-acting propranolol in migraine prophylaxis: results of a double-blind, placebo-controlled study. *Cephalalgia*. 1989;9(4):247-253.
35. Tfelt-Hansen P, Standnes B, Kanagasneimi P, Hakkarainen H, Olesen J. Timolol vs propranolol vs placebo in common migraine prophylaxis: a double-blind multicenter trial. *Acta Neurol Scand*. 1984;69:1-8.
36. Briggs RS, Millac PA. Timolol in migraine prophylaxis. *Headache*. 1979;19:379-381.
37. Stellar S, Ahrens SP, Meibohm AR, Reines SA. Migraine prevention with timolol. A double-blind crossover study. *JAMA*. 1984;252:2576-2580.

38. Andersson PG, Dahl S, Hansen JH, et al. Prophylactic treatment of classical and non-classical migraine with metoprolol—a comparison with placebo. *Cephalalgia*. 1983;3:207-212.
39. Kangasniemi P, Andersen AR, Andersson PG, et al. Classic migraine: effective prophylaxis with metoprolol. *Cephalalgia*. 1987;7:231-238.
40. Steiner TJ, Joseph R, Hedman C, Rose FC. Metoprolol in the prophylaxis of migraine: parallel-groups comparison with placebo and dose-ranging follow-up. *Headache*. 1988;28:15-23.
41. Brandes JL, Saper JR, Diamond M, et al. Topiramate for migraine prevention: a randomized controlled trial. *JAMA*. 2004;291:965-973.
42. Silberstein SD, Neto W, Schmitt J, Jacobs D. Topiramate in migraine prevention: results of a large controlled trial. *Arch Neurol*. 2004;61:490-495.
43. Diener H-C, Bussone G, Van Oene JC, Lahaye M, Schwalen S, Goadsby PJ. Topiramate reduces headache days in chronic migraine: a randomized, double-blind, placebo-controlled study. *Cephalalgia*. 2007;27:814-823.
44. Diener HC, Tfelt-Hansen P, Dahlöf C, et al. Topiramate in migraine prophylaxis—results from a placebo-controlled trial with propranolol as an active control. *J Neurol*. 2004; 251:943-950.
45. Freitag FG, Collins SD, Carlson HA, et al. A randomized trial of divalproex sodium extended-release tablets in migraine prophylaxis. *Neurology*. 2002;58(11):1652-1659.
46. Ozyalcin SN, Talu GK, Kiziltan E, Yucel B, Ertas M, Disci R. The efficacy and safety of venlafaxine in the prophylaxis of migraine. *Headache*. 2005;45:144-152.
47. Diener H-C, Dodick DW, Aurora SK, et al. OnabotulinumtoxinA for treatment of chronic migraine: results from the double-blind, randomized, placebo-controlled phase of the PREEMPT 2 trial. *Cephalalgia*. 2010;30:804-814.
48. Aurora SK, Dodick DW, Turkel CC, et al. OnabotulinumtoxinA for treatment of chronic migraine: results from the double-blind, randomized, placebo-controlled phase of the PREEMPT 1 trial. *Cephalalgia*. 2010;30:793-803.
49. Dodick DW, Turkel CC, DeGryse RE, et al. OnabotulinumtoxinA for treatment of chronic migraine: pooled results from the double-blind, randomized, placebo-controlled phases of the PREEMPT clinical program. *Headache*. 2010;50 :921-936.
50. Lipton RB, Göbel H, Einhäupl KM, Wilks K, Mauskop A. Petasites hybridus root (butterbur) is an effective preventive treatment for migraine. *Neurology*. 2004;63:2240-2244.
51. Schoenen J, Jacquy J, Lenaerts M. Effectiveness of high-dose riboflavin in migraine prophylaxis. A randomized controlled trial. *Neurology*. 1998;50:466-470.
52. Maizels M, Blumenfeld A, Burchette R. A combination of riboflavin, magnesium, and feverfew for migraine prophylaxis: a randomized trial. *Headache*. 2004;44(9):885-890.
53. Stovner LJ, Linde M, Gravdahl GB, et al. A comparative study of candesartan versus propranolol for migraine prophylaxis: a randomised, triple-blind, placebo-controlled, double cross-over study. *Cephalalgia*. 2014;34:523-532.
54. Lipton RB, Goadsby PJ, Smith J, et al. Efficacy and safety of eptinezumab in patients with chronic migraine: PROMISE-2. *Neurology*. 2020;94(13):e1365-e1377.
55. Goadsby PJ, Reuter U, Hallström Y, et al. A controlled trial of erenumab for episodic migraine. *N Engl J Med*. 2017;377:2123-2132.
56. Tepper SJ, Ashina M, Reuter U, et al. A phase 2, randomised, double-blind, placebo-controlled study to evaluate the efficacy and safety of erenumab in chronic migraine prevention. *Lancet Neurol*. 2017;16:425-434.
57. Reuter U, Goadsby PJ, Lanteri-Minet M, et al. Efficacy and tolerability of erenumab in patients with episodic migraine in whom two-to-four previous preventive treatments were unsuccessful: a randomised, double-blind, placebo-controlled, phase 3b study. *Lancet*. 2018;392:2280-2287.
58. Dodick DW, Silberstein SD, Bigal ME, et al. Effect of fremanezumab compared with placebo for prevention of episodic migraine: a randomized clinical trial. *JAMA*. 2018;319(19):1999-2008.
59. Silberstein SD, Dodick DW, Bigal ME, et al. Fremanezumab for the preventive treatment of chronic migraine. *N Engl J Med*. 2017;377:2113-2122.
60. Ferrari MD, Diener HC, Ning X, Galic M, et al. Fremanezumab versus placebo for migraine prevention in patients with documented failure to up to four migraine preventive medication classes (FOCUS): a randomised, double-blind, placebo-controlled, phase 3b trial. *Lancet*. 2019;394:1030-1040.
61. Stauffer VL, Dodick DW, Zhang Q, Carter JN, Ailani J, Conley RR. Evaluation of galcanezumab for the prevention of episodic migraine: the EVOLVE-1 randomized clinical trial. *JAMA Neurol*. 2018;75:1080-1088.
62. Detke HC, Goadsby PJ, Wang S, Friedman DI, Selzler K, Aurora SK. Galcanezumab in chronic migraine: the randomized, double-blind, placebo-controlled REGAIN study. *Neurology*. 2018;91:e2211-e2221.
63. Mulleners WM, Kim B-K, Lainez MJA, Lanteri-Minet M, Pozo-Roisch P, Wang S, et al. Safety and efficacy of galcanezumab in patients for whom previous migraine preventive medication from two to four categories had failed (CONQUER): a multicentre, randomised, double-blind, placebo-controlled, phase 3b trial. *Lancet Neurology*. 2020; 19:814-25.
64. Starling AJ, Tepper SJ, Marmura MJ, et al. A multicenter, prospective, single arm, open label, observational study of sTMS for migraine prevention (ESPOUSE study). *Cephalalgia*. 2018;38:1038-1048.
65. Schoenen J, Vandersmissen B, Jeangette S, et al. Migraine prevention with a supraorbital transcutaneous stimulator: a randomized controlled trial. *Neurology*. 2013;80:697-704.
66. The Sumatriptan Cluster Headache Study Group. Treatment of acute cluster headache with sumatriptan. *N Engl J Med*. 1991;325:322-326.
67. Ekbom K, Monstad I, Prusinski A, Cole JA, Pilgrim AJ, Noronha D. Subcutaneous sumatriptan in the acute treatment of cluster headache: a dose comparison study. The Sumatriptan Cluster Headache Study Group. *Acta Neurol Scand*. 1993;88:63-69.
68. van Vliet JA, Bahra A, Martin V, et al. Intranasal sumatriptan in cluster headache: randomized placebo-controlled double-blind study. *Neurology*. 2003;60:630-633.
69. Cittadini E, May A, Straube A, Evers S, Bussone G, Goadsby PJ. Effectiveness of intranasal zolmitriptan in acute cluster headache: a randomized, placebo-controlled, double-blind crossover study. *Arch Neurol*. 2006;63:1537-1542.
70. Rapoport AM, Mathew NT, Silberstein SD, et al. Zolmitriptan nasal spray in the acute treatment of cluster headache: a double-blind study. *Neurology*. 2007;69:821-826.
71. Fogan L. Treatment of cluster headache. A double-blind comparison of oxygen v air inhalation. *Arch Neurol*. 1985;42:362-363.

72. Cohen AS, Burns B, Goadsby PJ. High-flow oxygen for treatment of cluster headache: a randomized trial. *JAMA*. 2009;302:2451-2457.
73. Silberstein SD, Mechtler LL, Kudrow DB, et al. Non-invasive vagus nerve stimulation for the ACute treatment of cluster headache: findings from the randomized, double-blind, sham-controlled ACT1 study. *Headache*. 2016;56:1317-1332.
74. Goadsby PJ, de Coo IF, Silver N, et al. Non-invasive vagus nerve stimulation for the acute treatment of episodic and chronic cluster headache: a randomized, double-blind, sham-controlled ACT2 study. *Cephalalgia*. 2018;38:959-969.
75. Ambrosini A, Vandenheede M, Rossi P, et al. Suboccipital injection with a mixture of rapid- and long-acting steroids in cluster headache: a double-blind placebo-controlled study. *Pain*. 2005;118:92-96.
76. Leroux E, Valade D, Taifas I, et al. Suboccipital steroid injections for transitional treatment of patients with more than two cluster headache attacks per day: a randomised, double-blind, placebo-controlled trial. *Lancet Neurol*. 2011;10:891-897.
77. Jammes JL. The treatment of cluster headaches with prednisone. *Dis Nerv Syst*. 1975;36:375-376.
78. Leone M, D'Amico D, Frediani F, et al. Verapamil in the prophylaxis of episodic cluster headache: a double-blind study versus placebo. *Neurology*. 2000;54:1382-1385.
79. Bussone G, Leone M, Peccarisi C, et al. Double blind comparison of lithium and verapamil in cluster headache prophylaxis. *Headache*. 1990;30:411-417.
80. Gaul C, Diener HC, Silver N, et al. Non-invasive vagus nerve stimulation for PREVention and Acute treatment of chronic cluster headache (PREVA): a randomised controlled study. *Cephalalgia*. 2016;36:534-546.
81. Goadsby PJ, Dodick DW, Leone M, et al. Trial of galcanezumab in prevention of episodic cluster headache. *N Engl J Med*. 2019;381:132-141.

SUGGESTED READINGS

Charles AC, Baca SM. Cortical spreading depression and migraine. *Nat Rev Neurol*. 2013;9(11):637-644.

Cittadini E, Goadsby PJ. Hemicrania continua: a clinical study of 39 patients with diagnostic implications. *Brain*. 2010;133(pt 7):1973-1986.

Cittadini E, Matharu MS, Goadsby PJ. Paroxysmal hemicrania: a prospective clinical study of thirty-one cases. *Brain*. 2008;131:1142-1155.

Cohen AS, Matharu MS, Goadsby PJ. Short-lasting Unilateral Neuralgiform Headache Attacks with Conjunctival injection and Tearing (SUNCT) or cranial Autonomic features (SUNA)—a prospective clinical study of SUNCT and SUNA. *Brain*. 2006;129(pt 10):2746-2760.

GBD 2016 Headache Collaborators. Global, regional, and national burden of migraine and tension-type headache, 1990–2016: a systematic analysis for the Global Burden of Disease Study 2016. *Lancet Neurol*. 2018;17(11):954-976.

Goadsby PJ. Primary headache disorders: five new things. *Neurol Clin Pract*. 2019;9:233-240.

Goadsby PJ, Holland PR, Martins-Oliveira M, Hoffmann J, Schankin C, Akerman S. Pathophysiology of migraine: a disorder of sensory processing. *Physiol Rev*. 2017;97:553-622.

Gormley P, Winsvold BS, Nyholt DR, Kallela M, Chasman DI, Palotie A. Migraine genetics: from genome-wide association studies to translational insights. *Genome Med*. 2016;8(1):86.

International Headache Society. Headache Classification Committee of the International Headache Society (IHS). The International Classification of Headache Disorders, 3rd edition. *Cephalalgia*. 2018;38:1-211.

Hoffmann J, May A. Diagnosis, pathophysiology, and management of cluster headache. *Lancet Neurol*. 2018;17(1):75-83.

Karsan N, Goadsby PJ. Biological insights from the premonitory symptoms of migraine. *Nat Rev Neurol*. 2018;14:699-710.

Lance JW, Goadsby PJ. *Mechanism and Management of Headache*. 7th ed. New York, NY: Elsevier; 2005.

Lipton RB, Bigal M. *Migraine and Other Headache Disorders*. New York, NY: Marcel Dekker; 2006.

Lipton RB, Bigal ME, Diamond M, Freitag F, Reed ML, Stewart WF. Migraine prevalence, disease burden, and the need for preventive therapy. *Neurology*. 2007;68:343-349.

Olesen J, Tfelt-Hansen P, Ramadan N, Goadsby PJ, Welch KMA. *The Headaches*. Philadelphia, PA: Lippincott Williams & Wilkins; 2005.

Schankin CJ, Maniyar FH, Digre KB, Goadsby PJ. 'Visual snow'—a disorder distinct from persistent migraine aura. *Brain*. 2014;137(pt 5):1419-1428.

57 Facial Pain Disorders and Painful Cranial Neuralgias

Paul G. Mathew and Zahid H. Bajwa

KEY POINTS

1. Facial pain and cranial neuralgias (CN) are poorly understood by clinicians.
2. Facial pain and CN are currently undertreated for a variety of reasons.
3. These chronic pain disorders often lead to and are complicated by anxiety, depression, and insomnia.
4. Evaluation and optimal treatment of sleep disorders and other comorbid conditions is key to optimal therapy.
5. Mechanisms of trigeminal neuralgia and other CN are better defined and understood within the last 20 years.
6. Many behavioral, medical, pharmacologic, nerve blocking techniques, neuromodulation, and surgical interventions are often helpful.
7. Education is needed for all clinicians to understand application of state-of-the-art treatments using interdisciplinary approach.

INTRODUCTION

Painful cranial neuralgias and facial pain disorders are a set of disorders that can occur in isolation or commonly in addition to another headache disorder LEVEL 3.[1] By taking a thorough history and performing a comprehensive physical examination, a clinician can establish the correct diagnosis, which is critical in order to formulate an effective plan of care. Due to overlapping structures and symptoms, the diagnosis and treatment of painful cranial neuralgias and facial pain disorders can truly be a crossroads between neurology, ophthalmology, otolaryngology, and dentistry LEVEL 3.[2,3] Trauma, infections, tumors, and systemic illnesses can all serve as secondary causes for these disorders. As such, when clinical suspicion is elevated, there should be a low threshold for ordering appropriate diagnostic tests and generating referrals to other specialists for further evaluation.

The diagnostic criteria for primary and secondary painful cranial neuralgias and facial pain disorders are detailed in the *International Classification of Headache Disorders* (3rd edition, ICHD-3). ICHD-3 is divided into three parts. Part I focuses on primary headache disorders, covered in Chapter 56. Part II focuses on secondary headache disorders covered in Chapter 56 and in this chapter. Specifically, Part II includes a section on "Headaches or facial pain attributed to disorders of the cranium, neck, eyes, ears, nose sinuses, teeth, mouth or other facial and cervical structures". We cover the disorders that give rise to facial pain in this section. Part III, "Neuropathies and Facial Pains and Other Disorders," is unique in that it includes both primary and secondary disorders that give rise to facial pain, particularly cranial neuralgias and neuropathies. This chapter also includes many of these disorders. Table 57.1 details some of the etiologies of facial pain including primary peripheral nervous system disorders and disorders outside of the nervous system.

FACIAL PAIN DUE TO DISORDERS OF SINUSES, NOSE, AND EARS

Rhinosinusitis

Epidemiology and Pathobiology

Rhinosinusitis by definition is symptomatic inflammation of the nasal cavity (rhinitis) and paranasal sinuses (sinusitis). The terms sinusitis and rhinosinusitis are often used interchangeably because there is nasal cavity involvement in the vast majority of cases LEVEL 3.[4] Rhinosinusitis is extremely common, with adults experiencing one to three episodes per year and an incidence of 15 to 40 episodes per 1,000 patients per year. The inflammation of rhinosinusitis can be associated with genetic factors, environmental influences, occupational factors, infection, allergy, immune dysfunction, and systemic diseases LEVEL 3.[5] Sinus inflammation can activate the nociceptive neurons of the frontal, ethmoid, maxillary, and sphenoid sinuses. The ophthalmic division of the trigeminal nerve innervates the frontal and anterior ethmoid sinuses. The maxillary division of the trigeminal nerve innervates the maxillary, sphenoid, and posterior ethmoid sinuses.

Diagnosis

Rhinosinusitis commonly presents with nasal obstruction/congestion, nasal discharge, postnasal drip, facial pain/pressure, and reduction of smell. Depending on the etiology, other symptoms can also be present. For example, rhinosinusitis secondary to allergies can involve sneezing, watery rhinorrhea, nasal and ocular pruritus, and watery eyes. Likewise, rhinosinusitis secondary to infection can involve fever and purulent discharge.

According to ICHD-3, the diagnostic criteria for headache attributed to rhinosinusitis includes clinical, nasal endoscopic, and/or imaging evidence of current or past infection or other inflammatory process within the paranasal sinuses as well as evidence of causation demonstrated by at least two of the following: (1) Headache has developed in temporal relation to the onset of chronic rhinosinusitis; (2) headache waxes and wanes in parallel with the degree of sinus congestion and other symptoms of the chronic rhinosinusitis; (3) headache is exacerbated by pressure applied over the paranasal sinuses; and (4) in the case of a unilateral rhinosinusitis, headache is localized and ipsilateral to it.

TABLE 57.1 Etiologies of Facial Pain Including Primary Peripheral Nervous System Disorders and Disorders Outside of the Nervous System[a]

Nerve and Sensory Distribution	Primary PNS Disorders	Disorders Outside of the Nervous System	
Trigeminal nerve, ophthalmic division	Classical TN (idiopathic or with vascular loop)	Eyes[b]:	acute angle-closure glaucoma, iritis, uveitis, scleritis, conjunctivitis, trochleitis
	Painful trigeminal neuropathies: • Symptomatic TN (tumor, vascular malformation, multiple sclerosis plaque at dorsal root entry zone) • Herpes zoster ophthalmicus and postherpetic trigeminal neuropathy • Posttraumatic (anesthesia dolorosa)	Sinuses (frontal and anterior ethmoid):	acute rhinosinusitis, septal deflections, hypertrophic turbinates, nasal spurs
		Arteries:	giant cell arteritis (temporal arteritis)
	Paratrigeminal oculosympathetic syndrome (Raeder syndrome)		
Trigeminal nerve, maxillary division	Classical TN	Maxillary teeth:	pulpitis, cracked tooth syndrome, dentine sensitivity, dental abscess
	Painful trigeminal neuropathies: • Symptomatic TN • Acute herpes zoster and postherpetic trigeminal neuropathy • Posttraumatic (anesthesia dolorosa)	Oral cavity:	mucosal malignancies, infections, inflammation, blockage of a major salivary gland duct
		Sinuses (maxillary, sphenoid, posterior ethmoid):	acute rhinosinusitis, chronic rhinosinusitis
Trigeminal nerve, mandibular division	Classical TN	Mandibular teeth, oral cavity, tongue:	as per maxillary teeth and oral cavity
	Painful trigeminal neuropathies: • Symptomatic TN • Acute herpes zoster and postherpetic trigeminal neuropathy • Posttraumatic (anesthesia dolorosa)	Temporomandibular joint:	temporomandibular disorders: arthritic and degenerative joint disease, disk displacement, myalgia, and myofascial pain
	Auriculotemporal syndrome (Frey syndrome)	External auditory meatus, anterior pinna:	laceration and tumors of pinna: external otitis, foreign bodies, squamous cell and basal cell carcinomas, adenocarcinoma
	Burning mouth syndrome		
		Arteries:	giant cell arteritis (temporal arteritis)
Facial nerve, nervus intermedius branch	Nervus intermedius neuralgia	Mastoid cells and skin overlying the mastoid process:	otitis media, mastoiditis
	Trigeminal neuropathies: • Herpes zoster (Ramsey Hunt syndrome) and postherpetic neuralgia	External auditory meatus, lateral pinna:	external otitis, foreign bodies, local tumors
	Acoustic neuroma	Nasopharynx, palate:	local/infiltrative tumors, inflammation
Glossopharyngeal nerve and vagal nerve	Glossovagopharyngeal neuralgia	External ear canal and tympanic membrane:	external otitis, foreign bodies, squamous cell and basal cell carcinomas, adenocarcinoma, tympanic membrane perforation
	Nerve compression by elongated styloid process (Eagle syndrome)	Upper pharynx, posterior tonsils, base of tongue, soft palate:	local tumors, inflammation, infection

Abbreviations: CYP450, cytochromes P450; PNS, peripheral nervous system; TN, trigeminal neuralgia.
[a]Pain in a specific distribution should warrant consideration of the various etiologies listed in addition to consideration of central nervous system causes.
[b]Eye pain without ophthalmoplegia.

Although rhinosinusitis is very common, "sinus headache" as self-diagnosed by patients or diagnosed by physicians is more often due to migraine than actual sinus pathology. The Sinus, Allergy and Migraine Study recruited 100 participants over the age of 18 with self-diagnosed sinus headaches, and 86% of them were found to have migraine or probable migraine LEVEL 3.[6] Migraine and headaches secondary to sinus disease have many similarities, which is the reason for the frequent misdiagnosis. Both of these conditions can occur more frequently with the change of seasons, barometric pressure, and precipitation. The distribution of pain can involve V_1 and V_2 distributions of the trigeminal nerve for both conditions. Migraine can involve autonomic dysfunction including rhinorrhea, nasal congestion, and lacrimation, which can all occur with sinus disease. There is also an element of reinforcing behavior. Many patients will think they have a sinus infection causing their headaches, take a course of antibiotics, and experience a resolution of their headache. These patients assume that eradication of an infection lead

to the resolution of their headache, when in fact, the headache was due to migraine, which would have resolved with time regardless of intervention. To differentiate between these two conditions, sinus headaches do not typically involve migrainous features, such as throbbing/disabling pain, photophobia, phonophobia, and nausea. On the other hand, migraines do not typically involve fever or purulent nasal discharge. Another feature that can be used to different these two conditions is response to triptans because a triptan should be effective for the treatment of migraine but not sinus headache LEVEL 3.[2]

If sinus disease is suspected as the cause of headache, computed tomography (CT), magnetic resonance imaging (MRI), or endoscopic evaluation should be considered. It should be reinforced to patients that nonacute sinus mucosal changes are common in the general population and should not be considered an indication that a headache is secondary to sinus disease.

Management and Outcome

Rhinosinusitis depending on the etiology can resolve spontaneously. Over-the-counter therapies such as acetaminophen, ibuprofen, decongestants, and saline irrigation can be useful. Antibiotics should be considered if there is high clinical suspicion for bacterial infections. Symptoms suggestive of a bacterial infection include pain in the cheeks/teeth, a high fever that does not subside, purulent discharge, and lack of response to decongestants. In addition, intranasal glucocorticoids can be useful for the treatment of viral and bacterial rhinosinusitis. A Cochrane systematic review of using intranasal glucocorticoids for the treatment of rhinosinusitis demonstrated a moderate-sized benefit for the treatment of nasal blockage and a small benefit for the treatment of rhinorrhea. The use of intranasal glucocorticoids is not without risk because the chances of developing epistaxis is increased LEVEL 3.[7] Failure to adequately treat infectious rhinosinusitis can result in brain abscess, subdural empyema, meningitis, cavernous sinus thrombosis, epidural abscess, and osteomyelitis LEVEL 3.[8]

Facial Pain Attributed to Disorders of Intranasal Mucosal Contact Points

Epidemiology and Pathobiology

Intranasal mucosal contact points have been cited both in the neurology and otolaryngology literature as potential causes of facial pain. Contact points can occur between septal spurs, hypertrophic turbinates, and surrounding segments of mucosa. It is speculated that the intranasal contact point causes an irritation to the trigeminal system, which presents as retronasal, glabellar, or ipsilateral cheek pressure/pain. The prevalence of intranasal mucosal contact points varies tremendously between different studies. In one study involving 973 patients with a provisional diagnosis of rhinosinusitis, 4% of the patients had an intranasal contact point, and 42% of the patients had facial pain associated with their rhinosinusitis. There was no clear association between the presence of an intranasal contact point and facial pain. In another study involving 100 patients, 55% had intranasal contact points and 29% suffered from headaches, but the presence of a contact point was inversely related to the presence of pain. In a systemic review involving these and several other studies, it was found that the majority of patients with intranasal contact points did not have significant facial pain LEVEL 3.[9]

Diagnosis

Intranasal contact point–induced headache/facial pain is not listed as a specific diagnosis in ICHD-3 but more broadly fits under the category of "Headache and/or facial pain caused by a disorder of the cranium, neck, eyes, ears, nose, sinuses, teeth, mouth or other facial or cervical structure." The diagnostic criteria for this broad category includes headache and/or facial pain has developed in temporal relation to the onset of the disorder or appearance of the lesion, headache and/or facial pain is localized in accordance with the site of the lesion, headache and/or facial pain is exacerbated by pressure applied to the lesion as well as either or both of the following: (1) Headache and/or facial pain has significantly worsened in parallel with progression of the disorder or lesion and/or (2) headache and/or facial pain has significantly improved or resolved in parallel with improvement in or resolution of the disorder or lesion. In addition to these criteria, other diagnostic criteria include visualizing the contact point on CT, MRI, and/or endoscopy as well as improvement/resolution of pain with local anesthetic application to the contact point LEVEL 3.[10]

Management and Outcome

In general, intranasal contact points are often incidental findings and not predictive of headache or facial pain. In addition, surgical decompression of intranasal contact points in patients with headache/facial pain does not consistently result in a total elimination of pain. Surgical decompression should be considered when the headache and/or facial pain is ipsilateral to the side of the contact point. Although response to intranasal anesthetics can be a useful part of the evaluation, some patients with severe abutting of structures may not experience significant relief. In cases where there is a partial response to decompression, it is possible that the intranasal contact point may actually be serving as a trigger for a coexisting primary headache disorder such as migraine LEVEL 3.[11]

Surgical decompression of an intranasal contact point often involves both a septoplasty and turbinate reduction. In such cases, there can be significant improvement in the patency of the nose, which can lead to an improvement of sleep quality. In patients with sleep apnea/hypopnea, surgical reductions in airway resistance can lead to a reduction in required positive airway pressure, which can lead to better tolerability/compliance. Sleep dysfunction is a well-known trigger for numerous headache and facial pain disorders LEVEL 3.[12] As such, the potential improvement of sleep with intranasal contact point decompression may be another mechanism for the improvement of headache/facial pain.

Otalgia Attributed to Disorder of Ears and Referred Pain

Epidemiology and Pathobiology

The sensory innervation of the ear is highly complex (Fig. 57.1). Sensation is mediated by the auriculotemporal nerve/CN V (lateral surface of the tympanic membrane, external acoustic meatus, temporal scalp, preauricular area, tragus, temporomandibular joint), nervus intermedius/CN VII (lateral surface of the tympanic membrane, external acoustic meatus, concha), a branch of the glossopharyngeal nerve/CN IX (middle ear, medial surface of the tympanic membrane, mastoid air cells), a branch of the vagus nerve/CN X (lateral surface of the tympanic

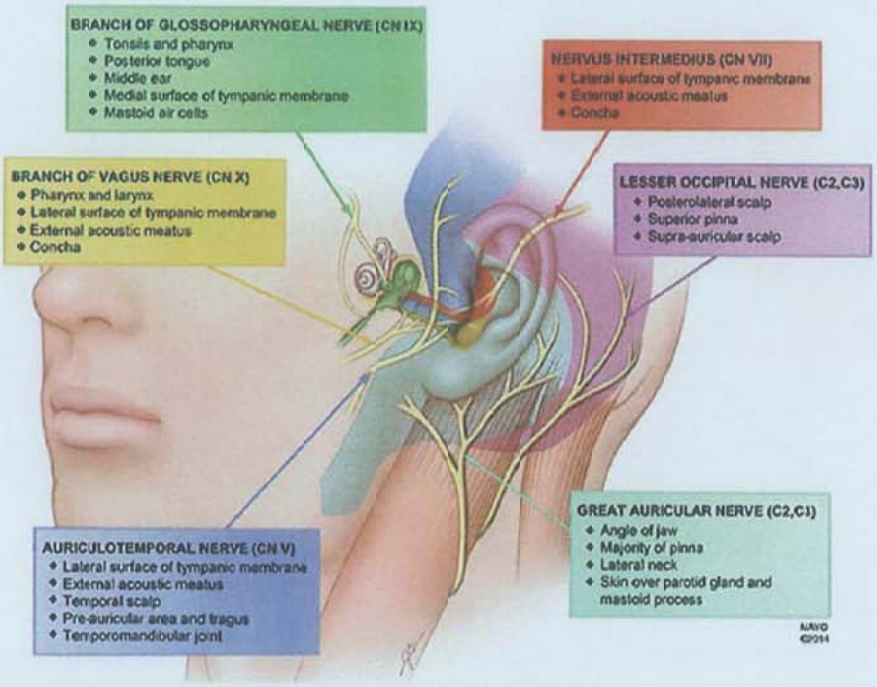

FIGURE 57.1 Sensory innervation of the ear. (From DeLange JM, Garza I, Robertson CE. Clinical reasoning: a 50-year-old woman with deep stabbing ear pain. *Neurology*. 2014;83[16]:e152-e157.)

membrane, external acoustic meatus, concha), and the lesser occipital nerve/C2-C3 (posterolateral scalp, superior pinna, supra-auricular scalp) LEVEL 3.[13] Nearly half of all cases of otalgia or ear pain are due to structural pathology of the external or middle ear, with the remainder of cases occurring as a result referred pain from remote structures LEVEL 3.[14]

Acute otitis media is a common primary ear disorder that can cause otalgia. In terms of global incidence, children younger than age 5 years have an incidence of 45 to 60 new episodes per 100 people per year, children 5 to 14 years of age have 19 to 22 new episodes per 100 people per year, patients 15 to 24 years of age have 3.1 to 3.5 new episodes per 100 people per year, and adults 25 to 85 years of age have 1.5 to 2.3 new episodes per 100 people per year LEVEL 3.[15]

Diagnosis

Depending on the etiology, pain can be accompanied by fullness, tenderness, burning, or itching. Routine otoscopy can be useful, but further evaluation with MRI or an otolaryngology referral should be considered based on clinical suspicion. In addition to otitis media, other diagnostic considerations should include external otitis; foreign bodies; as well as squamous cell, basal cell, and adenocarcinoma.

FACIAL PAIN DUE TO TEMPOROMANDIBULAR DISORDERS AND DISORDERS OF THE TEETH OR MOUTH

Pain within the oral cavity can have a wide differential diagnosis. If the pain involves a specific tooth or set of teeth, pulpitis, dentine sensitivity, dental abscess, and cracked tooth syndrome should all be considered. Other sources of oral cavity pain include mucosal malignancies, infections, inflammation, and blockage of a major salivary gland duct.

Temporomandibular Disorders

Epidemiology and Pathobiology

Temporomandibular disorder (TMD) is a term that is used to encompass disorders of the temporomandibular joint and/or associated structures. It is estimated that approximately 10% of adults older than the age of 18 experience TMD pain. It tends to involve young and middle age adults rather than pediatric and elderly populations. In addition, women are twice as likely to suffer from TMD LEVEL 3.[16] TMD tends to occur frequently in patients with primary headache disorders including migraine and tension-type headache. In the presence of a single TMD symptom, there tends to be associated headache in approximately 56.5% of cases LEVEL 3.[17]

The temporomandibular joint is a very complex joint, which receives its sensory innervation from the mandibular branch of the trigeminal nerve (Fig. 57.2). A cartilaginous disc facilitates the rotational and translational movements between the mandibular condyle and the temporal bone. TMD can be broken down into muscle disorders, disc displacements, arthralgia, osteoarthritis, and osteoarthrosis. Muscle overactivity in the form of clenching and bruxism can have deleterious effects on the joints and teeth. In addition to destruction of enamel, there can also be migration of the teeth within the gums, leading to gap formation and alteration of occlusion.

Clinical Manifestations and Diagnosis

The temporomandibular joint facilitates talking, chewing, and facial expressions. Jaw pain associated with TMD can result in restrictions of all of these activities. The quality of the pain can be variably described as throbbing, aching, or sharp with radiation to the masseters along the angle of the mandible, the temples, and the ear.

Due to pain and tightness of the joint, there can often be limited mouth open, which becomes particularly prominent in cases involving disc displacement. In severe cases, TMD can cause reductions in dietary intake, resulting in malnutrition and

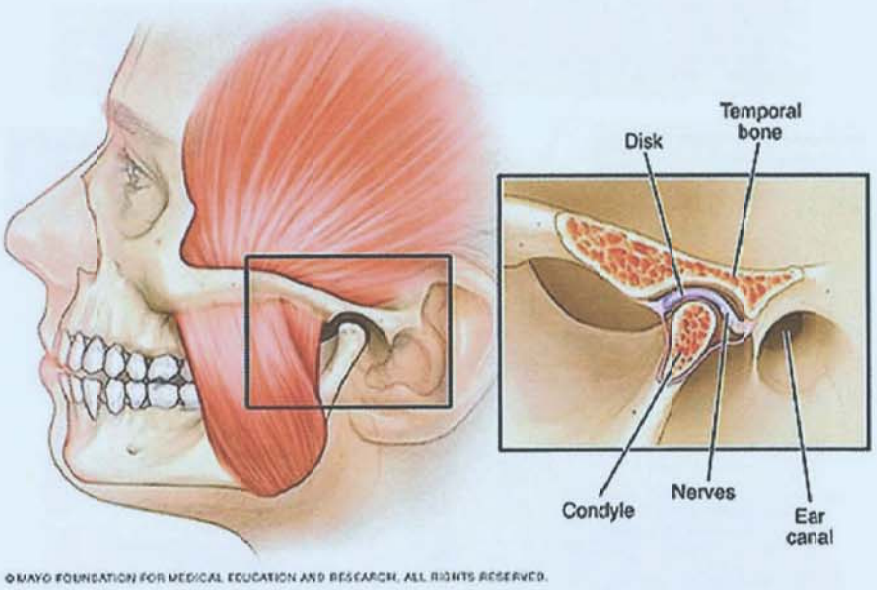

FIGURE 57.2 The temporomandibular joint. (From DeLange JM, Garza I, Robertson CE. Clinical reasoning: a 50-year-old woman with deep stabbing ear pain. *Neurology*. 2014;83[16]:e152-e157.)

pathologic weight loss. In addition to pain, audible popping/clicking can occur, which can be very bothersome to both the patient and others in close proximity. Chronic TMD can lead to compensatory postural changes, which can result in the development of chronic neck pain. The symptoms and referral patterns of TMD can be both unilateral or bilateral.

X-ray and CT imaging can be useful for confirming suspected bony changes to the anatomy including dislocation and degenerative changes to the joint. MRI tends to be more effective in demonstrating pathology of the cartilaginous disc and other soft tissue anatomy.

Treatment and Outcome

TMD symptoms can wax and wane over time. As such, symptomatic flares often resolve spontaneously without any intervention. Patients often reactively will avoid certain foods and limit jaw use, which can at times hasten the resolution of symptoms. Physical therapy, biofeedback, and oral appliances can be useful in cases with persistent symptoms. Oral appliances, which in some cases are worn continuously except during meals, can be an effective treatment for TMD by stabilizing potential occlusion issues and relaxing overactive muscles. Although over-the-counter appliances are available, they may not be the best choice. Over-the-counter appliances tend to be bulkier and less comfortable, which can lead to noncompliance and/or involuntary expulsion during sleep. Also, due to the noncustom nature of over-the-counter appliances, use can lead to worsening of a malocclusion and exacerbation of TMD.

Pharmacologic agents commonly used for the treatment of TMD include nonsteroidal anti-inflammatory drugs, muscle relaxants, corticosteroids, tricyclic antidepressants, anticonvulsants, and benzodiazepines LEVEL 1,[18] botulinum toxin (BTX) injections into the temporalis, masseters, and/or other muscles of mastication can also be an effective treatment. It is unclear whether the positive effect of BTX is due to muscle relaxation, a downregulation of sensory nerve transmission, or a combination of these factors LEVEL 1.[19] In clinic-based samples, TMD commonly occurs with migraine and can be an exacerbating factor.

CRANIAL NEURALGIAS

Trigeminal Neuralgia

Epidemiology and Pathobiology

Trigeminal neuralgia (TN) is a disabling condition that involves lancinating paroxysms of facial pain that is usually unilateral. The annual incidence of TN is 4 to 13 per 100,000 people. The incidence increases with age, and most idiopathic cases occur to those older than the age of 50 years. There is a male to female ratio of about 1:1.7 LEVEL 1.[20,21]

TN occurs when there is compression or irritation of the trigeminal nerve. Lesions that are more proximal will involve more divisions of the nerve. The term *classical* TN refers to TN that is caused by compression of the nerve by a blood vessel near the root entry zone of the pons. The blood vessel most commonly implicated in cases of vascular compression is the posterior inferior cerebellar artery.

It is thought that over time, chronic compression causes focal demyelination and aberrant sensory impulses. This is likely why age and hypertension are risk factors for the development of TN. There are some estimates that as many as 91% of TN cases are due to vascular compression LEVEL 1.[22]

In addition to vascular compression, acute herpes zoster/postherpetic neuralgia, trauma, multiple sclerosis, vestibular schwannomas/acoustic neuromas, cerebellopontine meningiomas, cysts including epidermoid cysts, saccular aneurysms, and arteriovenous malformations have all been associated with secondary TN LEVEL 1.[23]

Clinical Manifestations and Diagnosis

According to ICHD-3 criteria, the pain occurs in one or more divisions of the trigeminal nerve, with no radiation beyond the trigeminal distribution, and must involve at least three of the following four characteristics: (1) recurring in paroxysmal attacks lasting from a fraction of a second to 2 minutes; (2) severe intensity; (3) electric shock-like, shooting, stabbing, or sharp in quality; and/or (4) at least three attacks precipitated by innocuous stimuli to the affected side of the face.

In terms of distribution, TN usually involves the second and/or third divisions of the trigeminal nerve with first division involvement occurring in <5% of patients. Although individual attacks are short in duration, there can be many attacks per day, but between attacks, there are often interictal periods during which, trigger zones become inactive. Patients are usually pain free during these refractory periods, but a dull background pain may persist in some long-standing cases. Attack periods can last for weeks to months, which can be followed by remissions that can last months or even years, but the pain usually returns.

Attacks can be triggered by trivial stimuli including washing, shaving, smoking, eating, talking, and/or brushing the teeth but often occur spontaneously. By definition, at least three attacks should be triggered by contact in order to meet the diagnostic criteria for TN. Less frequently, attacks can be triggered by somatosensory stimuli outside the trigeminal area, such as a limb, or by other sensory stimulation such as bright lights, loud noises, or tastes. In some cases, TN pain can trigger ipsilateral facial spasm, which is why TN is at times referred to as *tic douloureux*.

TN does not typically involve ipsilateral autonomic features that can be seen with short-lasting unilateral neuralgiform headache with conjunctival injection and tearing (SUNCT) or short-lasting unilateral neuralgiform headache with autonomic symptoms (SUNA). As such, if a patient presents with conjunctival injection, lacrimation, nasal congestion, rhinorrhea, ptosis, miosis, and/or forehead/facial sweating ipsilateral to the side of facial pain, SUNCT and SUNA should be considered in the differential diagnosis. In clinical practice, patients often not only deny the presence of these features during an attack but also do not typically look in the mirror during an attack. As such, asking the patient to take photographs during an attack or having a friend/family member observe the patient during an attack are reasonable maneuvers that can be helpful to confirm the diagnosis.

Although vascular compression is the most common structural cause of TN, up to 15% of patients can have other structural causes. Features that increase risk of an underlying lesion include trigeminal sensory deficits, bilateral involvement of the trigeminal nerve, and younger age LEVEL 3.[24] Bilateral TN is extremely rare, but multiple sclerosis is an etiology that has been commonly implicated. Acute herpes zoster/postherpetic neuralgia most commonly affects the ophthalmic division of the trigeminal nerve.

MRI with contrast and fine cuts throughout the course of the trigeminal nerve can be very useful in order to confirm compression, determine surgical candidacy, and confirm that there is no other secondary cause for TN pain. Axial fast imaging employing steady-state acquisition and three-dimensional–spoiled gradient echo are multiplanar reconstruction sequences can be particularly useful.

Treatment and Outcome

The goal of TN treatment is to reduce the frequency and intensity of attacks. First-line treatment is with oral medications. With all therapies, it is recommended to start at a low dose, and titrate slowly until pain is in remission unless the patient experiences intolerable side effects. In refractory cases, it is not unusual for patients to be on multiple medications. Carbamazepine has level A evidence supporting its use in TN. Titrations can start at 100 mg daily and reach a dose of 600 mg twice a day. Prior to starting carbamazepine, testing for the HLA-B*1502 allele should be considered in patients of Asian ancestry because they are at high risk for Stevens-Johnson syndrome and toxic epidermal necrolysis. Some other medications that are probably effective include oxcarbazepine (level B, titration: 300 mg daily → 900 mg twice a day), baclofen (level C, titration: 5 mg every 8 h → 80 mg/d), lamotrigine (level C, titration: 50 mg daily → 400 mg daily). Phenytoin, valproic acid, gabapentin, pregabalin, and topiramate have small studies supporting their effectiveness in the treatment of TN LEVEL 2.[24] In the emergency department or urgent care settings, intravenous phenytoin, valproic acid, and levetiracetam can be a useful options LEVEL 3.[25-27] For TN cases that do not respond adequately to oral treatment, there is some evidence to suggest that onabotulinum toxin type A (BTX) treatment can be a relatively safe treatment option. When performing BTX injections for the treatment of TN, injections should be performed symmetrically regardless of the distribution of pain given the facial asymmetry that can result from unilateral facial weakness LEVEL 3.[28] Table 57.2 details medications, which are commonly used in the treatment of cranial neuralgias.

For refractory cases of TN, more invasive options could be considered. These options are divided into trigeminal nerve–sparing procedures and denervating/destructive procedures. In terms of nerve-sparing procedures, microvascular decompression is a procedure that can at times be curative. This procedure involves performing a craniotomy (approximately 2 in) to exposes area posterior to ear. Under microscope, blood vessels (usually the superior cerebellar artery, posterior inferior cerebellar artery) and any other adjustment abutting structures are decompressed from nerve, and Teflon felt is placed in between the structures. Microvascular decompression tends to generate faster improvement of pain and has longer lasting benefit than some of the nerve destructive procedures LEVEL 1.[29] As with any neurosurgical procedure, risks include meningitis, encephalitis, intracranial hemorrhage, stroke, cranial nerve deficits, neuralgias, and cerebral spinal fluid (CSF) leak.

In terms of denervating/destructive procedures, peripheral trigeminal neurectomies were among the first procedures that were performed. These procedures caused dense numbness, tended to have early recurrence of pain, and only treated small areas innervated by superficial branches of the trigeminal nerve. Over time, techniques targeting proximal targets were devised, and rhizotomies have replaced neurectomies. Targeting the root exit zone rather than superficial branches tends to treat larger areas of pain, have longer lasting results, and have fewer side effects. Rhizotomies are particularly useful in patients who have contraindications to microvascular decompression or have experienced inadequate relief.

Rhizotomies are performed via percutaneous needle insertion to the root exit zone of the trigeminal nerve under fluoroscopy (Fig. 57.3). Once the root exit zone is reached, mechanical disruption with balloon compression, chemical disruption with glycerol, or radiofrequency ablation can be performed. Balloon compression and glycerol rhizotomies are nonselective techniques, which means there is no way during the procedure to confirm that the desired nerve distribution is being treated and that nondesired nerve distributions are not being treated. In addition, with these techniques, other than visualization with fluoroscopy and CSF return from the needle, there is no other confirmation that the needle is in adequate proximity of the root exit zone for the procedure to have any effect. In review of multiple studies comparing rhizotomy techniques, it was found that balloon compression was more likely to affect mastication, and glycerol rhizotomies had the highest recurrence rates. Adverse

TABLE 57.2 Medications Commonly Used in Cranial Neuralgias

Medication	Maintenance Dose	Side Effects	Additional Considerations
Carbamazepine	300-1,200 mg/d	Sedation, dizziness, cognitive impairment, hyponatremia, rash, aplastic anemia	• Multiple drug interactions (CYP450 inducer) • Response can be seen within 48 h.
Oxcarbazepine	600-1,800 mg/d	Less severe than with carbamazepine but include sedation, dizziness, hyponatremia, rash	• Cross-allergy with carbamazepine in 25% of cases • Equally effective to carbamazepine
Gabapentin	600-2,400 mg/d	Sedation, peripheral edema	• Extra doses can be used for acute treatment.
Lamotrigine	150-400 mg/d	Stevens-Johnson syndrome, sedation, dizziness	• Very slow dose up titration necessary
Baclofen	30-80 mg/d	Sedation, ataxia, fatigue	• Risk of seizures if stopped rapidly
Phenytoin	200-400 mg/d	Sedation, ataxia, cognitive impairment, rash	• Multiple drug interactions (CYP450 inducer) • Used as an initial intravenous treatment but therapeutic effect lost quickly
Tizanidine	12 mg/d	Sedation, dizziness, orthostatic hypotension	• Therapeutic effects are lost within 1-3 mo.
Levetiracetam	3-4 g/d	Irritability, depression	• Used as an add-on therapy
Onabotulinum toxin A	75 units	Facial weakness, transient edema	• 5 units (0.1 mL) injected in 15 points in epidermis/dermis or submucosally to region affected

Abbreviation: CYP450, cytochromes P450.
[a]Evidence for use derived from trigeminal neuralgia clinical studies.

effects of denervating/destructive procedures include sensory loss, dysesthesias, and anesthesia dolorosa (painful numbness). In contrast, radiofrequency ablation is the only selective technique because stimulation is performed prior to ablation to ensure the correct target. This is of particular importance as unintended treatment or overtreatment of the ophthalmic branch of the trigeminal nerve can lead to reduction of corneal sensation, which can lead to exposure keratopathy and, in severe cases, permanent vision loss LEVEL 3.[30,31]

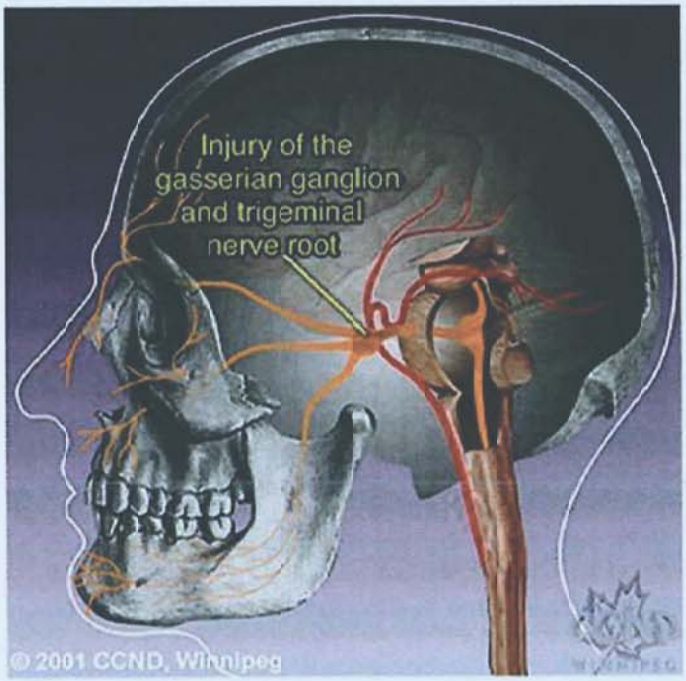

FIGURE 57.3 Rhizotomies are performed via percutaneous needle insertion to the root exit zone of the trigeminal nerve under fluoroscopy.

Among rhizotomy techniques, radiofrequency ablation tends to have the highest rates of initial pain relief and the lowest rates of pain recurrence. With balloon compression, pain control rates up to 91% at 6 months and 66% at 3 years have been reported. With glycerol rhizotomy, pain control rates up to 90% at 6 months and 54% at 3 years have been reported. With radiofrequency thermocoagulation, pain control rates up to 97% initially and 58% at 5 years have been reported. Some advantages of rhizotomies include shorter procedure duration, minimal anesthesia risk, and in the case of glycerol rhizotomy and radiofrequency thermocoagulation, immediate patient feedback LEVEL 3.[32]

Stereotactic radiosurgery (Gamma Knife, CyberKnife) is another denervating/destructive procedure that can be employed for the treatment of TN (Fig. 57.4). Stereotactic radiosurgery involves the use of highly focused beams of ionizing radiation

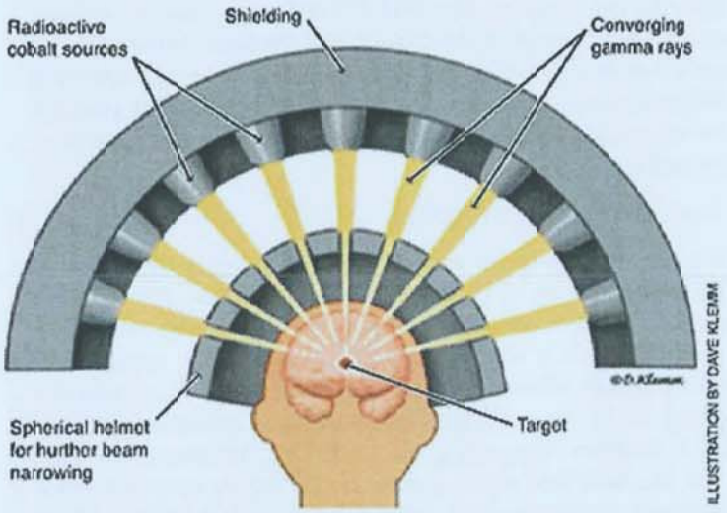

FIGURE 57.4 Schematic of Cyber Knife/Gamma Knife treatment.

that converge on a small target zone with high precision. This technique can be effective for the treatment of small tumors, vascular lesions, and functional disorders like TN. It is particularly useful for targets that are inaccessible for open surgery but not ideal for use with large targets. With stereotactic radiosurgery, pain relief can occur anywhere from 48 hours to 30 days post-procedure, pain recurrence can happen in over 30% of patients, and over 14% can experience hypoesthesia LEVEL 3.[33]

In clinical practice, isolated neuralgias can at times present in distal branches of the trigeminal nerve including the supraorbital, supratrochlear, and auriculotemporal nerves. Nerve blocks can provide transiently relief of pain after the injection in nearly all cases, but some patients will have lasting pain relief for weeks, months, or even years after the procedure (Fig. 57.5). The mechanism behind this lasting benefit is unclear, but one hypothesis is that injections using higher volumes of solution are expanding otherwise tight planes of fascia and muscle that are causing compression the nerves. If this technique provides inadequate relief of a trigeminal nerve branch focal neuralgia, surgical decompression could be considered LEVEL 3.[34,35]

Glossopharyngeal Neuralgia

Glossopharyngeal neuralgia (GN) is a disorder that involves pain in the posterior part of the tongue, tonsillar fossa, pharynx, beneath the angle of the lower jaw, and/or in the ear. According to ICHD-3 criteria, the pain must have at least three of the following four characteristics: (1) recurring in paroxysmal attacks lasting from a few seconds to 2 minutes; (2) severe intensity; (3) shooting, stabbing, or sharp in quality; and (4) precipitated by swallowing, coughing, talking, or yawning. Annual incidence rates for the disorder is 0.7 per 100,000 person-years. Overall, age-specific crude rates increased slightly with age. Bilateral presentations can occur in 25% of patients, and patients need surgical intervention for adequate relief of symptoms in 25% of cases LEVEL 3.[36]

The nerve distribution of GN includes sensory branches from the auricular and pharyngeal branches of the glossopharyngeal nerve as well as the vagus nerve. As such, the previously used term for this disorder is *glossovagopharyngeal neuralgia*, and some cases involve vagal symptoms including cough, hoarseness, syncope, and/or bradycardia. Due to these symptoms, patients can experience significant unintended weight loss due to reduced oral intake. GN can be episodic with weeks to months of being symptom free before the pain returns. GN tends to be responsive to anticonvulsants. In some cases, application of local anesthetic to the tonsil and pharyngeal wall can transiently prevent attacks. Like TN, imaging studies can demonstrate neurovascular compression, and microvascular decompression of the glossopharyngeal nerve and possibly the vagus nerve can lead to an improvement/resolution of symptoms. Adverse events associated with surgery include meningitis, encephalitis, intracranial hemorrhage, stroke, CSF leaks, unilateral hearing loss, imbalance, and difficulty swallowing. Rhizotomy and stereotactic radiosurgery are also therapeutic options for the treatment of refractory GN.

Nervus Intermedius Neuralgia

Nervus intermedius neuralgia (NIN) is a disorder that involves lancinating pain deep in the auditory canal, which can radiate to the parieto-occipital region. According to ICHD-3 criteria, the pain must have at least three of the following four characteristics: (1) recurring in paroxysmal attacks lasting from a few seconds to minutes; (2) severe intensity; (3) shooting, stabbing, or sharp in quality; and (4) precipitated by stimulation of a trigger area in the posterior wall of the auditory canal and/or periauricular region.

The other name for this disorder is facial nerve neuralgia because the nervus intermedius is a branch of CN VII, which innervates external auditory canal, middle ear, nasopharynx, and palate. Some cases of NIN can involve lacrimation, salivation, and/or taste alteration.

As part of the evaluation for NIN, MRI of the brain should be performed to look for secondary causes of ear pain. Visualization of nervus intermedius on MRI is challenging because it is much smaller than the trigeminal and glossopharyngeal nerves. When considering causes for ear pain, nervus intermedius neuropathy attributed to herpes zoster, also known as *Ramsay Hunt syndrome*, should be considered. As with any case of shingles, vesicular eruptions can occur in the ear and/or oral mucosa. Some cases can involve peripheral facial paresis. NIN tends to be responsive to anticonvulsants. Like TN, interventional/surgical techniques can be used for treatment of refractory cases of NIN.

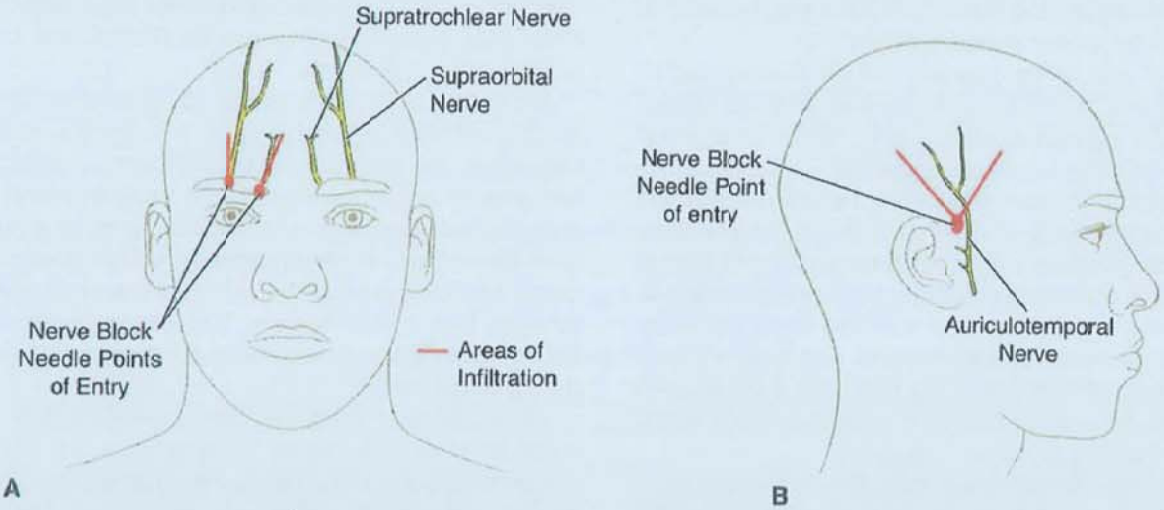

FIGURE 57.5 Nerve block sites for the trigeminal nerve.

Occipital Neuralgia

Epidemiology and Pathobiology

Occipital neuralgia (ON) is a disorder that involves pain in the distribution of the greater, lesser, and/or third occipital nerves. The pain can be unilateral or bilateral and can involve ipsilateral neck pain. There are limited data regarding the prevalence of ON, but it is highly underdiagnosed in clinical practice. In one study evaluating the prevalence of ON in a community hospital-based headache clinic, it was found that about 25% of patients presenting with a chief complaint of headache had ON. Among the patients with ON, only 15% presented with ON as the chief complaint without another headache disorder, whereas 85% of ON cases occurred in patients having a chief complaint of another headache disorder, which most commonly was common migraine. If undiagnosed, inadequate treatment of ON can trigger an increase in the frequency and intensity of other comorbid headache disorders and sleep dysfunction LEVEL 3.[37]

Clinical Manifestations and Diagnosis

According to ICHD-3 criteria, the pain must have at least two of the following three characteristics: (1) recurring in paroxysmal attacks lasting from a few seconds to minutes; (2) severe intensity; and (3) shooting, stabbing, or sharp in quality. The criteria also include that ON must involve dysesthesia and/or allodynia apparent during innocuous stimulation of the scalp and/or hair and one or both of the following: (1) tenderness over the affected nerve branches or (2) trigger points at the emergence of the greater occipital nerve or in the area of distribution of C2. A therapeutic response occipital nerve blocks is part of the diagnostic criteria for ON.

On physical examination, occipital Tinel's testing, which involves the examiner tapping his or her fingers along the skull base, can trigger lancinating pain/paresthesias confined to the corresponding nerve distribution. A positive Tinel sign is present in about 75% of patients with ON. In addition, neck passive range of motion can elicit similar lancinating pain/paresthesias.

Treatment and Outcome

Occipital nerve blocks are not only part of the diagnostic criteria for ON but also can be therapeutic. Nerve blocks are performed with an anesthetic (usually lidocaine, bupivacaine, or a combination) with or without a steroid. Methylprednisolone and triamcinolone are two of the more commonly used steroids. There are some data to support the use of steroid alone, but lack of immediate relief may reduce patient satisfaction.

Occipital nerve blocks are generally safe, well-tolerated office-based procedures, which can have prolonged effects beyond the duration of the injected anesthetic (Fig. 57.6). Factors that can influence variability of response include medications injected, technique, and volume of solution. In one retrospective chart review study involving 41 subjects with ON, large-volume nerve blocks (6 mL per side) were used to confirm the diagnosis. Among the patients, the average duration of ON complete remission was 206.95 days with a range of 4 to 840 days. This duration of benefit is an underestimate because pain may not have returned at the time of their follow-up visit, and it is unknown if and when their lancinating ON pain returned, which would make the actual duration of benefit unknown.

No long-term side effects were noted after any of the nerve blocks performed. A possible mechanism of action is that the hydrodynamic pressure generated by injecting the solution is causing an expansion of tissue planes. This tissue plane expansion may result in nerve decompression, which may correlate with long duration of benefit and even complete resolution of pain in certain patients LEVEL 3.[38] If nerve blocks do not provide adequate relief, preventative treatment with tricyclic antidepressants or anticonvulsants could be considered. In refractory cases, occipital nerve decompression surgery could be considered LEVEL 3.[39]

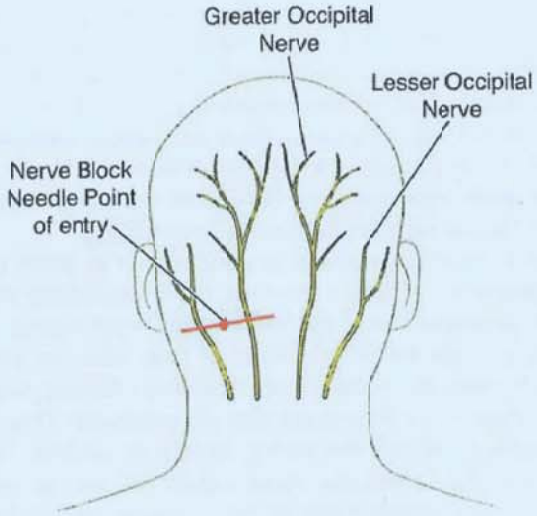

FIGURE 57.6 Occipital nerve block site.

IDIOPATHIC FACIAL PAIN

Burning Mouth Syndrome

Burning mouth syndrome (BMS) is a condition that involves intraoral burning or a dysesthesic sensation without any clear cause that occurs daily for more than 2 h/d for more than 3 months. When confined to the tongue, the names stomatodynia and glossodynia have been used to label this condition.

BMS most commonly affects peri- and postmenopausal females. BMS has an association with anxiety and depression, and psychosocial issues can trigger/exacerbate BMS. The underlying cause of BMS has not been fully elucidated. One possible mechanism is that there is a loss of epithelial and subpapillary small nerve fibers of the tongue. It has also been demonstrated that BMS can involve upregulation of the TRPV1 heat and capsaicin-activated cation channels.

According to ICHD-3 criteria, the pain must have a burning quality and must be felt superficially in the oral mucosa. On examination, the oral mucosa should have a normal appearance and sensory evaluation should be normal. It is important to rule out intraoral secondary causes of BMS including candidiasis, lichen planus, and hyposalivation as well as systemic secondary causes including medication side effect, anemia, vitamin B_{12} deficiency, folic acid deficiency, Sjögren syndrome, and diabetes. BMS is often bilateral, and the most commonly affected area is the tip of the tongue.

Although some cases can have a constant daily pattern, the intensity tends to fluctuate. Some patients may also experience perceived dry mouth and alteration of gustation. Dysgeusia may be due to denervation of the chorda tympani fibers that innervate the fungiform buds of the tongue.

Tricyclic antidepressants, selective serotonin reuptake inhibitors, serotonin norepinephrine reuptake inhibitors, and hormone replacement therapy have all demonstrated some efficacy. Topical treatments including clonazepam and capsaicin can also be useful. In refractory cases, polypharmacy, cognitive behavioral therapy, and transcranial magnetic stimulation are used LEVEL 3.[40,41]

Persistent Idiopathic Facial Pain

Persistent idiopathic facial pain (PIFP), which was previously known as atypical facial pain, is a facial and/or oral pain that occurs on a daily basis for at least 2 h/d for at least 3 months based on ICHD-3 criteria. By definition, PIFP has a dull, aching, or nagging quality and is poorly localized without following the distribution of a peripheral nerve. Part of the criteria specifies that dental causes must be excluded and a neurologic examination must be normal.

The lifetime prevalence of PIFP is estimated to be 0.03% (1 of 3,336) LEVEL 3.[42] PIFP tends to occur more often in women and frequently occurs in the setting of other chronic pain disorders, psychiatric diagnoses, and irritable bowel syndrome. PIFP can feel superficial or deep and can involve superimposed sharp pain. Stress can be a trigger of the pain, and over time, the pain can migrate to areas outside of the trigeminal distribution. PIFP can at times start after trauma or a procedure involving the face and/or oral cavity. Like many forms of neuropathic pain, even after tissue healing has occurred, pain can persist. If there is only pain of one or more teeth or after extraction without an identifiable cause of pain, the term *atypical odontalgia* has been used. If the insult is more significant and there are sensory deficits, the diagnosis of painful posttraumatic trigeminal neuropathy should be considered LEVEL 3.[23]

Pharmacologic treatment options include amitriptyline, gabapentin, topiramate, venlafaxine, and fluoxetine LEVEL 3.[43] For the treatment of refractory cases, pulsed radiofrequency ablation of the sphenopalatine ganglion, peripheral nerve field stimulation, and BTX injections can be considered LEVEL 3.[44]

Primary Headache Disorders Presenting as Facial Pain

The vast majority of primary headache disorders involve facial pain if facial pain is defined as involvement of one or more branches of the trigeminal nerve. In other words, it would be exceedingly unusual for a case of migraine, tension-type headache, or cluster headache to have no involvement of the forehead, orbits, or temples. On the other hand, if facial pain is defined as pain in the lower half of the face (V_2, V_3 excluding the temples), facial pain as a manifestation of a primary headache disorder becomes much less common. In the case of migraine, these cases are referred to as *facial migraine* or *lower half headache*. Facial pain can accompany the typical cranial distribution of migraine pain in 8.9% of patients with migraine, whereas isolated lower facial pain without the typical cranial distribution of migraine pain occurs in about 0.2% of patients with migraine. In addition, patients with a facial pain component to their migraines tend to experience more autonomic features with their attacks (47%) than patients with migraine without facial pain with autonomic features (7.9%) LEVEL 3.[44] The presence of migrainous features including photophobia, phonophobia, nausea, vomiting, and aura should prompt consideration of the possible diagnosis of a migraine variant with facial pain involvement. This should then prompt trials of migraine preventative and abortive agents, including triptans. An improvement of facial pain after triptan administration can further substantiate this diagnosis. Other primary headache disorders, including cluster headache and paroxysmal hemicrania, can present with lower half of facial pain.

LEVEL 1 EVIDENCE

1. Mathew PG, Najib U, Khaled S, Krel R. Prevalence of occipital neuralgia at a community hospital-based headache clinic [published online ahead of print December 12, 2019]. *Neurol Clin Pract*. doi:10.1212/CPJ.0000000000000789.
2. Mathew PG. Headache medicine: a crossroads of otolaryngology, ophthalmology, and neurology (otolaryngology installment). *Pract Neurol*. July 2014:35-36.
3. Mathew PG. Headache medicine: a crossroads of otolaryngology, ophthalmology, and neurology (ophthalmology installment). *Pract Neurol*. November/December 2014:45-47.
4. Meltzer EO, Hamilos DL, Hadley JA, et al. Rhinosinusitis: establishing definitions for clinical research and patient care. *Otolaryngol Head Neck Surg*. 2004;131(6 suppl):S1-S62.
5. Orlandi RR, Kingdom TT, Hwang PH, et al. International Consensus Statement on Allergy and Rhinology: rhinosinusitis. *Int Forum Allergy Rhinol*. 2016;6(suppl 1):S22-S209.
6. Eross E, Dodick D, Eross M. The Sinus, Allergy and Migraine Study (SAMS). *Headache*. 2007;47(2):213-224.
7. Chong LY, Head K, Hopkins C, Philpott C, Schilder AG, Burton MJ. Intranasal steroids versus placebo or no intervention for chronic rhinosinusitis. *Cochrane Database Syst Rev*. 2016;(4):CD011996.
8. Dolan RW, Chowdhury K. Diagnosis and treatment of intracranial complications of paranasal sinus infections. *J Oral Maxillofac Surg*. 1995;53(9):1080-1087.
9. Harrison L, Jones NS. Intranasal contact points as a cause of facial pain or headache: a systematic review. *Clin Otolaryngol*. 2013;38(1):8-22.
10. Rozen TD. Intranasal contact point headache: missing the "point" on brain MRI. *Neurology*. 2009;72(12):1107.
11. Behin F, Lipton RB, Bigal M. Migraine and intranasal contact point headache: is there any connection? *Curr Pain Headache Rep*. 2006;10(4):312-315.
12. Cevoli S, Giannini G, Favoni V, Pierangeli G, Cortelli P. Migraine and sleep disorders. *Neurol Sci*. 2012;33(suppl 1):S43-S46.
13. DeLange JM, Garza I, Robertson CE. Clinical reasoning: a 50-year-old woman with deep stabbing ear pain. *Neurology*. 2014;83(16):e152-e157.
14. Yugrakh MS, Chou DE. Cranial neuralgias and facial pain disorders. In: Louis ED, Mayer SA, Rowland LP, eds. *Merritt's Neurology*. 13th ed. Philadelphia, PA: Lippincott Williams & Wilkins; 2016:450-457.
15. Monasta L, Ronfani L, Marchetti F, et al. Burden of disease caused by otitis media: systematic review and global estimates. *PLoS One*. 2012;7(4):e36226.
16. LeResche L. Epidemiology of temporomandibular disorders: implications for the investigation of etiologic factors. *Crit Rev Oral Biol Med*. 1997;8(3):291-305.
17. Gonçalves DA, Bigal ME, Jales LC, Camparis CM, Speciali JG. Headache and symptoms of temporomandibular disorder: an epidemiological study. *Headache*. 2010;50(2):231-241.
18. Ouanounou A, Goldberg M, Haas DA. Pharmacotherapy in temporomandibular disorders: a review. *J Can Dent Assoc*. 2017;83:h7.

19. Mathew PG, Mathew T. Taking care of the challenging tension headache patient. *Curr Pain Headache Rep*. 2011;15(6):444-450.
20. Katusic S, Williams DB, Beard CM, Bergstralh EJ, Kurland LT. Epidemiology and clinical features of idiopathic trigeminal neuralgia and glossopharyngeal neuralgia: similarities and differences, Rochester, Minnesota, 1945-1984. *Neuroepidemiology*. 1991;10(5-6):276-281.
21. Katusic S, Beard CM, Bergstralh E, Kurland LT. Incidence and clinical features of trigeminal neuralgia, Rochester, Minnesota, 1945-1984. *Ann Neurol*. 1990;27(1):89-95.
22. Hamlyn PJ. Neurovascular relationships in the posterior cranial fossa, with special reference to trigeminal neuralgia. 2. Neurovascular compression of the trigeminal nerve in cadaveric controls and patients with trigeminal neuralgia: quantification and influence of method. *Clin Anat*. 1997;10(6):380-388.
23. Headache Classification Committee of the International Headache Society. The International Classification of Headache Disorders, 3rd edition. *Cephalalgia*. 2018;38(1):1-211.
24. Gronseth G, Cruccu G, Alksne J, et al. Practice parameter: the diagnostic evaluation and treatment of trigeminal neuralgia (an evidence-based review): report of the Quality Standards Subcommittee of the American Academy of Neurology and the European Federation of Neurological Societies. *Neurology*. 2008;71(15):1183-1190.
25. Tate R, Rubin LM, Krajewski KC. Treatment of refractory trigeminal neuralgia with intravenous phenytoin. *Am J Health Syst Pharm*. 2011;68(21):2059-2061.
26. Zakrzewska JM, Linskey ME. Trigeminal neuralgia. *BMJ Clin Evid*. 2009;2009:1207.
27. Mitsikostas DD, Pantes GV, Avramidis TG, et al. An observational trial to investigate the efficacy and tolerability of levetiracetam in trigeminal neuralgia. *Headache*. 2010;50(8):1371-1377.
28. Wu CJ, Lian YJ, Zheng YK, et al. Botulinum toxin type A for the treatment of trigeminal neuralgia: results from a randomized, double-blind, placebo-controlled trial. *Cephalalgia*. 2012;32(6):443-450.
29. Pollock BE. Surgical management of medically refractory trigeminal neuralgia. *Curr Neurol Neurosci Rep*. 2012;12(2):125-131.
30. Taha JM, Tew JM Jr. Comparison of surgical treatments for trigeminal neuralgia: reevaluation of radiofrequency rhizotomy. *Neurosurgery*. 1996;38(5):865-871.
31. Scrivani SJ, Mathews ES, Maciewicz R. Trigeminal neuralgia. In: Mehta N, Maloney GE, Bana D, Scrivani SJ, eds. *Head, Face and Neck Pain: Science, Evaluation and Management*. Hoboken, NJ: John Wiley & Sons; 2009:465-510.
32. Cheng JS, Lim DA, Chang EF, Barbaro NM. A review of percutaneous treatments for trigeminal neuralgia. *Neurosurgery*. 2014;10(suppl 1):25-33.
33. Tuleasca C, Carron R, Resseguier N, et al. Patterns of pain-free response in 497 cases of classic trigeminal neuralgia treated with Gamma Knife surgery and followed up for least 1 year. *J Neurosurg*. 2012;117(suppl):181-188.
34. Pareja JA, López-Ruiz P, Mayo D, et al. Supratrochlear neuralgia: a prospective case series of 15 patients. *Headache*. 2017;57(9):1433-1442.
35. Mathew PG, Robbins L. Cranial neuralgia vs entrapment neuropathy decompression . . . better names than migraine trigger site deactivation surgery. *Headache*. 2015;55(5):706-710.
36. Katusic S, Williams DB, Beard CM, Bergstralh E, Kurland LT. Incidence and clinical features of glossopharyngeal neuralgia, Rochester, Minnesota, 1945-1984. *Neuroepidemiology*. 1991;10(5-6):266-275.
37. Mathew PG, Najib U, Khaled S, Krel R. One and done: a case series of large volume occipital nerve blocks for the treatment of occipital neuralgia. Paper presented at: American Academy of Neurology Annual Meeting; May 2019; Philadelphia, PA.
38. Jose A, Nagori SA, Chattopadhyay PK, Roychoudhury A. Greater occipital nerve decompression for occipital neuralgia. *J Craniofac Surg*. 2018;29(5):e518-e521.
39. Imamura Y, Shinozaki T, Okada-Ogawa A, et al. An updated review on pathophysiology and management of burning mouth syndrome with endocrinological, psychological and neuropathic perspectives. *J Oral Rehabil*. 2019;46(6):574-587.
40. Umezaki Y, Badran BW, DeVries WH, Moss J, Gonzales T, George MS. The efficacy of daily prefrontal repetitive transcranial magnetic stimulation (rTMS) for burning mouth syndrome (BMS): A randomized controlled single-blind study. *Brain Stimul*. 2016;9(2):234-242.
41. Mueller D, Obermann M, Yoon MS, et al. Prevalence of trigeminal neuralgia and persistent idiopathic facial pain: a population-based study. *Cephalalgia*. 2011;31(15):1542-1548.
42. Cornelissen P, van Kleef M, Mekhail N, Day M, van Zundert J. Evidence-based interventional pain medicine according to clinical diagnoses. 3. Persistent idiopathic facial pain. *Pain Pract*. 2009;9(6):443-448.
43. Weiss AL, Ehrhardt KP, Tolba R. Atypical facial pain: a comprehensive, evidence-based review. *Curr Pain Headache Rep*. 2017;21(2):8.
44. Yoon MS, Mueller D, Hansen N, et al. Prevalence of facial pain in migraine: a population-based study. *Cephalalgia*. 2010;30(1):92-96.

Complex Regional Pain Syndrome 58

Steven P. Cohen, Michael L. Weinberger, and Thomas H. Brannagan III

KEY POINTS

1. Complex regional pain syndrome type 1 is characterized by pain that is disproportionate to the degree of injury and has now been designated to be nociplastic pain.
2. Complex regional pain syndrome type 2 is a pain syndrome following nerve injury.
3. Physical therapy and functional restoration programs form the cornerstone of treatment for complex regional pain syndrome.

INTRODUCTION

Complex regional pain syndrome (CRPS) has a long and changing history in medical practice. Veldman suggested that Ambrose Pare, in 1598, may have been the first to describe the syndrome of widespread limb pain accompanied by swelling, discoloration, and temperature change. Silas Weir Mitchell, a civil war era physician, discussed the relationship of central and peripheral mechanisms and "reflex transfers" in the spinal cord along with his description of soldiers who experienced intense nerve pain and autonomic dysregulation after gunshot wounds sustained in battle. The term *causalgia* is attributed to Mitchell, whereas the term *reflex sympathetic dystrophy* (RSD) was coined by Evans 80 years later. Other terms used to describe the constellation of signs and symptoms now known as *CRPS* include *hand-shoulder syndrome*, *sympathalgia*, *algodystrophy*, and *Sudeck atrophy*. A consensus conference held in Budapest in 1993 attempted to improve the diagnostic precision of these phenomena and renamed the condition "complex regional pain syndrome." CRPS I was intended to replace the term *reflex sympathetic dystrophy* and CRPS II to replace "causalgia." These changes were an attempt to eliminate the requirement that involvement of the sympathetic nervous system is necessary for the generation of symptoms. Clinical studies suggest that between 25% and 35% of individuals with CRPS have sympathetically maintained pain.

EPIDEMIOLOGY

In two population-based studies, the incidence of CRPS was estimated to range between 5.5 and 26.2 per 100,000 person-years. In Olmsted County, Minnesota, the prevalence was estimated at 20.6 per 100,000. A more recent study conducted by examining the Korea National Health Insurance Service reported an incidence of 28.0 to 32.4 per 100,000 person-years. Women are 3 times more likely to be affected, with postmenopausal woman having the highest risk. CRPS is most commonly diagnosed in middle age (40-60 y), with children and the elderly comprising smaller subsets. CRPS after an upper limb injury is more common than after a lower limb injury; following distal radius fracture, it occurs in more than one-fifth of individuals in some studies. There is some evidence that CRPS in children is associated with a more favorable prognosis.

CLINICAL FEATURES AND PATHOLOGY

CRPS I is a disorder characterized by pain that is disproportionate to the severity of the injury and accompanied by allodynia, vasomotor disturbances, motor disturbances, and/or trophic changes in the skin. Allodynia is defined as "pain resulting from a stimulus (such as lightly touching the skin) that would not normally provoke pain." The symptoms typically follow trauma, including mild trauma, but can occur after a myocardial infarction or varicella zoster infection. In approximately 10% of cases, the specific event is unknown. A bone fracture or other pathology requiring extremity surgery is the most common preceding event, occurring in about 45% of patients. The arm is affected more commonly than the leg.

The pain in CRPS is described by a multitude of terms, including "deep, sharp, sensitive, and hot." Patients, particularly those with sympathetically maintained pain, are often sensitive to cold sensations and frequently guard their limbs to avoid physical contact. Swelling, edema, heat, and color changes occur in the affected limb, which may be followed by osteoporosis and changes in hair, skin, and nail growth. The pain does not conform to a single nerve or root distribution and usually spreads beyond the area of injury. In more than 50% of cases, spread to a different extremity is noted, which sometimes occurs in a "mirror-image pattern." Some patients with CRPS I develop dystonic postures of a hand or foot. Features similar to psychogenic movement disorders have been noted by some authors, including difficulty initiating movement, chorea, and dystonia at rest. According to the most recent International Association for the Study of Pain (IASP) nomenclature, CRPS I is now classified as nociplastic pain. This category includes chronic pain syndromes not otherwise related to tissue insult or a somatosensory neural lesion. Some of the pathologic mechanisms implicated in nociplastic conditions include maladaptive cortical plasticity, central sensitization, decreases in the activity of descending inhibitory systems, and abnormal activity in the sympathetic nervous system.

CRPS II is defined by the presence of a nerve injury and consequently is categorized as neuropathic pain. Fewer than 10% of people with CRPS have CRPS II, with the most common etiology being missile injuries such as gunshot wounds.

In anatomic studies of a single autopsy case of a CRPS I patient, pathologic changes included loss of posterior horn cells and activation of microglia and astrocytes. These changes were most prominent at the site of injury but extended throughout the length of the spinal cord. A study of the remaining proximal limb after amputation, microvascular changes with thickened basal membranes in capillaries in muscle, and the loss of C fibers in some patients were noted. In skin biopsy, CRPS I, defined by the absence of an identifiable nerve injury, may show fewer small sensory epidermal nerve fibers than controls. In individuals with CRPS, functional magnetic resonance imaging has demonstrated cortical reorganization with shrinkage of the contralateral primary somatosensory cortex. These changes may reverse with pain relief.

PATHOBIOLOGY

There is little information about the pathophysiology of CRPS, with both peripheral and central neural mechanisms involved. Human leukocyte antigen associations have been described but not confirmed. Theories of the pathogenesis have centered on central sensitization, oxidative damage, and inflammation. After injury, an initial barrage of C fiber afferent activity may result in central sensitization (see Chapter 59) of dorsal horn neurons, resulting in allodynia and expansion of receptive fields. Patients with CRPS have increased levels of proinflammatory cytokines (interleukin [IL]-1β, IL-2, IL-6, tumor necrosis factor α) and markers of glial cell activation in the cerebrospinal fluid. An increase in markers indicating oxidative damage, including malondialdehyde, has also been reported, along with a loss of inhibitory dorsal horn neurons.

More recently, autoimmune mechanisms have been proposed. Studies have demonstrated autoantibodies to autonomic nervous system autoantigens in 30% to 40% of CRPS patients but not in control or neuropathy patients. Immunoglobulin G antibodies to autonomic receptors (β_2-adrenergic receptor and muscarinic-2 receptor) have also been demonstrated. Upregulation of α_1-adrenoreceptors on nociceptive afferents present in the periphery may augment pain and neuroinflammation in CRPS. This may explain the increased pain response in individuals with CRPS after administration of norepinephrine and alleviation of pain after infusion of phentolamine, an α-blocker. As noted earlier, approximately 25% of people with CRPS display prominent sympathetically maintained symptomatology.

DIAGNOSTIC CRITERIA

In addition to changes in terminology, diagnostic criteria have also evolved. Early attempts to define diagnostic criteria were based on anecdotal accumulation of signs and symptoms. Kozin et al established diagnostic criteria in 1976, including categories for definite, probable, and doubtful RSD. Gibbons proposed a diagnostic scale based on clinical signs and symptoms and laboratory tests including response to sympathetic nerve block. Blumberg proposed a numeric grading scale based on autonomic symptoms, motor symptoms, and sensory symptoms. Still, others described stages of RSD, with early stages being categorized as "warm" (associated with increased blood flow and edema), middle stages as "cool" (characterized by vasoconstriction and decreased temperature), and later stages as atrophic (eg, brittle nails, osteoporosis).

The IASP diagnostic criteria for CRPS from Merskey and Bogduk (1994) include the following:

1. The presence of an initiating noxious event or a cause of immobilization
2. Continuing pain, allodynia, or hyperalgesia in which the pain is disproportionate to any inciting event
3. Evidence at some time of edema, changes in skin blood flow, or abnormal sudomotor activity in the region of pain
4. This diagnosis is excluded by the existence of conditions that would otherwise account for the degree of pain and dysfunction: type 1, without evidence of major nerve damage; type 2, with evidence of major nerve damage.

A consensus workshop convened in 2003 proposed changes to these criteria because of concerns that the earlier criteria lack specificity in the face of high sensitivity. Validation studies suggested that overdiagnosis was a problem and that the inclusion of objective data beyond subjective and historical data would improve specificity at the expense of only modest diminution in sensitivity.

The Budapest criteria were accepted by the IASP for the third revision of formal taxonomy and diagnostic criteria of pain states. Clinical diagnostic criteria for CRPS include an array of painful conditions characterized by continuing (spontaneous or evoked) regional pain that is seemingly disproportionate in time or degree to the usual course of any known trauma or other lesion. The pain is regional (not in a specific nerve territory or dermatome) and typically shows a distal predominance of abnormal sensory, motor, sudomotor vasomotor, or trophic findings, all with variable progression over time. Clinically, CRPS I and II are indistinguishable.

Clinical Diagnostic Criteria

1. Continuing pain disproportionate to an inciting event
2. Must include at least one symptom in three of the four following categories:
   a. Sensory: hyperesthesia, allodynia, or both
   b. Vasomotor: temperature asymmetry, skin color changes, skin color asymmetry, or all of these
   c. Sudomotor/edema: edema, sweating, sweating asymmetry, or all three
   d. Motor/trophic: decreased range of motion, motor dysfunction (weakness, tremor, dystonic posture), trophic changes (hair, nail, skin), or all three
3. Must display at least one sign at the time of evaluation in two or more categories:
   a. Sensory: hyperalgesia (eg, to pinprick), allodynia (to light touch, temperature sensation, or deep somatic pressure or joint movement), or combinations of these
   b. Vasomotor: evidence of temperature asymmetry (>1°C), skin color changes or asymmetry, or combinations
   c. Sudomotor/edema: edema, sweating changes, or sweating asymmetry
   d. Motor/trophic: decreased range of motion, motor dysfunction (weakness, tremor, dystonia), or trophic changes (hair, skin, nails)
4. No other diagnosis better explains the sign and symptoms.

Research Diagnostic Criteria

1. Continuing pain disproportionate to an inciting event
2. Must include at least one symptom in each of the four following categories:
   a. Sensory: hyperesthesia, allodynia, or both
   b. Vasomotor: temperature asymmetry, skin color changes, skin color asymmetry, or all of these
   c. Sudomotor/edema: edema, sweating, sweating asymmetry, or all three
   d. Motor/trophic: decreased range of motion, motor dysfunction (weakness tremor, dystonic posture), trophic changes (hair, nail, skin), or all three
3. Must display at least one sign at the time of evaluation in two or more categories:
   a. Sensory: hyperalgesia (eg, to pinprick), allodynia (to light touch, temperature sensation, or deep somatic pressure or joint movement), or combinations of these
   b. Vasomotor: evidence of temperature asymmetry (>1°C), skin color changes or asymmetry, or combinations
   c. Sudomotor/edema: edema, sweating changes, or sweating asymmetry
   d. Motor/trophic: decreased range of motion, motor dysfunction (weakness, tremor, dystonia), or trophic changes (hair, skin, nails)
4. No other diagnosis better explains the sign and symptoms.

These criteria bear no relationship to etiology and have no known association with pathophysiology. Tests of these criteria demonstrated lower rates of overdiagnosis with little loss of sensitivity compared to the previously accepted IASP criteria.

Published data report that the clinical criteria result in a sensitivity of 85% and specificity of 69%, with the research criteria having a sensitivity and specificity of 70% and 95%, respectively, when compared to non-CRPS neuropathic pain disorders based on a CRPS database checklist consisting of signs and symptoms shown to be associated with CRPS but not incorporated in IASP diagnostic criteria. The more stringent criteria for research purposes, which is analogous to comparing selection criteria in a randomized trial compared to those used in clinical practice, prioritizes diagnostic specificity over sensitivity.

Other diagnostic tests employed to identify CRPS patients include thermography, triple-phase bone scans and other radiologic procedures, and quantitative sensory testing. All of these have been validated against a clinical diagnostic gold standard. Schurmann et al studied patients with acute radial fracture who met the 1994 IASP criteria and the 1999 Bruehl research criteria. Relative to a clinical diagnostic gold standard, they found that bone scans had high specificity but low sensitivity, making this a poor screening test. Results of thermography testing have demonstrated poor sensitivity and specificity. Similar to bone scanning, magnetic resonance imaging and plain x-rays yield high specificity but have poor sensitivity, with the positive and negative predictive values of plain films being 58% and 86%, respectively. The findings suggest that these tests are not useful for screening but may be indicated as selection tools for clinical trials (Table 58.1).

Historically, three stages of CRPS have been described. Recent analysis has not supported this categorization but has instead suggested three possible subtypes: (1) a self-limited syndrome with predominance of vasomotor signs, (2) a limited syndrome with predominance of neuropathic pain/sensory abnormalities, and (3) full-blown CRPS with a high degree of motor/trophic and disuse-related changes.

TABLE 58.1 The Accuracy of Diagnostic Tests for Complex Regional Pain Syndrome (CRPS)

Diagnostic Test	Accuracy	Comments
Bone scintigraphy	Low sensitivity, high specificity	Triple phase bone scan may be useful for research purposes.
Duplex ultrasound	Low sensitivity	May rule out deep vein thrombosis
Quantitative sensory testing	Pressure pain thresholds have moderate sensitivity and specificity compared to asymptomatic controls.	Lower thresholds increase sensitivity at the expense of specificity.
Electrodiagnostic testing	Low sensitivity for CRPS I, higher for CRPS II	May be useful in CRPS II; often used to rule out underlying nerve injury
Quantitative Sudomotor Axon Reflex Test	Intermediate sensitivity, high specificity when sudomotor changes are present	Sensitivity increases in individuals with sympathetically maintained pain
Resting sweat output	Intermediate sensitivity, high specificity when sudomotor changes are present	Sensitivity increases in individuals with sympathetically maintained pain
Radiographs	Low sensitivity	Osteoporosis present in <50% of cases
Magnetic resonance imaging	Low sensitivity; intermediate to high specificity	Can be used to detect or rule out soft tissue injury
Thermography	Low sensitivity and intermediate specificity	Sensitivity and specificity increase in the presence of vasomotor changes. >1°C change is considered significant.
Sympathetic blocks	Highly sensitive for sympathetically maintained pain; low to intermediate specificity	Lower volumes increase specificity, particularly for stellate ganglion blocks wherein spread to brachial plexus may occur. Validity dependent on technical success (ie, 2°C temperature increase) of block.
Intravenous phentolamine test	Lower sensitivity and higher specificity compared to sympathetic blocks for sympathetically maintained pain	Validity depends on increase in temperature; often associated with reflex tachycardia and hypotension.

MANAGEMENT

Because the etiologies of CRPS are multifarious and uncertain, and therapies have for the most part been anecdotally based rather than scientifically tested in placebo-controlled trials, the treatment of CRPS remains controversial (Table 58.2). In general, syndromes (eg, nociplastic pain conditions such as CRPS I, fibromyalgia, and irritable bowel syndrome) tend to have poorer prognoses than better defined disease entities. This may be attributable to lack of consistent and readily identifiable pathophysiologic mechanisms. This is because mechanistic-based treatment of pain is generally acknowledged to be more effective than etiologic- or disease-based treatment.

Physical Therapies

Physical therapy and functional restoration programs form the cornerstone of treatment for CRPS, and the use of procedural interventions and medications is often touted as a means to maximize functional restoration. Yet, current guidelines have been predominantly developed by consensus. A recent Cochrane review evaluating physiotherapies for chronic pain in CRPS found very low evidence to support clinically meaningful improvement with graded motor imagery and mirror therapy, with the evidence in favor of electrotherapy, multimodal physical therapy, and lymphatic drainage being either absent or unclear.

In clinical practice, physical therapies should employ progressive movement and limb usage, gradually increased load bearing, as well desensitization to a variety of sensory stimuli in individuals with allodynia and hyperalgesia. Nerve blocks, psychotherapy, cognitive behavioral techniques, and pharmacotherapy may be added to facilitate participation in occupational and physical therapy. Edema should be addressed with active motion and/or special garments. Overall, the goal of physical therapy is to progressively restore function through the use of desensitization techniques, increasing flexibility, edema control, range of motion exercises, stress loading (ie, scrubbing and carrying), interventions to promote normal postures and balance, and personalized vocational and functional rehabilitation.

Nonopioid Pharmacotherapy

Few placebo-controlled randomized trials of drug therapy for CRPS have been carried out, and current therapy is largely based

TABLE 58.2 Evidence for Treatments for Complex Regional Pain Syndrome

Treatment	Evidence	Comments
Physical and occupational therapy	Positive evidence, including for graded motor imagery and mirror therapy	First-line treatment with and without additional therapies
Bisphosphonates	Positive evidence	Both oral and intravenous formulations effective. The high doses clinically required may necessitate surveillance.
Acupuncture	Positive evidence	Useful with rehabilitation program
Neuromodulation	Positive evidence for spinal cord stimulation, dorsal root ganglion stimulation, transcutaneous electrical nerve stimulation, and repetitive transcranial magnetic stimulation	Transcutaneous electrical nerve stimulation may be used as first-line therapy in conjunction with physical therapy. Benefits decrease with time.
Corticosteroids	Positive evidence	For use in acute and subacute stages; may be more effective for CRPS II
Intravenous regional blockade	Positive for lidocaine and ketanserin; mixed for guanethidine and reserpine	Anecdotal evidence for labetalol, phenoxybenzamine, and clonidine
Intrathecal baclofen	Positive evidence	Based on a small, randomized trial, but a later trial demonstrated lack of dose-responsiveness
Intravenous therapies	Positive evidence for ketamine; negative for prolonged effect for lidocaine and IVIg	Evidence for dose-response effect with ketamine
Anticonvulsants	Positive for carbamazepine; mixed for gabapentin	Oxcarbazepine may be an alternative to carbamazepine based on similar mechanism of action and anecdotal evidence.
Antidepressants	Weak, positive evidence based on comparative-effectiveness study and guidelines	Tricyclic antidepressants and serotonin-norepinephrine reuptake inhibitors preferable over serotonin selective reuptake inhibitors and may be beneficial for concomitant depression and anxiety
Tadalafil	Positive evidence	May be more effective for "cold" CRPS
N-acetylcysteine	Positive	May be more effective for "cold" CRPS
Topical agents	Anecdotal for lidocaine; positive for dimethyl sulfoxide	Dimethyl sulfoxide may work better for "warm" CRPS.
Intravenous immunoglobulin	Mixed evidence	Largest study negative
Calcitonin	Mixed evidence	May be more effective in later stages
Psychological therapy	Anecdotal evidence	May be more effective in patients with psychiatric comorbidities
Sympathetic blocks	Negative evidence for intermediate or long-term benefit	May be useful to facilitate physical therapy or identify sympathetically maintained pain

Abbreviations: CRPS, complex regional pain syndrome; IVIg, intravenous immunoglobulin.

on treatment of neuropathic pain. As noted earlier, CRPS I is now considered to be in a separate category of pain termed *nociplastic*. Although nociplastic pain shares many mechanisms with neuropathic pain (eg, peripheral and central sensitization, diminished inhibitory activity, sympathetic overactivity), it does not involve direct nerve injury. Consequently, there is significant overlap between nociplastic and neuropathic pain conditions.

Bisphosphonates including clodronate and alendronate, have demonstrated efficacy in the treatment of CRPS I in several moderate- to high-quality placebo-controlled trials, with the evidence supporting calcitonin being mixed. One systematic review evaluating bisphosphonates that identified four moderate- to high-quality studies containing 181 individuals found moderate evidence for efficacy in the treatment of pain and quality of life for up to 3 months. Both intravenous (IV) and oral steroids (eg, methylprednisolone 32 mg for 2 wk, then tapering off for 2 wk or prednisone 30 mg for 12 wk) have been shown to be more effective than placebo, with their use generally limited to individuals with acute or subacute pain.

The anticonvulsants gabapentin, pregabalin, and carbamazepine (for trigeminal neuralgia) are first-line treatments for neuropathic pain, and there is substantial anecdotal evidence for their benefit in CRPS. A randomized, double-blind crossover trial that compared carbamazepine to morphine in 43 patients with CRPS I who underwent temporary deactivation of a working spinal cord stimulation found carbamazepine to be superior to morphine.

A randomized crossover study was performed comparing 1,800 mg/d of gabapentin to placebo in 58 individuals with refractory CRPS I, yielding mixed results. Although gabapentin proved superior to placebo at the end of the first 3-week treatment period, there was no significant difference between treatment groups when both periods were combined. A more recent randomized trial performed in 34 children with CRPS I or a neuropathic pain condition found similar effectiveness for gabapentin and amitriptyline for pain reduction and sleep improvement. No placebo-controlled trials have been conducted evaluating antidepressants, although tricyclic antidepressants and serotonin-norepinephrine reuptake inhibitors such as duloxetine and venlafaxine are considered first-line treatments along with the gabapentinoids for neuropathic pain.

Opioid Treatment

Opioids have been anecdotally reported to provide benefit for CRPS I, but their use is not supported by clinical trials. In the only randomized trial evaluating opioids, carbamazepine was found to provide superior pain reduction than oral morphine 90 mg/d over an 8-day period of deactivation of previously effective spinal cord stimulation. Given the high risks of opioid therapy, lack of documented long-term benefit compared to nonopioid therapy, and the relative refractoriness to treatment of neuropathic and nociplastic conditions to opioid therapy, there is only a weak recommendation for use for neuropathic pain by the IASP Neuropathic Pain Special Interest Group. If considered, they should be instituted only with careful risk stratification, clearly defined benchmarks for success, a drug monitoring strategy, and a predefined exit strategy.

Topical Creams

Topical agents such as dimethyl sulfoxide and topical lidocaine have been successfully used for CRPS, with only the former demonstrating benefit in a randomized trial. In this double-blind comparative-effectiveness study, dimethyl sulfoxide was found to work better for "warm" CRPS, whereas oral *N*-acetylcysteine proved more effective for "cold" CRPS. For compounded pain creams containing multiple analgesic substances (eg, ketamine, gabapentin, muscle relaxants, lidocaine, nonsteroidal anti-inflammatory drugs), a recent placebo-controlled study that randomized patients according to their classification of pain (eg, neuropathic, nonneuropathic, or mixed) found no significant benefit for a variety of different pain conditions, including CRPS.

Continuous Infusion Therapy

Infusion therapy has been implemented for CRPS but is limited by resource requirements, reimbursement concerns, and the duration of benefit. In a randomized controlled trial comparing 4 weekly IV lidocaine infusions (3 mg/kg) to saline administration in 42 patients with CRPS II or postherpetic neuralgia, Kim et al reported benefit favoring lidocaine immediately after the third and fourth infusions, but the relief did not persist at 1- or 4-week follow-ups. Two randomized controlled trials evaluated ketamine infusions for CRPS. In a study by Schwartzman et al evaluating an outpatient regimen with doses titrated up to 100 mg over 4 hours, the authors found small benefits favoring ketamine through 12-week follow-up that fell shy of statistical significance. The lack of significance was attributed to the low dosage used and the small number of participants enrolled (n = 19) because the study was terminated early. Another study by Sigtermans et al that evaluated an inpatient, 100-hour infusion reported significant benefit favoring ketamine that persisted for 8 weeks. However, in a meta-analysis evaluating IV ketamine infusions, Orhurhu and colleagues found no difference in response rate between CRPS and non-CRPS patients, or when the pain condition was broken down by category (ie, neuropathic vs nonneuropathic vs nociplastic). Recent multispecialty guidelines on IV ketamine infusions found that moderate evidence supporting ketamine infusions to improve pain for up to 12 weeks (grade B recommendation, low-to-moderate level of certainty) as well as evidence to support higher doses.

Intravenous Therapies and Intravenous Regional Blockade

A systematic review was published in 2016 evaluating IV therapies for CRPS I and II. Based on their review of the literature, the authors found strong evidence for bisphosphonates; mixed evidence for magnesium; mixed evidence for nonsteroid anti-inflammatory drugs; negative evidence for mannitol and tumor necrosis factor α inhibitors; weak (ie, positive flawed randomized trials) evidence for immunoglobulin; weak evidence for IV regional blockade (IVRB) with lidocaine and ketanserin; mixed evidence for IVRB with the sympatholytic drugs guanethidine and reserpine; and anecdotal (ie, uncontrolled studies) evidence for IVRB with clonidine, phenoxybenzamine, and labetalol. In a randomized, placebo-controlled, double-blind study, intravenous immunoglobulin 0.5 g/kg was not effective.

Sympathetic Blocks and Sympathectomy

A recent Cochrane review evaluated the effectiveness of sympathetic blocks. Among the 12 trials (n = 461) evaluated, 3 were placebo-controlled, with 2 reporting no benefit; the 1 that did

report benefit found no short-term benefit for thoracic sympathetic blockade but significant improvement compared with placebo at 1 year. Among the 2 studies that compared add-on sympathetic blockade to active rehabilitation, the only study that reported pain outcomes found no benefit. In the 8 studies that compared sympathetic blocks to other active treatments, most found no differences in pain outcomes. Overall, the authors concluded that the paucity of high-quality studies precluded drawing firm conclusions regarding the efficacy or lack thereof of sympathetic blocks for CRPS but that the limited data available did not support the routine use of local anesthetic sympathetic blocks. In individuals who do respond with good, albeit temporary, relief from sympathetic blocks, chemical (eg, clonidine) or surgical sympathectomy can be considered, although a recent systematic review found that the practice was based on scant high-quality evidence. Although sympathetic blocks have sometimes been used to provide a short- or intermediate-term window to optimize physical therapy including desensitization, the benefit from multiple blocks must be carefully weighed against the significant risks and costs.

Neuromodulation

Transcutaneous electrical nerve stimulation and repetitive transcranial magnetic stimulation have been shown in randomized trials to provide benefit. For spinal cord stimulation, there is evidence in the form of randomized and numerous uncontrolled studies for intermediate-term benefit, although the beneficial effects wane over time, and there is inconclusive evidence for functional and psychological improvement. Recently, the use of dorsal root ganglion stimulation was shown in two randomized trials to be superior to conventional dorsal column stimulation.

Pain Prevention

There are many risk factors for the persistence of pain after injury, including female gender, opioid use, young age, the extent and type of trauma, magnitude of acute pain, psychiatric factors such as catastrophizing, anxiety and depression, sleep abnormalities, genetics, and secondary gain. Because trauma is unpredictable, and many of the risk factors are unalterable (eg, gender, age) or require intensive resources (eg, psychological factors, sleep abnormalities), it is unlikely that CRPS can be reliably prevented. However, because of the high incidence following predictable (ie, surgical) trauma, efforts have been made to reduce the chance of developing CRPS. Given its neuroprotective and neuromodulary antioxidant properties, the use of vitamin C to reduce postsurgical pain and prevent CRPS has been extensively studied. In a systematic review, Chen et al found moderate-level evidence for the preoperative use of vitamin C to reduce postsurgical pain and opioid consumption and high-level evidence to support the use of vitamin C (1 g/d × 50 d) to reduce the incidence of CRPS after extremity surgery.

FUTURE RESEARCH

An inability to identify distinct mechanisms for CRPS is not synonymous with the absence of mechanisms (Table 58.3). In general syndromes, which do not have reliably recognizable mechanisms but rather constitute a constellation of signs and symptoms in the absence of another explanation, tend to be associated with poorer outcomes than diseases, which contain mechanisms that can be readily identified and directly addressed (eg, immunosuppressive therapy for autoimmune diseases, anti-inflammatory therapy for inflammatory diseases). Although considerable overlap in mechanisms has proved challenging for directing treatment, more research is necessary in categorizing CRPS because the evidence seems to support different treatments for different subtypes (eg, cold vs warm).

TABLE 58.3 Potential Mechanisms for Complex Regional Pain Syndrome

Peripheral sensitization
Central sensitization
Decreased inhibitory control
Nerve injury
Oxidative stress
Altered sympathetic nervous system function and sympatho-afferent coupling
Cortical and spinal reorganization
Inflammatory mediators
Immune dysfunction (eg, glial cells)
Altered cutaneous innervation
Psychological vulnerability
Genetics
Disuse

To date, there has been little incentive for industry to conduct large randomized trials evaluating pharmacologic treatments for CRPS, and the efficacy studies that have been conducted tend to have stringent selection criteria that limits generalization. Large-scale registries, as has been recommended by the NIH Pain Research Strategy, may allow researchers and clinicians to identify phenotypes of individuals who may respond to different treatments and to better assess effectiveness in large populations, which may inform clinical trials.

Neuromodulation is a rapidly evolving area that has experienced enormous growth, to include high-frequency stimulation, burst stimulation, and stimulation involving different targets (deep brain and motor cortex, peripheral nerves and plexuses, nerve roots and dorsal root ganglia). Comparative-effectiveness studies are needed to determine the relative effectiveness of these therapies and whether different subtypes of CRPS may respond differently.

Finally, preventive therapies in individuals at high risk for CRPS should be further studied to include psychological interventions in individuals with coexisting psychopathology, minimally invasive surgeries, and multimodal therapies.

CONCLUSIONS

CRPS is a challenging condition, with its classification as a syndrome posing particular barriers to treatment because treatment is predominantly empirically based, rather than based on mechanisms. Recently, CRPS I was reclassified as "nociplastic pain" given the overwhelming evidence in support of a primary disorder of central and peripheral pain processing. In contrast,

CRPS II remains a neuropathic pain condition, although clinically, the two conditions are clinically indistinguishable, with significant overlap in purported mechanisms. The diagnosis of CRPS is based on clinical signs and symptoms in the absence of other explanatory conditions, although certain diagnostic tests may be useful to enhance specificity for research purposes, to identify subtypes (eg, sympathetically maintained vs sympathetically independent pain), and to rule out alternative causes such as nerve entrapment. Physical therapies remain the cornerstone of treatment, although medications and procedures may be used to facilitate rehabilitation. Among pharmacologic treatments, the strongest evidence is for bisphosphonates, although the randomized trials evaluating their use are generally small and methodologically flawed. Neuromodulation in the form of spinal cord stimulation, and more recently dorsal root ganglion stimulation (which has been shown in some studies to be superior to conventional dorsal column stimulation), should be considered for refractory cases. Future research should consider preclinical studies focusing on identification of mechanistic subtypes, registries that seek to determine large population-based outcomes and identify phenotypes that may favorably respond to different treatments, and the indications and effectiveness for preventative measures such as vitamin C before high-risk surgery.

SUGGESTED READINGS

Agarwal S, Polydefkis M, Block B, Haythornthwaite J, Raja SN. Transdermal fentanyl reduces pain and improves functional activity in neuropathic pain states. *Pain Med*. 2007;8:554-562.

Albrecht PJ, Hines S, Eisenberg E, et al. Pathologic alterations of cutaneous innervation and vasculature in affected limbs from patients with complex regional pain syndrome. *Pain*. 2006;120:244-266.

Alexander GM, Perreault MJ, Reichenberger ER, Schwartzman RJ. Changes in immune and glial markers in the CSF of patients with complex regional pain syndrome. *Brain Behav Immun*. 2007;21:668-676.

Ali Z, Raja SN, Wesselmann U, Fuchs PN, Meyer RA, Campbell JN. Intradermal injection of norepinephrine evokes pain in patients with sympathetically maintained pain. *Pain*. 2000;88:161-168.

Bennett DS, Brookoff D. Complex regional pain syndromes (reflex sympathetic dystrophy and causalgia) and spinal cord stimulation. *Pain Med*. 2006;7(suppl):S64-S96.

Bhatia KP, Bhatt MH, Marsden CD. The causalgia-dystonia syndrome. *Brain*. 1993;116(pt 4):843-851.

Bilgili A, Çakır T, Do an K, Erçalık T, Filiz MB, Toraman F. The effectiveness of transcutaneous electrical nerve stimulation in the management of patients with complex regional pain syndrome: a randomized, double-blinded, placebo-controlled prospective study. *J Back Musculoskelet Rehabil*. 2016;29:661-671.

Birch R. Causalgia: a restatement. *Neurosurgery*. 2009;65(4 suppl):A222-A228.

Birklein F, O'Neill D, Schlereth T. Complex regional pain syndrome: an optimistic perspective. *Neurology*. 2015;84:89-96.

Breuhl S, Harden RN, Galer BS, et al. External validation of IASP diagnostic criteria for complex regional pain syndrome and proposed research diagnostic criteria. International Association for the Study of Pain. *Pain*. 1999;81:147-154.

Brown S, Johnston B, Amaria K, et al. A randomized controlled trial of amitriptyline versus gabapentin for complex regional pain syndrome type I and neuropathic pain in children. *Scand J Pain*. 2016;13:156-163.

Bratcher RE, Kurihara C, Bicket MC, et al. Compounded topical pain creams to treat localized chronic pain: a randomized controlled trial. 2019;170(5):309-318.

Cepeda MS, Lau J, Carr DB. Defining the therapeutic role of local anesthetic sympathetic blockade in complex regional pain syndrome: a narrative and systematic review. *Clin J Pain*. 2002;18:216-233.

Chen S, Roffey DM, Dion CA, Arab A, Wai EK. Effect of perioperative vitamin C supplementation on postoperative pain and the incidence of chronic regional pain syndrome: a systematic review and meta-analysis. *Clin J Pain*. 2016;32:179-185.

Chevreau M, Romand X, Gaudin P, Juvin R, Baillet A. Bisphosphonates for treatment of complex regional pain syndrome type 1: a systematic literature review and meta-analysis of randomized controlled trials versus placebo. *Joint Bone Spine*. 2017;84:393-399.

Christensen K, Jensen EM, Noer I. The reflex dystrophy syndrome response to treatment with systemic corticosteroids. *Acta Chir Scand*. 1982;148:653-655.

Cohen SP, Bhatia A, Buvanendran A, et al. Consensus guidelines on the use of intravenous ketamine infusions for chronic pain from the American Society of Regional Anesthesia and Pain Medicine, the American Academy of Pain Medicine, and the American Society of Anesthesiologists. *Reg Anesth Pain Med*. 2018;43:521-546.

Connolly SB, Prager JP, Harden RN. A systematic review of ketamine for complex regional pain syndrome. *Pain Med*. 2015;16(5):943-969.

Cooper DE, DeLee JC, Ramamurthy S. Reflex sympathetic dystrophy of the knee. Treatment using continuous epidural anesthesia. *J Bone Joint Surg Am*. 1989;71:365-369.

De Mos M, de Bruijn AGJ, Huygen FJPM, Dieleman JP, Stricker BH, Sturkenboom MCJM. The incidence of complex regional pain syndrome: a population-based study. *Pain*. 2007;129:12-20.

Deer TR, Levy RM, Kramer J, et al. Dorsal root ganglion stimulation yielded higher treatment success rate for complex regional pain syndrome and causalgia at 3 and 12 months: a randomized comparative trial. *Pain*. 2017;158:669-681.

Del Valle L, Schwartzman RJ, Alexander A. Spinal cord histopathological alterations in a patient with longstanding complex regional pain syndrome. *Brain Behav Immun*. 2009;23:85-91.

Eisenberg E, Shtahl S, Geller R, et al. Serum and salivary oxidative analysis in complex regional pain syndrome. *Pain*. 2008;138:226-232.

Finnerup NB, Attal N, Haroutounian S, et al. Pharmacotherapy for neuropathic pain in adults: systematic review, meta-analysis and updated NeuPSIG recommendations. *Lancet Neurol*. 2015;14:162-173.

Goebel A, Bisla J, Carganillo R, et al. *A Randomised Placebo-Controlled Phase III Multicentre Trial: Low-Dose Intravenous Immunoglobulin Treatment for Long-Standing Complex Regional Pain Syndrome (LIPS Trial)*. Southampton, United Kingdom: NIHR Journals Library; 2017.

Goh EL, Chidambaram S, Ma D. Complex regional pain syndrome: a recent update. *Burns Trauma*. 2017;5:2.

Harke H, Gretenkort P, Ladleif HU, Rahman S, Harke O. The response of neuropathic pain and pain in complex regional pain syndrome I to carbamazepine and sustained-release morphine in patients pretreated with spinal cord stimulation: a double-blinded randomized study. *Anesth Analg*. 2001;92:488-495.

Kemler MA, De Vet HC, Barendse GA, Wildenderg F, Van Kleef M. The effect of spinal cord stimulation in patients with chronic reflex sympathetic dystrophy: two years' follow-up of the randomized controlled trial. *Ann Neurol*. 2004;55:13-18.

Kiefer RT, Rohr P, Ploppa A, Altemeyer KH, Schwartzman RJ. Complete recovery from intractable complex regional pain syndrome, CRPS-type I, following anesthetic ketamine and midazolam. *Pain Pract*. 2007;7:147-150.

Kiefer RT, Rohr P, Ploppa A, et al. A pilot open-label study of the efficacy of subanesthetic isomeric S(+)-ketamine in refractory CRPS patient. *Pain Med*. 2008;9:44-54.

Kiefer RT, Rohr P, Ploppa A, et al. Efficacy of ketamine in anesthetic dosage for the treatment of refractory complex regional pain syndrome: an open-label phase II study. *Pain Med*. 2008;9:1173-1201.

Kim YC, Castañeda AM, Lee CS, Jin HS, Park KS, Moon JY. Efficacy and safety of lidocaine infusion treatment for neuropathic pain: a randomized, double-blind, and placebo-controlled study. *Reg Anesth Pain Med*. 2018;43:415-424.

Kosek E, Cohen M, Baron R, et al. Do we need a third mechanistic descriptor for chronic pain states? *Pain*. 2016;157(7):1382-1386.

Maleki J, LeBel AA, Bennett GJ, Schwartzman RJ. Patterns of spread in complex regional pain syndrome, type I (reflex sympathetic dystrophy). *Pain*. 2000;88:259-266.

Mitchell SW. *Injuries of the Nerves and Their Consequences*. New York, NY: Dover; 1865.

Morione LA, Scuteri D, Rombolà L, Mizoguchi H, Bagetta G. Opioids resistance in chronic pain management. *Curr Neuropharmacol*. 2017;15:444-456.

Nardone R, Brigo F, Höller Y, et al. Transcranial magnetic stimulation studies in complex regional pain syndrome type I: a review. *Acta Neurol Scand*. 2018;137:158-164.

Oaklander AL, Rissmiller JG, Gelman LB, Zheng Li, Chang Y, Gott R. Evidence of focal small-fiber axonal degeneration in complex regional pain syndrome-I (reflex sympathetic dystrophy). *Pain*. 2006;120:235-243.

O'Connell NE, Wand BM, Gibson W, Carr DB, Birklein F, Stanton TR. Local anaesthetic sympathetic blockade for complex regional pain syndrome. *Cochrane Database Syst Rev*. 2016;(7):CD004598.

Orhurhu V, Salisu M, Bhatia A, Cohen SP. Ketamine infusions for chronic pain: a systematic review and meta-analysis of randomized controlled trials. *Anesth Analg*. 2019;129:241-254.

Reddi D, Curran N. Chronic pain after surgery: pathophysiology, risk factors and prevention. *Postgrad Med J*. 2014;90:222-227.

Sandroni P, Benrud-Larson LM, McClelland RL, Low PA. Complex regional pain syndrome type I: incidence and prevalence in Olmsted County, a population-based study. *Pain*. 2003;103:199-207.

Schürmann M, Zaspel J, Löhr P, et al. Imaging in early posttraumatic complex regional pain syndrome: a comparison of diagnostic methods. *Clin J Pain*. 2007;23:449-457.

Schwartzman RJ, Alexander GM, Grothusen JR, Paylor T, Reichenberger E, Perreault M. Outpatient intravenous ketamine for the treatment of complex regional pain syndrome: a double-blind placebo controlled study. *Pain*. 2009;147:107-115.

Sigtermans MJ, van Hilten JJ, Bauer MCR, et al. Ketamine produces effective and long-term pain relief in patients with complex regional pain syndrome type 1. *Pain*. 2009;145:304-311.

Smart KM, Wand BM, O'Connell NE. Physiotherapy for pain and disability in adults with complex regional pain syndrome (CRPS) types I and II. *Cochrane Database Syst Rev*. 2016;(2):CD010853.

Straube S, Derry S, Moore RA, Cole P. Cervico-thoracic or lumbar sympathectomy for neuropathic pain and complex regional pain syndrome. *Cochrane Database Syst Rev*. 2013;(9):CD002918.

Stude P, Enax-Krumova EK, Lenz M, et al. Local anesthetic sympathectomy restores fMRI cortical maps in CRPS I after upper extremity stellate blockade: a prospective case study. *Pain Physician*. 2014;17:E637-E644.

van Bussel CM, Stronks DL, Huygen FJ. Dorsal column stimulation vs. dorsal root ganglion stimulation for complex regional pain syndrome confined to the knee: patients' preference following the trial period. *Pain Pract*. 2018;18:87-93.

Van Hilten BJ, van de Beek WJ, Hoff JI, Voormolen JH, Delhaas EM. Intrathecal baclofen for the treatment of dystonia in patients with reflex sympathetic dystrophy. *N Engl J Med*. 2000;343:625-630.

Veldman PH, Reynen HM, Arntz I, Goris RJ. Signs and symptoms of reflex sympathetic dystrophy: prospective study of 829 patients. *Lancet*. 1993;342:1012-1016.

Visnjevac O, Costandi S, Patel BA, et al. A comprehensive outcome-specific review of the use of spinal cord stimulation for complex regional pain syndrome. *Pain Pract*. 2017;17:533-545.

Weissmann R, Uziel Y. Pediatric complex regional pain syndrome: a review. *Pediatr Rheumatol Online J*. 2016;14:29.

Wertli MM, Kessels AG, Perez RS, Bachmann LM, Brunner F. Rational pain management in complex regional pain syndrome 1 (CRPS 1)—a network meta-analysis. *Pain Med*. 2014;15:1575-1589.

Xu J, Yang J, Lin P, Rosenquist E, Cheng J. Intravenous therapies for complex regional pain syndrome: a systematic review. *Anesth Analg*. 2016;122:843-856.

Neuropathic Pain 59

Jeffrey Shije and Thomas H. Brannagan III

KEY POINTS

1. Nociceptive pain serves a protective function. However, pathology of the somatosensory nervous system may result in neuropathic pain, which no longer serves that purpose.
2. In response to disease or injury, there are complex mechanisms that lead to sensitization of the peripheral and central nervous system, resulting in maladaptive pain.
3. Neuropathic pain is suspected based on symptomatic features (ie, numbness, paresthesia, spontaneous pain, allodynia, etc) and should have some neuroanatomic correlation with the underlying pathology. The initial step of diagnosis is to identify the underlying cause.
4. In addition to addressing the underlying cause, there are pharmacologic treatments for neuropathic pain, supported by various levels of evidence. Ongoing research is needed for treatments that produce better outcome.

INTRODUCTION

Pain is an unpleasant sensory and emotional experience associated with actual or potential tissue damage or described in terms of such damage. For the discussion of pain, it is important to be familiar with certain key terms, outlined in **Table 59.1**. Nociceptive pain has a protective function because it warns of injury or impending injury. Sensitization of peripheral nociceptors and central nervous system changes occur, protecting the damaged area, by avoiding contact. However, pathology of the nervous system may result in a maladaptive pain that no longer correlates with injury or disease activity. Neuropathic pain is a maladaptive pain, which results from nervous system damage and pain in the absence of nociceptor stimulation or an inappropriate response to nociceptor stimulation. Nociceptive and neuropathic pains are not synonymous with acute and chronic pain. Rheumatoid arthritis, for example, is a chronic pain, which is nociceptive. A herniated disk may acutely cause radicular pain, which is neuropathic. The International Association for the Study of Pain (IASP) defines neuropathic pain as pain caused by a lesion or disease of the somatosensory nervous system, although other more inclusive definitions exist. With neuropathic pain, in addition to sensory impairment, there are coexisting abnormal sensory symptoms (see **Table 59.1**). Once developed, these types of pain may persist even after resolution or adequate management of the underlying pathology, making the treatment of neuropathic pain relatively challenging. This chapter reviews the normal neurologic processing of nociception, the proposed mechanisms that give rise to neuropathic pain, its clinical relevance and treatment approaches, with a particular emphasis on painful neuropathy.

TABLE 59.1 Key Pain Terminology[a]

Nociceptive pain: pain that arises from actual or threatened damage to nonneural tissue and is due to the activation of nociceptors
Neuropathic pain: pain caused by a lesion or disease of the somatosensory nervous system
Allodynia: pain due to a stimulus that does not normally provoke pain
Hyperalgesia: increased pain from a stimulus that normally provokes pain
Paresthesia: an abnormal sensation, whether spontaneous or evoked (ie, tingling, crawling)
Dysesthesia: an unpleasant abnormal sensation, whether spontaneous or evoked (ie, paresthesia that is painful)
Sensitization: increased responsiveness of nociceptive neurons to their normal input and/or recruitment of a response to normally subthreshold inputs (may occur in peripheral and/or central nervous system)
Neuralgia: pain in the distribution of a single peripheral nerve
Neuropathy: a disturbance of function or pathologic change in peripheral nerves. (Mononeuropathy involves one nerve. Mononeuropathy multiplex involves several different nerves. Neuropathy is often used interchangeably with polyneuropathy; however, polyneuropathy is reserved for when the neuropathy is due to a diffuse disease process.)

[a]Adopted from Merskey H, Bogduk N. *Classification of Chronic Pain: Descriptions of Chronic Pain Syndromes and Definitions of Pain Terms.* 2nd ed. Seattle, WA: International Association for the Study of Pain; 1994.

EPIDEMIOLOGY

The challenge of estimating the prevalence of neuropathic pain stems from the fact that it is a clinical feature of a wide variety of different neurologic disorders. Often, it is described or categorized based on the underlying disease. For example, the prevalence of neuropathic pain due to diabetic neuropathy has been reported to range from 11% to 28%; neuropathic pain in cancer patients ranged from 18% to 21% in the United Kingdom. On the other hand, neuropathic pain may also be categorized based on clinical features (ie, numbness, burning, tingling, pins and needles, electric shock, etc) independent of the underlying cause. In a large survey using a validated neuropathic pain screening tool, the painDETECT questionnaire, which is based on abnormal sensation and pain characteristics, it was estimated that the prevalence of neuropathic pain in the United States was about 10%.

PATHOBIOLOGY

Normal Processing of Nociceptive Pain

In order to appreciate the neuroplastic changes that occur in neuropathic pain, one must be familiar with the normal processing of nociceptive pain, which can be described in a series

of events: (1) transduction of the noxious stimulus into electrical signal, (2) transmission of the electrical signal from peripheral to central nervous system, (3) modulation of the nociceptive signal, and ultimately (4) the perception of painful experience.

Transduction and Transmission

In general, nociceptors are high-threshold sensory receptors at the peripheral nerve endings that are activated by noxious stimuli (ie, thermal, chemical, mechanical), leading to depolarization of the distal nerve fibers. The axons of these nerve fibers belong to the first-order sensory dorsal root ganglion (DRG) neurons. The conversion of nonelectrical signals to electrical signals by nociceptors is termed *transduction*.

The resulting action potential is then transmitted via the peripheral axon of the DRG neuron to the dorsal horn of the spinal cord, to synapse with the second-order nociceptive neurons there. The DRG neurons can be classified by the degree of myelination and the conduction speed of their axon fibers. The heavily myelinated, rapidly conducting, low threshold Aβ-fibers are typically nonnociceptive. Those with nociceptive functions consist of the thinly myelinated, slower conducting, small-diameter Aδ-fibers and the unmyelinated, very slowly conducting, very-small-diameter C fibers. Aδ-fibers may transmit the initial sharp pain, whereas C fibers may transmit heat or the subsequent lingering pain.

If a noxious stimulus results in tissue damage, there may be erythema and edema, mediated by local proinflammatory factors (ie, histamine, bradykinin, prostaglandin, cytokines, etc). These proinflammatory mediators are sometimes referred to as *inflammatory soup*, which may sensitize the peripheral nociceptors, resulting in increasing firing at lower thresholds to less intense stimuli. Some of the nociceptive action potential may even rebound antidromically through other axonal branches back to the site of injury and release more proinflammatory mediators, in a process called *neurogenic inflammation*. Ultimately, nociceptive action potentials reach the spinal cord and release pronociceptive neurotransmitters such as substance P and calcitonin gene-related peptide to activate the second-order nociceptive neurons in the dorsal horn of the spinal cord.

The second-order nociceptive neurons in the dorsal horn project axons that cross midline via the anterior white commissure to travel with the contralateral spinothalamic tract and ultimately reach the contralateral ventroposterolateral thalamus. From there, third-order neurons convey primary nociceptive information through the posterior limb of the internal capsule to the postcentral gyrus (primary somatosensory cortex).

Modulation and Perception

The transmitted nociceptive signals may be modulated at the level of the dorsal horn, by descending pathways in the spinal cord, or in the brain.

The dorsal horn of the spinal cord is organized into layers called *Rexed laminae*. Aδ-fibers largely terminate in lamina I (the marginal zone), which is the most dorsal layer, although some also project to lamina V. Most of the C fibers terminate in lamina II (ie, substantia gelatinosa). These lamina layers contain complex networks of interneurons that have excitatory and inhibitory functions that modulate the transmission of nociceptive signals form the DRG to the dorsal horn neurons.

Nociceptive transmission in the dorsal horn is also influenced by descending modulatory mechanisms. A well described example of these mechanisms involves the periaqueductal gray (PAG) in the dorsal midbrain and the rostral ventromedial medulla (RVM). The PAG-RVM system receives inputs from spinothalamic tract and cortical projections and sends descending projections to the dorsal horn of the spinal cord. Norepinephrine, serotonin, γ-aminobutyric acid (GABA), as well as enkephalins (or endogenous opioids) play important roles in the inhibitory effect of the descending modulatory systems.

Ultimately, the perception of pain is produced in the brain by integrating the somatosensory, cognitive, and affective components of the experience. Functional magnetic resonance imaging studies have shown that during painful experiences, areas of increased metabolic activity include those involved in sensory processing, that is, ventrolateral thalamus and somatosensory cortex as well as those involved in emotional processing and integration, that is, anterior cingulate and insular cortex.

Mechanisms Underlying Neuropathic Pain

Unlike nociceptive pain, neuropathic pain no longer serves a protective purpose. Instead, it causes physical suffering and emotional distress without obvious benefit. The mechanisms underlying this maladaptive pain are complex and are thought to give rise to peripheral and central sensitization, as discussed in the following text.

Peripheral Sensitization

Pathology of the peripheral nervous system may take place at the level of the nerve, plexus or nerve root, and may be due to mechanical, inflammatory, toxic, or other etiology. Consequently, there may be increased nerve membrane potential excitability at the terminal nociceptors or proximal to them. When electrical impulses are generated from locations other than the terminal nociceptors, they are referred to as *ectopic discharges*. Ectopic discharges can be generated spontaneously or triggered by previously subthreshold stimuli.

Depending on the nature of the nerve damage, ectopic discharges may be generated from neuroma, axon segments or the DRG soma. For example, transection of a nerve is often followed by axonal sprouting from the proximal nerve stump in an attempt for regeneration; if these sprouts fail to enter a Schwann cell tube in the distal nerve segment, they may form a neuroma. (Trauma over the length of a nerve, even without transection may damage small axon fascicles and lead to formation of microneuromas.) Neuromas have been shown to be a source of ectopic discharges and electrical pacemaker activity. More proximally, axonal or demyelinating injuries of the nerve segments may lead to ectopic discharges, and these can spread to adjacent uninjured afferent axons by a process called *ephaptic transmission*. In some cases, these electrical currents may be sustained in a closed-circuit loop. Furthermore, adjacent uninjured axons, attempting to reinnervate the denervated areas, may produce collateral sprouts that may be hyperexcitable as well. Lastly, there is evidence from animal models of nerve injury that the DRG itself can be a source of ectopic discharges. For example, spinal nerve injury lead to increased subthreshold membrane potential oscillations in DRG neurons, and these oscillations often trigger bursts of action potentials.

Injury to the peripheral nervous system often results in the release of various inflammatory mediators and growth factors, which may alter the expression, distribution and posttranslational modification (ie, phosphorylation) of various ions channels that lead to nerve membrane potential hyperexcitability. Some of these ion channels are described in the following text.

Sodium Channels

Immunofluorescent labeling of injured nerve fibers has demonstrated that sodium ion channels can accumulate in demyelinated nerve segments, new axonal sprouts, or end-bulb neuroma. Furthermore, there are both down- and upregulation of various sodium ion channels after nerve injury. Among these, the voltage-gated sodium channel (Na_v)1.3 is typically not expressed in adult DRGs but is upregulated after nerve injury. Also, Na_v1.8 is predominantly expressed in nociceptors, and its levels are increased in axonal membrane after nerve injury. The reexpression of Na_v1.3 and increased expression of Na_v1.8 are seen in adjacent uninjured axons as well. Na_v1.7 expression is not increased in nerve injury nor predominantly expressed in nociceptors, but a gain of function mutation of Na_v1.7 can result in abnormal pain syndromes. These sodium ion channels would seem to be ideal therapeutic targets, but it was demonstrated that knockout of Na_v1.3, 1.7, and 1.8 in mice did not prevent the development of neuropathic pain behaviors, suggesting that the development of neuropathic pain does not depend solely on changes in sodium channel expression.

Potassium Channels

Potassium channels play important roles in stabilizing neuronal membrane potentials. One example of these is TRESK, a two-pore-domain potassium channel, which is highly expressed in the DRG. TRESK is downregulated after nerve injury, leading to decreased membrane potential stability. Another example is the low-voltage-activated K^+ channels, which are also downregulated in nerve injury. Opening these channels has been shown to have antinociceptive effects in animal models of neuropathic pain.

Calcium Channels

N-type calcium channels are present at high levels in the presynaptic terminals of DRG neurons. Influx of calcium ions through these channels leads to membrane depolarization and release of pronociceptive neurotransmitters from DRG to dorsal horn neurons. N-type calcium channels, particularly their $\alpha 2\delta$ subunits, are upregulated following nerve injury, further promoting transmission of nociceptive signals from the DRG to the dorsal horn neurons. It is believed that the gabapentinoids exert their effect in neuropathic pain by binding and interfering with the $\alpha 2\delta$ subunits of the N-type calcium channels.

Other Ion Channels

Vanilloid receptor 1 (TRPV1) is a nonselective cation channel that can be activated by various stimuli such as heat, low pH, and various chemical compounds including capsaicin. It is primarily expression on C- and Aδ-fibers, and its activation can produce painful and burning sensation. In response to nerve injury, Vanilloid receptor 1 expression may be increased, and the threshold for channel activation may be decreased. DRG neurons also express hyperpolarization-activated cyclic nucleotide-gated (HCN) channels (HCN1 in large DRG neurons and HCN2 in small DRG neurons), which generate slowly depolarizing currents. These channels open in response to hyperpolarization overshoot during the refractory phases of an action potential, thus allowing subsequent depolarization to occur. Expression of HCN channels is increased after peripheral nerve injury in rats, contributing to increased membrane potential oscillation in the DRG and subsequent ectopic discharges.

Regardless of the location or mechanism of the ectopic impulse generation, the frequent or unrelenting nociceptive input from the peripheral nervous system to the spinal cord further promotes sensitization of the central nervous system.

Central Sensitization

In theory, nociceptive potentials may be independently generated in the central nervous system. Here, we will primarily discuss central sensitization that occurs in response to nerve injury. This sensitization is the result of various changes (neuroplasticity) in the central nervous system that include a form of long-term potentiation (windup), increased nociceptive field of the dorsal horn neurons, sensitization of low-threshold Aβ fibers, and decreased inhibitory modulations.

Enhanced Windup

Repetitive nociceptive input from the DRG to the dorsal horn neuron can lead to increased synaptic strength, a form of long-term potentiation. One example of this is the phenomenon of windup, where C fiber firing at a low frequencies and repetitive train, can result in a progressive buildup response amplitude of the dorsal horn neuron. One proposed mechanism is that repetitive stimulation of the dorsal horn neuron by C fibers cause its membrane potential to be increasingly depolarized through activation of *N*-methyl-D-aspartate (NMDA) receptors. Consequently, increased intracellular calcium ions may activate protein kinase C, which further promotes calcium influx via NMDA ionophores or other calcium channels, promoting further depolarization. Windup is not necessarily pathologic, but it can be enhanced as a result of nerve injury–induced neuroplasticity, such that stronger temporal summation, higher amplitude, and longer duration of postsynaptic potentials are now featured in the windup process.

Altered Receptive Field

It is not uncommon for patients to report neuropathic pain in locations beyond the dermatomal representation of their nerve injury. One feature of central sensitization is that the nociceptive dorsal horn neurons now respond to peripheral inputs outside of their previous somatotopic field. After peripheral nerve injury, the aberrant rerouting of impulses within the spinal cord may result in the diversion of impulses from nonnociceptive pathways to nociceptive pathways. This has been demonstrated animal experiments, where evoked dorsal horn neuron activity may be induced by nonnociceptive stimulation of areas supplied by an uninjured nerve, suggesting spread of nonnociceptive impulses from normal routes into nociceptive pathways. This type of somatotopic reorganization could result from limited axonal sprouting over short distances within the dorsal horn of spinal cord, where formation of new synapses is prompted when primary sensory input is interrupted. However, this is not the only explanation.

Sprouting Versus Unmasking of Previous Synapses

A key feature of central sensitization is that the low-threshold Aβ-fibers are now able to trigger excitatory responses in the nociceptive dorsal horn neurons. This challenges the traditional understanding that the Aβ-fibers do not transmit nociceptive signals. One hypothesis for this phenomenon is that the low-threshold Aβ-fibers, which had few or no synapses to the superficial lamina (I and II) of the dorsal horn, are now able to sprout into the superficial lamina to synapse with the nociceptive

neurons there, in response to nerve injury. (Demonstrated by a retrograde axon tracer labeling of Aβ-fiber in superficial lamina after nerve injury, but later evidence suggested this may be due to C fiber phenotypic switching rather than Aβ-fiber sprouting.) Another hypothesis is that there are previously quiescent, polysynaptic pathways from the low-threshold Aβ-fibers to the superficial lamina, and these pathways are "unmasked" in response to nerve injury. Consequently, a nociceptive field may be broadened, and a previously nonnociceptive stimulus may now produce pain (ie, allodynia). Perhaps, decreased inhibition from the spinal cord interneurons and descending inputs contribute to the "unmasking" of these previously silent synapses.

Loss of Inhibition

Normally, inputs from the DRG to the dorsal horn neurons are under regulation by pre- and postsynaptic inhibitory inputs from spinal cord interneurons and descending pathways (ie, PAG and RVM). There is evidence that these inhibitory effects are reduced in peripheral nerve injury. For example, many of the interneurons use GABA as an inhibitory neurotransmitter, and a reduction of GABA in the spinal cord dorsal horn was demonstrated in chronic constriction and spared nerve injury models in animal experiments. There is evidence that repeated Aδ-fiber inputs to the dorsal horn may promote neuronal apoptosis, possibly through an excitotoxic mechanism, such as those mediated by excessive glutamate receptor activation. Furthermore, those experiments demonstrated that the nerve injury–induced neuronal apoptosis in the dorsal horn correlated with a reduction of GABA content and GABA-producing enzyme in the dorsal horn.

Microglia Mediated Hypersensitivity

Spinal glial cells, that is, microglia, are activated in response to nerve injury and produce proinflammatory cytokines and chemokines. These inflammatory mediators can induce hyperexcitability in nociceptive dorsal horn neurons and reduce inhibitory regulations, contributing to central sensitization.

DIAGNOSIS

In the clinical setting, there are no methods to determine whether an individual's pain is purely nociceptive or modified by sensitization. The suspicion of neuropathic pain is primarily based on the patients' description of pain and sensory abnormalities (ie, tingling, burning, electric shock, numbness, etc). There are neuropathic pain screening tools such as the painDETECT questionnaire that use these descriptive features to determine the likelihood of neuropathic pain. However, these are not diagnostic tools for the cause of neuropathic pain.

Because neuropathic pain can be a feature of various neurologic disorders, the initial step of diagnosis is to evaluate for any underling pathology; that is, is there objective evidence of mononeuropathy, polyneuropathy, radiculopathy, plexopathy, or pathology of the central nervous system? If so, how likely is it that the pain (and sensory symptom) is due to a direct consequence of the lesion or disease affecting the somatosensory nervous system? Based on this concept, a grading system for the diagnosis of possible, probable, and definite neuropathic pain has been proposed by the IASP for research and clinical use.

There are three distinct anatomic patterns of peripheral neuropathy: *mononeuropathy, mononeuropathy multiplex, and polyneuropathy*. Mononeuropathy may produce decreased sensation in the receptive sensory field of the nerve and/or weakness in the muscles it innervates, although the associated pain may extend beyond its normal receptive field (a feature of central sensitization). Mononeuropathy multiplex may produce deficits that correspond to the distributions of multiple individual nerves. Polyneuropathy implies a more diffuse involvement of the peripheral nerves. It may be length dependent or non–length dependent. When the sensory component is involved, length-dependent polyneuropathy produces numbness and often neuropathic pain in a stocking and glove distribution (feet, distal legs and hands, with feet often being the initial sites of symptoms, and leg and hands may be involved as the polyneuropathy progresses). Non–length-dependent polyneuropathies produce symptoms that may be asymmetrical or patchy. Examples of various causes of peripheral neuropathy are listed by anatomic pattern in **Table 59.2**. Similarly, neuropathic pain due to disease or injury of the nerve root, plexus, and the central nervous system that produce sensory deficits should have some neuroanatomic correlation. For example, even though the foot/leg pain from an L5 radiculopathy may be referred beyond the borders of the L5 dermatome, any correlating sensory deficit should still be within the corresponding dermatome.

The primary aim of diagnostic testing is to evaluate for evidence of underlying localization and etiology of the neuropathology. Nerve conduction study and electromyography can help demonstrate electrophysiologic evidence of mononeuropathy, polyneuropathy, plexopathy, or radiculopathy. In scenarios where polyneuropathy is suspected but is not demonstrated by nerve conduction study, other options such as skin biopsy and quantitative sudomotor axonal reflex test may provide evidence of small fiber neuropathy. Additional laboratory testing

TABLE 59.2 Causes of Painful Neuropathy by Anatomic Distribution

Mononeuropathy	Mononeuropathy Multiplex (multiple individual nerves)	Polyneuropathy (length dependent, symmetrical, stocking and glove pattern)
• Compressive (carpal tunnel syndrome, ulnar neuropathy at the elbow) • Trauma • Neoplastic	• Diabetes • Vasculitis • Sarcoidosis	• Diabetes/prediabetes[N,S] • Chemotherapy induced • Gammopathy (including POEMS syndrome) • Vitamin deficiency/toxicity (B_{12} deficiency, B_6 deficiency and toxicity) • Infectious (ie, HIV, shingles, Lyme disease) • Primary autoimmune (ie, GBS, CIDP) • Secondary autoimmune (ie, Sjogren sydrome,[N,S] celiac, lupus, Wegner, and other vasculitides[N]) • Amyloid (ie, AL, hATTR) • Paraneoplastic (ie, Anti-Hu) • Hereditary (ie, HSAN, Fabry cisease)[S]

Abbreviations: AL, light-chain amyloid; CIDP, chronic inflammatory demyelinating polyradiculoneuropathy; GBS, Guillain-Barré syndrome; hATTR: hereditary transthyretin amyloidosis; HIV, human immunodeficiency virus; HSAN, hereditary sensory autonomic neuropathy; [N], can be non–length dependent; POEMS, polyneuropathy organomegaly, endocrinopathy, M protein, skin changes; [S], can be small fiber predominant.

and when appropriate, nerve biopsy, are used to determine the etiology of the neuropathy. Imaging tests such as magnetic resonance imaging can be used to evaluate for certain causes (ie, mass lesion, compression, evidence of inflammatory) of neuropathy, plexopathy, radiculopathy, or pathology of the central nervous system (ie, multiple sclerosis, stroke, etc). Blood-based diagnostic tests can help establish metabolic (ie, diabetes, vitamin deficiency, etc), infectious (ie, Lyme disease), autoimmune, or paraneoplastic syndromes (refer to Chapters 90 and 91).

MANAGEMENT

General Principles

In general, the goal of management is to detect and treat any underlying pathology associated with the pain. If there is no treatment for the underlying pathology, or if the neuropathic pain become persistent despite resolution or adequate control of the underlying pathology, then the treatment of the pain itself becomes a focus of management. Although some patients may have complete resolution of their pain with treatment, most do not. Realistic expectations should be set early. If complete pain resolution is not achieved with available treatment options, the goal of care may be to reduce pain severity, promote physical function, and improve mood and sleep. Furthermore, it should be emphasized that neurologic symptoms such as loss of sensation, weakness, and other deficits are not expected to improve from medications meant to reduce neuropathic pain.

Pharmacologic Treatments

Historically, clinical trials for neuropathic pain have been based on the underlying etiology of the peripheral neuropathy (ie, evaluating pain treatments in diabetic neuropathy or postherpetic neuralgia, etc). It has been suggested that the mechanisms of neuropathic pain should be incorporated into the design of clinical trials, although this has been difficult to achieve. Current evidence supporting the use of various pharmacologic treatment come from randomized controlled trials (RCTs) of treatments for various painful neuropathies such as diabetic neuropathy, postherpetic neuralgia, chemotherapy-induced neuropathy, trigeminal neuralgia, and other painful neurologic disorders. Several professional societies including the European Federation of Neurological Societies, Canadian Pain Society, and the Special Interest Group on Neuropathic Pain of the IASP have produced evidence-based guidelines for pharmacologic treatments of neuropathic pain, and most of their recommendations are overlapping. Their recommendations for the first- and second-line pharmacologic options are summarized in Table 59.3. Drugs beyond the second-line options arguably have weaker evidence. In general, it is recommended that oral medications be started at low dose, then gradually increased as tolerated, to achieve the lowest dose that offers the most benefit with the least side effects (Table 59.4).

TABLE 59.3 Evidence-Based Guidelines for Pharmacologic Treatments of Neuropathic Pain From Three Groups

	EFNS	CPS	NeuPSIG
First line	**Diabetic neuropathy** Gabapentin Pregabalin TCAs Duloxetine Venlafaxine **Postherpetic neuralgia** Gabapentin Pregabalin TCAs Lidocaine 5% topical **Trigeminal neuralgia** Carbamazepine Oxcarbazepine	Gabapentin Pregabalin TCAs Duloxetine Venlafaxine Carbamazepine (for trigeminal neuralgia)	Gabapentin Pregabalin TCAs Duloxetine Venlafaxine
Second line	**Diabetic neuropathy** Tramadol **Postherpetic neuralgia** Topical Capsaicin Tramadol Other opioids	Tramadol Other opioids Topical lidocaine	Topical lidocaine Topical capsaicin Tramadol

Abbreviations: CPS, Canadian Pain Society; EFNS, European Federation of Neurological Societies; NeuPSIG, Special Interest Group on Neuropathic Pain of the International Association for the Study of Pain; TCAs, tricyclic antidepressants.

Gabapentinoids

It is believed that gabapentinoids exert their pain modulating effect by antagonizing the α2δ subunit of presynaptic DRG calcium channels, which has been shown to be upregulated after nerve injury. Systematic review and meta-analysis of high-quality RCTs have shown both gabapentin and pregabalin significantly reduce pain intensity and also improve function and quality of life, in diabetic neuropathy and postherpetic neuralgia LEVEL 2.[1-5] However, gabapentin was less effective when applied to multietiology neuropathic pain that included conditions such as poststroke, phantom limb, and complex regional pain syndrome. Gabapentinoids are generally well tolerated at low dose and may increase with escalating dose. Common side effects may include drowsiness, mental slowing, erectile dysfunction, and less commonly, peripheral edema as well as myoclonus. It is recommended that starting dose be no more than 300 mg for gabapentin and no more than 75 mg twice a day for pregabalin. Doses are titrated up gradually as tolerated. Doses of 1,800 to 3,600 mg a day for gabapentin and 300 to 600 mg a day for pregabalin may be required for efficacy.

Serotonin-Norepinephrine Reuptake Inhibitors and Tricyclic Antidepressants

Serotonin-norepinephrine reuptake inhibitors (SNRIs) decrease presynaptic uptake of norepinephrine and serotonin, increasing their availability in the synaptic junction. It is thought that these neurotransmitters are mediators of the descending inhibitory systems (ie, from the PAG) that modulate pain transmission between DRG and dorsal horn neurons. Examples of SNRIs include duloxetine and venlafaxine. Meta-analysis of high-quality RCTs concluded that duloxetine was an effective treatment option for diabetic neuropathy pain LEVEL 2.[6] Venlafaxine was also demonstrated to significantly reduce neuropathic pain in RCTs that included diabetic neuropathy, chemotherapy-induced neuropathy, and spinal cord injury LEVEL 2.[7] Duloxetine 60 to 120 mg a day and venlafaxine 75 to 150 mg a day are generally well tolerated, with minor side effects. However, caution is advised when used with concomitant selective serotonin reuptake inhibitor (SSRI) or monoamine oxidase inhibitor to avoid serotonin syndrome.

TABLE 59.4 Medications Used to Treat Neuropathic Pain

Medication	Starting Doses	Maintenance Doses	Data Supporting the Use	Selected Side Effects
Antidepressants				
Duloxetine	20-30 mg every day	60-120 mg/d	PCT—diabetic neuropathy	Diarrhea, nausea, dizziness
Amitriptyline	10-25 mg every night at bedtime	50-150 mg/d	PCT—diabetic neuropathy	Arrhythmia, urinary retention, sexual dysfunction
Nortriptyline	10-25 mg every night at bedtime	50-150 mg/d	RCT—herpetic neuralgia	Less somnolence and orthostatic hypotension than amitriptyline
Venlafaxine	37.5 mg every day	150-375 mg/d	RCT—diabetic neuropathy, chemotherapy-induced neuropathy	Hypertension, sexual dysfunction, nausea
Bupropion SR	150 mg every day	150 mg twice a day	PCT—neuropathic pain	Dry mouth, headache, insomnia, dizziness
Anticonvulsants				
Pregabalin	75 mg twice a day	150-300 mg twice a day	PCT—diabetic neuropathy, postherpetic neuralgia	Somnolence, fatigue, pedal edema, weight gain
Gabapentin	100 mg 3 times a day	300 mg 3 times a day to 1,200 mg 4 times a day	PCT—diabetic neuropathy, postherpetic neuralgia	Somnolence, fatigue, pedal edema
Lamotrigine	25 mg every day	100-250 mg twice a day	PCT—HIV neuropathy, diabetic neuropathy	Stevens-Johnson rash
Oxcarbazepine	75 mg every night at bedtime	300-1,200 mg twice a day	RCT—trigeminal neuralgia	Gastrointestinal ataxia, hyponatremia, rash
Topiramate	15-25 mg every night at bedtime	100-400 mg twice a day	Anecdotal reports—diabetic neuropathy, neuropathic pain	Somnolence, word-finding difficulties, kidney stones
Lacosamide	100 mg every day	400 mg every day	PCT—diabetic neuropathy	Dizziness, nausea
Other Medications				
Mexiletine	150 mg daily	600-1,200 mg daily	Anecdotal, subgroup analysis of PCT	Nausea/vomiting, palpitations, chest pain
Tramadol	25 mg daily	200-400 mg daily	PCT—diabetic neuropathy	Seizures, nausea, headache, constipation, somnolence
CR-oxycodone	10 mg every day	40 mg every day	PCT—diabetic neuropathy	Constipation, somnolence, nausea, dizziness, vomiting
Tapentadol ER	50 mg twice a day	100-250 mg twice a day	PCT—diabetic neuropathy	Constipation, somnolence, dizziness, nausea, vomiting, fatigue
Tizanidine	1 mg daily	4-36 mg daily	Open-label studies in neuropathic pain	Dizziness, drowsiness, fatigue, liver damage
Methadone	5 mg daily	10-20 mg daily	PCT—neuropathic pain	Nausea, dizziness, constipation
Capsaicin 8% patch	1 patch	1 patch every 12 wk	PCT—postherpetic neuralgia, HIV neuropathy	Application site reactions, including increase in pain, nausea
Lidocaine patch 5%	1 patch for 12 h	1-3 patches for 12 h	PCT—postherpetic neuralgia	Application site reactions

Abbreviations: CR, controlled release; ER, extended release; HIV, human immunodeficiency virus; PCT, placebo-controlled trials; RCT, randomized controlled trials; SR, sustained release.

Similarly, tricyclic antidepressants (TCAs) are older generation antidepressants that have reuptake inhibition for norepinephrine, serotonin, and dopamine. They may also promote the pain modulatory effects of the descending inhibitory pathways; however, there is evidence that TCAs may suppress voltage-gated ions channels of dorsal horn neurons as well. Examples of these include amitriptyline and desipramine, which were shown in RCTs to offer significant pain relief, including burning and lancinating pain, that were independent of depression, in diabetic neuropathy and postherpetic neuralgia LEVEL 1.[8-10] Nortriptyline is another TCA that has been shown to be as effective as amitriptyline for pain relief in postherpetic neuralgia but has fewer side effects compared to amitriptyline. Their benefits may not be apparent until 50 to 75 mg a day is reached. However, common side effects of TCAs include somnolence, weight gain, and anticholinergic effects, that is, dry mouth and constipation. Furthermore, there may be increased risk of dysrhythmia, including the prolonged QT syndrome. Therefore, because of their anticholinergic effects, TCAs may not be ideal for elderly patients. Again, caution is advised with concomitant SSRI and monoamine oxidase inhibitor to avoid serotonin syndrome.

Sodium Channel Antagonists

Local anesthetics such as lidocaine exert their analgesic effect by blocking voltage-gated sodium ion channels of the peripheral nerves, impairing the generation, or propagation of action potentials. Topical lidocaine 5% (plaster and patch) has been shown to reduce pain intensity and allodynia in postherpetic neuralgia and other neuropathic pain syndromes LEVEL 1.[11,12] Aside from possible local skin irritations, topical lidocaine has minimal systemic side effects if used as directed and may be preferred for patients with localized areas of neuropathic pain. A 5% patch

may be effective for 12 to 24 hours, although one could use up to three patches a day. However, increased absorption of lidocaine systemically carries some risk of cardiac arrhythmia; thus, use in excess of its daily recommended dose should be avoided.

Oral options of sodium channel antagonists, such as mexiletine, were reported to be efficacious for painful neuropathy in diabetes from early studies. However, systematic review of RCTs involving mexiletine showed that the degree of pain reduction was small, uncertain if clinically meaningful. Not surprisingly, mexiletine has been reported to be beneficial for the pain in various channelopathies such as congenital erythromelalgia, myotonia, and paramyotonia congenita. However, it is a nonselective antagonist of Na_v, thus associated with side effects involving the cardiac and central nervous system, that is, arrhythmia, dizziness, and drowsiness.

There are ongoing efforts to develop therapeutic agents that target the Na_v that are more selectively expressed in the peripheral nervous system.

Antiepileptics

In theory, the anticonvulsive medications carbamazepine and oxcarbazepine, may also exert their therapeutic effect for neuropathic pain by antagonizing sodium channels. Carbamazepine and oxcarbazepine are first-line treatments for trigeminal neuralgia, with oxcarbazepine being better tolerated LEVEL 2.[13,14] Carbamazepine and oxcarbazepine were effective in other neuropathic pain syndromes including in diabetic neuropathy in small RCTs, although other RCTs have reported inconsistent results. An RCT showed that oxcarbazepine was more effective for neuropathic pain with an "irritable nociceptor" phenotype, defined as hypersensitivity with preserved small fiber function determined by quantitative sensory testing, than those of a nonirritative nociceptor phenotype. Starting dose at 100 mg for carbamazepine and 300 mg for oxcarbazepine are reasonable, titrating up for optimal effect. Common side effects may include dizziness and hyponatremia.

Many of the other antiepileptics including lamotrigine, valproic acid, lacosamide, levetiracetam, topiramate, and phenytoin, have had at least some reported efficacy for various neuropathic pain syndromes from RCTs.

Capsaicin

Capsaicin patch 8% was demonstrated to reduce pain intensity in some patients with postherpetic neuralgia, human immunodeficiency virus neuropathy, and diabetic neuropathy in RCTs LEVEL 2.[15,16] Capsaicin activates the vanilloid receptors of the nociceptive DRGs, leading to subsequent depletion of substance P, a nociceptive neurotransmitter. However, until the depletion of substance P is reached, there may be an increase in pain for up to 1 to 2 weeks initially. If this initial increased pain can be tolerated, the subsequent improvement of pain intensity may last up to 12 weeks. Aside from local skin irritation, accidental contact with mucous membranes (ie, eyes) would result in severe irritation, thus application of this medication should be exercised with caution.

Opioids and Other Controlled Substances

The mechanism of action of opioid is complex. Different types of opioid receptors are found throughout the central and peripheral nervous system. The effect of the opioid depends on the type of receptor it activates, and the subsequent G protein coupled intracellular cascades that follow. With regard to neuropathic pain, activation of opioid receptors on nociceptive neurons may lead to decreased calcium influx and increased potassium efflux, which increase the threshold of action potential generation, reducing neuronal excitability. Other effects of opioid receptor activation include anticholinergic effects, sedation, and euphoria. Opioids can be effective for neuropathic pain, for example, oxycodone controlled release, levorphanol, and methadone were found to reduce pain intensity of painful neuropathy in RCTs. However, due to their numerous adverse effects associated with long-term use, potential for addiction, and a recent rise in overdose-related death, it is generally not the ideal option for neuropathic pain. Tramadol is a relatively weaker opioid with some norepinephrine reuptake inhibition activity. Systematically reviewed RCTs showed tramadol to be effective at significantly reducing pain intensity and have therapeutic effects on various aspects of neuropathic pain such as paresthesia, allodynia, and touch-evoked pain LEVEL 1.[17] Still, caution is advised when prescribing any opioid, and close monitoring of any signs of dependence is warranted.

Other Pharmacologic Agents

Considering the role of NMDA receptor activation in the development of sensitization in neuropathic pain, there has been some interest in utilizing drugs with NMDA receptor antagonist activity, such as dextromethorphan, ketamine, and memantine, for chronic pain. However, their benefit for neuropathic pain is uncertain.

In addition to SNRI and TCA, SSRIs have been thought to offer benefit for neuropathic pain. For example, escitalopram was shown to be effective in painful polyneuropathy in an RCT. However, evidence supporting the use of SSRI for neuropathic pain is relatively limited.

Bupropion is an antidepressant that has predominantly dopamine reuptake inhibition as well as some norepinephrine reuptake inhibition and NMDA antagonistic effect. One RCT showed bupropion sustained release reduced pain intensity and improve quality of life in patients with neuropathic pain due to a variety of etiologies that include diabetic neuropathy, phantom limb pain, radiculopathy, etc.

Systematic review of cannabinoids (including herbal cannabis, plant-derived or synthetic tetrahydrocannabinol [THC], oromucosal spray) found low to moderate quality evidence of reducing neuropathic pain intensity and sleep problems. However, the benefit may be outweighed by side effects that included dizziness, sleepiness, and confusion.

Alpha-lipoic acid is a coenzyme in the Krebs cycle, it has antioxidant effect and was shown to reduce diabetic microvascular complications in animal models. Intravenous alpha-lipoic acid has been shown to reduce diabetic neuropathy pain in short-term clinical trials. However, the benefit of its oral analogue, as well as its benefit for neuropathic pain from other disorders, are unclear.

Cognitive Behavioral and Physical Therapy

Cognitive behavioral therapy (CBT) and physical therapy are often used in the management of chronic pain. Results from RCTs evaluating the effect of psychological therapy on neuropathic pain have been conflicting, and the quality of some of these trials have been deemed suboptimal. Thus, the effect of CBT on neuropathic pain is inconclusive. Also, CBT methods may vary among different therapists. Despite the lack of rigorous evidence for efficacy in painful neuropathy, CBT is relatively safe and therefore may be a treatment option. Regarding physical therapy, there is insufficient evidence to conclude the effect of exercise on the functional outcome of patients with neuropathy pain (except

some improvement of muscle strength). On the other hand, for chronic pain in general, some RCTs showed exercise may reduce the severity of chronic pain, although these findings have not been consistent in other studies. Some of the inconsistency may stem from the variety of physical activities employed in different studies. However, considering the overall health benefit of regular exercise, its low risk of significant harm (especially with proper physical therapy guidance), and that it may offer benefit in some patients, physical therapy, and exercise are often recommended in conjunction with pharmacologic treatment for chronic pain.

Procedural Interventions

There is ongoing evaluation of various procedural interventions for the treatment of neuropathic pain. These include botulinum toxin A, transcranial cortical stimulation, as well as nerve root and peripheral nerve stimulation, with either inconclusive findings or weak evidence so far.

OUTCOME

Despite a wide variety of pharmacologic and nonpharmacologic treatment options for neuropathic pain, the result is often unsatisfactory for the patient. In a recent long-term prospective observational study for neuropathic pain (including central and peripheral causes), using the Canadian Pain Society treatment guidelines, only 32.4% of the patients achieved significant pain reduction (defined as 30% or greater pain reduction at 12 months) from baseline. It also showed central neuropathic pain was less likely to respond than pain of peripheral origin. Indeed, there are challenges to the pursuit of more effective treatments. Eligibility criteria for neuropathic pain trials are often based on etiologic categories such as diabetic neuropathy or trigeminal neuralgia. Individuals within the same etiologic category may have pain that arises from distinct mechanisms. This mechanistic heterogeneity may diminish our ability to measure benefits in randomized trials and to optimize treatment in clinical practice. Some have advocated a mechanism-based approach to pain diagnosis, emphasizing identifying the underlying neuroplastic changes (ie, those that lead to sensitization) that promote and perpetuate maladaptive pain. There are ongoing attempts to develop such methods. At least in theory, being able to identify and tailor treatments to the mechanisms that give rise to neuropathic pain may yield more satisfactory clinical results. In addition, the subjective pain scales and quality of life assessment tools that are used as outcome measures may not optimally measure the burden of illness or benefits of treatment. Identifying mechanism-based subgroups of patients with neuropathic pain, treatments that are most effect in these subgroups, and patient-centered measures offers hope for improving outcomes.

LEVEL 1 EVIDENCE

1. Backonja M, Beydoun A, Edwards KR, et al. Gabapentin for the symptomatic treatment of painful neuropathy in patients with diabetes mellitus: a randomized controlled trial. *JAMA*. 1998;280(21):1831-1836.
2. Bril V, England J, Franklin GM, et al. Evidence-based guideline: treatment of painful diabetic neuropathy: report of the American Academy of Neurology, the American Association of Neuromuscular and Electrodiagnostic Medicine, and the American Academy of Physical Medicine and Rehabilitation. *Neurology*. 2011;76(20):1758-1765.
3. Freeman R, Durso-Decruz E, Emir B. Efficacy, safety, and tolerability of pregabalin treatment for painful diabetic peripheral neuropathy: findings from seven randomized, controlled trials across a range of doses. *Diabetes Care*. 2008;31(7):1448-1454.
4. Moore RA, Straube S, Wiffen PJ, Derry S, McQuay HJ. Pregabalin for acute and chronic pain in adults. *Cochrane Database Syst Rev*. 2009;(3):CD007076.
5. Wiffen PJ, Derry S, Bell RF, et al. Gabapentin for chronic neuropathic pain in adults. *Cochrane Database Syst Rev*. 2017;(6):CD007938.
6. Kajdasz DK, Iyengar S, Desaiah D, et al. Duloxetine for the management of diabetic peripheral neuropathic pain: evidence-based findings from post hoc analysis of three multicenter, randomized, double-blind, placebo-controlled, parallel-group studies. *Clin Ther*. 2007;29 suppl:2536-2546.
7. Aiyer R, Barkin RL, Bhatia A. Treatment of neuropathic pain with venlafaxine: a systematic review. *Pain Med*. 2017;18(10):1999-2012.
8. Max MB, Culnane M, Schafer SC, et al. Amitriptyline relieves diabetic neuropathy pain in patients with normal or depressed mood. *Neurology*. 1987;37(4):589-596.
9. Max MB, Lynch SA, Muir J, Shoaf SE, Smoller B, Dubner R. Effects of desipramine, amitriptyline, and fluoxetine on pain in diabetic neuropathy. *N Engl J Med*. 1992;326(19):1250-1256.
10. Rowbotham MC, Reisner LA, Davies PS, Fields HL. Treatment response in antidepressant-naïve postherpetic neuralgia patients: double-blind, randomized trial. *J Pain*. 2005;6(11):741-746.
11. Binder A, Bruxelle J, Rogers P, Hans G, Bösl I, Baron R. Topical 5% lidocaine (lignocaine) medicated plaster treatment for post-herpetic neuralgia: results of a double-blind, placebo-controlled, multinational efficacy and safety trial. *Clin Drug Investig*. 2009;29(6):393-408.
12. Meier T, Wasner G, Faust M, et al. Efficacy of lidocaine patch 5% in the treatment of focal peripheral neuropathic pain syndromes: a randomized, double-blind, placebo-controlled study. *Pain*. 2003;106(1-2):151-158.
13. Cruccu G, Gronseth G, Alksne J, et al. AAN-EFNS guidelines on trigeminal neuralgia management. *Eur J Neurol*. 2008;15(10):1013-1028.
14. Gronseth G, Cruccu G, Alksne J, et al. Practice parameter: the diagnostic evaluation and treatment of trigeminal neuralgia (an evidence-based review): report of the Quality Standards Subcommittee of the American Academy of Neurology and the European Federation of Neurological Societies. *Neurology*. 2008;71(15):1183-1190.
15. Backonja M, Wallace MS, Blonsky ER, et al; for NGX-4010 C116 Study Group. NGX-4010, a high-concentration capsaicin patch, for the treatment of postherpetic neuralgia: a randomised, double-blind study. *Lancet Neurol*. 2008;7(12):1106-1112.
16. Derry S, Rice AS, Cole P, Tan T, Moore RA. Topical capsaicin (high concentration) for chronic neuropathic pain in adults. *Cochrane Database Syst Rev*. 2017;(1):CD007393.
17. Duhmke RM, Cornblath DD, Hollingshead JRF. Tramadol for neuropathic pain. *Cochrane Database Syst Rev*. 2004;(2):CD003726.

SUGGESTED READINGS

Aiyer R, Mehta N, Gungor S, Gulati A. A systematic review of NMDA receptor antagonists for treatment of neuropathic pain in clinical practice. *Clin J Pain*. 2018;34:450-467.

Amir R, Kocsis JD, Devor M. Multiple interacting sites of ectopic spike electrogenesis in primary sensory neurons. *J Neurosci*. 2005;25:2576-2585.

Argoff CE, Cole BE, Fishbain DA, Irving GA. Diabetic peripheral neuropathic pain: clinical and quality-of-life issues. *Mayo Clin Proc*. 2006;81:S3-S11.

Attal N, Cruccu G, Baron R, et al; for European Federation of Neurological Societies. EFNS guidelines on the pharmacological treatment of neuropathic pain: 2010 revision. *Eur J Neurol*. 2010;17:1113-e88.

Baron R, Maier C, Attal N, et al. Peripheral neuropathic pain: a mechanism-related organizing principle based on sensory profiles. *Pain*. 2017;158:261-272.

Bennett MI, Rayment C, Hjermstad M, Aass N, Caraceni A, Kaasa S. Prevalence and aetiology of neuropathic pain in cancer patients: a systematic review. *Pain*. 2012;153:359-365.

Birse F, Derry S, Moore RA. Phenytoin for neuropathic pain and fibromyalgia in adults. *Cochrane Database Syst Rev*. 2012;(5):CD009485.

Challapalli V, Tremont-Lukats IW, McNicol ED, Lau J, Carr DB. Systemic administration of local anesthetic agents to relieve neuropathic pain. *Cochrane Database Syst Rev*. 2005;(4):CD003345.

Chandra K, Shafiq N, Pandhi P, Gupta S, Malhotra S. Gabapentin versus nortriptyline in post-herpetic neuralgia patients: a randomized, double-blind clinical trial—the GONIP Trial. *Int J Clin Pharmacol Ther*. 2006;44:358-363.

Chaplan SR, Guo H-Q, Lee DH, et al. Neuronal hyperpolarization-activated pacemaker channels drive neuropathic pain. *J Neurosci*. 2003;23:1169-1178.

Coggeshall RE, Lekan HA, White FA, Woolf CJ. A-fiber sensory input induces neuronal cell death in the dorsal horn of the adult rat spinal cord. *J Comp Neurol*. 2001;435:276-282.

Collins S, Sigtermans MJ, Dahan A, Zuurmond WWA, Perez RSGM. NMDA receptor antagonists for the treatment of neuropathic pain. *Pain Med*. 2010;11:1726-1742.

Colloca L, Ludman T, Bouhassira D, et al. Neuropathic pain. *Nat Rev Dis Primers*. 2017;3:17002.

Costigan M, Scholz J, Woolf CJ. Neuropathic pain: a maladaptive response of the nervous system to damage. *Annu Rev Neurosci*. 2009;32:1-32.

Cui M, Feng Y, McAdoo DJ, Willis WD. Periaqueductal gray stimulation-induced inhibition of nociceptive dorsal horn neurons in rats is associated with the release of norepinephrine, serotonin, and amino acids. *J Pharmacol Exp Ther*. 1999;289:868-876.

Davies M, Brophy S, Williams R, Taylor, A. The prevalence, severity, and impact of painful diabetic peripheral neuropathy in type 2 diabetes. *Diabetes Care*. 2006;29:1518-1522.

Demant DT, Lund K, Vollert J, et al. The effect of oxcarbazepine in peripheral neuropathic pain depends on pain phenotype: a randomised, double-blind, placebo-controlled phenotype-stratified study. *Pain*. 2014;155:2263-2273.

DiBonaventura MD, Sadosky A, Concialdi K, et al. The prevalence of probable neuropathic pain in the US: results from a multimodal general-population health survey. *J Pain Res*. 2017;10:2525-2538.

Eccleston C, Hearn L, Williams AC. Psychological therapies for the management of chronic neuropathic pain in adults. *Cochrane Database Syst Rev*. 2015;(10):CD011259.

Finnerup NB, Attal N, Haroutounian S, et al. Pharmacotherapy for neuropathic pain in adults: a systematic review and meta-analysis. *Lancet Neurol*. 2015;14:162-173.

Finnerup NB, Haroutounian S, Kamerman P, et al. Neuropathic pain: an updated grading system for research and clinical practice. *Pain*. 2016;157:1599-1606.

Freynhagen R, Baron R, Gockel U, Tölle TR. painDETECT: a new screening questionnaire to identify neuropathic components in patients with back pain. *Curr Med Res Opin*. 2006;22:1911-1920.

Geneen LJ, Moore RA, Clarke C, Martin D, Colvin LA, Smith BH. Physical activity and exercise for chronic pain in adults: an overview of Cochrane Reviews. *Cochrane Database Syst Rev*. 2017;(1):CD011279.

Gill D, Derry S, Wiffen PJ, Moore RA. Valproic acid and sodium valproate for neuropathic pain and fibromyalgia in adults. *Cochrane Database Syst Rev*. 2011;(10):CD009183.

Gimbel JS, Richards P, Portenoy RK. Controlled-release oxycodone for pain in diabetic neuropathy: a randomized controlled trial. *Neurology*. 2003;60:927-934.

Hearn L, Derry S, Moore RA. Lacosamide for neuropathic pain and fibromyalgia in adults. *Cochrane Database Syst Rev*. 2012;(2):CD009318.

Hendrich J, Van Minh AT, Heblich F, et al. Pharmacological disruption of calcium channel trafficking by the $\alpha_2\delta$ ligand gabapentin. *Proc Natl Acad Sci U S A*. 2008;105:3628-3633.

Herrero JF, Laird JM, López-García JA. Wind-up of spinal cord neurones and pain sensation: much ado about something? *Prog Neurobiol*. 2000;61:169-203.

Hudson LJ, Bevan S, Wotherspoon G, Gentry C, Fox A, Winter J. VR_1 protein expression increases in undamaged DRG neurons after partial nerve injury. *Eur J Neurosci*. 2001;13:2105-2114.

Jarvis B, Coukell AJ. Mexiletine. A review of its therapeutic use in painful diabetic neuropathy. *Drugs*. 1998;56:691-707.

Jiang YQ, Xing GG, Wang SL, et al. Axonal accumulation of hyperpolarization-activated cyclic nucleotide-gated cation channels contributes to mechanical allodynia after peripheral nerve injury in rat. *Pain*. 2008;137:495-506.

Liu C-N, Devor M, Waxman SG, Kocsis JD. Subthreshold oscillations induced by spinal nerve injury in dissociated muscle and cutaneous afferents of mouse DRG. *J Neurophysiol*. 2002;87:2009-2017.

Li C-Y, Song Y-H, Higuera ES, Luo ZD. Spinal dorsal horn calcium channel $\alpha_2\delta$-1 subunit upregulation contributes to peripheral nerve injury-induced tactile allodynia. *J Neurosci*. 2004;24:8494-8499.

Luo ZD, Chaplan SR, Higuera ES, et al. Upregulation of dorsal root ganglion $\alpha_2\delta$ calcium channel subunit and its correlation with allodynia in spinal nerve-injured rats. *J Neurosci*. 2001;21:1868-1875.

Mijnhout GS, Alkhalaf A, Kleefstra N, Bilo HJG. Alpha lipoic acid: a new treatment for neuropathic pain in patients with diabetes? *Neth J Med*. 2010;68:158-162.

Moore KA, Kohno T, Karchewski LA, Scholz J, Baba H, Woolf CJ. Partial peripheral nerve injury promotes a selective loss of GABAergic inhibition in the superficial dorsal horn of the spinal cord. *J Neurosci*. 2002;22:6724-6731.

Morley JS, Bridson J, Nash TP, Miles JB, White S, Makin MK. Low-dose methadone has an analgesic effect in neuropathic pain: a double-blind randomized controlled crossover trial. *Palliat Med*. 2003;17:576-587.

Moulin D, Boulanger A, Clark AJ, et al. Pharmacological management of chronic neuropathic pain: revised consensus statement from the Canadian Pain Society. *Pain Res Manag*. 2014;19:328-335.

Moulin DE, Clark AJ, Gordon A, et al. Long-term outcome of the management of chronic neuropathic pain: a prospective observational study. *J Pain*. 2015;16:852-861.

Mücke M, Phillips T, Radbruch L, Petzke F, Häuser W. Cannabis-based medicines for chronic neuropathic pain in adults. *Cochrane Database Syst Rev*. 2018;(3):CD012182.

Murnion BP. Neuropathic pain: current definition and review of drug treatment. *Aust Prescr*. 2018;41:60-63.

Otto M, Bach FW, Jensen TS, Brøsen K, Sindrup SH. Escitalopram in painful polyneuropathy: a randomized, placebo-controlled, cross-over trial. *Pain*. 2008;139:275-283.

Pabbidi RM, Yu S-Q, Peng S, Khardori R, Pauza ME, Premkumar LS. Influence of $TRPV_1$ on diabetes-induced alterations in thermal pain sensitivity. *Mol Pain*. 2008;4:9.

Passmore GM, Selyanko AA, Mistry M, et al. KCNQ/M currents in sensory neurons: significance for pain therapy. *J Neurosci*. 2003;23:7227-7236.

Pathan H, Williams J. Basic opioid pharmacology: an update. *Br J Pain*. 2012;6:11-16.

Rowbotham MC, Twilling L, Davies PS, Reisner L, Taylor K, Mohr D. Oral opioid therapy for chronic peripheral and central neuropathic pain. *N Engl J Med*. 2003;348:1223-1232.

Schoffnegger D, Ruscheweyh R, Sandkühler J. Spread of excitation across modality borders in spinal dorsal horn of neuropathic rats. *Pain*. 2008;135(3):300-310.

Semenchuk MR, Sherman S, Davis B. Double-blind, randomized trial of bupropion SR for the treatment of neuropathic pain. *Neurology*. 2001;57:1583-1588.

Suzuki R, Kontinen VK, Matthews E, Williams E, Dickenson AH. Enlargement of the receptive field size to low intensity mechanical stimulation in the rat spinal nerve ligation model of neuropathy. *Exp Neurol*. 2000;163:408-413.

Takaishi K, Eisele JH Jr, Carstens E. Behavioral and electrophysiological assessment of hyperalgesia and changes in dorsal horn responses following partial sciatic nerve ligation in rats. *Pain*. 1996;66:297-306.

Taylor CP. Mechanisms of analgesia by gabapentin and pregabalin—calcium channel alpha2-delta [Cavalpha2-delta] ligands. *Pain*. 2009;142:13-16.

Tulleuda A, Cokic B, Callejo G, Saiani B, Serra J, Gasull X. TRESK channel contribution to nociceptive sensory neurons excitability: modulation by nerve injury. *Mol Pain*. 2011;7:30.

Van Acker K, Bouhassira D, De Bacquer D, et al. Prevalence and impact on quality of life of peripheral neuropathy with or without neuropathic pain in type 1 and type 2 diabetic patients attending hospital outpatients clinics. *Diabetes Metab*. 2009;35:206-213.

Vardeh D, Mannion RJ, Woolf CJ. Toward a mechanism-based approach to pain diagnosis. *J Pain*. 2016;17:T50-T69.

von Hehn CA, Baron R, Woolf CJ. Deconstructing the neuropathic pain phenotype to reveal neural mechanisms. *Neuron*. 2012;73:638-652.

Wager TD, Atlas LY, Lindquist MA, Roy M, Woo C-W, Kross E. An fMRI-based neurologic signature of physical pain. *N Engl J Med*. 2013;368:1388-1397.

Watson CP, Vernich L, Chipman M, Reed K. Nortriptyline versus amitriptyline in postherpetic neuralgia: a randomized trial. *Neurology* 1998;51:1166-1171.

White CM, Pritchard J, Turner-Stokes L. Exercise for people with peripheral neuropathy. *Cochrane Database Syst Rev*. 2004;(4):CD003904.

Wiffen PJ, Derry S, Lunn MPT, Moore RA. Topiramate for neuropathic pain and fibromyalgia in adults. *Cochrane Database Syst Rev*. 2013;(8):CD008314.

Wiffen PJ, Derry S, Moore RA. Lamotrigine for chronic neuropathic pain and fibromyalgia in adults. *Cochrane Database Syst Rev*. 2013;(12):CD006044.

Wiffen PJ, Derry S, Moore RA, Kalso EA. Carbamazepine for chronic neuropathic pain and fibromyalgia in adults. *Cochrane Database Syst Rev*. 2014;(4):CD005451.

Wiffen PJ, Derry S, Moore RA, Lunn MPT. Levetiracetam for neuropathic pain in adults. *Cochrane Database Syst Rev*. 2014;(7):CD010943.

Wolff M, Czorlich P, Nagaraj C, et al. Amitriptyline and carbamazepine utilize voltage-gated ion channel suppression to impair excitability of sensory dorsal horn neurons in thin tissue slice: an in vitro study. *Neurosci Res*. 2016;109:16-27.

Woolf CJ, Shortland P, Coggeshall RE. Peripheral nerve injury triggers central sprouting of myelinated afferents. *Nature*. 1992;355:75-78.

Wu G, Ringkamp M, Murinson BB, et al. Degeneration of myelinated efferent fibers induces spontaneous activity in uninjured C-fiber afferents. *J Neurosci*. 2002;22:7746-7753.

Yekkirala AS, Roberson DP, Bean BP, Woolf CJ. Breaking barriers to novel analgesic drug development. *Nat Rev Drug Discov*. 2017;16:545-564.

Yelland MJ, Poulos CJ, Pillans PI, et al. N-of-1 randomized trials to assess the efficacy of gabapentin for chronic neuropathic pain. *Pain Med*. 2009;10:754-761.

Zhou M, Chen N, He L, Yang M, Zhu C, Wu F. Oxcarbazepine for neuropathic pain. *Cochrane Database Syst Rev*. 2017;(12):CD007963.

Classification of Seizures and Epilepsy 60

Shraddha Srinivasan and Carl W. Bazil

KEY POINTS

1. Although seizures are the cardinal manifestation of epilepsy, not all seizures imply epilepsy.
2. Antiseizure prophylaxis is strongly recommended for a single unprovoked seizure accompanied by a significant magnetic resonance imaging abnormality and/or epileptiform EEG features.
3. Epilepsy syndrome identification aids in determining the cause of the epilepsy, its prognosis, and selection of appropriate antiseizure medication.
4. Frontal lobe seizures can involve bizarre hypermotor behaviors, vocalizations, and gesticulations that can be misdiagnosed as psychogenic nonepileptic seizures.
5. The new International League Against Epilepsy classification system recognizes two new categories: "combined generalized and focal epilepsy" and "unknown epilepsy."

INTRODUCTION

An epileptic seizure is the result of a temporary physiologic dysfunction of the brain caused by an abnormal, self-limited, and hypersynchronous electrical discharge of cortical neurons. There are many different kinds of seizures, each with characteristic behavioral changes and electrophysiologic disturbances that can usually be detected with scalp electroencephalography (EEG) recordings. The particular manifestations of any single seizure depend on several factors: whether most or only a part of the cerebral cortex is involved at the beginning, the functions of the cortical areas where the seizure originates, the subsequent pattern of spread of the electrical ictal discharge within the brain, and the extent to which subcortical and brainstem structures are engaged.

Although seizures are the cardinal manifestation of epilepsy, not all seizures imply epilepsy. Acute symptomatic seizures refer to seizures that occur only during the course of an acute medical or neurologic illness such as metabolic disarray or drug intoxication; they usually do not persist after the underlying disorder has resolved. Some people, for no discoverable reason, have a single unprovoked seizure. These seizures are not consistent with epilepsy.

Epilepsy is a chronic disorder, or group of chronic disorders, in which the indispensable feature is recurrence of seizures that are typically unprovoked and usually unpredictable. Each distinct form of epilepsy has its own natural history and response to treatment. This diversity presumably reflects the fact that epilepsy can arise from a variety of underlying conditions and pathophysiologic mechanisms.

The operational definition of epilepsy proposed by the International League Against Epilepsy (ILAE) is that it is a chronic disease of the brain defined by any of the following conditions:

1. At least two unprovoked (or reflex) seizures occurring more than 24 hours apart
2. One unprovoked (or reflex) seizure and a probability of further seizures similar to the general recurrence risk (at least 60%) after two unprovoked seizures, occurring over the next 10 years
3. Diagnosis of an epilepsy syndrome (see "Epilepsy Syndromes" ahead)

Reflex epilepsy is the condition of provoked reflex seizures (eg, to photic stimuli) that are recurrent. They can be focal, such as musicogenic epilepsy with temporal lobe seizures and visual seizures of photosensitive occipital lobe epilepsy, or generalized in onset. Patients with reflex epilepsy can have spontaneous seizures too, but very frequently have a precipitating factor for their seizures.

Each distinct form of epilepsy has its own natural history and response to treatment. This diversity presumably reflects the fact that epilepsy can arise from a variety of underlying conditions and pathophysiologic mechanisms, although most cases are classified as idiopathic (of presumed genetic origin).

EPIDEMIOLOGY

More than 50 million people worldwide have epilepsy, making it one of the most common neurologic diseases globally. An estimated proportion of the general population with active epilepsy (ie, continuing seizures or with the need for treatment) at a given time is between 4 and 10 per 1,000 people (https://www.who.int/news-room/fact-sheets/detail/epilepsy).

The annual incidence rates for epilepsy in the United States is estimated at 150,000 or 48 for every 100,000 people. Based on 1990 census figures, age-adjusted annual incidence rates for epilepsy range from 31 to 57 per 100,000 in the United States (Fig. 60.1). Incidence rates are highest among young children and the elderly.

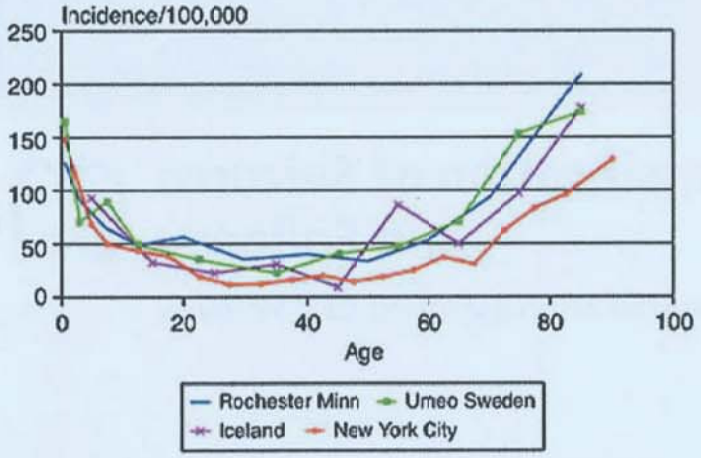

FIGURE 60.1 Age-specific incidence of epilepsy in Rochester, Minnesota, 1935-1984. (From Hauser WA, Annegers JF, Kurland LT. Incidence of epilepsy and unprovoked seizures in Rochester, Minnesota: 1935-1984. *Epilepsia*. 1993;34[3]:453-468.)

Focal impaired awareness seizures (previously called *complex partial seizures*) are the most common seizure type among newly diagnosed cases, but age-related variability occurs in the proportions of different seizure types (Fig. 60.2). The cause of epilepsy also varies somewhat with age. Despite advances in diagnostic capabilities, however, the "unknown" etiologic category remains larger than any other for all age groups (Fig. 60.3). Cerebrovascular disease, associated developmental neurologic disorders (eg, cerebral palsy and mental retardation), and head trauma are the other most commonly identified causes.

Although defined genetic disorders account for only about 1% of epilepsy cases, heritable factors are important. Monozygotic twins have a much higher concordance rate for epilepsy than do dizygotic twins. By age 25 years, nearly 9% of children of mothers with epilepsy and 2.4% of children of affected fathers develop epilepsy. The reason for an increased risk of seizures in children of women with epilepsy is not known.

Some forms of epilepsy are more heritable than others. For example, children of parents with absence seizures have a higher risk of developing epilepsy (9%) than do offspring of parents with other types of generalized seizures or focal seizures (5%). As a general rule though, even offspring born to a high-risk parent have a 90% or greater chance of being unaffected by epilepsy.

Many persons who experience a first unprovoked seizure never have a second. By definition, these people do not have epilepsy and generally do not require long-term drug treatment. Unfortunately, our ability to identify such individuals with accuracy is imperfect. Treatment decisions must be based on epidemiologic and individual considerations. Some seizure types, such as absence and myoclonic, are virtually always recurrent by the time the patient is seen by a physician. On the other hand, patients with convulsive seizures may seek medical attention after a first occurrence because of the dramatic nature of the episode. Prospective studies of recurrence after a first seizure indicate a 2-year recurrence risk of about 40%, which is similar in children and adults. The risk is lowest in people with an idiopathic generalized first seizure and normal EEG (about 24%), higher with idiopathic generalized seizures and an abnormal EEG (about 48%), and highest with symptomatic (ie, known preceding brain injury or neurologic syndrome) seizures and an abnormal EEG (about 65%). Epileptiform, but not nonepileptiform, EEG abnormalities impart a greater risk for recurrence. Additionally, if the first seizure is a focal seizure or a nocturnal seizure, the relative risk of recurrence is also increased. The risk for further recurrence after a second unprovoked seizure is greater than 80%; a second unprovoked seizure is, therefore, a reliable marker of epilepsy.

The American Academy of Neurology and the American Epilepsy Society evidence-based guidelines for the counseling and management of a first unprovoked seizure are summarized in the following text LEVEL 1.[1]

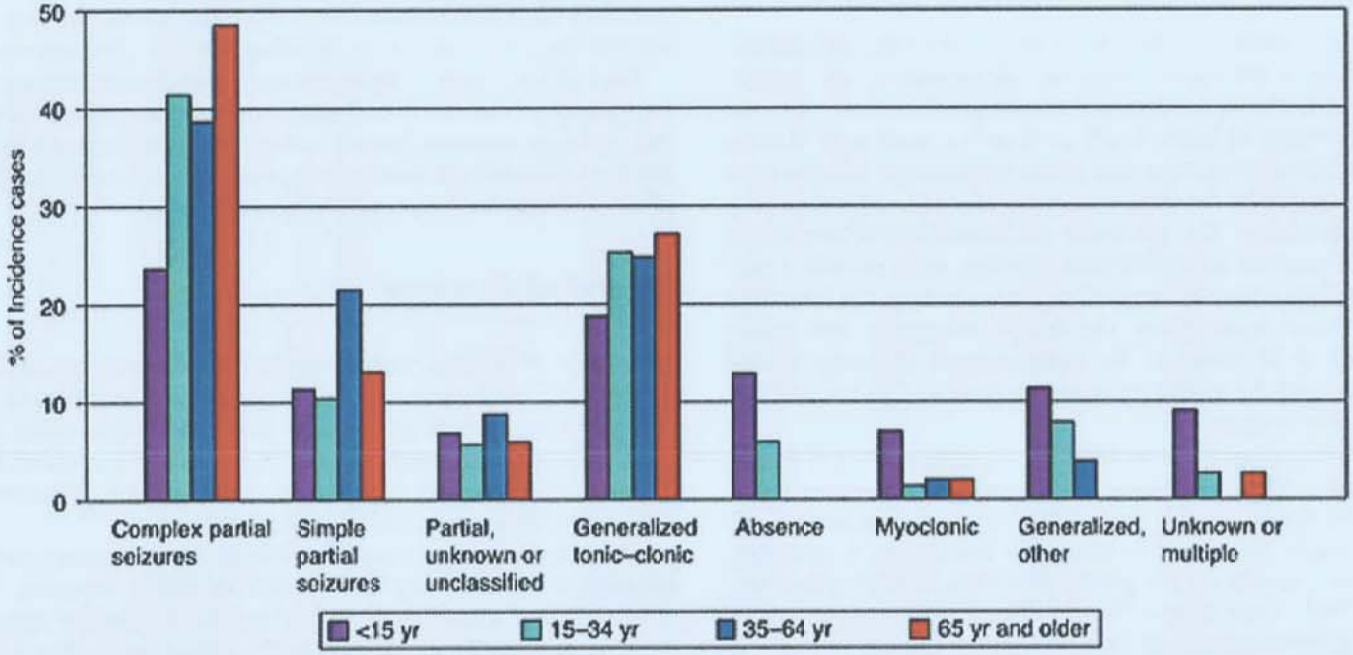

FIGURE 60.2 Proportion of seizure types in newly diagnosed cases of epilepsy in Rochester, Minnesota, 1935-1984. (From Hauser WA, Annegers JF, Kurland LT. Incidence of epilepsy and unprovoked seizures in Rochester, Minnesota: 1935-1984. *Epilepsia*. 1993;34[3]:453-468.)

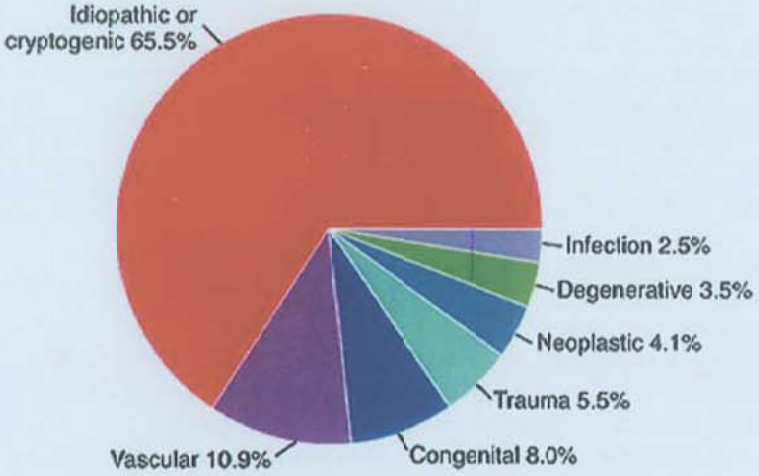

FIGURE 60.3 Etiology of epilepsy in all cases of newly diagnosed seizures in Rochester, Minnesota, 1935-1984. (From Hauser WA, Annegers JF, Kurland LT. Incidence of epilepsy and unprovoked seizures in Rochester, Minnesota: 1935-1984. *Epilepsia*. 1993;34[3]:453-468.)

Adults presenting with an unprovoked first seizure should be informed that the chance for a recurrent seizure is greatest within the first 2 years after a first seizure (21%-45%). Patients should be advised that clinical factors associated with an increased risk for seizure recurrence include a prior brain insult such as a stroke or trauma, an EEG with epileptiform abnormalities, a significant brain imaging abnormality, or a nocturnal seizure. Clinicians should advise patients that although immediate antiseizure medication therapy, as compared with delay of treatment pending a second seizure, is likely to reduce the risk for a seizure recurrence in the 2 years subsequent to a first seizure, it may not improve quality of life. Patients should be advised that over the longer term (>3 y), immediate antiepileptic drug (AED) treatment is unlikely to improve the prognosis for sustained seizure remission. Additionally, their risk for medication-related adverse effects ranges from 7% to 31% and that these adverse effects are predominantly mild and reversible.

About 4% of persons living to age 74 years have at least one unprovoked seizure. When provoked seizures (ie, febrile seizures or those related to an acute illness) are included, the likelihood of experiencing a seizure by age 74 years increases to at least 9%. The risk of developing epilepsy is about 3% by age 74 years.

Of persons with epilepsy, 60% to 70% achieve remission of seizures with AED therapy. Factors that favor remission include an idiopathic form of epilepsy, normal findings on neurologic examination, and onset in early to middle childhood (except neonatal seizures). Unfavorable prognostic factors include focal seizures, an abnormal EEG, an abnormal neurologic examination, and associated mental retardation or cerebral palsy (Table 60.1). Those who fail to achieve remission have drug-resistant epilepsy and may be candidates for alternative therapies, including surgery, devices or dietary therapies. Drug-resistant epilepsy is defined by the ILAE as "failure of adequate trials of two tolerated and appropriately used antiepileptic drugs to achieve sustained seizure freedom."

Mortality is increased in persons with epilepsy, but the risk is incurred mainly by symptomatic cases in which higher death rates are related primarily to the underlying disease rather than to epilepsy. Accidental deaths, especially drowning, are not uncommon, however, in all patients with epilepsy. Sudden unexplained death is nearly 25 times more common in patients with epilepsy than in the general population; estimates of incidence rates range from 1 in 500 to 1 in 2,000 per year in adults and 1 in 4,500 per year in children with epilepsy LEVEL 2.[2] Severe epilepsy, uncontrolled generalized convulsions, especially nocturnal, and need for multiple antiseizure medications are risk factors.

TABLE 60.1 Predictors of Intractable Epilepsy

Very young at onset (<2 y)
Frequent generalized seizures
Failure to achieve control readily
Evidence of brain damage
A specific cause of the seizures
Severe EEG abnormality
Low IQ
Presence of atonic seizures or atypical absence seizures

Abbreviation: EEG, electroencephalogram.

Gene Mutations in Epilepsy

Twin and population studies have supported a genetic contribution in both focal and generalized epilepsies. The concordance rate for monozygotic twins with idiopathic generalized epilepsy is well over 75%. Epilepsies resulting from pathogenic variants in single genes are rare, however, and include familial epilepsies with Mendelian inheritance and sporadic epilepsies associated with neurodevelopmental disability. The last 25 years have identified a number of genes responsible for these rare epilepsies. Moreover, it is increasingly recognized that focal epilepsies with (and even without) cortical malformations may be associated with somatic mosaicism, resulting from postzygotic mutations arising during development. The relationship between genotype and phenotype is complex with genetic heterogeneity (ie, one syndrome having multiple genetic causes) and phenotypic heterogeneity (ie, one gene manifesting with different phenotypes). Genetic testing includes cytogenetic approaches to evaluate copy number variation as well as sequencing approaches to investigate more discrete changes. The benefits of testing include termination of the diagnostic odyssey and in a growing number of situations, precision medicine approaches targeting the underlying pathology; for example, ketogenic diet for Glut1 deficiency syndrome caused by pathogenic variants in *SLC2A1* and pyridoxine (vitamin B_6) for pyridoxine-dependent epilepsy, a recessive condition caused by mutations in the *ALDH7A1* gene.

Examples of causative genes that have been identified in epilepsies with Mendelian inheritance include *KCNQ2* and *KCNQ3*, voltage-gated potassium channel genes associated with benign familial neonatal epilepsy; *CHRNA4* and *CHRNB2*, nicotinic acetylcholine receptor subunits associated with autosomal dominant nocturnal frontal lobe epilepsy; *SCN1A*, a voltage-gated sodium channel associated with genetic epilepsy with febrile seizures; *LGI1*, leucine-rich glioma inactivated 1, associated with autosomal dominant epilepsy with auditory features; and *DEPDC5*, associated with familial focal epilepsy with variable foci. For further details on genetics of epileptic disorders, refer to Chapter 143.

CLASSIFICATIONS OF SEIZURES AND EPILEPSY

Accurate classification of seizures and epilepsy is essential for understanding epileptic phenomena, developing a rational plan of investigation, making decisions about when and for how long to treat, choosing the appropriate AED, and conducting scientific investigations that require delineation of clinical and EEG phenotypes.

Classification of Seizures

The initial events of a seizure, described by either the patient or an observer, are usually the most reliable clinical indication to determine whether a seizure begins focally or is generalized from the moment of onset. Sometimes, however, a focal signature is lacking for several possible reasons:

1. The patient may be amnesic after the seizure, with no memory of early events.
2. Consciousness may be impaired so quickly or the seizure may generalize so rapidly that early distinguishing features are blurred or lost.
3. The seizure may originate in a brain region that is not associated with an obvious behavioral function. Thus, the seizure becomes clinically evident only when the discharge spreads beyond the ictal-onset zone or becomes generalized.

Additionally, generalized onset seizures can have focal features such as versive head turn; asymmetry or asynchrony in the clonic phase of a generalized tonic-clonic seizure; an episode of typical absence preceding a generalized tonic-clonic seizure, which can be misinterpreted as an aura or a complex partial seizure; as well as focal EEG abnormalities such as only fragments of a generalized spike wave.

The prior and current ILAE classification systems attempt to group seizures according to onset and clinical presentation and to group epilepsies according to seizure type, age of onset, probability of remission, EEG findings, radiologic findings, and genetics. Beginning in 2010, the term *focal seizure* officially replaced *partial seizure*. The new classification addresses some limitations of the 1981 seizure classification. Some seizures can have either focal or generalized onset such as tonic-clonic seizures, an unknown onset of a seizure, that makes it unclassifiable and difficult to place within the 1981 system; terms such as *complex partial* and *simple partial seizures* are difficult to understand and explain; and some seizure types such as myoclonic-atonic seizures and eyelid myoclonia were not included in the 1981 classification.

Focal Seizures

Focal seizures are further classified according to (1) the level of awareness, (2) the first and most prominent motor or nonmotor feature of the seizure, and (3) whether the focal seizure evolves to a bilateral tonic-clonic seizure. The term *secondary generalized tonic-clonic seizure* is now replaced by *focal to bilateral tonic-clonic seizure*. For instance, if a patient presents with an aura of deja vu followed by losing awareness and witnessed lip smacking, the seizure type is classified as focal impaired awareness seizure with automatisms. If the seizure involves tonic-clonic activity with no focal signature witnessed or reported by the patient, such as an aura or a focal clonic jerk, the seizure would be classified as unknown onset seizure with bilateral tonic-clonic activity. As previously mentioned, the term simple partial seizure is now replaced by focal aware seizure, and the term complex partial seizure is replaced by focal impaired awareness seizure.

Focal aware seizures result when the ictal discharge occurs in a limited and often circumscribed area of cortex. Almost any symptom or phenomenon can be the subjective (aura) or observable manifestation of a focal aware seizure, varying from elementary motor (jacksonian seizures, adversive seizures) and unilateral sensory disturbance to complex emotional, psychoillusory, hallucinatory, or dysmnesic phenomena. Especially common auras include an epigastric rising sensation, fear, a feeling of unreality or detachment, déjà vu (a familiar feeling) and jamais vu (feeling of unfamiliarity) experiences, and olfactory hallucinations. Patients can interact normally with the environment during focal aware seizures except for limitations imposed by the seizure on specific localized brain functions, such as aphasia during a dominant temporal lobe seizure, which could be confused for lack of awareness due to the patient's inability to speak.

Motor manifestations include automatisms; epileptic spasms; and atonic, clonic, hyperkinetic, myoclonic, or tonic movements. Automatisms are coordinated, purposeless, repetitive motor activities that may appear normal in other circumstances. Examples include oral automatisms such as lip smacking and manual automatisms including repetitive hand movements. Of note, automatisms can also be seen in absence seizures, which are discussed later.

Focal impaired awareness seizures, on the other hand, are defined by impaired consciousness and imply further spread of the seizure discharge at least to basal forebrain and limbic areas. In addition to impaired awareness, patients with these seizures usually exhibit automatisms, such as lip smacking, repeated swallowing, clumsy perseveration of an ongoing motor task, or some other complex motor activity that is purposeless. Postictally, patients are confused and disoriented for several minutes, and determining the transition from ictal to postictal state may be difficult without simultaneous EEG recording. Of focal impaired awareness seizures, 70% to 80% arise from the temporal lobe; foci in the frontal and occipital lobes account for most of the remainder.

Generalized Seizures

The new classification includes a few additional types of seizures in this category. The presence or absence of predominant motor activity further classifies these seizures (**Fig. 60.4**). Predominantly, motor seizure types are further classified as tonic, clonic, tonic-clonic, myoclonic, atonic, myoclonic-tonic-clonic, myoclonic-atonic, and epileptic spasms.

Generalized tonic-clonic seizures (▶ **Video 60.1**) are characterized by abrupt loss of consciousness with bilateral tonic extension of the trunk and limbs (*tonic phase*), often accompanied by a loud vocalization as air is forcedly expelled across contracted vocal cords (*epileptic cry*), followed by synchronous muscle jerking (*clonic phase*). Postictally, patients are briefly unarousable and then lethargic and confused, often preferring to sleep. Many patients report inconsistent nonspecific premonitory symptoms (*epileptic prodrome*) for minutes to a few hours before a generalized tonic-clonic seizure. Common symptoms include ill-defined anxiety, irritability, decreased concentration, and headache or other uncomfortable feelings; these are not auras. *Myoclonic* seizures are characterized by rapid brief muscle jerks that can occur bilaterally, synchronously or asynchronously, or unilaterally. Myoclonic jerks range from isolated small movements of face, arm, or leg muscles to massive bilateral jerks simultaneously affecting the head, limbs, and trunk.

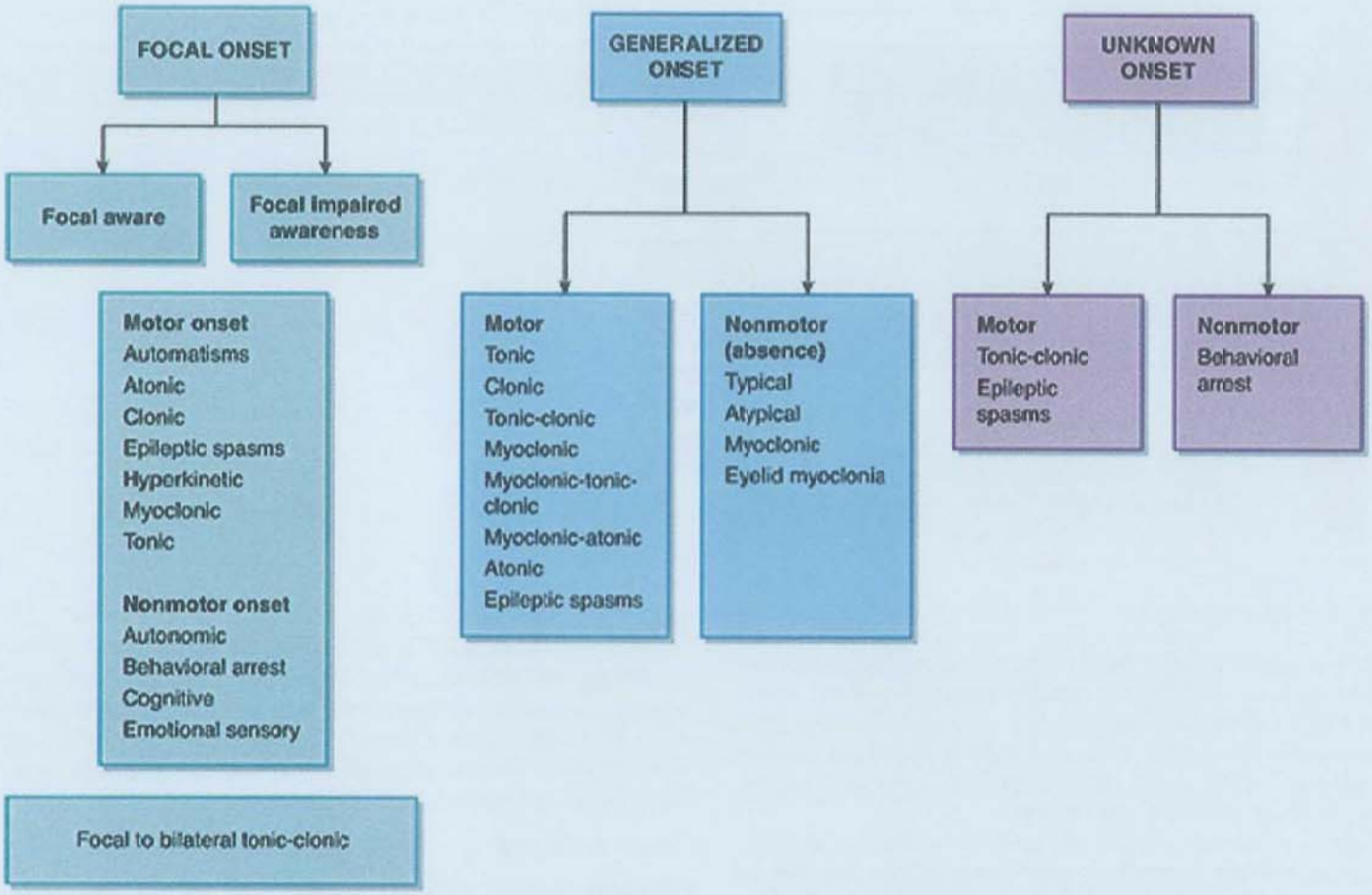

FIGURE 60.4 International League Against Epilepsy classification of seizure types. (From Fisher RS, Cross JH, D'Souza C, et al. Instruction manual for the ILAE 2017 operational classification of seizure types. *Epilepsia*. 2017;58[4]: 531-542. doi:10.1111/epi.13671.)

Atonic seizures (▷ Video 60.2), also called *drop attacks*, are characterized by sudden loss of muscle tone, which may be fragmentary (eg, head drop) or generalized, resulting in a fall. The term *astatic seizure* is now no longer in use.

Myoclonic-atonic seizures are atonic seizures that are preceded by a brief myoclonic seizure, resulting in an acceleratory force added to the fall, thereby contributing to the high rate of self-injury with this type of seizure. These seizures are a common characteristic of Doose syndrome.

Epileptic spasms are also brief and typically occur in clusters with flexion at the trunk and flexion or extension of the limbs. As with focal epileptic spasms, an EEG may be needed to distinguish whether the seizure is generalized.

Absence seizures, where the motor component is not predominant, are momentary lapses in awareness that are accompanied by motionless staring and arrest of any ongoing activity. Absence seizures begin and end abruptly; they occur without warning or postictal period. Mild myoclonic jerks of the eyelid or facial muscles, variable loss of muscle tone, and automatisms may accompany longer attacks. When the beginning and end of the seizure are less distinct, or if tonic and autonomic components are included, this is more likely an atypical absence seizure, which has an EEG correlate of slow spike and wave (less than 3 Hz frequency). Atypical absences are seen most often in children with epilepsy who are developmentally delayed or in epileptic encephalopathies, such as the Lennox-Gastaut syndrome (described later in this chapter).

A triad of eyelid myoclonia (eyelid fluttering) with and without absence seizures, eye closure–induced seizures and EEG paroxysms, and photosensitivity is characteristic of Jeavons syndrome, a type of idiopathic generalized epilepsy.

Unknown Onset Seizures

As described earlier, when a clear focal signature is not obtained by history or testing, seizures are classified under this category. They can be further classified as motor (eg, epileptic spasm, tonic-clonic) or nonmotor (eg, behavior arrest) in type.

Classification of Epilepsies

Similar to seizure classification, the epilepsies are classified as generalized or focal.

The new classification system additionally recognizes two new categories: *combined generalized and focal epilepsy* and *unknown epilepsy*. Patients with both focal and generalized onset seizures have electrophysiologic data that may reveal both focal and generalized electrographic findings. The epilepsy type here would conform to a *combined generalized and focal epilepsy*. Some examples include Dravet syndrome and Lennox-Gastaut syndrome.

If the patient's epilepsy is undetermined, it is classified under *unknown epilepsy*. Typically, EEGs or other supporting studies such as magnetic resonance imaging (MRI) and family history are either unavailable or inconclusive (Fig. 60.5).

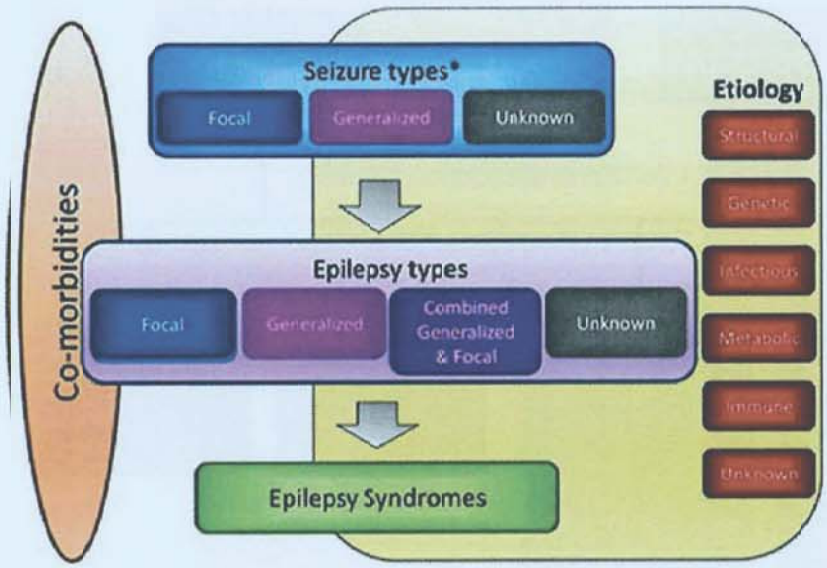

FIGURE 60.5 Framework for classification of the epilepsies. *Denotes onset of seizure. (From Scheffer IE, Berkovic S, Capovilla G, et al. ILAE Classification of the Epilepsies: position paper of the ILAE Commission for Classification and Terminology. *Epilepsia*. 2017;58[4]:512-521. doi:10.1111/epi.13709.)

Generalized Epilepsy

Patients with generalized epilepsy have one or more of the generalized seizure types, and their EEGs typically display generalized spike-wave activity. For individuals who have generalized seizure types and a normal EEG, other data are needed to determine whether the epilepsy is generalized. Having myoclonic jerks supports the diagnosis of a generalized epilepsy type.

Case 1. A 17-year-old girl presented for evaluation after experiencing a single generalized tonic-clonic seizure. Her history revealed that for the past 3 years, she would often have brief intermittent jerks of her arms or legs, typically in the morning. The larger jerks would result in her legs giving way and she would suddenly drop to the ground and feel confused for a split second. She took no medications and had no substance abuse history. Brain MRI was normal, and EEG revealed generalized spike-wave discharges (Fig. 60.6). Despite presenting with a single generalized seizure with no focal features, her history of morning myoclonus and EEG findings indicated that she may have an idiopathic generalized epilepsy syndrome. These findings indicated an at least 60% risk of a second unprovoked seizure within the next 10 years. She was diagnosed with juvenile myoclonic epilepsy (JME) and was initiated on levetiracetam.

Focal Epilepsy

Clinically, patients with one or more focal seizure types have focal epilepsy. Seizures in these epilepsies may arise from one or more than one focus. Although not always present, EEG findings such as focal slowing or focal epileptiform discharges support the diagnosis of focal epilepsy. Concordant focal MRI findings are also supportive.

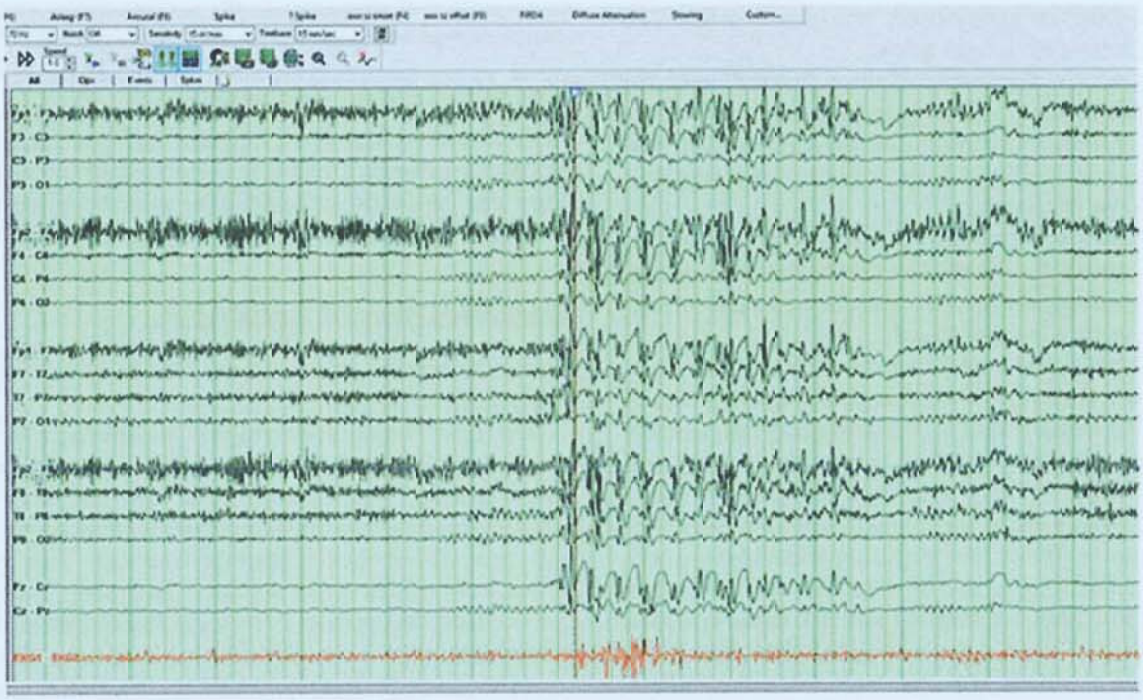

FIGURE 60.6 Electroencephalography in longitudinal bipolar montage demonstrating frontally predominant generalized 3- to 4-Hz epileptiform discharges.

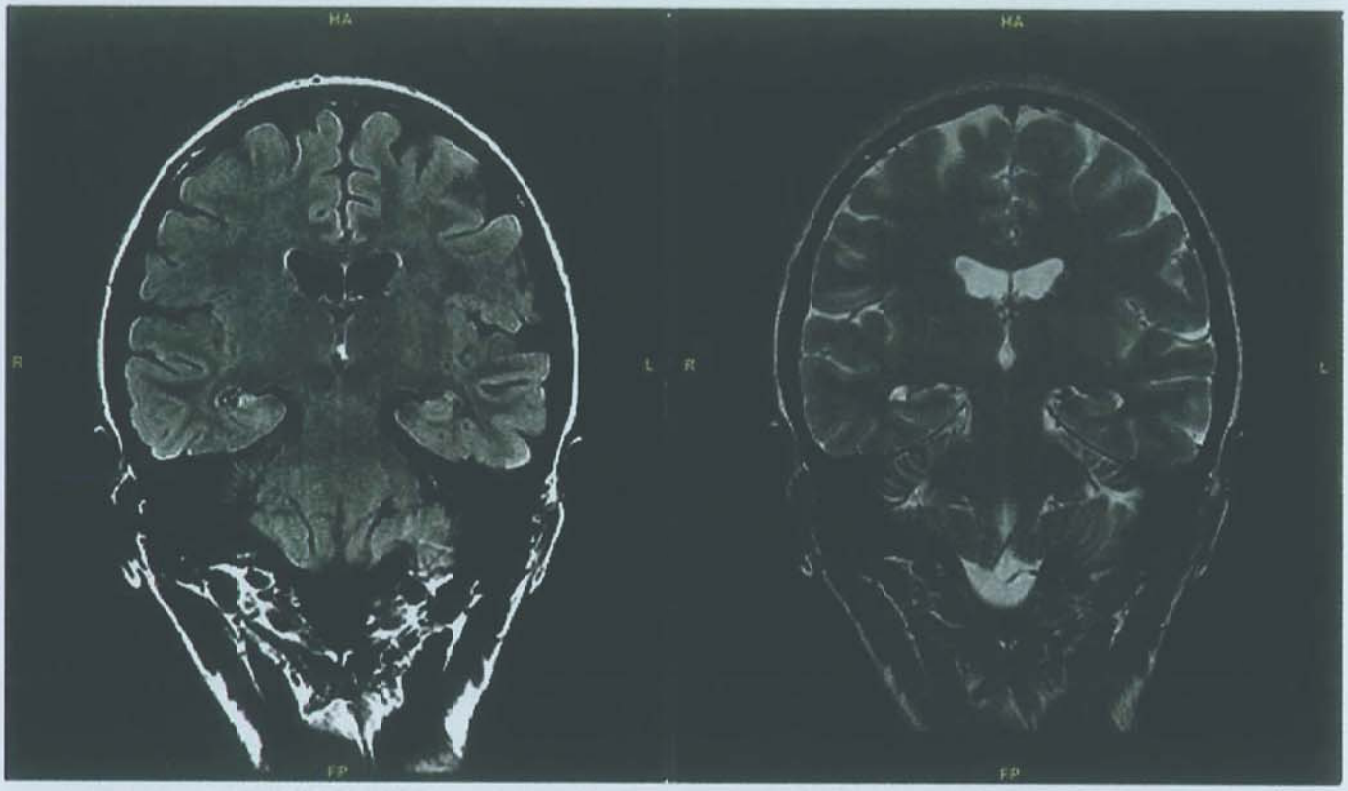

FIGURE 60.7 Brain magnetic resonance imaging coronal fluid-attenuated inversion recovery (FLAIR) and T2-weighted images demonstrating a smaller right hippocampus with increased FLAIR signal.

Temporal Lobe Epilepsy

Case 2. A 27-year-old woman presented with focal seizures with an aura of abdominal discomfort, and a cold sensation that would come over her followed by observed lip smacking and repetitive right hand movements, as well as dystonic posturing of her left hand. She had a prolonged febrile convulsion at age 20 months. Her brain MRI (Fig. 60.7) showed increased fluid-attenuated inversion recovery signal and atrophy of the right hippocampus consistent with mesial temporal sclerosis. The EEG showed epileptiform discharges and focal slowing in the right temporal region (Fig. 60.8). Her epilepsy would be classified as a focal (right temporal lobe) epilepsy, and the seizure type would be focal impaired awareness seizure with automatisms. In this scenario, antiseizure medication should be initiated, and if the seizures continue to occur despite adequate trials of two antiseizure medications, she should be referred to an epilepsy center for an epilepsy surgery work up.

Temporal lobe epilepsy is the most common epilepsy seen in adults. In most cases, the epileptogenic region involves mesial temporal lobe structures, especially the hippocampus,

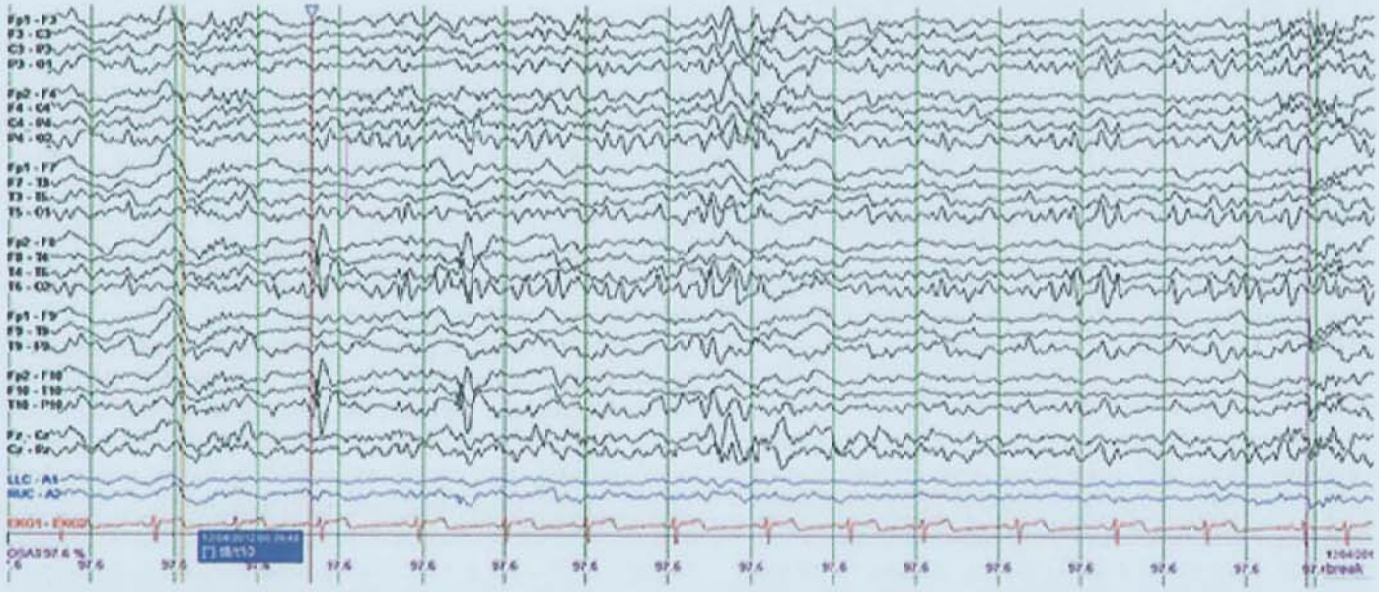

FIGURE 60.8 Electroencephalography in longitudinal bipolar montage demonstrating right anterior temporal epileptiform discharges.

amygdala, and parahippocampal gyrus. Seizures usually begin in late childhood or adolescence, and a history of febrile seizures is common. Virtually all patients have focal impaired awareness seizures, some of which evolve to bilateral tonic-clonic activity. Auras are frequent; visceral sensations are particularly common. Other typical behavioral features include a motionless stare, loss of awareness that may be gradual, and oral-alimentary automatisms, such as lip smacking. Ipsilateral manual automatisms are also common (▶ Video 60.3). A variable but often prolonged period of postictal confusion is the rule. Interictal EEGs show focal temporal slowing and epileptiform sharp waves or spikes over the anterior temporal region. The AEDs are usually successful in suppressing secondarily generalized seizures, but many patients continue to have less severe attacks. When seizures persist, workup for surgical treatment should be undertaken as up to 80% of selected patients will achieve complete seizure freedom (see following chapter).

Frontal Lobe Epilepsy

The particular pattern of the many types of frontal lobe seizures depends on the specific location where the seizure discharge originates and on the pathways subsequently involved in propagation. Despite this variability, the following features, when taken together, suggest frontal lobe epilepsy:

1. Brief seizures that begin and end abruptly with little, if any, postictal period
2. A tendency for seizures to cluster and to occur at night
3. Prominent, but often bizarre, motor manifestations, such as asynchronous thrashing or flailing of arms and legs; pedaling leg movements; pelvic thrusting; and loud, sometimes obscene, vocalizations, all of which may suggest psychogenic seizures (▶ Video 60.4)
4. Minimal abnormality on scalp EEG recordings
5. A history of status epilepticus

Epilepsy Syndromes

The epilepsy syndromes are a new addition to the current classification system, comprising a cluster of features involving seizure types, age of onset, natural history, prognosis, etiologies, EEG patterns, genetics, a predictable response to treatment, comorbidities such as intellectual impairment, psychiatric dysfunction, and, at times, imaging features. The identification of an epilepsy syndrome is useful as it provides information on which underlying etiologies should be considered and which antiseizure medication(s) might be most useful. Several epilepsy syndromes demonstrate seizure aggravation with particular antiseizure medications, which can be avoided through appropriate early diagnosis of the epilepsy syndrome.

The epileptic encephalopathies and self-limited neonatal and childhood epilepsy syndromes will be described in detail in Chapter 143.

Idiopathic Generalized Epilepsy Syndromes

These syndromes include childhood absence epilepsy, juvenile absence epilepsy, JME, and generalized tonic-clonic seizures alone (previously referred to as generalized tonic-clonic seizures upon awakening). The genetics of this syndrome can be inherited or acquired de novo. The EEGs in this epilepsy syndrome reveal generalized spike waves superimposed on a typically normal background.

Childhood Absence Epilepsy

Has an onset that is usually between 4 and 12 years of age, with remission usually in adolescence. Patients present with absence seizures and rare generalized tonic-clonic seizures. The EEG activity during an absence seizure is characterized by stereotyped, bilateral, 3-Hz spike-wave discharges. Generalized tonic-clonic seizures also occur in 30% to 50% of cases. Most children are intellectually and neurologically intact. Ethosuximide and valproate are equally effective in treating absence seizures, but valproate or lamotrigine are preferable if generalized tonic-clonic seizures coexist. Topiramate, levetiracetam, and zonisamide may also be effective in generalized onset seizures.

Juvenile Absence Epilepsy

Has onset in adolescence and early adulthood, with peak onset between 10 and 13 years of age. Seizure types include early-onset generalized tonic-clonic seizures, absence, and myoclonic seizures. This syndrome is not self-limiting.

Juvenile Myoclonic Epilepsy

The JME most often begins in otherwise healthy individuals between the ages of 8 years and mid-20s. The fully developed syndrome comprises morning myoclonic jerks, generalized tonic-clonic seizures that occur just after waking, normal intelligence, a family history of similar seizures, and an EEG that shows generalized spikes, 4- to 6-Hz spike waves, and multiple spike (polyspike) discharges. The myoclonic jerks vary in intensity from bilateral massive spasms and falls to minor isolated muscle jerks that many patients consider nothing more than "morning clumsiness." Absence seizures are rare. Most patients require lifelong antiseizure medication. Linkage studies have produced conflicting results with different groups reporting susceptibility loci on chromosomes 6p, 5q, and 15q. A mutation in the α_1 subunit of the γ-aminobutyric acid A receptor has been found in a large French Canadian family with JME but not in individuals with the common sporadic form of JME. Valproate, lamotrigine, zonisamide, levetiracetam, and topiramate can be equally effective in many patients, although lamotrigine sometimes exacerbates myoclonus.

Selected Focal Epilepsy Syndromes

Autosomal dominant epilepsy with auditory features is a focal epilepsy syndrome characterized by auditory symptoms with or without receptive aphasia as prominent ictal features. Auditory symptoms are simple sounds such as humming, buzzing, or ringing, and less commonly, volume changes or complex sounds such as specific songs or voices can occur. Most patients have focal to bilateral tonic-clonic seizures. Mutations in the *LGI1* have been identified in about 50% families with autosomal dominant epilepsy with auditory features.

Frontal lobe epilepsy occurs in some families as an autosomal dominant syndrome referred to as autosomal dominant nocturnal frontal lobe epilepsy. In these patients, seizures usually occur in clusters during sleep; they are often stereotyped and brief and vary from simple arousals to dramatic bizarre hyperkinetic movements. Most patients respond well to medication, and seizures do become milder and less frequent with advancing age. Molecular genetic testing reveals a heterozygous pathogenic variant in *CHRNA4*, *CHRNB2*, *CHRNA2*, *KCNT1*, *DEPDC5*, or *CRH*.

Self-limited Focal Epilepsy Syndromes of Childhood

Several self-limited focal epilepsies occur in children, of which the most common is the syndrome associated with central midtemporal spikes on EEG. This form of idiopathic focal epilepsy, known as *benign epilepsy with centrotemporal spikes*, also known as benign rolandic epilepsy, accounts for about 15% of all pediatric seizure disorders. This syndrome presents between 4 and 13 years of age with predominantly nocturnal focal motor seizures with preserved consciousness. There are frequent hemifacial twitching episodes; drooling; paresthesias of the tongue, lips, inner cheeks, and face; or speech arrest with or without bilateral tonic-clonic activity.

The interictal EEG abnormality is distinctive and shows stereotyped diphasic or triphasic sharp waves over the central midtemporal (rolandic) regions that are sleep potentiated. Discharges may be unilateral or bilateral. They increase in abundance during sleep and, when unilateral, switch from side to side on successive EEGs. In about 30% of cases, generalized spike-wave activity also occurs. The EEG pattern is inherited as an autosomal dominant trait with age-dependent penetrance. The inheritance pattern of the seizures, although clearly familial, is probably multifactorial and less well understood. More than half the children who show the characteristic EEG abnormality never have clinical attacks. Linkage has been reported in some families to chromosome 15q14.

The prognosis is usually good; however, neuropsychological deficits including linguistic, cognitive, and behavioral impairment have been described in some studies particularly when the seizures are more severe, cluster, and accompanied by tonic-clonic activity. The term *self-limited* is probably more accurate than *benign* for this reason. Seizures disappear by mid to late adolescence in all cases. Treatment is indicated when there is a high seizure burden disrupting sleep or frequent tonic-clonic seizures. Because seizures are easily controlled and self-limited, drugs with the fewest adverse effects, such as carbamazepine, oxcarbazepine, or gabapentin, should be used. Low doses, often producing subtherapeutic blood concentrations, are generally effective. Polytherapy should be avoided.

Panayiotopoulos syndrome is characterized by seizures in childhood that are often prolonged with predominantly autonomic symptoms of ictal nausea/retching/vomiting. These seizures can be mistaken for acute gastroenteritis. Ictal pallor, incontinence of urine, and hypersalivation are also noted at times; cardiac asystole is rare. Seizures are often prolonged and can evolve to clonic or hemiclonic activity. In the majority of children, the onset of seizures is between 3 and 6 years of age. Twenty-five percent of children will have a single seizure (which may be autonomic status epilepticus), and 50% may have six seizures or less. Seizures usually resolve by ages 11 to 13 years. Birth and developmental history are typically normal, as is the neurologic examination. The EEG characteristic is occipital or at times multifocal spikes with a normal background. Treatment with an antiseizure medication is often not necessary but can be considered in the setting of very frequent seizures.

Gastaut-type idiopathic occipital epilepsy of childhood, another self-limited benign focal epilepsy syndrome, is characterized by elementary visual hallucinations, typically multicolored and circular, appearing in the periphery of a hemifield, which may be flashing, may move across the visual field, or remain static. They are usually stereotyped. Ictal blindness and more complex visual hallucinations occur less commonly. Evolution to hemiclonic or bilateral tonic-clonic seizures is known to occur. The EEG is characterized by occipital paroxysms that are typically bilateral and synchronous and induced by eye closure (eliminating visual fixation). Some patients can have reflex photosensitive occipital lobe seizures and photoparoxysmal responses on EEG. Prognosis is not as predictable as in benign epilepsy with centrotemporal spikes and Panayiotopoulos syndrome. Children with this epilepsy often suffer from very frequent seizures, and therefore, the management typically includes an antiseizure medication. Nevertheless, within 2 to 4 years of onset, about 50% to 60% of children achieve remission.

Lennox-Gastaut Syndrome (A Type of Combined Focal and Generalized Epilepsy Syndrome)

This syndrome would be classified under combined focal and generalized epilepsy syndromes. The term *Lennox-Gastaut syndrome* is applied to a heterogeneous group of childhood epileptic encephalopathies that are characterized by mental retardation, uncontrolled seizures, and a distinctive EEG pattern. The syndrome is not a pathologic entity because clinical and EEG manifestations result from brain malformations, perinatal asphyxia, severe head injury, central nervous system infection, or, rarely, a progressive degenerative or metabolic syndrome. A presumptive cause can be identified in 65% to 70% of affected children. Seizures usually begin before age 4 years, and about 25% of children have a history of infantile spasms. No treatment is consistently effective, and 80% of children continue to have seizures as adults. Best results are generally obtained with broad-spectrum antiseizure medications, such as valproate, clobazam, lamotrigine, topiramate, or zonisamide. Rufinamide may be particularly effective for atonic seizures associated with this syndrome. Despite the higher incidence of severe side effects, felbamate is often effective when these other agents do not result in optimal seizure control. Refractory cases may be considered for vagus nerve stimulation or anterior corpus callosotomy. Both of these are palliative procedures, and complete seizure control is rare.

Infantile Spasms (West Syndrome)

The term *infantile spasms* denotes a unique age-specific form of generalized or focal epilepsy that may be either idiopathic or symptomatic. When all clinical data are considered, including results of imaging studies, only about 15% of patients are now classified as idiopathic. Symptomatic cases result from diverse conditions, including cerebral dysgenesis, tuberous sclerosis, phenylketonuria, intrauterine infections, or hypoxic-ischemic injury. Video EEG monitoring and a brain MRI may be needed to determine whether onset of infantile spasms is focal or generalized.

Seizures are characterized by sudden flexor or extensor spasms that simultaneously involve the head, trunk, and limbs. The attacks usually begin before 6 months of age. The EEG is grossly abnormal, showing chaotic high-voltage slow activity with multifocal spikes, a pattern termed *hypsarrhythmia*. The treatment of choice is corticotropin or prednisone; spasms are notoriously refractory to conventional AEDs. Exceptions are topiramate and zonisamide, which have been shown to be an effective alternative to corticotropin in selected cases. Vigabatrin is also effective, especially in children with tuberous sclerosis. Patients on this drug must be monitored for visual field deficits. Although treatment with corticotropin, vigabatrin, zonisamide, or topiramate usually controls spasms and reverses the EEG abnormalities, it has little effect on long-term prognosis. Only about 5% to 10% of children with infantile spasms have normal or near-normal intelligence, and more than 66% have severe disabilities.

Post-traumatic Seizures

Seizures occur within 1 year in about 7% of civilian and in about 34% of military head injuries. The differences relate mainly to the much higher proportion of penetrating wounds in military cases. The risk of developing posttraumatic epilepsy is directly related to the severity of the injury and also correlates with the total volume of brain lost as measured by computed tomography. Depressed skull fractures may or may not be a risk; the rate of posttraumatic epilepsy was 17% in one series but not increased above control levels in another. Head injuries are classified as *severe* if they result in brain contusion, intracerebral or intracranial hematoma, unconsciousness, or amnesia for more than 24 hours or in persistent neurologic abnormalities, such as aphasia, hemiparesis, or dementia. *Mild* head injury (brief loss of consciousness, no skull fracture, no focal neurologic signs, no contusion or hematoma) does not increase the risk of seizures significantly above general population rates.

Nearly 60% of those who have seizures have the first attack in the first year after the injury. In the Vietnam Head Injury Study, however, more than 15% of patients did not have epilepsy until 5 or more years later. Posttraumatic seizures are classified as *early* (within the first 1-2 wk after injury) or *late*. Only recurrent late seizures (those that occur after the patient has recovered from the acute effects of the injury) should be considered *posttraumatic epilepsy*. Early seizures, however, even if isolated, increase the chance of developing posttraumatic epilepsy. About 70% of patients have partial or secondarily generalized seizures. *Impact seizures* occur at the time of or immediately after the injury. These attacks are attributed to an acute reaction of the brain to trauma and do not increase the risk of later epilepsy.

Overt seizures should be treated according to principles reviewed later in this chapter. The most controversial issue concerns the prophylactic use of AEDs to prevent or abort the development of subsequent seizures. Based on the data of Temkin et al LEVEL 1,[3] we recommend treating patients with severe head trauma, as just defined, with an antiepileptic medication for the first week after injury to minimize complications from seizures occurring during acute management. If seizures have not occurred, we do not continue medication beyond the initial 1 to 2 weeks because evidence does not show that longer treatment prevents the development of later seizures or of posttraumatic epilepsy. Data suggest that valproate is less effective than phenytoin in suppressing acute seizures and is also ineffective in preventing the development of posttraumatic epilepsy.

Epilepsia Partialis Continua

Epilepsia partialis continua refers to unremitting focal motor seizures involving part or all of one side of the body. They typically consist of repeated clonic or myoclonic jerks that may remain focal or regional or may march from one muscle group to another, with the extent of motor involvement waxing and waning in endless variation (▶ Video 60.5). In adults, EPC occurs in diverse settings, such as acute strokes, metastases, and metabolic encephalopathies, especially hyperosmolar nonketotic hyperglycemia.

The most distinctive form of EPC, known as the *Rasmussen syndrome*, occurs in children; it usually begins before the age of 10 years. The underlying disorder is chronic focal encephalitis, although an infectious agent has not been identified consistently. About two-thirds of patients report an infectious or inflammatory illness 1 to 6 months before onset of EPC. Generalized tonic-clonic seizures are often the first sign and appear before the EPC establishes itself. About 20% of cases begin with an episode of convulsive status epilepticus. Slow neurologic deterioration inevitably follows, with development of hemiparesis, mental impairment, and, usually, hemianopia. If the dominant hemisphere is affected, aphasia occurs. The EEGs are always abnormal, but findings are not specific, and they frequently do not correlate with clinical manifestations. The MRI may be normal early but later shows unilateral cortical atrophy and signal changes consistent with gliosis. Autoantibodies to the GluR3 protein of the glutamate receptor have been found in some patients, suggesting that autoimmunity may play a role in the pathogenesis of the disorder in some patients, and immunotherapy is sometimes beneficial. The AEDs are usually ineffective in controlling seizures and preventing progression of the disease, as are corticosteroids and antiviral agents. When seizures have not spontaneously remitted by the time there is a severe degree of hemiparesis, functional hemispherectomy can control seizures and leads to substantial intellectual improvement in many patients. Controversy arises in the decision about the best time for hemispherectomy, for example, whether it should be performed earlier before there is serious motor or language impairment.

Videos can be found in the companion e-book edition. For a full list of video legends, please see the front matter.

LEVEL 1 EVIDENCE

1. Krumholz A, Wiebe S, Gronseth GS, et al. Evidence-based guideline: management of an unprovoked first seizure in adults. Report of the Guideline Development Subcommittee of the American Academy of Neurology and the American Epilepsy Society. *Neurology*. 2015;84(16):1705-1713.
2. Harden C, Tomson T, Gloss D, et al. Practice guideline summary: sudden unexpected death in epilepsy incidence rates and risk factors. Report of the Guideline Development, Dissemination, and Implementation Subcommittee of the American Academy of Neurology and the American Epilepsy Society. *Neurology*. 2017;88(17):1674-1680.
3. Temkin NR, Dikmen SS, Wilensky AJ, Keihm J, Chabal S, Winn HR. A randomized, double-blind study of phenytoin for the prevention of post-traumatic seizures. *N Eng J Med*. 1990;323(8):497-502.

SUGGESTED READINGS

Bazil CW. *Living Well With Epilepsy*. New York, NY: HarperCollins; 2004.

Bazil CW, Malow BA, Sammaritano MR, eds. *Sleep and Epilepsy: The Clinical Spectrum*. New York, NY: Elsevier; 2002.

Beghi E. Overview of studies to prevent posttraumatic epilepsy. *Epilepsia*. 2003;44(suppl 10):21-26.

Benardo LS. Prevention of epilepsy after head trauma: do we need new drugs or a new approach? *Epilepsia*. 2003;44(suppl 10):27-33.

Berg AT, Berkovic SF, Brodie MJ, et al. Revised terminology and concepts for organization of seizures and epilepsies: report of the ILAE Commission on Classification and Terminology, 2005-2009. *Epilepsia*. 2010;51(4):676-685.

Berg AT, Shinnar S. The risk of seizure recurrence following a first unprovoked seizure: a quantitative review. *Neurology*. 1991;41(7):965-972.

Berkovic SF. Genetics of epilepsy in clinical practice. *Epilepsy Curr*. 2015;15(4):192-196.

Caraballo R, Koutroumanidis M, Panayiotopoulos CP, Fejerman N. Idiopathic childhood occipital epilepsy of Gastaut: a review and differentiation from migraine and other epilepsies. *J Child Neurol*. 2009;24(12):1535-1542.

Cendes F. Febrile seizures and mesial temporal sclerosis. *Curr Opin Neurol*. 2004;17(2):161-164.

Commission on Classification and Terminology of the International League Against Epilepsy. Proposal for revised clinical and electroencephalographic classification of epileptic seizures. *Epilepsia*. 1981;12(4):489-501.

DeLorenzo RJ, Pellock JM, Towne AR, Boggs JG. Epidemiology of status epilepticus. *J Clin Neurophysiol*. 1995;12(24):316-325.

Engel J Jr. ILAE classification of epilepsy syndromes. *Epilepsy Res*. 2006;70(suppl 1): S5-S10.

Engel J Jr. *Surgical Treatment of the Epilepsies*. 2nd ed. New York, NY: Raven Press; 1993.

Engel J Jr, Pedley TA, eds. *Epilepsy: A Comprehensive Textbook*. Philadelphia, PA: Lippincott Williams & Wilkins; 1998.

First Seizure Trial Group. Randomized clinical trial on the efficacy of antiepileptic drugs in reducing the risk of relapse after a first unprovoked tonic–clonic seizure. *Neurology*. 1993;43(3 pt 1):478-483.

Gourfinkel-An I, Baulac S, Nabbout R, et al. Monogenic idiopathic epilepsies. *Lancet Neurol*. 2004;3(4):209-218.

Gutierrez-Delicado E, Serratosa JM. Genetics of the epilepsies. *Curr Opin Neurol*. 2004;17(2):147-153.

Hauser WA, Hesdorffer DC. *Epilepsy: Frequency, Causes and Consequences*. New York, NY: Demos; 1990.

Hauser WA, Rich SS, Lee JR, Annegers JF, Anderson VE. Risk of recurrent seizures after two unprovoked seizures. *N Engl J Med*. 1998;338(7):429-434.

Jackson GD, Berkovic SF, Tress BM, Kalnins RM, Fabinyi GC, Bladin PF. Hippocampal sclerosis can be reliably detected by magnetic resonance imaging. *Neurology*. 1990;40(12):1869-1875.

Karceski S, Morrell M, Carpenter D. The expert consensus guideline series: treatment of epilepsy. *Epilepsy Behav*. 2001;2(6):A1-A50.

Kwan P, Brodie MJ. Early identification of refractory epilepsy. *N Engl J Med*. 2000;342(5):314-319.

Musicco M, Beghi E, Solari A, Viani F. Treatment of first tonic-clonic seizure does not improve the prognosis of epilepsy. *Neurology*. 1997;49(4):991-998.

Noebels JL. The biology of epilepsy genes. *Annu Rev Neurosci*. 2003;26: 599-625.

Northcott E, Connolly AM, Berroya A, et al. The neuropsychological and language profile of children with benign rolandic epilepsy. *Epilepsia*. 2005;46(6):924-930.

Ottman R, Winawer MR, Kalachikov S, et al. *LGI1* mutations in autosomal dominant partial epilepsy with auditory features. *Neurology*. 2004;62(7): 1120-1126.

Pack AM, Epilepsy overview and revised classification of seizures and epilepsies. *Continuum (Minneap Minn)*. 2019;25(2):306-321.

Salazar AM, Jabbari B, Vance SC, Grafman J, Amin D, Dillon JD. Epilepsy after penetrating head injury. I. Clinical correlates: a report of the Vietnam Head Injury Study. *Neurology*. 1985;35(10):1406-1414.

Scheffer IE, Berkovic SF. The genetics of human epilepsy. *Trends Pharmacol Sci*. 2003;24(8):428-433.

Scheffer IE, Berkovic S, Capovilla G, et al. ILAE Classification of the Epilepsies: position paper of the ILAE Commission for Classification and Terminology. *Epilepsia*. 2017;58(4):512-521. doi:10.1111/epi.13709.

Sheen VL, Walsh CA. Developmental genetic malformations of the cerebral cortex. *Curr Neurol Neurosci Rep*. 2003;3:433-441.

Sillanpää M, Jalava M, Kaleva O, Shinnar S. Long-term prognosis of seizures with onset in childhood. *N Engl J Med*. 1998;338(24):1715-1722.

Spencer SS, Berg AT, Vickrey BG, et al. Predicting long-term seizure outcome after resective epilepsy surgery: the multicenter study. *Neurology*. 2005;65(6): 912-918.

Temkin NR. Antiepileptogeniesis and seizure prevention trials with antiepileptic drugs: meta-analysis of controlled trials. *Epilepsia*. 2001;42(4):515-524.

Temkin NR, Dikmen SS, Wilensky AJ, Keihm J, Chabal S, Winn HR. A randomized, double-blind study of phenytoin for the prevention of post-traumatic seizures. *N Engl J Med*. 1990;323:497-502.

Wang J, Lin Z-J, Liu L, et al. Epilepsy-associated genes. *Seizure*. 2017;44:11-20.

Wyllie E, ed. *The Treatment of Epilepsy: Principles & Practice*. 3rd ed. Philadelphia, PA: Lippincott Williams & Wilkins; 2001.

Management of Epilepsy 61

Carl W. Bazil and Shraddha Srinivasan

KEY POINTS

1. About 60% of patients with a diagnosis of epilepsy are completely controlled with medication; The remainder are refractory to medical treatment.
2. There are many appropriate drugs available; these vary in spectrum of efficacy, but when used for the appropriate epilepsy syndrome, all have approximately equal chance of seizure control.
3. Choice of drug for an individual patient should take into account adverse effect profile, ease of use, potential long-term toxicity (if present), drug interactions, potential effects on coexisting conditions, and cost.
4. When drug treatment results in incomplete seizure control, video-electroencephalogram monitoring should be performed to confirm the diagnosis and determine whether surgical treatment is an option.
5. For patients with refractory seizures, surgical treatment should be considered particularly when a well-defined onset site is localized and when resection is unlikely to result in neurologic deficits.
6. For refractory patients, particularly when surgical treatment is not a good option, treatment with implanted devices (vagus nerve stimulator, responsive neurostimulator, or deep brain stimulator) can result in further seizure reduction.

INTRODUCTION

Seizures are a very common phenomenon; approximately 10% of people will experience one at some point during their lifetime. But seizures may occur for many reasons, only one of which is epilepsy. The classification of epilepsy is explained in depth in Chapter 60; this chapter begins with distinguishing other seizures (particularly acute symptomatic and single seizures) from epilepsy. Once the diagnosis of epilepsy is made, management almost always consists of pharmacologic treatment; however, surgical and device treatment are considerations in patients refractory to medication. Complications of epilepsy and anticonvulsant drugs, psychosocial, and psychiatric issues are also of critical importance in the treatment of any patient with epilepsy.

Acute Symptomatic Seizures

These seizures are caused by, or associated with, an acute medical or neurologic illness (see Chapter 7). A childhood febrile seizure is the most common example of an acute symptomatic seizure, but other frequently encountered causes include metabolic or toxic encephalopathies, head trauma, and acute brain infections.

New Onset Refractory Status Epilepticus or NORSE, is a clinical presentation in a patient without epilepsy or preexisting relevant neurologic disorder, where there is no identifiable acute structural, toxic or metabolic cause. Febrile Infection Related Epilepsy Syndrome or FIRES could be considered a subcategory of NORSE that requires a prior febrile infection, with fever between 2 weeks and 24 hours prior to the onset of refractory status epilepticus, and applies to all ages. The pathophysiology of these two clinical presentations is under investigation. Refer to Chapter 7 on status epilepticus for further reading.

Prophylactic phenytoin has been shown to reduce the frequency of seizures in patients with severe traumatic brain injury from 14% to 4% during the first week after injury LEVEL 2[1]; however, currently, levetiracetam is more often prescribed due to lower incidence of adverse effects and lack of drug-drug interactions; a prospective trial found no difference in seizure recurrence between the two. To the extent that these conditions resolve without permanent brain damage, seizures are usually self-limited. The primary therapeutic concern in such patients should be identification and treatment of the underlying disorder. If antiepileptic drugs (AEDs) are needed to suppress seizures acutely, they generally do not need to be continued after the patient recovers from the causative condition.

The Single Seizure

About 25% of patients with unprovoked seizures come to a physician after a single attack, nearly always a generalized tonic-clonic seizure. Most of these people have no risk factors for epilepsy, have normal findings on neurologic examination, and have a normal first electroencephalogram (EEG). It is important to carefully question these patients regarding possible prior events suggestive of seizure (such as awakening with an unexplained, severe tongue laceration, or losing periods of time) because these may have previously been unrecognized as seizures. A large multicenter randomized study from Italy convincingly demonstrated that AEDs reduce the risk of relapse after the first unprovoked convulsive seizure. Among nearly 400 children and adults, treatment within 7 days of a first seizure was followed by a recurrence rate of 25% at 2 years. In contrast, untreated patients had a recurrence rate of 51%. When patients with previous "uncertain spells" were excluded from the analysis, treatment benefit was still evident, but the magnitude of the effect was reduced to a recurrence rate of 30% in the treated group and 42% in untreated patients.

Although treatment of first seizures reduces the relapse rate even in low-risk patients, there is no evidence that such treatment alters long-term prognosis. In 2015, a new evidence-based guideline for management of adults with a first unprovoked seizure identified the following risk factors for progression to epilepsy: a prior brain insult, an EEG with epileptiform abnormalities, a significant brain-imaging abnormality, and a nocturnal seizure LEVEL 2.[2] Largely for this reason, the new International League Against Epilepsy classification of epilepsy allows for a diagnosis of epilepsy

following only one unprovoked seizure if there is a substantial risk of recurrence. Clinicians' recommendations whether to initiate immediate AED treatment after a first seizure should be based on individualized assessments that weigh the risk of recurrence against the potential side effects of AED therapy and should consider patient preferences. Immediate treatment will not improve the long-term prognosis for seizure remission but will reduce seizure risk over the subsequent 2 years. In most patients with an unprovoked seizure and normal workup, deferring treatment until a second seizure occurs is a reasonable and often preferable decision.

INITIAL DIAGNOSTIC EVALUATION

The diagnostic evaluation has three objectives: to determine if the patient has epilepsy; to classify the type of epilepsy and identify an epilepsy syndrome, if possible; and to define the specific underlying cause. Accurate diagnosis leads directly to proper treatment and formulation of a rational plan of management. The differential diagnosis is considered in Section III, Chapter 6.

Because epilepsy comprises a group of conditions and is not a single homogeneous disorder and because seizures may be symptoms of both diverse brain disorders and an otherwise normal brain, it is neither possible nor desirable to develop inflexible guidelines for what constitutes a standard or minimal diagnostic evaluation. The clinical data from the history and physical examination should allow a reasonable determination of probable diagnosis, seizure and epilepsy classification, and likelihood of underlying brain disorder. Based on these considerations, diagnostic testing should be undertaken selectively.

History and Examination

A complete history is the cornerstone for establishing a diagnosis of epilepsy. Because patients frequently have no or only limited recall of their attacks, it is important to obtain additional information from family members, friends, or other witnesses who have seen the seizure(s). An adequate history should provide a clear picture of the clinical features of the seizures and the sequence in which manifestations evolve; the course of the epileptic disorder; seizure precipitants, such as alcohol or sleep deprivation; risk factors for seizures, such as abnormal gestation, febrile seizures, family history of epilepsy, head injury, encephalitis or meningitis, and stroke; and response to previous treatment. In children, developmental history is particularly important.

In describing the epileptic seizure, care should be taken to elicit a detailed description of any initial change in neurologic function (aura). The aura was once considered to be the warning of an impending attack, but it is actually a focal aware seizure consisting of subjective feelings or experiential phenomena observable only by the patient. Classic examples are paroxysmal fear, déjà vu, or visual distortion. Auras precede many focal unaware or generalized seizures and are experienced by 50% to 60% of adults with epilepsy. An epileptic aura rarely lasts longer than a minute or two; longer "prodromal" symptoms are sometimes described by patients with primary generalized convulsive seizures and are more vague. Auras confirm the suspicion that the seizure begins locally within the brain; they may also provide direct clues about the location or laterality of the focus. Information about later events in the seizure usually are obtained from an observer because of the patient's impaired awareness or frank loss of consciousness or because of postictal amnesia, even though responses to questions during the seizure indicate preserved responsiveness.

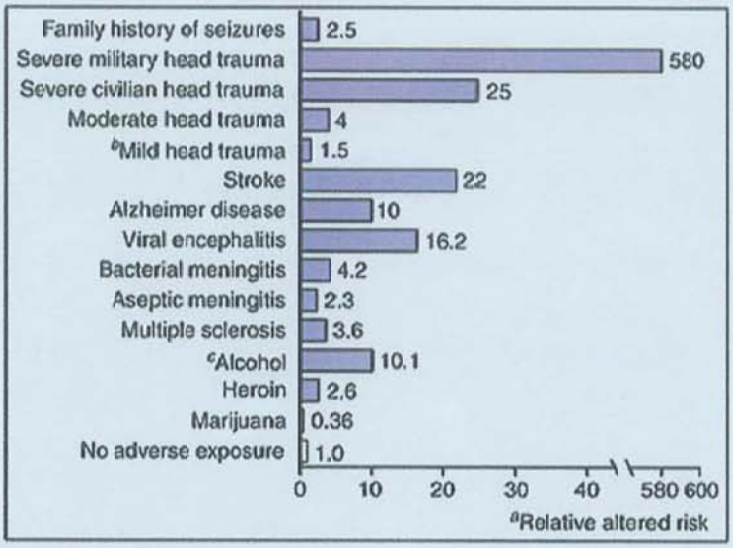

FIGURE 61.1 Risk factors for epilepsy. [a]Relative to people without these adverse exposures. [b]Not statistically significant. [c]One pint of 80 proof, 2.5 bottles of wine. (From Hauser WA, Hesdorffer DC. *Epilepsy: Frequency, Causes and Consequences.* New York, NY: Demos; 1990.)

During the seizure itself, a description confirming tonic and/or generalized clonic movements is helpful in confirming that a seizure has, in fact, occurred. Repetitive automatic or purposeless movements (automatisms), sustained postures, presence of myoclonus, and the duration of the seizure help to delineate specific seizure types or epileptic syndromes particularly when a bilateral convulsion has not occurred. Nonspecific postictal findings of lethargy and confusion must be distinguished from focal neurologic abnormalities, such as hemiparesis or aphasia, which could point to the hemisphere of seizure onset.

Information about risk factors (Fig. 61.1) may suggest a particular cause and assist in prognosis. In addition to these risk factors, migraines with auras and depression have been reported to be independent risk factors for unprovoked seizures. Discussion of risk factors with parents may be necessary because children or adults may be uninformed about, or may not recall, early childhood events, such as perinatal encephalopathy, febrile seizures, brain infections, head injuries, or intermittent absence seizures. Age at seizure onset and course of the seizure disorder should be clarified because these features differ in the various epilepsy syndromes.

Findings on neurologic examination are usually normal in patients with epilepsy but occasionally may provide etiologic clues. Focal signs indicate an underlying cerebral lesion. Asymmetry of the hand or face may indicate localized or hemispheric cerebral atrophy contralateral to the smaller side. Phakomatoses are commonly associated with seizures and are suggested by café au lait spots, facial angioma, conjunctival telangiectasia, hypopigmented macules, fibroangiomatous nevi, or lumbosacral shagreen patches.

Electroencephalography

Because epilepsy is fundamentally a physiologic disturbance of brain function, the EEG is the most important laboratory test in evaluating patients with seizures. The EEG helps both to establish the diagnosis of epilepsy and to characterize specific epileptic syndromes. The EEG findings may also help in management and in prognosis (see also Chapter 26).

Epileptiform discharges (spikes and sharp waves) are highly correlated with seizure susceptibility and can be recorded on the first

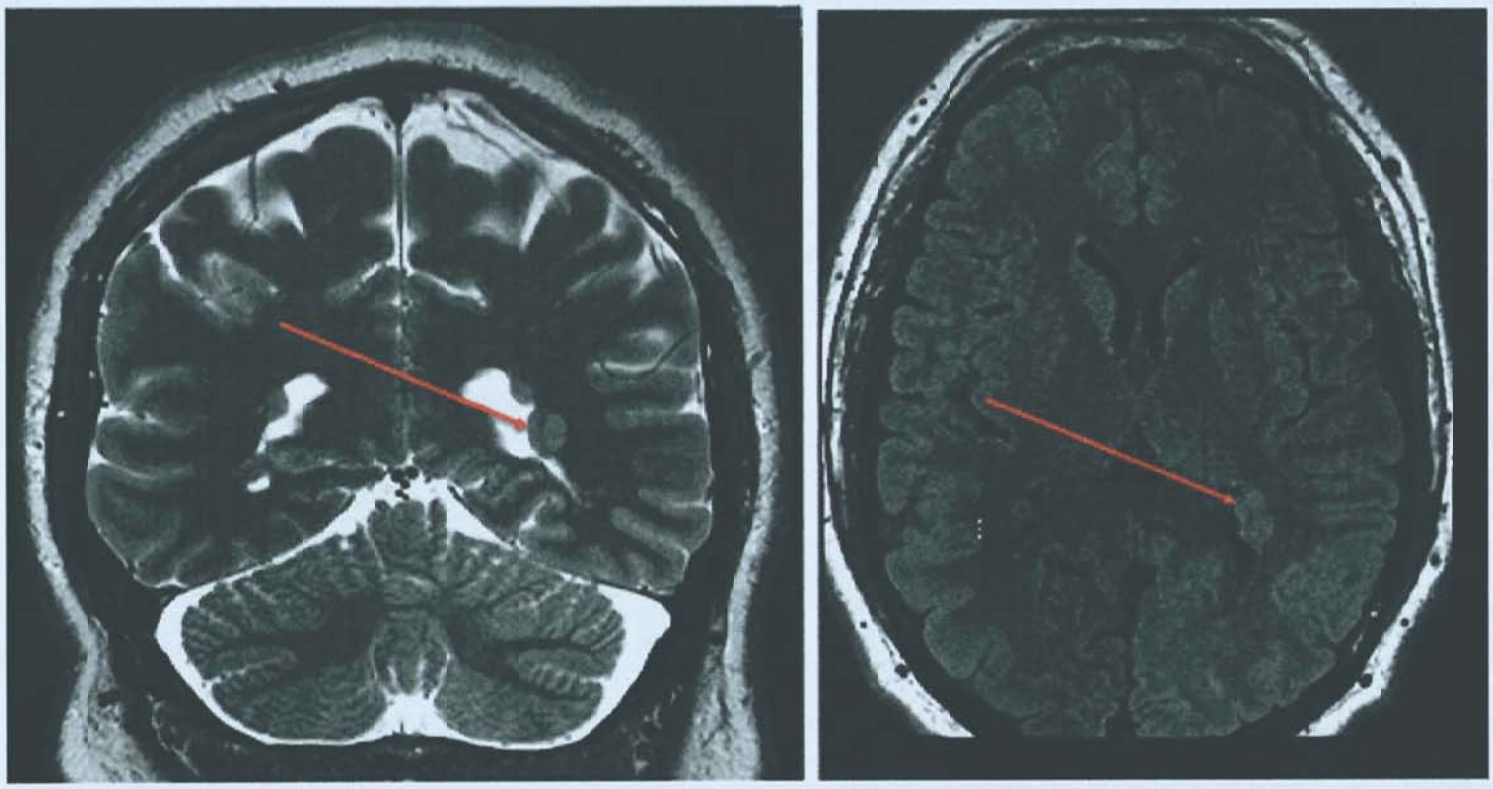

FIGURE 61.2 Multiple heterotopias in a 33-year-old man with refractory epilepsy, left temporal onset. The larger heterotopia *(arrows)* is likely responsible for seizures; stereo-electroencephalogram would be required to confirm seizure onset. Left, coronal T2. Right, axial T2 IR.

EEG in about 50% of patients with epilepsy. Similar findings are recorded in only 1% to 2% of normal adults and in a somewhat higher percentage of normal children. When multiple EEGs are obtained, epileptiform abnormalities eventually appear in 60% to 90% of adults with epilepsy, but the yield of positive studies does not increase substantially after three or four tests. Prolonged ambulatory or inpatient recordings increase the yield of interictal epileptiform abnormalities both because of the longer sampling times but also because complete sleep-wake cycles are included. It is important to remember, however, that 10% to 40% of patients with epilepsy do not show epileptiform abnormalities on routine EEG. Thus, a normal or nonspecifically abnormal EEG never excludes the diagnosis. Sleep, hyperventilation, photic stimulation, and special electrode placements are routinely used to increase the probability of recording epileptiform abnormalities. Different and distinctive patterns of epileptiform discharge occur in specific epilepsy syndromes as summarized in Chapter 60.

Brain Imaging

Magnetic resonance imaging (MRI) should be performed in all patients older than age 18 years and in children with abnormal development, abnormal findings on physical examination, or seizure types that are likely to be manifestations of symptomatic epilepsy. Computed tomography (CT) will often miss common epileptogenic lesions such as hippocampal sclerosis, cortical dysplasia, and cavernous malformations. Particularly in patients where a subtle structural abnormality is suspected, a 3T or higher study may be warranted. Because CT is very sensitive for detecting brain calcifications, a noncontrast CT (in addition to MRI) may be helpful in patients at risk for neurocysticercosis.

Routine imaging is not necessary for children with idiopathic epilepsy, including the benign focal epilepsy syndromes (see "Benign Epilepsy Syndromes" section in Chapter 60). Brain MRI, although more costly, is more sensitive than CT in detecting potentially epileptogenic lesions, such as heterotopias (Fig. 61.2), cortical dysplasia, hamartomas, differentiated glial tumors, and cavernous malformations. Both axial and coronal planes should be imaged using both T1 and T2 sequences. Gadolinium injection does not increase the sensitivity for detecting cerebral lesions but may assist in differentiating possible etiologies.

Imaging in the coronal plane perpendicular to the long axis of the hippocampus and other variations in technique have improved the detection of hippocampal atrophy and gliosis, findings that are highly correlated with mesial temporal sclerosis (see Fig. 59.8) and an epileptogenic temporal lobe. A focal increased signal particularly in the mesial temporal structures may be seen as a postictal phenomenon as well. An even more sensitive measure of hippocampal atrophy is MRI measurement of the volume of the hippocampus. Hippocampal volume measurements in an individual patient then can be compared with those of normal control subjects. In patients being considered for surgery, interictal positron emission tomography (PET) scans can add valuable localizing information, especially when the MRI scan is negative. Single-photon emission computed tomography (SPECT) scans are also used, although resolution is less than either MRI or PET. Subtraction ictal SPECT coregistered with MRI may also be helpful in localizing the epileptogenic brain region in some cases.

Other Laboratory Tests

Routine blood tests are necessary in newborns and in older patients with acute or chronic systemic disease to detect abnormal electrolyte, glucose, calcium, or magnesium values or impaired liver or kidney function that may contribute to seizure occurrence. They are rarely diagnostically useful in healthy children

or adults. Serum electrolytes, liver function tests, and a complete blood count should be obtained when infectious or metabolic abnormalities are suspected and are also useful as baseline studies before initiating AED treatment.

Any suspicion of meningitis or encephalitis mandates lumbar puncture. Particularly in patients with a more fulminant initial presentation, neoplastic and autoimmune panels should be considered to look for autoimmune encephalitis. Urine or blood toxicologic screens should be considered when otherwise unexplained new-onset generalized seizures occur.

LONG-TERM MONITORING

The most direct and convincing evidence of an epileptic basis for a patient's episodic symptoms is the electrographic recording of a seizure discharge during a typical behavioral attack. Such recordings are especially necessary if the history is ambiguous, EEGs are repeatedly normal or nonspecifically abnormal, and reasonable anticonvulsant treatment has failed. Because most patients have seizures infrequently, routine EEG rarely records an attack. Long-term monitoring permits continuous EEG recording for extended periods, thus increasing the likelihood of recording seizures or interictal epileptiform discharges. Two methods of long-term monitoring are now widely available: inpatient video-EEG monitoring in specialized units, and outpatient video-EEG monitoring with or without simultaneous video. Both have greatly improved diagnostic accuracy and the reliability of seizure classification and both provide continuous recordings through one or more complete sleep-wake cycles, which increases the likelihood of capturing actual ictal events. Each has its own specific advantages and disadvantages. The method chosen depends on the question posed by a particular patient.

Long-term monitoring using video-EEG, usually in a specially designed hospital unit, is the procedure of choice to document psychogenic seizures and other nonepileptic paroxysmal events. It can also establish electrical-clinical correlations, confirm seizure type, and direct further treatment including the localization of epileptogenic foci for possible resective surgery. The emphasis in monitoring units is usually on behavioral events, not interictal EEG activity. The availability of full-time technical and nursing staff ensures high-quality recordings and permits examination of patients during clinical events and helps to ensure patient safety. The AEDs can be reasonably decreased or discontinued in this carefully monitored environment to facilitate seizure occurrence. Computerized detection programs are used to screen EEG continuously for epileptiform abnormalities and subclinical seizures.

Ambulatory EEG is another method for long-term monitoring that is designed for outpatient use in the patient's home, school, or work environment. This is often especially helpful in evaluating children who are usually more comfortable in their familiar and unrestricted home environments. The major limitations of ambulatory monitoring are the variable technical quality resulting from lack of expert supervision and maintenance of electrode integrity, frequent distortion of EEG data by environmental contaminants, and the absence or unreliability of video documentation of behavioral changes. Some systems do allow simultaneous video recordings; however, the camera needs to be carefully positioned at all times to view that patient, and the actual event can be missed due to suboptimal placement. Ambulatory monitoring is most useful in documenting interictal epileptiform activity when routine EEGs have been repeatedly negative or in recording ictal discharges during typical behavioral events. It may also reveal the presence of unrecognized electrographic seizures (particularly absences) if frequent; however, there is a limit of a few day's recording, and infrequent events can be missed. Ambulatory EEG is not a substitute for inpatient video-EEG monitoring, especially when psychogenic seizures are an issue or when patients are being evaluated for epilepsy surgery.

MEDICAL TREATMENT

Therapy of epilepsy has three goals: (1) to eliminate seizures or reduce their frequency to the maximum extent possible, (2) to avoid side effects associated with long-term treatment, and (3) to assist the patient in maintaining or restoring normal psychosocial and vocational adjustment. No medical treatment now available can induce a permanent remission ("cure") or prevent development of epilepsy by altering the process of epileptogenesis.

The decision to institute AED therapy should be based on a thoughtful and informed analysis of the issues involved. Convulsive seizures carry some risk of injury particularly depending not on the seizure itself but on the unpredictable circumstances in which it occurs. Although most patients experiencing a convulsive seizure will recover uneventfully, in rare instances (eg, while swimming or bathing), this could result in death if unwitnessed. However, even relatively minor seizures, especially those associated with loss or alteration of alertness, can be associated with many psychosocial, vocational, and safety ramifications. Finally, the probability of seizure recurrence varies substantially among patients, depending on the type of epilepsy and any associated neurologic or medical problems. Drug treatment, although usually effective, carries some risk of adverse effects, which approaches 30% after initial treatment. Treatment of children raises additional issues, especially the unknown effects of long-term AED use on brain development, learning, and behavior.

These considerations mean that although drug treatment is indicated and is beneficial for nearly all patients with epilepsy, certain circumstances call for AEDs to be deferred or used only for a limited time. As a rule of thumb, AEDs should be prescribed when the potential benefits of treatment clearly outweigh possible adverse effects of therapy.

Antiepileptic Drugs

Selection of Antiepileptic Drugs

Selection of an appropriate AED starts with the one most likely to result in seizure freedom for the epilepsy syndrome. Many high-quality studies over several decades have failed to determine a clearly more effective drug when used for the correct seizure type. Two randomized, double-blind nationwide collaborative Veterans Administration Cooperative Studies (1985 and 1992) compared the effectiveness of the then available major AEDs for treating new-onset epilepsy. In the 1985 study, carbamazepine, phenytoin, primidone, and phenobarbital were equally effective in controlling complex partial and secondarily generalized seizures [LEVEL 1].[3] In the 1992 study, carbamazepine was slightly more effective than valproate in treating complex partial seizures, but both drugs were of equal efficacy in controlling secondarily generalized seizures [LEVEL 1].[4] These studies also demonstrated that despite their relatively uniform ability to suppress seizures, the drugs had different risks of adverse effects. Randomized trials in patients with focal seizures have also been conducted comparing the effectiveness of gabapentin,

lamotrigine, topiramate, levetiracetam, zonisamide, or oxcarbazepine to that of carbamazepine and/or phenytoin. None has shown definite superiority, although many have demonstrated that the newer agents have improved tolerability. The Standard and New Antiepileptic Drugs trial, a large open-label study, randomized patients with focal epilepsy to carbamazepine, lamotrigine, oxcarbazepine, or topiramate. Lamotrigine had a slight advantage in time to treatment failure, but as in previous comparative studies, the differences among agents in terms of effectiveness were minimal LEVEL 1.[5] Many smaller trials have directly compared various drugs against each other with similar findings; although there may be differences in tolerability, there are no clear advantages in efficacy when an appropriate agent is used at a therapeutic dose LEVEL 1.[6] Overall, for new-onset focal seizures carbamazepine, lamotrigine, gabapentin, levetiracetam, oxcarbazepine, pregabalin, and zonisamide are considered the most reasonable options.

For generalized onset seizures, valproate was long considered the gold standard of treatment; however, due mainly to tolerability and safety concerns lamotrigine, levetiracetam, topiramate, and zonisamide are now considered reasonable alternatives. A second arm of the Standard and New Antiepileptic Drugs trial compared the effectiveness of valproate, lamotrigine, and topiramate in patients with all types of generalized or unclassified seizures. Valproate was found to be slightly more effective overall, especially for idiopathic epilepsy, although the differences were minimal LEVEL 2.[7] Phenytoin, carbamazepine, eslicarbazepine, and oxcarbazepine are useful in suppressing generalized tonic-clonic seizures, but the response is less predictable than that with valproate. Carbamazepine, phenytoin, gabapentin, and lamotrigine can aggravate myoclonic seizures; all of these except lamotrigine also sometimes exacerbate absence seizures. Ethosuximide is as effective as valproate in controlling absence seizures and has fewer side effects. Ethosuximide is ineffective against tonic-clonic seizures, however, so its main use is as an alternative to valproate in patients who have only absence seizures.

Although not always initially approved in this group, most AEDs effective in adults have been subsequently proven effective for the same seizure type in children and, when not, can be tried off-label so long as sufficient safety data are present. Evidence also suggests that lamotrigine and topiramate are effective for adjunctive treatment of idiopathic generalized epilepsy in adults and children as well as treatment of the Lennox-Gastaut syndrome LEVEL 1.[8]

Clobazam was initially approved in the United States only for add-on therapy in severe epilepsies such as Lennox-Gastaut syndrome. It is also effective in focal epilepsies that are refractory to other medications and has been widely prescribed worldwide for this indication. Cannabidiol has been approved for treatment of seizures in Lennox-Gastaut and Dravet syndrome. Although this compound has gained considerable interest in the popular press, randomized trials show that, although it shows some efficacy in these hard-to-treat syndromes, it is not clearly greater than other available compounds, and adverse effects are comparable or possibly worse. Vigabatrin was approved by the U.S. Food and Drug Administration (FDA) for treating infantile spasms in children 1 month to 2 years of age.

Of the more recently introduced antiepileptic medications, lacosamide, eslicarbazepine, perampanel, brivaracetam, and cenobamate have been approved for use in focal epilepsies refractory to other medications, and rufinamide was additionally approved to treat seizures associated with Lennox-Gastaut syndrome.

Elderly patients with epilepsy require special consideration because of age-related changes in both pharmacokinetic profiles and pharmacodynamic characteristics. Relevant physiologic changes include decreased hepatic metabolism and plasma protein binding, decreased renal clearance, and slower gastrointestinal motility and absorption. There is greater sensitivity to both desirable and undesirable effects on brain function. Additionally, concurrent medical illnesses are common, and as a result, most elderly patients take multiple drugs, which increase the likelihood of clinically significant drug interactions. Several clinical trials involving elderly patients, including the large Veterans Administration cooperative study, have found that lamotrigine and gabapentin are better tolerated than carbamazepine, although, as in younger patients, differences in effectiveness, if any, are small. For practical reasons, clinicians tend to use agents with few or no drug interactions in this population (particularly gabapentin, lamotrigine, levetiracetam, and lacosamide).

Because there are many effective drugs available particularly for focal seizures, the choice is based on many factors including particular adverse effect profile, ease of use, speed of titration, drug-drug interactions, long-term safety, and cost. Any attempt to choose "first choice" is therefore necessarily somewhat arbitrary because individual factors may make one drug inappropriate in one individual when its overall profile is well suited for another. **Table 61.1** lists drugs most likely to be appropriate for first use, those in which

TABLE 61.1 Drugs[a] Used in Treating Different Types of Seizures

Type of Seizure	Drugs of First Choice	Drugs to Consider in Selected Patients	Drugs Generally Reserved for Highly Refractory Patients
Focal Seizures			
Focal and secondarily generalized	Carbamazepine, lamotrigine, levetiracetam, oxcarbazepine, pregabalin, gabapentin, zonisamide	Eslicarbazepine, topiramate, lacosamide, valproate, clobazam	Phenytoin, primidone, phenobarbital, perampanel, brivaracetam, felbamate, cenobamate
Primary Generalized Seizures			
Generalized tonic-clonic	Lamotrigine, topiramate, levetiracetam, valproate, zonisamide	Eslicarbazepine, clobazam, carbamazepine, oxcarbazepine	Phenytoin, perampanel, felbamate
Absence	Valproate, ethosuximide	Lamotrigine, zonisamide, clobazam	Felbamate
Myoclonic	Valproate, clonazepam, clobazam, levetiracetam	Zonisamide	
Tonic/atonic	Valproate, clonazepam, clobazam, zonisamide	Felbamate, rufinamide	Cannabidiol

[a]Not all drugs have U.S. Food and Drug Administration approval for listed uses.

specific patients may benefit, and those whose overall profile makes them generally suitable only after failing other options.

Adverse Effects of Antiepileptic Drugs

All AEDs have undesirable effects in some patients. Although interindividual variation occurs, most adverse drug effects are mild and dose related. Many are common to virtually all AEDs, especially when treatment is started. These include sedation, mental dulling, impaired memory and concentration, mood changes, gastrointestinal upset, and dizziness. The incidence of particular adverse effects varies with the individual agent. In general, sedation and cognitive effects are less likely with lamotrigine, gabapentin, levetiracetam, or lacosamide than with older agents, especially in elderly persons. Some other adverse effects are relatively specific for particular drugs.

Dose-Related Adverse Effects

These typically appear when a drug is first given or when the dosage is increased. They usually, but not always, correlate with blood concentrations of the parent drug or major metabolites (Table 61.2). Dose-related side effects are always reversible on lowering the dosage or discontinuing the drug. An exception to this is the peripheral vision loss with vigabatrin, which may progress despite stopping the drug. Adverse effects frequently determine the limits of treatment with a particular drug and have a major influence on compliance with the prescribed regimen. Because dose-related side effects are broadly predictable, they are often the major differentiating feature in choosing among otherwise equally effective therapies.

Idiosyncratic Reactions

Idiosyncratic responses account for most serious and virtually all life-threatening adverse reactions to AEDs. Many AEDs can cause similar serious side effects (see Table 61.2), but with the exception of rash, these are fortunately rare. For example, the risk of carbamazepine-induced agranulocytosis or aplastic anemia is about 2 per 575,000; with felbamate, the risk of aplastic anemia may be as high as 1 per 5,000. Idiosyncratic reactions are not dose related; rather they arise either from an immune-mediated reaction to the drug or from poorly defined individual factors, largely genetic, that convey an unusual sensitivity to the drug. An example of the genetic mechanism is valproate-induced fatal hepatotoxicity. Valproate, like most AEDs, is metabolized in the liver, but several biochemical pathways are available to the drug. Clinical and experimental data indicate that one of these pathways results in a hepatotoxic compound that may accumulate and lead to microvesicular steatosis with necrosis. The extent to which this pathway is involved in biotransformation is age dependent and promoted by concurrent use of other drugs that are eliminated in the liver. Thus, most patients who have had fatal hepatotoxicity were younger than 2 years of age and treated with polytherapy (Table 61.3). In addition, most had severe epilepsy associated with mental retardation, developmental delay, or congenital brain anomalies. No hepatic deaths have occurred in persons older than 10 years treated with valproate alone.

No laboratory test, certainly not untargeted routine blood monitoring, identifies individuals specifically at risk for valproate hepatotoxicity or any other drug-related idiosyncratic reaction. Clinical data, however, permit identification of groups of patients at increased risk for serious adverse drug reactions, including patients with known or suspected metabolic or biochemical disorders, a history of previous drug reactions, and medical illnesses affecting hematopoiesis or liver and kidney function.

TABLE 61.2 Toxicity of Antiepileptic Drugs

Dose-Related Adverse Effects	
Systemic Toxicity	**More Common With**
Gastrointestinal (dyspepsia, nausea, diarrhea)	Valproate, phenobarbital, phenytoin, carbamazepine, oxcarbazepine
Benign elevation in liver enzymes	Valproate, phenobarbital, phenytoin, carbamazepine, oxcarbazepine
Benign leukopenia	Carbamazepine, oxcarbazepine
Gingival hypertrophy	Phenytoin
Weight gain	Valproate, gabapentin, pregabalin
Anorexia and weight loss	Felbamate, topiramate, zonisamide
Hair loss, change in hair texture	Valproate
Hirsutism	Phenytoin, valproate
Hyponatremia (typically benign)	Carbamazepine, oxcarbazepine, eslicarbazepine
Coarsening of facial features	Phenytoin
Osteoporosis	Phenytoin, phenobarbital, carbamazepine, valproate
Impotence	Phenobarbital, phenytoin, carbamazepine, topiramate
Neurologic Toxicity	**More Common With**
Drowsiness, sedation	Phenobarbital, benzodiazepines
Impaired cognition	Phenobarbital, topiramate
Depression and mood changes	Phenobarbital, levetiracetam, perampanel, topiramate
Insomnia	Felbamate
Peripheral visual field restriction	Vigabatrin
Dizziness/vertigo	Carbamazepine, oxcarbazepine, lamotrigine, phenobarbital, phenytoin
Nystagmus, diplopia	Carbamazepine, oxcarbazepine, lamotrigine, phenobarbital, phenytoin
Sensory neuropathy	Phenytoin
Idiosyncratic Reactions	
Rash (rare with clobazam, gabapentin, levetiracetam, pregabalin, valproate)	
Stevens-Johnson syndrome (especially phenobarbital, phenytoin, carbamazepine, lamotrigine)	
Aplastic anemia (especially felbamate)	
Hepatic failure (especially felbamate, valproate)	
Pancreatitis (especially valproate)	
Thrombocytopenia (especially valproate)	

Rash can occur with virtually any drug, and rarely, this results in Stevens-Johnson syndrome. The frequency of severe rash is about the same with carbamazepine, phenytoin, phenobarbital, and (if started slowly over several weeks) lamotrigine. Certain Asian populations are more prone to rash with these agents, associated with a human leukocyte antigen B subtype. There is some cross-reactivity among these drugs so that a patient who develops a rash with one has a slightly increased risk of developing a rash with another. Rash is unusual with valproate, gabapentin, pregabalin, or levetiracetam, although it is important to remember that allergic reaction can occur not only to the drug itself but also to inert ingredients such as dyes.

TABLE 61.3 Effect of Age and Treatment on Risk of Developing Fatal Valproate Hepatotoxicity[a]

Age	Monotherapy	Polytherapy
<2 y	1/7,000	1/500
>2 y	1/80,000	1/25,000

[a]Modified from Dreifuss FE, Santilli N, Langer DH, Sweeney KP, Moline KA, Menander KB. Valproic acid hepatic fatalities: a retrospective review. *Neurology*. 1987;37:379-385.

To date, life-threatening idiosyncratic effects have not been reported with gabapentin, pregabalin, topiramate, oxcarbazepine, levetiracetam, or lacosamide.

Antiepileptic Drug Pharmacology

Table 61.4 provides summary information about dose requirements, pharmacokinetic properties, and therapeutic concentration ranges for the major AEDs available in the United States. Of patients with epilepsy, 60% to 70% achieve satisfactory control of seizures with currently available AEDs, but the remainder continues to have disabling seizures despite optimal medical therapy.

Treatment should start with a single AED chosen according to the type of seizure or epilepsy syndrome and then be adjusted as necessary, by considerations of side effects, required dosing schedule, and cost. Phenytoin, phenobarbital, gabapentin, zonisamide, and levetiracetam can be loaded acutely when necessary although there can be transient adverse effects. Most drugs are initially studied in refractory patients with focal epilepsy, and therefore, initial approval is sometimes restricted; however, subsequent experience as well as randomized trials confirms that all are effective as initial monotherapy. In the absence of status epilepticus (see Chapter 6), AEDs are usually started at low dosages to minimize acute toxicity. They can then be increased according to the patient's tolerance and the drug's pharmacokinetics. The initial target dose should produce a serum concentration in the low- to midtherapeutic range. Further increases can then be titrated according to the patient's clinical progress, which is measured mainly by seizure frequency and the occurrence of drug side effects. A drug should not be judged a failure unless seizures remain uncontrolled at the maximal tolerated dosage, regardless of the blood level.

Dosage changes generally should not be made until the effects of the drug have been observed at steady-state concentrations (a time about equal to five drug half-lives). If the first drug is ineffective, an appropriate alternative should be gradually substituted (see Table 61.1). Combination treatment using two drugs should be attempted only when monotherapy with at least one,

TABLE 61.4 Antiepileptic Drugs: Dosage and Pharmacokinetic Data[a]

Drug	Usual Adult Dose 24 h (mg)	Half-life (h)	Usually Effective Plasma Concentration (μg/mL)	Time-to-Peak Concentration (h)	Bound Fraction (%)
Phenobarbital[b]	90-180	100	15-40	2-8	45
Phenytoin[b,c]	300-400	22	10-20	3-8	90-95
Carbamazepine[b,c]	800-1,600	8-22	8-12	4-8	75
Valproate[b,c]	1,000-3,000	15-20	50-120	3-8	80-90
Ethosuximide	750-1,500	60	40-100	3-7	<5
Felbamate	2,400-3,600	14-23	20-140	2-6	25
Gabapentin[c]	1,800-3,600	5-7	4-16[d]	2-3	<5
Lamotrigine[c]	100-500	12-60[e]	2-16[d]	2-5	55
Topiramate[c]	200-400	19-25[e]	4-10[d]	2-4	9-17
Vigabatrin	1,000-3,000	5-7	NE	1-4	5
Levetiracetam[b,c]	1,000-3,000	6-8	5-45[d]	1	<10
Oxcarbazepine[c]	900-2,400	8-10[f]	10-35[d]	3-13	40[f]
Zonisamide	100-600	24-60[e]	10-40[d]	2-6	40
Pregabalin[c]	150-600	5-7	NE	1	<5
Lacosamide[b]	200-400	12-16	5-10[d]	1-4	<15
Rufinamide	2,400-3,200	6-10	NE	4-6	34
Clobazam	10-60	36-42	NE	0.5-4	80-90
Perampanel	8-12	105	NE	0.5-2.5	95
Eslicarbazepine	800-1600	13-20	NE	1-4	<40
Brivaracetam[b]	50-200	9	NE	1	<20
Cannabidiol	700-1400	56-62	NE	2.5-5	>94
Cenobamate	200	50-60	NE	1-4	60

Abbreviation: NE, not established.
[a]Drugs are listed roughly in order of commercial availability.
[b]Intravenous formulation available.
[c]Extended release formulation available.
[d]Not established; corresponds to usual range in patients treated with recommended dose.
[e]Highly dependent on concurrently administered drugs.
[f]Of metahydroxy derivative, the active metabolite.

and preferably two, primary AEDs fails. Combination therapy is sometimes effective, but the price of improved seizure control is often additional drug toxicity. Sometimes, combination therapy with relatively nonsedating drugs (eg, carbamazepine, lamotrigine, gabapentin, or levetiracetam) is preferable to high-dose monotherapy with a sedating drug (eg, phenobarbital or primidone). When used together, carbamazepine and lamotrigine result in a pharmacodynamic interaction that often produces neurotoxicity at dosages that are usually well tolerated when either drug is used alone.

Dosing intervals should ideally be less than one-third to one-half the drug's half-life to minimize fluctuations between peak and trough blood concentrations. Large fluctuations can result in drug-induced side effects at peak levels and in breakthrough seizures at trough concentrations. Sometimes, however, a drug has a relatively long pharmacodynamic half-life, so that twice a day dosing is reasonable even if the pharmacokinetic half-life is short. This is typically the case with valproate, pregabalin, gabapentin, and levetiracetam. Extended-release formulations of most commonly used AEDs are available, which allow less frequent dosing and decreased peak and trough levels, thereby potentially improving tolerability and compliance. Bioavailability is not necessarily equivalent to immediate-release formulations (particularly for lamotrigine and valproate), and different extended-release delivery systems with alternate manufacturers of the same drug can also create variation in peak and trough levels as well as in total absorption.

Therapeutic drug monitoring has greatly improved the care of patients with epilepsy, but published therapeutic ranges are only guidelines. Most patients whose drug concentrations are within a standard therapeutic range usually achieve adequate seizure control with minimal side effects, but notable exceptions occur. Some patients develop unacceptable side effects at "subtherapeutic" concentrations; other obtain maximal seizure control only at "toxic" concentrations without adverse effects.

Determining serum drug concentrations when seizure control has been achieved, when seizures recur, or when side effects appear can assist management decisions. Drug levels are also useful in documenting compliance and in assessing the magnitude and significance of known or suspected drug interactions. Therapeutic drug monitoring is an essential guide to treating neonates, infants, young children, elderly persons, and patients with diseases (eg, liver or kidney failure) or physiologic conditions (eg, pregnancy) that alter drug pharmacokinetics. Although the total blood concentrations that are routinely reported are satisfactory for most indications, unbound (free) concentrations are useful when protein binding is altered, as in renal failure, pregnancy, extensive third-degree burns, and combination therapy using two or more drugs that are highly bound to serum proteins (eg, phenytoin and valproate).

Specific Drugs

Phenytoin

Phenytoin is thought to control seizures through voltage-dependent blockade of sodium channels. It is unique among AEDs due to nonlinear elimination at therapeutically useful serum concentrations. That is, hepatic enzyme systems metabolizing phenytoin become increasingly saturated at plasma concentrations greater than 10 to 12 μg/mL, and metabolic rate approaches a constant value at high concentrations. With increasing doses, phenytoin plasma concentrations rise exponentially (**Fig. 61.3**) so that steady-state concentration at one dose cannot be used to predict directly the steady-state concentration at a higher dose. Clinically, this requires cautious titration within the therapeutic range, using dose increments of 30 mg to avoid toxic effects. Phenytoin is also a strong enzyme inducer, therefore affecting the metabolism of many coadministered agents including many other AEDs. It is also highly protein bound, and free (active) levels can be unexpectedly high when coadministered with other highly protein-bound drugs or in medical conditions where protein binding sites are low (hypoalbuminemia). These complicated pharmacokinetic properties, along with relatively higher number of adverse effects and long-term toxicities compared with other AEDs, means that phenytoin is no longer a drug of first choice in most patients.

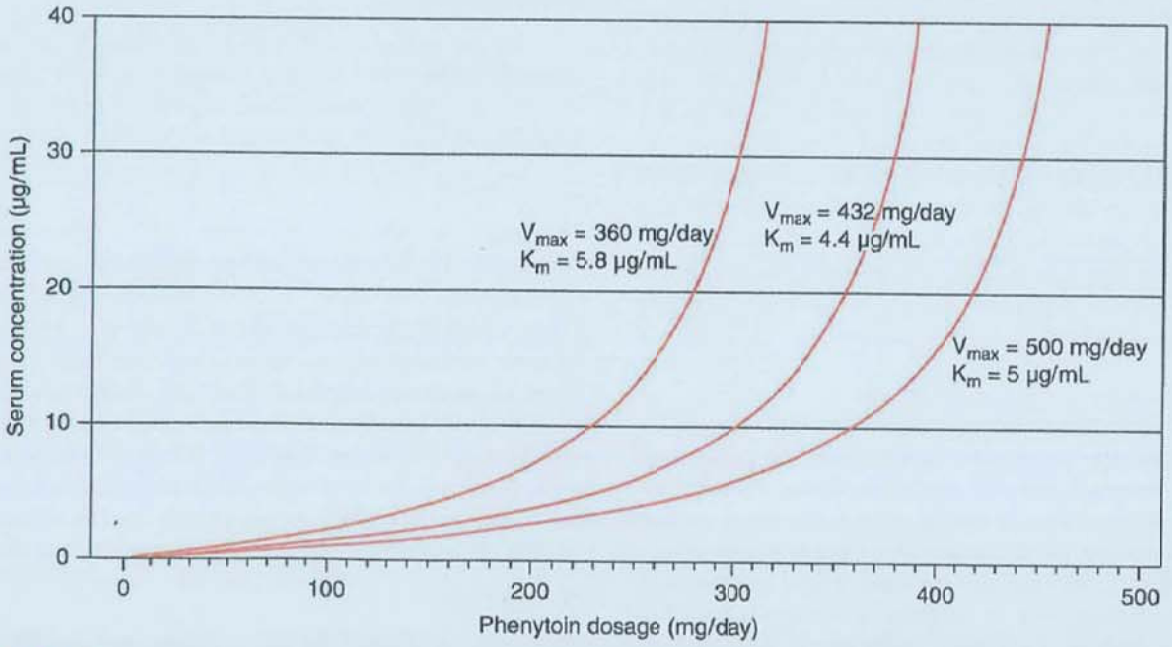

FIGURE 61.3 Phenytoin dose concentration curves from three representative adult patients. Note the markedly nonlinear relationship in the 200- to 400-mg dose range. Careful dose titration is necessary in this portion of the curve to avoid neurotoxicity. Abbreviations: K_m, Michaelis-Menten constant; V_{max}, maximum elimination rate.

Carbamazepine

Carbamazepine induces activation of the enzymes that metabolize it. The process, termed *autoinduction*, is time dependent. When carbamazepine is first introduced, the half-life approximates 30 hours. With increasing hepatic clearance in the first 3 to 4 weeks of therapy, however, the half-life shortens to 11 to 20 hours. As a result, the starting dose should be low and then increased gradually, and dosing should be frequent (3 or 4 times daily). Extended-release formulations permit twice a day administration. The principal metabolite is carbamazepine-10,11-epoxide, which is pharmacologically active. Under certain circumstances (eg, when coadministered with valproate or felbamate), the epoxide metabolite accumulates selectively, thereby producing neurotoxic effects even though the plasma concentration of the parent drug is in the therapeutic range or even low.

Oxcarbazepine

Oxcarbazepine and its active enantiomer, *eslicarbazepine*, are structurally similar to carbamazepine but are metabolized by a different pathway. As a result, there is no epoxide metabolite that is responsible for some of the adverse effects of carbamazepine. Although individual patients may tolerate oxcarbazepine or eslicarbazepine better than carbamazepine, the overall profiles of the drugs are similar, including development of leukopenia, mild increase in hepatic enzymes, and hyponatremia (all usually transient, asymptomatic, and benign). Pharmacologic half-life of the active metabolite of oxcarbazepine, a metahydroxy derivative, is 8 to 10 hours. Clinical studies support twice-daily dosing for oxcarbazepine, although peak toxicity can occur when this is done at higher dosages. The half-life of eslicarbazepine is longer (13-20 h) allowing once daily dosing.

Valproate

Valproate is highly bound to plasma proteins (like phenytoin), but the binding is concentration dependent and nonlinear. The unbound fraction increases at plasma concentrations greater than 75 μg/mL because protein-binding sites become saturated. For example, doubling the plasma concentration from 75 to 150 μg/mL can result in a more than sixfold rise in concentration of free drug (from 6.5 to 45 μg/mL). Therefore, as the dose of valproate is increased, side effects may worsen rapidly because of the increasing proportion of unbound drug. Furthermore, adverse effects may vary in the course of a single day or from day to day because concentrations of unbound drug fluctuate despite seemingly small changes in total blood levels. Additionally, circulating fatty acids displace valproate from protein-binding sites. If fatty acid levels are high, the amount of unbound valproate increases. Lamotrigine and felbamate prolong the half-life of valproate, and therefore, a reduced dosage is typically necessary when these drugs are added.

Gabapentin

Gabapentin requires an intestinal amino acid transport system for absorption. Because the transporter is saturable, the percentage of drug that is absorbed after an oral dose decreases with increasing dosage. More frequent dosing schedules using smaller amounts may therefore be necessary to increase blood levels. When dosages above 3,600 mg/day are used, blood levels can be helpful in demonstrating that an increase in dosage is reflected in an increased serum concentration. Gabapentin does not interact to any clinically significant degree with any other drugs, which makes it especially useful when AED polytherapy is necessary and in patients with medical illnesses that also require drug treatment. It is not metabolized in the liver, but as it is excreted unchanged by the kidneys, dose adjustment is required in patients with renal failure. Gabapentin binds to a subunit of a calcium channel thereby reducing calcium influx in overactive neurons. *Pregabalin* is structurally and mechanistically similar to gabapentin but does not show dose-dependent absorption. It has increased potency compared with gabapentin and can be effective with twice-daily dosing.

Lamotrigine

Lamotrigine is highly sensitive to coadministration of many other AEDs. Enzyme-inducing agents, such as phenytoin and carbamazepine, decrease the half-life of lamotrigine from 24 to 16 hours (or less) as do oral contraceptive agents. In contrast, enzyme inhibition by valproate increases the half-life of lamotrigine to 60 hours. Therefore, lamotrigine dosing depends very much on whether it is used as monotherapy or in combination with other AEDs. Lamotrigine concentrations are also lowered by administration of oral contraceptives, and levels can decrease dramatically during the latter months of pregnancy requiring frequent monitoring and dose adjustment. Lamotrigine has little or no effect on other classes of drugs. Rash occurs in about 10% of patients; it is more common in children and rarely leads to Stevens-Johnson syndrome. The incidence of rash can be minimized by slow titration schedules.

Levetiracetam

Levetiracetam, like gabapentin, has no appreciable interactions with other drugs and therefore has advantages in medically complicated patients. The plasma half-life is 6 to 8 hours, but clinical trials support twice-daily dosing, possibly owing to a longer pharmacodynamic half-life. Metabolism occurs in the liver, and there is also renal clearance. Adverse effects are generally mild and self-limited, although mood changes and even psychosis occur in a small subset of patients. No life-threatening idiosyncratic reactions have yet been described. It binds to a synaptic vesicle protein thereby limiting neurotransmitter release; this is felt to be its mechanism of seizure control.

Brivaracetam

Brivaracetam is structurally and mechanistically related to levetiracetam. Unlike levetiracetam, it does have some drug-drug interactions, notably increasing levels of phenytoin and carbamazepine epoxide. Adverse effects on mood are thought to be less common.

Topiramate

Topiramate is affected by other AEDs taken concurrently. Carbamazepine, phenytoin, and phenobarbital shorten its half-life; valproate has little effect. Topiramate does not affect most other drugs, although phenytoin blood levels may increase by 25%. Adverse cognitive effects, especially word-finding difficulty and impaired memory, frequently limit the dosage patients can tolerate. These are usually dose dependent and can be minimized with slow titration schedules. Cognitive effects are also less common in monotherapy. Glaucoma, anhydrosis, and renal stones occur rarely. Doses above 400 mg/day do not usually lead to better seizure control but are associated with an increasing incidence of side effects.

Zonisamide

Zonisamide is affected by other drugs that induce hepatic enzymes. As monotherapy, zonisamide's half-life is about 60 hours. When coadministered with enzyme-inducing drugs, its half-life

can be reduced to 24 hours. In either case, once-daily dosing is appropriate. Although its metabolism occurs primarily in the liver, zonisamide itself does not appear to affect other drugs. Rash, renal stones, and anhydrosis are rare side effects.

Felbamate

Felbamate has a much higher risk of serious adverse reactions, including aplastic anemia and hepatic failure, than other AEDs. The actual risk has been difficult to estimate but is probably between 1 per 5,000 and 1 per 20,000 exposures. For this reason, its use is currently restricted to patients who are refractory to other agents and in whom the risk of continued seizures outweighs the risk of side effects. Use of felbamate is also limited by other common but less serious adverse effects, including anorexia, weight loss, insomnia, and nausea, and by numerous complex drug interactions. Nonetheless, felbamate remains useful in cases of severe epilepsy such as Lennox-Gastaut syndrome.

Lacosamide

Lacosamide enhances the slow inactivation of sodium channels without affecting fast inactivation. It is approved for the treatment of partial-onset seizures. It may prolong the PR interval, which can result in cardiac conduction problems. A baseline electrocardiogram is suggested prior to initiating this drug in patients at risk for cardiac disease. Lacosamide is generally well tolerated and has no appreciable drug-drug interactions making it particularly useful as an add-on drug in refractory patients.

Rufinamide

Rufinamide is a triazole derivative whose exact mechanism is unknown. In vitro prolongs the inactive state of the sodium channels, thereby limiting repetitive firing of sodium ion–dependent action potentials mediating anticonvulsant effects. Its use is limited largely to refractory generalized epilepsies, especially in controlling tonic seizures.

Clobazam

Clobazam has been used in many countries around the world for both focal and generalized seizures, but it was only FDA approved in the United States for adjunctive treatment of Lennox-Gastaut syndrome. It is widely used off-label as monotherapy or adjunctive treatment for partial seizures. As a benzodiazepine there may be some increased risk of tolerance compared to other anticonvulsant drugs; however, this seems to occur much less frequently than with agents such as diazepam or lorazepam. There are also anxiolytic properties making this a useful agent when this is a comorbid condition. Serious reactions including Stevens-Johnson syndrome and toxic epidermal necrolysis have been reported.

Perampanel

Perampanel, which is FDA approved as an adjunctive medication in partial seizures, has a unique mechanism of action in that it is the first noncompetitive antagonist of the AMPA glutamate receptor. It comes with a boxed warning of dose-related serious neuropsychiatric events including homicidal thoughts and aggression. Being both an inducer and a substrate of the cytochrome P450 3A4 enzymes, drug interactions with other antiseizure medications exist.

Cannabidiol

Cannabidiol is a plant-based extract approved for treatment of refractory seizures associated with the Lennox-Gastaut syndrome and Dravet syndrome. Although placebo-controlled trials show efficacy in these conditions, it is not clearly more effective than other available compounds, adverse effects can occur, and as an extract administered in oil, absorption can be erratic. It is therefore reserved for when other treatments have failed to achieve sufficient results.

Cenobamate

Cenobamate is effective for focal onset seizures; some patients with refractory seizures became seizure free in clinical trials. Slow titration is required to reduce the possibility of severe reactions (drug reaction with eosinophilia and systemic symptoms). It may effect levels of several other AEDs including lamotrigine, carbamazepine, phenytoin and clobazam. It should be used with caution in patients with cardiac disease due to shortening of the QT interval.

Use of Generic Equivalents

Generic equivalents are available for the majority of anticonvulsant drugs, and these represent a more cost-effective treatment for most patients. Some degree of variability exists when changing between AED manufacturers, particularly with extended release preparations. Some studies suggest variability is not unlikely with drug peak and trough (due to variability in absorption time); however, total drug absorption is affected rarely. When in doubt, change in manufacturer should be limited whenever possible for an individual patient, and therapeutic drug monitoring can ensure no significant change in steady state level.

Discontinuing Antiepileptic Drugs

Epidemiologic studies indicate that 60% to 70% of patients with epilepsy become free of seizures for at least 5 years within 10 years of diagnosis. Similarly, prospective clinical trials of treated patients whose seizures were in remission for 2 years or more showed that a nearly identical percentage of patients remained seizure free after drug withdrawal LEVEL 1.[9] Chance of recurrence continues to decline with seizure freedom for 2 to 5 years. These studies also identified predictors that permit patients to be classified as being at low or high risk for seizure relapse after drug therapy ends. The risk of relapse was high if patients required more than one AED to control seizures, if seizure control was difficult to establish, if the patient had a history of generalized tonic-clonic seizures, and if the EEG was significantly abnormal when drug withdrawal was considered. Continued freedom from seizures is favored by longer seizure-free intervals (>4 y) before drug withdrawal is attempted, few seizures before remission, monotherapy, normal EEG, and no difficulty establishing seizure control.

All benign epilepsy syndromes of childhood carry an excellent prognosis for permanent drug-free remission. In contrast, juvenile myoclonic epilepsy has a high rate of relapse when drugs are discontinued, even in patients who have been seizure free for many years (at least 30%). The prognosis for most other epilepsy syndromes is largely unknown.

Discontinuing AED therapy in appropriate patients can be considered when they have been seizure free for at least 2 years. The most powerful argument for stopping AEDs is concern about long-term systemic and neurologic toxicity, which can be insidious and not apparent for many years after a drug has been introduced. On the other hand, however, is the concern of the patient or family about seizure recurrence. Even a single seizure can have disastrous psychosocial and vocational consequences,

particularly in adults. Therefore, the decision to withdraw drugs must be weighed carefully in the light of individual circumstances. For example, a woman who is considering pregnancy and has been seizure free for many years may wish to attempt withdrawal of AEDs before conceiving or a person who develops renal stones on topiramate could attempt withdrawal rather than change to another agent. If a decision is made to discontinue AEDs, we favor slow withdrawal, over 3 to 6 months, but this recommendation is controversial because few studies of different withdrawal rates have been conducted.

Reproductive Health Issues

Gender-based differences in AED pharmacokinetics, sex steroid hormones, and reproductive life events raise special issues for women with epilepsy. The management of pregnancy in a woman with epilepsy is discussed in detail in Chapter 129. This section focuses on the effects of reproductive hormones on seizures and on the effects of seizures and AEDs on reproductive health.

Although the prevalence of epilepsy is not higher in women, epilepsy in women can be specially affected by changes in reproductive steroids. Estrogen is a proconvulsant drug in animal models of epilepsy, whereas progesterone and its metabolites have anticonvulsant effects. Ovarian steroid hormones act at the neuronal membrane and on the genome to produce immediate and long-lasting effects on excitability. Estrogen reduces γ-aminobutyric acid–mediated inhibition, whereas progesterone enhances γ-aminobutyric acid effects. Estrogen also potentiates the action of excitatory neurotransmitters in some brain regions and increases the number of excitatory synapses. These dynamic and significant changes in neuronal excitability are observed with changes in estrogen and progesterone concentrations similar to those observed in the human menstrual cycle.

Approximately one-third of women with epilepsy report patterns of seizure occurrence that relate to phases of the menstrual cycle (*catamenial seizures*). Women with catamenial seizures indicate that seizures are more frequent, or more severe, just before menstruation and during the time of menstrual flow. In some women, seizures also increase at ovulation. These are times in the menstrual cycle when estrogen levels are relatively high and progesterone concentration is relatively low. Several small clinical trials have described benefit from chronic progesterone therapy in women with catamenial seizure patterns. Changes in seizures related to puberty and menopause are not well understood.

The pharmacokinetics of some AEDs can complicate epilepsy management in women. The AEDs that induce activity of the cytochrome P450 enzyme system (carbamazepine, phenytoin, phenobarbital, primidone, and, to a lesser extent, topiramate, clobazam, eslicarbazepine, oxcarbazepine, and perampanel) interfere with the effectiveness of estrogen-based hormonal contraception. In women taking these drugs, the metabolism and binding of contraceptive steroids is enhanced, thus reducing the biologically active fraction of steroid hormone. The failure rate of oral contraceptive pills exceeds 6% per year in women taking enzyme-inducing AEDs, in contrast to a failure rate of less than 1% per year in medication-compliant women without epilepsy. A woman motivated to avoid pregnancy should consider using a contraceptive preparation containing 50 μg or more of an estrogenic compound or using an additional barrier method of contraception. Alternatively, she should discuss with her physician the possibility of selecting an AED that does not alter steroid metabolism or binding. During pregnancy, clearance of many AEDs increases, requiring increasing doses to maintain an effective level. This is particularly true not only of lamotrigine, phenytoin, and carbamazepine but also can occur with levetiracetam, oxcarbazepine, and possibly other agents. Therapeutic monitoring monthly during pregnancy is recommended. If the dose has been substantially increased, this should be lowered over several weeks following delivery to avoid toxicity.

Reproductive health may be compromised in both women and men with epilepsy. Fertility rates for men and women with epilepsy are one-third to two-thirds those of men and women without epilepsy. Lower birth rates cannot be explained on the basis of lower marriage rates because marriage rates for women with epilepsy are now similar to those of nonepileptic women. Reduced fertility appears to be the direct result of a disturbance in reproductive physiology.

Men and women with epilepsy show a higher than expected frequency of reproductive endocrine disturbances. These include abnormalities both in the cyclic release and concentration of pituitary luteinizing hormone and prolactin and in the concentration of gonadal steroid hormones. Some of these abnormalities are likely to be a consequence of seizure activity. The AEDs can also alter concentrations of gonadal steroids by affecting steroid hormone metabolism and binding. The AEDs that increase steroid metabolism and binding reduce steroid hormone feedback at the hypothalamus and pituitary. The AEDs that inhibit steroid metabolism (eg, valproate) increase concentrations of steroid hormones, particularly androgens.

The polycystic ovary syndrome (PCOS) is a gynecologic disorder affecting approximately 7% of reproductive-age women. Women with epilepsy are at risk for developing features of this syndrome. Diagnostic requirements for PCOS are phenotypic or serologic evidence for hyperandrogenism and anovulatory cycles. Phenotypic signs of hyperandrogenism include hirsutism, truncal obesity, and acne. Hirsutism presents as increased facial and body hair, coarsening of pubic hair with extension down the inner thigh, and male-pattern scalp hair loss—temporal recession and thinning over the crown. Health consequences of PCOS include infertility, accelerated atherosclerosis, diabetes, and endometrial carcinoma, underscoring the importance of detection and treatment. As many as 30% of cycles in women with epilepsy are anovulatory, and anovulatory cycles appear to be most frequent in women receiving valproic acid. Women with epilepsy are more likely to have polycystic-appearing ovaries, which along with hyperandrogenism occur in as many as 40% of women with epilepsy receiving valproic acid. The long-term consequences of PCOS in women with epilepsy are unknown. Data such as these suggest that epilepsy and some AEDs individually affect fertility and that these effects may be additive. This implies that optimal therapy for epilepsy will consider disease-treatment effects on reproductive health.

Sexual dysfunction affects about one-third of men and women with epilepsy. Men report low sexual desire, difficulty achieving or maintaining an erection, or delayed ejaculation. Women with epilepsy can experience painful intercourse because of vaginismus and lack of lubrication. Although there are certainly psychosocial reasons for sexual dysfunction in some people with epilepsy, physiologic causes are demonstrable in others. Physiologic causes of sexual dysfunction include disruption of brain regions controlling sexual behavior by epileptogenic discharges, abnormalities of pituitary and gonadal hormones, and side effects of AEDs.

Although no anticonvulsant drug is known to be free of teratogenic effects, the risk is low and generally less than that of uncontrolled seizures during pregnancy. The exceptions to this are valproate and topiramate, both of which are associated with increased risk of congenital malformations in prospective monotherapy studies. Valproate has also been shown to carry a dose-dependent risk of decreased IQ compared with phenytoin, carbamazepine, and lamotrigine. In all cases, the lowest effective dose should be used, and polypharmacy should be avoided LEVEL 1 [13] particularly with valproate. Women with epilepsy who have difficulty conceiving, irregular or abnormal menstrual cycles, midcycle menstrual bleeding, sexual dysfunction, obesity, or hirsutism should be referred for a reproductive endocrine evaluation. Men with sexual dysfunction or difficulty conceiving should also have an endocrine evaluation and semen analysis. All the reproductive disorders seen in people with epilepsy are potentially treatable.

Bone Health

Persons with epilepsy are at greater risk for bone disease, which typically presents as pathologic fractures. Bone biochemical abnormalities described in people with epilepsy include hypocalcemia, hypophosphatemia, elevated serum alkaline phosphatase, elevated parathyroid hormone, and reduced levels of vitamin D and its active metabolites (Pack & Morrell, 2004). The most severe bone and biochemical abnormalities are found in patients receiving AED polytherapy and in those who have taken AEDs for a longer time. Effects are more pronounced with enzyme-inducing AEDs, especially phenytoin.

SURGICAL TREATMENT

Surgery should be considered when seizures are uncontrolled by optimal medical management and when they disrupt the quality of life. Quantifying these issues, however, has defied strict definition, perhaps deservedly, because intractability is clearly more than continued seizures. Only patients know how their lives differ from what they would like them to be; the concept of *disability* includes both physical and psychological components. Some patients with refractory seizures suffer little disability; others, for whatever reason, find their lives severely compromised by infrequent attacks. Still, others have had their seizures completely cured by surgery but are still disabled and incapable of functioning productively. Determining which patients are "medically refractory" and which are "satisfactorily controlled" can always be argued in the abstract. Fortunately in practice, there is usually general agreement about which patients should be referred for surgical evaluation.

Patients are less likely to benefit from further attempts at medical treatment if seizures have not been controlled after two trials of high-dose monotherapy using two appropriate drugs and one trial of combination therapy. These therapeutic efforts can be accomplished within 1 to 2 years; the detrimental effects of continued seizures or drug toxicity warrant referral to a specialized center after that time. The chance of surgical cure varies according to location and specific surgery but may be as high as 69% (Table 61.5).

There are few blanket contraindications to epilepsy surgery today, although patients with severe concurrent medical illness and progressive neurologic syndromes are usually excluded. Some centers prefer not to operate on patients with psychosis or other serious psychiatric disorder, those older than 60 years, and those with an IQ of less than 70. Patients in these categories, however, must be considered individually. Many patients who undergo corpus callosum section for atonic seizures associated with Lennox-Gastaut syndrome have IQs less than 70. Although surgery for epilepsy is increasingly performed in children, functional resections in infancy remain controversial for several reasons: the uncertain natural history of seizures in many of these patients; the unknown effects of surgery on the immature brain; and the lack of data about long-term neurologic, behavioral, and psychological outcomes.

Because of technical advances in imaging and electrophysiologic monitoring, epilepsy surgery is no longer automatically contraindicated in patients with multifocal interictal epileptiform abnormalities or even foci near language or other eloquent cortical areas.

TABLE 61.5 Outcome After Epilepsy Surgical Procedures[a]

Procedure	Seizure Free (%)	Improved (%)	Not Improved (%)	*n*
Anterior temporal lobectomy	69	22	9	3,579
Lesionectomy	67	22	12	293
Nonlesional extra-temporal neocortical resection	45	35	20	805
Hemispherectomy	67	21	12	190
Corpus callosum section	8	61	31	563

[a]Modified from Engel J Jr. *Surgical Treatment of the Epilepsies*. 2nd ed. New York, NY: Raven; 1993.

Resective Procedures

Focal brain resection is the most common type of epilepsy surgery. Resection is appropriate if seizures begin in an identifiable and restricted cortical area, if the surgical excision will encompass all or most of the epileptogenic tissue, and if the resection will not impair neurologic function. These criteria are met most often by patients with temporal lobe epilepsy, but extratemporal resections can also result in substantial benefit. The likelihood of complete seizure freedom varies somewhat by procedure; however, it is nearly always higher than with subsequent anticonvulsant trials. Very long-term outcome studies show some seizure recurrence, but most patients either have rare seizures or regain seizure freedom.

Anterior Temporal Lobe Resection

This resective procedure is the most common, but the operation varies in what is considered "standard," especially with regard to how much lateral neocortical and mesial limbic structures are removed. The traditional operation is Spencer's 1991 anteromedial temporal lobe resection, which includes removal of the anterior middle and inferior temporal gyri, parahippocampal gyrus, 3.5 to 4 cm of hippocampus, and a variable amount of amygdala. For nondominant foci, this approach may be slightly modified to include the anterior superior temporal gyrus as well. Patients with medial temporal lobe epilepsy associated with hippocampal sclerosis are ideal candidates because up to 80%

will become seizure free, with the remainder having substantial improvement. Results of a large multicenter study in the United States were reported by Spencer et al in 2003, confirming the high rates of complete seizure control following temporal lobe resection LEVEL 1.[11] A randomized controlled Canadian trial has demonstrated clear superiority of surgery over medical management in patients with medial temporal lobe epilepsy LEVEL 1.[12] Other methods of mesial temporal ablation have been reported, including Gamma Knife radiation and localized laser ablation. Overall, it is not clear if laser ablation is as efficatious for mesial temporal onset seizures as more traditional resection, however recovery time is much less, and there may be improved neuropsychological outcome as far less brain tissue is removed. If incompletely effective, a larger open resection could subsequently be performed.

Lesionectomy

Well-circumscribed epileptogenic structural lesions (cavernous angiomas, hamartomas, gangliogliomas, and mesial temporal sclerosis) can be removed by surgical resection or stereotactic laser ablation. The extent to which tissue margins surrounding the lesion are included in the resection depends on how the margins are defined (radiologic, visual, electrophysiologic, or histologic inspection) and the surgeon's preference. Seizures are controlled by this method in 50% to 60% of patients. A lesion involving the cerebral cortex should always be considered as the source of a patient's seizures, however for surgical treatment it must be supported by EEG (ictal and/or interictal, invasive when required).

Nonlesional Cortical Resections

When a lesion cannot be visualized by MRI, it is difficult to demonstrate a restricted ictal-onset zone outside the anterior temporal lobe. Although alternative imaging (PET or SPECT scan) may help identify the seizure-onset zone, this situation almost always requires placement of intracranial electrodes to map the extent of epileptogenic tissue and to determine its relation to functional brain areas. Outcome after nonlesional cortical resections is not as good as with anterior temporal lobectomy or lesionectomy, mainly because the boundaries of epileptogenic cortical areas often cannot be delineated precisely, and removal of all the epileptogenic tissue often is not possible.

Corpus Callosotomy

Section of the corpus callosum disconnects the two hemispheres and is indicated for treatment of patients with uncontrolled atonic or tonic seizures in the absence of an identifiable focus suitable for resection. Leaving the posterior 20% to 30% of the corpus callosum intact seems to reduce complications. Most patients referred for corpus callosotomy have severe and frequent seizures of multiple types, usually with mental retardation and a severely abnormal EEG (the Lennox-Gastaut syndrome).

Unlike resective surgery, corpus callosotomy is palliative, not curative. Nonetheless, it can be strikingly effective for generalized seizures, with 80% of patients experiencing complete or nearly complete cessation of atonic, tonic, and tonic-clonic attacks. This outcome is often remarkably beneficial because it eliminates falls and the associated self-injury. The effect on focal seizures, however, is inconsistent and unpredictable. Focal unaware seizures are reduced or eliminated in about half the patients, but seizures are exacerbated in about 25%. Therefore, refractory focal seizures alone are not an indication for corpus callosotomy. Similarly, absence, atypical absence, and myoclonic seizures either do not benefit or show an inconsistent response.

Hemispherectomy

Removal (hemispherectomy) or disconnection (functional hemispherectomy) of large cortical areas from one side of the brain is indicated when the epileptogenic lesion involves most or all of one hemisphere. Because hemispherectomy guarantees permanent hemiplegia, hemisensory loss, and usually hemianopia, it can be considered only in children with a unilateral structural lesion that has already resulted in those abnormalities and who have refractory unilateral seizures. Examples of conditions suitable for hemispherectomy include infantile hemiplegia syndromes, Sturge-Weber disease, Rasmussen syndrome, and severe unilateral developmental anomalies, such as hemimegalencephaly. In appropriate patients, the results are dramatic. Seizures cease, behavior improves, and development accelerates (see **Table 61.5**).

Preoperative Evaluation

The objective in evaluating patients for focal resection is to demonstrate that all seizures originate in a limited cortical area that can be removed safely. This determination requires more extensive evaluation than is necessary in the routine management of patients with epilepsy. The different tests used provide complementary information about normal and epileptic brain functions.

Video-EEG monitoring is necessary to record a representative sample of the patient's typical seizures to confirm the diagnosis and classification and also to localize the cortical area involved in ictal onset. Volumetric or other special MRI techniques may demonstrate unilateral hippocampal atrophy or other anatomic abnormalities that may be epileptogenic. The PET and ictal SPECT are useful in demonstrating focal abnormalities in glucose metabolism or cerebral blood flow that correspond to the epileptogenic brain region. Neuropsychological testing is useful in demonstrating focal cognitive dysfunction, especially language and memory. Intracarotid injection of amobarbital (the *Wada test*) to determine hemispheric dominance for language and memory competence is often necessary before temporal lobectomy (particularly involving a dominant or possibly dominant hemisphere), and mesial resection is typically not done if the remaining hemisphere has insufficient memory function. Although functional MRI reliably lateralizes language, determining memory competence of one temporal lobe has not yet been reliably established. Magnetoencephalogram (MEG) is an advanced non-invasive method of recording epileptic activity using magnetic fields produced by the flow of electrical current from epileptic cortex. This form of testing is used where other pre-surgical data are not helpful in localizing the epileptogenic zone, if the hypothesis about the epileptogenic zone is ambiguous, or if there is a paucity of interictal or ictal abnormalities on scalp EEG. It can also be used as a functional imaging test to map vital functions such as language, somatosensory and motor areas of the brain.

If noninvasive methods do not unequivocally localize the epileptogenic area, or if different noninvasive tests yield conflicting results, recording of seizures using intracranial electrodes is necessary before a definitive recommendation on surgical treatment. Intracranial electrode placement is also necessary when vital brain functions (language, motor cortex) must be mapped in relation to the planned resection. Two approaches are used

FIGURE 61.4 Position of stereotactic electroencephalogram electrodes in 51-year-old woman with refractory left temporal onset epilepsy, nonlesional (with brain lab left is left, reversed compared to magnetic resonance imaging). Electrodes of onset are circled. Bottom, electrographic onset. She became seizure free after laser ablation. Seizure onset in hippocampal head, body, and tail *(arrows)*.

with differing advantages and disadvantages. Stereotactically placed electrodes (stereo-EEG) allows the placement of multiple depth electrodes through small holes in the skull under MRI guidance. Deep structures (such as mesial temporal and insular) are more easily reached using this method, and targeting of specific lesions such as heterotopias is possible. Patients tolerate this well because no craniotomy is performed. Because each electrode pierces the cortex, however, there are relatively few contacts with the cortical surface, and mapping of eloquent cortex is limited (Fig. 61.4). Alternatively, grid and/or strips of electrodes can be placed directly on the cortical surface facilitating detailed mapping of both the seizure onset zone and eloquent cortex (Fig. 61.5). This does require a craniotomy and reasonable confidence in the zone of onset because extensive or bilateral implantation of grid electrodes carries greater risk of complications.

Neurostimulation in Drug-Resistant Epilepsy

When epilepsy surgery is not possible due to multiple foci of seizure onset or seizure onset in eloquent cortex that is not resectable, neurostimulation has emerged as an alternative to failed drug therapy.

Vagus Nerve Stimulation

The vagus nerve stimulator is an FDA-approved device for the treatment of medically refractory partial seizures. Like corpus callosotomy, vagus nerve stimulation (VNS) is a palliative procedure because very few patients become seizure free. The VNS is delivered via a stimulating lead attached to the left vagus nerve. The stimulus generator is implanted in the upper left chest. The device is usually programmed to give a 30-second electrical pulse every 5 minutes, although stimulus parameters can be adjusted to the requirements of an individual patient. In patients with aura, a magnetic wand can be used to deliver VNS on demand, which may abort seizure progression. About 55% of children have at least a 50% reduction in seizure frequency, which is comparable to the efficacy of new AEDs LEVEL 1.[13] In addition to stimulation on demand, newer models can be programmed to stimulate with increased heart rate (because this may be a signal of seizures onset); neither of these features has been subjected to randomized trials proving increased efficacy compared to standard VNS therapy. The VNS may be considered for seizures in children, for Lennox-Gastaut–associated seizures, and for improving mood in adults with epilepsy (Level C). The VNS may be considered to have improved efficacy over time. Children should be carefully monitored for site infection after VNS implantation. Chronic

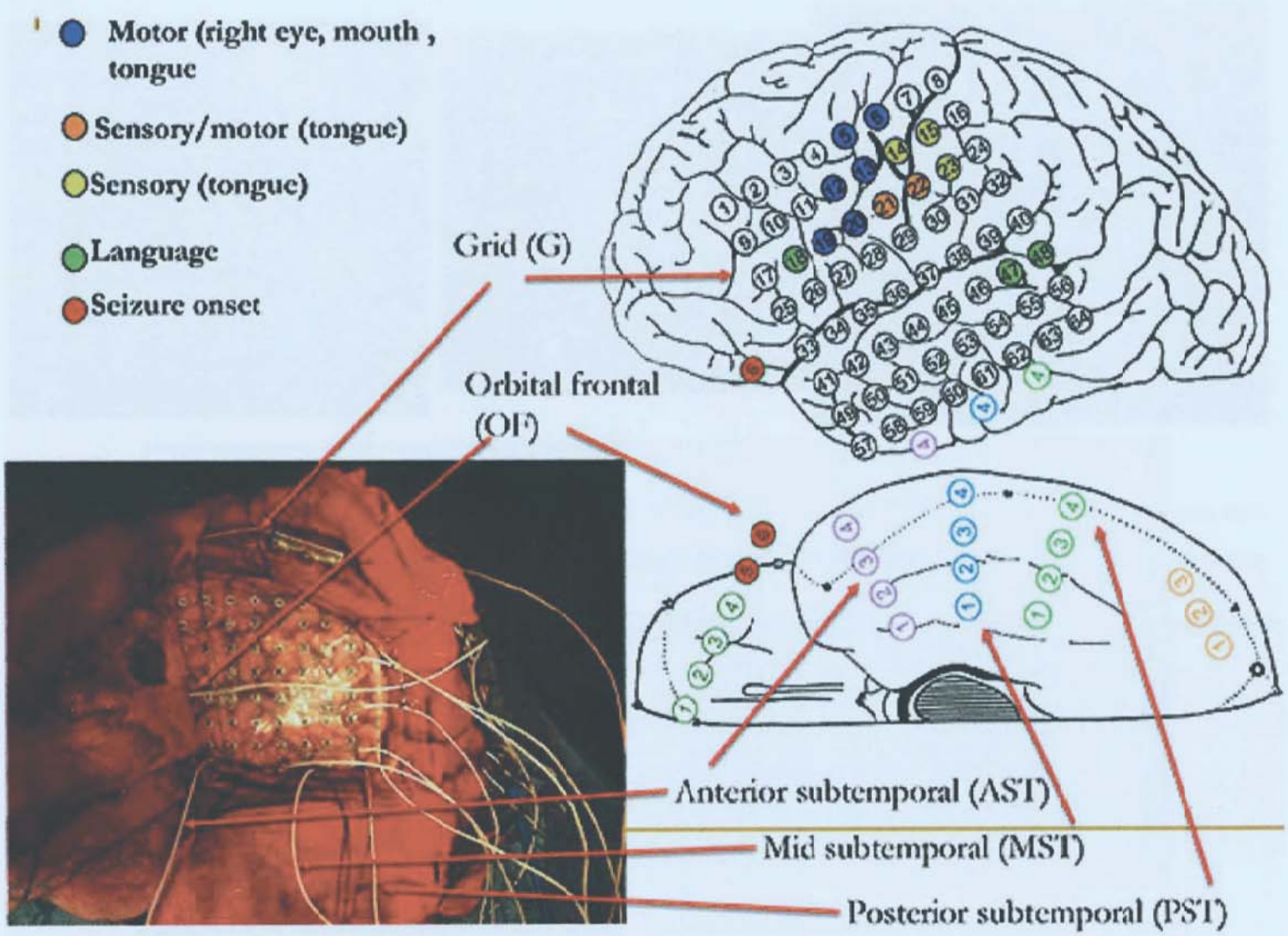

FIGURE 61.5 Intracranial grid implantation in a 29-year-old man with refractory focal epilepsy. Seizure onset maps to the electrode strip in the left anterior frontal region; this is distant from eloquent cortex demonstrated by cortical stimulation mapping.

adverse effects include hoarseness and difficulty swallowing, both of which increase at the time of stimulation.

Deep Brain Stimulation

Deep brain stimulation became FDA approved in 2018 for the add-on treatment of drug-resistant focal epilepsy in adults 18 years of age and older. The anterior nucleus of the thalamus, a core component of the Papez circuit, serves as a relay station that can amplify and synchronize seizure discharges from the hippocampus and the thalamus. Therefore, its inhibition by electrical stimulation is thought to abort or prevent seizures. Multicontact depth electrodes are implanted bilaterally into the anterior nuclei using a stereotactic approach. In the pivotal deep brain stimulation study, active stimulation was associated with a 40% decrease in seizure frequency compared with 14% reduction in the control (unstimulated) group. Depression (14.8% in active treatment vs 1.8% in controls) and memory impairment (13% in active treatment vs 1.8% in controls) were the most common adverse events. Asymptomatic hemorrhages occurred in 4.5% of subjects, but no disability or death was attributed to the hemorrhages. With long-term (open-label) follow-up, median seizure reduction at 5 years was 68% with 16% of subjects seizure free for at least 6 months.

Responsive Neurostimulation

The responsive neurostimulation system is FDA approved for individuals 18 years of age or older with drug-resistant epilepsy and partial-onset seizures that localize to no more than two epileptogenic foci. The NeuroPace device consists of a pulse generator, seizure detection software, and recording and stimulating intracranial electrodes. The intracranial electrodes may be depth or subdural strip electrodes and are placed at the seizure focus that is predetermined by surface/depth video EEG evaluation. Unlike the other systems described earlier which deliver a preprogrammed stimulation to prevent seizures, the responsive neurostimulation system continuously senses electrocorticographic activity at the seizure focus and responds with stimulation only when epileptiform activity is detected, with the aim of terminating the electrical component of the seizure at its point of origin. Responsive neurostimulation is tailored by the physician for each patient, according to the patient's report of their clinical response, as well as quantitative electrocorticographic data that the device provides. There may also be neuromodulatory effects of recurrent stimulation. The physician programs the stimulation pathway and the stimulation frequency, current, pulse width, and burst duration. The most common stimulation settings in the clinical trials were 100 to 200 Hz stimulation

frequency, 1.5 to 3 mA current, 160 μs pulse width, and 100 to 200 ms burst duration. In the pivotal trial which was randomized, prospective, double-blind, sham stimulation controlled, there was no difference in the rate of adverse events between the active and sham stimulation groups. However, the study demonstrated that patients with the device turned on had a 38% reduction in the average number of seizures per month, compared to a 17% reduction in the sham group. Long-term studies suggest further improvement over time, with median seizure reduction of 75% by year 9 and 19% with a seizure free period of at least 1 year.

Once the device is implanted, patients cannot have electroconvulsive therapy, transcranial magnetic stimulation, and diathermy procedures.

Status epilepticus is covered in Chapter 7.

PSYCHOSOCIAL AND PSYCHIATRIC ISSUES

The impact of epilepsy on the quality of life is usually greater than the limitations imposed by the seizures themselves. The diagnosis of epilepsy frequently carries other consequences that can greatly alter the lives of many patients. For adults, the most important problems are discrimination at work and driving restrictions, which lead to loss of mobility and independence. Children and adults alike may be shunned by uninformed friends. Patients must learn to avoid situations that precipitate seizures, and a change in lifestyle may be necessary. Common factors that increase the likelihood of seizure occurrence include sleep deprivation (whether due to lifestyle or to coexisting sleep disorders), alcohol (and other drugs), and emotional stress (**Table 61.6**). Compliance with AED treatment is often an issue, especially with adolescents. Psychiatric symptoms, especially depression, may complicate management.

Some restrictions are medically appropriate, at least for limited times. For example, when seizures impair consciousness or judgment, driving and certain kinds of employment (working at exposed heights or with power equipment) and a few other activities (swimming alone) should be avoided. On the other hand, legal prohibitions on driving vary in different states in the United States and in different countries and are often not medically justified. Employers frequently have unrealistic fears about the physical effects of a seizure, the potential for liability, and the impact on insurance costs. In fact, the Americans with Disabilities Act prohibits denying employment to persons with disability if the disability does not prevent them from meeting job requirements.

TABLE 61.6 Factors That Lower the Seizure Threshold

Common	Occasional
Sleep deprivation	Barbiturate/benzodiazepine withdrawal
Alcohol withdrawal	Hyperventilation (absence seizures)
Stress	Flashing lights (only photosensitive patients)
Dehydration	Diet and missed meals
Drugs and drug interactions	Specific "reflex" triggers
Systemic infection	
Trauma	
Malnutrition	
Noncompliance	

Children have special problems because their seizures affect the entire family. Parents may, with the best of intentions, handicap the child by being overly restrictive. The necessary and special attention received by the "sick" child may encourage passive manipulative behavior and overdependence while unintentionally exacerbating normal sibling rivalries.

The physician must be sensitive to these important quality of life concerns, even when they are not raised spontaneously by the patient or family. In fact, psychosocial issues often become the major focus of follow-up visits after the diagnosis has been made, the initial evaluation completed, and treatment started. We cannot emphasize too much the physician's responsibility to educate society to counter misperceptions and prejudices and to separate myth from medical fact. The Epilepsy Foundation (Landover, MD; www.epilepsy.com) and its nationwide system of affiliates have a wealth of materials about epilepsy suitable for patient, family, and public education.

Depression is common in people with epilepsy: Over half of patients with uncontrolled seizures are depressed. Even patients with well-controlled seizures have higher rates of depression than the general population. Suicide rates are tripled, with the highest rates seen in the 6 months after diagnosis. Patients should be observed for signs of depression and queried specifically about their mood, with attention to the potential need for psychiatric referral and initiation of antidepressant drugs. A simple screening tool developed specifically for use in people with epilepsy appears to allow rapid and accurate recognition of major depression. The FDA released an advisory indicating an increased risk of suicidal thoughts in patients enrolled in clinical trials (0.43% in patients adding any additional agent vs 0.22% for those adding placebo). Subsequent investigations suggest that increased suicidal ideation actually precedes AED prescription, suggesting that the AEDs do not exacerbate suicidality. Regardless, it is prudent to always consider depression particularly in newly diagnosed epilepsy patients.

Treatment of depression begins with optimal treatment of the seizure disorder. Barbiturate and succinimide drugs may adversely affect mood, inducing symptoms that mimic endogenous depression. Topiramate and levetiracetam seem to cause depression in a small minority of patients, whereas lamotrigine can occasionally improve depression. Levetiracetam and perampanel have also been associated with rare psychosis. Bupropion may lower the seizure threshold and is not a treatment of choice in patients with a diagnosis of epilepsy. Although tricyclic antidepressants reduce the seizure threshold in experimental models of epilepsy, this is not a practical concern because they only rarely trigger seizures or increase seizure frequency in humans. Monoamine oxidase inhibitors neither induce seizures nor increase seizure frequency. Modern electroconvulsive therapy does not worsen epilepsy. We have used all available selective serotonin reuptake inhibitors without exacerbating seizures.

Anxiety disorders are also common in epilepsy patients. When present, some AEDs can exacerbate the condition, mainly levetiracetam, topiramate, and zonisamide. Other agents (including gabapentin, pregabalin, and benzodiazepines) can improve anxiety. Of the benzodiazepines, only clonazepam and clobazam are used for chronic treatment of epilepsy.

The relation between psychosis and epilepsy is controversial. No convincing evidence shows that interictal psychosis is

a manifestation of epilepsy, but some demographic features are overrepresented in patients with epilepsy. Postictal psychosis is, however, a well-recognized and self-limited complication of epilepsy. Its cause is unknown, but it may represent a behavioral analog of Todd paresis. Symptoms typically appear 24 to 72 hours after a lucid interval following a prolonged seizure or cluster of seizures and are more common in patients with a history of encephalitis or a family history of neuropsychiatric problems. Postictal psychosis is more common with ambiguous localization on monitoring suggesting that broad, bilaterally distributed epileptogenic networks may be a risk factor. Delusions and paranoia are common. The psychosis is self-limited, usually to a few days, although symptoms occasionally last as long as 1 to 2 weeks. Treatment with haloperidol or risperidone is usually effective. In cases where postictal psychosis regularly follows clusters of seizures, chronic treatment with low-dose risperidone can be helpful. Long-term emphasis should be on improving seizure control. Phenothiazines, butyrophenones, and clozapine lower seizure threshold in experimental animals and occasionally seem to induce seizures in nonepileptic patients. Most occurrences have been associated with high drug doses or a rapid increase in dose. With the possible exception of clozapine, however, little evidence supports the notion that reasonable and conservative use of antipsychotic medications increases seizure frequency in patients with epilepsy.

Interictal aggressive behavior is not more common in people with epilepsy. Directed aggression during seizures occurs in less than 0.02% of patients with severe epilepsy; it is almost certainly less common in the general epilepsy population. Undirected pushing or resistance occasionally occur postictally when attempts are made to restrain confused patients.

Sudden Unexpected Death in Epilepsy

Patients with epilepsy overall are at a higher risk for unexpected death compared to the general population. This is particularly devastating as it can occur in otherwise young, healthy individuals. Death can be related to injury from seizures, status epilepticus, or suicide; however, the most common cause is sudden unexpected death in epilepsy (SUDEP), occurring at a rate of at least 0.35 per 1000 person-years, although other estimates are much higher. In candidates for epilepsy surgery, the risk is estimated at up to 9 per 1000 person-years. This is a standardized mortality ratio of at least 24 times that of the general population. The SUDEP rate peaks in young adulthood, however, may be underestimated in older individuals when sudden death may be attributed to other causes.

SUDEP is generally defined as sudden, unexpected, witnessed or unwitnessed death of people with epilepsy, with or without evidence of a preceding seizure, and not due to drowning or trauma. Increased risk is most strongly associated with uncontrolled generalized convulsions. This risk is yet another reason favoring aggressive treatment toward seizure freedom in all patients, particularly from convulsive seizures. Other associated risk factors include male sex, early-onset epilepsy, nocturnal seizures, sleeping alone, and intellectual disability. Some advocate use of smart watches to alert caregivers to unrecognized convulsions; however, it is not known whether these will reduce risk of SUDEP.

Compliance

The most common cause of breakthrough seizures is noncompliance with the prescribed therapeutic regimen. Only about 70% of patients take antiepileptic medications as prescribed. For phenytoin or carbamazepine, noncompliance can be inferred when sequential blood levels vary by more than 20%, assuming similarly timed samples and unchanged dosage. Persistently low AED levels in the face of increasing dosage also generally imply poor compliance. Caution is warranted with phenytoin, however, because as many as 20% of patients have low levels as a result of poor absorption or rapid metabolism.

Noncompliance is especially common in adolescents and elderly persons, when seizures are infrequent or not perceived as disabling, when AEDs must be taken several times each day, and when toxic effects persist. Compliance can be improved by patient education, by simplifying drug regimens (using less frequent dosing with extended-release preparations when appropriate), and by tailoring dosing schedules to the patient's daily routines. Pillbox devices that alert the patient to scheduled doses can be useful. When levels are inexplicably changed in patients who insist on compliance, variability in absorption (due to change in manufacturer or gastric motility) should be considered.

Psychogenic Seizures

Psychogenic nonepileptic seizures (PNES) are diagnosed in 20% to 30% of patients who present to epilepsy centers for difficult to control seizures. They are often misdiagnosed as epileptic seizures and are treated with antiseizure medications without adequate investigation, quite often resulting in significant morbidity. The estimates of prevalence of concurrent epilepsy among patients with PNES vary from 5% to 56%. PNES are believed to be a manifestation of an underlying psychological stress and are classified under conversion disorders, which are a type of somatoform disorder. A specific traumatic event at any point of time in the patient's life, including physical or sexual abuse, death of a loved one, divorce, or other similar loss may be identified in patients with PNES. The diagnosis of PNES can be challenging because the presentation of these seizures is very diverse; they can range from mimicking a generalized convulsion to less often an atonic event. Although no single semiologic feature is specific for diagnosing PNES, the motor manifestations usually are more asynchronous, variable, and fluctuating in intensity, and specific movements such as writhing, thrashing, pelvic thrusting, and opisthotonus are more suggestive of PNES (▶ Video 61.1). Ictal stuttering, weeping, and forced eye closure are relatively uncommon in epileptic seizures and are suggestive of, but not diagnostic of, PNES. In one study, the occurrence of an episode in the doctor's examination room was estimated to have a 75% predictive value for PNES. Video-EEG evaluation is almost always required to verify the diagnosis because descriptions of patients and onlookers are invariably incomplete and even trained medical personnel cannot reliably distinguish epileptic from nonepileptic seizures by visualization alone. The PNES also can occur in patients with concurrent epilepsy, further confounding accurate diagnosis of each event. Even with video-EEG recording, some frontal lobe seizures with bizarre semiologies can be misdiagnosed as PNES and often do not have an ictal EEG correlate. The key challenge is in presenting the diagnosis to patients because acceptance of the diagnosis is a very important factor in response to treatment and counseling. Psychiatric intervention is the mainstay of treating PNES and is individualized according to the underlying psychiatric comorbidity. Ideally after diagnosis, the patients should be followed by a neurologist and a psychiatrist with close dialogue between the two, and cautious decrease or discontinuation of the antiseizure medication should

be coordinated, where applicable. Neurologic follow-up should be maintained after the diagnosis, until the patient has been fully transitioned to psychiatric care.

Videos can be found in the companion e-book edition. For a full list of video legends, please see the front matter.

LEVEL 1 EVIDENCE

1. Temkin NR, Dikmen SS, Wilensky AJ, Chabal S, Winn HR. A randomized, double-blind study of phenytoin for the prevention of post-traumatic seizures. *N Engl J Med*. 1990;323:497-502.
2. Krumholz A, Wiebe S, Gronseth GS, et al. Evidence-based guideline: management of an unprovoked first seizure in adults: report of the Guideline Development Subcommittee of the American Academy of Neurology and the American Epilepsy Society. *Neurology*. 2015;84:1705-1713.
3. Mattson RH, Cramer JA, Collins JF, et al. Comparison of carbamazepine, phenobarbital, phenytoin, and primidone in partial and secondarily generalized tonic-clonic seizures. *N Engl J Med*. 1985;313:145-151.
4. Mattson RH, Cramer JA, Collins JF. A comparison of valproate with carbamazepine for the treatment of complex partial seizures and secondarily generalized tonic-clonic seizures in adults. The Department of Veterans Affairs Epilepsy Cooperative Study No. 264 Group. *N Engl J Med*. 1992;327:765-771.
5. Marson AG, Al-Kharusi AM, Alwaidh M, et al. The SANAD study of effectiveness of carbamazepine, gabapentin, lamotrigine, oxcarbazepine, or topiramate for treatment of partial epilepsy: an unblinded randomised controlled trial. *Lancet*. 2007;369(9566):1000-1015.
6. Kanner AM, Ashman E, Gloss D, et al. Practice guideline update summary: efficacy and tolerability of the new antiepileptic drugs I: treatment of new-onset epilepsy: report of the Guideline Development, Dissemination, and Implementation Subcommittee of the American Academy of Neurology and the American Epilepsy Society. *Neurology*. 2018;91(2):74-81.
7. Marson AG, Al-Kharusi AM, Alwaidh M, et al. The SANAD study of effectiveness of valproate, lamotrigine, or topiramate for generalised and unclassifiable epilepsy: an unblinded randomised controlled trial. *Lancet*. 2007;369(9566):1016-1026.
8. Kanner AM, Ashman E, Gloss D, et al. Practice guideline update summary: efficacy and tolerability of the new antiepileptic drugs II: treatment-resistant epilepsy: report of the Guideline Development, Dissemination, and Implementation Subcommittee of the American Academy of Neurology and the American Epilepsy Society. *Neurology*. 2018;91(2):82-90.
9. Medical Research Council Antiepileptic Drug Withdrawal Study Group. Randomised study of antiepileptic drug withdrawal in patients in remission. *Lancet*. 1991;337:1175-1180.
10. Harden CL, Meador KJ, Pennell PB, et al. Practice parameter update: management issues for women with epilepsy—focus on pregnancy (an evidence-based review): teratogenesis and perinatal outcomes: report of the Quality Standards Subcommittee and Therapeutics and Technology Assessment Subcommittee of the American Academy of Neurology and American Epilepsy Society. *Neurology*. 2009;73:133-141.
11. Spencer SS, Berg AT, Vickrey BG, et al. Initial outcomes in the multicenter study of epilepsy surgery. *Neurology*. 2003;61:1680-1685.
12. Wiebe S, Blume WT, Girvin JP, et al. A randomized, controlled trial of surgery for temporal-lobe epilepsy. *N Engl J Med*. 2001;345:311-318.
13. Morris GL III, Gloss D, Buchhalter J, Mack KJ, Nickels K, Harden C. Evidence-based guideline update: vagus nerve stimulation for the treatment of epilepsy: report of the Guideline Development Subcommittee of the American Academy of Neurology. *Neurology*. 2013;81:1453-1459.

SUGGESTED READINGS

Ali A, Wu S, Issa NP, et al. Association of sleep with sudden unexpected death in epilepsy. *Epilepsy Behav*. 2017;76:1-6.

Alper K, Kuzniecky R, Carlson C, et al. Postictal psychosis in partial epilepsy: a case-control study. *Ann Neurol*. 2008;63(5):602-610.

Bazil CW. *Living Well With Epilepsy*. New York, NY: HarperCollins; 2004.

Beghi E. Overview of studies to prevent posttraumatic epilepsy. *Epilepsia*. 2003;44(suppl 10):21-26.

Benardo LS. Prevention of epilepsy after head trauma: do we need new drugs or a new approach? *Epilepsia*. 2003;44(suppl 10):27-33.

Benbadis SR. Nonepileptic behavioral disorders: diagnosis and treatment. *Continuum (Minneap Minn)*. 2013;19(3 Epilepsy):715-729.

Berg AT, Shinnar S. The risk of seizure recurrence following a first unprovoked seizure: a quantitative review. *Neurology*. 1991;41:965-972.

Brodie MJ, French JA. Management of epilepsy in adolescents and adults. *Lancet*. 2000;356:323-329.

Cendes F. Febrile seizures and mesial temporal sclerosis. *Curr Opin Neurol*. 2004;17:161-164.

Chong DJ, Lerman AM. Practice update: review of anticonvulsant therapy. *Curr Neurol Neurosci Rep*. 2016;16:39

Christensen J, Vestergaard M, Mortensen PB, Sidenius P, Agerbo E. Epilepsy and risk of suicide: a population-based case-control study. *Lancet Neurol*. 2007;6 693-698.

Devinsky O, Hesdorffer DC, Thurman DJ, Lhatoo S, Richerson G. Sudden unexpected death in epilepsy: epidemiology, mechanisms, and prevention. *Lancet Neurol*. 2016;15(10):1075-1088.

Drugs for epilepsy. *The Medical Letter*. 2017;59:121-130.

Engel J Jr. *Surgical Treatment of the Epilepsies*. 2nd ed. New York, NY: Raven Press; 1993.

Engel J Jr, Pedley TA, eds. *Epilepsy: A Comprehensive Textbook*. 2nd ed. Philadelphia, PA: Lippincott Williams & Wilkins; 2008.

First Seizure Trial Group. Randomized clinical trial on the efficacy of antiepileptic drugs in reducing the risk of relapse after a first unprovoked tonic-clonic seizure. *Neurology*. 1993;43(3, pt 1):478-483.

Fisher R, Salanova V, Witt T, et al. Electrical stimulation of the anterior nucleus of thalamus for treatment of refractory epilepsy. *Epilepsia*. 2010;51(5): 899-908.

Gilliam FG, Barry JJ, Hermann BP, Meador KJ, Vahle V, Kanner AM. Rapid detection of major depression in epilepsy: a multicentre study. *Lancet Neurol*. 2006;5(5):399-405.

Hauser WA, Hesdorffer DC. *Epilepsy: Frequency, Causes and Consequences*. New York, NY: Demos; 1990.

Hauser WA, Rich SS, Lee JR, Annegers JF, Anderson VE. Risk of recurrent seizures after two unprovoked seizures. *N Engl J Med*. 1998;338:429-434.

Hirsch LJ, Hauser WA. Can sudden unexplained death in epilepsy be prevented? *Lancet*. 2004;364(9452):2157-2158.

Jones KE, Puccio AM, Harshman KJ, et al. Levetiracetam versus phenytoin for seizure prophylaxis in severe traumatic brain injury. *Neurosurg Focus*. 2008;25(4):E3.

Kanner AM, Nieto JC. Depressive disorders in epilepsy. *Neurology*. 1999;53(5 suppl 2):S26-S32.

Karceski S, Morrell M, Carpenter D. The expert consensus guideline series: treatment of epilepsy. *Epilepsy Behav*. 2001;2:A1-A50.

Kwan P, Brodie MJ. Early identification of refractory epilepsy. *N Engl J Med*. 2000;342:314-319.

Morrell MJ. Reproductive and metabolic disorders in women with epilepsy. *Epilepsia*. 2003;44(suppl 4):11-20.

Morrell MJ. Responsive cortical stimulation for the treatment of medically intractable partial epilepsy. *Neurology*. 2011;77(13):1295-1304.

Morrell MJ, Flynn K, eds. *Women With Epilepsy*. Cambridge, United Kingdom: Cambridge University Press; 2003.

Musicco M, Beghi E, Solari A, Vianin F. Treatment of first tonic-clonic seizure does not improve the prognosis of epilepsy. *Neurology*. 1997;49:991-998.

Pack AM, Morrell MJ. Epilepsy and bone health in adults. *Epilepsy Behav*. 2004;5(suppl 2):S24-S29.

Pedley TA, Hauser WA. Sudden death in epilepsy: a wake-up call for management. *Lancet*. 2002;359:1790-1791.

Pellock JM, Willmore LJ. A rational guide to routine blood monitoring in patients receiving antiepileptic drugs. *Neurology*. 1991;41:961-964.

Pennell PB. Use of antiepileptic drugs during pregnancy: evolving concepts. *Neurotherapeutics*. 2016;13:811-820.

Salazar AM, Jabbari B, Vance SC, Grafman J, Amin D, Dillon JD. Epilepsy after penetrating head injury. I. Clinical correlates: a report of the Vietnam Head Injury Study. *Neurology*. 1985;35:1406-1414.

Sillanpää M, Jalava M, Kaleva O, Shinnar S. Long-term prognosis of seizures with onset in childhood. *N Engl J Med*. 1998;338:1715-1722.

Spencer SS, Berg AT, Vickrey BG, et al. Predicting long-term seizure outcome after resective epilepsy surgery: the multicenter study. *Neurology*. 2005;65(6):912-918.

Sperling MR, Feldman H, Kirman J, Liporace JD, O'Connor MJ. Seizure control and mortality in epilepsy. *Ann Neurol*. 1999;46:45-50.

Sullivan JE, Dlugos DJ. Idiopathic generalized epilepsy. *Curr Treat Options Neurol*. 2004;6:231-242.

U.S. Food and Drug Administration. *Information for Healthcare Professionals: Suicidality and Antiepileptic Drugs*. Rockville, MD: U.S. Food and Drug Administration; 2008.

Watkins L, Shankar R, Sander JW. Identifying and mitigating sudden unexpected death in epilepsy (SUDEP) risk factors. *Expert Rev Neurother*. 2018;18(4):265-274.

62 Ménière Syndrome, Benign Paroxysmal Positional Vertigo, and Vestibular Neuritis

Ian S. Storper

KEY POINTS

1. Symptoms of Ménière disease include episodic hearing loss, tinnitus, vertigo, and/or aural fullness; not all patients get all symptoms.
2. Treatment of Ménière disease is tailored to the patient and can include low-sodium diet, diuretics, corticosteroid therapy, intratympanic gentamicin, and surgery.
3. Benign paroxysmal positional vertigo is characterized by episodic short-lived episodes of vertigo that occur with positional changes. Diagnosis is established by history and positive Dix-Hallpike maneuver. Usual treatment is by canalith repositioning maneuvers on a patient who can tolerate them.
4. Vestibular neuritis typically causes severe vertigo of sudden onset, which improves over days to weeks.
5. It is important to rule out central processes when the diagnosis is not absolutely clear.

INTRODUCTION

Three of the most common causes of peripheral vertigo are Ménière syndrome, benign paroxysmal positional vertigo (BPPV), and vestibular neuritis. Each syndrome has its own distinct type of vertigo. The purpose of this chapter is to explain the clinical presentation and current treatment principles of each syndrome to aid the clinician in diagnosis and management.

MÉNIÈRE DISEASE

Although Ménière disease was described over 140 years ago, little about it is understood. The condition is often progressive; with medical and surgical treatment options, however, disability may be averted or ameliorated. A recent study using health claims data from 60 million patients in the United States reports prevalence as 190 per 100,000 with a female-to-male ratio of 1.89:1. The prevalence increases with age.

This disease was first reported by Prosper Ménière in Paris in 1861. As described, patients typically suffered recurrent attacks of vertigo lasting from hours to days. Coincident with the attacks were episodes of unilateral hearing loss and roaring tinnitus. At first, the hearing loss and tinnitus occurred only with the attacks, but as the disease progressed, they became permanent. In 1943, Cawthorne added a fourth symptom: fullness in the affected ear. Table 62.1 lists the clinical features of Ménière disease. Although the cause of Ménière disease still remains unknown, it was postulated by Knapp in 1871 that symptoms were caused by dilatation of the endolymphatic compartment of the inner ear during attacks and renormalization afterward. This idea is still widely accepted because the vast majority of patients respond to sodium management.

TABLE 62.1 Ménière Disease Clinical Features

Episodes of the following:
• Unilateral hearing loss
• Tinnitus in affected ear
• Vertigo
• Fullness in affected ear

Definitions

Ménière disease is defined as the *idiopathic* occurrence of attacks of vertigo, hearing loss, tinnitus, or fullness in the affected ear. If a cause is assumed, the term is *Ménière syndrome*. The causes of Ménière syndrome are listed in Table 62.2.

Episodes typically last from hours to days. After an attack, the patient often feels "foggy" or tired. Initially, only one or two symptoms may be present, for example, a patient may experience only episodic vertigo; the hallmark is fluctuation. In the early stages, patients are often asymptomatic between attacks. With progression, low-frequency hearing loss can become permanent and may progress to all frequencies. Tinnitus is usually loud and roaring. Vertigo can be severe, a true spinning sensation of the patient or surroundings. Nausea, vomiting, sweating, and pallor are typical because the vertigo arises in the inner ear rather than in the brain. Some describe a linear motion or feel as if they are on a boat. Rarely, vertigo is noted only with change of position, mimicking BPPV. It is distinguishable because positional vertigo of Ménière disease occurs in attacks.

TABLE 62.2 Some Causes of Ménière Syndrome

• Trauma of the inner ear or rupture of the inner ear membranes
• Postinfectious: labyrinthitis, meningitis, Lyme disease, or otosyphilis
• Congenital anatomic abnormality
• Tumor, for example, vestibular Schwannoma pressing on the eighth nerves
• Vertebrobasilar insufficiency—central signs and symptoms are also seen

If left untreated, disequilibrium may persist between attacks of vertigo. More than half of Ménière sufferers are women, a fact possibly a ributable to hormonal causes of increased water retention. Symptoms may be worse prior to the menstrual cycle.

Typically, attacks become less frequent and less severe over time, with or without medical management. Within about 2 years of diagnosis, more than half of all patients are better, even without treatment. Treatment decreases the frequency and severity of attacks and minimizes permanent hearing or balance loss. Only 5% of medically treated patients progress to surgery.

About 10% of patients never experience vertigo; their disorder is termed *cochlear Ménière disease*. Ten percent of patients never experience auditory symptoms. The term *burned out Ménière disease* applies to the patient who has totally lost auditory and vestibular function. There is no loss of consciousness during Ménière attacks; if it occurs, neurologic disease is likely. A rare entity associated with Ménière disease is referred to as *drop attack* or *crisis of Tumarkin*, where the patient suddenly drops to the ground. Head injury may ensue.

Diagnosis

Ménière disease is diagnosed clinically; no test has sufficient sensitivity and specificity to be pathognomonic. Tests are used to rule out other disorders and to help confirm the diagnosis. Careful history and physical examination are essential. Ménière disease should be considered in any patient without other obvious cause who suffers episodic vertigo, hearing loss, tinnitus, or fullness in the ear. Ménière disease is not diagnosed unless symptoms have occurred at least twice. Between attacks, the examination is often normal, especially early in the disease. During an attack, a patient typically appears acutely vertiginous, with horizontal nystagmus beating toward the affected ear. If nystagmus is vertical, central nervous system disease is considered.

Tests that aid in the diagnosis of Ménière disease include audiometry (complete audiologic evaluation), videonystagmography, and magnetic resonance imaging (MRI). If the symptoms are bilateral, blood tests for autoimmune inner ear disease and infections are ordered. Early in the disease, the complete audiologic evaluation is often normal. Later, low-frequency sensorineural hearing loss can develop. Ultimately, hearing loss may also involve high frequencies. Rarely, the hearing asymmetries may be in the high frequencies rather than the low frequencies. During an attack, there may be hearing loss in the affected ear, which may resolve afterward. If conductive hearing loss is found, other diagnoses, such as superior semicircular canal dehiscence or cholesteatoma, should be considered.

Early in Ménière disease, the videonystagmography is usually normal because vestibular function recovers between attacks. As the disease progresses, caloric testing often yields a unilateral vestibular weakness. If testing is inadvertently performed during an attack, hyperfunction of the affected ear is usually seen. In end-stage disease, there is complete weakness (100%) in the affected ear. If central pathology is the cause of vertigo, caloric test results are usually normal. Gaze and positional testing, as well as optokinetic nystagmus testing, are often abnormal.

MRI is recommended for every patient with recurrent vertigo, asymmetric sensorineural hearing loss, or unilateral constant tinnitus. The study should include the brain and internal auditory canals, with and without gadolinium. This test evaluates intracranial pathology such as vestibular Schwannoma, stroke, or demyelination, which can cause these symptoms. If symptoms begin after age 60 years, Doppler examinations are performed to evaluate possible cerebrovascular disease. Electrocochleography is helpful in diagnosing Ménière disease. The test demonstrates high ratios of the summating potential/action potential in Ménière patients; sensitivity and specificity are not high enough for routine use. Once other causes are excluded, the most accurate way to establish the diagnosis is to determine whether it responds to treatment.

Medical Treatment

Therapy begins with diet and medication. Approximately 85% of patients respond very well, with significant decrease in frequency and severity of attacks. About 5% of patients find that therapy with diet and medication is inadequate and requires middle ear injections or surgery.

The standard for medical management is a low-sodium diet and thiazide diuretic. First, it should be ascertained that this is safe for the patient by consultation with their internist. A new patient should be started on a diuretic between attacks of vertigo. Diet should be a strict 1,500 mg/d sodium regimen; the patient should be informed that this requires checking labels carefully. If patients eat outside the home, it should be in places where they can limit the amount of sodium. Sodium intake should be even with each meal to avoid surges in pressure. Patients are advised to drink copious amounts of water to help flush out the sodium and maintain blood pressure. They are urged to avoid caffeine and alcohol, which are thought to aggravate symptoms. Emotional stress can also aggravate Ménière disease, and psychiatric consultation may be necessary.

Because sodium levels are hormonally regulated, adding a diuretic is useful. Typically, the patient is started on hydrochlorothiazide 37.5 mg/triamterene 25 mg once daily. This diuretic sheds sodium well and is required only once daily. Triamterene typically protects the potassium level. Electrolyte levels and renal function should be monitored periodically while this diuretic is being taken. Discontinuation or dose adjustment may be required. Patients should be advised that it can take a few weeks to know if this regimen is beneficial.

Vestibular suppressants can help control vertigo during attacks. Anticholinergic drugs are useful because they are not severely sedating. The author prefers glycopyrrolate 2 mg orally twice daily as needed during attacks. An alternative is meclizine 12.5, 25, or 50 mg orally up to 3 times daily. Although meclizine is effective, it is sedating. Benzodiazepines are also vestibular suppressants. Diazepam 5 mg orally 3 times daily during attacks can be useful but is also sedating and habit-forming. It should be used with caution if vertigo does not respond to the other drugs mentioned. Corticosteroids may also be beneficial. Table 62.3 summarizes medical treatment of Ménière disease.

TABLE 62.3 Medical Treatment of Ménière Disease

• 1,500 mg/d sodium diet and increased water intake
• Thiazide diuretic
• Vestibular suppressants
• Anticholinergics
• Antihistamines
• Benzodiazepines
• Corticosteroids

In the event of intractable vertigo with nausea and vomiting, an emergency room visit may be necessary. Intravenous hydration should be administered, being careful not to overload the patient with sodium. Promethazine 75 mg intramuscularly or droperidol 0.625 mg intravenously are useful for emergencies, but both are heavily sedating.

Surgical Management

Surgical treatments for Ménière disease may be destructive or conservative. In all cases, these operations are performed only if symptoms persist despite medical optimization.

Conservative Procedures

Endolymphatic Shunt

These procedures are designed to decrease the pressure in the endolymphatic compartment by shunting the fluid out of it. Current shunting procedures are performed under general anesthesia by drilling medially through the mastoid cortex down to the endolymphatic sac, opening it, and allowing the fluid to drain into the mastoid cavity.

In the past, shunts were controversial. The controversy arose in the 1980s when a Danish group found similar vertigo control in patients who had undergone endolymphatic shunts to those who had undergone only mastoidectomy ("sham procedures"). However, the same data were reevaluated in 2000 by Welling and Nagaraja LEVEL 1.[1] In comparing the shunt group to the sham group, vertigo control was significantly better in the shunt group, nausea and vomiting were significantly less in the shunt group, and tinnitus was significantly less in the shunt group. Sood et al in 2014 published a meta-analysis of all articles citing results from this operation according to current guidelines from 1970 to 2013. They report that endolymphatic shunt controls vertigo effectively in 75% of patients who failed medical treatment LEVEL 3.[2] Complications of shunt procedures are rare and do not differ significantly from those of mastoidectomy. It is a reasonable first procedure for patients with good hearing and mild to moderate vertigo.

Vestibular Neurectomy

The vestibular nerve can be separated from the cochlear nerve and sectioned. Although the vestibular nerve is cut, this procedure is generally considered a conservative procedure because hearing is preserved. The risks of craniotomy must be considered, and the indications are more stringent. Patient selection criteria for vestibular neurectomy include episodic disabling vertigo owing to Ménière disease, serviceable hearing in the affected ear, and failure of medical management. Moreover, there must be unilateral vestibular weakness in the affected ear on caloric testing but not 100%. This procedure should not be performed on the side of an only hearing or significantly better hearing ear. The results of vestibular neurectomy are excellent. Vertigo is controlled in 94% of patients. Hearing loss, tinnitus, and fullness are unaffected; the patient must continue on low-sodium diet and diuretic. Complications include sensorineural hearing loss in 2% to 3% of patients, cerebrospinal fluid leak in 5% to 12%, temporary unsteadiness in up to 25%, headache in 10%, and tinnitus in 7%. As intratympanic gentamicin injection theoretically provides a similar result without having to undergo craniotomy (see text which follows), it is often tried prior to vestibular neurectomy. Vestibular neurectomy should be performed in patients with disabling episodic vertigo or in those who have failed shunt surgery and/or intratympanic gentamicin treatment.

TABLE 62.4 Surgical Options for Ménière Disease

• Endolymphatic shunt
• Vestibular neurectomy
• Labyrinthectomy

Destructive Procedures Labyrinthectomy

In this operation, the vestibular portion of the inner ear is destroyed and all five end organs are removed. Because the hearing in the operated ear is destroyed, this procedure is limited to patients with no serviceable hearing in the affected ear; who suffer from episodic, disabling vertigo; and in whom medical management has failed. This is the standard for vertigo control in patients with no hearing. Vestibular weakness must be shown in the affected ear on caloric testing but not 100%. Labyrinthectomy typically eradicates attacks of vertigo about 95% of the time. Aside from temporary postoperative unsteadiness in 10% of patients, the risks of this procedure do not differ significantly from those of mastoidectomy. Table 62.4 lists surgical options for Ménière disease.

Other Treatment Methods

Intratympanic and Oral Corticosteroids

Intratympanic dexamethasone given at regular intervals has been described as a method of controlling episodes of Ménière disease, which continue despite adherence to low-sodium diet and diuretic therapy LEVEL 2.[3] Typically, three perfusions of dexamethasone 24 mg/mL separated by 10 minutes are performed for a total of 1 mL. Repeat injections may be necessary for recurrent symptoms. This modality may also be used for severe episodes of vertigo or hearing loss, along with or without oral corticosteroids depending on whether a patient can take them safely; consultation with an internist, endocrinologist, gastroenterologist, and/or psychiatrist is recommended if there is any question about patient safety with oral corticosteroids. In general, intratympanic doses do not cause systemic effects.

Intratympanic Gentamicin

Gentamicin is instilled into the middle ear, which provides a pathway into the inner ear via the round window. This aminoglycoside preferentially destroys vestibular hair cells over cochlear hair cells. Results vary. Vertigo control is about 80%, but there is significant incidence of sensorineural hearing loss. In one study, it was found that patients given intratympanic gentamicin had a statistically significant decrease in pure tone average and speech discrimination scores but that patients undergoing vestibular neurectomy did not. Vertigo control was achieved in 80% of patients given gentamicin and in 95% of patients with neurectomy. In another study, 90% of patients had complete initial control of vertigo after gentamicin, but 29% had recurrence after 4 months. In a third more recent study, 85% of patients had complete control of vertigo from gentamicin perfusion, but hearing was decreased in 25.6% LEVEL 2.[4-6] Gentamicin is less effective for vertigo control than surgery. There is risk of postprocedure long-term unsteadiness. In 2014, Casani et al demonstrated less long-term unsteadiness and hearing loss using a lower dose regimen. With these lower risks, because this modality does not require craniotomy, it is now often performed instead of vestibular neurectomy.

Vestibular neurectomy may still be performed in certain cases or when intratympanic gentamicin is ineffective and the patient has serviceable hearing.

Meniett Device

This device delivers pressure pulses to the inner ear via a tympanostomy tube to generate gradients in the endolymphatic compartment via the round window. The device is worn for 5 minutes 3 times per day. Significant benefit from the use of this device has not been clearly demonstrated.

Streptomycin

This drug has been banned by the U.S. Food and Drug Administration because of its inner ear toxicity. However, it is useful for end-stage patients with bilateral Ménière disease who still have attacks of vertigo and no hearing. The drug is administered intramuscularly, in regular doses, until caloric responses disappear. The drug eradicates the remaining vestibular function. Obtaining and administering this drug requires government approvals. Use of this drug has largely been replaced with intratympanic gentamicin.

BENIGN PAROXYSMAL POSITIONAL VERTIGO

BPPV has been described as the most common cause of peripheral vertigo with prevalence from 10.7 to 64 cases per 100,000 and prevalence over a lifetime of 2.4%. The average age of onset is from 50 to 60 years, with a 2 to 3:1 female-to-male ratio. It was first described by Barany in 1921. Patients report episodic vertigo sensations, which are caused by head motion; often, patients describe it as being aggravated by arising from or getting into bed or tossing during sleep. These episodes can be intense and can cause a fall. Characteristically, there is no vertigo if there is no head motion. Each episode typically lasts for less than a minute. There is no hearing loss, tinnitus, or fullness in the ear associated with this condition. The incidence increases with age and there is a slight female-to-male predominance. Approximately half of cases occur after head trauma.

This disorder is thought to be caused by dislodgment of otoconia—calcium carbonate crystals normally present in the utricle or saccule—into the semicircular canals. These crystals add inertia to the torsion-pendulum model of semicircular canal activation. When there is a mismatch of inertia between the two ears, there is disagreeing signal sent along the right and left vestibular nerves, resulting in nystagmus and a sensation of vertigo until the inner ear motion has stopped. This condition is self-limited; it, however, can be present for an extended period of time prior to dissipating. This condition most commonly occurs in the posterior semicircular canal and occasionally the horizontal semicircular canal; it rarely occurs in the superior semicircular canal.

Diagnosis is established by provocative positional maneuvers. For posterior canal BPPV, the Dix-Hallpike maneuver is performed, where the patient's head is turned toward the affected side and they lie back quickly, extending the neck. If the maneuver is positive, vertical-torsional nystagmus is seen for a number of seconds, with latency and fatigability. For horizontal canal BPPV, diagnosis is established by seeing horizontal nystagmus with latency and fatigability when rolling the head to the affected side in the supine position. Diagnosing superior canal

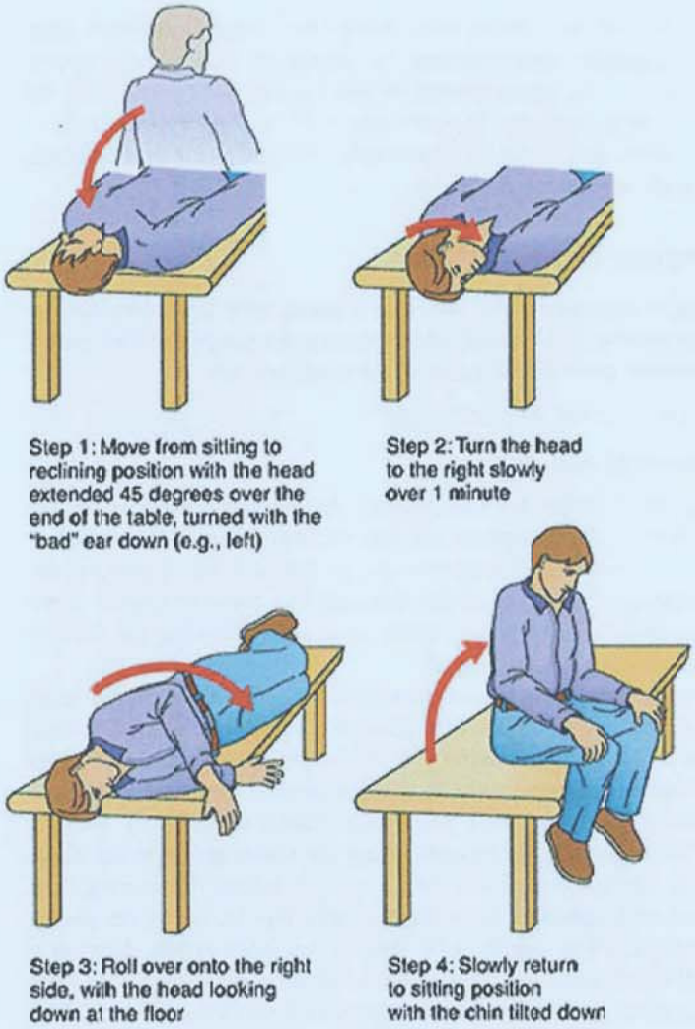

FIGURE 62.1 The Modified Epley maneuver. (From Mayer SA, Marshall RS, eds. Headache. In: *On Call: Neurology*. 4th ed. St. Louis, MO: Elsevier; 2020:211.)

BPPV involves eliciting vertical nystagmus and central lesions need to be excluded. These maneuvers should not be performed unless neurovascular problems have been excluded first.

Treatment involves canalith repositioning maneuvers, thought to dislodge the crystals and allow them to drop out into a safe compartment of the inner ear. Although there are numerous maneuvers, the most common ones are those described by Epley in 1992. For posterior semicircular canal BPPV, the maneuver consists of five steps: (1) Dix-Hallpike maneuver; (2) turning the head to the opposite side; (3) rolling over onto the opposite side, head downward; (4) sitting up and then turning the head forward; and (5) tucking the chin (Fig. 62.1). The maneuver is repeated until nystagmus dissipates. The patient is instructed to keep their head level for the next 48 hours. This maneuver is highly successful but sometimes has to be repeated over multiple sessions. Physical therapists can be consulted. For severe, recalcitrant cases, singular neurectomy can be offered.

VESTIBULAR NEURITIS

Vestibular neuritis (or vestibular neuronitis) was described by Dix and Hallpike in 1952. It is a clinical syndrome where a patient develops severe vertigo, often associated with nausea, vomiting, and/or prostration, which resolves over a period of

days to weeks. There are no other neurologic deficits, and there is no loss of consciousness. In general, older age portends a prolonged and possibly incomplete recovery. Vestibular neuritis has an incidence of about 3.5 cases per 100,000 persons. Typical age of onset is between 30 and 60 years, and there is no gender difference. Approximately 30% of affected individuals suffered an upper respiratory infection preceding their symptoms.

The cause of this condition has been postulated to be reactivation of herpes simplex or other neurotropic virus, but this has not been proven. Histologic findings performed postmortem on individuals who have suffered this condition have shown an atrophic superior vestibular nerve and ganglion.

Treatment is supportive. Hydration may be required, and during the intense period, vestibular suppressants are helpful. They should be discontinued as soon as reasonable as they can prolong recovery time. Imaging studies such as MRI and computed tomography angiography are typically ordered to rule out neurovascular or other central causes. Patients usually exhibit nonfatigable horizontal nystagmus at presentation. After the initial severe vertigo has dissipated, recovery time can be prolonged in some individuals whence vestibular rehabilitation can be beneficial. A recent study showed that corticosteroids administered over the first 3 weeks after onset improved symptoms more quickly than vestibular rehabilitation but that long-term results were similar LEVEL 1.[7] For patients taking a long time to recover, vestibular rehabilitation may be beneficial.

CONCLUSION

The clinical syndromes of three of the most common types of peripheral vertigo have been discussed. It should be remembered that there are numerous other causes of peripheral and central vertigo to be considered when evaluating patients.

LEVEL 1 EVIDENCE

1. Welling DB, Nagaraja HN. Endolymphatic mastoid shunt: a reevaluation of efficacy. *Otolaryngol Head Neck Surg*. 2000;122:340-345.
2. Sood AJ, Lambert PR, Nguyen SA, Meyer TA. Endolymphatic sac surgery for Ménière's disease: a systematic review and meta-analysis. *Otol Neurotol*. 2014;35(6):1033-1045.
3. McRackan TR, Best J, Pearce EC, et al. Intratympanic dexamethasone as a symptomatic treatment for Ménière's disease. *Otol Neurotol*. 2014;35:1638-1640.
4. Hillman TA, Chen DA, Arriaga MA. Vestibular neurectomy vs intratympanic gentamicin for Meniere's disease. *Laryngoscope*. 2004;114:216-222.
5. Kaplan DM, Nedzelski JM, Chen JM, Shipp DB. Intratympanic gentamicin for the treatment of unilateral Meniere's disease. *Laryngoscope*. 2000;110:1298-1305.
6. Wu IC, Minor LB. Long-term hearing outcome in patients receiving intratympanic gentamicin for Ménière's disease. *Laryngoscope*. 2003;113:815-820.
7. Goudakos JK, Markou KD, Psillas G, Vital V, Tsaligopoulos M. Corticosteroids and vestibular exercises in vestibular neuritis. Single-blind randomized clinical trial. *JAMA Otolaryngol Head Neck Surg*. 2014;140:434-440.

SUGGESTED READINGS

Alexander TH, Harris JP. Current epidemiology of Meniere's syndrome. *Otolaryngol Clin North Am*. 2010;43:965-970.

Barany R. Diagnose von krankheitserscheinungen im bereiche des Otolithenapparates. *Acta Otolaryngol*. 1921;2:434-437.

Brackmann DE. Surgical treatment of vertigo. *J Laryngol Otol*. 1990;104:849-859.

Casani AP, Cerchiai N, Navari E, et al. Intratympanic gentamicin for Meniere's disease: short- and long-term follow-up of two regimens of treatment. *Otolaryngol Head Neck Surg*. 2014;150:847-852.

Coelho DH, Lalwani AK. Medical management of Ménière's disease. *Laryngoscope*. 2008;118(6):1099-1108.

Dix M, Hallpike C. The pathology, symptomatology and diagnosis of certain common disorders of the vestibular system. *Proc R Soc Med*. 1952;45:341-354.

Epley JM. The canalith repositioning procedure: for treatment of benign paroxysmal positional vertigo. *Otolaryngol Head Neck Surg*. 1992;107:399-404.

Gates GA, Green JD. Intermittent pressure therapy of intractable Meniere's disease using Meniett device: a preliminary report. *Laryngoscope*. 2002;112:1489-1493.

Kim J-S, Zee DS. Clinical practice. Benign paroxysmal positional vertigo. *N Engl J Med*. 2014;370:1138-1147.

Knapp H. A clinical analysis of the inflammatory affections of the inner ear. *Arch Ophthalmol*. 1871;2:204-283.

McKenzie KG. Intracranial division of the vestibular portion of the auditory nerve for Meniere's disease. *CMAJ*. 1936;34:369-381.

Ménière P. Memoire sur des lesions de l'orielle interne donnant lieu a des symptoms de congestion cerebrale apoplectiforme. *Gaz Med Paris*. 1861;16:597-601.

Paparella MM, Hanson DG. Endolymphatic sac drainage for intractable vertigo (method and experiences). *Laryngoscope*. 1976;86:697-703.

Parry RH. A case of tinnitus and vertigo treated by division of the auditory nerve. *J Laryngol Otol*. 1904;19:402-406.

Portmann G. Vertigo: surgical treatment by opening the saccus endolymphaticus. *Arch Otolaryngol*. 1927;6:309-319.

Richard C, Linthicum FH Jr. Vestibular neuritis: the vertigo disappears, the histological traces remain. *Otol Neurotol*. 2012;33:e59-e50.

Sekitani T, Imate Y, Noguchi T, Inokuma T. Vestibular neuronitis: epidemiological survey by questionnaire in Japan. *Acta Otolaryngol Suppl*. 1993;503:9-12.

Storper IS, Spitzer JB, Scanlan M. Use of glycopyrrolate in the treatment of Meniere's disease. *Laryngoscope*. 1998;108:1442-1445.

Thirlwall AS, Kundu S. Diuretics for Ménière's disease or syndrome. *Cochrane Database Syst Rev*. 2006;(3):CD003599.

Thomsen J, Bretlau P, Tos M, et al. Placebo effect in surgery for Meniere's disease. A double-blind, placebo-controlled study on endolymphatic sac shunt surgery. *Arch Otolaryngol*. 1981;107:271-277.

Transient Global Amnesia 63

John C. M. Brust

KEY POINTS

1. Transient global amnesia is characterized by sudden onset of anterograde and retrograde amnesia, with gradual clearing over hours.
2. Attacks recur in a minority of patients.
3. Neither transient ischemic attack nor seizure disorder appear to be the cause in the great majority of cases.

INTRODUCTION

Transient global amnesia (TGA) is characterized by sudden inability to form new memory traces (*anterograde amnesia*) in addition to retrograde memory loss for events of the preceding days, weeks, or even years.

EPIDEMIOLOGY

Patients are usually middle aged or elderly and otherwise healthy. Recurrent attacks occur in 15% to 30% of cases, and fewer than 3% have more than three attacks. Intervals between attacks range from 1 month to 19 years.

PATHOBIOLOGY

The cause of TGA is uncertain. Case-control series and anecdotal reports variably implicate seizures, stroke, or migraine. Against an epileptic basis for TGA are the infrequency of recurrence, absence of other seizure phenomena, and normal electroencephalogram even during attacks. In transient epileptic amnesia, attacks are usually less than an hour in duration, tend to occur on awakening, are often accompanied by other ictal symptoms, and are likely to recur; ictal and interictal electroencephalogram abnormalities are often present, and symptoms respond to anticonvulsant therapy.

TGA has been anecdotally described in association with carotid artery occlusion and amaurosis fugax, with infarction of the inferomedial temporal lobe, the cingulate gyrus, or the retrosplenial corpus callosum and as a complication of cerebral angiography (especially vertebral). In large series, however, major risk factors for stroke (hypertension, diabetes mellitus, tobacco, ischemic heart disease, atrial fibrillation, and past stroke or transient ischemic attack [TIA]) are no more common among patients with TGA than in age-matched controls, and TGA is not a risk factor for stroke. The vast majority of TGA attacks last more than an hour; the vast majority of TIAs last less than an hour. Studies addressing a possible association of TGA with cardiac valvular disease or patent foramen ovale have been inconsistent. Patients with amnestic stroke owing to documented posterior cerebral artery occlusion do not report previous TGA; their neurologic signs usually include more than simple amnesia (eg, visual impairment), and they infrequently exhibit repetitive queries. Reduced blood flow to the thalamus or temporal lobes has been documented during attacks of TGA but could be secondary to neuronal dysfunction rather than its cause. TGA symptoms were reported in nine patients with aortic dissection, five of whom had no chest pain.

Valve incompetence of the internal jugular vein is present in many patients with TGA, raising the possibility of cerebral venous congestion during Valsalva-like activities. Intracranial venous reflux during Valsalva maneuver could not be demonstrated in the same patients, however, and such a mechanism is unlikely to explain symptoms that last hours and seldom recur.

Epidemiologic studies confirm an association of TGA with migraine, even though in most migraine patients, headache attacks are recurrent, whereas attacks of TGA are not. Sometimes, both amnestic and migrainous attacks (including visual symptoms and vomiting) occur simultaneously or follow one another. A case report described a man with repeated episodes of TGA associated with sexual activity whose spells cleared as long as he took the β-blocker metoprolol. Cortical spreading depression (possibly the pathophysiologic basis of cerebral symptoms of migraine) could, by affecting the hippocampus, explain some cases of TGA.

CLINICAL MANIFESTATIONS

During attacks, which affect both verbal and nonverbal memory, there is often bewilderment or anxiety and a tendency to repeat one or several questions (eg, "Where am I?"). Physical and neurologic examinations, including mental status, are otherwise normal. Immediate registration of events (eg, serial digits) is intact, and self-identification is preserved. Attacks last minutes or hours, rarely longer than a day, with gradual recovery. Retrograde amnesia clears in a forward fashion, often with permanent loss for events occurring within minutes or a few hours of the attack; there is also permanent amnesia for events during the attack itself. Headache frequently accompanies attacks; less often, there is nausea, dizziness, chills, flushing, or limb paresthesias. TGA is frequently precipitated by physical or emotional stress, such as sexual intercourse, driving an automobile, pain, photogenic events, or swimming in cold water. Because amnesia can accompany a variety of neurologic disturbances, such as head trauma, intoxication, partial complex seizures, or dissociative states, criteria for diagnosing TGA should include observation of the attack by others.

Permanently impaired memory following an acute attack is rare, although subtle defects have been reported.

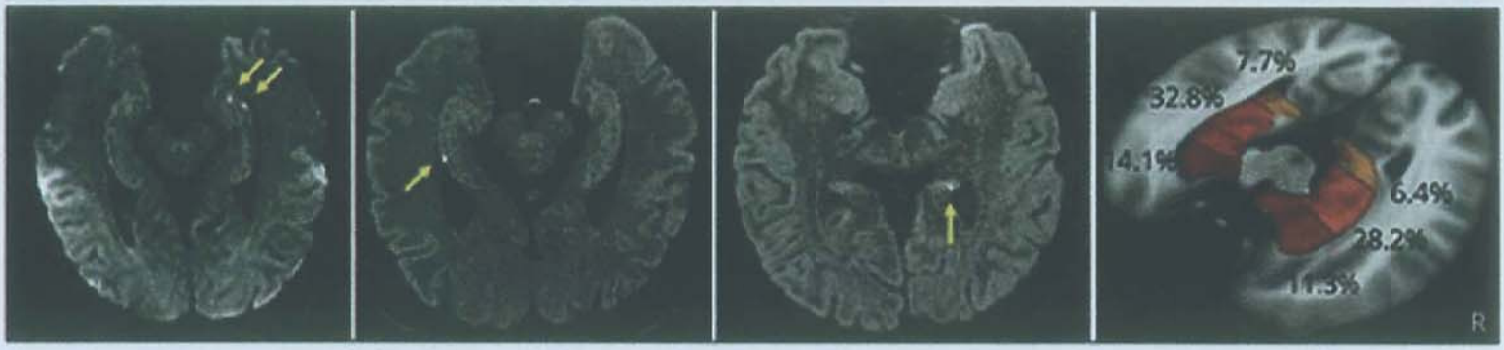

FIGURE 63.1 Examples of lesions in the head, body, and tail of the hippocampus (arrows) as well as the frequency of lesion locations in the different hippocampal areas. (Reproduced with permission from Szabo K, Hoyer C, Caplan LR, et al. Diffusion-weighted MRI in transient global amnesia and its diagnostic implications. *Neurology*. 2020;95[2]:e206-e212.)

DIAGNOSIS

Diffusion-weighted magnetic resonance imaging detects highly focal lesions in the CA1 field of the hippocampus in 70% of TGA patients, bilaterally in only 12%, with maximum sensitivity 12-48 hours after TGA onset (ie, not neccessarily during the acute memory impairment) and disappearing over several weeks (Fig. 63.1). Magnetic resonance spectroscopy identified reversible lactate peaks within the same lesions, consistent with ischemia. Functional magnetic resonance imaging during the acute phase of amnesia identified reversible reduced functional connectivity bilaterally in hippocampi and other temporolimbic regions considered part of an "episodic memory network."

TREATMENT

A study of 142 cases plus literature review suggested three subgroups of TGA (excluding patients with epilepsy or TIA). In women, TGA was mainly associated with an emotional precipitating event and a history of anxiety or depression. In men, attacks are more often followed a physical precipitating event perhaps associated with a Valsalva maneuver. In younger patients, an association with migraine was most prominent. Thus, even when strict diagnostic criteria are applied, TGA probably has diverse origins. In patients in whom epilepsy and migraine can be excluded and who have risk factors for cerebrovascular disease, antiplatelet drugs should be considered, but the benign natural history makes it difficult to evaluate any preventive treatment.

SUGGESTED READINGS

Agosti C, Akkawi NM, Borroni B, Padovani A. Recurrency in transient global amnesia: a retrospective study. *Eur J Neurol*. 2006;13:986-989.

April MD, Fossum K, Hounshell C, Stolper K, Spear L, Semelrath K. A sinister cause of anterograde amnesia: painless aortic dissection. *Am J Emerg Med*. 2015;33:e5-e7.

Baracchini C, Tonello S, Farina F, et al. Jugular veins in transient global amnesia: innocent bystanders. *Stroke*. 2012;43:2289-2292.

Bartsch T, Alfke K, Deuschl G, Jansen O. Evolution of hippocampal CA-1 diffusion lesions in transient global amnesia. *Ann Neurol*. 2007;62:475-480.

Bartsch T, Alfke K, Wolff S, Rohr A, Jansen O, Deuschl G. Focal MR spectroscopy of hippocampal CA-1 lesions in transient global amnesia. *Neurology*. 2008;70:1030-1035.

Bartsch T, Butler C. Transient amnestic syndromes. *Nat Rev Neurol*. 2013;9:86-97.

Berli: P. Successful prophylaxis of recurrent transient global amnesia with metoprolol. *Neurology*. 2000;55:1937-1938.

Bilo L, Meo R, Ruosi P, de Leva MF, Striano S. Transient epileptic amnesia: an emerging late-onset epileptic syndrome. *Epilepsia*. 2009;50(suppl 5):58-51.

Chen ST, Tang LM, Lee TH, Ro LS, Lyu RK. Transient global amnesia and amaurosis fugax in a patient with common carotid artery occlusion—a case report. *Angiology*. 2000;51:257-261.

Eustache F, Desgranges B, Laville P, et al. Episodic memory in transient global amnesia: encoding, storage, or retrieval deficit? *J Neurol Neurosurg Psychiatry*. 1999;66:148-154.

Gallardo-Tur A, Romero-Godoy J, de la Cruz A, Arboix A. Transient global amnesia associated with an acute infarction at the cingulate gyrus. *Case Rep Clin Med*. 2014;2014:418180. doi:10.1155/2014/418180.

LaBar KS, Gitelman DR, Parrish TB, Mesulam MM. Functional changes in temporal lobe activity during transient global amnesia. *Neurology*. 2002;58:638-641.

Lin K-H, Chen Y-T, Fuh J-L, et al. Migraine is associated with a higher risk of transient global amnesia: a nationwide cohort study. *Eur J Neurol*. 2014;21:718-724.

Mangla A, Navi BB, Layton K, Kamel H. Transient global amnesia and the risk of ischemic stroke. *Stroke*. 2014;45:389-393.

Peer M, Nitzan M, Goldberg I, et al. Reversible functional connectivity disturbances during transient global amnesia. *Ann Neurol*. 2014;75:634-643.

Quinette P, Guillery-Girard B, Dayan J, et al. What does transient global amnesia really mean? Review of the literature and thorough study of 142 cases. *Brain*. 2006;129(pt 7):1640-1658.

Romero JR, Mercado M, Beiser AS, et al. Transient global amnesia and neurological events: the Framingham Heart Study. *Front Neurol*. 2013;4:47. doi:10.3389//fneur.2013.00047.

Sedlaczek O, Hirsch JG, Grips E, et al. Detection of delayed focal MR changes in the lateral hippocampus in transient global amnesia. *Neurology*. 2004;62(12):2165-2270.

Szabo K, Hoyer C, Caplan LR, et al. Diffusion-weighted MRI in transient global amnesia and its diagnostic implications. *Neurology*. 2020;95(2):e206-e212.

Toledo M, Pujadas F, Grivé E, et al. Lack of evidence for arterial ischemia in transient global amnesia. *Stroke*. 2008;39:476-479.

Acute Bacterial Meningitis 64

Karen L. Roos

KEY POINTS

1. Acute bacterial meningitis is a purulent infection in the meninges and the subarachnoid space that is rapidly complicated by diffuse cerebral edema, increased intracranial pressure, hydrocephalus, ischemic and hemorrhagic stroke, seizures, and coma.
2. The clinical presentation of bacterial meningitis includes two or more of the following four symptoms and signs: (1) fever (≥38.5°C), (2) headache, (3) nuchal rigidity, and (4) an altered level of consciousness. A symptom that is often present, but underrecognized as a symptom of central nervous system infection, is vomiting.
3. When acute bacterial meningitis is a possibility, obtain Gram stain and blood cultures, serum procalcitonin, and C-reactive protein and begin empiric adjunctive and antimicrobial therapy. Empiric antimicrobial therapy should include therapy for viral encephalitis and a tickborne bacterial infection during the season when ticks are biting.

INTRODUCTION

Acute bacterial meningitis is a purulent infection in the meninges and the subarachnoid space that is rapidly complicated by diffuse cerebral edema, increased intracranial pressure, hydrocephalus, ischemic and hemorrhagic stroke, seizures, cerebritis, and cranial nerve palsies. The complications associated with acute bacterial meningitis make this infection distinctly different than acute viral meningitis. In the latter, infection is limited to the meninges and the subarachnoid space. Bacterial meningitis involves "more than the meninges." When the clinical presentation raises a suspicion for bacterial meningitis, empiric therapy is initiated prior to the diagnostic workup, and modified once the disease is either ruled out, or the meningeal pathogen is identified and treatment guided by antimicrobial sensitivities.

ETIOLOGY

The most common causative organisms of community-acquired bacterial meningitis are *Streptococcus pneumoniae* and *Neisseria meningitidis*.

The most important antecedent illnesses for pneumococcal meningitis are pneumonia, acute otitis media, and acute sinusitis. Whereas the pneumococcal conjugate vaccines have decreased the incidence of otitis media and bacteremia due to *S pneumoniae*, the number of serotypes of *S pneumoniae* in the vaccines is 13% of the number of serotypes of *S pneumoniae*, and the increased incidence of pneumococcal meningitis due to a serotype not in the vaccines is concerning.

In children and adolescents ages 2 to 18 years, *N meningitidis* has been the most common pathogen, but the incidence of meningitis due to this organism has decreased with the immunization of children and adolescents with the tetravalent (serogroups A, C, W-135, and Y) meningococcal vaccine. No vaccine was available in the United States for serogroup B until an outbreak of meningococcal meningitis due to serogroup B occurred at Princeton University followed by outbreaks at eight other American Universities between 2013 and 2016. Vaccination against serogroup B meningococcus (MenB vaccine) has since become a standard recommendation from the Advisory Committee on Immunization Practices as part of the compulsory vaccination schedule of many American universities and for person aged 10 years and older with complement deficiency and anatomic or functional asplenia (including sickle cell disease).

Although *S pneumoniae* and *N meningitidis* are the most common causative organisms of community-acquired meningitis, age, predisposing, and associated conditions put the individual at risk for meningitis due to other organisms (Table 64.1). In the neonatal age group, group B streptococci and *Escherichia coli* are the most common meningeal pathogens. The causative organisms of meningitis associated with otitis media, mastoiditis, or sinusitis are *Streptococci* species (including *S pneumoniae*), gram-negative anaerobes, *Staphylococcus aureus*, *Haemophilus* species, or Enterobacteriaceae. Patients with congenital or acquired deficiency in the terminal common complement pathway (C3 and C5-C9), immunoglobulin deficiency or asplenia are at risk for meningitis due to encapsulated organisms, specifically *N meningitidis* and *S pneumoniae*. Patients with meningitis due to encapsulated organisms should have diagnostic testing for deficiencies of complement or immunoglobulins and functional asplenia (ie, sickle cell disease).

Listeria monocytogenes is a causative organism of bacterial meningitis and brainstem encephalitis in individuals with impaired cell-mediated immunity from age (neonates and adults older than 50 years of age), immunosuppressive therapy, pregnancy, and chronic illness.

Meningitis complicating endocarditis may be due to viridans streptococci, *S aureus*, *Streptococcus bovis*, the HACEK group, or enterococci. The vegetation on the heart valve is a source of septic emboli to the brain. Infective endocarditis causes bacterial meningitis, brain abscess, ischemic and hemorrhagic stroke, and cerebral mycotic aneurysms.

Staphylococci, gram-negative bacilli, or anaerobes are the most common organisms causing meningitis in the postneurosurgical

TABLE 64.1 Meningeal Pathogen Based on Predisposing and Associated Conditions

Predisposing Condition	Bacterial Pathogen
Neonate	Group B streptococcus, *Escherichia coli*, *Listeria monocytogenes*
Children and adults—community acquired	*Streptococcus pneumoniae* and *Neisseria meningitidis*
Otitis, mastoiditis, sinusitis	Streptococci species (anaerobic, aerobic, and viridans) Gram-negative anaerobes (*Bacteroides* species, *Fusobacterium* species), Enterobacteriaceae (*Proteus* species, *E coli*, *Klebsiella* species, *Enterobacter* species, *Serratia* species) *Staphylococcus aureus*, *Haemophilus influenzae*
Adults older than the age of 55 and those with chronic illness	*S pneumoniae*, gram-negative bacilli, *N meningitidis*, *L monocytogenes*, *H influenzae*
Endocarditis	Viridans streptococci, *S aureus*, *Streptococcus bovis*, HACEK group,[a] Enterococci
Immunosuppressed	*S pneumoniae*, *L monocytogenes*, *H influenzae*
Postneurosurgical	Staphylococci, gram-negative bacilli
Intraventricular device	Staphylococci, gram-negative bacilli, anaerobes

[a]The HACEK group is *Haemophilus* species, *Actinobacillus actinomycetemcomitans*, *Cardiobacterium hominis*, *Eikenella corrodens*, and *Kingella kingae*.

patient. Head trauma with basilar skull fracture and chronic medical conditions, such as diabetes and alcoholism, also increase the risk of meningitis.

PATHOBIOLOGY

Both *N meningitidis* and *S pneumoniae* are transmitted by aerosolized droplets of respiratory secretions and initially colonize the nasopharynx by attaching to the nasopharyngeal epithelial cells. Following colonization of the nasopharynx, the bacteria enter the bloodstream and gain access to the cerebrospinal fluid (CSF) through the choroid plexus of the lateral ventricles. Most meningeal pathogens are bloodborne organisms, with the exception of those that gain access to the subarachnoid space from a contiguous site of infection.

It is not simply the presence of bacteria in the subarachnoid space that induces the inflammatory response. Rather, the lysis of bacteria with the subsequent release of bacterial cell wall components into the subarachnoid space is the initial step in the induction of the inflammatory response and the formation of a purulent exudate in the subarachnoid space. The specific bacterial cell wall components that induce inflammation are teichoic acid, a component of the cell wall of most gram-positive bacteria, and endotoxin, a lipopolysaccharide molecule of the outer membrane of gram-negative bacteria.

Bacterial cell wall components induce meningeal inflammation by stimulating the release of the inflammatory cytokines, interleukin-1β (IL-1β), and tumor necrosis factor α (TNF-α). Both IL-1β and TNF-α are produced by monocytes and macrophages and brain astrocytes and microglial cells (central nervous system macrophage-equivalent cells) that are "activated" by exposure to lipopolysaccharide and other bacterial cell wall components. In experimental models, the intracisternal inoculation of IL-1β and TNF-α induces meningeal inflammation (neutrophil emigration into CSF) and impaired blood-brain barrier permeability in a time and dose dependent manner.

The pathophysiologic consequences that result from the presence of the inflammatory cytokines in CSF are demonstrated in **Figure 64.1**. There is an increased permeability of the blood-brain barrier that contributes to vasogenic edema and allows for the leakage of serum proteins into the subarachnoid space contributing to the formation of a purulent exudate. The purulent exudate of proteinaceous material and leukocytes that forms in the subarachnoid space obstructs the flow of CSF through the ventricular system and diminishes the resorptive capacity of the arachnoid granulations in the dural sinuses. This results in obstructive and communicating hydrocephalus and interstitial edema. The combination of vasogenic and interstitial edema leads to increased intracranial pressure and an altered level of consciousness.

The purulent exudate surrounds and narrows the diameter of the lumen of the large arteries at the base of the brain with infiltration of inflammatory cells in the arterial walls (vasculitis). The procoagulant state results in arterial and venous thrombosis. Systemic hypotension due to sepsis contributes to global cerebral hypoperfusion.

Bacteria and the inflammatory cytokines induce the production of excitatory amino acids, reactive oxygen, and nitrogen species that induce apoptosis of neurons. Neurocognitive deficits are the result of apoptosis of neurons in the dentate gyrus of the hippocampus.

Cortical inflammation, cortical ischemia, intraparenchymal hemorrhage, and cerebral edema cause epileptogenic foci. Seizures are common in bacterial meningitis. Hearing loss in bacterial meningitis is due to direct damage to the inner ear by inflammation.

CLINICAL MANIFESTATIONS

The classic triad of meningitis is fever, headache, and meningismus. The classic triad applies only to viral meningitis. The clinical presentation of bacterial meningitis includes two or more of the following four symptoms and signs: (1) fever (≥38.5°C), (2) headache, (3) nuchal rigidity, and (4) an altered level of consciousness. A symptom that is often present, but underrecognized as a symptom of central nervous system infection, is vomiting.

The classic signs of meningeal irritation are nuchal rigidity (*stiff neck*, *meningismus*), Kernig sign, and Brudzinski sign. Nuchal rigidity is present when the neck resists passive flexion. Kernig sign is typically elicited with the patient in the supine position, but the patient can be in the seated position if their level of consciousness is normal. The thigh and the knee are flexed. Passive extension of the leg elicits pain when meningeal irritation is present. Brudzinski sign is positive when passive flexion of the neck results in spontaneous flexion of the hips and knees.

Patients with bacterial meningitis have either a fulminant illness that develops over a matter of hours or a subacute illness that progresses over 24 to 72 hours. The patient's level of consciousness may become progressively worse over a short

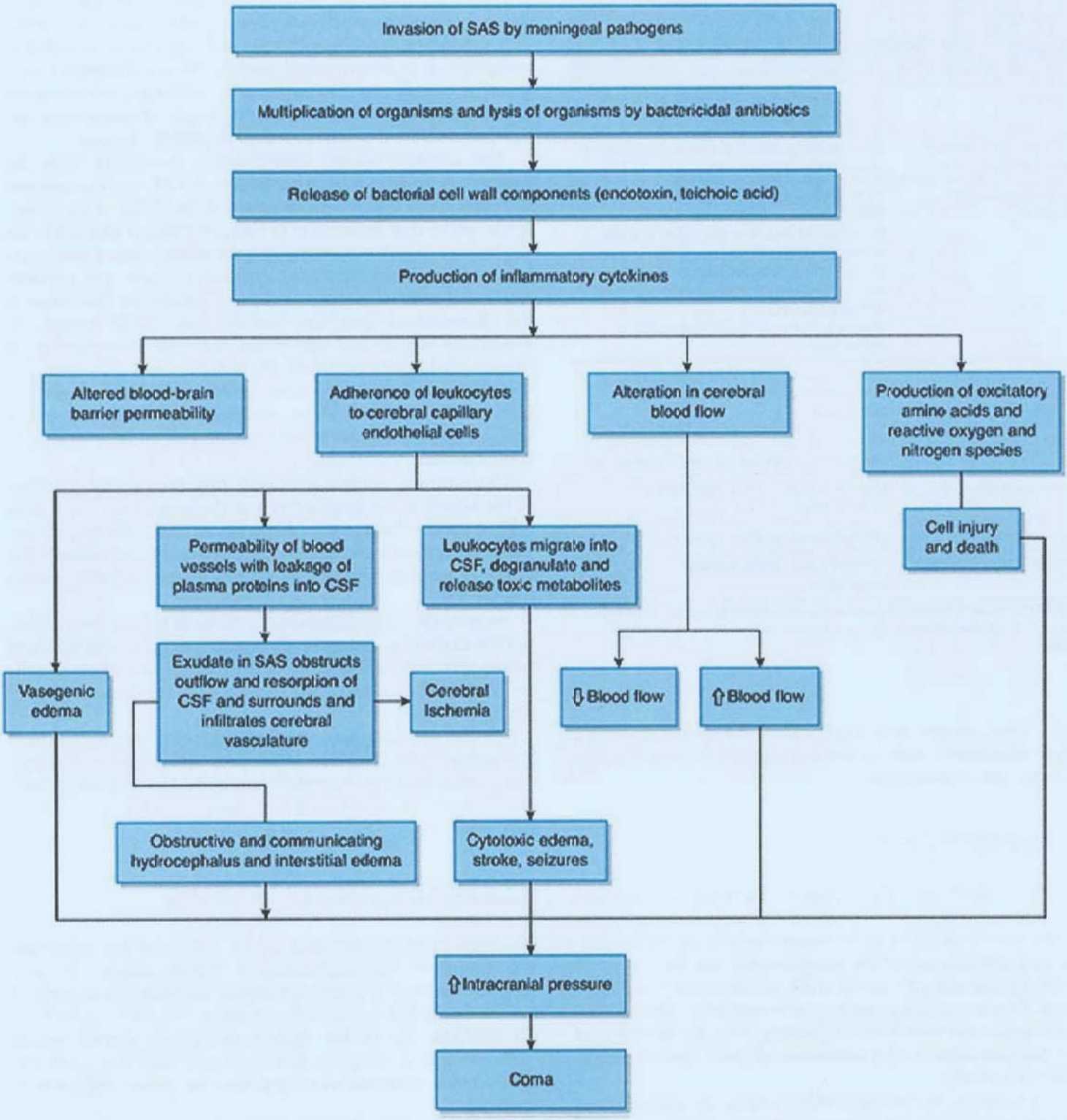

FIGURE 64.1 The pathophysiology of the neurologic complications of bacterial meningitis. Abbreviations: CSF, cerebrospinal fluid; SAS, subarachnoid space. (Reproduced with permission from McGraw-Hill.)

period of time. The tempo of the illness, and the time to presentation to the emergency department from the onset of illness, affects the signs and symptoms at presentation. As the disease progresses, and the complications of seizures, increased intracranial pressure, and cerebral ischemia and intracerebral hemorrhage occur, the patient's level of consciousness evolves from lethargy to stupor to obtundation to coma, and focal neurologic deficits may develop.

DIAGNOSIS

When acute bacterial meningitis is a possibility, obtain Gram stain and blood cultures, serum procalcitonin, and C-reactive protein and begin empiric adjunctive and antimicrobial therapy (Level 2). Empiric antimicrobial therapy should include therapy for viral encephalitis and a tickborne bacterial infection during the season when ticks are biting.

Serum procalcitonin (>2 ng/mL) and C-reactive protein (>40 mg/L) are significantly higher in patients with bacterial meningitis than in those with viral meningitis and can help in diagnosis when the results of spinal fluid analysis does not clearly differentiate one disease from the other.

Empiric therapy of bacterial meningitis is based on predisposing and associated conditions (Table 64.2). If *S pneumoniae* is a possible meningeal pathogen, empiric therapy is based on the possibility that the organism is penicillin- and cephalosporin-resistant and includes a third- or fourth-generation cephalosporin plus vancomycin. Metronidazole is added to the empiric regimen to cover anaerobic bacteria in patients with the predisposing conditions of otitis, mastoiditis, and sinusitis. Ampicillin should be added to the empiric regimen in individuals at risk for meningitis due to *L monocytogenes*. Gentamicin should be added for patients with possible *L monocytogenes* meningitis who are stuporous, obtunded, or comatose. Dexamethasone is administered either 15 to 20 minutes before the first dose of an antimicrobial agent or with the first dose of an antimicrobial agent.

Acyclovir is added to the empiric regimen for the treatment of herpes simplex virus encephalitis and doxycycline is added to the empiric regimen during the season when ticks are biting.

Once adjunctive and antimicrobial therapy have been initiated, a computed tomography (CT) scan can be obtained followed by spinal fluid analysis. The need or lack thereof for CT prior to lumbar puncture has always been controversial. In 2004, *Practice Guidelines for the Management of Bacterial Meningitis* were published by the Infectious Diseases Society of America. The practice guidelines were written by internists, a neurologist, and a pediatrician. The guidelines recommend CT prior to lumbar puncture in adult patients who meet any of the following criteria: (1) immunocompromised state due to human immunodeficiency virus infection, immunosuppressive therapy, and/or bone marrow or solid organ transplantation; (2) history of central nervous system disease (mass lesion, stroke, or focal infection); (3) new-onset seizure (within 1 wk of presentation); (4) papilledema; (5) abnormal level of consciousness; and (6) focal neurologic deficit (Level 2). The authors of the guidelines also state that some authorities would delay or not perform lumbar puncture in patients with seizures because seizures may be associated with transient increases in intracranial pressure. The 2008 European Federation of Neurological Societies guideline on the management of acute bacterial meningitis in older children and adults not only recommend that patients have brain imaging before lumbar puncture but also state that the initiation of antibiotic therapy should not be delayed beyond 3 hours after first contact with patient. The decision to perform lumbar puncture without CT if the patient has none of the six criteria listed above is certainly reasonable. As an opening pressure should be obtained in all patients with suspected bacterial meningitis, there is a degree of comfort in knowing the CT did not show a mass lesion or impending herniation when the CSF rises to the top of the manometer.

The CSF abnormalities characteristic of bacterial meningitis include the following: (1) an opening pressure greater than 180 mm H_2O, (2) a polymorphonuclear pleocytosis, (3) a low

TABLE 64.2 Empiric Antimicrobial Therapy Based on the Predisposing Condition and Meningeal Pathogen

Predisposing Condition	Bacterial Pathogen	Antibiotic
Neonates	Group B streptococcus, *Escherichia coli*, *Listeria monocytogenes*	Cefotaxime plus ampicillin
Children and adults—community acquired	*Streptococcus pneumoniae* and *Neisseria meningitidis*	Third- or fourth-generation cephalosporin plus vancomycin
Otitis, mastoiditis, sinusitis	Streptococci species, gram-negative anaerobes (*Bacteroides* species, *Fusobacterium* species), *Staphylococcus aureus*, *Haemophilus* species, Enterobacteriaceae	Third- or fourth-generation cephalosporin plus vancomycin plus metronidazole
Adults older than the age of 55 and those with chronic illness	*S pneumoniae*, gram-negative bacilli, *N meningitidis*, *L monocytogenes*, *Haemophilus influenzae*	Third- or fourth-generation cephalosporin plus vancomycin plus ampicillin
Endocarditis	Viridans streptococci, *S aureus*, *Streptococcus bovis*, HACEK group,[a] Enterococci	Third- or fourth-generation cephalosporin plus vancomycin
Immunosuppressed	*S pneumoniae*, *L monocytogenes*, *H influenzae*	Third- or fourth-generation cephalosporin or meropenem plus vancomycin plus ampicillin
Postneurosurgical	Staphylococci, gram-negative bacilli	Vancomycin plus meropenem or vancomycin plus ceftazidime
Intraventricular device	Staphylococci, gram-negative bacilli, anaerobes	Vancomycin plus meropenem or vancomycin plus ceftazidime plus metronidazole

[a]The HACEK group is *Haemophilus* species, *Actinobacillus actinomycetemcomitans*, *Cardiobacterium hominis*, *Eikenella corrodens*, and *Kingella kingae*.

glucose concentration (<40 mg/dL), and (4) an elevated protein concentration. The CSF should be examined within 90 minutes after it is obtained because white blood cells begin to degrade fairly quickly and may yield a false-negative result. In patients with an elevated serum glucose concentration, a CSF-to-serum glucose ratio should be obtained. A normal CSF-to-serum glucose ratio is 0.6. A CSF-to-serum glucose ratio of less than 0.31 is seen in approximately 70% of patients with bacterial meningitis. Gram stain is positive in identifying the organism in 60% to 90% of cases of bacterial meningitis.

The CSF lactate concentration is, in general, nonspecific and the measurement of the CSF lactate concentration is not recommended for patients with suspected community-acquired bacterial meningitis. The CSF lactate concentration, however, does appear to be valuable for the diagnosis of bacterial meningitis in postoperative neurosurgical patients. In the postoperative neurosurgical patient, empiric antimicrobial therapy should be initiated if the CSF lactate concentration is greater than or equal to 4.0 mmol/L.

In clinical practice, it is important to determine early on if this is bacterial meningitis or viral meningitis in the patient presenting with fever, headache, and stiff neck. There are four tests that are most helpful in doing this: (1) the C-reactive protein, (2) the serum procalcitonin, (3) the CSF Gram stain, and (4) the CSF reverse transcriptase polymerase reaction for enteroviruses. A normal C-reactive protein has a high negative predictive value in the diagnosis of bacterial meningitis. An elevated serum procalcitonin concentration occurs in severe bacterial infections. The serum procalcitonin is an additional helpful test in differentiating bacterial meningitis from viral meningitis when the CSF Gram stain is negative. The results of a CSF Gram stain are usually available in 4 hours. The results of the CSF reverse transcriptase polymerase reaction for enteroviruses is also usually available within a short period of time.

Differential Diagnosis

As discussed, the clinical presentation of bacterial meningitis includes *two or more* of the following four symptoms and signs: (1) fever (≥38.5°C), (2) headache, (3) nuchal rigidity, and (4) an altered level of consciousness. Viral meningitis is the leading disease in the differential diagnosis of the classic triad of fever, headache, and nuchal rigidity. Spinal fluid analysis demonstrates a normal opening pressure, a lymphocytic pleocytosis, and a normal glucose concentration. Infection with *Borrelia burgdorferi* may manifest as headache and cranial nerve palsies. Spinal fluid analysis will demonstrate a lymphocytic pleocytosis with a normal glucose concentration. When impaired consciousness, focal neurologic deficits or new-onset seizures are added to the classic triad; the differential diagnosis includes viral encephalitis, intracranial venous thrombosis, tickborne bacterial infections, and infectious intracranial mass lesions. Viral encephalitis and tickborne bacterial infections often present with fever and altered level of consciousness. The opening pressure is typically elevated in viral encephalitis and tickborne bacterial infections, there is a lymphocytic pleocytosis and a normal glucose concentration. Tuberculous meningitis may also present with the apoplectic onset of fever and headache. Spinal fluid analysis demonstrates a lymphocytic pleocytosis and a decreased glucose concentration. Subarachnoid hemorrhage presents with headache and nuchal rigidity.

The differential diagnosis in human immunodeficiency virus–infected patients who present with meningeal signs, includes meningitis caused by *Cryptococcus neoformans*, *Mycobacterium tuberculosis*, and *Treponema pallidum*.

The greatest mimic for bacterial meningitis is medication-induced "aseptic" meningitis, which may have a similar clinical presentation and spinal fluid formula as bacterial meningitis. The clinical presentation includes fever, headache, stiff neck, lethargy, confusion, seizures, and coma. Spinal fluid analysis may demonstrate an increased opening pressure, a pleocytosis of polymorphonuclear leukocytes, and a decreased glucose concentration. There may be diffuse enhancement of the meninges post the administration of contrast on CT or magnetic resonance imaging. The CSF Gram stain and culture are negative, and the symptoms resolve promptly when the offending medication is discontinued.

Cerebrospinal Fluid Analysis for the Differential Diagnosis

The CSF Gram stain and bacterial culture can identify the meningeal pathogen in approximately 80% of patients. The CSF PCR assays detect bacterial nucleic acid in CSF. A 16S rRNA conserved sequence broad-based bacterial PCR can detect small numbers of viable and nonviable organisms in the CSF, but this assay has been replaced by newer nucleic acid assays. A commonly used PCR panel is the FilmArray Meningitis/Encephalitis panel that tests six bacterial meningeal pathogens, including *S pneumoniae*, *N meningitidis*, *H influenzae*, *E coli*, group B streptococcus, and *L monocytogenes*. Specific advantages of this PCR panel are its rapid turnaround time. The sensitivity and specificity of the FilmArray Meningitis/Encephalitis panel for bacterial pathogens is not known at this time. A CSF analysis should include a nucleic acid amplification test for *Mycobacterium tuberculosis* and acid fast smear and *M tuberculosis* culture.

Metagenomic next-generation sequencing (mNGS) is a newer nucleic acid assay to identify the meningeal pathogen LEVEL 1.[1] A limitation to mNGS is that the results take time. An mNGS is particularly helpful in those instances when the pathogen is difficult to detect. The PCR assays have eliminated the need for the latex particle agglutination test, which had high specificities but variable sensitivities. A false-positive PCR is a possibility with both the meningitis/encephalitis panel and mNGS. The results of a PCR assay can be confirmed by a conventional test, such as culture, CSF immunoglobulin M, and/or acute and convalescent serology. Table 64.3 lists the CSF diagnostic studies for bacterial meningitis. In clinical practice, when bacterial meningitis is a possibility, most physicians treat with empiric therapy until CSF analysis and/or the clinical course suggests an alternative diagnosis.

TREATMENT

Once the causative organism has been identified by culture, and antimicrobial sensitivities of the organism are known, empiric therapy is modified accordingly (Table 64.4).

Both the Infectious Diseases Society of America Practice Guidelines for the Management of Bacterial Meningitis and the European Federation of Neurological Societies Guideline on the Management of Community-Acquired Bacterial Meningitis recommend the use of dexamethasone in adults with suspected or proven pneumococcal meningitis LEVEL 1.[2] The Infectious Diseases

TABLE 64.3 Cerebrospinal Fluid Diagnostic Studies for Meningitis

Cell count with differential
Glucose and protein concentration
Stain and culture
• Gram stain and bacterial culture
• India ink and fungal culture
• Viral culture
• Acid fast smear and *Mycobacterium tuberculosis* culture
Antigens
• Cryptococcal polysaccharide antigen
• Histoplasma polysaccharide antigen
PCR
• Meningitis/encephalitis panel
• PCR for West Nile virus
• PCR for Epstein-Barr virus
• PCR for *Mycobacterium tuberculosis*
• PCR for HIV RNA
• PCR for *Borrelia burgdorferi*
Antibodies
• Herpes simplex virus (serum and CSF IgG to calculate antibody ratio)
• Varicella zoster virus IgM and IgG antibody index
• Arthropod-borne viruses (West Nile virus IgM)
• *B burgdorferi* antibody index
• *Coccidioides immitis* complement fixation antibody

Abbreviations: CSF, cerebrospinal fluid; HIV, human immunodeficiency virus; IgG, immunoglobulin G; IgM, immunoglobulin M; PCR, polymerase chain reaction.

TABLE 64.4 Recommended Doses for the Antibiotics for Bacterial Meningitis

Antibiotic Agent	Total Daily Dosage (Dosing Interval in Hours)
Ampicillin	Infants and children: 300 mg/kg/d (q6h) Adults: 12 g/d (q4-6h)
Cefepime	Infants and children: 150 mg/kg/d (q8h) Adults: 6 g/d (q8h)
Cefotaxime	Infants and children: 225-300 mg/kg/d (q6-8h) Adults: 8-12 g/d (q4-6h)
Ceftazidime	Infants and children: 150-200 mg/kg/d (q8h) Adults: 8 g/d (q8h)
Ceftriaxone	Infants and children: 80-100 mg/kg/d (q12h) Adults: 4 g/d (q12h)
Gentamicin	Infants and children: 7.5 mg/kg/d (q8h) Adults: 5 mg/kg/d (q8h)
Meropenem	Infants and children: 120 mg/kg/d (q8h) Adults: 6 g/d (q8h)
Metronidazole	Infants and children: 30 mg/kg/d (q6h) Adults: 2,000 mg/d (q6h)
Nafcillin	Infants and children: 200 mg/kg/d (q6h) Adults: 9-12 g/d (q4h)
Penicillin G	Infants and children: 0.3 mU/kg/d (q4-6h) Adults: 24 million U/d (q4-6h)
Rifampin	Infants and children: 10-20 mg/kg/d (q12-24h) Adults: 600-1,200 mg/d (q12h)
Vancomycin[a]	Infants and children: 60 mg/kg/d (q6h) Adults: 45-60 mg/kg/d (q5-12h)
Chemoprophylaxis Neisseria meningitidis	Rifampin 600 mg twice daily for 2 d or ceftriaxone 250 mg intramuscular

[a]Vancomycin can safely be given by intraventricular administration. The adult dose is 20 mg/d. The pediatric dose is 10 mg/d.

Society of America practice guidelines also acknowledged that "some authorities would initiate dexamethasone in all adults with suspected bacterial meningitis because the etiology of meningitis is not always ascertained at initial evaluation." A favorable trend toward reduced rates of death and hearing loss and no evidence that dexamethasone was harmful in patients with meningococcal meningitis has been subsequently demonstrated since the publication of the 2004 guidelines LEVEL 2.[3] Dexamethasone decreases the production of the inflammatory cytokines and stabilizes the blood-brain barrier (Fig. 64.2). As such, dexamethasone is efficacious in attenuating the neurologic complications that evolve as a result of the production of inflammatory cytokines and an increased blood-brain barrier permeability. The recommended dose is 0.6 mg/kg daily in four divided doses (0.15 mg/kg/dose) given intravenously for the first 4 days of antibiotic therapy for infants 2 months of age and older and children. The dose of dexamethasone for adults is 10 mg every 6 hours for the first 4 days of antibiotic therapy. The first dose of dexamethasone should be administered 15 to 20 minutes before or at least with the first dose of antibiotics.

The American Academy of Pediatrics recommends the consideration of dexamethasone for bacterial meningitis in infants and children 6 weeks of age or older. The recommended dose is the same as for adults, and the first dose should be administered 15 to 20 minutes before or at least with the first dose of antibiotics. Results of clinical trials of dexamethasone therapy in children have demonstrated its efficacy in decreasing meningeal inflammation and neurologic sequelae and in reducing the incidence of sensorineural hearing loss in bacterial meningitis from any cause.

COMPLICATIONS

Patients with bacterial meningitis should be admitted to the neurocritical care unit. Eradicating the meningeal pathogen is the easy step. The neurologic complications of cerebral edema, focal and diffuse cortical hypoperfusion, disturbed cerebral autoregulation, septic sinus thrombosis, intracerebral hemorrhage, hydrocephalus, and seizures are responsible for both the mortality and the sequelae of bacterial meningitis. The management of the neurologic complications is thus critical to the patient's outcome. Increased intracranial pressure is treated with elevation of the head of the bed, osmotic diuretics (eg, mannitol), and hyperventilation (see Chapter 111). Sedation with anesthetic agents to decrease cerebral metabolism should also be considered. An intracranial pressure monitoring device should be used in stuporous or comatose patients to guide therapy of intracranial pressure. Cerebral perfusion pressure should be maintained between 50 and 70 mm Hg. Cerebral ischemia and intracerebral hemorrhage have a high risk of morbidity, and therapeutic agents that treat these complications would be of tremendous benefit to patients.

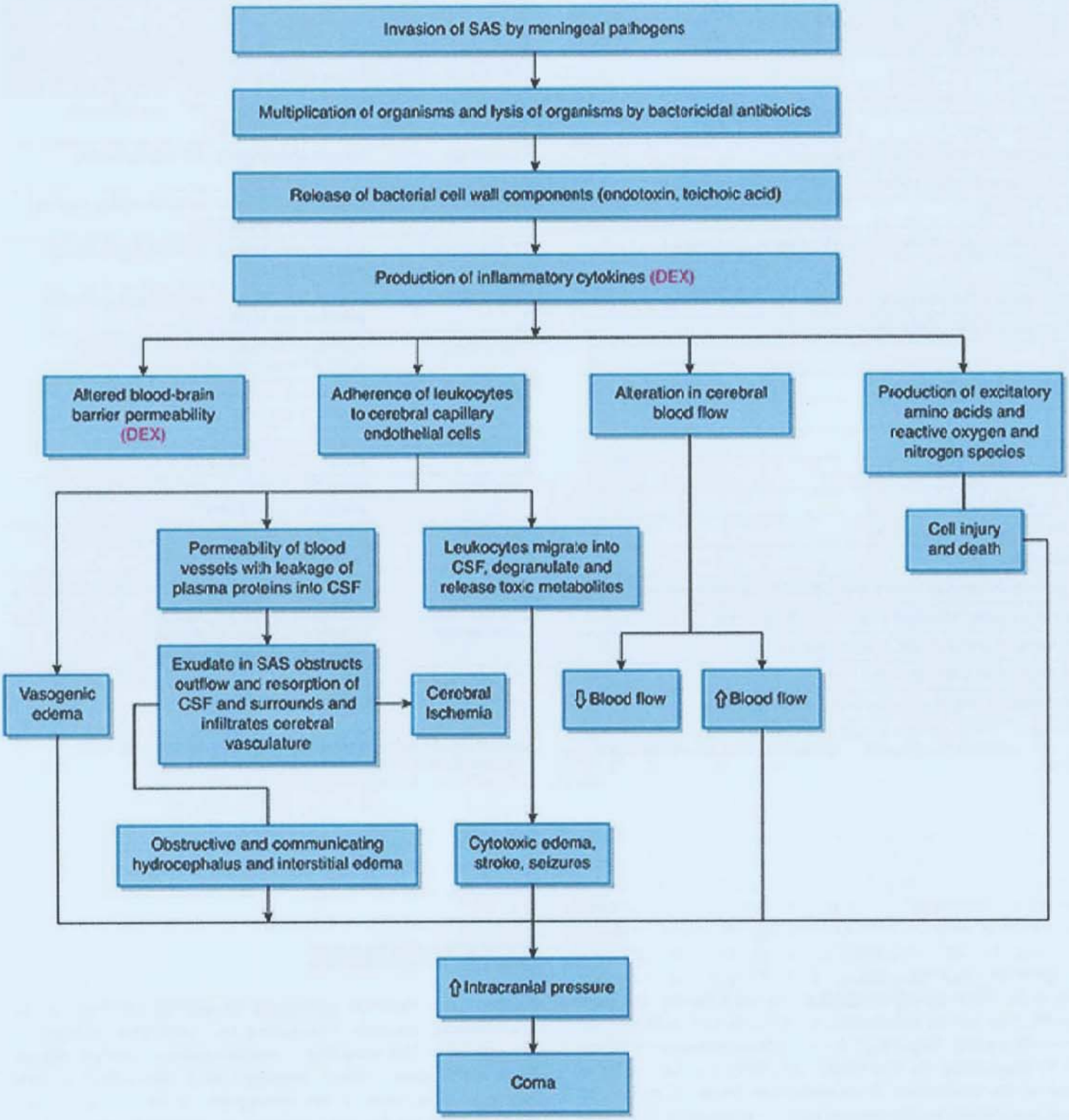

FIGURE 64.2 Dexamethasone attenuates two critical steps in the pathophysiology of the neurologic complications of bacterial meningitis. Abbreviations: CSF, cerebrospinal fluid; SAS, subarachnoid space. (Reproduced with permission from McGraw-Hill.)

LEVEL 1 EVIDENCE

1. Wilson MR, Sample HA, Zorn KC, et al. Clinical metagenomic sequencing for diagnosis of meningitis and encephalitis. *N Engl J Med*. 2019;380:2327-2340.
2. de Gans, van de Beek D. Dexamethasone in adults with bacterial meningitis. *N Engl J Med*. 2002;347:1549-1556.
3. Heckenberg SGB, Brouwer MC, van der Ende A, van de Beek D. Adjunctive dexamethasone in adults with meningococcal meningitis. *Neurology*. 2012;79:1563-1569.

SUGGESTED READINGS

Amaya-Villar R, García-Cabrera E, Sulleiro-Igual E, et al. Three-year multicenter surveillance of community-acquired *Listeria monocytogenes* meningitis in adults. *BMC Infect Dis*. 2010;10:324.

Brouwer MC, Tunkel AR, van de Beek D. Epidemiology, diagnosis, and antimicrobial treatment of acute bacterial meningitis. *Clin Microbiol Rev*. 2010; 23(3):467-492.

Brouwer MC, van de Beek D, Heckenberg SG, et al. Community-acquired *Listeria monocytogenes* meningitis in adults. *Clin Infect Dis*. 2006;43(10): 1233-1238.

Durand ML, Calderwood SB, Weber DJ, et al. Acute bacterial meningitis in adults: a review of 493 episodes. *N Engl J Med*. 1993;328:21-28.

Erdem H, Elaldi N, Oztoprak N, et al. Mortality indicators in pneumococcal meningitis: therapeutic implications. *Int J Infect Dis*. 2014;19:13-19.

Hasbun R, Abrahams J, Jekel J, Quagliarello VJ. Computed tomography of the head before lumbar puncture in adults with suspected meningitis. *N Engl J Med*. 2001;345:1727-1733.

Lai WA, Chen SF, Tsai NW, et al. Non-cephalosporin-susceptible, glucose nonfermentative Gram-negative bacilli meningitis in post-neurosurgical adults: clinical characteristics and therapeutic outcome. *Clin Neurol Neurosurg*. 2014;116:61-66.

Lorber B. Listeria monocytogenes. In: Mandell GL, Bennet JE, Dolin R, eds. *Principles and Practice of Infectious Diseases*. Philadelphia: Churchill Livingstone; 2005:2478-2484.

Mylonakis E, Hohmann EL, Calderwood SB. Central nervous system infection with *Listeria monocytogenes*. 33 years' experience at a general hospital and review of 776 episodes from the literature. *Medicine (Baltimore)*. 1998;77(5): 313-336.

Pintado V, Pazos R, Jimenez-Mejias ME, et al. Methicillin-resistant *Staphylococcus aureus* meningitis in adults: a multicenter study of 86 cases. *Medicine*. 2012; 91(1):10-17.

Pomar V, Benito N, Lopez-Contreras J, et al. Spontaneous gram-negative bacillary meningitis in adult patients: characteristics and outcome. *BMC Infect Dis*. 2013;13:451.

Prouox N, Frechette D, Toye B, et al. Delays in the administration of antibiotics are associated with mortality from adult acute bacterial meningitis. *QJM*. 2005;98:291-198.

Stockmann C, Ampofo K, Byington CL, et al. Pneumococcal meningitis in children: epidemiology, serotypes, and outcomes from 1997-2010 in Utah. *Pediatrics*. 2013;132(3):421-428.

Tacon CL, Flower O. Diagnosis and management of bacterial meningitis in the paediatric population: a review. *Emerg Med Int*. 2012;2012:320309.

Thigpen MC, Whitney CG, Messonnier NE, et al. Bacterial meningitis in the United States, 1998-2007. *N Engl J Med*. 2011;364(21):2016-2025.

Tunkel AR, Hartman BJ, Kaplan SL, et al. Practice guidelines for the management of bacterial meningitis. *Clin Infect Dis*. 2004;39:1267-1284.

van de Beek D, Brouwer MC, Thwaites GE, et al. Advances in treatment of bacterial meningitis. *Lancet*. 2012;380(9854):1693-1702.

van de Beek D, de Gans J, Spanjaard L, et al. Clinical features and prognostic factors in adults with bacterial meningitis. *N Engl J Med*. 2004;35: 1849-1859.

van de Beek D, de Gans J, Tunkel AR, et al. Community acquired bacterial meningitis in adults. *N Engl J Med*. 2006;354:44-53.

van de Beek D, Drake JM, Tunkel AR. Nosocomial bacterial meningitis. *N Engl J Med*. 2010;362(2):146-154.

van de Beek D, Farrar JJ, de Gans J, et al. Adjunctive dexamethasone in bacterial meningitis: a meta-analysis of individual patient data. *Lancet Neurol*. 2010;9(3):254-263.

Weisfelt M, de Gans J, van de Beek D. Bacterial meningitis: a review of effective pharmacotherapy. *Expert Opin Pharmacother*. 2007;8:1493-1504.

Weisfelt M, van de Beek D, Spanjaard L, et al. Clinical features, complications, and outcomes in adults with pneumococcal meningitis: a prospective case series. *Lancet Neurol*. 2006;5:123-129.

65 Brain, Spinal, and Epidural Abscess and Other Parameningeal Infections

Tracey A. Cho

KEY POINTS

1. Brain abscess may result from direct extension of infection in the frontal or ethmoid sinuses (frontal lobe), middle ear (cerebellum or temporal lobe), or odontogenic infection (frontal lobe).
2. Multiple abscesses in the distribution of the middle cerebral artery are most likely due to hematogenous spread from an extracranial source.
3. Restricted diffusion on magnetic resonance imaging (MRI) may be useful in distinguishing bacterial brain abscess from tumor.
4. The standard treatment of bacterial brain abscess is stereotactic aspiration to identify the pathogen and reduce the abscess burden.
5. An MRI of bacterial brain abscess may show some persistent enhancement even after adequate treatment, and this MRI finding should not be used in isolation to guide any further treatment.
6. Subdural empyema progresses more rapidly than brain abscess, typically with fever, focal headache, and rapidly progressive neurologic deficits and/or seizures.
7. Spinal epidural abscess is a surgical emergency because medical management alone is often insufficient, and the degree of neurologic deficit prior to treatment is the most important modifiable factor in outcomes.

BRAIN ABSCESS

A brain abscess is a focal purulent infection within the brain parenchyma caused by bacteria, mycobacteria, fungi, protozoa, or helminths. A brain abscess starts as a localized area of cerebritis; abscesses vary in size from a microscopic collection of inflammatory cells to an area of purulent necrosis presenting as a mass lesion.

Advances in the diagnosis and treatment of brain abscesses have been achieved with the use of computed tomography (CT), magnetic resonance imaging (MRI), especially diffusion-weighted imaging (DWI), stereotactic brain biopsy and aspiration, and newer broad-spectrum antibiotics.

Epidemiology

The incidence of brain abscess ranges from 0.4 to 0.9 cases per 100,000 person-years. A brain abscess is 2 to 3 times more common in males than in females, with the highest incidence occurring in fourth decade of life. Up to 86% of patients have a predisposing condition, with an increasing number of patients developing abscess in the setting of iatrogenic immunosuppression. Over the past several decades, advances in management of brain abscesses have resulted in a significant decline in mortality from 30% to 50% before 1980, to 4% to 20% more recently. Up to 25% of all cases occur in children younger than 15 years old, with a cluster in the 4- to 7-year-old age group, usually the result of cyanotic congenital heart disease or an otic infection.

Source of Infection in Brain Abscess

Classifying brain abscess based on the likely source of infection is useful for determining the evaluation for predisposing factors and identifying appropriate empiric antimicrobial therapy. A brain abscess may develop from any of the following predisposing or associated conditions: (1) direct extension of cranial infection, ethmoid or frontal sinusitis, subacute or chronic otitis media, mastoiditis, or dental infection; (2) direct inoculation via wounds, fracture of the skull, or neurosurgical procedures; and (3) hematogenous dissemination of infection from elsewhere in the body (eg, lung abscess, bacterial endocarditis, intra-abdominal infections, dental infections, congenital heart disease). Twenty percent to 30% of brain abscesses have no obvious source and are so-called cryptogenic brain abscesses; many of these are presumed to be odontogenic.

Infection in the middle ear or mastoid may spread to the cerebellum or temporal lobe through involvement of bone and meninges or by seeding of bacteria through valveless emissary and sinus veins that drain these regions. Infection may originate from tonsils or abscessed teeth, or frontal, ethmoid, or rarely the maxillary sinuses, with sinus infections often spreading to frontal lobes through erosion of the skull. Odontogenic brain abscess occurs in the setting of tooth extraction or other dental manipulation, most commonly in the frontal lobe. Brain abscess rarely complicates bacterial meningitis, with the exception of neonatal meningitis due to gram-negative enteric organisms including *Proteus* and *Enterobacter* species; for unclear reasons, these species tend to cause abscesses in neonates.

For hematogenous spread, cerebral lesions are found in distal territories of the middle cerebral artery and frequently are multiple, often seen at the junction of gray-white matter. Potential sources for hematogenous spread of infection include upper respiratory tract (lung abscess or empyema), bacterial endocarditis, skin infections, intra-abdominal, or pelvic infections. Congenital cardiac defects and pulmonary arteriovenous malformations (eg, hereditary hemorrhagic telangiectasia) predispose to brain abscess. In these two disorders, infected emboli bypass pulmonary filtration system and gain access to the cerebral arterial system. Similarly, cases of cryptogenic brain abscess caused by vegetations on patent foramen ovale or right-to-left shunting

TABLE 65.1 Brain Abscess

Source	Pathogen
Oral cavity, hematogenous spread (intra-abdominal/pelvic infections), otitis, mastoiditis, paranasal sinusitis	Streptococci species (aerobic and anaerobic), *Staphylococcus aureus*, *Bacteroides* species, *Pseudomonas* species, *Haemophilus* species, *Enterobacteriaceae*, *Prevotella melaninogenica*, *Fusobacterium* species
Trauma/neurosurgical procedure	*S aureus* or *Staphylococcus epidermidis*, *Streptococcus* species, *Enterobacteriaceae*, *Pseudomonas* species, *Clostridium* species
Pyogenic lung infections	Streptococci, staphylococci, *Bacteroides* species, *Fusobacterium* species, *Enterobacteriaceae*
Cardiac origin (eg, cyanotic heart disease, right-to-left shunts, bacterial endocarditis)	*Streptococcus* species, *Serratia marcescens*, methicillin-resistant *S aureus* (MRSA)
Immunocompromised	*Pseudomonas*, *Toxoplasma*, *Listeria*, *Nocardia*, *Aspergillus*, *Cryptococcus*, *Coccidioides*, *Mycobacterium tuberculosis*, *Enterobacteriaceae*, other fungal pathogens
Parasitic infections	*Cysticercosis*, *Entamoeba histolytica*, *Schistosoma*, *Paragonimus*

via patent foramen ovale have been reported. In infants and children, congenital heart disease is a common predisposing factor for brain abscess. The predisposing conditions of hereditary hemorrhagic telangiectasia or Rendu-Osler-Weber disease can be the source of a brain abscess via paradoxical septic emboli from lung.

A brain abscess can occur following penetrating head injury or neurosurgical procedures, although occurrence of abscesses after penetrating brain injury is low.

Causative Organisms of Brain Abscess

The infecting organism varies with site of entry, age of the patient, and immune status. Although variations exist across continents and age, the most common causes overall are streptococci (anaerobic, aerobic, or microaerophilic species), *Staphylococcus aureus*, gram-negative enteric organisms (*Proteus* species, *Klebsiella pneumoniae*, *Escherichia coli*, *Enterobacteriaceae*), *Pseudomonas* species, and anaerobes such as *Bacteroides* species (Table 65.1). In infants, gram-negative organisms are the most frequent isolates. In adult patients with direct spread of infection from an otogenic source, the most common organisms are streptococci, *Bacteroides* species, *Pseudomonas* species, *Enterobacteriaceae*, and *Haemophilus*. Other causative organisms from oral or hematogenous spread include streptococci, *S aureus*, *Bacteroides* species, and *Fusobacterium* species. After penetrating head injury or neurosurgical procedure, abscess formation is usually due to *S aureus* (methicillin-resistant *S aureus* or MRSA), *Staphylococcus epidermidis*, streptococci, *Enterobacteriaceae*, *Pseudomonas* species, or *Clostridium* species. Brain abscesses as a complication of bacterial endocarditis are due to streptococci, MRSA, and *Serratia marcescens*.

In the immunocompromised host, *Toxoplasma*, *Listeria*, *Nocardia*, *Aspergillus*, *Cryptococcus*, *Coccidioidomycosis*, *Mycobacterium tuberculosis*, *Enterobacteriaceae*, and other fungal pathogens are causative organisms of brain abscess. In resource-rich countries, *Toxoplasma gondii* is the most common cause of rim-enhancing mass lesions of the brain in advanced human immunodeficiency virus (HIV), whereas tuberculosis is an important cause in both low and high resource settings. In solid organ transplant patients, up to 90% of brain abscesses are due to fungal infection. Brain abscess may also be due to a parasitic infection such as *Entamoeba histolytica*, cysticercosis, *Schistosoma*, or toxocariasis; the imaging pattern (cystic) and demographic exposure usually distinguish these parasitic infections from more typical pyogenic abscess.

Cultures may be sterile in patients who have received antimicrobial therapy before biopsy, but any material obtained should be sent to the laboratory. A positive Gram stain guides therapy even when the culture is negative. Depending on the study, microbiologic diagnosis is obtained in 68% to 83% of cases; brain abscess is polymicrobial in 23% of cases.

Pathobiology

The pathologic changes in brain abscesses are similar regardless of the origin: direct extension to the brain from a contiguous site of infection, retrograde thrombosis of veins, or hematogenous dissemination (Fig. 65.1).

Based on animal models and human imaging studies, abscess formation occurs through a continuum of changes. Focal infection (cerebritis) starts as an area of inflammation, which correlates with patchy T2 hyperintensity on MRI (hypodensity on CT), followed by central necrosis with surrounding edema, leading to rim-enhancement along the edge of inflammation and

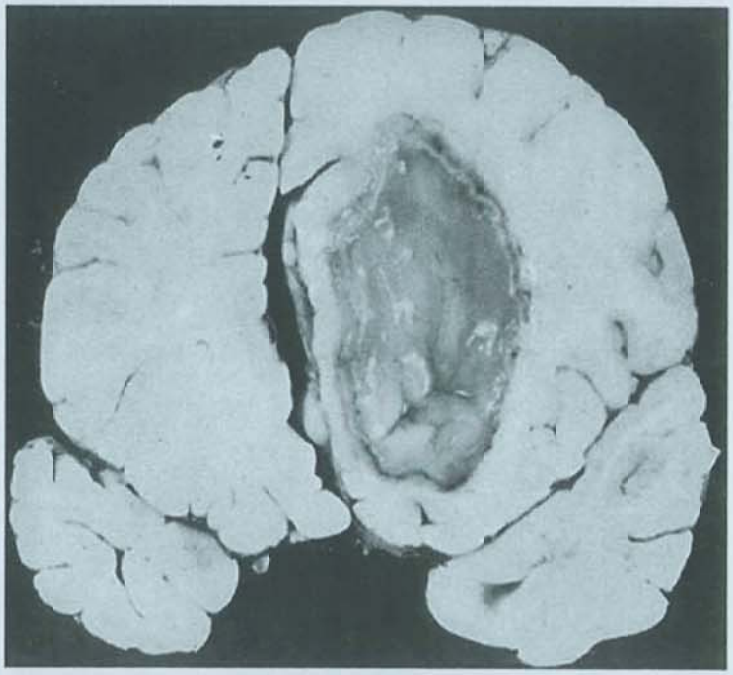

FIGURE 65.1 Brain abscess. Abscess in frontal lobe secondary to pulmonary infection. (Courtesy of Dr. Abner Wolf.)

surrounding T2 hyperintensity. When host defenses control the spread of the infection, macroglia and fibroblasts proliferate in an attempt to surround the infected and necrotic tissue, and granulation tissue and fibrous encapsulation develop, often thicker on the cortical versus ventricular side owing to increased vascular supply. If the capsule ruptures, purulent material is released into the ventricular system, a process associated with a high mortality rate. Edema surrounding a brain abscess is common. The process from brain inoculation to mature capsule formation takes 2 weeks or longer depending on the organism.

Two signal-mediated central nervous system immune responses to invading pathogens that may be important in the developing abscess include the Toll-like and Nod-like receptors systems. Activation of Toll-like receptor by invading pathogens leads to a complex array of immune-mediated response including control of infection burden, immune infiltrates, and inflammatory mediators. Likewise, Nod-like receptor activates a number of immune-specific interleukins responsible for bacterial recognition and subsequent cytokine release that acts to restrict bacterial spread during abscess formation.

Clinical Manifestations

The symptoms of a brain abscess are typical of an expanding mass lesion in the brain with elevated intracranial pressure (ICP) and include headache with or without fever as the initial symptoms, followed by nausea, vomiting, lethargy, and focal neurologic deficits. Headache occurs in about 70% of patients. Sudden worsening of preexisting headache, new-onset nuchal rigidity, and seizures may herald rupture of brain abscess into the ventricular space. The average duration of symptoms prior to presentation is 8.3 days. The abrupt onset of a severe headache is less common with abscess and is more often associated with acute bacterial meningitis or subarachnoid hemorrhage. Fever is present in 53% of patients and focal neurologic deficits in 48%, but the classic combination of headache, fever, and focal deficits occurs in only 20%.

Focal neurologic deficits vary with abscess location. Hemiparesis, apathy, and confusion may be seen with lesions of the frontal lobe, hemianopia, and aphasia, particularly anomia, with abscesses in the temporal or parietooccipital lobes and ataxia, intention tremor, nystagmus, with cerebellar abscess (**Fig. 65.2**). Seizures (focal or generalized), nuchal rigidity, and papilledema are also common with abscess (around 30% of cases for each symptom). The presence of papilledema and/or third or sixth cranial nerve palsies are typically due to increased ICP.

Abscesses in the brainstem are rare. The classic findings of brainstem syndromes are often lacking because abscess tends to expand longitudinally along fiber tracts rather than transversely. Subdural or, rarely, epidural infections in the frontal regions

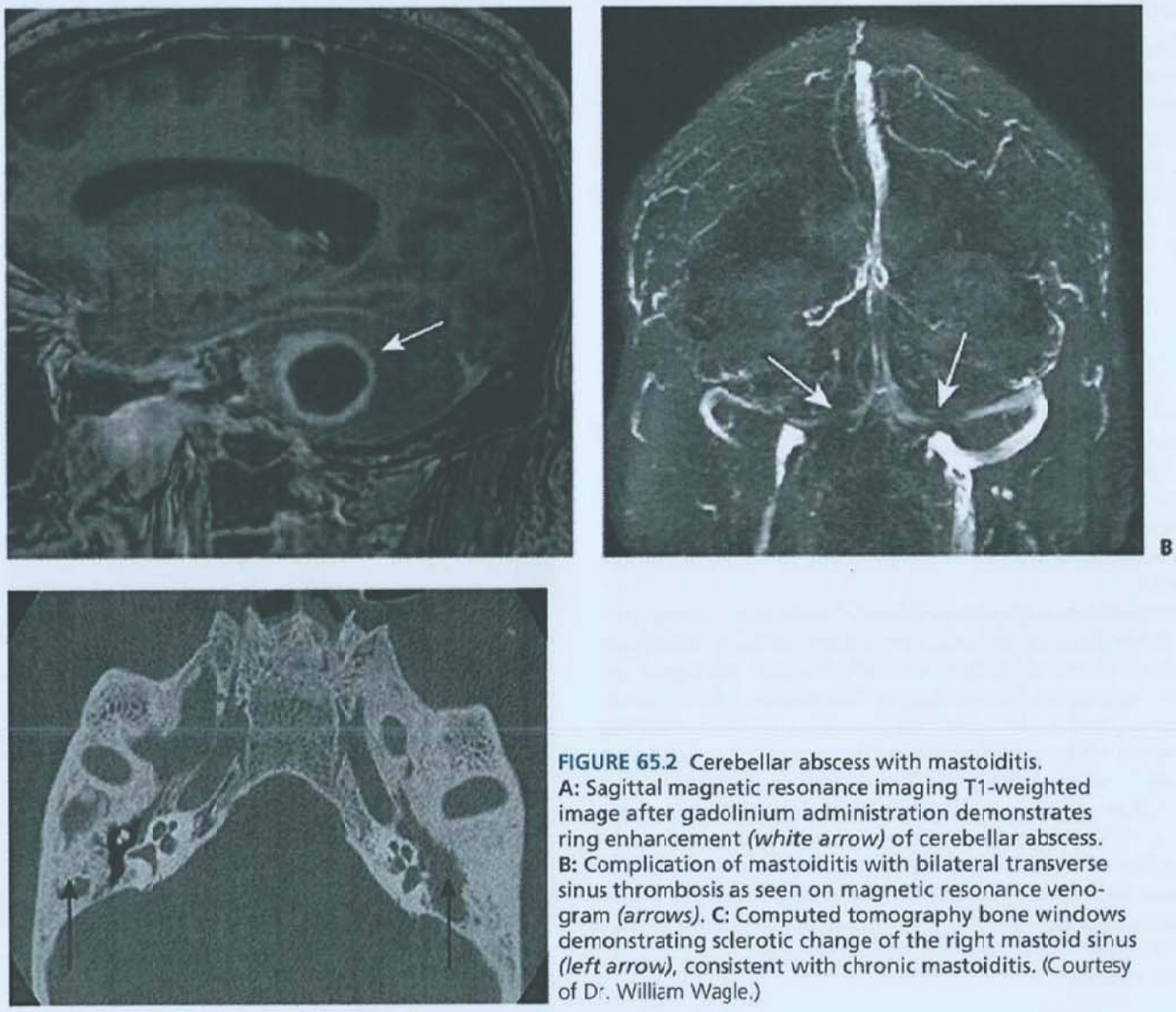

FIGURE 65.2 Cerebellar abscess with mastoiditis. **A:** Sagittal magnetic resonance imaging T1-weighted image after gadolinium administration demonstrates ring enhancement *(white arrow)* of cerebellar abscess. **B:** Complication of mastoiditis with bilateral transverse sinus thrombosis as seen on magnetic resonance venogram *(arrows)*. **C:** Computed tomography bone windows demonstrating sclerotic change of the right mastoid sinus *(left arrow)*, consistent with chronic mastoiditis. (Courtesy of Dr. William Wagle.)

may present with the same signs and symptoms as those of an abscess in the frontal lobe. Fever and focal seizures favor the diagnosis of subdural rather than intraparenchymal abscess, although these findings are not specific.

Transverse sinus thrombosis often follows middle ear or mastoid infection (see Fig. 65.2) and may be accompanied by seizures and signs of increased ICP, making the clinical differentiation between this condition and abscess of the temporal lobe or hemispheres difficult. With transverse sinus thrombosis, papilledema may result from blockage of venous drainage from the brain. Focal neurologic signs favor the diagnosis of abscess.

Diagnosis

Brain abscess should be suspected when seizures, focal neurologic signs, or increased ICP develops in a patient with known acute or chronic infection in the middle ear, mastoid, nasal sinuses, heart, or lungs and in those with congenital heart disease. Neuroimaging by CT or MRI is essential to making the diagnosis.

Although CT scan can be useful for identifying hemorrhage or calcification, MRI is the neuroimaging study of choice both for diagnosis and treatment of brain abscess and should include basic T2 and T1 pre- and postcontrast sequences, plus fluid-attenuated inversion recovery (FLAIR), DWI, apparent diffusion coefficient (ADC), and susceptibility weighted imaging. Abscesses are frequently found in the gray-white junction in watershed regions between vascular territories. Imaging features of abscess include a T2/FLAIR hyperintense, T1 hypointense core; T2/FLAIR hypointense periphery; and rim-enhancement on postcontrast T1 sequences (Fig. 65.3). Due to the dense purulent core, water movement is usually impaired leading to hyperintensity on DWI and hypointensity on ADC. With a mature encapsulated abscess, both contrast CT and MRI with gadolinium reveal the ring-enhancing mass with surrounding vasogenic edema. As noted earlier, the cortical edge of the abscess often demonstrates thickening compared to the medial edge, which can help differentiate abscesses from tumors or demyelination.

An MRI permits accurate localization of cerebritis or abscess and serial assessment of the size of the lesion, its demarcation, the extent of surrounding edema, and total mass effect and allows for staging of the abscess. Although magnetic resonance spectroscopy has been studied as a way to help differentiate brain abscesses based on metabolic patterns of lactate, amino acids, or acetate from other similar-appearing lesions (eg, tumor), its value beyond that of DWI in this setting is limited, and it is not routinely used in practice.

The differential diagnosis, based on the appearance of lesions seen on CT or MRI, includes glioblastoma, metastatic tumor, infarct, arteriovenous malformation, resolving hematoma, and granuloma. Features supporting the diagnosis of brain abscess include gas within the center of a ring-enhancing lesion, a thinner enhancing rim (<5 mm) than with brain tumors, more

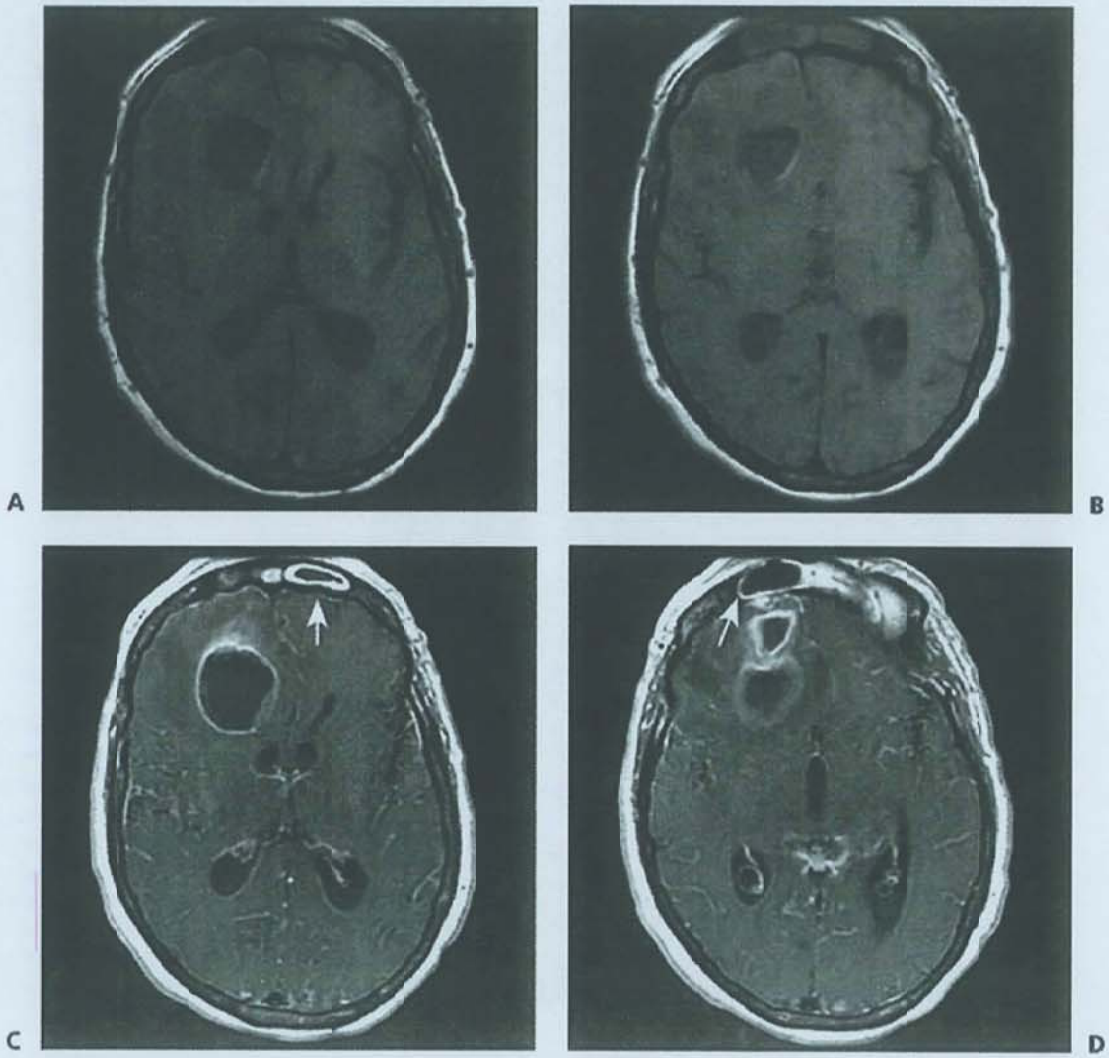

FIGURE 65.3 Brain abscesses. **A-I:** Magnetic resonance imaging (MRI) T1-weighted images **(A,B)** show right frontal lobe abscess with adjacent, smaller anterior-located abscess with typical ring enhancement after gadolinium administration **(C,D)**. Note enhancement of right frontal sinuses *(arrows)* as source of infection. *(continued)*

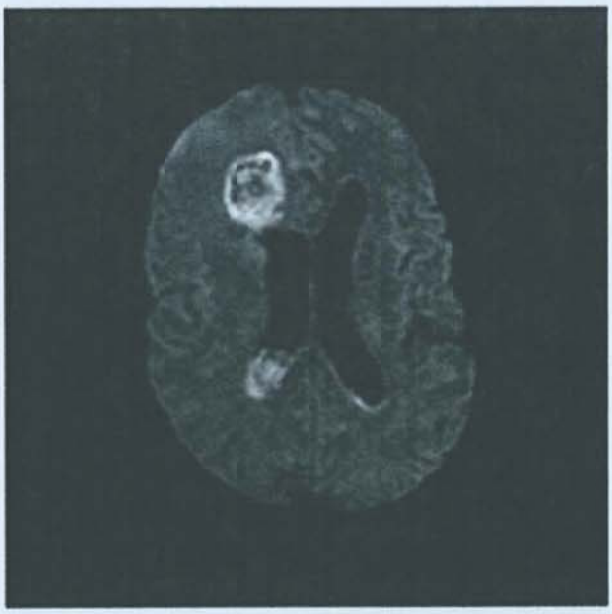

E

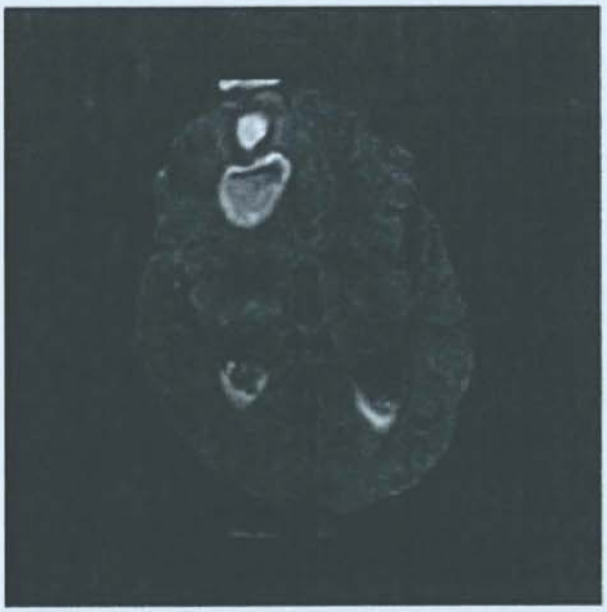

F

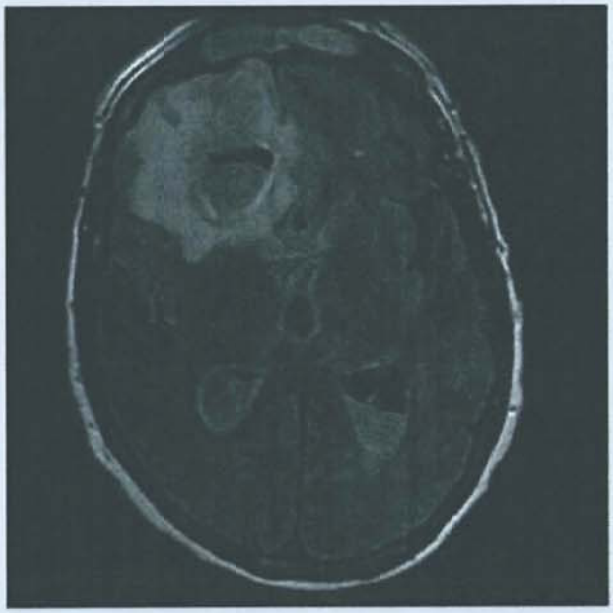

G

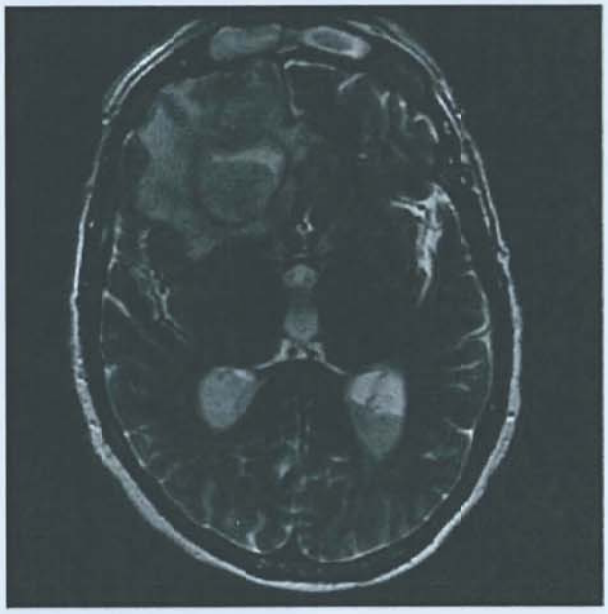

H

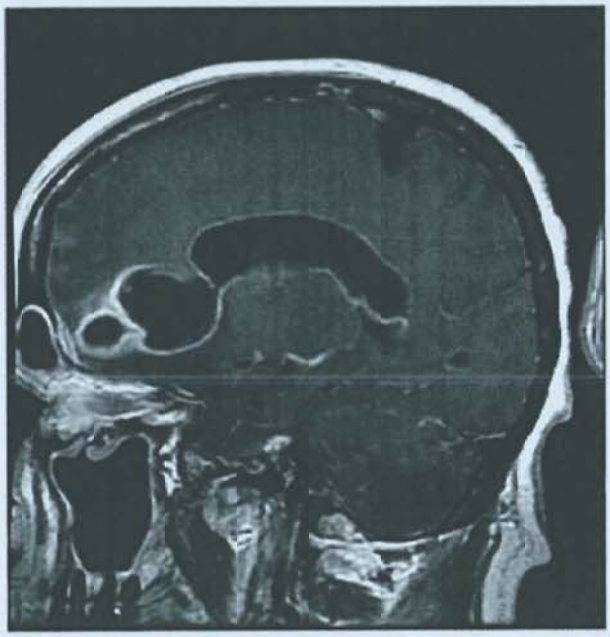

I

FIGURE 65.3 *(continued)* MRI diffusion-weighted images show typical bright-appearing lesions of abscess **(E,F)**. The brain abscesses with evidence of edema and mass effect are seen on MRI fluid-attenuated inversion recovery and T2-weighted images **(G,H)**. MRI sagittal T1-weighted images postgadolinium show enhancing frontal sinus infection with direct extension to brain parenchyma and ventricles **(I)**. Bright signal seen in ventricles on T1-weighted image after gadolinium is indicative of ventriculitis. (Courtesy of Dr. James Thomas.)

regular borders with ringlike enhancement, and ependymal enhancement associated with ventriculitis or ventricular rupture (see Fig. 65.3). An MRI with DWI and ADC may aid in differentiating tumor from abscess. With brain abscess, MRI DWI signal is hyperintense with associated low ADC values, compared to brain tumor with isointense or hypointense DWI appearance but high ADC. In one study of 147 cystic brain lesions, this pattern had a sensitivity of 96% and a specificity of 96% for differentiating abscess from noninfectious causes. Unlike pyogenic brain abscesses, the signal of *Toxoplasma* abscesses may not be hyperintense on DWI MRI. In the right setting, empiric treatment for *Toxoplasma* can be initiated with evaluation for responsiveness to treatment using follow-up MRI imaging several weeks later.

Either CT or MRI may distinguish abscess from mycotic aneurysms or herpes encephalitis, each of which may cause similar symptoms and signs. Mycotic aneurysm, usually in the distribution of the middle cerebral arteries, may be accompanied by meningitis in bacterial endocarditis. A CT or MRI may exclude abscess, but CT angiography is often necessary to identify the aneurysm before rupture. Herpes simplex encephalitis presents with headache, fever, and an acute temporal lobe or frontal lobe syndrome. On CT or MRI, the temporal lobe is swollen, with irregular lucency and patchy contrast enhancement.

Both erythrocyte sedimentation rate (ESR) and C-reactive protein (CRP) may be elevated in patients with brain abscess, 72% and 60%, respectively, in a large meta-analysis but with many patients demonstrating normal values. Blood cultures are positive in patients with hematogenous dissemination as the source of infection, up to 28% of cases overall. An HIV status should be confirmed in all patients with suspected brain abscess; if HIV-positive, serum toxoplasma immunoglobulin G should be tested.

Lumbar puncture adds little to the diagnosis outside the setting of meningitis and is contraindicated in patients suspected of having a brain abscess prior to neuroimaging because of the risk of transtentorial or uncal herniation.

Extension of the abscess to the meninges or ventricles is accompanied by findings associated with acute meningitis or ventriculitis. Rupture of an abscess into the ventricles is signaled by a sudden rise in ICP and the presence of free pus, with marked increases in cerebrospinal fluid cell count to levels of 20,000/mm^3 to 50,000/mm^3. A decrease in glucose content below 40 mg/dL indicates that the meninges have been invaded by bacteria. Only rarely are cerebrospinal fluid cultures positive.

Management

The introduction of CT revolutionized the management of brain abscess. Now, with MRI, it is possible to diagnose and localize cerebritis or abscess, dictate choice of treatment, and monitor patient response. Current recommended treatment for most brain abscesses is stereotactic aspiration to obtain specimens for culture and special studies and guide treatment with appropriate antimicrobial therapy.

Surgical treatment in the past included open evacuation and excision or freehand needle aspiration through burr hole. Currently, most surgeons prefer CT- or MRI-guided stereotactic aspiration and drainage. This method is the treatment of choice for most abscesses, particularly those that are deep-seated, multiple, or located in eloquent areas of the brain. Empiric antimicrobial therapy is based on Gram stain results from the specimen obtained by stereotactic aspiration and on the presumptive source of the abscess. Open craniotomy with excision is now performed

TABLE 65.2 Specific Intravenous Antimicrobials for Treatment of Brain Abscess

Vancomycin[a]	45-60 mg/kg/d, every 6-12 h
Meropenem	2 g every 8 h (used as first-line or second-line therapy)
Cefotaxime	2 g every 4-8 h (maximum 12 g/d)
Ceftriaxone	2 g every 12 h (maximum 4 g/d)
Ceftazidime	1-2 g every 4-8 h (maximum 6 g/d)
Cefepime	2 g every 8 h (maximum 6 g/d)
Metronidazole	500 mg every 6 h (1,500-2,000 mg/d)
Voriconazole	Loading dose of 6 mg/kg every 12 h × 2, followed by 4 mg/kg every 12 h

[a]Doses adjusted based on serum peak and trough levels; adjusted based on creatinine clearance.

infrequently and is reserved for patients with multiloculated abscesses, those with antimicrobial-resistant pathogens, abscesses due to *Nocardia*, abscesses containing gas resistant to antibiotics, and posttraumatic abscesses containing foreign bodies or contaminated bone fragments.

Choosing the appropriate antimicrobial therapy depends on the ability of the drug to penetrate the abscess cavity and its activity against the suspected pathogen. Penicillin and chloramphenicol were standard therapy for brain abscesses at one time, but they are rarely used today. These have been replaced by vancomycin, third- and fourth-generation cephalosporins (eg, cefotaxime, ceftriaxone, ceftazidime, and cefepime), metronidazole, and meropenem (Table 65.2). Combination therapy with third- or fourth-generation cephalosporins and vancomycin appears to be highly effective for empiric treatment of most brain abscesses. Metronidazole is added when otitis, mastoiditis, or paranasal sinusitis is the suspected source of infection. Additional antibiotic coverage may be needed for some organisms (eg, *Actinomyces* species) when the abscess is secondary to dental procedures or dental abscess. Special consideration of antimicrobial coverage must be given for *Enterobacteriaceae* or *Pseudomonas aeruginosa*, particularly when an otogenic source of brain abscess is suspected. Vancomycin plus a third-generation cephalosporin may be given initially in cases of brain abscess from neurosurgical procedures while awaiting final culture results. Vancomycin is also used in cases of MRSA abscesses. The rare tuberculosis abscesses can be treated with combination of isoniazid, rifampin, ethambutol, and pyrazinamide for 2 to 4 months, and thereafter, isoniazid and rifampin are given for at least 1 year. Aspergillosis abscesses are most effectively treated with voriconazole. Amphotericin B may be considered if voriconazole cannot be given. The duration of antibiotics for most abscesses is 4 to 8 weeks depending on the context, although randomized clinical trials are lacking. For cerebritis without capsule formation, and for simple abscesses surgically drained, a shorter duration (4-6 wk) is sufficient. When there are complicating factors such as multilobulated abscess, immunocompromised, or lesions inaccessible to drainage, then longer courses (6-8 wk or longer) are recommended.

Clinical improvement and CT or MRI are used to monitor the effectiveness of antibiotic treatment. The appropriate frequency of imaging surveillance is variable. For patients who are clinically improving, a 6-week interval is reasonable; patients with ongoing fever or incomplete clinical response require more frequent imaging. Follow-up CT and MRI may show a small area of residual enhancement even after adequate antimicrobial therapy

and should not be used in isolation to guide ongoing antimicrobials if clinical and other imaging parameters are improving. Occasionally, a previously ring-enhancing lesion on CT disappears with medical management, suggesting that these reversible lesions are forms of suppurative cerebritis.

Seizures may occur in up to 50% of patients with brain abscess early in the course, but the incidence is variable and unpredictable; one large retrospective study found seizures in only 16% of patients with brain abscess. Extrapolating from studies in brain tumors, anticonvulsants should not be used routinely for primary prophylaxis.

The use of corticosteroids for these patients is controversial. In patients with life-threatening cerebral edema, midline shift, or impending herniation, a short course of high-dose corticosteroids (dexamethasone 10 mg intravenously once, then 4 mg intravenously every 6 h) may be appropriate. Corticosteroids should be discontinued once the patient is improved. Prolonged use of corticosteroids is not recommended because the steroids may interfere with granulation tissue formation and reduce the concentration of antibiotics within the infected tissue. Patients with severe brain edema may require intubation with intensive care management to control elevated ICP. Hemicraniectomy may be considered in cases of increased ICP refractory to medical therapy.

Outcome

The outcome of untreated brain abscess is, with rare exceptions, death. Mortality in pre-CT series varied from 35% to 55%. In the era of advanced neuroimaging with CT and MRI, the mortality rate of brain abscesses is as low as 10%. Overall morbidity and mortality of brain abscess is related to delayed diagnosis, presence of single or multiple abscesses, intraventricular rupture, presence of coma or rapidly declining neurologic status at the time of diagnosis, or fungal infections. Patients with depressed level of consciousness on admission tend to do poorly. Intraventricular rupture of a brain abscess and posterior fossa location are associated with mortality rates exceeding 80%. In a univariate analysis of mortality, Glasgow Coma Scale score on admission of less than or equal to 9 was an independent predictor of in-hospital mortality in one study. Immunocompromised individuals have worse outcomes and higher mortality rates. The highest death rate is found when the primary infection is in the lungs.

Sequelae of brain abscess include recurrence of the abscess or the development of new abscesses if the primary focus persists. Residual neurologic sequelae with hemiparesis, seizures, or intellectual or behavioral impairment are common; however, over five decades up to 2012, the number of patients with full recovery increased from about 30% to 70% of patients.

SUBDURAL EMPYEMA

A subdural empyema is a collection of loculated pus in the subdural space. The symptoms are similar to those of a brain abscess, although symptoms progress more rapidly.

Epidemiology

Unlike other suppurative infections of the cranium and parameningeal space, most patients are healthy without predisposing conditions apart from sinusitis. A subdural infection in adults usually arises from a contiguous spread of infection; paranasal sinusitis is the most common source. Otitis, head trauma, and neurosurgical procedures are other sources of infection. The most common pathogens in subdural empyema are anaerobic organisms and microaerophilic streptococci. In a minority of cases, *S aureus* and multiple organisms, including gram-negative organisms such as *E coli* and anaerobic organisms, such as *Bacteroides*, may be present. *P aeruginosa* or *S epidermidis* may be found in cases following neurosurgical procedures. In addition, *Clostridium perfringens* subdural empyemas can occur from the site of recent surgical wound or trauma.

Pathobiology

The infection spreads to the subdural space through retrograde thrombophlebitis via venous sinuses or direct extension through bone and dura. Once the infection develops, it may spread over the convexities and along the falx, although characteristic loculation is common. Associated complications include septic cortical vein thrombosis, brain or epidural abscess, and meningitis. Infratentorial empyema is a rare complication of bacterial meningitis and can present with nonlocalizing symptoms of neck stiffness and decreased level of consciousness.

Clinical Manifestations

Subdural empyema typically presents with focal headache, fever, and in 80% to 90% of patients, focal neurologic signs. The combination of fever, rapidly progressive neurologic deterioration, and focal seizures is particularly suggestive of this disorder. Symptoms of subdural empyema may begin 1 to 2 weeks after a sinus infection, but the organisms most frequently involved point to chronic sinusitis as the cause in most cases.

Diagnosis

Neuroimaging with either CT or MRI reveals a typical crescent-shaped area of hypodensity or hyperintensity, respectively, over a hemisphere, along the dura, or adjoining the falx, with enhancement of the margins around the empyema after administration of contrast. The diagnostic test of choice is MRI with gadolinium enhancement for the delineation of the presence and extent of the subdural empyema and to identify concurrent intracranial infections. As with brain abscess, DWI may help distinguish empyema from noninfectious subdural collections (**Fig. 65.4**). The CT may miss some lesions that can be detected by MRI, but given the rapid progression and the potential involvement of sinus defects, CT remains an essential part of the evaluation. Lumbar puncture is generally contraindicated for the same reason it is with brain abscess, that is, because of mass effect and potential for herniation as well as the low yield.

Management

Treatment of nearly all cases of subdural empyema is immediate surgical drainage and antibiotic therapy. Intravenous antibiotics are given depending on the organism identified, or if unknown, empiric treatment with third-generation cephalosporin plus metronidazole, with adjustments based on predisposing or associated conditions. Anticonvulsants are used if patients develop seizure. There is controversy about which type of neurosurgical technique is useful for drainage of subdural empyema. A CT

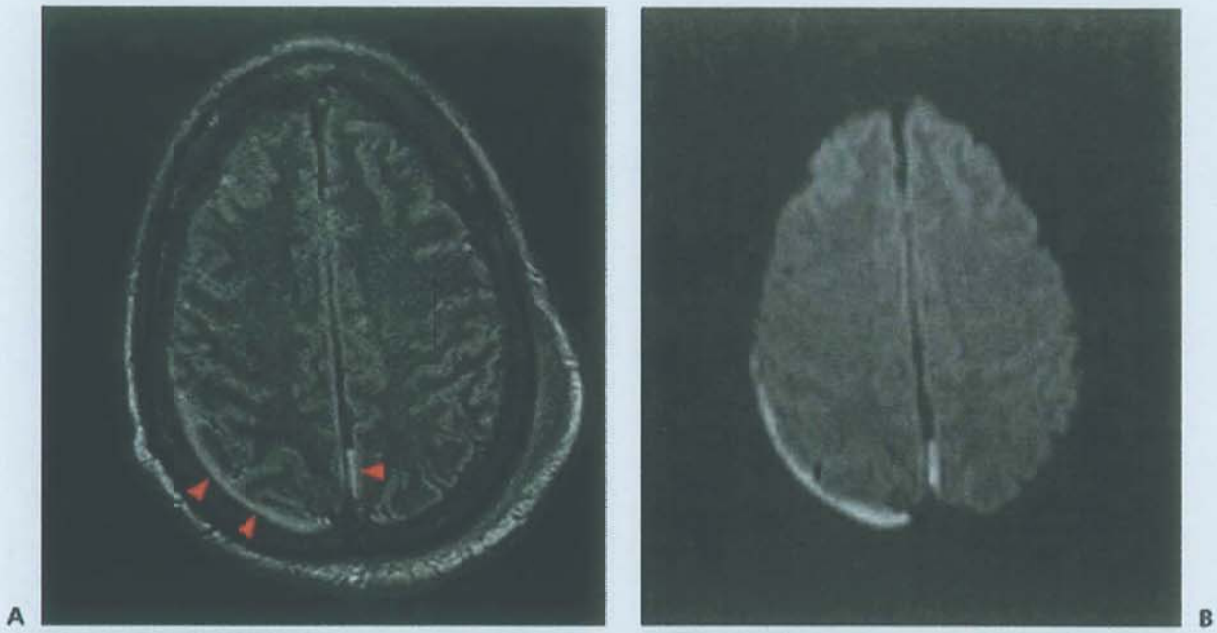

FIGURE 65.4 Subdural empyema. Magnetic resonance imaging fluid-attenuated inversion recovery **(A)** and diffusion-weighted imaging **(B)** images showing hyperintense signal in the right parietal convexity and left posterior parafalcine subdural spaces *(arrowheads)* consistent with subdural empyema (no evidence of blood products on susceptibility weighted imaging; no contrast-enhanced images obtained due to renal failure). (Courtesy of Drs. Girish Bathla and Michihiko Goto.)

accurately localizes the pus collection, and some advocate drainage through selective burr holes. Others prefer open craniotomy for more complete removal of the infection, especially when the empyema is loculated. Limited craniotomy is also used for placement of a drain into the subdural space and for local infusion of antibiotics. Use of either burr hole or craniotomy for drainage of subdural empyema is individualized. Neuroendoscopic technique for drainage of both brain abscess and subdural empyema is an alternative to surgical treatment. In cases of fulminant subdural empyema, decompressive craniectomy, irrigation of the empyema, and subdural drainage may be required. Further surgery to address sinusitis or bony defects is often performed simultaneously. The recommended duration of antibiotic therapy is 4 to 6 weeks after surgical drainage, with at least 2 weeks given intravenously.

Outcome

Antibiotics and advances in neuroimaging have dropped the mortality in subdural empyema to around 6% to 15%. Despite this improved survival, morbidity remains high with seizures, hemiparesis, or other residual neurologic deficits in about 50% of cases.

SPINAL EPIDURAL ABSCESS

Spinal epidural abscess is infection in the epidural space around the spinal cord.

Epidemiology and Pathobiology

Spinal epidural abscess may arise from hematogenous spread from a distant site; direct inoculation; or contiguous spread from skin, soft tissue, or bone infection. Typically, spinal epidural abscess is associated with diabetes, trauma, intravenous drug use, alcohol, age, or immunosuppression with the single most important risk factor being diabetes. The most important pathogen for spinal epidural abscess is *S aureus* found in over 60% of cases. Most common sources of infection are skin abscesses and bony infections involving the spine. An outbreak of fungal infection from contaminated corticosteroids used for epidural injection highlights the importance of identifying potential sources of direct inoculation. The most common location of spinal epidural abscesses is in dorsal epidural space, although one 10-year study found up to 30% may be located in the ventral epidural space. Due to the increased epidural space and fat, thoracic and lumbar regions are more commonly affected than cervical.

Clinical Manifestations

The clinical presentation of spinal epidural abscess includes back pain in about 75% and fever in about 50% of patients. These symptoms commonly are followed by focal neurologic deficits in about 30%, including radiculitis, paraparesis, sensory level, bladder or bowel dysfunction, and eventual para- or quadriplegia.

Diagnostic Testing

Both ESR and CRP are invariably elevated. Complete blood count and blood cultures should be obtained. Lumbar puncture is generally contraindicated because it can lead to introduction of infection into subarachnoid space and carries a low microbiologic yield. The MRI is more sensitive than CT with contrast in identifying spinal epidural abscess, with MRI approaching 90% sensitivity in some studies. Additional benefits of MRI include the ability to detect cord involvement (swelling or necrosis), diskitis, and osteomyelitis (Fig. 65.5).

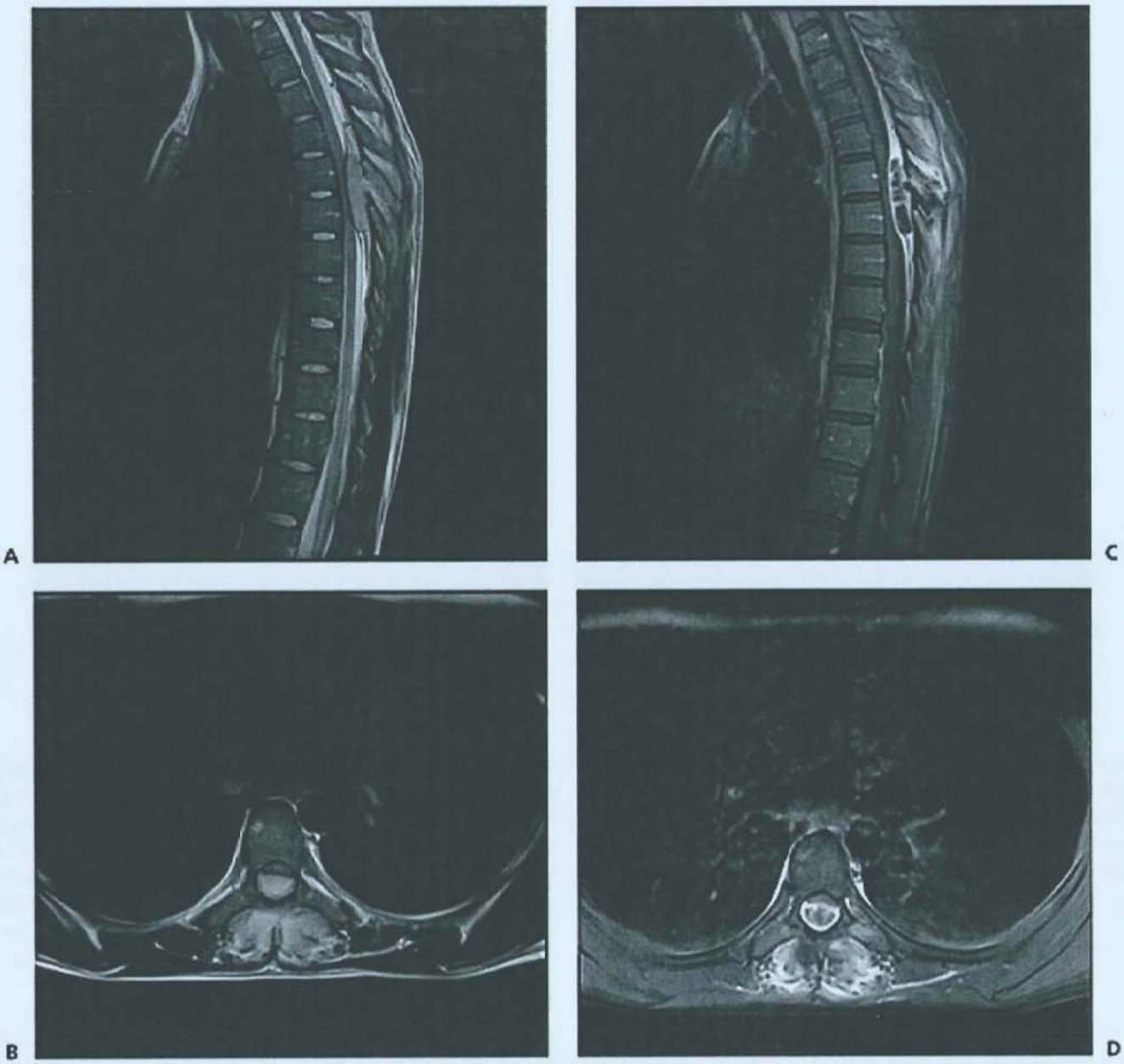

FIGURE 65.5 Spinal epidural abscess. Sagittal and axial magnetic resonance imaging T2-weighted images showing hyperintense signal **(A,B)** and sagittal and axial T1-weighted postcontrast images showing contrast-enhancement **(C,D)** in posterior epidural space at the T5-T6 spinal levels, consistent with abscess. Note additional involvement of posterior vertebral elements, paravertebral soft tissues, and paravertebral muscles consistent with contiguous osteomyelitis and myositis. (Courtesy of Drs. Girish Bathla and Michihiko Goto.)

Management

Treatment for spinal epidural abscess includes emergent surgery (eg, decompression with laminectomy) and antibiotics. Initial antimicrobial therapy should include antibiotics for MRSA and gram-negative bacilli. A combination of a third- or fourth-generation cephalosporin and vancomycin are recommended. Once the specific organism is identified from surgical specimen and antimicrobial sensitivity, then antibiotic therapy is modified accordingly. Some reports suggest spinal epidural abscess can be successfully treated with antibiotics alone (before neurologic symptoms appear); however, surgical decompression and drainage remains the mainstay of treatment in most cases.

Outcome

The prognosis in spinal epidural abscess is dependent on the degree of injury prior to treatment. The mechanism causing the neurologic deficits may also impact recovery: Compression of the cord can be helped by prompt surgical decompressions, but deficits due to vascular ischemia, with thrombosis or thrombophlebitis involving surrounding leptomeningeal vessels, or inflammatory response of glial cells, are not improved by surgery. Rehabilitation can significantly affect outcome in spinal epidural abscess, and improvement may be seen for up to a year after treatment.

MALIGNANT OTITIS EXTERNA

Malignant (necrotizing) otitis externa is an invasive infection of the external auditory canal and skull base; it penetrates epithelium and spreads to surrounding soft tissue to cause cellulitis and abscess. If untreated, the infection may extend to the temporomandibular joint, mastoid, or more commonly to soft tissues below the temporal bone.

Epidemiology and Pathobiology

Malignant otitis externa occurs more frequently in elderly diabetic patients and immunocompromised persons (eg, patients with HIV, chemotherapy, or organ transplantation) than in immunocompetent individuals.

In most cases, *P aeruginosa* is the causative organism. Less often, cases of malignant otitis externa have been reported due to *Klebsiella*, *S aureus*, *Proteus mirabilis*, and other *Pseudomonas* species. In HIV-positive individuals or in AIDS, either *P aeruginosa* or the fungus *Aspergillus fumigatus* may be isolated. In some patients with AIDS, *Streptococcus*, *Staphylococcus*, and *Proteus* species may be isolated as mixed or sole pathogens. Interestingly, ear irrigation with water contaminated with *Pseudomonas* species is often the causative event leading to malignant otitis externa.

Clinical Manifestations

Common symptoms of malignant otitis externa are severe otalgia that worsens at night, purulent otorrhea, and painful swelling of surrounding tissues. Conductive hearing loss may result from obstruction of the external auditory canal. Trismus may indicate irritation of the masseter muscles or involvement of the temporomandibular joint. Owing to its anatomic location in the temporal bone and petrous apex, the facial nerve may be affected as the first symptom in up to 30% of patients. Facial nerve involvement is most common, followed (in order) by glossopharyngeal, vagal, and spinal accessory nerves at the jugular foramen; hypoglossal nerve as it exits the hypoglossal canal; and trigeminal and abducens nerves at the petrous apex. Olfactory, oculomotor, and trochlear nerves are spared. Rarely, dysphagia results from lesions of cranial nerves IX to XII, and the findings may be mistaken for laryngeal carcinoma. Fever and weight loss are uncommon. Mastoid tenderness is evident on examination. The diagnostic finding of granulation tissue, stemming from extension of infection to the cartilaginous portion of the ear canal, may be seen on otoscopic examination. In rare cases, meningitis, brain abscess, and dural sinus thrombophlebitis can occur and are often fatal.

Diagnosis

The diagnosis of malignant otitis externa is often initially missed but can be made by combination of clinical, laboratory, and radiologic findings. General laboratory testing is invariably normal with the exception of ESR and CRP, which are elevated. The ESR is almost always elevated at greater than 50 mm/h. Both ESR and CRP can be useful in monitoring disease activity.

A CT is most useful in showing the location and extent of disease and evaluating evidence of bony erosion but may appear normal early in the illness. Initial CT can help predict severity of disease course based on early findings of extension of infection beyond the external auditory canal. The presence of bone erosion along with soft-tissue abnormalities in the subtemporal area is almost pathognomonic for the disease. An MRI with and without gadolinium is not useful in detecting bony changes but can provide useful information regarding the extent of skull-base and intracranial soft-tissue involvement. Bone scanning with technetium 99m (scans) methylene diphosphonate can be very sensitive but not specific. Gallium 67 single-photon emission computed tomography may be more sensitive and accurate in early detection of malignant external otitis, sensitive in measuring ongoing infectious process, and beneficial in monitoring response to therapy. However, it remains less frequently used compared to serial CT scanning.

The differential diagnosis of malignant otitis externa includes squamous cell carcinoma of the temporal bone. Radiologic testing cannot differentiate tumor from necrotizing infection of malignant otitis externa and biopsy is often necessary to distinguish between these two processes. Findings of positive culture for *Pseudomonas* species along with elevated ESR and CRP confirm the diagnosis of malignant otitis externa.

Management and Outcome

Antipseudomonal agents are the agents of choice for treatment of malignant otitis externa (Table 65.3). Rare cases of fungal (eg, *Aspergillus* species) malignant external otitis do exist. In the preantibiotic era, mortality rates were greater than 50%, and surgical debridement was the treatment of choice. Later, standard treatment with intravenous antibiotics consisted of an antipseudomonal penicillin for 4 to 8 weeks, combined with an aminoglycoside for at least 2 weeks, or if tolerated, 4 to 6 weeks. Current successful treatment is based on single-drug therapy. Advantages of quinolones include low toxicity, excellent penetration into bone, and no dosage adjustment required in the elderly patient with renal impairment. Double-antibiotic therapy may be considered with more extensive lesions. Fluoroquinolone-resistant strains exist, so alternative therapy must be considered. Such alternative treatment includes antipseudomonal β-lactams, including piperacillin, combination piperacillin-tazobactam, ceftazidime, and cefepime. In some drug-resistant cases, use of cephalosporins and antipseudomonal penicillins in combination with debridement may be necessary. Rare complications of retropharyngeal abscesses are drained surgically. For *Aspergillus* species, voriconazole has been successful as first-line treatment and shown superiority to amphotericin B in a randomized trial. Despite these newer treatments, the mortality rate is still 10% to 20% and may be as high as 50% if treatment is delayed.

Hyperbaric oxygen therapy efficacy remains unproven and is rarely now used for refractory cases of malignant otitis externa. Recent studies suggest that facial cranial nerve involvement may be a marker for extension of disease but by itself not an adverse

TABLE 65.3 Antimicrobial Agents for Treatment of Malignant Otitis Externa

Antipseudomonal agents	Ciprofloxacin 400 mg IV every 8 h Levofloxacin 750 mg IV daily Ceftazidime 2 g IV every 8 h Cefepime 2 mg IV every 8 h
Antimicrobials for *Aspergillus* species	Voriconazole 4-6 mg/kg IV every 12 h Liposomal amphotericin B 5-7.5 mg/kg/d IV Amphotericin B + itraconazole 5 mg/kg/d + 600 mg oral daily

Abbreviation: IV, intravenous.

prognostic factor. If untreated or inadequately treated, malignant external otitis may result in osteomyelitis of the base of the skull, sigmoid sinus thrombosis, abscess formation, meningitis, and death.

OSTEOMYELITIS OF THE SKULL BASE

Osteomyelitis of the base of the skull is a rare complication of malignant external otitis, chronic mastoiditis, or paranasal sinus infection.

Epidemiology and Pathobiology

As with malignant otitis, the patients are usually elderly, diabetic, or immunocompromised. Osteomyelitis may occur in conjunction with otitis but usually appears weeks or months after starting antibiotics.

Clinical Manifestations

Symptoms include headache, otalgia, hearing loss, and otorrhea, but patients are frequently without fever. As the process spreads, cranial nerves may be affected, especially the VII and VIII nerves. Extension of skull base osteomyelitis to the jugular foramen or hypoglossal canal may affect cranial nerves IX to XII, leading to dysphagia. In advanced cases, spread to the petrous pyramid may affect III, IV, V, and VI cranial nerves to cause ocular palsies or trigeminal neuralgia.

Diagnosis

Laboratory abnormalities include a normal or slightly elevated white blood cell count and high ESR. In general, leukocytosis is not common and not useful to diagnosis and management. The use of thin-cut CT sections through the skull base and temporal bones to visualize bony involvement plays an important role in the diagnosis of osteomyelitis and in assessing extent of disease. However, because more than 30% of affected bone needs to be demineralized to appear eroded on CT, early disease may escape detection by CT.

An MRI is useful in delineating soft-tissue involvement but has not proved beneficial for initial diagnosis or determining efficacy of treatment for skull-base osteomyelitis. Technetium bone scanning is a sensitive indicator of osteomyelitis but is not helpful in determining resolution of disease. Technetium uptake is nonspecific and may be seen in a number of conditions such as infection, trauma, neoplasm, and postoperatively. Gallium 67 citrate scans may be useful in tracking resolution of disease over time. Neither bone nor gallium scans are useful in determining the exact extent of the infection. Unlike technetium 99m scans, gallium 67 scans return to normal sooner once the infection is resolved and can be useful to signal clearing of infection. *S aureus* is now the most common isolated organism in osteomyelitis. Other potential causative agents include *P aeruginosa*, *S epidermidis*, *Proteus*, *Salmonella*, *Mycobacterium*, *Aspergillus*, and *Candida*.

Management and Outcome

Therapy for osteomyelitis consists of intravenous administration of antibiotics, usually a combination of an antipseudomonal penicillin or cephalosporin. Ciprofloxacin, with its strong bone penetration, has been effective when used alone or with other antibiotics. Ceftazidime has bactericidal activity against *Pseudomonas* species and has been used successfully as monotherapy. The disease is usually extensive, and conservative management of skull-base osteomyelitis is still an extended course of therapy. In rare cases of *Aspergillus* osteomyelitis, surgical debridement with radical mastoidectomy is usually required, in addition to long-term antifungal therapy. Monthly gallium scans may help to determine the response and duration of antibiotic therapy. In refractory cases, hyperbaric oxygen has been used as adjuvant therapy. Antibiotics should be continued for at least 1 week after the gallium scan becomes normal. Duration of antibiotic therapy varies but is usually for at least 1 month and, in some cases, may extend up to 6 months after diagnosis. Follow-up gallium scans may be performed 1 week after completion of antibiotic therapy to detect early recurrence and at 3 months for late recurrence. Mortality rates of 40% have been reported, but with prolonged antibiotic therapy, complete cure may be achieved. Recurrences may manifest up to 1 year later; true cure is considered when the patient is disease-free for a year after the treatment is begun.

SUGGESTED READINGS

Brain Abscess, Subdural Empyema, and Spinal Epidural Abscess

Alderson D, Strong AJ, Ingham HR, Selkon JB. Fifteen-year review of the mortality of brain abscess. *Neurosurgery*. 1981;8:1-5.

Auvichayapat N, Auvichayapat P, Aungwarawong S. Brain abscess in infants and children: a retrospective study of 107 patients in northeast Thailand. *J Med Assoc Thai*. 2007;90:1601-1607.

Baggish AL, Nadiminti H. Intracranial abscess from embolic *Serratia marcescens* endocarditis. *Lancet Infect Dis*. 2007;7:630.

Balasubramaniam P, Madakira PB, Ninan A, Swaminathan A. Response of central nervous system aspergillosis to voriconazole. *Neurol India*. 2007;55:301-303.

Bernardini GL. Diagnosis and management of brain abscess and subdural empyema. *Curr Neurol Neurosci Rep*. 2004;4(6):448-456.

Brouwer MC, Coutinho JM, van de Beek D. Clinical characteristics and outcome of brain abscess: systematic review and meta-analysis. *Neurology*. 2014;82(9):806-813.

Carpentier PA, Duncan DS, Miller SD. Glial toll-like receptor signaling in central nervous system infection and autoimmunity. *Brain Behav Immun*. 2008;22:140-147.

Chen FC, Tseng YZ, Wu SP, et al. Vegetation on patent foramen ovale presenting as a cryptogenic brain abscess. *Int J Cardiol*. 2008;124:e49-e50.

Chiller TM, Roy M, Nguyen D, et al. Clinical findings for fungal infections caused by methylprednisolone injections. *N Engl J Med*. 2013;369(17):1610-1619.

Chong-Han CH, Cortez SC, Tung GA. Diffusion-weighted MRI of cerebral *Toxoplasma* abscess. *AJR Am J Roentgenol*. 2003;181:1711-1714.

Courville CB, Nielsen JM. Fatal complications of otitis media, with particular reference to intracranial lesions in a series of 10,000 autopsies. *Arch Otolaryngol*. 1934;19:451-501.

Cunha BA, Krol V, Kodali V. Methicillin-resistant *Staphylococcus aureus* (MRSA) mitral valve acute bacterial endocarditis (ABE) in a patient with Job's syndrome (hyperimmunoglobulin E syndrome) successfully treated with linezolid and high-dose daptomycin. *Heart Lung*. 2008;37:72-75.

de Falco R, Scarano E, Cigliano A, et al. Surgical treatment of subdural empyema: a critical review. *J Neurosurg Sci*. 1996;40:53-58.

Dill ST, Cobbs CG, McDonald CK. Subdural empyema: analysis of 32 cases and review. *Clin Infect Dis*. 1995;20:372-386.

Finsterer J, Hess B. Neuromuscular and central nervous system manifestations of *Clostridium perfringens* infections. *Infection*. 2007;35:396-405.

Greenlee JE. Subdural empyema. *Curr Treat Options Neurol*. 2003;5:13-22.

Guzman R, Barth A, Lövblad KO, et al. Use of diffusion-weighted magnetic resonance imaging in differentiating purulent brain processes from cystic brain tumors. *J Neurosurg*. 2002;97:1101-1107.

Hakan T, Ceran N, Erdem I, Berkman MZ, Gökta P. Bacterial brain abscesses: an evaluation of 96 cases. *J Infect*. 2006;52:359-366.

Harvey FH, Carlow TJ. Brainstem abscess and the syndrome of acute tegmental encephalitis. *Ann Neurol*. 1980;7:371-376.

Heilpern KL, Lorber B. Focal intracranial infections. *Infect Dis Clin North Am*. 1996;10:879-898.

Infection in Neurosurgery Working Party of the British Society for Antimicrobial Chemotherapy. The rational use of antibiotics in the treatment of brain abscess. *Br J Neurosurg*. 2000;14(6):525-530.

Jaggi RS, Husain M, Chawla S, Gupta A, Gupta RK. Diagnosis of bacterial cerebellitis: diffusion imaging and proton magnetic resonance imaging spectroscopy. *Pediatr Neurol*. 2005;32:72-74.

Jansson AK, Enblad P, Sjölin J. Efficacy and safety of cefotaxime in combination with metronidazole for empirical treatment of brain abscess in clinical practice: a retrospective study of 66 consecutive cases. *Eur J Clin Microbiol Infect Dis*. 2004;23:7-14.

Kaushik K, Karade S, Kumar S, Kapila K. Tuberculous brain abscess in a patient with HIV infection. *Indian J Tuberc*. 2007;54:196-198.

Kawamata T, Takeshita M, Ishizuka N, Hori T. Patent foramen ovale as a possible risk factor for cryptogenic brain abscess: report of two cases. *Neurosurgery*. 2001;49:204-206.

Kielian T. Microglia and chemokines in infectious diseases of the nervous system: views and reviews. *Front Biosci*. 2004;9:732-750.

Lai PH, Hsu SS, Ding SW, et al. Proton magnetic resonance spectroscopy and diffusion-weighted imaging in intracranial cystic mass lesions. *Surg Neurol*. 2007;68(suppl 1):S25-S36.

Lefebvre L, Metellus P, Dufour H, Bruder N. Linezolid for treatment of subdural empyema due to *Streptococcus*: case reports. *Surg Neurol*. 2009;71(1):89-91.

Lu CH, Chang WN, Lui CC. Strategies for the management of bacterial brain abscess. *J Clin Neurosci*. 2006;13:979-985.

Macewen W. *Pyogenic Infective Diseases of the Brain and Spinal Cord: Meningitis, Abscess of Brain, Infective Sinus Thrombosis*. Glasgow, United Kingdom: James Maclehose & Sons; 1893.

Mathisen GE, Johnson JP. Brain abscess. *Clin Infect Dis*. 1997;25:763-779.

Menon S, Bharadwaj R, Chowdhary A, Kaundinya DV, Palande DA. Current epidemiology of intracranial abscesses: a prospective 5 year study. *J Med Microbiol*. 2008;57(pt 10):1259-1268.

Merritt HH, Fremont-Smith F. *The Cerebrospinal Fluid*. Philadelphia, PA: WB Saunders; 1938.

Miranda HA, Castellar-Leones SM, Elzain MA, Moscote-Salazar LR. Brain abscess: current management. *J Neurosci Rural Pract*. 2013;4(suppl 1):S67-S81.

Mueller-Mang C, Castillo M, Mang TG, Cartes-Zumelzu F, Weber M, Thurnher MM. Fungal versus bacterial brain abscesses: is diffusion-weighted MR imaging a useful tool in the differential diagnosis? *Neuroradiology*. 2007;49:651-657.

Muthusamy KA, Waran V, Puthucheary SD. Spectra of central nervous system melioidosis. *J Clin Neurosci*. 2007;14:1213-1215.

Muzumdar D, Jhawar S, Goel A. Brain abscess: an overview. *Int J Surg*. 2011;9:136-144.

Nathoo N, Nadvi SS, Narotam PK, van Dellen JR. Brain abscess: management and outcome analysis of a computed tomography era experience with 973 patients. *World Neurosurg*. 2011;75(5-6):716-726.

Osborn MK, Steinberg JP. Subdural empyema and other suppurative complications of paranasal sinusitis. *Lancet Infect Dis*. 2007;7(1):62-67.

Reddy JS, Mishra AM, Behari S, et al. The role of diffusion-weighted imaging in the differential diagnosis of intracranial cystic mass lesions: a report of 147 lesions. *Surg Neurol*. 2006;66(3):246-250.

Rosenblum ML, Hoff JT, Norman D, Weinstein PR, Pitts L. Decreased mortality from brain abscesses since advent of computerized tomography. *J Neurosurg*. 1978;49:658-668.

Saigal G, Nagornaya N, Post MJD. Infection. *Handb Clin Neurol*. 2016;135:365-397.

Seydoux C, Francioli P. Bacterial brain abscesses: factors influencing mortality and sequelae. *Clin Infect Dis*. 1992;15:394-401.

Shaw MDM, Russell JA. Cerebellar abscess. A review of 47 cases. *J Neurol Neurosurg Psychiatry*. 1975;38:429-435.

Senneville R, Ruimy R, Benzonana N, et al. An update on bacterial brain abscess in immunocompetent patients. *Clin Microbiol Infect*. 2017;23(9):614-620.

Tattevin P, Bruneel F, Clair B, et al. Bacterial brain abscesses: a retrospective study of 94 patients admitted to an intensive care unit (1980 to 1999). *Am J Med*. 2003;115:143-146.

Ulivieri S, Oliveri G, Filosomi G. Brain abscess and Rendu-Osler-Weber disease. Case report and review of the literature. *J Neurosurg Sci*. 2007;51:77-79.

van de Beek D, Campeau NG, Wijdicks EF. The clinical challenge of recognizing infratentorial empyema. *Neurology*. 2007;69:477-481.

Wada Y, Kubo T, Asano T, Senda N, Isono M, Kobayashi H. Fulminant subdural empyema treated with a wide decompressive craniectomy and continuous irrigation—case report. *Neurol Med Chir (Tokyo)*. 2002;42:414-416.

Weingarten K, Zimmerman RD, Becker RD, Heier LA, Haimes AB, Deck MD. Subdural and epidural empyemas: MR imaging. *AJR Am J Roentgenol*. 1989;152:615-621.

Weisberg LA. Nonsurgical management of focal intracranial infection. *Neurology*. 1981;31:575-580.

Wispelwey B, Dacey RG Jr, Scheld WM. Brain abscess. In: Scheld WM, Whitley RJ, Durack DT, eds. *Infections of the Central Nervous System*. 2nd ed. New York, NY: Raven Press; 1991:457-486.

Yadav YR, Sinha M, Neha, Parihar V. Endoscopic management of brain abscesses. *Neurol India*. 2008;56:13-16.

Ziai WC, Lewin JJ III. Advances in the management of central nervous system infections in the ICU. *Crit Care Clin*. 2007;22:661-694.

Zimmerman RA. Imaging of intracranial infections. In: Scheld WM, Whitley RJ, Durack DT, eds. *Infections of the Central Nervous System*. 2nd ed. New York, NY: Raven Press; 1991:887-908.

Malignant External Otitis and Osteomyelitis

Bernstein JM, Holland NJ, Porter GC, Maw AR. Resistance of *Pseudomonas* to ciprofloxacin: implications for the treatment of malignant otitis externa. *J Laryngol Otol*. 2007;121:118-123.

Dinapoli RF, Thomas JE. Neurologic aspects of malignant external otitis: report of three cases. *Mayo Clin Proc*. 1971;46:339-344.

Grandis JR, Curtin HD, Yu VL. Necrotizing (malignant) external otitis: prospective comparison of CT and MR imaging in diagnosis and follow-up. *Radiology*. 1995;196:499-504.

Herbrecth R, Denning DW, Patterson TF, et al. Voriconazole versus amphotericin B for primary therapy of invasive aspergillosis. *N Engl J Med*. 2002;347:408-415.

Hern JD, Almeyda J, Thomas DM, Main J, Patel KS. Malignant otitis externa in HIV and AIDS. *J Laryngol Otol*. 1996;110:770-775.

Ismail H, Hellier WP, Batty V. Use of magnetic resonance imaging as the primary imaging modality in the diagnosis and follow-up of malignant external otitis. *J Laryngol Otol*. 2004;118:576-579.

Karantanas AH, Karantzas G, Katsiva V, Proikas K, Sandris V. CT and MRI in malignant external otitis: a report of four cases. *Comput Med Imaging Graph*. 2003;27:27-34.

Kondziella D, Skagervik I. Malignant external otitis with extensive cranial neuropathy but no facial paralysis. *J Neurol*. 2007;254:1298-1299.

Mani N, Sughoff H, Rajagopal S, Moffat D, Axon PR. Cranial nerve involvement in malignant external otitis: implications for clinical outcome. *Laryngoscope*. 2007;117:907-910.

Mardinger O, Rosen D, Minkow B, Tulzinsky Z, Ophir D, Hirshberg A. Temporomandibular joint involvement in malignant external otitis. *Oral Surg Oral Med Oral Pathol Oral Radiol Endod*. 2003;96:398-403.

Meyers BR, Mendelson MH, Parisier SC, Hirschman SZ. Malignant external otitis. Comparison of monotherapy vs combination therapy. *Arch Otolaryngol Head Neck Surg*. 1987;113:974-978.

Narozny W, Kuczkowski J, Stankiewicz C, Kot S, Mikaszewski B, Przewozny T. Value of hyperbaric oxygen in bacterial and fungal malignant external otitis treatment. *Eur Arch Otorhinolaryngol*. 2006;263:680-684.

Nicolai P, Lombardi D, Berlucchi M, Farina D, Zanetti D. Drainage of retroparapharyngeal abscess: an additional indication for endoscopic sinus surgery. *Eur Arch Otorhinolaryngol*. 2005;262:722-730.

Okpala NC, Siraj QH, Nilssen E, Pringle M. Radiological and radionuclide investigation of malignant otitis externa. *J Laryngol Otol*. 2005;119:71-75.

Parize P, Chandesris MO, Laternier F, et al. Antifungal therapy of *Aspergillus* invasive otitis externa: efficacy of voriconazole and review. *Antimicrob Agents Chemother*. 2009;53:1048-1053.

Peleg U, Perez R, Raveh D, Berelowitz D, Cohen D. Stratification for malignant external otitis. *Otolaryngol Head Neck Surg*. 2007;137:301-305.

Ress BD, Luntz M, Telischi FF, Balkany TJ, Whiteman ML. Necrotizing external otitis in patients with AIDS. *Laryngoscope*. 1997;107:456-460.

Rubin Grandis J, Branstetter BF IV, Yu VL. The changing face of malignant (necrotising) external otitis: clinical, radiological, and anatomic correlations. *Lancet Infect Dis*. 2004;4:34-39.

Soudry E, Joshua BZ, Sulkes J, Nageris BI. Characteristics and prognosis of malignant external otitis with facial paralysis. *Arch Otolaryngol Head Neck Surg*. 2007;133:1002-1004.

Sreepada GS, Kwartler JA. Skull base osteomyelitis secondary to malignant otitis externa. *Curr Opin Otolaryngol Head Neck Surg*. 2003;11:316-323.

Sudhoff H, Rajagopal S, Mani N, Moumoulidis I, Axon PR, Moffat D. Usefulness of CT scans in malignant external otitis: effective tool for the diagnosis, but of limited value in predicting outcome. *Eur Arch Otorhinolaryngol*. 2008;265:53-56.

Tierney MR, Baker AS. Infections of the head and neck in diabetes mellitus. *Infect Dis Clin North Am*. 1995;9:195-216.

66 Other Bacterial Central Nervous System Infections and Toxins

Kyle J. Coleman

KEY POINTS

1. Rickettsial infections, such as spotted fever rickettsioses and typhus group rickettsiae, are transmitted by arthropods that cause various neurologic syndromes, including meningoencephalitis, and are treated with doxycycline.
2. Zoonoses are caused by animal-to-person transmission and can uncommonly induce neurologic symptoms following a preceding systemic illness.
3. Diphtheria, botulism, and tetanus are diseases induced by toxin-producing bacteria that leads to disruption of peripheral nerves or the neuromuscular junction.

INTRODUCTION

This chapter discusses the bacterial infections that are classified as rickettsial infections. Rickettsial infections are acquired from invertebrates such as ticks, mites, fleas, and lice. Zoonotic infections are acquired from vertebrates, typically mammals. Infections can also occur by human-to-human transmission. This chapter reviews the spotted fever rickettsioses (SFR), ehrlichiosis and anaplasmosis, typhus, Q fever, brucellosis, leptospirosis, cat-scratch disease (CSD), anthrax, Whipple disease, and bacterial toxins.

RICKETTSIAL INFECTIONS

Rickettsiae are a group of obligate, intracellular coccobacilli that are transmitted via arthropod vectors to humans, which serve as dead-end hosts. Tickborne rickettsial diseases in the United States include the spotted fever rickettsioses, ehrlichioses, and anaplasmosis (Table 66.1). These tickborne rickettsial diseases have all been associated with neurologic manifestations. The most common SFR is Rocky Mountain spotted fever (RMSF). Additional rickettsial diseases that are associated with neurologic manifestations include murine typhus, epidemic typhus, and scrub typhus, which are transmitted by fleas, lice, and mites, respectively (Table 66.2).

Spotted Fever Rickettsiosis

SFR is a closely related group of obligate intracellular, gram-negative bacteria that includes *Rickettsia rickettsii*, *Rickettsia parkeri*, and *Rickettsia* species 364D. By far, the most common of these is *R rickettsii*, which is the causative bacterium of RMSF. Most commonly transmitted by the American dog tick, *Dermacentor variabilis*, it is found in the eastern, central, and western regions of the United States. Less common tick vectors include the Rocky Mountain wood tick, *Dermacentor andersoni*, seen in the western United States, and the brown dog tick, *Rhipicephalus sanguineus*, which is an important vector in Arizona and along the U.S.-Mexico border. The larval and nymphal stages of *Dermacentor* species usually do

TABLE 66.1 Tickborne Rickettsial Diseases

Disease	Cutaneous Findings	Neurologic Features	Diagnosis	Treatment
Spotted fever rickettsioses	Maculopapular rash in most 2-4 d from fever onset that begins in the wrists and ankles and spreads to extremities and trunk; can become petechial and involve palms and soles with sparing of face	Meningoencephalitis, cranial neuropathies, ataxia, deafness, seizures, rigidity, and tremor	Indirect immunofluorescence assay (IFA), immunostaining of biopsied skin rash	Doxycycline
Human monocytic ehrlichiosis	One-third with maculopapular or petechial rash involving trunk and extremities; typically spares the palms, soles, and face	Meningitis, meningoencephalitis, seizures, and coma; cranial neuropathies rare	IFA, whole blood polymerase chain reaction (PCR), visualization of morulae in monocytes on Wright and Giemsa staining	Doxycycline
Human ewingii ehrlichiosis	Rarely seen	Meningitis or encephalitis uncommon	IFA, whole blood PCR	Doxycycline
Human granulocytic anaplasmosis	Rarely seen	Cranial nerve palsies, brachial plexopathies, and demyelinating polyneuropathies; meningitis or encephalitis uncommon	IFA, whole blood PCR, visualization of morulae in granulocytes on Wright and Giemsa staining	Doxycycline

TABLE 66.2 Typhus Group Rickettsiae and Scrub Typhus

Disease	Causative Organism	Vector	Cutaneous Findings	Neurologic Features	Diagnostic Tests	Treatment
Epidemic typhus	*Rickettsia prowazekii*	Lice	Eschar with associated edema and regional lymphadenopathy	Meningoencephalitis most common Cranial nerve palsies, cerebellitis, transverse myelitis, neuropsychiatric involvement less common	Indirect immunofluorescence assay (IFA), real-time polymerase chain reaction (PCR) of biopsied skin lesions	Doxycycline
Murine typhus	*Rickettsia typhi*	Flea	Erythematous and blanching macule that begins in the trunk. May spread to extremities but spares palms and soles; eschars absent	Headache most prevalent Meningitis or encephalitis rare	IFA, real-time PCR of biopsied skin lesions	Doxycycline
Scrub typhus	*Orientia tsutsugamushi*	Trombiculid mite (chigger)	Same as murine typhus	Coma and seizures in up to 80% Meningitis and encephalitis common	Serum: enzyme-linked immunosorbent assay, IFA CSF: PCR	Doxycycline

not bite humans, and the adult ticks have maximum activity during late spring through early summer. The principal hosts include deer, dogs, livestock, and rodents.

Epidemiology

The reported incidence of SFR in the United States has risen dramatically from approximately 500 cases in the year 2000 to greater than 6,000 cases in the year 2017. Although the disease has been reported in every state in the continental United States, there is a notable geographic preference (Fig. 66.1). Greater than 60% of cases can be found in one of five states: Arkansas, Missouri, North Carolina, Oklahoma, and Tennessee. Men are twice as likely to be affected as women, and the highest incidence is found in ages 60 to 69 years, although the highest fatality rate is among children aged younger than 10 years old. Disease also has a seasonal preference with 90% occurring between the months of April and September.

Pathophysiology

After entry of rickettsiae into the epidermis following a tick bite, hematogenous dissemination occurs. There is a predilection for the endothelium of capillaries and arterioles, and the clinical manifestations are a direct result of the vascular inflammation. The most common organ affected is the skin. The heart, lungs, kidneys, spleen, and central nervous system (CNS) are also involved to varying degrees. Endothelial infection leads to a perivascular infiltrate composed of lymphocytes and macrophages. This increases vascular permeability with leakage of fluid into surrounding tissues. In the CNS, this can lead to cerebral edema and petechial hemorrhages. Occlusion of arterioles also commonly occurs with resultant microinfarctions.

Clinical Manifestations

Symptoms typically present 3 to 12 days after a tick bite, although only 50% to 60% of patients recall tick exposure. Some might describe a pruritic or erythematous lesion that they associate with a mosquito bite or other insect. The onset of symptoms is sudden and nonspecific and includes fever, chills, headache, and malaise. Abdominal pain, nausea or vomiting, anorexia, and delirium also commonly occur. A rash appears 2 to 4 days after fever onset and is initially a blanching, pink macule on the wrists and ankles. It quickly spreads centripetally to the arms and legs first, then to the trunk with sparing of the face. Over the next several days, the rash will become maculopapular with centralized petechiae. This will evolve into a generalized petechial rash that includes the palms and soles by days 5 to 6 (Fig. 66.2).

Neurologic manifestations are as high as 40% even when headache, the most common neurologic symptom, is excluded. Altered mental status is common and can range from irritability to decreased level of consciousness to coma in severe cases. Focal neurologic deficits are often transient in mild disease and include unilateral facial paresis, cranial nerve palsies, hemiparesis, and ataxia. In more severe forms of disease, progression to tremor, rigidity, deafness, and seizures occur. The most feared neurologic complication is encephalitis, which occurs in approximately 2%. Approximately 5% to 10% of patients with SFR meningoencephalitis will have permanent CNS dysfunction that includes cognitive impairment, hearing loss, weakness, dysarthria, and blindness. Other severe complications of SFR include myocarditis, cardiac dysrhythmias, and hepatic or renal injury, all of which are less frequent than neurologic involvement.

Diagnosis

Common serum laboratory tests are of variable importance. The white blood cell count will be normal or slightly elevated. Thrombocytopenia, mild elevations in hepatic transaminases, and hyponatremia are common in the mid to late stages of the disease, but platelet counts, liver function tests, and serum sodium are often normal in the early stages. Cerebrospinal fluid (CSF) testing is necessary when meningoencephalitis is suspected. A pleocytosis of white blood cells will be present (typically <100 cells/mm^3 total) with a lymphocytic predominance in most, although a neutrophilic predominance occurs in up to one-third. The protein concentration will be moderately elevated (100-200 mg/dL), and the glucose concentration is usually normal.

The majority will have abnormal neuroimaging findings. Brain magnetic resonance imaging (MRI) with gadolinium is the preferred modality. RMSF has a classic appearance on MRI known as the *starry sky* pattern (Fig. 66.3). This is caused by vasculitic

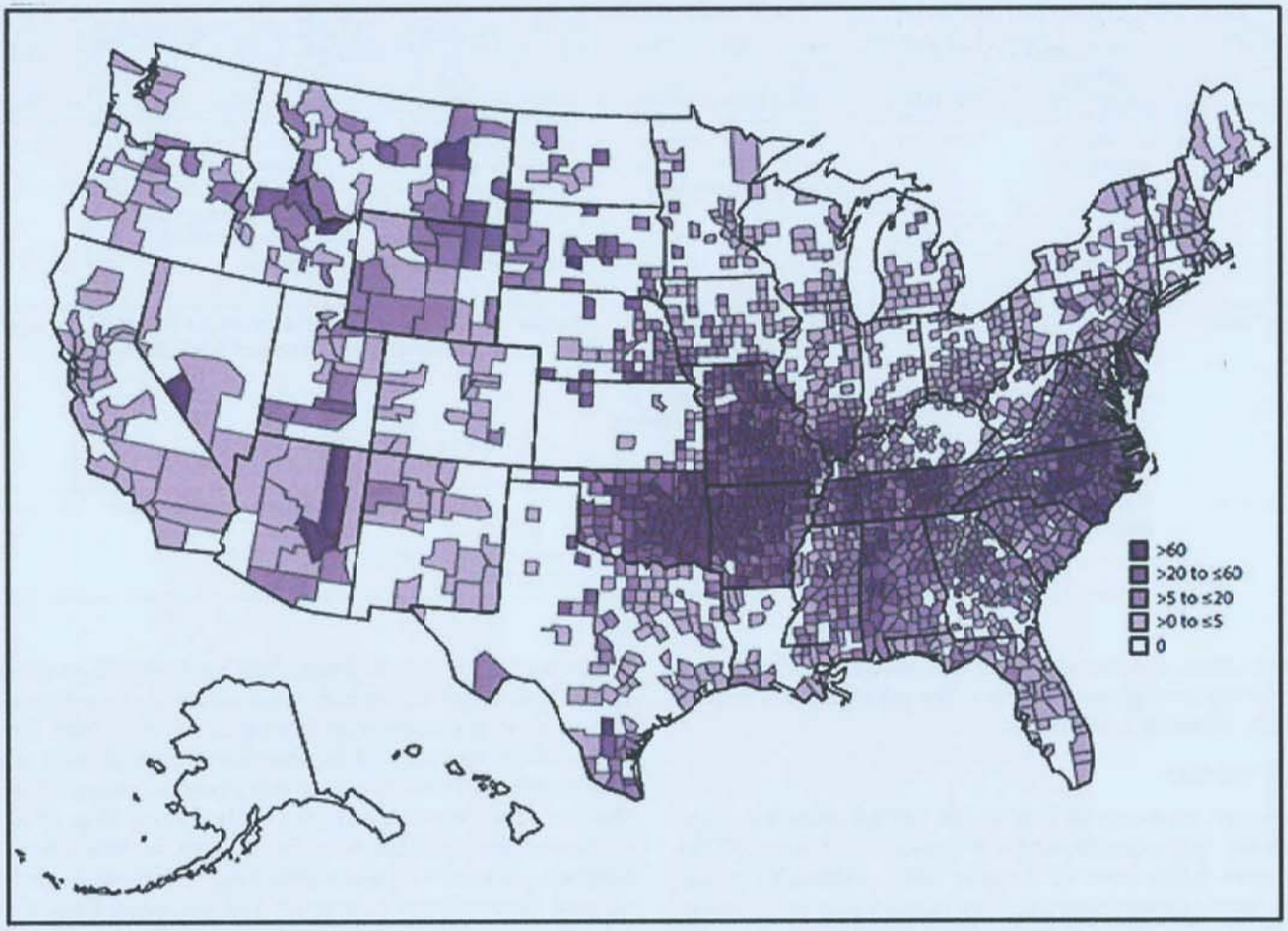

FIGURE 66.1 Map of reported incidence rate of spotted fever rickettsiosis, by county—United States, 2000-2013. (Photo/Centers for Disease Control and Prevention.)

changes resulting in subcortical and periventricular infarcts in a perivascular distribution. Within the appropriate clinical context, this finding strongly supports the diagnosis of SFR meningoencephalitis, particularly in children. However, its absence does not exclude the diagnosis, especially in adults. Other neuroimaging abnormalities of SFR include meningeal enhancement and nonspecific punctate abnormalities in the subcortical white matter and deep gray structures, such as the thalamus.

FIGURE 66.2 Late-stage petechial purpuric rash involving the sole of the foot in a patient with Rocky Mountain spotted fever. (Photo/Centers for Disease Control and Prevention.)

The most sensitive method of diagnosing SFR is via indirect immunofluorescence antibody assay using paired acute and convalescent sera. This method requires obtaining a serum sample as soon as the diagnosis is suspected, and immunoglobulin G (IgG) to rickettsial antigens is quantified. A second serum sample is obtained 2 to 4 weeks later. The diagnosis of SFR is confirmed if there is a fourfold or greater increase in antibody titers between the two samples. Testing of whole blood by polymerase chain reaction (PCR) is available for SFR but has a low sensitivity, although it is more likely to be positive if the disease is severe. Immunostaining of a skin biopsy obtained from a rash or eschar can provide a pathogen-specific diagnosis if the aforementioned methods are unrevealing.

Treatment and Outcome

Doxycycline is the treatment of choice for all tickborne rickettsial diseases regardless of age and should be started empirically if the diagnosis is suspected LEVEL 1. This includes children younger than 8 years old as the benefits of doxycycline far outweigh the risks. Recent studies with children younger than the age of 8 years who received doxycycline demonstrated no teeth or enamel abnormalities. Chloramphenicol is a potential alternative treatment for RMSF in pregnant women. The recommended dose of doxycycline is 100 mg twice a day for adults and 2.2 mg/kg body weight twice daily for children weighing <45 kg. Duration of treatment

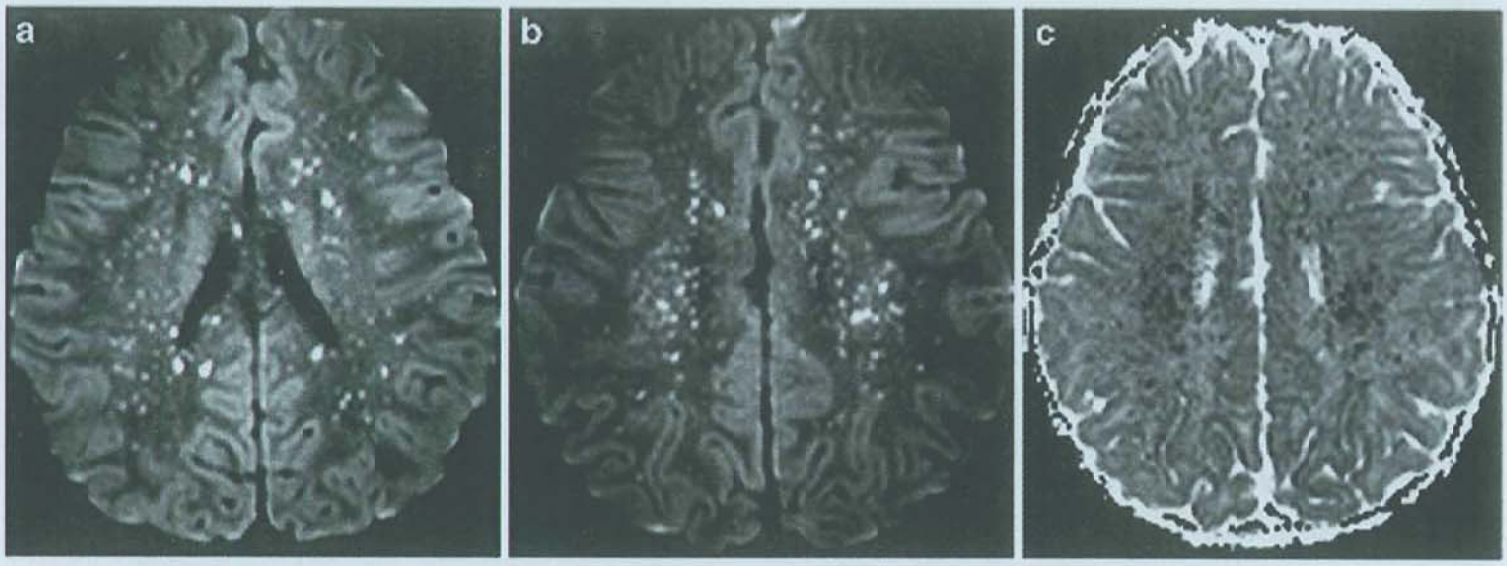

FIGURE 66.3 Rocky Mountain spotted fever in pediatric patient with "starry-sky appearance." Diffusion-weighted magnetic resonance with apparent diffusion coefficient images. **A,B:** Diffusion-weighted magnetic resonance images at the same level as **Fig. 1** show multiple punctate foci of increased signal corresponding to the T2 white matter lesions. **C:** Corresponding apparent diffusion coefficient map confirms restricted diffusion. (From Crapp S, Harrar D, Strother M, Wushensky C, Pruthi S. Rocky Mountain spotted fever: 'starry sky' appearance with diffusion-weighted imaging in a child. *Pediatr Radiol.* 2011;42:499-502.)

is variable, although should be for a minimum of 5 to 7 days. The Centers for Disease Control and Prevention (CDC) recommends treatment for at least 3 days after the fever resolves and until clinical improvement is noted. Typical treatment duration is for 1 to 2 weeks.

Despite the dramatic decrease in fatality rates since the introduction of doxycycline, SFR remains the most deadly of the rickettsial diseases. Approximately 5% to 10% will die from the illness, with the remaining survivors experiencing permanent sequelae such as epilepsy, hearing loss, and cognitive impairment if meningoencephalitis developed.

Prevention is based on proactive measures. Persons should inspect themselves, their pets, and their children after spending time outdoors in woody or grassy areas. Common locations for tick attachment include the scalp, axillae, and groin. The belt line and areas under socks should be carefully inspected as well. Pets in general, and dogs in particular, should be inspected around and inside the ears. Bathing shortly after outdoor recreational activity has been shown to be an effective protective measure for tickborne diseases. Other preventative measures include tucking pants into socks, using permethrin coated clothing, and spraying skin with N,N-diethyl-meta-toluamide. If a tick is found, it should be carefully removed with tweezers with strict avoidance of the tick with other areas of the skin.

Ehrlichiosis and Anaplasmosis

Ehrlichiosis and anaplasmosis are diseases due to tick-borne, gram-negative, obligate intracellular bacteria that infect leukocytes that are part of the family *Anaplasmataceae*. The three predominant species in the United States are *Ehrlichia chaffeensis*, which causes human monocytic ehrlichiosis (HME); *Ehrlichia ewingii*, which causes human ewingii ehrlichiosis (HEE); and *Anaplasma phagocytophilum*, which causes human granulocytic anaplasmosis (HGA).

Epidemiology

Like other tick-borne diseases, such as SFR, infections are predominantly in the summer months. HME is transmitted by the lone star tick, *Amblyomma americanum*, acquiring it from its host, the white-tailed deer. Four states (Missouri, Arkansas, Virginia, and New York) account for the majority of reported cases and are known for woodland habitats with large white-tailed deer populations. HEE is also transmitted by the lone star tick but occurs at a much lower frequency than HME, and the reported cases are mainly confined to Missouri. Anaplasmosis is transmitted by the species *Ixodes*, the same tick that transmits Lyme disease and coinfection is possible. *Ixodes scapularis* transmits HGA in the northeast and midwest United States, whereas *Ixodes pacificus* is the primary vector on the west coast.

The incidence of ehrlichiosis and anaplasmosis is on the rise. The incidence of HME has risen over eightfold since the start of the century with a total incidence of approximately 1,700 cases in 2017. HGA has increased nearly sixfold in the past decade with approximately 6,000 cases in 2017. HEE continues to remain much less common with approximately 200 total cases in the past decade. Like SFR, ehrlichiosis and anaplasmosis has a predominance of infections in males and adults older than 60 years of age.

Pathophysiology

E chaffeensis infects monocytes and macrophages where the organism will multiply and form packed clusters of bacteria called *morulae*. In a similar way, *E ewingii* and *A phagocytophilum* infect granulocytes. The greatest distribution of bacteria is found where these cells typically reside: the spleen, lymph nodes, and bone marrow. The resulting damage is caused by a systemic inflammatory response rather than the direct endothelial injury observed in SFR, making vasculitis rare in ehrlichiosis and anaplasmosis.

Clinical Manifestations

Symptoms of ehrlichiosis and anaplasmosis develop 5 to 14 days after a tick bite beginning with a nonspecific illness with fever, headache, malaise, and myalgia. A rash, which characterizes SFR, is much less common. In HME, about one-third will develop a maculopapular or petechial rash 5 days after illness onset that will involve the extremities and trunk but often spare the palms, soles, and face. A rash is rarely seen with HEE or HGA.

CNS complications are most likely to occur in HME with at least 20% developing an isolated meningitis or meningoencephalitis. Seizures and coma are commonly reported complications with cranial nerve palsies being rare. CNS involvement is uncommon in HGA with meningitis or encephalitis reported in approximately 1% of cases. In contrast to HME, peripheral nervous system involvement is more common with cranial nerve palsies, brachial plexopathies, and demyelinating polyneuropathies all reported with HGA. Although HEE has been associated with meningitis, the frequency of neurologic complications is currently unknown.

Diagnosis

Diagnosis of ehrlichiosis and anaplasmosis can be difficult given the nonspecific symptoms reported. A high degree of suspicion should be kept for reported tick exposure or time spent outdoors in endemic regions. Standard blood laboratory tests are useful. Leukopenia, thrombocytopenia, and elevated transaminases are present in the majority of patients. Wright and Giemsa staining can allow for visualization of morulae in monocytes and granulocytes on peripheral smear (Fig. 66.4). Whole blood PCR, which has a low sensitivity in SFR, allows for rapid detection in up to 85% in the acute stages of the illness. CSF analysis is most useful in HME and usually demonstrates a lymphocytic pleocytosis (<100 cells), normal glucose concentration, and mildly elevated protein concentration. MRI with gadolinium may demonstrate leptomeningeal enhancement in those with suspected meningoencephalitis.

Despite the usefulness of the aforementioned tests, serologic testing remains the standard for diagnostic confirmation. Like SFR, fourfold or greater rise in antibody titers between acute and convalescent serum samples drawn 2 to 4 weeks apart with IFA IgG testing is required. In those with a rash, skin biopsy with immunostaining is another option for diagnostic confirmation with a high sensitivity.

Treatment and Outcome

The recommended treatment and duration for ehrlichiosis is the same as for SFR. Doxycycline in both adults and children should be used until 3 days after fever dissipation and until evidence of clinical improvement. The CDC recommends that anaplasmosis also be treated with doxycycline but for a longer minimum of 10 days given the possibility of coinfection with Lyme disease LEVEL 1. For pregnant women and those with a tetracycline allergy, rifampin 300 mg twice daily is an alternative therapy. The outcomes are very good in HEE and HGA with fatalities being rare. Death is more common with HME but, at 3%, is still less than SFR.

Scrub Typhus

Scrub typhus is a rickettsial infection caused by the bacterium *Orientia tsutsugamushi*. Transmission to humans requires a bite from the larval stage of the trombiculid mite (chigger). Because chiggers prefer areas of heavy vegetation and torrential downpours, scrub typhus is largely confined to rural areas of Asia and islands in the Pacific. It is extremely uncommon in North America, but infection can be acquired in travelers to endemic areas.

Clinical Manifestations

The disease occurs 1 to 3 weeks following a chigger bite. In the early stages, fever and headache are invariably present, and conjunctival injection and gastrointestinal symptoms are common. By day 5 of the illness, the majority will demonstrate an eschar at the site of the chigger bite with an associated

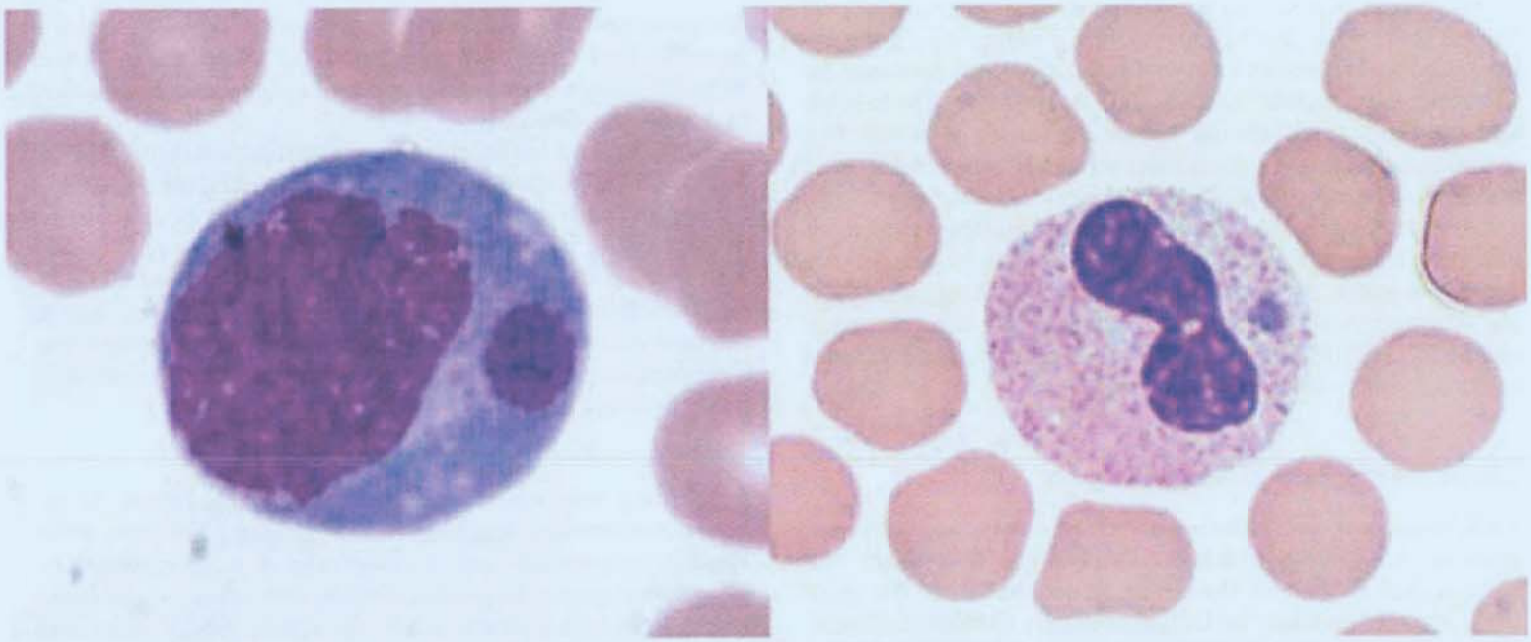

FIGURE 66.4 Wright stain of peripheral blood smears showing an intramonocytic morula associated with *Ehrlichia chaffeensis* infection (**left**) and an intragranulocytic morula (**right**), such as associated with *Ehrlichia ewingii* or *Anaplasma phagocytophilum* infection. (Photos/J. Stephen Dumler, University of Maryland [left]; Bobbi S. Pritt, Mayo Clinic [right].)

regional lymphadenopathy. The eschar contains a high bacterial load, which allows *O tsutsugamushi* to invade peripheral endothelial cells and spread through the blood and lymphatic systems. The result is a systemic vasculitis with potential involvement of the heart, lungs, liver, spleen, and CNS.

When the CNS is involved, a multitude of potential complications may arise. Meningoencephalitis is by far the most common complication and may occur in up to two-thirds of patients with scrub typhus. In these patients, status epilepticus is frequent. Additional neurologic manifestations are protean, but include cranial nerve palsies, cerebellitis, transverse myelitis, peripheral nervous system involvement, and neuropsychiatric involvement that include visual hallucinations.

Diagnosis

The diagnosis of scrub typhus is supported by the clinical presentation along with a history of residing or traveling to known endemic areas. The presence of one or more eschars is particularly helpful, but given an eschar is not present in all patients, serology becomes paramount. The gold standard for diagnosis is the indirect immunofluorescence assay (IFA). However, IFA has numerous limitations including its expense and the possibility for false-negative results early in the disease course. Enzyme-linked immunosorbent assay (ELISA) is the most practical test given its ease of use, ability to detect immunoglobulin M (IgM) antibodies early in the disease course, and sensitivity and specificity greater than 90%, respectively.

For those with meningoencephalitis, CSF analysis reveals a mononuclear pleocytosis and an elevated protein concentration. Hypoglycorrhachia may be seen in up to one-fourth with the remainder having a normal CSF glucose concentration. Neuroimaging is unrevealing in the vast majority. PCR testing of the CSF is available, although its reliability is unknown.

Treatment and Outcome

Scrub typhus responds exquisitely to antibiotic therapy and improvement is seen within 48 hours of treatment, even in meningoencephalitis. Given its relationship to other rickettsial organisms, doxycycline remains the antibiotic of choice. Alternatives include azithromycin and rifampicin, which have a similar efficacy to doxycycline. For those who travel to endemic areas, preventative measures should be undertaken. This includes using an appropriate insect repellant, such as N,N-diethyl-meta-toluamide, permethrin-infused clothing, and possibly chemoprophylaxis with a weekly dose of doxycycline.

Typhus Group Rickettsiae

The two most prominent illnesses of the typhus group rickettsiae (TGR) are epidemic typhus and murine typhus. The causative agent of epidemic typhus is *Rickettsia prowazekii*. The organism is transmitted through the feces of *Pediculus humanis corporis*, a body louse. In contrast, murine typhus is caused by *Rickettsia typhi* and is transmitted to humans by the rat flea, *Xenopsylla cheopis*. The flea acquires the bacterium by feeding on rat's blood and excretes the organism in its feces onto human skin. For both epidemic and murine typhus, humans become infected after rubbing or scratching skin that contains the feces.

Epidemiology

Epidemics of TGR still occur frequently throughout the world. Although several thousand cases occurred yearly in the United States in the first part of the 20th century, epidemic typhus is rarely seen today. Epidemic typhus occurs in crowded, unsanitary conditions where lice outbreaks can occur such as prisons, refugee camps, and areas of extreme poverty. Sporadic cases have been associated with the flying squirrel. Murine typhus, given its spread by fleas, prefers warmer climates and coastal regions with a recent increase in reported cases in California and Texas. Like other rickettsial infections, murine typhus has a predilection for the summer months.

Clinical Manifestations

Like SFR, systemic and neurologic symptoms of TGR arise from rickettsiae infecting endothelial cells, resulting in a vasculitis. Multiple organs are affected with the lungs and brain being the most prominent. Other organs variably affected include the heart, liver, and kidneys. The incubation period is 1 to 2 weeks, and the illness starts with 1 to 3 days of generalized malaise followed by the abrupt onset of high fever and severe headache. In a large proportion, primary involvement of the lungs with a resultant pneumonia is common. A relapsing form of epidemic typhus, Brill-Zinsser disease, occurs years to decades after an initial attack. It is believed that the rickettsiae remain dormant in macrophages until a subsequent reactivation occurs. The symptoms that arise in Brill-Zinsser are similar to the first attack but generally milder in comparison.

A rash, appearing as an erythematous and blanching macule initially, is common with TGR but still less so than in SFR. Other skin lesions, such as petechiae and purpura are seen in up to one-third, but eschars are notably absent. Also in contrast to SFR, the rash begins in the trunk and axilla and either remains localized or spreads centrifugally to the extremities with sparing of the palms and soles.

When compared to epidemic typhus, murine typhus is much less concerning. Its signs and symptoms, although similar to epidemic typhus, occur with a more gradual onset and a less severe intensity. Neurologic abnormalities beyond headache are uncommon, and meningitis or encephalitis is rare. In epidemic typhus, CNS complications such as coma, delirium, and seizures occur in up to 80%. Meningoencephalitis is a complication of epidemic typhus with hearing loss being a common sequela.

Diagnosis

Serology remains the standard diagnostic test for TGR. Like other rickettsial infections, IFA is the best method for diagnosis. A fourfold rise in IgG antibody titers between acute and convalescent sera taken 2 to 4 weeks apart is necessary for confirmation. Real-time PCR of skin lesions is available, but its reliability is dependent on the bacterial number present in the biopsied tissue. CSF analysis, most likely performed in epidemic typhus, shows mononuclear pleocytosis, elevated protein concentration, and normal glucose concentration and helps to support suspicion of CNS involvement.

Treatment and Outcome

Doxycycline is the treatment of choice for TGR. The recommendations for duration of treatment are the same as SFR. In epidemic typhus, delousing is necessary to prevent spread of infection or reinfection. If appropriate antimicrobial treatment and duration is given for epidemic typhus, the mortality rate is approximately 4%. Complications of vascular compromise, including gangrene of distal fingers and toes, have been reported. In murine typhus, complete recovery is the general expectation, even in the absence of antimicrobial therapy.

ZOONOTIC INFECTIONS

Zoonoses are infections acquired by humans from other animals, usually mammals. These infections are found worldwide and are often observed in rural, agricultural communities where infected livestock are prevalent. In addition, poor hygiene or sanitation can contribute to the spread of these diseases. Although zoonotic infections are common throughout many regions of the world, they are usually rare in the United States and often confined to travelers to endemic regions. A summary of zoonoses can be found in Table 66.3.

Q Fever

Q fever is caused by *Coxiella burnetti*, a gram-negative, obligate intracellular pathogen. Its primary reservoirs are livestock. Infection typically occurs by inhaling aerosolized particles from placental products. Importantly, Q fever has both an acute and a chronic phase. It is considered a rickettsial-like organism and responds well to tetracyclines.

Epidemiology

Infection with *Coxiella* occurs throughout the world. The primary reservoirs are sheep, cattle, and goats, which are typically asymptomatic. As a result, Q fever is most commonly seen in rural and agricultural regions and in persons who have direct contact with these animals, such as veterinarians, farm workers, and butchers. The most common mode of transmission is inhalation of aerosolized particles from placental tissue and fluids. As *Coxiella* is resistant to most physical forces, it can survive for months to years. Dust contaminated with placental products can travel by wind and infect those miles from the initial source. Q fever can also be obtained through ingestion of unpasteurized dairy products as *Coxiella* can be shed in the milk of infected animals. Other modes of transmission, such as human-to-human contact, acquisition from blood transfusions or bone marrow transplantation from infected donors, or an infected tick bite, are extremely rare.

Clinical Manifestations

There are two recognized forms of *Coxiella* infection in humans: acute Q fever and chronic Q fever. In the acute form, half of infected individuals are asymptomatic. In symptomatic patients, acute Q fever is typically characterized by a self-limited, nonspecific febrile illness that begins 2 to 3 weeks following inhalation or ingestion. Pneumonia is commonly seen and results from aerosolized organisms proliferating in the lungs. Hepatitis may also be seen, particularly in those infected as a result of ingestion of contaminated dairy products.

A severe headache is the most common neurologic manifestation and is almost always seen with Q fever. As a result, lumbar

TABLE 66.3 Zoonoses

Disease	Causative Agent	Reservoirs	Systemic Features	Neurologic Features	Diagnostic Tests	Treatment
Q Fever	*Coxiella burnetti*	Sheep, cattle, and goats	Acute: pneumonia most common, hepatitis Chronic: endocarditis, osteomyelitis, hepatitis	Meningitis or encephalitis in 1%-2%	Serum: immunofluorescence assay Cerebrospinal fluid (CSF): polymerase chain reaction (PCR)	Doxycycline
Brucellosis	*Brucella melitensis, Brucella abortus, Brucella suis*	Goats, sheep, cattle, and pigs	Intermittent and chronic fever, migratory arthralgias, spondylitis, hepatitis, and orchitis	Isolated meningitis or meningoencephalitis most common; cranial neuropathies, myelitis, epidural abscess	Serum: serum agglutination test, enzyme-linked immunosorbent assay (ELISA) CSF: Test agglutination with Coombs test.	Systemic disease: doxycycline and rifampin Neurobrucellosis: doxycycline, rifampin, and ceftriaxone
Leptospirosis	*Leptospira*	Rodents	Nonspecific febrile illness, uveitis, conjunctival suffusion, headache Later, cardiac arrhythmias, pulmonary disease, renal failure, jaundice, and bleeding diathesis	Meningitis most common; Guillain-Barré syndrome, myelopathy, encephalitis, subarachnoid hemorrhage, and cranial neuropathies	Serum: microscopic agglutination test (MAT), ELISA, PCR CSF: PCR	Septicemic phase: doxycycline Immune phase: penicillin or ceftriaxone
Cat-scratch disease	*Bartonella henselae*	Cats	Erythematous papules or pustules at site of infection; painful lymphadenopathy proximal to skin lesions	Encephalitis, neuroretinitis, hemiparesis, cranial neuropathies, infectious myelitis, Guillain-Barré syndrome	Serum: immunofluorescence assay, ELISA Biopsy: PCR of lymph node aspirates CSF: PCR	Azithromycin
Anthrax	*Bacillus anthracis*	Goats, sheep, and cattle	Cutaneous: pruritic and painless papule that evolves into a black eschar Ingestion: sore throat, dysphagia, diarrhea Inhalation: fever, chills, cough, shortness of breath Injection: soft tissue infection	Rapidly progressive and highly fatal hemorrhagic meningitis	Serum: ELISA, PCR Culture: blood, pleural fluid, nasal swab	Uncomplicated: ciprofloxacin or doxycycline Meningitis: ciprofloxacin, meropenem, and linezolid

puncture is typically performed to exclude meningitis, although either meningitis or encephalitis is found in no more than 1% to 2% of patients.

Chronic Q fever is seen months to decades following an acute infection, even if asymptomatic. In adults, a culture-negative endocarditis of the native valve or infection of vascular prostheses is the most common manifestation and is fatal if left untreated. Chronic pulmonary infections, osteomyelitis, and chronic hepatitis are possible but less common. In the pediatric population, a relapsing osteomyelitis is frequently seen. Despite the severe manifestations of chronic disease, it arises in less than 5%.

Diagnosis

Q fever is best diagnosed by serology with IFA. Interpretation of this serology is dependent on the understanding of the two antigenic phases of *C burnetii*. In acute infection, phase II antibodies to *Coxiella* appear first and in higher titers than phase I antibodies. Diagnosis of acute infection is made by demonstrating a fourfold or greater rise in phase II IgG antibodies between acute and convalescent sera collected 3 to 6 weeks apart. Use of whole blood PCR in the first week of the illness, prior to seroconversion, is useful in diagnosis if positive but lacks sensitivity because the sample is dependent on bacterial load. Phase I antibodies are associated with persistent infection, although they almost never exceed phase II antibodies in quantity. High titers of phase I antibodies that continue to rise months to years following acute infection correlate with the development of endocarditis and other chronic Q fever presentations.

Meningitis or encephalitis is supported by the presence of a lymphocytic pleocytosis, elevated protein concentration, and normal glucose concentration on CSF testing, although these findings are only variably seen. PCR of CSF is available with a high specificity but can be falsely negative. Neuroimaging is generally normal.

Treatment and Outcome

The majority of acute Q fever cases resolve spontaneously within a few weeks, even without antimicrobial therapy. Although treatment is not routinely recommended for asymptomatic individuals, chronic Q fever might still occur. The recommendation for treatment of acute Q fever is doxycycline, and its maximum effect is achieved if initiated within 3 days of symptom onset. Alternative antibiotics include moxifloxacin, clarithromycin, and rifampin if a tetracycline allergy exists. Prevention with an inactivated, whole-cell vaccine (Q-Vax) is available for those in high-risk professions or in highly endemic regions. Neurologic sequelae are rare but hemiparesis, paresthesias, and peripheral neuropathies have been reported.

The treatment of chronic Q fever is a greater challenge. A combination of doxycycline 100 mg twice daily and hydroxychloroquine 200 mg 3 times daily for a minimum of 18 months for native valve infections, and 24 months for prosthetic valve infections, is recommended by the CDC LEVEL 1. Monthly serologic testing of phase I and II IgG/IgM antibodies to *Coxiella* are performed to ensure treatment response. Even after treatment completion, serology should be checked twice yearly for a minimum of 5 years.

Brucellosis

Brucellosis is a common zoonotic disease present throughout the world with several highly endemic areas interspersed. It is acquired by a gram-negative, facultative intracellular, coccobacilli termed *Brucella*. Transmission requires direct contact with infected animals, consumption of unpasteurized dairy products, or airborne particles.

Epidemiology

The Mediterranean and the Middle East have traditionally been the highest risk regions. Other highly endemic regions include South and Central America, the Caribbean, Eastern Europe, Asia, and Africa. *Brucella melitensis* is the most likely species to cause human infection and usually affects goats or sheep, whereas *Brucella abortus* and *Brucella suis* are the causative organisms that infect cattle and pigs, respectively. The majority of cases in humans are acquired after consumption of unpasteurized dairy products. Direct contact with infected animals as seen in farmers, veterinarians, or butchers are observed in a sizable minority. Rarely, inhalation of aerosolized particles or direct inoculation of an open wound can account for infection.

Clinical Manifestations

Brucellosis classically presents with an acute febrile illness that coexists with other constitutional symptoms such as chills, malaise, anorexia, and headache. Fever is often irregular and intermittent and, along with malodorous perspiration, can be highly suggestive of brucellosis. Migratory arthralgias, myalgias, and severe back pain with spondylitis are common and can be debilitating. Abdominal pain with associated hepatosplenomegaly is seen in up to one-fourth of patients. These symptoms can persist for weeks or months. A chronic form, which is often relapsing, exists in a smaller number of patients with endocarditis, orchitis, and chronic fatigue being frequent complications. Given its protean manifestations, essentially any organ system can be affected and a detailed history, which includes travel and occupational history, is mandatory.

Neurologic complications can be seen in approximately 5%. The most frequent neurologic manifestation is an isolated meningitis or meningoencephalitis. The chief complaint will be a severe, unrelenting headache that may persist for weeks to months prior to presentation. Cranial neuropathies are frequent with resultant sensorineural hearing loss, facial weakness, or diplopia. Neuropsychiatric manifestations and seizures are common with encephalitis or brain abscess. Myelopathy may be seen in up to 10% of neurobrucellosis cases and can be due directly from an acute or postinfectious myelitis or indirectly due to spinal cord compression from epidural abscess or spondylitis.

Diagnosis

Although isolation of *Brucella* on culture from blood or other infected organ system is considered the gold standard, it is often negative. Real-time PCR with its ability to give reliable results in as little as 30 minutes is likely the best test, although it is often unavailable in endemic regions. Serologic methods with serum agglutination test (SAT) or ELISA are the standard modalities for diagnosis given their cost-effectiveness. SAT works by measuring antibody production against known *Brucella* lipopolysaccharides.

In neurobrucellosis, CSF analysis typically demonstrates a mononuclear pleocytosis, elevated protein concentration, and low glucose concentration. *Brucella* test agglutination with Coombs test in CSF has a high sensitivity and specificity, and with a titer of 1:8 or greater, secures the diagnosis. Neuroimaging may be abnormal with leptomeningeal enhancement, white matter involvement, brain abscess, or cerebral edema being the most likely findings.

Treatment and Outcome

Antibiotic treatment with a combination of doxycycline and rifampin for at least 6 weeks is expected. Neurobrucellosis requires either a combination of doxycycline and an aminoglycoside or triple therapy with doxycycline, rifampin, and ceftriaxone. Proposed regimens range from 4 to 6 months or until resolution of CSF abnormalities. A short course of adjunctive corticosteroids is often used with myelitis.

Mortality is less than 1%, with endocarditis being the most likely cause of death. The prognosis of neurobrucellosis is good especially if an isolated meningitis, and residual neurologic deficits are uncommon. Deficits that may persist include irreversible hearing impairment, and weakness when myelopathy is present. Preventative measures include hygiene education for farmers and other workers with animals, preparation and treatment of unpasteurized dairy products, and development of human vaccines in highly endemic regions.

Leptospirosis

Leptospirosis is a common and underdiagnosed zoonotic infection caused by the obligate, aerobic spirochete, *Leptospira*. Humans obtain the organism after contact with water contaminated by the urine of infected animals. Although typically self-limited, it can lead to serious complications involving the renal, hepatic, and neurologic systems.

Epidemiology

Although present worldwide, leptospirosis has a predilection for tropical climates in parts of Asia, the Caribbean, Africa, and Latin America. In the United States, there are 100 to 200 cases most years. The peak incidence is during the summer and fall months. Rodents, most notably rats, are important hosts for the spread of human disease. An infected rat can be asymptomatic its entire life with the spirochete surviving long-term in the renal tubules and being shed continually in the urine. *Leptospira* can survive for weeks in the soil in warm weather where it comes in contact with humans. Epidemics are associated with flooding or heavy rainfall in endemic areas with poor sanitation and housing conditions. Travelers who engage in recreational, freshwater activities such as swimming or boating, particularly after flooding or heavy rainfall, are at increased risk.

Clinical Manifestations

The majority of infections are asymptomatic. If clinical symptoms do occur, they begin typically 1 to 2 weeks following exposure. Approximately 90% of symptomatic patients will experience a self-limited febrile illness characterized by fever, severe headaches, nausea, vomiting, and myalgias that classically involve the calves and back. Ocular abnormalities can also be common and include conjunctival suffusion or uveitis. The most common neurologic manifestations during this stage are headache, altered mentation, and meningismus. This first phase is known as the *septicemic* (or anicteric) *phase* and lasts for about 1 week.

After cessation of the fever, and the end of the septicemic phase, there is a recurrence of the illness after a 1 to 3 day interval in 5% to 10%. This second immune (or icteric) phase is associated with the development of antibodies and leads to severe systemic manifestations. Cardiac arrhythmias and pulmonary disease including hemorrhages can be seen. Weil syndrome may occur during this time and has a classic triad of jaundice, renal failure, and bleeding diathesis. During the immune phase, involvement of the CNS occurs in up to 25%. Meningitis, with or without systemic symptoms, is the most common manifestation. Other less common neurologic complications include cranial neuropathies, Guillain-Barré syndrome (GBS), myelopathy, encephalitis, and subarachnoid hemorrhage.

Diagnosis

The gold standard for diagnosis is by serology using the microscopic agglutination test comparing acute and convalescent serum samples. However, microscopic agglutination test is not widely available. ELISA has an extremely high sensitivity and specificity and is more readily available. Real-time PCR can detect *Leptospira* accurately in the blood and CSF during the septicemic phase and in the urine during the immune phase. CSF analysis reveals elevated intracranial pressure and elevated protein concentration. A lymphocytic pleocytosis is usually observed but may be neutrophilic early in the course. CSF glucose concentration is usually normal but can be slightly decreased in one-third.

Treatment and Outcome

Doxycycline 100 mg twice daily is the antibiotic of choice for the septicemic phase and should be started empirically if the disease is suspected. For alternatives to tetracyclines, amoxicillin and ampicillin are alternatives. For those presenting in the immune phase, including those with meningitis, intravenous penicillin or ceftriaxone should be given. Treatment duration is generally 5 to 7 days. The overall outcomes are excellent in most. In Weil syndrome, the fatality rate is the highest (5%-10%), and is typically from acute renal failure, pulmonary hemorrhage, or cardiovascular collapse. Most neurologic complications resolve without sequelae.

Prevention is based on controlling the spread of leptospirosis. This includes avoiding stagnant water and runoff from farms, rodent control, and vaccination of livestock. Chemoprophylaxis with doxycycline in people at high risk for exposure can be considered, although no strong recommendations exist.

Cat-Scratch Disease

CSD is a zoonotic disease primarily transmitted to humans by a gram-negative bacterium, *Bartonella henselae*. The disease is spread among felines by the cat flea, *Ctenocephalides felis*, and is ultimately spread to humans by the scratches and bites of cats, particularly kittens.

Epidemiology

CSD is distributed worldwide and is a nonepidemic disease. In the United States, the highest incidence of the disease is found in children younger than 14 years of age and in the southern states. There is a seasonal predilection from August to January, and females are more likely than males to be infected. At least 90% of cases will report cat exposure in the preceding 2 weeks, and the majority will be able to identify the site of the cat scratch or bite. Infected cats do not display manifestations of the disease, and it is likely that a large proportion of infected individuals will remain asymptomatic.

Clinical Manifestations

The symptoms of CSD arise approximately 1 week following inoculation with the appearance of erythematous papules or pustules at the site of the cat scratch or bite. The predominant

feature of CSD, painful lymphadenopathy, will develop proximal to the papule or pustule 1 to 3 weeks later. Infected lymph nodes are commonly located in the axilla, inguinal, and neck regions and have associated erythema and induration. The lymphadenopathy will spontaneously resolve within 2 to 4 months.

Systemic symptoms do develop in the majority but are generally mild. A self-resolving low-grade fever develops in up to one-half. Follicular conjunctivitis is a common ocular finding. Additional nonspecific symptoms occur less frequently and include fatigue, nausea and vomiting, malaise, and headache. Severe manifestations such as endocarditis or osteomyelitis are rare. Bacillary angiomatosis can be seen in those with severe immunosuppression (eg, AIDS) and is characterized by red papules or nodules that are present on or under the skin. It can spread to other organs including the brain, bone, spleen, and liver. Biopsy is often necessary to distinguish it from Kaposi sarcoma.

Neurologic involvement in CSD is uncommon. Neuroretinitis, an optic neuropathy with an associated macular exudate referred to as a *macular star*, is an entity most commonly seen in CSD, and its presence can aid in the diagnosis (Fig. 66.5).

Encephalitis characterized by lethargy or combative behavior, variable focal neurologic deficits that include hemiparesis or cranial neuropathies, and seizures can occur. The encephalitis typically resolves without sequelae. Other less common neurologic syndromes include an infectious myelitis and GBS.

Diagnosis

Diagnosis is often made clinically based on a combination of a history of recent cat exposure along with physical examination findings of papules and tender lymphadenopathy. This alone is sufficient for beginning treatment. Serology can be useful in atypical cases, or if the diagnosis is unclear, and uses IFA with a fourfold or greater rise in antibody titers between acute and convalescent serum samples taken 6 weeks apart. The best test is likely the IgM capture-based ELISA, which has an extremely high sensitivity and specificity. If the diagnosis is still unclear, PCR or culture of lymph node aspirates is necessary to both confirm the diagnosis and exclude a mimicker such as neoplasm.

CSF analysis in encephalitis will show a mild lymphocytic pleocytosis, mildly elevated protein concentration, and normal glucose concentration. PCR to detect *Bartonella* in CSF is available. Neuroimaging is usually normal and, if abnormalities do exist, are often transient.

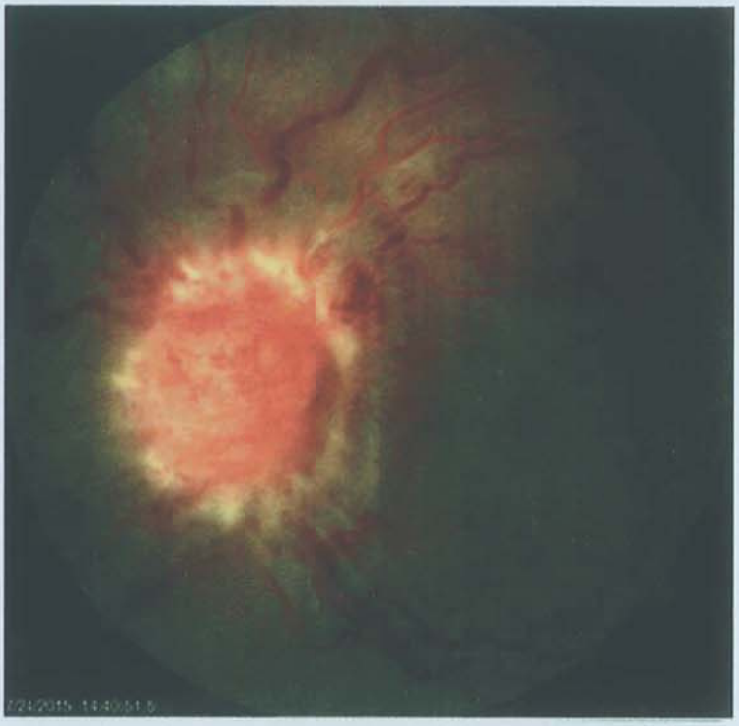

FIGURE 66.5 Neuroretinitis with severe swelling of the optic nerve and associated macular exudates ("macular star"). (From Holdeman NR, Ma L, Tang RA. Cat scratch neuroretinitis. *Int J Ophthalmol Clin Res.* 2017;4:71.)

Treatment and Outcome

Most patients with CSD recover without the need for antibiotics, although they may shorten the length of the disease. Multiple antibiotics have shown efficacy but azithromycin is the most commonly used. In adults, the CDC recommends azithromycin 500 mg on day 1 followed by 250 mg daily for 4 additional days LEVEL 4. For suppurative lymph nodes, aspiration is suggested, although incision and drainage should be avoided given the potential complication of fistula formation. Treatment of neurologic disease is largely supportive and most recover fully.

Anthrax

A zoonotic disease caused by a gram-positive and spore-forming bacterium, *Bacillus anthracis*, anthrax can arise in several distinct ways. Of these, the cutaneous route is the most prevalent with inhalation, injection, and intestinal modes being additional forms of infection. Hemorrhagic meningoencephalitis that is rapidly progressive and fatal is a distinguishing feature of anthrax.

Epidemiology

B anthracis primarily infects livestock such as goats, sheep, and cattle who acquire the bacterium by ingesting vegetation or from contaminated soil or water. Humans are incidental hosts and can become infected from consumption or contact with animal products or the environment. Anthrax is present in agricultural regions in Asia, South America, Sub-Saharan Africa, and eastern Europe. In the United States, outbreaks in livestock still occur, although human infection is rare.

Clinical Manifestations

There are four main clinical presentations. The first, cutaneous anthrax, accounts for greater than 95% of all human anthrax cases. Cutaneous anthrax begins within a week after exposure to infected animals or animal products, usually through an abrasion in the skin. The site becomes pruritic and a painless papule develops shortly after. The papule will enlarge, evolve into a vesicular lesion with serosanguineous fluid, and then ulcerate over 7 to 10 days, ultimately becoming a painless, black eschar (Fig. 66.6). Edema around the site and regional lymphadenopathy is typical.

The second clinical presentation, ingestion anthrax, develops within a week after consumption of contaminated animal products. The disease begins with fever and chills and will subdivide into two types. The oropharyngeal type is characterized by sore throat and dysphagia with airway compromise possible, whereas the intestinal type is characterized by nausea, vomiting, and bloody diarrhea. Altered mentation with cardiovascular arrest and death occurs within 5 days in over a third of both types.

The third clinical presentation, injection anthrax, occurs in intravenous drug users beginning with the development of a

FIGURE 66.6 Cutaneous anthrax. (**A** from Esfandbod M, Malekpour M. Cutaneous anthrax. *N Engl J Med*. 2009;361:178. **B** from Public Health Image Library.)

soft tissue infection at the site of injection that can spread hematogenously. This form is primarily seen with heroin users in Europe. The fourth clinical presentation is inhalation anthrax that begins with fever, chills, malaise, cough, and shortness of breath. It can be difficult to distinguish from pneumonia or influenza in the early stages. This will evolve over several days with the addition of altered mentation and headache. Inhalation anthrax has special interest given its association with bioterrorism but is rare.

Anthrax meningoencephalitis develops as the result of hematogenous spread from any of the four clinical forms or can occur in isolation. It generally presents with high fever, headache, vomiting, confusion, or agitation and progresses rapidly to coma with decerebrate posturing. Other clinical findings include myoclonus, focal or generalized seizures, and generalized rigidity. A pathologic feature of neurologic involvement is extensive hemorrhage of the leptomeninges, and hemorrhagic meningitis should raise suspicion for anthrax.

Diagnosis

Treatment should never be delayed while awaiting the return of diagnostic tests if anthrax is suspected. Clinical history in combination with exam findings, particularly if exposure to potentially infected animals or travel to endemic areas, is usually sufficient. In cutaneous anthrax, the black eschar is highly suggestive of the disease. In inhalational anthrax, chest radiographs often demonstrate a widened mediastinum and pleural effusions. Multiple serum tests exist for confirmation of the diagnosis of anthrax. This includes ELISA, serology comparing acute and convalescent serum samples 1 week apart, and PCR. Anthrax can also be diagnosed by blood culture, culture of pleural fluid, and nasal swab.

In meningoencephalitis, the CSF is grossly abnormal with a large neutrophilic pleocytosis (500-5,000 cells), elevated protein concentration, and low glucose concentration. The CSF itself will range from yellowish or pinkish in color to grossly bloody, and the supernatant frequently demonstrates xanthochromia. CSF culture shows large gram-positive rods singly or in chains. Neuroimaging is useful and demonstrates intracerebral, subarachnoid, or intraventricular hemorrhages.

Treatment and Outcome

For uncomplicated cutaneous anthrax, 7 to 10 days of oral ciprofloxacin or doxycycline is sufficient. For other forms of anthrax, with or without meningoencephalitis, triple therapy with intravenous ciprofloxacin, meropenem, and linezolid is recommended. The duration is at least 2 at 3 weeks or until clinical stabilization, whichever is longer. For inhalation anthrax, the duration should be extended to 60 days.

Outcomes are dependent on the anthrax type. Cutaneous anthrax has a mortality rate of less than 2% in treated persons. Ingestion, injection, and inhalation anthrax have mortality rates between 25% and 50% when treated. In meningoencephalitis, most cases are fatal with two-thirds dying within 24 hours of presentation. As most cases are uncomplicated cutaneous anthrax, sequelae are uncommon overall.

DISEASES OF HUMAN-TO-HUMAN TRANSMISSION

Human-to-human transmission is a common mechanism for the spread of disease. Represented in this section is Whipple disease, which is a rare entity with many neurologic manifestations, and mycoplasma pneumonia, which is a very common entity with rare neurologic complications.

Whipple Disease

Caused by the gram-positive bacterium *Tropheryma whipplei*, Whipple disease is a rare entity with diverse and chronic complications. Although classically affecting the gastrointestinal and musculoskeletal systems, any additional organ may be affected with neurologic disease being extremely common. Whipple disease remains a diagnostic and treatment challenge for practitioners.

Epidemiology

Although *T whipplei* has caused disease worldwide, the number of total cases reported is approximately 1,000. Humans are the

only known host of *T whipplei*, and the mode of transmission is believed to be through human-to-human contact. How humans acquire the organism is not completely understood. One possible mechanism of infection is through contaminated soil or water, and the bacterium has been detected in both saliva and stool samples of healthy controls.

Clinical Manifestations

The disease is characterized by two stages: a prodromal stage and a steady-state stage. The prodromal stage can be marked by many symptoms, although migratory polyarthritis and arthralgias tend to predominate. The steady-state stage manifests as weight loss and diarrhea. The duration between the prodromal and steady-state stages is 6 years on average, but this can be shortened by the use of immunosuppressive drugs. Cardiac involvement is common with pericarditis, and culture-negative endocarditis is also associated with the disease.

Neurologic manifestations are prevalent and diverse. A classic triad of cognitive dysfunction, ophthalmoplegia, and myoclonus is associated with the disease, but the entire triad is only present in 15%. Oculomasticatory myorhythmia, which entails synchronous contractions of the masticatory muscles with vergence of eye movements, is considered pathognomonic for Whipple disease. Cognitive impairment is subacute to chronic in duration and can advance to a dementia that coexists with substantial behavioral changes. Hypothalamic involvement may also be seen with hypersomnolence, hyperphagia, and autonomic dysfunction. Cerebellar ataxia, seizures, supranuclear ophthalmoplegia, and cranial neuropathies may also occur.

Diagnosis

Diagnosis remains a challenge. In classic Whipple disease, small bowel biopsy with periodic acid–Schiff staining and PCR testing is necessary. Multiple sites should be biopsied because the organism can be both focal and limited in number. If periodic acid–Schiff staining is positive, the diagnosis is probable but requires follow-up with PCR to confirm definite Whipple disease. A positive PCR need not come from the small bowel and can be used from any affected site, including the synovial fluid and CSF.

Treatment and Outcome

Antibiotic treatment starts with 2 weeks of induction therapy with either intravenous ceftriaxone or meropenem. This is followed by 1 year of maintenance antibiotics with either oral sulfamethoxazole-trimethoprim or combination of oral doxycycline and hydroxychloroquine. There are similar efficacies between the oral maintenance regimens, although doxycycline and hydroxychloroquine are often preferred when neurologic involvement is present.

The prognosis for CNS infection is poor, and the fatality rate is 25% within 4 years of onset. Survivors have significant sequelae as the neurologic symptoms are not transient. Even in the absence of neurologic involvement, relapses are common with some patients ultimately placed on life-long antibiotic therapy.

Mycoplasma pneumoniae

Mycoplasma pneumonia is a generally benign respiratory illness, often referred to as *walking pneumonia*, that is caused by the atypical bacterium *Mycoplasma pneumoniae*. Its lack of a cell wall allows it to fuse and enter cells in the lungs, thus evading the host immune response and resisting the effects of antibiotics. Although typically confined to the lungs, extrapulmonary manifestations, including neurologic complications, do occur.

Epidemiology

The disease is ubiquitous worldwide. The estimated incidence is approximately 1 case per 1,000 individuals per year and accounts for up to 40% of community-acquired pneumonias. Children and the elderly are most susceptible, and transmission occurs following inhalation of aerosolized particles obtained from the cough of a close contact. As a result, outbreaks tend to occur in schools, households, military quarters, and nursing homes.

Clinical Manifestations

Pulmonary manifestations are the mainstay of *Mycoplasma* infections and are dependent on age. Children younger than 5 years of age tend to develop upper respiratory infections, persons aged 5 to 20 years develop either bronchitis or pneumonia, and older adults typically develop pneumonia. The classic presentation is a dry cough, fever, and headache that develop several days after exposure. Findings on pulmonary auscultation will be minimal or absent, although chest radiographs will clearly demonstrate pulmonary infiltrates. Extrapulmonary complications do occur and include hemolytic anemia, thrombocytopenic purpura, retinal vasculitis, renal disease, and neurologic involvement.

Neurologic complications are rare but occur in 5% to 7% of hospitalized patients with *M pneumoniae* infection. The most frequent presentation is childhood encephalitis that notably may lack preceding respiratory involvement. Postinfectious complications are more common and thought to be immune-mediated with a predilection for the pediatric population and include myelitis, GBS, and acute disseminated encephalomyelitis.

Diagnosis

In uncomplicated disease, clinical history and chest radiograph are usually sufficient for diagnosis. Serologic testing with enzyme immunoassay comparing acute and convalescent serum samples is the most readily available test. PCR of sputum or nasopharynx samples is a superior test given its higher specificity and speed, but it is often inhibited by cost. Classically, detection of serum cold agglutinins can support the diagnosis early in the disease course, but specificity is limited by its cross-reactivity with other organisms, and enzyme immunoassay and PCR are preferred.

Results of CSF analysis are dependent on the neurologic syndrome. In encephalitis, a lymphocytic pleocytosis, elevated protein concentration, and normal or mildly decreased glucose concentration is present. Albuminocytologic dissociation is seen with GBS. In postinfectious disease syndromes, PCR is often negative, and the diagnosis is confirmed by serology. In myelitis, neuroimaging with MRI demonstrates T2 hyperintensities in the thoracic cord that may be longitudinally extensive.

Treatment and Outcome

Treatment has traditionally been with azithromycin, although macrolide resistance is increasing. Doxycycline is an alternative, and it is often preferred with neurologic involvement given its perceived superior CNS penetration. Corticosteroids are often added to antibiotics in postinfectious neurologic syndromes and additional immunotherapies, such as intravenous immunoglobulin or plasma exchange (PLEX), may be considered.

Clinical recovery often takes several weeks in uncomplicated disease even with appropriate antimicrobial agents. In the absence of antibiotics, recovery may take months. Neurologic sequelae are minimal in GBS or acute disseminated encephalomyelitis and severe with encephalitis. At least one-third of encephalitis patients will have sequelae that include persistent focal neurologic deficits, seizures, and cognitive impairment.

TOXINS

Bacteria can produce toxins that mediate neurologic disease. The most common diseases associated with toxins are diphtheria, botulism, and tetanus (Table 66.4). These disorders are able to cause peripheral nervous system dysfunction by inducing demyelination of peripheral nerves or by preventing release of neurotransmitters at presynaptic terminals.

Diphtheria

Corynebacterium diphtheriae is a gram-positive bacillus that is the causative agent of diphtheria. Humans are the only known host and may be asymptomatic when infected. Transmission occurs either through the lungs (pharyngeal diphtheria) or the skin (cutaneous diphtheria) and is mediated by an exotoxin that induces cell death by interfering with protein synthesis. With neurologic involvement, the toxin induces Schwann cell apoptosis leading to demyelination of peripheral nerves.

Epidemiology

Diphtheria became rare in the United States when widespread vaccination was introduced in the 20th century with less than 10 cases reported since the year 2000. Comparatively, there is approximately 5,000 cases reported worldwide yearly. The majority of these cases occur in India and Madagascar, and other countries in Asia and Africa are known to be endemic areas as well. Cases are usually attributed to lack of immunization or incomplete immunization.

Clinical Manifestations

The most common presentation of pharyngeal diphtheria is pharyngitis with a low-grade fever. Pharyngeal pseudomembranes, a dense gray patch on the posterior pharynx, are classically seen. If the larynx becomes involved, stridor and respiratory arrest can occur. Congestive heart failure from myocarditis and renal failure are other common complications. In contrast, cutaneous diphtheria, which typically involves infection of preexisting skin lesions, often lacks systemic complications.

The likelihood of developing neuropathy is dependent on the severity of the illness. The disease course is biphasic. Lower cranial

TABLE 66.4 Toxins

Disease	Causative Bacterium	Mechanism of Action	Neurologic Features	Diagnosis	Treatment
Diphtheria	*Corynebacterium diphtheriae*	Exotoxin inhibits protein synthesis in Schwann cells leading to demyelination.	Peripheral neuropathy: lower cranial neuropathies with profound bulbar weakness most common (dysarthria, dysphagia, and facial weakness) followed by extraocular muscle weakness and autonomic dysfunction Extremity weakness occurs weeks later with quadriplegia common.	Throat culture of pharyngeal exudates with polymerase chain reaction for toxin detection Electromyography: consistent with demyelinating polyneuropathy	Antibiotics: erythromycin or intramuscular procaine penicillin PLUS Antitoxin
Botulism	*Clostridium botulinum*	Toxin inhibits acetylcholine release at presynaptic nerve terminals. Leads to diminished transmission of peripheral motor and autonomic nerves	Infant botulism: hypotonic infant with weak cry and suck, absent gag reflex, ptosis, mydriatic pupils, ophthalmoplegia, respiratory distress Foodborne botulism: pentad of dry mouth, nausea/vomiting, dysphagia, diplopia, and fixed dilated pupils; also upper extremity and facial weakness, ptosis, and decreased gag reflex	Detection of toxin in serum, stool, or suspected food sources with mouse-based assay or enzyme-linked immunosorbent assay Electromyography: Repetitive stimulation demonstrates facilitation with high-frequency repetitive stimulation.	Infant botulism: human-derived botulism immunoglobulin Foodborne botulism: equine-derived heptavalent botulism antitoxin Wound botulism: same as foodborne botulism with addition of wound debridement and antibiotics
Tetanus	*Clostridium tetani*	Toxin inhibits neurotransmitter release at presynaptic nerve terminals of inhibitory neurons. Leads to hyperactivity of peripheral motor, cranial, and autonomic nerves	Severe muscle spasms starting with involvement of cranial nerve-innervated muscles: facial spasms (sardonicus), lockjaw (trismus), and laryngospasm Spasms later involve axial and extremity muscles (opisthotonos); autonomic dysfunction with labile heart rates and blood pressures	Diagnosis made clinically	Intramuscular antitoxin, benzodiazepines or neuromuscular blockade for spasms, and tetanus toxoid vaccine; antibiotics if wound present

neuropathies occur first with profound bulbar symptoms. Dysarthria and dysphagia are universally seen with most having facial weakness. Weakness of extraocular muscles and autonomic dysfunction are also common. Extremity weakness occurs weeks later, either following resolution of cranial neuropathies or during their recovery, and is severe with almost half becoming quadriplegic at the nadir.

Diagnosis

Diagnosis can be made with throat culture in pharyngeal diphtheria along with PCR to detect if the bacterium is toxigenic. As neuropathy develops following resolution of pharyngeal infection, throat cultures are likely to be negative. In addition, detection of IgG against diphtheria toxin is of little use because this is expected to be present in previously vaccinated individuals. The diagnosis then is based on the history of pharyngitis with a dense gray patch on the posterior pharynx. If CSF analysis is performed, albuminocytologic dissociation is observed in the majority. Nerve conduction studies are particularly helpful because they will be consistent with a demyelinating polyneuropathy.

Treatment and Outcome

Recommendations by the CDC for treatment of pharyngeal diphtheria include antibiotics and antitoxin LEVEL 1. Oral or intravenous erythromycin or intramuscular (IM) procaine penicillin should be given for 14 days. Antitoxin should be given as early as possible to reduce the likelihood of developing neurologic complications. Close contacts should receive antibiotic prophylaxis for 7 to 10 days with oral erythromycin or one dose of IM benzathine penicillin along with a booster dose of diphtheria toxoid vaccine if more than 5 years from last booster.

Approximately 5% to 10% infected with pharyngeal diphtheria will die. This may be higher in those with diphtheria neuropathy, likely due to autonomic dysfunction and cardiovascular compromise. Survivors recover to some extent with 90% reporting mild deficits 1 year later.

Botulism

Botulism is caused by a gram-positive and spore-producing bacillus, *Clostridium botulinum*. Human disease is induced by botulinum toxin with seven known subtypes (A-G). Botulism can be classified clinically into five types: infant botulism, foodborne botulism, wound botulism, adult intestinal colonization botulism, and iatrogenic botulism.

Pathophysiology

Disease is caused by the botulinum toxin, which acts to inhibit acetylcholine release at presynaptic nerve terminals by interfering with proteins involved in neurotransmitter vesicle fusion. These proteins include SNAP-25, which is affected by botulinum toxin types A, C, and E; synaptobrevin, which is affected by types B, D, F, and G; and syntaxin, which is affected by type C. The ultimate result is diminished neural transmission of both peripheral motor and autonomic nerves.

Epidemiology

Botulism is uncommon in the United States with approximately 150 cases per year. Infant botulism is the most common of the five types of botulism, accounting for approximately 70% of cases. Ingestion of honey is considered the main risk factor, although with increased education and awareness, the number of cases has been dramatically reduced. Adult intestinal colonization botulism and iatrogenic botulism make up less than 1% of cases. Foodborne and wound botulism make up about 15% of cases each. Foodborne botulism is typically caused by homemade canning or fermentation because this provides the proper environment for germination of *C botulinum* spores. Prevention is through proper refrigeration and cooking, which inactivates the toxin and spores. Wound botulism can infect any preexisting skin lesion, although it is particularly prevalent in persons who inject black tar heroin.

Clinical Manifestations

Infant botulism manifests as hypotonia with weak cry and suck, diminished or absent gag reflex, and ptosis. Mydriatic pupils, ophthalmoplegia, and respiratory distress are also common with 50% requiring intubation. Recovery can be slow, although mortality is low and most make a full recovery.

Foodborne botulism presents with ophthalmoplegia and prominent bulbar weakness accompanied by gastrointestinal symptoms and is followed by a rapidly progressive descending paralysis. The majority will have three or more features of the classic pentad: dry mouth, nausea/vomiting, dysphagia, diplopia, and fixed dilated pupils. On examination, upper extremity and facial weakness, ptosis, and diminished gag reflex are expected. Wound botulism, adult intestinal colonization botulism, and iatrogenic botulism present similarly to foodborne botulism.

Diagnosis

The CDC, in conjunction with local state authorities, conduct laboratory testing for botulism. Diagnosis is confirmed by detection of botulinum toxin in serum, stool, or suspected food sources. Toxin detection is performed with a mouse-based assay or ELISA, although PCR can also be used to detect *Clostridium*. Electromyography can be useful in diagnosis because it can distinguish botulism from mimickers such as GBS, particularly Miller Fisher syndrome, and myasthenia gravis. Because botulism is a presynaptic neuromuscular junction disorder, it shares electrophysiologic features with Lambert-Eaton myasthenic syndrome. Repetitive stimulation is of particular importance because this will demonstrate incremental response (facilitation) to high-frequency repetitive stimulation, a finding not found in GBS or myasthenia gravis.

Treatment and Outcome

The mainstay of treatment is supportive care, usually in the intensive care unit (ICU) because intubation is frequently required. Infant botulism is treated with human-derived botulism immunoglobulin, which is available through the California Department of Public Health. The remaining botulism types are treated with equine-derived heptavalent botulism antitoxin, which is available through the CDC. In wound botulism, wound debridement and antibiotics are added to antitoxin use.

The mortality rate of infant botulism is 1% with most making a complete recovery even in the absence of antitoxin, although it significantly reduces length of hospitalization and ventilator use. The mortality rate is closer to 5% in foodborne botulism, and sequelae of weakness, fatigue, dry mouth, and dizziness are reported in survivors years later.

Tetanus

Tetanus is caused by *Clostridium tetani*, a gram-positive, spore-producing bacillus. *C tetani* spores are found in the soil and the intestinal tract of humans and other animals. Disease is caused when tetanus spores enter areas of skin breakdown and germinate, producing tetanus toxin (tetanospasmin) in the process.

Pathophysiology

The toxin travels in the blood to peripheral nerve terminals, undergoing retrograde transport in axons to peripheral nerve cell bodies. The toxin then travels across the synapse to presynaptic nerve terminals of inhibitory neurons of the spinal cord and brainstem. There, it cleaves synaptobrevin, a protein necessary for fusion of synaptic vesicles, thus preventing neurotransmitter release and decreasing inhibitory signals. This produces hyperactive peripheral motor, autonomic, and cranial nerves.

Epidemiology

Tetanus is rare in the United States with an average of 30 cases yearly. Approximately 30% of tetanus cases in the United States occur in intravenous drug users and those with diabetes mellitus due to infection of chronic ulcers. Asia and Sub-Saharan Africa have a much higher incidence with India reporting more than 2,000 cases yearly. The increased use of tetanus vaccine has decreased the worldwide incidence by 10-fold since the early 1980s.

Approximately 35% of tetanus cases worldwide occur in neonates, which is most often due to infection of the umbilical stump in infants born to unvaccinated mothers. Infection of the umbilical stump is usually precipitated by use of unhygienic instrumentation. Excluding neonatal and maternal tetanus, men are more likely than women to become infected, presumably due to lower vaccination rates and increased occupational injuries.

Clinical Manifestations

The incubation from injury to onset of symptoms in adult tetanus is 7 to 10 days. The most prominent feature is muscle spasms due to disinhibition of peripheral and cranial motor neurons, beginning 2 to 4 days after onset of symptoms and lasting for approximately 2 weeks. When muscles that are innervated by cranial nerves are affected, features such as sardonicus (facial spasm that produces a smiling appearance), trismus (lockjaw), and laryngospasm are common. Axial and extremity involvement results in rigidity with spasms of the limbs, abdominal, and paraspinal muscles. Opisthotonos, with arching of the back resulting from head, neck, and spine extension, is also common. Autonomic dysfunction can develop by the second week with labile blood pressures, excessive sweating, and tachycardia or bradycardia. ICU care is necessary for several weeks because severe bulbar weakness makes intubation necessary.

Neonatal tetanus is similar to adult tetanus in presentation. Signs present in adults, such as risus sardonicus and opisthotonos, are also commonly present in neonates. Key differences include a more rapid progression and a refusal to feed early in the course. Umbilical sepsis is also found in the majority and, with the combination of spasms, should raise suspicion for the diagnosis.

Diagnosis

Tetanus remains a clinical diagnosis because culture is neither sensitive nor specific. Given that tetanus is rare with protective concentrations of antibody, the diagnosis of tetanus should be reconsidered if serum antibody titers with ELISA are greater than 0.1 IU/mL. Although electromyography is usually unnecessary, certain features can support the diagnosis such as continuous and involuntary spontaneous motor activity due to disinhibition of motor neurons. Other mimickers include hypocalcemia, which can easily be excluded by blood testing and clinically by the presence of perioral and extremity paresthesias. In neonatal tetanus, electroencephalogram may be required to differentiate spasms from seizures.

Treatment and Outcome

Acute management centers on airway management, toxin neutralization, treatment of spasms, and, if necessary, wound treatment. Intubation in an ICU setting is usually required, although early tracheostomy may be considered if endotracheal tube compromise due to laryngeal spasm develops. IM injections of antitoxin, either human tetanus immunoglobulin or equine antitoxin, should be administered to neutralize circulating toxin and prevent further neurologic complications. Spasms can be managed with high doses of benzodiazepines, which are considered first line. Neuromuscular blockade may be necessary if spasms remain uncontrolled. If wounds are present, they should be cleaned thoroughly and debrided with administration of oral or IV metronidazole or penicillin G for 7 to 10 days. Tetanus toxoid vaccine is also given in acute tetanus because it may act as a competitive inhibitor for binding sites in the spinal cord and brainstem.

Mortality rates are highest in neonates and are dependent on access to ICU intervention. Approximately 5% to 10% will die with ICU care versus 60% to 80% without ICU care. Long-term sequelae occur in a quarter of infants with developmental delay, cognitive impairment, and cerebral palsy being frequent. For adults, prevention of tetanus with vaccination remains important. For those with wounds of any type, a dose of tetanus toxoid vaccine should be administered if vaccination status is unknown or if fewer than three doses of vaccine have been administered. For persons with major wounds such as burns, punctures, frostbite, animal bites, or necrotic tissue, tetanus immunoglobulin in addition to tetanus toxoid vaccine should be administered prophylactically.

SUGGESTED READINGS

Rickettsial Infections

Bechah Y, Capo C, Mege JL, Raoult D. Epidemic typhus. *Lancet Infect Dis*. 2008;08(7):417-426.

Biggs HM, Behravesh C, Bradley KK, et al. Diagnosis and management of tick-borne rickettsial diseases: Rocky Mountain spotted fever and other spotted fever group rickettsioses, ehrlichioses, and anaplasmosis—United States. *MMWR Recomm Rep*. 2016;65(2):1-44.

Bradshaw MJ, Carpenter Byrge K, Ivey KS, Pruthi S, Bloch KC. Meningoencephalitis due to spotted fever rickettsioses, including Rocky Mountain spotted fever. *Clin Infect Dis*. 2020;71(1):188-195.

Dantes-Torres F. Rocky Mountain spotted fever. *Lancet Infect Dis*. 2007;7:724-732.

Mahajan SK, Mahajan SK. Neuropsychiatric manifestations of scrub typhus. *J Neurosci Rural Pract*. 2017;8(03):421-426.

Murray KO, Evert N, Mayes B, et al. Typhus group rickettsiosis, Texas, USA, 2003-2013. *Emerg Infect Dis*. 2017;23:645-648

Paris DH, Dumler JS. State of the art of diagnosis of rickettsial diseases: the use of blood specimens for diagnosis of scrub typhus, spotted fever group rickettsiosis, and murine typhus. *Curr Opin Infect Dis*. 2016;29(5):433-439.

Tsioutis C, Zafeiri M, Avramopoulos A, Prousali E, Miligkos M, Karageorgos SA. Clinical and laboratory characteristics, epidemiology, and outcomes of murine typhus: a systematic review. *Acta Trop*. 2017;166:16-24.

Weitzel T, Dittrich S, López J, et al. Endemic scrub typhus in South America. *N Engl J Med*. 2016;375(10):954-961.

Zoonotic Infections

Anderson A, Bijlmer H, Fournier PE, et al. Diagnosis and management of Q fever—United States, 2013: recommendations from CDC and the Q fever working group. *MMWR Recomm Rep*. 2013;62(RR03):1-23.

Angelakis E, Raoult D. Pathogenicity and treatment of *Bartonella* infections. *Int J Antimicrob Agents*. 2014;44(1):16-25.

Brett-Major DM, Coldren R. Antibiotics for leptospirosis. *Cochrane Database Syst Rev*. 2012;(2):CD008264.

Centers for Disease Control and Prevention. *CDC Yellow Book 2020: Health Information for International Travel*. New York, NY: Oxford University Press; 2017.

Chiappe-Gonzalez A, Ticona-Huaroto C, Hoerster V, et al. Primary neuroleptospirosis: a case report and literature review. *Infect Dis Clin Pract*. 2017;25:329-331.

Eldin C, Melenotte C, Mediannikov O, et al. From Q fever to *Coxiella burnetii* infection: a paradigm change. *Clin Micro Rev*. 2016;30(1):115-190.

Guven T, Ugurlu K, Ergonul O, et al. Neurobrucellosis: clinical and diagnostic features. *Clin Infect Dis*. 2013;56(10):1407-1412.

Hendricks KA, Wright ME, Shadomy SV, et al. Centers for Disease Control and Prevention expert panel meetings on prevention and treatment of anthrax in adults. *Emerg Infect Dis*. 2014;20(2):e130687.

Katharios-Lanwermeyer S, Holty JE, Person M, et al. Identifying meningitis during an anthrax mass casualty incident: systematic review of systemic anthrax since 1880. *Clin Infect Dis*. 2016;62:1537-1545.

Melenotte C, Protopopescu C, Million M, et al. Clinical features and complications of *Coxiella burnetii* infections from the French National Reference Center for Q fever. *JAMA Netw Open*. 2018;1(4):e181580.

Nelson CA, Saha S, Mead PS. Cat-scratch disease in the United States, 2005–2013. *Emerg Infect Dis*. 2016;22(10):1741-1746.

Pappas G, Akritidis N, Bosilkovski M, Tsianos E. Brucellosis. *N Engl J Med*. 2005;352:2325-2336.

Diseases of Human-to-Human Transmission

Daxboeck F. *Mycoplasma pneumoniae* central nervous system infections. *Curr Opin Neurol*. 2006;19:374-378.

Fenollar F, Puéchal X, Raoult D. Whipple's disease. *N Engl J Med*. 2007;356:55-66.

Kuwahara M, Samukawa M, Ikeda T, Morikawa M, et al. Characterization of the neurological diseases associated with *Mycoplasma pneumoniae* infection and anti-glycolipid antibodies. *J Neurol*. 2017;264:467-475.

Marth T, Moos V, Müller C, Biagi F, Schneider T. *Tropheryma whipplei* infection and Whipple's disease. *Lancet Infect Dis*. 2016;16(3):e13-e22.

Toxins

Berkowitz A. Tetanus, botulism, and diphtheria. *Continuum (Minneap Minn)*. 2018;24(5, Neuroinfectious Disease):1459-1488.

Sobel J. Botulism. *Clin Infect Dis*. 2005;41(8):1167-1173.

Vitek CR. Diphtheria. *Curr Top Microbiol Immunol*. 2006;304:71-94.

Yen LM, Thwaites CL. Tetanus. *Lancet*. 2019;393(10181):1657-1668.

Chronic Meningitis 67

Prashanth S. Ramachandran, Joseph R. Zunt, Kelly J. Baldwin, and Michael R. Wilson

KEY POINTS

1. The evaluation of a patient with chronic meningitis requires careful history taking regarding immune status, occupational, travel, and contact history. The sensitivity and specificity of the appropriate investigations should be known by the clinicians because each potential pathogen has a test of choice, and the wrong test can lead to incorrect diagnoses.
2. Despite multiple standard investigations, a causative pathogen may not be found, and more agnostic testing such as 16s and 18s polymerase chain reaction or metagenomic next-generation sequencing should be considered to try and arrive at a diagnosis early. Meningeal biopsy should be considered in cases for which serum and cerebrospinal fluid testing do not yield a diagnosis.

INTRODUCTION

Chronic meningitis is commonly defined as inflammation of the meninges, most often accompanied by a pleocytosis of greater than 5 white blood cells per microliter in the cerebrospinal fluid (CSF), that has persisted for at least 1 month without spontaneous resolution. Clinical presentation often includes symptoms of elevated intracranial pressure (ICP)-like headache, nausea, vomiting, or focal neurologic deficits like cranial neuropathies (Table 67.1). The most common etiologies of chronic meningitis fall into three broad categories: infectious, autoimmune, and neoplastic. This chapter focuses on the most common infectious etiologies of chronic meningitis, including fungal, bacterial, and parasitic pathogens. Increasing use of immunosuppressant medications for autoimmune disease and posttransplantation immunosuppression as well as predisposing conditions, such as impaired cellular and humoral immunity, have led to a larger population at risk for infectious causes of chronic meningitis.

GENERAL DIAGNOSTIC APPROACH

The first step to diagnosing a patient with chronic meningitis will always be a careful history to assess for risk factors and exposures to narrow the list of candidate infectious and noninfectious etiologies. Risk factors can be divided into host risk factors and environmental risk factors. With regard to the host, it is critical to assess a patient's immune status because certain pathogens primarily infect the immunocompromised. Careful history taking regarding intravenous (IV) drug use and sexual history are important aspects. Environmental factors mainly focus on potential infectious exposures based on migration or travel as well as sick contacts and exposures to animals and arthropods. Next, a comprehensive physical examination is necessary to assess for evidence of infection, malignancy, or rheumatologic disease systemically as well as a detailed neurologic examination to uncover abnormalities including papilledema (suggestive of raised ICP), cranial nerve palsies, and other focal neurologic signs, which can help direct downstream investigations like neuroimaging and neurophysiologic studies.

Neuroimaging with magnetic resonance imaging (MRI) can help identify the type of meningitis (pachymeningitis vs leptomeningitis) and also whether the meningitis is diffuse or more focal such as in cases of basilar meningitis or ventriculitis. MRI also allows one to assess for other associated abnormalities including the presence of subarachnoid or parenchymal cysts or associated encephalitis or myelitis. All these factors can help provide clues about which potential types of pathogens or noninfectious etiologies to prioritize for more targeted investigation with blood and CSF testing. Blood is useful for cultures, specific fungal testing (eg, cryptococcal antigen), pathogen-specific serologies and noninfectious conditions including a rheumatologic evaluation, evidence for neoplasm, and toxicology studies. From CSF, different patterns of abnormalities in the basic CSF parameters (ie, cell count and differential, protein, and glucose) can be very helpful in directing more specific diagnostic tests as discussed in the following text. It is important to culture CSF for Bacteria, acid fast bacilli, and fungi as well as appropriate pathogen-specific polymerase chain reaction (PCR) tests, serologies, cytology, and antigen testing.

Despite a careful workup, a large proportion of patients with chronic meningitis fail to have an etiology identified. If a diagnosis is not readily made with these initial tests, it is recommended to proactively consider more broad-based testing strategies. These can include assessing levels of galactomannan, 1,3-β-D-glucan (BDG) in CSF, which are elevated in the context of many different types of fungal infections as well as more unbiased, hypothesis-free testing such as 16s and 18s ribosomal RNA (rRNA) PCR for bacteria and fungi, respectively, as well as CSF metagenomic next-generation sequencing (mNGS), which can identify RNA and DNA viruses, fungi, bacteria, and parasites. Ultimately, a meningeal biopsy may be required (Tables 67.2 and 67.3).

FUNGAL MENINGITIS

Fungi exist in two forms, molds and yeasts. Molds are the tubular form, consisting of hyphae that can be branched or contain a single filament. Yeasts are thick-walled, single-celled organisms that live inside cells. Dimorphic yeasts assume tubular forms at lower temperature but become encapsulated at temperatures above 35°C. Either fungal form can infect the nervous system, producing meningitis, vasculitis, abscess, granulomas, or encephalitis.

TABLE 67.1 Neurologic and Systemic Symptoms and Imaging Characteristics of Chronic Infectious Meningitis

Condition	Neurologic Presentation	Systemic Symptoms	Neuroimaging
Cryptococcosis	Headache and fever (75%), nausea and vomiting (50%), altered mental status (50%), visual symptoms, seizures	Pulmonary, multiorgan involvement	Hydrocephalus, cerebral edema, leptomeningeal enhancement, and cryptococcomas
Coccidioidomycosis	Headache (75%); nausea and vomiting (40%); altered mental status (39%-73%); focal neurologic deficits, including ataxia, gait disturbance, diplopia, or facial palsies (33%-80%); and nuchal rigidity (20%)	Pulmonary, lymph nodes, skin	Hydrocephalus, meningeal enhancement, nodular enhancement, basilar meningitis, cerebral infarction
Blastomycosis	Focal neurologic deficits, seizures, and altered mental status Less common: fever, headache, and meningismus	Pulmonary, verrucous or fungating skin lesions, bones, joints, genitourinary system	Single or multiple abscesses, granuloma, meningeal enhancement, epidural extensions, and overlying osteomyelitis
Histoplasmosis	Headache and altered mental status	Acute pulmonary infection with fever, chills, and pulmonary opacities Multiorgan, including bone marrow	Normal, granuloma, meningeal enhancement
Aspergillosis	Solitary mass lesion, cavernous sinus thrombosis, multiple intracranial abscesses, acute or chronic basilar meningitis, vasculitis, or myelitis	Pulmonary, sinusitis, multiorgan involvement	Multiple abscesses, meningeal enhancement, infarction, hemorrhage, sinusitis with extension
Tuberculosis	Headache, vomiting, meningeal signs, focal deficits, vision loss, cranial nerve palsies	Pulmonary, malaise, anorexia, fatigue, weight loss, fever, myalgia	Enhancement of the basilar meninges, thick exudates, obstructive hydrocephalus, miliary pattern, tuberculoma, and periventricular infarcts
Syphilis	Meningitis (headache, photophobia, nausea and vomiting, cranial nerve deficits), general paresis, psychiatric illness, cognitive decline, tabes dorsalis, or vascular disease	Genital ulcers, fever, lymphadenopathy, headache, malaise, myalgia, and a macular or pustular rash of the palms and soles Multiorgan involvement	Leptomeningeal enhancement, white matter disease in the brain and posterior columns, ischemic stroke
Borreliosis	Early: septic lymphocytic meningitis, cranial neuritis, or painful polyradiculitis Late: myelitis, encephalitis, and neurobehavioral changes	Rash, fever, diffuse aches and pains, headaches, malaise, fatigue, carditis	White matter edema with enhancement

Fungi are universal saprophytic organisms found as spores in soil, on the skin of mammals and birds, and in bat or bird guano. They commonly enter the body through inhalation; direct invasion through the skin, mucus membranes, or sinuses; or via penetrating wounds. Fungal infections of the nervous system mainly occur in the presence of immunosuppression as a consequence of AIDS, cancer, hematologic malignancy, hereditary immune defects, organ or stem cell transplantation, or other conditions requiring therapeutic immunosuppression. However, some organisms such as *Coccidioides* and certain *Cryptococcus gatii* species can also affect immunocompetent individuals.

Cryptococcal Meningitis

Epidemiology and Pathobiology

Cryptococcal meningitis is most often caused by the encapsulated yeast *Cryptococcus neoformans*, but other cryptococcal species, such as *Cryptococcus gattii*, are emerging as pathogens that affect immunocompetent individuals. With a worldwide distribution, *C neoformans* is ubiquitous, found primarily in bird droppings, soil, and citrus peel. *C gattii* is more commonly associated with the bark of several tree species. Infection usually occurs through inhalation of the organism, followed by a respiratory infection and dissemination. Cryptococcal meningitis is most common in people with impaired cell-mediated immunity, especially those with human immunodeficiency virus (HIV) infection, hematologic malignancies, solid organ transplant recipients, and patients on chronic corticosteroids or other immunosuppressive therapy. In patients immunocompromised due to HIV infection, *C neoformans* is the most frequent CNS infection, with a prevalence varying from 10% in the United States to as high as 30% in sub-Saharan Africa.

Clinical Features

Cryptococcus neoformans

The clinical manifestations of *C neoformans* infection depends largely on the host immune status. Severity of infection varies from asymptomatic incidental pulmonary nodules to widely disseminated disease. HIV-infected patients with CD4 counts of less than 50 cells/μL are especially vulnerable to disseminated infection and meningitis. Cryptococcal meningitis typically begins insidiously, with 75% of patients developing headache and fever over a 2- to 4-week period. As the infection evolves, 50% of people develop nausea, vomiting, and altered mental status. Visual symptoms and seizures are also common. Over half of immunocompromised patients develop intracranial hypertension; this is even more common in immunocompetent hosts. As increased ICP develops, patients become obtunded, and without intervention, herniation will follow.

TABLE 67.2 Cerebrospinal Fluid Characteristics and Serum Diagnostics for Chronic Infectious Meningitis

Condition	Microscopic Appearance	LP Opening Pressure	CSF WBC	CSF Differential	CSF Glucose	CSF Protein	CSF Diagnostics	Serum Diagnostics
Cryptococcosis	Encapsulated fungi; yeast-like cells with budding daughter cells; capsule visualized by India ink (halo effect)	High	High or normal	Mononuclear	Low	High	Fungal smear, fungal culture, India ink stain, CrAg LFA	Blood culture
Coccidioidomycosis	Yeast form endosporulating spherules; branched septate hyphae with alternating arthroconidia	Normal	High	Early PMN, lymphocytic, eosinophilic (70%)	Low	High	Fungal culture, microscopy, complement fixation antibody assay, PCR	Microscopy from BAL fluid, or other body fluid, or a positive culture from any location
Blastomycosis	Mycelium at room temperature; yeast phase at 37°C; conidia, yeast cells with multinucleate broad budding	High	High	Early PMN, lymphocytic	Low	High	Fungal culture, biopsy of involved tissue with microscopy	Direct visualization of the organism via microscopy
Histoplasmosis	Hyphae large macroconidia and smaller infectious microconidia. At temperatures <35°C, yeast form; hyphal elements possible	Normal	High	Mononuclear	Low	High	Fungal smear and culture, antigen titers	Fungal culture from involved organ, antigen titers
Aspergillosis	Septate hyphae branched at 45° angles with conidiophores. Hyphae develop terminal buds forming small conidia.	Normal	High	Early neutrophil, lymphocytic	Low	High	Fungal culture, biopsy of affected tissue with microscopy, PCR	Galactomannan and β-D-glucan; microscopy, culture, or PCR from BAL or affected tissue
Tuberculosis	Intracellular aerobic gram-positive acid-fast pleomorphic bacillus	High	High or normal	Mixed pleocytosis	Low	High	AFB smear and culture, PCR; GeneXpert, MODS	QuantiFERON, PPD, BAL for AFB smear and culture; GeneXpert Ultra
Syphilis	Spirochetal bacterium	Normal	High or normal	Lymphocytic	Normal	High or normal	Darkfield microscopy, VDRL, PCR	RPR, VDRL (FTA-ABS), and *Treponema pallidum* particle agglutination tests (MHA-TP)
Borreliosis	Spirochetal bacterium	Normal	High	Lymphocytic	Normal	High or normal	Darkfield microscopy, IgG and IgM antibody index, PCR	Two-tier testing (ELISA and IgM/IgG immunoblot)

Abbreviations: AFB, acid-fast bacillus; BAL, bronchoalveolar lavage; CrAg, cryptococcal capsular polysaccharide antigen; CSF, cerebrospinal fluid; ELISA, enzyme-linked immunosorbent assay; FTA-ABS, fluorescent treponemal antibody absorption; IgG, immunoglobulin G; IgM, immunoglobulin M; LFA, lateral flow assay; LP, lumbar puncture; MHA-TP, Microhemagglutination assay – *Treponema pallidum*; MODS, microscopic observation drug susceptibility; PCR, polymerase chain reaction; PMN, polymorphonuclear; PPD, purified protein derivative; RPR, rapid plasma reagin; VDRL, Venereal Disease Research Laboratory; WBC, white blood cell.

Cryptococcus gattii

This is a rare pathogen, with disease previously confined to tropical and subtropical climates, particularly the highly endemic regions of Australia and Papua New Guinea. In 2004, an outbreak of *C gattii* infections was documented in the United States Pacific Northwest states of Oregon and Washington. A large retrospective review of the Pacific Northwest *C gattii* infections revealed important clinical differences between *C gattii* infections in the Pacific Northwest and historically endemic areas. Although *C gattii* in historically endemic areas has been reported to infect primarily immunocompetent persons, causing meningoencephalitis, *C gattii* infections in Oregon and Washington state occurred most frequently in immunocompetent persons and presented most often as respiratory illness. Time from symptom onset to diagnosis of *C gattii* infection was significantly longer among patients with pulmonary infections (50 d) than those with either CNS (24 d)

TABLE 67.3 Treatment of Chronic Infectious Meningitis

Condition	Treatment	Alternatives and Other Considerations
Cryptococcosis	AmB 0.7-1 mg/kg/d IV plus flucytosine 100 mg/kg/d × 14 d then fluconazole 400 mg orally daily × 8 wk then fluconazole 200 mg daily lifelong	Repeat LP to keep opening pressures in normal range; CSF shunting when needed
Coccidioidomycosis	Induction therapy with oral fluconazole 400-1,200 mg/d, followed by 800-1,200 mg/d indefinitely	Itraconazole 400-600 mg/d or amphotericin B 0.5-0.7 mg/kg/d. Intrathecal amphotericin B in addition to an azole; shunting for hydrocephalus when needed
Blastomycosis	Liposomal amphotericin B, 5 mg/kg/d for 4-6 wk, followed by an oral azole. Possible options for azole therapy include fluconazole (800 mg/d), itraconazole (200 mg 2 or 3 times per day), or voriconazole (200-400 mg twice per day) for at least 12 mo and until resolution of CSF abnormalities.	Surgical drainage of any epidural abscess
Histoplasmosis	Liposomal amphotericin B (5.0 mg/kg daily for a total of 175 mg/kg given over 4-6 wk). Fluconazole (800 mg/d) should be continued for 9-12 mo.	Chronic fluconazole maintenance therapy (800 mg/d) in relapsing patients. Intrathecal amphotericin B.
Aspergillosis	Voriconazole 6 mg/kg IV twice a day on day 1 followed by 4 mg/kg IV twice daily, followed by maintenance therapy of voriconazole 200 mg every 12 h.	Voriconazole plus caspofungin for invasive disease
Tuberculosis	Intensive four-drug regimen × 2 mo then continuation two-drug regimen × 10 mo based on resistance patterns	Choice of treatment should be directed by resistance patterns. Steroids should be considered for meningitis.
Syphilis	Aqueous penicillin G 18-24 million U/d administered as 3-4 million units IV every 4 h or as continuous infusion for 10-14 d	Procaine penicillin 2.4 million units IM daily with probenecid 500 mg orally 4 times daily for 10-14 d
Borreliosis	Ceftriaxone 2 g IV daily for 14 d Doxycycline 100 mg twice daily for 10-21 d	IV cefotaxime or IV penicillin G; oral doxycycline

Abbreviations: AmB, amphotericin B; CSF, cerebrospinal fluid; IM, intramuscular IV, intravenous; LP, lumbar puncture.

or bloodstream infections (27 d). There were no differences in immune status between patients with bloodstream infections and either pulmonary or CNS infections.

Diagnosis

The diagnosis of cryptococcal meningitis should be considered in patients presenting subacutely with headache and fever, especially in the setting of HIV infection or immunosuppression. Computed tomography (CT) and MRI are nonspecific for the diagnosis of cryptococcal meningitis but may reveal hydrocephalus, cerebral edema, leptomeningeal enhancement, or cryptococcomas. Classic MRI findings for fungal meningitis are shown in Figure 67.1. Lumbar puncture, the diagnostic procedure of choice, demonstrates an increased opening pressure, a mild mononuclear pleocytosis, increased protein, and low glucose concentrations. Patients with severe immunosuppression may lack this typical CSF profile. The cryptococcal capsular polysaccharide antigen (CrAg) assay is both sensitive and specific for detecting *C neoformans* in CSF samples and can be quantitated for prognostication. The CrAg titer is not reliable for determining response to therapy. Although a positive CrAg assay in serum cannot confirm the diagnosis of cryptococcal meningitis, a negative CrAg assay virtually excludes the diagnosis, at least in HIV-infected patients. Because the CrAg lateral flow assay has nearly 100% sensitivity and specificity on CSF samples, it is considered the optimal point-of-care diagnostic assay for cryptococcal meningitis. In areas where CrAg is not available, direct CSF examination with India ink preparation is often used. Fungal culture for the organism is 90% sensitive and can also be useful for speciation, although it typically requires days for culture to grow. *C neoformans* cultured from CSF, blood, or other sites produces white mucoid (depending on the capsule thickness) colonies, usually within 48 to 72 hours, on most bacterial and

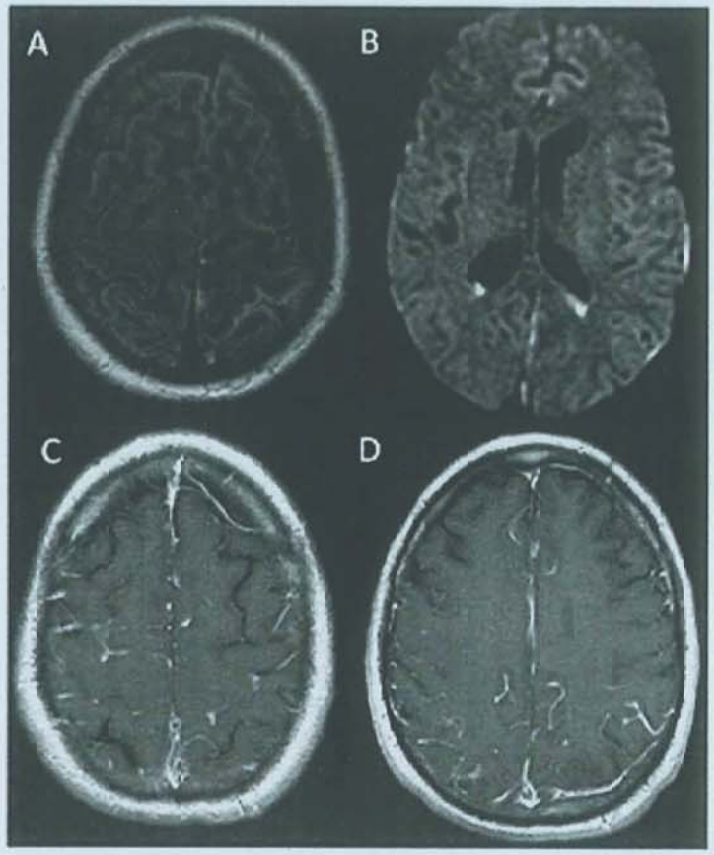

FIGURE 67.1 Axial brain magnetic resonance imaging. **A:** T2 fluid-attenuated inversion recovery with leptomeningeal hyperintensity in the posterior frontal lobe. **B:** Diffusion-weighted imaging demonstrating pus in the posterior horn of the lateral ventricle. **C,D:** T1 postcontrast with avid leptomeningeal enhancement.

fungal media. Although *C neoformans* grows at 37°C, a temperature of 30°C to 35°C is optimal. HIV-1 infected patients with a $CD4^+$ count lower than 100 cells/mm^3 in regions where the burden of cryptococcal antigenemia is high should be screened with a serum CrAg and treated with oral fluconazole to prevent development of cryptococcal meningitis. Patients who are serum CrAg-positive should be screened for neurologic symptoms and a lumbar puncture should be performed. Treating these high-risk patients presumptively with combination antifungal therapy for cryptococcal meningitis can be considered.

Treatment Update

A combination of antifungal medication and aggressive management of hydrocephalus is integral to the successful treatment of patients with cryptococcal meningitis. Antifungal therapy is divided into induction therapy, consolidation and maintenance. Amphotericin B (AmB) plus flucytosine, as compared with AmB alone, is associated with improved survival of patients with cryptococcal meningitis for induction therapy LEVEL 1.[1] When AmB cannot be administered due to drug access or safety, the oral combination of fluconazole plus flucytosine is an effective alternative LEVEL 1.[2] Fluconazole is then used for consolidation and maintenance therapy. Adjunctive dexamethasone use among patients with HIV with cryptococcal meningitis resulted in poorer outcomes LEVEL 1.[3] In patients with untreated HIV-1, antiretroviral therapy initiation should be delayed to minimize the risk of cryptococcal meningitis immune reconstitution inflammatory syndrome. Delaying antiretroviral therapy initiation for more than 4 weeks of cryptococcal meningitis induction therapy is associated with improved survival LEVEL 1.[4]

Elevated ICP can be managed through a variety of treatments. Patients should initially undergo daily lumbar punctures to reduce opening pressure until normal opening pressure is consistently maintained; some patients may require multiple daily lumbar punctures. For patients requiring frequent lumbar punctures, placement of a lumbar drain or ventriculostomy can provide a temporary means for controlling ICP. Ventriculoperitoneal shunt can be considered for patients with persistently elevated ICP. A recent retrospective study of elevated ICP in patients with cryptococcal meningitis determined that aggressive management of ICP during the initial 5 days of illness was associated with lower mortality than initial antifungal management alone.

Although guidelines for treatment of cryptococcal disease are based primarily on data from *C neoformans* infections in HIV and solid organ transplant patients, these guidelines are intended to apply to patients with *C neoformans* or *C gattii* infections. A limited number of *C gattii*–specific recommendations were included for the first time in the 2010 Infectious Diseases Society of America guidelines and are based on data from *C gattii* infections in historically endemic areas. These recommendations pertain mainly to patients with cryptococcomas, which previous data have suggested are more common in patients infected with *C gattii* than *C neoformans*, and include consideration of surgery for patients with large cryptococcomas, increased radiologic and follow-up evaluations for those with cryptococcomas or hydrocephalus, and possible use of AmB/flucytosine in patients with large and/or multiple pulmonary cryptococcomas.

Outcomes

Poor prognostic factors include low CSF glucose concentration, high CSF cryptococcal antigen titer (>1:1,024), high CSF lactate level, altered level of consciousness, hydrocephalus, and elevated ICP.

Coccidioidomycosis

Epidemiology and Pathobiology

Coccidioides immitis is a fungus endemic to the Southwestern United States, Northern Mexico, and areas of South America. The mycelial phase of *Coccidioides* species is able to withstand extreme desert climates and after rainfalls will multiply to form arthroconidia. Infection in humans occurs when aerosolized arthroconidia are inhaled. Once inhaled, *C immitis* usually results in a self-limited respiratory infection, commonly known as *valley fever*. In susceptible populations, a pulmonary infection can progress to severe disseminated disease. Dissemination is more likely to occur in patients of African or Asian descent, pregnant women, and people who are immunocompromised, especially due to HIV infection or long-term immunosuppressive therapy.

Clinical Features

Similar to tuberculosis (TB), chronic meningitis due to *C immitis* classically involves the basilar meninges. The most common symptom is headache, which is present in over 75% of patients. Other presenting signs and symptoms are related to elevated ICP and include nausea and vomiting (40%); altered mental status (39%-73%); focal neurologic deficits, including ataxia, gait disturbance, diplopia, or facial palsies (33%-80%); and nuchal rigidity (20%).

In patients with HIV infection, coccidioidomycosis can resemble *Pneumocystis jiroveci* pneumonia, producing a unique reticulonodular diffuse infiltrative pulmonary disease and constitutional symptoms of dyspnea, fever, and night sweats. Coccidioidomycosis frequently disseminates in patients with HIV infection, with common sites of dissemination including the meninges, lymph nodes, and skin. Although patients who are HIV-positive can present with unique symptoms, most HIV-infected patients present with symptoms similar to those seen in immunocompetent patients. Hydrocephalus, cerebral infarction, and vasculitis are potential complications of *C immitis* meningitis. Communicating hydrocephalus is a well-known complication of basilar meningitis, secondary to obstruction of arachnoid villi blocking reabsorption of CSF and may develop during the initial or later stages of the infection. Hydrocephalus develops in about 20% to 50% of patients with *C immitis* meningitis and is associated with a 12-fold increased risk of mortality. Cerebral infarction, as well as venous and dural thrombosis, has been reported during the initial and later stages of infection. Perivascular inflammation is typically associated with infarction of the basal ganglia, thalamus, and cerebral white matter.

Diagnosis

Coccidioidomycosis can be diagnosed using serologic testing, histopathology, or culture of tissue or fluid from the infected site. Identification of *C immitis* spherules in tissue, sputum, and bronchoalveolar lavage (BAL) fluid, or a positive culture from any location in the body, is diagnostic of coccidioidal infection. Definitive diagnosis of *C immitis* meningitis requires identification or culture of the organism from the brain or CSF. Unfortunately, CSF culture is often negative and presumptive diagnosis is typically made through a combination of CSF and serologic testing. CSF is typically abnormal, with a lymphocytic pleocytosis with early neutrophil predominance and low glucose concentration. Of note, this pathogen may cause a CSF eosinophilia in up to 70% of patients with meningitis, a finding that is relatively uncommon with other fungal pathogens.

Detection of antibodies to *C immitis* in the CSF using the complement fixation antibody assay is the most sensitive test for confirming meningeal infection. Repeated CSF sampling is sometimes required to confirm the diagnosis because antibody test results can be negative early during the course of infection (71%-94% sensitive). Enzyme immunoassay for immunoglobulin M and immunoglobulin G (IgG) and latex agglutination tests are less sensitive in CSF samples. Although PCR assays have been used to detect *C immitis* infection, they are not routinely available.

Treatment

Oral fluconazole is recommended for the treatment of *C immitis* meningitis. Practice guidelines recommend oral fluconazole 400 to 1,200 mg/d. Higher rates of treatment failure have been noted at 400 mg/d, and most experts recommend dosing at the higher end of the spectrum (800-1,200 mg) Itraconazole, administered in dosages of 400 to 800 mg/d, has been reported to be comparably effective. Intrathecal AmB in addition to an azole-based therapy can be used as a rescue therapy when azole therapy is ineffective.

Hydrocephalus nearly always requires a neurosurgical shunt for decompression. Patients who do not respond to fluconazole or itraconazole are candidates for intrathecal AmB therapy with or without continuation of azole treatment. The most common life-threatening complication of coccidioidal meningitis is CNS vasculitis leading to cerebral ischemia, infarction, and hemorrhage. Some physicians endorse the use of concomitant high-dose, IV, short-term corticosteroids, but larger randomized studies are lacking.

Outcomes

Approximately 66% to 80% of patients treated with oral azoles alone achieved initial clinical improvement or remission of meningitis. However, up to 75% of patients relapse; therefore, lifelong prophylaxis with fluconazole 400 mg/d is recommended. Without treatment, the frequency of relapse is high and outcome poor.

Blastomycosis and Histoplasmosis

Epidemiology

Blastomyces dermatitidis and *Histoplasma capsulatum* are dimorphic fungi endemic to the Mississippi and Ohio River valleys. Although isolated cases of infection have been reported outside this geographic area, most patients reside within these areas. *Histoplasma* and *Blastomyces* species are ubiquitous environmental organisms, existing in the mycelial phase and then converting to the yeast phase at body temperature. Both organisms produce a large spectrum of disease, ranging from subclinical infection to disseminated disease.

Pathobiology

B dermatitidis, a thick-walled yeast with broad-based budding daughter cells, is endemic to the Great Lakes and Mississippi and Ohio River valleys. Like histoplasmosis, infection with blastomycosis is acquired via inhalation of spores into the lung and can manifest as pulmonary or extrapulmonary disease. Chest radiographs commonly demonstrate nodular or lobar infiltrates with cavitations. If the organism evades nonspecific host defense mechanisms in the lungs, it will convert into the yeast phase and multiply. The organism then spreads hematogenously to other organs. Cutaneous involvement is seen in 60% of patients with blastomycosis, manifesting as verrucous or fungating lesions with irregular borders. Other sites less frequently involved include bones, joints, genitourinary system, and the CNS.

H capsulatum, like *B dermatitidis*, is primarily found in the Mississippi and Ohio River valleys, and infection is acquired via inhalation. Histoplasmosis may produce an acute pulmonary infection with fever, chills, and lung opacities on chest imaging. Patients with impaired cellular immunity, such as HIV-infected individuals, typically present with chronic pulmonary symptoms with progression to severe disseminated disease. Infection disseminates hematogenously to distant sites, such as the liver, spleen, and CNS. Bone marrow involvement is common and often manifests as thrombocytopenia, anemia, or leukopenia.

Clinical Features

CNS infection with blastomycosis occurs in less than 10% of people with disseminated disease and manifests as solitary or multiple abscesses and acute or chronic meningitis. Unlike other fungal CNS infections, blastomycosis is more likely to present with focal neurologic deficits, seizures, and altered mental status, whereas symptoms of fever, headache, and meningismus are less common. Although intracranial infection results most frequently from hematogenous seeding of the brain parenchyma from the lungs, epidural extension from overlying vertebral or skull osteomyelitis has been described.

Most patients with pulmonary histoplasmosis are asymptomatic and have resolution of the infection without therapy. It is common for individuals in the Mississippi and Ohio River valleys to have asymptomatic pulmonary nodules. Dissemination occurs during both primary infection and reactivation of latent infection. CNS involvement occurs in less than 20% of patients with disseminated infection and most frequently affects patients with severely impaired cellular immunity, such as people who are HIV-infected. Presenting symptoms typically include headache and altered mental status; although less common, patients may also present with focal neurologic deficits, seizures, ischemic stroke, and mass lesions.

Diagnosis

Direct visualization of blastomycosis via microscopy is the only method of rapid diagnosis but has variable sensitivity. Lumbar puncture typically reveals elevated opening pressure, and CSF is notable for elevated protein concentration, low glucose concentration, and a pleocytosis with neutrophilic predominance early in the disease course followed by a lymphocytic predominance. The gold standard for diagnosis remains CSF culture, which is positive in 70% of patients with blastomycosis. Growth of *B dermatitidis* on culture media can occur within 5 to 10 days but may take 2 to 4 weeks for definitive identification of the organism. More invasive procedures, such as brain biopsy and ventricular sampling of CSF, are more likely to provide sufficient material for definitive diagnosis and are often needed for diagnosing intracranial disease. The use of CSF and serum antigen titers and antibodies are useful, although as with histoplasmosis, significant cross-reactivity occurs with other dimorphic fungi.

In histoplasmosis meningitis, CSF frequently demonstrates a mononuclear pleocytosis, increased protein concentration, and decreased glucose concentration. CSF culture is not sensitive for diagnosing histoplasmosis. The use of CSF and serum antigen titers and antibodies are useful, although as with blastomycosis, significant cross-reactivity occurs with other dimorphic fungi.

Because meningitis is typically the result of disseminated infection, testing for the organism in the blood or bone marrow should also be considered.

Treatment

AmB should be given for blastomycosis infection as a lipid formulation at a dosage of 5 mg/kg/d for 4 to 6 weeks, followed by an oral azole. Possible options for azole therapy include fluconazole (800 mg/d), itraconazole (200 mg 2 to 3 times per day), or voriconazole (200-400 mg twice per day) for at least 12 months and until resolution of CSF abnormalities. Patients with immunodeficiency due to HIV or immunosuppressive therapy have high rates of relapse and should be maintained on long-term secondary prophylaxis with fluconazole indefinitely. For selected patients with neurologic dysfunction caused by focal CNS blastomycosis, surgery may be beneficial. Surgical drainage of an epidural abscess may be necessary for reducing morbidity and mortality from this disorder.

Treatment of CNS histoplasmosis is challenging. Despite treatment with AmB, mortality ranges from 20% to 40% of patients with meningitis, and up to half of responders relapse after therapy is discontinued. The optimal treatment for *H capsulatum* meningitis is liposomal AmB (5.0 mg/kg daily for a total of 175 mg/kg given over 4-6 wk). To reduce the risk of relapse, fluconazole (800 mg/d) should be continued for 9 to 12 months after completion of AmB. Chronic fluconazole maintenance therapy (800 mg/d) should be considered for patients who relapse after completing a full course of therapy. Itraconazole, although more active against *H capsulatum* in animal models, does not cross the blood-brain barrier in adequate amounts to treat CNS infection. Intrathecal administration of amphotericin directly into the ventricles, cisterna magna, or lumbar arachnoid space should be reserved for severe infections that do not respond to conventional therapy.

Aspergillosis

Epidemiology and Pathobiology

Aspergillus species are ubiquitous soil inhabitants that grow and survive on organic debris. This fungus sporulates abundantly, releasing conidia into the atmosphere in large quantities. The conidia are small in diameter, making it possible to reach smaller areas of the lung, including the alveoli. Although humans inhale several hundred conidia per day, inhalation of organisms rarely results in disease because the conidia are efficiently eliminated by host immune mechanisms. Alveolar macrophages and neutrophils constitute the first line of host defense against aerosolized conidia.

Historically, disease was limited to individuals with repetitive exposure to pathogens, producing a mild condition known as *farmer's lung*. *Aspergillus* species can also produce lung aspergillomas, characterized as an overgrowth of fungus in preexisting cavitary lung lesions. More recently, the incidence and severity of *Aspergillus* species infections has increased due to a growing number of people living with immunosuppression, leading to the disease known as *invasive aspergillosis*. Populations significantly at risk for invasive aspergillosis include patients undergoing treatment for hematologic malignancies, recipients of allogeneic hematopoietic stem cell transplant and solid organ transplant, people who are HIV infected, and individuals with chronic granulomatous disease.

Clinical Features

Cerebral aspergillosis occurs in approximately 10% to 20% of patients with invasive disease and results from hematogenous dissemination of the organism or via direct extension from rhinosinusitis. CNS infection can present as a solitary mass lesion, cavernous sinus thrombosis, multiple intracranial abscesses, acute or chronic basilar meningitis, vasculitis, or myelitis. Pathologically, cerebral aspergillosis has a propensity for vascular invasion, infarction, hemorrhage, and aneurysm formation; as a result, the clinical presentation may mimic cerebral vasculitis, ischemic or hemorrhagic infarction, or subarachnoid hemorrhage. In patients with suspected cerebral aspergillosis, it is important to examine the lungs and sinuses for evidence of infection and potential sites for obtaining biopsy or culture material.

Diagnosis

Diagnosis of aspergillosis in immunocompromised patients remains difficult. As with many invasive fungal CNS infections, diagnosis is often achieved through examination of the primary entry site of infection. Thus, in patients with suspected CNS aspergillosis, it is important to examine the lungs and sinuses for evidence of infection and potential sites for obtaining biopsy or culture material. MRI of the brain typically reveals a manifestation of infection, such as cerebral infarction, hemorrhagic lesions, solid-enhancing aspergillomas, or ring-enhancing abscesses. Dural enhancement is usually seen in lesions adjacent to infected paranasal sinuses and indicates direct extension of disease.

Several serum laboratory markers can aid in the diagnosis of invasive aspergillosis. Enzyme-linked immunosorbent assay (ELISA) testing for the fungal cell wall constituents galactomannan and BDG should be considered. The CSF galactomannan assay using latex agglutination or ELISA may be a useful adjunct to serum testing; however, data is limited to small sample sizes with variable performance and reliability (sensitivity of 70%-90%). BDG is the major cell wall component of most fungal species, and BDG antigen testing is used as a broad test for detection of fungal pathogens. *Cryptococcus* species do not contain high levels of BDG in their cell walls and therefore are not detected. BDG antigen testing is helpful for detecting invasive aspergillosis and candidiasis. Several PCR assays can detect *Aspergillus* species in blood and BAL fluid samples; a recent study to detect *Aspergillus* species in fresh tissue and BAL fluid reported a sensitivity and specificity of 86% and 100%, respectively. Experience with PCR to detect *Aspergillus* species in CSF samples is limited.

Treatment

Unfortunately, cerebral aspergillosis, especially in an immunocompromised patient, is difficult to treat and has a high mortality rate. The use of voriconazole, a newer antifungal agent, has reduced the mortality of an infection that was previously associated with almost universal mortality. Clinical trials have demonstrated that voriconazole is more effective than AmB as initial therapy for invasive aspergillosis and is associated with significantly improved survival (71% vs 58%, respectively). In vitro studies evaluating combination therapy with voriconazole and caspofungin for *Aspergillus* species have provided promising results in patients with invasive aspergillosis.

TUBERCULOSIS

Epidemiology and Pathobiology

Mycobacterium tuberculosis is an intracellular aerobic gram-positive acid-fast pleomorphic bacillus that can cause chronic meningitis. Transmission occurs primarily by inhalation of airborne droplet nuclei into the lungs. *M tuberculosis* multiplies in alveolar macrophages, and within weeks, the bacilli can hematogenously disseminate to extrapulmonary sites, including the meninges and adjacent brain parenchyma. Tuberculous meningitis is an aggressive form of extrapulmonary disease that is more common in patients infected with HIV.

Clinical Features

Meningitis is typically preceded by nonspecific symptoms of malaise, anorexia, fatigue, weight loss, fever, myalgia, and headache. In immunocompetent patients, headache, vomiting, meningeal signs, focal deficits, vision loss, cranial nerve palsies, and raised ICP are characteristic clinical features. Cerebral vessels may be affected by adjacent meningeal inflammation, producing vasospasm, constriction, and eventually thrombosis with cerebral infarction. As the disease progresses, the patient will become comatose from elevated ICP and obstructive hydrocephalus.

Diagnosis

Despite its many limitations, tuberculin skin testing remains in widespread use. The Centers for Disease Control and Prevention (CDC), the American Thoracic Society, and the Infectious Diseases Society of America's guidelines recommend that one should not obtain a tuberculin skin test unless treatment would be offered in the event of a positive test result. Negative results from the purified protein derivative test do not rule out TB; if the 5-tuberculin skin test result is negative and suspicion for TB is high, the test can be repeated with the 250-tuberculin test. Note that this test is often nonreactive in persons with tuberculous meningitis.

Diagnosing tuberculous meningitis can be difficult and typically involves a combination of neuroimaging, serologic studies, and CSF analysis. Meningitis in the setting of concomitant pulmonary TB is highly suggestive of tuberculous meningitis. Both CT and MRI of the brain are valuable for diagnosing TB meningitis and evaluating for complications. The hallmark pathologic feature of tuberculous meningitis is the presence of a thick exudate most prominent in the basilar meninges. Thus, characteristic abnormalities include enhancement of the basilar meninges, thick exudates, obstructive hydrocephalus, and periventricular infarcts (Fig. 67.2). Chest CT is sensitive for detecting pulmonary abnormalities in patients with tuberculous meningitis.

Characteristic CSF abnormalities include a mononuclear pleocytosis, low glucose concentration, and elevated protein concentration. CSF pleocytosis can be lower in HIV-infected patients. Of note, 16% of patients with confirmed cryptococcal meningitis, 5% with TB, and 4% with bacterial meningitis will have normal CSF cell counts and biochemistry. Although CSF acid-fast bacillus smear and culture are crucial for making a diagnosis of tuberculous meningitis, there is a wide range of reported sensitivities for acid-fast bacillus smear; sensitivities can reach as high as 52% when large volume CSF samples (>6 mL) are evaluated by microscopy for at least 30 minutes. Conventional CSF culture for *M tuberculosis* on Lowenstein-Jensen medium is positive in approximately 45% to 90% of cases but usually takes several weeks for a positive result. The microscopic observation drug susceptibility assay was recently endorsed for rapid screening of multidrug-resistant TB. This technology uses an inverted light microscope to examine liquid culture for growth of the characteristic "cord"-like structures of TB. This can be completed in 7 to 10 days, compared to conventional solid culture that takes several weeks. Other assays that may prove more sensitive include detection of intracellular bacteria by a modified Ziehl-Neelsen stain and early secretory antigenic target-6 in CSF leukocytes. Detection of *M tuberculosis* DNA in CSF by PCR assay

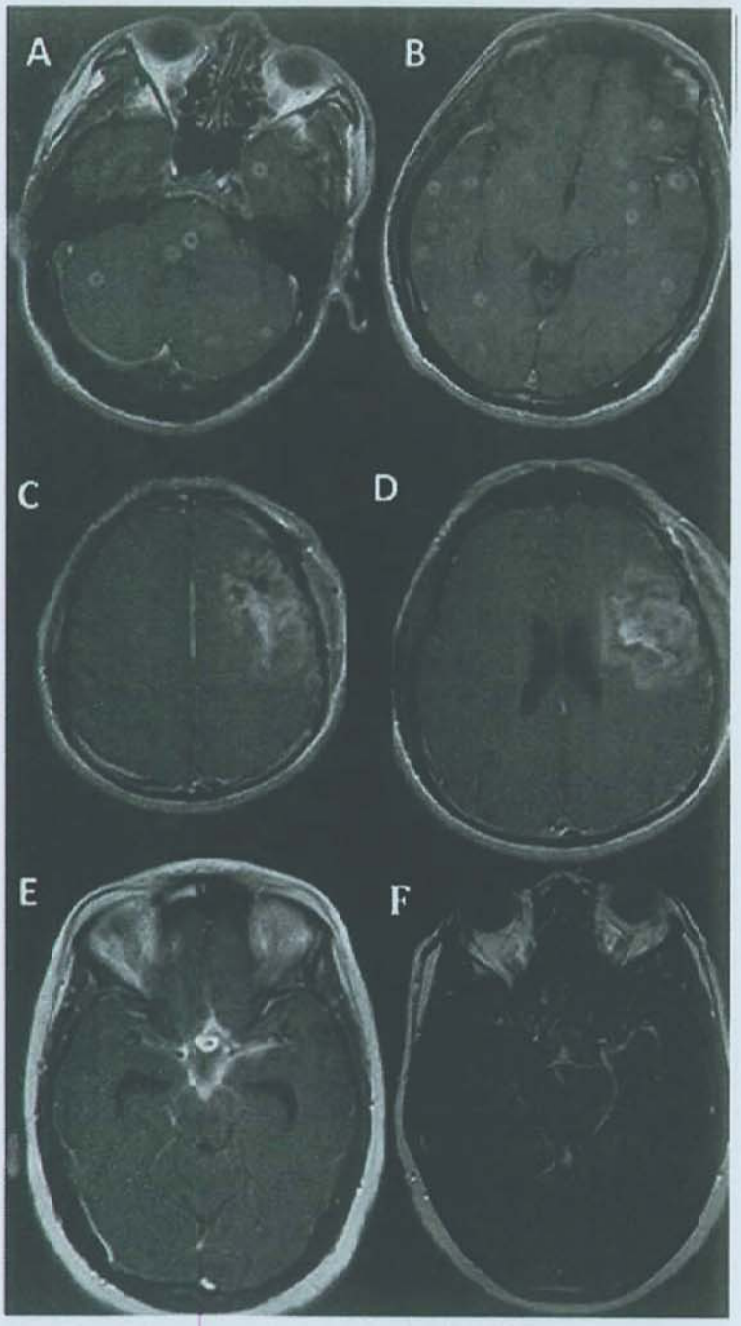

FIGURE 67.2 Axial brain magnetic resonance imaging. **A,B:** T1 postcontrast with multiple ring-enhancing lesions seen in miliary tuberculosis. **C,D:** T1 postcontrast with large L frontal tuberculoma. **E,F:** T1 postcontrast demonstrating avid basilar meningitis with leptomeningeal enhancement.

is a useful ancillary diagnostic test, with nearly 100% specificity, but sensitivity varies between 30% and 50%, thus limiting its usefulness. The GeneXpert Ultra is currently the most sensitive test available for the detection of TB meningitis. It relies on fully automated, nested DNA-PCR technique for detection of TB and rifampicin resistance. Compared to a microbiologic composite, it has a sensitivity of 95%. However, against a uniform clinical definition of tuberculous meningitis used for research purposes, it only had a sensitivity of 70%.

Treatment

Empiric treatment should be initiated when tuberculous meningitis is initially suspected because the organism grows slowly, speciation and resistance patterns can take weeks, and earlier treatment is associated with better outcomes. First-line antituberculous medications include rifampicin, isoniazid, pyrazinamide, and ethambutol LEVEL 2.[5] Multidrug-resistant and extremely drug-resistant TB pose a serious and growing problem, and treatment should be individualized based on sensitivity testing. Adjunctive corticosteroids significantly reduce death and disabling residual neurologic deficits LEVEL 1[6] and are currently used regardless of HIV status, although evidence for added benefit for HIV-infected patients is inconclusive, and studies are ongoing.

NEUROSYPHILIS

Neurosyphilis has played an important role in the evolution of modern neurology. Paretic neurosyphilis was the first psychiatric disorder for which a specific cerebral pathology and treatment was reported. Erb described spinal syphilis tabes dorsalis in 1892. Quincke introduced lumbar puncture, and CSF examination was used to diagnose infection, even in asymptomatic people. *Treponema pallidum* was identified in the brain by Noguchi and Moore in 1913. The first effective treatment came in 1918 when Wagner-Jaurregg gave fever therapy for paresis. He was the first psychiatrist to win the Nobel Prize. Then came arsenical chemotherapy, the first planned use of a drug that would attack the organism without harming host tissues; this was Ehrlich's concept of "the magic bullet." Safer and more effective therapy came in 1945 with the introduction of penicillin, which has been in use since and has revolutionized treatment of the disease. Following the introduction of penicillin in the 1940s and 1950s, the incidence of neurosyphilis declined for two main reasons: (1) Fewer people spread the disease because those affected were being identified and treated, and (2) many neurosyphilis infections were prevented because penicillin was being used to treat gonorrhea and other infections. For instance, the frequency of neurosyphilis as a cause of first admission to a psychiatric hospital plummeted from 5.9 cases per 100,000 population in 1942 to 0.1 cases per 100,000 in 1965. New cases became so rare that many hospitals discarded routine testing to detect syphilis.

During the next few decades, some investigators detected a shift in clinical patterns, but this finding was debated. The population at highest incidence was young homosexual men. Finally, in 1981, the AIDS epidemic occurred. The incidence of primary and secondary syphilis rose from 13.7 cases per 100,000 in 1981 to 18.4 cases per 100,000 in 1989, an increase of 34%. In the ensuing years, the incidence of syphilis declined. In 1997, fewer than 8,000 cases of early syphilis were reported in the United States, the lowest rate in 38 years and a sixfold decline from 1990. Unfortunately, since 2000, there has been an unexpected increase in new cases of primary and secondary syphilis in the United States. Trends in Western Europe, Brazil, and Canada were similar, presumably because of a resurgence of unsafe sexual practices. In addition to the alarming increase in the incidence of syphilis in industrialized countries, syphilis, like HIV, is an enormous health problem in developing countries. For instance, syphilis seropositivity among pregnant women in sub-Saharan Africa may be higher than 10%. Even before the HIV era, there had been a shift in clinical manifestations because of the widespread use of antibiotics. Previously common parenchymal forms became rare, whereas the incidence of meningeal (including meningitis, radiculitis, and cranial neuritis) and vascular syndromes have increased.

Epidemiology and Pathobiology

Syphilis is caused by the thin, motile corkscrew bacterium *T pallidum*. This organism cannot be routinely cultured in the laboratory and is difficult to visualize using traditional light microscopy. Transmission is primarily via sexual contact with an infected individual or by vertical transmission from mother to fetus. Without treatment, the disease will inevitably progress through a series of clinical stages. In general, syphilis can be classified as early or late infection. Early infection encompasses primary, secondary, and early latent syphilis. Late infection refers to tertiary syphilis.

Clinical Features

After sexual exposure to the organism, an asymptomatic incubation period of approximately 3 weeks occurs, followed by the development of a painless genital ulceration or chancre. If left untreated, the chancre will resolve in 3 to 5 weeks, and the disease will progress to secondary syphilis. Secondary syphilis is a syndrome of fever, lymphadenopathy, headache, malaise, myalgia, and a macular or pustular rash of the palms and soles. During this stage, involvement of other organ systems produces clinical symptoms, including mucosal lesions, renal failure, hepatitis, and neurologic symptoms. The signs and symptoms of secondary syphilis typically resolve in 4 to 10 weeks, and the patient is deemed latently infected. About one-third of patients with untreated latent syphilis will progress to develop late or tertiary syphilis, which can affect any organ in the body, particularly the nervous system, manifesting with a variety of symptoms.

T pallidum spreads hematogenously to the CNS early in the course of disease, and clinical signs and symptoms are not limited to any particular disease stage. Patterns of meningitis or vascular disease may be more common earlier in disease, whereas late disease presents as parenchymal or spinal cord pathologies. Although neurosyphilis can produce a wide variety of manifestations, including general paresis, psychiatric illness, cognitive decline, tabes dorsalis, or vascular disease, this section limits the discussion to syphilitic meningitis.

Syphilitic meningitis typically presents in the secondary stage of syphilis within 2 years of acquiring infection. Although meningitis is less common than other forms of neurosyphilis, abnormal CSF with a mononuclear pleocytosis and elevated protein concentration occurs in up to 25% of patients. The most common presenting symptoms include headache, photophobia, nausea and vomiting, meningismus, and cranial nerve deficits. Although any cranial nerve can be affected, cranial nerves VII and VIII are most commonly affected.

Diagnosis

The diagnosis of neurosyphilis is typically made through a combination of history, physical examination, and results of serologic and CSF analyses. Two forms of serologic testing are used in the diagnosis of syphilis: nontreponemal testing, such as the Venereal Disease Research Laboratory (VDRL) and rapid plasma reagin (RPR) assays, and treponemal testing, such as fluorescent treponemal antibody absorption and *T pallidum* particle agglutination (TPPA) tests. Nontreponemal assays detect IgG and immunoglobulin M antibodies to a cardiolipin-lecithin cholesterol antigen and can normalize with treatment or even in chronically infected patients who have not been treated. Treponemal assays measure treponemal antibodies and remain positive for life, even with appropriate treatment. The order of treponemal or nontreponemal testing is dependent on local institutional practices. Generally, treponemal testing is performed first (TPPA) to screen for current or past infection followed by a nontreponemal assay (RPR) to assess for a possible treatment response. The 2018 CDC neurosyphilis diagnostic criteria require a positive serum RPR, a positive serum TPPA, and CSF abnormalities. In syphilitic meningitis, CSF typically has a mononuclear-predominant pleocytosis, elevated protein concentration (>45 mg/dL), and normal or decreased glucose concentration. Although CSF immunologic tests, such as VDRL, are very specific and are usually abnormal in syphilitic meningitis (70% sensitivity), a negative result does not rule out neurosyphilis. More recently, PCR assays have been developed to detect *T pallidum* in the CSF, but 50% of patients with syphilitic involvement of the CNS have a negative PCR. Other new techniques include using CSF fluorescent treponemal antibody and percentage of CSF B cells when CSF-VDRL is negative to aid in establishing the diagnosis of neurosyphilis.

Treatment

Penicillin is the first-line therapy for neurosyphilis. The CDC recommends 18 to 24 million units of aqueous penicillin G per day administered as 3 to 4 million units IV every 4 hours or as a continuous infusion for 10 to 14 days. An alternative is procaine penicillin 2.4 million units intramuscular daily with probenecid 500 mg orally 4 times daily for 10 to 14 days

LYME DISEASE

Epidemiology

North American Lyme borreliosis, or Lyme disease, is the most common tick-borne infection in the United States. The CDC reports that 300,000 cases of Lyme disease are diagnosed in the United States each year, with 96% of cases concentrated in 13 states (Connecticut, Delaware, Maine, Maryland, Massachusetts, Minnesota, New Hampshire, New Jersey, New York, Pennsylvania, Vermont, Virginia, and Wisconsin). In humans, the signs and symptoms of Lyme borreliosis most frequently appear in spring, summer, and early autumn, coinciding with the activity of nymphs and with the increasing recreational use of tick habitats by the public.

Pathobiology

Lyme disease is caused by *Borrelia burgdorferi*, which is transmitted by specific *Ixodes* species ticks. In Europe, at least five species of Lyme *Borrelia* (*Borrelia afzelii*, *Borrelia garinii*, *B burgdorferi*, *Borrelia spielmanii*, and *Borrelia bavariensis*) can cause the disease, leading to a wider variety of possible clinical manifestations in Europe than in North America. Transmission of the organism occurs through injection of tick saliva during feeding. A feeding period of more than 36 hours is usually required for transmission of *B burgdorferi* by *Ixodes scapularis* or *Ixodes pacificus*. In North America, the only species of Lyme *Borrelia* known to cause human disease are *B burgdorferi*, *Borrelia miyamotoi*, and *Borrelia mayonii*.

Clinical Features

Spirochetes initially proliferate at the site of the tick bite. When sufficiently numerous, they slowly migrate centrifugally from the site of inoculation, typically for up to 30 days after the bite. The associated skin lesion associated with this proliferating, spreading infection is known as *erythema migrans*. Erythema migrans consists of an area of erythroderma that enlarges over days to weeks, often reaching several inches in diameter. Depending on the location on the body, the rash may be round or elliptical. Central pallor may be present.

Early disseminated disease is usually characterized by a multifocal rash, with each new focus representing a nidus of spirochetes that spread hematogenously from the initial site. The bacterial dissemination is accompanied by the usual host inflammatory reaction to bacteremia: fever, diffuse aches and pains, headaches, malaise, and fatigue. Up to 5% of infected individuals develop heart block, known as *Lyme carditis*, sometimes requiring a temporary pacemaker. Early dissemination affects the nervous system in 10% to 15% of patients, primarily in the first few months after the initial infection, during what is often termed *acute disseminated infection*. Most commonly, patients present with an aseptic lymphocytic meningitis, cranial neuritis, or painful polyradiculitis. First described in Europe, Garin-Bujadoux-Bannwarth syndrome is now considered to include all or part of a classic triad: lymphocytic meningitis, cranial neuritis, and polyradiculitis. Cranial and peripheral nerve involvement can occur anywhere along the course of affected nerves, not preferentially in the subarachnoid space. Approximately three-fourths of patients with Lyme-associated cranial neuropathies present with a facial nerve palsy. Early studies suggested this could be bilateral in up to one quarter of cases.

Late Lyme disease can manifest as arthritis or the skin disorder known as *acrodermatitis chronica atrophicans*, a tissue paper thinning of the skin. Neurologic manifestations of late Lyme disease include myelitis, encephalitis, and neurobehavioral changes. Much attention has focused on patients who have persistent fatigue and cognitive difficulty after receiving treatment for Lyme disease with regimens that should be highly effective even for severe infections, a disorder often referred to as *post–Lyme syndrome*. This topic is controversial and is beyond the scope of this chapter.

Diagnosis

Typical erythema migrans is usually sufficiently distinctive to allow a clinical diagnosis in the absence of a supporting laboratory test. Serologic assays for antibodies to Lyme *Borrelia* are positive infrequently at this stage and thus should be obtained only in atypical cases and then in conjunction with convalescent phase serologic testing 2 to 6 weeks after obtaining the acute sample. Treatment at this stage will prevent progression to neurologic Lyme disease.

The majority of patients with early Lyme disease are seropositive on serum two-tier testing (ELISA and IgG immunoblot). Those who are seronegative at presentation will convert in 2 weeks after acute phase. CSF testing for intrathecal antibody production and lumbar puncture showing lymphocytic meningitis are useful to confirm diagnosis. CSF PCR is insensitive for the diagnosis of neurologic Lyme disease and should not be routinely used. Late neurologic Lyme disease requires a positive serum two-tier (ELISA and IgG immunoblot) seropositivity and evidence of intrathecal antibody production. CSF examination generally supports an active infection with a lymphocytic meningitis, elevated protein concentration, and normal glucose concentration.

Treatment

For adult patients with early Lyme disease and the acute neurologic presentation of meningitis or radiculopathy, ceftriaxone 2 g IV daily for 14 days is recommended. Parenteral therapy with cefotaxime LEVEL 1[7,8] or penicillin G LEVEL 1[9,10] may be acceptable alternatives. Oral doxycycline has good oral absorption and CNS penetration and may also be an alternative LEVEL 1.[11] Late neurologic Lyme disease may present as encephalomyelitis, peripheral neuropathy, or encephalopathy. These patients should be treated with ceftriaxone 2 g IV once daily for 2 to 4 weeks. Cefotaxime or penicillin G may be acceptable alternatives. Retreatment is not indicated for persistent or recurrent symptoms.

HYPOTHESIS-FREE INVESTIGATIONS

On many occasions, despite high clinical suspicion for an infectious cause of chronic meningitis, no pathogen is detected via conventional investigations. In addition to the many pathogen-specific serologic, antigen, and PCR-based tests described earlier, more broad-based infectious disease diagnostics are being increasingly used, especially in difficult-to-diagnose cases. These included 16s and 18s rRNA PCR assays to detect bacteria and fungi, respectively, as well as mNGS of CSF. The latter is now a clinically validated test for detecting infections in patients with meningitis, myelitis, and/or encephalitis.

The 16s rRNA gene is a highly conserved region in bacteria, whereas the 18s and 28s rRNA genes are highly conserved in fungi. PCR amplification of these genes allows identification of a variety of bacterial and fungal species. In culture-proven cases of meningitis, 16s rRNA PCR was 94% sensitive and specific and was positive in 30% of culture-negative cases. The main reason for discordance was pretreatment with antibiotics before lumbar puncture, leading to diminished culture results.

mNGS allows for the most unbiased approach to diagnosis by amplifying and sequencing all nucleic acid present in a CSF sample with random primers. After extensive bioinformatics processing of the resulting sequences to filter out low quality, redundant, and human sequences, the origin of the nonhuman sequences is determined by searching the remaining sequences in large, public databases to determine whether there might be a pathogen present. Recent papers have demonstrated the use of mNGS in the sphere of chronic meningitis and encephalitis with favorable results. mNGS was able to detect several pathogens causing subacute or chronic meningitis that had not been considered by the treating team as well as aid with management decisions. However, mNGS was more insensitive for the detection of infections that primarily rely on antibody testing as the mainstay of diagnosis, such as *T pallidum* and West Nile virus.

LEVEL 1 EVIDENCE

1. Day JN, Chau TTH, Wolbers M, et al. Combination antifungal therapy for cryptococcal meningitis. *N Engl J Med*. 2013;368(14):1291-1302.
2. Molloy SF, Kanyama C, Heyderman RS, et al; for ACTA Trial Study Team. Antifungal combinations for treatment of cryptococcal meningitis in Africa. *N Engl J Med*. 2018;378:1004-1017.
3. Beardsley J, Wolbers M, Kibengo FM, et al. Adjunctive dexamethasone in HIV-associated cryptococcal meningitis. *N Engl J Med*. 2016;374(6):542-554.
4. Boulware DR, Meya DB, Muzoora C, et al; for COAT Trial Team. Timing of antiretroviral therapy after diagnosis of cryptococcal meningitis. *N Engl J Med*. 2014;370(26):2487-2498.
5. Heemskerk AD, Bang ND, Mai NT, et al. Intensified antituberculosis therapy in adults with tuberculous meningitis. *N Engl J Med*. 2016;374(2):124-134.
6. Thwaites GE, Nguyen DB, Nguyen HD, et al. Dexamethasone for the treatment of tuberculous meningitis in adolescents and adults. *N Engl J Med*. 2004;351(17):1741-1751.
7. Pfister HW, Preac-Mursic V, Wilske B, Einhäupl KM. Cefotaxime vs penicillin G for acute neurologic manifestations in Lyme borreliosis. A prospective randomized study. *Arch Neurol*. 1989;46(11):1190-1194.
8. Pfister HW, Preac-Mursic V, Wilske B, Schielke E, Sörgel F, Einhäupl KM. Randomized comparison of ceftriaxone and cefotaxime in Lyme neuroborreliosis. *J Infect Dis*. 1991;163(2):311-318.
9. Karlsson M, Hammers-Berggren S, Lindquist L, Stiernstedt G, Svenungsson B. Comparison of intravenous penicillin G and oral doxycycline for treatment of Lyme neuroborreliosis. *Neurology*. 1994;44(7):1203-1207.
10. Kohlhepp W, Oschmann P, Mertens HG. Treatment of Lyme borreliosis. Randomized comparison of doxycycline and penicillin G. *J Neurol*. 1989;236(8):464-469.
11. Ljøstad U, Skogvoll E, Eikeland R, et al. Oral doxycycline versus intravenous ceftriaxone for European Lyme neuroborreliosis: a multicentre, non-inferiority, double-blind, randomised trial. *Lancet Neurol*. 2008;7(8):690-695.

SUGGESTED READINGS

Ackermann R, Rehse-Küpper B, Gollmer E, Schmidt R. Chronic neurologic manifestations of erythema migrans borreliosis. *Ann N Y Acad Sci*. 1988;539:16-23.

Alspaugh JA, Perfect JR. Fungal infections of the central nervous system. In: Roos KL, ed. *Principles of Neurologic Infectious Disease*. New York, NY: McGraw-Hill; 2005:175.

Ampel NM. Coccidioidomycosis in persons infected with HIV type 1. *Clin Infect Dis*. 2005;41(8):1174-1178.

Arsura EL, Johnson R, Penrose J, et al. Neuroimaging as a guide to predict outcomes for patients with coccidioidal meningitis. *Clin Infect Dis*. 2005;40(4):624-627.

Blair JE. Coccidioidal meningitis: update on epidemiology, clinical features, diagnosis, and management. *Curr Infect Dis Rep*. 2009;11(4):289-295.

Boulware DR, Meya DB, Muzoora C, et al. Timing of antiretroviral therapy after diagnosis of cryptococcal meningitis. *N Engl J Med*. 2014;370(26):2487-2498.

Bush JW, Wuerz T, Embil JM, Del Bigio MR, McDonald PJ, Krawitz S. Outcomes of persons with blastomycosis involving the central nervous system. *Diagn Microbiol Infect Dis*. 2013;76(2):175-181.

Cecchini D, Ambrosioni J, Brezzo C, et al. Tuberculous meningitis in HIV-infected and non-infected patients: comparison of cerebrospinal fluid findings. *Int J Tuberc Lung Dis*. 2009;13(2):269-271.

Centers for Disease Control and Prevention. 2010 Guidelines for treatment of sexually transmitted diseases. *MMWR Morb Mortal Wkly Rep*. 2010;59(RR-12):1-110.

Centers for Disease Control and Prevention. Syphilis (*Treponema pallidum*). 2018 Case definition. Centers for Disease Control and Prevention Web site. https://wwwn.cdc.gov/nndss/conditions/syphilis/case-definition/2018/. Accessed July 24, 2019.

Chapman SW, Dismukes WE, Proia LA, et al. Clinical practice guidelines for the management of blastomycosis: 2008 update by the Infectious Diseases Society of America. *Clin Infect Dis*. 2008;46:1801-1812.

Day J. Cryptococcal meningitis. *Pract Neurol*. 2004;4:274-285.

Day JN, Chau TTH, Wolbers M, et al. Combination antifungal therapy for cryptococcal meningitis. *N Engl J Med*. 2013;368(14):1291-1302.

de Vedia L, Arechavala A, Calderón MI, et al. Relevance of intracranial hypertension control in the management of *Cryptococcus neoformans* meningitis related to AIDS. *Infection*. 2013;41(6):1073-1077.

Diekema DJ, Messer SA, Hollis RJ, Jones RN, Pfaller MA. Activities of caspofungin, itraconazole, posaconazole, ravuconazole, voriconazole, and amphotericin B against 448 recent clinical isolates of filamentous fungi. *J Clin Microbiol*. 2003;41(8):3623-3626.

Drake KW, Adam RD. Coccidioidal meningitis and brain abscesses: analysis of 71 cases at a referral center. *Neurology*. 2009;73(21):1780-1786.

Ellner JJ, Bennett JE. Chronic meningitis. *Medicine (Baltimore)*. 1976;55:341-369.

Feng GD, Shi M, Ma L, et al. Diagnostic accuracy of intracellular *Mycobacterium tuberculosis* detection for tuberculous meningitis. *Am J Respir Crit Care Med*. 2014;189(4):475-481.

Flood JM, Weinstock HS, Guroy ME, Bayne L, Simon RP, Bolan G. Neurosyphilis during the AIDS epidemic, San Francisco, 1985-1992. *J Infect Dis*. 1998;177(4):931-940.

Galgiani JN, Ampel NM, Blair JE, et al. Coccidioidomycosis. *Clin Infect Dis*. 2005;41(9):1217-1223.

Garcia-Monco JC. CNS tuberculosis and mycobacteriosis. In: Roos KL, ed. *Principles of Neurologic Infectious Disease*. New York, NY: McGraw-Hill; 2005:195.

Graybill JR, Sobel J, Saag M, et al. Diagnosis and management of increased intracranial pressure in patients with AIDS and cryptococcal meningitis. The NIAID Mycoses Study Group and AIDS Cooperative Treatment Groups. *Clin Infect Dis*. 2000;30(1):47-54.

Guo XS, Bu H, He JY, et al. Current diagnosis and treatment of cryptococcal meningitis without acquired immunodeficiency syndrome. *Neuroimmunol Neuroinflammation*. 2016;3:249-256.

Halperin JJ. Lyme disease: a multisystem infection that affects the nervous system. *Continuum (Minneap Minn)*. 2012;18(6 Infectious Disease):1338-1350.

Halperin JJ. Lyme disease: neurology, neurobiology, and behavior. *Clin Infect Dis*. 2014;58(9):1267-1272.

Halperin JJ, Logigian EL, Finkel MF, Pearl RA. Practice parameters for the diagnosis of patients with nervous system Lyme borreliosis (Lyme disease). *Neurology*. 1996;46:619-627.

Herbrecht R, Denning DW, Patterson TF, et al. Voriconazole versus amphotericin B for primary therapy of invasive aspergillosis. *N Engl J Med*. 2002;347(6):408-415.

Hook EW, Chansolme DH. Neurosyphilis. In: Roos KL, ed. *Principles of Neurologic Infectious Disease*. New York, NY: McGraw-Hill; 2005:215.

Jain KK, Mittal SK, Kuman S, Gupta RK. Imaging features of central nervous system fungal infections. *Neurol India*. 2007;55(3):214-250.

Johnson R, Ho J, Fowler P, Heidari A. Coccidioidal meningitis: a review on diagnosis, treatment, and management of complications. *Curr Neurol Neurosci Rep*. 2018;18:19.

Kabanda T, Siedner MJ, Klausner JD, Muzoora C, Boulware DR. Point-of-care diagnosis and prognostication of cryptococcal meningitis with the cryptococcal antigen lateral flow assay on cerebrospinal fluid. *Clin Infect Dis*. 2014;58(1):113-116.

Kalina P, Decker A, Kornel E, Halperin J. Lyme disease of the brainstem. *Neuroradiology*. 2005;47:903-907.

Kleinschmidt-DeMasters BK. Central nervous system aspergillosis: a 20-year retrospective series. *Hum Pathol*. 2002;33(1):116-124.

Latgé JP. *Aspergillus fumigatus* and aspergillosis. *Clin Microbiol Rev*. 1999;12(2):310-350.

Lemos LB, Guo M, Baliga M. Blastomycosis: organ involvement and etiologic diagnosis. A review of 123 patients from Mississippi. *Ann Diagn Pathol*. 2000;4(6):391-406.

Lu CH, Chang WN, Chang HW, Chuang YC. The prognostic factors of cryptococcal meningitis in HIV-negative patients. *J Hosp Infect*. 1999;42(4):313-320.

Macsween KF, Bicanic T, Brouwer AE, Marsh E, Macallan DC, Harrison TS. Lumbar drainage for control of raised cerebrospinal fluid pressure in cryptococcal meningitis: case report and review. *J Infect*. 2005;51(4):e221-e224.

Mamidi A, DeSimone JA, Pomerantz RJ. Central nervous system infections in individuals with HIV-1 infection. *J Neurovirol*. 2002;8(3):158-167.

Marra CM, Tantalo LC, Maxwell CL, Dougherty K, Wood B. Alternative cerebrospinal fluid tests to diagnose neurosyphilis in HIV-infected individuals. *Neurology*. 2004;63(1):85-88.

Marra CM, Tantalo LC, Maxwell CL, Ho EL, Sahi SK, Jones T. The rapid plasma reagin test cannot replace the venereal disease research laboratory test for neurosyphilis diagnosis. *Sex Transm Dis*. 2012;39(6):453-457.

Meyer T, Franke G, Polywka SK, et al. Improved detection of bacterial central nervous system infections by use of a broad-range PCR assay. *J Clin Microbiol*. 2014;52(5):1751-1753.

Mitchell TG, Perfect JR. Cryptococcosis in the era of AIDS—100 years after the discovery of *Cryptococcus neoformans*. *Clin Microbiol Rev*. 1995;8(4):515-548.

Molloy SF, Kanyama C, Heyderman RS, et al; for ACTA Trial Study Team. Antifungal combinations for treatment of cryptococcal meningitis in Africa. *N Engl J Med*. 2018;378:1004-1017.

Moore DA, Evans CA, Gilman RH, et al. Microscopic-observation drug-susceptibility assay for the diagnosis of TB. *N Engl J Med*. 2006;355(15):1539-1550.

Moore JE, Hopkins HH. Asymptomatic neurosyphilis: VI. The prognosis of early and late asymptomatic neurosyphilis. *JAMA*. 1930;95(22):1637-1661.

Powderly WG. Current approach to the acute management of cryptococcal infections. *J Infect*. 2000;41(1):18-22.

Prasad K, Singh MB. Corticosteroids for managing tuberculous meningitis. *Cochrane Database Syst Rev*. 2008;(1):CD002244.

Ragland AS, Arusa E, Ismail Y, Johnson R. Eosinophilic pleocytosis in coccidioidal meningitis: frequency and significance. *Am J Med*. 1993;95(3):254-257.

Ramachandran PS, Wilson MR. Diagnostic testing of neurologic infections. *Neurol Clin*. 2018;36:687-703.

Reinwald M, Spiess B, Heinz WJ, et al. Aspergillus PCR-based investigation of fresh tissue and effusion samples in patients with suspected invasive aspergillosis enhances diagnostic capabilities. *J Clin Microbiol*. 2013;51(12):4178-4185.

Roos KL, Bryan JP, Maggio WW, Jane JA, Scheld WM. Intracranial blastomycoma. *Medicine (Baltimore)*. 1987;66(3):224-235.

Saccente M, Woods GL. Clinical and laboratory update on blastomycosis. *Clin Microbiol Rev*. 2010;23(2):367-381.

Segal BH, Walsh TJ. Current approaches to diagnosis and treatment of invasive aspergillosis. *Am J Respir Crit Care Med*. 2006;173(7):707-717.

Smith JE, Aksamit AJ Jr. Outcome of chronic idiopathic meningitis. *Mayo Clin Proc*. 1994;69(6):548-556.

Smith RM, Mba-Jonas A, Tourdjman M, et al. Treatment and outcomes among patients with *Cryptococcus gattii* infections in the United States Pacific Northwest. *PLoS One*. 2014;9(2):e88875.

Solomons RS, van Elsland SL, Visser DH, et al. Commercial nucleic acid amplification tests in tuberculous meningitis—a meta-analysis. *Diagn Microbiol Infect Dis*. 2014;78(4):398-403.

Srinivasan L, Pisapia JM, Shah SS, Halpern CH, Harris MC. Can broad-range 16S ribosomal ribonucleic acid gene polymerase chain reactions improve the diagnosis of bacterial meningitis? A systematic review and meta-analysis. *Ann Emerg Med*. 2012;60(5):609.e2-620.e2.

Stanek G, Wormser GP, Gray J, Strle F. Lyme borreliosis. *Lancet*. 2012;379:461-473.

Stewart SM. The bacteriological diagnosis of tuberculous meningitis. *J Clin Pathol*. 1953;6(3):241-242.

Targeted tuberculin testing and treatment of latent tuberculosis infection. *Am J Respir Crit Care Med*. 2000;161(4, pt 2):S221-S247.

Tenforde MW, Shapiro AE, Rouse B, et al. Treatment for HIV-associated cryptococcal meningitis. *Cochrane Database of Syst Rev*. 2018;2018(7):CD005647.

Thwaites GE, Chau TT, Farrar JJ. Improving the bacteriological diagnosis of tuberculous meningitis. *J Clin Microbiol*. 2004;42(1):378-379.

van der Horst CM, Saag MS, Cloud GA, et al. Treatment of cryptococcal meningitis associated with the acquired immunodeficiency syndrome. National Institute of Allergy and Infectious Diseases Mycoses Study Group and AIDS Clinical Trials Group. *N Engl J Med*. 1997;337(1):15-21.

Walusimbi S, Bwanga F, De Costa A, Haile M, Joloba M, Hoffner S. Meta-analysis to compare the accuracy of GeneXpert, MODS and the WHO 2007 algorithm for diagnosis of smear-negative pulmonary tuberculosis. *BMC Infect Dis*. 2013;13:507.

Wheat LJ, Freifeld AG, Kleiman MB, et al. Clinical practice guidelines for the management of patients with histoplasmosis: 2007 update by the Infectious Diseases Society of America. *Clin Infect Dis*. 2007;45:807-825.

Wilson MR, Naccache SN, Samayoa E, et al. Actionable diagnosis of neuroleptospirosis by next-generation sequencing. *N Engl J Med*. 2014;370(25):2408-2417.

Wilson MR, O'Donovan BD, Gelfand JM, et al. Chronic meningitis investigated via metagenomic next-generation sequencing. *JAMA Neurol*. 2018;75(8):947-955.

Wilson MR, Sample HA, Zorn KC, et al. Clinical metagenomic sequencing for diagnosis of meningitis and encephalitis. *N Engl J Med*. 2019;380:2327-2340.

Woodworth GF, McGirt MJ, Williams MA, Rigamonti D. The use of ventriculoperitoneal shunts for uncontrollable intracranial hypertension without ventriculomegally secondary to HIV-associated cryptococcal meningitis. *Surg Neurol*. 2005;63(6):529-531.

World Health Organization. *Consolidated Guidelines on the Use of Antiretroviral Drugs for Treating and Preventing HIV Infection: Recommendations for a Public Health Approach*. 2nd ed. Geneva, Switzerland: World Health Organization; 2016.

Wormser GP, Dattwyler RJ, Shapiro ED, et al. The clinical assessment, treatment, and prevention of Lyme disease, human granulocytic anaplasmosis, and babesiosis: clinical practice guidelines by the Infectious Diseases Society of America. *Clin Infect Dis*. 2006;43(9):1089-1134.

Parasitic Infections 68

Gustavo C. Román

KEY POINTS

1. Neurologic parasitic infections are no longer confined to the tropics.
2. Malaria is the commonest parasitic infection in the world.
3. Due to its elevated mortality, cerebral malaria is a medical emergency.
4. Sleeping sickness (Africa) and Chagas disease (South America) are human trypanosomiasis.
5. Amebic meningitis may occur after swimming in fresh water.
6. Seizures are the main manifestation of neurocysticercosis.
7. Larva migrans is acquired by eating raw meats.
8. Raccoons are the reservoir of North American larva migrans.
9. Bilharziasis often presents with lumbosacral myelopathy.

INTRODUCTION

Parasitic infections are a tremendous public health burden in tropical and subtropical regions of the world. Parasitic tropical diseases of the nervous system can be found also in temperate regions due to the exponential increase in international travel, tourism, and migration. One important factor is the disregard of tourists and business travelers for the prophylactic measures recommended before traveling to parts of the world where potential exposure to endemic parasitic diseases may occur. When neurologists elicit a travel history preceding the onset of the disease, a high index of suspicion should lead to a differential diagnosis of the most common parasitic neurologic diseases in order to diagnose and treat these exotic conditions.

Parasitic Neurologic Diseases

Table 68.1 lists the most common types of parasitic infections of the human nervous system. Parasitic diseases are divided into *protozoan infections* caused by unicellular organisms (malaria, trypanosomiasis, amebiasis) and *metazoan infections* caused by worms (helminths), mainly cestodes or tapeworms (cysticercosis), nematodes or round worms (larva migrans, baylisascariasis, gnathostomiasis, strongyloidiasis), and trematodes or flukes (paragonimiasis). Not included in this chapter are neurologic diseases transmitted by ectoparasites, such as ticks and other arthropods, including Lyme disease (a spirochetal infection caused by *Borrelia burgdorferi*) (see Chapter 67); other forms of borreliosis presenting as relapsing fevers transmitted to humans by lice or ticks (see Chapter 67); and gram-negative bacterial infections, such as the Rickettsial typhus group (caused by *Rickettsia prowazekii* and *Rickettsia typhi*, transmitted respectively by the body louse *Pediculus humanus* and the rat flea *Xenopsylla cheopis*) as well as the spotted fevers transmitted by ticks and caused by *Rickettsia rickettsii* (see Chapter 66). *Toxoplasma gondii* infection is discussed in the context of human immunodeficiency virus infection (see Chapter 70).

CEREBRAL MALARIA

Introduction

Malaria is the most important human protozoan infection worldwide. The rapid development of multidrug resistance *Plasmodium falciparum* malaria in Cambodia and neighboring countries in Southeast Asia increases the mortality and threatens malaria eradication efforts. Resistance to chloroquine and antifolates has been present in Africa and tropical South America for a long time, and there is evidence of early emerging resistance to artemisinin derivatives.

Epidemiology

According to the World Health Organization, in 2018, an estimated 206 million malaria cases occurred worldwide with 405,000 deaths, mainly young children in sub-Saharan Africa. In 2011, the number of malaria cases reported in the United States was the largest since 1971, representing a 48% increase from 2008. Most malaria infections in the United States occurred among travelers to regions with active malaria transmission.

Pathobiology

Cerebral malaria is an acute encephalitis caused by *P falciparum*, the most virulent of the four *Plasmodium* species that infect humans, when a female *Anopheles* mosquito inoculates the protozoan parasites through the skin. Parasites are carried to the liver where they mature and multiply to enter the red cells in the bloodstream.

Diagnosis

Clinical Features

Malaria presents with typical bouts of intermittent fever with chills, rigors, and anemia. Pregnant women are at increased risk for malaria. Cerebral malaria may be heralded by headache, vomiting, and a clinical picture of encephalopathy developing over days in a febrile patient, accompanied by confusion, decreased responsiveness, and somnolence rapidly progressing to stupor and coma. Psychomotor agitation and psychiatric manifestations may precede cerebral malaria. Focal findings are uncommon,

TABLE 68.1 Parasitic Infections of the Nervous System

Name	Agent	Reservoir	Transmission
Metazoan Infections			
Neurocysticercosis	*Taenia solium*	Pigs, humans	Human *Taenia* carriers
Gnathostomiasis	*Gnathostoma spinigerum*	Fish, poultry, dogs, cats	Undercooked fish, poultry
Hydatid cysts	*Echinococcus* species	Dogs, foxes, sheep, cows	Dogs' feces
Larva migrans	*Toxocara canis, Toxocara cati, Ascaris* species	Dogs, cats	Dogs' and cats' feces
Baylisascariasis	*Baylisascaris procyonis*	Raccoon (*Procyon lotor*)	Raccoons' feces
Paragonimiasis	*Paragonimus westermani*	Fresh water crustaceans, snails	Eating uncooked crustaceans
Schistosomiasis/ bilharziasis	*Schistosoma* species	Fresh water snails	Skin penetration by larval forms (cercariae) in infected water
Sparganosis	*Spirometra mansoni*	Reptiles, amphibians	Eating uncooked frogs or snakes
Strongyloidiasis	*Strongyloides stercoralis*	Human	Infected soil contact
Trichinosis	*Trichinella spiralis*	Pigs	Eating undercooked pork
Protozoan Infections			
African trypanosomiasis Sleeping sickness	*Trypanosoma brucei*	Ungulates	Tsetse flies (*Glossina*)
American trypanosomiasis Chagas disease	*Trypanosoma cruzi*	Opossum, dogs	Triatomine bugs
Amebiasis	*Entamoeba histolytica*	Human	Ingestion of food contaminated with feces
Primary amebic meningoencephalitis	*Naegleria* species	Warm fresh water ponds	Nasal route while swimming
Granulomatous amebic encephalitis	*Acanthamoeba* species	Fresh and brackish water	Nasal route while swimming
Cerebral malaria	*Plasmodium falciparum*	Human	*Anopheles* mosquitoes
Toxoplasmosis	*Toxoplasma gondii*	Cat	Cats' feces in contaminated soil or vegetables

except when stroke occurs concurrently. In children, tonic-clonic seizures occur, followed by postictal unresponsiveness.

In adults, cerebral malaria may occur in the setting of severe malaria presenting with acute respiratory distress; pulmonary edema; acute renal failure and hemoglobinuria ("blackwater fever"); jaundice and liver failure; severe anemia; thrombocytopenia; disseminated intravascular coagulation; and bleeding complications, including intracranial hemorrhages. Severe hypoglycemia must be assumed to be present in children with cerebral malaria and should be treated promptly and aggressively.

Retinal hemorrhages and exudates are usually seen on funduscopic examination and reflect the cerebral small-vessel vasculopathy. Meningeal signs do not occur, and cerebrospinal fluid (CSF) is normal; however, spinal tap is mandatory to exclude other causes of encephalopathy. Brain imaging may show evidence of brain swelling and herniation or small hemorrhages.

Diagnostic Methods

Malaria should be considered a potential medical emergency in the United States in a febrile patient with the clinical features mentioned above and with recent history of travel to a tropical region. Rapid diagnosis and treatment improves the prognosis and minimizes the risk of infecting indigenous mosquito populations. Confirmation of malaria requires laboratory diagnosis by an experienced pathologist demonstrating the presence of the *Plasmodium* parasite in the red cells in a Wright- or Giemsa-stained thick or thin blood smear.

A positive BinaxNOW rapid diagnostic test for malaria detects specific malaria antigens and confirms the diagnosis but does not eliminate the need for the blood stain because the type of *Plasmodium* parasite must by confirmed by microscopy. The indirect fluorescent antibody serologic test for malaria becomes positive during convalescence and is not useful in acute malaria. The Centers for Disease Control and Prevention provides diagnostic support for suspected cases of malaria as well as artesunate for treatment of severe cases.

Management

The drugs of choice for treatment of cerebral malaria are the derivatives of artemisinin, such as artesunate, artemether, or arteether. Quinine is an equivalent alternative for cerebral malaria. Development of drug resistance to artemisinin derivatives has occurred in South East Asia and combination therapy for *P falciparum* malaria with other antimalarial drug is recommended. Cerebral malaria is a critical condition and requires intensive care treatment; complications such as hypoglycemia, respiratory distress syndrome, and acute renal and liver failure must be promptly recognized and treated. Severe anemia or bleeding diathesis may require blood transfusions. Steroids are not recommended in cerebral malaria. Despite treatment, the mortality is over 25%, but survivors usually recover without sequelae; however, residual hemiplegia, extrapyramidal symptoms, blindness, deafness, psychiatric symptoms, and epilepsy may occur.

There is intensive research on the immune mechanisms of cerebral malaria leading to vascular occlusion by parasitized erythrocytes, vasoconstriction, and alterations of the blood-brain barrier with decreased cerebral blood flow, edema, demyelination, ischemia, hypoxia, acidosis, and death. Potential therapies based on nitric oxide bioavailability, high levels of endothelin-1, and angiopoietin dysfunction appear promising.

Malaria prevention relies on avoiding exposure to mosquitoes using repellents and insecticide-treated bed nets and prophylactic use of antimalarial drugs prior to, during, and after travel to endemic malaria regions. The *P falciparum* malaria vaccine (RTS,S Mosquirix, GlaxoSmithKline Biologicals S.A.) has been approved by World Health Organization for pilot use in children in three African countries.

TRYPANOSOMIASIS

Two human infections with protozoa of the genus *Trypanosoma* have neurologic importance: African trypanosomiasis (sleeping sickness) and American trypanosomiasis (Chagas disease); both are transmitted by infected arthropods, the tsetse fly (*Glossina* species) in Africa, and triatomine (reduviid) vectors (Fig. 68.1) in South America. The use of organophosphate insecticidal paint (Inesfly 5A IGR) as well as radiation-sterilized male tsetse flies appears promising for vector control.

African Trypanosomiasis

This fatal encephalitis is caused by infection with *Trypanosoma brucei rhodesiense* and *Trypanosoma brucei gambiense*, endemic respectively to East and West Africa. Tsetse fly infests one-third of Africa's landmass representing a problem of appalling magnitude. African trypanosomiasis or *sleeping sickness* is a chronic encephalitis, with diencephalic involvement resulting in disruption of the circadian sleep-wake cycle manifested by excessive daytime sleepiness, sleep attacks similar to those of narcolepsy, and nocturnal insomnia. There are also psychiatric manifestations, seizures, coma, and finally death. The CSF shows lymphocytic pleocytosis and moderate increase in protein concentration and intrathecal production of immunoglobulin M. African trypanosomes can be identified by fine needle aspirate of enlarged cervical lymph nodes as well as in blood and CSF. Oral fexinidazole and the parenteral combination of nifurtimox and eflornithine appear to be promising treatments.

American Trypanosomiasis

Human infection with *Trypanosoma cruzi* (Chagas disease) affects an estimated 10 million people in Latin America causing about 50,000 annual deaths. Presence of infected asymptomatic blood donors in the United States led blood banks to perform routine trypanosome screening with radioimmunoprecipitation.

Acute infection following the bite of triatomine bugs (see Fig. 68.1A) causes subcutaneous swelling typically located in the orbital region (Romaña sign) (see Fig. 68.1B), cervical lymph node enlargement, and acute myocarditis or encephalitis. A striking feature of Chagas disease is the selective neuronal destruction with denervation of the myenteric plexus of the intestine causing megaesophagus and megacolon and denervation of the conduction system of the heart leading to a chronic dilated cardiomyopathy. The dilated heart becomes an important cause of embolic stroke. At autopsy, one-third of patients with chronic Chagas disease have left ventricular thrombi.

T cruzi can be demonstrated in blood or CSF or by serologic testing. Treatment of acute disease or reactivations includes nifurtimox, benznidazole, or itraconazole. There is no effective therapy for chronic Chagas disease. Secondary prevention of stroke with long-term anticoagulation is recommended.

AMEBIC MENINGOENCEPHALITIS

Primary amebic meningoencephalitis is due to infection with the free-living ameba *Naegleria fowleri*. Infection is acquired by swimming in warm bodies of natural or man-made fresh water. The organisms penetrate the cribriform plate and reach the brain causing acute meningoencephalitis and brain abscess.

FIGURE 68.1 A: Triatomine vectors of Chagas disease. *Triatoma dimidiata capitata* **(left)** and *Rhodnius prolixus* **(right). B:** Romaña's sign in a child with acute infection by *Trypanosoma cruzi* following triatomine bite causing subcutaneous swelling in the orbital region with cervical lymph node enlargement. (From Toro G, Román G, Navarro de Román LI, eds. *Neurología Tropical: Aspectos Neuropatológicos de la Medicina Tropical*. Bogotá, Colombia: Editorial Printer Colombiana, Ltda; 1983.)

The clinical presentation is typical of purulent meningitis. The organisms are seldom isolated. Treatment with intravenous and intrathecal amphotericin B, intravenous and intrathecal miconazole, and oral rifampin should be started based on clinical suspicion in patients with meningitis and history of swimming in warm fresh waters.

A chronic granulomatous form of amebic meningoencephalitis often accompanied by cutaneous infection and keratitis is caused by infection with the opportunistic free-living amoebae *Balamuthia mandrillaris* and by several species of *Acanthamoeba* affecting immunosuppressed patients, transplant recipients, or malnourished individuals. Treatment is often unsuccessful.

NEUROCYSTICERCOSIS

Introduction

Neurocysticercosis is the human infection with larval forms (cysticerci) of the pig tapeworm *Taenia solium*. This is the most common cause of epilepsy in the world. Most cases observed in the United States occur in migrants from endemic countries, mainly Mexico and Central and South America. Autochthonous cases also occur from contact with asymptomatic carriers of *T solium*.

Epidemiology

Neurocysticercosis is the most common neurologic infection caused by helminthes (cestodes) in humans (Fig. 68.2). Contrary to common belief, consumption of poorly cooked pork infected with *T solium* cysticerci does not cause neurocysticercosis but results in intestinal tapeworm infection or human taeniasis. Neurocysticercosis occurs from human-to-human transmission of fertilized *T solium* eggs from a human carrier of intestinal *Taenia*. Humans become intermediate hosts in the life cycle of *T solium* by ingesting *Taenia* eggs due to fecal contamination of water or food. Failure of intestinal *Taenia* carriers to wash their hands after defecation is the most common source of infection.

Pathobiology

Ingested eggs hatch in the intestine, enter the bloodstream, and are carried into the host tissues including heart, muscles, and the brain and spinal cord where cysticerci develop into cystic forms called *Cysticercus racemosus* (Latin *racemus*, bunch of grapes). Neurocysticercosis can be prevented with handwashing, clean water, environmental sanitation, and proper pig farming.

Cysticerci are found in the brain parenchyma, the subarachnoid spaces, the ventricular system, the eye, the spinal cord, and intrathecal nerve roots as well as in the heart, the muscles, and subcutaneous tissues. Although many cysticerci fail to elicit a foreign body reaction, inflammation around each cysticercus eventually develops, accompanied by edema, reactive gliosis, and formation of dense exudates in the subarachnoid space composed of collagen, lymphocytes, multinucleated giant cells, eosinophils, and hyalinized parasitic membranes found in parenchymal lesions, but also causing eosinophilic meningitis, ventriculitis, and radiculitis. Stroke may result from involvement of the blood vessels by the inflammation. Even calcified lesions may develop perilesional edema associated with seizure activity.

Diagnosis

Neurocysticercosis is the most common cause of epilepsy in tropical areas of Latin America, Africa, and Asia. It results in 50,000 deaths per year and is a frequent cause of chronic neurologic disorders due to irreversible brain or spinal cord damage. Neurocysticercosis is becoming increasingly prevalent in industrialized countries because of travel and migration. In the United States, 1,494 patients with neurocysticercosis were reported between 1980 and 2004, making it the most common imported disease of the nervous system. According to the Centers for Disease Control and Prevention, each year, an estimated 1,000 new patients are hospitalized in the United States with neurocysticercosis.

Clinical Features

Cysticercosis is a pleomorphic disease capable of producing epilepsy, stroke with focal neurologic deficits, intracranial hypertension, and reversible dementia. Diagnostic criteria have been clearly established. Reported cases in the United States presented with seizures (66%), hydrocephalus (16%), and headaches (15%) due to parenchymal neurocysticercosis brain lesions (91%); the remainder had ventricular cysts (6%), subarachnoid cysts (2%), and spinal cord lesions (0.2%). Calcified neurocysticercosis has been associated with increased risk of cognitive decline.

Diagnostic Methods

The diagnosis of neurocysticercosis is based on clinical findings, a history of travel to endemic regions or potential exposure to *Taenia* carriers, and immunologic tests. The possibility that a patient harbors an intestinal *Taenia* should be explored with repeated examinations of stools for ova and parasites. On neuroimaging, parenchymal neurocysticercosis shows single or multiple cysts in the parenchyma, with the typical "hole-in-donut" appearance with presence of the radiodense scolex of the parasite. In subarachnoid neurocysticercosis, there is abnormal enhancement of the leptomeninges, hydrocephalus, and cystic lesions located at the Sylvian fissure or basal cisterns. Multiple calcified lesions ("starry sky") on computed tomography indicate spontaneous resolution. The CSF usually shows lymphocytic pleocytosis, presence of eosinophils, increased protein (up to 2,000 mg/dL), and normal glucose. Serum immunoblot and CSF enzyme-linked immunosorbent assay are useful confirmatory tests.

Management

The recommended treatment for patients with one to two viable subarachnoid or parenchymal cysts is albendazole for 8 to 15 days; for patients with more than two viable parenchymal cysts, albendazole (15 mg/kg/d) combined with praziquantel (50 mg/kg/d) is recommended usually in combination with dexamethasone to avoid the risk of stroke or brain edema LEVEL 2.[1] Dexamethasone administration should begin prior to the start of albendazole therapy and should be prolonged for several days. Isolated intraventricular cysts in the fourth ventricle are best treated with endoscopic surgery. Shunt placement must be considered before the start of albendazole in patients with hydrocephalus.

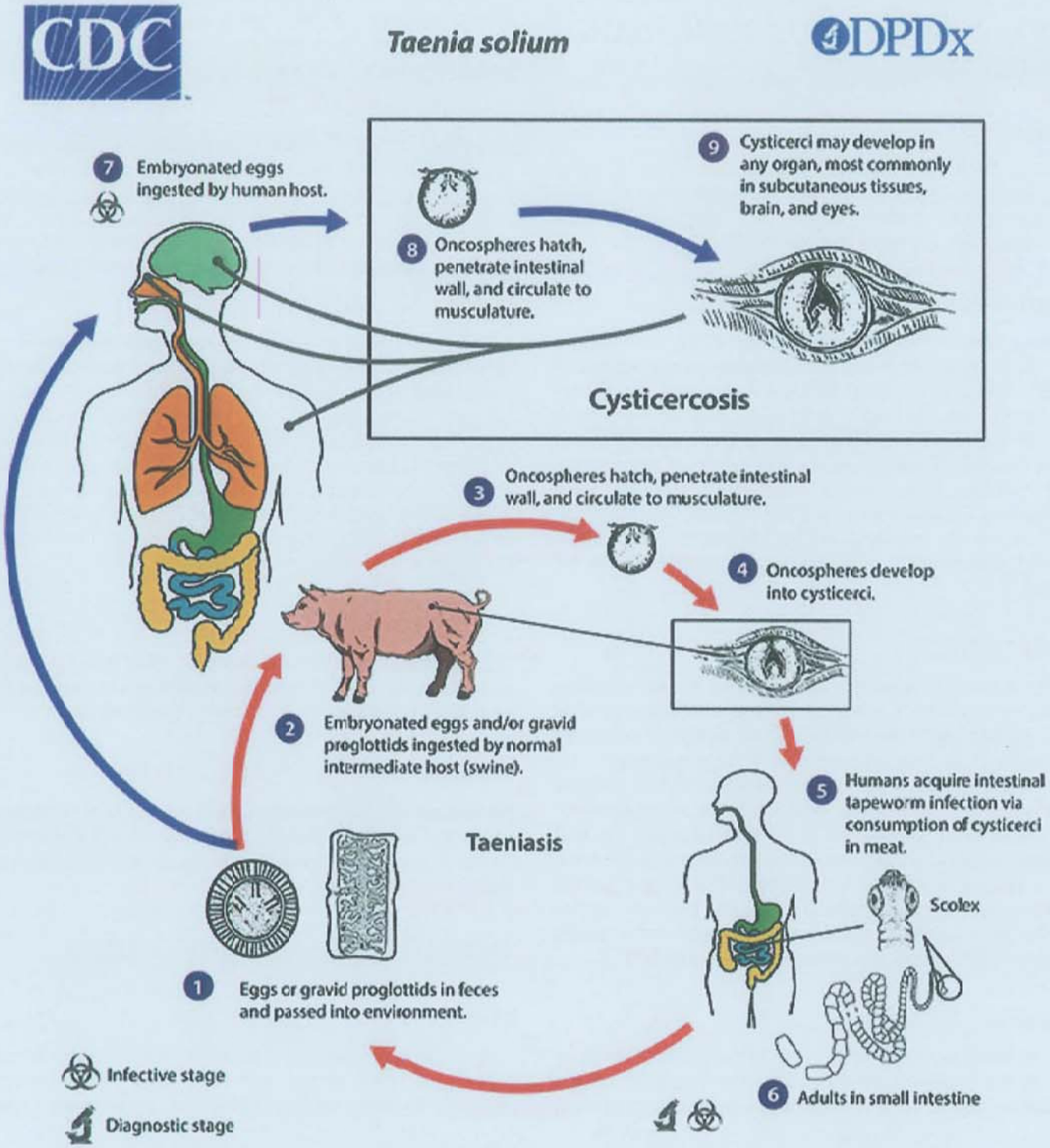

FIGURE 68.2 *Taenia solium* life cycle. Cysticercosis is an infection of both humans and pigs with the larval stages of the parasitic cestode, *Taenia solium*. This infection is caused by ingestion of eggs shed in the feces of a human tapeworm carrier ❶. These eggs are immediately infectious and do not require a developmental period outside the host. Pigs and humans become infected by ingesting eggs or gravid proglottids ❷, ❼. Humans are usually exposed to eggs by ingestion of food/water contaminated with feces containing these eggs or proglottids or by person-to-person spread. Tapeworm carriers can also infect themselves through fecal-oral transmission (e.g. caused by poor hand hygiene). Once eggs or proglottids are ingested, oncospheres hatch in the intestine ❸, ❽ invade the intestinal wall, enter the bloodstream, and migrate to multiple tissues and organs where they mature into cysticerci over 60–70 days ❹, ❾. Some cysticerci will migrate to the central nervous system, causing serious sequellae (neurocysticercosis). This differs from taeniasis, which is an intestinal infection with the adult tapeworm. Humans acquire intestinal infections with *T. solium* after eating undercooked pork containing cysticerci ❺. Cysts evaginate and attach to the small intestine by their scolices. Adult tapeworms develop to maturity and may reside in the small intestine for years ❻. (Reprinted from https://www.cdc.gov/parasites/cysticercosis/biology.html.)

LARVA MIGRANS AND EOSINOPHILIC MENINGITIS

Introduction

Infection of the nervous system by nematodes or roundworms occurs when humans become hosts to the parasite and the moving worms migrate producing the clinical syndrome called *larva migrans* usually accompanied by eosinophilic meningitis.

Epidemiology

The most common form of larva migrans of the nervous system in North America is caused by highly motile *Ascaris* of the North American raccoon *Baylisascaris procyonis*, usually acquired by children playing in sand boxes contaminated with raccoon stools. In other parts of the world, the severity of the infection depends mainly on the size and vitality of the parasite, ranging from the severe meningoencephalitis or myelitis caused by the tracts of the spike-covered worm *Gnathostoma spinigerum* in Thailand to the relatively benign eosinophilic meningitis caused in Southeast Asia by *Angiostrongylus cantonensis*, the rat lungworm.

Pathobiology

A history of travel is usually elicited because humans become hosts to the parasite by ingestion of contaminated Japanese-style raw fish, such as sushi and sashimi, and consumption of natural and exotic foods, such as raw mollusks, shrimp, freshwater crustaceans, snails, snakes, frogs, or insufficiently cooked chicken or duck contaminated with the infective larvae of the parasite. Once ingested, the highly motile larvae cross the intestinal wall and migrate to subcutaneous tissues causing cutaneous larva migrans, continuing to visceral larva migrans with involvement of internal organs, skeletal muscles, the eye, and the nervous system. Table 68.2 summarizes the main geographic forms of the larva migrans syndromes and eosinophilic meningitis.

Diagnosis

These conditions usually present with eosinophilic pleocytosis in the CSF demonstrated with the use of the Giemsa or Wright stain showing greater than 10 eosinophils per mL or more than 10% of the total CSF leukocyte count. Eosinophils are effectors of the adaptive immune response (helper T cell type 2) directed against destruction of metazoan multicellular parasites.

Clinical Features

Neurologic forms of presentation include the relatively benign eosinophilic meningitis of angiostrongyliasis to the more severe cases with encephalitis, transverse myelitis, seizures, meningitis, subarachnoid hemorrhage, and focal neurologic deficits associated with parenchymal brain hemorrhages that occur with larger parasites causing gnathostomiasis and baylisascariasis.

Diagnostic Methods

A CSF examination may range from the normal appearance and mild eosinophilic meningitis of angiostrongyliasis to the usually bloody and xanthochromic CSF of gnathostomiasis and baylisascariasis, typically showing severe eosinophilic pleocytosis (up to 3,000 cells/mm^3), mild increase in protein concentration, and normal glucose concentration. Blood eosinophilia is usually present. Neuroimaging shows the tracts of the parasites as long or multiple parenchymal brain hemorrhages or evidence of multiple foci of myelitis. Diagnosis is confirmed by identification of the larvae in CSF or tissue samples.

Management

The recommended treatment of eosinophilic meningomyelitis is a combination of anthelmintics and intravenous corticosteroids, such as albendazole with intravenous dexamethasone.

Outcome

Baylisascariasis and gnathostomiasis may be fatal when undiagnosed and untreated. Deficits may result from spinal cord injuries or brain hemorrhages. Angiostrongyliasis usually causes a benign eosinophilic meningitis.

SCHISTOSOMIASIS (BILHARZIA)

Introduction

Human schistosomiasis is a parasitic disease caused by trematode flukes of the genus *Schistosoma*. Some *Schistosoma* species cause chronic liver damage with portal hypertension, whereas

TABLE 68.2 Nematode (Round Worm) Infections of the Nervous System Causing Larva Migrans Syndrome and Eosinophilic Meningitis

Name	Agent	Geographic Location	Clinical Presentation
Angiostrongyliasis Eosinophilic meningitis	*Angiostrongylus cantonensis* *Angiostrongylus costaricensis*	China, Southeast Asia, Taiwan, Thailand, Vietnam, Australia, South Pacific islands Costa Rica, Central America	Eosinophilic aseptic meningitis
Gnathostomiasis	*Gnathostoma spinigerum*	Southeast Asia	Meningoencephalitis, myelitis, eosinophilic meningitis, cutaneous and visceral larva migrans
Baylisascariasis	*Baylisascaris procyonis*	North America	Meningoencephalitis, myelitis, eosinophilic meningitis, eye involvement, cutaneous larva migrans
Toxocariasis Larva migrans	*Toxocara canis, Toxocara cati* *Ascaris* species	Worldwide	Eosinophilic meningitis, eye involvement, myelitis, encephalitis, cutaneous larva migrans

TABLE 68.3 Clinical Syndromes and Geographic Distribution of Schistosomiasis

Clinical Syndromes	Agent	Geographic Location
Parasitic myelitis (conus medullaris)	*Schistosoma mansoni*	Africa, Middle East, Caribbean, Brazil, Venezuela, Suriname
Intestinal schistosomiasis	*Schistosoma japonicum*	China, Indonesia, Philippines
Liver fibrosis with portal hypertension		
Meningoencephalitis	*Schistosoma haematobium*	Africa, Middle East
Urogenital schistosomiasis	*Schistosoma intercalatum*	West Africa
Squamous cell carcinoma of the bladder	*Schistosoma guineensis*	East Africa
	Schistosoma mekongi	Mekong river basin

others produce bladder and urogenital lesions in chronic carriers. Involvement of the spinal cord and meningoencephalitis are the main neurologic complications.

Epidemiology

Some 230 million people worldwide are infected with *Schistosoma* species. The geographic distribution of different agents of schistosomiasis is summarized in Table 68.3. Parasitic adult worms remain in the venous circulation for years, evading the immune system and excreting over 100,000 fertile eggs daily. Immune responses of the host to the parasites' eggs explain the pathology of schistosomiasis.

Pathobiology

Neurologic involvement occurs during the early postinfective stage when *Schistosoma japonicum* eggs reach the brain causing meningoencephalitis; infection with *Schistosoma mansoni* and *Schistosoma haematobium* produce preferential involvement of the spinal cord (myelitis and myeloradiculitis), particularly of the conus medullaris, cauda equina, or the spinal cord. *Schistosoma* ectopic eggs reach the central nervous system through retrograde venous flow into the Batson venous plexus.

Diagnosis

Clinical Manifestations

The parasitic myelopathy of schistosomiasis can be manifested as an acute painful flaccid paraplegia with areflexia, sphincter dysfunction, urinary incontinence, impotence, and sensory disturbances; acute transverse myelitis, spastic paraplegia, painful lumbosacral radiculopathy with backache, and cauda equina syndrome also occur.

Diagnostic Methods

The diagnosis must be suspected on the basis of a clinical presentation of acute painful lumbosacral myelopathy or conus medullaris syndrome with imaging findings suggestive of bilharziasis in a patient with history of travel or exposure to *Schistosoma* cercariae after swimming in fresh water. The diagnosis is confirmed by demonstration of *Schistosoma* antibodies in serum and/or CSF and presence of *Schistosoma* eggs in biopsy of rectal mucosa or in stools and urine.

Management and Outcome

The myelitis of schistosomiasis usually responds to treatment with the schistosomicidal drug praziquantel in combination with steroids; other schistosomicidal drugs are oxamniquine and metrifonate. Surgery with decompressive laminectomy and debridement is usually reserved for cases of acute myelitis that deteriorate despite intensive schistosomicidal treatment.

Preventive measures in countries affected by schistosomiasis include the use of chemotherapy, snail control measures, and behavioral modification.

LEVEL 1 EVIDENCE

1. White AC Jr, Coyle CM, Rajshekhar V, et al. Diagnosis and treatment of neurocysticercosis: 2017 clinical practice guidelines by the Infectious Diseases Society of America (IDSA) and the American Society of Tropical Medicine and Hygiene (ASTMH). *Clin Infect Dis*. 2018;66(8):e49-e75.

SUGGESTED READINGS

Akpek G, Uslu A, Huebner T, et al. Granulomatous amebic encephalitis: an under-recognized cause of infectious mortality after hematopoietic stem cell transplantation. *Transpl Infect Dis*. 2011;13:366-373.

Babokhov P, Sanyaolu AO, Oyibo WA, Fagbenro-Beyioku AF, Iriemenam N. A current analysis of chemotherapy strategies for the treatment of human African trypanosomiasis. *Pathog Glob Health*. 2013;107:242-252.

Bauer C. Baylisascariosis—infections of animals and humans with 'unusual' roundworms. *Vet Parasitol*. 2013;193:404-412.

Brunel F. Human cerebral malaria: 2019 mini review. *Rev Neurol (Paris)*. 2019;175:445-450.

Carabin H, Ndimubanzi PC, Budke CM, et al. Clinical manifestations associated with neurocysticercosis: a systematic review. *PLoS Negl Trop Dis*. 2011;5(5):e1152.

Carod-Artal FJ. American trypanosomiasis. *Handb Clin Neurol*. 2013;114:103-123.

Carod-Artal FJ, Gascon J. Chagas disease and stroke. *Lancet Neurol*. 2010;9:533-542.

Carvalho LJ, Moreira A, Daniel-Ribeiro CT, Martins YC. Vascular dysfunction as a target for adjuvant therapy in cerebral malaria. *Mem Inst Oswaldo Cruz*. 2014;109(5):577-588.

Centers for Disease Control and Prevention. *CDC Yellow Book 2020: Health Information for International Travel*. New York, NY: Oxford University Press; 2019.

Clarke GM, Rockett K, Kivinen K, et al. Characterisation of the opposing effects of G6PD deficiency on cerebral malaria and severe malarial anaemia. *Elife*. 2017;6:e15085.

Colley DG, Bustinduy AL, Secor WE, King CH. Human schistosomiasis. *Lancet*. 2014;383:2253-2264.

Conrad MD, Rosenthal PJ. Antimalarial drug resistance in Africa: the calm before the storm? *Lancet Infect Dis*. 2019;19(10):e338-e351.

Cook GC, ed. *Manson's Tropical Diseases*. 20th ed. London, United Kingdom: WB Saunders; 1996.

Deeks ED. Fexinidazole: first global approval. *Drugs*. 2019;79:215-220.

Deeks ED, Lyseng-Williamson KA. Fexinidazole in human African trypanosomiasis: a profile of its use. *Drugs & Therapy Perspectives*. 2019;35:529-535.

Del Brutto OH, Garcia HH. Neurocysticercosis. *Handb Clin Neurol*. 2013;114:313-325.

Del Brutto OH, Mera RM, Zambrano M, Costa AF, Román GC. The association between calcified neurocysticercosis and cognitive performance: a case-control study nested to a population-based cohort. *Am J Trop Med Hyg*. 2019;100(2):323-326.

Del Brutto OH, Rajshekhar V, White AC Jr, et al. Proposed diagnostic criteria for neurocysticercosis. *Neurology*. 2001;57:177-183.

Garcia HH, Tanowitz HB, Del Brutto OH, eds. *Neuroparasitology and Tropical Neurology*. Amsterdam, Netherlands: Elsevier B.V.; 2013. *Handbook of Clinical Neurology*; vol 114 (3rd series).

Graeff-Teixeira C, da Silva AC, Yoshimura K. Update on eosinophilic meningoencephalitis and its clinical relevance. *Clin Microbiol Rev*. 2009;22:322-348.

Hamilton WL, Amato R, van der Pluijm RW, et al. Evolution and expansion of multidrug-resistant malaria in Southeast Asia: a genomic epidemiology study. *Lancet Infect Dis*. 2019;19(9):943-951.

Hannisch W, Hallagan LF. Primary amebic meningoencephalitis: a review of the clinical literature. *Wilderness Environ Med*. 1997;8:211-213.

Harvey K, Esposito DH, Han P, et al; and Centers for Disease Control and Prevention. Surveillance for travel-related disease—GeoSentinel Surveillance System, United States, 1997-2011. *MMWR Surveill Summ*. 2013;62:1-23.

Higgins SJ, Kain KC, Liles WC. Immunopathogenesis of falciparum malaria: implications for adjunctive therapy in the management of severe and cerebral malaria. *Expert Rev Anti Infect Ther*. 2011;9:803-819.

Kennedy PG. The continuing problem of human African trypanosomiasis (sleeping sickness). *Ann Neurol*. 2008;64:116-127.

Lejon V, Bentivoglio M, Franco JR. Human African trypanosomiasis. *Handb Clin Neurol*. 2013;114:169-181.

Lorenz V, Karanis G, Karanis P. Malaria vaccine development and how external forces shape it: an overview. *Int J Environ Res Public Health*. 2014;11:6791-6807.

Lv S, Zhang Y, Steinmann P, Zhou XN, Utzinger J. Helminth infections of the central nervous system occurring in Southeast Asia and the Far East. *Adv Parasitol*. 2010;72:351-408.

Marks M, Gupta-Wright A, Doherty JF, Singer M, Walker D. Managing malaria in the intensive care unit. *Br J Anaesth*. 2014;113(6):910-921.

Marquez JM, Arauz A. Cerebrovascular complications of neurocysticercosis. *Neurologist*. 2012;18:17-22.

Molehin AJ. Schistosomiasis vaccine development: update on human clinical trials. *J Biomed Sci*. 2020;27:28.

Nash TE, Pretell EJ, Lescano AG, et al. Perilesional brain oedema and seizure activity in patients with calcified neurocysticercosis: a prospective cohort and nested case-control study. *Lancet Neurol*. 2008;7:1099-1105.

Noubiap JJN. Shifting from quinine to artesunate as first-line treatment of severe malaria in children and adults: saving more lives. *J Infect Public Health*. 2014;7(5):407-412.

Pelfrene E, Allchurch MH, Ntamabyaliro N, et al. The European Medicines Agency's scientific opinion on oral fexinidazole for human African trypanosomiasis. *PLoS Negl Trop Dis*. 2019;13(6):e007381.

Pitulla JE. Pathology of CNS parasitic infections. *Handb Clin Neurol*. 2013;114:65-88.

Plewes K, Turner GDH, Dondorp AM. Pathophysiology, clinical presentation, and treatment of coma and acute kidney injury complicating falciparum malaria. *Curr Opin Infect Dis*. 2018;31(1):69-77.

Postels DG, Birbeck GL. Cerebral malaria. *Handb Clin Neurol*. 2013;114:91-102.

Reiterer E, Reider S, Lackner P, et al. A long-term follow-up study on otoacoustic emissions testing in paediatric patients with severe malaria in Gabon. *Malar J*. 2019;18:212.

Roggelin L, Cramer JP. Malaria prevention in the pregnant traveller: a review. *Travel Med Infect Dis*. 2014;12:229-236.

Román GC. The neurology of parasitic diseases and malaria. *Continuum (Minneap Minn)*. 2011;17(1 Neurologic Complications of Systemic Disease):113-133.

Román GC. Tropical myelopathies. *Handb Clin Neurol*. 2014;121:1521-1548.

Sahu PV, Satpathi S, Behera PK, Mishra SJ, Mohanty S, Wassmer SC. Pathogenesis of cerebral malaria: new diagnostic tools, biomarkers, and therapeutic approaches. *Front Cell Infect Microbiol*. 2015;5:75.

Sarkar PK, Ahluwalia G, Vijayan VK, Talwar A. Critical care aspects of malaria. *J Intensive Care Med*. 2010;25:93-103.

Schiøler KL, Alifrangis M, Kitron U, Konradsen F. Insecticidal paints: a realistic approach to vector control? *PLoS Negl Trop Dis*. 2016;10(4):e0004518.

Schmutzhard E. Eosinophilic myelitis, a souvenir from South East Asia. *Pract Neurol*. 2007;7:48-51.

Shikani HJ, Freeman BD, Lisanti MP, Weiss LM, Tanowitz HB, Desruiseaux MS. Cerebral malaria: we have come a long way. *Am J Pathol*. 2012;181:1484-1492.

Varo R, Crowley VM, Sitoe A, et al. Adjunctive therapy for severe malaria: a review and critical appraisal. *Malar J*. 2018;17(1):47.

Visvesvara GS. Infections with free-living amebae. *Handb Clin Neurol*. 2013;114:153-168.

World Health Organization, Centers for Disease Control and Prevention. Severe falciparum malaria. *Trans R Soc Trop Med Hyg*. 2000;94(suppl 1):S1-S90.

World Health Organization. *World Malaria Report 2019*. Geneva, Switzerland: World Health Organization; 2019.

Viral Infections 69

Shibani S. Mukerji, Maria Martinez-Lage, and Kiran T. Thakur

KEY POINTS

1. Neurotropic viruses enter the central nervous system (CNS) using multiple mechanisms including neural and hematogenous pathways.
2. Introduction and propagation of vector-borne neurotropic viruses into immunologically naive populations can give rise to explosive infectious disease outbreaks.
3. Viral nucleic acid amplification and detection of virus-specific immunoglobulin M in cerebrospinal fluid and blood are common modes of diagnostic testing in CNS infections.
4. Mononuclear lymphocytic infiltrates in the subarachnoid space and perivascular spaces characterize meningitides.
5. Viral encephalitis commonly demonstrates multifocal perivascular and parenchymal lymphocytic infiltrates, which are typically T-cell predominant.
6. Therapeutic antiviral agents are few, and treatment in many CNS viral infections remains supportive.
7. Prevention is the best approach to combating viral diseases and requires vaccination programs, mosquito repellents, protective gear, animal surveillance programs, and education.

INTRODUCTION

Viral infections of the central nervous system (CNS) are a diverse group of diseases that have plagued mankind for centuries. Infections can occur in the spinal cord (myelitis), brain parenchyma (encephalitis), meninges (meningitis), brainstem (rhombencephalitis), or any of these in combination. Viral infections can cause damage directly in the CNS or via immune-mediated mechanisms. This chapter highlights the common causes of CNS viral infections (aside from human immunodeficiency virus [HIV], which is discussed in a separate chapter) and discusses the clinical manifestations and the methods of detection and management.

Viruses invade humans by a variety of mechanisms. This can include skin penetration, infection of mucosal membranes, or by direct inoculation into the bloodstream. After primary inoculation, neurotropic viruses gain entry into the CNS by one of a number of mechanisms. Experiments with several viral strains show that replication occurring in tissue, such as skeletal muscle or skin, allows access to peripheral nerve endings. Some neurotropic viruses are able to infect nerves and then spread by retrograde and anterograde transport to the sensory ganglia. Characteristic of this are the herpes viruses, which replicate in the skin and infect adjacent sensory nerve endings. The virus is then able to tether its capsid onto the host's transport complex, travel toward the dorsal root ganglia, and establish latency.

In contrast, infection within the bloodstream is dependent on the site of inoculation and ability to infect endothelial cells or cell populations within plasma (eg, HIV infection). Once in the blood, a virus must cross the blood-brain barrier (BBB) to spread into brain parenchyma. In cases like HIV, when infected inflammatory cells, such as lymphocytes or macrophage mononuclear cells cross the BBB, the virus gains entry in a process termed the *Trojan horse*. In other cases, high viremic loads lead to passive transport into the brain or spinal cord. Individual viruses can use multiple mechanisms of viral CNS entry, and in fact, many viruses are able to spread to the CNS using both neural and hematogenous pathways as will be discussed with poliovirus and varicella-zoster virus (VZV).

The widespread availability of viral nucleic acid amplification has revolutionized diagnostics in CNS viral infections and reduced the need to perform open brain biopsies. The polymerase chain reaction (PCR) technique is ideally suited for organisms that are difficult to culture and can retain its sensitivity even after small doses of antiviral therapies. However, this technique relies on a viral load high enough for detection by PCR, a factor not always present in cerebrospinal fluid (CSF), leading to false negatives. False negatives also occur when heme breakdown from a bloody lumbar puncture interferes with nucleic acid detection. False-positive CSF PCR results occur with viruses that associate themselves with peripheral blood cells and enter the CNS during an inflammatory process but are themselves not the source of the CNS disorder. This phenomenon occurs with Epstein-Barr virus (EBV), as peripheral blood mononuclear cells are latently infected. The EBV's relevance as a pathologic agent in the CSF can be unclear and is discussed further in this chapter.

Additional diagnostic methods for CNS viral infections include detection of virus-specific immunoglobulin (Ig) M that relies on the host's ability to mount an immunologic response to the infecting agent. The detection of virus-specific antibodies requires a competent immune system and sufficient time to develop antibodies. Interpretation of antibody levels can be confusing, as some serum antibodies last for months or even years after infection that is often asymptomatic, as seen in West Nile virus (WNV) where IgM-specific antibodies can persist for months and is not reflective of acute infection. Occasionally, antibody cross-reactivity can also lead to false-positive detection. In contrast to serum antibodies, the presence of virus-specific IgM antibodies in CSF is indicative of intrathecal synthesis and diagnostic of neuroinvasive disease.

Serum virus-specific IgG can be helpful when a corresponding rise in titer between acute and convalescent phases occurs. One limitation here is in the setting of postinfectious complications, where antibody detection in the acute phase was not pursued.

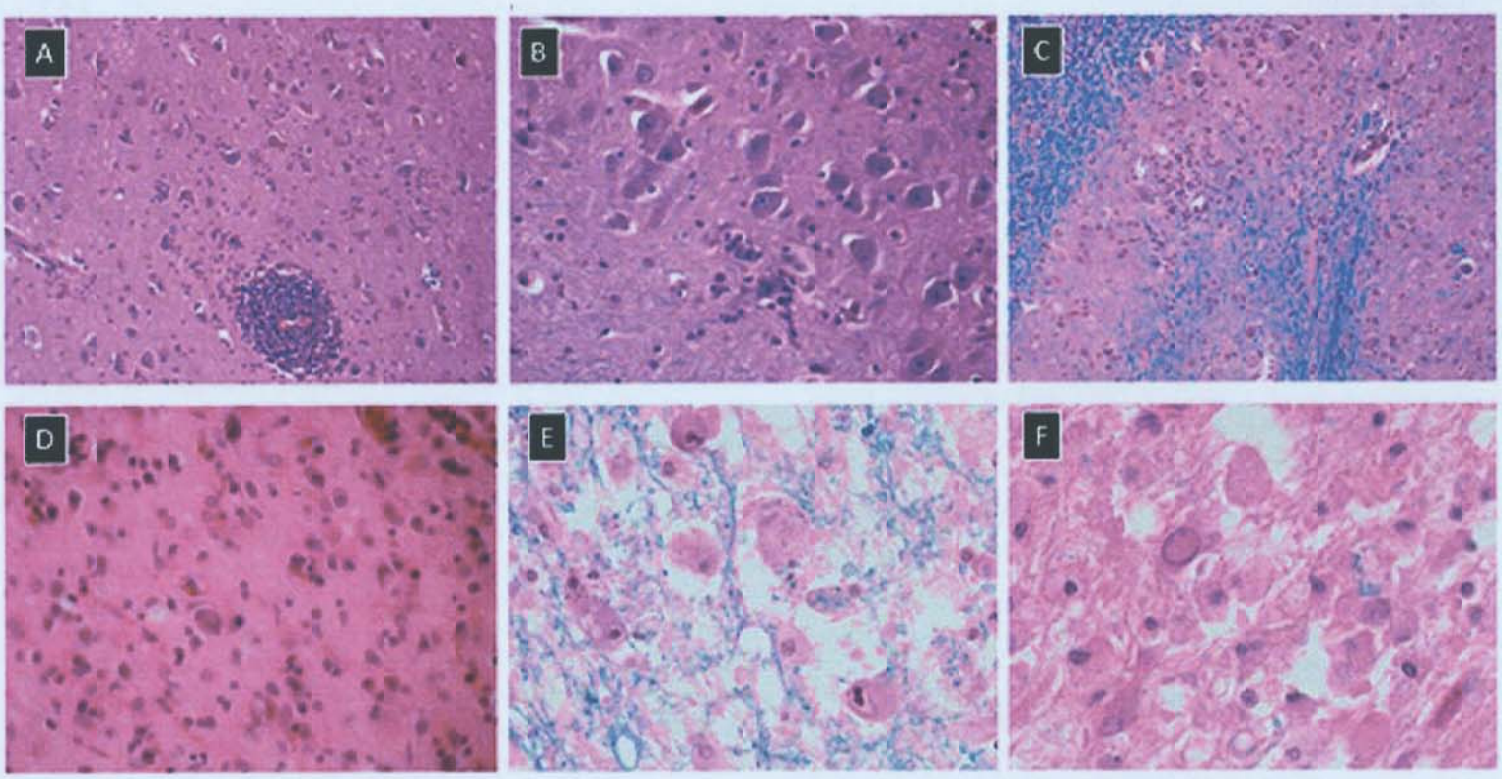

FIGURE 69.1 Common neuropathologic features of viral encephalitis. **A:** Luxol-hematoxylin and eosin-stained section of the basal ganglia shows dense perivascular and scattered parenchymal small round cells representing lymphocytic inflammatory infiltrates, characteristic of many viral infections. **B:** Luxol-hematoxylin and eosin-stained section of the pyramidal layer of the hippocampus shows neuronophagia, consisting of microglial cells and macrophages engulfing dying neurons. **C:** Luxol-hematoxylin and eosin-stained section of the dentate nucleus of the cerebellum shows two microglial nodules characterized by focal collections of small mononuclear microglial cells. Intranuclear inclusions of diverse morphology can be seen in a variety of viral central nervous system infections. **D:** Hematoxylin and eosin-stained section of the cerebral cortex in a patient with measles related subacute sclerosing panencephalitis shows the characteristic round eosinophilic inclusion with surrounding clearing halo in one cell. **E:** Luxol-hematoxylin and eosin-stained section of the cerebrum in a neonate with congenital cytomegalovirus encephalitis demonstrates typical intranuclear cytomegaloviral inclusions in multiple cells. **F:** Luxol-hematoxylin and eosin-stained section of the cerebral white matter from a patient with progressive multifocal leukoencephalitis demonstrates the glassy appearance of a viral intranuclear inclusion with a rim of dark chromatin in an enlarged glial cell containing John Cunningham virus particles.

Isolated IgG detection, especially in infections that are common and usually asymptomatic, is of limited use. Advanced diagnostic platforms including multiplex PCR and next-generation sequencing are laboratory techniques, which are being increasingly deployed to aid in diagnosis of viral CNS infections.

Although tissue assessment is uncommon in CNS viral infections, autopsy studies demonstrate certain patterns of involvement that can suggest an underlying viral encephalitis in an otherwise uncertain neurologic syndrome (Fig. 69.1). Mononuclear lymphocytic infiltrates in the subarachnoid space and perivascular (Virchow-Robin) spaces characterize all meningitides. Viral encephalitis commonly demonstrates multifocal perivascular and parenchymal lymphocytic infiltrates, usually T-cell predominant. Activated microglia with a focal distribution in the form of microglial nodules, and neuronophagia characterized by microglia and macrophages engulfing dying neurons are histologic features frequently associated with viral encephalitis. In certain specific viral infections, such as cytomegalovirus (CMV) or John Cunningham virus (JCV), characteristic abnormalities can be seen in infected cells called *viral cytopathic change*, namely, intranuclear inclusions or nuclear clearing, and rarely cytoplasmic inclusions. Multiple domains are frequently affected pathologically, such as cerebral gray or white matter, brainstem, spinal cord, spinal roots, and leptomeninges in diverse combinations. Although the pattern of viral encephalitis described is most common in many viral CNS infections, there are other potential histologic characteristics, such as necrotizing encephalitis in herpes simplex virus (HSV) infection, for example.

Antiviral agents are few in number, and treatment in many cases of CNS viral infections remains supportive. The HSV, VZV, CMV, HIV, and influenza have targeted therapies with varying efficacy. The lack of options in many cases leads physicians to focus on managing the complications of these diseases, often including use of anti-inflammatory agents, such as corticosteroids, to suppress immune-mediated injury. As seen in almost every aspect of medicine, prevention is the best approach to combating viral diseases and requires comprehensive vaccination programs, mosquito repellents, appropriate protective gear, animal surveillance programs, and education.

PICORNAVIRUS

Picornaviruses are some of the oldest and most diversified viruses to cause human disease. The picornavirus family has four primary groups resulting in human pathogenesis: enteroviruses

(eg, polioviruses, coxsackieviruses, and echoviruses), rhinoviruses, hepatoviruses (eg, hepatitis A), and parechoviruses. These viruses are nonenveloped, single-stranded RNA viruses. It is estimated that the majority of viral meningitis cases globally are caused by picornaviruses, specifically enteroviruses, as are most cases of acute flaccid paralysis.

Enteroviruses

Human enteroviruses, named for their transmission route via the intestine, contain a positive-sense, single-stranded RNA genome. Seventy-one human serotypes of enteroviruses exist and are classified into groups A, B, C, and D. Polioviruses are part of the human enterovirus C group, whereas the nonpolio enteroviruses include coxsackievirus A and B and various echoviruses and enteroviruses. Enteroviruses cause a wide range of symptomatology, with neurologic symptoms being the most serious.

Poliomyelitis

Poliomyelitis is a disease that plagued the world in the early 20th century, as widespread epidemics resulted in paralysis or death. The name *poliomyelitis* is derived from two Greek words, *polios* ("gray") and *myelon* ("marrow" or "spinal cord"). The control of polio following the development of both the inactivated polio vaccine (inactivated poliomyelitis vaccinations [IPVs]) and live-attenuated oral vaccines (oral poliomyelitis vaccinations [OPVs]) is a remarkable achievement in science, and since the launch of the Global Polio Eradication Initiative in 1988, the incidence of poliomyelitis has been reduced by over 95%, although global eradication has ongoing challenges. Poliomyelitis was declared a public health emergency of international concern in 2014 after there was international spread of poliovirus to a range of polio-free countries. War-torn regions are at particular risk, and at the beginning of 2019, Afghanistan and Pakistan were the only remaining two countries in which wild poliovirus transmission continues to be reported. Another challenge is the emergence of outbreaks of vaccine-derived poliovirus, rare strains that have genetically mutated from the poliovirus contained in the oral polio vaccine. The recently published Polio Endgame Strategy 2019-2023 by the World Health Organization (WHO) addresses three key risks associated with global wild poliovirus eradication including insecurity and conflict; weak or fragile health systems; and operational, management, and resource risks.

Pathobiology

Poliomyelitis virus main route of human infectivity is via the gastrointestinal tract, although during epidemics, humans can be infected via pharyngeal spread. Infectious spread is highly influenced by hygiene standards. All three serotypes of poliovirus are neurotropic, although poliovirus type 1 is the most frequently encountered in human infections around the world. Although the disease occurs in all age groups, it is rarely seen before 6 months of age. Previously, poliomyelitis was endemic and widespread immunity occurred in babies due to protection through maternal antibodies. However, given the lack of endemic poliomyelitis, immunity no longer exists and vaccination strategies are key to elimination.

Viruses multiply in the pharynx and intestine during an incubation period, which typically occurs over a few weeks, before there is bloodstream involvement. The virus replicates initially in the gastrointestinal tract's lymphatic system (Peyer patches), followed by viremia and immune activation. How the virus gains access to the nervous system remains uncertain. One hypothesis is the poliomyelitis virus, which is able to replicate in skeletal muscles, can spread into peripheral motor axons and access anterior horn cells of the spinal cord via retrograde transport. This hypothesis has been tested in mouse models with expression of transgenic poliomyelitis virus receptor. A second hypothesis is by direct spread from the blood due to a breakdown in the BBB. These mechanisms for CNS entry are not mutually exclusive. Viral replication in the CNS leads to motor neuron death associated with inflammatory infiltrates (initially polymorphonuclear cells and later lymphocytes) and neuronophagia, consisting of microglia and macrophages engulfing dying neurons. Retrograde transport leads to further neuronal injury.

Clinical Manifestations

Although CNS complications are the most feared and well-known result of polio infection, it is a not a common occurrence when evaluating poliomyelitis infections as a whole. Nearly 90% of infections are asymptomatic and recognized only by isolation of the virus from the oropharynx or in feces. Approximately 4% to 8% of those infected will have a minor, self-limited illness such as other enteroviral infections with headache, anorexia, abdominal pain, and a sore throat. These cases are typically identified during epidemics. In 1% to 2% of infected individuals, fever, headache, and meningismus occur. Frank paralysis occurs in only 0.1% of all poliovirus infections, and the clinical course can be divided into two phases. A prodromal phase of sore throat, fever, and upper respiratory infection symptoms is most common in young patients. Mild gastrointestinal symptoms and meningeal irritation are more common in adults. There is a short recovery period for 2 to 3 days before an abrupt onset of fever, chills, myalgias, headache, and symptoms consistent with meningitis. Paresthesias and muscle fasciculations can precede muscle weakness and paralysis. When paralysis occurs, it is typically asymmetric, and the lower extremities are more commonly involved than the upper extremities. When quadriplegia occurs, it is more frequently seen in adults than in infants. Paralysis of the diaphragm and intercostal muscles in spinal poliomyelitis occurs more often in young adults than in the extreme age groups. Bulbar paralysis is due to weakness of muscle groups innervated by cranial nerves, and in polio, the glossopharyngeal and vagus nerves are most commonly affected, followed by the oculomotor nerve. Older adults are more likely to have medullary involvement, and these patients are at high risk for aspiration and need for mechanical ventilation.

Diagnosis

The diagnosis of paralytic polio is clinically suspected with the development of asymmetric acute flaccid paralysis following a febrile illness. It is more likely to be suspected in those who are unvaccinated coming from endemic countries or those with immunodeficiencies. Other viruses to consider in the differential are other enteroviruses, especially enterovirus 71, and arboviral infections, such as WNV (discussed later in the chapter).

The CSF pleocytosis is evident as early as meningeal symptoms are present, with an initial polymorphonuclear profile that eventually shifts to a lymphocytic predominance. An increased protein concentration is most prominently seen if there is severe paralysis. These abnormalities are not distinguishable from other viral causes of aseptic meningitis, and thus, identification of the poliomyelitis virus is necessary to confirm the diagnosis. Isolation of poliomyelitis virus by CSF culture is challenging and is not typically performed. Polio is more easily isolated from

oral secretions and feces, and with rapid identification of polioviruses by genomic amplification using PCR, clinicians can distinguish poliomyelitis viral infections from other enteroviruses or other infectious causes.

Treatment

There are no antiviral drugs for treatment of poliomyelitis, and symptom management is the primary focus. Respiratory muscle paralysis or cases of bulbar poliomyelitis frequently require mechanical ventilation and aggressive management of secretions. Bowel function also requires special attention in spinal poliomyelitis. Long-term management of physical and psychiatric sequelae obliges a comprehensive team of both physical and occupational therapy along with orthopedic services and psychiatry.

The IPV and OPV have been used effectively for controlling paralytic poliomyelitis but differ in terms of asymptomatic viral shedding and risk of contracting vaccine-related disease. The IPV is an injectable preparation containing antigen units for all three polio serotypes. In the United States, the IPV is the only version administered and is typically given with other childhood vaccines at 2, 4, 6 to 18 months, and 4 to 6 years. Children develop little to no secretory antibody response to the IPV. If exposed to live polioviruses, these children are more likely to have asymptomatic infections but still shed virus in their feces, exposing nonimmunized contacts. Most OPV preparations also immunize against all three serotypes. The prevalence of poliomyelitis-specific antibody to all three serotypes following three doses of OPV is approximately 96%. Nonimmune OPV recipients will shed vaccine viruses in feces and the oropharynx that can be spread to nonimmunized children. This aspect can be advantageous in poorly vaccinated communities, as children can develop OPV-specific antibodies despite not having received the vaccine. A rare event is the development of vaccine-associated paralytic poliomyelitis, an occurrence in 1 per 2.6 million vaccine doses and is only associated with OPV. This is more commonly seen in immunodeficient patients. Vaccine-derived poliomyelitis refers to outbreaks of acute flaccid paralysis caused by circulating poliovirus strains derived from one of the three Sabin poliovirus strains in OPV. This occurs in regions where there are low immunization rates which allowed the vaccine-derived poliovirus to mutate and to acquire biologic properties similar to those of naturally occurring wild-type polioviruses. The WHO still recommends the use of the trivalent OPV in underdeveloped nations because of cost, ease of administration, and greater secretory immunity in the gastrointestinal tract.

Outcome

The prognosis of paralytic poliomyelitis depends on age (infants and children are more likely to recover) and severity of paralysis (ie, partial vs complete paralysis). Permanent weakness from polio paralytic infections occurs in approximately two-thirds of patients. Complete recovery is unlikely in cases with severe acute flaccid paralysis or in those requiring mechanical ventilation. Increased mortality is typically seen in those with polio encephalitis, bulbar involvement due to glossopharyngeal and/or vagus nerve impairment, and/or respiratory muscle paralysis.

Following the epidemics in the early 20th century, some individuals with partial or full recovery from paralytic polio experienced a new onset of neuromuscular weakness, pain, and fatigue. In such cases, muscle weakness and atrophy were identified in muscles that had been previously affected. Management is symptomatic and supportive and typically involves a multidisciplinary approach. These symptoms have been collectively called the *postpolio syndrome* and, in those with slowly progressive weakness, atrophy, and fasciculations, termed *postpolio progressive muscular atrophy* (discussed separately). The cause of progressive neurologic deterioration is unknown, but contributing factors include ongoing damage of reinnervated motor units, persistence of poliovirus in nerve tissue, and secondary autoimmune destruction of neural structures. Evidence suggests that reinnervated motor units are perhaps that excessive exercise or overuse may predispose to new weakness.

Enterovirus D68

Enterovirus D68 is unique among enteroviruses in that it behaves biologically more like human rhinoviruses because it optimally grows at 33°C and is both heat and acid labile. Given these features, enterovirus D68 is transmitted primarily via respiratory rather than fecal-oral route. Although enterovirus D68 was first isolated in 1962 from respiratory specimens in four children with lower respiratory tract infections, it has not been until recent history that it has been associated with neurologic manifestations. In August 2014, there was an outbreak of respiratory illness predominantly in children due to enterovirus D68 in western United States. Beginning in 2012, an increasing number of cases of acute flaccid paralysis associated with spinal cord motor neuron lesions were reported in the United States, and then in 2014, a cluster of children with acute flaccid paralysis presented in the midst of an enterovirus D68 respiratory outbreak. Since the initial descriptions, there have been biannual peaks in cases characterized by acute flaccid weakness, with associated gray matter spinal cord lesions, typically longitudinally extensive. In the summer and fall of 2018, cases peaked with 230 confirmed cases in 41 states. Most have occurred approximately 1 week after a prodromal illness. Like poliomyelitis, most patients report clinical improvement in their prodromal illness before the patient often develops meningeal signs, followed by extremity weakness, often with respiratory muscle involvement. There is significant morbidity associated with specific enteroviral strains, including enterovirus D68. The Centers for Disease Control and Prevention (CDC) detected coxsackievirus A16, enterovirus A71, and enterovirus D68 in the spinal fluid of 4 of 563 confirmed cases of acute flaccid myelitis since 2014. Additional patients with acute flaccid myelitis were diagnosed with enterovirus D68 infections using respiratory samples.

Enteroviruses 70 and 71

Acute hemorrhagic conjunctivitis was first recognized in 1970 and is the result of either enterovirus 70 or an antigenic variant of coxsackievirus A24. The disease is characterized by the rapid onset of painful conjunctivitis and subconjunctival hemorrhage. Complete recovery is typically seen within 1 to 2 weeks. Epidemics predominantly occur in tropical and subtropical regions in Southeast Asia and Africa. Associated with cases of acute hemorrhagic conjunctivitis are cases of an often asymmetric acute flaccid paralysis. Those affected appear clinically similar to those with spinal poliomyelitis except for the preceding association with acute hemorrhagic conjunctivitis. Prodromal symptoms for acute hemorrhagic conjunctivitis-associated paralysis include fever and malaise then an acute, severe radicular pain. This is followed by flaccid, asymmetric weakness of the legs with proximal muscles (eg, quadriceps muscle) more affected. Reflexes are diminished or absent. Clinically, as in other enteroviruses,

the main lesion is believed to be in the anterior horn cells of the spinal cord and the cranial motor neurons. Permanent paralysis or residual weakness is present in over half the cases. The virus is difficult to isolate in the CSF by PCR when neurologic symptoms arise, but high titers of virus-specific antibodies are typically detectable in the CSF and/or serum in those with paralysis.

Clinically, enterovirus 71 is associated systemically with hand-foot-and-mouth disease in children and neurologically can present with acute flaccid paralysis, encephalomyelitis, or a rhombencephalitis. Enterovirus 71 is the etiologic agent responsible for several encephalitis epidemics throughout the world, resulting in substantial mortality and morbidity. The largest enterovirus 71 epidemic occurred in Taiwan in 1988, resulting in 1.5 million people affected, of which 405 children developed serious neurologic complications with 78 deaths. Every 2 to 3 years, large enterovirus 71 outbreaks occur around the Asia-Pacific rim, affecting thousands. As such, enterovirus 71 is now recognized as an emerging neurotropic virus. Enterovirus 71 can cause hand-foot-and-mouth disease as well as upper respiratory infections and gastroenteritis. In those affected neurologically, manifestations include myoclonic jerks, tremors, ataxia, cranial nerve palsy, meningitis, and meningoencephalitis. Polio-like flaccid paralysis occurs in about 10% of patients. Fulminant neurogenic pulmonary edema and apnea from rhombencephalitis occurred in epidemics affecting children in Taiwan and Malaysia, and these disease manifestations are the primary cause of death in enterovirus 71-infected individuals. Most of the patients had magnetic resonance imaging (MRI) T2-weighted high-intensity lesions in the brainstem. In Catalonia, Spain, an outbreak of brainstem encephalitis and encephalomyelitis occurred in 2016 with a new strain of enterovirus 71. The new strain was associated with a high degree of neurotropism of the virus. Diagnosis may be made by virus isolation from throat, feces, or vesicles; by antibody studies; and CSF reverse transcriptase polymerase chain reaction (RT-PCR). Treatment is supportive, and patients are often administered intravenous immunoglobulin (IVIG) and/or plasma exchange with mixed results.

Coxsackievirus and Echoviruses

Although most infections are mild or asymptomatic, neurologic manifestations of human viral infections caused by group A and B coxsackieviruses and echoviruses primarily are meningitides. Historically, group B coxsackieviruses and echoviruses are the most frequently implicated serotypes in meningitis; exceptions include when a single serotype causes a widespread outbreak. For example, coxsackievirus A9 was responsible for most cases in an outbreak in the Gansu Province, China, in 2005 and Alberta, Canada, in 2010.

The symptoms and signs of meningeal involvement of coxsackieviruses and echoviruses are similar to other viruses that cause meningitis. The severity of disease varies, with the extremes of life having the more severe meningitis. Headache is frequent, and if meningismus is present, it can vary in severity and typically begins 24 to 48 hours following onset of symptoms. In infants, the dominant symptoms are fever and irritability, with less than 10% having evidence of meningeal irritation. Frequently, there is a prodromal or associated upper respiratory tract infection or symptoms. Acute CNS complications include febrile seizures, elevated intracranial pressure, and coma. When considering alternate diagnoses for enterovirus meningitis, bacterial meningitis needs to be considered and should be treated empirically with broad-spectrum antibiotics. Commonly, adults will have associated myocarditis and pericarditis, and all patients should undergo cardiac evaluation.

Although encephalitis is not commonly caused by coxsackievirus or echovirus (except for enterovirus 71), it can occur in immunocompromised patients. The severity of encephalitis is variable, with seizures, hemichorea, and acute cerebellar ataxia being described. In patients with agammaglobulinemia, hematopoietic transplantation, or B-cell depletion with immunotherapy agents, enterovirus can cause a chronic, severe, and fatal meningitis and encephalitis. In such cases, enterovirus can be recovered in the CSF by PCR at different time points throughout the disease course. The IVIG and pleconaril have been used with some success.

Sporadic cases of acute flaccid paralysis have been seen with coxsackieviruses and are typically less severe than in poliovirus associated disease. For example, in an 11-year program monitoring of acute flaccid paralysis in the Slovak Republic as part of the WHO strategy for polio eradication, coxsackievirus B and echoviruses were the most common etiologies for acute flaccid paralysis in the post–polio vaccine era. These viruses are also reported etiologies for oculomotor palsies, Guillain-Barré syndrome (GBS), opsoclonus-myoclonus, and transverse myelitis.

The CSF analysis typically demonstrates clear fluid with normal to mildly elevated pressure. There is a mild to moderate pleocytosis that ranges from 10 to 500/mm^3 and rarely exceeds 1,000/mm^3. Initial differential cell counts demonstrate a high percentage of neutrophils but an eventual shift to a lymphocytic predominance. The CSF glucose concentration is generally normal and protein concentrations are normal to slightly elevated. PCR is the primary means of virus detection with greater than 95% sensitivity and specificity.

Containment during outbreaks is critical, with good hygiene practices and protective equipment for high-risk groups. The broad-spectrum antipicornaviral agent pleconaril is an orally administered inhibitor of enterovirus replication. There have been two placebo-controlled clinical trials that showed a shortened course of illness compared to placebo, but the benefit was modest. The drug has not been approved for use in the United States.

ARBOVIRUSES

Arthropod-borne viruses (arboviruses), as their name implies, are transmitted to humans through the bites of infected mosquitoes and ticks. A bite from an infected mosquito can infect with WNV, La Crosse, Jamestown Canyon, St. Louis encephalitis, and eastern equine encephalitis (EEE) viruses, and ticks can transmit Powassan virus. In symptomatic people, both nonneuroinvasive and neuroinvasive infection occurs. In the United States, WNV is the leading cause of arboviral disease. Human infection due to arboviruses follows patterns of vector activity. Seasons and years when the insects are most abundant logically see higher rates of infections. Most arboviruses have vertebrate reservoirs, such as birds or small mammals, and are transmitted by mosquitoes or ticks. Continuation of the life cycle relies on a constant interaction between hosts (eg, birds, mammals) and vectors (eg, ticks, mosquitoes). Animals that act as hosts maintain high enough levels of viremia and can retransmit infections back to arthropods when bitten. However, humans and horses are "dead-end" hosts, as they are not able to sustain elevated levels of viremia without succumbing to disease. Endemicity varies widely, as do outcomes. Neurologically, patients can present with meningitis, myelitis,

and/or encephalitis. Less common neurologic syndromes can include cranial and peripheral neuritis or other neuropathies, including GBS. Neuroinvasion is usually coupled with an intense inflammatory reaction and/or edema, the effects of which can be devastating. Alternatively, neurologic disease can occur as a parainfectious inflammatory disorder in the setting of systemic disease without specific evidence of nervous system infection per se. Fortunately, for the most part, exposure leads to asymptomatic seroconversion or a mild self-limited illness; typically, only a fraction progress to severe neurologic disease and/or death.

Acute arboviral infections are diagnosed typically by serum and/or CSF antibody detection via enzyme-linked immunosorbent assay for virus-specific IgM antibodies. Given the high prevalence of asymptomatic infection and potential for persistence of IgM in serum, antibody detection must be confirmed with a fourfold titer increase in IgG between the acute and convalescent phase (4 weeks after the acute phase). In general, though, the presence of CSF virus-specific IgM antibodies is indicative of intrathecal synthesis and is diagnostic for neuroinvasive disease. The CSF RNA detection is highly specific for active infection, but its sensitivity in arboviral infections is not nearly as high as seen in herpes simplex DNA detection. The CSF PCR can be especially helpful in immunocompromised people who are unable to mount or have a delayed antibody response. Culturing arboviruses is not routinely performed, as they are difficult to isolate due to low levels of viremia in humans. There are no specific antiviral therapies for the treatment of neuroinvasive arboviral infections and the focus remains on supportive care and exposure prevention. Anecdotally, people have been treated with IVIG, especially in the context of WNV neuroinvasive disease.

Flaviviruses

Flaviviruses are positive-sense, single-stranded RNA, enveloped viruses with icosahedral capsids. The most well-known members include dengue virus (DENV), yellow fever virus, Zika virus and WNV. Most are transmitted by biting arthropods, usually mosquitoes or ticks (**Table 69.1**).

Dengue

Dengue is the second most common mosquito-borne disease affecting human beings. There are four serotypes of this flavivirus, and infection with one does not confer protection from infection with the others. All serotypes can cause severe disease, including neurologic manifestations, although serotypes 2 and 3 most commonly lead to neuroinvasive disease. Dengue is carried by the *Aedes* species of mosquito and is endemic in most tropical and subtropical regions, with the highest reported incidence in Asia and Central and South America. As with other flaviviruses, inoculation proceeds to local immune cell infection and carriage to a lymphatic center, where replication occurs and viremia results. The virus makes its way to the CNS, although mechanisms of infection are not well understood. Virus is detected in the CNS, although it is not known if this occurs passively across an altered BBB or as an active infection. Vasogenic edema results, and a systemic inflammatory response can elicit immune-mediated damage of multiple organs and the neuraxis.

After exposure and subsequent incubation of several days to just over a week, those who are symptomatic will experience fever, myalgias, and malaise most commonly, occasionally with a rash. Severe systemic disease can follow over a matter of days, characterized by thrombocytopenia, multifocal hemorrhage, shock, and death. Neurologic manifestations can accompany severe disease and range from encephalopathy to direct nervous system infection accompanied by an inflammatory response causing meningoencephalitis and/or myelitis to a parainfectious immune diseases such as GBS and acute disseminated encephalomyelitis (ADEM). Acute encephalopathy is the most common neurologic syndrome associated with DENV, often precipitated by systemic shock. Risk factors for developing severe disease include young age, certain human leukocyte antigen genotypes, female gender, and superinfection with a second serotype.

Diagnosis

Given the protean neurologic complications, there is no specific neuroimaging finding related to dengue, and computed tomography (CT) or MRI of the brain may be entirely normal. Similarly, CSF may be normal or only demonstrate elevated protein concentration depending on the neurologic syndrome. In DENV-associated encephalopathy, the CSF basic profile is typically normal, whereas opening pressures can be elevated. If there is a pleocytosis, it is generally lymphocytic. If caught early, RNA can be detected from the blood and/or CSF; otherwise, antibody detection from blood and/or CSF demonstrating active or recent production is diagnostic. However, cross-reactivity is frequent with other flaviviruses. In endemic areas, a tourniquet test to assess capillary fragility can be performed at the bedside in the appropriate clinical context to make a presumptive diagnosis.

Treatment

No vaccine or specific therapies exist for dengue infection, although aggressive supportive treatment early on, with platelet transfusions, rehydration, and management of elevated intracranial pressure, may improve survival. Although there is little data to support such treatment, some have used steroids, and IVIG in patients with neurologic effects from dengue. Overall, case fatality rate is 4% to 5%, although some 25% of survivors will suffer residual neurologic deficits (see **Table 69.1**).

Tick-Borne Encephalitis Virus

Tick-borne encephalitis virus is carried by the Ixodes tick. Tick-borne encephalitis is endemic in 19 European countries and parts of Asia, with a significant amount of infections noted in Russia, and is responsible for thousands of infections each year. Men are more commonly affected than women. Viral infection results in replication in lymphatic cells, vascular dispersion, and entry into brain parenchyma by means of brain microvascular endothelial cells. Viral presence in the brain incites an inflammatory reaction that precipitates widespread damage throughout the cerebrum, cerebellum, brainstem, and sometimes the spinal cord. After an incubation period of about a week, patients develop a fever that lasts several days and in the second phase of illness progresses to headache, nausea, and occasionally meningismus. A severe encephalitis developed in approximately half of patients. Associated spinal cord inflammation sometimes occurs, often presenting as a flaccid paralysis due to anterior horn cell involvement. Diagnosis is best made by demonstration of intrathecal tick-borne encephalitis virus-specific antibody production; serum antibodies can be useful in the patient who has never received vaccination. As with other flavivirus infections, cross-reactivity is common with antibody testing. The CSF usually shows a modest lymphocytic pleocytosis, which transitions to monocytic and elevated protein concentration, although in some cases, a polymorphonuclear pleocytosis has been demonstrated.

TABLE 69.1 Nervous System Disease Caused by Flaviviruses

Virus	Endemic Locale	No. of Infections Annually	Systemic Symptomatic Disease (% of Infections)	Neurologic Disease (% of Symptomatic Infections)	Neurologic Manifestations	Case Fatality Rate	Long-term Sequelae	Preventive Strategies
Japanese encephalitis virus	Southeast Asia, Japan, Pacific Islands	30,000-50,000	0.30	0.001-0.02	Encephalitis with brainstem and occasionally spinal cord involvement	25%	30%	Vector control, vaccine
West Nile virus	Africa, Middle East, Continental United States, Puerto Rico	~150,000 (United States)	20	1	Meningoencephalitis and/or acute flaccid paralysis	10% overall, 15%-30% in age older than 70 y	50%	Vector control, blood and organ donation restrictions
Dengue virus	Central and South America, Puerto Rico, Africa, Middle East, India, Southeast Asia, Pacific Islands, Northern Australia	50-400 million	0.5-1	4-50	Meningoencephalitis, ADEM, GBS, CNS hemorrhage	4%-5%	~25%	Vector control
Murray Valley encephalitis virus	Northern Australia, New Guinea	Occurs in outbreaks	Outbreaks of 21-114 cases	0.1-0.7 of all infections	Meningoencephalitis	20%-40%	30%-50%	Vector control
Tick-borne encephalitis virus	Europe, Southern Russia, East Asia	~35,000	2-33	25-30	Meningoencephalitis	1%-2% (Western Europe), 30%-40% (Eastern Russia)	35%-60%	Vector control, vaccine
Kunjin virus	Northern Australia, New Guinea	Occurs in outbreaks	Minority	Minority	Mild meningoencephalitis or encephalomyelitis	<1%	NA	Vector control
St. Louis encephalitis virus	Continental United States	~1,000; higher in outbreaks	<1	>60	Meningoencephalitis	5%-15%	Up to 50%	Vector control
Powassan virus	Canada, Northern United States, Russia	NA; seroprevalence 0%-5% in endemic areas	Minority	NA; <50 cases reported 2001-2018 but incidence rising	Meningoencephalitis and/or encephalomyelitis	10%	50%	Vector control

Abbreviations: ADEM, acute disseminated encephalomyelitis; CNS, central nervous system; GBS, Guillain-Barré syndrome; NA, not applicable.

Treatment of tick-borne encephalitis virus is supportive. Mortality varies by location, at 1% to 2% for Western Europe but up to 40% for Eastern Russia (see **Table 69.1**). Long-term neuropsychiatric sequelae occur in more than half of the survivors.

Japanese Encephalitis Virus

Japanese encephalitis (JE) virus is transmitted by the *Culex* mosquito. The JE virus is the most commonly diagnosed epidemic encephalitis in the world and is found throughout South and Southeast Asia (see **Fig. 69.1A**). Like its sibling flaviviruses, initial replication is in lymphoid tissue followed by transient viremia that carries the virus to the brain; once inside the CNS, it imparts damage both by infection and reactive inflammation. Unlike many other flaviviruses, neurologic manifestations occur in the majority of patients who are symptomatic.

In symptomatic cases, after an incubation period of a little over a week, fever sets in, along with chills, myalgias, and occasionally meningismus. In children, abdominal pain and nausea are common. Symptoms can quickly progress to limb weakness and extrapyramidal signs and subsequently to coma and death. Imaging and pathologic specimens show thalamic and cerebral peduncular involvement, but viral involvement is typically widespread throughout the brain and even into the spinal cord occasionally. Parkinsonian features may be significant; other movement disorders include lip smacking, bruxism, choreoathetosis, and hemiballismus. Poliomyelitis-like flaccid paralysis indicates damage of anterior horn cells in the spinal cord, and cranial nerve signs include facial palsies, ptosis and abnormalities of eye movements. Obvious generalized tonic-clonic seizures can occur, and subtle motor seizures can also be observed in some instances, especially in advanced disease in children. The CSF typically shows a lymphocytic pleocytosis of up to 1,000 cells/μL and a modestly increased protein concentration. Diagnosis is usually by antibody detection from CSF or by serologic increases between acute and convalescent phases; RNA isolation from CSF is diagnostic as well. As with other flavivirus infections that are usually asymptomatic and/or have vaccines available, a single positive IgG in endemic areas may not indicate active disease.

Treatment is supportive, keeping in mind that death commonly is secondary to cerebral edema and increased intracranial pressure. Of those who survive, about 30% will have long-term deficits (see **Table 69.1**), again making prevention strategies key. These include vector control and vaccination; however, vaccine use has resulted in a decrease in JE virus incidence in many Asian countries, but estimates suggest that 80% of cases still occur in areas with JE virus vaccine programs. This is likely multifactorial including possible waning immunity and vaccine ineffectiveness and problems with the cold chain.

West Nile Virus

The WNV was originally isolated in Africa, but since introduction to New York in 1999 which led to an outbreak, the virus has been endemic in the United States (see **Fig. 69.1A**). The WNV has a worldwide distribution with outbreaks identified throughout the globe. Its vector is the *Culex* mosquito, although infected donated blood has been another mode of transmission. As of 2012, all 48 contiguous states in the United States had reported cases. Most cases of WNV are asymptomatic and go unreported; there were an estimated 1.8 million infections in North America between 1999 and 2010. Hundreds to thousands of symptomatic cases are reported to the CDC each year. As such, seroprevalence of WNV IgG in endemic areas is actually quite high. Of the symptomatic cases, the most common symptoms are fever and malaise. Less than 1% will go on to develop what is considered neuroinvasive disease: meningitis, encephalitis, or myeloradiculitis. Risk factors for developing neuroinvasive disease are age older than 50 years, immune suppression, homelessness, chronic renal disease, hepatitis C infection, and CCR5 mutations.

The WNV has an incubation period of 2 to 14 days, after which replication occurs in lymph tissue, followed by viremia and carriage to the CNS, where it infects neurons and anterior horn cells. How it does so remain elusive, as receptors have not been identified, nor is it known how the virus crosses the BBB. As with many viral CNS diseases, though, its mechanism of neuronal injury and death is directly related not only to viral infection but also to the intense inflammatory reaction that imparts bystander damage to the delicate resident cells in the brain and spinal cord.

The majority of individuals infected by WNV do not have symptoms or a febrile illness. Neuroinvasive disease occurs in less than 1% of WNV cases, although may be underreported. The WNV neuroinvasive disease may present as West Nile meningitis, West Nile encephalitis, or acute flaccid paralysis. New parkinsonism points to basal ganglia involvement and is seen commonly in patients with WNV encephalitis. Detection of IgM antibody in serum or CSF is the diagnostic test of choice. Because IgM antibody does not cross the BBB, its presence in CSF indicates CNS infection. Most patients with meningoencephalitis have IgM antibodies in CSF by about 1 week after symptom onset and IgG testing has no utility in patients with acute neurologic symptoms. Recent vaccination with other flaviviruses or recent infection with a related flaviviruses may produce a positive WNV-IgM antibody result. The plaque-reduction neutralization test can help distinguish serologic cross-reactions among the flaviviruses, but the test is only available in reference laboratories and takes a significant amount of time to return.

As with many viruses, WNV is a monophasic illness for which there is no proven specific therapy other than supportive therapy. An IVIG, a WNV-specific IgG, and a ribavirin all have been not clearly beneficial though have been used anecdotally. Long-term sequelae are the rule for survivors of neuroinvasive disease especially those with encephalitis, and about 10% die (see **Table 69.1**), making prevention of mosquito bites the most logical management strategy. No vaccine is available for WNV.

Murray Valley Encephalitis Virus

Murray Valley encephalitis virus is carried by the *Culex* mosquito and is endemic to Northern Australia and Guinea. It mostly has occurred in outbreaks with case numbers in the teens to low hundreds, making it much less of a threat than most other flaviviruses, especially those with a global presence. At least four outbreaks may have occurred in the early part of the 20th century under the moniker "Australian X" disease, and in 1951, the virus was isolated during the first documented Murray Valley encephalitis virus outbreak. Subsequent outbreaks occurred in 1956, 1974, and 2011. The 2011 outbreak was associated with high seasonal rainfall and flooding, serving as a nidus for increased mosquito vectors. There have been sporadic cases additionally. Given its outbreak potential, Murray Valley encephalitis virus is a "notifiable" disease in all Australian states and territories.

Incubation time averages 2 to 4 weeks. The vast majority of cases is asymptomatic or gives rise to a mild febrile illness with headache that does not come to medical attention. About 1 out

of 150 to 1,000 infections develop more severe symptoms several days later of lethargy, encephalopathy, and occasionally seizures that can progress to brainstem symptoms, flaccid paralysis due to myelitis, and death. The case fatality rate is 15% to 30%, and about 30% to 50% suffer long-term neurologic deficits (see **Table 69.1**).

In severe cases, T2-weighted MRI of the brain shows bilateral thalamic and brainstem hyperintensities, similar to other flaviviruses. Pathologically, virus has been recovered from brain tissue, and additionally, there is a striking widespread reactive inflammatory infiltrate throughout the gray matter. Diagnosis is often by serology, suggesting that specific Murray Valley encephalitis virus IgM appears several days after infection and persists for months. Antibodies can also be evaluated in CSF, as well, and there are Murray Valley encephalitis virus RNA assays for detection in serum. Management is supportive.

St. Louis Encephalitis Virus

St. Louis encephalitis virus is carried by *Culex* species mosquitoes and is a cause of epidemic encephalitis in both North and South America but mostly in the United States. Epidemics typically occur during the summer season. The vast majority of individuals have asymptomatic infections. Otherwise, presenting symptoms mimic a flulike illness and include fever, headache, and lethargy. Neurologic features can include seizures, ataxia, confusion, hemiparesis, and myoclonus.

The CSF analysis demonstrates a predominantly lymphocytic pleocytosis. St. Louis encephalitis virus is rarely isolated from blood or serum and diagnosis largely requires demonstration of St. Louis encephalitis virus-specific CSF IgM. An MRI can show T2-hyperintensities in the basal ganglia, and in some cases, abnormal signal is seen within the substantia nigra. Similar to other arboviral encephalitis, St. Louis encephalitis virus pathologic findings include perivascular, meningeal, and capillary lymphocytic infiltrates and activated microglia in gray and white matter. There are widespread neuronal degenerative changes, more obvious in cortex, basal ganglia, and cerebellum. A few St. Louis encephalitis virus cases have evidence of inflammation and neuronal loss in the spinal cord.

Treatment is supportive. Mortality varies considerably in case series and has been reported as high as 20%; long-term morbidity occurs in up to 50% of cases (see Table 69.1). Prognosis is worse with those who develop seizures.

Powassan Virus

This flavivirus is carried by the *Dermacentor* species and *Ixodes* ticks and is endemic in Canada, the northern United States, and far east Russia. It derives its name from the town in Canada where disease was first identified in 1958. Powassan virus is an emerging tick-borne illness with 2 US neuroinvasive cases identified in 2008 to 33 US cases identified in 2017. Symptoms occur after an incubation period of 1 to 4 weeks and begin with malaise, fever, and pharyngitis but can progress to hemiplegia, vomiting, marked brainstem dysfunction, coma, and death. The CSF studies, as with nearly all viral encephalitides, usually demonstrate a moderate lymphocytic pleocytosis and modestly elevated protein concentration. The gold standard for diagnosis is a screening Powassan antibody test followed by a confirmatory plaque reduction neutralization test, and referral to state laboratories in the United States is advised. Other tick-borne–related infections should be ruled out.

Pathologic studies demonstrate intense lymphocytic infiltrates and necrosis of gray matter mostly in the basal ganglia, thalamus, and mesial temporal lobes, corresponding to areas of abnormal brain MRI T2 hyperintense signal, although involvement is widespread (Fig. 69.2). There is no specific therapy

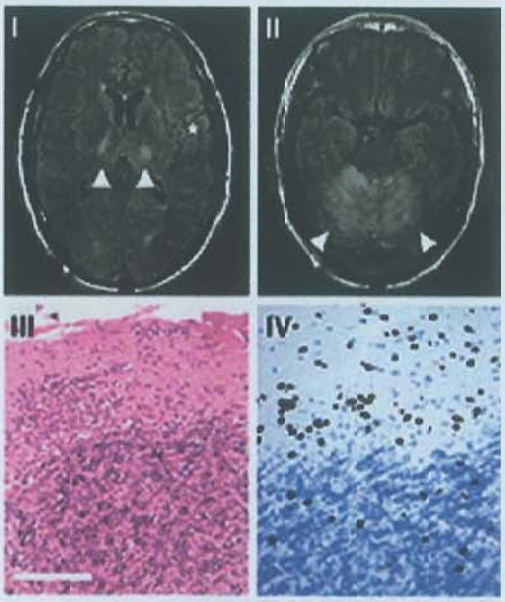

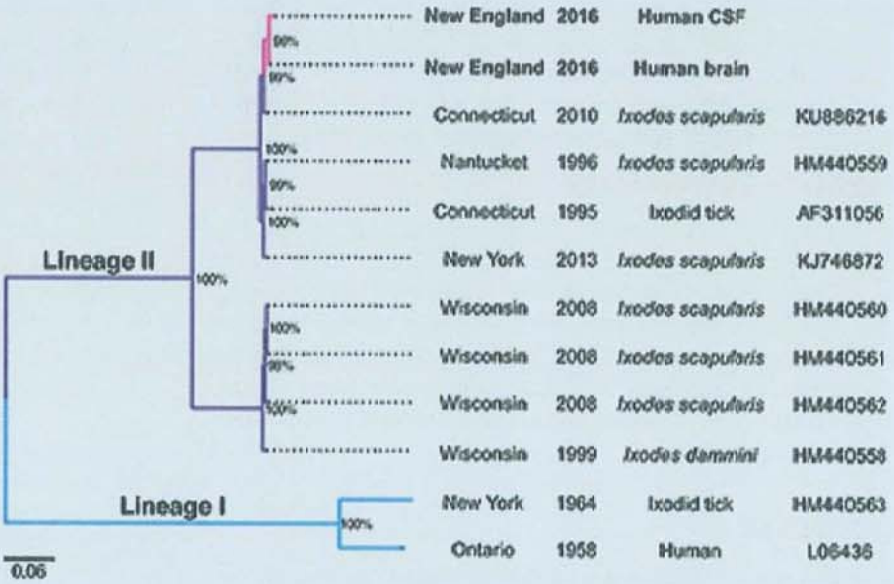

FIGURE 69.2 **Left panel:** Axial brain magnetic resonance images show focal T2-weighted/fluid-attenuated inversion recovery hyperintensities of the bilateral thalamus (**panel I**, *arrowheads*) and cortex (**panel I**, *asterisk*) and confluent hyperintensities of the cerebellum (**panel II**, *arrowheads*). Hematoxylin and eosin staining of a posterior fossa biopsy performed shows extensive lymphocytic infiltration and thickening of dura and diffuse inflammation of the cerebellum (**panel III**). The CD3 staining of the cerebellum reveals a predominantly T-cell lymphocytic infiltrate in the granule cell and molecular layers (**panel IV**). Scale bar = 100 μm. **Right panel:** Phylogenetic tree of Powassan virus genomes. Branches are labeled with the location, date, source, and GenBank ID of each Powassan virus genome. Nodes with at least 80% bootstrap support are labeled with percentage of bootstrap support. (Modified from Piantadosi A, Kanjilal S, Ganesh V, et al. Rapid detection of Powassan virus in a patient with encephalitis by metagenomic sequencing. *Clin Infect Dis*. 2018;66[5]:789-792, doi:10.1093/cid/cix792.)

for this disease, and treatment is supportive, although isolated cases have treated with IVIG. About half of the survivors suffer permanent sequelae (see Table 69.1).

Bunyaviruses

Bunyaviruses are negative-sense, single-stranded helical RNA viruses that are encapsulated. Although some are arboviruses, several are spread by rodents and are not associated with significant neurologic disease. Those that do result in encephalitis have less epidemiologic significance than most of the flaviviruses, which are found in densely populated areas, are widespread globally, and/or are much more neurovirulent.

Lacrosse Virus

Lacrosse virus is transmitted by the *Aedes triseriatus* mosquito. Lacrosse virus is endemic to the United States, and symptomatic cases are most commonly seen across the Ohio River Valley, mid-Atlantic, and Midwest. In these areas, the incidence is about 10 to 30 per 100,000 population, but only about 0.3% to 4% are symptomatic. Most cases are reported in children.

Initial infection causes viral replication in muscle followed by viremia and CNS invasion. The mechanism of entry into the CNS is unknown, but neurons and glial cells in the frontal, temporal, and parietal lobes are mostly affected. Presentation is of headache and fever, which progresses over days to seizures and encephalopathy about 25% to 50% of the time. The CSF demonstrates a lymphocytic pleocytosis with modestly elevated protein concentration, although results can be entirely normal. Lacrosse virus encephalitis presents similarly to herpes simplex virus encephalitis (HSE). Lacrosse virus IgM in CSF is diagnostic; otherwise, diagnosis comes from fourfold increase in IgG antibody titers from acute to convalescent phase. Alternatively, antigen detection on biopsy specimen provides the diagnosis. Treatment is supportive and the disease monophasic; mortality is less than 1%. If concern for HSE, treatment with acyclovir should be started immediately, until this is ruled out by CSF HSV PCR testing. Although there is a lack of evidence for its efficacy, ribavirin has been used on a compassionate use basis.

Jamestown Canyon Virus

This virus infects many species of mosquitoes and flies and is found throughout the United States into Canada. It is a rare cause of meningoencephalitis but is considered an emerging disease and likely underdiagnosed. Symptoms mirror those of other arboviruses, with onset of a mild febrile illness followed by severe headaches. Serologic studies are diagnostic when a fourfold rise in IgG is seen between acute and convalescent phases; treatment is supportive.

Togaviruses

Togaviruses are positive-sense, single-stranded, enveloped viruses with icosahedral capsids. There are two genera: *Alphavirus* and *Rubivirus*. *Alphavirus* species are arboviruses, whereas *Rubivirus* contains rubella, which is transmitted via droplet or mother-child transmission.

Alphavirus (Equine Encephalitis)

There are three types of equine encephalitis, all belonging to the genus *Alphavirus*, that occur in the Americas and include EEE, Venezuelan equine encephalitis (VEE), and western equine encephalitis (WEE). These viruses affect horses primarily but in 1938 were found to cause human disease in those having close contact with affected animals.

Equine encephalitides are rare human infections and occur either in isolated cases or in short-lived epidemics when environmental conditions favor viral amplification. The WEE and EEE are seen on the coasts of the United States and Canada with some overlap into the Midwest and Great Lakes regions. The VEE occurs throughout Central America into the northern part of South America.

The EEE is the most severe of the equine encephalitides, frequently progressing to coma and death. The disease begins with a short prodrome (~5 d) of a flulike illness: fever, headache, malaise, nausea, and vomiting. This quickly is followed by confusion, stupor or coma, and possibly seizures. Focal neurologic signs can be present, including tremor, cranial nerve palsies, and plegia. In a recent case series, the median CSF white blood cell count was 370 cells/mm^3 (median 70% neutrophils). The median total protein concentration was 97 mg/dL, and the CSF glucose concentration was normal. Diagnosis of EEE encephalitis relies on the detection of IgM antibodies in the serum and/or CSF. The PCR and genomic amplification is available for EEE, and virus isolation from CSF or brain remains the diagnostic gold standard. The majority of those with EEE and neurologic symptoms have abnormal brain MRI. Lesions are best seen on T2-weighted sequences with the basal ganglia and thalamus most affected (Fig. 69.3).

Pathologic findings on gross examination in EEE are similar to other arboviral infections and notable for diffuse cerebral edema. There is typically chronic perivascular and meningeal inflammation seen within the basal ganglia, thalamus, cortex, brainstem, and spinal cord. Lymphocytic infiltrates, microglial nodules, neuronal death, and rarefied white matter can correlate to changes seen on MRI. The EEE immunohistochemistry has shown clusters of infected cells primarily in gray matter, with neurons as the predominant cell type affected (Fig. 69.4). In cases of myelitis, anterior horn cells are affected.

Estimates of case fatalities of EEE range from 30% to 70%. In children, length of prodrome was statistically associated with clinical outcome at the time of discharge, with longer prodromes having more favorable outcomes. This relationship is not as clear

FIGURE 69.3 Axial T2 fluid-attenuated inversion recovery (FLAIR)-weighted magnetic resonance imaging in a patient with encephalitis due to eastern equine encephalitis shows hyperintensities in the basal ganglia bilaterally.

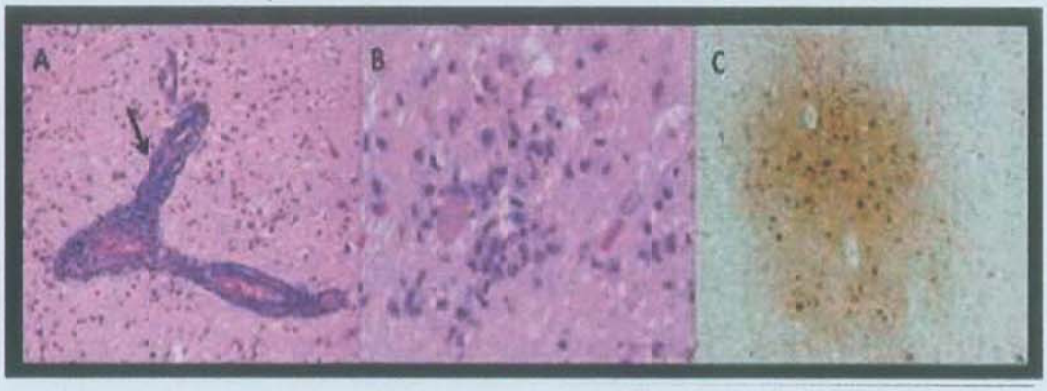

FIGURE 69.4 Histopathologic features in eastern equine encephalitis (EEE). **A:** Hematoxylin and eosin-stained section of thalamus showing perivascular cuffing (*arrow*) (magnification ×20). **B:** Hematoxylin and eosin-stained section showing neuronal degeneration and inflammation. **C:** EEE virus-specific antibody stained section of frontal cortex. (Courtesy of Dr. Pedro Ciarlianì.)

in adults, although patients with more favorable outcomes tended to have longer prodromes. In patients who recover, the morbidity from EEE is high, with sequelae ranging from intellectual disabilities, cranial nerve palsies, hemiplegia, aphasia, and seizures.

The WEE and VEE infections are less severe. The majority have a flulike illness with fever and malaise lasting up to 2 weeks. Risk for neuroinvasive disease includes extremes of age but less than 10% progress to coma. Hemiparesis, tremors, and cranial nerve palsies may occur with long-term sequelae that include cognitive decline and intellectual disabilities.

Rubivirus

Rubella

Rubella, also known as the *German measles*, is caused by a positive-sense, single-stranded RNA virus. The name *rubella* is derived from Latin, meaning "little red," as it generally produces a mild exanthematous disease in children and adults. However, infection occurring during pregnancy, particularly in the first trimester, can result in severe consequences including miscarriage, stillbirth, or infants born with congenital malformations and severe neurologic deficits, known as *congenital rubella syndrome*. Rubella also produces a rare chronic form of progressive encephalitis termed *progressive rubella panencephalitis*, which can be seen in children with congenital rubella syndrome or those with postnatal infections.

In the 1970s, rubella infections occurred in epidemics in the United States approximately every 6 to 9 years prior to licensing of the rubella vaccine. In 2004, after implementation of a universal vaccination program, elimination of endemic rubella virus transmission was documented in the United States. Rubella infections are still prevalent worldwide, as the virus continues to circulate where vaccination programs have not been established. Transmission of the virus is by the respiratory route, and replication occurs in the nasopharynx and lymph nodes.

There can be severe neurologic morbidity from rubella arising when a pregnant woman is infected. The frequency of congenital defects is highest in the first trimester of pregnancy. Infants with congenital rubella syndrome may shed virus from the nasopharynx, eye, or CSF, producing a chronic, persistent infection in the fetus. Neurologic abnormalities are observed by 18 months of age. Infants with rubella encephalitis are hypotonic, inactive, and irritable with a typically full anterior fontanel. Eventually, opisthotonic posturing, rigidity, paresis, seizures, and developmental delays can occur. The syndrome includes sensorineural hearing loss, cardiovascular anomalies, thrombocytopenia, and areas hyperpigmentation about the navel, forehead, and cheeks. In postnatal infections, rubella results in a mild systemic illness with a 2- to 3-week incubation period. Lymphadenopathy is often the initial clue with a subsequent erythematous rash on the face and trunk. The neurologic symptoms are rare, occurring in less than 0.1% of rubella cases. Rubella can produce an encephalitis, meningitis, or myelitis, and there are case reports of GBS following a rash.

Serum abnormalities seen with rubella infections include leukopenia with atypical lymphocytosis or thrombocytopenia. The CSF in postnatal rubella or in congenital rubella syndrome contains a lymphocytic pleocytosis and moderately increased protein concentration. Diagnosis of rubella is supported by detecting rubella-specific IgM and confirmed by detecting rubella virus in throat washings or rubella virus RNA in CSF or urine by using RT-PCR. Rubella virus can be recovered from the CSF of approximately 25% of patients and may persist in the CSF for more than 1 year after birth. On MRI of the brain in congenital rubella syndrome, there are basal ganglia, periventricular and cortical calcifications, multifocal T2 hyperintensities, and evidence of delayed myelination. Pathologically, congenital rubella is characterized by microcephaly, hydrocephalus, and periventricular white matter injury with mineralization (calcification) of the basal ganglia and thalamus.

Prevention is vital in combating rubella. The rubella vaccine is a live attenuated virus typically delivered as part of the MMR (measles, mumps, and rubella) vaccine. Due to risk of congenital rubella syndrome, rubella vaccination is particularly important for nonimmune women who may become pregnant.

Progressive Rubella Panencephalitis

Progressive rubella panencephalitis is an extremely rare and fatal neurodegenerative disorder that can follow either congenital or postnatal rubella infections. Neurologic deterioration following years after a rubella infection was first described in *The New England Journal of Medicine* in two consecutive papers in 1975. Several clinical and neuropathologic features seen in progressive rubella panencephalitis mirror that of subacute sclerosing panencephalitis (SSPE) following measles infections (discussed under "Measles Encephalitis"). Progressive rubella panencephalitis is typically seen in the second decade of life. The syndrome begins with a dementing illness and ataxia, the latter being the

most consistent neurologic sign in progressive rubella panencephalitis. As the disease progresses, the ataxia worsens with dysmetria, dysdiadochokinesia, and truncal titubation. Dysarthria is prominent. The development of pyramidal tract involvement, retinopathy, seizures, and multifocal myoclonus can occur over a protected period of time over 8 to 10 years.

Headache and meningismus are not seen.

Progressive rubella panencephalitis and SSPE occur in people who have elevated antiviral antibodies and apparent intact cellular immunity. In the cases reported of progressive rubella panencephalitis, there were high titers of rubella-specific IgG in CSF and sera. The high ratio of CSF to sera of rubella-specific antibodies suggests intrathecal synthesis. The rubella virus is rarely isolated. In these cases, it is important to rule out the presence of measles-specific antibodies given the similarity in presentations. Electroencephalogram (EEG) reveals diffuse slowing but without the characteristic pattern in SSPE.

Some neuropathologic features of progressive rubella panencephalitis on gross examination include atrophy of the rhombencephalon, centrum semiovale, and basal ganglia with ventricular dilatation, particularly in the fourth ventricle. Microscopically, the cerebellum has atrophy of all cell layers. Neuronal loss is present and widespread. Inclusion bodies seen in SSPE are not present in progressive rubella panencephalitis. There is evidence of chronic inflammation and demyelination with diffuse astrogliosis of the white matter with perivascular lymphocytic and plasma cell infiltrates. Progressive rubella panencephalitis produces a picture similar to vasculitis. There are IgG deposits in cerebral vessels as well as multinucleated giant cells and lymphocytes in vessel walls. Most of the extracted IgG is specific to rubella.

The diagnosis of progressive rubella panencephalitis is easier in children with congenital rubella syndrome. In those who had postnatal rubella infections, the differential should include SSPE as well as dementing illness of childhood. However, with the onset of ataxia, the diagnosis is clearer and demonstration of CSF and sera rubella-specific antibodies is diagnostic. The emphasis remains on preventative measures through vaccination programs, as there are no specific treatments.

CORONAVIRUSES: SEVERE ACUTE RESPIRATORY SYNDROME VIRUS

Epidemiology

The ongoing global pandemic of the novel coronavirus, severe acute respiratory syndrome coronavirus 2 (SARS-CoV-2), has had a tremendous impact on global health, resulting in over 19 million cases worldwide with over 700,000 deaths as of August 2020. The SARS-CoV-2 emerged initially from a cluster of pneumonia cases in Wuhan, China, in the end of December 2019. By early January, the China National Institute for Viral Disease Control and Prevention had confirmed the genetic sequence of SARS-CoV-2. By the end of January, WHO declared the coronavirus disease 2019 (COVID-19) outbreak, caused by SARS-CoV-2, a Public Health Emergency of International Concern, and 6 weeks later, WHO characterized the COVID-19 epidemic as a pandemic.

The clinical spectrum of COVID-19 includes respiratory symptoms with approximately 15% to 25% of hospitalized patients developing severe acute respiratory distress and multiorgan damage. Disease severities are associated with older age and underlying comorbidities such as diabetes, hypertension, and cardiovascular disease. While vaccine development is rapidly underway in several clinical trials, the containment of SARS-CoV-2 is currently based on interrupting transmission through rapid identification and isolation of infected individuals. Infection is transmitted primarily through large droplets generated during coughing and sneezing by symptomatic patients but can also occur from asymptomatic individuals.

Human coronaviruses (HCoVs) are a family of large positive-sense single-stranded RNA viruses. The genus is subdivided into four lineages (A-D), with lineage A containing HCoV OC43, HCoV-NL63, HCoV-229E, and HCoV-HKU1; lineage B containing SARS-CoV and SARS-CoV-2; and lineage C containing the Middle East respiratory syndrome-related coronavirus (Fig. 69.5). Data suggests that SARS-CoV, HCoV-229E,

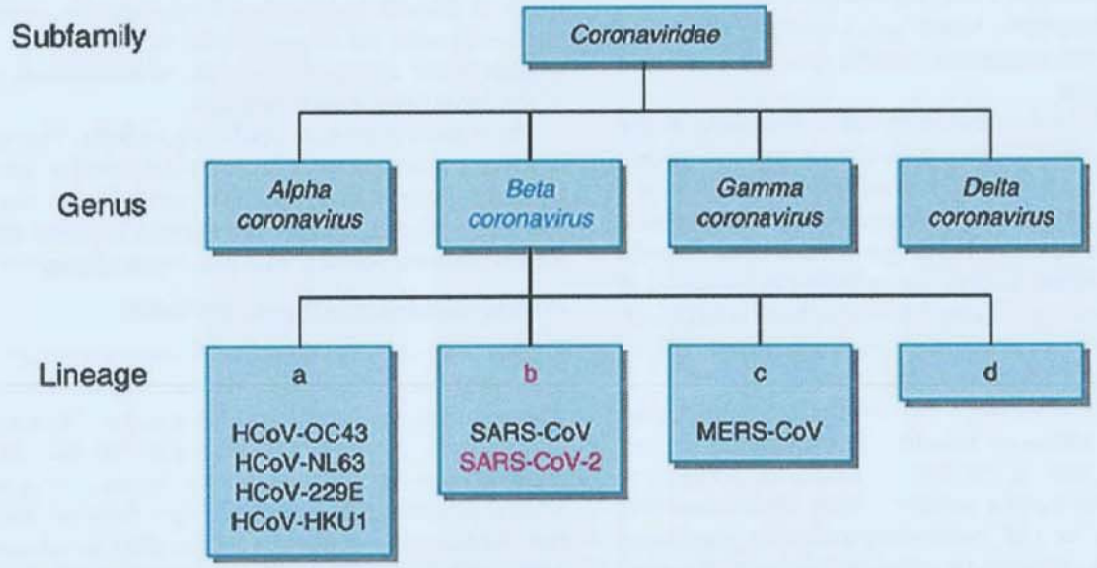

FIGURE 69.5 Schematic of the coronaviridae subfamily depicting the coronaviruses that can infect humans. Abbreviations: HCoV, human coronavirus; MERS-CoV, Middle East respiratory syndrome-related coronavirus; SARS-CoV, severe acute respiratory syndrome coronavirus.

and HCoV-OC43 can infect human neural-cell lines and lead to encephalitis in animal models. These viruses are also detected in CSF, and the SARS-CoV nucleocapsid protein has been identified in the cytoplasm of neurons.

Neurologic Clinical Features Associated With COVID-19

Although the most common manifestations of COVID-19 are respiratory symptoms, extrapulmonary manifestations, including neurologic symptoms and conditions, may also occur. To date, the majority of published cases describing neurologic findings associated with COVID-19 have focused on hospitalized patients. One of the earliest reports of 214 inpatients from three hospitals in Wuhan, China, suggested 36% of adult patients with COVID-19 had neurologic symptoms, including headache, dizziness, confusion, and anosmia. Additional retrospective cohorts from Spain and France reported the prevalence of neurologic symptoms to be 58% and 84%, respectively. At this time, only a few outpatient cohorts detailing neurologic symptoms are available for review. One series suggested that headache was present in 68% and confusion present in 15% out of a total of 248 US outpatients with SARS-CoV-2 PCR-positive tests.

Transient smell and taste disturbances are particularly characteristic of COVID-19 and include anosmia and ageusia. Other neurologic findings include myalgia and rhabdomyolysis, impairment of consciousness, coma, GBS, necrotizing encephalitis, encephalopathy, and myelopathy (Fig. 69.6). Cerebrovascular disease has been a particular concern given evidence of vasculopathy and thrombi in lungs and other organs in COVID-19. As of August 2020, there have been over 100 patients with ischemic or hemorrhagic stroke in the setting of COVID-19 reported in the literature. The majority of reported cases had a history of vascular comorbidities, were older than 60 years, or had a severe systemic illness in the setting of COVID-19. In one US series, large vessel occlusion as a presenting symptom for COVID-19 was reported in five cases in patients younger than 50 years old; prevalence estimates or incidence of stroke in the young during COVID-19 is still unknown. Mechanisms associated with COVID-19–associated strokes include those secondary to sepsis-induced coagulopathy, the production of antiphospholipid antibodies in select cases, and the potential impact of SARS-CoV-2 on brain endothelial and smooth muscle cells. Additional factors include medical comorbidities including hypertension, coronary artery disease, and diabetes seen in those who develop severe COVID-19 infection and the risk of medical complication predisposing to cerebrovascular accidents (ie, atrial arrhythmias, myocardial infarction, myocarditis).

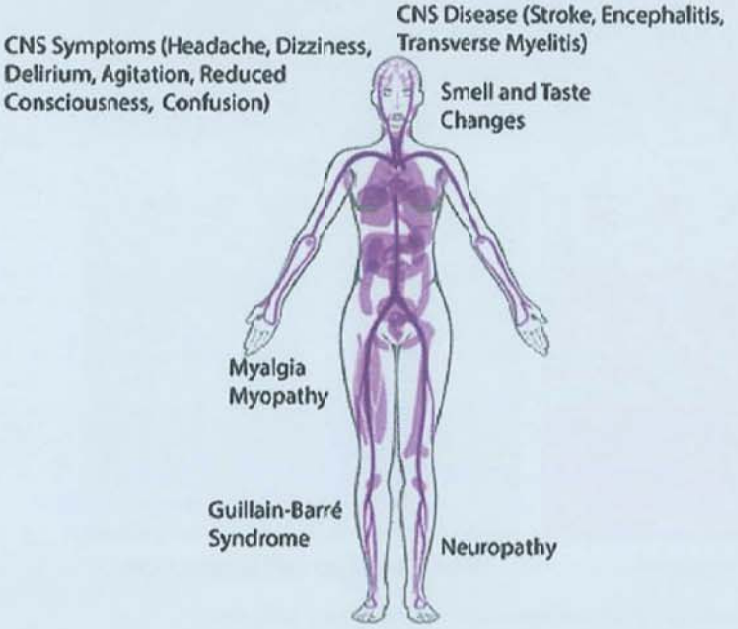

FIGURE 69.6 Neurologic symptoms and diseases associated with COVID-19.

Cerebrospinal Fluid Analyses and Neuroradiographic Imaging in COVID-19

In the majority of COVID-19 cases with lumbar punctures, the CSF cell counts, protein, and glucose were normal; less than 10 publications report elevated opening pressure, CSF leukocytosis, elevated protein, or positive oligoclonal bands in patients with COVID-19. Although the SARS-CoV-2 RT-PCR assay can be run on CSF, the assay has not been validated for clinical use. Most papers report negative CSF SARS-CoV-2 RNA using RT-PCR assays despite patients having abnormal brain imaging or acute neurologic symptoms such as impaired consciousness, stroke, or seizures, or postinfectious syndromes such as GBS. Of the published cases with positive CSF SARS-CoV-2 RNA, three reported elevated CSF leukocytosis or protein, whereas others reported normal cell counts or did not provide details.

Neuroimaging reports have been limited during the pandemic, and reports have focused on MRI in severe or critically ill patients. In several multicenter case series, neuroimaging findings included signal abnormalities in the medial temporal lobe, nonconfluent multifocal subcortical and deep white matter hyperintense lesions on fluid-attenuated inversion recovery, and diffusion with variable enhancement. Extensive and isolated white matter microhemorrhages have also been additionally detected, including punctate hemorrhages in the corpus callosum and subcortical white matter. In one case series, those with hemorrhagic lesions were more likely to be identified in critically ill patients with acute respiratory distress syndrome and pathologic wakefulness once sedation was stopped. The presence of white matter microangiopathy was associated with 2-week poor outcomes. Other MRI features reported include acute necrotizing encephalitis (Fig. 69.7).

Histopathologic Findings Associated With COVID-19

Studies on neuropathologic findings associated with COVID-19 remain a focus of intense interest. In an autopsy series of 18 patients, the primary neuropathologic finding was acute hypoxic injury, with loss of neurons in the cerebral cortex, hippocampus, and cerebellar Purkinje cell layer (Fig. 69.8). There has been limited evidence for diffuse microthrombi or a robust inflammatory response in majority of neuropathologic case series. Thus far, two autopsy series report low copy levels of SARS-CoV-2 RNA in brain tissue, with no definitive evidence of viral protein in a CNS cell; thus, the cellular source of viral RNA in brain tissue remains an open question.

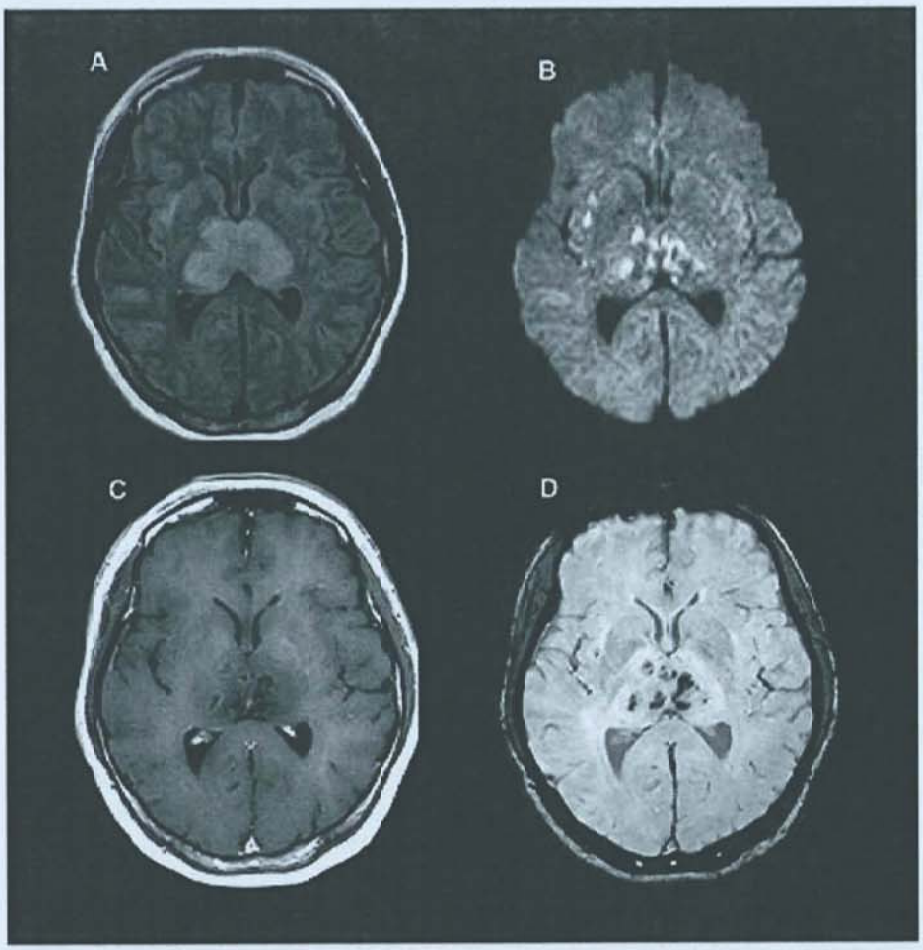

FIGURE 69.7 Magnetic resonance imaging in a patient with acute necrotizing encephalopathy and COVID-19. T2-weighted fluid attenuated inversion recovery scan shows hyperintensity in the bilateral medial temporal lobes and thalami **(A)**. There are hyperintense lesions in thalami and cingulate on diffusion-weighted imaging **(B)** with rim enhancement on gadolinium-enhanced images **(C)** and evidence of hemorrhage on susceptibility-weighted images **(D)**. (Images courtesy Dr. Elissa K. Fory.)

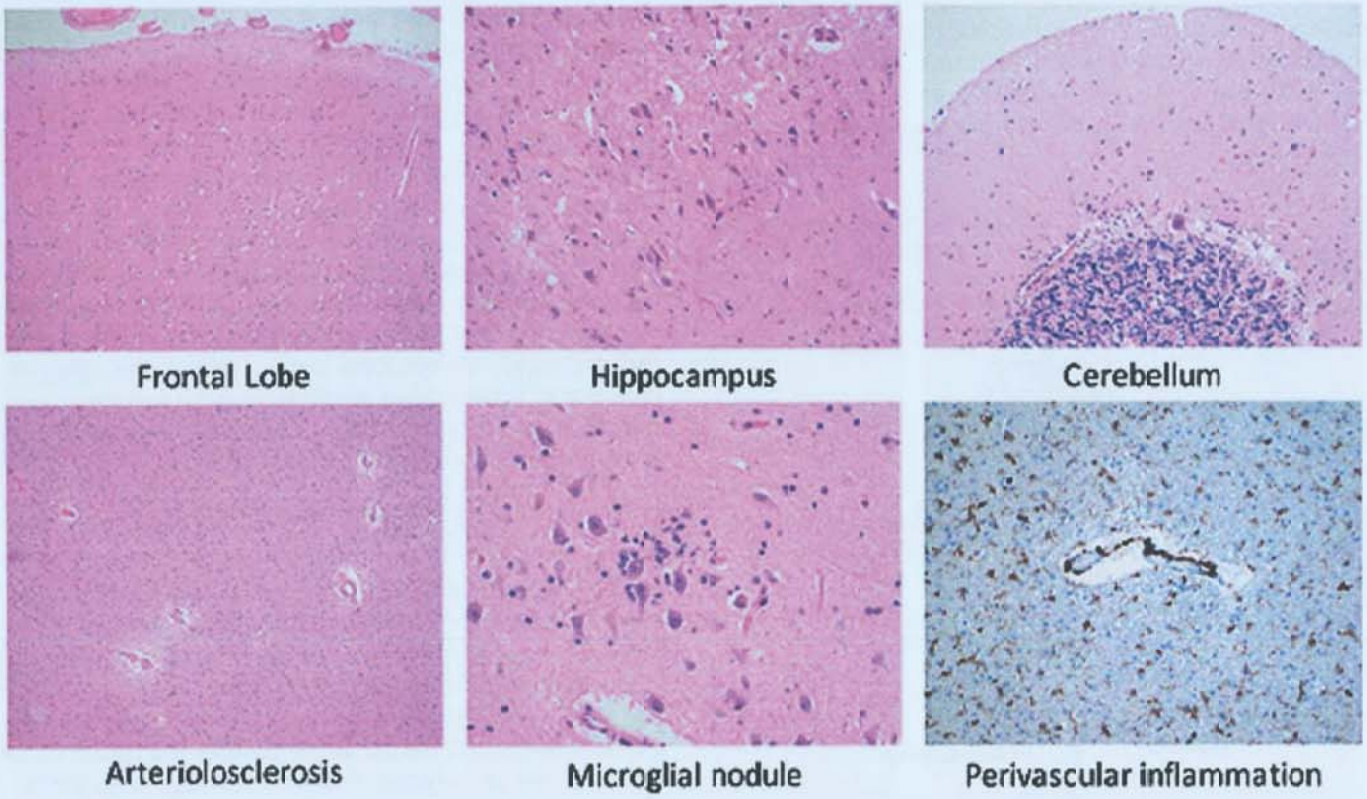

FIGURE 69.8 Histologic findings in patients with COVID-19 illustrating acute hypoxic-ischemic injury with neuronal loss and presence of red neurons in the frontal lobe, hippocampus, and cerebellum; arteriolosclerosis with perivascular rarefaction; a microglial nodule; and perivascular inflammation with scattered microglia (CD45). (Picture from Solomon IH, Normandin E, Bhattacharyya S, et al. Neuropathological features of Covid-19 [published online ahead of print June 12, 2020]. *N Engl J Med*. doi:10.1056/NEJMc2019373.)

ORTHOMYXOVIRUSES: INFLUENZA VIRUS

Influenza is a negative-sense RNA virus with three subtypes (A, B, and C). Further delineation is based on hemagglutinins (H) and neuraminidases (N). The majority of symptomatic infections result in a monophasic, febrile, respiratory illness, but certain hemagglutinin and neuraminidase types confer particularly severe virulence, raising morbidity and mortality.

Neurologic complications are most severe with influenza A and are more commonly seen in children. Additionally, direct CNS infection by influenza is rare, and parainfectious or postinfectious autoimmune and toxin-mediated diseases are more common neurologic complications. Febrile seizures, encephalopathy, Reye syndrome, GBS, and encephalitis have all been described. Influenza-associated encephalopathy typically presents early in the course of the respiratory disease about 1 to 2 days after fever onset. Depressed level of consciousness is invariable. Seizure occurs approximately 80% of the time, and EEG is abnormal. Symptoms can progress to coma and death. The CT and MRI demonstrate focal abnormalities or more widespread edema and are uncommon to have normal neuroimaging in influenza-associated encephalopathy. Treatment for the neurologic complications is aimed at reducing inflammation and edema.

PARAMYXOVIRUSES

Henipaviruses

Hendra virus and Nipah virus are single-stranded, enveloped, negative-sense RNA paramyxoviruses. In the CNS, they cause encephalitis. Their reservoir is the *Pteropus* fruit bat, which resides in Southeast Asia, Madagascar, India, and northern Australia. Outbreaks of Hendra virus have occurred predominantly in Australia, and Nipah virus outbreaks have occurred in Southeast Asia. These are primarily nonhuman viruses: Hendra is an equine virus and Nipah a swine virus, but human transmission has occurred due to both exposure to the fruit bat and exposure to infected animals, usually via saliva. This is extremely rare.

Pathogenesis in the CNS is related both to parenchymal infection and widespread, severe vasculitis. Initial invasion of the CNS seems to occur in a retrograde fashion through the trigeminal nerve or directly across the BBB.

Presentation of Hendra or Nipah virus infection is that of a rapidly progressive encephalitis occurring 1 to 2 weeks after exposure, typically starting as a flulike illness progressing to confusion, seizure, coma, and death over the course of several days. Mortality rate is 40% to 75%, and no definitive treatment exists.

Measles Encephalitis

Measles virus is a small single-stranded RNA virus belonging to the genus *Morbillivirus* of the *Paramyxoviridae* family. Measles virus is highly infectious, spreading rapidly between individuals primarily through aerosolized respiratory droplets over short distances. Measles virus can also be suspended in the air for long periods of time via small-particle aerosols. Infection spread can occur swiftly in a sparsely vaccinated population due to poor herd immunity. The most common manifestation of measles is a febrile childhood exanthem.

Infection with measles virus is associated with a robust cell-mediated immune response and downstream upregulation of cytokines. The virus does not usually replicate extensively in brain tissue, and it is thought that key mutations may be needed to confer a neurovirulent phenotype. Hypothesized viral routes to CNS include migration of infected leukocytes through the BBB, via endothelial cells, or through neuronal viral transport. The virus and subsequent immune response can result in severe brain injury.

There are three main neurologic complications that can arise from measles infections: post–measles encephalomyelitis (PME), measles inclusion body encephalitis (MIBE), and SSPE. The PME is akin to ADEM and is seen weeks after a measles infection. Symptoms include headaches, changes in mental status, and seizures, and most PME cases had preceding morbilliform rash and fever that are typically seen with measles virus. In patients with myelitis, back pain with bladder and bowel dysfunction is prominent. The CSF analysis can show a mild lymphocytic pleocytosis and elevated protein concentrations. The MRI scans demonstrate T2 hyperintensities in the white matter of the brain and spinal cord. In histopathologic studies of the brain, there is evidence of inflammation and demyelination; however, measles virus is not present, suggesting that PME is likely a postviral autoimmune phenomenon.

The MIBE, also known as *immunosuppressive measles encephalitis*, typically occurs months after a measles infection and affects immunocompromised individuals who are unable to clear measles virus. The disease has been described in those with hematologic malignancies, HIV, and solid organ and stem cell transplantation. Nearly all reported MIBE cases have altered mental status and seizures. The seizures are typically refractory focal motor seizures, but generalized seizures and epilepsia partialis continua have been reported. Focal motor deficits, speech impairment, and visual symptoms are also seen. There is progressive deterioration in the level of consciousness typically leading to coma and death in weeks to months. The CSF analysis is usually normal, but a mild pleocytosis and elevated protein concentration may be seen. Brain biopsy is necessary to establish a definitive diagnosis and shows many intranuclear inclusion bodies that contain measles virus nucleocapsids. Measles hemagglutinin and matrix proteins can be visualized by immunohistochemical staining, and intranuclear and intracytoplasmic paramyxovirus particles are seen in neurons, glia, and endothelial cells with electron microscopy. In cases of MIBE and SSPE, it is thought that the virus is likely replication defective making culturing measles virus difficult and the presence of measles is best demonstrated by RT-PCR. The measles vaccine has been implicated as a cause in immunocompromised patients with MIBE.

General supportive measures are the primary treatment. The role of postexposure Ig prophylaxis is unclear. In several patients, intravenous ribavirin treatment has resulted in temporary improvement but is not approved for the treatment. The measles vaccine has been successfully used without serious complications in many immunocompromised patients including those with HIV who do not have evidence of severe immunosuppression. Recent major outbreaks in the United States and abroad have occurred in communicated where groups of people are unvaccinated. Over 1,000 cases of measles have been reported in the United States in the last year alone.

Subacute Sclerosing Panencephalitis

An SSPE is a rare, slowly progressive, fatal disease of the CNS typically occurring in children and young adults. An SSPE develops in immunocompetent persons after a prolonged latent period following a measles infection. There is a higher risk of SSPE associated with a measles infection before the age of 2 years. The disease follows a stereotypic pattern beginning with behavioral changes after a period of weeks to months. Eventually, there is the appearance of myoclonus and focal deficits (speech disorder, ataxia, paresis, or vision loss). If epilepsy is present, generalized tonic-clonic seizures are the most common. As the disease progresses, there is increased pyramidal and extrapyramidal tone and whole-body myoclonic jerks. There have been very few reports of remission; the disease is typically prolonged over months to years and ends in death.

The presence of periodic complexes on EEG is classic for SSPE, with a spike and delta wave component of 0.5- to 3-second duration and intercomplex intervals of 4 to 30 seconds. These complexes are recognizable in the early stages. Those affected with SSPE have elevated levels of measles-specific IgG antibodies in the CSF and serum, unlike in MIBE. There are no specific MRI findings for SSPE. Striking histologic features of SSPE are hypertrophic astrocytes and microglial proliferation. A perivascular infiltration occurs in the cortex and white matter with plasma and other mononuclear cells. Patchy areas of demyelination and gliosis occur in the white matter and deeper layers of the cortex. The neurons of the cortex, basal ganglia, pons, and inferior olives show degenerative changes, sometimes resembling neurofibrillary tangles. Intranuclear inclusions are sparse (see Fig. 69.1D). The measles virus extracted from brain tissue in SSPE is highly defective due to lack of membrane protein production, which renders the virus incapable of being fully assembled and shed from the cell surface.

No drug treatments are available to clear the persistent measles virus from the CNS. Intraventricular interferon with intravenous or intraventricular ribavirin has resulted in clinical improvement or stopped progression in case reports but has not cured the disease. No controlled studies have been performed for SSPE. The focus remains on symptomatic and supportive treatments including treatment of myoclonus and seizures, but the disease and its sequelae are entirely preventable by maintaining measles immunization rates greater than 90% in populations.

RHABDOVIRUS: RABIES

Rabies is one of the most deadly and feared viruses with fatality rates essentially at 100%. The disease is present in all continents, except in Antarctica, with the predominant burden of illness in Asia and Africa. It has a variable incubation period followed by pain or paresthesia at the site of the bite and ultimately a progressive encephalomyelitis and death.

Epidemiology

Rabies is underreported in many areas around the world with estimated worldwide mortality of approximately 59,000 per year and remains one of the deadliest viruses on the plant. The typical route of transmission is via the bite of an infected animal, allowing breakdown of the dermal barrier and deposition of the virus into tissues. Although rabid dogs remain the principle vector for human rabies and is the cause of >95% of human rabies death worldwide, bat-acquired rabies is becoming increasingly common, especially in regions where rabies is controlled via vaccination programs in dogs and other carnivores. During 1960-2018, there were 89 US acquired cases of human rabies, 62 (70%) were attributed to bats. Dog bites acquired during international travel were the cause of 26 cases. Humans are considered dead-end hosts, with human-to-human transmissions occurring only in rare circumstances, such as in transplantations. Airborne transmission of rabies has been reported in spelunkers of bat-infested caves and laboratory workers with no known bat bites.

Pathobiology

Rabies is derived from a negative-sense, single-stranded RNA virus belonging to the genus *Lyssavirus*. The virus is enveloped and bacilliform (bullet-shaped). Once transcribed by the host, viral replication and transcription occur in cytoplasmic inclusions within neuronal cells termed *Negri bodies*. The virus then is able to use the host cell machinery to travel retrograde by axonal transport mechanisms to the dorsal root ganglia or cell bodies in the spinal cord or brainstem. In the CNS, viral replication is enhanced and clinical disease develops.

Clinical Features

There are two clinical forms of rabies described, encephalitic and paralytic, and presentations may depend on transmission type (eg bat vs dog bite). The earliest symptom reported is pain or paresthesia at the site of infection in about half of patients due to viral replication in the local dorsal root ganglia. Other symptoms include fever, headache, and lethargy. The encephalitic course is heralded by hypersalivation, alternating patterns of agitation and lucidity, and hydrophobia leading to pharyngeal spasms, all ultimately leading to coma and death. The paralytic form classically begins with limb weakness early; there are no convulsions or laryngeal spasms. The paralysis results in flaccid tone and can spread to involve other limbs. The paralytic form of rabies has a longer prodromal period and a more protracted course. The typical incubation period is 1 to 6 months. Longer incubations (including a case 8 y postexposure) have been reported.

Diagnosis

Diagnostic tests rely on the widespread dissemination of the virus. An MRI of the affected brain shows a pattern of mild T2 hyperintensities primarily in the brainstem, hippocampus, thalamus, and cerebral white matter (Fig. 69.9). Postcontrast enhancement in the brain is observed late in the course. In paralytic rabies, the brachial plexus can enhance in the prodromal phase. The MRI changes seen in rabies are preferential to the brainstem.

The diagnosis can be made by fluorescent antibody staining of corneal smears or nuchal skin biopsies, although both false-negative and false-positive results occur, and/or by the detection of viral nucleic acid using RT-PCR in biologic fluids including saliva and CSF. Although viral shedding in saliva is used for testing, sensitivity on single sample testing can be as low as 70%. This is attributed to intermittent shedding, and thus, multiple successive saliva samples or skin biopsies reach sensitivities greater than 95%.

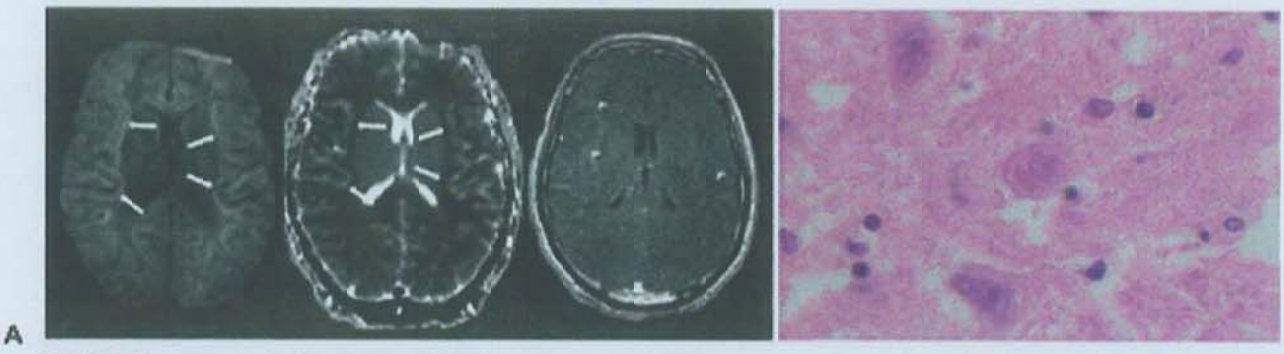

FIGURE 69.9 **A:** Axial diffusion-weighted imaging **(far left)**, apparent diffusion coefficient **(middle)**, and T1-weighted magnetic resonance imaging after administration of gadolinium **(right)** at the level of the caudate heads in a patient with rabies encephalitis demonstrate diffusion restriction within the subcortical white matter *(arrows)* and diffuse leptomeningeal enhancement *(arrowheads)*. The white matter diffusion restriction is thought secondary to wallerian degeneration and leptomeningeal enhancement to leptomeningitis. **B:** Hematoxylin and eosin-stained section of neurons within the spinal cord shows the characteristic sharply defined eosinophilic inclusion called *Negri body* in a patient with rabies encephalitis.

Histopathologic diagnosis of rabies was for many years dependent on visualization of Negri bodies in infected neurons on biopsies. These are cytoplasmic inclusions, which are classically round or ovoid eosinophilic bodies. Negri bodies are most prominent in the brainstem, hippocampus, and in Purkinje cells but can been seen in cortical neurons and spinal ganglia. A histologic picture of gray matter-centric encephalitis and/or myelitis can occur but is not universal, as considerable variability in the inflammatory response may be due to differences in the infecting rabies virus strain. Rabies viral antigen is frequently identified in cases where Negri bodies are absent and can be shown in non-CNS tissue including the cornea and nasal mucosa.

Treatment

No effective therapies exist for rabies after the development of symptoms. Of the individuals who have survived, one received preexposure immunization and eight received postexposure prophylaxis prior to the onset of symptoms. There has been a single case of a 15-year-old girl who was in contact with a bat 1 month prior to symptom onset and did not receive postexposure prophylaxis who survived after treatment with a combination of medical therapies, which included therapeutic coma with ribavirin, amantadine, benzodiazepines, and ketamine, dubbed the "Milwaukee protocol." This paradigm with case-by-case modifications for the treatment of rabies remains controversial, as at least 26 subsequent cases have failed to repeat this isolated success. Additional therapies for rabies, including Ig plus vaccination, ribavirin, and interferon α, have not been successful to date. Thus, the best approach to rabies is exposure avoidance and vaccinating those anticipating potential exposure. Access to postexposure prophylaxis may be lifesaving for those who do become exposed.

ARENAVIRUSES

Arenaviruses are present throughout the world and infect mammalian, largely rodent, species and reptiles endemic to their respective geographic region. Currently, there are 41 distinct viral species recognized in the genus *Mammarenavirus* that encompasses virus that infect mammals. These are negative-sense single-stranded RNA viruses. "Old world" arenaviruses include Lassa and Luho virus, largely confined to the African continent, and lymphocytic choriomeningitis virus (LCMV), which has a global distribution via its *Mus musculus* host. "New world" arenaviruses include Whitewater Arroyo virus in North America, Junin virus in Argentina, and Machupo virus in Bolivia and parts of Paraguay. Recent surveillance indicates there are novel arenavirus strains circulating in Asia, which are phylogenetically similar to "old world" arenaviruses, and some strains have the capacity to cause human infection.

In rodent hosts, a typically nonpathogenic chronic viremia can result in transmission to humans via direct contact that includes animal bites or through inhalation of infectious urine and feces. The LCMV causes neurologic diseases further described in the following section. Lassa, Whitewater Arroyo virus, Junin, and Machupo all cause hemorrhagic fever, with mortality rates of 15% to 35%. Symptoms start as a febrile illness that can progress to encephalopathy and severe thrombocytopenia and platelet aggregation inhibition, resulting in multifocal hemorrhage. These infections tend to occur in outbreaks, and men are more frequently affected than women, a feature potentially related to exposure patterns.

Lymphocytic Choriomeningitis Virus

A common mode of LCMV infection is via exposure to infected rodents and is typically asymptomatic when the host is immune competent. Although LCMV is common in the house mouse, LCMV outbreaks in humans have also been linked to pet hamsters. Reported outbreaks in the setting of solid organ transplantation occur rarely, but with uniformly fatal outcomes. Many solid organ donors in whom the transplant recipients died from LCMV infection were unaware of being infected. Vertical transmission can also occur.

Clinical Manifestations

In humans, LCMV incubation time is typically 1 to 2 weeks followed by fevers, chill, and general malaise. The LCMV is neurotropic, and viremia can result in carriage of virus to brain. The most common neurologic complication is self-limited viral meningitis, eponymously known as *Wallgren syndrome*; encephalitis is rare, although in a study of undiagnosed encephalitis, 2.3% individuals had LCMV infection, suggesting the infection may

be underdiagnosed. There are cases of LCMV infection associated with acute hydrocephalus. Other complications include orchitis, arthritis, pericarditis, pancreatitis, and cutaneous rash.

Diagnosis and Treatment

Although CSF studies in the immunocompromised may be acellular, in immune competent hosts, moderate to striking lymphocytic pleocytosis can occur (exceeding 1,000 cells/μL) in addition to elevated protein concentrations and hypoglycorrhachia. Pleocytosis can persist for over 1 month, an unusual feature in viral meningitis. The LCMV RNA can occasionally be detected in blood or CSF, but diagnosis is more reliably made by serology. To our knowledge, there are no current trials of antiviral agents in human LCMV disease, and treatment remains supportive (level III: expert opinion).

The LCMV is also an important teratogen, and reported cases are largely described in the United States. About half of the mothers had symptomatic infections, and one-third had rodent exposures, which suggests an education potential for prevention purposes. Children born to these mothers suffered chorioretinitis, hydrocephalus, and/or periventricular calcifications.

Adenovirus

Adenovirus is a nonenveloped, double-stranded DNA virus with an icosahedral capsid belonging to the *Adenoviridae* family. Infection primarily occurs in mucoepithelial cells of the respiratory tract, conjunctiva, and gastrointestinal tracts, followed by lymphoid tissue replication and subsequent viremia. Infections can be monophasic, but the virus can alternatively establish latency and oncologic transformation.

Adenovirus infection of the nervous system in immunocompetent adults is rare and described in case reports. In at least four large, prospective cohorts identifying clinical causes for encephalitis with approximately 1,000 individuals, most adults, none were attributed to adenovirus. Neurologic symptoms, including seizures, encephalitis, and visual hallucinations in the setting of adenovirus infection, has been reported in 3% to 5% of infected children in cohort studies; most cases do have adenovirus detected in the CSF but detected in the respiratory or gastrointestinal tract. Adenovirus infection in adults typically occurs in the setting of primary or secondary immunodeficiency and can be devastating in when disseminated. Meningoencephalitis may progress to involve the spinal cord resulting in myelitis with other features that include headache, fever, stupor, and coma. The CSF may show elevated protein concentration and detectable adenovirus DNA. Adenovirus has tropism for ependymal cells resulting in its inflammation; other viruses that have tropism for the ependyma include CMV and mumps virus. The MRI abnormalities are nonspecific with T2 hyperintense signal in temporal lobes, bilateral limbic systems, brainstem, and cerebellum along with mild patchy enhancement, mass effect, and hemorrhage in some cases.

Pathology demonstrates widespread gliosis, neuronal loss, lymphocytic infiltrates, microglial nodules, necrosis, and adenoviral neuronal inclusions most prominent in the brainstem and diencephalon, with the posterior horns predominantly affected in myelitis (**Fig. 69.10**). Although limited epidemiologic data on outcomes exist, reported outcomes are poor in immunosuppressed individuals with adenoviral meningoencephalitis. Observational case series have supported limited efficacy for cidofovir and riboviran in the treatment of adenovirus infections in immunocompromised hosts, but no controlled trials determining efficacy of these agents in adenoviral meningoencephalitis are available (optional, level III: expert opinion). Brincidofovir is an investigational orally administered conjugate of cidofovir developed for the treatment of adenovirus infection, although its efficacy for CNS infection is unknown (**Table 69.2**).

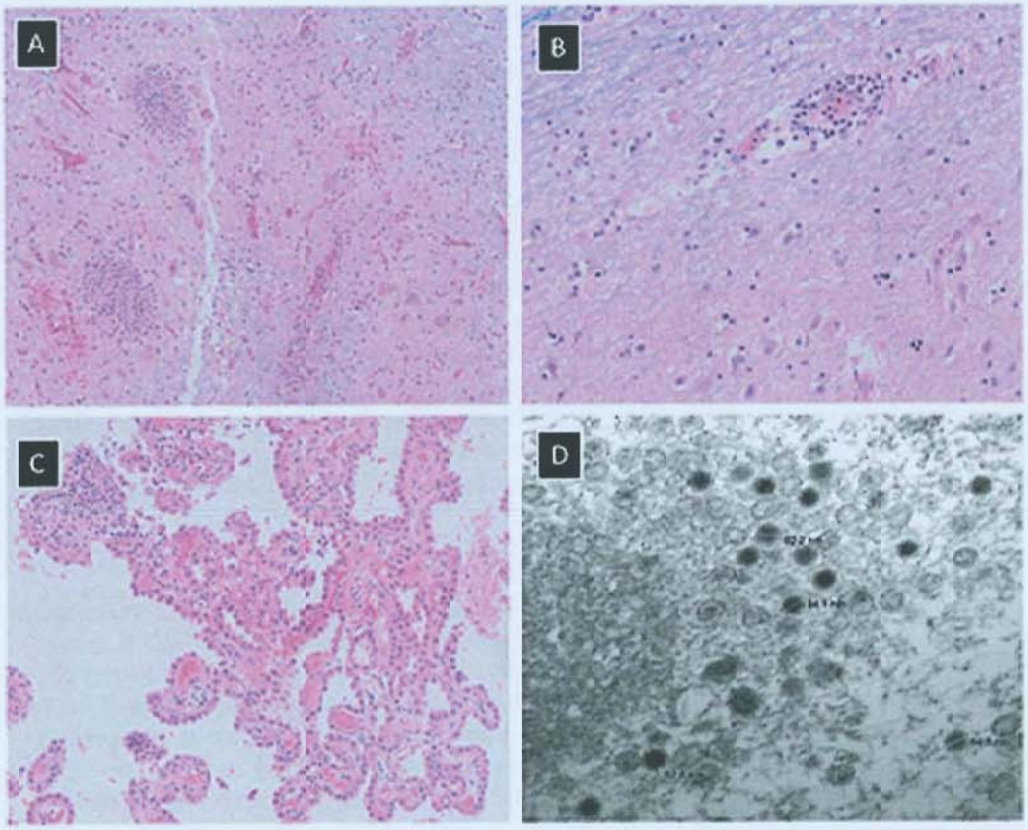

FIGURE 69.10 Neuropathology of adenovirus encephalitis. **A:** Hematoxylin and eosin-stained section of the cerebellar dentate nucleus shows two prominent microglial nodule with associated lymphocytic infiltrates. **B:** Hematoxylin and eosin-stained section of the basal ganglia shows the perivascular nature of lymphocytic infiltrates. **C:** Hematoxylin and eosin-stained section of the choroid plexus of the lateral ventricle shows inflammation present within the structures of the choroid plexus, which leads to ventriculitis. **D:** Electron microscopy image shows multiple icosahedral viral particles within the nuclei of a neuron, consistent with adenovirus.

TABLE 69.2 Antiviral Agents for Prophylaxis and Treatment of Herpes Central Nervous System Disease[a]

Antiviral Agents for Treatment of CNS Disease	HSV	VZV	CMV	EBV	HHV-6
Commercially Available					
Acyclovir (IV)	x	x			
Ganciclovir (IV)		Alternative	x + foscarnet[b]		x[c]
Foscarnet (IV)			x + ganciclovir[b]		x
Cidofovir (IV)			Second-line agent[d]		Second-line agent
Activity of Antiviral Agents Used in Prophylaxis	**HSV**	**VZV**	**CMV**	**EBV**	**HHV-6**
Commercially Available					
Acyclovir/valacyclovir/famciclovir[e]	x	x	High dose +/−		
Ganciclovir (IV)/valganciclovir (orally)	x	x	x		x
Letermovir			x		x
Novel/Investigational Antiviral Agents					
Brincidofovir (cidofovir prodrug)[f]	x	x	x	x	x
Maribavir[g]	x			x	

Abbreviations: CMV, cytomegalovirus; CNS, central nervous system; EBV, Epstein-Barr virus; HHV-6, human herpesvirus 6; HSV, herpes simplex virus; IV, intravenous; VZV, varicella-zoster virus.
[a]Prophylaxis table courtesy of Dr. Camille Kotton, MGH.
[b]Dual therapy in cases of severe CNS disease (eg, encephalitis); monotherapy can be considered if unable to tolerated dual therapy or in mild disease (eg, CMV mononeuritis multiplex with mild motor deficits).
[c]Ganciclovir may not be active against HHV-6A due to resistance.
[d]Cidofovir is alternative in patients who are unable to tolerate other options; no trial data for CNS neurologic disease, evidence for use in CMV retinitis.
[e]Specifically in prophylaxis.
[f]Outside of CMV, no clinical data on therapeutic efficacy with other herpes viruses; primarily in vitro studies.
[g]Primarily in vitro data.
Note: x indicates therapeutic efficacy.

HERPESVIRUSES

Human herpesviruses are neurotropic viruses that establish latent infections within the nervous system for the lifetime of their host. These viruses contain double-stranded DNA molecules and consist of eight members: herpes simplex virus 1 and 2 (HSV-1, HSV-2); VZV; CMV; EBV; and human herpesvirus 6, 7, and 8 (HHV-6, HHV-7, HHV-8, respectively). These are pleiotropic viruses capable of tissue injury, vasculitis, angiogenesis, and tumorigenesis. Antiviral therapeutics for herpes viruses are shown in Table 69.2.

Herpes Simplex Virus 1 and 2

The HSV-1 and HSV-2 share 70% genomic homology, and both establish latent infections in dorsal root ganglia. These viruses can reactivate years later and cause meningitis (HSV-2 predominantly) or encephalitis (HSV-1 primarily). In adults, seroprevalence for HSV-1 and HSV-2 is 50% to 90% and 4% to 40%, respectively.

Herpes Simplex Virus Encephalitis

The HSE is the most common cause of encephalitis in immunocompetent people in the United States, Europe, and Australia. Two to three cases per million population per year occur with peak incidence in the 60s. Most commonly, infection is associated with HSV-1, although HSV-2 can be responsible for HSE in immunosuppressed individuals or in neonates. The pathogenesis for HSE involves reactivation within the trigeminal ganglion with axonal spread into the frontal and temporal lobes, CNS reactivation, and/or primary infection of the CNS.

Clinical Manifestations

Clinical presentations represent symptoms associated with temporal lobe involvement and include headache and fever, with personality or behavioral changes, disorientation, and/or seizures. The combination of fever and headache with personality changes or confusion is seen in the majority of cases, although only rarely will an individual have the complete triad of symptoms (Fig. 69.11).

Diagnosis

The CSF is abnormal in more than 95% of HSE patients, revealing a moderate pleocytosis with predominately mononuclear cells. Red blood cells are frequently present. There can be a moderate increase in CSF protein concentration, whereas hypoglycorrhachia is seen only occasionally and not expected. The PCR for HSV-1 is 98% sensitive and 94% specific. False-negative results can be seen during the first 72 hours of illness, and testing can turn positive 1 to 2 days later. The PCR results can remain positive even while on treatment in 40% of HSE patients, although by and large, these statistics do not come from therapy with acyclovir. The CSF white blood cell count in immunocompromised hosts may not be elevated, and in general, immunocompromised patients have lower white blood cell count numbers in comparison to those with healthy immune systems. The EEG changes are nonspecific and classically demonstrate periodic lateralized epileptiform discharges or seizures. The MRI is the superior imaging modality, demonstrating abnormalities 24 to 48 hours earlier than CT. The diagnosis of HSE is supported by T2 hyperintensities in cortical and subcortical regions of the medial temporal lobes, insula, orbitofrontal, and cingulate gyri (see Fig. 69.11A).

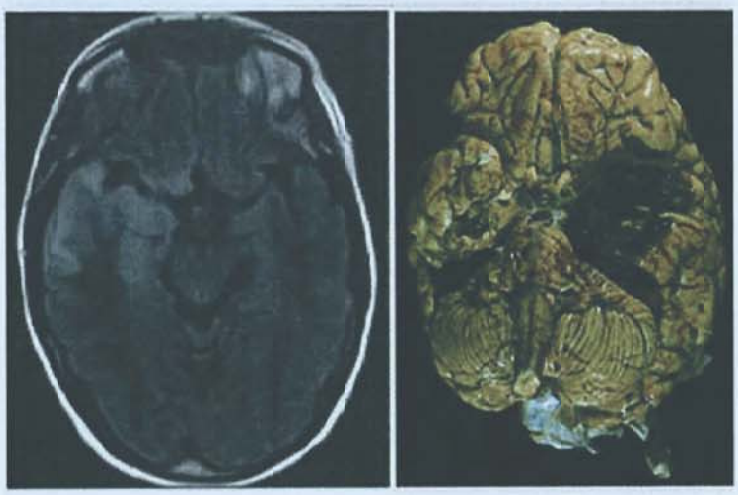

A B

FIGURE 69.11 A: Axial T2-weighted fluid-attenuated inversion recovery magnetic resonance imaging at the level of the superior cerebellar peduncle and tentorium cerebelli in a patient with limbic encephalitis due to herpes simplex virus 1 demonstrates T2 hyperintensity and edema in the anterior temporal lobe on the right. B: Macroscopic view of the base of the brain after fixation shows hemorrhagic necrosis of the left temporal lobe and cavitated necrosis of the right temporal lobe in this case of herpetic encephalitis.

There may be additional evidence of subacute hemorrhages within edematous brain tissue. Restricted diffusion correlates with cytotoxic edema and is present early in disease. Because the clinical and radiologic features together with CSF analysis are typically sufficient for diagnosis, pathologic evaluation is seldom needed. Characteristic neuropathologic changes of herpetic encephalitis include extensive necrotizing involvement of the temporal lobes with associated hemorrhage (see Fig. 69.11B), and microscopically abundant inflammatory infiltrates dominated by macrophages and lymphocytes, with limited evidence of viral cytopathic changes. In the chronic phase, the lesions evolve into cavitary spaces with surrounding gliosis. The presence of HSV-1/HSV-2 particles can be confirmed by immunohistochemistry or electron microscopy.

Treatment

The introduction of acyclovir in 1984, which prevents viral replication by DNA polymerase inhibition, resulted in dramatically reduced mortality rates from HSE. Acyclovir for HSE is dosed at 10 mg/kg every 8 hours for 21 days in patients with normal renal function LEVEL 2[1,2]; relapse is an issue in undertreated patients. If the patient is not clinically improving, foscarnet can be substituted for acyclovir.

Resistance to acyclovir is uncommon in patients who have not received treatment in the past. Acyclovir resistance stems from viral thymidine kinase mutations in 95% of cases or in viral DNA polymerase genes. In immunocompromised patients receiving long-term prophylactic acyclovir, the risk of acyclovir-resistant HSV and VZV increases, and treatment with foscarnet and cidofovir are considered second-line agents (expert opinion).

Outcome

The HSE is a medical emergency, as prognosis is dependent on early initiation of treatment. Despite highly favorable results with acyclovir, treatment initiation continues to be delayed primarily due to failure to recognize the disease early, and predictors of adverse outcomes despite treatment include age (older than 30 y old), Glasgow Coma Scale score less than 6, and duration of symptoms prior to starting acyclovir. The HSE can trigger an autoimmune encephalitis in 5% to 27% of cases with neurologic deterioration similar in clinical features to HSE reactivation. The development of antibodies targeting neuronal antigens (*N*-methyl-D-aspartate receptor or other antibodies) proceeded clinical symptoms and occurs on average 2 months after initial infection. Based on case series and expert opinion publications, treatment for autoimmune encephalitis post-HSE infection can include steroids, IVIG, and other immunomodulatory therapies once HSV infection is confirmed to be negative.

Neonatal Herpes Simplex Virus 2 Encephalitis

Neonatal HSV infections are life-threatening infections in newborns. In the United States, neonatal HSV encephalitis affects approximately 1,500 to 2,220 babies per year, and HSV-2 accounts for 70% of these cases. The HSV infections in infants are grouped into three categories: disseminated disease; CNS involvement; and limited disease to the skin, eyes, and/or mouth, and classification is predictive of morbidity and mortality. Factors influencing outcomes in neonatal HSE include prematurity, seizures, and multiple dermatologic infections of the skin. The clinical manifestations include nonspecific signs of encephalitis/meningitis such as lethargy, poor feeding, labile temperature, seizures, opisthotonus, and bulging fontanels. The median age of presentation for HSV-2 encephalitis is day 16 to 19 of life. Pathologically, as opposed to typical herpetic encephalitis, the necrotizing lesions do not show a preference for specific brain regions, and nuclear viral inclusions are more frequent due to an overall high viral burden.

Neonatal CSF HSV PCR is highly sensitive and specific for herpes DNA. The HSV DNA is detectable in the first week of illness even while on antiviral therapy. Initiation of acyclovir should ideally occur before the development of CNS disease, disseminated disease, or depressed consciousness as this has been shown to improve outcomes. The first-line treatment for neonatal HSE is intravenous acyclovir at 60 mg/kg/d divided three times a day for 21 days LEVEL 2.[3] It is recommended to obtain a repeat CSF HSV PCR at the end of therapy and, if HSV DNA is still present, to continue therapy. There is higher morbidity and mortality associated with prolonged HSV infection despite therapy. Mortality in the era of antiviral therapy is 4% for CNS HSV disease at 1 year. Long-term neurologic consequences include cerebral palsy, intellectual disabilities, attention deficits, and epilepsy.

Benign Recurrent Lymphocytic Meningitis

A syndrome of recurrent episodes of benign, self-limited, sterile meningitis were first described by Mollaret in 1944. For years, the condition was referred to as *Mollaret meningitis*.

Pathobiology

Benign recurrent lymphocytic meningitis has been associated with herpes virus infections. In recent years, detection of HSV-2 genome by PCR has been most often, but not uniformly, reported.

Other cases have been linked to varicella-zoster infection. The CNS epidermoid cysts can give rise to Mollaret meningitis especially with surgical manipulation of cyst contents. A familial association, where more than one family member had Mollaret, has been documented. Recently, evidence has shown that some patients develop autoimmune encephalitis after HSV encephalitis, particularly in children. These patients may respond to immunomodulatory treatment.

Clinical Manifestations

The syndrome is characterized by recurrent and spontaneously remitting attacks of headache and nuchal rigidity, usually recurring for 3 to 5 years. Meningitis usually last 2 or 3 days and typically mild without associated neurologic abnormalities. The initial attack can occur anytime between childhood and late adult years, and both genders are equally affected.

Diagnosis

The CSF pleocytosis, mild elevation of protein concentration, and normal glucose is typical during attacks. The cell count ranges from 200 to several thousand cells per cubic millimeter; most cells are mononuclear. Although large endothelial cells are found in the CSF in the early phases, their presence is variable and not required for diagnosis.

Diagnosis and Treatment

Patients with Mollaret meningitis recover rapidly and spontaneously without specific therapy. There is no effective therapy for shortening the attack or preventing attacks. In anecdotal reports, acyclovir was beneficial (level III).

Varicella-Zoster Virus

The VZV is a human herpesvirus that causes both a primary infection (chickenpox) and can reactivate, producing shingles (zoster), meningitis, vasculitis, and encephalitis. After primary infection, the virus persists in a latent form within cranial nerve or dorsal root ganglia and has periods of reactivation and shedding. A VZV reactivation primarily occurs from the spinal ganglia, with the thorax being the most common site of latent infection, followed by lumbar, cervical, and then sacral regions. A VZV encephalitis is more common in those with immunodeficiency or immunosenescence (waning T-cell immunity to varicella). Neurologic complications can occur without prodromal symptoms including rash. Diagnosis is confirmed with either VZV DNA or anti-VZV IgM detection in the CSF. Intravenous acyclovir 10 to 15 mg/kg every 8 hours for 10 to 14 days is the recommended treatment, with oral prophylaxis prescribed afterward.

Herpes Zoster

Herpes zoster primarily is seen in those older than age 50 years and in immunocompromised people, particularly those with HIV or transplant recipients. Over 30% of the population will have herpes zoster at some point in their life. There is an age-specific rise in incidence rates in those older than age 80 years to 8 to 12 per 1,000 person-years. It is estimated the number of zoster infections worldwide is rising because the general population is aging, the availability of antiviral treatment has had the effect of more people being diagnosed, and those who are immunocompromised are living longer.

Pain typically heralds the onset of zoster. The pain of zoster is described as severe, sharp, radicular pain in the distribution of the affected nerve root. The pain can be associated with pruritus and paresthesia. A unilateral dermatomal vesicular rash in the area supplied by the affected root or roots typically follows days later. The vesicles are usually clustered and contain clear fluid, which then desquamate and scab within 5 to 10 days. Occasionally, the pain is present without the ensuing rash in a condition known as *zoster sine herpete*. Treatment choices for uncomplicated zoster include oral acyclovir, valacyclovir, or famciclovir with preferential use of valacyclovir or famciclovir due to similar dosing and better CNS pharmacokinetics. A 7- to 10-day course of antiviral therapy is recommended LEVEL 1.[4]

Cranial ganglia are affected in approximately 20% of people. In those with cranial nerve involvement, the trigeminal nerve is most often affected. Zoster ophthalmicus, within the cranial nerve V1 distribution of the trigeminal nerve, is often accompanied by keratitis and can lead to blindness. A vesicular rash at the tip of the nose (Hutchinson sign) is a strong predictor of ocular involvement, indicating involvement of the nasociliary branch of V1, which also supplies the cornea and conjunctiva. A herpes zoster rash can precede optic neuritis or ophthalmoplegia. The combination of facial palsy and vesicles in the external auditory canal, tympanic membrane, or on the ipsilateral anterior tongue or hard palate is termed *Ramsay Hunt syndrome*. This syndrome is an indicator of zoster involvement of the facial nerve. The facial palsy in Ramsay Hunt syndrome can be severe, and those affected are less likely to recover.

A common complication of zoster is the development of postherpetic neuralgia (PHN), occurring in at least one-third of people affected by shingles. The definition of PHN varies but is generally defined as continued pain in the affected dermatome that persists beyond 4 to 6 weeks after resolution of a rash. The risk of developing PHN varies and is highest in the elderly as well as those who are immunocompromised. Several prospective studies report that 30% to 50% of patients with PHN experience pain lasting over 1 year and with some experiencing pain lasting up to 10 years. The central mechanisms for PHN remain unknown. Treatment of PHN is difficult, and pain can be refractory to multiple analgesics. Combinations of topical treatments (lidocaine or capsaicin) and oral analgesics (tricyclic antidepressants, anticonvulsants, and opioids) are typically used. Interventions such as sympathetic nerve blocks, epidural injections of lidocaine or steroids, or pulsed radiofrequencies have either failed to demonstrate benefit or the data is not robust to recommend these procedures.

A VZV infection can rarely result in muscle weakness affecting bulbar, limb, or truncal muscles and is typically within the distribution predicted by the rash. For example, peripheral facial weakness is seen with VZV oticus or unilateral diaphragmatic paresis when affecting the cervical myotomes. Sacral herpes zoster can result in neurogenic bladder and loss of anal sphincter control. Segmental zoster paresis is highly associated with PHN. In patients with postganglionic lesions, an MRI can show T2 signal hyperintensity within the affected plexus or nerve, enlargement of the nerve, or enhancement.

Symptomatic ataxia can occur with primary varicella infections and is traditionally seen in children. Acute cerebellar ataxia is due to either direct viral infection of the cerebellum or is a parainfectious process. Ataxia can be antecedent to or present up to 14 days after the onset of a primary varicella rash. Those with varicella-related acute cerebellar ataxia tend to have worse ataxia than seen in other viral syndromes but have more rapid rates of recovery with good neurologic outcomes (Fig. 69.12).

FIGURE 69.12 Midsagittal T2-weighted **(far left)** and postcontrast T1-weighted **(middle)** images of the thoracic spine from a patient with varicella-zoster myelopathy show multiple levels of intrinsic cord T2 hyperintensity **(left)** with patchy enhancement **(middle)** from T10 to T12 *(arrow)*; axial T2-weighted image **(right)** at the level of T12 demonstrates both white and gray matter involvement by the lesion.

Additionally, the VZV is emerging as a relevant ischemic and hemorrhagic stroke risk factor. Large population studies in the United Kingdom and Taiwan show an increase in the incidence of stroke or transient ischemic attack the year following herpes zoster, with a greater relative risk (4.5-fold higher) after herpes zoster ophthalmicus. In pediatric populations, nearly one-third of ischemic arteriopathies are associated with varicella infections.

The hypothesis is that reactivation from ganglia results in viral spread to the adventitia of local blood vessels and eventual transmural migration into the media. The VZV is the only virus known to replicate within arterial vessels. Inflammatory cells including neutrophils in early VZV vasculopathy and T cells are directed to the infected sites secreting inflammatory factors that result in remodeling of the vessel. Pathology demonstrates lymphocytes and multinucleated giant cells, intranuclear viral inclusion bodies, and viral particles in endothelial and vessel wall cells within arteries. The VZV vasculopathy affects small and large arteries with an emphasis on small artery involvement. In contrast, immunocompromised hosts can develop the entire spectrum of small, large, and mixed artery involvement with VZV vasculopathy.

Those affected with VZV vasculopathy do not necessarily have a history of zoster or varicella rash. In cases when a zoster rash is present, there was often a time delay of an average of 4 months between the rash and neurologic symptoms. Anti-VZV IgM in the CSF is more sensitive than CSF VZV DNA for detecting VZV-associated vasculopathy. When VZV vasculopathy is suspected or confirmed, treatment with intravenous acyclovir for a minimum of 14 days is suggested based on category 3 evidence (expert opinion). Oral prednisone at 1 mg/kg for 5 days without taper has been given as an adjuvant to suppress the inflammatory response in arteries, but this dosing is arbitrary.

Myelitis may complicate acute varicella infection or can be a consequence of reactivation. Clinical features include paraparesis with a sensory level approximately 1 to 2 weeks following a dermatomal rash. The T2-weighted MRIs can show focal areas of hyperintense lesions (see Fig. 69.9). Immunocompromised hosts have a more progressive, insidious course that can be ultimately fatal. Histopathology shows areas of necrosis and inflammation with involvement of the spinal cord by VZV. Diagnosis is confirmed by presence of VZV DNA and/or anti-VZV IgM in the CSF. Aggressive treatment with intravenous acyclovir and consideration of corticosteroids may produce a favorable response, although evidence is lacking.

Prevention

To date, there are two vaccines for the prevention of herpes zoster, Zostavax and Shingrix, available in the United States. Zostavax is a live attenuated vaccine that was approved in 2006, whereas Shingrix is an adjuvanted recombinant subunit vaccine that was approved in 2017. A large phase 3 trial for the Shingrix vaccine was performed in 14,759 immunocompetent patients 50 years or older who had not had a previous history of herpes zoster or had an immunosuppressive condition. This trial showed effectiveness in reducing the rate of herpes zoster in vaccinated adults compared to placebo. Current CDC guidelines recommend Shingrix vaccination in immunocompetent adults ages 50 years and older, irrespective if they had a prior episode of shingles or received the Zostavax vaccination, and individuals with chronic medical conditions, those on low-dose immunosuppressive medications or anticipating immunosuppression.

Epstein-Barr Virus

The EBV is a double-stranded, helical DNA gamma herpesvirus that infects B lymphocytes primarily and subsequently establishes latency. In the nervous system, primary infection is associated with meningitis, encephalitis, myelitis, radiculitis, cerebellar ataxia, GBS, and ADEM. These entities and associations are rare. The CNS disease due to reactivation is primarily seen in the setting of profound immune suppression, whereby primary CNS lymphoma is precipitated by EBV-mediated B-cell transformation; this is most closely associated with advanced HIV infection. However, there are case reports of meningoencephalomyelitis occurring in the setting of apparent reactivation.

The EBV is one of the most common infections worldwide. Primary inoculation occurs usually by adolescence through infected saliva transfer. The virus replicates in the pharyngeal tonsils and transforms short-lived B lymphocytes to prevent their apoptosis. Primary infection is usually asymptomatic, but infectious mononucleosis can also occur about a month into infection. This is characterized by profound fatigue, lymphadenopathy, splenomegaly, and fever. The nervous system complications mentioned earlier rarely follow. In ADEM or GBS, pathophysiology is due to parainfectious inflammation. For the other entities, there is at least a component of inflammation, and the degree of direct viral pathogenesis is unknown but likely small if any.

Diagnosis of primary EBV infection is by serology. The detection of viral capsid antigen IgM indicates recent infection; in chronic/latent infection, this antibody wanes in favor of viral capsid antigen IgG and EBV nuclear antigen. The EBV DNA can be detected in blood and CSF as well, but this does not indicate pathogenic connection to the disease. Treatment is supportive aside from EBV-associated primary CNS lymphoma, which is treated as a neoplasm with chemotherapy and/or radiation. In the setting of primary infection nervous system complications, treatment often involves corticosteroids, IVIG, and/or plasmapheresis.

Pathologic studies of CNS EBV infections unrelated to primary CNS lymphoma are lacking. Although the virus is detectable in CSF, its positive predictive value is low. Furthermore, replication can occur in the setting of other infections or illnesses, which makes caution in interpreting results of paramount importance, as this finding could very well be an epiphenomenon. In AIDS-related disease, detection of EBV DNA from CSF has a high sensitivity and specificity for CNS lymphoma.

Cytomegalovirus

The CMV is a common cause of viral opportunistic infections in persons who are immunocompromised from either HIV (CD4 counts <50 cells/mm^3) or those who have undergone transplantation. The CMV is also the most common cause of congenital viral infection resulting in neurologic impairments. In the general population, CMV seroprevalence varies considerably, ranging from 50% to 80% in sexually active adults. Symptomatic CMV infections of the nervous system in adults can result in retinitis, encephalitis, polyradiculitis (usually of the lumbosacral nerve roots), myelitis, or vasculitic mononeuritis multiplex. Since the advent of antiretroviral therapy (ART), the incidence of CMV infections affecting the CNS has decreased.

Clinical Manifestations

The CMV encephalitis clinically presents as a subacute encephalopathy with features of disorientation, lethargy, apathy, and possibly fever. Focal neurologic deficits include seizures and cranial nerve palsies. Clinical signs of brainstem or cerebellar involvement occur in about 30% of those affected. Additionally, CMV can produce a lumbosacral polyradiculopathy that is often associated with concurrent infection elsewhere. Those with polyradiculopathy develop subacute lower extremity weakness, paresthesia, and lumbar pain with progression to flaccid paraplegia and areflexia. Ascending sensory loss is often asymmetric. Sacral involvement includes urinary retention and fecal incontinence. If perianal anesthesia is present, there is likely anal sphincter dysfunction and conus medullaris involvement, similar to Elsberg syndrome most commonly seen in the setting of HSV-2 reactivation.

Although congenital CMV infections are mainly asymptomatic, 10% to 15% of infants will develop symptoms. The incidence varies in different populations around the world with rates ranging from 0.2% to 3% of all births. Vertical CMV transmission can result from primary maternal infection in pregnancy, can follow reactivation of a previous infection, or can be seen by reinfection with a new strain. Long-term sequelae include sensorineural hearing loss, microcephaly, chorioretinitis and/or optic atrophy, seizures, and a wide range of intellectual developmental disorders.

Diagnosis and Treatment

The MRI of the brain can show periventricular enhancement or increased T2 hyperintensity on the ependymal surfaces or can be entirely normal. A CSF pleocytosis is rare, and if present, it is a mild lymphocytic pleocytosis with an elevation in CSF protein concentration. The diagnosis in the correct clinical setting is strongly supported by a positive CSF CMV PCR (sensitivity 60%-100%; specificity 89%-100%). Although there are different histologic patterns of cytomegaloviral congenital encephalitis typical findings include inflammatory infiltrates with lymphocytes, microglial nodules, necrosis, ventriculitis, and typical intranuclear darkly eosinophilic cytomegalic inclusions in infected cells (which may be neurons, glia, and endothelial cells). If inclusions are difficult to identify, immunohistochemistry can be used to demonstrate the presence of CMV.

Anti-CMV treatments can be effective if given early in the disease course. Treatment guidelines for severe CMV infections affecting the nervous system (eg, CMV encephalitis with obtundation) in the adult suggest combination induction therapy with IV ganciclovir 5 mg/kg and IV foscarnet 90 mg/kg twice daily to stabilize disease, if tolerated. The duration is continued until neurologic improvement is evident, which can take weeks to months. If dual therapy is not tolerated, monotherapy IV ganciclovir or foscarnet can be considered. Cidofovir is alternative for treatment for those who are unable to other options (see Table 69.2). Oral valganciclovir is recommended for CMV infections as maintenance therapy for life or until evidence of immune recovery (ie, >100 cells/μL for at least 3-6 mo) with ART is demonstrated. Oral agents for active CNS infection are unlikely to be effective.

Human Herpesvirus 6

Neurologic complications of HHV-6 only occur in the setting of immune suppression, predominantly the posttransplant population. The most frequent scenario is after hematopoietic cell transplantation, when the virus reactivates and causes a limbic encephalitis and occasionally myelitis. Incidence of HHV-6 encephalitis is approximately 4% after first transplantation and 11% in the setting of a second transplant.

Patients with HHV-6 encephalitis will develop headaches and encephalopathy, usually consisting of disorientation, short-term memory dysfunction, seizure, and depressed consciousness, which in the scenario of immune suppression should always raise red flags toward intracranial pathology. The HHV-6 replication can be detected in CSF, and especially when disparate to that in blood, this along with characteristic neuroimaging and clinical scenario support the diagnosis. The caveat is that HHV-6 reactivation is common in this setting, and so isolated detection of viral DNA is not unilaterally diagnostic.

Neuroimaging typically demonstrates bilateral mesial temporal hyperintensities perhaps with extension into the thalamus; pathologic examination has correlated increased HHV-6 DNA to these areas. Antiviral treatment, typically with foscarnet and/or ganciclovir, can reduce viral burden and prevent mortality, although long-term deficits frequently remain (see Table 69.2).

JOHN CUNNINGHAM VIRUS

The JCV is a double-stranded, circular DNA polyomavirus with an icosahedral capsid and no envelope. The virus has a worldwide distribution with a seroprevalence of 39% to 69% in adults (15% seropositive in second decade, up to 80% by the seventh and eighth decade) and viral DNA is detectable in the urine of

20% to 30% of healthy adults. There are seven types and multiple subtypes of JCV, all originating in Africa, resulting in trackable migration patterns.

Pathobiology

Initial infection with JCV occurs via ingestion or inhalation of virions leading to subacute, typically asymptomatic, infection. The JCV can infect and establish latency in the uroepithelium of the kidney or may escape into the peripheral circulation and establish latent infection in lymphoid tissues, including the bone marrow. Reactivation is precipitated in the setting of immune compromise, particularly in the setting of cell-mediated immunosuppression, where JCV can remain in circulating B cells or as cell-free virions. Although mechanisms of viral entry into the brain are not fully understood, JCV productively infects oligodendroglial cells and produces the catastrophic pathologic opportunistic infection known as progressive multifocal leukoencephalopathy (PML). More recently described, JCV can also infect cerebellar granule cells and result in a symptomatic neuronopathy (Fig. 69.13).

Original cases of PML were in patients with lymphoproliferative diseases and those on immune suppression after organ transplantation. In the 1980s, the main risk factor for PML was advanced HIV-1 infection with a CD4 count of less than 200. The early initiation of combined ART has dramatically reduced risk of PML in people living with HIV. In the last 15 years, there has been increased awareness that specific biologic agents can trigger JCV reactivation and result in PML. The most notable is natalizumab, a monoclonal antibody to $\alpha4\beta1$ and $\alpha4\beta7$ integrin and used to prevent multiple sclerosis relapses. In 2019, PML was reported in more than 750 patients taking natalizumab and requires providers to use a PML risk minimization program. Other biologic agents associated with PML risk includes but is not limited to fingolimod, dimethyl fumarate, efalizumab, and rituximab. Patients on natalizumab and other disease-modifying agents who develop PML are not systemically immune suppressed and other opportunistic infections are not common in these individuals. This suggests that PML pathogenesis is likely to be more nuanced than simply a lack of immune surveillance.

The JCV genome has three main regions that include the regulatory region (also termed *noncoding control region*), early viral gene, and late viral gene. The regulatory region is hypervariable and contains mutations that are thought to be crucial for JCV virulence and neurotropism. The late viral gene encodes for viral structural proteins such as major viral capsid protein-1, which can also acquire mutations, which may additionally contribute to neuropathogenesis. Once across the CNS barriers, the virus binds cell surface glycoproteins and can use serotonin ($5\text{-}HT_{2A}$) receptors to gain entry. Clathrin-coated vesicles initiate transport into the cell, where the virus travels in a retrograde fashion to the nucleus to establish productive infection. As mentioned earlier, although oligodendrocytes are the primary targets of infection in the brain, certain variants have the rare capability to infect cerebellar granule cells or pyramidal neurons in the cortex. Productive infection leads to cell destruction, demyelination, and macrophage infiltration. This occurs at multiple foci in the brain, and as the infection spreads, plaques form and coalesce.

Clinical Features

Clinically, symptoms manifest with dependence on localization of demyelination. Typical presentations are that of a subacute, focal deficits occurring over several weeks. Cortical weakness, ataxia, language disturbance, visual disturbance, hemispatial neglect, and impaired gait have all been well described in PML. Notably absent are signs/symptoms localizable to the spinal cord, which is spared in this entity.

The JCV is a known precipitant of the immune reconstitution inflammatory syndrome (IRIS) seen with rapid viral clearance upon initiation of combination ART in advanced HIV infection (also in the setting of natalizumab withdrawal). This entity is rare

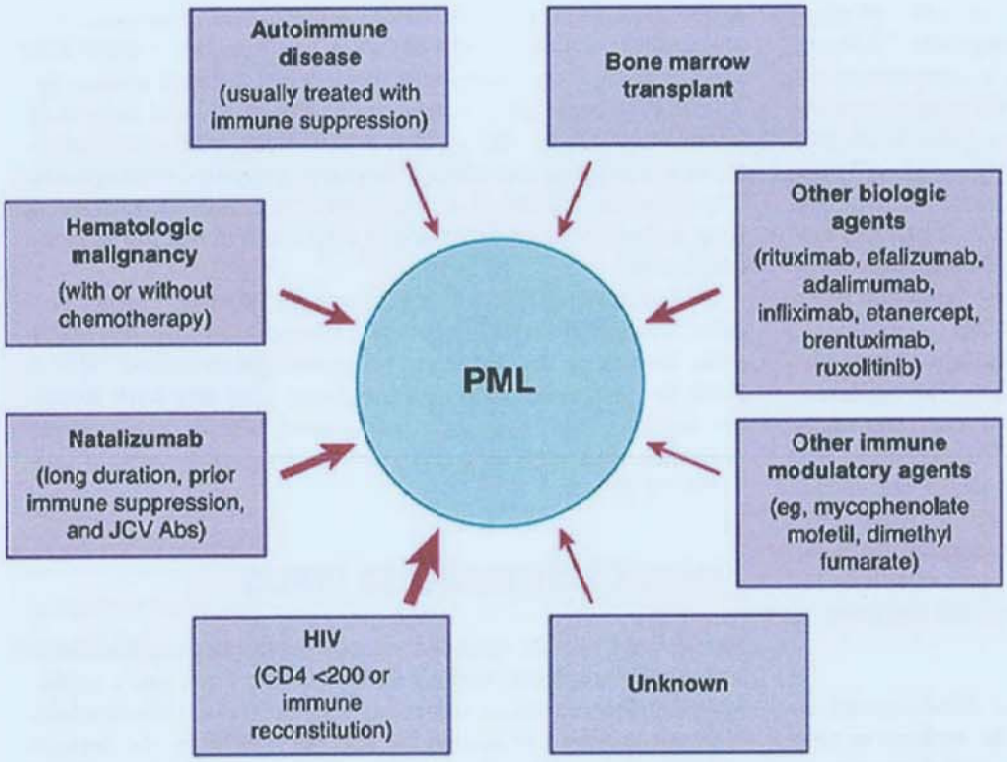

FIGURE 69.13 Predisposing factors for progressive multifocal leukoencephalopathy (PML). Relative number of cases is depicted by arrow size. By far, advanced human immunodeficiency virus (HIV) infection or immune reconstitution has been the most frequent predisposing factor. Natalizumab therapy for the treatment of multiple sclerosis has emerged in the 21st century as an important risk factor, with duration of treatment, prior immune suppression, and John Cunningham virus (JCV) antibody positivity on treatment conferring highest risk. Hematologic malignancy has been the longest standing risk factor. Autoimmune diseases, bone marrow transplant, and other biologic or immune modulatory agents predispose as well, although autoimmune disease contribution unilaterally is controversial, as patients with PML in this setting are nearly always treated with corticosteroids or immune modulatory agents. Finally, some cases are idiopathic. Abbreviation: Abs, antibodies.

in the CNS but occurs in about 1% of treated HIV infections; when opportunistic infection is present at the time of HIV diagnosis, reduction in antigen load prior to initiation of combination ART is one strategy to prevent IRIS. In the setting of PML IRIS, however, this is not possible, as there are no known treatments available for reducing antigen burden. As such, there is no good way to prevent PML IRIS. If it does occur, treatment is supportive and most commonly involves corticosteroids to manipulate the intracranial inflammatory response (level III; expert opinion).

Diagnosis

Although brain biopsy remains the gold standard for in PML diagnosis, structural MRI is vital and assists in clinical staging of the disease. Distinguishing imaging features of PML lesions are involvement of subcortical white matter and involvement of U-fibers best seen as T2 hyperintense lesions and T1-hypointensity as part of the same lesion and diffusion-weighted imaging hyperintensity. Middle cerebellar peduncular involvement is common (Fig. 69.14). Although gadolinium contrast enhancement is rare in HIV-associated PML observed in up to 15% of cases, contrast enhancement is more often present in non–HIV-associated PML diseases, occurring in up to 40% of natalizumab-associated PML. Mass effect is not typically associated with PML lesions. In a rarer form of PML, infection of neurons in the granular cell layer of the cerebellum can result in clinical neuronopathy and detected as cerebellar atrophy on MRI. There is no current clinical role for other neuroimaging techniques (eg, positron emission tomography, magnetic resonance spectroscopy) in the diagnosis and disease monitoring in PML. In the setting of immune compromise, gadolinium enhancement is seen only about 15% of the time, whereas in the setting of immune reconstitution, this number increases but only to about 40%.

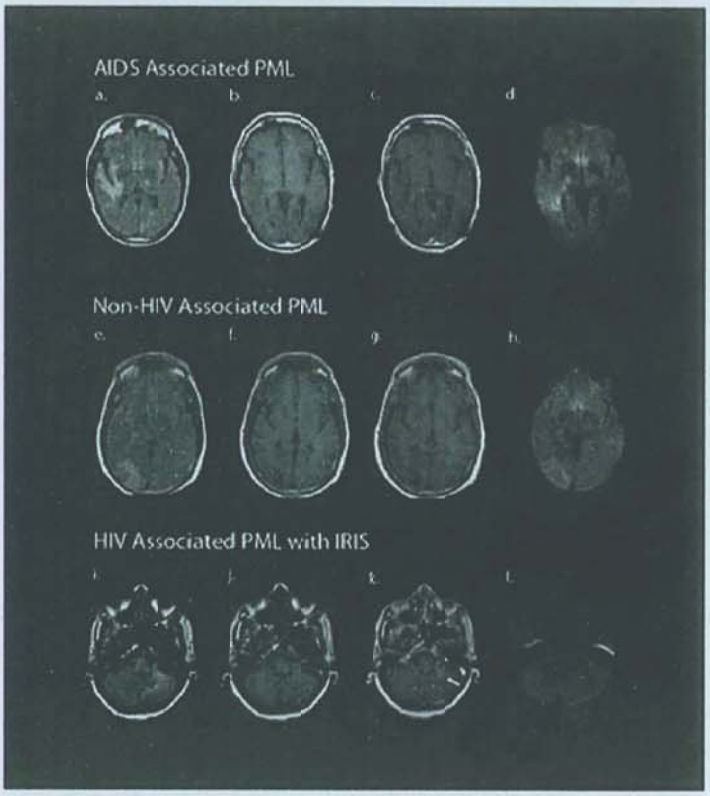

FIGURE 69.14 Axial magnetic resonance images of patients with human immunodeficiency virus (HIV)/AIDS and progressive multifocal leukoencephalopathy (PML) **(top)**, non–HIV-associated PML **(middle)**, and immune reconstitution inflammatory syndrome (IRIS) **(bottom)**. T2-weighted fluid-attenuated inversion recovery images show asymmetrical plaque-like subcortical white matter hyperintense signal **(A,E,I)**, and T1-weighted magnetic resonance imaging after administration of gadolinium shows enhancement in IRIS **(K)** and is not typically seen without immune reconstitution **(C,G)**. Diffusion restriction can be a feature of PML **(D)** but is not seen in all cases **(H,L;** signal consistent with T2-weighted shine through due to long T2 decay time **[H])**.

In a large series of HIV-associated PML cases, CSF cell counts are less than 20 cells/mm^3 with mildly elevated protein observed in over 50% of patients and normal glucose (low glucose was observed in less than 15% of patients). At early stages of PML observed in non–HIV-associated cases and in HIV-infected patients on ART, CSF JCV DNA viral load may be low or undetectable. Thus, in individuals with an MRI pattern suggestive of PML, repeat CSF analysis or brain biopsy can be pursued to make a definitive diagnosis.

The CSF studies otherwise can be normal or can show a modest lymphocytic pleocytosis with normal or slightly elevated protein concentration. These findings notably are all but indistinguishable from acute or chronic HIV meningitis. Hypoglycorrhachia is not found.

The characteristic neuropathologic features of PML are those of confluent demyelinating lesions. Grossly, irregular foci of white-matter brown-gray discolored lesions of diverse sized are typical, with occasional central necrosis and cavitation. Occasionally, these lesions may extend into the adjacent gray matter. Histologically, the lesions demonstrate demyelination, consisting of myelin loss with abundant foamy macrophages some of which contain myelin debris, associated with varying degrees of lymphocytic perivascular inflammation. In cases of IRIS, abundant $CD3^+$ and mostly $CD8^+$ cytotoxic T cells with largely perivascular distribution are seen. Atypical large pleomorphic astrocytes can be admixed with the inflammatory component. Lastly, the characteristic viral cytopathic inclusions seen in enlarged oligodendrocytes in the periphery of the lesion are homogeneous and amphophilic, occupying most of the nucleus, and consist of abundant viral particles (Fig. 69.15). Immunohistochemistry with the SV40 antibody, as well as in situ hybridization, can be used to highlight the presence of virus in infected cells.

Treatment and Prognosis

Current therapy for PML is to restore the host immune response to control JCV replication as there are no current PML-specific treatments. In HIV-infected patients who are not on suppressive ART, ART should be started immediately (level II; nonrandomized trials or observational studies with long-term clinical outcomes). The PML progression stops in more than half of HIV-infected patients started on ART, and although neurologic deficits persist, some individuals experience clinical improvement. In a case series, peripheral blood CD4 T-cell count <100 cells/mm^3 was associated with 2.7 times higher odds ratio for death when compared to higher $CD4^+$ T-cell counts; other factors associated with poor prognosis in PML includes high plasma HIV RNA levels, poor virologic response to ART, and brainstem lesions.

In cases of PML from immunosuppressive agents as in the case of organ transplantation, cessation or dose reduction should strongly be considered (level II; nonrandomized trials or observational studies with long-term clinical outcomes). Although plasmapheresis has been considered in patients on

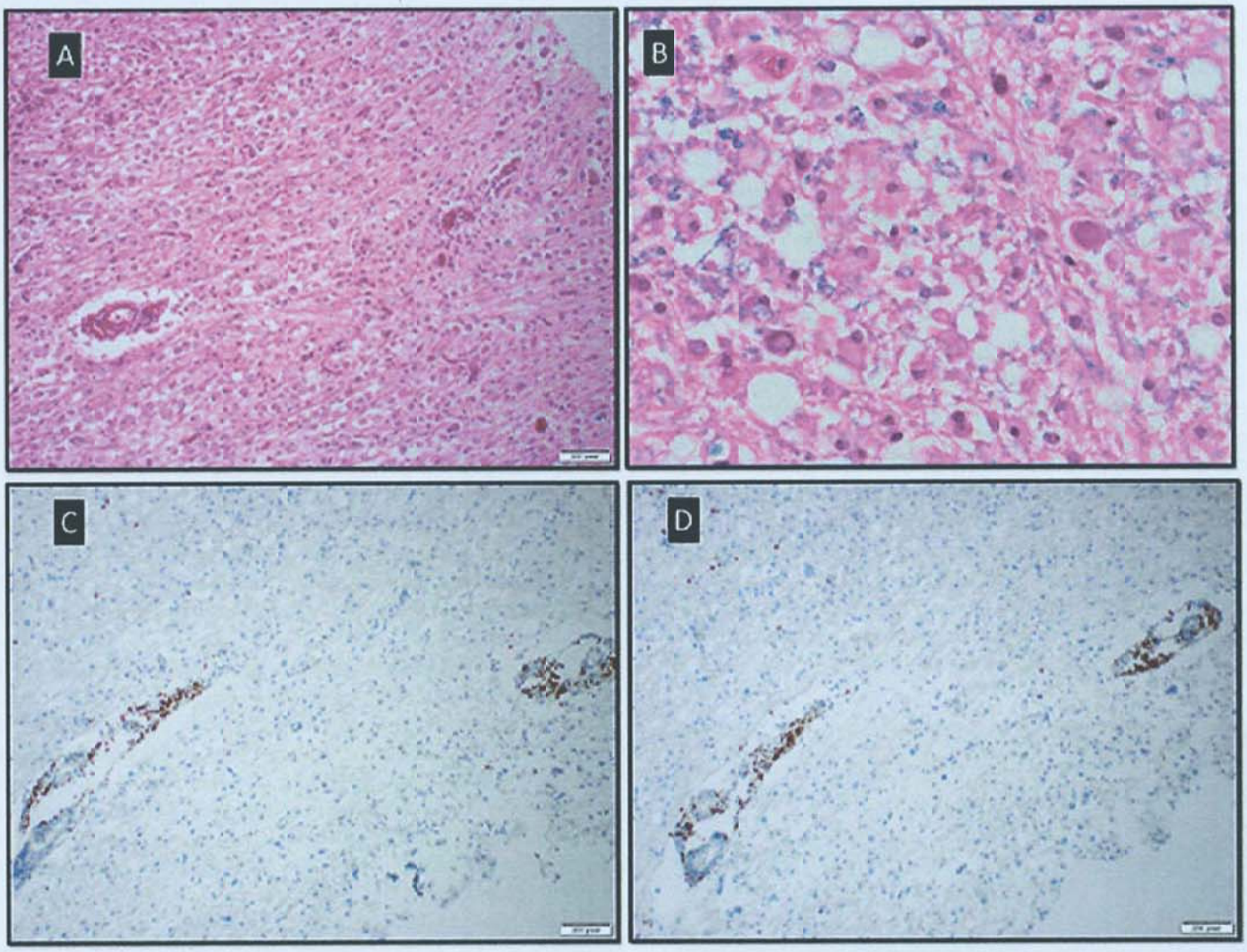

FIGURE 69.15 Neuropathology of progressive multifocal leukoencephalopathy (PML). **A:** Luxol hematoxylin and eosin-stained section of the cerebral white matter shows sheets of macrophages and a striking loss of myelin (expected to be labeled with the blue dye in this stain) consistent with a demyelinating lesion. Focal perivascular lymphocytic infiltrates are present. **B:** Luxol hematoxylin and eosin-stained section on higher magnification demonstrates two glial cells with nuclear viral cytopathic effect consisting of glassy chromatin. **C:** Immunohistochemistry for CD3 demonstrates that most perivascular inflammatory cells are $CD3^+$ T lymphocytes. **D:** Immunohistochemistry for CD8 shows that most of the T cells are $CD8^+$ cytotoxic lymphocytes. In this case, the amount of lymphocytes is compatible with PML and was not sufficient to warrant a histologic diagnosis of the immune reconstitution inflammatory syndrome.

monoclonal antibody therapy, which may accelerate normalization of the immune system, a retrospective review concluded that mortality and morbidity were not altered with plasmapheresis (level III; expert opinion).

There are no specific treatments for PML except to reconstitute the immune system. Cytarabine, cidofovir, and mefloquine have all been studied in either randomized or open-label clinical trials and have not demonstrated efficacy against PML (performed primarily in HIV-associated cases). Therefore, treatment with these agents is not recommended (level II; nonrandomized trials or observational studies with long-term clinical outcomes). Based on in vitro data that the $5\text{-}HT_{2A}$ receptor can serve as mechanism for JCV entry, drugs that block the receptor have been used in the treatment for PML, which includes mirtazapine, olanzapine, and risperidone. There are no clinical trials supporting the use of these agents.

There has been recent interest in use of modified T cells to treat individuals with PML, with a recent case series of three patients treated with human leukocyte antigen–matched BK virus–specific T cells (BK virus is a member of the *Polymoaviridae* family). An additional case series of patients treated with programmed cell death protein 1 inhibitor has also been recently reported. Although these new therapies are compelling, no large-scale trials are currently available to determine the effectiveness of this approach and not clinically approved for use at this time.

LEVEL 1 EVIDENCE

1. Sköldenberg B, Forsgren M, Alestig K, et al. Acyclovir versus vidarabine in herpes simplex encephalitis. Randomised multicentre study in consecutive Swedish patients. *Lancet*. 1984;2(8405):707-711.
2. Whitley RJ, Alford CA, Hirsch MS, et al. Vidarabine versus acyclovir therapy in herpes simplex encephalitis. *N Engl J Med*. 1986;314:144-149.

3. Whitley R, Arvin A, Prober C, et al. A controlled trial comparing vidarabine with acyclovir in neonatal herpes simplex virus infection. Infectious Diseases Collaborative Antiviral Study Group. *N Engl J Med*. 1991;324(7):444-449.
4. Beutner KR, Friedman DJ, Forszpaniak C, Andersen PL, Wood MJ. Valaciclovir compared with acyclovir for improved therapy for herpes zoster in immunocompetent adults. *Antimicrobial Agents Chemother*. 1995;39(7):1546-1553.

SUGGESTED READINGS

Abdullah S, Tan CT. Henipavirus encephalitis. *Handb Clin Neurol*. 2014;123:663-670.

Aicardi J, Goutieres F, Arsenio-Nunes ML, Lebon P. Acute measles encephalitis in children with immunosuppression. *Pediatrics*. 1977;59(2):232-239.

AIDSinfo. Guidelines for the prevention and treatment of opportunistic infections in HIV-infected adults and adolescents. AIDSinfo Web Site. https://aidsinfo.nih.gov/guidelines/html/4/adult-and-adolescent-opportunistic-infection/0. Accessed June 22, 2019.

Anders HJ, Weiss N, Bogner JR, Goebel FD. Ganciclovir and foscarnet efficacy in AIDS-related CMV polyradiculopathy. *J Infect*. 1998;36(1):29-33.

Anlar B, Aydin OF, Guven A, Sonmez FM, Kose G, Herguner O. Retrospective evaluation of interferon-beta treatment in subacute sclerosing panencephalitis. *Clin Ther*. 2004;26(11):1890-1894. doi:10.1016/j.clinthera.2004.11.002.

Armangue T, Spatola M, Vlagea A, et al. Frequency, symptoms, risk factors, and outcomes of autoimmune encephalitis after herpes simplex encephalitis: a prospective observational study and retrospective analysis. *Lancet Neurol*. 2018;17(9):760-772.

Armstrong PM, Andreadis TG. Eastern equine encephalitis virus—old enemy, new threat. *N Engl J Med*. 2013;368(18):1670-1673. doi:10.1056/NEJMp1213696.

Benson PC, Swadron SP. Empiric acyclovir is infrequently initiated in the emergency department to patients ultimately diagnosed with encephalitis. *Ann Emerg Med*. 2006;47(1):100-105. doi:10.1016/j.annemergmed.2005.07.019.

Berger JR, Aksamit AJ, Clifford DB, et al. PML diagnostic criteria: consensus statement from the AAN Neuroinfectious Disease Section. *Neurology*. 2013;80:1430-1438.

Bitnun A, Shannon P, Durward A, et al. Measles inclusion-body encephalitis caused by the vaccine strain of measles virus. *Clin Infect Dis*. 1999;29(4):855-861. doi:10.1086/520449.

Black EM, Lowings JP, Smith J, Heaton PR, McElhinney LM. A rapid RT-PCR method to differentiate six established genotypes of rabies and rabies-related viruses using TaqMan technology. *J Virol Methods*. 2002;105(1):25-35.

Boland TA, McGuone D, Jindal J, et al. Phylogenetic and epidemiologic evidence of multiyear incubation in human rabies. *Ann Neurol*. 2014;75(1):155-160. doi:10.1002/ana.24016.

Bonthius DJ, Stanek N, Grose C. Subacute sclerosing panencephalitis, a measles complication, in an internationally adopted child. *Emerg Infect Dis*. 2000;6(4):377-381. doi:10.3201/eid0604.000409.

Bradley H, Markowitz LE, Gibson T, McQuillan GM. Seroprevalence of herpes simplex virus types 1 and 2—United States, 1999-2010. *J Infect Dis*. 2014;209(3):325-333. doi:10.1093/infdis/jit458.

Buchanan R, Bonthius DJ. Measles virus and associated central nervous system sequelae. *Semin Pediatr Neurol*. 2012;19(3):107-114. doi:10.1016/j.spen.2012.02.003.

Carod-Artal FJ. Neurological complications associated with dengue virus infection. *Rev Neurol*. 2019;69(3):113-122.

Centers for Disease Control and Prevention. Notes from the field: acute hemorrhagic conjunctivitis outbreaks caused by coxsackievirus A24v—Uganda and southern Sudan, 2010. *MMWR Morb Mortal Wkly Rep*. 2010;59(32):1024.

Cerna F, Mehrad B, Luby JP, Burns D, Fleckenstein JL. St. Louis encephalitis and the substantia nigra: MR imaging evaluation. *AJNR Am J Neuroradiol*. 1999;20(7):1281-1283.

Chopra JS, Banerjee AK, Murthy JM, Pal SR. Paralytic rabies: a clinico-pathological study. *Brain*. 1980;103(4):789-802.

Connolly AM, Dodson WE, Prensky AL, Rust RS. Course and outcome of acute cerebellar ataxia. *Ann Neurol*. 1994;35(6):673-679. doi:10.1002/ana.410350607.

Conomy JP, Leibovitz A, McCombs W, Stinson J. Airborne rabies encephalitis: demonstration of rabies virus in the human central nervous system. *Neurology*. 1977;27(1):67-69.

Cui A, Yu D, Zhu Z, et al. An outbreak of aseptic meningitis caused by coxsackievirus A9 in Gansu, the People's Republic of China. *Virol J*. 2010;7:72. doi:10.1186/1743-422X-7-72.

Dacheux L, Reynes JM, Buchy P, et al. A reliable diagnosis of human rabies based on analysis of skin biopsy specimens. *Clin Infect Dis*. 2008;47(11):1410-1417. doi:10.1086/592969.

Dalakas MC, Elder G, Hallett M, et al. A long-term follow-up study of patients with post-poliomyelitis neuromuscular symptoms. *N Engl J Med*. 1986;314(15):959-963. doi:10.1056/NEJM198604103141505.

Debiasi RL, Tyler KL. Molecular methods for diagnosis of viral encephalitis. *Clin Microbiol Rev*. 2004;17(4):903-925. doi:10.1128/CMR.17.4.903-925.2004.

Demir N, Cokar O, Bolukbasi F, et al. A close look at EEG in subacute sclerosing panencephalitis. *J Clin Neurophysiol*. 2013;30(4):348-356. doi:10.1097/WNP.0b013e31829ddcb6.

Deresiewicz RL, Thaler SJ, Hsu L, Zamani AA. Clinical and neuroradiographic manifestations of eastern equine encephalitis. *N Engl J Med*. 1997;336(26):1867-1874. doi:10.1056/NEJM199706263362604.

Dittmar S, Harms H, Runkler N, Maisner A, Kim KS, Schneider-Schaulies J. Measles virus-induced block of transendothelial migration of T lymphocytes and infection-mediated virus spread across endothelial cell barriers. *J Virol*. 2008;82(22):11273-11282. doi:10.1128/JVI.00775-08.

Dubé M, Le Coupanec A, Wong AHM, Rini JM, Desforges M, Talbot PJ. Axonal transport enables neuron-to-neuron propagation of human coronavirus OC43. *J Virol*. 2018;92(17):e00404-18.

Duckworth JL, Hawley JS, Riedy G, Landau ME. Magnetic resonance restricted diffusion resolution correlates with clinical improvement and response to treatment in herpes simplex encephalitis. *Neurocrit Care*. 2005;3(3):251-253. doi:10.1385/NCC:3:3:251.

Ellul MA, Benjamin L, Singh B, et al. Neurological associations of COVID-19 [published online ahead of print July 2, 2020]. *The Lancet Neurology*. doi:10.1016/S1474-4422(20)30221-0.

Finnerup NB, Attal N, Haroutounian S, et al. Pharmacotherapy for neuropathic pain in adults: a systematic review and meta-analysis. *Lancet Neurol*. 2015;14:162-173.

Fooks AR, Banyard AC, Horton DL, Johnson N, McElhinney LM, Jackson AC. Current status of rabies and prospects for elimination. *Lancet*. 2014;384(9951):1389-1399. doi:10.1016/S0140-6736(13)62707-5.

Frey TK. Neurological aspects of rubella virus infection. *Intervirology*. 1997;40(2-3):167-175.

Fu Y-C, Chi C-S, Jan S-L, et al. Pulmonary edema of enterovirus 71 encephalomyelitis is associated with left ventricular failure: implications for treatment. *Pediatr Pulmonol*. 203;35(4):263-268. doi:10.1002/ppul.10258.

Gilden D. Varicella zoster virus and central nervous system syndromes. *Herpes*. 2004;11(suppl 2):89A-94A.

Gilden DH, Beinlich BR, Rubinstien EM, et al. Varicella-zoster virus myelitis: an expanding spectrum. *Neurology*. 1994;44(10):1818-1823.

Gilden DH, Kleinschmidt-DeMasters BK, LaGuardia JJ, Mahalingam R, Cohrs RJ. Neurologic complications of the reactivation of varicella-zoster virus. *N Engl J Med*. 2000;342(9):635-645. doi:10.1056/NEJM200003023420906.

Gnann JW Jr. Varicella-zoster virus: atypical presentations and unusual complications. *J Infect Dis*. 2002;186(suppl 1):S91-S98. doi:10.1086/342963.

Greenlee JE. The equine encephalitides. *Handb Clin Neurol*. 2014;123:417-432. doi:10.1016/B978-0-444-53488-0.00019-5.

Greer DM, Robbins GK, Lijewski V, Gonzalez RG, McGuone D. Case records of the Massachusetts General Hospital. Case 1-2013. A 63-year-old man with paresthesias and difficulty swallowing. *N Engl J Med*. 2013;368(2):172-180. doi:10.1056/NEJMcpc1209935.

Griffin DE, Ward BJ, Jauregui E, Johnson RT, Vaisberg A. Immune activation in measles. *N Engl J Med*. 1989;320(25):1667-1672. doi:10.1056/NEJM198906223202506.

Griffiths P. Cytomegalovirus infection of the central nervous system. *Herpes*. 2004;11(suppl 2):95A-104A.

Guess HA, Broughton DD, Melton LJ III, Kurland LT. Population-based studies of varicella complications. *Pediatrics*. 1986;78(4, pt 2):723-727.

Guo T, Fan Y, Chen M, et al. Cardiovascular implications of fatal outcomes of patients with coronavirus disease 2019 (COVID-19). *JAMA Cardiol*. 2020;5(7):1-8.

Hall WW, Choppin PW. Measles-virus proteins in the brain tissue of patients with subacute sclerosing panencephalitis: absence of the M protein. *N Engl J Med*. 1981;304(19):1152-1155. doi:10.1056/NEJM198105073041906.

Hardie DR, Albertyn C, Heckmann JM, Smuts HEM. Molecular characterisation of virus in the brains of patients with measles inclusion body encephalitis (MIBE). *Virol J*. 2013;10:283. doi:10.1186/1743-422X-10-283.

Hardy GE Jr, Hopkins CC, Linnemann CC Jr, Hatch MH, Witte JJ, Chambers JC. Trivalent oral poliovirus vaccine: a comparison of two infant immunization schedules. *Pediatrics*. 1970;45(3):444-448.

Helms J, Kremer S, Merdji H, et al. Neurologic features in severe SARS-CoV-2 infection. *N Engl J Med*. 2020;382(23):2268-2270.

Hemachudha T, Ugolini G, Wacharapluesadee S, Sungkarat W, Shuangshoti S, Laothamatas J. Human rabies: neuropathogenesis, diagnosis, and management. *Lancet Neurol*. 2013;12(5):498-513. doi:10.1016/S1474-4422(13)70038-3.

Herrmann KL. Rubella in the United States: toward a strategy for disease control and elimination. *Epidemiol Infect*. 1991;107(1):55-61.

Hopkins CC, Hollinger FB, Johnson RF, Dewlett HJ, Newhouse VF, Chamberlain RW. The epidemiology of St. Louis encephalitis in Dallas, Texas, 1966. *Am J Epidemiol*. 1975;102(1):1-15.

Jackson AC, Warrell MJ, Rupprecht CE, et al. Management of rabies in humans. *Clin Infect Dis*. 2003;36(1):60-63. doi:10.1086/344905.

Jensenius M, Myrvang B, Størvold G, Bucher A, Hellum KB, Bruu AL. Herpes simplex virus type 2 DNA detected in cerebrospinal fluid of 9 patients with Mollaret's meningitis. *Acta Neurol Scand*. 1998;98:209-212.

Johnson RT, Griffin DE, Hirsch RL, et al. Measles encephalomyelitis—clinical and immunologic studies. *N Engl J Med*. 1984;310(3):137-141. doi:10.1056/NEJM198401193100301.

Jones LK Jr, Reda H, Watson JC. Clinical, electrophysiologic, and imaging features of zoster-associated limb paresis. *Muscle Nerve*. 2014;50(2):177-185. doi:10.1002/mus.24141.

Kandemirli SG, Dogan L, Sarikaya ZT, et al. Brain MRI findings in patients in the intensive care unit with COVID-19 infection. *Radiology*. 2020:201697.

Kang J-H, Ho J-D, Chen Y-H, Lin H-C. Increased risk of stroke after a herpes zoster attack: a population-based follow-up study. *Stroke*. 2009;40(11):3443-3448. doi:10.1161/STROKEAHA.109.562017.

Kawai K, Gebremeskel BG, Acosta CJ. Systematic review of incidence and complications of herpes zoster: towards a global perspective. *BMJ Open*. 2014;4(6):e004833. doi:10.1136/bmjopen-2014-004833.

Kimberlin DW. Advances in the treatment of neonatal herpes simplex infections. *Rev Med Virol*. 2001;11(3):157-163.

Kimberlin DW. Neonatal herpes simplex infection. *Clin Microbiol Rev*. 2004;17(1):1-13.

Kimberlin DW, Lakeman FD, Arvin AM, et al. Application of the polymerase chain reaction to the diagnosis and management of neonatal herpes simplex virus disease. National Institute of Allergy and Infectious Diseases Collaborative Antiviral Study Group. *J Infect Dis*. 1996;174(6):1162-1167.

Kimberlin DW, Lin CY, Jacobs RF, et al. for Infectious Diseases Collaborative Antiviral Study Group. Natural history of neonatal herpes simplex virus infections in the acyclovir era. *Pediatrics*. 2001;108(2):223-229.

Kimberlin DW, Lin CY, Jacobs RF, et al. for Infectious Diseases Collaborative Antiviral Study Group. Safety and efficacy of high-dose intravenous acyclovir in the management of neonatal herpes simplex virus infections. *Pediatrics*. 2001;108(2):230-238.

Klement C, Kissova R, Lengyelova V, et al. Human enterovirus surveillance in the Slovak Republic from 2001 to 2011. *Epidemiol Infect*. 2013;141(12):2658-2662. doi:10.1017/S0950268813000553.

Kremer S, Lersy F, De Sèze J, et al. Brain MRI findings in severe COVID-19: a retrospective observational study [published online ahead of print June 16, 2020]. *Radiology*. doi:10.1148/radiol.2020202222.

Lal H, Cunningham AL, Godeaux O, et al. Efficacy of an adjuvanted herpes zoster subunit vaccine in older adults. *N Engl J Med*. 2015;372(22):2087-2096.

Langan SM, Minassian C, Smeeth L, Thomas SL. Risk of stroke following herpes zoster: a self-controlled case-series study. *Clin Infect Dis*. 2014;58(11):1497-1503. doi:10.1093/cid/ciu098.

Laothamatas J, Sungkarat W, Hemachudha T. Neuroimaging in rabies. *Adv Virus Res*. 2011;79:309-327. doi:10.1016/B978-0-12-387040-7.00014-7.

Letko M, Marzi A, Munster V. Functional assessment of cell entry and receptor usage for SARS-CoV-2 and other lineage B betacoronaviruses. *Nat Microbiol*. 2020;5(4):562-569.

Lindquist L. Tick-borne encephalitis. *Handb Clin Neurol*. 2014;123:531-559.

Linnoila JJ, Binnicker MJ, Majed M, Klein CJ, McKeon A. CSF herpes virus and autoantibody profiles in the evaluation of encephalitis. *Neurol Neuroimmunol Neuroinflamm*. 2016;3(4):e245. doi:10.1212/NXI.0000000000000245.

Mandell GL, Bennett JE, Dolin R. *Mandell, Douglas, and Bennett's Principles and Practice of Infectious Diseases*. 7th ed. Philadelphia: Churchill Livingstone/Elsevier; 2010.

Mao L, Jin H, Wang M, et al. Neurologic manifestations of hospitalized patients with coronavirus disease 2019 in Wuhan, China. *JAMA Neurol*. 2020;77(6):1-9.

Mease PJ, Ochs HD, Wedgwood RJ. Successful treatment of echovirus meningoencephalitis and myositis-fasciitis with intravenous immune globulin therapy in a patient with X-linked agammaglobulinemia. *N Engl J Med*. 1981;304(21):1278-1281. doi:10.1056/NEJM198105213042107.

Miller E, Cradock-Watson JE, Pollock TM. Consequences of confirmed maternal rubella at successive stages of pregnancy. *Lancet*. 1982;2(8302):781-784.

Modlin JF, Dagan R, Berlin LE, Virshup DM, Yolken RH, Menegus M. Focal encephalitis with enterovirus infections. *Pediatrics*. 1991;88(4):841-845.

Morfopoulou S, Brown JR, Davies EG, et al. Human coronavirus OC43 associated with fatal encephalitis. *N Engl J Med*. 2016;375(5):497-498.

Mori Y, Miyamoto T, Nagafuji K, et al. High incidence of human herpes virus 6-associated encephalitis/myelitis following a second unrelated cord blood transplantation. *Biol Blood Marrow Transplant*. 2010;16(11):1596-1602.

Moturi EK, Porter KA, Wassilak SG, et al. Progress toward polio eradication—worldwide, 2013–2014. *MMWR Morb Mortal Wkly Rep*. 2014;63(21):468-472.

Mulder DW, Parrott M, Thaler M. Sequelae of western equine encephalitis. *Neurology*. 1951;1(4):318-327.

Mulders MN. Global measles and rubella laboratory network support for elimination goals, 2010-2015. *MMWR Morb Mortal Wkly Rep*. 2016;65:438-442.

Mustafa MM, Weitman SD, Winick NJ, Bellini WJ, Timmons CF, Siegel JD. Subacute measles encephalitis in the young immunocompromised host: report of two cases diagnosed by polymerase chain reaction and treated with ribavirin and review of the literature. *Clin Infect Dis*. 1993;16(5):654-660.

Nagel MA, Gilden D. Complications of varicella zoster virus reactivation. *Curr Treat Options Neurol*. 2013;15(4):439-453. doi:10.1007/s11940-013-0246-5.

Nau R, Lantsch M, Stiefel M, Polak T, Reiber H. Varicella zoster virus-associated focal vasculitis without herpes zoster: recovery after treatment with acyclovir. *Neurology*. 1998;51(3):914-915.

Oberste MS, Maher K, Schnurr D, et al. Enterovirus 68 is associated with respiratory illness and shares biological features with both the enteroviruses and the rhinoviruses. *J Gen Virol*. 2004;85(9):2577-2584.

Ohya T, Yamashita Y, Shibuya I, et al. A serial ^{18}FDG-PET study of a patient with SSPE who had good prognosis by combination therapy with interferon alpha and ribavirin. *Eur J Paediatr Neurol*. 2014;18(4):536-539. doi:10.1016/j.ejpn.2014.03.001.

Oldstone MB, Lewicki H, Thomas D, et al. Measles virus infection in a transgenic model: virus-induced immunosuppression and central nervous system disease. *Cell*. 1999;98(5):629-640.

Omland LH, Vestergaard BF, Wandall JH. Herpes simplex virus type 2 infections of the central nervous system: a retrospective study of 49 patients. *Scand J Infect Dis*. 2008;40(1):59-62.

O'Neil KM, Pallansch MA, Winkelstein JA, Lock TM, Modlin JF. Chronic group A coxsackievirus infection in agammaglobulinemia: demonstration of genomic variation of serotypically identical isolates persistently excreted by the same patient. *J Infect Dis*. 1988;157(1):183-186.

Oxley TJ, Mocco J, Majidi S, et al. Large-vessel stroke as a presenting feature of Covid-19 in the young. *N Engl J Med*. 2020;382(20):e60.

Pabbaraju K, Wong S, Chan EN, Tellier R. Genetic characterization of a coxsackie A9 virus associated with aseptic meningitis in Alberta, Canada in 2010. *Virol J*. 2013;10:93. doi:10.1186/1743-422X-10-93.

Pahud BA, Glaser CA, Dekker CL, Arvin AM, Schmid DS. Varicella zoster disease of the central nervous system: epidemiological, clinical, and laboratory features 10 years after the introduction of the varicella vaccine. *J Infect Dis*. 2011;203(3):315-323. doi:10.1093/infdis/jiq066.

Peckham CS, Chin KS, Coleman JC, Henderson K, Hurley R, Preece RM. Cytomegalovirus infection in pregnancy: preliminary findings from a prospective study. *Lancet*. 1983;1(8338):1352-1355.

Peters AC, Vielvoye GJ, Versteeg J, Bots GT, Lindeman J. ECHO 25 focal encephalitis and subacute hemichorea. *Neurology*. 1979;29(5):676-681.

Phuapradit P, Roongwithu N, Limsukon P, Boongird P, Vejjajiva A. Radiculomyelitis complicating acute haemorrhagic conjunctivitis. A clinical study. *J Neurol Sci*. 1976;27(1):117-122.

Piantadosi A, Kanjilal S, Ganesh V, et al. Rapid detection of Powassan virus in a patient with encephalitis by metagenomic sequencing. *Clin Infect Dis*. 2018;66(5):789-792. doi:10.1093/cid/cix792.

Pieracci EG, Pearson C, Wallace RM, et al. Vital signs: trends in human rabies deaths and exposures—United States, 1938–2018. *MMWR Morb Mort Wkly Rep*. 2019;68(23):524-528.

Pierelli F, Tilia G, Damiani A, et al. Brainstem CMV encephalitis in AIDS: clinical case and MRI features. *Neurology*. 1997;48(2):529-530.

Pottage JC Jr, Kessler HA. Herpes simplex virus resistance to acyclovir: clinical relevance. *Infect Agents Dis*. 1995;4(3):115-124.

Poyiadji N, Shahin G, Noujaim D, Stone M, Patel S, Griffith B. COVID-19-associated acute hemorrhagic necrotizing encephalopathy: CT and MRI features. *Radiology*. 2020;296(2):E119-E120.

Puelles VG, Lütgehetmann M, Lindenmeyer MT, et al. Multiorgan and renal tropism of SARS-CoV-2. *N Engl J Med*. 2020;383(6):590-592.

Rabenau HF, Buxbaum S, Preiser W, Weber B, Doerr HW. Seroprevalence of herpes simplex virus types 1 and type 2 in the Frankfurt Am Main Area, Germany. *Med Microbiol Immunol*. 2002;190(4):153-160.

Radmanesh A, Raz E, Zan E, Derman A, Kaminetzky M. Brain imaging use and findings in COVID-19: a single academic center experience in the epicenter of disease in the United States. *AJNR Am J Neuroradiol*. 2020;41(7):1179-1183.

Reda H, Watson JC, Jones LK Jr. Zoster-associated mononeuropathies (ZAMs): a retrospective series. *Muscle Nerve*. 2012;45(5):734-739. doi:10.1002/mus.23342.

Ren R, Racaniello VR. Poliovirus spreads from muscle to the central nervous system by neural pathways. *J Infect Dis*. 1992;166(4):747-752.

Reyes MG, Gardner JJ, Poland JD, et al. St Louis encephalitis. Quantitative histologic and immunofluorescent studies. *Arch Neurol*. 1981;38(6):329-334.

Romero-Sánchez CM, Díaz-Maroto I, Fernández-Díaz E, et al. Neurologic manifestations in hospitalized patients with COVID-19: the ALBACOVID registry [published online ahead of print June 1, 2020]. *Neurology*. doi:10.1212/WNL.0000000000009937.

Roos RP, Graves MC, Wollmann RL, Chilcote RR, Nixon J. Immunologic and virologic studies of measles inclusion body encephalitis in an immunosuppressed host: the relationship to subacute sclerosing panencephalitis. *Neurology*. 1981;31(10):1263-1270.

Rorabaugh ML, Berlin LE, Heldrich F, et al. Aseptic meningitis in infants younger than 2 years of age: acute illness and neurologic complications. *Pediatrics*. 1993;92(2):206-211.

Rotbart HA, Webster AD; for Pleconaril Treatment Registry Group. Treatment of potentially life-threatening enterovirus infections with pleconaril. *Clin Infect Dis*. 2001;32(2):228-235. doi:10.1086/318452.

Sabin AB. Pathogenesis of poliomyelitis; reappraisal in the light of new data. *Science*. 1956;123(3209):1151-1157.

Sauerbrei A, Bohn K, Heim A, et al. Novel resistance-associated mutations of thymidine kinase and DNA polymerase genes of herpes simplex virus type 1 and type 2. *Antivir Ther*. 2011;16(8):1297-1308. doi:10.3851/IMP1870.

Schaller T, Hirschbühl K, Burkhardt K, et al. Postmortem examination of patients with COVID-19. *JAMA*. 2020;323(24):2518-2520.

Schultz DR, Barthal JS, Garrett G. Western equine encephalitis with rapid onset of parkinsonism. *Neurology*. 1977;27(11):1095-1096.

Selvey LA, Johansen CA, Broom AK, et al. Rainfall and sentinel chicken seroconversions predict human cases of Murray Valley encephalitis in the north of Western Australia. *BMC Infect Dis*. 2014;14(1):672.

Silverman MA, Misasi J, Smole S, et al. Eastern equine encephalitis in children, Massachusetts and New Hampshire, USA, 1970-2010. *Emerg Infect Dis*. 2013;19(2):194-201. doi:10.3201/eid1902.120039.

Solomon IH, Normandin E, Bhattacharyya S, et al. Neuropathological features of Covid-19 [published online ahead of print June 12, 2020]. *N Engl J Med*. doi:10.1056/NEJMc2019373.

Spinsanti LI, Diaz LA, Glatstein N, et al. Human outbreak of St. Louis encephalitis detected in Argentina, 2005. *J Clin Virol*. 2008;42(1):27-33. doi:10.1016/j.jcv.2007.11.022.

Tan IL, McArthur JC, Venkatesan A, Nath A. Atypical manifestations and poor outcome of herpes simplex encephalitis in the immunocompromised. *Neurology*. 2012;79(21):2125-2132. doi:10.1212/WNL.0b013e3182752ceb.

Tenforde MW, Rose EB, Lindsell CJ, et al. Characteristics of adult outpatients and inpatients with COVID-19—11 Academic Medical Centers, United States, March-May 2020. *MMWR Morb Mortal Wkly Rep*. 2020;69(26):841-846.

Thomas SL, Minassian C, Ganesan V, Langan SM, Smeeth L. Chickenpox and risk of stroke: a self-controlled case series analysis. *Clin Infect Dis*. 2014;58(1):61-68. doi:10.1093/cid/cit659.

Tomoda A, Nomura K, Shiraishi S, et al. Trial of intraventricular ribavirin therapy for subacute sclerosing panencephalitis in Japan. *Brain Dev*. 2003;25(7):514-517.

Townsend CL, Forsgren M, Ahlfors K, Ivarsson S-A, Tookey PA, Peckham CS. Long-term outcomes of congenital cytomegalovirus infection in Sweden and the United Kingdom. *Clin Infect Dis*. 2013;56(9):1232-1239. doi:10.1093/cid/cit018.

Townsend JJ, Baringer JR, Wolinsky JS, et al. Progressive rubella panencephalitis. Late onset after congenital rubella. *N Engl J Med*. 1975;292(19):990-993. doi:10.1056/NEJM197505082921902.

Tunkel AR, Glaser CA, Bloch KC, et al. The management of encephalitis: clinical practice guidelines by the Infectious Diseases Society of America. *Clin Infect Dis*. 2008;47(3):303-327. doi:10.1086/589747.

Turner KM, Lee HC, Boppana SB, Carlo WA, Randolph DA. Incidence and impact of CMV infection in very low birth weight infants. *Pediatrics*. 2014;133(3):e609-e615. doi:10.1542/peds.2013-2217.

Turtle L, Solomon T. Japanese encephalitis—the prospects for new treatments. *Nat Rev Neurol*. 2018;14(5):298-313.

Tyler KL, McPhee DA. Molecular and genetic aspects of the pathogenesis of viral infections of the central nervous system. *Crit Rev Neurobiol*. 1987;3(3):221-243.

Wadia NH, Katrak SM, Misra VP, et al. Polio-like motor paralysis associated with acute hemorrhagic conjunctivitis in an outbreak in 1981 in Bombay, India: clinical and serologic studies. *J Infect Dis*. 1983;147(4):660-668.

Wasay M, Diaz-Arrastia R, Suss RA, et al. St Louis encephalitis: a review of 11 cases in a 1995 Dallas, Tex, epidemic. *Arch Neurol*. 2000;57(1):114-118.

Weil ML, Itabashi H, Cremer NE, Oshiro L, Lennette EH, Carnay L. Chronic progressive panencephalitis due to rubella virus simulating subacute sclerosing panencephalitis. *N Engl J Med*. 1975;292(19):994-998. doi:10.1056/NEJM197505082921903.

Weinstein L, Shelokov A, Seltser R, et al. A comparison of the clinical features of poliomyelitis in adults and in children. *N Engl J Med*. 1952;246(8):297-302.

Whitley RJ, Alford CA, Hirsch MS, et al. Vidarabine versus acyclovir therapy in herpes simplex encephalitis. *N Engl J Med*. 1986;314(3):144-149. doi:10.1056/NEJM198601163140303.

Whitley R, Arvin A, Prober C, et al. A controlled trial comparing vidarabine with acyclovir in neonatal herpes simplex virus infection. Infectious Diseases Collaborative Antiviral Study Group. *N Engl J Med*. 1991;324(7):444-449. doi:10.1056/NEJM199102143240703.

Williams KH, Hollinger FB, Metzger WR, Hopkins CC, Chamberlain RW. The epidemiology of St. Louis encephalitis in Corpus Christi, Texas, 1966. *Am J Epidemiol*. 1975;102(1):16-24.

Willoughby RE Jr, Tieves KS, Hoffman GM, et al. Survival after treatment of rabies with induction of coma. *N Engl J Med*. 2005;352(24):2508-2514. doi:10.1056/NEJMoa050382.

Wolinsky JS, Waxham MN, Hess JL, Townsend JJ, Baringer JR. Immunochemical features of a case of progressive rubella panencephalitis. *Clin Exp Immunol*. 1982;48(2):359-366.

Wood MJ, Johnson RW, McKendrick MW, Taylor J, Mandal BK, Crooks J. A randomized trial of acyclovir for 7 days or 21 days with and without prednisolone for treatment of acute herpes zoster. *N Engl J Med*. 1994;330(13):896-900. doi:10.1056/NEJM199403313301304.

World Health Organization. *Global polio eradication initiative: annual report 2017: securing a lasting world free of all polioviruses (No. WHO/POLIO/18.01)*. Geneva, Switzerland: World Health Organization; 2018.

Xu J, Zhong S, Liu J, et al. Detection of severe acute respiratory syndrome coronavirus in the brain: potential role of the chemokine mig in pathogenesis. *Clin Infect Dis*. 2005;41(8):1089-1096.

Yan JJ, Wang JR, Liu CC, Yang HB, Su IJ. An outbreak of enterovirus 71 infection in Taiwan 1998: a comprehensive pathological, virological, and molecular study on a case of fulminant encephalitis. *J Clin Virol*. 20;17(1):13-22.

Zhang Y, Xiao M, Zhang S, et al. Coagulopathy and antiphospholipid antibodies in patients with Covid-19. *N Engl J Med*. 2020;382(17):e38.

Zhu N, Zhang D, Wang W, et al. A novel coronavirus from patients with pneumonia in China, 2019. *N Engl J Med*. 2020;382(8):727-733.

70 Human Immunodeficiency Virus (HIV) and Acquired Immunodeficiency Syndrome (AIDS)

Anne Damian Yacoub, Deanna Saylor, Ned Sacktor, Kiran T. Thakur, Carolyn Barley Britton, and Barbara S. Koppel

KEY POINTS

1. Mild forms of cognitive impairment and distal sensory polyneuropathy are common neurologic manifestations of human immunodeficiency virus (HIV) infection.
2. The diagnosis of a primary HIV-related neurologic syndrome requires the exclusion of secondary opportunistic infections, neoplasms, and toxic/metabolic disturbances.
3. Opportunistic infections remain prevalent in HIV+ patients with advanced immunosuppression and in patients not adherent to or unable to receive antiretroviral medications.

INTRODUCTION

AIDS is the most devastating pandemic of the 20th and early 21st centuries. It was first recognized in 1981 through a growing number of reports of rare opportunistic infections, including *Pneumocystis carinii* pneumonia, and malignancies, such as Kaposi sarcoma, occurring in previously healthy men who have sex with men. Similar cases were also discovered in intravenous (IV) drug users. In 1983, human immunodeficiency virus (HIV) type-1 was isolated from human peripheral blood lymphocytes, and shortly thereafter, this retrovirus was established as the cause of AIDS. Central nervous system (CNS) complications due to infection by HIV-1 were first described early in the epidemic when severe neurocognitive disease attributable to the virus was common in individuals with profound immunodeficiency.

Classification of HIV Disease

In 1986, the Centers for Disease Control and Prevention (CDC) proposed staging criteria for HIV infection. Revisions, in 1993, added three laboratory categories that are stratified by CD4 cell numbers and three clinical categories (Table 70.1).

AIDS-defining illnesses were expanded to include positive HIV serology and pulmonary tuberculosis (TB), recurrent bacterial pneumonia, invasive cervical carcinoma, or a CD4 lymphocyte count less than 200 cells/μL. These revisions define the end stage of HIV infection and clarify the relationship of specific clinical syndromes, especially those affecting the nervous system that are not themselves diagnostic of AIDS, to advanced immunosuppression. In contrast to the CDC system, the World Health Organization (WHO) Clinical Staging and Disease Classification System revised in 2006 can be used readily in resource-constrained settings without access to CD4 cell count measurements or other diagnostic and laboratory testing methods (Table 70.2).

The WHO system classified HIV disease on the basis of clinical manifestations that can be recognized and treated by clinicians in diverse settings and by clinicians with varying levels of HIV expertise and training. This classification system guides medical management of HIV-infected persons. CD4 lymphocyte

TABLE 70.1 1993 Centers for Disease Control and Prevention (CDC) Classification of HIV Infection[a]

Laboratory Categories
Category 1—CD4 lymphocyte count >500 cells/μL
Category 2—CD4 lymphocyte count from 200 through 499 cells/μL
Category 3—CD4 lymphocyte count <200 cells/μL
Clinical Categories
Category A—asymptomatic infection, persistent generalized lymphadenopathy, and acute primary HIV infection
Category B—symptomatic conditions not included in the CDC 1987 surveillance case definition of AIDS that are judged by a physician to be HIV related or where medical management is complicated by HIV infection (eg, sepsis, bacterial endocarditis, pulmonary TB, cervical dysplasia or carcinoma, vulvovaginal candidiasis)
Category C—any of the 23 conditions listed in CDC 1987 case definition for AIDS

Abbreviation: HIV, human immunodeficiency virus.
[a]Adapted from U.S. Congress. *The CDC's Case Definition of AIDS: Implications of Proposed Revisions. OTA-BP-H-89.* Washington, DC: U.S. Government Printing Office; 1992.

TABLE 70.2 World Health Organization (WHO) Clinical Staging of Established Human Immunodeficiency Virus (HIV) Infection[a]

HIV-Associated Symptoms	WHO Clinical Stage
Asymptomatic	1
Mild symptoms	2
Advanced symptoms	3
Severe symptoms	4

[a]Adapted from World Health Organization. *HIV/AIDS Programme: Strengthening Health Services to Fight HIV/AIDS. WHO Case Definitions of HIV for Surveillance and Revised Clinical Staging and Immunological Classification of HIV-Related Disease in Adults and Children.* Geneva, Switzerland: World Health Organization; 2007. http://www.who.int/hiv/pub/guidelines/HIVstaging150307.pdf. Accessed October 12, 2020.

count levels and viral load assays have mostly supplanted staging criteria for decisions about antiretroviral therapy. Staging is still useful for prognosis and decisions about opportunistic infection prophylaxis and identifying patients most at risk for opportunistic infections and malignancy.

When a clinical suspicion of HIV exists, both a screening immunoassay as well as HIV virologic testing by polymerase chain reaction (PCR) should be performed. A negative screening immunoassay with positive viral load suggests early HIV infection. A positive screening immunoassay and positive viral load can be seen in either early or established HIV infection. A positive screening immunoassay should prompt a second, antibody only, immunoassay. A negative result on this second test suggests early or acute HIV infection; however, a second positive result does not exclude early infection, and the clinical context should be considered. In all patients with newly diagnosed HIV, genotype drug resistance testing should be performed.

EPIDEMIOLOGY

Epidemiology of HIV Infection in Adults

HIV infection is still an enduring pandemic affecting virtually all population groups and countries. According to the 2018 Joint United Nations Programme on HIV and AIDS (UNAIDS) report, in 2017 there were 36.9 million people worldwide living with HIV infection. There were estimated to be a total of 1.8 million newly infected with HIV in 2017, with 66% of these occurring in sub-Saharan Africa. AIDS-related deaths in 2017 numbered 940,000. Globally, greater reduction in mortality due to AIDS as compared to new HIV infections has seen the total number of people living with HIV rise steadily in recent years. HIV-2 is restricted to West Africa and those countries with historical and socioeconomic ties to the region and commonly co-occurs with HIV-1. Retrospective analysis of banked blood showed that HIV was present in the United States in the 1970s. In 2019, the CDC estimated the prevalence of HIV/AIDS at 1.1 million Americans (Table 70.3). Estimates were that 16% of infected individuals were unaware of their HIV status.

In 2000, AIDS became the leading cause of death among African American men aged 35 to 44 years and women aged 25 to 34 years living in the United States. The disproportionate representation of African American and Hispanic men was felt to be related to IV drug use. More recently, 2017 statistics from the CDC indicate that African Americans represent approximately 13% of the United States population in 2017 but accounted for an estimated 43% of new HIV infections. Hispanic/Latinos accounted for 26% of new HIV infections in the United States in 2016. Although affected by drug use, unprotected heterosexual activity has become the predominant transmission risk for minority women, whereas unprotected homosexual activity remains the main cause of transmissions in males. There has also been a significant increase in the incidence of HIV infection among the elderly. Nearly half of people living in the United States with HIV are age 50 years or older, although new diagnoses of HIV decline in this age category.

The introduction of combination antiretroviral therapy (cART) in 1996 profoundly changed HIV/AIDS epidemiology in the United States and other resource-rich countries. Since the introduction of cART, there has been a 38% decline in incident AIDS cases and a 67% decline in deaths from AIDS in the United States. Progress in some developing countries remains hampered by limited access to formal cART programs. Through President's Emergency Plan for AIDS Relief, UNAIDS, and the WHO as well as nongovernmental organizations and local ministries of health, there has been an increase in formal cART programs in many developing regions, with the hopes of disease stabilization in the next 5 to 10 years.

TABLE 70.3 Epidemiology of Human Immunodeficiency Virus (HIV)/AIDS: United States and Global Data: 2019 and 2018[a]

United States—Through 2018	
Adults/adolescents	1,140,400
Pediatric (<13 y)	1,323
Total	1,141,723
Demographics (Adult)	
Race	
African American	42%
Non-Hispanic white	25%
Hispanic	27%
Gender	
Men	76%
Women	24%
Global—2018	
Total cases through 2012	36,700,000
Sub-Saharan Africa	25,700,000
Asia and the Pacific	5,200,000
Number of new HIV infections in 2017	1,700,000
Deaths due to AIDS in 2017	940,000
Children with AIDS (<15 y) 2017	1,800,000

[a]Adapted from World Health Organization. *HIV/AIDS Programme: Strengthening Health Services to Fight HIV/AIDS. WHO Case Definitions of HIV for Surveillance and Revised Clinical Staging and Immunological Classification of HIV-Related Disease in Adults and Children.* Geneva, Switzerland: World Health Organization; 2007. http://www.who.int/hiv/pub/guidelines/HIVstaging150307.pdf. Accessed October 12, 2020.

The major routes of HIV transmission include sexual contact, mother to child, injection drug use with contaminated needles, and exposure to infected blood or blood products, with sexual transmission being the most common route of exposure worldwide. Worldwide, heterosexual activity is the most common mode of transmission. In 2016 in the United States, homosexual activity was the most common reason for new HIV infection (67%) followed by high-risk heterosexual behavior and injection drug use.

Recipients of blood products or clotting factor for hemophilia, or other coagulation/blood disorders, account for less than 1% of adult AIDS cases. In the United States, routine testing of blood products has largely eliminated this source of infection. Occupational exposure with validated transmission and seroconversion is well documented but rare. Most percutaneous or mucocutaneous exposures have been to blood or bloody fluid. Prospective studies of known exposures estimate the average risk for HIV transmission following percutaneous exposure ("needlestick") to be approximately 0.3%, and after mucous membrane exposure, 0.09%.

Epidemiology of HIV Infection in Children

By the end of 2016, nearly 1,300 children in the United States younger than the age of 13 years were living with HIV infection.

Most children are infected perinatally. Since 1992, perinatal transmission in the United States has declined sharply, from a peak of 1,000 to 2,000 cases annually to only 38 cases in 2006, resulting from successful implementation of CDC guidelines for maternal counseling, testing, and antiretroviral treatment. Between 2012 and 2016, perinatal diagnoses decreased by 41%.

Worldwide, however, perinatal transmission continues to post a large burden on worldwide incidence of HIV infection. In 2017, there were an estimated 1.8 million children younger than age 15 years living with HIV, with 180,000 new infections in 2017. Encouraging is that in Eastern and Southern Africa, a region wide drive to eliminate mother-to-child transmission of HIV continues to yield results. Ninety-three percent of the 940,000 pregnant women living with HIV in the region received antiretroviral prophylaxis in 2017, resulting in an average rate of mother-to-child transmission of under 10%, the lowest in the world. Perinatal infection of children depends on maternal viral load and the stage of pregnancy during which the infection is acquired. After delivery, a substantial number of children return to seronegative status. Hallmarks of early infection include developmental delay and cognitive dysfunction, loss of previously acquired milestones, and vasculopathy that can cause stroke or hemorrhage. In Africa, some studies show no difference in neuropsychological measures and school success in HIV+ children, compared with HIV-negative (HIV−) controls who have similar nutritional and socioeconomic status. However, a mortality rate of 61% by age 4 years for very ill children must qualify such a comparison.

Etiology

HIV is an enveloped RNA lentivirus. It contains an RNA-dependent DNA polymerase (reverse transcriptase) that produces a provirus capable of integrating into host cell DNA. In the target cell, the virus exists in both free and integrated states.

Human HIV infection is considered a cross-species (zoonotic) infection, arising from monkeys infected with simian immunodeficiency virus through multiple independent transmissions. Of the two recognized viral species, HIV-1 is found worldwide and is more prevalent, whereas HIV-2 is found in Western Africa and in Europe among African immigrants and their sexual partners. Sporadic cases of HIV-2 occur in the United States, but they are rare in comparison to HIV-1. A variety of evidence suggests that the AIDS pandemic most likely originated in equatorial Western Africa. HIV-1 is characterized by extensive genetic diversity and can be divided into three classes: group M (major), group O (outlier), and group N (new, non-M, and non-O). Group M is responsible for 90% of cases of HIV infection globally and is represented by nine major subtypes or clades. The HIV-1 subtypes in the United States and Europe differ from the subtypes seen elsewhere in the world. In the United States and Europe, clade B is the predominant subtype, whereas in Sub-Saharan Africa, clades A, C, and D are predominant subtypes.

PATHOBIOLOGY

Primary HIV Infection

The primary infectious event includes breach of a mucosal barrier, enhancing viral entry. Viremia drives infection and massive depletion of CD4 T cells, particularly in the gut-associated lymphoid tissue. The immune reaction to the virus causes activation of CD8 T cells and virus-specific antibody production, which in turn promotes rebound of CD4 T cells and slowed viral replication, although importantly the mucosal lymph system does not recover to its preinfective condition. Progression of HIV is caused in part by this constant immune activation that detrimentally affects the immune system through a combination of direct loss of infected CD4 T lymphocytes and bystander cell killing. Infection of CD4 lymphocytes by HIV, mediated by viral attachment to the cell surface CD4 receptor, leads to cell death. In humans, the CD4 receptor is expressed on several cell types, including neurons and glia in the brain, but there is no evidence of viral replication in cells other than lymphocytes, macrophages, monocytes, and their derivatives. In 1996, a chemokine receptor was identified as a coreceptor that is necessary for viral entry into cells. In acute and early HIV infection, an M-tropic viral strain that prefers to replicate in macrophages with the chemokine receptor CCR5 predominates (R5 strain). In advanced infection, a T-tropic viral strain that prefers T cells with the chemokine receptor CXCR4 evolves and becomes predominant (X4 virus). Genetic variation in the chemokine receptor may affect susceptibility to HIV infection. Relative resistance to infection is observed in individuals who are homozygous for a 32 base-pair deletion in CCR5. Primary HIV infection can be asymptomatic or, in 50% to 70% of the cases, results in an acute, self-limited mononucleosis-like illness with fever, headache, myalgia, malaise, lethargy, sore throat, lymphadenopathy, and maculopapular rash. Painful ulceration of the buccal mucosa may impede swallowing (odynophagia).

Acute infection is characterized by viremia, high viral replication rates (up to 1 million RNA molecules per milliliter), viral isolation from peripheral blood lymphocytes, and high serum levels of a viral-core antigen, p24. Cytotoxic lymphocytes and soluble factors from CD8 lymphocytes are effective in reducing viral load to a set point that differs for each individual. Despite the effective early immune response, there is almost simultaneous immune dysfunction. Neutralizing antibodies, initially immunoglobulin (Ig) M and later IgG, appear in 2 to 6 weeks, resulting in clearance of viremia and a decrease in serum p24 levels. Rarely, antibodies do not appear for several months or, exceptionally, not at all.

Adverse immunologic effects occur early and are more severe in symptomatic persons. An early absolute lymphopenia affects both CD4 helper and CD8 suppressor cells with lymphocyte hyporesponsiveness to mitogens and antigens and thrombocytopenia. Lymphocytosis, especially of CD8 lymphocytes, usually follows with inversion of the CD4/CD8 ratio. Atypical lymphocytes are sometimes seen. Early changes in the CD4/CD8 ratio are usually transient, but reversion to more normal values is accompanied by persistent functional abnormalities. Cutaneous anergy is a direct result of the viral effects on CD4 cells.

After acute infection and seroconversion, clinical latency may last several years before onset of symptoms due to development of secondary infection, malignancy, or neurologic disease. There is no biologic latency, however. HIV infection is a chronic, persistent infection of variable viral replication rate.

Progression to AIDs

The viral load set point after acute infection correlates with rate of progression to symptomatic infection or AIDS. Several proprietary assays provide quantitative measurement of plasma

HIV RNA. The branched (b) DNA assay detects as few as 20 to 50 copies per milliliter. Recognition of acute infection is important because early antiretroviral treatment may prevent extensive seeding of lymphoid tissues or even eliminate infection. Without treatment, viral replication is robust, and even in the absence of a decline in CD4 count may cause cardiovascular disease, nephropathy, and non–AIDS-related cancers.

It is estimated that 10 billion virions enter the plasma daily in untreated people. Virus is found mainly in tissues, not plasma; total lymphoid viral burden is 3 times that of plasma, the majority in follicular dendritic cells within germinal centers, where virus is passively adherent. The total body viral load is 100 billion HIV RNA copies. Approximately 10% of latently infected cells contain replication-competent provirus. Cellular destruction of lymphoid tissue is mediated by direct HIV-cytopathic effects, autoimmunity, and other mechanisms. Eventually, the lymphoid system is overwhelmed by the viral burden, which increases with advancing disease and culminates in AIDS.

Other factors that may augment HIV replication and the onset of symptoms include the following: the biologic variability of HIV and the appearance of increasingly virulent strains; host immunogenetics; and interactions with concomitant infection by cytomegalovirus (CMV), herpes simplex virus (HSV), hepatitis B and C viruses, human herpesvirus (HHV)-6, and human T-lymphotropic virus 1 (HTLV-1) that upregulate expression of HIV and cell-killing ability by cytokines. Cytokines and chemokines are released by immune cells in response to infection and may upregulate or downregulate viral replication.

Other immunologic abnormalities in AIDS are caused by effects of HIV on B cells or macrophages, which result in hypergammaglobulinemia, impaired antibody responses to new antigens (including encapsulated bacteria), and increased levels of immune complexes. Antibodies to platelets may cause thrombocytopenia.

Impact of Antiretroviral Therapy

cARTs and specific prophylaxis have reduced the incidence of AIDS-related opportunistic infections and neoplasms in the United States and other countries where treatment is readily available. cART refers to the use of three or more antiretroviral drugs from two antiretroviral drug classes. The major classes of antiretroviral drugs include nucleotide reverse transcriptase inhibitors, nonnucleotide reverse transcriptase inhibitors, protease inhibitors, integrase inhibitors, entry inhibitors, and fusion inhibitors. These antiretroviral drug classes interfere with different stages of HIV replication. The types of infections or neoplasms that complicate HIV infection have not changed and are similar worldwide, with varying frequencies dependent on local factors. In untreated HIV infection, *Pneumocystis carinii* pneumonia is the most common opportunistic pathogen. Other opportunistic infections are often multiple and include fungal, viral, bacterial, and parasitic organisms. Many of these infections involve the CNS, usually secondarily, but sometimes as the primary infection. For example, the papovavirus that causes progressive multifocal leukoencephalopathy (PML) causes a primary brain infection. Infections that are common in developing countries, such as trypanosomiasis, cysticercosis, and malaria, are sometimes seen in recent immigrants to the United States. Hepatitis B and C infections are important comorbid conditions, especially among those who acquire HIV from injection drug use. Kaposi sarcoma, (an AIDS-defining erythematous macular or nodular patch typically involving the face, oral mucosa, or upper trunk), Hodgkin and non-Hodgkin lymphoma, and cervical cancer, the most commonly encountered neoplasms related to immunosuppression, have become very rare in the setting of effective antiretroviral treatment. Non–AIDS-defining malignancies are now more common in treated populations, including anal cancer, lung cancer, liver cancer, and cancers of the head and neck. With the use of cART, HIV+ individuals live significantly longer, and indeed more than 75% of HIV+ individuals older than 50 years of age now die from non–HIV-related causes.

Central Nervous System Pathogenesis

HIV enters the CNS at the time of primary infection and can result in no apparent disease, in acute self-limited syndromes, or in chronic disorders. Neurologic disorders are found in up to 70% of patients in clinical series, and more than 80% of autopsy series, of AIDS patients. In 10% to 20% of patients, the neurologic disorder is the first manifestation of AIDS. Uncommonly, a neurologic disorder is the sole evidence of chronic HIV infection and the cause of death. A high prevalence of neurologic disorders is observed in all populations studied, including those in sub-Saharan Africa and Asian regions bordering the Pacific Ocean. Despite the reduction in incidence of primary HIV-related syndromes, autopsy series of cART-treated patients who died of AIDS or unrelated causes show abnormalities in most brains, which in some cases were the cause of death. Cognitive impairment or HIV-associated neurocognitive disorder (HAND) is the most important HIV-related clinical syndrome.

Evidence of early CNS invasion includes isolation of virus from cerebrospinal fluid (CSF) or neural tissue (brain, spinal cord, peripheral nerve) and intrathecal production of antibodies to HIV. How HIV enters the CNS is not known. Possible mechanisms include intracellular transport across the blood-brain barrier within infected macrophages, as free-virus seeding of the leptomeninges, or as free virus after replication within the choroid plexus or vascular epithelium. In vitro studies using a proteomic platform suggest that HIV-1–infected monocyte-derived macrophages upregulate a large number of human brain microvascular endothelial cells, causing blood-brain barrier dysfunction that facilitates the development of CNS disease. Chemokines seem to play an important role in enhanced transmigration of HIV-infected lymphocytes across the blood-brain barrier. In vitro studies show enhanced HIV-infected leukocyte transmigration in response to the chemokine CCL2 (monocyte chemoattractant protein-1) with disruption of the blood-brain barrier, enhanced permeability, reduction of tight junction proteins, and expression of the matrix metalloproteinase-2 and matrix metalloproteinase-9. In the brain, viral infection (with active replication) is detected only in microglial cells or macrophages by in situ hybridization techniques; it is not found in neurons (and rarely detected in glial cells), even though these cells have CD4 and chemokine receptors.

The high frequency of neurologic disorders in HIV infection has led to the designation of HIV as a *neurotropic virus*. The term *neurotropic* implies selective vulnerability and targeting of brain by the virus. Alternatively, the high frequency of neurologic disorders may be explained by the chronicity of infection, which results in continued seeding of the CNS and chronic immune activation. Specific neurotropism is not needed for continued accrual of neurologic damage. It has been difficult

to establish correlation of neurologic syndromes with productive viral replication in the affected tissue. There is, however, an increase in the viral burden or viral load with advancing disease that parallels dementia and other neurologic syndromes. The mechanism of neurologic injury is believed to be indirect. Potential mechanisms include immune-mediated indirect injury; restricted persistent cellular infection; cellular injury due to cytokines released by infected monocytes and macrophages; excitotoxic amino acid injury; voltage-mediated increase of intracellular calcium; free radical damage; potentiation of inflammatory damage by chemokines and lipid inflammatory mediators (arachidonic acid and platelet-activating factor); direct cellular toxicity of HIV gene products, such as the envelope gp120, tat, and gp41; and cross-reacting antibody to an HIV glycoprotein binding a cell membrane epitope, resulting in cell receptor blockade. Studies show the involvement of double-stranded RNA-activated protein kinase in apoptotic neuronal death due to HIV-gp120. This enzyme is elevated in brain tissue of patients with HIV dementia. More than one mechanism may be important. Genetic changes in the virus in the host may result in noncytopathic CNS virus with enhanced replicative capacity in monocytes and macrophages, leading to a greater viral burden in the CNS than is apparent in the periphery. Phenotypic and viral load discordance is documented in several studies of plasma and CSF.

This compartmentalization of virus may explain the occurrence of neurologic syndromes when peripheral viral replication appears to be well controlled. CSF escape, when HIV RNA is present in the CSF but undetectable in the plasma (or increased in the CSF compared to a detectable plasma level), may occur in 5% to 10% of HIV+ individuals receiving cART.

DIAGNOSIS

Initial Diagnostic Approach

The diagnostic evaluation of patients with a suspected HIV-related illness includes an enzyme-linked immunosorbent assay for HIV serology. Positive results are confirmed by Western blot. Depending on local laws, serologic tests may require informed consent and counseling. In patients with otherwise typical viral syndromes, such as aseptic meningitis or transverse myelitis, HIV infection must be suspected even in the absence of known high-risk behavior. Absence of antibodies during the acute illness does not negate the diagnosis because these disorders typically occur at the time of seroconversion. A plasma HIV viral load can be obtained if a seroconversion illness is suspected in order to achieve a definitive diagnosis. Other helpful diagnostic studies include determination of CD-lymphocyte subset ratio, serum protein electrophoresis, quantitative Igs, and platelet count.

Evaluation for specific neurologic syndromes should be preceded by a general physical examination to assist in excluding opportunistic infections or tumor. Evaluation may require biopsy of skin, lymph nodes, or bone marrow as well as chest radiography. Blood culture for viruses and fungi may also prove necessary.

Accurate neurologic diagnosis requires systematic evaluation, including assessment for the possibility of multiple diseases. CSF is most helpful in syphilis, viral, and fungal infections. PCR of CSF can be helpful for pathogenic diagnosis of HSV, varicella zoster virus (VZV), CMV, toxoplasma, and PML, but negative results do not exclude infection. CSF abnormalities are common in asymptomatic HIV infection and must be interpreted with caution in considering other possible conditions, computed tomography (CT) and, especially, magnetic resonance imaging (MRI) are useful in distinguishing focal from diffuse brain lesions. Magnetic resonance spectroscopy and thallium–single-photon emission CT (SPECT) can help in distinguishing tumor from infection. Brain biopsy may be required for definitive diagnosis of some conditions, especially PML and primary CNS lymphoma.

Myelopathy is evaluated by MRI with gadolinium to exclude a compressive lesion. CSF is a useful adjunct test to rule out infectious etiologies. Electromyography (EMG) and nerve conduction studies are useful in evaluating chronic inflammatory demyelinating polyneuropathy (CIDP), anterior horn cell disease, polyradiculopathy, peripheral neuropathy, and myopathy. Nerve or muscle biopsy may be required.

Neurological HIV-Related Syndromes

Neurologic disorders may occur at any stage from seroconversion to AIDS. Dementia and myelopathy are diagnostic of AIDS even without opportunistic infections; cognitive impairment and neuropathy are the most common direct HIV-related neurologic diseases. All levels of the neuraxis may be affected, including multisystem disorders. Neurologic disorders are likely to be transient in early HIV infection, but they become progressive or chronic with persistent infection and worsening immunosuppression in the absence of cART. In patients receiving cART, cognitive impairment and neuropathy may remain stable without progression for years and potentially decades.

The neurologic syndromes in early HIV infection are indistinguishable from disorders that occur with infection by other viruses (Table 70.4). These include aseptic meningitis, reversible encephalopathy, leukoencephalitis, seizures, transverse myelitis, cranial and peripheral neuropathy (Bell palsy, Guillain-Barré syndrome), polymyositis, and myoglobinuria. Brachial neuritis and ganglioneuritis have been reported only rarely. The course is typically self-limited, and patients often experience full neurologic recovery. Older HIV+ individuals in the cART era experience a higher incidence of neurologic disease compared to age-matched HIV-negative individuals, including nervous system infections,

TABLE 70.4 Primary Human Immunodeficiency Virus–Related Neurologic Syndromes: Acute Infection

Acute aseptic meningitis
Acute encephalopathy
Leukoencephalitis
Seizures, generalized or focal
Transverse myelitis
Cranial and peripheral neuropathies
Bell palsy
Acute inflammatory demyelinating polyneuropathy of the Guillain-Barré type
Polymyositis
Myoglobinuria

dementia, seizures/epilepsy, and peripheral nervous system disorders. In addition, HIV+ individuals experience neurologic diagnoses at an earlier age compared to HIV-negative individuals.

CSF abnormalities (pleocytosis up to 200 cells/μL and oligoclonal bands) differentiate HIV syndromes from postinfectious disorders. Tests for HIV antibody may be negative because these syndromes may precede or accompany seroconversion, and the tests must be repeated in several weeks. If acute HIV infection is strongly suspected, p24 antigen and viral load assay should be considered if serology is negative. Hepatitis B and hepatitis C serology should be determined in all HIV-seropositive patients. Early antiretroviral therapy may be offered to decrease the high viral load typical of acute infection quickly, thereby lowering the viral load set point. No specific treatment is indicated for these self-limited disorders except that plasmapheresis or Ig are used in cases of Guillain-Barré syndrome and steroids for polymyositis.

In chronic HIV infection, neurologic disorders may accompany systemic HIV disease or secondary disorders (Table 70.5).

Chronic or recurrent CSF pleocytosis sometimes occurs with meningeal symptoms but is often asymptomatic. Chronic pleocytosis does not predict any specific neurologic complication. Ascribing CSF pleocytosis to HIV infection requires exclusion of secondary pathogens or tumor. In a cross-sectional study, HIV-related CSF pleocytosis was uncommon in individuals with blood CD4 counts below 50 cells/μL or in those on effective antiretroviral therapy.

HIV Associated Neurocognitive Disorder

Cognitive impairment is a well-recognized complication of chronic HIV infection in all populations; it can range from mild to severe (Table 70.6). HIV-associated dementia refers to HIV+ individuals with moderate-to-severe cognitive impairment on neuropsychological testing and marked difficulties in activities of daily living due to the cognitive impairment. HIV-associated dementia, known variously as *HIV-1–associated dementia complex*, *HIV dementia*, or *AIDS dementia complex*, is diagnostic of AIDS. Older designations are subacute encephalitis, subacute encephalopathy, or HIV encephalitis. In the pre-cART era, HIV dementia, the most severe stage of HAND, was a common stage of cognitive impairment among HIV+ individuals with advanced immunosuppression. In HIV+ individuals on cART, HIV dementia is rarely seen (2%-5% of HIV+ individuals on cART), and less severe stages of HAND such as asymptomatic neuropsychological impairment (ANI) and HIV-associated mild neurocognitive disorder (MND) are the most common stages of cognitive impairment. HAND, including all three stages (ANI, MND, and HIV dementia), may be seen in 30% to 50% of HIV+ individuals with advanced infection. Peripheral neuropathy coexists in 25% of patients.

TABLE 70.5 Primary HIV Related Neurologic Syndromes: Chronic Infection

Persistent or recurrent meningeal pleocytosis with or without meningeal symptoms
Diffuse and focal cerebral syndromes
Dementia, static or progressive with or without motor signs
Mild cognitive impairment, neuropsychological test criteria only
Organic psychiatric disorder
Cerebrovascular syndromes
Cerebellar ataxia
Seizure disorder
Multisystem degeneration
Chronic progressive myelopathy
Cranial and peripheral neuropathies
Bell palsy
Hearing loss
Phrenic nerve paralysis
Lateral femoral cutaneous nerve
Chronic inflammatory demyelinating polyneuropathy
Distal symmetric sensory neuropathy
Mononeuritis multiplex
Motor neuron disease
Autonomic neuropathy
Myopathy

TABLE 70.6 HIV-1 Associated Neurocognitive Disorder

Severe Manifestations
HIV-1–associated dementia
Mild Manifestations
HIV-1–associated mild neurocognitive disorder
Asymptomatic neuropsychological impairment

The International HIV Dementia Scale is a brief screening test which can be performed by nonneurologists and has been validated as a potential screening test for dementia in HIV+ individuals in resource-limited settings. There are several scales for classification of HIV-associated cognitive impairment, including revision of the AIDS Task Force of the American Academy of Neurology criteria.

HIV dementia in the pre-cART was an insidiously progressive subcortical dementia with prominent motor signs including slow movements, tremor, parkinsonian features, leg weakness, and gait ataxia. However, in the cART era, HIV dementia now presents with more prominent cortical features and less prominent motor signs. Early symptoms include slow thinking, poor concentration, forgetfulness, apathy, social withdrawal, and diminished libido. Neuropsychological testing manifestations of HAND include poor executive function, impaired speed of information processing, and poor mental flexibility. Memory is relatively spared until the later stages of the dementia; impaired memory reflects problems with retrieval rather than encoding, in contrast to Alzheimer disease. Psychiatric syndromes, such as psychosis, depression, or mania, are sometimes profound and may be the first manifestation of HIV infection. There may also be headaches, seizures, or frontal release signs. Although the disorder is usually progressive in HIV+ individuals not on cART, some patients on cART develop a static level of disability, and others may improve in response to medical treatment for HIV or complicating disorders. When progressive, the disease culminates in akinetic mutism, an immobile bedridden state with global cognitive impairment and urinary incontinence.

In children, there may be a similar static or progressive encephalopathy. Most affected children meet criteria for AIDS, but progressive encephalopathy can occur before immunologic dysfunction is severe. Neurologic findings include intellectual

deterioration, microcephaly, loss of developmental milestones, and progressive motor impairment that may culminate in spastic quadriparesis and pseudobulbar palsy. Seizures are usually due to fever. Myoclonus and extrapyramidal rigidity are rare.

CSF Examination

The CSF is usually normal or shows a mild pleocytosis, protein elevation, and oligoclonal bands. Virus can be cultured from CSF. In HIV+ individuals not on cART, both CSF and plasma viral load correlate with occurrence of dementia but may be discordant in some cases where CSF load is greater than plasma. In HIV+ individuals on cART, CSF and plasma viral load do not correlate with HAND stage. Most HIV+ individuals on cART have an undetectable CSF HIV RNA. CSF markers of immune activation, such as HIV p24 antigen, β_2-microglobulin, tumor necrosis factor, and antimyelin basic protein, and markers of oxidative stress such as CSF sphingomyelin and ceramide in cART-treated HIV+ individuals do not correlate with severity of dementia. None of these markers is predictive of, or specific for, dementia. CSF markers such as neopterin lack predictive value and specificity but can correlate with severity of dementia. Elevated levels of CSF neurofilament protein, a marker of axonal injury, are found in HIV-infected patients with dementia. Plasma neurofilament protein levels which correlate with CSF neurofilament protein levels are currently being evaluated as a potential peripheral surrogate marker of HIV dementia.

Imaging

In adults, CT or MRI scans show cortical atrophy, basal ganglia atrophy particularly within the caudate nucleus, and ventricular dilatation, sometimes with white matter changes. On CT, there is attenuation of white matter; MRI shows hyperintense white matter lesions on T2-weighted and proton density sequences, ranging from discrete foci to large confluent periventricular lesions (Fig. 70.1). CT in children shows basal ganglia calcification and cerebral atrophy. MRI white matter changes may not correlate with dementia and may disappear spontaneously or with antiretroviral therapy. The primary role of neuroimaging with CT or MRI in the evaluation of an HIV+ patient is to exclude a CNS focal lesion such as a CNS opportunistic infection, malignancy, or stroke.

Abnormalities in functional neuroimaging are detected in HIV-infected individuals, whether they have dementia or not. The abnormalities become worse or change with progressive cognitive impairment. Fluorodeoxyglucose–positron emission tomography shows relative hypermetabolism in the thalamus and basal ganglia in HIV-infected individuals. Progressive dementia is accompanied by cortical and subcortical hypometabolism. SPECT shows multifocal cortical perfusion deficits in the frontal lobes, worse in those with dementia. Cerebral metabolite abnormalities demonstrated by magnetic resonance spectroscopy include elevated myoinositol and choline levels in frontal white matter indicative of glial proliferation in patients with mild cognitive impairment. Severe dementia is associated with decreased levels of *N*-acetyl aspartate, a neuronal marker. Diffusion tensor imaging may show abnormalities in white matter tracts in patients with HAND. Dynamic cerebral blood volume studies by functional MRI (fMRI) show increased cerebral blood volume in deep and cortical gray matter in HIV-positive individuals and even greater increases in the deep gray matter of those with dementia. Continuous arterial spin label MRI showed reduced caudate blood flow and volume in patients with cognitive impairment. Functional neuroimaging abnormalities may improve with antiretroviral treatment.

Pathology

Pathologic abnormalities in brain include microglial nodules, multinucleated giant cells, focal perivascular demyelination and gliosis, and neuronal loss in frontal cortex. Although there is often

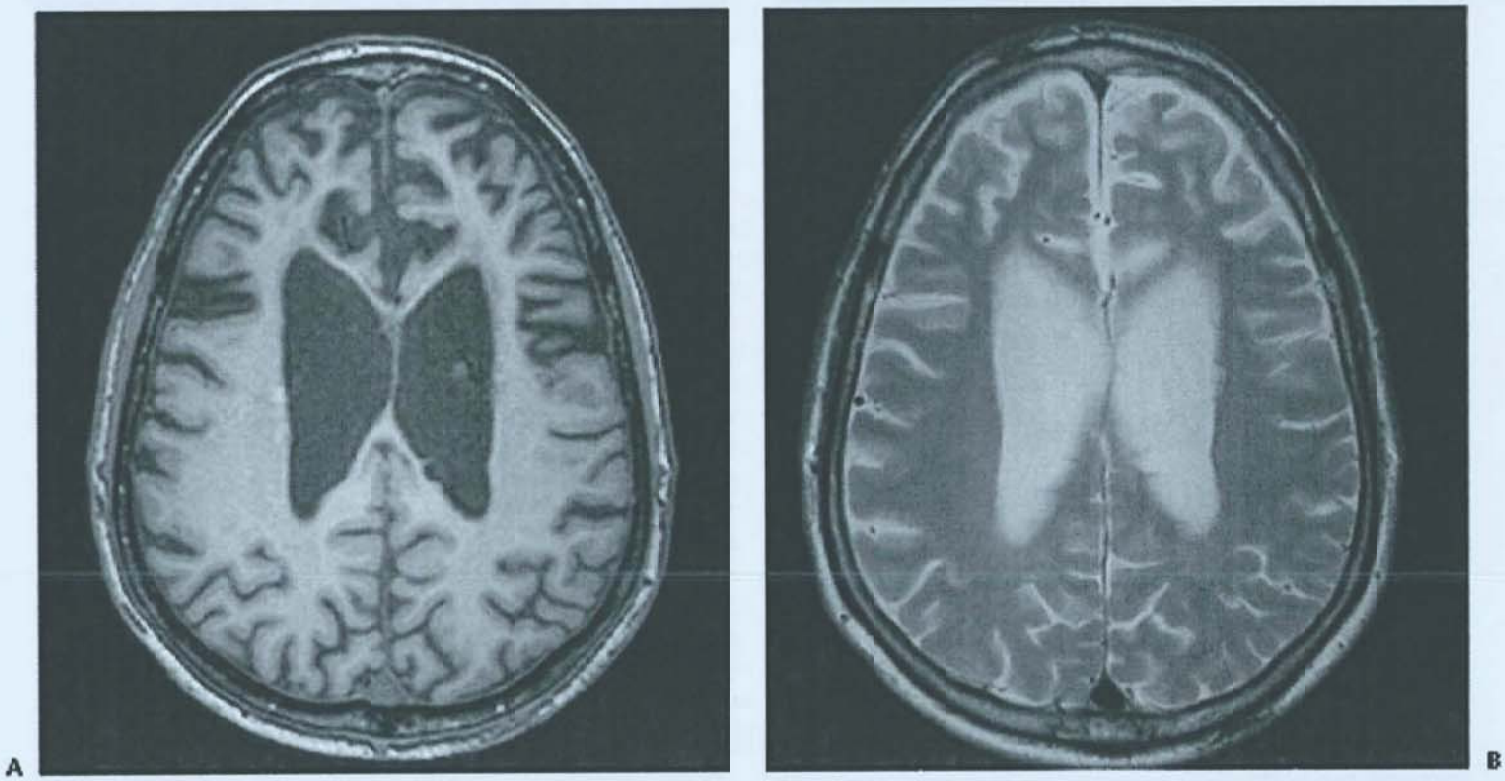

FIGURE 70.1 Human immunodeficiency virus–positive subject with progressive dementia. T1-weighted **(A)** and T2-weighted **(B)** magnetic resonance imaging scans show ventricular enlargement and cortical atrophy, particularly in the frontal lobe. There is also some mild periventricular T2 hyperintensity.

no correlation between the severity of these pathologic changes and the severity of dementia, studies suggest that neuronal injury may be missed by standard pathologic survey techniques. In a prospective study, severity of neurocognitive impairment was correlated with microneuroanatomic injury to dendritic structures that resulted in dendritic simplification but not to viral burden or presence of microglial nodules and multinucleated giant cells. Astrocyte cell death through apoptotic mechanisms may reduce the neuroprotective functions of this cellular population. In vitro studies show that soluble Fas ligand from HIV-infected macrophages triggers apoptosis of uninfected astrocytes. A study of pre-cART HIV-infected patients with dementia showed elevated CSF soluble Fas ligand levels in this group compared with HIV-negative controls and HIV+ nondemented patients. More prospective data are needed to understand the role of apoptosis in HIV dementia and the utility of markers for apoptosis as predictors of dementia.

Differential Diagnosis

The diagnosis of HIV-associated dementia requires exclusion of secondary opportunistic infections or neoplasms. Other confounding variables include drug use, vitamin B_{12} deficiency, metabolic disorders, concurrent infections such as hepatitis C infection, CNS side effects of medications (eg, efavirenz which can cause CNS side effects in 50% of HIV+ individuals after initiation, medications with anticholinergic properties), and age-related comorbidities in an aging HIV-infected population due to successful antiretroviral treatment.

Management

In most studies, antiretroviral therapy reduces the incidence and mortality of HIV dementia. The primary treatment for HAND is cART, which is associated with cognitive improvement in the majority of antiretroviral-naïve HIV+ individuals. Treatment of comorbid conditions frequently associated with HAND such as depression is also beneficial. A trial of the selective serotonin reuptake inhibitor, paroxetine, showed a trend for improved cognitive performance even after controlling for depression status, but further studies are warranted. Several additional adjunctive treatments targeting specific immune and inflammatory products are currently being evaluated.

Antiretroviral therapy using drugs with good CNS penetration may benefit the symptomatic patient with CNS virologic escape, but some studies suggest that the beneficial effect of treatment is independent of CNS penetration. A randomized clinical trial of cART with good CNS penetration compared to cART with poor CNS penetration showed no clinical benefit for the group randomized to cART with good CNS penetration. Suppression of viral replication in both the blood and CSF is critical for effective treatment of HAND. Initiation of cART is usually associated with immune system recovery and cognitive benefits. However, some HIV+ individuals after initiation of cART may experience clinical deterioration despite recovery of the immune system from immunodeficiency, a condition known as *immune reconstitution inflammatory syndrome* (IRIS). When IRIS involves the CNS, opportunistic infections of the CNS such as cryptococcal meningitis or PML may present. In addition, an acute syndrome of fulminant HIV encephalitis can occur in rare cases in which cognition worsens despite virologic suppression and immune system recovery. Risk factors for IRIS include a low CD4 nadir at initiation of cART, the presence of an underlying opportunistic infection, and a sharp decline in viral load after starting cART. Corticosteroids have been used in HIV+ individuals with noninfectious encephalitis after cART initiation with clinical improvement in some cases. Additional studies of the role of corticosteroids for the treatment of IRIS are needed.

HIV eradication strategies (eg, "shock and kill") are currently being evaluated to treat HIV infection in research studies in an attempt for a cure. As part of these eradication strategies, latent viral reservoirs are activated with a latency-reversing agent and then targeted for elimination. It should be recognized that the CNS may serve as a potential reservoir site, and the CNS should be closely monitored, as these eradication strategies are rolled out.

Stroke

Most studies show an association with stroke incidence and HIV status in the post-cART era that extends beyond traditional risk factors including hypertension, dyslipidemia, diabetes mellitus, and smoking, particularly in younger patients. Although modification of these risk factors is an important strategy to decrease stroke risk among HIV-infected individuals, studies have demonstrated an excess risk of stroke in HIV infection. Multiple mechanisms unique to HIV infection may cause an increased stroke risk. Impaired fibrinolysis resulting in a hypercoagulable state may occur. Intracranial vasculopathy has been described in untreated, severely immunocompromised HIV-infected individuals with and without strokes, often in combination with aneurysmal arteriopathy and, at times, with concomitant infections including VZV and CMV. Marked clinical and radiographic improvement of vasculopathy documented after initiation of cART suggests that this mechanism is likely of considerably less clinical relevance for virologically suppressed individuals on cART. In fact, the epidemiology of stroke in HIV-infected individuals has shifted as the average age of persons living with HIV has increased, the use of cART has become more widespread and the prevalence of opportunistic infections has decreased. A further shift has been the increasing prevalence of traditional risk factors in lower-income and middle-income countries due to globalization. In addition, cumulative exposure to cART may lead to a rise in vascular risk over time. Insulin resistance as well as dyslipidemia due to antiretroviral therapy may also add to stroke risk. More recently, it has been suggested that women with HIV may have increased relative risk of stroke as compared with men, although the mechanisms for this remain unclear. In addition, stroke syndromes may follow secondary infections or neoplasms, such as cryptococcus or other fungi, toxoplasmosis, TB, herpes zoster, CMV, syphilis, or lymphoma. Other causes include HIV-related vasculitis, cardiogenic emboli, thrombogenic conditions such as hyperviscosity, disseminated intravascular coagulation, and the presence of lupus anticoagulant. Cerebral hemorrhage may follow HIV-associated thrombocytopenia or toxoplasmosis.

Evaluation of cerebrovascular syndromes includes screening for classical risk factors including high blood pressure, impaired glucose tolerance, and hyperlipidemia. Additional studies which should be obtained include imaging; CSF examination; cultures for viruses, bacteria, mycobacteria, and fungi; serum and CSF antibodies for cryptococcus, syphilis, and toxoplasmosis; plasma and CSF HIV viral load; PCR of CSF for suspect pathogens; echocardiography; carotid Doppler; lipid profiles; coagulation profiles; platelet count; and determination of procoagulants. If vasculitis is suspected, angiography or brain or meningeal biopsy may be useful. Additionally, intracranial vessel wall (black blood) MRI is an emerging tool, which may aid in the differentiation between stroke due to vasculitis versus accelerated intracranial atherosclerosis. Management is directed to the underlying mechanism and may include a change in antiretroviral therapy.

Seizures

The prevalence of seizures and epilepsy in patients with HIV is significantly higher than the general population, with higher mortality rates. Seizure activity complicating HIV infection should raise the suspicion for an underlying structural brain lesion, especially in the setting of focal seizure activity, in patients whose CD4 counts are less than 400, and if focal neurologic signs are present on examination. If seizures are generalized, common etiologies include an underlying metabolic derangement or diffuse meningoencephalitis. Underlying infectious and noninfectious causes to consider, especially in those patients with low CD4 counts, include toxoplasmosis, cryptococcoma, primary CNS lymphoma, and PML. In a study of 100 consecutive cases, secondary pathogens were identified in 53% and HIV encephalopathy in 24%; there was no identified cause in 23%. In another study, status epilepticus was associated with CNS infection in a third of patients, most commonly toxoplasmosis. It has, therefore, also been suggested that HIV infection alone may be the sole cause of seizures. Seizure is a common disease-defining presentation, reported to occur as the initial presentation of HIV in 18% of patients. A recent meta-analysis including 6,639 cases, comprising studies from the United States, Europe, Asia, and Africa, found the pooled prevalence of seizures in HIV to be 62 per 1,000, and the pooled incidence to be 60 per 1,000. Sixty-three percent of patients experienced seizure recurrence, and 82% of patients had a diagnosis of AIDS at time of first seizure. Infections were the primary identifiable etiology, with toxoplasmosis diagnosed in 21% of patients and cryptococcus in 14%. An additional 14% of patients were found to have PML. Thirty-two percent of patients were not found to have an etiology, with seizures hypothesized to be caused by HIV alone.

The diagnosis of seizures in HIV patients includes basic laboratory parameters, drug levels if available, neuroimaging, lumbar puncture, and electroencephalogram. If antiepileptics are indicated, one should consult guidelines for the initiation of antiepileptic medications and dosage adjustments of antiretroviral drugs due to antiepileptic drug–antiretroviral drug interactions by a joint panel of the American Academy of Neurology and the International League Against Epilepsy.

Leukoencephalopathy

Leukoencephalopathies in acute or chronic HIV infection include acute fulminating and fatal leukoencephalitis, multifocal vacuolar leukoencephalopathy presenting as rapid dementia, and a relapsing-remitting leukoencephalitis that may simulate multiple sclerosis. The pathogenesis of these syndromes is uncertain. A severe demyelinating leukoencephalopathy with intense perivascular infiltration by HIV-gp41 immunoreactive monocytes/macrophages and lymphocytes is described in patients who failed highly active antiretroviral therapy treatment despite good virologic response in one case. Some speculate this illness is a form of IRIS.

Movement Disorders

Movement disorders in patients with HIV infection were frequently described in the pre-cART era, including patients presenting with tremors, chorea, facial or paroxysmal dyskinesias, and athetosis, most commonly associated with opportunistic infections such as toxoplasmosis. Segmental or generalized myoclonus has also been described. Toxoplasmosis and cryptococcus have a predilection for the basal ganglia, and in particular, toxoplasmosis can be associated with hemichorea-hemiballismus due to lesions in the subthalamic nucleus or its connections. Treatment of the underlying opportunistic infection may not necessarily reverse the movement disorder. Hyperkinetic movement disorders (tremors) or parkinsonism can not only be observed in the context of opportunistic infections but also as an initial clinical manifestation of the viral infection in the post-cART era. The movement disorder associated with HAND is best described as psychomotor retardation, with slow rapid alternating movements, increased muscle tone, and mild bilateral postural tremor. Cognitive decline typically precedes tremor and gait disturbance. Interestingly, there appears to be a greater susceptibility to drug-induced parkinsonism in HIV-infected patients, likely related to dopaminergic neuron dysfunction from primary HIV infection, which occurs early in infection. Movement disorders related to peripheral neuropathy have also been frequently described in HIV, including restless legs syndrome as well as painful legs and moving toes syndrome.

Myelopathy

HIV can involve any segment of the spinal cord and adjacent nerve roots, leading to myelopathy, to radiculomyelopathy, and to involvement of the gray or white matter of the spinal cord. There are some reports that at the time of seroconversion or early in infection, an HIV-associated transverse myelitis can develop. In contrast, in patients who have a CD4 count of less than 500, the differential diagnosis for myelopathy in the context of HIV infection includes HIV myelitis, vacuolar myelopathy, primary CNS lymphoma, CMV radiculomyelitis, HSV sacral radiculomyelitis, VZV myelitis, spinal cord syphilis, and spinal cord TB among others. The myelopathy syndrome most unique to HIV of these is a chronic progressive myelopathy, an AIDS-defining illness that is characterized by progressive spastic paraparesis, ataxia, and sphincter dysfunction. Vacuolar myelopathy presents with a subacute onset of clinical signs and symptoms, developing over weeks to months. Common symptoms include bilateral lower extremity weakness with spasticity. Patients also experience bowel, bladder, and erectile dysfunction with variable sensory disturbances. Deep tendon reflexes are hyperactive with an extensor plantar response. Pathologic findings are similar to those of subacute combined degeneration due to vitamin B_{12} deficiency and include vacuolar change with intramyelin swelling or demyelination that is most severe in the lateral and posterior columns. Microglial nodules and giant cells are sometimes seen, and HIV can be sometimes cultured or detected by hybridization techniques, although there is no known correlation between HIV levels in the CSF and the presence or severity of vacuolar myelopathy. Pathologic abnormalities are more common than clinical symptoms. Diagnosis requires ruling out causes by measuring serum vitamin B_{12} levels, copper levels, rapid plasma reagin, and HTLV-1 antibodies before making the diagnosis. Lumbar puncture should be performed to rule out infection with HSV, VZV, CMV, and neurosyphilis. In HIV-associated vacuolar myelopathy, the CSF may be normal, or it may show mild pleocytosis with mild elevation in protein. Neuroimaging should be performed, although it is important to note that the spinal MRI may be normal, or it may show spinal atrophy or patchy abnormalities on T2-weighted images. Somatosensory-evoked potentials help to confirm myelopathy, whereas nerve conduction studies can detect coexistent neuropathy if present. No specific treatment is available for myelopathy. The impact of cART is unknown. A pilot study assessing the role

of intravenous immunoglobulin (IVIG) remained inconclusive. Antispasticity drugs such as baclofen or bladder relaxants such as imipramine must be used cautiously to avoid sedation or exacerbating weakness.

Motor Neuron Disease

Several cases of an amyotrophic lateral sclerosis (ALS)-like illness have been reported as the initial neurologic syndrome in patients with varying degrees of immunosuppression, ranging from profoundly reduced to near-normal CD4 lymphocyte levels. Clinically, HIV-associated ALS differs from sporadic ALS in that the patients present with symptoms at a younger age, have a more rapid progression, have a high CSF protein, and may recover after initiation of cART. There are additional descriptions of a solely lower motor neuron phenotype. EMG features have been shown to be consistent with ALS in one series of six patients. It is important to note that because of the potential reversibility of ALS-like symptoms in HIV infection, testing for HIV infection is generally recommended in younger patients presenting with motor neuron symptoms. The actual pathology underlying HIV-associated motor neuron disease has not been well defined.

Peripheral Neuropathy

Distal sensory polyneuropathy (DSPN) is one of the most common neurologic manifestations of HIV infection with more than 50% of patients with advanced HIV having evidence of DSPN on neurologic examination. It may be caused by antiretroviral toxicity, or HIV-mediated inflammatory pathways. Risk factors for development of sensory neuropathy include advanced age, lower CD4 nadir, current antiretroviral therapy use, and past "D-drug" use (specific dideoxynucleoside analog antiretrovirals, ie, ddI [didanosine], ddC [zalcitabine], and d4T [stavudine]). Overall, the incidence of neuropathy has increased because of the longer survival of HIV-infected patients, likely related to comorbidities including diabetes mellitus, alcohol abuse, and vitamin B_{12} deficiency. Symptoms are typically symmetric, predominantly distal and sensory. Patients may experience numbness, tightness, pain, burning, or hyperalgesia in the feet. Signs include stocking-glove sensory loss, mild muscle wasting and weakness, and loss of ankle jerks. Conduction studies show sensorimotor neuropathy with mixed axonal and demyelinating features; however, they may also be normal. Both clinically and with nerve conduction studies, HIV-related DSPN is indistinguishable from the neuropathy due to nucleoside reverse transcriptase inhibitors, although neuropathy due to nucleoside reverse transcriptase inhibitors may develop more rapidly. The association between DSPN and CD4 count is diminishing in cART era, with some studies showing an association between higher CD4 count and DSPN. A skin biopsy may show evidence of small-fiber neuropathy. Pathologic findings include axonal degeneration, loss of large myelinated fibers, and variable inflammatory cell infiltration. CSF may be normal or show mild pleocytosis and elevated protein. HIV can rarely be cultured from nerve, but the cellular localization of the virus is not known. The neuropathy may be mediated by the binding of gp120 envelope viral glycoprotein to sensory ganglion cells.

Neuropathic pain is associated with significant disability in daily activities, unemployment, and overall reduced quality of life. It is sometimes responsive to anticonvulsants (gabapentin, pregabalin, lamotrigine), tricyclic antidepressants, selective serotonin-norepinephrine reuptake inhibitors (duloxetine), topical anesthetic patches or creams, high-concentration capsaicin patch, and nonsteroidal or narcotic analgesics. There are also reports that smoked cannabis is effective for pain but may be associated with CNS side effects.

Other clinical manifestations of HIV infection include mononeuropathies, mononeuritis multiplex, inflammatory demyelinating polyneuropathy, and ganglioneuritis. Inflammatory demyelinating polyneuropathy may occur in its acute form, shortly after seroconversion when the CD4 count is still more than 500 cells/μL. Chronic inflammatory demyelinating polyneuropathy may also occur early in infection, when there is immune dysregulation. It is distinguished from Guillain-Barré syndrome by a subacute or progressive course and variable response to corticosteroids, IVIG, or plasmapheresis. Electrodiagnostic studies show demyelination with variable axonal damage. Histopathologic studies reveal epineurial inflammatory cell infiltrates, demyelination, and axonal degeneration. CSF may show a pleocytosis, which is not typically characteristic of acute inflammatory demyelinating polyneuropathy. The treatment of acute inflammatory demyelinating polyneuropathy with close monitoring and IVIG or plasmapheresis is the same regardless of HIV status. Mononeuropathies due to entrapment neuropathies are also commonly seen in patients with HIV infection. It is important to note that focal cranial neuropathies warrant further evaluation including neuroimaging and CSF analysis. Mononeuropathy multiplex due to peripheral nerve infarction associated with vasculitis is rarely described secondary to primary HIV infection and is more frequently described with CMV opportunistic infection as described in the following text.

Myopathy

HIV-associated myopathy may range from mild symptoms to severe rhabdomyolysis, with HIV-associated polymyositis being the most frequent clinical syndrome. HIV-related myopathy may also be due to zidovudine therapy, vasculitis, and infection (*Staphylococcus aureus*, *Mycobacterium*, CMV, and *Toxoplasma*). The presentation varies based on the underlying cause, and serum CK levels are variably elevated. HIV-associated polymyositis is clinically and pathologically similar to autoimmune polymyositis and is characterized by proximal limb weakness, mild creatine kinase elevation, and myopathic features on EMG. The mechanism by which HIV leads to inflammatory myopathy is not fully understood, but a T-cell–mediated and major histocompatibility complex I–restricted cytotoxic process triggered by HIV has been proposed. HIV-associated myopathy has also been described as part of an IRIS. Although treatment is not established in HIV-associated myopathy, patients may respond to steroids or IVIG. Stavudine (d4T) can cause HIV-associated neuromuscular weakness syndrome, which is characterized by a rapidly progressive weakness, resembling Guillain-Barré syndrome, with associated lactic acidosis due to mitochondrial dysfunction. Some patients respond well to steroid therapy without accelerated progression of HIV disease.

Opportunistic Infections

The spectrum of viral, bacterial, and fungal opportunistic infections, well described for their devastating consequences prior to the cART era, remain prevalent in many countries where cART medications remain poorly accessible, in patients not adherent to their HIV drug regimen, and as immune reconstitution phenomenon (**Table 70.7**).

Meningitis may be caused by such viruses including HSV, VZV, CMV, Epstein-Barr virus; fungi (*Cryptococcus*, *Histoplasma*,

TABLE 70.7 Secondary Neurologic Syndromes in Human Immunodeficiency Virus Infection and AIDS: Opportunistic Infections and Neoplasms

Leptomeninges	
Viral	CMV, HSV, VZV, EBV, hepatitis B
Fungal	*Cryptococcus, Histoplasma, Coccidioides, Candida*
Bacterial	*Listeria, Treponema pallidum*, pyogenic bacteria (*Salmonella, Staphylococcus aureus*), atypical or conventional mycobacteria
Neoplasm	Lymphoma
Cerebral Syndromes	
Diffuse encephalopathy or encephalitis	
Viral	CMV, HSV, VZV, hepatitis C
Bacterial	Atypical mycobacteria
Parasitic	Acanthamoeba, toxoplasma
Neoplasm	Lymphoma
Focal Cerebral Syndromes	
Viral	HSV, VZV, PML
Fungal	Abscess due to *Cryptococcus, Candida, Zygomycetes, Histoplasma, Aspergillus*
Bacterial	Abscess due to pyogenic bacteria, mycobacteria (tuberculoma), *Listeria, Nocardia*
Parasitic	*Trypanosoma cruzi, Taenia solium*, toxoplasma
Neoplasm	Primary or metastatic lymphoma, glioma, metastatic Kaposi sarcoma
Cerebrovascular Syndromes and Seizures	
Viral	VZV, HSV, PML
Fungal	*Cryptococcus, Aspergillus*
Bacterial	*T pallidum, Mycobacterium tuberculosis*
Parasitic	*Toxoplasma*
Neoplasm	Lymphoma, lymphomatoid granulomatosis, metastatic Kaposi sarcoma
Other	Cerebral hemorrhage, cardiac emboli, vasculitis
Movement Disorders	
Viral	PML, HIV
Bacterial	CNS Whipple disease
Parasitic	*Toxoplasma*
Neoplasm	Primary CNS lymphoma
Spinal Cord Syndromes	
Viral	VZV, CMV, HSV, HTLV-1
Bacterial	Mycobacteria, myogenic bacteria, *T pallidum*
Parasitic	Toxoplasmosis
Neoplasm	Lymphoma, Kaposi sarcoma
Cranial and Peripheral Neuropathy	
Viral	CMV (retinitis, polyradiculitis, mononeuritis multiplex)
Bacterial	*T pallidum*
Fungal	*Candida* (retinitis)
Parasitic	*Toxoplasma* (retinitis)
Myositis	
Bacterial	*Staphylococcus aureus*, mycobacteria
Parasitic	*Toxoplasma*

Abbreviations: CMV, cytomegalovirus; CNS, central nervous system; EBV, Epstein-Barr virus; HIV, human immunodeficiency virus; HSV, herpes simplex virus; HTLV-1, human T-lymphotropic virus 1; PML, progressive multifocal leukoencephalopathy; VZV, varicella zoster virus.

Coccidioides, *Candida*); bacteria (*Listeria*, *Treponema pallidum*, atypical or conventional mycobacteria, pyogenic bacteria such as *Salmonella*, *S aureus*); and neoplasm (carcinomatous meningitis due to lymphoma).

Focal brain syndromes may be caused by *Toxoplasma*, PML, and abscesses related to *Nocardia*, *Listeria*, *Taenia solium*, *Candida*, *Cryptococcus*, *Histoplasma*, *Aspergillus*, *Coccidioides*, *Mycobacterium tuberculosis*, atypical mycobacteria, and pyogenic bacteria.

Viral Infections

The pattern of opportunistic viral infection associated with AIDS has changed since the introduction of effective HIV therapy. Early in the AIDS epidemic, syndromes such as shingles or recurrent aseptic meningitis raised suspicion of an immunodeficient state, and the encephalitis eventually attributed to HIV itself was initially attributed to CMV infection. In contrast, contemporary concerns include facilitation of HIV spread by simultaneous herpes genital infection, use of vaccinations in households of AIDS patients, and other epidemiologic considerations. However, in severely immunosuppressed patients, viral infections of the nervous system remain prominent. For further information about viral infections, see Chapter 69.

Progressive Multifocal Leukoencephalopathy

PML was recognized early in the HIV pandemic as a complication of AIDS in profoundly immunosuppressed patients. PML is caused by John Cunningham (JC) virus, which is a ubiquitous polyomavirus. CNS disease is characterized by lytic infection of oligodendrocytes causing demyelination. Clinically, patients develop a subacute neurologic decline with focal neurologic symptoms and signs. Localization is hemispheric in 85% to 90% of cases; the posterior fossa is affected in the remainder. Rare cases of spinal cord PML have also been reported. Focal or generalized seizures occur in 6% of patients and become more common as the disease progresses. Imaging shows hypodense subcortical lesions on CT, and T2 hyperintense lesions on MRI that spare the cortical gray matter and have corresponding T1 hypointensity (Fig. 70.2). In PML-IRIS, MRI may show contrast enhancement on T1 postgadolinium sequences, most commonly associated pathologically with CD8+ T cells infiltrating the perivascular spaces. JC virus has also been reported to cause granular cell neuronopathy leading to a progressive cerebellar syndrome as well as meningitis. CSF analysis should be performed for JC virus detectable on PCR, although a negative study does not exclude the diagnosis, and repeat testing and potentially a brain biopsy are recommended if clinical and radiographic imaging is consistent with the diagnosis.

cART has led to significant improvement in survival, although patients are often left with serious neurologic sequelae. Despite anecdotal reports of efficacy, clinical trials have not shown any benefit from IV or intrathecal cytosine arabinoside, topotecan, mefloquine, or cidofovir. In vitro reports suggest mirtazapine blocks JC virus uptake into new oligodendrocytes, and anecdotal reports have suggested this may be beneficial clinically. However, it has never been studied in a randomized trial. Immune reconstitution following antiretroviral therapy favorably impacts the clinical

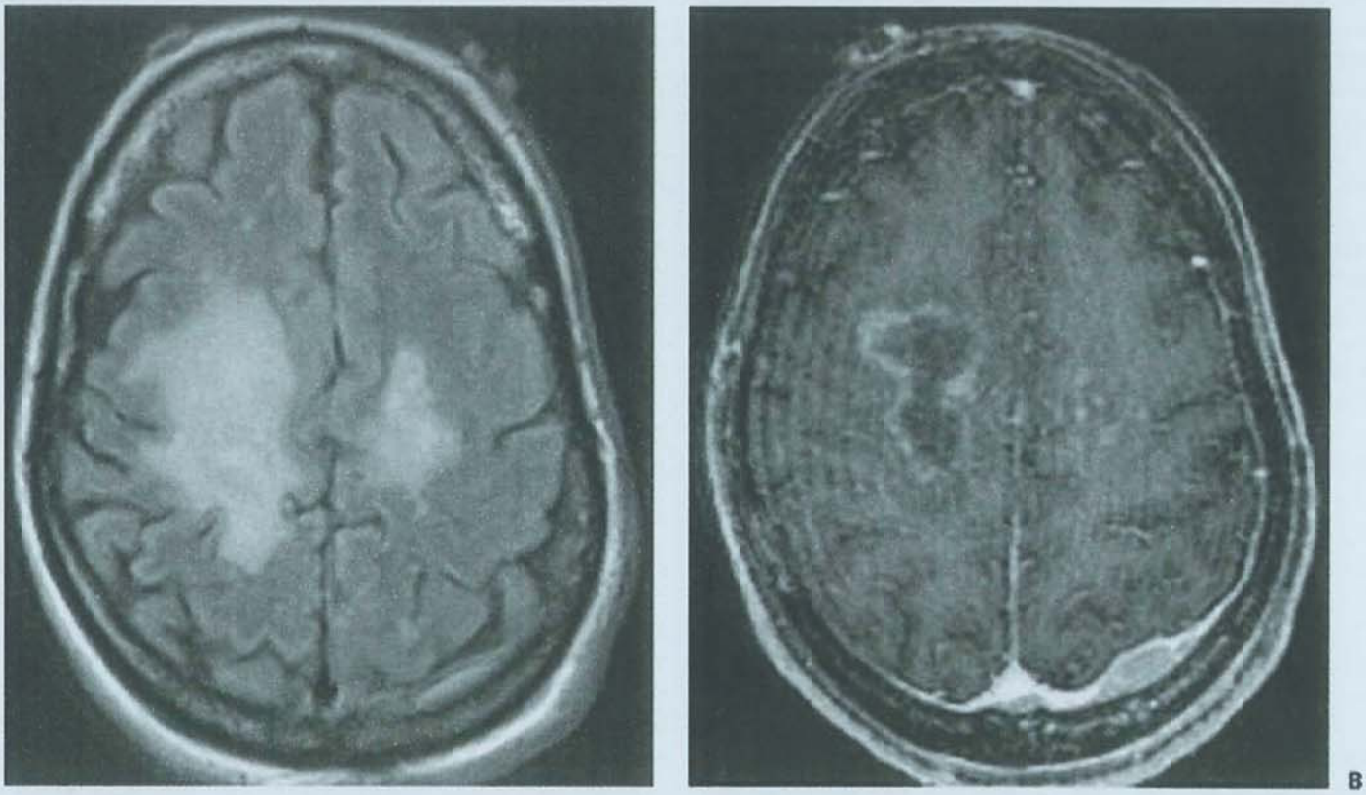

FIGURE 70.2 A 38-year-old woman with a history of human immunodeficiency virus/AIDS recently resumed antiretroviral medication with CD4 count rising from 23 to 78 cells/μL in 2 months, viral load of 340,000, presenting with left-sided weakness that became worse after 2 weeks and diagnosed with progressive multifocal leukoencephalopathy as a complication of immune reconstitution inflammatory syndrome. Fluid-attenuated inversion recovery **(A)** hyperintense lesions in bilateral frontoparietal white matter extending to the subcortical regions, larger on the right than left, associated with irregular peripheral enhancement **(B)**. (Courtesy of Dr. Doris Lin, Department of Radiology, Johns Hopkins University School of Medicine.)

course in some but not all patients with PML. The IRIS with either emergence or clinical progression of PML has been reported. When PML is the AIDS-defining illness, improved prognosis is associated with CD4 cell counts greater than 300 cells/μL, evidence of inflammatory response indicated by gadolinium enhancement on MRI, and reduction in the JC virus viral load in CSF.

Varicella Zoster Virus

VZV, the causative agent of varicella (chicken pox) and herpes zoster (shingles), is common in the general population with a lifetime prevalence of 15% to 30%. A ubiquitous latent virus, VZV remains dormant in the dorsal root ganglia after primary infection, characterized by fever and vesicular rash, most commonly occurring in early childhood. In severely immunosuppressed patients, the infection is reactivated leading, in some cases, to disseminated diseases with manifestations including pneumonia, diffuse rash, and visceral involvement.

Shingles beginning with painful dysesthesias or paresthesias (often described as itching) is followed in 7 to 10 days by a contagious vesicular rash that eventually crusts. The acute phase lasts up to a month and may be followed by chronic neuralgic pain for years, although this is less likely if effective antiviral treatment is started promptly. Location is most commonly thoracic, followed by cervical and trigeminal dermatomal distributions. Neurologic complications in addition to postherpetic neuralgia include large- or small-vessel stroke due to vasculitis induced in the vessel wall by the virus, myelitis, segmental myoclonus, and meningitis or encephalitis. *Zoster ophthalmicus*, which involves the first division of the trigeminal nerve, can lead to blindness from corneal scarring. Neurologic manifestations may occur weeks to months after a typical shingles rash.

Diagnosis is made by CSF PCR analysis or antibody detection. VZV antibodies can be detected in 2.5% to 7% of HIV-infected patients with meningitis, encephalitis, myelitis, or retinitis who have a history of shingles. MRI of the brain or spinal cord may show focal or meningeal enhancement. In patients with encephalitis, CSF shows a mononuclear pleocytosis, increased protein, and, sometimes, low glucose.

Treatment of VZV complications with acyclovir or famciclovir should be started within 72 hours of the rash to prevent pain. Vaccination with two doses of live attenuated virus is recommended even in HIV-infected patients if their CD4 cell count is greater than 200 because this may decrease future complications.

Herpes Simplex Viruses

HSV is a neurotropic virus, causing encephalitis in both immunocompetent and immunosuppressed patients. The virus targets structures of the mesial temporal lobe, producing symptoms including headache, fever, confusion, language and memory impairment, and, in severe cases, depressed consciousness and status epilepticus. In those who are immunosuppressed, a more indolent course may present due to the limited inflammatory response that can be mounted. Diagnosis is made with PCR on CSF, although false-negative CSF PCR has occurred. It is important to note that CSF pleocytosis may be absent in HIV-infected patients. Quantifying the viral load offers prognostic information: Mortality is 22% in patients who have greater than 100,000 copies/μL, whereas sequelae are mild to moderate (seizures, permanent memory impairment) in those with fewer viral copies. Neuroimaging may show edema and hemorrhagic necrosis in the temporal lobes and basal frontal lobes, reflecting the path of viral entry from its latent presence in the trigeminal nerve. In a retrospective analysis, immunocompromised adults had more extensive involvement of the brain with involvement of the brainstem, cerebellum, and atypical regions including scattered lesions in the cerebrum, sometimes in the absence of temporal lobe involvement. Electroencephalogram shows focal slowing, often with periodic complexes or other epileptiform discharges in the same areas. Abundant viral inclusions (Cowdry type A bodies) can be seen in patients without necrosis or hemorrhage on pathologic examination. Serum antibodies to HSV-1 are present in up to 70% of the general population and to HSV-2 in 16% to 33%. Because of this, the presence of antibodies does not help in diagnosis. Morbidity and mortality of HSV encephalitis in HIV patients remain high despite acyclovir as patients may present atypically and may have associated acyclovir resistance.

HHV-6 and *HHV-7* are important causes of encephalitis, meningitis, and myelitis in patients with AIDS that also have predilection for the temporal lobes. *HHV-8* is responsible for Kaposi sarcoma, which rarely involves the CNS.

Cytomegalovirus

CMV is typically a manifestation of severe immunocompromised state (CD4 count <50 cells/μL) and most commonly presents with retinitis and gastrointestinal symptoms but may also present with a primary neurologic syndrome including rhombencephalitis, ventriculitis, micronodular encephalitis, or polyradiculitis. CMV-associated polyradiculitis is a common neurologic presentation with rapid development of flaccid paraplegia, urinary retention, and prominent pain radiating into the lumbar and sacral root distributions. CMV encephalitis may present with subcortical diffuse white matter abnormalities and may be clinically difficult to differentiate from HIV-associated encephalopathy. A neuropathology study of HIV-infected patients reported 28 (17%) cases of CMV encephalitis, most of them with premortem diagnosis of HIV-associated cognitive decline. Neurologic infections from CMV often occur in the setting of systemic CMV infections.

Diagnostic workup should include ophthalmologic examination because 30% of patients with neurologic CMV complications present with concomitant CMV retinitis, and CSF should be tested for CMV-PCR. Treatment recommendations for neurologic CMV complications vary and include ganciclovir, foscarnet, valganciclovir, or a combination. Induction therapy is recommended for at least 2 to 4 weeks, with maintenance therapy for at least 3 to 6 months with monitoring of CSF PCR and immune reconstitution.

Human T-Lymphotropic Virus 1 and 2

HTLV is also neurotropic and a member of the same family of retroviruses as HIV. HTLV-1 causes a chronic spastic paraparesis with gradual onset and its most frequent symptoms are gait disturbance and urinary symptoms. There is conflicting evidence on whether HTLV-1 coinfection accelerates or slows HIV infection and whether HIV coinfection predisposes to clinical manifestations of tropical spastic paraparesis. Some evidence suggests HIV-1/HTLV-1 coinfection may lead to production of HIV-1 particles with expanded cell tropism and the ability to directly infect female genital epithelial cells, which normally act as an important barrier to HIV infection in females. Contrary to the conflicting evidence of HTLV-1 coinfection, it is generally accepted that HTLV-2 coinfection exerts a negative effect on HIV-1 replication by modulating the cellular microenvironment favoring its own viability and inhibiting HIV-1 progression.

Hepatitis B and C

Due to shared mode of transmission, coinfection of HIV and hepatitis B virus is common with an estimated 4 million people worldwide being coinfected. Neurologic conditions caused primarily by hepatitis B infection including peripheral neuropathy and encephalopathy related to hyperammonemia, may increase the severity of cognitive decline and peripheral neuropathy symptoms seen with primary HIV infection. HIV and hepatitis C virus (HCV) share large worldwide populations. In the United States, an estimated 25% to 40% of HIV-infected individuals are coinfected with HCV. The highest rates of coinfection are seen in those who are IV drug users. HCV alone is known to be neurotoxic. However, controversy remains regarding whether HCV coinfection worsens cognitive function in HIV-infected individuals because data to date are conflicting. This is also becoming less clinically important in the setting of newly available curative treatments for most HCV infections. HCV coinfection has been also correlated with an increased risk of primary intracranial hemorrhage, although the role for HCV coinfection in the risk of ischemic stroke is less well-defined.

Fungal Infections

Fungal infections and their treatment are discussed in detail in Chapter 67, so only those aspects important for HIV-infected patients are presented here.

Cryptococcosis

Cryptococcal infection, the most common cause of meningitis in individuals with HIV infection, was a presenting illness in 25% to 50% of AIDS patients in older clinical series. Although less common in much of the West, it remains prevalent in many regions worldwide especially sub-Saharan Africa, which accounts for approximately three-quarters of cases. The yeast is an ubiquitous environmental encapsulated fungi found in soil and bird feces and enters the body via inhalation. CNS involvement emerges from latent infection most commonly when CD4 counts fall below 100 cells/μL. Cryptococcal meningitis most commonly presents as a subacute meningitis or meningoencephalitis. Some patients demonstrate more severe symptoms such as seizures, lethargy, and coma resulting from elevated intracranial pressure. In protracted meningeal infection, small cryptococcomas can be found, and stroke may occur due to vasculitis. CT and MRI can be normal early on but show hydrocephalus and meningeal enhancement as the infection evolves. Cryptococcomas can be visualized near the ventricles and adjacent to subarachnoid spaces. CSF should be tested for cryptococcal antigen and cultured for fungus. In resource-limited settings, India ink staining is frequently used because cryptococcal antigen testing may not be available. CSF opening and closing pressure should be measured because it is elevated in the majority of patients with cryptococcal meningitis. In settings where CSF studies are unavailable, a positive serum cryptococcal antigen in a patient with a compatible clinical syndrome correlates well with CNS disease with higher titers having higher sensitivity and specificity for CNS cryptococcal infection. The principles of treatment for patients with cryptococcal meningitis include (1) antifungal therapy, (2) lowering elevated intracranial pressure, (3) initiating or optimizing antiretroviral therapy to improve immune function, and (4) management of immune reconstitution if it develops. Induction therapy includes amphotericin B plus flucytosine. A clinical trial in sub-Saharan Africa revealed equal efficacy and reduced adverse effects with a shorter (1-wk) duration of amphotericin and flucytosine therapy compared to the previous standard of 2 weeks of induction treatment. Fluconazole is the basis of maintenance therapy and must be continued until there is recovery of immune function. Patients with elevated opening pressure should undergo daily therapeutic lumbar punctures with measurement of closing pressures until pressures have normalized.

Primary prophylaxis using fluconazole or another azole may be instituted if the CD4 count falls below 200 cells/μL. Early initiation of antiretroviral therapy in the setting of cryptococcal meningitis has been shown to increase mortality, and treatment is typically delayed for 5 weeks after treatment of fungal infection.

Candidiasis

Candida is a rare cause of meningitis in severely immunosuppressed patients. Autopsies have occasionally shown *Candida* in brain parenchyma. Resistant organisms may emerge in patients who have been treated with fluconazole for primary prophylaxis.

Coccidioidomycosis

Coccidioidomycosis is endemic to the southwestern United States and certain areas of Mexico and Central and South America. Immunosuppressed patients more commonly develop disseminated infection, although rarely present with CNS involvement. Basilar meningitis is the most common presentation in those with neurologic involvement, which is typically accompanied by a reticulonodular diffuse infiltrative pneumonia. As the organism is often difficult to grow on CSF culture, presumptive diagnosis is often made through identification of *Coccidioides immitis* spherules in tissue, sputum, bronchoalveolar lavage fluid, or other body fluid. Chronic meningitis due to *C immitis* occurs in about 10% of patients from endemic areas with CD4 counts less than 200 cells/mL. The most common symptoms are headache and slowly worsening mental status changes. Symptoms are usually severe only in patients who develop endarteritis obliterans or hydrocephalus. Treatment of disseminated coccidioidomycosis includes systemic antifungal therapy with amphotericin B or azoles. Amphotericin B remains the drug of choice for life-threatening disease.

Histoplasmosis

Histoplasma capsulatum var *capsulatum* primarily affects those living in the valleys of the Ohio and Mississippi Rivers in the United States and those living in Latin America. *H capsulatum* var *duboisii* is described only in Africa and is a common endemic mycoses in HIV-infected patients. In patients with advanced HIV infection, histoplasmosis typically manifests with disseminated disease as opposed to the asymptomatic or limited pulmonary infection observed in the majority of healthy individuals exposed to *H capsulatum*. Neurologic symptoms include headache and encephalopathy with findings of a lymphocytic meningitis and focal parenchymal lesions in the brain or spinal cord.

Aspergillosis

Aspergillus fumigatus is a rare cause of brain abscess in HIV patients. *Aspergillus* is an angiotropic fungus that causes a necrotizing angiitis in the brain. Secondary thrombosis and hemorrhage can occur with the anterior and middle cerebral arteries being most commonly involved. Evolving hemorrhagic infarcts convert into septic infarcts with associated abscesses and cerebritis. Intracranial spread of *Aspergillus* infection occurs less frequently

through direct or contiguous spread. Direct extension from the sinuses or orbit has been reported causing abscess formation in the frontal lobes. Meningitis, less frequent than abscess, tends to involve the base of the brain. *Aspergillus* myelitis and invasion of the cavernous sinus have also been reported in AIDS patients. *Mucorales* can cause a similar picture, but this organism is not increased in frequency in AIDS patients.

Neuroimaging should be obtained prior to lumbar puncture to determine whether there is abscess formation. Organisms are rarely found in CSF, and surgical removal of *Aspergillus* abscesses may be the only manner of diagnosis. Amphotericin B combined with flucytosine and treatment of the source of infection is the treatment of choice.

Parasitic Infections

The geographic and patient ecologies of parasitic and HIV infections intersect in many areas including the tropical environments of sub-Saharan Africa, Central and South America, Thailand, and India, which foster the presence of malaria and other parasitic infections. Discussion in the following text focuses on the interaction of parasitic infections in HIV-infected individuals.

Toxoplasmosis

For many years, toxoplasmosis was the most common cause of brain lesions in patients with AIDS and a frequent cause of death. Today, *Toxoplasma gondii* accounts for less than 2% of AIDS deaths in the United States, although it remains a major contributor to death in HIV-infected patients worldwide. Most of this gain is due to effective antiretroviral treatment, but effective and well-tolerated drugs for both treatment and prophylaxis of toxoplasmosis infection have also contributed. Neurologic symptoms are referable to the sites of mass lesions. These most often occur at the gray-white junction and in the thalamus or basal ganglia. With multiple lesions, the clinical picture may appear nonfocal with seizures and signs of increased intracranial pressure. Meningitis, ventriculitis, and hydrocephalus have been described in the AIDS population, although they are less common presentations than focal mass lesions. Fever and headache are present in up to 70% of patients. CT and magnetic resonance scans demonstrate ring-enhancing or nodular lesions with marked surrounding edema. With MRI, lesions have decreased signal with T1-weighted sequences but increased signal on T2-weighted images (Fig. 70.3). Multiple lesions are seen in 60% of cases. Thallium brain SPECT shows decreased uptake with a toxoplasmosis abscess, which can be helpful in distinguishing CNS toxoplasmosis from primary CNS lymphoma which shows increased uptake. A radiologic and clinical response to treatment should be seen in 7 to 10 days after the initiation of treatment. If none is seen, brain biopsy should be obtained to evaluate for primary CNS lymphoma. As a result, most cases are now diagnosed by therapeutic response rather than brain biopsy. PCR for toxoplasma can be done on CSF but has a low yield, and serum toxoplasmosis IgG levels are sensitive but nonspecific for the diagnosis.

Treatment is with sulfadiazine or sulfadoxine and pyrimethamine. Folinic acid should be given to avoid vitamin B deficiency in the patient. Inadvertent substitution of folic acid will allow survival of the parasite. Patients allergic to sulfa can undergo desensitization or receive atovaquone, clindamycin plus pyrimethamine, or cotrimoxazole, which can also be used for primary prophylaxis. Concomitant corticosteroid therapy is occasionally needed due to severe edema but should be avoided whenever possible because it can interfere with the diagnosis of primary CNS lymphoma if the brain lesion does not respond to treatment as expected.

FIGURE 70.3 Fluid-attenuated inversion recovery magnetic resonance imaging **(A)** and contrast-enhanced computed tomography **(B)** in a human immunodeficiency virus-positive patient with toxoplasmosis. Extensive bilateral white matter T2 hyperintensity and multiple contrast-enhancing lesions are present.

Malaria

Malaria is widespread in many of the same areas where HIV is prevalent, although the effects of coinfection are poorly understood. Patients at highest risk for cerebral manifestations of malaria include those with a lack of acquired immunity toward *Plasmodium falciparum*. When it involves the brain, *P falciparum* infection causes seizures, including status epilepticus, cerebral edema, alteration of consciousness and coma, and signs of brainstem dysfunction. A recent meta-analysis of studies of malaria and HIV coinfection in sub-Saharan Africa suggested that coinfection was associated with an increased frequency of clinical parasitemia and severe malaria in children, pregnant women, and other adults. Treatment strategies do not differ for either infection in the setting of coinfection, but malaria prevention efforts are ultimately key in reducing the associated morbidity of this coinfection.

Trypanosomiasis

Infection by *Trypanosoma brucei gambiense* or *rhodesiense* causes sleeping sickness in Africa, and *Trypanosoma cruzi* causes Chagas disease in South America; in AIDS patients, it may rarely lead to mass lesions or meningoencephalitis.

Cysticercosis

Immunosuppression does not affect the virulence and prevalence of *T solium* infection, but neurocysticercosis should be considered in the differential of an HIV-infected patient from a region endemic for cysticerci. Lesions are most often calcified, although cysts containing live organisms in the larval state are occasionally seen. Anticonvulsant drugs are necessary to treat seizures, but antiparasitic agents, such as praziquantel and albendazole, are rarely needed.

Bacterial and Mycobacterial Infection

Syphilis

Neurosyphilis, which is caused by *T pallidum*, occurs with greater frequency in individuals coinfected with HIV. Although not an opportunistic infection, syphilitic infection behaves differently in the presence of AIDS, and genital syphilis facilitates acquiring HIV infection. About 15% of patients with primary syphilis are seropositive for HIV. Conversely, positive serology for syphilis may occur in over 35% of some HIV-infected populations. Progression from primary syphilis (painless chancre) to later stages is typically more rapid in HIV-infected patients with lower CD4 counts. Syphilis can affect many parts of the nervous system including the meninges, brain, brainstem, spinal cord, nerve roots, and cerebral and spinal blood vessels. Syndromes of early neurosyphilis are more common than late syndromes (general paresis and tabes dorsalis). Syphilitic meningitis is the earliest neurologic complication of syphilis and is caused by invasion of the meninges by the spirochete. These can sometimes lead to cerebral vasculitis and stroke, most commonly involving the middle cerebral artery. Late stages of neurosyphilis include meningovascular involvement of the medium and large vessels as well as parenchymatous disease. Parenchymatous neurosyphilis is typified by tabes dorsalis, involving the dorsal roots and posterior columns, and general paresis. More recently, neurosyphilis mimicking HSV encephalitis, temporal lobe epilepsy, and limbic encephalitis have been reported. All patients who are HIV positive and also seropositive for syphilis require an analysis of CSF to detect and treat neurosyphilis before it has permanent and disabling consequences. Although a positive CSF serology using fluorescent treponemal antibody (FTA) or Venereal Disease Research Laboratory (VDRL) is enough to initiate treatment, the CSF in neurosyphilis also usually contains white cells (usually mononuclear) and may also have increased protein. CSF VDRL, however, may be negative. Treatment with IV penicillin or 4 weeks of doxycycline or minocycline should be continued until there is a fourfold drop in serum titers. Ceftriaxone has a 23% failure rate, so its use is not recommended. HIV patients should have serology tested monthly for 3 months and at 3-month intervals thereafter. Lumbar puncture should be repeated after 6 months to assure an adequate response to treatment. If serologic titers remain stable or rise, retreatment is indicated. Complete normalization of CSF VDRL reactivity is less likely in those with higher baseline values and peripheral blood CD4 counts less than 200 cells/μL.

Mycobacteria

Mycobacterium avium-intracellulare: *Mycobacterium avium-intracellulare* was one of the earliest opportunistic infections described in patients with AIDS, although neurologic involvement was usually detected only at autopsy. The organism has been responsible for cases of immune reconstitution syndrome when antiviral treatment is started. Patients with disseminated *M avium-intracellulare* may develop meningoencephalitis, cranial neuropathies, and epidural abscess, but defining neurologic syndromes due to *M avium-intracellulare* has been difficult due to coinfection with several opportunistic organisms.

Mycobacterium tuberculosis: Worldwide, over 14 million people are coinfected with TB and HIV. In 2012, an estimated 1.3 million died of TB, including 320,000 coinfected with HIV. Tuberculous meningitis (TBM), which is the most deadly form of the disease, is 5 times more frequent in HIV-infected individuals. The elevated risk of TB in HIV-infected persons is due in part to impairment of T cell–mediated immunity, with TB risk increasing as CD4 cell count declines. In addition, the Beijing strain of TB, which has particularly high virulence, is associated with HIV infection and multidrug resistance.

CNS manifestations of TB occur from hematogenous dissemination of the bacteria from primary lung involvement with formation of small subpial and subependymal foci. In HIV-infected individuals, clinical presentation is typically similar to those who are HIV negative, although those who have very low CD4 counts can present atypically with more disseminated disease and altered consciousness. The most common presentation is meningitis, which is frequently a subacute or chronic presentation, followed by tuberculomas. Meningitis preferentially involves the basilar meninges and is associated with hydrocephalus, multiple cranial neuropathies, and ischemic stroke. TB may also present with spine disease, affecting the vertebral bodies (Pott disease) or the spinal cord. Diagnosis can be particularly challenging as the clinical picture often mimics other opportunistic infections, including cryptococcal meningitis. CSF may show an early neutrophilic response followed by lymphocytic predominance, low glucose, and elevated protein, although studies have shown that there is a reduced CSF white blood cell count in HIV-infected adults not receiving cART compared to HIV-uninfected adults. CSF protein has also been noted to be normal in HIV-positive patients. When cultured from CSF, the organism takes 3 to 4 weeks to grow and can be difficult to detect. Acid-fast bacillus (AFB) can also be detected by PCR, although the sensitivity is low. Although the PCR-based CSF GeneXpert test

shows improved sensitivity compared to other diagnostics for TBM and a faster turnaround time than culture, it has not been shown to reduce mortality in high-TB burden settings and has less than optimal sensitivity. Treatment for TBM is extrapolated from clinical trials for pulmonary TB and includes rifampicin, isoniazid, pyrazinamide, and streptomycin (or ethambutol) for intensive phase, followed by rifampicin and isoniazid for maintenance along with adjunctive corticosteroids. Recent studies have shown that high-dose rifampicin and a fluoroquinolone early in treatment may decrease mortality. It is important to note that there is an increased risk for drug resistance to isoniazid and rifampicin in HIV-positive patients with TB, causing further challenges to treatment. For those who are cART naive, delay in treatment initiation for up to 2 months is recommended because studies suggest this reduces the rate of life-threatening adverse events but does not alter overall mortality.

Neoplasms

Lymphoma incidence has declined markedly, from a range of 0.6% to 3% of patients in pre-cART clinical series to rare or no occurrence in post-cART series. Clinical signs are nonspecific and include focal neurologic signs, seizures, cranial neuropathy, and headache. CT may be normal or show hypodense lesions as well as single or multiple lesions with patchy or nodular enhancement. Thallium SPECT shows increased uptake in lymphoma, which aids in distinguishing it from toxoplasmosis which shows decreased uptake. Epstein-Barr virus DNA is found in PCR studies of CSF but is not predictive of the diagnosis. Brain biopsy is required for diagnosis. Response to therapy with radiation and chemotherapy (especially high-dose methotrexate in combination with cART) is improved by current antiretroviral regimens, with longer survivals and reports of complete tumor regression, although this is rare. Opportunistic infections may coexist with tumor and should be excluded by appropriate studies.

Other neoplasms reported rarely in AIDS patients include metastatic Kaposi sarcoma (associated with HHV-8) and primary glial tumors, but their incidence has also been dramatically decreased by cART. Non–AIDS-defining malignancies are now more important in the treated HIV population and occur with increased frequency compared with the uninfected population. An elevated risk is reported for the following cancers: anal, vaginal, Hodgkin lymphoma, liver, lung, melanoma, oropharyngeal, leukemia, colorectal, and renal. Routine cancer screening and smoking cessation are therefore important in this population.

Nutritional and Metabolic Consequences

Nutritional deficiency may result from inadequate amounts of thiamine, vitamin B_{12}, folic acid, and glutathione, which in turn may cause encephalopathy, dementia, neuropathy, or spinal cord disorders. Metabolic abnormalities often occur in late-stage disease and are reversible causes of encephalopathy. Testosterone deficiency is increasingly recognized in long survivors and may contribute to encephalopathy.

MANAGEMENT

cART has transformed the course of AIDS from a fatal disease to a chronic illness. Even before cART, prophylactic treatment of common opportunistic infections had reduced AIDS deaths. Improved medical care has also reduced the need for hospital admissions in this population.

Antiretroviral drugs improve morbidity due to HIV and extend survival. More than 40 drugs in seven classes, including combination drugs, have been approved for use, and more are in clinical trials or development (Table 70.8). New drugs are in development that target various phases of the viral cycle and include attachment inhibitors and chemokine receptor inhibitors.

Current recommendations regarding initiation of cART include starting antiretroviral therapy for all HIV+ patients regardless of CD4 count, a strategy known as *test and treat*. Deliberately delaying initiation of antiviral treatment (eg, until a particular CD4 threshold) contributes to non-AIDS events, such as cardiovascular, renal, and hepatic disease, that can occur as a result of an infection's ongoing inflammatory effects and is associated with higher mortality.

Adverse Neurologic Effects of Drug Treatment for HIV Infection

The most important adverse effect of initiation of cART in an immunosuppressed patient is immune reconstitution syndromes.

Vaccination of patients with HIV infection (or their household contacts) is considered worth the risk if the percentage of CD4 lymphocytes is above 15% in children or greater than 200 cells/μL. With varicella vaccine, clinicians should be prepared to use acyclovir if symptoms of varicella infection develop. Measles vaccine has rarely led to subacute sclerosing panencephalitis. Other antimicrobials used for prevention or maintenance therapy of fungal and parasitic infections can have neurologic side effects, such as testosterone deficiency with azole use, neuropathy with isoniazid if supplemental vitamin B_6 is not given, and seizures from ganciclovir. Increased sensitivity to psychotropic drugs leading to prominent extrapyramidal effects is seen in AIDS patients. Because new medications with different mechanisms of action are introduced, it is important that any adverse effects be reported using systems like the U.S. Food and Drug Administration's Sentinel Initiative to detect trends that will allow practitioners to best balance risks and benefits in treating HIV infection.

Table 70.8 lists medications in current use by class, with neurologic toxicities. The following is a brief summary of the most important toxicities.

Zidovudine causes a mitochondrial myopathy with ragged red fibers with muscle energy failure. Severe anemia (which can be corrected using erythropoietin growth factor) also contributes to fatigue.

The "D-drugs," didanosine (ddI), zalcitabine (ddC), and stavudine (d4T), cause a sensory neuropathy that is often painful and sometimes difficult to distinguish from the neuropathy caused by HIV itself. D-drugs are now rarely used because of the risk of sensory neuropathy.

Efavirenz, a nonnucleoside reverse transcriptase inhibitor, causes sleep disruption, psychiatric symptoms, and nightmares that can lead to its discontinuation by patients.

Protease inhibitors such as ritonavir and nelfinavir cause lipodystrophy. The cosmetic consequences often result in patients avoiding these drugs. The associated metabolic syndrome contributes to higher rates (16% per year) of myocardial infarction and stroke in long-term users. Some protease inhibitors, including indinavir, saquinavir, and ritonavir, are also associated with neuropathy, probably resulting from effects on dorsal root ganglia.

TABLE 70.8 Categories of Drugs Used to Treat Human Immunodeficiency Virus

Name	Former Name	Brand Name	Side Effect	Year Introduced
Nucleoside Reverse Transcriptase Inhibitors				
Abacavir		Ziagen	Cognitive, myopathy, seizures	1998
Didanosine	DDI	Videx	Neuropathy, myopathy	1991
Lamivudine	3TC	Epivir	Neuropathy, lactic acidosis	1995
Stavudine[a]	d4T	Zerit	Neuropathy, myopathy	1994
Zalcitabine[a]	ddC	Hivid	Neuropathy	1992
Zidovudine	AZT	Retrovir	Neuropathy, myopathy, cognitive, seizures	1987
Nucleotide Reverse Transcriptase Inhibitors				
Emtricitabine	FTC	Emtriva	Lactic acidosis	2003
Tenofovir disoproxil fumarate		Viread	Encephalopathy	2001
Nonnucleoside Reverse Transcriptase Inhibitors				
Delavirdine		Rescriptor	Rash	1997
Efavirenz		Sustiva	Cognitive, insomnia, hallucinations	1998
Etravirine		Intelence	Rash	2008
Nevirapine		Viramune	Hepatotoxicity, rash	1996
Rilpivirine		Edurant	Hepatotoxicity, rash	2011
Protease Inhibitors				
Amprenavir[a]		Agenerase	Lipodystrophy, metabolic syndrome, myopathy (if combined with statins)	1999
Atazanavir		Reyataz	Same as Amprenavir	2003
Darunavir		Prezista	Same	2006
Fosamprenavir		Lexiva	Same	2007
Indinavir[a]		Crixivan	Same plus neuropathy	1996
Nelfinavir		Viracept	Same plus visual symptoms	1997
Ritonavir		Norvir	Same plus neuropathy and visual symptoms	1996
Saquinavir		Invirase	Same plus neuropathy	1995
Tipranavir		Aptivus	Same plus neuropathy	2006
Integrase Inhibitors				
Raltegravir		Isentress	Muscle necrosis	2007
Dolutegravir		Tivicay	Hepatotoxicity, rash	2013
Entry Inhibitors				
Maraviroc		Selzentry	Hepatotoxicity, rash	2008
Fusion Inhibitors				
Enfuvirtide		Fuzeon	Sleep disruption	2007
Pharmacokinetic Enhancers				
Cobicistat		Tybost	Renal toxicity	2014
Combination Drugs				
Lamivudine/zidovudine		Combivir	See above	1997
Abacavir/lamivudine		Epzicom	See above	2005
Abacavir/lamivudine/zidovudine		Trizivir	See above	2000
Emtricitabine/tenofovir		Truvada	Lactic acidosis	2004
Emtricitabine/tenofovir/efavirenz		Atripla	Insomnia, hallucinations	2006
Lopinavir/ritonavir		Kaletra	Same as above	2000
Emtricitabine/rilpivirine/tenofovir		Complera	See above	2011
Elvitegravir/cobicistat/emtricitabine/tenofovir		Stribild	See above	2012
Elvitegravir/cobicistat/emtricitabine/tenofovir alafenamide		Genvoya	See above	2015
Abacavir/dolutegravir/lamivudine		Triumeq	See above	2014
Emtricitabine/rilpivirine/tenofovir alafenamide		Odefsey	See above	2016
Bictegravir/emtricitabine/tenofovir alafenamide		Biktarvy	See above	2018

[a]Rarely used in the United States.

Muscle necrosis with myoglobinuria has been reported with raltegravir, an integrase inhibitor. Lactic acidosis is associated with some nucleoside reverse transcriptase inhibitors.

Precautions for Clinical and Laboratory Services

Strict observation of contamination management procedures or universal precautions is mandatory. Hospital patients with known or suspected HIV infection are not isolated unless they have respiratory infection, such as TB, or severe neutropenia. Strict precautions should be observed in handling all waste, body fluids, and surgical specimens. Gloves must be worn to prevent skin and mucocutaneous contact with blood, excretions, secretions, and tissues of infected patients. Goggles or glasses should be used if heavy aerosol contamination with blood or other secretions is anticipated (eg, in the operating room). Masks are not needed unless the patient requires respiratory isolation for other reasons. Needles and other sharp instruments in contact with infected blood should be disposed of in proper safety containers. Health care workers should not recap needles to avoid needlestick injury.

The risks to health care workers are small but real. HIV seroconversion has been documented following needlestick injury or mucocutaneous exposure. The converse risk to patients from infected workers is exceedingly small, but HIV-positive workers should not perform or assist with invasive procedures in which cuts may occur. Postexposure prophylaxis with two drugs is recommended for HIV exposure through percutaneous or mucosal routes, and with three drugs for significant blood exposure (visibly contaminated needle or device with deep penetration). HIV and hepatitis B and C serologies should be determined immediately. Problems encountered with postexposure prophylaxis include side effects of therapy, lack of efficacy, and false-positive HIV tests on rapid screening assays. Postexposure treatment is estimated to reduce HIV transmission risk by 80%.

HIV is readily inactivated by heat and standard sterilization solutions, including 70% alcohol. Special sterilization procedures may not be necessary but are often used.

OUTCOMES

People living with HIV may die of HIV infection, opportunistic infections, causes unrelated to HIV infection, or of complications related to treatment. In general, people living with HIV who are on effective cART with systemic viral suppression can have near normal life spans. With more people surviving to older ages with HIV infection, however, has come increased awareness of geriatric syndromes associated with HIV infection, including frailty, sarcopenia, and incontinence. For example, frailty is a complex geriatric syndrome, which is essentially a measure of multimorbidity characterized by decreased physiologic reserves and increased vulnerability to a variety of serious adverse health outcomes. It occurs earlier and at higher rates among people with HIV than age- and sex-match counterparts. Furthermore, many medical comorbidities common in geriatric populations tend to occur earlier—often a decade or more earlier—in people with HIV infection. This "accelerated aging" is thought to be due to low levels of chronic inflammation that persists despite effective cART and leads to early immunosenescence. As such, all people with HIV infection need rigorous evaluation for systemic and neurologic syndromes irrespective of their stage of HIV infection because of the risk for multiple, coexistent, or sequential problems, including disorders unrelated to HIV.

Great strides have been made in the medical management of HIV infection, with the prevalence of some neurologic sequelae seen with profound immunosuppression reduced. Nonetheless, HIV infection remains a serious diagnosis with common neurologic manifestations and is rapidly fatal in countries where access to effective treatment is limited. Therapy does not eliminate latent provirus and may fail if resistant mutants arise. Candidate vaccines are in clinical trials in areas of high seroprevalence and seroconversion. The complex biology of the virus and the host immunogenetic response to infection pose significant challenges to successful vaccine development. Additional strategies to "cure" HIV infection include the "shock and kill" strategy, which uses drugs to "shock" latent HIV virus into replicating, and then the active virus and cells producing the active virus would be "killed" by antiretroviral therapy, normal immune system processes, or other interventions designed to kill infected cells. Elimination of viral reservoirs, including the CNS, remains as potential problem to this strategy for "cure" and is a subject of significant active investigation.

SUGGESTED READINGS

Alfahad T, Nath A. Retroviruses and amyotrophic lateral sclerosis. *Antiviral Res.* 2013;99:180-187.

Antinori A, Arendt G, Becker JT, et al. Updated research nosology for HIV-associated neurocognitive disorders. *Neurology.* 2007;69:1789-1799.

Behar R, Wiley C, McCutchan JA. Cytomegalovirus polyradiculoneuropathy in acquired immune deficiency syndrome. *Neurology.* 1987;37:557-561.

BeLue R, Okoror TA, Iwelunmor J, et al. An overview of cardiovascular risk factor burden in sub-Saharan African countries: a socio-cultural perspective. *Global Health.* 2009;5(1):10.

Bhatia NS, Chow FC. Neurologic complications in treated HIV-1 infection. *Curr Neurol Neurosci Rep.* 2016;16(7):62.

Bicanic T, Brouwer A, Meintjes G, et al. Relationship of cerebrospinal fluid pressure, fungal burden and outcome in patients with cryptococcal meningitis undergoing serial lumbar punctures. *AIDS.* 2009;23(6):701-706.

Birbeck GL, French JA, Perucca E, et al. Antiepileptic drug selection for people with HIV/AIDS: evidence-based guidelines from the ILAE and AAN. *Epilepsia.* 2012;53:207-214.

Bogorodskaya M, Chow FC, Triant VA. Stroke in HIV. *Can J Cardiol.* 2019;35(3):280-287.

Boissé L, Gill MJ, Power C. HIV infection of the central nervous system: clinical features and neuropathogenesis. *Neurol Clin.* 2008;26:799-819.

Bozzette SA, Ake CF, Tam HK, Chang SW, Louis TA. Cardiovascular and cerebrovascular events in patients treated for human immunodeficiency virus infection. *N Engl J Med.* 2003;348:702-710.

Carroll E, Sanchez-Ramos J. Hyperkinetic movement disorders associated with HIV and other viral infections. *Handb Clin Neurol.* 2011;100:323-334.

Centers for Disease Control and Prevention. Racial/ethnic disparities in diagnoses of HIV/AIDS—33 states, 2001-2005. *MMWR Morb Mortal Wkly Rep.* 2007;56:189-193.

Cettomai D, McArthur J. Mirtazapine use in human immunodeficiency virus-infected patients with progressive multifocal leukoencephalopathy. *Arch Neurol.* 2009;66:255-258.

Cherry CL, Skolasky RL, Lal L, et al. Antiretroviral use and other risks for HIV-associated neuropathies in an international cohort. *Neurology.* 2005;66:867-873.

Chetty R. Vasculitides associated with HIV infection. *J Clin Pathol.* 2001;54:275-278.

Chow FC, Regan S, Feske S, Meigs JB, Grinspoon SK, Triant VA. Comparison of ischemic stroke incidence in HIV-infected and non-HIV-infected patients in a U.S. health care system. *J Acquir Immune Defic Syndr.* 2012;60:351-358.

Chow FC, Wilson MR, Wu K, Ellis RJ, Bosch RJ, Linas BP. Stroke incidence is highest in women and non-Hispanic blacks living with HIV in the AIDS Clinical Trials Group Longitudinal Linked Randomized Trials cohort. *AIDS.* 2018;32(9):1125-1135.

Cornblath DR, McArthur JC, Kennedy PG, Witte AS, Griffin JW. Inflammatory demyelinating peripheral neuropathies associated with human T-cell lymphotropic virus type III infection. *Ann Neurol*. 1987;21:32-40.

De Clerq E. Emerging antiviral drugs. *Expert Opin Emerg Drugs*. 2008;13:393-416.

de Rosso AL, de Mattos JP, Correa RB, Nicaretta DH, Novis SA. Parkinsonism and AIDS: a clinical comparative study before and after HAART. *Arq Neuropsiquiatr*. 2009;67:827-830.

Durand M, Sheehy O, Baril JG, LeLorier J, Tremblay CL. Risk of spontaneous intracranial hemorrhage in HIV-infected individuals: a population-based cohort study. *J Stroke Cerebrovasc Dis*. 2013;22:e34-e41.

Elbott DJ, Peress N, Burger H, et al. Human immunodeficiency virus type 1 in spinal cords of acquired immunodeficiency syndrome patients with myelopathy: expression and replication in macrophages. *Proc Natl Acad Sci U S A*. 1989;86:3337-3341.

Ellis RJ, Rosario D, Clifford DB, et al. Continued high prevalence and adverse clinical impact of human immunodeficiency virus-associated sensory neuropathy in the era of combination antiretroviral therapy: the CHARTER Study. *Arch Neurol*. 2010;67:552-558.

Epstein LG, Gendelman HE. Human immunodeficiency virus type 1 infection of the nervous system: pathogenetic mechanisms. *Ann Neurol*. 1993;33:429-436.

Epstein LG, Sharer LR, Oleske JM, et al. Neurologic manifestations of human immunodeficiency virus infection in children. *Pediatrics*. 1986;78:678-687.

Gray F, Chrétien F, Vallat-Decouvelaere AV, Scaravilli F. The changing pattern of HIV neuropathology in the HAART era. *J Neuropathol Exp Neurol*. 2003;62:429-440.

Hammer SM, Eron JJ Jr, Reiss P, et al. Antiretroviral treatment of adult HIV infection: 2008 recommendations of the International AIDS Society-USA panel. *JAMA*. 2008;300;555-570.

Hollander H, Stringari S. Human immunodeficiency virus-associated meningitis. Clinical course and correlations. *Am J Med*. 1987;83:813-816.

Illa I, Nath A, Dalakas M. Immunocytochemical and virological characteristics of HIV-associated inflammatory myopathies: similarities with seronegative polymyositis. *Ann Neurol*. 1991;29:474-481.

Kassaye SG, Wang C, Ocampo JMF, et al. Viremia trajectories of HIV in HIV-positive women in the United States, 1994-2017. *JAMA Netw Open*. 2019;2(5):e193822.

Kellinghaus C, Engbring C, Kovac S, et al. Frequency of seizures and epilepsy in neurological HIV-infected patients. *Seizure*. 2008;17(1):27-33.

Kwan CK, Ernst JD. HIV and tuberculosis: a deadly human syndemic. *Clin Microbiol Rev*. 2011;24:351-376.

Kwenti TE. Malaria and HIV coinfection in sub-Saharan Africa: prevalence, impact, and treatment strategies. *Res Rep Trop Med*. 2018;9:123-126.

Leng SX, Margolick JB. Aging, sex, inflammation, frailty, and CMV and HIV infections. *Cell Immunol*. 2020;348:104024.

Letendre SL, Cherner M, Ellis RJ, et al. The effects of hepatitis C, HIV, and methamphetamine dependence on neuropsychological performance: biological correlates of disease. *AIDS*. 2005;19 suppl 3:S72-S78.

Levin SN, Lyons JL. HIV and spinal cord disease. *Hand Clin Neurol*. 2018;152:213-227.

Liner KJ II, Hall CD, Robertson KR. Impact of human immunodeficiency virus (HIV) subtypes on HIV-associated neurological disease. *J Neurovirol*. 2007;13:291-304.

Luft BJ, Haffner R, Korzun AH, et al. Toxoplasmic encephalitis in patients with the acquired immunodeficiency syndrome. Members of the ACTG 077p/ANRS 009 Study Team. *N Engl J Med*. 1993;329:995-1000.

Makadzange AT, Ndhlovu CE, Takarinda K, et al. Early versus delayed initiation of antiretroviral therapy for concurrent HIV infection and cryptococcal meningitis in sub-Saharan Africa. *Clin Infect Dis*. 2010;50:1532-1538.

Manabe YC, Campbell JD, Sydnor E, Moore RD. Immune reconstitution inflammatory syndrome: risk factors and treatment implications. *J Acquir Immune Defic Syndr*. 2007;46:456-462

Mandell DM, Mossa-Basha M, Qiao Y, et al. Intracranial vessel wall MRI: principles and expert consensus recommendations of the American Society of Neuroradiology. *Am J Neuroradiol*. 2016;38(2):218-229.

Mateen F, Shinohara R, Carone M, et al. Neurological disorders incidence in HIV+ vs. HIV− men: multicenter AIDS Cohort Study, 1996-2011. *Neurology*. 2012;79:669-683.

Modi G, Modi M, Martinus I, Saffer D. New-onset seizures associated with HIV infection. *Neurology*. 2000;55:1558-1561.

Molloy SF, Kanyama C, Heyderman RS, et al. Antifungal combinations for treatment of cryptococcal meningitis in Africa. *N Engl J Med*. 2018;378:1004-1017.

Morgello S, Estanislao L, Simpson D, et al. HIV-associated distal sensory polyneuropathy in the era of highly active antiretroviral therapy: the Manhattan HIV Brain Bank. *Arch Neurol*. 2004;61:546-551.

Moulignier A, Moulonguet A, Pialoux G, Rozenbaum W. Reversible ALS-like disorder in HIV infection. *Neurology*. 2001;57:995-1001.

Murdoch DM, Venter WDF, Feldman C, Van Rie A. Incidence and risk factors for the immune reconstitution inflammatory syndrome in HIV patients in South Africa: a prospective study. *AIDS*. 2008;22:601-610.

Nath A, Jankovic J, Pettigrew LC. Movement disorders and AIDS. *Neurology*. 1987;37:37-41.

Navia BA, Cho ES, Petito CK, Price RW. The AIDS dementia complex: II. *Neuropathology Ann Neurol*. 1986;19:525-535.

Navia BA, Jordan BD, Price RW. The AIDS dementia complex: I. Clinical features. *Ann Neurol*. 1986;19:517-526.

Ovbiagele B, Nath A. Increasing incidence of ischemic stroke in patients with HIV infection. *Neurology*. 2011;76:444-450.

Panlilio AL, Cardo DM, Grohskopf LA, Heneine W, Ross CS. Updated U.S. Public Health Service guidelines for the management of occupational exposures to HIV and recommendations for postexposure prophylaxis. *MMWR Recomm Rep*. 2005;54(RR-9):1-17.

Park MK, Hospenthal DR, Bennett JE. Treatment of hydrocephalus secondary to cryptococcal meningitis by use of shunting. *Clin Infect Dis*. 1999;28:629-633.

Petito CK, Navia BA, Cho ES, Jordan BD, George DC, Price RW. Vacuolar myelopathy pathologically resembling subacute combined degeneration in patients with the acquired immunodeficiency syndrome. *N Engl J Med*. 1985;312:874-879.

Postels DG, Birbeck GL. Cerebral malaria. *Handb Clin Neurol*. 2013;114:91-102.

Price RW, Spudich S. Antiretroviral therapy and central nervous system HIV-1 infection. *J Infect Dis*. 2008;197(suppl 3):S294-S306.

Qureshi AI, Janssen RS, Karon JM, et al. Human immunodeficiency virus infection and stroke in young patients. *Arch Neurol*. 1997;54(9):1150-1153.

Rozenberg F, Deback C, Agut H. Herpes simplex encephalitis: from virus to therapy. *Infect Disord Drug Targets*. 2011;11:235-250.

Sacktor N, Skolasky RL, Tarwater PM, et al. Response to systemic HIV viral load suppression correlates with psychomotor speed performance. *Neurology*. 2003;61:567-569.

Sacktor NC, Wong M, Nakasujja N, et al. The International HIV Dementia Scale: a new rapid screening test for HIV dementia. *AIDS*. 2005;19:1367-1374.

San-Andrés FJ, Rubio R, Castilla J, et al. Incidence of acquired immunodeficiency syndrome-associated opportunistic diseases and the effect of treatment on a cohort of 1115 patients infected with human immunodeficiency virus, 1989-1997. *Clin Infect Dis*. 2003;36:1177-1185.

Sanchez-Ramos JR, Factor SA, Weiner WJ, Marquez J. Hemichorea-hemiballismus associated with acquired immune deficiency syndrome and cerebral toxoplasmosis. *Mov Disord*. 1989;4:266-273.

Satishchandra P, Sinha S. Seizures in HIV-seropositive individuals: NIMHANS experience and review. *Epilepsia*. 2008;49(suppl 6):33-41.

Saylor D. Neurologic complications of human immunodeficiency virus infection. *Continuum (Minneap Minn)*. 2018;24(5, Neuroinfectious Disease):1397-1421.

Saylor D, Dickens AM, Sacktor N, et al. HIV-associated neurocognitive disorder—pathogenesis and prospects for treatment. *Nat Rev Neurol*. 2016;12(4):234-248.

Schiffito G, McDermott MP, McArthur JC, et al. Incidence of and risk factors for HIV-associated distal sensory polyneuropathy. *Neurology*. 2002;58:1764-1768.

Sellier P, Monsuez JJ, Evans J, et al. Human immunodeficiency virus-associated polymyositis during immune restoration with combination antiretroviral therapy. *Am J Med*. 2000;109:510-512.

Sevigny JJ, Albert SM, McDermott MP, et al. An evaluation of neurocognitive status and markers of immune activation as predictors of time to death in advanced HIV infection. *Arch Neurol*. 2007;64:97-102.

Sillman B, Woldstad C, Mcmillan J, Gendelman HE. Neuropathogenesis of human immunodeficiency virus infection. *Handb Clin Neurol*. 2018;152:21-40.

Simpson DM, Bender AN. Human immunodeficiency virus-associated myopathy: analysis of 11 patients. *Ann Neurol*. 1988;24:79-84.

Sloan D, Dlamini S, Paul N, Dedicoat M. Treatment of acute cryptococcal meningitis in HIV infected adults, with an emphasis on resource-limited settings. *Cochrane Database Syst Rev*. 2008;(4):CD005647.

Smyth K, Affandi JS, McArthur JC, et al. Prevalence of and risk factors for HIV-associated neuropathy in Melbourne, Australia 1993-2006. *HIV Med*. 2007;8:367-373.

Ssentongo P. Prevalence and incidence of new-onset seizures and epilepsy in patients with human immunodeficiency virus (HIV): systematic review and meta-analysis. *Epilepsy Behav*. 2019;93:49-55.

Tan IL, McArthur JC, Venkatesan A, Nath A. Atypical manifestations and poor outcome of herpes simplex encephalitis in the immunocompromised. *Neurology*. 2012:79:2125-2132.

Thakur KT, Boubour A, Saylor D, Das M, Bearden DR, Birbeck GL. Global HIV neurology: a comprehensive review. *AIDS*. 2019;33(2):163-184.

Thurnher MM, Post JM, Rieger A, Kleibl-Popov C, Loewe C, Schindler E. Initial and follow-up MR imaging findings in AIDS-related progressive multifocal leukoencephalopathy treated with highly active antiretroviral therapy. *AJNR*. 2001;22:977-984.

UNAIDS. UNAIDS data 2018. UNAIDS Web site. http://www.unaids.org/sites/default/files/media_asset/unaids-data-2018_en.pdf. Accessed May 20, 2019.

Valcour VG, Shikuma CM, Watters MR, Sacktor NC. Cognitive impairment in older HIV-1-seropositive individuals: prevalence and potential mechanisms. *AIDS*. 2004;18(suppl 1):S79-S86.

Venkataramana A, Pardo CA, McArthur JC, et al. Immune reconstitution inflammatory syndrome in the CNS of HIV-infected patients. *Neurology*. 2006;67:383-388.

Wake RM, Britz E, Sriruttan C, et al. High cryptococcal antigen titers in blood are predictive of subclinical cryptococcal meningitis among human immunodeficiency virus-infected patients. *Clin Infect Dis*. 2018;66:686-692.

Wiley CA, Schrier RD, Nelson JA, Lampert PW, Oldstone MB. Cellular localization of human immunodeficiency virus infection within the brains of acquired immune deficiency syndrome patients. *Proc Natl Acad Sci U S A*. 1986;83:7089-7093.

Wong MH, Robertson K, Nakasujja N, et al. Frequency of and risk factors for HIV dementia in an HIV clinic in sub-Saharan Africa. *Neurology*. 2007;68:350-355.

Multiple Sclerosis and Related CNS Neuroimmune Diseases 71

Erin E. Longbrake and Sarah F. Wesley

KEY POINTS

1. Multiple sclerosis (MS) is a chronic central nervous system autoimmune disease characterized by inflammation and neurodegeneration. There are both genetic and environmental risk factors.
2. MS typically begins in young adulthood. It is the most common cause of nontraumatic neurologic disability in young people in the United States.
3. Both T and B lymphocytes are dysregulated in MS.
4. Diagnostic criteria for MS (McDonald criteria) incorporate clinical/radiologic/cerebrospinal fluid findings to establish dissemination in time and space.
5. MS may follow either a relapsing or progressive clinical course.
6. Disease activity (a clinical relapse or new/enlarging T2-weighted or gadolinium-enhancing lesions on MRI) may occur in both relapsing and progressive MS.
7. Disease progression (slow/steady worsening of neurologic dysfunction) may be punctuated by periods of stability.
8. Numerous immunomodulatory therapies are effective for treating relapsing MS, and outcomes are best when treatment is initiated early.
9. Neuromyelitis optica spectrum disorders and anti-myelin oligodendrocyte glycoprotein disease have pathologic autoantibodies and are distinct from MS.

INTRODUCTION

Multiple sclerosis (MS) is a chronic autoimmune disease. Although it remains the leading cause of nontraumatic neurologic disability in young people, the last decade has brought significant advances in understanding MS pathophysiology with new treatments and diagnostic modalities. The identification of a pathologic aquaporin 4 (AQP4) autoantibody has definitively established neuromyelitis optica spectrum disorders (NMOSD) as a distinct disease entity, where they were previously considered an MS subtype. Myelin oligodendrocyte glycoprotein (MOG) spectrum disease is another increasingly understood neuroinflammatory entity that can present with symptoms and signs overlapping with MS and NMOSD.

MULTIPLE SCLEROSIS

Introduction

MS is a chronic autoimmune disease of the CNS characterized by inflammation and neurodegeneration that develops in genetically susceptible hosts and that has a variable clinical course. MS was initially identified by Scottish pathologist Robert Carswell in 1838, but it was not until the 1860s that French physician Jean Marie Charcot at the Pitié-Salpêtrière Hospital in Paris comprehensively described and termed *MS, sclérose en plaques disseminées*. Significant advances in understanding and treating the disease have occurred in the past several decades. The natural history of MS can follow a relapsing-remitting pattern or present in a progressive manner. Diagnosis is made based on clinical history and exam as well as cerebrospinal and radiographic characteristics. Individual differences in prognosis depend on a combination of genetic and environmental factors as well as access to early effective immunotherapy.

Epidemiology

The prevalence rate of MS in the United States has been estimated around 309 per 100,000, with a prevalence varying depending on latitude, which is discussed in detail later in this chapter. It is a leading cause of nontraumatic disability in young adults. The median age of onset is 23 to 24 years, with the first symptoms rarely occurring before the age of 10 or after the age of 60. Women are affected approximately twice as often as men except in individuals with the primary progressive form of the disease where there is no gender discrepancy.

Pathobiology

Immunobiology

MS is considered an autoimmune disease that results from a complex interplay of genetic and environmental factors. Ultimately, MS develops when proinflammatory, myelin-reactive or more recently identified β-synuclein T cells target the CNS. B cells are also involved in disease pathogenesis, presumably as antigen-presenting cells, evidenced by the success of B-cell

depleting immunotherapies, but the mechanisms by which they influence disease are still being elucidated.

The immune system is dysregulated in MS patients at many levels. The initial loss of self-tolerance may occur when genetically susceptible individuals develop an immune response against pathogenic epitopes that share antigen cross-reactivity to myelin peptides. Antigen-presenting cells then present relevant self-antigens to peripheral $CXCR3^+CD4^+$ T cells, leading to their activation and the subsequent generation of autoreactive proinflammatory T-helper (Th) 1 and 17 subsets. B cells and monocytes are also activated. These autoreactive T cells interact with adhesion molecules on the endothelial surface of CNS venules and, with antibodies and monocytes, cross the disrupted blood–brain barrier with the aid of proteases (eg, matrix metalloproteinases) and chemokines. Within the CNS, target antigens are recognized, T cells are reactivated, and the immune response is amplified. Proinflammatory T-helper cells proliferate, and B cells mature to antibody-secreting plasma cells, whereas monocytes become activated macrophages. Together, these immune cells produce inflammatory cytokines (eg, interleukin [IL]-12, IL-23, interferon γ, tumor necrosis factor-α), proteases, free radicals, antibodies, nitric oxide, glutamate, and other stressors that collectively lead to damage of myelin and oligodendrocytes.

Depending on the location and extent of damage, demyelination may impair or block nerve conduction and result in neurologic symptoms. These may be transient or permanent. Spontaneous improvement of symptoms is attributed to resolution of inflammation, adaptive mechanisms (eg, reorganization of sodium channels), or remyelination. In contrast, loss of trophic support from oligodendrocytes causes axon degeneration and irreversible neurologic deficits.

The older classification of autoimmune diseases as being either T cell or B cell mediated has been replaced by the realization that the genetic variants leading to lower threshold of immune activation involves CD4, CD8, and regulatory T cells (Tregs) along with B cells. The dramatic clinical success of B-cell depleting therapies along with the intrathecal production of immunoglobulin in most MS patients, histologic identification of myelin-specific antibodies and antibody-associated demyelination in some MS lesions, and the discovery of ectopic lymphoid tissue containing B cells in the meninges provides strong evidence of a critical role of B cells triggering T cells in patients with MS. Pathologic studies have shown that B-cell clones are shared between the meninges and parenchyma of individual MS patients. B cells may act as antigen-presenting cells to autoreactive T lymphocyte cells. B cells may also directly produce proinflammatory cytokines, such as IL-6.

Pathology

The pathologic hallmark of MS is circumscribed demyelination that occurs in white and gray matter (Fig. 71.1A), most frequently in the periventricular white matter, juxtacortical white matter, brainstem, cerebellum, cortex, and spinal cord. White matter lesions are formed through an inflammatory process involving infiltration with macrophages, and to a lesser degree, lymphocytes. The histologic features of acute lesions include hypercellularity caused by macrophages and hypertrophic astrocytes, intense infiltration of perivascular spaces with lymphocytes and monocytes (Fig. 71.1B), and loss of myelin with relative preservation of axons (Fig. 71.1C). Acute lesions may evolve into chronic active (also mixed active/inactive) lesions, a state in which they can persist for many years. These lesions display smoldering inflammation with minor demyelinating activity at the lesion rim, and

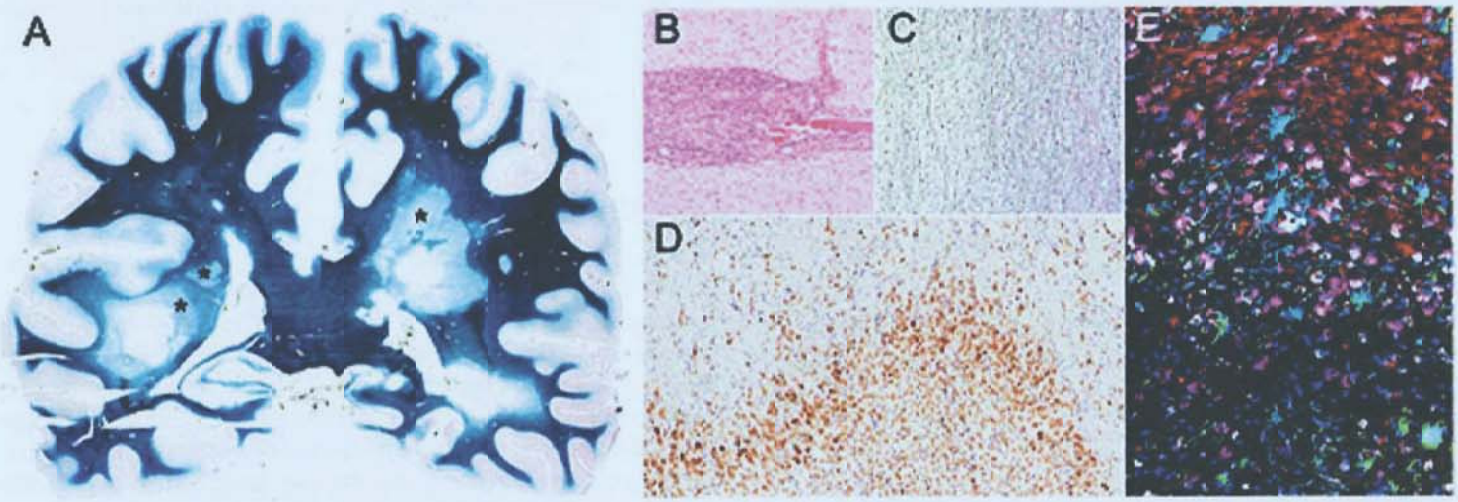

FIGURE 71.1 **A:** Coronal section of a patient with chronic multiple sclerosis, stained with Luxol fast blue. The section shows several white matter lesions, some of which have partial remyelination (shadow plaques, asterisks). In addition, there is widespread cortical demyelination, particularly of the temporal lobes, with preservation of cortical myelin in the parietal lobes. **B:** Perivascular cuff within a demyelinating lesion consisting of mononuclear cells, including lymphocytes, monocytes, and plasma cells (hematoxylin & eosin). **C:** Lesion edge showing reduced axonal density in the lesion (left half of picture) compared to the adjacent white matter (Bodian silver staining). Axons are relatively preserved compared to the complete loss of myelin. **D:** Recently demyelinating lesion with numerous CD68-positive macrophages at the lesion edge and smaller macrophages containing processed myelin within the lesion center (CD68, brown; hematoxylin). **E:** Multiplexed immunofluorescence imaging of the same lesion as in **D**, labeled with antibodies against proteolipid protein (myelin marker, red), glial fibrillary acidic protein (astrocyte marker, green), vimentin (astrocyte marker, cyan), Iba1 (microglial marker, magenta), CD68 (macrophage marker, white) and Hoechst (nuclear marker, blue). The image shows a section of the lesion rim with macrophages, reactive astrocytes, and intact myelin in the upper part of the picture.

a hypocellular lesion center with denuded axons and astroglial scar tissue. Chronic, silent lesions consist of astroglial scar tissue without inflammation. Compared to white matter lesions, cortical demyelination is characterized by relatively minor inflammatory activity and typically associated with meningeal inflammation.

Genetic Risk Factors

Data from the haplotype map (HapMap) project has been pivotal to the understanding of the genetics of MS, with genome-wide association studies using single nucleotide polymorphisms providing an unbiased and widespread approach to scanning the whole genome and identifying haplotypes associated with risk of developing human diseases. Recent work has identified approximately half of the genetic susceptibility for risk of developing MS. Of interest, MS shares allelic variants with other autoimmune diseases, meaning that there are likely shared pathways of immune system regulation. Twin studies also show that there is a genetic risk for MS, with a monozygotic concordance rate of 30% versus a dizygotic rate of 5%. Approximately 15% to 20% of people with MS have a family history of MS. When both parents are affected, there is at least a 9% risk to their offspring of developing MS. It has been understood for some time that MS is associated with the major histocompatibility complex haplotype containing human leukocyte antigen (HLA)-DRB1*1501. Genome-wide association studies in patients with MS and other autoimmune diseases identified 233 additional autosomal susceptibility variants outside the major histocompatibility complex associated with MS risk.

Environmental Influences

Multiple environmental factors might influence the risk of MS. In general, there is a latitudinal gradient with an increased prevalence of MS further from the equator in both hemispheres. However, several regions with similar latitude have vastly different MS prevalence rates, which in some instances can be accounted for by differences in ethnic susceptibility. Western Europe and North America have the highest prevalence of MS, whereas Asia, the Middle East, and Africa have the lowest prevalence. Further evidence of an environmental effect comes from migration studies. In general, immigrants who move from one area to another before the age of 15 years acquire the MS risk associated with the new region.

Vitamin D deficiency has emerged as a risk factor for MS. The active form of vitamin D, 1,25-dihydroxyvitamin D_3, has immunomodulatory properties and can prevent or ameliorate experimental autoimmune encephalitis (EAE; a mouse model of MS). Numerous studies found an inverse correlation between sunlight exposure (the most common source of vitamin D) or dietary intake of vitamin D and the risk of MS. Indeed, the relationship to sunlight exposure may help explain the latitudinal variation of MS prevalence. A study of U.S. military personnel found that higher serum levels of 25-hydroxyvitamin D_3 were associated with a lower risk of MS. Similar findings in the Netherlands were reported, but only in women, as well as a negative correlation between 25-hydroxyvitamin D_3 levels and disability. However, it is not known whether vitamin D supplementation modifies the disease in people already diagnosed with MS. It has also been found that a highly conserved vitamin D–responsive element exists in the promoter region of the HLA-DRB*1501 haplotype, which could indicate that people with this risk allele might experience a beneficial effect from vitamin D supplementation.

Among the possible infectious causes, the case for Epstein-Barr virus (EBV) has long been of interest. The frequency of MS is low in people who are seronegative for EBV, and the risk of MS is increased in those who have had infectious mononucleosis. Moreover, over 99% of people with MS have had prior exposure to EBV, compared to 90% in the general population. The evidence for other microbial agents is less compelling, but it is possible that a number of viruses or bacteria might act as a nonspecific trigger of MS in genetically susceptible individuals.

The role of diet has also been investigated, with particular focus on whether high salt or fat intake impacts MS risk. High-salt diets increase the severity of EAE and facilitate the development of pathogenic IL-23–dependent T_H17 cells in vitro, which in turn leads to increased production of proinflammatory cytokines. This has been hypothesized to explain in part the increasing incidence of MS and other autoimmune diseases in countries consuming a "Western diet." Furthermore, research aimed at pediatric populations with MS found a greater risk of MS in extremely obese girls, compared to no increased risk in obese boys.

Although tobacco smoking has not been shown to be a direct environmental risk factor for developing MS, it has a major effect on disease severity and course. Smoking is associated with increased rates of progression and a higher risk of having the primary progressive subtype of MS. Smokers also have a faster rate of progression from relapsing-remitting MS (RRMS) to secondary progressive MS (SPMS).

Emerging work on the gut microbiome suggests that symbiotic bacteria may plan an important role in bridging environmental risk factors and immune changes. Gut bacteria and their byproducts play an important role in shaping the function of the immune system, and the composition of the gut flora is dysregulated in MS. Cross-sectional studies of MS patients have demonstrated a similar level of species richness among MS patients and healthy individuals, but underlying differences in the bacterial community structure have been consistently observed. Germ-free mice developed more severe EAE after colonization with gut microbes harvested from MS patients. The mechanisms by which the gut microbiota impact MS are still being elucidated.

Diagnosis

Disease Course

The course of MS is determined clinically. There are no biologic markers or magnetic resonance imaging (MRI) features that objectively separate the disease phenotypes, and the current classification system is based on consensus. Accurate classification is imperative for appropriate treatment with the disease-modifying drugs.

Broadly, MS cases are classified as having a relapsing or progressive phenotype. Additional characterization is achieved by incorporating the modifiers "disease activity" and "disease progression." Disease activity is manifested by clinical relapses or by the presence of new gadolinium-enhancing or incontrovertibly enlarging T2 lesions on MRI scans. Disease activity provides evidence of ongoing inflammation. An asymptomatic individual with relapsing MS and gadolinium-enhancing lesions on MRI therefore has relapsing disease with evidence of disease activity. An individual with progressive MS and gadolinium-enhancing lesions would likewise be characterized as demonstrating "active" disease. In contrast, disease progression refers to accumulation of neurologic disability, independent of relapses, in persons with an overall progressive disease course. Disease progression in MS does not take place at a steady rate, and thus, persons with progressive MS frequently remain relatively stable for long periods of time (Fig. 71.2).

Disease activity and disease progression likely have unique pathophysiologies. Disease activity is attributed to localized inflammation and influx of infiltrating immune cells. Disease progression,

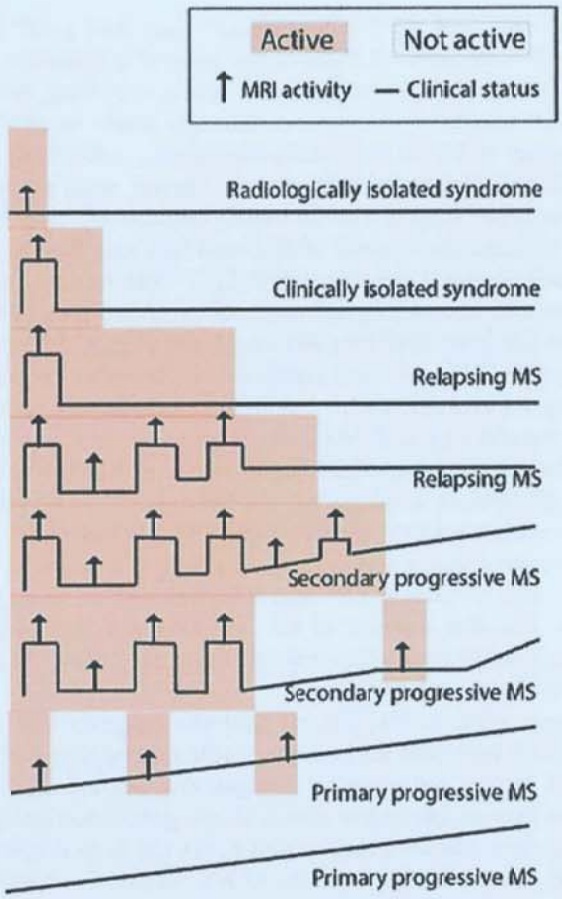

FIGURE 71.2 Multiple sclerosis (MS) can be described as either relapsing or progressive. Either subtype may also exhibit *disease activity* and patients with progressive disease may exhibit either clinical stability or *disease progression*. Radiologically isolated syndromes are identified when suggestive brain lesions are observed in the absence of a clinical event *(line 1)*. Clinically isolated syndromes *(line 2)* occur when patients present with a single clinical event, but dissemination in time and space cannot be demonstrated. Relapsing-remitting MS (RRMS) is the most common clinical phenotype, occurring in approximately 85% of patients at the time of diagnosis. Patients with RRMS may exhibit disease activity in the form of relapses *(solid lines)* or new/enlarging T2 or gadolinium-enhancing lesions on magnetic resonance imaging (MRI) *(asterisks)*. *Lines 3* and *4* show that disease is labeled as RRMS irrespective of whether recovery from relapses is complete *(line 3)* or incomplete *(line 4)*, as long as a stable baseline is reestablished. Many patients eventually follow a secondary progressive MS (SPMS) pattern (*lines 5* and *6*). Patients with SPMS may still exhibit disease activity in the form of relapses or new MRI lesions, as long as the disease is slowly worsening over time. Approximately 10% to 15% of patients have primary progressive MS (*lines 7* and *8*). These patients do not have clinical relapses but may have disease activity identified with MRI. Patients with progressive MS may experience periodic plateaus, where no disease progression is observed *(line 6)*. *Solid lines* represent clinical phenotype. *Asterisks* represent new/enlarging T2 lesions or gadolinium enhancing lesions on MRI.

however, most likely represents sequelae of chronic, low-grade inflammation that is trapped behind the blood–brain barrier. Chronically activated glial cells and collections of lymphocytes in meningeal tertiary lymphoid organs may contribute to neurodegeneration and disease progression.

The diagnosis of MS requires clinical symptoms and the demonstration of lesions disseminated in time and space (see discussion in the following text). Brain lesions highly suggestive of MS may be identified in asymptomatic individuals who have undergone brain MRI for an unrelated reason (often headaches or after a motor vehicle accident). In the absence of clinical symptoms, a diagnosis of MS cannot be made, and these individuals are diagnosed with a *radiologically isolated syndrome* (RIS). This likely represents a preclinical stage of disease, and it can be argued that if spinal fluid examination reveals inflammation then it is not unreasonable to attempt short-term immunotherapy in an attempt to prevent clinical disease. There is as yet no evidence that this approach will change outcomes; however, virtually every MS study to date has found that early treatment is associated with improved prognosis. Several large clinical trials testing the efficacy of immunomodulatory therapy in patients with RIS are underway. Approximately two-thirds of individuals with RIS develop additional brain lesions within 5 years, and one-third develop a clinical event concerning for MS during that timeframe.

The next point on the MS continuum is the *clinically isolated syndrome* (CIS). This is diagnosed when an individual experiences one typical demyelinating event, such as optic neuritis or transverse myelitis, and the brain MRI is suggestive of MS but there is insufficient evidence to demonstrate dissemination in time. Patients with CIS frequently go on to develop MS; the 2-year probability of conversion to definite MS is approximately 57%. Initiation of effective disease-modifying therapy should be recommended at this stage. Modern diagnostic criteria for MS (McDonald 2017 criteria) have decreased the frequency with which CIS is diagnosed because a larger proportion of patients can be diagnosed with definite MS at the time of presentation due to imaging or spinal fluid characteristics.

RRMS is the initial form of the disease in 85% to 90% of patients. It is characterized by acute relapses interspersed with clinical remissions, as previously discussed. Symptoms from a relapse typically evolve over several days to a week before reaching a nadir. Recovery is variable, but approximately 40% of relapses result in persistent neurologic deficits and patients may accumulate disability in a stepwise fashion as a result of recurrent relapses. When left untreated, most patients with RRMS ultimately enter the *secondary progressive* phase of MS (SPMS), which is characterized by an overall phenotype of gradual deterioration (disease progression) with or without superimposed disease activity.

Primary progressive MS (PPMS) patients make up 10% to 15% of individuals with the disease. PPMS is characterized by disease progression from the time of onset (eg, a slowly progressive monoparesis). There may be plateaus and minor fluctuations, but clinical relapses never occur in PPMS. A subset of these patients may, however, exhibit disease activity in the form of new gadolinium-enhancing brain lesions or new T2 lesions on MRI.

The *Marburg variant* of MS is a rare, fulminant, and usually monophasic illness that typically results in death within 1 year. It is characterized by extensive acute demyelination manifested by tumefactive appearance, mass effect, and widespread gadolinium enhancement on MRI scans.

Clinical Manifestations

MS typically presents with a relapse or an episode of neurologic dysfunction localizable to the brain, spine, or optic nerve. Common presentations include optic neuritis, transverse myelitis, weakness, numbness/tingling, or cerebellar signs (**Table 71.1**).

Although the manifestations of MS are many and varied, a handful of clinical syndromes are strongly associated with the disease. These include acute optic neuritis, brainstem syndromes, and transverse myelitis. Lhermitte phenomenon and Uhthoff phenomenon are also frequently associated with MS.

TABLE 71.1 Classic Signs and Symptoms of Relapsing Multiple Sclerosis

Symptom	Sign	Localization
Blurred vision	Relative afferent pupillary defect Optic disc pallor Papillitis Red desaturation[a]	Optic nerve
Diplopia	Nystagmus Internuclear ophthalmoplegia One-and-a-half syndrome[b]	III, IV, and VI nerve nuclei and outflow tracts MLF PPRF
Vibratory or electrical sensation with neck flexion ("Lhermitte phenomenon")	Elicitation with neck flexion	Cervical spine, posterior columns
Tonic spasms (sometimes called *paroxysmal dystonia*)	Brief, stereotyped, often painful, unilateral muscle contractions lasting seconds to minutes May involve limbs or manifest as paroxysmal dysarthria or facial spasms	Corticospinal tracts
Pseudobulbar affect	Laughing or crying uncontrollably without emotional congruence with the displayed affect	Brainstem, also frontal and parietal subcortical white matter
Recrudescence of old neurologic symptoms with warmer temperatures ("Uhthoff phenomenon")	None	Hypothesized to be due to heat-linked blockade of partially demyelinated axons

Abbreviations: MLF, medial longitudinal fasciculus; PPRF, paramedian pontine reticular formation.
[a]Red desaturation: decreased ability to perceive the color red.
[b]One-and-a-half syndrome: eye movement abnormality including a conjugate horizontal gaze palsy in one direction and an intranuclear ophthalmoplegia in the other.

Acute Optic Neuritis

Acute optic neuritis is one of the most common manifestations of MS. Patients typically note unilateral visual loss that evolves over a few days and is preceded or accompanied by orbital pain that occurs with or is exacerbated by eye movement. On physical examination, patients with acute optic neuritis invariably exhibit a relative afferent pupillary defect, unless there is a prior history of or current optic neuritis in the opposite eye. Patients also typically exhibit color vision loss (dyschromatopsia), with red hues being lost first. Visual field defects are common, prototypically a central scotoma, but almost all types of visual field defects may be seen. Vision loss ranges from mild to severe; visual acuity of 20/200 or worse develops in about one-third of patients. The absence of a relative afferent pupillary defect in a person with acute visual loss raises the possibility of uveitis, which occurs with increased frequency in MS, although it is not directly caused by the disease. Fundoscopy in acute optic neuritis is often normal, but swelling of the optic disc may be observed in up to a third of patients. Retinal hemorrhages and exudates are uncommon.

Spontaneous recovery of vision usually occurs within the first month, even when visual loss is severe. Lack of improvement suggests an alternative diagnosis because 98% of optic neuritis patients with visual acuity 20/50 or worse improve by at least three lines on a Snellen letter chart within 6 months after the onset of symptoms. Optic atrophy, noted as pallor on funduscopic exam, is frequently found after the acute episode resolves. Progressive visual failure over years is uncommon.

Brainstem Syndromes

Oculomotor abnormalities are common in MS. Patients may exhibit diplopia, usually attributable to a sixth nerve palsy, or internuclear ophthalmoplegia. Intranuclear ophthalmoplegia, caused by lesions in the medial longitudinal fasciculus, can be recognized by impaired adduction of the affected eye with associated nystagmus with abduction of the contralateral eye. Gaze-evoked or pendular nystagmus is also common. Less commonly, smooth pursuit and saccadic eye movement abnormalities may be observed. Third or fourth nerve palsies, the one-and-a-half syndrome (reflecting damage to the parapontine reticular formation or the sixth nerve nucleus causing ipsilateral gaze palsy as well as impaired adduction in contralateral gaze due to damage to the medial longitudinal fasciculus), opsoclonus, and symptomatic homonymous field defects are rare.

Facial sensory deficits (eg, numbness or trigeminal neuralgia) and weakness may develop. Facial weakness typically follows an upper motor neuron pattern, although inflammatory demyelination involving the facial nucleus can mimic an idiopathic Bell palsy.

Vertigo can occur and may be difficult to distinguish from peripheral vestibular dysfunction. Sudden hearing loss is uncommon and should raise the possibility of an alternative diagnosis (eg, Susac syndrome). Intractable hiccups are rare but may result from lesions in the medulla or upper cervical spine. However, the occurrence of intractable nausea/vomiting and hiccups should precipitate concern for neuromyelitis optica rather than MS. Dysphagia, particularly with liquids, may develop in advanced MS.

Pyramidal Signs/Symptoms

Approximately 70% of patients exhibit spasticity, most often in the legs and accompanied by painful spasms. Spasticity can impair mobility and activities of daily living and disrupts sleep. In nonambulatory patients, it may interfere with transfers and personal hygiene. In some instances, however, spasticity of the leg extensors permits weight bearing and actually improves gait.

Patients with MS also frequently exhibit other pyramidal signs, including weakness in an upper motor neuron pattern and hyperreflexia.

Sensory Signs/Symptoms

Paresthesias, dysesthesias, and allodynia are common initial manifestations of MS and occur in most patients at some point during their disease. On physical examination, vibratory and proprioceptive loss is commonly observed. This sensory loss often contributes to gait disturbances and falls.

Lhermitte phenomenon refers to an electric sensation, which shoots down the body in response to neck flexion. It is caused by stretching of nerve fibers passing through a lesion in the cervical spine. Lhermitte phenomenon is common in MS patients with

C-spine disease, although it can also occur in individuals with other types of C-spine pathology.

Cerebellar Signs/Symptoms

An action tremor of the arms is common in MS patients. This is often accompanied by other signs of cerebellar disease, including gait ataxia, dysmetria, dysdiadochokinesia, and dysarthria. Tremor of the head, trunk, and legs is less frequent. Incapacitating tremor, scanning speech, and truncal ataxia are seen in advanced disease. Cerebellar symptoms, when present, can be severely disabling among MS patients.

Transverse Myelitis

Transverse myelitis refers to inflammation of the spinal cord. This is most often seen in the cervical and thoracic spine. It manifests clinically with numbness and weakness, with the affected limbs depending on the location of the lesion. In some cases, bladder and bowel dysfunction can manifest. Transverse myelitis has a broad differential diagnosis, including MS, neuromyelitis optica, infectious or parainfectious, nutritional deficiency, manifestations of a systemic rheumatologic disease, or may be idiopathic. The emergence of transverse myelitis warrants a thorough workup for its etiology, including evaluation for underlying demyelinating disease.

Uhthoff Phenomenon

Temporary worsening of vision with physical activity was originally described by Uhthoff in 1890. Uhthoff phenomenon now refers to new or worsening neurologic symptoms that occur in association with elevations in temperature (often during exercise or a hot shower). Symptoms are transient and attributed to reversible conduction block along demyelinated nerve fibers. The presence of Uhthoff phenomenon does not represent an MS relapse or provide evidence for ongoing neurologic damage. Indeed, whereas for some patients Uhthoff phenomenon may limit day-to-day activities, many other patients are not sensitive to heat, and accordingly, do not need to make any lifestyle adjustments.

Paroxysmal Signs/Symptoms

Paroxysmal symptoms in MS are brief, repetitive, stereotyped attacks of neurologic dysfunction that are thought to result from ephaptic spread of abnormal electrical discharges from partially demyelinated nerve fibers ("cross-talk"). These discharges can arise from areas with acute inflammation and demyelination or chronic tissue damage. The symptoms usually last a few seconds to a few minutes and may occur anywhere from a few to 200 times per day. Attacks may occur spontaneously or be provoked by sudden noises, emotion, movement, hyperventilation, or tactile stimulation. The most common paroxysmal symptoms in MS are trigeminal neuralgia and tonic spasms. Paroxysmal dysarthria, ataxia, diplopia, itching, paresthesias, pain, hemifacial spasm, and glossopharyngeal neuralgia have rarely been described.

Trigeminal neuralgia occurs in about 2% of MS patients. The character and quality of the pain is usually indistinguishable from idiopathic trigeminal neuralgia. However, trigeminal neuralgia in MS is more likely to involve both sides of the face and is often accompanied by trigeminal neuropathy or other signs of brainstem dysfunction. Trigeminal neuralgia attributable to MS is often less amenable to surgical interventions and must be managed medically.

Tonic spasms are usually stereotyped, painful attacks of unilateral dystonic posturing of the limbs. They are occasionally bilateral and rarely involve the face. The attacks last between 30 seconds and 2 minutes and can occur up to 60 times a day. Tonic spasms are probably caused by demyelinating lesions involving the corticospinal tract. However, they are not pathognomonic for MS and are occasionally seen in patients with other types of CNS pathology such as cerebral ischemia or spinal cord trauma.

Pseudobulbar affect is characterized by episodes of laughing or crying that are not congruent with the individual's emotional state. This can cause significant emotional distress to both patients and caregivers.

Bladder, Bowel, and Sexual Signs/Symptoms

Bladder dysfunction in MS encompasses both urgency and retention, or some combination of the two. It is common, affecting approximately 75% of patients. In 15%, symptoms are severe enough to prevent the patients from leaving home or attending social activities. Demyelinating lesions above the level of the pons may result in detrusor hyperreflexia with uninhibited bladder contractions, resulting in urinary urgency accompanied by frequency, nocturia, and urge incontinence. Lesions involving the reticulospinal pathways above S2 and below the pons may also lead to involuntary bladder contractions or cause simultaneous contraction of the bladder wall and urethra, a condition known as *detrusor-sphincter dyssynergia*. Patients with detrusor-sphincter dyssynergia have storage and emptying dysfunction and a combination of urgency, frequency, difficulty initiating voiding, incomplete emptying, and incontinence. Hypocontractility and failure of the bladder to empty properly occurs with demyelination of the lower sacral anterior horn cells. Complete inability to void is uncommon.

Bowel dysfunction often coexists with bladder dysfunction and is present in up to 70% of patients. It typically manifests as constipation, which may be compounded by immobility, decreased fluid intake, or medication side effects.

Sexual dysfunction is present in up to 90% of patients. The most common symptoms among men are erectile and ejaculatory dysfunction. Women have difficulties achieving orgasm, decreased vaginal lubrication, and reduced vaginal sensation. Both men and women may have reduced libido. Physiologic (eg, fatigue, weakness, spasticity, pain, hypesthesia) and psychological factors (eg, depression, anxiety about bladder and bowel dysfunction) both contribute to sexual dysfunction. Many of the medications used to treat other MS symptoms, including anticholinergics, antidepressants, and muscle relaxants, also adversely affect sexual function.

Nonspecific Multiple Sclerosis Signs/Symptoms

Fatigue is one of the most common and disabling MS symptoms, which may emerge very early. It is estimated to impact between 75% and 95% of MS patients. Indeed, fatigue (among other nonspecific symptoms) may precede the first clinical demyelinating event by months or years. Pathologic MS fatigue is out of proportion to physical activities and is typically worse late in the day. The etiology of MS-related fatigue is poorly understood.

Mood disorders are common in MS. Depression is the most common, with a lifetime prevalence of 50% before age 60 years. The etiology of depression is likely multifactorial with both psychosocial and biologic factors contributing. Among MS disease–modifying therapies, β-interferons may cause or exacerbate depression and are relatively contraindicated among patients experiencing depressive symptoms. Bipolar disorder and anxiety are also more prevalent in patients with MS than in healthy individuals.

Cognitive impairment occurs in up to 65% of MS patients and often develops early in the disease. Short-term memory, attention, concentration, verbal intelligence, visuospatial skills, and

TABLE 71.2 Multiple Sclerosis (MS) Diagnostic Criteria (McDonald 2017 Criteria)[a,b,c]

Clinical Presentation	Additional Data Required for MS Diagnosis
Two or more attacks with objective evidence of two or more lesions supported by clinical examination or MRI	None
Two or more attacks with objective clinical/MRI evidence of one lesion and reasonable historical evidence of a prior attack	None
Two or more attacks with objective evidence of one lesion on clinical examination	Dissemination in space (DIS) demonstrated by one of the following: 1. DIS on MRI[d] 2. Second clinical attack implicating a different CSF location
One attack with objective evidence of two or more lesions on clinical examination	Dissemination in time (DIT) demonstrated by one of the following: 1. DIT criteria on MRI[e] 2. Second clinical attack 3. Presence of CSF-specific oligoclonal bands
One attack with objective evidence of one lesion on clinical examination	DIS demonstrated by one of the following: 1. DIS on MRI[d] 2. Second clinical attack implicating a different DNS location *and* DIT demonstrated by one of the following: 1. DIT criteria on MRI[e] 2. Second clinical attack 3. Presence of CSF-specific oligoclonal bands
Insidious neurologic progression suggestive of MS (ie, a clinical presentation consistent with primary progressive MS)	One year of disease progression *and* two of the following: 1. DIS in brain according to 2017 McDonald criteria 2. Spinal cord MRI with two T2 lesions 3. Presence of CSF-specific oligoclonal bands

Abbreviations: CSF, cerebrospinal fluid; MRI, magnetic resonance imaging.
[a]Note: These guidelines should be applied only to patients with a "typical" demyelinating event or clinically isolated syndrome. 2017 McDonald criteria cannot be summarily applied to patients who present with an atypical clinical phenotype.
[b]Adapted from Thompson AJ, Banwell BL, Barkhof F, et al. Diagnosis of multiple sclerosis: 2017 revisions of the McDonald criteria. *Lancet Neurol.* 2018;17(2):162-173.
[c]If all criteria are fulfilled and alternative diagnoses have been excluded, the diagnosis is MS. If there is a suspicion of MS but only some of the criteria are met, the diagnosis is "possible MS."
[d]See Table 71.3 for MRI criteria for dissemination in space.
[e]See Table 71.4 for MRI criteria for dissemination in time.

information processing are the domains most commonly affected, with slowed cognitive processing being the most common cognitive abnormality. Disturbances of language and immediate- and long-term memory occur less frequently. Cognitive impairment is not directly correlated with physical disability or disease duration. However, cognitively impaired patients have more lesions, more severe tissue damage, and smaller brain volumes than unimpaired patients as measured by conventional and nonconventional MRI techniques. In many patients, cognitive dysfunction is subtle and goes undetected in the neurologist's office. The Mini-Mental State Examination failed to identify nearly 75% of MS patients deemed to be cognitively impaired by detailed neuropsychological testing. The Symbol Digit Modalities Test, which specifically evaluates information processing speed/efficiency, has better efficacy for screening MS patients and is the single test common to all cognitive screening batteries used for this disease.

Approximately 70% of MS patients experience pain related to the disease. Pain can occur during an acute exacerbation (eg, ocular pain with optic neuritis or dysesthesias with demyelinating plaques involving spinal cord), but almost half of MS patients have chronic pain which can be severe. In addition to painful muscle spasms, paroxysmal phenomena, and the sensory symptoms discussed earlier, MS patients are more likely to have joint, muscular, and extremity pain than age- and sex-matched controls.

Diagnostic Criteria

The diagnosis of MS is established based on clinical, radiologic, and cerebrospinal fluid (CSF) criteria as well as exclusion of several mimicking etiologies. No single test result is pathognomonic of MS.

MS diagnostic criteria, referred to as the *McDonald criteria* (after the late Ian McDonald), were established in 2001 and revised in 2005, 2010, and 2017 (Table 71.2). The terminology of *dissemination in space* and *time* has been used and redefined over the course of these revisions. Dissemination in space (Tables 71.2 and 71.3) refers to the involvement of anatomically distinct locations, demonstrating a multifocal CNS process. Dissemination in time indicates that the process is chronic/multiphasic (Tables 71.2 and 71.4), as opposed to monophasic. The diagnosis of RRMS requires at least one episode of neurologic dysfunction consistent with inflammation and demyelination occurring in the absence of fever or infection and lasting at least 24 hours along with objective evidence of lesions disseminated in space and time. The diagnosis of PPMS requires at

TABLE 71.3 Magnetic Resonance Imaging Criteria for Dissemination in Space[a]

One or more T2 lesion in at least two of the following four areas:
- Periventricular
- Juxtacortical or cortical
- Infratentorial
- Spinal cord

[a]Adapted from Thompson AJ, Banwell BL, Barkhof F, et al. Diagnosis of multiple sclerosis: 2017 revisions of the McDonald criteria. *Lancet Neurol.* 2018;17(2):162-173.

TABLE 71.4 Magnetic Resonance Imaging (MRI) Criteria for Dissemination in Time[a]

One of the following: • One new T2 and/or contrast-enhancing lesion on any follow-up MRI • Presence of gadolinium-enhancing and nonenhancing lesions at any one time

[a]Adapted from Thompson AJ, Banwell BL, Barkhof F, et al. Diagnosis of multiple sclerosis: 2017 revisions of the McDonald criteria. *Lancet Neurol.* 2018;17(2):162-173.

least 1 year of insidious neurologic progression combined with a variety of MRI and CSF abnormalities (see Table 71.2).

MRI abnormalities may be used to demonstrate dissemination in both space and time, provided an individual has had one episode of neurologic dysfunction consistent with demyelinating disease. More recently, MS can be diagnosed in patients who have the presence of oligoclonal bands in the CSF in conjunction with a CIS and demonstration of dissemination in space. Both of these changes have allowed for an earlier diagnosis. This is of great importance because MS disease-modifying drugs seem to be most effective when given early in the disease, and a delay in treatment can result in irreversible neurologic damage.

Characteristic MS lesions are occasionally discovered on MRI in individuals with no history of neurologic symptom and a normal examination. In the absence of clinical evidence of demyelination, even if MRI abnormalities are accompanied by the presence of CSF oligoclonal bands, an elevated IgG index, and delayed visual-evoked potentials (VEPs), a diagnosis of MS cannot be established by formal criteria, and this is termed *radiologically isolated syndrome*, established in 2009 (Table 71.5). As discussed earlier, clinical trials are now in progress to determine whether short-term immunotherapy should be initiated.

TABLE 71.5 Radiologically Isolated Syndrome[a,b]

CNS white matter abnormalities meet the following criteria:
• Ovoid well circumscribed and homogeneous foci with or without involvement of corpus callosum
• T2 hyperintensities ≥3 mm^2 and meeting three of four Barkhof criteria (listed below) for dissemination in space
  • At least one gadolinium-enhancing lesion *or* at least nine T2 lesions
  • At least three periventricular lesions
  • At least one juxtacortical lesion
  • At least one infratentorial lesion
• CNS anomalies do not fit vascular pattern.

No history of remitting clinical symptoms consistent with neurologic dysfunction
MRI anomalies do not account for any clinically apparent impairments.
MRI anomalies are not related to toxic substances or a medical condition.
MRI anomalies are not better accounted for by another disease.

Abbreviations: CNS, central nervous system; MRI, magnetic resonance imaging.

[a]Note: These guidelines cannot be applied to patients with MRI phenotypes of leukoaraiosis or extensive white matter involvement without involvement of corpus callosum.

[b]Adapted from Okuda D, Mowry EM, Beheshtian A, et al. Incidental MRI anomalies suggestive of multiple sclerosis: the radiologically isolated syndrome. *Neurology.* 2009;72(9):800-805.

Imaging

MRIs are critical for diagnosis, disease monitoring, and treatment monitoring in MS. Brain MRI abnormalities are present in more than 95% of recently diagnosed MS patients. The MRI lesions may be clinically silent, and 5 to 10 new or enlarging gadolinium-enhancing or T2 brain lesions are identified for every clinical exacerbation in patients with relapsing MS. Spinal cord lesions are detected by MRI in 75% to 90% of those with established MS. Fifty percent to 70% of CIS patients have asymptomatic T2-weighted brain lesions, and 27% to 42% have clinically silent spinal cord lesions.

On T2-weighted imaging, brain lesions are typically 3 to 15 mm in diameter, round or ovoid, and have specific location patterns that are important for distinguishing them from other T2 hyperintense lesions, such as those representing small vessel ischemic change (Figs. 71.3 and 71.4; see Table 71.3). Active lesions tend to demonstrate postcontrast enhancement on T1-weighted images. Larger lesions in the cerebral hemispheres associated with mass effect, edema, or ring enhancement can resemble tumors and are known as *tumefactive lesions* (Fig. 71.5). Cortical lesions are sometimes not well visualized by standard MRI techniques but can certainly be present.

In patients with relapsing MS, gadolinium enhancement, which represents active inflammation and disruption of the blood–brain barrier, is the earliest phase of lesion development seen on conventional MRI (Fig. 71.6). Almost all new brain T2 lesions demonstrate enhancement on postgadolinium T1-weighted imaging, and 65% to 80% are hypointense on the corresponding pregadolinium T1-weighted sequence. Gadolinium enhancement typically resolves after 2 to 4 weeks. Persistent enhancement raises the possibility of an alternative diagnosis because only 3% to 5% of MS lesions enhance for more than 8 weeks. T2 lesions may become smaller, but they rarely disappear, whereas the majority of T1-hypointense lesions become isointense in 6 to 12 months, presumably as a result of resolution of edema and remyelination.

Spinal cord lesions are more common in the cervical than thoracic spine, appear hyperintense on T2-weighted imaging, and have a predilection for the white matter in the lateral and posterior columns. Adjacent gray matter is commonly involved. Lesions typically occupy less than half of the cross-sectional area of the cord and extend fewer than two vertebral segments (Fig. 71.7). Hypointense lesions on T1-weighted spinal cord MRI are uncommon in MS patients. Unlike gadolinium-enhancing brain lesions, active spinal cord lesions are frequently accompanied by clinical symptoms. However, asymptomatic spinal cord lesions are also common. Clinically silent spinal cord lesions are particularly useful for diagnosing MS in patients with vague neurologic symptoms and nonspecific findings on brain MRI because intramedullary cord lesions are rare in healthy people.

In general, RRMS patients have more gadolinium-enhancing lesions than those with progressive disease. Patients with SPMS tend to have more chronic black holes than those with the relapsing-remitting or primary progressive disease (Fig. 71.8). PPMS patients are more likely to have few T2 brain lesions and diffuse spinal cord abnormalities. However, MRI characteristics are not diagnostic of the subtypes of MS—these remain clinically based.

Conventional MRI lacks pathologic specificity, and areas of edema, demyelination, axonal damage, gliosis, and remyelination all appear as T2 hyperintensities. Furthermore, there is poor correlation between disability and T2-weighted abnormalities. Novel imaging techniques are emerging but remain in the research

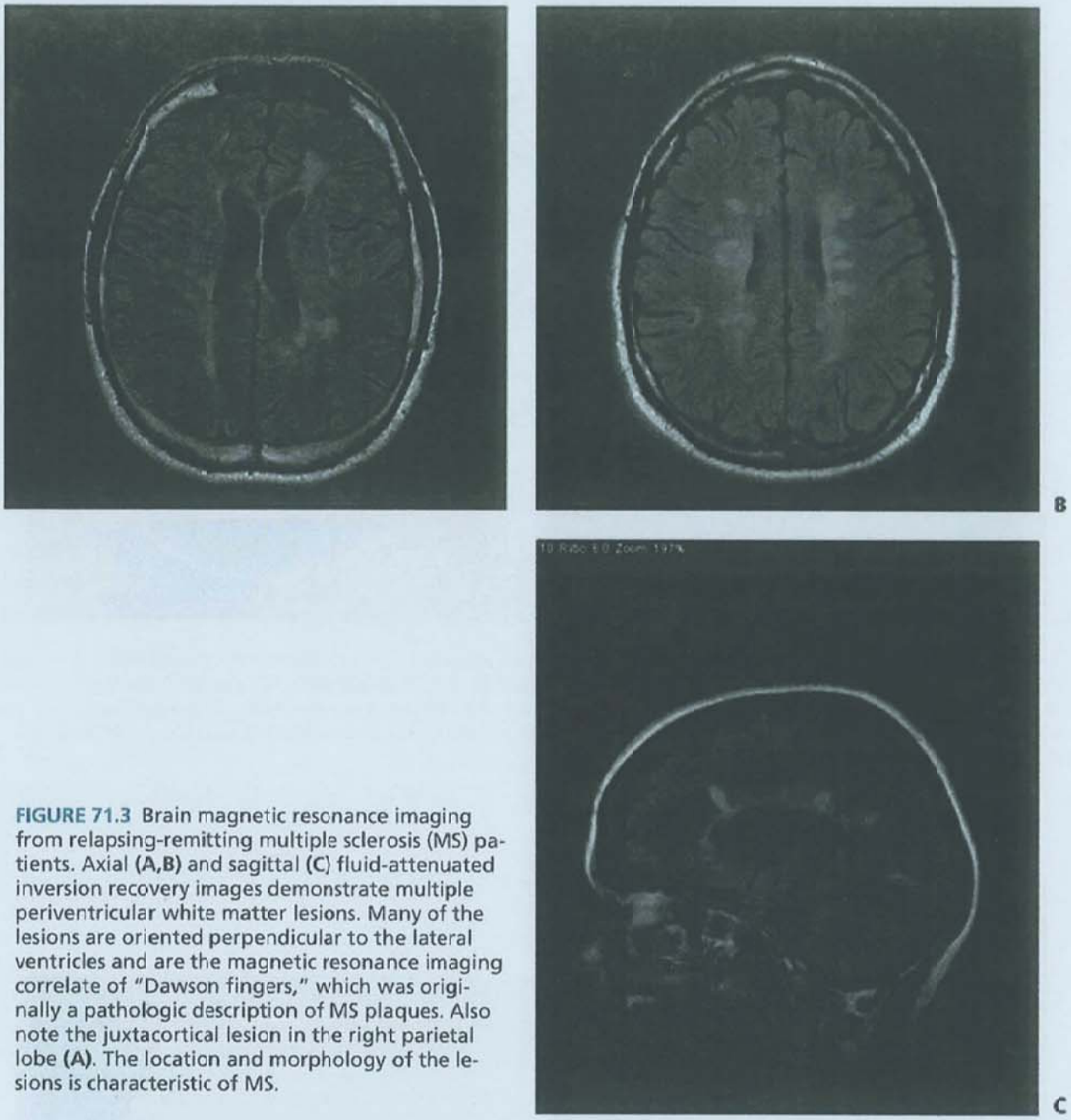

FIGURE 71.3 Brain magnetic resonance imaging from relapsing-remitting multiple sclerosis (MS) patients. Axial **(A,B)** and sagittal **(C)** fluid-attenuated inversion recovery images demonstrate multiple periventricular white matter lesions. Many of the lesions are oriented perpendicular to the lateral ventricles and are the magnetic resonance imaging correlate of "Dawson fingers," which was originally a pathologic description of MS plaques. Also note the juxtacortical lesion in the right parietal lobe **(A)**. The location and morphology of the lesions is characteristic of MS.

realm for MS. These include quantitative susceptibility mapping, which can show iron deposition in the activated microglia of chronically activated lesions, even after the resolution of contrast enhancement. Central vein imaging is also being studied to help potentially distinguish demyelinating white matter lesions from nondemyelinating white matter lesions of unclear etiology.

Biomarkers

Examination of the CSF is a necessary aid for diagnosing MS and excluding alternative diagnoses. CSF typically contains fewer than six white blood cells (WBCs) per cubic millimeter and has a normal protein content in most patients with a CIS or established MS. A mild lymphocytic pleocytosis or elevated protein level is seen in about 35%. More than 50 WBCs per cubic millimeter or a protein content over 100 mg/dL are rarely observed and raise the possibility of an alternative diagnosis.

CSF immunoglobulin abnormalities are common. The immunoglobulin G (IgG) index, which measures intrathecal production of IgG, is elevated in 70% to 85% of MS patients. Isoelectric focusing followed by immunoblotting detects oligoclonal bands in more than 95% of patients (two or more bands detected in the CSF that are not present in the serum are considered abnormal). Treatment with corticosteroids lowers the IgG index but has no effect on oligoclonal bands. An elevated IgG index and the presence of oligoclonal bands are not specific to MS and are observed in 20% to 40% of patients with other inflammatory, demyelinating, or infectious diseases and occasionally other neurologic disorders, including the Guillain-Barré syndrome and other peripheral neuropathies. They can be seen transiently in the setting of CNS ischemia and CNS infections. Moreover, oligoclonal bands have been reported in up to 5% of healthy controls. Therefore, CSF abnormalities should always be considered in conjunction with clinical and MRI findings.

A single immunoglobulin band restricted to the CSF is of unclear significance and may be found in healthy individuals, as well as in a variety of illnesses, including CIS, MS, infectious and inflammatory diseases, CNS lymphoma, peripheral neuropathy, or migraine headaches. However, when the CSF is reexamined

FIGURE 71.4 Brain magnetic resonance imaging of the posterior fossa in a multiple sclerosis patient. A: An axial T2-weighted image reveals multiple infratentorial lesions consistent with multiple sclerosis. B: The lesions are not well visualized on the fluid-attenuated inversion recovery image. Although fluid-attenuated inversion recovery is a more sensitive sequence than T2 for demonstrating supratentorial lesions, it is suboptimal for detecting infratentorial lesions.

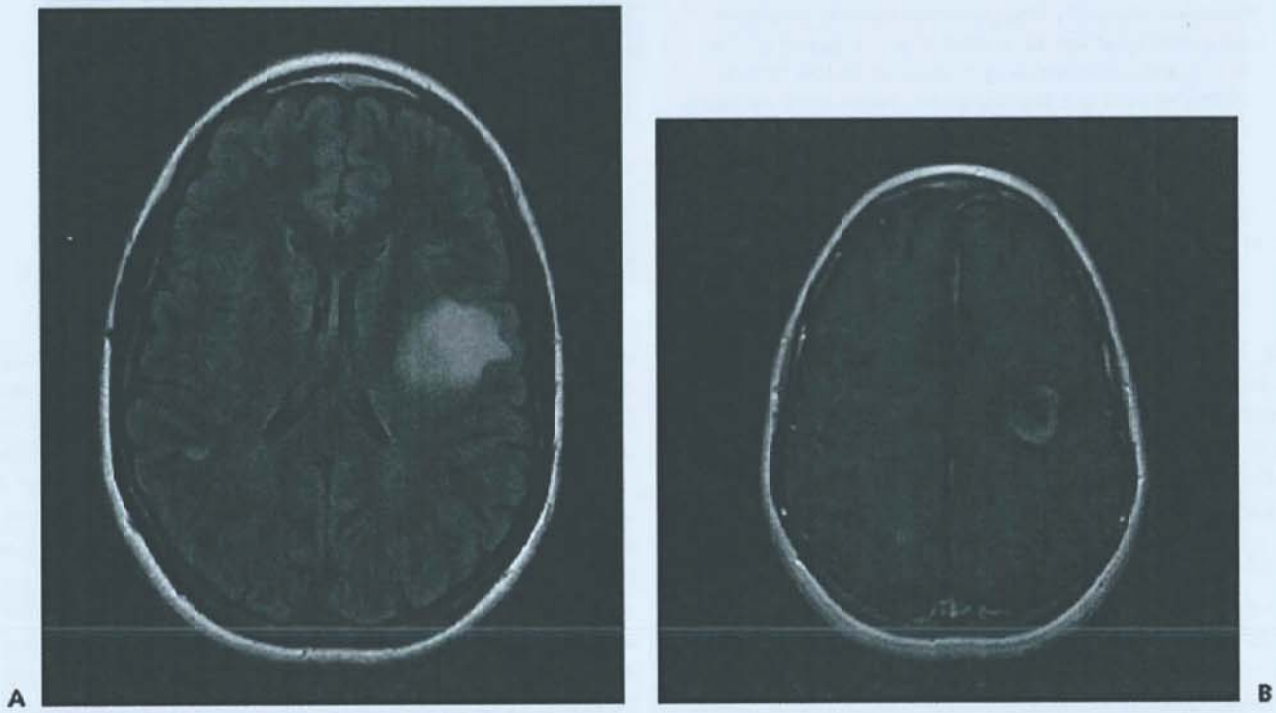

FIGURE 71.5 Brain magnetic resonance imaging from a patient with relapsing-remitting multiple sclerosis. Axial fluid-attenuated inversion recovery **(A)** and postgadolinium T1-weighted **(B)** images reveal a large ring-enhancing mass-like lesion with surrounding vasogenic edema in the left hemisphere. There is also a much smaller nonenhancing lesion in the right hemisphere. The findings are consistent with tumefactive multiple sclerosis.

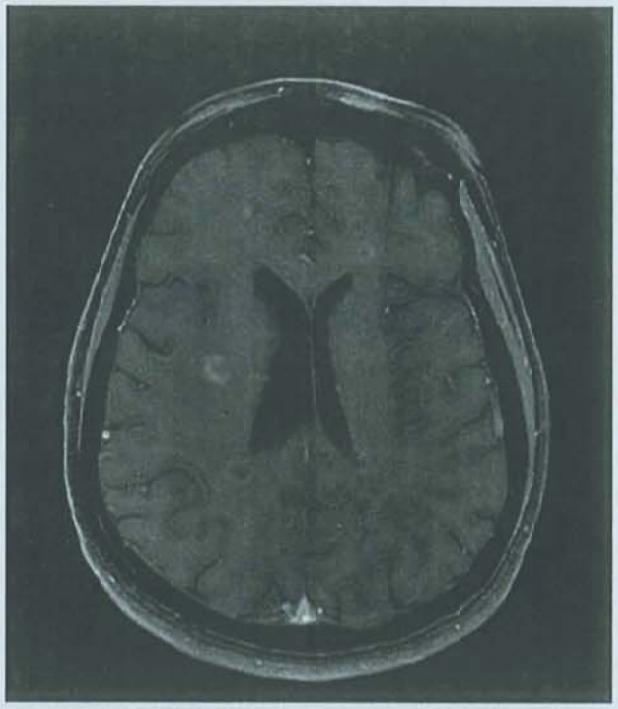

FIGURE 71.6 Brain magnetic resonance imaging from a relapsing-remitting multiple sclerosis patient. A postcontrast T1-weighted image reveals multiple gadolinium-enhancing lesions. Gadolinium enhancement, which represents disruption of the blood-brain barrier and active inflammation, is the earliest phase of lesion development that can be detected on conventional magnetic resonance imaging.

after an average of 6 months, one-third of patients, the majority of whom have demyelinating disease, show a change from a monoclonal to oligoclonal pattern.

A high CSF level of myelin basic protein indicates damage to myelin and is not useful in differentiating MS from other illnesses, including cerebrovascular disease, infections, neoplasms, or inflammatory diseases. It is not recommended as a standard CSF test when evaluating for MS.

VEPs are sensitive for detecting clinically silent lesions in the anterior visual pathways, although they are no longer included in the MS diagnostic criteria. VEPs are abnormal (prolonged P100 latency or >6 ms interocular difference if the latencies are normal) in approximately 30% of patients with CIS other than optic neuritis and more than 50% of MS patients without a history of visual symptoms or clinical evidence of optic nerve dysfunction. However, abnormal VEPs may be observed in patients with other disorders, including compressive lesions of the optic nerve or chiasm, glaucoma, retinal disease, vitamin B_{12} deficiency, infectious diseases (eg, neuroborreliosis, neurosyphilis), systemic lupus erythematosus, and neurosarcoidosis.

MRI has largely supplanted the use of somatosensory and brainstem auditory-evoked potentials, which are rarely useful for identifying patients at increased risk for developing MS and are not included in the MS diagnostic criteria.

Optical coherence tomography (OCT) is a noninvasive technique that uses low-frequency infrared light to measure retinal nerve fiber layer (RNFL) thickness and macular volume. It has been used by ophthalmologists since 1990 to monitor glaucoma, and is now used in MS. Thinning of the RNFL occurs after optic neuritis as a result of loss of retinal axons. The eyes of MS patients without a history of optic neuritis also undergo thinning of the RNFL. OCT is used as a secondary and tertiary outcome measure in clinical trials and by some neurologists and ophthalmologists to follow patients with or without a history of optic neuritis.

Differential Diagnosis

In the absence of a definite diagnostic test, MS remains a diagnosis of exclusion, although revisions to the McDonald criteria have allowed for increased sensitivity and specificity of diagnosis. Most of the disorders that may mimic MS can be excluded by a detailed history, thorough examination, and appropriate laboratory tests and diagnostic studies.

Infections that may mimic MS include neuroborreliosis, neurosyphilis, and rarely progressive multifocal leukoencephalopathy (PML). Human T-lymphotropic virus type-1 and human

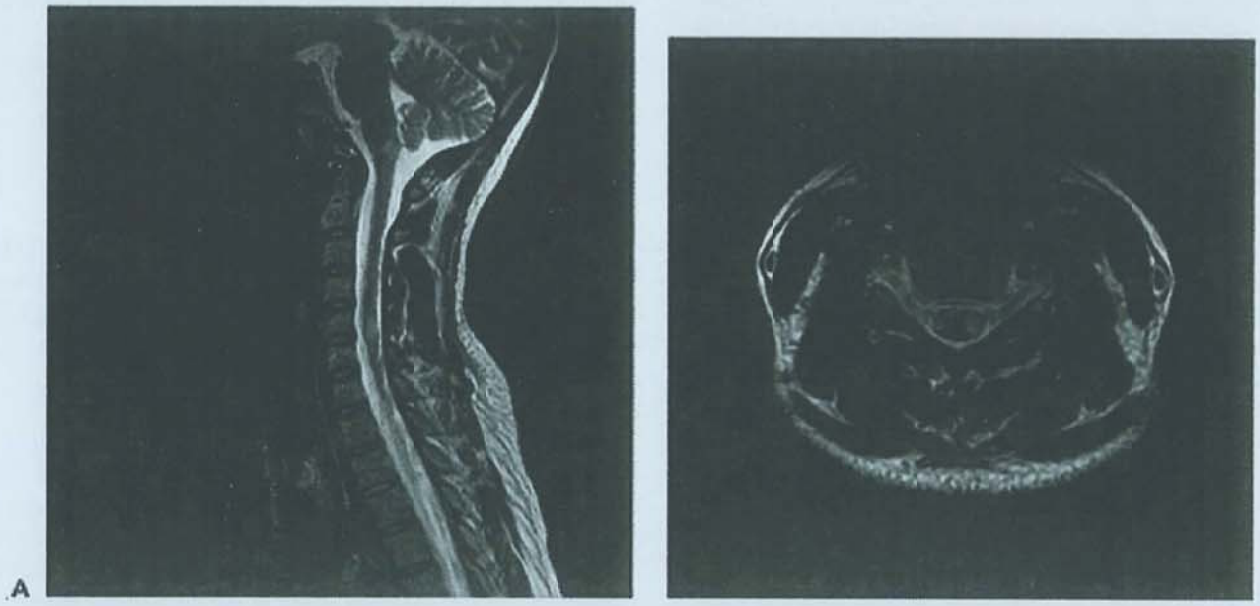

FIGURE 71.7 Cervical spine magnetic resonance imaging from a relapsing-remitting multiple sclerosis patient. Axial **(A)** and sagittal **(B)** T2-weighted images reveal intramedullary lesions at C5-C6 consistent with demyelination. Also note the lesion at the cervicomedullary junction.

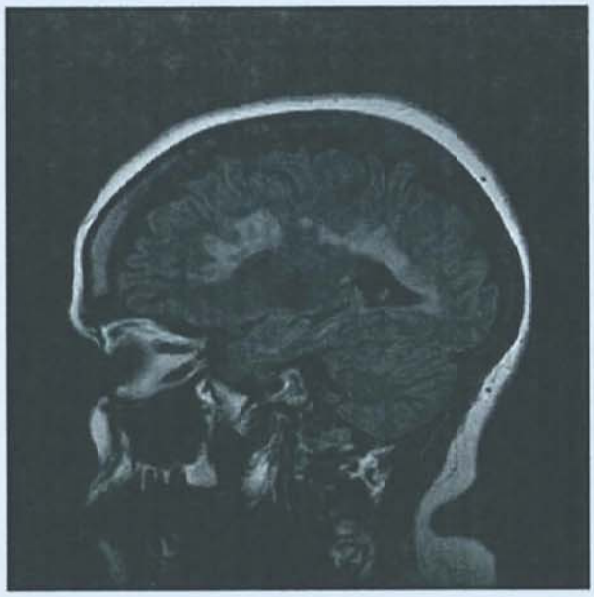

FIGURE 71.8 Brain magnetic resonance imaging from a patient with secondary progressive multiple sclerosis. A sagittal fluid-attenuated inversion recovery image reveals multiple periventricular white matter lesions consistent with multiple sclerosis. Note that many of the lesions are hypointense on the pregadolinium T1-weighted image.

immunodeficiency virus should be considered in patients with a progressive myelopathy.

Acute disseminated encephalomyelitis (ADEM) may be impossible to distinguish from a first attack of MS. However, it is more likely to follow an infection or vaccination and is significantly more common in children. Patients with ADEM are typically encephalopathic, which is rare in MS. Although patients with sarcoidosis may initially present with neurologic symptoms, evaluation usually reveals evidence of systemic sarcoidosis.

Other systemic autoimmune diseases and vasculitides that should be considered in the differential of MS include Behçet syndrome, vasculitis, Sjögren syndrome, lupus, antiphospholipid antibody syndrome, and Susac syndrome. Behçet disease is a form of vasculitis that can involve blood vessels of all sizes within both the arterial and venous circulation. It is commonly associated with genital/oral ulcers and may also cause cutaneous, ocular, and neurologic disease. Behçet disease is more common along the ancient Silk Road, from East Asia to the Mediterranean, and it is most common in Turkey. Other vasculitides may mimic MS as well. Granulomatosis with polyangiitis (Wegener) causes necrotizing inflammation involving small- to medium-sized vessels along with the upper and lower respiratory tract. Eosinophilic granulomatosis with polyangiitis (Churg-Strauss) causes an eosinophilic, necrotizing vasculitis that also affects small- to medium-sized vessels and the respiratory tract. Both granulomatosis with polyangiitis and eosinophilic granulomatosis with polyangiitis are associated with antinuclear cell antibodies and are referred to as antinuclear cell antibodies–associated vasculitides. They may have neurologic manifestations, which can include peripheral and cranial neuropathies along with CNS mass lesions, external ophthalmoplegia, and sensorineural hearing loss. Sjögren syndrome is a systemic autoimmune disease characterized by dry eyes/mouth along with a wide variety of other clinical symptoms. It can be associated with neurologic symptoms including peripheral neuropathies and focal lesions involving the brain, optic nerves, and/or spinal cord. Systemic lupus erythematosus may have neurologic manifestations including headache, stroke, neuropsychiatric symptoms, optic neuritis, transverse myelitis, and white matter lesions on brain MRI. Antiphospholipid syndromes may be associated with lupus or occur as a primary condition. Antiphospholipid syndromes are characterized by arterial, venous, and/or small vessel thromboembolic events and are associated with the persistent presence of antiphospholipid antibodies. It has been associated with white matter lesions on brain MRIs, which can mimic MS lesions. Susac syndrome is an autoimmune microangiopathic endotheliopathy that affects brain, retina, and cochlea and results in encephalopathy, hearing loss, and branch retinal artery occlusions. It may be mistaken for MS because of prominent white matter lesions that are observed on brain MRI.

Demyelinating episodes have also been associated with certain medications. Drug-induced demyelination has been associated with anti-tumor necrosis factor monoclonal antibodies and should be considered in patients with Crohn disease or rheumatoid or psoriatic arthritis. Anti-PD-1, PD-L1, and CTLA4 molecules are checkpoint inhibitors used for many types of malignancy. Neurologic complications, including apparent demyelination, have been described with these medications as well.

NMOSD may be difficult to distinguish from MS, particularly early in the disease, in patients with recurrent optic neuritis and minimally abnormal brain MRI or in patients with brain MRI findings more characteristic of MS. AQP4-IgG seropositivity may help differentiate the diseases. MOG spectrum disease can also be difficult to distinguish from MS, and it can overlap with a number of conditions, such as ADEM, optic neuritis, NMOSD, and even MS. These disorders are covered in detail later in this chapter.

Neoplasms (especially primary CNS lymphoma and gliomas) occasionally enter the differential diagnosis. Hyperacute onset of symptoms suggests stroke. Primary lateral sclerosis may simulate PPMS but does not relapse and is monosymptomatic. The MRI and CSF analysis usually help differentiate the two diseases. Hereditary spastic paraparesis should be considered in patients with a progressive spastic paraparesis, especially if there is a family history of similar illness. Other causes of a progressive myelopathy that should be considered in patients suspected of having progressive MS include adrenomyeloneuropathy, vitamin B_{12} deficiency, copper deficiency, spondylotic myelopathy, spinal cord tumors, and a spinal dural arteriovenous fistula.

Management

Three different categories of medications are used for MS: medications for acute exacerbations, disease-modifying medications, and symptomatic medications. Optimal disease management often requires a multidisciplinary approach implementing pharmacologic and nonpharmacologic strategies.

Treatment of Acute Exacerbations

High-dose intravenous (IV) corticosteroids hasten recovery from acute exacerbations but do not seem to affect the degree of recovery. A typical regimen consists of a 3- to 5-day course of 1,000 mg of IV methylprednisolone, typically without an oral prednisone taper, because there is no significant adrenal gland suppression with a short period of IV steroids, and lower dose oral steroids were not effective in treating demyelinating events. Some patients with severe attacks seem to respond better to an

additional 2 to 5 days of treatment. Because treatment does not seem to affect long-term outcome, not every MS exacerbation (eg, mild sensory symptoms) requires corticosteroid treatment. In the Optic Neuritis Treatment Trial, patients who received oral prednisone 1 mg/kg/d did not improve any more quickly than the placebo-treated group. Furthermore, treatment with oral prednisone was associated with an increased risk of subsequent optic neuritis. Therefore, there does not appear to be a role for low-dose oral corticosteroids in the treatment of MS acute exacerbations LEVEL 1.[1] High-dose oral steroids, however, have been shown to be equivalent to IV dosing and can be substituted for IV steroids.

Fever and infections, including otherwise asymptomatic urinary tract infections, can cause transient worsening or recurrence of MS symptoms without evidence for new brain inflammation indicative of new disease activity. This is known as a *pseudoexacerbation*. Infections should be excluded in the setting of new or worsening symptoms before treatment with corticosteroids is initiated and fevers should be treated aggressively.

Plasma exchange may be warranted for the treatment of acute relapses that result in significant disability despite high-dose IV corticosteroid therapy. In a small but well-designed study, 42% of patients with severe demyelinating events that did not respond to high-dose IV corticosteroids had marked functional improvement after seven plasma exchanges, which took place an average of more than 40 days after the onset of symptoms. The investigators of a larger retrospective study reported similar results and concluded that plasma exchange may be effective, even when initiated more than 60 days after the onset of an acute demyelinating event.

Disease-Modifying Drugs

Disease-modifying therapies are the mainstay of treatment for MS. These medications are most effective for relapsing MS, where they have been shown to reduce the frequency of relapses and the accumulation of disease on MRI. Most also appear to slow confirmed disability progression over time. Emerging evidence strongly supports that disease-modifying therapies are most effective when initiated early in the course of disease, at the time of first clinical presentation, and that treating patients with highly effective therapies at the time of disease onset results in better outcomes. There has therefore been a paradigm shift in treatment philosophies for MS, and most experts now recommend early treatment with highly effective medications.

Disease-modifying medications are far less effective in patients with a progressive disease phenotype. When progressive MS patients continue to exhibit disease activity (eg, new lesions on MRI or clinical relapses superimposed on a progressive course), there may be a continued role for disease-modifying medications. Among the currently approved therapies, siponimod was recently approved for use in active SPMS, and ocrelizumab is approved for use in PPMS LEVEL 1.[2,3]

The treatment landscape for MS has changed considerably over the last decade. The U.S. Food and Drug Administration (FDA) approved the first oral therapy, fingolimod in 2010. This was followed by the approval of teriflunomide (2012), dimethyl fumarate (2013), alemtuzumab (2014), ocrelizumab (2016), siponimod (2019) and cladribine (2019). Table 71.6 summarizes available therapies for relapsing forms of MS. Treatment decisions should be based on efficacy in relationship to potential side effects and concomitant medical issues. The lack of rationale for "escalation therapy" has been recently addressed because patients with more severe disease who were treated with natalizumab or alemtuzumab at disease onset had less accumulation of disability over 5 years than patients with more mild disease who were treated with less effective therapies. This is consistent with clinical trials in MS indicating that outcomes are significantly better with earlier as compared to delayed therapy. Thus, for most patients, highly effective treatments should be initiated at the time of diagnosis.

Ocrelizumab and Rituximab

Ocrelizumab is a monoclonal antibody against CD20, a surface marker for mature B cells. It depletes B cells while sparing stem cells and plasma cells and is highly effective for reducing relapses and new brain lesions in relapsing MS LEVEL 1.[4] In phase 3 clinical trials, RRMS patients receiving ocrelizumab developed 94% fewer gadolinium-enhancing lesions than patients treated with high-dose interferon β-1a. Ocrelizumab was also modestly effective for reducing disability progression in PPMS patients, making it the first disease-modifying therapy to affect PPMS LEVEL 1.[2] Ocrelizumab is a humanized version of the chimeric anti-CD20 antibody, rituximab, which has a similar mechanism of action. Rituximab is not FDA approved for MS but has been used off-label for over a decade to treat relapsing disease. Both ocrelizumab and rituximab may increase risks of infection, particularly with long-term use, and infusion reactions are fairly common during drug administration.

Alemtuzumab

Alemtuzumab is a monoclonal antibody directed against CD52. It transiently depletes both T and B cells effectively "rebooting" the immune system. Alemtuzumab is highly effective for treating relapsing MS, reducing relapses, MRI evidence of disease, and disability progression LEVEL 1.[5,6] It is given in two courses of therapy, separated by 12 months. Beyond that time, patients require further immunotherapy only if they develop new evidence of disease activity. Among patients enrolled in the phase 3 trials of alemtuzumab, approximately 60% required no retreatment for 3 years after their last alemtuzumab infusion.

Although highly effective for preventing MS disease activity, alemtuzumab has substantial side effects as approximately one-third of treated patients develop secondary autoimmunity in the form of thyroiditis or kidney disease, and a small number of patients had strokes/intracerebral hemorrhages/arterial dissections in conjunction with their infusions. Extensive monitoring is needed during infusions and for 5 years after the last infusion.

Natalizumab

Natalizumab is a humanized monoclonal antibody against the α4-subunit of α4β1 integrin expressed on the surface of activated T cells. It blocks the binding between α4β1 integrin and its receptor, vascular cell receptor molecule-1 on the vascular endothelial surface. Because this interaction is essential for lymphocyte migration, the drug prevents activated T cells from accessing the CNS. Natalizumab is highly effective for reducing relapses and MRI evidence of disease activity in relapsing MS LEVEL 1.[7,8] However, because it is associated with PML, a sometimes fatal brain infection, it is used in conjunction with antibody testing for John Cunningham virus to predict risk of PML. Six percent of patients develop persistent anti-natalizumab antibodies, which are associated with a clear loss of efficacy and an increased risk of infusion-related hypersensitivity reactions.

TABLE 71.6 Overview of Disease-Modifying Therapies for Relapsing Forms of Multiple Sclerosis Listed by Relative Efficacy

Treatment	Dosage	Potential Side Effects	Monitoring	Monitoring Frequency	Efficacy
Ocrelizumab	2 doses of 300 mg IV q2wk for initiation 600 mg IV q6mo for maintenance	Slight increase in risk of infection Infusion reactions	CBC, CMP QuantiFERON or TB skin test Quantitative immunoglobulins Chronic hepatitis panel Lymphocyte subsets	Baseline	High
			CBC, CMP	q6mo	
			Hepatitis panel Quantitative immunoglobulins	Periodically	
Rituximab (off-label use)	1,000 mg × 2 doses, 2 wk apart (initiation) 500-2,000 mg q6mo Dosing varies.	Slight increase in risk of infection Infusion reactions	As for ocrelizumab Lymphocyte subsets may be monitored and subsequent dosing based on whether circulating B cells are detectable.	As for ocrelizumab	High
Alemtuzumab	5 doses of 12 mg IV daily for initiation 3 doses of 12 mg IV daily after 12 mo Further treatment only as needed	Increased risk of infection Infusion reactions Secondary autoimmunity (thyroid, kidney) Risk of stroke/intracerebral hemorrhage/arterial dissection with infusions	UA, TFT, CBC, CMP, VZV titer, QuantiFERON or TB skin test, lymphocyte subsets Skin check GYN/Pap recommended	Baseline	High
			UA, BMP, CD4 counts (until normal), TFT	Monthly until 48 months after last infusion	
			LFTs, lymphocyte subsets Skin check GYN/Pap recommended	Annually	
Natalizumab	300 mg IV q4wk	Progressive multifocal leukoencephalopathy LFT abnormalities Hypersensitivity reaction	JCV Ab LFTs MRI brain	JCV⁻ patients: Check labs q6mo and MRI annually.	High
				JCV⁺ patients: Check JCV q3mo and MRI q6mo.	
Cladribine	Year 1: 1.75 mg/kg First course: administered over 4-5 d Second course: administered over 4-5 d; 23-27 d after first course	Malignancy Teratogenicity Infections Lymphopenia LFT abnormalities	CBC, LFTs Pregnancy test HIV Hepatitis screen (B and C) Varicella immunity	Before each treatment course	Moderate to high
	Year 2: 1.75 mg/kg First course: administered over 4-5 d Second course: administered over 4-5 d; 23-27 d after first course		CBC	2 and 6 mo after start of each treatment course	
			Standard cancer screening CBC, LFTs	Periodically or as recommended	
Fingolimod	0.5 mg orally daily	Bradycardia at first dose LFT abnormalities Lymphopenia Macular edema Reactivation of herpes virus (zoster, oral or genital herpes) Other serious infections (Cryptococcus, PML)	First-dose observation (6 h) ECG VZV immunity Macula exam CBC, LFTs	Prior to first dose	Moderate
			CBC, LFTs Macula exam	3-4 months after initiation	
			CBC, LFTs	q6mo	

TABLE 71.6 Overview of Disease-Modifying Therapies for Relapsing Forms of Multiple Sclerosis, Listed by Relative Efficacy *(continued)*

Treatment	Dosage	Potential Side Effects	Monitoring	Monitoring Frequency	Efficacy
Siponimod	Titration Maintenance dose is 1-2 mg daily depending on CYP2C9 genotype	As for fingolimod	As for fingolimod EXCEPT first-dose observation done only if cardiac history CYP2C9 genotype	Prior to first dose	Moderate
			Macula exam Spirometry	If visual or respiratory symptoms	
			CBC, LFTs	q6mo	
Dimethyl fumarate	240 mg orally twice a day	Gastrointestinal upset Flushing LFT abnormalities Lymphopenia	CBC, LFTs	Baseline and q6mo	Moderate
Teriflunomide	7 mg or 14 mg orally daily	Gastrointestinal side effects Hair thinning LFT abnormalities (black box warning: hepatic failure) Hypertension Tuberculosis reactivation	QuantiFERON gold or TB skin test CBC, LFTs	Baseline	Low to moderate
			LFTs	Monthly for first 6 months after initiation	
			CBC, LFTs	q6mo	
IFNβ-1b IFNβ-1a IFNβ-1a pegylated IFNβ-1a	250 μg SC every other day 30 μg IM every week 22 μg or 44 μg SC three times weekly 125 μg SC every other week	Flulike symptoms Injection site reactions LFT abnormalities Leukopenia Neutralizing antibodies Depression Injection site necrosis (rare)	CBC LFTs TFTs	q6-12mo	Low to moderate
Glatiramer acetate	20 mg SC daily or 40 mg SC three times weekly	Site reactions Lipoatrophy Immediate postinjection reactions	None	NA	Low to moderate

Abbreviations: BMP, basic metabolic panel; CBC, complete blood count; CMP, complete metabolic panel; CYP2C9, Cytochrome P450 Family 2 Subfamily C Member 9; ECG, electrocardiogram; GYN/Pap, gynecologic exam with Pap smear; HIV, human immunodeficiency virus; IFNβ, interferon β; IM, intramuscular; IV, intravenous; JCV, John Cunningham virus; LFT, liver function test; MRI, magnetic resonance imaging; PML, progressive multifocal leukoencephalopathy; SC, subcutaneous; TB, tuberculosis; TFT, thyroid function test; UA, urinalysis; VZV, varicella-zoster virus.

Cladribine

Cladribine is an oral medication for MS that reduces relapses, MRI activity, and disease progression in relapsing forms of MS LEVEL 2.[9] Its effects are thought to be mediated by cytotoxic effects on B and T lymphocytes through impairment of DNA synthesis. Cladribine is moderately to highly effective and is administered in two treatment cycles over the course of 2 years. After completing a 2-year course of cladribine, no further immunotherapy is recommended unless new disease activity develops. Cladribine may increase risk of malignancy, so patients should remain up-to-date on all recommended malignancy screenings.

Fingolimod

Fingolimod is a functional antagonist of the sphingosine-1-phosphate receptors 1, 2, 3 and 5. It prevents egress of lymphocytes from peripheral lymph nodes. Reduction in relapse rate and MRI outcomes was significant compared to placebo and to weekly intramuscular interferon β-1a in two large randomized, double-blind, placebo-controlled trials LEVEL 1.[10,11] Fingolimod has rarely been associated with serious infections, including cryptococcal infections, disseminated herpes, and PML.

Siponimod

Siponimod is a second-generation sphingosine-1-phosphate modulator, differing from fingolimod in that it affects primarily sphingosine-1-phosphate receptors 1 and 5. It reduced relapse frequency and MRI activity and slowed disease progression for patients with active SPMS LEVEL 1[3] and is approved for patients with relapsing and active progressive disease. Side effects are similar to those of fingolimod, although due to its recent approval, less follow-up data is available.

Dimethyl Fumarate

Dimethyl fumarate is a fumaric acid ester shown to be effective in reducing relapse frequency and MRI activity in relapsing forms of MS LEVEL 3.[12,13] Its mechanism of action is hypothesized to be related to scavenging free radicals and acting through modulation of NF-kB and Nrf2 pathways. It also has direct effects on lymphocytes, reducing the frequency of memory B and T cells and expanding the circulating naïve lymphocyte population. The drug also downregulates aerobic glycolysis in vitro. A minority of patients treated with dimethyl fumarate develop profound lymphopenia, and PML has rarely been reported among treated patients.

Teriflunomide

Teriflunomide is a pyrimidine synthesis inhibitor, which slows expansion of activated effector lymphocytes. Modest efficacy in relapse rate reduction as well as reduction in sustained disability progression was shown in large double-blind, placebo-controlled trials LEVEL 1.[14,15]

β-Interferons and Glatiramer Acetate

The β-interferons and glatiramer acetate were early therapies used to treat RRMS, but in the present era of more effective therapies, they are of limited use save for glatiramer acetate, which appears to be relatively safe during pregnancy. Although they reduce relapses and improve outcomes compared to placebo, they are significantly less effective than more recently approved immunotherapies LEVEL 1.[4,16-19] Interferons have multiple mechanism of action. Their therapeutic effects may be due to antiproliferative action, downregulation of costimulatory molecules, decrease of proinflammatory cytokines, or through effects on matrix metalloproteinases and adhesion molecules, which limit trafficking of T lymphocytes into the CNS. The beneficial effects of glatiramer acetate, a synthetic polypeptide composed of the four amino acids L-alanine, L-glutamic acid, L-lysine, and L-tyrosine, may result from reactive Th2 cells that cross the blood-brain barrier and increase the secretion of suppressor-type cytokines and downregulate inflammatory activity within the CNS, a process known as *bystander suppression*.

Neutralizing antibodies (NAbs) develop in 15% to 25% of patients treated with high-dose interferons, typically developing between 6 and 18 months after the initiation of treatment and only rarely after more than 2 years of therapy. Although they may be transient, persistent high-titer NAbs (>100 NU/mL) are associated with a reduced therapeutic effect. Individuals developing evidence of NAbs should discontinue interferon treatment permanently and initiate a different disease-modifying therapy.

Mitoxantrone

Mitoxantrone is an anthracenedione with immunosuppressive and immunomodulatory properties. It is FDA approved for SPMS as well as highly active relapsing MS. However, due to a substantial risk for cardiac toxicity, it is no longer used in clinical practices.

Symptom Management

Therapies to alleviate the daily symptoms of MS are integral part of patient care. Successful treatment often involves a combination of pharmacotherapy with nonpharmacologic measures, such as rehabilitation, exercise, or lifestyle and environmental modifications. See **Table 71.7** for an overview of symptomatic management of common MS symptoms.

Spasticity

Management of spasticity includes evaluation and treatment of potentially exacerbating factors. Once exacerbating factors are minimized, a combination of physical therapy interventions and pharmacologic management is optimal. The most commonly used agents are baclofen and tizanidine alone or in combination. Common adverse effects of baclofen include limb weakness, sedation, and confusion. At higher doses, weakness may negate the benefit of spasticity reduction. Abrupt discontinuation of baclofen can result in seizures, confusion, hallucinations, and a marked increase in muscle tone. Some of the systemic side effects of baclofen can be mitigated by intrathecal administration in selected patients with substantial lower extremity spasticity. The use of tizanidine is mainly limited by drowsiness. The use of benzodiazepines has largely been supplanted by baclofen and tizanidine, which are better tolerated. Botulinum toxin is effective for focal spasticity and has been approved for this purpose.

Gait Disturbance

Occupational and physical therapy are the mainstays of treatment for motor impairment. For optimal effectiveness, therapists should be familiar with MS and take the diagnosis into account when formulating a rehab plan. The potassium channel blocker dalfampridine, which is a sustained release formulation of 4-aminopyridine, enhances conduction across demyelinated nerve fibers. It improved leg strength and walking speed in some patients with relapsing and progressive forms of MS in two therapeutic trials LEVEL 1.[20] Dalfampridine increases the risk of seizures, especially at higher doses, and is contraindicated in those with history of seizures or impaired kidney function. The risk of seizure appears to be low with the approved dose of dalfampridine, which is 10 mg twice daily.

Mood Disturbance

Depression responds well to psychotherapy and antidepressants, alone or in combination. Amitriptyline is effective for pseudobulbar affect (pathologic laughing or crying), as is a mixture of dextromethorphan and quinidine LEVEL 1.[21]

Cognitive Impairment

Cognitive impairment may develop early in MS, and formal neuropsychological testing is warranted at the time of diagnosis to establish a baseline. An MS-related cognitive decline is frequently confounded by mood disorders, sleep disturbances, and fatigue. Thus, although there are no clearly effective treatments for MS-related cognitive impairment, eliminating confounding factors may lead to improvements for some patients. Patients may benefit from cognitive remediation and strategies to compensate for deficits. Physical exercise may also improve cognitive symptoms. Medications, including donepezil and memantine, have not been helpful for MS-induced cognitive dysfunction, and polypharmacy can worsen cognitive function. Disease-modifying drugs that minimize lesion development, tissue destruction, or brain atrophy may limit cognitive decline.

Bladder/Bowel Dysfunction

Bladder dysfunction in MS can be well characterized by a urologic evaluation and urodynamic studies. A combination of anticholinergic therapy and an α-adrenergic antagonist (doxazosin, prazosin, tamsulosin, terazosin) may facilitate emptying in individual with sphincter detrusor dyssynergia. Catheterization (preferably clean intermittent catheterization) is the mainstay of therapy in patients with detrusor hypocontractility and emptying difficulties. Those unable to tolerate medications or perform self-catheterization may require an indwelling catheter. Urologic follow-up is necessary for patients with a chronic indwelling catheter to monitor for the development of urinary tract and genital complications.

Tremor

Numerous medications have been evaluated for treating MS tremor, including carbamazepine, clonazepam, gabapentin, levetiracetam, primidone, ondansetron, propranolol, and tetrahydrocannabinol. However, these agents are rarely effective, and

TABLE 71.7 Management of Multiple Sclerosis Symptoms

Symptom	Nonpharmacologic Approaches	Pharmacologic Approaches (Starting Dosage)
Spasticity	Physical and occupational therapy Exercise Evaluation of aggravating factors which may include the following: • Urinary tract infection • Decubitus ulcers • Pain • Constipation • Tight-fitting garments	Baclofen (oral 10 mg three times a day or intrathecal) Tizanidine (4 mg every bedtime) Benzodiazepines (varies) Botulinum toxin Gabapentin (300 mg three times a day)
Weakness	Physical and occupational therapy	Dalfampridine (10 mg twice a day)
Depression	Psychotherapy Support groups	Selective serotonin reuptake inhibitors Serotonin norepinephrine reuptake inhibitors
Pseudobulbar affect	Psychotherapy to manage triggers	Dextromethorphan/quinidine (20/10 mg twice a day) Amitriptyline (10 mg every bedtime)
Fatigue	Improve sleep habits • Cognitive behavioral therapy • Sleep hygiene Energy conservation techniques Evaluation of other causes of fatigue including the following: • Anemia • Thyroid dysfunction • Sleep apnea • Elevated core body temperature • Side effects of other medications	Amantadine (150 mg twice a day) Modafinil (100 mg once a day) Armodafinil (150 mg once a day) Methylphenidate (10 mg once a day)
Sexual dysfunction	Psychotherapy and relationship counseling to help couples manage sexual difficulties Mechanical vibrators and vacuum devices to enhance blood flow, increase lubrication, and stimulate orgasm	Selective phosphodiesterase 5 inhibitors for erectile dysfunction Estrogen creams for vaginal dryness
Cognitive impairment	Neuropsychological testing to define areas of deficit, identify areas of relative strength for compensatory strategies Cognitive remediation	No clearly effective pharmacotherapy
Urinary dysfunction	Urodynamic studies to define specific type of dysfunction—failure to store or empty Biofeedback Evaluate for infection. Intermittent catheterization	Anticholinergics Mirabegron (25 mg once a day) α-Adrenergic antagonist Botulinum toxin Desmopressin for nocturia (0.1 mg every bedtime)
Bowel dysfunction	Biofeedback Dietary changes to increase fiber Increase water intake for constipation. Scheduled defecation	Stool softener Stimulant laxative Osmotic laxative
Tremor	Deep brain stimulation	Primidone (25 mg every bedtime) Propranolol (20 mg twice a day) Clonazepam (0.5 mg twice a day) Ondansetron (8 mg twice a day)
Paroxysmal symptoms (trigeminal neuralgia, paroxysmal dystonia)	Avoidance of triggers	Carbamazepine (100 mg twice a day) Acetazolamide (250 mg twice a day) Phenytoin (100 mg three times a day) Lamotrigine (100 mg once a day) Baclofen (10 mg three times a day)
Pain	Avoidance of triggers Exercise/physical therapy	Gabapentin (300 mg three times a day) Pregabalin (75 mg twice a day) Amitriptyline (25 mg every bedtime) Duloxetine (30 mg daily) Venlafaxine (37.5 mg twice a day)

tremor can be the most difficult MS symptom to treat. Thalamic deep brain stimulation may result in dramatic improvement. Stable MS patients with disabling tremor for at least 1 year despite medical therapy who have no significant cognitive dysfunction, speech or swallowing problems, or other deficits in the affected limbs may be good candidates.

Pain

If treatment is warranted, dysesthesias and pain usually respond to anticonvulsants and antidepressants, either used alone or in combination. Gabapentin, pregabalin, amitriptyline, nortriptyline, and duloxetine commonly provide relief. Myelopathic pain responds to opioids, which may be necessary in some patients.

Referral to a pain specialist may be helpful for patients with refractory pain.

Pregnancy and Breastfeeding

Pregnancy is mildly protective in MS, particularly during the third trimester when there is a 70% reduction in the annualized relapse rate compared with the year prior to pregnancy. However, when MS is left untreated, about 30% of women have a relapse in the first 3 months postpartum before the risk returns to the prepregnancy rate at 4 to 6 months after delivery. These effects may be the result of changes in Th1 and Th2 immune responses mediated by estriol or vitamin D, both of which are markedly elevated during the final trimester of pregnancy and fall abruptly after delivery; other hormonal changes that occur during pregnancy may also play a role.

Women with relapses during pregnancy or in the year prior to pregnancy are more likely to have a relapse in the first 3 months postpartum than women without relapses during these periods, but it is impossible to accurately predict who will have a relapse. Steroids may be used during pregnancy if necessary to treat relapses.

Most women desiring pregnancy discontinue MS disease-modifying therapy prior to conception and remain off treatment during pregnancy. If therapy is continued during pregnancy, glatiramer acetate is most often used. There may be an emerging role for longer acting disease-modifying therapies in women who are planning future pregnancies, but this has not been formally studied and it is not recommended to give these medications during a known pregnancy.

Mothers with MS who wish to attempt breastfeeding may do so, although close monitoring is warranted. One study found that exclusive breastfeeding for the 2 months after delivery decreased the relapse risk, but other studies had conflicting results. Breastfeeding should not be considered a substitute for disease-modifying therapy. Clinical and radiologic reassessment should be performed postpartum, and decisions about ongoing breastfeeding should be made based on those assessments. Limited data are available related to the safety of disease-modifying therapies while breastfeeding. Glatiramer acetate appears to be safe. Large monoclonal antibodies (eg, natalizumab and ocrelizumab) are unlikely to be secreted into breast milk in large quantities and would most likely be destroyed in the infant's gastrointestinal tract. Direct data on their use during lactation is lacking. No evidence is available regarding the safety of oral MS medications during lactation, and most neurologists recommend avoiding them during breastfeeding.

Vaccination

Infections, including minor upper respiratory infections, increase the risk of MS exacerbations. Strategies that minimize the risk of infection should be incorporated. A prospective, randomized, double-blind, placebo-controlled trial showed that influenza immunization did not increase the risk of relapse or disease progression LEVEL 1.[22] Hepatitis B, tetanus, and varicella vaccines also appear to be safe in MS patients. Because there is no evidence that vaccines trigger MS exacerbations, most MS patients should be encouraged to receive all routine immunizations. In a patient who is undergoing an MS relapse, it is probably best to delay immunizations for 4 to 6 weeks because the goal of relapse management is to diminish the immune system's reactivity, and vaccination has the opposite effect.

Several of the immunosuppressive medication therapies used to treat MS may increase the risk of certain vaccines. Live vaccines should not be administered to patients currently treated with ocrelizumab, rituximab, alemtuzumab, mitoxantrone, fingolimod, and siponimod. Any necessary live vaccines should be administered at least 4 weeks before initiating treatment with these medications. Patients receiving these and other immunomodulatory medications for MS can safely receive nonlive vaccines, however. The resultant immune response to vaccination is frequently less robust than for individuals not on immunomodulatory medications but is typically sufficient for immunity.

Pediatric Multiple Sclerosis

Between 3% and 10% of MS patients present before age 16, and less than 1% of cases present at ages younger than 10. Pediatric MS cases are highly likely to present with a relapsing variant of the disease (98% have RRMS), and the female predominance is even more striking in adolescent patients compared to adults, with a female:male ratio of about 4.5:1. In patients younger than age 11, however, the female:male ratio is closer to 1:1. Pediatric MS patients are more likely than adults to experience an aggressive disease onset with multifocal presentations and high relapse rates early in disease. Pediatric patients also present with encephalopathy (eg, ADEM) more frequently than adults.

Although they frequently recover well from early relapses, patients with pediatric MS experience a failure of age-expected brain growth. Cognitive impairment is consistently reported in about one-third of patients. Moreover, although the time to SPMS is longer in pediatric-onset MS compared to adult-onset MS, the young age of onset means that these patients are still developing substantial physical disability in early adulthood.

As with adult-onset disease, early treatment is key to minimizing disability in pediatric-onset MS. Existing evidence suggests that pediatric and adult MS patients share pathophysiology, but only a few immunomodulatory therapies have been formally tested in the pediatric populations, and the rarity of the diagnosis has made recruitment for trials challenging. Retrospective studies of interferon β and glatiramer acetate have been performed, and these drugs are considered safe and frequently used. Natalizumab, dimethyl fumarate, and fingolimod have undergone trials in pediatric populations. In the phase 3 fingolimod trial, fingolimod was superior to subcutaneous interferon β-1a LEVEL 2.[23] Trials of teriflunomide and alemtuzumab are ongoing. B-cell depleting agents are also frequently used off-label in the pediatric population.

Schilder disease, or myelinoclastic diffuse sclerosis, is a vanishingly rare pediatric form of demyelinating disease characterized by formation of bilateral plaques in the centrum semiovale with pathology consistent with MS without additional lesions in the CNS in the setting of normal peripheral nervous system function, normal adrenal function, and no deficit in very long-chain fatty acids. A handful of cases have been reported since the original description by Schilder in 1912. There is controversy regarding the potential contamination of case series with children eventually found to have adrenoleukodystrophy.

Outcomes

MS is an extremely variable illness, and much of the data on the natural history of MS precede the availability of highly effective treatments. In patients who have been treated early with highly effective treatment, one might suspect that the individual risk of disability is less than that of the untreated patient. However, there have not been recent long-term studies to determine prognosis or to update statistics on chance of progression from RRMS

to SPMS. Therefore, counseling patients with early MS poses a major challenge for clinicians.

Brain MRI abnormalities after an initial demyelinating event provide important prognostic information regarding the development of MS. Fifty-one percent of optic neuritis patients with at least three brain MRI T2 hyperintense lesions will meet diagnostic criteria for clinically definite MS within 5 years compared to 16% of those with optic neuritis and a normal brain MRI. Using older definitions of CIS (prior to the 2017 McDonald criteria, which incorporates oligoclonal bands into diagnosis), definite MS developed within 20 years for 82% of CIS patients with at least one brain MRI T2 lesion compared with 21% with a normal baseline brain MRI. In previous CIS trials, 41% to 50% of patients were diagnosed with definite MS within 2 to 3 years. The risk of developing MS was greatest in patients with more than eight T2 hyperintense lesions or at least one gadolinium-enhancing lesion on their baseline brain MRI.

In general, higher numbers of brain MRI lesions at the time of clinical presentation is associated with greater risk of long-term disability. There is also a modest correlation between changes in MRI T2 lesion volume over the first 5 years and long-term disability. However, possible outcomes are wide ranging. In one natural history study, 45% of those with at least 10 lesions on initial brain MRI had reached estimated disability status scale (EDSS) of 6 (a score indicative of needing a walking aid of any sort) after 20 years, but 35% had only mild disability. However, the EDSS does not measure cognitive impairment or neuropsychiatric disability well, and such changes were therefore likely missed in these historical studies.

Although the course of MS is essentially impossible to predict in an individual patient, female sex, younger age at onset, and little disability 5 years after onset are generally favorable prognostic signs. Male sex, older age at onset, frequent attacks early in the course of the disease, a short interval between the first two attacks, incomplete recovery from the first attack, rapidly accumulating disability, cerebellar involvement as a first symptom, and progressive disease from onset are associated with worse outcome. Optic neuritis as a first attack is associated with a favorable short- and intermediate-term outcome, but 20-year disability is similar among patients who present with optic neuritis, brainstem, or spinal cord syndromes.

In one natural history study, 24% of patients with a CIS under pre-2017 definitions, who were followed for an average of 4 years, reached an EDSS score of 6 or more (EDSS 6 is defined as unable to walk 100 m without unilateral assistance), and 40% of those followed for 6 to 15 years entered the secondary progressive phase of the disease. These findings indeed demonstrate that our prior concepts of "CIS" were in large part semantics because these patients ultimately had MS pathology.

Some patients have a very mild form of RRMS with minimal or no disability at least 10 years after disease onset, which is often referred to as *benign multiple sclerosis*. This term, however, should be used with caution and is truly a matter of controversy because there are many measures of disability that are not being measured adequately by scales such as the EDSS, with cognitive dysfunction being the most concerning example. Neuropsychological testing reveals cognitive impairment in approximately 20% to 45% of patients considered to have benign MS. Therefore, the diagnosis of benign MS should include an assessment of cognitive function and only be considered in retrospect and after prolonged follow-up.

The Marburg variant of MS is a rare, fulminant, and usually monophasic illness that typically results in death within 1 year. It can be difficult to differentiate from severe ADEM. Pathologically, it is characterized by robust macrophage infiltrate and destruction of axons as well as demyelination and prominent tissue necrosis.

NEUROMYELITIS OPTICA SPECTRUM DISORDER

Introduction

NMOSD is a severe inflammatory demyelinating disease of the CNS that is distinct from MS. Formerly called *Devic disease*, it was originally considered a subtype of MS characterized by the co-occurrence of acute or subacute optic neuritis and transverse myelitis. It is now recognized that NMOSD actually has a broader clinical phenotype. Although there is overlap with the presentation of MS, NMOSD has a distinct pathologic antibody and pathologic features of the optic neuritis and myelitis are distinct from those seen in MS.

Epidemiology

The true incidence and prevalence of NMOSD are unknown. However, the disease is much less common than MS with an estimated prevalence of approximately 5 per 100,000 individuals. NMOSD usually begins in the fourth decade, but the onset may occur during childhood or after age 70 years. The reported incidence is up to 10 times higher in women, and nonwhite individuals are more commonly affected than whites.

Pathobiology

AQP4-IgG is a sensitive and highly specific serum autoantibody that is present in serum for about 70% of NMOSD patients. The antibody may also be detected in CSF, but serologic testing has a higher sensitivity and is preferred. Pathogenicity of the AQP 4-IgG has been demonstrated by passive transfer in animal models. AQP4 is the main water channel in the CNS and is the target antigen for seropositive cases of NMOSD. AQP4 is located primarily in perivascular and subpial astrocytic foot processes. It is expressed at high levels within the optic nerves, hypothalamus, brainstem, periventricular regions, and gray matter of the spinal cord. AQP4 loss may impair water homeostasis and glutamate transport and lead to oligodendrocyte injury, demyelination, and axonal damage. The circumventricular organs around the third and fourth ventricles contain a high density of AQP4, and this may explain the clinical syndrome of intractable nausea, vomiting, and hiccups as well as hypothalamic dysfunction.

Acute NMOSD lesions are far more destructive than those seen in MS. The NMOSD lesions are characterized by extensive demyelination and axonal damage and contain an inflammatory infiltrate consisting mainly of macrophages, B lymphocytes, eosinophils, and granulocytes. T lymphocytes are sparse. The immunoglobulin and products of complement activation are deposited in a distinctive perivascular rim and rosette pattern. Intramedullary lesions typically extend over several spinal levels, involve both gray and white matter, and are often necrotic. Gliosis, cystic degeneration, cavitation, and atrophy are typical of chronic spinal cord and optic nerve and chiasmal lesions. A marked loss of AQP4 immunoreactivity is observed in all

TABLE 71.8 Classic Presentations of Neuromyelitis Optica Spectrum Disorder

Symptom	Sign	Localization
Blurred vision Pain with eye movement	Relative apparent pupillary defect Red desaturation[a]	Optic nerve
Limb weakness Bladder/bowel dysfunction	Paraparesis or monoparesis	Spinal cord
Intractable nausea, vomiting or hiccups	NA	Area postrema

[a]Red desaturation: decreased ability to perceive the color red.

NMOSD-demyelinating lesions regardless of location, stage, or degree of necrosis and occurs in regions with extensive vasculocentric immunoglobulin and complement deposition.

AQP4 autoantibodies are not detected in a minority of patients who meet clinical criteria for NMOSD. These individuals may have autoantibodies against MOG. Anti-MOG syndromes are described further in the following text.

Diagnosis

Clinical Manifestations

Patients typically experience frequent and severe exacerbations of optic neuritis or myelitis interspersed with periods of remissions. See **Table 71.8** for a description of classic NMOSD presentations. Disability typically accumulates with successive exacerbations and does not follow a slowly progressive course, in contrast to MS.

Optic neuritis (unilateral or bilateral) and/or longitudinally extensive transverse myelitis (more than three spinal segments) are the most common presenting symptoms of NMOSD, and symptoms may be severe. Disease outside of the spinal cord and optic nerves occurs in 10% to 15% of patients. These symptoms may include vomiting, intractable hiccups, narcolepsy, facial weakness or numbness, diplopia, vertigo, dysarthria, trigeminal neuralgia, tremor, ataxia, hearing loss, hemiparesis, and encephalopathy. There is often improvement after the first attack, but a second episode occurs in 60% of patients within 1 year and in 90% within 3 years.

NMOSD can be diagnosed in patients who exhibit at least one core clinical characteristic (**Table 71.9**) and have a positive blood test for AQP4, when other diagnoses have been excluded. When patients are seronegative for AQP4, they must exhibit at least two core clinical characteristics occurring as a result of one or more clinical episodes. In this situation, at least one of the core clinical characteristics must be optic neuritis, longitudinally extensive transverse myelitis, or area postrema syndrome. Additional MRI characteristics apply to the diagnosis of seronegative cases.

Radiologic Manifestations

Brain MRIs are normal in 55% to 84% of patients with NMOSD, apart from sequelae of optic neuritis. Over time, however, brain lesions may develop in up to 85% of patients. These lesions tend to occur in the hypothalamus, thalamus, brainstem, and around the third and fourth ventricles, which are all sites of high AQP4 expression. Large lesions in the cerebral hemispheres are occasionally observed. Optic nerve lesions may be longitudinally extensive and involve the optic chiasm or optic tracts.

TABLE 71.9 Neuromyelitis Optica Diagnostic Criteria[a]

Core clinical characteristics:

1. **Optic neuritis**
2. **Acute myelitis**
3. **Area postrema syndrome: episode of acute nausea, vomiting or unexplained hiccups**
4. Acute brainstem syndrome
5. Symptomatic narcolepsy or acute diencephalic syndrome with NMOSD-typical diencephalic brain lesions on MRI
6. Symptomatic cerebral syndrome with NMOSD-typical brain lesions on MRI

MRI criteria for AQP4-negative or AQP4-unknown cases

1. Acute optic neuritis
   - Brain MRI must be normal or with only nonspecific white matter lesions
   - *Or* optic nerve MRI showing T2 hyperintense or T1 gadolinium-enhancing lesion extending over one-half the optic nerve length or involving the optic chiasm
2. Acute myelitis
   - Spinal MRI must demonstrate intramedullary lesion extending ≥3 contiguous segments
   - *Or* ≥3 contiguous segments of focal spinal cord atrophy and a clinical history of myelitis
3. Area postrema syndrome
   - Brain MRI must show dorsal medulla/area postrema lesions.
4. Acute brainstem syndrome
   - Brain MRI must show periependymal brainstem lesions.

Abbreviations: AQP4, aquaporin 4 autoantibodies; MRI, magnetic resonance imaging; NMOSD, neuromyelitis optica spectrum disorder.

[a]Adapted from Wingerchuk DM, Banwell B, Bennett JL, et al. International consensus diagnostic criteria for neuromyelitis optica spectrum disorders. *Neurology*. 2015;85(2):177-189.

Such brain lesions may occasionally fulfill McDonald criteria for MS; however, in the presence of AQP4 autoantibodies, the diagnosis of NMOSD is a better descriptor of the clinical syndrome.

In the setting of myelitis, spinal cord MRI is the most sensitive diagnostic test for NMO. Longitudinally extensive T2 lesions involving more than three vertebral segments, and frequently more than six, are characteristic of NMO (see **Fig. 71.8**). Spinal lesions are frequently edematous, occupying the gray matter of the central cord and demonstrating contrast enhancement during an acute episode. The MRI lesions frequently become less radiologically prominent during remissions, but spinal cord atrophy may be seen. Preferential central gray matter involvement as well as gadolinium enhancement and spinal cord swelling are common. Lesions often become smaller over weeks to months, either spontaneously or in response to corticosteroids, and spinal cord atrophy may develop. Although characteristic of NMO, longitudinally extensive lesions are not specific to the disease and are also seen in a variety of illnesses, including infectious and other inflammatory diseases, as well as in patients with vascular lesions and tumors (**Figs. 71.9** and **71.10**).

Biomarkers

Anti-AQP4-IgG is detected in approximately 85% of patients with NMOSD. The antibody has 72% to 91% sensitivity and 100% specificity for the diagnosis of NMOSD. The minority of patients who are AQP4 seronegative may have a different epidemiology and disease course.

Although not part of NMO diagnostic criteria, CSF analysis may be informative in some patients and useful for excluding alternative diagnoses. When examined within 4 weeks of the onset of an exacerbation, CSF typically reveals a mild pleocytosis

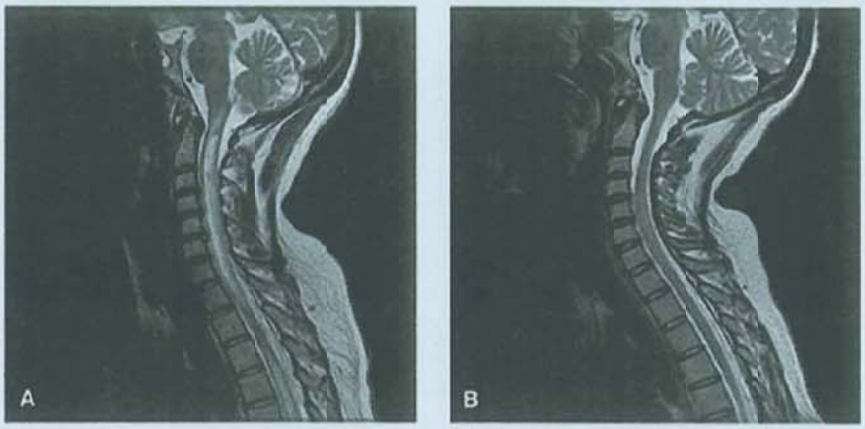

FIGURE 71.9 Neuromyelitis optica spectrum disorder patient with an acute myelitis. **A:** Sagittal T2-weighted image of the cervical spine shows an intramedullary lesion extending from C1 to T1 accompanied by spinal cord swelling. A second lesion is seen in the visualized portion of the upper thoracic spine. **B:** A follow-up magnetic resonance imaging 8 months later shows marked improvement.

(this may be monocytic, lymphocytic, or neutrophilic) and an elevated protein. Up to 35% of patients have WBC of ≥50/μL. Oligoclonal bands are typically absent (in 70%-85% of cases) in contrast to MS.

Non–organ-specific autoantibodies, especially antinuclear or extractable nuclear antibodies, are frequently detected in the serum of patients with NMOSD. Rheumatoid factor or double-stranded DNA antibodies may also be observed. Patients with NMOSD often exhibit concurrent systemic autoimmune diseases, such as Sjögren, myasthenia, autoimmune thyroiditis, and sarcoidosis.

Management

The NMO exacerbations are usually treated with IV methylprednisolone 1 g daily for 5 to 7 days. Plasma exchange, which is indicated for severe exacerbations that do not respond to high-dose IV corticosteroids, results in functional improvement in up to 60% of patients. Early incorporation of plasma exchange improves outcomes.

Recently, three phase 3 clinical trials of NMOSD have been completed and demonstrated efficacy in relapse reduction. These trials tested the complement inhibitor eculizumab, the IL-6 receptor inhibitor, satralizumab, and the B-cell depleting monoclonal antibody, inebilizumab. Eculizumab significantly decreased the risk of relapse in AQP4-positive patients compared to those taking placebo (study drugs were administered as add-ons to preexisting oral immunomodulators during the trial) LEVEL 1[24] and it was FDA approved for treating AQP4-positive NMOSD in 2019. Inebilizumab and satralizumab also significantly reduced the risk of an NMOSD attack compared to placebo LEVEL 1.[25,26] Rituximab, azathioprine, and mycophenolate are also commonly used off-label to treat NMOSD. Interferon-β, glatiramer acetate, and fingolimod appear to worsen the course of NMOSD, underscoring the importance of correctly distinguishing NMOSD from MS.

Therapies aimed at treating spasticity, pain, sphincter dysfunction, and other chronic NMOSD symptoms play an integral part in patient management and are similar to the ones described earlier for treating daily symptoms associated with MS.

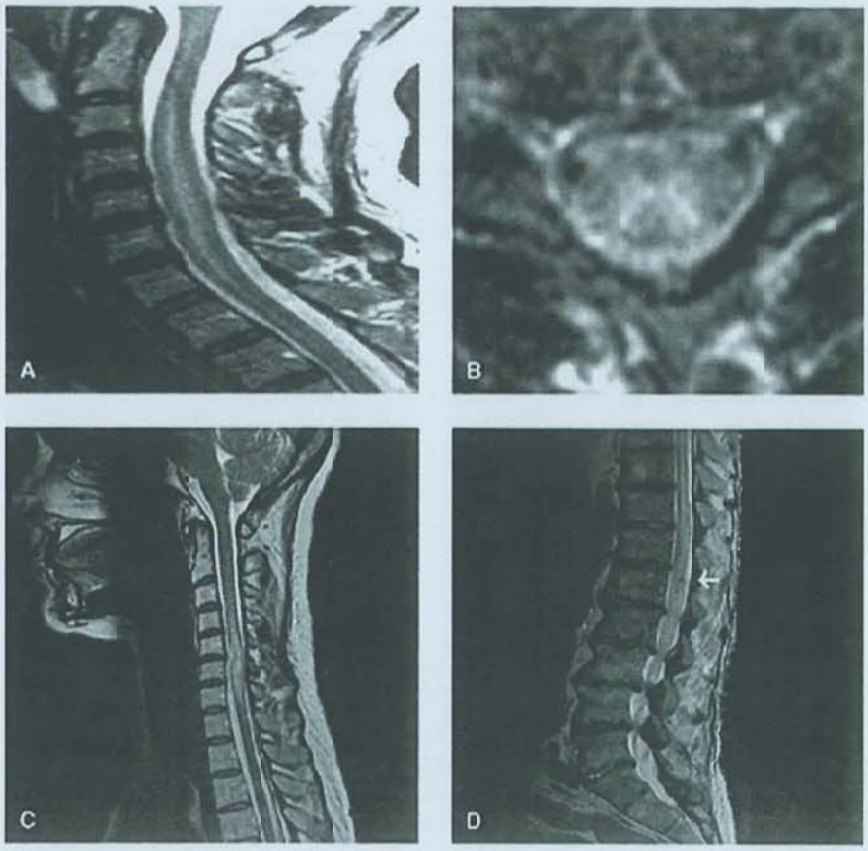

FIGURE 71.10 Longitudinally extensive spinal cord lesions in other diseases. Sagittal **(A)** and axial **(B)** T2-weighted images of the cervical spine show an intramedullary lesion predominantly involving gray matter from C2 to C6 in a patient with neuroborreliosis. **C:** A sagittal T2-weighted image of the cervical spine shows an intramedullary lesion extending from C4 to T1 and spinal cord swelling at C5-C6 in a patient with neurosarcoidosis. **D:** A sagittal T2-weighted image of the distal spinal cord and conus medullaris shows increased signal in the lower thoracic spinal cord, a small hemorrhage *(arrow)* at the conus tip, and numerous flow voids along the posterior spinal cord surface in a patient with a dural arteriovenous fistula.

Outcomes

The prognosis of untreated NMOSD is poor, with the potential for profound visual loss and paresis developing early in the course of the disease as a result of incomplete recovery from attacks. Myelopathic pain, spasticity, dysesthesias, and tonic spasms as well as bowel and bladder dysfunction are common. In a cohort of patients seen at the Mayo Clinic, 60% were legally blind in at least one eye and more than 50% had either mono- or paraplegia within 8 years of disease onset. The 5-year survival rate was only 68%, and all deaths were attributable to respiratory failure from acute intramedullary cervical spine lesions.

Treated cases of NMOSD appear to have a far better prognosis, although the dearth of clinical trial data makes this difficult to quantify. In one randomized, controlled phase 3 trial, relapses occurred in 3% of patients treated with eculizumab (sometimes in combination with additional immunotherapies including azathioprine and mycophenolate) compared to 43% of patients treated with placebo (sometimes in combination with additional immunotherapy, as earlier). In another trial, 12% of patients had an attack on inebilizumab compared with 39% of placebo-treated patients.

ANTI–MYELIN OLIGODENDROCYTE GLYCOPROTEIN SYNDROMES

Anti-MOG antibodies have recently been identified as mediating a distinct set of neurologic syndromes. Although these antibodies can be detected in a subset of seronegative NMOSD patients, the clinical spectrum for anti-MOG disease is far broader than that of AQP4-mediated disease.

Epidemiology

No large-scale epidemiologic studies of anti-MOG syndromes have been performed. Currently available data are based on small case series. Overall incidence is estimated at 0.16 per 100,000 individuals. There does not appear to be a sex predominance in anti-MOG disease; affected individuals are approximately 50% female. Caucasians represented 78% to 90% of cases. Anti-MOG syndromes appear to be more common in pediatric patients (estimated incidence of 0.31 per 100,000 compared to 0.13 per 100,000 in adults), and they may develop in the setting of recent infections or vaccines.

Pathobiology

Patients with anti-MOG syndromes demonstrate demyelination without the astrocytic pathology observed in AQP4-positive disease. Anti-MOG antibodies are felt to mediate pathology based on in vitro studies and animal models of disease.

Diagnosis

Clinical Manifestations

Anti-MOG syndromes may mimic AQP4-positive NMOSD by presenting with optic neuritis or longitudinally extensive transverse myelitis. Some patients have only relapsing optic neuritis, and many patients diagnosed with chronic relapsing inflammatory optic neuritis were discovered to have anti-MOG antibodies once testing became available. In addition to optic neuritis and transverse myelitis, patients with anti-MOG disease may exhibit encephalitis, ADEM, or other atypical demyelinating syndromes. The most common clinical manifestation of anti-MOG syndromes are optic neuritis for adults and ADEM for children.

Diagnostic Criteria

The diagnosis of an anti-MOG syndrome is based on positive serologic autoantibody testing in a patient presenting with suggestive neurologic symptoms.

Biomarkers

Anti-MOG antibodies are detected in the serum using cell-based assays. A CSF testing may reveal mild pleocytosis. Oligoclonal bands are typically negative.

Management

Chronic immunosuppression is not always necessary because anti-MOG syndromes were reported to be monophasic in 41% to 70% of cases. When patients convert from seropositive to seronegative for anti-MOG antibodies, a monophasic course is more likely.

There are no randomized controlled trials of anti-MOG disease. In the acute setting, patients are treated with steroids and/or plasmapheresis, similar to MS or NMOSD exacerbations. Once the disease has been determined to be relapsing, immunomodulators such as rituximab, mycophenolate, azathioprine, and IVIG have been used. Mitoxantrone and natalizumab have failed to reduce relapses in small studies of patients with anti-MOG disease.

LEVEL 1 EVIDENCE

1. Beck RW, Cleary PA, Anderson MM Jr, et al. A randomized, controlled trial of corticosteroids in the treatment of acute optic neuritis. The Optic Neuritis Study Group. *N Engl J Med.* 1992;326:581-588.
2. Montalban X, Hauser SL, Kappos L, et al. Ocrelizumab versus placebo in primary progressive multiple sclerosis. *N Engl J Med.* 2017;376:209-220.
3. Kappos L, Bar-Or A, Cree BAC, et al. Siponimod versus placebo in secondary progressive multiple sclerosis (EXPAND): a double-blind, randomised, phase 3 study. *Lancet.* 2018;391:1263-1273.
4. Hauser SL, Bar-Or A, Comi G, et al. Ocrelizumab versus interferon beta-1a in relapsing multiple sclerosis. *N Engl J Med.* 2017;376:221-234.
5. Cohen JA, Coles AJ, Arnold DL, et al. Alemtuzumab versus interferon beta 1a as first-line treatment for patients with relapsing-remitting multiple sclerosis: a randomised controlled phase 3 trial. *Lancet.* 2012;380:1819-1828.
6. Coles AJ, Twyman CL, Arnold DL, et al. Alemtuzumab for patients with relapsing multiple sclerosis after disease-modifying therapy: a randomised controlled phase 3 trial. *Lancet.* 2012;380:1829-1839.
7. Polman CH, O'Connor PW, Havrdova E, et al. A randomized, placebo-controlled trial of natalizumab for relapsing multiple sclerosis. *N Engl J Med.* 2006;354:899-910.
8. Rudick RA, Stuart WH, Calabresi PA, et al. Natalizumab plus interferon beta-1a for relapsing multiple sclerosis. *N Engl J Med.* 2006;354:911-923.
9. Giovannoni G, Comi G, Cook S, et al. A placebo-controlled trial of oral cladribine for relapsing multiple sclerosis. *N Engl J Med.* 2010;362:416-426.

10. Kappos L, Radue EW, O'Connor P, et al. A placebo-controlled trial of oral fingolimod in relapsing multiple sclerosis. *N Engl J Med*. 2010;362:387-401.
11. Cohen JA, Barkhof F, Comi G, et al. Oral fingolimod or intramuscular interferon for relapsing multiple sclerosis. *N Engl J Med*. 2010;362:402-415.
12. Gold R, Kappos L, Arnold DL, et al. Placebo-controlled phase 3 study of oral BG-12 for relapsing multiple sclerosis. *N Engl J Med*. 2012;367:1098-1107.
13. Fox RJ, Miller DH, Phillips JT, et al. Placebo-controlled phase 3 study of oral BG-12 or glatiramer in multiple sclerosis. *N Engl J Med*. 2012;367:1087-1097.
14. O'Connor P, Wolinsky JS, Confavreux C, et al. Randomized trial of oral teriflunomide for relapsing multiple sclerosis. *N Engl J Med*. 2011;365:1293-1303.
15. Confavreux C, O'Connor P, Comi G, et al. Oral teriflunomide for patients with relapsing multiple sclerosis (TOWER): a randomised, double-blind, placebo-controlled, phase 3 trial. *Lancet Neurol*. 2014;13:247-256.
16. The IFNB Multiple Sclerosis Study Group. Interferon beta-1b is effective in relapsing-remitting multiple sclerosis. I. Clinical results of a multicenter, randomized, double-blind, placebo-controlled trial. *Neurology*. 1993;43:655-661.
17. Ebers GC. Randomised double-blind placebo-controlled study of interferon β-1a in relapsing/remitting multiple sclerosis. PRISMS (Prevention of Relapses and Disability by Interferon β-1a Subcutaneously in Multiple Sclerosis) Study Group. *Lancet*. 1998;352:1498-1504.
18. Comi G, Filippi M, Wolinsky JS. European/Canadian multicenter, double-blind, randomized, placebo-controlled study of the effects of glatiramer acetate on magnetic resonance imaging—measured disease activity and burden in patients with relapsing multiple sclerosis. European/Canadian Glatiramer Acetate Study Group. *Ann Neurol*. 2001;49:290-297.
19. Johnson KP, Brooks BR, Cohen JA, et al. Copolymer 1 reduces relapse rate and improves disability in relapsing-remitting multiple sclerosis: results of a phase III multicenter, double-blind placebo-controlled trial. The Copolymer 1 Multiple Sclerosis Study Group. *Neurology*. 1995;45:1268-1276.
20. Goodman AD, Brown TR, Krupp LB, et al. Sustained-release oral fampridine in multiple sclerosis: a randomised, double-blind, controlled trial. *Lancet*. 2009;373:732-738.
21. Panitch HS, Thisted RA, Smith RA, et al. Randomized, controlled trial of dextromethorphan/quinidine for pseudobulbar affect in multiple sclerosis. *Ann Neurol*. 2006;59:780-787.
22. Miller AE, Morgante LA, Buchwald LY, et al. A multicenter, randomized, double-blind, placebo-controlled trial of influenza immunization in multiple sclerosis. *Neurology*. 1997;48:312-314.
23. Chitnis T, Arnold DL, Banwell B, et al. Trial of fingolimod versus interferon beta-1a in pediatric multiple sclerosis. *N Engl J Med*. 2018;379:1017-1027.
24. Pittock SJ, Berthele A, Fujihara K, et al. Eculizumab in aquaporin-4-positive neuromyelitis optica spectrum disorder. *N Engl J Med*. 2019;381:614-625.
25. Cree BAC, Bennett JL, Kim HJ, et al. Inebilizumab for the treatment of neuromyelitis optica spectrum disorder (N-MOmentum): a double-blind, randomised placebo-controlled phase 2/3 trial. *Lancet*. 2019;394:1352-1363.
26. Yamamura T, Kleiter I, Fujihara K, et al. Trial of satralizumab in neuromyelitis optica spectrum disorder. *N Engl J Med*. 2019;381(22):2114-2124.

SUGGESTED READINGS

Multiple Sclerosis

Ascherio A, Munger KL. Environmental risk factors for multiple sclerosis. Part I: the role of infection. *Ann Neurol*. 2007;61:288-299.
Ascherio A, Munger KL. Environmental risk factors for multiple sclerosis. Part II: noninfectious factors. *Ann Neurol*. 2007;61:504-513.
Aubert-Broche B, Fonov V, Narayanan S, et al. Onset of multiple sclerosis before adulthood leads to failure of age-expected brain growth. *Neurology*. 2014;83(23):2140-2146.
Barnett MH, Prineas JW. Relapsing and remitting multiple sclerosis: pathology of the newly forming lesion. *Ann Neurol*. 2004;55:458-468.
Bitsch A, Kuhlmann T, Stadelmann C, Lassmann H, Lucchinetti C, Brück W. A longitudinal MRI study of histopathologically defined hypointense multiple sclerosis lesions. *Ann Neurol*. 2001;49:793-796.
Bloomgren G, Richman S, Hotermans C, et al. Risk of natalizumab-associated progressive multifocal leukoencephalopathy. *N Engl J Med*. 2012;366:1870-1880.
Briggs FB, Acuna E, Shen L, et al. Smoking and risk of multiple sclerosis: evidence of modification by NAT1 variants. *Epidemiology*. 2014;25(4):605-614.
Brooks BR, Thisted RA, Appel SH, et al. Treatment of pseudobulbar affect in ALS with dextromethorphan/quinidine: a randomized trial. *Neurology*. 2004;63(8):1364-1370.
Brownlee WJ, Hardy TA, Fazekas F, Miller DH. Diagnosis of multiple sclerosis: progress and challenges. *Lancet*. 2017;389(10076):1336-1346.
Cao Y, Goods BA, Raddassi K, et al. Functional inflammatory profiles distinguish myelin-reactive T cells from patients with multiple sclerosis. *Sci Transl Med*. 2015;7(287):287ra74.
CHAMPS Study Group. MRI predictors of early conversion to clinically definite MS in the CHAMPS placebo group. *Neurology*. 2002;59:998-1005.
Cole SR, Beck RW, Moke PS, Kaufman DI, Tourtellotte WW. The predictive value of CSF oligoclonal banding for MS 5 years after optic neuritis. Optic Neuritis Study Group. *Neurology*. 1998;51:885-887.
Comi G, Radaelli M, Soelberg Sørensen P. Evolving concepts in the treatment of relapsing multiple sclerosis. *Lancet*. 2017;389(10076):1347-1356.
Confavreux C, Hutchinson M, Hours MM, Cortinovis-Tourniaire P, Moreau T. Rate of pregnancy-related relapse in multiple sclerosis. Pregnancy in Multiple Sclerosis Group. *N Engl J Med*. 1998;339:285-291.
Confavreux C, Suissa S, Saddier P, et al. Vaccinations and the risk of relapse in multiple sclerosis. Vaccines in Multiple Sclerosis Study Group. *N Engl J Med*. 2001;344:319-326.
Cotton F, Weiner HL, Jolesz FA, Guttmann CR. MRI contrast uptake in new lesions in relapsing-remitting MS followed at weekly intervals. *Neurology*. 2003;60:640-646.
Dominguez-Villar M, Baecher-Allan CM, Hafler DA. Identification of T helper type 1-like, Foxp3+ regulatory T cells in human autoimmune disease. *Nat Med*. 2011;17(6):673-675.
Durelli L, Verdun E, Barbero P, et al. Every-other-day interferon beta-1b versus once-weekly interferon beta-1a for multiple sclerosis: results of a 2-year prospective randomised multicentre study (INCOMIN). *Lancet*. 2002;359:1453-1460.
Farh KK, Marson A, Zhu J, et al. Genetic and epigenetic fine mapping of causal autoimmune disease variants. *Nature*. 2015;518(7539):337-343
Fazekas F, Lublin FD, Li D, et al. Intravenous immunoglobulin in relapsing-remitting multiple sclerosis: a dose-finding trial. *Neurology*. 2008;71:265-271.
Feinstein A, Freeman J, Lo AC. Treatment of progressive multiple sclerosis: what works, what does not, and what is needed. *Lancet Neurol*. 2015;14:194-207.
Filippi M, Rocca MA, Ciccarelli O, et al. MRI criteria for the diagnosis of multiple sclerosis: MAGNIMS consensus guidelines. *Lancet Neurol*. 2016;15(3):292-303. doi:10.1016/S1474-4422(15)00393-2
Fisniku LK, Brex PA, Altmann DR, et al. Disability and T2 MRI lesions: a 20-year follow-up of patients with relapse onset of multiple sclerosis. *Brain*. 2008;131(pt 3):808-817. doi:10.1093/brain/awm329.
Francis GS, Rice GP, Alsop JC. Interferon beta-1a in MS: results following development of neutralizing antibodies in PRISMS. *Neurology*. 2005;65:48-55.
Freedman MS. Long-term follow-up of clinical trials of multiple sclerosis therapies. *Neurology*. 2011;76(1 suppl 1):S26-S34.
Frohman EM, Racke MK, Raine CS. Multiple sclerosis—the plaque and its pathogenesis. *N Engl J Med*. 2006;354:942-955.
Frohman TC, Castro W, Shah A, et al. Symptomatic therapy in multiple sclerosis. *Ther Adv Neurol Disord*. 2011;4(2):83-98.

Ghalie RG, Edan G, Laurent M, et al. Cardiac adverse effects associated with mitoxantrone (Novantrone) therapy in patients with MS. *Neurology*. 2002;59:909-913.

Ghalie RG, Mauch E, Edan G, et al. A study of therapy-related acute leukaemia after mitoxantrone therapy for multiple sclerosis. *Mult Scler*. 2002;8:441-445.

Goodin DS, Ebers GC, Johnson KP, Rodriguez M, Sibley WA, Wolinsky JS. The relationship of MS to physical trauma and psychological stress: report of the Therapeutics and Technology Assessment Subcommittee of the American Academy of Neurology. *Neurology*. 1999;52:1737-1745.

Goodkin DE, Kinkel RP, Weinstock-Guttman B, et al. A phase II study of i.v. methylprednisolone in secondary-progressive multiple sclerosis. *Neurology*. 1998;51:239-245.

Hafler DA, Compston A, Sawcer S, et al. Risk alleles for multiple sclerosis identified by a genomewide study. *N Engl J Med*. 2007;357:851-862.

Harding K, Williams O, Willis M, et al. Clinical outcomes of escalation vs early intensive disease-modifying therapy in patients with multiple sclerosis. *JAMA Neurology*. 2019;76(5):536-541.

Hartung HP, Gonsette R, Konig N, et al. Mitoxantrone in progressive multiple sclerosis: a placebo-controlled, double-blind, randomised, multicentre trial. *Lancet*. 2002;360:2018-2025.

Hauser SL, Bar-Or A, Comi G, et al. Ocrelizumab versus interferon beta-1a in relapsing multiple sclerosis. *N Engl J Med*. 2017;376(3):221-234.

Hawkins SA, McDonnell GV. Benign multiple sclerosis? Clinical course, long term follow up, and assessment of prognostic factors. *J Neurol Neurosurg Psychiatry*. 1999;67:148-152.

Healy BC, Ali EN, Guttmann CRG, et al. Smoking and disease progression in multiple sclerosis. *Arch Neurol*. 2009;66(7):858-864.

Hogancamp WE, Rodriguez M, Weinshenker BG. The epidemiology of multiple sclerosis. *Mayo Clin Proc*. 1997;72:871-878.

Howell OW, Reeves CA, Nicholas R, et al. Meningeal inflammation is widespread and linked to cortical pathology in multiple sclerosis. *Brain*. 2011;134(pt 9):2755-2771.

International Multiple Sclerosis Genetics Consortium. The multiple sclerosis genomic map: role of peripheral immune cells and resident microglia in susceptibility [published online ahead of print July 13, 2017]. *bioRxiv*. doi:10.1101/143933.

Kappos L, Mehling M, Arroyo R, et al. Randomized trial of vaccination in fingolimod-treated patients with multiple sclerosis. *Neurology*. 2015;84(9):872-879.

Kappos L, Weinshenker B, Pozzilli C, et al. Interferon beta-1b in secondary progressive MS: a combined analysis of the two trials. *Neurology*. 2004;63:1779-1787.

Kearney H, Miller DH, Ciccarelli O. Spinal cord MRI in multiple sclerosis—diagnostic, prognostic, and clinical value. *Nat Rev Neurol*. 2015;11(6):327-338.

Keegan M, Pineda AA, McClelland RL, Darby CH, Rodriguez M, Weinshenker BG. Plasma exchange for severe attacks of CNS demyelination: predictors of response. *Neurology*. 2002;58:143-146.

Kleinewietfeld M, Manzel A, Titze J, et al. Sodium chloride drives autoimmune disease by the induction of pathogenic TH17 cells. *Nature*. 2013;496(7446):518-522.

Kutzelnigg A, Lucchinetti CF, Stadelmann C, et al. Cortical demyelination and diffuse white matter injury in multiple sclerosis. *Brain*. 2005;128(pt 11):2705-2712.

Lassmann H, van Horssen J, Mahad D. Progressive multiple sclerosis: pathology and pathogenesis. *Nat Rev Neurol*. 2012;8(11):647-656.

Le Page E, Veillard D, Laplaud DA, et al. Oral versus intravenous high-dose methylprednisolone for treatment of relapses in patients with multiple sclerosis (COPOUSEP): a randomised, controlled, double-blind, non-inferiority trial. *Lancet*. 2015;386(9997):974-981.

Lincoln MR, Montpetit A, Cader MZ, et al. A predominant role for the HLA class II region in the association of the MHC region with multiple sclerosis. *Nat Genet*. 2005;37:1108-1112.

Link H, Huang YM. Oligoclonal bands in multiple sclerosis cerebrospinal fluid: an update on methodology and clinical usefulness. *J Neuroimmunol*. 2006;180(1-2):17-28.

Lovato L, Willis SN, Rodig SJ, et al. Related B cell clones populate the meninges and parenchyma of patients with multiple sclerosis. *Brain*. 2011;134(pt 2):534-541.

Lublin FD, Baier M, Cutter G. Effect of relapses on development of residual deficit in multiple sclerosis. *Neurology*. 2003;61:1528-1532.

Lublin FD, Reingold SC, Cohen JA, et al. Defining the clinical course of multiple sclerosis: the 2013 revisions. *Neurology*. 2014;83:278-286.

Lucchinetti CF, Bruck W, Lassmann H. Evidence for pathogenic heterogeneity in multiple sclerosis. *Ann Neurol*. 2004;56:308.

Lucchinetti CF, Parisi J, Bruck W. The pathology of multiple sclerosis. *Neurol Clin*. 2005;23(1):77-105.

Lucchinetti CF, Popescu BF, Bunyan RF, et al. Inflammatory cortical demyelination in early multiple sclerosis. *N Engl J Med*. 2011;365:2188-2197.

Magliozzi R, Howell O, Vora A, et al. Meningeal B-cell follicles in secondary progressive multiple sclerosis associate with early onset of disease and severe cortical pathology. *Brain*. 2007;130(pt 4):1089-1104.

Mahad DH, Trapp BD, Lassmann H. Pathological mechanisms in progressive multiple sclerosis. *Lancet Neurol*. 2015;14(2):183-193.

Mailand MT, Frederiksen JL. Vaccines and multiple sclerosis: a systematic review. *J Neurol*. 2017;264(6):1035-1050.

Manzel A, Muller D, Hafler D, Erdman SE, Linker RA, Kleinewietfeld M. Role of "Western diet" in inflammatory autoimmune diseases. *Curr Allergy Asthma Rep*. 2014;14(1):404.

Mikol DD, Barkhof F, Chang P, et al. Comparison of subcutaneous interferon beta-1a with glatiramer acetate in patients with relapsing multiple sclerosis (the REbif vs Glatiramer Acetate in Relapsing MS Disease [REGARD] study): a multicentre, randomised, parallel, open-label trial. *Lancet Neurol*. 2008;7:903-914.

Miller DH, Chard DT, Ciccarelli O. Clinically isolated syndromes. *Lancet Neurol*. 2012;11(2):157-169. doi:10.1016/S1474-4422(11)70274-5.

Miller DH, Weinshenker BG, Filippi M, et al. Differential diagnosis of suspected multiple sclerosis: a consensus approach. *Mult Scler*. 2008;14:1157-1174.

Montalban X, Hauser SL, Kappos L, et al. Ocrelizumab versus placebo in primary progressive multiple sclerosis. *N Engl J Med*. 2017;376(3):209-220.

Munger KL, Levin LI, Hollis BW, Howard NS, Ascherio A. Serum 25-hydroxyvitamin D levels and risk of multiple sclerosis. *JAMA*. 2006;296:2832-2838.

Munger KL, Zhang SM, O'Reilly E, et al. Vitamin D intake and incidence of multiple sclerosis. *Neurology*. 2004;62(1):60-65.

Okuda DT, Mowry EM, Beheshtian A, et al. Incidental MRI anomalies suggestive of multiple sclerosis: the radiologically isolated syndrome. *Neurology*. 2009;72(9):800-805.

Okuda DT, Siva A, Kantarci O, et al. Radiologically isolated syndrome: 5-year risk for an initial clinical event. *PLoS One*. 2014;9(3):e90509.

Olsson T, Barcellos LF, Alfredsson L. Interactions between genetic, lifestyle and environmental risk factors for multiple sclerosis. *Nat Rev Neurol*. 2017;13(1):25-36. doi:10.1038/nrneurol.2016.187.

Ontaneda D, Fox RJ, Chataway J. Clinical trials in progressive multiple sclerosis: lessons learned and future perspectives. *Lancet Neurol*. 2015;14(2):208-223.

Optic Neuritis Study Group. The 5-year risk of MS after optic neuritis. Experience of the optic neuritis treatment trial. *Neurology*. 1997;49:1404-1413.

Otallah S, Banwell B. Pediatric multiple sclerosis: an update. *Curr Neurol Neurosci Rep*. 2018;18(11):76.

Panitch H, Goodin DS, Francis G, et al. Randomized, comparative study of interferon beta-1a treatment regimens in MS: the EVIDENCE Trial. *Neurology*. 2002;59:1496-1506.

Paty DW, Li DK. Interferon beta-1b is effective in relapsing-remitting multiple sclerosis. II. MRI analysis results of a multicenter, randomized, double-blind, placebo-controlled trial. UBC MS/MRI Study Group and the IFNB Multiple Sclerosis Study Group. *Neurology*. 1993;43:662-667.

Plavina T, Subramanyam M, Bloomgren G, et al. Anti-JC virus antibody levels in serum or plasma further define risk of natalizumab-associated progressive multifocal leukoencephalopathy. *Ann Neurol*. 2014;76(6):802-812.

PRISMS Study Group and the University of British Columbia MS/MRI Analysis Group. PRISMS-4: long-term efficacy of interferon-beta-1a in relapsing MS. *Neurology*. 2001;56:1628-1636.

Pulicken M, Gordon-Lipkin E, Balcer LJ, Frohman E, Cutter G, Calabresi PA. Optical coherence tomography and disease subtype in multiple sclerosis. *Neurology*. 2007;69:2085-2092.

Sawcer S, Franklin RJM, Ban M. Multiple sclerosis genetics. *Lancet Neurol*. 2014;13(7):700-709.

Sayao AL, Devonshire V, Tremlett H. Longitudinal follow-up of "benign" multiple sclerosis at 20 years. *Neurology*. 2007;68:496-500.

Schlaeger R, Papinutto N, Panara V, et al. Spinal cord gray matter atrophy correlates with multiple sclerosis disability. *Ann Neurol*. 2014;76(4):568-580.

Secondary Progressive Efficacy Clinical Trial of Recombinant Interferon-Beta-1a in MS (SPECTRIMS) Study Group. Randomized controlled trial of interferon-beta-1a in secondary progressive MS: clinical results. *Neurology*. 2001;56:1496-1504.

Simon JH, Jacobs LD, Campion M, et al. Magnetic resonance studies of intramuscular interferon beta-1a for relapsing multiple sclerosis. The Multiple Sclerosis Collaborative Research Group. *Ann Neurol*. 1998;43:79-87.

Sorensen PS, Koch-Henriksen N, Ross C, et al. Appearance and disappearance of neutralizing antibodies during interferon-beta therapy. *Neurology*. 2005;65:33-39.

Thompson AJ, Banwell BL, Barkhof F, et al. Diagnosis of multiple sclerosis: 2017 revisions of the McDonald criteria. *Lancet Neurol*. 2018;17(2):162-173.

Trapp BD, Peterson J, Ransohoff RM, Rudick R, Mörk S, Bö L. Axonal transection in the lesions of multiple sclerosis. *N Engl J Med*. 1998;338:278-285.

van Waesberghe JH, Kamphorst W, De Groot CJ, et al. Axonal loss in multiple sclerosis lesions: magnetic resonance imaging insights into substrates of disability. *Ann Neurol*. 1999;46:747-754.

Vukusic S, Hutchinson M, Hours M, et al. Pregnancy and multiple sclerosis (the PRIMS study): clinical predictors of post-partum relapse. *Brain*. 2004;127(pt 6):1353-1360.

Waldman A, Ness J, Pohl D, et al. Pediatric multiple sclerosis: clinical features and outcome. *Neurology*. 2016;87(9 suppl 2):S74-S81.

Wallin MT, Culpepper WJ, Campbell JD, et al. The prevalence of MS in the United States. *Neurology*. 2019;92(10):e1029-e1040.

Weinshenker BG, Bass B, Rice GP, et al. The natural history of multiple sclerosis: a geographically based study. 1. Clinical course and disability. *Brain*. 1989;112(pt 1):133-146.

Weinshenker BG, Bass B, Rice GP, et al. The natural history of multiple sclerosis: a geographically based study. 2. Predictive value of the early clinical course. *Brain*. 1989;112(pt 6):1419-1428.

Weinshenker BG, O'Brien PC, Petterson TM, et al. A randomized trial of plasma exchange in acute central nervous system inflammatory demyelinating disease. *Ann Neurol*. 1999;46:878-886.

Wolinsky JS, Narayana PA, O'Connor P, et al. Glatiramer acetate in primary progressive multiple sclerosis: results of a multinational, multicenter, double-blind, placebo-controlled trial. *Ann Neurol*. 2007;61:14-24.

Zivadinov R, Rudick RA, De Masi R, et al. Effects of IV methylprednisolone on brain atrophy in relapsing-remitting MS. *Neurology*. 2001;57:1239-1247.

Neuromyelitis Optica and Myelin Oligodendrocyte Glycoprotein Spectrum Disorders

Bonnan M, Valentino R, Debeugny S, et al. Short delay to initiate plasma exchange is the strongest predictor of outcome in severe attacks of NMO spectrum disorders. *J Neurol Neurosurg Psychiatry*. 2018;89(4):346-351.

Cree B. Neuromyelitis optica: diagnosis, pathogenesis, and treatment. *Curr Neurol Neurosci Rep*. 2008;8:427-433.

Cree BA, Lamb S, Morgan K, Chen A, Waubant E, Genain C. An open label study of the effects of rituximab in neuromyelitis optica. *Neurology*. 2005;64:1270-1272.

Jarius S, Paul F, Franciotta D, et al. Mechanisms of disease: aquaporin-4 antibodies in neuromyelitis optica. *Nat Clin Pract Neurol*. 2008;4:202-214.

Kitley J, Waters P, Woodhall M, et al. Neuromyelitis optica spectrum disorders with aquaporin-4 and myelin-oligodendrocyte glycoprotein antibodies: a comparative study. *JAMA Neurol*. 2014;71(3):276-283.

Lennon VA, Wingerchuk DM, Kryzer TJ, et al. A serum autoantibody marker of neuromyelitis optica: distinction from multiple sclerosis. *Lancet*. 2004;364:2106-2112.

Mealy MA, Wingerchuk DM, Greenberg BM, Levy M. Epidemiology of neuromyelitis optica in the United States: a multicenter analysis. *Arch Neurol*. 2012;69(9):1076-1080.

Papadopoulos MC, Bennett JL, Verkman AS. Treatment of neuromyelitis optica: state-of-the-art and emerging therapies. *Nat Rev Neurol*. 2014;10(9):493-506.

Pittock SJ, Lennon VA, de Seze J, et al. Neuromyelitis optica and non organ-specific autoimmunity. *Arch Neurol*. 2008;65:78-83.

Pittock SJ, Lennon VA, Krecke K, Wingerchuk DM, Lucchinetti CF, Weinshenker BG. Brain abnormalities in neuromyelitis optica. *Arch Neurol*. 2006;63:390-396.

Pittock SJ, Weinshenker BG, Lucchinetti CF, Wingerchuk DM, Corboy JR, Lennon VA. Neuromyelitis optica brain lesions localized at sites of high aquaporin 4 expression. *Arch Neurol*. 2006;63:964-968.

Roemer SF, Parisi JE, Lennon VA, et al. Pattern-specific loss of aquaporin-4 immunoreactivity distinguishes neuromyelitis optica from multiple sclerosis. *Brain*. 2007;130(pt 5):1194-1205.

Takahashi T, Fujihara K, Nakashima I, et al. Anti-aquaporin-4 antibody is involved in the pathogenesis of NMO: a study on antibody titre. *Brain*. 2007;130(pt 5):1235-1243.

Tenembaum S, Chitnis T, Nakashima I, et al. Neuromyelitis optica spectrum disorders in children and adolescents. *Neurology*. 20160;87(9 suppl 2):S59-S56.

Wingerchuk DM, Banwell B, Bennett JL, et al. International consensus diagnostic criteria for neuromyelitis optica spectrum disorders. *Neurology*. 2015;85(2):177-189.

Wingerchuk DM, Pittock SJ, Lucchinetti CF, Lennon VA, Weinshenker BG. A secondary progressive clinical course is uncommon in neuromyelitis optica. *Neurology*. 2007;68:603-605.

Transverse Myelitis 72

Eoin P. Flanagan and Brian G. Weinshenker

KEY POINTS

1. Transverse myelitis (TM) is a clinical syndrome of acute or subacute myelopathy. It is broadly categorized as disease-associated or idiopathic, but it has a broad differential diagnosis. Many noninflammatory disorders can mimic TM, including vascular, toxic/metabolic, and neoplastic myelopathies.
2. The time course of development of neurologic symptoms is among the most important clues to the etiology of a myelopathy. The onset to nadir (maximal deficit) in TM is defined as being between 4 hours and 21 days. Apoplectic onset suggests spinal cord infarction, whereas progression beyond 21 days should raise suspicion for an alternative etiology, such as neoplasm, sarcoidosis, or dural arteriovenous fistula.
3. The presence of longitudinally extensive TM with a sagittal T2 hyperintense lesion extending three or more vertebral segments should prompt assessment of the blood biomarkers aquaporin-4 immunoglobulin G (IgG) and myelin oligodendrocyte glycoprotein-IgG, which are associated with this radiologic finding, and may lead to a diagnosis of an antibody-mediated TM.
4. Careful scrutiny of the gadolinium enhancement pattern on magnetic resonance imaging of TM lesions may provide critical clues to the underlying cause.
5. Acute treatment of TM is initially with high-dose intravenous steroids but in those with a severe residual deficit despite steroids, plasma exchange for 5 to 7 sessions is recommended.
6. A TM may be monophasic or the presenting manifestation of a relapsing disease (eg, multiple sclerosis or neuromyelitis optica), and ancillary testing with brain magnetic resonance imaging, blood biomarkers, and cerebrospinal fluid analysis can help distinguish monophasic disease from those with a relapsing disease.

INTRODUCTION

Transverse myelitis (TM) is a clinical syndrome characterized by acute or subacute myelopathy accompanied by inflammation of the spinal cord. The term *transverse* is based on the sensory level that is clinically detected in many patients, but not all cases of TM are associated with inflammation across the entire cross-section of the spinal cord as the name suggests, and partial TM with inflammation extending across only a portion of the spinal cord is well recognized. Furthermore, many patients do not have "transverse" pathology but pathology that extends over the long axis of the spinal cord and may affect most of the spinal cord. The TM has traditionally been divided into disease-associated and idiopathic etiologies (Table 72.1). Disease-associated TM may occur in the context of a monophasic or relapsing central nervous system (CNS) inflammatory demyelinating disease (IDD) (eg, multiple sclerosis [MS]), neurosarcoidosis, or an infection (eg, varicella zoster virus myelitis) in which case myelitis is monophasic. New autoantibody biomarker discoveries of CNS IDDs (eg, aquaporin-4 immunoglobulin G [AQP4-IgG] accompanying neuromyelitis optica spectrum disorder [NMOSD]) and improved recognition of the neuroimaging features of myelopathies have transformed the classification of

TABLE 72.1 Transverse Myelitis Etiologies

Disease-Associated Transverse Myelitis	Clinical/MRI Clues
Inflammatory Demyelinating Disease	
• Multiple sclerosis	Short-peripheral T2 lesions in dorsal/lateral columns
• Aquaporin-4 antibody seropositive NMOSD	Longitudinally-extensive T2-lesion
• Myelin oligodendrocyte glycoprotein (MOG) antibody disease	Long or short T2-lesion; conus involvement; nonenhancing
• Acute disseminated encephalomyelitis	Coexisting deep gray brain lesions
Inflammatory, Confirmed Etiology	
• Spinal cord sarcoidosis	Linear dorsal subpial/trident enhancement
• Connective tissue disease associated (Behçet, lupus, Sjögren's syndrome)[a]	Systemic features of connective tissue disease
• Paraneoplastic	Known cancer; cancer risk factors; tract-specific lesion, especially gadolinium enhancing
• Immune checkpoint inhibitor associated	Recent use of checkpoint inhibitor
Infectious	
• Bacterial (Lyme, syphilis, tuberculosis)	Recent tick bite/rash; high-risk behavior
• Viral (VZV, HSV 1, HSV 2 [may be associated with lumbar myeloradiculitis, Elsberg syndrome], CMV, West Nile, enterovirus-associated acute flaccid myelitis; HIV)	Zoster rash, genital herpes, endemic region for enterovirus/West Nile virus; high-risk behavior
• Parasitic (schistosomiasis)	Endemic region
Idiopathic Transverse Myelitis	

Abbreviations: CMV, cytomegalovirus; HIV, human immunodeficiency virus; HSV, herpes simplex virus; MRI, magnetic resonance imaging; NMOSD, neuromyelitis optica spectrum disorder; VZV, varicella zoster virus.
[a]Can be due to coexisting aquaporin-4 immunoglobulin G seropositive NMOSD.

many TM from "idiopathic" to "disease-associated." Many other disorders (eg, spinal cord infarct) can mimic TM (**Table 72.2**). The broad differential diagnosis (see **Tables 72.1** and **72.2**) requires clinicians to scrutinize the acuity of onset, neuroimaging characteristics, cerebrospinal fluid (CSF) findings, and blood biomarkers to reach the correct diagnosis. Once a diagnosis of TM is reasonably suspected (ie, compression and infarction are excluded), acute treatment is administered even before an etiology is determined to reduce disability from the TM attack. If a disease-associated etiology is identified (eg, MS), chronic maintenance treatments may prevent future attacks targeting the spinal cord or other parts of the CNS.

TABLE 72.2 Mimics of Transverse Myelitis

Etiologies Stratified by Onset	Clues to Diagnosis
Acute	
Vascular	
• Spinal cord infarct (anterior or posterior spinal artery)	Vascular risk factors
• Fibrocartilaginous embolism	Valsalva, disc adjacent to lesion
• Hematoma (hematomyelia, epidural hematoma)	Bleeding diathesis, trauma
Structural/trauma	
• Surfer's myelopathy	Novice surfer
• Spinal cord contusion	Recent trauma
Chronic Progressive (May Have Subacute Onset/Worsening)	
Vascular	
• Dural arteriovenous fistula	Clinical worsening after exertion or steroids
• Cavernous malformation/other AVM	"Popcorn" appearance[a]
Inflammatory or demyelinating	
• Progressive solitary sclerosis	Single MS-lesion in lateral columns, pyramids of medulla
• Primary progressive MS	Multiple short T2 lesions in cord
• Spinal cord sarcoidosis	Milder deficit despite large lesion
• Paraneoplastic	Known cancer, smoking
Infectious	
• Bacterial (syphilis, tuberculosis)	High-risk behavior, endemic region
• Viral (HIV, HTLV-1)	High-risk behavior, endemic region, dorsal/lateral column signal abnormality
Neoplastic	
• Primary spinal cord gliomas (astrocytoma, ependymoma)	Prior radiation, expansile, mass effect, cap sign[b]
• Primary intramedullary spinal cord lymphoma	Expansile lesion, persistent enhancement (>3 mo), steroid responsive, immunosuppressed
• Metastatic disease (intramedullary, extramedullary compressive)	Known solid organ cancer
Structural	
• Spondylotic myelopathy	Known neck osteoarthritis
Hereditary	
• Adrenomyeloneuropathy	Neuropathy, progressive cord atrophy, adrenal involvement
• HSP	Spasticity disproportionate to weakness, progressive spinal cord atrophy
• Mitochondrial disorders (eg, *DARS2* gene)	Dorsal/lateral signal abnormality, ↑lactate
• Other genetic	
Toxic/metabolic	
• Nutritional deficiency (vitamin B12, copper)	Gastric bypass, zinc supplements, malabsorption
• Toxic (intrathecal methotrexate, heroin)	Toxic exposure
Iatrogenic	
• Radiation	Prior radiation exposure

Abbreviations: ↑, increased; AVM, arteriovenous malformation; HIV, human immunodeficiency virus; HSP, hereditary spastic paraplegia; HTLV-1, human T-lymphotropic virus type 1; MS, multiple sclerosis.

[a]Popcorn appearance—mixed intensity at the center of the lesion from vascular components with a T2 hypointense rim from blood products.

[b]A cap of T2 hypointensity secondary to hemosiderin is present at the top or bottom of the lesion.

EPIDEMIOLOGY

TM can affect patients of any age, both men and women. Depending on the etiology, the ratio of affected men to women and the mean age can vary greatly. Children are particularly predisposed to myelin oligodendrocyte glycoprotein (MOG) antibody disease and the acute flaccid myelitis associated with enterovirus infection. TM occurring as a manifestation of MS (female-to-male ratio 2:1) or AQP4-IgG seropositive NMOSD (female-to-male ratio 9:1) disproportionately affects women. MS is more common in Caucasians and in regions further from the equator, whereas those of African descent are particularly predisposed to AQP4-IgG seropositive NMOSD and sarcoidosis. The incidence of idiopathic TM is 6.1 to 8.6 per million person-years, but when disease-associated TM cases are included, the incidence increases to 24.6 per million person-years. Epidemic outbreaks of acute flaccid myelitis associated with enterovirus infections also impact the incidence.

PATHOBIOLOGY

The pathology of TM is dependent on the underlying disease causing TM and may include disease-specific findings, such as granulomas in neurosarcoidosis and selective loss of AQP4 immunoreactivity in nonnecrotic tissue. The pathology of TM includes variable degrees of tissue and perivascular inflammation, demyelination, and axonal injury and occasionally necrosis. Many conditions that lead to myelitis may target multiple CNS structures (eg, MS and sarcoidosis) and extra CNS structures (eg, sarcoidosis). In NMOSD, AQP4-IgG targets the dominant water channel of the CNS, AQP4, the expression of which is greatest in optic nerve and spinal cord, the two structures of the CNS that are predominantly targeted in this condition. The AQP4-IgG results in severe necrosis associated with markers of complement activation, consistent with current understanding of pathogenesis of this condition (see Chapter 73).

DIAGNOSIS

Clinical Presentation

The clinical approach to myelopathy is summarized in Figure 72.1. TM may be preceded by an infection or vaccination (particularly for MOG-IgG) while preceding nausea, vomiting or hiccups suggest concomitant area postrema involvement of AQP4-IgG positive NMOSD.

Patients with TM typically present with subacute numbness often accompanied by a sensory level on the torso, weakness, neurogenic bowel, neurogenic bladder, or sexual dysfunction. The time course of development of neurologic symptoms is among the most important clues to the etiology of the syndrome. The onset to nadir (maximal deficit) in TM is defined as being between 4 hours and 21 days. More rapid onset of severe symptoms (paraplegia/quadriplegia), sometimes followed by rapid spontaneous improvement, suggests spinal cord ischemia or infarction instead of myelitis, whereas progression of symptoms beyond 21 days is characteristic of sarcoidosis or a nonmyelitis alternative etiology for myelopathy (eg, spondylosis, dural arteriovenous fistula, tumor). Mixed upper and lower motor neuron findings (eg, inverted brachioradialis reflex) may suggest a compressive etiology with root damage at the site of most severe stenosis and myelopathy below that from the accompanying cord compression. Worsening symptoms and signs with exertion, stepwise worsening, or exacerbation with corticosteroids (resulting from transient fluid retention and worsened venous engorgement) strongly suggest dural arteriovenous fistula.

Lhermitte symptom (a usually painless electrical or vibrating sensation down the spine and occasionally into the extremities precipitated by neck flexion), paroxysmal painful tonic spasms (involuntary [usually flexor] contractions lasting seconds to minutes following a TM episode and responsive to low-dose carbamazepine), or McArdle sign (increased pyramidal weakness with neck flexion) suggests CNS demyelinating disease as the cause of TM. A sensory level on the torso, upper motor neuron pattern weakness, hyperreflexia, spasticity, and a Babinski sign suggest spinal cord localization. Spinal shock can occur in acute TM and result in flaccid paraplegia with hypo- or areflexia, incorrectly suggesting a peripheral nervous system etiology, such as acute inflammatory demyelinating polyneuropathy. When bowel and bladder function are affected severely, the localization is usually the spinal cord, and not peripheral nervous system. However, a concomitant cauda equina syndrome may occur in association with a caudal myelitis in individuals with Elsberg syndrome, a lumbar myeloradiculitis characteristically accompanying herpes simplex virus type 2 genital infection. Myeloradiculitis may also occur in the setting of cytomegalovirus-associated cauda equina syndrome often occurring in patients with underlying immunosuppression, such as human immunodeficiency virus infection.

Traditionally, TM has been classified accordingly: partial TM, which involves only a portion of the spinal cord often with unilateral sensory or motor symptoms/signs or with sensory *or* motor, but not both, and mild impairment that is typical of MS; complete TM, which involves the entire cross-section of the spinal cord with bilateral symptoms/signs and severe disability that lead to central and usually "longitudinally extensive TM" with pathology extending over long rostrocaudal segments of the spinal cord, characteristic of AQP4-IgG seropositive NMOSD. However, the clinical distinction between partial and complete myelitis does not consistently correlate with pathology and etiology. Other considerations such as the interval between onset to nadir, severity of the clinical deficit, and length of the T2 hyperintense lesion on magnetic resonance imaging (MRI) spine are more useful indicators of etiology (see Tables 72.1 and 72.2). Coexisting clinical features of a connective tissue disorder (lupus, Sjögren's syndrome, or anti-phospholipid syndrome) should prompt assessment of AQP4-IgG because NMOSD commonly coexists with these disorders. Oral and genital ulcers are a clue to Behçet, whereas concomitant genital herpes infection can suggest Elsberg syndrome.

MAGNETIC RESONANCE IMAGING

An MRI of the cervical and thoracic spine with and without gadolinium is recommended to both exclude an extrinsic compressive cause and to identify intrinsic spinal cord abnormalities that accompany TM (Fig. 72.2) but also mimics of TM (Fig. 72.3). The pattern of gadolinium enhancement is particularly useful in discriminating between these causes. The MRI characteristics of spinal cord lesions in TM subtypes and its common mimics are outlined in Table 72.3.

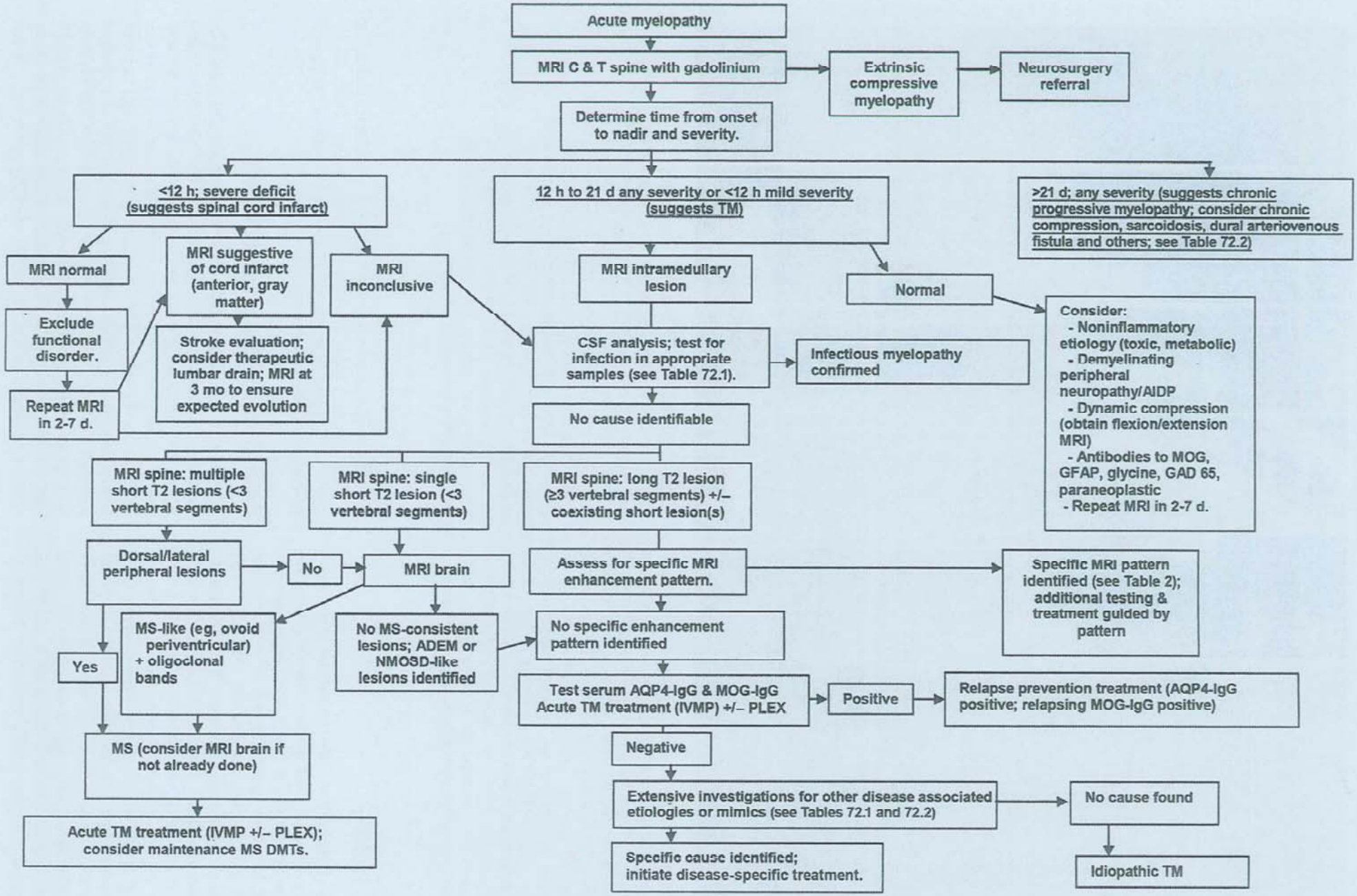

FIGURE 72.1 Transverse myelitis (TM) diagnostic and treatment algorithm. Abbreviations: ADEM, acute disseminated encephalomyelitis; AIDP, acute inflammatory demyelinating polyradiculoneuropathy; AQP4, aquaporin 4; C, cervical; CSF, cerebrospinal fluid; DMTs, disease-modifying therapies; GAD, glutamic acid decarboxylase; GFAP, glial fibrillary acidic protein; IgG, immunoglobulin G; IVMP, intravenous methylprednisolone; MOG, myelin oligodendrocyte glycoprotein; MRI, magnetic resonance imaging; MS, multiple sclerosis; NMOSD, neuromyelitis optica spectrum disorder; PLEX, plasma exchange; T, thoracic.

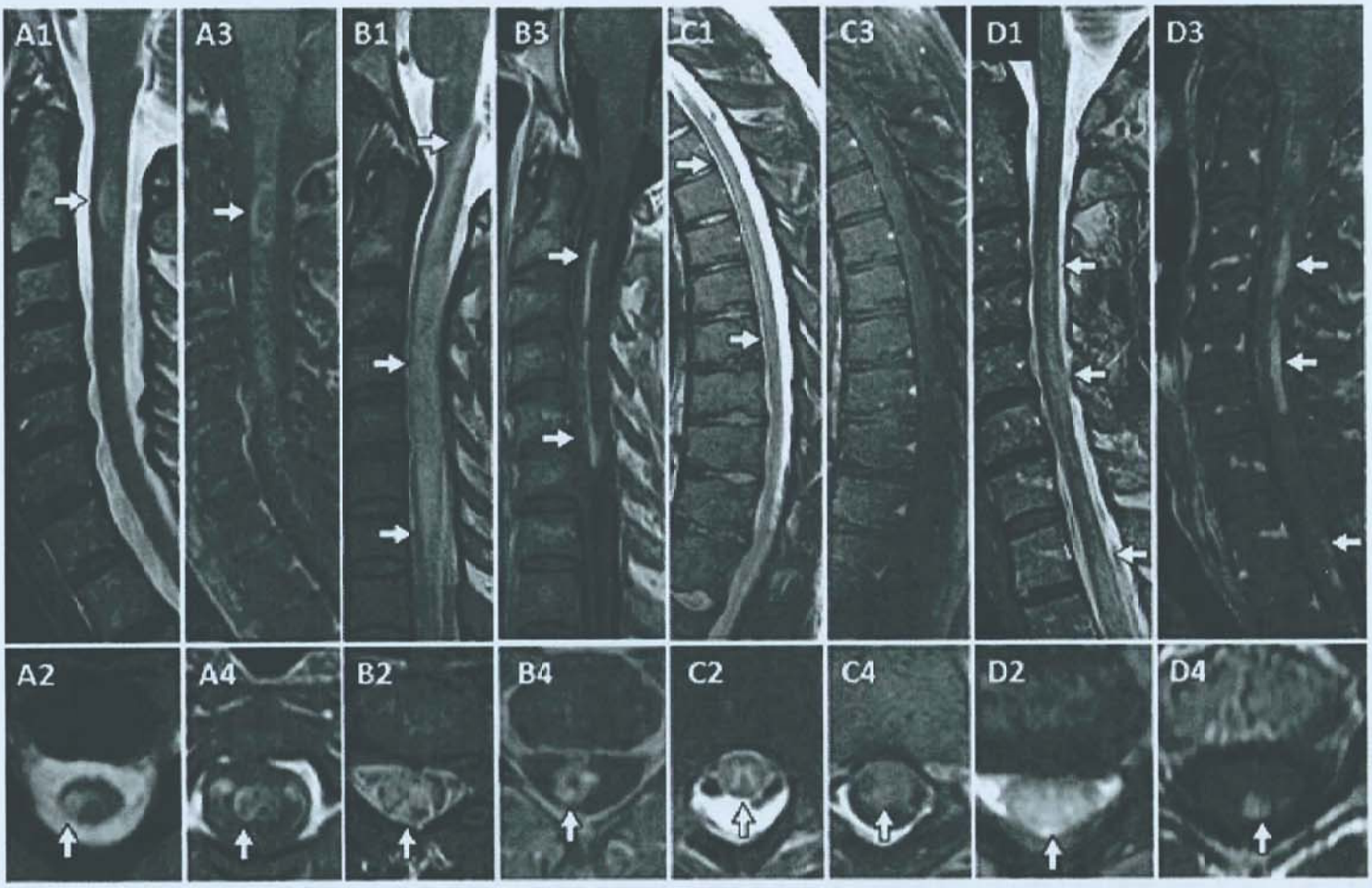

FIGURE 72.2 Examples of disease-associated transverse myelitis. **A:** Multiple sclerosis myelitis with a short T2 hyperintense lesion (**A1**, *arrow*) in the right lateral column on axial sequences (**A2**, *arrow*) associated with ringlike on T1-weighted sequences following gadolinium administration (**A3** and **A4**, *arrows*). **B:** Aquaporin-4 immunoglobulin G (IgG) seropositive neuromyelitis optica spectrum disorder reveals a longitudinally extensive (more than three vertebral segments) T2 hyperintense lesion (**B1**, *arrows*) that was centrally located within the spinal cord on axial sequences (**B2**, *arrow*) and enhanced following gadolinium administration (**B3**, *arrows*) in a ringlike pattern on axial T1-weighted sequences (**B4**, *arrow*). **C:** Myelin oligodendrocyte glycoprotein–IgG myelitis with a longitudinally extensive T2 hyperintense lesion (**C1**, *arrows*) that is restricted to gray matter on axial sequences in an H pattern (**C2**, *arrow*) and without gadolinium enhancement (**C3** and **C4**, *arrow*). **D:** Spinal cord sarcoidosis revealed a longitudinally extensive T2 hyperintense lesion (**D1**, *arrows*) that was central on axial sequences (**D2**, *arrow*) and had accompanying linear dorsal subpial enhancement following gadolinium administration extending over multiple vertebral segments (**D3** and **D4**, *arrows*).

Cerebrospinal Fluid

Pleocytosis, usually lymphocytic, and increased protein are typically detected in TM, and their absence should raise some concern about the accuracy of the diagnosis. CSF unique oligoclonal bands are found in approximately 85% of patients with MS but in less than a quarter of patients with AQP4-IgG and less than 15% of MOG-IgG-associated TM. Normal or mildly elevated white blood cell count (<50/μL) is typical of MS, but elevations above 50/μL should raise suspicion for alternative etiologies, including NMOSD or sarcoidosis. Absence of CSF indicators of inflammation should raise concern for a noninflammatory cause. High protein with normal cell count (albuminocytologic dissociation) may indicate a spinal block from tumor or spondylosis or may suggest an alternative cause such as Guillain-Barré syndrome. CSF Gram stain, smear cultures (bacterial, fungal, mycobacterial), and other infectious testing can be useful to assess for infectious etiologies including viral polymerase chain reaction and serology (see Table 72.1). CSF cytology and flow cytometry are useful when a neoplastic myelopathy is a consideration.

Biomarkers of Transverse Myelitis

AQP4-IgG is a highly specific (>99%) biomarker of NMOSD. Cell-based immunoassays using target cells that have been transfected with recombinant antigen yield optimal sensitivity and specificity by presenting conformationally intact antigen as the substrate in the assay. TM associated with AQP4-IgG is more severe than MS frequently resulting in an inability to ambulate unaided. Detection of AQP4-IgG in a patient with TM predicts that the patient will relapse. MOG-IgG is a recently discovered antibody biomarker of TM and similarly is best detected in serum using a cell-based assay. MOG-IgG myelitis tends to be more

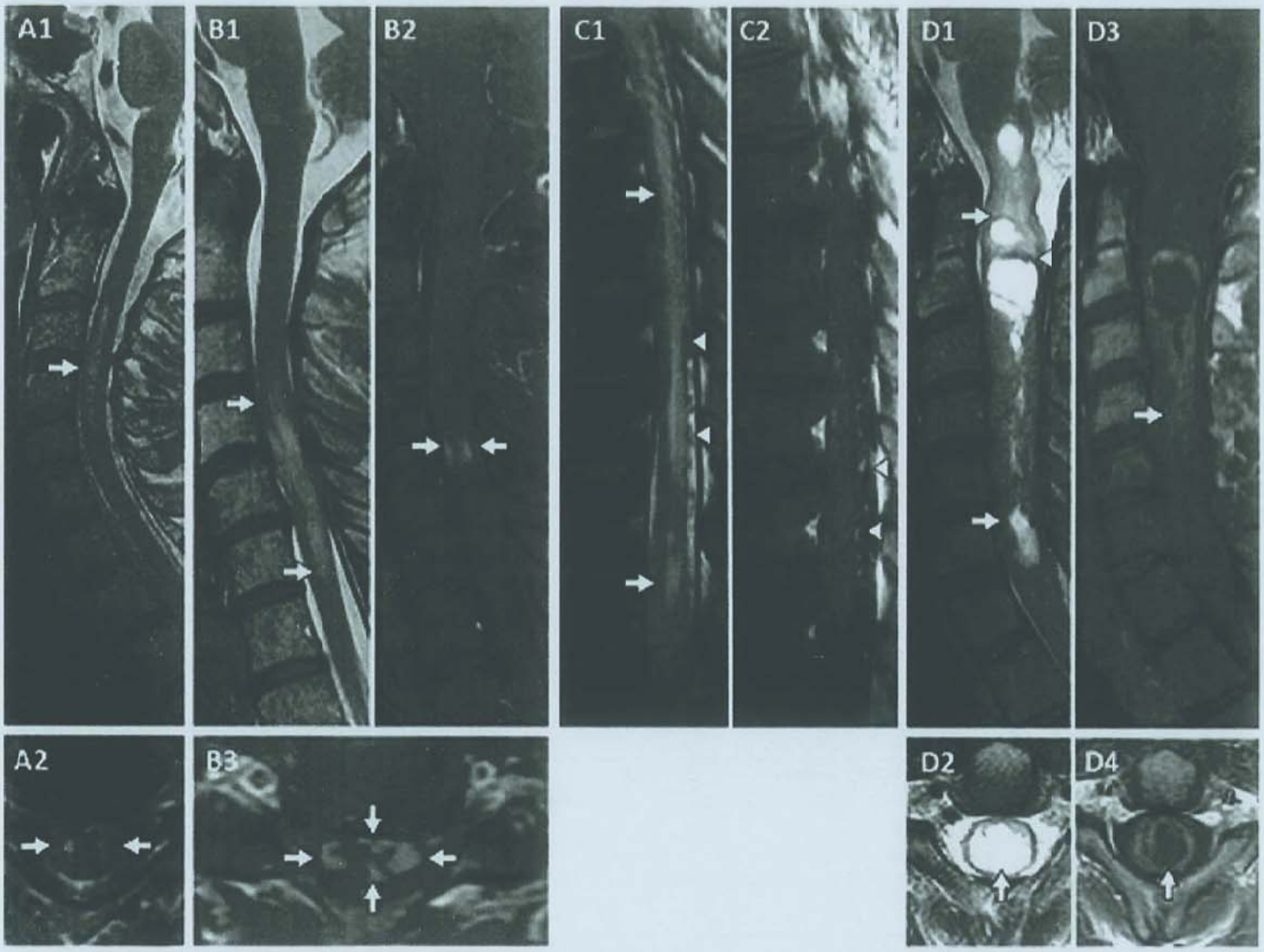

FIGURE 72.3 Longitudinally extensive myelopathies that mimic transverse myelitis. A patient with an ischemic myelopathy has a pencil-like longitudinally extensive T2 hyperintense lesion extending three vertebral segments in the anterior part of the cervical cord (**A1**, *arrows*); axial images show a typical owl/snake eye pattern (**A2**, *arrows*). A patient with cervical spondylotic myelopathy is shown with a longitudinally extensive spindle-shaped T2 hyperintensity (**B1**, *arrows*) with associated moderate spondylotic changes and spinal cord swelling. A transverse band of pancake-like enhancement at the center of the T2 hyperintensity is noted (**B2**, *arrows*), which on axial postgadolinium T1 images is characteristically located in the periphery of the spinal cord and spares central gray matter (**B3**, *arrows*). A dural arteriovenous fistula is shown with a typical longitudinally extensive lesion (more than three vertebral segments) in the thoracic cord extending to the conus (**C1**, *arrows*) with accompanying flow voids noted in the dorsal cord (**C1**, *arrowheads*). On postgadolinium images, enhancing veins dorsal to the cord are seen (**C2**, *arrowheads*). An ependymoma is shown with a longitudinally extensive expansile lesion, which is mixed T2 hyperintense and T2 isotense (**D1**, *arrows*) with evidence of syringohydromyelia (**D1-D4**, *arrows*) and a "cap sign" with a T2 hyopintense hemosiderin rim (**D1**, *arrowhead*) all typical of an ependymoma. (Reprinted from Flanagan EP. Autoimmune myelopathies. *Handb Clin Neurol*. 2016;133:327-151; Figure 5.)

severe than attacks of MS but is associated with better recovery than attacks of AQP4-IgG TM.

Paraneoplastic myelitis is a rare condition that can present as an acute, subacute, or chronic myelopathy and may be associated radiologically with corticospinal or other tract-specific signal abnormality, occasionally with gadolinium enhancement. Various autoantibodies have been associated with this syndrome, including collapsin response–mediator protein 5 IgG (CV2) and amphiphysin-IgG, which are the two most commonly encountered antibodies; small-cell lung and breast the most frequent associated neoplasms.

Other Investigations

In the setting of acute flaccid myelitis, nasopharyngeal swabs for viral culture and serologic testing of serum and CSF assessment for enterovirus D68 or other enterovirus serotypes is appropriate. Serology for other infections (see **Table 72.1**) should be considered in TM and recommendations and may vary by region depending on epidemiologic considerations.

Serologic markers for connective tissue disorders should be assessed and include antinuclear antibody, SSA/SSB, double-stranded

TABLE 72.3 Magnetic Resonance Imaging Findings in Transverse Myelitis and Its Mimics

	Spinal Location	T2 Lesion Number	Sagittal T2 Length (Short: <3 Vert Segments; Long: ≥3 Vert Segments)	Axial T2	Post-Gad Pattern	Other Feature(s)
Disease-Associated TM						
MS	C or T	Multiple	Short	Peripheral (dorsal or lateral columns)	Ringlike, homogeneous	
AQP4-IgG	C or T	Single	Long 85%; short 15%;	Central (gray and white matter)	Ringlike, patchy	Bright spotty T2[a]
MOG-IgG	C or T	Multiple	Long 70%; short 30%	Central (30% gray matter restricted/ H sign[b]])	Faint or no enhancement	Conus
Sarcoidosis	C or T	Single	Usually long	Central	Dorsal subpial[c] or axial trident[d]	
Acute flaccid myelitis	C or T	Single	Long or short	Central gray/H sign[a]	Faint or no enhancement	
Paraneoplastic	C or T	Single	Long	Tract-specific signal (dorsal/lateral column)	Tract-specific enhancement (dorsal/ lateral columns)	MRI normal in up to 50%
Elsberg syndrome (HSV-2 or other virus)	L	Single	Short	Central	Variable	Cauda equina enhancement
Most Common Mimics of TM						
Spondylosis	C	Single	Long or short	Central owl eye[e]	Sag: Pancake-like[f] Axial: circumferential sparing gray matter	Cervical canal stenosis, other spondylotic changes
Spinal cord infarct	C or T	Single	Long or short	Owl eye[e]	Linear strip[g] Owl eye[e]	Diffusion restriction; vertebral body infarct; adjacent artery dissection
Dural AVF	T	Single	Long	Central	Patchy, missing piece,[h] enhancing large veins; 40% no enhancement	Flow voids dorsal to cord
Nutritional (Vitamin B12, copper)	C or T	Single	Long	Tracts (dorsal/lateral columns)	None	
Intramedullary metastases	C or T	Single or multiple	Long or short	Central or peripheral	Rim and flame[i]	

Abbreviations: AQP4, aquaporin-4; AVF, arteriovenous fistula; C, cervical; Gad, gadolinium; HSV-2, herpes simplex virus type 2; IgG, immunoglobulin G; L, lumbar; MOG, myelin oligodendrocyte glycoprotein; MRI, magnetic resonance imaging; MS, multiple sclerosis; T, thoracic; TM, transverse myelitis; Vert, vertebral.
[a]Very bright T2 hyperintensity of similar consistency to cerebrospinal fluid (syrinx-like) spotted within less bright T2 hyperintense lesion.
[b]T2-signal abnormality restricted to gray matter on axial image forming an H.
[c]Parenchymal enhancement extending inward from the dorsal surface of the cord.
[d]Dorsal subpial enhancement combined with central canal enhancement creates a three-pronged appearance on axial sequences with the appearance of a trident.
[e]Bilateral anterior horn cell involvement with the appearance of owl eyes (or snake eyes).
[f]Transverse band of enhancement in which the width is greater than or equal to the height that appears squashed like a "pancake."
[g]A linear strip of enhancement along in the anterior cord on sagittal images.
[h]Area of absent enhancement within a long segment of homogeneous enhancement appearing as if the enhancement has a "missing piece."
[i]A rim of enhancement around a less enhancing central region of milder enhancement with a flame appearance at the top or the bottom of the lesion.

DNA, and C3 and C4 complement. Computed tomography chest or ^{18}F-fluorodeoxyglucose positron emission tomography can be considered to detect evidence for systemic sarcoidosis or for a neoplasm in suspected neoplastic or paraneoplastic myelopathy. Testing for other mimics of TM may also be considered (see Table 72.2).

MANAGEMENT

The initial treatment for acute TM associated with CNS demyelinating disease (see Table 72.1) is 1 g of intravenous methylprednisolone once daily for 3 to 5 days. In patients with prominent residual deficits despite high-dose steroids, a course of plasma exchange (PLEX) for five to seven sessions is recommended. A randomized sham-controlled double-masked study of PLEX in acute CNS IDD (including TM) patients who failed to recover with corticosteroids experienced moderate or greater recovery 9 fold more often (45% vs 5%) with PLEX than the sham treatment LEVEL 1.[1] Treatment of infectious TM is aimed at the underlying cause (see Table 72.1), but for some infections (acute flaccid myelitis associated with enterovirus D68), no effective treatments

are available and symptomatic treatment is the mainstay. Rehabilitation with physical and occupational therapy are also essential strategies to train patients to compensate for their neurologic impairments and to overcome disability.

OUTCOME

It is important to consider both recovery from the individual attack of TM and to consider the risk of relapse, either with another episode of TM or another neurologic syndrome, such as optic neuritis. The prognosis of both outcomes varies according to the specific diagnosis of the TM.

Recovery of function following MS- and MOG-IgG–associated TM is better than for AQP4-IgG–associated TM. Approximately, a quarter to one-third of TM episodes will have a poor outcome often defined as a modified Rankin score of ≥3 at last follow-up. The presence of severe disability at presentation, complete TM, flaccid paraplegia, motor and urinary symptoms, and peripheral nervous system involvement predict poor outcome.

In terms of recurrence risk, patients with partial TM or MRI lesions characteristic of MS are at risk of developing MS. The risk of developing symptoms that lead to diagnosis of MS within 5 years after partial TM may be stratified based on findings on brain MRI. Detection of multiple typical MS lesions indicate a high risk (>80%), whereas absence of MS brain lesions indicate low risk (<20%) of developing MS; the presence of positive oligoclonal bands in CSF also predicts a higher risk of developing MS. Therefore, MS disease–modifying medications are often initiated to reduce the risk of future relapses in patients with TM and typical MS brain lesions but not in those without brain lesions who have a low risk of MS relapses. An AQP4-IgG seropositivity accompanying a TM episode is sufficient for a diagnosis of AQP4-IgG seropositive NMOSD. Attack-preventing immunosuppressive treatments are strongly recommended to reduce the risk of future potentially devastating relapses in patients with AQP4-IgG seropositive with an attack of TM (see Chapter 73: NMO spectrum disorder). MOG-IgG seropositivity is associated with risk of future demyelinating events (particularly optic neuritis), but the risk of relapse is less well defined in this situation, and the role of attack prevention treatments after an initial TM remains to be determined; if a patient who is MOG-IgG seropositive relapses, immunosuppression to prevent subsequent attacks would be indicated.

LEVEL 1 EVIDENCE

1. Weinshenker BG, O'Brien PC, Petterson TM, et al. A randomized trial of plasma exchange in acute central nervous system inflammatory demyelinating disease. *Ann Neurol*. 1999;46(6):878-886.

SUGGESTED READINGS

Barreras P, Fitzgerald KC, Mealy MA, et al. Clinical biomarkers differentiate myelitis from vascular and other causes of myelopathy. *Neurology*. 2018;90(1):e12-e21.

Dubey D, Pittock SJ, Krecke KN, et al. Clinical, radiologic, and prognostic features of myelitis associated with myelin oligodendrocyte glycoprotein autoantibody. *JAMA Neurol*. 2019;76(3):301-309.

Flanagan EP, Kaufmann TJ, Krecke KN, et al. Discriminating long myelitis of neuromyelitis optica from sarcoidosis. *Ann Neurol*. 2016;79(3):437-447.

Flanagan EP, Krecke KN, Marsh RW, Giannini C, Keegan BM, Weinshenker BG. Specific pattern of gadolinium enhancement in spondylotic myelopathy. *Ann Neurol*. 2014;76:54-65.

Flanagan EP, McKeon A, Lennon VA, et al. Paraneoplastic isolated myelopathy: clinical course and neuroimaging clues. *Neurology*. 2011;76:2089-2095.

Jarius S, Paul F, Akias O, et al. MOG encephalomyelitis: international recommendations on diagnosis and antibody testing [in German]. *J Neuroinflammation*. 2018;15(1):134.

Lennon VA, Wingerchuk DM, Kryzer TJ, et al. A serum autoantibody marker of neuromyelitis optica: distinction from multiple sclerosis. *Lancet*. 2004;364(9451):2106-2112.

Mariano R, Flanagan EP, Weinshenker BG, Palace J. A practical approach to the diagnosis of spinal cord lesions. *Pract Neurol*. 2018;18(3):187-200.

Messacar K, Schreiner KL, Maloney JA, et al. A cluster of acute flaccid paralysis and cranial nerve dysfunction temporally associated with an outbreak of enterovirus D68 in children in Colorado, USA. *Lancet*. 2015;385(9978):1662-1671.

Montalvo M, Cho T. Infectious myelopathies. *Neurol Clin*. 2018;36(4):789-808.

Rabinstein AA. Vascular myelopathies. *Continuum (Minneap Minn)*. 2015;21(1 Spinal Cord Disorders):67-83.

Sechi E, Shosha E, Williams JP, et al. Aquaporin-4 and MOG autoantibody discovery in idiopathic transverse myelitis epidemiology. *Neurology*. 2019;93(4):e414-e420.

Thompson AJ, Banwell BL, Barkhof F, et al. Diagnosis of multiple sclerosis: 2017 revisions of the McDonald criteria. *Lancet Neurol*. 2018;17:162-173.

Transverse Myelitis Consortium Working Group. Proposed diagnostic criteria and nosology of acute transverse myelitis. *Neurology*. 2002;59:499-505.

Wingerchuk DM, Banwell B, Bennett JL, et al. International consensus diagnostic criteria for neuromyelitis optica spectrum disorders. *Neurology*. 2015;85(2):177-189.

Young J, Quinn S, Hurrell M, Taylor B. Clinically isolated acute transverse myelitis: prognostic features and incidence. *Mult Scler*. 2009;15(11):1295-1302.

Zalewski NL, Flanagan EP, Keegan BM. Evaluation of idiopathic transverse myelitis revealing specific myelopathy diagnoses. *Neurology*. 2018;90(2):e96-e102.

73 Neuromyelitis Optica Spectrum Disorder

Iris Vanessa Marin Collazo and Brian G. Weinshenker

KEY POINTS

1. Neuromyelitis optica spectrum disorder (NMOSD) is a central nervous system inflammatory disease, usually with a relapsing course, that has a particular predilection to cause optic neuritis and transverse myelitis.
2. NMOSD is classified based on whether or not it is associated with antibodies to aquaporin-4 immunoglobulin G (AQP4-IgG). AQP4-IgG–seropositive cases account for approximately 70% of patients.
3. A second autoantibody, myelin oligodendrocyte glycoprotein IgG (MOG-IgG), is associated with 20% to 40% of AQP4-IgG–seronegative cases; the epidemiology and clinical presentation of MOG-IgG–associated disease differs from that associated with AQP4-IgG.
4. Clinical "red flags" that should prompt to consider alternate diagnosis include a progressive course, hyperacute onset, partial myelitis, and detection of oligoclonal bands in cerebrospinal fluid.
5. Management of NMOSD is directed to rescue treatments for acute attacks, primarily corticosteroids and plasma exchange, and maintenance immunotherapies including eculizumab, a complement 5 inhibitor, inebilizumab, an anti-CD19 B cell depleting antibody, satralizumab, and anti-IL6 receptor antibody.

INTRODUCTION

Neuromyelitis optica spectrum disorders (NMOSD) are a family of syndromes, dominated by optic neuritis (ON) and myelitis, but also including a variety of syndromes, mainly affecting the brain but occasionally affecting other organ systems including muscle. Untreated relapses tend to be more severe than those of multiple sclerosis (MS) and may be fatal, primarily due to respiratory failure occurring in the context of cervical myelitis. It is a relapsing-remitting syndrome that was often confused with MS until the start of the 21st century and even its existence as a condition separate from MS was debated. However, recently developed clinical criteria can confidently distinguish NMOSD from MS. Aquaporin-4 immunoglobulin G (AQP4-IgG), an IgG1 autoantibody biomarker first reported in 2004, has now been accepted as a highly specific diagnostic test for this disease in approximately 70% of patients. More recently, in the second decade of the 21st century, a second IgG1 autoantibody, reactive to myelin oligodendrocyte glycoprotein IgG (MOG-IgG), has been associated with NMOSD in between 20% to 40% AQP4-IgG seronegative patients. Roughly 10% to 15% of patients with this syndrome remain seronegative for both of these biomarkers.

Cases of ON and myelitis occurring simultaneously or nearly simultaneously were reported in the mid-19th century, but Eugène Devic (1858-1930) and his student Fernand Gault, whose thesis reviewed 16 additional historic cases, attracted the greatest attention with their published case description in 1894. The disease became known as *Devic disease*, although no formal diagnostic requirements were delineated. Based on characteristics of Devic's description, 20th century dogma required that the patient have simultaneous or nearly simultaneous bilateral ON and myelitis and no further relapse, relapse being considered an indication of MS rather than Devic disease, in order to establish a diagnosis. In the 1990s, proposed criteria were liberalized to allow for unilateral ON and for relapses. Long spinal cord lesions on magnetic resonance imaging (MRI) in the context of acute myelitis were found to be extremely helpful in differentiating myelitis of Devic disease from that of MS. In Japan, a relatively common form of MS, compared to typical or "Western" MS, that similarly targeted the optic nerve and spinal cord preferentially was labeled opticospinal MS.

Investigators at Mayo Clinic collaborated to identify a pattern of immunostaining by serum of patients with this condition that was characteristic of and specific for NMOSD. A year later, they identified AQP4 as the target of the autoantibody by deducing the antigen based on patterns of immunostaining in AQP4 knockout mice and cell lines transfected with AQP4 or vector alone. Immunoprecipitation confirmed the nature of the antigen.

Discovery of myelin oligodendrocyte glycoprotein (MOG) as a target antigen began with studies of a demyelinating antibody and subsequent development of a double knock-in mouse with both T-cell receptor and immunoglobulin reactive to MOG. A high proportion of these transgenic animals spontaneously developed predominant ON and myelitis but lacked AQP4-IgG. Subsequently, patients seropositive for MOG-IgG demonstrated phenotypic characteristics that resembled NMOSD more closely than MS. However, MOG-IgG–associated NMOSD is often clinically and radiologically distinguishable from AQP4-IgG–associated NMOSD. Furthermore, MOG-IgG is more commonly associated with recurrent ON than AQP4-IgG–associated NMOSD and may be associated with other non-NMOSD clinical syndromes including encephalitic syndromes and leukodystrophies.

EPIDEMIOLOGY

Worldwide Distribution/Ethnicity

Descriptions of the epidemiology of NMOSD are limited by its relatively recent recognition as a disease independent of MS. Early reports were based on inadequate diagnostic criteria for classification, and criteria and terminology varied across the world. Indeed, criteria have continued to evolve; recent internationally accepted criteria have increased the frequency of NMOSD almost two fold, primarily by liberalizing the criteria for AQP4-IgG–seropositive disease, which now requires only a single attack for diagnosis. Screening of all diagnosed MS cases in a community typically will yield additional cases of individuals in whom the diagnosis was not considered in the past. With those caveats, the prevalence of NMOSD is approximately 0.5 to 10/100,000 (**Table 73.1**).

In studies with populations of mixed ethnicity, the risk of NMOSD in Africans is higher than in Caucasians, the opposite of what is seen in MS. However, the disease occurs worldwide at similar frequency. Differences in the ratio of MS to NMOSD across the world are mostly explained by variation in the frequency of MS rather than NMOSD.

Predilection for Africans and Asians not seen in those with MOG-IgG–associated NMOSD. NMOSD can manifest at any age. Approximately 4% of AQP4-IgG–seropositive NMOSD occur in children, and 30% present in those who are older than age 50 years; indeed, there are multiple reports of NMOSD onset in octogenarians. The median age of onset of MOG-IgG–associated NMOSD is younger than that of AQP4-IgG–associated NMOSD.

Sex

The ratio of women to men affected by AQP4-IgG–associated NMOSD is approximately 8:1, whereas it is close to 1:1 for MOG-IgG–associated NMOSD.

Familial Occurrence

There are several reports of familial occurrence; approximately 3% of individuals with NMOSD report affected first-degree relatives, which is in keeping with complex genetic inheritance reflecting interaction of multiple genes or genes and environmental causative factors.

Risk Factors

Individuals with AQP4-IgG NMOSD are more likely to have systemic autoimmune disease than unaffected individuals; up to 25% have one or more autoimmune disease, and the spectrum of autoimmune disease with AQP4-IgG–associated NMOSD is very broad. Approximately half of AQP4-IgG NMOSD patients have one or more high-titer autoantibodies, most commonly thyroperoxidase autoantibodies and Sjögren syndrome A and B autoantibodies usually without clinical manifestations of their corresponding autoimmune diseases. However, the converse is not true, and AQP4-IgG is rarely encountered in patients with type 1 diabetes, rheumatoid arthritis, or systemic lupus erythematosus, except when the latter is complicated by myelitis or ON, in which case it likely represents coassociation of systemic lupus and NMOSD. In Caucasians, distinct from MS, HLA DRB1*03 is positively associated with NMOSD, and there is a negative association with DRB1*1501. In populations of mixed ancestry, NMOSD is overrepresented in non-Caucasians by roughly two- to threefold. No other environmental exposure or illness convincingly correlates with disease risk. No risk factors have been associated with MOG-IgG–associated NMOSD.

PATHOBIOLOGY

AQP4-IgG– and MOG-IgG–Mediated Immunopathology

The main characteristic of NMOSD pathogenesis is antibody-mediated, complement-mediated injury resulting from interaction of a pathogenic antibody with its target antigen (**Fig. 73.1**). This has been best characterized for AQP4-IgG–mediated disease and is less clear for MOG-IgG, the pathologic effects of which have been less clear in experimental studies, in part because of lack of affinity for rodent MOG in passive transfer studies. The discussion here therefore concentrates on AQP4-IgG.

AQP4-IgG is generated in the peripheral immune system, and the concentration in blood is far greater than in cerebrospinal fluid (CSF). Therefore, the autoantibody is more sensitively detected in serum than in CSF. It is an IgG1 autoantibody and thus requires CD4 T cells' help in its generation. The nature of the inciting antigen and defects of immunoregulation are considered in the next section. AQP4-IgG is able to circulate for many years before causing clinical disease, as demonstrated by

TABLE 73.1 Epidemiology of Neuromyelitis Optica Spectrum Disorders (Selected Studies)[a]

Country	Year	Incidence/100,000/y (95% CI)	Prevalence/100,000 (95% CI)	Number of Cases Identified (Number AQP4-IgG+)	Approximate Population Studied
Denmark	2011	0.4 (0.3-0.54)	4.4 (3.1-5.7)	42 (26)	1 million
United Kingdom	2013	0.08 (0.03-0.16)	0.72 (0.31-1.42)	13 (11)	1 million
Iran	2014	NA	1.9 (1.6-2.3)	95	4 million
India	2014	NA	2.6	11	400,000
Martinique	2015	7.3 (4.5-10.1)	10 (6.8-13.2)	39 (31)	400,000
United States	2015	0.7 (0.0-2.1)	3.9 (0.8-7.1)	6 (5)	150,000

Abbreviations: AQP4-IgG, aquaporin-4 immunoglobulin G; CI, confidence interval; NA, not available.
[a]Modified from Weinshenker BG, Wingerchuk DM. Neuromyelitis spectrum disorders. *Mayo Clin Proc.* 2017;92(4):663-679.

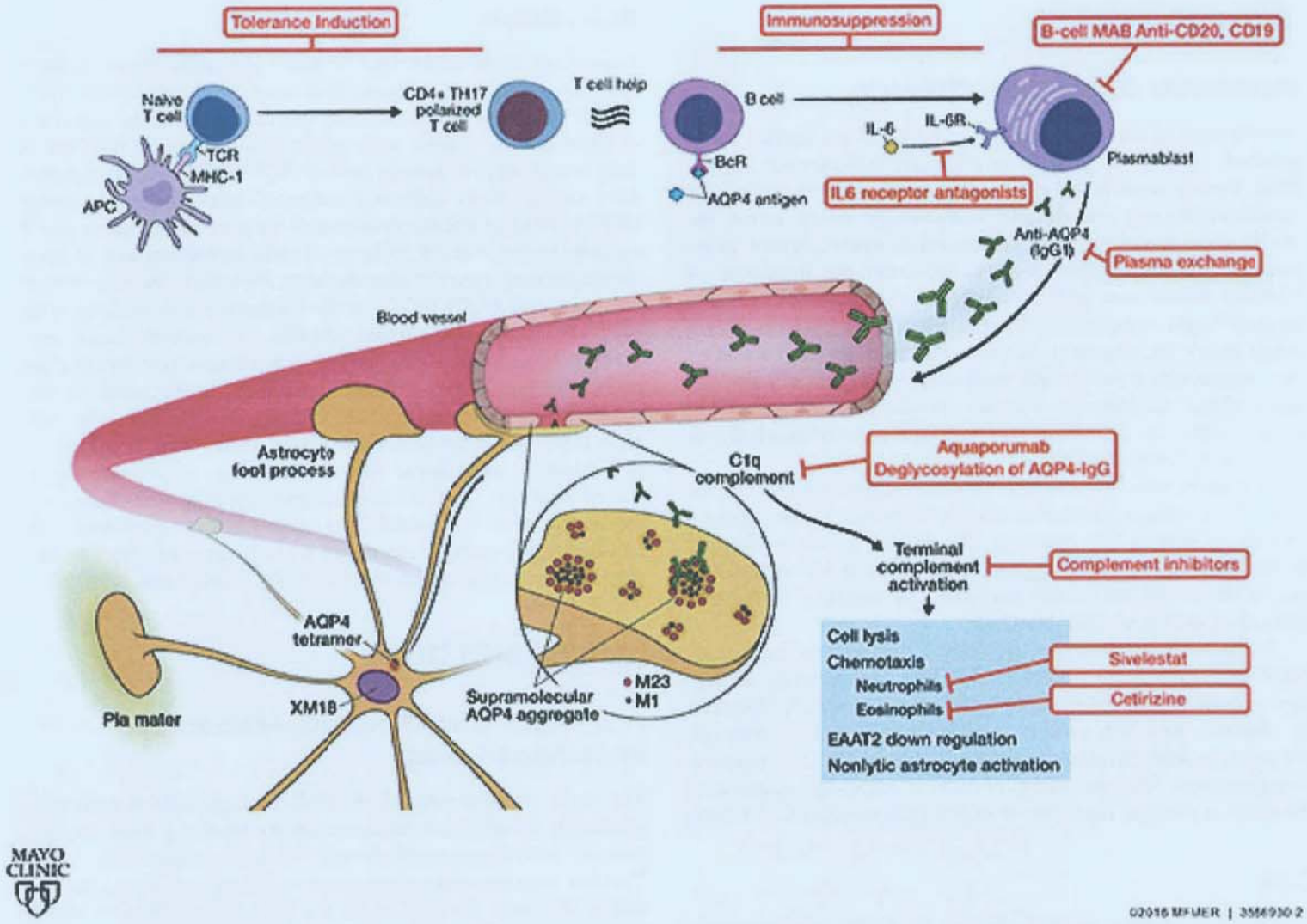

MAYO CLINIC
©2016 MFMER | 3584930-2

FIGURE 73.1 Pathophysiology of aquaporin-4 immunoglobulin G (AQP4-IgG)-associated neuromyelitis optica spectrum disorder and therapeutic strategies shown in *red*. AQP4 peptides are recognized by T cells, which then are polarized to a helper T cell 17 phenotype and provide help to B cells that are activated by conformationally intact AQP4 proteins, which then differentiate into plasmablasts that secrete AQP4-IgG; this occurs outside of the central nervous system (top half of the figure). AQP4-IgG circulates in the blood and enters the central nervous system (bottom half of the figure), where it interacts with AQP4 proteins, encoded on chromosome 18, and are expressed on astrocyte end feet that abut blood vessels and the pia mater and leads to complement activation by classical pathway of C1q binding. AQP4 supramolecular aggregates consisting of the M23 isoform decorated on their periphery by M1 isoform are particularly prone to C1q binding and complement activation when they interact with AQP4-IgG. The AQP4 binding may lead to lytic damage due to complement activation or may lead to activation of astrocytes and an inflammatory milieu due to nuclear factor kappa B signaling. Intervention strategies or drugs that are being considered or are in current use are shown in red font where they are thought to act in the pathophysiology of neuromyelitis optica spectrum disorder. Abbreviations: AQP4, aquaporin 4; EAAT2, excitatory amino acid transporter 2; IL-6, interleukin 6; IL-6R, interleukin 6 receptor; M1, M23, dominant isoforms of AQP4; MHC-1, major histocompatibility complex I protein; TcR, T-cell receptor. (Modified from Weinshenker BG, Wingerchuk DM. Neuromyelitis spectrum disorders. *Mayo Clin Proc*. 2017;92[4]:663-679.)

its detection in serum obtained years earlier from individuals who ultimately developed clinical NMOSD (because they had previously developed other autoimmune diseases or had donated blood for purposes of transfusion). The factors leading to a breach of the blood-brain barrier are unclear, but one of the early sites of pathology is the area postrema, which has a relatively permeable blood-brain barrier and is responsible for the symptoms of intractable vomiting and hiccup that are present in a quarter of patients at disease presentation. Experimentally, systemic administration of antibody to generate passively generated pathology requires measures to disrupt the blood-brain barrier, which can vary from prior induction of experimental autoimmune encephalomyelitis with T cells or administration of adjuvants. AQP4-IgG in the CSF is primarily due to ingress of peripherally circulating antibody, but clones of AQP4-IgG–producing B cells are readily isolated from CSF.

AQP4 is a water channel critically involved in mass water transport, and impairment of AQP4 function predisposes to vasogenic edema; this may explain the uncommon but reported occurrence of posterior reversible encephalopathy in patients with NMOSD, believed to be a manifestation of vasogenic edema. AQP4 is capable of "supramolecular aggregation" of

its component heterotetrameric subunits, particularly in optic nerve and spinal cord, where it is highly expressed, and these aggregates provide an antigenic configuration able to bind dense arrays of AQP4 antibody and facilitate binding of complement component 1q (C1q) and complement activation by the classic pathway. AQP4-IgG binding can internalize AQP4 water channels. More importantly, it leads to complement activation and antibody-mediated natural killer cell cytotoxicity, leading to a cascade of downstream effector functions, including chemotaxis of neutrophils and eosinophils and activation of membrane attack complex, which can be demonstrated immunopathologically in recent lesions of NMO. However, some lesions, despite evidence of loss of AQP4 immunoreactivity, do not have immunopathology markers of terminal complement activation and maintain tissue viability; such lesions are associated with clinical recovery. Blocking synthesis of immunoglobulin by targeting B cells (eg, inebilizumab) or trophic factors of plasmablasts (eg, satralizumab), and blocking complement activation with drugs that target C5a generation (eg, eculizumab) are effective strategies for preventing NMO attacks. Plasma exchange is an effective acute treatment for attacks of NMO.

AQP4-expressing non-CNS tissues are relatively but not absolutely spared by this disease. Myalgia may occur coincidentally with attacks of NMOSD and may be accompanied by increases in creatine kinase but rarely by weakness. Muscle biopsy has identified marked loss of immunoreactivity of AQP4 on muscle tissues accompanied by inflammation, similar to findings detected in affected CNS tissues.

The pathogenicity of MOG autoimmunity was recognized from in vivo models of experimental autoimmune encephalomyelitis induced by immunization with MOG; the distribution of affected tissues was primarily determined by major histocompatibility antigens. Brown Norway-genotype rats had a distribution of lesions most reminiscent of NMO. Rodent-derived MOG-IgG is capable of generating prominent demyelination either with or without concomitant T cell–induced experimental autoimmune encephalomyelitis. However, pathogenicity of the human antibody has been difficult to demonstrate in some experimental systems, in part because human MOG-IgG does not recognize rodent MOG. Human MOG lesion pathology in biopsies appears to be similar to acute disseminated encephalomyelitis with overrepresentation of CD4, rather than CD8 cells as seen in MS. Lesions tend to be less necrotic than those associated with AQP4-IgG, as might be expected from the overall better prognosis.

T-cell Activation, Helper T Cell 17 Polarization, B-cell Recognition, and "Upstream" Pathogenesis

The source of the inciting antigen is unknown for either AQP4-associated or MOG-associated NMOSD. Infrequently, patients with AQP4-IgG–associated NMOSD have underlying AQP4-expressing cancers that are suspected of inciting the autoimmune response by "molecular mimicry." However, in the majority of patients with AQP4-IgG–associated NMOSD, the source of the inciting antigen is unknown. Titers of antibody are much greater in the periphery suggesting that this is an "outside-in" disease, but clones of antibody-producing cells are identifiable in the CSF. There is evidence of overexpression of immune cytokines, including those involved in helper T cell 17 (Th17)-mediated disease, for example, interleukin (IL)-6 and IL-17. The pathology of the disease, which includes prominent infiltration with neutrophils and pattern of response to immunotherapy, is also consistent with Th17-facilitated autoimmunity. Recent studies implicate central and peripheral defects in immune tolerance in NMOSD as occurs in other autoimmune disease.

DIAGNOSIS

Characteristic Symptoms and Diagnostic Criteria

NMOSD usually presents as a relapsing central nervous system demyelinating disease with attacks of ON and transverse myelitis. Approximately 5% to 10% of patients have monophasic (nonrelapsing) and up to 3% have a secondary progressive course. The discovery of AQP4-IgG allowed clinicians to identify a broader clinical spectrum of the disease because of the demonstrated specificity of the marker. Other NMOSD syndromes include diencephalic, cerebral, brainstem, and dorsal medulla syndrome (area postrema).

ON in NMOSD typically presents as a severe, acute, painful, visual impairment that can lead to blindness in one or both eyes, either simultaneously or sequentially. Transverse myelitis presents with acute sensory, motor, and sphincter impairments, often severe, associated with a central intramedullary spinal cord lesion extending over three or more contiguous vertebral segments, often referred to as *longitudinally extensive transverse myelitis*, as distinguished from short, generally peripheral spinal cord lesions in MS. Myelitis may be associated with lesions shorter than vertebral segments in approximately 15% of patients and may lead to misdiagnosis of MS, but typically lesions are central in the cord, similar to longitudinally extensive myelitis. Paroxysmal tonic spasms are dystonic spasms that should be distinguished from spasticity repeat in a highly stereotyped fashion. Typically, they are preceded with a sensory "rush," which is rapidly followed by a dystonic posture of one or more limbs, either unilateral or bilateral. This phenomenon is thought to be due to ephaptic transmission of propagating action potentials in demyelinated axons. While they occur in MS, paroxysmal tonic spasms are more common and severe in patients with transverse myelitis due to AQP4-IgG–associated NMOSD and respond to treatment with carbamazepine or oxcarbazepine.

Area postrema syndrome is characterized by unexplained intractable hiccups or nausea or vomiting, generally associated with either paired lesions in the dorsal medulla or myelitis lesions with rostral extension into the dorsal medulla. About 20% of patients present with this syndrome, and 40% will experience it at some stage of their disease, particularly those who are AQP4-IgG seropositive.

Diencephalic syndromes include hypersomnolence, narcolepsy, anorexia, hypothermia, hyponatremia, and behavioral changes associated with a lesion in the thalamus, hypothalamus, or in the walls of the third ventricle. Other cerebral syndromes in NMOSD include hemiparesis, hemisensory loss, encephalopathy, postchiasmal visual loss, and cortical vision loss that are typically associated with large, confluent subcortical, or deep white-matter lesions or lesions that conform to the distribution of long tracts within the brain. Cerebral and diencephalic syndromes are more common in children and in patients with aggressive disease.

Diagnosis of NMOSD relies on clinical, radiographic, and laboratory features. Diagnostic criteria, first proposed by Wingerchuk et al in 1999, was revised in 2006 and, most recently supplanted in 2015 by the International Panel for NMO Diagnosis (Table 73.2). The 2006 revision incorporated AQP4-IgG serology status. In 2015, NMOSD was proposed as the umbrella term for traditional neuromyelitis optica and its more recently recognized brain syndromes; the diagnosis was further stratified in two groups: those seropositive for AQP4-IgG and those who were either seronegative or whose status was unknown. In AQP4-IgG–seropositive individuals, only a single compatible clinical syndrome is necessary (eg, ON or TM), and the diagnosis may be made at first presentation. In AQP4-IgG–seronegative individuals, more than one syndrome in more than one affected location (eg, ON and brainstem) is required and at least one must be a cardinal syndrome (ON, longitudinally extensive transverse myelitis, or area postrema syndrome). Potential mimics of NMOSD should be excluded. A 2017 study found that the application of the 2015 criteria increased the rate diagnosis of NMOSD in clinically suspected cases by 76%, primarily in AQP4-IgG–seropositive cases; however, the specificity of the new diagnostic criteria require further validation.

TABLE 73.2 Neuromyelitis Optica Spectrum Disorder Diagnostic Criteria

Diagnostic Criteria for NMOSD With AQP4-IgG

1. At least one core clinical characteristic
2. Positive test for AQP4-IgG using best available detection method (cell-based assay strongly recommended)
3. Exclusion of alternative diagnoses

Diagnostic Criteria for NMOSD Without AQP4-IgG or NMOSD With Unknown AQP4-IgG Status

1. At least two core clinical characteristics occurring as a result of one or more clinical attacks and meeting all of the following requirements:
   A. At least one core clinical characteristic must be optic neuritis, acute myelitis with LETM, or area postrema syndrome.
   B. Dissemination in space (two or more different core clinical characteristics)
   C. Fulfillment of additional MRI requirements, as applicable
2. Negative tests for AQP4-IgG using best available detection method, or testing unavailable
3. Exclusion of alternative diagnoses

Core Clinical Characteristics

1. Optic neuritis
2. Acute myelitis
3. Area postrema syndrome: episode of otherwise unexplained hiccups or nausea and vomiting
4. Acute brainstem syndrome
5. Symptomatic narcolepsy or acute diencephalic clinical syndrome with NMOSD-typical diencephalic
6. Symptomatic cerebral syndrome with NMOSD-typical brain lesions

Additional MRI Requirements for NMOSD Without AQP4-IgG and NMOSD With Unknown AQP4-IgG Status

1. Acute optic neuritis: requires brain MRI showing (1) normal findings or only nonspecific white matter lesions OR (2) optic nerve MRI with T2-hyperintense lesion or T1-weighted gadolinium-enhancing lesion extending over >1/2 optic nerve length or involving optic chiasm
2. Acute myelitis: requires associated intramedullary MRI lesion extending over 3 contiguous segments (LETM) or more than or equal to three contiguous segments of focal spinal cord atrophy in patients with prior history compatible with acute myelitis
3. Area postrema syndrome: requires associated dorsal medulla/area postrema lesions
4. Acute brainstem syndrome: requires associated periependymal brainstem lesions AQP4-IgG

Abbreviations: AQP4-IgG, aquaporin-4 immunoglobulin G; LETM, longitudinally extensive transverse myelitis; MRI, magnetic resonance imaging; NMOSD, neuromyelitis optica spectrum disorder.

Serologic Testing and Cerebrospinal Fluid

AQP4-IgG is a highly sensitive (73%) and specific (91%) biomarker and is detected in sera of most NMOSD patients (68%-91%). Detection of AQP4-IgG is now an integral aspect of establishing the diagnosis, although the diagnosis can be made on clinical grounds. Cell-based assays, in which the substrate for antibody detection is recombinant antigen expressed in a cell line in native conformation, are the preferred methodology, although other assays have acceptable, although imperfect specificity, which depend on the clinical probability of the diagnosis. A meta-analysis found the approximate sensitivity for the cell-based assay, the tissue-based assay, and the enzyme-linked immunosorbent assay test to be 0.76 (95% CI, 0.67-0.82), 0.59 (95% CI, 0.50-0.67), and 0.65 (95% CI, 0.53-0.75), respectively, whereas the specificity of the cell-based assay was 0.99 (95% CI, 0.97-0.99), tissue-based assay 0.98 (95% CI, 0.97-0.99), and enzyme-linked immunosorbent assay 0.97 (95% CI, 0.96-0.99).

CSF examination is not part of the latest revised diagnostic criteria. However, CSF pleocytosis of more than or equal to 50 WBC/mm^3 or more than or equal to 5 neutrophils/mm^3, usually detected during an acute attack, and absence of oligoclonal bands support diagnosis of NMOSD, whereas unique oligoclonal bands are present in 80% to 90% of patients with MS. Mild pleocytosis less than 50 WBC/mm^3 with lymphocyte predominance is nonspecific and can be seen in either condition. The CSF glial fibrillary acidic protein, a marker for oligodendrocyte injury, is an additional diagnostic biomarker in NMOSD, which increases by several orders of magnitude during relapses and the degree of elevation may predict level of impairment at 6 months follow-up.

In AQP4-IgG–seronegative patients with NMOSD, testing for MOG-IgG is valuable and this autoantibody may be present in up to 50%.

Red Flags, Comorbid Conditions, and Differential Diagnosis

The 2015 International Panel for NMO Diagnosis diagnostic criteria describe a number of caveats to be considered when evaluating a patient with NMOSD. Clinical and radiographic "red flags" to consider at diagnosis of NMOSD are summarized in Table 73.3.

NMOSD can coexist with other autoimmune disorders such as myasthenia gravis, systemic lupus erythematosus, Sjögren syndrome, undifferentiated connective thyroid disease, and pernicious anemia. An AQP4-IgG or MOG-IgG NMOSD may coexist with anti–*N*-methyl-D-aspartate–receptor encephalitis. A CV2/collapsin response mediator 5 antibody (CV2/CRMP5 IgG) mediated disease may be associated with ON or TM and mimicking NMOSD. However, distinguishing NMOSD from other inflammatory, demyelinating, infectious, metabolic, and neoplastic process can be challenging. The differential diagnosis of NMOSD is wide

TABLE 73.3 "Red Flags" in Diagnosis of NMOSD

Red Flags	Comments
Clinical	
Progressive course	More common in MS
Hyperacute onset	Suggestive of spinal cord infarct
Oligoclonal bands in CSF	More typical of MS but detected in up to 20% of cases of NMOSD
Systemic illness including HIV, sarcoid, cancer, syphilis	Potential mimics of NMOSD
Radiographic	
Short spinal cord lesions	More typical of MS
Peripheral spinal cord lesions	More typical of MS
Periventricular lesion in brain, especially oriented perpendicular to ventricles	More typical of MS
Persistently gadolinium enhancement (>3 mo)	Suggestive of neoplasm or infection

Abbreviations: CSF, cerebrospinal fluid; HIV, human immunodeficiency virus; MS, multiple sclerosis; NMOSD, neuromyelitis optica spectrum disorder.

and depends on whether the presentation is suggestive of ON, TM, or both (**Table 73.4**). The MOG-IgG NMOSD and MS are the main differential diagnoses, although other entities listed in **Table 73.4** should be considered, particularly acute disseminated encephalomyelitis, neurosarcoidosis, and paraneoplastic disorders.

Neuromyelitis Optica Spectrum Disorder Versus Multiple Sclerosis

Distinguishing NMOSD from MS has important prognostic and therapeutic implications because a number of MS disease-modifying treatments are ineffective and possibly harmful to patients with NMOSD. Relative to NMOSD, patients with MS are older at onset, more often women, and non-Caucasian, rarely developing a secondary progressive course. Attacks of NMOSD are more severe and more often associated with incomplete recovery. An MRI brain is often normal at first diagnosis in NMOSD, whereas it rarely is in MS. Attacks of myelitis are associated with longitudinally extensive spine MRI lesions in NMOSD but rarely in MS. Lesions in ON in AQP4-IgG–seropositive NMOSD are more often long and associated with posterior optic nerve or chiasm involvement than are lesions in MS-associated ON. Other lesions in the brain that are distinctive are longitudinally extensive corpus callosum lesions and hypothalamic and thalamic lesions, often bilateral. Optical coherence tomography shows greater thinning of retinal nerve fiber layer than seen in MS, reflecting greater axonal injury. The CSF unique oligoclonal bands are detected in less than 20% of patients with NMOSD, whereas they are found in over 85% of patients with MS.

AQP4-IgG– Versus MOG-IgG–Associated NMOSD

MOG-IgG–associated disease can present with clinical and radiologic features similar to NMOSD and MS. Table 73.5 summarizes key clinical and radiologic differences. Compared to patients with AQP4-IgG, patients who are seropositive for MOG-IgG have a higher frequency of bilateral simultaneous ON, acute disseminated encephalomyelitis syndrome, or encephalitis with seizures and

TABLE 73.4 Differential Diagnosis of NMOSD

Combinations of Optic Neuritis, Myelitis, and/or Brain Disease
Multiple sclerosis
Acute disseminated encephalomyelitis
Neurosarcoidosis
Neuro-Behçets disease
Paraneoplastic disease (especially associated with CRMP5)
Adult-onset Alexander disease (long segments of spinal cord atrophy with enhancing brainstem lesions)
Optic Neuritis
CRION
Leber optic neuropathy
Optic nerve tumor
Brain Lesions
Wernicke encephalopathy
Marchiafava-Bignami disease (corpus callosum lesions and diffuse white matter lesions)
Central nervous system lymphoma
Primary angiitis of the central nervous system
Rhombencephalitis
Gliomatosis cerebri
X-linked adrenoleukodystrophy (enhancing lesions in splenium of corpus callosum and deep white matter)
Transverse Myelitis
Spinal cord infarction
Spinal cord arteriovenous fistula
Idiopathic transverse myelitis
Infectious transverse myelitis (varicella zoster, enterovirus, flavivirus, syphilis, tuberculosis)

Abbreviations: CRION, chronic relapsing inflammatory optic neuropathy; CRMP5, collapsin response mediator protein 5; NMOSD, neuromyelitis optica spectrum disorder.

TABLE 73.5 Clinical and Radiologic Features in AQP4-IgG– Versus MOG-IgG–associated NMOSD

	AQP4-IgG NMOSD	MOG IgG-NMOSD
Bilateral simultaneous optic neuritis	+	++
Optic disc edema or papillitis	+	+++
Acute spinal cord syndrome	+	++
ADEM syndrome	+	++
Encephalitis with seizure syndrome	Not reported	+
Multifocal cortical and subcortical radiographic lesions (**Fig. 73.2**)	Not reported	++
Gadolinium enhancing spinal cord lesion (**Fig. 73.4**)	+++	+
Linear nonenhancing spinal cord lesion on sagittal images (**Figs. 73.4 and 73.5**)	+	+++
Monophasic (nonrelapsing) course	+	++

Abbreviations: +, occurs but <10%; ++, well described but <50% of cases; +++, occurs in the majority of cases; ADEM, acute disseminated encephalomyelitis; AQP4-IgG, aquaporin-4 immunoglobulin G; MOG-IgG, myelin oligodendrocyte glycoprotein IgG; NMOSD, neuromyelitis optica spectrum disorder.

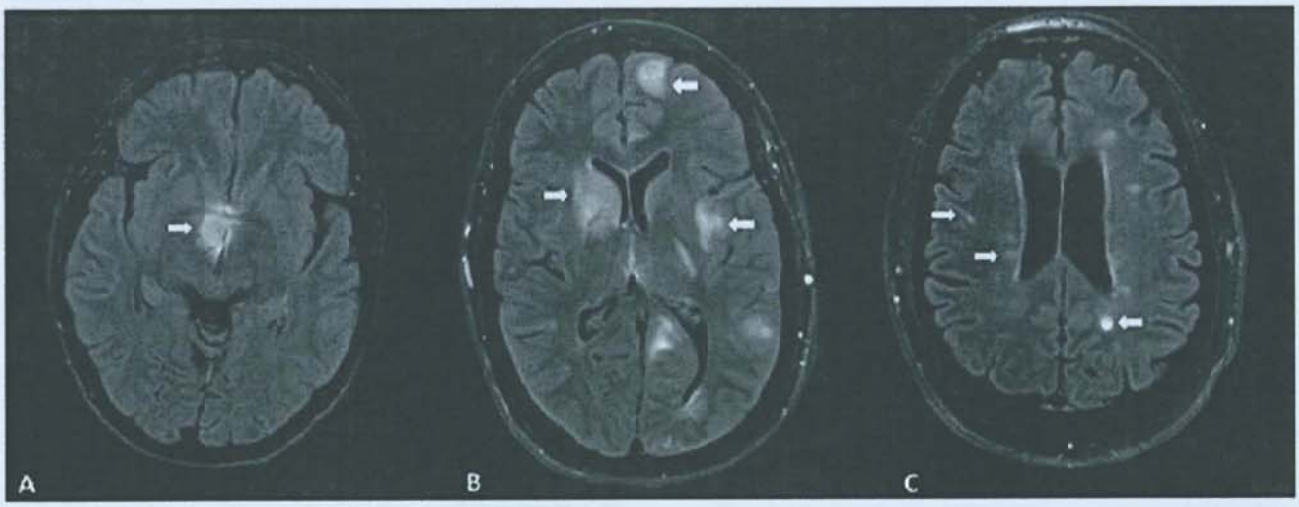

FIGURE 73.2 Magnetic resonance imaging brain, T2/fluid-attenuated inversion recovery sequences. **A:** Aquaporin-4 immunoglobulin G–positive neuromyelitis optica spectrum disorder showing isolated lesion in the hypothalamus; usually magnetic resonance imaging of the brain is normal. **B:** Myelin oligodendrocyte glycoprotein immunoglobulin G–positive neuromyelitis optica spectrum disorder showing multifocal large hyperintensities. **C:** Multiple sclerosis showing multiple small periventricular, subcortical, and juxtacortical hyperintensities.

multifocal cortical and subcortical lesions (**Fig. 73.2**) and may not satisfy criteria for NMOSD. The acute myelitis lesions associated with MOG-IgG tend to be long, similar to those associated with AQP4-IgG, but less extensive and demonstrate less and occasionally no enhancement (**Figs. 73.3** and **73.4**) and occasionally have a long linear ("string sign") appearance on sagittal T2 sequences of the spinal cord (**Fig. 73.5**). Up to 50% of those who are MOG-IgG seropositive may not relapse, especially patients who revert to seronegative. Therefore, and given the relatively better outcome of attacks in MOG-IgG–seropositive patients, observation only after a first attack may be appropriate in those with MOG-IgG–associated disease.

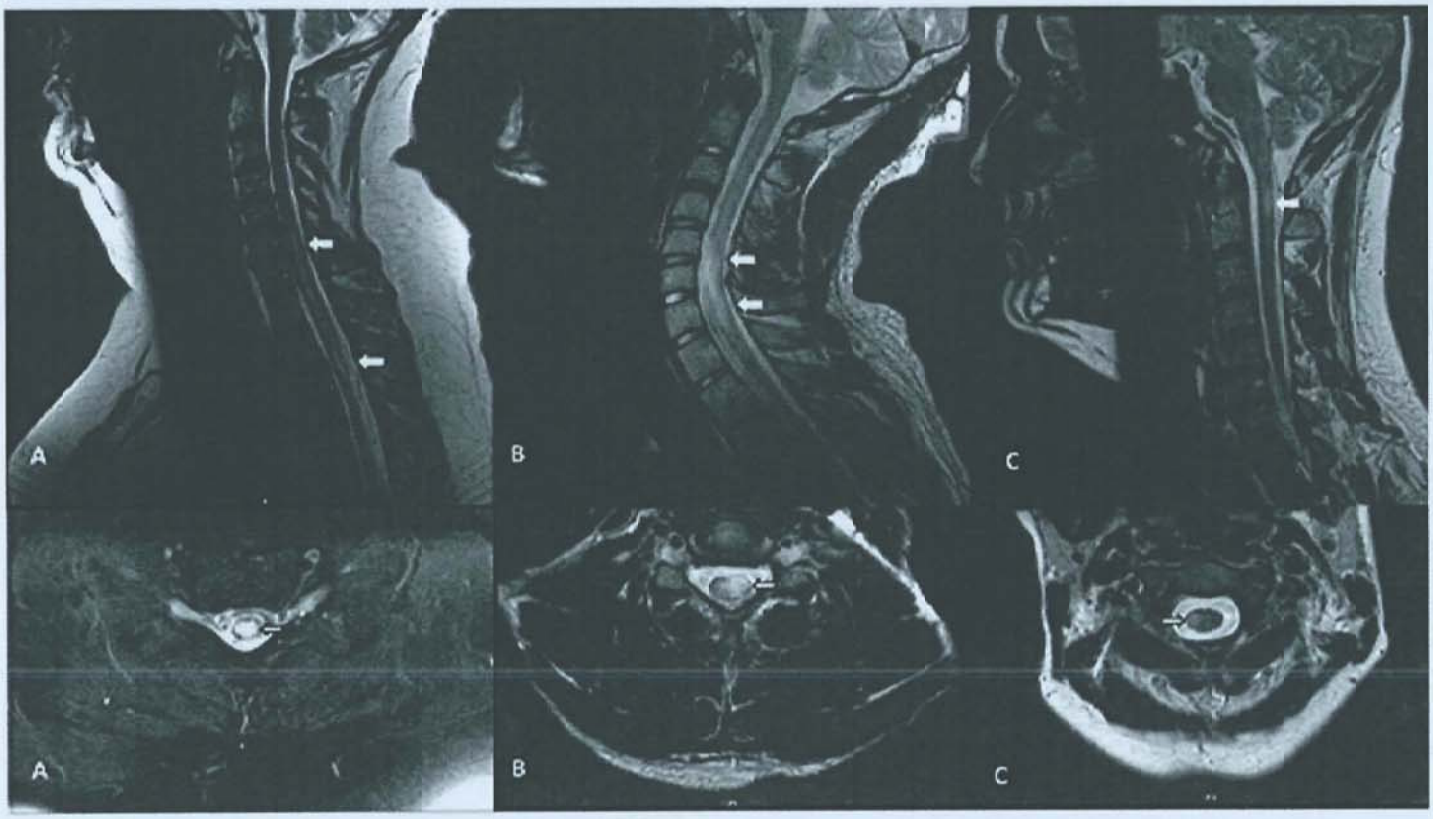

FIGURE 73.3 Magnetic resonance imaging cervical spine, sagittal (**top tier**) and axial T2 (**bottom tier**) sequences showing transverse myelitis in patients with neuromyelitis optica spectrum disorder. **A:** Aquaporin-4 immunoglobulin G positive, showing swollen large central spinal cord lesion. **B:** Myelin oligodendrocyte glycoprotein immunoglobulin G positive showing less extensive central lesion affecting gray matter. **C:** Multiple sclerosis with discrete short lesion extending over less than one vertebral segment eccentrically located in the lateral column.

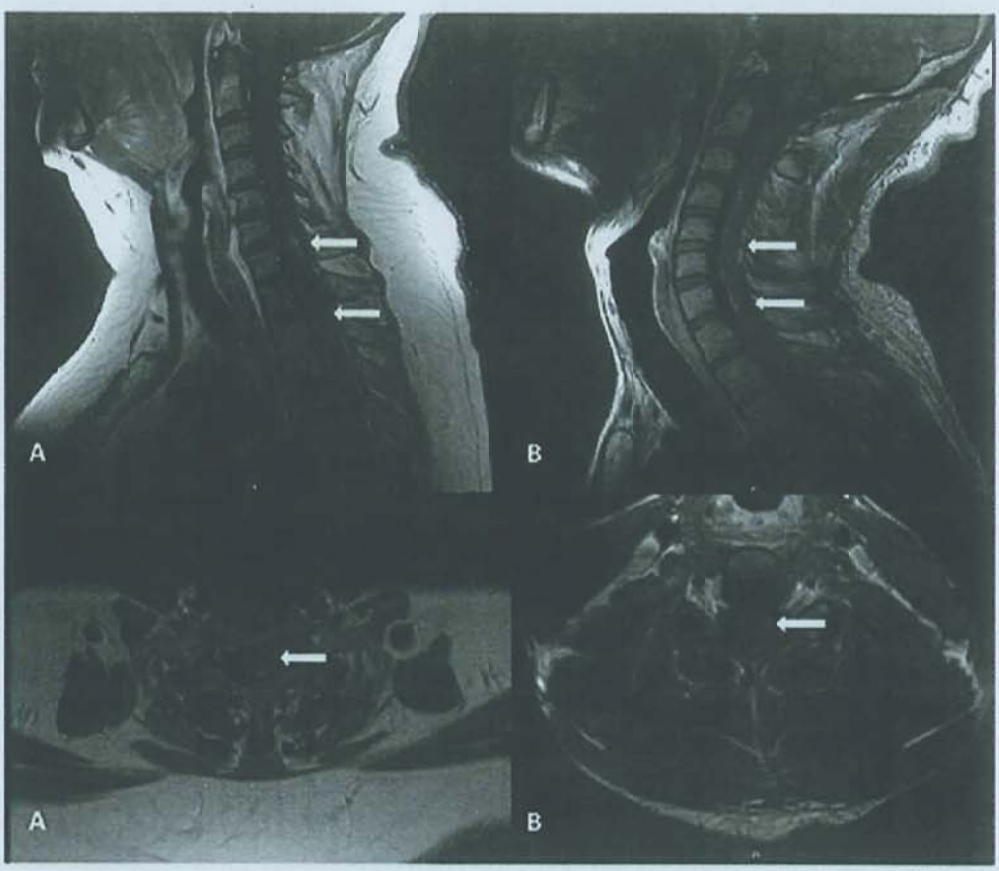

FIGURE 73.4 Magnetic resonance imaging cervical spine, sagittal (**top tier**) and axial (**bottom tier**) sequences following gadolinium administration, showing transverse myelitis in patients with neuromyelitis optica spectrum disorder. **A:** Aquaporin-4 immunoglobulin G positive with ring enhancement that is moderately extensive. **B:** Myelin oligodendrocyte glycoprotein immunoglobulin G positive, with much less extensive enhancement confined to periphery of the spinal cord, primarily anteriorly.

FIGURE 73.5 Magnetic resonance imaging cervical spine, sagittal T2 sequences, showing "string sign" in a patient with myelitis due to myelin oligodendrocyte glycoprotein immunoglobulin G–associated neuromyelitis optica spectrum disorder.

MANAGEMENT

Management is directed to treatment for acute attacks and maintenance treatment to prevent such attacks and accompanying accumulation of incremental disability. Maintenance treatment for AQP4-IgG NMOSD should be instituted at time of diagnosis in all patients due to the high risk of disabling relapses. Until recently, NMOSD was often managed with treatments directed to MS with which NMOSD was often confused. Several MS treatments appear to be either ineffective (glatiramer acetate), or possibly deleterious to patients with NMOSD (interferon-β, natalizumab, fingolimod, and alemtuzumab). Hence, an accurate diagnosis and distinction from MS is essential to successful treatment of patients with NMOSD. In 2019, the results of four phase 3 clinical trials were announced of three agents in treating NMOSD, and as of the writing of this chapter, one, eculizumab, has been approved by the U.S. Food and Drug Administration for treatment of AQP4-IgG–seropositive NMOSD.

Acute Attacks

NMOSD exacerbations or acute attacks are usually treated with intravenous methylprednisolone (IVMP) 1,000 mg daily, for 3 to 7 consecutive days. Corticosteroids inhibit the inflammation cascade by suppressing the production of inflammatory cytokines, T-cell activation, and decreasing permeability of the blood-brain barrier.

Because NMOSD relapses tend to be severe and not respond well to corticosteroids, plasmapheresis (PLEX) is used as a rescue or possibly an adjunctive treatment. PLEX is usually administered

as five to seven exchanges of approximately 1.5 plasma volumes every other day. PLEX eliminates pathogenic plasma factors including cytokines, autoantibodies, and complement components. PLEX treatment results in functional improvement in up to 40% of patients with CNS demyelinating disorders, including NMOSD, who failed corticosteroids during a relapse LEVEL 1.[1] Treatment with IVMP immediately followed by PLEX may result in improved recovery compared to IVMP alone. Better outcomes were reported in patients who received PLEX and were on concomitant treatment with long-term immunosuppressive therapy for NMOSD. Another large retrospective study reported better outcomes of myelitis in patients who were treated with PLEX as primary treatment rather than corticosteroids.

The efficacy of PLEX in NMOSD is not seen exclusively in those who are AQP4-IgG seropositive. Nevertheless, it is important to remember that the only randomized controlled trial experience supporting PLEX efficacy in NMOSD is based on outcomes of a controlled trial of patients with severe CNS demyelinating disease, which included patients with NMOSD and a variety of other acute CNS demyelinating syndromes and by several retrospective studies. A dedicated randomized NMOSD clinical trial of PLEX has not yet been undertaken. Intravenous immunoglobulin, which is effective in a variety of immune-mediated neurologically conditions, has been reported to be somewhat efficacious in patients who failed to respond to IVMP with or without PLEX. Intravenous cyclophosphamide has also been used in a small number of patients as a rescue therapy for attacks of NMOSD longitudinally extensive transverse myelitis refractory to IVMP, PLEX, and intravenous immunoglobulin.

Maintenance Therapy for Neuromyelitis Optica Spectrum Disorder

A number of immunotherapies (Table 73.6), supported mainly by retrospective and observational data, have until the writing of this chapter been the mainstay of treatment of NMOSD. Rituximab, an anti-CD20 monoclonal antibody, administered alone or azathioprine (AZA) or mycophenolate mofetil (MMF) combined with prednisone for 4 to 6 months is considered first-line treatment. Rituximab treated patients had no relapses versus 37% in placebo controlled multicenter study LEVEL 1.[2] Inebilizumab, a CD19 monoclonal antibody, was approved in June, 2020 (United States) to help reduce risk of relapses and disability in NMOSD. Inebilizumab targets a broader spectrum of B cells than rituximab, including plasmablasts and some plasma cells. When inebilizumab was compared to placebo 12% vs. 39% experienced relapses in a phase 3 clinical trial LEVEL 1.[3] Common adverse events are similar to those of rituximab, another B cell depleting agent. Inebilizumab became the second regulator-approved treatment for AQP4-IgG seropositive NMOSD in June, 2020. Alternative maintenance preventative treatments include AZA, mycophenolate mofetil, cyclophosphamide, and methotrexate.

Rituximab was more effective than AZA treatment in a randomized clinical trial and was further established to be effective compared to placebo LEVEL 1.[2] Chen et al found both MMF and AZA to be equally effective in reducing relapse risk, but MMF was associated with fewer or milder adverse events than AZA in patients with NMOSD.

Eculizumab, a C5 complement inhibitor, became the first United States regulator-approved immunotherapy for prevention of attacks in AQP4-IgG–seropositive NMOSD in June 2019 LEVEL 1.[4] It reduced the risk of the first NMOSD relapse following randomization by greater than 90%. Eculizumab predisposes to meningococcal sepsis, but this complication can be substantially prevented by immunization to meningococcus, both with standard conjugate and group B meningococcus vaccinations. Given its recent regulatory approval, eculizumab will likely become widely used particularly for those failing other treatments but considering the lack of long-term efficacy and safety and its high cost, its role in treating NMOSD remains to be established.

Interleukin 6 (IL-6) inhibitors have proven to be effective and safe as an attack prevention strategy for NMOSD. The IL-6

TABLE 73.6 Immunotherapy for Neuromyelitis Optica Spectrum Disorder

Immunotherapy	Dosage	Mechanism	Classification	Common Adverse Events
Rituximab	Two doses 1,000 mg IV in 2 wk apart and repeat every 6 mo	Anti-CD20 monoclonal antibody; B-cell depletion	First line	Infections, leukopenia, hepatotoxicity, reactivation hepatitis B, PML
Azathioprine	2.5-3 mg/kg/d oral	Thiopurine antagonist of endogenous purines; interferes with lymphocyte proliferation	First line	Liver toxicity, leukopenia, recurrent infections, nausea, diarrhea, rash, increased risk of lymphoma
Mycophenolate mofetil	500 mg oral twice a day for 2 wk, then 1,000 mg twice a day thereafter	Inhibitor of inosine monophosphate dehydrogenase, interferes with lymphocyte proliferation	First line	Photosensitivity, leukopenia, infections, headache, abdominal pain, constipation, congenital malformations
Eculizumab	900 mg IV once a week for 4 wk, 1,200 mg IV on week 5, then 1,200 mg IV every 2 wk thereafter	C5 complement inhibitor	Recently approved	Hypertension, headache, fever, diarrhea, nausea, leukopenia, anemia, infections especially meningococcus
Methotrexate	7.5 mg oral or IV weekly, then titrate up weekly up to 22-50 mg weekly	Folic acid antagonist	Second line	Pneumonitis, nausea, diarrhea, cytopenia, hepatotoxicity
Tocilizumab	8 mg/kg IV monthly	IL-6 receptor inhibitor	Third line	Infections, leukopenia, hypercholesterolemia, hepatotoxicity
Satralizumab	120 mg subQ at weeks 0, 2, and 4, then every 4 wk	IL-6 monoclonal antibody	Recently approved	Injection site reactions, infections, headache
Inebilizumab	Two doses 300 mg IV in 2 wk apart, then 300 mg IV every 6 mo	Anti-CD19 monoclonal antibody; B cell depletion	Recently approved	Infections, leukopenia, hepatitis B reactivation, PML

Abbreviations: IL-6, interleukin 6; IV, intravenous; PML, progressive multifocal leukoencephalopathy.

is elevated in NMOSD and enhances AQP4-IgG secretion by promoting plasmablast survival. Two recently completed clinical trials of a modified version of tocilizumab, an IL-6 receptor inhibitor that is modified to extend its action compared to its parent compound, tocilizumab, showed greater than 70% suppression of attacks in AQP4-IgG–seropositive cases, although it did not show convincing evidence of benefit in NMOSD patients seronegative for AQP4-IgG.

Satralizumab, became the third regulator-approved treatment for prevention of attacks of AQP4-IgG seropositive NMOSD in August, 2020 (United States). Satralizumab is associated with risk of injection related reactions, neutropenia, infections, including opportunistic infection, and liver function abnormalities. LEVEL 1.[5]

The choice of treatment depends on availability, cost, comorbidities, side effects, and patient preference. Individualization based on efficacy indicators is not currently possible. However, available data suggest that anti-CD19 monoclonal antibody and IL-6 inhibition may be less effective in treating AQP4-IgG–seronegative than AQP4-IgG–seropositive patients in the phase 3 clinical trials and all regulator-approved treatments are indicated only for patients who are seropositive for AQP4-IgG.

In the event of breakthrough disease after an adequate trial period or if cost, availability, or tolerance is problematic, it is reasonable to switch from one maintenance treatment to another.

Maintenance for Myelin Oligodendrocyte Glycoprotein Immunoglobulin G Disease

It remains unclear when to initiate maintenance immunotherapy in patients with MOG-IgG–associated diseases. Up to 50% of patients with MOG-IgG–related disease may not relapse, especially those who revert to seronegative status. Factors to consider prior to initiating maintenance therapy include whether relapse has occurred following the initial attack, the severity of, and degree of recovery from relapses. There are no current guidelines or clinical trial data for the treatment of MOG-IgG disease. Preliminary experience with this recently recognized disease defined largely by the antibody suggests that maintenance immunotherapies for MOG-IgG disease should be similar to the agents used for AQP4-IgG–associated NMOSD.

OUTCOMES

Mortality in Neuromyelitis Optica Spectrum Disorder

Mortality rates in NMOSD have improved in recent years. Pre–AQP4-IgG studies reported 5-year survival rate of 68% and median survival of 17.5 years. More recent studies report mortality rates under 25% in those with disease duration of less than 10 years. Most NMOSD-related deaths result from respiratory failure in the context of cervical myelitis, brainstem inflammation, and diencephalic dysfunction accompanied by manifestations such as syndrome of inappropriate secretion of antidiuretic hormone and hypothermia. The improvement in mortality rate is probably the result of early diagnosis and prompt institution of effective treatment.

In a study of 427 NMOSD patients of whom 30 were deceased, the average age at death was 52 years and at a mean disease duration of 7 years. African Americans and Afro-Caribbean Hispanics had higher mortality rates than whites. Early attack frequency, poor recovery from first attack, and older age of onset may increase the risk of death in NMOSD.

Disability in Neuromyelitis Optica Spectrum Disorder

AQP4-IgG–associated NMOSD is associated with poor recovery from relapses with severe disability, but this is variable, and "benign" cases have been described. Disability in NMOSD mainly affects visual, motor, and ambulatory functions. Cognitive impairment has also been described in 30% to 50% of patients, although less commonly than in MS.

About 20% to 40% of NMOSD patients experience severe permanent motor and visual disability after the initial event. Recent studies find that 40% of patients are unable to walk without assistance and 20% have visual acuity of 20/200 or worse in at least one eye after first attack. The disability accumulation is stepwise. The average time to require gait assistance with a cane, crutches, or walker is 6 to 8 years and to become wheelchair confided is 22 years.

Age, gender, and ethnicity have been inconsistently associated with outcome. However, younger age at onset and male sex are more likely to predict visual disability, whereas older age onset is more predictive of motor disability. Afro-Caribbeans may have higher relapse rates than whites. An AQP4-IgG status is not convincingly associated with specific outcomes among patients with NMOSD with or without positive AQP4-IgG. High disability at onset predicts poor outcomes, and long-term immunotherapy reduces disability from attacks.

Around 50% of patients with MOG-IgG disease are permanently disabled after 2 years from onset. These disabilities include visual dysfunction in 16%, mobility limitation in 7%, bladder and bowel dysfunction (20%-30%), and erectile dysfunction (20% of men). About 35% relapsed after median disease duration of 16 months. Patients who present with ON are more likely to recover than those presenting with TM.

LEVEL 1 EVIDENCE

1. Weinshenker BG, O'Brien PC, Petterson TM, et al. A randomized trial of plasma exchange in acute central nervous system inflammatory demyelinating disease. *Ann Neurol*. 1999;46:878-886.
2. Tahara M, Oeda T, Okada K, et al. Safety and efficacy of rituximab in neuromyelitis optica spectrum disorders (RIN-1 study): a multicenter, randomised, double-blind, placebo-controlled trial. *Lancet Neurol*. 2020;19:298-306.
3. Cree B, Bennett J, Kim H, et al. Inebilizumab for the treatment of neuromyelitis optica spectrum disorder (N-MOmentum): a double blind, randomised placebo-controlled phase 2/3. *Lancet*. 2019;394:1352-1363.
4. Pittock SJ, Berthele A, Fujihara K, et al. Eculizumab in aquaporin-4-positive neuromyelitis optica spectrum disorder. *N Engl J Med*. 2019;381(7):614-625.
5. Yamamura T, Kleiter I, Fujihara K, et al. Trial of satralizumab in neuromyelitis spectrum disorder. *N Engl J Med*. 2019;381:2114-2124.

SUGGESTED READINGS

Chen H, Qiu W, Zhang Q, et al. Comparisons of the efficacy and tolerability of mycophenolate mofetil and azathioprine as treatments for neuromyelitis optica and neuromyelitis optica spectrum disorder. *Eur J Neurol*. 2017;24(1):219-226.

Elsone L, Panicker J, Mutch K, Boggild M, Appleton R, Jacob A. Role of intravenous immunoglobulin in the treatment of acute relapses of neuromyelitis optica: experience in 10 patients. *Mult Scler*. 2014;20(4):501-504.

Flanagan EP. Neuromyelitis optica spectrum disorder and other non-multiple sclerosis central nervous system inflammatory diseases. *Continuum (Minneap Minn)*. 2019;25(3):815-844.

Flanagan EP, Cabre P, Weinshenker BG, et al. Epidemiology of aquaporin-4 autoimmunity and neuromyelitis optica spectrum. *Ann Neurol*. 2016;79(5):775-783.

Flanagan EP, Weinshenker BG, Krecke KN, et al. Short myelitis lesions in aquaporin-4-IgG-positive neuromyelitis optica spectrum disorders. *JAMA Neurol*. 2015;72(1):81-87.

Jarius S, Ruprecht K, Kleiter I, et al. MOG-IgG in NMO and related disorders: a multicenter study of 50 patients. Part 2: epidemiology, clinical presentation, radiological and laboratory features, treatment responses, and long-term outcome. *J Neuroinflammation*. 2016;13(1):280.

Jarius S, Ruprecht K, Wildemann B, et al. Contrasting disease patterns in seropositive and seronegative neuromyelitis optica: a multicentre study of 175 patients. *J Neuroinflammation*. 2012;9:14.

Jurynczyk M, Messina S, Woodhall MR, et al. Clinical presentation and prognosis in MOG-antibody disease: a UK study. *Brain*. 2017;140(12):3128-3138.

Keegan M, Pineda AA, McClelland RL, Darby CH, Rodriguez M, Wienshenker BG. Plasma exchange for severe attacks of CNS demyelination: predictors of response. *Neurology*. 2002;58:143-146.

Kitley J, Leite MI, Nakashima I, et al. Prognostic factors and disease course in aquaporin-4 antibody-positive patients with neuromyelitis optica spectrum disorder from the United Kingdom and Japan. *Brain*. 2012;135(pt 5):1834-1849.

Kleiter I, Gahlen A, Borisow N, et al. Apheresis therapies for NMOSD attacks: a retrospective study of 207 therapeutic interventions. *Neurol Neuroimmunol Neuroinflamm*. 2018;5(6):e504.

Kleiter I, Gahlen A, Borisow N, et al. Neuromyelitis optica: evaluation of 871 attacks and 1,153 treatment courses. *Ann Neurol*. 2016;79(2):206-216.

Lennon VA, Wingerchuk DM, Kryzer TJ, et al. A serum autoantibody marker of neuromyelitis optica: distinction from multiple sclerosis. *Lancet*. 2004;364:2106-2112.

López-Chiriboga AS, Majed M, Fryer J, et al. Association of MOG-IgG serostatus with relapse after acute disseminated encephalomyelitis and proposed diagnostic criteria for MOG-IgG-associated disorders. *JAMA Neurol*. 2018;75(11):1355-1363.

Lucchinetti CF, Mandler RN, McGavern D, et al. A role for humoral mechanisms in the pathogenesis of Devic's neuromyelitis optica. *Brain*. 2002;125(pt 7):1450-1461.

Mealy MA, Kessler RA, Rimler Z, et al. Mortality in neuromyelitis optica is strongly associated with African ancestry. *Neurol Neuroimmunol Neuroinflamm*. 2018;5(4):e468.

Narayan R, Simpson A, Fritsche K, et al. MOG antibody disease: a review of MOG antibody seropositive neuromyelitis optica spectrum disorder. *Mult Scler Relat Disord*. 2018;25:66-72.

Ramanathan S, Mohammad S, Tantsis E, et al. Clinical course, therapeutic responses and outcomes in relapsing MOG antibody-associated demyelination. *J Neurol Neurosurg Psychiatry*. 2018;89(2):127-137.

Trebst C, Jarius S, Berthele A, et al. Update on the diagnosis and treatment of neuromyelitis optica: recommendations of the Neuromyelitis Optica Study Group (NEMOS). *J Neurol*. 2014;261(1):1-16.

Wingerchuk DM, Banwell B, Bennett JL, et al. International consensus diagnostic criteria for neuromyelitis optica spectrum disorders. *Neurology*. 2015;85:177-189.

74 Autoimmune Encephalitis and Meningitis

Andrew McKeon, Divyanshu Dubey, Eoin P. Flanagan, Anastasia Zekeridou, and Sean J. Pittock

KEY POINTS

1. Autoimmune encephalitis and meningitis are recognized as common entities in neurologic practice. Incidence is equivalent to infectious causes.
2. Autoimmune encephalitis clinical phenotypes include classical disorders, such as limbic and brainstem encephalitis, and restricted phenotypes, such as autoimmune epilepsy.
3. *N*-methyl-D-aspartate receptor encephalitis classically has a neuropsychiatric prodrome.
4. Some recognizable clinico-radiologic-serologic entities include autoimmune glial fibrillary acidic protein astrocytopathy (a form of meningoencephalitis) and γ-aminobutyric acid A receptor encephalitis.
5. Magnetic resonance imaging of brain is often normal in autoimmune encephalitis. Positron emission tomography imaging and serum and cerebrospinal fluid neural antibody testing aid clinical diagnosis. Testing both serum and cerebrospinal fluid improves overall sensitivity.
6. Neural antibody testing is often negative in autoimmune encephalitis. Other clinical clues include rapid-onset, fluctuating disease course and personal history of autoimmunity.
7. Certain immunoglobulin Gs have association with specific cancer types (paraneoplastic), which should prompt a cancer search.
8. Early immunotherapy is critical in definite autoimmune encephalitis cases.

INTRODUCTION

Neurologic disorders attributable to infection or inflammation of brain parenchyma (encephalitis) or the meninges (meningitis) are common referrals in both hospital and ambulatory neurologic practices. For many patients, a straightforward diagnosis, such as herpes simplex encephalitis, or autoimmune limbic encephalitis is rapidly discerned. For other patients, diagnostic uncertainty persists. Historically, and to a lesser extent currently, many patients are repeatedly investigated for an infectious cause, without consideration of noninfectious causes, or are treated empirically for an inflammatory or autoimmune cause after limited testing for one or two rare disorders.

Over the course of the last two decades, autoimmune causes for encephalitis and meningitis (predominantly encephalitis) have been increasingly recognized. Much of this recognition has been spurred by the discovery of a multitude of autoantibody (immunoglobulin G [IgG] isotype) biomarkers of central nervous system (CNS) autoimmune diseases. In addition, diagnostic criteria and detailed descriptions of the phenotypic spectrum have emerged.

In addition to limbic encephalitis, where patients have a triad of cognitive, psychiatric, and epileptic symptoms, other phenotypic manifestations of CNS autoimmunity are now recognized. Examples include psychiatric prodrome (encountered in *N*-methyl-D-aspartate receptor [NMDAR] encephalitis) and meningeal symptoms and signs (characteristic of autoimmune glial fibrillary acidic protein [GFAP] astrocytopathy). Improved disease recognition has led to increased incidence, with autoimmune causes of encephalitis now on an epidemiologic par with infectious causes.

Discovery of neural-specific IgG autoantibodies has provided some clues to understanding disease pathophysiology. Because some autoimmune CNS disorders have a paraneoplastic cause (neurologic disease occurring in the context of a neural protein-expressing neoplasm), a search for occult systemic cancer may be undertaken. Treatment of any underlying neoplasm may contribute to neurologic improvements. Recognition of encephalitis as having an autoimmune cause prompts initiation of immune therapies (such as corticosteroids, plasma exchange, or immune suppressants). Early treatment is known to improve neurologic prognosis in many patients. Serologic diagnosis can also be informative for treatment choices and prognosis.

Although these novel neural IgG biomarkers have improved diagnostic sensitivity for autoimmune CNS disorders, improved clinical recognition has also been informative for the existence of seronegative cases (as high as 50% of cases in some series). Careful evaluation of the history, examination, and nonneural IgG antibody testing (eg, thyroid autoantibodies) may assist in reaching an autoimmune diagnosis in the absence of neural IgG positivity. In those patients, an objectively defined sustained response to immune therapy may confirm the diagnosis.

EPIDEMIOLOGY

Evaluation of 761 cases of encephalitis of uncertain etiology in individuals aged 30 years, or younger, referred to the California Encephalitis Project between September 2007 and February 2011 demonstrated the frequency of NMDAR encephalitis matched

viral etiologies. A recent population-based epidemiology study of autoimmune encephalitis in Olmsted County, Minnesota, demonstrated that autoimmune encephalitis had a prevalence of 13.7 per 100,000 people. The age- and sex-adjusted prevalence of autoimmune encephalitis was found to be comparable to infectious encephalitis (11.6 per 100,000). Furthermore, the incidence of autoimmune encephalitis is increasing over time from 0.4 per 100,000 person-years in 1995-2005 to 1.2 per 100,000 person-years in 2006-2015, mostly attributable to increased detection of autoantibody-positive cases. The most frequently identified neural autoantibodies associated with autoimmune encephalitis were myelin oligodendrocyte glycoprotein (MOG) and glutamic acid decarboxylase 65 kDa isoform, detected in cerebrospinal fluid (CSF) or in serum at high titer [>20.0 nmol/L]). Of note, the incidence and prevalence of autoimmune encephalitis was found to be higher among African Americans than Caucasians.

PATHOBIOLOGY

Immunobiology

Antigenic proteins undergoing immune surveillance are processed by antigen-presenting cells (dendritic cells in the early stages, B lymphocytes later in the immune response) and presented to antigen-specific cluster of differentiation (CD) 4^+ T helper lymphocytes. These in turn have the potential to trigger generation of cell lineages producing immunologic effectors. Some differentiate into $CD8^+$ cytotoxic T cells. Some B-cell populations mature into antibody-producing plasma cells. The subcellular location of the antigen targeted during the autoimmune response, intracellular or plasma membrane bound, may give some clues to the pathophysiology of autoimmune encephalitis (Fig. 74.1), at the effector stage, either cytotoxic T lymphocyte or IgG autoantibody mediated, respectively.

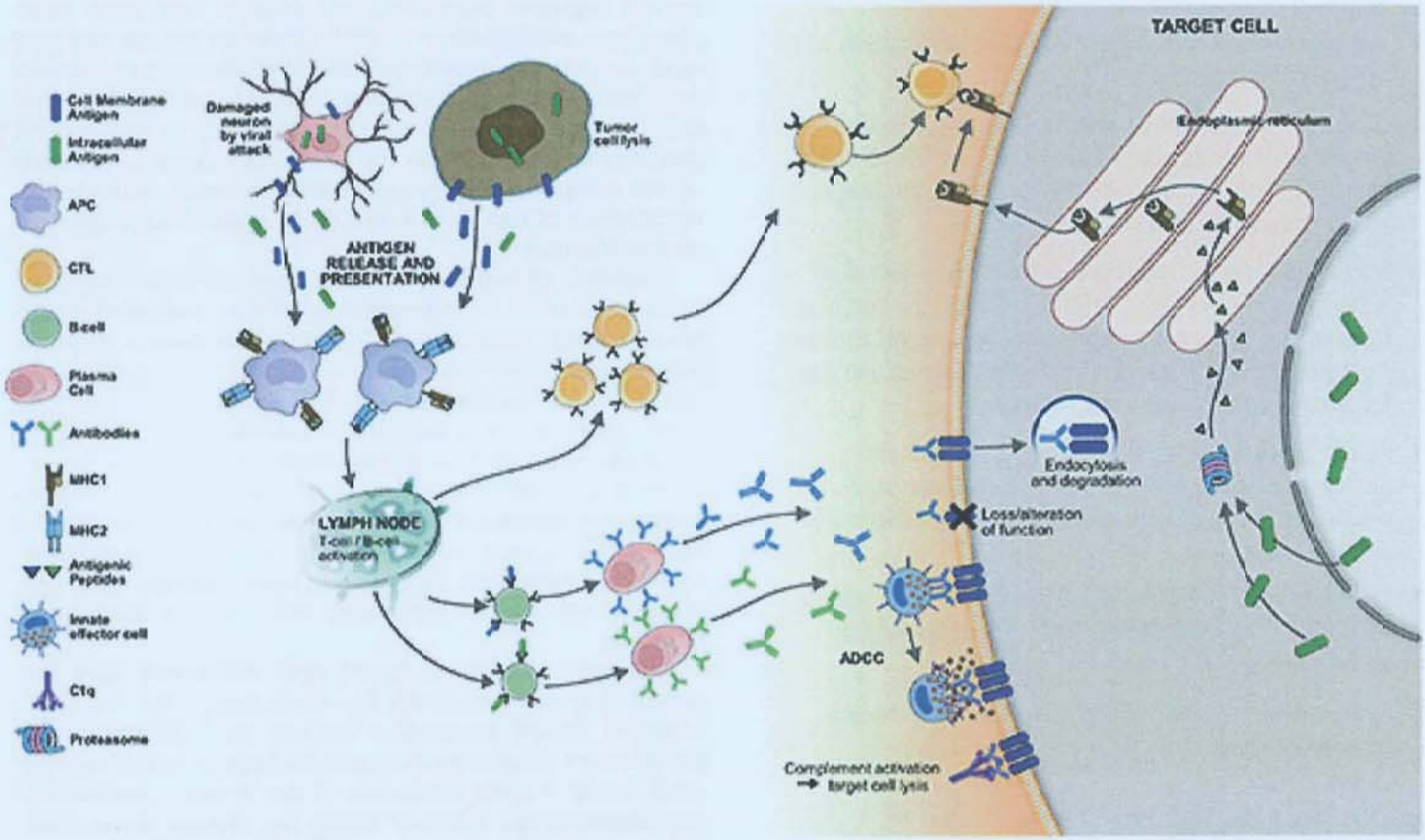

FIGURE 74.1 Mechanisms of neurologic autoimmunity. Neural antigens released (intracellular in *green*, cell membrane in *blue*) from lysed tumor cells, after initial attack by innate effectors, or from damaged neurons after viral attack, are phagocytosed and processed by antigen-presenting cells (APCs). The APCs migrate to regional lymph nodes and prime naive cluster of differentiation (CD) 4^+ T lymphocytes via the major histocompatibility complex (MHC) 2 pathway. Activated T cells proliferate and differentiate into helper (and regulatory) cells. The $CD4^+$ helper cells activate B cells that have engaged the same antigen on their receptors and differentiate into plasma cells secreting high-affinity antibodies. Cross-presentation of antigenic peptides via the MHC1 pathway from the APCs prime antigen-specific $CD8^+$ cytotoxic effector T lymphocytes (CTLs). Circulating CTLs attack cells expressing MHC1-complexed antigenic peptides, which arise from degradation of intracellular neural antigens by the proteasome, and are subsequently loaded on MHC1 molecules in the endoplasmic reticulum. Immunoglobulin Gs that bind to the extracellular domain of neural plasma membrane proteins may lead to antigen internalization, functional blockade, antibody-dependent cellular cytotoxicity (ADCC) or complement activation and cell lysis.

The trigger of autoimmunity in cases of autoimmune encephalitis is often unknown. Some are associated with malignancies or prior viral CNS infections. Paraneoplastic neurologic disorders occur in the context of robust antitumor immune responses against neural antigens expressed in cancers that are also physiologically expressed in the nervous system (known as *onconeural antigens*; see Fig. 74.1). Onconeural antigens can be expressed by tumors in both native and mutated forms (neo-epitopes). In the tumor bed, antigen is released after tumor cell death, processed, and presented by antigen-presenting cells to the T cells in regional lymph nodes. The $CD4^+$ helper T cells primed via the major histocompatibility complex (MHC) 2 pathway, activate antigen-specific B cells to differentiate into plasma cells and produce antibodies. Cross-presentation of an antigen via the MHC class I pathway primes $CD8^+$ cytotoxic T cells that then migrate to both cancer site and CNS and can exert their cytotoxic effect. In the last decade, immune checkpoint inhibitors for cancer treatment have become available. These monoclonal autoantibodies target coinhibitory, negative regulatory steps of the immune response and thus enhance antitumor immunity but also autoimmunity. Neurologic manifestations have been reported.

Neuronal and glial synaptic membrane proteins can be targeted by IgGs that are potentially pathogenic and responsible for the disease manifestations. These IgGs bind to extracellular epitopes of ionotropic and metabotropic receptors, water channels, and neural adhesion proteins. The effects of these autoantibodies have been recapitulated in live neuronal and astrocytic cultures in vitro. A major mechanism of action of multiple synaptic IgGs implicated in autoimmune encephalitis is antigen binding, cross-linking, and subsequent internalization and antigen degradation. This mechanism has been studied in detail in patients with IgGs specific for NMDAR or aquaporin-4 (AQP4) CNS water channel, and this effect of the antibodies is reversible upon antibody removal in vitro. Antibody-dependent cell-mediated cytotoxicity and complement cascade activation have also been implicated in AQP4 autoimmunity. Disruption of protein-protein interactions by autoantibodies, and thus interference with the protein target's function, is likely the major mechanism of action in diseases that are primarily mediated by IgG4 autoantibodies, such as leucine-rich glioma–inactivated protein 1 (LGI1) and contactin-associated protein 2 encephalitides. Animal models of passive transfer of synaptic autoantibodies delivered directly to the CNS compartment (in NMDAR encephalitis) or to the periphery (contactin-associated protein 2 encephalitis) have reproduced clinical and histopathologic findings of these diseases.

In contrast to IgGs targeting neural synapses, IgGs specific for intracellular neural antigens do not exert cell-specific cytotoxicity themselves, but nonetheless are biomarkers of likely effector T cell–mediated disease. Cytotoxic T cells can only recognize antigen if presented as a MHC1-complexed antigen-derived peptide (see Fig. 74.1).

In recent years, postinfectious autoimmune encephalitides have been recognized, mainly after herpes simplex virus encephalitis. It is hypothesized that local release of neural antigens from neuronal death leads to immune system activation and antigen-specific autoimmunity rather than molecular mimicry. This has also been reproduced in an animal model. Genetic susceptibility to autoimmunity has also been implicated. Human leukocyte antigen associations have been found for some patients with antibody-associated neurologic autoimmunity, such as LGI1 encephalitis. At the time pf writing, the coronavirus 2019/2020 (COVID19) outbreak has presented opportunities to explore the pathophysiology of postinfectious inflammatory encephalitis further.

Immunopathology

Tumors from patients with paraneoplastic neurologic autoimmunity often contain inflammatory onconeural antigen-directed plasma cells and T cells within the tumors. Brain pathology often reflects the pathophysiologic mechanisms described earlier (Fig. 74.2). In patients with T cell–mediated autoimmunity, such as that targeting amphiphysin or Hu, there is extensive immune infiltration consisting mostly of cytotoxic T cells and macrophages and neuronal loss. In contrast, in autopsy samples from patients with NMDAR encephalitis, there are moderate inflammatory infiltrates, consisting of plasma cells, IgG deposition, and microglial activation. In AQP4 autoimmunity, complement plays an important role in the disease pathogenesis. In AQP4 autoimmunity lesions, there are products of complement activation around blood vessels and immunoglobulin deposits. In contrast, in MOG autoimmunity, demyelination is the primary pathologic feature.

DIAGNOSIS

Clinical Manifestations

Autoimmune Meningitis

Autoimmune meningitis can present with one or more of headache, blurred vision, hearing loss, tinnitus, fever, vomiting, and, sometimes, cranial nerve signs. The only disorder in which a neural IgG has been described in a meningitic context is autoimmune GFAP astrocytopathy. Those patients generally have encephalitic signs also. However, autoimmune pachymeningitis and leptomeningitis can occur in patients with or without systemic and other organ-specific autoimmune disorders, such as systemic lupus erythematous, rheumatoid arthritis, and Crohn disease. Pachymeningitis may occasionally arise in patients with a fibroinflammatory disorder known as *IgG4-related disease*, so called because of the dense infiltration of IgG4-positive plasma cells in a variety of organs (pancreas, salivary glands, thyroid, mediastinum, retroperitoneum, kidney, retro-orbital space). Other patients may have a chronic inflammatory meningitis complicating CNS inflammatory disorders such as sarcoidosis or Behçet disease or occurring in isolation without further case definition. A form of recurrent idiopathic meningitis, known as *Mollaret meningitis*, may have an autoimmune or other inflammatory cause.

Autoimmune Encephalitis: General Features

Autoimmune encephalopathy typically presents with subacute onset of cognitive decline, delirium, and psychiatric symptoms (mood change or psychosis). Accompanying symptoms include headache, blurred vision, and disrupted sleep. In addition, patients may have one or more of accompanying movement disorders (ataxia, myoclonus or chorea) (▶ Videos 74.1 and 2). There may be additional clues to an autoimmune diagnosis (Table 74.1). For patients with a paraneoplastic cause, encephalopathy may be a component of a multifocal neurologic disorder. Comorbid neurologic disorders may include myelopathic symptoms and signs, peripheral neuropathy, or neuromuscular junction disorder (myasthenia gravis or Lambert-Eaton syndrome).

There are certain clinical syndromes that are clinically classical, and most have diverse neural antibody associations (eg, limbic encephalitis). Other clinical syndromes, or clinico-radiologic entities, are synonymous with particular IgG findings (eg, NMDAR

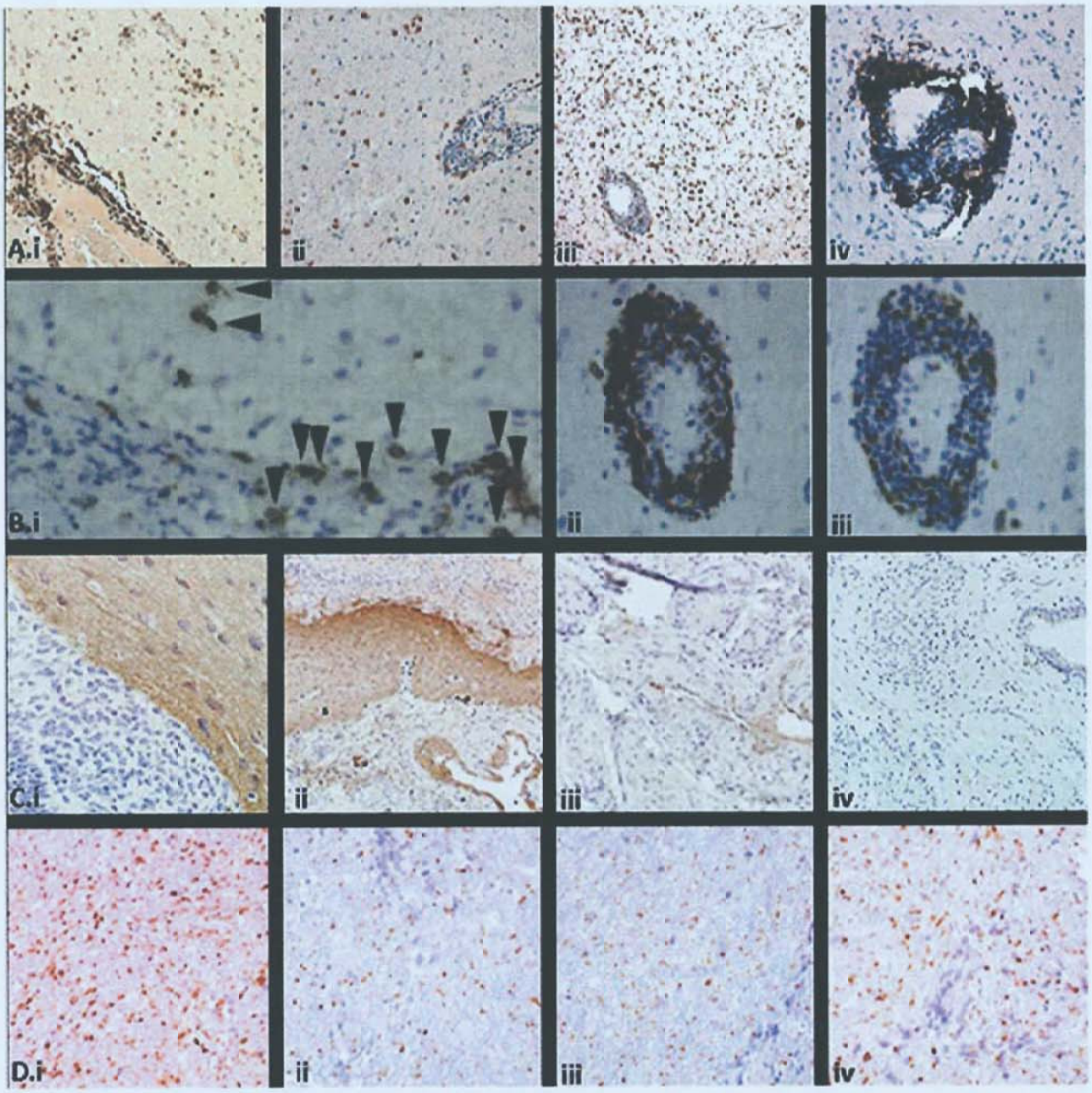

FIGURE 74.2 Examples of brain and tumor immunopathology from patients with neurologic autoimmunity. **A:** Perivascular and parenchymal mononuclear leukocyte infiltrates in the brain of a patient with amphiphysin-immunoglobulin G (IgG) autoimmunity **(i)**; in the parenchyma are mostly cluster of differentiation (CD) 8^+ **(ii)** or macrophages **(iii)**, whereas B-cells are located in the perivascular locations **(iv)**. (From Pittock SJ, Lucchinetti CF, Parisi JE, et al. Amphiphysin autoimmunity: paraneoplastic accompaniments. *Ann Neurol*. 2005;58[1]:96-107, Fig. 3A-D.) **B:** Plasma cells **(i)**, B cells **(ii)**, and T cells **(iii)** in tissue from a patient with *N*-methyl-D-aspartate receptor (NMDAR) encephalitis. Note that plasma cells (*arrowheads* in **i**) are in perivascular regions and along the brain surface delineating spaces containing cerebrospinal fluid and small vessels. (From Martinez-Hernandez EM, Horvath J, Shiloh-Malawsky Y, Sangha N, Martinez-Lage M, Dalmau J. Analysis of complement and plasma cells in the brain of patients with anti-NMDAR encephalitis. *Neurology*. 2011;77[6]:589-593, Fig. 3K.) **C:** Immunohistochemical staining of a mature ovarian teratoma from a patient with autoimmune glial fibrillary acidic protein (GFAP) astrocytopathy reveals varying degrees of GFAP expression **(i and ii)**, faint NMDAR expression in the endothelial cells **(iii)**, and no aquaporin-4 expression **(iv)**, which matched the patients IgG serologic profile. (From Dubey D, Hinson SR, Jolliffe EA, et al. Autoimmune GFAP astrocytopathy: prospective evaluation of 90 patients in1 year. *J Neuroimmunol*. 2018;321:157-163, Fig. 3A-D.) **D:** Immunohistochemical staining of a Merkel cell metastatic carcinoma from a patient with neuronal intermediate filament autoimmunity (NIF) reveals expression of α internexin **(i)**, NIF light chain **(ii)**, NIF medium chain **(iii)**, and NIF heavy chain **(iv)**, which matched the patients IgG serologic profile. (From Basal E, Zalewski N, Kryzer TJ, et al, Paraneoplastic neuronal intermediate filament autoimmunity. *Neurology*. 2018;91[18]:e1677-e1689, Fig. 6.)

TABLE 74.1 Clues to an Autoimmune Encephalitis Diagnosis

Subacute onset with rapid progression of cognitive, behavioral, psychiatric symptoms, seizures
Fluctuating clinical course, with partial or full spontaneous remissions
Tremulousness, myoclonus
Headache, meningism, blurred vision
Personal or family history of autoimmune disease
History of cancer
Nonneural antibodies positive (eg, thyroid autoantibodies)
CNS inflammation on MRI or global hypometabolism on PET imaging
CNS inflammation in CSF (elevated white cell count, IgG index or synthesis rate, oligoclonal bands)
Dramatic objective response to immune therapies

Abbreviations: CNS, central nervous system; CSF, cerebrospinal fluid; IgG, immunoglobulin G; MRI, magnetic resonance imaging; PET, positron emission tomography.

encephalitis). Many patients present with restricted forms of these (eg, autoimmune epilepsy in LGI1 encephalitis) or have unique or rare presentations. Diagnostic criteria for autoimmune encephalopathy have been proposed by Graus et al (2016).

Classical Encephalitis Syndromes

Limbic Encephalitis

Limbic encephalitis is a classic CNS autoimmune disorder. Patients typically present with delirium, mood change, memory and personality disturbance, and focal seizures of mesial temporal type with or without secondary generalization. Head magnetic resonance imaging (MRI) usually reveals unilateral or bilateral T2 sequence signal abnormalities in mesial temporal regions, with or without enhancement visible on T1 sequence postgadolinium. Electroencephalography (EEG) may reveal unilateral or bilateral temporal slowing or epileptiform discharges. Neural autoantibody findings are diverse. Some are highly predictive of cancer (eg, anti-Hu), whereas other are predictive of a response to immunotherapy (eg, LGI1 antibody) (▶ Video 74.3).

Brainstem Encephalitis

Presenting symptoms include one or more of cranial neuropathies, eye movement disorders, vertigo, nausea and vomiting (sometimes intractable), postural instability, and parkinsonism. Jaw closing dystonia is particularly associated with brainstem encephalitis accompanying antineuronal nuclear antibody (ANNA) 2 (anti-Ri) (▶ Video 74.4). Brainstem encephalitis is a common presentation for patients with either Ma2 antibody (also known as *anti-Ta*, usually young men with testicular carcinoma) or both Ma1 and Ma2 antibodies (also known as *anti-Ma*, men and women with heterogenous cancer types). Sensorineural hearing loss and tinnitus frequently accompanies Kelch-like protein 11 autoimmune brainstem encephalitis. The MRI of brain may be normal or demonstrate T2 abnormalities in the brainstem and/or cerebellum.

Opsoclonus-Myoclonus Syndrome

Opsoclonus-myoclonus syndrome (also known as "dancing-eyes, dancing-feet syndrome") is pathognomonic for an autoimmune diagnosis, either parainfectious, paraneoplastic, or idiopathic autoimmune (see Video 74.1). Patients present with vertigo, dizziness, nausea and vomiting, tremulousness, and imbalance. Neurologic exam reveals generalized myoclonic jerks and lightning-like haphazard eye movements, consistent with myoclonus of the extraocular muscles (opsoclonus). Commonly encountered neoplasms include neuroblastoma and lung carcinoma and breast carcinoma (in adults). Rather than opsoclonus-myoclonus syndrome, some patients may present with opsoclonus or limb and truncal myoclonus in isolation, with or without encephalopathy.

Morvan Syndrome

Morvan syndrome is a rare multifocal disorder, usually accompanying contactin-associated protein 2 autoimmunity. Features include encephalitis, sleep disturbance, dysautonomia, and peripheral nerve hyperexcitability. Thymoma is the typical oncologic accompaniment.

Progressive Encephalomyelitis With Rigidity and Myoclonus

Progressive encephalomyelitis with rigidity and myoclonus (PERM) is within the spectrum of CNS hyperexcitability disorders, also known as *stiff-person spectrum disorders*. Exaggerated startle response, hypertonia and superimposed spasms are common to both stiff-person syndrome (▶ Video 74.5) and PERM. However, PERM is more widespread and severe and generally includes encephalopathic features. The glutamic acid decarboxylase 65 kDa isoform antibody is detected in some of these patients, although historically, most PERM patients had been seronegative. Glycine receptor and dipeptidyl-peptidase-like protein 6 antibodies are now recognized as diagnostic markers of PERM.

Clinically Restricted Forms

Autoimmune Epilepsy

Some patients with autoimmune encephalitis present with seizures only or a predominance of seizures. These more restricted clinical presentations merit special mention, as they may be overlooked as having an autoimmune cause because of the nonclassical presentations. Autoimmune epilepsy may be defined as seizures as the exclusive or major presenting symptom, where an autoimmune cause was suspected on the basis of detection of neural antibody, inflammatory CSF, or head MRI, consistent with the diagnosis. Patients with autoimmune epilepsy are typically lacking classical epilepsy risk factors, such as a history of acquired brain injury and family history of epilepsy. Most affected patients have several of these factors, and one factor in isolation is poorly predictive of an autoimmune cause. Two additional syndromes are suspected to have an autoimmune cause because of the rapidity of onset and severe clinical course, although most patients have an idiopathic illness without immunologic biomarkers detected. These are known as *new-onset refractory status epilepticus* in adults and *fever-induced refractory epileptic encephalopathy syndrome* in children. Dramatic clinical responses attributed to an interleukin 1 receptor antagonist (anakinra) in some reported cases is supportive of an immunologic etiology.

Autoimmune Dementia

Other patients do not have seizures or altered sensorium but present with rapidly progressive cognitive loss. Autoimmune dementia phenotypes may resemble Creutzfeldt-Jakob disease or rapidly progressive Alzheimer disease or Lewy body disease. Tremulousness and headache at presentation, marked fluctuations in the clinical course, and spontaneous remission suggest an autoimmune cause.

Nonlimbic Encephalitis: Serologically Defined Entities

NMDA Receptor Antibody Encephalitis

Patients with NMDAR antibody (targeting the GluN1 [NR1] subunit) have a fairly stereotyped neurologic disorder, as described below by Dalmau and colleagues. Prodromal symptoms include headache, fever, nausea, vomiting, diarrhea, or upper respiratory tract symptoms. Patients develop psychiatric symptoms (anxiety, insomnia, fear, delusions, mania, and paranoia), and many initially come to the attention of psychiatrists. Other behavioral changes include social withdrawal and stereotyped behavior. Amnesia and an unusual language disorder (noncortical aphasia) are common. The behavioral changes in children may be less specific and include temper tantrums and hyperactivity. Neurologic disorders including seizures and dyskinesias are frequent. After these initial symptoms, in both adults and children, decreased responsiveness often ensues. Movement disorders include oro-lingual-facial dyskinesias, generalized chorea, oculogyric crisis, dystonia, and rigidity. Frequent autonomic manifestations include hyperthermia, tachycardia, hypersalivation, hypertension, bradycardia, hypotension, urinary incontinence, and erectile dysfunction. Hypoventilation, necessitating prolonged ventilatory support (often months) may be required. Dissociative responses similar to those caused by NMDAR antagonists (eg, phencyclidine or ketamine) have been observed (eg, resisting eye opening despite lack of response to painful stimuli).

Autoimmune GFAP Astrocytopathy

Affected patients present with symptoms of meningitis (headache and neck ache), encephalitis (delirium, tremor, seizures, or psychiatric symptoms), and myelitis (sensory symptoms and weakness). Optic papillitis (disc swelling causing blurred vision) is common. The CNS inflammation is evident on T1 postgadolinium (enhancement of GFAP-enriched CNS regions; Fig. 74.3F) and in lymphocyte-predominant CSF white cell count elevation. The CSF is more sensitive and specific than serum for GFAP-IgG testing. Ovarian teratoma commonly coexists, particularly among patients with accompanying NMDAR or AQP4 autoimmunity. Corticosteroid responsiveness is a hallmark of the disease. Relapses occur in approximately 20% of patients, necessitating transition to a steroid-sparing drug during prednisone taper.

$GABA_A$ Receptor Encephalitis

Affected patients (adults or children) typically present with multifocal antiepileptic drug-refractory seizures, other encephalitic symptoms, and abnormalities on brain MRI (multifocal, non–diffusion-restricting, nonenhancing, medium- to large-sized cortical, juxtacortical, and subcortical lesions) (Fig. 74.3B).

Encephalitis Accompanying Neuromyelitis Optica Spectrum Disorders, Optic Neuritis, or Myelitis

Optic neuritis and transverse myelitis (radiologically longitudinally extensive), either single episode or recurrent, are characteristic of both AQP4 autoimmunity and MOG autoimmunity. Encephalitis can occur with either disorder also. Acute disseminated encephalomyelitis is a characteristic syndrome accompanying MOG autoimmunity. Patients, most commonly children, present with fever, encephalopathy, and multifocal neurologic dysfunction. The MRI demonstrates large inflammatory-appearing lesions of the brain (Fig. 74.3E) and, often also, the spinal cord. Although optic neuritis and myelitis predominate in AQP4 autoimmunity, patients may present with brain symptoms or develop asymptomatic brain lesions radiologically during the clinical course.

Neural IgG Seronegative Autoimmune Encephalopathy

In some instances, the more generic term of autoimmune encephalopathy, or encephalitis, without reference to a specific neural antibody is appropriate. This is because the neural antibody detected has less specificity for encephalitis (eg, P/Q type calcium channel antibody), or no neural antibody has been detected, but other clues for an autoimmune diagnosis are discovered (see Table 74.1). These clues could include one or more of a history of coexisting autoimmune diseases (eg, thyroid disease or pernicious anemia), the detection of nonneural autoantibodies (such as thyroid peroxidase or connective tissue disease autoantibodies) in serum, an inflammatory spinal fluid, an encephalitic-appearing head MRI, and a response to immunotherapy. Both Hashimoto encephalopathy and steroid-responsive encephalopathy associated with autoimmune thyroiditis refer to a triad of encephalopathy (commonly with stroke-like episodes, negative MRI), thyroid autoimmunity, and clinical improvements with immunotherapy. Because both thyroid autoantibodies and cognitive symptoms are generally common, including among healthy individuals, this example serves to underline the importance of objectifying reported cognitive improvements with immunotherapy.

Imaging

MRI Brain Imaging

Head MRI with gadolinium is an essential diagnostic test in the evaluation of autoimmune encephalitis and meningitis. The presence of unilateral (Fig. 74.3A1) or bilateral (Fig. 74.3C) mesial temporal lobe T2 hyperintensities is supportive of autoimmune limbic encephalitis and may be accompanied by gadolinium enhancement. Occasionally, seizure-related signal abnormalities in those with status epilepticus can result in mesial temporal T2 hyperintensities mimicking limbic encephalitis. Focally restricted diffusion, thalamic hyperintensities, and gyral enhancement are also recognized as seizure-related MRI findings. In NMDAR encephalitis, most patients have normal brain MRI. In those with abnormalities, a wide variety of T2-signal abnormalities have been reported, and there may be an overlap with other disorders which routinely produce MRI abnormalities (such as MOG and GFAP autoimmunity).

The MOG autoantibodies, in addition to optic neuritis and myelitis, are associated with acute disseminated encephalomyelitis-like multifocal T2 hyperintensities in the white matter and deep gray matter (thalamus and basal ganglia; see Fig. 74.3E). In addition to typical radiologic findings of optic neuritis and myelitis, patients with AQP4-IgG seropositive neuromyelitis optica spectrum disorders develop brain lesions in two-thirds of cases, with or without clinical accompaniments, such as encephalopathy. Peri-third and fourth ventricular lesions (including the area postrema) are typical.

The γ-aminobutyric acid (GABA) A receptor antibody encephalitis T2-signal abnormalities are multifocal involving the white and gray matter (see Fig. 74.3B). Diencephalic lesions adjacent to the third ventricle are reported with Ma2 encephalitis with an accompanying narcolepsy/cataplexy phenotype (Fig. 74.3A2). Basal ganglia T2 hyperintensities with accompanying hyperkinetic movement disorders have been reported with phosphodiesterase

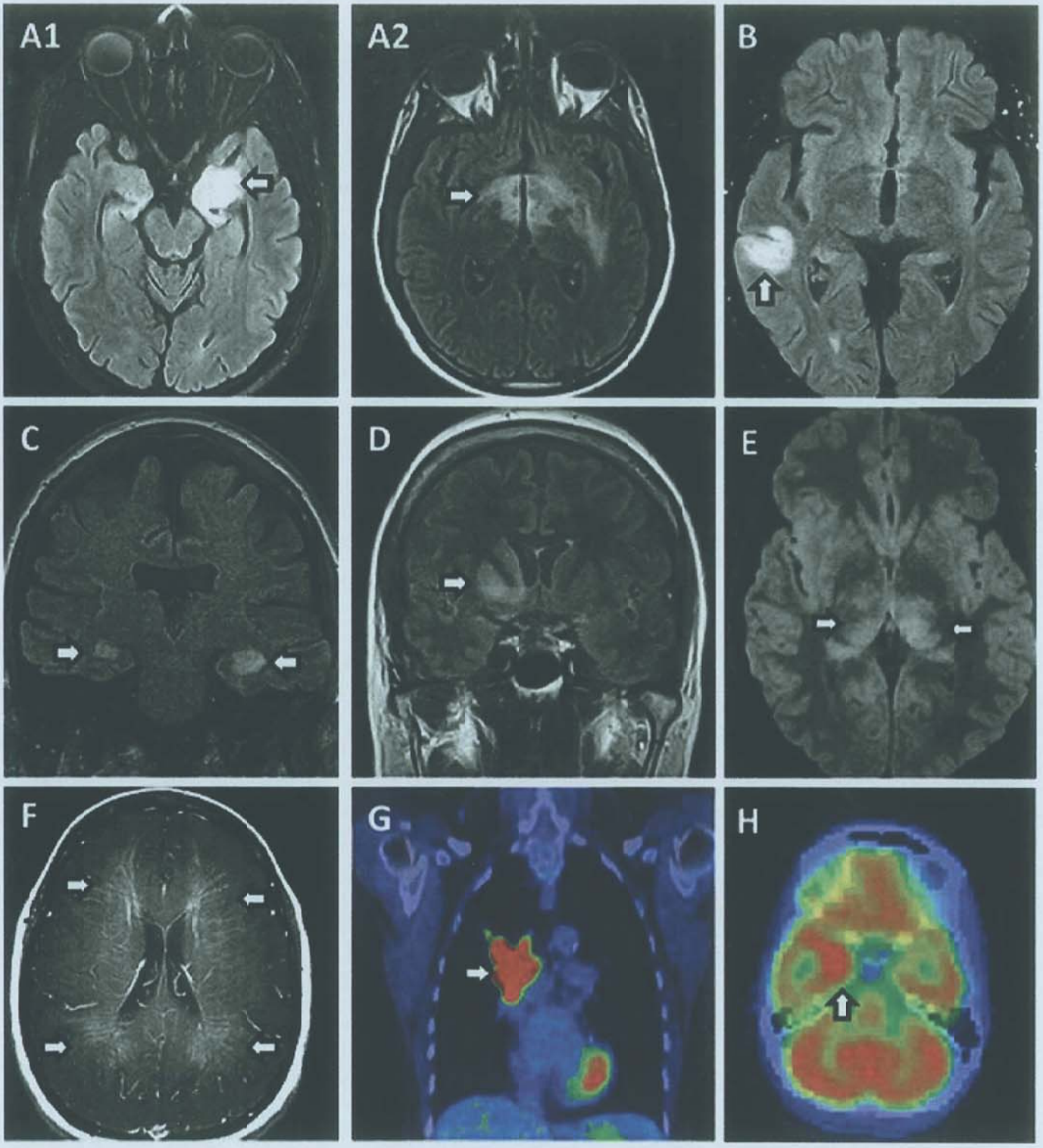

FIGURE 74.3 Imaging abnormalities in autoimmune encephalitis. In a patient with Ma2 encephalitis, axial magnetic resonance imaging (MRI) reveals T2 hyperintensity in the left mesial temporal lobe (**A1**, *arrow*) which is accompanied by bilateral midline T2 hyperintensity in the hypothalamus (**A2**, *arrow*). **B:** In a patient with γ-aminobutyric acid A receptor encephalitis, axial MRI shows a corticosubcortical T2 hyperintensity in the right temporal lobe *(arrow)*. **C:** In a patient with α-amino-3-hydroxy-5-methyl-4-isoxazolepropionic (AMPA) receptor antibody encephalitis, coronal MRI reveals bilateral T2 hyperintensities in the mesial temporal lobe *(arrows)*. **D:** In a patient with leucine-rich glioma–inactivated protein 1 antibody encephalitis, coronal MRI reveals right caudate and putamen T2 hyperintensity *(arrow)*. **E:** In a patient with acute disseminated encephalomyelitis (myelin oligodendrocyte glycoprotein-immunoglobulin G positive), axial MRI reveals bilateral thalamic T2 hyperintensities *(arrows)*. **F:** Axial postgadolinium MRI reveals radial perivascular enhancement *(arrows)* in autoimmune glial fibrillary acidic protein astrocytopathy. **G:** In a patient with AMPA receptor antibody encephalitis, whole-body ^{18}F-fluorodeoxyglucose positron emission tomography (FDG-PET) reveals a hypermetabolic lung mass *(arrow)*, confirmed to be small cell carcinoma at histology. **H:** Axial brain FDG-PET reveals right mesial temporal hypermetabolism *(arrow)*.

10A and collapsin-response mediator protein (CRMP) 5 antibodies. Basal ganglia T1 or T2 hyperintensities occasionally accompany faciobrachial dystonic seizures in LGI1 encephalitis (Fig. 74.3D).

The presence of linear radial perivascular enhancement extending outward from the ventricles is suggestive of autoimmune GFAP astrocytopathy and isolated leptomeningeal enhancement is also frequently encountered (see Fig. 74.3F).

Several other disorders, with possible autoimmune cause, but no antibody biomarker known, also have classical radiologic findings. The presence of infarcts, microhemorrhages, and leptomeningeal enhancement is suggestive of primary CNS vasculitis or amyloid-β related angiitis. Circular "snowball-like" T2 hyperintensities of the corpus collosum suggest Susac syndrome, a disorder characterized by a triad of encephalopathy, branch retinal artery occlusions, and hearing loss. Behçet disease is frequently associated with brainstem lesions but also may result in cerebral venous sinus thrombosis or be associated with leptomeningeal (pia and arachnoid) enhancement in association with a chronic meningitis. Other inflammatory etiologies of meningitis associated with leptomeningeal enhancement include neurosarcoid (which has a predilection for the basilar meninges) and rheumatoid arthritis-associated meningitis. Autoimmune disorders most often associated with pachymeningeal (dural) enhancement include IgG4-related disease and granulomatosis with polyangiitis (previously termed *Wegener granulomatosis*).

Positron Emission Tomography

^{18}F-Flourodeoxyglucose positron emission tomography (PET) is one of the most sensitive tests for early changes in autoimmune encephalitis, although lacking specificity. Glucose hypometabolism is the most common finding in autoimmune encephalitis, but hypermetabolism may occasionally coexist or rarely occur in isolation (Fig. 74.3H). Mesial occipital glucose hypometabolism has been reported to be the most common finding in NMDAR encephalitis. Basal ganglia hyper- or hypometabolism may accompany faciobrachial dystonic seizures in LGI1 antibody encephalitis.

Electroencephalography

The EEG plays a vital role in diagnosis and management of autoimmune encephalitis. Although not specific for autoimmune encephalitis, demonstration of encephalopathy electrographically (diffuse delta or theta slowing) assists in objectifying cerebral dysfunction and serves as a baseline for future comparison during treatment and patient follow-up. The NMDAR and LGI1 encephalitides are sometimes accompanied by specific EEG findings or semiologies.

Extreme delta brush was described as a characteristic finding in NMDAR encephalitis patients on continuous EEG monitoring in the neurointensive care unit (Fig. 74.4). Extreme delta brush consists of rhythmic delta activity at 1 to 3 Hz with superimposed

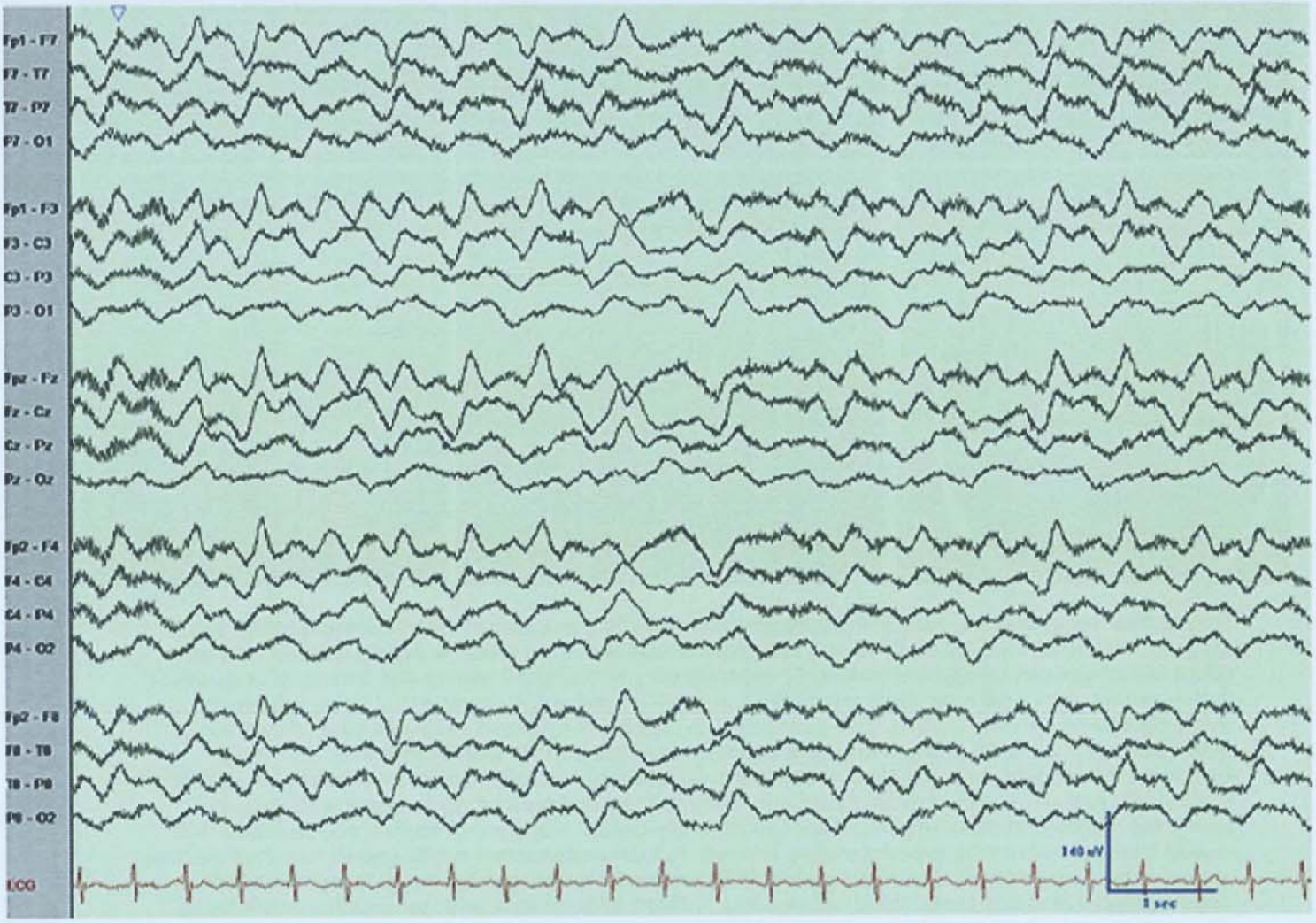

FIGURE 74.4 Extreme delta brush in a patient with *N*-methyl-D-aspartate receptor encephalitis. Fast beta rhythm "riding on" diffuse slow waves. (Courtesy Dr. Jeffrey Britton, Mayo Clinic.)

burst of rhythmic beta activity at 20 to 30 Hz riding on each delta wave. It is usually present in severely affected patients, in both adult and pediatric age groups. Faciobrachial dystonic seizures are pathognomonic for LGI1 encephalitis (see Video 74.3). Ictal EEG during faciobrachial dystonic seizures is usually obscured by prominent muscle artifact. However, rhythmic slow wave activity over the contralateral frontal or frontotemporal region followed by diffuse EEG attenuation can occasionally be seen.

Antibody Testing

Evaluations of serum and CSF for neural-specific IgG biomarkers and less specific clues (such as thyroid antibodies or elevated CSF white cell count) should be undertaken in suspected autoimmune encephalitis cases.

Informative nonneural autoantibody specificities may be organ specific (such as thyroid autoantibodies) or non–organ specific (such as antinuclear, antismooth muscle, or antimitochondrial antibodies). These markers per se lack specificity for neurologic autoimmunity. The detection in CSF of elevated protein, white cell count, CSF-exclusive oligoclonal bands, IgG index, or IgG synthesis rate also supports an autoimmune etiology. However, these parameters lack specificity for an autoimmune cause and may be detected in other inflammatory CNS disorders for which there are no specific biomarkers (eg, multiple sclerosis).

Antigen targets of neural IgG autoantibodies fall into two broad classes based on subcellular location: intracellular and cell-surface (extracellular) (Tables 74.2 and 74.3). Screening tests for these autoantibodies include immunohistochemistry (tissue-based or cell-based; Fig. 74.5), enzyme-linked immunosorbent assay, and immunoprecipitation assays. In some instances, reflex testing may be indicated to confirm antigen-specificity (by Western blot or cell based) or to quantitate an end point value or titer. Some autoantibodies are more readily detected in serum (eg, LGI1-IgG) and others in CSF (NMDAR antibody); thus, the diagnostic yield is maximized by testing both serum and CSF, simultaneously or sequentially.

TABLE 74.2 Neural Immunoglobulin G Autoantibodies With Specificity for Intracellular Antigens (Nuclear, Cytoplasmic, or Nucleolar) in Autoimmune Encephalitis

Antibody	Antigen	Neurologic Presentations	Oncologic Association
AGNA	SOX-1	Limbic encephalitis, neuropathy, Lambert-Eaton syndrome	Small cell carcinoma
Amphiphysin	Amphiphysin	Limbic encephalitis, aphasia, other subacute-onset dementias, stiff-person phenomena, myelopathy, neuropathy	Small cell carcinoma, breast adenocarcinoma
ANNA-1	ELAVL (Hu)	Limbic encephalitis, brainstem encephalitis, sensory autonomic and other peripheral neuropathies	Small cell carcinoma
ANNA-2	Nova 1, Nova 2 (Ri)	Dementia, limbic encephalitis, brainstem encephalitis, jaw dystonia, myelopathy, opsoclonus-myoclonus syndrome, peripheral neuropathy	Small cell carcinoma, breast adenocarcinoma
ANNA-3	Unknown	Brainstem encephalitis, limbic encephalitis, myelopathy, peripheral neuropathy	Aerodigestive carcinomas
AP3B2	AP3B2	Gait disorders (cerebellar, dorsal column, sensory ganglionopathy) and dysautonomia	None known
CRMP-5	CRMP-5	Cognitive disorders, chorea, ataxia, myelopathy, radiculopathy, neuropathy, Lambert-Eaton syndrome	Small cell carcinoma, thymoma
GAD65 (high titer)	GAD65	Limbic encephalitis, brainstem encephalitis, stiff-man syndrome, stiff-man phenomena, ataxia, seizures, ophthalmoplegia, parkinsonism, myelopathy	Thymoma; renal cell, breast or colon adenocarcinoma
GFAP	GFAP-α/GFAP-ε isoforms	Meningoencephalomyelitis	Teratoma, diverse other
GRAF/ARHGAP26	GRAF	Brainstem signs (eye movement abnormalities) and ataxia	GI hematologic
ITPR1	ITPR1	Brainstem signs (eye movement abnormalities) and ataxia	Breast, lung hematologic
Kelch-like protein 11	Kelch-like protein 11	Brainstem encephalitis, cerebellar ataxia, limbic encephalitis accompanied by hearing loss	Testicular germ cell tumors
Ma1, Ma2	PNMA1, PNMA2	Limbic encephalitis, brainstem encephalitis, ataxia	Testicular germ cell tumors (Ma2 only), diverse (Ma1, Ma2)
NIF	NF-L, NF-H, α-internexin	Encephalopathy, ataxia, myelopathy	Small cell carcinoma (NF-L–IgG)
PDE10A	PDE10A	Encephalopathy, movement disorders	Renal cell adenocarcinoma
PCA-1	CDR2, CDR2-like	Brainstem encephalitis, cerebellar ataxia, myelopathy, neuropathies	Müllerian/breast adenocarcinoma
PCA-2	MAP1B	Limbic encephalitis, ataxia, brainstem encephalitis, Lambert-Eaton syndrome, peripheral and autonomic neuropathies	Small cell carcinoma
Septin-5	Septin-5	Brainstem signs (eye movement abnormalities) and ataxia	None known

Abbreviations: AGNA, antiglial/neuronal nuclear antibody; ANNA, antineuronal nuclear antibody; CDR2, cerebellar degeneration protein-2; CRMP, collapsin-response mediator protein; ELAVL, ELAV-like protein; GAD65, glutamic acid decarboxylase, 65 kDa isoform; GFAP, glial fibrillary acidic protein; GI, gastrointestinal; IgG, immunoglobulin G; ITPR1, inositol triphosphate receptor-1; MAP1B, microtubule associated protein 1B; NF-H, neurofilament heavy chain; NF-L, neurofilament light chain; NIF, neuronal intermediate filament; PCA, Purkinje cell cytoplasmic antibody; PNMA, paraneoplastic Ma protein; SOX, SRY-Box; AP3B2, adaptor protein 3B2; GRAF, GTPas regulator associated with focal adhesion kinase 1; ARHGAP26, Rho GTPase activating protein 26; PDE10A, phosphodiesterase 10A.

TABLE 74.3 Neural Immunoglobulin G Autoantibodies With Specificity for Extracellular Domain of Receptors and Channels in Autoimmune Encephalitis

Antibody	Antigen	Oncologic Association	Neurologic Presentation
AMPA receptor	GluR1, GluR2	Thymic tumors, lung carcinomas, breast carcinoma	Limbic encephalitis, nystagmus, seizures
DPPX	DPPX (DPP6)	Rarely B-cell neoplasia	Encephalomyelitis
$GABA_A$ receptor	$GABA_A$ receptor	Thymoma	Multifocal lesional encephalitis
$GABA_B$ receptor	$GABA_B$ receptor	Small cell lung carcinoma, other neuroendocrine neoplasia	Limbic encephalitis, intractable seizures, orolingual dyskinesias
Glycine receptor	α_1 Subunit GlyR	Thymoma, lymphoma	Progressive encephalomyelitis with rigidity and myoclonus, stiff-person syndrome
IgLON-5	IgLON5	None known	Sleep disorders, encephalopathy, chorea, parkinsonism
LGI1/CAPSR2	LGI1, CASPR2	Thymoma	Limbic encephalitis, faciobrachial dystonic seizures and other seizure types, neuromuscular hyperexcitability
mGluR1	mGluR1	Hodgkin lymphoma, prostate adenocarcinoma	Ataxia, dysgeusia, vertigo, cognitive symptoms, seizures
mGluR5	mGluR5	Hodgkin lymphoma	Limbic encephalitis
MOG	MOG	None known	ADEM-like presentation in children, relapsing optic neuritis, transverse myelitis
Neuronal ganglionic AChR	Neuronal ganglionic AChR	Adenocarcinoma, thymoma, small cell carcinoma	Dysautonomia, peripheral somatic neuropathies, encephalopathies
NMDA receptor	GluN1	Ovarian teratoma	Anxiety, psychosis, seizures, encephalopathy, dyskinesia, hypoventilation, coma.
NMO	Aquaporin-4	Some reports of thymoma and other solid tumors	ADEM-like presentation in children, relapsing optic neuritis, transverse myelitis; circumventricular organ involvement (intractable nausea vomiting, hiccups, narcolepsy)
P/Q- and N-type calcium channel	P/Q and N-type calcium channels	Small cell carcinoma, breast or gynecologic adenocarcinoma	Encephalopathies, myelopathies, neuropathies, Lambert-Eaton syndrome

Abbreviations: AChR, acetylcholine receptor; ADEM, acute disseminated encephalomyelitis; AMPA, α-amino-3-hydroxy-5-methyl-4-isoxazolepropionic; CASPR2, contactin-associated protein 2; DPPX, dipeptidyl-peptidase-like protein 6; $GABA_A$, γ-aminobutyric acid type A; $GABA_B$, γ-aminobutyric acid type B; GluR1, glutamate receptor 1; GluR2, glutamate receptor 2; GlyR, glycine receptor; IgLON5, immunoglobulin-like protein family member 5; LGI1, leucine-rich glioma–inactivated protein 1; mGluR1, metabotropic glutamate receptor 1; mGluR5, metabotropic glutamate receptor 5; MOG, myelin oligodendrocyte glycoprotein; NMDA, *N*-methyl-D-aspartate; NMO, neuromyelitis optica; GluN1, glutamate receptor, NMDA type, subunit 1; GluR1, glutamate receptor 1; GluR2, glutamate receptor 2.

Antibodies detected in most classic paraneoplastic encephalitides recognize intracellular antigens (see Table 74.2). These antibodies usually have positive predictive values for very specific cancer types greater than 70% and thus help direct the search for cancer. Some more recently discovered examples have cancer significance less commonly (eg, GFAP-IgG). Antibodies directed at neural cell plasma membrane antigens (see Table 74.3) are more recently described and have varying positive predictive cancer values (eg, <10% for glycine receptor antibody vs 50% or greater for antibodies targeting NMDA, α-amino-3-hydroxy-5-methyl-4-isoxazolepropionic, and $GABA_B$ receptors). The response to one or more of steroids, intravenous immunoglobulin (IVIG), and plasma exchange is often excellent, with full neurologic remission possible.

Algorithmic testing for autoantibody profiles is a more sensitive diagnostic strategy than nominal physician-selected single antibody testing. For example, seropositivity for amphiphysin-IgG predicts either small cell carcinoma or breast adenocarcinoma, but the presence or absence of coexisting small cell carcinoma associated antibodies narrows that differential diagnosis.

The profile of antibodies detected may also guide immunotherapy and may also be informative for neurologic prognosis. Studies suggest that autoimmune neurologic disorders for which the antigens of marker IgGs are intracellular such as Hu (the target ANNA-1) rarely improve with antibody-depleting therapies. On the other hand, IgGs targeting neural cell surface receptors (such as the NMDAR IgG) do have a pathogenic role in effecting autoimmune CNS disorders, which may remit after antibody-depleting immunotherapy.

Cancer Workup

The cancer types encountered in paraneoplastic disorders, known antibody associations, and testing modalities that can assist in cancer detection and diagnosis are listed in Table 74.4. In the context of paraneoplastic disorders, the neurologic symptoms appear first in 70% of cases. Neoplasms are commonly limited to the primary site or may just be detectable at a regional lymph node or small, distant metastatic site. Thus, these neoplasms may be difficult to identify on conventional imaging. An informative neural autoantibody profile can assist in radiologic modality selection. For example, thymoma is identified in 85% of patients seropositive for all of muscle striational, acetylcholine receptor, and CRMP-5 autoantibodies. Lung carcinoma is identified in 80% of patients seropositive for all of P/Q-type and N-type calcium channel antibodies and SRY-Box (SOX) 1-IgG. In women, amphiphysin-IgG alone directs the physician toward

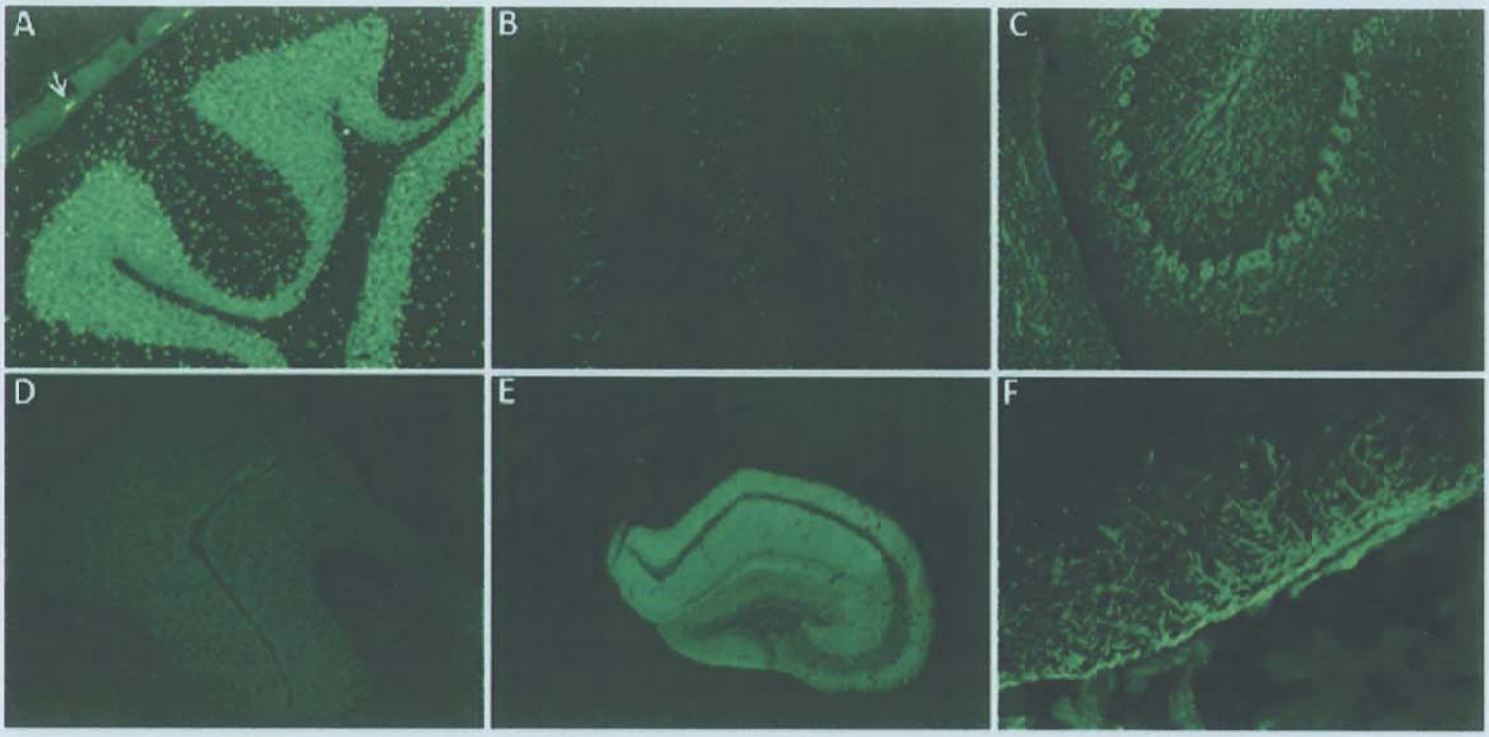

FIGURE 74.5 Characteristic immunoglobulin G (IgG) staining patterns of mouse tissue-based indirect immunofluorescence assay. **A:** Antineuronal nuclear antibody 1 (anti-Hu) produces staining of nuclei and myenteric plexus of adjacent gut *(arrow)* but not parietal cells **(top left). B,C:** Purkinje cell cytoplasmic antibody 2 **(B,** MAP1B-IgG) and neuronal intermediate filament IgG **(C)** can be differentiated by differences in synaptic and filamentous staining of cerebellum. **D,E:** α-Amino-3-hydroxy-5-methyl-4-isoxazolepropionic receptor antibody produces synaptic (neuropil) staining of the cerebellum **(D)** and hippocampus **(E). F:** Glial fibrillary acidic protein-IgG produces staining of the periventricular ependyma and astrocyte precursor-enriched subependymal layer but spares the choroid **(bottom left).**

either breast or lung cancer, but the coexistence of ANNA-1 (Hu) or CRMP-5-IgG predicts small cell lung cancer.

For suspected lung cancer or thymoma, high-resolution computed tomography (CT) of the chest is recommended in the first instance. The MRI of the chest is also a sensitive testing modality for thymoma. The PET is sensitive for evaluation of mediastinal lymph nodes for local metastatic disease. Tissue diagnosis should be pursued aggressively if a thoracic lesion or lymphadenopathy is identified. Fine-needle aspiration biopsy guided by transesophageal ultrasonography, transbronchial endoscopy, or CT yields tissue confirmation with varying success and complications. The CT of the abdomen and pelvis is helpful in identifying large primary visceral malignancies and metastases. Endoscopies are most sensitive and specific for identifying primary gastrointestinal malignancies.

For breast cancer evaluation, mammography is the gold standard. Tissue diagnosis of subtle abnormalities should be pursued. The MRI of the breast or sonography is helpful in some cases.

Evaluation of gynecologic cancer status may require sonography of the pelvis in addition to CT and manual pelvic examination. For Purkinje cell cytoplasmic antibody 1 (anti-Yo)-positive patients whose breast evaluation, pelvic imaging and examination, and serum cancer antigen 125 levels are all normal, exploratory laparotomy may reveal pelvic carcinoma (ovarian, fallopian tubal, or serous surface papillary adenocarcinoma). The most useful screening tests for ovarian teratoma (eg, in females with NMDAR encephalitis) include MRI and pelvic ultrasound with transvaginal views (if age appropriate). Serologic tumor markers (cancer antigen 125, β-human chorionic gonadotropin, α-fetoprotein, or testosterone) are not recommended in the diagnostic workup of such patients. In general, testicular ultrasonography is warranted in men with subacute brainstem/cerebellar/limbic encephalitis, whether or not Ma2 or Kelch-like protein 11 antibodies are detected.

If radiologic investigation fails to indicate an abnormality suspicious for cancer, whole-body fluorodeoxyglucose PET can be helpful in identifying cancers such as pulmonary and extrapulmonary small cell carcinoma, thyroid malignancies, and lymphoma) (Fig. 74.3G). The PET-CT is inadequate for evaluation of possible thymoma, teratoma, GI malignancy, and primary testicular tumors.

If the patient's autoantibody profile is highly predictive of cancer, and no cancer is detected at initial evaluation, repeat screening is recommended at 6- to 12-month intervals for up to 5 years. Patient-specific factors should also be considered. For children and women of childbearing age, MRI is preferred over CT to minimize radiation exposure. The total radiation exposure of PET body is equivalent to CT chest, abdomen, and pelvis with and without contrast, approximately 25 mSv, comparable to 8 years of natural background radiation.

MANAGEMENT

A rational therapeutic approach to autoimmune encephalitis and meningitis can be devised based on treatments that have been successfully applied in the past to a variety of other autoimmune disorders. For paraneoplastic encephalitis or meningitis, where

TABLE 74.4 Diagnostic Evaluation for Cancer in Suspected Paraneoplastic Neurologic Disorders[a]

Cancer Type	Neural Ab Specificities Associated	Diagnostic Imaging Tests	Blood Tests/Tumor Biomarkers	Comments
Breast adenocarcinoma	**High risk:** ANNA-2 (Ri), Ma1 and Ma2, amphiphysin, PCA-1 (Yo) **Low risk:** recoverin (anti-CAR), P/Q- and N-type VGCC, AQP4, GFAP, ITPR1, ARHGAP26 (GRAF1), AMPA receptor	Mammogram Breast MRI	CA 15-3 CA 27-29	Familial breast cancer—BRCA1 and BRCA2 Measurement of ER, PR, and HER2 should be performed on tissue.
Lung: pulmonary and extrapulmonary small cell cancer Also some non–small cell	**High risk:** ANNA-1 (Hu), ANNA-2 (Ri), ANNA-3, Zic4, SOX1, amphiphysin, CRMP-5, PCA-2 (MAP1B), recoverin **Low risk:** Ma1 and Ma2, Ma2 alone, $GABA_B$ receptor, muscle AChR, P/Q- and N-type VGCC, neuronal ganglionic AChR, GFAP, ITPR1; AMPA receptor, NIF	Chest x-ray, chest CT with contrast PET	Multiple biomarkers reported but lack high enough specificity and sensitivity for current clinical practice	Environmental factors such as smoking history important in risk assessment
Testicular: germ cell/seminoma	**High risk:** Ma2 alone, KLHL11	Testicular US PET (for mediastinal, extra scrotal metastases)	α-Fetoprotein Human chorionic gonadotrophin	NA
Teratoma	**High risk:** NMDA receptor (NR1) **Low risk:** GFAP, AQP4	Pelvic CT Pelvic MRI Vaginal US	Generally negative	FDG-PET not recommended—teratomas show little or no FDG uptake
Ovarian carcinoma	**High risk:** PCA-1 (Yo) **Low risk:** Ma2, recoverin, P/Q- and N-type VGCC, GFAP, ARHGAP26 (GRAF1)	CT MRI pelvis PET	CA 125 (79%)	If PCA-1 positive but cancer workup negative, consider diagnostic laparoscopy.
Müllerian duct	**High risk:** PCA-1 (Yo)	CT MRI pelvis PET	NA	NA
Endometrial/cervical	**Low risk:** recoverin, P/Q- and N-type VGCC	Hysteroscopy Cervical smear, colposcopy	NA	NA
Gastrointestinal	**High risk:** PCA-1 (Yo) in men **Low risk:** neuronal ganglionic AChR, ARHGAP26 (GRAF1)	Upper and lower gastrointestinal endoscopy CT abdomen	CEA	Rarely associated with paraneoplastic disorders
Hematologic including Hodgkin lymphoma	**Low risk:** anti–Ta, anti-Ma2, α1 subunit GlyR, DPPX GFAP (rare), ITPR1, ARHGAP26 (GRAF1), α1 subunit GlyR **High risk:** PCA type Tr (delta/notch-like epidermal growth factor-related receptor); mGluR1, mGluR5	Chest x-ray, PET, MRI, and CT	CBC, bone marrow biopsy, blood smear, immunophenotyping (flow cytometry), β_2 microglobulin, serum creatinine, lactate dehydrogenase	NA
Thymoma	**High risk:** ANNA-1 (Hu), CRMP-5-IgG, LGI1[+] CASPR2, AMPA receptor **Low risk:** GAD65, AQP4-IgG, neuronal ganglionic AChR, muscle AChR, α1 subunit GlyR, LGI1, CASPR2, $GABA_A$ receptor	Chest CT with contrast	NA	NA
Neuroendocrine, Merkel cell, neuroblastoma, other	**High risk:** ANNA-1 (Hu)—especially children, NF-L **Low risk:** $GABA_B$ receptor	CT PET	Considerations: chromogranin A, NSE, u-5HIAA, plasma gastrin, insulin, glucagon, somatostatin, VIP, PP, others (plasma calcitonin, GHRH, IGF1, ACTH, PTH-rp)	NA

TABLE 74.4 Diagnostic Evaluation for Cancer in Suspected Paraneoplastic Neurologic Disorders[a] *(continued)*

Cancer Type	Neural Ab Specificities Associated	Diagnostic Imaging Tests	Blood Tests/Tumor Biomarkers	Comments
Prostate	Low risk: mGluR1, neuronal ganglionic AChR	MRI	PSA	Rarely associated with paraneoplastic disorders
Bladder/urothelial	Low risk: GFAP (rare)	Cystoscopy	NA	Rarely associated with paraneoplastic disorders
Renal	Low risk: Ma2, PDE10A	Abdomen CT, renal US	NA	Rarely associated with paraneoplastic disorders

Abbreviations: Ab, antibody; AChR, acetylcholine receptor; ACTH, adrenocorticotropin; AMPA, α-amino-3-hydroxy-5-methyl-4-isoxazolepropionic; ANNA, anti-neuronal nuclear antibody; AQP, aquaporin; CA, cancer antigen; CAR, cancer-associated retinopathy; CASPR2, contactin-associated protein 2; CBC, complete blood count; CRMP, collapsin-response mediator protein; CT, computed tomography; DPPX, dipeptidyl-peptidase-like protein 6; ER, estrogen receptor; FDG, fluorodeoxyglucose; $GABA_A$, γ aminobutyric acid type A; $GABA_B$, γ-aminobutyric acid type B; GAD65, glutamic acid decarboxylase, 65 kDa isoform; GFAP, glial fibrillary acidic protein; GHRH, growth hormone–releasing hormone; GlyR, glycine receptor; HER2, human epidermal growth factor receptor-2; IGF1, insulin-like growth factor 1; IgG, immunoglobulin G; ITPR1, inositol triphosphate receptor-1; KLHL11, Kelch-like protein 11; LGI1, leucine-rich glioma–inactivated protein 1; MAP1B, microtubule associated protein 1B; mGluR1, metabotropic glutamate receptor 1; mGluR5, metabotropic glutamate receptor 5; MRI, magnetic resonance imaging; NF-L, neurofilament light chain; NIF, neuronal intermediate filament; NMDA, *N*-methyl-D-aspartate; NSE, plasmatic neuron-specific enolase; PCA, Purkinje cell cytoplasmic antibody; PET, positron emission tomography; PP, pancreatic polypeptide; PR, progesterone receptor; PTH-rp, parathyroid-hormone like hormone; SOX, SRY-Box; u-5HIAA, urinary 5-hydroxy-indolacetic acid; US, ultrasound; VGCC, voltage-gated calcium channel; VIP, vasoactive intestinal peptide; BRCA1, breast cancer type 1 susceptibility protein; BRCA2, breast cancer type 2 susceptibility protein; Zic4, zinc finger protein of the cerebellum 4; CEA, carcinoma embyronic antigen; PSA, prostate specific antigen; PDE10A, phosphodiesterase 10A.

[a]High risk indicates >50% likelihood of malignancy, and low risk indicates <10% likelihood of malignancy (if antibody occurring in isolation).

cancer is identified, the general goal is to surgically remove the tumor in its entirety. Unfortunately, this generally does not result in significant clinical improvement. At the current time, we recommend standard oncologic therapy for such cases.

At the current time, there is no level 1 evidence or standardized guidelines to inform immunotherapeutic decisions in autoimmune encephalitis. The authors typically use a protocol divided into acute and chronic therapeutic phases. Before starting treatment, baseline neurologic and ancillary evaluations (eg, EEG, MRI, cognitive testing) should be performed to establish baseline parameters for objective treatment response monitoring. Antibody titers have limited use as a surrogate of clinical outcome.

Acute Therapy

For acute therapy, a trial of high-dose pulse intravenous or oral corticosteroids therapy is usually the first treatment tried. The IVIG may be used in patients who are unlikely to tolerate corticosteroids or are at risk for diabetes. Typical treatment protocols are outlined in Table 74.5. In patients with limited early responses to steroids, plasma exchange can be given as every other day exchanges (five to seven treatments) for 10 to 14 days. If IVIG is the primary treatment used, a weekly infusion of 0.4 to 1 g/kg can be used, or alternatively, 3 to 5 consecutive days on a monthly basis.

After the initial trial of therapy, the patient should be reevaluated to objectively determine the response to immunotherapy. If a rapid series of trials of immunotherapy are not beneficial in an acutely ill hospitalized patient with a well-characterized antibody-mediated encephalitis or meningitis, steroid or IVIG therapy should be continued, and an immunosuppressant (such as rituximab or cyclophosphamide) should be introduced early. In addition, therapeutic levels of antiepileptic drugs and supportive therapy for weeks to months are required. Supportive therapies will be required in an intensive care unit setting. This scenario is particularly relevant for patients with NMDAR encephalitis, who frequently require months of supportive care in addition to immunosuppression. In the author's experience, patients with isolated meningitis of unknown cause are generally treatable with corticosteroids and slow taper, once infectious causes and cancer have been excluded. Rituximab and corticosteroids tend to be used first line for the treatment of IgG4-related meningitis.

Chronic Therapy

Objective improvements should prompt consideration of maintenance immunotherapy over the longer term particularly if symptoms relapse on withdrawal of short-term acute therapies. Medium- (6 mo to 1 y) to long-term therapy (>1 y) with corticosteroids or IVIG is sometimes required, but the overall goal is for the eventual discontinuation of these. Oral immunosuppressants such as azathioprine or mycophenolate mofetil are useful to permit elimination of steroids or IVIG, where longer term treatment is planned (due to a prior relapse or patient known to be at risk for relapse). In the authors' practice, the interval between infusions of intravenous methylprednisolone or IVIG is extended over a period of 4 to 6 months from weekly to fortnightly, every 3 weeks, and then monthly, and eventual discontinuation. A faster taper of intravenous therapy can result in a relapse. When daily oral prednisone is being used, a slow reduction from 60-mg prednisone by 10 mg per month is preferable, with the last 10 mg being eliminated by 1 mg/mo. Some overlap of treatment with corticosteroid or IVIG and an oral long-term immunosuppressant is needed (a minimum of 12 wk for azathioprine and 8 wk for mycophenolate mofetil). Nonetheless, some patients remain dependent on corticosteroids or IVIG, despite appropriate dosing of oral long-term immunosuppression. Rituximab and cyclophosphamide can be considered as chronic therapies in patients who required these agents during the acute phase or patients who relapse and fail to respond to first-line therapies, although cyclophosphamide exposure should generally not exceed 18 months total, because of the risk of secondary hematologic malignancy. The authors recommend a trial of withdrawal of chronic therapy after 3 to 5 years, where no relapses have occurred.

For patients with paraneoplastic encephalitis where CNS injury is presumed to be predominantly cytotoxic T cell mediated (eg, Purkinje cell cytoplasmic antibody 1–associated cerebellar ataxia, ANNA-1–associated limbic encephalitis), with evidence of continuing neurologic deterioration, the authors tend to treat as early as possible with 12 weeks of intravenous methylprednisolone and initiate 6 to 12 months of oral or intravenous cyclophosphamide (see Table 74.5).

Emerging therapies also warrant consideration, especially in treatment refractory cases. In one study, patients with rituximab-refractory autoimmune encephalitis treated with tocilizumab (anti–interleukin 6) had better long-term outcomes compared

TABLE 74.5 Acute and Maintenance Immunotherapies for Autoimmune Encephalitis and Meningitis[a]

Therapy	Route/Dose/ Frequency	Monitoring/Other Recommendations	Mechanism of Action	Major Side Effects
Methylprednisolone (IVMP)	IV: 1,000 mg, daily for 3 consecutive days then once weekly for 5-11 wk	Trimethoprim/sulfamethoxazole (Bactrim DS) one tablet 3 times per week for *Pneumocystis carinii* prophylaxis. If allergic to sulfa, alternatives include dapsone 50 mg orally daily or pyrimethamine 50 mg orally weekly or leucovorin 25 mg orally weekly or atovaquone 1500mg orally daily or aerosolized pentamidine 300 mg every 4 wk. Proton-pump inhibitor (omeprazole) or H2 inhibitor (ranitidine) for gastrointestinal prophylaxis; calcium 1,500 mg and vitamin D 800 U daily	Inhibition of NF-κB, critical for the synthesis of cytokines/other components of the immune response pathway reduction in both T-cell and B-cell proliferation	Immunodeficiency, hyperglycemia and diabetogenesis, osteoporosis, avascular necrosis (hip or other joints), fat redistribution and weight gain, muscle breakdown, gastrointestinal ulcers, and memory and attention deficits. Prolonged usage (>1 wk) is also associated with adrenal suppression and atrophy of the adrenal glands, which may take months to recover.
IVIG	0.4 g/kg daily for 3 d followed by 0.4 g/kg every week for 5-11 wk	Check total immunoglobulin (Ig) and Ig isotypes to *exclude selective IgA deficiency*. Use with caution in patients with renal impairment or a history of thrombotic events.	Precise mechanism(s) of action not established: Include binding of anti-idiotypic antibodies to pathogenic antibodies, inhibition of the complement cascade, or increased degradation of existing autoantibodies.	Headache, infusion reactions, autoimmune hemolytic anemia, aseptic meningitis, deep venous thromboses, pulmonary emboli, acute tubular necrosis, renal failure, and pulmonary edema
Plasma exchange	Three to six plasma exchanges over consecutive or alternating days via a large-bore catheter	Administered in conjunction with other immunotherapies that are aimed at suppressing autoantibody production. The notable exception to this is GBS, which is a monophasic disorder and for which plasmapheresis is considered first line.	Removal of large molecular weight entities, including the antibody compartment and inflammatory cytokines and immune complexes while preserving the other components of the blood.	Central line infections, pneumothorax at line placement, hypotension
Rituximab (also consider ocrelizumab)	IV: 2 × 1,000 mg 14 d apart or 4 weekly doses of 375 mg/m^2, each cycle can be given routinely every 6 mo without monitoring of CD20/CD19 counts or by dosing as soon as CD20/CD19 >1%.	Baseline and follow-up HBV serology; baseline and monthly CBC; monthly consider CD20/CD19 B cells starting immediately postinfusion; if CD20/CD19 count exceeds 1% of total lymphocytes, redose with rituximab. If suppression of CD20/CD19 count does not occur, consider switching to alternative. Monitor immunoglobulins yearly. Premedicate with acetaminophen and an antihistamine.	Depletion of the B-cell compartment by promoting B-cell auto-apoptosis, complement-mediated cytotoxicity, and antibody-mediated cytotoxicity. Note: CD20 is not expressed on B-cell progenitors in the bone marrow (which allows for repopulation following rituximab therapy) or following terminal B-cell differentiation into the antibody-secreting lineages (plasmablasts and plasma cells).	Significant reactions can include infusion reactions, which may include edema, hypertension, fever, fatigue, chills, headache, insomnia, rash, pruritus, nausea, diarrhea, cytopenias, neutropenic fever, angioedema, bronchospasm, urticaria, and, in more severe cases, myocardial infarction, ventricular fibrillation, cardiogenic shock, and/or anaphylactic shock. Reactivation of hepatitis B causing fulminant hepatitis or latent tuberculosis may be fatal. Rarely, viral reactivation has been associated with rituximab, including JC virus which can cause PML.

TABLE 74.5 Acute and Maintenance Immunotherapies for Autoimmune Encephalitis and Meningitis[a] *(continued)*

Therapy	Route/Dose/ Frequency	Monitoring/Other Recommendations	Mechanism of Action	Major Side Effects
Cyclophosphamide	IV: 500-1,000 mg/m^2 monthly for 3-6 mo Orally: 1-2 mg/kg in morning	The blood count nadir typically occurs between 8 and 14 d postinfusion. For WBC nadir of <3,000 cells/mm^3 of blood but >1,500 cells/mm^3 of blood, reduce next dose by 25%. For WBC nadir <1,500 cells/mm^3 of blood or absolute neutrophil count <500 cells/mm^3 of blood, reduce dose by 50%. For hemoglobin <8.3 g/dL, the dose should be reduced by 25%. For platelet counts <80,000 cells/mm^3 of blood, reduce dose by 50%. For serum Cr <2.0 mg/dL, the standard dose may be used. For serum Cr 2.0 mg/dL, give 75% of standard dose. For serum Cr >3.5 mg/dL, give 50% of the standard dose. For serum bilirubin 3.1-5 mg/dL or transaminases elevation, 75% of the dose should be administered. For serum bilirubin >5 mg/mL, cyclophosphamide should not be used. Follow UA every month. Severe, potentially fatal acute hemorrhagic cystitis may occur. Therefore, mesna prophylaxis and prehydration are important.	Alkylating agent that causes irreversible DNA cross-linking during cell replication, leading to apoptosis	Marrow suppression, hemorrhagic cystitis, infertility, cardiotoxicity, and an increased risk of secondary malignancies including bladder carcinoma and acute myeloid leukemia. alopecia (40%-60%): Hair will usually regrow, although it may be a different color and/or texture. Hair loss usually begins 3-6 wk after the start of therapy. Sterility: Cyclophosphamide may cause sterility through interfering with oogenesis and spermatogenesis. This may be irreversible in some patients. Nausea and vomiting: This usually begins 6-10 h after administration; anorexia, diarrhea, mucositis, and stomatitis may also occur.
Tocilizumab (also consider satralizumab)	8 mg/kg administered for two or more cycles in regular 1-mo intervals	Consider in rituximab/cyclophosphamide refractory encephalitis/meningitis. Screening for latent TB infection and chronic HBV infection	Blocks IL-6 mediated proinflammatory signaling, reduction in APC survival; reduction in proinflammatory B-cell activity	Hypersensitivity reactions, including anaphylaxis. and increased risk of infection, including opportunistic infections
Bortezomib	IV: 1.3 mg/m^2 per dose twice-weekly for 2 wk, followed by a 10-d rest period (21-d treatment cycle) for a maximum of eight treatment cycles	Monitor CBC and LFTs regularly throughout treatment. Use a lower starting dose for patients with moderate or severe hepatic impairment. Women should avoid becoming pregnant. Patients with preexisting severe neuropathy should be treated only after careful risk-benefit assessment. Valacyclovir prophylaxis (500 mg orally per day) required to prevent against disseminated zoster infection	Binds catalytic site of 26S proteasome, reduces autoantibody titers, enhanced apoptosis of APC	Most commonly reported adverse reactions (incidence ≥20%) in clinical studies include nausea, diarrhea, thrombocytopenia, neutropenia, peripheral neuropathy, fatigue, neuralgia, anemia, leukopenia, constipation, vomiting, lymphopenia, rash, pyrexia, and anorexia. Also reported arrhythmia, heart failure, PRES, thrombocytopenia, hepatic toxicity, thromboses.
Azathioprine (+ prednisone)	Orally: 2-3 mg/kg/d	Initial: TPMT activity assay, CBC, Cr, LFTs. Periodic: Target MCV↑ ≥5 fL weekly CBC, LFTs for 1 mo, monthly for 6 mo, and then twice per year; maintain absolute neutrophil counts >1,000 cells/μL.	Inhibition of purine (and therefore DNA) synthesis affects rapidly proliferating cells—especially effector B and T cells and promoting T-cell apoptosis upon costimulation.	Hypersensitivity reactions, fever, malaise, myalgias, nausea/vomiting, and diarrhea are common. Low WBC count Leukopenia, anemia, thrombocytopenia, liver toxicity or pancreatitis may occur. Rarer complications include infection, skin neoplasia, and lymphoma. Limit sun and ultraviolet light exposure

(table continues on page 770)

TABLE 74.5 Acute and Maintenance Immunotherapies for Autoimmune Encephalitis and Meningitis[a] *(continued)*

Therapy	Route/Dose/ Frequency	Monitoring/Other Recommendations	Mechanism of Action	Major Side Effects
Mycophenolate mofetil (+ prednisone)	Orally: 1,000-3,000 mg/d	Initial: CBC, Cr, and LFTs. Periodic: ALC target of 1,000-1,500 cells/μL; weekly CBC, LFT for 1 mo, monthly for 6 mo, and then twice per year Drug levels can be measured to avoid undertreatment or toxicity. The level of mycophenolic glucuronide (an enzyme that metabolizes mycophenolate) may be indicative of risk for drug toxicity or a subtherapeutic drug level.	Inhibits B- and T-cell proliferation due to the fact that these lymphocytes lack an alternative nucleotide salvage pathway, thereby causing T-cell apoptosis and reducing B-cell antibody production	Gastrointestinal, including diarrhea, dyspepsia, and nausea. Other common side effects include hypertension and edema. Serious side effects, although rare, include CNS lymphoma or other malignancies and opportunistic infection. Thrombocytopenia, leukopenia, or neutropenia can occur. Mycophenolate is associated with an increased risk of congenital malformations and first trimester pregnancy loss.
Prednisone	Orally: 15-30 mg daily dose; taper after 1 y	See IVMP.	See IVMP.	See IVMP.
Calcineurin inhibitors CsA Tacrolimus	Orally: started at 2-5 mg/kg/d twice daily Orally: 0.15-0.30 mg/kg two divided oral doses	Narrow therapeutic window. Frequent monitoring of CsA/ tacrolimus blood concentrations is necessary to minimize side effects and optimize efficacy of immunosuppression. Frequent CBC and Cr.	Both cyclosporine and tacrolimus prevent the activity of calcineurin, thereby reducing IL-2 production and T-cell activation. CsA has also been shown to inhibit B-cell proliferation and activation.	Mild gingival hyperplasia, hirsutism, and tremor to potentially severe hypertension with posterior reversible encephalopathy syndrome, nephrotoxicity, neurotoxicity, and malignancy. Tacrolimus, which has a very similar mechanism of action to CsA, appears to be better tolerated, with milder reported side effects.
Methotrexate (+ prednisone)	Orally:15-25 mg weekly	Check LFTs every 3 mo; recommend 1 mg of folate supplementation; avoid NSAIDs. Avoid if Cr >3 mg/dL. Monitor CBC monthly.	Folic acid analog that inhibits purine and pyrimidine synthesis, thus interrupting DNA replication and consequently cell proliferation	Gastrointestinal distress, fatigue, neutropenia, and rarely hepatotoxicity

Abbreviations: ALC, absolute lymphocyte count; ALT, alanine aminotransferase; APC, antigen-presenting cell; CBC, complete blood count; CD, cluster of differentiation; CNS, central nervous system; Cr, creatinine; CsA, cyclosporin A; GBS, Guillain-Barré syndrome; HBV, hepatitis B virus; IL, interleukin; IV, intravenous; IVIG, intravenous immunoglobulin; IVMP, intravenous methylprednisolone; JC, John Cunningham; LFTs, liver function tests; MCV, mean corpuscular volume; NF-κB, nuclear factor kappa-light-chain-enhancer of activated B cells; NSAID, nonsteroidal anti-inflammatory drug; PML, progressive multifocal leukoencephalopathy; PRES, posterior reversible encephalopathy syndrome; TB, tuberculosis; TPMT, thiopurine methyltransferase; UA, urinalysis; WBC, white blood cell.
[a]Female patients of reproductive potential should have a negative pregnancy test immediately before therapy, and the test should be repeated 8-10 d later. Pregnancy tests should be repeated during routine follow-up visits. Acceptable forms of contraception should be used during treatment and for 6 wk after therapy is discontinued.

with those patients who continued rituximab or received no subsequent treatment. The plasma cell-depleting proteasome inhibitor bortezomib has resulted in clinical improvement in otherwise treatment-refractory NMDAR encephalitis. Other promising agents include inebilizumab (targets CD19 and thus allows targeting of plasmablasts) and anakinra (targets the proinflammatory cytokine, interleukin 1).

Careful monitoring for side effects of long-term immunotherapy is critical. Surveillance include monitoring of blood counts, liver, and renal function. Where azathioprine is the oral agent chosen, thiopurine methyltransferase deficiency needs to be eliminated prior to treatment initiation. Experience suggests that monitoring for a rise of mean corpuscular volume of at least 5 points from baseline is an indicator of efficacy.

Patients on glucocorticoids must also take elemental calcium 1,500 mg/d and vitamin D 1,000 IU/d, either dietary or in supplement form. Deterioration of bone mineral density may occur shortly after initiating steroids. Baseline and follow-up bone densitometry and bisphosphonate treatment should be considered in those needing more than 3 months of steroid treatment. *Pneumocystis jiroveci* pneumonia prophylaxis should consist of trimethoprim/sulfamethoxazole one double-strength tablet 3 times per week (or one single-strength tablet daily) for patients on chronic corticosteroids or azathioprine. Alternatives for sulfa-allergic patients include daily oral atovaquone 1,500 mg/d.

PREDICTIVE SCORES

Application of predictive scores in neurologic practice could optimize utilization of neural autoantibody evaluation and immunotherapeutic trials. To aid with this selection, a composite score was formulated: Antibody Prevalence in Epilepsy and Encephalopathy (APE2). The APE2 score is based on clinical features suggestive of autoimmune encephalitis and initial neurologic assessment (Table 74.6). For prediction of neural-specific antibody seropositivity among patients presenting with encephalopathy, an APE2 score ≥4 was 99% sensitive and 93% specific. The Response to Immunotherapy in Epilepsy and Encephalopathy score (see Table 74.6) also incorporates

TABLE 74.6 Antibody Prevalence in Epilepsy and Encephalopathy (APE2) Score and Response to Immunotherapy in Epilepsy and Encephalopathy (RITE2) Score[a]

APE2 Score	Value	RITE2 Score	Value
New-onset, rapidly progressive mental status changes that developed over 1-6 wk or new-onset seizure activity (within 1 y of evaluation)	(+1)	New-onset, rapidly progressive mental status changes that developed over 1-6 wk or new-onset seizure activity (within 1 y of evaluation)	(+1)
Neuropsychiatric changes; agitation, aggressiveness, emotional lability	(+1)	Neuropsychiatric changes; agitation, aggressiveness, emotional labiality	(+1)
Autonomic dysfunction (sustained atrial tachycardia or bradycardia, orthostatic hypotension, hyperhidrosis, persistently labile blood pressure, ventricular tachycardia, cardiac asystole, or gastrointestinal dysmotility)[a]	(+1)	Autonomic dysfunction (sustained atrial tachycardia or bradycardia, orthostatic hypotension, hyperhidrosis, persistently labile blood pressure, ventricular tachycardia, cardiac asystole or gastrointestinal dysmotility)[a]	(+1)
Viral prodrome (rhinorrhea, sore throat, low-grade fever) to be scored in the absence of underlying systemic neoplasm within 5 y of neurologic symptom onset	(+2)	Viral prodrome (rhinorrhea, sore throat, low-grade fever) only to be scored in the absence of underlying neoplasm within 5 y of neurologic symptom onset	(+2)
Faciobrachial dystonic seizures	(+3)	Faciobrachial dystonic seizures	(+3)
Facial dyskinesias, to be scored in the absence of faciobrachial dystonic seizures	(+2)	Facial dyskinesias, to be scored in the absence of faciobrachial dystonic seizures	(+2)
Seizure refractory to at least to two antiseizure medications	(+2)	Seizure refractory to at least to two antiseizure medications	(+2)
CSF findings consistent with inflammation (elevated CSF protein >50 mg/dL and/or lymphocytic pleocytosis >5 cells/μL, if the total number of CSF RBC is <1,000 cells/μL)	(+2)	CSF findings consistent with inflammation (elevated CSF protein > 50 mg/dL and/or lymphocytic pleocytosis >5 cells/μL, if the total number of CSF RBC is <1,000 cells/μL)	(+2)
Brain MRI suggesting encephalitis (T2/FLAIR hyperintensity restricted to one or both medial temporal lobes or multifocal in gray matter, white matter, or both compatible with demyelination or inflammation)	(+2)	Brain MRI suggesting encephalitis (T2/FLAIR hyperintensity restricted to one or both medial temporal lobes, or multifocal in gray matter, white matter, or both compatible with demyelination or inflammation)	(+2)
Systemic neoplasm diagnosed within 5 y of neurologic symptom onset (excluding cutaneous squamous cell carcinoma, basal cell carcinoma, brain tumor, cancer with brain metastasis)	(+2)	Systemic neoplasm diagnosed within 5 y of neurologic symptom onset (excluding cutaneous squamous cell carcinoma, basal cell carcinoma, brain tumor, cancer with brain metastasis)	(+2)
	Total (max: 18)	Immunotherapy initiated within 6 mo of symptom onset	(+2)
		Neural plasma membrane autoantibody detected (NMDAR, $GABA_A$ receptor, $GABA_B$ receptor, AMPAR, DPPX, mGluR1, mGluR5, LGI1, CASPR2, neurexin-3α, MOG)	(+2)
			Total (max: 22)

Abbreviations: AMPAR, amino-3-hydroxy-5-methyl-4-isoxazolepropionic receptor; CASPR2, contactin-associated protein 2; CSF, cerebrospinal fluid; DPPX, dipeptidyl-peptidase-like protein 6; FLAIR, fluid-attenuated inversion recovery; $GABA_A$, γ-aminobutyric acid type A; $GABA_B$, γ-aminobutyric acid type B; LGI1, leucine-rich glioma–inactivated protein 1; mGluR1, metabotropic glutamate receptor 1; mGluR5, metabotropic glutamate receptor 5; MOG, myelin oligodendrocyte glycoprotein; MRI, magnetic resonance imaging; NMDAR, *N*-methyl-D-aspartate receptor; RBC, red blood cell.

[a]Scored only if no history of autonomic dysfunction prior to onset of suspected autoimmune syndrome and the autonomic dysfunction not attributable to medications, hypovolemia, plasmapheresis, or infection.

two independent predictors of favorable outcome: initiation of immunotherapy within 6 months of symptom onset and presence of neural-specific cell surface autoantibodies in serum or CSF. For encephalopathy patients receiving first-line immunotherapy trials, Response to Immunotherapy in Epilepsy and Encephalopathy score ≥7 had 96% sensitivity and 86% specificity for favorable response to initial immunotherapy. Specifically for NMDAR encephalitis, a 5-point grading system can also be used: NMDAR Encephalitis One-Year Functional Status score.

OUTCOME

Autoimmune encephalitis can be severe with mortality rates of up to 20%. As a general rule, those with antibodies to cell-surface antigens (eg, NMDAR, LGI1, $GABA_A$ receptor) have better prognosis than those with antibodies reactive with intracellular targets (eg, ANNA-1 [anti-Hu], Ma2). A notable exception is autoimmune GFAP astrocytopathy that responds well to steroids and often has a favorable long-term outcome. In those with antibodies to cell surface targets, a severe initial presentation (such as coma or status epilepticus) does not reliably predict a bad long-term outcome, and a poor prognosis should not be prematurely considered. Indeed, a slow and prolonged recovery with a favorable outcome is often achievable with aggressive immunotherapy. In NMDAR encephalitis, improvement can continue up to 18 months after onset. In NMDAR encephalitis, the addition of second-line immunotherapy (rituximab or cyclophosphamide) has been associated with better outcomes than first-line treatments alone (steroids, IVIG, plasma exchange), where no improvement was observed after those initial treatments.

In patients with LGI1 encephalitis, seizures and cognitive symptoms tend to respond quickly and often completely to immunotherapy (corticosteroids and plasma exchange in particular), but cognitive deficits may take longer to recover. In addition, early treatment (within a few weeks of onset) portends better recovery.

Videos can be found in the companion e-book edition. For a full list of video legends, please see the front matter.

SUGGESTED READINGS

Albert ML, Darnell RB. Paraneoplastic neurological degenerations: keys to tumour immunity. *Nat Rev Cancer*. 2004;4(1):36-44.

Armangue T, Spatola M, Vlagea A, et al; for the Spanish Herpes Simplex Encephalitis Study Group. Frequency, symptoms, risk factors, and outcomes of autoimmune encephalitis after herpes simplex encephalitis: a prospective observational study and retrospective analysis. *Lancet Neurol*. 2018;17(9):760-772.

Balu R, McCracken L, Lancaster E, Graus F, Dalmau J, Titulaer MJ. A score that predicts 1-year functional status in patients with anti-NMDA receptor encephalitis. *Neurology*. 2019;92(3):e244-e252.

Boronat A, Gelfand JM, Gresa-Arribas N, et al. Encephalitis and antibodies to dipeptidyl-peptidase-like protein-6, a subunit of Kv4.2 potassium channels. *Ann Neurol*. 2013;73(1):120-128.

Boronat A, Sabater L, Saiz A, Dalmau J, Graus F. GABA(B) receptor antibodies in limbic encephalitis and anti-GAD-associated neurologic disorders. *Neurology*. 2011;76(9):795-800.

Carvajal-González A, Leite MI, Waters P, et al. Glycine receptor antibodies in PERM and related syndromes: characteristics, clinical features and outcomes. *Brain*. 2014;137(pt 8):2178-2192.

Casado JL, Gil-Peralta A, Graus F, Arenas C, Lopez JM, Alberca R. Anti-Ri antibodies associated with opsoclonus and progressive encephalomyelitis with rigidity. *Neurology*. 1994;44(8):1521-1522.

Castillo P, Woodruff B, Caselli R, et al. Steroid-responsive encephalopathy associated with autoimmune thyroiditis. *Arch Neurol*. 2006;63(2):197-202.

Chen DS, Mellman I. Oncology meets immunology: the cancer-immunity cycle. *Immunity*. 2013;39(1):1-10.

Cortese I, Chaudhry V, So YT, et al. Evidence-based guideline update: plasmapheresis in neurologic disorders: report of the Therapeutics and Technology Assessment Subcommittee of the American Academy of Neurology. *Neurology*. 2011;76(3):294-300.

Dalmau J, Graus F, Villarejo A, et al. Clinical analysis of anti-Ma2-associated encephalitis. *Brain*. 2004;127(pt 8):1831-1844.

Dalmau J, Lancaster E, Martinez-Hernandez E, Rosenfeld MR, Balice-Gordon R. Clinical experience and laboratory investigations in patients with anti-NMDAR encephalitis. *Lancet Neurol*. 2011;10(1):63-74.

Dubey D, Kothapalli N, McKeon A, et al. Predictors of neural-specific autoantibodies and immunotherapy response in patients with cognitive dysfunction. *J Neuroimmunol*. 2018;323:62-72.

Dubey D, Pittock SJ, Kelly CR, et al. Autoimmune encephalitis epidemiology and a comparison to infectious encephalitis. *Ann Neurol*. 2018;83(1):166-177.

Flanagan EP, Hinson SR, Lennon VA, et al. Glial fibrillary acidic protein immunoglobulin G as biomarker of autoimmune astrocytopathy: analysis of 102 patients. *Ann Neurol*. 2017;81:298-309.

Flanagan EP, McKeon A, Lennon VA, et al. Autoimmune dementia: clinical course and predictors of immunotherapy response. *Mayo Clin Proc*. 2010;85(10):881-897.

Gable MS, Sheriff H, Dalmau J, Tilley DH, Glaser CA. The frequency of autoimmune *N*-methyl-D-aspartate receptor encephalitis surpasses that of individual viral etiologies in young individuals enrolled in the California Encephalitis Project. *Clin Infect Dis*. 2012;54(7):899-904.

Gadoth A, Kryzer TJ, Fryer J, McKeon A, Lennon VA, Pittock SJ. Microtubule-associated protein 1B: novel paraneoplastic biomarker. *Ann Neurol*. 2017;81(2):266-277.

Geschwind MD, Tan KM, Lennon VA, et al. Voltage-gated potassium channel autoimmunity mimicking Creutzfeldt-Jakob disease. *Arch Neurol*. 2008;65(10):1341-1346.

Graus F, Titulaer MJ, Balu R, et al. A clinical approach to diagnosis of autoimmune encephalitis. *Lancet Neurol*. 2016;15(4):391-404.

Graus F, Vincent A, Pozo-Rosich P, et al. Anti-glial nuclear antibody: marker of lung cancer-related paraneoplastic neurological syndromes. *J Neuroimmunol*. 2005;165(1-2):166-171.

Horta ES, Lennon VA, Lachance DH, et al. Neural autoantibody clusters aid diagnosis of cancer. *Clin Cancer Res*. 2014;20(14):3862-3869.

Kenney-Jung DL, Vezzani A, Kahoud RJ, et al. Febrile infection-related epilepsy syndrome treated with anakinra. *Ann Neurol*. 2016;80(6):939-945.

Klaas JP, Ahlskog JE, Pittock SJ, et al. Adult-onset opsoclonus-myoclonus syndrome. *Arch Neurol*. 2012;69(12):1598-1607.

Lai M, Hughes EG, Peng X, et al. AMPA receptor antibodies in limbic encephalitis alter synaptic receptor location. *Ann Neurol*. 2009;65(4):424-434.

Lai M, Huijbers MG, Lancaster E, et al. Investigation of LGI1 as the antigen in limbic encephalitis previously attributed to potassium channels: a case series. *Lancet Neurol*. 2010;9(8):776-785.

Lancaster E, Lai M, Peng X, et al. Antibodies to the GABA(B) receptor in limbic encephalitis with seizures: case series and characterisation of the antigen. *Lancet Neurol*. 2010;9(1):67-76.

Lee W-J, Lee S-T, Moon J, et al. Tocilizumab in autoimmune encephalitis refractory to rituximab: an institutional cohort study. *Neurotherapeutics*. 2016;13(4):824-832.

Mandel-Brehm C, Dubey D, Kryzer TJ, et al. Kelch-like protein 11 antibodies in seminoma-associated paraneoplastic encephalitis. *N Engl J Med*. 2019;381:47-54.

McKeon A, Ahlskog JE, Britton JA, Lennon VA, Pittock SJ. Reversible extralimbic paraneoplastic encephalopathies with large abnormalities on magnetic resonance images. *Arch Neurol*. 2009;66(2):268-271.

McKeon A, Apiwattanakul M, Lachance DH, et al. Positron emission tomography-computed tomography in paraneoplastic neurologic disorders: systematic analysis and review. *Arch Neurol*. 2010;67(3):322-329.

Pittock SJ, Kryzer TJ, Lennon VA. Paraneoplastic antibodies coexist and predict cancer, not neurological syndrome. *Ann Neurol*. 2004;56(5):715-719.

Pittock SJ, Lucchinetti CF, Parisi JE, et al. Amphiphysin autoimmunity: paraneoplastic accompaniments. *Ann Neurol*. 2005;58(1):96-107.

Pittock SJ, Yoshikawa H, Ahlskog JE, et al. Glutamic acid decarboxylase autoimmunity with brainstem, extrapyramidal, and spinal cord dysfunction. *Mayo Clin Proc*. 2006;81(9):1207-1214.

Probasco JC, Solnes L, Nalluri A, et al. Abnormal brain metabolism on FDG-PET/CT is a common early finding in autoimmune encephalitis. *Neurol Neuroimmunol Neuroinflamm*. 2017;4(4):e352.

Quek AM, Britton JW, McKeon A, et al. Autoimmune epilepsy: clinical characteristics and response to immunotherapy. *Arch Neurol*. 2012;69(5):582-593.

Sabater L, Gaig C, Gelpi E, et al. A novel non-rapid-eye movement and rapid-eye-movement parasomnia with sleep breathing disorder associated with antibodies to IgLON5: a case series, characterisation of the antigen, and post-mortem study. *Lancet Neurol*. 2014;13(6):575-586.

Schmitt SE, Pargeon K, Frechette ES, Hirsch LJ, Dalmau J, Friedman D. Extreme delta brush: a unique EEG pattern in adults with anti-NMDA receptor encephalitis. *Neurology*. 2012;79(11):1094-1100.

Titulaer MJ, McCracken L, Gabilondo I, et al. Treatment and prognostic factors for long-term outcome in patients with anti-NMDA receptor encephalitis: an observational cohort study. *Lancet Neurol*. 2013;12(2):157-165.

Vernino S, O'Neill BP, Marks RS, O'Fallon JR, Kimmel DW. Immunomodulatory treatment trial for paraneoplastic neurological disorders. *Neuro Oncol*. 2004;6(1):55-62.

Neurosarcoidosis 75

Siddharama Pawate and Barney J. Stern

KEY POINTS

1. Optimal diagnosis of systemic sarcoidosis and neurosarcoidosis typically includes pathologic documentation of granulomatous inflammation.
2. The diagnosis of sarcoidosis and neurosarcoidosis is most secure if infection and malignancy are excluded.
3. Neurosarcoidosis patients with progressive or relapsing disease are best managed with low-dose corticosteroid and adjunct immunosuppressive drugs.

INTRODUCTION

Sarcoidosis is a multisystemic inflammatory disease of unknown etiology, characterized histopathologically by noncaseating granulomas that do not show the presence of infectious organisms. The pathogenesis is presumed to be immune-mediated and directed against as yet unidentified antigen(s).

Intrathoracic sarcoidosis (pulmonary sarcoidosis and mediastinal lymphadenopathy) occurs in 9 out of 10 patients. Neurologic involvement due to sarcoidosis, termed *neurosarcoidosis*, occurs in 10% to 15% of patients and can affect any part of the central or peripheral nervous system (PNS), resulting in highly varied clinical manifestations. Isolated neurosarcoidosis without systemic involvement is thought to represent as many as 17% of neurosarcoidosis patients.

EPIDEMIOLOGY

Sarcoidosis can be asymptomatic in a substantial proportion of patients, making the determination of its true incidence and prevalence difficult. It is a global disease, with available studies reporting an incidence ranging from 0.2 per 100,000 people in Brazil to 19 per 100,000 people in Sweden. In the United States, the incidence of sarcoidosis is estimated at 3 to 10 per 100,000 per year among Caucasians and 35 to 80 per 100,000 per year among African Americans. The majority of patients (70%) are between the ages of 25 and 45 years at diagnosis, and in women in Europe and Japan, there is a second peak incidence after age 50 years.

Genetic as well as environmental factors influence sarcoidosis. First- and second-degree relatives of patients with sarcoidosis, but not spouses, have a fivefold higher risk, indicating a genetic predisposition. The study of genes associated with sarcoidosis is in its infancy. Given the critical role major histocompatibility plays in antigen presentation, it is not surprising that a majority of the genes associated with sarcoidosis to date are predominantly those of human leukocyte alloantigen regions, and different human leukocyte alloantigen regions associate with different clinical phenotypes of sarcoidosis. Genome-wide association studies have also implicated inflammatory mediators such as toll-like receptor 4, transforming growth factor β, and tumor necrosis factor (TNF). Occupational exposure to microbe-rich environments such as mold and mildew, insecticides, and pesticides resulted in a higher risk. Although sarcoidosis is not an infectious disease, an exaggerated immune response to antigens is thought to be the likely mechanism, and thus, microbial exposure may play an indirect role. Cigarette smokers have a risk of sarcoidosis one-fifth of nonsmokers, presumably due to the immunosuppressive effect of tobacco exposure.

PATHOBIOLOGY

Sarcoidosis is mediated primarily by $CD4^+$ T helper 1 cells and mononuclear phagocytes, with participation of numerous cytokines and chemokines that include interleukins, adhesion molecules, interferon-γ, TNF-α, and transforming growth factor β. Lesions may affect any organ, especially lungs, lymph nodes, skin, bones, eyes, and salivary glands. When nervous system disease complicates systemic sarcoidosis, it usually does so within 2 years of onset.

In the central nervous system (CNS), sarcoid granulomas most often involve the meninges, especially at the base of the brain, with secondary infiltration of cranial nerves and obstruction of cerebrospinal fluid (CSF) flow. Lesions tend to be perivascular and thereby may extend into the parenchyma, frequently affecting the hypothalamus and, less often, other CNS structures, including the spinal cord. Granulomas also occur in peripheral nerves and muscle.

CLINICAL MANIFESTATIONS

The clinical manifestations of neurosarcoidosis are heterogeneous as granulomatous inflammation may affect any anatomic substrate pertaining to the meninges, cranial nerves, brain, spinal cord, meninges, peripheral nerves, and muscles resulting in diverse clinical forms of the disease.

Cranial Nerves

Unilateral or bilateral lower motor neuron facial nerve palsy is the most common cranial nerve presentation. A peripheral facial nerve palsy can herald sarcoidosis, which may remain unrecognized for years. Other relatively frequent cranial neuropathies are optic neuropathy and vestibulocochlear nerve dysfunction, which can be unilateral or bilateral. Optic nerve involvement (Fig. 75.1A) typically presents as a subacute or chronic optic neuritis. Vision loss can also be rarely due to extrinsic compression of the optic nerve from granulomatous inflammation.

Isolated hearing loss or vertigo due to selective vestibulocochlear nerve involvement can occur, and bilateral sensorineural hearing loss should prompt an evaluation for neurosarcoidosis. Other cranial nerves are involved less frequently. Multiple cranial neuropathies can occur.

Meninges

Meningeal involvement can present as a subacute lymphocytic meningitis, with headache and variable nuchal rigidity with or without fever. Chronic meningitis frequently occurs and may or may not be associated with headache. Leptomeningeal involvement is typical (Fig. 75.1B), but dural involvement (pachymeningitis) can also occur (Fig. 75.1C). Hydrocephalus, either communicating or noncommunicating, can complicate meningitis. Occasionally, a dural inflammatory mass mimics a meningioma.

Brain Parenchyma

The manifestations of granulomas within the brain parenchyma depend on the location and size of the lesions. Figure 75.1D shows a left temporal lesion suspicious for a neoplasm that was intensely fluorodeoxyglucose avid (Fig. 75.1E). Small subcortical or periventricular white matter lesions may be asymptomatic. Seizures are a fairly common presentation. Neurosarcoidosis has a predilection for the hypothalamus, resulting in a range of disturbances including hypothyroidism, hypogonadism, and resetting of the "osmostat" or the syndrome of inappropriate antidiuretic hormone.

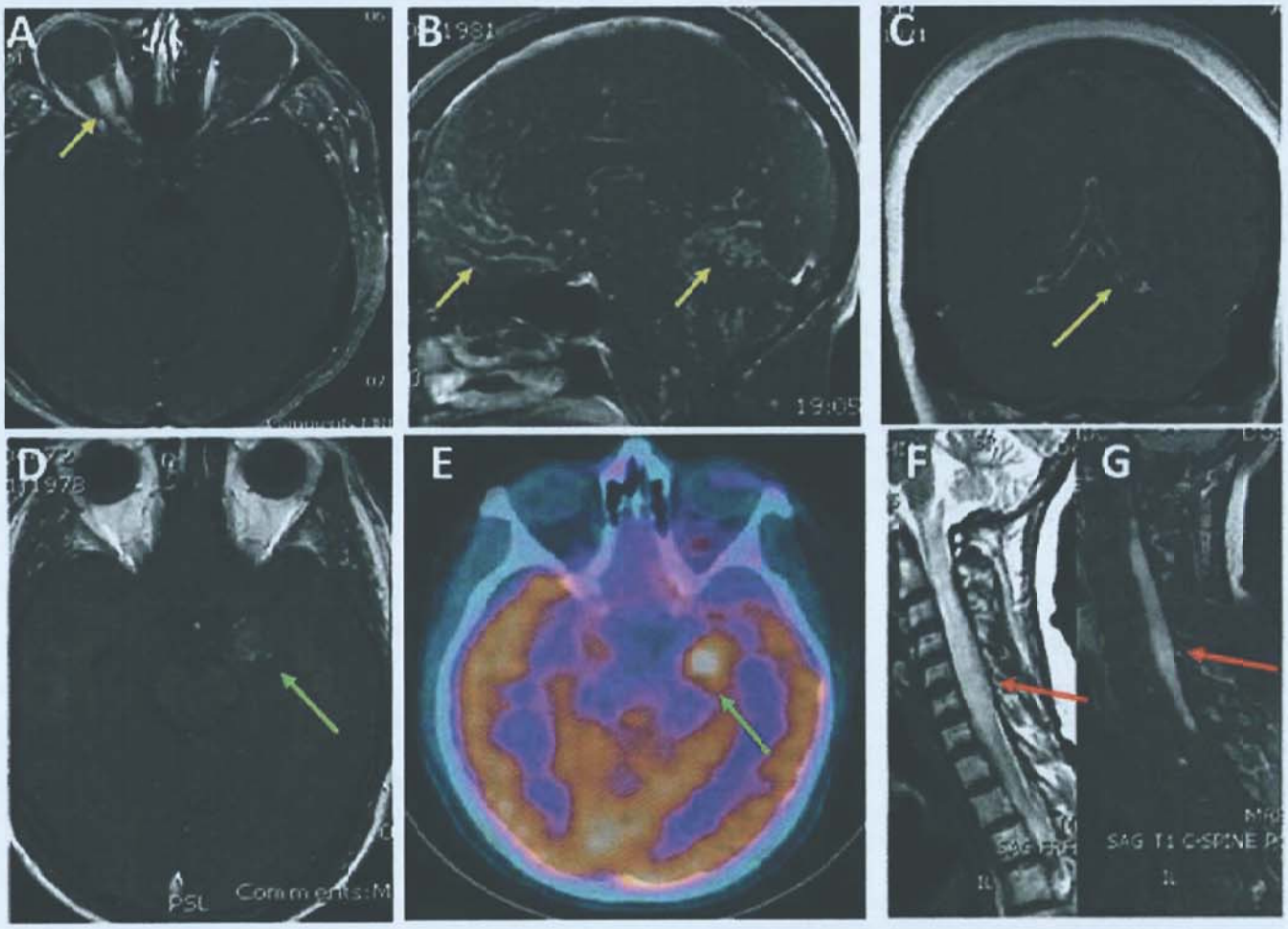

FIGURE 75.1 **A:** Sarcoid optic neuropathy. A brain magnetic resonance imaging shows thickening and intense contrast enhancement of the right optic nerve *(arrow)*, consistent with an infiltrating process. The resolution of contrast enhancement after steroid therapy (not shown) made it unlikely to be a neoplastic process. **B,C:** Meningeal sarcoidosis. **B:** Sagittal postcontrast T1 images show extensive leptomeningeal enhancement in the posterior fossa as well as in the frontal lobe *(arrows)*. **C:** Coronal postcontrast T1 images show thickening and enhancement of the dura in the tentorium. **D,E:** Parenchymal sarcoidosis. Axial postcontrast magnetic resonance imaging images show a contrast-enhancing lesion in the left temporal lobe in this patient with new-onset seizures, concerning for a neoplasm as fludeoxyglucose positron emission tomography showed the lesion to be intensely fluorodeoxyglucose avid. However, the patient had biopsy-proven lung sarcoidosis and was treated with high-dose steroids, and the lesion resolved. **F,G:** Spinal cord sarcoidosis. **F:** T2 sequence showed a longitudinally extensive hyperintense lesion associated with cord swelling *(arrow)*. **G:** The postcontrast T1 sequence showed enhancement *(arrow)* of the spinal cord as well as the overlying meninges posteriorly.

Spinal Cord

Patients may have gradually worsening myelopathic (typically, a combination of motor, sensory, and bladder/bowel manifestations) symptoms developing over months. A subpial intramedullary lesion is typical (Fig. 75.1F,G), but in up to half the patients, the overlying meninges are involved as well. The thoracic region is most commonly involved followed by cervical disease.

DIAGNOSIS

When patients with known, active systemic sarcoidosis present with neurologic symptoms, neurosarcoidosis is usually prominent in differential diagnostic considerations and if the initial evaluation points to neurosarcoidosis, a therapeutic trial with high-dose corticosteroids may be justified. Patients with no prior history of systemic sarcoidosis are more challenging and diagnosis requires a high index of suspicion.

Imaging provides a noninvasive way to look for evidence of granulomatous inflammation. Typically, patients will require brain and/or spine MRI (see Fig. 75.1). Parenchymal brain and spinal cord lesions are typically seen as T1-isointense, T2-hyperintense areas with variable gadolinium enhancement. Leptomeningeal involvement may not be apparent T1 or T2 sequences, but a contrasted T1 study often shows linear or nodular meningeal enhancement. For patients with contraindications to MRI, computed tomography (CT) is an option but has much lower sensitivity and specificity. Iodinated contrasted CT scans can sometimes highlight more lesions and meningeal involvement.

Systemic imaging is helpful to establish extraneural sarcoidosis and provide possible targets for biopsy. Chest CT is more sensitive than chest x-ray. Fluorodeoxyglucose positron emission tomography can help identify extrathoracic lesions amenable for biopsy.

Serologic and CSF testing is often used. CSF typically shows pleocytosis and increased protein as nonspecific markers of inflammation, and less commonly, decreased glucose. Serum and CSF angiotensin converting enzyme levels can be elevated in sarcoidosis but lack sensitivity and specificity. Most authorities do not recommend relying on these levels for neurosarcoidosis diagnosis.

Ultimately, histopathology is necessary for confident diagnosis. This was reflected in consensus definition and diagnostic criteria issued by the Neurosarcoidosis Consortium Consensus Group. They proposed criteria to stratify diagnostic probability of neurosarcoidosis into definite, probable, and possible neurosarcoidosis (Table 75.1).

In PNS sarcoidosis, clinical, nerve conduction studies, and electromyogram findings are nonspecific and often indistinguishable from primary immune-mediated neuromuscular disorders (eg, polymyositis or chronic inflammatory demyelinating polyneuropathy), which respond to corticosteroids and other immunotherapies used for sarcoidosis. Thus, histologic confirmation of the affected tissue or evidence of systemic disease is required for a definite or probable diagnosis of peripheral neurosarcoidosis, respectively. Fortunately, in most cases of muscle and nerve involvement, the affected tissue is more readily accessible for biopsy in contrast to patients with CNS disease.

Conditions that can present similarly to sarcoidosis include CNS neoplasms such as gliomas or lymphoma; demyelinating disease; and fungal, tuberculous, or bacterial infections. A detailed list of differential diagnosis considerations is presented in Table 75.2.

TABLE 75.1 Criteria for the Diagnosis of Neurosarcoidosis as Proposed by the Neurosarcoidosis Consortium Consensus Group[a,b]

Definite	Nervous system pathology is consistent with neurosarcoidosis. • Extraneural sarcoidosis is evident. • No extraneural sarcoidosis is evident (ie, isolated central nervous system sarcoidosis).
Probable	There is pathologic confirmation of systemic granulomatous disease consistent with sarcoidosis.
Possible	There is no pathologic confirmation of granulomatous disease.

[a]In patients whose clinical presentation and diagnostic evaluation suggests neurosarcoidosis as defined by the clinical manifestations and magnetic resonance imaging, cerebrospinal fluid, and/or electromyogram/nerve conduction study findings typical of granulomatous inflammation of the nervous system and rigorous exclusion of other causes, neurosarcoidosis can be diagnosed at three levels of certainty; definite, probable, and possible.
[b]Modified from Stern BJ, Royal W III, Gelfand JM, et al. Definition and consensus diagnostic criteria for neurosarcoidosis: from the Neurosarcoidosis Consortium Consensus Group. *JAMA Neurol.* 2018;75(12):1546-1553.

Magnetic Resonance Imaging Findings

A gadolinium-enhanced brain or spine magnetic resonance imaging (MRI) is the most important imaging modality to evaluate CNS sarcoidosis; it is highly sensitive but nonspecific. Granulomatous inflammation is associated with breakdown of the blood-brain barrier, causing enhancement of affected areas. Leptomeningeal enhancement occurs especially along the skull base. Dural thickening and enhancement can be focal or diffuse and may be hypointense on T2-weighted sequences. Cranial nerve enhancement may be seen. Intraparenchymal granulomas can be seen as subcortical white matter lesions mimicking multiple sclerosis or micro-ischemic lesions, or can involve the deep grey matter. Large solitary aggregations of granulomas can masquerade as neoplasms.

Cerebrospinal Fluid Findings

CSF findings are nonspecific but help establish the presence of intrathecal inflammation and rule out infectious and neoplastic processes. Nonspecific CSF markers of CNS inflammation (pleocytosis, elevated protein, hypoglycorrhachia, oligoclonal bands, and elevated immunoglobulin G index) are seen in overall in 50% to 70% of patients with neurosarcoidosis. CSF abnormalities are most likely in patients with leptomeningeal enhancement.

Peripheral Nervous System and Muscle Presentations

Symptomatic involvement of the PNS in sarcoidosis is rare, occurring in only 1% to 2% of patients with systemic disease. Granulomatous inflammation may result in vasculitis, infiltration, or direct compression of peripheral nerve and muscle fibers.

A small fiber neuropathy with sensory or autonomic nervous system symptoms can occur in patients with systemic sarcoidosis or neurosarcoidosis. Granulomas are not evident on skin biopsy analysis of small fiber terminals, and this manifestation can be considered a "parasarcoidosis" phenomenon, thought to be mediated by circulating inflammatory mediators.

TABLE 75.2 Selected Differential Diagnostic Considerations for Neurosarcoidosis

Category	Examples	Comments
Systemic and CNS Infections	Tuberculosis Atypical mycobacterium (very rare in the absence of prior neurosurgery or hardware) CNS fungal infections - coccidiomycosis, histoplasmosis, cryptococcus, sporotrichosis, blastomycosis Spirochetal infections – Neurosyphilis, neuroborreliosis (Lyme disease) Tropheryma (Neuro-Whipple's disease) Progressive multifocal leukoencephalopathy Parasitic infection (in the appropriate neuroimaging, CSF exam or epidemiological context)	Cultures, Serologies, PCR as appropriate to detect infectious organisms may help establish an infectious etiology.
Malignancy	Lymphoma (Primary CNS or Systemic with neurological involvement) CNS tumors (glioma, germ cell tumor, craniopharyngioma) Meningeal carcinomatosis	Histopathology will detect neoplasms.
Other Neuro-inflammatory Disorders	Histiocytosis (Erdheim-Chester disease) Multiple Sclerosis, especially tumefactive lesions Acute Disseminated Encephalomyelitis Neuromyelitis optica spectrum disorders CNS Vasculitis Autoimmune astrocytopathy with anti-GFAP antibodies Anti-MOG syndrome	Histopathology may help detect other etiologies. CT angiogram or conventional cerebral angiogram may be required when vasculitis is suspected. AQP4 or MOG antibodies may be detected in patients with NMOSD.
Neurologic Involvement from a Systemic Disorder	Systemic lupus erythematosus IgG4-related hypertrophic pachymeningitis Sjogren's syndrome Behcet's disease Vogt-Koyanagi-Harada disease Common variable immunodeficiency (CVID)	Clinical and rheumatologic criteria may help point to systemic inflammatory diseases. Histopathology is definitive for IgG4 related disease
Vascular	Dural arterio-venous fistula (brain or spinal cord) or other vascular malformations such as AVM Stroke	Clinical context and vascular imaging

Abbreviations: AQP4, Aquaporin 4; CNS, central nervous system; CSF, cerebrospinal fluid; CT, computed tomography; GFAP, glial fibrillary acidic protein; MOG, myelin oligodendrocyte glycoprotein; NMOSD, neuromyelitis optica spectrum disorder; PCR, polymerase chain reaction.

[a]Magnetic resonance imaging and cerebrospinal fluid studies are sensitive in detecting CNS pathology but do not differentiate between sarcoidosis, other immune mediated conditions, infectious and neoplastic etiologies. Thus additional studies are required to discern other possibilities as indicated by the clinical context.

[b]Reprinted from Pawate S. Sarcoidosis and the nervous system. *Continuum (Minneap Minn)*. 2020;26(3):695-715.

Another common phenomenon attributed to parasarcoidosis is *brain fog*, an informal term patients use to describe cognitive difficulties in the absence of evident brain involvement in the disease.

MANAGEMENT

The clinical course of neurosarcoidosis varies widely and is difficult to predict. However, in general, about two-thirds of patients with neurosarcoidosis have a self-limited monophasic illness such as isolated facial nerve palsy or aseptic meningitis. In these patients, a short course of corticosteroids is usually beneficial. Those with more severe disease such as parenchymal, optic nerve, or spinal cord involvement require prolonged therapy. In the absence of randomized clinical trials to guide therapy, the treatment of neurosarcoidosis is based primarily on clinical experience and small clinical case series. A daily dose of 40 to 80 mg prednisone may be given for a few weeks and then slowly tapered, either to a lowest possible maintenance dose or, if possible, to discontinuation. Higher initial doses may be necessary in some patients. Severe presentations may require pulse dose corticosteroids (1 g intravenous methylprednisolone daily for 3-5 d), followed by a prolonged oral taper. The long-term use of corticosteroids is limited by their well-known toxicity, including hyperglycemia, weight gain, osteoporosis, risk of infection, epidural lipomatosis, etc. Therefore, "steroid-sparing agents" are typically used (**Table 75.3**). Anecdotally, reported adjunctive immunosuppressive treatment for refractory patients includes, but is not limited to, mycophenolate mofetil, azathioprine, methotrexate, cyclophosphamide, and rituximab. Infliximab, an anti-TNF monoclonal antibody, has emerged as an effective agent in the treatment of neurosarcoidosis that is refractory to other agents. Early infliximab treatment should be considered in patients with aggressive neurosarcoidosis.

The role of surgery is typically limited to biopsy. Hydrocephalus may require a ventriculoperitoneal shunt.

OUTCOMES

In general, the outcome of patients with neurosarcoidosis is favorable. As noted above, "mild" disease such as facial nerve palsy and aseptic meningitis typically recovers completely. In more severe cases, the extent of permanent CNS or PNS damage contributes to less than optimal clinical recovery. In some patients, clinical deficits may take significantly longer to recover than imaging findings.

TABLE 75.3 Agents Used in the Treatment of Neurosarcoidosis[a]

Agent	Dosage	Adverse Effects	Monitoring
Corticosteroids			
Prednisone	Start 40 mg/d or up to 1 mg/kg/d depending on severity, with aim to taper as fast as feasible to minimum required	Numerous side effects include effects on blood glucose, Cushing syndrome, fluid retention, gastrointestinal upset, osteoporosis, cataracts; with pulse steroids, a 1 in 10,000 chance of avascular hip necrosis (1 in 1000 after repeated courses)	Clinical monitoring
IV methylprednisolone pulse	Initial treatment of moderate to severe cases, 1000 mg/dfor 3-5 days, followed by transition to oral prednisone regimen above	Numerous side effects include effects on blood glucose, Cushing syndrome, fluid retention, gastrointestinal upset, osteoporosis, cataracts; with pulse steroids, avascular hip necrosis has a 1 in 10,000 chance (1 in 1000 after repeated courses)	Clinical monitoring
Steroid sparing agents			
Azathioprine	50-150 mg/d	Bone marrow suppression, gastrointestinal upset 1 in 300 whites are deficient in thiopurine methyltransferases, an enzyme that metabolizes azathioprine, and azathioprine should be avoided in them.	CBC with differential counts, liver functions monthly initially, then every 3-6 months; check thiopurine methyltransferase before initiation
Methotrexate	10-25 mg/wk along with folic acid 1 mg/d	Bone marrow suppression, gastrointestinal upset	CBC with differential counts liver functions every 4-6 weeks initially and once every 3-6 months after stabilized
Mycophenolate mofetil	1000-1500 mg 2 times a day	Gastrointestinal upset, headaches, leukopenia	CBC with differential counts every 6 weeks for 6 months, then every 3-6 months
Cyclophosphamide	Pulse dosing 500-750 mg/m2 IV every 4 weeks, typically for 6-9 months as 'induction' therapy	Hemorrhagic cystitis (can be avoided by careful hydration), leukopenia, infections	CBC with differential counts, urinalysis per infusion protocol
Rituximab	1000 mg IV infusion on day 1 and day 15, then 1000 mg every 6-8 months depending on CD19 counts	Well tolerated, opportunistic infections are a concern; after prolonged use, may require IgG repletion	Lymphocyte subsets to guide dosing or may dose once every 6 months scheduled
Anti-tumor necrosis factor therapy			
Infliximab	3-7 mg/kg IV infusions, week 0, 2, and 6, then every 4 to 6 weeks	Infusion reactions, central nervous system demyelination, opportunistic infections	Confirm the absence of tuberculosis before initiation
Adalimumab	40 mg subcutaneously every 2 weeks	Infusion reactions, central nervous system demyelination, opportunistic infections, injection site reactions	Confirm the absence of tuberculosis before initiation

Abbreviations: IV, intravenous; CBC, complete blood count; IgG, immunoglobulin G.
[a]Reprinted from Pawate S. Sarcoidosis and the nervous system. *Continuum (Minneap Minn)*. 2020;26(3):695-715.

SUGGESTED READINGS

Bargagli E, Prasse A. Sarcoidosis: a review for the internist. *Intern Emerg Med*. 2018;13:325-331.

Bathla G, Singh AK, Policeni B, Agarwal A, Case B. Imaging of neurosarcoidosis: common, uncommon, and rare. *Clin Radiol*. 2016;71(1):96-106.

Fingerlin TE, Hamzeh N, Maier LA. Genetics of sarcoidosis. *Clin Chest Med*. 2015;36(4):569-584.

Fritz D, van de Beek D, Brouwer MC. Clinical features, treatment and outcome in neurosarcoidosis: systematic review and meta-analysis. *BMC Neurol*. 2016;16(1):220.

Fritz D, Voortman M, vandeBeek D, Drent M, Brouwer MC. Many faces of neurosarcoidosis: from chronic meningitis to myelopathy. *Curr Opin Pulm Med*. 2017;23(5):439-446.

Gelfand JM, Bradshaw MJ, Stern BJ, et al. Infliximab for the treatment of CNS sarcoidosis: a multi-institutional series. *Neurology*. 2017;89(20):2092-2100.

Nozaki K, Scott TF, Sohn M, Judson MA. Isolated neurosarcoidosis: case series in 2 sarcoidosis centers. *Neurologist*. 2012;18(6):373-377.

Patterson KC, Chen ES. The pathogenesis of pulmonary sarcoidosis and implications for treatment. *Chest*. 2018;153(6):1432-1442.

Pawate S. Sarcoidosis and the nervous system. *Continuum (Minneap Minn)*. 2020;26(3):695-715.

Pawate S, Moses H, Sriram S. Presentations and outcomes of neurosarcoidosis: a study of 54 cases. *QJM*. 2009;102(7):449-460

Sohn M, Culver DA, Judson MA, Scott TF, Tavee J, Nozaki K. Spinal cord neurosarcoidosis. *Am J Med Sci*. 2014;347(3):195-198.

Stern BJ, Royal W III, Gelfand JM, et al. Definition and consensus diagnostic criteria for neurosarcoidosis: from the Neurosarcoidosis Consortium Consensus Group. *JAMA Neurol*. 2018;75(12):1546-1553.

Valeyre D, Prasse A, Nunes H, Uzunhan Y, Brillet P-Y, Müller-Quernheim J. Sarcoidosis. *Lancet*. 2014;383(9923):1155-1167.

Vital A, Lagueny A, Ferrer X, Louiset P, Canron M-H, Vital C. Sarcoid neuropathy: clinico-pathological study of 4 new cases and review of the literature. *Clin Neuropathol*. 2008;27(2):96-105.

Essential Tremor 76

Elan D. Louis

KEY POINTS

1. Essential tremor (ET) is a chronic, progressive neurologic disease. The hallmark motor feature is a 4- to 12-Hz kinetic tremor that involves the arms and hands.
2. Tremor may eventually spread to involve the head (ie, the neck), voice, and jaw.
3. The ET patients have about a fourfold increased risk of developing incident Parkinson disease (PD), thereby developing what is referred to as *essential tremor–Parkinson disease* (ET-PD).
4. Recent years have witnessed an increasing appreciation of the presence of nonmotor features in ET patients, which may broadly be classed into cognitive, psychiatric, and sensory.
5. Controlled postmortem studies have revealed an array of degenerative changes in the cerebellar cortex.
6. β-Blockers (especially propranolol) and primidone, alone or in combination, are the most effective pharmacologic therapies. High-frequency thalamic stimulation markedly reduces the severity of the tremor and magnetic resonance imaging–guided focused ultrasound thalamotomy is another emerging surgical therapy.

INTRODUCTION

Essential tremor (ET) is a chronic, progressive neurologic disease. The hallmark motor feature is a 4- to 12-Hz kinetic tremor (tremor occurring during voluntary movements, such as writing or eating) that involves the arms and hands (Fig. 76.1). Tremor may eventually spread to involve the head (ie, the neck), voice, and jaw. Given the presence of etiologic, clinical, pharmacologic response profile, and pathologic heterogeneity, there is growing support for the notion that ET may be a family of diseases whose central defining feature is kinetic tremor of the arms and which might more accurately be referred to as *the essential tremors*.

EPIDEMIOLOGY

The ET is among the most prevalent adult-onset movement disorders, although it may occur at any age, and pediatric cases, with age of onset in the first decade of life have been reported. In a meta-analysis of data from 28 population-based prevalence studies in 19 countries, the pooled prevalence of ET across all ages was 0.9%. The prevalence increases markedly with age and especially with advanced age. In the meta-analysis, prevalence among persons aged 65 years and older was 4.6%, and in some studies, the prevalence among persons aged 95 years and older reached values in excess of 20%. The rate at which new ET cases arise (ie, the incidence rate) has been estimated as 619 per 100,000 person-years among individuals age 65 years and older; this incidence rises with age. Established risk factors for ET include older age and family history of ET.

ETIOLOGY

Both genetic and environmental (ie, toxic) factors are likely contributors to disease etiology. Many large kindreds show an autosomal dominant pattern of inheritance, and first-degree relatives of ET patients are approximately 5 times more likely to develop the disease than are members of the population and 10 times more likely if the proband's tremor began at an early age. The prevalence of a family history of ET is high in ET patients seen in neurologic clinics and even higher in younger onset than older onset ET cases. A variant in the *LINGO1* gene has been most consistently associated with ET; however, no major causal genes have been identified so far, and this is likely due to phenocopies, incomplete penetrance, bilineal inheritance, or possibly other modes of inheritance. The existence of sporadic cases (ie, cases without apparent family history), variability in age at onset in familial cases, and lack of complete disease concordance in monozygotic twins all argue for nongenetic (ie, environmental) causes as well. A number of environmental toxins are under investigation, including β-carboline alkaloids (eg, harmane, a dietary toxin) and lead. One epidemiologic study indicated a possible protective role of cigarette smoking and another suggested that higher levels of premorbid ethanol consumption raise the risk of developing ET with the presumed mechanism being Purkinje cell toxicity. The identification of modifiable risk factors would have important implications in terms of disease prevention.

PATHOBIOLOGY

The olivary model of ET, first proposed in the early 1970s, posited that a tremor pacemaker in the inferior olivary nucleus was driving the tremor in ET. However, there are major problems with this model, including the absence of direct empirical support, and therefore, there has been trend to move away from this model. In more recent years, mechanistic research on ET has focused more on the cerebellum and the role it seems to

FIGURE 76.1 Spirals drawn by patients with essential tremor who have moderate arm tremor (A) and severe arm tremor (B).

play in the biology of ET. Interest in the cerebellum was initially motivated by neuroimaging studies, which strongly implicate the importance of this brain region in ET, and clinical studies, which frequently note the presence of cerebellar signs in patients with ET. More recently, controlled postmortem studies have revealed an array of degenerative changes in the cerebellar cortex (Fig. 76.2). These changes, which are centered on the Purkinje cell and neighboring neuronal populations, include an increase in the number of torpedoes and related Purkinje cell axonal changes, an increase in number of Purkinje cell dendritic swellings and a truncation of the Purkinje cell dendritic arbor, increased numbers of heterotopic Purkinje cells, changes at the Purkinje cell–climbing fiber synaptic interface, and changes at the Purkinje cell–basket cell interface. In well-designed studies, there is actual Purkinje cell loss and an increase in the numbers of empty basket cell plexuses—a marker of Purkinje cell loss. A smaller group of ET cases demonstrates a pattern of Lewy bodies that are relatively restricted to the locus ceruleus. Of mechanistic interest is that the noradrenergic neurons of the locus ceruleus project to the cerebellum and synapse with Purkinje cells. Hence, there is growing support for the notion that the cerebellum may be central to disease pathobiology and that the pathobiology is neurodegenerative.

CLINICAL MANIFESTATIONS

Introduction

Symptoms and signs of ET can begin at any age, and about 5% begin in childhood, although the incidence increases markedly with advancing age, and most prevalent cases are age 60 years or older.

Tremor

The cardinal feature of ET is kinetic tremor, evidenced during a variety of activities on neurologic examination (eg, finger-nose-finger maneuver, spiral drawing) (▶ Video 76.1). The tremor is generally mildly asymmetric, affecting one arm more than the other, with on average an approximate 30% difference between sides; in approximately 5% of patients, the tremor is markedly asymmetric or even unilateral. In approximately 50% of patients, the tremor has an intentional component, worsening on finger-nose-finger maneuver as the patient approaches one or both of the two targets (▶ Video 76.2). Intention tremor is not limited to the arms; in 10% of patients, it is detectable in the head when the patient's head approaches a target (eg, as head moves down toward target while drinking from a cup or a spoon). Postural tremor also occurs in patients with ET and is generally worse in the wing-beat position than when the arms are held straight in front of the patient. The tremor in the two arms is generally out of phase, sometimes creating a seesaw effect when the arms are held in a wing-beat position and contributing to the observation that functionality may improve when two rather than one hand is used (eg, while holding a cup). The postural tremor of ET is generally greatest in amplitude at the wrist or elbow joints rather than more proximal or distal joints and generally involves wrist flexion extension rather than wrist rotation supination. As a rule, the amplitude of kinetic tremor exceeds that of postural tremor, and the converse pattern should raise questions about the diagnosis. Tremor at rest, without other cardinal features of parkinsonism, occurs in approximately 20% of patients with ET attending a specialty clinic, but in contrast to that of Parkinson disease (PD), it is a late feature, and it has only been observed in the arm rather than the arm and leg.

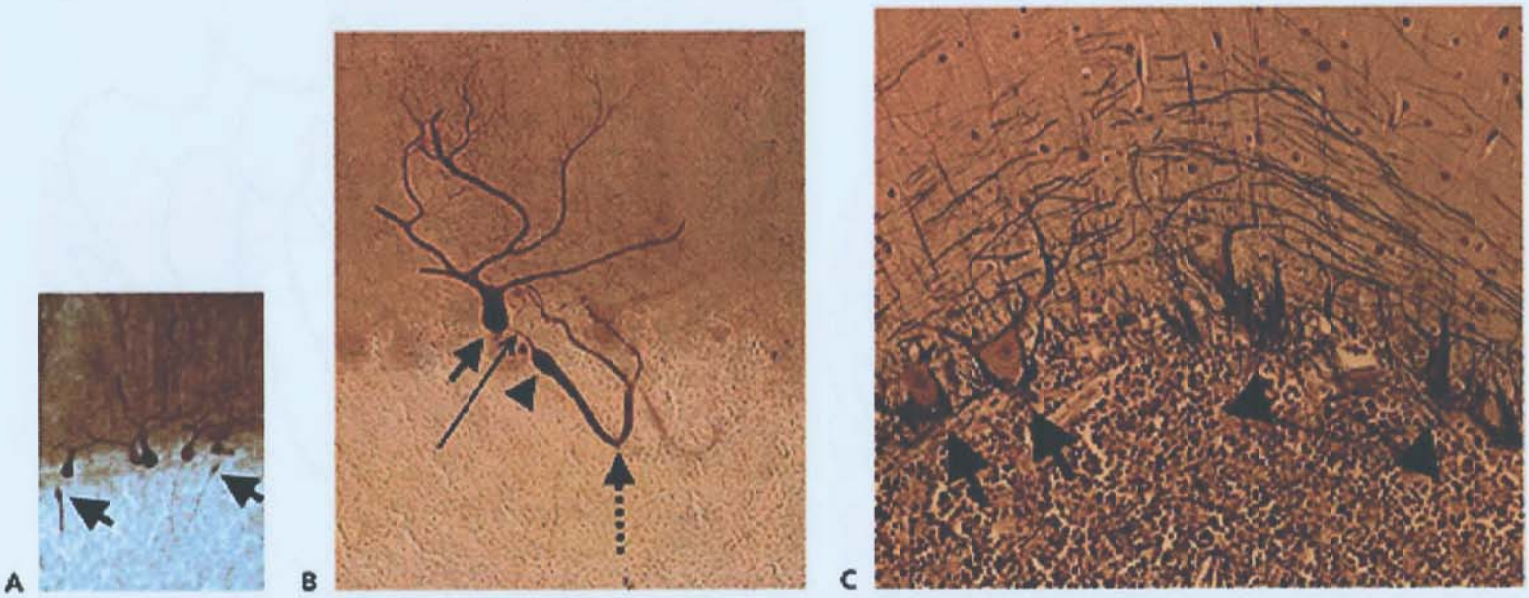

FIGURE 76.2 **A:** Calbindin-stained section of the cerebellar vermis of an essential tremor (ET) case (×100). Torpedoes (two *arrows*, ovoid swellings of the proximal portion of the Purkinje cell axon) occur in significantly greater numbers in ET cases than controls and are markers of an abnormal Purkinje cell biology. **B:** Calbindin-stained section of the cerebellar cortex of an ET case (×200). From left to right, one can see the Purkinje cell body *(arrow)*, the normal thin initial axonal segment *(long, thin arrow)*, the torpedo *(arrowhead)*, and the thickened axon with recurrent collateral formation *(dotted arrow)* and terminal branching of the Purkinje axon. These morphologic changes occur to a greater degree in ET cases than controls and are markers of an abnormal Purkinje cell biology. **C:** Calbindin-stained section of the cerebellar cortex of an ET case (×200). Hypertrophy of the basket cell processes is seen (two *arrows*, "hairy baskets"); in some instances, there is Purkinje cell loss and the baskets are empty (two *arrowheads*). These changes occur to a greater degree in ET cases than controls and are markers of both an abnormal Purkinje cell biology and reactive changes in the surrounding neuronal populations.

Other Motor Features

Another motor feature of ET, aside from tremor, is gait ataxia, which is in excess of that seen in similarly aged controls. In most patients, this is mild, although in some, it may be of moderate severity. There is some evidence that gait ataxia is more pronounced in patients with midline cranial tremors (eg, neck, jaw, voice). Saccadic eye movement abnormalities have also been detected in ET patients in several physiologic studies, although these are of a subclinical nature.

Nonmotor Features

Recent years have witnessed an increasing appreciation of the presence of nonmotor features in ET patients, which may broadly be classed into cognitive, psychiatric, and sensory. Cognitive changes are in excess of those seen in similarly aged controls and range from mild changes across several domains, but especially executive function, to mild cognitive impairment and dementia, both of which occur to a greater extent than in age-matched controls. Indeed, epidemiologic studies demonstrate that the presence of ET increases the risk of incident dementia by more than 50%. The pathobiology of these cognitive changes is unclear at present but is likely to be multifactorial, involving cerebellar as well as more widespread degenerative pathologies. Psychiatric manifestations include secondary anxiety and depression. The presence of a primary mood disturbance, which precedes the motor manifestations, is supported by at least one prospective study. A harm avoidant personality has been reported in studies that have assessed personality traits in ET, and this may be one feature, which makes patients reluctant to undergo therapeutic surgery even in the setting of severe and disabling tremor. Sensory changes include diminished hearing in excess of that seen in age-matched controls and a mild olfactory deficit in some although not all studies.

Natural History

Initially, the tremor may be mild and asymptomatic and it may not worsen for years, but in most individuals, the tremor worsens over time. Several patterns of progression have been described (Fig. 76.3). The two most common are (1) late life onset and (2) early life onset with mild, stable tremor for many years and then a late life worsening. The least common pattern is that of early life onset with marked worsening over the ensuing years to decade. There are few prospective, longitudinal natural history studies, but the best estimates of rate of change indicate that arm tremor worsens by 2% to 5% per year. With the progression of time, there is a tendency for the spread of tremor beyond the arms, such that patients develop cranial tremors (neck, voice, jaw), particularly in women with ET, among whom the risk of neck tremor is several-fold higher than that of men with ET. The prevalence of neck tremor is the highest of these, with voice tremor being less so and jaw tremor being even less so. Neck tremor is generally of either a "no-no" (ie, horizontal) variety or a "yes-yes" (ie, vertical) tremor and, as the disease progresses, may develop into a more complex tremor with a rotatory component. Unless severe, the neck tremor, which is a postural tremor, should subside and resolve when the patient is recumbent. Isolated neck tremor, with minimal or no accompanying arm tremor, is extremely rare and should raise suspicion that the diagnosis is dystonia rather than ET.

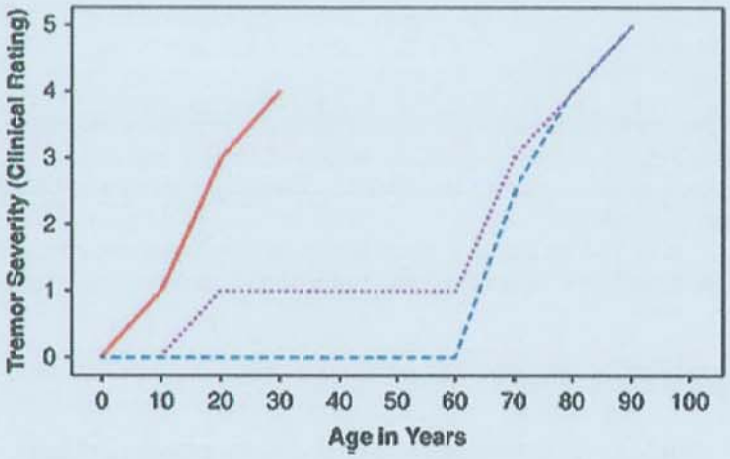

FIGURE 76.3 Three patterns of progression in essential tremor. The two most common are (1) late life onset *(blue dashed line)* and (2) early life onset with mild, stable tremor for many years followed by late life worsening *(purple dotted line)*. The least common pattern is that of (3) early life onset with marked worsening over the ensuing years to decade *(red solid line)*.

A curious feature of the neck tremor is that patients are often unaware of its presence, particularly when it is mild. The presence of dystonic postures in ET cases is controversial, although it is likely that the presence of mild dystonia in some cases does not preclude a diagnosis of ET, especially when the dystonia is a late finding in a case with long-standing and severe ET.

Associated Morbidity and Mortality

Although in the past ET was often viewed as a "benign" problem, the term *benign essential tremor* is no longer considered appropriate. Indeed, the majority of patients have tremor-related disability, and 15% to 25% are sufficiently motorically disabled by high-amplitude shaking that they cannot continue to work. Studies of risk of mortality are limited; the one longitudinal, prospective study that enrolled a controlled group reported an increased risk of mortality in ET of 45%.

The ET patients have about a fourfold increased risk of developing incident PD, thereby developing what is referred to as *essential tremor–Parkinson disease* (ET-PD). The pathobiology of this connection is not fully understood.

DIAGNOSIS

The ET is a clinical diagnosis, made without accompanying laboratory tests because there is no biomarker for ET. Thirty percent to 50% of "ET" cases are misdiagnosed and do not have ET, with many of these cases having dystonia or PD. Differentiation may be made readily, however, by the absence of rigidity or bradykinesia or other signs of parkinsonism (eg, hypomimia) in these cases. The characteristics of the tremor are also important in distinguishing an ET patient from one with PD (Table 76.1). The presence of isolated postural tremor (with minimal kinetic tremor), a postural tremor involving the metacarpophalangeal joints rather than the wrist, and a postural tremor characterized by greater wrist rotation than flexion and extension are all indicators that the likely diagnosis is emerging PD rather than ET (see Table 76.1). Reemergent tremor is a postural tremor that commences after a brief latency, rather than immediately, and is a feature of PD. Dystonia in the arm is characterized by dystonic posturing (eg, "spooning of the fingers" [ie, the tendency during arm extension to flex the wrist and hyperextend the metacarpophalangeal and phalangeal joints]) and the presence of a tremor that is neither rhythmic nor oscillatory. The possibility of neck dystonia should be assessed and is characterized by head tilt or rotation with head tremor, hypertrophy of the sternocleidomastoid muscle, the presence of a tremor null point, and a sensory trick by history (Table 76.2). Absence of cerebellar speech (ie, either scanning or dysarthric) and nystagmus distinguishes ET from the spinocerebellar ataxias. Hyperthyroidism or the use of medications such as lithium or valproate is usually excluded by clinical history. A difficult differential is between a mild case of ET and enhanced physiologic tremor, although the presence of neck tremor should exclude the latter. Computerized tremor analysis, with inertial loading, can assist with this differential. In patients with a tremor of central origin (ET), the primary tremor frequency should not change with inertial loading.

TABLE 76.1 Clinical Examination Features That Help Distinguish Essential Tremor From Parkinson Disease

	ET	PD
Rest tremor (arms)	+[a]	+
Rest tremor (legs)	−[a]	+
Kinetic tremor (arms)	+	+[b]
Postural tremor (arms)	+	+[c]
Intention tremor (arms)	Common	Rare
Reemergent tremor	−	+
Head tremor	Common	Rare
Jaw tremor	+[d]	+
Voice tremor	+	−
Rigidity	−[e]	+
Bradykinesia	−[f]	+
Hypomimia	−	+
Tachyphemia	−	+

Abbreviations: +, present; −, absent; ET, essential tremor; PD, Parkinson disease.
[a]When present, rest tremor generally occurs in ET cases with disease of longer duration and greater severity rather than mild cases of short duration. It is restricted to the arms.
[b]The kinetic tremor of ET is generally of higher amplitude than that of PD, although this is not always the case.
[c]A postural tremor involving the metacarpophalangeal joints rather than the wrist or elbow and a postural tremor characterized by greater wrist rotation than flexion and extension are both indicators that the likely diagnosis is emerging PD rather than ET. An isolated postural tremor (with minimal or no kinetic tremor) is a feature of PD rather than ET. The presence of flexed posturing of the fingers during arm extension is often a sign of PD.
[d]The jaw tremor in ET generally occurs when the mouth is open (eg, while talking or while saying "ahhhhh"); in PD, it generally occurs while the mouth is closed.
[e]During passive movement, the movement may be ratchety, with cogwheeling, but there should be no rigidity.
[f]Older ET patients may have ratings of 1 on the motor portion of the Unified Parkinson's Disease Rating Scale.

TREATMENT

The tremor may be severe enough to result in embarrassment and functional disability, and these are the main motivations for treatment. β-Blockers (especially propranolol) LEVEL 2[1] and

TABLE 76.2 Clinical Examination Features That Help Distinguish Essential Tremor From Dystonia

	ET	Dystonia
Rhythmic and oscillatory tremor	+	+/−
Tremor has a directional quality.	−[a]	+
Tremor null point	−[b]	+
Head tremor resolves while supine.	+	−
Head tremor with little or no arm tremor	Rare[c]	+
Head tilt or rotation	−	+
Hypertrophy of the sternocleidomastoid or other neck muscles	−	+
Voice breaks with voice tremor.	−	+/−
Dystonic posturing in hands (eg, "spooning")	−	+

Abbreviations: +, can be present; −, absent; ET, essential tremor.
[a]Dystonic tremor often has a directional quality seeming to move in one direction more than the opposite.
[b]Tremors, in general, are very positionally dependent in ET, but this should not be confused with a null point.
[c]Isolated head tremor should be a clue that the diagnosis is likely to be dystonia rather than ET.

primidone LEVEL 1,[2] alone or in combination, are the most effective pharmacologic therapies, although many patients chose to discontinue these medications due to their limited efficacy. Propranolol has been used in doses up to 360 mg daily, although doses in excess of 100 mg are rarely tolerated in the elderly due to bradycardia. Asthma is a relative contraindication to the use of propranolol but is not an absolute contraindication and must be assessed on a case-by-case basis; in general, more severe and more recent history of asthma are of greater concern. Primidone is given in doses up to 1,500 mg daily, although lower doses are often effective. An acute nausea and/or ataxia is observed in approximately 25% of patients who are prescribed this medication, and preloading the patient with phenobarbital (eg, 30 mg twice a day for 3 days) is one method that is used to avoid this unwanted side effect. Somnolence and cognitive effects may further limit the use of primidone in older patients. These drugs reduce the amplitude of tremor in 30% to 70% of patients, but they do not abolish it unless the tremor is mild. Other agents that have been used include topiramate LEVEL 1,[3] gabapentin LEVEL 1,[4] and benzodiazepines (alprazolam or clonazepam) LEVEL 1.[5] Many patients note that tremor is temporarily suppressed by drinking ethanol, but a rebound exacerbation sometimes follows the next day. Botulinum toxin injections have been shown to be effective in the treatment of wrist and other upper limb tremors in ET, although muscle weakness may occur LEVEL 1.[6] Weighted utensils and utensils with sensors that use activation cancellation of tremor technology may also provide limited benefit in some patients. High-frequency thalamic stimulation markedly reduces the severity of the tremor and has replaced stereotactic thalamotomy as the treatment of choice for severe pharmacologically refractory tremor. Several other emerging surgical therapies are currently under evaluation, particularly magnetic resonance imaging–guided focused ultrasound thalamotomy.

OUTCOME

As noted in detail earlier, ET is in general a progressive disorder (see Fig. 76.3), with a gradual worsening and spread of tremor over time. At this time, there are no medications that slow or halt this progression.

Videos can be found in the companion e-book edition. For a full list of video legends, please see the front matter.

LEVEL 1 EVIDENCE

1. Winkler GF, Young RR. Efficacy of chronic propranolol therapy in action tremors of the familial, senile or essential varieties. *N Engl J Med*. 1974;290(18):984-988.
2. Findley LJ, Cleeves L, Calzetti S. Primidone in essential tremor of the hands and head: a double blind controlled clinical study. *J Neurol Neurosurg Psychiatry*. 1985;48(9):911-915.
3. Ondo WG, Jankovic J, Connor GS, et al. Topiramate in essential tremor: a double-blind, placebo-controlled trial. *Neurology*. 2006;14;66(5):672-677.
4. Gironell A, Kulisevsky J, Barbanoj M, López-Villegas D, Hernández G, Pascual-Sedano B. A randomized placebo-controlled comparative trial of gabapentin and propranolol in essential tremor. *Arch Neurol*. 1999;56(4):475-480.
5. Gunal DI, Afsar N, Bekiroglu N, Aktan S. New alternative agents in essential tremor therapy: double-blind placebo-controlled study of alprazolam and acetazolamide. *Neurol Sci*. 2000;21(5):315-317.
6. Jankovic J, Schwartz K, Clemence W, Aswad A, Mordaunt J. A randomized, double-blind, placebo-controlled study to evaluate Botulinum toxin type A in essential hand tremor. *Mov Disord*. 1996;1(3):250-256.

SUGGESTED READINGS

Babij R, Lee M, Cortés E, Vonsattel JP, Faust PL, Louis ED. Purkinje cell axonal anatomy: quantifying morphometric changes in essential tremor versus control brains. *Brain*. 2013;136(pt 10):3051-3061.

Bagepally BS, Bhatt MD, Chandran V, et al. Decrease in cerebral and cerebellar gray matter in essential tremor: a voxel-based morphometric analysis under 3T MRI. *J Neuroimaging*. 2012;22(3):275-278.

Bain PD, Findley LJ, Thompson PD, et al. A study of hereditary essential tremor. *Brain*. 1994;117(pt 4):805-824.

Benito-León J, Louis ED, Bermejo-Pareja F. Population-based case-control study of cognitive function in essential tremor. *Neurology*. 2006;66(1):69-74.

Bermejo-Pareja F. Essential tremor—a neurodegenerative disorder associated with cognitive defects? *Nat Rev Neurol*. 2011;7(5):273-282.

Bermejo-Pareja F, Louis ED, Benito-León J. Risk of incident dementia in essential tremor: a population-based study. *Mov Disord*. 2007;22(11):1573-1580.

Cerasa A, Messina D, Nicoletti G, et al. Cerebellar atrophy in essential tremor using an automated segmentation method. *AJNR Am J Neuroradiol*. 2009;30(6):1240-1243.

Choe M, Cortés E, Vonsattel JPG, Kuo SH, Faust PL, Louis ED. Purkinje cell loss in essential tremor: random sampling quantification and nearest neighbor analysis. *Mov Disord*. 2016;31:393-401.

Critchley M. Observations on essential (heredofamial) tremor. *Brain*. 1949;72(pt 2):113-139.

Diaz NL, Louis ED. Survey of medication usage patterns among essential tremor patients: movement disorder specialists vs. general neurologists. *Parkinsonism Relat Disord*. 2010;16(9):604-607.

Elias WJ, Huss D, Voss T, et al. A pilot study of focused ultrasound thalamotomy for essential tremor. *N Engl J Med*. 2013;369(7):640-648.

Erickson-Davis CR, Faust PL, Vonsattel JGV, Gupta S, Honig LS, Louis ED. "Hairy baskets" associated with degenerative Purkinje cell changes in essential tremor. *J Neuropathol Exp Neurol*. 2010;69:262-271.

Farrell K, Cosentino S, Ida M, et al. Quantitative assessment of pathological tau burden in essential tremor: a postmortem study. *J Neuropathol Exp Neurol*. 2019;78:31-37.

Gitchel GT, Wetzel PA, Baron MS. Slowed saccades and increased square wave jerks in essential tremor. *Tremor Other Hyperkinet Mov (N Y)*. 2013;3:tre-03-178-4116-2.

Haubenberger D, Hallett M. Essential tremor. *N Engl J Med*. 2018;378:1802-1810.

Helmchen C, Hagenow A, Miesner J, et al. Eye movement abnormalities in essential tremor may indicate cerebellar dysfunction. *Brain*. 2003;126(pt 6):1319-1332.

Hubble JP, Busenbark KL, Pahwa R, Lyons K, Koller WC. Clinical expression of essential tremor: effects of gender and age. *Mov Disord*. 1997;12(6):969-972.

Kim CY, Louis ED. "Spooning": a subtle sign of limb dystonia. *Tremor Other Hyperkinet Mov (N Y)*. 2018;8:607.

Kuhlenbäumer G, Hopfner F, Deuschl G. Genetics of essential tremor: meta-analysis and review. *Neurology*. 2014;82(11):1000-1007.

LaRoia H, Louis ED. Association between essential tremor and other neurodegenerative diseases: what is the epidemiological evidence? *Neuroepidemiology*. 2011;37(1):1-10.

Lee JS, Kerridge CO, Chatterjee D, Koeppen AH, Faust PL, Louis ED. A quantitative study of empty baskets in essential tremor and other motor neurodegenerative diseases. *J Neuropathol Exp Neurol*. 2019;78:113-122.

Lin C-Y, Louis ED, Faust PL, Koeppen AH, Vonsattel JPG, Kuo S-H. Abnormal climbing fibre-Purkinje cell synaptic connections in the essential tremor cerebellum. *Brain*. 2014;137(pt 12):3149-3159.

Louis ED. "Essential tremor" or "the essential tremors": is this one disease or a family of diseases? *Neuroepidemiology*. 2014;42(2):81-89.

Louis ED. From neurons to neuron neighborhoods: the rewiring of the cerebellar cortex in essential tremor. *Cerebellum*. 2014;13(4):501-512.

Louis ED. Non-motor symptoms in essential tremor: a review of the current data and state of the field. *Parkinsonism Relat Disord*. 2016;22(suppl 1):S115-S118.

Louis ED. Re-thinking the biology of essential tremor: from models to morphology. *Parkinsonism Relat Disord*. 2014;20(suppl 1):S88-S93.

Louis ED. The primary type of tremor in essential tremor is kinetic rather than postural: cross-sectional observation of tremor phenomenology in 369 cases. *Eur J Neurol*. 2013;20(4):725-727.

Louis ED, Agnew A, Gillman A, Gerbin M, Viner AS. Estimating annual rate of decline: prospective, longitudinal data on arm tremor severity in two groups of essential tremor cases. *J Neurol Neurosurg Psychiatry*. 2011;82(7):761-765.

Louis ED, Benito-León J, Ottman R, Bermejo-Pareja F. A population-based study of mortality in essential tremor. *Neurology*. 2007;69:1982-1989.

Louis ED, Faust PL, Vonsattel JP, et al. Neuropathological changes in essential tremor: 33 cases compared with 21 controls. *Brain*. 2007;130(pt 12):3297-3307.

Louis ED, Ferreira JJ. How common is the most common adult movement disorder? Update on the worldwide prevalence of essential tremor. *Mov Disord*. 2010;25(5):534-541.

Louis ED, Ford B, Frucht S, Barnes LF, X-Tang M, Ottman R. Risk of tremor and impairment from tremor in relatives of patients with essential tremor: a community-based family study. *Ann Neurol*. 2001;49(6):761-769.

Louis ED, Galecki M, Rao AK. Four essential tremor cases with moderately impaired gait: how impaired can gait be in this disease? *Tremor Other Hyperkinet Mov (N Y)*. 2013;3:tre-03-200-4597-1.

Louis ED, Jiang W, Pellegrino KM, et al. Elevated blood harmane (1-methyl-9h-pyrido[3,4-b]indole) concentrations in essential tremor. *Neurotoxicology*. 2008;29(2):294-300.

Louis ED, Joyce JL, Cosentino S. Mind the gaps: what we don't know about cognitive impairment in essential tremor. *Parkinsonism Relat Disord*. 2019;63:10-19.

Louis ED, Lenka A. The olivary hypothesis of essential tremor: time to lay this model to rest? *Tremor Other Hyperkinet Mov (N Y)*. 2017;7:473. doi:10.7916/D8FF40RX.

Louis ED, Rios E, Henchcliffe C. How are we doing with the treatment of essential tremor (ET)? Persistence of patients with ET on medication: data from 528 patients in three settings. *Eur J Neurol*. 2010;17(6):882-884.

Ondo WG, Sutton L, Dat Vuong K, Lai D, Jankovic J. Hearing impairment in essential tremor. *Neurology*. 2003;61(8):1093-1097.

Passamonti L, Cerasa A, Quattrone A. Neuroimaging of essential tremor: what is the evidence for cerebellar involvement? *Tremor Other Hyperkinet Mov (N Y)*. 2012;2:02-67-421-3.

Phibbs F, Fang JY, Cooper MK, Charles DP, Davis TL, Hedera P. Prevalence of unilateral tremor in autosomal dominant essential tremor. *Mov Disord*. 2009;24(1):108-111.

Prasad S, Shah A, Bhalsing KS, et al. Abnormal hippocampal subfields are associated with cognitive impairment in essential tremor. *J Neural Transm (Vienna)*. 2019;126(5):597-606. doi:10.1007/s00702-019-01992-3.

Robakis D, Louis ED. Head tremor in essential tremor: "yes-yes", "no-no," or "round and round"? *Parkinsonism Related Disord*. 2016;22:98-101.

Schrag A, Münchau A, Bhatia KP, Quinn NP, Marsden CD. Essential tremor: an overdiagnosed condition? *J Neurol*. 2000;247(12):955-959.

Stefansson H, Steinberg S, Petursson H, et al. Variant in the sequence of the LINGO1 gene confers risk of essential tremor. *Nat Genet*. 2009;41(3):277-279.

Tarakad A, Jankovic J. Essential tremor and Parkinson's disease: exploring the relationship. *Tremor Other Hyperkinet Mov (N Y)*. 2019;8:589. doi:10.7916/D8MD0GVR.

Yilmaz NH, Akbostanci MC, Yilmaz N. Sensorineural hearing loss in non-depressed essential tremor cases and controls: a clinical and audiometric study. *Tremor Other Hyperkinet Mov (N Y)*. 2015;5:281. doi:10.7916/D8XW4HKQ.

Zesiewicz TA, Elble RJ, Louis ED, et al. Evidence-based guideline update: treatment of essential tremor: report of the Quality Standards Subcommittee of the American Academy of Neurology. *Neurology*. 2011;77(19):1752–1755.

Tics and Tourette Syndrome 77

Harvey S. Singer

KEY POINTS

1. Tourette syndrome is a complex heterogeneous disorder consisting of variable chronic motor and vocal (phonic) tics and coexisting neuropsychological problems.
2. Tics typically appear in the first decade of life and, in many, diminish in the teenage to early adulthood years.
3. About 85% of Tourette syndrome patients have at least one coexisting neuropsychological condition—the most common being attention deficit hyperactivity disorder, obsessive-compulsive disorder, anxiety, depression, disruptive behaviors, and academic issues.
4. Although the precise etiology for Tourette syndrome is unknown, there is increasing evidence for it being a polygenic combination of several different genes plus environmental factors.
5. Pathophysiologic models of Tourette syndrome suggest involvement of different components of cortico-basal ganglia-thalamo-cortical circuits and their neurotransmitters.
6. An effective therapeutic plan involves the careful assessment of both tics and comorbidities, providing education, and the stepwise use of behavioral therapy, first tier (α-adrenergic agonist, topiramate) and second tier (typical and atypical antipsychotics, vesicular monoamine transporter 2 inhibitors).

INTRODUCTION

Tourette syndrome, officially listed in *Diagnostic and Statistical Manual of Mental Disorders*, fifth edition (DSM-5), as Tourette disorder, is named after the French physician Georges Gilles de la Tourette, who in 1885 described nine patients with chronic involuntary motor and vocal tics. Historically, there are earlier reports including a case report by Jean Itard in 1825. Tourette syndrome is a highly heterogeneous disorder characterized by the presence of variable motor and vocal tics and a variety of co-occurring problems including attention deficit hyperactivity disorder (ADHD), obsessive-compulsive disorder (OCD), anxiety, mood disorder, and other issues. Estimated to have a prevalence around 1%, this syndrome can have a significant negative impact on quality of life. The etiology is complex and currently believed to be polygenic, involving a variety of genes, with contributing environmental factors. The pathophysiology remains undetermined with ongoing controversies involving neuronal circuitry and specific neurotransmitters. There is no cure for Tourette syndrome, and treatment includes education, behavioral and pharmacotherapy, and neuromodulation.

EPIDEMIOLOGY

The prevalence (number of cases in population at a given time) of tics, especially simple tics in childhood ranges from 4% to 24%. Data on chronic tic disorders, those present for greater than 1 year, has varied enormously (0.25%-5.7%), in part due to wide differences in study methodologies. Studies based on the clinical diagnosis of Tourette syndrome range from 0.3% to 0.76% with those evaluating the general population reporting rates around 1%. A meta-analysis of 13 studies identified a prevalence 0.77%, but when solely boys were assessed, the prevalence rose to 1.06%. Another estimate includes an additional 10 to 30 per 1,000 children and adolescents with a mild, unidentified form. Tic phenomenology and severity appear to be similar between children and adults. Adult-onset tic disorders, however, are often associated with potential environmental triggers, severe symptoms, greater social morbidity, and a poorer response to medications. Tourette syndrome is common in children with autism, Asperger syndrome, fragile X syndrome, and other autistic spectrum disorders, but its presence appears to be unrelated to the severity of autistic symptoms. In one study, 22.8% of Tourette syndrome patients met autistic spectrum disorder criteria using a repetitive and restricted behavioral subscale rather than indicators of social communication.

Mortality rates are reportedly higher in Tourette syndrome and chronic motor or vocal tic disorder, irrespective of the presence of comorbidities. Parents of children with chronic tic disorders have higher rates of psychiatric illnesses, greater in mothers than fathers, although whether this is associated with parental stress or environmental, genetic, or other factors is unclear.

PATHOBIOLOGY

Neurobiology

Motor Circuits

Cortico-basal ganglia-thalamo-cortical (CBGTC) pathways have a major role in the generation of tics, however, which component contains the primary pathophysiologic abnormality is an area of ongoing controversy. Proponents have generally focused on the cortex and basal ganglia, although others have noted the essential integrating activity of the thalamus, the motivational and reward aspects of the ventral striatum, or the underrecognized influence of the cerebellum. Lastly, there are those investigators who have suggested that a disruption in multiple sites within the CBGTC circuit, or alterations in brain regions inputting to the circuit, could produce an aberrant message arriving at the primary motor cortex and enabling the tic. Several recent reviews provide an extensive discussion of available clinical and animal model investigative data.

The most frequently presented and simplistic model of motor behavioral control suggests the basal ganglia controls cortical excitability through an interplay of direct and indirect pathways. Three cortical regions (associative/cognitive, motor, and limbic) innervate the striatum with excitatory glutamatergic input: The associative/cognitive pathway arises in dorsolateral prefrontal and parietal regions and projects to the caudate, the motor pathway projects from motor/supplementary motor cortical areas to the putamen, and the limbic (emotional) pathway projects from orbital and medial prefrontal regions to the ventral striatum. Direct and indirect pathways originate from medium spiny neurons (MSNs) within the striatum. The direct pathway transmits striatal information monosynaptically from dopamine D_1 receptor containing MSNs to the globus pallidus interna/substantia nigra pars reticulata (GPi/SNpr), whereas the indirect system conveys information from D_2 receptor containing MSNs to these same regions via a disynaptic relay from globus pallidus externa to the subthalamic nucleus and then to the GPi/SNpr. Each pathway has an opposing effect on GABAergic GPi /SNpr output neurons; the direct pathway GABAergic MSNs inhibit and the indirect pathway, via glutamatergic input from the subthalamic nucleus, stimulates. Functionally, these pathways have a reverse effect on thalamocortical neurons and, in turn, the facilitation/inhibition of motor activity, that is, activation of the direct pathway facilitates motor activity via disinhibition of thalamocortical neurons, whereas activation of the indirect pathway reduces motor activity by increasing the inhibition of thalamocortical neurons. Although many investigators focus on this "two pathway model," it is essential to recognize that the CBGTC circuit is very complex with extensive interactions among its various components.

Neurotransmitters

Neurochemical hypotheses regarding dysfunctional synaptic mechanisms in tic pathology have implicated virtually all neurotransmitter systems located in CBGTC circuits (ie, dopamine, glutamate, γ-aminobutyric acid, serotonin, acetylcholine, histamine, norepinephrine, adenosine, endogenous cannabinoids, and opioids). Unfortunately, like other aspects involving the pathophysiology of tics, the final answer remains unknown. In general, published evidence associating a neurotransmitter with tics has included clinical responses to specific classes of medications, quantitative measurements, imaging protocols, genetic protocols, postmortem brain tissue analyses, and data from animal studies. Several published reviews extensively discuss the evidence supporting individual neurotransmitter abnormalities in Tourette syndrome.

Available neurochemical evidence in Tourette syndrome supports a role for dopamine, including presynaptic and postsynaptic dysfunctions and a preferred intrasynaptic abnormality involving the phasic (stimulus-induced) release. Nevertheless, human and animal studies have identified imbalances in other neurotransmitter systems. For example, glutamate (excitatory) and γ-aminobutyric acid (inhibitory) are major transmitters in CGBTC pathways and disruption of their balance in either the cortex or striatum of animal models has induced tic-like behaviors. Furthermore, it is essential to recognize that within complex integrated motor circuits, a change in one neurotransmitter has a significant effect on the function of other interconnected transmitters. Hence, a successful response to a dopamine antagonist does not necessarily indicate that dopamine is the primary neurotransmitter.

Genetics

Both twin and family studies support a genetic, non-mendelian, etiology for Tourette syndrome. Data includes (1) a positive family history for tics in about one-half of patients, (2) a greater concordance rate with chronic tic disorder in monozygotic twins (86%) compared to dizygotic twins (20%), and (3) a population-based heritability estimate of 0.77—a value of 1 indicating 100% heritability. Nevertheless, despite the support for heritability, numerous studies of multigenerational families have failed to identify a definitive major effect gene. In contrast, current reports suggest a polygenic disorder, that is, one due to a variety of genes (common, rare, low and high effect) plus environmental factors. Several susceptibility (risk) genes have emerged but are not fully confirmed. These include the *SLITRK1* gene, located at 13q31.1, and a mutation in the gene encoding L-histidine decarboxylase. Studies searching for copy number variations (microdeletions or duplications) have identified a few significant changes conferring increased risk including deletions in *NRXN1* (encodes neurexin 1) and duplications of *CNTN6* (encodes contactin 6). Genome-wide association studies have not identified a single significant marker, and the top Tourette syndrome–associated single nucleotide protein was on chromosome 12q22 32kb distal to netrin-4; hence, another possible Tourette syndrome susceptibility gene. Lastly, in expanded whole exome sequencing studies, individuals with unaffected parents had several de novo variants including genes for cadherin and those relating to cell polarity. Clearly, further studies are required to clarify the link between susceptibility genes, clinical findings, and pathophysiology. Investigations pursuing a shared genetic link between Tourette syndrome and OCD have not identified shared gene variants but have shown a significant overlap of de novo sequence variants. Polygenic heritability in Tourette syndrome is shared with OCD, ADHD, and migraine.

Immune System

Autoimmune factors are suggested as both primary and contributing influences for tics. Initially described more than two decades ago, pediatric autoimmune neuropsychiatric disorder associated with a streptococcal infection (PANDAS) is an extremely controversial disorder. Symptoms include the acute, dramatic, explosive onset of a tic and OCD and the presence of infection-related group-A β-hemolytic streptococcal exacerbations. Its proposed pathophysiologic mechanism is the presence of streptococcal-induced polyreactive antibodies, which, through the process of molecular mimicry, recognize and disrupt either neuronal extracellular surface or intracellular antigens. Numerous studies, however, have raised significant concerns about the existence of this entity based on both its clinical criteria and proposed presence of antineuronal antibodies.

A microglial (glial cells belonging to the monocyte/macrophage lineage) hypothesis suggests that various factors (environmental, psychological, infectious, genetic) can "prime" these cells, which in turn alter synaptic formation and elimination. Supporting data includes a postmortem study showing upregulation of inflammatory response transcripts, a positron emission tomography study demonstrating increased binding to the translocator protein receptor present in activated microglia, and an RNA sequencing study of postmortem striatum identifying upregulated genes involved with microglial activation. Some patients with Tourette syndrome also have a variety of isolated immune findings including abnormal

T regulatory cells, elevated cytokines, an impaired innate immune response to bacterial infections, elevated adhesion molecules, and intrathecal oligoclonal bands.

CLINICAL MANIFESTATIONS

Tics, both motor and vocal (also called *phonic*), are sudden, rapid, brief, recurrent, nonrhythmic movements or vocalizations that have a limitless repertoire and variable amplitude and frequency. They often occur repetitively within a short inter-tic interval and are separable into simple and complex categories (Table 77.1). Although often considered a hallmark of Tourette syndrome, coprolalia occurs in only approximately 10% of cases.

The frequency and intensity of tics varies greatly. In some individuals, tics are barely noticeable, whereas in others, they can be very frequent, forceful, intrusive, and even self-injurious. Stress, anxiety, fatigue, elevated temperatures, and infections exacerbate tics. In some, tics are induced by seeing or hearing other people's actions/words or worsened by discussions about their tics. These changes, however, do not usually account for the more prolonged fluctuations and variability of tics. Tics tend to be reduced when individuals are involved in activities that require concentrating and being focused, such as when given tasks to perform during their physical examination, playing the piano, or participating in sports. Although, the typical history includes the absence of tics during sleep, formal polysomnograms have documented their presence during various sleep cycle stages.

The majority (about 90%) of older children and adults describe an uncomfortable sensation that occurs just before the tic (premonitory sensation) and many report an "urge" to tic. Expressed as a feeling of tightness, tingling, tension, pressure, itchiness, distress or "difficult to define," the premonitory sense is often localized to the region of the tic and resolves when the motor/vocal tic is performed. Some report a brief feeling of relief after the tic has occurred. Others are able to briefly suppress their tics for a limited period of time—often at the expense of a mounting discomfort. Neurologic examination and neuroradiographic studies are typically normal. "Soft" signs, including abnormalities of coordination and fine motor performance, synkinesis, and motor restlessness, are frequently present in affected children especially those with ADHD.

TABLE 77.1 Motor and Vocal Tics

Simple motor tics	Simple motor tics include eye blinking, nose twitching, facial grimaces, head jerks, and shoulder shrugs, etc.
Complex motor tics	More elaborate movements that include: 1. A combination of simple movements in a fixed pattern 2. Coordinated actions such as touching, jumping, bending, and gyrating 3. A prolonged "tonic" action (sustained posturing, ocular deviation, torticollis) that can last for a few seconds to minutes 4. Obscene gestures (copropraxia) 5. Imitation of observed movements (echopraxia)
Simple vocal tics	Sudden sounds or noises (throat clearing, sniffs, grunts, barks, hoots, hollers, moans, groans, and other animal sounds)
Complex vocal tics	More meaningful utterances that include: 1. Repetition of syllables, words, or phrases 2. Echolalia (repeating other people's words) 3. Palilalia (repeating one's own words) 4. Coprolalia (the utterance of obscene words)

DIAGNOSIS

DSM-5 Tic Disorder Diagnoses

A tic disorder diagnosis is based on the history and observation of the movement or vocalization. There is no confirmatory laboratory test. The DSM-5 includes five categories: provisional tic disorder, chronic (motor or vocal) tic disorder, Tourette disorder, other specified tic disorder, and unspecified tic disorder (Table 77.2).

Adult-onset tic disorders do occur and often include more severe symptoms, greater social difficulties, and a poorer response to medications. Tics occur in association with a variety of sporadic, genetic, and neurodegenerative disorders including neuroacanthocytosis, Huntington disease, Hallervorden-Spatz syndrome, neurocutaneous syndromes, and Creutzfeldt-Jakob disease. Tics have also been reported in association with infections (encephalitis, Sydenham chorea), drugs, toxins (carbon monoxide), stroke, head trauma, peripheral trauma, and surgery. Drugs reported to induce tics include cocaine, lamotrigine, and neuroleptics. Proof for a substance-induced tic disorder requires that the tics developed either during or within 1 month of substance intoxication or withdrawal. There is little scientific evidence to support the belief that stimulant medications are a precipitating agent for tics.

TABLE 77.2 Tic Disorder Diagnoses

Provisional tic disorder	Indicates an individual whose tics (motor and/or vocal) have been present for less than 1 year since first tic onset and onset is before age 18 years. The disturbance cannot be attributable to the psychological effects of a substance or other medical conditions.
Chronic motor or vocal tic disorder	Indicates the presence of either motor or vocal tics, but not both, for a duration of greater than 1 year, without regard to tic frequency. Onset must be before the age of 18 years and not be attributed to the use of drugs or other medical conditions.
Tourette disorder (also commonly called Tourette syndrome)	Requires an onset before age 18 years, the presence of multiple motor and at least one vocal tic, a waxing and waning course, a duration of longer than 1 year, and that tics are neither substance-induced nor due to a general medical condition
Other specified tic disorder	This diagnosis is appropriate when the patient has tics but fails to fulfill criteria for any of the above tics disorders. In the "other specified tic disorder" category, the reason why the individual failed to meet the aforementioned criteria must be provided, for example, other specific tic disorder "due to an age of onset older than 18 years" or "due to the presence of substance-induced disorder."
Unspecified tic disorder	This diagnosis is appropriate when the patient has tics but fails to fulfill criteria for any of the above tics disorders. In the "Unspecified tic disorder" category, the reason why the individual failed to meet the aforementioned criteria is not provided.

Scales

A variety of clinical rating scales can be used to monitor tic severity. The Yale Global Tic Severity Scale, a semistructured clinical interview, is the most widely used tic assessment instrument. It was recently revised based on its psychometric properties. The scale ranks motor and vocal tics based on their number, frequency, intensity, complexity, and interference. A separate Tic Impairment Score ranks impairment based on the impact of tics on self-esteem, family life, and social acceptance. Other rating scales include the Motor tic, Obsessions and compulsions, Vocal tic Evaluation Survey and the Modified Rush Video-based Rating Scale. The Premonitory Urge for Tics Scale characterizes and quantifies premonitory urges on a global scale, whereas the Individualized Premonitory Urge for Tics Scale provides complementary information on the presence, frequency, and intensity of urges for individual tics. Recognizing that tic severity does not necessarily correlate with overall quality of life, the Gilles de la Tourette syndrome Health-Related Quality of Life Scale, with psychological, physical, obsessional, and cognitive subscales, can provide an important assessment.

Coexisting Conditions

Although the diagnosis of Tourette syndrome only requires the presence of tics, approximately 85% of patients with this disorder have coexisting neuropsychological conditions, that is, only 10% have "pure" Tourette syndrome. For many individuals, these additional issues have a greater negative clinical impact than those directly caused by tics. Several, such as ADHD and OCD, appear genetically linked to Tourette syndrome, although the relationship is complex. Other frequent co-occurring conditions, with a less likely genetic association, include anxiety and depressive disorders, disruptive behaviors, conduct problems, suicidality, sleep disturbances, self-injurious behaviors, academic difficulties, and migraine headaches. A recent study has also suggested that cardiovascular problems and obesity are common in Tourette syndrome patients, unrelated to the use of antipsychotic medications.

Attention Deficit Hyperactivity Disorder

The ADHD, defined by the presence of impulsivity, hyperactivity, and a decreased ability to maintain attention to an impairing degree, occurs in about 60% of referred Tourette syndrome patients (range 21%-90%). Symptoms usually begin at age 4 to 5 years and typically precede the onset of tics. The presence of ADHD, not tics, typically correlates with increased psychosocial difficulties, disruptive behavior, emotional problems, functional impairment, learning disabilities, and school problems.

Obsessive-Compulsive Behaviors and Obsessive-Compulsive Disorder

Obsessive-compulsive behaviors are common in individuals with Tourette syndrome (about 60%-90%) with about 40% to 60% having the diagnosis of OCD—the later requiring behaviors to be present for more than 1 hour a day, result in marked distress, or to have a significant impact on normal function or relations. Symptoms usually emerge several years after the onset of tics. Obsessive-compulsive symptoms vary in patients with and without tics. Those associated with tics have a need for order, a requirement for symmetry, frequent checking for errors, hoarding, touching, tapping, rubbing, and a higher frequency of aggressive, sexual, religious, and symmetry-related obsessions. In contrast, symptoms occurring in individuals without tics include cleaning rituals, compulsive washing, and fears of contamination. Clinically differentiating obsessive-compulsive behaviors from complex tics may be difficult. Clues that favor obsessive compulsive symptoms include a cognitive-based drive ("unless I do this, something will happen"), need to perform the action in a particular fashion (ie, a specific number of times, until it feels "just right," or equally on both sides of the body), and the absence of a premonitory urge.

Anxiety and Depression

Anxiety and depression have an increased prevalence in patients with Tourette syndrome; depression affecting from 13% to 76% and anxiety from 19% to 80% depending on the study. In contrast to earlier reports, the age of onset for these symptoms is earlier than originally believed with high-risk periods for anxiety and mood disorders beginning at ages 4 and 7 years, respectively. The etiology of these symptoms appears to be multifactorial but not genetic. Anxiety and disruptive behaviors are partially mediated by ADHD, whereas mood disorders are influenced by comorbid OCD.

Other Psychopathologies

Disruptive antisocial and oppositional behaviors, aggression, personality disorder, problems with anger control, nonobscene socially inappropriate behaviors, and schizotypal traits are more frequent in Tourette syndrome. Self-injurious behaviors occur in a minority of patients. Like anxiety and depression, these behavioral and emotional problems are associated with obsessionality, ADHD, and impulsivity, rather than just the presence of tics. Suicidality, both thoughts and attempts, have a higher incidence in Tourette syndrome. Children with Tourette syndrome are also more likely to have sensory hypersensitivity.

Academic Issues

Individuals with Tourette syndrome typically have normal intellectual functioning, although learning problems may coexist in about 30% to 40%. Documented issues have included concurrent executive dysfunction, impaired visual-motor and visual-perceptual skills, and discrepancies between performance and IQ testing. Poor academic performance may also be secondary to severe tics, psychosocial issues and bullying, ADHD, OCD, learning difficulties, sleep problems, or side effects from prescribed medications.

Sleep Disorders

A wide range of sleep difficulties, including difficulties falling asleep, staying asleep, restless sleep, frequent arousals, and parasomnias, are common in Tourette syndrome. Whether all of these problems are primarily due to coexisting problems is unclear. The effective management of sleep problems has improved the severity of tics and quality of life.

MANAGEMENT

Initial Management

The initial step in establishing a treatment plan for Tourette syndrome (Fig. 77.1) includes (1) the evaluation of tics, their severity, and resulting impairment; (2) determining the presence of coexisting conditions and their impact on daily functioning

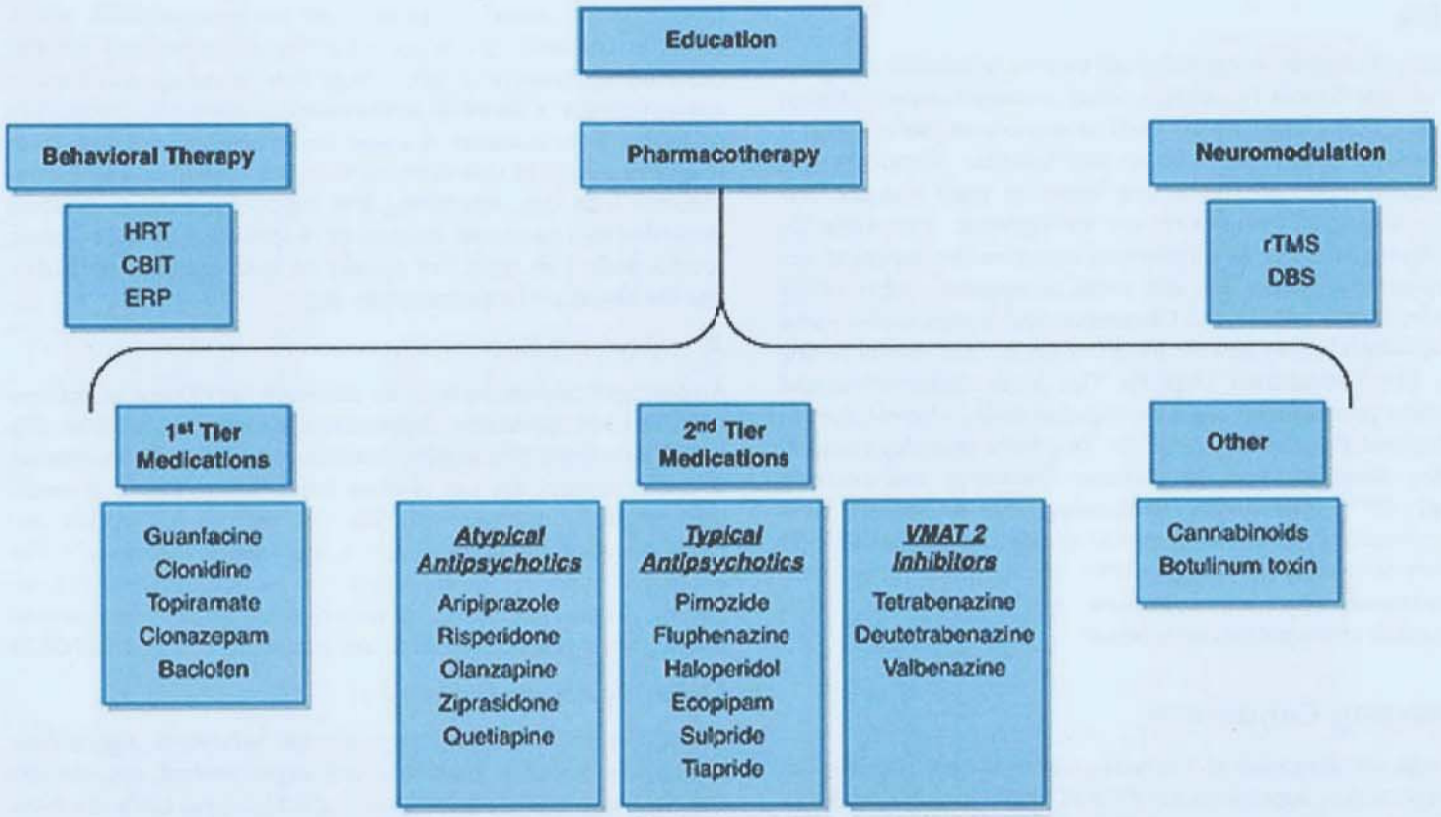

FIGURE 77.1 Management of tics. Abbreviations: CBIT, comprehensive behavioral intervention for tics; DBS, deep brain stimulation; ERP, exposure response prevention; HRT, habit reversal training; rTMS, repetitive transcranial magnetic stimulation; VMAT2, vesicular monoamine transporter 2.

and quality of life; and (3) in conjunction with the patient, family, and school/work personnel, determining which symptoms are the most prominent and disabling. An early discussion of tics and comorbid symptoms as separate entities enables families and health care specialists to focus on the patient's immediate needs more effectively. For example, in many instances, ADHD, OCD, anxiety, disruptive behaviors, or mood symptoms may cause more immediate problems than tics. Furthermore, providing clear and accurate information and allowing adequate time for questions and answers enhances the ability of patients and families to understand the numerous issues surrounding this complex and heterogeneous disorder. Lastly, all need to recognize that there is no cure for tics, only symptomatic therapy.

Therapy is reserved for functionally disabling tics. The treatment of a child with Tourette syndrome often requires a comprehensive multidisciplinary approach, especially in those individuals with academic or psychiatric difficulties. Regarding tics, for many, educational insight about their diagnosis, outcome, coexisting problems, etiology, neurobiology, and indications for therapy often obviates or delays the need for treatment. Tics fluctuate, and supportive care is often adequate for individuals with milder tics. Specific criteria for initiating tic-suppressing therapy includes either (1) the presence of psychosocial problems (eg, loss of self-esteem; peer problems; difficulty participating in academic, work, family, social, and after-school activities), (2) tic-induced musculoskeletal/physical difficulties (eg, neck discomfort associated with frequent head jerks), (3) and the disruption of classroom/work settings (eg, sounds, noises, or movements that interfere with a classmate's ability to concentrate on the lesion). If tics warrant treatment, behavioral interventions are first-line therapy. The goal of treatment is to reduce tics to a degree at which they are no longer causing significant problems.

Behavioral Treatment for Tics

Behavioral interventions include habit reversal training (HRT), comprehensive behavioral intervention for tics (CBIT), and exposure response prevention (ERP). The neurobehavioral model acknowledges the neurobiologic nature of tics but suggests tics are influenced by internal (premonitory urges) and external (stress, environmental) factors. The behavioral strategies taught in treatment are aimed at interrupting (and ultimately discontinuing) the reinforcement of tics by these internal and external factors. Despite the efficacy of behavior therapy for Tourette syndrome, a limited number of providers are trained to deliver this treatment, which poses a barrier to its use in the community.

Habit Reversal Training

While HRT can consist of several components, there are three components that are considered central to treatment: awareness training (recognizing the urge or tic occurrence), competing response training (performing a socially discrete behavior that is physically incompatible with the tic and can be maintained for up to 1 min, eg, for an arm jerking tics, a competing response might be folding arms across the chest for up to 1 min or until the urge resolves), and social support (a home-based provider to deliver developmentally appropriate praise for correct implementation). Individual tics are addressed at a rate of one per week.

Comprehensive Behavioral Intervention for Tics

The CBIT is an extension of HRT. Whereas HRT primarily focuses on internal factors, CBIT incorporates additional skills to address external factors that influence the expression of tics. Specifically, CBIT incorporates the three core components of HRT and also includes relaxation training to manage anxiety and stress and functional-based interventions to address external factors that influence tic expression. The CBIT also provides patients and families psychoeducational training about Tourette syndrome and a reward procedure to enhance compliance (when needed). A typical program includes weekly sessions over a 10-week period but may vary depending on the number of tics. Several studies have confirmed the efficacy of CBIT to reduce tics in children and adults, both short-term and in 6-month follow-up studies, without adverse effects LEVEL 1.[1,2] Treatment is beneficial for patients with tics plus ADHD/OCD, and individuals not receiving tic-suppressing medications did better than those on medication. The precise biologic mechanism underlying tic improvement is unknown but may involve habituation to the premonitory urge or inhibition of the tic. The CBIT is the recommended behavioral approach—it is effectively delivered in person, via teleconferencing, and Internet.

Exposure Response Prevention

The ERP is another promising behavioral intervention that shares some similarities to HRT. Whereas HRT targets individual tics using compensatory behavioral responses, ERP seeks to target all tics simultaneously by capitalizing on a patient's inherent ability to suppress tics. Over time, patients habituate and/or develop a tolerance for the premonitory urge. Treatment begins with patients practicing simultaneously suppressing all tics, and the duration of this practice increases over subsequent sessions. As the patient develops initial mastery over tic suppression, greater exposures are completed to increase the difficulty of therapeutic exercises (ie, focusing on premonitory urges, talking about tics, focusing on the part of the body experiencing the urge, exposure to situations that exacerbate tics) that strengthens tic suppression abilities.

Complementary and Alternative Medications

The use of complementary and alternative medications (CAMs) in Tourette syndrome is widespread. In a clinic-based survey of Tourette syndrome patients, 64% reported using at least one CAM, and 29% used more than three agents. The list of CAMs is extensive and includes nutritional supplements (vitamins B, C, and E; magnesium; calcium; fish oil; flaxseed oil; omega-3 fatty acids) and herbal medicines (Ningdong Granule, 5-Ling Granule, qufeng zhidong recipe, clerodendrum inerme plant). Few randomized controlled trials have been reported, and the majority contain only a small study population. Ningdong Granule and the 5-Ling Granule were more effective than placebo. Acupuncture, self-hypnosis, music therapy, biofeedback, and plum-blossom needle therapy have limited scientific support. Physicians should be aware of CAM because patients/families independently implement these treatments.

Pharmacotherapy

Pharmacotherapy should be prescribed, if the patient meets criteria for initiating tic therapy (see earlier discussion) and has either failed behavioral therapy or none is available. Most medications are off-label, with only three (pimozide, haloperidol, and aripiprazole) being U.S. Food and Drug Administration approved. Recent reviews have integrated the current understanding of Tourette syndrome pathophysiology with pharmacotherapy and evaluated the extent of supporting evidence for each medication. The selection of pharmacologic therapy is generally based on personal experience despite the availability of published individual and group guidelines. Medications should initially be prescribed at their lowest effective dosage and gradually increased as needed (Table 77.3). Periodic evaluations are essential to assess medication efficacy, side effects, and the requirement for continued therapy. On average, medications reduce tic symptoms by 25% to 70%, and there is no treatment efficacious for all affected individuals. If tics do not respond to a medication and there is no other resulting benefit (eg, ADHD, anxiety, or mood), it should be withdrawn and another medication substituted in its place. In general, there is a two-tiered approach to tic-suppressing pharmacotherapy: tier 1 medications for milder and tier 2 medications for more difficult to control tics. Recognizing that tics often decline during adolescence, if they are under good control for a significant period, a gradual taper of medication during a nonstressful time is appropriate.

Tier 1 Medications

As a category, tier 1 medications are less effective in suppressing tics but have a preferable adverse-effect profile as compared to tier 2 drugs. Medications in this category include clonidine, guanfacine, topiramate, clonazepam, and baclofen. Therapeutically, the two α-adrenergic agonists (clonidine and guanfacine) are superior to placebo and have beneficial effects for both tic suppression and treatment of ADHD LEVEL 1.[3-6] With both medications, tic reduction effect sizes are greater in children who have comorbid ADHD as compared to those without ADHD. A study comparing extended-release guanfacine to placebo did not identify a clinically meaningful effect size LEVEL 1.[5] Common side effects of α-agonists include sedation, hypotension, and bradycardia. Topiramate was superior to placebo in reducing tics LEVEL 1.[7] Clonazepam and baclofen fall within the insufficient evidence category.

Tier 2 Medications

As a category, tier 2 are more effective than tier 1 medications, but are associated with more significant side effects that frequently limit their usefulness. Medications in this category include dopamine receptor antagonists (typical and atypical antipsychotics) and the vesicular monoamine transporter 2 inhibitors. Randomized clinical trials support the tic-suppressing efficacy of typical (pimozide, haloperidol, tiapride) and atypical (aripiprazole, risperidone, ziprasidone) antipsychotics over placebo LEVEL 1.[3,4,8,9] Comparative studies have, however, failed to establish the clear superiority of any single medication. Fluphenazine, a combined D_1 and D_2 receptor inhibitor, was effective in several small studies, and the D_1 receptor antagonist, ecopipam, has been effective in small adult and pediatric trials. Tiapride and sulpiride have been beneficial in European trials but are not available in the United States. Potential long-term side effects in patients receiving either typical or atypical antipsychotics include weight gain, sedation, drowsiness, hyperprolactinemia, tardive dyskinesia, akathisia, and QTc prolongation.

Vesicular monoamine transporter 2 inhibitors exert their effect by blocking the transport of dopamine into presynaptic vesicles, thereby depleting levels at the synaptic terminal. Tetrabenazine has been shown to be beneficial in open-label trials, although concerns exist about its use in individuals with depression and suicidality. Two new vesicular monoamine transporter 2 inhibitors, deutetrabenazine and valbenazine, are currently in clinical trials. Possible benefits may include fewer side effects and less frequent dosing.

TABLE 77.3 Pharmacologic Treatments of Tics and Supporting Evidence

	Mechanism of Action	Starting Dose (mg)	Daily Dosing (mg)	Side Effects	Supporting Evidence: RCT[a]	Supporting Evidence: "Confidence in evidence"[b]	Supporting Evidence: "More likely than placebo to reduce tics"[c]
Tier 1							
α-Adrenergic agonists							
Guanfacine ER (Intuniv)	α_2-Agonist	1	1-4	Sedation, hypotension, dry mouth, bradycardia, irritability, headache, abdominal pain, fatigue, insomnia, dysphoria	3		
Guanfacine (Tenex)							
Clonidine (Catapres)	α_2-Agonist	0.05	0.1-0.4		1	Moderate	Probably
Clonidine (patch)		0.1		Rash			
Anticonvulsants							
Topiramate	GABAA agonist;	25	25-200	Headache, sedation, diarrhea, confusion, paresthesia, weight loss	1	Low	Possibly
Clonazepam	AMPA antagonist	0.25-0.5	0.5-4	Sedation, fatigue, confusion, dizziness, hyperactivity		N/A	N/A
Other							
Baclofen	GABAB agonist	5-10	10-60	Sedation, drowsiness, GI problems, confusion, anxiety, headache	1	Very low	N/A
Tier 2							
Typical neuroleptics							
Pimozide (Orap)	D_2 antagonist, calcium channel blocker	0.5-1.0	0.5-10	DIMD, sedation, orthostatic hypotension; prolonged QTc, hyperprolactinemia, restlessness, anxiety, weight gain, fatigue, somnolence, gynecomastia, neuroleptic malignant syndrome	6	Low	Possibly
Fluphenazine	D_1/D_2 antagonist	0.5-1	5-10				N/A
Haloperidol (Haldol)	D_2 antagonist	0.25-0.5	0.75-10		5	Moderate	Probably
Atypical neuroleptics							
Aripiprazole (Abilify)	Partial D_2-D_4 agonist; partial 5-HT_{1A}/5-HT_{2C} agonist	2	2.0-20	DIMD, increased appetite, sedation, weight gain, dyslipidemia, hyperprolactinemia, insulin resistance, fatigue, somnolence	4	Moderate	Probably
Risperidone (Risperdal)	5-HT_2 antagonist at low dose; D_2 antagonist at high dose	0.25-4.0	1-4.0	Prolonged QTc, orthostatic hypotension	6	Moderate	Probably
Olanzapine	Antagonist: D_1-D_4, 5-HT_{2A}, 5-HT_{2C}, H_1, muscarinic	2.5-5.0	5-10		0	N/A	N/A
Ziprasidone	Antagonist: D_2 and 5-HT_2	5	10-40		1	Low	Possibly
Quetiapine	Antagonist: D_1, D_2, 5-HT_{1A}, 5-HT_2, and H_1	12.5-25	300-400		N/A	N/A	N/A
VMAT2 inhibitor							
Tetrabenazine		12.5	50-150	Sedation, depression, parkinsonism, insomnia, anxiety, hypotension, akathisia, fatigue, irritability	0	N/A	N/A
Deutetrabenazine		6	18-36		0	N/A	N/A

TABLE 77.3 Pharmacologic Treatments of Tics and Supporting Evidence *(continued)*

	Mechanism of Action	Starting Dose (mg)	Daily Dosing (mg)	Side Effects	Supporting Evidence		
					RCT[a]	"Confidence in evidence"[b]	"More likely than placebo to reduce tics"[c]
Tier 2 *(continued)*							
Other							
Botulinum toxin	Inhibits neuromuscular transmission	N/A	N/A	Weakness and hypophonia	N/A	Moderate	Probably
Tetrahydrocannabinol (THC)	CB_1/CB_2 agonist	N/A	N/A	Sedation, dizziness, headaches, a "high" (euphoria feeling), red eyes, increased appetite, psychosis, depression, and cognitive impairment	N/A	Low	Possible

Abbreviations: 5-HT, serotonin; AMPA, α-amino-3-hydroxy-5-methyl-4-isoxazole propionic acid; CB, cannabinoid; D, dopamine; DIMD, drug-induced movement disorders; ER, extended release; GABA, γ-aminobutyric acid; GI, gastrointestinal; H, histamine; N/A, not applicable; RCT, randomized control trial; VMAT2, vesicular monoamine transporter 2.

[a]From Essoe JK-Y, Grados MA, Singer HS, Myers NS, McGuire JF. Evidence-based treatment of Tourette's disorder and chronic tic disorders. *Expert Rev Neurother*. 2019;19:1103-1115.

[b]From Pringsheim T, Holler-Managan Y, Okun MS, et al. Comprehensive systematic review summary: treatment of tics in people with Tourette syndrome and chronic tic disorders. *Neurology*. 2019;92:907-915.

[c]From Pringsheim T, Okun MS, Müller-Vahl K, et al. Practice guideline recommendations summary: treatment of tics in people with Tourette syndrome and chronic tic disorders. *Neurology*. 2019;92:896-906.

Other Medications

Botulinum Toxin Injections for Tics

Botulinum toxin injections with onabotulinum toxin A are reserved for severe localized tics (violent head thrusts), dystonic motor tics, and vocal tics. Treatment maybe effective for 12 to 16 weeks, and repeat injections are required. Side effects include weakness and hypophonia.

Cannabis-Based Medications

Several small randomized studies and case reports have suggested that cannabinoids may have a beneficial effect on tics, but evidence is limited. Pharmacologic approaches have included smoking marijuana or using extracts from the cannabis plant, including Δ-9-tetrahydrocannabinol, cannabidiol, and nabiximols (combinations of Δ-9-tetrahydrocannabinol and cannabidiol). The most common side effects are sedation, dizziness, headaches, a "high" (euphoria feeling), red eyes, increased appetite, psychosis, depression, and cognitive impairment. Several reviews have emphasized the lack of evidence with regard to the use of cannabinoids and the requirement for additional testing. A second investigative approach, currently under investigation, involves attempts to modulate the brain's existing endocannabinoid system.

Neuromodulation

Noninvasive Neuromodulation

Repetitive transcranial magnetic stimulation is a noninvasive technique that uses brief repetitive intense magnetic fields generated by a coil placed over the scalp to produce an electromagnetic field in the underlying brain region. To date, there is insufficient evidence to evaluate the efficacy of repetitive transcranial magnetic stimulation of the supplementary motor area, left motor, and parietal cortex. A single, double-blind randomized placebo trial showed no significant difference between active and sham treatment. Similarly, a small study using cathodal transcranial direct current stimulation was unsuccessful in two-thirds of patients with severe tics.

Invasive Neuromodulation

Deep brain stimulation is a stereotactic treatment that has significant potential for the treatment of tics and a recommended patient selection criterion has been published. There is no consensus regarding the optimal brain target for tics, larger studies targeting the centromedian parafascicular complex of the thalamus and GPi and others the dorsomedial thalamus, globus pallidus externa, subthalamic nucleus, ventral striatum, and internal capsule. Appropriate patient selection and a multidisciplinary assessment are essential. Although reports describe a beneficial effect, interpretation is confounded by variations in methodologies, differences in complications, variable use of standard outcome measures, and the lack of a control population. Deep brain stimulation for individuals younger than age 18 years should only be considered for urgent cases of tics causing acute bodily harm and after an ethics committee review.

OUTCOME

Tics usually have their onset in the first decade of life, typically between 4 and 8 years of age. They are more common in males in a ratio of about 3 to 4:1. Motor tics usually precede the appearance of vocal tics and often first occur in the face, head, or neck. Tics have a waxing, waning, and evolving course, some resolving, others recurring or being replaced by new tics. Statistically, peak tic severity occurs between 10 and 12 years of age and is followed by a gradual decline in severity. The author's rule of thirds suggests that in the teenage to early adulthood years, approximately one-third have a resolution of tics, one-third are better, and one-third continue to fluctuate. Whether tics fully resolve is a difficult question because many adults who claim to

be tic free actually have persisting tics when carefully observed. Studies in adults have identified a reemergence or exacerbation of a childhood disorder with prominent facial, neck, and trunk tics. Assumptions that one can predict the outcome of tics based on clinical examination or imaging results are controversial.

CONCLUSION

Tourette syndrome is a complex heterogeneous disorder characterized by the presence of variable fluctuating motor and vocal tics plus a variety of co-occurring neuropsychiatric conditions. The disorder remains a challenge for the patient and their family, the treating physician, and researchers attempting to better understand its etiology and underlying pathophysiology. Improved insights into the neurobiology of Tourette syndrome will hopefully lead to the development of new and innovative disease modifying therapies.

LEVEL 1 EVIDENCE

1. Piacentini J, Woods DW, Scahill L, et al. Behavior therapy for children with Tourette disorder: a randomized controlled trial. *JAMA*. 2010;303:1929-1937.
2. Wilhelm S, Peterson AL, Piacentini J, et al. Randomized trial of behavior therapy for adults with Tourette syndrome. *Arch Gen Psychiatry*. 2012;69:795-803.
3. Pringsheim T, Okun MS, Müller-Vahl K, et al. Practice guideline recommendations summary: treatment of tics in people with Tourette syndrome and chronic tic disorders. *Neurology*. 2019;92:896-906.
4. Essoe JK-Y, Grados MA, Singer HS, Myers NS, McGuire JF. Evidence-based treatment of Tourette's disorder and chronic tic disorders. *Expert Rev Neurother*. 2019;19:1103-1115.
5. Biederman J, Melmed RD, Patel A, et al. A randomized, double-blind, placebo-controlled study of guanfacine extended release in children and adolescents with attention-deficit/hyperactivity disorder. *Pediatrics*. 2008;121(1):e73-e84.
6. Wang S, Wei YZ, Yang J, Zhou Y, Zheng Y. Clonidine adhesive patch for the treatment of tic disorders: a systematic review and meta-analysis. *Eur J Paediatr Neurol*. 2017;21(4):614-620.
7. Yu L, Yan J, Wen F, et al. Revisiting the efficacy and tolerability of topiramate for tic disorders: a meta-analysis. *J Child Adolesc Psychopharmacol*. 2020;30(5):316-325.
8. Pringsheim T, Marras C. Pimozide for tics in Tourette's syndrome. *Cochrane Database Syst Rev*. 2009;2009(2):CD006996.
9. Yoo HK, Joung YS, Lee JS, et al. A multicenter, randomized, double-blind, placebo-controlled study of aripiprazole in children and adolescents with Tourette's disorder. *J Clin Psychiatry*. 2013;74(8):e772-e780.

SUGGESTED READINGS

Augustine F, Singer HS. Merging the pathophysiology and pharmacotherapy of tics. *Tremor Other Hyperkinet Mov (N Y)*. 2018;8:598.

Cavanna AE. Gilles de la Tourette syndrome as a paradigmatic neuropsychiatric disorder. *CNS Spectr*. 2018;23:213-218.

Cavanna AE. The neuropsychiatry of Gilles de la Tourette syndrome: the état de l'art. *Rev Neurol (Paris)*. 2018;174:621-627.

Dale R. Tics and Tourette: a clinical, pathophysiological and etiological review. *Curr Opin Pediatr*. 2017;29:665-673.

Davis LK, Yu D, Keenan CL, et al. Partitioning the heritability of Tourette syndrome and obsessive compulsive disorder reveals differences in genetic architecture. *PLoS Genet*. 2013;9:e1003864.

Eapen V, Cavanna AE, Robertson MM. Comorbidities, social impact, and quality of life in Tourette syndrome. *Front Psychiatry*. 2016;7:97.

Eapen V, Robertson MM. Are there distinct subtypes in Tourette syndrome? Pure-Tourette syndrome versus Tourette syndrome-plus, and simple versus complex tics. *Neuropsychiatr Dis Treat*. 2015;11:1431-1436.

Fernandez TV, State MW, Pittenger C. Tourette disorder and other tic disorders. In: Geschwind DH, Paulson HL, Klein C, eds. *Handbook of Clinical Neurology*. Cambridge, MA: Elsevier; 2018:343-354.

Ganos C, Martino D, Pringsheim T. Tics in the pediatric population: pragmatic management. *Mov Disord Clin Pract*. 2017;4:160-172.

Gilbert DL, Mink JW, Singer HS. A pediatric neurology perspective on pediatric autoimmune neuropsychiatric disorder associated with streptococcal infection and pediatric acute-onset neuropsychiatric syndrome. *J Pediatr*. 2018;199:243-251.

Groth C, Debes NM, Rask CU, Lange T, Skov L. Course of Tourette syndrome and comorbidities in a large prospective clinical study. *J Am Acad Child Adolesc Psychiatry*. 2017;56:304-312.

Hartmann A, Worbe Y. Tourette syndrome: clinical spectrum, mechanisms and personalized treatments. *Curr Opin Neurol*. 2018;31:504-509.

Hartmann A, Worbe Y, Black KJ. Tourette syndrome research highlights from 2017. *F1000Res*. 2018;7:1122.

Hirschtritt ME, Lee PC, Pauls DL, et al. Lifetime prevalence, age of risk, and etiology of comorbid psychiatric disorders in Tourette syndrome. *JAMA Psychiatry*. 2015;72:325-333.

Kumar A, Duda L, Mainali G, Asghar S, Byler D. A comprehensive review of Tourette syndrome and complementary alternative medicine. *Curr Dev Disord Rep*. 2018;5:95-100.

Martinez-Ramirez D, Jimenez-Shahed J, Leckman JF, et al. Efficacy and safety of deep brain stimulation in Tourette syndrome: the international Tourette syndrome deep brain stimulation public database and registry. *JAMA Neurol*. 20108;75:353-359.

Martino D, Ganos C, Pringsheim TM. Tourette syndrome and chronic tic disorders: the clinical spectrum beyond tics. *Int Rev Neurobiol*. 2017;134:1461-1490.

Martino D, Pringsheim TM. Tourette syndrome and other chronic tic disorders: an update on clinical management. *Expert Rev Neurother*. 2018;18:125-137.

Martino D, Zis P, Battiglione M. The role of immune mechanisms in Tourette syndrome. *Brain Res*. 2015;1617:126-143.

Mataix-Cols D, Isomura K, Pérez-Vigil A, et al. Familial risks of Tourette syndrome and chronic tic disorders. A population-based cohort study. *JAMA Psychiatry*. 2015;72:787-793.

McGuire JF, Piacentini J, Storch EA, et al. A multicenter examination and strategic revisions of the Yale Global Tic Severity Scale. *Neurology*. 2018;90:e1711-e1719.

Mogwitz S, Buse J, Wolff N, Roessner V. Update on the pharmacological treatment of tics with dopamine-modulating agents. *ACS Chem Neurosci*. 2018;9:651-672.

Pandey S, Dash D. Progress in pharmacological and surgical management of Tourette syndrome and other chronic tic disorders. *Neurologist*. 2019;24:93-108.

Pringsheim T, Holler-Managan Y, Okun MS, et al. Comprehensive systematic review summary: treatment of tics in people with Tourette syndrome and chronic tic disorders. *Neurology*. 2019;92:907-915.

Quezada J, Coffman KA. Current approaches and new developments in the pharmacological management of Tourette syndrome. *CNS Drugs*. 2018;32:33-45.

Robertson MM, Eapen V, Singer HS, et al. Gilles de la Tourette syndrome. *Nat Rev Dis Primers*. 2017;3:16097.

Sharp AN, Singer HS. Standard, complementary, and future treatment options for tics. *Curr Dev Disord Rep*. 2018;5:101-107.

Singer HS, Augustine F. Controversies surrounding the pathophysiology of tics. *J Child Neurol*. 2019;34(13):851-862.

Singer HS, Szymanski S, Giuliano J, et al. Elevated intrasynaptic dopamine release in Tourette's syndrome measured by PET. *Am J Psychiatry*. 2002;159:1329-1336.

Sukhodolsky DG, Woods DW, Piacentini J, et al. Moderators and predictors of response to behavior therapy for tics in Tourette syndrome. *Neurology*. 2017;88:1029-1036.

Verdellen CWJ, Keijsers GPJ, Cath DC, Hoogduin CAL. Exposure with response prevention versus habit reversal in Tourettes's syndrome: a controlled study. *Behav Res Ther*. 2004;42:501-511.

Restless Legs Syndrome 78

Brian B. Koo

KEY POINTS

1. The diagnosis of restless legs syndrome (RLS) is clinical and made by determining the presence of an uncomfortable urge to move the legs which occurs at night and with inactivity and which is relieved by movement. It is essential to rule out any one of several RLS mimics which fulfill the above criteria but do not constitute RLS.
2. The pathophysiology of RLS is complex. The RLS is associated with decreased iron in the striatum and low cerebrospinal fluid ferritin. In RLS, the brain's dopaminergic and glutamatergic systems are hyperactive, whereas central nervous system endorphin pathways have decreased activity.
3. The most important step in treating RLS is to outline and consider elimination of factors which result in exacerbation of RLS. These factors include dietary substances (eg, alcohol, simple sugars, caffeine), habitual factors (eg, smoking, blood donation), over-the-counter medications (eg, antihistamines, melatonin), prescribed medications (antipsychotics, antihistamines, antidepressants), and factors which adversely affect sleep (eg, sleep apnea).
4. The $\alpha 2\delta$ ligands, gabapentin and pregabalin, are first line for the treatment of RLS.
5. If dopamine agonists are to be used to treat RLS, the maximum dosages for RLS (ropinirole 4.0 mg; pramipexole 0.75-1.0 mg; rotigotine 4.0 mg) should not be exceeded as higher doses are associated with high levels of augmentation.
6. Augmentation consists of a worsening of RLS in the setting of long-term dopaminergic therapy and consists of RLS symptoms occurring at earlier times in the day, spreading to previously uninvolved body parts, or having increased intensity. Treatment of augmentation consists of eliminating or at least lowering the dose of the offending dopaminergic agent while using another nondopaminergic agent to treat RLS symptoms.

INTRODUCTION

Restless legs syndrome (RLS), also known as *Willis-Ekbom disease*, is a neurologic sensorimotor disease defined by the presence of four essential criteria: (1) an urge to move the limbs occurring with or without uncomfortable sensations, (2) worsening of the symptoms at rest, (3) improvement with activity, and (4) occurrence of symptoms in the evening or night. The RLS severity and frequency vary greatly from individual to individual. In mild cases, RLS symptoms may occur a few times per year and have minimal clinical impact, whereas in severe cases, RLS can occur nightly and have a profound negative impact on sleep and overall well-being. It is important to note that RLS severity and frequency are influenced by a myriad of factors which include other disease states, medications, foods or beverages, and mental state. The RLS is often chronic, and in severe cases, lifelong treatment is needed. Other clinical features typical for RLS include the tendency for symptoms to gradually worsen with age, a positive therapeutic effect of dopaminergic medications, a positive family history, and the co-occurrence of periodic limb movements during sleep (PLMS). Traditionally, the neurologic examination is normal in RLS; however, leg/feet stereotypies are sometimes present later in the day, although usually suppressible.

The RLS may be split into primary and secondary forms. In primary or idiopathic RLS, onset is often in childhood or young adulthood, and there are no associated comorbid disease states, whereas in secondary RLS, RLS occurs in the setting of a disease state which predisposes to RLS, such as end-stage renal disease, Parkinson disease, multiple sclerosis, or pregnancy.

EPIDEMIOLOGY

The epidemiology of RLS has been studied extensively. In general, the prevalence of RLS occurring at any frequency or severity in North America and Western Europe is between 5% and 10%, whereas the prevalence of clinically significant RLS (occurring twice per week with at least moderate distress) is about 2% to 4%. In general, northern European countries have demonstrated the highest prevalence of RLS, followed by Germanic/Anglo-Saxon, and then Mediterranean countries, following a north-south gradient of declining RLS prevalence. The prevalence of RLS in the United States and Canada is similar to that seen in Western Europe. The RLS prevalence is low in Asia and Africa, with prevalence of RLS at any frequency in Asia around 2% to 4%. One study in Tanzania found only 1 person out of 7,654 people interviewed had RLS. Although this has not been adequately studied, anecdotally African Americans only rarely present with RLS. Women have RLS at a rate compared to men of 2:1. This increased prevalence of RLS is thought to be related to childbearing as the prevalence of RLS increases linearly with parity and is equal to that in men for nulliparous women.

PATHOBIOLOGY

A family history of RLS is present in 40% to 60% of those with idiopathic RLS, and RLS is thought to be inherited in an autosomal dominant pattern. Concordance in the expression of RLS in monozygotic twins is about 80%, but severity and age of onset is variable. To date, eight susceptibility loci for familial

RLS have been identified through familial linkage studies, but a responsible gene has not been identified. Genome-wide association studies have identified association between variants in several genes and RLS. The most robust associations showing genome-wide association included variants in broad-complex, tramtrack, and bric a brac domain-containing 9, myeloid ecotropic viral integration site 1, and protein phosphatase receptor type D genes.

Although there has been significant research to clarify the biologic mechanisms underlying RLS, the pathophysiology of RLS remains incomplete. The most robust and durable observations include those of reduced central nervous system (CNS) iron stores, even in the setting of normal systemic iron levels. The RLS patients show reduced cerebrospinal fluid (CSF) ferritin, reduced iron on magnetic resonance imaging, especially in the striatum and red nucleus, reduced iron on CNS ultrasonography in the substantia nigra, and, most importantly, reduced iron and iron-related proteins at autopsy, including reduced H-ferritin staining, iron staining, and increased transferrin stains, but also reduced transferrin receptors. In two separate studies comparing ferritin and transferrin in RLS patients compared to healthy controls without RLS, CSF ferritin was significantly lower and CSF transferrin significantly higher in RLS patients, but there was no difference in either ferritin or transferrin in the serum. These findings suggest that there is iron deficiency and iron handling abnormalities specific to the CNS in persons with RLS.

The dopaminergic system has also been rigorously studied in RLS pathobiologic research. The impetus to study the dopamine system in RLS has mainly been driven by the clinical observations that dopamine-blocking medications worsen RLS and dopamine agonist (DA) medications lessen RLS symptoms. Findings related to studying the dopamine system in RLS have generally suggested a state of relative dopamine excess in the brain of RLS patients, despite the predominant early belief of most in the RLS field of the opposite. The first CSF studies in RLS patients demonstrated normal dopaminergic metabolites in persons with RLS, but later studies by a separate group showed significantly higher CSF levels of dopamine metabolites in RLS patients. Findings resulting from neuroimaging studies have been conflicting and difficult to interpret. Positron emission tomography studies have shown increased binding potential of dopamine D_2 receptors in the striatum of RLS patients, no difference in striatal dopamine D_2 receptor binding potential, and reduced binding potential in putaminal dopamine D_2 receptors. A postmortem study of RLS brain tissue revealed significantly increased tyrosine hydroxylase in the substantia nigra and putamen of RLS patients and significantly decreased putaminal dopamine D_2 receptor density, also consistent with an overly active dopaminergic system.

Opioid pathways are also implicated in RLS pathobiology by a nearly universal treatment response of RLS to opioid medications. A postmortem analysis of brains in a limited number of RLS patients and controls found a reduction in β-endorphin–positive and Met-enkephalin–positive cells. The glutamatergic system is also involved in RLS pathobiology. Magnetic resonance spectroscopy has shown that glutamatergic activity is significantly increased in the thalamus of RLS patients compared to matched control individuals and that this activity correlates highly with arousal from sleep. This hyperactivity in the glutamate system may be modulated by yet another neural system, the adenosinergic system. In an iron-deficient rodent model of RLS, iron deficiency was associated with a downregulation of adenosine A_1 receptors and hypersensitive striatal glutamatergic terminals. Furthermore, in this model, both DAs and the $\alpha_2\delta$ ligand, gabapentin, counteracted excessive glutamate release, all suggesting that changes in the adenosine system may modulate overactivity in the glutamate and dopamine systems.

DIAGNOSIS

The diagnosis of RLS is solely clinical and not at all based on information derived from a polysomnogram. Consensus criteria for RLS diagnosis were established by leading experts at a National Institutes of Health conference in 2003, which laid out four essential criteria for RLS diagnosis that are still used to this day. These criteria include (1) an urge to move the legs, usually accompanied by uncomfortable or unpleasant sensations in the legs; (2) the urge to move or unpleasant sensations begin or worsen during periods of rest or inactivity; (3) the urge to move or unpleasant sensations are partially or totally relieved by movement; and (4) the urge to move or unpleasant sensations are worse in the evening or night. In 2012, the RLS diagnostic criteria were revised in the third edition of the International Classification of Sleep Disorders; in addition to the above four essential RLS criteria, these new criteria outlined that the four essential features not be accounted for by another medical or behavioral condition and that the symptoms cause some amount of distress, sleep disturbance, or impairment in mental, physical, social, or occupational functioning (Table 78.1). Indeed, these revised criteria stress the importance of ruling out common RLS mimics (Table 78.2) and demonstrating negative functional consequences of RLS symptoms.

Although not part of the diagnostic nosology of RLS, the classification of RLS into primary idiopathic RLS and secondary RLS may be helpful (Table 78.3). Primary idiopathic RLS often occurs in the first to third decade of life, runs in the family, and has a female predominance. Secondary RLS is RLS which occurs in the setting of diagnoses known to be associated with RLS, such as iron deficiency anemia, Parkinson disease, multiple sclerosis,

TABLE 78.1 International Classification of Sleep Disorders: Three Diagnostic Criteria for Restless Legs Syndrome

1. An urge to move the legs, usually accompanied by or thought to be caused by uncomfortable and unpleasant sensations in the legs. These symptoms must
   A. Begin or worsen during periods of rest or inactivity such as lying down or sitting;
   B. Be partially or totally relieved by movement, such as walking or stretching, at least as long as the activity continues; and
   C. Occur exclusively or predominantly in the evening or night rather than during the day
2. The above features are not solely accounted for as symptoms of another medical or behavioral condition (eg, leg cramps, positional discomfort, myalgia, venous stasis, leg edema, arthritis, habitual foot tapping).
3. The symptoms of restless legs syndrome cause concern, distress, sleep disturbance, or impairment in mental, physical, social, occupational, educational, behavioral, or other important areas of functioning.

TABLE 78.2 Differential Diagnosis of Restless Legs Syndrome (Mimics)

Condition	How Different From Restless Legs Syndrome
Akathisia	Whole body urge to move, associated with dopamine blockers, not as circadian
Cramp	Chaotic visible/palpable muscle contraction, can be stopped by stretching muscle, little urge to move
Myalgia	Muscle ache, may be worse at night but no true urge to move
Neuropathic pain	Usually superficial, burning, electric, feet most involved
Radiculopathy	Usually asymmetric, more position dependent but no urge to move other than to move from painful position
Body positional discomfort	Cannot get comfortable in any position but not a true urge to move
Moving toes, painful legs	Slow writhing dystonic movement of toes/feet, not suppressible

peripheral neuropathy, end-stage renal disease, and pregnancy. Clinically primary and secondary RLS may be indistinguishable on the basis of symptom description and may respond to similar medications. However, the choice of medical treatment can be tailored depending on if RLS co-occurs with specific disorders, such that an α2δ ligand may be favored in the setting of neuropathy or a dopamine agent may be favored when RLS occurs in a patient with Parkinson disease. The RLS, whether primary or secondary, is a chronic disease which often becomes progressively more severe and frequent. Primary or early-onset RLS is more likely to be familial and appears to progress slowly with age. Late-onset, usually secondary, RLS occurs after the age of 45 years, and its severity seems to be associated more with serum ferritin levels, although progression with age also cannot be ruled out.

It should be noted that although frank iron deficiency anemia can be associated with secondary RLS, in primary idiopathic RLS, there is a deficiency of iron and ferritin in the brain, whereas systemic iron deficiency is often not present.

TABLE 78.3 Primary and Secondary Restless Legs Syndrome (RLS)

	Primary RLS	Secondary RLS
Definition	Idiopathic RLS	RLS occurring with a predisposing condition
Onset	First to third decade	Third to seventh decade
Comorbidity	NA	Pregnancy, end-stage renal disease, Parkinson disease, multiple sclerosis, neuropathy, iron deficiency anemia
Treatment	See Table 78.4.	α2δ Ligand if neuropathy; dopamine drug if Parkinson
Prognosis	Progressive	May depend on severity of comorbidity (not necessarily for multiple sclerosis or Parkinson disease)

Abbreviation: NA, not applicable.

MANAGEMENT

Figure 78.1 serves as a flow diagram and an approach to treating RLS. The severity and frequency of RLS symptoms are influenced by numerous dietary, pharmacologic, lifestyle, and biologic factors. Thus, the first step in the management of RLS is to determine if such factors are present. Dietary factors which worsen RLS include alcohol, caffeine, and high amounts of refined, simple sugars. Lifestyle factors which worsen RLS include smoking and too much or too little exercise. Medications which aggravate RLS are first-generation antihistamines (eg, diphenhydramine or any sleeping medicine containing diphenhydramine); dopamine-blocking agents, including antipsychotic and antinausea medications; and antidepressant medications. Whereas any antidepressant which blocks reuptake of serotonin can worsen RLS, those medicines with prominent antihistaminergic activity are most likely to cause RLS worsening, including doxepin, mirtazapine, and amitriptyline. Unfortunately, these medicines are often prescribed in RLS patients with the thought that they will improve sleep. Antidepressant medications which are thought not to cause RLS worsening are bupropion and desipramine. Any factor which interrupts sleep or prevents sleep will also worsen RLS. Insufficient sleep, environmental factors which disturb sleep, and obstructive sleep apnea can all provoke RLS symptoms in a vulnerable individual. The threshold to perform polysomnography to rule out sleep apnea should be low, as the treatment of sleep apnea in particular is important in treating RLS as many times the prescription of medication for RLS can be avoided by treating sleep apnea when comorbid with RLS. Low iron or ferritin levels can also precipitate or worsen RLS.

There are several different medical treatment options for RLS. The development of validated rating scales (International Restless Legs Syndrome Study Group Severity Scale) and standardized diagnostic criteria have vastly improved the quality of RLS treatment trials. Multiple medications have demonstrated efficacy in well-designed class 1 trials, especially the dopaminergics, α2δ ligands, opioids, and iron (Table 78.4). With the possible exception of iron, all are felt to provide only symptomatic relief rather than any curative effect. Therefore, treatment should only be initiated when the benefits are felt to justify any potential side effects and costs. Over time, both dosing and drug changes may be required to maximize benefit and minimize the risk of side effects.

The DAs are the most widely investigated medical treatments for RLS. The improvement is immediate and often very dramatic. The DAs consistently demonstrate dramatic improvement in PLMS but modest or no improvement in other sleep parameters. No direct evidence favors any particular DA. Rotigotine patch, pramipexole, and ropinirole are best studied, and all have level 1 evidence supporting their use LEVEL 1.[1-4] The dopamine precursor levodopa also effectively treats RLS and may have a more rapid onset of action. However, several comparative studies have favored DA over levodopa.

Immediate-release oral DAs work best if administered at least 90 minutes before the onset of symptoms. The effect is immediate, so titration to the smallest effective dose can be fairly rapid. Based on pharmacokinetics, many people may benefit from more than one dose despite the formal indications, which recommend dosing 1 to 3 hours before bed. Extended-release preparations of pramipexole and ropinirole are also effective but have not been formally studied. Nausea, sedation, and impulse control disorders can occur, but hallucinations and hypotension

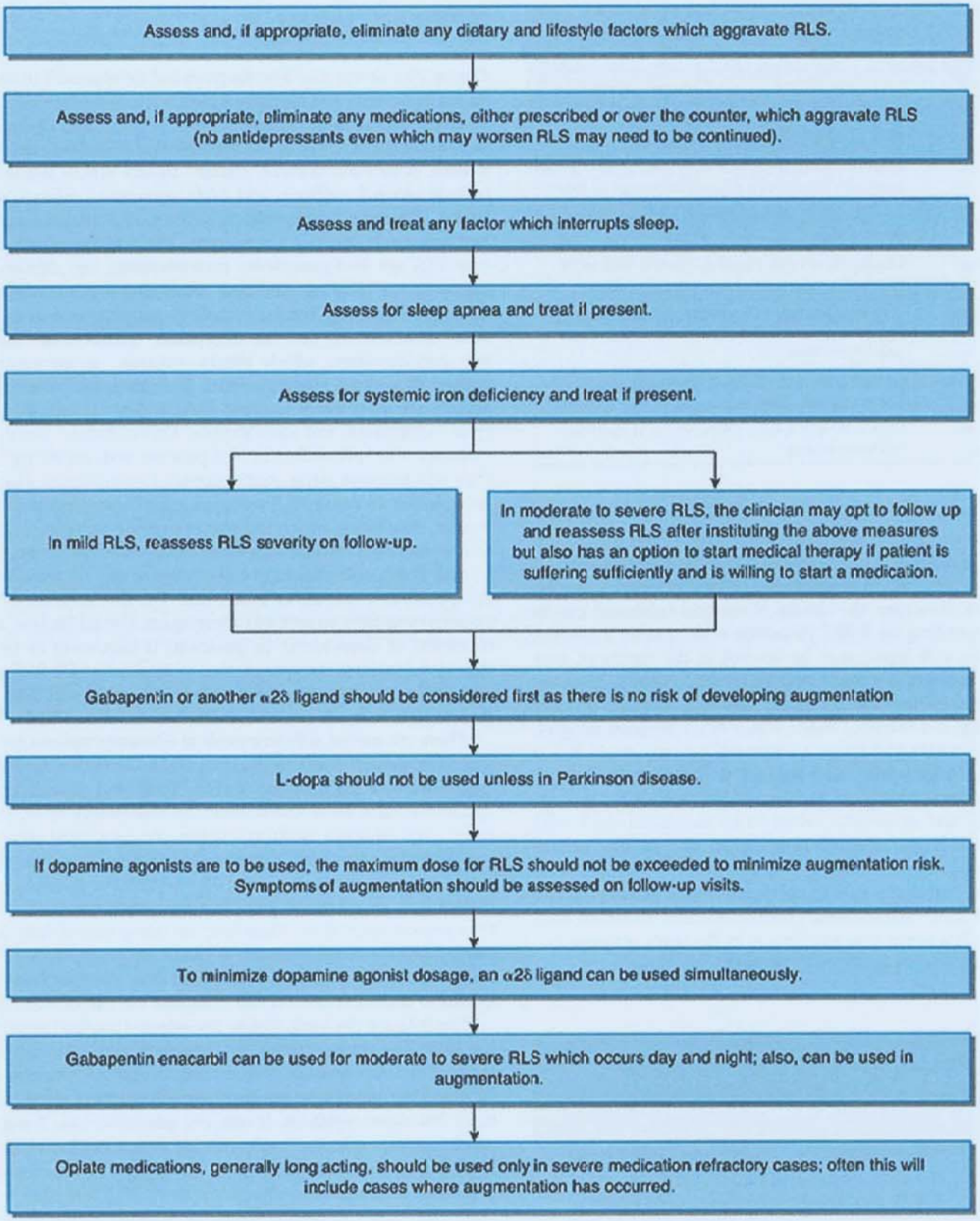

FIGURE 78.1 Algorithm for restless legs syndrome (RLS) treatment.

rarely occur in RLS, making these drugs better tolerated in RLS compared to Parkinson disease. Any patient started on a dopamine drug should be warned about the potential of developing impulsive behavior such as pathologic gambling, shopping, or sexual behavior.

Despite their initial dramatic effect in treating RLS, the long-term use of DAs and levodopa is limited by the occurrence of augmentation, a paradoxical worsening of RLS which occurs in the setting of long-term DA or levodopa usage for RLS. Worsening in augmentation consists of earlier onset of RLS symptoms, involvement of previously unaffected body parts such as the arms, decreased relief of the urge to move offered by movement, or an increased intensity in RLS symptoms like the urge to move. Levodopa may be associated with the highest rates of augmentation

TABLE 78.4 Medications and Doses Used for Restless Legs Syndrome (RLS)

Drug	Amount per Dose (mg)	Duration of Effect (h)	Comment
Dopaminergics: immediate effect, considered first-line therapy			
L-Dopa	100-250	2-6	Positive class 1 trials, fast onset, can use as needed; highest augmentation rates limit the use of L-Dopa, and therefore, it is rarely used for RLS.
Pramipexole	0.125-1	5-12	Positive class 1 trials, commonly used, slower onset but longer duration, extended release available; doses should not exceed 1.0 mg as higher doses may indicate augmentation.
Ropinirole	0.25-4	4-8	Positive class 1 trials, extended-release preparations available; doses should not exceed 4.0 mg as higher doses may indicate augmentation.
Rotigotine	1-4	24	Positive class 1 trials, commonly used patch preparation; doses should not exceed 4.0 mg as higher doses may indicate augmentation.
Pergolide	0.125-1	6-14	Well studied (class 2) but seldom used due to risk of cardiac valve fibrosis and other possible ergot AE
Apomorphine	1-3	1	Injection of short-acting powerful drug, rarely used, anecdotal PRN use
Cabergoline	0.25-2	>24	Longest acting but may have same AEs as other ergot DAs
Bromocriptine	5-20	4-6	Rarely used in RLS
Opioids: Numerous opioids are used.			
Methadone	2-15	8-12	Open label data only, very good long-term tolerability and efficacy, several-day latency to benefit
Hydrocodone	5-10	4-10	Faster acting, shorter duration
Oxycodone	5-20	5-10	Best studied opioid; oxycontin is preferable at a dose of 10-20 mg
Buprenorphine	2-4	5-12	Long-acting opioid
α2δ Blockers			
Gabapentin	300-1,200	4-8	Small controlled trials; may help painful component of RLS; can be dosed nightly or once in the evening and also at night if there are evening plus nighttime symptoms
Pregabalin	50-300	6-12	Positive class 1 and 2 trials
Gabapentin enacarbil	600-1,800	8-16	Gabapentin prodrug with better absorption/bioavailability; positive class 1 trials, approved in the United States
Iron Supplementation: Can be effective both with normal or serum ferritin levels.			
Oral iron	>50	[a]	No specific iron salt superior, titrate up as tolerated; minimal data of efficacy
IV iron	1,000	[a,b]	Usually not repeated before 3 months, several-day latency to benefit, long-term safety unknown, patients with normal serum ferritin equally responsive. Anecdotal evidence favors iron dextran preparations.

Abbreviations: AE, adverse events; DAs, dopamine agonists; IV, intravenous; PRN, as necessary; RLS, restless legs syndrome.
[a]Iron treatment does not have an effect which lasts hours, rather maintaining appropriate iron levels may decrease the frequency (days per week) or intensity of RLS symptoms.
[b]Some patients find with IV iron that the therapeutic effects which make RLS less frequent and severe lasts weeks to months.

with one study showing that 91% of patients on levodopa for RLS developed definite or probable augmentation over an average period of 2.7 years. For this reason, levodopa is rarely used to treat RLS. Augmentation rates are also high for the DAs, ropinirole and pramipexole, and are estimated to occur at rates of 8% per year. This is particularly problematic as severe RLS requires lifelong medical treatment. Risk factors for augmentation include low serum ferritin, high dose of a dopaminergic, severe RLS, and long duration of treatment. For this reason, the treatment of RLS with a DA, especially when used over long periods of time (more than 4-5 y) should be done with caution. The maximum doses of dopaminergic medication should not be exceeded (see Table 78.2), and it should be noted that these dose maximums are far lower than those used to treat Parkinson disease.

Drugs that bind to the α2δ subunit of the voltage-dependent calcium channel also improve RLS and are currently favored over the DAs as there is no concern for the development of augmentation. As a class, they seem to improve International Restless Legs Scale scores similarly to DA; however, sleep studies show less improvement in PLMS but better sleep architecture. Gabapentin is the least studied but shows benefit. The gabapentin enacarbil sustained-release tablet is a novel preparation that is absorbed much more effectively in the gastrointestinal tract and can achieve higher and more sustained serum levels

of gabapentin. Multiple large class 1 trials have demonstrated efficacy, and gabapentin enacarbil is approved for treatment of RLS in multiple countries LEVEL 1.[5,6] Pregabalin is also effective in high-quality studies but is not approved by regulatory agencies.

Opioid medications, also known as *narcotics*, have long been known to successfully treat RLS. Open-label trials consistently demonstrate good initial and long-term results, with relatively little tolerance, dependence, or addiction. Low-dose methadone especially shows excellent long-term efficacy and tolerability. However, only oxycodone has been evaluated in a placebo-controlled multicenter trial. Prolonged-release oxycodone-naloxone was shown to be effective in treating severe RLS which was inadequately controlled with nonopioid medications LEVEL 1.[7] It should be said that in practice, oxycodone-naloxone is rarely used to treat RLS, rather short-acting oxycodone or long-acting oxycodone is more commonly used to treat RLS. Opioid medications are usually reserved for treatment of severe refractory RLS, especially when augmentation has taken place on a dopaminergic agent.

Augmentation occurs in RLS patients who have been treated with a DA or levodopa over a long period of time. The treatment of augmentation includes decreasing the dose or eliminating the DA. Doing this will lead to a temporary severe worsening of RLS, and after approximately 2 to 6 weeks, RLS becomes less severe and less bothersome during the day. Treatment of augmentation can also be achieved by switching form a short-acting DA (eg, ropinirole) to a longer acting DA (eg, rotigotine patch). However, even on a long-acting DA, there is risk of developing augmentation.

Both oral and intravenous iron are effective in treating RLS. A randomized double-blind, placebo-controlled study in patient with moderate to severe RLS with normal or low serum ferritin found that ferrous sulfate 325 mg orally twice daily improved RLS to a greater degree than placebo LEVEL 1.[8] Oral iron, however, can have limitations related to absorption and tolerance. In contrast, the administration of high-dose intravenous iron can dramatically increase serum ferritin levels. Intravenous iron comes in several different preparations. There is evidence from open-label studies for the efficacy of low molecular weight iron dextran in the treatment of RLS. Low molecular weight iron dextran can be given safely in a single infusion of 1,000 mg or in four weekly 250-mg infusions. There is level 1 evidence to support the use of the intravenous iron preparation, ferric carboxymaltose, at a dose of 500 mg split into two doses for the treatment of RLS LEVEL 1.[9] Intravenous iron sucrose may be effective in the treatment of RLS.

Numerous other agents including other antiepileptic medications, benzodiazepines, clonidine, baclofen, tramadol, and magnesium have been reported to help RLS but suffer from limited data and cannot be recommended as either first- or second-line therapy. Physical measures that increase activity or create a sensory stimulus can also improve RLS but are often problematic when one desires sleep.

OUTCOME

Severity of RLS varies greatly across cases. Although up to 10% of Western European and North American populations have RLS at any degree or frequency, about 2% to 4% of these populations have clinically significant RLS, 2 times per week or more and causing some amount of distress. By far, the symptom which bothers RLS patients the most is the disruption of sleep. When RLS is severe, sleep onset can be vastly prolonged, and sleep may also be interrupted numerous times in the middle of the night. As sleep is adversely effected in RLS, the disease can negatively impact all aspects of life, including social, occupational, physical, and mental aspects. These adverse consequences are stressed in updated RLS diagnostic criteria as put forth by both the American Academy of Sleep Medicine and also the International Restless Legs Syndrome Study Group. Not surprisingly, depression is highly comorbid with RLS, occurring at a rate 2 to 4 times higher than in age-matched individuals without RLS. Persons with RLS are more likely in their lifetime to have had a suicide plan or attempt compared to age-matched and demographically matched controls without RLS. The RLS also results in decreased work productivity as those with RLS have more work absenteeism and more hospitalization than persons without RLS. The RLS may also confer increased cardiovascular burden as those with RLS have been found to have increased incidence of myocardial infarction, stroke, and hypertension. This increased cardiovascular burden may be more pertinent to persons with secondary than primary RLS.

LEVEL 1 EVIDENCE

1. Hening WA, Allen RP, Ondo WG, et al. Rotigotine improves restless legs syndrome: a 6-month randomized, double-blind, placebo-controlled trial in the United States. *Mov Disord*. 2010;25(11):1675-1683.
2. Oertel WH, Stiasny-Kolster K, Bergtholdt B, et al. Efficacy of pramipexole in restless legs syndrome: a six-week, multicenter, randomized, double-blind study (effect-RLS study). *Mov Disord*. 2007;22(2):213-219.
3. Trenkwalder C, Garcia-Borreguero D, Montagna P, et al. Ropinirole in the treatment of restless legs syndrome: results from the TREAT RLS 1 study, a 12 week, randomised, placebo controlled study in 10 European countries. *J Neurol Neurosurg Psychiatry*. 2004;75(1):92-97.
4. Garcia-Borreguero D, Kohnen R, Silber MH, et al. The long-term treatment of restless legs syndrome/Willis-Ekbom disease: evidence-based guidelines and clinical consensus best practice guidance: a report from the International Restless Legs Syndrome Study Group. *Sleep Med*. 2013;14(7):675-684.
5. Kushida CA, Becker PM, Ellenbogen AL, Canafax DM, Barrett RW; and XP052 Study Group. Randomized, double-blind, placebo-controlled study of XP13512/GSK1838262 in patients with RLS. *Neurology*. 2009;72(5):439-446.
6. Ellenbogen AL, Thein SG, Winslow DH, et al. A 52-week study of gabapentin enacarbil in restless legs syndrome. *Clin Neuropharmacol*. 2011;34(1):8-16.
7. Trenkwalder C, Beneš H, Grote L, et al; for RELOXYN Study Group. Prolonged release oxycodone-naloxone for treatment of severe restless legs syndrome after failure of previous treatment: a double-blind, randomised, placebo-controlled trial with an open-label extension. *Lancet Neurol*. 2013;12(12):1141-1150.
8. Wang J, O'Reilly B, Venkataraman R, Mysliwiec V, Mysliwiec A. Efficacy of oral iron in patients with restless legs syndrome and a low-normal ferritin: a randomized, double-blind, placebo-controlled study. *Sleep Med*. 2009;10(9):973-975.
9. Allen RP, Adler CH, Du W, Butcher A, Bregman DB, Earley CJ. Clinical efficacy and safety of IV ferric carboxymaltose (FCM) treatment of RLS: a multi-centred, placebo-controlled preliminary clinical trial. *Sleep Med*. 2011;12(9):906-913.

SUGGESTED READINGS

Allen RP, Barker PB, Horská A, Earley CJ. Thalamic glutamate/glutamine in restless legs syndrome: increased and related to disturbed sleep. *Neurology*. 2013;80(22):2028-2034.

Allen RP, Barker PB, Wehrl F, Song HK, Earley CJ. MRI measurement of brain iron in patients with restless legs syndrome. *Neurology*. 2001;56(2):263-265.

Allen RP, Chen C, Garcia-Borreguero D, et al. Comparison of pregabalin with pramipexole for restless legs syndrome. *N Engl J Med*. 2014;370(7):621-631.

Allen RP, Picchietti DL, Auerbach M, et al; for the International Restless Legs Syndrome Study Group. Evidence-based and consensus clinical practice guidelines for the iron treatment of restless legs syndrome/Willis-Ekbom disease in adults and children: an IRLSSG task force report. *Sleep Med*. 2018;41:27-44.

Allen RP, Picchietti DL, Garcia-Borreguero D, et al; for the International Restless Legs Syndrome Study Group. Restless legs syndrome/Willis-Ekbom disease diagnostic criteria: updated International Restless Legs Syndrome Study Group (IRLSSG) consensus criteria—history, rationale, description, and significance. *Sleep Med*. 2014;15(8):860-873.

Allen RP, Picchietti DL, Hening WA, et al; for the International Restless Legs Syndrome Study Group. Restless legs syndrome: diagnostic criteria, special considerations, and epidemiology. A report from the restless legs syndrome diagnosis and epidemiology workshop at the National Institutes of Health. *Sleep Med*. 2003;4(2):101-119.

Allen RP, Walters AS, Montplaisir J, et al. Restless legs syndrome prevalence and impact: REST general population study. *Arch Intern Med*. 2005;165(11):1286-1292.

Beneš HD, García-Borreguero D, Ferini-Strambi L, Schollmayer E, Fichtner A, Kohnen R. Augmentation in the treatment of restless legs syndrome with transdermal rotigotine. *Sleep Med*. 2012;13(6):589-597.

Connor JR, Wang XS, Patton SM, et al. Decreased transferrin receptor expression by neuromelanin cells in restless legs syndrome. *Neurology*. 2004;62(9):1563-1567.

Earley CJ, Connor JR, Beard JL, Malecki EA, Epstein DK, Allen RP. Abnormalities in CSF concentrations of ferritin and transferrin in restless legs syndrome. *Neurology*. 2000;54(8):1698-1700.

Earley CJ, Connor J, Garcia-Borreguero D, et al. Altered brain iron homeostasis and dopaminergic function in restless legs syndrome. *Sleep Med*. 2014;15(11):1288-1301.

Earley CJ, Kuwabara H, Wong DF, et al. Increased synaptic dopamine in the putamen in restless legs syndrome. *Sleep*. 2013;36(1):51-57.

Furudate NY, Komada Y, Kobayashi M, Nakajima S, Inoue Y. Daytime dysfunction in children with restless legs syndrome. *J Neurol Sci*. 2014;336(1-2):232-236.

Garcia-Borreguero D. Dopaminergic augmentation in restless legs syndrome/Willis-Ekbom disease: identification and management. *Sleep Med Clin*. 2015;10(3):287-292.

Garcia-Borreguero D, Kohnen R, Silber MH, et al. The long-term treatment of restless legs syndrome/Willis-Ekbom disease: evidence-based guidelines and clinical consensus best practice guidance: a report from the International Restless Legs Syndrome Study Group. *Sleep Med*. 2013;14(7):675-684.

Garcia-Borreguero D, Silber MH, Winkelman JW et al. Guidelines for the first-line treatment of restless legs syndrome/Willis-Ekbom disease, prevention and treatment of dopaminergic augmentation: a combined task force of the IRLSSG, EURLSSG, and the RLS-Foundation. *Sleep Med*. 2016;21:1-11.

Godau JU, Klose U, Di Santo A, Schweitzer K, Berg D. Multiregional brain iron deficiency in restless legs syndrome. *Mov Disord*. 2008;23(8):1184-1187.

Högl B, Garcia-Borreguero D, Kohnen R, et al. Progressive development of augmentation during long-term treatment with levodopa in restless legs syndrome: results of a prospective multi-center study. *J Neurol*. 2010;257(2):230-237.

Koo BB. Restless legs syndrome across the globe: epidemiology of the restless legs syndrome/Willis-Ekbom disease. *Sleep Med Clin*. 2015;10(3):189-205.

Merlino GA, Serafini A, Young JJ, Robiony F, Gigli GL, Valente M. Gabapentin enacarbil, a gabapentin prodrug for the treatment of the neurological symptoms associated with disorders such as restless legs syndrome. *Curr Opin Investig Drugs*. 2009;10(1):91-102.

Ondo W, Romanyshyn J, Voung KD, Lai D. Long-term treatment of restless legs syndrome with dopamine agonists. *Arch Neurol*. 2004;61(9):1393-1397.

Picchietti DL, Bruni O, de Weerd A, et al; for the International Restless Legs Syndrome Study Group. Pediatric restless legs syndrome diagnostic criteria: an update by the International Restless Legs Syndrome Study Group. *Sleep Med*. 2013;14(12):1253-1259.

Schormair BD, Kemlink D, Roeske D, et al. PTPRD (protein tyrosine phosphatase receptor type delta) is associated with restless legs syndrome. *Nat Genet*. 2008;40(8):946-948.

Silber MH, Becker PM, Buchfuhrer MJ, et al; for the Scientific and Medical Advisory Board, Restless Legs Syndrome Foundation. The appropriate use of opioids in the treatment of refractory restless legs syndrome. *Mayo Clin Proc*. 2018;93(1):59-67.

Silber MH, Becker PM, Earley C, Garcia-Borreguero D, Ondo WG; for the Medical Advisory Board of the Willis-Ekbom Disease Foundation. Willis-Ekbom Disease Foundation revised consensus statement on the management of restless legs syndrome. *Mayo Clin Proc*. 2013;88(9):977-986.

Silver N, Allen RP, Senerth J, et al. A 10-year, longitudinal assessment of dopamine agonists and methadone in the treatment of restless legs syndrome. *Sleep Med*. 2011;12(5):440-444.

Stiasny-Kolster K, Pfau DB, Oertel WH, Treede R-D, Magerl W. Hyperalgesia and functional sensory loss in restless legs syndrome. *Pain*. 2013;154(8):1457-1463.

Trenkwalder C, Allen R, Högl B, et al. Comorbidities, treatment, and pathophysiology in restless legs syndrome. *Lancet Neurol*. 2018;17(11):994-1005.

Walters AS, Ondo WG, Zhu W, Le W. Does the endogenous opiate system play a role in the restless legs syndrome? A pilot post-mortem study. *J Neurol Sci*. 2009;279(1-2):62-65.

Winkelmann J, Schormair B, Lichtner P, et al. Genome-wide association study of restless legs syndrome identifies common variants in three genomic regions. *Nat Genet*. 2007;39(8):1000-1006.

Winkelmann J, Schormair B, Xiong L, Dion PA, Rye DB, Rouleau GA. Genetics of restless legs syndrome. *Sleep Med*. 2017;31:18-22.

The Dystonias 79

Hyder A. Jinnah

KEY POINTS

1. Dystonia is not a single disease entity. It is a heterogeneous group of disorders that share certain features. The fundamental shared feature is excessive muscle contractions leading to involuntary abnormal movements and/or postures.
2. The many varied clinical manifestations of dystonia are classified according to four main dimensions, which include age at onset, body region affected, temporal aspects, and whether or not dystonia is combined with other neurologic or medical features.
3. The causes for dystonia also are heterogeneous. The majority of cases are idiopathic, but there are many known etiologies, both inherited and acquired.
4. Many effective treatments are available including oral medications, botulinum toxin injections, and surgical procedures.

INTRODUCTION

Defining Features of Dystonia

Oppenheim described a series of patients in 1911 who had reduced muscle tone (hypotonia) when they were resting but exaggerated muscle tone (hypertonia) with any attempted movement. He viewed the fundamental problem as a defect in the regulation of muscle tone; hence, the term *dys-tonia*. Since then, *dystonia* has become an umbrella term that includes a number of related conditions. Dystonia is no longer viewed primarily as a disorder of muscle tone. Instead, an international panel of experts agreed to the following definition:

> Dystonia is a movement disorder characterized by sustained or intermittent muscle contractions causing abnormal, often repetitive movements, postures, or both. Dystonic movements are typically patterned, twisting, and may be tremulous. Dystonia is often initiated or worsened by voluntary action and associated with overflow muscle activation.

This definition encompasses a broad range of abnormalities. The physical appearance of dystonic movements depends on the distribution of muscles involved and the strengths of individual muscle contractions. The mildest expressions appear as only subtle exaggerations of otherwise normal movements. Moderately severe expressions appear as movements that are cramped, stiff, twisting, and sometimes jerky. In the most severe expressions, dystonia can appear as fixed postures or deformities with severe disability. These movements may occur in nearly any region of the body.

Although dystonic movements are often slow and sustained, they can sometimes be rapid and jerky. Whether slow or fast, they tend to follow a recurring pattern. Dystonic movements are usually worsened by voluntary action, a phenomenon that is termed *action dystonia*. In some cases, abnormal movements emerge only with very specific actions, and the term *task-specific dystonia* is used. Dystonic movements are often accompanied by overflow muscle activation, a phenomenon that refers to activation extraneous muscles that are not needed for a movement. There often is something an affected individual can do to suppress the abnormal movements, such as touching the cheek in cervical dystonia or touching the brow in blepharospasm. This phenomenon has variably been termed *geste antagoniste* or *sensory trick* or *alleviating maneuver*. The geste can be a very helpful diagnostic clue when it is present because it is relatively unique to dystonia.

Discrimination of Dystonia From Related Disorders

Dystonia can be discriminated from other movement disorders by several features (Table 79.1). The movements of chorea are typically random, fluid, and more often rapid. In comparison, dystonic movements tend to be more patterned, less fluid, and more often slower than chorea. However, dystonia and chorea may be combined, and distinctions between them can be difficult to define. Motor tics are often patterned, and they sometimes can be relatively slow and twisting. However, dystonic movements lack the premonitory urge or the voluntary suppressibility of tics. Dystonic movements can sometimes be rapid and repetitive, resembling tremor. However, unlike more common tremors, dystonic tremors tend to be jerky and irregular in their rate and amplitude. Dystonic jerking and dystonic tremors also have a *null point*, a specific position where the abnormal movements abate or disappear.

The increased muscle tone of dystonia must be discriminated from other disorders of hypertonia (Table 79.2). Increased muscle tone in spasticity is more prominent in extensors compared with flexors, there is a rate-dependent increase in tone when the limb is passively moved, and there are usually accompanying corticospinal signs such as hyperreflexia and the extensor toe reflex. Muscle tone in dystonia increases with voluntary action, but it is usually normal or occasionally reduced at rest. In dystonia, tone is not more prominent in extensor muscles, there is no rate-dependent increase in tone with passive flexion, and there is no spastic catch. In rigidity, there is a waxy increase in extensor and flexor muscle tone with passive movement, no rate dependence, and often coexisting cogwheeling. Tone in rigidity is not significantly affected by action or rest. Paratonia refers to the inability of some subjects to fully relax when tone is tested. Some patients involuntarily aid the examiner during movements

TABLE 79.1 Distinguishing Dystonia From Related Movement Disorders

Clinical Feature	Dystonia	Chorea	Athetosis	Tremor	Tic	Myoclonus
Sustained muscle contractions or postures	Often	No	No	No	Occasionally	No
Movements are worsened with action	Often	No	No	Sometimes	No	Rarely
Movements are task specific	Often	No	No	Sometimes	No	Rarely
Overflow to extraneous muscles	Often	Sometimes	No	No	Sometimes	No
Movements are patterned	Often	No	No	Yes	Yes	Sometimes
Movement speed	Slow or fast	Medium to fast	Slow to medium	Medium to fast	Slow or fast	Very fast
Movements appear flowing	No	Yes	Yes	No	Occasionally	No
Movements have a twisting quality	Often	No	No	No	Occasionally	No
Movements have a premonitory urge	No	No	No	No	Yes	No
Movements are suppressible	No	No	No	No	Yes	No
Movements have a null point where they abate	Often	No	No	Sometimes	No	No
Geste antagoniste	Often	No	No	No	No	No

(mitgegen, or "go with"), leaving the impression of reduced or normal tone. Others involuntarily resist passive movements (gegenhalten, or "go against"), leaving the impression of increased tone. Both forms of paratonia often occur in association with dementia but may occur in cognitively normal children and adults too. Although each of these abnormalities of muscle tone can occur in isolation, they can also be combined in the same individual. Cerebral palsy is an example where there often are varying combinations of spasticity, dystonia, and rigidity.

Additional Relevant Terminology

There are a number of additional terms in common usage (Table 79.3). Dystonia is considered a disorder of a network of brain regions that control movements. However, excessive muscle contractions leading to abnormal movements or postures resembling dystonia can sometimes be seen in disorders of the spinal cord (eg, stiff person syndrome), peripheral nerves (eg, neurotonia), or muscles (eg, myotonia). Abnormal postures can also result from defects in the bones and joints (eg, joint contractures). The movements or postures associated with these other disorders can resemble dystonia, but the term *pseudodystonia* is used to discriminate them from dystonia caused by the brain's motor network. Some examples of pseudodystonias are listed in Table 79.4.

The term *dyskinesia* literally means *abnormal movement*. It is an umbrella term that encompasses all abnormal movements including dystonia. By convention, there are some more specific types of dyskinesia, such as *tardive dyskinesia* caused by exposure to neuroleptics. Another more specific type of dyskinesia is *levodopa-induced dyskinesia*. In both tardive dyskinesia and levodopa-induced dyskinesia, dystonia may be part of the syndrome along with other abnormal movements.

There also are a number of terms that juxtapose the word *dystonia* with another word. The term *myoclonus-dystonia* refers to a syndrome in which both myoclonus and dystonia occur together. The term *myoclonic dystonia* refers to dystonic movements that resemble myoclonus because movements are sudden and shock-like. The term *dystonic tic* refers to tics that have a dystonic appearance by virtue of their slow, sustained, or twisting quality. A motor seizure where abnormal tonic movements resemble dystonia is sometimes called a *dystonic seizure*. The term *spastic dystonia* refers to the combination of spasticity with dystonia, as in cerebral palsy. Although these hybrid terms are in common usage, it is the opinion of this author that they are best avoided when talking to patients or other individuals who lack expertise

TABLE 79.2 Distinguishing Dystonia From Other Hypertonias

Clinical Feature	Dystonia	Spasticity	Rigidity	Paratonia
Muscle tone increases with voluntary action	Yes	No	No	Sometimes
Muscle tone decreases at rest	Yes	No	No	Sometimes
Hypotonia at rest	Sometimes	No	No	No
Rate-dependent increase in muscle tone with passive flexion	No	Yes	No	Yes
Muscle tone is greater in extensors than flexors	No	Yes	No	No
Baseline abnormal postures	Variable depending on muscle involvement	Classical postures dominated by flexors	Often slight flexion	No
Additional helpful features	Geste antagoniste	Corticospinal signs	Cogwheeling	Associated often with dementia; tone normalizes with distraction

TABLE 79.3 Glossary of Dystonia Terms

Term	Explanation
Apraxia of eyelid opening	Difficulty opening the eyes without overt eye spasms, caused by failure of palpebral muscles to relax
Camptocormia	Forward bending of the spine, sometimes caused by dystonia or orthopedic issues
Dyskinesia	A generic term that literally means "abnormal movement"
Dystonic seizure	Seizure with tonic and sometimes twisting movements that mimic dystonia
Dystonic tic	Tic with tonic and sometimes twisting movements that mimic dystonia
Dystonic tremor	Dystonia with rapid, repetitive, and rhythmical movements that mimic tremor
Functional or psychogenic dystonia	A psychiatric disorder that includes abnormal movements resembling dystonia
Geste antagoniste	Something the patient can do to alleviate their dystonia; also known as *sensory trick* or *alleviating maneuver*
Mirror movements	Voluntary movements on one side of the body provoke similar involuntary movements on the opposite side of the body
Myoclonic dystonia	Dystonic movements with a very rapid and jerky quality mimicking myoclonus
Myoclonus-dystonia	Syndrome that combines both myoclonus and dystonia
Oculogyric crisis	Involuntary conjugate version of the eyes, usually upward and laterally
Opisthotonus	Backward arching of the trunk, from dystonic truncal extensor muscles
Overflow	Contractions of muscles for a movement spread to nearby muscles that are not required
Pisa syndrome	Sideways bending of the trunk, sometimes caused by dystonia or orthopedic issues
Pseudodystonia	Abnormal movements or postures not resulting from the brain's motor network
Spastic dystonia	Syndrome that combines spasticity with dystonia, such as cerebral palsy
Striatal toe	Extensor movement of the great toe that closely resembles the Babinski reflex; also known as *dystonic toe*
Tardive dystonia	A subtype of tardive dyskinesias caused by dopamine receptor antagonists
Task-specific dystonia	Dystonia that is triggered only by a specific task, such as writing

in neurology because they readily lead to confusion regarding whether the abnormal movements being described are a type of dystonia, some other movement disorder, a combination of abnormal movements, or a named syndrome.

Classification of Dystonia Subtypes

The modern definition of dystonia encompasses a large group of abnormal movements that are very heterogenous in terms of their clinical manifestations and underlying causes. For practical reasons, it is useful to have a simple strategy to lump and split this large group into smaller subgroups. The dystonias are currently grouped according to two main axes. Axis I addresses clinical manifestations, and axis II addresses etiologies.

TABLE 79.4 Examples of Some Pseudodystonias

Orthopedic Defects	Examples
Arthritic joint deformities	Abnormal finger postures Abnormal wrist postures
Joint contractures	Dupuytren hand Erb deformity Congenital muscular torticollis
Joint subluxations	Atlanto-axial joint Shoulder joint Hip joint
Vertebral abnormalities	Compression fractures Klippel-Feil anomaly Scoliosis
Neuromuscular Defects	**Examples**
Defects in spinal inhibition	Stiff person syndrome Tetanus
Head drop due to neck weakness	Motor neuron disease Myasthenia gravis Myopathy
Muscle hyperexcitability	Myotonia congenita Paramyotonia congenita
Neuromyotonia	Isaac syndrome
Behavioral Compensations	**Examples**
Head tilt	Ocular misalignment Vestibular imbalance
Pain guarding behavior	Abdominal cramping Protected hand/arm postures

Axis I: Clinical Manifestations

The clinical manifestations are classified according to four factors (Fig. 79.1). The first factor is the age when dystonia started. The age groups are divided according to standard ages used for many other disorders and include infancy, childhood, adolescence, and early and late adulthood. Age at onset is important because early-onset cases are more likely to progress compared to cases that emerge first in older adults. The early-onset cases are also more likely to have a discoverable cause, compared to most late-onset cases where a cause typically cannot be found.

The second factor is the distribution of the body affected with dystonia. The most common manifestation is focal dystonia, which affects one region of the body. Typical examples include cervical dystonia (neck muscles), blepharospasm (orbicularis oculi and associated muscles of the upper face), laryngeal dystonia (also known as *spasmodic dysphonia*), and hand dystonia (eg, writer's cramp). Segmental dystonia involves at least two contiguous regions. A common example is Meige syndrome, where there is involvement of the upper and lower face and sometimes the jaw and tongue. Multifocal dystonia involves at least two noncontiguous regions. An example might be blepharospasm combined with writer's cramp. Generalized dystonia involves a broader distribution of muscles. By convention, generalized dystonia must include the trunk and at least two other body regions. Hemidystonia can be viewed as a subtype of generalized dystonia when it involves the trunk and ipsilateral arm and leg.

The third factor that is useful in classifying the dystonias involves variations in the severity of dystonia over time.

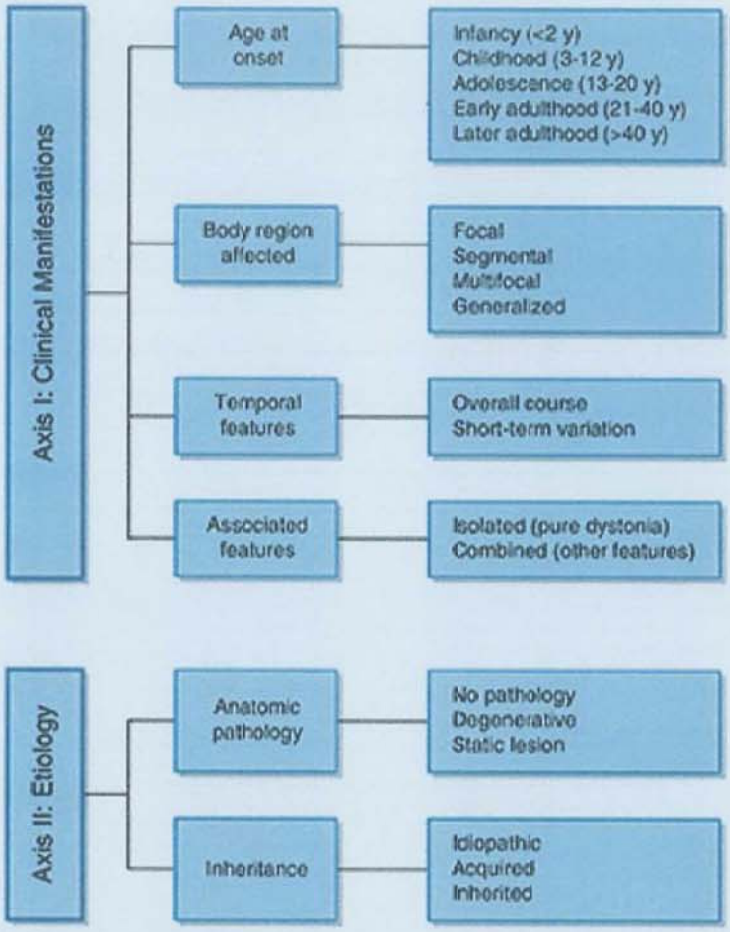

FIGURE 79.1 Classification of the dystonias.

These temporal changes include the long-term evolution over years because dystonia may be relentlessly progressive, it may evolve in a stepwise fashion, or it may remain static. The temporal changes also include short-term changes, such as the diurnal variations with worsening each evening that are typical of dopa-responsive dystonia or transient attacks of dystonia typical of the paroxysmal dyskinesias.

Finally, the last factor is whether dystonia is isolated (pure) or combined with other neurologic or medical problems. In the context of the dystonia classification system, the term *isolated* refers only to whether or not dystonia is the sole problem. The term *isolated* does not refer to dystonia limited to a single body region. More than one region may be involved in isolated dystonia, as in segmental or generalized dystonia. Because tremor occurs in at least half of all patients with dystonia, the diagnosis of isolated dystonia may include accompanying tremor. Other accompanying features are important because there are numerous well-recognized syndromes where dystonia is combined with another movement disorder such as parkinsonism, ataxia, or myoclonus. There also are numerous well-recognized syndromes where dystonia is combined with other neurologic (eg, neuropathy, retinopathy, epilepsy) or medical (eg, hepatic or hematologic) problems.

Axis II: Etiologies

Known etiologies for dystonia are grouped according to two main factors (see Fig. 79.1). The first factor is based on neuropathology. In the majority of dystonias, overt structural defects are absent. In rare cases, there may be evidence that dystonia is caused by a focal lesion or a neurodegenerative process. Some of these lesion-based dystonias are described further in the following text.

The second factor is based on whether dystonia is inherited or acquired. The majority of dystonias are sporadic, and a cause cannot be identified. In some cases, there is evidence for an acquired or inherited cause. Examples of some of the acquired causes are listed in Table 79.5 and described further in the following text. The inherited subgroups include the usual common patterns of dominant, recessive, sex-linked, and mitochondrial. Some of the more common inherited causes for dystonia also are described further in the following text.

Axes I and II are not mutually exclusive and were envisioned to work together. The goal of defining the four factors of axis I is to emphasize the clinical features that are most relevant for delineating dystonia syndromes, which often have specific etiologies described by axis II.

EPIDEMIOLOGY

Isolated Dystonia Syndromes

Isolated dystonia, previously known as *primary dystonia*, refers to a group of disorders where dystonia occurs in the absence of other relevant neurologic or medical problems. Estimates for the prevalence of isolated dystonia vary widely due to methodologic differences. Meta-analyses of the most rigorous studies place the overall prevalence of all isolated dystonia syndromes combined at approximately 16 cases per 100,000 population. The vast majority of these cases are adult-onset focal and segmental dystonias, with an overall prevalence of approximately 15 cases per 100,000 population. Among these, cervical dystonia is the most common, followed by blepharospasm, and then upper limb dystonias. Oromandibular and laryngeal dystonias are less common. The early-onset generalized dystonias consist of a very small fraction of total cases with isolated dystonia.

Although the dystonias are considered rare disorders, it is widely believed that their prevalence is underestimated because of poor recognition of the many varied manifestations. By comparison, there are more definitive data on the prevalence of essential tremor and Parkinson disease. Meta-analyses of the most rigorous epidemiologic studies reveal an overall prevalence per 100,000 population of approximately 450 cases for essential tremor and 113 for Parkinson disease. For both tremor and Parkinson disease, prevalence varies by age. For Parkinson disease, for example, age-adjusted prevalence estimates per 100,000 population are 41 cases (ages 40-49 y), 107 cases (ages 50-59 y), 428 cases (ages 60-69 y), 1,087 cases (ages 70-79 y), and 1,903 cases (age >80 y).

Other Syndromes With Dystonia

There are many disorders where dystonia is combined with other neurologic problems. The epidemiology of dystonia for most of these disorders has not been methodically evaluated in large-scale studies, although it is likely that the combined prevalence of dystonia in these mixed disorders is higher than in the isolated dystonia syndromes.

For example, dystonia is a common accompanying feature of Parkinson disease. In the most methodical studies, 30% to 40% of patients with Parkinson disease have dystonia at some

TABLE 79.5 Some Acquired Etiologies for Dystonia

Vascular Etiologies	**Autoimmune-Paraimmune**
Antiphospholipid syndrome	Behçet disease
Arteriovenous malformations	Multiple sclerosis
Hemorrhagic stroke	PANDAS
Ischemic stroke	Paraneoplastic syndromes
Subarachnoid hemorrhage	Sjögren syndrome
Vascular malformations	Systemic lupus erythematosus
Vasculitis	Sydenham chorea
Toxins	**Infections**
3-Nitropropionic acid	Abscess
Carbon monoxide	Encephalitis
Carbon disulfide	HIV/AIDS
Cyanide	Subacute sclerosing panencephalitis
Disulfiram	**Others**
Manganese	Brain tumors
Methanol	Cerebral palsy
Wasp sting	Hypoparathyroidism
Medications	Kernicterus
Anticonvulsants	Tics and Tourette syndrome
Antidepressants	Trauma
Calcium channel blockers	
Dopamine receptor antagonists	
Ergots	
Fenfluramine	
Levodopa	

Abbreviation: PANDAS, pediatric autoimmune disorders associated with anti-streptococcal antibodies.

point in their illness. In 10% to 15% of these patients, dystonia is the main problem at disease onset. Dystonia also occurs later in the disease as a complication of levodopa treatment. Dystonia is most common during trough periods between doses and affects 10% to 20% of patients. Dystonia is even more common in the Parkinson imitator disorders such as corticobasal syndrome, progressive supranuclear palsy, and multiple system atrophy.

Another disorder where dystonia is common is cerebral palsy, which is estimated to have an overall prevalence of approximately 150 to 400 cases per 100,000. In the most methodical studies encompassing all types of cerebral palsy, approximately 80% have dystonia. In cerebral palsy, dystonia is most often combined with varying degrees of spasticity or rigidity, although dystonia can be the dominant movement disorder in 10% to 15% of children with the dyskinetic subtype of cerebral palsy.

Dystonia also occurs in numerous other neurologic disorders. Dystonia is common in Huntington disease, and dystonia often dominates the movement disorder in juvenile-onset cases. Dystonia also is common in the spinocerebellar ataxias, and in some cases, dystonia is the dominant movement disorder. Dystonia also is an accompanying feature of tardive syndromes caused by neuroleptics, and the term *tardive dystonia* is used to refer to those in which dystonia is the main problem. The prevalence of dystonia in these many different disorders has not been well characterized.

PATHOBIOLOGY

Anatomic Underpinnings of Dystonia

Dystonia is currently viewed as a disorder of a motor network that involves the basal ganglia, cerebellum, sensorimotor cortex, and probably other regions, too. Available evidence suggests that different types of dystonia may arise from defects in different areas of the motor network. For example, there is compelling evidence that the basal ganglia are responsible for some types of dystonia, such as dopa-responsive dystonia, which is caused by inherited defects in the synthesis of dopamine, a critical neurotransmitter of the basal ganglia. On the other hand, the cerebellum has been implicated in other types of dystonia, for example, cervical dystonia. Other studies have implicated the sensorimotor cortex, thalamus, and midbrain or brainstem.

Most of the regions implicated in dystonia are interconnected in a "motor network." The challenge in understanding the neuroanatomic substrates for dystonia has been to elucidate how the motor network is disrupted to cause different types of dystonia (Fig. 79.2). Different types of dystonia might originate in individual nodes of the network. Alternatively, dystonia might originate from combined dysfunction of two nodes, the so-called "two-hit hypothesis." Finally, dystonia might arise from defects in the communication among the nodes.

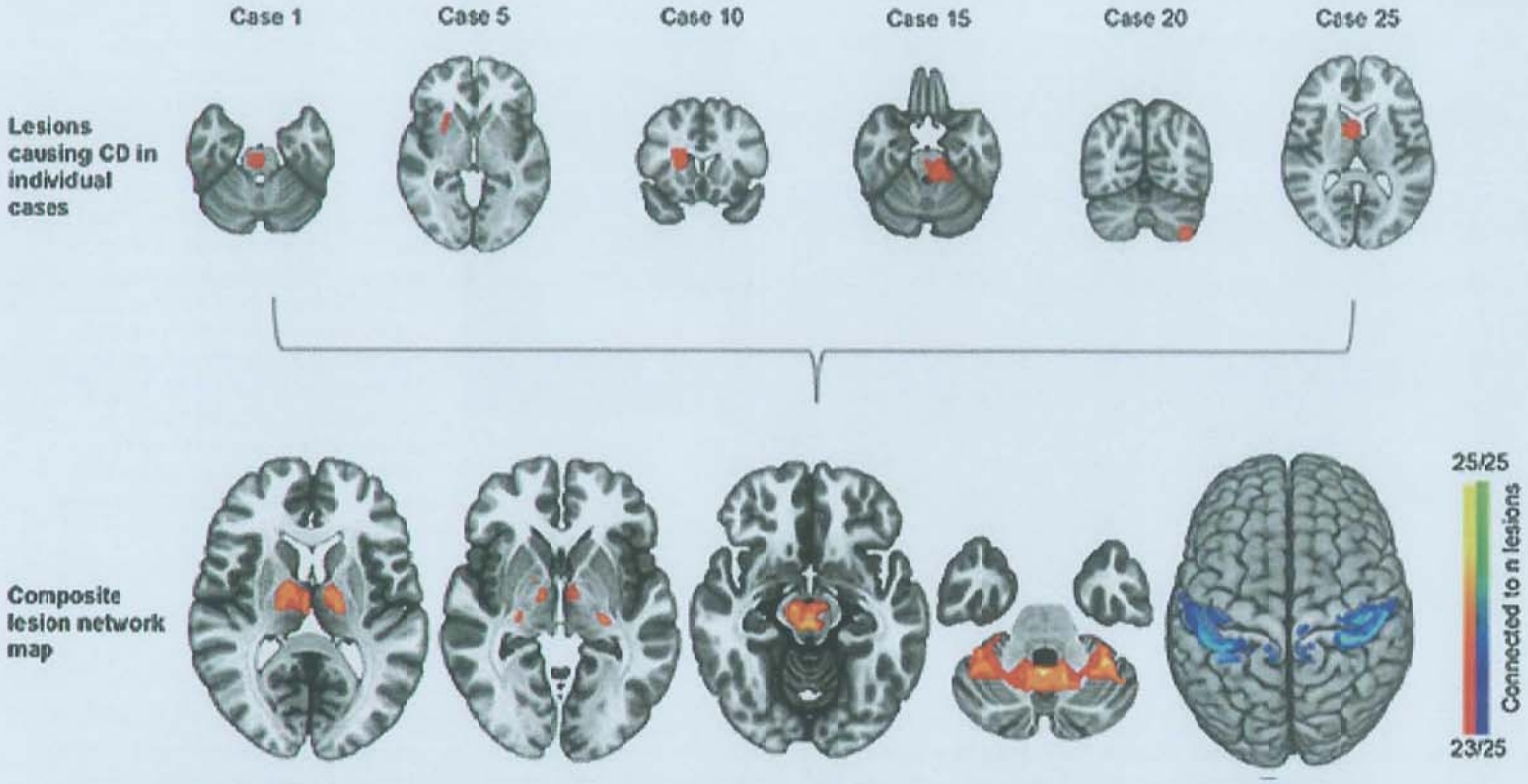

FIGURE 79.2 The functional neuroanatomy of cervical dystonia (CD). Although focal lesions are uncommon causes of cervical dystonia, lesions have been described for different parts of the brain in different patients, with some examples shown in the top row. When these different lesions for different patients are mapped onto a shared atlas of brain connectivity, a network of interconnected regions becomes apparent. This network involves the cerebellum, basal ganglia, and sensorimotor cortex. (Modified from Daniel DT, Joutsa J, Darby RR, et al. Network localization of cervical dystonia based causal brain lesions. *Brain*. 2019;142[6]:1660-1674.)

Understanding how the motor network is affected in different types of dystonia is important because it has direct implications for neurosurgical treatments. Notably, surgical interventions targeting different regions of the basal ganglia provide significant relief for some types of dystonia, such as early-onset generalized dystonia associated with defects in the *TOR1A* gene. However, targeting the same region is not effective for other types of dystonia, such as rapid-onset dystonia parkinsonism caused by defects in the *ATP1A3* gene. Presumably, alternative targets need to be considered in such cases.

Physiologic Underpinnings of Dystonia

Muscle Activity

A core defect underlying dystonia is excessive and often repetitive contraction of muscles. It is often claimed that a cardinal feature of dystonia involves cocontraction of agonist and antagonist muscles. However, cocontraction of antagonistic muscles is not universal in dystonia. Instead, the cardinal feature of dystonia is muscle overcontraction leading to excessive force, or spread of contractions to nearby muscles. When this spreading involves antagonistic muscles, then cocontraction of antagonists may occur.

Electromyography (EMG) can be used to detect excessive and repetitive muscle contractions, spreading, and cocontraction of antagonistic muscles. However, these EMG findings are not specific to dystonia. Excessive and repetitive muscle contractions can be seen with voluntary overcontractions in normal individuals or stiff person syndrome. Cocontraction of antagonistic muscles can be seen with voluntary isometric contractions in normal individuals. Because no EMG feature is specific to dystonia, EMG is not routinely used as a diagnostic tool. However, EMG can sometimes be used to rule out other disorders, including some of the pseudodystonias. The EMG can also be valuable for localization of muscles that are most appropriate to inject with botulinum toxin for treatment.

Neuronal Physiology

Most forms of dystonia are not associated with overt structural abnormalities of the brain, and only subtle morphologic changes of individual neurons are found. There is limited information regarding neuronal function in human dystonia. Quantitative electroencephalography has revealed abnormal oscillatory activity in the cerebral cortex of patients with isolated dystonia. Recordings of local field potentials during deep brain stimulation (DBS) surgery have revealed abnormal activity in the basal ganglia and thalamus from several types of dystonia, too. The biologic basis for this activity and how it may contribute to cause dystonia are not well understood. Similar abnormalities have been reported for patients with psychogenic (functional) dystonia and other movement disorders, raising questions regarding whether it may be a consequence of abnormal movement rather than a cause.

Because of the challenges associated with physiologic evaluation of neurons in the human brain, animal models have been explored. A number of experimental manipulations in animals can produce abnormal movements that have characteristics typical of human dystonias (Fig. 79.3). Several animal studies have pointed to abnormalities of the basal ganglia, whereas others have pointed to the cerebellum. For example, mouse models associated with defects in the *TOR1A* gene demonstrate abnormal dopamine release from nigrostriatal afferents in the basal ganglia along with abnormalities in corticostriatal and cholinergic interneuron activity. In primate models, electrophysiologic recordings have pointed to an

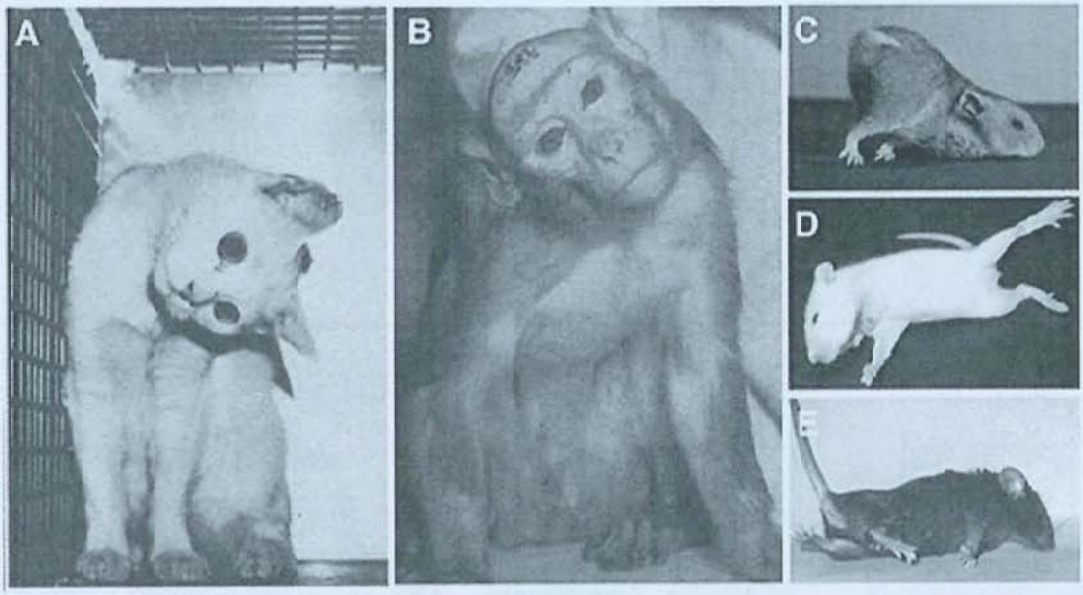

FIGURE 79.3 Animal models of dystonia. **A:** Cervical dystonia in a cat caused by injection of a glutamate agonist into the midbrain tegmentum. **B:** Cervical dystonia in a rhesus monkey caused by electrolytic lesions of the brainstem reticular formation. Generalized dystonia has been observed in rodent species including hamsters **(C)**, rats **(D)**, and mice **(E)**. (Modified from Jinnah HA, Prudente CN, Rose SJ, Hess EJ. The neurobiology of dystonia. In: Johnston MV, Adams HP, Fatemi A, eds. *Neurobiology of Disease*. 2nd ed. New York, NY: Oxford University Press; 2016:60-74.)

imbalance between the direct and indirect pathways of the basal ganglia, or rate-dependent alterations in basal ganglia output.

Studies of other mouse models of dystonia have pointed to abnormalities of the cerebellum. One common finding in these models involves abnormal burst firing of Purkinje neurons. This phenomenon has been demonstrated in a rat model of early-onset generalized dystonia, a mouse model of paroxysmal dystonia, mouse models of rapid-onset dystonia parkinsonism syndrome, and several other genetically engineered rodent models with specific defects in the cerebellum.

Network Physiology

Three overarching conceptual models have been proposed to explain the physiologic basis for dystonia. One model proposes an imbalance between the normal inhibitory and excitatory influences in the nervous system. An impairment in normal inhibitory processes has been found in many types of dystonia and in multiple regions of the nervous system such as the cerebral cortex, brainstem, and even the spinal cord. This model is intuitively attractive because the fundamental problem in dystonia is excessive muscle contraction. However, impaired inhibition is not specific to dystonia and can be found in other neurologic disorders. These observations have led to questions regarding whether the impairment of inhibition may be a consequence of abnormal movement, rather than a cause.

Another model involves abnormalities of sensory feedback to the nervous system or abnormal integration of sensory feedback with motor output. A defect in sensorimotor integration also is intuitively attractive because of the obvious need to match motor output with sensory feedback during and after movement. Overt sensory defects are not usually detected during the routine neurologic exam in most patients with dystonia; but quantitative studies have revealed subclinical defects in spatial discrimination, the ability to detect two distinct but simultaneous stimuli that close to each other. Other studies have revealed subclinical defects in temporal discrimination, the ability to detect two distinct stimuli delivered in rapid sequence. There also is evidence for abnormal feedback from muscle spindles, which regulate muscle tone.

The third model involves neural plasticity. The nervous system is known to change its responses with experience, a phenomenon known as *adaptive plasticity*. Abnormalities of these processes (maladaptive plasticity) may occur, and abnormalities of neuronal plasticity have been documented for dystonia. This mechanism is intuitively attractive because some forms of dystonia arise from repetitive overuse or overtraining, such as task-specific dystonias. Whether this mechanism can also apply to dystonias that emerge without repetitive motor behavior remains unclear.

Developmental or Degenerative Processes

Several experts have proposed that dystonia is a developmental disorder. In fact, the majority of inherited dystonias arise during childhood, and many of the responsible genes affect neurodevelopmental mechanisms without causing any obvious neurodegenerative abnormalities.

However, there also are many subtypes of dystonia that are associated with degenerative mechanisms. Some of these degenerative disorders arise during childhood, and others arise later in adulthood. For the most common types of adult-onset dystonia, evidence for developmental or degenerative mechanisms is scarce. In these cases, some physiologic disturbance in the motor network may occur.

Etiologies for Dystonia

Idiopathic Dystonias

There are many known etiologies for dystonia, some of which are outlined in the following text. However, it is important to emphasize at the outset that the majority of cases are idiopathic, and often, a cause cannot be identified. The likelihood of finding a cause for dystonia depends on a number of factors including age at onset, family history, and nature of dystonia syndrome. A cause is more likely to be disclosed in early onset cases, especially if there is a family history. Such cases are relatively rare. In contrast, a cause is only rarely disclosed for the more common sporadic adult-onset dystonias, even after extensive diagnostic testing. For these cases, the etiology is thought to reflect a combination of genetic predisposition along with some environmental contingency.

The nature of the environmental contribution is not always apparent, although some risk factors have been identified. The best known risk factor involves highly repetitive movement, leading to a task-specific dystonia. Epidemiologic studies have identified a number of other potential risk factors, although a causal role has been difficult to establish. Women outnumber

men for many adult-onset focal dystonias such as cervical dystonia and blepharospasm. Some studies have identified prior trauma to the head or the body region affected with dystonia as a risk factor for dystonia. Dry or irritated eyes and exposure to bright light have been associated with blepharospasm. Viral or other types of laryngitis have been associated with laryngeal dystonia. Whether or not these environmental factors reflect a recall bias or they contribute to the development of dystonia remains unclear. The following text describes some of the more common dystonia syndromes that are most often idiopathic.

Cervical Dystonia

Cervical dystonia is the most common of all isolated dystonia syndromes. It is characterized by excessive involuntary contractions of muscles in the neck, leading to abnormal head postures and/or repetitive head movements (**Fig. 79.4**). Common patterns include torticollis (turning of the chin right or left), laterocollis (tilting of the ear toward one shoulder or the other), anterocollis (flexion of the chin toward the chest), and backward bending of the head (retrocollis). Less commonly, the entire head and neck may shift forward or laterally on the shoulders. Abnormal movements may be relatively tonic or more dynamic, occasionally with sudden, intermittent, and large-amplitude jerky movements of the head (spasmodic torticollis). On other occasions, movements may be lower in amplitude and regular, resulting in a head tremor. Neck and/or shoulder pain occurs in approximately two-thirds of patients.

Cervical dystonia may emerge at any age, but it is most common in adults >40 years of age. Two-thirds of cases are female. Most cases start insidiously with obvious worsening of symptoms over 3 to 12 months. In approximately 20% of cases, there is continued worsening over 5 to 10 years, with spread to nearby body regions such as the head, larynx, or upper limb.

Craniofacial Dystonia

Blepharospasm is characterized by excessive involuntary contractions of the muscles of the upper face, particularly the orbital portion of the orbicularis oculi and nearby muscles (**Fig. 79.5**). The most common manifestations are excessive blinking with superimposed spasms of eye closure bilaterally. A less common manifestation involves difficulty opening the eyes with no apparent spasms of the orbicularis oculi. This difficulty may develop following years of excessive blinking and spasms, or it may occur on its own. It has been labeled as *apraxia of eyelid opening*, although it may be a consequence of dystonia due to excessive contraction of the palpebral portion of the orbicularis oculi, preventing eyelid opening.

Blepharospasm may emerge at any age, but it is most common in adults >50 years of age. Two-thirds of cases are female. It usually begins insidiously, with irritating sensations in the eyes and excessive blinking preceding more obvious eye spasms. Approximately half of all patients will experience spread of excessive contractions to the oromandibular region over 5 years. Involvement of the lower face leads to grimacing or other movements (see **Fig. 79.5**). Involvement of the jaw leads to involuntary jaw opening, involuntary jaw closing, lateral deviation of the jaw, and/or jaw pain. Abnormal jaw movements are often

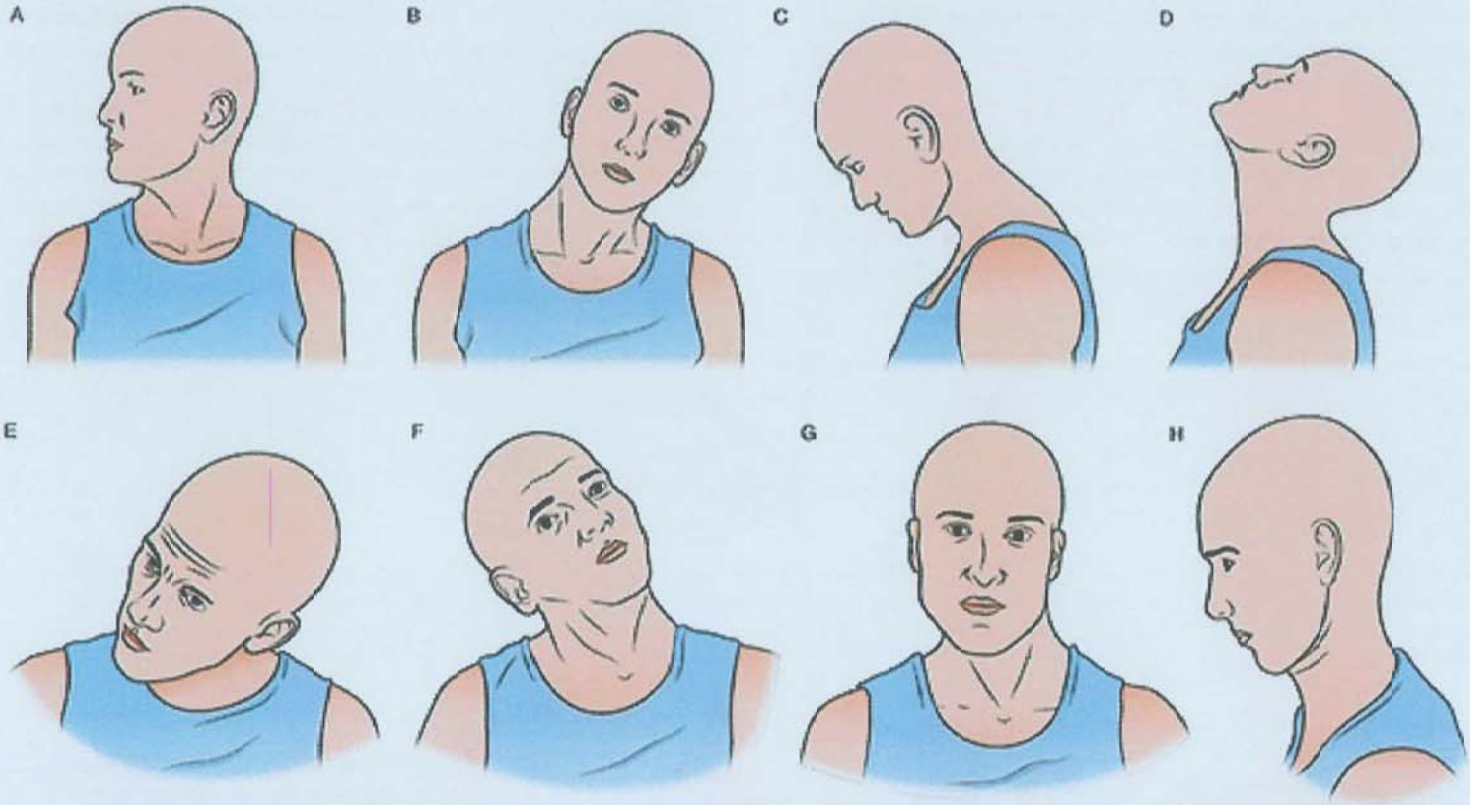

FIGURE 79.4 Cervical dystonia. Abnormal head postures seen in cervical dystonia include torticollis (**A**), laterocollis (**B**), anterocollis (**C**), and retrocollis (**D**). The majority of patients have various combinations of these abnormal postures. The common combination of laterocollis, torticollis, and anterocollis is shown in **E**. The combination of laterocollis, torticollis, and retrocollis is shown in **F**. Occasionally, the head and neck can move in opposing directions. The combination of right bending of the neck (laterocollis) and left bending of the head (laterocaput) is shown in **G**. The combination of backward extension of the neck (retrocollis) combined with forward flexion of the head (anterocaput) is shown in **H**.

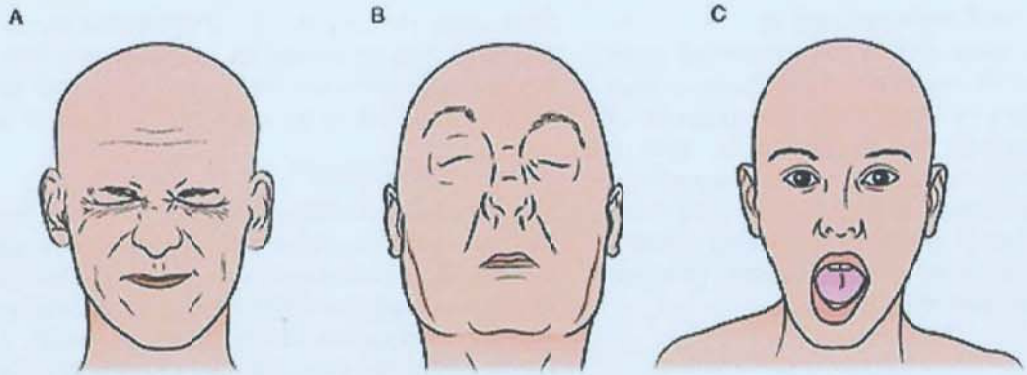

FIGURE 79.5 Craniofacial dystonia. **A:** The most common abnormality in blepharospasm involves spasms of the orbital portion of the orbicularis oculi with eyes squeezing tightly closed. **B:** Apraxia of eyelid opening involves spasms of the palpebral portion of the orbicularis oculi with no apparent squeezing of the eyes, although there often is compensatory activation of the muscles of the forehead during voluntary efforts to open the eyes. **C:** Involvement of the lower face with grimacing or other facial contortions occurs in approximately 50% of patients. Rarely, the jaw may also be involved with involuntary opening, closing, or lateral deviations.

task specific and triggered by chewing or speaking. The tongue may also be involved, with excessive protrusion, retraction, rolling, sideways movements, or other abnormal movements.

Limb Dystonias

In adults, upper limb dystonias are far more common than lower limb dystonias. They are typically task specific with the most common types being writer's cramp and musicians who play string or keyboard instruments (Fig. 79.6). When they lack task specificity, the possibilities of Parkinson disease or a Parkinson imitator disorder must be considered. Unlike other focal dystonias, the limb dystonias appear to affect men and women equally.

Limb dystonias may also started at any age but are more common in adults >40 years of age. Adult-onset limb dystonia may start out with high task specificity, such as inability to write a single letter or number. This specificity may then extend over time to include difficulty with most letters and numbers. Specificity may degrade further over time to include other tasks, such as using eating utensils or buttoning a shirt. In children, limb dystonias are more common, and there is a high risk of progression toward generalized dystonia.

Laryngeal Dystonia

Laryngeal dystonia is characterized by excessive contraction of muscles in the larynx. The most common manifestation involves the adductors of the vocal cords (adductor spasmodic dysphonia) with excessive closure of the cords leading to an intermittently strained and strangled voice, along with voice breaks when there is transient complete closure of the cords. The abductors of the vocal cords are less commonly involved (abductor spasmodic dysphonia), with excessive opening of the vocal cords leading to an intermittently strained but breathy voice, also with occasional voice breaks, where there is transient opening of the cords during phonation. The spasmodic dysphonias are task specific and triggered by speaking.

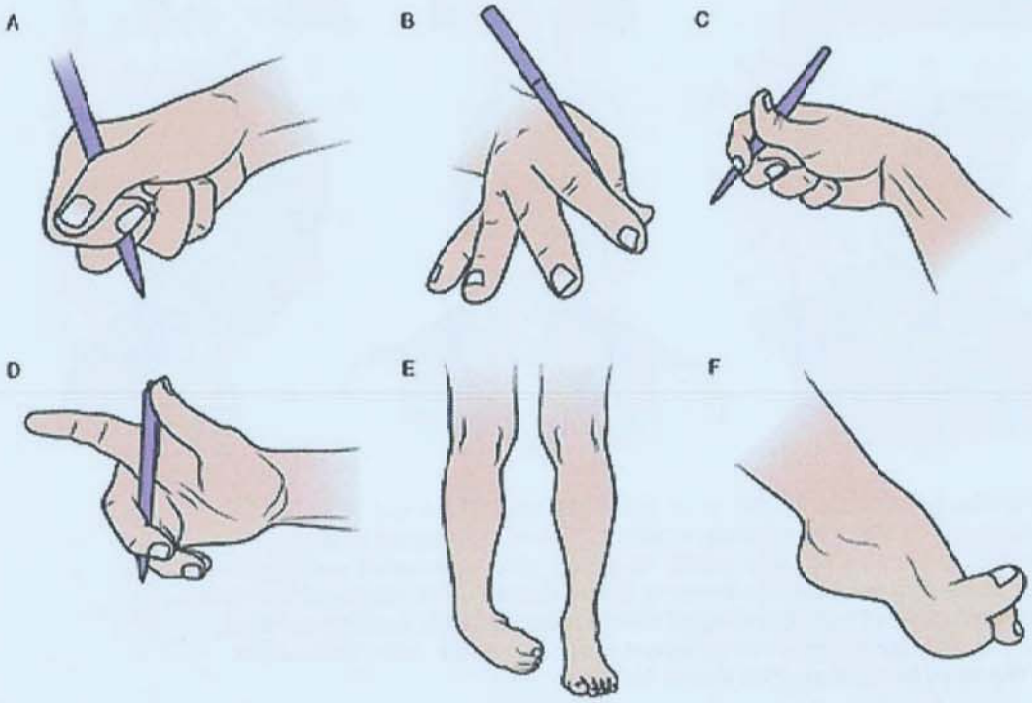

FIGURE 79.6 Limb dystonias. Abnormal postures in writer's cramp may involve various combinations of the fingers, wrist, or upper arm **(A-D)**. Abnormal postures may also involve the lower limb **(E)**. Extensor posturing of the great toe **(F)**, also known as the *striatal toe* or *dystonic toe*, is a form of dystonia that is often mistaken for the Babinski sign.

Rarely, patients may have both adductor and abductor spasmodic dysphonia combined. Another rare subtype of laryngeal dystonia is breathing dystonia, where there is dystonic closure of the vocal cords during inspiration, often with stridor. Other rare subtypes of laryngeal dystonia may mimic coughing, sneezing, or hiccups. Laryngeal dystonia is frequently accompanied by vocal tremor, which is expressed as regular oscillations of laryngeal muscles leading to audible oscillations of the voice.

Segmental and Multifocal Dystonias

As noted in the preceding text, most of the adult-onset focal dystonia syndromes begin insidiously with worsening over the first few weeks or months, followed by slower progression thereafter. Spread to a contiguous region (segmental dystonia) or a remote region (multifocal dystonia) is not uncommon. The rate of spread depends on the site of origin. The 5-year risk of spread is approximately 50% for blepharospasm in adults. This 5-year risk is 10% to 20% for cervical dystonia, laryngeal dystonia, and hand dystonias.

Truncal Dystonias

Truncal dystonias are uncommon. They include backward bending (opisthotonus), forward bending (camptocormia), and sideways bending (Pisa syndrome). Scoliosis may occasionally reflect a truncal dystonia. Opisthotonic posturing in a child often is a sign of an inherited metabolic disorder. Opisthotonus in an adult raises concern for a tardive syndrome. Camptocormia and Pisa syndrome in adults are most often seen in Parkinson disease or the Parkinson imitator syndromes, although these postural defects may be due to causes other than dystonia, such as myopathy. Generalized dystonia refers to truncal dystonia accompanied by at least two other body regions.

Acquired Dystonias

Dystonia may be acquired from many different processes (see Table 79.5). Dystonia resulting from structural damage to the nervous system may be caused by focal lesions, such as vascular insults (ischemic or hemorrhagic stroke) or space-occupying lesions (tumors or abscesses). One of the more common syndromes caused by lesions is cerebral palsy, which is most often caused by perinatal hypoxic-ischemic injury to the brain. Approximately 80% of children with cerebral palsy have dystonia, most often combined with spasticity and/or rigidity. One unusual aspect of dystonia caused by focal lesions is that symptoms sometimes do not emerge immediately following the lesion. Dystonia may develop over weeks or months, and it is sometimes delayed by many years.

Dystonia also may be acquired from exposure to toxins, illicit drugs, or medications. Toxin-induced dystonia typically emerges over days or weeks, often accompanied by basal ganglia damage that can be visualized by magnetic resonance imaging (MRI). One of the more common causes of acquired dystonia is exposure to medications that block dopamine receptors. This group of medications includes both classical and atypical antipsychotics as well as medications used for gastrointestinal discomfort such as metoclopramide and prochlorperazine. These drugs can cause two different dystonic syndromes, neither of which is associated with any obvious abnormality in routine clinical neuroimaging. Acute dystonic reactions emerge within a few minutes to an hour after exposure and are typically expressed as sudden and often jerky backward or sideways bending of the head, sometimes combined with tonic upward and/or horizontal deviation of the eyes. Forced version of the eyes is sometimes called *oculogyric crisis*. Treatment requires terminating the offending drug and temporary institution of anticholinergics and/or benzodiazepines. Tardive dystonia emerges usually after several months of exposure but may emerge after shorter durations. The typical appearance involves backward bending of the head and trunk, although involvement of the face and arms may also occur.

Some studies have linked head trauma with dystonia. Others have linked trauma to other parts of the body with dystonia that may then develop in the same region. This phenomenon is sometimes called *peripheral dystonia* and is often associated with pain in the same region. Approximately half of all patients with complex regional pain syndrome will have dystonic posturing of the affected body region.

Perhaps the most common of the acquired dystonias are the task-specific dystonias. Writing and typing predispose to writer's cramp or typist's cramp. Professional speakers are predisposed to laryngeal or oromandibular dystonia. Professional musicians are at risk for developing task-specific dystonias specific to their musical instruments. A wide array of tasks appears capable of provoking task-specific dystonias (Table 79.6). In most cases, the triggering task is highly repetitive, very precise, and often performed under some type of stress such as a time constraint or need for extreme precision. Whether task-specific dystonias are entirely acquired or reflect some interaction between repetitive motor behavior and innate variables remains to be determined.

Dystonia is rarely acquired as a result of infections of the nervous system. A variety of different organisms may be responsible, including viruses, bacteria, and others. In many cases, the pathomechanism involves direct invasion and injury of specific regions in the nervous system that cause dystonia. In other cases, the pathomechanism involves immunologic responses that indirectly damage the nervous system. For example, individuals with mycoplasma pneumonia rarely develop acute striatal necrosis during the convalescent period, a phenomenon that may reflect a delayed autoimmune mechanism. Dystonia may also result from autoimmune mechanisms with no apparent preceding infection or a manifestation of a paraneoplastic process.

Some of the more challenging syndromes are psychiatric disorders that mimic dystonia. Frank malingering (feigning dystonia for secondary gain) is relatively uncommon, but unintentional

TABLE 79.6 Examples of Some Task-Specific Dystonias

Work Related	Musicians
Typists	Drummers
Carpenters	Wind instrument players
Computer mousers	Keyboard players
Money counters	String instrument players
Painters	**Athletes**
Professional speakers	Bowlers
Tailors	Dancers
Surgeons	Darts throwers
Writers	Golfers
	Runners
	Tennis players

TABLE 79.7 Some Clues for Functional (Psychogenic) Dystonia

Clinical Feature	Psychogenic Dystonia	Nonpsychogenic Dystonia
Abrupt onset	Abnormalities often reach maximum severity in a short period of time, sometimes overnight.	Most have insidious progression, although some may have abrupt onset such as rapid-onset dystonia parkinsonism, acute dystonic reactions, and acute striatal necrosis.
Fixed abnormal postures	Posture is fixed and immobile, such as foot intorsion preventing walking, often from the outset.	Most are at least partially mobile, although fixed postures with contractures may occur in longstanding cases.
Change in body distribution	Abnormalities move from one area of the body to another.	Most follow a recurring pattern in the same body region, although spread to other regions may occur over months or years.
Change in type of movement	Dystonic-looking movements are sometimes replaced by other movement abnormalities such as slowing, tremor, jerking, or paresis.	Most are relatively patterned, although they may be position dependent or may combine slowness, tremor, and jerking.
Unexplained variation over time	Multiple remissions, sudden worsening or attacks of abnormal movements	Most are persistent, although they may wax and wane in severity; remissions may rarely occur, and paroxysmal phenotypes are recognized.
Suggestibility	Abnormal movements may be induced by talking about them.	Most are not suggestible, although talking about them may make them appear worse.
Intentional slowness	Movements are extremely slow and effortful when being evaluated but may appear normal at other times.	Movements may be slow, and action dystonia worsens with effort.
Nonorganic signs	Examples include functional blindness, functional sensory abnormalities, functional weakness, etc.	Functional signs are uncommon, although subjective nature of reporting can be misleading.

dystonia-like movements are common. The preferred names for these disorders have evolved over the years. In psychiatry, the *Diagnostic and Statistical Manual of Mental Disorders* (4th ed) used terms *somatoform disorder* or *somatization disorder*, but in *Diagnostic and Statistical Manual of Mental Disorders* (5th ed), the preferred terms included *conversion disorder* and *somatic symptom disorder*. Neurologists more frequently use terms such as *nonorganic dystonia* or *psychogenic dystonia* or *functional neurologic disorder*. There are several clues that point to the diagnosis of these disorders including abrupt-onset, relatively fixed, and immobile postures, changing distribution or type of abnormal movements, unexplained variation over time, "intentional" slowness, nonorganic neurologic signs, suggestibility, and others (**Table 79.7**). A history of psychiatric disorders or evidence for active psychiatric distress is helpful but not always evident. Although these clues are helpful, they are not foolproof, and diagnostic agreement is poor even among experts. However, the discrimination of these psychiatric disorders from other causes of dystonia is important because the treatment strategy is different.

Inherited Dystonias

By now, more than 100 genes have been linked with various dystonia syndromes. All together, these genes account for no more than 5% of cases, so other genetic or nongenetic contributions remain to be found. Only a small fraction of these genes typically cause isolated dystonia syndromes (**Table 79.8**). The remaining genes cause more complex syndromes that include other neurologic or medical problems (**Table 79.9**). However, most of the genes that usually cause combined dystonia syndromes may occasionally cause isolated dystonia, at least during early stages. This section summarizes some general principles. More details regarding the many specific inherited dystonia syndromes can be found in published reviews.

The increasing number of dystonia genes combined with advances in clinical diagnostic testing have stimulated revision of many traditional beliefs. For example, early studies emphasized that inherited isolated dystonias usually emerge first in childhood or adolescence. However, it is now recognized that some patients may present later during adulthood. The late-onset cases often have atypical manifestations. For example, pathogenic genetic variants in the *TOR1A* gene are typically associated with childhood-onset limb dystonia with progression to generalized dystonia. On the other hand, occasional cases develop adult-onset focal dystonia with minimal progression over time.

Another new trend has involved the diagnostic approach for the many combined dystonia syndromes. The traditional approach has emphasized the importance of delineating characteristic syndromes to guide diagnostic testing of specific genes. However, syndromes caused by different genes overlap considerably, and atypical syndromes are increasingly recognized. For example, pathologic genetic variants in the *ATM* gene are typically associated with ataxia-telangiectasia, where the most commonly recognized phenotype is ataxia and ocular telangiectasias, occasionally combined with mild dystonia. For occasional cases with *ATM* defects, dystonia may be the dominant or even the sole motor defect, sometimes without telangiectasias. Such atypical phenotypes are being increasingly recognized for many genes, making the syndromic approach to diagnostic testing increasingly challenging.

Another traditional belief has been that considering genetic causes for dystonia is important only when there is a family history. It is now better appreciated that de novo gene defects cause many sporadic cases, too, with no family history. The frequency at which sporadic cases occur depends on the gene. For some genes, up to 90% of cases are sporadic.

TABLE 79.8 Inherited Isolated Dystonias

Gene	Protein	Inheritance	Typical Age of Onset	Typical Body Distribution
ANO3	Anoctamin-3	Autosomal dominant with partial penetrance	Adulthood	Neck, with prominent tremor
CIZ1	Cip1-interacting zinc finger protein 1	Autosomal dominant with partial penetrance	Adulthood	Neck
COL6A3	α_3 Subunit of type VI collagen	Autosomal recessive	Early childhood	Neck, upper body
GNAL	G-protein subunit alpha L	Autosomal dominant with partial penetrance	Adult	Head, neck, upper body
THAP1	Thanatos-associated domain-containing apoptosis protein 1	Autosomal dominant with partial penetrance	Adolescence	Head, neck, upper body
TOR1A	TorsinA	Autosomal dominant with partial penetrance	Childhood	Upper or lower limbs, often generalized

For other genes, heritability is more obvious and less than 10% of cases are sporadic. In addition, many pathologic variants in dystonia genes are only partly penetrant, so identifying typical dominant or recessive patterns of inheritance can be a challenge. Finally, some genes are associated with very different phenotypes, even among members of the same family. As a result, identifying a clear pattern of inheritance is sometimes difficult.

One big surprise that has come from the advances in genetics has been the relevance of inherited causes for disorders traditionally considered to be acquired. For example, dystonia is common in cerebral palsy and may be the dominating feature. Cerebral palsy has been viewed for many years as a disorder that is acquired from perinatal brain injury, such as hypoxia/ischemia or hemorrhage. However, multiple studies have now demonstrated that up to 30% of cases diagnosed with cerebral palsy may have a genetic explanation.

Although each of the inherited dystonias is rare, a molecular diagnosis is becoming increasingly important for two major reasons. First, many patients move from one doctor to the next, seeking a definitive answer. This process is frustrating and expensive for both patient and clinician and has become known as the *diagnostic odyssey*. Second, there are increasing numbers of disorders for which specific treatments are available.

DIAGNOSIS

Approach to Clinical Evaluation

Patients with dystonia often complain that they have seen multiple doctors over many years prior to reaching a diagnosis. Even for the most common adult-onset focal dystonias, there is a

TABLE 79.9 Examples of Inherited Combined Dystonia Syndromes[a]

Syndrome	Phenotype	Typical Age at Onset	Some Responsible Genes	Notes
Dopa-responsive dystonia	Arm or leg dystonia with diurnal worsening each evening	Childhood through adolescence	*GCH1* is most common; less commonly *TH, SPR, PTS, PRKN*, or *PINK1*	Rare cases may emerge in adulthood; may be axial-dominant; often mistaken for cerebral palsy
Myoclonus-dystonia	Dystonia and myoclonus most often in neck or upper limbs	Childhood through adolescence	*SGCE, KCTD17, RELN*	Some cases may have myoclonus or dystonia alone; often alcohol-responsive
Dystonia-parkinsonism	Progressive dystonia combined with parkinsonism	Childhood through young adulthood	*ATP1A3, GCH1, ATP7B, SLC30A10, SLC39A14*	Includes also most of the NBIA disorders
Dystonia-ataxia	Dystonia combined with ataxia	Childhood through older adulthood	*ATM, CTX, NPC1, NPC2, POLG*, many SCA disorders	Includes also many SCA disorders
Dystonia with MRI evidence of heavy metal accumulation	Slowly progressive dystonia and parkinsonism	Childhood through young Adulthood	*ATP7B, SLC30A10, SLC39A14*	Includes many of the NBIA disorders
Rapid-onset dystonia	Acute or subacute onset of dystonia, often involving bulbar muscles, often combined with parkinsonism	Childhood or adolescence	*ATP1A3, GCHD, MUT, PCCA, PCCB, SLC19A3*	Often triggered by physical or psychological stress
Paroxysmal dyskinesias	Sudden onset of mixed abnormal movements with dystonia superimposed on a normal or near-normal baseline	Childhood through adolescence	*PRRT2, MRI, SLC2A1*	Often mistaken for epilepsy

Abbreviations: MRI, magnetic resonance imaging; NBIA, neurodegeneration with brain iron accumulation; SCA, spinocerebellar ataxia.
[a]This is a partial list of some combined dystonia syndromes. More complete lists can be found in prior reviews.

delay of 2 to 10 years from the onset of symptoms to diagnosis. The delay is often longer for less common types of dystonias. The main reason for the delay is poor recognition of the many different manifestations of dystonia. The diagnosis is easy for the most severe manifestations where multiple regions of the body are affected by twisting movements and abnormal postures. The diagnosis takes longer for less severe or less common syndromes.

Once a diagnosis of dystonia is made, it is important to delineate the subtype. Many diagnostic algorithms have been published, each focusing on certain subgroups of dystonia. Universal diagnostic algorithms are difficult to use because of the wide variety of clinical manifestations and etiologies. The diagnostic approach must be customized for each patient, but there are some helpful general principles.

The diagnostic approach starts with a careful clinical history and examination aimed at complete delineation of the dystonia syndrome, with attention to each of the factors relevant to clinical classification: age at onset, body distribution, temporal evolution, and any associated findings. Delineating the clinical syndrome helps to guide the laboratory workup and treatment. The application of additional tests is summarized in the following text.

Diagnostic Imaging

The value of clinical imaging depends on the nature of the dystonia syndrome. The most common dystonia syndromes are the adult-onset focal dystonias that arise after 40 years of age. They include cervical dystonia, blepharospasm, task-specific hand dystonia, and laryngeal dystonia. In these cases, brain imaging is usually unrevealing, so it often is not conducted. For laryngeal dystonia, imaging the vocal apparatus via laryngoscopy can be useful for excluding structural defects that may cause voice problems mimicking dystonia. For adult-onset hemidystonia or generalized dystonia, brain MRI is important to exclude structural causes. Brain MRI also is valuable in adults when the dystonia syndrome includes other features such as ataxia or parkinsonism and in adults with rapid worsening of symptoms. Imaging of dopamine systems is not usually conducted unless there is concern that dystonia is an early manifestation of Parkinson disease.

For dystonias that begin in younger individuals (<40 y of age), brain imaging is valuable for virtually all cases because it can guide further diagnostic workup. For example, a history of difficult birth together with periventricular leukomalacia on MRI raises concern for cerebral palsy. The discovery of white matter abnormalities may raise concern for an autoimmune disorder or an inherited disorder of white matter. Lesions of the basal ganglia can point a mitochondrial disorder, neurodegeneration with brain iron accumulation, or an immune process. These neuroimaging signs are useful when they are found, but for many patients with dystonia, imaging may be normal, or there may be abnormalities that are nonspecific. In these cases, additional laboratory investigations may be required.

Routine Laboratory Investigations

For all age groups, routine hematology or chemistry studies are only rarely helpful. However, specific tests may be useful in certain circumstances. Similar to imaging studies, the types of laboratory studies depend on the nature of dystonia syndrome. For example, testing serum ceruloplasmin is mandatory for all early-onset dystonias to rule out Wilson disease because it is treatable. On the other hand, ceruloplasmin is rarely useful in dystonia that emerges in older adults. In older adults, ceruloplasmin is evaluated only when there are other features that raise suspicion for Wilson disease such as coexisting liver disease or corneal Kaiser-Fleischer rings.

Other specific tests may also be warranted. Examples include blood acanthocytes (neuroacanthocytosis) or autoantibodies (autoimmune and neoplastic disorders). Cerebrospinal fluid studies are sometimes advocated to rule out neurotransmitter disorders with dystonia, such as dopa-responsive dystonia. However, cerebrospinal fluid studies are not routinely conducted for patients with dopa-responsive dystonia for a number of reasons. These include the simpler approach of levodopa challenge, the requirement for lumbar puncture, need for special preservative-containing tubes, which may not be available in the clinic, uncertain sensitivity and specificity for various subtypes of dopa-responsive dystonia, and availability of more definitive blood-based gene tests to identify most subtypes.

Genetic Testing

The many recent advances in genetic technology have led to a nearly constant evolution of diagnostic testing strategies for all inherited neurologic disorders. Different experts often recommend different testing strategies, although there are some common principles.

Genetic testing is not usually conducted when dystonia emerges in older adults (>40 y of age), unless there are affected family members. Genetic testing can also be useful in adults when additional clinical features point to a known inherited syndrome.

For dystonias that begin in younger individuals (<40 y of age), genetic testing can be guided by the recognition of specific "red flags" or a syndromic *pattern* that points to a specific disorder or group of disorders. A good example of a red flag is the corneal Kayser-Fleischer ring of Wilson disease. An example of a syndromic pattern might be Lesch-Nyhan disease where this is a combination of generalized dystonia, intellectual disability, self-injurious behavior, and elevated serum uric acid. In both of these disorders, the clinical syndrome is relatively specific for a single disorder. As a result, targeted laboratory testing may be conducted in these situations. Although red flags and characteristic syndromes are useful when they are found, they are lacking for many types of dystonia. In addition, red flags may be absent when they should be present, and atypical syndromes are common.

When the clinical picture is not helpful to narrow the scope of diagnostic tests, there has been an increasing tendency to go directly to large dystonia gene panels or clinical exome sequencing. It is important to avoid serial genetic testing, a strategy that involves predicting the most likely responsible gene and following a negative result with sequential testing until the answer is found. This strategy is more expensive than ordering a whole panel, and it is frustrating to patients and families. Similar to other early-onset neurologic disorders (eg, epilepsy, intellectual disability, ataxia), currently available gene panels or clinical exome sequencing generate a clinically useful result in about a third of all cases in studies of large undiagnosed cohorts of subjects with dystonia. If a gene panel is used, it is important to know what it includes. Different diagnostic testing labs include different numbers of genes from only a few to more than 100.

Even when a diagnostic result cannot be found, it remains important to follow patients over time. Patients may develop additional problems that make the diagnosis more obvious, or previously obtained exome results may be reinterrogated for newly discovered dystonia genes. For example, approximately 10% to 15% of patients with Parkinson disease may present with focal dystonia of an arm or leg, closely resembling a sporadic adult-onset isolated limb dystonia. However, signs of parkinsonism may develop within years or months, making the diagnosis of Parkinson disease more obvious. In younger individuals, this type of progression may suggest an inherited disorder that combines dystonia and parkinsonism.

MANAGEMENT

There are many treatment options for the dystonias. They include oral medications, botulinum toxin injections, surgical interventions, and others. Each of these options is described further in the text that follows. The broad strategy for how these options may be used for different types of dystonia is shown in Figure 79.7. This schematic provides only a general guide, and treatments must be individualized.

In recent years, there has been increasing enthusiasm for providing treatment recommendations from "evidence-based medicine." The processes for evaluating evidence for specific treatments have been standardized, and reaching the highest levels of evidence for treatment recommendations requires the availability of data from multiple large randomized and placebo-controlled clinical trials. For example, "level 1" evidence requires at least one large properly designed randomized clinical trial. The process for delineating recommendations was developed for common disorders, not rare disorders. For many reasons, multiple large clinical trials are rarely conducted for rare disorders, including the dystonias. As a result, many established treatment options for dystonia fail to reach the highest levels of evidence for their recommendation.

For example, one of the most reliably effective treatments across all subtypes of dystonia is levodopa for dopa-responsive dystonia. However, there are no large randomized clinical trials proving the efficacy of levodopa for any form of dystonia.

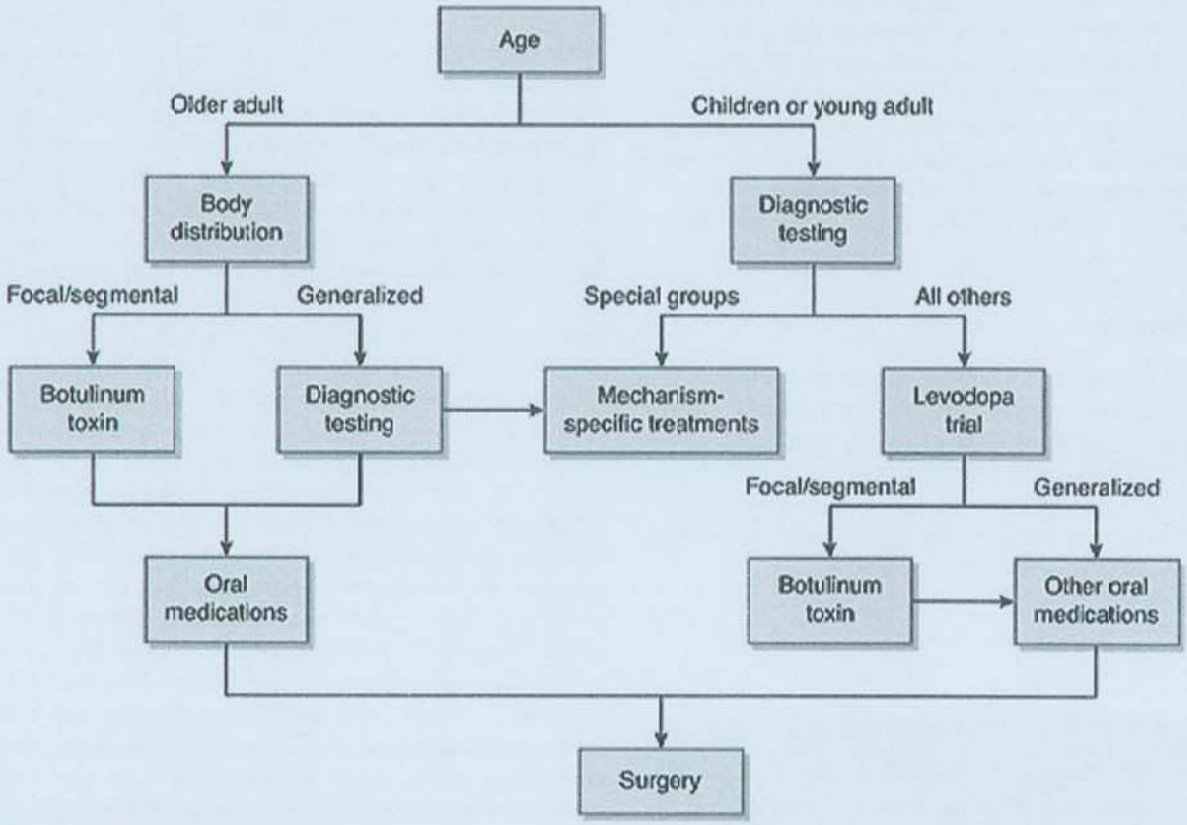

FIGURE 79.7 Basic algorithm for management. This algorithm provides a basic strategy for the approach to most patients with dystonia. The actual management should be done on a case-by-case basis because exceptions to this plan may occur. Management depends on the clinical diagnostic evaluation because the subtype of dystonia determines the optimal treatments strategies. Age plays a key starting role. For children, diagnostic testing is important because there are special populations with specific treatments (see **Table 79.10**). All other children should have a trial of oral levodopa to rule out dopa-responsive dystonia. The use of other oral agents or feasibility of using botulinum toxin will depend on the body distribution of dystonia. For most adults, dystonia is idiopathic, and the treatment approach depends more on body distribution. For adult-onset focal dystonias, botulinum toxins are the treatment of first choice. Oral medications may play an adjunctive role, and those who have unsatisfactory responses proceed to surgery. For adults with generalized dystonia or dystonia combined with other neurologic problems, laboratory testing may be more valuable for disclosing a treatable cause.

Therefore, this treatment does not reach criterial for level 1 evidence. In this situation, "evidence-based medicine" becomes "evidence-limited medicine," and recommendations must be made on the basis of good clinical practice. With these caveats in mind, there is level 1 evidence for the use of specific botulinum toxins for patients with cervical dystonia and blepharospasm. There also is level 1 evidence for the use of DBS for patients with generalized and segmental dystonia as well as for patients with cervical dystonia who fail botulinum toxin. A summary of treatment studies summarizing levels of evidence can be found in the suggested reading list at the end of this chapter.

Counseling

Counseling plays an important role for all patients with dystonia. Except for the rare subtypes of dystonia with specific treatments described in the preceding text, patients must be prepared for a trial and error approach to finding the best solutions. Customization of the treatment plan can take several months for oral agents, botulinum toxins, and surgery. Frustration can be avoided if patients are adequately informed in advance, and patients should be prepared, so they do not abandon treatment too early.

In addition to frustration associated with the time required to work out optimal treatments, there is a high frequency of psychiatric comorbidities for many types of dystonia. The adult-onset focal dystonias are associated with high rates of depression, anxiety, and social withdrawal. Specific psychiatric comorbidities are even more common in certain genetically determined subtypes of dystonia, such as the myoclonus-dystonia syndrome associated with *SGCE* mutations. It is important to ask about these problems and provide guidance where needed.

Oral Medications

There are no U.S. Food and Drug Administration-approved drugs specific for the treatment of any type of dystonia. Large placebo-controlled and double-blinded clinical trials are scarce. However, many drugs have been empirically found to be helpful (Table 79.10). These have been summarized in several evidence-based, or expert-consensus reviews. The most commonly used drugs are summarized in text that follows.

TABLE 79.10 Some Oral Medications for Dystonia

Medication Type	Typical Examples
Anticholinergics	Benztropine, biperiden, ethopropazine, orphenadrine, procyclidine, trihexyphenidyl
Dopaminergics	Levodopa, deutetrabenazine, tetrabenazine, valbenazine
GABAergics	Alprazolam, baclofen, chlordiazepoxide, clonazepam, diazepam
Muscle relaxers	Carisoprodol, chlorzoxazone, cyclobenzaprine, metaxalone, methocarbamol, orphenadrine
Miscellaneous	Carbamazepine, cannabidiol, cyproheptadine, gabapentin, lithium, mexiletine, nabilone, riluzole, tizanidine, zolpidem

Drugs Targeting Acetylcholine Pathways

Drugs that suppress brain acetylcholine signaling can be useful for many types of dystonia, regardless of the underlying cause. For example, anticholinergics can be helpful for inherited childhood-onset generalized dystonias as well as sporadic adult-onset focal dystonias. Although trihexyphenidyl is commonly prescribed, other anticholinergics are also effective. Despite their broad application, efficacy is limited and side effects can be problematic because unusually high doses are sometimes required.

Common side effects for adults include dry mouth or dry eyes, constipation or urinary retention, blurry vision or worsening of narrow-angle glaucoma, and depression. In older adults, memory loss and confusion are not uncommon. It is said that children tolerate high doses better than adults. However, it is important to monitor school performance because side effects may cause more subtle effects on behavior or cognition. In some children, anticholinergics may worsen abnormal movements.

Drugs Targeting Dopamine Pathways

Drugs that augment dopamine signaling can be useful for selected subtypes of dystonia. Levodopa is usually remarkably effective for children with dopa-responsive dystonia. Many children respond within a few days to small doses, for example, two tablets of 25/100 of carbidopa/levodopa daily. However, it is a common error to assume that all children respond quickly to such small doses. Higher doses and longer durations of treatment are required in approximately 10% to 20% of cases. Current recommendations call for titrating the levodopa total amount to 20 mg/kg per day split across three to four daily doses, given for at least 1 month. Levodopa also is usually effective for dystonia in juvenile-onset Parkinson disease. It may also be useful for dystonia that occasionally occurs in spinocerebellar ataxia type 3, ataxia-telangiectasia, and several other inherited dystonias. However, levodopa is not generally effective in more common adult-onset isolated focal or segmental dystonias. In view of these observations, a levodopa trial is not generally conducted for adult-onset dystonias, but it is mandatory for dystonia that begins in children and young adults.

Conversely, drugs that reduce dopamine signaling may be helpful for other types of dystonia. The reason that drugs augmenting or reducing dopamine signaling may be beneficial for different types of dystonia is not clear but probably reflects different pathologic processes underlying different types of dystonia. Drugs that deplete dopamine stores (eg, tetrabenazine, deutetrabenazine, valbenazine) may reduce symptoms in tardive dystonia. In the past, dopamine receptor antagonists were sometimes offered to patients with dystonia. This class of medications is no longer encouraged because side effects may include acute dystonic reactions or tardive dystonia. In a patient who already has dystonia, worsening symptoms can cause confusion regarding progression of the underlying condition versus superimposed side effects.

Drugs Targeting γ-Aminobutyric Acid Pathways

Drugs that amplify γ-aminobutyric acid signaling can also be useful for many types of dystonia regardless of underlying cause. The most commonly used are the benzodiazepines such as clonazepam and alprazolam. These drugs must be used with caution because they may be habit-forming, and abrupt discontinuation

can lead to withdrawal reactions. Typical side effects include drowsiness, impaired memory and concentration, imbalance, and depression.

Baclofen is most often used in childhood-onset dystonias that are combined with spasticity. High doses are often required, and typical side effect may include dizziness, altered mentation, and sometimes loss of muscle tone. When side effects become limiting, baclofen can be delivered intrathecally via implanted minipumps. Abrupt discontinuation or pump failures can cause severe withdrawal reactions that include seizures and altered mental status. Oral baclofen is sometimes also prescribed for more common adult-onset dystonias, although efficacy is limited in most cases.

Miscellaneous Drugs

Because the core problem in dystonia involves excessive muscle contractions, patients often request treatment with "muscle relaxants." This category has drugs with varied mechanisms of action such as baclofen, benzodiazepines, carisoprodol, chlorzoxazone, cyclobenzaprine, metaxalone, methocarbamol, orphenadrine, and many others. These medications can sometimes be useful for patients who have pain from muscle spasms.

The literature contains numerous anecdotal and uncontrolled reports of other drugs. They include amphetamines, cannabis-related products such as cannabidiol oil, cyproheptadine, gabapentin, lithium, mexiletine, nabilone, riluzole, tizanidine, zolpidem, zonisamide, and others. These medications are not widely used because experience is limited.

Special Populations

There are highly effective therapies for some subtypes of dystonia (Table 79.11). Although all of these treatable dystonic disorders are rare, they should not be missed because treatment can be life-altering.

For example, there are several disorders where dystonia results from the accumulation of a substance that is toxic to the nervous system. Patients with Wilson disease respond to treatments that reduce copper stores, and patients with disorders of manganese transport respond to treatments that reduce manganese. Other disorders respond to supplementation of the diet with vitamins or other supplements, such as biotin-thiamine responsive basal ganglia disease. Some disorders respond at least in part to avoidance of known triggers or specific dietary modifications.

In addition, there are several disorders that respond to specific medications targeting specific mechanisms. The best known is dopa-responsive dystonia, which responds to levodopa and other strategies that augment dopamine levels. Paroxysmal kinesigenic dyskinesia often responds to low doses of carbamazepine or related anticonvulsants. Alcohol is beneficial in the myoclonus-dystonia syndrome, but it is not usually recommended as routine therapy because of the risk for alcohol dependence.

Botulinum Neurotoxins

Injections of botulinum neurotoxins (BoNT) provide the treatment of first choice for many forms of dystonia. The use of BoNT is supported by multiple double-blind, randomized, placebo-controlled trials, and several evidence-based reviews have been published. Several BoNT formulations are available, and there are numerous articles that summarize their similarities and differences (Table 79.12). There also are numerous resources that describe their applications in various disorders. This section provides a summary of their more common uses and caveats.

Applications

For cervical dystonia, BoNT suppresses abnormal head and neck movements, reduces pain from neck muscle pulling, and improves quality of life. Improvements are typically seen 2 to 7 days following injection, and benefits last for an average of 12 weeks. The first treatment usually begins with a conservative dose, which must be titrated upward with customization of the distribution of muscles injected over 2 to 3 treatment cycles. Therefore, it is important to caution patients that this process may take several months. Good results may be achieved in the majority of patients with cervical dystonia, but some patients are more difficult to treat than others. Subtypes that are more difficult to treat include patients with predominant anterocollis, patients with prominent head tremor, and long-standing abnormal postures that may be accompanied by contractures.

For blepharospasm, BoNT suppresses excessive blinking and orbicularis oculi muscle spasms, reduces vision-related disability, and improves overall quality of life. Good results can be achieved in the majority of patients with blepharospasm. Blepharospasm patients who develop apraxia of eyelid opening are more difficult to treat, unless the palpebral muscles are injected. Patients who develop lower facial muscle spasms also are more challenging to treat because muscles around the mouth are very sensitive and there is a risk for loss of smile or facial asymmetry, drooling, slurred speech, or lip biting. Similar to cervical dystonia, benefits in blepharospasm emerge within a few days and last for an average of 12 weeks.

BoNT is also widely used for laryngeal dystonia and has been shown to reduce abnormal voice breaks and the effort associated with speaking. The abductor spasmodic dysphonia subtype is more challenging to treat than the adductor spasmodic dysphonia subtype. BoNT may also be used for other focal dystonias including oromandibular dystonia, upper or lower limb dystonias, and truncal dystonia. BoNT can be helpful for segmental and multifocal dystonia too, but feasibility becomes increasingly challenging as the number of muscle groups affected increases. Nevertheless, BoNT can be useful even in generalized dystonia, by targeting the regions that are most affected. For example, the lower limbs can be targeted in patients with generalized dystonia to alleviate pain and long-term consequences of contractures.

Contraindications and Side Effects

Contraindications to BoNT include neuromuscular disorders that cause weakness, such as myasthenia gravis, Eaton-Lambert syndrome, or motor neuron disease. The contraindications are not absolute, and these patients may benefit from BoNT with proper dose adjustments.

In experienced hands, side effects from BoNT injections are usually minor and transient. Short-term side effects depend on the region injection. For cervical dystonia, these may include dysphagia, head drop, and dry mouth. Side effects of BoNT treatment in blepharospasm may include ptosis, dry or irritated eyes, facial asymmetry, and rarely diplopia. Incomplete eyelid closure may also occur. If the eyes remain partly open while sleeping at night, corneal drying and permanent corneal scarring can occur. Transient voice hoarseness is a common side effect of BoNT treatment of laryngeal dystonias, sometimes with dysphagia.

TABLE 79.11 Treatable Inherited Dystonias

Disorder	Gene	Typical Age of Onset	Typical Clinical Features	Treatment
Abetalipoproteinemia (Bassen-Kornzweig)	*MTTP*	Childhood to early adulthood	Progressive ataxia, chorea, dystonia (often oromandibular), seizures, acanthocytosis, retinitis pigmentosa, fat malabsorption	Early treatment with vitamin E and reduced fat diet can prevent or reduce symptoms.
Aromatic amino acid decarboxylase deficiency	*AADC*	Infancy	Motor delay, hypotonia and dystonia, oculogyric crises, autonomic dysfunction	Dopamine agonists and monoamine oxidase inhibitors can partly reverse symptoms in some cases.
Ataxia with vitamin E deficiency	*TTPA*	Childhood to early adulthood	Ataxia, visual loss, neuropathy; occasional patients present instead with dystonia	Early treatment with vitamin E can prevent or reduce symptoms.
Biotin-thiamine responsive basal ganglia disorder	*SLC19A3*	Childhood	Encephalopathic crisis with generalized dystonia	Biotin and thiamine can reverse or prevent symptoms.
Biotinidase deficiency	*GTD*	Infancy	Encephalopathy, motor delay, dystonia, seizures, visual and auditory impairment, skin rash	Early treatment with biotin can prevent or reduce symptoms.
Cerebral folate deficiency	*FLR1, SLC46A1*	Early childhood to adolescence	Developmental delay, ataxia, dystonia, seizures, neuropsychiatric disturbances	Folinic acid can prevent or reduce symptoms.
Cerebrotendinous xanthomatosis	*CYP27A*	Late childhood to adulthood	Ataxia, spasticity, dementia, dystonia, myoclonus, tendon xanthomas	Chenodeoxycholic acid may prevent progression or reverse some features.
Cobalamin deficiencies (subtypes A-G)	Multiple	Infancy	Encephalopathy, motor delay, ataxia, spasticity, dystonia, seizures, bone marrow abnormalities	Cobalamin derivatives and/or protein restriction can mitigate symptoms.
Coenzyme Q10 deficiency	Multiple	Any age	Varied phenotypes of progressive ataxia or encephalopathy, sometimes with dystonia	Coenzyme Q10 can prevent or reduce symptoms.
Cerebral creatine deficiency (type 3)	*GAMT, AGAT*	Infancy	Global delay, myopathy, generalized dystonia	Creatine ± arginine restriction can mitigate symptoms.
Dopa-responsive dystonia (classic)	*GCH1*	Early childhood to late adulthood	Dystonia often combined with parkinsonism	Levodopa can reverse symptoms.
Dopa-responsive dystonia (complicated)	*TH, PTPS, SPR*	Infancy to adolescence	Dystonia often combined with parkinsonism, oculogyric crises, autonomic disturbances	Levodopa, 5-hydroxytryptophan, and/or tetrahydrobiopterin can completely or partly reverse symptoms.
Dystonia with brain manganese accumulation	*SLC30A10, SLC39A14*	Childhood	Progressive dystonia with parkinsonism, liver disease, polycythemia	Chelation therapy can prevent or at least partly reverse symptoms.
Galactosemia		Childhood to early adulthood	Ataxia, tremor, lactose intolerance, sometimes with mild dystonia	Lactose restriction can prevent or mitigate symptoms.
GLUT1 deficiency	*SLC2A1*	Childhood to adolescence	Developmental delay, seizures; sometimes paroxysmal exertional dystonia	Ketogenic diet or triheptanoin can prevent or reduce symptoms.
Glutaric aciduria (type 1)	*GCDH*	Early childhood to early adulthood	Developmental delay with encephalopathic crisis and generalized dystonia	Avoiding or treating intercurrent illness with lysine restriction can prevent encephalopathic crises.
Homocystinuria	*CBS*	Childhood	Neurocognitive dysfunction, myopia, ectopic lens; sometimes generalized or paroxysmal dystonia	Methionine restriction prevents most symptoms.
Maple syrup urine disease	*BCKDHA, BCKDHB, DBT*	Childhood	Intermittent encephalopathy with ataxia; sometimes with focal or paroxysmal dystonia	Leucine restriction ± thiamine can prevent or mitigate symptoms.
Methylmalonic aciduria	*MUT*	Childhood	Developmental delay, renal insufficiency, pancytopenia, encephalopathic crisis with generalized dystonia	Avoiding or treating intercurrent illness with protein restriction can prevent encephalopathic crises.
Molybdenum cofactor deficiency (sulfite oxidase)	*MOCS1*	Adolescence	Developmental delay, encephalopathy, seizures, rare patients present with dystonia and parkinsonism	Cyclic pyranopterin monophosphate can prevent symptoms.
Niemann Pick (type C)	*NPC1, NPC2*	Early childhood to early adulthood	Dementia, ataxia, spasticity, seizures, supranuclear gaze palsy; sometimes with progressive generalized dystonia	*N*-butyl-deoxynojirimycin (miglustat) can prevent or mitigate some symptoms.

TABLE 79.11 Treatable Inherited Dystonias *(continued)*

Disorder	Gene	Typical Age of Onset	Typical Clinical Features	Treatment
Propionic aciduria	*PCCA, PCCB*	Early childhood to adolescence	Developmental delay, encephalopathic crisis with generalized dystonia	Avoiding or treating intercurrent illness with protein restriction can prevent encephalopathic crises.
Pyruvate dehydrogenase deficiency	Multiple genes	Infancy	Progressive generalized or paroxysmal dystonia	Thiamine, ketogenic diet, dichloroacetate can mitigate symptoms.
Rapid-onset dystonia—parkinsonism	*ATP1A3*	Early childhood to late adulthood	Psychomotor delay, encephalopathic crisis with bulbar or generalized dystonia	Avoiding or treating intercurrent illness can prevent encephalopathic crises.
Wilson disease	*ATP7B*	Early childhood to late adulthood	Liver disease, Kayser-Fleischer rings, progressive dystonia, cognitive impairment, neuropsychiatric abnormalities	Zinc; tetrathiomolybdate can prevent or reduce symptoms.

Occasionally, there are systemic side effects from location injections, such as a flu-like syndrome with fatigue and myalgias.

There do not appear to be any consistent long-term side effects, even after decades of treatment. Muscle atrophy is a common side effect of BoNT treatment, but it is not permanent. Many patients may develop detectable antibodies to BoNT, although a poor correlation between antibodies and responses has questioned their clinical significance. The development of resistance to therapy from immune mechanisms is rare with current preparations of BoNT. When patients have decremental responses to therapy or appear to stop responding entirely, alternative mechanisms must be considered before concluding that they are resistant.

Surgical Treatments

There are several surgical treatment options, and these can have an enormous impact on some of the most severely affected patients with dystonia. DBS has been the most extensively studied, and there are numerous reviews describing methods, patient selection, outcomes, and side effects. Procedures that involve making focal brain lesions also remain useful for some cases. In some cases, permanent destruction of peripheral nerves or muscles can be a viable option. This section provides a brief overview of the main issues to consider when counseling or referring patients for surgical options.

Deep Brain Stimulation

DBS involves the chronic implantation of a device for low-level continuous stimulation of specific brain targets. The impulse generator is usually implanted under the clavicle or sometimes in the abdomen. It is connected to subcutaneous wires that are tunneled to specific brain targets. The most common target is the internal segment of the globus pallidus, although other targets such as the subthalamic nucleus and the thalamus are sometimes used. Chronic stimulation results in reduced dystonic movements, reduced pain, and improved quality of life.

DBS is effective for numerous types of dystonia, but not all types. As a result, a careful clinical diagnostic evaluation is critical for selecting patients most likely to respond. Dramatic improvements are reliably seen for some etiologies, such as early-onset dystonia associated with *TOR1A* or tardive dystonia acquired from neuroleptic exposure. However, DBS is ineffective for other etiologies, such as rapid-onset dystonia parkinsonism associated with *ATP1A3* and cases of cerebral palsy with imaging evidence of significant brain injury. Certain clinical features can also predict outcomes. Dynamic movements in dystonia seem to respond well, whereas tonic postures or fixed contractions may not. Isolated dystonia syndromes respond more reliably than more complex syndromes that may combine spasticity or other neurologic defects. Better responses are seen for patients with shorter disease durations, compared with those who have had dystonia for decades. Some experts believe that better outcomes are more reliably seen with younger patients, although patients of any age may respond, and those who are very young typically experience higher rates of surgical complications.

Following surgical implantation, it is important to have ready access to teams that are experienced in managing the stimulation parameters. Many patients do not experience immediate benefits, and stimulator adjustments may be required for 3 to 12 months for optimal effects. Overall, the long-term outcomes for DBS surgery are very good, with benefits lasting for many years. However, return visits should be anticipated every year to verify that the device is working optimally and assess the potential need for battery replacement.

Complications can include both acute and long-term problems. There is a small risk of acute complications related to

TABLE 79.12 Most Commonly Used Botulinum Toxins[a]

Characteristic	AbobotulinumtoxinA	IncobotulinumtoxinA	OnabotulinumtoxinA	RimabotulinumtoxinB
Preparation supplied	Freeze dried	Powder	Vacuum dried	Liquid
Dose sizes (units)	300; 500	50; 100	100; 200	2,500; 5,000; 10,000
Storage conditions	Refrigerate	Room temperature	Refrigerate	Refrigerate
Approximate dose equivalents	2.5-3.0	1.0	1.0	40

[a]As the first US Food and Drug Administration–approved botulinum neurotoxin, onabotulinumtoxinA was defined as having a strength of 1.0. The approximate dose equivalents of the other preparations are shown relative to the strength of onabotulinumtoxinA.

surgery such as infection of the surgical sites or hemorrhagic stroke relating to implantation of deep electrodes. There also is a risk of stimulation-dependent side effects if the electrodes are too close to nearby structures such as the corticospinal pathways. Long-term complications include unexpected stimulator failure, lead fracture, lead migration, and infection of the equipment. In one particularly thorough study, 47 patients with *TOR1A*-associated dystonia were followed for more than 10 years. During this period, 8.5% experienced equipment failures that required reoperation and 8.5% experienced infections of the equipment that sometimes required its removal. Another 4.3% required second operations to reposition electrodes that had migrated or were found to be in suboptimal locations following surgery.

There have been several important technological advances in DBS in recent years. These include the development batteries with longer life spans or those that can be recharged, smaller impulse generators that may be more appropriate for younger children and very thin adults, electrodes that can be controlled more precisely, and adaptation of stimulation to specific physiologic signals. Overall, DBS is a valuable therapy that can have a huge impact on certain patients with dystonia. It should be provided by multidisciplinary centers that have experience with the latest technologies, experience in selecting the right patients, and experience with managing stimulator settings and complications.

Procedures Involving Focal Ablation

Decades ago, neurosurgeons often provided focal lesions of various parts of the brain for dystonia. Outcomes were unreliable, and side effects were often permanent. After DBS became available, it rapidly became more popular, because it was reversible and adjustable. However, focal ablations have again become popular for several reasons.

First, experience has shown that small lesions of the thalamus can be reliably effective for some focal dystonias, particularly task-specific dystonias involving the hand. The complication rates are very low, and there are few long-term side effects. Second, there are circumstances where lesions may be preferable over DBS. They include particularly young or thin adults who want to avoid the cosmetic consequences of DBS, individuals who prefer to avoid the long-term requirements for lifelong management of implanted equipment, patients who may be at increased risk for infection, patients with progressive degenerative disorders requiring a palliative procedure, and individuals who live far from centers with expertise in DBS.

There also has been growing interest in focused ultrasound, which can be used to make focal brain lesions by rapid local heating of tissue. This method has been promoted as "noninvasive" because it does not carry risks associated with making an incision and passing an electrode through the brain. However, the size of the lesion made with ultrasound can be more difficult to control because it depends on many factors including target location and characteristics of the skull. The durability of the effect has also come into question, as many patients experience reemergence of symptoms after several months. Although experience is still relatively limited, this approach may become more widely available in the near future.

Procedures Involving Peripheral Nerve or Muscle

Surgically resecting peripheral nerves or muscles was routinely used for treatment of dystonia before BoNT and modern neuromodulation procedures were developed. Procedures targeting nerve or muscle are still used in certain circumstances. For example, selective peripheral denervation can be useful for cervical dystonia when BoNT fails and other surgical options are not an option. Several procedures are still occasionally offered by oculoplastic surgeons for blepharospasm when BoNT fails. These include stripping of orbicularis oculi muscles (myectomy), frontalis suspension, shortening of the levator palpebrae, and resection of excess eyelid skin. Other procedures may be offered by otolaryngologists for laryngeal dystonia. These include restructuring of the muscles or nerves and or cartilaginous structure of the larynx.

Experience with surgical strategies focusing on peripheral targets is relatively limited because they are offered only by small numbers of centers. Peripheral denervation for cervical dystonia has been the most extensively studied. In experienced hands, this procedure produces benefits that are comparable to those of DBS. Potential complications from peripheral denervation surgery in cervical dystonia include local scarring, local muscle atrophy and weakness, local sensory loss and dysesthesia, and dysphagia. Anecdotal reports describe success with oculoplastic strategies for blepharospasm and otolaryngology strategies for laryngeal dystonia, but large-scale studies summarizing efficacy and complication rates are not available.

Physical and Occupational Therapy

Many patients with dystonia request referral for additional procedures to address the discomfort associated with excessive muscle pulling. These include physiotherapy, chiropractic therapy, massage therapy, stretching exercises, acupuncture or dry needling, yoga, and others. These procedures can sometimes be useful. Some patients seem to benefit, and there are numerous unblinded reports describing benefits for various strategies. Unfortunately, the largest and most rigorous trials have failed to show any consistent benefit, and benefits are usually transient.

Although there is limited evidence-based medicine to support the use of these procedures in dystonia, they may be offered according to patient preferences. It is important to identify a therapist who has experience with dystonia because some traditional procedures may worsen dystonia or cause too much pain.

OUTCOMES

The long-term outcomes for the dystonias vary according to subtype. For the more common adult-onset focal dystonias, some worsening is expected over the first few months or years. Complete remission is uncommon, and relapse is frequent. Nevertheless, symptoms can be managed in the majority of cases with BoNT, oral medications, and sometimes surgical intervention.

For childhood-onset dystonias, progression to segmental and generalized dystonia is more frequent. Outcomes depend on the subtype. For most subtypes, symptoms can be managed with oral medications, surgical interventions, and sometimes BoNT. For certain rare subtypes, there are very specific life-altering interventions (see **Table 79.11**). As research in dystonia continues to uncover novel causes and biologic pathways, the list of dystonias with more specific interventions is likely to grow.

ACKNOWLEDGMENTS

I would like to thank Margi Patel, Laura Scorr, and Stewart Factor for providing helpful comments during development of this chapter.

SUGGESTED READINGS

Albanese A, Bhatia K, Bressman SB, et al. Phenomenology and classification of dystonia: a consensus update. *Mov Disord*. 2013;28:863-873.

Berlot R, Bhatia KP, Kojovi M. Pseudodystonia: a new perspective on an old phenomenon. *Parkinsonism Relat Disord*. 2019;62:44-55.

Cury RG, Kalia SK, Shah BB, Jimenez-Shahed J, Prashanth LK, Moro E. Surgical treatment of dystonia. *Expert Rev Neurother*. 2018;18:477-492.

Fahn S. The varied clinical expressions of dystonia. *Neurol Clin*. 1984;2:541-554.

Fung VS, Jinnah HA, Bhatia K, Vidailhet M. Assessment of the patient with dystonia: an update on dystonia syndromes. *Mov Disord*. 2013;28:889-898.

Hallett M, Albanese A, Dressler D, et al. Evidence-based review and assessment of botulinum neurotoxin for the treatment of movement disorders. *Toxicon*. 2013;67:94-114.

Jethwa A, Mink J, Macarthur C, Knights S, Fehlings T, Fehlings D. Development of the Hypertonia Assessment Tool (HAT): a discriminative tool for hypertonia in children. *Dev Med Child Neurol*. 2010;52:e83-e87.

Jinnah HA, Albanese A, Bhatia K, et al. Treatable inherited rare movement disorders. *Mov Disord*. 2018;33:21-35.

Jinnah HA, Sun YV. Dystonia genes and their biological pathways. *Neurobiol Dis*. 2019;129:159-168.

Jost W, Valerius KF. *Pictorial Atlas of Botulinum Toxin Injection: Dosage, Localization, Application*. Berlin, Germany: Quintessence Publishing; 2008.

Neychev VK, Gross RE, Lehéricy S, Hess EJ, Jinnah HA. The functional neuroanatomy of dystonia. *Neurobiol Dis*. 2011;42:185-201.

Patel N, Jankovic J, Hallett M. Sensory aspects of movement disorders. *Lancet Neurol*. 2014;13:100-112.

Sadnicka A, Kassavetis P, Pareés I, Meppelink AM, Butler K, Edwards M. Task-specific dystonia: pathophysiology and management. *J Neurol Neurosurg Psychiatry*. 2016;87:968-974.

Simpson DM, Hallett M, Ashman EJ, et al. Practice guideline update summary: botulinum neurotoxin for the treatment of blepharospasm, cervical dystonia, adult spasticity, and headache: report of the Guideline Development Subcommittee of the American Academy of Neurology. *Neurology*. 2016;86:1818-1826.

Truong D, Dressler D, Hallett M. *Manual of Botulinum Toxin Therapy*. Cambridge, United Kingdom: Cambridge University Press.

Hemifacial Spasm 80

Paul Greene

KEY POINTS

1. Hemifacial spasm (HFS) produces unilateral, synchronous twitches in muscles innervated by cranial nerve VII. It can produce twitches, trains of twitches, and sustained muscle contraction.
2. Synkinesis after Bell palsy, myokymia, and less commonly tics or dystonia of the face may be misdiagnosed as HFS.
3. Epilepsia partialis continua mimics the movements of HFS but often involves the masseter muscle and the movements are rarely limited to the face.
4. Most people with HFS have something irritating the root exit zone of the facial nerve, usually an aberrantly placed artery but occasionally a tumor, an arteriovenous malformation, or other mass.
5. HFS can be treated with medications, botulinum toxin injections, or microvascular decompression surgery.

INTRODUCTION

In hemifacial spasm (HFS), there are involuntary contractions on one side of the face in muscles innervated by the facial nerve (cranial nerve VII) (Figs. 80.1 and 80.2). According to Digre and Corbett, the condition was first described in 1875 by Schultze but was first separated from other forms of facial twitching by Gowers in 1888.

EPIDEMIOLOGY

HFS is rare in United States. The age- and sex-adjusted incidence was 0.78 per 100,000 per year in Olmsted County, Minnesota, only 3% of the incidence of Bell palsy. Based on patients seeking treatment, the prevalence of HFS was 1/100,000 in Olmstead County, Minnesota (7.4/100,000 in men, 14.5/100,000 in women, and about 28/100,000 in patients between the ages of 40 and 59 years). Using similar techniques in Oslo, Norway, the prevalence of HFS was 9.8 per 100,000 (39.7/100,000 in people over 70 years).

PATHOBIOLOGY

The pathogenesis of HFS is thought to be compression of the facial nerve where it exits the brainstem (the root exit zone), usually by an aberrant artery, such as the anterior inferior cerebellar artery, posterior inferior cerebellar artery, or internal auditory artery, or a normal vein. Irritation of the nerve at this site is felt to generate spontaneous electrical activity, causing muscle contractions, and "cross-talk" or simultaneous activation of axons going to different parts of the face. However, other causes of compression at the root exit zone besides normal arteries rarely occur, such as draining veins of arteriovenous malformations, aneurysms, tumors, or plaques of multiple sclerosis in the central myelin at the root exit zone of the facial nerve. This is known as *secondary HFS*. For this reason, all patients with HFS should have magnetic resonance imaging with attention to the posterior fossa. If compression by aberrant arteries is the most common

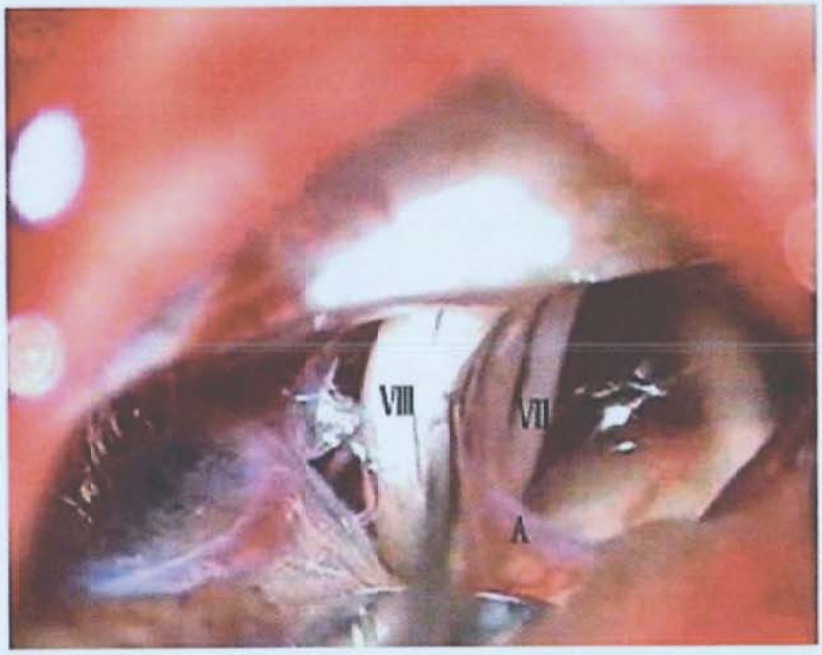

FIGURE 80.1 The anterior inferior cerebellar artery (A) runs between cranial nerves VII and VIII and compresses nerve VII. (From Ma Z, Li M, Cao Y, Chen X. Keyhole microsurgery for trigeminal neuralgia, hemifacial spasm and glossopharyngeal neuralgia. *Eur Arch Otorhinolaryngol.* 2010;267:449-454.)

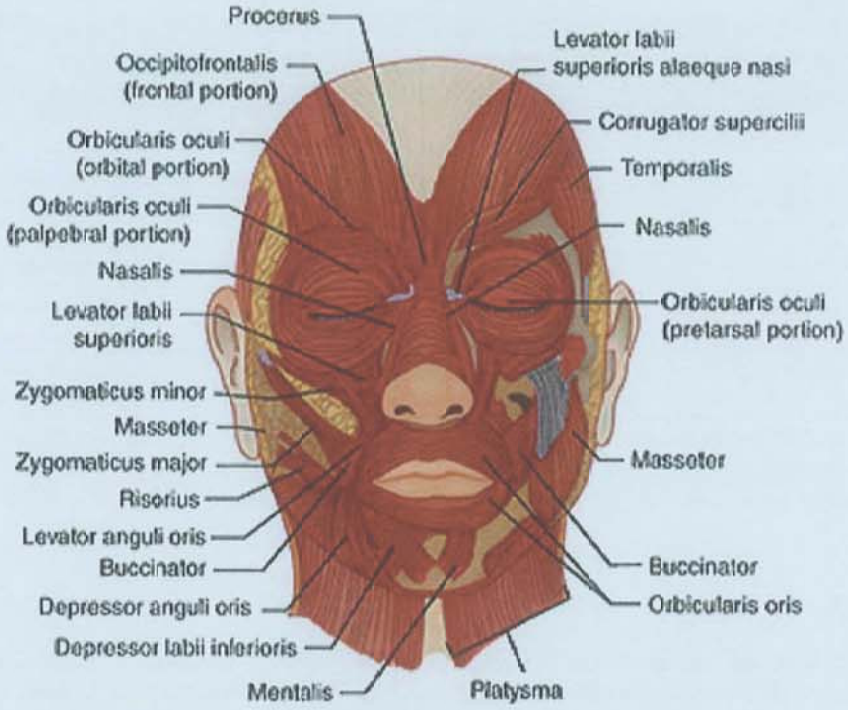

FIGURE 80.2 Muscles innervated by the facial nerve.

cause for HFS, it would be reasonable that arterial hypertension causing ectatic vessels might be a risk factor for HFS. Older studies suggested this, but recent carefully controlled studies failed to find such an association.

Occasionally, HFS has been seen after Bell palsy, bony overgrowth as in Paget disease pinching the stylomastoid foramen, and other peripheral lesions of the facial nerve. This has led to speculation that facial nerve compression induces a change in the facial nucleus, which is necessary for HFS to occur. The likelihood of such a facial nucleus change would increase as the site of compression gets closer to the nucleus. This alternative hypothesis is strengthened by the small number of cases of HFS associated with central lesions at the site of the facial nerve nucleus. In addition, there is evidence in HFS suggesting hyperexcitability of the facial nerve nucleus, including enhancement of F waves and other findings.

CLINICAL FEATURES

The contractions in HFS usually start as individual muscle twitches in the eyelids. Over time, twitches spread to other facial nerve–innervated muscles including the frontalis, paranasal muscles, zygomaticus major, perioral muscles, platysma, and occasionally, the periauricular muscles. The onset of contractions in these muscles is so close together that the twitching looks synchronous in all the muscles. Trains of twitches may develop and, when severe, there may be periods of sustained muscle contraction causing complete eye closure. Pain in HFS is very rare, usually from patients with concurrent involvement of the trigeminal nerve producing tic douloureux (the combination is called *tic convulsif*). Contractions in HFS diminish, but do not disappear, during sleep and patients often report worsening with stress. This is surprising for what is usually presumed to be a peripheral nerve disease (see the following discussion). HFS usually progresses slowly if at all but may produce facial weakness in patients with long duration of disease. About 1% of reported cases of HFS are bilateral (with twitching that is asynchronous from side to side). The majority of cases of HFS are sporadic, although there are occasional reports of familial cases (▶ Video 80.1).

DIAGNOSIS

There are few other diseases that produce twitches, trains of twitches, and occasionally, episodes of sustained muscle contraction (**Table 80.1**). Facial dystonia is usually more sustained and bilateral and muscle contractions are not usually synchronous. The rippling movements of facial myokymia are often unilateral but are slow and asynchronous. Motor tics in the face may be unilateral and rapid, but there is usually a warning sensation before the movements, and the movements are usually suppressible, at least briefly. Synkinesis after Bell palsy or other cause produces synchronous contractions but only during blinking or voluntary movement. However, some patients develop HFS in addition to a synkinesis after nerve injury. Epilepsia partialis continua does mimic the movements of HFS precisely but usually involves the masseters (cranial nerve V) and is rarely limited to the face. Spastic paretic hemifacial contracture (associated with lesions in the neighborhood of the facial nerve nucleus in the brainstem) has unilateral muscle contraction in the face but there is no twitching and there is usually myokymia.

MANAGEMENT

HFS can be treated with medications, botulinum toxin (BTX) injections, or by craniectomy and separation of an arterial loop from the root exit zone of the facial nerve (microvascular decompression).

TABLE 80.1 Differential Diagnosis of Hemifacial Spasm

Condition	Similarities to HFS	Differences from HFS
Facial dystonia	May include rapid contractions	Very rarely unilateral; mostly slower contractions; spasms not usually synchronous in different facial muscles
Myokymia	May be unilateral	Slower contractions; spasms usually asynchronous in different muscles
Motor tics	May be rapid, unilateral, and synchronous in different muscles	Usually an inner sensation before the movements; movements usually suppressible at least briefly; rarely persist during sleep
Synkinesis (eg, after Bell palsy)	May be rapid, unilateral, and synchronous in different muscles	Spasms only occur with blinking or voluntary movement.
EPC	May be rapid, unilateral, and synchronous in different muscles	Unlike HFS, may involve the masseter muscle; usually involves extracranial muscles
Spastic paretic hemifacial contracture	Unilateral contractions of facial muscles	Unlike HFS, there are no twitches. Myokymia usually accompanies the contractions.

Abbreviations: EPC, epilepsia partialis continua; HFS, hemifacial spasm.

Medication

Medications are rarely used because they are generally the least successful treatment. Medications used in the past include orphenadrine, dimethylaminoethanol, carbamazepine, clonazepam, baclofen, gabapentin, and felbamate.

Botulinum toxin injections

BTX has proved extremely useful in treating HFS, especially for orbicularis oculi contractions. Because the distribution of muscle contractions and the sensitivity to BTX varies from patient to patient, there are few specific rules for injecting the toxin. General guidelines for the injections are shown in Table 80.2.

Surgery

Microvascular decompression, first popularized by Jannetta in the 1970s, appears to be the definitive treatment for HFS. When a vessel is compressing the facial nerve, a sponge is placed between the nerve and the vessel. However, up to about 10% of patients experience return of spasms and require repeat operation, possibly when the sponge is dislodged. In addition, vascular compression of the root exit zone of the facial nerve is not found in all cases, and current magnetic resonance imaging techniques are not yet sufficient to guarantee that an offending vessel will be found. For all these reasons, many patients prefer to avoid surgery if possible, and BTX injections are the treatment of first choice for most patients.

OUTCOME

Medication

There is a single controlled study suggesting benefit from orphenadrine and dimethylaminoethanol, but this was never repeated, and this treatment is rarely used today. Successful treatment of HFS in small numbers of patients has been reported with carbamazepine, clonazepam, baclofen, gabapentin, and felbamate but improvement was "rare" in several hundred patients treated with anticonvulsants in one large series. Even when spasms improve with medications, the improvement is usually temporary.

Botulinum toxin injections

Most series describing the results of BTX injections report an almost 100% success rate, at least for spasms in the orbicularis oculi. The success rate is lower for lower facial muscles (although this is rarely reported) due to the development of facial weakness before resolution of the spasms in some patients.

TABLE 80.2 Botulinum Toxin Treatment of Hemifacial Spasm

1. Some people have dramatically different sensitivity to BTX, so initially inject just the muscle causing the most troublesome symptom (usually the Oo).
2. Optimal concentration of toxin, volume per injection, and number of sites per muscle are not known for most muscles (including the Oo). Most people use concentrations of 5-10 U/0.1 mL. The general rule is as follows: Use more dilute toxin to get a greater effect and use more concentrated toxin to get less spread to nearby muscles.
3. Major side effects are as follows:
   - Ptosis (from leakage to the levator palpebrae)
   - Ecchymoses
   - Dermatochalasis (usually in the lower lid)
   - Xerophthalmia or epiphora (usually short lasting)
   - Excess weakness of the injected muscle (not usually the Oo)
   - Diplopia (uncommon)—from lateral canthus injections
   - Entropion (rare)—from lower lid injections
4. In the Oo, avoid injecting the upper lid in the midline (to minimize the risk of ptosis). Lower lid injections are always necessary; injections in the orbital portion of the Oo are sometimes necessary.
5. Start with a small dose and increase the dose gradually to minimize side effects. Some reasonable starting doses are as follows:
   - Orbicularis oculi—2.5 units per site with one site in the lower lid, lateral canthus, medial and lateral pretarsal components of the Oo, and orbital component of the Oo
   - Frontalis—2.5 units in two or three sites
   - Nasalis—2.5 units
   - Zygomaticus major—1 unit in one site
   - Depressor anguli oris, depressor labii inferioris, mentalis—2.5 units, one site in each
   - Platysma—2.5 units in three or four sites
6. Instruct patients to always notify you about problems arising after BTX injections: Patients may coincidentally develop an unrelated problem in the weeks following a BTX injection.

Abbreviations: BTX, botulinum toxin; Oo, orbicularis oculi.

Excess weakness of the orbicularis oculi is very rare, although leakage to the levator palpebrae causing ptosis is common. The risk of ptosis depends on the volume of toxin injected (greater volume produces greater risk) and the injection site (closer to the insertion of the levator at the middle of the upper lid increases the risk). Other less common side effects include ecchymoses at the injection site, entropion of the lower lid, dry eye, excess tearing, and bagginess under the eye. Diplopia occasionally occurs, probably from spread of toxin to one or both lateral recti. All side effects from BTX injections are transient, and there is no evidence that chronic BTX injections induce any permanent change. Benefit from BTX injections for HFS lasts 3 to 6 months, after which symptoms return and repeat injections are required. Benefits from BTX injections have been so dramatic and prolonged that there has only been one small prospective, placebo-controlled crossover study and that showed significant improvement from BTX compared to placebo LEVEL 1.[1]

Surgery

In a large series describing microvascular decompression, 1,327 patients were followed for up to 3 years and 90.5% were felt to have an excellent outcome after the first surgery. There were 2.3% of patients who did not improve and had a second surgery (in the opinion of the surgeons, the wrong vessel had been decompressed), and 90% of these were felt to have an excellent response. However, up to about 10% of patients experience return of spasms and require repeat operation, possibly when the sponge is dislodged. Serious complications (death, stroke, or cerebellar hematoma) occur in less than 1% in most series. Permanent facial weakness or hearing loss is uncommon, occurring in about 5%. After surgery, delay in the onset of both facial weakness and, less often, hearing loss has been reported but the cause is not known and the deficits are usually not permanent. Other rare surgical complications including wound infection or hematoma, cerebrospinal fluid leak, bacterial meningitis, and pseudomeningocele are also possible.

Videos can be found in the companion e-book edition. For a full list of video legends, please see the front matter.

LEVEL 1 EVIDENCE

1. Yoshimura DM, Aminoff MJ, Tami TA, Scott AB. Treatment of hemifacial spasm with botulinum toxin. *Muscle Nerve*. 1992;15:1045-1049.

SUGGESTED READINGS

Auger RG, Whisnant JP. Hemifacial spasm in Rochester and Olmsted County, Minnesota, 1960 to 1984. *Arch Neurol*. 1990;47:1233-1234.

Barker FG II, Jannetta PJ, Bissonette DJ, Shields PT, Larkins MV, Jho HD. Microvascular decompression for hemifacial spasm. *J Neurosurg*. 1995;82:201-210.

Colosimo C, Chiarese M, Romano S, Vanacore N. Is hypertension associated with hemifacial spasm? *Neurology*. 2003;61:587.

Digre K, Corbett JJ. Hemifacial spasm: differential diagnosis, mechanism, and treatment. *Adv Neurol*. 1988;49:151-176.

Ehni G, Woltman HW. Hemifacial spasms: review of one hundred and six cases. *Arch Neurol Psychiatry*. 1945;53:205-211.

Ferguson JH. Hemifacial spasm and the facial nucleus. *Ann Neurol*. 1978;4:97-103

Gowers WR. *A Manual of Disease of the Nervous System*. Philadelphia, PA: P. Blakiston; 1888.

Hua Z, Da TY, Hui WX, et al. Delayed facial palsy after microvascular decompression for hemifacial spasm. *J Craniofacial Surg*. 2016;27:781-783.

Huang T, Xiong N-X, Fu P, Abdelmaksoud A, Wang L, Zhao H-Y. Synchronous bilateral hemifacial spasm: case-report and literature review. *Acta Neurochir (Wien)*. 2019;161(3):509-515.

Hughes EC, Brackmann DE, Weinstein RC. Seventh nerve spasm: effect of modification of cholinergic balance. *Otolaryngol Head Neck Surg*. 1980;88:491-499.

Ishikawa M, Ohira T, Namiki J, et al. Electrophysiological investigation of hemifacial spasm after microvascular decompression: F waves of the facial muscles, blink reflexes, and abnormal muscle responses. *J Neurosurg*. 1997;86:654-661.

Jannetta PJ, Abbasy M, Maroon JC, Ramos FM, Albin MS. Etiology and definitive microsurgical treatment of hemifacial spasm. Operative techniques and results in 47 patients. *J Neurosurg*. 1977;47:321-328.

Lee MH, Lee S, Park S-K, Lee J-A, Park K. Delayed hearing loss after microvascular decompression for hemifacial spasm. *Acta Neurochir (Wien)*. 2019;161(3):503-508.

Leonardos A, Greene PE, Weimer LH, Khandji AG, Mazzoni P. Hemifacial spasm associated with intraparenchymal brain stem tumor. *Mov Disord*. 2011;26:2325-2326.

Martinelli P, Giuliani S, Ippoliti M. Hemifacial spasm due to peripheral injury of facial nerve: a nuclear syndrome? *Mov Disord*. 1992;7:181-184.

Miwa H, Mizuno Y, Kondo T. Familial hemifacial spasm: report of cases and review of literature. *J Neurol Sci*. 2002;193:97-102.

Nielsen VK. Pathophysiology of hemifacial spasm: I. Ephaptic transmission and ectopic excitation. *Neurology*. 1984;34:418-426.

Palaram H, Carrera E, Vargas MI, Kleinschmidt A, Fleury V. Familial hemifacial spasm of young-onset: report of two cases. *J Neurol Sci*. 2017;373:83-85.

Schultze F. Linksseitiger facialiskrampf in folge eines aneurysma der arteria vertebralis sinistra. *Archiv f Pathol Anat*. 1875;65:385-391.

Wang L, Hu X, Dong H, et al. Clinical features and treatment status of hemifacial spasm in China. *Chin Med J (Engl)*. 2014;127(5):845-849.

Yaltho TC, Jankovic J. The many faces of hemifacial spasm: differential diagnosis of unilateral facial spasms. *Mov Disord*. 2011;26:1582-1592.

Zhong J, Li ST, Zhu J, et al. A clinical analysis on microvascular decompression surgery in a series of 3000 cases. *Clin Neurol Neurosurg*. 2012;114:846-851.

Myoclonus 81

Pichet Termsarasab and Steven J. Frucht

KEY POINTS

1. Myoclonus is the fastest hyperkinetic phenomenology characterized by lightning-like jerking movements.
2. Phenomenologic characterization of myoclonus guides the anatomic localization and differential diagnoses.
3. Anatomically, myoclonus can originate from cortical, subcortical (including brainstem), spinal, or peripheral locations.
4. Myoclonus can also be etiologically classified into physiologic, essential, epileptic, and symptomatic.
5. Anatomic localization guides differential diagnoses and treatment selection.

INTRODUCTION

Myoclonus is characterized by lightning-like muscle jerks and is considered to be the fastest hyperkinetic phenomenology. Electrophysiologically, these jerks are associated with electromyographic discharges that are relatively short in duration compared to voluntary jerks. Myoclonic jerks may be positive due to active muscle contractions or negative in which jerks occur due to lapses of postural tone. The classic example of negative myoclonus is asterixis.

GENERAL CONSIDERATIONS

Epidemiology

Data on epidemiology of myoclonus are scarce. Based on a study in Olmsted County published in 1999, myoclonus has a prevalence rate of 8.6 cases per 100,000 and an annual incidence rate of 1.3 cases per 100,000 person-years. In this study, symptomatic (secondary) myoclonus was the most common (72%), followed by epileptic and essential myoclonus.

Phenomenologic Characterization of Myoclonus

When myoclonus is observed, one should attempt to answer the following questions in order to elucidate the cause:

1. What is the distribution of myoclonus? What body part(s) is(are) affected? Is it focal, segmental (affecting multiple contiguous body regions), multifocal (multiple noncontiguous body regions), or generalized?
2. Is myoclonus positive or negative (due to lapse of muscle tone) (Fig. 81.1)? The classic example of negative myoclonus is asterixis, seen in hepatic encephalopathy or uremia. Negative myoclonus of the legs when standing can be seen in patients with posthypoxic myoclonus (Lance-Adams syndrome), producing a so-called bouncing gait.
3. Is myoclonus spontaneous (occurring at rest), action induced, stimulation induced, or reflex induced? One example of stimulation-induced myoclonus is hyperekplexia, which is typically induced by somesthetic (typically in mantle area including forehead and nose), auditory, and, less commonly, visual stimuli. Reflex-induced myoclonus (a hallmark of cortical myoclonus) can be tested by using the examiner's finger to tap a body region, such as a patient's finger, hand, or arm, which then would produce a myoclonic jerk. The latency between reflex stimuli and myoclonic jerks in cortical myoclonus is relatively short, suggesting efferent conduction via the corticospinal pathway. Longer latency would suggest slower conducting pathways such as the propriospinal pathway.
4. Is the myoclonus rhythmic or nonrhythmic? Is it synchronous?
5. Are there any other associated phenomena such as dystonia or ataxia?

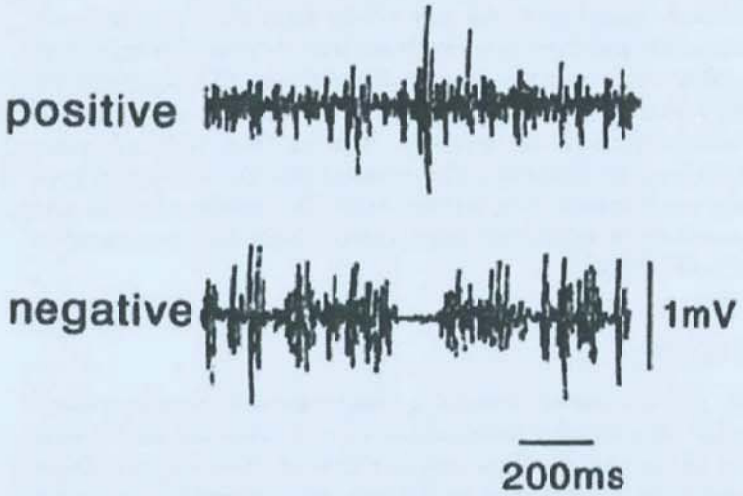

FIGURE 81.1 Positive and negative myoclonus. Electromyographic recordings from a patient with progressive myoclonic epilepsy during sustained muscle contraction. Positive myoclonus is seen as bursts of muscle jerks with a typical burst duration of less than 200 milliseconds. Negative myoclonus is demonstrated as a pause of electromyographic activities during sustained muscle contraction due to lapse of muscle tone. (Modified from Shibasaki H, Hallett M. Electrophysiological studies of myoclonus. *Muscle Nerve*. 2005;31:157-174.)

Myoclonus can be classified based on either anatomic localization or etiology. Anatomically, myoclonus can originate from either the central or peripheral nervous system. In the central nervous system, the location is further subdivided into cortical, subcortical including brain stem, and spinal cord origins. Anatomic classification of myoclonus is practically useful for formulation of differential diagnoses and treatment selection. The electrophysiology, etiology, and clinical characteristics of

TABLE 81.1 Classification of Myoclonus[a]

Clinical	Anatomic	Etiology
1. At rest Action Reflex 2. Focal Multifocal Generalized 3. Irregular Oscillatory Rhythmic	1. Cortical 2. Subcortical Thalamic Brainstem Reticular Hyperekplexia Palatal 3. Spinal Segmental Propriospinal 4. Peripheral	1. Physiologic 2. Essential 3. Epileptic 4. Symptomatic Storage diseases Cerebellar degenerations Basal ganglia degenerations Dementias Infectious encephalopathy Metabolic encephalopathy Toxic encephalopathy Hypoxia Focal damage

[a]Myoclonus can be classified according to clinical features, by anatomic origin of the pathophysiology of the jerks, and by etiology.

myoclonus from each anatomic location are discussed in the following text. Alternatively, myoclonus can be classified based on etiology as proposed by Marsden, Fahn, and Shibasaki as *physiologic*, *essential*, *epileptic*, and *symptomatic* (or secondary) (Table 81.1). Examples of physiologic myoclonus are jerks during sleep (hypnic jerks) and hiccups (diaphragmatic myoclonus). Symptomatic myoclonus occurs as a part of or secondary to main disorders such as storage diseases, neurodegenerative disorders, metabolic encephalopathies, etc.

After the phenomenologic characterization of myoclonus, the next step is anatomic localization, which will subsequently guide etiologic diagnosis. Here, we will classify myoclonus mainly according to anatomic localization and will integrate etiologic classification to show correlations between these two approaches.

CORTICAL MYOCLONUS

Pathobiology

The electrophysiology of myoclonus has been extensively studied. Myoclonus originating in the cortex has unique electrophysiologic features, as described in Table 81.2. The first three are unique to cortical myoclonus and are not seen in subcortical or spinal myoclonus.

Jerk-locked back-averaging technique (also known as *back-averaged electroencephalography* [EEG]) is very helpful in identifying cortical spikes prior to the jerks, but the technique is not routinely available. It is done by averaging at least 150 to 200 myoclonic jerks and capturing their preceding *cortical spikes*. A short duration between the spike and the jerk indicates fast conduction from the cortex to the muscles via the corticospinal pathway, usually less than 50 milliseconds.

Giant somatosensory-evoked potentials (SEPs) are very large cortical potentials seen by SEP recording techniques such as by stimulation of the median nerve while recording EEG. A typical SEP has negative (upward) phase followed by positive (downward) and negative phases, respectively. Only the positive and the second negative phases are enlarged in cortical myoclonus. These two latter phases are motor volleys, whereas the first negative phase is a sensory volley.

TABLE 81.2 Characteristic Electrophysiologic Features of Myoclonus From Different Anatomic Origins

Cortical Myoclonus
• Focal spikes or sharp waves of 10-40 ms duration preceding the jerk on back-averaged EEG
• Giant SEPs
• Enhanced C-reflexes
• EMG burst duration typically shorter than in subcortical or spinal myoclonus; <100 ms and usually 20-50 ms in duration
• Rostrocaudal recruitment pattern on polymyography with very fast spreading (Jerks may appear almost at the same time on regular polymyography.)
Subcortical Myoclonus Including Brainstem Myoclonus
• EMG burst durations vary among subtypes, generally longer than that seen in cortical myoclonus, as long as 100 ms.
• Typical recruitment pattern
◦ *Reticular reflex myoclonus* typically originates in the lower brainstem, most commonly CN XI–innervated muscles such as SCM. It spreads up to CNs VII– and V–innervated muscles and simultaneously down to muscles in the upper cervical levels.
◦ *Hyperekplexia* spreads between CN-innervated muscles. It can start from CN in the midbrain such as orbicularis oculi then spreading down to lower CN-innervated muscles. Jerks occur after somesthetic (touch), auditory, or, less commonly, visual stimuli.
Spinal Myoclonus
• EMG burst durations are typically longer than 100 ms.
• Spinal segmental myoclonus
◦ Recruitment pattern: Jerks start from one or two spinal segments and spread up and down along spinal segments. For example, jerking in the upper extremity from a structural lesion in the C7 spinal segment could be identified by an initial jerk of the ipsilateral triceps muscles with possible upward spreading to biceps and trapezius muscles and simultaneous downward spreading to C8-innervated intrinsic hand muscles.
◦ Velocity of spread is slower than in cortical myoclonus because it is not via fast-conducting corticospinal pathways.
• Propriospinal myoclonus
◦ Typical recruitment pattern up and down along axial muscles on polymyography. For example, jerks can originate in T12 rectus abdominis muscles and spread up and down to axial muscles above and below, respectively (eg, up to higher level rectus abdominis and down to iliopsoas).
◦ Slow velocity of spread as it is conducted through the slow propriospinal fibers (slowest among all forms of myoclonus described above).

Abbreviations: CN, cranial nerve; EEG, electroencephalography; EMG, electromyography; SCM, sternocleidomastoid muscles; SEP, somatosensory-evoked potential.

The *C-reflex* is a form of a long-latency reflex. When muscle fibers are stimulated, the afferent pathway is conducted through Ia sensory fibers, spinal cord, nucleus cuneatus or gracilis, and ultimately to the primary somatosensory cortex. Then, the efferent pathway is conducted through the corticospinal tract to the alpha-motoneuron. This typically takes about 40 to 50 seconds in the upper extremities. Therefore, when a muscle is electrically stimulated, the C-reflex will be seen on electromyography (EMG) recording about 40 to 50 milliseconds after the stimulation. C-reflexes are typically enhanced in cortical myoclonus.

Multichannel EMG recording, also called *polymyography*, can also be helpful in visualization of patterns of spread from one muscle to another, called the *recruitment pattern*. Typical recruitment patterns in cortical myoclonus are described in Table 81.2.

Clinical Manifestations

Cortical myoclonus can be focal, multifocal, or generalized. Focal cortical myoclonus usually affects the distal limbs such as the hands and fingers. It can be positive or negative, may occur either at rest or with action, and is often stimulus sensitive. It can be continuous and rhythmic, for example, *epilepsia partialis continua* in which patients have myoclonic jerks on one side of the body (▶ Video 81.1). Cortical myoclonus may occur as a fragment of epilepsy (epileptic myoclonus, see "Diagnosis" section). Posthypoxic myoclonus is typically generalized, nonrhythmic, synchronous, and stimulus sensitive (to tactile or auditory stimuli) but can also occur at rest (▶ Video 81.2).

Familial cortical myoclonic tremor with epilepsy (also called *benign adult familial myoclonic epilepsy* or *cortical tremor*) is a rare autosomal dominant genetic condition, characterized by small-amplitude myoclonic jerks in distal limbs that may look like and be misdiagnosed as essential tremor. There is a genetic heterogeneity in familial cortical myoclonic tremor with epilepsy. Several genes and loci have been identified.

Diagnosis

Cortical myoclonus can be epileptic or symptomatic, according to Marsden, Fahn, and Shibasaki's classification (see the preceding text). *Epileptic myoclonus* is fragments of epilepsy or myoclonic epilepsy and is cortical in origin. *Epilepsia partialis continua* can occur from a focal structural lesion typically seen in *Rasmussen encephalitis*, an autoimmune disorder leading to gliosis and hemiatrophy of one cerebral hemisphere (see ▶ Video 81.1).

The differential diagnosis of progressive myoclonic epilepsy is described in Table 81.3. An EEG is helpful in identifying epileptiform discharges. Investigations to confirm the diagnosis depend on the specific etiology, for example, a skin biopsy to search for Lafora bodies in Lafora body disease, or a muscle biopsy to look for ragged red fibers in myoclonic epilepsy with ragged red fibers. Genetic testing with appropriate genetic counseling is also used to confirm these entities.

Cortical myoclonus may be symptomatic, secondary to systemic or heredodegenerative disorders, for example, storage diseases or mitochondrial disorders mentioned previously. On the other hand, symptomatic myoclonus may be either cortical, brainstem, spinal, or peripheral in origin. The list of symptomatic myoclonus disorders is lengthy, and further workup depends on the suspected location and etiology. Patients with *posthypoxic myoclonus* have a history of mainly respiratory rather

TABLE 81.3 Differential Diagnosis of Myoclonus Classified by Anatomic Localization[a]

Cortical Myoclonus
• Epileptic
• Epilepsy partialis continua: Etiology can be Rasmussen encephalitis or focal cortical lesion.
• Progressive myoclonic epilepsy
• Unverricht-Lundborg disease (Baltic myoclonus, *EPM1* mutations, encoding for cystatin B)
• Lafora body disease (autosomal recessive, *EPM2A* mutations, encoding for laforin or *EPM2B* [*NHLRC1*] mutations)
• Neuronal ceroid lipofuscinosis (Batten disease, multiple mutations)
• Sialidosis (*NEU1* mutations encoding for neuraminidase)
• Myoclonic epilepsy with ragged red fibers (mitochondrial disorder)
• Dentatorubral-pallidoluysian atrophy (DRPLA, CAG repeat expansions in the *ATN1* gene encoding for atrophin)
• Symptomatic
• Posthypoxic myoclonus
• Secondary to systemic diseases or metabolic causes
• Renal or hepatic failure
• Infection related
• Subacute sclerosing panencephalitis, Creutzfeldt-Jakob disease
• Myoclonus associated with neurodegenerative disorders
• DRPLA, corticobasal syndrome, and Alzheimer disease
• Heredodegenerative disorders
• Storage diseases
• Mitochondrial disorders
• Spinocerebellar ataxia (SCA), such as SCA14

Subcortical Myoclonus Including Brainstem Myoclonus
• Subcortical
• Myoclonus-dystonia syndrome (essential myoclonus)
• Brainstem
• Physiologic
• Hypnic jerks
• Hiccups
• Hyperekplexia
• Variants include progressive encephalomyelitis, rigidity and myoclonus, and excessive startle syndromes.
• Palatal myoclonus
• Essential palatal myoclonus
• Symptomatic palatal myoclonus
• Opsoclonus-myoclonus (brainstem and cerebellum)
• Symptomatic: secondary to structural lesions in brainstem
Spinal Myoclonus
• Spinal segmental myoclonus
• Symptomatic: secondary to structural lesions in spinal cord
• Propriospinal myoclonus
Peripheral Myoclonus
• Hemifacial spasm
• Symptomatic
• Secondary to nerve root, plexus, or peripheral nerve lesions

[a]This table lists the differential diagnoses of myoclonus, primarily classified by anatomic locations. We also integrate the original etiologic classification of Marsden, Fahn, and Shibasaki, with the anatomic locations. Note that the list of symptomatic cortical myoclonus is extensive, and we include only examples. Symptomatic myoclonus (such as myoclonus from focal structural lesion) can occur anywhere within the neuraxis.

than cardiac arrest. Anoxic brain damage can be seen on neuroimaging. *Subacute sclerosing panencephalitis* is another example of symptomatic cortical myoclonus. The EEG typically reveals generalized periodic discharges every 4 to 14 seconds. *Dentatorubral-pallidoluysian atrophy* or Haw River syndrome, an autosomal dominant disorder of CAG repeat expansions in the *ATN1* gene encoding for atrophin protein, is another example in which patients can have cortical myoclonus associated with chorea, ataxia, dementia, and epilepsy. It was originally described in Japanese populations but is also found in other ethnic groups. The differential diagnoses of myoclonus associated with dementia also include *Creutzfeldt-Jakob disease*, *corticobasal syndrome*, and *Alzheimer disease*, among others. Myoclonus can also be seen in *spinocerebellar ataxia type 14*.

SUBCORTICAL INCLUDING BRAINSTEM MYOCLONUS

Pathobiology

Subcortical myoclonus originates from subcortical regions such as globus pallidus, thalamus, or brainstem. *Myoclonus-dystonia syndrome*, previously called *essential myoclonus* (also known as *DYT11 dystonia*), is thought to have a subcortical origin, given a lack of electrophysiologic features of cortical myoclonus described in the preceding text, but the exact location remains unknown. Another example of subcortical myoclonus is myoclonus occurring after thalamic stroke (typically negative myoclonus or asterixis affecting one arm). The three main types of brainstem myoclonus are reticular reflex myoclonus, hyperekplexia, and palatal myoclonus. The electrophysiologic findings are described in **Table 81.2**.

Reticular reflex myoclonus has a typical origin and recruitment pattern as described in **Table 81.2**.

Hyperekplexia, or exaggerated startle, has the nucleus gigantocellularis as a generator. It shows recruitment patterns, as described in **Table 81.2**. Lack of habituation is a feature of hyperekplexia: In the normal startle response, jerks will be less frequent and less severe clinically and electrophysiologically after repetitive stimuli, but in hyperekplexia, jerks fail to habituate.

Palatal myoclonus is another form of brainstem myoclonus, with rhythmic jerky movements of the soft palate at the rate of 2 to 2.5 Hz. Some may debate to use the term *palatal tremor*, given its regularity, but it is electrophysiologically myoclonus.

Clinical Manifestations

In *myoclonus-dystonia syndrome* (▶ **Video 81.3**), patients typically have myoclonic jerks mixed with dystonia, in the same or adjacent body regions. Myoclonus usually involves the neck and upper body such as the shoulders, arms, or hands. Dystonia seen in this condition also has similar involvement in the upper body such as the neck or hands (eg, patients can present with writer's cramp) but is usually much less prominent than the myoclonic component.

Hyperekplexia typically does not occur at rest, induced instead by a typical stimulus (▶ **Video 81.4**). Patients typically do not habituate to repeated stimuli. Nevertheless, we do not recommend examining patients with hyperekplexia with repetitive stimuli because repeated nose taps can lead to severe body stiffness and respiratory depression especially in infants.

In *reticular reflex myoclonus*, patients usually have myoclonic jerks involving the sternocleidomastoid and facial and neck muscles with the pattern of spread correlating with electrophysiologic recruitment, usually rostral and caudal.

The clinical features of *palatal* myoclonus are described in the following text.

Diagnosis

Myoclonus-dystonia syndrome is caused by a mutation in the *SGCE* gene (ε-sarcoglycan gene). This gene normally has maternal imprinting, that is, even in a normal state, maternal allele does not express. Thus, the abnormal gene is typically inherited from the father. In one rare condition, Russell-Silver syndrome where there is uniparental disomy, both alleles are from the mother, and therefore, both copies of the normal *SGCE* gene are imprinted leading to a lack of expression of one normal allele. This can cause the phenotype of myoclonus-dystonia syndrome. Symptoms of myoclonus-dystonia syndrome are usually relieved by alcohol and associated neuropsychiatric features such as anxiety and obsessive-compulsive disorder are common. Myoclonus-dystonia syndrome has also been reported to be due to other genes such as *KCTD17*.

Hyperekplexia may be hereditary or secondary. The genetics of hyperekplexia is complex: There are autosomal dominant and recessive forms. One of the well-known hereditary forms is autosomal dominant, caused by mutations in the glycine receptor gene, but other genes have also been reported. Secondary (ie, symptomatic) hyperekplexia has been reported due to brainstem encephalitis from an autoimmune or paraneoplastic process. Sometimes, it can be associated with severe muscle rigidity and stiffness, also called *progressive encephalomyelitis with rigidity and myoclonus*.

Certain excessive startle syndromes may be culturally related and also can manifest as echolalia and automatic obedience. These syndromes are known by colorful regional names, such as *The Jumping Frenchmen of Maine* (Quebec), *myriachit* (Siberia), *Latah* (Indonesia, Malaysia), and *Ragin' Cajun* (Louisiana). These syndromes are not true forms of myoclonus because the movements are more prolonged in duration and subject to conscious suppression.

Palatal myoclonus can be further classified into two forms: essential and symptomatic. In essential palatal myoclonus, patients have ear clicks from contraction of the tensor veli palatini leading to movements of the opening of the eustachian tube. Symptomatic palatal myoclonus (SPM) is a delayed phenomenon that usually occurs weeks or months after a lesion in Guillain-Mollaret triangle, which is defined by the line between dentate nucleus, contralateral red nucleus, and contralateral inferior olivary nucleus (**Fig. 81.2**). The central tegmental tract runs between red nucleus and inferior olivary nucleus, which then sends fibers to contralateral dentate nucleus through the inferior cerebellar peduncle. Then, the dentate nucleus sends a projection to the red nucleus via the superior cerebellar peduncle. Lesions in this triangle may be ischemic, demyelinating, infectious, or postinfectious, among others. Hypertrophy and hyperintensity of the inferior olivary nucleus on T2 image on magnetic resonance imaging (MRI) can be seen in SPM. Unlike essential palatal myoclonus, patients do not usually have ear clicks. Pendular nystagmus can also be seen in SPM. *Progressive ataxia with palatal tremor* is a syndrome that when seen suggests the possibility of adult-onset Alexander disease, a disorder caused by *GFAP* gene mutations. Sagittal view of the MRI in adult-onset Alexander disease can reveal atrophy of the spinal cord from the cervical portion down, giving the so-called tadpole sign. Diagnosis is confirmed by genetic testing.

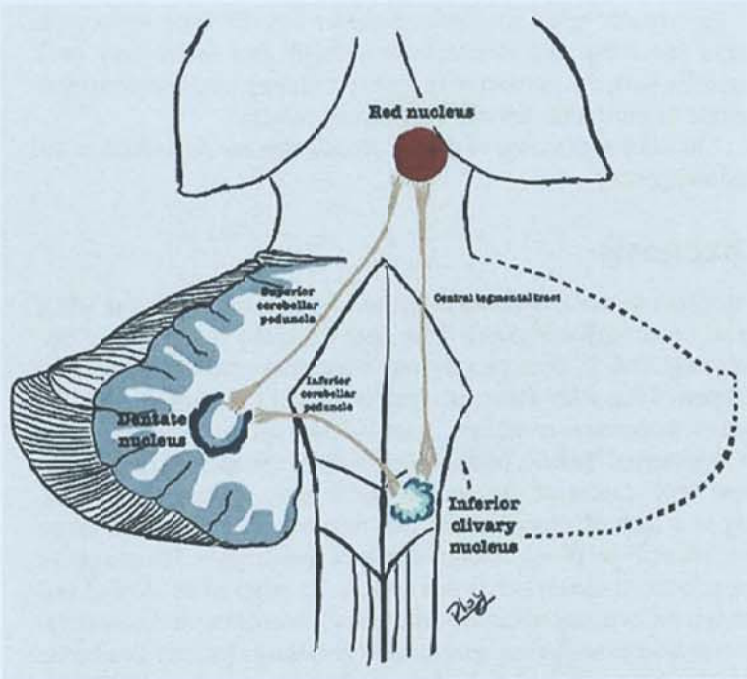

FIGURE 81.2 Guillain-Mollaret triangle. Red nucleus, inferior olivary nucleus, and dentate nucleus on contralateral sides form the three corners of this triangle. The central tegmental tract runs from the red nucleus to the inferior olivary nucleus, which sends the projection to the dentate nucleus via the inferior cerebellar peduncle. Dentate nucleus sends the projection through the red nucleus via superior cerebellar peduncle. Lesions in this triangle can lead to palatal myoclonus. (Courtesy of Thananan Thammongkolchai, MD.)

In addition to the classic subcortical myoclonus mentioned in the preceding text, here we will also mention opsoclonus-myoclonus, which is due to dysfunction of brainstem and cerebellum.

Opsoclonus-myoclonus-ataxia syndrome (*Kinsbourne disease*) is diagnosed by a constellation of opsoclonus, myoclonus, and ataxia. In children, it can occur as a paraneoplastic process, typically seen with neuroblastoma associated with anti-Ri antibody, and abdominal imaging is required to screen for this cancer. In adults, it is associated with postinfectious (such as postviral), autoimmune, or paraneoplastic processes affecting the brainstem. Neuroimaging, cerebrospinal fluid studies including paraneoplastic panel in blood and cerebrospinal fluid are helpful in diagnosis. A course of steroids and/or intravenous immunoglobulin is warranted.

SPINAL MYOCLONUS

Pathobiology

Two major forms of spinal myoclonus exist: spinal segmental and propriospinal myoclonus. The typical recruitment pattern and the velocity of spread are described in Table 81.2.

Spinal segmental myoclonus typically originates within a few or several adjacent spinal segments, typically cervical or lumbar.

Propriospinal myoclonus refers to axial jerks that originate in spinal cord segments, with spread up and down along the longitudinal axis of spinal cord. The very slow–conducting propriospinal pathway helps coordinate forelimb and hind limb movements in animals, such as cats, but the role of this pathway in humans is unclear.

It has been reported in the literature that the Bereitschaftspotentials are associated with propriospinal myoclonus. The Bereitschaftspotential is a form of voluntary, movement-related potential seen on back-averaged EEG technique. It is also called a *premovement* or *readiness potential*. It is helpful in differentiating organic from psychogenic myoclonus. Thus, a psychogenic cause has been proposed in propriospinal myoclonus. However, there is evidence that there is disruption of fiber tracts in spinal cord seen on diffusion tensor imaging in patients with propriospinal myoclonus, suggesting that some forms of propriospinal myoclonus are organic.

Clinical Manifestations

In *spinal segmental myoclonus*, muscles in one or two adjacent spinal segments are typically affected. It can occur at rest or with action, may be rhythmic or nonrhythmic, but is usually not reflex induced. When patients present with myoclonic jerks in one limb, one should always think about possible pathology in the spinal cord, such as a primary spinal cord malignancy.

Propriospinal myoclonus typically presents with axial jerks (▷ Video 81.5). Patients typically have truncal flexion, usually nonrhythmic, at rest or with action or reflex induced, with a relatively long latency due to slow conduction via propriospinal pathways. The differential diagnosis of axial jerks includes propriospinal myoclonus and reticular reflex myoclonus, but in the latter form, it usually involves a higher truncal region than propriospinal myoclonus.

Diagnosis

Spinal segmental myoclonus is symptomatic until proven otherwise; therefore, neuroimaging of the spine at appropriate levels is needed. In *propriospinal myoclonus*, despite the controversies about its psychogenic versus organic origin, we also suggest obtaining neuroimaging of the spine to rule out a structural lesion.

PERIPHERAL MYOCLONUS

Pathobiology

A typical example of peripheral myoclonus is hemifacial spasm, but peripheral myoclonus can also occur from irritation of spinal nerve roots, plexus, or peripheral nerves. The EMG burst duration varies, and there is lack of electrophysiologic patterns of cortical, subcortical, and spinal myoclonus.

Clinical Manifestations

Peripheral myoclonus from nerve root, plexus, or peripheral nerve involvement typically affects a limb in the distribution corresponding to neural structures that are innervated. It usually occurs at rest and does change with action. Sometimes, it is difficult to differentiate from spinal segmental myoclonus, and spine imaging is required to rule out spinal pathology. *Hemifacial spasm* is a form of peripheral myoclonus. It is characterized by clonic, sometimes tonic, contraction of cranial nerve VII–innervated muscles, most commonly the orbicularis oculi, zygomaticus, frontalis, and platysma.

Diagnosis

Peripheral myoclonus of the limbs requires workup such as nerve conduction studies and EMG to confirm the location of the lesions, that is, neural structure involved or myotomal level. In hemifacial spasm, an MRI with visualization of the facial nerve and nearby vascular structures should be obtained. Sometimes, a vascular loop can be seen abutting the facial nerve.

MANAGEMENT

Specific treatment of myoclonus depends on the etiologic diagnosis, for example, treatment of hepatic encephalopathy when it presents with asterixis or employing antiepileptic agents in myoclonic epilepsy. Symptomatic treatment can be pursued to control symptoms along with specific treatment or when specific treatment is not available. Pharmacologic treatments commonly employed are clonazepam, levetiracetam, and valproic acid. There are no clear guidelines regarding which medication should be initiated, although anatomic localization guides treatment. The treatment is shown in Table 81.4.

TABLE 81.4 Treatment of Myoclonus[a]

Specific Treatment Depending on the Etiologies
• **Pharmacologic treatment**
• Levetiracetam (considered first-line in cortical myoclonus); 1,000-3,000 mg/d divided twice a day; dose up to 4,000 mg/d has been used.
• Two other drugs related to levetiracetam, piracetam (1,600-4,800 mg/d) and brivaracetam (50-200 mg/d; twice-daily dosing), may also be considered. Piracetam is not available in the United States. Brivaracetam failed to show efficacy as an adjunctive therapy for action myoclonus in Unverricht-Lundborg disease.
• Clonazepam (considered first-line in subcortical and spinal myoclonus); starting dose 0.5-1 mg/d; typical dose 3 mg/d or more; sometimes up to 15 mg/d
• Valproic acid; typical dose 1,000-1,500 mg/d
• Zonisamide, primidone, and perampanel (used less commonly when the aforementioned conventional medications fail); dosing for zonisamide 100-200 mg/d; for primidone, 500-750 mg/d but usually poorly tolerated at such high doses; for perampanel 2-12 mg/d
• Others (nonconventional treatments)
• Sodium oxybate in some forms of myoclonus that responds to alcohol such as myoclonus-dystonia syndrome and posthypoxic myoclonus; average dose 6.5 mg/d, maximum 9 mg/d
• 5-Hydroxytryptophan in posthypoxic myoclonus
• **Botulinum toxin injection**
• Hemifacial spasm (treatment of choice)
• **DBS**
• Pallidal DBS has been reported to improve both dystonia and myoclonus in myoclonus-dystonia syndrome, compared to VIM DBS, which improves only myoclonus but not dystonia. Data remains limited.
• Pallidal DBS has also been reported to be beneficial in posthypoxic myoclonus.

Abbreviations: DBS, deep brain stimulation; VIM, ventral intermediate nucleus.
[a]Specific treatment of myoclonus depends on the etiologic diagnosis. Symptomatic treatment can be considered along with specific treatment or when specific treatment is not available.

OUTCOME

The prognosis and natural history of myoclonus depend on its specific etiology. For example, prognosis is generally good after treating an underlying systemic disorder, removing a structural lesion, or treating an underlying autoimmune or paraneoplastic process. The outcome of other forms of myoclonus is variable.

Videos can be found in the companion e-book edition. For a full list of video legends, please see the front matter.

SUGGESTED READINGS

Bakker MJ, van Dijk JG, van den Maagdenberg AM, Tijssen MA. Startle syndromes. *Lancet Neurol*. 2006;5:513-524.

Brown P, Thompson PD, Rothwell JC, Day BL, Marsden D. Axial myoclonus of propriospinal origin. *Brain*. 1991;114(pt 1A):197-214.

Caviness JN. Pathophysiology and treatment of myoclonus. *Neurol Clin*. 2009;27:757-777.

Caviness JN. Treatment of myoclonus. *Neurotherapeutics*. 2014;11:188-200.

Caviness JN, Alving LI, Maraganore DM, Black RA, McDonnell SK, Rocca WA. The incidence and prevalence of myoclonus in Olmsted County, Minnesota. *Mayo Clin Proc*. 1999;74:565-569.

Chang VC, Frucht SJ. Myoclonus. *Curr Treat Options Neurol*. 2008;10:222-229.

Deuschl G, Mischke G, Schenck E, Schulte-Mönting J, Lücking CH. Symptomatic and essential rhythmic palatal myoclonus. *Brain*. 1990;113(pt 6):1645-1672.

Deuschl G, Wilms H. Clinical spectrum and physiology of palatal tremor. *Mov Disord*. 2002;17(suppl 2):S63-S66.

Dreissen YE, Bakker MJ, Koelman JH, Tijssen MA. Exaggerated startle reactions. *Clin Neurophysiol*. 2012;123:34-44.

Erro R, Bhatia KP, Edwards MJ, Farmer SF, Cordivari C. Clinical diagnosis of propriospinal myoclonus is unreliable: an electrophysiologic study. *Mov Disord*. 2013;28:1868-1873.

Fahn S, Marsden CD, Van Woert MH. Definition and classification of myoclonus. *Adv Neurol*. 1986;43:1-5.

Franceschetti S, Michelucci R, Canafoglia L, et al. Progressive myoclonic epilepsies: definitive and still undetermined causes. *Neurology*. 2014;82:405-411.

Ghosh D, Indulkar S. Primary myoclonus-dystonia: a diagnosis often missed in children. *J Child Neurol*. 2013;28:1418-1422.

Gorman MF. Update on diagnosis, treatment, and prognosis in opsoclonus–myoclonus–ataxia syndrome. *Curr Opin Pediatr*. 2010;22:745-750.

Guettard E, Portnoi MF, Lohmann-Hedrich K, et al. Myoclonus–dystonia due to maternal uniparental disomy. *Arch Neurol*. 2008;65:1380-1385.

Ikeda A, Kakigi R, Funai N, Neshige R, Kuroda Y, Shibasaki H. Cortical tremor: a variant of cortical reflex myoclonus. *Neurology*. 1990;40:1561-1565.

Kälviäinen R, Genton P, Andermann E, et al. Brivaracetam in Unverricht-Lundborg disease (EPM1): results from two randomized, double-blind, placebo-controlled studies. *Epilepsia*. 2016;57:210-221.

Klaas JP, Ahlskog JE, Pittock SJ, et al. Adult-onset opsoclonus-myoclonus syndrome. *Arch Neurol*. 2012;69:1598-1607.

Lance JW, Adams RD. The syndrome of intention or action myoclonus as a sequel to hypoxic encephalopathy. *Brain*. 1963;86:111-136.

Marsden CD, Hallett M, Fahn S. The nosology and pathophysiology of myoclonus. In: Marsden CD, Fahn S, eds. *Movement disorders*. London, United Kingdom: Butterworth & Co; 1981:196-248.

Mencacci NE, Bruggemann N. KCTD17 is a confirmed new gene for dystonia, but is it responsible for SGCE-negative myoclonus-dystonia? *Parkinsonism Relat Disord*. 2019;61:1-3.

Ramdhani RA, Frucht SJ, Kopell BH. Improvement of post-hypoxic myoclonus with bilateral pallidal deep brain stimulation: a case report and review of the literature. *Tremor Other Hyperkinet Mov (N Y)*. 2017;7:461.

Raymond D, Ozelius L. Myoclonus-dystonia. In: Pagon RA, Adam MP, Ardinger HH, et al, eds. *GeneReviews*. Seattle, WA: University of Washington, Seattle; 1993.

Roze E, Bourolleau F, Ducreux D, et al. Propriospinal myoclonus revisited: clinical, neurophysiologic, and neuroradiologic findings. *Neurology*. 2009;72:1301-1309.

Rughani AI, Lozano AM. Surgical treatment of myoclonus dystonia syndrome. *Mov Disord*. 2013;28:282-287.

Samuel M, Torun N, Tuite PJ, Sharpe JA, Lang AE. Progressive ataxia and palatal tremor (PAPT): clinical and MRI assessment with review of palatal tremors. *Brain*. 2004;127:1252-1268.

Shibasaki H, Hallett M. Electrophysiological studies of myoclonus. *Muscle Nerve*. 2005;31:157-174.

Stahl CM, Frucht SJ. An update on myoclonus management. *Expert Rev Neurother*. 2019;19:325-331.

Termsarasab P, Thammongkolchai T, Frucht SJ. Spinal-generated movement disorders: a clinical review. *J Clin Mov Disord*. 2015;2:18.

Turner MR, Irani SR, Leite MI, Nithi K, Vincent A, Ansorge O. Progressive encephalomyelitis with rigidity and myoclonus: glycine and NMDA receptor antibodies. *Neurology*. 2011;77:439-443.

van den Ende T, Sharifi S, van der Salm SMA, van Rootselaar A-F. Familial cortical myoclonic tremor and epilepsy, an enigmatic disorder: from phenotypes to pathophysiology and genetics. A systematic review. *Tremor Other Hyperkinet Mov (N Y)*. 2018;8:503.

van der Salm SM, Tijssen MA, Koelman JH, van Rootselaar A-F. The Bereitschaftspotential in jerky movement disorders. *J Neurol Neurosurg Psychiatry*. 2012;83:1162-1167.

Zutt R, van Egmond ME, Elting JW, et al. A novel diagnostic approach to patients with myoclonus. *Nat Rev Neurol*. 2015;11:687-697.

Hereditary and Acquired Ataxias 82

Sheng-Han Kuo and Vikram G. Shakkottai

KEY POINT

1. Cerebellar ataxia may result from a heterogeneous group of conditions, including nutritional, immune, inherited and degenerative etiologies.
2. Identification of nutritional and immune-mediated ataxias is important as these are treatable entities.
3. A tiered approach to genetic testing is the most cost-effective way to make a diagnosis of inherited ataxia. Start with testing for repeat-expansion associated ataxia, and if negative consider whole-exome sequencing.
4. In addition to symptomatic pharmacological therapy, intensive coordinative training can provide benefit for ataxia symptoms.

INTRODUCTION

The cerebellum controls the coordination of human movement, and the dysfunction of the cerebellum and its efferent or afferent connections leads to incoordination, which is termed *ataxia*. The diversity in the causes of cerebellar ataxia can pose significant diagnostic challenges; the treatment options for cerebellar ataxias have been traditionally thought to be ineffective, leaving many patients with ataxia untreated. In addition, the nonmotor symptoms, such as depression and mood disorders, are just beginning to be understood as part of the clinical presentation in ataxic disorders. Many emerging therapies for ataxia are on the horizon, accelerated by the advancement of scientific understanding of the neuroanatomy and neurophysiology of the cerebellum in both the normal state as well as in the disease. Therefore, cerebellar ataxia has been at the forefront of neurologic discoveries and novel therapy development.

This chapter starts with a brief introduction of cerebellar anatomy and physiology and details the clinical symptoms and signs commonly seen in ataxia patients. A discussion on the diagnostic modalities, including laboratory, neuroimaging, and genetics tests follows. An algorithm to pinpoint the etiology is outlined. Although an entire chapter can be devoted to each cause of cerebellar ataxia, a comprehensive overview of each ataxia diagnosis is provided. Finally, therapy under development for cerebellar ataxia is highlighted, a source of hope for patients. Recent developments in ataxia therapeutics make this an area of considerable promise in clinical neurology.

Neuroanatomy of the Cerebellum

The neural circuitry of the cerebellum is very distinctly organized with defined affect and efferent connections with other brain regions (Fig. 82.1). Disturbance of these brain structures leads to cerebellar ataxia. The cerebellum receives various sensory afferent inputs, such as vestibular and proprioceptive input. Another important input to the cerebellum is from the cortex through corticopontocerebellar fibers. All these inputs become mossy fibers that project to the cerebellar cortex, where they form synapses with granule cells whose axons become parallel fibers. In addition to mossy fibers, axons of the neurons in the inferior olivary nucleus provide another important afferent to the cerebellar cortex, known as *climbing fibers*. Purkinje cells, the principal neurons of the cerebellar cortex, receive two excitatory synaptic inputs; one from parallel fibers and the other from climbing fibers. Parallel fibers form synapses with thin, distal parts of Purkinje cell dendrites, whereas climbing fibers form synapses with proximal parts

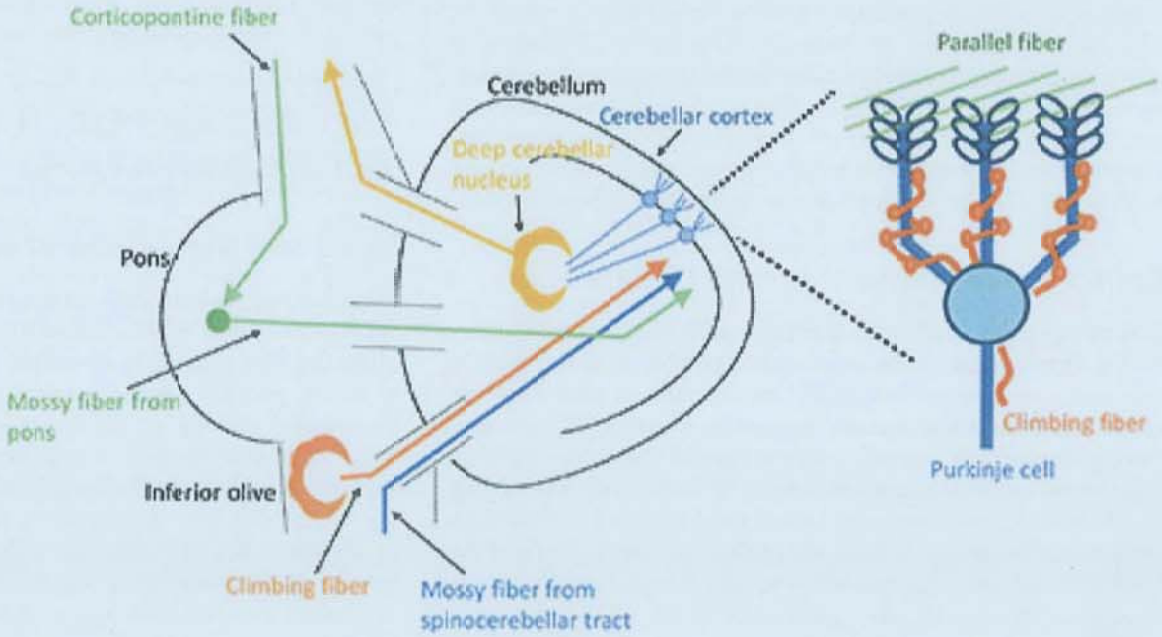

FIGURE 82.1 Neuroanatomy of the cerebellum.

of Purkinje cell dendritic shafts. The proper climbing fiber and parallel fiber wiring on Purkinje cells is critical for normal cerebellar function. Other inhibitory interneurons, such as Golgi and basket cells, are also important to shape Purkinje cell firing. Purkinje cells are the sole output neurons in the cerebellar cortex and Purkinje cell axons project to deep cerebellar nuclei (dentate nucleus, interposed nucleus, and fastigial nucleus), which send axonal projections to the thalamus and subsequently to motor cortex and other associated brain regions.

The anterior lobe of the cerebellum is important for motor control, whereas, the majority of the posterior lobe of the cerebellum may be related to cognitive processing. Within the motor cerebellum, lesions in the midline structure often result in truncal or gait ataxia, whereas damage to the paravermal regions is more likely to result in appendicular ataxia. Understanding the relationship between cerebellar neuroanatomy and cerebellar behavioral function can help with lesion localization.

CEREBELLAR NEUROPHYSIOLOGY

Cerebellar Circuits

Cerebellar Purkinje cells and nuclear neurons are autonomously active with high baseline firing rates. Purkinje cell projections, the major input to the neurons of the cerebellar nuclei, are inhibitory. Input into the cerebellum is predominantly through excitatory mossy fibers, which excite Purkinje cells through granule cells. Mossy fiber collaterals also directly excite cerebellar nuclear neurons. Bidirectional modulation of Purkinje cell firing frequency is possible through excitation mediated by parallel fiber synapses and inhibition mediated by cerebellar cortical interneurons, such as stellate cells or basket cells. One set of Purkinje cells can be excited with simultaneous inhibition of flanking sagittally oriented Purkinje cells by a distinct patch of granule cells. Distinct Purkinje cells are presumed to receive excitatory input representing distinct agonist muscle groups and inhibitory input from antagonist muscles. Similarly, cerebellar nuclear neurons receive input from distinct groups of Purkinje cells, whose inhibitory input would be expected to reduce their firing frequency. Bidirectional modulation of cerebellar nuclear neuron firing frequency would be expected through release of inhibition (and stimulation through mossy fiber collaterals) and increased inhibition through Purkinje cells. Another important modulator for Purkinje cell firing is by climbing fibers. Climbing fibers are axons of inferior olivary neurons, and a Purkinje cell only receive synaptic connections with one climbing fiber in the mature cerebellum. Climbing fibers can modulate Purkinje cell synchrony, which will result in strong modulatory effect in the downstream cerebellar nuclear neurons.

Control of Movement by the Cerebellum

Recordings from nonhuman primates performing simple movements, demonstrate characteristic patterns of activity in Purkinje cells and cerebellar nuclear cells. Simple spikes of most Purkinje cells occur at high maintained frequencies of about 70 Hz at rest. During flexion and extension movements at the wrist, Purkinje cell simple spike frequency alternates between rates higher (up to 400-500 Hz) and lower than the resting rate with a consistent temporal relationship to each successive movement cycle. Purkinje cells and cerebellar nuclear neurons change firing frequency in relation to whether muscles are active during a motor task. Distinct Purkinje cells (and downstream nuclear neurons) are likely involved in the timing of muscle activity. Because the majority of cerebellar nuclear neurons are excitatory, it suggests that an increase in firing of cerebellar nuclear neurons corresponds temporally with facilitation of muscle activity, and a decrease in firing frequency reduces facilitation of muscle groups. Although the firing of some Purkinje cells correlates positively with muscle activation, it is unclear how these data may be integrated into models of cerebellar control of limb movement. Only a subset of cerebellar output neurons are presumed to directly regulate motor activity of the limb, with others that discharge in relation to joint position, and the direction of the intended next movement. Although some investigators favor the view that the cerebellum solely plans and controls movements in a kinematic framework, without directly encoding force-related parameters, at least a subset of cerebellar output neurons do appear to directly activate muscle groups as evidenced by electrical stimulation of interposed and dentate nuclei in primates. Also, optogenetic manipulation of Purkinje cells in mice shows that inhibiting Purkinje cell firing can cause muscle contraction. In addition to real-time control of movement by the cerebellum, activity of cerebellar neurons can be modified by plasticity at various sites in the cerebellar circuit. Long-term depression of synaptic activity at parallel fiber synapses, is a particularly well-studied and important learning mechanism in the cerebellum. Additionally, an interaction between the cerebellar and basal ganglia motor control systems may allow cerebellar output neurons to influence muscle activity.

EPIDEMIOLOGY

The prevalence of ataxia is estimated to be 25 to 30 cases per 100,000 in the United States; however, this estimate mostly comes from referral centers, and there are few population-based studies. Nongenetic ataxia outnumbers genetic ataxia in most studies. Among the autosomal dominant ataxias or spinocerebellar ataxias (SCAs), SCA3 is the most common, followed by SCA2, SCA6, and SCA1. Friedreich ataxia is the most common autosomal recessive ataxia. The prevalence of genetic forms of ataxia varies in different geographic regions and ethnic backgrounds. Even with a family history of ataxia, approximately 30% of patients have no known genetic mutations identified. The prevalence of undiagnosed inherited forms of ataxia is expected to decrease due to advances in genetic technologies.

CLINICAL APPROACH TO CEREBELLAR ATAXIA

Signs and Symptoms of Ataxia

The first step to approach ataxia patients is to recognize early symptoms (Table 82.1). Difficulty walking and imbalance are often the first symptoms in ataxia patients. In the early stages of ataxia, patients may experience difficulty going upstairs and downstairs, and report having to hold onto the railing. Other early symptoms in gait ataxia include difficulty in running, walking in high heels, walking barefoot on the beach, and veering toward one side. A commonly used question to probe early symptoms of ataxia is "do you walk as if you are drunk?" Along this line, some patients will exhibit sensitivity to a small amount of ethanol. Patients with more severe ataxia often fall frequently.

TABLE 82.1 Signs and Symptoms for Cerebellar Ataxia

Early Signs and Symptoms
Difficulty in running, jumping, walking, or turning
Difficulty in walking on high heels
Difficulty in walking upstairs and downstairs without holding on to the railings
Sensitive to alcohol—balance become worse after a small amount of alcohol
Slurred speech—occasionally difficult to be understood; could be intermittent in early stage
Clumsiness in handwriting
Dizziness
Double vision—particularly when turning head quickly
Incidental finding of cerebellar atrophy on neuroimaging studies
Hand tremor
Late Signs and Symptoms
Falls
Difficulty in balance
Walking as if drunk
Swallowing difficulty
Blurry vision
Clumsiness in hands—difficulty in dressing and using utensils

Other than gait, visual problems can also occur. In the early stages of ataxia, patients may experience double vision when turning their heads quickly. As a result of transient and mild double vision, some may have blurry vision. Slurred speech is often not the initial symptom but can develop with disease progression. Patients can also have loss of hand dexterity with impaired handwriting and difficulty in performing delicate hand tasks.

It is very important to determine the timing of the development of ataxia (acute vs subacute vs chronic vs episodic), which has important diagnostic implications. Table 82.2 lists the common causes for ataxia with different chronicity. Toxic, metabolic, infectious, and vascular etiologies often develop quickly, whereas immune-mediated ataxias have subacute onset courses. Degenerative and genetic ataxias usually progress relatively slowly.

Besides recognizing ataxia symptoms, other associated symptoms can often point toward the diagnosis and thus are an important part of the history. These symptoms include peripheral neuropathy, parkinsonism, sleep dysfunction, autonomic symptoms, seizures, hearing loss, and a family history for ataxia and other balance problems. History of toxin and medication exposure, such as antiepileptic medications and chemotherapy, could also be the key to identifying the etiology of ataxia.

It is also very important to consider ataxia mimics, such as sensory neuropathy, parkinsonism, normal pressure hydrocephalus, vestibular problems, spasticity, muscle weakness, orthopedic issues, and pain-related gait disturbance (Table 82.3).

Neurologic Examination

The cerebellum is important for coordination and motor control throughout the body; therefore, cerebellar ataxia can be divided into several domains: eyes, speech, hands, legs, and gait, which should be the main focus on the neurologic examination.

TABLE 82.2 Acute, Subacute, Chronic, and Episodic Causes of Cerebellar Ataxia

Acute Causes of Cerebellar Ataxia (Minutes to Few Days)
Vascular causes: ischemic or hemorrhagic cerebellar strokes
Alcohol intoxication
Toxin (mercury, thallium, toluene, solvents)
Medication induced (phenytoin, carbamazepine, phenobarbital, lithium)
Demyelinating diseases, including multiple sclerosis
Meningitis, particularly basilar meningitis
Viral cerebellitis
Cerebellar abscess
Wernicke encephalopathy/thiamine deficiency
Subacute Causes of Cerebellar Ataxia (Weeks to Months)
Paraneoplastic cerebellar degeneration
Brain tumors
Creutzfeldt-Jakob disease
Superficial siderosis
Anti-GAD ataxia
Tuberculosis meningitis
Sarcoidosis
Chronic Causes of Cerebellar Ataxia (Months to Years)
Ataxia associated with gluten sensitivity
Genetic ataxia
Mitochondrial disease
Multiple system atrophy
Idiopathic late-onset cerebellar ataxia
Episodic Causes of Cerebellar Ataxia
Genetic episodic ataxia
Psychogenic ataxia
Mitochondrial disease
Multiple sclerosis

Abbreviation: GAD, glutamic acid decarboxylase.

TABLE 82.3 Differential Diagnosis and Conditions That Can Mimic Cerebellar Ataxia

Sensory neuropathy/neuronopathy
Parkinsonism
Magnetic gait/normal pressure hydrocephalus
Vestibular problems
Upper motor neuron symptoms/spasticity
Muscle weakness
Orthopedic issues
Pain-related gait disturbance
Psychogenic movement disorders

The classical motor examination of ataxia can be divided into eight different categories, as outlined by the Scale for Assessment and Rating of Ataxia, a validated measure of ataxia severity. This scale has been extensively used by ataxia specialists to track ataxia progression. However, this scale does not assess eye movement abnormalities in ataxia. Video 82.1 demonstrates a complete Scale for Assessment and Rating of Ataxia examination.

Cerebellar dysarthria is often described as "scanning speech," which refers to words broken up into individual syllables. The speed of speech is slow, possibly to compensate for slurred speech, and the volume of speech is variable, which is the core feature of cerebellar dysfunction. To test for hand dexterity in ataxia, three tasks are commonly used: (1) finger-nose testing (the patient points repeatedly with his index finger from his or her nose to examiner's finger), (2) finger chase (the patient's index finger follow examiner's moving index finger as precisely as possible), and (3) fast alternating movements (the patient performs cycles of repetitive alternation of pronation and supination of the hand on his or her thigh). Patients with cerebellar ataxia overshoot on the finger chase exam and demonstrate intention tremor on finger-nose testing. During fast alternating movements, ataxic patients have irregular movements and often make errors of timing. To assess for lower extremity cerebellar function, patients are asked to perform the knee-shin-slide (the patient straightens one leg and uses the heel of the other leg to slide down the shin from the knee smoothly and precisely). Ataxia patients usually have difficulty performing a smooth sliding motion and/or having difficulty maintaining the position of the heel on the shin.

To assess stance, patients are asked to stand at a natural position to observe for truncal sway and/or titubation, which is an uncontrollable shaking movement of the trunk, especially during standing or walking. To bring out mild ataxia in stance exam, patients are instructed to stand with feet together, to stand in a tandem stance, to stand on either foot, or to hop on one foot. A useful test is to ask patients to close eyes while performing these maneuvers. A significant worsening in balance with eyes closed may indicate a component of sensory neuropathy, dorsal column disorders, or vestibulopathy.

The classical gait abnormality in ataxia is a wide-based gait. However, not all the ataxia patients have such gait. With mild ataxia, patients may only exhibit variable stride length and direction. Turning, especially when performed abruptly and rapidly, can sometimes bring out deficits in patients with mild ataxia. A wide-based gait is often a strategy that patient develop in more severe stages of the disease to compensate for loss of balance. The variability of walking direction and step length is a core feature of ataxia gait. The gait abnormalities in different stages of ataxia are demonstrated in Video 82.2. If a patient only experiences difficulty in walking upstairs, downstairs, or running, observing a patient performing such a task will usually yield important information to make a diagnosis.

Examining eye movements is an important component of the cerebellar examination. Specific abnormalities are often associated with different causes of ataxia. (1) Saccadic intrusion in fixed gaze (ie, square wave jerks) can be seen in Friedreich ataxia, (2) horizontal or vertical end-gaze nystagmus can occur in many types of ataxia, (3) hypo- or hypermetric saccades can be observed in many types of ataxia, (4) breakdown of smooth pursuit is often encountered SCA3, (5) slow saccades are typical for SCA2, (6) ophthalmoplegia/ophthalmoparesis that can be observed in sensory axonal neuropathy with dysarthria and ophthalmoplegia [SANDO]), and (7) ptosis can occur in SANDO and mitochondrial ataxia. Among these eye signs, nystagmus and hypo- or hypermetric saccades are most commonly encountered in many ataxic disorders; therefore, these signs can be helpful to differentiate cerebellar ataxia from sensory neuropathy, especially in the early stages of the disease when no cerebellar atrophy is found on neuroimaging. Video 82.3 demonstrates some of the eye movement abnormalities seen in ataxia patients.

The above-mentioned neurologic examination is helpful to establish the presence of ataxia. Other associated signs can, however, be critical to identify the specific etiology. Special attention should be paid to signs of parkinsonism, tremor, dystonia, myoclonus, sensory neuropathy, hyperreflexia, and upgoing toes, which can occur in some types of SCAs and also multiple system atrophy. Other signs during the physical examination can possibly aid the diagnosis, including telangiectasia (for ataxia telangiectasia), splenomegaly (for Niemann-Pick type C), scoliosis, and pes cavus (for Friedreich ataxia). Sensory neuropathy should be emphasized as an important part of the exam as several genetic forms of ataxia have prominent sensory neuropathy without cerebellar atrophy in the early stage of the diseases, such as Friedreich ataxia and *POLG* ataxia.

Once cerebellar ataxia has been established, a step-by-step approach should be implemented to pinpoint the specific causes (Fig. 82.2).

Laboratory Testing

Blood biomarkers can be useful to diagnose nutritional and immune-mediated causes for ataxia. Blood levels of vitamin B_{12} and vitamin E can be tested for vitamin deficiency associated ataxias. Blood vitamin B_1 levels and red blood cell transketolase activity can be measured for thiamine deficiency, but it is not clear whether these lab tests can accurately detect the thiamine deficiency in the brain. Clinicians should have a high clinical suspicion of Wernicke encephalopathy in individuals with a history of alcoholism, malnutrition associated with cancer, and those who have undergone gastric bypass surgery. Empirical treatment with thiamine should be implemented in ataxia patients with altered mental status and nystagmus.

Serum antibody levels can be very helpful to identify specific immune-mediated ataxia. For example, anti–glutamic acid decarboxylase (GAD) antibody can be associated with pure cerebellar ataxia or in the spectrum of stiff person syndrome. Additionally, serum antigliadin antibodies and tissue transglutaminase antibodies are associated with ataxia with gluten sensitivity. Anti-thyroperoxidase antibody can possibly indicate ataxia associated with steroid-responsive encephalopathy. Whether these antibodies are causal is still not entirely clear, but these antibodies are suggestive of an immune etiology for which treatment should be initiated.

Cerebrospinal fluid (CSF) analysis should be performed in acute or subacute ataxia patients with testing for viruses, bacteria, intrathecal immunoglobulin production, pleocytosis, glucose, and protein levels, to identify infectious and inflammatory causes of ataxia. CSF levels of protein 14-3-3 and RTQuic can aid the diagnosis of Creutzfeldt-Jakob disease. Low CSF glucose levels might indicate ataxia with glucose transporter type 1 deficiency, which has very diverse clinical presentations and sometimes predominantly cerebellar ataxia.

If acquired causes of cerebellar ataxia have been excluded and/or there is a family history of ataxia, particularly first-degree relatives, genetic tests should be ordered, which is detailed in the following text.

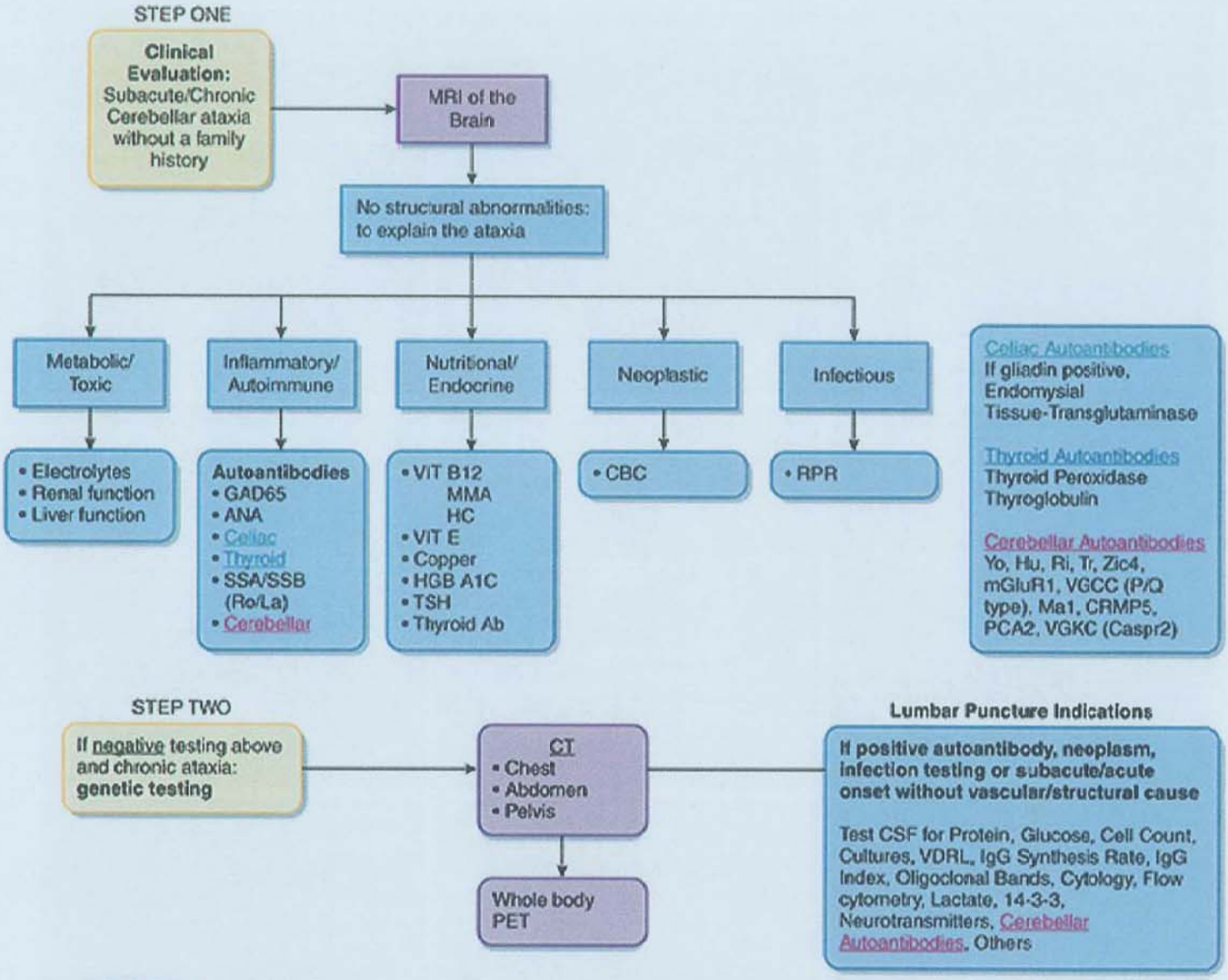

FIGURE 82.2 Flowsheet for ataxia diagnosis. Abbreviations: ANA, antinuclear antibody; CBC, complete blood count; CSF, cerebrospinal fluid; CT, computed tomography; GAD65, glutamic acid decarboxylase, 65 kDa isoform; HgbA1c, hemoglobin A1c; IgG, immunoglobulin G; mGluR1, metabotropic glutamate receptor 1; MRI, magnetic resonance imaging; PET, positron emission tomography; RPR, rapid plasma reagin; TSH, thyroid-stimulating hormone; vit, vitamin; VDRL, Venereal Disease Research Laboratory; VGCC, voltage-gated calcium channel.

Neuroimaging

Brain magnetic resonance imaging (MRI) is the most commonly employed neuroimaging for ataxia and it used to identify any structural and vascular lesions: brain tumors, abscess, ischemic and hemorrhagic strokes, or demyelinating lesions of multiple sclerosis, and to assess the degree of cerebellar atrophy. Clinicians should evaluate the size of the cerebellum at the vermis, paravermis, and hemispheric regions (Fig. 82.3A-D), which might correspond to clinical symptoms. As the cerebellum degenerates, the foliation of cerebellar lobules becomes prominent. The anterior lobules of the cerebellum are critical for motor control, and the atrophy in this region is often associated with ataxia. On the other hand, the posterior lobules of the cerebellum may be related to the nonmotor features of cerebellar dysfunction such as depression and emotional lability; therefore, atrophy in the posterior lobules in patients might present with prominent cognitive and emotional dysfunction, termed the *cerebellar cognitive affective syndrome*. As mentioned earlier, vermal atrophy might be associated with trunk and gait ataxia, whereas paravermal atrophy might be related to appendicular ataxia. Interestingly, some forms of ataxia may not be associated with cerebellar atrophy on brain MRI, especially in the early stage. These ataxias have predominantly sensory neuronopathy, such as Friedriech ataxia, ataxia with vitamin E deficiency, and *POLG* ataxia.

Besides cerebellar atrophy, other brain MRI findings might indicate a specific diagnosis. A hot cross bun sign (a cross sign

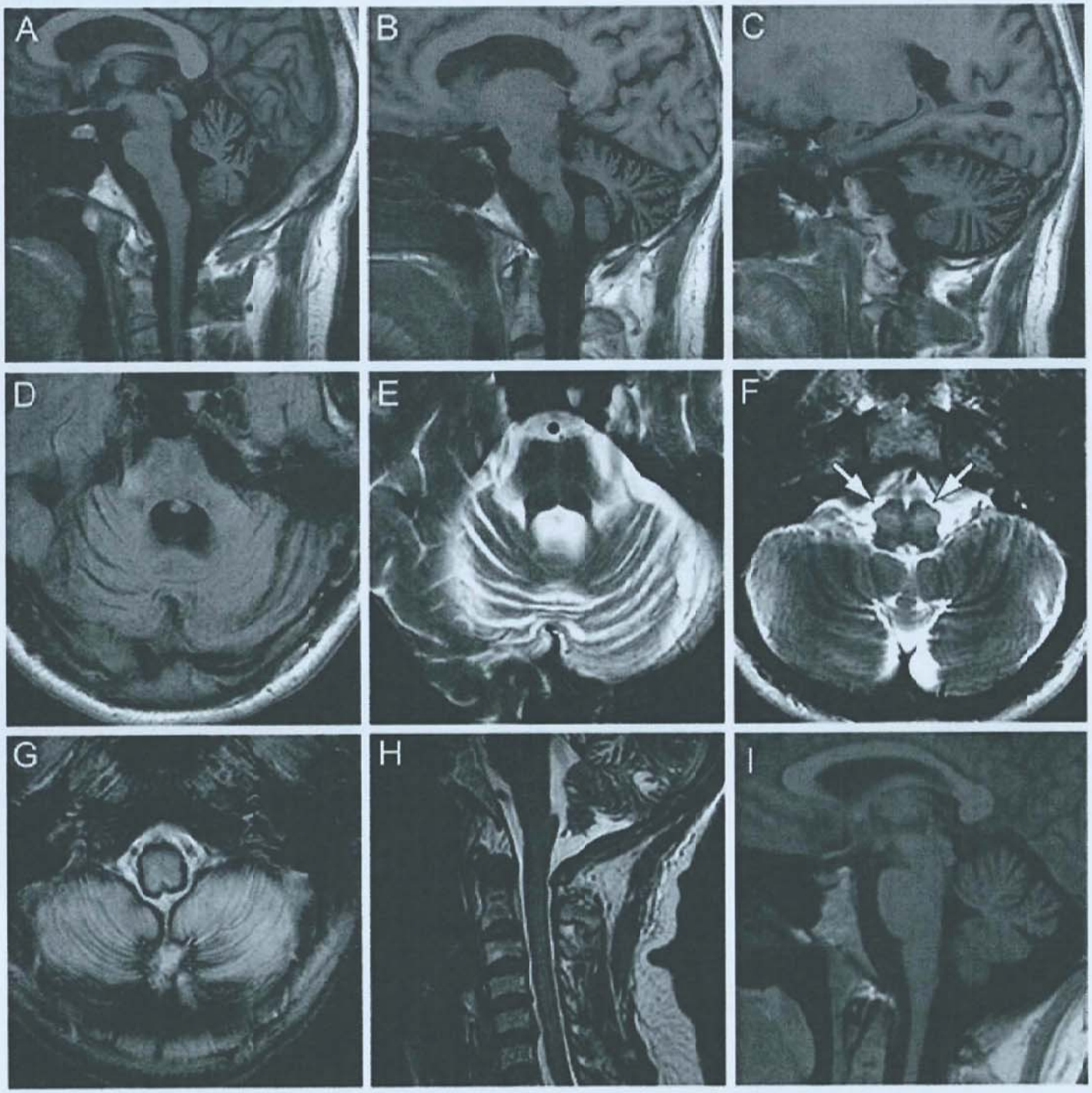

FIGURE 82.3 Neuroimaging of ataxia. Sagittal T1 brain magnetic resonance imaging (MRI) demonstrates cerebellar atrophy in a multiple system atrophy patient. Note that there is prominent cerebellar foliation and sulci in the vermis **(A)**, paravermis **(B)**, and hemisphere **(C)** along with pontine atrophy **(A)**. **D:** Prominent sulci also noted in the axial fluid-attenuated inversion recovery sequence in the same case. **E:** T2 sequence of the axial brain MRI shows the hot cross bun sign in the pons of a case of multiple system atrophy. **F:** T2 sequence of the axial brain MRI demonstrates hyperintensities in the bilateral inferior olivary nuclei in a case of *POLG* ataxia *(arrows)*. T2 sequence of the axial and sagittal MRI demonstrated T2 hypointensity surrounding the brainstem and the cerebellum **(G)** and the spinal cord **(H)** in a case of superficial siderosis. **I:** T1 sequence of the sagittal MRI of the brain showed no cerebellar atrophy but spinal cord atrophy in a case of Friedreich ataxia.

in the pons on T2 brain MRI), although nonspecific, is often seen in multiple system atrophy (Fig. 82.3E). A typical MRI finding in Wernicke encephalopathy is T2 hyperintensity in the mammillary bodies, periaqueductal grey, and paraventricular thalamus. Cerebrotendinous xanthomatosis and adult-onset Alexander disease can have bilateral, periventricular white matter changes. T2 hyperintensity in the bilateral inferior olivary nucleus suggesting hypertrophic neuronal degeneration can occur in *POLG* ataxia, adult-onset Alexander disease, and ataxia with gluten sensitivity (Fig. 82.3F). Special MRI sequences can be helpful to distinguish specific types of ataxia. For example, the gradient echo sequence demonstrating linear hypointensity along the cerebellum, brainstem, and spinal cord is typical of superficial siderosis (Fig. 82.3G,H), and diffusion-weighted imaging showing cortical ribboning is suggestive of Creutzfeldt-Jakob disease. Other than the cerebellum, special attention should be paid to the spinal cord and the brainstem because spinal cord atrophy can be seen in Friedreich ataxia (Fig. 82.3I), and brainstem atrophy is often present in adult-onset Alexander disease.

Other Diagnostic Tests

Other tests to confirm the extracerebellar symptoms might aid in narrowing the differential diagnosis for the etiology of ataxia. Autonomic nervous system testing showing orthostatic hypotension and/or urinary disturbance and a sleep study demonstrating rapid eye movements behavior disorder is helpful to diagnose multiple system atrophy. A dopamine transporter scan can be used to determine whether there is presynaptic dopamine terminal loss. Sensory neuropathy, which may occur in many forms of autosomal recessive ataxia, can be evaluated by electromyography/nerve conduction studies. An electroencephalogram with characteristic periodic sharp wave complex can help diagnose Creutzfeldt-Jakob disease.

ACQUIRED ATAXIA

Cerebellar signs and symptoms result from a variety of insults to the cerebellum and its connections. Broadly, cerebellar dysfunction that is due to specific environmental, toxic, metabolic, or vascular insults is considered acquired ataxias. A list of potential etiologies for acquired ataxia is presented in Table 82.4. As noted in Table 82.4, it is important to determine the acuity of symptom onset and duration of symptoms to determine possible etiologies for ataxia. This is particularly important because some of the acquired causes for ataxia are treatable, particularly when duration of symptoms is brief. Two categories of particularly relevant ataxias are considered here: vascular and immune ataxias.

Cerebellar Stroke

The most common cause for acute cerebellar ataxia is vascular insult to the cerebellum. Vascular etiologies include cerebellar infarcts or hemorrhage. Cerebellar dysfunction may

TABLE 82.4 Acquired Causes of Ataxia

Entity	Diagnostic Process
Vascular disease	History of strokes, imaging
Hypoxic encephalopathy	History of hypoxic episodes
Demyelinating disease	Remitting and relapsing episodes, imaging, CSF analysis
Tumors in the posterior fossa	Imaging, with contrast
Craniovertebral junction anomalies	Imaging
Toxic disorders:	History
Alcohol	
Chemotherapy (5-fluorouracil, ara-C, methotrexate)	
Metals (mercury, bismuth, lithium, lead)	
Solvents (toluene)	
Anticonvulsants (phenytoin, lithium)	
Infectious/inflammatory disease:	History, imaging, serology, CSF analysis
Acute cerebellar ataxia of childhood, acute cerebellitis	History, imaging, CSF analysis
Postinfectious	Imaging, CSF analysis
Bickerstaff encephalitis	Serology
Human immunodeficiency virus	CSF 14-3-3, imaging, electroencephalogram, biopsy
Creutzfeldt-Jakob disease	Small intestine biopsy
Whipple disease	CSF analysis for JC virus
Progressive multifocal leukoencephalopathy	
Autoimmune	Serology
Paraneoplastic	Anti-Hu, anti-Yo, anti-Ri, others
Gluten sensitivity	Antigliadin, antitissue transglutaminase
Anti-GAD ataxia	Anti-GAD
Anti-GluRδ2	Anti-GluRδ2
Superficial siderosis	Imaging
Nutritional	Blood
Vitamin B_1 deficiency	Vitamin B_1 level
Vitamin B_{12} deficiency	Vitamin B_{12} level
Vitamin E deficiency	Vitamin E level

Abbreviations: CSF, cerebrospinal fluid; GAD, glutamic acid decarboxylase.

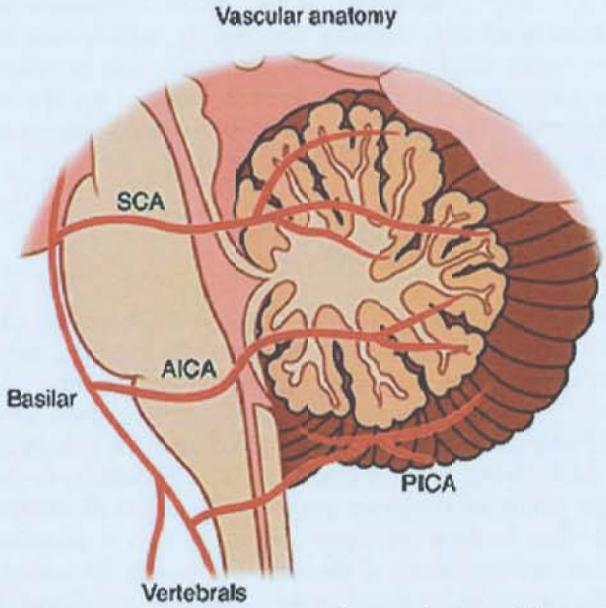

FIGURE 82.4 Vascular anatomy of the cerebellum. Abbreviations: AICA, anterior inferior cerebellar artery; PICA, posterior inferior cerebellar artery; SCA, superior cerebellar artery.

be a component of a broader stroke syndrome such as due to infarcts resulting from occlusion of the posterior inferior cerebellar artery (vascular supply to the cerebellum summarized in Fig. 82.4). Isolated cerebellar ataxia may result from a branch occlusion of the superior cerebellar artery. Occlusion of the anterior inferior cerebellar artery may result in cerebellar ataxia with deafness on the affected side.

Spontaneous cerebellar hemorrhage most often presents as altered consciousness, with nausea or vomiting due to elevated intracranial pressure, but can present with cerebellar ataxia.

Paraneoplastic and Autoimmune Ataxia

Autoimmune cerebellar syndromes represent a small subset of ataxias. These are however, important to recognize for two reasons. These disorders may be responsive to treatment, particularly when recognized early, and also because some of the autoimmune ataxias help understand disease pathogenesis in inherited forms of ataxia. A subset of autoimmune ataxias is associated with an underlying, often occult malignancy. The neurologic symptoms, believed to be a result of immune cross-reactivity between the tumor and cerebellar antigens, may suggest the presence of a previously unidentified tumor. The ataxia would therefore be considered a paraneoplastic syndrome: a remote effect of an underlying tumor. Specific immune ataxias are described in the following text.

Classic Paraneoplastic Cerebellar Ataxia

The canonical paraneoplastic ataxias are associated with circulating antibodies directed against Yo (also known as *PCA1*), Hu (also known as *ANNA1*), Tr, Ri, CRMP5 (also known as *CV2*), and Ma. The epitopes are intracellular antigens, and there is considerable controversy as to whether the antibodies themselves are causal, versus the manifestation of a T cell–mediated process of autoimmunity. There is a strong association between breast and ovarian cancer with anti-Yo antibodies. Anti-Hu antibodies are strongly associated with detection of small cell lung cancer. The detection of the underlying malignancy may follow the cerebellar syndrome by months to years. An occult malignancy may be detected up to 4 years after symptoms onset; therefore, tumor surveillance at least annually is needed for patients who do not have identifiable malignancy.

Cerebellar Ataxias Resulting from Ion Channel Antibodies

Patients with elevated levels of antibodies directed against voltage-gated calcium channels (VGCC, P/Q, and N type), and voltage-gated potassium channels (Caspr2) may present with cerebellar ataxia. P/Q type calcium channels are particularly highly expressed in Purkinje cells, and in mouse models, reduced channel activity is associated with ataxia. In humans, mutations in *CACNA1A*, the gene encoding the P/Q calcium channel results in episodic ataxia type 2, as well as SCA6. Patients with antibodies against P/Q VGCC may also present with concomitant Lambert-Eaton myasthenic syndrome. Although small cell lung cancer is associated with VGCC-related ataxia, a substantial proportion of patients never have an underlying malignancy.

Ataxia Due to Other Accessible/Cell-Surface Antigens

Unlike the classic paraneoplastic ataxias, antibodies directed against metabotropic glutamate receptor 1 (mGluR1), GluRδ2, and glutamic acid decarboxylase, 65 kDa isoform (GAD65) antibodies are likely causal in disease. Although GAD65 is intracellularly located, access to the antigen is likely possible during synaptic vesicle release. Note that anti-GAD antibody is also associated with diabetes and stiff person syndrome and could coexist with cerebellar ataxia.

Gluten Ataxia

Cerebellar ataxia is a neurologic manifestation of celiac disease, a disorder that is associated with gluten sensitivity. Clinically, gastrointestinal symptoms may or may not be present, with characteristic changes, including changes in villus and crypt morphology, and inflammation in the epithelium on duodenal biopsies. Antibodies directed against gliadin, tissue-transglutaminase (specifically transglutaminase 6) are markers of disease because transglutaminase 6 is important for brain function, whereas antibodies against tissue transglutaminase 2 is a hallmark for celiac disease. Interestingly, a rare genetic form of ataxia results from mutations in transglutaminase 6, causing SCA35. Importantly, a gluten-free diet reduces antibody levels over time and can improve neurologic symptoms.

Neurosarcoidosis

Sarcoidosis (see also Chapter 75) could involve multiple brain regions, including the cerebellum and also meninges, causing cerebellar ataxia and often other associated cranial nerve deficits. Pathologic examination often shows typical granuloma formation (Fig. 82.5).

INHERITED ATAXIAS

Spinocerebellar Ataxia

The spinocerebellar ataxias (SCAs) are a group of dominantly inherited disorders that result from dysfunction and degeneration of the cerebellum and its associated pathways. Although over 40 genes are currently recognized to result in SCA, shared mechanisms for disease pathogenesis exist. The most common SCAs result from a glutamine encoding CAG repeat in the respective

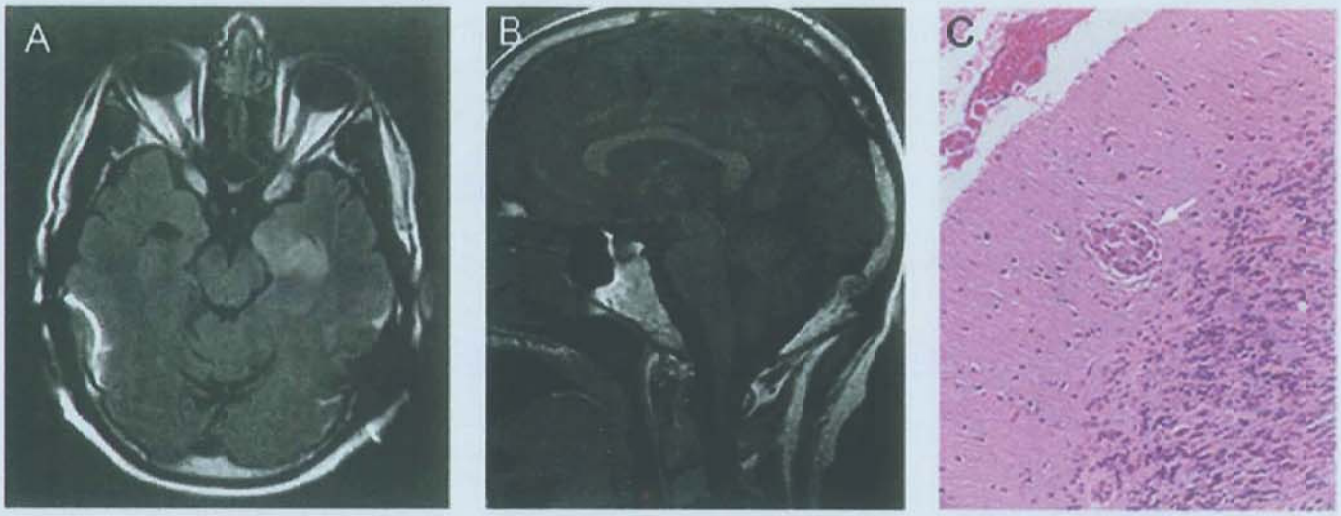

FIGURE 82.5 Neurosarcoidosis. A 51-year-old man with bilateral hearing loss and progressive ataxia. His brain magnetic resonance imaging (MRI) demonstrates hyperintensity in the left medial temporal region on an axial fluid-attenuated inversion recovery sequence **(A)** and cerebellar atrophy on a sagittal T1 sequence **(B)**. Postmortem examination shows that granuloma in the cerebellar cortex **(C)** *(arrow)*, confirming the diagnosis of neurosarcoidosis.

disease genes. In this section, we discuss the varied genetic etiology of SCA and attempt to categorize these disorders based on shared mechanisms of disease. We also summarize the evaluation and management for SCAs.

Introduction

The autosomal dominant cerebellar ataxias (ADCAs), currently known primarily by the designation SCA, are a heterogeneous group of degenerative disorders. Cerebellar ataxia is a core symptom of the SCAs. Other symptoms and signs are variable and disease-specific, including parkinsonism, dystonia, tremor, long-tract signs, peripheral neuropathy, cognitive decline, and seizures (Table 82.5). The polyglutamine (polyQ) ataxias, including SCA1, SCA2, and SCA3, are progressive disorders and lead to shortened lifespan. Several other autosomal dominant ataxias, such as SCA6, cause motor dysfunction, often leading to wheelchair confinement but are not associated with premature death. The first widely accepted systematic classification of dominantly inherited ataxias was proposed in 1993 by Harding. This scheme included ADCA type I in which cerebellar ataxia is variably associated with other neurologic features including dysfunction of the central and/or peripheral nervous system; SCA1, SCA2, and SCA3 all represent type I and are among the most common SCAs. For example, dystonia is commonly seen in SCA3 patients (Fig. 82.6A). In ADCA type II, ataxia is associated with a pigmentary retinopathy; SCA7 is the only ADCA belonging to type II (Fig. 82.6B). ADCA type III is characterized by relatively pure cerebellar ataxia, of which SCA6 is the most common. Although this classification currently has limited clinical utility, it remains useful to classify the ADCAs into those typically presenting with relatively pure ataxia and those accompanied by other neurologic symptoms and signs.

Genetics and Molecular Pathogenesis

An array of genetic causes leads to SCAs. The specific genes and associated features are summarized in Table 82.5. Distinct genes account for more than 35 dominantly inherited ataxias. Groups of disorders can be recognized, however, based on shared mechanisms of disease. These groups include the CAG repeat polyQ ataxias, ataxias associated with noncoding repeats, ataxias associated with ion channel dysfunction, and ataxias associated with mutations in signal transduction molecules.

CAG Repeat Polyglutamine Ataxias

Expansion of a glutamine-encoding CAG repeat accounts for disease in several of SCAs, including SCA1, SCA2, SCA3, SCA6, SCA7, SCA12, SCA17, and dentatorubral pallidoluysian atrophy. SCA1, SCA2, SCA3, and SCA6 represent the majority of SCAs. Additionally, SCA8 likely results from the combined gain-of-function effects of a noncoding CTG repeat expansion leading to toxic messenger RNA and noncanonical translation of peptides from the repeat (so-called RAN translation products) as well as from the generation of a pure polyQ protein from the corresponding CAG repeat on the opposite strand. The polyQ disorders commonly show the phenomenon of anticipation, in which disease onset tends to occur earlier in successive generations. Anticipation is due to CAG repeat instability in the germ line leading to further repeat expansion in successive generations. Anticipation is most prominent in SCA7, which displays marked anticipation of approximately 20 years per generation. The polyQ SCAs frequently are associated with additional neurologic features that vary among the SCAs and even within an SCA, in part due to variation in CAG repeat length (summarized in Table 82.5; video demonstration in ▷ Video 82.4 and ▷ Video 82.5).

It is likely that multiple mechanisms account for disease in the polyQ ataxias. Several mechanisms have been proposed. These include the following:

- Transcriptional dysregulation
- Alterations in membrane excitability due to ion channel dysfunction
- Protein misfolding
- Formation of toxic oligomeric complexes
- Mitochondrial dysfunction
- Impaired axonal transport
- RNA toxicity

Recent work suggests the protein context of the polyQ expansion is important in order to understand disease pathogenesis.

TABLE 82.5 Summary of Clinical Features, Genes, and Molecular Pathogenesis of Autosomal Dominant Ataxias

Name	Symptoms/Signs[a]	Locus	Gene	Protein/Mutation[b]	Normal Function
SCA1	Pyramidal signs Extrapyramidal signs Amyotrophy Ophthalmoparesis	6p23	*ATXN1*	Ataxin-1 (ATXN1) CAG repeats, 41-81 (normal 25-36)	Gene transcription and RNA splicing
SCA2	Slow saccades Extrapyramidal signs Peripheral neuropathy Ophthalmoplegia Pyramidal signs Dementia (rare)	12p24	*ATXN2*	Ataxin-2 (ATXN2) CAG repeats, 35-59 (normal 15-24)	RNA processing
SCA3 (MJD)	Pyramidal signs Amyotrophy Exophthalmos Extrapyramidal signs Ophthalmoparesis	14q24.3-q31	*ATXN3*	Ataxin-3 (ATXN3) CAG repeats, 62-82 (normal 13-36)	Deubiquitinating enzyme
SCA4	Sensory axonal neuropathy Pyramidal signs	16q22.1	Unknown but distinct from SCA31	Unknown	Unknown
SCA5	Pure cerebellar ataxia (late onset) Pyramidal signs (early onset)	11q13	*SPTBN2*	β-III spectrin	Scaffolding protein involved in glutamate signaling
SCA6	Pure cerebellar ataxia Late onset, usually >50 y	19p13.2	*CACNA1A*	Cav2.1 CAG repeats, 21-30 (normal 6-17)	Calcium channel important in Purkinje cells
SCA7	Pigmentary macular degeneration Ophthalmoplegia Pyramidal signs	3p21.1-p12	*ATXN7*	Ataxin-7 CAG repeats, 38-130 (normal 7-17)	Gene transcription
SCA8	Pyramidal signs Diminished vibratory sense Spastic and ataxic dysarthria	13q21.33	*ATXN8OS/ATXN8*	CAG/CTG repeats, 80-250 (normal 15-50) Toxic mRNA Pure polyglutamine protein	Unknown
SCA9	Extrapyramidal signs Ophthalmoplegia Posterior column dysfunction Pyramidal tract signs Central demyelination (one patient)	Unknown	Unknown	Unknown	Unknown
SCA10	Seizures Cognitive/neuropsychiatric impairment Polyneuropathy Pyramidal signs	22q13.31	*ATXN10*	Ataxin-10 Intronic ATTCT repeats, 800-4,500 (normal 10-32)	Involved in neuron survival, neuron differentiation, and neuritogenesis
SCA11	Pure cerebellar ataxia	15q15.2	*TTBK2*	τ-tubulin kinase 2	Serine-threonine kinase Regulates ciliogenesis
SCA12	Upper extremity tremor Mild/absent gait dysfunction Hyperreflexia	5q32	*PPP2R2B*	Protein phosphatase PP2A CAG repeats in 5′-UTR, 51-78 (normal 7-32)	Serine-threonine phosphatase Negative control of cell growth and division
SCA13	Intellectual disability (in French pedigree) Pure cerebellar ataxia (in Filipino pedigree)	19q13.3-13.4	*KCNC3*	Kv3.3	Potassium channel involved in regulating Purkinje cell excitability
SCA14	Pure cerebellar ataxia Rare chorea and cognitive deficits	19q13.4	*PRKCG*	Protein kinase Cγ	Neuronal serine-threonine protein kinase
SCA15/ SCA16	Pure cerebellar ataxia Rare tremor or cognitive impairment	3p26.1	*ITPR1*	Inositol 1,4,5-triphosphate receptor type 1	Intracellular calcium channel Regulation of neuronal excitability
SCA17/ HDL4	Chorea Dementia Extrapyramidal features Hyperreflexia Psychiatric symptoms	6q27	*TBP*	TATA box-binding protein CAG repeats, 46-63 (normal 25-42)	Gene transcription
SCA18/ SMNA	Posterior column dysfunction Amyotrophy Early onset, usually <20 y Hyporeflexia	7q22-q32	Unknown	Unknown	Unknown

TABLE 82.5 Summary of Clinical Features, Genes, and Molecular Pathogenesis of Autosomal Dominant Ataxias *(continued)*

Name	Symptoms/Signs[a]	Locus	Gene	Protein/Mutation[b]	Normal Function
SCA19/ SCA22	Pure cerebellar ataxia Cognitive impairment Myoclonus Postural tremor	1p13.3	*KCND3*	Kv4.3	Potassium channel involved in regulating neuronal excitability
SCA20	Spasmodic dysphonia or spasmodic coughing Palatal tremor	11p11.2-q13.3	Unknown	Gene duplication	Unknown
SCA21	Early onset Cognitive impairment Akinesia Resting tremor Rigidity Dysgraphia Hyporeflexia Postural tremor	7p21.3-p15.1	Unknown	Unknown	Unknown
SCA23	Late onset, usually >50 y Decreased vibratory sense	20p13	*PDYN*	Prodynorphin	Processed to form opioid peptides that bind to κ-type opioid receptors
SCA25	Areflexia Peripheral sensory neuropathy	2p21-p15	Unknown	Unknown	Unknown
SCA26	Pure cerebellar ataxia	19p13.3	*EEF2*	Eukaryotic translational elongation factor 2	Protein synthesis
SCA27	Orofacial dyskinesia Cognitive impairment Tremor	13q34	*FGF14*	Fibroblast growth factor 14	Interacts with voltage-gated sodium channels Regulates Purkinje neuron excitability
SCA28	Early onset, usually <20 y Hyperreflexia Ophthalmoparesis Ptosis	18p11.22-q11.2	*AFG3L2*	ATPase family gene 3-like 2	Mitochondrial protein synthesis
SCA29	Congenital Nonprogressive	3p26.1	*ITPR1*	Inositol 1,4,5-triphosphate receptor	Intracellular calcium channel Regulation of neuronal excitability
SCA30	Late onset, usually >50 y Pure cerebellar ataxia	4q34.3-q35.1	Unknown	Unknown	Unknown
SCA31	Pure cerebellar ataxia Late onset, usually >50 y Sensorineural hearing loss	16q22	*BEAN1* and *TK2*	Brain expressed, associated with NEDD4 Thymidine kinase 2 TGGAA repeat in intron shared by both genes	Unknown
SCA32	Cognitive impairment if onset <40 y Azoospermia	7q32-q33	Unknown	Unknown	Unknown
SCA34	Skin erythema and keratosis Nystagmus Decreased DTRs	6p12.3-q16.2	*ELOVL4*	Elongation of very long chain fatty acids protein 4	Fatty acid synthesis
SCA35	Pyramidal signs Pseudobulbar palsy	20p13	*TGM6*	Transglutaminase 6	Posttranslational modifications of glutamine residues
SCA36	Lower motor neuron involvement Tongue atrophy	20p13	*NOP56*	Nucleolar protein 56 Intronic GGCCTG repeat	Pre-mRNA processing
SCA37	Abnormal vertical eye movements Nystagmus	1p32.2	*DAB1*	Drosophila homolog of disabled 1	Microtubule function, neuronal migration
SCA38	Pure cerebellar ataxia Axonal neuropathy	6p12.1	*ELOVL5*	Elongation of very long chain fatty acids protein 5	Fatty acid synthesis
SCA39	Spasticity Horizontal gaze palsy	11q21-q22.3	Unknown	Unknown	Unknown
SCA40	Spasticity	14q32.11	*CCDC88C*	DAPLE	Signal transduction regulation

(table continues on page 842)

TABLE 82.5 Summary of Clinical Features, Genes, and Molecular Pathogenesis of Autosomal Dominant Ataxias *(continued)*

Name	Symptoms/Signs[a]	Locus	Gene	Protein/Mutation[b]	Normal Function
SCA41	Pure cerebellar ataxia	4q27	*TRPC3*	Transient receptor potential cation channel subfamily c member 3 (TRPC3)	Ion channel involved in setting membrane excitability
SCA42	Pure cerebellar ataxia in the majority of patients	17q21	*CACNA1G*	Cav3.1	Calcium channel involved in setting membrane excitability
SCA43	Peripheral neuropathy	3q25	*MME*	Membrane metalloendopeptidase	Inactivates peptide hormones
SCA44	Pure cerebellar ataxia	6q24	*GRM1*	Metabotropic glutamate receptor 1	G-protein–coupled receptor involved in glutamate signaling
SCA45	Pure cerebellar ataxia	5q33	*FAT2*	Homolog of Drosophila fat tumor suppressor 2	Tumor suppressor gene
SCA46	Sensory ataxic neuropathy Cerebellar dysarthria in some	19q13.2	*PLD3*	Phospholipase D family, member 3	Membrane protein involved in APP processing
SCA47	Pure cerebellar ataxia	1p35.2	*PUM1*	Homolog of Drosophila pumilio 1	RNA binding protein that negatively regulates ATXN1
SCA48	Cognitive dysfunction	16p13.3	*STUB1*	STIP1 homologous and U box containing protein 1	E3 ubiquitin ligase that promotes ubiquitylation
DRPLA	Myoclonic epilepsy Choreoathetosis Dementia	12p13.31	*ATN1*	Atrophin 1 CAG repeats, 49-75 (normal 7-23)	Transcriptional coregulator

Abbreviations: DRPLA, dentatorubral pallidoluysian atrophy; HDL4, Huntington disease-like 4; MJD, Machado-Joseph disease; mRNA, messenger RNA; PP2A, protein phosphatase 2; SCA, spinocerebellar ataxia; SMNA, sensorimotor neuropathy with ataxia; UTR, untranslated region.
[a]Not all patients have all the symptoms/signs mentioned.
[b]Mutation refers to point mutations in the respective genes, unless otherwise specified.

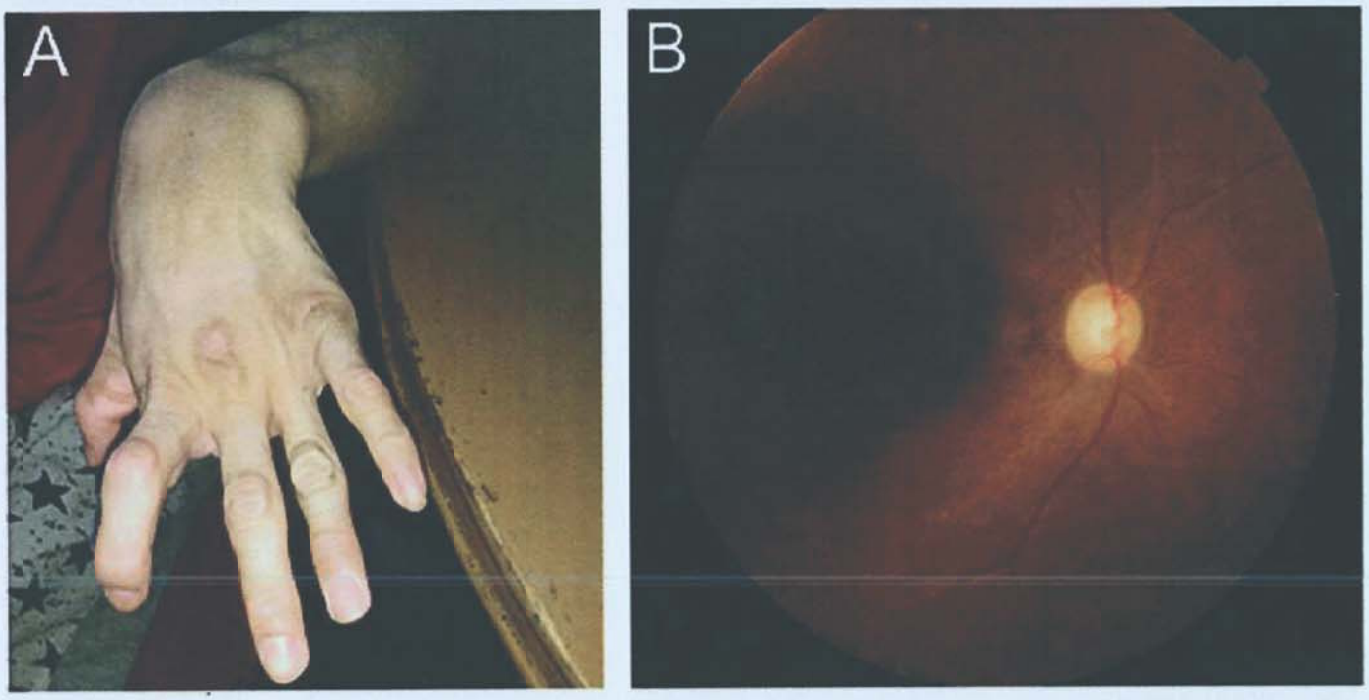

FIGURE 82.6 Associated signs and symptoms in spinocerebellar ataxias (SCAs). Hand dystonia in an SCA3 patient **(A)** and pigmentary retinal degeneration in an SCA7 patient **(B)**.

For example, in SCA1, the polyQ expansion alone is insufficient to cause disease if the protein interaction of the disease associated protein ATXN1 is disrupted.

Ataxias Associated With Noncoding Repeats

Expansion of repeats in nontranscribed regions likely underlies disease in SCA8, SCA10, SCA12, SCA31, and SCA36. Recent work has suggested that repeat associated non-AUG translation (RAN translation) may play a role in both noncoding RNA and in CAG repeat containing genes. These noncoding RNAs elicit a variety of toxic function, leading to cerebellar dysfunction.

Ataxias Associated With Ion Channel Dysfunction

Dysfunction of ion channels has been implicated in the pathogenesis of several SCAs. In some cases, channel dysfunction directly reflects ion channel mutations, whereas in others secondary channel dysfunction has been implicated.

- SCA5 results from mutations in the β-III spectrin gene. The disease protein is highly expressed in Purkinje cells and functions to stabilize the Purkinje cell–specific glutamate transporter. In SCA5, these neurons also exhibit reduced spontaneous firing and smaller sodium currents potentially also contributing to disease. In a transgenic mouse model of SCA5, Purkinje cell dysfunction appears to be related to β-III spectrin interaction with and dysregulation of the mGluR1.
- SCA6 is caused by polyQ expansion in a neuronal P/Q-type VGCC, Cav2.1. The mechanism by which this mutation causes disease remains unclear but may include both altered channel function due to haploinsufficiency and gain of function associated with a polyQ expansion harboring C-terminal fragment. Recent work in SCA6 has identified alternative transcript of the *CACNA1A* gene that results in a transcription factor, α1ACT, which coordinates expression of a program of genes involved in Purkinje cell development.
- SCA13 is caused by mutations in the *KCNC3* gene, which encodes the voltage-gated potassium channel Kv3.3. This potassium channel is expressed throughout the brain but is enriched in Purkinje cells, a susceptible cell population in SCA13. Mutations are thought to lead to a dominant-negative suppression of current through this channel or altered channel gaiting.
- SCA15/16 results from mutations in the inositol 1,4,5-triphosphate receptor 1, an intracellular ligand-gated calcium channel highly expressed in Purkinje cells.
- SCA19/22 results from loss-of-function mutations in the *KCND3* gene, encoding the Kv4.3 potassium channel. Loss of channel function is the presumed cause of ataxia in this disorder.
- SCA27 is caused by mutations in *FGF14* that likely lead to abnormal expression of voltage-gated sodium channels in cerebellar neurons. Mice lacking FGF14 are noted to be phenotypically similar to humans with SCA27 and have altered Purkinje cell firing attributed to reduced expression of Nav1.6, a sodium channel necessary for repetitive firing.
- SCA41 is caused by mutations in *TRPC3*, a nonselective cation channel, that is, enriched in the cerebellum and influences Purkinje cell membrane excitability.
- SCA42 is caused by mutations in the calcium channel, Cav3.1, which is highly expressed in the cerebellum.
- SCA44 is caused by mutations in *GRM1*, which codes for mGluR1. Notably, the abnormal gain of function of mGluR1 in SCA44 differs from the loss of mGluR1 function seen in SCA5.

Ataxias Associated With Mutations in Signal Transduction Molecules

Mutations in genes implicated in signal transduction cause ataxia in SCA11, SCA12, SCA14, SCA23, and SCA40, although alterations in signal transduction pathways likely are indirectly involved in most SCAs.

- SCA11 is caused by loss-of-function mutations in *TTBK2*, a serine-threonine kinase in the casein kinase 1 family. There is evidence that this enzyme regulates the initiation of ciliogenesis.
- SCA12 is caused by a CAG repeat expansion in the 5′-untranslated region of the protein phosphatase PP2A. The exact mechanism by which this expansion leads to disease is unclear. There are likely shared features with other noncoding repeat disorders.
- SCA14 results from mutations in protein kinase C γ, an isoform highly expressed in Purkinje cells. Data from a mouse model suggests that this protein is important for synapse pruning, synaptic plasticity, and synaptic transmission in Purkinje cells.
- SCA23 results from mutations in *PDYN*, which encodes prodynorphin, an opioid neuropeptide precursor protein that is processed to α-neoendorphin and dynorphins A and B. Putative mechanisms of disease based on cellular models include glutamate neurotoxicity causing Purkinje cell degeneration and ataxia induced by alterations in a dynorphin A activity and/or impaired secretory pathways by mutant PDYN.
- SCA40 is caused by a missense mutation in *CCDC88C* that results in a gain of function ultimately triggering c-Jun N-terminal kinase–mediated neuronal apoptosis.

Animal models have significantly contributed to current knowledge of the SCAs, including the underlying pathophysiology. These models have provided a useful mechanism for understanding how genetics inform disease processes and will likely serve as critical tools for developing potential therapies in the future.

Genetic Testing

Although there is considerable phenotypic variability within the SCAs, certain clinical features often are helpful in prioritizing genetic testing (see Table 82.5). Geographic origin and ethnicity are also frequently helpful (eg, SCA3 in Brazil/Portugal, SCA2 in Cuba). In general, a reasonable approach is to pursue genetic testing in a sequential, stratified fashion based on phenotype. This is most applicable in cases where a clearly associated feature is present in addition to ataxia, such as vision loss in SCA7. Most associated features in other SCAs do not reach this level of reliability, and in these cases, screening for the most common autosomal dominant SCAs as a first step is likely of higher yield.

A suggested approach for genetic testing in sporadic and familial ataxias is to first test for the most common SCAs, such as types SCA1, SCA2, SCA3, SCA6, and SCA7, as well as for Friedreich ataxia, before pursuing testing such as whole exome sequencing (see the following text).

Currently, there are commercially available targeted genetic tests for SCA1, SCA2, SCA3, SCA4, SCA5, SCA6, SCA7, SCA8, SCA10, SCA11, SCA12, SCA13, SCA14, SCA15/16, SCA17, SCA18, SCA19/22, SCA23, SCA27, SCA28, SCA29, SCA31, SCA35, SCA36, and dentatorubral pallidoluysian atrophy. Recently, technology for genome-wide sequencing has become

available clinically. Sequencing the exome, the approximately 1% of the genome expressed as protein, allows for simultaneous evaluation of the entire human genome to localize protein-altering sequence variation. If acquired causes have been fully evaluated and testing for the most common heritable causes is unrevealing, whole exome sequencing is a reasonable next step. Limitations of this technology include its relatively poor ability to detect certain types of mutations including repeat expansions, noncoding variants, and large deletions/duplications.

Autosomal Recessive Ataxia

Autosomal recessive ataxia can be divided into three categories: (1) cerebellar ataxia with predominant sensory neuronopathy, (2) cerebellar ataxia with sensorimotor axonal neuropathy, (3) cerebellar ataxia without sensory neuropathy. Table 82.6 lists common causes of autosomal recessive ataxia in the respective categories. As compared to autosomal dominant ataxia, recessive ataxia usually has earlier age of onset in childhood and presents with involvement of retina, cerebral cortex, basal ganglia, corticospinal tracts, and peripheral nerves, leading to complex multisystem phenotypes. The involvement of peripheral nerves is the key feature of the exam in identifying the genetic basis of autosomal recessive ataxia as detailed in the following text.

Cerebellar Ataxia With Predominant Sensory Neuropathy (Friedreich Ataxia)

The prototypical disease for the category of cerebellar ataxia with predominant sensory neuronopathy is Friedreich ataxia, which is the most common recessive ataxia. Friedreich ataxia patients have an age of onset from childhood to third decade. Clinical features often include pes cavus, scoliosis, square wave jerks, areflexia, vibratory, and proprioceptive sensory loss. Large fiber sensory neuronopathy is a key feature of Friedreich ataxia with pain and temperature sensation relatively preserved. Approximately 25% of patients with Friedreich ataxia can have atypical presentation with onset after age 25 years, slow progression, and prominent spasticity with hyperreflexia. Diabetes and cardiomyopathy are also common in Friedreich ataxia. Impaired glucose tolerance has been found in one-third of Friedreich ataxia patients, whereas overt diabetes occurs in 15%. Another systemic feature is hypertrophic cardiomyopathy, which can present as arrhythmia or heart failure. Therefore, routine glucose tolerance test and cardiac evaluation, including electrocardiogram and echocardiogram, are indicated in Friedreich ataxia patients.

Friedreich ataxia is caused by an expanded intronic GAA repeat in the first exon of the *FXN* gene, which results in inefficient production of frataxin protein and leading to disturbed mitochondrial function. About 5% of Friedreich ataxia patients have one allele carrying a point mutation in *FXN* gene and another allele with a repeat expansion. Therefore, a neurologist should still have a high suspicion of Friedreich ataxia even if the expanded repeat is only detected in one allele, in patients who otherwise exhibit characteristic clinical features of Friedreich ataxia. Frataxin is a protein that is ubiquitously expressed; therefore, blood or saliva frataxin levels have been used as biomarkers for target engagement for therapy development in Friedreich ataxia.

Friedreich ataxia belongs to a group of autosomal recessive ataxias with predominant sensory neuronopathy (see Table 82.6). Other diseases in this group include SANDO, ataxia

TABLE 82.6 Common Causes of Autosomal Recessive Cerebellar Ataxia

Disease	Genetic Mutations	Age at Onset	Associated Clinical Features
Cerebellar Ataxia With Predominant Sensory Neuronopathy			
Friedreich ataxia	Repeat expansions in intron 1 of *FXN* gene	From childhood to third decade	Pes cavus, scoliosis, square wave jerks, hyporeflexia, spasticity (adult onset)
Sensory axonal neuropathy with dysarthria and ophthalmoplegia	*POLG* mutations	20-60 y	Ophthalmoplegia, dysarthria, ptosis, myoclonus, epilepsy
Ataxia with vitamin E deficiency	*TTPA* mutations	2-50 y	Retinitis pigmentosa, head tremor
Abetalipoproteinemia	*MTP* mutations	Birth	Diarrhea, neonatal steatorrhea
Cerebellar Ataxia With Sensorimotor Axonal Neuropathy			
Ataxia telangiectasia	*ATM* mutations	<5 y	Telangiectasia, chorea, dystonia, susceptibility to infections and cancer, radiosensitivity, elevated α-fetoprotein
Ataxia with oculomotor apraxia type 1	*APTX* mutations	<20 y	Oculomotor apraxia, chorea, dystonia
Ataxia with oculomotor apraxia type 2	*SETX* mutations	From childhood to third decade	Oculomotor apraxia, chorea, dystonia, elevated α-fetoprotein
Cerebrotendinous xanthomatosis	*CYP27* mutations	Childhood	Spasticity, mental retardation, tendon xanthoma, chronic diarrhea, premature cataract
Late-onset GM2 gangliosidosis	*HEXA* or *HEXAB* mutations	15-45 y	Spasticity, weakness, dystonia, epilepsy, cognitive decline, psychosis
Cerebellar Ataxia Without Neuropathy			
Autosomal recessive cerebellar ataxia type 1	*SYNE1* mutations	From second to fifth decade	Spasticity, lower motor neuron signs
Autosomal recessive cerebellar ataxia type 2	*ADCK3* mutations	<10	Mental retardation, myoclonus, epilepsy, exercise intolerance
Niemann-Pick type C	*NPC1* and *NPC2* mutations	From first to third decade	Vertical supranuclear ophthalmoplegia, splenomegaly, dystonia, cognitive decline

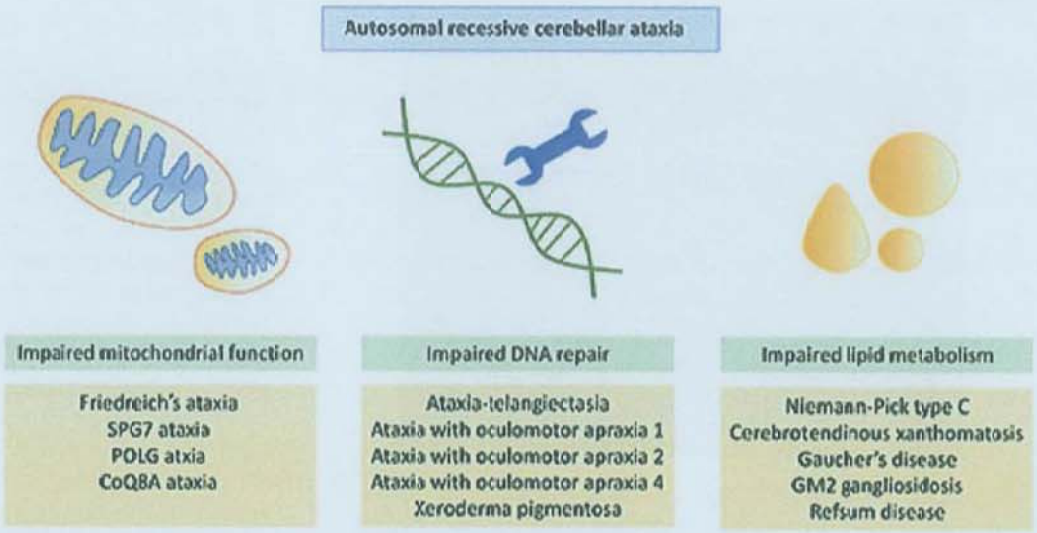

FIGURE 82.7 The major pathomechanisms of autosomal recessive cerebellar ataxia.

with vitamin E deficiency, and abetalipoproteinemia. In this particular group, cerebellar atrophy might not be evident on brain MRI, at least in the early stages of disease. SANDO is caused by *POLG* mutations. The age of onset is in adulthood often with ophthalmoplegia, ptosis, myoclonus, and epilepsy. Bilateral inferior olivary nucleus T2 hyperintensity can sometimes be observed on a brain MRI (**Fig. 82.3F**). Ataxia with vitamin E deficiency is associated with head tremor and retinitis pigmentosa. Patients with abetalipoproteinemia have very early disease onset with neonatal steatorrhea.

Cerebellar Ataxia with Sensorimotor Axonal Neuropathy

The second group of autosomal recessive ataxia is cerebellar ataxia with sensorimotor axonal neuropathy. This group includes ataxia telangiectasia, ataxia with oculomotor apraxia types 1 and 2, cerebrotendinous xanthomatosis, and late-onset GM2 gangliosidosis (see **Table 82.6**). The age of ataxia onset is variable in this group, but sensorimotor neuropathy is often present. Other features such as chorea, dystonia, and spasticity are common observed. α-Fetoprotein levels are elevated in ataxia telangiectasia and ataxia with oculomotor apraxia type 2, which can be used as a screening tool for these diseases. Ataxia telangiectasia patients have increased risk for cancer and infection, in addition to sensitivity to radiation. Oculomotor apraxia may be seen in the ataxias with oculomotor apraxia. Increased cholestanol levels and hexosaminidase activity deficiency are useful diagnostic tests for cerebrotendinous xanthomatosis and late-onset GM2 gangliosidosis, respectively.

Cerebellar Ataxia Without Neuropathy

The third category of recessive ataxia is those without neuropathy. This includes autosomal recessive cerebellar ataxia type 1 with *SYNE1* mutations, autosomal recessive cerebellar ataxia type 2, and Niemann-Pick type C. Autosomal recessive cerebellar ataxia type 1 is usually adult onset, with upper or lower motor neuron signs, pes cavus, and scoliosis. Autosomal recessive cerebellar ataxia type 2 can present with mental retardation, myoclonus, and epilepsy. Niemann-Pick type C patients have characteristic vertical supranuclear ophthalmoplegia (▶ **Video 82.3**) in addition to mental retardation, dystonia, and cognitive decline.

Autosomal recessive ataxia can sometimes be identified in patients without a family history of ataxia. In a study of a large cohort of sporadic ataxia, autosomal recessive cerebellar ataxia type 1 with *SYNE1* mutations is the most commonly identified and accounts for 4% of cases. There is also an increasing recognition that mutations in genes traditionally associated with autosomal recessive spastic paraplegia can also produce ataxia. One such example is mutations in *SPG7*, which can cause isolated cerebellar ataxia.

The disease pathogenic mechanism for autosomal recessive ataxia is usually the loss of function of protein associated with genetic mutations; therefore, the therapeutic development has been focused on (1) enhancing or stabilizing the deficient protein, (2) exogenous protein expression by gene therapy, and (3) reducing toxic substrates as the result of protein function deficiency. The results of loss of function of proteins in autosomal recessive ataxia usually lead to three major biologic consequences: (1) impaired mitochondrial function, (2) impaired DNA repair, and (3) impaired lipid metabolism (Fig. 82.7). Dysfunction of these pathways may partially explain the selective vulnerability of the cerebellum in these diseases, and targeting these downstream pathways might pose opportunities to treat a broad range of autosomal recessive ataxia.

Other Inherited Ataxias

X-Linked Ataxia

The most common X-linked ataxia is fragile X–associated tremor and ataxia syndrome (FXTAS), which is caused by 55 to 200 CGG repeat expansion within the *FMR1* gene. Expansion of this unstable repeat in *FMR1* in successive generations, can lead to fragile X syndrome, characterized by intellectual disability in childhood. Premature ovarian failure in women can also be a clinical presentation of repeat expansions in *FMR1* gene. Therefore, FXTAS should be considered in the context of family history of mental retardation and premature ovarian failure. Parkinsonism and autonomic dysfunction can also occur; therefore, FXTAS should be on the differential diagnosis for multiple system atrophy. T2 hyperintensity in the middle cerebellar peduncles (Fig. 82.8) and corpus callosum in the brain MRI are characteristic FXTAS and can help make the diagnosis.

Mitochondrial Ataxia

Mitochondrial DNA mutations can also cause ataxia. The common causes in this category are Kearns-Sayre syndrome, myoclonus epilepsy with ragged-red fibers, and mitochondrial encephalopathy,

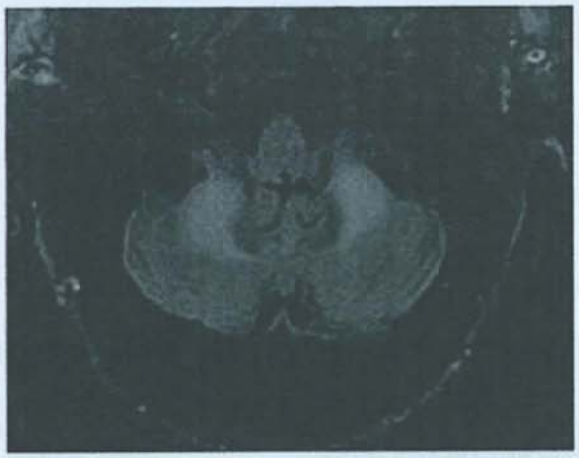

FIGURE 82.8 Axial brain magnetic resonance imaging fluid-attenuated inversion recovery sequence demonstrates hyperintensity of bilateral middle cerebellar peduncles in a patient with fragile X–associated tremor and ataxia syndrome.

lactic acidosis, and stroke-like episodes. Because genetic mutations in the mitochondrial genome can be tissue specific (ie, heteroplasmy), a muscle biopsy should be performed because mitochondrial defects are more likely to be detected in the nondividing cells such as muscles, for which biochemical assessment and mitochondrial DNA content determination can be performed.

Episodic Ataxia

Episodic ataxia (types 1-8) constitutes a group of dominantly inherited causes for intermittent ataxia attacks, lasting from minutes to days. There might be underlying progressive ataxia in addition to episodic attacks. The pathogenic mechanism of episodic ataxias is due to either channelopathy (episodic ataxia types 1 and 2) or dysfunctional glutamate transport (episodic ataxia type 6). Interestingly, episodic ataxia is caused by mutations in *CACNA1A* gene, and mutations of such genes can have diverse disease presentations, including SCA6 and familial hemiplegic migraine, indicating the importance of the encoded protein, Cav2.1, in cerebellar neuronal function.

Other major differential diagnoses for episodic ataxia are multiple sclerosis and psychogenic ataxia.

Cerebellar Ataxia, Neuropathy, and Vestibular Areflexia Syndrome

Recent work has identified biallelic pentanucleotide expansions in the *RFC1* gene as a common cause for a syndrome consisting of cerebellar ataxia, sensory neuropathy/neuronopathy, and vestibular areflexia. Surprisingly, a significant proportion of late-onset sporadic ataxias result from the same biallelic mutations in *RFC1*. In a Caucasian population, biallelic mutations in *RFC1* should be considered in cases of sporadic adult-onset ataxia, particularly if neuropathy and vestibulopathy are also present.

Degenerative Ataxia

Degenerative forms of ataxia usually occur after the age of 60 years in individuals without a family history of ataxia. In this category, multiple system atrophy and idiopathic late-onset cerebellar ataxia are the two most common diseases with degenerative pathology.

Multiple System Atrophy

Multiple system atrophy is a disease involving multiple brain regions resulting in cerebellar ataxia, parkinsonism, autonomic instability (orthostatic hypotension, impotence, urinary frequency, urgency, and incontinence), and pyramidal signs (hyperreflexia and upgoing toes). The pathologic hallmark of multiple system atrophy is glial cytoplasmic inclusions, containing α-synuclein, in the oligodendrocytes, along with microglial activation, reactive astrogliosis, and neuronal death in the basal ganglia and the cerebellum. Depending on the predominant clinical features, multiple system atrophy can be divided into multiple system atrophy–parkinsonism type or multiple system atrophy–cerebellar type (MSA-C). In this section, we discuss MSA-C, in which ataxia is predominant feature of disease at symptom onset. MSA-C constitutes approximately 13% to 42% of all multiple system atrophy cases, but this can vary in different ethnic backgrounds. MSA-C generally has a slower disease progression than multiple system atrophy–parkinsonism. In the early stages of the disease, patients may present with relatively isolated cerebellar ataxia. Therefore, the history and neurologic examination should focus on searching for signs of parkinsonism, autonomic dysfunction, and upper motor neuron dysfunction. Rapid eye movement sleep behavior disorder is often present, which can be very helpful to indicate the underlying synucleinopathy associated with multiple system atrophy. Respiratory stridor and obstructive sleep apnea can be present and sometimes can be a cause of death. Therefore, for patients with onset of cerebellar ataxia later in life, autonomic tests and sleep studies can provide additional evidence to support the diagnosis of multiple system atrophy when clinical symptoms are not yet evident. The brain MRI in multiple system atrophy cases often shows the "hot cross bun" sign (see **Fig. 82.3E**). This sign may not be evident in the early stages of disease but can show up later after the disease progresses. ▶ **Video 82.6** demonstrates a patient with multiple system atrophy.

Idiopathic Late-Onset Cerebellar Ataxia

Multiple system atrophy is a disease with relatively fast progression with death within 6 to 10 years of symptom onset. On the other hand, idiopathic late-onset cerebellar ataxia is a disease with slower progression and usually does not compromise life span. Idiopathic late-onset cerebellar ataxia patients will not usually develop other neurologic features such as autonomic dysfunction or parkinsonism. Practically, the presence of parkinsonism and autonomic dysfunction in elderly ataxia patients often suggests a poor prognosis because the diagnosis is likely to be multiple system atrophy. If there is no parkinsonism or autonomic dysfunction within 5 years of the onset of ataxia, these patients are likely to follow a benign clinical course with the diagnosis of idiopathic late-onset cerebellar ataxia. Within newer technologies such as exome sequencing, a subset of the idiopathic late-onset ataxias have now been determined to have a genetic basis.

Essential tremor is a very common movement disorder, characterizing primarily by upper extremity tremor. Recent work has challenged the idea that this is a disorder that presents solely with tremor because patients with essential tremor can have difficulty in tandem gait, particularly in individuals with more severe disease. Kinematic analysis has revealed imprecise foot placement consistent with an ataxic gait, suggesting true cerebellar dysfunction. Degenerative changes in the cerebellum, including cerebellar Purkinje cell loss, have been identified in the postmortem brain

in essential tremor, but to a lesser degree when compared to patients with SCAs and multiple system atrophy; therefore, essential tremor could be considered a cerebellar disorder.

Psychogenic Ataxia

Psychogenic ataxia is a psychogenic movement disorder. Patients usually experience a major life event preceding the onset of ataxia symptoms. They usually can recall the exact date or time when the first symptom occurred. The disease course is often fluctuating or episodic in nature. There are four core features of psychogenic ataxia: (1) inconsistency, (2) variability, (3) distractibility, (4) associated atypical features. An example of inconsistency is a patient who might not be able to walk well but might be able to run or hop on either foot, which requires better balance than walking. Variability and episodic neurologic attacks can also suggest psychogenic ataxia, with a major differential diagnosis of episodic ataxia and multiple sclerosis in mind. Distractibility means that patients might perform much better when distracted and/or when instructed to perform other tasks such as counting during the ataxia examination. Finally, psychogenic ataxia has many "atypical" features, not seen in other causes of ataxia; for example, extreme exhaustion, light sensitivity, or give-way weakness. Identification of psychogenic ataxia is very important to avoid further genetic or other testing and treatment of ataxia. Referral to a psychiatrist is critical in the care of these patients.

MANAGEMENT AND FUTURE DEVELOPMENTS

The treatment for ataxia can be categorized into symptomatic and disease-modifying therapies. Disease-modifying therapy exists for ataxia, especially for acquired cases; for example, thiamine for Wernicke encephalopathy, gluten-free diet for ataxia associated with gluten sensitivity, and intravenous immunoglobulin, plasmapheresis, and other immunosuppressive agents, such as rituximab for anti-GAD ataxia and paraneoplastic ataxia. There are some disease-modifying therapies for genetic ataxia, particularly autosomal recessive ataxias: vitamin E replacement for ataxia of low vitamin E levels (ataxia associated with vitamin E deficiency and abetalipoproteinemia), miglustat for Niemann-Pick type C, chenodeoxycholic acid for cerebrotendinous xanthomatosis, dietary modification to restrict phytanic acid for Refsum disease. Glucose transporter type 1 deficiency is autosomal dominantly inherited disorder with diverse neurologic presentation, including ataxia, and can be treated with ketogenic diet.

Two important avenues of research hold promise in the treatment of the SCAs. Nucleotide-based strategies to reduce expression of pathogenic gene products have been applied to the SCAs, including RNA interference and antisense oligonucleotides. Recent success with antisense oligonucleotides to reduce expression of the SCA1, SCA2, and SCA3 gene products in mouse models of disease provide hope for eventual testing of similar disease gene-silencing molecules in human trials. The second avenue for treatment involves the identification of shared neuronal dysfunction tied to dysfunction of specific potassium channels. Targeting potassium channels may provide an avenue for treatment of symptoms in a variety of ataxias.

There is a pipeline of therapy development for Friedreich ataxia that target various molecular pathways, which includes (1) improving mitochondrial function and reducing oxidative stress, (2) modulating frataxin-controlled metabolic pathways, (3) stabilizing frataxin protein, or (4) increasing *FXN* gene expression.

Certain commonly used treatment options are often used by ataxia experts. Riluzole 50 mg twice a day has been shown to improve dysarthria and gait ataxia. Liver function monitoring is necessary while patients are treated with riluzole. Varenicline 1 mg twice a day is suggested to help ataxia in SCA3 patients and could benefit patients with other forms of ataxia. The side effect of depression should be closely monitored, particularly as many SCA3 patients already suffer from depression. 4-Aminopyridine 15 mg daily has been shown to be effective to suppress the number of attacks in episodic ataxia type 2 and may be useful to treat nystagmus in ataxia patients. Other medications such as amantadine, baclofen, and chloroxazone can also be tried to treat ataxia. For the dizziness sensation, commonly seen in cerebellar ataxia, neuropathy, and vestibular areflexia syndrome, or anti-GAD ataxia, diazepam might be useful. Symptoms other than ataxia, such as tremor, dystonia, and depression, should be identified and treated with conventional symptomatic therapy. For instance, postural tremor can be treated by primidone or propranolol, and dystonia using botulinum toxin injections.

Exercise can provide benefit for ataxia patients as exercise has been shown to enhance the lifespan in an SCA1 mouse model of disease. Coordinated training and balance exercise has been demonstrated to provide long-standing benefits for ataxia patients, and these exercises focus on the core strength and balance. Whether aerobic and other forms of exercise will also have additional benefits remains to be tested in the future.

Cerebellar ataxias represent a heterogeneous group of disorders. Recognition of the time course of symptoms, in addition to knowing if motor symptoms are truly cerebellar in origin is critical to make the diagnosis and identify potentially treatable entities. Early recognition of immune causes of ataxia is important to prevent progressive disability. A significant subset of the ataxias are due to genetic causes. Knowing the genetic basis for ataxia can help with planning for future disability. Although no approved pharmacologic treatment currently exists for inherited and degenerative ataxia, research on the horizon is promising for both treatment of symptoms and slowing disease progression. Intensive balance training is the mainstay of current treatment and should be recommended for all patients with ataxia.

Videos can be found in the companion e-book edition. For a full list of video legends, please see the front matter.

SUGGESTED READINGS

Anheim M, Tranchant C, Koenig M. The autosomal recessive cerebellar ataxias. *N Engl J Med*. 2012;366:636-646.

Ashizawa T, Figueroa KP, Perlman SL, et al. Clinical characteristics of patients with spinocerebellar ataxias 1, 2, 3 and 6 in the US; a prospective observational study. *Orphanet J Rare Dis*. 2013;8:177.

Bird TD. Hereditary ataxia overview. In: Adam MP, Ardinger HH, Pagon RA, et al, eds. *GeneReviews®*. Seattle, WA: University of Washington; 1993.

Bushart DD, Shakkottai VG. Ion channel dysfunction in cerebellar ataxia. *Neurosci Lett*. 2019;688:41-48.

Dürr A. Autosomal dominant cerebellar ataxias: polyglutamine expansions and beyond. *Lancet Neurol*. 2010;9:885-894.

Dürr A, Cossee M, Agid Y, et al. Clinical and genetic abnormalities in patients with Friedreich's ataxia. *N Engl J Med*. 1996;335:1169-1175.

Fanciulli A, Wenning GK. Multiple-system atrophy. *N Engl J Med*. 2015;372:249-263.

Fogel BL, Perlman S. Clinical features and molecular genetics of autosomal recessive cerebellar ataxias. *Lancet Neurol*. 2007;6:245-257.

Ilg W, Brötz D, Burkard S, Giese MA, Schöls L, Synofzik M. Long-term effects of coordinative training in degenerative cerebellar disease. *Mov Disord*. 2010;25:2239-2246.

Jen JC, Wan J. Episodic ataxias. *Handb Clin Neurol*. 2018;155:205-215.

Louis ED, Galecki M, Rao AK. Four essential tremor cases with moderately impaired gait: how impaired can gait be in this disease? *Tremor Other Hyperkinet Mov (N Y)*. 2013;3:tre-03-200-4597-1. doi:10.7916/D8QV3K7G.

Louis ED, Kerridge CA, Chatterjee D, et al. Contextualizing the pathology in the essential tremor cerebellar cortex: a patholog-omics approach. *Acta Neuropathol*. 2019;138(5):859-876. doi:10.1007/s00401-019-02043-7.

Paulson HL, Shakkottai VG, Clark HB, Orr HT. Polyglutamine spinocerebellar ataxias—from genes to potential treatments. *Nat Rev Neurosci*. 2017;18:613-626.

Schmahmann JD, Sherman JC. The cerebellar cognitive affective syndrome. *Brain*. 1998;121(pt 4):561-579.

Schmitz-Hübsch T, du Montcel ST, Baliko L, et al. Scale for the assessment and rating of ataxia: development of a new clinical scale. *Neurology*. 2006;66:1717-1720.

Thach WT. Correlation of neural discharge with pattern and force of muscular activity, joint position, and direction of intended next movement in motor cortex and cerebellum. *J Neurophysiol*. 1978;41:654-676.

Thach WT. Discharge of Purkinje and cerebellar nuclear neurons during rapidly alternating arm movements in the monkey. *J Neurophysiol*. 1968;31:785-797.

Zesiewicz TA, Wilmot G, Kuo SH, et al. Comprehensive systematic review summary: treatment of cerebellar motor dysfunction and ataxia: report of the Guideline Development, Dissemination, and Implementation Subcommittee of the American Academy of Neurology. *Neurology*. 2018;90:464-471.

83 Tardive Dyskinesia and Other Neuroleptic-Induced Syndromes

Un Jung Kang and Stanley Fahn

KEY POINTS

1. Dopamine receptor antagonists can produce a variety of motor and sensory abnormalities as an iatrogenic condition.
2. Dopamine receptor antagonists produce parkinsonism and other side effects associated with hypodopaminergic state that are reversible upon discontinuation of the offending medication.
3. Tardive dyskinesia syndrome usually occurs after chronic exposure to dopamine receptor antagonists and often persists even after discontinuation of the offending agent.
4. The pathophysiology of tardive dyskinesia is still poorly understood but may involve maladaptive plasticity of brain circuits.
5. The best established treatments for tardive dyskinesia are tetrabenazine derivatives that deplete monoamines.

INTRODUCTION

Neuroleptics are medications that are named for its neurologic side effects of inducing parkinsonism (called drug-induced parkinsonism), a variety of other movement disorders, sensory disorders and an altered state of consciousness with fever. The most common neuroleptic-induced movement disorders are acute dystonic reactions (involuntary sustained twisting movements and postures), parkinsonism, and tardive dyskinesia syndromes (TDS). TDS can manifest as repetitive rhythmic movements most often affecting the mouth and limbs as well as other types of movement disorders (Table 83.1). TDS have variable delayed onset after the initiation of the offending drugs and persists even after they are discontinued (see Table 83.1). The common pathophysiologic mechanisms of neuroleptics are binding to and antagonizing dopamine D_2 receptors. The dopamine receptor blocking agents (DRBAs) are used not only as antipsychotic agents, such as the phenothiazines and the butyrophenones, but also for gastrointestinal disorders, such as metoclopramide. By definition, these disorders are iatrogenic and hence can be prevented, their risk minimized, and potentially reversed by making the diagnosis early and instituting appropriate treatment. Although the second-generation antipsychotics, often also called *atypical* antipsychotics have been developed to reduce these side effects, they are not entirely free of them.

EPIDEMIOLOGY

The prevalence of neuroleptic-induced neurologic disorders ranges from 20% to 50%. Drug-induced parkinsonism is the most common form. Neuroleptic exposure increases the risk of parkinsonism by twofold, increasing with age and female gender. Acute dystonic reactions occur in about 2% to 5% of patients exposed to neuroleptics, more commonly in children and young adults and in males than females. TDS may occur in about one quarter of patients exposed to these drugs but estimation of true incidence and prevalence vary and is often confounded by the fact that DRBAs mask the clinical manifestation of TDS. Classic tardive dyskinesia involving orofacial movements is most common with an annual incidence rate of about 5% in the first 4 to 5 years. TDS increase with cumulative exposure to DRBAs factoring in the dosage and the duration of treatment. Advanced age is the most consistent demographic risk factor. Gender difference is not consistently found. Prevalence and incidence vary

TABLE 83.1 Adverse Neurologic Effects of D_2 Receptor–Blocking Agents

Clinical Syndromes	Major Features
Acute dystonic reaction	Sustained twisting movements occurring within the first few days of exposure to DRBA including oculogyric crisis
Acute akathisia	Inability to sit still with motor and sensory features within a few days or weeks of DRBA treatment
Drug-induced parkinsonism	Clinical features mimicking idiopathic Parkinson disease in the setting of DRBA
Neuroleptic malignant syndrome	An idiosyncratic combination of fever, dysautonomia, and movement disorder that can be severe and fatal
Tardive Dyskinesia Syndromes	Delayed-onset abnormal involuntary movements or sensory symptoms that persist even after discontinuation of a DRBA
• Withdrawal emergent syndrome	Choreic movements in children after stopping DRBA
• Tardive dyskinesia	The classic tardive dyskinesia consisting of orobuccolingual and limb dyskinesia
• Tardive dystonia	Focal or generalized sustained twisting movements associated with chronic DRBA treatment
• Tardive akathisia	Restlessness consisting of subjective sensation of inability to sit still and stereotypic restless movements
• Tardive pain	Painful sensation that is often a focal form of tardive akathisia
• Tardive tics	Motor and vocal tics associated with chronic DRBA
• Tardive myoclonus	Lightning like jerky movements associated with chronic DRBA
• Tardive tremor	Tremor associated with chronic DRBA

Abbreviation: DRBA, dopamine receptor blocking agent.

in different regions of the world. Genetic studies have implicated variants in genes involved in drug metabolism or dopaminergic system to influence the risk of TDS. Tardive dystonia is rarer than the classic type and is more common in younger patients. Other TDS, including tardive akathisia, accounts for about 10% of all TDS.

PATHOBIOLOGY

The pathogenesis of neuroleptic-induced neurologic disorders such as parkinsonism is due to antagonization of dopamine effect at the D_2 receptors. The DRBAs that bind most tightly to the receptors are the ones most likely to induce parkinsonism and TDS. The second-generation antipsychotics are atypical in that they have less propensity to produce these complications, but most are not free of inducing these side effects. Clozapine (Clozaril), a drug that predominantly blocks the D_4 receptor and serotonin receptor subtypes, is relatively free of these complications, except for acute akathisia. The monoamine-depleting drugs, reserpine and tetrabenazine derivatives, can induce acute akathisia and drug-induced parkinsonism. Tetrabenazine has also been implicated in acute dystonic reactions and neuroleptic malignant syndrome. But none of the dopamine-depleting drugs has been convincingly implicated in causing persistent TDS. In addition, calcium channel blockers such as flunarizine and cinnarizine, and rarely selective serotonin reuptake inhibitors and lithium, produce parkinsonism and TDS, and the mechanism by which these drugs produce these complications is not known.

The pathogenesis of TDS, which can persist even after the discontinuation of the DRBAs is not well understood. Dopamine receptor upregulation occurs with the use of DRBAs, but its causality to produce TDS is not established. To explain its delayed onset and persistence, maladaptive synaptic plasticity has been proposed as an underlying mechanism. Others proposed a neurodegenerative process triggered by oxidative stress or by the drugs binding to neuromelanin with resulting internalization of the cell membrane, but all these hypotheses remain to be validated. Genetic polymorphism studies have noted association of variations of drug metabolism genes, monoamine receptors or transporters, and those associated with synaptic plasticity, but these findings need to be confirmed.

DIAGNOSIS

It is important to recognize the different phenomenologies caused by the DRBAs; each requires specific treatment.

Acute Dystonic Reaction

Acute dystonic reaction manifests as sustained, twisting movements and postures of the cranial, cervical, and other body parts. Severe sustained twisting and uncomfortable postures of limbs, trunk, neck, tongue, and face are dramatic. *Oculogyric crisis* is a form of dystonia in which the eyes are deviated conjugately in a fixed posture for minutes or hours. The diagnosis is made in the setting of recent exposure to a DRBA. Acute dystonic reaction tends to occur within the first few days of exposure to the DRBA and predominantly affects children and young adults, males more than females.

Acute Akathisia

Akathisia consists of a *subjective* sense of restlessness and the most characteristic complaint is the inability to sit still. Akathisia is associated with *motor* features of restlessness. These include frequent and repetitive stereotyped movements, such as pacing, repeatedly caressing the scalp, crossing and uncrossing the legs, and repetitive body rocking. Acute akathisia occurs within the first few days or weeks of DRBA use. It may also appear later in treatment as dosage is being increased. It can occur in subjects of any age. It is self-limiting if the offending drug is stopped.

Drug-Induced Parkinsonism

The diagnosis of drug-induced parkinsonism is based on the cardinal features of tremor at rest, bradykinesia and rigidity, plus the history of current or recently discontinuation of a neuroleptic drug.

Neuroleptic Malignant Syndrome

The neuroleptic malignant syndrome (see also Chapter 133) is a rare complication characterized by a triad of fever, signs of autonomic dysfunction (eg, pallor, diaphoresis, blood pressure instability, tachycardia, pulmonary congestion, tachypnea), and a movement disorder (usually akinesia and rigidity) with the history of recent exposure to a DRBA. The level of consciousness may be depressed with obtundation and confusion, eventually leading to stupor or coma; death may occur. Neuroleptic malignant syndrome can occur any time during DRBA treatment.

Tardive Dyskinesia Syndromes

The diagnosis of TDS depends on the recognition of a typical pattern of abnormal involuntary movements or sensory symptoms plus documented use of the offending agents. *Diagnostic and Statistical Manual of Mental Disorders* (5th ed) criteria notes at least 1 to 3 months of exposure for the diagnosis, depending on the age of the patient. The symptoms should have either started while the patient was still taking the drug or within 3 months of discontinuing the drug and persists at least 1 month after medication change or discontinuation. The timing is a continuous spectrum, however, and TDS has been noted even after a few days of DRBA exposure. The TDS is the most feared complications of antipsychotic medications because the symptoms can be long-lasting and often permanent.

Withdrawal Emergent Syndrome

Withdrawal emergent syndrome may be a mild variant of TDS. "Emergent" implies that the symptoms emerge after abrupt cessation of the chronic use of an antipsychotic drug. The syndrome is primarily one of children and persist only for a few weeks before dissipating. The abnormal movements resemble those of Sydenham chorea; they are not stereotyped and repetitive, as seen in classic TDS.

Classic Tardive Dyskinesia

Classic tardive dyskinesia consists of repetitive (stereotypic) movements. The lower part of the face is most often involved. This orobuccolingual dyskinesia resembles continual chewing movements, with the tongue intermittently darting out of the mouth. Movements of the trunk may cause a repetitive pattern of flexion and extension (body rocking). The distal parts of the limbs may show incessant flexion-extension movements.

The proximal muscles are usually spared, but respiratory dyskinesias may occur.

The classic tardive dyskinesia should be differentiated from other movement disorders affecting the face. Patients with Huntington disease show facial chorea. They are frequently treated with antipsychotic drugs; a resulting tardive dyskinesia may be superimposed on the chorea; the presence of akathisia or repetitive (stereotyped) involuntary movements suggests the additional diagnosis of tardive dyskinesia. Other differential diagnoses to be considered include chorea and stereotypies involving face from other drugs such as levodopa, anticholinergic drugs, phenytoin, antihistamines, and tricyclic antidepressants. Other neurologic disorders such as hepatocerebral degeneration and cerebellar and brainstem stroke should be considered as are the abnormal involuntary movements from edentulous malocclusion.

Several other important forms of TDS are now recognized. Unlike the classic orobuccolingual dyskinesia described earlier, these other forms can be more disabling.

Tardive Dystonia

Tardive dystonia is a chronic dystonia caused by DRBAs. Individuals of all ages are susceptible to tardive dystonia, and younger individuals are more likely to have a more severe generalized form. In older individuals, tardive dystonia is usually focal (affecting a single body part), often in the face or neck, and may remain confined to these regions or may spread to the arms and trunk. The legs are infrequently affected. Often, neck involvement consists of retrocollis and the trunk arches backward. The arms are typically rotated internally, the elbows extended, and the wrists flexed. The differential diagnosis includes all the many causes of dystonia. Oromandibular dystonia is probably the most common form of spontaneous oral dyskinesia. Often, oromandibular dystonia takes the appearance of a repetitive opening and closing of the jaw as the patient attempts to overcome the muscle pulling. To discern if the repetitive movements are volitional or spontaneous, the examiner should ask the patient not to fight the movements but to let them come out as they want to. In dystonia, there will usually be a sustained contraction, such as jaw opening or clenching. Wilson disease, in particular, must be excluded specifically in patients with psychiatric symptoms and dystonia.

Tardive Akathisia

Tardive akathisia is another important disabling variant of tardive dyskinesia. It is a chronic akathisia consisting of a subjective aversion to being still. Motor signs of restlessness include frequent, repeated, stereotyped movements, such as marching in place, crossing and uncrossing the legs, and repetitively rubbing the face or hair with the hand. Patients may make moaning sounds. Patients may not use the word "restless" to describe their symptoms, instead they may use expressions such as "going to jump out of my skin" or "jittery" or "exploding inside." In contrast to acute akathisia, the delayed type tends to become worse when antipsychotic medication is withdrawn, similar to other TDS on discontinuance of these drugs. As with other types of TDS, tardive akathisia tends to persist. Usually, tardive akathisia is associated with classic orobuccolingual dyskinesia. Classic tardive dyskinesia, tardive dystonia, and tardive akathisia may occur together. Akathisia can appear as focal discomfort, such as pain, which can be exceedingly distressing. The diagnosis of focal akathisia is challenging and is discussed further in the following text.

Other Tardive Syndromes

Less common variants of tardive dyskinesia include tardive pain, tardive tics, tardive myoclonus, and tardive tremor. Tardive pain most commonly manifests as painful or burning mouth or vagina. These may be the unpleasant symptoms of focal akathitic complaint that patients often refer to as pain. Tardive tics are rare and similar to phenomenology of chronic motor tics or Tourette syndrome. Myoclonus can occur from many different etiologies and neuroleptics may induce them as a delayed-onset tardive syndrome. Tardive tremors are distinguished from essential tremor, Parkinson disease, cerebellar tremor, and other facial tremors by its etiology. The tardive syndromes involving facial movements need to be differentiated from hemifacial spasm, myokymia, and synkinesis of facial muscles from faulty regeneration after facial nerve injury based on their difference in phenomenology.

MANAGEMENT

Efforts should be made to prevent the neuroleptic-induced complications because these are iatrogenic disorders. Antipsychotic drugs should be given only when indicated, namely, to control psychosis or a few other conditions where no other effective agent has been helpful, as in some choreic disorders or tics. These drugs should not be used indiscriminately, and when they are used, the dosage and duration should be as low and as brief as possible. If the psychosis has been controlled, the physician should attempt to reduce the dosage and even try to eliminate the drug, if possible. In nonpsychotic disorders, such as tics, other drugs should be tried first, and only if they fail should a DRBA be used.

Acute Dystonic Reaction

Acute dystonic reaction is easily reversible with parenteral administration of antihistamines (eg, diphenhydramine 50 mg intravenously), anticholinergic drugs (eg, benztropine mesylate 2 mg intramuscularly), or diazepam (5-7.5 mg intramuscularly).

Acute Akathisia

Acute akathisia disappears on discontinuance of the offending drug. Acute akathisia sometimes improves with the β-adrenergic blocker propranolol given in doses of 20 to 80 mg/d or mirtazapine (15 mg/d).

Drug-Induced Parkinsonism

Drug-induced parkinsonism has a variable response to levodopa (titrated up to 600-1,500 mg). Oral anticholinergic drugs (trihexyphenidyl 2-15 mg/d) and amantadine (up to 300 mg/d) are effective. On withdrawal of the offending antipsychotic drug, the symptoms slowly disappear in weeks or months.

Neuroleptic Malignant Syndrome

Neuroleptic malignant syndrome, a potentially lethal condition, treatment needs to be started immediately with hospitalization, initiating supportive therapy including intravenous hydration and cooling to address medical complications such as fever, rhabdomyolysis, and renal failure. The withdrawal of the antipsychotic medication is critical. Although controlled trials have

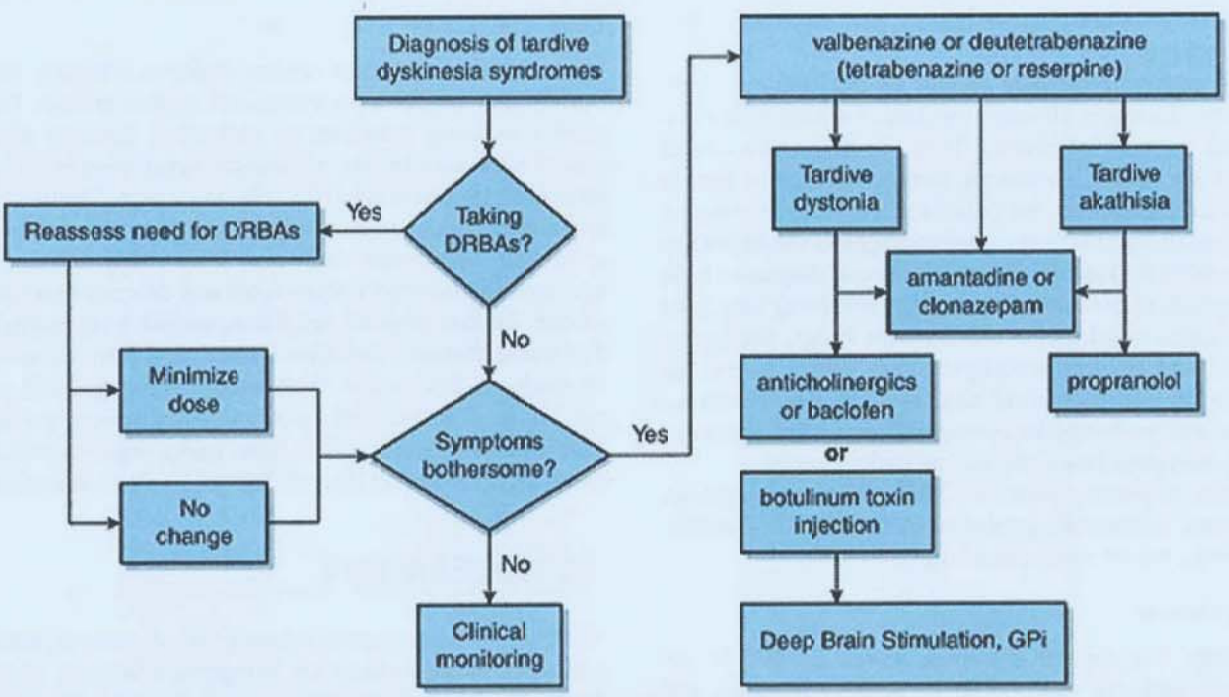

FIGURE 83.1 Treatment algorithm for tardive dyskinesia syndromes. Abbreviation: DRBAs, dopamine receptor blocking agents.

not been conducted, numerous reports suggest that dantrolene sodium, a muscle relaxant, and levodopa or direct-acting dopamine agonists, may be beneficial. Carbamazepine is also effective. In most patients, the antipsychotic medication can be restarted later without recurrence of the syndrome.

Tardive Dyskinesia Syndromes

Once TDS have appeared, the logical treatment approach calls for eliminating or reducing the dosage of the causative agents, DRBAs, especially in cases where alternative approaches are available and the indication was a short-term relief of gastrointestinal or psychiatric problems (Fig. 83.1). It is prudent to taper DRBAs slowly to avoid worsening of the original indication and TDS. Reducing the dosage or discontinuing the offending drug can worsen the disorder in the first few weeks after withdrawal or even unmask the TDS that were not noticed. Switching from the first-generation antipsychotic medication to the newer antipsychotics is also reasonable because the incidence of TDS is less with many of the newer antipsychotics, but there is no evidence that such a switch improves TDS once it started. Paradoxically, starting or increasing the dose of DRBAs can reduce TDS, by masking the movements. Because DRBAs are the offending agents, such approach is used as the last resort and temporarily. The withdrawal emergent syndrome is self-limiting but may take weeks to resolve. Reintroducing the antipsychotic drug and then slowly tapering the dosage can eliminate the choreic movements of withdrawal emergent syndrome.

If the TDS symptoms are too distressing, treatment with vesicular monoamine transporter (VMAT) inhibitors that depletes monoamines may suppress the TDS (see Table 83.2 and Fig. 83.1). Reserpine (0.75-1.5 mg/d) is a nonspecific VMAT inhibitor and tetrabenazine (25-150 mg/d) and its analogs are more selective inhibitors for VMAT2, which is present preferentially in the central nervous system, and therefore produce less side effects. Deutetrabenazine is a modified form of tetrabenazine that has slower metabolism and can be started at 6 mg twice a day and increased by 6 mg a day up to 24 mg twice a day. Most patients improve on 24 to 36 mg/d. A short-term trial up to 3 months did not show significant side effects LEVEL 1.[1,2] Valbenazine is another selective VMAT2 inhibitor that can be used at 40 to 80 mg once daily LEVEL 2.[3] Side effects of these VMAT inhibitors may consist of worsening or producing parkinsonism, depression, sedation, akathisia, dry mouth, and lowered blood pressure. The dosage should be increased gradually to minimize the side effects. Tardive dystonia may also be treated by anticholinergic drugs such as trihexyphenidyl, baclofen, or botulinum toxin injections if focal tardive dystonia is the predominant concern (see Table 83.2 and Fig. 83.1). Deep brain stimulation targeted to globus pallidus interna can be considered when medication therapy fails. For tardive akathisia, propranolol may be tried (see Table 83.2 and Fig. 83.1).

OUTCOME

Neuroleptic-induced movement disorders can be a diagnostic challenge and difficult to manage. In general, they improve with reduction or discontinuation of the neuroleptics, but TDS can persist despite discontinuation of the offending drugs. There are only a few published data on remission of TDS after complete withdrawal of DRBAs; the prevalence of the remission is surprisingly low, ranging from 2% to 13% although improvement is seen in about 20% to 30%. For those who remain on the DRBAs may also show apparent disappearance of tardive dyskinesia in up to 60% of cases, but their symptoms are likely masked by DRBAs because their improvement is often associated with worsening of parkinsonism. The best outcome we should aim for is to minimize the risk of this iatrogenic disorder by judicious use of neuroleptics.

Videos can be found in the companion e-book edition. For a full list of video legends, please see the front matter.

TABLE 83.2 Treatment Options for Tardive Dyskinesia Syndromes

Medication	Dose Range	Side Effects
Valbenazine	6-24 mg twice a day	QT prolongation, somnolence, akathisia
Deutetrabenazine	40-80 mg once daily	Depression, QT prolongation, akathisia, neuroleptic malignant syndrome, parkinsonism
Tetrabenazine	25-150 mg/d divided in three or four doses	Depression, QT prolongation, akathisia, neuroleptic malignant syndrome, parkinsonism
Reserpine	0.75-1.5 mg/d divided in three or four doses	Depression, hypotension, akathisia
Clonazepam	0.25-6 mg/d divided in three or four doses	Drowsiness, dizziness, fatigue, irritability
Amantadine	100-400 mg/d divided in three or four doses	Hallucinations, dizziness, peripheral edema, nausea
Ginkgo biloba	80-240 mg/d divided in three doses	Bleeding disorders, headache, dizziness, constipation
Deep brain stimulation	Globus pallidus interna	Infection, intracerebral hemorrhage, gait and speech disturbances, paresis, confusion
For Tardive Dystonia Only		
Trihexyphenidyl	1-40 mg/d divided in three or four doses	Blurred vision, dizziness, confusion, drowsiness, constipation, urinary retention
Baclofen	10-100 mg/d divided in three or four doses	Drowsiness, dizziness, weakness, confusion, fatigue
Botulinum toxin	Local injection	Excessive weakness of injected muscles
For Tardive Akathisia Only		
Propranolol	20-160 mg/d divided in three or four doses	Fatigue, dizziness, bradycardia, hypotension, depression

LEVEL 1 EVIDENCE

1. Anderson KE, Stamler D, Davis MD, et al. Deutetrabenazine for treatment of involuntary movements in patients with tardive dyskinesia (AIM-TD): a double-blind, randomised, placebo-controlled, phase 3 trial. *Lancet Psychiatry*. 2017;4(8):595-604.
2. Fernandez HH, Factor SA, Hauser RA, et al. Randomized controlled trial of deutetrabenazine for tardive dyskinesia: the ARM-TD study. *Neurology*. 2017;88(21):2003-2010.
3. Hauser RA, Factor SA, Marder SR, et al. KINECT 3: a phase 3 randomized, double-blind, placebo-controlled trial of valbenazine for tardive dyskinesia. *Am J Psychiatry*. 2017;174(5):476-484.

SUGGESTED READINGS

Bakker PR, de Groot IW, van Os J, van Harten PN. Long-stay psychiatric patients: a prospective study revealing persistent antipsychotic-induced movement disorder. *PLoS One*. 2011;5(10):e25588.

Bhidayasiri R, Fahn S, Weiner WJ, Gronseth GS, Sullivan KL, Zesiewicz TA. Evidence-based guideline: treatment of tardive syndromes: report of the Guideline Development Subcommittee of the American Academy of Neurology. *Neurology*. 2013;81(5):463-469.

Bhidayasiri R, Jitkritsadakul O, Friedman JH, Fahn S. Updating the recommendations for treatment of tardive syndromes: a systematic review of new evidence and practical treatment algorithm. *J Neurol Sci*. 2018;389:67-75.

Burke RE, Kang UJ, Jankovic J, Miller LG, Fahn S. Tardive akathisia: an analysis of clinical features and response to open therapeutic trials. *Mov Disord*. 1989;4:157-175.

Carbon M, Hsieh CH, Kane JM, Correll CU. Tardive dyskinesia prevalence in the period of second-generation antipsychotic use: a meta-analysis. *J Clin Psychiatry*. 2017;78(3):e264-e278.

Frei K, Truong DD, Fahn S, Jankovic J, Hauser RA. The nosology of tardive syndromes. *J Neurol Sci*. 2018;389:10-16.

Glazer WM, Morgenstern H, Schooler N, Berkman CS, Moore DC. Predictors of improvement in tardive dyskinesia following discontinuation of neuroleptic medication. *Br J Psychiatry*. 1990;157:585-592.

Henderson VW, Wooten GF. Neuroleptic malignant syndrome: a pathogenetic role for dopamine receptor blockade? *Neurology*. 1981;31:132-137.

Kane JM, Woerner M, Borenstein M, Wegner J, Lieberman J. Integrating incidence and prevalence of tardive dyskinesia. *Psychopharmacol Bull*. 1986;22:254-258.

Kang UJ, Burke RE, Fahn S. Natural history and treatment of tardive dystonia. *Mov Disord*. 1986;1:193-208.

Kenney C, Hunter C, Jankovic J. Long-term tolerability of tetrabenazine in the treatment of hyperkinetic movement disorders. *Mov Disord*. 2007;22(2):193-197.

Kiriakakis V, Bhatia KP, Quinn NP, Marsden CD. The natural history of tardive dystonia. A long-term follow-up study of 107 cases. *Brain*. 1998;121(pt 11):2053-2066.

Leucht S, Cipriani A, Spineli L, et al. Comparative efficacy and tolerability of 15 antipsychotic drugs in schizophrenia: a multiple-treatments meta-analysis. *Lancet*. 2013;382(9896):951-962.

Miller DD, Caroff SN, Davis SM, et al. Extrapyramidal side-effects of antipsychotics in a randomised trial. *Br J Psychiatry*. 2008;193(4):279-288.

Muscettola G, Barbato G, Pampallona S, Casiello M, Bollini P. Extrapyramidal syndromes in neuroleptic-treated patients: prevalence, risk factors, and association with tardive dyskinesia. *J Clin Psychopharmacol*. 1999;19:203-208.

Oosthuizen PP, Emsley RA, Maritz JS, Turner JA, Keyter N. Incidence of tardive dyskinesia in first-episode psychosis patients treated with low-dose haloperidol. *J Clin Psychiatry*. 2003;64:1075-1080.

Paulsen JS, Caligiuri MP, Palmer B, McAdams LA, Jeste DV. Risk factors for orofacial and limbtruncal tardive dyskinesia in older patients: a prospective longitudinal study. *Psychopharmacology (Berl)*. 1996;123:307-314.

Pringsheim T, Gardner D, Addington D, et al. The assessment and treatment of antipsychotic-induced akathisia. *Can J Psychiatry*. 2018;63:719-729.

Savica R, Grossardt BR, Bower JH, Ahlskog JE, Mielke MM, Rocca WA. Incidence and time trends of drug-induced parkinsonism: a 30-year population-based study. *Mov Disord*. 2017;32(2):227-234.

Seeman P. Dopamine D_2 receptors as treatment targets in schizophrenia. *Clin Schizophr Relat Psychoses*. 2010;4(1):56-73.

Seeman P, Tallerico T. Antipsychotic drugs which elicit little or no parkinsonism bind more loosely than dopamine to brain D_2 receptors, yet occupy high levels of these receptors. *Mol Psychiatry*. 1998;3:123-134.

Seeman P, Tinazzi M. Loss of dopamine neuron terminals in antipsychotic-treated schizophrenia; relation to tardive dyskinesia. *Prog Neuropsychopharmacol Biol Psychiatry*. 2013;44:178-183.

Smith JM, Baldessarini RJ. Changes in prevalence, severity, and recovery in tardive dyskinesia with age. *Arch Gen Psychiatry*. 1980;37:1368-1373.

Choreas 84

Ruth H. Walker and Joseph Jankovic

KEY POINTS

1. Chorea can be due to a wide variety of causes, including pharmacologic, genetic, structural, autoimmune, and metabolic factors.
2. Sydenham disease is the most likely cause of acute-onset childhood chorea.
3. Management should be directed at the most clinically limiting symptoms of the underlying disease, which may not be the movement disorder.
4. Management of chorea primarily involves decreasing dopaminergic neurotransmission, either pre- or postsynaptically, and should be periodically tapered to evaluate efficacy.

INTRODUCTION

Chorea is a hyperkinetic movement disorder characterized by continual, jerk-like movements that flow randomly from one body part to another. Patients may be able to partially suppress the involuntary movements or "camouflage" them by incorporating them into semipurposeful activities (parakinesia). As a result of chorea, patients have difficulty maintaining a sustained voluntary contraction, such as tongue protrusion or a persistent hand grip, resulting in intermittent contractions and relaxations (milkmaid grip). Chorea should be differentiated from "pseudochoreoathetosis" due to loss of proprioception. Choreic movements can be associated with many disorders; the most common are listed in **Table 84.1**.

EPIDEMIOLOGY

Chorea is nearly always secondary to some underlying disorder. In addition to the genetic disorders, such as Huntington disease (HD) (covered elsewhere in this volume), of which it is a typical feature, chorea can be an atypical feature of other genetic disorders such as the inherited ataxias. The list of possible genetic causes of chorea continues to grow, as evolving molecular diagnostic methods identify patients with atypical phenotypes of specific genetic disorders, in addition to novel genetic etiologies.

Similarly, although chorea is a typical feature of Sydenham disease (SD), it can be variably present in the setting of other autoimmune disorders, such as systemic lupus erythematosus. A number of metabolic derangements, most commonly diabetic nonketotic hyperglycemia, can cause chorea, although why certain patients develop this, and why the symptoms are classically asymmetric, is unknown.

PATHOBIOLOGY

In terms of the direct/indirect pathway of basal ganglia functioning, chorea can be conceptualized as an overall decrease in activity of the indirect pathway. This can be a result of loss of γ-aminobutyric acid-ergic neurons projecting from the putamen to the external segment of the globus pallidus, resulting in disinhibition and increased activity of this nucleus. The increased activity of these γ-aminobutyric acid-ergic neurons inhibits the glutamatergic neurons of the subthalamic nucleus. This has an effect analogous to a lesion of this nucleus, as in hemiballismus. This decreased output may result in a loss of inhibition at the level of the thalamocortical motor pattern generator and hence breakthrough of involuntary movements.

In general, functional imaging demonstrates a hypometabolic state of the basal ganglia in neurodegenerative disorders and a hypermetabolic state in autoimmune disorders. It is intriguing that these opposite changes can result in an identical movement disorder; it is possible that the indirect pathway neurons, as described above, which bear dopaminergic D2 receptors, are more vulnerable to metabolic or neurochemical disruption than the D1 dopaminergic neurons of the direct pathway.

CAUSES OF CHOREA

Autoimmune Choreas

Sydenham Disease

SD (acute chorea, St. Vitus dance, chorea minor, rheumatic chorea) is a disease of childhood characterized by chorea, which is often asymmetric or may be unilateral (hemichorea) in about 20% of the cases (▷ **Video 84.1**). The term *Sydenham disease*, rather than *Sydenham chorea*, is preferred, as chorea is only one of many manifestations, including a variety of neurologic, psychiatric, cardiac, rheumatologic, and other problems.

SD is a consequence of infection with group A β-hemolytic *Streptococcus*, which is thought to induce antibodies that cross-react with neuronal cytoplasmic antigens on neurons of caudate and subthalamic nuclei. Unlike arthritis and carditis, which occur soon after the infection, the appearance of chorea may be delayed for 6 months or longer.

Acute chorea is almost exclusively a disease of childhood; over 80% of the cases occur in patients between the age of 5 and 15 years. Onset of the first attack after the age of 15 years is uncommon. Girls are affected more than twice as frequently as boys.

The chorea, with some exceptions, is self-limited, and fatalities are rare except as a result of cardiac complications. On average, the motor symptoms persist for 3 to 6 weeks, but the neuropsychiatric symptoms, particularly obsessive-compulsive

TABLE 84.1 Differential Diagnosis of Chorea[a]

Developmental Choreas
Physiologic chorea of infancy
Chorea minima
Idiopathic Choreas
Oral-lingual dyskinesia and edentulous orodyskinesia
Hereditary Choreas
Huntington disease
Chorea-acanthocytosis (*VPS13A* gene)
McLeod syndrome (*XK* gene)
Brain-Lung-Thyroid (*NKX2-1*) Syndrome
Other heredodegenerative disorders: Huntington disease–like disorders (eg, prion protein [*PRNP*], junctophilin-3 [*JPH3*] gene mutations), dentatorubral-pallidoluysian atrophy (*ATN1* gene mutations), spinocerebellar ataxias (SCA types 1, 2, 3, 8, 17), *C9orf72* expansions, ataxia-telangiectasia, ataxia with oculomotor apraxia type 1 (aprataxin gene), ataxia with oculomotor apraxia type 2 (due to mutations in the senataxin gene), ADCY5 disease and other paroxysmal dyskinesias, tuberous sclerosis of basal ganglia, phospholipase-associated neurodegeneration (*PLA2G6* mutations), neuroferritinopathy, aceruloplasminemia, other neurodegenerations with brain iron accumulation, Wilson disease, infantile bilateral necrosis
Neurometabolic Disorders
Lesch-Nyhan syndrome, lysosomal storage disorders, amino acid disorders, Leigh disease, porphyria
Drugs
Neuroleptics (tardive dyskinesia, withdrawal emergent syndrome), dopaminergic drugs, anticholinergics, amphetamines, cocaine, tricyclics, oral contraceptives
Toxins
Alcohol intoxication and withdrawal, anoxia, carbon monoxide, manganese, mercury, thallium, toluene
Metabolic and Endocrine Disorders
Hypernatremia, hyponatremia, hypomagnesemia, hypocalcemia, hypoglycemia, hyperglycemia (nonketotic diabetic)
Pregnancy (*chorea gravidarum*—likely due to recrudescence of Sydenham disease)
Acquired hepatocerebral degeneration
Renal failure
Nutritional (eg, ketogenic diet, beriberi, pellagra, vitamin B_{12} deficiency, particularly in infants)
Infectious and Postinfectious
Sydenham disease
Encephalitis lethargica
Various other infectious and postinfectious encephalitis, Creutzfeldt-Jakob disease
Immunologic
Systemic lupus erythematosus, antiphospholipid syndrome, *chorea gravidarum*
Henoch-Schönlein purpura
NMDA antibody (and other autoantibodies) encephalitis
HIV infection
Vascular/Structural
Infarction or hemorrhage
Arteriovenous malformation, moyamoya disease
Polycythemia rubra vera
Antiphospholipid syndrome
Migraine
Following cardiac surgery with hypothermia and extracorporeal circulation in children (choreoathetosis and orofacial dyskinesia, hypotonia, and pseudobulbar signs or CHAP syndrome)
Intracranial hypotension due to cerebrospinal fluid leak
Tumors
Trauma
Other Secondary Choreas
Cerebral palsy (anoxic), kernicterus, sarcoidosis, toxoplasmosis, multiple sclerosis, Behçet disease, polyarteritis nodosa, mitochondrial disorders

Abbreviation: NMDA, *N*-methyl-D-aspartate.
[a]Modified from Fahn S, Jankovic J. *Principles and Practice of Movement Disorders*. Philadelphia, PA: Churchill Livingstone/Elsevier; 2007.

behavior, may persist for months to years, recur, or even be lifelong. After spontaneous remission, some female patients have a recurrence during pregnancy, so-called *chorea gravidarum*, or with the use of oral contraceptives or hormone replacement therapy.

SD is associated with a variety of neurobehavioral problems, such as irritability, emotional lability, anxiety, obsessive-compulsive behavior, and other psychiatric manifestations. Speech impairment can occur, and, more rarely, encephalopathy, reflex changes, weakness, gait disturbance, headache, seizures, and cranial neuropathy.

The diagnosis is made without difficulty from the appearance of the acute or subacute onset of characteristic choreic movements in a child with relatively recent history of streptococcal infection. Although serum antistreptolysin O and anti-DNase B titers are elevated in less than 30% of cases, these tests have a high specificity. Neuroimaging is typically normal but may show enlargement of the striatum and globus pallidus.

When the severity of the movements interferes with proper rest, dopamine-depleting drugs or a short course of dopamine receptor-blocking drugs may be considered. Other drugs, such as benzodiazepines, valproate, or carbamazepine, may be also effective. If the syndrome is debilitating, for example, in the severely hypotonic form, immunosuppressive therapies, such as corticosteroids, intravenous immunoglobulin, or plasmapheresis, may be required. Treatment of the precipitating streptococcal infection generally consists of a full 10-day course of oral penicillin V therapy or an injection of benzathine penicillin G. Prophylactic administration of penicillin for at least 10 years is recommended to prevent other manifestations of rheumatic fever, of which SD may be its sole manifestation.

Systemic Lupus Erythematosus

Chorea in systemic lupus erythematosus, often fluctuating and intermittent, has been associated with the presence of serum antiphospholipid antibodies (lupus anticoagulant), a heteroge-

neous group of antibodies that can cause platelet dysfunction and result in thrombosis. Treatment is directed at the immunologic features of the disorder and anticoagulation.

Antiphospholipid Antibody Syndrome

Primary antiphospholipid antibody syndrome also causes chorea, particularly in young women. Systemically, patients may have migraine, spontaneous abortions, venous and arterial thromboses, thickened cardiac valves, livedo reticularis, and Raynaud phenomenon. The central nervous system is involved with strokes, multi-infarct dementia, and chorea. Activated partial thromboplastin time is prolonged due to the presence of lupus anticoagulant, and there are high titers of anticardiolipin antibodies exist. Anticoagulation, immunosuppressive drugs, and plasmapheresis have had variable success; it is difficult to interpret the effectiveness of therapeutic interventions because spontaneous remission occurs frequently.

Chorea due to Other Autoantibodies

Chorea associated with anti–*N*-methyl-D-aspartate (NMDA) receptor encephalitis is particularly important to recognize because there is the potential for good outcomes with appropriate therapies. Often presenting as a subacute neuropsychiatric disorder, anti-NMDA encephalitis is characterized by a variety of movement disorders including chorea, stereotypy, dystonia, and myorhythmia. A search for ovarian teratoma or other benign tumors should be initiated because their removal is a critical part of the treatment. Immunoglobulin G antibodies against the NR1 subunit of the NMDA receptor are often identified.

Other autoantibodies, either as paraneoplastic or idiopathic autoimmune disorders, may cause chorea. If total body imaging does not reveal a neoplasm which can be surgically removed, immunosuppressive therapies should be employed. Aggressive and persistent immunosuppressive management is critical and can result in good outcomes despite a prolonged disease course. The list of causative autoantibodies continues to expand but includes anti-LGI1, anti-CV2/CRMP5, anti-Ma, and others.

Structural and Vascular Chorea and Ballism

Choreic movements confined to the arm and leg on one side of the body (hemichorea, hemiballism) may develop abruptly in middle-aged or elderly patients. Ballistic movements are a more violent form of chorea and are characterized by large amplitude uncoordinated activity of the proximal appendicular muscles, so vigorous that the limbs are forcefully and aimlessly thrown about. Padding of the limbs or bed side rails may be necessary to prevent injury. The movements are present at rest and may be suppressed during voluntary limb movement.

Sudden onset of chorea suggests a vascular basis; indeed, it may be preceded by hemiplegia or hemiparesis. In such instances, the choreic or ballistic movements appear when motor function returns. This type of movement disorder may be the result of a destructive lesion of the contralateral putamen, subthalamic nucleus or their connections. Vascular lesions, hemorrhagic or occlusive in nature, are the most common cause, but hemiballism has been found in association with structural lesions, for example, due to toxoplasmosis in immunocompromised patients, tumors, and multiple sclerosis. In general, the movements tend to diminish over time, but they may be persistent and require therapeutic intervention. The agents noted elsewhere in this chapter for the control of choreic movements in general have proved effective.

Asymmetric chorea-ballism may be a feature of diabetic hyperosmolar hyperglycemic nonketotic syndrome. The characteristic magnetic resonance imaging (MRI) finding is high signal in the contralateral putamen on T1 sequences. Older women, especially those of East Asian ancestry, appear to be most vulnerable to this condition. The underlying pathophysiology is unclear. The symptoms typically resolve as the metabolic abnormalities are corrected; however, the improvement may be delayed for weeks or months and in rare cases is persistent.

Choreoathetosis as a sequela to surgery for congenital heart disease appears to be associated with prolonged time on pump, deep hypothermia, and circulatory arrest. The incidence is decreasing most likely due to technologic improvements.

Occasionally, chorea can be due to intracranial hypotension due to spontaneous cerebrospinal fluid leaks. The mechanism is unknown but is likely due to disruption of basal ganglia pathways due to structural shifts.

Genetic Causes of Chorea

Autosomal Recessive

Chorea-acanthocytosis

Chorea-acanthocytosis (ChAc) is one of the neuroacanthocytosis syndromes and is also, somewhat confusingly, often referred to as "neuroacanthocytosis." The ChAc is due to autosomal recessive mutations of the gene *VPS13A* on 9q21.2, which codes for the protein chorein. The chorea is typically less prominent than that seen in HD but occasionally can be just as severe. In addition to chorea, patients with ChAc often have tics, seizures, parkinsonism, cognitive decline, amyotrophy, dysphagia, absent tendon reflexes, feeding dystonia (the tongue pushes food out of the mouth), and self-mutilation with lip and tongue biting. Age at onset is typically in late adolescence and young adulthood but occasionally may be later. The diagnosis is supported by finding more than 10% spiky erythrocytes (acanthocytes) in blood smears, although this is not an invariable feature. Detection of acanthocytes can be enhanced if a wet smear of blood is diluted 1:1 with normal saline (Fig. 84.1). Occasionally, electron microscopy is needed to confirm the presence of acanthocytes. The diagnosis can be made by Western blot to determine the absence of chorein and by identification of mutations of the affected gene (Fig. 84.2). Elevated creatine kinase, and sometimes liver enzymes, strongly supports the diagnosis in the presence of typical clinical features.

Positron emission tomography scan typically shows hypometabolism in the caudate nucleus as well as reduced fluorodopa uptake and decreased dopamine receptor binding in the striatum.

The Autosomal Recessive Ataxias

Chorea can be a feature of several of the autosomal recessive ataxias, specifically ataxia-telangiectasia (AT), ataxia with oculomotor apraxia (AOA) types 1 and 2, and Friedreich ataxia. These typically present in childhood, although occasionally develop later. Serologic findings such as elevated α-fetoprotein and hypoalbuminemia can be informative in AT and the AOAs.

X Linked

McLeod Syndrome

McLeod syndrome has historically been known as an X-linked form of neuroacanthocytosis. It is due to mutations of the *XK*

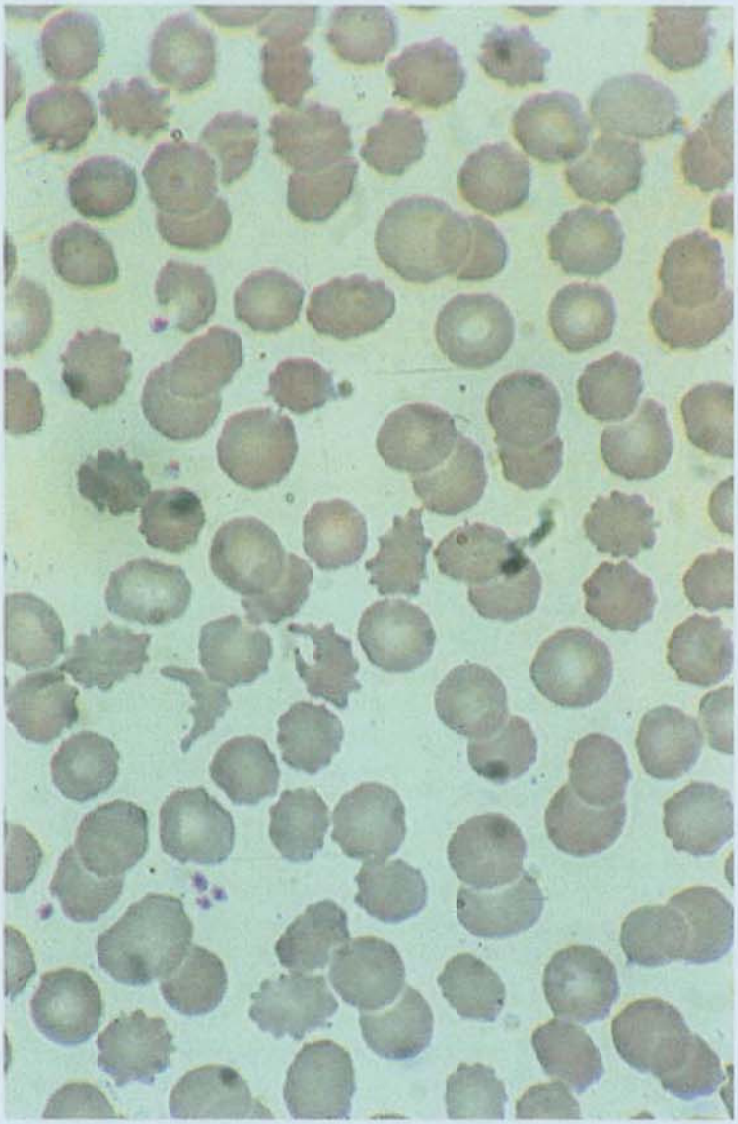

FIGURE 84.1 Acanthocytes in a patient with chorea-acanthocytosis.

gene on Xp21. Besides allelic variants of the *XK* gene, McLeod syndrome may be part of a contiguous gene deletion syndrome involving *XK* and adjacent genes, including those for chronic granulomatous disease, Duchenne muscular dystrophy, and retinitis pigmentosa. The affected protein, XK, typically expresses an antigen, known as Kx on the surface of erythrocytes. When XK is abnormal, due to the genetic mutation, expression of the Kx antigen is absent. There is also reduced expression of the antigens of the Kell protein, which is covalently linked to XK in the erythrocyte membrane; this antigen presentation is known as the "McLeod phenotype" and has implications for blood transfusion.

McLeod syndrome typically presents in middle-aged men, although, rarely, heterozygous carrier females can be affected. The clinical features are very similar to ChAc, with chorea, dystonia, tics, parkinsonism, seizures, neuropathy, cognitive decline, and psychiatric symptoms. Feeding dystonia and self-mutilation are not usually seen. Similar to ChAc, the presence of acanthocytosis is informative, when present, but elevated creatine kinase and liver enzyme levels may be more useful in making the diagnosis. Distinct features of McLeod syndrome are cardiomyopathy and dysrhythmia, which are potentially treatable causes of morbidity and mortality.

Autosomal Dominant

The most common cause of autosomal dominant chorea is HD (covered elsewhere in this volume). In this chapter, we briefly mention other forms of autosomal dominant chorea.

C9orf72 Disease

Mutations of *C9orf72* can cause a spectrum of neurologic symptoms, including frontotemporal dementia, motor neuron disease, and an HD-like phenotype. The mutation is an expansion of a hexanucleotide repeat of 9p21.2 and after HD is one of the most common causes of genetic chorea in non-African populations. Hyperreflexia and signs of frontal lobe dysfunction suggest the diagnosis.

The Spinocerebellar Ataxias

Although labeled as a spinocerebellar degeneration, several of the spinocerebellar ataxias (SCAs) can present with a choreic

FIGURE 84.2 Absence of chorein in patient (*155a*) with chorea-acanthocytosis (Western blot). (Courtesy Dr. Benedikt Bader, Munich, Germany.)

phenotype, including SCA types 1, 2, 3, 8, and 17 (which has also been reported as "HDL4"). There does not appear to be a correlation between the size of the trinucleotide repeat expansion and the clinical presentation. A variety of movement disorders, including parkinsonism and dystonia, in addition to chorea, can be seen.

Dentatorubral-Pallidoluysian Atrophy

Once thought to be found only in the Japanese population, this autosomal dominant disorder is now known to be more widespread, thanks to discovery of expanded cytosine-adenine-guanine (CAG) repeats in the dentatorubral-pallidoluysian atrophy gene (*DRPLA* or *ATN1*) on chromosome 12p13.31 that codes for the atrophin-1 protein, which is phosphorylated by c-Jun NH-terminal kinase. The abnormal polyQ protein has reduced affinity for c-Jun NH-terminal kinase. Also called the *Haw River syndrome* because of its occurrence in some African Americans in North Carolina, DRPLA clinically overlaps with HD and manifests combinations of chorea, myoclonus, seizures, ataxia, and dementia. The phenotype varies according to triplet (CAG) repeat length, and anticipation and excess of paternal inheritance in younger onset cases with longer repeat lengths are seen. The neuropathologic spectrum is centered around the cerebellofugal and pallidofugal systems, but neurodegenerative changes can be found in many nuclei. In contrast to HD, DRPLA is typically associated with white matter degeneration.

Huntington Disease–like 1

Huntington disease–like 1 is an autosomal dominant disorder mapped to the prion protein gene (*PRNP*) on chromosome 20p with eight extra octapeptide repeats in the prion protein. The time course of the disease, over decades, is more suggestive of HD than of a prion disorder. Presentation is typically in young adulthood; symptoms can be variable, even within a single family, and can include ataxia, in addition to features suggestive of HD. Neuroimaging tends to show generalized brain atrophy; abnormal discharges such as triphasic waves are typically found on electroencephalography.

Huntington Disease–like 2

The autosomal dominant Huntington disease–like 2 appears to be present exclusively in individuals of African ancestry. It is due to cytosine-thymine-guanine and CAG repeat expansions of the gene on chromosome 16q24.2, encoding junctophilin-3, a protein of the junctional complex linking the plasma membrane, and the endoplasmic reticulum. Clinical, radiologic, and neuropathologic features strongly resemble those seen in HD. Subtle changes in thalamic volumes can be detected using volumetric methods, but otherwise, Huntington disease–like 2 is clinically indistinguishable from HD.

Brain-Lung-Thyroid (*NKX2-1*) Syndrome

This childhood-onset, choreic disorder has been previously considered to be relatively benign and nonprogressive, but the phenotype has been expanding since the discovery of mutations in the *NKX2-1* (previously called *TITF1*) gene on chromosome 14q13.3, coding for a transcription factor essential for the organogenesis of the lung, thyroid, and basal ganglia. This autosomal dominant syndrome has been also described in patients with deletion of not only the *NKX2-1* gene but also the contiguous *PAX9* gene. These mutations should be considered in children and adults with chorea, motor delay, short stature, gait ataxia, dystonia, myoclonus, tics, intellectual impairment, congenital hypothyroidism, and chronic lung disease. The term *brain-lung-thyroid syndrome* has been used to draw attention to the multiorgan involvement in this condition and rather than employing the misleading designation of "benign hereditary chorea."

Brain MRI has been generally reported to be unremarkable, but some cases showed hypoplastic pallida, lack of differentiation of medial and lateral components, and bilateral signal hyperintensities on T2-weighted MRI images. About half of the patients spontaneously improve in adulthood.

Other Choreas

There are many other genetic causes of chorea. For example, mutations in the *ADCY5* gene that codes for adenylate cyclase 5, a striatal-specific enzyme that converts adenosine triphosphate into cyclic adenosine monophosphate, have been increasingly recognized as a cause of a multisymptomatic disorder. The manifestations may include a combination of initially paroxysmal and subsequently progressive dystonia, chorea, myoclonus, spasticity in the legs, and hypotonia (in the neck and trunk). The course is often fluctuating with episodic exacerbations observed upon awakening, triggered by sleep, intercurrent illnesses, excitement, or stress. Many attacks represent medial frontal lobe seizures. Often misdiagnosed as cerebral palsy, additional features include language delay, "myopathic facial appearance," and heart failure.

Dyskinetic cerebral palsy, manifested by a combination of chorea and athetosis (choreoathetosis) and a variety of other neurologic abnormalities, including intellectual impairment, seizures, dystonia, ataxia, and spasticity, is one of the most common causes of childhood-onset chorea. This condition is usually attributed to damage in the developing fetal or infant brain, such as perinatal hypoxia-ischemia, intracranial hemorrhage or cerebral infarction, neonatal hyperbilirubinemia (Fig. 84.3), and brain maldevelopment. Cerebral palsy is the most frequent cause of disability in early childhood, with the prevalence estimated to be 1.7 to 3.1 per 1,000 live births. Although cerebral palsy is usually attributed to perinatal injury, there is a growing number of metabolic and genetic disorders that may mimic this condition.

Other common causes of chorea are drug-induced dyskinesia, such as levodopa-induced dyskinesia and tardive dyskinesia. It should also be noted that chorea may be a manifestation in many forms of paroxysmal dyskinesias. Finally, patients with functional (psychogenic) movement disorders, most typically manifested by tremor and dystonia, may rarely also exhibit features of chorea, athetosis, or ballism.

It is beyond the scope of this review to describe all causes of choreas, but the reader is directed to Table 84.1 and "Suggested Readings" section for less common forms of choreic disorders.

DIAGNOSIS

The diagnosis of chorea is based on the presence of characteristic phenomenology, and the search for etiology is guided by the following factors: the presence or absence of a family history of a similar disorder, concurrent medical conditions, current and previous medication history, time course and exacerbating/relieving factors, and other clinical and neurologic signs and symptoms. Evaluation of the patient with chorea typically

FIGURE 84.3 Magnetic resonance imaging of an 11-year-old boy with kernicterus. The T2-weighted image shows abnormal pallidal signal *(arrows)*. See also Video 84.2.

requires neuroimaging, ideally brain MRI; testing of peripheral blood for metabolic (eg, thyroid function tests) and autoimmune (eg, autoantibodies) abnormalities and for specific protein markers (eg, ceruloplasmin in Wilson disease, α-fetoprotein in AT and AOA type 2, chorein in ChAc); and, in some cases, cerebrospinal fluid analysis (eg, autoantibodies, 14-3-3 protein, cell count). Targeted genetic testing, specifically for HD, may be considered relatively early in the diagnostic process, especially if there is a suggestive family history.

Ancillary informative evaluations may include electroencephalography (which can be abnormal in prion diseases and neuroacanthocytosis syndromes) and electrophysiologic examination of nerve and muscle function (which can be abnormal in some of the degenerative cerebellar disorders and neuroacanthocytosis syndromes).

MANAGEMENT

Treatment of chorea should focus on identification of specific and potentially reversible causes, such as medications, infectious, autoimmune, or paraneoplastic etiologies. Symptomatic relief of chorea is similar to that in patients with HD and typically involves the use of medications which reduce dopaminergic neurotransmission. Dopamine receptor blocking agents such as the typical or atypical antipsychotic agents can be used; it is preferable to avoid, or at least minimize, the use of either of these agents, but especially the typical antipsychotics, due to the risk of inducing tardive dyskinesia. Of the atypical antipsychotic agents, quetiapine is probably the least likely to cause this long-term side effect; if quetiapine is not tolerated due to sedation or metabolic syndrome, clozapine is the best option, if practical.

There is level 1 evidence to support the efficacy and safety of tetrabenazine LEVEL 1[1] and deutetrabenazine LEVEL 1,[2] both causing presynaptic dopamine depletion by blocking the vesicular monoamine transporter type 2, in the treatment of chorea associated with HD, an indication approved by the U.S. Food and Drug Administration. These two drugs have been found to be useful therapeutic options for a large range of hyperkinetic movement disorders. Deutetrabenazine has additionally been approved by the U.S. Food and Drug Administration only for the treatment of tardive dyskinesia. Medications should be periodically tapered to determine if they are continuing to be therapeutically beneficial, as symptoms may resolve or evolve over time. For example, if the patient becomes parkinsonian, this might be due to medication or to disease progression. Especially in the progressive neurodegenerative syndromes, behavioral, psychiatric, cognitive, and nonmotor symptoms, such as dysphagia, can be more disabling than the movement disorder and can require multidisciplinary management. If chronic and disabling, deep brain stimulation of the internal segment of the globus pallidus may be considered; however, this option is probably best suited to nonprogressive conditions, such as chorea due to structural lesions, rather than neurodegenerative disorders such as HD.

OUTCOME

Chorea secondary to structural lesions, autoimmune, or metabolic disturbances tends to resolve over time. As a symptom of neurodegenerative disorders such as HD or ChAc, it may also resolve and be replaced by a bradykinetic, parkinsonian phenotype.

Videos can be found in the companion e-book edition. For a full list of video legends, please see the front matter.

LEVEL 1 EVIDENCE

1. Huntington Study Group. Tetrabenazine as antichorea therapy in Huntington disease: a randomized controlled trial. *Neurology*. 2006;66(3):366-372.
2. Huntington Study Group. Effect of deutetrabenazine on chorea among patients with Huntington disease: a randomized clinical trial. *JAMA*. 2016;316(1):40-50.

SUGGESTED READINGS

Sydenham Disease

Dean SL, Singer HS. Treatment of Sydenham's chorea: a review of the current evidence. *Tremor Other Hyperkinet Mov (N Y)*. 2017;7:455.

Autoimmune Chorea

Baizabal-Carvallo JF, Bonnet C, Jankovic J. Movement disorders in systemic lupus erythematosus and the antiphospholipid syndrome. *J Neural Transm (Vienna)*. 2013;120(11):1579-1589.

Baizabal-Carvallo JF, Jankovic J. Autoimmune and paraneoplastic movement disorders: an update. *J Neurol Sci*. 2018;385:175-184.

Vascular Chorea-ballism

Gómez-Ochoa SA, Espín-Chico BB, Pinilla-Monsalve GD, Kaas BM, Téllez-Mosquera LE. Clinical and neuroimaging spectrum of hyperglycemia-associated chorea-ballism: systematic review and exploratory analysis of case reports. *Funct Neurol*. 2018;33(4):175-187.

Mehanna R, Jankovic J. Movement disorders in cerebrovascular disease. *Lancet Neurol*. 2013;12(6):597-608.

Chorea-acanthocytosis

Velayos Baeza A, Dobson-Stone C, Rampoldi L, et al. Chorea-acanthocytosis. In: Adam MP, Ardinger HH, Pagon RA, et al, eds. *GeneReviews®*. Seattle, WA: University of Washington; 1993-2020. http://www.ncbi.nlm.nih.gov/books/NBK1387/. Accessed October 10, 2019.

Walker RH. Management of neuroacanthocytosis syndromes. *Tremor Other Hyperkinet Mov*. 2015;5:346.

Walker RH. Untangling the thorns: advances in neuroacanthocytosis syndromes. *J Mov Disord*. 2015;8(2):41-54.

Walker RH, Miranda M, Jung HH, Danek A. Life expectancy and mortality in chorea-acanthocytosis and McLeod syndrome. *Parkinsonism Relat Disord*. 2019;60:158-161.

McLeod Syndrome

Jung HH, Danek A, Walker RH, Frey BM, Gassner C. McLeod neuroacanthocytosis syndrome. In: Adam MP, Ardinger HH, Pagon RA, et al, eds. *GeneReviews®*. Seattle, WA: University of Washington; 1993-2019. https://www.ncbi.nlm.nih.gov/books/NBK1354/. Accessed October 10, 2019.

Roulis E, Hyland C, Flower R, Gassner C, Jung HH, Frey BM. Molecular basis and clinical overview of McLeod syndrome compared with other neuroacanthocytosis syndromes: a review. *JAMA Neurol*. 2018;75(12):1554-1562.

Spinocerebellar Ataxias

Rossi M, Perez-Lloret S, Cerquetti D, Merello M. Movement disorders in autosomal dominant cerebellar ataxias: a systematic review. *Mov Disord Clin Pract*. 2014;6;1(3):154-160.

Dentatorubral-Pallidoluysian Atrophy

Carroll LS, Massey TH, Wardle M, Peall KJ. Dentatorubral-pallidoluysian atrophy: an update. *Tremor Other Hyperkinet Mov (N Y)*. 2018;8:577.

Huntington Disease–like Syndromes

Anderson DG, Walker RH, Connor M, Carr J, Margolis RL, Krause A. A systematic review of the Huntington like-2 phenotype. *J Huntingtons Dis*. 2017;6(1):37-46.

Bourinaris T, Houlden H. C9orf72 and its relevance in parkinsonism and movement disorders: a comprehensive review of the literature. *Mov Disord Clin Pract*. 2018;5(6):575-585.

Hensman Moss DJ, Poulter M, Beck J, et al. C9orf72 expansions are the most common genetic cause of Huntington disease phenocopies. *Neurology*. 2014;82(4):292-299.

Brain-Lung-Thyroid (NKX2-1) Syndrome

Carecchio M, Mencacci NE, Iodice A, et al. ADCY5-related movement disorders: frequency, disease course and phenotypic variability in a cohort of paediatric patients. *Parkinsonism Relat Disord*. 2017;41:37-43.

Parnes M, Bashir H, Jankovic J. Is benign hereditary chorea really benign? Brain-lung-thyroid syndrome caused by NKX2-1 mutations. *Mov Disord Clin Pract*. 2019;6(1):34-39.

Peall KJ, Lumsden D, Kneen R, et al. Benign hereditary chorea related to NKX2.1: expansion of the genotypic and phenotypic spectrum. *Dev Med Child Neurol*. 2014;56(7):642-648.

Other Choreas and Related Topics

Baizabal-Carvallo JF, Hallett M, Jankovic J. Pathogenesis and pathophysiology of functional (psychogenic) movement disorders. *Neurobiol Dis*. 2019;127:32-44.

Bashir H, Jankovic J. Deutetrabenazine for the treatment of Huntington's chorea. *Expert Rev Neurother*. 2018;18(8):625-631.

Bashir H, Jankovic J. Treatment options for chorea. *Exp Rev Neurother*. 2018;18(1):51-63.

Chinnery PF. Neuroferritinopathy. In: Adam MP, Ardinger HH, Pagon RA, et al, eds. *GeneReviews®*. Seattle, WA: University of Washington; 1993-2019. https://www.ncbi.nlm.nih.gov/books/NBK1141/. October 10, 2019.

Edwards TC, Zrinzo L, Limousin P, Foltynie T. Deep brain stimulation in the treatment of chorea. *Mov Disord*. 2012;27(3):357-363.

Ehrlich DJ, Walker RH. Functional imaging of chorea: a systematic review *J Clin Mov Disord*. 2017;4:8.

Erro R, Bhatia KP. Unravelling of the paroxysmal dyskinesias. *J Neurol Neurosurg Psychiatry*. 2019;90(2):227-234.

Feinstein E, Walker RH. An update on the treatment of chorea. *Curr Treat Options Neurol*. 2018;20(10):44.

Feinstein E, Walker RH. Treatment of secondary chorea: a review of the current literature. *Tremor Other Hyperkinet Mov (NY)*. In press.

Jankovic J. Dopamine depleters in the treatment of hyperkinetic movement disorders. *Expert Opin Pharmacother*. 2016;17(18):2461-2470.

Jinnah HA, Albanese A, Bhatia KP, et al. Treatable inherited rare movement disorders. *Mov Disord*. 2018;33(1):21-35.

Miyajima H, Hosoi Y. Aceruloplasminemia. In: Adam MP, Ardinger HH, Pagon RA, et al, eds. *GeneReviews®*. Seattle, WA: University of Washington; 1993-2019. https://www.ncbi.nlm.nih.gov/books/NBK1493/. Accessed October 10, 2019.

Monbaliu E, Himmelmann K, Lin J-P, et al. Clinical presentation and management of dyskinetic cerebral palsy. *Lancet Neurol*. 2017;16(9):741-749.

O'Toole O, Lennon VA, Ahlskog JE, et al. Autoimmune chorea in adults. *Neurology*. 2013;80(12):1133-1144.

Pearson TS, Pons R, Ghaoui R, Sue CM. Genetic mimics of cerebral palsy. *Mov Disord*. 2019;34(5):625-636.

Savitt D, Jankovic J. Tardive syndromes. *J Neurol Sci*. 2018;389:35-42.

Vijayakumar D, Jankovic J. Drug-induced dyskinesia, part 1: treatment of levodopa-induced dyskinesia. *Drugs*. 2016;76(7):759-777.

Vijayakumar D, Jankovic J. Drug-induced dyskinesia, part 2: treatment of tardive dyskinesia. *Drugs*. 2016;76(7):779-787.

Watchko JF, Tiribelli C. Bilirubin-induced neurologic damage—mechanisms and management approaches. *N Engl J Med*. 2013;369(21):2021-2030.

Huntington Disease 85

Karen S. Marder and Richard A. Hickman

KEY POINTS

1. Huntington disease (HD) is an autosomal dominant disorder caused by a cytosine-adenine-guanine (CAG) polyglutamine expansion in exon 1 of the Huntington gene on chromosome 4p16.3.
2. Age of onset, defined by an extrapyramidal movement disorder, is inversely related to CAG repeat length.
3. Forty or more CAG repeats will develop HD; 36 to 39 repeats: incomplete penetrance; 27 to 35 repeats: meiotic instability. Juvenile HD usually have more than 50 CAG repeats.
4. Neurodegeneration of the neostriatum and intracellular aggregation of mutant Huntingtin protein are pathologic hallmarks of Huntington disease.
5. Cognitive and psychiatric signs may occur 10 to 15 years before motor onset. The primary motor feature is chorea.
6. Treatment is symptomatic. There are no approved disease-modifying therapies.

INTRODUCTION

Huntington disease (HD) is an autosomal dominant neurodegenerative disorder caused by a cytosine-adenine-guanine (CAG) polyglutamine repeat expansion in exon 1 of the Huntington (*HTT*) gene on chromosome 4p16.3. The age of onset, defined based on the presence of a characteristic extrapyramidal movement disorder, is inversely related to CAG repeat length such that higher CAG repeat length is associated with earlier age at onset. HD is characterized by a triad of symptoms and signs including motor, cognitive, and psychiatric manifestations. Studies of premanifest HD have demonstrated changes in imaging biomarkers (putamen and caudate) that predate onset of motor signs more than 15 years prior to onset and cognitive changes that occur 10 years prior to motor onset. Symptomatic treatment for chorea is currently available; however, disease-modifying agents are not. The development of imaging, biofluid, and quantitative cognitive and motor testing will facilitate clinical trial development in both symptomatic and prodromal HD.

EPIDEMIOLOGY

George Huntington provided the classical description of the disease and its inheritance pattern in 1872. An analysis of 82 prevalence studies from 1930 to 2015 revealed a 10-fold difference in prevalence worldwide, with consistently higher prevalence in the United Kingdom (6.68 per 100,000; [95% confidence interval, 6.40-6.97]) and North America 7.33 (95% confidence interval, 6.94-7.4) compared to far lower prevalence among Asians (Hong Kong, Japan, South Korea, Taiwan) 0.4 per 100,000 (95% confidence interval, 0.36-0.44) and Black Africans (0.02 per 100,000 in South Africa). The prevalence of HD has increased 15% to 20% per decade between 1954 and 1996 despite stable incidence rates. Prevalence of HD among men and women is similar within each population. One reason for the increase in prevalence may be the application of genetic testing for diagnosis. Worldwide, the incidence of HD has ranged from 0 to 8 per million person years and has remained unchanged in the past three decades, with incidence much lower in Asia compared to those of European ancestry. Seven common haplotypes have been identified in the *HTT* gene, with a single ancestral haplotype accounting for 50% of all European chromosomes, supporting the theory that HD may have originated in Northern Europe and spread worldwide. Specific haplotypes may be more or less likely to be associated with CAG repeat expansion, which may also explain the heterogeneity of age at onset among populations.

PATHOBIOLOGY

Genetics

Age of onset of HD, defined by the presence of extrapyramidal motor signs, occurs most often between 40 and 50 years (mean age 45 y); however, cases have been reported as young as age 2 years and as old as 87 years. Between 5% and 10% develop HD before age 20 years (juvenile HD) and about 10% after 60 years. CAG repeat length is inversely correlated with age at onset and accounts for 50% to 70% of the variance in age at onset. Repeat lengths of 26 or less are normal. Repeats between 27 and 35 are considered intermediate or "high normal" and represent 3% to 5% of all "normal" alleles. Although carriers of 27 to 35 repeats will not develop manifest HD, this range confers meiotic instability, and parents, especially fathers, may transmit CAG repeats that are within the HD range to their children. Carriers of 27 to 35 repeats may evidence subtle behavioral changes, an "endophenotype," although they do not have motor or cognitive impairment. Repeats between 36 and 39 are associated with incomplete or reduced penetrance, meaning that some individuals will develop HD, generally late onset, and others will not. Diagnosis of HD in the 36 to 39 repeat range may be difficult due to confounding with age-associated signs. Individuals with 40 or more repeats will develop HD (fully penetrant) if they live long enough. Most individuals with HD have between 40 and 50 repeats. Those with juvenile HD usually have greater than 50 repeats, although greater than 100 repeats have been reported (**Table 85.1**).

There is a greater chance for CAG expansion in sperm than in ova, which explains the concept of "genetic anticipation," an earlier age at onset in the next generation. Mothers with HD pass

TABLE 85.1 CAG Repeat Ranges

Category	CAG Repeat Range	Phenotype	Additional Comments
Normal allele	≤26	Normal	
Mutable normal allele	27-35	Normal	3%-5% of all "normal" alleles May have subtle behavioral signs (endophenotype)
HD allele with reduced penetrance	36-39	Normal or HD (late onset)	0.26% of European populations May develop HD if the individual lives long enough
HD allele	≥40 repeats	HD	Repeat lengths greater than 50 associated with juvenile HD

Abbreviations: CAG, cytosine-adenine-guanine; HD, Huntington disease.

on approximately the same number of repeats (±3), whereas fathers with HD, because of meiotic instability, often pass on a higher CAG repeat length. Ninety percent of juvenile HD cases have inherited the disease from their fathers. Despite the inverse correlation of CAG repeat length with age at onset, there is significant variability of age of onset of HD even among individuals with the same CAG repeat length. Recent studies of genetic modifiers have identified a locus on chromosome 15 that delays onset by 6.1 years, a second on chromosome 15 that delays onset by 1.4 years, and a single nucleotide polymorphism (SNP) on chromosome 8 that is associated with earlier onset disease (1.6 y). In an analysis of progression of clinical and imaging data using genome-wide association, an SNP in MSH3 on chromosome 5 was associated with slower clinical progression.

Neuropathology

Neuronal loss begins in the neostriatum (caudate nucleus and putamen). A five-point grading system that ranges from 0 (no pathology) to grade 4 is based on macroscopic and microscopic criteria, which correlates with the Shoulson-Fahn Total Functional Capacity scale (Fig. 85.1). The earliest macroscopic changes are seen in the tail of the caudate nucleus. Over time, the disease appears to progress within the neostriatum in a caudorostral, medial-lateral, and dorsal-to-ventral direction with progressive involvement of the caudate nucleus and putamen. Fifty percent of neurons are lost in the caudate nucleus in grade 1, whereas 95% are lost in grade 4. Astrocytosis is associated with areas of neuronal loss and increases steadily from grades 2 to 4, with severe gliosis in stage 4. Although neuronal loss of the γ-aminobutyric acid (GABA)ergic medium spiny neurons in the neostriatum is the hallmark of HD, HD is a diffuse disease of the central nervous system with varying regional vulnerabilities. For instance, the

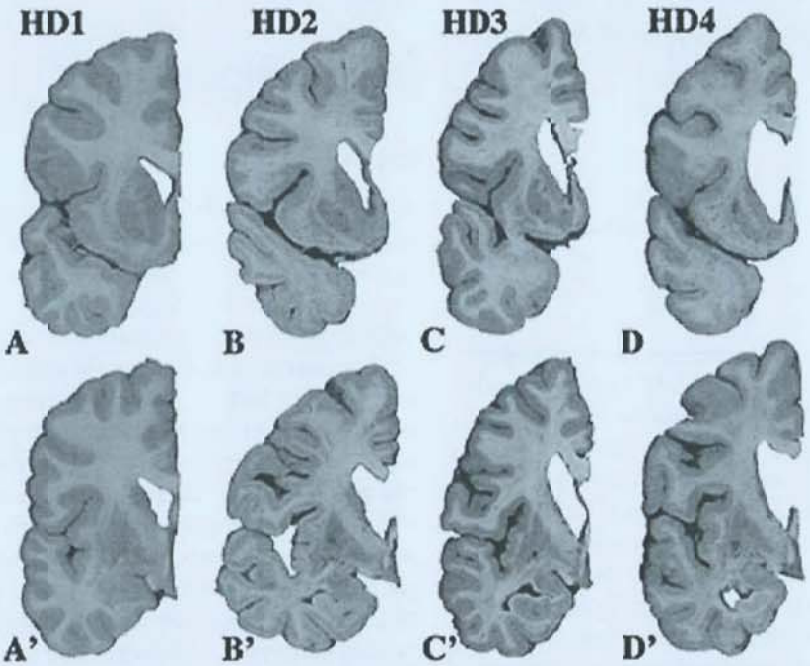

FIGURE 85.1 Gradations of Huntington disease (HD) pathology. Neuropathologic gradations of HD using a 5-point scale (0-4). **A-D:** Coronal sections passing through the nucleus accumbens including the head of the caudate nucleus and putamen. **A'-D':** Coronal sections passing through the globus pallidus including the putamen and caudal segment of the head of the caudate nucleus. **A,A':** Neuropathologic grade of severity 1 (HD1) (about 5% of all HD brains): There is minimal detectable change on gross examination at the sites shown in A and A'; however, the body and tail of the caudate nucleus are atrophic. **B,B':** Neuropathologic grade of severity 2 (HD2) (about 15% of HD brains): The volume loss of the neostriatum is moderate with relative preservation of its shape. **B:** The medial outline of the head of the caudate nucleus is only slightly convex, but it still bulges into the lateral ventricle. **B':** The medial edge of the lenticular nucleus lost its medial convexity. **C,C':** Neuropathologic grade of severity 3 (HD3) (about 50% of HD brains): The medial outline of the head of the caudate nucleus forms a straight line or is slightly concave medially **(C)**. **C':** The volume loss of the lenticular nucleus (putamen and globus pallidus) is discrete, and its medial outline is parallel to the anterior limb of internal capsule or is slightly concave medially. **D,D':** Neuropathologic grade of severity 4 (HD4) (about 30% of HD brains): The striatum is severely atrophic. **D:** The medial contour of the head of the caudate nucleus is concave, as is the anterior limb of internal capsule. (Courtesy of JP Vonsattel, MD.)

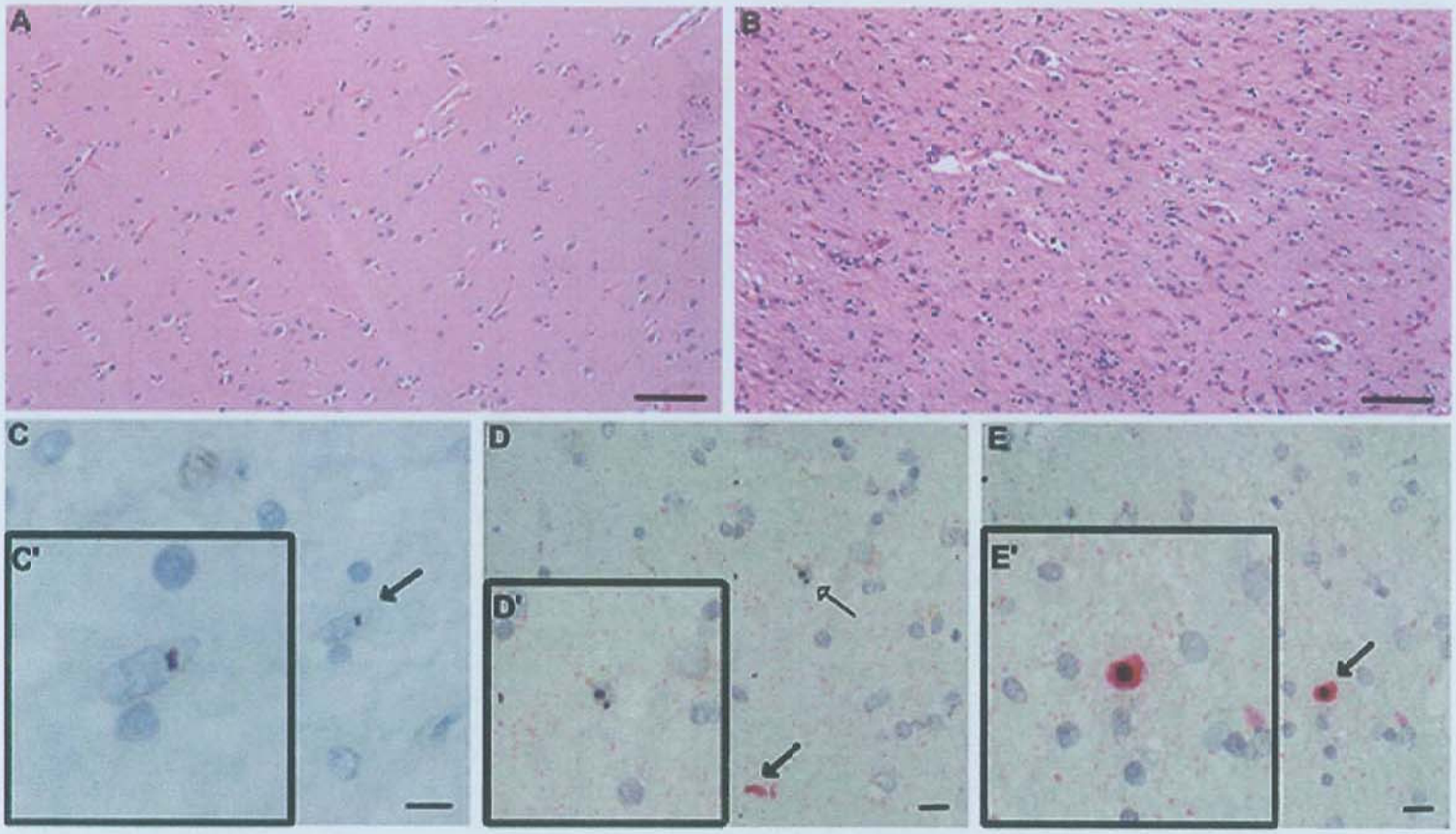

FIGURE 85.2 Photomicrographs of the head of the caudate nucleus **(B,C)** and the prefrontal neocortex in HD **(D,E)** and of the head of the caudate nucleus of a control brain **(A)**. **A,B:** The cellularity of the caudate nucleus is markedly increased in Huntington disease (B with an increased density of oligodendrocytes and a prominent astrocytosis). **C:** Photomicrographs of p62 immunostained sections of the head of the caudate nucleus demonstrates intranuclear inclusions (*closed arrow*; magnified further in inset C'). The neocortex also harbors abnormal protein inclusions. **D,E:** Double immunolabeling of p62 (red chromagen) and Huntingtin (HTT; brown chromagen) is shown in the prefrontal neocortex (Brodmann area 9). Both intranuclear (D, *open arrow*; further magnified in D') HTT aggregates and extranuclear HTT aggregates are seen. A dystrophic p62+/HTT- neurite is also apparent in D (*closed arrow*). E: An extranuclear HTT aggregate is enwrapped by p62 (*closed arrow*; E'). Scale bars: **A,B:** 100 μm; **C-E:** 10 μm.

nucleus accumbens is relatively resistant and neurodegeneration is seen in the later stages of the disease course. Extrastriatal involvement (subthalamic nucleus, substantia nigra pars reticulata, thalamus, brainstem, cerebellum, and neocortex) does occur, although the neurodegeneration is typically less severe than that seen in the neostriatum (see **Fig. 85.1**). Huntingtin aggregates have also been recently reported in the cervical and lumbar segments of the spinal cord of HD patients.

Microscopically, there is neuronal loss and gliosis within the caudate nucleus and putamen (**Fig. 85.2B**). A subset of neurons harbor abnormal protein inclusions that label with antibodies against ubiquitin and p62 (**Fig. 85.2C-E**). Both of these proteins are important for the intracellular degradation of misfolded proteins and within a large subset of these inclusions, Huntingtin protein (HTT) may be seen by immunohistochemistry (see **Fig. 85.2E**). Exactly how Huntingtin protein accumulates within neurons of HD patients is unclear, although experimental mouse studies have suggested that impairments in autophagy may play a role. HTT is ubiquitously expressed within the body and has been proposed to function as a scaffold for a wide variety of cellular events, ranging from gene transcription to vesicular trafficking. Because the *HTT* gene encodes for the HTT protein, the neuropathology of HD is believed to arise primarily from a toxic gain of function from an abnormal conformation of mutant HTT; however, partial loss of function of HTT and toxicity from RNA may also contribute.

Knockout and knockdown murine models have provided compelling evidence that HTT is necessary for early embryonic development. However, despite an abundance of neurodevelopmental work in murine models and cell culture systems, developmental abnormalities in the human HD brain are not clearly defined. There is a small body of evidence that suggests that children with presymptomatic HD have smaller head circumferences, and male patients tend to have smaller intracranial volumes than age-matched controls. Further work in human neuropathology is needed to explore the neurodevelopmental aspects of HD on the brain.

Neurochemistry

Up to 95% of the GABAergic medium spiny neurons that project to the globus pallidus and the substantia nigra are lost, whereas large cholinergic interneurons are selectively spared. Loss of the medium spiny neurons may be due to excessive stimulation of excitatory amino acid receptors, especially *N*-methyl-D-aspartate receptors. Although dopamine, glutamate, and GABA are thought to be most affected in HD and have been targets for therapy, multiple neurotransmitters and their receptors are involved.

Cannabinoid and adenosine A2a receptor binding in the striatum and globus pallidus externa are affected early. There is typically loss of dopamine D_1 receptors in the striatum as well as cannabinoid and D_1 receptors in the substantia nigra as the disease progresses. Loss of substance P/dynorphin neurons occurs in the late stages and correlates clinically with dystonia.

DIAGNOSIS

Diagnosis is based on the unequivocal presence of an extrapyramidal movement disorder in the setting an expanded CAG repeat or a family history of HD based on autopsy or a close family member who has undergone genetic testing. The differential diagnosis of chorea is presented in Chapter 84.

Individuals from confirmed HD families who present with signs and symptoms of HD should undergo a careful history and physical examination. As in sporadic cases, there should be consideration of causes of chorea including thyroid function tests, vitamin B_{12}, antinuclear antibody, antistreptolysin O, and human immunodeficiency virus. Because HD is the most likely etiology of the extrapyramidal movement disorder in a family with documented HD, genetic testing for the expanded CAG repeat is a more cost-effective approach. It is essential that any individual (symptomatic or presymptomatic) who is considering genetic testing be offered genetic counseling performed according to published guidelines. A center specialized in HD with a team of professionals including a neurologist, psychiatrist, and a genetic counselor is preferable.

Differential Diagnosis

From 1% to 12.4% of individuals with a clinical presentation of HD test negative for the HD gene mutation and are known as *phenocopies*. The etiology of phenocopies is heterogeneous, and often, there are clues based on ethnicity and clinical features. C9orf72 hexanucleotide repeat expansions, usually associated with amyotrophic lateral sclerosis and frontotemporal dementia may be the most common HD phenocopy, followed by SCA17, associated with triplet repeat expansions in the TATA box binding protein. Huntington disease-like 2 (HDL2) caused by a mutation in Junctophilin-3 (JPH3), which is located on chromosome 16q24.3, is associated with African or Middle Eastern ancestry and dentatorubral-pallidoluysian atrophy caused by a mutation in *ATN1* has been primarily described among Japanese. These are reviewed in Chapter 84 along with a more complete differential diagnosis of chorea.

If there is no family history of HD, a careful medication history including dopamine antagonist exposure resulting in tardive dyskinesia, use of oral contraceptives, or antiepileptic medications (phenytoin, carbamazepine, gabapentin), all of which can be associated with chorea, should be sought. Cocaine and amphetamines may also cause chorea. Additional tests would include glucose (hyperglycemia), complete blood count (polycythemia vera), thyroid function tests (hyperthyroidism), vitamin B_{12}, a sedimentation rate (to evaluate autoimmune disorders such as Sydenham chorea or lupus), ceruloplasmin (for Wilson disease), and paraneoplastic panel. Nonpaternity may also be an explanation for lack of a family history of HD.

In individuals with HD, routine studies of blood, urine, and cerebrospinal fluid (CSF) are normal. Structural magnetic resonance imaging (MRI) may show enlargement of the lateral ventricles due to atrophy of the caudate and putamen, but this may not be apparent early in the disease (**Fig. 85.3**). In a longitudinal study PREDICT-HD, mean striatal volume decline was faster in premanifest (prior to motor onset) and manifest HD compared to age-matched controls and was seen 10 years before diagnosis of "phenoconversion," defined as the emergence of the unequivocal motor signs associated with HD.

Clinical Manifestations

The triad of symptoms and signs associated with HD is an extrapyramidal movement disorder, cognitive impairment, and behavioral impairment (**Table 85.2**). Any one of the triad may

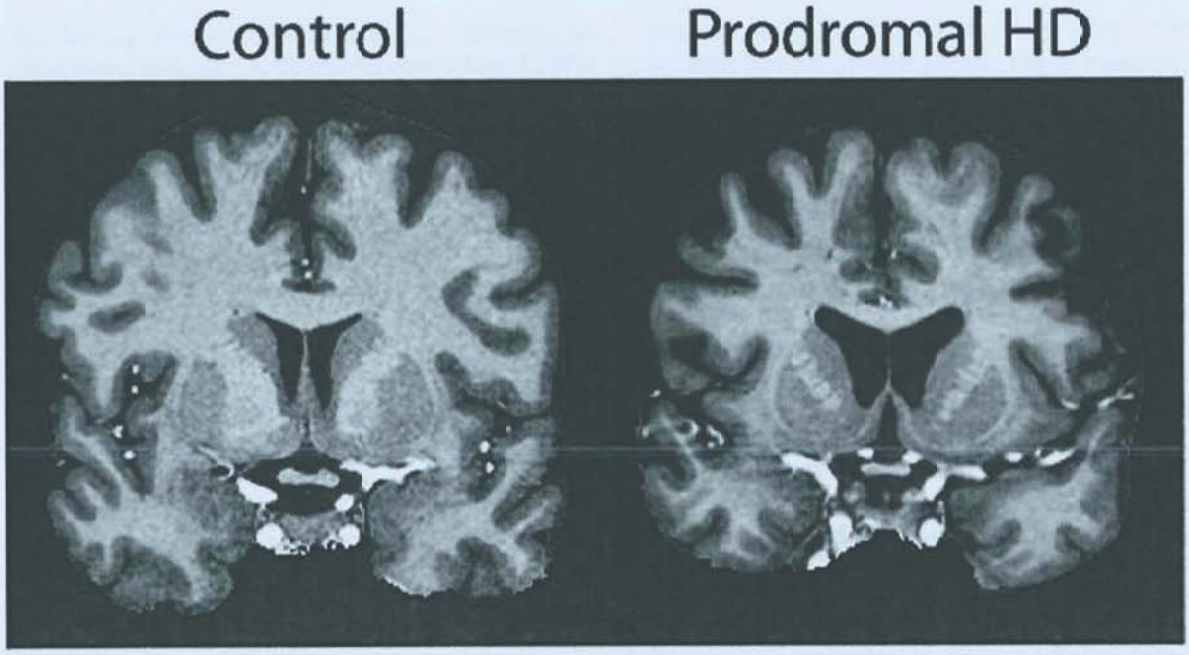

FIGURE 85.3 7T MP2RAGE images at 0.65-mm resolution showing striatal volume loss and brain shrinkage in other regions in prodromal Huntington disease (HD) (**right**, 38-y-old woman, 6.5 y to predicted onset vs control; **left**, 38-y-old woman). (Courtesy of Christopher A. Ross, MD, PhD, and Jun Hua, PhD.)

TABLE 85.2 Clinical Manifestations of Huntington Disease[a]

Clinical Domain	Signs
Motor	Involuntary movements • Chorea, dystonia, dysphagia, dysarthria Voluntary movements • Slow saccade initiation and interrupted pursuit • Finger tapping/pronation supination, gait, and balance
Cognitive	Processing speed, executive function, visuospatial perception, episodic memory, smell identification
Psychiatric	Irritability, obsessive-compulsive symptoms, perseverative behavior, depression, apathy, anosognosia

[a]Clinical Manifestations of Huntington Disease occur in three domains: motor (defining feature of the disease), cognitive, and psychiatric.

occur first. Three carefully designed observational studies including individuals at risk for HD and early symptomatic HD (PHAROS, PREDICT-HD, TRACK-HD) have facilitated in-depth characterization of individuals followed longitudinally including the period of phenoconversion. The course of HD can be divided into several periods. During the premanifest period (from birth to approximately 10-15 y prior to phenoconversion), individuals are clinically indistinguishable from controls (presymptomatic phase). The prodromal phase, which follows, is characterized by subtle motor, cognitive, and psychiatric features leading up to phenoconversion. Phenoconversion is defined clinically, as unequivocally manifesting the extrapyramidal motor signs of HD, when HD is diagnosed.

Motor Signs

The extrapyramidal movement disorder is the defining feature of HD and is characterized by both involuntary movements (chorea, dystonia) and impairment in voluntary movements (eye movements, gait, swallowing). The Unified Huntington's Disease Rating Scale includes a 124-point assessment of the motor signs of HD including eye movements (reduced saccades and breakdown of smooth pursuit), fine motor coordination, chorea, dystonia, and gait and balance (▶ Video 85.1). Chorea, derived from the Greek word "dance," is an involuntary movement that is brief but not as lightening-like as myoclonus. These random movements may be present in the limbs, face, or trunk (see ▶ Video 85.1). They are exacerbated with stress and are thought to disappear during sleep. Chorea tends to be present in the early symptomatic phase, peak middisease, and decline or disappear in the late phase of the disease. In contrast, bradykinesia, dystonia, and rigidity increase, particularly during the late stages of the disease, and affect voluntary movements. Most individuals need some assistance with walking, for example, assistive devices, approximately 7 years from onset of motor signs. Falls and choking are frequent mid-to-late stage events that may be life-threatening. In addition to chorea, other motor features include motor impersistence. Examples of motor impersistence include the inability to maintain tongue protrusion for 10 seconds or to maintain voluntary contraction while gripping, colloquially known as *milkmaid grip*. Impairments in fine motor activity that may include slowing and irregularity can be measured clinically or with quantitative motor assessment including speed of finger tapping and paced tapping. Variability of the inter tap interval or the pace of walking are among the earliest detectable signs of motor impairment, at a time when impairment is not detectable on neurologic examination or recognized by the individual. The earlier the disease onset, the less likely there will be chorea.

Children with juvenile HD present with an akinetic rigid form of the disease. Stiffness in the legs may also be accompanied by scissoring of gait, bradykinesia, and clumsiness. Chorea is uncommon among those who develop HD less than 10 years of age but may be seen in adolescents. Seizures occur in 25% of juvenile HD cases.

Cognitive Impairment

Although HD is diagnosed based on the presence of an extrapyramidal motor disorder, numerous cross-sectional and longitudinal studies have documented impairment primarily in executive function and psychomotor slowing that may begin 10 to 15 years prior to motor onset during the prodromal phase. Deficits in executive function including the ability to plan, organize, and monitor behavior are particularly prominent. These cognitive domains have been closely associated with the frontal lobes and the frontostriatal circuits and are similar to the cognitive impairment seen in Parkinson disease or vascular dementia. Patients with HD do not have a primary disorder of memory retention but have difficulty acquiring information efficiently or consistently retrieving it. In contrast to patients with Alzheimer disease, patients with HD show marked improvement in response to cued recall, similar to that in other patients with frontal lobe disease. Unlike the cortical dementias, such as Alzheimer disease, HD does not prominently involve language until late in the illness. Among individuals who are in the premanifest stage, deficits in motor planning/speed (eg, paced tapping, two-choice reaction time) and sensory-perceptual processing (emotional recognition and University of Pennsylvania smell identification test) best predict time to diagnosis after motor symptoms and CAG repeat length and age. Using traditional neuropsychological tests, 40% of premanifest individuals meet criteria for mild cognitive impairment (MCI) (using cutoff scores 1.5 standard deviation below the mean of a comparison group in at least one domain) and displayed mild impairments in episodic memory, processing speed, executive functioning, and/or visuospatial perception. The prevalence of MCI increases over the 10 years prior to diagnosis, as individuals get closer to their estimated age at onset of diagnosis. The majority have nonamnestic MCI (18%), followed by amnestic MCI (7.5%) in premanifest HD. During the premanifest period, individuals may recognize subtle functional decline in capacity to perform their jobs and handle financial affairs. Children present a special case. They often have cognitive decline, manifesting as poor school performance, characterized by poor attention and may be misdiagnosed as attention deficit disorder.

Behavioral Signs

A range of psychiatric manifestations can be seen in both premanifest and manifest HD including most commonly irritability, obsessive-compulsive symptoms (OCS), depression (in up to 50%), and apathy. Apathy may increase significantly in premanifest HD and is associated with prediction of functional decline.

Like apathy, OCS are referable to frontostriatal circuits, in particular the orbitofrontal cortex. OCS also increase over time as the individual approaches phenoconversion. Perseverative behavior that is not ego dystonic, for example, getting stuck on an idea, may also be seen. Anosognosia is frequent in HD. Individuals with HD are less likely to report motor symptoms that are present on exam than Parkinson disease patients. Almost half of the participants in the PREDICT-HD study who phenoconverted did not report motor symptoms, reflective of unawareness. Using the Problem Behavior Assessment Scale, three clusters of symptoms identified in manifest HD were depression, apathy, and irritability. Among HD patients, there is no clear relationship between psychiatric symptoms and disease progression, except for apathy, which correlates with disease duration. This lack of a relationship may reflect the availability of effective treatment for affective symptoms and the episodic nature of these symptoms. Suicidal ideation and suicide are more common in HD compared to age-matched controls. Completed suicide has been reported to be 7- to 12-fold more common in HD than controls. Psychosis is rare. Critical periods for suicidal ideation have been identified close to the time of phenoconversion and early in the early symptomatic stage. In children, behavioral changes may include depression, aggression, impulsivity, and obsessions.

Measures of Disease Progression

Clinical Progression Composite Measures

Composite measures of age, CAG repeat length, Total Motor Score (TMS) derived from the Unified Huntington's Disease Rating Scale (UHDRS), and the Symbol Digit Modalities Test can be used to predict probability of phenoconversion. A composite motor (UHDRS motor score), cognitive (Symbol Digit Modalities Test) and Stroop Word Reading (SWR) tests, and global function (Total Functional Capacity) all derived from the Unified Huntington's Disease Rating scale have been shown to provide an improved measure of disease progression in 1,668 individuals with early HD followed for up to 36 months. This measure is also associated with measures of corticostriatal atrophy.

Structural and Molecular Imaging

Structural MRI measures of striatal atrophy may be the earliest changes referable to HD but are not sufficiently sensitive or specific as a diagnostic marker for an individual patient. In longitudinal studies, these structural and functional imaging markers correlate with calculated time to disease onset based on CAG repeat length and UHDRS motor score. Diffusion tensor imaging, functional MRI, and fluorodeoxyglucose positron emission tomography are used in research settings as potential surrogate markers, however, are not yet useful for diagnostic purposes. A variety of neurotransmitters have been implicated in HD. Positron emission tomography studies have consistently demonstrated dysfunction of the dopaminergic system, primarily postsynaptic terminals (primarily D_2, but also D_1). Other neurotransmitter systems studied in small numbers of symptomatic and premanifest individuals include the GABAergic, endocannabinoids, adenosine, and phosphodiesterase, especially phosphodiesterase 10a. There has been recent interest in measures of neuroinflammation targeting activated microglia (Fig. 85.4).

Fluid Biomarkers

The most notable advance in the HD biomarkers field has been the development of sensitive and ultrasensitive assays for mutant and total HTT and the ability to measure neurofilament light (NfL) in CSF and plasma. CSF mutant huntingtin (mHTT) concentration has been associated in cross-sectional studies with clinical severity after adjustment for age and CAG repeat length and was shown to decrease in the first phase 1 or 2 Huntingtin-lowering trial, thus demonstrating applicability as a pharmacodynamics marker. NfL, a marker of neuronal damage is increased almost fourfold in plasma of manifest HD compared to controls and shows a clear gradient from premanifest to manifest, correlating with age, CAG repeat length, and whole brain volume. CSF NfL correlates with all brain measurements, more strongly than plasma NfL, although the CSF and plasma measurements are highly correlated. In a head to head comparison, NfL in plasma and CSF was significantly better than CSF mHTT in discriminating between premanifest and manifest HD, and NfL also showed stronger prediction for clinical and imaging measures in a cross-sectional study of 80 participants (20 controls, 20 premanifest, 40 early moderate symptomatic), suggesting the possibility that plasma and CSF NfL might be better measures of progression/discrimination in mutation carriers than mHTT. These two biomarkers that are restricted to clinical trials are early sensitive biomarkers that may improve efficiency of clinical trials.

MANAGEMENT

Treatment of Movement Disorder

Antidopaminergic Agents for Chorea

About 90% of people with HD develop chorea. Symptomatic treatment is advised if the chorea is functionally or emotionally disabling. Tetrabenazine (TBZ) LEVEL 1[1] and deutetrabenazine LEVEL 1,[2] a deuterated form of TBZ, are the only U.S. Food and Drug Administration (FDA)-approved medications for the symptomatic treatment of chorea. In a double-blind placebo-controlled study including 54 HD randomized to TBZ up to 100 mg and 30 to placebo, chorea was reduced by 23.5% after 12 weeks (NCT00219804). TBZ reversibly inhibits the central vesicular monoamine transporter type 2 and depletes presynaptic dopamine more selectively than norepinephrine and serotonin. The highest binding density for TBZ is in the caudate, putamen, and nucleus accumbens, where HD pathology is the greatest. Starting dose of TBZ is 12.5 mg daily titrated to 3 times daily with a maximum dose of 100 mg. At 50 mg, the FDA requires that cytochrome P450 2D6 (CYP2D6) genotyping be done. Poor metabolizers of CYP2D6 should not exceed the 50-mg dose. Because it is metabolized by CYP2D6, drug interactions that might raise TBZ need to be considered. It is generally well tolerated, but dose-dependent side effects include worsening depression, fatigue, parkinsonism, and akathisia. Tardive dyskinesia is not described. It was approved by the FDA in 2008. Deutetrabenazine was approved in 2017 for the treatment of chorea after a 12-week double blind placebo controlled study of 90 patients (NCT01795859) LEVEL 1.[2] Deutetrabenazine LEVEL 1[2] has a longer half-life than TBZ allowing for less frequent dosing. There have been no head to head comparisons of TBZ and deutetrabenazine.

A 26-week dose phase 2 dose ranging study of pridopidine (NCT02006472) LEVEL 1,[3] a dopamine stabilizer via D_2 receptors, including 408 participants, did not improve the UHDRS total motor score when compared to placebo.

Neuroleptics and atypical neuroleptics that block postsynaptic D_2 receptors have been studied in smaller trials but may

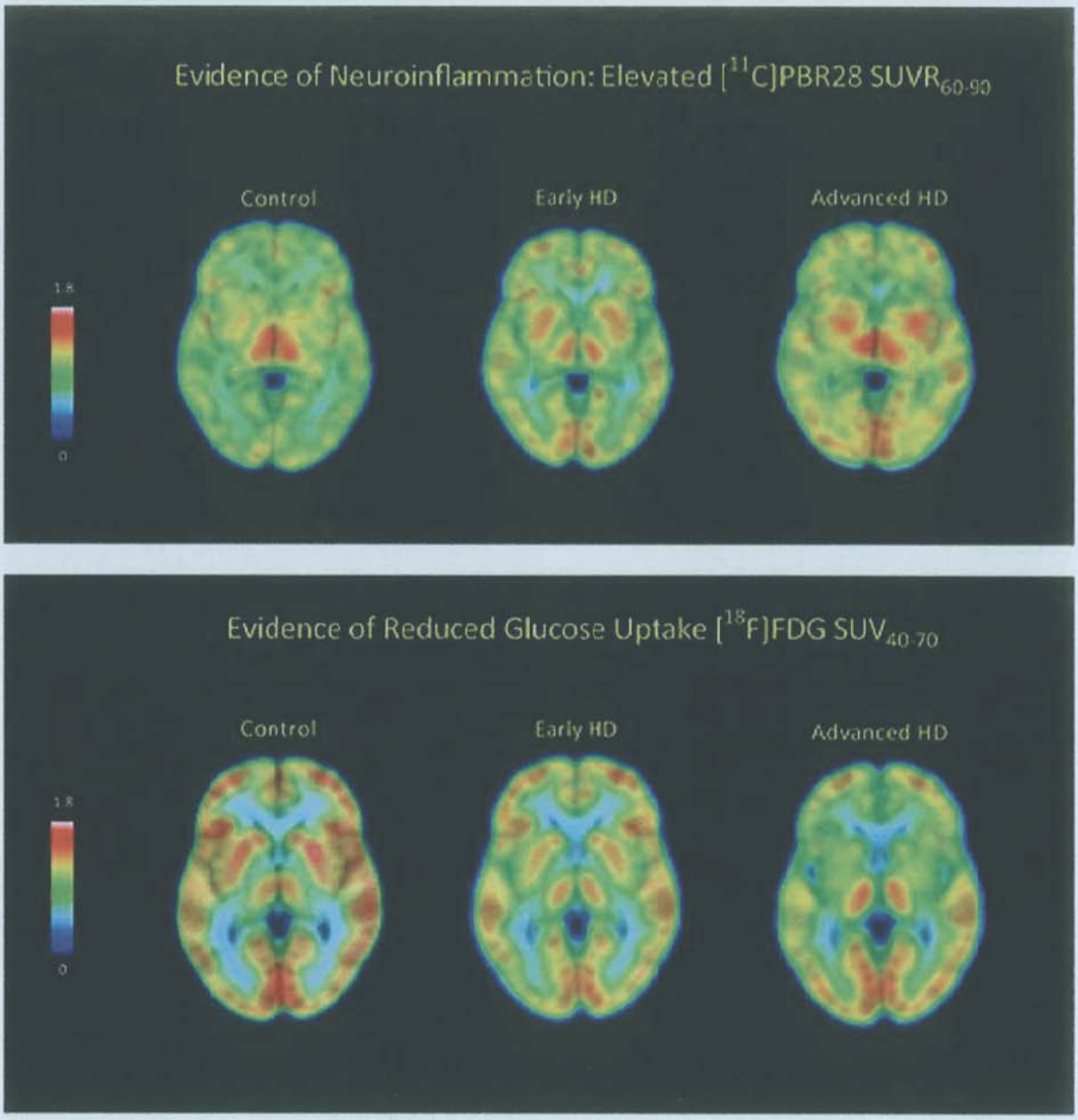

FIGURE 85.4 Positron emission tomography scans. Abbreviation: HD, Huntington disease. (Courtesy of H. Diana Rosas MD.)

be limited by side effects especially tardive dyskinesia and worsening gait and swallowing. Haloperidol, fluphenazine, and pimozide are high-potency typical antipsychotics that can suppress chorea but do have dose-limiting side effects. Similarly, small trials of atypical neuroleptics such as olanzapine, risperidone, quetiapine, and ziprasidone have been performed with mixed results. Treatment with these typical and atypical antipsychotics rather than TBZ or deutetrabenazine is advised if both motor and behavioral symptomatology is being addressed simultaneously.

Antiglutamatergic Therapy for Chorea

Glutamate toxicity resulting in degeneration of medium spiny striatal neurons is the concept behind treatment with *N*-methyl-D-aspartate receptor antagonists such as amantadine or compounds that disrupt glutamate transmission such as riluzole (NCT00277602) LEVEL 1.[4] These have been shown to have none to minimal symptomatic or neuroprotective benefits in level 1 studies.

Treatment of Dystonia

There have been no class 1 studies for dystonia in the setting of HD. Botulinum toxin injections can be also used for focal dystonia associated with HD.

Treatment of Voluntary Motor Impairment (Gait and Swallowing)

There are no medical treatments for the voluntary motor impairments (gait, swallowing); however, physical, occupational, and swallowing therapy could provide benefit in terms of reduced fall risk and psychological well-being and increased caloric intake. There have been no randomized controlled trials of exercise in manifest or premanifest HD.

Treatment of Weight Loss

Weight loss is also common as HD progresses. Increased caloric intake is necessary to maintain body mass index even in

the presymptomatic state when there are no obvious movements to account for increased energy expenditure. In manifest HD, weight loss is correlated with rate of disease progression. Weight loss may not only be attributable to severity of the extrapyramidal movement disorder, decreased caloric intake due to dysphagia, or depression but may also be due to a hypermetabolic state associated with HD. Attention to increasing caloric intake to maintain weight, particularly as the disease progresses, is essential for well-being. Pureed foods and thickened liquids and frequent small meals may improve caloric intake. Feeding tube placement is an individual decision that should be discussed well before the need in the later stages of the disease.

Treatment of Cognitive Impairment

There are no approved treatments for cognitive impairment in HD. Small studies have been conducted with cholinesterase inhibitors including donepezil and rivastigmine with no significant improvement. A randomized controlled trial of citalopram (NCT00271596) LEVEL 2[5] in nondepressed HD patients showed no change in executive function after 20 weeks; however, there was improvement in mood suggesting an effect on subsyndromal depression. The largest study to date included 403 HD participants at 64 centers followed for 6 months, randomized to latrepirdine (20 mg) versus placebo (NCT00497159) LEVEL 2.[6] This agent, thought to be a mitochondrial stabilizer, did not show a difference in performance on Mini-Mental Status Examination or Clinician Interview–Based Impression of Change.

Treatment of Psychiatric Symptoms

The FDA-approved medications for depression, irritability, obsessive-compulsive behaviors, and general anxiety and aggression have been used to treat individuals with HD. Data are confined to case series and small open-label studies. There are no class I studies specifically for the treatment of psychiatric symptomatology. A recently completed phase 2 trial (NT02507284) of SRX246, vasopressin 1a receptor antagonist, was evaluated for safety and tolerability in two doses compared to placebo in HD patients with irritability.

Disease-Modifying Therapies

No disease-modifying therapies have been approved for HD. Disease-modifying therapies have been directed primarily at oxidative stress and mitochondrial mechanisms of action but more recently have focused on reducing inflammation and strategies to lower mHTT.

Improving Mitochondrial Function and Reducing Oxidative Stress

A 5-year phase 3 study including 609 HD participants randomized to CoQ10 2,400 mg or placebo and followed for 60 months was stopped early because of futility in 2014 (NCT00608881) LEVEL 2.[7] A 3-year phase 3 study of creatine 40 mg/d was also stopped early in 2014 for futility (NCT00712426) LEVEL 2.[8]

Immune Modulation

Laquinomod (NCT02215616) is a small molecule immunomodulator that raises levels of brain derived neurotrophic factor (BDNF) failed to improve the total motor score when compared to placebo. An ongoing study of the first monoclonal antibody for treatment of HD is testing safety and tolerability of antisemaphorin 4D in 240 individuals (NCT2481274).

mHTT Huntingtin-Lowering Strategies

There are currently three main strategies for reducing HTT messenger RNA (mRNA) through posttranscriptional inhibition: antisense oligonucleotides (ASO), RNA interference compounds and small molecule splicing molecules.

Reduction of expression of mHTT has focused on preventing posttranscriptional processes and promoting early degradation of mRNA with ASO, through the recruitment of RNasesH1, an endogenous enzyme that recognizes RNA/DNA duplexes and degrades HTT pre-mRNA. There are two types of ASOs that are in clinical development, one that is nonspecific lowering both the mutant and normal HTT and the other allele-specific targeting two specific SNPs within the mutation but not the wild-type allele, accounting for 75% of all HD patients. The first trial using the nonspecific HTT-lowering ASO (1b/2a) has been completed in 46 early HD patients over 3 months (NCT02519036) LEVEL 2.[9] The compound, administered intrathecally by lumbar puncture every 4 weeks, was well tolerated and resulted in a dose-dependent 40% lowering of CSF HTT concentration. An open-label study is now ongoing, and a phase 3 study has begun. The allele-specific phase I to II studies (NCT03225833/46) are ongoing. It is currently unknown what the long-term effects of lowering normal HTT are, so potentially an allele-specific strategy that targets only mutant HTT may be important.

Administration of small interfering RNA results in cleavage and degradation of mature, spliced *HTT* RNA in the cytosol. Because double-stranded RNA does not distribute well throughout brain tissue, it is necessary to deliver the small interfering RNA stereotactically to striatum or cortex via viral vector such as adeno-associated virus. Because the virally delivered RNA interference permanently transduce central nervous system cells (gene therapy), this is envisioned as a one-time therapy that will suppress mHTT. Several different enhanced delivery methods are under consideration, and both cortex and striatum are being considered as targets.

Other strategies that are not yet in human clinical trials include DNA targeting techniques such as zinc finger proteins and CRISPR/Cas9.

Small fetal transplant trials have been conducted, and one multicenter longitudinal study is ongoing. Results have been mixed, in part due to small sample size and patient selection criteria and differences in methodology (tissue type transplanted and numbers of cells transplanted).

Nonpharmacologic Treatments

There is preclinical evidence that exercise has the potential to modify disease progression from several mouse models. A systematic review of 20 studies found support for benefits of exercise and physical activity on motor function, gait speed, and balance LEVEL 2.[10,11] There has been no evaluation of long-term exercise interventions on participants' health and quality of life. The type of exercise (aerobic, strength training) has not been established, nor its effect on energy expenditure and potential weight loss. It may also be important to assess the effects of exercise in combination with pharmacologic disease-modifying interventions.

OUTCOME

The course of HD is generally 15 to 20 years from the time of diagnosis based on the presence of an extrapyramidal syndrome consistent with HD. The course of juvenile HD rarely exceeds 15 years. The most frequent cause of death is aspiration pneumonia, although accidents, especially subdural hematoma, are common. Increasing attention to the benefits of weight maintenance and balance training may be life prolonging. The completion of three well-designed observational studies of at risk and early symptomatic individuals (PHAROS, TRACK-HD, and PREDICT-HD) as well as a large multinational clinical platform ENROLL-HD for clinical and biologic data will facilitate the design of new clinical trials that are adequately powered to detect change at all stages of the illness.

Videos can be found in the companion e-book edition. For a full list of video legends, please see the front matter.

LEVEL 1 EVIDENCE

1. Huntington Study Group. Tetrabenazine as antichorea therapy in Huntington disease: a randomized controlled trial. *Neurology*. 2006;66(3):366-372.
2. Frank S, Testa CM, Stamler D, et al; for Huntington Study Group. Effect of deutetrabenazine on chorea among patients with Huntington disease: a randomized clinical trial. *JAMA*. 2016;316(1):40-50.
3. Reilmann R, McGarry A, Grachev ID, et al. Safety and efficacy of pridopidine in patients with Huntington's disease (PRIDE-HD): a phase 2, randomised, placebo-controlled, multicentre, dose-ranging study. *Lancet Neurol*. 2019;18(2):165-176.
4. Landwehrmeyer GB, Dubois B, de Yébenes JG, et al. Riluzole in Huntington's disease: a 3-year, randomized controlled study. *Ann Neurol*. 2007;62(3):262-272.
5. Beglinger LJ, Adams WH, Langbehn D, et al. Results of the citalopram to enhance cognition in Huntington disease trial. *Mov Disord*. 2014;29(3):401-405.
6. Kieburtz K, McDermott MP, Voss TS, et al. A randomized, placebo-controlled trial of latrepirdine in Huntington disease. *Arch Neurol*. 2010;67(2):154-160.
7. McGarry A, McDermott M, Kieburtz K, et al. A randomized, double-blind, placebo-controlled trial of coenzyme Q10 in Huntington disease. *Neurology*. 2017;88(2):152-159.
8. Hersch SM, Schifitto G, Oakes D, et al. The CREST-E study of creatine for Huntington disease: a randomized controlled trial. *Neurology*. 2017;89(6):594-601.
9. Tabrizi SJ, Leavitt BR, Landwehrmeyer GB, et al. Targeting huntingtin expression in patients with Huntington's disease. *N Engl J Med*. 2019;380(24):2307-2316.
10. Quinn L, Busse M, Carrier J, et al. Physical therapy and exercise interventions in Huntington's disease: a mixed methods systematic review protocol. *JBI Database System Rev Implement Rep*. 2017;15(7):1783-1799.
11. Fritz NE, Rao AK, Kegelmeyer D, et al. Physical therapy and exercise interventions in Huntington's disease: a mixed methods systematic review. *J Huntingtons Dis*. 2017;6(3):217-235.

SUGGESTED READINGS

Biglan KM, Shoulson I, Kieburtz K, et al; for Huntington Study Group PHAROS Investigators. Clinical-genetic associations in the Prospective Huntington at Risk Observational Study (PHAROS): implications for clinical trials. *JAMA Neurol*. 2016;73(1):102-110.

Byrne LM, Rodrigues FB, Blennow K, et al. Neurofilament light protein in blood as a potential biomarker of neurodegeneration in Huntington's disease: a retrospective cohort analysis. *Lancet Neurol*. 2017;16(8):601-609.

Byrne LM, Rodrigues FB, Johnson EB, et al. Evaluation of mutant huntingtin and neurofilament proteins as potential markers in Huntington's disease. *Sci Transl Med*. 2018;10(458):eaat7108.

Croce KR, Yamamoto A. A role for autophagy in Huntington's disease. *Neurobiol Dis*. 2019;122:16-22.

Fritz NE, Rao AK, Kegelmeyer D, et al. Physical therapy and exercise interventions in Huntington's disease: a mixed methods systematic review. *J Huntingtons Dis*. 2017;6(3):217-235.

Genetic Modifiers of Huntington's Disease Consortium. Identification of genetic factors that modify clinical onset of Huntington's disease. *Cell*. 2015;162(3):516-526.

Godin JD, Poizat G, Hickey MA, Maschat F, Humbert S. Mutant huntingtin-impaired degradation of beta-catenin causes neurotoxicity in Huntington's disease. *EMBO J*. 2010;29(14):2433-2445.

Gusella JF, Wexler NS, Conneally PM, et al. A polymorphic DNA marker genetically linked to Huntington's disease. *Nature*. 1983;306(5940):234-238.

Hensman Moss DJ, Poulter M, Beck J, et al. *C9orf72* expansions are the most common genetic cause of Huntington disease phenocopies. *Neurology*. 2014;82(4):292-299.

Humbert S. Is Huntington disease a developmental disorder? *EMBO Rep*. 2010;11(12):899.

Koga H, Martinez-Vicente M, Arias E, Kaushik S, Sulzer D, Cuervo AM. Constitutive upregulation of chaperone-mediated autophagy in Huntington's disease. *J Neurosci*. 2011;31(50):18492-18505.

Lee JK, Mathews K, Schlaggar B, et al. Measures of growth in children at risk for Huntington disease. *Neurology*. 2012;79(7):668-674.

Long JD, Langbehn DR, Tabrizi SJ, et al. Validation of a prognostic index for Huntington's disease. *Mov Disord*. 2017;32(2):256-263.

MacDonald M, Ambrose CM, Duyao MP, et al. A novel gene containing a trinucleotide repeat that is expanded and unstable on Huntington's disease chromosomes. *Cell*. 1993:72(6):971-983.

Malek N, Newman EJ. Hereditary chorea—what else to consider when the Huntington's disease genetics test is negative? *Acta Neurol Scand*. 2017;135(1):25-33.

Moss DJH, Fardiñas AF, Langbehn D, et al. Identification of genetic variants associated with Huntington's disease progression: a genome-wide association study. *Lancet Neurol*. 2017;16(9):701-711.

Nopoulos PC, Aylward EH, Ross CA, et al. Smaller intracranial volume in prodromal Huntington's disease: evidence for abnormal neurodevelopment. *Brain*. 2011;134(pt 1):137-142.

Paulsen JS, Long JD, Ross CA, et al. Prediction of manifest Huntington's disease with clinical and imaging measures: a prospective observational study. *Lancet Neurol*. 2014;13(12):1193-1201.

Quinn L, Busse M, Carrier J, et al. Physical therapy and exercise interventions in Huntington's disease: a mixed methods systematic review protocol. *JBI Database System Rev Implement Rep*. 2017;15(7):1783-1799.

Rawlins MD, Wexler NS, Wexler AR, et al. The prevalence of Huntington's disease. *Neuroepidemiology*. 2016;46(2):144-153.

Reilmann R, McGarry A, Grachev ID, et al. Safety and efficacy of pridopidine in patients with Huntington's disease (PRIDE-HD): a phase 2, randomised, placebo-controlled, multicentre, dose-ranging study. *Lancet Neurol*. 2019;18(2):165-176.

Schobel SA, Palermo G, Auinger P, et al. Motor, cognitive, and functional declines contribute to a single progressive factor in early HD. *Neurology*. 2017;89(24):2495-2502.

Sciacca G, Cicchetti F. Mutant huntingtin protein expression and blood-spinal cord barrier dysfunction in Huntington disease. *Ann Neurol*. 2017;82(6):981-994.

Tabrizi SJ, Ghosh R, Leavitt BR. Huntingtin lowering strategies for disease modification in Huntington's disease. *Neuron*. 2019;101(5):801-819.

Tabrizi SJ, Leavitt BR, Landwehrmeyer GB, et al. Targeting huntingtin expression in patients with Huntington's disease. *N Engl J Med*. 2019;380(24):2307-2316.

Tabrizi SJ, Scahill RI, Owen G, et al. Predictors of phenotypic progression and disease onset in premanifest and early-stage Huntington's disease in the TRACK-HD study: analysis of 36-month observational data. *Lancet Neurol*. 2013;12(7):637-649.

Tong Y, Ha TJ, Liu L, Nishimoto A, Reiner A, Goldowitz D. Spatial and temporal requirements for huntingtin (Htt) in neuronal migration and survival during brain development. *J Neurosci*. 2011;31(41):14794-14799.

Vonsattel JP, Myers RH, Stevens TJ, Ferrante RJ, Bird ED, Richardson EP Jr. Neuropathological classification of Huntington's disease. *J Neuropathol Exp Neurol*. 1985;44(6):559-577.

Wexler NS, Collett L, Wexler AR, et al. Incidence of adult Huntington's disease in the UK: a UK-based primary care study and a systematic review. *BMJ Open*. 2016;6(2):e009070.

Wild EJ, Boggio R, Langbehn D, et al. Quantification of mutant huntingtin protein in cerebrospinal fluid from Huntington's disease patients. *J Clin Invest*. 2015;125(5):1979-1986.

Wild EJ, Tabrizi SJ. Therapies targeting DNA and RNA in Huntington's disease. *Lancet Neurol*. 2017;16(10):837-847.

Parkinson Disease 86

Peter LeWitt

KEY POINTS

1. Beyond classic motor impairments, Parkinson disease (PD) patients often develop nonmotor problems (autonomic, cognitive, psychiatric, or behavioral).
2. Although PD is generally a sporadic disorder, genetic mutations associated with Parkinsonism have highlighted a variety of disease mechanisms.
3. Symptomatic therapy for PD has several medication and surgical options, some of them recently introduced.

INTRODUCTION

Parkinson disease (PD) is the most common movement disorder associated with neurodegeneration. Most of its characteristic features were elegantly described in an 1817 monograph written by a British general practitioner, James Parkinson, MD. What he described is in part a motor disorder, variable in symptoms and disabilities but with core manifestations of slowed movement (bradykinesia), decreased dexterity, gait disorder, and, in some instances, increased muscle tone (rigidity) and limb tremors at rest. Some patients don't initially (or ever) experience the full range of signs and symptoms possible in this disorder, and the clinical course often varies greatly from patient to patient. Early on, the experience of developing PD can be insidious and subtle, remaining undiagnosed for months to years. Eventually, many patients find resonance with the engaging descriptions of the disorder reported by James Parkinson, such as ". . . the hand fails to answer with exactness to the dictates of the will."

Clinical Features constituting unequivocal diagnostic criteria are still a matter of opinion. As a practical matter, even experienced clinicians recognize that PD diagnosis is a probabilistic decision because clinical manifestations of PD overlap with those of other neurodegenerative disorders that also can develop in patients at a similar age. PD is just the most frequently encountered of disorders manifesting motor impairments of *parkinsonism* (also termed as *parkinsonian syndrome*). The clinical grounds for making the diagnosis of PD is somewhat based on exclusion of other options. For a firm diagnosis of PD to be established, some authorities have argued that at least two "cardinal" features are needed, with at least one of them resting tremor or bradykinesia.

Most clinical forms of Parkinsonism (Table 86.1) arise from neuronal loss or degeneration in a discrete pathway of the brain originating in the substantia nigra pars compacta (SNpc), which projects to the striatum. As one of the early pioneers of PD research, Oleh Hornykiewicz, termed it, ". . . parkinsonism can be envisioned as a striatal dopamine deficiency disorder." Conceptualizing the varieties of parkinsonism can be by division of them into categories representing etiology: primary neuronal degeneration, secondary (acquired) due to structural and similar lesions, or as parkinsonism with neuronal degeneration associated with additional clinical manifestations (the so-called Parkinson-plus syndromes). Parkinsonism can also be due to a specific neurotransmitter synthesis deficit, such as an inherited disorder that is specifically lacking in enzymatic synthesis of dopamine. This condition, which generally has a benign clinical course, is known as *dopa-responsive* or *diurnally fluctuating dystonia* and is discussed elsewhere in this book under discussion of dystonia syndromes.

For the most part, *primary parkinsonism* refers solely to PD, which has characteristic pathologic and neurochemical changes. PD is sometimes referred to as *idiopathic PD* because its cause (or causes) is unknown. Recent studies have emphasized the challenges even experienced clinicians face for making a definitive diagnosis. For example, using rigorous consensus diagnostic criteria (based on autopsy-proven cases [United Kingdom Parkinson's Disease Society Brain Bank criteria]), the Parkinson Progression Markers Initiative has enrolled more than 400 cases of early PD for biomarker studies. Of these enrollees, more than 1 in 7 initially did not show evidence for a deficit in dopaminergic neurotransmission on radioisotope neuroimaging of striatal dopamine transporter (DaT) concentration. Such cases have been described as *symptomatic without evidence of dopaminergic deficits* (SWEDDs). The pathologic basis for SWEDD has not been established, and the existence of a clinical syndrome indistinguishable from PD challenges prior assumptions that we have a complete understanding of what produces all the signs and symptoms of PD. In any case, the clinical disorder we know as parkinsonism—that is, with its characteristic clinical features along with unmistakable neuropathologic and neurochemical changes—can be either sporadic or familial. Its clinical phenotype hasn't changed in several decades over which it has undergone intensive study by the neurologic research community. PD is the second most common neurodegenerative disease after Alzheimer disease (AD). In addition to motor manifestations, PD has several nonmotor features whose importance have been increasingly being recognized as adding to the long-term disabilities of PD. These problems range from fatigue, impaired sleep, behavioral disturbances, autonomic dysfunction, and various sensory symptoms.

Despite the SWEDD paradox, the motor symptomatology of PD seems to be a consequence of decreased dopaminergic neurotransmission primarily in the putamen. This neurochemical pathology can be modeled in animals rendered parkinsonian by neurotoxins or by substantia nigra (SN) lesioning. For most of the parkinsonian disorders listed in Table 86.1, there is a shared finding of degeneration in the dopaminergic projections due to loss of SNpc neurons. In some of these disorders, the brain pathology is more extensive than in PD; among their degenerative changes is the additional loss of postsynaptic dopaminergic receptors within the striatum. The lack of therapeutic effect by

TABLE 86.1 Classification of Major Parkinsonian Syndromes

Extrapyramidal Syndromes
• Parkinson disease—sporadic and genetic (Mendelian and non-Mendelian inheritance)
Secondary (Acquired) Parkinsonism
• Drug induced by dopamine receptor antagonist or dopamine depletor
• Hemiatrophy—hemiparkinsonism-syndrome
• Hydrocephalus; normal pressure hydrocephalus
• Hypoxic encephalopathy
• Various viral infections causing encephalitis; encephalitis lethargica
• Metabolic; parathyroid dysfunction with cerebral calcium deposition
• Toxicity from manganese, carbon monoxide, cyanide, or 1-methyl-4-phenyl-1,2,3,6-tetrahydropyridine exposure
• Trauma in region of midbrain extending to basal ganglia
• Tumor in basal ganglia, midbrain, or interrupting nigrostriatal pathway
• Vascular; multi-infarct state
The Most Common Parkinson-Plus Syndromes
• Corticobasal degeneration
• Dementia syndromes
◦ Alzheimer disease (some cases)
◦ Dementia with Lewy bodies (some cases)
◦ Frontotemporal dementia (some cases)
◦ Lytico-Bodig (Guam parkinsonism-dementia-ALS)
◦ Motor neuron disease–parkinsonism
• Multiple system atrophy (MSA) syndromes and their abbreviations
◦ Parkinsonism: formerly known as *striatonigral degeneration* (MSA-P)
◦ Autonomic impairment: formerly known as *Shy-Drager syndrome* (MSA-A)
◦ Cerebellar impairment: formerly known as *sporadic olivopontocerebellar degeneration* (MSA-C)
• Progressive pallidal atrophy
• Progressive supranuclear palsy
Heredodegenerative Diseases
• Neurodegeneration with brain iron accumulation
• Huntington disease (Westphal variant)
• Lubag (X-linked dystonia-parkinsonism)
• Mitochondrial cytopathies with striatal necrosis
• Neuroacanthocytosis
• Wilson disease
Parkinsonism With Neurotransmitter Enzyme Deficit
• Enzymatic deficiencies of dopamine synthesis

Abbreviation: ALS, amyotrophic lateral sclerosis.

dopaminergic therapy in these disorders is probably explained by the degenerative changes beyond the limited loss of presynaptic dopaminergic innervation characteristic of PD. In man, the motor symptomatology of parkinsonism can be created by reversible pharmacologic interventions with drugs (reserpine and tetrabenazine) that deplete presynaptic dopamine or inhibit its neurotransmission by blocking postsynaptic receptors (such as most antipsychotic drugs, prochlorperazine, and metoclopramide). The basis for how certain structural conditions leads to parkinsonism (such as hydrocephalus or striatal deposition of calcium) is uncertain. Studies of striatal electrophysiology have provided a picture of the deranged signaling in parkinsonism, in which decreased dopaminergic activity results in altered "downstream" neuronal firing in circuits passing to the subthalamic nucleus (STN) and the globus pallidus interna (GPi).

During the 1960s, emerging knowledge about the biochemical pathology of the brain culminated in dopamine replacement therapy. Subsequently, understanding about physiologic changes in poststriatal brain pathways led to surgical interventions for improving tremor, dyskinesia, and other problems of PD with ablation and, later, with electrical stimulation of GPi, the STN, or ventrointermediate nucleus of the thalamus. Today, the latter approaches have become the most prevalent treatment approaches beyond medications for PD. Modulating downstream circuitry beyond the striatum through localized electrical stimulation (termed *deep brain stimulation* [DBS]) has the potential to go beyond the best that medications can offer for managing PD.

As mentioned above, the symptomatology and disabilities of PD are more than dysfunctional striatal and poststriatal circuitry and the corresponding motor impairments. Sleep disturbance, orthostatic hypotension, anxiety, depression, cognitive decline, drooling, constipation, and other nonmotor problems are commonly reported by patients as adding to difficulties of living with PD. For most of these problems, their origin and treatment are unrelated to impaired striatal dopaminergic neurotransmission. Underlying these disturbances are the more extensive involvement of neuronal degeneration (particularly in the brainstem), and other neurotransmission changes found throughout in the PD brain and systemically.

EPIDEMIOLOGY

The predominant cause of parkinsonism is PD (see Table 86.1), a disorder whose incidence and prevalence increases with age. In the general population, the prevalence of PD is estimated to be 1% to 2% in the older than 60-year general population. The median age for onset of motor symptoms has been reported from many research groups to hover between 55 and 60 years, although an estimated 5% of cases begin younger than 45 years. When age of onset is younger than 20 years, the term *juvenile Parkinsonism* has been used. In the general, the development of parkinsonism earlier than the fifth decade increases the likelihood that disorder might differ from typical PD pathology, possibly due to one of the genetically associated forms of parkinsonism (Table 86.2) or to another neurodegenerative disorder. Several heredodegenerative diseases, including Huntington disease, Wilson disease, and pantothenate kinase 2-associated degeneration, rarely present as juvenile parkinsonism. By convention, the onset of parkinsonism between 20 and 40 years is defined as *young-onset PD*. In this group, there is also increased likelihood for a hereditary disorder.

TABLE 86.2 The Major Genetic Forms of Parkinsonism

Name and Locus	Gene	Mode of Inheritance	Pathologic and Clinical Features	Protein Function	Where Found
PARK1 and 4 4q22.1	*SCNA*	Autosomal dominant	Lewy bodies; earlier onset and more aggressive course; L-dopa–responsive parkinsonism, dementia, hallucinations, autonomic dysfunction	*α-Synuclein* possibly synaptic vesicle trafficking, elevated in bird song learning	Families in Germany, Italy, United States (Contursi kindred), Greece, Spain
PARK8 12q12	*LRRK2*	Autosomal dominant	Pathologic pleomorphism; indistinguishable from idiopathic PD	Dardarin, a GTPase and kinase, has diverse functions in signalling pathways and cellular functions	Worldwide
PARK2 5q26	*PRKN*	Autosomal recessive	Often juvenile onset without Lewy bodies; slowly progressive; no dementia	Parkin, a ubiquitin E3 ligase, attaches short ubiquitin peptide chains to a range of proteins, likely to mark degradation; supports mitophagy	Ubiquitous, originally in Japan, very common in juvenile onset
PARK6 1p36.12	*PINK-1*	Autosomal recessive	Juvenile onset	Mitochondrial kinase, modulates mitochondrial dynamics; supports mitophagy	Families in Italy, Spain, Philippines, Taiwan, Israel, Japan, Ireland, and North America
PARK7 1p36.23	*DJ-1*	Autosomal recessive	Early onset	Possible atypical peroxiredoxin and may play a role in apoptosis	Families in Holland, Italy, Uruguay
Glucocerebrosidase 1q22	*GBA*	Autosomal dominant; susceptibility gene; low penetrance; most common genetic risk factor gene	Indistinguishable from idiopathic PD	Lysosomal enzyme	About 13% of sporadic PD in Ashkenazi Jews; found in all ethnic groups

Abbreviation: GTPase, guanosine triphosphate hydrolase; PD, Parkinson disease.

PD arises more commonly in men, with a male-to-female ratio of approximately 3:2. Estimates of PD prevalence in modern populations vary widely but seems to be between 100 and 200 per 100,000. Annual incidence has been estimated as about 20 per 100,000. Because both prevalence and incidence increase exponentially with age, the prevalence is approximately 550 per 100,000 in individuals at age 70 years, whose incidence is approximately 120 per 100,000 annually. In addition to clinically diagnosed parkinsonism, autopsy studies show that the pathologic substrate of PD can be found in individuals not manifesting parkinsonism during life, indicating that studies of incidence and prevalence of occult PD underestimate the disease.

PATHOBIOLOGY

Pathology

The pathology of PD is distinctive and is easily distinguished from other parkinsonian disorders. Degeneration of the neuromelanin-containing neurons in the upper and lower brainstem is prominent. In the midbrain, involvement is selective for the loss of dopamine-synthesizing neurons in the ventral tier of the SNpc and in the norepinephrine-synthesizing neurons of the locus ceruleus. In addition to marked attrition of neurons, many of the remaining neurons in these nuclei contain characteristic cytoplasmic proteinaceous inclusions known as *Lewy bodies*, a pathologic hallmark of PD. Dopaminergic neurons from the SNpc project to the putamen and, to a lesser extent, to caudate nuclei (the neostriatum). Clinicopathologic correlations have shown that, by the time that parkinsonian symptoms arise, at least 60% of dopaminergic neurons in the SNpc already have been lost, and the striatal dopamine content is also greatly reduced. Brains of persons without clinical features of PD can have incidental findings of Lewy bodies at neuropathologic examination, perhaps representing the earliest stages of this disorder.

The Lewy body has become the topic of great interest in PD research because this intraneuronal eosinophilic inclusion is largely composed of ubiquitin and aggregated α-synuclein (αSyn). αSyn is a synaptic protein normally present in the brain and throughout the body. In addition to Lewy bodies (Fig. 86.1), clumps of αSyn positive can be found intra-axonally in involved neurons; these are termed *Lewy neurites* (Fig. 86.2). Lewy bodies and neurites are not exclusive to PD; these inclusions are also the hallmark of neurodegeneration within nondopaminergic cortical neurons of patients with one form of progressive dementia, whether or not they are also present in SNpc or locus coeruleus. Next to AD, cognitive decline associated with Lewy bodies (cortical Lewy body disease) is the most common form of progressive dementia. Other neurodegenerative disorders are recognized to have aggregated and misfolded αSyn, (although without the characteristic appearance of Lewy bodies with their intraneuronal rounded inclusions with a hyaline core). These alternative disorders, termed *synucleinopathies*, include multiple system atrophy (MSA), in which αSyn inclusions are exclusively within oligodendrocytes. Misfolded αSyn deposition can be found also in neurodegeneration with brain iron accumulation, which also exhibits cerebral neuronal pathology composed of axonal spheroids containing αSyn.

Neuropathologic studies of brains from elderly individuals either with or without PD have revealed an ontologic pattern for

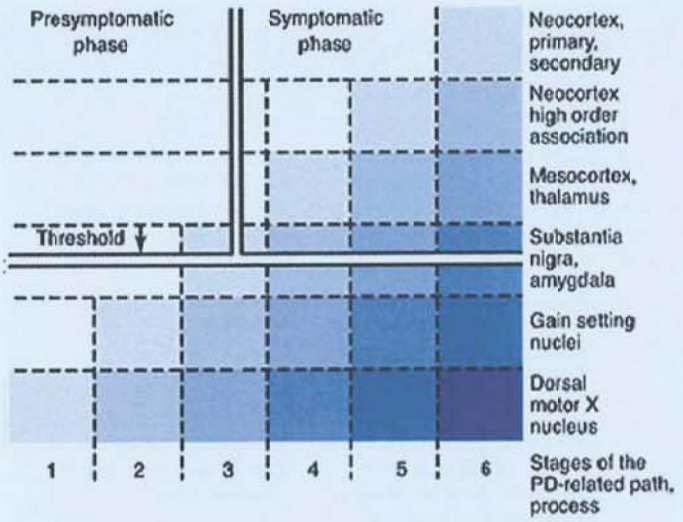

FIGURE 86.1 Six stages of Parkinson disease (PD) based on distribution of Lewy neurites in the brain. Staining for α-synuclein in Lewy neurites reveals their distribution. The *darkest color* represents the most intense deposition of Lewy neurites and their earliest appearance, which is in the olfactory tubercle and dorsal motor nucleus of the vagus. The substantia nigra develops Lewy neurites at stage 3, following which symptoms of PD appear (Braak stage 4). The neocortex is involved in stages 5 and 6. The susceptible neurons belong to the class of projection neurons with an axon that is disproportionately long, thin, and poorly myelinated or unmyelinated. (From Braak H, Bohl JR, Müller CM, et al. Stanley Fahn lecture 2005: the staging procedure for the inclusion body pathology associated with sporadic Parkinson's disease reconsidered. *Mov Disord*. 2006;21[12]:2042-2051.)

development of αSyn pathology. In these studies, αSyn antibody staining for Lewy bodies and Lewy neurites indicates that this protein aggregates first in the anterior olfactory nucleus and in nuclei of the caudal brainstem, especially in the dorsal motor nucleus of the vagus in the medulla (see **Fig. 86.1**). Such findings arise without pathologic involvement of SNpc, from which PD's motor features emerge. After an extensive study of aging brains from persons without clinical manifestations of PD, Braak and colleagues proposed a staging system for the αSyn pathology of PD based on the timing, location, and relative abundance of Lewy bodies. From these observations, he proposed a hypothesis that the Lewy body–related pathology follows a characteristic pattern of progressive rostral spread from brainstem to the telencephalon and cerebral cortex (see **Fig. 86.1**). Braak's research suggested a pattern of initial vulnerability possessed by certain neuronal groups as well as neuron-to-neuron transmission of the disease process. Although an appealing hypothesis, Lewy body pathology does not fully correlate with loss of neurons or their function, and many cases seem to differ from this hypothetical pattern of progression. Recent research has highlighted the evolution of Lewy body pathology from an origin in the gut or the olfactory bulb instead of lower brainstem. Considerable evidence supports the notion that misfolded αSyn behaves in a templating manner throughout a neuronal adjacent neuronal population like prion disorders.

The observations of Braak and colleagues have provided insights that have stimulated research seeking origins of PD throughout the body. Recent work supports the notion that aggregated αSyn could be generated initially in autonomic plexus of the colon. Some evidence has been presented that these aggregates could migrate (possibly retrograde via the vagus nerve) to the dorsal motor vagus nucleus in the medulla, where early Lewy body formation is often found. Aggregated αSyn can also be found in skin, salivary glands, and other sites throughout the body. One characteristic of cells susceptible for harboring Lewy neurites is their identity as a class of projection neurons with a thin axon that is disproportionately long as well as either partially or totally lacking in myelination.

Etiology

The cause or causes of PD remain unknown. Although more than two dozen genes have been associated with this disorder (a few determinant genes clearly linked to causing the disease, others known to enhance risk for developing parkinsonism), most patients with PD lack identified hereditary factors. Genome-wide association studies have probed increasingly larger populations in the search of additional mutation or other genetic factors, leading to new loci reported from time to time. One question raised from the frequency of incidental Lewy body disease is whether nongenetic mechanisms are a necessary part of some of the genetically linked disorders. On this basis, research into PD causation has searched for environmental or lifestyle factors contributing to worldwide occurrence of PD. Undoubtedly, aging provides a strong component of the "backbone" for PD risk. However, it is unclear if increased occurrence of PD in the sixth decade and beyond necessarily reflects enhanced vulnerability at that period of life or, alternatively, just the result of cumulative lifelong events that haven't reach a threshold of disease expression at younger ages. Even advanced aging does not hold the answer—most centurions lack PD changes in their brains. Apart from the rare families whose parkinsonism reveals strong patterns of Mendelian inheritance (see below), PD in the general population is not found in clusters associated with work exposures, geographic location, exercise profile, diet, or other lifestyle factors. One of few exceptions to the latter is cigarette smoking, which, in dozens of epidemiologic investigations, has had a strong inverse-and dose-related association with reduced risk for acquiring PD. The reason for this lifestyle influence is unknown. A clinical trial using transdermal nicotine administration didn't demonstrate disease modification, but there is no other explanation of why chronic smoking confers an apparent protective effect. Although it has less of an apparent protective effect than smoking, caffeine intake is another life-experience factor shown to diminish risk for PD. Another unexplained inverse relationship with both occurrence and progression rate of PD has been concentration in serum and cerebrospinal fluid of the purine compound urate (a natural antioxidant which shares a chemical similarity with caffeine). The chronic use of lipid-lowering statin drugs, certain calcium channel blockers, and glucagon-like peptide 1 agonists have also provided evidence for lowering of risk.

Searches for causes of PD among the contemporary diet and modern lifestyle exposures to hundreds of synthetic chemicals need to consider that the same clinical disorder was well described by 19th-century physicians. Causation by a neurotoxic substance capable of the selective regional neuronal losses found in the PD brain seems unlikely. Years ago, an industrial chemical, 1-methyl-4-phenyl-1,2,3,6-tetrahydropyridine (MPTP) was found to cause parkinsonism in exposed persons. This discovery raised the possibility that a similar compound in the environment might be responsible for PD. Rodents and nonhuman primates rendered parkinsonian by MPTP exposure have been useful laboratory models for testing symptomatic PD therapies.

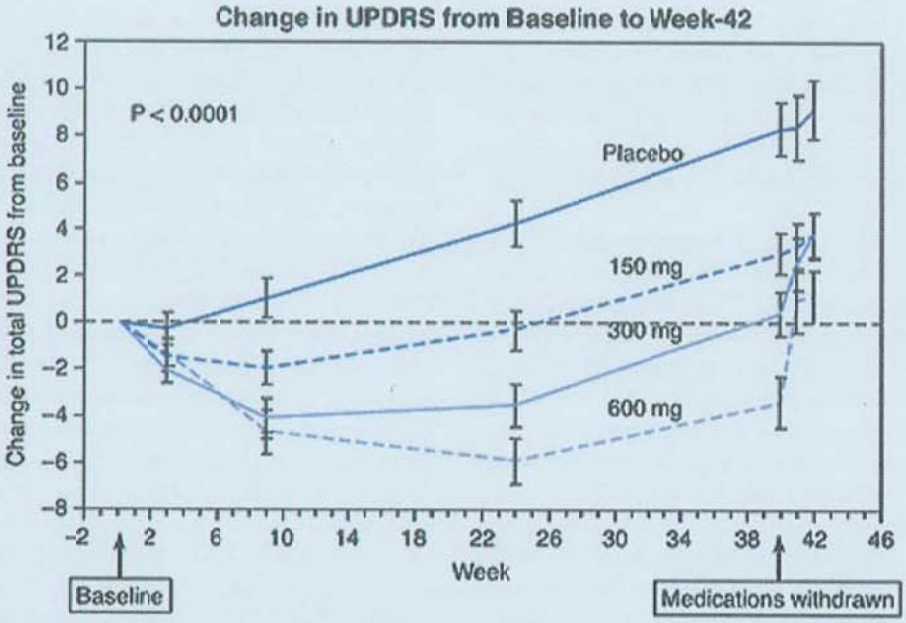

FIGURE 86.2 Effect of different dosages of levodopa on the severity of Parkinson disease based on changes in the Unified Parkinson Disease Rating Scale (UPDRS). Data are from the ELLDOPA study in which subjects with early, untreated Parkinson disease were randomized equally to one of three doses of levodopa (with carbidopa) or placebo. Treatment lasted 40 weeks, after which the medication was tapered to zero over 3 days, and the subjects were evaluated 7 and 14 days later. The changes in subjects treated with levodopa at different dosages or with placebo were determined based on the total score of UPDRS. The scores were obtained by the blinded treating investigator who performed the evaluations before the morning dose of the daily dose of the study drug. The points on the curves represent mean changes from baseline in the total scores at each visit. Improvement in parkinsonism is represented by lower scores and worsening by higher scores. Negative scores on the curves indicate improvement from baseline. The bars indicate standard error. The last 2 weeks (weeks 40-42) allowed a return of symptoms and signs, but those on levodopa did not reach the same degree of worsening seen in those treated with placebo. (Data from Fahn S, Oakes D, Shoulson I, et al; and Parkinson Study Group. Levodopa and the progression of Parkinson's disease. *N Engl J Med.* 2004;351[24]:2498-2508.)

Although this compound imparts highly selective damage acutely to the dopaminergic neurons in the SNpc as in PD, MPTP exposure doesn't recapitulate the range of brain changes such as development of Lewy bodies. Other chemical exposures have been under suspicion for causing PD. For example, epidemiologic investigation of agricultural workers found an increase in PD risk associated with exposure to chemicals used in that industry. However, searching for the cause(s) of PD needs to consider that it lacks regional clustering or enhanced prevalence among occupations or lifestyle habits. As further confirmation of its ubiquity in the human population, PD is found in societies not engaged in the modern Western world's lifestyles.

In the absence of an identified cause for sporadic PD, research needs to contend with the possibility that it might arise from innocuous experiences in everyday life (such as viral upper respiratory infections) or factors derived from microorganisms in the colon (the microbiome). Genome-wide searches have regularly expanded the connection between PD and various genes and epigenetic factors. Another insight to the nature of PD was a 20th century disorder that was termed *encephalitis lethargica*, or von Economo disease. This seemingly epidemic form of parkinsonism spread over a worldwide for over a decade starting in 1918. Although its cause was never determined, it was suspected to arise in the aftermath of the worldwide influenza pandemic. Despite its clinical similarities to PD (including levodopa responsiveness), the full clinical syndrome of encephalitis lethargica and its neuropathology is greatly different.

Genetics

Although careful concordance studies of identical twins didn't find strong evidence for a genetic side to PD, a revolutionary change arose from the 1997 report of Mendelian inheritance of parkinsonism. Observed in a few families in the Contursi region of Southern Italy, these findings provided insights not only into these rare instances of hereditary parkinsonism but also into sporadic PD. The Contursi parkinsonian's shared feature was a mutation in a gene coding for αSyn. As mentioned above, an aggregated form of αSyn is the signature constituent of Lewy bodies. The role of the mutation (A53T) in the αSyn gene (*SNCA*) drew attention to the universal role of this vulnerable protein, even in cases regarded as "sporadic disease." With discovery of the role played by A53T, the search began for other gene mutations that might enhance risk for acquiring parkinsonism. These findings also reinforced thinking that PD etiology might be multifactorial, combining genetics with environmental contributions. The reporting of familial parkinsonism has swelled the number of identified genes (see Table 86.2). The varied clinical phenotypes of genetic forms of parkinsonism, as well as their neuropathologic findings, have raised questions as to whether each of these forms of parkinsonism should necessarily be classified as PD. In any case, the most salient features of genetic parkinsonism have to do with age of onset and their brain pathology (specifically, whether Lewy bodies are present). Several gene mutations listed in Table 86.2 are associated with parkinsonism

beginning before 50 years of age. In general, younger onset PD has a higher likelihood of an underlying genetic association. In the latter disorders, additional neurologic deficits beyond typical changes of PD parkinsonism can be found. Brain tissue deposition of iron and the absence of Lewy body pathology in some of the genetic forms of parkinsonism add to the puzzle of how closely they are related to sporadic PD.

As mentioned above, the first insight into genetic parkinsonism was discovery of mutations on *SNCA* (chromosome 4q22.1), which codes for αSyn. Also termed *PARK1*, this autosomal dominant genotype results in parkinsonism closely resembling sporadic PD, although age of onset is typically younger. Occasional instances of novel single nucleotide polymorphisms in the *SNCA* gene have been found in cases without a family history of parkinsonism. Although the mutant form of αSyn inevitably forms the aggregates found in Lewy bodies, another identified genetic aberration offers insight into why sporadic PD is associated with the protein in its normal ("wild-type") form. In another familial parkinsonian disorder classified as PARK4 (see **Table 86.2**), the mechanism is just the overproduction of native (wild-type) αSyn. In this instance, parkinsonism results from dysregulated gene activity (either from duplication or triplication of gene translation). These findings suggest the intrinsic vulnerability of αSyn as a precursor for forming Lewy bodies based on rate of synthesis or its intraneuronal concentration. Researchers are uncertain whether the Lewy body imparts toxicity to the neurons that harbor them, or, alternatively, if their formation constitutes a protective mechanism to sequester misfolded αSyn before it spreads and overwhelms vital cell functions.

In addition to highlighting αSyn's role in neuronal degeneration, genetic research has unearthed other mechanisms pertinent to neuronal degeneration. PARK8 (see **Table 86.2**) is gene defect (in leucine-rich repeat serine/threonine-protein kinase 2 [*LRRK2*]) that contributes to familial risk for parkinsonism. This mutation usually leads to a gain of enzymatic function. LRRK2 is ubiquitously expressed throughout the central nervous system and serves multiple functions. The full story of LRRK2's relationship to the development of parkinsonism is uncertain. However, mutant LRRK2 protein has been associated with diminished degradation of αSyn and decreased autophagy. Many pathogenic *LRRK2* mutations have been identified. *LRRK2* mutations constitute the most frequent genetic cause of parkinsonism, accounting to up to 5% of familial cases arising in the European population. Certain ethnic groups have even higher prevalence. For example, the most common *LRRK2* mutation, G2019S, has an increased frequency among Ashkenazi Jewish heritage (18.3% of those with parkinsonism) and in North African Berbers (39%).

LRRK2 mutations result in an autosomal dominant form of parkinsonism that closely resembles sporadic PD. Genome-wide association studies have shown that *LRRK2* polymorphisms also can be found exist in populations of sporadic PD. Although the neuropathology associated with *LRRK2* mutations tends to be highly variable (some cases exhibit Lewy bodies, whereas others manifest only neurofibrillary tangle pathology), degeneration of dopaminergic neurons within the SNpc is a constant feature.

When familial parkinsonism develops younger than the age of 30 years, the most common gene defect has been found in the PARK2 locus (*PRKN*). This gene codes for an E2-dependent E3 ubiquitin–protein ligase, parkin. Parkin gene mutations result in a slowly progressive, autosomal recessive parkinsonism characterized by resting tremor and clinical improvement after sleep. In contrast to typical sporadic PD, PARK2 offers a more benign long-term clinical outcome. In this disorder, no Lewy bodies are found even though SNpc neurons undergo degeneration. To add to the complexity of the story, a few adult-onset cases of PARK2 have been found to possess a single heterozygotic gene mutation; in these cases, SNpc Lewy bodies have been found. Two additional recessively inherited forms of younger onset parkinsonism include those with PTEN-induced putative kinase 1 (*PINK1*; PARK6) and *DJ-1* (PARK7) mutations. These mutations lead to defective regulation of the mitophagy pathway. These disorders have been associated with impaired mitochondrial functions such as management of intracellular oxidative stress. For both disorders, their clinical characteristics include an autosomal dominant early-onset form of parkinsonism and slow clinical progression.

Another relatively common site for mutation-associated with parkinsonism is the gene for glucocerebrosidase (*GBA*), located on chromosome 1q21. In homozygous individuals, a mutation in *GBA* has consequences for lysosomal function that lead to Gaucher disease. Heterozygous carriers of *GBA* mutations have increased risk for developing parkinsonism. Their clinical presentation is mostly indistinguishable from the sporadic disorder, although it can begin at a younger age and its outcome is associated with increased incidence of cognitive decline. Epidemiologic research has shown that about 13% of PD patients with Ashkenazi Jewish heritage possess this mutation (which is also found, less frequently, in other populations).

Pathogenesis

Evidence from examination of the PD brain and from various animal models of this disorder has provided a wealth of information about this disorder, although many gaps remain in understanding its pathogenesis. Two major themes of disease origin and progression have been discussed above, one centering on misfolded αSyn and the other guided by mechanistic insights from genetic forms of parkinsonism. The emerging role of the colonic microbiome has added another dimension of an endogenous bioenvironment capable of modulating immune system function, inflammatory molecules, neurotransmitter synthesis, and αSyn aggregation (among other options). In the still-fragmentary view of PD pathogenesis, concepts of a common final pathway have emerged with a focus on proteinopathy, impaired mitochondrial function, and multiple sources of oxidative stress. Insights from neurotoxins that can cause experimental parkinsonism also have been influential in considerations of how PD arises. Some of these toxins selectively target mitochondria function and generate oxidative stress. Postmortem biochemical observations have shown that complex I activity of mitochondria is reduced in SNpc of patients with PD. Such a defect will result in decreased adenosine triphosphate synthesis and buildup of free electrons, leading to release of free radicals. The brain in PD (particularly, the SNpc) shows depletion of reduced glutathione, one of the major intracellular antioxidants for quenching reactive oxygen species. Similar changes have been found in brains manifesting incidental Lewy bodies. Reduced glutathione synthesis might be the one of the earliest biochemical abnormalities of PD. It is not known, however, if such changes could cause PD or might just be a consequence of chronic oxidative stress from other causes.

Iron deposited in the SNpc may contribute to oxidative stress because the ferrous ion catalyzes the formation of the highly

reactive hydroxyl radical from hydrogen peroxide, which is a product of mitochondrial metabolism. Recessive genes with mutations associated with parkinsonism (as discussed above) may have roles at contributing to a mitochondrial etiology of parkinsonism. For example, *PRKN* and *PINK1* mutations confer wide-ranging effects on mitochondrial quality control such as regulating mitochondria biogenesis, maintaining fission-fusion balance to remove damaged mitochondria, mitochondrial transport, and turnover of damaged mitochondria by recruiting autophagic machinery. Another recessive gene, *DJ-1* is implicated in a pathway that handles oxidative stress. Endogenous factors may also predispose melanin-containing monoaminergic neurons to neurodegeneration. Cellular oxidation reactions (such as enzymatic oxidation and autooxidation of dopamine and other monoamines) result in the formation of reactive oxygen species such as dopamine quinone and other metabolic products that can damage the monoamine neurons in SNpc and locus coeruleus. Dopaminergic and noradrenergic neurons (the latter found in locus coeruleus) are autonomous pacemakers and possess long, highly arborized axons. These features lead to high metabolic demands in their cell bodies. The presence of a vulnerable calcium channel may predispose these neurons to basal metabolic stress by excessive calcium entry (another mechanism possibly predisposing to cell death).

Most of the genes whose mutations are associated with parkinsonism interact with multiple cellular functions. Nonetheless, those genes linked to recessive forms of PD have been implicated more for altering mitochondrial and metabolic pathways, whereas genes associated with autosomal dominant forms of PD tend to be involved with protein degradation homeostasis. As mentioned above, new evidence points to toxicity of protofibrillar forms of αSyn. Intriguing experimental evidence suggests that abnormal forms of αSyn may exert a prion-like property of propagating its abnormal conformation, with spread along the neuronal projections and even across synaptic connections. Another consequence of aggregated αSyn is interference with neuronal vesicle recycling. LRRK2 plays a role in vesicular trafficking and cytoskeletal function. Another gene whose mutation is associated with parkinsonism, vacuolar protein sorting 35 (*VPS35*) has been associated with autosomal dominant and levodopa-responsive parkinsonism. *VPS35* encodes a subunit of the retromer complex involved in endosomes and vesicular recycling. Both αSyn and LRRK2 influence protein degradation pathways, including autophagy (a process of cell degradation against dysfunctional cellular components by lysosomes). As mentioned above in the section on genetic forms of parkinsonism, a gene mutation limiting synthesis of the lysosomal enzyme *GBA* has been recognized as one of the most common risk factors.

CLINICAL MANIFESTATIONS

Signs and Symptoms

PD's clinical manifestations impairments emerge insidiously from a prodromal phase. The only category of evidence currently available for recognizing a preclinical stage of PD is detection by neuroimaging of diminished dopamine synthesis. This can be inferred from diminished striatal dopamine turnover or reuptake ^{18}F-fluorodopa positron emission tomography (PET) or DaT scans. Imaging of αSyn, although a current goal of research, hasn't been achieved although promising breakthroughs in this goal have been reported.

Tremor

Often, the earliest manifestation of clinical PD is tremor (a repetitive to-and-fro flexion-extension or rotatory movement) that is experienced when a limb is at rest. When engaged in any motion, this tremor is abolished until that body part returns to inactivity and then, after short delay, re-emerges. Resting tremor can be limited to one finger but generally involves the entire hand. It tends to be a distal manifestation in limbs but can involve proximal muscles. The lips, tongue, and jaw can also exhibit a tremor of a similar frequency. The classic "pill-rolling" tremor of PD involves the thumb and forefinger (▶ Video 86.1). The resting hand tremor often increases during walking. Stress, concentration, or excitement leads to exacerbation. Some PD patients will have an action tremor and postural maintenance tremor.

The localization of resting tremor can remain unilateral. Some patients feel an internal sense of tremor not outwardly observed. Because such tremor can respond well to antiparkinsonian medication, its origins would seem to be the same as observed tremor. Resting tremor may be the sole feature of PD for long periods of time, although eventually, it is joined by additional manifestations. For most patients, the diagnosis of PD is based on the concurrence of multiple clinical signs.

Evaluation of tremor in PD is sometimes confounded by tremor found with posture maintenance or during action. The latter type of tremor is the hallmark of essential tremor (ET). Ordinarily, these two tremor disorders are easy to distinguish, because the tremor of PD typically is abolished during action, the opposite of ET. Both PD and ET can manifest tremor with arms held in a forward-extended position. Sometimes, all three forms of tremor are found in the same patient, who might be affected by both PD and ET.

Bradykinesia

Another core feature of PD is *bradykinesia*. Although its literal meaning is "slowed movement," the clinical expression of bradykinesia is a spectrum of motor impairments that impart much of the disability and discomfort PD patients experience. All movements of an affected limb can be substantially slowed; for example, a patient may require several seconds for arising from a chair. The pace of gait may be at a fraction of normal. One of the most reliable indicators of bradykinesia (and one that patients can use as a guide to effectiveness of their medication regimen) is repetitive tapping of the fingers or feet. In addition to a slowed rate of movement, tapping also exhibits sequentially decreased amplitude as performance continues, a phenomenon termed *decrementing*. The progressive slowing of movements sometimes has interruptions that are momentary or last for several seconds. Another correlate of bradykinesia is *paucity of movement* (sometimes described as an en bloc quality of movement). These impairments reflect a reduction in the seemingly automatic features of movement. For example, the walking PD patient lacks fluidity of movement and exhibits reduced arm swing, smaller step length, extra steps at turns, and an overall reduction in use of supplementary muscle groups. Walking can be slowed with a shortened stride length a tendency to shuffle, and lack of a heel strike. The subjective experience of bradykinesia is sometimes described as clumsiness or incoordination. Such complaints should be kept in mind during the clinical examination because other motor deficits can coexist with parkinsonism. A careful exam should evaluate whether pyramidal tract deficits, action tremor, dyssynergia, or aspects of cerebellar system dysfunction are also present.

Patients commonly convey their experience of bradykinesia to the clinician as a feeling of weakness. A sense of fatigue, another common complaint reported by some PD patients even with mild symptoms, is sometimes tied correlated to the features of bradykinesia. Perceived weakness might also be regarded by some patients as feeling excessively tired, although it can be experienced in the absence of sleepiness. Evidence for bradykinesia is detectable in subtle behavioral manifestations such as the way a patient shrugs the shoulders. The underlying motor disorder of bradykinesia can also be brought out in everyday tasks for which slowness is not the only problem. For example, the lack of facility in handwriting leads to the execution of letters and words that are reduced in size, imprecise, and tending to trail off. Decreased dexterity in daily tasks is observed in difficulties at buttoning or placing arms in sleeves. Even face expression often provides a clue for bradykinesia. PD patients often develop parted lips and facial "masking," characterized a reduction in the muscular movements of blinking and facial expression. On this basis, PD patients are often thought be staring or experiencing a depressed mood.

Rigidity

Another clinical feature sometimes encountered in PD is a characteristic increase of muscle tone in limbs or axial musculature. This finding is termed *rigidity*. There can be an irregular quality of intermittent resistance during passive range of motion around the wrist or elbow joints, a phenomenon termed *cogwheel rigidity*. The tremorous or ratchety quality of cogwheeling is not the same thing as resting tremor superimposed on increased limb tone, nor is muscle rigidity the basis for bradykinesia. Cogwheel rigidity, like tremor and bradykinesia, is often regarded as a cardinal feature of PD. In some diagnostic schemes, criteria for establishing a "probable" diagnosis of this disorder can require observation of at least two of these manifestations. However, cogwheel rigidity is found in only about half of PD patients. Something like cogwheeling can also be observed in some patients with ET; this is termed *Froment sign*. For testing the latter phenomenon, an examiner carries out passive range of motion in a limb, whereas the other limb is engaged in voluntary active movement.

Postural Instability

Forward-flexed posture is a characteristic feature of PD. Commonly, it is first noticed in one or both arms and subsequently involves neck, trunk, and the legs. When severe, patients may have their trunk and head bowed downward (*camptocormia*).

Chronic flexion postures in the limbs lead to ulnar deviation deformities of the hands, flexion at the metacarpophalangeal joints, and extension of the interphalangeal joints (leading to the so-called *striatal hand* position). Inversion of the feet may develop, and the big toes may be dorsiflexed (the so-called *striatal toe*), whereas other toes curl downward. In addition to a forward-flexed position, the trunk in PD can be laterally tilted, a condition termed *Pisa syndrome*.

Dystonia

A dystonic equinovarus posture of the foot can evolve, sometimes with painful muscle spasms. The latter problem often arises early in the morning after awakening. Although imbalance generally does not occur in the first few years after parkinsonism emerges, afterward, a patient may evolve a characteristic balance problem.

Loss of postural reflexes is a unique PD feature that can be associated with falling backward despite the tendency for forward flexion of posture. This selective directionality of imbalance constitutes a milestone of PD progression that, for some patients, signals the end of safe walking or even standing unassisted. *Retropulsion* (a tendency to fall backward) can occur when a patient arises from seating or when walking backward. This problem can lead to falls because patients are unable to generate adequate response to prevent toppling even though there may be capability for recovery from the same extent of perturbed balance when occurring in a forward or sideways direction. To test postural reflexes, an examiner should use the *pull test*. The pull test is performed from behind a patient by abruptly pulling backward on the shoulders—this action is undertaken only after explaining the maneuver to the patient (▶ Videos 86.2 and 86.3). Normally, recovery of balance is achieved in one or two steps. If postural reflexes are greatly impaired, the patient may need to be caught, or else multiple steps may be needed to brake retropulsion. With impaired postural reflexes, a patient can collapse into a chair when attempting to sit. *Festination of gait* is another indicator of lost postural reflexes. In attempting to avoid falling backward, a festinating patient accelerates in quick forward steps.

Speaking and Swallowing

Another motor feature of PD is a change in quality of speech. Voice can become softer (*hypophonia*), and a monotonous tone can be acquired, with a lack of inflection (*aprosody*). Sometimes, enunciation becomes indistinct (*dysarthria*), or all generation of speech trails off to a whisper. Analysis of impaired speech might reveal that syllables are inadequately separated, resulting in words that run together (*tachyphemia*). An extreme version of stammering with characteristic repetition of a word's initial syllable is termed *palilalia*.

Swallowing may become impaired with advancing disease; with it, choking and aspiration can become concerns. Drooling of saliva can occur in PD, especially those with diminished facial motility. Drooling results from diminished spontaneous swallowing, not the excessive production of saliva in PD. In general, PD patients can swallow properly on a volitional basis, although it may require constant reminders from other to swallow so that drooling is avoided. Similarly, forward-flexed posture and arm swing can be normalized if the patient intentionally makes the effort to overcome these typical parkinsonian features.

Freezing

Freezing of gait is another distinctive PD phenomenon. Freezing is a sudden and transient event lasting from a few seconds to several minutes. It should not be confused with an undermedicated state because fully medicated patients can experience it. The triggers causing freezing can vary from patient to patient. As illustrated in ▶ Video 86.3, gait freezing can come on suddenly, with the impression of feet seemingly "glued to the floor". Abruptly afterward, the feet become "unstuck" and gait resumes. The distinctive patterns of freezing occur at the start of walking (*start hesitation*), freezing while executing a turn, and when approaching a destination. Freezing can be induced by walking through a crowded space. Passing through a doorway or walking in a crowd can trigger gait freezing. Patients may report that this problem might develop when hurrying while carrying out simultaneous tasks (such as holding an item in the hands), speaking, or during mental concentration. Curiously, freezing can be associated with "sensory tricks" that permit overcoming this problem by responding to visual clues (such as stepping over an imaginary object). The combination of freezing of gait and loss of postural reflexes together can lead to enhanced risk for falls. Besides gait, freezing can develop for other motor tasks. These include impaired eyelid opening (*apraxia*

of eyelid opening) or speech (the so-called *tip of the tongue* phenomenon), and pauses in handwriting.

Another curious feature of advanced stages of PD can occur when a patient is in an akinetic state. There can be the sudden reversal of immobility (termed *kinesia paradoxica*). As a phenomenologic mirror image of freezing, kinesia paradoxica refers the ability to quickly arise, walk, or use the limbs in response to a sudden and unexpected stimulus or emotional state. This phenomenon was first described in patients during the pre-levodopa era. The extremely brief reprise from immobility indicates that even with severe deficiency of dopaminergic neurotransmission in the PD brain, circuitry capable of enacting motor function is preserved.

Parkinson Mimics

At times of diagnosis and later during a parkinsonian disorder, clinical features may emerge that may point to a diagnosis other than PD. Often, it is the decline or lack of benefit from dopaminergic therapy. Additional problems may be clues such as incoordination, eye movement disturbance, autonomic impairment, or frequent falls. Because PD itself is not a uniform disorder in its signs and symptoms, it is important to highlight core diagnostic features while simultaneously excluding conditions mimicking PD. Surveys investigating large clinic populations of persons diagnosed with parkinsonism find progressive supranuclear palsy (PSP) to be the most common neurodegenerative disorder initially thought to be PD. Another less common disorder, MSA, can present with features of cerebellar system dysfunction or autonomic impairment.

Because both management and prognosis of PSP and MSA differ greatly from that of typical PD, early recognition is important (because it may be in the future if each of the parkinsonian disorders achieves specific disease-modifying therapy for these different neurodegenerative pathologies). Both PSP and MSA have distinctive brain magnetic resonance imaging (MRI) findings not found even in advanced PD. These are the *hummingbird sign* in a midline sagittal MRI view, which in the PSP brain is associated with midbrain atrophy. In MSA, atrophy in the cerebellum can be obvious on MRI, and a distinctive finding in the pontine tegmentum, termed the *hot cross bun sign*, is a characteristic finding. The development of severe imbalance and unexplained falling within 2 years of onset is typical of PSP but not PD. Symptomatic orthostatic hypotension and other autonomic impairment developing early in the course of parkinsonism is often the warning sign of MSA.

Clinical Course

PD is generally thought of as a progressive disorder. This description is accurate for most cases, although with the use of effective symptomatic therapy, any further progression of the underlying disorder remains hidden. The PD patient receiving effective treatment may exhibit a plateau in further clinical change for many years thereafter. The earliest months of clinical expression, when the first inklings of PD are observed, may provide the strongest evidence for disease progression. Initially, symptoms may be experienced only intermittently or during stressful situations, such as following a surgical operation or when pain is experienced. In about two-thirds of PD patients, resting tremor (often unilateral and intermittent) is the first recognized symptom (Table 86.3). Other single-sided presentations of PD, such as micrographia, are common and can persist for years. Eventually, most patients have bilateral symptoms and signs, although asymmetry can persist. The pace of progression in PD signs and symptoms has been followed prospectively in several clinical trials using the Unified Parkinson Disease Rating Scale (UPDRS), which catalogs parkinsonian features. Worsening in motor and functional disability generally result in roughly linear UPDRS score increases over several years of follow-up (see Fig. 86.2).

TABLE 86.3 Initial Symptoms in Parkinson Disease

Symptoms	No. of Cases (n = 183)	Percentage
Tremor	129	70.5
Stiffness or slowness of movement	36	19.7
Loss of dexterity and/or handwriting disturbance	23	12.6
Gait disturbance	21	11.5
Muscle pain, cramps, aching	15	8.2
Depression, nervousness, or other psychiatric disturbance	8	4.4
Speech disturbance	7	3.8
General fatigue, muscle weakness	5	2.7
Drooling	3	1.6
Loss of arm swing	3	1.6
Facial masking	3	1.6
Dysphagia	1	0.5
Paresthesia	1	0.5
Average number of initial symptoms per patient		1.4

From Fahn S, Kang UJ. Parkinson disease. In: Louis ED, Mayer SA, Rowland LP, eds. *Merrit's Neurology*. 13th ed. Philadelphia: Lippincott Williams and Wilkins; 2016:704–721.

Not all patients with PD become wheelchair-bound or bedridden, although this is an eventual outcome for a small fraction despite medications now available. Most commonly, this disorder, whether progressive or not, remains responsive to symptomatic therapy with levodopa and other medications. In addition, the option of electrical stimulation of basal ganglia structures—DBS—has expanded the options for achieving symptomatic control. However, the development of retropulsive imbalance—a finding which is generally unresponsive to either medication or DBS—calls for the use of supportive devices (like rolling walking frames) in order to maintain safe ambulation. The use of a cane is not likely to offer sufficient protection against falls.

The Hoehn and Yahr clinical staging scale (Table 86.4) captures typical aspects of PD progression. This scale was devised in the 1960s and was based on unmedicated PD patients (some of whom had been symptomatic for many years). It charts the transition from unilateral to bilateral manifestations (from stage 1 to 2) and, subsequently, to the loss of postural reflexes (stage 3). With the advent of levodopa, disability constituting stages 4 and 5 (wheelchair bound and bed bound, respectively) is much less common. Other ways to describe the impact of PD on activities of daily living are the Schwab and England scale and a section of the UPDRS dealing with independent functioning. The UPDRS has been updated and validated into a version that encompasses more of the nonmotor features of PD; this revision is termed *The Movement Disorder Society–UPDRS*.

TABLE 86.4 The Modified Hoehn and Yahr Staging Scale for Parkinson Disease

Stage 0	No signs of disease
Stage 1	Unilateral disease
Stage 1.5	Unilateral plus midline/axial involvement
Stage 2	Bilateral disease, without impairment of balance
Stage 2.5	Mild bilateral disease, with an abnormal pull test but with recovery to avoid falling
Stage 3	Mild to moderate bilateral disease; some postural instability (would fall on the pull test if not caught); physically independent
Stage 4	Severe disability; still able to walk or stand unassisted, but a walking aid is advisable to prevent falling
Stage 5	Wheelchair-bound or bedridden unless aided

From Fahn S, Elton RL, Members of the UPDRS Development Committee. The Unified Parkinson's Disease Rating Scale. In Fahn S, Marsden CD, Calne DB, et al, eds. *Recent Developments in Parkinson's Disease*. Vol 2. Florham Park, NJ: Macmillan Healthcare Information; 1987:153-163, 293-304.

Non-Motor Manifestations

Not surprisingly, some of the nonmotor symptoms of PD can be more troublesome than its motor manifestations. They are often more difficult to treat, or impossible. Nonmotor features comprise a wide range of problems that can arise either early or late during PD. Among them are behavioral and personality changes, including indecisiveness, apathy, social withdrawal, increased dependency, and passivity. Various changes suggesting of cognitive impairment can develop, including reduced attention span, impaired working memory and executive function, and visuospatial impairment. These changes can evolve even in the absence of overt cognitive decline. Eventually, some patients will undergo global worsening in cognitive abilities and will meet diagnostic criteria for dementia.

In PD, the patterns of cognitive impairment can be distinctive experiences. For example, many patients complain of hindered multitasking in everyday activities or a sense of slowed (although accurate) recall. The impact of nondementia cognitive impairments can intrude on work and social relationships. In some instances, these subtle declines in the thinking process will lead a spouse or another family member to take over decision-making tasks. Because of altered speaking and writing capabilities that some PD patients experience, the net effect may be diminished communicativeness. An aversion to participating in fatigue-generating tasks like exercise and long walks is a characteristic of some PD patients, even those who are physically quite fit. The prevalence of depression is increased in patients with PD compared to their healthy peers of similar age. It is important to recognize that depression is just as likely to be medication-responsive in PD as it is for others. Anxiety is another common problem, sometimes exacerbated by the daily challenge of inconsistent medication benefits and frustrations imposed by delays and impaired capabilities at participating in everyday activities.

Global cognitive decline in PD, like AD, is not inevitable, although a population older than 70 years of age has an increasing risk of dementia from several causes (of which AD is the most common). When cognitive impairment develops in a PD patient, it might be attributable to a second most common cause of progressive dementia, the formation of Lewy bodies throughout the cerebral cortex. In cortical Lewy body disease, short-term memory impairment may be less prominent as an early feature than typically encountered in AD. In contrast, PD dementia is often initially characterized by slowed responses to questions and other evidence of delay in cognitive processing—a condition that has been termed *bradyphrenia*. Some of the subtle features of bradyphrenia include deficiencies in mental and personality flexibility of thinking and difficulty at rapid change in mental sets (as, for example might be evident in psychological tasks requiring categorization). In a cross-sectional analysis of a typical PD clinic population, as many as one-fifth eventually experience go on to develop cognitive decline in association with cortical Lewy body disease, occurring within 10 years after diagnosis. Some estimates indicate that PD with duration greater than 10 years has an even higher prevalence of dementia. Whether a PD patient with progressive cognitive decline has abundant Lewy bodies in cortical neurons or AD pathology is not readily distinguishable during life. One distinguishing clinical feature that provides a clue for Lewy body pathology is the early occurrence of hallucinosis (even without the intake of drugs known to cause hallucinations).

Another nonmotor manifestation of PD is the perception of various sensory symptoms such as deep aches, burning pain, and tingling. These problems can arise in the absence of deficits in primary sensation modalities. A clue to the relationship of such sensory symptoms with PD is that they typically occur on the body side where PD first evolves, and they can remit with levodopa therapy. Sometimes, PD presents with a dull, diffuse pain in the upper arm pain in association with decreased arm swing while walking; this can be mistakenly attributed to a "frozen" shoulder until levodopa responsiveness is demonstrated. Akathisia (a near-constant state of discomfort leading to voluntary movements) and the restless limb syndrome (RLS) can be encountered in some PD patients. In both syndromes, uncomfortable sensations remit when the patient moves. Distinguishing these conditions can be difficult; akathisia is usually experienced throughout the day, whereas RLS typically arises in the evening. RLS also is characterized by crawling sensations in the legs and may be associated with periodic limb movements during sleep.

Sleep problems are common in PD, sometimes described by patients as frequent awakenings or fragmented sleep. One aspect of disordered sleep is attributable to a change in normal sleep architecture toward enhanced periods of dream-stage sleep during which rapid eye movement (REM) sleep predominates. The consequence of excessive REM sleep is the occurrence of a distinctive behavior disorder characterized by acting out of dreams in talking during sleep and repeated limb movements. This behavioral disorder can be responsive to treatment with benzodiazepine drugs. PD patients who have missed getting adequate rest during the night may go on to experience excessive daytime drowsiness. This problem can be exacerbated by treatment during the day with drugs that can cause sedation (like dopaminergic agonists).

Various patterns of autonomic disturbance can be encountered in PD. Some patients exhibit clear evidence of this when they have asymmetrical manifestations of PD, in that their skin temperature is cooler on the side with more motor symptoms. One common feature of autonomic impairment in PD is constipation, which is a frequent complaint in PD patients even if they take appropriate measures to avoid it. In PD, bladder emptying can be compromised, penile erection may be difficult to achieve, and symptomatic orthostatic blood pressure drops

may be experienced. Orthostatic hypotension can be exacerbated by dopaminergic medications. If there is prominent autonomic dysfunction early during parkinsonism, consideration of the diagnosis of MSA is warranted because the development of dysautonomia can predominate over the motor impairments. However, PD patients without MSA can also exhibit autonomic deficits.

Other systemic features of PD can be seborrhea and seborrheic dermatitis. In up to one-third of PD patients, marked reduction (hyposmia) or complete loss in sense of smell can precede the development of motor impairments, sometimes by years.

Muscle stretch reflexes are not impaired in PD, although a spontaneous extensor plantar posturing of the great toes is a dystonic manifestation that sometimes occurs with equinovarus foot posturing. This manifestation (termed *striatal toe*) mimics a Babinski sign, and often, the other toes are held in a flexed position. These dystonic manifestations tend to develop on the more affected side of the body when PD develops unilaterally. An unsuppressed reflex of obligate blinking (known as the *glabellar reflex* or *Myerson sign*) is commonly found, together with decreased spontaneous blinking.

DIFFERENTIAL DIAGNOSIS

For clinicians, the diagnosis of PD is based on both the typical profile of motor impairments and the absence of clinical features that would point to another disorder (such as the cerebellar dysfunction or autonomic impairments of MSA). The insidious onset of PD typically is often asymmetric (see **Tables 86.1** and **86.5**). The presence of resting tremor and cogwheel rigidity, although not a feature of all cases, is strongly supportive of the diagnosis. Added to examination features is the information gained from medication trials. In strong support of the diagnosis of PD is the improvement of tremor by amantadine or an anticholinergic drug and relief of all PD symptoms by levodopa. Because tremor is so commonly the earliest motor feature of PD, ET is not uncommonly confused with PD (see Chapter 76). ET is characterized by both postural and kinetic tremor but not the rest tremor characteristic of PD. ET can coexist with PD, but there is no obvious etiologic connection.

In PD, the morphology of the brain is normal on computerized axial tomography and MRI unlike PSP and MSA (as mentioned above). In PD, testing for impaired dopaminergic neurotransmission can be achieved with a commercially available study, DaT single-photon emission computed tomography (SPECT) using ^{131}I-ioflupane. Similarly, PET brain scans with ^{18}F-fluorodopa also can provide images to demonstrate decreased dopaminergic nerve terminals in the striatum. In interpretation of the DaT scan, the earliest stages of PD involve dopaminergic terminal deficit in the caudal region of the putamen region. DaT SPECT can be used to distinguish the diagnosis of PD from ET because in the latter condition, results are normal. Another PET study with a different ligand, ^{18}F-fluorodeoxyglucose PET can be used to reveal a distinctive hypermetabolism pattern in the lentiform nuclei and a metabolic network pattern that correlates with disease progression. A different metabolic network pattern in some PD patients has been associated with progressive cognitive decline, such a pattern also arises in other parkinsonian syndromes.

Clues that suggest that a parkinsonian patient is affected by a pathology different from PD can be subtle initially. Factors in favor of the diagnosis of PD include a one-sided presentation. In contrast, patients with other parkinsonian disorders commonly show symmetrical bilateral involvement (although a notable exception is corticobasal syndrome). Parkinsonism resulting from a localized head lesion, such as a subdural hematoma, can also be quite asymmetrical. Resting tremor also is in support of PD except when it is found in the context of drug-induced parkinsonism. As useful as these generalizations may be, they are not the final word on diagnosis of PD because patients can lack unilateral onset or resting tremor. One of the most important diagnostic aids beyond a convincing clinical story is improvement from a trial with a 300 to 600 mg/d levodopa regimen. Although PSP and other parkinsonian disorders can also show responsiveness early on, higher doses are generally needed for detecting responsiveness, and often, the benefits from levodopa are limited. Resting tremor in PD, however, can be unresponsive to all available medications (and sometimes, this is the reason for enlisting DBS as a therapy). Chapter 87 provides clinical descriptions of other parkinsonian disorders.

A number of rare neurodegenerative conditions can present with parkinsonism, including pantothenate kinase–associated neurodegeneration (which often shows a distinctive MRI abnormality, the "eye-of-the-tiger" sign) and neuroacanthocytosis (which has laboratory evidence including elevated creatinine phosphokinase and abundant acanthocytes on red blood cell smear). Huntington disease, which generally is a hyperkinetic movement disorder, can rarely present with prominent parkinsonism. Similarly, Wilson disease can lack its typical presentations with tremor and dystonia and instead can closely mimic PD. Virtually, all cases of neurologic Wilson disease will have abnormalities on MRI brain scans, but laboratory testing of urinary copper excretion or serum ceruloplasmin concentration can sometimes yield ambiguous results.

OVERVIEW OF PARKINSON DISEASE TREATMENT

At present, PD treatment is entirely symptomatic, targeted at controlling both motor and nonmotor symptoms of PD. The range of treatment options are listed in **Table 86.6** LEVEL 3.[1,2] For most patients, therapeutic choices should follow standardized guidelines, although to some extent the choice of medications can be individualized. For example, most patients don't need drugs that specifically target tremor because levodopa provides global effectiveness for most signs and symptoms. However, anticholinergic drugs and amantadine are available for addition to levodopa for enhancing tremor control. Response to medications (particularly levodopa) is dependent on the drug quantity at each dosing, and timing of medications may need to be tailored to a patient's report of benefits and various side effects (such as involuntary movements).

Among the general principles guiding treatment of PD is recognition that there is no reason to hold back on starting medication "early" (that is, when only mild symptoms have emerged). Patients sometimes encounter a myth that levodopa and other PD medications have a limited duration of benefit; using this logic, the argument of this misinformation is that putting off the start of treatment might be in their best interest. Another myth is that first-line treatment should be an inhibitor of monoamine oxidase B (MAO-B). The marketing of dopaminergic agonists over the past 35 years has sometimes implied that these drugs should be chosen as initial therapy or included with levodopa

TABLE 86.5 Clues Indicate the Likely Type of Parkinsonism

Clinical	Alternative Diagnoses
Never responding to levodopa	Other than PD
Predominantly unilateral parkinsonism	PD; HP–HA syndrome; CBS
Symmetric onset	PD; most forms of parkinsonism
Presence of rest tremor	PD; secondary parkinsonism
Lack of rest tremor	PD; Parkinson-plus syndromes
History of encephalitis	Postencephalitic parkinsonism
History of toxin exposure	Parkinsonism caused by the toxin
Use of neuroleptics	Drug-induced parkinsonism
Shuffling gait much greater than upper limb bradykinesia	Normal pressure hydrocephalus; vascular parkinsonism
Severe unilateral rigidity	CBS
Cortical sensory signs	CBS
Unilateral cortical myoclonus	CBS
Unilateral apraxia	CBS
Alien limb syndrome	CBS
Early onset of dementia	Dementia with Lewy bodies; AD; frontotemporal dementia
Psychotic sensitivity to levodopa	Dementia with Lewy bodies; AD
Early loss of postural reflexes	Progressive supranuclear palsy
Early onset of falling	Progressive supranuclear palsy
Impaired downgaze and opticokinetic nystagmus	Progressive supranuclear palsy
MRI: caudate atrophy	HD; neuroacanthocytosis
MRI: decreased T2 signal in striatum	Multiple system atrophy
MRI: midbrain atrophy ("humming bird" sign)	Progressive supranuclear palsy
"Apraxia" of eyelid opening	Progressive supranuclear palsy
Deep nasolabial folds	Progressive supranuclear palsy
Furrowed forehead and eyebrows (quizzical look)	Progressive supranuclear palsy
Excessive hesitation between words when speaking	Progressive supranuclear palsy; CBS
Nuchal dystonia	Progressive supranuclear palsy
Abducted arms when walking	Progressive supranuclear palsy
Square wave jerks in eye movement	Progressive supranuclear palsy; multiple system atrophy; CBS
Gait freezing	Progressive supranuclear palsy
Symptomatic orthostatic hypotension	Multiple system atrophy
Urinary or fecal incontinence	Multiple system atrophy
Cerebellar dysarthria and dysmetria	Multiple system atrophy, SCA2, SCA3, SCA17
Laryngeal stridor (vocal cord paresis)	Multiple system atrophy
Lower motor neuron findings	Multiple system atrophy; neuroacanthocytosis
Upper motor neuron findings	Multiple system atrophy
Early orofacial dyskinesia with levodopa	Multiple system atrophy
Laboratory	
Fresh blood smear: acanthocytes (>20%)	Neuroacanthocytosis
Greatly elevated creatine kinase	Neuroacanthocytosis
MRI: many lacunes	Vascular parkinsonism
MRI: "eye of the tiger" in pallidum	Pantothenate kinase–associated neurodegeneration type 2 (PKAN-2)
MRI: enlarged ventricles	Normal pressure hydrocephalus
Abnormal autonomic function tests	Multiple system atrophy
Denervation on sphincter EMG	Multiple system atrophy

Abbreviations: AD, Alzheimer disease; CBS, cortical-basal syndrome; EMG, electromyography; HD, Huntington disease; HP–HA, hemiparkinsonism–hemiatrophy; MRI, magnetic resonance imaging; PD, Parkinson disease; SCA, spinocerebellar atrophy.

TABLE 86.6 Therapeutic Options for Managing Parkinson Disease

- Dopamine precursor: levodopa combined with carbidopa (or outside of the United States, benserazide); available as immediate-release and sustained-release formulations, inhaled levodopa micropowder, and as intestinal gel for infusion
- Dopaminergic agonist: pramipexole, ropinirole, rotigotine (transdermal), and apomorphine (subcutaneous injection and sublingual tablets)
- Catechol-O-methyltransferase inhibitor: entacapone, tolcapone, opicapone
- Glutamate (NMDA receptor) antagonist: amantadine
- Monoamine oxidase type B inhibitor: selegiline, rasagiline, safinamide
- Anticholinergics: trihexyphenidyl, benztropine, ethopropazine
- Adenosine A_{2A} receptor antagonist: istradefylline
- Muscle relaxants: cyclobenzaprine, benzodiazepines, baclofen
- Peripheral antidopaminergic for nausea: domperidone
- Antidepressants: amitriptyline and other tricyclics, serotonin reuptake inhibitors
- Antianxiety drugs: benzodiazepines, buspirone
- Treatment of hallucinations and psychosis: clozapine, quetiapine, pimavanserin
- Treatments for dementia: rivastigmine, donepezil, galantamine, and memantine
- REM sleep behavior disorder: clonazepam, melatonin
- Antisoporific (daytime drowsiness): modafinil, caffeine
- Treatment for restless limb syndrome: dopaminergic agonists, gabapentin, and opioid compounds
- Treatment for sialorrhea: glycopyrrolate, propantheline, atropine drops, botulinum toxin injection into salivary glands
- Treatment for postural hypotension: fludrocortisone, midodrine, droxidopa, indomethacin

Surgical Approaches

- Ablative surgery and focused ultrasound
  - Thalamotomy
  - Pallidotomy
- Deep brain stimulation
  - Thalamic (Vim) stimulation for tremor
  - Pallidal (GPi) stimulation for parkinsonism
  - Subthalamic nucleus stimulation for parkinsonism

Abbreviations: GPi, globus pallidus interna; NMDA, *N*-methyl-D-aspartate, REM, rapid eye movement; Vim, ventrcintermedius.

from the start. Although several studies have investigated this question, there is no compelling evidence that there will be an advantage for starting with this class of drugs. Patients experiencing only resting tremor can obtain highly satisfactory responses to the anticholinergic drugs benztropine and trihexyphenidyl, or to amantadine; these might be the drugs of choice for some patients if levodopa fails against tremor. The choice of optimal PD medication is often conducted on a trial-and-error basis, governed by the understanding that medications should be introduced gradually and downward titrated if side effects intervene. Patients should engage in a cost-benefit analysis when expensive medications are considered. For example, choosing a sustained-release carbidopa-levodopa formulation may impose a financial burden for a patient whose convenience from a longer duration of action may be offset by the much higher out-of-pocket expense than its immediate-release generic alternative.

Levodopa

Since recognition of its effectiveness in 1967, L-dihydroxyphenylalanine (also known as *levodopa*) has been the mainstay of PD therapeutics LEVEL 1.[1,2] This large neutral amino acid serves as a precursor for dopamine synthesis occurring at nerve terminals within the caudate and putamen. At this location, endogenous dopamine production is reduced more than 50% by the time motor features of PD have emerged. As a charged molecule, dopamine doesn't cross the blood-brain barrier, but the entrance of levodopa is readily facilitated by an amino acid transport system. The transfer is highly dependent on serum concentration of levodopa and is saturable. Experimental evidence has shown that a plasma concentration of approximately 0.9 μg/mL is the threshold needed for generating an antiparkinsonian effect from levodopa. For many patients, this is achieved from oral ingestion of a levodopa dose of 100 mg combined with a peripherally acting levodopa-decarboxylase inhibitor (either carbidopa or benserazide). The latter decarboxylase inhibitors are equipotent on a per-milligram basis, and there is no advantage of one over the other. Benserazide is not available in the United States. Throughout the day, at least 75 mg of a decarboxylase inhibitor needs to be coadministered with levodopa for sufficient enzyme inhibition so that enough of the dopamine precursor will reach the brain for reversing parkinsonian symptoms. Without a decarboxylase inhibitor, several grams of levodopa would be needed daily to achieve optimal antiparkinsonian effect. For some patients, each levodopa dose needs to consist of quantities larger than 100 mg per dose to achieve full relief of parkinsonism. Occasionally, larger daily intake of the decarboxylase inhibitor is beneficial (and in the United States, carbidopa is available by itself).

A typical regimen of immediate-release carbidopa-levodopa 25 to 100 mg (or benserazide-levodopa) is taken 3 times per day (typically at 4- to 5-h intervals). The rationale for this regimen is the approximately 2.5- to 3-hour plasma clearance half-life of immediate-release levodopa which, for some patients, correlates with duration of its clinical effect. Although plasma concentration of levodopa are not monitored in clinical practice, a prescriber can assume that most patients will achieve a therapeutic (suprathreshold) levodopa effect with an intake of no more than 200 mg. Sustained-release carbidopa-levodopa formulations are designed to emit their contents slowly. Available formulations each offer less uptake from the gut (reduced bioavailability) than the immediate-release product, for which levodopa uptake is close to 100%.

Levodopa plus a decarboxylase inhibitor can be taken without food. Some patients recognize a delay in onset of levodopa effect when this medication is ingested with a meal. Hence, a plan for dosing 30 minutes before or 1 hour afterward can minimize drug uptake competition from meals. Another factor that can interfere with full absorption of a levodopa dose is the simultaneous intake of protein or other sources of amino acids. The proximal small intestine is where most L-large neutral amino acids are absorbed, and its facilitated transport mechanism has saturable kinetics. Hypothetically, dietary amino acids could compete with levodopa uptake to the extent that antiparkinsonian

effect is reduced. Some patients notice diminished effect when levodopa is dosed during a meal and attribute this result to the meal's protein content. However, most patients don't experience such an interaction. Patients can easily test whether protein restriction of their morning and midday meals results in improving levodopa responses.

In general, the major factor governing variable medication action with levodopa is irregular drug release from the stomach. Patients need to be instructed that fluid intake with swallowed tablets is necessary for facilitating reliable uptake. Using levodopa in the form of a tablet that melts in the mouth does not enhance uptake because levodopa is absorbed only in the proximal small intestine. The fastest that orally administered immediate-release levodopa reaches a circulating therapeutic concentration is 15 to 20 minutes. Crushing the tablets before swallowing, placing them in a carbonated beverage, or ingesting a warmed beverage, although sometimes advocated, does not lead to improved uptake. A reminder of the irregularity many patients experience with levodopa, even when it is taken on a 3-hour schedule, is summarized by a recent report in which endoscopy revealed an intact carbidopa-levodopa tablet in the stomach 1.5 hours after it was swallowed.

Although a pharmaceutical, levodopa also is an intermediate in the synthetic pathway of dopamine throughout the body. Levodopa is created from phenylalanine, which is subsequently converted to tyrosine. Supplementation with these amino acids, however, is not effective at increase dopamine synthesis. Once it enters the brain, levodopa is rapidly converted to dopamine and temporarily stored in presynaptic nerve terminals before its release or metabolism. Studies in rabbit brain showed that the turnover of dopamine molecules after arrival of levodopa to the brain lasts 15 minutes or less. Hence, the regularity of levodopa delivery is the key factor in maintaining uniform clinical effect for patients experiencing variability in levodopa effects. However, there is somewhat of a mystery involved in its action—the persistence of antiparkinsonian action long after a dose has been cleared from the circulation and passed through the striatum (where there is no storage or sustained release of either levodopa or dopamine).

What permits an enduring effect lasting for several hours (and to a lesser extent, up to 1 or more days later) is an inadequately understood phenomenon termed the *long-duration response* (LDR). The LDR is the basis for the common observation that, when levodopa is first started as a therapy, patients virtually never experience fluctuations in medication effect, even when oral intake is at intervals of 8 hours or longer. Study of the LDR suggests that the improvements of parkinsonian features outlast any possible effects of dopaminergic neurotransmission, implying that the explanation must be a downstream mechanism. The LDR is not specific to levodopa therapy because it has been detected with the use of the dopaminergic agonist, apomorphine. The loss of the LDR—which is when patients begin to experience dose-by-dose effects of immediate-release levodopa—leads to the *short-duration response* (SDR). The SDR is a milestone of levodopa therapeutics that, after 2 of more years of continued therapy, affects up to one-half or more of PD patients. For patients with SDR, this transition makes constancy of levodopa delivery to the brain critical for maintaining control of parkinsonism. At this point of a PD patient's "career" with levodopa, overlapping doses of medication and the use of adjunctive drugs become necessary for managing dose-by-dose fluctuations.

Improving on pharmacokinetic limitations of oral levodopa intake has been the theme of pharmaceutical development for many years. The concept of achieving continuous dopaminergic stimulation by enteral infusion of a carbidopa-levodopa microsuspension (also known as *levodopa-carbidopa intestinal gel*), is one product available in the United States. Its levodopa concentration is 20 mg/mL. Levodopa-carbidopa intestinal gel requires the insertion of an infusion tube through the abdominal wall into the stomach and passed beyond the pylorus to the duodenum or jejunum. The rate of infusing the microsuspension is adjusted for optimizing control of motor fluctuations. Less invasive approaches to gain better levodopa constancy has been the goal of several sustained-release carbidopa (and benserazide)-levodopa products. However, the performance of several marketed forms has been less than satisfactory at abolishing motor fluctuations. Currently, under investigation is subcutaneous administration of a solubilized carbidopa-levodopa formulation in order to achieve continuous infusion. As mentioned above, the problem of delayed or minimal onset of levodopa effect can be a consequence of ingested levodopa remaining in the stomach. A novel way to achieve rapid and reliable onset of levodopa effect has been created for on-demand use by patients experiencing the wearing off of levodopa effect. This product uses levodopa as a micropowder, which is inhaled in a fixed dose for an onset of effect that can be as short as 10 minutes later.

Levodopa-Induced Dyskinesias

Involuntary movements (dyskinesias) are an enduring pharmacologic consequence of chronic levodopa therapy. Their phenomenology comprises features of chorea, ballism, and dystonia, sometimes combining these categories of movement disorders. Dyskinesias emerge for up to one-third of levodopa-treated patients after 3 or more years of treatment, although these involuntary movements can be absent even after 10 or more years of levodopa use. Dyskinesias range in severity and are sometimes mild enough to be unnoticed by the patient. More severe forms can be disabling and limiting as to how much levodopa can be used. The incidence and severity of dyskinesias often increase as a function of duration and dosage of levodopa therapy. Sometimes they emerge early on, especially in young-onset PD and in those patients with severe clinical features of parkinsonism. The phenomenology of dyskinesias can be categorized according to the timing of levodopa dosing:

- Peak-effect dyskinesias, occurring simultaneous with timing of maximal relief of parkinsonian symptoms (typically, 30 min to 2 h after a dose of immediate-release levodopa).
- Diphasic dyskinesias, which begin to occur within 20 minutes after immediate-release levodopa is ingested and are absent during the peak-effect period. Curiously, dyskinetic movements again reemerge later at the end of the dosing cycle. Sometimes, the diphasic dyskinesia pattern is experienced by the patient only at the end of the dose effect when its occurrence can blend into the emergence of tremor or dystonia during "off" state (see ▷ Video 86.4).
- "Off" dystonia, characterized by painful, sustained cramps and occurring during undermedicated states. Initially, "off" dystonia may occur just after awakening in the morning ("early-morning dystonia"). It can be experiencing as painful foot cramps that are typically relieved by the first dose of levodopa and may be prevented by overnight use of a dopaminergic agonist.

Dyskinesias often keep company with wearing off motor fluctuations. In some patients, the levodopa cycle may change rapidly from severe peak-effect dyskinesias to severe "off" states; this process has been termed *yo-yoing*. During a levodopa cycle, such patients may experience only a brief "on" state. This situation has been described conceptually as a "narrow therapeutic window," although pharmacologic proof for such a phenomenon is lacking. Patients with yo-yoing can have prolonged periods of good antiparkinsonian control without any occurrence of dyskinesia or dystonia; however, the variability in drug effect (which is governed largely by the peripheral pharmacokinetics of levodopa) can result in a chaotic and disabling pattern of involuntary movements and "off" states.

Pharmacologic management of dyskinesias can be challenging because the balance between optimal control of parkinsonism and the side effect may be difficult to achieve consistently. It often requires a complicated medication regimen, with varying levodopa doses and timing between oral intakes as short as 2 hours. Risk factors for levodopa-induced dyskinesias have not been well defined. Among recognized contributions to the development of dyskinesias are certain dopamine D_2 receptor polymorphisms and younger age of PD onset. Why all patients don't develop dyskinesias is somewhat of a mystery because virtually all nonhuman primates rendered parkinsonian with the neurotoxin MPTP will develop involuntary movements after relatively short period of continued levodopa administration. Experience with animal models of parkinsonism have highlighted a possible role for pulsatile dopaminergic stimulation as a key factor in the generation of dyskinesias (which, once initiated, persist). The prevention of levodopa-induced dyskinesias has been a challenge to researchers and clinicians alike. Avoiding any use of levodopa should be successful but this comes with the price of depriving patients from the most effective means for controlling parkinsonism. Using sustained-release preparations of levodopa has been proposed to lessen the risks, based on the notion that reduced pulsatile dopaminergic stimulation of the striatum might be beneficial. However, randomized controlled studies testing this hypothesis with comparison to immediate-release (and, hence, more pulsatile) levodopa formulations did not find that dyskinesias were avoided or were less frequent.

Limiting daily levodopa intake (by an arbitrarily defined maximal dose) does not appear to reduce risk for dyskinesias. Researching the question of dyskinesia avoidance can be problematic because a patient receiving a low-dose levodopa regimen and not manifesting dyskinesias might nonetheless have initiated the mechanism for involuntary movements, but these are never observed if the levodopa regimen is insufficient for unmasking the latent dyskinesias. Monotherapy with a dopaminergic agonist or coadministration with levodopa has also been posited as a means for avoiding the development of involuntary movements. However, a randomized controlled clinical trial showed that this strategy did not achieve its intended goal.

Levodopa and Adjunctive Therapies

Practical considerations in managing PD include the notion of tailoring therapy to a patient's needs and giving a thorough explanation for the treatment choices. Although polypharmacy might seem to be undesirable strategy (especially given the effectiveness of levodopa alone), combining levodopa with extension strategies (such as MAO-B and COMT inhibitors) can achieve a dosing schedule more convenient than the 2- to 3-hour intervals needed in patients experiencing the SDR and using immediate-release carbidopa-levodopa LEVEL 2.[1-5] Control of tremors may require adding an anticholinergic drug or amantadine to a levodopa regimen. The symptomatic benefit of a dopaminergic agonist combined with levodopa can be an extended relief of parkinsonian symptoms and improved control of dystonic symptoms. Maintaining independent functionality for as long as possible can require adjustment of medication to reflect new problems such as the onset of levodopa-induced dyskinesias, for which amantadine can be helpful as well as levodopa reduction to lower its peak concentrations.

Most patients do not need to use DBS to accomplish optimal control of parkinsonism. However, for those whose quality of life can be greatly improved by this procedure, it is important for clinicians to offer a balanced viewpoint on the benefits and of this intervention so that it can be realistically appraised. The physician treating PD should also be a strong advocate for regular exercise because there is compelling evidence of its impact on improved symptomatic control and quality of life LEVEL 1.[2,6,7] In some instances, referral to physical therapy may guide patients toward more independence and safer ambulation LEVEL 2.[8] A widely available physical therapy program targeted at the problems of PD goes by the name of Lee Silverman Voice Therapy (LSVT)–BIG. This program, developed by the same organization that also created PD-specific speech therapy, has further information available at www.lsvtglobal.com.

In the past, options for starting symptomatic treatment were regarded as a topic of controversy, the modern (and evidence-based) view is that there is no threat from starting medication even when symptoms are relatively mild. Even the earliest symptoms such as a mild tremor or facial impassiveness can have an impact on a patient's livelihood, social interactions, and other indicators for quality of life. Hence, it is important to recognize that a decision to withhold treatment may come with a price for the patient.

Concerns that levodopa might hasten dropout of dopaminergic neurons have been countered by the results of two randomized controlled trials, the 2004 ELLDOPA (see Fig. 86.2) and a delayed-start study of carbidopa-levodopa (published in 2019 by Verschuur and colleagues). Each of these studies provides evidence that levodopa treatment doesn't accelerate striatal neuronal loss. The ELLDOPA study provided a suggestion of a dose-related protective effect (see Fig. 86.2).

COMT Inhibitors

Efforts to improve consistent control of parkinsonism with levodopa can become increasingly challenging over time, even in patients for whom the underlying disease has not progressed. The waning of the LDR over the first 3 to 5 years after the start of levodopa therapy has inspired a search for other options to improve medication effectiveness. One way to extend the duration of levodopa effect is to block its metabolism to an inactive metabolite, 3-O-methyldopa, in the periphery. Much as the decarboxylase inhibitors block diversion of circulating levodopa to form dopamine, inhibitors of catecholamine-O-methyltransferase (COMT) can lessen the conversion of levodopa to 3-O-methyldopa. Three drugs in clinical use—entacapone, tolcapone, and opicapone—are reversible COMT inhibitors whose action extend the therapeutic plasma concentration of orally administered levodopa. The net result of adjunctive use of COMT inhibitors is approximately one-third extension of daily "on" time in patients experiencing wearing off with an immediate-release formulation of levodopa LEVEL 1.[5] The three COMT inhibitors differ in their dosing schedule; entacapone is given at 4-hour

intervals, whereas opicapone is administered once daily. Tolcapone is marketed as a 3-times-a-day medication. Unlike the others, tolcapone has been associated with extremely rare cases of hepatic failure, and so, monitoring of liver enzymes is recommended for prescribers. Although opicapone and entacapone are entirely peripheral in their COMT inhibitory actions, tolcapone has limited penetration across the blood-brain barrier and so might confer some of its antiparkinsonian action by retarding degradation of dopamine in the brain.

MAO-B Inhibitors

Another means for extending levodopa effect for the PD patient with motor fluctuations is through MAO inhibitors that are selective for the type B isoform (MAO-B). MAO-B provides one of the enzymatic pathways in the brain by which dopamine is degraded (the other pathway uses COMT). The three marketed MAO-B inhibitors—selegiline, rasagiline, and safinamide—act by retarding the catabolism of dopamine so that each neurotransmitter molecule remains for longer in the synapse. The net clinical result is like improvements gained from COMT inhibitors: approximately one-third more daily "on" time for patients experiencing wearing off between doses LEVEL 1.[1-5] MAO-B inhibitors used as a monotherapy also confer a small antiparkinsonian effect. They do so by amplifying dopaminergic neurotransmission in patients with relatively mild PD. Although clinically measurable, the clinical benefits of MAO-B inhibition are much less than levodopa would accomplish in the same patient. For this reason, there is little rationale for using MAO-B inhibitors as initial treatment. However, many clinicians do so, presumably with an unproven notion that "sparing" the use of levodopa achieves some useful purpose. Both selegiline and rasagiline have been studied in large-scale randomized controlled clinical trials testing a hypothesis that they might exert disease modification. The hypothetical mechanism of what MAO-B inhibition might achieve is diminished generation of free radicals produced by dopamine catabolism. Neither drug provided proof for achieving neuroprotection as a monotherapy in hundreds of newly diagnosed PD patients. However, there is a persisting perception of disease-modifying efficacy held by some clinicians, and so, MAO-B inhibitors continue to be prescribed as a first-line or an adjunctive treatment.

Amantadine

A serendipitous discovery in the late 1960s brought an antiviral drug, amantadine, into the PD armamentarium. For some patients, it has been the most effective treatment for tremor (even in patients for whom dopaminergic or anticholinergic drugs have failed). Subsequently, amantadine was found to be highly effective in some patients for suppression of levodopa-induced involuntary movements. This indication has recently become more established with the United States launch of a sustained-release amantadine formulation. Amantadine has also been found to extend the duration of action of levodopa in patients experiencing wearing off between doses LEVEL 1.[1-3]

The pharmacology of amantadine still has unanswered questions as to how it acts to achieve antiparkinsonian effects. For suppression of dyskinesias, evidence supports blockade at *N*-methyl-D-aspartate glutamate receptors. Amantadine also has anticholinergic properties, although this property is unlikely to explain its tremor suppression. Amantadine is particularly useful as an adjunct to dopaminergic therapy. It can also be used as a monotherapy for tremorous patients not needing additional antiparkinsonian effects.

Amantadine in its generic immediate-release form is typically dosed as 100 mg 2 to 4 times per day. The two sustained-release products in the United States are designed to deliver quantities like the immediate-release formulations. Amantadine is excreted largely unchanged, and so, its renal clearance needs consideration in patients with compromised kidney function is compromised. The drug's clinical benefits suggest that dosing at 4- to 6-hour intervals is optimal.

Adverse effects with amantadine include dryness of the mouth and eyes, and an increased tendency toward constipation. It can be sedating and can cause vivid dreaming and hallucinations. Some patients experience bilateral ankle swelling. A distinctive change in the appearance of the skin, livedo reticularis, develops in some patients treated with amantadine. This asymptomatic change in the skin is not an allergic reaction or reason to discontinue the drug except based on its cosmetic implications. Livedo reticularis (which can have other causes as well) is a prominent reddened and reticular mottling due to prominence of capillary fields. It especially evident in the skin surfaces distally in the legs and in the volar forearm skin.

Anticholinergic (Antimuscarinic) Drugs

Anticholinergic drugs were the first effective medications used for PD, preceding the levodopa era by several decades. However, they do not offer the range of benefits offered by levodopa, particularly for slowed movement and decreased dexterity. Anticholinergics act to lessen resting tremor and dystonic features of PD. The role of cholinergic neurotransmission in generating parkinsonian symptomatology is not well understood. For example, administration of centrally acting acetylcholinesterase inhibitors for cognitive impairment only rarely leads to exacerbation of motor impairments in PD. The effectiveness of anticholinergic drugs for resting tremor can be quite substantial, even in patients not showing response to dopaminergic therapy or amantadine.

Currently in the United States, only two anticholinergic drugs are marked for PD: trihexyphenidyl and benztropine. Another useful antitremor drug and available elsewhere is a phenothiazine-class drug, ethopropazine (used in a dose range of 25-50 mg 3 times a day). The central nervous system actions of anticholinergic drugs may be targeted at circuitry of striatal cholinergic interneurons, although the specific pharmacology of anticholinergics drugs hasn't undergone much investigation in the modern pharmacology era. Despite concerns about their tolerability and the limited range of parkinsonian symptoms that they can control, anticholinergic drugs are useful for augmenting dopaminergic therapy and amantadine.

With trihexyphenidyl 2-mg tablets, a common starting dose is one-half or one tablet, taken 3 times daily at 4- to 6-hour intervals. If showing efficacy, a few patients will benefit from and tolerate higher doses, increasing to as much as 15 mg/d. Benztropine has a greater per-milligram potency of antiparkinsonian effect (about 4 times greater than trihexyphenidyl) and so, typical dosing ranges from 0.5 to 2 mg 3 times a day. The doses of trihexyphenidyl and benztropine used in PD are the same as those that can be effective for treating both resting tremor and rigidity in parkinsonism induced by dopamine receptor blocking drugs. Anticholinergic drugs do not benefit all types of tremor such as ET and cerebellar outflow tremor.

Adverse effects from anticholinergic drugs are common, particularly in older patients. The central actions of the drug can interfere with short-term recall and other effects on cognition and the mind can include drowsiness, "fogginess" of thinking, and prominent hallucinations, or other psychotic manifestations (such as extreme suspiciousness). The peripheral side effects of anticholinergic drugs can be bothersome, especially when constipation, urinary retention (particularly in males), and dry mouth are experienced. Some guidelines advocate not using anticholinergics in elderly patients, but with cautious advance of a low starting dose, some patients with advanced age can both tolerate and benefit from the unique antitremor effect these drugs can confer. Other drugs with anticholinergic properties, such as amitriptyline, diphenhydramine, clozapine, and cyclobenzaprine, can also help in tremor suppression, and their sedative profile can make them useful choices for a PD patient bothered by tremor interfering with sleep.

For the frequently occurring peripheral side effects (often, the reason for discontinuing or limiting the dosage of anticholinergic drugs), there are some pharmacologic strategies to manage side effects: Pilocarpine eye drops can overcome dilated pupils leading to blurred vision. Pyridostigmine (up to 60 mg 3 times per day) can help to overcome dry mouth, urinary retention, and constipation.

Dopaminergic Agonists

Drugs that mimic the actions of dopamine had their first use in 1951, when a few patients briefly treated with apomorphine provided evidence that this drug could offer relief for parkinsonian symptoms. At the time, apomorphine dopaminergic properties were unknown, and discovery of dopamine's role in PD was still a few years away. The next phase of this story, reported in 1967, was the use of a dopaminergic compound related to apomorphine, N-propylaporphine, for relief of parkinsonism. Adverse effects limited further development of this drug. An orally administered semisynthetic ergot compound, bromocriptine, entered clinical practice for PD in 1974 as a potential alternative to levodopa. In addition, when used as an adjunctive therapy, bromocriptine offered improvement over maximal responses achievable with levodopa. The success of bromocriptine set off a search for other dopaminergic compounds that might provide improved potency, selectivity of effect, and better pharmacokinetic properties than levodopa.

Since 1974, more than two dozen dopaminergic agonists were developed and tested in clinical trials for antiparkinsonian effects. Due to similar effectiveness with most of these compounds, only a few went on to marketing. One of these, the ergoline pergolide, was withdrawn when it was determined that it conferred a risk for the development of heart valve fibrosis. Similar problems have been associated with the use of another ergoline, cabergoline. As risk for developing fibrosis affecting pleura, pericardium, and elsewhere was demonstrated for bromocriptine, fibrotic disorders appear to be an idiosyncratic outcome from chronic therapy with ergot-derived compounds. For this reason, compounds with different chemical structures now are the mainstay of dopaminergic agonist therapy, and fibrotic disorders haven't been reported with them.

Currently in the United States, pramipexole and ropinirole are available for treating PD as orally administered drugs. Another dopaminergic agonist, rotigotine, is administered by means of a transdermal patch. Each is for chronic use as monotherapy or combined with other PD medication. Although their pharmacologic properties differ somewhat, each is a potent dopaminergic agonist at D_2/D_3 dopamine receptor sites, which are abundant in the striatum. The per-milligram potency of pramipexole is approximately 4 to 5 times greater than that of ropinirole and rotigotine (which are approximately 1:1). Although these drugs can differ in their side effect profile, their overall antiparkinsonian effectiveness is similar. Overnight switch among them is possible because of cross-tolerance mechanisms for dopaminergic side effects. Although both ropinirole and pramipexole are marketed in sustained-release forms for once-daily administration, the immediate-release forms exert long durations of effect, as shown by several days required for washout of their clinical actions. While transdermal administration of rotigotine might seem to be a better way to achieve more continuous control of parkinsonism than the oral dopaminergic agonists, there isn't evidence in support.

The usual dosing schedule for both ropinirole and pramipexole is 3 times per day at intervals of 4 to 5 hours during the day. Rotigotine patches are applied once daily. The maximal daily dose of pramipexole is 6 mg/d (although patients rarely build up to that dose because of adverse effects or lack of further efficacy). Results from a dose-finding trial found that no further antiparkinsonian effect with daily intake greater than 1.5 mg. For ropinirole, the optimal dose range for ropinirole is much wider, and the drug can be prescribed up to 24 mg/d. One large-scale randomized clinical trial found that optimal daily dose averaged 15.5 mg/d. Rotigotine is typically used from 4-12 mg per day.

Apomorphine is available in the United States and elsewhere for intermittent subcutaneous administration when a patient determines that an "off" state needs reversal, often within 10 minutes. Doses of apomorphine for this purpose range from 2 to 6 mg, and injections can be used several times per day. Recently, a sublingual formulation of apomorphine has been approved in the U.S. Elsewhere in the world, apomorphine is also available for used as a subcutaneous infusion by a miniature pump in order to maintain continuous dopaminergic stimulation throughout the day and, in exceptional circumstances, throughout the night as well.

The place in therapy for dopaminergic agonists has evolved over the past three decades because clinical trials were conducted to learn if better outcomes could be achieved than with levodopa alone. Each of the marketed dopaminergic agonists can be used as monotherapy. Even with buildup to maximally tolerated doses, they lack the overall effectiveness of levodopa. For example, a long-term randomized clinical trial of ropinirole as monotherapy found that, starting in the second year, patients increasingly chose to augment this dopaminergic agonist with levodopa so that by the end of the study, only a small number successfully remained on ropinirole alone.

Dopaminergic agonists confer several adverse effects, including the risk of daytime sedation. Although drowsiness can be lessened by the slow buildup of dose, this side effect drowsiness is a dose-limiting effect for many patients. Other problems associated with each of the agonists can be lowering of blood pressure and ankle swelling. Dopaminergic agonists have a greater chance than levodopa for inducing hallucinations, particularly among elderly patients or those who have cognitive impairment. Vivid dreaming throughout the night can also accompany the start of a dopaminergic agonist.

Beyond the realm of adverse effects described above is another class of adverse effects for dopaminergic agonists that have been termed *impulse control disorders* (ICDs). Surveys have shown that up to 17% of patients treated with dopaminergic agonists at any dose can experience some form of ICDs (even those receiving these drugs for restless leg syndrome). ICDs are idiosyncratic

problems, without identified risk factors. Patients developing ICDs can take on one or more dysfunctional psychosocial behaviors, such as uncontrolled gambling, hypersexual acting out, binge eating, compulsive shopping, excessive hobby activities, and even unwarranted generosity. The consequences of an ICD can be devastating to the patient and family.

The risk for an ICD should be made known to patients and their families because this disorder can emerge at any time following the start of a dopaminergic agonist. Reduction in drug dose can sometimes help to improve the situation, but discontinuation may be the safest management strategy. Fortunately, ICDs usually are relatively rapidly reversible, and they do not persist when patients return to levodopa therapy alone. Abruptly, stopping a dopaminergic agonist poses the risk for a syndrome of withdrawal that can be avoided by slower reduction of this medication. The dopaminergic agonist withdrawal syndrome is a cluster of symptoms that can involve anxiety, irritability, other types of psychological distress, and various autonomic symptoms (nausea and vomiting, hypotension, flushing, and diaphoresis). There also can be a craving for return to use of the dopaminergic agonist in this syndrome, which can last for weeks to months.

Dopaminergic drugs can lead to other behavioral consequences. Punding (also known as *utilization behavior*) is a rare, idiosyncratic disorder with some resemblance to ICDs. This disorder, which has been described in amphetamine abusers, refers to intense repetitive handling and examining of objects, such as picking at oneself, taking apart devices, or continued sorting and arranging of commonplace objects. Punding behaviors have been reported in PD patients receiving levodopa or dopaminergic agonists. The only treatment is to discontinue the dopaminergic drug.

Adenosine A_{2A} Antagonists

A new class of drugs has joined the other nondopaminergic options for treating PD. Istradefylline, a highly selective antagonist of the adenosine A_{2A} receptor, has been recently approved for treatment of "off" episodes. Istradefylline is now marketed in the United States after several years of use in Japan. Studies with daily intake at 20 or 40 mg showed that levodopa-treated patients experiencing motor fluctuations had a reduction in daily "off" time. This clinical improvement was observed in patients who were receiving maximal treatment with dopaminergic therapies, including agonists and inhibitors of MAO-B and COMT. Istradefylline has a benign adverse action profile, the main side effect being a small increase in dyskinesias for some patients. The site of action for istradefylline is inhibition of adenosine type A_{2A} receptors that are selectively found in the indirect striatal outflow pathway.

TREATING THE NONMOTOR PROBLEMS OF PARKINSON DISEASE

Nonmotor features often arise concurrent with the development of tremor, slowed movements, and decreased dexterity. Some of these features, such as impaired sense of smell and REM sleep behavioral disorder, can precede the onset of motor features by several years and suggest earlier central nervous system involvement at sites beyond the nigrostriatal pathway. Collectively, nonmotor features may have the greatest impact on declining quality of life in PD 5 to 10 years after onset and beyond. Of course, the aging process is superimposed on the progression of PD, confounding the assessment of various changes in features such as ease of swallowing, balance, and voice dynamics. However, the challenge for the caring physician is to recognize and use available therapeutic interventions for treatable nonmotor problems.

Mental and Behavioral Complications

Although PD patients can develop cognitive decline due to progressive neuronal loss, the effects of medication can also be a cause (or can add to the problem). Like dopaminergic drugs, amantadine and anticholinergics can be the culprits. The range of problems can be sedation, confusion, agitation, vivid dreams, hallucinations, or paranoid thinking. The brain locations from which these problems arise are not known for dopaminergic drugs. Activation of dopamine receptors in nonstriatal regions (cortical and limbic structures) are likely sources, based on pharmacologic evidence of lowering dose or using dopamine receptor blocking drugs. Dose and potency of dopaminergic stimulation is a factor in this problem, as shown by the good tolerability of conventional levodopa doses in patients developing toxic mental side effects with even low doses of the much more potent dopaminergic agonists. On this basis, elderly PD patients are often suspected to be unable to tolerate the adjunctive use of dopaminergic agonists. However, published experience argues otherwise. In general, all PD patients (regardless of age or duration of disease) can develop dose-related psychosis from excessive intake of levodopa or dopaminergic agonists, amantadine, or anticholinergics. Because some patients experience delayed or incomplete emptying of orally administered medications from the stomach, sometimes an episode of confusion or hallucination can arise from an apparent overdosage of medication even when a patient is receiving a conventional regimen.

As in primary psychotic disorder like schizophrenia, hallucinations and other psychotic phenomena in PD patients can be lessened or completely blocked by medications targeting dopaminergic D_2 receptors in the brain. All members of the latter class of psychiatric drugs can be used for this purpose; however, they carry the risk of simultaneously diminishing striatal dopaminergic neurotransmission (and thereby worsening control of parkinsonism). Two antipsychotic drugs that can control hallucinations without exacerbating parkinsonism are clozapine and quetiapine (both dosed 12.5-50 mg/d and, occasionally, at larger doses) LEVEL 3.[8,9] The specific pharmacologic properties of these drugs making them useful in PD has not been defined, and they don't provide benefit for all patients. Clozapine is the more potent of the two, and it also uniquely has an antitremor action. The main drawback of clozapine is its rare risk of causing agranulocytosis. For this reason, regular blood testing (weekly for the first 6 months and at less frequent intervals thereafter) is mandatory for safe use of clozapine. Another option for treating psychotic symptoms in PD patients is pimavanserin. This drug does not block dopamine receptors but, instead, is a selective inverse agonist and antagonist selectively of serotonin 5-HT_{2A} receptors; it also has a low affinity interaction with 5-HT_{2C} receptors. Used at a standard once-daily dose of 34 mg/d, pimavanserin has been safe and effective at controlling hallucinations without exacerbating motor features of parkinsonism. There haven't been head-on comparisons between pimavanserin and the other antipsychotic treatment options. However, most clinical experience suggests that the effectiveness of pimavanserin differs from the others and may be complementary.

When a patient experiences develop the new onset of hallucination, agitation, or a confusional state, clinicians should keep in mind the possibility that other exacerbating factors may be

the cause. These include a low-grade infection (urinary tract or respiratory), dehydration, and adverse effects of other medications (such as urinary tract antispasmodics with anticholinergic properties). The onset of a progressive dementia can also cause episodic cognitive and behavioral symptoms. Supportive measures against "sundowning" (such as lights or soft music left on in the bedroom at night) can help. Lowering doses of medication and reassessing the continuing need for any adjunctive drugs besides levodopa can also help in the management of hallucinations and agitation. The reduction of dopaminergic agonists should be done gradually to avoid the possibility of causing the dopaminergic agonist withdrawal syndrome.

In the realm of disabling nonmotor features, none has as profound an impact as cognitive decline. Apart from the common problem of AD in persons of the same age range, impaired cognition can be encountered in PD patients due to intraneuronal aggregated αSyn. Like the β-amyloid burdened cortical and subcortical neurons in the AD brain, the pathology of cognitive decline in PD patients is extensive formation of Lewy bodies in brain regions linked to cognitive processes. Lewy body disease affecting cortical and subcortical structures comprises the second most common pathology associated with progressive cognitive decline. Lewy body pathology can coexist with AD. The consequences of neuronal dropout can add to the problems of increased sensitivity to medications used to treat PD. The clinician has a few clues that can point specifically to diffuse Lewy body disease pathology as the source of cognitive and behavioral disturbances. Early in the process (and sometimes unassociated with medications capable of causing hallucinations), hallucinatory phenomena, paranoid thinking, and failure of executive task completion (adequate decision making) may be evident. Although similar problems can occur in AD, their incidence seems to be increased in Lewy body disease.

If dementia develops in a PD patient, the goals of maintaining independent functionality can be challenging. Making the distinction between Lewy body and AD pathology isn't necessary for therapeutic decisions. A trial of an acetylcholinesterase inhibitor is generally the first choice LEVEL 2.[8-10] Drugs in this class include rivastigmine (1.5-6 mg/d), donepezil 5 to 10 mg/d, and galantamine (4-24 mg/d). Another drug that has shown effectiveness for symptomatic improvement of impaired cognition is memantine (5-20 mg/d). The combination of memantine with an acetylcholinesterase inhibitor may provide further benefit. Usually, clinical improvements are evident within a month of initiating these drugs (which offer only symptomatic benefits, not arrest in disease progression).

Developing depression is at increased risk for the PD patient. The same antidepressant medications effective in the general population can be used (except for nonselective MAO inhibitors). Selective serotonin uptake inhibitors are often chosen for this problem. However, a randomized, controlled clinical studies investigating treatment of depression in PD compared paroxetine with nortriptyline; the latter drug proved to be more efficacious.

Alprazolam, diazepam, and other benzodiazepines are usually well tolerated for treating anxiety. They can also help to lessen tremor by reducing reactions to stress that exacerbate tremor. The clinician should be alert to the occasional paradoxical excitation and agitation that benzodiazepines can cause, particularly in the elderly with dementia. Fragmented sleep, a common complaint of PD patients, can lead to daytime drowsiness. The clinician should attempt to differentiate PD-related causes for sleep disruption from those that can affect the general population (such as obstructive sleep apnea, restless leg syndrome, and nocturia). Many PD patients report frequent occurrence of vivid dreaming. Often, this is associated with changes in sleep architecture that can be identified on polysomnography (or from reports of the patient or bed partner) as REM sleep behavior disorder. There are only a few treatment options and include evening dosing with melatonin (4-6 mg) and clonazepam (0.5-1 mg). Unfortunately, not all patients respond adequately. REM sleep behavior disorder should be distinguished from nighttime hallucinations because the treatment options differ.

Hallucinations can seem to be a continuum from vivid dreaming. Sometimes, nightmare content is reported. For this condition, drugs with antipsychotic properties such as quetiapine, clozapine, and pimavanserin can be used (see descriptions and dosing considerations above). For excessive daytime drowsiness, the treatment options include morning dosing with sustained-release caffeine tablets or modafinil (100-200 mg). Reducing intake of daytime medications causing drowsiness (especially dopaminergic agonists and amantadine) can also be helpful.

Other Non-Motor Symptoms

Other nonmotor features associated with PD can develop with more advanced stages of the disorder. Orthostatic hypotension leading to postural faintness can be related to dopaminergic drugs; if so, changing the dosing regimen can help. Other measures include ensuring adequate daily intake of water and salt (the latter can be achieved by encouraging daily intake of a high-sodium food such as bouillon). Elevating the bedframe at the head of the bed can lessen overnight diuresis and blood pressure drop upon arising in the morning. Specific treatments for postural blood pressure drop include midodrine (5-10 mg 3 times a day) and droxidopa (100-200 mg 3 times a day). For the latter drug, limiting the daily intake of carbidopa may be necessary for obtaining maximal benefit. Avoidance of supine hypertension is a necessary component of treating postural hypotension.

Sialorrhea can be both an annoyance in PD. It is attributable due to a decreased rate of spontaneous swallowing (not excessive saliva secretion). A peripherally acting anticholinergic drug such as glycopyrrolate can be effective both when ingested orally or swished around the mouth in a small volume of water. If this option is ineffective, bilateral injection of botulinum toxin into salivary glands is often beneficial, lasting 3 months or more.

SURGICAL THERAPY

In PD therapeutics, functional neurosurgery is defined as the targeted use of lesioning or electrical stimulation to achieve improvements in tremors, dyskinesias, "off" times, and overall parkinsonian symptomatology LEVEL 3.[6,7] In general, functional neurosurgery is used for achieving goals that can't be achieved through medications (although PD drugs are generally continued). Stereotaxic lesioning of a region of the thalamus for tremor control—the ventrointermedius (Vim) nucleus—preceded the development of levodopa. Subsequently, with better understanding of basal ganglia motor circuitry, an ablative lesion in the GPi was determined to be a site for improvements in features of PD beyond tremor. For the past two decades, functional neurosurgery has shifted from lesioning to localized electrical stimulation with a methodology termed *DBS*. The "deep" in DBS refers to the

insertion of stimulating electrodes several centimeters from the skull into the target nuclei of the brain, which include the thalamic Vim, the GPi, and the STN. DBS has become an important way for treating PD if medication management has become suboptimal. After widespread international experience in more than 250,000 patients and several technologic advances, DBS has become an established option, although with limitations for what it can accomplish LEVEL 2.[6,7] DBS has capitalized on the discovery in the PD brain of functional roles conferred by "downstream" striatal outflow pathways. By use of high-frequency (60-150 Hz) DBS with 1 to 4 volt pulses, DBS therapeutics has had a major impact on quality of life in advanced PD. The procedure has also gained approval for use earlier during PD, with the notion that later problems of dyskinesias and motor fluctuations might be averted. However, most experienced clinicians use DBS today primarily for the treating problems of resting tremor and levodopa-induced dyskinesias or dystonia. Commonly, these problems can be completely abolished. DBS directed to the GPi is especially likely to provide control of dyskinesias or dystonia LEVEL 2.[6,7] Experienced clinicians at DBS sites generally develop a good idea of whether to use the GPi or STN for controlling other problems of PD, although stimulation at both sites can produce similar results. Although GPi and STN can also result in reduction of tremor for some patients, the best results will come from electrode placement in the Vim thalamus. However, this target poses risk for dysphagia or speech disturbance when carried out bilaterally; hence, a unilateral DBS procedure is sometimes chosen. The choice of DBS for advanced PD needs to keep in mind its limits; certain problems like retropulsive imbalance do not respond. Because electrode placement passes through frontal cerebral cortex, patients chosen for DBS should not have significant cognitive impairment. DBS electrode placement has been quite safe extensive clinical experience. However, it does pose the rare risks for intracerebral hemorrhage during the procedure or localized infection postoperatively.

A recent addition to therapeutic options for PD tremor is unilateral thalamic lesioning by means of focused ultrasound (FUS). Like the older surgical procedure of stereotaxic surgical lesioning of the thalamic Vim nucleus, FUS produces a localized thermolesion. FUS is carried out with an awake patient whose head is surrounded by multiple ultrasound transducers. The methodology of FUS involves ultrasound beams focused to intersect at a precise location within the skull, guided by real-time MRI imaging. Although a U.S. Food and Drug Administration–approved procedure, FUS is currently available at only a few treatment centers in the United States and internationally. Besides FUS, another surgery-free approach uses γ radiation to produce a localized lesion in the thalamic Vim nucleus for tremor control. This technique, termed *Gamma Knife*, has been available for many years. Like FUS, beams of γ rays are positioned around the skull to intersect around the desired thalamic target and using exposure parameters that have been generated by past experience in radiation-induced lesioning. The localized neuronal damage produced by a Gamma Knife procedure generally requires 6 months or longer to evolve and, like other methods of thalamic lesioning, is limited to unilateral use. Although excellent results have been accomplished at experienced centers, the procedure is not always successful at abolishing tremor, and some patients have developed radiation-induced necrosis with neurologic consequences beyond the targeted zone intended for selective lesioning. Most experienced clinicians would not regard Gamma Knife treatment as a first-line treatment for control of parkinsonian tremor.

OUTCOME

PD is often described as a "progressive' disorder, and, indeed, many patients will experience increasing symptomatology and disability over time. However, most PD patients are greatly improved by the various available treatment options and live normal lifespans. In the premedication era, the diagnosis of PD was followed by an expectation of premature death and inevitable loss of independent functioning. Although these stereotypes of PD continue from an earlier era, the PD patient today has very good chances of achieving control of PD motor symptoms.

One component of the image of PD as a progressive, disabling disorder is the subset of parkinsonian patients who turn out to have another diagnosis. The rapidly progressing patient initially might be recognized eventually as suffering from PSP or MSA. These disorders are sometimes recognized only after a period of medication unresponsiveness and the development of additional neurologic deficits. A PD patient affected with imbalance has the special challenge for avoiding falls that pose a risk for orthopedic and head injuries; these problems figure into the most common explanation for why a PD patient might have increased morbidity and occasional fatal outcomes.

Clinicians counseling patients with PD as to their future should always seek the "bright side" of PD. Most patients do well even on a long-term basis. The challenge for promoting this well-justified optimism is by becoming familiar with studies that have followed long-term outcomes of this disorder. Patients with PD should consider themselves as healthy and have a good chance to have a normal life ahead. For most PD patients, medication responsiveness can be counted on for 10 years or more. Patients do not become "immune" to levodopa, in a common myth they might encounter from nonauthoritative sources.

The worsening of consistent symptomatic control, as described above, is generally a problem of drug delivery that often can be improved on. Patients often ask about why PD sometimes appears as a cause of death in obituary listings, and a realistic explanation of why this is usually incorrect can be a comforting discussion to have. Because many PD patients are fortunate enough to have years (if not decades) of continuing symptomatic control, lack of progressive motor disability like imbalance, and avoidance of dementia, counseling should consider such a realistic appraisal. Certain subgroups of PD patients—those with resting tremor or predominantly unilateral presentations—are especially likely to have benign outcomes. It is also important for clinicians to share with patients that much of what is available to read about PD highlights the various problems of PD rather than how benign it can be.

A much-debated point in the treatment of PD is why declining efficacy can occur from continuing treatment with levodopa. End-stage PD can be denoted as an unfortunate state at which response to levodopa is inadequate for independent activities of daily living. Progression of the illness with further loss of dopamine storage sites in the presynaptic terminals is an unlikely explanation for this outcome because loss of these terminals in postencephalitic parkinsonism was reported to result in greater, not lower, sensitivity to levodopa.

Long-term studies have shown that, after 15 or more years, many PD patients encounter some form of disability (whether due to motor or nonmotor problems). The mortality rate at this stage of the illness exceeds that of an age-matched population. Despite very effective medications for the early symptoms of PD, problems of increasing bradykinesia, freezing of gait, postural disturbance, and retropulsive imbalance tend to predominate.

Falls leading to injuries becomes increasingly more common. Dysphagia with choking and aspiration, immobility with development of decubitus ulcers, and marked difficulty in communication capabilities are common events in very advanced PD. Dementia is at increasing risk to develop, along with psychosis, hallucinations, or paranoid ideation. As a result, placement in nursing homes often is necessary. Such a trajectory of the disease over time emphasizes the importance of better understanding the pathogenesis and the need for disease-modifying therapy.

Videos can be found in the companion e-book edition. For a full list of video legends, please see the front matter.

LEVEL 1 EVIDENCE

1. Goetz CG, Koller WC, Poewe W, et al. Management of Parkinson's disease: an evidence-based review. *Mov Disord*. 2002;17(suppl 4):S1-S166.
2. Fox SH, Katzenschlager R, Lim SY, et al; for Movement Disorder Society Evidence-Based Medicine Committee. International Parkinson and Movement Disorder Society evidence-based medicine review: update on treatments for the motor symptoms of Parkinson's disease. *Mov Disord*. 2018;33:1248-1266.
3. Pahwa R, Factor SA, Lyons KE, et al; for Quality Standards Subcommittee of the American Academy of Neurology. Practice parameter: treatment of Parkinson disease with motor fluctuations and dyskinesia (an evidence-based review): report of the Quality Standards Subcommittee of the American Academy of Neurology. *Neurology*. 2006;66:983-995.
4. Talati R, Reinhart K, Baker W, White CM, Coleman CI. Pharmacologic treatment of advanced Parkinson's disease: a meta-analysis of COMT inhibitors and MAO-B inhibitors. *Parkinsonism Relat Disord*. 2009;15:500-505.
5. Binde CD, Tvete IF, Gåsemyr J, Natvig B, Klemp M. A multiple treatment comparison meta-analysis of monoamine oxidase type B inhibitors for Parkinson's disease. *Br J Clin Pharmacol*. 2018;84:1917-1927.
6. Mansouri A, Taslimi S, Badhiwala JH, et al. Deep brain stimulation for Parkinson's disease: meta-analysis of results of randomized trials at varying lengths of follow-up. *J Neurosurg*. 2018;128:1199-1213.
7. Peng L, Fu J, Ming Y, Zeng S, He H, Chen L. The long-term efficacy of STN vs GPi deep brain stimulation for Parkinson disease: a meta-analysis. *Medicine (Baltimore)*. 2018; 97(35):e12153. doi:10.1097/MD.0000000000012153.
8. Uhrbrand A, Stenager E, Pedersen MS, Dalgas U. Parkinson's disease and intensive exercise therapy—a systematic review and meta-analysis of randomized controlled trials. *J Neurol Sci*. 2015;353:9-19
9. Miyasaki JM, Shannon K, Voon V, et al; for Quality Standards Subcommittee of the American Academy of Neurology. Practice parameter: evaluation and treatment of depression, psychosis, and dementia in Parkinson disease (an evidence-based review): report of the Quality Standards Subcommittee of the American Academy of Neurology. *Neurology*. 2006;66:996-1002.
10. Seppi K, Weintraub D, Coelho M, et al. The Movement Disorder Society evidence-based medicine review update: treatments for the non-motor symptoms of Parkinson's disease. *Mov Disord*. 2011;26:S42-S80.
11. Meng YH, Wang PP, Song YX, Wang JH. Cholinesterase inhibitors and memantine for Parkinson's disease dementia and Lewy body dementia: a meta-analysis. *Exp Ther Med*. 2019;17:1611-1624.

SUGGESTED READINGS

Anderson E, Nutt J. The long-duration response to levodopa: phenomenology, potential mechanisms and clinical implications. *Parkinsonism Relat Disord*. 2011;17:587-592.

Berg D, Lang AE, Postuma RB, et al. Changing the research criteria for the diagnosis of Parkinson's disease: obstacles and opportunities. *Lancet Neurol*. 2013;12:514-524.

Connolly BS, Lang AE. Pharmacological treatment of Parkinson disease: a review. *JAMA*. 2014;311:1670-1683.

Del Tredici K, Braak H. Review: sporadic Parkinson's disease: development and distribution of α-synuclein pathology. *Neuropathol Appl Neurobiol*. 2016;42(1):33-50.

Deleu D, Northway MG, Hanssens Y. Clinical pharmacokinetic and pharmacodynamic properties of drugs used in the treatment of Parkinson's disease. *Clin Pharmacokinet*. 2002;41(4):261-309.

Dickson DW. Parkinson's disease and parkinsonism: neuropathology. *Cold Spring Harb Perspect Med*. 2012;2:a009258.

Fahn S, Oakes D, Shoulson I, et al; and Parkinson Study Group. Levodopa and the progression of Parkinson's disease. *N Engl J Med*. 2004;351:2498-2508.

Francardo V, Schmitz Y, Sulzer D, Cenci MA. Neuroprotection and neurorestoration as experimental therapeutics for Parkinson's disease. *Exp Neurol*. 2017;298(pt B):137-147.

Gibb WR, Lees AJ. The relevance of the Lewy body to the pathogenesis of idiopathic Parkinson's disease. *J Neurol Neurosurg Psychiatry*. 1988;51: 745-752.

Goetz CG, Tilley BC, Shaftman SR, et al. Movement Disorder Society-sponsored revision of the Unified Parkinson's Disease Rating Scale (MDS-UPDRS): scale presentation and clinimetric testing results. *Mov Disord*. 2008;23(15): 2129-2170.

Hely MA, Reid WG, Adena MA, Halliday GM, Morris JG. The Sydney multicenter study of Parkinson's disease: the inevitability of dementia at 20 years. *Mov Disord*. 2008;23:837-844.

Holloway RG, Shoulson I, Fahn S, et al. Pramipexole vs levodopa as initial treatment for Parkinson disease: a 4-year randomized controlled trial. *Arch Neurol*. 2004;61:1044-1053.

Hughes AJ, Daniel SE, Kilford L, Lees AJ. Accuracy of clinical diagnosis of idiopathic Parkinson's disease: a clinico-pathological study of 100 cases. *J Neurol Neurosurg Psychiatry*. 1992;55:181-184.

Jankovic J, McDermott M, Carter J, et al. Variable expression of Parkinson's disease: a base-line analysis of the DATATOP cohort. The Parkinson Study Group. *Neurology*. 1990;40:1529-1534.

Kempster PA, Williams DR, Selikhova M, Holton J, Revesz T, Lees AJ. Patterns of levodopa response in Parkinson's disease: a clinico-pathological study. *Brain*. 2007;130:2123-2128.

Khoo TK, Yarnall AJ, Duncan GW, et al. The spectrum of nonmotor symptoms in early Parkinson disease. *Neurology*. 2013;80:276-281.

Kulisevsky J, Oliveira L, Fox SH. Update in therapeutic strategies for Parkinson's disease. *Curr Opin Neurol*. 2018;31(4):439-447.

Latella D, Maggio MG, Maresca G, et al. Impulse control disorders in Parkinson's disease: a systematic review on risk factors and pathophysiology. *J Neurol Sci*. 2019;398:101-106.

LeWitt PA. Levodopa therapy for Parkinson's disease: pharmacokinetics and pharmacodynamics. *Mov Disord*. 2015;30:64-72.

LeWitt PA, Fahn S. Levodopa therapy for Parkinson disease: a look backward and forward. *Neurology*. 2016;86(14 suppl 1):S3-S12.

LeWitt PA, Jenner P. Adenosine A_{2A} receptor antagonism in the treatment paradigm of Parkinson's disease: the WHY and the HOW. *Parkinsonism Relat Disord*. 2020;80(suppl 1):1-64. doi.org/10.1016/j.parkreldis.2020.10.001.

Lunati A, Lesage S, Brice A. The genetic landscape of Parkinson's disease. *Rev Neurol (Paris)*. 2018;174:628-643.

Marek K, Seibyl J, Eberly S, et al; for Parkinson Study Group PRECEPT Investigators. Longitudinal follow-up of SWEDD subjects in the PRECEPT study. *Neurology*. 2014;82:1791-1797.

Martino R, Candundo H, Lieshout PV, et al. Onset and progression factors in Parkinson's disease: a systematic review. *Neurotoxicology*. 2017;61:132-141.

McDonnell MN, Rischbieth B, Schammer TT, Seaforth C, Shaw AJ, Phillips AC. Lee Silverman Voice Treatment (LSVT)-BIG to improve motor function in people with Parkinson's disease: a systematic review and meta-analysis. *Clin Rehabil*. 2018;32:607-618.

Nutt JG, Chung KA, Holford NH. Dyskinesia and the antiparkinsonian response always temporally coincide: a retrospective study. *Neurology*. 2010;74(15): 1191-1197.

Noyce AJ, Bestwick JP, Silveira-Moriyama L, et al. Meta-analysis of early nonmotor features and risk factors for Parkinson disease. *Ann Neurol*. 2012;72:893-901.

Parkinson J. An essay on the shaking palsy. 1817. *J Neuropsychiatry Clin Neurosci*. 2002;14(2):222-236.

Parkinson Study Group. Pramipexole vs levodopa as the initial treatment for Parkinson disease: a randomized controlled trial. Parkinson Study Group. *JAMA*. 2000;284:1931-1938.

Parnetti L, Gaetani L, Eusebi P, et al. CSF and blood biomarkers for Parkinson's disease. *Lancet Neurol*. 2019,18(6):573-586.

Poulopoulos M, Levy OA, Alcalay RN. The neuropathology of genetic Parkinson's disease. *Mov Disord*. 2012;27:831-842.

Pringsheim T, Jette N, Frolkis A, Steeves TDL. The prevalence of Parkinson's disease: a systematic review and meta-analysis. *Mov Disord*. 2014;29:1583-1590.

Schapira AH, McDermott MP, Barone P, et al. Pramipexole in patients with early Parkinson's disease (PROUD): a randomised delayed-start trial. *Lancet Neurol*. 2013;12:747-755.

Schindlbeck KA, Eidelberg D. Network imaging biomarkers: insights and clinical applications in Parkinson's disease. *Lancet Neurol*. 2018;17(7):629-640.

Selikhova M, Williams DR, Kempster PA, et al. A clinico-pathological study of subtypes in Parkinson's disease. *Brain*. 2009;132:2947-2957.

Strafella AP, Bohnen NI, Perlmutter JS, et al. Molecular imaging to track Parkinson's disease and atypical parkinsonism: new imaging frontiers. *Mov Disord*. 2017;32(2):181-192.

Tanner CM, Goldman SM. Epidemiology of Parkinson's disease. *Neurol Clin*. 1996;14:317-335.

Verschuur CVM, Suwijn SR, Boel JA, et al. for LEAP Study Group. Randomized delayed-start trial of levodopa in Parkinson's disease. *N Engl J Med*. 2019;380:315-324.

Whone AL, Watts RL, Stoessl AJ, et al; for REAL-PET Study Group. Slower progression of Parkinson's disease with ropinirole versus levodopa: the REAL-PET study. *Ann Neurol*. 2003;54:93-101.

Zeuner KE, Schäffer E, Hopfner F, Brüggemann N, Berg D. Progress of pharmacological approaches in Parkinson's disease. *Clin Pharmacol Ther*. 2019;105:1106-1120.

Parkinson-Plus Syndromes 87

Paul Greene

KEY POINTS

1. Diseases that include a deficiency in dopamine share clinical features. The most common condition is Parkinson disease. The next most common conditions are progressive supranuclear palsy (PSP), multiple system atrophy (MSA), and corticobasal degeneration (CBD).
2. Some features that predict the pathology of PSP are supranuclear gaze palsy, lack of response to levodopa, early loss of balance, and/or freezing troubled and growling voice.
3. Some features that predict the pathology of MSA are combinations of scanning speech, ataxia and dysmetria, marked autonomic disturbances, and Parkinson features.
4. Some features that predict the pathology of CBD are apraxia, agnosia and cortical myoclonus, unilateral dystonia, and levodopa-unresponsive Parkinsonism.
5. The Parkinson features of PSP, CBD, and MSA usually do not respond to anti-Parkinson medications.
6. Some symptoms of PSP, MSA, and PSP can be treated, such as painful muscle cramps, apraxia of eyelid opening/blepharospasm, constipation, urinary disturbances, and depression.
7. Centrally acting medications that block the dopamine receptor or deplete dopamine can mimic the motor signs and symptoms of Parkinson disease.

INTRODUCTION

Parkinson disease (PD) is the most common cause for a dopamine deficiency syndrome, but other causes for this syndrome had been identified from a small number of pathologic examinations since the early 20th century. It was not until the introduction of levodopa to treat PD in the late 1950s and early 1960s that clinicians began to identify patients who had dopamine deficiency signs but, unlike patients with PD, had minimal or no improvement with levodopa. Because multiple causes for levodopa-unresponsive dopamine deficiency states were soon identified, such patients were said to have parkinsonism or Parkinson-plus syndromes. The three most common Parkinson-plus syndromes are progressive supranuclear palsy (PSP), multiple system atrophy (MSA), and corticobasal degeneration (CBD). In addition to these degenerative conditions, there are a number of other Parkinson-like conditions that also share clinical features with PD.

PARKINSON-PLUS SYNDROMES

Progressive Supranuclear Palsy

History

In 1964, Steele, Richardson, and Olszewski reviewed autopsies of patients who had a syndrome of pseudobulbar palsy, supranuclear ocular palsy (chiefly affecting vertical gaze), axial rigidity and dystonia, early loss of postural reflexes, and dementia. They found a pattern of neuronal degeneration and neurofibrillary tangles (NFTs), chiefly affecting the pons and midbrain. This condition became known as the *Steele-Richardson-Olszewski syndrome* or PSP. As more autopsies became available, it became clear that this characteristic pathology could also produce other patterns of initial symptoms in addition to the originally described disease now called *Richardson syndrome*. In progressive supranuclear palsy-parkinsonism (PSP-P), patients in the early stage of the disease resemble idiopathic PD. However, occasional patients with PSP pathology may also present with corticobasal syndrome (see the following text), progressive nonfluent aphasia (PNFA), akinesia with gait freezing, primarily ataxia, or even pure dementia.

Pathobiology

Atrophy of the dorsal midbrain, globus pallidus, and subthalamic nucleus; depigmentation of the substantia nigra; and mild dilatation of the third and fourth ventricles and aqueduct are seen on gross visual inspection of the postmortem brain in typical PSP. Light microscopy shows neuronal loss with gliosis, numerous NFTs, and neuropil threads in many subcortical structures, including the subthalamic nucleus, pallidum, substantia nigra, locus ceruleus, periaqueductal gray matter, superior colliculi, nucleus basalis, inferior olive, red nucleus, oculomotor nuclei, and cerebral cortex, especially the prefrontal and precentral areas. The NFTs appear as skeins of fine fibrils, often globose in shape in brainstem neurons. Ultrastructurally, they are composed of short, straight 12- to 15-nm tubules arranged in circling and interlacing bundles containing neurofilament proteins and the neurotubule-associated protein tau. In PSP, inclusion of exon 10 of tau creates a predominance of four repeated microtubule-binding domains, compared with a mixture of three and four repeated domains in Alzheimer disease. The typical astrocytic lesion in PSP is the tufted astrocyte, in contrast to the astrocytic lesion in CBD, the astrocytic plaque (see following text). Coiled bodies consisting of NFTs are found in astrocytes in both PSP and CBD (Fig. 87.1).

Symptoms and Signs

Patients with classical PSP or Richardson syndrome have an akinetic rigid Parkinson-like syndrome with early loss of postural

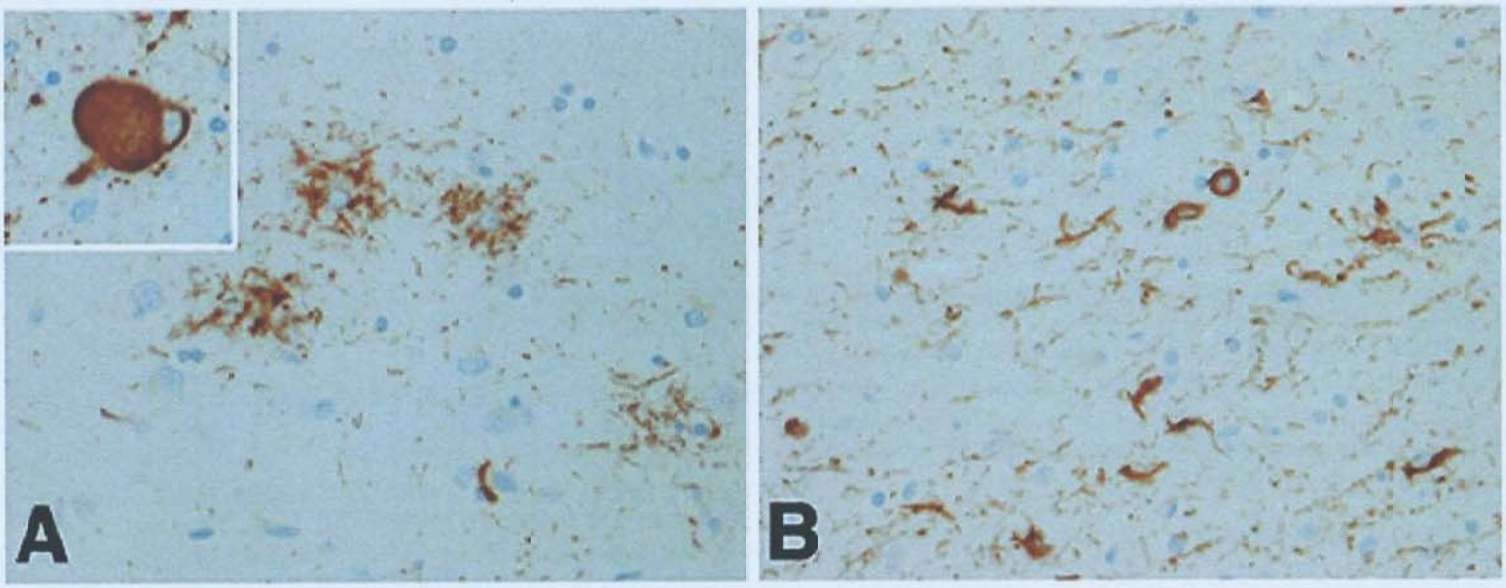

FIGURE 87.1 Pathology of progressive supranuclear palsy. The typical pathologic findings in progressive supranuclear palsy are tufted astrocytes (**A**), globose neurofibrillary tangle (*inset* in **A**), and coiled bodies (**B**). (Modified from Dickson DW. Neuropathology of non-Alzheimer degenerative disorders. *Int J Clin Exp Pathol.* 2009;3:1-23.)

reflexes, falls, and dementia and usually have a supranuclear palsy early in the course. Rest tremor, asymmetric onset, and improvement with levodopa are uncommon. Axial rigidity often exceeds limb rigidity, and the posture may be erect. Patients have facial dystonia with deep nasolabial folds and furrowed brow (Procerus sign), an appearance of surprise or concern. When the patient walks, the neck may be extended and the arms abducted at the shoulders and flexed at the elbows. Dysphagia and dysarthria usually appear early and become severe. The voice is slurred and sometimes hoarse or growling, and some patients become anarthric as the disease progresses. Gait "freezing" may be prominent, and transient arrest of motor activity interrupts walking, speaking, and/or other actions.

The first visual symptoms in Richardson syndrome are failure to maintain eye contact in social interactions and difficulty with tasks requiring downgaze, such as reading, eating, or descending stairs. Hesitation on voluntary downgaze is found on examination accompanied by loss of vertical opticokinetic nystagmus on downward movement of the target. Patients often complain of diplopia, blurred vision, or difficulty reading. Disturbances of eyelid motility are also common, including lid retraction (resulting in a staring expression), blepharospasm, and apraxia of eyelid opening or closing (inability to open or close the eyes to command despite normal strength and normal understanding of the command). Eyelid opening and closing apraxia (which are probably not true apraxia) are far more common in PSP than in any other extrapyramidal disorder. Fixation instability with coarse square-wave jerks and faulty suppression of the vestibulo-ocular reflex are common.

The cognitive impairment of PSP syndromes has been considered the archetype of subcortical dementia. The striking features are severe bradyphrenia (slowed thought), impaired verbal fluency, and difficulty with sequential actions or shifting from one task to another. Cognitive tests that depend on visual performance are especially affected. Apathy and disinhibition are common. Impulsiveness compounds postural instability and often leads to behavior that accentuates fall risk. Emotional incontinence is dominated by inappropriate weeping or, less frequently, laughing.

The course of PSP is aggressive; 3 to 4 years after onset, patients cannot walk without assistance and at a median of 5 years after onset, they are confined to bed and chair. They succumb to infection (from aspiration or pressure ulcers) or the sequelae of falls. The course varies according to the clinical syndrome, but Richardson syndrome has inexorable deterioration, culminating in death in 6 to 10 years in most cases.

In PSP-P, falls, dementia, and supranuclear palsy develop later, and patients are more likely to have an asymmetric onset, rest tremor, and response to levodopa early in the course (although these usually do not persist). In some patients with PSP pathology, depending on the distribution of pathology, language difficulty may precede motor signs, presenting as a dysarthric, slow expressive aphasia (called *primary progressive aphasia* or *progressive nonfluent aphasia*). In a small number of patients, variation in pathology may produce other initial syndromes: freezing and balance difficulty without significant rigidity (akinesia with gait freezing), pure dementia without significant motor deficits, cerebellar syndrome, or corticobasal syndrome (see the following text) (▶ Videos 87.1 and 87.2).

Multiple System Atrophy

History

It was noticed as early as 1900 that some patients with parkinsonian signs had additional signs and symptoms referable to other brain systems: cerebellar dysfunction (called *olivopontocerebellar atrophy* or OPCA) or autonomic dysfunction (termed *Shy-Drager syndrome* or SDS). Another syndrome of rapidly progressive parkinsonism with neuronal loss and gliosis primarily in the putamen and substantia nigra but no Lewy bodies on autopsy was termed *striatonigral degeneration* (SND). It was eventually noticed that some patients had elements of all these syndromes, and that patients with one clinical syndrome might have pathology overlapping with the other syndromes. The term *multiple system atrophy* was introduced to indicate that SND, SDS, and OPCA were all part of a single disease spectrum. The later identification of a common pathology (synuclein-containing glial cytoplasmic

TABLE 87.1 Clinical Forms of Progressive Supranuclear Palsy (PSP)[a]

Phenotype	Abbreviation	Description/Key Features
PSP-Richardson syndrome	PSP-RS	Vertical ocular motor dysfunction, early onset postural instability and falls
PSP-ocular motor	PSP-OM	Predominant ocular motor dysfunction
PSP-postural instability	PSP-PI	Predominant postural instability
PSP-parkinsonism	PSP-P	Clinical phenotype resembling Parkinson disease (later development of symptoms of PSP-RS)
PSP-frontal	PSP-F	Behavioral or frontal cognitive presentation (can be similar to behavioral variant frontotemporal dementia)
PSP-progressive gait freezing	PSP-PGF	Presentation with an isolated gait disorder with start hesitation and progressive freezing of gait
PSP-corticobasal syndrome	PSP-CBS	Corticobasal syndrome (one movement disorder sign and one cortical sign)
PSP-speech/language disorder	PSP-SL	Progressive apraxia of speech and/or nonfluent/agrammatic primary progressive aphasia
PSP-primary lateral sclerosis	PSP-PLS	Primary lateral sclerosis
PSP-cerebellar ataxia	PSP-C	Cerebellar ataxia as initial and predominant symptom

[a]From Armstrong M. Progressive supranuclear palsy: an update. *Curr Neurol Neurosci Rep*. 2018;18:12.

inclusions) confirmed the suspicion that these conditions represented one disease (Table 87.1). Some patients with MSA have upper motor neuron signs, and one of the original SDS patients had lower motor signs as well. It is not clear how many patients with parkinsonism and motor neuron disease have the pathology of MSA so that the current criteria for MSA do not include the parkinsonism-amyotrophy syndrome. Because most patients have some degree of autonomic dysfunction, the disease is now characterized according to the presenting motor dysfunction: MSA-parkinsonism when parkinsonism dominates the picture and MSA-cerebellar dysfunction when cerebellar dysfunction predominates.

Pathobiology

The full pathologic spectrum of MSA consists of neuronal loss and gliosis in the neostriatum, substantia nigra, globus pallidus, cerebellum, inferior olives, basis pontine nuclei, intermediolateral horn cells, corticospinal tracts, and, rarely, anterior horn cells. A characteristic pathologic feature is the presence of widespread glial cytoplasmic inclusions, particularly in oligodendroglia. These argyrophilic, α-synuclein–positive, perinuclear structures are primarily composed of straight microtubules containing ubiquitin and tau protein. In SND, nerve cell loss and gliosis are found predominantly in the substantia nigra and neostriatum. In SDS, the preganglionic sympathetic neurons in the intermediolateral horns are lost. In addition, other areas may be affected, particularly the substantia nigra (to produce parkinsonism), the cerebellum (to cause ataxia), and the striatum (to cause lack of response to levodopa). In OPCA, there is degeneration of the olives, pons, and cerebellum as well as neuronal loss in the striatum and substantia nigra. Less often, the anterior horn cells are involved (to cause amyotrophy) (Fig. 87.2).

Symptoms and Signs

The defining symptoms of SND are those of parkinsonism without tremor. Progression is usually rapid, and beneficial response to levodopa is absent or slight, presumably because striatal neurons containing dopamine receptors are usually lost.

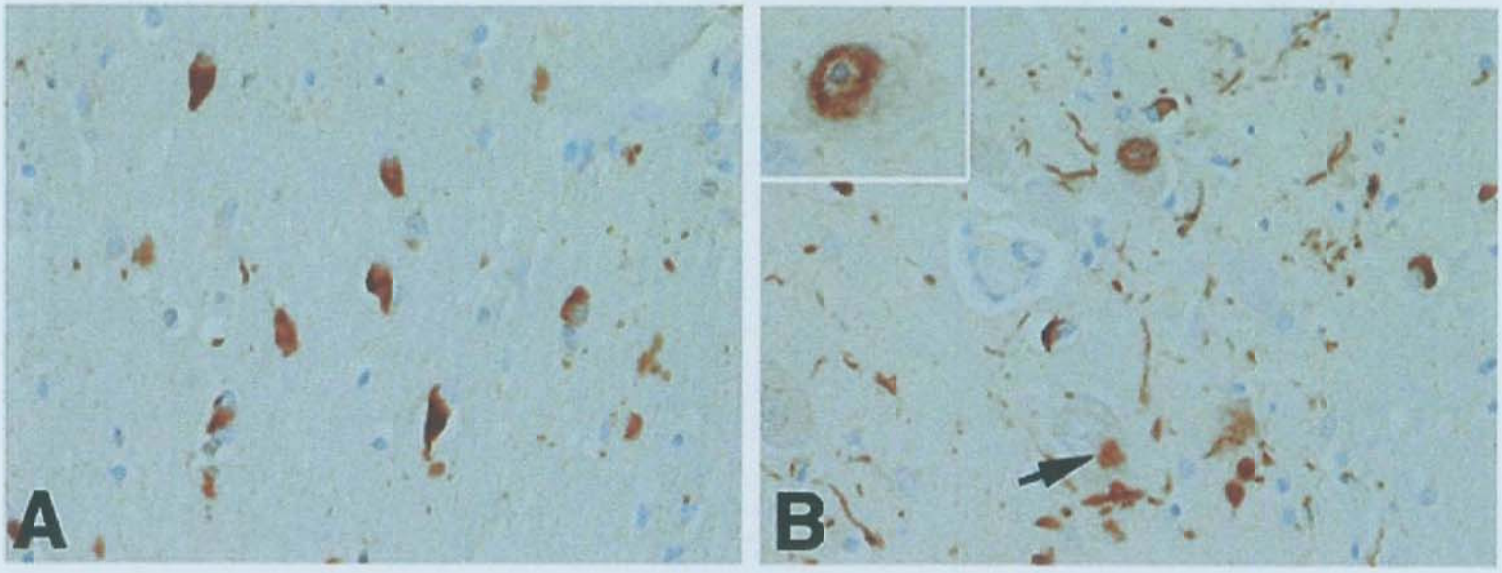

FIGURE 87.2 Pathology of multiple system atrophy. The typical pathologic findings in multiple system atrophy are glial cytoplasmic inclusions (**A**), but they may be accompanied by neuronal inclusions (*arrow* in **B**) and α-synuclein–positive fibrillar neuronal inclusions (*inset* in **B**). (Modified from Dickson DW. Neuropathology of non-Alzheimer degenerative disorders. *Int J Clin Exp Pathol*. 2009;3:1-23.)

Dystonic reactions are common following low-dosage levodopa therapy. In these patients, sustained facial, neck, or limb contractions occur after exposure to levodopa. Orthostatic hypotension is a common presenting symptom of SDS syndrome (sometimes with labile blood pressure), but other dysautonomic symptoms are also troublesome, including impotence, urge incontinence, incomplete bladder emptying, and gastrointestinal motility disorders. Laryngeal stridor (often at night but sometimes during the day as well) strongly suggests SDS syndrome and can be life-threatening. Other sleep symptoms include dysrhythmic breathing, sleep, and central apnea. OPCA is characterized by a mixture of parkinsonism and cerebellar syndrome, including gait ataxia, dysmetria, scanning speech, nystagmus, hypometric saccades, supranuclear upgaze impairment, and other cerebellar eye movement abnormalities. The least common presentation of MSA involves amyotrophy mimicking amyotrophic lateral sclerosis (often combined with parkinsonism). Some patients with pathologic MSA may have pure autonomic failure for many years before developing other symptoms (and some may have the pathology and eventually develop symptoms of Lewy body disease). Dementia in MSA is rarely severe. As noted earlier, combinations of these symptoms often occur. Most patients progress rapidly and are in a wheelchair by a median 6 to 7 years after onset, although patients with cerebellar deficit predominance seem to progress more slowly. As in other Parkinson-plus syndromes, patients die from pulmonary, urinary tract and pressure ulcer infections, and complications of falls. Unlike the other syndromes, patients with MSA are also at risk for cardiopulmonary arrest due to autonomic dysfunction.

Corticobasal Degeneration

History

Initially reported as corticodentatonigral degeneration with neuronal achromasia in 1967, this disorder was characterized clinically by a combination of levodopa-unresponsive parkinsonism with early loss of balance, severe unilateral limb dystonia, and almost any focal cortical deficit. The pathology was also characteristic: enlarged achromatic neurons in cortical areas (particularly parietal and frontal lobes) along with nigral and striatal neuronal degeneration without Lewy bodies. The syndrome, also called *cortical-basal ganglionic degeneration* in the past, is now usually called *corticobasal degeneration*. As with PSP, it is now recognized that this pathology can also present clinically in other ways: as a frontal behavioral-spatial syndrome, PNFA, a PSP-like syndrome, dementia without motor abnormalities, or even as PD. Because patients with the pathology of PSP may mimic CBD, the original clinical syndrome is now called *corticobasal syndrome*. The overlap in both pathology and clinical features between CBD and PSP has raised concerns that the two diagnoses may represent a spectrum of a single disease despite a small number of pathologic findings unique to each diagnosis.

Pathobiology

In CBD, there is asymmetric atrophy usually most severe in the frontoparietal region with relative sparing of the occipital lobes. Swollen vacuolated neurons are found in the atrophic cortical areas and to a lesser degree in the affected subcortical regions. These swollen or ballooned neurons contain phosphorylated neurofilaments and sometimes tau and ubiquitin. There is neuronal loss and gliosis in affected cortex and in the globus pallidus, putamen, red nucleus, thalamus, subthalamic nucleus, substantia nigra, locus ceruleus, and to a lesser degree in the dentate nucleus. Remaining neurons in affected areas contain the globose tangles common in PSP, in this setting called *corticobasal bodies*. As in PSP, white matter is affected with a variety of abnormalities including tau-containing fibrils coiling around the nuclei of oligodendroglia (coiled bodies). The typical glial finding in CBD is not the tufted astrocyte common in PSP but tau-containing processes surrounding astrocytes called *astrocytic plaques*. As in PSP, four-repeat tau predominates, but the insoluble tau fragments in CBD have a different ultrastructure from the insoluble fragments of tau in PSP (Fig. 87.3).

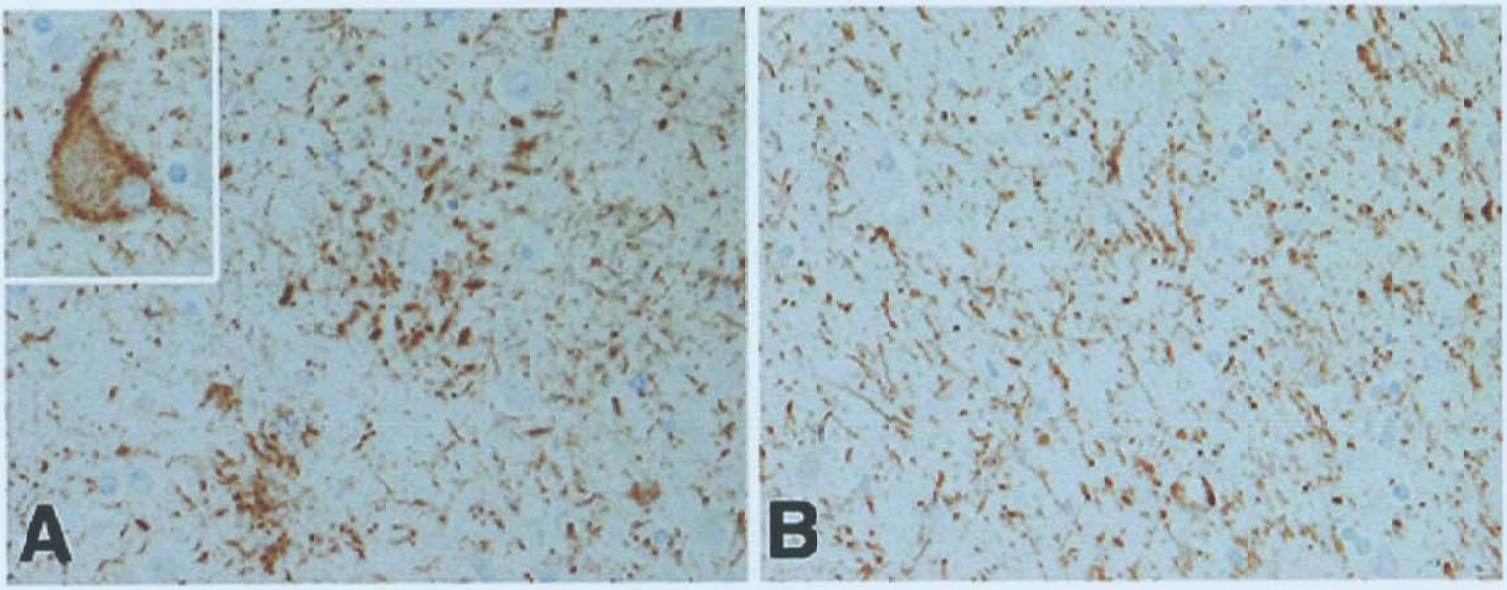

FIGURE 87.3 Pathology of corticobasal degeneration. The typical pathologic findings in corticobasal degeneration are astrocytic plaques (clusters of tau-positive processes around a central astrocyte) **(A)**, ballooned neurons (*inset* in **A**), and threadlike processes **(B)**. (Modified from Dickson DW. Neuropathology of non-Alzheimer degenerative disorders. *Int J Clin Exp Pathol*. 2009;3:1-23.)

Symptoms and Signs

The onset of CBD is insidious and typically unilateral, with focal cortical deficits, and often marked rigidity—dystonia in the involved arm and/or leg. Sustained postures leading to contractures are common. Bradykinesia is usually present but may be hard to detect in the dystonic limb or limbs. Cortical signs of apraxia (inability to perform complex movements when comprehension and strength are intact), agnosia (inability to interpret complex sensory input even when primary sensation and comprehension are intact), alien limb phenomenon (when complex movements are performed by a limb out of the person's control), cortical sensory loss, cortical reflex myoclonus, and, occasionally, aphasia are usually dramatic. In addition to focal signs, global cortical dysfunction (dementia) is common. Speech is hesitant and dysarthric, gait is poor, and, occasionally, action tremor is evident. Falls usually occur shortly after onset of the disease. The disease usually spreads slowly to involve both sides of the body, and supranuclear gaze difficulties can occur late in the course. Patients with CBD pathology may present with several other syndromes. In the frontal behavioral-spatial syndrome, patients present with some combination of executive dysfunction, behavioral change, and visuospatial deficits. CBD at the onset may also look like PSP, PNFA, or a dementia without characteristic motor or focal cortical features (▶ Video 87.3).

EPIDEMIOLOGY

The reported prevalence of each syndrome varies dramatically. In part, this is because clinical studies tend to underestimate the prevalence, whereas autopsy studies tend to overestimate the prevalence (because unusual cases are more likely to come to autopsy). PSP is the most common, generally reported in clinical studies to have a prevalence of 1 to 20 per 100,000 (compared to 100-200 per 100,000 for PD). In a community-based study of 233 autopsies, 19% had PD, 3% had PSP, 0.9% had MSA, and 0.4% had CBD. Although PSP, CBD, MSA, and their syndromes are usually sporadic, recently a small number of rare genetic conditions were identified that may clinically resemble PSP, MSA, or CBD, including mutations in the genes *MAPT* and *PGRN* (for tau and progranulin), *C9orf72* (commonly causing familial amyotrophic lateral sclerosis and frontotemporal dementia), *TARDBP*, *CHMP2B*, and rare genetic mutations.

DIAGNOSIS

There have now been consensus criteria for the diagnosis of each of these syndromes. They were developed primarily for clinical research but are commonly used for clinical diagnosis as well (Tables 87.2-87.4).

Levodopa-unresponsive parkinsonism with early involvement of gait and balance suggests a Parkinson-plus syndrome, most commonly PSP, MSA, or CBD. Currently, dopamine transporter scans are available to detect a dopamine deficiency state, but the sensitivity is not known. There are two challenges: (1) Can we identify patients with signs and symptoms of one disease but the pathology of another? (2) Can we identify patients who seem to have idiopathic PD early in the course but actually have one of these syndromes?

It is not possible to predict the underlying pathology 100% of the time. Supranuclear vertical ophthalmoplegia suggests Richardson disease. Vertical eye movements are usually affected first in PSP, whereas eye movement problems develop late in CBD and are usually horizontal in MSA. Significant cerebellar deficits are most common in MSA but are rarely present in PSP. Autonomic failure is a hallmark of MSA and is uncommon in PSP and CBD but can be prominent in diffuse Lewy body disease (DLBD). Significant cognitive impairment is common in PSP and CBD but uncommon in MSA. Focal cortical deficits are a defining feature of CBD but occur in a minority of patients with PSP. Visual hallucinations and dopa-dyskinesias are more likely to be present in PD than in PSP-P or the other syndromes. Vascular parkinsonism often meets criteria for a Parkinson-plus syndrome and can be mistaken for PSP if eye movements are involved. Vascular parkinsonism can only be present with significant magnetic resonance imaging (MRI) abnormality, but white matter disease on MRI does not exclude PSP, MSA, or CBD. Frontotemporal lobar degeneration parkinsonism can mimic any of these conditions, especially if the dementia lags behind the motor symptoms.

PSP or CBD may present as dementia without motor abnormalities or as levodopa-responsive parkinsonism without incompatible signs and there may be no clinical way to correctly identify the disease until it progresses. Any patient with symmetric parkinsonian signs or where the lower body is more affected than the upper body may eventually develop a Parkinson-plus syndrome but this is neither sensitive nor specific.

^{18}F-fluorodeoxyglucose positron emission tomography (PET) can accurately distinguish between PD and all Parkinson-plus syndromes but is not generally available. There are other imaging markers for each of these syndromes but none is yet accepted as sensitive and specific. Midbrain atrophy can be quantified on computed tomography or MRI and is often different for PSP, MSA, and CBD. Rostral midbrain atrophy greater than pons atrophy may resemble the beak of a hummingbird in PSP. There may be hyperintensity in the dorsolateral margin of the putamen ("putaminal slit" sign) and cruciform increased signal in the pons ("hot cross bun" sign) in MSA. Focal cortical atrophy suggests CBD. Autonomic failure in MSA affects preganglionic sympathetic neurons (plasma epinephrine is normal when the patient is supine but fails to rise when the patient stands), and this may differentiate it from orthostasis in DLBD.

In the past, these syndromes were thought to be sporadic, but recently a small number of genetic conditions have been identified that may be clinically diagnosed as PSP, MSA, or CBD.

TREATMENT

The treatment of all Parkinson-plus syndromes is difficult, and the approaches are similar in PSP, CBD, and MSA and so are discussed together. Medications are usually ineffective for parkinsonian symptoms in these conditions but are more likely to be effective in MSA-cerebellar dysfunction when the striatum is relatively spared. Levodopa, however, can exaggerate orthostatic hypotension in MSA. Measures to overcome this problem include wearing support hose, ingesting salt, and taking fludrocortisone, midodrine, and other hypertensive agents. Patients can sleep with head elevated to avoid nocturnal hypertension and, if this is a problem, the dose of fludrocortisone should be kept to a minimum. If the striatum becomes more involved, with presumed loss of dopamine receptors, the benefit of levodopa diminishes. Treatment with levodopa requires increasing the dose to the maximum-tolerated dose or up to 2 g/d (in the presence of carbidopa) to determine whether any therapeutic

TABLE 87.2 Movement Disorder Society Diagnostic Criteria for Progressive Supranuclear Palsy[a]

Basic Features

1. Mandatory inclusion criteria	1. Sporadic occurrence 2. Age 40 y or older at onset of first PSP-related symptom 3. Gradual progression of PSP-related symptoms
2. Mandatory exclusion criteria	Clinical findings 1. Predominant, otherwise unexplained impairment of episodic memory, suggestive of AD 2. Predominant, otherwise unexplained autonomic failure, for example, orthostatic hypotension (orthostatic reduction in blood pressure after 3 min standing ≥30 mm Hg systolic or ≥15 mm Hg diastolic), suggestive of multiple system atrophy or Lewy body disease 3. Predominant, otherwise unexplained visual hallucinations or fluctuations in alertness, suggestive of dementia with Lewy bodies 4. Predominant, otherwise unexplained multisegmental upper and lower motor neuron signs, suggestive of motor neuron disease (pure upper motor neuron signs are not an exclusion criterion) 5. Sudden onset or stepwise or rapid progression of symptoms, in conjunction with corresponding imaging or laboratory findings, suggestive of vascular etiology, autoimmune encephalitis, metabolic encephalopathies, or prion disease 6. History of encephalitis 7. Prominent appendicular ataxia 8. Identifiable cause of postural instability, for example, primary sensory deficit, vestibular dysfunction, severe spasticity, or lower motor neuron syndrome Imaging findings 1. Severe leukoencephalopathy, evidenced by cerebral imaging 2. Relevant structural abnormality, for example, normal pressure or obstructive hydrocephalus; basal ganglia, diencephalic, mesencephalic, pontine or medullary infarctions, hemorrhages, hypoxic-ischemic lesions, tumors, or malformations
3. Context dependent exclusion criteria	Imaging findings 1. In syndromes with sudden onset or stepwise progression, exclude stroke, cerebral autosomal dominant arteriopathy with subcortical infarcts and leukoencephalopathy (CADASIL) or severe cerebral amyloid angiopathy, evidenced by diffusion-weighted imaging (DWI), fluid-attenuated inversion recovery, or T2*-MRI 2. In cases with very rapid progression, exclude cortical and subcortical hyperintensities on DWI-MRI suggestive of prion disease. Laboratory findings 1. In patients with PSP-CBS, exclude primary AD pathology (typical CSF constellation [ie, both elevated total tau/phospho-tau protein and reduced β-amyloid 42] or pathologic β-amyloid PET imaging). 2. In patients aged younger than 45 y, exclude other causes of parkinsonism, such as Wilson disease, Niemann-Pick disease, neuroacanthocytosis, etc. 3. In rapidly progressive patients, exclude prion disease and paraneoplastic disease. 4. In patients with suggestive features (ie, gastrointestinal symptoms, arthralgias, etc.) exclude Whipple disease. Genetic findings 1. MAPT rare variants (mutations) are no exclusion criterion, but their presence defines inherited, as opposed to sporadic PSP. MAPT H2 haplotype homozygosity renders the diagnosis unlikely. 2. LRRK2 and Parkin rare variants have been observed in patients with autopsy-confirmed PSP, but their causal relationship is unclear so far. 3. Known rare variants in other genes are exclusion criteria because they may mimic aspects of PSP clinically but differ neuropathologically; these include non-MAPT associated FTD, PD, AD, and others.

Core Clinical Features

	Functional Domain			
Levels of Certainty	**Ocular Motor Dysfunction**	**Postural Instability**	**Akinesia**	**Cognitive Dysfunction**
High	O1: Vertical supranuclear gaze palsy	P1: Repeated unprovoked falls within 3 y	A1: Gait freezing within 3 y	C1: Speech/language disorder
Medium	O2: Slow velocity of vertical saccades	P2: Falls on pull-test within 3 y	A2: Levodopa resistant, akinetic-rigid	C2: Frontal cognitive/behavioral presentation
Low	O3: Frequent macro square wave jerks or "eyelid opening apraxia"	P3: Abnormal pull-test within 3 y	A3: Rest tremor and/or asymmetric and/or levodopa responsive	C3: Corticobasal syndrome

Supportive Features

Clinical Clues	Imaging Findings
CC1: Levodopa-resistance	IF1: Predominant midbrain atrophy or hypometabolism
CC2: Hypokinetic, spastic dysarthria	IF2: Postsynaptic striatal dopaminergic degeneration
CC3: Dysphagia	
CC4: Photophobia	

Abbreviations: AD, Alzheimer disease; CSF, cerebrospinal fluid; LRRK2, leucine-rich repeat kinase 2; MAPT, microtubule associated protein tau; MAPT H2, microtubule associated protein tau haplotype 2; MRI, magnetic resonance imaging; PET, positron emission tomography; PSP, progressive supranuclear palsy; PSP-CBS, progressive supranuclear palsy–corticobasal syndrome.

[a]Modified from Höglinger GU, Respondek G, Stamelou M, et al; for Movement Disorder Society-endorsed PSP Study Group. Clinical diagnosis of progressive

TABLE 87.3 Diagnostic Criteria for Multiple System Atrophy[a]

Possible MSA
Gradually progressive sporadic disease starting older than age 30 y
• At least one feature suggesting autonomic dysfunction:
◦ Unexplained urinary urgency, frequency, or incomplete bladder emptying
◦ Erectile dysfunction in males
◦ Significant orthostatic hypotension
• At least one additional feature of MSA (see in the following text)
• Either
◦ Parkinsonism (bradykinesia with rigidity, tremor, or postural instability)
◦ Cerebellar syndrome (gait ataxia with cerebellar dysarthria, limb ataxia, cerebellar oculomotor dysfunction)
Probable MSA
Gradually progressive sporadic disease starting older than age 30 y
• Autonomic failure with either
◦ Urinary incontinence (inability to control the release of urine from the bladder) with erectile dysfunction in men
◦ Orthostatic decrease of blood pressure within 3 min of standing by at least 30 mm Hg systolic or 15 mm Hg diastolic
• Either
◦ Poorly levodopa-responsive parkinsonism (bradykinesia with rigidity, tremor, or postural instability)
◦ Cerebellar syndrome (gait ataxia with cerebellar dysarthria, limb ataxia, cerebellar oculomotor dysfunction)
• Possible MSA-P or MSA-C
Additional Features of Possible MSA
◦ Babinski sign with hyperreflexia
◦ Stridor
• Possible MSA-P
◦ Rapidly progressive parkinsonism
◦ Poor response to levodopa
◦ Postural instability within 3 y of motor onset
◦ Gait ataxia, cerebellar dysarthria, limb ataxia, or cerebellar oculomotor dysfunction
◦ Dysphagia within 5 y of motor onset
◦ Atrophy on MRI of putamen, middle cerebellar peduncle, pons, or cerebellum
• Possible MSA-C
◦ Parkinsonism (bradykinesia and rigidity)
◦ Atrophy on MRI of putamen, middle cerebellar peduncle or pons
◦ Hypometabolism on FDG-PET in putamen
◦ Presynaptic nigrostriatal dopaminergic denervation on SPECT or PET

Abbreviations: FDG-PET, ^{18}F-fluorodeoxyglucose positron emission tomography; MSA, multiple system atrophy; MSA-C, MSA-cerebellar dysfunction; MSA-P, MSA-parkinsonism; MRI, magnetic resonance imaging; SPECT, single-photon emission computed tomography.

[a]Modified from Gilman S, Wenning GK, Low PA, et al. Second consensus statement on the diagnosis of multiple system atrophy. *Neurology*. 2008;71:670-676.

response can be obtained. Apraxia of eyelid opening (mainly in PSP) and painful dystonia or rigidity can be treated with botulinum toxin when the symptoms are relatively focal, and the muscles can be located and injected. Tricyclic antidepressants or dextromethorphan/quinidine may suppress inappropriate crying or laughing. Anticholinergic drugs in modest doses or botulinum toxin injections may be useful in controlling drooling. Patients with Parkinson-plus syndromes are at high risk for swallowing difficulty, so botulinum toxin should be used with care. Antidepressants may be helpful for depression in all Parkinson syndromes (it is not known if some antidepressants are more effective than others), although most patients do not tolerate dopamine receptor–blocking agents that are sometimes used to treat depression. 1-Deamino-8-D-arginine vasopressin at bedtime may help avoid nocturnal incontinence (and also help orthostasis). Constipation is managed as with idiopathic PD but may be less responsive to treatment. As with other Parkinson-plus syndromes, painful cramps may respond to botulinum toxin injections. Some families use enteric feeding when there is risk of aspiration. Gastric tubes do not prevent regurgitation followed by aspiration. Duodenal tubes do prevent aspiration but require continuous feeding, not bolus feeding (**Table 87.5**).

Recently, there has been a hypothesis that misfolded tau (in PSP and CBD) and misfolded α-synuclein (in MSA) may act like prions and cause the progression of these conditions. Studies are now underway to slow or stop the spread of these proteins inside the brain.

OTHER PARKINSON-LIKE SYNDROMES

Drug/Toxin-Induced Parkinsonism

Dopamine Receptor–Blocking Drugs

Drugs that block striatal dopamine D2 receptors (eg, phenothiazines, butyrophenones, thioxanthenes, and other centrally acting dopamine receptor blockers including some antinausea medications and some calcium channel blockers) or deplete striatal dopamine and serotonin (eg, reserpine, tetrabenazine) can induce a parkinsonian state. It may take weeks to months for the parkinsonism to resolve after the offending agent is withdrawn. Parkinsonism that persists longer than 6 months after drug withdrawal is attributed to underlying PD that became evident during exposure to these antidopaminergic drugs. Anticholinergic drugs can ameliorate drug-induced parkinsonian signs and symptoms. The atypical antipsychotic agents, clozapine, quetiapine, and more recently, pimavanserin, are the antipsychotics least likely to induce or worsen parkinsonism.

1-Methyl-4-Phenyl-1,2,3,6-Tetrahydropyridine

Although rare, parkinsonism induced by this toxin is important because it selectively destroys the dopamine nigrostriatal neurons, and the mechanism has been investigated intensively for possible clues to the etiology and pathogenesis of PD. 1-Methyl-4-phenyl-1,2,3,6-tetrahydropyridine (MPTP) is a protoxin, being converted to membrane palmitoylated protein 1 (MPP1) by the action of the enzyme monoamine oxidase type B. MPP1 is taken up selectively by dopamine neurons and terminals via the dopamine transporter system. MPP1 inhibits complex I in the mitochondria, depletes

TABLE 87.4 Diagnostic Criteria for Corticobasal Degeneration[a]

Probable CBD
• Insidious onset and gradual progression
• Onset on or after age 50 y, present for at least 1 y, less than two affected relatives
• Either
◦ Probable CBS
◦ FBS
◦ NAV with at least one probable CBS feature (see in the following text)
Probable CBS
Asymmetric presentation of both
• At least two of the following:
◦ Limb rigidity or akinesia
◦ Limb dystonia
◦ Limb myoclonus
• At least two of the following:
◦ Orobuccal or limb apraxia
◦ Cortical sensory deficit
◦ Alien limb (more than just overflow levitation)
FBS Syndrome
Two of the following:
• Executive dysfunction
• Behavioral or personality change
• Visuospatial deficits
Nonfluent/Agrammatic Variant of Primary Progressive Aphasia
Effortful, agrammatic speech with at least one of the following:
• Impaired grammar/sentence comprehension with relatively preserved single-word comprehension
• Groping, distorted speech production (apraxia of speech)
PSPS
Three of the following:
• Axial or symmetric limb rigidity or akinesia
• Postural instability or falls
• Urinary incontinence
• Behavioral change
• Supranuclear vertical gaze palsy or decreased vertical saccade velocity
Possible CBD
• Insidious onset and gradual progression
• Present for at least 1 y
• Either
◦ Probable CBS
◦ NAV or FBS
◦ PSPS with at least one possible CBS feature (see in the following text)
Possible CBS
Asymmetric or symmetric presentation of both
• At least one of the following:
◦ Limb rigidity or akinesia
◦ Limb dystonia
◦ Limb myoclonus
• At least one of the following:
◦ Orobuccal or limb apraxia
◦ Cortical sensory deficit
◦ Alien limb (more than just overflow levitation)

Abbreviations: CBD, corticobasal degeneration; CBS, corticobasal syndrome; FBS, frontal behavioral-spatial syndrome; NAV, nonfluent/agrammatic variant; PSP, progressive supranuclear palsy; PSPS, PSP syndrome.
[a]Modified from Armstrong MJ, Litvan I, Lang AE, et al. Criteria for the diagnosis of corticobasal degeneration. *Neurology*. 2013;80:496-503.

ATP, and increases the content of superoxide ion radicals. Superoxide in turn can react with nitric oxide to form the oxyradical peroxynitrite. MPTP-induced parkinsonism has occurred in drug abusers who used it intravenously and possibly also in some laboratory workers exposed to the toxin. The clinical syndrome is indistinguishable from PD and responds to levodopa. PET indicates that a subclinical exposure to MPTP results in a reduction of fluorodopa uptake in the striatum, thereby making the person liable to future development of parkinsonism.

Other Drugs Besides Dopamine Receptor Blockers and 1-Methyl-4-Phenyl-1,2,3,6-Tetrahydropyridine

Many other medications are occasionally reported to cause reversible parkinsonism, including antidepressants, anticonvulsants, antihypertensive medications, antiarrhythmics, immunosuppressants, and others. In some cases, parkinsonism is relatively common; in others, parkinsonism is reported only rarely. In the rare cases, other medications known to cause parkinsonism may have also played a role, and some may be coincidental idiopathic PD. For a partial list of drugs causing parkinsonism, see **Table 87.6**.

Lytico-Bodig (Parkinson-Dementia-Amyotrophic Lateral Sclerosis Complex of Guam)

Although not definitely a drug-induced disorder, epidemiologic evidence supports a probable environmental cause for Lytico-Bodig, with exposure occurring during adolescence or early adult years. Lytico-Bodig was identified when Chamorro natives on Guam in the Western Pacific were found to have a surprising incidence of parkinsonism, dementia, and motor neuron disease. The incidence has declined gradually with modernization of the culture. One hypothesis is that environmental exposure to the neurotoxin found in the seed of the plant *Cycas circinalis* was responsible for the neuronal degeneration. Natives on Guam used this seed to make flour in World War II. However,

TABLE 87.5 Treatment of Progressive Supranuclear Palsy, Multiple System Atrophy, and Corticobasal Degeneration

Indication	Treatment	Potential Side Effects
Motor difficulty	Sinemet to tolerance: Attempt to treat with 600-800 mg/d of levodopa per day if possible divided in three times a day dosing.	Orthostasis (esp. MSA), dystonia (esp. MSA), nausea, psychosis, others
Apraxia of eyelid opening (esp. PSP)	BTX-A injections: usually requires higher doses than used for blepharospasm, range of 25 100 units per eye. To achieve higher doses without ptosis, must concentrate the toxin to give higher dose without higher volume per injection site.	Ptosis, others
Depression	Antidepressants (except DRBA): same dose range per medication as for patients without parkinsonism	Lethargy, agitation, others
Drooling	Anticholinergics: as tolerated, usually very low doses (2-5 mg/d in this age group) BTX-B: varies dramatically from person to person, usually starting with 500 units per side and increase as tolerated if necessary	Dry mouth, confusion (anticholinergics), dysphagia (esp. BTX)
Nocturnal incontinence	DDAVP: 0.1 mg, 10 μg from 1 to 3 sprays per nostril each night at bedtime	Hypertension
Constipation	As with PD	—
Painful muscle cramps	BTX-A: usually very small dose per muscle is sufficient to reduce painful spasm, from 25-50 units per muscle depending on muscle size	Excess muscle weakness
Aspiration	Gastric or duodenal tube	—

Abbreviations: BTX, botulinum toxin; DDVAP, 1-deamino-8-D-arginine vasopressin; DRBA, dopamine receptor blocking agents; esp., especially; MSA, multiple system atrophy; PD, Parkinson disease; PSP, progressive supranuclear palsy.

TABLE 87.6 Drugs Causing Drug-Induced Parkinsonism[a,b]

Drugs/Indications	Mechanism of Action
High Risk of DIP	
First-generation antipsychotics: haloperidol, chlorpromazine, pimozide, thioxanthenes, trifluoperazine, others	Dopamine receptor blockade
Second-generation antipsychotics: risperidone, olanzapine, ziprasidone, aripiprazole	Dopamine receptor blockade
Dopamine depletors: tetrabenazine, valbenazine, deutetrabenazine, reserpine	Dopamine depletion
Antiemetics: metoclopramide, prochlorperazine	Dopamine receptor blockade
Ca^{++} channel blockers: flunarizine, cinnarizine	Dopamine receptor blockade
MPTP	Destruction of dopamine-producing neurons
Intermediate Risk of DIP	
Atypical antipsychotics: quetiapine, clozapine	Dopamine receptor blockade
Ca^{++} channel blockers: diltiazem, verapamil	—
Antiepileptics: valproic acid, phenytoin, levetiracetam	—
Mood stabilizers: lithium	—
Low Risk of DIP	
Antiarrhythmics: amiodarone	—
Immunosuppressants: cyclosporine	—
Antidepressants: SSRIs: fluoxetine, sertraline	—
MAO inhibitors: moclobemide, phenelzine	MAO inhibition
Antivirals: acyclovir, vidarabine, anti-HIV drugs	—
Statins: lovastatin	—
Antifungals: amphotericin B	—
Hormones: medroxyprogesterone, levothyroxine sodium	—
Cholinesterase inhibitors: donepezil, rivastigmine	—

Abbreviations: Ca^{++}, calcium ion; DIP, drug-induced parkinsonism; HIV, human immunodeficiency virus; MPTP, 1-methyl-4-phenyl-1,2,3,6-tetrahydropyridine; MAO, monoamine oxidase; SSRIs, selective serotonin reuptake inhibitors.

[a]Reports of parkinsonism in the low-risk category may be contaminated by coincidental idiopathic Parkinson disease or by polypharmacy.

[b]Data from López-Sendón J, Mena MA, de Yébenes JG. Drug-induced parkinsonism. *Expert Opin Drug Saf.* 2013;12:487-496.

this hypothesis has been refuted. Besides parkinsonism, dementia, and motor neuron disease in various combinations, supranuclear gaze defects also appear. A characteristic pathologic finding is the presence of NFTs in the degenerating neurons, including the substantia nigra. Lewy bodies and senile plaques are absent.

Hemiparkinsonism-Hemiatrophy Syndrome

This relatively benign syndrome consists of hemiparkinsonism in association with ipsilateral body hemiatrophy and/or contralateral brain hemiatrophy. The parkinsonism usually begins in young adults and may remain as hemiparkinsonism, sometimes with hemidystonia, or progress to generalized parkinsonism. It tends to be nonprogressive or slowly progressive compared with PD. The disorder is thought to result from brain injury early in life, possibly even perinatally. It sometimes responds to medications.

Normal Pressure Hydrocephalus

The gait disorder in normal pressure hydrocephalus (see Chapter 110) resembles that of parkinsonism, with shuffling short steps and loss of postural reflexes and sometimes freezing. Features of urinary incontinence and dementia occur later. Tremor is rare. The grossly enlarged ventricles lead to the correct diagnosis, with the symptoms often improving on removal or shunting of cerebrospinal fluid. The gait disorder is in striking contrast to the lack of parkinsonism in the upper part of the body. The major differential diagnoses for lower body parkinsonism include vascular parkinsonism, Parkinson-plus syndromes, and even PD.

Parkinson-Dementia Syndromes

Although bradyphrenia is common in PD, dementia also occurs in about 30% of PD patients in clinics. The prevalence of dementia increases with age (affecting over 80% of patients with PD for 20 y), and those with dementia have a higher mortality rate. The two most common pathologic substrates for dementia in parkinsonism are pathologic changes typical of Alzheimer disease and the presence of Lewy bodies diffusely in the cerebral cortex. It is not known if the Alzheimer changes are coincidental because of the elderly population of affected individuals or whether Alzheimer disease and PD are somehow related. A clinical distinction has been made between patients who develop dementia before motor symptoms (or within a year of developing motor symptoms), labeled *DLBD* and those who develop dementia long after motor symptoms appear, labeled *Parkinson disease dementia*. Because these conditions are similar in most other pathologic and clinical features, it is not known if these represent the spectrum of one disease or multiple separate diseases. Similarly, it is not known whether the spread of Lewy bodies into the cortex is a feature of progression of PD or a distinct entity.

Postencephalitic Parkinsonism

Although rarely encountered today, postencephalitic parkinsonism was common in the first half of the 20th century. Parkinsonism was the most prominent sequel of the pandemics of encephalitis lethargica (von Economo encephalitis) that occurred between 1919 and 1926. Although the causative agent was never established, it affected mainly the midbrain, thus destroying the substantia nigra. The pathology is distinctive because of the presence of NFTs in the remaining nigral neurons and absence of Lewy bodies. In addition to slowly progressive parkinsonism, with features similar to those of PD, oculogyric crises often occurred in which the eyes deviate to a fixed position for minutes to hours. Dystonia, tics, behavioral disorders, and ocular palsies may be present. Patients with postencephalitic parkinsonism are more sensitive to levodopa, with development of dyskinesias, mania, or hypersexuality at low dosages. Anticholinergics are tolerated and are effective against oculogyria.

Vascular Parkinsonism

Vascular parkinsonism resulting from lacunar disease is not common but can be diagnosed by neuroimaging, with MRI evidence of hyperintense T2-weighted signals compatible with small infarcts. Hypertension is usually required for the development of this disorder. The onset of symptoms, usually with a gait disorder, is insidious, and the course is progressive. A history of a major stroke preceding the onset of parkinsonism is rare, although a stepwise course is sometimes seen. Gait is profoundly affected (lower body parkinsonism) with freezing and loss of postural reflexes. Tremor is rare. Response to the typical antiparkinsonian agents is usually minimal or absent.

Videos can be found in the companion e-book edition. For a full list of video legends, please see the front matter.

SUGGESTED READINGS

Armstrong MJ. Diagnosis and treatment of corticobasal degeneration. *Curr Treat Options Neurol*. 2014;16:282.

Armstrong MJ. Lewy body dementias. *Continuum (Minneap Minr)*. 2019;25:128-146.

Armstrong MJ, Litvan I, Lang AE, et al. Criteria for the diagnosis of corticobasal degeneration. *Neurology*. 2013;80:496-503.

Ayers JI, Giasson BI, Borchelt DR. Prion-like spreading in tauopathies. *Biol Psychiatry*. 2018;83(4):337-346.

Baizabal-Carvallo JF, Jankovic J. Parkinsonism, movement disorders and genetics in frontotemporal dementia. *Nature Rev Neurol*. 2016;12(3):175-185.

Cheyette SR, Cummings JL. Encephalitis lethargica: lessons for contemporary neuropsychiatry. *J Neuropsychiatry Clin Neurosci*. 1995;7:125-134.

FitzGerald PM, Jankovic J. Lower body parkinsonism: evidence for vascular etiology. *Mov Disord*. 1989;4:249-260.

Friedman DI, Jankovic J, McCrary JA III. Neuro-ophthalmic findings in progressive supranuclear palsy. *J Clin Neuroophthalmol*. 1992;12:104-109.

Giladi N, Burke RE, Kostic V, et al. Hemiparkinsonism-hemiatrophy syndrome: clinical and neuroradiological features. *Neurology*. 1990;40:1731-1734.

Gilman S, Wenning GK, Low PA, et al. Second consensus statement on the diagnosis of multiple system atrophy. *Neurology*. 2008;71:670-676.

Goetz CG, Emre M, Dubois B. Parkinson's disease dementia: definitions, guidelines, and research perspectives in diagnosis. *Ann Neurol*. 2008;64(suppl 2):S81-S92.

Gupta A, Lang AE. Potential placebo effect in assessing idiopathic normal pressure hydrocephalus. *J Neurosurg*. 2011;114:1428-1431.

Höglinger GU, Respondek G, Stamelou M, et al; for Movement Disorder Society-Endorsed PSP Study Group. Clinical diagnosis of progressive supranuclear palsy: the Movement Disorder Society criteria. *Mov Disord*. 2017;32(6):853-864.

Langston JW, Ballard P, Tetrud JW, et al. Chronic parkinsonism in humans due to a product of meperidine-analog synthesis. *Science*. 1983;219:979-980.

Lanska DJ. The history of movement disorders. In: Finger S, Boller F, Tyler KL, eds. *Handbook of Clinical Neurology, History of Neurology*. Vol 95. Amsterdam, Netherlands: Elsevier B.V.; 2010:501-546.

Lee SL. Guam dementia syndrome revisited in 2011. *Curr Opin Neurol*. 2011;24:517-524.

Lippa CF, Duda JE, Grossman M, et al. DLB and PDD boundary issues: diagnosis, treatment, molecular pathology, and biomarkers. *Neurology*. 2007;68:812-819.

Liscic RM, Srulijes K, Gröger A, Maetzler W, Berg D. Differentiation of progressive supranuclear palsy: clinical, imaging and laboratory tools. *Acta Neurol Scand*. 2013;127:362-370.

Litvan I, Bhatia KP, Burn DJ, et al. Movement Disorders Society Scientific Issues Committee report: SIC Task Force appraisal of clinical diagnostic criteria for Parkinsonian disorders. *Mov Disord*. 2003;18:467-486.

López-Sendón J, Mena MA, de Yébenes JG. Drug-induced parkinsonism. *Expert Opin Drug Saf*. 2013;12:487-496.

McGirt MJ, Woodworth G, Coon AL, Thomas G, Williams MA, Rigamonti D. Diagnosis, treatment and analysis of long-term outcomes in idiopathic normal-pressure hydrocephalus. *Neurosurgery*. 2005;57:699-705.

Rebeiz JJ, Kolodny EH, Richardson EP Jr. Corticodentatonigral degeneration with neuronal achromasia: a progressive disorder of late adult life. *Trans Am Neurol Assoc*. 1967;92:23-26.

Respondek G, Kurz C, Arzberger T, et al; for Movement Disorder Society-endorsed PSP Study Group. Which ante mortem clinical features predict progressive supranuclear palsy pathology? *Mov Disord*. 2017;32:995-1005.

Seppi K, Poewe W. Brain magnetic resonance imaging techniques in the diagnosis of parkinsonian syndromes. *Neuroimag Clin N Am*. 2010;20:29-55.

Stamelou S, Quinn NP, Bhatia KP. "Atypical" atypical parkinsonism: new genetic conditions presenting with features of progressive supranuclear palsy, corticobasal degeneration, or multiple system atrophy—a diagnostic guide. *Mov Disord*. 2013;28:1184-1199.

Steele JC, Richardson JC, Olszewski J. Progressive supranuclear palsy. A heterogenous degeneration involving the brain stem, basal ganglia and cerebellum with vertical gaze and pseudobulbar palsy, nuchal dystonia and dementia. *Arch Neurol*. 1964;10:333-359.

Thobois S, Guillouet S, Broussolle E. Contributions of PET and SPECT to the understanding of the pathophysiology of Parkinson's disease. *Neurophysiol Clin*. 2001;31:321-340.

Vargas JY, Grudina C, Zurzolo C. The prion-like spreading of α-synuclein: from in vitro to in vivo models of Parkinson's disease. *Ageing Res Rev*. 2019;50:89-101.

Wenning GK, Krismer F. Multiple system atrophy. *Handb Clin Neurol*. 2013;117:229-241.

Zijlmans JC, Daniel SE, Hughes AJ, Révész T, Lees AJ. Clinicopathological investigation of vascular parkinsonism, including clinical criteria for diagnosis. *Mov Disord*. 2004;19:630-640.

Amyotrophic Lateral Sclerosis and Motor Neuron Diseases 88

Neil A. Shneider

KEY POINTS

1. Amyotrophic lateral sclerosis (ALS) is the most common adult-onset motor neuron disease, predominantly involving the degeneration of corticospinal, bulbar and spinal motor neurons.
2. ALS is a genetically complex disease for which pathogenic mutations have been identified in over 30 genes. Still, approximately 85-90% of ALS patients have no family history or known ALS gene mutation.
3. Common pathological features in the vast majority of ALS cases suggest shared underlying mechanisms of disease.
4. Clinical, pathological and genetic evidence links ALS to the related neurodegenerative disorder, frontotemporal dementia (FTD). Approximately half of all ALS patients have some degree of frontotemporal dysfunction.
5. Treatment for ALS largely remains supportive. Two FDA approved drugs for ALS—riluzole and edaravone—have a modest impact on the disease course.

INTRODUCTION

Motor neuron diseases comprise several disorders that are characterized primarily by the progressive degeneration of motor neurons in the spinal cord with or without the involvement of motor nuclei of the brainstem. *Motor neuron disease* is used to describe the typically adult-onset disease, *amyotrophic lateral sclerosis* (ALS), in which both corticospinal neurons, or "upper" motor neurons *and* lower motor neurons are affected. The terms *motor neuron disease* and *amyotrophic lateral sclerosis* are used interchangeably in the United States, where the disease is colloquially called *Lou Gehrig disease* after the famous baseball player who died of ALS in 1941. In Europe, ALS is named after Jean-Martin Charcot who first described the key clinical and pathologic features of the disease in 1869. As Charcot reported, ALS is predominantly a motor neuron disease, but clinical, genetic, and neuropathologic evidence have demonstrated that ALS is a multisystem neurodegenerative disorder, often associated with frontotemporal dementia (FTD), as described in Chapter 52.

The term *spinal muscular atrophy* refers to syndromes characterized solely by lower motor neuron signs. By conventional usage, the term *spinal muscular atrophy* is reserved for the childhood form, which is heritable, as described in Chapter 146.

TABLE 88.1 Motor Neuron Disease Variants

Amyotrophic lateral sclerosis (ALS)	Upper and lower motor neuron degeneration
Progressive muscular atrophy (PMA)	Purely lower motor neuron involvement
Primary lateral sclerosis (PLS)	Purely upper motor neuron involvement
Progressive bulbar palsy	Bulbar symptoms only or bulbar-onset ALS
Monomelic muscular atrophy	Lower motor neuron predominant, one arm
Bibrachial amyotrophy	Lower motor neuron predominant, both arms

Other motor neuron disease variants include progressive muscular atrophy (PMA), in which patients show only lower motor neuron signs; primary lateral sclerosis (PLS), in which only upper motor neuron signs; progressive bulbar palsy, in which weakness is limited to bulbar muscles; and monomelic amyotrophy, in which lower motor neuron findings are typically restricted to a single limb. These motor neuron disease subtypes are described more in detail in the following sections (Table 88.1).

It should be noted that there is some clinical overlap between motor neuron diseases, pure motor neuropathies (particularly those that are hereditary), and the hereditary spastic paraplegias (HSPs). Distinguishing and classifying clinical phenotypes that lie in the overlap between these diagnoses is often clinically challenging at present because of lack of diagnostic biomarkers.

Amyotrophic Lateral Sclerosis

ALS is defined pathologically as a disease in which there is degeneration of both *upper* motor neurons in the motor cortex and the *lower* motor neurons to which they project in the brainstem and spinal cord (Fig. 88.1). Clinically, ALS is defined by evidence of both lower motor neuron dysfunction (weakness, wasting, and fasciculation) and upper motor neuron dysfunction (spasticity, hyperactive tendon reflexes, or clonus) in the same limbs. There is no definitive test to establish a diagnosis of ALS, which remains a clinical diagnosis

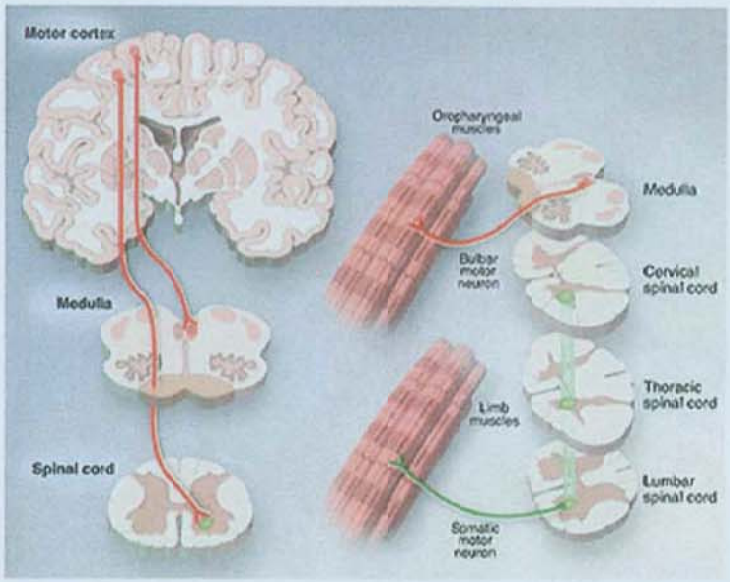

FIGURE 88.1 Selective motor degeneration in amyotrophic lateral sclerosis. Degeneration of corticospinal neurons in the motor cortex leads to clinically apparent signs of upper motor neuron abnormalities: overactive tendon reflexes, Hoffmann signs, Babinski signs, and clonus. Degeneration of motor neurons in the brainstem and spinal cord causes muscle atrophy, weakness, and fasciculation. (From Rowland LP, Shneider NA. Amyotrophic lateral sclerosis. *N Engl J Med.* 2001;344[22]:1688-1700.)

based on the presence of upper and lower motor neuron signs in patients with progressive, painless muscle weakness in whom no alternative explanation is found.

EPIDEMIOLOGY

ALS has an annual incidence of approximately 2 to 3 per 100,000 and a prevalence of 10 to 12 per 100,000 in Europe and the United States. However, significant geographic differences exist; for example, the incidence of ALS in Asia is below 1 per 100,000 per year. Although considered rare, the estimated cumulative lifetime risk for developing ALS is 1 in 350 for men, and 1 in 400 for women. On average, the age of symptom onset varies between 58 to 63 years for sporadic disease and 40 to 60 years for familial ALS (fALS). Most commonly a disease of middle and late life, only 10% of ALS cases begin before age 40 years; 5% begin before age 30 years, with a greater proportion of younger cases associated with a pathogenic mutation in an ALS gene. There is no known ethnic predilection except slightly higher incidence in Norway because of the concentration of some genetic mutations.

Other than genetics, age, and male gender, no other factors have been identified in controlled studies that increase one's risk for ALS. The possible role of lifestyle choices (smoking, physical fitness, body mass index, and physical exercise), occupational and environmental exposures (electromagnetic fields, metals, pesticides, β-methylamino-L-alanine, and viral infection), and potential links between ALS and other medical conditions (head trauma, metabolic diseases, cancer, and inflammatory diseases) have been considered, but no causal relationship has been convincingly demonstrated.

PATHOBIOLOGY

Genetics

ALS is a genetically complex disease. Mutations in over 30 genes have been causally associated with ALS and the related neurodegenerative disorder, FTD. Approximately 5% to 10% of ALS cases are fALS—most often, inherited in an autosomal dominant pattern, although recessive and X-linked inheritance has been reported. In addition, because of de novo mutations, incomplete penetrance, or limited family history, pathogenic mutation are also found in a significant percentage of apparently "sporadic" cases of ALS. Mutations in known ALS genes account for approximately 60% of fALS cases in Europeans, but less than half of Asian fALS patients, and the genetic basis of these heritable cases of ALS still have to be identified (Fig. 88.2).

The most common, known cause of ALS is a mutation in the gene *C9orf72*. In 2011, an expansion of the GGGGCC hexanucleotide repeat in this gene was discovered and found to be responsible for 30% to 50% of fALS cases and 5% to 10% of sporadic disease in Europe. The mutation is less common in Asian patients (see Fig. 88.2). The *C9orf72* expansion is also the most common cause of FTD, and either or both of these clinical phenotypes occurs in individuals and families with this mutation.

Mutations in the gene encoding the enzyme superoxide dismutase 1 (*SOD1*) are the second most common genetic cause of ALS in Europeans, and the most common cause in Asia, accounting for 15% and 30% of fALS cases, respectively (see Fig. 88.2). In 1993, *SOD1* was the first ALS gene to be found, and over 150 pathogenic mutations have since been identified in this gene, associated with a range of clinical phenotypes. Although the molecular mechanisms by which mutant SOD1 causes neurodegeneration are not fully known, evidence from animal and cellular models and in vitro studies have shown that toxicity results from a gain of function, and not a loss of SOD1 activity. This suggested that selective gene silencing may be an effective therapeutic strategy for ALS patients with SOD1 mutations, and in 2015, clinical trials began to test the efficacy of an antisense oligonucleotide targeting the SOD1 transcript; similar efforts have begun for C9orf72, FUS, and other ALS-related genes.

A list of the currently identified mutations in fALS at the time of publication of this text are listed in Table 88.2.

Neuropathology

Neuropathologic examination of the brain and spinal cord of ALS patients reveals selective vulnerability of corticospinal neurons in layer V of the primary motor cortex and large-diameter (α) motor neurons in the brainstem and spinal cord. The pathologic hallmark of ALS is neuronal inclusions that include Bunina bodies—small eosinophilic intraneuronal inclusions—and ubiquitinated, skein, or dash-like aggregates. In the vast majority (>95%) of ALS patients, including cases of sporadic disease and heritable cases associated with mutations in *C9orf72* and *TARDBP*, as well as most other ALS-related genes, these cytoplasmic and neuritic inclusions are characterized by the presence of abnormally phosphorylated and ubiquitinated TAR DNA binding protein 43 (TDP-43), a DNA-/RNA-binding protein encoded by the gene *TARDBP* (Fig. 88.3).

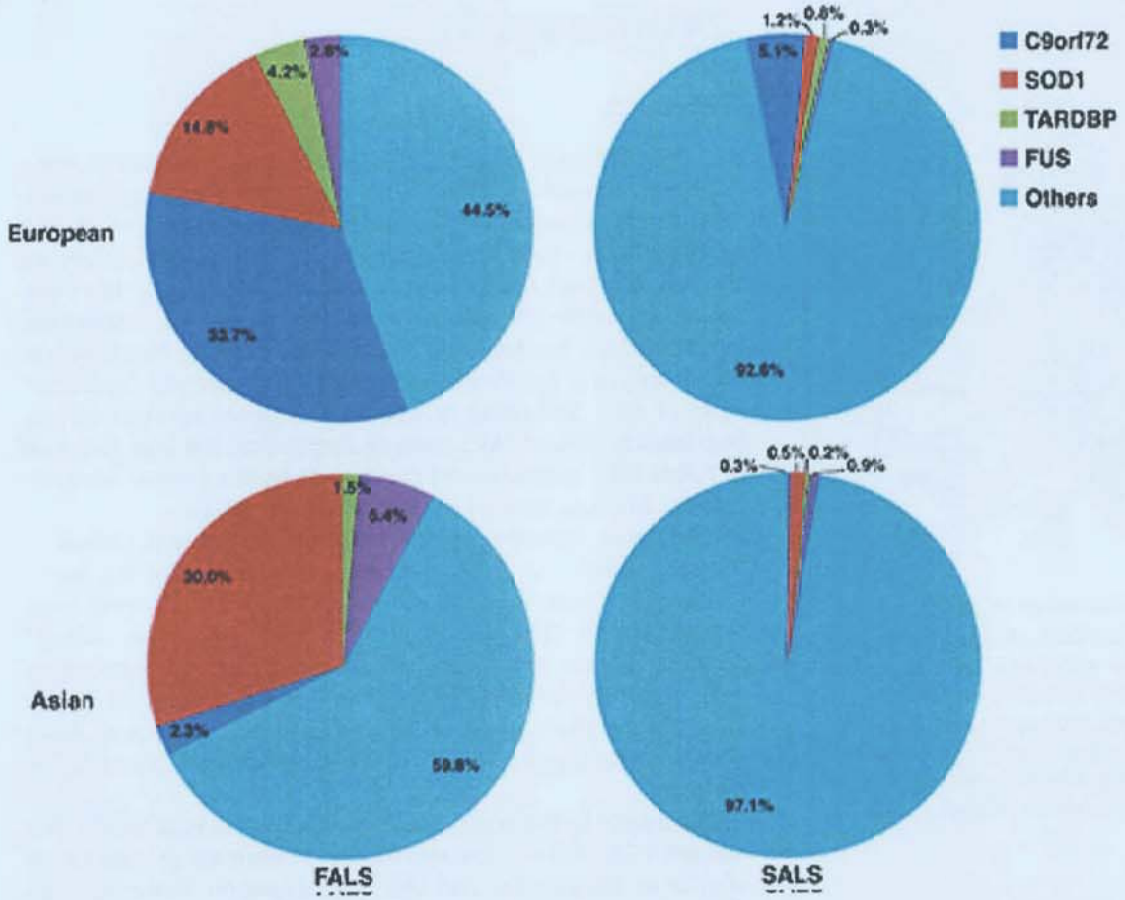

FIGURE 88.2 Genetic architecture of familial amyotrophic lateral sclerosis (FALS) and sporadic amyotrophic lateral sclerosis (SALS) in European and Asian populations. (From Zou ZY, Zhou ZR, Che CH, Liu CY, He RL, Huang HP. Genetic epidemiology of amyotrophic lateral sclerosis: a systematic review and meta-analysis. *J Neurol Neurosurg Psychiatry*. 2017;88:540-549. doi:10.1136/jnnp-2016-315018.)

First implicated as a key histopathologic player in ALS and FTD of unclear significance to disease mechanism, rare mutations in *TARDBP* (TDP-43) were identified in 2008 that were causally associated with ALS and FTD, providing a genetic link between these clinically and pathologically related disorders, and implicating TDP-43 as an active mediator of neurodegeneration. Pathogenic mutations in *FUsed in Sarcoma* (*FUS*)—a gene encoding a DNA-/RNA-binding protein closely related to TDP-43—were subsequently identified in individuals and families with ALS, including cases of juvenile-onset disease characterized by rapid clinical progression, and distinct, FUS-positive neuronal cytoplasmic inclusions on neuropathologic examination. FUS immunoreactive inclusions are basophilic bodies, related but distinct from hyaline conglomerates, neuronal intermediate filament inclusions found in ALS and related forms of FTD. Rare *FUS* mutations and FUS pathology are also associated with a subtype of FTD with a distinct cognitive/behavioral phenotype (**Fig. 88.4**).

Another notable exception to the finding of TDP-43 pathology in ALS are those cases associated with *SOD1* mutations in which abnormal inclusions stain positive for SOD1. The role of these inclusions in the pathogenesis of ALS remain to be fully elucidated, but the common features of these cellular abnormalities found in all ALS subtypes, including phenotypic variants like PMA and PLS suggest a shared underlying mechanism for these motor syndromes as well as for FTD.

Genetic studies have provided important insight into the cause of ALS and related motor neuron disorders, but the molecular and cellular mechanisms that underlie neurodegeneration in ALS remain the subject of investigation. ALS-associated mutations in *TARDPB*, *FUS*, and other genes encoding ribonucleoproteins (eg, *hnRNPA1*, *TAF15*) suggest that defects in RNA metabolism represent key pathogenic mechanism. Combined with the genetic evidence, the prominence of these proteins in the histopathology of ALS in the absence of a genetic mutation suggest that these mechanisms are shared between sporadic and fALS. Mutations in genes encoding proteins involved in autophagy and other protein quality control pathways (eg, TBK1, OPTN, p62[SQSTM1], and possibly C9orf72) suggest that defects in proteostasis also contribute to the pathogenesis of ALS. ALS genes encoding proteins involved in cytoskeletal dynamics and axonal transport (eg, profilin 1 [PFN1], KIF5A, DCTN1, TUBA4A) have also implicated these processes in the pathobiology of ALS.

Amyotrophic Lateral Sclerosis and Frontotemporal Dementia

The clinical, pathologic, and genetic links between ALS and FTD have become increasingly obvious (see **Fig. 88.4** and Chapter 52). Approximately 50% of patients with ALS have some degree of frontotemporal dysfunction, which manifests in a variable degree of impairment of executive and language function and behavioral changes. In about 10% to 15% of ALS patients, criteria for behavioral variant FTD or primary progressive aphasia are met, and a diagnosis of ALS-FTD can be made. A growing number of genes have been causally associated with both ALS and FTD including *C9orf72*, *TARDBP* (TDP-43), *FUS*, *VCP*, *CHMP2B*, *hnRNPA1*, *CHCHD10*, *SQSTM1/p62*, *TBK1*, and *UBQLN2*. On neuropathologic examination, TDP-43 and FUS pathology are each observed in FTD as well as ALS patients.

TABLE 88.2 Amyotrophic Lateral Sclerosis–Associated Genes[a]

Name	Site	Gene	Inheritance	Comment
FTD-ALS	9p21	C9orf72	AD	ALS and FTD Hexanucleotide expansion Most common cause of ALS
ALS1	21q22.1	SOD1	AD	Adult 15%-20% of familial ALS
ALS2	2q33	Alsin	AR	Juvenile; may resemble PLS
ALS3	18q21	—	—	—
ALS4	9q34	Senataxin (SETX)	AD	Juvenile; slow progression; allelic to CMT2
ALS5	15q15.1-q21.1	SPG11	AR	Juvenile Most common AR ALS Also seen in HSP
ALS6	16p11.2	FUsed in Sarcoma (FUS)	AD	Adult and juvenile onset
ALS7	20p13	—	AD	Adult
ALS8	20q13.33	VAPB	AD	Adult
ALS9	14q11.2	ANG	AD	—
ALS10	1p36.22	TARDBP	AD	Some with FTD
ALS11	6q21	FIG4	AD	Allelic to CMT 4J (AR)
ALS12	10p13	OPTN	AD/AR	—
ALS13	12q24.12	ATXN2	AD	CAG expansions and increased ALS risk Expansions also seen with SCA2
ALS14	9p13.3	VCP	AD	Mutations also seen with IBMPFD
ALS15	Xp11.21	UBQLN2	X-linked	Reduced penetrance in women
ALS16	9p13.3	SIGMAR1	AR	Juvenile
ALS17	3p11.2	CHMP2B	AD	May cause FTD
ALS18	17p13.2	PFN1(Profilin 1)	AD	—
ALS19	2q34	ERBB4	AD	—
ALS20	12q13.13	HNRNPA1	AD	May cause multisystem proteinopathy
ALS21	5q31.2	MATR3	AD	Formerly distal myopathy 2, VCPDM
ALS22	2q35	TUBA4A	AD	ALS and FTD
ALS23	10q22.3	ANXA11	AD	
ALS24	4q33	NEK1	AD	
ALS25	12q13.3	KIF5A	AD	Adult Also seen in HSP

Abbreviations: AD, autosomal dominant; ALS, amyotrophic lateral sclerosis; AR, autosomal recessive; CAG, cytosine-adenine-guanine; CMT2, Charcot-Marie-Tooth hereditary neuropathy type 2; CMT4J, Charcot-Marie-Tooth neuropathy type 4J; FTD, frontotemporal dementia; HSP, hereditary spastic paraplegia; IBMPFD, inclusion body myopathy with Paget disease and frontotemporal dementia; PLS, primary lateral sclerosis; SCA2, spinocerebellar ataxia type 2; VCPDM, vocal cord and pharyngeal dysfunction with distal myopathy.

[a]Other genes described and implicated in familial ALS-DAO, NEFH, HNRNPA2B1, SQSTM1/p62.

CLINICAL MANIFESTATIONS

The clinical onset of ALS is variable. Patients are characterized by the site of symptom onset: **Bulbar onset** patients first have difficulty with speech or swallowing (dysarthria or dysphagia), whereas in those with **spinal onset** disease, weakness may begin in the upper or lower extremities. Respiratory insufficiency is often a late complication of disease but can also be an initial symptom in ALS patients. Axial muscle weakness and head drop are also common in later stages of disease but can be presenting symptoms. Clinical distinctions in ALS are also made on the basis of age of onset, rate of progression, the relative degree of upper versus lower motor neuron signs, and the presence or absence of nonmotor signs and symptoms, including frontotemporal dysfunction or pseudobulbar affect (PBA).

Progressive, painless weakness is the typical primarily clinical feature of ALS, which typically begins focally and "spreads" to contiguous anatomical regions (eg, right arm to left arm, or right arm to right leg). Often, the hands are affected first, usually asymmetrically, and with muscle atrophy (Fig. 88.5) and fasciculation, which occur as a result of spontaneous depolarization of a motor neuron and the synchronous contraction of all fibers of a single motor unit. Gait is impaired because leg muscles are weak, and foot drop is characteristic, although

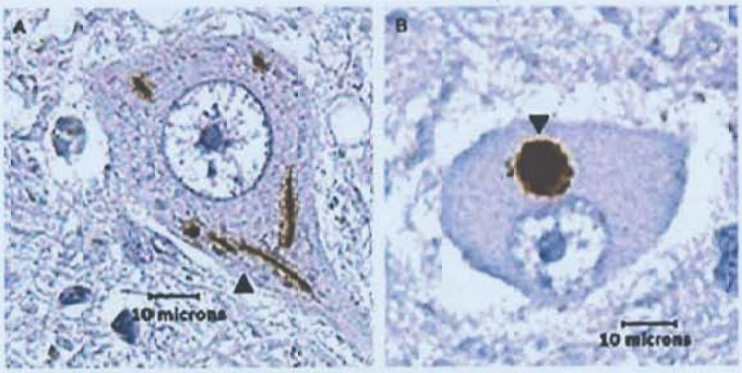

FIGURE 88.3 TDP-43 positive cytoplasmic aggregates in spinal motor neurons in amyotrophic lateral sclerosis. A: Skeins: multiple string-like TDP-43–positive aggregates *(arrowhead)*. B: Dense round inclusions: These appear as dense, round TDP-43–positive aggregates *(arrowhead)*. (Scale bar = 10 μm.) (From Bodansky A, Kim JM, Tempest L, Velagapudi A, Libby R, Ravits J. TDP-43 and ubiquitinated cytoplasmic aggregates in sporadic ALS are low frequency and widely distributed in the lower motor neuron columns independent of disease spread. 2010;11[3]:321-327.)

FIGURE 88.5 Hand atrophy in amyotrophic lateral sclerosis.

proximal limb muscles are sometimes affected first. In upper motor neuron–predominant disease, a spastic gait disorder may be evident, as well as defects in motor control. Muscle cramps are sudden, painful, and involuntary contractions of a muscle associated with bursts of high-frequency (up to 150 Hz) firing of affected motor neurons. Weight loss is commonly seen in ALS as a result of muscle wasting, dysphagia and anorexia, but hypermetabolism—defined as a significant elevation in measured versus predicted resting energy expenditure—also contributes to weight loss in ALS. Respiratory impairment results from involvement of the diaphragm and accessory muscles of breathing. Dysphagia may lead to aspiration and pneumonitis, which are commonly fatal events for ALS patients. Typically, bowel and bladder continence and sexual function are preserved in ALS, attributed to the sparing of Onuf nucleus in the sacral spinal cord. Extraocular motor nuclei are also rarely affected in ALS, which accounts for the typical sparing of the muscles that control eye movement. No sensory loss is observed clinically unless an associated neuropathy is present. Pain is not a primary symptom in ALS but may occur when limbs are immobile due to severe spasticity and joint contracture.

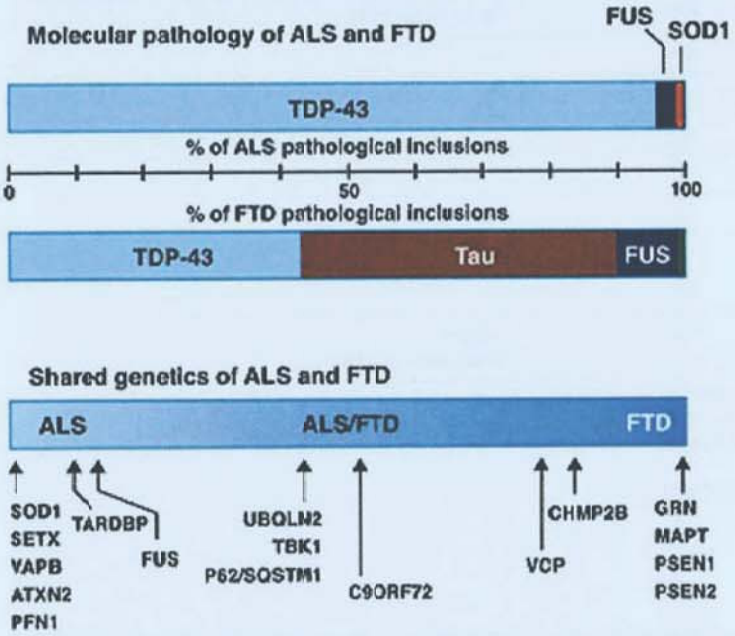

FIGURE 88.4 Amyotrophic lateral sclerosis (ALS) and frontotemporal dementia (FTD) are related disorders that share a variety of genetic and cytopathologic features. While TDP-43 pathology is observed in the vast majority of ALS cases, SOD1 and FUS inclusions are found in ALS patients with causal mutations in the respective gene. TDP-43, FUS, and tau (MAPT) pathology are hallmarks of frontotemporal lobar degeneration in FTD patients. On the ALS-FTD spectrum, some genetic mutations cause ALS or FTD, but a number of these ALS-associated mutations also cause FTD in families and individuals—most notably, the hexanucleotide expansion in the C9orf72 gene. (Adapted from Ling SC, Polymenidou M, Cleveland DW. Converging mechanisms in ALS and FTD: disrupted RNA and protein homeostasis. *Neuron*. 2013;79[3]:416-438.)

Lower motor neuron signs must be evident if the diagnosis is to be considered valid. Fasciculations may be seen in the tongue, even without dysarthria. If there is weakness and wasting of limb muscles, fasciculations are almost always seen. Tendon reflexes may be increased or decreased; the combination of overactive reflexes with Hoffmann signs in arms with weak, wasted, and fasciculating muscles is virtually pathognomonic of ALS. Unequivocal signs of upper motor neuron disorder are spasticity, Hoffmann or Babinski signs, and clonus. If a spastic gait disorder is seen without lower motor neuron signs in the legs, weakness in the legs may not be found, but incoordination is evident by clumsiness and slowness in the performance of alternating movements (Table 88.3).

The cranial nerve motor nuclei are implicated by dysarthria, lingual wasting and fasciculations, and impaired movement of the uvula (Fig. 88.6). Facial weakness and wasting can be discerned, especially in the mentalis muscle, but is usually not prominent. Dysarthria and dysphagia caused by upper motor neuron disease is made evident by movements of the uvula that are more vigorous on reflex innervation than on volition; that is, the uvula does not move well (or at all) on phonation, but a vigorous response is seen in the pharyngeal or gag reflex.

Pseudobulbar palsy is an upper motor neuron palsy caused by loss of corticobulbar tract input to the cranial motor nuclei. Patients with pseudobulbar palsy have a lack of facial expression, difficulty chewing, and emotional lability (PBA). They present with upper motor neuron signs (spastic tongue, exaggerated gag, and

TABLE 88.3 Typical Clinical Findings in Amyotrophic Lateral Sclerosis

Upper Motor Neuron Symptoms and Signs
Spasticity
Hyperreflexia in deep tendon reflexes and/or clonus
Babinski sign/extensor plantar response
Hoffman sign
Increased jaw jerk
Spastic dysarthria
Pseudobulbar affect
Lower Motor Neuron Symptoms and Signs
Decreased muscle tone
Muscle atrophy
Fasciculations
Cramps
Hyporeflexia
Tongue atrophy and fasciculations
Facial weakness
Dysphagia
Dysarthria
Respiratory weakness
Neck weakness, head drop

jaw jerk reflexes), in contrast to patients with bulbar palsy who show lower motor neuron signs (atrophy and fasciculations of the tongue, absent gag reflex). PBA is a common nonmotor manifestation of ALS characterized by involuntary and uncontrollable laughter or crying that is disproportionate to an event. Episodes may also be mood incongruent in that a person may laugh uncontrollably when angry or frustrated, for example. PBA may often be misdiagnosed as clinical depression. Although not usually disabling as are the physical symptoms of ALS, PBA can have a negative social impact on one's interpersonal relationships, leading to isolation. Fortunately, symptoms of PBA respond well to a mixture of dextromethorphan hydrobromide and quinidine sulfate.

FIGURE 88.6 Tongue atrophy in amyotrophic lateral sclerosis.

DIAGNOSIS

ALS is primarily a clinical diagnosis and electrodiagnostic, radiographic, and laboratory test results must be combined with clinical finding to determine the diagnosis. Ultimately, a clinical history and a comprehensive physical and neurologic exam are the most important diagnostic tools in ALS evaluation. The combination of upper and lower motor neuron findings in multiple limbs with bulbar muscle involvement has little differential diagnosis.

Amyotrophic Lateral Sclerosis Diagnostic Criteria

Several sets of criteria have been proposed for the clinical and research diagnosis of ALS. The most commonly used are the revised El Escorial criteria (Table 88.4), which for the diagnosis of definite ALS, requires the combination of upper and lower motor neuron findings in three of four potential anatomic regions (cranial, cervical, thoracic, and lumbosacral). The Awaji ALS criteria were developed in 2008 with the intention of including a greater number of ALS patients earlier in their clinical course through some adjustments to the electrodiagnostic and clinical criteria required (Table 88.5). The Awaji criteria are primarily designed for research purposes, and many patients are diagnosed with and treated for ALS before they fully meet this standard.

Motor Neuron Disease Variants

ALS comprises multiple motor phenotypes that are mainly classified on the basis of the relative degree of upper versus lower motor neuron dysfunction and the regional distribution of clinical involvement.

Progressive Muscular Atrophy

PMA is the term used to describe the lower motor neuron only form of motor neuron disease. Clinical findings and course are similar to ALS but without the associated upper motor neuron signs, such as hyperreflexia, Babinski or Hoffman signs, or spasticity. Approximately 30% of patients diagnosed with PMA will develop upper motor neuron signs in the course of their disease, so pathologically true PMA likely accounts for less than 8% of cases of motor neuron disease. Patients with lower motor neuron–predominant ALS and PMA usually live longer than typical ALS patients.

TABLE 88.4 Revised El Escorial Criteria for the Diagnosis of Amyotrophic Lateral Sclerosis

• Suspected ALS: a pure LMN syndrome in two or more regions
• Possible ALS: UMN and LMN signs present together in one region or UMN signs alone in two or more regions or LMN signs rostral to UMN signs
• Laboratory-supported ALS: UMN and LMN signs in one region or UMN signs alone in one region with LMN signs identified by EMG in two regions
• Probable ALS: UMN and LMN signs in more than two regions, and some UMN signs must be rostral to (above) LMN signs
• Definite ALS: UMN and LMN signs in three or more regions
All require absence of electrophysiologic or pathologic evidence of another disease process to explain clinical findings.

Abbreviations: ALS, amyotrophic lateral sclerosis; EMG, electromyogram; LMN, lower motor neuron; UMN, upper motor neuron.

TABLE 88.5 Awaji Criteria for the Diagnosis of Amyotrophic Lateral Sclerosis

The diagnosis of amyotrophic lateral sclerosis (ALS) requires the presence of the following:
• Evidence of lower motor neuron (LMN) degeneration by clinical, electrophysiologic, or neuropathologic examination
• Evidence of upper motor neuron (UMN) degeneration by clinical examination
• Progressive spread of symptoms or signs within a region or to other regions, as determined by history, physical examination, or electrophysiologic tests
The absence of the following:
• Electrophysiologic or pathologic evidence of other disease processes that might explain the signs of LMN and/or UMN degeneration
• Neuroimaging evidence of other disease processes that might explain the observed clinical and electrophysiologic signs
Diagnostic Categories
• Clinically definite ALS is defined by clinical or electrophysiologic evidence by the presence of LMN as well as UMN signs in the bulbar region and at least two spinal regions or the presence of LMN and UMN signs in three spinal regions.
• Clinically probable ALS is defined on clinical or electrophysiologic evidence by LMN and UMN signs in at least two regions with some UMN signs necessarily rostral to (above) the LMN signs.
• Clinically possible ALS is defined when clinical or electrophysiologic signs of UMN and LMN dysfunction are found in only one region, or UMN signs are found alone in two or more regions, or LMN signs are found rostral.

The diagnosis of PMA should always be made with caution because it raises the question of a potentially treatable motor neuropathy, such as multifocal motor neuropathy (MMN). Diagnostic testing should include electrodiagnostic testing (electromyography and nerve conducting studies) with proximal stimulation on nerve conduction studies (NCS) to exclude areas of conduction block and demyelinating findings, lab testing to evaluate for antibodies often seen in motor neuropathies, and consideration for spinal fluid testing to look for elevated protein. Magnetic resonance imaging (MRI) of the brain and transcranial magnetic stimulation (TMS) can be used to look for subclinical upper motor neuron involvement.

Primary Lateral Sclerosis

PLS refers to the clinical syndrome of progressive motor neuron disease affecting only upper motor neurons. Typically, symptoms of PLS begin symmetrically in the legs, but bulbar onset disease is also common. For a diagnosis of PLS, no lower motor neuron signs (muscle atrophy, visible fasciculations, or electrophysiologic evidence of denervation) can be present. A majority of PLS patients develop lower motor neuron signs within 3 to 4 years of disease onset, and the clinical picture becomes one of upper motor neuron–predominant ALS. PLS represents only about 3% to 5% of all cases of motor neuron disease.

The clinical symptoms and signs in PLS include spasticity and associated gait dysfunction, spastic dysarthria, and associated pathologic reflexes. Testing must include neuroimaging to exclude structural causes of upper motor neuron injury, lab testing to evaluate for metabolic disorders mimicking the clinical picture, and consideration for spinal fluid testing for infectious and inflammatory causes. Electrodiagnostic testing is critical for evaluating for lower motor neuron involvement, even in patients without clinical atrophy or fasciculations, and may need to be repeated over months to years to confirm the absence of denervation. The appearance of lower motor neuron signs can be delayed in some patients initially diagnosed with PLS, whose disease morphs into an upper motor neuron–predominant form of ALS. For this reason, a diagnosis of PLS requires at least 4 years of observation. When spasticity and upper motor neuron findings are restricted to the legs or spare bulbar muscles, the clinician must consider the alternative diagnosis of hereditary spastic paraplegia.

Progressive Bulbar Palsy

The term *progressive bulbar palsy* has been used to describe motor neuron disease selectively affecting the bulbar muscles, causing dysarthria and dysphagia. This term is falling out of favor because most of these patients do have at least some limb involvement, which may be subclinical at the time that bulbar symptoms begin. The term *bulbar-onset ALS* is more appropriate to describe those patients presenting with early or prominent bulbar symptoms.

Monomelic Muscular Atrophy

Monomelic muscular atrophy is a focal motor neuron disease restricted to one limb, usually an arm and a hand rather than a leg. Other names for the syndrome include *monomelic amyotrophy*, *benign focal amyotrophy*, *spinal muscular atrophy of the unilateral upper extremity*, and *Hirayama syndrome*.

Monomelic muscular atrophy affects men 10 times more often than women and starts at about 20 years of age, in contrast to typical sporadic ALS, which has a much older age of onset. The disease is most commonly seen in southeastern Asia, particularly in Japan and India, although cases have been reported in Western countries. The weakness typically involves the hand and forearm, involving C7-T1 innervated muscles. Tendon reflexes are generally reduced in the affected arm. Upper motor neuron signs in other limbs are not seen. The condition progresses for 1 or 2 years and then seems to become arrested in most cases, although some patients continue to progress slowly for many years. The origin of the disorder is not known.

A *pseudopolyneuritic* variant of ALS, also known as *flail leg syndrome*, is also a lower motor neuron–predominant disorder characterized by progressive, asymmetrical, distal-onset weakness and wasting in the lower extremities, without initial involvement of the upper extremities or bulbar region. Compared to typical ALS, patients with monomelic syndromes have a significantly longer expected survival after symptom onset.

The differential diagnosis for monomelic muscular atrophy should include the initial onset of a more generalized ALS, MMN, or polio-like infectious syndromes, as in those seen with West Nile virus.

Bibrachial Amyotrophy

A few percent of patients develop a lower motor neuron syndrome restricted to both arms. As in monomelic amyotrophy, it is more common in men than women, with a ratio of 8 to 9:1. It usually presents with proximal arm and shoulder muscle weakness. The progression is much slower than typical ALS. Arm posture is typically pronated, and arms are dangling; sometimes, it is called *brachial amyotrophic diplegia* or *man-in-the-barrel syndrome*. Usually, lower motor neuron findings predominate, but, sometimes, upper motor neuron signs are present.

Diagnostic Testing

Electrodiagnostic Testing

Electrodiagnostic testing including NCS and EMG are critical to demonstrating lower motor neuron involvement in ALS and excluding motor neuropathy mimics. NCS may not only show low motor amplitudes but may also be normal, particularly early in the disease course. NCS are done primarily to exclude findings suggestive of motor neuropathy, with conduction block or other demyelinating features. Abnormal sensory responses should not be seen in ALS unless related to an unrelated condition (eg, diabetic neuropathy). Needle EMG should demonstrate evidence of active denervation (fibrillation and fasciculation potentials) and chronic denervation in three body segments (cranial, cervical, thoracic, and lumbosacral) to meet Awaji or El Escorial criteria. It should be noted that the electrodiagnostic testing must be combined with radiographic data and finding on clinical exam because a severe polyradiculopathy or motor neuropathy could cause similar EMG abnormalities.

TMS is an electrodiagnostic method used to assess central nerve conductions as a functional measure of upper motor neuron abnormalities in ALS. TMS is most useful when the predominant clinical picture is of lower motor neuron dysfunction, which may mask upper motor neuron findings. Stimulation over the motor cortex, cervical spine, and lumbar spine is performed with recording of a compound motor action potential, assessing for delayed latency, and central conduction. TMS is not widely available.

Neuroimaging

Imaging of the brain and spine, with MRI is typically recommended to exclude structural processes, including mass lesions and degenerative spine disease that may mimic the signs and symptoms of ALS. In most cases of ALS, neuroimaging is normal or demonstrates mild incidental abnormalities; however, occasionally, MRI shows abnormally high-signal intensity in the intracranial corticospinal tract on T2-weighted and proton density–weighted images and fluid-attenuated inversion recovery sequences. Although the relationship of these abnormalities to upper motor neuron dysfunction are not clear, hyperintensity in the corticospinal tract is diagnostic evidence in support of upper motor involvement in ALS, especially when found in the subcortical precentral gyrus, centrum semiovale, and cerebral peduncles levels. MRI evidence of atrophy in frontal and temporal regions is evidence of associated FTD in ALS patients.

Lab Testing

Spinal fluid studies are not required in the assessment of a patient with suspected ALS. However, in atypical cases, lower motor neuron (PMA) or upper motor neuron variants (PLS), or when there is concern for a motor neuropathy mimic, these studies should be done to look for elevation in protein, white blood cells, abnormal cytology, or elevated immunoglobulin G synthesis.

Blood tests are recommended to evaluate for metabolic, endocrine, or inflammatory conditions that might mimic ALS. Testing for monoclonal gammopathy, antiganglioside antibodies, angiotensin-converting enzyme levels, parathyroid hormone, and paraneoplastic markers rarely result in an alternative diagnosis. Creatine kinase levels are often modestly elevated in ALS and are not inconsistent with the diagnosis. As gene silencing and other targeted therapeutics are developed for genetic forms of ALS, and given the implications for family members at risk, genetic testing for ALS-associated mutations should be considered in all cases of ALS, including those in which no family history is suggested. This is best performed with the help of a genetic counselor or physician experienced in genetic testing.

Muscle Biopsy

Muscle biopsy is not routinely recommended in the evaluation of ALS and associated motor neuron disorders and typically demonstrates findings consistent with active and chronic denervation. The primary indication for muscle biopsy when considering a diagnosis of ALS is if there are clinical findings suggestive of inclusion body myositis (IBM), which may have some overlap in clinical presentation.

Differential Diagnoses

Although the typical clinical picture of ALS is difficult to confuse with other neurologic disorders, cases occur that raise the question of other neuromuscular disorders with similar clinical phenotypes. Given that there is currently no disease-modifying treatment for ALS, the focus of testing when this diagnosis is considered is on excluding these other potentially treatable disorders (Table 88.6).

Multifocal Motor Neuropathy

MMN or MMN with conduction block is a clinical syndrome of pure motor neuropathy, with conduction block in more than one nerve and not at sites of entrapment neuropathy. Anti-GM1 or other ganglioside antibodies are often associated. Symptoms often begin or predominate in the upper extremities. Although frank upper motor neuron findings should not be present, deep tendon reflexes are sometimes relatively preserved and muscle atrophy is often minimal given the degree of weakness. MMN is a potentially treatable autoimmune condition, treated with intravenous immunoglobulin or other immunosuppressing drugs, so the focus of NCS is often on assessing for this treatable diagnosis.

Myasthenia Gravis

Myasthenia gravis is a common cause of dysarthria and dysphagia in people who are in the age range of those afflicted with ALS and may be considered in the differential diagnosis when bulbar symptoms predominate. If there is concomitant ptosis or ophthalmoparesis, if diurnal fluctuation in severity is marked, or if remissions have occurred, myasthenia gravis is more likely. If there is suspicion for this diagnosis, testing should include blood testing of antibodies to acetylcholine receptor and muscle-specific tyrosine kinase and repetitive stimulation with NCS. Myasthenia gravis is reviewed further in Chapter 93.

Spinal Stenosis

Although spinal disease should not cause bulbar symptoms, cervical and lumbosacral polyradiculopathy due to spinal stenosis can cause a combination of upper and lower motor neuron symptoms and exam findings in patients with pure limb symptoms, which may be difficult to distinguish from limb-onset ALS. Spine imaging with MRI is thus recommended for all patients in whom the diagnosis of ALS is considered. Spinal stenosis is reviewed further in Chapter 114.

Myopathy

Myopathy, most notably IBM, may present with a clinical syndrome similar to ALS, with prominent arm weakness (typically affecting finger flexors and quadriceps disproportionately) and

TABLE 88.6 Differential Diagnosis of Motor Neuron Diseases

Multifocal motor neuropathy	• Primarily lower motor neuron syndrome but may have preserved reflexes • Conduction block on nerve conduction studies • Lab testing for GM1 antibodies
Chronic inflammatory demyelinating polyneuropathy	• Sensorimotor involvement is clinically typical. • Demyelinating findings on nerve conduction studies • Elevated CSF protein
Myasthenia gravis	• Ocular symptoms, fluctuation, and fatigability are more typical. • Decrement on repetitive stimulation with nerve conduction studies and no denervation on needle EMG • Acetylcholine receptor and muscle-specific kinase antibodies if clinically appropriate
Spinal stenosis	• Typically more pain and sensory symptoms • MRI or other imaging demonstrates structural abnormalities • No bulbar or facial involvement
Inclusion body myositis	• Typically affects quadriceps and finger flexors more severely • Needle EMG shows myopathic findings. • Greater elevations in CK levels • Muscle biopsy to confirm diagnosis if clinical suspicion
Postpolio syndrome	• History of polio with later life decline in strength
Hereditary spastic paraparesis	• Upper motor neuron syndrome affecting primarily the legs • Family history may be useful. • Genetic testing when clinically appropriate
Benign fasciculation syndrome/cramp fasciculation syndrome	• Absence of weakness, muscle wasting • Electrodiagnostics may show fasciculations but no other abnormalities.
Paraneoplastic syndromes	• Paraneoplastic panel/antibody testing
Other systemic disorders	• Diabetes, sarcoidosis, parathyroid disease, hexosaminidase A deficiency

Abbreviations: CK, creatine kinase; CSF, cerebrospinal fluid; EMG, electromyogram; MRI, magnetic resonance imaging.

bulbar symptoms. Needle EMG testing is usually suggestive of a myopathic disorder, but, sometimes, neurogenic findings are seen. Creatine kinase levels should be higher in IBM than in ALS. Fasciculations and upper motor neuron findings should not be seen in muscle disorders. Muscle biopsy is recommended when inflammatory myopathies are considered.

Postpolio Syndrome

Postpolio syndrome is characterized by clinical worsening of weakness years after full or partial recovery from viral poliomyelitis. This syndrome is likely a consequence of the slow loss of anterior horn cells with normal aging in postpolio patients who previously lost a large fraction of motor neurons in certain motor pools. The function of these previously paralyzed muscles depends on the giant motor units that result from the reinnervation of denervated muscle fibers through terminal axonal sprouting during the recovery phase of acute polio. As these units degenerate with age, new weakness progresses slowly in these previously paralyzed muscles.

Benign Fasciculations

Fasciculations, with or with muscle cramps, in the absence of weakness or upper motor neuron findings is nearly always a benign finding. There is no increased risk for future motor neuron disease in these patients. Electrodiagnostic testing may be useful to demonstrate no evidence of active or chronic denervation and to reassure the patient regarding the diagnosis.

Spinobulbar Muscular Atrophy (Kennedy Disease)

Although not considered a form of fALS, X-linked recessive spinobulbar muscular atrophy (SBMA), commonly known as *Kennedy disease*, is a hereditary motor neuron disease that should be included in the differential diagnosis of ALS. SBMA is a progressive debilitating neurodegenerative disorder resulting in muscle cramps and progressive weakness due to degeneration of motor neurons in the brainstem and spinal cord. SBMA is caused by expansion of a trinucleotide cytosine-adenine-guanine (CAG) repeat in the first exon of the androgen receptor gene, which maps to Xq11-q12. Early symptoms often include dysarthria and dysphagia with prominent tongue and mentalis fasciculations. Increasing weakness of limb muscles with muscle wasting gradually ensues. Upper motor neuron signs are often absent. In contrast to ALS, there is often an associated large-fiber sensory peripheral neuropathy. Gynecomastia is present in most but not all patients. Diagnostic clues include the characteristic distribution of signs, lack of upper motor neuron signs, slow progression, and a family history suggesting X-linked inheritance. Symptoms usually begin after age 40 years, and the disease progresses very slowly but can eventually lead to extreme disability. Earlier symptom onset and increased severity of the disease correlate with the length of the expansion of the CAG repeat. Neuromuscular management is supportive.

MANAGEMENT

Pharmacotherapy

Despite advances in our understanding of ALS genetics and the mechanisms that underlie neurodegeneration, there is no effective disease-modifying drug therapy for ALS or related motor neuron diseases.

Riluzole, a glutamate inhibitor, was the first drug approved by the U.S. Food and Drug Administration (FDA) for the treatment of ALS. In two randomized controlled trials, it was shown to improve 12- and 18-month survival, although the benefits were small LEVEL 1.[1,2] The usual dose is 50 mg twice daily. The most common side effects are nausea and dizziness, and hepatic function monitoring is recommended.

Edaravone (Radicava) was approved for the treatment of ALS in Japan in June 2015 and by the FDA in May 2017. Administered by intravenous infusion, edaravone is known to be an antioxidant, but the mechanism by which it might be effective in ALS is unknown.

Multidisciplinary Supportive Care

Given the limited efficacy of pharmacotherapy, treatment is primarily symptomatic (Table 88.7). Management by a multidisciplinary ALS care center is one of the few interventions

TABLE 88.7 Treatment for Amyotrophic Lateral Sclerosis and Motor Neuron Disorders

Disease Modifying
• Riluzole: only FDA-approved disease-modifying therapy for ALS
Improving Quality of Life and/or Survival
• Multidisciplinary ALS center care
• Noninvasive positive pressure ventilation/cough assist machine
• Physical therapy and rehabilitation
• Durable medical equipment and assistive devices to prevent falls and improve mobility
• Nutritional/calorie maintenance and percutaneous gastrostomy tube
• Tracheostomy and mechanical ventilation
Symptomatic Therapies
• Treatment of sialorrhea—atropine, glycopyrrolate, amitriptyline, botulinum toxin injections
• Treatment of spasticity—baclofen, cyclobenzaprine, benzodiazepines, intrathecal baclofen
• Communication devices
• Pseudobulbar symptom management—dextromethorphan-quinidine, SSRIs
• Treatment of depression and associated mood disorders—SSRI, SNRI, tricyclic antidepressants
• Treatment of fatigue—modafinil, pyridostigmine
• Emotional support for patient and family caregivers
Comfort Measures, Pain Control, Palliative Care, and Hospice

Abbreviations: ALS, amyotrophic lateral sclerosis; FDA, U.S. Food and Drug Administration; SNRI, serotonin-norepinephrine reuptake inhibitors; SSRIs, selective serotonin reuptake inhibitors.

shown to improve survival and quality of life LEVEL 2.[3] Early in the course, patients should try to continue to perform routine activities as long as they can. There is difference of opinion about exercising weak muscles, but physical therapy can help maintain function as long as possible. Drooling of saliva (sialorrhea) may be helped by atropine sulfate, glycopyrrolate, amitriptyline, or botulinum toxin injections into the salivary glands. Antispasticity agents are of limited use in the treatment of spastic gait disorder, but intrathecal administration of baclofen might be considered in some patients, particularly those with PLS and upper motor neuron–predominant ALS. Dysphagia often leads to the placement of a feeding tube to maintain nutrition and hydration, but it does not prevent aspiration. Augmentative communication devices are used to support patients with severe dysarthria/anarthria. Noninvasive positive pressure ventilation has been used with increasing frequency to manage nocturnal dyspnea, insomnia, and overall respiratory discomfort, and it is likely not only to prolong life but also to improve quality of life LEVEL 2.[4] Use of a mechanical in-exsufflation or cough assist device together with noninvasive positive pressure ventilation can also have a positive effect on patients' survival. Medications may also help with pseudobulbar symptoms, including the use of the combination drug dextromethorphan-quinidine LEVEL 2.[5]

The long-term care of patients with ALS has been addressed by evidence-based medicine recommendations made by a committee of the American Academy of Neurology. These guidelines state that management by a multidisciplinary ALS care team results in better symptomatic treatment, improved quality of life, and prolonged survival. Advance care planning is an important aspect of disease management. In Western countries, only a minority of ALS patients undergo tracheostomy and mechanical ventilation, and such interventions commonly occur under emergency conditions in the absence of advance directives. Palliative care medicine—a practice focused on treating the symptoms, discomfort and stress of illness, an on giving physical and emotional support to patients and families—has become a standard of ALS care (see also Chapter 158).

OUTCOME

The natural history of ALS is highly variable, so it is not possible to predict disease course and outcome accurately in individual patients. This complicates risk assessment and counseling of those newly diagnosed with ALS as well as the stratification of patients in clinical trials. For the ALS patient population as a whole, certain clinical features of the disease are associated with shorter survival, including bulbar and respiratory onset, advanced age at onset of symptoms, and a rapid functional decline (as measured by the ALS functional rating scale revised). Based on these determinants, a predictive model of survival has been developed for individual patients with ALS, which may serve as useful tools for personalized patient management, counseling, and innovative trial design. As noted, some specific ALS-related mutations are also associated with rapid progression and reduced survival (eg, A4V in *SOD1* and P525L in *FUS*). In general, the course is progressive without remission or stable plateaus. Death typically results from respiratory failure, aspiration pneumonitis, or pulmonary embolism after prolonged immobility. The mean duration of symptoms is about 4 years; nearly 10% of patients live longer than 10 years. Once a tracheostomy has been placed, the patient may be kept alive for years, although paralyzed except perhaps for eye movement. In exceptional cases, patients die in the first year or live longer than 25 years.

LEVEL 1 EVIDENCE

1. Bensimon G, Lacomblez L, Meininger V. A controlled trial of riluzole in amyotrophic lateral sclerosis. ALS/Riluzole Study Group. *N Engl J Med*. 1994;330:585-591.
2. Lacomblez L, Bensimon G, Leigh PN, Guillet P, Meininger V. Dose-ranging study of riluzole in amyotrophic lateral sclerosis. Amyotrophic Lateral Sclerosis/Riluzole Study Group II. *Lancet*. 1996;347:1425-1431.
3. Van den Berg JP, Kalmijn S, Lindeman E, et al. Multidisciplinary ALS care improves quality of life in patients with ALS. *Neurology*. 2005;65:1264-1267.
4. Bourke SC, Tomlinson M, Williams TL, Bullock RE, Shaw PJ, Gibson GJ. Effects of non-invasive ventilation on survival and quality of life in patients with amyotrophic lateral sclerosis: a randomised controlled trial. *Lancet Neurol*. 2006;5:140-147.
5. Brooks BR, Thisted RA, Appel SH, et al; for AVP-923 ALS Study Group. Treatment of pseudobulbar affect in ALS with dextromethorphan/quinidine: a randomized trial. *Neurology*. 2004;63:1364-1370.

SUGGESTED READINGS

Andersen PM, Abrahams S, Borasio GD, et al; for EFNS Task Force on Diagnosis and Management of Amyotrophic Lateral Sclerosis. EFNS guidelines on the clinical management of amyotrophic lateral sclerosis (MALS)—revised report of an EFNS task force. *Eur J Neurol*. 2012;19:360-375.

Ashworth NL, Satkunam LE, Deforge D. Treatment for spasticity in amyotrophic lateral sclerosis/motor neuron disease. *Cochrane Database Syst Rev*. 2012;(2):CD004156.

Baldinger R, Katzberg HD, Weber M. Treatment for cramps in amyotrophic lateral sclerosis/motor neuron disease. *Cochrane Database Syst Rev*. 2012;(4): CD004157.

Blexrud MD, Windebank AJ, Daube JR. Long-term follow-up of 121 patients with benign fasciculations. *Ann Neurol*. 1993;34:622-625.

Brooks BR, Miller RG, Swash M, et al; for World Federation of Neurology Research Group on Motor Neuron Diseases. El Escorial revisited: revised criteria for the diagnosis of amyotrophic lateral sclerosis. *Amyotroph Lateral Scler Other Motor Neuron Disord*. 2000;1:293-299.

Brown RH, Al-Chalabi A. Amyotrophic lateral sclerosis. *N Engl J Med*. 2017;377: 162-172.

Byrne S, Walsh C, Lynch C, et al. Rate of familial amyotrophic lateral sclerosis: a systematic review and meta-analysis. *J Neurol Neurosurg Psychiatry*. 2011;82:623-627.

Chancellor AM, Warlow CP. Adult onset motor neuron disease: worldwide mortality, incidence and distribution since 1950. *J Neurol Neurosurg Psychiatry*. 1992;55:1106-1115.

Chiò A, Logroscino G, Hardiman O, et al; and Eurals Consortium. Prognostic factors in ALS: a critical review. *Amyotroph Lateral Scler*. 2009;10(5-6): 310-323. doi:10.3109/17482960802566824.

Dalakas MC, Elder G, Hallett M, et al. A long-term follow-up study of patients with post-poliomyelitis neuromuscular symptoms. *N Engl J Med*. 1986;314:959-963.

D'Amico E, Pasmantier M, Lee YW, Weimer L, Mitsumoto H. Clinical evolution of pure upper motor neuron disease/dysfunction (PUMMD). *Muscle Nerve*. 2013;47:28-32.

de Carvalho M, Dengler R, Eisen A, et al. Electrodiagnostic criteria for diagnosis of ALS. *Clin Neurophysiol*. 2008;119:497-503.

DeJesus-Hernandez M, Mackenzie IR, Boeve BF, et al. Expanded GGGGCC hexanucleotide repeat in noncoding region of *C9ORF72* causes chromosome 9p-linked FTD and ALS. *Neuron*. 2011;72:245-256.

Dimos JT, Rodolfa KT, Niakan KK, et al. Induced pluripotent stem cells generated from patients with ALS can be differentiated into motor neurons. *Science*. 2008;321:1218-1221.

Donofrio PD, Berger A, Brannagan TH III, et al. Consensus statement: the use of intravenous immunoglobulin in the treatment of neuromuscular conditions report of the AANEM ad hoc committee. *Muscle Nerve*. 2009;40:890-900.

Floyd AG, Yu QP, Piboolnurak P, et al. Transcranial magnetic stimulation in ALS: utility of central motor conduction tests. *Neurology*. 2009;72:498-504.

GBD 2015 Motor Neuron Disease Collaborators. Global, regional, and national burden of motor neuron diseases 1990-2016: a systematic analysis for the Global Burden of Disease Study 2016. *Lancet Neurology*. 2018;17:1083-1097.

Gordon PH, Cheng B, Katz IB, Mitsumoto H, Rowland LP. Clinical features that distinguish PLS, upper motor neuron-dominant ALS, and typical ALS. *Neurology*. 2009;72:1948-1952.

Gordon PH, Cheng B, Katz IB, et al. The natural history of primary lateral sclerosis. *Neurology*. 2006;66:647-653.

Gourie-Devi M, Nalini A. Long-term follow-up of 44 patients with brachial monomelic amyotrophy. *Acta Neurol Scand*. 2003;107:215-220.

Hardiman O, Al-Chalabi A, Chio A, et al. Amyotrophic lateral sclerosis. *Nat Rev Dis Primers*. 2017;3:17085.

Hirayama K, Tokumaru Y. Cervical dural sac and spinal cord in juvenile muscular atrophy of distal upper extremity. *Neurology*. 2000;54:1922-1926.

Huang YC, Ro LS, Chang HS, et al. A clinical study of Hirayama disease in Taiwan. *Muscle Nerve*. 2008;37:576-582.

Ince PG, Evans J, Knopp M, et al. Corticospinal tract degeneration in the progressive muscular atrophy variant of ALS. *Neurology*. 2003;60:1252-1258.

Ingre C, Roos PM, Piehl F, Kamel F, Fang F. Risk factors for amyotrophic lateral sclerosis. *Clin Epidemiol*. 2015;7:181-193. doi:10.2147/CLEP.S37505.

Joint Task Force of the European Federation of Neurological Societies and the Peripheral Nerve Society. European Federation of Neurological Societies/Peripheral Nerve Society guideline on management of multifocal motor neuropathy. Report of a joint task force of the European Federation of Neurological Societies and the Peripheral Nerve Society—first revision. *J Peripher Nerv Syst*. 2010;15:295-301.

Kaufmann P, Pullman SL, Shungu DC, et al. Objective tests for upper motor neuron involvement in amyotrophic lateral sclerosis (ALS). *Neurology*. 2004;62: 1753-1757.

Kim WK, Liu X, Sandner J, et al. Study of 962 patients indicates progressive muscular atrophy is a form of ALS. *Neurology*. 2009;73:1686-1692.

Lawyer T Jr, Netsky MG. Amyotrophic lateral sclerosis. *AMA Arch Neurol Psychiatry*. 1953;69:171-192.

Logroscino G, Traynor BJ, Hardiman O, et al; for EURALS. Incidence of amyotrophic lateral sclerosis in Europe. *J Neurol Neurosurg Psychiatry*. 2010;81:385-390.

Marin B, Boumédiene F, Logroscino G, et al. Variation in worldwide incidence of amyotrophic lateral sclerosis: a meta-analysis. *Int J Epidemiol*. 2017;46:57-74.

Miller RG, Jackson CE, Kasarskis EJ, et al; for Quality Standards Subcommittee of the American Academy of Neurology. Practice parameter update: the care of the patient with amyotrophic lateral sclerosis: drug, nutritional, and respiratory therapies (an evidence-based review): report of the Quality Standards Subcommittee of the American Academy of Neurology. *Neurology*. 2009;73:1218-1226.

Miller RG, Jackson CE, Kasarkis EJ, et al; for Quality Standards Subcommittee of the American Academy of Neurology. Practice parameter update: the care of the patient with amyotrophic lateral sclerosis: multidisciplinary care, symptom management, and cognitive/behavioral impairment (an evidence-based review): report of the Quality Standards Subcommittee of the American Academy of Neurology. *Neurology*. 2009;73:1227-1233.

Miller RG, Mitchell JD, Moore DH. Riluzole for amyotrophic lateral sclerosis (ALS)/motor neuron disease (MND). *Cochrane Database Syst Rev*. 2012; (3):CD001447.

Mitsumoto H, Chad D, Pioro E. *Amyotrophic Lateral Sclerosis*. Philadelphia, PA: FA Davis; 1998.

Nagai M, Re DB, Nagata T, et al. Astrocytes expressing ALS-linked mutated SOD1 release factors selectively toxic to motor neurons. *Nat Neurosci*. 2007;10:615-622.

Pouget J, Trefouret S, Attarian S. Transcranial magnetic stimulation (TMS): compared sensitivity of different motor response parameters in ALS. *Amyotroph Lateral Scler Other Motor Neuron Disord*. 2000;1(suppl 2):S45-S49.

Re DB, Le Verche V, Yu C, et al. Necroptosis drives motor neuron death in models of both sporadic and familial ALS. *Neuron*. 2014;81:1001-1008.

Renton AE, Majounie E, Waite A, et al. A hexanucleotide repeat expansion in *C9ORF72* is the cause of chromosome 9p21-linked ALS-FTD. *Neuron*. 2011;72:257-268.

Rosen DR, Siddique T, Patterson D, et al. Mutations in Cu/Zn superoxide dismutase gene are associated with familial amyotrophic lateral sclerosis. *Nature*. 1993;362:59-62.

Rowland LP. Diagnosis of amyotrophic lateral sclerosis. *J Neurol Sci*. 1998; 160(suppl 1):S6-S24.

Rowland LP. Progressive muscular atrophy and other lower motor neuron syndromes of adults. *Muscle Nerve*. 2010;41:161-165.

Rowland LP, Shneider NA. Amyotrophic lateral sclerosis. *N Engl J Med*. 2001;344:1688-1700.

Ryan M, Heverin M, McLaughlin RL, Hardiman O. Lifetime risk and heritability of amyotrophic lateral sclerosis. *JAMA Neurol*. 2019;76(11):1367-1374.

van Es MA, Hardiman O, Chio A. Amyotrophic lateral sclerosis. *Lancet*. 2017; 390:2084-2098.

Wang MD, Little J, Gomes J, Cashman NR, Krewski D. Identification of risk factors associated with onset and progression of amyotrophic lateral sclerosis using systematic review and meta-analysis. *Neurotoxicology*. 2017;61: 101-130. doi:10.1016/j.neuro.2016.06.015.

Westeneng HJ, Debray TPA, Visser AE, et al. Prognosis for patients with amyotrophic lateral sclerosis: development and validation of a personalised prediction model. *Lancet Neurol*. 2018;17(5):423-433. doi:10.1016/S1474-4422(18)30089-9.

Wijesekera LC, Mathers S, Talman P, et al. Natural history and clinical features of the flail arm and flail leg ALS variants. *Neurology*. 2009;72:1087-1094.

Bell's Palsy and Cranial Neuropathies 89

Comana M. Cioroiu and Thomas H. Brannagan III

KEY POINTS

1. Cranial neuropathies can occur together (as in cases of cancer, infarct, and central nervous system inflammatory diseases) or in isolation.
2. Loss of olfactory sensation can be caused by either congenital or acquired causes and is typically accompanied by loss of taste and appetite.
3. Trigeminal neuralgia is a syndrome of extremely severe facial pain characterized by recurrent paroxysms of sharp stabbing pains in the distribution of one or more nerve branches and is treated first line with carbamazepine. Glossopharyngeal neuralgia is a clinically similar entity affecting the sensory distribution of the ninth cranial nerve.
4. Central lesions of the facial nerve above the level of the facial nucleus cause weakness of the lower face with sparing of forehead muscles.
5. Lesions of the nerve peripherally (at or below the level of the nucleus) cause weakness of the entire ipsilateral face and depending on the location of the lesion may also include a loss of taste, salivation, and lacrimation.
6. Steroids should be offered to patients with Bell's palsy within 72 hours of symptom onset, and prognosis is typically very favorable.
7. Reactivation of a latent varicella-zoster virus infection in the geniculate ganglion leads to inflammation of the facial nerve and Ramsay Hunt syndrome, in which facial pain is common.
8. The vagus nerve (cranial nerve X) has a parasympathetic efferent pathway, a motor efferent pathway to the larynx and pharynx, and afferent pathways.
9. Unilateral injury to the hypoglossal nucleus causes atrophy and paralysis of the muscles of half the tongue causing deviation toward the paralyzed side upon protrusion.

INTRODUCTION

Isolated cranial neuropathies are not uncommon, the most frequently encountered of which is Bell's palsy. These syndromes can be seen in both the inpatient and outpatient settings, and all have a very varied differential diagnosis. The cranial nerve examination is a crucial component of a complete neurologic exam. Cranial nerve injury can be implicated in various diseases with widespread neurologic involvement such as stroke, multiple sclerosis, and demyelinating neuropathies, particularly when other pathways and neuroanatomic regions are involved as well. Cranial neuropathies can occur together (with involvement of more than one nerve) or in isolation (with involvement of only one nerve). Multiple cranial neuropathies are most often caused by cancer, central nervous system (CNS) inflammatory diseases, infarct, and trauma, and these etiologies must be considered and carefully excluded when evaluating these patients, with particular attention paid to the brainstem where several cranial nerves localize together (Fig. 89.1). However, occasionally, there may be abnormal findings limited to one cranial nerve in isolation. In these instances of isolated cranial neuropathies, the differential diagnosis depends on the nerve involved and the clinical picture as a whole. This chapter addresses common cranial mononeuropathies and their evaluation and management. Several of these are addressed in other chapters of this text and are referred to when appropriate. In particular, the cranial nerves II, III, IV, and VI are covered elsewhere covering visual disturbances (Chapter 10), eighth cranial nerve disorders are described in Chapter 62.

THE OLFACTORY NERVE (CRANIAL NERVE 1)

The ability to smell is a special quality relegated to the olfactory cells in the nasal mucosa. The molecular biology of smell is uncertain, but transcription-activating factors, such as Olf-1, found exclusively in neurons with olfactory receptors, probably direct cellular differentiation. Smell may be impaired after injury of the nasal mucosa, the olfactory bulb or its filaments, or CNS connections. Nerve injury causes diminution or loss of the sense of smell. The most common complaint of patients with olfactory nerve injury, however, is not loss of smell but diminished taste; olfaction plays a key role in taste perception because of the volatile substances in many food and beverages. A loss of sense of smell may be congenital or acquired and occurs in various conditions (Table 89.1). The sense of smell is most commonly impaired, transiently, because of allergic nasal congestion or the common cold. The most common traumatic olfactory nerve injury occurs in head injury, usually of the acceleration-deceleration variety, including motor vehicle accidents. The delicate olfactory nerve filaments are sheared by the perforations of the cribriform plate. The olfactory bulb can also be contused or lacerated in head injuries. Leigh and Zee (2006) reported altered olfactory sense in 7.2% of patients with head injuries at a military hospital, with complete loss in 4.1% and partial loss in 3.1%. Recovery of smell occurred in only 6 of 72 patients. In a study of head injuries in civilians, Friedman and Merritt (1944) found that the olfactory nerve was damaged in 11 (2.6%) of 430 patients. In all patients, anosmia was bilateral. In three, the loss was transient and disappeared within 2 weeks of injury. *Parosmia* (ie, perversion of sense of smell) was present in 12 patients.

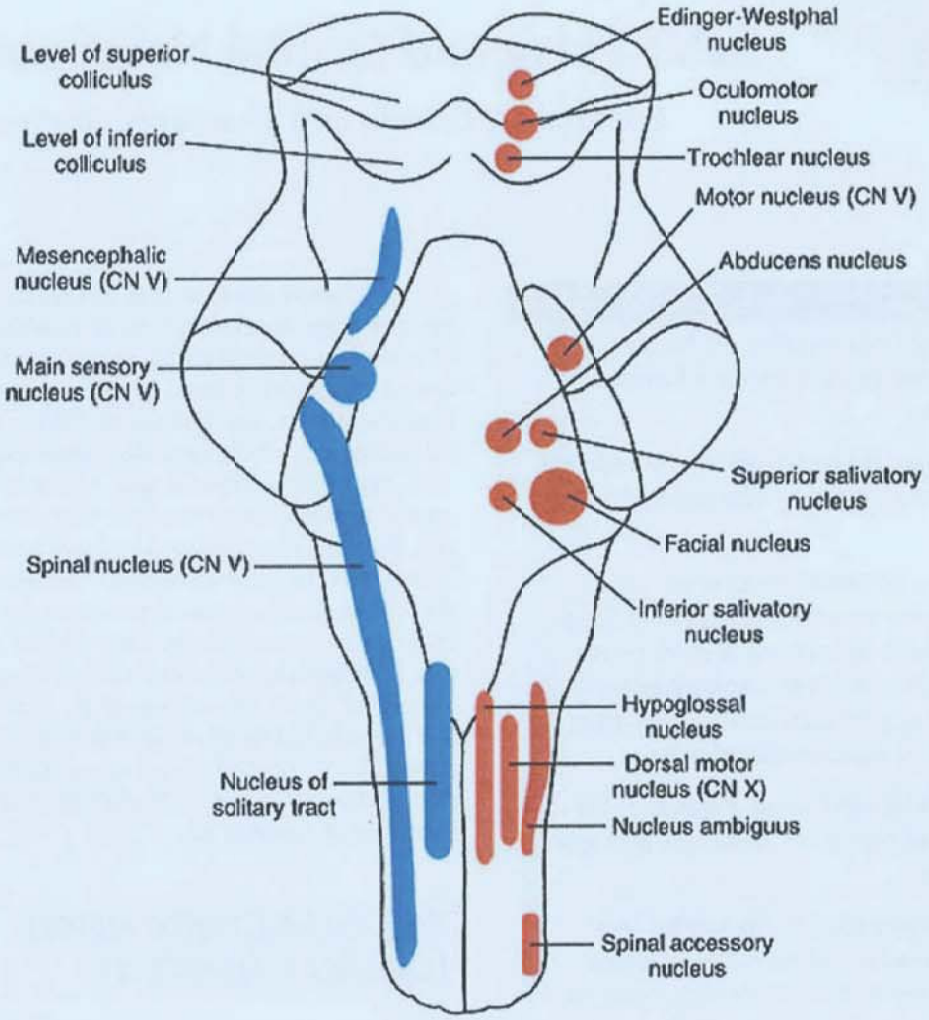

FIGURE 89.1 Cranial nerve nuclei. (From Siegel A, Sapru HN. *Essential Neuroscience*. 3rd ed. Philadelphia, PA: Wolters Kluwer; 2015.)

TABLE 89.1 Causes of Loss of Smell Related to Olfactory Nerve Injury

Congenital	Refsum disease Kallmann syndrome Congenital anosmia
Acquired	Inflammatory • Rhinitis • Meningitis • Mononeuritis multiplex Head trauma Tumor • Meningioma at olfactory groove • Frontal lobe glioma • Metastasis Neurodegenerative • Parkinson disease • Alzheimer disease Toxic • Cocaine • Cadmium • Smoking • Chemotherapeutic agents Vitamin deficiency • Thiamine (B_1) • B_{12} Psychiatric disease

Inflammatory or neuritic lesions of the bulb or tract are uncommon, but these structures are sometimes affected in meningitis or in mononeuritis multiplex. Rarely, patients with diabetes mellitus have impaired smell, sometimes stemming from olfactory nerve infarction. Hyposmia or anosmia is also common early in Refsum disease (an autosomal recessive disease leading to an overaccumulation of phytanic acid). Kallmann syndrome is an X-linked inherited disorder causing hypogonadism and anosmia due to olfactory tract hypoplasia. The olfactory bulb or tract may be compressed by meningiomas (particularly at the olfactory groove or sphenoidal ridge), metastatic tumors, or aneurysms in the anterior fossa or by infiltrating tumors of the frontal lobe. The Foster-Kennedy syndrome is a classic syndrome caused by a tumor invading the orbitofrontal region, leading to unilateral and ipsilateral optic atrophy, contralateral papilledema, and anosmia. Neurodegenerative diseases at times may be heralded by a loss of smell, and this is seen particularly with Parkinson disease, where loss of smell may be a presenting sign. Certain drugs are often implicated in a loss of smell, particularly cocaine when used intranasally, although other toxins such as cadmium and chemotherapeutic agents have been implicated as well.

Parosmia is not accompanied by impairment of olfactory acuity and is most commonly caused by lesions of the temporal lobe, although it has been reported with injury to the olfactory bulb

or tract. Olfactory hallucinations may occur in psychosis or as a seizure aura that involves the hippocampal or uncinate gyrus; perceptions are described as strange, unpleasant, and ill-defined odors. Increased sensitivity to olfactory stimuli is generally rare, although it may occur in migraineurs and in patients with reactive airways disease, perhaps because of prior sensitization to olfactory triggers. Cases in which the sense of smell is so acute that it is a source of continuous discomfort, however, may be psychogenic.

THE TRIGEMINAL NERVE (CRANIAL NERVE V)

The fifth cranial nerve, or the trigeminal nerve, has both a large sensory component as well as a smaller motor component. The nerve has three major branches—the ophthalmic division (V1), the maxillary division (V2), and the mandibular division (V3). These three branches carry sensory information from distinct dermatomes of the face, head, and mucous membranes and converge on the trigeminal or gasserian ganglion located in Meckel cave (which serves as the dorsal root ganglion). Sensory fibers from all three divisions ascend in the pons to terminate in the three parts of the trigeminal nucleus. The spinal trigeminal nucleus receives afferent fibers related to facial pain and temperature sensation, the principal sensory nucleus receives fibers related to light touch and mechanoreception, whereas the mesencephalic nucleus contains cell bodies with fibers carrying information regarding jaw proprioception. Motor branches originate in the motor nucleus of the trigeminal nerve and are distributed in the mandibular division to innervate the muscles of mastication.

Injury to the fifth cranial nerve causes loss of soft tactile, thermal, and pain sensation in the face; loss of the corneal and sneezing (ie, sternutatory) reflexes; and paralysis of the muscles of mastication. Lesions of the trigeminal pathways in the pons usually affect the motor and chief sensory nuclei causing paralysis of the muscles of mastication and loss of light touch perception in the face; lesions in the medulla affect only the descending tract and cause loss of facial pain and temperature sensation. Brain magnetic resonance imaging (MRI) with contrast is often useful to search for mass lesions, ischemia, and inflammation, whereas electrophysiologic testing (eg, blink reflex testing) may help quantitate both the afferent (ie, trigeminal nerve) and efferent (ie, facial nerve) components of the corneal reflex. The fifth cranial nerve may be injured by trauma, neoplasm, aneurysm, or meningeal infection. Infarcts and other vascular lesions, as well as intramedullary tumors, may damage the sensory and motor nuclei in the pons and medulla. Isolated lesions of the descending tract may occur in syringobulbia or in multiple sclerosis. Common causes of trigeminal nerve injury with facial numbness include dental or cranial trauma, herpes zoster, head and neck tumors, intracranial tumors, and idiopathic trigeminal neuropathy. Less common causes include multiple sclerosis, systemic sclerosis, mixed connective tissue diseases, amyloidosis, and sarcoidosis. Isolated facial numbness may also occur without a clearly identifiable cause (ie, *idiopathic trigeminal neuropathy*), but these patients must be carefully evaluated to ensure an occult process is not overlooked. Although restricted loss of sensation over the chin (ie, the *numb chin syndrome*) usually is caused by dental trauma, dental or surgical procedures, or even poorly fitting dentures, this syndrome is a recognized initial feature of a systemic malignancy such as lymphoma, metastatic breast carcinoma, melanoma, or prostate cancer. MRI of the mandible may help separate these disorders. Painful facial numbness may herald nasopharyngeal or metastatic carcinoma. Isolated weakness of the trigeminal innervated muscles of mastication may be seen in motor neuron disease where patients often develop jaw weakness and dysphagia. This can also be seen with diseases of the neuromuscular junction, that is, myasthenia gravis.

Trigeminal Neuralgia

Epidemiology and Pathobiology

Trigeminal neuralgia, also commonly known as *tic douloureux*, is a syndrome of extremely severe facial pain without numbness or objective findings in the fifth cranial nerve distribution (see also Chapter 57). This disorder of the trigeminal nerve is characterized by recurrent paroxysms of sharp, stabbing pains in the distribution of one or more nerve branches. Unlike herpes zoster, the second and third divisions of the trigeminal nerve are the most commonly involved, and the first is primarily affected in only less than 5% of patients. Onset is usually in middle or late life but may occur at any age. Typical trigeminal neuralgia occasionally affects children but rarely occurs before age 35 years—presentation at that age should prompt an investigation for demyelinating disease. The incidence of trigeminal neuralgia is slightly greater in women than in men and found to be about 12.6 per 100,000 people in some studies.

The cause remains unknown. In most cases, no organic disease of the fifth cranial nerve or the CNS is identified. Degenerative or fibrotic changes in the gasserian ganglion have been described but are too variable to be considered causal. Trigeminal nerve compression related to an anomalous blood vessel, usually in the vicinity of the ganglion, is a long-standing but controversial etiology of the disorder. Most commonly, this is thought to be compression by a loop of either the anterior inferior cerebellar or superior cerebellar artery. Painful symptoms typical of trigeminal neuralgia occasionally occur with demyelinating brainstem lesions including those produced by multiple sclerosis as well as vascular ischemia affecting the descending root of the fifth cranial nerve. When trigeminal neuralgia has a known structural cause, it is categorized as symptomatic, as opposed to the idiopathic form that has no known etiology. Although trigeminal neuralgia usually follows other symptoms of multiple sclerosis rather than precedes them, up to 10% of patients may have facial pain as part of their initial presentation. Tumors invading the gasserian ganglion or the cerebellopontine angle may also cause symptoms of trigeminal neuralgia, although usually in the setting of an abnormal neurologic examination. The paroxysmal attacks of facial pain in trigeminal neuralgia may be related to excessive discharge within the descending nucleus of the nerve triggered by an influx of impulses. Relief of symptoms by section of the greater auricular or occipital nerves in some patients suggests a role for peripheral excitation and interruption of an episode by intravenous phenytoin, as well as a general therapeutic response to antiepileptic agents, suggests aberrant neuronal discharge may also play an important part in the pathophysiology of this disorder. Trigeminal neuralgia is the most common of all neuralgias.

Diagnosis

The pain is extremely severe and is described by many patients as among the worst pain imaginable, and in severe and refractory cases, the risk of suicide is increased. The pain appears in paroxysms and typically lasts seconds, although episodes of

up to 15 minutes can occur. Between episodes, the patient is free of symptoms, except for fear of an impending attack. The pain is searing or burning, coming in lightning-like jabs. The frequency of attacks varies from many times a day to a few times a month. The patient ceases to talk when the pain strikes and may rub or pinch the face; movements of the face and jaw may accompany the pain. Sometimes, ipsilateral lacrimation is prominent. No objective loss of cutaneous sensation is found during or after the paroxysms, but the patient may complain of facial hyperesthesia.

A characteristic feature in the presentation is the *trigger zone*, stimulation of which sets off a typical paroxysm of pain. This zone is a small area on the cheek, lip, or nose that may be stimulated by facial movement, chewing, brushing teeth, or touch. The patient may avoid making facial expressions during conversation, may go without eating for days, or may avoid the slightest breeze to prevent an attack. The pain is limited strictly to one or more branches of the fifth cranial nerve and does not spread beyond the distribution of that nerve. The second division is involved more frequently than the third. Pain may spread to one or both of the other divisions. In cases of long duration, all three divisions are affected in 15% of patients. The pain is occasionally bilateral (5%) for some but rarely occurs at the same time. Bilateral trigeminal neuralgia is encountered most often in patients with multiple sclerosis. A new classification scheme differentiates classic trigeminal neuralgia with paroxysms of pain from a different form, in which the paroxysms are associated with a concomitant dull, constant facial pain.

The diagnosis of trigeminal neuralgia is usually made from the history. Neurologic examination in patients with trigeminal neuralgia is usually normal, although some patients may also have concurrent hemifacial spasm, and patients whose attacks are provoked by eating may appear thin or cachectic. The results of serum studies and other diagnostic evaluations are also normal. Characteristically, patients avoid touching the area of origin when asked to point it out, instead holding the tip of the index finger a short distance from the face. On examination, patients will show no clinical sensory or motor deficits in the trigeminal nerve distribution, although the affected area is often very sensitive. Computed tomography or MRI of the brain is reasonable to exclude structural causes and, at times, may demonstrate an aberrant vessel causing compression. However, the sensitivity and specificity of MRI for identifying neurovascular compression is variable, and thus, its role for this purpose is controversial. In 2008, the American Academy of Neurology put forth a practice parameter concerning the diagnosis and treatment of trigeminal neuralgia, which stated that electrodiagnostic evaluation of the trigeminal reflex is a reasonable first step in excluding symptomatic trigeminal neuralgia and can be considered before imaging.

Trigeminal neuralgia must be differentiated from other types of facial pain or headache, especially infections of the teeth and nasal sinuses. These pains are usually steady instead of episodic, are often throbbing, and persist for many hours. However, it is not uncommon for patients with trigeminal neuralgia to undergo surgical treatment of the sinuses and/or tooth extractions before the diagnosis is established. Conversely, patients with diseased teeth may be referred to neurology with a diagnosis of trigeminal neuralgia, although careful dental examination usually identifies the teeth as the source of pain in these patients.

Temporomandibular joint disease may also mimic trigeminal neuralgia, but the pain is not paroxysmal and, although exacerbated by eating, no trigger point may be identified and symptoms are usually less severe between meals. Cluster headaches are another consideration but occur in protracted clusters rather than as brief events and are accompanied by ipsilateral nasal congestion, ipsilateral conjunctival injection and lacrimation, and an ipsilateral Horner syndrome. Atypical facial pain may have a trigeminal distribution, but the individual paroxysms always last longer than a few seconds (usually minutes or hours). The pain itself is dull, aching, crushing, or burning. Surgical treatment is not effective in atypical facial pain, and its etiology remains obscure, although it may be associated with depression.

A more detailed discussion of headache and facial pain syndromes can be found in Chapter 9.

Management and Outcome

Although surgical options now exist, medical therapy remains first line as far as treatment options. Trigeminal neuralgia is most effectively treated with carbamazepine at 800 mg/d to a maximum dose of 1,600 mg/d in four divided doses LEVEL 2.[1] A Cochrane Database review found carbamazepine to be consistently effective, with a number needed to treat of 1.8. However, dosing should be titrated to effect, and doses producing serum levels above the therapeutic range for seizure control may be needed as long as potentially dose-limiting side effects are tolerated. Overdosage is manifested by drowsiness, dizziness, ataxia, unsteady gait, and nausea. Hepatotoxicity may occur but is usually reversible with discontinuation. Another more rare but serious complication is aplastic anemia, and both periodic liver function testing and monitoring of the blood count are needed. In some patients, tolerance may develop over time. Baclofen is also effective in many cases in doses of 40 to 80 mg/d; phenytoin is less effective but may be used as adjunctive therapy. Some of the newer antiepileptic agents may also provide some relief, and oxcarbazepine, a derivative of carbamazepine, in doses of 600 to 1,800 mg/d is thought to be as effective as carbamazepine. Pimozide (a dopamine receptor antagonist) was found to be effective in a randomized, double-blind crossover trial to be effective at doses of 2 to 12 mg/d; however, its clinical use is limited given risk of serious side effects including arrhythmias and acute parkinsonism. Other medications which have been shown to be effective in some cases (although no controlled trials exist) include lamotrigine, gabapentin, pregabalin, levetiracetam, phenytoin, and topiramate. More recently, both intravenous lidocaine and onabotulinum toxin A have been found to be successful in treating acute episodes of trigeminal neuralgia, although more rigorous trials are needed. Topical ophthalmic anesthesia is probably ineffective for controlling pain. Surgical procedures used to treat this condition include microvascular decompression, radiofrequency ablation, balloon microcompression, and chemical gangliolysis and rhizotomy. More recently, stereotactic radiosurgery using Gamma Knife has been used with noted improvements in pain scores. Of these methods, radiofrequency ablation has met with the greatest success in initial treatment, although recurrence rates have not been studied carefully. As compression of the trigeminal nerve by arterial loops may play a role in some cases, posterior fossa exploration with decompression has sometimes been used for refractory cases. Other chronic masses, such as arteriovenous malformation, aneurysm, and cholesteatoma, may also cause compression of the ganglion and may be more amenable to surgical correction.

THE FACIAL NERVE (CRANIAL NERVE VII)

The seventh cranial nerve (facial nerve), although predominantly motor, also serves an important parasympathetic and sensory function (Fig. 89.2). On exiting the brainstem ventrally via the internal acoustic meatus in the petrous part of the temporal bone near the pontomedullary junction, the facial nerve forms two divisions: the nervus intermedius and the motor root. The motor root is composed of nerve fibers arising from the facial motor nucleus, and after exiting the nucleus, these axons travel dorsomedially in the pons to circle the abducens nucleus (thus forming the facial colliculus) and travel down to meet the nervus intermedius to form the facial nerve. The nervus intermedius arises from superior salivatory and lacrimal nuclei (eventually sending parasympathetic innervation to the salivary glands, specifically the submaxillary and sphenopalatine ganglia), the nucleus solitarius (fibers of which ultimately relays afferent taste sensation from the anterior two-thirds of the tongue), and the spinal trigeminal nucleus (carrying somatosensory afferent fibers to parts of the face and ear). The fibers of the seventh cranial nerve arising from the spinal trigeminal nucleus may also relay proprioceptive impulses from the facial muscles and cutaneous sensation from the posteromedial surface of the pinna and the external auditory canal. The fibers arising from the nucleus solitarius and spinal trigeminal nucleus together synapse in the geniculate ganglion in close proximity to the brainstem. Distal to the geniculate ganglion, the facial nerve forms several branches. Axons from the superior lacrimal nucleus form the greater petrosal nerve, which synapses in the sphenopalatine ganglion prior to innervating the lacrimal glands. Fibers originating from the nucleus solitarius and the superior salivatory and nuclei travel further distally in the facial nerve prior to forming the chorda tympani, a branch of the nerve which crosses the middle ear and exits the skull to join the lingual nerve. Just prior to the chorda tympani, the facial nerve also gives off a motor

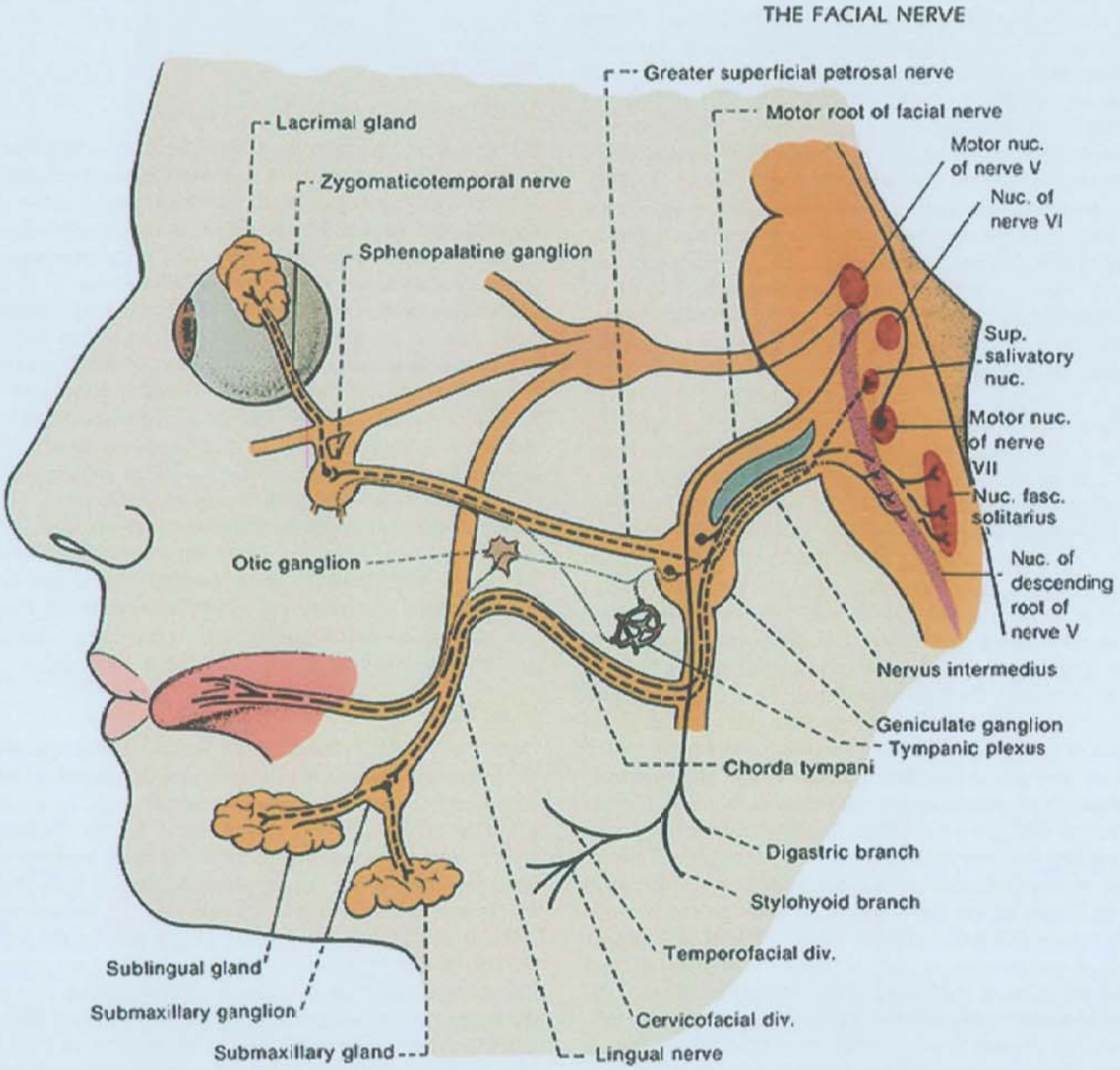

FIGURE 89.2 Anatomy of the facial nerve. (From Campbell WW. *DeJong's The Neurologic Examination*. 6th ed. Philadelphia, PA: Lippincott Williams and Wilkins; 2005.)

branch to the stapedius muscle. Distal to the chorda tympani, the motor root of the facial nerve runs through the facial canal and exits the skull via the stylomastoid foramen. At this point, it gives rise to the posterior auricular nerve innervating the scalp and ear as well as a motor branch to the stylohyoid muscle and digastric muscle. The nerve then continues on into the parotid gland, where it divides into its five major branches—temporal, zygomatic, buccal, marginal mandibular, and cervical.

Lesions near the origin of the nerve, or in the vicinity of the geniculate ganglion, are accompanied by loss of motor, gustatory, and autonomic functions. Lesions between the geniculate ganglion and the origin of the chorda tympani typically spare lacrimation, whereas lesions near the stylomastoid foramen spare taste and lacrimation, causing only ipsilateral facial paralysis of the upper and lower face. Lesions of the facial nerve nucleus in the brainstem also cause ipsilateral paralysis of all facial muscles, both upper and lower.

The pattern of peripheral or nuclear injury (the peripheral seventh nerve lesion) must be distinguished from that associated with central motor pathway lesions above the level of the nucleus, which cause weakness and paralysis in the lower half of the face while sparing forehead wrinkling because of redundancy of central pathways subserving upper face muscles (central facial weakness; supranuclear palsy) (**Fig. 89.3**). In supranuclear lesions, voluntary contractions of the face differ, being more or less intense, from those occurring during spontaneous emotional expression, particularly when accompanied by laughing or crying. Depending on the precise site and extent of associated injury within the CNS, other neurologic signs may also appear.

Owing to this anatomic organization, the signs of peripheral facial nerve injury are somewhat variable (**Table 89.2**). More severe injury produces obvious facial paralysis at rest with sagging of the muscles of the lower ipsilateral face. The normal folds and lines around the lips, nose, and forehead are attenuated; the palpebral fissure is wider than normal; and voluntary movement of the facial and platysmal muscles is absent. Smiling highlights the weakness by contrasting the normal and unaffected orbicularis oris with the droop of the affected side. Although weakness of both the upper and lower halves of the face is seen, occasionally, the lower muscles may be weaker than the upper, or more rarely, the upper muscles may be weaker than the lower, with partial nerve injury. Saliva may seep from the paralyzed side of the mouth at rest, and food or fluids may leak out when eating. Closure of the eyelid is incomplete, and the upward and inward deviation of the eye may be seen during examination when eye closure is attempted (Bell phenomenon). This common complication assumes great importance because early patching and lubrication of the affected eye after seventh cranial nerve injury is critical to prevent corneal desiccation and potentially permanent scarring. Tear production is diminished only if the lesion is proximal to the geniculate ganglion. With lesions peripheral to the ganglion, lacrimation is spared, but tears may still be sequestered in the conjunctival sac because incomplete eyelid closure no longer moves them effectively through the lacrimal duct. The corneal reflex is also impaired by paralysis of the upper lid, although preservation of corneal sensation and the afferent portion of the reflex is confirmed by consensual blinking of the contralateral eyelid during corneal reflex testing. Decreased salivation and loss of taste in the anterior two-thirds of the tongue are present when the chorda tympani is affected. Loss of somatic sensation to the external auditory canal, however, is less common. The seventh nerve also supplies the stapedius muscle, and patients may develop increased sensitivity to loud sounds (ie, hyperacusis) when the small muscle is paralyzed, and its dampening effect on the tympanic membrane is lost. Recovery from facial paralysis depends on the severity of the lesion and the specific cause. If the nerve is completely crushed or severed, the chances of even partial recovery are remote, especially if the intraneural scaffolding necessary to guide axonal regeneration is lost. In contrast, in purely demyelinative lesions without axonal injury, excellent and often complete recovery is expected. When the facial nerve attempts to regenerate through proximal axonal growth across an injured segment, axonal extension sometimes results in aberrant reinnervation. This faulty circuit results in the movement of previously unrelated facial muscles when the patient attempts isolated activation of a separate muscle, a process known as *synkinesis*. In such patients, for example, lip movement may occur with each eye blink. Aberrant reinnervation may also cause excessive lacrimation during activation of the facial muscles or when the salivary glands are activated during eating (eg, producing "crocodile tears"). In addition, some patients develop paroxysmal clonic contractions of the hemifacial muscles (ie, hemifacial spasm) that may simulate focal seizures.

Bell's Palsy

Epidemiology and Pathobiology

Bell's palsy, named after the Scottish anatomist Charles Bell, is a common clinical syndrome of uncertain etiology in which acute, unilateral paresis or paralysis of muscles innervated by the facial nerve appears spontaneously, over hours to days, and is the most common cause of facial nerve injury and acute mononeuropathy. It occurs at all ages but is slightly more common in the third to fifth decades and is equally likely to affect the right or left sides. Bell's palsy is the common cause of facial nerve paralysis and in one study accounted for 65% of cases of peripheral facial paralysis in a pediatric population (excluding congenital causes). Recurrence, either on the same or on the opposite side, is rare and raises the question of a more generalized disorder. Familial Bell's palsy is reported but is also rare. Risk factors are not well defined, although some patients report exposure of the affected side to a steady breeze or fan for several hours just prior to onset. It has also found to be associated with diabetes mellitus, pregnancy, and hypertension. Some postulate that it may be caused by reactivation of a latent herpes simplex virus or varicella-zoster and possibly human herpesvirus 6. Lyme disease is also often implicated particularly in cases of bilateral facial palsy.

Diagnosis

Pain is not typical except in the Ramsay Hunt syndrome (see the following section), which is caused by herpes zoster and is usually accompanied by vesicular eruption in the sensory distribution of the seventh cranial nerve in the ipsilateral ear. Patients typically present with unilateral facial weakness or complete paralysis, which can be scored from 1 to 6 on the House-Brackmann scale, which is determined by measurements of eyebrow and mouth movements. Depending on the location of the lesion, facial weakness may be associated with diminished lacrimation and/or impaired taste in the anterior two-thirds of the tongue on the affected side, and a weakened or absent blink reflex is always present. Given the innervation of the stapedius muscle, there may be an increased sensitivity to noise on the affected side. There should not, however, be any impairment of eye movements, change in vision, or other bulbar symptoms such as dysphagia or facial numbness. When present, any of those signs

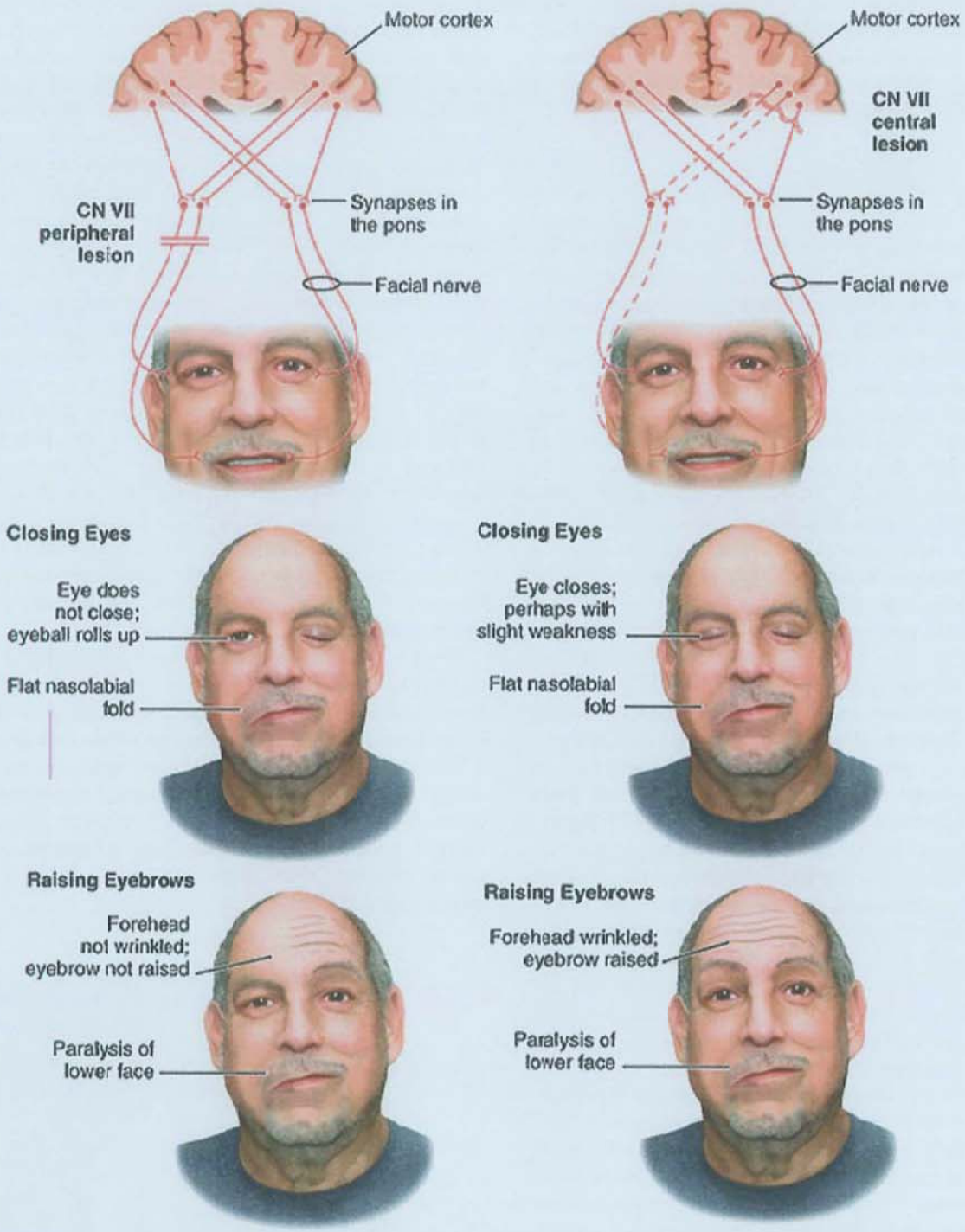

FIGURE 89.3 Central versus peripheral seventh nerve palsy. (From Dugani S, Alonsi JE, Agur AMR, Dalley AF. *Clinical Anatomy Cases*. Philadelphia, PA: Wolters Kluwer; 2017.)

TABLE 89.2 Clinical Manifestations of Lesions of the Facial Nerve

Location of Lesion	Motor Function	Gustatory Sensation	Lacrimation
At facial nerve nucleus in pons	Impaired	Impaired	Impaired
Origin of nerve/geniculate ganglion	Impaired	Impaired	Impaired
Between geniculate ganglion and chorda tympani	Impaired	Impaired	Spared
At stylomastoid foramen	Impaired	Spared	Spared

or symptoms should prompt one to look for an alternative diagnosis. In 2013, the American Academy of Otolaryngology—Head and Neck Surgery Foundation published a new clinical practice guideline on the diagnosis and treatment of Bell's palsy. Regarding appropriate diagnostic workup, it was concluded that in the appropriate clinical scenario following a complete history and examination, there is no role for laboratory investigation, diagnostic imaging, or electrodiagnostic testing (unless there is complete facial paralysis). Patients should, however, be referred to a specialist in cases of new or worsening findings, ocular symptoms, or incomplete recovery 3 months after onset. Nevertheless, nerve conduction studies of the extracranial portion of the facial nerve are at times performed (particularly in cases of complete

paralysis) along with needle recordings from its myotomes (eg, facial muscle electromyography) to help determine the nature and degree of injury. Injury to the intracranial portion may be detected by blink reflex testing.

Treatment and Outcome

Although permanent deficits may occur in severe cases, the vast majority of patients with Bell's palsy experience full, functional recovery with minimal to no residual signs. Long-term prognosis is typically very favorable, although there is some recent limited evidence that these patients may be at a slightly higher risk for developing cancer (particularly oral cancer) and a slightly higher risk of stroke. Inflammation, herpes simplex virus infection, and swelling with compression may be involved in the pathogenesis of Bell's palsy, so steroids, antiviral medication (acyclovir), and surgical decompression have been advocated as acute therapy. A large, randomized controlled study showed that 94% receiving prednisolone 25 mg twice a day for 10 days had a good recovery at 9 months compared with 82% who did not receive steroids LEVEL 2.[2,3] The same study showed no benefit for the antiviral agent acyclovir at doses of 400 mg five times per day for 10 days, although another large study showed benefit for valacyclovir at 1 g/d for 5 days. Surgical intervention has been looked at as well, and a recent Cochrane Database review found insufficient evidence to decide whether it is beneficial or harmful, but given the generally good prognosis and spontaneous recovery is often not recommended. Early physical therapy may be beneficial particularly in cases of very severe paresis or complete paralysis. The 2013 American Academy of Otolaryngology—Head and Neck Surgery Foundation practice guidelines recommend offering antiviral therapy in addition to oral steroids with 72 hours of symptom onset, although made no recommendation regarding the use of physical therapy, acupuncture, or surgical referral. The American Academy of Neurology published an update regarding recommendations on steroids and antiviral therapy which stated that steroids should be offered to those with new-onset palsy and that antiviral may be offered although are likely to be of modest benefit at best. It is important that affected patients patch the weak eye overnight because weakness of eye closure may lead to dry eyes and corneal abrasions. Eye drops such as artificial tears and lubricating ointments should be given as well. The prognosis of facial nerve injury after Bell's palsy has also been the focus of much discussion. In general, preservation of motor amplitudes on nerve conduction studies after 7 to 10 days supports retained axonal integrity and suggests a favorable prognosis for recovery. In contrast, rapid loss of motor amplitudes suggests prominent axonal involvement, wallerian degeneration, and poorer chance for functional improvement. Needle electromyography examination may also aid in detecting denervation change, further supporting axonal injury. Electroneurography has recently been looked at with regard to its prognostic value, and electroneurography value was found to be positively correlated with a higher chance of recovery in both Bell's palsy and Ramsay Hunt syndrome, although it is not commonly used in practice. In the long term, patients may develop synkinesis as described earlier. In patients with incomplete or poor recovery, facial reanimation surgery may be offered.

Ramsay Hunt Syndrome

Ramsay Hunt syndrome, also known as *herpes zoster oticus*, is another cause of facial mononeuropathy, although much less common than Bell's palsy and tends to affect younger patients. Mean incidence is thought to be about five cases per 100,000 person-years. It is caused by a reactivation of a latent varicella-zoster virus infection affecting the geniculate ganglion leading to inflammation of the facial nerve and therefore is seen commonly in immunocompromised conditions (ie, posttransplant, in the setting of malignancy). Typically, in addition to facial weakness, as in Bell's palsy, there is associated hyperacusis, diminished taste, and impaired salivation and lacrimation. The degree of weakness in these patients is often more severe than in those with Bell's palsy, and pain is a distinguishing factor. Pain is very common and can be in deep to the face; in the ear; or in the orbit, tongue, or palate (particularly if sensory fibers are involved). Most commonly, there is pain behind the ear on the affected side. On examination, one may see herpetic vesicles in the external auditory canal or behind the ear and at times may also be found on the neck and palate (Fig. 89.4). However, a rash is not always seen (or may erupt after the onset of weakness), and one must have a high index of clinical suspicion based on the patient's history and presentation in order to consider this diagnosis rather than Bell's palsy. Herpetic infection can spread to the eighth cranial nerve leading to complaints of nausea, tinnitus, and vertigo and infrequently to other cranial nerves as well.

Both steroids and antivirals have been used to treat Ramsay Hunt syndrome with varying degrees of success. Although there have been no randomized controlled trials, several studies have noted that early administration of steroids and antivirals (within 3-5 d) leads to improved facial and vestibulocochlear nerve recovery. Some suggest using intravenous methylprednisolone in those patients not improving or with poor prognostic factors. Overall, patients with Ramsay Hunt syndrome have an overall poorer prognosis than those with Bell's palsy and often have an incomplete recovery.

FIGURE 89.4 Ramsay Hunt rash. (From Chung EK, Atkinson-McEvoy LR, Lai NL, Terry M. *Visual Diagnosis and Treatment in Pediatrics*. 3rd ed. Philadelphia, PA: Wolters Kluwer; 2015.)

Other Causes of Facial Nerve Injury

Many other processes may significantly damage the facial nerve. Intracranially, it may be injured by tumors, aneurysms, meningeal infections, leukemia, osteomyelitis, herpes zoster, Paget disease, sarcomas, and bony tumors, among others. It may also be damaged by leprous polyneuritis, Guillain-Barré syndrome, and diphtheritic polyneuropathy. Diabetic seven cranial nerve mononeuropathies may also occur but are less common than other cranial mononeuropathies in that disorder. The peripheral segment of the nerve may be compressed by tumors of the parotid gland, sarcoidosis, and, more rarely, mumps. Bilateral facial palsy also may be caused by many of the same conditions producing unilateral paralysis but is most often seen in sarcoidosis, Guillain-Barré syndrome, leprosy, leukemia, and meningococcal meningitis. Sarcoid, in fact, can be implicated in most cranial neuropathies and a full discussion of neurosarcoidosis can be found in Chapter 75. *Melkersson-Rosenthal syndrome* is a syndrome presenting in childhood characterized by a constellation of clinical symptoms and signs including facial and lip edema, a furrowed and fissured tongue (lingua plicata), and recurrent attacks of facial weakness. Although there is no known etiology, it is thought to be familial in some instances. Other congenital causes of facial palsy include Möbius syndrome, in which facial weakness is associated with impaired lateral eye movement due to poor development of both the seventh and sixth cranial nerves. The facial nucleus, itself, may be damaged by vascular lesions, multiple sclerosis, intraparenchymal tumors, inflammatory lesions, and acute poliomyelitis, among others. The relatively superficial peripheral branches of the seventh cranial nerve are vulnerable to stab and gunshot wounds, cuts, and in neonates, birth trauma. Occasionally, the nerve is also injured in surgeries involving the mastoid and parotid glands, acoustic neuroma resection, and trigeminal ganglion decompression as well as in fractures of the temporal bone.

Cases of facial nerve injury with a specific, identifiable cause may require aggressive intervention. Microsurgical anastomosis may be performed in some cases of transection of the extracranial nerve or its branches. However, when the nerve is damaged proximal to the stylomastoid foramen, operative anastomosis becomes more difficult. Surgery may still be indicated, however, if a mass lesion is found before excessive damage is done. In cases of partial or inaccessible intracranial facial nerve injury, compensatory surgical reinnervation may be provided by suturing the distal portion of the 7th cranial nerve to the central portion of either the 11th or the 12th cranial nerve. With rehabilitative training, these patients may learn to reroute impulses formerly destined for the sternocleidomastoid (SCM) muscle, or half of the tongue, to the newly rewired facial musculature. However, use of the 11th cranial nerve for this procedure causes permanent paralysis of the SCM and upper fibers of the trapezius muscle, whereas use of the 12th cranial nerve causes atrophy and paralysis of one-half of the tongue. Anastomosis of the facial nerve with either the 11th or the 12th cranial nerve should be performed as soon as possible following acute injury, such as with surgical misadventure by surgery of the mastoid or removal of an acoustic neuroma, for instance. In other situations, surgery may need to be delayed for up to 6 months or more to determine whether spontaneous regeneration occurs.

Hemifacial spasm is a disorder involving involuntary muscle contractions of facial muscles on one side of the face and is covered in detail in Chapter 80.

THE GLOSSOPHARYNGEAL NERVE (CRANIAL NERVE IX)

The 9th cranial nerve contains both motor and sensory (general as well as taste) fibers. The motor fibers originating in the nucleus ambiguus supply the stylopharyngeus muscle and the constrictors of the pharynx, whereas other efferent fibers innervate secretory glands in the pharyngeal mucosa. The sensory fibers carry general sensation from the upper part of the pharynx (as well as the tonsil, tympanic membrane, and external ear) and the special sensation of taste from the posterior one-third of the tongue. The glossopharyngeal nerve also conveys sensory afferent fibers from the carotid sinus and body by way of the nucleus solitarius and provides parasympathetic innervation to the parotid gland via the otic ganglion through the lesser petrosal nerve. Isolated lesions of the nerve, or its nuclei, are rare and are not accompanied by perceptible disability. Taste is lost on the posterior one-third of the tongue, and the gag reflex is absent on the side of the lesion. Injuries of the 9th cranial nerve by infections or tumors are rarely isolated and are usually accompanied by signs of injury to nearby cranial nerves. As the 9th, 10th, and 11th cranial nerves exit the jugular foramen together, tumors at that point produce multiple cranial nerve palsies (ie, *jugular foramen syndrome*). Within the brainstem, the tractus solitarius receives taste fibers from both the 7th and the 9th cranial nerves and is commonly injured by vascular or neoplastic lesions in the brainstem.

Glossopharyngeal Neuralgia

Glossopharyngeal neuralgia (GN), also known as *tic douloureux* of the ninth cranial nerve, is characterized by paroxysms of excruciating pain in the region of the tonsils, posterior pharynx, and back of the tongue with radiation to the middle ear. The cause of GN is unknown, and no significant pathologic changes occur in most cases. Idiopathic GN must be differentiated from pain in the distribution of the nerve following its injury in the neck by tumors. GN is rare, with a frequency of approximately 5% that of trigeminal neuralgia. Unlike trigeminal neuralgia, men and women are affected equally, and GN is more likely to be bilateral than trigeminal neuralgia. The paroxysms consist of burning or stabbing pain and may occur spontaneously but are often precipitated by swallowing, talking, or touching the tonsils or posterior pharynx. The attacks usually last only a few seconds but sometimes may last several minutes, and they may occur many times daily or once every few weeks. Patients may become emaciated because of the fear that chewing each morsel of food will precipitate a pain paroxysm; general quality of life may be seriously affected, especially in severe cases. On occasion, attacks may lead to syncope, arrhythmia, or convulsions due to stimulation of the carotid sinus reflex.

The diagnosis of GN is best made by history and may be confirmed by provocative testing (eg, precipitation by stimulation of the tonsils, posterior pharynx, or base of the tongue) or by transient relief of pain following the application of topical anesthetic to the ninth cranial nerve dermatome. Following this procedure, the pain is no longer precipitated by stimulation, and the patient may swallow food and talk without discomfort until the anesthetic wears off. The differential diagnosis is limited but includes neuralgia of the mandibular branch of the fifth cranial nerve. There may be long remissions, during which pain is no longer triggered. The pains usually recur, however, unless

prevented by medical therapy or surgical resection of the nerve. Medications used to treat trigeminal neuralgia are equally effective with GN, and carbamazepine alone or in combination with phenytoin often provides effective control and induces a pharmacologic remission. Duloxetine as well as certain newer antiepileptic drugs such as pregabalin, gabapentin, topiramate, and lamotrigine might also be effective.

If medical therapy is unsuccessful and the pain is intractable, surgical interventions have been shown to be effective, including microvascular decompression, radiofrequency ablation, and Gamma Knife ablation. Intracranial transection of the nerve may also provide relief. Following this procedure, the mucous membrane supplied by the 9th cranial nerve is permanently anesthetized, with ipsilateral loss of the gag reflex and ipsilateral loss of taste on the posterior one-third of the tongue. Motor symptoms, such as dysphagia or dysarthria, are not typical unless the 10th cranial nerve is injured during surgery.

THE VAGUS NERVE (CRANIAL NERVE X)

Efferent fibers of the vagus nerve arise from both the nucleus ambiguus and the dorsal motor nucleus. Fibers from the nucleus ambiguus ultimately innervate the somatic muscles of the pharynx and larynx through the pharyngeal, superior laryngeal, and recurrent laryngeal nerves, whereas those from the dorsal motor nucleus supply autonomic innervation to the heart, lungs, esophagus, and stomach. The vagus nerve also relays sensory fibers from the mucosa in the oropharynx and upper part of the gastrointestinal tract to the spinal nucleus of the trigeminal nucleus and relays sensory fibers from the thoracic and abdominal organs to the tractus solitarius. Central lesions of the above nuclei in the brainstem cause a number of symptoms. Unilateral lesions of the nucleus ambiguus result in dysarthria and dysphagia, although rarely is the condition severe. However, because the nucleus has a considerable longitudinal extent in the medulla, such lesions may produce dysarthria without dysphagia or vice versa (ie, caudal nuclear lesions cause dysphagia, whereas rostral lesions produce dysarthria). Hoarseness may also occur, but speech is usually intelligible. Dysphagia is usually slight, although occasionally, a more severe transient aphagia necessitates the use of a feeding tube for days to weeks. On examination, contraction of the palatal muscles is absent on the affected side during gag reflex testing. The palate on the affected side is lax at rest, and the uvula deviates to the opposite side on phonation, drawn away from the paralyzed muscles by normal, contralateral, palatal contraction (ie, contralateral uvular deviation).

In contrast to the mild deficits typically seen with unilateral lesions, bilateral lesions of the nucleus ambiguus cause complete aphonia and aphagia. Focused bilateral injury of this type is rare but may be seen in advanced amyotrophic lateral sclerosis (ALS) in the setting of pseudobulbar palsy. Selective destruction of portions of the nucleus ambiguus may be produced by syringobulbia, intramedullary tumors, or ischemia and may cause a clinical syndrome of vocal cord paralysis during adduction. The patient may talk and swallow without difficulty, but inspiratory stridor and dyspnea may appear and progress sufficiently to require tracheotomy. Unilateral lesions of the dorsal motor nucleus are not accompanied by any significant symptoms, but bilateral lesions may produce life-threatening autonomic instability. The dorsal nucleus may be damaged by infection (eg, acute poliomyelitis), intramedullary tumor, ischemia, and polyneuropathy, especially that associated with diphtheria and Guillain-Barré syndrome.

Individual branches of the vagus nerve are most amenable to injury in the neck, thorax, and, less commonly, the abdomen. Injury to the pharyngeal branches of the vagus nerve causes dysphagia, whereas lesions of the superior laryngeal nerve produce anesthesia of the upper part of the larynx and paralysis of the cricothyroid muscle. In these cases, the voice is weak and easily fatigable. Injury to a single, recurrent laryngeal nerve (ie, frequently seen with aneurysms of the aorta, tumors or trauma of the neck, and occasionally after operations in the neck) causes unilateral paralysis of the vocal cords with hoarseness and dysphonia; bilateral injury causes complete vocal cord paralysis with aphonia and inspiratory stridor. Partial bilateral paralysis may produce a paralysis of both abductors, with severe dyspnea and inspiratory stridor, but does not usually cause any alteration in the voice. Bilateral lesions of the vagus nerve invariably lead to death via cardiac arrhythmias, irregular respirations, gastrointestinal atonia, and complete paralysis of the pharynx and larynx.

THE SPINAL ACCESSORY NERVE (CRANIAL NERVE XI)

The spinal accessory nerve is composed of two primary branches—the first is a small accessory cranial branch contributing visceral efferent fibers to the vagus nerve, which emerges from the jugular foramen to blend with the vagus as it descends (primarily in the recurrent laryngeal nerve). The majority of the accessory nerve, the spinal portion, innervates the SCM and part or all of the trapezius muscles. Its fibers originate in the upper cervical spinal cord (C2, C3, and C4), enter the skull via the foramen magnum, and travel through the jugular foramen along the carotid artery to innervate the SCM muscle. Another branch emerges in the mid-SCM at its posterior border and crosses the posterior triangle of the neck to innervate the upper trapezius. It is important to note that supranuclear efferents to the SCM are primarily ipsilateral, whereas inputs to the trapezius cross contralaterally from the motor cortex. Therefore, on examination, a lesion of the ipsilateral hemisphere or accessory spinal nerve will result in an inability to turn the head contralaterally (as the SCM turns the head in the opposite direction). Fibers of the spinal accessory nerve also travel in the medial longitudinal fasciculus, where they make connections with the oculomotor, trochlear, abducens, and vestibular nuclei and help coordinate eye movements with head motion in response to external stimuli.

Lesions of the spinal portion of the 11th cranial nerve produce weakness and atrophy of the trapezius muscle and SCM, impairing rotary movements of the neck and chin to the opposite side, and weakness of shrugging movements of the shoulder. Weakness of the upper portion of the trapezius results in winging of the scapula, which must be differentiated from that produced by weakness of the serratus anterior. Scapular winging from weakness of the trapezius is present at rest (eg, arms at side) and becomes worse on abduction of the shoulder. Scapular winging from weakness of the serratus anterior is negligible at rest and worsens during flexion of the shoulder (holding or pushing the arm forward). Bilateral paralysis of the trapezius may present with "dropped head syndrome" due to weakness of head extension. With unilateral SCM weakness, there is typically little head tilt, as there are contributions

from several other muscles to head rotation, although the patient will have difficulty turning the head to the contralateral side. The accessory or cranial portion of the nerve originates in the nucleus ambiguus and passes through the jugular foramen with the 10th cranial nerve, traveling with the spinal fibers (see earlier), eventually innervating the larynx, and functionally is considered by some to be a part of the vagus nerve complex.

The nucleus of the 11th cranial nerve may be destroyed by infections and degenerative disorders in the medulla, such as syringobulbia or ALS. The nerve itself may be injured by polyneuropathy, meningeal infection, extramedullary tumor (eg, meningioma and neurinoma), trauma (ie, basilar skull fracture), or by destructive processes in the occipital bone. It is particularly vulnerable to damage along its course in the posterior triangle of the neck, for instance, during lymph node biopsy, radiation, cannulation of the internal jugular vein, or carotid endarterectomy. The SCM and trapezius are also often involved in cases of extrapyramidal dysfunction (discussed in later chapters), such as torticollis due to cervical dystonia. Idiopathic focal mononeuropathies of the spinal accessory nerve exists although are rare, and the nerve at times may be involved in cases of Parsonage-Turner syndrome. Primary diseases of muscle and the neuromuscular junction also commonly involve the muscles innervated by the 11th cranial nerve, such as in fascioscapulohumeral dystrophy, myotonic dystrophy, and myasthenia gravis. Diagnosis of a spinal accessory nerve palsy is made clinically but can be supported with imaging and electrodiagnostic testing. Recent reports point to a potential role for ultrasound in diagnosis and in determining etiology.

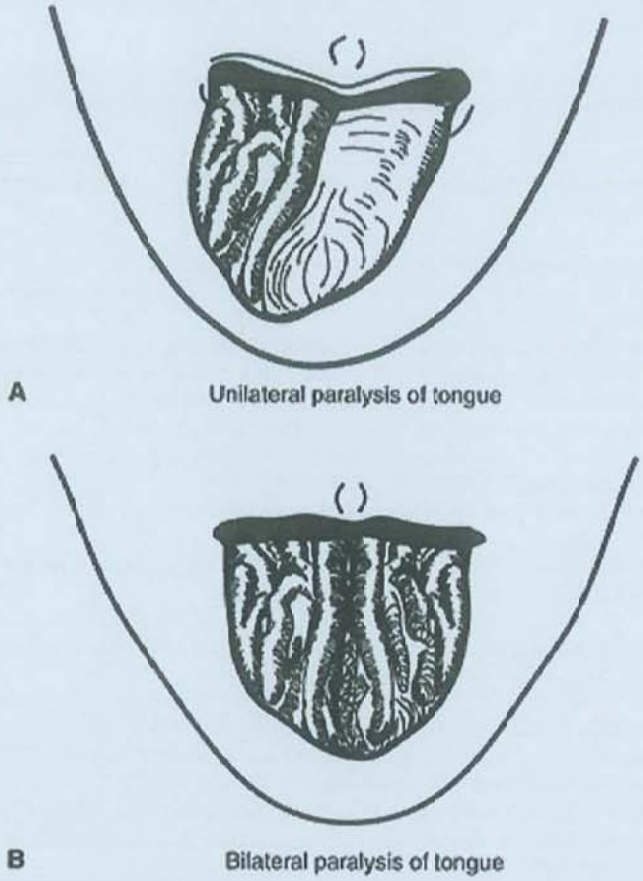

FIGURE 89.5 Tongue weakness. (From Bhatnagar SC. *Neuroscience for the Study of Communicative Disorders*. 4th ed. Philadelphia, PA: Wolters Kluwer; 2013.)

THE HYPOGLOSSAL NERVE (CRANIAL NERVE XII)

The hypoglossal nerve (a pure motor nerve) emerges from the medulla between the ventrolateral sulcus, between the olive and the pyramids, as a number of rootlets that converge into the hypoglossal nerve. The nerve then exits the cranium through the hypoglossal foramen in the posterior cranial fossa traveling close to cranial nerves IX, X, and XI and passing downward near the inferior ganglion of the vagus to lie between the internal carotid artery and internal jugular vein. It then crosses laterally to the bifurcation of the common carotid artery and loops above the hyoid bone before moving ventrally to supply the genioglossus (which has crossed supranuclear innervation) and other muscles of the tongue with the exception of the palatoglossus (innervated by the vagus nerve). The 12th cranial nerve and its nucleus may be injured by most of the same processes that damage the 10th and 11th nuclei. Occlusions of the short branches of the basilar artery supplying the paramedian medulla cause paralysis of the tongue on one side and paralysis of the arm and leg on the opposite side (ie, alternating hemiplegia). Unilateral injury to the nucleus results in atrophy and paralysis of the muscles of one-half of the tongue causing deviation toward the paralyzed side with protrusion (Fig. 89.5).

Fibrillation of the muscles is seen with chronic injury to the hypoglossal nerve or its nucleus in syringobulbia or ALS and may be observed as miniscule twitching of the surface of the tongue on visual inspection. Bilateral paralysis of the nucleus or nerve produces atrophy of both sides of the tongue and paralysis of all movements with severe dysarthria and difficulty manipulating food in the mouth. The tongue is only rarely affected by supranuclear lesions within the CNS; unilateral weakness may accompany severe hemiplegia with slight deviation of the tongue to the paralyzed side when protruded. Moderate weakness of the tongue may accompany pseudobulbar palsy but is never as severe as that caused by destruction of both medullary nuclei. The hypoglossal nerve is susceptible to injury anywhere along its course (both intra and extramedullary) and can be involved in cases of meningitis, neoplastic infiltration, trauma, lymphadenopathy, radiation, and processes involving the skull base. Occasionally, muscle diseases may involve the tongue, such as in myotonic dystrophy where percussion of the tongue may cause a temporary contraction along the line of percussion.

LEVEL 1 EVIDENCE

1. Gronseth G, Cruccu G, Alksne J, et al. Practice parameter: the diagnostic evaluation and treatment of trigeminal neuralgia (an evidence-based review): report of the Quality Standards Subcommittee of the American Academy of Neurology and the European Federation of Neurological Societies. *Neurology*. 2008;71(15):1183-1190.
2. Hato N, Tamada H, Kohno H, et al. Valacyclovir and prednisclone treatment for Bell's palsy: a multicenter, randomized, place-controlled study. *Otol Neurotol*. 2007;28:408-413.
3. Sullivan FM, Swan IR, Donnan PT, et al. Early treatment with prednisolone or acyclovir in Bell's palsy. *N Engl J Med*. 2007;357:1598-1607.

SUGGESTED READINGS

Ashkan K, Marsh H. Microvascular decompression for trigeminal neuralgia in the elderly: a review of the safety and efficacy. *Neurosurgery*. 2004;55(4):840-850.

Auger RG, Piepgras DG, Laws ER Jr. Hemifacial spasm: results of microvascular decompression of the facial nerve in 54 patients. *Mayo Clin Proc*. 1986;61:640-644.

Baugh RF, Basura GJ, Ishii LE, et al. Clinical practice guideline: Bell's palsy. *Otolaryngol Head Neck Surg*. 2013;149(3 suppl):S1-S27.

Boghen DR, Glaser JS. Ischaemic optic neuropathy. The clinical profile and history. *Brain*. 1975;98:689-708.

Brin MF, Blitzer A, Stewart C, Fahn S. Treatment of spasmodic dysphonia (laryngeal dystonia) with local injections of botulinum toxin: review and technical aspects. In: Blitzer A, Brin MF, Sasaki CT, Fahn S, Harris KS, eds. *Neurological Disorders of the Larynx*. New York, NY: Thieme Medical Publishers; 1992:214-218.

Brisman R. Repeat Gamma Knife radiosurgery for trigeminal neuralgia. *Stereotact Funct Neurosurg*. 2003;81(1-4):43-49.

Brisman R. Trigeminal neuralgia and multiple sclerosis. *Arch Neurol*. 1987;44:379-381.

Ceylan S, Karaku A, Duru S, Baykal S, Koca O. Glossopharyngeal neuralgia: a study of 6 cases. *Neurosurg Rev*. 1997;20:196-200.

Cheuk AV, Chin LS, Petit JH, Herman JM, Fang HB, Regine WF. Gamma Knife surgery for trigeminal neuralgia: outcome, imaging, and brainstem correlates. *Int J Radiat Oncol Biol Phys*. 2004;60(2):537-541.

Cruccu G, Gronseth G, Alksne J, et al. AAN-EFNS guidelines on trigeminal neuralgia management. *Eur J Neurol*. 2008;15(10):1013-1028.

Dunphy EB. Alcohol and tobacco amblyopia: a historical survey. XXXI Deschweinitz lecture. *Am J Ophthalmol*. 1969;68:569-578.

Eldridge PR, Sinha AK, Javadpour M, Littlechild P, Varma TRK. Microvascular decompression for trigeminal neuralgia in patients with multiple sclerosis. *Stereotact Funct Neurosurg*. 2003;81(1-4):57-64.

Ford FR, Woodhall B. Phenomena due to misdirection of regenerating fibers of cranial, spinal and autonomic nerves: clinical observations. *Arch Surg*. 1938;36:480-496.

Friedman AP, Merritt HH. Damage to cranial nerves resulting from head injury. *Bull Los Angeles Neurol Soc*. 1944;9:135-139.

Fukuda H, Ishikawa M, Okumura R. Demonstration of neurovascular compression in trigeminal neuralgia and hemifacial spasm with magnetic resonance imaging: comparison with surgical findings in 60 consecutive cases. *Surg Neurol*. 2003;59(2):93-100.

Furuta Y, Fukuda S, Chida E, et al. Reactivation of herpes simplex virus type 1 in patients with Bell's palsy. *J Med Virol*. 1998;54:162-166.

Gouda JJ, Brown JA. Atypical facial pain and other pain syndromes. Differential diagnosis and treatment. *Neurosurg Clin N Am*. 1997;8:87-100.

Jankovic J, Ford J. Blepharospasm and orofacial-cervical dystonia: clinical and pharmacological findings in 100 patients. *Ann Neurol*. 1983;13:402-411.

Jannetta P. Observations on the etiology of trigeminal neuralgia, hemifacial spasm, acoustic nerve dysfunction and glossopharyngeal neuralgia. Definitive microsurgical treatment and results in 117 patients. *Neurochirurgia (Stuttg)*. 1977;20:145-154.

Jitpimolmard S, Tiamkao S, Laopaiboon M. Long term results of botulinum toxin type A (Dysport) in the treatment of hemifacial spasm: a report of 175 cases. *J Neurol Neurosurg Psychiatry*. 1998;64:751-757.

Juncos JL, Beal MF. Idiopathic cranial polyneuropathy: a fifteen-year experience. *Brain*. 1987;110:197-211.

Kalovidouris A, Mancuso AA, Dillon W. A CT-clinical approach to patients with symptoms related to the V, VII, IX-XII cranial nerves and cervical sympathetics. *Radiology*. 1984;151:671-676.

Keane JR. Mutiple cranial nerve palsies: analysis of 979 cases. *Arch Neurol*. 2005;62(11):1714-1717.

Kemp LW, Reich SG. Hemifacial spasm. *Curr Treat Options Neurol*. 2004;6(3):175-179.

Lecky BRF, Hughes RAC, Murray NMF. Trigeminal sensory neuropathy. *Brain*. 1987;110:1463-1486.

Leigh RJ, Zee DS. *The Neurology of Eye Movements*. 4th ed. Oxford, United Kingdom: Oxford University Press; 2006.

Lopez BC, Hamlyn PJ, Zakrzewska JM. Stereotactic radiosurgery for primary trigeminal neuralgia: state of the evidence and recommendations for future reports. *J Neurol Neurosurg Psychiatry*. 2004;75(7):1019-1024.

Lossos A, Siegal T. Numb chin syndrome in cancer patients: etiology, response to treatment, and prognostic significance. *Neurology*. 1992;42:1181-1184.

Ludlow CL, Naunton RF, Sedory SE, Schulz SE, Hallett M. Effects of botulinum toxin injections on speech in adductor spasmodic dysphonia. *Neurology*. 1988;38:1220-1225.

Majoie CB, Hulsmans FJ, Castelijns JA, et al. Symptoms and signs related to the trigeminal nerve: diagnostic yield of MR imaging. *Radiology*. 1998;209:557-562.

Murakami S, Nakashiro Y, Mizobuchi M, Hato N, Honda N, Gyo K. Varicella-zoster virus distribution in Ramsay Hunt syndrome revealed by polymerase chain reaction. *Acta Otolaryngol*. 1998;118:145-149.

Nadeau SE, Trobe JD. Pupil sparing in oculomotor palsy: a brief review. *Ann Neurol*. 1983;13:143-148.

Nielsen VK. Electrophysiology of the facial nerve in hemifacial spasm: ectopic/ephaptic excitation. *Muscle Nerve*. 1985;8:545-555.

Özkale Y, Erol I, Saygı S, Yilmaz I. Overview of pediatric peripheral facial nerve paralysis: analysis of 40 patients. *J Child Neurol*. 2015;30(2):193-199.

Pearce JM. Melkersson's syndrome. *J Neurol Neurosurg Psychiatry*. 1995;58:340.

Portenoy RK, Duma C, Foley KM. Acute herpetic and postherpetic neuralgia: clinical review and current management. *Ann Neurol*. 1986;20:651-664.

Rozen TD. Trigeminal neuralgia and glossopharyngeal neuralgia. *Neurol Clin*. 2004;22(1):185-206.

Rush JA, Younge BR. Paralysis of cranial nerves III, IV and VI. Cause and prognosis in 1,000 cases. *Arch Ophthalmol*. 1981;99:76-79.

Searles RP, Mladinich EK, Messner RP. Isolated trigeminal sensory neuropathy: early manifestations of mixed connective tissue disease. *Neurology*. 1978;28:1286-1289.

Shaya M, Jawahar A, Caldito G, Sin A, Willis BK, Nanda A. Gamma Knife radiosurgery for trigeminal neuralgia: a study of predictors of success, efficacy, safety, and outcome at LSUHSC. *Surg Neurol*. 2004;61(6):529-535.

Spillane JD, Wells CEC. Isolated trigeminal neuropathy. A report of 16 cases. *Brain*. 1959;82:391-416.

Stevens H. Melkersson's syndrome. *Neurology*. 1965;15:263-266.

Tan EK, Chan LL. Clinico-radiologic correlation in unilateral and bilateral hemifacial spasm. *J Neurol Sci*. 2004;222(1-2):59-64.

Tankére F, Maisonobe T, Lamas G, et al. Electrophysiological determination of the site involved in generating abnormal muscle responses in hemifacial spasm. *Muscle Nerve*. 1998;21:1013-1018.

Tenser RB. Trigeminal neuralgia: mechanisms of treatment. *Neurology*. 1998;51:17-19.

Troost BT, Daroff RB. The ocular motor defects in progressive supranuclear palsy. *Ann Neurol*. 1977;2:397-403.

Van Zandycke M, Martin JJ, Vande Gaer L, Van den Henyning P. Facial myokymia in the Guillain-Barré syndrome: a clinicopathologic study. *Neurology*. 1982;32:744-748.

Victor M, Dreyfus PM. Tobacco-alcohol amblyopia. Further comments on its pathology. *Arch Ophthalmol*. 1965;74:649-657.

Wang A, Jankovic J. Hemifacial spasm: clinical findings and treatment. *Muscle Nerve*. 1998;21:1740-1747.

Wartenberg R. *Hemifacial Spasm: A Clinical and Pathological Study*. London, United Kingdom: Oxford University Press; 1952.

Wiffen PJ, Derry S, Moore RA, Kalso EA. Carbamazepine for chronic neuropathic pain and fibromyalgia in adults. *Cochrane Database Syst Rev*. 2014;2014(4):CD005451.

Willoughby EW, Anderson NE. Lower cranial nerve motor function in unilateral vascular lesions of the cerebral hemisphere. *Br Med J (Clin Res Ed)*. 1984;289:791-794.

Yoshino N, Akimoto H, Yamada I, et al. Trigeminal neuralgia: evaluation of neuralgic manifestation and site of neurovascular compression with 3D CISS MR imaging and MR angiography. *Radiology*. 2003;228(2):539-545.

90 Mononeuropathies and Compression Neuropathies

Thomas H. Brannagan III

KEY POINTS

1. Carpal tunnel syndrome is one of the most common mononeuropathies, caused by compression of the median nerve at the wrist.
2. The brachial plexus is composed of the upper, middle, and lower trunks and medial, posterior, and lateral cords.
3. Electromyography showing myokymia is frequently seen in plexus lesions caused by radiation.

APPROACH TO PERIPHERAL NERVE DISORDERS

Mononeuropathy indicates a disorder of a single nerve often resulting from local trauma, compression, or entrapment. *Mononeuropathy multiplex* signifies focal involvement of two or more nerves, usually as a result of a generalized disorder such as diabetes mellitus or vasculitis. This chapter discusses an approach to mononeuropathies, including plexus disorders.

Epidemiology

Mononeuropathies are common disorders. One mononeuropathy, carpal tunnel syndrome, is estimated to occur in 3% to 5.8% and is 3 times more common in women than men. People in occupations, doing tasks, requiring high force and repetition, such as food processing, carpentry, and roofing are at higher risk.

Clinical Features

In *mononeuropathy* or *mononeuropathy multiplex*, focal motor, sensory, and reflex changes are restricted to areas innervated by specific nerves. When multiple distal nerves are affected in mononeuropathy multiplex, the pattern may coalesce into more symmetric involvement suggesting polyneuropathy. Mononeuropathy multiplex is discussed in Chapter 91.

Processes that affect nerve roots are termed *radiculopathies* and affect a single or multiple myotomes or dermatomes. Focal compression is most common, but other processes also target nerves at these proximal sites. Electric-like pain radiating down a specific segment is most characteristic; loss of sensation or strength in a specific territory occurs with more severe involvement. *Plexopathy* occurs with compromise of the brachial or lumbosacral plexus and often displays a pattern of multiple contiguous nerves or nerve root impairment.

Etiology and Diagnosis

Trauma, compression, and entrapment are considered in the differential diagnosis of mononeuropathies, especially median neuropathy at the wrist, ulnar nerve at the elbow, or fibular nerve across the fibular head. Patients with any form of polyneuropathy are more vulnerable to mechanical and toxic nerve injury; cachectic or immobile patients may develop focal neuropathy from pressure or trauma.

Outcome

With mononeuropathies, the prognosis is affected by the extent of nerve degeneration. With removal or treatment of the inciting cause, recovery is more rapid if macroscopic continuity of the nerves is maintained. Conversely, recovery may be delayed for many months or remain incomplete if significant wallerian degeneration occurs. Axonal regeneration proceeds at a rate of 1 to 2 mm/d and may be further delayed where the axons must penetrate scar tissue, injured nerve segments, or other barriers. Aberrant growth of axonal sprouts may lead to formation of persistent neuromas. After severe wallerian degeneration, there may be permanent weakness, muscular wasting, diminution of reflexes, and sensory loss.

THE SPINAL ROOTS AND BRACHIAL PLEXUS

At each cervical spinal level, numerous rootlets containing both motor and sensory fibers join after leaving the spinal cord to form the spinal roots that exit the spinal canal through the intervertebral foramen of the spinal column, immediately branching into anterior and posterior rami. The nerve roots are commonly injured by degenerative joint disease and disk herniation at the cervical and lumbosacral levels. Importantly, the dorsal root ganglia (ie, the cell bodies of the sensory nerves) are located outside the foramen and are spared in foraminal compression, meaning the remainder of the sensory nerve will remain viable and will appear normal on nerve conduction studies, even though it is disconnected from the central nervous system and the patient reports numbness and pain. Before forming the brachial plexus, the C5 nerve root gives off a proximal branch, the *dorsal scapular nerve* (to the rhomboid muscles), whereas the C5, C6, and C7 roots give proximal branches that join to form the *long thoracic nerve*, supplying the serratus anterior muscle. The C5 and C6 roots then join to form the *upper trunk* of the brachial plexus, whereas the C7 root forms the *middle trunk*, and the C8 and T1 roots form the *lower trunk*. The upper trunk gives off a small branch, the *suprascapular* nerve, which supplies the supra- and infraspinatus muscles. All trunks pass through the supraclavicular fossa under the cervical and scalene muscles.

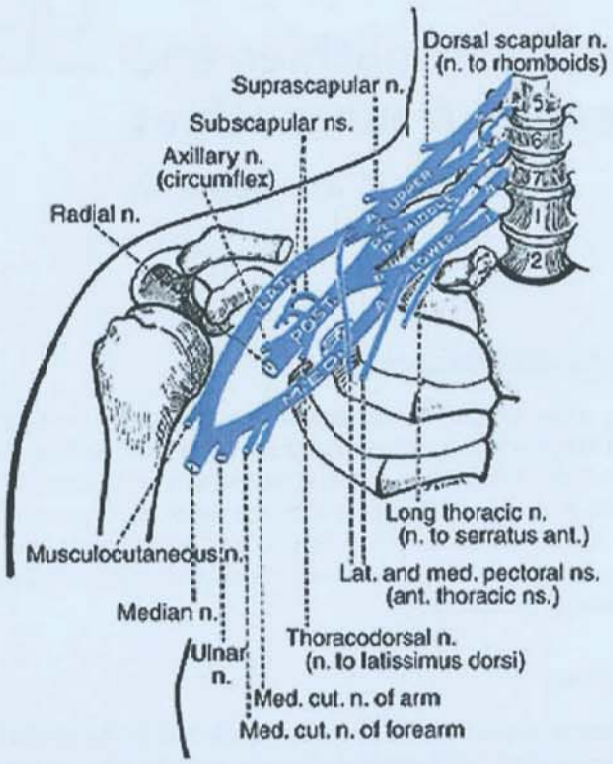

FIGURE 90.1 The brachial plexus. (From Haymaker W, Woodhall B. *Peripheral Nerve Injuries*. Philadelphia, PA: WB Saunders; 1945.)

Each trunk then forms two branches, and these branches regroup to form new divisions, the cords, as they course through the *thoracic outlet*, between the first rib and the clavicle, along with the subclavian artery. The lateral branches of the upper and middle trunks contribute to the *lateral cord* (ie, C5, C6, C7), whereas the medial branches join with the lateral branch of the lower trunk and move dorsally to form the *posterior cord* (ie, C5, C6, C7, C8). Finally, the lower trunk gives rise to the *medial cord* (ie, C8, T1). The *lateral and medial pectoral nerves* branch off near the juncture of the trunks and the lateral and medial cords, respectively, supplying the pectoralis major muscle.

The *thoracodorsal nerve* that supplies the latissimus dorsi and the *subscapular* nerve that supplies the teres major each branch medially off the posterior cord. The posterior cord persists distally, becoming the *radial nerve*, after giving off a smaller lateral branch, the *axillary nerve*, which supplies the deltoid. The lateral and medial cords then each contribute a branch to form the *median nerve*, composed of the medial branch of the lateral cord and the lateral branch of the medial cord, joined in the middle of the plexus. The lateral branch of the lateral cord persists distally, becoming the *musculocutaneous nerve*, whereas the medial branch of the medial cord becomes the *ulnar nerve* (**Fig. 90.1**; **Tables 90.1** and **90.2**).

The brachial plexus may be injured by traumatic, neoplastic, infectious, radiation, and other processes. Careful history and neurologic examination, in concert with a detailed understanding of plexus anatomy, is the first step in recognizing plexus injury and differentiating it from injury to the nerve roots or peripheral nerves. Electrophysiologic assessment with electromyography (EMG) and nerve conductions is often critical in confirming the diagnosis, and imaging studies may also be indicated. Mixed syndromes of radicular plexus and peripheral nerve injury may also occur, making localization even more challenging. The roots or trunks of the brachial plexus may be damaged by lacerations, gunshot wounds, or direct trauma. They may be compressed by tumors or aneurysms or stretched and torn by violent movements of the shoulder in falls, dislocation of the shoulder, carrying heavy loads on or over the shoulder, and by traction during birth. The syndromes of the roots and trunks cause deficits principally in the distribution of the affected nerve roots. Partial paralysis and incomplete sensory loss are common because many muscles of the arm receive innervation from two or more roots.

TABLE 90.1 Innervation of the Muscles of the Shoulder Girdle

Muscle	Nerve	Spinal Nerve Roots
Sternocleidomastoid	Accessory	X1, C2, C3
Trapezius	Accessory	C3, C4
Serratus anterior	Long thoracic	C5, C7
Levator scapulae	Dorsal scapular	C5, C6
Rhomboideus major	Dorsal scapular	C5, C6
Rhomboideus minor	Dorsal scapular	C5, C6
Subclavius	Subclavian	C5, C6
Supraspinatus	Suprascapular	C5, C6
Infraspinatus	Suprascapular	C5, C6
Pectoralis major	Medial and lateral pectoralis	C5, C6
Pectoralis minor	Medial pectoralis	C5, C6
Teres major	Subscapular	C5, C6
Latissimus dorsi	Thoracodorsal	C6, C7
Subscapularis	Subscapular	C5, C6
Deltoid	Axillaris	C5, C6
Teres minor	Axillaris	C5, C6

TABLE 90.2 Innervation of Muscles of the Arm and Forearm

Muscle	Nerve	Root
Biceps brachii *Brachialis*	Musculocutaneous	C5, C6
Triceps	Radialis	C7, C8
Anconeus	Radialis	C7, C8
Brachioradialis	Radialis	C5, C6
Extensor carpi radialis	Radialis	C6, C7
Pronator teres	Medianus	C6, C7
Flexor carpi radialis	Medianus	C7, C8
Palmaris longus	Medianus	C7, C8
Flexor digitorum sublimis	Medianus	C7, C8
Flexor digitorum profundus	Medianus, ulnaris	C7, C8
Flexor carpi ulnaris	Ulnaris	C7, C8
Supinator	Radialis	C7, C8
Extensor digitorum communis	Radialis	C7, C8
Extensor digiti minimi	Radialis	C7, C8
Extensor carpi ulnaris	Radialis	C7, C8
Abductor pollicis longus and brevis	Radialis	C7, C8
Extensor indicis proprius	Radialis	C7, C8

Trunk and Root Injury

Upper Radicular Syndrome

Upper radicular syndrome (Erb or Erb-Duchenne palsy) results from damage to the upper roots (C4, C5, or C6) or the upper trunk. Such lesions are most commonly the result of stretch injuries during difficult deliveries, especially when forceps are used, and cause paralysis of the deltoid, biceps, brachioradialis, pectoralis major, supraspinatus, infraspinatus, subscapularis, and teres major muscles in varying combinations. If the lesion is near the roots, the serratus anterior, rhomboids, and levator scapulae are also paralyzed. Clinically, this causes weakness of flexion at the elbow and of abduction and internal and external rotation of the arm. There is also weakness or paralysis of apposition of the scapula and backward-inward movements of the arm. Sensory loss is incomplete and consists of hypesthesia on the outer surface of the arm and forearm. The biceps reflex is absent. Unless treated by passive range-of-motion exercise, these patients may develop chronic contractures with the arm extended at the side, fully adducted, and pronated, with the hand flexed and facing rearward (eg, the waiter's tip position).

Middle Radicular Syndrome

Middle radicular syndrome results from damage to the seventh cervical root (C7) or the middle trunk. Such lesions cause paralysis primarily of the muscles supplied by the radial nerve except the brachioradialis, which is entirely spared. Clinical weakness parallels that of injury to the radial nerve below the level of its branch to the brachioradialis. Sensory loss is variable and, when present, is limited to hypesthesia over the dorsal surface of the forearm and the external part of the dorsal surface of the hand.

Lower Radicular Syndrome (Klumpke Palsy)

Lower radicular syndrome (Klumpke palsy) results from injury to the lower trunk or lower roots (C7-T1), which causes paralysis of the flexor carpi ulnaris, the flexor digitorum, the interossei, and the thenar and hypothenar muscles. This pattern mimics a combined lesion of the median and ulnar nerves. Clinically, a flattened or simian hand is seen, with loss of all intrinsic hand musculature and with loss of sensation on the inner side of the arm and forearm and on the ulnar side of the hand. The triceps reflex is lost. If the communicating branch to the inferior cervical ganglion is injured, there is paralysis of the sympathetic nerves, causing a Horner syndrome.

Cord Injury

Lesions of the cords cause motor and sensory loss resembling that seen after injury to two or more peripheral nerves. *Lateral cord* injury causes weakness in the distribution of the musculocutaneous nerve and the lateral head of the median nerve, including weakness in the pronator teres, flexor carpi radialis, and flexor pollicis. *Posterior cord* injury causes weakness paralleling that resulting from combined damage to the radial and axillary nerves, whereas *medial cord* injury mimics combined damage to the ulnar nerve and the medial head of the median nerve (finger-flexion weakness).

Diffuse Plexus Injury

Generalized injury to the brachial plexus is usually unilateral but occasionally appears bilaterally. Such injury results from a more diffuse polyneuropathy, such as chronic inflammatory demyelinating neuropathy, or from multifocal motor neuropathy. A variety of insults may produce injury selectively affecting the brachial plexus, but tumor infiltration, radiation plexitis, and idiopathic plexitis are among the most important. Almost any neoplasm with a propensity for the chest may affect the plexus, but those cancers originating locally, such as lung and breast cancer, are most likely to cause injury. Such tumors may cause extrinsic compression of the plexus as they grow or may directly infiltrate the nervous tissue. Other neoplasms, such as lymphoma, may infiltrate the plexus and cause progressive deficits without any apparent mass effect or enlargement of the plexus itself in the initial stages. Magnetic resonance imaging (MRI) with contrast is the best way to confirm these lesions.

Idiopathic brachial plexitis (also known as the *Parsonage-Turner syndrome* or *neuralgic amyotrophy*) usually begins with a sudden, sharp pain affecting one shoulder, often with radiation down the ipsilateral arm, later followed by arm or shoulder weakness. The pain persists for hours or a few days with gradual improvement and usually resolves completely within days to weeks, leaving some sensory and motor dysfunction. It may be bilateral or asymmetric. Localization is often difficult because plexus involvement ranges from diffuse to multifocal and often includes patchy injury to the nerve branches off the plexus (eg, the axillary nerve).

Electrodiagnostic studies, if performed at least 14 to 21 days after onset, usually localize the injury to the plexus but may demonstrate multifocal involvement. Patterns of both axonal and demyelination injury have been reported. The diversity of physiologic disorders in different nerves or even within the same nerve is attributed to involvement of the terminal nerve twigs or to patchy damage of discrete bundles of fibers within the cords or trunks of the brachial plexus or its branches. The long thoracic and anterior interosseous nerves are commonly affected. Autoimmune or infectious causes have been suggested, but the etiology is obscure. Some cases have occurred in small epidemics, and the disorder may follow intravenous heroin use, human immunodeficiency virus seroconversion, surgery, and delivery.

There is no clear evidence that immunosuppressive therapy alters the course of the disease. However, short courses of tapering oral steroids are often prescribed if the patient presents shortly after symptom onset. Variants of this syndrome have also been described, including one with isolated, pure sensory injury affecting the lateral, antebrachial, cutaneous, and the median nerves.

A hereditary form that is frequently recurrent and bilateral is rarely encountered. Lumbosacral plexitis also occurs but much less frequently. Recovery depends on the severity of the initial insult. Although most patients recover well over 6 to 12 months, some are left with permanent disability. It is considered good in about 66%, fair in 20%, and poor in 14%. Clinical recovery may take 2 months to 3 years.

Thoracic Outlet Syndrome

The term *thoracic outlet syndrome* (TOS) encompasses different syndromes that arise from compression of the nerves in the brachial plexus or blood vessels (ie, subclavian or axillary arteries, or veins in the same area). The putative compression sources are also diverse. How often these lesions are actually responsible for symptoms and how the symptoms should be treated are matters of intense debate. Studies done mainly by orthopedists, vascular surgeons, and neurosurgeons have included reports on several hundred patients who were treated surgically for this syndrome. When neurologists write about the neurogenic form of TOS, however, the tone is always skeptical, and the syndrome is described as exceedingly rare, with an annual incidence of about 1 per 1 million persons.

Pathology

The T1 and C8 nerve roots and the lower trunk of the brachial plexus are exposed to compression and angulation by anatomic anomalies that include cervical ribs and fibrous bands of uncertain origin. Other nearby structures, such as scalene muscles, are dubious sources of compression. Cervical ribs are commonly found in asymptomatic people, and it is therefore difficult to assume that the presence of a cervical rib necessarily explains local symptoms. In addition to the neural syndromes, the same anomalies may compress local blood vessels and cause vascular syndromes, usually separated into arterial and venous entities. These conditions are also rare and may cause neurogenic symptoms by distal nerve ischemia but not pressure on the brachial plexus. Some cases follow local trauma.

Clinical Features

Patients have pain in the shoulders, arms, and hands, or sometimes in all three locations. Hand pain is often most severe in the fourth and fifth fingers. The pain is aggravated by use of the arm, and arm "fatigue" may be prominent, meaning local discomfort after brief effort. There may or may not be hypesthesia in the affected area.

Critics have divided cases into two groups: the *true* neurogenic TOS and the *disputed* syndrome. In the *true* syndrome, there are definite clinical and electrodiagnostic abnormalities. This disorder is rare and is almost always caused by a taut fibrous band extending from a cervical rib or abnormally elongated C7 transverse process; the band stretches the distal C8 and T1 roots or lower brachial plexus trunk. There is unequivocal wasting and weakness of hand muscles innervated by these segments. Changes are almost always unilateral.

Electromyography and nerve conduction studies demonstrate a pattern of low-amplitude median motor, ulnar sensory, and medial antebrachial cutaneous-evoked responses. Ulnar motor responses to hypothenar muscles may be involved to a lesser degree. EMG signs of active and chronic denervation are limited to involved muscles, most severely in the abductor pollicis brevis, and are attributed to a major contribution from T1.

In the *disputed* form, there are no objective motor or sensory signs or consistent laboratory abnormalities. Attempts to reproduce the syndrome by passive abduction of the arm (ie, the Adson test) or other maneuvers have been cited, but the same abnormalities may be found in normal people and have no specific diagnostic value. The diagnosis is usually made by the treating surgeon; symptoms are frequently bilateral and complicated by legal or other nonmedical issues.

Similarly, studies of the application of electrodiagnostic techniques have not been blinded or controlled, so less specific abnormalities have been noted; the findings include isolated abnormalities of ulnar sensory nerve amplitude, conduction velocity after stimulation of the Erb point, ulnar F waves, and ulnar somatosensory-evoked potentials. MRI may show deviation or distortion of nerves or blood vessels, bands extending from the C7 transverse process, or other local anomalies. MRI quantitative estimates of the size of the thoracic outlet may show smaller than average dimensions, as were the cases in blinded reviews of series that compared vascular and neurogenic patients together with controls but do not prove that the differences are causative. Magnetic resonance angiography and Doppler ultrasonography may help assess possible vascular compression.

Diagnosis and Treatment

In cases of *true* TOS, diagnosis must exclude entrapment syndromes in the arm and compressive lesions in the cervical spine. The "upper limb tension test" is said to be comparable to straight leg raising, is carried out by abducting the arms to 90° in external rotation, bringing on symptoms within 60 seconds. EMG, MRI, and sonography after raising the arm have been used to aid in diagnosis. However, warnings continue to appear about false-positive maneuvers to evoke pain. Danielson and Oddersen injected botulinum toxin into the anterior scalene muscle under ultrasound guidance. Subclavian artery flow rates were measured with Doppler ultrasound. Three weeks later, symptoms had improved and blood flow in the artery, tested with the arm extended, had improved. A placebo-controlled formal study of this "scalene muscle chemodenervation" would help resolve the uncertainty of the procedure, which could be used for diagnosis, treatment, and screening for surgery. However, no consensus has been achieved for the surgical procedure of choice, which may or may not include botulinum, rib resection, brachial plexus neurolysis, scalenectomy, or release of the subclavian artery and vein. Exercise programs have also been advocated.

In the *disputed* form, when no objective findings are noted on neurologic examination, there are problems. Each case must be evaluated separately, but caution is reasonable when symptoms are not accompanied by objective changes. Conservative therapy should be given an adequate trial; postural adjustments, passive exercise to increase mobility of shoulder muscles, and an exercise program have all been advocated. The results of surgery are difficult to evaluate without objective signs or diagnostic laboratory abnormalities to track; placebo effects are rarely considered in the evaluation of surgery. Symptomatic improvement also appears to be unrelated to the surgical procedure or the particular structure that has been excised or resected. Surgery is not without hazard; complications may include causalgia, injury of the long thoracic nerve, infection, and laceration of the subclavian artery.

THE SPINAL ROOTS AND LUMBAR AND SACRAL PLEXUSES

The Lumbar Plexus

The spinal roots at L2, L3, and L4 join to form the *lumbar plexus* in the psoas major muscle. This plexus gives off a number of principally sensory nerves, including the iliohypogastric, the ilioinguinal, the genitofemoral, and the lateral femoral cutaneous. The *femoral nerve* is derived from the L2, L3, and L4 roots, passing to the anterior leg along the lateral aspect of the psoas muscle (which it supplies); exiting the pelvis; and passing under the inguinal ligament to supply the pectineus, sartorius, rectus femoris, vastus lateralis, vastus intermedius, and vastus medialis muscles; and terminates as the pure sensory saphenous nerve in the medial lower leg.

The *obturator nerve* arises from anterior branches of the L2, L3, and L4 roots, forming in the psoas muscle and entering the pelvis anteriorly to the sacroiliac joint. It passes through the obturator canal, branching anteriorly to supply the adductor longus and brevis, and the gracilis, as well as posteriorly to supply the obturator externus, and half of the adductor magnus. It carries sensation from a small and variable area on the inner surface of the medial thigh, knee, and occasionally just below the medial knee.

The Sacral Plexus

The sacral plexus is formed from the L5, S1, and S2 roots, with variable contributions from L4. The *superior gluteal nerve* arises from the L4, L5, and S1 roots and supplies the gluteus medius and minimus and tensor fascia lata; the *inferior gluteal nerve* arises from the L5 and S1 roots and supplies the gluteus maximus.

The *sciatic nerve* is formed from the posterior fusion of the L4, L5, and S1 roots, exiting the pelvis via the greater sciatic foramen and passes through or under the piriformis muscle. It is functionally divided into a lateral fibular portion, which supplies the short head of the biceps femoris, and a medial tibial portion, which supplies the long head of the biceps femoris, the semitendinosus, and the semimembranosus. The nerve divides into the common fibular (formerly called the *peroneal*) and tibial nerves above the posterior knee.

The *common fibular nerve* branches laterally from the sciatic trunk in the popliteal fossa then moves superficially to wind around the head of the fibula. It then divides into the *superficial fibular nerve* to supply the peroneus longus and peroneus brevis and the *deep fibular nerve*, which supplies the tibialis anterior, extensor hallucis longus, peroneus tertius, and extensor digitorum brevis. The *tibial nerve* supplies the gastrocnemius and soleus, tibialis posterior, flexor digitorum longus, and flexor hallucis longus. It descends through the lower leg between the medial malleolus and the flexor retinaculum, dividing into the *medial plantar nerve* to supply the abductor hallucis, flexor digitorum brevis and flexor hallucis brevis, and the *lateral plantar nerve* to supply the abductor digiti minimi, flexor digiti minimi, abductor hallucis, and interosseous muscles. Both the tibial and fibular nerves supply sensory branches, which join to form the *sural nerve* below the popliteal space.

Radiation Plexopathy

Irradiation for carcinoma may damage nervous tissue, especially with high-voltage therapy. Brachial plexopathy is seen after radiotherapy for breast cancer; caudal roots and lumbosacral plexus are sometimes affected by radiation therapy for testicular cancer or Hodgkin disease. The first symptom is usually severe pain, followed by paresthesia and sensory loss. There may be a latent period of 12 to 20 months; in milder cases, several years may elapse before symptoms appear. Limb weakness peaks many months later. Latency intervals of up to 20 years have been reported. The damage may affect a single peripheral nerve initially and then progress slowly to involve others. Clinically, tendon reflexes disappear before weakness and atrophy becomes obvious; fasciculation and myokymia may be prominent. EMG and conduction studies reveal evidence of axonal damage; myokymic discharges are characteristic and can help differentiate plexopathy caused by radiation from plexopathy caused by tumor infiltration. High-resolution MRI is also potentially useful. No effective treatment is known. Radiation-induced fibrosis and microvascular injury are suspected mechanisms.

THE PROXIMAL NERVES OF THE ARM

The Axillary Nerve

The axillary nerve is the last branch of the posterior cord of the brachial plexus before forming the radial nerve. It arises from C5 and C6, supplies the deltoid and teres minor muscles, and transmits cutaneous sensation from a small patch on the lateral shoulder. Axillary neuropathy may be caused by trauma, fracture, humeral head dislocation, and brachial plexitis. Weakness of arm abduction after the first 15° to 30° of movement is typical. Outward, backward, and forward movements of the arm are also weakened, although less dramatically. Sensory loss is limited to a small patch over the lateral deltoid.

The Long Thoracic Nerve

The long thoracic nerve arises from C5, C6, and C7 and supplies the serratus anterior muscle. This nerve is most commonly injured in isolation by forceful, downward pressure on the shoulder, which stretches and compresses it. Typically, such pressure is caused by carrying excessively heavy loads on the shoulder (eg, furniture, carpets, heavy sacks, backpacks slung over one shoulder), although it may also appear after acute impact, such as that occurring while playing football. A more archaic term, although one still in use, is *hod carrier's palsy*, in reference to the hod or container bricklayers formerly placed on the shoulder to carry bricks up to roof tops when constructing chimneys. Injury of this nerve destabilizes the scapula, causing winging, and prevents the rotation of the scapula needed to enable the last few degrees of abduction of the arm from 90° to 180° over the head. Injury following acute or chronic trauma is characterized by weakness in elevation of the arm above the horizontal plane. Winging of the scapula is most prominent when the arm is fully abducted or elevated anteriorly (Fig. 90.2). Winging is often not readily apparent with the arm resting at the side.

The Brachial Cutaneous and Antebrachial Cutaneous Nerves

The brachial and antebrachial cutaneous nerves branch directly from the C8 to T1 plexus and provide sensation to the medial arm and upper two-thirds of the forearm. These nerves are usually injured in conjunction with the medial cord of the brachial plexus and are rarely injured in isolation.

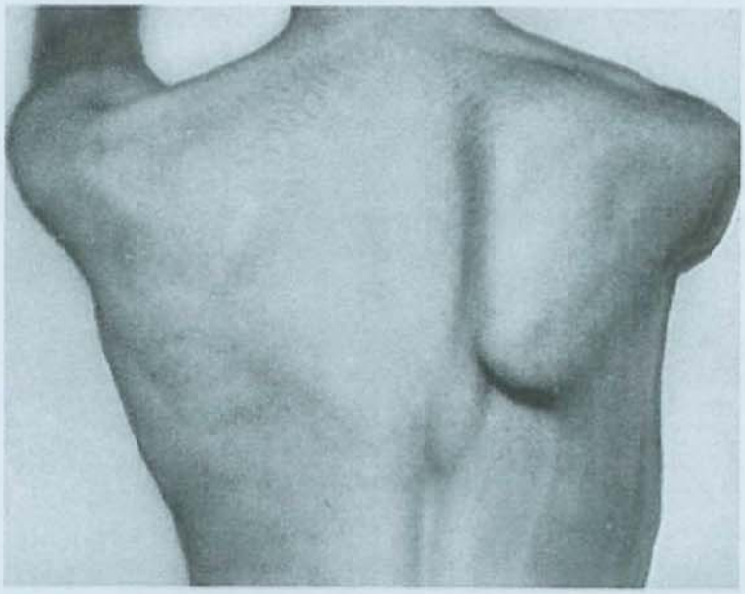

FIGURE 90.2 Paralysis of the serratus anterior muscle with winging of the scapula.

The Suprascapular Nerve

The suprascapular nerve fibers arise from C5 and C6, ultimately branching from the upper trunk of the brachial plexus. This primarily motor nerve innervates the supraspinatus and infraspinatus muscles. Affected patients have difficulty moving the arm from the side through the first 15° to 30° of abduction and with external shoulder rotation. Shoulder trauma or more diffuse brachial plexus injury is most common; isolated nerve injury is rare.

THE PERIPHERAL NERVES

The Radial Nerve

The radial nerve is a continuation of the posterior cord and contains elements of the C5, C6, C7, C8, and T1 nerve roots. It is predominantly a motor nerve and innervates the chief extensors of the forearm, wrist, and fingers. It descends through the axilla to supply the triceps, giving off three minor sensory branches to the upper arm and then winds posteriorly around the humerus in the *spiral groove*. After exiting the spiral groove, the nerve innervates the brachioradialis and extensor carpi radialis longus muscles then moves laterally to enter the forearm between the brachialis and brachioradialis muscles. There, it branches into a primary sensory component, the *superficial radial nerve*, which supplies sensation to the dorsoradial aspect of the distal forearm and the dorsal surface of the hand, and a motor component, the *posterior interosseous nerve*, which supplies all the remaining forearm extensor muscles and often the supinator as well (Table 90.3).

The clinical findings after radial nerve injury depend on the level of the lesion. Injury in the axilla, classically caused by improperly fitting crutches that are too long, causes triceps weakness as well as weakness of the remaining radial myotome and numbness in the radial dermatome. Injury in the spiral groove caused by humeral fracture or extrinsic compression (eg, *Saturday night palsy*) causes weakness of the radial myotome below the elbow, with prominent wrist-drop, weakness of finger extension, and sensory loss in the distribution of the superficial radial nerve but preserved elbow extension. Mild elbow flexor weakness may be present as a result of involvement of the brachioradialis, which should be easy to distinguish on physical examination. The posterior interosseous branch may also be injured by entrapment as it passes through the supinator muscle in the tight space of the arcade of Frohse.

Injury of the posterior interosseous nerve spares the brachioradialis and the extensor carpi radialis longus, as well as the superficial radial nerve, causing radial deviation of the wrist with attempted wrist extension but no sensory loss (ie, posterior interosseous neuropathy). Damage to the superficial radial branch may occur at the wrist as a result of tight-fitting jewelry or handcuffs, causing pure sensory loss over the dorsum of the hand without weakness. Evaluation of radial nerve injury often includes electrodiagnostic studies and may include imaging studies, depending on the site of the lesion. Treatment focuses on relieving the cause of compressive injury, if possible. Posterior interosseous nerve syndrome is sometimes treated with surgical release.

The Median Nerve

The median nerve derives from the C6 to T1 nerve roots, passing through the lateral and medial cords of the brachial plexus, which each contributes a segment to the nerve. The median nerve passes down the arm and through the two heads of the pronator teres at the level of the forearm, ultimately supplying the pronator teres as well as the flexor carpi radialis, palmaris longus, and flexor digitorum superficialis muscles. It then branches into the pure motor *anterior interosseous nerve*, which supplies the flexor pollicis longus, pronator quadratus, and flexor digitorum profundus I and II, and into a main branch, which passes through the carpal tunnel, further branching into the *recurrent thenar nerve*, supplying the abductor and the lateral flexor pollicis brevis and the opponens pollicis before terminating in the palm, where it supplies lumbricals I and II. Pronation is mediated by the pronator quadratus and pronator teres, wrist flexion by the flexor carpi radialis and palmaris longus, flexion of the thumb and the index and middle fingers by the superficial and deep flexors, and opposition of the thumb by the opponens pollicis (Table 90.4).

The median nerve supplies sensation to the radial side of the palm, the ventral thumb, index and middle fingers, the radial half of the ring finger, as well as the dorsal surfaces of the distal phalanx of the thumb, and the middle and terminal phalanges of the index and middle fingers. Isolated lesions of the median nerve cause weakness and sensory loss in the aforementioned distributions, but only a few movements are paralyzed because of the synergistic contributions of muscles innervated by other nerves to these movements. However, there may be absence of flexion in the index finger and near-complete paralysis of the opponens pollicis. The median nerve may be injured by trauma, ischemia, and other processes but most commonly is damaged by anatomic compression. It may be entrapped between the heads of the pronator teres muscle, causing weakness and sensory loss in the above distributions, with sparing of the pronator teres itself, which is innervated more proximally (ie, the pronator teres syndrome).

Entrapment of the anterior interosseous nerve (ie, the anterior interosseous neuropathy) often presents with pain but produces no sensory loss. Symptoms include weakness of the flexor pollicis longus, flexor digitorum profundus I and II, and the

TABLE 90.3 Muscles Innervated by the Radial Nerve

Triceps	Extensor digiti minimi
Anconeus	Extensor carpi ulnaris
Brachioradialis	Abductor pollicis longus
Extensor carpi radialis longus and brevis	Extensor pollicis longus and brevis
Supinator	Extensor indicis proprius
Extensor digitorum communis	

TABLE 90.4 Muscles Innervated by the Median Nerve

Pronator teres	Pronator quadratus
Flexor carpi radialis	Abductor pollicis brevis
Palmaris longus	Opponens pollicis
Flexor digitorum sublimis	Flexor pollicis brevis
Flexor digitorum profundus	Lumbricales (digits 1 and 2)
Flexor pollicis longus	

pronator quadratus. Attempts to make the "OK" sign with the thumb and index finger produces a triangle rather than a circle (eg, the pinch sign). The most common of all the nerve entrapment syndromes is the *carpal tunnel syndrome*. This syndrome results from entrapment of the median nerve as it passes through the tunnel defined by the carpal bones and the transverse carpal ligament, resulting in pain and sensory loss in a distal median distribution; wasting and weakness of thenar muscles and median innervated lumbricals is seen in severe cases. Although the diagnosis is primarily clinical, electrophysiologic studies may confirm the lesion and provide information on severity. Conservative treatment with application of a neutral position wrist splint is often effective. More severe or refractory cases, especially when motor deficits appear or splinting or other conservative measures fail to provide relief, may be treated by surgical release of the carpal tunnel. Many underlying disorders may predispose to the condition including diabetes, uremia, hypothyroidism, amyloidosis, and pregnancy.

The Ulnar Nerve

The ulnar nerve arises from C8 to T1 roots and the medial cord of the brachial plexus. It passes between the biceps and triceps, moving posteriorly to pass behind the medial epicondyle in the ulnar groove. It enters the forearm through the cubital tunnel, supplying the flexor carpi ulnaris and the flexor digitorum profundus II and IV, then moves medially to enter the hand through Guyon canal, where it divides into a superficial sensory branch and a deep motor branch, which supplies the abductor, opponens, and flexor digiti minimi medially. It then moves laterally to the adductor pollicis and the medial half of the flexor pollicis brevis (Table 90.5).

The nerve supplies sensation to the palmar and dorsal surfaces of the little finger, the medial half of the ring finger, and both the palmar and dorsal sides of the ulnar portion of the hand. Complete lesions of the proximal ulnar nerve are characterized by weakness of flexion and adduction of the wrist and of flexion of the ring and the little fingers, paralysis of abduction and opposition of the little finger, paralysis of adduction of the thumb, and paralysis of adduction and abduction of the fingers, along with atrophy of the hypothenar muscles and the interossei. Atrophy of the first dorsal interosseous is especially obvious on the dorsum of the hand between the thumb and the index finger. Sensory loss is greatest in the little finger and is present to a lesser extent on the inner side of the ring finger. Chronic lesions result in clawing of ulnar innervated fingers. The ulnar nerve may be injured by trauma, ischemia, and other causes but similar to the median nerve, it is most commonly injured by compression. Entrapment primarily occurs in three locations. The most common site is at the elbow, in or just proximal to the ulnar groove. Just distal to the elbow, the nerve may become entrapped in the cubital tunnel, the tunnel formed by the aponeurosis connecting the two heads of the flexor carpi ulnaris. Proximal nerve injury causes weakness in the ulnar myotomes of the hand and may include the flexor carpi ulnaris and flexor digitorum profundus III and IV, depending on the precise site of the compression. The nerve is potentially compressed at the elbow by direct pressure from arms of chairs, table edges, and excessive elbow flexion. A protective elbow pad is useful in some cases. Various forms of surgical decompression are available for the most extreme cases. Guyon canal stenosis in the wrist, most commonly associated with a ganglion cyst, causes weakness and atrophy of intrinsic hand muscles. Sensory symptoms may be minimal, although nerve conduction studies to the digits are abnormal. However, the flexor carpi ulnaris and flexor digitorum profundus III and IV are spared, in addition to sensation on the dorsal hand surface, which is innervated by the dorsal ulnar cutaneous nerve that arises in the distal forearm. The innervation of hand muscles is summarized in Table 90.2.

TABLE 90.5 Muscles Innervated by the Ulnar Nerve

Flexor carpi ulnaris	Flexor digiti minimi
Flexor digitorum profundus (digits four and five)	All interossei
Palmaris brevis	Lumbricales (digits three and four)
Abductor digiti minimi	Flexor pollicis brevis
Opponens digiti minimi	

The Musculocutaneous Nerve

The musculocutaneous nerve originates from the C5 and C6 nerve roots and the main branch of the upper trunk of the brachial plexus. It provides innervation to the coracobrachialis, biceps brachii, and brachialis muscles and provides sensation to the ventrolateral forearm (lateral antebrachial sensory nerve) as well as to a small area on the dorsolateral outer surface of the forearm. Isolated injuries of the nerve are rare and it is not typically prone to focal compression. Lesions of the musculocutaneous nerve produce weakness of flexion and supination of the forearm, sensory loss in the musculocutaneous myotomes, and loss of the biceps reflex. Forearm flexion may still be performed by the brachioradialis muscle innervated by the radial nerve. However, because the bicep is the chief supinator of the forearm, this movement is paralyzed. Excessive windsurfing is associated with compression of the lateral antebrachial sensory branch.

THE NERVES OF THE LEG

The Obturator Nerve

Lesions of the obturator nerve are uncommon and may be caused by pelvic tumors, obturator hernias, and by passage of the head of the fetus during difficult labor. Injuries to the obturator nerve result in severe weakness of adduction and to a lesser extent, internal and external rotation of the thigh. Pain in the knee joint is sometimes caused by pelvic involvement of the geniculate branch of the obturator.

The Iliohypogastric Nerve

The iliohypogastric nerve is a predominately sensory nerve that originates from the uppermost part of the lumbar plexus. It provides sensation to the outer and upper parts of the buttocks and the lower part of the abdomen and supplies partial innervation to the internal oblique and transversalis muscles. Lesions of the iliohypogastric nerve are rare. It may be divided by incisions in kidney operations or together with the ilioinguinal nerve in operations in the inguinal region, such as hernia repair. Lesions of these nerves produce no significant motor loss and only a small area of cutaneous anesthesia.

The Ilioinguinal Nerve

The ilioinguinal nerve is also a branch of the upper lumbar plexus. It provides sensation to the upper inner portion of the thigh, the pubic region, and the external genitalia and supplies the transversalis, internal oblique, and external oblique muscles. The ilicinguinal nerve is usually injured in concert with the iliohypogastric nerve and is only rarely injured in isolation.

The Genitofemoral Nerve

This predominately sensory nerve originates from the second lumbar root and provides sensation to the scrotum and the contiguous area of the inner surface of the thigh. Lesions of the genitofemoral nerve are rare. Irritative lesions of the nerve in the abdominal wall are accompanied by painful hyperesthesia at the root of the thigh and the scrotum.

The Lateral Femoral Cutaneous Nerve of the Thigh

This nerve is formed by fibers from the second and third lumbar roots. It crosses beneath the fascia iliaca to emerge at the anterosuperior iliac spine, descends in the thigh beneath the fascia lata, and divides into two branches. The posterior branch passes obliquely backward through the fascia lata and provides sensation to the superior external buttock. The anterior branch, which is more important clinically, pierces the fascia lata through a small fibrous canal located about 10 cm below the ligament and provides sensation to the outer surface of the thigh.

Lesions to this nerve principally affect the anterior branch, causing the clinical syndrome of *meralgia paresthetica*, and includes dysesthesias and sensory loss along the lateral thigh. The use of tight, heavy, utility belts or corsets and religious talismans; obesity; weight loss; and pregnancy are implicated as possible contributors to compression. Pains in the lateral thigh may also be caused by spinal lesions or pelvic tumors, which must be excluded by appropriate diagnostic studies. The course of meralgia paresthetica is variable. Occasionally, symptoms disappear spontaneously. In most patients, removal of contributing factors aids in resolution of symptoms.

The Femoral Nerve

The femoral nerve may be compressed by tumors, other pelvic lesions, pubic ramus, or femur fractures, as well as by ischemia in diabetic neuropathy and other conditions. Assessment of hip adduction helps to separate this condition from lumbar plexopathy or radiculopathy.

Injury to the nerve produces weakness of leg extension and thigh flexion. Walking on level ground is possible so long as the leg is extended, but if the slightest flexion occurs, the patient's knee may collapse. Climbing stairs or walking uphill is difficult or impossible. The quadriceps reflex is lost on the affected side. Saphenous sensory loss is also diagnostically useful. In severe cases, orthopedic appliances that fix the knee joint in extension or tendon transposition may be considered.

The Sciatic Nerve

The main trunk of the sciatic nerve is derived from the lower lumbosacral nerve roots and retains a strict segregation of fibular and tibial fibers. Total paralysis of muscles innervated by the sciatic nerve is rare. Even with a lesion in the thigh, the common fibular division is often more severely damaged than the tibial.

Important sources of injury include gunshot, shrapnel, or stab wounds to the leg or pelvis; fractures of the pelvis or femur; dislocations of the hip; pressure of the fetal head during delivery; or pelvic tumors. The nerve is sometimes inadvertently injured by intramuscular injection of drugs, especially in infants. Compression can occur in the posterior thigh by sharp chair edges or operating room tables. Injury by the piriformis muscle (*piriformis syndrome*) is controversial but very rare, but convincing cases are described. *Sciatica* is a term used to describe pain in the low back and in the leg along the course of the nerve, but the vast majority of these patients have nerve root injury at the L5-S1 level, often caused by intervertebral disk herniation. The clinical features of cervical and lumbar disk herniation are considered in Chapters 113 and 114.

Complete injury of the sciatic nerve causes paralysis of all the movements of the ankle and toes as well as weakness or paralysis of knee flexion. Gait is marked by foot drop and the ankle jerk is lost, along with sensation on the outer surface of the leg, on the instep and sole of the foot, and over the toes.

The Common Fibular Nerve

The common fibular branch of the sciatic nerve is a mixed nerve innervating the extensor muscles of the ankle and toes and the foot evertors. It provides sensation from the outer side of the leg, the front of its lower one-third, the instep, and the dorsal surface of the four inner toes over their proximal phalanges. The common fibular nerve is highly subjected to trauma. It may be damaged by wounds near the knee. The nerve is readily compressed or stretched as it curves around the fibular head by leg crossing, squatting, or resting the edge of the leg against a hard surface while sleeping, intoxicated, or anesthetized. Ganglion cysts, sometimes palpable at the fibular head, are well described. Common fibular neuropathy results in foot drop and weak foot eversion. The patient may not dorsiflex the ankle, straighten or extend the toes, or evert the foot, and there is sensory loss in the nerve distribution. Recovery is dependent on the extent of injury, which usually correlates with the degree and duration of extrinsic compression. Ambulation in patients with footdrop may be greatly aided by ankle-foot orthoses.

The Tibial Nerve

Tibial neuropathy is uncommon. It may be injured by gunshot wounds or leg fractures. A complete lesion of the nerve produces paralysis of plantarflexion and inversion of the foot, flexion and separation of the toes, and sensory loss in the nerve distribution. The ankle jerk and plantar reflex are lost. Rarely, compression of the posterior tibial branch of the nerve at the medial malleolus produces pain and paresthesia in the soles of the feet in a manner similar to compression of the median nerve at the wrist (*tarsal tunnel syndrome*); however, this process is much less prevalent. Other conditions that produce foot pain and/or numbness, including digital neuropathy, focal disorders of the foot, plantar fasciitis, early polyneuropathy, and Morton neuroma that produce foot pain and numbness are all more frequent.

MONONEUROPATHIES IN DIABETES MELLITUS

It is generally believed but incompletely proven that focal neuropathies are more frequent in diabetic patients than in the general population. The syndromes are usually localized to common sites of nerve entrapment or external compression and may imply an increased liability to pressure palsies. This applies to the median nerve at the carpal tunnel, the ulnar at the elbow, and the fibular at the fibular head. The electrophysiologic features are similar to those seen in nondiabetic patients with pressure palsies, except that abnormalities outside the clinically affected areas sometimes indicate that the palsies are superimposed on a generalized neuropathy. Cranial nerve palsies are most often localized to the third and sixth nerves. They start abruptly and usually spontaneously resolve completely within 6 months; relapses are rare.

SUGGESTED READINGS

Brachial Neuritis

Evans BA, Stevens JC, Dyck PJ. Lumbosacral plexus neuropathy. *Neurology*. 1981;31:1327-1330.

Kuhlenbäumer G, Hannibal MC, Nelis E, et al. Mutations in SEPT9 cause hereditary neuralgic amyotrophy. *Nat Genet*. 2005;37:1044-1046.

Sumner AJ. Idiopathic brachial neuritis. *Neurosurgery*. 2009;65(4 suppl): A150-A152.

van Alfen N, van Engelen BG, Hughes RA. Treatment for idiopathic and hereditary neuralgic amyotrophy (brachial neuritis). *Cochrane Database Syst Rev*. 2009;(3):CD006976.

Thoracic Outlet Syndrome

Cherington M, Cherington C. Thoracic outlet syndrome: reimbursement patterns and patient profiles. *Neurology*. 1992;42:943-945.

Danielson K, Odderson IR. Botulinum toxin type A improves blood flow in vascular thoracic outlet syndrome. *Am J Phys Med Rehabil*. 2008;87:956-959.

Demondion X, Bacqueville E, Paul C, Duquesnoy B, Hachulla E, Cotton A. Thoracic outlet: assessment with MR imaging in asymptomatic and symptomatic populations. *Radiology*. 2003;227:461-468.

Gilliatt RW, Le Quesne PL, Logue V, Summer AJ. Wasting of the hand associated with a cervical rib or band. *J Neurol Neurosurg Psychiatry*. 1970;33:615-624.

Kothari MJ, Macintosh K, Heistand M, Logigian EL. Medial antebrachial cutaneous sensory studies in the evaluation of neurogenic thoracic outlet syndrome. *Muscle Nerve*. 1998;21:647-649.

Levin KH, Wilbourn AJ, Maggiano HJ. Cervical rib and median sternotomy-related brachial plexopathies: a reassessment. *Neurology*. 1998;50:1407-1413.

Nord KM, Kapoor P, Fisher J, et al. False positive rate of thoracic outlet syndrome diagnostic maneuvers. *Electromyogr Clin Neurophysiol*. 2008;48(2): 67-74.

Roos DB. Thoracic outlet syndrome is underdiagnosed. *Muscle Nerve*. 1999;22:126-129.

Sanders RJ, Hammond SL, Rao N. Diagnosis of thoracic outlet syndrome. *J Vasc Surg*. 2007;46:601-604.

Simon NG, Ralph JW, Chin C, Kilot M. Sonographic diagnosis of true neurogenic thoracic outlet syndrome. *Neurology*. 2013;81:1965.

Tsao BE, Ferrante MA, Wilbourn AJ, Shields RW. Electrodiagnostic features of true neurogenic thoracic outlet syndrome. *Muscle Nerve*. 2014;49:724-727.

Wilbourn AJ. Thoracic outlet syndrome is overdiagnosed. *Muscle Nerve*. 1999;22:130-136.

Radiation Plexopathy

Dropcho EJ. Neurotoxicity of radiation therapy. *Neurol Clin*. 2010;28(1): 217-234.

Foley KM, Woodruff JM, Ellis FT, Posner JB. Radiation-induced malignant and atypical peripheral nerve sheath tumors. *Ann Neurol*. 1980;7:311-318.

Lalu T, Mercier B, Birouk N, et al. Pure motor neuropathy after radiation therapy: 6 cases [in French]. *Rev Neurol (Paris)*. 1998;154:40-44.

Pradat PF, Delanian S. Late radiation injury to peripheral nerves. *Handb Clin Neurol*. 2013;115:743-758.

Mononeuropathies

Buchthal F, Rosenfalck A, Trojaborg W. Electrophysiological findings in entrapment of the median nerve at wrist and elbow. *J Neurol Neurosurg Psychiatry*. 1974;37:340-360.

Cartwright MS, Hobson-Webb LD, Boon AJ, et al. Evidence-based guideline: neuromuscular ultrasound for the diagnosis of carpal tunnel syndrome. *Muscle Nerve*. 2012;46(2):287-293.

Padua L, Coraci D, Erra C, et al. Carpal tunnel syndrome: clinical features, diagnosis, and management. *Lancet Neurol*. 2016;15(12):1273-1284.

Stewart JD. *Focal Peripheral Neuropathies*. 4th ed. West Vancouver, Canada: JBJ Publishing; 2009.

Sunderland S. *Nerves and Nerve Injuries*. 2nd ed. Edinburgh, United Kingdom: Churchill Livingstone; 1979.

Yuen EC, Olney RK, So YT. Sciatic neuropathy: clinical and prognostic features in 73 patients. *Neurology*. 1994;44:1669-1674.

Acquired Peripheral Neuropathies 91

Thomas H. Brannagan III and Kurenai Tanji

KEY POINTS

1. Characterizing a polyneuropathy as multifocal demyelinating, uniform demyelinating, multifocal axonal, or generalized axonal may help narrow the differential diagnosis of the cause of a polyneuropathy.
2. Diabetes mellitus is now the most common cause of polyneuropathy worldwide.
3. Patients with distal polyneuropathies should be assessed for diabetes, a monoclonal protein, and vitamin B_{12}.
4. Even after a thorough evaluation, approximately 20% of all polyneuropathies and 50% of small-fiber polyneuropathy is idiopathic.
5. There is level 1 evidence for efficacy for intravenous immunoglobulin for Guillain-Barré syndrome, chronic inflammatory demyelinating polyneuropathy, and multifocal motor neuropathy.
6. There is level 1 evidence for efficacy for transthyretin stabilizers, such as diflunisal and tafamidis and RNA silencers, such as patisiran and inotersen for polyneuropathy associated with hereditary transthyretin amyloidosis.

APPROACH TO PERIPHERAL NERVE DISORDERS

The peripheral nervous system is composed of multiple cell types and elements that subserve diverse motor, sensory, and autonomic functions. The clinical manifestations of neuropathies depend on the severity, distribution, and functions affected. *Peripheral neuropathy* and *polyneuropathy* are terms that describe syndromes resulting from diffuse lesions of peripheral nerves, usually manifested by weakness, sensory loss, pain, and autonomic dysfunction. *Mononeuropathy* indicates a disorder of a single nerve often resulting from local trauma, compression, or entrapment. *Mononeuropathy multiplex* signifies focal involvement of two or more nerves, usually as a result of a generalized disorder such as diabetes mellitus or vasculitis. This chapter discusses an approach to peripheral nerve disorders and specific acquired polyneuropathies. Inherited neuropathies are discussed in Chapter 92, and mononeuropathies, including plexus disorders, are discussed in Chapter 90.

Epidemiology

Peripheral neuropathies of various causes are common disorders. A prevalence of 2% to 7% of symmetric polyneuropathy has been found in studies conducted around the world. Currently, the most common cause of peripheral neuropathy worldwide is diabetes, although prior to 1994, the most common cause of peripheral neuropathy worldwide was leprosy. The prevalence of peripheral neuropathy increases with age, affecting 15% of the population older than the age of 40 years and 24% older than the age of 70 years.

Clinical Features

Polyneuropathy may occur at any age, although particular syndromes are more likely to occur in certain age groups. Charcot-Marie-Tooth (CMT) disease, for example, often begins in childhood or adolescence, whereas neuropathy associated with paraproteinemia is seen more frequently with increasing age. The onset and progression differ; the Guillain-Barré syndrome (GBS), tick paralysis, and porphyria begin acutely and may remit. Others, such as vitamin B_{12} deficiency or carcinomatous neuropathy, begin insidiously and progress slowly. Still others, such as chronic inflammatory demyelinating polyneuropathy (CIDP), may begin acutely or insidiously and then progress with remissions and relapses.

The myelin sheaths or the motor or sensory axons or neurons themselves may be predominantly affected, or the neuropathy may be mixed, axonal, or demyelinating. Most polyneuropathies, especially those with primary demyelination, affect both motor and sensory functions. A predominantly motor polyneuropathy is seen in lead toxicity, dapsone or *n*-hexane intoxication, tick paralysis, porphyria, some cases of GBS, and multifocal motor neuropathy (MMN). Sensory neuropathy is divided into loss of large-diameter and small-diameter nerve fibers, although a combination of fiber types is most typical. Predominantly small-fiber neuropathy, often with concomitant autonomic dysfunction, is seen in diabetes mellitus, amyloidosis, Fabry disease, and lepromatous leprosy. Less prevalent, predominant large-fiber neuropathy occurs with thallium poisoning, paraneoplastic ganglioneuritis, Sjögren disease, pyridoxine (vitamin B_6) toxicity, and syphilis. Predominant involvement of the autonomic system can be seen in acute or chronic autonomic neuropathy or in amyloidosis.

Symptoms of polyneuropathy include distal pain, paresthesias, weakness, and sensory loss. Pain may be spontaneous or elicited by stimulation of the skin and may be sharp or burning. Paresthesias are usually described as numbness (a dead sensation), tingling, buzzing, stinging, burning, or a feeling of constriction. Lack of pain perception may result in repeated traumatic injuries with degeneration of joints (*arthropathy* or *Charcot joints*) and in chronic ulcerations.

Weakness is greatest in distal limb muscles in most neuropathies; there may be paralysis of the intrinsic foot and hand muscles with footdrop or wrist-drop. Tendon reflexes are often lost, especially in demyelinating neuropathy. In severe polyneuropathy, the patient may become quadriplegic and respirator dependent. The cranial nerves may be affected, particularly in GBS and diphtheritic neuropathy. Cutaneous sensory loss appears in a stocking-and-glove distribution. All modes of sensation

may be affected, or there may be selective impairment of "large" myelinated fiber functions (position and vibratory sense) or "small" unmyelinated fiber functions (pain and temperature perception). Often, detection of painful stimuli is impaired with a delayed and greater than normal reaction. Inappropriate pain perception is often paradoxically present despite loss of pain fibers.

Involvement of autonomic nerves may cause miosis (small pupil), Adie pupils, anhidrosis (impaired sweating), orthostatic hypotension, sphincter disturbance, gastrointestinal dysmotility, impotence, and vasomotor abnormalities; these may occur without other evidence of neuropathy but are more commonly seen in association with symmetric distal polyneuropathy. Diabetes mellitus is the most common cause. Amyloidosis causes notably severe autonomic neuropathy. The majority of neuropathy types produce distal impairment of sweating, vasomotor reflexes, and local influences that help produce the typical trophic signs in the feet of neuropathy patients. Distal loss of sweating may induce symptomatic excessive sweating proximally as a compensatory response.

In *mononeuropathy multiplex*, focal motor, sensory, and reflex changes are restricted to areas innervated by specific nerves. When multiple distal nerves are affected in mononeuropathy multiplex, the pattern may coalesce into more symmetric involvement suggesting polyneuropathy. The most frequent causes of mononeuropathy multiplex are vasculitic neuropathy, diabetes mellitus, rheumatoid arthritis, brachial neuropathy, leprosy, or sarcoidosis. Asymmetric neuropathy is also seen in MMN with conduction block, sometimes with increased anti-GM1 antibody titers, multifocal demyelinating sensory and motor neuropathy (Lewis-Sumner syndrome), and brachial neuritis.

Superficial cutaneous nerves may be thickened and visibly enlarged secondary to Schwann cell proliferation and collagen deposition from repeated episodes of segmental demyelination and remyelination or from amyloid or polysaccharide deposition in the nerves. Hypertrophic nerves may be observed or palpated in the demyelinating form of CMT (type 1), Dejerine-Sottas neuropathy, Refsum disease, von Recklinghausen disease (neurofibromatosis), and various other disorders.

Etiology and Diagnosis

Peripheral nerve disorders may be divided into hereditary and acquired forms. The most common hereditary disorder is CMT type 1A (peroneal muscular atrophy), which is associated with duplication of the peripheral myelin protein 22 gene. Deletion of the same region produces hereditary neuropathy with liability to pressure palsies. The most commonly acquired neuropathies in the United States are associated with diabetes mellitus; selected other causes of polyneuropathy are listed in Table 91.1.

In the evaluation of a patient with peripheral neuropathy, a detailed family, social, and medical and medication history; neurologic examination; and electrodiagnostic and laboratory testing are usually necessary for diagnosis. The American Academy of Neurology has made recommendations for evaluation of distal symmetric polyneuropathy (Table 91.2). Well over 200 individual causes are known, many of which are evident from initial screening measures. Skin or nerve biopsy studies are indicated in some cases. Despite these efforts, the cause of a significant minority remains idiopathic after a comprehensive evaluation. A classification of the most common acquired and hereditary polyneuropathies and their laboratory evaluation are presented in Table 91.1.

Treatment

Treatment of patients with peripheral nerve disorders can be divided into two phases: removal or treatment of the inciting condition and symptomatic therapy. Specific treatments are considered in discussions of individual disorders.

Symptomatic treatment of polyneuropathy consists of general supportive measures, amelioration of pain, and physiotherapy. Tracheal intubation and respiratory support may be needed in GBS. The corneas are protected if significant eye closure weakness is present. The bed is kept clean and the sheets are kept smooth to prevent injury to the anesthetic skin; a special mattress can be used to prevent pressure sores. In chronic polyneuropathy with footdrop, a foot orthosis often improves gait. Treatment of neuropathic pain (see Chapter 59) and autonomic failure (see Chapter 116) are discussed elsewhere in the book.

Outcome

Polyneuropathy may be progressive or remitting, and the prognosis is affected by the extent of nerve degeneration. With removal or treatment of the inciting cause, recovery is more rapid if continuity of the nerves is maintained. Conversely, recovery may be delayed for many months or remain incomplete if significant wallerian degeneration occurs. Axonal regeneration proceeds at a rate of 1 to 2 mm/d and may be further delayed where the axons must penetrate scar tissue, injured nerve segments, or other barriers. Aberrant growth of axonal sprouts may lead to formation of persistent neuromas. After severe wallerian degeneration, there may be permanent weakness, muscular wasting, diminution of reflexes, and sensory loss. In demyelinating neuropathies, recovery is sometimes more rapid and complete because of remyelination or resolution of conduction block.

SPECIFIC ACQUIRED POLYNEUROPATHIES

Guillain-Barré Syndrome

The GBS is characterized by acute onset of peripheral and cranial nerve dysfunction. Viral respiratory or gastrointestinal infection, immunization, or surgery often precedes neurologic symptoms by 5 days to 4 weeks. Symptoms and signs include rapidly progressive symmetric weakness, loss of tendon reflexes, facial diplegia, oropharyngeal and respiratory paresis, and impaired sensation in the hands and feet. The condition worsens for several days to 3 weeks, followed by a period of stability and then gradual improvement to normal or nearly normal function. Early plasmapheresis or intravenous immunoglobulin (IVIG) (2 g/kg in divided doses) accelerates recovery and diminishes the incidence of long-term neurologic disability.

In North America and Europe, acute inflammatory demyelinating polyneuropathy accounts for over 90% of GBS. A GBS also includes acute motor axonal neuropathy (AMAN), acute motor and sensory axonal neuropathy (AMSAN), Miller Fisher syndrome, and acute autonomic and sensory neuropathies.

Epidemiology

The GBS is the most frequently acute acquired demyelinating neuropathy, with an incidence of 0.6 to 1.9 cases per 100,000 population. The incidence increases gradually with age, but the disease may occur at any age. Men and women are affected equally.

TABLE 91.1 Neuropathy Diagnosis and Laboratory Tests

Cause or Diagnosis	Manifestations	Laboratory Tests
Vitamin deficiency/excess	S, SM, SYM	Vitamin B_{12}, pyridoxine (vitamin B_6), vitamin B_1, folate, vitamin E, methylmalonic acid
Infectious		
Lyme disease	S, SM, SYM, MF, CN	Serology, PCR
HIV-1	S, SM, SYM, MF, CN	Serology, PCR
Hepatitis C	S, SM, SYM, MF, CN	Serology, PCR
Herpes zoster	S, radicular	Serology, PCR
CMV	SM, M, SYM, MF	Serology, PCR, culture
Immune Mediated		
Guillain-Barré and variants	SM, S, M, SYM, MF, CN	IgG antiganglioside antibodies (GM1, GD1a, GQ1b, GD1b), urine porphyrins
IgM antibody associated	M, MF	IgM anti-GM1, GD1a
	S, SM, SYM	IgM anti-MAG, sulfatide, GD1b, GQ1b
Monoclonal gammopathy	M, S, SM, SYM, MF	Serum immunofixation electrophoresis, quantitative immunoglobulins
Autonomic neuropathy	Autonomic dysfunction	Antinicotinic acetylcholine receptor antibodies, anti-Hu
Vasculitis	SM, S, MF, SYM	ESR, cryoglobulins, hepatitis C serology, or PCR
Sarcoidosis	SM, S, MF, SYM	ACE, chest radiograph
Celiac disease	S, SM, MF, SYM	Antigliadin, endomysial, transglutaminase antibodies
Rheumatologic diseases Sjögren syndrome Lupus Wegener granulomatosis Rheumatoid arthritis	SM, S, MF, SYM	SSA-Ro, SSB-La antibodies ANA, ANCA (PR3, myeloperoxidase), dsDNA, Ab, RNP, rheumatoid factor
Paraneoplastic		
Lung cancer	S, SYM	Anti-Hu Ab, chest radiograph/CT
Waldenström syndrome	SM, S, M, SYM, MF	Serum immunofixation electrophoresis
Myeloma	SM, M, SYM, MF	Serum and urine immunofixation electrophoresis, skeletal survey
Hereditary		
CMT-1	Demyelinating, SM, SYM, MF	DNA tests for PMP-22, MPZ, EGR2, Cx32, others
CMT-2	Axonal, SM, SYM	DNA tests for NF-L, Cx32, MPZ, others
Mitochondrial	NARP, SM, MF	Serum lactate, thymidine phosphorylase, DNA testing
Other	Axonal, S, SM, amyloid, porphyria	DNA tests for transthyretin, periaxin, urine porphyrins
Metabolic/Toxic		
Diabetes	S, SM, SYM, MF, CN	Fasting glucose, HbA_{1c}, glucose tolerance test
Renal failure	S, SM, SYM	Chem 7
Thyroid disease	S, SM, SYM, MF	TSH, T4
Heavy metal toxicity	S, SM, SYM, MF	Urine lead, mercury, arsenic, thallium

Abbreviations: Ab, antibody; ACE, angiotensin-converting enzyme; ANA, antinuclear antibody; ANCA, antineutrophil cytoplasmic antibodies; CMT-1, Charcot-Marie-Tooth type 1; CMT-2, Charcot-Marie-Tooth type 2; CMV, cytomegalovirus; CN, cranial nerve; CT, computed tomography; Cx32, connexin; dsDNA, double stranded DNA; EGR, early growth response protein; ESR, erythrocyte sedimentation rate; GM1, GD1a, ganglioside components of myelin; HbA_{1c}, hemoglobin A_{1c}; HIV-1, human immunodeficiency virus type 1; IgG, immunoglobulin G; IgM, immunoglobulin M; M, motor; MAG, myelin-associated glycoprotein; MF, multifocal; MPZ, myelin protein zero; NARP, neuropathy, ataxia, and retinitis pigmentosa; NF-L, neurofilament light chain; PCR, polymerase chain reaction; PMP, peripheral myelin protein; PR3, proteinase 3; RNP, ribonucleoprotein; S, sensory; SM, sensorimotor; SSA-Ro, Sjögren syndrome with anti-Ro antibody; SSB-La, Sjögren syndrome with anti-La antibody; SYM, symmetric; T4, thyroxine; TSH, thyroid-stimulating hormone.

The incidence increases in patients with Hodgkin disease as well as with pregnancy or general surgery.

Pathobiology

The cause of GBS is incompletely understood. There is evidence that it is immune mediated. There is inflammatory pathology and patients improve with immunomodulatory therapy. A disease with similar clinical features (ie, similar pathologic, electrophysiologic, and cerebrospinal fluid [CSF] alterations) can be induced in experimental animals by immunization with whole peripheral nerve, peripheral nerve myelin, or, in some species, peripheral nerve myelin P2 basic protein or galactocerebroside. An important first step in autoimmune disease is the impairment of self-tolerance, and there is evidence that this

TABLE 91.2 American Academy of Neurology Recommendations for Testing for Distal Symmetric Polyneuropathy[a]

Basic Laboratory Evaluation for Distal Symmetric Neuropathy
CBC, ESR, or CRP
Vitamin B_{12}[b] and if vitamin B_{12} is low normal, metabolites, including methylmalonic acid and/or homocysteine[b]
Comprehensive metabolic panel, including fasting blood glucose,[b] glucose tolerance test[b] if indicated to look for impaired glucose tolerance
Serum protein immunofixation electrophoresis[b]
Urine analysis; urine electrophoresis
Inquire about drugs and toxins
Other Laboratory Testing That May Be Performed in Selected Patients
ANA, rheumatoid factor, anti-Ro/SSA, anti-La/SSB, ANCA, cryoglobulins
Campylobacter jejuni, CMV, hepatitis panel (B and C), HIV, Lyme antibodies, herpesviruses tests, West Nile virus tests, CSF analysis
Antigliadin; IgA transglutaminase antibodies; endomysial antibodies; vitamins E, B_1, and B_6
Serum ACE, CSF analysis with CSF ACE
Arsenic, lead, mercury, thallium
Antiganglioside antibodies (GM1, GD1a, GD1b, GD3, GQ1b, GT1b), anti-MAG, paraneoplastic antibodies (anti-Hu, anti-CV2), CSF oligoclonal bands
Molecular tests for Charcot-Marie-Tooth, HNPP, familial amyloidosis
Skeletal survey; computed tomography or MRI of chest, abdomen, or pelvis; ultrasound of abdomen and pelvis; PET, CSF cytology

Abbreviations: ACE, angiotensin-converting enzyme; ANA, antinuclear antibody; ANCA, antineutrophil cytoplasmic antibodies; CBC, complete blood count; CMV, cytomegalovirus; CRP, C-reactive protein; CSF, cerebrospinal fluid; ESR, erythrocyte sedimentation rate; HIV, human immunodeficiency virus; HNPP, hereditary neuropathy with tendency to pressure palsy; IgA, immunoglobulin A; MAG, myelin-associated glycoprotein; MRI, magnetic resonance imaging; PET, positron emission tomography; SSA, Sjögren syndrome with anti-Ro antibody; SSB, Sjögren syndrome with anti-La antibody.
[a]Data from England JD, Gronseth GS, Franklin G, et al. Practice parameter: evaluation of distal symmetric polyneuropathy: role of laboratory and genetic testing (an evidence-based review). *Neurology*. 2009;72:185-192.
[b]Tests with highest yield.

occurs by molecular mimicry in two forms of GBS, AMAN, and Miller Fisher syndrome, with cross-reactive epitopes between *Campylobacter jejuni* and peripheral nerve. When GBS is preceded by a viral infection, there is no evidence of direct viral infection of peripheral nerves or nerve roots.

Clinical Features

The GBS often appears days to weeks after symptoms of a viral upper respiratory or gastrointestinal infection. Usually, the first neurologic symptoms are a result of symmetric limb weakness, often with paresthesia. In contrast to most other neuropathies, proximal muscles are sometimes initially affected more than distal muscles. Occasionally, facial, ocular, or oropharyngeal muscles are affected first; more than 50% of patients have facial diplegia, and dysphagia and dysarthria develop in a similar number. Some patients require mechanical ventilation. Tendon reflexes may be normal for the first few days but are then lost. The degree of sensory impairment varies. In some patients, all sensory modalities are preserved; others have marked diminution in perception of joint position, vibration, pain, and temperature in stocking-and-glove distribution. Patients occasionally exhibit papilledema, sensory ataxia, and transient extensor plantar responses. Autonomic dysfunction, including orthostatic hypotension, labile blood pressure, tachyarrhythmia, and bradyarrhythmia or resting tachycardia is frequent in more severe cases and an important cause of morbidity and mortality. Many have muscle tenderness, and the nerves may be sensitive to pressure, but there are no signs of meningeal irritation such as nuchal rigidity.

Variants

The AMAN is a variant of GBS. There is motor axonal degeneration and little or no demyelination or inflammation. Despite the axonal involvement, recovery is similar to the demyelinating form. An AMAN may follow infection with *C jejuni*, *Mycoplasma pneumoniae*, or parenteral injection of gangliosides.

The *Miller Fisher syndrome* is characterized by gait ataxia, areflexia, and ophthalmoparesis; pupillary abnormalities are sometimes present. It is considered a variant of GBS because it is often preceded by respiratory infection, it progresses for weeks and then improves, and CSF protein content is increased. There is no limb weakness, however, and nerve conductions are generally normal; however, H reflexes may be affected. In some cases, MRI shows brainstem hyperintense lesions.

Other GBS variants include *AMSAN*, acute sensory neuropathy or neuronopathy, and acute autonomic neuropathy or pandysautonomia (see Chapter 116).

Diagnosis and Differential Diagnosis

The characteristic history of subacute development of symmetric motor or sensorimotor neuropathy after a viral illness, delivery, or surgery, together with compatible electrophysiology and an elevated CSF protein content with normal cell count, defines GBS.

In the past, the principal diseases to be differentiated from GBS were diphtheritic polyneuropathy and acute poliomyelitis. Both are now rare in the United States. Diphtheritic polyneuropathy can usually be distinguished by the long latency period between the respiratory infection and onset of neuritis, the frequency of paralysis of accommodation, and the relatively slow evolution of symptoms. Acute anterior poliomyelitis was distinguished by asymmetry of paralysis, signs of meningeal irritation, fever, and CSF pleocytosis. Acute West Nile viral infection, however, can lead to a similar picture. Acute encephalitis is the most common West Nile neurologic manifestation, but an acute paralytic syndrome is the next most frequent. Asymmetric or monomelic weakness is characteristic, but some cases develop in a GBS-like manner. Some cases have a flulike prodrome without notable encephalitis. Occasionally, patients with HIV infection have a disorder identical to GBS. Porphyric neuropathy resembles GBS clinically but is differentiated by normal CSF protein, recurrent abdominal crisis, mental symptoms, onset after exposure to barbiturates or other drugs, and high urinary levels of δ-aminolevulinic acid and porphobilinogen. Development of a GBS-like syndrome during prolonged parenteral feeding should raise the possibility of hypophosphatemia-induced neural dysfunction. Toxic neuropathies caused by *n*-hexane inhalation or thallium or arsenic ingestion may begin acutely or subacutely. Botulism may be difficult to discriminate on clinical grounds from purely motor forms of GBS, but ocular muscles and the pupils are frequently affected. Electrophysiologic tests in botulism reveal normal nerve conduction velocities and a facilitating

response to repetitive nerve stimulation. Tick paralysis, which occurs almost exclusively in children, should be excluded by careful scalp examination.

Laboratory Data

The CSF protein content is elevated in most patients with GBS but may be normal in the first few days after onset. The CSF cell count is usually normal, but some patients with otherwise typical GBS have 10 to 100 mononuclear cells/μL of CSF. Antecedent infectious mononucleosis, cytomegalovirus (CMV) infection, viral hepatitis, human immunodeficiency virus (HIV) infection, or other viral diseases may be documented by serologic studies. Increased titers of immunoglobulin G (IgG) or immunoglobulin A (IgA) antibodies to GM1 or GD1a gangliosides may be found in the axonal form of GBS; anti-GQ1b antibodies are closely associated with the Miller Fisher syndrome.

Electrophysiology and Pathology

Nerve conduction velocities are reduced in GBS, but values may be normal early in the course. Distal motor latencies may be prolonged. Because of demyelination of nerve roots, minimal F-wave latency is often increased or responses are absent from proximal conduction block. Conduction slowing may persist for months or years after clinical recovery. In general, the severity of neurologic abnormality is not related to the degree of conduction slowing but is related to the extent of conduction block or axonal loss. Long-standing weakness is most apt to occur when compound motor action potential amplitudes are reduced to less than 20% of normal.

Histologically, GBS is characterized by focal segmental demyelination (Fig. 91.1) with perivascular and endoneurial infiltrates of lymphocytes and monocytes or macrophages (Fig. 91.2). These lesions are scattered throughout the nerves, nerve roots, and cranial nerves. In particularly severe lesions, there is both axonal degeneration and segmental demyelination. During recovery, remyelination occurs, but the lymphocytic infiltrates may persist.

Treatment

Early plasmapheresis LEVEL 1[1,2] or IVIG LEVEL 1[3] therapy has proved useful in patients with GBS. Glucocorticoid administration does not shorten the course or affect the prognosis. Mechanically assisted ventilation is sometimes necessary, and precautions against aspiration of food or stomach contents must be taken if oropharyngeal muscles are affected. Exposure keratitis must be prevented in patients with facial diplegia.



FIGURE 91.1 Focal demyelination in acute Guillain-Barré syndrome. (Courtesy of Dr. Arthur Asbury.)



FIGURE 91.2 Diffuse mononuclear infiltrate in peripheral nerve in Guillain-Barré syndrome. (Courtesy of Dr. Arthur Asbury.)

Outcome

Symptoms are usually most severe within 1 week of onset but may progress for 3 weeks or more. Death is uncommon but may follow aspiration pneumonia, pulmonary embolism, intercurrent infection, or autonomic dysfunction. The rate of recovery varies. In some, it is rapid, with restoration to normal function within a few weeks. In most, recovery is slow and not complete for many months. Recovery is accelerated by early institution of plasmapheresis or IVIG therapy. In untreated series, about 35% of patients have permanent residual hyporeflexia, atrophy, and weakness of distal muscles or facial paresis. A biphasic illness, with partial recovery followed by relapse, is present in fewer than 10% of patients. Recurrence after full recovery occurs in about 2%.

Chronic Inflammatory Demyelinating Polyneuropathy

A CIDP may begin insidiously or acutely, as GBS, and then follow a chronic progressive or relapsing course. It often follows nonspecific viral infections, although less often than in GBS. Segmental demyelination and lymphocytic infiltrates are present in peripheral nerves, and a similar disease can be induced in experimental animals by immunization with peripheral nerve myelin. The CSF protein content is often increased but less consistently than in GBS. An infantile form of CIDP begins with hypotonia and delayed motor development. Nerves may become enlarged because of Schwann cell proliferation and collagen deposition after recurrent segmental demyelination and remyelination (Figs. 91.3 and 91.4).

In contrast to GBS, glucocorticoid therapy is often beneficial. The CIDP is also responsive to plasmapheresis LEVEL 1[4] or IVIG LEVEL 1.[5] Immunosuppressive drug therapy may be effective in resistant cases. Research criteria for the diagnosis of CIDP have been recommended, but there is no specific test, and the diagnosis is often made on clinical grounds. A predominantly sensory or distal form of CIDP and a multifocal form (the Lewis-Sumner syndrome) have been described. Tests for HIV-1, monoclonal paraproteins, antibodies to myelin-associated glycoprotein, and, occasionally, CMT type 1 or hereditary neuropathy with liability

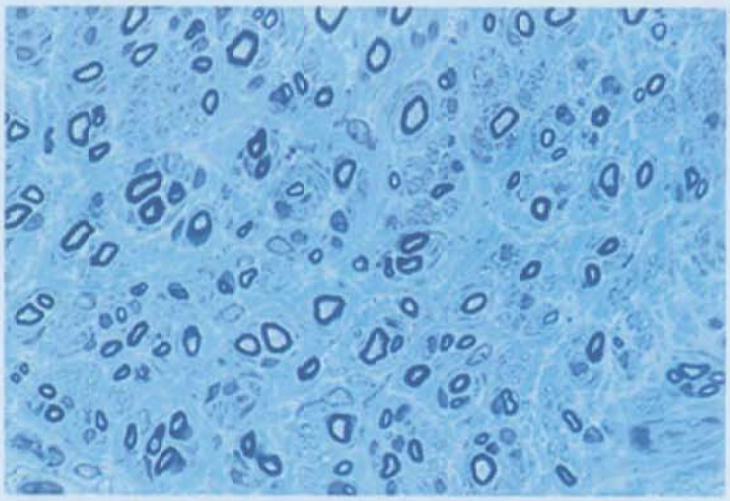

FIGURE 91.3 Semithin section showing multifocal thinly myelinated fibers in a patient with chronic inflammatory demyelinating polyneuropathy (magnification ×600).

to pressure palsy are performed in suspected patients to evaluate possible causes of demyelinating neuropathy.

Multifocal Motor Neuropathy

An MMN is a clinical syndrome of lower motor neuron dysfunction. Typically, there is weakness, wasting, and fasciculation with preserved or absent tendon reflexes. The findings are typically asymmetric and affect the arms and hands more than the legs.

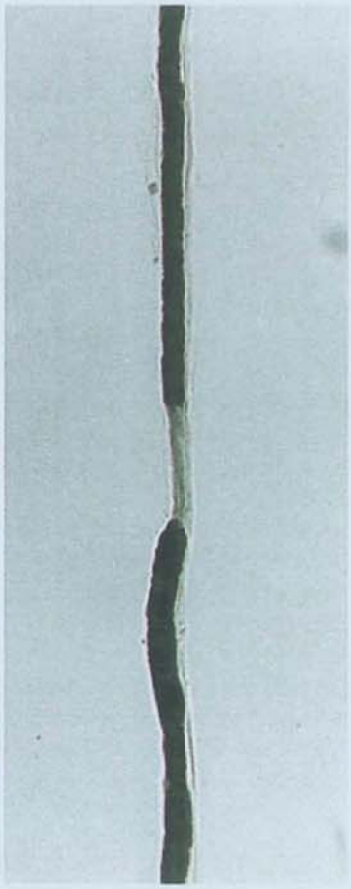

FIGURE 91.4 Teased fiber showing demyelination in a patient with chronic inflammatory demyelinating polyneuropathy (magnification ×400).

Electrophysiologic evidence of denervation is accompanied by the defining abnormality, physiologic evidence of multifocal motor conduction block, at sites other than typical compression sites. Other signs of demyelination are also described; conduction block is not present in all patients, including some with positive antibody titers. The MMN is associated with increased titers of immunoglobulin M (IgM) anti-GM1 in approximately 60% of patients; less frequently, anti-GD1a antibodies are found. The clinical syndrome also occurs in patients with normal anti-GM1 antibody titers. It is important to distinguish these patients from patients with typical motor neuron disease because the weakness of MMN is potentially reversible with IVIG LEVEL 1[6] or immunosuppressive drug therapy.

Sensory Neuronopathy and Neuropathy

Sensory neuropathy may result from primary involvement of the sensory root ganglia, as in ganglioneuritis or sensory neuronitis, or the nerve may be directly affected as in distal sensory neuropathy. *Ganglioneuritis* may be acute or subacute in onset and is characterized by numbness, paresthesia, and pain that can be distal or radicular or can involve the entire body, including the face. Ataxia and autonomic dysfunction may be evident. Small- or large-fiber sensation or both may be affected to varying degrees. Tendon reflexes may be present or absent, and strength is normal. The disease may be self-limiting or chronic, with relapses or slow progression. Motor nerve conduction velocities are normal or near normal, but sensory potentials are reduced in amplitude or absent. Routine electrophysiologic studies may be normal if the disease is mild or if only small fibers are affected. The CSF protein content is normal or slightly elevated. Response to glucocorticoids or immunosuppressive therapy is variable. Pathologic studies of spinal root ganglia show inflammatory infiltrates with a predominance of T cells and macrophages. Some patients have sicca or Sjögren syndrome with anti-Ro and anti-La antibodies.

Several autoantibodies to peripheral nerve antigens are associated with sensory neuropathy. Some patients with sensory axonal neuropathies have monoclonal or polyclonal IgM anti-sulfatide antibodies, and monoclonal IgM autoantibodies with anti-GD1b and disialosyl ganglioside antibody activity have been associated with large-fiber sensory neuropathy. Other causes of sensory neuropathy include HIV-1 infection, vitamin B_6 deficiency or toxicity, celiac disease, paraneoplastic neuropathy, amyloidosis, and toxic neuropathy.

Idiopathic Autonomic Neuropathy

This condition is characterized by sympathetic, parasympathetic, or enteric nerve dysfunction. Acute, subacute, and chronic forms are known and discussed in Chapter 116.

Vasculitic and Cryoglobulinemic Neuropathies

Vasculitic neuropathy is manifested as mononeuritis multiplex or distal symmetric polyneuropathy. Nerve conduction studies may show electrical inexcitability of nerve segments distal to an injury caused by vascular occlusion. If some nerve fascicles are spared, conduction proceeds at a normal rate, but summated response amplitude is diminished. The diagnosis of peripheral nerve involvement may be established by nerve and muscle

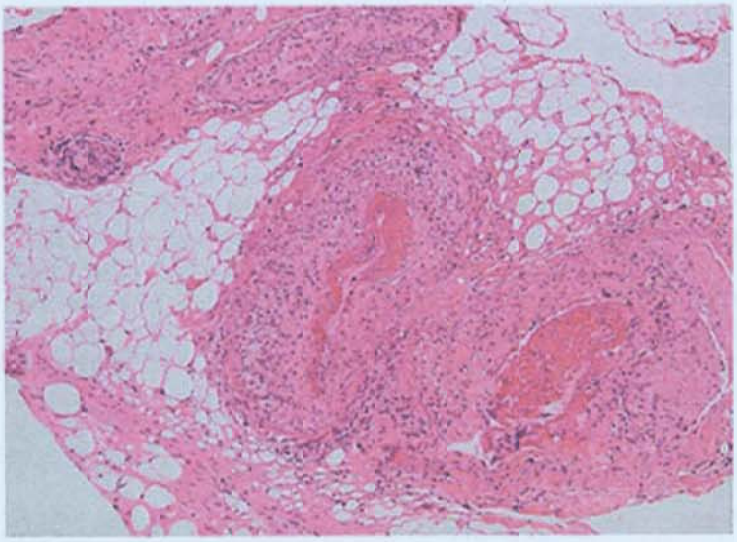

FIGURE 91.5 Necrotizing vasculitis (magnification ×200).

biopsies (Fig. 91.5), which typically show inflammatory cell infiltrates and necrosis of blood vessel walls. The biopsy specimen, however, may show only axonal degeneration if vasculitis produced a nerve injury that is proximal to the biopsy site or if no affected vessels are encountered in the specimen.

Vasculitis may be confined to the peripheral nerves or may be associated with systemic disease, such as polyarteritis or cryoglobulinemia. The most common systemic cause of vasculitic neuropathy is polyarteritis nodosa, which may cause purpuric skin lesions, renal failure, Raynaud phenomenon, constitutional symptoms, and sometimes mixed polyclonal cryoglobulinemia; hepatitis B or C virus or HIV infection may be found. Cryoglobulins are immunoglobulins that precipitate in the cold and are classified as types I to III. Type I contains a monoclonal immunoglobulin only, type II contains both monoclonal and polyclonal immunoglobulins, and type III contains mixed polyclonal immunoglobulins. Types I and II are associated with plasma cell dyscrasia, and type III may be associated with polyarteritis nodosa and hepatitis B or C infection. Cryoglobulin testing samples must be kept warm to prevent precipitation prior to laboratory analysis.

Other causes of vasculitic neuropathy include the Churg-Strauss syndrome with asthma and eosinophilia; Sjögren syndrome with xerophthalmia, xerostomia, and anti-Ro and anti-La antibodies; and Wegener granulomatosis with necrotizing granulomatous lesions in the upper or lower respiratory tract, glomerulonephritis, and antineutrophil cytoplasmic antibodies. Less commonly, vasculitic neuropathy is seen in rheumatoid arthritis, systemic lupus erythematosus, and systemic sclerosis. Vasculitis may respond to therapy with prednisone (60 mg every day) and cyclophosphamide (1 g/m^2 every month × 6 months). Plasmapheresis is also useful in the treatment of cryoglobulinemia.

Neuropathies Associated With Myeloma and Nonmalignant Immunoglobulin G or Immunoglobulin A Monoclonal Gammopathies

Peripheral neuropathy is found in approximately 50% of patients with osteosclerotic myeloma and IgG or IgA monoclonal gammopathies. Some patients have the POEMS syndrome (polyneuropathy, organomegaly, endocrinopathy, M protein, and skin changes) or Crow-Fukase syndrome with hyperpigmentation of skin, edema, excessive hair growth, hepatosplenomegaly, papilledema, elevated CSF protein content, hypogonadism, and hypothyroidism. The POEMS syndrome is sometimes associated with nonosteosclerotic myeloma or with nonmalignant monoclonal gammopathy. The IgG or IgA light-chain type is almost always λ. Electrophysiologic and pathologic abnormalities are consistent with demyelination and axonal degeneration; the patterns may resemble CIDP.

Malignant or nonmalignant IgG or IgA monoclonal gammopathy may also be associated with neuropathy in primary amyloidosis, in which fragments of the monoclonal light chains are deposited as amyloid in peripheral nerve, and in types I and II cryoglobulinemia, in which the monoclonal immunoglobulins are components of the cryoprecipitates.

The significance of IgG or IgA monoclonal gammopathies is uncertain in the absence of myeloma, POEMS syndrome, amyloidosis, or cryoglobulinemia. Nonmalignant monoclonal gammopathies are found more frequently in patients with neuropathy of otherwise unknown etiology; however, they are also present in approximately 1% of normal adults, and the frequency increases with age or in chronic infections or inflammatory diseases, so the association with neuropathy in some cases could be coincidental. Other causes of neuropathy, particularly inflammatory conditions such as CIDP, should be considered. In cases of myeloma, irradiation, chemotherapy, or bone marrow transplantation may be beneficial. Some patients with neuropathy associated with IgG and IgA monoclonal proteins of undetermined significance improve with plasmapheresis.

Neuropathies Associated With Immunoglobulin M Monoclonal Antibodies That React With Peripheral Nerve Glycoconjugate Antigens

In several syndromes, peripheral neuropathy is associated with polyclonal or monoclonal IgM autoantibodies that react with glycoconjugates in peripheral nerve. The IgM antibodies that react with myelin-associated glycoprotein are associated with a chronic demyelinating sensorimotor neuropathy. Pathologic studies show deposits of the monoclonal IgM and complement on affected myelin sheaths (Fig. 91.6) and passive transfer of the autoantibodies in experimental animals reproduces the neuropathy. Treatment consisting of plasmapheresis and chemotherapy to reduce autoantibody concentrations, or IVIG, frequently results in clinical improvement.

Other syndromes associated with monoclonal or polyclonal IgM autoantibodies include the following: MMN or lower motor neuron syndrome–associated anti-GD1a ganglioside antibodies, large-fiber sensory neuropathy with anti-GD1b and disialosyl ganglioside antibodies, and axonal sensory neuropathy associated with antisulfatide antibodies. Antisulfatide antibodies typically are associated with small-fiber or small- and large-fiber neuropathy, but 25% of cases demonstrate a CIDP-like demyelinating neuropathy.

Progressive Inflammatory Neuropathy (Among Swine Slaughterhouse Workers)

Beginning in 2007, 24 patients who worked in three different pork-processing plants developed an inflammatory neuropathy

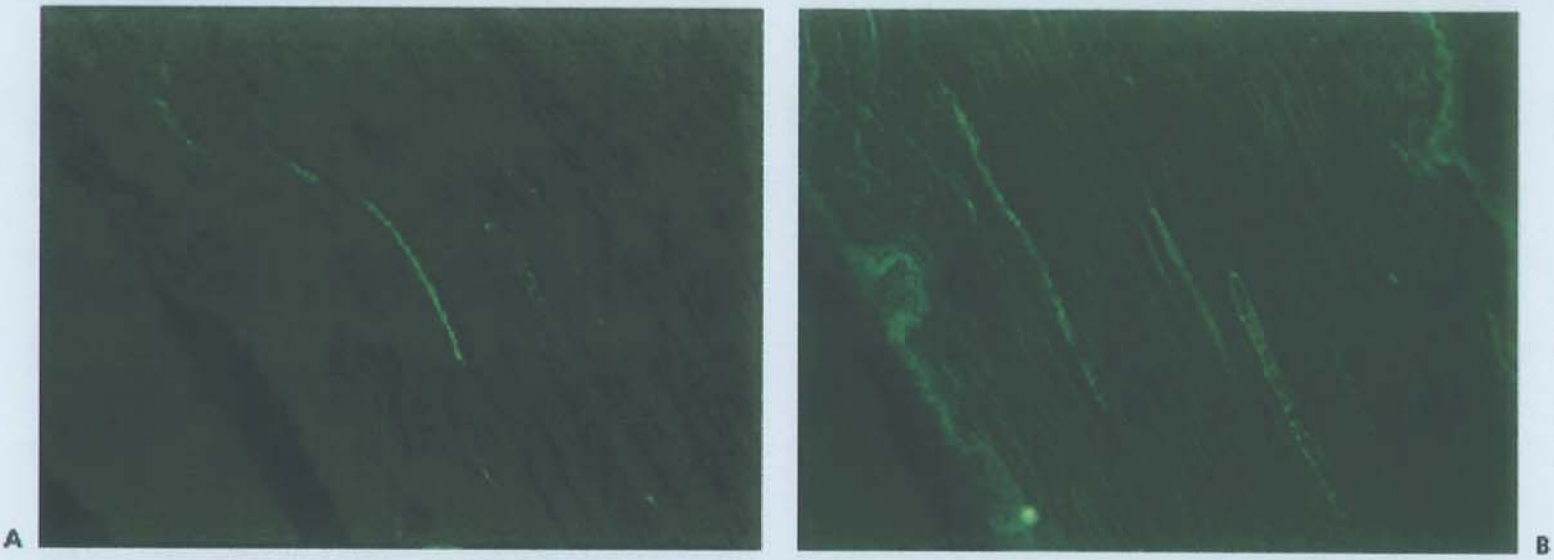

FIGURE 91.6 Patient with an immunoglobulin M (IgM) κ monoclonal protein and anti–myelin-associated glycoprotein neuropathy showing IgM (A) and κ (B) staining on immunofluorescence.

that resembled CIDP. Those affected worked at the head table, where a compressed air device was used to extract pig brains. Patients had a polyradiculoneuropathy with weakness and pain. Some patients had facial neuropathy. The symptoms progressed from 8 to 213 days. The CSF protein was elevated in the majority from 63 to 210 mg/dL, with pleocytosis in only one patient. Nerve conduction studies showed demyelinating and axonal changes. Serum from the patients demonstrated IgG staining of neural tissue.

Amyloid Neuropathy

Amyloid is an insoluble extracellular aggregate of proteins that forms in nerve or other tissues when any of several proteins is produced in excess. The two principal forms of amyloid protein that cause neuropathy are immunoglobulin light chains in patients with primary amyloidosis and plasma cell dyscrasias and transthyretin in hereditary amyloidosis. The syndrome is often that of a painful, small-fiber sensory neuropathy with progressive autonomic failure, symmetric loss of pain and temperature sensations with spared position and vibratory senses, carpal tunnel syndrome, or some combination of these symptoms. The diagnosis of amyloid neuropathy can be established by histologic demonstration of amyloid in nerve (Fig. 91.7), followed by immunocytochemical characterization of the deposits with the use of antibodies to immunoglobulin light chains or transthyretin. The responsible protein forming amyloid can also be detected by microdissection and mass spectrometry. Mutation of the transthyretin gene is detected by DNA analysis. The prognosis is poor if untreated. Other hereditary amyloidosis causes, such as apolipoprotein A1 and gelsolin, lead to less severe and less frequent neuropathy. Electrophoresis of serum and urine with immunofixation can assist in the diagnosis of primary amyloid neuropathy. Liver transplantation has been reported to be beneficial for hereditary amyloidosis, and high-dose chemotherapy followed by bone marrow transplantation has been reported to help some patients with primary amyloidosis. Medications that stabilize the transthyretin tetramer and decrease the formation of amyloid, including tafamidis 20 mg every day LEVEL 1[7] and diflunisal 250 mg twice a day LEVEL 1,[8] may improve the neuropathy. The RNA silencers, which block the production of transthyretin, including patisiran LEVEL 1[9] and inotersen LEVEL 1,[10] can stop the progression of the neuropathy and some patients actually improve.

Neuropathy Associated With Carcinoma (Paraneoplastic Neuropathy)

Both direct and indirect effects of malignant neoplasms on the peripheral nervous system are recognized. In some patients, the nerves or nerve roots are compressed or infiltrated by neoplastic cells. In others, there is no evidence of damage to the nerves by

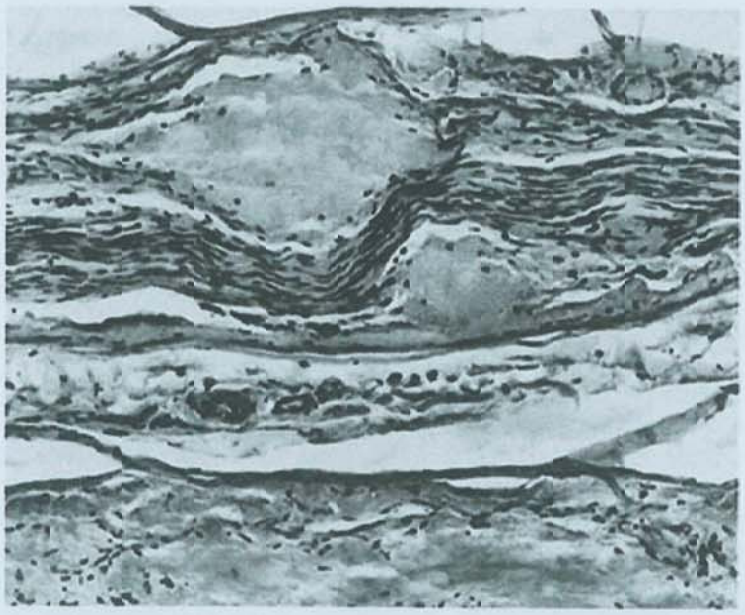

FIGURE 91.7 Amyloid neuropathy. Massive deposits of endoneurial amyloid compress nerve fiber bundles. (Courtesy of Dr. Arthur Asbury.)

the neoplasm, and dietary deficiency or metabolic, toxic, or immunologic factors may be responsible.

The most characteristic paraneoplastic disorder is a sensory neuropathy of subacute onset associated with small cell carcinoma of the lung. Electrodiagnostic studies reveal loss of sensory-evoked responses. Autoantibodies against the Hu antigen (antineuronal nuclear or ANNA-1) are characteristic, and postmortem studies show loss of neurons, deposition of antibodies, and inflammatory cells in dorsal root ganglia.

Less consistently associated with carcinoma is a distal sensorimotor polyneuropathy without specific features. Nerve biopsy may reveal infiltration by tumor cells, axonal degeneration, or demyelination. A primarily motor syndrome of subacute onset rarely occurs in Hodgkin disease and other lymphomas. In these patients, the predominant lesion is degeneration of anterior horn cells, but demyelination, perivascular mononuclear cell infiltrates, and alterations in Schwann cell morphology in ventral roots are also observed.

The diagnosis of malignancy should be suspected in a middle-aged or elderly patient with a subacute sensory neuropathy or polyradiculopathy of obscure cause, particularly with weight loss. The course is often progressive unless the primary malignancy is successfully treated. The CSF examination for malignant cells is valuable in the diagnosis of malignant meningeal infiltration. In some instances of meningeal infiltration, radiotherapy or intrathecal chemotherapy may be valuable.

Hypothyroid Neuropathy

Entrapment neuropathies are relatively common in patients with hypothyroidism, probably because acid mucopolysaccharide protein complexes (mucoid) are deposited in the nerve. Painful paresthesia in the hands and feet is the most common symptom of hypothyroidism. Weakness is not a feature. Tendon reflexes are reduced or absent and, when present, may show the characteristic delayed or "hung-up" response. Direct muscle percussion produces transient mounding of the underlying skin and muscle (myoedema). Nerve conduction studies show mild slowing of motor nerve conduction and decreased sensory response amplitude. Morphologic studies show evidence of demyelination, axonal loss, and excessive glycogen within Schwann cells. The CSF protein content is often more than 100 mg/dL. Rarely, dysfunction of cranial nerves IX, X, and XII causes hoarseness and dysarthria, probably as a result of local myxedematous infiltration of the nerves. The peripheral neuropathy may occur before there is laboratory evidence of hypothyroidism. Once identified, thyroid replacement causes clinical, electrophysiologic, and morphologic improvement.

Acromegalic Neuropathy

Entrapment neuropathy is also relatively common in patients with acromegaly. Rarely, acromegalic patients note distal paresthesia, but in contrast to myxedematous patients, weakness may be severe and peripheral nerves may be palpable. There is a significant correlation between total exchangeable body sodium and the severity of the neuropathy. The nerves are enlarged because there is increased endoneurial and perineurial connective tissue, perhaps stimulated by increased levels of somatomedin C (insulin-like growth factor 1). Tendon reflexes are reduced. Nerve conduction velocities are mildly slow with low evoked response amplitudes.

Hyperthyroid Neuropathy

Hyperthyroidism can produce a syndrome consisting of diffuse weakness and fasciculations with preserved or hyperactive tendon reflexes, resembling amyotrophic lateral sclerosis. However, the symptoms and signs disappear with treatment of the toxic state. No convincing pathologic studies have established the presence of chronic sensorimotor neuropathy with hyperthyroidism.

Celiac Neuropathy

Celiac disease is a chronic inflammatory enteropathy with a prevalence of 1:250. Peripheral neuropathy is the most common neurologic condition associated with celiac disease. It is not thought to be a result of nutritional deficiency. In over half of patients with celiac neuropathy, gastrointestinal complaints are absent. Celiac disease is caused by exposure to ingested gluten, the storage proteins of wheat, and similar proteins found in barley and rye. Patients have specific HLA-DQ2 and HLA-DQ8 alleles.

The neuropathy is usually predominantly sensory. Multifocal involvement is frequent, with early involvement of the hands and face, although some have a length-dependent pattern. A small-fiber neuropathy is more common initially, but a sensorimotor polyneuropathy is also seen. Diagnosis is suspected with elevated gliadin or transglutaminase antibodies and confirmed by a duodenal biopsy demonstrating inflammation, crypt hyperplasia, and villous atrophy in the small intestine mucosa. Gastrointestinal symptoms improve with a gluten-free diet. The symptoms of peripheral neuropathy have improved in some, but not all, patients on a gluten-free diet. Only small amounts of gluten exposure can trigger an active immune response.

Uremic Neuropathy

Peripheral neuropathy is only one of the neuromuscular syndromes associated with chronic renal failure. Restless legs, cramps, and muscle twitching may be early manifestations of peripheral nerve disease. Peripheral neuropathy is present in 70% of patients with chronic renal failure, but most are subclinical and are identified only by nerve conduction studies. Symptoms include painful dysesthesia and glove-stocking loss of sensation as well as weakness of distal muscles. Electrodiagnostic studies show a sensorimotor neuropathy with axonal features. Pathologic studies confirm the axonopathy. Secondary demyelination may result from axonal loss. Dialysis rarely reverses the neuropathy but may stabilize symptoms; peritoneal dialysis is more effective than hemodialysis. Serial nerve conduction studies can measure the effectiveness of hemodialysis but is no longer routinely used. Renal transplantation often resolves the neuropathy following surgery.

Mononeuropathy, particularly carpal tunnel syndrome, often appears distal to an implanted arteriovenous fistula, suggesting ischemia as a possible mechanism. Distal ischemia from implanted bovine shunts may cause a more severe ischemic neuropathy in the median, ulnar, and radial nerves, possibly from excessive arteriovenous shunting. Chronic hemodialysis (>10 y) causes excessive accumulation of β_2-microglobulin (generalized amyloidosis), another possible cause of carpal tunnel syndrome and uremic polyneuropathy.

The cause of uremic neuropathy is uncertain. An accumulation of a toxic metabolite is most likely, but its identity is unknown. A 2- to 60-kDa molecular weight compound in the plasma of uremic patients induced an axonal neuropathy in experimental animals.

Neuropathy Associated With Hepatic Disease

Peripheral neuropathy is rarely associated with primary diseases of the liver. A painful sensory neuropathy is seen with primary biliary cirrhosis, probably caused by xanthoma formation in and around nerves. Electrodiagnostic studies may be normal, or the amplitude of the sensory-evoked response may be low or absent. Nerve biopsy shows loss of small-diameter nerve fibers. Sudanophilic material is seen in cells of the perineurium. Treatment is directed at pain control. Tricyclic antidepressants or anticonvulsants may relieve paresthesia.

Infectious diseases of the liver may also be associated with peripheral neuropathy. Viral hepatitis (especially hepatitis C associated with cryoglobulinemia), HIV or CMV infection, and infectious mononucleosis may be associated with acute demyelinating neuropathy (GBS), chronic demyelinating neuropathy, or mononeuropathy multiplex. Immunologically mediated diseases such as polyarteritis and sarcoidosis may also cause liver abnormalities and mononeuropathy multiplex.

Peripheral neuropathy is often seen with toxic liver disease or hepatic metabolic diseases such as acute intermittent porphyria and abetalipoproteinemia.

Neuropathies Associated With Infection

Neuropathy of Leprosy

Direct infiltration of small-diameter peripheral nerve fibers by *Mycobacterium leprae* causes the neuropathy of leprosy. It was formerly the most common neuropathy in the world, although it is now overtaken by diabetic neuropathy, largely because of a recent sharp decline in incidence in many endemic areas, especially India. From 2002 to 2007, the incidence globally had dramatically decreased at an average rate of nearly 20% per year based on World Health Organization reports. In the United States, the disease is less endemic but is seen in immigrants from India, Southeast Asia, and Central Africa.

Peripheral nerves are affected differently in tuberculoid and lepromatous forms. In tuberculoid leprosy, there are small hypopigmented areas with superficial sensory loss, and the underlying subcutaneous sensory nerves may be visibly or palpably enlarged. Large nerve trunks, such as the ulnar, fibular, facial, and posterior auricular nerves, may be enmeshed in granulomas and scar tissue. Endoneurial caseation necrosis may occur. The clinical picture is one of mononeuritis or mononeuritis multiplex.

In lepromatous leprosy, Hansen bacilli proliferate in large numbers within Schwann cells and macrophages in the endoneurium and perineurium of subcutaneous nerve twigs (Fig. 91.8), particularly in cool areas of the body (pinnae of the ears and dorsum of the hands, forearms, and feet). Loss of cutaneous sensibility is observed in affected patches; these may later coalesce to cover large parts of the body. Position sense may be preserved in affected areas, whereas pain and temperature sensibility is lost, a dissociation similar to that in syringomyelia. Tendon reflexes are preserved.

Acute mononeuritis multiplex may appear during chemotherapy of lepromatous leprosy in conjunction with erythema nodosum. This complication is treated with thalidomide, which is also associated with neuropathy.

Treatment is designed to eradicate the bacterium and to prevent secondary immune reactions that may damage nerves.

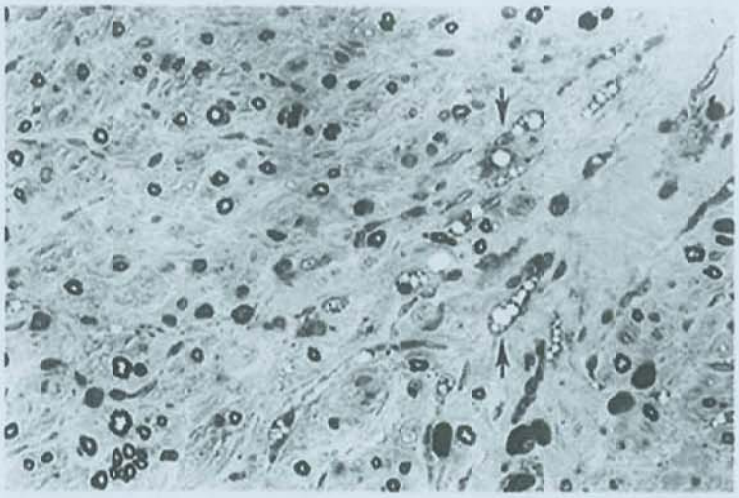

FIGURE 91.8 Lepromatous leprous neuritis. Few myelinated fibers are scattered in fibrotic endoneurium. Abundant foam cells *(arrows)* contain *Mycobacterium leprae* bacilli when viewed at higher magnification. (Courtesy of Dr. Arthur Asbury.)

Multidrug therapy is recommended by the World Health Organization. Adult patients with paucibacillary or multibacillary disease are prescribed rifampin. For patients with multibacillary leprosy, an extra drug, clofazimine, is prescribed. Dapsone is also recommended for both paucibacillary and multibacillary adult patients. Dapsone is effective but may cause toxic motor neuropathy. Because of the dense sensory loss, painless and inadvertent traumatic injuries, such as self-inflicted burns, may occur without extreme caution to avoid trauma to the anesthetic areas.

Diphtheritic Neuropathy

Although diphtheria itself is rare, diphtheritic neuropathy occurs in approximately 20% of infected patients. *Corynebacterium diphtheriae* infects the larynx and pharynx as well as cutaneous wounds. The organisms release an exotoxin that causes myocarditis and, later, symmetric neuropathy. The neuropathy often begins with impaired visual accommodation and paresis of ocular and oropharyngeal muscles, and quadriparesis follows. Nerve conduction velocities are slow, reflecting the underlying demyelinating neuropathy. Diphtheria may be prevented by immunization, and if infection occurs, antibiotic therapy may be used. Recovery may be slow, and physiologic measures resolve after the clinical syndrome.

HIV-Related Neuropathies

Several neuropathies afflict patients infected with HIV, depending on the stage of the illness and the immunocompetence of the patient. An acute demyelinating neuropathy indistinguishable from sporadic GBS may occur early in the course of infection, often with no signs of immunodeficiency or at the time of seroconversion, as well as once AIDS develops. Sometimes, a CSF pleocytosis is present, which is not typical of GBS in non–HIV-infected patients.

Subacute demyelinating neuropathy, clinically indistinguishable from idiopathic CIDP, is usually found in HIV-positive patients before there is evidence of immunodeficiency (AIDS). The CSF protein content is increased in both idiopathic CIDP and HIV-associated demyelinating neuropathy. Steroids, plasmapheresis, and IVIG therapy have been reported to be effective treatments.

In patients who fulfill diagnostic criteria for AIDS, there is frequently a distal sensorimotor polyneuropathy with axonal

features. The syndrome is dominated by severe painful paresthesia most intensely affecting the feet. This painful neuropathy can be the most functionally disabling manifestation of AIDS. Nerve conduction studies may be normal, but reduced intraepidermal nerve fiber density is seen on skin biopsy. The exact mechanism is uncertain. The HIV infection of dorsal root ganglion neurons has been demonstrated. Because of the scarcity of neuronal infection, other causes such as toxicity of activated macrophages and cytokines and viral protein toxicity have been considered. No treatment reverses the symptoms, but symptomatic medications, such as lamotrigine or gabapentin, may help. One form of neuropathy in HIV-infected patients is the diffuse infiltrative lymphocytosis syndrome, a hyperimmune reaction to HIV infection.

Mononeuropathy multiplex can occur in HIV-infected patients at any stage of the disease, sometimes with hepatitis. When CD4 cells number fewer than 50/mm^3, the likely cause of the mononeuropathy is CMV, and prompt treatment with ganciclovir sodium (Cytovene) may be lifesaving. The CMV infection is also associated with polyradiculopathy.

The dideoxynucleotide antiretroviral medications, used to treat HIV infection, may cause painful sensory neuropathy, which is problematic to separate from primary painful HIV sensory neuropathy.

Neuropathy of Herpes Zoster

Varicella-zoster virus infection of the dorsal root ganglion produces radicular pain that may precede or follow the appearance of the characteristic skin eruption. Although primarily a sensory neuropathy, weakness from motor involvement occurs in 0.5% to 5% of infected patients. Herpes zoster (shingles) is a common phenomenon most frequent in elderly patients, cancer patients, or immunosuppressed patients. Post-rash pain (postherpetic neuralgia) usually in the same distribution as the dermatomal rash occurs in a minority, but risk increases significantly with age (50% over 70 y). For diagnosis, pain should persist for 1 to 6 months after the rash disappears. Severe acute pain, more intense rash, scarring, sensory loss, and fever increase the risk of postherpetic neuralgia. Zoster infections are also associated with GBS and CSF pleocytosis. Zoster infection often occurs in patients with HIV infection; the combination of herpes infection and focal weakness in a young person should alert the clinician to the possibility of HIV infection.

Herpes zoster may affect any level of the neuraxis, but it most often involves thoracic dermatomes and cranial nerves with sensory ganglia (V and VII). Ophthalmic herpes infection characteristically involves the gasserian ganglion and the first division of the trigeminal nerve. There may be weakness of ocular muscles and ptosis. Infection of the geniculate ganglion of the facial nerve (cranial nerve VII) causes a vesicular herpetic eruption in the external auditory meatus, vertigo, deafness, and facial weakness (Ramsay Hunt syndrome). Pain is constant and burning and may include paroxysms of very severe pain.

Treatment with acyclovir (Zovirax), 4 g/d in five doses for 7 to 10 days or other antiviral agents decreases the incidence of segmental motor neuritis and sensory axonopathy. They may also reduce the incidence of postherpetic neuralgia. Tricyclic antidepressants, opioids, anticonvulsants (pregabalin), and lidocaine patches may show symptomatic benefit, some verified in randomized clinical trials. An attenuated varicella-zoster virus vaccine is recommended in adults 60 years and older, without contraindications, to prevent the development of herpes zoster.

Lyme Neuropathy

Lyme disease is commonly diagnosed in the United States and Europe. It is caused by a tick-borne spirochete, *Borrelia burgdorferi*. The most common clinical feature of neuroborreliosis is a painful sensory radiculitis, which may appear about 3 weeks after the erythema migrans. Pain intensity varies from day to day and is often severe, jumping from one area to another and often associated with patchy areas of unpleasant dysesthesia. Onset may be subacute potentially simulating GBS but with significant CSF pleocytosis and without clear signs of demyelination. Focal neurologic signs are common and may present as cranial neuropathy (61%), limb paresis (12%), or both (16%), but detailed electrodiagnostic signs often point to mononeuropathy multiplex. The clinical pattern may appear as a mononeuropathy, plexopathy, mononeuropathy multiplex, or distal symmetric polyneuropathy. The facial nerve is frequently affected; involvement is unilateral twice as often as bilateral. Ophthalmoparesis occasionally occurs. Myeloradiculitis and chronic progressive encephalomyelitis are rare. In some, the disorder is associated with dilated cardiomyopathy. Arthralgia is common among patients in the United States but rare among Europeans (6%). The triad of painful radiculitis, predominantly cranial mononeuritis multiplex, and lymphocytic pleocytosis in the CSF is known as *Bannwarth syndrome* in Europe. Peripheral nerve biopsy shows perineurial and epineurial vasculitis and axonal degeneration. The diagnosis of neuroborreliosis is based on the presence of inflammatory CSF changes and specific intrathecal *B burgdorferi* antibodies. In some infected patients, however, no free antibodies are detectable. Antigen detection in CSF is sometimes helpful. Polymerase chain reaction technique for detecting spirochetes or spirochetal DNA is less specific. The prognosis is good after high-dose penicillin or ceftriaxone treatment. Disabling sequelae are rare and occur mainly in patients with previous CNS lesions.

Sarcoid Neuropathy

Neurologic symptoms appear in 4% of patients with sarcoidosis. Most commonly, there are single or multiple cranial nerve palsies that fluctuate in intensity. Of the cranial nerves, the seventh is most commonly affected, and, as in diabetes mellitus, the facial nerve syndrome in sarcoidosis is indistinguishable from idiopathic Bell palsy. Some cranial neuropathies in sarcoidosis result from basilar meningitis. One distinguishing feature of sarcoid mononeuropathy is a large area of sensory loss on the trunk.

Patients with sarcoidosis occasionally experience symmetric polyneuropathy months or years after the diagnosis is established. The neuropathy may be the first manifestation before the diagnosis of sarcoidosis is made. The clinical syndromes may include GBS, lumbosacral plexopathy, mononeuritis multiplex, pure sensory neuropathy, and small-fiber and autonomic neuropathy. Cranial nerve symptoms are seen in close to one-half of patients.

Nerve biopsy shows a mixture of wallerian degeneration and segmental demyelination with sarcoid granulomas in endoneurium and epineurium (Fig. 91.9). Sarcoid neuropathy may respond to steroid therapy, intravenous immune globulin, or anti–tumor necrosis factor therapy.

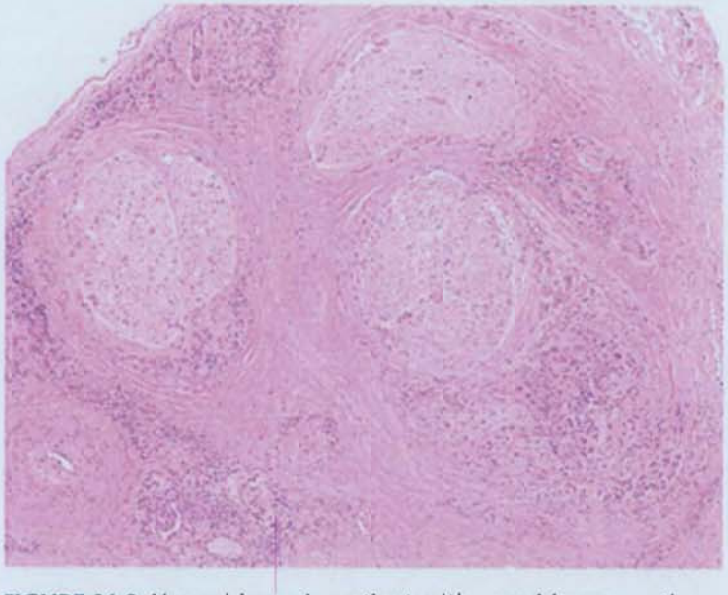

FIGURE 91.9 Nerve biopsy in patient with sarcoid neuropathy showing granuloma (magnification ×40).

Polyneuropathy Associated With Dietary States

Thiamine deficiency may cause two clinical syndromes: *wet beriberi*, in which congestive heart failure is the predominant syndrome, and *dry beriberi*, in which peripheral neuropathy is the predominant symptom. Patients with thiamine deficiency have severe burning dysesthesia in the feet more than in the hands, weakness and wasting of distal muscles more than of proximal muscles, trophic changes (shiny skin, hair loss), and distal sensory loss. An electromyogram and a nerve conduction studies reveal the presence of a diffuse sensorimotor peripheral neuropathy that is axonal. Axonal degeneration is also the principal finding seen on nerve biopsy specimens. Treatment of both beriberis should include parenteral B-complex vitamins followed by oral thiamine. Recovery is slow; there may be residual muscular weakness and atrophy.

Niacin (nicotinic acid) deficiency causes pellagra characterized by hyperkeratotic skin lesions. Peripheral neuropathy is usually present in niacin-deficient patients, but the neuropathy does not improve solely with niacin supplementation, likely because of multivitamin deficiency. Symptoms usually improve when additional thiamine and pyridoxine are added to the diet.

Vitamin B_{12} deficiency causes the classic clinical syndrome of subacute combined degeneration of the spinal cord. Separation of the peripheral neuropathic symptoms from spinal cord involvement is difficult. Painful paresthesias are present, but sensory ataxia with loss of vibration and joint position sense is most severe. Despite the myelopathy, tendon reflexes are often diminished or absent. Vitamin B_{12} deficiency neuropathy may be present with low normal vitamin B_{12} levels and can be established with measurement of the elevated metabolites methylmalonic acid and homocysteine.

Nitrous oxide also irreversibly inactivates cobalamin, producing the same syndrome. A single anesthetic dose in a vulnerable individual or chronic exposure usually with abuse of dental or medical sources or commercial propellants (whipped cream) may result in vitamin B_{12} deficiency. Hematologic abnormalities are usually absent in abuse cases.

Vitamin B_6 (pyridoxine) deficiency produces a peripheral neuropathy, and the most common cause of pyridoxine deficiency is ingestion of the antituberculous drug isoniazid. Isoniazid increases the excretion of pyridoxine. The resulting neuropathy affects sensory fibers more than motor fibers and is caused by axonal loss. Treatment consists of supplemental pyridoxine to compensate for the added excretion. The neuropathy can be prevented by prophylactic pyridoxine administration. Pyridoxine excess can lead to severe sensory neuropathy as well.

Vitamin E deficiency contributes to neuropathy in fat malabsorption syndromes—including abetalipoproteinemia, congenital biliary atresia, pancreatic dysfunction, and surgical removal of large portions of the small intestine. The clinical syndrome of vitamin E deficiency resembles spinocerebellar degeneration with ataxia, severe sensory loss of joint position and vibration, and hyporeflexia. Motor nerve conduction studies are normal, but sensory-evoked responses are of low amplitude or absent.

Somatosensory-evoked responses show a delay in central conduction. The electromyogram is usually normal. Serum vitamin E levels can be measured. Repletion with large oral doses is often sufficient if initiated early in the disease course.

Copper deficiency can result in a neuropathy, which is often accompanied by a myelopathy and leukopenia. Some patients develop copper deficiency from excessive use of zinc. Copper supplementation stops the progression, although recovery is often not complete.

Strachan syndrome includes visual loss, oral ulcers, skin changes, and painful neuropathy. The syndrome was originally described in Jamaican sugar workers and caused an epidemic in Cuba in 1991. A nutrient-poor diet with deficient B vitamins has been implicated.

Gastric bypass surgery is associated with subacute and sometimes severe axonal neuropathy that accompanies the rapid postoperative weight loss. Vitamin deficiency of various types is to play a crucial role.

Critical Illness Polyneuropathy

Severe sensorimotor peripheral neuropathy is seen in many patients who are critically ill, suffering from sepsis and multiple organ failure. The diagnosis may arise when a patient experiences difficulty being weaned from a ventilator after a bout of sepsis. Electrodiagnostic studies show a severe sensorimotor axonal neuropathy, but conventional studies may be unable to distinguish this entity from the more common critical illness myopathy, discussed in detail in Chapter 95. Recovery of neuronal function may occur if the underlying cause of multiple organ failure is treated successfully.

Neuropathies Caused by Heavy Metals

Arsenic

Neuropathy may follow chronic exposure to small amounts of arsenic or ingestion or parenteral administration of a large amount. Chronic exposure may occur in industries in which arsenic is released as a by-product, such as in copper or lead smelting. Because of the prevalence of these by-products, arsenic neuropathy is the most common of all heavy metal–induced neuropathies. Acute gastrointestinal symptoms, vomiting, and diarrhea occur when a toxic quantity of arsenic is ingested, but these symptoms may be absent if the arsenic is given parenterally or taken in small amounts over long periods. Acute exposure may lead to encephalopathy or coma. The evolution of polyneuropathy is much slower in chronic arsenic poisoning. Sensory symptoms

are prominent in the early stages. Pain and paresthesia in the legs may be present for several days or weeks before onset of weakness. The weakness may progress to complete flaccid paralysis of the legs and sometimes the arms, depending on the dosage. Cutaneous sensation is impaired in a stocking-and-glove distribution, with vibration and position sensation being most affected. Tendon reflexes are lost. Pigmentation and hyperkeratosis of the skin and changes in the nails (*Mees lines*) are frequently present. Arsenic is present in the urine in the acute stages of poisoning but is quickly cleared; levels persist in the hair and nails. Nerve conduction velocities may be normal or mildly diminished; the amplitude of sensory- and motor-evoked responses may be reduced. Pathologic examination of nerves shows axonal degeneration. Arsenic polyneuropathy is generally treated with a chelating agent, but the effectiveness is uncertain, given the rapid clearance in most patients.

Lead

Most toxic neuropathies cause symmetric weakness and loss of sensation in distal regions more than proximal regions, feet worse than legs. Lead neuropathy is atypical because of motor predominance and arm involvement.

Lead neuropathy occurs almost exclusively in adults. Infants poisoned with lead usually develop encephalopathy. Lead may enter the body through the lungs, skin, or gut. Occupational lead poisoning was common in earlier eras, notably in silver miners, but rarely is encountered in battery workers, painters, and pottery glazers. Accidental lead poisoning follows ingestion of lead in food or beverages or occurs in children who ingest lead paint. Lead poisoning may cause abdominal distress (lead colic). The classic description is focal wrist-drop in a radial neuropathy pattern; however, weakness is not generally limited to one nerve and produces bilateral arm weakness and wasting and lesser or later leg involvement. Footdrop is the most common leg sign. Sensory symptoms and signs are usually absent. Rarely, upper motor neuron signs occur with the lower motor neuron disorder and mimic amyotrophic lateral sclerosis. Laboratory findings include anemia with basophilic stippling of the red cells, increased serum uric acid, and slight elevation of CSF protein content. Urinary lead excretion is elevated, particularly after administration of a chelating agent. Urinary porphobilinogen excretion is also elevated, but δ-aminolevulinic acid is normal. Primary therapy is prevention of further exposure to lead. With termination of exposure and use of chelation therapy, recovery is gradual over several months.

Mercury

Mercury is used in the electrical and chemical industries. There are two forms of mercury: elemental and organic. The organic form of mercury (methyl and ethyl mercury) is most toxic to the CNS, although distal paresthesia and sensory ataxia are prominent (presumably secondary to dorsal root ganglion degeneration). Ventral roots and motor function are spared. Inorganic mercury may be absorbed through the gastrointestinal tract, and elemental mercury may be absorbed directly through the skin or lungs (it is volatile at room temperature). Elemental mercury exposure is a rare cause of weakness and axonal motor and sensory fiber loss.

Thallium

This element is used as a rodenticide and in other industrial processes. Children exposed to thallium, as with lead, may develop encephalopathy, whereas neuropathy occurs in adults. In contrast to lead poisoning, thallium neuropathy primarily affects sensory and autonomic fibers. Severe disturbing dysesthesia appears acutely, and diffuse alopecia is a characteristic feature. Signs of cardiovascular autonomic neuropathy are sometimes delayed and recover slowly. Electrophysiologic findings are consistent with an axonal neuropathy.

Other Chemicals

Acrylamide monomer is used to prepare polyacrylamide. It is used in chemical laboratories and for the treatment of liquid sewage. Exposure to the monomer produces a distal sensorimotor neuropathy that may be associated with trophic skin changes and a mild dementia. Polyacrylamides, however, are not neurotoxic. Carbon disulfide is rarely inhaled in industrial settings. Exposure may lead to sensorimotor axonal neuropathy.

Many organophosphates, used in insecticides and rodenticides, are acetylcholinesterase inhibitors and may cause delayed neuropathy. The clinical and electrophysiologic features are similar to those of neuropathies caused by chemotherapeutics. Some, however, affect the CNS, as well as peripheral nerves, and some have certain specific features. *Triorthocresyl phosphate* (Jamaica ginger or jake), an adulterant used in illegal liquor (moonshine) and as a cooking oil contaminant, was responsible for neuropathy epidemics. *Dimethylaminopropionitrile*, which is used to manufacture polyurethane foam, causes urologic dysfunction and sensory loss localized to sacral dermatomes. Exposure to *methylbromide*, an insecticide, results in a mixture of pyramidal tract, cerebellar, and peripheral nerve dysfunction. Accidental ingestion of *pyriminil*, a rat poison marketed under the name Vacor, gives rise to an acute severe distal axonopathy with prominent autonomic involvement accompanied by acute diabetes mellitus secondary to necrosis of pancreatic β cells.

Drugs of abuse may lead to neuropathy, notably *n*-hexane and methyl-*N*-butyl ketone, found in widely available household solvents, fuels, and cleaning agents. Inhalation of these materials through the nose or mouth (huffing) occurs in teens and young adults. Axonal degeneration with sensory and motor impairment is seen, but focal conduction block associated with giant axonal swellings is also characteristic. The phenomenon is similar to the rare hereditary entity, giant axonal neuropathy, linked to a defect in the gigaxonin gene.

Ingested neurotoxins from various sea creatures harboring toxins can induce nerve dysfunction, mostly through sodium channel blockade and block in nerve conduction, mostly producing sensory neuropathy, cramps, diarrhea, and vomiting. Examples include ciguatera from reef fish exposed to a ciguatoxin-producing dinoflagellate, saxitoxin (paralytic shellfish poisoning), brevetoxin B (neurotoxic shellfish poisoning), and tetrodotoxin (puffer fish [fugu]). A number of insect venoms are also neurotoxic. Most cause neuromuscular junction blockade, but some, including tick paralysis and frog skin toxins, block sodium channels and peripheral nerve conduction.

Neuropathies Caused by Therapeutic Drugs

Many medications have been suspected of causing neuropathy, but relatively few have convincing clinical features, laboratory support, or reproduction in animal models. Different aspects of the problem are discussed in Chapters 109 and 133. Most of these neuropathies are dose related, presenting with predominantly sensory symptoms and signs or with a combination of sensory,

motor, and autonomic involvement. Most cause toxicity by targeting the axon or dorsal root ganglion neurons directly, but toxicity to Schwann cells and myelin occurs with some agents as well. Pathogenic mechanisms are agent specific and varied. Identification of a toxic effect is most simple when symptoms occur soon after drug exposure or a change in dosage. Most patients fall into this category. In contrast, it is problematic to diagnose a slowly progressive neuropathy starting many months or years on a chronic agent. For example, statin drugs provide a case in point and are discussed later. "Coasting" is a phenomenon in which neuropathy may continue to progress, usually for 2 to 3 weeks, despite drug discontinuation. Improvement after drug cessation helps support the toxic effect, but recovery may be delayed for many months or be incomplete when significant axonal degeneration occurs. Discussion of all of the numerous substances temporally linked to neuropathy is outside the scope of this chapter, and the interested reader should consult comprehensive reviews cited in the "Suggested Readings" section. Some of the more important and best established causes are discussed.

Chemotherapy is an area in which some toxicity is tolerable assuming the agent is efficacious. The most commonly used antineoplastic agents linked with neuropathy are *vincristine*, *cisplatin* (Platinol), *carboplatin*, *oxaliplatin*, and *taxoids* (paclitaxel, docetaxel). Vincristine causes a dose-dependent, symmetric, progressive sensorimotor distal neuropathy that begins in the legs and is associated with areflexia. The CMT type 1A patients are especially vulnerable, and treatment may unmask subclinical cases. In contrast, platin neuropathy is a purely sensory distal neuropathy with paresthesia, impaired vibration sense, and loss of ankle jerks, likely owing to toxicity and drug access to dorsal root ganglia but not α-motor neurons. The drug binds to and alters DNA and may trigger apoptosis if DNA repair fails. An additional acute, transient syndrome of cold-induced paresthesias, painful throat and jaw tightness, and occasionally focal weakness is associated with oxaliplatin infusion; peripheral nerve hyperexcitability has been demonstrated.

Paclitaxel (Taxol) is used to treat cancers of the breast, ovary, and lung. It causes a predominantly sensory neuropathy, but administration of a single high dose may affect motor and autonomic fibers as well. Disordered arrays of microtubules are induced. Neuropathy is also a prominent feature in chemotherapy with suramin (axonal or demyelinating), bortezomib (Velcade), misonidazole, ixabepilone, and thalidomide (sensory). Many chemoprotectant agents to blunt the neurotoxic effects have been studied; none are routinely used in humans, but some show promise. Use of numerous other therapeutic drugs may produce neuropathy, including colchicine (myoneuropathy), gold salts, isoniazid (without vitamin B_6), metronidazole, nitrofurantoin, and podophyllotoxin resin. Amiodarone (Cordarone) may cause a severe symmetric distal sensorimotor neuropathy, an autonomic or demyelinating neuropathy resembling CIDP. Phenytoin (Dilantin) may produce minor distal sensory impairment and areflexia but mostly after long-standing high dosage and is likely overdiagnosed. The major toxicity of some nucleoside analog antiretroviral medications (didanosine, zalcitabine, and stavudine) is peripheral neuropathy, which may be difficult to distinguish from HIV neuropathy. Others, such as azidothymidine, are not linked to neuropathy. A predominantly motor neuropathy has been related to disulfiram (Antabuse) and to dapsone. Statin use was associated with idiopathic neuropathy in a single large study, especially in those with definite neuropathy and longer term exposure. The methods of this study have been criticized, and the link remains controversial. Another large study in patients with diabetes mellitus found statin use protective against developing neuropathy.

Alcoholic Neuropathy

Peripheral neuropathy in alcohol abusers is well known, but the cause is still debated. A widely held belief is that the neuropathy of alcoholism is owing entirely to nutritional deficiency, particularly vitamin B_1 (thiamine). Koike and colleagues, however, provide the best support for a direct toxic effect of ethanol. Alcoholics with normal thiamine levels develop predominantly small-fiber sensory neuropathy, the most frequent clinical type. More subacute onset with motor involvement is also seen in alcoholics with thiamine deficiency and nondrinkers with primary thiamine deficiency. Symptoms of small-fiber neuropathy, such as burning and pain, are common in chronic alcohol drinkers. Later, loss of vibration sense, proprioception, and tendon reflexes may occur. Sensory ataxia may be problematic to separate from alcoholic cerebellar degeneration. Abstinence can lead to meaningful recovery; vitamin supplements alone are not clearly effective but advised.

Diabetic Neuropathy

Peripheral neuropathy occurs in approximately 50% of patients with diabetes mellitus, most commonly as a distal symmetric neuropathy. There are, however, several other distinct neuropathy syndromes that occur in patients with diabetes.

In one form, the symptoms and signs are transient; in the other, they progress steadily. The transient category includes acute painful neuropathies, mononeuropathies, and radiculopathies. The painful type starts abruptly with a disabling and continuous pain, often a burning sensation in a stocking distribution. Sometimes, the pain is localized to the thighs as a femoral neuropathy. The onset is often associated with weight loss. This disorder has been designated "diabetic neuropathic cachexia." The pain may last for months. Recovery from severe pain, however, is usually complete within 1 year, and the disorder does not necessarily progress to a conventional sensory polyneuropathy.

The progressive type comprises sensorimotor polyneuropathies with or without autonomic symptoms and signs. Although the actual cause of diabetic neuropathies is unknown, focal nerve involvement is considered to be immune mediated, and progressive symmetric polyneuropathy is probably owing to microvascular disease resulting from hyperglycemia. There may be as many causal factors as there are clinical pictures. There is evidence of oxidative damage and activation of protein kinase C β-activation in endothelial cells. However, it seems that hyperglycemic hypoxia is mainly responsible for the conduction changes seen in damaged diabetic nerves. Dysfunction of ion conductances, especially voltage-gated ion channels, could contribute to abnormalities in the generation and conduction of action potentials.

Impaired glucose tolerance is also associated with peripheral neuropathy. A 2-hour glucose tolerance test or a hemoglobulin A_{1c} can be used to screen for diabetes or impaired glucose tolerance in patients with neuropathy.

A syndrome recognized by a triad of pain; severe asymmetric muscle weakness; and wasting of the iliopsoas, quadriceps, and adductor muscles is named *diabetic amyotrophy* or *diabetic lumbosacral radiculoplexus neuropathy*. Onset is usually acute, but it may evolve

over weeks. It occurs primarily in older non–insulin-dependent diabetics and is often accompanied by severe weight loss and (diabetic neuropathic cachexia). Knee reflexes are absent, but there is little or no sensory loss. Although long described as involving the proximal leg muscles, this syndrome can also involve the arms and even respiratory system. The condition improves spontaneously but may last 1 to 3 years with incomplete recovery.

Generalized Polyneuropathies

The most common diabetic neuropathy is a diffuse distal symmetric and predominantly sensory neuropathy with or without autonomic manifestations. Balance may be impaired from proprioceptive loss. Distal limb weakness is usually minimal. The neuropathy develops slowly and is related to the duration of the diabetes, but not all patients are so afflicted. Once present, it does not resolve or significantly recover. Intensive glucose control limited complications, including peripheral neuropathy, in the diabetes control and complication trial with significant differences in nerve conduction values between intensive and standard glucose control groups LEVEL 1.[11] Pain and temperature sensation transmitted through the smallest fibers may be affected before the large-fiber modalities (vibration, light touch, position sense). Small-fiber function can be evaluated by determining perception thresholds for warming and cooling or increasingly by assessment of epidermal nerve fiber density from skin biopsy samples (Fig. 91.10). Many patients with diabetic neuropathy do not have pain but do have numb or anesthetic feet. Diabetic neuropathy is the major predictor of foot ulcers and amputations.

The prevalence of diabetic autonomic neuropathy (DAN) may be underestimated because nonspecific symptoms are undiagnosed or the condition may be asymptomatic. Symptoms appear insidiously after the onset of diabetes. The process progresses slowly and is usually irreversible. The DAN is an important prognostic indicator with a mortality rate in diabetics without other initial complications of 23% at 8 years compared to 3% at 8 years in diabetics without DAN and similar disease duration. Noninvasive autonomic screening batteries can be performed, and dedicated autonomic testing laboratories are becoming widely available (see Chapter 28).

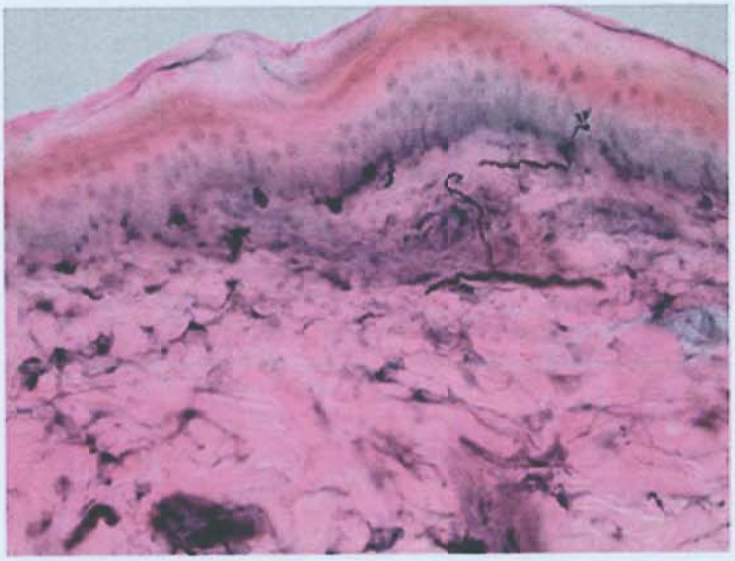

FIGURE 91.10 Skin biopsy with staining for protein gene product 9.5, which shows a reduced number of nerve fibers crossing the epidermal-dermal border (magnification ×400).

Mild slowing of motor and sensory conduction is a common finding in diabetics, even among those without overt neuropathy. It is generally attributed to axonal degeneration with secondary demyelination. Therapeutic attempts, including continuous subcutaneous insulin infusion to correct hyperglycemia to prevent the diabetic complications, have been unsuccessful in most instances. Although combined pancreas and kidney transplantation may halt the progression of diabetic polyneuropathy, the long-term effect is still doubtful. Patients with pain may benefit from duloxetine or pregabalin, but side effects may preclude treatment in some.

Idiopathic Neuropathy

Patients with a peripheral neuropathy of undiagnosed cause may be later found to have an immune-mediated or hereditary neuropathy with more intensive evaluation. Even then, however, 10% to 35% of patients remain without an identified cause. Among those with painful sensory neuropathy involving the feet, this percentage is even higher. Although no cure is available for the neuropathy, treatment may include management of pain, physical therapy, and counseling related to prognosis. When there is no identifiable cause of a symmetric predominantly sensory neuropathy, after a thorough evaluation, the neuropathy rarely progresses to loss of ambulation or disability. Persistent pain is a frequent problem. Care must be taken to conduct an adequate search for treatable underlying disorders.

LEVEL 1 EVIDENCE

1. French Cooperative Group on Plasma Exchange in Guillain-Barré Syndrome. Plasma exchange in Guillain-Barré syndrome: one-year follow-up. *Ann Neurol*. 1992;32:94-97.
2. The Guillain-Barré Syndrome Study Group. Plasmapheresis and acute Guillain-Barré syndrome. *Neurology*. 1985;35:1096-1104.
3. Plasma Exchange/Sandoglobulin Guillain-Barré Syndrome Trial Group. Randomised trial of plasma exchange, intravenous immunoglobulin, and combined treatments in Guillain-Barré syndrome. *Lancet*. 1997;349:225-230.
4. Dyck PJ, Daube J, O'Brien P, et al. Plasma exchange in chronic inflammatory demyelinating polyradiculoneuropathy. *N Engl J Med*. 1986;314:461-465.
5. Hughes RA, Donofrio PD, Bril V, et al; for ICE Study Group. Intravenous immune globulin (10% caprylate-chromatography purified) for the treatment of chronic inflammatory demyelinating polyradiculoneuropathy: a randomised placebo-controlled trial. *Lancet Neurol*. 2008;7:136-144.
6. Hahn AF, Beydoun SR, Lawson V, et al; and IVIG in MMN Study Team. A controlled trial of intravenous immunoglobulin in multifocal motor neuropathy. *J Peripher Nerv Syst*. 2013;18:321-330.
7. Coelho T, Maia LF, Martins da Silva A, et al. Tafamidis for transthyretin familial amyloid polyneuropathy: a randomized, controlled trial. *Neurology*. 2012;79:785-792.
8. Berk JL, Suhr OB, Obici L, et al; for Diflunisal Trial Consortium. Repurposing diflunisal for familial amyloid polyneuropathy: a randomized clinical trial. *JAMA*. 2013;310(24):2658-2667.
9. Adams D, Gonzalez-Duarte A, O'Riordan WD, et al. Patisiran, an RNAi therapeutic, for hereditary transthyretin amyloidosis. *New Engl J Med*. 2018;379:11-21.

10. Benson MD, Waddington-Cruz M, Berk JL, et al. Inotersen treatment for patients with hereditary transthyretin amyloidosis. *New Engl J Med*. 2018;379:22-31.
11. The Diabetes Control and Complications Trial Research Group. The effect of intensive diabetes therapy on the development and progression of neuropathy. *Ann Intern Med*. 1995;122:561-568.

SUGGESTED READINGS

General

Callaghan BC, Price RS, Feldman, EL. Distal symmetric polyneuropathy: a review. *JAMA*. 2015;314:2117-2181.

Cashman CR, Höke A. Mechanisms of distal axonal degeneration in peripheral neuropathies. *Neurosci Lett*. 2015;596:33-50.

Cioroiu C, Brannagan TH III. Peripheral neuropathy. *Curr Geriatr Reports*. 2014;3:83-90.

Dyck PJ, Thomas PK, eds. *Peripheral Neuropathy*. Philadelphia, PA: WB Saunders; 2005.

England JD, Gronseth GS, Franklin G, et al. Practice parameter: evaluation of distal symmetric polyneuropathy: role of laboratory and genetic testing (an evidence-based review). *Neurology*. 2009;72:185-192.

Martyn CN, Hughes RA. Epidemiology of peripheral neuropathy. *J Neurol Neurosurg Psychiatry*. 1997;62:310-318.

Guillain-Barré Syndrome and Variants

Al-Shekhlee A, Katirji B. Electrodiagnostic features of acute paralytic poliomyelitis associated with West Nile virus infection. *Muscle Nerve*. 2004;29:376-380.

Feasby TE, Gilbert JJ, Brown WP, et al. An acute axonal form of Guillain-Barré polyneuropathy. *Brain*. 1986;109:1115-1126.

Hafer-Macko C, Hsieh ST, Li CY, et al. Acute motor axonal neuropathy: an antibody-mediated attack on axolemma. *Ann Neurol*. 1996;40:635-644.

Hughes RAC, Cornblath DR, Willison HJ. Guillain-Barré syndrome in the 100 years since its description by Guillain, Barré and Strohl. *Brain*. 2016;139:3041-3047.

Jacobs BC, van den Berg B, Verboon C, et al. International Guillain-Barré syndrome outcome study: protocol of a prospective observational cohort study on clinical and biological predictors of disease course and outcome in Guillain-Barre syndrome. *J Peripher Nerv Sys*. 2017;22:68-76.

Ropper AH, Wijdicks EF, Truax BT. *Guillain–Barré Syndrome*. Philadelphia, PA: FA Davis; 1991.

Walgaard C, Lingsma HF, Ruts L, et al. Early recognition of poor prognosis in Guillain-Barre syndrome. *Neurology*. 2011;76:968-975.

Wijdicks EE, Klein CJ. Guillain-Barré syndrome. *Mayo Clin Proceed*. 2017;92:467-479.

Willison H, Scherer SS. Ranvier revisited: novel nodal antigens stimulate interest in GBS pathogenesis. *Neurology*. 2014;83:106-108.

Chronic Inflammatory Demyelinating Polyneuropathy

Ad Hoc Subcommittee of the American Academy of Neurology AIDS Task Force. Research criteria for diagnosis of chronic inflammatory demyelinating polyneuropathy (CIDP). *Neurology*. 1991;41:617-618.

Berger AR, Bradley WG, Brannagan TH III, et al. Guidelines for the diagnosis and treatment of chronic inflammatory demyelinating polyneuropathy. *J Peripher Nerv Syst*. 2003;8:282-284.

Brannagan TH III. Current diagnosis of CIDP: the need for biomarkers. *J Peripher Nerv Syst*. 2011;16(suppl):3-13.

Dyck PJ, Lais AC, Ohta M, Bastron JA, Okazaki H, Groover RV. Chronic inflammatory polyradiculoneuropathy. *Mayo Clin Proc*. 1975;50:621-637.

Kleyman I, Brannagan TH III. Treatment of CIDP. *Curr Neurol Neurosci Rep*. 2015;15:47.

Querol L, Siles AM, Alba-Rovira R, et al. Antibodies against peripheral nerve antigens in chronic inflammatory demyelinating polyradiculoneuropathy. *Sci Rep*. 2017;7:14411.

Shije J, Brannagan TH III. Chronic inflammatory demyelinating polyneuropathy. *Sem Neurol*. 2019;39:596-607.

van Dijk GW, Notermans NC, Franssen H, Oey PL, Wokke JH. Response to intravenous immunoglobulin treatment in chronic inflammatory demyelinating polyneuropathy with only sensory symptoms. *J Neurol*. 1996;243:318-322.

Multifocal Motor Neuropathy

Hahn AF, Feydoun SR, Lawson V, et al. A controlled trial of intravenous immunoglobulin in multifocal motor neuropathy. *J Peripheral Nerv Syst*. 2013;18:321-330.

Joint Task Force of the EFNS and the PNS. European Federation of Neurological Societies/Peripheral Nerve Society guideline on management of multifocal motor neuropathy. Report of a joint task force of the European Federation of Neurological Societies and the Peripheral Nerve Society—first revision. *J Peripher Nerv Syst*. 2010;15:295-301.

Kinsella L, Lange D, Trojaborg T, Sadiq SA, Younger DS, Latov N. The clinical and electrophysiologic correlates of anti-GM1 antibodies. *Neurology*. 1994;44:1278-1282.

Idiopathic Sensory Neuronopathy or Ganglioneuritis

Griffin JW, Cornblath DR, Alexander E, et al. Ataxic sensory neuropathy and dorsal root ganglioneuritis associated with Sjögren's syndrome. *Ann Neurol*. 1990;27:304-315.

Quattrini A, Corbo M, Dhaliwal SK, et al. Anti-sulfatide antibodies in neurological disease: binding to rat dorsal root ganglia neurons. *J Neurol Sci*. 1992;112:152-159.

Sobue G, Yasuda T, Kachi T, Sakakibara T, Mitsuma T. Chronic progressive sensory ataxic neuropathy: clinicopathological features of idiopathic and Sjögren's syndrome–associated cases. *J Neurol*. 1993;240:1-7.

Willison HJ, O'Leary CP, Veitch J, et al. The clinical and laboratory features of chronic sensory ataxic neuropathy with anti-disialosyl IgM antibodies. *Brain*. 2001;124:1968-1977.

Windebank AJ, Blexrud MD, Dyck PJ, Daube JR, Karnes JL. The syndrome of acute sensory neuropathy: clinical features and electrophysiologic and pathologic changes. *Neurology*. 1990;40:584-589.

Idiopathic Autonomic Neuropathy

Mericle RA, Triggs WJ. Treatment of acute pandysautonomia with intravenous immunoglobulin. *J Neurol Neurosurg Psychiatry*. 1997;62:529-531.

Vernino S, Low PA, Fealey RD, Stewart JD, Farrugia G, Lennon VA. Autoantibodies to ganglionic receptors in autoimmune autonomic neuropathies. *N Engl J Med*. 2000;343:847-855.

Vasculitic and Cryoglobulinemic Neuropathies

Brannagan TH III. Retroviral-associated vasculitis of the nervous system. *Neurol Clin*. 1997;15:927-944.

Collins MP, Periquet MI, Mendell JR, Sahenk Z, Nagaraja HN, Kissel JT. Nonsystemic vasculitic neuropathy: insights from a clinical cohort. *Neurology*. 2003;61:623-630.

Dyck PJ, Benstead TJ, Conn DL, Stevens JC, Windebank AJ, Low PA. Nonsystemic vasculitic neuropathy. *Brain*. 1987;110:845-854.

Ferri C, La Civita L, Longombardo R, Zignego AL, Pasero G. Mixed cryoglobulinaemia: a cross-road between autoimmune and lymphoproliferative disorders. *Lupus*. 1998;7:275-279.

Gwathmey KG, Burns TM, Collins MP, Dyck PJB. Vasculitic neuropathies. *Lancet Neurol*. 2014;13:67-82.

Nemni R, Corbo M, Fazio R, Quattrini A, Comi G, Canal N. Cryoglobulinemic neuropathy: a clinical, morphological and immunocytochemical study of 8 cases. *Brain*. 1988;111:541-552.

Said G, Lacroix-Claudo C, Fujimura H, Blas C, Faux N. The peripheral neuropathy of necrotizing arteritis: a clinicopathological study. *Ann Neurol*. 1988;23:461-466.

Neuropathies Associated With Myeloma and Nonmalignant Immunoglobulin G or Immunoglobulin A Monoclonal Gammopathies

Dingli D, Tan TS, Kumar SK, et al. Stem cell transplant in patients with autonomic neuropathy amyloid due to primary (AL) amyloid. *Neurology*. 2010;74:913-918.

Dispenzieri A. POEMS syndrome: 2017 update on diagnosis, risk stratification and management. *Am J Hematol*. 2017;92:814-829.

Dyck PJ, Low PA, Windebank AJ, et al. Plasma-exchange in polyneuropathy associated with monoclonal gammopathy of undetermined significance. *N Engl J Med*. 1991;325:1482-1486.

Kelly JJ Jr, Kyle RA, Latov N. *Polyneuropathies Associated With Plasma Cell Dyscrasias*. Boston, MA: Martinus-Nijhoff; 1987.

Mauermann ML. The peripheral neuropathies of POEMS syndrome and Castleman disease. *Hematol Oncol Clin North Am*. 2018;32:153-163.

Neuropathies Associated With Immunoglobulin M Monoclonal or Polyclonal Autoantibodies to Peripheral Nerve

Dalakas MC. Advances in the diagnosis, immunopathogenesis and therapies of IgM-anti-MAG antibody-mediated neuropathies. *Ther Adv Neurol Disord*. 2018;11:1756285617746640.

Dalakas MC, Rakocevic G, Salajegheh M, et al. Placebo-controlled trial of rituximab in IgM anti-myelin-associated glycoprotein antibody demyelinating neuropathy. *Ann Neurol*. 2009;65:286-293.

Latov N. Pathogenesis and therapy of neuropathies associated with monoclonal gammopathies. *Ann Neurol*. 1995;37(suppl 1):S32-S42.

Nobile-Orazio E, Bianco M, Nozza A. Advance in the treatment of paraproteinemic neuropathy. *Curr Treat Options Neurol*. 2017;19:43.

Pedersen SF, Pullman SL, Latov N, Brannagan TH III. Physiological tremor analysis of patients with anti-myelin-associated glycoprotein associated neuropathy and tremor. *Muscle Nerve*. 1997;20:38-44.

Quattrini A, Corbo M, Dhaliwal SK, et al. Anti-sulfatide antibodies in neurological disease: binding to rat dorsal root ganglia neurons. *J Neurol Sci*. 1992;112:152-159.

Renaud S, Gregor M, Fuhr P, et al. Rituximab in the treatment of polyneuropathy associated with anti-MAG antibodies. *Muscle Nerve*. 2003;27:611-615.

Progressive Inflammatory Neuropathy

Center for Disease Control and Prevention. Investigation of progressive inflammatory neuropathy among swine slaughterhouse worker—Minnesota, 2007–2008. *MMWR Morb Mortal Wkly Rep*. 2008;57:122-124.

Meeuser JW, Klein CJ, Pirko I, et al. Potassium channel complex autoimmunity induced by inhaled brain tissue aerosol. *Ann Neurol*. 2012;71:417-426.

Amyloid Neuropathy

Benson MD, Kincaid JC. The molecular biology and clinical features of amyloid neuropathy. *Muscle Nerve*. 2007;36:411-423.

Kelly JJ Jr, Kyle RA, O'Brien PC, Dyck PJ. The natural history of peripheral neuropathy in primary systemic amyloidosis. *Ann Neurol*. 1979;6:1-7.

Neuropathy Associated With Carcinoma (Paraneoplastic Neuropathy)

Antoine JC, Camdessanché JP. Paraneoplastic neuropathies. *Curr Opin Neurol*. 2017;30:513-520.

Camdessanché J-P, Antoine JC. Honnorat J, et al. Paraneoplastic peripheral neuropathy associated with anti-Hu antibodies. A clinical and electrophysiologic study of 20 patients. *Brain*. 2002;125:166-175.

Dalmau J, Graus F, Rosenblum MK, Posner JB. Anti-Hu–associated paraneoplastic encephalomyelitis/sensory neuropathy: a clinical study of 71 patients. *Medicine*. 1992;71:59-72.

Lancaster E. Paraneoplastic disorders. *Continuum*. 2015;21:452-475.

Schold SC, Cho ES, Somasundaram M, Posner JB. Subacute motor neuronopathy: a remote effect of lymphoma. *Ann Neurol*. 1979;5:271-287.

Hypothyroid Neuropathy

Dyck PJ, Lambert EH. Polyneuropathy associated with hypothyroidism. *J Neuropathol Exp Neurol*. 1970;9:531-658.

Misiunas A, Niepomniszcze H, Ravera B, Faraj G, Faure E. Peripheral neuropathy in subclinical hypothyroidism. *Thyroid*. 1995;5:283-286.

Nemni R, Bottacchi E, Fazio R, et al. Polyneuropathy in hypothyroidism: clinical, electrophysiological and morphological findings in four cases. *J Neurol Neurosurg Psychiatry*. 1987;50:1454-1460.

Acromegalic Neuropathy

Jamal GA, Kerr DJ, McLellaan AR, Weir AI, Davies DL. Generalized peripheral nerve dysfunction in acromegaly: a study by conventional and novel neurophysiological techniques. *J Neurol Neurosurg Psychiatry*. 1987;50:885-894.

Khaleeli AA, Levy RD, Edwards RHT, et al. The neuromuscular features of acromegaly: a clinical and pathological study. *J Neurol Neurosurg Psychiatry*. 1984;47:1009-1015.

Low PA, McLeod JG, Turtle JR, Donnelly P, Wright RG. Peripheral neuropathy in acromegaly. *Brain*. 1974;97:139-152.

Celiac Neuropathy

Brannagan TH III, Hays AP, Chin SS, et al. Small fiber neuropathy/neuronopathy associated with celiac disease: skin biopsy findings. *Arch Neurol*. 2005;62:1574-1578.

Chin RL, Sander HW, Brannagan TH III, et al. Celiac neuropathy. *Neurology*. 2003;60:1581-1585.

Cicarelli G, Della Rocca G, Amboni M, et al. Clinical and neurological abnormalities in adult celiac disease. *J Neurol Sci*. 2003;24:311-317.

Cooke WT, Smith WE. Neurological disorders associated with adult coeliac disease. *Brain*. 1966;89:683-722.

Kaplan JG, Pack D, Horoupian D, DeSouza T, Brin M, Schaumburg H. Distal axonopathy associated with chronic gluten enteropathy: a treatable disorder. *Neurology*. 1988;38:642-645.

Thawani SP, Brannagan TH III, Lebwhol B, Green PHR, Ludvigsson JF. Risk of neuropathy among 28,232 patients with biopsy-verified celiac disease. *JAMA Neurology*. 2015;72:806-811.

Uremic Neuropathy

Bolton CF. Peripheral neuropathies associated with chronic renal failure. *Can J Neurol Sci*. 1980;7:89-96.

Cantaro S, Zara G, Battaggia C, et al. In vivo and in vitro neurotoxic action of plasma ultrafiltrate from uraemic patients. *Nephrol Dial Transplant*. 1998;13:2288-2293.

Neuropathy Associated With Hepatic Disease

Inoue A, Tsukada M, Koh CS, Yanagisawa N. Chronic relapsing demyelinating polyneuropathy associated with hepatitis B infection. *Neurology*. 1987;37:1663-1666.

Taukada N, Koh CS, Inoue A, Yanagisawa N. Demyelinating neuropathy associated with hepatitis B virus infection. Detection of immune complexes composed of hepatitis B virus surface antigen. *Neurol Sci*. 1987;77:203-210.

Zaltron S, Puoti M, Liberini P, et al. High prevalence of peripheral neuropathy in hepatitis C virus infected patients with symptomatic and asymptomatic cryoglobulinaemia. *J Gastroenterol Hepatol*. 1998;30:391-395.

Neuropathy of Leprosy

Nascimento OJ. Leprosy neuropathy: clinical presentations. *Arq Neuropsiquiatr*. 2013;71:661-666.

Rosenberg RN, Lovelace RE. Mononeuritis multiplex in lepromatous leprosy. *Arch Neurol*. 1968;19:310-314.

Smith CS, Aerts A, Saunderson P, Kawuma J, Kita E, Virmond M. Multidrug therapy for leprosy: a game changer on the path to elimination. *Lancet Infect Dis*. 2017;17: e293-e297.

World Health Organization. Leprosy elimination. Leprosy today. World Health Organization Web site. http://www.who.int/lep/en. Accessed April 29, 2015.

Diphtheritic Neuropathy

Kurdi A, Abdul-Kader M. Clinical and electrophysiological studies of diphtheritic neuritis in Jordan. *J Neurol Sci*. 1979;42:243-250.

Sanghi V. Neurologic manifestations of diphtheria and pertussis. *Handb Clin Neurol*. 2014;121:1355-1359.

Solders G, Nennesmo I, Persson A. Diphtheritic neuropathy: an analysis based on muscle and nerve biopsy and repeated neurophysiological and autonomic function tests. *J Neurol Neurosurg Psychiatry*. 1989;52:876-880.

HIV-Related Neuropathies

Behar R, Wiley C, McCutchan JA. Cytomegalovirus polyradiculopathy in AIDS. *Neurology*. 1987;37:557-561.

Brannagan TH III, Nuovo GJ, Hays AP, Latov N. Human immunodeficiency virus infection of dorsal root ganglion neurons detected by polymerase chain reaction in situ hybridization. *Ann Neurol*. 1997;42:368-372.

Brannagan TH III, Zhou Y. HIV-associated Guillain–Barré syndrome. *J Neurol Sci*. 2003;208:39-42.

Cornblath DR, McArthur JC, Kennedy PGE, Witte AS, Griffin JW. Inflammatory demyelinating peripheral neuropathies associated with human T-cell lymphotropic virus type III infection. *Ann Neurol*. 1987;21:32-40.

Gherardi RK, Chrétien F, Delfau-Larue MH, et al. Neuropathy in diffuse infiltrative lymphocytosis syndrome. *Neurology*. 1998;50:1041-1044.

Kaku M, Simpson DM. HIV, antiretrovirals and peripheral neuropathy: a moving target. *Muscle Nerve*. 2018;57:347-349.

Said G, Lacroix C, Chemoulli P, et al. Cytomegalovirus neuropathy in acquired immunodeficiency syndrome: a clinical and pathological study. *Ann Neurol*. 1991;29:139-195.

Schütz SG, Robinson-Papp J. HIV-related neuropathy: current perspectives. *HIV AIDS*. 2013;5:243-251.

Neuropathy of Herpes Zoster

Denny-Brown D, Adams RD, Brady PJ. Pathologic features of herpes zoster: a note on "geniculate herpes." *Arch Neurol Psychiatry*. 1944;51:216-231.

Dubinsky RM, Kabbani H, El-Chami Z, et al. Practice parameter: treatment of postherpetic neuralgia: an evidence-based report of the Quality Standards Subcommittee of the American Academy of Neurology. *Neurology*. 2004;63:959-965.

Dworkin RH, Johnson RW, Breuer J, et al. Recommendations for the management of herpes zoster. *Clin Infect Dis*. 2007;44:S1-S26.

Hales CM, Harpaz R, Ortega-Sanchez I, Bialek SR; for Centers for Disease Control and Prevention. Update on recommendations for use of herpes zoster vaccine. *MMWR Morb Mortal Wkly Rep*. 2014;63:729-731.

Mondelli M, Romano C, Passero S, Porta D, Rossi A. Effects of acyclovir on sensory axonal neuropathy, segmental motor paresis and postherpetic neuralgia in herpes zoster patients. *Eur Neurol*. 1996;36:288-292.

Raja SN, Haythornthwaite JA, Pappagallo M, et al. Opicids versus antidepressants in postherpetic neuralgia. A randomized placebo-controlled trial. *Neurology*. 2002;59:1015-1021.

Tick Paralysis

Swift TR, Ignacio OJ. Tick paralysis: electrophysiologic signs. *Neurology*. 1975;25:1130-1133.

Vedanarayanan VV, Evans OB, Subramony SH. Tick paralysis in children; electrophysiology and possibility of misdiagnosis. *Neurology*. 2002;59:1088-1090.

Sarcoid Neuropathy

Burns TM, Dyck PJB, Aksamit AJ, Dyck PJ. The natural history and long-term outcome of 57 limb sarcoidosis neuropathy cases. *J Neurol Sci*. 2006;244:77-87.

Hoitsma E, Marziniak M, Faber CG, et al. Small fibre neuropathy in sarcoidosis. *Lancet*. 2002;359:2085-2086.

Said G. Sarcoidosis of the peripheral nervous system. *Handb Clin Neurol*. 2013;115:485-495.

Tavee JO, Karwa K, Ahmed Z, Thompson N, Parambil J, Culver DA. Sarcoidosis-associated small fiber neuropathy in a large cohort: clinical aspects and response to IVIG and anti-TNF alpha treatment. *Respir Med*. 2017;126:135-138.

Polyneuropathy Associated With Dietary States

Green R, Kinsella LJ. Current concepts in the diagnosis of cobalamin deficiency. *Neurology*. 1995;45:1435-1440.

Kumar N, Elliott MA, Hoyer JD, Harper CM Jr, Ahlskog JE, Phyliky RL. "Myelodysplasia," myeloneuropathy, and copper deficiency. *Mayo Clin Proc*. 2005;80:943-946.

Parry GJ, Bredeson DE. Sensory neuropathy with low-dose pyridoxine. *Neurology*. 1985;35:1466-1468.

Saperstein DS, Wolfe GI, Gronseth GS, et al. Challenges in the identification of cobalamin-deficiency polyneuropathy. *Arch Neurol* 2003;60:1296-1301.

Schaumburg H, Kaplan J, Windebank A, et al. Sensory neuropathy from pyridoxine abuse. A new megavitamin syndrome. *N Engl J Med*. 1983;309:445-448.

Sokol RJ, Guggenheim MA, Iannaccone ST, et al. Improved neurologic function after long-term correction of vitamin E deficiency in children with chronic cholestasis. *N Engl J Med*. 1985;313:1580-1586.

Victor M, Adams RD, Collins GH. *The Wernicke–Korsakoff Syndrome*. Philadelphia, PA: FA Davis; 1971.

Critical Illness Polyneuropathy

Bolton CF, Laverty DA, Brown JD, Witt NJ, Hahn AF, Sibbald WJ. Critically ill polyneuropathy: electrophysiological studies and differentiation from Guillain–Barré syndrome. *J Neurol Neurosurg Psychiatry*. 1986;49:563-573.

Neuropathy Produced by Metals, Toxins, and Therapeutic Agents

Buchthal F, Behse F. Electromyography and nerve biopsy in men exposed to lead. *Br J Ind Med*. 1979;36:135-147.

Cavaletti G. Chemotherapy-induced peripheral neurotoxicity (CIPN): what we need and what we know. *J Peripher Nerv Syst*. 2014;19:66-76.

Chang AP, England JD, Garcia CA, Sumner AJ. Focal conduction block in n-hexane polyneuropathy. *Muscle Nerve*. 1998;21:964-969.

Chen H, Clifford DB, Deng L, et al. Peripheral neuropathy in ART-experienced patients: prevalence and risk factors. *J Neurovirol*. 2013;19:557-564.

Chu CC, Huang CC, Ryu SJ, Wu TN. Chronic inorganic mercury-induced peripheral neuropathy. *Acta Neurol Scand*. 1998;98:461-465.

Cioroiu C, Weimer LH. Update on chemotherapy neuropathy. *Curr Neurol Neurosci Rep*. 2017;17:47.

Davis LE, Standefer JC, Kornfeld M, Abercrombie DM, Butler C. Acute thallium poisoning: toxicological and morphological studies of the nervous system. *Ann Neurol*. 1981;10:38-44.

Davis TM, Yeap BB, Davis WA, Bruce DG. Lipid-lowering therapy and sensory peripheral neuropathy in type 2 diabetes mellitus: the Fremantle Diabetes Study. *Diabetologia*. 2008;51:562-566.

Gaist D, Jeppesen U, Andersen M, et al. Statins and risks of polyneuropathy: a case-control study. *Neurology*. 2002;58:1333-1337.

Gignoux L, Cortinovis-Tourniaire P, Grimaud J, Moreau T, Confavreux C. A brachial form of motor neuropathy caused by lead poisoning. *Rev Neurol (Paris)*. 1998;154:771-773.

Goebel HH, Schmidt PF, Bohl J, Tettenborn B, Krämer G, Gutmann L. Polyneuropathy due to acute arsenic intoxication: biopsy studies. *J Neuropathol Exp Neurol*. 1990;49:137-149.

Iñiguez C, Larrodé P, Mayordomo JI, et al. Reversible peripheral neuropathy induced by a single administration of high-dose paclitaxel. *Neurology*. 1998;51:868-870.

Koike H, Iijima M, Sugiura M, et al. Alcoholic neuropathy is clinicopathologically distinct from thiamine-deficiency neuropathy. *Ann Neurol*. 2003;54:19-29.

Leis AA, Stokic DS, Olivier J. Statins and polyneuropathy: setting the record straight. *Muscle Nerve*. 2005;32:428-430.

Nordentoft T, Andersen EB, Mogensen PH. Initial sensorimotor and delayed autonomic neuropathy in acute thallium poisoning. *Neurotoxicology*. 1998;19:421-426.

Oh S. Electrophysiological profile in arsenic neuropathy. *J Neurol Neurosurg Psychiatry*. 1991;54:1103-1105.

Thawani SP, Tanji K, De Sousa E, et al. Bortezomib associated demyelinating neuropathy—clinical and pathologic features. *J Clin Neuromusc*. 2015;16:202-209.

Diabetic Neuropathy

Brannagan TH III, Promisloff RA, McCluskey LF, Mitz KA. Proximal diabetic neuropathy presenting with respiratory weakness. *J Neurol Neurosurg Psychiatry*. 1999;67:539-541.

Dyck PJ, Albers JW, Andersen H, et al; for Toronto Expert Panel on Diabetic Neuropathy. Diabetic polyneuropathies: update on research definition, diagnostic criteria and estimation of severity. *Diabetes Metab Res Rev*. 2011;27:620-628.

Dyck PJ, Giannini C. Pathologic alterations in the diabetic neuropathies of humans: a review. *J Neuropathol Exp Neurol*. 1996;55:1181-1193.

Dyck PJB, Windebank AJ. Diabetic and nondiabetic lumbosacral radiculoplexus neuropathies: new insights into pathophysiology and treatment. *Muscle Nerve*. 2002;25:477-491.

Feldman EL, Callaghan BC, Pop-Busui R, et al. Diabetic neuropathy. *Nat Rev Dis Primers*. 2019;5:41.

Hur J, Sullivan KA, Callaghan BC, Pop-Busui R, Feldman EL. Identification of factors associated with sural nerve regeneration and degeneration in diabetic neuropathy. *Diabetes Care*. 2013;36:4043-4049.

Llewelyn JG, Thomas PK, King RH. Epineurial microvasculitis in proximal diabetic neuropathy. *J Neurol*. 1998;245:159-165.

Navarro X, Sutherland DE, Kennedy WR. Long-term effects of pancreatic transplantation on diabetic neuropathy. *Ann Neurol*. 1998;44:149-150.

Pop-Busui R, Boulton AJ, Feldman EL, et al. Diabetic neuropathy: a position statement by the American Diabetes Association. *Diabetes Care*. 2017;40:136-154.

Stino AM, Smith AG. Peripheral neuropathy in prediabetes and the metabolic syndrome. *J Diabet Investig*. 2017;8:646-655.

Lyme Neuropathy

Coyle PK, Deng Z, Schutzer SE, et al. Detection of *Borrelia burgdorferi* antigens in cerebrospinal fluid. *Neurology*. 1993;43:1093-1098.

Halperin JJ. Lyme disease and the peripheral nervous system. *Muscle Nerve*. 2003;28:133-143.

Halperin JJ, Luft BJ, Volkman DJ, Dattwyler RJ. Lyme neuroborreliosis. Peripheral nervous system manifestations. *Brain*. 1990;11:1207-1221.

Hansen K, Lebech AM. The clinical and epidemiological profile of Lyme neuroborreliosis in Denmark 1985–1990: a prospective study of 187 patients with *Borrelia burgdorferi* specific intrathecal antibody production. *Brain*. 1992;115:399-423.

Pachner AR, Steere AC. The triad of neurologic manifestations of Lyme disease: meningitis, cranial neuritis, and radiculoneuritis. *Neurology*. 1985;35:47-53.

Idiopathic Neuropathy

Chia L, Fernandez A, Lacroix C, Adams D, Planté V, Said G. Contribution of nerve biopsy findings to the diagnosis of disabling neuropathy in the elderly. A retrospective review of 100 consecutive patients. *Brain*. 1996;119:1091-1098.

De Sousa EA, Hays AP, Chin RL, Sander HW, Brannagan TH III. Characteristics of patients with sensory neuropathy diagnosed by abnormal small nerve fibres on skin biopsy. *J Neurol Neurosurg Psychiatry*. 2006;77:983-985.

Dyck PJ, Oviatt KF, Lambert EH. Intensive evaluation of referred unclassified neuropathies yields improved diagnosis. *Neurology*. 1981;10:222-226.

Farhad K, Traub R, Ruzhansky KM, Brannagan TH III. Causes of neuropathy in those referred with idiopathic neuropathy. *Muscle Nerve*. 2016;53:856-861.

Notermans NC, Wokke JHJ, Franssen H, et al. Chronic idiopathic polyneuropathy presenting in middle or old age: a clinical and electrophysiological study of 75 patients. *J Neurol Neurosurg Psychiatry*. 1993;56:1066-1071.

Wolfe GI, Baker NS, Amato AA, et al. Chronic cryptogenic sensory polyneuropathy: clinical and laboratory characteristics. *Arch Neurol*. 1999;56:540-547.

Inherited Peripheral Neuropathies 92

Chiara Pisciotta and Michael E. Shy

KEY POINTS

1. Inherited neuropathies, or Charcot-Marie-Tooth (CMT) disease, are genetically heterogeneous conditions, but the type of CMT can be determined by distinguishing characteristics.
2. The prevalence of the various mutations, inheritance pattern, nerve conductions, and age of onset help in deciding what genetic testing should be ordered.
3. Next-generation sequencing technology has identified a growing number of candidate gene mutations with complex and sometimes uncertain phenotypic correlations.
4. CMT is a rapidly evolving field where better understanding of pathophysiology is paving the way to develop potentially effective treatments.

INTRODUCTION

Inherited neuropathies, collectively known as *Charcot-Marie-Tooth* (CMT) *disease*, are a group of genetically and phenotypically heterogeneous peripheral neuropathies associated with mutations or copy number variations in approximately 100 different genes, many uncovered recently thanks to next-generation sequencing technology. Named after the three neurologists who first described the condition in 1886, CMT is the most common inherited neuromuscular disease. Hereditary neuropathies are classified as CMT (or hereditary motor sensory neuropathy) if motor and sensory system are both affected; as hereditary sensory/autonomic neuropathy (HSN or HSAN), if sensory and/or autonomic dysfunction prevail; and as distal hereditary motor neuropathy (dHMN), if motor deficit is predominant. These three disorders represent a continuum and are often collectively termed *Charcot-Marie-Tooth and related disorders*.

According to electrophysiologic criteria, CMT neuropathies are classified into two main subgroups: the demyelinating type CMT1 with reduced nerve conduction velocities (NCVs) in the arms of less than 38 m/s, and the axonal type CMT2 with primarily axonal loss characterized by normal NCV and decreased amplitude of motor (CMAP) and sensory nerve action potentials (SNAP). An intermediate CMT form with median motor NCV between 25 and 45 m/s has been defined.

Further subdivision of CMT are based on the inheritance pattern and the molecular genetic defects. Inheritance in CMT can be autosomal dominant (AD), autosomal recessive (AR), or X-linked. By convention, AR demyelinating forms of CMT1 are referred to as *CMT4* and AR axonal forms are also known as *AR-CMT2*. X-linked CMT is usually referred to as *CMTX*.

The term *Dejerine-Sottas neuropathy* (DSN) is currently used primarily to denote severe early-onset clinical phenotypes regardless of the inheritance pattern. The classification of CMT has been divided further into subtypes, identified by letters, as defined by the mutated gene.

Gene discoveries within the past two decades have challenged the simplistic classification of CMT, as for example, we have reached all 26 alphabet letters for CMT2. A modification of the current nomenclature of CMT and related disorders, which takes into account the causative gene defect, inheritance pattern, and primary pathologic phenotype (axonal, demyelinating, or intermediate), has been recently proposed but needs further discussion and widespread agreement.

EPIDEMIOLOGY

The prevalence of CMT is about 1 in 2,500 people, with a global distribution and no ethnic predisposition. Epidemiologic studies are still scarce, and knowledge of CMT frequency in different parts of the world remains extremely limited. The European prevalence rate is believed to be 10 to 28/100,000.

CMT1A, associated with a 17p11.2 duplication in the region containing the peripheral myelin protein 22 gene (*PMP22*), is the most common form of CMT and accounts for about 60% of patients with genetic diagnosis and about half of all patients with CMT. Mutations in the gap junction beta 1 (*GJB1*) gene cause CMT1X, which comprises approximately 10% to 20% of CMT cases, and CMT1B associated with mutations in the myelin protein zero (*MPZ*) gene accounts for about 7%. Patients with CMT2 are about 15% to 20% of all cases, and CMT2A (*mitofusin 2* mutation) is the most frequent form comprising roughly 20% of patients with CMT2. Fifty percent of CMT2 genes have yet to be identified. The prevalence of hereditary neuropathy with liability to pressure palsies (HNPP) is about 3% of patients with genetic diagnosis.

Many studies find that about 90% of patients with genetically confirmed CMT diagnosis have a mutation in one of these four genes: *PMP22* (duplication), *GJB1*, *MPZ*, and either *MFN2* or *GDAP1*, according to the geographic area. The former is more frequent in North America and Northern Europe, the latter in the Mediterranean area.

PATHOBIOLOGY

A common feature of most genes mutated in CMT is the role they play in maintaining the structure or function of cellular components of the peripheral nervous system, myelinating Schwann cells, and the axons they ensheath. Schwann cells and axons interact at multiple points along the peripheral nerve, including the adaxonal (opposing the axon) membrane, paranodal myelin loops, microvilli, and juxtaparanodal basal lamina. These interactions are mutually beneficial, providing trophic support

to the axon and myelinating cues to the Schwann cell. An example of this important interaction is the occurrence of secondary axonal degeneration in all forms of demyelinating CMT. Indeed, although the primary metabolic or structural defect often affects either the myelin or the axon, axonal degeneration represents the final common pathway in both forms of peripheral neuropathies. In demyelinating neuropathies, the secondary axonal degeneration presumably occurs because of inadequate Schwann cell support of the axon. In these neuropathies, secondary axonal degeneration may contribute more to clinical impairment than the primary demyelination. Impaired interactions between axons and mutant Schwann cells seem to be the common process linking all forms of demyelinating CMT. Most cases of CMT1 are caused by mutations in myelin-specific genes including *PMP22* (CMT1A), *MPZ* (CMT1B), and *GJB1* (CMTX1) or other genes associated with Schwann cell function, including those that exert transcriptional control of myelination and intracellular trafficking. At a pathologic level, dysmyelination, demyelination, remyelination, and axonal loss are characteristic features of the various demyelinating forms of CMT1. In DSN, myelin may never have formed normally, which is referred to as *dysmyelination*. In CMT1, onion bulbs of concentric Schwann cell lamellae are usually present on nerve biopsies, with loss of both small- and large-diameter myelinated fibers and a decrease in the number of myelinated axons. Focal, sausage-like thickenings of the myelin sheath (tomacula) are characteristic of HNPP but may also be found in other forms of CMT1, particularly CMT1B. In CMT1, disability typically correlates better with secondary axonal degeneration than with demyelination itself, again demonstrating the importance of Schwann cell–axonal interactions in demyelinating disease (**Fig. 92.1**).

Several recent studies have demonstrated a susceptibility of Schwann cells to mutations yielding misfolded proteins, as seen in certain *PMP22* and *MPZ* point mutations. Misfolded proteins may accumulate in the endoplasmic reticulum (ER) of Schwann cells inducing an unfolded protein response (UPR), a series of cellular events that help the ER to cope with the increased metabolic demand caused by retention of the misfolded protein. This, in turn, causes downregulation of the myelination program genes and dedifferentiation of Schwann cells, a toxic gain of function that worsens with the demyelination and is potentially amenable to therapeutic intervention.

Spinal motor neurons and dorsal root ganglion sensory neurons that are affected in CMT have particular challenges in maintaining homeostasis because their axons extend up to 1 m distal from the cell body. Because the majority of neuronal proteins are synthesized in the cell body, intensive transport of proteins must occur between the soma and the axonal extremity via anterograde transport. Additionally, signals from the periphery containing toxic or prosurvival factors, as well as damaged proteins, return to the cell body via retrograde transport. Indeed, axonal trafficking is emerging as a common theme of various seemingly diverse genes that are associated with CMT type 2. Mutations in genes associated with axonal structure and function result in CMT2. Some examples include mutations in proteins of the neuronal cytoskeleton (neurofilament light chain-NEFL, CMT2E), proteins associated with axonal mitochondrial dynamics (mitofusin 2-MFN2, CMT2A, and ganglioside-induced differentiation protein 1-GDAP1, CMT2K), and protein associated with regulation of membrane and intracellular trafficking (eg, Ras-associated protein RAB7, CMT2B). The pathologic hallmark of CMT2 is axonal degeneration with loss of all types of nerve fibers in the absence of onion bulb formation.

The advanced discovery of new causative genes unraveled previously unrecognized and unexpected neuropathy mechanism including nuclear envelope structure, mitochondrial dynamics, protein biosynthesis, Ca2+ homeostasis, phosphoinositide metabolism, sugar synthesis metabolic pathway, and transcriptional regulation.

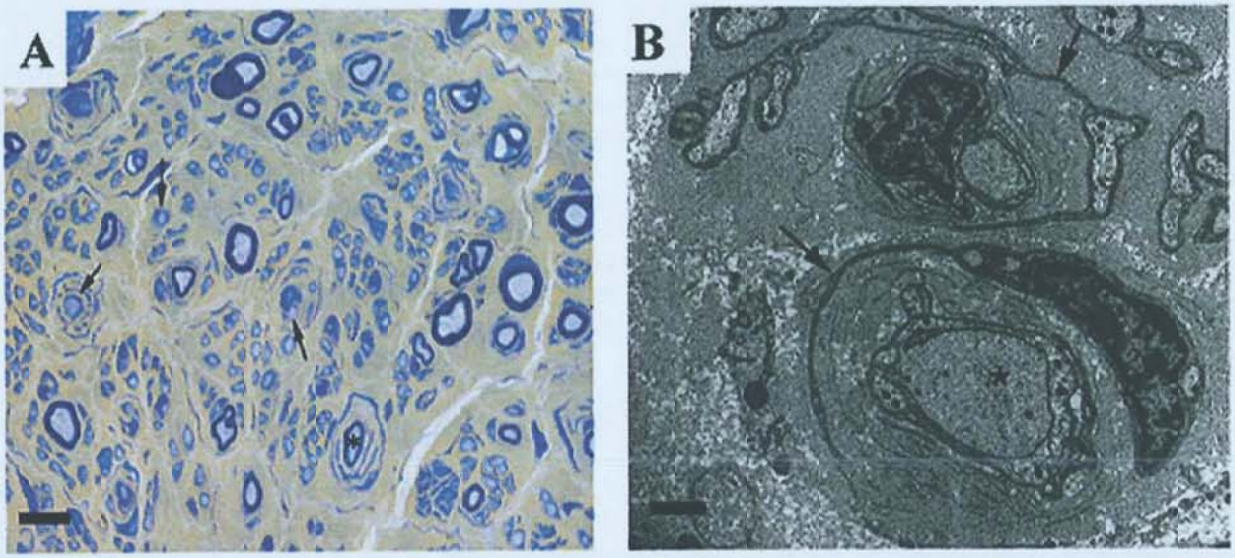

FIGURE 92.1 Pathologic findings in demyelinating Charcot-Marie-Tooth disease. **A:** Cross-section of a sural nerve biopsy of a patient with demyelinating Charcot-Marie-Tooth showing numerous demyelinated axons *(arrows)* and occasional classical onion bulbs *(asterisk)*. Thionine and acridine orange stain. Bar = 10 μm. **B:** Electron micrograph showing a demyelinated axon *(asterisk)* surrounded by some excess basal lamina. The Schwann cells associated with small, unmyelinated axons are abnormally long and attenuated *(arrows)*. Bar = 1 μm. (From Saporta MA, Shy ME. Inherited peripheral neuropathies. *Neurol Clin*. 2013;31:597-619.)

CLINICAL PRESENTATION

Despite phenotypic variability, there are characteristic clinical patterns for many types of CMT. The "classical" CMT phenotype consists of normal early milestones such as beginning to walk by approximately a year of age. This is followed by gradually progressing weakness and sensory loss during the first two decades of life. The classic phenotype typically features a steppage gait, pes cavus, sensory loss in a stocking or glove distribution, inverted champagne bottle legs, and atrophy in the hands (Fig. 92.2). Although both motor and sensory nerves are usually affected, the more prominent phenotypic characteristic is related to motor difficulty in most cases. Physical examination shows decreased or absent deep tendon reflexes often diffusely but always involving the Achilles tendon. Findings are usually symmetric. Pronounced asymmetries in symptoms suggest HNPP if they are episodic. Otherwise, they are more consistent with acquired disorders. Patients with classical CMT almost always have impaired proprioception with balance difficulty. Affected children are usually slow runners and have difficulty with activities that require balance (eg, skating, walking along a log across a stream). Ankle-foot orthotics is frequently required by the third decade.

FIGURE 92.2 **A:** Wasting of distal muscles in lower limbs leading to inverted champagne bottle legs. **B:** Example of wasting of intrinsic muscles of the hands. **C:** Pes cavus with hammer toes.

Fine movements of the hands for activities such as turning a key or using buttons and zippers may be impaired, but the hands are rarely as affected as the feet. Deep and superficial muscles that are innervated by the peroneal nerve, such as the tibialis anterior and peroneus brevis and longus muscles, often cause more symptoms than do the plantar flexion muscles innervated by the tibial nerve, such as the gastrocnemius. As a result, tripping and spraining one's ankle are frequent symptoms. Most patients remain ambulatory throughout life and have a normal life span.

However, CMT may be clinically, as well as genetically heterogeneous, with variability in the age of onset, speed of progression, and electrophysiologic findings. Onset may differ depending on the genetic subtype, including early-onset, infantile forms with delayed milestones (historically designated DSN), and late-onset adult forms. Symptoms are usually slowly progressive, especially for the classic and late-onset phenotype but can be severe, particularly in early-onset forms (Table 92.1).

DIAGNOSIS

Peripheral neuropathy is one of the most common reasons for referrals to neurologic clinics. The first step is to determine whether the patient has a genetic neuropathy. Where there is an affected parent, either an AD or X-linked (if there is no definite male-to-male transmission) inheritance is likely. If there are multiple affected siblings, no parents affected, and/or consanguineous parents, then AR inheritance is likely. However, recognizing CMT can be challenging particularly when there is no family history or if families are small. Factors pointing to an inherited neuropathy in such circumstances include presentations in childhood, slow progression, the presence of foot deformities, and the lack of positive sensory symptoms (dysesthesias, paresthesias) in the presence of clear sensory signs. Patients may have undergone foot surgery in childhood or reported difficulties with sports at school.

Genetic Testing

Genetic testing is the "gold standard" for the diagnosis of inherited neuropathies. However, it is a challenge to keep the costs reasonable particularly because there are so many known genetic causes. Although there are many genes associated with CMT, in North America, mutations in only four genes (*PMP22* duplication/deletion, *GJB1*, *MPZ*, and *MFN2*) account for over 90% of CMT cases. These data justify a stepwise diagnostic algorithm based on phenotype, inheritance pattern, NCVs, frequency of subtypes, and ethnicity. Although this approach is reasonably successful, with over 60% of patients with CMT achieving a genetic diagnosis, it is no longer the most efficient, rapid, or cost-effective method of achieving a molecular diagnosis, especially for CMT2, dHMN, and HSAN. In fact, diagnostic approaches are shifting to incorporate rapidly developing next-generation sequencing panels because the cost of these drops below that of serial candidate gene screening. Therefore, a practical approach is to consider commercial panels that contain the common CMT genes (*PMP22*, *GJB1*, *MPZ*, *MFN2*, *GDAP1*, *HSPB1*, *HSPB8*), taking into account the clinical data. Current multigene panel testing is increasingly the first-line approach for many patients with whole exome sequencing as back up, although initial targeted testing for *PMP22* duplication in patients with demyelinating CMT is appropriate. Most mutations that change the amino acid sequence in *PMP22*, *MPZ*, and *GJB1* cause disease, but polymorphisms are frequent in

TABLE 92.1 Specific Phenotypes of Charcot-Marie-Tooth (CMT)

Type	Specific Phenotype
CMT1	
CMT1A	Classic CMT phenotype with disease onset in the first two decades of life. Patients complain of walking difficulties, distal weakness associated with wasting, sensory loss, and foot deformities. Slow progression and AFOs often required. MNCVs are uniformly slow (mean range 17-21 m/s).
CMT1B	Associated with distinct phenotypes: late mild phenotype, adult-onset, and intermediate MNCVs; DSN with early infantile onset, severe phenotype, delayed walking, and MNCV <10 m/s; classic CMT phenotype (see CMT1A)
CMT1C	CMT1 (frequently resemble those with CMT1A)
CMT1D	Usually presents with DSN
CMT1E	Distinct phenotypes depending on the location and amino acid change: DSN with early onset, delay in walking, severe phenotype (deafness may also be present), very slow MNCVs; CMT1 with later onset and milder phenotype; HNPP
CMT1F	"Demyelinating" form of CMT2E with earlier onset (infancy or childhood), more severe phenotype (delayed motor milestones), and slower MNCVs
HNPP	Recurrent episodic painless mononeuropathies, typically at entrapment sites, in response to nerve injury from pressure or stretching; superimposed, length-dependent, sensory-predominant neuropathy of large fibers
X-Linked CMT	
CMT1X	Males have a more severe phenotype than females. MNCVs in the intermediate range (male MNCVs < female MNCVs). Nerve conduction can be patchy with temporal dispersion and conduction blocks, especially in females.
CMT2	
CMT2A	Usually severe phenotype with onset in infancy or early childhood, progressive course, and predominant motor involvement with many patients requiring a wheelchair to ambulate by the age of 20 years. Rarely, later onset and milder phenotype. Additional clinical features may be present as optic atrophy or pyramidal signs.
CMT2B	Predominant sensory involvement with ulcerations, infections, and sometimes amputations. Patients usually have in addition the typical motor symptoms of CMT. Autonomic dysfunctions can be also observed.
CMT2C	Predominant motor involvement, vocal cord paralysis (hoarseness and stridor), and respiratory dysfunction. Other distinctive clinical features may include bone deformities such as scoliosis, short stature, and/or scapular winging. The age of onset is often in the first decade of life.
CMT2D	It usually presents in the second decade with more pronounced weakness and wasting of the distal upper extremities compared to the lower extremities. Sensory findings are usually mild and may even be absent. In this situation, the disorder has been classified as dHMN type V.
CMT2E	The age of onset ranges from infancy and childhood typically with severe impairment to adulthood with mild impairment. Weakness and wasting start in the legs with all sensory modalities reported to be affected. MNCVs can be normal, intermediate, or slow (CMT1F).
CMT2F	Most patients have a dHMN phenotype (dHMN type IIB). Typically, this is a motor distal length-dependent neuropathy with slow progression proximally of symptoms. Sensory findings may be present, especially later in the disease course. The age of onset is typically late adolescence to early adulthood
CMT2L	CMT2 or dHMN-IIA if sensory involvement is not present (see CMT2F)
CMT2K	Typically results in a much milder phenotype than the recessive form (CMT4A) with no vocal cord involvement and onset ranging from adolescence to adulthood
CMT4/AR-CMT2	
CMT4A	Infantile-onset, severe progressive neuropathy with a variable vocal cord involvement and diaphragm paralysis
CMT4B1	Infantile onset with severe phenotype (both proximal and distal) cranial nerve involvement, especially facial weakness. Wheelchair dependent by adulthood.
CMT4C	The phenotype can be severe with early and severe scoliosis. The onset is slightly later than other AR-CMT.
CMT4F	Severe early-onset neuropathy with prominent sensory involvement and ataxia
CMT4J	Onset in early childhood with a severe motor phenotype, sometimes asymmetric. Rapid progression to a wheelchair has been described in adulthood.
AR-CMT2A	Severe axonal neuropathy with proximal involvement and rapid progression. Cardiomyopathy can be an associated feature. Onset usually in the second decade of life.

Abbreviations: AFOs, ankle-foot orthotics; AR, autosomal recessive; CMT1, autosomal dominant demyelinating Charcot-Marie-Tooth; CMT2, autosomal dominant axonal Charcot-Marie-Tooth; CMT4, autosomal recessive demyelinating Charcot-Marie-Tooth; dHMN, distal hereditary motor neuropathy; DSN, Dejerine-Sottas neuropathy; HNPP, hereditary neuropathy with liability to pressure palsies; MNCV, motor nerve conduction velocity.

most other genes and interpretation of disease-causing mutations are a challenge. We suggest following the recommendations of the American College of Human Genetics (see "Suggested Readings" section) in determining whether a variant is disease causing, which includes whether the variant segregates with disease, is present in the population, is conserved throughout evolution, and is predicted to be damaging.

The authors also believe it is still reasonable to provide some information about how to pursue genetic testing that must take into account the frequency of the subtypes, the phenotype and electrophysiologic characteristics, and the inheritance pattern. This can be quite challenging because the same gene can be involved in demyelinating, axonal, or intermediate forms and can display AD or AR inheritance depending on the nature and position of the mutation.

Age of Onset and Progression

Three different categories can be identified. Patients with a classical phenotype, who begin walking on time and develop weakness or sensory loss during the first two decades of life, belong to the first group. Impairment slowly increases and patients rarely require ambulation aids beyond ankle-foot orthotics. The large majority of patients with CMT1A and males with CMT1X fall into this category.

The second group is the early-onset phenotypes in which patients do not begin walking until they are at least 15 months of age. These patients are often severely affected and are likely to require above-the-knee bracing, walkers, or wheelchairs for ambulation by 20 years of age. The genetic spectrum of early-onset CMT is very heterogeneous, including both dominant and recessive forms. The majority of these represent demyelinating phenotypes with very slow motor nerve conduction velocities (MNCVs) and the most common are CMT1A, CMT1B, and CMT1E for the dominant forms and CMT4A, CMT4C, and CMT4F for the recessive ones. In addition to the demyelinating phenotypes, severe early-onset axonal neuropathies can be due to *MFN2* (CMT2A) or *GDAP1* (AR-CMT2K) mutations. Patients with CMT2A are frequently, although not always severely affected in infancy and childhood and present with a predominant motor neuropathy.

The third phenotype is defined as adult onset, in which patients do not develop symptoms of CMT until adulthood, often not until approximately 40 years of age. A large group of patients with axonal CMT and patients with a later onset CMT1B fall into this group.

Associated Symptoms and Signs

The recognition of additional symptoms and signs can lead to a better definition of the type of CMT. A recurrent nerve palsy history is typical of HNPP, which presents with transient focal motor and/or sensory deficits in the distribution of individual nerves or plexuses, usually precipitated by pressure. A split hand syndrome (the abductor pollicis brevis being more wasted and weaker than the first dorsal interosseous) is a distinctive sign of CMT1X, especially males. Transient CNS dysfunction and stroke-like episodes characterized by dysarthria, episodic weakness, and ataxia are also rarely reported by young males with CMT1X. Optic atrophy and pyramidal signs are occasionally observed in patients with *MFN2* mutations. Vocal cord paralysis is frequent in CMT2C, caused by mutations in *TRPV4* (transient receptor potential cation channel subfamily V member 4) gene as well as by mutations in MFN2 and several other genes. Tonic pupils can be an additional clinical feature of some axonal late-onset forms due to *MPZ* mutations (eg, Thr124Met). Amputations and skin ulcers are the main feature of CMT2B and other autonomic symptoms, as light-headedness or hypo-/hyperhidrosis, can be reported. Mutations in *SH3TC2* (SH3 domain and tetratricopeptide repeat domain 2) gene, causing CMT4C, are a frequent cause of significant scoliosis.

Neurophysiologic Pattern

CMT1 are characterized by MNCVs at upper limbs below 38 m/s with widespread uniform slowing of conduction velocities, as opposed to the multifocal segmental slowing found in demyelinating acquired neuropathies in which temporal dispersion and conduction blocks are frequently seen. Exceptions to this rule are patients with HNPP and patients with mutations in *FIG4* (CMT4J). In these cases, focal demyelination with temporal dispersion or conduction block can be seen. In CMT1A, MNCVs are uniformly slow in all nerves with a mean range of 17 to 21 m/s. Very slow MNCVs (<10 m/s) are suggestive of early-onset CM1B, *PMP22* point mutations, or demyelinating recessive phenotypes (CMT4).

Preserved or mildly slowed MNCV (mostly >45 m/s at upper limbs) and reduced compound muscle sction potential (CMAP) amplitude are in keeping with CMT2. Especially for severe phenotypes, in which CMAP and SNAP are unobtainable distally, it is recommended to perform nerve conductions on proximal nerves for a proper diagnostic workup to fully investigate the possibility of a severe demyelinating rather than an axonal pathology. Sensory nerve conduction evaluation is required to differentiate CMT2 from dHMN, and it should be performed especially at lower limbs because SNAP amplitude could be normal at upper limbs in mild phenotypes. Some forms of dHMN can have a minimal sensory impairment, and in these cases, the discrepancy between CMAP and SNAP amplitude reduction should be taken into account for the differential diagnosis.

"Intermediate" MNCV, in the range of 25 to 45 m/s, is consistent with I-CMT. MNCVs are not uniformly slow and can differ among different nerves in the same individuals or among family members. Therefore, although a single nerve can be sufficient to make a diagnosis of CMT1, multiple nerve evaluation must be performed especially in these cases. Temporal dispersion and conduction blocks can also be present. The most common intermediate forms of CMT are due to *MPZ* and *GJB1* mutations. Focal slowing at typical sites of compression (median nerve at wrist, ulnar nerve at elbow, and peroneal nerve at fibular head) and a superimposed, diffuse, sensory neuropathy is suggestive of HNPP.

Inheritance Pattern

The AD transmission is the most common pattern of inheritance in CMT with a vertical transmission from a generation to another. If there is no male-to-male transmission, X-linked inheritance should be taken into account, whereas in case of consanguinity, AR inheritance is likely. However, many patients present with no clear family history and these cases should be considered as sporadic cases due to de novo mutation, reduced penetrance/intrafamilial variability, or proband of an AR inheritance. So, the absence of a family history of neuropathy should not dissuade clinicians from considering an underlying genetic cause.

At-Risk Populations

It is important to be aware of the specific mutation frequencies occurring in certain populations because some genetic mutations have been reported in specific race-ethnic groups. In northern Europe and the United States, AD inheritance is much more common than AR, which should be considered for those patients coming from countries where consanguinity is more frequent, such as Mediterranean and Middle Eastern populations.

MANAGEMENT

Despite the great improvement in our biologic understanding of inherited neuropathies, derived mostly from developments in molecular biology and transgenic animal models in the last 25 years, there is still no treatment available for any type of CMT. Physical therapy, occupational therapy, and a few orthopedic procedures are still the cornerstone of CMT treatment. A detailed family history and often examination of family members are required for prognosis and genetic counseling.

A dedicated, multidisciplinary rehabilitation team can significantly contribute to the management of patients with CMT and improve functionality and quality of life. Physical therapy strategies to maintain muscle strength and tone, prevent muscle contractures, and improve balance are a common need for most patients with CMT. Orthotics also are an important component of treating these patients, providing support and improving balance for ambulation. Occupational therapy focused on developing tools and strategies to help patients with activities of daily living will benefit patients with CMT, especially those with hand weakness. Tendon lengthening and tendon transfers can benefit a subset of CMT patients with muscle contractures and tendon shortening and patients with significant weakness in functionally relevant muscles, respectively; however, the optimal timing of such procedures is still controversial. Foot surgery is sometimes offered to correct inverted feet, pes cavus, and hammertoes. This surgical intervention may improve walking, alleviate pain over pressure points, and prevent plantar ulcers. However, foot surgery is generally unnecessary and does not improve weakness and sensory loss (**Table 92.2**).

However, many promising compounds are being tested in cellular and animal models and may reach the phase of assessing tolerability and effectiveness in clinical trials.

TABLE 92.2 Treatments and Aims

Physical therapy	To maintain muscle strength and tone, prevent muscle contractures, and improve balance
Orthotics	To provide support and improve balance for ambulation
Occupational therapy	To provide tools and strategies for activities of daily living, especially for patients with hand weakness
Tendon lengthening	For patients with muscle contractures and tendon shortening
Tendon transfers	For patients with significant weakness in functionally relevant muscles
Foot surgery	To correct inverted feet, pes cavus, and hammer toes. It may improve walking and prevent plantar ulcers.

Gene Therapy

Gene therapy is becoming reality for many previously incurable neuromuscular disorders. Reducing the expression of PMP22 in Schwann cells (hence treating the overexpression of PMP22) is a biologic strategy already tested to treat CMT1A. Recently, Zhao et al treated two rodent models of CMT1A with PMP22-targeting antisense oligonucleotides and showed a 35% reduction in PMP22 messenger RNA (mRNA). This reduction was not only adequate in slowing disease progression but also improved the CMT1A-associated phenotypes in both models, offering evidence that another previously untreatable neuromuscular disease is becoming a treatable disorder.

Regulation of a mutant allele by an allele-specific small interfering RNA can represent a therapeutic approach as well. Lee at al designed allele-specific small interfering RNAs for a mouse model harboring a missense mutation (L16P) in *PMP22*, a model of CMT1E. The treatment reduced L16P-*PMP22* mRNA in Schwann cells and improved the mouse phenotype.

A gene therapy approach has been successfully performed by Kleopa and colleagues using intrathecal injection of *GJB1*, with both lentivirus and AAV9 vectors and the myelin-specific *MPZ* promoter, in *GJB1*-knocked-out mice lacking Cx32 expression. Gene delivery appeared to result in stable Cx32 expression in Schwann cells and peripheral nerves and clinical improvement. The same approach was successfully used by the group in the *SH3TC2*/mouse model of CMT4C.

Normalization of Gene Dosage

As previously mentioned, reducing the expression of PMP22 in Schwann cells is a strategy to treat CMT1A. High-dose ascorbic acid (vitamin C) was shown to decrease PMP22 levels and symptoms in mice with CMT1A, so that they were able to stay on a rotating rod longer, cross a beam more rapidly, and grip for longer than untreated mice. Several studies have been performed in humans with CMT1A, testing different doses of vitamin C (1-4 g/d) for up to 2 years. Unfortunately, all studies failed to meet their primary outcome measures and did not show a significant effect on phenotype.

A phase III trial in CMT1A is in progress employing PXT3003, a mixture of low-dose sorbitol, naltrexone, and baclofen, after encouraging results in the animal model and a phase II trial.

Steroid hormones are epigenetic regulators of gene expression, and progesterone can stimulate PMP22 expression in cultured Schwann cells. Progesterone antagonists have been shown to decrease PMP22 expression in a rat model of CMT1A, improving their phenotype (specifically, the axonal loss seen during disease progression). Unfortunately, onapristone, the compound shown to have therapeutic effects in this study, do not have an appropriate safety profile to be administered in humans. Efforts to develop bioequivalent compounds with a better safety profile are ongoing.

Neurotrophic Support

The growth factor neurotrophin 3 promotes nerve regeneration after injury and the survival of Schwann cells. Accordingly, injection of recombinant neurotrophin 3 improved regeneration and remyelination in animal models. A pilot study in eight patients with CMT1A resulted in an increase in myelinated fiber density, a reduction in the neurologic impairment score, and improved sensory

modalities as compared with placebo controls, calling for a larger randomized controlled trial. An additional study provided preclinical data demonstrating efficacy of adeno-associated virus–mediated neurotrophin 3 gene therapy in a mouse model of CMT1A.

Neuregulin1-III (Nrg1-III) activity determines myelin thickness and is regulated by the secretases β-site APP cleaving enzymes 1 (BACE1) and TNFα-converting enzyme (TACE). It is reasonable that modulating Nrg1-III activity may constitute a general therapeutic strategy to treat CMT that are characterized by de/dysmyelination. Recently, genetic overexpression of Nrg1-III has been shown to ameliorate the neurophysiologic and morphologic parameters in a mouse model of CMT1B and stimulating Nrg1-III signaling by pharmacologic suppression of the Nrg1-III inhibitor TACE also ameliorated the neuropathy. Conversely, increasing TACE activity with the commercially available niacin (Niaspan) is of benefit in different models of hypermyelination neuropathies, as CMT4B.

Reduction of Neurotoxic Aggregates/ Misfolded Proteins

Recent studies have demonstrated the role of ER accumulation of misfolded proteins and UPR activation in the pathogenesis of several animal models of CMT associated with point mutations in myelin-related genes, including *PMP22* and *MPZ*. Furthermore, treatment with an agent that relieves ER stress (curcumin) improved the phenotype of both models. Therefore, compounds that either relieve ER stress or reduced UPR activation are promising therapeutic strategies to treat patients with mutations that cause misfolded proteins to accumulate in the ER of Schwann cells. For example, Sephin1, which attenuates the inositol-requiring enzyme 1 (IRE1) branch of the UPR, may be an effective approach to improve myelination in those cases of CMT1B in which the UPR is active.

Targeting Transport Defects

An important therapeutic target is axonal transport, which likely plays a key role in several CMT subtypes, but treatment strategies for axonal forms of CMT have not been as easily identified as for demyelinating forms. Histone deacetylase-6 inhibitors have been shown to correct axonal transport defects in a mouse model of CMT2F associated with point mutations in the *HSPB1* gene, rescuing the axonal loss and clinical phenotype of these mice. It remains to be shown whether this same strategy could be useful in other forms of axonal CMT because correcting axonal transport defects may be a common treatment option for most of these CMT types.

Cellular Reprogramming and High-Throughput Therapeutic Screening

Two new technologies recently developed hold enormous potential in the search for compounds to treat CMT: cellular reprogramming and high-throughput therapeutic screening. Cellular reprogramming is a technique that allows the generation of specific cell types (including stem cell–like cells, neurons, and glia) by genetically modifying readily available somatic cells such as fibroblasts or lymphocytes. Using this technology, researchers are able to generate unlimited supplies of patient-specific cell lines for use in mechanistic studies and drug development. These patient-specific cell lines will be particularly useful when combined with high-throughput screening of drug libraries containing thousands of compounds. In these highly automated platforms, the process of identifying compounds capable of correcting certain disease-related cell phenotypes is streamlined, allowing for a faster target selection of compounds to be tested in phase 1 animal studies. The use of patient-derived human cells offer the theoretical advantage of a more translational platform, which could facilitate the process of moving from phase 1 studies to human clinical trials. Whether this is actually true remains to be proven.

OUTCOME

Phenotypic variability occurs within given phenotypes, and natural history studies of most forms of CMT are lacking. Nevertheless, most patients remain ambulatory throughout life and life span is not typically shortened. Some patients do not develop symptoms until adult years.

The attempt in searching for genetic modifiers that may account for the phenotypic variability is an emerging research field. CMT1A is a valuable target for modifier gene studies because it is by far the most common form of CMT, and despite its genetic homogeneity, patients present with considerable clinical phenotypic variability. Recently, signal-induced proliferation-associated 1 like 2 (*SIPA1L2*) gene has been found as a potential genetic modifier of CMT1A phenotypic expressions and offering a new pathway to therapeutic interventions.

As novel treatments are approaching, a parallel research line is aimed at preparing clinical trials and finding responsive outcome measures to detect treatment efficacy in a reasonable time period and with feasible sample sizes. With neuropathies that progress slowly over many years, this can be challenging. To this end, a validated scoring system (CMT neuropathy score) based on symptoms, signs, and neurophysiologic data has been developed for adults with excellent inter- and intraobserver correlations and which can detect changes over 1 year. A more sensitive CMT pediatric score (CMTPedS) exists for those patients between the ages of 3 and 21 years, which takes into account growth-related changes and should prove useful in future clinical trials. Sequential yearly magnetic resonance imaging of limb muscles looking at progressive replacement of muscle with fatty tissue proved to be a valuable outcome measurement in a cohort of CMT1A and HSAN1 patients. Nerve and muscle ultrasound echography and magnetic resonance neurography are providing accurate images in different peripheral neuropathies including CMT and might become useful also for follow-up studies. Meaningful biomarkers are actively searched for in skin biopsies, blood, and cerebrospinal spinal fluid. For this reason, skin biopsies have been increasingly used in the diagnostics and research of hereditary peripheral neuropathies by both morphologic and morphometric analysis of cutaneous nerve fibers. Moreover, changes of the level of certain myelin proteins and respective mRNA can be quantified. Indeed, Svaren et al recently developed a novel method for precise evaluation of *PMP22* levels in skin biopsies in CMT1A, and the analysis showed reproducible evaluation in CMT1A versus controls skin biopsies, particularly after normalization to Schwann cell-specific genes. Lastly, a proteomics-based approach performed on lymphoblasts from CMT2 patients resulted in the identification of profilin 2 (PFN2) and guanidinoacetate methyltransferase (GAMT) as commonly downregulated proteins in different genotypes, unveiling two molecular determinant as potential biomarkers in CMT2.

SUGGESTED READINGS

Berciano J, García A, Gallardo E, et al. Intermediate Charcot-Marie-Tooth disease: an electrophysiological reappraisal and systematic review. *J Neurol*. 2017;264:1655-1677.

Burns J, Ouvrier R, Estilow T, et al. Validation of the Charcot-Marie-Tooth disease pediatric scale as an outcome measure of disability. *Ann Neurol*. 2012;71:642-652.

Fridman V, Bundy B, Reilly MM, et al. CMT subtypes and disease burden in patients enrolled in the Inherited Neuropathies Consortium natural history study: a cross-sectional analysis. *J Neurol Neurosurg Psychiatry*. 2015;86:873-878.

Murphy SM, Herrmann DN, McDermott MP, et al. Reliability of the CMT neuropathy score (second version) in Charcot-Marie-Tooth disease. *J Peripher Nerv Syst*. 2011;16:191-198.

Pareyson D, Reilly MM, Schenone A, et al; for CMT-TRIAAL and CMT-TRAUK groups. Ascorbic acid in Charcot–Marie–Tooth disease type 1A (CMT-TRIAAL and CMT-TRAUK): a double-blind randomised trial. *Lancet Neurol*. 2011; 10:320-328.

Pareyson D, Saveri P, Pisciotta C. New developments in Charcot-Marie-Tooth neuropathy and related diseases. *Curr Opin Neurol*. 2017;30:471-480.

Pisciotta C, Shy ME. Neuropathy. *Handb Clin Neurol*. 2018;148:653-665.

Richards S, Aziz N, Bale S, et al. Standards and guidelines for the interpretation of sequence variants: a joint consensus recommendation of the American College of Medical Genetics and Genomics and the Association for Molecular Pathology. *Genet Med*. 2015;17:405-424.

Rossor AM, Kalmar B, Greensmith L, Reilly MM. The distal hereditary motor neuropathies. *J Neurol Neurosurg Psychiatry*. 2012;83:6-14.

Rossor AM, Tomaselli PJ, Reilly MM. Recent advances in the genetic neuropathies. *Curr Opin Neurol*. 2016;29:537-548.

Rotthier A, Baets J, Timmerman V, Janssens K. Mechanisms of disease in hereditary sensory and autonomic neuropathies. *Nat Rev Neurol*. 2012;8:73-85.

Svaren J, Moran JJ, Wu X, et al. Schwann cell transcript biomarkers for hereditary neuropathy skin biopsies. *Ann Neurol*. 2019;85(6):887-898.

Tao F, Beecham GW, Rebelo AP, et al. Variation in SIPA1L2 is correlated with phenotype modification in Charcot-Marie-Tooth disease type 1A. *Ann Neurol*. 2019;85:316-330.

Wallace A, Pietrusz A, Dewar E, et al. Community exercise is feasible for neuromuscular diseases and can improve aerobic capacity. *Neurology*. 2019;92(15):e1773-e1785.

Weis J, Claeys KG, Roos A, at al. Towards a functional pathology of hereditary neuropathies. *Acta Neuropathol*. 2017;133:493-515.

93 Myasthenia Gravis and Other Disorders of the Neuromuscular Junction

Christina M. Ulane

KEY POINTS

1. Disorders of the neuromuscular junction cause fluctuating weakness, without sensory symptoms or findings.
2. Myasthenia gravis is the prototypical autoimmune postsynaptic neuromuscular junction disorder with autoantibodies most commonly against the acetylcholine receptor (also against other postsynaptic membrane proteins).
3. Treatment of myasthenia gravis is highly individualized and includes symptomatic treatments, immediate/acute treatment for exacerbations, and long-term immunomodulatory treatment to reduce disease activity.
4. Numerous new and exciting treatment options are now available for myasthenia gravis.
5. Lambert-Eaton myasthenic syndrome and botulism are prototypical presynaptic neuromuscular junction disorders, which are rarer but important entities to recognize.
6. Much progress has been made in understanding the pathobiology of congenital myasthenic syndromes and the underlying genetic causes, and specific symptomatic treatment is available for certain syndromes.

INTRODUCTION

Pathology at the neuromuscular junction (NMJ) can occur at the presynaptic or postsynaptic membrane. Autoimmune disorders, hereditary diseases, and toxins are the main types of disease which affect the NMJ.

MYASTHENIA GRAVIS

Myasthenia gravis (MG) is caused by a defect of neuromuscular transmission owing to antibody-mediated attack on nicotinic acetylcholine receptors (AChR) or other functionally related proteins at the postsynaptic membrane of the NMJ, such as muscle-specific tyrosine kinase (MuSK), agrin, and lipoprotein receptor–related protein 4 (LRP4). It is characterized by fluctuating weakness restricted to the skeletal muscles, which can be focal or generalized and almost always includes eye muscles. The weakness in the limbs is symmetrical and typically more proximal than distal. Respiratory and bulbar muscles may also become involved. There are several different subgroups of MG, which have treatment and prognostic implications (Table 93.1).

Epidemiology

The prevalence of MG is 150 to 250 cases per million, with an incidence of 8 to 10 cases per million persons. These numbers have increased with greater awareness and improved diagnosis. MG is equally present in men and women older than the age of 40 years; however, it is 3 times more common in women than men younger than 40 years of age. MuSK myasthenia is also more common in women.

Systemic autoimmune disorders are found with greater incidence in patients with MG. Thyroid disorders are present in up to 15% of patients with MG. Other autoimmune disorders with increased incidence in patients with MG include rheumatoid arthritis and systemic lupus erythematosus (SLE).

Familial cases are rare; single members of pairs of fraternal twins and several sets of identical twins have been affected. Young women with MG tend to have human leukocyte antigen (HLA)-B8, HLA-DR3, and HLA-DQB1*0102 haplotypes; in young Japanese women, HLA-A12 is prominent. These observations imply the presence of a linked immune response gene that encodes a protein involved in the autoimmune response. First-degree relatives show an increased incidence of other autoimmune diseases (SLE, rheumatoid arthritis, thyroid disease) and HLA-B8 haplotype.

Pathobiology

Acquired MG is an autoimmune disorder, which results in dysfunction at the NMJ and subsequent weakness. The purpose of the NMJ is to transmit the electrical impulse from the motor neuron to the muscle fiber and trigger contraction. The complex synapse is depicted in **Figure 93.1**. An electrical signal reaching the

TABLE 93.1 Subgroups of Myasthenia Gravis

• Early onset (before 50 y of age); associated with certain HLA haplotypes, 3 times more likely in females
• Late onset (50 y or older); distinct HLA haplotypes; males slightly outnumber females[a]
• Thymoma (10%)
• MuSK (1%-10%)
• LRP4 (1%-3%)
• Seronegative
• Ocular (15%)

Abbreviations: HLA, human leukocyte antigen; LRP4, lipoprotein receptor–related protein 4; MG, myasthenia gravis; MuSK, muscle-specific tyrosine kinase.

[a]Early and late onset account for two-thirds of MG patients.

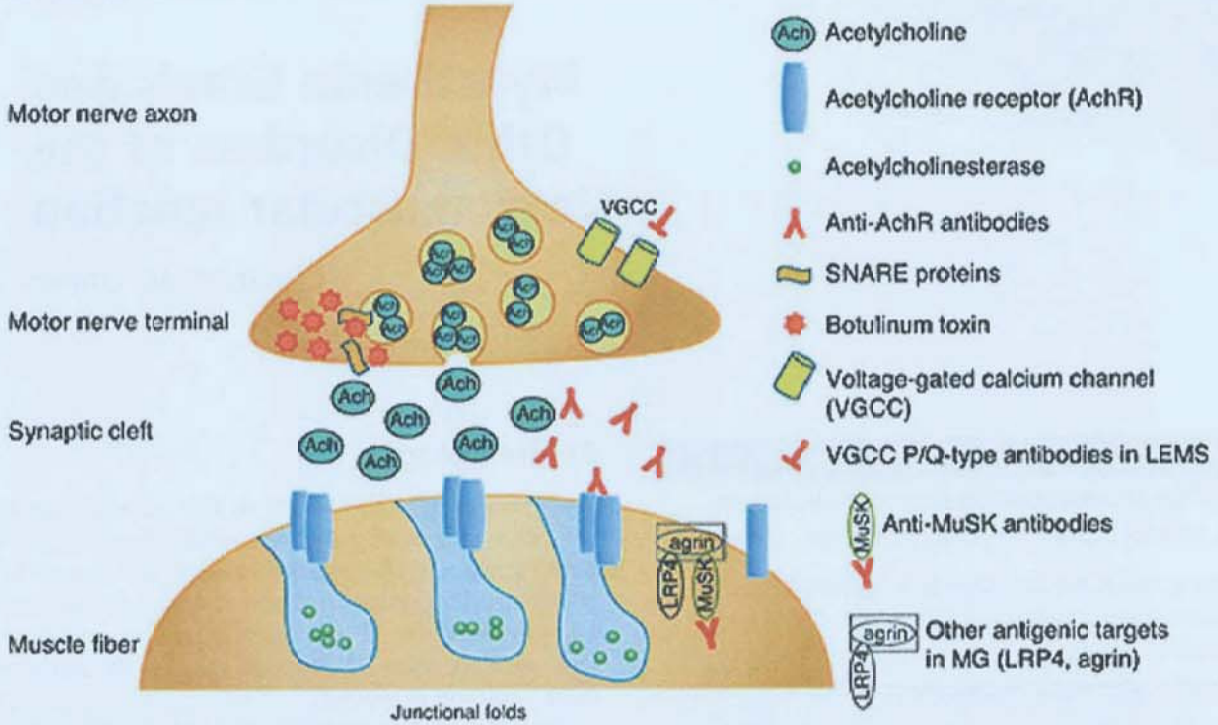

FIGURE 93.1 The neuromuscular junction. Key components of the neuromuscular junction are depicted including the motor axon and muscle endplate, the synaptic cleft, and the muscle fiber. When an action potential reaches the terminal, acetylcholine (ACh) is released into the synapse and binds to the nicotinic ACh receptors on the sarcolemma, triggering a muscle fiber action potential and contraction. The antigenic targets in myasthenia gravis (MG) and Lambert-Eaton myasthenic syndrome (LEMS) are indicated, as is the site of action of botulinum toxin. Abbreviations: LRP4, lipoprotein receptor–related protein 4; MuSK, muscle-specific tyrosine kinase.

terminal motor axon results in the release of acetylcholine (ACh) quanta into the synaptic cleft through fusion of vesicles with the membrane. The released ACh serves as a chemical signal, which then travels across the synaptic cleft and binds to AChR on the postsynaptic muscle fiber membrane, triggering a muscle fiber action potential and subsequent contraction or twitch.

Autoimmune Antibodies

The NMJ is susceptible to autoimmune pathology because there is no blood-nerve barrier to protect the NMJ. The precise mechanisms triggering autoimmunity at the NMJ are unknown, but the thymus is known to play a role.

Extensive research has shown the complex autoimmune nature of MG. Antibodies against the AChR are found in approximately 80% of patients with MG and are of the immunoglobulin (Ig) G1 or IgG3 subclass. False-positive AChR antibodies are extremely rare (<1%) and often are seen in related disorders (Lambert-Eaton myasthenic syndrome [LEMS]) or motor neuron disease. A majority of these are AChR-"binding" antibodies. AChR-"modulating" antibodies are found in less than 1% of MG patients without binding antibodies, and "blocking" antibodies are found in approximately 10% of MG patients without binding antibodies. The polyclonal IgG antibodies to AChR are produced by plasma cells in peripheral lymphoid organs, bone marrow, and thymus. These cells are derived from B cells that have been activated by antigen-specific T-helper (CD41) cells. The T cells have also been activated, in this case, by binding to AChR antigenic peptide sequences (epitopes) that rest on the histocompatibility antigens on the surface of antigen-presenting cells.

Most common are anti-AChR binding antibodies, which bind to the AChR on the postsynaptic membrane and cause the complement-mediated destruction of the junctional folds and accelerate internalization and degradation of AChR. Blocking antibodies prevent ACh binding to the AChR. Modulating antibodies distort the NMJ and folds. The end result in all cases is a loss of functional AChR.

The AChR antibodies react with multiple determinants, and enough antibodies circulate to saturate up to 80% of all AChR sites on muscle. A small percentage of the anti-AChR molecules interfere directly with the binding of ACh, but the major damage to endplates seems to result from actual loss of receptors owing to complement-mediated lysis of the membrane and to acceleration of normal degradative processes (internalization, endocytosis, lysosomal hydrolysis) with inadequate replacement by new synthesis. As a consequence of the loss of AChR and the erosion and simplification of the endplates, the amplitude of miniature endplate potentials is about 20% of normal, and patients are abnormally sensitive to the competitive antagonist curare. The characteristic decremental response to repetitive stimulation of the motor nerve reflects failure of endplate potentials to reach threshold so that progressively fewer fibers respond to arrival of a nerve impulse. Most AChR antibodies are directed against antigenic determinants on the extracellular portion of the protein farthest out from the membrane rather than the ACh-binding site. The summed effects of the polyclonal anti-AChR antibodies, especially those that fix complement, result in destruction of the receptors. Physiologic studies indicate impaired postsynaptic responsiveness to ACh, which accounts for the physiologic abnormalities, clinical symptoms, and beneficial effects of drugs that inhibit acetylcholinesterase.

The complement pathway is a critical component of innate immunity and involves activation of a cascade of more than

30 proteins. In MG, complement is activated via the classical pathway by antigen-antibody complex triggering the cascade of many proteins with C5 activation as one of the final steps resulting in activation of the membrane attack complex, ultimately leading to destruction of the postsynaptic membrane of the NMJ. The role of complement in MG has led to the development of treatments, which inhibit complement.

The MuSK protein is localized to the inner surface of the muscle membrane and is involved in AChR clustering. Approximately 10% of all patients with MG and 50% of patients without antibodies to the AChR will have antibodies against MuSK. There is prominent atrophy of muscles in anti-MuSK MG. Anti-MuSK antibodies are pathogenic by inhibiting the clustering of the AChR, demonstrated in passive transfer of human IgG from patients with anti-MuSK MG to rodents.

Beginning in 2011, multiple groups of researchers found other antigenic targets in seronegative MG patients. LRP4 is essential for NMJ formation; it is a transmembrane protein serving as an agrin receptor and participating in agrin-activated MuSK and AChR clustering. Antibodies against LRP4 (mainly IgG1 subtype) were found in MG patients seronegative for AChR antibodies and MuSK antibodies. Antibodies against agrin were identified in patients both with anti-AChR antibodies and in seronegative patients. Antibodies against cortactin, another downstream protein involved in AChR clustering have also been found not only in seronegative patients but also in other autoimmune conditions. There are likely additional autoantibodies to components of the NMJ, which are yet to be discovered and account for the remainder of the "seronegative" MG patients.

T Cell Autoimmunity

How the autoimmune disorder begins is not known, but it is T cell–dependent and antibody-mediated process. In human disease, in contrast to experimental MG in animals, the thymus gland is almost always abnormal; often, multiple lymphoid follicles show germinal centers ("hyperplasia of the thymus"), and in about 15% of patients, there is an encapsulated benign tumor, a thymoma. These abnormalities are impressive because the normal thymus is responsible for the maturation of T cells that mediate immune protection without promoting autoimmune responses. AChR antibodies are synthesized by B cells in cultures of hyperplastic thymus gland. The hyperplastic glands contain all the elements needed for antibody production: class II HLA-positive antigen-presenting cells, T-helper cells, B cells, and AChR antigen; that is, messenger RNA for subunits of AChR has been detected in thymus, and "myoid cells" are found in both normal and hyperplastic thymus. The myoid cells bear surface AChR and contain other muscle proteins. When human myasthenic thymus was transplanted into severely congenitally immunodeficient mice, the animals produced antibodies to AChR that bound to their own motor endplates, even though weakness was not evident.

T lymphocytes are responsible for initiating and maintaining the autoantibody response, and the thymus gland is the site of overt pathology. About 70% of thymus glands from adult patients with MG are not involuted, weigh more than normal, and demonstrate lymphoid hyperplasia. In contrast, germinal centers in nonmyasthenics are numerous in the lymph nodes and spleen but are sparse in the thymus. Immunocytochemical methods indicate that the thymic germinal centers in myasthenics contain B cells, plasma cells, HLA class II DR-positive T cells, and dendritic cells. Approximately 10% of patients with MG will have lymphoepithelial thymomas, and the neoplastic thymic epithelial cells express self-antigens including the AChR and other skeletal muscle proteins such as titin and the ryanodine receptor. The lymphoid cells in these tumors are T cells; the neoplastic elements are epithelial cells. Benign thymomas may nearly replace the gland with only residual glandular material at the edges, or they may rest within a large hyperplastic gland. Thymomas tend to occur in older patients, but in one series, 15% were found in patients between ages 20 and 29 years. They may invade contiguous pleura, pericardium, or blood vessels or seed onto more distant thoracic structures, including the diaphragm; however, they almost never spread to other organs. In older patients without thymoma, the thymus gland appears involuted, often showing hyperplastic foci within fatty tissue on microscopic examination of multiple samples. Excessive and inappropriately prolonged synthesis of thymic hormones that normally promote differentiation of T-helper cells may contribute to the autoimmune response. Still, another possible initiating factor is immunogenic alteration of the antigen AChR at endplates; penicillamine therapy in patients with rheumatoid arthritis may initiate a syndrome that is indistinguishable from MG except that it subsides when administration of the drug is stopped.

New Insights

There are few familial cases of the acquired autoimmune disease, but disproportionate frequency of some HLA haplotypes (B8, DR3, DQB1) in MG patients suggests that genetic predisposition may be important. Other autoimmune diseases also seem to occur with increased frequency in patients with MG, especially hyperthyroidism and other thyroid disorders, SLE, rheumatoid arthritis, pernicious anemia, and pemphigus.

MicroRNAs (miRNAs) have recently been shown to be dysregulated in MG and a potential biomarker for MG disease severity. miRNAs are small, noncoding endogenous RNA molecules that are associated with many biologic processes as well as with many human diseases. Studies have shown the upregulation of specific profiles of miRNAs in AChR antibody–positive MG and MuSK antibody–positive MG, with dynamic changes in levels after thymectomy or with immunotherapy.

While overt inflammation is generally absent in the muscle, there is some evidence that the muscle is not a passive target in MG but rather that it responds dynamically. Numerous cytokines are upregulated in the muscle of experimental models of MG. Complement activation at the postsynaptic muscle membrane does not induce apoptosis, but significant activation of molecular transcription and signaling pathways in response.

Interest in the gut microbiome as it relates to autoimmune disease has increased significantly in recent years, particularly those with an imbalance of T-cell populations such as multiple sclerosis and rheumatoid arthritis. Large amounts of microorganisms live in the human gut in a symbiotic relationship that coevolved with the gut-associated lymphoid tissue. While there have not been any studies in humans on the gut microbiome alterations in MG, in animal models there is evidence that probiotics can alter disease course.

Diagnosis

The symptoms of MG have three general characteristics that together provide a diagnostic combination (Table 93.2). Formal diagnosis depends on clinical features, demonstration of the response to cholinergic drugs, electrophysiologic evidence of abnormal neuromuscular transmission, and demonstration of circulating antibodies to AChR or MuSK.

TABLE 93.2 Cardinal Clinical Features of Myasthenia Gravis

• **Fluctuating weakness**
  • Proximal arms or legs
  • Sometimes distal arms/hands
  • Axial: neck flexors > neck extensors

• **Diplopia**
  • Extraocular muscle weakness
  • May resemble INO

• **Ptosis**   • Often asymmetric

• **Dysarthria**
  • Nasal speech
  • LMN

• **Dysphagia**

• **Respiratory insufficiency**
  • Dyspnea
  • Hypoxia is a late finding.

Abbreviations: INO, internuclear ophthalmoplegia; LMN, lower motor neuron.

Clinical Features

The fluctuating nature of myasthenic weakness is unlike any other disease. The weakness varies in the course of a single day, sometimes within minutes, and it varies from day to day or over longer periods. Major prolonged variations are termed *remissions* or *exacerbations*; when an exacerbation involves respiratory muscles to a degree that intubation and assisted mechanical ventilation, it is called a *crisis*. An "exacerbation" may be ameliorated by noninvasive ventilation or may be a transient worsening without respiratory distress. Variations sometimes seem related to exercise; this and the nature of the physiologic abnormality have long been termed *excessive fatigability*, but there are practical reasons to de-emphasize fatigability as a central characteristic of MG. Patients with the disease less often complain of fatigue or symptoms that might be construed as fatigue except when there is incipient respiratory muscle weakness. Myasthenic symptoms are always owing to weakness and not to rapid tiring. Fatigue is common in MG, and at times can be difficult (especially for patients) to differentiate from true myasthenic exacerbation.

The second characteristic of MG is the distribution of weakness. Ocular muscles are affected first in about 40% of patients and are ultimately involved in about 85%. Ptosis and diplopia are the symptoms that result. Other common symptoms affect facial or oropharyngeal muscles, resulting in dysarthria, dysphagia, and limitation of facial movements. Together, oropharyngeal and ocular weakness cause symptoms in virtually all patients with acquired MG. Limb and neck weakness is also common in conjunction with cranial weakness. Almost never are the limbs affected alone. MuSK myasthenia particularly involves ocular, facial, and bulbar muscles and has high risk of respiratory insufficiency. MuSK myasthenia can follow a rapidly progressive and more severe course.

Aside from the fluctuating nature of the weakness, MG is not a steadily progressive disease. The general nature of the disease, however, is usually established within weeks or months after the first symptoms. If myasthenia is restricted to ocular muscles for 2 years, certainly if it is restricted after 3 years, it is likely to remain restricted, and only in rare cases does it then become generalized. Distinguishing solely ocular myasthenia from generalized myasthenia soon after onset is challenging.

Vital signs and findings on general physical examination are usually normal, unless the patient is in crisis. Weakness of the facial and levator palpebrae muscles produces a characteristic expressionless appearance with drooping eyelids, which can be asymmetric (**Fig. 93.2A**). Weakness of ocular muscles (**Fig. 93.2B**) may cause paralysis or weakness of isolated ocular muscles, limitation of conjugate gaze, complete ophthalmoplegia in one or both eyes, or a pattern resembling internuclear ophthalmoplegia. Proximal limb weakness is manifest by difficulty in raising the arms above the head (**Fig. 93.2C**) and difficulty climbing stairs, whereas weakness of the neck flexor and extensor muscles may result in head drop (**Fig. 93.2D**). Weakness of oropharyngeal or limb muscles, when present, can be shown by appropriate tests. Respiratory muscle weakness can be detected by pulmonary function tests, which should not only be limited to measurement of vital capacity but should also include inspiratory and expiratory pressures, the measurement of which may be abnormal even before overt symptoms are evident. Muscular wasting of variable degree is found in about 10% of patients but is not focal and is usually encountered only in patients with malnutrition caused by severe dysphagia. Fasciculations do not occur, unless the patient has received excessive amounts of cholinergic drugs. Sensation is normal, and the reflexes are preserved, even in muscles that are weak.

Crisis is most likely to occur in patients with oropharyngeal or respiratory muscle weakness. It seems to be provoked by respiratory infection in many patients or by surgical procedures, including thymectomy, although it may occur with no apparent provocation. Both emotional stress and systemic illness may aggravate myasthenic weakness for reasons that are not clear; in patients with oropharyngeal weakness, aspiration of secretions may occlude lung passages to cause rather abrupt onset of respiratory difficulty. Major surgery may be followed by respiratory weakness without aspiration, however, so this cannot be the entire explanation.

Clear clinical picture of fluctuating weakness, improved with rest, and ocular symptoms can make diagnosis of MG straightforward. However, ocular MG can at times be challenging to diagnose when clinical signs are minimal during examination, symptoms do not significantly fluctuate, and symptoms are mild. The ice test is performed at bedside on patients with ptosis: A pack of ice is placed over the ptotic eye for 1 to 2 minutes, and resolution or improvement in the ptosis is considered positive and highly specific for MG.

The dramatic improvement that follows the injection of neostigmine bromide (Prostigmin) or edrophonium (Tensilon) made the use of these drugs helpful in the diagnosis of MG. Despite the overall low risk of complications, because of the need to have atropine and a crash cart when administering these drugs, this test is hardly performed currently. The Tensilon test administers the short-acting acetylcholinesterase inhibitor edrophonium; improvement in a subsequent clinical assessment is considered similarly positive and specific for MG. A test dose of 2-mg edrophonium is given intravenously, followed by up to 8 mg intravenously. Muscles weak from MG will respond within 30 to 45 seconds, with a response lasting up to 5 minutes; an objective improvement in muscle strength is considered a positive result. Although risk of serious cardiac complications is low, life-threatening bradyarrhythmias and ventricular fibrillation can occur with the Tensilon test, and it should be carried

FIGURE 93.2 Clinical features of myasthenia gravis. **A:** Bifacial weakness and asymmetric ptosis. **B:** Weakness of extraocular muscles causing dysconjugate gaze. **C:** Proximal arm weakness. **D:** Neck flexor weakness causing head drop. (Courtesy of C. M. Ulane.)

out with close monitoring and atropine at the bedside. False positives can occur in motor neuron and other diseases, and the sensitivity of the Tensilon test is 60%. Both the ice test and Tensilon test require objectively measurable outcomes and thus are most useful in cases of ptosis and oculomotor abnormalities, rather than limb weakness. The only other conditions in which clinical improvement has been documented after use of edrophonium are other disorders of neuromuscular transmission: botulinum intoxication, snake bite, organophosphate intoxication, or unusual disorders that include features of both MG and the Lambert-Eaton syndrome. Denervating disorders, such as motor neuron disease or peripheral neuropathy, do not show a reproducible or unequivocal clinical response to edrophonium or neostigmine.

Laboratory Testing and Electrophysiologic Testing

Routine examinations of blood, urine, and cerebrospinal fluid are normal. Antibodies to AChR are found in 85% to 90% of patients of all ages with generalized MG if human muscle is used as the test antigen (**Table 93.3**). Antibodies may not be detected in patients with strictly ocular disease, in some patients in remission (or after thymectomy), or even in some patients with severe symptoms. The titer does not match the severity of symptoms; patients in complete clinical remission may have high titers. For pure ocular MG, AChR antibodies present in serum support the diagnosis; however, the sensitivity is rather low (range, 25%-70%). Antibodies to myofibrillar proteins (titin, myosin, actin, actomyosin) are found in 85% of patients with thymoma and may be the first evidence of thymoma in some cases. In the first report of seronegative myasthenia, there were no clinical differences between patients who had or lacked AChR antibodies. Subsequently, more than half of these seronegative patients were found to have antibodies to MuSK. Patients with anti-MuSK antibodies were found to have a similar clinical picture almost always with generalized MG with predominantly bulbar signs, poor and inconsistent responses to pyridostigmine, immunosuppressants, or thymectomy but excellent response to plasmapheresis. Antibodies to rapsyn-clustered AChR were detected on human embryonic kidney cells by fluorescence-activated cell sorting in 66% (25/38) of sera from

TABLE 93.3 Diagnostic Testing for Myasthenia Gravis

Laboratory Test	Comments
AChR antibodies	
• AChR binding • AChR blocking • AChR modulating	• 80%-85% of all MG • 50% of ocular MG • Binding most common • Blocking positive in ~10% of MG with negative binding • Modulating positive in <1% of MG with negative binding
MuSK antibodies	• 10% of all MG • 50% of AChR-negative MG
Other antibodies	
• Striational • Titin, RyR, myosin, actin • LRP4, agrin	• Present in 75%-85% of thymomatous MG, frequent in ICI-induced MG • May be associated with more severe disease (titin, RyR) • LRP4 present in 1%-3% of MG; both may be found in other disorders.
Electrodiagnostic Test	
Nerve conduction studies	• Repetitive nerve stimulation reveals decrement (≥10%). • Sensitivity 53%-100% in generalized MG • Sensitivity 10%-48% in ocular MG • Not specific
Single-fiber EMG	• Most sensitive test for MG (>95%) but not specific (~70%)
Radiology	
Computed tomography of the chest	• 10% thymoma

Abbreviations: AChR, acetylcholine receptor; EMG, electromyography; ICI, immune checkpoint inhibitor; LRP4, lipoprotein receptor–related protein 4; MG, myasthenia gravis; MuSK, muscle-specific tyrosine kinase; RyR, ryanodine receptor.

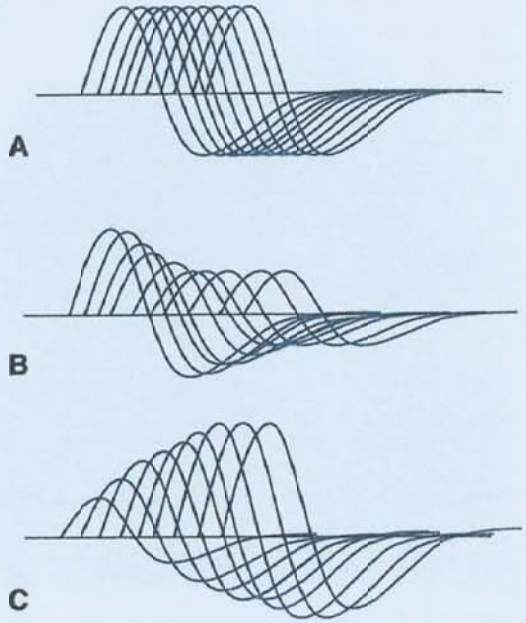

FIGURE 93.3 Repetitive nerve stimulation (RNS). Slow (3 Hz) RNS of the median nerve-abductor pollicis brevis system reveals normal response, decrement and facilitation of the compound muscle action potential. **A:** Normal response to RNS with minimal decrement. **B:** Decremental response in myasthenia gravis. **C:** Facilitation in Lambert-Eaton myasthenic syndrome and botulism.

patients that had previously tested negative for binding to AChR in solution. Other serologic abnormalities are encountered with varying frequency, and in several studies, antinuclear factor, rheumatoid factor, and thyroid antibodies were encountered more often than in control populations.

Recently, antibodies against lipoprotein-related protein 4 (LRP4) were discovered in "seronegative" MG patients, ranging in frequency from 1% to 3%. LRP4 is expressed in the postsynaptic muscle and activates MuSK and binds agrin, critical components of NMJ signal transmission.

The characteristic electrodiagnostic abnormality is progressive decrement in the amplitude of compound muscle action potentials evoked by repetitive nerve stimulation at 3 or 5 Hz (Fig. 93.3). In generalized MG, the decremental response can be demonstrated in about 90% of patients if at least three neuromuscular systems are used (median-thenar, ulnar-hypothenar, accessory-trapezius). Repetitive nerve stimulation testing is often negative in ocular MG (in both distal and proximal muscles). In single-fiber electromyography (EMG), a small electrode measures the interval between evoked potentials of the muscle fibers in the same motor unit. This interval normally varies, a phenomenon called *jitter*, and the normal temporal limits of jitter have been defined. In MG, the jitter is increased, and an impulse may not appear at the expected time; this is called *blocking*, and the number of blockings is increased in myasthenic muscle. All these electrophysiologic abnormalities are characteristic of MG, but blocking and jitter are also seen in other disorders. Single-fiber EMG is the most sensitive test for MG but is not specific.

The standard-needle EMG is usually normal, occasionally shows a myopathic pattern, and almost never shows signs of denervation unless some other condition supervenes. Similarly, nerve conduction velocities are normal.

All patients diagnosed with MG should be screened for the presence of thymoma. Computed tomography (CT) of the mediastinum demonstrates all but microscopic thymomas. Magnetic resonance imaging (MRI) is not more sensitive than CT.

The differential diagnosis includes all diseases that are accompanied by weakness of oropharyngeal or limb muscles, such as the muscular dystrophies, amyotrophic lateral sclerosis, progressive bulbar palsy, ophthalmoplegia of other causes, and the asthenia of psychoneurosis or hyperthyroidism. There is usually no difficulty in differentiating these conditions from MG by the findings on examination and by the failure of symptoms in these conditions to improve after parenteral injection of neostigmine or edrophonium. Occasionally, blepharospasm is thought to mimic ocular myasthenia, but the forceful eye closure in that condition involves both the upper and the lower lids; the narrowed palpebral fissure and signs of active muscle activity are distinctive.

Management

Treatment for MG is tailored to the individual patient. A general algorithm for treatment of MG is presented in Figure 93.4. Clinicians must choose the sequence and combination of therapy: anticholinesterase drug therapy, corticosteroids, immunosuppressives, plasmapheresis, intravenous immunoglobulins (IVIG), biologics (monoclonal antibodies) and thymectomy (Table 93.4).

Acetylcholinesterase Inhibitors

In 1934, Dr. Mary Walker discovered the beneficial effects of acetylcholinesterase inhibitors in patients with MG. To this day, this remains a mainstay of treatment, yet there are no randomized trials of these agents in MG. A Cochrane review in 2011 reaffirmed the lack of controlled studies but concluded that the results from observational studies were so clear that it would be difficult to justify a trial. It is generally agreed that anticholinesterase drug therapy should be given as soon as the diagnosis is made. Of the three available drugs—neostigmine, pyridostigmine bromide, and ambenonium—pyridostigmine is the most popular but has not been formally assessed in controlled comparison with the other drugs. The muscarinic side effects of abdominal cramps and diarrhea are the same for all three drugs but are least severe with pyridostigmine; none has more beneficial or adverse effects than another and all can be regarded as safe. The usual starting dose of pyridostigmine is 60 mg given orally every 4 hours while the patient is awake. Depending on clinical response, the dosage may be increased, but incremental benefit is not to be expected in amounts greater than 120 mg every 2 hours. If patients have difficulty eating, doses can be taken about 30 minutes before a meal. If patients have special difficulty on waking in the morning, an extended-release 180-mg tablet of pyridostigmine can be taken at bedtime. Muscarinic symptoms can be ameliorated by preparations containing atropine (0.4 mg) with each dose of pyridostigmine. Excessive doses of atropine can cause psychosis, but the amounts taken in this regimen have not had that effect. Other drugs may be taken if diarrhea is prominent. Combinations of two drugs are no better than any single drug alone.

Although cholinergic drug therapy sometimes gives impressive results, there are serious limitations. In ocular myasthenia, ptosis may be helped, but some diplopia almost always persists. In generalized MG, patients may improve remarkably, but some symptoms usually remain. Cholinergic drugs do not return function to normal, and the risk of crisis persists because the disease is not cured. Therefore, one of the other treatments is used promptly to treat generalized MG. MuSK MG patients often do not respond as well to anticholinesterases.

Glucocorticoids

Despite the widespread use and agreed upon efficacy of glucocorticoids in the treatment of MG, there are no randomized controlled studies, and at this point, it would be unethical to withhold a known beneficial treatment. Several controlled and blinded studies initially suggested the benefit of steroids for MG. Numerous retrospective studies show that steroids can induce remission in 27% to 42% and marked improvement in 29% to 52% of patients with MG. Prednisone, 60 to 100 mg daily, will achieve a response within a few days or weeks. Within the first 2 weeks of starting prednisone, patients may experience worsening of their symptoms, and caution must be taken in those with prominent bulbar or respiratory symptoms. An equally satisfactory response can be seen with a lower dosage, but it takes longer; for instance, if the dose is 25 to 40 mg, benefit may be seen in 2 to 3 months. Once improvement is achieved, the dosage should be gradually tapered to 20 to 35 mg every other day. This has become a popular treatment for disabled patients, but there has been no controlled trial. If the patient does not improve in about 6 months or if there are unacceptable side effects from the steroids, treatment with steroid-sparing agents is pursued.

Prednisone, 15 to 35 mg on alternate days, is also recommended by some clinicians for ocular myasthenia, weighing risks against potential benefit. For some patients in sensitive occupations, the risks of prednisone therapy may be necessary (eg, actors, police officers, roofers or others who work on heights, or those who require stereoscopic vision). Ocular myasthenia is not a threat to life, and pyridostigmine may alleviate ptosis. An

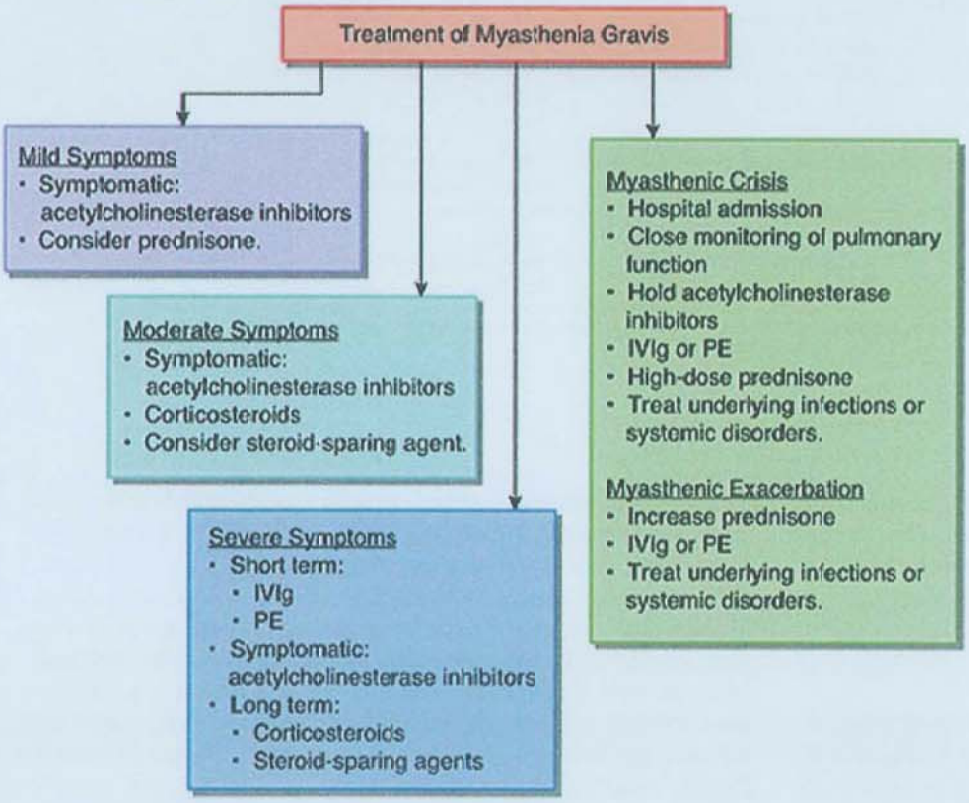

FIGURE 93.4 General treatment guidelines for myasthenia gravis (MG). Treatment of MG is highly individualized and depends on many factors. Shown here are general principles to guide physicians in the treatment of MG based on severity of symptoms. Abbreviations: IVIG, intravenous immunoglobulins; PE, plasma exchange.

TABLE 93.4 Medications Used to Treat Myasthenia Gravis

Agent	Dose	Monitoring Parameters	Side Effects
Pyridostigmine	30-90 mg q4-6h Extended release: 180 mg every night	Clinical response	Common: fasciculations, diarrhea Overdose: cholinergic crisis, weakness, dysphagia, respiratory failure Rare: bromism (acute psychosis)
Prednisone	1 mg/kg/d (usually 60-80 mg/d) Alternate-day dosing Taper over months after sustained clinical response Concomitant: PPIs, H2 blockers Calcium, vitamin D	May cause initial worsening Blood pressure Serum glucose Yearly ophthalmologic exam	Hyperglycemia Hypertension Weight gain Fluid retention Cataracts/glaucoma Osteoporosis/avascular necrosis Steroid myopathy Peptic ulcer disease Depression/psychiatric effects
IVIG	2 g/kg over 4-5 d	Heart rate Blood pressure Clinical response (usually within 1 wk)	Common: headache, chills, fever, nausea Rare: acute renal failure (solute-induced), aseptic meningitis, thrombosis (DVT/PE, stroke, MI), leukopenia
Plasma exchange	Five to six exchanges	Heart rate Blood pressure Coagulation studies Fibrinogen Ionized calcium	Paresthesias Hypotension Transient arrhythmias Nausea, light-headedness, chills Complications of central lines
Azathioprine	Start at 50 mg/d Titrate up to 2-3 mg/kg/d	Complete blood count Hepatic function	Infections Gastrointestinal upset Hepatoxicity Cytopenias Malignancy
Mycophenolate mofetil	1 g twice a day, up to 3 g total daily[a]	Complete blood count Hepatic function	Infections Cytopenias Nausea Diarrhea Abdominal pain If used with other immunosuppressives: PML
Cyclosporine A	5-6 mg/kg twice a day Goal trough: 75-150 ng/mL	Blood pressure Renal function	Infections Renal toxicity Hypertension Many medication interactions
Tacrolimus	3-5 mg/d	Blood pressure Renal function Glucose	Infections Hyperglycemia Renal toxicity Hypertension Malignancy
Cyclophosphamide	Monthly pulsed doses 500 mg/m^2[b]	Complete metabolic panel Urine studies Complete blood count	Myelosuppression Hemorrhagic cystitis Hyponatremia Seizures Opportunistic infection Malignancy

Abbreviations: DVT, deep vein thrombosis; IVIG, intravenous immunoglobulin; MI, myocardial infarction; PE, pulmonary embolism; PML, progressive multifocal leukoencephalopathy; PPIs, proton pump inhibitors.
[a]Recent randomized controlled trials suggest no benefit.
[b]Usually reserved for severe refractory myasthenia gravis.

eye patch can end diplopia, and prisms help some patients with stable horizontal diplopia. Currently, the Efficacy of Prednisone in the Treatment of Ocular Myasthenia trial is ongoing and seeks to study the safety and efficacy of prednisone for ocular MG in a multicenter, randomized controlled trial.

Steroid-Sparing Agents

Azathioprine is one of the most studied in this category. It is a purine antimetabolite, which acts by inhibiting T- and B-cell proliferation. It is often well tolerated, but it can take more than 12 months to achieve maximal benefit. Common side effects include gastrointestinal upset and an idiosyncratic flu-like reaction. In addition, azathioprine may cause hepatotoxicity, and transaminases need to be monitored. Rare but serious adverse effects include leukopenia and pancytopenia, which can occur at any time during treatment. In 1998, a randomized controlled trial demonstrated the benefit of azathioprine in addition to prednisolone. Patients receiving both had fewer exacerbations, longer remission, and lower total daily dose of maintenance prednisolone LEVEL 2.[1] Another study suggests that azathioprine alone may be

as effective or more effective than prednisone alone in preventing clinical deterioration after 2 to 4 years of treatment LEVEL 1.[2]

Mycophenolate mofetil inhibits T- and B-cell proliferation by selectively blocking purine synthesis. Initial pilot and retrospective studies showed promising benefit for the treatment of MG. In one report, 73% of 85 patients improved; adverse effects led to discontinuation of treatment in 6% LEVEL 1.[3] However, two randomized controlled trials in 2008 showed no benefit over placebo LEVEL 1.[4,5] Many experts still use mycophenolate and consider it effective, and it has a favorable side effect profile. Critiques of the negative studies suggested that the patients chosen had mild disease, a better than expected response to low-dose prednisone and the overall short duration of the trial may have obscured a positive effect.

Cyclosporine acts as a calcineurin inhibitor, thus reducing the function of effector T cells. It is used less due to renal toxicity; however, it has been shown to be effective in several randomized, controlled trials LEVEL 1.[6,7]

Cyclophosphamide can also be considered in doses up to 2.5 mg/kg daily for an adult LEVEL 3.[8] It is often reserved for refractory cases due to toxicity. Another agent with benefit is tacrolimus LEVEL 1.[9]

Methotrexate (MTX) may also be considered as a second-line agent for the treatment of MG and had been used despite minimal quality data about its effectiveness. MTX is a selective inhibitor of dihydrofolate reductase, which inhibits nucleic acid synthesis in rapidly dividing cells such as lymphocytes, thus resulting in immunosuppression. Side effects are often mild with mucositis, alopecia, and gastrointestinal intolerance, but serious adverse events such as interstitial pneumonitis, hepatotoxicity, and bone marrow suppression can occur. Recently, a randomized, double-blind, placebo-controlled trial was conducted to assess the efficacy of MTX as a steroid-sparing agent by measuring the primary outcome of area under the dose-time curve. Although there was no difference at up to 12 months in terms of area under the dose-time curve or secondary clinical outcome measures LEVEL 1,[10] the authors note that it is unclear whether the study was underpowered or whether MTX truly does not work for MG. A second study was done assessing the degree of polyglutamation of MTX (which in other diseases correlates with its anti-inflammatory effects) in these same patients at the end of this study. The study group found that the degree of MTX polyglutamation correlated with clinical therapeutic effect for MG.

The numerous side effects of prednisone must be weighed against the possibilities of marrow suppression, susceptibility to infection, or delayed malignancy in patients who are given immunosuppressive drugs.

Plasma Exchange and Intravenous Immunoglobulins

Plasma exchange (PE) is also used for exacerbations; the resulting improvement, seen in most patients, may be slight or dramatic and may last only a few days or several months. PE is safe but expensive and is not convenient for many patients. Indwelling catheters may lead to bleeding, thrombosis, or infection. In general, five sessions of PE are given every other day.

IVIG therapy is usually given in five daily doses to a total of 2 g/kg body weight. There is some evidence that 1 g/kg may be sufficient for treating exacerbation LEVEL 3.[11] A randomized, double-masked, placebo-controlled trial of IVIG for the treatment of moderate to severe MG exacerbations found benefit that was both statistically significant and clinically meaningful LEVEL 3.[12] Side effects include headache, aseptic meningitis, and a flu-like syndrome that can be alarming but subsides in 1 or 2 days. Thromboembolic events, including stroke, can occur. IVIG is easier to administer but is even more expensive. It is preferred over PE in those with poor venous access, including children.

There is recent interest in the use of subcutaneous Ig (SCIg) as an alternative to IVIG for many autoimmune disorders because it provides patients with greater autonomy to self-administer, requiring less health care resources and theoretically has fewer side effects and better tolerability. A systematic review of SCIg in MG found only limited and uncontrolled studies but overall that SCIg may improve disability in MG with only local and mild adverse events.

Both IVIG and PE are also available for management of exacerbations. Given the differences in availability at various treatment centers and different side effect profiles, it is important to consider each carefully. A study compared IVIG to PE for moderate to severe exacerbations in a randomized, masked fashion and found both to be equally effective treatments for worsening MG with similar duration of benefits and safety profiles LEVEL 1.[13]

Other Immunomodulatory Treatments

Rituximab

There is great interest in new immunosuppressive and modulatory therapies to treat MG. Rituximab was originally developed for the treatment of cancer and other autoimmune disorders. It is a monoclonal antibody to $CD20^+$ B-cells, which acts to deplete B-cell reserves. The potential benefits in MG were reported by several groups in retrospective or prospective case series. In addition, there seemed to be a particularly robust response in patients with MuSK antibody MG. A large prospective blinded review comparing MuSK MG patients treated with rituximab compared to other immunosuppressive medications showed that rituximab increased the probability of a favorable clinical outcome. A phase II trial of rituximab (BeatMG study) was a randomized, double-blind, placebo-controlled trial to determine the safety and efficacy of rituximab for AChR antibody–positive generalized MG, failed to meet the primary outcome in terms of steroid-sparing effects; however, overall disease may have been milder, and ad hoc subgroup analysis suggests that rituximab may be more effective in moderate to severe disease. Yet, several retrospective studies suggest a benefit for AChR-positive MG and a meta-analysis showed a 26% response rate for AChR-positive MG patients treated with rituximab. A retrospective study suggests that rituximab is safe and effective for late-onset MG, and in a prospective extended study, rituximab showed sustained clinical improvement for both AChR and MuSK MG. Thus, while evidence more clearly suggests a benefit for MuSK MG, there may be some benefit for certain patients with AChR MG. Rituximab is generally considered safe and well tolerated; however, there is a low risk of progressive multifocal leukoencephalopathy and hepatitis B reactivation.

Complement Inhibition: Eculizumab

Given the role of complement-mediated destruction of the NMJ in MG, interest has grown in the use of complement inhibition as a treatment for MG. Eculizumab is a monoclonal antibody against the terminal C5 component of complement, preventing its activation and therefore inhibiting formation of the membrane attack complex; therefore, it likely functions to preserve AChR and the postsynaptic membrane thus sustaining NMJ transmission in MG.

A large phase III clinical trial (REGAIN) showed major clinical benefits for patients with refractory generalized MG treated with eculizumab compared to placebo for secondary clinical endpoints (even though primary endpoint did not reach significance), leading to U.S. Food and Drug Administration (FDA) approval for use of eculizumab in refractory MG. An open-label extension of REGAIN has shown that benefits of eculizumab treatment remained up to 3 years; clinical parameters including minimal manifestations of disease or pharmacologic remission. The most serious side effect of eculizumab is meningococcal meningitis, which mandates appropriate vaccination prior to initiation of therapy and initial prophylaxis as needed.

Complement Inhibition: Zilucoplan

Zilucoplan is a small synthetic peptide that binds to the C5 component of complement, preventing cleavage and activation of the complement cascade. A phase II randomized, double-blind, placebo-controlled trial explored the efficacy of subcutaneous zilucoplan at two different doses in patients with AChR MG. It was found to be well tolerated and met the primary endpoint of clinically meaningful change in quantitative myasthenia gravis score (QMG) score at week 12 (QMG score is a scale assessing muscle weakness) as well as most secondary endpoints. Maximal complement inhibition at the higher dose of zilucoplan administered demonstrated the most rapid and robust disease suppression, although partial complement inhibition at the lower dose was superior to placebo.

Neonatal Fc Receptor Inhibition

A novel treatment approach involves targeting the neonatal Fc receptor (FcRn). The FcRn plays an essential role in prolonging the half-life of IgG molecules by salvaging them from lysosomal degradation. When the FcRn is inhibited, IgG half-life is significantly reduced, and both total IgG levels and pathogenic IgG autoantibody levels are reduced.

Efgartigimod

Efgartigimod is a monoclonal antibody against FcRn, preventing lysosomal degradation of circulating IgG. It is administered by intravenous infusion. Single-dose administration causes a 50% reduction in IgG levels and repeated dosing further lowers IgG levels by 75%. A randomized, double-blind, placebo-controlled trial of efgartigimod in patients with generalized AChR antibody–positive MG showed very promising results. Not only was it safe and well tolerated, the trial demonstrated a correlation between reduced AChR antibody levels and disease improvement, and several different efficacy scales demonstrated that 75% of patients had rapid and long-lasting disease improvement.

Other Neonatal Fc Receptor Inhibitors

Rozanclixizumab is a subcutaneous monoclonal antibody against the FcRn for which a recent phase II study reported clinically meaningful improvements in patients with MG with concomitant reductions in autoantibody titers (results to be published). Other FcRn inhibitors being investigated include nipocalimab and RVT-1401.

Other Treatments

Additional interest is ongoing in several other emerging therapies for MG. These include numerous other mechanisms of B-cell inhibition (bortezomib—a proteasome inhibitor that depletes short and long-lived B cells); belimumab, monoclonal antibody against the B cell–activating factor, which inhibits differentiation of B cells; and stem cell therapy (marrow depletion followed by autologous hematopoietic stem cell transplantation).

Tirasemtiv, an investigational drug that activates the fast skeletal muscle troponin complex, was studied as a means to increase strength and reduce muscle fatigue in MG by amplifying downstream muscle response in a hypothesis-generating phase II double-blind, placebo-controlled, randomized study. It was found to be well tolerated and may improve function in MG, with dose-related improvements in QMG scores.

Case reports have shown beneficial effects for refractory MG with the use of tocilizumab (anti–interleukin 6 receptor monoclonal antibody) and ofatumumab (fully human monoclonal antibody against a distinct CD20 B-cell epitope).

Thymectomy

Thymectomy was originally reserved for patients with serious disability because the operation had a high mortality. With advances in surgery and anesthesia, however, the operative mortality is now negligible in major centers. Although thymectomy had been a mainstay of treatment for MG, there had been no conclusive evidence regarding its benefit until the completion and publication in 2017 of the thymectomy trial in non-thymomatous myasthenia gravis patients receiving prednisone therapy (MGTX) trial, a multicenter, international randomized, rater-blinded trial of extended transsternal thymectomy plus alternate-day prednisone compared to alternate-day prednisone alone. This trial demonstrated that thymectomy for nonthymomatous AChR antibody–positive MG is probably more effective than prednisone alone in terms of achieving minimal manifestation status, lower dose of prednisone, reduced need for other immunosuppressives or rescue therapy, and reduced hospitalizations at 3 years LEVEL 1.[14] Approximately half of the patients participated in an extension study showing that these benefits persisted at 5 years. A systematic review and meta-analysis found that thymectomy may be considered effective as treatment for nonthymomatous MG with significantly higher remission rates. Thus, expert guidelines recommend that thymectomy be discussed with nonthymomatous AChR antibody–positive MG patients who are between the ages of 18 and 65 years of age. There are no randomized controlled trials for MuSK or seronegative MG and the role of thymectomy; however, a retrospective review of MuSK MG data collected for a trial of rituximab found that thymectomy was not associated with additional clinical improvement in patients with MuSK MG.

Decisions made for children, patients older than 65 years, and seronegative MG must be individualized. Although the trial demonstrated thymectomy to be safe, it is still a major operation. Minimally invasive techniques are available, but these have the potentially higher risk of leaving residual thymic tissue. Mantegazza et al found a remission rate of about 50% at 6 years after surgery with either the standard transsternal operation or a minimally invasive thoracoscopic operation.

Patients with thymoma are likely to have more severe MG and are less likely to improve after thymectomy; nevertheless, many of these patients also improve if the surrounding thymus gland is excised in addition to the tumor.

Myasthenic Crisis

Myasthenic crisis arises in about 10% of myasthenic patients. It is more likely to occur in patients with dysarthria, dysphagia, and documented respiratory muscle weakness, presumably

TABLE 93.5 Signs of Impending Respiratory Failure in Myasthenia Gravis

Clinical features	Significant bulbar dysfunction • Dysarthria, dysphagia • Impaired gag reflex Tachypnea, dyspnea Use of accessory muscles Paradoxical breathing Count out loud in single exhale Poor cough Impaired secretion clearance
Laboratory signs	**Pulmonary function tests:** VC <15-20 mL/kg (or VC <1 L) NIF > −20 cm H_2O MEP <40 cm H_2O Tidal volume <4-5 mL/kg **Laboratory:** Pco_2 ≥50 mm Hg[a]

Abbreviations: MEP, maximal expiratory pressure; NIF, negative inspiratory force; VC, vital capacity.
[a]Hypoxia is a late finding.

TABLE 93.6 Medications That Exacerbate Myasthenia Gravis

Contraindicated	α-Interferon Penicillamine Telithromycin Botulinum toxin
Use with caution (may worsen MG)	**Cardiac medications** • β-Blockers (propranolol, timolol maleate eye drops) • Calcium channel blockers • Quinine, quinidine, procainamide **Neuromuscular blocking agents** • Succinylcholine • d-Tubocurarine **Antibiotics** • Aminoglycosides (gentamicin, kanamycin, streptomycin, neomycin) • Macrolides (erythromycin, azithromycin) • Quinolones (ciprofloxacin, levofloxacin, norfloxacin, ofloxacin) **Magnesium salts** (laxatives, antacids)

Abbreviation: MG, myasthenia gravis.

because they are liable to aspirate oral secretions, but crisis may also occur in other patients after respiratory infection or major surgery (including thymectomy). The principles of treatment are those of respiratory failure in general. Numerous retrospective studies have investigated what clinical and laboratory factors in MG crisis predict the need for mechanical ventilation. See **Table 93.5** for clinical and laboratory features of impending respiratory failure in patients with MG. Cholinergic drug therapy is usually discontinued once an endotracheal tube has been placed and positive pressure respiration started; this practice avoids questions about the proper dosage or cholinergic stimulation of pulmonary secretions. Crisis is viewed as a temporary exacerbation that subsides in a few days or weeks. The therapeutic goal is to maintain vital functions and to avoid or treat infection until the patient spontaneously recovers from the crisis. Cholinergic drug therapy need not be restarted unless fever and other signs of infection have subsided, there are no pulmonary complications, and the patient is breathing without assistance. Myasthenic crisis and exacerbations can be triggered by infections, surgery, and medications (**Table 93.6**).

Vaccination in Myasthenia Gravis

A population-based cohort study in Canada found that patients with MG are at a 39% higher risk of serious infections compared to matched controls, although this study did not account for the use of immunosuppressant medication. Given the importance of vaccines in preventing spread of infectious disease at the population level and the role in preventing serious infectious disease in patients with MG, vaccine safety for is often of great concern to patients with MG. Safety of vaccination in autoimmune diseases is not well studied but small, observational studies have suggested that influenza vaccination in MG is safe and does not affect AChR antibody titers in patients with MG. A randomized, double blind, placebo-controlled trial in AChR antibody–positive MG patients showed that influenza vaccination is safe and did not result in MG exacerbation and induced an immune response comparable to controls and independent of immunosuppression.

Pregnancy and Myasthenia Gravis

MG affects women of childbearing age, and pregnancy presents a unique situation. Although MG itself does not affect fertility, immunosuppressive medications can affect fertility and have teratogenic effects.

It is difficult to predict the course of MG during pregnancy due to high variability. One third of women experience first-trimester worsening of MG; however, there may be improvement or remission in the second and third trimesters.

Ideally, the patient should meet with her neurologist to discuss pregnancy planning as early as possible. One consideration is thymectomy if not already performed, given the benefits for patients with MG, and that thymectomy may be associated with lower likelihood of neonatal myasthenia.

Treatment of choice during pregnancy is pyridostigmine and corticosteroids at the lowest effective dose. It is not recommended to begin other immunosuppressives during pregnancy due to long time of onset to benefit and potential harm to infant. Patients who are already taking cyclosporine or azathioprine therapy can be continued if needed, whereas MTX and mycophenolate mofetil should be discontinued prior to pregnancy. Rituximab may be safe during pregnancy, but there is a lack of information and current recommendations suggest discontinuing for 12 months prior to pregnancy.

Exacerbations may be treated with IVIG and PE as needed.

Outcome

Before the advent of intensive care units and the introduction of positive pressure respirators in the 1960s, crisis was a life-threatening event. In the past 60 to 70 years, advances in pulmonary critical care and in the diagnosis of MG have reduced mortality rates for myasthenic crisis from 33% to 60% to approximately 4%. With improved respiratory care, patients rarely die of MG, except when cardiac, renal, or other disease complicates the picture. Even so, pulmonary intensive care is now so effective that crisis is almost never fatal and many patients go into a remission after recovery from crisis. Because of advances in therapy, MG is still serious but not so grave.

CONGENITAL MYASTHENIC SYNDROMES

Neonatal Myasthenia Gravis

About 12% of infants born to myasthenic mothers have a syndrome characterized by impaired sucking, weak cry, limp limbs, and, exceptionally, respiratory insufficiency. Symptoms begin in the first 48 hours and may last several days or weeks, after which the children are normal. The mothers are usually symptomatic but may be in complete remission; in either case, AChR antibodies are demonstrable in both mother and child. Symptoms disappear as the antibody titer in the infant declines. Severe respiratory insufficiency may be treated by exchange transfusion, but the natural history of the disorder is progressive improvement and total disappearance of all symptoms within days or weeks. Respiratory support and nutrition are the key elements of treatment. Rare instances of arthrogryposis multiplex congenita (a syndrome of multiple joint contractures present at birth) have been attributed to transplacental transfer of antibodies that inhibit fetal AChR.

Congenital Myasthenic Syndromes

Congenital myasthenic syndromes (CMS) comprise at least 30 distinct entities, with many recently discovered due to both increased awareness and use of next-generation sequencing methods. The most common and well defined will be considered here.

Children with congenital MG, although rarely encountered, show several characteristics. The mothers are asymptomatic and do not have circulating anti-AChR in the blood. Usually, no problem occurs in the neonatal period; instead, ophthalmoplegia is the dominant sign later in infancy. Limb weakness may be evident. The condition is often familial. Antibodies to AChR are not found, but there are decremental responses to repetitive stimulation. The CMS may be classified according site of pathology: presynaptic, synaptic, postsynaptic.

Presynaptic Congenital Myasthenic Syndromes

Presynaptic CMS results from defects in genes encoding for proteins essential for neuromuscular transmission along the presynaptic nerve terminal membrane. Most common is the choline acetyltransferase deficiency, which prevents the synthesis of ACh. Some infants may be severely hypotonic and apneic at birth, whereas others may be normal at birth but develop sudden and seemingly unprovoked episodes of apnea. Severity of this disease is associated with site of genetic mutation.

SNAP-25B deficiency is due to a defect in initiating formation of synaptic vesicle exocytosis at the endpoint, resulting in reduced number of ACh containing quanta at the nerve terminal with each nerve impulse.

Paucity of synaptic vesicles and reduced quantal release syndrome has not had a genetic defect identified.

Synaptotagmin 2 deficiency affects calcium sensing in the presynaptic nerve terminal.

Synaptic Basal Lamina-Associated Syndromes

Deficiency of acetylcholinesterase at the endplate may be due to mutations in COLQ, which is responsible for anchoring acetylcholinesterase to the basal lamina. Deficiency results in prolonged synaptic currents and action potentials due to increased ACh in the synaptic space. Patients may be severely affected at birth or develop symptoms later on. Weakness may present in a limb-girdle distribution.

Laminin-B2 deficiency results in misalignment of the nerve terminal with the postsynaptic region. This results in reduced quantal release, and other organs may be affected such as the kidney.

Defects in the Acetylcholine Receptor

One of the most common CMS results from defects in the muscle nicotinic AChR. Primary AChR deficiency occurs from different types of mutations, but the end result is that endplate AChR is reduced to approximately 10% of the normal concentration, and the response to ACh in the synapse is significantly reduced. Most patients have ptosis, ophthalmoplegia that becomes fixed, and variable limb weakness.

The slow-channel syndrome results from dominant mutations in the ligand-binding pore of the AChR and results in prolonged synaptic currents and action potentials. This triggers a repetitive compound motor action potential, which is enhanced by edrophonium and a depolarization block on repetitive stimulation. Cervical, scapular and dorsal forearm muscles are often affected and ocular muscles are usually spared.

The fast-channel syndrome is caused by mutations in different domains of the AChR that cause abnormally fast decay of endplate currents and action potentials.

Defects in Postsynaptic Membrane

Defects in the development and maintenance of the endplate have been found in mutations of several postsynaptic genes.

Agrin deficiency or malfunction affects not only AChR clustering and signal transduction but also structural maintenance of the NMJ, which is essential for synapse formation.

LRP4 mutations affect its ability to bind both MuSK and agrin, thus disrupting postsynaptic signal transduction.

MuSK mutations disrupt its function and show extensive remodeling of the endplates. Patients often present with ptosis and respiratory distress at birth and develop weakness in facial, ocular, and limb muscles later.

Dok-7 is an activator of MuSK and many mutations have been identified that inhibit its function and postsynaptic signaling. Patients all demonstrate marked limb-girdle weakness with relative preservation of facial, ocular, and bulbar muscles.

Rapsyn is a protein that anchors the AChR in the postsynaptic membrane and are essential for developing junctional folds and, when mutated, the endplate degenerates. These patients often present in the first year of life, with arthrogryposis and other congenital malformations.

Defects in Glycosylation

Glycosylation affects the solubility, stability, and assembly of peptides. Glycosylated proteins are found at the postsynaptic membrane; thus, NMJ transmission may be compromised by defects in glycosylation. Defects in several glycosylation enzymes were found to cause CMS. On electron microscopy, there are tubular aggregates seen in the sarcoplasmic reticulum, which may be a clue to diagnosis. Defects in GFPT1 result in underdeveloped endplates and suggest hypoglycosylation of postsynaptic proteins such as MuSK, agrin, and dystroglycans. Defects in

DPAGT1 resulted in decrease to 50% of normal of ACh release, postsynaptic ACh response, and AChR concentration.

Other Congenital Myasthenic Syndromes

PREPL deletion syndrome (hypotonia-cystinuria syndrome) results in cystinuria, growth hormone deficiency, muscle weakness, poor feeding, and ptosis. PREPL is essential for filling synaptic vesicles with ACh and thus results in decreased ACh release.

Plectin is a protein that crosslinks intermediate filaments and provides cytoskeletal support. Defects cause a wide variety of syndromes including muscular dystrophy, CMS, and epidermolysis bullosa simplex. In CMS, the junctional folds degenerate with loss of structure and AChR.

Defects in the sodium channel Na1.4 (SCN4A) results in compromised safety margin for NMJ transmission due to fast inactivation and use-dependent inactivation.

Treatment of Congenital Myasthenic Syndromes

Treatment for CMS include cholinergic agonists, drugs which increase the amount of available ACh at the NMJ (pyridostigmine and 3,4-diaminopyridine [3,4-DAP]), open-channel blockers of the AChR ion channel (fluoxetine and quinidine), and β-adrenergic agonists, which stabilize the NMJ and reduce AChR dispersion (salbutamol and ephedrine). Pyridostigmine blocks acetylcholinesterase and thus increases the amount of ACh available for NMJ transmission. 3,4-DAP is a potassium channel blocker on the presynaptic membrane that prolongs the nerve action potential thus increase the release of ACh quanta into the synapse. Both increase the amplitude of the endplate potential and help meet the safety margin for NMJ transmission.

β-Adrenergic agonists are thought to function by stabilizing the NMJ and reducing dispersion of the AChR. Response to treatment is usually over months and even up to a year. Salbutamol and albuterol are the most commonly utilized. Blood pressure should be monitored and laboratory testing for hypokalemia.

Fluoxetine and quinidine are long-lived open-channel blockers of the acetylcholine receptor. These function by keeping the AChR channel in the open state, reducing the opening time of the receptor and is most helpful for the slow-channel syndrome where prolonged channel opening time causes depolarization block (Table 93.7).

TABLE 93.7 Treatment of Congenital Myasthenic Syndromes

Treatment	CMS	Notes
Pyridostigmine 3,4-DAP	ChAT, RAPSN, glycosylation defects, AChR subunit, fast-channel syndrome	**May worsen slow-channel syndrome, COLQ, Dok-7
Salbutamol Albuterol	COLQ, Dok-7, agrin, MuSK, LRP4	Monitor BP and for hypokalemia
Quinidine Fluoxetine	Slow-channel syndrome	**Quinidine-arrhythmias Fluoxetine-may prolong QTc at high doses.

Abbreviations: 3,4-DAP, 3,4-diaminopyridine; AChR, acetylcholine receptor; BP, blood pressure; ChAT, choline acetyltransferase; CMS, congenital myasthenic syndromes; LRP4, LRP4 lipoprotein receptor–related protein 4; MuSK, muscle-specific tyrosine kinase.

DRUG-INDUCED MYASTHENIA GRAVIS

Penicillamine

Until recently, the best example of this condition occurs in patients treated with penicillamine for rheumatoid arthritis, scleroderma, or hepatolenticular degeneration (Wilson disease). The clinical manifestations and AChR antibody titers are similar to those of typical adult MG, but both disappear when drug administration is discontinued. Cases attributed to the anticonvulsant trimethadione have been less thoroughly studied.

Immune Checkpoint Inhibitors

Immune checkpoints are a normal part of the immune system and act to prevent an immune response from being too strong and destroying healthy tissues. Immune checkpoint proteins bind to the surface of T cells and inhibit their function. Two major immune checkpoint proteins are programmed cell death protein 1 (PD-1) and cytotoxic T-lymphocyte–associated protein 4 (CTLA-4). This process can prevent the immune system from destroying cancer cells and thus became a target of investigation for cancer treatment. Since 2011, seven immune checkpoint inhibitors (ICIs) have been approved by the FDA for treatment of cancers: PD-1 inhibitors (pembrolizumab, nivolumab, cemiplimab), programmed cell death-ligand 1 (PD-L1) inhibitors (durvalumab, avelumab, atezolizumab), and cytotoxic T-lymphocyte–associated protein 4 inhibitors (ipilimumab). ICIs were originally developed and approved for metastatic melanoma but are now approved for use in a wide-range of cancers, and their use in treatment is increasing. Despite their promising benefits in treating cancers, serious side effects known as *immune-related adverse events* (irAEs) have developed and can limit treatment. These irAEs can affect numerous different organ systems in the body and cause numerous different neurologic syndromes (thought to affect approximately 1%-3% of patients treated with checkpoint inhibitors), including MG and myositis. Exacerbation of preexisting MG and the development of new-onset MG in patients treated with ICIs has become a well recognized treatment-associated irAE. Clinically, the onset is often acute (within 4 wk of ICI treatment initiation) with rapid deterioration (can be 7 d from MG symptom onset to severe progression), and a majority may have severe muscle weakness with respiratory dysfunction (approximately 45%). AChR antibody titers in patient with prior MG have been shown to increase with ICI treatment, and a significant number were found to have anti-striated antibodies, and many also have elevated creatine kinase. Several cases of concomitant MG and myositis have been reported. Treatment involves cessation of the ICI and aggressive immunotherapy (steroids, IVIG, PE, etc) for MG. There are reports of rechallenge with ICI after recovery from MG in which MG was not precipitated upon rechallenge. Of the ICIs on the market, most have been reported to cause MG and MG/myositis overlap syndromes.

Medications Which may Exacerbate Myasthenia Gravis

Numerous classes of medications can have effects on neuromuscular transmission and thus cause an exacerbation of MG. These include antibiotics (especially aminoglycosides, fluoroquinolones), magnesium and magnesium-containing medications (ie, laxatives, antacids), botulinum toxin, β-blockers and calcium channel blockers, neuromuscular blockers, anesthetics and ICIs.

LAMBERT-EATON MYASTHENIC SYNDROME

Introduction

LEMS is an autoimmune disease of presynaptic NMJ. Antibodies are directed against the P/Q-type voltage-gated calcium channels in peripheral motor nerve terminals (see Fig. 93.1).

Epidemiology

LEMS is rare and found essentially only in adults. A 2017 study of a Veterans Affairs population in the United States confirmed 2.6 cases per 1 million, which is similar to prior studies from the Netherlands. It can be either autoimmune or paraneoplastic. About half of LEMS cases are paraneoplastic, and of these, 80% occur with small cell carcinoma of the lung. The neurologic symptoms almost always precede those of the tumor; the interval may be as long as 5 years. Other tumors have also been implicated, but about 33% of cases are not associated with a tumor. Tumor-free individuals tend to show the HLA-B8 and HLA-DR3 haplotype, which are not found in those with neoplasms.

Pathobiology

The P/Q-type voltage-gated calcium channels on the presynaptic nerve terminal membrane allows the calcium influx in response to nerve impulse, which then triggers ACh quanta release into the synapse, resulting in failure of neuromuscular transmission and muscle weakness. The abnormality of neurotransmission is attributed to inadequate release of ACh from nerve terminals at both nicotinic and muscarinic sites and therefore both neuromuscular weakness and autonomic dysfunction occur in this syndrome. When IgG from affected patients is injected into mice, the number of ACh quanta released by nerve stimulation is reduced, and there is disarray of the active zone particles that can be detected by freeze-fracture ultrastructural analysis.

Purified calcium channel proteins can be directly radiolabeled. An alternative label can be generated by the use of specific ligand, omega-conotoxin, which is prepared from a marine snail (*Conus magus*) and has been used to identify P/Q-type calcium channels in extracts of small cell carcinoma, neuroblastoma, and other neuroendocrine cell lines. A diagnostic test for the autoantibodies is based on radiolabeled preparations, but it is not fully specific. In one series, 92% of 72 patients had a positive reaction. A glial cell nuclear antigen identified in small cell lung carcinoma (SCLC) (a developmental transcription factor) is reactive in 22% of SCLC patients and has been identified in 64% of patients with both LEMS and SCLC but none of those with LEMS alone. This could provide a marker of concurrent SCLC in patients with LEMS. There have been a few positive tests for this antigen in paraneoplastic cerebellar disorders. Some patients have both LEMS and a cerebellar syndrome.

Diagnosis

Clinical Features

LEMS may be suspected in patients with symptoms of proximal limb weakness who have lost knee and ankle jerks and complain of dry mouth or myalgia. Other less common autonomic symptoms include impotence, constipation, and hypohidrosis. LEMS differs clinically from MG because diplopia, dysarthria, dysphagia, and dyspnea are lacking. Autonomic symptoms are more common in LEMS than in MG.

Electrodiagnosis and Laboratory Testing

The disease is defined, and the diagnosis made, by the characteristic incremental response to repetitive nerve stimulation, a pattern that is the opposite of MG. The first evoked potential has an abnormally low amplitude, which decreases even further at low rates of stimulation. At rates greater than 10 Hz, however, there is a marked increase in the amplitude of evoked response (2-20 times the original value) (see Fig. 93.3C). The increment results from facilitation of release of transmitter at high rates of stimulation, which can also be achieved by exercise. At low rates, the number of quanta released per impulse (quantal content) is inadequate to produce endplate potentials that reach threshold. Similar abnormalities are found in preparations exposed to botulinum toxin or to a milieu low in calcium or high in magnesium.

Appropriate search for malignancy should be done in all patients diagnosed with LEMS, including CT chest, and possibly positron emission tomography scan. If initially negative, screening should be repeated in the ensuing years because the LEMS may precede the malignancy.

Some patients with LEMS have ptosis with antibodies to AChR. This combined syndrome may be an example of multiple autoimmune diseases in the same individual.

Management

Treatment is directed to the concomitant tumor in paraneoplastic LEMS. The neuromuscular and autonomic symptoms are treated with drugs that facilitate release of ACh, such as 3,4-DAP and amifampridine. Both improve symptoms in approximately 85% of patients. These two drugs were approved by the FDA in 2018 for the treatment of adults with LEMS (amifampridine) and children aged 6 to 17 years (3,4-DAP) after two phase III clinical trials showed safety and efficacy of 3,4-DAP for LEMS LEVEL 1.[15,16] Seizures may be provoked at high doses and patients with hepatic or renal dysfunction need to be monitored. A combination of pyridostigmine and 3,4-DAP also improves strength and the pyridostigmine can help dry mouth.

Other treatments that may be helpful include PE, IVIG, steroids, and immunosuppressive agents. A small, randomized placebo-controlled crossover trial showed short-term benefit in strength for LEMS patients treated with IVIG, presumably due to the lower levels of circulating antibodies LEVEL 1.[17]

BOTULISM

Epidemiology and Pathobiology

Botulism is a disease in which nearly total paralysis of nicotinic and muscarinic cholinergic transmission is caused by botulinum toxin, which acts on presynaptic mechanisms for release of ACh in response to nerve stimulation. The heavy chain of the toxin mediates binding of the toxin to surface receptors on motor nerve terminals. This allows the toxin molecule to be internalized via endocytosis, and the light chain is then translocated into the cytoplasm. The light chain functions as a zinc-dependent protease that cleaves different components of synaptic vesicles depending on the serotype of the toxin. Botulinum toxin serotypes A and E cleave the SNAP-25 protein; serotype B cleaves synaptotagmin; serotypes B, F and G cleave synaptobrevin. The effect of each of these toxins cleaving different proteins of the synaptic vesicle is to disrupt exocytosis (see Fig. 93.1).

The toxins are produced by spores of clostridial agents. *Clostridium botulinum*, which may contaminate foods grown in soil, produces types A, B, F, and G or in fish, type E; *Clostridium butyricum* produces type E; and *Clostridium barati* produces type F. Intoxication results if contaminated food is inadequately cooked and the spores are not destroyed or if fish are not eviscerated before drying or salt curing. Toxin can be produced in anaerobic wounds that have been contaminated by organisms and spores. Ingestion or inhalation of spores by infants may cause botulism when toxins type A or B are produced in the gastrointestinal tract during periods of constipation. An analogous syndrome occurs in adults with growth of *C botulinum* in the intestine after surgery from gastric achlorhydria or from antibiotic therapy. The toxin does not cause cell death, although it disrupts exocytosis. The effects slowly disappear over several months.

Diagnosis

Clinical Features

Isolated cases in children and adolescents may be thought to be Guillain-Barré syndrome, MG, or even diphtheria. Ptosis has responded to intravenous edrophonium chloride in a few patients, but response to anticholinesterase drugs is neither sufficiently extensive nor sufficiently prolonged to be therapeutic. Infants with botulism are usually younger than 6 months. They show generalized weakness, which is manifested by reduced spontaneous movements, lethargy, poor sucking, and drooling. Sucking and gag reflexes are decreased or absent. There is facial diplegia, ptosis, and ophthalmoparesis.

Laboratory and Electrodiagnostic Testing

Diagnosis is made by the following characteristics: symmetry of signs, dry mouth or absence of saliva, pupillary paralysis, and the characteristic incremental response to repetitive nerve stimulation (see Fig. 93.3C). The Centers for Disease Control and Prevention (with a dedicated emergency 24-h telephone number) or appropriate state laboratories should be notified so that the toxin can be identified in refrigerated samples of serum, stool, or residual food samples. In suspected infantile botulism, feces should be evaluated for the presence of *C botulinum* as well as toxin.

Electrophysiologic evidence of severely disturbed neuromuscular transmission includes an abnormally small single-muscle action potential evoked in response to a supramaximal nerve stimulus. When the synapse is driven by repetitive stimulation at high rates (20-50 Hz), the evoked response is potentiated up to 400% (see Fig. 93.3C). In affected infants, muscle action potentials are unusually brief, of low amplitude, and overly abundant. This is presumably related to involvement of terminal nerve twigs in endings of many motor units. In patients treated for blepharospasm or other movement disorders by intramuscular injections of botulinum toxin, single-fiber EMG shows increased jitter in muscles remote from those injected, and the jitter is maximally increased at low firing rates. These abnormalities are not symptomatic but imply an effect of circulating toxin.

C botulinum toxin is called the *most poisonous poison* (the lethal dose for a mouse is 10^{-12} g/kg body weight). If a patient survives and reaches a hospital, symptoms include dry, sore mouth and throat; blurred vision; diplopia; nausea; and vomiting. Signs include hypohidrosis; total external ophthalmoplegia; and symmetric descending facial, oropharyngeal, limb, and respiratory paralysis. Pupillary paralysis, however, is not invariable. Not all patients are equally affected, suggesting variable toxin intake or variable individual responses. When cases occur in clusters, the diagnosis is usually suspected immediately.

Management

Patients should be treated in intensive care facilities for respiratory care. Specific therapy includes antitoxin (a horse serum product that may cause serum sickness or anaphylaxis), available from the Centers for Disease Control and Prevention, and guanidine hydrochloride, which promotes release of transmitter from residual spared nerve endings but may depress bone marrow. Botulinum immune globulin is given in cases of infant botulism to reduce time on ventilator as well as time in the hospital.

ACKNOWLEDGMENT

The author wishes to recognize the contributions of Lewis P. Rowland (deceased) to previous versions of this chapter.

LEVEL 1 EVIDENCE

1. Palace J, Newsom-Davis J, Lecky B; for Myasthenia Gravis Study Group. A randomized double-blind trial of prednisolone alone or with azathioprine in myasthenia gravis. *Neurology*. 1998;50(6):1778-1783.
2. Myasthenia Gravis Clinical Study Group. A randomised clinical trial comparing prednisone and azathioprine in myasthenia gravis. Results of the second interim analysis. *J Neurol Neurosurg Psychiatry*. 1993;56(11):1157-1163.
3. Meriggioli MN, Ciafaloni E, Al-Hayk KA, et al. Mycophenolate mofetil for myasthenia gravis: an analysis of efficacy, safety, and tolerability. *Neurology*. 2003;61(10):1438-1440.
4. Sanders DB, Hart IK, Mantegazza R, et al. An international, phase III, randomized trial of mycophenolate mofetil in myasthenia gravis. *Neurology*. 2008;71(6):400-406.
5. Muscle Study Group. A trial of mycophenolate mofetil with prednisone as initial immunotherapy in myasthenia gravis. *Neurology*. 2008;71(6):394-399.
6. Tindall RS, Rollins JA, Phillips JT, Greenlee RG, Wells L, Belendiuk G. Preliminary results of a double-blind, randomized, placebo-controlled trial of cyclosporine in myasthenia gravis. *N Engl J Med*. 1987;316(12):719-724.
7. Tindall RS, Phillips JT, Rollins JA, Wells L, Hall K. A clinical therapeutic trial of cyclosporine in myasthenia gravis. *Ann N Y Acad Sci*. 1993;681:539-551.
8. De Feo LG, Schottlender J, Martelli NA, Molfino NA. Use of intravenous pulsed cyclophosphamide in severe, generalized myasthenia gravis. *Muscle Nerve*. 2002;26(1):31-36.
9. Nagane Y, Utsugisawa K, Obara D, Kondoh R, Terayama Y. Efficacy of low-dose FK506 in the treatment of myasthenia gravis—a randomized pilot study. *Eur Neurol*. 2005;53(3):146-150.
10. Pasnoor M, He J, Herbelin L, et al. A randomized controlled trial of methotrexate for patients with generalized myasthenia gravis. *Neurology*. 2016;87:57-64.
11. Gajdos P, Tranchant C, Clair B, et al. Treatment of myasthenia gravis exacerbation with intravenous immunoglobulin: a randomized double-blind clinical trial. *Arch Neurol*. 2005;62(11):1689-1693.
12. Zinman L, Ng E, Bril V. IV immunoglobulin in patients with myasthenia gravis: a randomized controlled trial. *Neurology*. 2007;68(11):837-841.

13. Barth D, Nabavi Nouri M, Ng E, Nwe P, Bril V. Comparison of IVIg and PLEX in patients with myasthenia gravis. *Neurology*. 2011;76(23):2017-2023.
14. Wolfe GI, Kaminski HJ, Aban IB, et al. Randomized trial of thymectomy in myasthenia gravis. *N Engl J Med*. 2016;375(6):511-522.
15. Sanders DB, Juel VC, Harati Y, et al. 3,4-Diaminopyridine base effectively treats the weakness of Lambert-Eaton myasthenia. *Muscle Nerve*. 2018;57(4):561-568.
16. Oh SJ, Shcherbakova N, Kostera-Pruszczyk A, et al. Amifampridine phosphate (Firdapse®) is effective and safe in a phase 3 clinical trial in LEMS. *Muscle Nerve*. 2016;53(5):717-725.
17. Bain PG, Motomura M, Newsom-Davis J, et al. Effects of intravenous immunoglobulin on muscle weakness and calcium-channel autoantibodies in the Lambert-Eaton myasthenic syndrome. *Neurology*. 1996;47(3):678-683.

SUGGESTED READINGS

Beeson D, Higuchi O, Palace J, et al. Dok-7 mutations underlie a neuromuscular junction synaptopathy. *Science*. 2006;313:1975-1978.

Benatar M, Rowland LP. The muddle of mycophenolate mofetil in myasthenia. *Neurology*. 2008;71(6):390-391.

Benatar M, Sanders DB, Wolfe GI, McDermott MP, Rawil R. Design of the efficacy of prednisone in the treatment of ocular myasthenia (EPITOME) trial. *Ann N Y Acad Sci*. 2012;1275:17-22.

Bever CT Jr, Chang HW, Penn AS, Jaffe IA, Eock E. Penicillamine-induced myasthenia gravis: effects of penicillamine on acetylcholine receptor. *Neurology*. 1982;32:1077-1082.

Burke G, Cossins J, Maxwell S, et al. Distinct phenotypes of congenital acetylcholine receptor deficiency. *Neuromuscul Disord*. 2004;14:356-364.

Ciafaloni E, Massey JM. Myasthenia gravis and pregnancy. *Neurol Clin*. 2004;22(4):771-782.

Donaldson JO, Penn AS, Lisak RP, Abramsky O, Brenner T, Schotland DL. Antiacetylcholine receptor antibody in neonatal myasthenia gravis. *Am J Dis Child*. 1981;135:222-226.

Drachman DB, Adams RN, Hu R, Jones RJ, Brodsky RA. Rebooting the immune system with high-dose cyclophosphamide for treatment of refractory myasthenia gravis. *Ann N Y Acad Sci*. 2008;1132:305-314.

Eaton LM, Lambert EH. Electromyography and electric stimulation of nerves in diseases of motor unit: observations on myasthenic syndrome associated with malignant tumors. *J Am Med Assoc*. 1957;163:1117-1124.

Engel AG, Sine SM. Current understanding of congenital myasthenic syndromes. *Curr Opin Pharmacol*. 2005;5:308-321.

Evoli A, Tonali PA, Padua L, et al. Clinical correlates with anti-MuSK antibodies in generalized seronegative myasthenia gravis. *Brain*. 2003;126(pt 10):2304-2311.

Gajdos P, Chevret S, Toyka K. Intravenous immunoglobulin for myasthenia gravis. *Cochrane Database Syst Rev*. 2008;(1):CD002277.

Gronseth GS, Barohn RJ. Practice parameter: thymectomy for autoimmune myasthenia gravis (an evidence-based review): report of the Quality Standards Subcommittee of the American Academy of Neurology. *Neurology*. 2000;55(1):7-15.

Guillermo GR, Téllez-Zenteno JF, Weder-Cisneros N, et al. Response of thymectomy: clinical and pathological characteristics among seronegative and seropositive myasthenia gravis patients. *Acta Neurol Scand*. 2004;109:217-221.

Guptill JT, Sanders DB, Evoli A. Anti-MuSK antibody myasthenia gravis: clinical findings and response to treatment in two large cohorts. *Muscle Nerve*. 2011;44:36-40.

Hoff JM, Daltveit AK, Gilhus NE. Myasthenia gravis: consequences for pregnancy, delivery, and the newborn. *Neurology*. 2003;61:1362-1366.

Howard FM Jr, Lennon VA, Finley J, Matsumoto J, Elveback LR. Clinical correlations of antibodies that bind, block, or modulate human acetylcholine receptors in myasthenia gravis. *Ann N Y Acad Sci*. 1987;505:526-538.

Howard JF Jr, Barohn RJ, Cutter GR, et al. A randomized, double-blind, placebo-controlled phase II study of eculizumab in patients with refractory generalized myasthenia gravis. *Muscle Nerve*. 2013;48:76-84.

Illa I, Diaz-Manera J, Rojas-Garcia R, et al. Sustained response to rituximab in anti-AChR and anti-MuSK positive myasthenia gravis patients. *J Neuroimmunol*. 2008;201-202:90-94.

Jaretzki A, Steinglass KM, Sonett JR. Thymectomy in the management of myasthenia gravis. *Semin Neurol*. 2004;24(1):49-62.

Juel V. Evaluation of neuromuscular junction disorders in the electromyography laboratory. *Neurol Clin*. 2012;30:621-639.

Katzberg HD, Barnett C, Merkies ISJ, Bril V. Minimal clinically important difference in myasthenia gravis: outcomes from a randomized trial. *Muscle Nerve*. 2014;49:661-665.

Kondo K, Monden Y. Thymoma and myasthenia gravis: a clinical study of 1,089 patients from Japan. *Ann Thorac Surg*. 2005;79(1):219-224.

Leite MI, Jacob S, Viegas S, et al. IgG1 antibodies to acetylcholine receptors in 'seronegative' myasthenia gravis. *Brain*. 2008;131(pt 7):1940-1952.

Lindstrom J, Seybold M, Lennon VA, Whittingham S, Duane DD. Antibody to acetylcholine receptor in myasthenia gravis. Prevalence, clinical correlates, and diagnostic value. *Neurology*. 1976;26:1054-1059.

Mantegazza R, Baggi F, Bernasconi P, et al. Video-assisted thoracoscopic extended thymectomy and extended transsternal thymectomy ($T_{-3}b$) in non-thymomatous myasthenia gravis patients: remission after 6 years of follow-up. *J Neurol Sci*. 2003;212(1-2):31-36.

McGrogan A, Sneddon S, de Vries CS. The incidence of myasthenia gravis: a systematic literature review. *Neuroepidemiology*. 2010;34:171-183.

Mehndiratta MM, Pandey S, Kuntzer T. Acetylcholinesterase inhibitor treatment for myasthenia gravis. *Cochrane Database Syst Rev*. 2014;(10):1-17.

Padua L, Stalberg E, LoMonaco M, Batocchi A, Tonali P. SFEMG in ocular myasthenia gravis diagnosis. *Clin Neurophysiol*. 2000;111:1203-1207.

Pasnoor M, He J, Herbelin L, Dimachkie M, Barohn RJ and Muscle Study Group. Phase II trial of methotrexate in myasthenia gravis. *Ann N Y Acad Sci*. 2012;1275:23-28.

Patrick J, Lindstrom J. Autoimmune response to acetylcholine receptor. *Science*. 1973;180:871-872.

Phillips LH II. The epidemiology of myasthenia gravis. *Ann N Y Acad Sci*. 2003;998:407-412.

Pinching AJ, Peters DK, Davis JN. Remission of myasthenia gravis following plasma-exchange. *Lancet*. 1976;308(8000):1373-1376.

Prigent H, Orlikowski D, Letilly N, et al. Vital capacity versus maximal inspiratory pressure in patients with Guillain-Barré syndrome and myasthenia gravis. *Neurocrit Care*. 2012;17:236-239.

Rowland LP, Hoefer PFR, Aranow H Jr. Myasthenic syndromes. *Res Publ Assoc Res Nerv Ment Dis*. 1961;38:548-600.

Rowland LP, Hoefer PF, Aranow H Jr, Merritt HH. Fatalities in myasthenia gravis: a review of 39 cases with 26 autopsies. *Neurology*. 1956;6:307-326.

Ruff RL, Lennon VA. How myasthenia gravis alters the safety factor for neuromuscular transmission. *J Neuroimmunol*. 2008;201-202:13-20.

Sanders DB, El-Salem K, Massey JM, McConville J, Vincent A. Clinical aspects of MuSK antibody positive seronegative MG. *Neurology*. 2003;60:1978-1980.

Silvestri NJ, Wolfe GI. Treatment-refractory myasthenia gravis. *J Clin Neuromuscul Dis*. 2014;15(4):167-178.

Sonett JR, Jaretzki A III. Thymectomy for nonthymomatous myasthenia gravis: a critical analysis. *Ann N Y Acad Sci*. 2008;1132:315-328.

Toyka KV, Brachman DB, Pestronk A, Kao I. Myasthenia gravis: passive transfer from man to mouse. *Science*. 1975;190:397-399.

Vincent A. Autoantibodies in different forms of myasthenia gravis and in the Lambert-Eaton syndrome. *Handb Clin Neurol*. 2008;91:213-227.

Vincent A, McConville J, Farrugia ME, Newsom-Davis J. Seronegative myasthenia gravis. *Semin Neurol*. 2004;24(1):125-133.

Vissing J, Jacob S, Fujita KP, O'Brien F, Howard, JF; and REGAIN Study Group. 'Minimal symptom expression' in patients with acetylcholine receptor antibody-positive refractory generalized myasthenia gravis treated with eculizumab. *J Neurol*. 2020;267(7):1991-2001.

Wolfe GI, Barohn RJ, Foster BM, et al. Randomized, controlled trial of intravenous immunoglobulin in myasthenia gravis. *Muscle Nerve*. 2002;26(4):549-552.

Wolfe GI, Kaminski HJ, Aban IB, et al; for MGTX Study Group. Long-term effect of thymectomy plus prednisone versus prednisone alone in patients with non-thymomatous myasthenia gravis: 2-year extension of the MGTX randomised trial. *Lancet Neurol*. 2019;18:259-268.

Wu JY, Kuo PH, Fan PC, Wu HD, Shih FY, Yang PC. The role of non-invasive ventilation and factors predicting extubation outcome in myasthenic crisis. *Neurocrit Care*. 2009;10:35-42.

Zhang B, Tzartos JS, Belimezi M, et al. Autoantibodies to lipoprotein-related protein 4 in patients with double-seronegative myasthenia gravis. *Arch Neurol*. 2012;69(4):445-451.

94 Inflammatory and Autoimmune Myopathies

Rebecca Traub, Kurenai Tanji, and Christina M. Ulane

KEY POINTS

1. Recent developments in understanding of the pathophysiology of inflammatory myopathies have led to a new classification with five main subtypes: dermatomyositis, antisynthetase syndrome and overlap myositis, immune-mediated necrotizing myopathy, sporadic inclusion body myositis, and polymyositis.
2. Most inflammatory myopathies present with symmetrical proximal limb weakness and variable systemic features, whereas inclusion body myositis can have distal and asymmetrical limb weakness.
3. Cancer and interstitial lung disease can be associated with most inflammatory myopathies and should be screened for.
4. Dermatomyositis is an autoimmune microvasculitis affecting skin, muscle, and sometimes lung; the pathologic hallmarks are perifascicular inflammation and necrosis, with both B- and T-cell infiltrates and immunohistochemical staining for myxovirus resistance protein A positive.
5. Antisynthetase syndrome and overlap myositis are often associated with other autoimmune diseases and interstitial lung disease and pathology reveals T cell predominant inflammation.
6. Immune-mediated necrotizing myopathy can be seen in the context of statin use but can also occur in isolation or with other autoimmune diseases.
7. Immune-mediated necrotizing myopathy is clinically more aggressive, and although pathology shows predominant myonecrosis and less inflammation, aggressive immunotherapy with multiple agents is often required.
8. Sporadic inclusion body myositis is distinct in that it is not responsive to immunotherapy and may be a degenerative disease with secondary inflammatory features.

INTRODUCTION

Myopathies, or disorders of skeletal muscle, are due to a variety of hereditary and acquired causes. Myopathies with genetic underpinnings are discussed in Chapters 97 and 99 and throughout Section 19. Acquired myopathies due to systemic disorders and toxins are the subject of Chapter 96. This chapter focuses on acquired inflammatory and autoimmune myopathies. The focus is on prototypical, noninfectious myositis or idiopathic inflammatory myopathies (IIMs): dermatomyositis (DM), antisynthetase syndrome (ASS) and overlap myositis, inclusion body myositis (IBM), polymyositis (PM), and immune-mediated necrotizing myopathy (IMNM). Of note, true PM has become a rarer entity, and diagnosis of exclusion as most patients formerly characterized as having PM would now be categorized under other subtypes. IBM is included here; however, the lack of response to conventional immunotherapies has promoted the idea that it may not belong among the IIMs. IIMs are heterogenous disorders characterized by muscle inflammation, but frequently display other organ involvement, namely skin, lung, and joints. Distinguishing these disorders from hereditary or toxic myopathies is essential for appropriate management of patients with muscle diseases, which may have similar clinical presentations.

The classification and diagnosis of myositis originally developed by Bohan and Peter in 1975 remains widely used to this day (Table 94.1). Numerous additional classification systems have been proposed over the years to take into account clinical, pathologic, and serologic discoveries. Currently, there are five main subtypes of IIMs that are now widely recognized, which will be discussed here: DM, ASS and overlap myositis, IMNM, PM, and IBM. Subtypes of the IIMs can be distinguished based on clinical features, myositis-specific and myositis-associated antibodies, and histopathologic correlates. Treatment is still largely based on expert opinion, but certain therapies have been shown effective in studies for particular subtypes.

TABLE 94.1 Bohan and Peter Criteria for Myositis[a]

Criterion	Description
Symmetric proximal weakness (over weeks to months)	Neck flexors, limb-girdle musculature
Consistent muscle biopsy findings	Necrosis, regeneration, phagocytosis, atrophy, mononuclear cell infiltrates
Elevated muscle enzymes	Creatine kinase, aldolase, transaminases, lactate dehydrogenase
Electromyographic evidence for myopathy	Muscle fiber irritability (positive sharp waves, fibrillations), short duration, small amplitude, polyphasic motor unit potentials, with spontaneous bizarre high-frequency discharges
Characteristic skin rash	Gottron sign, Gottron papules, heliotrope

[a]Definite polymyositis: four criteria; definite dermatomyositis: three or four criteria plus rash; possible polymyositis: two criteria; possible dermatomyositis: one criterion plus rash.

DERMATOMYOSITIS

Introduction

DM classically consists of characteristic rash and myositis; amyopathic or hypomyopathic forms have also been described.

Epidemiology

DM is rare and exact epidemiologic data is lacking. A recent systematic review and meta-analysis estimates an incidence of approximately 7.98 cases per million per year and a prevalence of 14 per 100,000 (range 2.4-33.8 per 100,000) for all inflammatory myopathies.

DM occurs in all decades of life, with peaks of incidence before puberty and at about age 40 years. In young adults, women are more likely to be affected. Familial cases are rare. Adult cases are associated with an increased risk of malignant neoplasms; most often ovarian, lung, or breast cancer, although others such as nasopharyngeal carcinoma have been reported. Most studies report 15% to 25% of adult DM is associated with malignancy.

Juvenile DM is extremely rare, with estimated incidence of 2 to 5 per 1 million children per year younger than 16 years of age. It much more common in girls than boys (5:1) and essentially never associated with malignancy.

Pathobiology

DM is thought to be an autoimmune disease with vasculopathy of muscle and skin. The antigenic target appears to be the endothelium of intramuscular microvessels, activating complement pathways to cause vascular injury. The loss of capillaries is thought to cause muscle ischemia resulting in myofiber injury and loss. Lymphocytic infiltrates are composed of both B and T cells, as contrasted to the T-cell–predominant inflammatory process of PM and IBM.

Clinical Features

The typical clinical presentation of DM is a combination of proximal limb weakness with characteristic skin findings (Fig. 94.1). The rash may precede weakness by several weeks, but weakness alone is almost never the first symptom. Sometimes, the rash is so typical that the diagnosis can be made even without evidence of myopathy (amyopathic DM). In other cases, weakness may not be evident, but there is electrophysiologic, pathologic, or serum creatine kinase (CK) evidence of myopathy.

Weakness in DM primarily affects the proximal muscles in the arms and legs and may be accompanied by discomfort (myalgias) and tenderness. Patients often describe difficulty going up stairs, standing from a seated position, and lifting arms above the head. Cranial muscles may be involved, causing facial weakness, dysphagia, and esophageal involvement. Neck weakness may occur, causing head drop. Sensation is preserved and reflexes are lost only when the myopathy is severe.

The typical rash is on the face, often on the upper eyelids as a purplish discoloration with edema (heliotrope rash). An erythematous macular rash may be found on the face, neck and chest (V-sign), and upper back (shawl sign). The initial redness may be replaced later by brownish pigmentation. Gottron sign is denoted by red-purple scaly macules on the extensor surfaces of finger joints.

FIGURE 49.1 Common violaceous rashes identified in dermatomyositis. **A:** Linear extensor erythema on the dorsum of the hand. **B:** Heliotrope rash in a periorbital distribution. **C:** Shawl sign over a patient's back. **D:** Holster sign, as seen over the lateral hip.

Subcutaneous calcifications can occur, more often in chronic cases and in pediatric DM. These calcifications may erode through the skin and cause ulceration and secondary infection.

Interstitial lung disease (ILD) may accompany DM, but mainly with anti-melanoma differentiation-associated gene 5 (MDA5) antibodies in which case it is severe. Patients should be questioned about respiratory symptoms and referred for pulmonary evaluation when appropriate. Cardiac involvement can occur, so clinical history should include questions of chest pain, palpitations, and syncope, and cardiac screening is advised.

Juvenile DM presents with a similar rash and proximal weakness.

Diagnosis

DM is a clinical diagnosis aided by muscle and skin biopsy (see the "Muscle Pathology" section later in this chapter), but more recently subtypes can be diagnosed based on myositis-specific antibodies (see **Table 94.1**). There should be elevations in muscle enzymes, including CK and aldolase. Approximately 70% of DM patients will have DM-specific autoantibodies. The anti–Mi-2 antibody is associated with classic DM with significant skin involvement and proximal weakness. Antibodies against nuclear matrix protein (NXP)-2 more often have both proximal and distal weakness, edema, dysphagia, and calcinosis. Patients with either anti–NXP-2 or anti–transcription intermediary factor (TIF)-1 are at higher risk for malignancy. Muscle is moderately involved in patients with anti–Mi-2 and anti–NXP-2 antibodies, whereas there is only mild or no muscle involvement in patients with anti–TIF-1, anti-small ubiquitin-like modifier activating enzyme (SAE), anti-MDA5 antibodies, and seronegative DM. Severe lung and skin involvement is seen in DM with anti-MDA5 antibodies (**Table 94.2**).

Electrodiagnostic testing typically demonstrates normal nerve conduction studies with myopathic findings on electromyogram (EMG) with fibrillations, positive sharp waves, complex repetitive discharges, and sometimes myotonia or waning discharges, suggesting an inflammatory process. Magnetic resonance imaging (MRI) of the muscles can be used to look for evidence of inflammation and direct a target for muscle biopsy.

The differential diagnosis for DM includes the other immune-mediated myopathies, hereditary muscular dystrophies, and toxic myopathies. Clinical features, electrodiagnostic findings, muscle pathology, and genetic testing can help distinguish these entities (see **Table 94.4**).

Once the diagnosis of DM is suspected, testing should include evaluation for underlying malignancy and associated pulmonary fibrosis. Computed tomography of the chest, abdomen, and pelvis is usually sufficient, with the addition of pelvic ultrasound and mammogram in woman, although positron emission tomography may be indicated in some cases.

TABLE 94.2 Dermatomyositis-Specific Antibodies

Autoantibody	Clinical Features
Anti–Mi-2	Moderate muscle involvement, classic skin rash
Anti–NXP-2	Moderate muscle involvement (proximal and distal), classic skin rash, calcinosis, edema, dysphagia, increased risk of malignancy
Anti–TIF-1	Mild muscle involvement, classic skin rash, strong association with malignancy (may include amyopathic DM)
Anti-MDA5	Minimal or no muscle involvement, severe skin involvement, severe ILD
Anti-SAE	Mild muscle involvement with classic skin rash
Seronegative DM	Mild muscle involvement, moderate skin involvement

Abbreviations: DM, dermatomyositis; ILD, interstitial lung disease; MDA5, melanoma differentiation-associated gene 5; NXP-2, nuclear matrix protein-2; SAE, small ubiquitin-like modifier activating enzyme; TIF-1, transcription intermediary factor-1.

Management

Treatment for DM and the other IIMs is similar. The initial treatment for DM is prednisone, typically starting with high dose (60 mg daily or higher) and then tapering slowly over months in conjunction with the addition of steroid-sparing immunomodulating therapies.

The usual first-line steroid-sparing agent used in inflammatory myopathies is methotrexate. Methotrexate can be given orally or subcutaneously (start 7.5 mg/wk, titrate up by 2.5 mg weekly to goal of 10-20 mg weekly; given with folic acid 1 mg daily) with close monitoring of cell counts, hepatic function, and renal function. Because of the risk of pulmonary fibrosis as a complication of methotrexate therapy, it should be avoided in patients with ASS if possible. Another first- or second-line steroid-sparing agent is azathioprine LEVEL 1.[1,2] Azathioprine is started at a low dose (50 mg daily) and slowly increased (goal of 2-3 mg/kg/d), with monitoring of cell counts and hepatic function. Patients should be tested for thiopurine S-methyltransferase enzyme deficiency prior to initiating azathioprine because this can help predict patients at high risk for bone marrow toxicity. In patients with myositis refractory to these agents or with intolerable side effects, second-line options include rituximab (1,000 mg intravenous on days 1 and 15 may be repeated every 24 wk) and intravenous immunoglobulin (IVIG) (doses vary, typically 1-2 g/kg intravenous every 2-4 wk). Rituximab, a monoclonal anti-CD20 antibody, when studied for treatment of DM and PM in a randomized controlled trial, failed to meet the primary outcome measure, but clinical improvement and a significant reduction in steroid dose was seen in all patients receiving the treatment LEVEL 1.[3] A randomized controlled trial of IVIG in treatment-resistant cases of DM showed it to be effective in 9 of 12 cases LEVEL 1.[4] The American Academy of Neurology 2012 guidelines recommend IVIG as a possibly effective therapy for refractory DM. Other medications occasionally used for refractory cases include cyclosporine (starting 2.5 mg/kg daily divided twice a day), tacrolimus (0.075 mg/kg/d divided twice a day), mycophenolate mofetil (starting 500-1,000 mg daily), and cyclophosphamide (doses starting at 300 mg/m^2 every 4 wk). Many of these second- and third-line immunosuppressive medications have significant toxicities and side effects and should be prescribed by specialists familiar with their use. For refractory disease, additional biologic agents that may be considered include abatacept and tocilizumab.

Treatment must include management of associated systemic manifestations, with close coordination between rheumatology, neurology, pulmonology, cardiology, and oncology when appropriate.

Physical therapy, occupational therapy, and low-intensity exercise are generally recommended for all patients with inflammatory myopathies to prevent deconditioning, help with gait training, and improve muscle strength.

Treatment of juvenile DM is similar, and high-dose daily oral prednisone or pulsed intravenous methylprednisolone is considered the gold standard and must be initiated promptly to prevent significant morbidity and mortality. Other steroid-sparing immunosuppressives in those who do not respond to or cannot tolerate steroids including methotrexate and cyclosporine may be used.

ANTISYNTHETASE SYNDROME AND OVERLAP MYOSITIS

Introduction

Overlap myositis and ASS are types of myopathies associated with other autoimmune diseases such as systemic lupus erythematosus (SLE), rheumatoid arthritis, Sjögren syndrome or systemic sclerosis. In terms of the myopathic weakness, the presentation and treatment is similar to DM, absent the typical dermatologic findings of the latter. Overlap myositis and ASS are much more likely to have significant lung involvement compared to DM. Pathologically, these are distinct entities from DM. Treatment is similar to that for DM, but distinguishing these entities is important for monitoring of other organ involvement and cancer risk.

Epidemiology

IIMs as a whole are reported with a prevalence of approximately 14 in 100,000. The percentage of inflammatory myopathies identified as PM vary widely from 2% to over 50% in different series.

Pathobiology

The ASS is most representative of this category and the autoantibodies target the aminoacyl transfer RNA synthetases. It is considered an autoimmune disease of disordered cellular immunity (in contrast to the presumed humoral abnormalities of DM). The antigenic target is not known; however, and the nature of the immunologic aberration is uncertain. Although there is some increased risk of malignancy in association with ASS and overlap myositis, the association is not as high as that seen in DM.

Clinical Features

The myopathy of the overlap myositis and ASS is nonspecific and typically affects proximal limb muscles, similar to DM; patients have difficulty climbing stairs or rising from low seats, lifting packages or dishes, or working with the arms overhead. Weakness of neck muscles may result in head drop. Typically, cranial muscles are spared, although dysphagia can occur when the disease is severe. Respiratory muscles are only rarely affected. Pain, or myalgias, may be present, but sensory symptoms are otherwise absent.

Systemic features associated with overlap myositis and ASS include ILD, arthritis, Raynaud syndrome, fever, and mechanic's hands (hyperkeratotic lesions, which appear as dusky discoloration of the knuckles). Some have rashes similar to those seen in DM. Patients with anti–Jo-1 antibodies have more severe and frequent weakness, whereas anti–PL-12 antibodies are associated with ILD but no muscle involvement, and the most severe ILD is seen in anti–PL-7 and anti–PL-12.

Diagnosis

The diagnosis of ASS and overlap myositis is made in the appropriate clinical setting with a combination of autoantibody testing, electrodiagnostic, and muscle biopsy findings (see "Muscle Pathology" section for the latter). The differential diagnosis includes other inflammatory myopathies, toxic myopathies, and hereditary muscle diseases (see Table 94.4). Motor neuron disease (amyotrophic lateral sclerosis) may be included in the differential diagnosis because of modestly elevated CK levels, although the clinical and electrodiagnostic findings are distinctive in amyotrophic lateral sclerosis.

The electrodiagnostic findings of ASS and overlap myositis are indistinguishable from those in DM. Nerve conduction studies are normal except in the case of severe myopathy, in which case motor compound motor action potential (CMAP) amplitudes may be reduced. Needle EMG shows fibrillations, complex repetitive discharges, and other "inflammatory" findings in combination with myopathic motor unit potentials, which are low amplitude, short duration, polyphasic, and with early recruitment.

Lab testing will demonstrate elevations in serum CK and aldolase as markers of muscle inflammation. Autoantibodies present in ASS and overlap myositis help distinguish subtypes (Table 94.3). Antibody testing may be suggestive of an underlying rheumatologic disorder in overlap myositis, including positive antinuclear antibody or scleroderma antibodies.

As in DM, muscle MRI is sometimes useful in targeting muscle biopsy.

Differential diagnosis is similar to the other inflammatory myopathies (Table 94.4).

Management

Treatment of overlap myositis and ASS is similar to DM. First-line and initial treatment is with high-dose steroids, typically prednisone, with the same consideration for steroid-sparing agents and options for refractory disease as elaborated in the DM treatment section earlier.

TABLE 94.3 Antisynthetase Syndrome and Overlap Myositis Antibodies

Autoantibody	Clinical Features
Antisynthetase Antibodies	
Anti–Jo-1	Moderate muscle involvement, progressive lung involvement
Anti–PL-7	Moderate muscle involvement with severe lung involvement
Anti–PL-12	Mild muscle involvement and severe lung involvement
Overlap Myositis Antibodies	
Anti-PM/Scl	Mild muscle, lung, and skin involvement with features of scleroderma
Anti-Ku	Mild muscle and lung involvement
Anti–U1-RNP	Mild muscle involvement, features of scleroderma and SLE, possible renal involvement

Abbreviations: SLE, systemic lupus erythematosus; U1-RNP, U1 ribonucleoprotein.

TABLE 94.4 Differential Diagnosis of Inflammatory Myopathies

Mimic	Differentiating Characteristics
Dermatomyositis	Associated characteristic rash, specific pathologic findings on muscle biopsy, myositis-specific antibodies
Antisynthetase syndrome	Significant lung involvement, specific muscle pathology, myositis-specific antibodies
Overlap myositis	Associated rheumatologic diagnosis (eg, lupus, rheumatoid arthritis)
Immune-mediated necrotizing myopathy	Specific pathologic findings on muscle biopsy, drug/statin exposure, more resistant to immunosuppressant therapy, specific antibodies
Inclusion body myositis	Slower progression, older age of onset, male precominance, asymmetric and distinct distribution of muscle weakness, specific pathologic findings on muscle biopsy, lack of response to immunosuppressants
Muscular dystrophy	Age of onset, slower progression, family history, specific pathologic findings on muscle biopsy, genetic testing, lack of response to immunosuppressants
Metabolic myopathy	Age of onset, slower progression, family history, pathology, genetic testing, lack of response to immunosuppressants
Fibromyalgia	Prominent pain, no weakness, normal EMG and muscle biopsy
Polymyalgia rheumatica	High ESR/CRP, normal CK, normal EMG

Abbreviations: CK, creatine kinase; CRP, C-reactive protein; EMG, electromyogram; ESR, erythrocyte sedimentation rate.

SPORADIC INCLUSION BODY MYOSITIS

Introduction

IBM is still considered an inflammatory myopathy, although it is quite distinct in clinical features and treatment response. In addition, IBM exhibits unique pathologic features, suggesting that IBM may have dual aspects of inflammatory and degenerative muscle diseases.

Epidemiology

The prevalence of IBM varies from 4.9 per million in the Netherlands to 71 per million in Olmstead County, Minnesota. Both prevalence and incidence increase if restricted to age older than 50 years. There is a 2:1 to 3:1 male predominance, unlike most autoimmune disorders with female predominance. Up to 15% will have an associated autoimmune disease such as lupus, Sjögren syndrome, thrombocytopenia, or sarcoidosis.

Pathobiology

The cause of IBM is unknown, but it is thought to be both autoimmune and neurodegenerative. The inflammatory response in the muscle and acquired nature suggest an immune etiology (see "Muscle Pathology" section). A novel autoantibody has been identified from sera of 50% of patients with IBM that recognized a 43 kDa muscle protein, the cytosolic 5′-nucleotidase 1A (encoded by *NT5C1A*).

Poor responsiveness to immunotherapy suggests a degenerative component of the disease. Histologically, protein aggregates are found in the vacuolated muscle fibers of IBM that are not typically seen in other inflammatory myopathies. These aggregates, which are thought to be accumulation of misfolded proteins, share similar components to those found in other neurodegenerative diseases (see "Muscle Pathology" section).

In contrast to sporadic IBM, *hereditary inclusion body myopathy*, which shares some clinical features and pathologic features with sporadic IBM, is not immune mediated. These genetic disorders are caused by mutations in a number of genes, most often *GNE* and *VCP*, but other genes have been implicated.

Clinical Features

The clinical symptoms of IBM, in its classic form, are distinct from other inflammatory myopathies in the distribution and time course of weakness. The onset of weakness is typically slow, with very gradual progression over the course of years. Many patients will have symptoms for years before diagnosis is established. Muscles first affected are usually proximal legs, with predilection for the quadriceps muscle group, as opposed to other myopathies affecting proximal muscles, which typically have more hip flexor involvement. In the arms, distal muscles tend to be first and more severely affected, with prominent involvement of the finger and wrist flexors in the forearm. Atrophy is often greater than is seen in other inflammatory myopathies and is often asymmetric. Pronounced atrophy and weakness, which can be asymmetric distinguishes IBM from other types of myositis, and is cause for diagnostic confusion with motor neuron disease. Muscle pain (myalgia) is present in approximately 40% of patients. Neck muscles are often involved and can lead to head drop. Dysphagia occurs in half or more of patients, making it a more common symptom in IBM than in other inflammatory myopathies and may be the initial symptom. Rarely, there is involvement of respiratory muscles. Prognosis is for slow progression over years, typically leading to use of wheelchair. Death may occur as complication of respiratory infection or aspiration, but this may be 10 or more years after symptoms begin.

Diagnosis

The diagnosis of IBM is often suspected based on history and physical exam findings, supported by electrodiagnostic studies, but relying on muscle pathology for confirmation (see "Muscle Pathology" section). Lab testing shows mild elevations in CK, up to 15 times the upper limit of normal but may be normal. Antibodies recognizing cytosolic 5′-nucleotidase 1A are found in around 50% of patients with IBM, but up to 5% to 10% of patients with other types of inflammatory myositis and in up to 20% of patients with SLE or Sjögren syndrome. There should be no elevation in erythrocyte sedimentation rate or other inflammatory markers, although there are reports of an association with antinuclear antibody and Sjögren antibodies. Testing should include antibodies for systemic rheumatologic disorders and myositis-specific antibodies.

TABLE 94.5 Differential Diagnosis for Inclusion Body Myositis

Dermatomyositis	Associated skin findings Muscle pathology
Antisynthetase syndrome, overlap myositis, polymyositis	Associated autoantibodies Muscle pathology
Hereditary distal myopathies	Family history Early age of onset Genetic testing
Drug-induced (toxic) myopathies	History of toxic or medication exposure
Motor neuron disease	Upper motor neuron findings Electrodiagnostic testing Muscle biopsy—neurogenic changes
Myasthenia gravis	Ocular and prominent bulbar symptoms Acetylcholine receptor or muscle-specific kinase antibodies Abnormal repetitive stimulation Response to immunotherapy

Electrodiagnostic studies show primarily a myopathic pattern with inflammatory features, similar to that seen in DM and PM. There are fibrillations and abnormal spontaneous activity consistent with an inflammatory process, with short duration and low-amplitude motor unit potentials and early recruitment. In some patients with IBM, however, there is a mixed electrodiagnostic picture, with both short duration and long duration motor unit potentials. These mixed findings on EMG in combination with normal sensory responses can make the diagnosis more challenging and occasionally leads to the misdiagnosis of motor neuron disease in patients with IBM.

Muscle MRI is increasingly being used for diagnosis in inflammatory myopathies, and in IBM, it will show atrophy and/or fatty replacement of muscle with predominant involvement of the anterior thigh muscles.

Given the unique features of IBM, there is a somewhat different differential diagnosis to be considered (**Table 94.5**). There have been a number of diagnostic criteria used to establish the definite or probable diagnosis of IBM for clinical and research use. The most recent of these is the criteria defined in the European Neuromuscular Center workshop in 2011 (Table 94.6).

Management

IBM is notorious for being refractory to the treatments that are effective for other inflammatory myopathies. In some patients, there is an initial response to corticosteroids; however, all will eventually become refractory. Other immunosuppressive agents have not proven to alter the natural course of IBM. A randomized controlled trial of methotrexate showed improved CK levels but no effect on strength. Randomized controlled trials of IVIG with and without steroids also have not shown significant benefits for patients with IBM. Two randomized controlled pilot studies by the Muscle Study Group did not show any benefit for IBM patients treated with interferon. Despite negative trials, some neuromuscular specialists will treat patients with IBM with prednisone, steroid-sparing agents, such as methotrexate or azathioprine, or IVIG on a trial basis based on the observation that a small subset of patients appear to improve or stabilize with regard to muscle strength with treatment, but whether to offer immunotherapy is a controversial topic.

Based on the pathobiologic findings of protein aggregation suggesting a degenerative physiology, several treatments targeting these pathways have been tried. Arimoclomol, which prolongs the activity of heat shock proteins, which in turn prevents protein aggregation, is currently being investigated in a phase II/III trial. Inhibition of myostatin (which is itself an inhibitor of skeletal muscle development) and modulation

TABLE 94.6 Diagnostic Criteria for Inclusion Body Myositis From the European Neuromuscular Center Workshop, 2011[a]

Classification	Clinical Features	Pathologic Features
Clinicopathologically defined IBM	Duration over 12 mo Age at onset older than 45 y Quadriceps weakness greater than hip flexor weakness and/or finger flexor weakness greater than shoulder abductor weakness Serum CK not greater than 15× the upper limit of normal	Endomysial inflammation and rimmed vacuoles and protein accumulation (amyloid or other proteins) Or Filaments 15-18 nm
Clinically defined IBM		One or more of the following: Endomysial inflammation Or increased MHC-1 staining Or rimmed vacuoles Or protein accumulation (amyloid or other proteins) Or filaments 15-18 nm
Probable IBM		One or more of the following: Endomysial exudate Or increased MHC-1 staining Or rimmed vacuoles Or protein accumulation (amyloid or other proteins) Or filaments 15-18 nm

Abbreviations: CK, creatine kinase; IBM, inclusion body myositis; MHC-1, major histocompatibility complex-1.

[a]Adapted from Dimachkie M, Barohn R. Inclusion body myositis. *Neurol Clin*. 2014;32:629-646 and Machado P, Brady S, Hanna MG. Update in inclusion body myositis. *Curr Opin Rheumatol*. 2013;25(6):763-771.

of autophagy are other degenerative pathways under investigation as treatment options.

Given the limited, if any, benefit with immunomodulating therapy for IBM, treatment should focus on symptomatic and supportive therapies to improve quality of life. Low-intensity physical therapy can help with strength and mobility. Falls prevention and gait training are important for preventing complications of worsening weakness. Speech therapy can help in managing dysphagia and preventing aspiration.

IMMUNE-MEDIATED NECROTIZING MYOPATHY

Introduction

IMNM is a distinct type of immune-mediated myopathy that shows on biopsy various degree of myofiber necrosis associated with little or no inflammatory response except for myophagocytosis. IMNM may occur in isolation (with or without anti–signal recognition particle [SRP] antibodies) or in association with statin use (with anti–3-hydroxy-3-methylglutaryl-coenzyme A reductase [HMGCR] antibodies) with certain connective tissue disorders and possibly with malignancies.

Epidemiology

Cases of IMNM in the context of statin use were reported initially in the 1980s, and subsequent case series describe myopathy that progress after statin cessation, with features on biopsy of IMNM and response to immunosuppressant medication. The exact incidence of IMNM is unclear. However, 21% of IMNM is associated with SLE, and in patients with anti-SRP antibodies, most are female, with an average age of onset of 45 years, 65% have comorbid hypertension, 23% have diabetes mellitus, and up to 37% will have ILD. One-third of IMNM cases do not have any myositis-specific antibodies, and these are most often associated with SLE and systemic scleroderma.

Pathobiology

IMNM is characterized by muscle biopsies showing necrosis and degeneration but without the typical inflammatory cell infiltrate seen in DM and PM, despite its autoimmune physiology.

In the case of the statins, there is increased expression of HMGCR on regenerating muscle fibers, which likely triggers and immune response and the subsequent development of anti-HMGCR antibodies. This upregulation persists even after statins have been discontinued, which is presumably why the symptoms continue and even progress after the statin is discontinued. Whether these antibodies are pathogenic or an associated finding is unknown, especially as the target is an intracellular protein. HMGCR is the rate-limiting enzyme in cholesterol synthesis and is the target of statin medications.

Beginning in 1986, antibodies recognizing the SRP on the endoplasmic reticulum membrane were found in association with myopathy. It is also unclear if this antibody is pathogenic because it is too intracellular. However, titers of anti-SRP antibodies and serum CK are found to correlate with one another during treatment.

Clinical Features

Similar to other types of myositis, patients with IMNM present with symmetric proximal weakness over the course of weeks to months. However, in patients with anti-SRP antibodies, the onset may be acute and severe, and 66% to 80% of this group will have myalgias. Anti-SRP myopathy patients can have dyspnea (50%), which may be due to either neuromuscular weakness or lung involvement (13%-22%). Symptoms in statin-related cases can occur at any time in treatment (2 mo to 3 y) but on average, after 3 years of treatment. Symptoms continue or even worsen with cessation of statin and myalgias are a prominent feature (75%). Less commonly, patients can present with HMGCR-positive myopathy in the absence of statin exposure. There are pediatric forms of IMNM, which can mimic muscular dystrophies and must be considered in the differential diagnosis.

Diagnosis

As in other inflammatory myopathies, IMNM is diagnosed with a combination of clinical, lab, and electrodiagnostic features but often relying on muscle pathology to confirm diagnosis (see "Muscle Pathology" section) (Table 94.7).

Serum CK levels are often extremely elevated, usually more than 5,000 U/mL, as in other inflammatory myopathies. Serum can be tested for the presence of anti-SRP and anti-HMGCR antibodies, which are extremely helpful in each case. Patients with anti-SRP myopathy typically do not have any other myositis-specific antibodies. Patients with non-IMNM statin-induced myotoxicity do not have anti-HMGCR antibodies. Anti-SRP antibodies and anti-HMGCR antibodies around found in approximately two-thirds of patients with IMNM. Anti-HMGCR antibodies have been found in patients without prior statin exposure.

Electrodiagnostic testing shows findings similar to that seen in PM and DM with normal nerve conduction studies, unless weakness is severe, in which case CMAP amplitudes may be reduced. There is abnormal spontaneous activity, with fibrillations and other irritable features. Motor unit potentials are myopathic, with short duration and low amplitude, and recruitment is early.

Muscle MRI shows findings similar to other inflammatory myopathies, with muscle edema, atrophy, and fatty replacement. MRI is sometimes helpful in targeting muscle biopsy.

Differential diagnosis is similar to the other inflammatory myopathies (see Table 94.4).

TABLE 94.7 Immune-Mediated Necrotizing Myositis Antibodies

Antibodies in Immune-Mediated Necrotizing Myopathy	
Anti-SRP	Severe muscle involvement with dysphagia, mild lung involvement
Anti-HMGCR	Severe muscle involvement, can be associated with statin exposure
Seronegative immune-mediated necrotizing myopathy	Associated with cancer

Abbreviations: HMGCR, 3-hydroxy-3-methylglutaryl-coenzyme A reductase; SRP, signal recognition particle.

Management

Treatment of IMNM relies on both discontinuing any toxic trigger for the disease process (ie, stopping statins) when implicated. Although typical statin-induced myopathy will improve after discontinuation of the medication, the course of IMNM is of worsening weakness despite stopping the triggering medication. Immunosuppressive treatment is necessary to address the underlying autoimmune pathophysiology in IMNM. Most patients respond to corticosteroids. Other steroid-sparing agents, which have been used with success, include methotrexate, azathioprine, mycophenolate mofetil, rituximab, and IVIG.

POLYMYOSITIS

With the advancement of the understanding of the different autoantibodies and clinical syndromes associated with myositis, most cases of PM can now be classified as having ASS, IBM, or one of the other types of defined myositis. True PM is likely rare and is a diagnosis of exclusion of other types of myositis.

MUSCLE PATHOLOGY

Dermatomyositis

Muscle biopsy in DM shows perimysial, and particularly perivascular, inflammation often composed of a mixed population including macrophages, $CD4^+$ and $CD8^+$ T cells, B lymphocytes, and plasmacytoid dendritic cells. The extent and the degree of inflammation, however, can vary greatly from patient to patient. Except in cases of amyopathic DM, necrotic/degenerative or regenerating fibers are found across the biopsy sections or in a perifascicular pattern. The endomysial capillary density may be significantly reduced. Immunohistochemically, major histocompatibility complex (MHC) class I immunoreactivity is ubiquitous or with a perifascicular predominance, and there is variable MHC class II expression. Immune complexes containing immunoglobulin G, immunoglobulin M, and complement, especially the membrane attack complex (MAC) can be found deposited in the microvessels. In conjunction with the discovery of the distinct effect of interferon type 1 on the microvasculature and muscle in DM, the recognition of sarcoplasmic immunohistochemical staining with the antibody against myxovirus resistance protein A, a key mediator of the interferon-induced antiviral response, has been found to be useful for distinction between DM and ASS (including anti–Jo-1 myopathy). Ultrastructurally, endothelial cells of affected microvessels may show necrosis, swelling, or reactive/degenerative changes. Reactive/degenerative endothelial cells may exhibit tubuloreticular structures that appear closely related to endoplasmic reticulum and are thought to reflect interferon type 1 exposure (Fig. 94.2).

Antisynthetase Syndrome

Antisyntetase syndromes such as anti–Jo-1, anti-OJ, and anti–PL-7–associated myopathy can show similar histologic features to those in DM such as perifascicular patterns of myocyte injury and perimysial inflammation. $CD8^+$ cytotoxic T cells can be more abundant in ASS than in DM, and plasma cells are seen. In typical cases, interstitial connective tissue is markedly fragmented, and perimysial staining of alkaline phosphatase is observed. Immunohistochemically, besides MHC class I positivity, MHC class II is often expressed in a unique perifascicular fashion, and sarcolemmal staining of MAC is seen also among nonnecrotic perifascicular fibers. Unlike DM, immunoreactions of myxovirus resistance protein A antibody are generally absent. Ultrastructurally, nuclear actin aggregation has been reported as a hallmark of ASS.

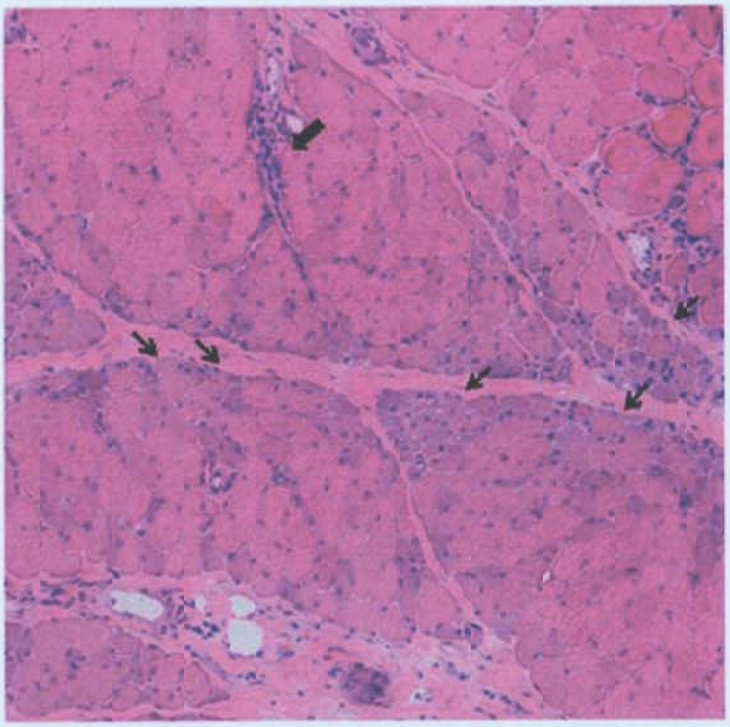

FIGURE 94.2 Muscle pathology in dermatomyositis. Perivascular inflammation *(large arrow)* and perifascicular pattern *(small arrows)* of myocyte injury. (Hematoxylin and eosin stain, ×200 magnification.)

Polymyositis and Inclusion Body Myositis

PM and IBM histologically share certain features including fiber necrosis and regeneration, and inflammatory infiltration mainly in the endomysium, predominantly consisting of T cells with a large subset of $CD8^+$ cytotoxic cells and macrophages/histiocytes. Occasionally, cytotoxic T cells invading into nonnecrotic appearing sarcoplasm can be captured using immunohistochemical staining for CD8. In IBM, myeloid dendritic cells and plasma cells also appear in the inflammatory infiltrates. Typically, PM and IBM immunohistochemically reveal ubiquitous MHC class I upregulation, whereas often in IBM, patchy or scattered MHC class II expression is observed as well. It is noted that IBM tends to show on biopsy a greater degree of chronic myopathic histoarchitectural changes than PM: markedly increased fiber size variation and endomysial fibrosis may

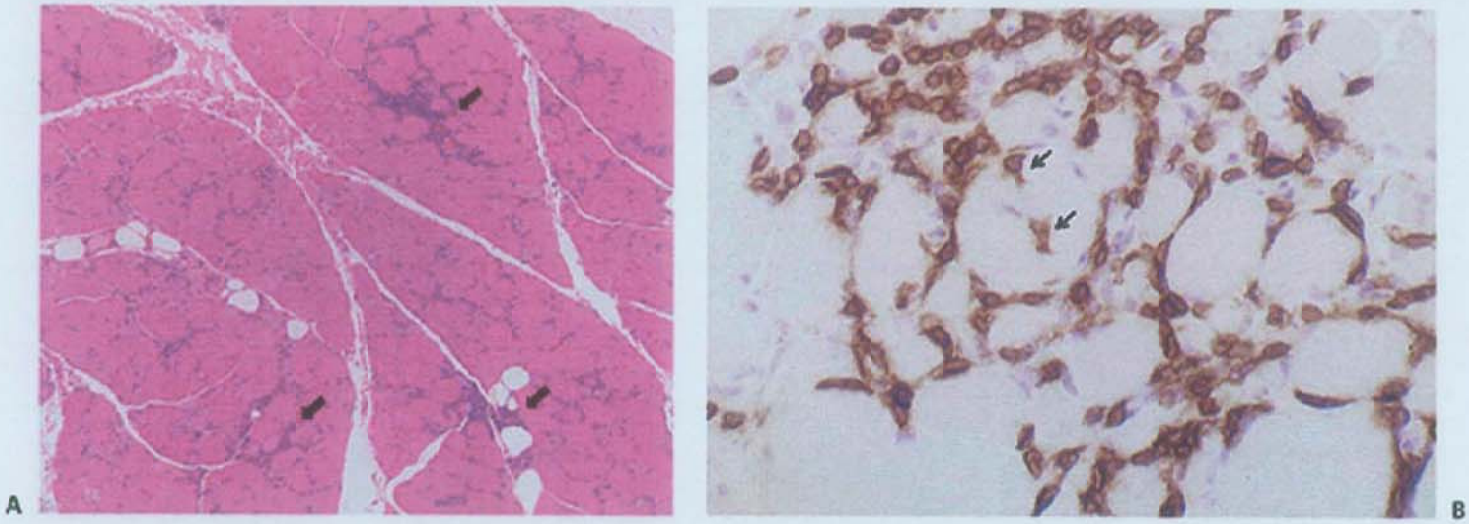

FIGURE 94.3 Muscle pathology in polymyositis. **A:** Endomysial lymphocytic infiltration *(arrows)* (hematoxylin and eosin stain, ×200 magnification). **B:** Cytotoxic T-cell infiltrate invading myofibers *(arrows)* (immunohistochemical staining for CD8, ×400 magnification).

be observed along with amyloid-laden rimmed vacuole formation. Often, mitochondrial abnormalities are recognized by ragged red and/or cytochrome C oxidase deficient fibers. Intravacuolar amyloid deposition can be well visualized by the fluorescence microscopic examination using rhodamine. The scientific premise of intracellular protein aggregates and faulty proteostasis in IBM has prompted supplemental immunostaining using the antibodies against, for example, β-amyloid, phosphorylated tau, TAR DNA–binding protein 43, ubiquitin, and p62. As no single protein is, however, proven to be solely pathogenic for vacuole formation in IBM, the detection of p62 (a marker of autophagy) immunoreactivity, combined with MHC class I immunoexpression and endomysial T-cell infiltration, are thought to be most informative to establish the morphologic diagnosis of IBM with high specificity and sensitivity (Figs. 94.3 and 94.4).

Immune-Mediated (Autoimmune) Necrotizing Myopathy

IMNM shows scattered necrotic myofibers associated with phagocyte (macrophage) infiltration. Typically, there is little T-lymphocytic infiltration; yet, this may be seen in a subset of cases. In severe cases, especially in younger patients, the disease may progress and become chronic, in which case the muscle biopsy may reveal similar features to those of muscular dystrophy. Immunohistochemically, MHC class I is variably expressed on nonnecrotic/nonregenerating fibers, and MAC deposition can occur on the sarcolemma of nonnecrotic fibers. Morphologic features on muscle biopsy cannot further subclassify the type of IMNM; therefore, serologic testing is required to distinguish antibody-associated IMNM such as anti-SRP and anti-HMG IMNM from seronegative cases (Fig. 94.5).

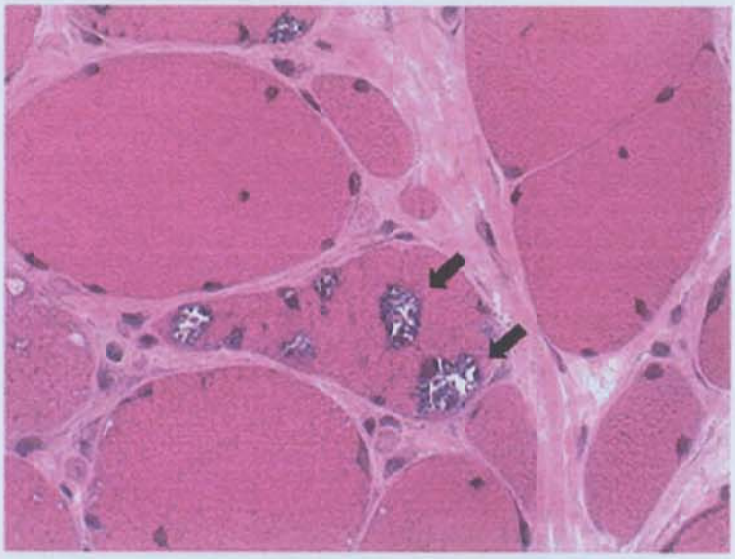

FIGURE 94.4 Muscle pathology in inclusion body myositis. Rimmed vacuoles *(arrows)*. (Hematoxylin and eosin stain, ×400 magnification.)

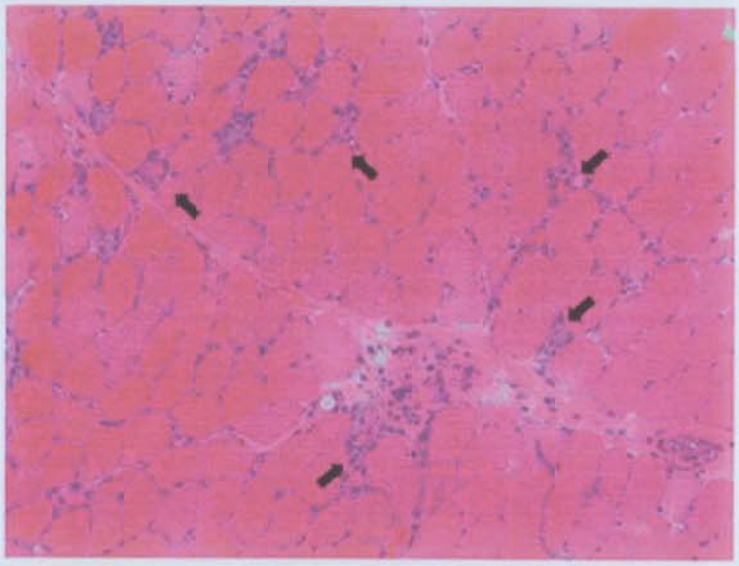

FIGURE 94.5 Muscle pathology in necrotizing autoimmune myopathy. Necrotic myofibers with minimal inflammation *(arrows)*. (Hematoxylin and eosin stain, ×200 magnification.)

LEVEL 1 EVIDENCE

1. Bunch TW. Prednisone and azathioprine for polymyositis: long-term followup. *Arthritis Rheum*. 1981;24:45-48.
2. Bunch TW, Worthington JW, Combs JJ, Ilstrup DM, Engel AG. Azathioprine with prednisone for polymyositis. A controlled, clinical trial. *Ann Intern Med*. 1980;92:365-369.
3. Oddis CV, Reed AM, Aggarwal R, et al; and Rituximab in Myositis (RIM) Study Group. Rituximab in the treatment of refractory adult and juvenile dermatomyositis and adult polymyositis: a randomized, placebo-phase trial. *Arthritis Rheum*. 2013;65:314-324.
4. Dalakas MC, Illa I, Dambrosia JM, et al. A controlled trial of high-dose intravenous immune globulin infusions as treatment for dermatomyositis. *N Engl J Med*. 1993;329:1993-2000.

SUGGESTED READINGS

Inflammatory Myopathies (General)

Dalakas MC. Inflammatory muscle diseases. *N Engl J Med*. 2015;372:1734-1747.

Ibrahim F, Choy E, Gordon P, et al. Second-line agents in myositis: 1-year factorial trial of additional immunosuppression in patients who have partially responded to steroids. *Rheumatology (Oxford)*. 2015;54:1050-1055.

Mariampillai K, Granger B, Amelin D, et al. Development of a new classification system for idiopathic inflammatory myopathies based on clinical manifestations and myositis-specific autoantibodies. *JAMA Neurol*. 2018;75(12):1528-1537.

McGrath ER, Doughty CT, Amato AA. Autoimmune myopathies: updates on evaluation and treatment. *Neurotherapeutics*. 2018;15:976-994.

Nalotto L, Iaccarino L, Zen M, et al. Rituximab in refractory idiopathic inflammatory myopathies and antisynthetase syndrome: personal experience and review of the literature. *Immunol Res*. 2013;56:362-370.

Oddis CV, Aggarwal R. Treatment in myositis. *Nat Rev Rheumatol*. 2018;14:279-289.

Selva-O'Callaghan A, Pinal-Fernandez I, Trallero-Araguás E, Milisenda JC, Grau-Junyent JM, Mammen AL. Classification and management of adult inflammatory myopathies. *Lancet Neurol*. 2018;17:816-828.

Dermatomyositis

Bendewald MJ, Wetter DA, Li X, Davis MD. Incidence of dermatomyositis and clinically amyopathic dermatomyositis: a population-based study in Olmsted County, Minnesota. *Arch Dermatol*. 2010;146:26-30.

Bohan A, Peter JB. Polymyositis and dermatomyositis (first of two parts). *N Engl J Med*. 1975;292:344-347.

Bohan A, Peter JB. Polymyositis and dermatomyositis (second of two parts). *N Engl J Med*. 1975;292:403-407.

Engel AG, Hohlfeld R. The polymyositis and dermatomyositis syndromes. In: Engel AG, Franzini-Armstrong C, eds. *Myology*. 3rd ed. New York, NY: McGraw-Hill; 2004:1321-1388.

Uruha A, Nishikawa A, Tsuburaya RS, et al. Sarcoplasmic MxA expression: a valuable marker of dermatomyositis. *Neurology*. 2017;88:493-500.

Antisynthetase Syndrome and Overlap Myositis

Marie I, Josse S, Hatron PY, et al. Interstitial lung disease in anti-Jo-1 patients with antisynthetase syndrome. *Arthritis Care Res (Hoboken)*. 2013;65:800-808.

Witt LJ, Curran JJ, Strek ME. The diagnosis and treatment of antisynthetase syndrome. *Clin Pulm Med*. 2016;23:218-226.

Inclusion Body Myositis

Badrising UA, Maat-Schieman ML, Ferrari MD, et al. Comparison of weakness progression in inclusion body myositis during treatment with methotrexate or placebo. Ann Neurol. 2002;51:369-372.

Benveniste O, Guiguet M, Freebody J, et al. Long-term observational study of sporadic inclusion body myositis. *Brain*. 2011;134:3176-3184.

Dalby R, Lange DJ, Trojaborg W, et al. Inclusion body myositis mimicking motor neuron disease. *Arch Neurol*. 2001;58:1253-1256.

Dalakas MC, Koffman B, Fujii M, Spector S, Sivakumar K, Cupler E. A controlled study of intravenous immunoglobulin combined with prednisone in the treatment of IBM. Neurology. 2001;56:323-327.

Dalakas MC, Sonies B, Dambrosia J, Sekul E, Cupler E, Sivakumar K. Treatment of inclusion-body myositis with IVIg: a double-blind, placebo-controlled study. Neurology. 1997;48:712-716.

Dimachkie MM, Barohn RJ. Inclusion body myositis. *Neurol Clin*. 2014;32:629-646.

Greenberg SA. Inclusion body myositis: clinical features and pathogenesis. *Nat Rev Rheumatol*. 2019;15:257-272.

Muscle Study Group. Randomized pilot trial of high-dose betaINF-1a in patients with inclusion body myositis. Neurology. 2004;63:718-720.

Larman HB, Salajegheh M, Nazareno R, et al. Cytosolic 5′-nucleotidase 1A autoimmunity in sporadic inclusion body myositis. *Ann Neurol*. 2013;73:408-418.

Naddaf E, Barohn RJ, Dimachkie MM. Inclusion body myositis: update on pathogenesis and treatment. *Neurotherapeutics*. 2018;15:995-1005.

Pluk H, van Hoeve BJ, van Dooren SH, et al. Autoantibodies to cytosolic 5′-nucleotidase 1A in inclusion body myositis. *Ann Neurol*. 2013;73:397-407.

Immune-Mediated Necrotizing Myopathy

Allenbach Y, Benveniste O. Acquired necrotizing myopathies. *Curr Opin Neurol*. 2013;26:554-560.

Ellis E, Ann Tan J, Lester S, et al. Necrotizing myopathy: clinicoserologic associations. *Muscle Nerve*. 2012;45:189-194.

Kassardjian CD, Lennon VA, Alfugham NB, Mahler M, Milone M. Clinical features and treatment outcomes of necrotizing autoimmune myopathy. *JAMA Neurol*. 2015;72:996-1003.

Mammen AL, Chung T, Christopher-Stine L, et al. Autoantibodies against 3-hydroxy-3-methylglutaryl-coenzyme A reductase in patients with statin-associated autoimmune myopathy. *Arthritis Rheum*. 2011;63:713-721.

Mammen AL, Tiniakou E. Intravenous immune globulin for statin-triggered autoimmune myopathy. *N Engl J Med*. 2015;373:1680-1682.

Miller T, Al-Lozi MT, Lopate G, Pestronk A. Myopathy with antibodies to the signal recognition particle: clinical and pathological features. *J Neurol Neurosurg Psychiatry*. 2002;73:420-428.

Mohassel P, Mammen AL. Anti-HMGCR myopathy. *J Neuromuscul Dis*. 2018;5:11-20.

Pinal-Fernandez I, Casal-Dominguez M, Mammen AL. Immune-mediated necrotizing myopathy. *Curr Rheumatol Rep*. 2018;20(4):21. doi:10.1007/s11926-018-0732-6.

Pinal-Fernandez I, Parks C, Werner JL, et al. Longitudinal course of disease in a large cohort of myositis patients with autoantibodies recognizing the signal recognition particle. *Arthritis Care Res (Hoboken)*. 2017;69:263-270.

Suzuki S, Nishikawa A, Kuwana M, et al. Inflammatory myopathy with anti-signal recognition particle antibodies: case series of 100 patients. *Orphanet J Rare Dis*. 2015;10:61.

95 Critical Illness Myopathy and Neuropathy

Ahmad Riad Ramadan, Michio Hirano, and Louis H. Weimer

KEY POINTS

1. Critical illness myopathy (CIM) and critical illness polyneuropathy (CIP) are among the most common causes of intensive care unit–acquired weakness and failure to wean patients from mechanical ventilation.
2. The main risk factors for CIM are nondepolarizing neuromuscular blocking agents and corticosteroids use. For CIP, they are sepsis and multiorgan failure.
3. Loss of thick filaments seen on electron microscopy is a hallmark of CIM. Increased nerve microvasculature permeability has been linked to CIP.
4. Intensive insulin therapy (target blood glucose 80-110 mg/dL) has been shown to reduce the incidence of CIP and CIM.
5. Limiting use of corticosteroids and paralytics, treatment of sepsis, and early physical therapy are cornerstones of the treatment of CIP and CIM.
6. Patients with CIM tend to have a faster and more complete recovery than patients with CIP.

INTRODUCTION

Although critically ill individuals in intensive care units (ICUs) are typically weak due to their severe medical illnesses, a subgroup of patients develops critical illness myopathy (CIM), critical illness polyneuropathy (CIP), or both. The first case of acute quadriplegic myopathy (later renamed CIM) was reported in 1977 by MacFarlane and Rosenthal in a 24-year-old woman who received high-dose corticosteroids for status asthmaticus. In 1984, Bolton and colleagues described five critically ill patients with sepsis and multiorgan failure who developed severe sensorimotor peripheral neuropathies. Since then, hundreds of patients with CIM and CIP have been reported. Together, these disease entities represent two of the most common etiologies of failure to liberate patients from mechanical ventilation in the ICU.

EPIDEMIOLOGY

Although incidence rates of CIM and CIP vary in reported series based on patient populations and detection methods, the disorders appear frequently common in the ICU setting. In one report, about 25% of patients in the ICU developed weakness, whereas electrophysiologic studies have detected neuromuscular abnormalities in up to 84% of patients. Among patients with sepsis or systemic inflammatory response syndrome, the incidence has been estimated to be 70% and virtually 100% in patients with septic shock or sepsis plus coma. In one study, up to a third of all patients receiving mechanical ventilation for at least 4 to 7 days manifested signs of CIP/CIM. In most case series, the incidence of CIM has been greater than CIP; however, some patients manifest both, an overlap condition referred to as *critical illness polyneuromyopathy* (CIPNM).

PATHOBIOLOGY

For CIM, corticosteroids, nondepolarizing neuromuscular blocking agents, or both are considered the prime inciting factors, but it has appeared in some individuals who received neither agent. Patients undergoing treatment for status asthmaticus, organ transplantation, and severe trauma seem to be particularly vulnerable. Female gender was found to be independently linked to the development of CIPNM. In contrast, for CIP, sepsis, systemic inflammatory response syndrome, and multiorgan failure are risk factors. Other factors that may contribute to CIM and CIP include severity of the illness, duration of ICU stay, duration of organ dysfunction, renal failure, hyperosmolarity, hyperglycemia, and vasopressor and catecholamine supportive treatment.

Pathophysiologic mechanisms responsible for these conditions are not fully understood. Loss of myosin is a hallmark of the more traditional form of CIM and can be appreciated as selective rarefaction of the thick filaments on electron microscopy. In patients with CIM, direct muscle stimulation has shown a loss of muscle fiber excitability, which has been attributed to voltage-gated sodium channel fast inactivation, based on animal models of steroid-treated denervated muscle as well as biopsied muscle. Enhanced expression of ubiquitin, lysosomal enzymes, and calcium-activated proteases (calpains) has been observed in muscle and could play a pathogenic role. These catabolic pathways may be activated in muscle by induction of transforming growth factor-β/mitogen-activated protein kinase pathways. Immune activation by cytokines may also contribute to the myopathy.

Although direct evidence is lacking, CIP has been attributed to microcirculation defects including increased vessel permeability and vasodilation leading to the axonal degeneration. Peripheral nerve biopsies from CIP patients have revealed expression of E-selectin in the vascular endothelium of epineural and endoneurial vessels. Because E-selectin is not normally expressed in vascular endothelium, its presence may increase nerve microvasculature permeability, which would allow circulating neurotoxins to enter the endoneurium and promote endoneurial edema.

TABLE 95.1 Major Characteristics of Critical Illness Myopathy and Critical Illness Polyneuropathy

	Critical Illness Myopathy	Critical Illness Polyneuropathy
Clinical features	Weakness, typically diffuse including respiratory muscles. Muscle atrophy is common.	Distal limb weakness and sensory loss with diminished or absent tendon reflexes. Respiratory muscle weakness is common.
Risk factors	Treatment with corticosteroid, nondepolarizing neuromuscular blocking agent, or both	Sepsis, systemic inflammatory response syndrome, multiorgan failure
Nerve conduction study and electromyography abnormalities	Myogenic abnormalities	Neurogenic abnormalities with signs of acute denervation
Muscle biopsy findings	Myofiber atrophy predominantly affecting type 2 fibers. Loss of thick (myosin) filaments is characteristic but is not always seen.	Signs of acute denervation
Treatment	Reduce exposure to corticosteroids and nondepolarizing neuromuscular blocking agents.	Intensive insulin treatment to maintain normal blood glucose levels

DIAGNOSIS

Clinical Manifestations

In CIM, severe quadriplegia and muscle atrophy commence 4 to more than 100 days after initiation of intensive care therapy. The weakness may be primarily distal or proximal but is usually diffuse; many patients lose tendon reflexes. Ophthalmoparesis and facial muscle weakness are occasionally present. Persistent respiratory muscle weakness complicates weaning patients from mechanical ventilation. Improvement is generally evident in 1 to several months in most individuals who survive their critical illness, but protracted recovery or persistent deficits are common.

CIP presents as acute distal limb weakness and sensory loss with diminished or absent tendon reflexes. Involvement of the phrenic and intercostal nerves causes respiratory muscle weakness that often requires prolonged mechanical ventilation therapy (Table 95.1). Autonomic failure and pupillary changes are not expected manifestations of CIP or CIM.

Diagnosis of CIM and CIP is typically suspected when patients have unexplained severe limb weakness, inability to wean patients off mechanical ventilation, or both. Marked muscle atrophy is common in CIM, whereas areflexia and stocking-glove sensory loss (in alert patients) are characteristics of CIP. CIM and CIP must be distinguished from the persistent weakness that may follow administration of nondepolarizing blocking agents to a person with impaired hepatic metabolism, reduced renal excretion, or both.

Laboratory Testing and Electrophysiology

In patients with CIM, serum creatine kinase levels are usually normal but can be elevated in the acute necrotizing subtype of CIM. Nerve conduction studies demonstrate absent or low-amplitude compound motor action potentials with decreased duration and polyphasia. Sensory nerve action potentials are usually normal in CIM, but they can be reduced or absent due to coexisting neuropathy or technical constraints in the ICU environment such as interference from surrounding devices, hypothermia, or limb edema. Electromyography variably shows signs of denervation from muscle necrosis and myogenic or normal motor unit action potentials; however, motor unit and recruitment analysis are frequently suboptimal owing to severe weakness, encephalopathy, sedation, or other confounding factors. Direct muscle stimulation has shown a loss of muscle fiber excitability. Increased insertional activity in the form of fibrillation potentials, positive sharp waves, or both is seen in most cases of CIM.

In CIP, nerve conduction studies typically show signs of axonopathy with decreased or absent sensory nerve action potentials and compound motor action potentials with mildly reduced conduction velocities; these changes may appear as early as 72 hours after ICU admission and can precede clinical manifestations. Electrophysiologic studies of the peroneal nerve have been proposed as a rapid and sensitive diagnostic test for CIP. Electromyography shows fibrillations and positive sharp waves due to acute denervation, which can be difficult to distinguish acute muscle necrosis.

Muscle Biopsy

Muscle biopsies in CIM demonstrate myopathic changes. Three distinct histologic features have been described in skeletal muscle biopsies; the abnormalities may be present in isolation or in variable combinations. Muscle fiber atrophy, often more prominent in type 2 fibers, is routinely seen. In patients with markedly elevated creatine kinase levels, necrosis of muscle fibers has been observed. The most striking feature revealed by electron microscopy is loss of thick (myosin) filaments, corroborated by antimyosin-antibody stains and reduced myosin messenger RNA levels but is not seen in many cases.

Muscle biopsies in CIP can show signs of acute denervation and reinnervation. Nerve biopsies are generally not useful in CIP, which typically manifests nonspecific signs of axonal neuropathy affecting both motor and sensory nerves; however, if other forms of peripheral neuropathy (eg, vasculitis or chronic inflammatory demyelinating polyneuropathy) are suspected, then nerve biopsies may be indicated.

MANAGEMENT

Treatment of patients with CIM and CIP is primarily directed at the underlying acute medical condition(s). Supportive care, particularly mechanical ventilation, is important. Because corticosteroids and neuromuscular blocking agents appear to trigger CIM, reducing exposure to these agents is generally recommended. Venous thromboembolism prophylaxis and pressure ulcer prevention are central to the care of patients with CIM and CIP.

Two randomized trials of ICU patients have demonstrated that intensive insulin treatment aimed at maintaining normal glucose levels reduces the incidence of CIP and CIM by nearly half (relative risk, 0.65; 95% confidence interval, 0.55-0.77) as well as duration of mechanical ventilation and 180-day mortality compared to conventional insulin treatment LEVEL 1.[1,2] Immune modulation is currently being investigated in the treatment of ICU-acquired weakness. So far, intravenous immunoglobulin has not shown benefit in a randomized controlled trial. Physical therapy to passively stretch muscles may reduce muscle atrophy and may increase functional independence. In one randomized controlled trial, electrical muscle stimulation was shown to improve muscle strength and reduce the duration of weaning from mechanical ventilation in patients with CIPNM

OUTCOME

Both CIM and CIP cause prolonged and often severe disability. The weakness can persist for months to years or even indefinitely. About 28% of patients with CIP, CIM, or both may not recover ability to ambulate independently or wean completely off ventilation. CIP is more likely to cause permanent disability than CIM. The majority of patients with CIM recover in 3 to 6 months. Of those patients with CIP who completely recover, most will do so within 6 to 12 months, with a quarter recovering between 12 and 24 months.

LEVEL 1 EVIDENCE

1. Van den Berghe G, Schoonheydt K, Becx P, Bruyninckx F, Wouters PJ. Insulin therapy protects the central and peripheral nervous system of intensive care patients. *Neurology*. 2005;64:1348-1353.
2. Hermans G, Wilmer A, Meersseman W, et al. Impact of intensive insulin therapy on neuromuscular complications and ventilator dependency in the medical intensive care unit. *Am J Respir Crit Care Med*. 2007;175:480-489.

SUGGESTED READINGS

Allen DC, Arunachalam R, Mills KR. Critical illness myopathy: further evidence from muscle-fiber excitability studies of an acquired channelopathy. *Muscle Nerve*. 2008;37:14-22.

Apostolakis E, Papakonstantinou NA, Baikoussis NG, Papadopoulos G. Intensive care unit-related generalized neuromuscular weakness due to critical illness polyneuropathy/myopathy in critically ill patients. *J Anesth*. 2015;29:112-121.

Argov Z, Latronico N. Neuromuscular complications in intensive care patients. *Handb Clin Neurol*. 2014;121:1673-1685.

Bird SJ. Diagnosis and management of critical illness polyneuropathy and critical illness myopathy. *Curr Treat Options Neurol*. 2007;9:85-92.

Bolton CF, Gilbert JJ, Hahn AF, Sibbald WJ. Polyneuropathy in critically ill patients. *J Neurol Neurosurg Psychiatry*. 1984;47:1223-1231.

Brunner R, Rinner W, Haberler C, et al. Early treatment with IgM-enriched intravenous immunoglobulin does not mitigate critical illness polyneuropathy and/or myopathy in patients with multiple organ failure and SIRS/sepsis: a prospective, randomized, placebo-controlled, double-blinded trial. *Crit Care*. 2013;17(5):R213.

Coakley JH, Nagendran K, Yarwood GD, Honavar M, Hinds CJ. Patterns of neurophysiological abnormality in prolonged critical illness. *Intensive Care Med*. 1998;24:801-807.

De Jonghe B, Sharshar T, Lefaucheur JP, et al. Paresis acquired in the intensive care unit: a prospective multicenter study. *JAMA*. 2002;288:2859-2867.

De Letter MA, van Doorn PA, Savelkoul HF, et al. Critical illness polyneuropathy and myopathy (CIPNM): evidence for local immune activation by cytokine-expression in the muscle tissue. *J Neuroimmunol*. 2000;106:206-213.

Di Giovanni S, Molon A, Broccolini A, et al. Constitutive activation of MAPK cascade in acute quadriplegic myopathy. *Ann Neurol*. 2004;55:195-206.

Fenzi F, Latronico N, Refatti N, Rizzuto N. Enhanced expression of E-selectin on the vascular endothelium of peripheral nerve in critically ill patients with neuromuscular disorders. *Acta Neuropathol*. 2003;106:75-82.

Goodman BP, Harper CM, Boon AJ. Prolonged compound muscle action potential duration in critical illness myopathy. *Muscle Nerve*. 2009;40:1040-1042.

Guarneri B, Bertolini G, Latronico N. Long-term outcome in patients with critical illness myopathy or neuropathy: the Italian multicentre CRIMYNE study. *J Neurol Neurosurg Psychiatry*. 2008;79:838-841.

Helliwell TR, Wilkinson A, Griffiths RD, McClelland P, Palmer TE, Bone JM. Muscle fibre atrophy in critically ill patients is associated with the loss of myosin filaments and the presence of lysosomal enzymes and ubiquitin. *Neuropathol Appl Neurobiol*. 1998;24:507-517.

Hermans G, De Jonghe B, Bruyninckx F, Van den Berghe G. Interventions for preventing critical illness polyneuropathy and critical illness myopathy. *Cochrane Database Syst Rev*. 2014;(1):CD006832.

Hirano M, Ott BR, Raps EC, et al. Acute quadriplegic myopathy: a complication of treatment with steroids, nondepolarizing blocking agents, or both. *Neurology*. 1992;42:2082-2087.

Koch S, Spuler S, Deja M, et al. Critical illness myopathy is frequent: accompanying neuropathy protracts ICU discharge. *J Neurol Neurosurg Psychiatry*. 2011;82:287-293.

Koch S, Wollersheim T, Bierbrauer J, et al. Long-term recovery in critical illness myopathy is complete, contrary to polyneuropathy. *Muscle Nerve*. 2014;50:431-436.

Kraner SD, Novak KR, Wang Q, Peng J, Rich MM. Altered sodium channel-protein associations in critical illness myopathy. *Skelet Muscle*. 2012;2:17.

Lacomis D, Petrella JT, Giuliani MJ. Causes of neuromuscular weakness in the intensive care unit: a study of ninety-two patients. *Muscle Nerve*. 1998;21:610-617.

Latronico N, Tomelleri G, Filosto M. Critical illness myopathy. *Curr Opin Rheumatol*. 2012;24:616-622.

MacFarlane IA, Rosenthal FD. Severe myopathy after status asthmaticus. *Lancet*. 1977;2:615.

Matsuda N, Kobayashi S, Tanji Y, Hasegawa A, Tase C, Ugawa Y. Widespread muscle involvement in critical illness myopathy revealed by MRI. *Muscle Nerve*. 2011;44:842-844.

Minetti C, Hirano M, Morreale G, et al. Ubiquitin expression in acute steroid myopathy with loss of myosin thick filaments. *Muscle Nerve*. 1996;19:94-96.

Routsi C, Gerovasili V, Vasileiadis I, et al. Electrical muscle stimulation prevents critical illness polyneuromyopathy: a randomized parallel intervention trial. *Crit Care*. 2010;14(2):R74.

Segredo V, Caldwell JE, Matthay MA, Sharma MA, Gruenke LD, Miller RD. Persistent paralysis in critically ill patients after long-term administration of vecuronium. *N Engl J Med*. 1992;327:524-528.

Tennilä A, Salmi T, Pettilä V, Roine RO, Varpula T, Takkunen O. Early signs of critical illness polyneuropathy in ICU patients with systemic inflammatory response syndrome or sepsis. *Intensive Care Med*. 2000;26:1360-1363.

Trojaborg W, Weimer LH, Hays AP. Electrophysiologic studies in critical illness associated weakness: myopathy or neuropathy—a reappraisal. *Clin Neurophysiol*. 2001;112:1586-1593.

Weber-Carstens S, Deja M, Koch S, et al. Risk factors in critical illness myopathy during the early course of critical illness: a prospective observational study. *Crit Care*. 2010;14:R119.

Weber-Carstens S, Schneider J, Wollersheim T, et al. Critical illness myopathy and GLUT4: significance of insulin and muscle contraction. *Am J Respir Crit Care Med*. 2013;187:387-396.

Witt NJ, Zochodne DW, Bolton CF, et al. Peripheral nerve function in sepsis and multiple organ failure. *Chest*. 1991;99:176-184.

Zink W, Kollmar R, Schwab S. Critical illness polyneuropathy and myopathy in the intensive care unit. *Nat Rev Neurol*. 2009;5:372-379.

Endocrine and Toxic Myopathies 96

Christina M. Ulane

KEY POINTS

1. Thyroid disorders and corticosteroid abnormalities (most often from exogenous sources) are the most common endocrinopathies associated with myopathy.
2. Weakness patterns due to corticosteroids used in autoimmune neuromuscular disorders, such as myasthenia gravis, can overlap with the underlying condition.
3. Workup involves identifying underlying conditions as well as creatine kinase and electromyography.
4. Toxic myopathies are an important consideration, either due to environmental exposures such as alcohol or as a side effect of medications, particularly statins and certain chemotherapeutics.

INTRODUCTION

Muscle comprises a large proportion of all tissues in the body, and the energy required for its function renders it susceptible to metabolic abnormalities from endocrine dysfunction and toxic effects of medications and environmental exposures. Muscle tissue is affected by the metabolic and trophic effects of various components of the endocrine system and by direct and indirect effects of toxins. With the rapid development of new treatments for a wide variety of diseases, particularly the immune checkpoint inhibitors used in cancer, new causes for toxic myopathies arise. This chapter highlights features of the most common endocrinopathies and toxins affecting muscle, concisely reviews the many others, and emphasizes the fundamental principles in diagnosis and treatment of these disorders.

ENDOCRINE MYOPATHIES

Epidemiology

Myopathy in endocrine disorders is rather common, but the earlier diagnosis and treatment of endocrinopathies has reduced the severity of myopathic symptoms. Thyroid disorders and corticosteroid abnormalities (most often from exogenous sources) are the most common endocrinopathies encountered and thus discussed in most detail. Exogenous corticosteroid administration at doses of 30 mg or more per day of prednisone confers the highest risk.

Neuromuscular symptoms in hypothyroidism are reported to be found in up to 80% of patients. Historical studies suggest that up to 75% of patients with hyperthyroidism will experience myopathy, but current data regarding incidence of true myopathy in endocrinopathies is not available, likely a result of earlier diagnosis and treatment. Myopathy is also found in association with acromegaly, hypopituitarism, hyperparathyroidism, and hypoparathyroidism.

Pathobiology

The exact basis of myopathy in endocrinopathy is unknown and may be multifactorial. Often, weakness and fatigue are out of proportion to muscle wasting, suggesting energy failure as a mechanism. Thyroxine has catabolic effects on muscle, may reduce efficiency of muscle contraction, alter membrane excitability and lead to reduced potassium in muscle and serum, leading to weakness in hyperthyroidism. Hypothyroidism reduces glycogenolysis (animal studies indicate this occurs via reduced expression of β-adrenergic receptors on muscle cells), which may be responsible for cramps and fatigue. Hypothyroidism can also reduce mitochondrial oxidation, and studies in rats demonstrate changes in myosin from fast-twitch to slow-twitch muscle types. Thyroid-associated ophthalmopathy leads to edema in the extraocular muscles from both glycoprotein accumulation and inflammation. Corticosteroids cause muscle catabolism and stimulate protein degradation.

Diagnosis

Clinical Features

Myopathy from endocrine disorders causes nonspecific symptoms of myopathy. Proximal limb weakness, fatigue, and cramps are common. In some cases, myalgias are present. In corticosteroid myopathy, symptoms may occur as early as after a few weeks of treatment. See **Table 96.1** for clinical features of thyroid-associated myopathies and **Table 96.2** for other endocrine-associated myopathies, including that due to exogenous corticosteroid administration.

Diagnostic Testing

Other features related to specific endocrine disorders are usually apparent and suggest the diagnosis (see **Tables 96.1** and **96.2**). However, if corticosteroids are being used for the treatment of a disease that also causes weakness (such as inflammatory myositis or myasthenia gravis), it can be challenging to determine whether progression of the underlying disorder or the corticosteroid treatment is the cause of weakness. Laboratory testing for serum levels of thyroid function, adrenocorticotrophic hormone, cortisol, metabolic panel, parathormone, and growth hormone can be diagnostic. Serum creatine kinase (CK) and electrolyte levels are helpful in many cases.

Electromyography (EMG) testing may be normal but will often show myopathic abnormalities and, occasionally, signs of irritative myopathy. Muscle biopsy may be required to distinguish other underlying causes, but findings in endocrine

TABLE 96.1 Myopathies Associated With Thyroid Disorders

Disorder	Clinical	Diagnostics	Treatment
Hypothyroidism	• Muscle stiffness, pain, and cramps, especially with cold and exercise • Delayed relaxation (pseudomyotonia) • May have associated sensorimotor polyneuropathy • Can result in rhabdomyolysis • Associated with fatigue, weight gain, cold intolerance, constipation, dry skin, bradycardia	• TSH is elevated; free T_3 and T_4 are low. • CK normal or elevated up to 10× normal • EMG: normal or myopathic, +/− fibrillations, positive sharp waves • Biopsy: normal or nonspecific changes such as type 2 fiber atrophy • Rarely due to central hypothyroidism: normal TSH but low free T_4	• T_4 supplementation (Start 25-50 μg daily, increase to 1.6 μg/kg/d, and monitor TSH.)
Hyperthyroidism	• May be acute or insidious in onset • Proximal weakness, wasting (shoulder girdle, scapular winging) • May involve respiratory, bulbar, or distal muscles • Ophthalmopathy with Graves disease • Associated with anxiety, tremor, palpitations, weight loss, heat intolerance, tachycardia	• CK is normal (except in thyroid storm). • EMG: normal or myopathic in proximal muscles • Biopsy: nonspecific, type 1 and 2 fiber atrophy	• Correction of T_4 levels to normal (antithyroid medications, radioactive iodine, thyroidectomy) • Weakness may take months to resolve. • Propranolol (start 10 mg 3 times a day-4 times a day; may increase to 40 mg 4 times a day) may hasten recovery.
Thyrotoxic periodic paralysis	• Severe weakness lasting hours to days, precipitated by cold, exercise, or high-carbohydrate intake, insulin or β-agonists (causing hypokalemia) • Associated with hyperthyroid state • More common in men from Japan and China	• Potassium levels low during attacks • +/− Low magnesium or phosphorus • Associated HLA haplotypes	• Correction of thyroid abnormality • Potassium supplementation as needed • Propranolol (start 10 mg 3 times a day-4 times a day; may increase to 40 mg 4 times a day) may prevent attacks.
Thyroid ophthalmopathy	• Exophthalmos, pain, diplopia • May have compressive optic neuropathy • Mostly occurs with hyperthyroidism (sometimes with hypothyroidism, euthyroidism)	• Edema of extraocular muscles on MRI	• Correction of thyroid abnormality • Guanethidine eye drops (β-adrenergic) • Local steroid injection • Systemic steroids (prednisone 30-100 mg orally daily for at least 4 wk followed by taper or methylprednisolone 500 mg IV for one dose followed by 250 mg IV weekly) • Selenium 100 mg twice a day for 6 mo

Abbreviations: CK, creatine kinase; EMG, electromyography; HLA, human leukocyte antigen; IV, intravenous; MRI, magnetic resonance imaging; T_3, triiodothyronine; T_4, thyroxine; TSH, thyroid-stimulating hormone.

myopathies are usually nonspecific. Please see Tables 96.1 and 96.2 for laboratory, EMG, and muscle biopsy findings in various endocrine myopathies.

Management

Treatment is directed at correcting the underlying endocrine abnormality, through hormone replacement therapy or by reducing circulating hormone levels. In the case of hyperthyroid myopathy, propranolol may improve time to recovery through β-adrenergic blockade. If exogenous corticosteroids are the cause for myopathy, treatment of the disease for which the steroids are indicated must be balanced with reducing the contribution of steroids to the myopathy. Several strategies can be helpful, including alternate-day dosing and the use of steroid-sparing agents when possible (see Tables 96.1 and 96.2).

Outcome

Most persons with endocrinopathy causing myopathy will recover completely with correction of the underlying abnormality. Rarely, in Cushing disease, recovery may be incomplete.

TOXIC MYOPATHIES

Epidemiology

Toxic myopathies arise from environmental exposures and increasingly often from medications (Table 96.3). The large number of people prescribed statin medications makes this potentially myotoxic agent a commonly encountered clinical problem. Up to 20% of people taking statins will experience myalgias or cramps, and asymptomatic CK elevation occurs in up to 5% of patients treated with statins. Symptom onset is most commonly within the first 6 months of statin use but may occur at any time. It is important to note that 30% to 50% of patients taking statins who experience myalgias have another possible cause for the myalgias. Most statin myotoxicity is mild and self-limited; however, severe necrotizing myopathy can occur in rare cases. Only about 0.08% of patients taking lovastatin, simvastatin, or pravastatin were found to develop severe myopathy with pain and proximal weakness. Certain statins pose greater risk (atorvastatin, simvastatin, and pravastatin), whereas others are associated with lower risk (fluvastatin, rosuvastatin) for toxicity. In 2001, cerivastatin was withdrawn from

TABLE 96.2 Myopathies Associated With Other Endocrinopathies

Disorder	Clinical	Diagnostics	Treatment
Cushing disease/ exogenous corticosteroid administration	• Painless proximal weakness (legs affected more than arms) • +/− Muscle wasting • Fluorinated corticosteroids more likely to cause myopathy (triamcinolone, betamethasone, dexamethasone)	• CK is normal. • EMG: may be normal or show myopathic features • Biopsy: type 2 fiber atrophy; increased glycogen	• Treat underlying Cushing etiology, but recovery may be slow or incomplete. • Reduce exogenous steroid dose to minimum possible. • Alternate-day steroid dosing • Use of nonfluorinated corticosteroids • Use of steroid-sparing agents
Adrenal insufficiency	• General weakness • Fatigue, cramps	• CK is normal. • EMG: normal • Biopsy: nonspecific	• Glucocorticoid replacement. Hydrocortisone 5 mg/m^2 total daily; given twice a day with two-thirds of dose in AM and one-third in PM
Acromegaly	• Slowly progressive proximal weakness and pain • Decreased exercise tolerance • Minimal muscle wasting • Associated carpal tunnel syndrome, radiculopathies	• CK is normal or mildly elevated. • EMG: +/− myopathy • Biopsy: hypertrophy or atrophy of type 1 and 2 fibers, excess lipofuscin, glycogen	Correction of excess GH: • Bromocriptine: Start 1.25-1.5 mg daily; increase to 20-30 mg daily. • Pituitary adenoma resection • Irradiation
Hyperparathyroidism	• Generalized weakness, stiffness • Proximal weakness, wasting (especially legs) • Tongue fasciculations • +/− Hyperreflexia • Encephalopathy, hallucinations • Chronic renal failure (secondary hyperparathyroidism)	• CK is normal. • Hypercalcemia, hypophosphatemia, hypomagnesemia • EMG: +/− myopathic • Biopsy: nonspecific	• Parathyroidectomy
Osteomalacia	• Proximal weakness and myalgias	• CK is normal or mildly elevated. • EMG: myopathic • Biopsy: nonspecific	• Vitamin D supplementation (50,000 units vitamin D_2 or D_3 weekly for 6 wk and then 800 units D_3 daily) • Supplementation as needed: calcium 1,000 mg daily and phosphorus 30-80 mmol total daily given 3 times a day or 4 times a day.

Abbreviations: CK, creatine kinase; EMG, electromyography; GH, growth hormone.

the market in connection with cases of fatal rhabdomyolysis. Rhabdomyolysis due to statins is rare, with an incidence of 2 to 3 per 100,000 patient-years.

Myotoxicity from statin use is increased in patients with obesity, preexisting hepatic or renal disease, hypothyroidism, and advanced age. There is also a dose-dependent myotoxic effect: For patients on simvastatin, 1.6% show symptoms on 80 mg/d versus 0.1% on 20 mg/d. Risk of statin myotoxicity is increased with concomitant use of medications that inhibit cytochrome P450 3A4 (*CYP3A4*) pathway, which affects statin metabolism. In particular, statin use with gemfibrozil or cyclosporine significantly increases the risk of statin toxicity. Use of other medications metabolized by the *CYP3A4* pathway (such as calcium channel blockers, antibiotics, antidepressants, and antiretrovirals) can increase serum levels of statins and thus the risk of myotoxicity.

Genome-wide association studies identified a single nucleotide polymorphism in the *SLCO1B1* gene that predisposes to statin-induced myopathy. This gene encodes a protein involved in the hepatic uptake of statins, and persons homozygous for the polymorphism (2% of the general population) have increased serum levels of statins and 15% develop self-limited statin myopathy (not the immune-mediated necrotizing myopathy).

Immune checkpoint inhibitors have emerged recently as an etiology for myotoxicity, with unclear incidence but overall immune-related neurologic events are estimated to occur in up to 2.9% of patients treated with anti–program cell death protein 1 (PD-1) inhibitors.

Pathobiology

Toxins cause myopathy either by directly affecting the muscle or indirectly through electrolyte imbalance or triggering immune reactions. Various types of pathophysiology account for toxic myopathies (see Table 96.3). Toxins may induce necrotizing myopathy, as with alcohol and statins. Autophagic lysosomal pathology is seen with amphiphilic agents such as chloroquine and amiodarone. Colchicine and vincristine-induced myopathy through antimicrotubular effects. Many agents can cause an inflammatory myopathy. Antiretroviral agents lead to mitochondrial myopathy, and diuretics and laxatives among others cause hypokalemic myopathy. Self-limited statin myotoxicity likely is due to muscle membrane destabilization secondary to reduced levels of lipid precursors, vitamin D, dysfunction of mitochondrial electron transport, and coenzyme Q10 production (Fig. 96.1). Statins may cause a severe toxic necrotizing myopathy, or an immune-mediated necrotizing myopathy associated with anti-HMGCR antibodies and upregulation of complement membrane attack complex (MAC) and major histocompatibility complex class 1 (*MHC-1*) receptors on biopsied nonnecrotic muscle fibers. The immune-mediated necrotizing myopathy caused by statins is discussed in detail in Chapter 94.

Immune checkpoint inhibitors act by targeting the mechanisms used by cancer to evade the immune response and result in upregulation of the immune system. This in turn causes diverse off-target immune-related adverse events affecting many different organ systems including neurologic effects such as neuropathy, encephalopathy, meningitis, and myositis/myasthenia gravis.

TABLE 96.3 Toxic Myopathies

Pathophysiology	Medications/Toxins and Associated Features
Necrotizing[a]	Statins[c] • Severe toxic necrotizing myopathy or immune-mediated necrotizing myopathy: associated with anti-HMGCR antibodies, upregulation of *MHC-1* and MAC on nonnecrotic fibers on muscle biopsy Other cholesterol-lowering agents (fibrates, red yeast rice)[c] Immunophilins • Cyclosporine[c] • Tacrolimus Ethanol Labetalol, propofol (rare) Snake venom
Amphiphilic (autophagic lysosomal)	Chloroquine/hydroxychloroquine[c] • Often with polyneuropathy • May have associated cardiomyopathy • Correlates with duration of use and dose • Vacuoles on muscle biopsy Amiodarone • Often with polyneuropathy • Also causes hypothyroidism, tremor, ataxia • Vacuoles on muscle biopsy
Antimicrotubular	Colchicine[c] • Often with polyneuropathy • Vacuoles on muscle biopsy Vincristine
Hypokalemic	Diuretics Laxatives Amphotericin Toluene Licorice Corticosteroids • Normal EMG • Type 2 fiber atrophy on muscle biopsy Ethanol • Normal EMG • Type 2 fiber atrophy on muscle biopsy
Mitochondrial[b]	Zidovudine Other antiretrovirals
Inflammatory	Immune checkpoint inhibitors (often myositis with myasthenia gravis) L-tryptophan D-penicillamine Phenytoin Lamotrigine Interferon-α Hydroxyurea Imatinib (20%-50% will have myalgias) Tumor necrosis factor inhibitors Cimetidine (rare; with interstitial nephritis)
Unknown/other	Omeprazole Levetiracetam Finasteride Isotretinoin Emetine Febuxostat

Abbreviations: EMG, electromyography; HMGCR, 3-hydroxy-3-methylglutaryl coenzyme A reductase.
[a]May be acute in onset and painful.
[b]Ragged red/blue fibers on muscle biopsy.
[c]May exhibit myotonic discharges on EMG.

Diagnosis

Clinical Features

Symptoms of toxic myopathies are nonspecific, and clinical presentation may be diverse. Proximal weakness is common, with or without associated pain. Rarely are the respiratory and bulbar muscles affected. In general, myopathy due to drugs is infrequent, and thus, a high index of suspicion is essential to identify the connection. Depending on the drug, dose, and patient characteristics, the symptoms may vary from mild (cramps and myalgias) to severe (necrotizing myopathy with weakness, rhabdomyolysis). Although most patients will exhibit symptoms shortly after beginning a medication, in others, symptoms may develop more insidiously over time, and thus, causality can be difficult to establish.

Myositis from immune checkpoint inhibitors begins early (often within a month) after therapy initiation and can occur with cytotoxic T-lymphocyte-associated protein 4 (CTLA-4), PD-1, or programmed death-ligand 1 (PD-L1) inhibitors. Proximal weakness and occasionally bulbar and respiratory involvement are seen; there is also overlap with myasthenia gravis (CK levels can help distinguish).

Diagnostic Testing

History and temporal correlation with medication use are crucial in determining whether a toxin is the cause of myopathy. Resolution of symptoms following withdrawal of the potentially offending agent is helpful in diagnosis.

Laboratory studies including CK, metabolic panel, hepatic function testing, thyroid function testing, and vitamin D can not only assist in diagnosis but also aid in identifying readily correctable abnormalities that may worsen myopathy. EMG may show myopathic findings. In rare instance, a muscle biopsy may be necessary, and on occasion, a myotoxic medication may identify an underlying metabolic or hereditary myopathy.

Management

Most often, removal of exposure to the offending agent will reduce or resolve myopathy completely. In the case of statin-associated immune-mediated necrotizing myopathy, ongoing immunosuppressive treatment is needed (see Chapter 94). Results are mixed as to whether supplementation with coenzyme Q10 is beneficial for statin-associated myopathy. Vitamin D supplementation is recommended only for those with laboratory evidence of deficiency, and it is unclear if it is helpful in the absence of deficiency. The high prevalence of dyslipidemia and ensuing statin use suggests a tiered approach to the treatment of statin-associated myopathy (Table 96.4). The American College of Cardiology provides an online tool called the *ACC's Statin Intolerance Tool* to help risk stratify and clarify whether a patient is truly intolerant of a statin or whether treatment modifications can be made. There is also the "Statin-Associated Muscle Symptom Clinical Index," which can help clinicians assess the likelihood that a patient's muscle symptoms are due to statin use.

Outcome

Prognosis for toxic myopathies depends on the etiology and specific syndrome. In general, withdrawal of the offending agent results in resolution or significant improvement of myopathy.

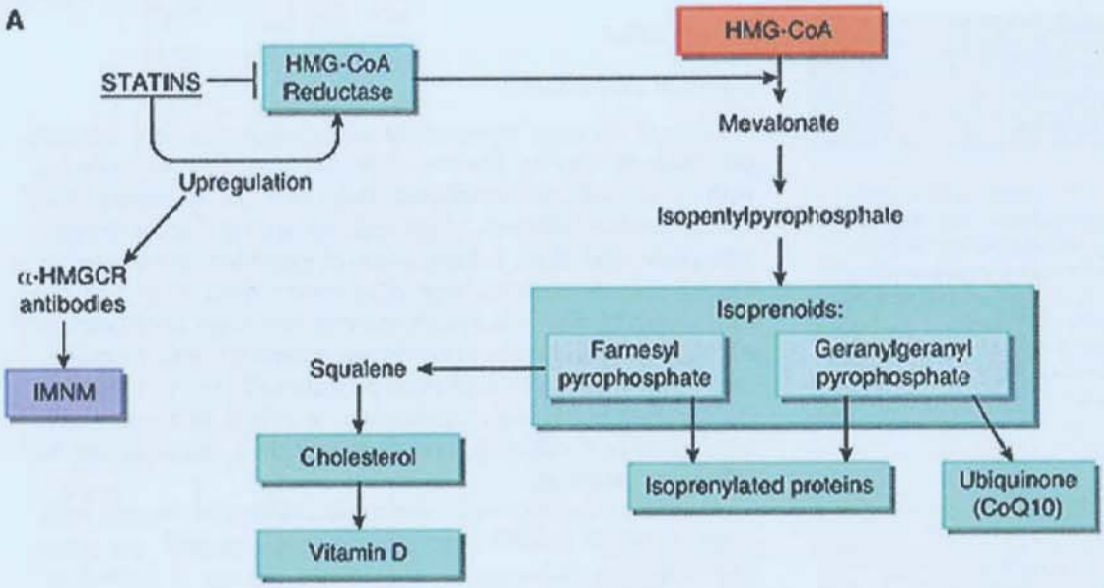

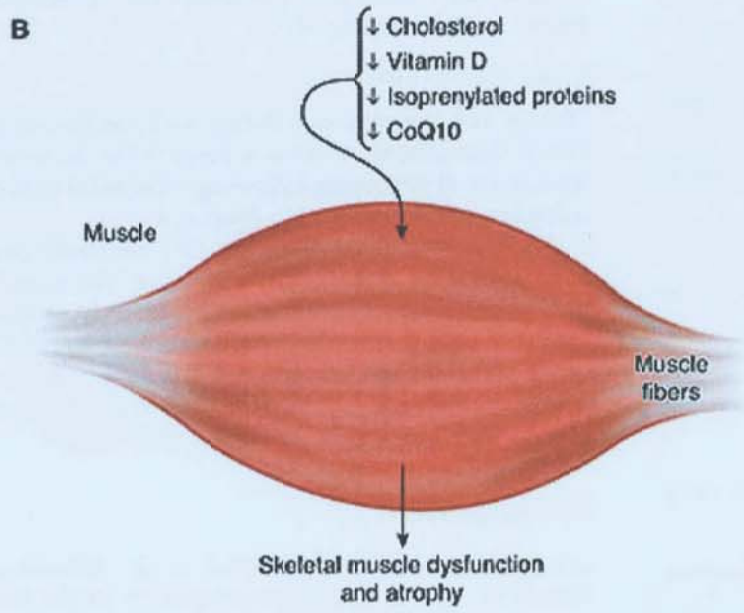

FIGURE 96.1 **A:** Simplified schematic for cholesterol synthesis, the generation of isoprenylated proteins and coenzyme Q10 (CoQ10) and the role of statins (β-hydroxy β-methylglutaryl-coenzyme A [HMG-CoA] reductase inhibitors) in this pathway. **B:** Downstream effects of statins on muscles. Reduced levels of cholesterol, vitamin D, and isoprenylated proteins have pleiotropic effects on skeletal muscle function. Abbreviations: HMGCR, 3-hydroxy-3-methylglutaryl coenzyme A reductase; IMNM, immune-mediated necrotizing myopathy .

TABLE 96.4 Myotoxicity Associated With Statins

Syndrome	Management
Asymptomatic hyperCKemia	• May continue statin • Monitor CK and for clinical symptoms.
Myalgias, cramps	• Discontinue statin; most symptoms will resolve in 2-3 mo. • Retrial at lower dose or switch to lower risk statin • If symptoms persist or progress, consider muscle biopsy for underlying neuromuscular disorder or myositis. • Potential role for vitamin D (mainly in those with deficiency), coenzyme Q10
Toxic necrotizing myopathy	• Discontinue statin (improve within 2-3 mo). • Hospital admission • Intravenous hydration • Supportive measures • Hemodialysis if needed • Risk/benefit analysis regarding need for statin
Immune-mediated necrotizing myopathy (with anti-HMGCR antibodies)	• Discontinue statin (myopathy persists or progresses despite discontinuation). • Long-term immunosuppressive treatment (see Chapter 94)

Abbreviations: CK, creatine kinase; HMGCR, 3-hydroxy-3-methylglutaryl coenzyme A reductase.

SUGGESTED READINGS

Allenbach Y, Mammen AL, Benveniste O, Stenzel W; for Immune-Mediated Necrotizing Myopathies Working Group. 224th ENMC International Workshop: clinico-sero-pathological classification of immune-mediated necrotizing myopathies Zandvoort, The Netherlands, 14–16 October 2016. *Neuromuscul Disord*. 2018;28(1):87-99. doi:10.1016/j.nmd.2017.09.016.

American College of Cardiology. Statin intolerance. American College of Cardiology Web site. https://tools.acc.org/StatinIntolerance/. Updated December 2016. Accessed December 13, 2020.

Brahmer JR, Lacchetti C, Schneider BJ, et al; for National Comprehensive Cancer Network. Management of immune-related adverse events in patients treated with immune checkpoint inhibitor therapy: American Society of Clinical Oncology clinical practice guideline. *J Clin Oncol*. 2018;36(17):1714-1768. doi:10.1200/JCO.2017.77.6385.

Cham S, Evans MA, Denenberg JO, Golomb BA. Statin-associated muscle-related adverse effects: a case series of 354 patients. *Pharmacotherapy*. 2010;30(6):541-553. doi:10.1592/phco.30.6.541.

Duyff RF, Van den Bosch J, Laman DM, van Loon BJ, Linssen WH. Neuromuscular findings in thyroid dysfunction: a prospective clinical and electrodiagnostic study. *J Neurol Neurosurg Psychiatry*. 2000;68(6):750-755. doi:10.1136/jnnp.68.6.750.

Harper CR, Jacobson TA. Evidence-based management of statin myopathy. *Curr Atheroscler Rep*. 2010;12:322-330.

Ishii M. Neurologic complications of nondiabetic endocrine disorders. *Continuum (Minneap Minn)*. 2014;20(3):560-579

Kendall-Taylor P, Turnbull DM. Endocrine myopathies. *Br Med J (Clin Res Ed)*. 1983;287:705-708.

Kung AW. Neuromuscular complications of thyrotoxicosis. *Clin Endocrinol (Oxf)*. 2007;67(5):645-650. doi:10.1111/j.1365-2265.2007.02909.x.

Liewluck T, Kao JC, Mauermann ML. PD-1 inhibitor-associated myopathies: emerging immune-mediated myopathies. *J Immunother*. 2018;41(4):208-211. doi:10.1097/CJI.0000000000000196.

Mammen AL. Toxic myopathies. *Continuum (Minneap Minn)*. 2013;19(6):1634-1649.

Mammen AL, Tiniakou E. Intravenous immune globulin for statin-triggered autoimmune myopathy. *N Engl J Med*. 2015;373(17):1680-1682. doi:10.1056/NEJMc1506163.

Mastaglia FL, Needham M. Update on toxic myopathies. *Curr Neurol Neurosci Rep*. 2012;12:54-61.

Orrell RW. Endocrine myopathies. *Handb Clin Neurol*. 2007;86:343-355.

Pasnoor M, Barohn RJ, Dimachkie MM. Toxic myopathies. *Neurol Clin*. 2014;32:647-670.

Rosenson RS, Miller K, Bayliss M, et al. The Statin-Associated Muscle Symptom Clinical Index (SAMS-CI): revision for clinical use, content validation, and inter-rater reliability. *Cardiovasc Drugs Ther*. 2017;31(2):179-186. doi:10.1007/s10557-017-6723-4.

Shah M, Tayar JH, Abdel-Wahab N, Suarez-Almazor ME. Myositis as an adverse event of immune checkpoint blockade for cancer therapy. *Semin Arthritis Rheum*. 2019;48(4):736-740. doi:10.1016/j.semarthrit.2018.05.006.

Touat M, Maisonobe T, Knauss S, et al. Immune checkpoint inhibitor-related myositis and myocarditis in patients with cancer. *Neurology*. 2018;91(10):e985-e994. doi:1212/WNL.0000000000006124.

97 Periodic Paralysis and Other Channelopathies

Comana M. Cioroiu

KEY POINTS

1. Muscle channelopathies comprise a heterogeneous group of diseases of skeletal muscle that include both syndromes of episodic weakness (periodic paralyses) and muscle fiber hyperexcitability (nondystrophic myotonias) and these entities can overlap.
2. Most of these disorders are inherited in an autosomal dominant manner due to specific channel mutations.
3. Hypokalemic periodic paralysis occurs with episodes lasting greater than 2 hours triggered by rest after exercise, alcohol, and meals rich in carbohydrates. It is associated with mutations in the *CACNA1S* calcium channel gene or *SCN4A* sodium channel gene.
4. Hyperkalemic periodic paralysis occurs with episodes lasting less than 2 hours triggered by potassium-rich foods, exercise, fasting, and exposure to cold. It may coexist with paramyotonia congenita and is associated with mutations in the *SCN4A* sodium channel gene.
5. Andersen-Tawil syndrome is a syndrome characterized by a clinical triad of periodic paralysis, ventricular arrhythmias with a prolonged QT interval, and dysmorphic features.
6. Paramyotonia congenita is characterized by stiffness that worsens with repeat exercise and cold temperatures and is associated with a mutation in the *SCN4A* sodium channel gene.
7. Myotonia congenita (Thomsen disease) is characterized by stiffness that improves with repeat exercise ("warm-up phenomenon") and is associated with a mutation in the *CLCN1* chloride channel gene.
8. Episodes of periodic paralysis may be prevented by treatment with carbonic anhydrase inhibitors acetazolamide and dichlorphenamide.

INTRODUCTION

Muscle channelopathies comprise a heterogeneous group of diseases of skeletal muscle that include both syndromes of episodic weakness (periodic paralyses) and muscle fiber hyperexcitability (nondystrophic myotonias). The clinical phenotype depends on the particular channel mutation involved, and attacks can vary in severity, duration, and constellation of symptomatic triggers (**Table 97.1**). Most of these disorders are inherited in an autosomal dominant fashion, although sporadic mutations do exist. Changes in neuronal membrane depolarization secondary to various ion channel mutations can either lead to sustained depolarization and resultant overt muscle weakness or to a more mild constant depolarization (or reduced repolarization) leading to myotonia and stiffness. On occasion, there is overlap between the two, and some patients may have episodes of both myotonia and paralysis. There are three main types of periodic paralysis: hypokalemic periodic paralysis (hypoKPP), hyperkalemic periodic paralysis (hyperKPP), and Andersen-Tawil syndrome (periodic paralysis with cardiac arrhythmia and dysmorphic features). The nondystrophic myotonic disorders are primarily composed of myotonia congenita (MC), paramyotonia congenita (PC), as well as a subgroup of potassium-aggravated myotonic disorders. Electrodiagnostic testing is important in helping to identify particular patterns and make a correct diagnosis. Needle electromyogram (EMG) is needed to detect myotonic discharges or other abnormal spontaneous activity. In addition to routine nerve conduction studies, short and long exercise tests are uniquely used to help characterize specific patterns. In short exercise testing, the patient is asked to exercise a muscle (typically the abductor digiti minimi), and a compound muscle action potential (CMAP) is recorded every 10 seconds thereafter and compared to a baseline. In the long exercise test, the patient is asked to exercise the muscle for an extended amount of time (usually 5 min), and CMAPs are recorded every 2 minutes thereafter for about 1 hour and compared to baseline. Changes in CMAP amplitude in both short and long exercise testing can be used to differentiate between the various channelopathies. For instance, CMAP amplitudes typically increase in the periodic paralyses and decrease in the myotonias. Different electrodiagnostic patterns diagnostic of each particular disease were described in 2004 by Emmanuel Fournier and are still used today and are known as *Fournier patterns*. Targeted confirmatory genetic testing is often done thereafter to confirm the diagnosis. Although patients with these diseases have a normal life expectancy, they may struggle with persistent pain or progressive weakness causing significant functional impairment.

HYPOKALEMIC PERIODIC PARALYSIS

Epidemiology and Pathobiology

Hypokalemic periodic paralysis is the most common of the periodic paralyses; yet, it is still rare, affecting only about 1.7 per 1,000,000 people in England. Clinical onset is usually within the first 2 years of life (although it may be delayed into the sixth decade) and is more prevalent in men than women in a ratio of about 2:1. Most of these patients have mutations in either the *CACNA1S* gene (CaV1.1, chromosome 1q31-32) encoding an L-type calcium channel or, less commonly, the *SCN4A* sodium channel gene (NaV1.4, chromosome 17q23). In the presence of these mutations and low extracellular potassium, muscle fibers become

TABLE 97.1 Clinical Features of Hereditary Periodic Paralysis and Nondystrophic Myotonias[a]

	Hypokalemic Periodic Paralysis	Hyperkalemic Periodic Paralysis	Andersen-Tawil Syndrome	Paramyotonia Congenita	Myotonia Congenita
Gene	*CACNA1S* or *SCN4A*	*SCN4A*	*KCNJ2*	*SCN4A*	*CLCN-1* (AD) or *SCN4A* (AR)
Age of onset	Usually second or latter part of first decade	First decade	First or second decade	First decade	First decade
Sex	Male preponderance	Equal	Equal	Equal	Male preponderance
Frequency of paralytic episodes	Daily to yearly	Hourly to daily	Daily to yearly	May not be present; otherwise, weekly to monthly	Usually not present, variable frequency in AR form
Degrees of paralysis	Tends to be severe	Tends to be mild but can be severe	Variable	Tends to be mild but can be severe	Lasting seconds to minutes in AR form, usually not present in AD form
Effect of cold	May induce an attack	May induce an attack	May induce an attack	Tends to induce an attack	No effect
Oral potassium	Relieves or prevents an attack	Precipitates an attack	May relieve or prevent an attack	May precipitate an attack	No effect
Myotonia	Absent	May be present	Absent	Present	Present
Precipitants	Carbohydrate-rich food, cold	Fasting, stress, rest after exercise, K-rich foods	Carbohydrate-rich food, rest after exercise	Fasting, stress, cold, rest after exercise	Exercise
Exercise testing	Increase in CMAP with gradual decline with long exercise testing; short exercise testing normal (Fournier V)	Increase in amplitudes with gradual decrease in both short and long exercise testing (Fournier IV)	Unknown	Prominent drop in amplitudes with cooling in both long and short exercise testing; PEMPs present (Fournier I)	AD: drop in amplitude on short exercise testing, less drop with repeated testing AR: drop in amplitude with slow recovery (Fournier II)

Abbreviations: AD, autosomal dominant; AR, autosomal recessive; CMAP, compound muscle action potential; K, potassium; PEMP, postexercise myotonic potential.
[a]Modified from Hudson AJ. Progressive neurological disorder and myotonia congenita associated with paramyotonia. *Brain*. 1963;86:811-826.

depolarized and electrically inexcitable, leading to weakness. Just how these mutations cause persistent depolarization is unknown; however, one mouse model of such a calcium channel mutation proposed a possible explanation via a "gating pore current," described as an anomalous inward current at the resting potential triggered by low extracellular potassium content, leading to depolarization and sodium channel inactivation. At the structural level, mutations in the calcium channel lead to a vacuolar myopathy, whereas sodium channel mutations are associated with the development of transverse tubular aggregates and less vacuolization.

Clinical Manifestations and Diagnosis

Patients with hypoKPP typically note transient weakness after a period of rest after exercise with associated hypokalemia. These episodes are often more prominent during sleep or on rising in the morning and are worse after alcohol or a meal rich in sodium or carbohydrates. The extent of paralysis can be variable and asymmetric and can vary from slight leg weakness to complete flaccid quadriplegia. Bulbar and respiratory muscles are typically spared, but urinary or fecal retention may be seen. Attacks commonly occur between age 5 and 35 years and decrease with age. The duration of attacks can be variable and last anywhere from a few hours to several days. The interval between attacks may be as long as 1 year, although in some patients, attacks can occur daily. Patients have normal strength in between attacks, but some eventually develop fixed proximal weakness. Attacks may be associated with pain either preceding or following weakness. In a mild attack, tendon reflexes are diminished in proportion to the degree of weakness and are completely absent in a severe attack. Sensation remains normal. These patients are at increased risk for weakness in the setting of anesthesia.

Diagnosis can be made on the basis of the presence of similar attacks of transient weakness in family members. Confirmatory tests include the finding of low potassium content (3.0 mEq/L or less) and high sodium content in the serum during an attack and the ability to induce an attack with an intravenous infusion of glucose and regular insulin. Serum creatine kinase (CK) levels are typically normal or mildly elevated. Short exercise electrodiagnostic testing is usually normal, but an increase in CMAP amplitude with a delayed decline can be seen with long exercise testing (Fournier pattern V). Needle EMG does not show myotonic discharges. Prior to making a diagnosis of hypoKPP, it is of crucial importance to exclude other conditions that may also lead to periodic paresis and hypokalemia including hyperaldosteronism, diuretic use, gastrointestinal loss, and thyrotoxicosis (Table 97.2). The latter in particular must be considered (particularly in those of Asian ancestry). Also, attacks of hypoKPP have been described in patients with hyperthyroidism linked to the potassium channel β subunit gene *KCNE3*, which responds completely with treatment of the thyroid disorder.

Management and Outcome

Acute attacks may be treated safely with oral potassium (20-100 mEq), and rarely, intravenous potassium can be used, although it comes with the risk of subsequent hyperkalemia and cardiac arrhythmias. Prophylaxis of recurrent attacks is usually accomplished with the carbonic anhydrase inhibitor acetazolamide (Diamox) in doses of 250 to 1,000 mg daily. About 50% of patients respond to acetazolamide, and there is a greater benefit in patients with the *CACNA1S* calcium mutation than in those with the *SCN4A* sodium channel mutation. In fact, on occasion,

TABLE 97.2 Potassium and Paralysis: Noninherited Forms

Hypokalemic
• Excessive urinary loss
• Hyperaldosteronism (Conn syndrome)
• Drugs: glycyrrhizae (licorice), thiazide diuretics, furosemide, chlorthalidone, ethacrynic acid, amphotericin B, duogastrone, barium, corticosteroids
• Pyelonephritis, renal tubular acidosis
• Recovery from diabetic acidosis
• Ureterocolostomy
• Excessive gastrointestinal loss (diarrhea, vomiting, fistula)
• Malabsorption syndrome
• Laxative abuse
• Pancreatic tumor, villous adenoma
• Thyrotoxicosis
Hyperkalemic
• Uremia
• Hypoaldosteronism
• Addison disease
• Potassium-sparing diuretics (ie, spironolactone)
• Excessive intake/supplementation of potassium
• Iatrogenic
• Geophagia

it may worsen attacks in patients with sodium channel mutations. The mechanism whereby it helps attacks of weakness is uncertain but may be related to induction of a mild metabolic acidosis, improved chloride conductance, or activation of the KCa^{2+} channel. There are no randomized controlled studies to support the use of acetazolamide and data to support its use is based on anecdotal evidence and few nonrandomized single blind trials. However, dichlorphenamide, another carbonic anhydrase inhibitor, has been shown to be efficacious in reducing attacks in both hyper- and hypoKPP in randomized placebo-controlled trials LEVEL 2[1] and was recently approved by the U.S. Food and Drug Administration in their treatment at doses of 50 to 200 mg/d. In patients treated with dichlorphenamide, these studies demonstrated not only a significant reduction in both attack frequency and severity but also in quality of life in patients with hypoPP. Other agents that may be beneficial include triamterene (50-100 mg/d) or spironolactone (25-100 mg/d), which promote retention of potassium. More recently, bumetanide (an Na-K-2Cl inhibitor) has been effective in preventing recurrent attacks of weakness and restoring force in a mouse model of hypoKPP with either a NaV1.4 sodium channel or CaV1.1 calcium channel mutation. Patients should be counseled about triggering factors and encouraged to avoid alcohol, strenuous exercise, and meals rich in carbohydrates as well as ensuring adequate hydration. In those cases of hypoKPP secondary to a general medical condition (ie, thyroid disease), the underlying disorder must be treated.

With time, patients with hypoKPP experience less attacks as they age and attacks may cease altogether after age 40 or 50 years. The disease does not shorten overall survival, and death due to respiratory involvement is rare. A progressive and persistent proximal myopathy may develop with time and cause functional impairment and disability. Finally, it should be mentioned that susceptibility to malignant hyperthermia has been linked to the *CACNA1S* gene (although it is usually caused by a mutation in the RYR1 gene encoding a ryanodine receptor), and cases of malignant hyperthermia have been described in patients with hypoKPP. However, to date, no conclusive evidence of a clear genetic link has been found.

HYPERKALEMIC PERIODIC PARALYSIS

Epidemiology and Pathobiology

hyperKPP was first described by Frank Tyler at the University of Utah in 1951, when he recognized a form of periodic paralysis not accompanied by a decrease in serum potassium. The disease is caused by an autosomal dominant genetic mutation with complete penetrance, affecting the *SCN4A* sodium channel gene. It is thought to cause defective inactivation of the sodium channel, thereby resulting in a complete loss of membrane excitability and weakness. Mutations involving the *SCN4A* gene cause three clinical variations of hyperKPP—episodic weakness without myotonia, episodic weakness with myotonia, and episodic weakness associated with PC triggered by cold (to be discussed in a subsequent section of this chapter). Overall prevalence is estimated to be about 1.3 per 1,000,000 people with onset before the age of 10 years. The pathophysiology of hyperKPP was first studied by Rüdel et al in the 1980s and led to the suspicion that a defective sodium channel protein might be responsible. First, using microelectrode studies of intercostal muscle, they confirmed that muscle isolated from patients with hyperKPP was partially depolarized at rest. The abnormal depolarization was blocked by tetrodotoxin, which specifically affects the α subunit of the sodium channel. Patch clamp experiments showed faulty inactivation, leading to the conclusion that excessive sodium influx causes repetitive firing of action potentials (myotonia) and eventual inactivation of the membrane (weakness). Cloning and analysis of the gene encoding the voltage-gated sodium channel identified more than 20 missense mutations in the *SCN4A* gene. Some mutations exhibit both interfamilial and intrafamilial phenotypic variability. Muscle biopsy may reveal intracytoplasmic vacuoles.

Clinical Manifestations and Diagnosis

As opposed to hypoKPP, attacks in hyperKPP tend to occur more frequently in the daytime and are shorter (less than 2 h on average) and less severe. Involvement of bulbar or respiratory muscles is rare. The frequency of attacks varies but they tend to occur more often than those in hypoKPP. Attacks may be precipitated by potassium-rich food, rest after exercise, fasting, stress, and cold temperature. Strength is normal in between attacks, and during attacks, patients are areflexic. Fixed proximal weakness may develop over time in many patients. Minimal clinical myotonia may be observed in about half of patients between attacks, with myotonic lid lag or lingual myotonia.

Serum potassium levels may be normal or elevated during an attack, at times in excess of 5.0 mEq/L. Serum CK can also be normal or mildly elevated. Needle EMG may show fibrillations or myotonic discharges in up to 50% to 75% of patients

(indicative of hyperexcitability and muscle irritation), and later in the clinical course, motor units may become myopathic in appearance. Both short and long exercise testing reveal a rise in CMAP amplitude that decreases over time (Fournier pattern IV). Confirmatory genetic testing for the responsible mutation is often done. As with hypoKPP, noninherited causes of hyperkalemia must be excluded, such as uremia, Addison disease, and excessive potassium supplementation.

Management and Outcome

Attacks may be terminated by administration of calcium gluconate, glucose, and insulin to stabilize cardiac membranes and reduce serum potassium levels. Mild exercise and carbohydrate ingestion at the onset of an attack may also be helpful. Acetazolamide in doses of 250 mg to 1 g orally may reduce the number of attacks or completely abolish them. Dichlorphenamide recently gained U.S. Food and Drug Administration approval for both hypoKPP and hyperKPP as above. Potassium-wasting diuretics such as thiazides can promote urinary excretion of potassium and also be effective clinically. Rarely, β-adrenergic agents can be used as well, although come with a risk of cardiac arrhythmias. In those patients with myotonia, mexiletine may give symptomatic relief but comes with a small risk of cardiovascular effects (including arrhythmias) and an electrocardiogram (ECG) is needed prior to its initiation. Patients are encouraged to avoid fasting, potassium-rich foods, and exposure to cold temperatures. As in hypoKPP, life expectancy is not affected but patients' morbidity may be related to episodic and progressive proximal weakness, and myalgia with muscle stiffness may result from myotonia.

ANDERSEN-TAWIL SYNDROME

Epidemiology and Pathobiology

Also known as *Klein-Lisak-Andersen syndrome*, this rare disease is inherited in an autosomal dominant fashion (with some sporadic cases) and is most frequently due to mutations in the KCNJ2 gene encoding an inward-rectifying potassium channel, and several mutations in this gene exist. However, only about 60% of patients will have a known gene mutation, whereas in the remaining 40%, the cause remains unknown. It accounts for less than 10% of all people with periodic paralysis. The syndrome is characterized by the clinical triad of periodic paralysis, ventricular arrhythmias with a prolonged QT interval, and dysmorphic features, which are usually skeletal abnormalities. Episodes of paralysis can be hyperkalemic, normokalemic, or hypokalemic. Not all patients show the complete triad. The disease typically starts with episodes of periodic paralysis in the first or second decade, and serum levels of potassium vary.

Clinical Manifestations and Diagnosis

Attacks are highly variable in frequency, duration, and severity. There is usually no associated myotonia or weakness in between episodes, but some patients demonstrate mild neck flexor or facial weakness. Developmental abnormalities include hypertelorism, clinodactyly, low-set ears, scoliosis, and syndactyly, and patients are usually short statured and may have a cleft or high-arched palate with a small mandible. Some patients may have cognitive abnormalities. The associated cardiac manifestations of Andersen-Tawil syndrome are inherent and unique to the diagnosis. Over 50% of patients have a prolonged QT syndrome, and an even larger proportion develops arrhythmias such as bidirectional or polymorphic ventricular tachycardia. Ventricular tachyarrhythmias are less frequent and often asymptomatic, although cardiac arrest may occur in up to 10% of patients. Patients must be questioned about any unexplained syncopal events, which may be indicative of an underlying arrhythmia. An ECG is a crucial component of the diagnostic workup because some patients may benefit from pacing or antiarrhythmic agents. Serum potassium concentrations should be assessed at baseline and during attacks of severe weakness. Electrophysiologic testing is often useful, as long as exercise testing shows an immediate increase in CMAP amplitude with a subsequent decline. Genetic testing for the *KCNJ2* gene mutation is confirmatory. As with hyper- and hypoKPP, secondary causes of periodic paralysis must be excluded (including thyroid disease, renal failure, and others).

Management and Outcome

Management of Andersen-Tawil syndrome is aimed at treatment of both the episodic paralysis and the cardiac manifestations, and a multidisciplinary approach is therefore crucial. Treatment of attacks depends on whether they are associated with low or high levels of potassium. Carbonic anhydrase inhibitors may decrease the frequency of clinical attacks, as in other forms of periodic paralysis. Cardiac evaluation includes yearly ECG and Holter monitoring because some patients benefit from a pacemaker or defibrillator. More often, however, pharmacologic agents such as β-blockers and other antiarrhythmics are used to control arrhythmias. Patients must be counseled to avoid medications that may further prolong the QT interval.

NONDYSTROPHIC MYOTONIAS

Epidemiology and Pathobiology

PC (sometimes known as *Eulenburg disease*) is also caused by a mutation in the *SCN4A* sodium channel gene and, given the shared genetic locus, often overlaps with hyperKPP and different phenotypes may exist in the same family. It is typically inherited as an autosomal dominant disorder and symptoms begin early in life. Infants may have difficulty opening their eyes while crying (eyelid-opening myotonia). In PC, poor inactivation of the sodium channel prolongs the neuronal action potential and slows the rate of repolarization, thereby causing a mild state of persistent depolarization leading to clinical myotonia. This phenotype differs from hyperKPP, and there is probably a different kind of functional defect in the *SCN4A* gene in the two syndromes accounting for this variability. Genetic defects causing persistent sodium currents may lead to paralysis via stable and persistent depolarization (hyperKPP), whereas myotonic discharges result from instability of channel activation that is more variable. Histopathologically, muscle biopsy may show myopathic features with intracytoplasmic vacuolization and tubular aggregates.

Also known as *Thomsen disease*, MC is also autosomal dominant and is caused by mutations in the *CLCN1* chloride channel gene. Men are affected more than women. In the autosomal dominant form, changes in chloride channel function lead to a loss of chloride conductance, thereby leading to delayed repolarization

and increased neuronal excitability due to potassium accumulation in T-tubules and resultant membrane depolarization. An autosomal recessive form also exists, also known as *Becker disease*, and involves a mutation in the *SCN4A* sodium channel gene.

Clinical Manifestations and Diagnosis

The first clinical signs of PC are typically seen in the first decade of life. Patients demonstrate "paradoxical" myotonia, which is defined as myotonia or stiffness that worsens with repeated exercise (as opposed to the "warm-up phenomenon" seen in other myotonic syndromes, in which myotonia decreases with exercise). Cold ambient temperatures worsen clinical myotonia and stiffness, and short and long exercise testing in a cooled limb shows a drop in amplitude with a slow recovery (Fournier pattern I). With more trials, a further drop in amplitude can be seen, which is an electrophysiologic equivalent of the paradoxical myotonia seen clinically. Many patients demonstrate postexercise myotonic potentials, which are after discharges of decreasing amplitude seen after exercise. Needle EMG may show signs of muscle irritability in the form of fibrillations and myotonic discharges, which disappear completely with colder temperatures as the muscle weakens. Given the occasional overlap with periodic paralysis, in some patients, cold temperature or potassium intake can induce a paretic attack. Fixed progressive muscle weakness may develop with time.

Symptoms of Thomsen disease begin in the first decade of life with clinical signs of myotonia—for instance, infants may have trouble opening their eyes after crying and may fall when learning to walk. In MC, myotonia demonstrates the classic warm-up phenomenon, whereby the myotonia improves with exercise and repeated muscle contraction. Both percussion and grip myotonia may be observed. Patients are described as being "Herculean" with excessive muscle mass attributed to the nearly constant state of muscle contraction, although they usually do not complain of pain. Episodes of weakness are rare in the autosomal dominant form, but in Becker disease, they may occur at the onset of physical activity, lasting seconds to minutes. Moreover, in these patients, symptoms commence later in life, and they may also develop proximal weakness. Serum CK is typically normal, as is serum potassium. Short exercise testing shows a transient drop in amplitude (more pronounced with cooling in autosomal dominant form) with a smaller drop with repeated trials (corresponding to the warm-up phenomenon seen clinically), consistent with a Fournier II pattern. Long exercise testing shows little if any change and postexercise myotonic potentials may be seen. Genetic testing confirms the diagnosis.

Management and Outcome

Muscle stiffness related to myotonia is often the primary complaint of patients with PC and MC, and strategies aimed at mitigating this pain vary. Mexiletine, a class IB antiarrhythmic medication, has been used for many years for symptomatic relief in both dystrophic and nondystrophic myotonic syndromes. One placebo-controlled trial done by Statland et al in 2012 demonstrated significant improvement in stiffness after mexiletine treatment for 4 weeks in patients with nondystrophic myotonia. Mexiletine is thought to work via enhancement of fast inactivation of sodium channels, although its efficacy is not restricted to only those patients with myotonia related to *SCN4A* (sodium channel) mutations. The medication is generally well tolerated and is typically started at a dose of 150 mg daily and then slowly increased to a dose of 300 mg 3 times per day. Cardiac testing including an ECG is often done prior to initiating the drug trial, particularly in patients with cardiac symptoms or known cardiovascular disease. Some patients may find relief from other medications with different mechanisms of action such as carbamazepine, phenytoin, or diuretics such as acetazolamide or hydrochlorothiazide.

ACKNOWLEDGMENT

The author wishes to acknowledge the contributions of Dr. Lewis P. Rowland (deceased) to prior versions of this chapter.

LEVEL 1 EVIDENCE

1. Sansone V, Burge J, McDermott MP, et al. Randomized, placebo-controlled trials of dichlorphenamide in periodic paralysis. *Neurology*. 2016;86:1408-1416.

SUGGESTED READINGS

Bendahhou S, Donaldson MR, Plaster NM, Tristani-Firouzi M, Fu Y-H, Ptácek LJ. Defective potassium channel Kir2.1 trafficking underlies Andersen-Tawil syndrome. *J Biol Chem*. 2003;278(51):51779-51785.

Bendheim PE, Reale EO, Berg BO. Beta-adrenergic treatment of hyperkalemic periodic paralysis. *Neurology*. 1985;35(5):746-749.

Benstead TJ, Camfield PR, King DB. Treatment of paramyotonia congenita with acetazolamide. *Can J Neurol Sci*. 1987;14(2):156-158.

Borg K, Hovmöller M, Larsson L, Edström L. Paramyotonia congenita (Eulenburg): clinical, neurophysiological and muscle biopsy observations in a Swedish family. *Acta Neurol Scand*. 1993;87(1):37-42.

Cannon SC. An expanding view for the molecular basis of familial periodic paralysis. *Neuromuscul Disord*. 2002;12(6):533-543.

Cannon SC. Pathomechanisms in channelopathies of skeletal muscle and brain. *Annu Rev Neurosci*. 2006;29:387-415.

Cavel-Greant D, Lehmann-Horn F, Jurkat-Rott K. The impact of permanent muscle weakness on quality of life in periodic paralysis: a survey of 66 patients. *Acta Myol*. 2012;31(2):126-133.

Comi G, Testa D, Cornelio F, Comola M, Canal N. Potassium depletion myopathy: a clinical and morphological study of six cases. *Muscle Nerve*. 1985;8(1):17-21.

Dias Da Silva MR, Cerutti JM, Arnaldi LA, Maciel R. A mutation in the KCNE3 potassium channel gene is associated with susceptibility to thyrotoxic hypokalemic periodic paralysis. *J Clin Endocrinol Metab*. 2002;87(11):4881-4884.

Donaldson MR, Yoon G, Fu YH, Ptácek LJ. Andersen-Tawil syndrome: a model of clinical variability, pleiotropy, and genetic heterogeneity. *Ann Med*. 2004;36(suppl 1):92-97.

Evers S, Engelien A, Karsch V, Hund M. Secondary hyperkalaemic paralysis. *J Neurol Neurosurg Psychiatry*. 1998;64(2):249-252.

Fournier E, Arzel M, Sternberg D, et al. Electromyography guides toward subgroups of mutations in muscle channelopathies. *Ann Neurol*. 2004;56(5):650-661.

Griggs RC, Engel WK, Resnick JS. Acetazolamide treatment of hypokalemic periodic paralysis. Prevention of attacks and improvement of persistent weakness. *Ann Intern Med*. 1970;73(1):39-48.

Heatwole CR, Statland JM, Logigian EL. The diagnosis and treatment of myotonic disorders. *Muscle Nerve*. 2013;47(5):632-648.

Horga A, Raja Rayan DL, Matthews E, et al. Prevalence study of genetically defined skeletal muscle channelopathies in England. *Neurology*. 2013;80(16):1472-1475.

Jurkat-Rott K, Lehmann-Horn F. Periodic paralysis mutation MiRP2-R83H in controls: interpretations and general recommendation. *Neurology*. 2004;62(6):1012-1015.

Jurkat-Rott K, Lerche H, Lehmann-Horn F. Skeletal muscle channelopathies. *J Neurol*. 2002;249(11):1493-1502.

Kostera-Pruszczyk A, Potulska-Chromik A, Pruszczyk P, et al. Andersen-Tawil syndrome: report of 3 novel mutations and high risk of symptomatic cardiac involvement. *Muscle Nerve*. 2015;51(2):192-196.

Layzer RB, Lovelace RE, Rowland LP. Hyperkalemic periodic paralysis. *Arch Neurol*. 1967;16(5):455-472.

Lehmann-Horn F, Rüdel R, Ricker K, Lorković H, Dengler R, Hopf HC. Two cases of adynamia episodica hereditaria: in vitro investigation of muscle cell membrane and contraction parameters. *Muscle Nerve*. 1983;6(2):113-121.

Levitt JO. Practical aspects in the management of hypokalemic periodic paralysis. *J Transl Med*. 2008;6:18.

Lisak RP, Lebeau J, Tucker SH, Rowland LP. Hyperkalemic periodic paralysis and cardiac arrhythmia. *Neurology*. 1972;22(8):810-815.

Marchan: CL, Ellis FR, Halsall PJ, Hopkins PM, Robinson RL. Mutation analysis of two patients with hypokalemic periodic paralysis and suspected malignant hyperthermia. *Muscle Nerve*. 2004;30(1):114-117.

Matthews E, Portaro S, Ke Q et al. Acetazolamide efficacy in hypokalemic periodic paralysis and the predictive role of genotype. *Neurology*. 2011;77(22):1960-1964.

Minaker KL, Meneilly GS, Flier JS, et al. Insulin-mediated hypokalemia and paralysis in familial hypokalemic periodic paralysis. *Am J Med*. 1988;84(6):1001-1006.

Moxley RT III, Ricker K, Kingston WJ, Böhlen R. Potassium uptake in muscle during paramyotonic weakness. *Neurology*. 1989;39(7):952-955.

Ponce SP, Jennings AE, Madias NE, Harrington JT. Drug-induced hyperkalemia. *Medicine (Baltimore)*. 1985;64(6):357-370.

Ptácek LJ, Trimmer JS, Agnew WS, Roberts JW, Petajan JH, Leppert M. Paramyotonia congenita and hyperkalemic periodic paralysis map to the same sodium-channel gene locus. *Am J Hum Genet*. 1991;49(4):851-854.

Rajabally YA, El Lahawi M. Hypokalemic periodic paralysis associated with malignant hyperthermia. *Muscle Nerve*. 2002;25(3):453-455.

Rüdel R, Ricker K, Lehmann-Horn F. Genotype-phenotype correlations in human skeletal muscle sodium channel diseases. *Arch Neurol*. 1993;50(11):1241-1248.

Sansone V, Griggs RC, Meola G, et al. Andersen's syndrome: a distinct periodic paralysis. *Ann Neurol*. 1997;42(3):305-312.

Sansone V, Tawil R. Management and treatment of Andersen-Tawil syndrome (ATS). *Neurotherapeutics*. 2007;4(2):233-237.

Statland JM, Barohn RJ. Muscle channelopathies: the nondystrophic myotonias and periodic paralyses. *Continuum (Minneap Minn)*. 2013;19(6 Muscle Disease):1598-1614.

Statland JM, Bundy BN, Wang Y, et al; and Consortium for Clinical Investigation of Neurologic Channelopathies. Mexiletine for symptoms and signs of myotonia in non-dystrophic myotonia: a randomized controlled trial. *JAMA*. 2012;308(13):1357-1365.

Statland JM, Fontaine B, Hanna MG, et al. Review of the diagnosis and treatment of periodic paralysis. *Muscle Nerve*. 2018;57(4):522-530.

Striessnig J, Hoda JC, Koschak A, et al. L-type Ca2+ channels in Ca2+ channelopathies. *Biochem Biophys Res Commun*. 2004;322(4):1341-1346.

Tawil R, McDermott MP, Brown R Jr, et al. Randomized trials of dichlorphenamide in the periodic paralyses. Working Group on Periodic Paralysis. *Ann Neurol*. 2000;47(1):46-53.

Tricarico D, Barbieri M, Camerino DC. Acetazolamide opens the muscular Kca^{2+} channel: a novel mechanism of action that may explain the therapeutic effect of the drug in hypokalemic periodic paralysis. *Ann Neurol*. 2000;48(3):304-312.

Tricarico D, Servidei S, Tonali P, Jurkat-Rott K, Camerino DC. Impairment of skeletal muscle adenosine triphosphate–sensitive K^+ channels in patients with hypokalemic periodic paralysis. *J Clin Invest*. 1999;103(5):675-682.

Tristani-Firouzi M, Jensen JL, Donaldson MR, et al. Functional and clinical characterization of KCNJ2 mutations associated with LQT7 (Andersen syndrome). *J Clin Invest*. 2002;110(3):381-388.

Venance SL, Cannon SC, Fialho D, et al; for CINCH Investigators. The primary periodic paralyses: diagnosis, pathogenesis and treatment. *Brain*. 2006;129(pt 1):8-17.

Venance SL, Jurkat-Rott K, Lehmann-Horn F, Tawil R. SCN4A-associated hypokalemic periodic paralysis merits a trial of acetazolamide. *Neurology*. 2004;63(10):1977.

Vicart S, Sternberg D, Fournier E, et al. New mutations of SCN4A cause a potassium-sensitive normokalemic periodic paralysis. *Neurology*. 2004;63(11):2120-2127.

Vijayakumar A, Ashwath G, Thimmappa D. Thyrotoxic periodic paralysis: clinical challenges. *J Thyroid Res*. 2014;2014:649502.

Vroom FW, Jarrell MA, Maren TH. Acetazolamide treatment of hypokalemic periodic paralysis. Probable mechanism of action. *Arch Neurol*. 1975;32(6):385-392.

Webb J, Cannon SC. Cold-induced defects of sodium channel gating in atypical periodic paralysis plus myotonia. *Neurology*. 2008;70(10):755-761.

Wu F, Mi W, Cannon SC. Beneficial effects of bumetanide in a CaV1.1-R528H mouse model of hypokalaemic periodic paralysis. *Brain*. 2013;136(12):3766-3774.

Wu F, Mi W, Cannon SC. Bumetanide prevents transient decreases in muscle force in murine hypokalemic periodic paralysis. *Neurology*. 2013;80(12):1110-1116.

Wu F, Mi W, Hernández-Ochoa EO, et al. A calcium channel mutant mouse model of hypokalemic periodic paralysis. *J Clin Invest*. 2012;122(12):4580-4591.

98 Stiff Person Syndrome and Peripheral Nerve and Muscle Hyperexcitability

Jonathan Perk and Christina M. Ulane

KEY POINTS

1. Excessive muscular excitability may result from inappropriate activation or dysfunction of inhibitory systems.
2. Stiff person syndrome is a central nervous system autoimmune disorder in which the clinical hallmarks are muscle stiffness, episodic spasms, and psychiatric symptoms.
3. Neuromyotonia (Isaacs syndrome) is a peripherally mediated neuronal hyperexcitability syndrome, which may be autoimmune or paraneoplastic.
4. Neuroleptic malignant syndrome and malignant hyperthermia may be fatal and are associated with dopamine blockade and anesthetic agents, respectively.
5. Muscle cramps are common, and most often benign, however, may accompany serious conditions as motor neuron disease.

INTRODUCTION

The terms *muscle stiffness* and *cramps* are used for commonly experienced symptoms that are often transient and benign. Rarely, they may be harbingers of more serious pathology. Persistent limb muscle stiffness arises from involuntary continuous muscle contraction, whereas cramps and spasms are brief contractions. Lesions throughout the motor system have been implicated in generating muscle stiffness or spasm. Excessive muscular activation may result from dysfunction of inhibitory systems in central nervous system (CNS) pathology or inappropriate activation or hyperexcitability in peripheral nervous system pathology. Table 98.1 outlines features of various causes of muscle cramps and stiffness.

STIFF PERSON SYNDROME

In 1956, Moersch and Woltman, senior neurologists at the Mayo Clinic, described patients with a rare clinical syndrome

TABLE 98.1 Disorders Causing Muscle Stiffness and Hyperexcitability

Localization of Abnormality	Disorder	Principal Manifestations	Treatment
Brain, brainstem, and spinal cord	Stiff person syndrome	Rigidity and reflex spasms Anti-GAD65 antibodies	Diazepam, IVIG, treatment of underlying cancer if paraneoplastic
	PERM	Rigidity and reflex spasms, focal neurologic deficits Anti-GlyRα1 antibodies	Similar to stiff person syndrome
	Tetanus	Rigidity and reflex spasms	Diazepam, supportive care
Peripheral nerve	Acquired neuromyotonia (Isaac syndrome)	Stiffness, myokymia, delayed relaxation Anti-VGKC antibodies (anti-CASPR2, anti-LGI1)	Immunotherapy, phenytoin, carbamazepine, mexiletine, treatment of underlying cancer if paraneoplastic
	Schwartz-Jampel syndrome	Stiffness and myotonia	Phenytoin, carbamazepine
	Tetany	Carpopedal spasm	Correction of calcium, magnesium, or acid-base derangement
Muscle	Myotonic disorders	Delayed relaxation, percussion myotonia	Mexiletine, phenytoin, carbamazepine (see Chapter 147)
	Metabolic myopathies	Cramps during intense or ischemic exercise	See Chapter 99 and Section 19.
	Neuroleptic malignant syndrome	Rigidity during dopamine block	Supportive care, bromocriptine, dantrolene
	Malignant hyperthermia	Rigidity during anesthesia	Supportive care, dantrolene
Unknown	Ordinary muscle cramps	Cramps during sleep or ordinary activity	Stretching affected muscle to relieve cramp; medications may be used if severe (see text).

Abbreviations: CASPR2, contactin-associated protein-like 2; GAD65, glutamic acid decarboxylase-65; GlyRα1, glycine receptor subunit alpha 1; IVIG, intravenous immunoglobulin; LGI1, leucine-rich glioma-inactivated protein 1; PERM, progressive encephalomyelitis with rigidity and myoclonus; VGKC, voltage-gated potassium channel.

of progressive fluctuating muscular rigidity and painful spasms. This condition is currently known by the gender neutral name *stiff person syndrome* (SPS). A focal variant of the disorder has been called the *stiff limb syndrome*.

Epidemiology

SPS occurs more often in women, but both men and women can be affected (average age of symptom onset is 35 years) and develop progressive symptoms over several months or years. SPS is quite rare and exact epidemiologic data is lacking; the estimated prevalence is one in a million. It is most often an immunologically mediated disorder with the presence of anti–glutamic acid decarboxylase-65 (anti-GAD65) antibodies; it may coexist with other autoimmune disorders including type 1 diabetes mellitus (in at least 35% of patients with SPS), Hashimoto thyroiditis, Graves disease, pernicious anemia, vitiligo, and celiac disease. A paraneoplastic form of SPS accounts for about 5% of cases most often associated with breast cancer but also reported with thyroid, renal, or colon cancer. The disorder is extremely rare in children; however, several case reports are available.

Pathobiology

CNS γ-aminobutyric acid (GABA)-secreting neurons play a major role in the normal inhibition of excessive continuous motor activation. GABA synthesis from glutamic acid is catalyzed by the enzyme glutamic acid decarboxylase (GAD). The discovery of antibodies against the 65-kDa GAD protein in most patients suggests immunologically mediated dysfunction of inhibitory synapses. **Figure 98.1** illustrates the inhibitory synapse and subcellular localization of antigenic targets of antibodies found in SPS. Reported association of SPS with autoimmune diseases as pernicious anemia, thyroid disease, type 1 diabetes mellitus, and others provides further support for the role of autoimmunity. The presence of anti-GAD65 antibodies with other neurologic disorders, including cerebellar ataxia (with or without coexisting SPS), epilepsy, or progressive encephalomyelitis with rigidity and myoclonus (PERM) suggests a spectrum of pathology associated with neuronal disinhibition in which SPS is one subtype. Although there is often an association of anti-GAD65 antibodies and SPS, the direct pathogenic role of anti-GAD65 antibodies remains uncertain. One major puzzle is that the antigenic GAD65 enzyme is intracellular and therefore supposedly hidden from the offensive antibodies. Furthermore, unlike myasthenia gravis, another antibody-mediated autoimmune disease where antibodies are directed against surface nicotinic acetylcholine receptors, passive transmission of antibodies (eg, in maternal placental transfer) does not confer the SPS. It has been suggested that CNS pathology is mediated by glutamic acid decarboxylase-specific $CD4^+$ T cells rather than the antibodies.

It may be that other associated antibodies are the pathologic culprits as, for example, the anti-GABA receptor–associated protein autoantibody. Dalmau and colleagues found that antibodies directed against the glycine receptor subunit alpha 1 (GlyRα1) immunoglobulin G antibodies are present in 12% of SPS patients and are found in other hyperexcitable disorders affecting brainstem and spinal cord, most often PERM. Anti-GlyRα1 antibodies may predict good response to immunotherapy. Mutations in the gene encoding the GlyRα1 cause *hyperekplexia* or *startle disease*.

Over the years, a paraneoplastic subgroup form of SPS patients was identified. Many of those patients were positive for autoantibodies directed against other molecules in the inhibitory synapse such as amphiphysin (breast and small cell lung cancer) and gephyrin (mediastinal cancer).

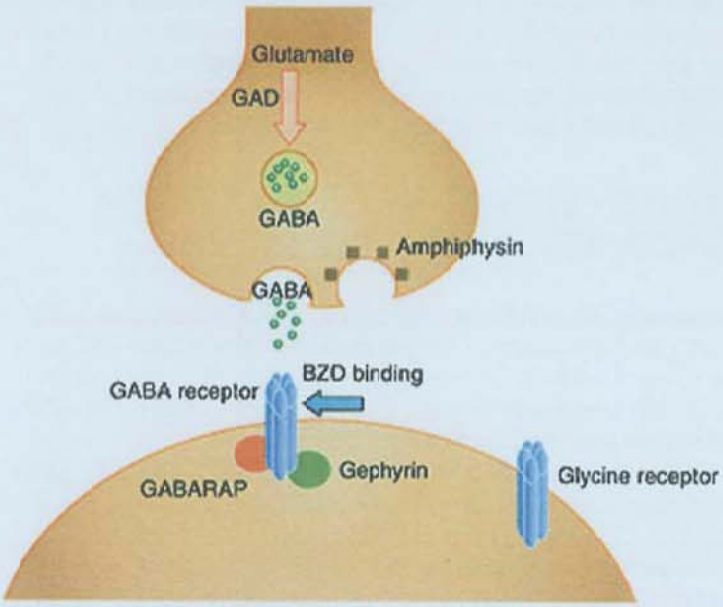

FIGURE 98.1 The neuronal inhibitory synapse. γ-Aminobutyric acid (GABA) and glycine are primary inhibitory neurotransmitters. Dysfunction of components of the synapse (presynaptic, synaptic, and postsynaptic) can lead to loss of inhibition and clinical stiffness and spasms. Abbreviations: BZD, benzodiazepine; GABARAP, GABA receptor–associated protein; GAD, glutamic acid decarboxylase.

Clinical Manifestations

Progressive stiffness and intermittent spasms of the axial musculature characterize the classic form of SPS, but distal limb muscles may also be affected. Aching discomfort and stiffness tend to predominate in the axial and proximal limb muscles, causing a hyperlordotic posture, with awkward gait and slowness of movements. Unlike tetanus, trismus does not occur, but facial and oropharyngeal muscles may be affected. In some cases, respiratory muscles are involved. The stiffness diminishes during sleep and under general anesthesia, differentiating it from other motor unit hyperexcitable syndromes such as neuromyotonia. The spasms may lead to joint deformities and are powerful enough to rupture muscles, rip surgical sutures, and fracture bones. Painful reflex spasms and falls occur in response to movement, sensory stimulation, or emotional changes. Fear of attacks elicited by environmental stimulation may lead to a debilitating avoidance of public places. Anxiety and task-specific phobias can be dominant features in SPS and may contribute to the often-observed delay in diagnosis or misdiagnosis notably because the spasms and rigidity improve with anxiety targeted treatment. Physical examination shows markedly increased axial and proximal muscle tone. However, strength, coordination, and sensation are preserved. Passive muscle stretch provokes an exaggerated reflex contraction that lasts several seconds. **Table 98.2** highlights the dominant features of classic SPS. The startle reactions of SPS are similar to those in hyperekplexia.

TABLE 98.2 Defining Characteristics of the Stiff Person Syndrome[a]

- Prodromal stiffness of axial muscles
- Slow progress to proximal limbs, walking awkward
- Fixed deformity of the spine, lordosis, "permanent shrug" (neck drawn down to shoulder girdle)
- Spasms precipitated by startle, jarring, noise, emotional upset
- Otherwise normal findings on motor and sensory examination
- Anxiety and task-specific phobias
- Normal intellect and affect
- Continuous motor activity in affected muscles relieved by intravenous or oral diazepam

[a]Modified from Lorish TR, Thorsteinsson G, Howard FM Jr. Stiff-man syndrome updated. *Mayo Clin Proc.* 1989;64(6):629-636.

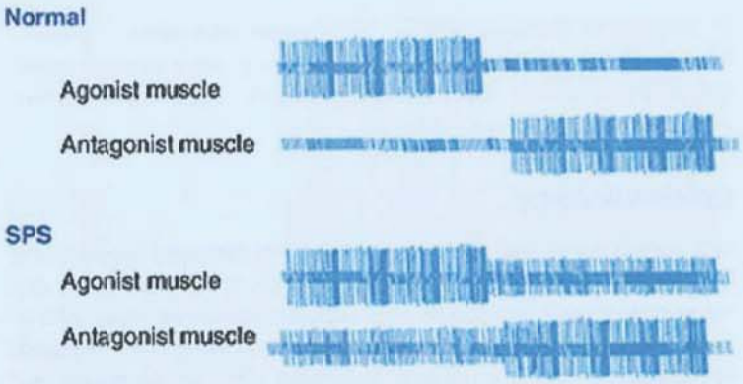

FIGURE 98.2 Schematic depiction of simultaneous agonist/antagonist electromyography recordings in stiff person syndrome (SPS). The normal response tracings **(top)** show runs of agonist muscle motor unit action potentials associated with inhibition of motor unit action potentials in the antagonist and vice versa. In contrast, paired tracings recorded in a stiff person patient **(bottom pair)** show uninhibited simultaneous activation of both agonist and antagonist muscles.

Diagnosis

Laboratory Data

The diagnosis of SPS is aided by the presence of serum or cerebrospinal fluid antibodies against GAD65 in high titers (2,000 U/mL or more), which are found in approximately 80% of cases. Anti-GAD65 antibodies are supportive of the diagnosis of SPS but not specific; they are found in other neurologic disorders (including cerebellar ataxia, PERM, and Batten disease), and low titers are associated with other autoimmune diseases (up to 22% of persons with type 1 diabetes mellitus). Other autoantibodies present in SPS include anti-GABA receptor–associated protein in 65% of SPS cases, anti-GlyRα1 antibodies in up to 10% of cases, antiamphiphysin in up to 5% (found in paraneoplastic cases most commonly with breast cancer), and antigephyrin (found in one case of paraneoplastic SPS).

Electrophysiology

Electromyography (EMG) reveals continuous firing of normal motor unit action potentials even at rest. This excessive firing may be inhibited by administration of intravenous diazepam. Another hallmark of the SPS is cocontraction of agonist and antagonist muscles. Normally, contraction of an agonist muscle is associated with inhibition of the activity of the antagonist, but this is not so in SPS (Fig. 98.2).

Imaging

Magnetic resonance imaging of the brain and spinal cord is normal in SPS and are most useful in ruling out other pathologies. Brain magnetic resonance spectroscopy, however, shows a marked reduction of the inhibitory GABA neurotransmitter.

Treatment and Outcomes

Until the discovery of anti-GAD and other autoantibodies, GABA-enhancing medications were used both for diagnosis and symptomatic treatment. The realization that autoimmunity likely plays a role opened new diagnostic and treatment possibilities. Dalakas showed clear benefit for patients with SPS treated with intravenous immunoglobulin in a randomized, double-blind, placebo-controlled study involving 16 patients with SPS LEVEL 1.[1] Although most patients experience benefit after initial dose of intravenous immunoglobulin, many require repeat treatment to sustain response. Steroids and rituximab (antibodies directed against B cells) have not been shown to be effective.

Benzodiazepines are the mainstay for rigidity and spasms (as well as anxiety), and patients often require titration up to high doses; on average, 40 mg/d, but some require several hundred milligrams per day. Baclofen may be used as an adjunct, and doses of 60 to 100 mg/d may be required. Other medications that may be helpful are gabapentin (300-1,200 mg three times daily), pregabalin (50-100 mg three times daily), levetiracetam (500-1,500 mg twice daily), and, in refractory cases, dantrolene sodium (starting at 25 mg daily and titrating up to a maximum of 100 mg four times daily). Dantrolene should be used with caution and monitoring for cardiac side effects and hepatotoxicity. Some may respond to intrathecal baclofen. Dalakas and his group recently reported long-term follow-up of up to 8 years of a very large series of 57 SPS patients showing that SPS, especially when left untreated, is a progressive disorder leading to disability over time.

OTHER CENTRAL NERVOUS SYSTEM DISORDERS OF MUSCLE STIFFNESS

Common CNS disorders can show increased muscle tone. Stroke, multiple sclerosis, amyotrophic lateral sclerosis, and primary lateral sclerosis are examples where loss of normal inhibition of the motor system occurs. These relatively more common entities are discussed elsewhere in this book.

Although tetanus and tetany share a similar name and also some clinical features, they are entirely distinct. Tetanus is discussed in Chapter 66 and is only briefly mentioned here because of the pathogenic similarities to SPS at the inhibitory synapse. Tetanus is caused by the toxin tetanospasmin released from the bacteria *Clostridium tetani* in contaminated wounds. This toxin reaches nerve terminals and travels by retrograde axonal transport to reach inhibitory interneurons in the spinal cord and brainstem. Tetanospasmin prevents the release of GABA and glycine into the synapse, effectively blocking inhibitory neurotransmission in a similar mechanism to SPS. However, unlike SPS, tetanus has a predilection for the brainstem, possibly due to the shorter length of cranial nerve axons, eliciting distinct

features such as trismus and forceful satanic-like smile ("risus sardonicus"). Opisthotonic spasm of axial muscles may cause fractures and respiratory failure. Treatment includes respiratory support, antibiotics, antitoxin treatment, and muscle relaxants. Tetanus is best prevented by immunization, which is unfortunately unavailable in many developing countries. Risus sardonicus is also seen in strychnine intoxication with a similar mechanism of action; however, the clinical setting and toxin exposure set the two syndromes apart.

Tropical spastic paraparesis is caused by the human T-lymphotrophic virus 1 retrovirus and is prevalent in the adult population of the Caribbean islands. This infectious myelopathy primarily affects the thoracic spinal cord and is manifest by progressive spasticity and weakness, bladder dysfunction, and minor sensory symptoms. There are no current effective disease-modifying agents which alter the long term debilitating course. Corticosteroids, interferon-α and interferon-β, as well as other agents have been tried with limited success. Treatment is largely symptomatic and directed to relieve spasticity, painful muscle spasms, and loss of bladder control.

There are hereditary forms of spastic paraparesis, most notably the hereditary spastic paraplegias. These are clinically and genetically heterogeneous. Clinical syndromes may be "pure" if only manifesting as spasticity and weakness in the legs with bladder dysfunction or "complicated" if additional neurologic and systemic symptoms are present. These can be autosomal dominant, autosomal recessive, or X-linked and may be diagnosed genetically.

PERIPHERAL NERVE AND MUSCLE HYPEREXCITABILITY

Acquired Neuromyotonia (Isaac Syndrome)

Isaac first described this disorder as a state of "continuous muscle fiber activity." The invariable clinical manifestation is myokymia, visibly apparent constant muscle twitching likened to a bag of writhing worms. As a result of the continuous activity, patients may develop muscle cramps or abnormal postures of the limbs, which may be persistent or intermittent and are identical to carpal or pedal spasm.

Epidemiology

Neuromyotonia is a rare disorder; no specific information regarding incidence or prevalence is available. The acquired autoimmune forms can be seen in association with multiple other autoimmune diseases, either neurologic (such as myasthenia gravis) or systemic. Neuromyotonia is at times a paraneoplastic syndrome associated mainly with thymoma or small cell lung cancer but also with breast carcinoma or lymphoma.

Pathobiology

In the autoimmune form, neuromyotonia was first attributed to the presence of antibodies directed against voltage-gated potassium channels (VGKC). These channels are necessary to stabilize conduction at nodes of Ranvier, prevent repetitive firing, and maintain resting potential. Anti-VGKC complex antibodies were also found in some patients with limbic encephalitis and additionally in patients with the syndrome of benign fasciculations with cramps. This wide phenotypic spectrum associated with anti-VGKC was puzzling. However, advances in specific antibody identification have improved our understanding of the hyperexcitability syndromes and aided in clinical classification. More recent studies show that, rather than binding the potassium channel itself, the "anti-VGKC antibodies" bind antigenic neuronal targets of the macromolecular complex associated with the channel. The two main antigens are the leucine-rich glioma-inactivated protein 1 (LGI1) and contactin-associated protein-like 2 (CASPR2). Anti-LGI1 antibodies target CNS structures and are more commonly associated with limbic encephalitis. Anti-CASPR2 antibodies on the other hand, target both central and peripheral nervous tissue. They may be associated with neuromyotonia as well as the cramp-fasciculation syndrome, which may be a mild variant of Isaac syndrome. It is reasonable therefore to consider this spectrum of phenotypes under the umbrella of *autoimmune peripheral nerve hyperexcitability disorders*.

Clinical Manifestations

Isaac syndrome affects children, adolescents, or young adults and begins insidiously, progressing slowly for months or a few years. Symptoms most often begin in the distal arms and legs. Slow movement, clawing of the fingers, and toe walking are later joined by stiffness of proximal and axial muscles; occasionally, oropharyngeal or respiratory muscles are affected. The motor symptoms are often accompanied by the profuse sweating syndrome of hyperhidrosis. The stiffness and myokymia are seen at rest but, unlike SPS, continue in sleep and under general anesthesia. Voluntary contraction may induce a spasm that persists during attempted relaxation.

If patients develop higher cortical dysfunction manifest by sleep disorders, personality changes, and delirium, the condition is named the *Morvan syndrome*. The fixed postures of the limbs in Isaac syndrome can be simulated by the rare genetic Schwartz-Jampel syndrome (SJS). However, SJS is characterized by the additional features of a unique facial appearance (blepharophimosis), short stature, and bony abnormalities. In "ocular neuromyotonia," the limbs and cranial muscles are spared and the disorder is confined to one or more extraocular muscles.

Diagnosis

Antibodies reactive against the VGKC are detected in 30% to 40% of patients with Isaac syndrome and in 80% of those with coexisting thymoma but may also be seen at very low titers in asymptomatic people (2%). They may also be found in patients with painful small-fiber neuropathy. The prevalence of distinct antibodies to CASPR2 and LGI1 in this population is unknown. It is reasonable to perform a malignancy screening because 20% to 25% of patients with Isaac syndrome have an underlying malignancy (although the Isaac syndrome may precede malignancy by many years).

EMG shows characteristic findings. The EMG recorded from stiff muscles reveals prolonged myokymic or neuromyotonic discharges. In electrical myokymia, grouped fasciculations fire at rates up to 60 Hz and sound like marching soldiers. Myokymia may be found in the EMG of some individuals without any clinically visible twitching. Furthermore, myokymia is not restricted to Isaac syndrome; it may appear in other clinically distinct entities as postradiation neuropathy, multiple sclerosis, or after exposure to the Timber rattlesnake venom. In electrical *neuromyotonia*, on the other hand, continuous discharges occur at

rates of 150 to 300 Hz, tend to start or stop abruptly, and sound like a "NASCAR engine" or a "dive bomber." Voluntary effort triggers more intense discharges that persist during relaxation, accounting for the myotonia-like aftercontraction, but electrical myotonia is not found. In SJS, the more frequent EMG pattern is that of myotonic discharges, but there may be continuous motor activity with both myokymic and neuromyotonic discharges.

Treatment

The treatment of the peripheral nerve hyperexcitability disorders is multitiered. The muscle contraction symptoms are usually controlled with anticonvulsants as carbamazepine (200-1,200 mg daily in divided doses) or phenytoin (100-300 mg daily). Mexiletine may also be used at doses of 100 to 300 mg three times daily but with caution in patients at risk of cardiac arrhythmias (monitor for QTc prolongation) and can rarely cause hepatotoxicity. Plasmapheresis (three to five sessions every other day) and intravenous immunoglobulin therapy (2 g/kg over 4-5 d) are effective in some patients, and in the paraneoplastic group, treatment is directed primarily against the underlying cancer.

Tetany

Tetany is a clinical syndrome characterized by convulsions, paresthesia, prolonged spasms of limb muscles, or laryngospasm; it is accompanied by signs of hyperexcitability of peripheral nerves. Tetany occurs in patients with hypocalcemia, hypomagnesemia, or alkalosis. Hyperventilation may unmask latent hypocalcemic tetany, but respiratory alkalosis itself only rarely causes outright tetany.

Intense circumoral and digital paresthesia generally precede the typical carpopedal spasms, which consist of adduction and extension of the fingers, flexion of the metacarpophalangeal joints, and equinovarus postures of the feet. In severe cases, the spasms spread to the proximal and axial muscles, eventually causing opisthotonus. In all forms of tetany, the nerves are hyperexcitable, as manifested by the reactions to ischemia (Trousseau sign) or percussion (Chvostek sign). The spasms are owing to spontaneous firing of peripheral nerves, starting in the proximal portions of the longest nerves. EMG shows individual motor units discharging independently at a rate of 5 to 25 Hz (at times up to 300 Hz); each discharge consists of a group of two or more identical potentials.

The treatment of tetany consists of correcting the underlying metabolic disorder. Hypomagnesemia may lead to secondary hypocalcemia because it is necessary for the secretion of the parathormone. Therefore, treatment of tetany requires normal restoration of both.

Neuroleptic Malignant Syndrome and Malignant Hyperthermia

Acute diffuse symptoms of muscle stiffness maybe associated with exposure to neuroleptic medications that inhibit dopamine. The neuroleptic malignant syndrome (NMS) may be dramatic and life-threatening if not aggressively treated (see also Chapter 133). The syndrome comprises acute alteration of mental status, fever, autonomic dysfunction, and muscle breakdown with high serum levels of creatine kinase (CK). Muscle necrosis may release intracellular potassium and myoglobin into the serum; the resulting hyperkalemia may lead to cardiac arrhythmias and renal failure. An often overlooked cause of sudden dopamine loss with possible similar consequences may occur with abrupt discontinuation of dopaminergic medications used by patients with Parkinson disease. The mainstay treatment of NMS is supportive with body cooling, intravenous fluids, and respiratory support. Dopamine agonists such as bromocriptine (5-10 mg three to four times daily) and the potentially hepatotoxic muscle relaxant dantrolene may be helpful (start 25 mg daily, titrate up to 100 mg three to four times daily).

Another syndrome similar to NMS is seen in patients exposed to anesthetic agents causing the malignant hyperthermia syndrome. The most common offensive agents are the neuromuscular blocking agent succinylcholine and the inhaled general anesthetics like halothane, sevoflurane, and desflurane. High fever is the hallmark of the syndrome, but muscle stiffness, consequences of muscle breakdown ("rhabdomyolysis" or myoglobinuria), and cardiorespiratory collapse are virtually undistinguishable from NMS. Treatment is similar to that of NMS as well. Patients with the rare inherited myopathy central core disease have mutations in the ryanodine receptor RYR1 and are most susceptible to malignant hyperthermia syndrome.

Muscle Cramps

The common *muscle cramp* is a sudden, forceful, painful muscle contraction that lasts from a few seconds to several minutes. Muscle cramps are most often benign but can also accompany various neuromuscular disorders such as peripheral nerve hyperexcitability syndromes, lower motor neuron disease, medications, and myopathies (metabolic, mitochondrial, or dystrophic).

Epidemiology

Most adults have at least one episode of benign leg cramps during a lifetime, with no significant prevalence difference between men and women. In some populations, such as elderly veterans, up to 50% experience nocturnal leg cramps, as do 30% to 50% of pregnant women, worsening as pregnancy progresses. Most cramps occur only at night, some have both day and nighttime cramps, and a few have daytime-only cramps. In many, the attacks occur several times per week, and some experience daily cramps. Cramps are common in children with Charcot-Marie-Tooth disease and are a major source for discomfort in patients with amyotrophic lateral sclerosis. Frequent cramps tend to accompany hypothyroidism, uremia, profuse sweating or diarrhea, hemodialysis, electrolyte abnormalities, and hypoglycemia. Statins and diuretics may provoke cramps as well.

Pathobiology

A cramp often starts with fasciculations, after which the muscle becomes intermittently hard and knot-like as the involuntary contraction waxes and wanes, passing from one part of the muscle to another. Normally, when an α-motor neuron fires, acetylcholine is released into the neuromuscular junction, which then binds to and elicits an action potential in the muscle fiber. This action potential is then translated into contraction by release of calcium from the sarcoplasmic reticulum and the interaction of actin and myosin to cause muscle shortening (twitch or contraction). The process ends when calcium concentration decreases; both muscle contraction and relaxation require adenosine triphosphate. If calcium levels remain elevated, relaxation cannot occur. Stretch of the muscle spindle Ia fiber excites the motor neuron and also causes muscle contraction (monosynaptic muscle stretch reflex). Inhibition occurs within the spinal cord by inhibitory interneurons.

The neuroanatomic origin and propagation of cramps is a topic of ongoing debate, and both peripheral and central mechanisms are invoked. Cramps may result from hyperexcitability of the motor neurons (induced by afferent input) resulting in an autonomous positive feedback loop, implicating a spinal contribution. Cramps can be induced distal to a peripheral nerve block with electrical stimulation, and such cramps can be terminated by stretching the muscle, favoring a nerve terminal site of origin.

Clinical Manifestations

Muscle cramps are experienced as abrupt, painful spasms lasting seconds to minutes. Cramps may be provoked by a trivial movement or by voluntary contraction of a shortened muscle. They may occur during vigorous exercise but are more likely to occur after exercise ceases. Benign fasciculations or myokymia may be associated with frequent muscle cramps in apparently healthy people. The legs and in particular the calves are most often affected by cramps. Nocturnal cramps typically cause forceful flexion of the ankle and toes. However, cramps can affect almost any voluntary muscle.

Most people have cramps at some time, but a few people have inordinately frequent cramps, often accompanied by fasciculations. This syndrome of *benign fasciculations* is disproportionately more frequent among physicians and other medical workers because they are more likely to know the ominous implications of fasciculations for the diagnosis of motor neuron disease. However, motor neuron disease almost never starts with fasciculations alone. If neither weakness nor wasting is seen, motor neuron disease is essentially excluded. The syndrome of benign fasciculation has been reported many times with variations on the name.

True cramps must be distinguished from cramp-like muscle pain unaccompanied by spasm. The cramps of McArdle disease (myophosphorylase deficiency) occur during exercise due to the block of glycogen metabolism. Because no electrical activity is evident in the EMG during the painful shortening of muscle affected by McArdle disease, the term *contracture* is used. The origin of the contracture is not known, but depletion of adenosine triphosphate in muscle has long been suspected. Muscle breakdown is associated with myoglobinuria and elevated CK values in serum.

Mild dystrophinopathies, with little or no clinical weakness, may be manifested by exertional muscle pain and myoglobinuria. These symptoms have been referred to as *muscle cramps*, but actual muscle spasm has not been described in such cases; the pain may simply be a measure of muscle injury. The dystrophic and nondystrophic myotonic disorders are discussed elsewhere in this textbook.

Myalgia and cramps are believed to be especially common in *myoadenylate deaminase deficiency*, but because this condition is common in asymptomatic people (found in 1%-3% of all muscle biopsies), the association is difficult to confirm. Moreover, in affected families, the muscle enzyme deficiency and clinical symptoms are not well linked.

Diagnosis

The diagnosis of the common muscle cramp is essentially based on the clinical history. It is important to exclude underlying medical and neurologic causes for cramps. Routine laboratory testing for electrolytes and other underlying medical disorders can be performed as clinically indicated on a case-by-case basis. Tests may include complete blood cell count, metabolic panel, and CK.

Electrodiagnostic testing is useful in diagnosing an underlying peripheral nerve or muscle disorder as well as characterizing any abnormal spontaneous muscle activity. EMG of a cramp shows brief, periodic bursts of motor unit potentials discharging at a frequency of 200 to 300 Hz, appearing irregularly, and intermingling with similar discharges from adjacent motor units. Several foci within the same muscle may discharge independently. This electrical activity clearly arises within the lower motor neuron.

Treatment

Passive stretching of the affected muscle usually terminates a cramp. However, a 2010 analysis by the American Academy of Neurology found insufficient evidence for nonpharmacologic treatment (such as stretching and hydration) of muscle cramps LEVEL 1.[2]

A Cochrane Review in 2010 found that the administration of quinine derivatives at doses of 200 to 500 mg per day were effective, although modestly, with few serious adverse events LEVEL 1.[3] Rare but serious adverse effects of quinine include thrombocytopenia, bleeding diathesis, cardiac arrhythmias, and acute hypersensitivity reactions, which may occur in 2% to 4% of persons treated. Other serious adverse effects include hypoglycemia, vision loss, psychosis, tinnitus, and esophagitis. Given the adverse effect profile, the U.S. Food and Drug Administration has issued multiple warnings, and both the U.S. Food and Drug Administration and American Academy of Neurology recommend against the use of quinine for the routine treatment of muscle cramps. Use of quinine is recommended only when cramps are disabling, not relieved by other agents, and with full patient education and monitoring for possibly serious side effects LEVEL 1.[1]

Despite the frequency of common cramps, no other agents have been sufficiently studied, but agents that may be effective for cramps include vitamin B complex (thiamine 50 mg, cobalamin 250 μg, pyridoxine 30 mg, riboflavin 5 mg), naftidrofuryl (not available in the United States; 100 mg 3 times daily), and diltiazem (30 mg daily). Other agents commonly used with variable success include baclofen, benzodiazepines, carbamazepine, oxcarbazepine, verapamil, magnesium citrate, and gabapentin; however, evidence is insufficient regarding these agents. For cramps associated with hemodialysis, vitamin E and C may be effective, and zinc sulfate and branched chain amino acids may be helpful in cramps associated with cirrhosis. For cramps occurring in association with amyotrophic lateral sclerosis, gabapentin and tetrahydrocannabinol are ineffective.

Outcome

The common muscle cramp has a good prognosis, but pain and discomfort can be troublesome. Nocturnal cramps can interrupt sleep.

LEVEL 1 EVIDENCE

1. Dalakas MC. The role of IVIg in the treatment of patients with stiff person syndrome and other neurological diseases associated with anti-GAD antibodies. *J Neurol*. 2005;252(suppl 1): I19-I25.
2. Katzberg HD, Khan AH, So YT. Assessment: symptomatic treatment for muscle cramps (an evidence-based review): report of the therapeutics and technology assessment subcommittee of the American Academy of Neurology. *Neurology*. 2010;74(8):691-696.
3. El-Tawil S, Al Musa T, Valli H, Lunn MP, El-Tawil T, Weber M. Quinine for muscle cramps. *Cochrane Database Syst Rev*. 2010;(12):CD005044.

SUGGESTED READINGS

Stiff Person Syndrome

Alexopoulos H, Dalakas MC. A critical update on the immunopathogenesis of stiff person syndrome. *Eur J Clin Invest*. 2010;40(11):1018-1025.

Barker RA, Revesz T, Thom M, Marsden C, Brown P. Review of 23 patients affected by the stiff man syndrome: clinical subdivision into stiff trunk (man) syndrome, stiff limb syndrome, and progressive encephalomyelitis with rigidity. *J Neurol Neurosurg Psychiatry*. 1998;65:633-640.

Butler MH, Hayashi A, Ohkoshi N, et al. Autoimmunity to gephyrin in stiff-man syndrome. *Neuron*. 2000;26(2):307-312.

Carvajal-González A, Leite MI, Waters P, et al. Glycine receptor antibodies in PERM and related syndromes: characteristics, clinical features and outcomes. *Brain*. 2014;137(pt 8):2178-2192.

Chang T, Alexopoulos H, McMenamin M, et al. Neuronal surface and glutamic acid decarboxylase autoantibodies in nonparaneoplastic stiff person syndrome. *JAMA Neurol*. 2013;70(9):1140-1149.

De Camilli P, Thomas A, Cofiell R, et al. The synaptic vesicle-associated protein amphiphysin is the 128-kD autoantigen of stiff-man syndrome with breast cancer. *J Exp Med*. 1993;178:2219-2223.

Levy LM, Levy-Reis I, Fujii M, Dalakas MC. Brain gamma-aminobutyric acid changes in stiff-person syndrome. *Arch Neurol*. 2005;62(6):970-974.

Lorish TR, Thorsteinsson G, Howard FM Jr. Stiff-man syndrome updated. *Mayo Clin Proc*. 1989;64(6):629-636.

McKeon A, Martinez-Hernandez E, Lancaster E, et al. Glycine receptor autoimmune spectrum with stiff-man syndrome phenotype. *JAMA Neurol*. 2013;70(1):44-50.

McKeon A, Robinson MT, McEvoy KM, et al. Stiff-man syndrome and variants: clinical course, treatments, and outcomes. *Arch Neurol*. 2012;69(2):230-238.

Moersch FP, Woltman HW. Progressive fluctuating muscular rigidity and spasm ("stiff-man" syndrome): report of a case and some observations in 13 other cases. *Proc Staff Meet Mayo Clin*. 1956;31:421-427.

Petzold GC, Marcucci M, Butler MH, et al. Rhabdomyolysis and paraneoplastic stiff-man syndrome with amphiphysin autoimmunity. *Ann Neurol*. 2004;55:286-290.

Rakocevic G, Floeter MK. Autoimmune stiff person syndrome and related myelopathies: understanding of electrophysiological and immunological processes. *Muscle Nerve*. 2012;45(5):623-634.

Rakocevic G, Alexopoulos H, Dalakas MC. Quantitative clinical and autoimmune assessments in stiff person syndrome: evidence for a progressive disorder. *BMC Neurol*. 2019;19(1):1.

Cramps and Related Disorders

Alvarez MV, Driver-Dunckley EE, Caviness JN, Adler CH, Evidente VGH. Case series of painful legs and moving toes: clinical and electrophysiologic observations. *Mov Disord*. 2008;23(14):2062-2066.

Blexrud MD, Windebank AJ, Daube JR. Long-term follow-up of 121 patients with benign fasciculations. *Ann Neurol*. 1993;34:622-625.

Layzer RB. The origin of muscle fasciculations and cramps. *Muscle Nerve*. 1994;17:1243-1249.

Minetto MA, Holobar A, Botter A, Farina D. Origin and development of muscle cramps. *Exerc Sport Sci Rev*. 2013;41(1):3-10.

Rowland LP. Cramps, spasms and muscle stiffness. *Rev Neurol (Paris)*. 1985;141:261-273.

Rowland LP, Trojaborg W, Haller RG. Muscle contracture: physiology and clinical classification. In: Serratrice G, Pouget J, Azulay J-P, eds. *Exercise Intolerance and Muscle Contracture*. Paris, France: Springer; 1999:161-170.

Thompson PD. Muscle cramp syndromes. *Handb Clin Neurol*. 2007;86:389-396.

Neuromyotonia

Binks SNM, Klein CJ, Waters P, Pittock SJ, Irani SR. LGI1, CASPR2 and related antibodies: a molecular evolution of the phenotypes. *J Neurol Neurosurg Psychiatry*. 2018;89(5):526-534.

Hart IK, Maddison P, Newsom-Davis J, Vincent A, Mills KR. Phenotypic variants of autoimmune peripheral nerve hyperexcitability. *Brain*. 2002;125(pt 8):1887-1895.

Irani SR, Alexander S, Waters P, et al. Antibodies to Kv1 potassium channel-complex proteins leucine-rich, glioma inactivated 1 protein and contactin-associated protein-2 in limbic encephalitis, Morvan's syndrome and acquired neuromyotonia. *Brain*. 2010;133(9):2734-2748.

Klein CJ, Lennon VA, Aston PA, et al. Insights from LGI1 and CASPR2 potassium channel complex autoantibody subtyping. *JAMA Neurol*. 2013;70(2):229-234.

Lai M, Huijbers MG, Lancaster E, et al. Investigation of LGI1 as the antigen in limbic encephalitis previously attributed to potassium channels: a case series. *Lancet Neurol*. 2010;9(8):776-785.

Lancaster E, Huijbers MG, Bar V, et al. Investigations of Caspr2, an autoantigen of encephalitis and neuromyotonia. *Ann Neurol*. 2011;69(2):303-311.

Maddison P. Neuromyotonia. *Clin Neurophysiol*. 2006;117(10):2118-2127.

Paterson RW, Zandi MS, Armstrong R, Vincent A, Schott JM. Clinical relevance of positive voltage-gated potassium channel (VGKC)-complex antibodies: experience from a tertiary referral centre. *J Neurol Neurosurg Psychiatry*. 2014;85:625-630.

Takahashi H, Mori M, Sekiguchi Y, et al. Development of Isaacs' syndrome following complete recovery of voltage-gated potassium channel antibody-associated limbic encephalitis. *J Neurol Sci*. 2008;275(1-2):185-187.

Taylor RG, Layzer RB, Davis HS, Fowler WM Jr. Continuous muscle fiber activity in the Schwartz-Jampel syndrome. *Electroencephalogr Clin Neurophysiol*. 1972;33:497-509.

Vincent A. Autoimmune channelopathies: John Newsom-Davis's work and legacy: a summary of the Newsom-Davis Memorial Lecture 2008. *J Neuroimmunol*. 2008;201-202:245-249.

99 Metabolic and Mitochondrial Myopathies in Adults

Michio Hirano, H. Orhan Akman, and Salvatore DiMauro

KEY POINTS

1. Metabolic myopathies encompass a clinically and etiologically diverse group of rare inherited disorders due to defects in cellular energy metabolism, including the breakdown of carbohydrates and fatty acids to generate adenosine triphosphate, predominantly through mitochondrial respiratory chain oxidative phosphorylation.
2. Adult glycogen storage disorders can present as slowly progressive myopathies (eg, acid maltase deficiency) or as acute muscle cramps with or without myoglobinuria after short bursts of intense exercise.
3. Myopathies due to fatty acid oxidation defects often present with myalgias, fatigue, and myoglobinuria, typically without cramps, after prolonged exercise.
4. Mitochondrial disease due to primary defects of oxidative-phosphorylation can present as isolated myopathies often with extraocular muscle weakness and exercise intolerance disproportionate to the level of muscle weakness.

INTRODUCTION

Metabolic myopathies comprise a clinically and etiologically diverse group of disorders due to defects in cellular energy metabolism, including the breakdown of carbohydrates and fatty acids to generate adenosine triphosphate (ATP), predominantly through mitochondrial respiratory chain oxidative phosphorylation. Accordingly, metabolic myopathies can be etiologically classified into three broad categories: glycogen storage diseases, fatty acid oxidation disorders, and mitochondrial diseases. These metabolic myopathies present with a clinical spectrum ranging from severe infantile-onset multisystemic diseases to mild adult-onset isolated myopathies. In this chapter, we focus on metabolic myopathies that affect adults.

EPIDEMIOLOGY

Metabolic myopathies are rare diseases. The most common of these disorders is Pompe (acid maltase deficiency) disease with variable ethnic and geographic incidence at newborn screening from 1:4,400 births annually in Austria to 1:165,000 in people in New York State. Prevalence of late-onset Pompe disease has been estimated to be 1:60,000. Other frequent metabolic myopathies include McArdle disease (myophosphorylase deficiency) and carnitine palmitoyltransferase II (CPT II) deficiency. The prevalence of McArdle disease has been estimated to be 1:100,000 in the Dallas–Fort Worth, Texas, region and a minimum of 1:170,000 in Spain. The prevalence of CPT II deficiency is unknown; however, over 300 patients have been reported. Although individual mitochondrial diseases are rare, collectively, the prevalence of mitochondrial disorders in adults is approximately 1:4,300.

PATHOBIOLOGY

Energy in the form of ATP is required to drive numerous cellular functions including muscle contraction. The main fuels used to generate ATP are glycogen, glucose, and free fatty acids. Glycogen is metabolized in the cytoplasm to pyruvate, which enters mitochondria (Fig. 99.1). Short- and medium-chain fatty acids cross freely into the mitochondria, whereas long-chain fatty acids require binding to carnitine for transport across the mitochondrial membrane, a process mediated by carnitine-acylcarnitine translocase and CPTs I and II (Fig. 99.2). Once in the mitochondria, all these substrates are converted into acetyl-coenzyme A (CoA), which feeds into the Krebs cycle. In this critical cycle, reducing equivalents (electrons) combined with protons are bound to intermediate molecules, nicotinamide adenine dinucleotide and flavin adenine dinucleotide, reduced, which deliver the electrons to the mitochondrial respiratory chain to produce ATP and water.

Defects in any of these pathways—glycogen catabolism (glycogenolysis and glycolysis), fatty acid oxidation, Krebs cycle, and mitochondrial respiratory chain and oxidative phosphorylation—cause human disorders that often predominantly affect muscle due to its high energy requirements, particularly during exercise. Because most of the enzyme defects are partial, many of these diseases manifest in adulthood with muscle symptoms either in isolation or with other clinical features.

Abundant glucose is stored in liver and skeletal muscle in the form of a polysaccharide called *glycogen*. The glycogenoses include disorders characterized by genetic mutations in glycogen synthesis (glyconeogenesis), degradation (glycogenolysis), or glucose degradation (glycolysis). To date, 15 glycogenoses have been identified (see Fig. 99.1); most are autosomal recessive except for phosphoglycerate kinase (PGK) and phosphorylase *b* kinase deficiency, which are X-linked.

Fatty acids are the primary energy source for muscle at rest and during periods of prolonged low-intensity exercise. Fatty acids are catabolized by the β-oxidation enzymes, which cleave two-carbon fragments with each cycle. Thus, lipidoses arise due to failure of fatty acid transport into mitochondria secondary

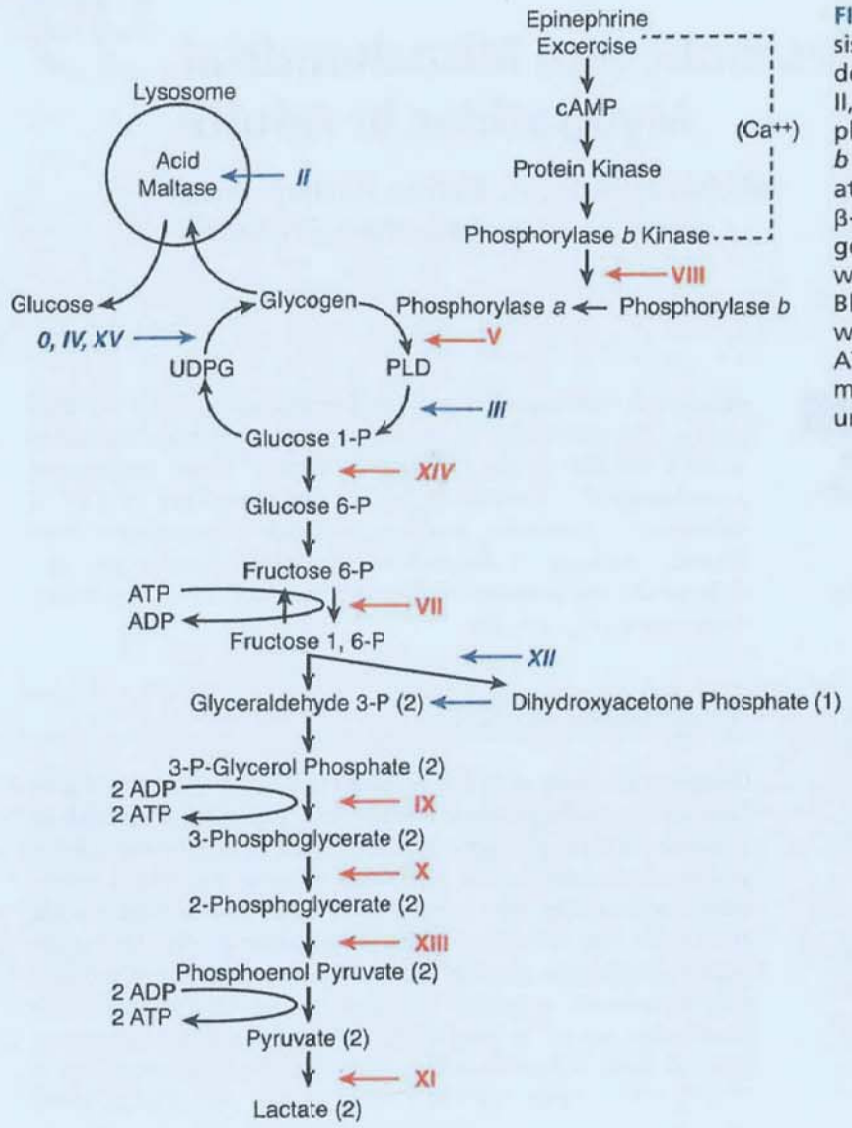

FIGURE 99.1 Scheme of glycogen metabolism and glycolysis. Roman numerals denote muscle glycogenoses due to defects in the following enzymes: 0, glycogen synthase; II, acid maltase; III, debrancher; IV, brancher; V, myophosphorylase; VII, phosphofructokinase; VIII, phosphorylase *b* kinase; IX, phosphoglycerate kinase; X, phosphoglycerate mutase; XI, lactate dehydrogenase; XII, aldolase; XIII, β-enolase; XIV, phosphoglucomutase 1; and XV, glycogenin-1. Red numerals designate glycogenoses associated with exercise intolerance, cramps, and myoglobinuria. Blue italic numerals correspond to glycogenoses causing weakness. Abbreviations: ADP, adenosine diphosphate; ATP, adenosine triphosphate; cAMP, cyclic adenosine monophosphate; PLD, phosphorylase-limit dextra; UDPG, uridine diphosphate glucose.

to carnitine or CPT I or II deficiencies or to defects of intramitochondrial β-oxidation. These disorders are inherited as autosomal recessive traits. The more severe variants present in infancy or childhood with primary involvement of liver or brain, whereas the milder adult forms are predominantly myopathic and include the myopathic variant of CPT II deficiency, trifunctional protein (TFP) deficiency, and very long chain acyl-CoA dehydrogenase (VLCAD) deficiency.

In addition to catabolizing lipids, mitochondria perform additional essential functions including Krebs cycle and amino acid metabolism as well as energy production through the respiratory chain and oxidative phosphorylation. The respiratory chain is composed of four multisubunit enzymatic complexes (I, II, III, and IV), which generate a proton gradient across the inner mitochondrial membrane that, in turn, drives ATP synthesis by complex V. In addition, coenzyme Q_{10} (CoQ_{10}) and cytochrome *c* are critical components of the mitochondrial respiratory chain, serving as "electron shuttles" between the complexes. Originally restricted to primary defects of the respiratory chain and oxidative phosphorylation, mitochondrial diseases have expanded to encompass defects of mitochondrial transcription, translation, mitochondrial DNA maintenance, protein importation, lipid membranes, and organellar dynamics (fusion, fission, and movement) (see Chapter 144).

DIAGNOSIS

From a clinical point of view, metabolic myopathies can be categorized into two different groups: (1) those that show symptoms and signs related to exercise (exercise intolerance, cramps, myalgias, myoglobinuria) with normal interictal examination and (2) those with fixed symptoms such as muscle weakness often associated with systemic involvement (such as encephalopathies or endocrinopathies). When evaluating a patient with exercise-related symptoms, clinicians should ask two questions: (1) What type of exercise provokes symptoms? (2) Are there associated triggering factors? If short bursts of high-intensity exercise cause muscle cramps or myoglobinuria, the patient may have a defect of glycogen metabolism. Examples of this type of activity include weight lifting or sprinting. In young patients who play baseball or softball, the "home run" sign (Haller sign), inability to sprint around the bases due to exercise-induced muscle spasms, is a typical complaint in patients with glycogenoses, such as McArdle disease. In contrast, if the patient complains that prolonged exercise (such as hiking or playing soccer) triggers myalgias, fatigue, and myoglobinuria without acute contractures, the patient is likely to have a defect of fatty acid oxidation. The symptoms often occur when the patient is fasting or under stress. A prototypical example is a young adult

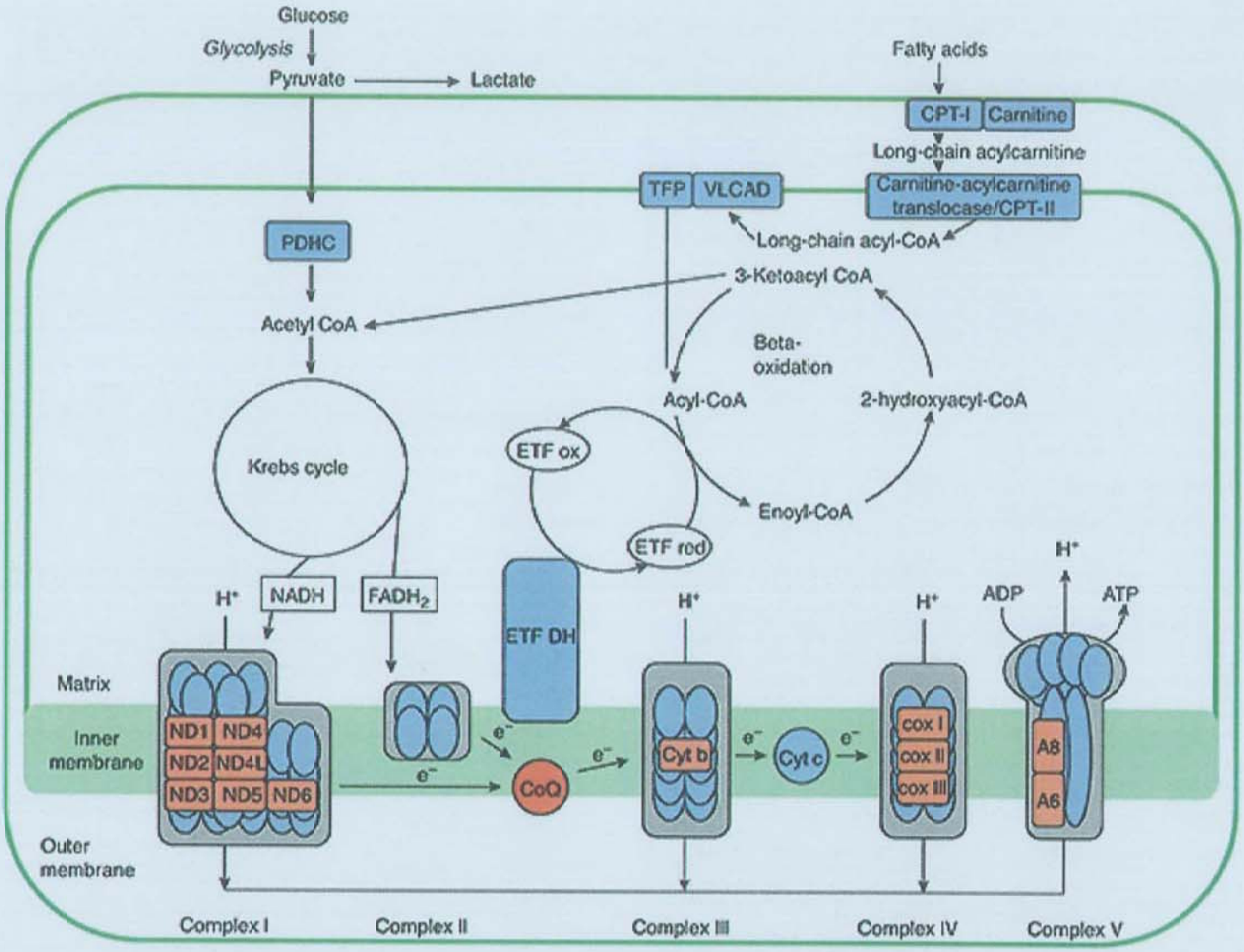

FIGURE 99.2 Schematic representation of mitochondrial metabolism. Abbreviations: ADP, adenosine diphosphate; ATP, adenosine triphosphate; CoA, coenzyme A; CoQ, coenzyme Q; CPT, carnitine palmitoyltransferase; Cyt c, cytochrome c; ETF DH, electron transfer flavoprotein dehydrogenase; ETF ox, electron transfer flavoprotein oxidized and reduced; ETF red, electron transfer flavoprotein and reduced; $FADH_2$, flavin adenine dinucleotide, reduced; NADH, nicotinamide adenine dinucleotide; PDHC, pyruvate dehydrogenase complex; TFP, trifunctional protein; VLCAD, very long chain acyl-CoA dehydrogenase.

with CPT II deficiency who enlists in military service and has difficulty completing long marches due to fatigue and myalgias followed by myoglobinuria.

In the past, the term *myoglobinuria* was reserved for grossly pigmented urine, but modern techniques can detect amounts of this protein so minute that discoloration may not be evident. (Determination of serum myoglobin content by radioimmunoassay has similar diagnostic significance as measurement of serum creatine kinase [CK] activity.) The clinically important syndromes, however, are associated with gross pigmenturia. Numerous conditions cause myoglobinuria (Table 99.1). Sometimes, the disorder can be recognized without direct demonstration of myoglobin in the urine: For instance, acute renal failure in a patient with levels of serum CK activity over 20,000 U/L would indicate myoglobinuric renal failure. Inexplicably, the cumbersome neologism *rhabdomyolysis* was favored for many years, but a 2020 PubMed search revealed that "myoglobinuria" is holding fast. Myoglobin is the visible pigment in the urine, and it is a toxin that contributes to kidney injury; the syndrome originates with muscle necrosis (rhabdomyolysis) and does not need a new and imprecise name.

Disorders of Glycogen Metabolism (Glycogenoses)

Some patients with glycolytic, lipid, or mitochondrial disorders can develop isolated progressive myopathy and persistent weakness. More typically, patients with mitochondrial diseases can show a wide range of extramuscular manifestations. In this section, general clinical aspects of these metabolic myopathies with emphasis on the more common forms are described.

Clinical presentations of muscle glycogenoses are protean, ranging from profound multisystem disease in infancy to exercise intolerance or isolated progressive muscle weakness in adults. Here, we focus on the adult patients. Myophosphorylase deficiency (McArdle disease, glycogenosis type V) is a prototypical glycogenolytic disorder with episodic muscle dysfunction and myoglobinuria. It is the most common disorder of skeletal muscle

TABLE 99.1 Classification of Human Myoglobinuria

Hereditary Myoglobinuria
Disorders of Glycogen Metabolism
Myophosphorylase deficiency (McArdle [1951]; MIM 232600)
Phosphofructokinase deficiency (Tarui et al [1965]; MIM 171840)
Phosphoglycerate kinase (MIM 311800)
Phosphoglycerate mutase (MIM 261670)
Lactate dehydrogenase (Kanno et al [1980]; MIM 150000)
Disorders of Lipid Metabolism
Carnitine palmitoyltransferase II deficiency (DiMauro & DiMauro-Melis [1973]; MIM 255110)
LPIN1 mutations (MIM 268200)
VLCAD deficiency (MIM 201375)
Trifunctional protein deficiency (MIM 609015)
Mitochondrial Myopathies
Mitochondrial DNA (MTCYB) mutations
Coenzyme Q_{10} deficiency
Other Genetic Myopathies
RYR1 deficiency (with malignant hyperthermia MIM 145600, without malignant hyperthermia MIM 117000 and 255320)
Becker/Duchenne muscular dystrophy
FSHD
Limb-girdle muscular dystrophy 1C (Caveolin deficiency)
Limb-girdle muscular dystrophy 2C (SGCG, γ-sarcoglycan deficiency)
Limb-girdle muscular dystrophy 2D (SGCA, α-sarcoglycan deficiency)
Limb-girdle muscular dystrophy 2E (SGCB, β-sarcoglycan deficiency)
Limb-girdle muscular dystrophy 2I (FKRP deficiency)
Limb-girdle muscular dystrophy 2L (ANO5 mutations)
Sporadic Myoglobinuria
Exertion in Untrained Individuals
"Squat-jump" and related syndromes
Anterior tibial syndrome
Convulsions
High-voltage electric shock, lightning stroke
Agitated delirium, restraints
Status asthmaticus
Prolonged myoclonus or acute dystonia
Crush Syndrome
Compression by fallen weights
Compression by body in prolonged coma

Sporadic Myoglobinuria
Ischemia
Arterial occlusion
Cardioversion
Coagulopathy in sickle cell disease or disseminated intravascular coagulation
Ischemia in compression and anterior tibial syndromes
Laparoscopic nephrectomy
Ligation of vena cava
Surgery on morbidly obese people, including bariatric surgery
Metabolic Depression
Barbiturate, carbon monoxide, narcotic coma
Cold exposure
Diabetic acidosis
General anesthesia
Hyperglycemic, hyperosmolar coma
Hypothermia
Exogenous Toxins and Drugs
Alcohol abuse
Amphotericin B
Carbenoxolone
Clopidogrel (and heart transplant)
Gemfibrozil (plus statin)
Glycyrrhizae
Haff disease
Heatstroke
Heroin
Hypokalemia, chronic, any cause
Interferon α-2b
Isotretinoin
Malayan sea-snake bite poison
Malignant neuroleptic syndrome
Plasmocid
Phenylpropanolamine
Statin drugs
Succinylcholine
Toxic shock syndrome
Viral infection (CMV, influenza, others)
Wasp stings
Progressive Muscle Disease
Alcoholic myopathy
Polymyositis or dermatomyositis
Cause unknown

Abbreviations: CMV, cytomegalovirus; FSHD, fascioscapulohumeral dystrophy; VLCAD, very long chain acyl-coenzyme A dehydrogenase.

carbohydrate metabolism and one of most frequent genetic myopathies. Patients with McArdle disease typically exhibit intolerance to static or isometric muscle contractions and also to dynamic exercise that can trigger episodes of reversible "muscle crises." Acute crises manifest mainly in the form of premature fatigue and contractures, frequently accompanied by muscle breakdown (rhabdomyolysis) with elevated serum CK and sometimes by myoglobinuria. In addition to McArdle disease, six other forms of glycogenoses manifest exercise-induced myoglobinuria: type VII (phosphofructokinase [PFK] deficiency, Tarui disease), type VIII (phosphorylase *b* kinase), type IX (PGK deficiency), type X (phosphoglycerate mutase [PGAM] deficiency), type XI (lactate dehydrogenase deficiency), and type XIV (phosphoglucomutase 1 deficiency).

Another important sign considered pathognomonic is the "second wind," which is a marked improvement in exercise tolerance about 10 minutes into aerobic exercise involving large muscle masses (jogging or cycling). The second wind, as manifested by a marked decrease in early exertional tachycardia (eg, a decrease from ~140-150 beats per minute to ~120 beats per minute) starting after around 7 minutes of exercise, does not occur in patients with other disorders that are also associated with exercise intolerance, such as PFK deficiency and other glycogenoses, mitochondrial myopathies, or disorders of lipid metabolism. This phenomenon is due to increased uptake of glucose and use of fatty acid.

Hemolytic anemia (elevated indirect bilirubin and reticulocytes) is seen in glycogenosis due to defects in genes partially expressed in erythrocytes such as PFK, PGK, and aldolase A. Cognitive deficits are often associated with the adult polyglucosan body disease (APBD) form of branching enzyme deficiency (type IV) and PGK deficiency.

Acid maltase or acid α–glucosidase (GAA) is an enzyme responsible for the catabolism of glycogen within lysosomes. Infantile-onset acid maltase deficiency (type II, Pompe disease) presents as a myopathy and cardiomyopathy, which, if untreated, is typically fatal in the first year of life. In contrast, in the late-onset form of Pompe disease beginning in childhood through adulthood, patients have slowly progressive fixed proximal muscle weakness and early respiratory insufficiency. Although myopathy is the predominant manifestation, patients with Pompe disease also develop basilar artery and aortic aneurysms, bladder or bowel incontinence, and dysphagia. An autopsy study of a late-onset Pompe patient revealed ultrastructural abnormalities in the smooth muscle of blood vessels, gastrointestinal tract, and bladder, thereby accounting for the extraskeletal muscle manifestations. Hearing loss has also been reported in this disease. It is important to diagnose Pompe disease because enzyme replacement therapy with recombinant human GAA (rhGAA) dramatically improves the cardiomyopathy in the infantile form and less effectively improves the myopathy in both infantile and late-onset forms.

In other cases, such as debrancher deficiency (type III, Cori-Forbes disease), distal muscle weakness can be combined with cardiomyopathy and peripheral neuropathy in patients who had shown in infancy hepatomegaly, hypoglycemia, and failure to thrive, all of which usually improve around puberty. Thus, adult patients with debrancher deficiency can manifest distal muscle weakness and wasting with electromyographic myogenic and neurogenic abnormalities.

Branching enzyme deficiency (type IV) presents with heterogeneous phenotypes ranging from congenital or infantile neuromuscular disorders to late-onset APBD, which manifests as progressive upper and lower motor neuron dysfunction, stocking-glove sensory loss, bladder dysfunction, and dementia. Muscle and nerve biopsies of APBD patients reveal periodic acid-Schiff–positive but diastase-resistant polyglucosan bodies. Although reported in various ethnic groups, APBD is particularly frequent in the Ashkenazi Jewish population due to founder mutations. Polyglucosan bodies are also characteristic of a juvenile-onset myopathy often accompanied by cardiomyopathy due to mutations in *RBCK1*, which encodes a ubiquitin ligase.

Striking absence of glycogen is characteristic of two disorders: glycogenosis type 0, glycogen synthase (GS1) deficiency, and glycogenosis type XV, glycogenin-1 deficiency. Both enzymes are required for the synthesis of glycogen. GS1 deficiency has presented as childhood exercise intolerance, cardiomyopathy, sudden death, or cardiomyopathy and myopathy. Glycogenin-1 deficiency has been associated with two phenotypes: a late adult-onset pure skeletal myopathy and young adult-onset myopathy with cardiomyopathy; muscle biopsies have polyglucosan bodies.

Disorders of Lipid Metabolism

Since DiMauro and DiMauro-Melis described the first patients with CPT II deficiency, this disease has been the most frequently diagnosed disorder of lipid metabolism. The first symptoms most often occur between 6 and 20 years of age, but age at onset may be older than 50 years. The symptomatology usually consists of recurrent attacks of myalgias and muscle stiffness or weakness, often associated with myoglobinuria. The attacks are usually acute and the consequences may be prolonged up to several weeks. The patients are usually asymptomatic between attacks. The frequency of these attacks is highly variable. The rhabdomyolysis may occasionally be complicated by two types of life-threatening events: more commonly, acute renal failure secondary to myoglobinuria and, much less frequently, respiratory insufficiency secondary to respiratory muscle involvement. Symptoms are usually prompted by prolonged exercise and less commonly by prolonged fasting, high-fat intake, exposure to cold, mild infection (especially in children), fever, emotional stress, general anesthesia, or drugs such as diazepam or ibuprofen. In all cases, the clinical symptomatology is restricted to skeletal muscle without liver or heart involvement.

Defects of most β-oxidation enzymes typically manifest in infancy with severe multisystem disease; however, the clinical presentation of VLCAD deficiency may be indistinguishable from CPT II deficiency. Trifunctional enzyme catalyzes three steps in long-chain fatty acid β-oxidation: enoyl-CoA hydratase, long-chain 3-hydroxyacyl-CoA dehydrogenase, and acylthiolase (see **Fig. 99.2**). Adults with TFP deficiency present with recurrent rhabdomyolysis triggered by prolonged exercise, fasting, or infections similar to CPT II and VLCAD deficiencies; however, TFP mutations are often associated with peripheral neuropathy and pigmentary retinopathy.

Multiple acyl-CoA dehydrogenation deficiency (MADD), also known as *glutaric aciduria type II*, is an autosomal recessive disorder due to mutations in genes encoding either one of the two subunits of the electron transferring flavoprotein (*ETFA* and *ETFB*) or to mutations in the gene encoding the electron transfer flavoprotein dehydrogenase (*ETFDH*) and resulting in abnormal fatty acid, amino acid, and choline metabolism. Less severely affected patients might present with progressive muscle weakness

and lipid storage myopathies with secondary muscle CoQ_{10} deficiency, mainly in adulthood and are sometimes responsive to riboflavin treatment (riboflavin responsive MADD), CoQ_{10} supplementation, or both.

The myopathic form of CoQ_{10} deficiency is characterized by proximal myopathy with premature fatigue, weakness, and increased serum levels of CK and lactate. Muscle biopsies show excessive numbers of lipid droplets, predominantly in type 1 fibers, combined deficiency of respiratory chain complexes I and III, and CoQ_{10} levels below 50% of normal. Mutations in the *ETFDH* gene, leading to a decrement in complex electron transfer flavoprotein-ubiquinone oxidoreductase (ETF:QO) activity, have been identified in adult-onset MADD and some cases of myopathy with CoQ_{10} deficiency indicating that they can be allelic diseases.

Neutral lipid storage disease (NLSD) present with mild to moderate proximal limb weakness with striking accumulation of lipid in skeletal muscle and other tissues as well as in leukocytes (Jordan anomaly). CK is persistently elevated and has preceded weakness. Mutations in *PNPLA2* encoding adipocyte triglyceride lipase cause neutral lipid storage myopathy, whereas mutations in *ABHD5*, which encodes CGI-58 (activator of adipocyte triglyceride lipase), cause lipid storage myopathy with ichthyosis (Chanarin-Dorfman syndrome).

Mitochondrial Diseases

Although mitochondrial diseases frequently present as infantile- or childhood-onset multisystemic diseases, many adult patients have myopathy as the predominant or only manifestation with either fixed weakness, exercise intolerance, or both. Myoglobinuria is less common in respiratory chain oxidative phosphorylation disorders relative to other metabolic myopathies.

Like most myopathies, mitochondrial myopathies cause proximal limb weakness, but extraocular muscles are also frequently affected, leading to ptosis and chronic progressive external ophthalmoplegia (CPEO). CPEO begins in childhood or adulthood and typically manifests with symmetric and slowly progressive impairment of eye movements accompanied by ptosis. Occasionally, the extraocular muscle weakness can be strikingly asymmetric. CPEO is sometimes misdiagnosed as myasthenia gravis; however, fixed weakness with minimal or no fluctuations, absence of acetylcholine receptor and muscle specific tyrosine kinase antibodies, as well as absence of neuromuscular junction dysfunction on electrophysiologic studies should lead clinicians to screen for myopathies such as CPEO.

CPEO often remains a pure myopathy with limb weakness and variable dysphagia and respiratory muscle involvement. In contrast, CPEO can be part of a multisystemic disease such as Kearns-Sayre syndrome (KSS) or sensory ataxic neuropathy dysarthria ophthalmoplegia (SANDO) (see Chapter 144). Some individuals are classified as CPEO-plus because they develop additional neurologic manifestations but lack features to fulfill criteria for KSS, SANDO, or other defined clinical syndromes. CPEO can be due to maternally inherited mitochondrial DNA (mtDNA) point mutations, sporadic single large-scale deletions of mtDNA, or primary autosomal dominant or recessive mutations that cause secondary multiple deletions of mtDNA.

In patients with mitochondrial myopathies, exercise intolerance presents with premature fatigue with activities as mild as walking up a single flight of stairs. After a short rest, patients usually can resume their activity but symptoms recur. Mitochondrial disease patients often report subjective heaviness or burning of muscles with exertion but, in contrast to patients with glycogenoses, do not typically manifest stiffness, cramps, or second wind phenomenon. The exercise intolerance is often disproportionately severe relative to muscle weakness. This symptom can be isolated or associated with muscle weakness and multisystemic involvement. Exercise testing is particularly helpful as an evaluation and screening tool in mitochondrial myopathies. Elevated lactate levels at rest and exaggerated lactate responses after even trivial exercise are useful clues to the diagnosis of mitochondrial disease. One of the hallmarks of mitochondrial myopathies is a reduction in maximal whole-body oxygen consumption (VO_2 max) demonstrated by a characteristic deficit in peripheral oxygen extraction (arteriovenous oxygen difference) and an enhanced oxygen delivery (hyperkinetic circulation). Alternatively, in specialized referral centers, phosphorus-31 nuclear magnetic resonance spectroscopy can reveal prolonged recovery of levels of high-energy phosphate compounds (eg, ATP and phosphocreatine) after exercise in patients with mitochondrial myopathies.

An unusual group of mitochondrial disease patients present with sporadic isolated myopathies with exercise intolerance variably accompanied by proximal muscle weakness and myoglobinuria. It is important for clinicians to be aware of this condition, which in several cases, was misdiagnosed as chronic fatigue syndrome or fibromyalgia. Resting venous lactic acid is elevated in most patients with this condition; therefore, blood lactate is a useful noninvasive screening test for this syndrome. In most cases, muscle biopsies reveal ragged-red fibers that are cytochrome *c* oxidase–positive because the gene defect is often a mutation in the cytochrome *b* gene, which encodes a subunit of complex III, or in an ND gene, encoding a subunit of complex I. In addition, other mutations in mtDNA have been associated with exercise intolerance, including transfer RNA (tRNA) mutations as well as mutations in protein coding genes for subunits of respiratory chain complex I or IV. Because the mutations are not detectable in blood in most of these patients, muscle biopsy is generally required to make the diagnosis.

A rare clinical form of CoQ_{10} deficiency presents as encephalomyopathy in childhood with the triad of encephalopathy (seizures, mental retardation, or ataxia), muscle weakness often with myoglobinuria, and ragged-red fibers in muscle. Patients have been diagnosed in adolescence or adulthood and have improved with CoQ_{10} supplementation.

A rare childhood-onset mitochondrial myopathy has been identified in Northern Swedish patients who have exercise intolerance. In these patients, modest exercise triggers fatigue, tachycardia, shortness of breath, and myoglobinuria due to a founder splice site mutation in *ISCU*, which encodes the iron-sulfur scaffold protein required by iron-sulfur subunit containing enzymes such as aconitase and complexes I, II, and III of the mitochondrial respiratory chain.

Approach to Diagnostic Testing

The diagnosis of glycogenosis should be considered in patients with recurrent myoglobinuria triggered by brief intense exercise. Presence of the "second wind" is indicative of McArdle disease (myophosphorylase deficiency), whereas in adults, signs of hemolytic anemia with elevated uric acid (and occasionally gout) is suggestive of PFK or PGK deficiency in adults. The specific glycolytic defect can be identified by sequencing blood DNA or by measuring biochemical activity of seven glycolytic enzymes

(myophosphorylase, PFK, phosphorylase *b* kinase, phosphoglycerate kinase, PGAM, lactate dehydrogenase, and phosphoglucomutase 1). In patients with limb weakness, early respiratory muscle involvement, and electromyography evidence of prominent spontaneous activity of paraspinal muscles, the diagnosis of Pompe disease should be considered. A dried blood spot test can detect acid maltase deficiency. Definitive diagnosis is made by sequencing *GAA* or by a muscle biopsy showing increased membrane-bound glycogen with markedly reduced acid maltase activity. Debrancher enzyme deficiency should be considered in patients with fixed distal greater than proximal limb weakness with electromyography myogenic and neurogenic abnormalities and visceral organ involvement. Branching enzyme deficiency is clinically recognizable by the combination of upper and lower motor neuron dysfunction, sensorimotor neuropathy, sphincter dysfunction, and dementia. Both debrancher and branching enzyme deficiencies can be diagnosed by DNA sequencing. In many cases, muscle histology showing excessive free glycogen lead to the diagnosis of debrancher deficiency, whereas detection of polyglucosan bodies is indicative of APBD. Detecting biochemical defects of muscle debrancher or branching enzyme is diagnostic, particularly in cases when DNA sequencing reveals variants of uncertain significance.

In patients with recurrent myoglobinuria triggered by prolonged exercise, fasting, or both, defects of fatty acid oxidation should be considered. Acylcarnitine profile may reveal elevated acylcarnitines (eg, long-chain acylcarnitines in CPT II and VLCAD deficiencies), particularly after overnight fasting; however, the profiles are often normal. The diagnosis can be made by blood DNA testing. CPT II activity can be measured in skeletal muscle or cultured fibroblasts.

In patients with suspected mitochondrial myopathy, measurement of free-flowing blood lactate and pyruvate can be useful; elevated resting lactate especially when the lactate-to-pyruvate ratio is high (ie, >20:1) is indicative of a mitochondrial respiratory chain oxidative phosphorylation defect. In patients with evidence of maternal inheritance, whole mtDNA sequencing offers a cost-effective approach to identifying mtDNA point mutations. Individuals with sporadic CPEO, CPEO-plus, or KSS should be screened for single large-scale mtDNA deletions, which are usually undetectable in blood and occasionally identified in urine sediment or buccal swabs but most reliably detected in muscle biopsies. In patients with autosomal CPEO, CPEO-plus, and SANDO, sequencing of nuclear genes, particularly *POLG* encoding the mtDNA polymerase catalytic subunit, can reveal the causative mutation(s). If blood and urine DNA screening is negative or ambiguous, muscle biopsy for histology, measurement of mitochondrial respiratory chain activities, and potential molecular genetic testing (eg, screening for mtDNA deletions or depletion) are often useful.

Although not a metabolic disorder, mutations in *RYR1* encoding the skeletal muscle ryanodine receptor are frequent causes of recurrent exercise-induced myoglobinuria. Heat, and to a lesser degree, viral infections, alcohol, and drugs can trigger episodes of myoglobinuria.

MANAGEMENT

Treatment of metabolic myopathies is limited. Enzyme replacement therapy for Pompe disease is the only disease-modifying therapy; however, efficacy is limited in adults. There is level 1 evidence of mild beneficial effects of enzyme replacement therapy on respiratory function and ambulation in patients with late-onset Pompe disease LEVEL 1.[1] Avoidance of precipitating factors (eg, intense exercise in patients with myoglobinuria due to glycogenesis) is critical.

Glucose or sucrose intake before exercise exacerbates muscle's symptoms (out-of-wind phenomenon) in PFK deficiency where the metabolic block occurs below the entry of glucose into glycolysis, whereas in McArdle disease, sugar intake ameliorates symptoms because the metabolic block is upstream of glucose catabolism. In other cases, such as PGAM or PFK deficiencies, this intervention does not produce changes in the exercise performance.

In patients with fatty acid oxidation disorders, a carbohydrate-rich diet and avoidance of fasting is often beneficial. In patients with CPT II, VLCAD, and TFP deficiencies, supplementation with medium-chain triglycerides can be beneficial.

For patients with mitochondrial myopathies, symptomatic therapy is important. Patients with severe ptosis that impairs vision, scleral contact lenses, eyelid crutches, or eyelid slings can be beneficial. Screening for heart block in patients with KSS or CPEO is important because timely placement of a pacemaker can be lifesaving. Aerobic exercise training improves oxidative capacity in patients with heteroplasmic mtDNA mutations.

OUTCOME

The long-term prognosis of patients with metabolic myopathies due to defects of glycogen or lipid metabolism is generally favorable. In patients with severe myoglobinuria, compartment syndrome and renal failure are serious complications that must be treated aggressively. In patients with recurrent myoglobinuria due to myophosphorylase or PFK deficiency, moderate fixed weakness often develops late in life. In contrast, patients with late-onset Pompe disease can develop severe restrictive lung disease that is amenable to bilevel positive airway pressure support.

The prognosis for patients with mitochondrial myopathies is variable. Patients with CPEO can have a very benign outcome with moderate to severe extraocular weakness as the main problem; however, some patients with CPEO have developed symptomatic dysphagia, restrictive lung disease, and marked limb weakness. Patients with KSS, SANDO, and other multisystemic mitochondrial diseases frequently progress and can develop severe encephalopathies and in the case of KSS, severe cardiomyopathy or visceral organ dysfunction that can be fatal in early to mid adulthood.

LEVEL 1 EVIDENCE

1. van der Ploeg AT, Clemens PR, Corzo D, et al. A randomized study of alglucosidase alfa in late-onset Pompe's disease. *N Engl J Med*. 2010;362:1396-1406.

SUGGESTED READINGS

Akman HO, Aykit Y, Amuk OC, et al. Late-onset polyglucosan body myopathy in five patients with a homozygous mutation in GYG1. *Neuromuscul Disord*. 2016;26:16-20.

Andreu AL, Hanna MG, Reichmann H, et al. Exercise intolerance due to mutations in the cytochrome b gene of mitochondrial DNA. *N Engl J Med*. 1999;341:1037-1044.

Auré K, Ogier de Baulny H, Laforêt P, Jardel C, Eymard B, Lombès A. Chronic progressive ophthalmoplegia with large-scale mtDNA rearrangement: can we predict progression? *Brain*. 2007;130:1516-1524.

Bao Y, Kishnani P, Wu JY, Chen YT. Hepatic and neuromuscular forms of glycogen storage disease type IV caused by mutations in the same glycogen-branching enzyme gene. *J Clin Invest*. 1996;97:941-948.

Berardo A, DiMauro S, Hirano M. A diagnostic algorithm for metabolic myopathies. *Curr Neurol Neurosci Rep*. 2010;10:118-126.

Bertrand C, Largilière C, Zabot MT, Mathieu M, Vianey-Saban C. Very long chain acyl-CoA dehydrogenase deficiency: identification of a new inborn error of mitochondrial fatty acid oxidation in fibroblasts. *Biochim Biophys Acta*. 1993;1180:327-329.

Bodamer OA, Scott CR, Giugliani R; for Pompe Disease Newborn Screening Working Group. Newborn screening for Pompe disease. *Pediatrics*. 2017;140(suppl 1):S4-S13.

Bruno C, Dimauro S. Lipid storage myopathies. *Curr Opin Neurol*. 2008;21:601-606.

DiMauro S. Mitochondrial encephalomyopathies—fifty years on: the Robert Wartenberg Lecture. *Neurology*. 2013;81:281-291.

DiMauro S, DiMauro-Melis PM. Muscle carnitine palmitoyltransferase deficiency and myoglobinuria. *Science*. 1973;182:929-931.

DiMauro S, Schon EA, Carelli V, Hirano M. The clinical maze of mitochondrial neurology. *Nat Rev Neurol*. 2013;9:429-444.

Dlamini N, Voermans NC, Lillis S, et al. Mutations in RYR1 are a common cause of exertional myalgia and rhabdomyolysis. *Neuromuscul Disord*. 2013;23:540-548.

Garone C, Rubio JC, Calvo SE, et al. *MPV17* mutations causing adult-onset multisystemic disorder with multiple mitochondrial DNA deletions. *Arch Neurol*. 2012;69:1648-1651.

Haller RG, Vissing J. Spontaneous "second wind" and glucose-induced second "second wind" in McArdle disease: oxidative mechanisms. *Arch Neurol*. 2002;59:1395-1402.

Kanno T, Sudo K, Takeuchi I, et al. Hereditary deficiency of lactate dehydrogenase M-subunit. *Clin Chim Acta*. 1980;108:267-276.

Kaufmann P, El-Schahawi M, DiMauro S. Carnitine palmitoyltransferase II deficiency: diagnosis by molecular analysis of blood. *Mol Cell Biochem*. 1997;174(1-2):237-239.

Kearns TP, Sayre GP. Retinitis pigmentosa, external ophthalmophegia, and complete heart block: unusual syndrome with histologic study in one of two cases. *AMA Arch Ophthalmol*. 1958;60:280-289.

Kishnani PS, Steiner RD, Bali D, et al. Pompe disease diagnosis and management guideline. *Genet Med*. 2006;8:267-288.

Kollberg G, Tulinius M, Gilljam T, et al. Cardiomyopathy and exercise intolerance in muscle glycogen storage disease 0. *N Engl J Med*. 2007;357:1507-1514.

Laforêt P, Malfatti E, Vissing J. Update on new muscle glycogenosis. *Curr Opin Neurol*. 2017;30:449-456.

Lossos A, Barash V, Soffer D, et al. Hereditary branching enzyme dysfunction in adult polyglucosan body disease: a possible metabolic cause in two patients. *Ann Neurol*. 1991;30:655-662.

Malfatti E, Nilsson J, Hedberg-Olfors C, et al. A new muscle glycogen storage disease associated with glycogenin-1 deficiency. *Ann Neurol*. 2014;76:891-898.

McArdle B. Myopathy due to a defect in muscle glycogen breakdown. *Clin Sci*. 1951;10:13-33.

Mochel F, Knight MA, Tong WH, et al. Splice mutation in the iron-sulfur cluster scaffold protein ISCU causes myopathy with exercise intolerance. *Am J Hum Genet*. 2008;82:652-660.

Moraes CT, DiMauro S, Zeviani M, et al. Mitochondrial DNA deletions in progressive external ophthalmoplegia and Kearns-Sayre syndrome. *N Engl J Med*. 1989;320:1293-1299.

Moslemi AR, Lindberg C, Nilsson J, Tajsharghi H, Andersson B, Oldfors A. Glycogenin-1 deficiency and inactivated priming of glycogen synthesis. *N Engl J Med*. 2010;362:1203-1210.

Ogasahara S, Engel AG, Frens D, Mack D. Muscle coenzyme Q deficiency in familial mitochondrial encephalomyopathy. *Proc Natl Acad Sci U S A*. 1989;86:2379-2382.

Ogilvie I, Pourfarzam M, Jackson S, Stockdale C, Bartlett K, Turnbull DM. Very long-chain acyl coenzyme A dehydrogenase deficiency presenting with exercise-induced myoglobinuria. *Neurology*. 1994;44(3 pt 1):457-473.

Oldfors A, DiMauro S. New insights in the field of muscle glycogenoses. *Curr Opin Neurol*. 2013;26:544-553.

Olsson A, Lind L, Thornell LE, Holmberg M. Myopathy with lactic acidosis is linked to chromosome 12q23.3-24.11 and caused by an intron mutation in the ISCU gene resulting in a splicing defect. *Hum Mol Genet*. 2008;17:1666-1672.

Paradas C, Gutiérrez Rios P, Rivas E, Carbonell P, Hirano M, DiMauro S. *TK2* mutation presenting as indolent myopathy. *Neurology*. 2013;80:504-506.

Ronchi D, Garone C, Bordoni A, et al. Next-generation sequencing reveals DGUOK mutations in adult patients with mitochondrial DNA multiple deletions. *Brain*. 2012;135(pt 11):3404-3415.

Rowland LP. Progressive external ophthalmoplegia. In: Vinken PJ, Bruyn GW, Klawans HL, eds. *Handbook of Clinical Neurology*. Amsterdam, Netherlands: Elsevier Sciences; 1992:287-329.

Schaefer J, Jackson S, Dick DJ, Turnbull DM. Trifunctional enzyme deficiency: adult presentation of a usually fatal beta-oxidation defect. *Ann Neurol*. 1996;40:597-602.

Sharp LJ, Haller RG. Metabolic and mitochondrial myopathies. *Neurol Clin*. 2014;32:777-799.

Sobreira C, Hirano M, Shanske S, et al. Mitochondrial encephalomyopathy with coenzyme Q10 deficiency. *Neurology*. 1997;48:1238-1243.

Stojkovic T, Vissing J, Petit F, et al. Muscle glycogenosis due to phosphoglucomutase 1 deficiency. *N Engl J Med*. 2009;361:425-427.

Tarui S, Okuno G, Ikura Y, Tanaka T, Suda M, Nishikawa M. Phosphofructokinase deficiency in skeletal muscle. A new type of glycogenosis. *Biochem Biophys Res Commun*. 1965;19:517-523.

Tsujino S, Shanske S, DiMauro S. Molecular genetic heterogeneity of myophosphorylase deficiency (McArdle's disease). *N Engl J Med*. 1993;329:241-245.

Tyynismaa H, Sun R, Ahola-Erkkilä S, et al. Thymidine kinase 2 mutations in autosomal recessive progressive external ophthalmoplegia with multiple mitochondrial DNA deletions. *Hum Mol Genet*. 2012;21:66-75.

Vissing J, Haller RG. The effect of oral sucrose on exercise tolerance in patients with McArdle's disease. *N Engl J Med*. 2003;349:2503-2509.

Zeviani M, Viscomi C, DiMauro S. Disorders in mitochondrial DNA maintenance. MedLink Neurology. http://www.medlink.com. Published November 13, 2000. Updated March 11, 2017.

Gliomas 100

J. Ricardo McFaline-Figueroa and Patrick Y. Wen

KEY POINTS

1. Gliomas comprise the majority of primary tumors of the brain parenchyma in adults, and of these, glioblastoma is both the most common and most aggressive.
2. Mutations in isocitrate dehydrogenase 1 (*IDH1*) and 2 (*IDH2*) drive the growth of a subset of astrocytomas and oligodendrogliomas and is associated with a more positive prognosis compared to their IDH wild-type counterparts.
3. As of 2016, the World Health Organization classifies tumors of the central nervous system by *integrated diagnoses* that incorporate histology, grade, and molecular profiling.
4. Maximal safe resection, radiation therapy, and chemotherapy, specifically alkylating chemotherapy, are the mainstays of glioma management.

INTRODUCTION

Gliomas comprise a group of primary central nervous system (CNS) neuroepithelial tumors that arise from glial progenitor cells in the brain and spinal cord. Historically, gliomas were classified into different tumor types based solely on their histologic resemblance to glial cell lineages, including astrocytomas, oligodendrogliomas, ependymomas, and several uncommon types of gliomas and glioneuronal tumors. Recently, the World Health Organization (WHO) redefined gliomas into entities comprising characteristic histologic and molecular signatures, arriving at *integrative diagnoses*. Poorly defined histologic diagnoses, such as oligoastrocytomas, have been removed except for cases in which molecular characterization is not available.

Gliomas rarely metastasize outside of the CNS and are not staged like systemic malignancies. Instead, gliomas are graded based on histopathologic features that predict aggressiveness. Tumors with malignant features are often referred to as *high-grade gliomas*, in contrast to *low-grade gliomas* (LGGs), which in spite of their more benign histologic appearance, are often not clinically benign. The location and invasiveness of most LGGs that occur in adults often makes them difficult to completely resect, leading to recurrent disease, as well as significant morbidity and mortality. The lowest grade gliomas (such as pilocytic astrocytomas) are an exception and are often surgically curable, but they rarely occur in adults.

This chapter focuses on astrocytomas and oligodendrogliomas, the most common glioma subtypes in adults. Other glioma subtypes that are rare in adults but commonly encountered in children, including ependymoma and glioneuronal tumors, are described separately in Chapter 150 *Congenital Brain Tumors in Children*.

Epidemiology

Gliomas are relatively rare tumors with an estimated annual incidence of 4.67 to 5.73 per 100,000 persons but are the most common malignant primary brain tumors in adults. Glioblastoma, a WHO grade IV astrocytoma, is the most common, and unfortunately, the most aggressive of all gliomas. Despite their rarity, gliomas rank as some of the most devastating cancers in terms of years of life lost.

In general, the incidence of gliomas is higher in men than in women and in non-Hispanic whites compared to blacks, Hispanics, Asians, or Native Americans. High-grade gliomas are commonly diagnosed in the seventh and eighth decades of life, whereas LGGs peak in incidence in the fourth and fifth decades.

There are very few known risk factors for the development of gliomas. The only clear environmental risk factor is exposure to high-dose ionizing radiation to the brain or spinal cord (eg, prophylactic cranial irradiation in children and adolescents with leukemia), while there is a negative association with atopy. To date, an association between gliomas and nonionizing radiation, such as cellular phone use, has not been established. Several rare genetic tumor predisposition syndromes are associated with increased incidence of gliomas, including germline *NF1* or *NF2* mutation in neurofibromatosis types I and II, *TSC1* or *TSC2* mutation in tuberous sclerosis, mutations in the mismatch repair machinery in Lynch syndrome and *TP53* mutation in Li-Fraumeni syndrome, among others.

Pathobiology

Like patients with brain metastases, patients with gliomas present with diverse clinical symptoms and signs that are related to tumor location, size, and growth rate, rather than tumor type. One exception is a subset of LGGs including oligodendrogliomas and some glioneuronal tumors which are associated with a high incidence of epilepsy. Gliomas can arise in the supra- or infratentorial brain, spinal cord or less commonly, spread to the cerebrospinal fluid and leptomeninges. Extracranial metastases are rare but have been described. Focal symptoms such as hemiparesis, aphasia, ataxia, visual field deficits, or cranial neuropathies result from localized invasion or compression of critical brain structures, whereas generalized symptoms such as headache, vomiting, lethargy, and confusion tend to be the result of increased intracranial pressure from tumor mass, edema, or obstructive

hydrocephalus. Seizures resulting from an underlying glioma are invariably focal in origin but may rapidly generalize, making it difficult to recognize their partial onset. Although seizures or symptoms from intratumoral hemorrhage appear suddenly, most other symptoms produced by gliomas present over days to weeks. High-grade gliomas tend to present with more rapidly progressive focal or generalized symptoms, whereas LGGs frequently present with seizure without progressive neurologic deficits. Depending on location, even large tumors can produce surprisingly few symptoms, as in the case of LGGs, to which the brain can gradually adapt. Consequently, an apparently normal neurologic exam cannot rule out an underlying glioma, and a thorough history and physical exam must be coupled with a high degree of clinical suspicion in order to know when to consider the diagnosis and obtain neuroimaging.

Molecular Features of Gliomas

Recent studies have shed light on the mechanisms underlying gliomagenesis, that is, the formation and development of gliomas. Table 100.1 summarizes some of the most characterized genomic alterations associated with certain glioma subtypes. The presence of an isocitrate dehydrogenase (*IDH1* or *IDH2*) mutation is the single most important prognostic factor in astrocytomas and oligodendrogliomas, which are the most common gliomas in adults. This recognition has led to the stratification of these tumors by the presence or absence of an *IDH* mutation, defining new disease entities. Although not directly involved in tumor formation, *MGMT* promoter methylation has strong prognostic importance in glioma survival and response to therapy.

IDH1 and IDH2 Mutations

IDH1 and IDH2 are enzymes that catalyze the conversion of isocitrate to α-ketoglutarate in the cytoplasm and in the mitochondrion, respectively. Mutations in the *IDH1* or *IDH2*, can confer a neo-enzymatic function whereby α-ketoglutarate is converted to 2-hydroxyglutarate. This "oncometabolite" competitively inhibits α-ketoglutarate–dependent dioxygenases resulting in DNA hypermethylation, complex changes in gene expression, and ultimately tumorigenesis. Mutations in IDH are associated with both gliomas and some forms of leukemia and other solid tumors.

IDH mutation, most commonly a point mutation that substitutes a histidine for an arginine at amino acid position 132 (*IDH1 R132H*), is identified in the majority of low-grade astrocytomas and oligodendrogliomas but only about 5% of glioblastoma. Most IDH-mutant glioblastoma are "secondary" high-grade tumors, that is, they arise from precursor lower grade IDH-mutant astrocytomas. IDH-mutant gliomas have a significantly better prognosis than their IDH wild-type counterparts, and IDH mutation is a stronger prognostic determinant than histologic grade. Moreover, IDH mutation is potentially a clinically targetable alteration, and a number of clinical trials are currently exploring the efficacy of inhibitors of mutant IDH.

TABLE 100.1 Genomic Alterations Associated with Glioma Subtypes

Glioma Subtype	Genomic Alteration(s)	Identification
Dysembryoplastic neuroepithelial tumors (WHO grade I)	***BRAF-V600E*** mutation	Genetic sequencing IHC against BRAF-V600E mutant protein
Ganglioglioma (WHO grade I, rarely WHO grade III)	***BRAF-V600E*** mutation	Genetic sequencing IHC against BRAF-V600E mutant protein
Pilocytic astrocytoma (WHO grade II)	***BRAF*** fusions, incl. ***KIAA1549-BRAF*** ***BRAF*** mutations Other MAPK pathway mutations Germline **NF1** mutations	IHC for KIAA1549-BRAF fusion protein Genetic sequencing Clinical diagnosis of NF1
Pleomorphic xanthoastrocytoma (WHO grade II)	***BRAF*** mutations (incl. ***BRAF-V600E***)	Genetic sequencing
Subependymal giant cell astrocytoma (WHO grade I)	Germline or sporadic ***TSC1/TSC2*** mutations	Genetic sequencing Clinical or genetic diagnosis of tuberous sclerosis
IDH wild-type astrocytomas • Diffuse astrocytoma, IDH wild type (WHO grade II) • Anaplastic astrocytoma, IDH wild type (WHO grade III) • Glioblastoma, IDH wild type (WHO grade IV)	Gain of chromosome 7 (incl. **EGFR**) Loss of chromosome 9 (incl. **CDKN2A/B**) Loss of chromosome 10 (incl. **PTEN**) ***TERT*** promoter mutations No ***IDH*** mutation	FISH or CGH for chromosomal aberrations IHC for EGFR amplification Genetic sequencing
IDH-mutant astrocytomas • Diffuse astrocytoma, IDH-mutant (WHO grade II) • Anaplastic astrocytoma, IDH-mutant (WHO grade III) • Glioblastoma, IDH-mutant (WHO grade IV)	***IDH1*** or ***IDH2*** mutation ***ATRX*** mutation ***TP53*** mutation	IHC for canonical *IDH1-R132H* mutation or genetic sequencing for noncanonical mutations IHC for ATRX (loss of staining in mutation) IHC for p53 (increased staining in mutation) Genetic sequencing
Oligodendroglioma • Diffuse oligodendroglioma, IDH-mutant (WHO grade II) • Anaplastic oligodendroglioma, IDH-mutant (WHO grade III)	***IDH1*** or ***IDH2*** mutation Codeletion of chromosome arms 1p and 19q ***TERT*** promoter mutations	IHC for canonical *IDH1-R132H* mutation or genetic sequencing for noncanonical mutations FISH or CGH for 1p/19q codeletion
Diffuse midline glioma (WHO grade IV)	***H3K27M*** mutation	Genetic sequencing IHC for H3K27M mutant protein
Ependymoma (WHO grade II or III)	Multiple chromosomal aberrations ***RELA*** and ***YAP1*** gene fusions in a subset of ependymoma	Genetic sequencing FISH for RELA fusion

Abbreviations: ATRX, alpha-thalassemia X-linked mental retardation; CGH, comparative genomic hybridization; EGFR, epidermal growth factor receptor; FISH, fluorescence in situ histochemistry; IDH, isocitrate dehydrogenase; IHC, immunohistochemistry; incl., including; MAPK, mitogen-activated protein kinase; NF1, neurofibromatosis type 1; PTEN, phosphatase and tensin homolog; WHO, World Health Organization.

O^6-Methylguanine-DNA Methyltransferase Promoter Methylation

O^6-methylguanine-DNA methyltransferase (MGMT) is a DNA repair protein capable of repairing the DNA cross-linking created by alkylating agents and is associated with resistance to alkylating chemotherapy (eg, temozolomide, lomustine [CCNU]). In a subset of gliomas, the promoter for the *MGMT* gene is hypermethylated, such that the gene is epigenetically silenced, and MGMT is not expressed. High-grade glioma patients with tumors that have methylated *MGMT* promoters show significantly increased survival compared to patients with unmethylated *MGMT*. For example, in a pivotal trial by Stupp and colleagues of patients with glioblastoma treated with concurrent chemoradiation with temozolomide followed by adjuvant temozolomide versus radiation therapy (RT) alone, patients with methylated *MGMT* promoters showed an improvement in median survival from 15.3 to 23.4 months, whereas those with unmethylated *MGMT* had only minimal improvement from 11.8 to 12.6 months. Thus, *MGMT* promoter methylation is a potent prognostic factor in gliomas.

Approximately 40% of glioblastoma patients have methylated *MGMT* promoters, and *MGMT* promoter methylation status plays a prominent role in medical decision making, particularly as *MGMT* methylation status does not tend to change at recurrence. *IDH* mutation is also associated with *MGMT* promoter methylation, given the hypermethylation phenotype of IDH-mutant gliomas. However, the prognostic significance of *MGMT* promoter methylation has not been established in LGGs.

Diagnosis

Brain or spinal cord magnetic resonance imaging (MRI) with and without gadolinium contrast is the imaging modality of choice when a CNS tumor is suspected. MRI provides superior resolution and tissue characterization compared to computed tomography scanning and has become an integral part of tumor diagnosis, treatment planning, surveillance, and therapeutic monitoring. MRI sequences required for adequate tumor characterization include T2/fluid-attenuated inversion recovery (FLAIR) and T1 pre– and post–gadolinium contrast–enhanced images. High-resolution three-dimensional T1-weighted sequences allow improved visualization in multiple orientations and are often used in presurgical planning and subsequent monitoring. Additional useful imaging includes diffusion-weighted images with apparent diffusion coefficient maps to assess for hypercellularity as well as susceptibility-weighted images to identify the presence of blood products or calcification.

Gliomas generally appear as infiltrating, poorly defined white matter lesions that are hyperintense on T2/FLAIR and hypointense on T1-weighted images. They predominantly arise in the cerebral hemispheres, although brain stem and cerebellar lesions are common in children. Although there are exceptions, most LGGs in adults tend to be infiltrative and nonenhancing with mild to moderate mass effect, whereas high-grade gliomas are more often heterogeneously enhancing, frequently with regions of necrosis and marked surrounding T2/FLAIR hyperintense edema contributing significant mass effect. Gadolinium enhancement is the result of contrast extravasation from abnormal tumor vessels, and although the extent of enhancement does not always correlate with degree of malignancy, the development of new contrast enhancement can signal transformation to higher grade. It is important to remember that the area of enhancement does not define the extent of the tumor, particularly in diffuse gliomas. Because of their abnormal vasculature, various tumor types, including high-grade gliomas, can present with hemorrhage. For this reason, it is important to obtain delayed follow-up imaging in any patient presenting with an unexplained intracerebral hemorrhage to rule out an underlying tumor. Similarly, although restricted diffusion on MRI is often equated with infarction or abscess, hypercellular tumors like gliomas can similarly restrict diffusion of water. This finding can lead to some confusion about the diagnosis in patients presenting with acute symptoms, although gliomas tend to spare cortical gray matter and do not remain confined to a single vascular territory.

In recent years, advanced imaging techniques have been developed to improve diagnostic capability and surgical planning for glioma patients. Many of these techniques aim to move beyond anatomic characterization in order to gain greater insights into tumor biology. Some of the techniques being studied for their use in glioma include magnetic resonance (MR) diffusion tensor imaging, MR perfusion, MR spectroscopy including for 2-hydroxyglutarate, and positron emission tomography/computed tomography.

The diagnosis of a glioma is ultimately made by tissue sampling. Traditionally, morphologic similarity to normal glial cells is used to assign tumors to particular glioma subtypes, including astrocytoma, oligodendroglioma, ependymoma, and glioneuronal tumors. Within each of these tumor types, the presence or absence of specific histologic features is used to infer tumor behavior and growth rate and to assign tumors to pathologic grades, with implications for prognosis and treatment. Some of the features that determine tumor grade include cellular atypia, anaplasia, mitotic activity, endothelial proliferation, and necrosis. Gliomas are graded using the WHO classification system that includes grades I to IV. WHO grades I and II are considered low-grade tumors, whereas WHO grades III and IV are considered high-grade, malignant tumors. Based on their pathologic appearance, LGGs have occasionally been referred to as *benign*; however, this term is a misnomer because the clinical course of LGGs in adults almost always includes recurrence and progression to higher grade malignancy and death.

Advances in our understanding of the molecular features defining brain tumors and their prognosis led to a revision of the *WHO Classification of Tumours of the Central Nervous System* in 2016. Rather than diagnoses based purely on histology, primary brain tumors are now largely classified by *integrated diagnoses*, which incorporate histology, grade, and molecular alterations that might better predict prognosis and response to therapy. Perhaps most importantly for adult neurooncology, astrocytomas and oligodendrogliomas are now defined by their IDH mutational status as well as other accompanying mutations (discussed in detail in the sections in the following text). For high-grade gliomas, MGMT promoter methylation status is also incorporated into the integrated diagnosis.

Management

There are a number of challenges that clinicians face in the treatment of gliomas, including their infiltrative nature, often poor response to RT and chemotherapy and the impact of treatment on healthy brain tissue. General management considerations are presented in this section, whereas recommendations based on specific diagnoses are discussed in the sections that follow.

Surgery

Surgery serves both a diagnostic and therapeutic purpose in glioma management. Although stereotactic biopsy can establish a diagnosis, usually, craniotomy and open tumor resection are preferred to avoid a misdiagnosis from undersampling the lesion and for therapeutic benefit. Unfortunately, even when all radiographically visible tumor is excised, viable microscopic glioma cells generally remain and eventually regrow. Therefore, except in cases of certain WHO grade I gliomas where gross total resection can be curative, surgery alone is not definitive therapy in the management of gliomas.

Extent of resection is an important prognostic factor in gliomas and impacts overall survival. The exact extent of resection that confers a survival benefit or how much more is gained with increasing resection (ie, 80% vs 90% resection) is unknown and likely depends on the histology and molecular factors such as IDH mutational and MGMT promoter methylation status. Prior experience does show that overly aggressive resection at the expense of neurologic function can have a detrimental effect on survival and certainly on functional status. For this reason, the goal of most glioma surgery is *maximal safe resection* of the lesion, which may be guided by functional imaging such as functional MRI, intraoperative functional mapping and intraoperative imaging, as well as the use of 5-aminolevulinic acid to identify residual tumor under fluorescent light. Extent of resection in high-grade gliomas should be measured by a postoperative MRI within 48 hours of the procedure, when it is easiest to discern residual tumor from postoperative blood products.

Radiation Therapy

RT induces DNA strand breaks either directly (in the case of particle therapy) or indirectly through the production of reactive oxygen free radicals (in the case of photon therapy). Cells undergoing mitosis are more sensitive to the damaging effects of RT, and cancer cells are targeted by virtue of their rapid division and impaired DNA repair mechanisms. RT is generally delivered in repeated doses known as *fractions* in order to allow normal cells to repair sublethal damage. Most RT for glioma involves fractionated external beam photon therapy generated by linear accelerators that is delivered from multiple angles toward the tumor location. Dose varies depending on the tumor type, but fractions of 1.8 to 2 Gy are typically delivered to a total dose of 40 to 60 Gy. RT planning involves targeting the T2/FLAIR-defined glioma volume plus a 1.5- to 2-cm margin for subclinical infiltrative disease and a small volume for uncertainties in planning or treatment delivery.

A number of RT techniques improve the ability to more precisely target tumor while sparing normal surrounding brain tissue with the intent of minimizing toxicity. Intensity-modulated radiation therapy, together with three-dimensional conformal planning, allows for delivery of RT that better conforms to the contours of the intended treatment area. Single-fraction stereotactic radiosurgery or stereotactic radiotherapy, given in one or a few fractions, involves the use of focused radiation beams to deliver very high doses of radiation to a small, well-defined area while delivering minimal dose to surrounding structures. Because of its small well-defined target volume, stereotactic radiosurgery/stereotactic radiotherapy is not ideal for most infiltrating gliomas and is not used routinely for initial radiotherapy, although it is occasionally used for focal recurrences. Proton beam RT is a particle-based therapy whose advantage is the delivery of ionizing radiation at a defined target depth while sparing tissue both superficial and deep to the target. Because of limited availability, high cost, and long wait times, proton therapy is generally reserved for pediatric patients with low-grade tumors who are likely to benefit most from decreased risk of long-term side effects following RT to a developing brain. In spite of high-dose focal RT, most gliomas eventually recur at the original site of treatment.

The main adverse effects of RT include fatigue, headache, and focal neurologic deficits related to the irradiation of healthy brain, particularly inattention and memory impairment, and these may be immediately evident after treatment or delayed. RT can result in capillary permeability and brain necrosis that can mimic the radiographic appearance of high-grade glioma and may be symptomatic, a phenomenon termed *pseudoprogression*, *treatment-related changes*, or *radiation necrosis*. Higher doses of RT, reirradiation, concurrent chemotherapy and possibly MGMT promoter methylation increase the risk of pseudoprogression.

Chemotherapy

Systemic therapies aim to target viable cancer cells that extend beyond the margins of surgical resection and irradiation and/or to enhance the effect of RT. Numerous chemotherapeutic agents have been used in the treatment of both LGGs and high-grade gliomas, including alkylating agents, antimetabolites, and topoisomerase inhibitors (Table 100.2). Most traditional chemotherapeutics work by inducing DNA damage or blocking DNA replication, with the greatest effect seen in rapidly dividing cells. Unfortunately, very few drugs have been proven to be effective in the treatment of gliomas. Alkylating agents such as the nitrosoureas and temozolomide have been the most successful agents in the treatment of glioma and remain a mainstay of current therapy.

More recently, multiple molecularly targeted agents and immunotherapy have been developed in an attempt to inhibit glioma growth. The only U.S. Food and Drug Administration (FDA)-approved targeted therapies for gliomas are everolimus for subependymal giant cell astrocytomas in patients with tuberous sclerosis and bevacizumab, a humanized monoclonal antibody that binds vascular endothelial growth factor (VEGF) preventing activation of VEGF receptors, one of the major signals used by tumors to recruit new blood vessels. Bevacizumab has been particularly useful as palliative chemotherapy in glioblastoma, given a potent normalizing effect on the tumor vasculature that improves symptom burden by inhibiting cerebral edema. Unfortunately, numerous phase III studies have failed to show a survival benefit of treatment with bevacizumab in glioblastoma. Recently, the FDA-approved pembrolizumab, an immune checkpoint inhibitor for solid tumors with high microsatellite instability and larotrectinib, a small molecule inhibitor of tropomyosin receptor kinase proteins, for neurotrophic receptor kinase 1 (NTRK) fusion proteins in a tissue-agnostic fashion. However, these represent only a very small proportion of gliomas.

Outcome

The prognosis for patients with glioma varies substantially based on the specific diagnosis. As a general rule, these tumors are incurable despite aggressive multimodality therapy, recur, and are associated with significant morbidity and mortality. WHO grade I gliomas are the exception, as gross total resection can be curative. In high-grade gliomas, age, functional status, extent of resection, IDH mutational status, and MGMT promoter methylation

TABLE 100.2 Overview of Chemotherapeutic Agents Frequently Used in the Treatment of Glioma

Drug	Indication	Dose Regimen	Side Effects	Monitoring
Temozolomide	GBM Anaplastic astrocytoma/ oligodendroglioma Low-grade glioma	Chemoradiation: 75 mg/m²/d orally daily for 6 wk Adjuvant: 150-200 mg/m²/d for 5 d every 28 d	Nausea, vomiting Fatigue Myelosuppression—especially lymphopenia, thrombocytopenia	CBC with differential weekly during chemoradiation, days 21 and 28 during adjuvant dosing, or more frequently
Lomustine/CCNU (alone or in combination as PCV)	GBM (recurrent) Anaplastic astrocytoma/ oligodendroglioma Low-grade glioma	100-130 mg/m² orally as single dose every 6 wk	Nausea, vomiting Myelosuppression—especially lymphopenia, thrombocytopenia Pulmonary fibrosis	CBC with differential weekly × 6 wk Hepatic and renal function Pulmonary function at baseline and periodically thereafter
Carmustine/BCNU	GBM (recurrent)	150-200 mg/m² IV as single dose every 6 wk	Nausea, vomiting Myelosuppression Pulmonary fibrosis Headache Rare infusion reaction	
Carmustine wafers	GBM	Up to eight wafers (61.6 mg) implanted in the surgical bed at time of resection	CNS edema/local inflammation Infection CSF leak Seizures	Clinical monitoring for seizure/CNS infection/ edema
Procarbazine (PCV)	Low-grade glioma Anaplastic Oligodendroglioma	60-75 mg/m² orally days 8-21 every 6 wk	Nausea, vomiting Myelosuppression Encephalopathy	CBC with differential Hepatic and renal function tests
Vincristine (PCV)	Low-grade glioma Anaplastic Oligodendroglioma	1.4 mg/m² IV days 8 and 29 every 6 wk	Sensorimotor peripheral neuropathy Seizures	CBC with differential, electrolytes, hepatic function, uric acid levels
Bevacizumab	GBM (recurrent)	10 mg/kg IV every 2 wk	Hemorrhage Thrombosis Impaired wound healing HTN Proteinuria RPLS	CBC with differential, blood pressure, urine protein

Abbreviations: CBC, complete blood count; CNS, central nervous system; CSF, cerebrospinal fluid; GBM, glioblastoma; HTN, hypertension; IV, intravenous; PCV, procarbazine, lomustine, and vincristine; IV, intravenous, RPLS, reversible posterior leukoencephalopathy syndrome.

dictate prognosis. In IDH-mutant gliomas, the majority of which are low-grade tumors, tumors with 1p/19q codeletion (ie, oligodendrogliomas) have a more favorable prognosis compared to noncodeleted tumors (ie, astrocytomas).

In the following sections, we review the most common gliomas with respect to their presentation, management, and prognosis.

ASTROCYTOMAS

Pilocytic Astrocytoma

Introduction

Pilocytic astrocytomas are relatively well-circumscribed WHO grade I tumors that primarily occur in children and young adults. Molecularly, they are characterized by mutations in the mitogen-activated protein kinase (MAPK) pathway. The mainstay of management is surgical resection, which can be curative in a large number of cases.

Epidemiology

Pilocytic astrocytomas make up about 5% of all gliomas and are the most common glioma in children, accounting for 15.3% of brain tumors in those younger than 19 years of age. Their incidence decreases with age, and they only rarely occur in older adults. Pilocytic astrocytomas are associated with neurofibromatosis type I, where they are estimated to occur in 15% to 20% of patients.

Pathobiology

Most pilocytic astrocytomas harbor alterations in the MAPK signaling pathway. The most common alteration involves duplication of a region of chromosome 7q34 to form a constitutively-active *BRAF* fusion protein, *KIAA1549-BRAF*. This mutation is most commonly associated with cerebellar pilocytic astrocytomas. Other mutations associated with these tumors include other *BRAF* fusion products, point mutations in *BRAF* such as *BRAF-V600E*, *NTRK* gene fusions and mutations in *FGFR1*. There is a strong association between *NF1* mutation and pilocytic astrocytomas in neurofibromatosis type I, specifically as optic pathway gliomas. Identification of an IDH mutation in a presumed pilocytic astrocytoma should raise suspicion for an alternative diagnosis.

Pilocytic astrocytomas can occur anywhere in the neuraxis, although they most frequently arise in the cerebellum. They also have a predilection for the anterior optic pathway, particularly in NF1, where they display an even more indolent course than sporadic tumors. In fact, optic pathway pilocytic astrocytomas are so characteristic of NF1 that any child diagnosed with this tumor should be evaluated for NF1. Pilocytic astrocytomas present insidiously with symptoms related to their location. Infratentorial tumors often present with progressive headache, nausea, and vomiting related to hydrocephalus, whereas optic pathway tumors present with progressive visual loss or proptosis. Seizures are an uncommon presentation because these tumors rarely involve the cerebral cortex.

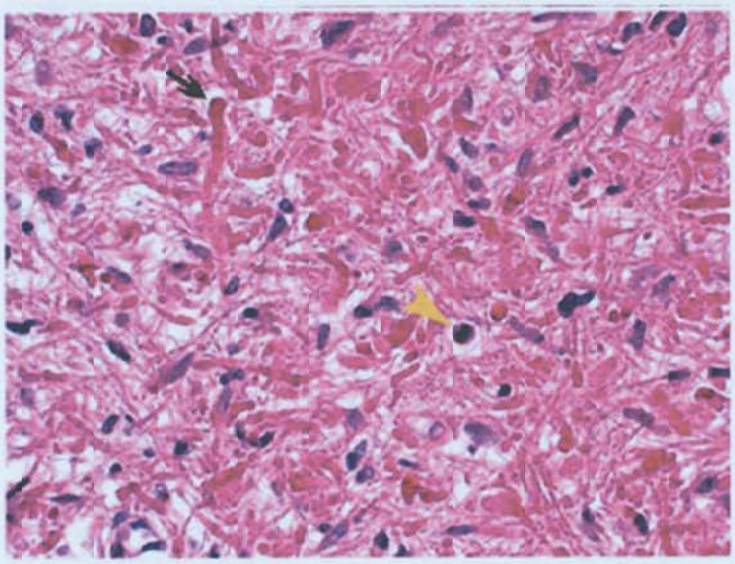

FIGURE 100.1 Pilocytic astrocytoma. Hematoxylin and eosin–stained section of histologic specimen highlighting the bipolar cells and thin processes of pilocytic astrocytomas. The *black arrow* denotes a Rosenthal fiber. The *yellow arrowhead* denotes a single mitosis. (Photos courtesy of Derek H. Oakley.)

Diagnosis

On MRI, pilocytic astrocytomas appear well-circumscribed with bright contrast enhancement and frequent cyst formation. Diagnosis requires biopsy or resection for tissue sampling. Histologically, there is a biphasic pattern of growth with areas of bipolar cells with Rosenthal fibers and loose-textured multipolar cells with microcysts (Fig. 100.1). Despite the radiographic appearance of a defined border, pilocytic astrocytomas do not have a true capsule, and although they are considered noninvasive, they often microscopically infiltrate surrounding brain parenchyma. As detailed in the previous section, molecular testing of the tumor can confirm the diagnosis of pilocytic astrocytoma, especially if it uncovers a *BRAF* fusion.

Management

Gross total resection of pilocytic astrocytomas can be curative and should be the primary treatment consideration whenever possible. Even partial resection can lead to long-term survival, with up to 87% and 82% of patients surviving at 10 and 20 years. Regardless of the extent of resection, patients must be followed long-term to monitor for infrequent progression. Because of their indolent natural history, even partially resected pilocytic astrocytomas can be subsequently monitored without adjuvant therapy until there is evidence of further growth. Documented cases of spontaneous remission following partial resection appear to validate this wait-and-see approach. RT or chemotherapy (temozolomide, bevacizumab, and irinotecan have been used) can be considered in cases with inoperable or progressive tumors, although the long-term benefits of these modalities are uncertain.

Outcome

The prognosis from pilocytic astrocytoma depends on resectability, as those that cannot be completely resected tend to recur. However, data from the 2011-2015 Central Brain Tumor Registry of the United States demonstrates 10-year survival rate of 92.2% for all documented cases, suggesting an overall positive prognosis. Malignant transformation only occurs in a minority of cases, although there is unfortunately no way to predict which tumors will transform.

Diffuse Astrocytoma

Introduction

Diffuse astrocytomas are WHO grade II infiltrative astrocytic tumors that typically affect otherwise healthy young adults. As is the case with high-grade astrocytomas, the presence of an IDH mutation defines a disease category with a better prognosis compared to IDH wild-type astrocytomas. Management involves maximal safe resection, RT, and chemotherapy, although the timing of these can be influenced by multiple factors including symptom burden, rate of growth, and presence of an IDH mutation. Although termed *low-grade gliomas*, the recurrence rate of these tumors and their potential for malignant transformation are high.

Epidemiology

Diffuse astrocytomas make up 7% of all gliomas with an annual incidence of 0.46 per 100,000 and a peak incidence in the fourth decade of life. There is a slight male predominance.

Pathobiology

The mechanism by which diffuse astrocytomas develop from astrocyte precursor cells remains poorly understood. Mutations in *IDH1* or *IDH2* are found in 68% to 90% of all diffuse astrocytomas and are likely drivers of gliomagenesis in these tumors. As opposed to their oligodendroglial counterparts, IDH-mutant diffuse astrocytomas tend to harbor loss of function mutations in *ATRX* and *TP53*. IDH wild-type diffuse astrocytomas are rare and likely represent a heterogeneous group of astrocytomas. In a recent update to their *Classification of Tumours of the Central Nervous System*, the WHO has advocated for the designation of "diffuse astrocytic glioma, IDH wild type with molecular features of glioblastoma, WHO grade IV" for IDH-wild type diffuse astrocytomas with TERT promoter mutation, epidermal growth factor receptor (EGFR) amplification, or combined whole chromosome 7 gain and chromosome 10 loss given their more aggressive clinical course.

Diffuse astrocytomas can occur anywhere in the CNS, although they preferentially arise in the cerebral hemispheres in adults. They frequently present with seizures but depending on the location and size can also cause focal symptoms or cognitive and behavioral change.

Diagnosis

Diffuse astrocytomas generally appear as ill-defined homogeneous regions of T1 hypointense signal and T2/FLAIR hyperintensity, although they tend to infiltrate beyond the T2/FLAIR margins visible on MRI. Diffuse astrocytomas generally have minimal contrast enhancement, and the development of new contrast enhancement can signal progression to higher grade (Fig. 100.2).

Definitive diagnosis requires biopsy or resection for tissue sampling. Histologically, diffuse astrocytomas appear as hypercellular tissue with cells resembling well-differentiated astrocytes and occasionally demonstrate nuclear atypia but only rare mitotic activity (Fig. 100.3, panel A). Markers of cellular proliferation such as Ki-67 or MIB E3 ubiquitin protein ligase 1 (MIB-1) typically show a growing fraction of less than 4%. By definition, diffuse astrocytomas have no necrosis or endovascular proliferation.

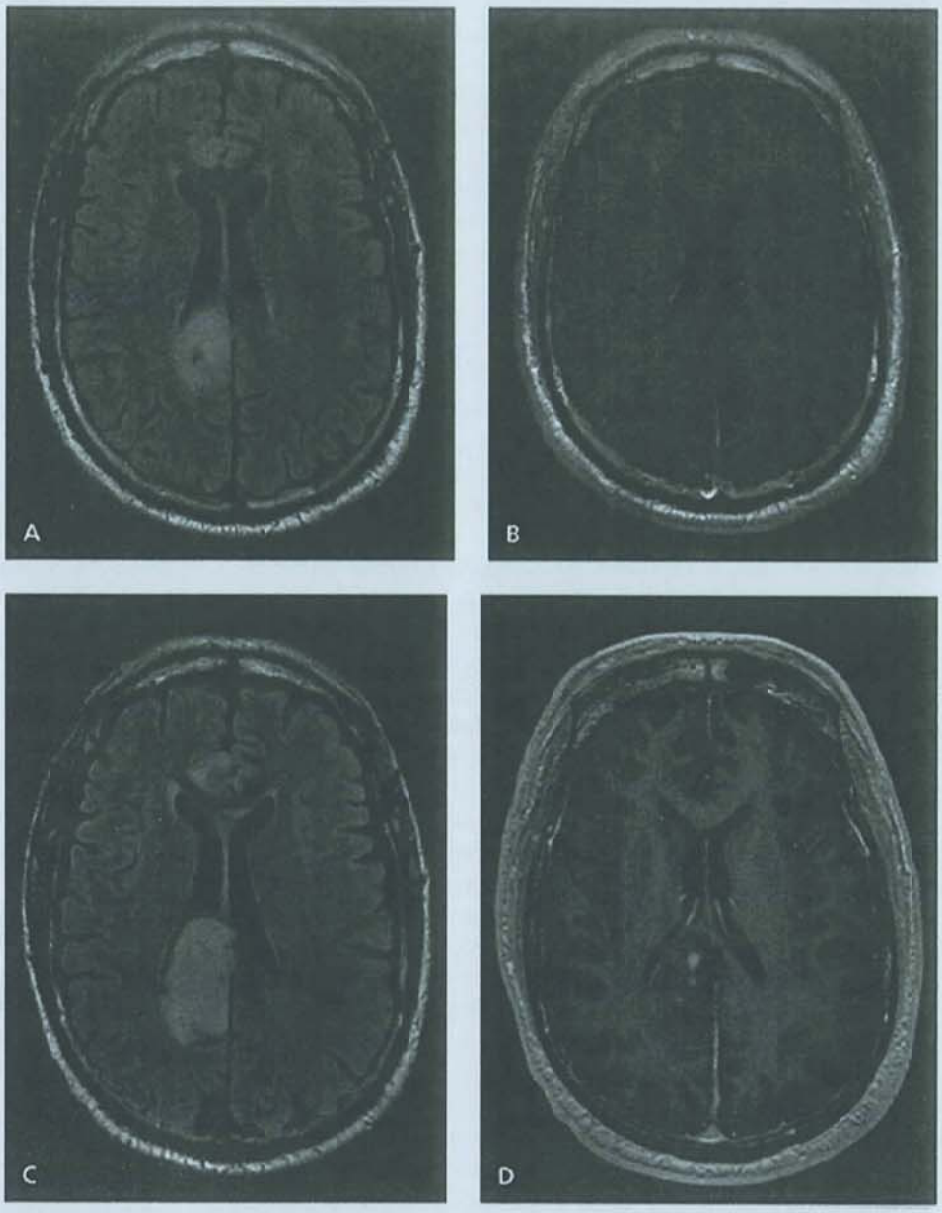

FIGURE 100.2 World Health Organization (WHO) grade II diffuse astrocytoma with progression to WHO grade III anaplastic astrocytoma. Initial T2-weighted fluid-attenuated inversion recovery (FLAIR) (A) and gadolinium contrast–enhanced T1-weighted (B) magnetic resonance imaging sequences of a patient with diffuse astrocytoma that despite radiation therapy recurred with more extensive T2/FLAIR signal (C) and new patchy enhancement (D) that was proven by biopsy to represent transformation to WHO grade III anaplastic astrocytoma.

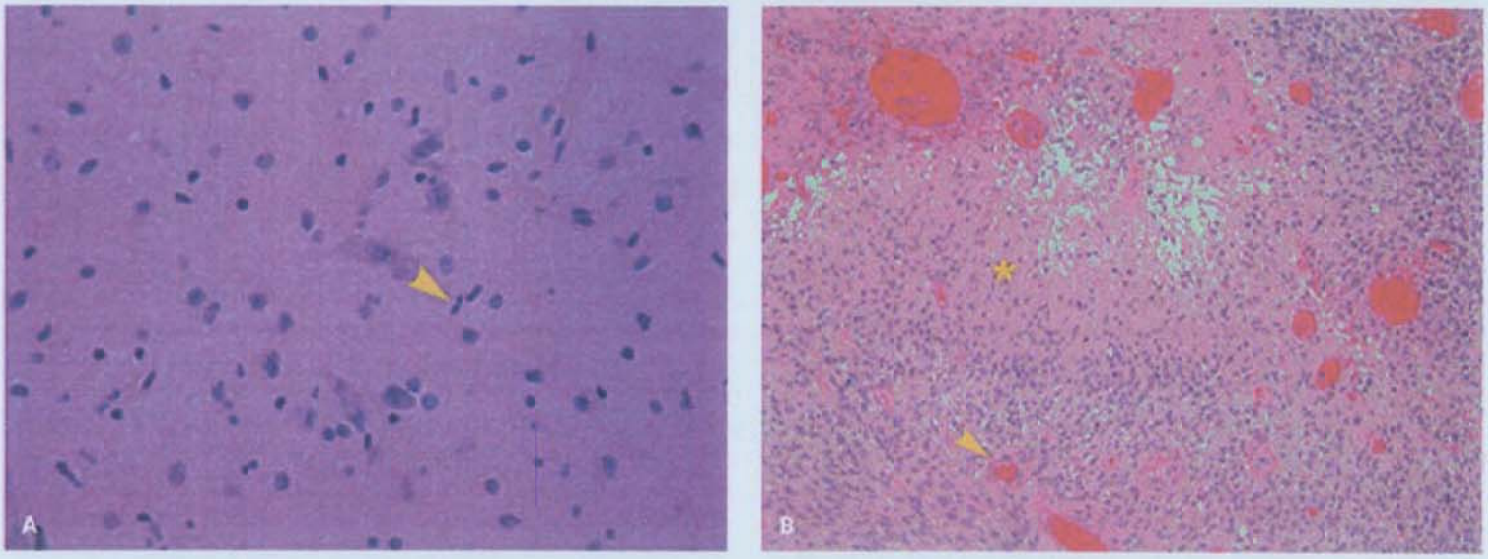

FIGURE 100.3 Astrocytomas. **A:** Hematoxylin and eosin (H&E)-stained section of a World Health Organization (WHO) grade II diffuse astrocytoma showing hypercellular brain tissue infiltrated by cells with elongated nuclei *(yellow arrowhead)*. **B:** WHO grade IV glioblastoma on H&E-stained section with high hypercellularity and marked atypia. *Asterisk* denotes necrosis with pseudopalisading architecture. *Yellow arrowhead* highlights an abnormal capillary with two stacked endothelial cell nuclei characteristic of microvascular proliferation. (Photos courtesy of Derek H. Oakley.)

Diffuse astrocytomas should stain positive for glial fibrillary acidic protein (GFAP).

IDH mutation is typically identified by immunohistochemistry against mutant *IDH1 R132H* or genetic sequencing to look for noncanonical *IDH1* or *IDH2* mutations. In IDH-mutant diffuse astrocytomas, *ATRX* mutation leads to loss of ATRX staining on immunohistochemistry, whereas *TP53* mutation leads to strong nuclear staining. As above, IDH wild-type diffuse astrocytomas typically harbor molecular signatures more suggestive of glioblastoma on genetic sequencing.

Management

The approach to diffuse astrocytoma is complex, and a number of questions remain regarding various aspects of treatment. Management incorporating observation, surgery, RT, and chemotherapy is individualized based on tumor location, molecular profile, and patient characteristics.

Available evidence increasingly supports surgical resection over observation and retrospective studies suggest a survival benefit from more extensive resection. Early surgery is generally recommended for patients with large symptomatic tumors, although the management of patients with small incidentally found or minimally symptomatic tumors is less clear. It is possible that early resection in this patient population confers a survival benefit as well, but in the absence of reliable evidence, monitoring for clinical or radiographic progression is also an option. It is current practice to attempt a maximal safe resection by an experienced brain tumor neurosurgeon in patients undergoing surgery, although the diffuse nature of this disease may in some cases limit surgical options to a biopsy to establish a diagnosis.

Approved adjuvant therapies include RT and chemotherapy, although the optimal timing and dosing of these remains unclear. One seminal study showed that postoperative RT delayed the time to progression but did not prolong overall survival LEVEL 1.[1] In light of the potential long-term neurocognitive effects of RT, these results have been used to justify delaying RT, although tumor progression may also negatively impact cognitive function. Retrospective studies have helped define a population of "high-risk" LGG patients, which may benefit from immediate postoperative therapy, including age older than 40 years, large preoperative tumor size, subtotal resection, high tumor proliferation rate by immunohistochemistry (MIB-1 >3%) and absence of an IDH mutation. IDH-mutant diffuse astrocytomas are at relatively higher risk for tumor progression compared to IDH-mutant diffuse oligodendrogliomas, which are characterized by loss of chromosome arms 1p and 19q in addition to IDH mutation.

Immediate or delayed postoperative RT is advised for all patients with diffuse astrocytomas receiving adjuvant treatment. Two studies addressing RT dose found that lower doses of RT (either 45 or 50.4 Gy) were equivalent to higher dose (59.4 or 64.8 Gy) LEVEL 1.[2,3] As a result, most patients currently receive 50 to 54 Gy.

The role of chemotherapy in diffuse astrocytomas is recently being defined. The Radiation Therapy Oncology Group (RTOG) 9802 study, which did not make a distinction between diffuse astrocytomas and diffuse oligodendrogliomas, found a significant benefit on median survival to adjuvant RT followed by chemotherapy with procarbazine, cyclophosphamide, vincristine (PCV) compared to RT alone in patients with high-risk LGGs (13.3 vs 7.8 y, respectively) LEVEL 2.[4] It is currently common practice to use either sequential RT followed by adjuvant PCV or temozolomide, or concurrent chemoradiation with temozolomide followed by adjuvant temozolomide for patients with diffuse astrocytoma after surgical resection. Close monitoring with contrast-enhanced MRI brain is advised for all patients with diffuse astrocytoma.

Outcome

Despite aggressive treatment, most diffuse astrocytomas will recur or undergo malignant transformation. Prognosis depends on age, functional status, neurologic deficits, tumor size and degree of resection, presence of enhancement on MRI brain, and molecular features including IDH mutation, which is a strong positive prognostic factor. The 5-year survival for adults with diffuse astrocytoma is 72.2% for those 15 to 39 years of age and 31.2% for those older than 40 years old according to Central Brain Tumor Registry of the United States 2011-2015 data. It should be noted, however, that these data predate the stratification of diffuse astrocytomas by IDH mutation as well as recent changes in standard of care such as the incorporation of early chemotherapy.

Anaplastic Astrocytoma and Glioblastoma

Introduction

WHO grade III anaplastic astrocytoma and WHO grade IV glioblastoma make up the high-grade astrocytomas. These are aggressive tumors that tend to progress quickly despite multimodality therapy. A subset of these harbor mutations in *IDH* and have evolved from precursor IDH-mutant diffuse astrocytomas. Methylation of the *MGMT* promoter is associated with an improved prognosis and response to therapy. Management includes maximal safe resection, concurrent chemoradiation followed by adjuvant chemotherapy, and tumor-treating fields. However, they are associated with significant morbidity and severely shortened lifespan in virtually all cases.

Epidemiology

Glioblastoma is the most common primary malignant brain tumor, making up 14.7% of all primary brain tumors and 56.6% of all gliomas. The annual incidence of glioblastoma is 3.21 per 100,000 and has a median age at diagnosis of 65 years. Anaplastic astrocytomas make up just 6.7% of all gliomas and have an annual incidence of 0.41 per 100,000. Both are much less frequent in children than in adults and have a male predominance.

Pathobiology

As for diffuse astrocytomas, the development of anaplastic astrocytomas and glioblastoma from glial precursor cells is not completely understood. Secondary glioblastoma, which arise from malignant transformation of low-grade diffuse astrocytomas are strongly associated with IDH mutation (85%-88%), as are anaplastic astrocytomas (73%). On the other hand, the majority of primary glioblastoma (ie, those not arising in patients with prior diagnosis of low-grade astrocytoma) are IDH wild type, with only 5% harboring IDH mutations. Whereas IDH mutation is the likely driver of gliomagenesis in IDH-mutant tumors, no single mutation is associated with the evolution of IDH wild-type astrocytomas. Rather, recent studies in IDH wild-type glioblastoma suggest that the earliest genetic events involve large chromosomal gains or losses, particularly gains of chromosome 7 and loss of chromosome 9 or 10, leading to alterations in *EGFR*, *CDKN2A/B*, and *PTEN*, respectively.

Anaplastic astrocytomas and glioblastoma preferentially arise in the white matter of the cerebral hemispheres. Symptoms result from tumor location and mass effect and can include focal neurologic deficits, seizures, and headaches. Seizures are more common in anaplastic gliomas than glioblastoma.

Diagnosis

On MRI brain, high-grade astrocytomas usually appear as heterogeneously contrast-enhancing mass lesions surrounded by T2/FLAIR hyperintense signal with poorly defined margins that represent a combination of cerebral edema and nonenhancing tumor (Fig. 100.4). Diagnosis is made through tissue sampling. Histologically, both anaplastic astrocytomas and glioblastoma appear as hypercellular infiltrating astrocytic tumors with significant atypia and anaplasia as well as frequent mitoses suggestive of a high proliferation rate (Fig. 100.3, panel B). Glioblastoma additionally has evidence of necrosis, which may take on a pseudopalisading appearance, and/or microvascular proliferation. The diagnosis of an IDH mutation can be made by immunohistochemistry against mutant *IDH1 R132H*, or by genetic sequencing to look for noncanonical mutations in *IDH1 or IDH2*.

IDH-mutant anaplastic astrocytomas and glioblastoma typically display mutations in *ATRX* and *TP53* that may be evident on immunohistochemistry as *ATRX* loss and strong nuclear *TP53* staining. High-grade gliomas, especially IDH wild-type tumors, are very heterogeneous and genetic sequencing frequently reveals alterations in a number of pathways related to cancer, including *TERT* promoter mutations and mutations in receptor kinase signaling (eg, EGFR signaling), phosphoinositide 3-kinase/protein kinase B/mammalian target of rapamycin, retinoblastoma and MAPK pathways. *MGMT* promoter methylation is an important prognostic factor in glioblastoma and should be routinely tested in these patients.

Management

The overall approach to the treatment of high-grade gliomas involves maximal safe resection, concurrent chemoradiation followed by adjuvant chemotherapy, and tumor-treating fields

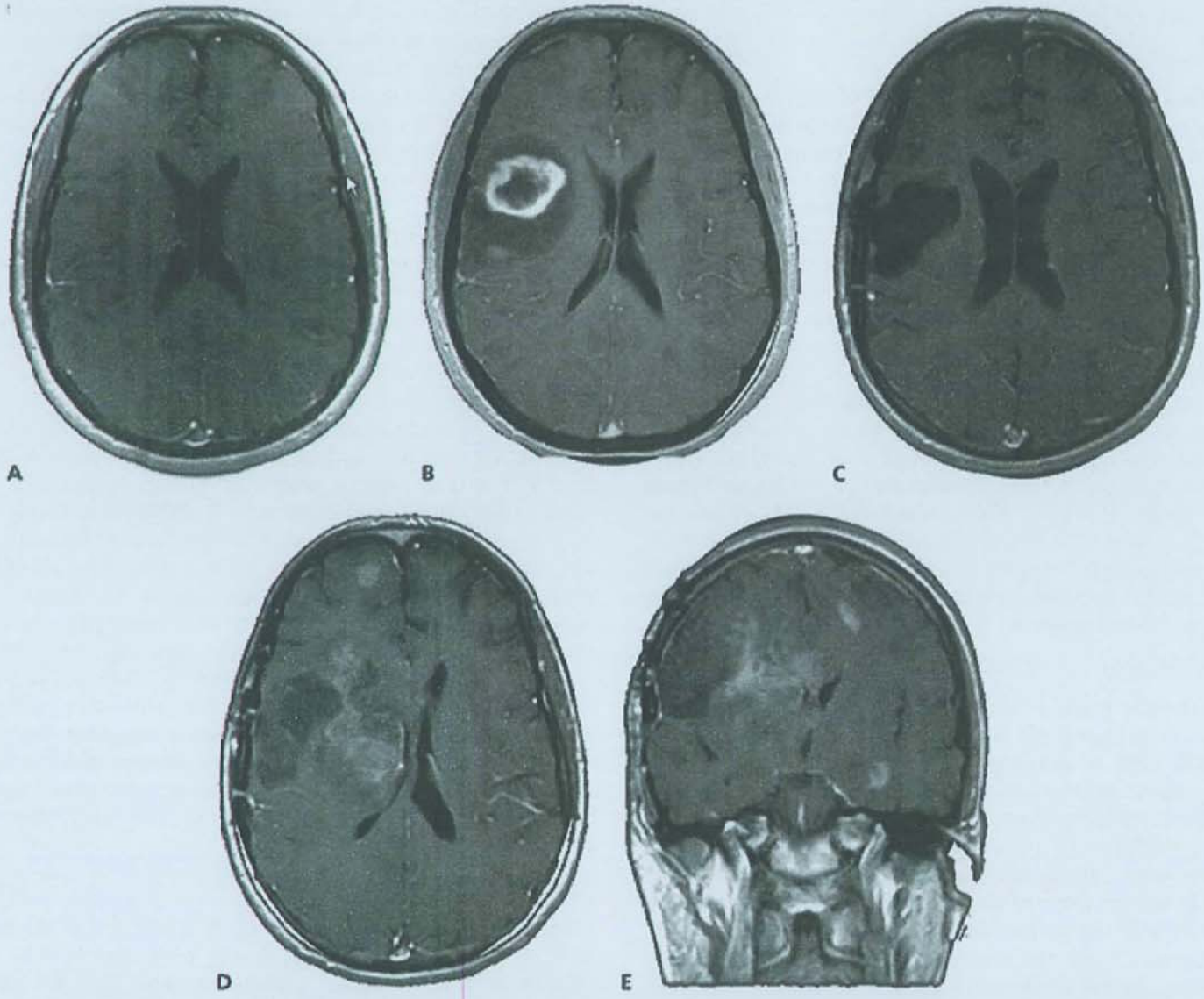

FIGURE 100.4 Glioblastoma. **A:** Gadolinium contrast–enhanced T1-weighted magnetic resonance imaging (MRI) scans of a patient who initially presented with headaches and had unremarkable imaging. **B:** The patient developed facial weakness that led to a repeat MRI just 3 months later that revealed a centrally necrotic peripherally enhancing mass. Gross total resection led to the diagnosis of glioblastoma **(C)**, but despite chemoradiation, within 6 months, the patient's tumor recurred **(D)** and infiltrated the contralateral hemisphere **(E)**.

(for glioblastomas). However, survival remains very poor, and experts advocate for the consideration of clinical trial enrollment for all patients with high-grade gliomas who are trial candidates.

Surgery

Maximal safe resection of the contrast-enhancing tumor by an experienced brain tumor neurosurgeon is recommended for all patients with anaplastic astrocytoma and glioblastoma. Extent of resection correlates with overall survival, although the exact amount of tumor resection that confers a survival advantage remains poorly defined. A recent meta-analysis of 37 studies evaluating extent of resection and overall or progression-free survival confirmed a survival advantage for patients with glioblastoma treated with gross total resection compared to subtotal resection, subtotal resection compared to biopsy, and any resection compared to biopsy, although the quality of the data was moderate to low. Overall, the literature suggests that resection of 70% to 80% of the enhancing tumor is sufficient to confer a survival advantage. Tumor resection is also preferred over biopsy because it enhances diagnostic accuracy and provides tissue for molecular testing that is important for prognostication and some treatment decisions.

Radiation Therapy

RT plays a central role in the treatment of patients with high-grade astrocytoma and is important for treating both gross and microscopic infiltrative disease that cannot be resected. Postoperative RT prolongs overall survival on average from 3 to 4 months to 7 to 12 months in glioblastoma and should be considered in all patients with WHO grade III and IV astrocytomas. Typically, it consists of involved field external beam RT delivered 5 days per week in fractions of 2 Gy to a total dose of 60 Gy. Importantly, in up to 40% of patients receiving initial treatment with RT with or without chemotherapy, early imaging can demonstrate increased enhancement and edema. Although these findings appear consistent with early tumor progression, in up to half of patients, the changes are actually the result of increased vessel permeability secondary to treatment, a phenomenon known as *pseudoprogression*. Patients with a methylated MGMT promoter may be at higher risk for pseudoprogression. A role for MR spectroscopy, MR perfusion, and positron emission tomography is being explored to better diagnose malignant glioma and to distinguish tumor progression from treatment-related pseudoprogression.

Chemotherapy

Chemotherapy plays an important role in the management of patients with high-grade astrocytomas. Interim results of the CATNON trial of non-1p/19q codeleted anaplastic gliomas (ie, anaplastic astrocytomas) suggest that treatment with RT and adjuvant temozolomide provides a survival benefit over RT alone in WHO grade III anaplastic astrocytoma (5-year survival of 55.9% vs 44.1%, respectively) LEVEL 1.[5] The study is also designed to answer the question of whether concurrent administration of daily temozolomide during RT followed by adjuvant temozolomide is superior to sequential RT followed by adjuvant temozolomide, but these results are not yet available. Although those data are pending for anaplastic astrocytoma, a landmark 2005 randomized phase III study comparing RT alone to RT plus concurrent and adjuvant temozolomide in patients with glioblastoma, firmly established the role of concurrent chemoradiation and adjuvant chemotherapy in glioblastoma LEVEL 1.[6,7] The addition of temozolomide prolonged median survival from 12.1 to 14.6 months and led to significantly higher 2- (26.5% vs 10.4%) and 5-year survival rates (10% vs 2%). A post hoc analysis of the results on the basis of *MGMT* methylation status tried to determine which patients benefited the most from the addition. The study found that patients whose tumors had a methylated *MGMT* promoter (ie, silenced MGMT) derived a greater benefit from temozolomide (21.7-month median survival and 46% 2-year survival) compared with patients without promoter methylation (12.7-month median survival, 13.8% 2-year survival) LEVEL 1.[8] In the current standard of care, temozolomide, an oral DNA alkylating agent with good brain penetration, is administered concurrently with RT followed by at least six monthly adjuvant cycles for patients with high-grade gliomas LEVEL 1.[6,7]

Recent evidence has suggested a role for more aggressive chemotherapy as initial treatment of glioblastoma with a methylated *MGMT* promoter. In 2019, Herrlinger and colleagues reported on a randomized, open-label, phase III trial of concurrent chemoradiation and adjuvant chemotherapy with CCNU plus temozolomide compared to temozolomide alone in patients with glioblastoma and *MGMT* promoter methylation suggested an improvement in overall survival from 31.4 to 48.1 months. The combination chemotherapy group has significantly more grade 3 or higher adverse events compared to the temozolomide arm. The study recruited a relatively small number of patients for a phase III study (n = 129), so the authors advise cautious interpretation of the results, and the practice has not yet become standard of care.

Another chemotherapeutic approach to the treatment of high-grade astrocytomas involves the use of biodegradable polymers containing the alkylating agent carmustine, also known as *BCNU*. These wafers, which can be implanted into a tumor bed immediately after resection, gradually release carmustine into the tissue surrounding the resection cavity in order to kill residual tumor cells. A phase III trial for newly diagnosed glioblastoma suggested a modest survival benefit from wafer implantation at the time of resection, with median survival increasing from 11.6 to 13.9 months, which led to FDA approval for the initial treatment of high-grade glioma LEVEL 3.[9] However, the up-front use of carmustine wafers has not been compared with oral temozolomide chemotherapy, so data are lacking to indicate whether there is a survival advantage over the current standard of care. Carmustine wafers are associated with significant toxicity including increased brain edema, infection, and seizures, and they can confound MRI interpretability. There are no trials assessing the safety or efficacy of adding carmustine wafers to standard chemoradiation. The uncertainty regarding the risks and benefits of carmustine wafers in conjunction with standard chemoradiation has limited the adoption of this approach in the initial treatment of high-grade glioma, and they have fallen out of favor in recent years.

Tumor Treating Fields

Tumor-treating fields are a relatively new addition to the standard of care for glioblastoma, having been approved by the FDA in 2011 for recurrent glioblastoma and 2015 for newly diagnosed glioblastoma LEVEL 1.[10-12] For this therapy, electrodes adhered to the scalp provide alternating electric fields with the goal of disrupting the mitotic spindle of rapidly proliferating cells. A phase III open-label clinical trial randomized newly diagnosed glioblastoma patients to standard of care concurrent

chemoradiation followed by adjuvant temozolomide along with the Novo-TTF-100A device or adjuvant temozolomide alone and revealed improved overall survival of 20.9 months in the tumor-treating fields group compared to 16.0 months in the control arm. The current iteration of the device requires a shaved head for electrode placement and has a small battery unit that must accompany the patient during use. It is advised that the device be worn for at least 18 hours a day.

Recurrent Astrocytoma

Most patients with high-grade astrocytomas will recur months to a few years after initial treatment. Repeat surgical resection may be considered for localized recurrences, particularly in cases where there is uncertainty in whether new contrast enhancement represents true recurrence or treatment-related changes (ie, pseudoprogression). However, surgery alone is usually not sufficient to alter the course of the disease. A randomized phase III trial suggests that carmustine wafers may modestly improve survival compared with placebo (31 vs 23 weeks) LEVEL 1.[13] Re-irradiation remains an option as well, particularly in cases of distant recurrences outside of the initial radiation field or recurrences years after initial irradiation. Tumor-treating fields are also FDA approved for recurrent glioblastoma, based on randomized open-label trial of tumor-treating fields versus physician's choice chemotherapy demonstrating comparable rates of survival in the two groups.

Systemic chemotherapeutic options for recurrence are limited and of limited efficacy. In patients with adequate performance status, participation in clinical trials should be seriously considered. In patients who are not clinical trial candidates, a number of salvage chemotherapy options exist. Rechallenge with temozolomide or other alkylating agents such as nitrosoureas (eg, lomustine, also known as *CCNU*) may be of benefit, particularly if the patient responded well to initial chemotherapy and in cases of tumors with methylated *MGMT* promoters. The antiangiogenic agent bevacizumab is also approved for treatment of recurrent glioblastoma and may be administered alone or in combination with cytotoxic chemotherapy. Bevacizumab is a humanized monoclonal antibody directed against VEGF, a key mediator of vascular permeability and angiogenesis. In high-grade glioma, bevacizumab often results in normalization of tumor blood vessels and a rapid decrease in enhancement, peritumoral edema, and mass effect. A phase II study of bevacizumab with or without concurrent irinotecan in glioblastoma demonstrated radiographic responses, which led to accelerated FDA approval of bevacizumab for recurrent glioblastoma. However, one phase III study of lomustine plus bevacizumab compared to lomustine alone in recurrent glioblastoma and two phase III trials of bevacizumab in combination with temozolomide and RT in newly diagnosed disease failed to show an overall survival benefit to the addition of bevacizumab LEVEL 1.[14-16] At this time, bevacizumab appears to be most beneficial as palliative chemotherapy for patients with significant symptoms who could benefit from tumor shrinkage or decreased peritumoral edema, either at the time of initial treatment or at recurrence.

Outcome

The median survival for patients with anaplastic astrocytoma is approximately 3 years, whereas patients with glioblastoma have a median survival of around 15 months. Of course, prognosis varies significantly between individuals and a small subset of patients live a decade or longer with anaplastic astrocytoma or rarely, with glioblastoma. Prognosis is influenced by patient factors, such as age and functional status, as well as tumor-related factors such as grade, location, extent of resection, and molecular determinants such as the presence of IDH1/IDH2 mutation and MGMT promoter methylation. Older literature correlates increased survival in high-grade astrocytomas with codeletion of chromosome 1p and 19q, but these molecular changes are now recognized to be markers of a different disease, oligodendroglioma. The best prognosis is generally found among young, otherwise healthy, patients with a gross total resection and MGMT methylation and IDH1/IDH2 mutation, but even in these cases, the tumor inevitably recurs. In light of the significant morbidity and mortality from anaplastic astrocytoma and glioblastoma, there is a desperate need for improved treatment in this disease.

OLIGODENDROGLIOMAS

Introduction

Oligodendrogliomas are diffusely infiltrating gliomas composed of neoplastic cells that morphologically resemble oligodendrocytes. Although these tumors exist on a continuum from well differentiated to overtly malignant, they are categorized into two distinct prognostic groups: low-grade WHO grade II diffuse oligodendrogliomas and high-grade WHO grade III anaplastic oligodendrogliomas. As opposed to astrocytomas, there is no WHO grade IV oligodendroglioma. Molecularly, oligodendrogliomas are associated with the presence of *IDH* mutation and codeletion of chromosome arms *1p* and *19q*. These tumors are significantly more chemo- and radiosensitive than their astrocytic counterparts and are generally associated with a more indolent disease course.

Epidemiology

Oligodendrogliomas make up about 5% of all gliomas and the vast majority are WHO grade II tumors. The median age at diagnosis for all oligodendrogliomas is 43 years, with WHO grade III tumors occurring at slightly older age. These tumors are rare in children.

Pathobiology

The majority of oligodendrogliomas in adults display mutations in *IDH1* or *IDH2*, suggesting that the oncometabolite 2-hydroxyglutarate plays a role in development of these tumors from precursor cells. As opposed to IDH-mutant astrocytomas, *IDH* mutation in these tumors usually coexists with codeletion of chromosomes 1p and 19q as well as *TERT* promoter mutations. Interestingly, given the relatively indolent nature of oligodendrogliomas, *TERT* promoter mutations are also the hallmark of the most aggressive high-grade glioma, IDH wild-type glioblastoma. How the same genetic alteration can be associated with such divergent disease courses remains unclear.

Oligodendrogliomas preferentially arise in the cortex and subcortical white matter of the cerebral hemispheres, most frequently in the frontal lobe. Approximately two-thirds of patients present with seizures, although headache or focal deficits are also common. Anaplastic oligodendrogliomas can arise de novo or as

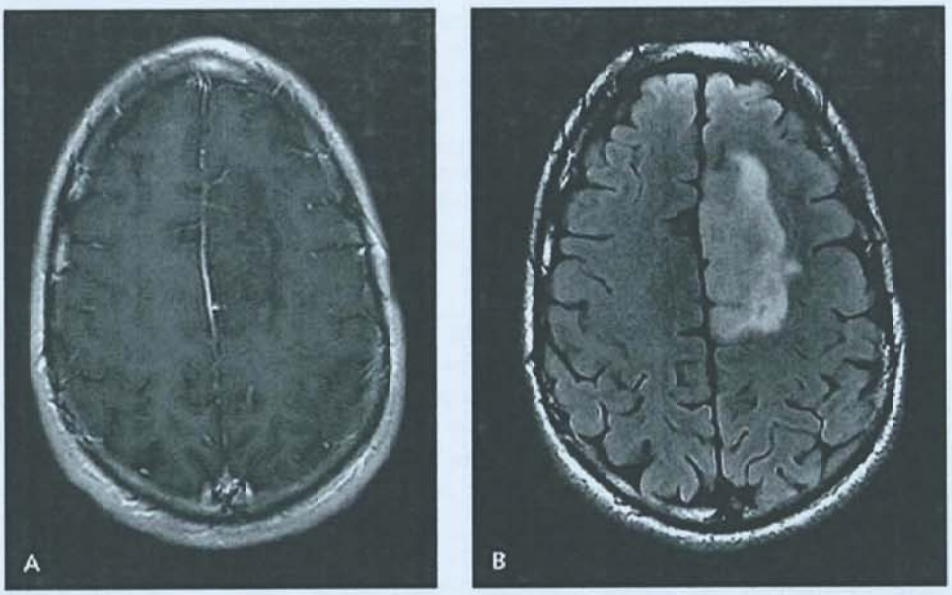

FIGURE 100.5 Low-grade oligodendroglioma (WHO grade II). Gadolinium contrast–enhanced T1- **(A)** and T2-weighted **(B)** MRI of a patient with a largely nonenhancing infiltrative oligodendroglioma.

a result of progression from a WHO grade II oligodendroglioma, on average 6 to 7 years after initial diagnosis.

Diagnosis

On MRI brain oligodendrogliomas are classically T2/FLAIR hyperintense and infiltrative mass lesions without distinct borders (**Fig. 100.5**). Low-grade WHO grade II diffuse oligodendrogliomas are generally nonenhancing, whereas high-grade WHO grade III anaplastic lesions frequently have some degree of enhancement. Calcification is characteristic of oligodendrogliomas, although this finding is not specific.

Definitive diagnosis of an oligodendroglioma requires tissue sampling. On histology, oligodendrogliomas are composed of monomorphic cells with round nuclei and characteristic perinuclear halos that give it an appearance of "fried eggs" in a dense "chicken wire" network of branching capillaries (**Fig. 100.6**, panel A). WHO grade II diffuse oligodendrogliomas may have marked cellular atypia and occasional mitoses, but significant mitotic activity, necrosis, or microvascular proliferation indicates a diagnosis of WHO grade III anaplastic oligodendroglioma (**Fig. 100.6**, panel B).

The majority of oligodendrogliomas display mutations in IDH1 or IDH2 that can be identified by immunohistochemistry for *IDH1 R132H* or by genetic sequencing for noncanonical mutations. Loss of the short arm of chromosome 1 (1p) and the long arm of chromosome 19 (19q) on fluorescence in situ hybridization or comparative genomic hybridization (ie, 1p/19q codeletion) is a hallmark of these tumors and used to distinguish IDH-mutant oligodendrogliomas from IDH-mutant astrocytomas. *MGMT* promoter methylation status is commonly used as a prognostic indicator in WHO grade III anaplastic oligodendrogliomas, but its role in low-grade oligodendrogliomas is not clear.

Oligodendrogliomas that lack IDH-mutation are exceedingly rare but occasionally encountered in children. In these cases, lack of an IDH mutation should prompt consideration of alternate diagnoses.

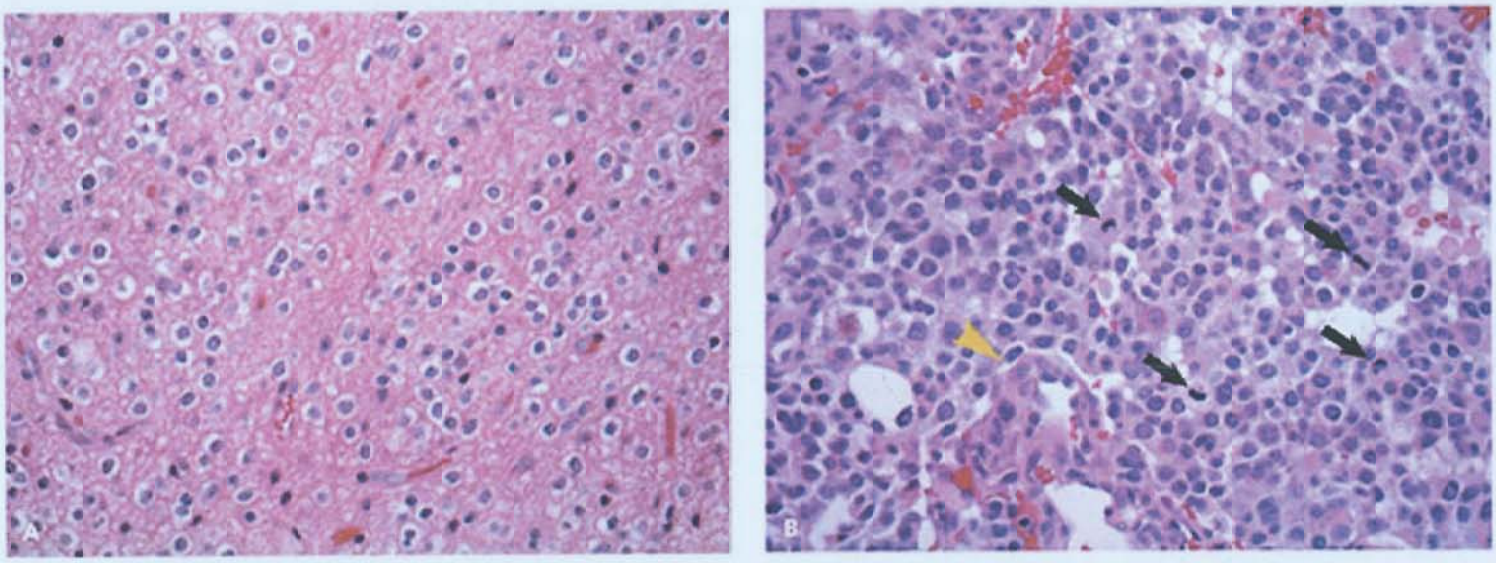

FIGURE 100.6 Oligodendroglioma. **A:** Hematoxylin and eosin–stained section of a WHO grade II oligodendroglioma. Note the characteristic perinuclear halos given the appearance of "fried eggs." The adjacent WHO grade III anaplastic oligodendrogliomas **(B)** displays increased hypercellularity, marked nuclear atypia, frequent mitoses *(arrows)* and microvascular proliferation *(yellow arrowhead)*. (Photos courtesy of Derek H. Oakley.)

Management

Management of WHO Grade II Diffuse Oligodendrogliomas

The indolent but incurable nature of low-grade oligodendrogliomas makes management quite nuanced and requires a balance between efforts to extend lifespan and the preservation of neurocognitive function. Surgery is generally recommended for all patients with a goal of maximal safe resection of all T2/FLAIR hyperintense disease. Surgery is not curative because these tumors tend to infiltrate significantly past the visible radiographic margin. However, the timing of adjuvant RT and chemotherapy varies based on patient characteristics and extent of resection.

In patients younger than the age of 40 years with confirmed WHO grade II diffuse oligodendroglioma who underwent gross total resection, it is possible to delay adjuvant chemoradiation and monitor clinically. This recommendation is partly based on the observation that immediate RT delays progression-free survival in LGG patients but does not alter overall survival compared to delayed radiation LEVEL 1.[1] Thus, this strategy aims to delay the neurotoxicity of adjuvant RT without affecting survival. Given the ultimately incurable nature of these tumors, current guidelines also advocate for enrollment into clinical trials even for these low-risk patients.

In patients older than 40 years of age, or after subtotal resection, immediate adjuvant RT, and chemotherapy is almost always indicated. As with IDH-mutant astrocytomas, combination therapy is recommended given evidence from the RTOG 9802 trial of radiotherapy followed by chemotherapy with PCV, which demonstrated a survival benefit of 13.3 versus 7.8 years in LGG patients LEVEL 1.[4] Temozolomide also has activity against these tumors and is commonly used given its better tolerability compared to PCV, but there is no published data directly comparing it to PCV.

Management of WHO Grade III Anaplastic Oligodendrogliomas

Anaplastic oligodendrogliomas behave more aggressively than their low-grade counterparts and require early intervention. Following the paradigm for high-grade astrocytomas, maximal safe resection is immediately followed by RT and chemotherapy, although data is lacking to determine the optimal regimen. RTOG 9402 compared RT alone to RT with sequential PCV in patients with WHO grade III anaplastic oligodendroglioma and did not show a survival benefit to combination therapy. However, the study defined oligodendrogliomas exclusively on the basis of histology, rather than their molecular signature. A post hoc analysis of patients stratified by 1p/19q codeletion showed that patients with 1p/19q codeleted tumors (ie, what we now define as oligodendrogliomas) who received combination chemoradiation had a median survival twice as long as those who received RT alone, whereas those without 1p/19q codeleted tumors derived no benefit LEVEL 1.[17] The ongoing CODEL trial (Alliance-N0577, European Organisation for Research and Treatment of Cancer (EORTC)-26081/2208, NRG-1071, NCIC-CEC-2) initially looked to compare survival in patients treated RT and temozolomide versus temozolomide alone, but the temozolomide monotherapy was closed due to concerns regarding decreased progression-free survival. Currently, the CODEL trial is directly comparing RT with sequential PCV to RT with concurrent and adjuvant temozolomide, but until results are published, the comparative effectiveness of PCV or temozolomide in this disease remains unknown.

Options for management of recurrent oligodendroglioma are limited regardless of grade. Re-resection or reirradiation can be considered in select patients depending on the location and timing of the recurrent tumor. In addition, both temozolomide and PCV have been shown to have activity at the time of recurrence. Other agents with some minor evidence of activity include paclitaxel, irinotecan, carboplatin, and etoposide. Bevacizumab may also have a palliative role in recurrent oligodendroglioma as in high-grade astrocytomas, but its effect on overall survival is unclear.

Outcome

Despite their relatively indolent nature compared to astrocytomas, oligodendrogliomas invariably recur and are not considered curable tumors. Data for median survival predates the use of 1p/19q codeletion for diagnosis, which is known to be a strong positive prognostic indicator. WHO grade II diffuse oligodendroglioma as defined by histology is associated with a median survival of about 10 years and a 5-year survival of 81.6%, compared to approximately 5 years and 57.6% survival for WHO grade III anaplastic oligodendroglioma. Presence of an IDH mutation and 1p/19q codeletion as well as more aggressive care with combination chemoradiation likely portend better outcomes than this historical data, but how much is unclear.

LEVEL 1 EVIDENCE

1. van den Bent MJ, Afra D, de Witte O, et al; for EORTC Radiotherapy and Brain Tumor Groups, UK Medical Research Council. Long-term efficacy of early versus delayed radiotherapy for low-grade astrocytoma and oligodendroglioma in adults: the EORTC 22845 randomised trial. *Lancet*. 2005;366(9490):985-990.
2. Karim AB, Maat B, Hatlevoll R, et al. A randomized trial on dose-response in radiation therapy of low-grade cerebral glioma: European Organization for Research and Treatment of Cancer (EORTC) Study 22844. *Int J Radiat Oncol Biol Phys*. 1996;36(3):549-556.
3. Shaw EG, Arusell R, Scheithauer B, et al. Prospective randomized trial of low- versus high-dose radiation therapy in adults with supratentorial low-grade glioma: initial report of a North Central Cancer Treatment Group/Radiation Therapy Oncology Group/Eastern Cooperative Oncology Group study. *J Clin Oncol*. 2002;20(9):2267-2276.
4. Shaw EG, Wang M, Coons SW, et al. Randomized trial of radiation therapy plus procarbazine, lomustine, and vincristine chemotherapy for supratentorial adult low-grade glioma: initial results of RTOG 9802. *J Clin Oncol*. 2012;30(25):3065-3070.
5. van den Bent MJ, Baumert B, Erridge SC, et al. Interim results from the CATNON trial (EORTC study 26053-22054) of treatment with concurrent and adjuvant temozolomide for 1p/19q non-co-deleted anaplastic glioma: a phase 3, randomised, open-label intergroup study. *Lancet*. 2017;390(10103):1645-1653.
6. Stupp R, Mason WP, van den Bent MJ, et al; for European Organisation for Research and Treatment of Cancer Brain Tumor and Radiotherapy Groups, National Cancer Institute of Canada Clinical Trials Group. Radiotherapy plus concomitant and adjuvant temozolomide for glioblastoma. *N Engl J Med*. 2005;352(10):987-996.

7. Stupp R, Hegi ME, Mason WP, et al; for European Organisation for Research and Treatment of Cancer Brain Tumour and Radiation Oncology Groups, National Cancer Institute of Canada Clinical Trials Group. Effects of radiotherapy with concomitant and adjuvant temozolomide versus radiotherapy alone on survival in glioblastoma in a randomised phase III study: 5-year analysis of the EORTC-NCIC trial. *Lancet Oncol*. 2009;10(5):459-466.
8. Hegi ME, Diserens A-C, Gorlia T, et al. MGMT gene silencing and benefit from temozolomide in glioblastoma. *N Engl J Med*. 2005;352(10):997-1003.
9. Westphal M, Hilt DC, Bortey E, et al. A phase 3 trial of local chemotherapy with biodegradable carmustine (BCNU) wafers (Gliadel wafers) in patients with primary malignant glioma. *Neuro Oncol*. 2003;5(2):79-88.
10. Stupp R, Taillibert S, Kanner AA, et al. Maintenance therapy with tumor-treating fields plus temozolomide vs temozolomide alone for glioblastoma: a randomized clinical trial. *JAMA*. 2015;314(23):2535-2543.
11. Stupp R, Taillibert S, Kanner AA, et al. Effect of tumor-treating fields plus maintenance temozolomide vs maintenance temozolomide alone on survival in patients with glioblastoma: a randomized clinical trial. *JAMA*. 2017;318(23):2306-2316.
12. Stupp R, Wong ET, Kanner AA, et al. NovoTTF-100A versus physician's choice chemotherapy in recurrent glioblastoma: a randomised phase III trial of a novel treatment modality. *Eur J Cancer*. 2012;48(14):2192-2202.
13. Brem H, Piantadosi S, Burger PC, et al. Placebo-controlled trial of safety and efficacy of intraoperative controlled delivery by biodegradable polymers of chemotherapy for recurrent gliomas. The Polymer-brain Tumor Treatment Group. *Lancet*. 1995;345(8956):1008-1012.
14. Gilbert MR, Dignam JJ, Armstrong TS, et al. A randomized trial of bevacizumab for newly diagnosed glioblastoma. *N Engl J Med*. 2014;370(8):699-708.
15. Chinot OL, Wick W, Mason W, et al. Bevacizumab plus radiotherapy-temozolomide for newly diagnosed glioblastoma. *N Engl J Med*. 2014;370(8):709-722.
16. Taal W, Oosterkamp HM, Walenkamp AME, et al. Single-agent bevacizumab or lomustine versus a combination of bevacizumab plus lomustine in patients with recurrent glioblastoma (BELOB trial): a randomised controlled phase 2 trial. *Lancet Oncol*. 2014;15(9):943-953.
17. Cairncross G, Wang M, Shaw E, et al. Phase III trial of chemoradiotherapy for anaplastic oligodendroglioma: long-term results of RTOG 9402. *J Clin Oncol*. 2013;31(3):337-343.

SUGGESTED READINGS

General Considerations in Glioma

Andronesi OC, Kim GS, Gerstner E, et al. Detection of 2-hydroxyglutarate in IDH-mutated glioma patients by in vivo spectral-editing and 2D correlation magnetic resonance spectroscopy. *Sci Transl Med*. 2012;4:116ra4.

Bondy ML, Scheurer ME, Malmer B, et al; for Brain Tumor Epidemiology Consortium. Brain tumor epidemiology: consensus from the Brain Tumor Epidemiology Consortium. *Cancer*. 2008;113:1953-1968.

Jansen M, Yip S, Louis DN. Molecular pathology in adult gliomas: diagnostic, prognostic, and predictive markers. *Lancet Neurol*. 2010;9:717-726.

Louis D, Ohgaki H, Wiestler OD, Cavenee WK, eds. *WHO Classification of Tumours of the Central Nervous System*. 4th ed. Lyon, France: International Agency for Research on Cancer; 2016.

Noushmehr H, Weisenberger DJ, Diefes K, et al. Identification of a CpG island methylator phenotype that defines a distinct subgroup of glioma. *Cancer Cell*. 2010;17(5):510-522.

Omuro A, DeAngelis LM. Glioblastoma and other malignant gliomas: a clinical review. *JAMA*. 2013;310:1842-1850.

Ostrom QT, Bauchet L, Davis FG, et al. The epidemiology of glioma in adults: a "state of the science" review. *Neuro Oncol*. 2014;16(7):896-913.

Ostrom QT, Gittleman H, Truitt G, Boscia A, Kruchko C, Barnholtz-Sloan JS. CBTRUS statistical report: primary brain and other central nervous system tumors diagnosed in the United States in 2011-2015. *Neuro Oncol*. 2018;20(suppl 4):iv1-iv86.

Pardo FS, Aronen HJ, Kennedy D, et al. Functional cerebral imaging in the evaluation and radiotherapeutic treatment planning of patients with malignant glioma. *Int J Radiat Oncol Biol Phys*. 1994;30:663-669.

Upadhyay N, Waldman AD. Conventional MRI evaluation of gliomas. *B J Radiol*. 2011;84(spec iss 2):S107-S111.

Wen PY, Macdonald DR, Reardon DA, et al. Updated response assessment criteria for high-grade gliomas: response assessment in Neuro-Oncology Working Group. *J Clin Oncol*. 2010;28:1963-1972.

Xu W, Yang H, Liu Y, et al. Oncometabolite 2-hydroxyglutarate is a competitive inhibitor of α-ketoglutarate-dependent dioxygenases. *Cancer Cell*. 2011;19(1):17-30.

Principles of Treatment

Batchelor TT, Sorensen AG, di Tomaso E, et al. AZD2171, a pan-VEGF receptor tyrosine kinase inhibitor, normalizes tumor vasculature and alleviates edema in glioblastoma patients. *Cancer Cell*. 2007;11:83-95.

Beiko J, Suki D, Hess KR, et al. *IDH1* mutant malignant astrocytomas are more amenable to surgical resection and have a survival benefit associated with maximal surgical resection. *Neuro Oncol*. 2014;16:81-91.

Mayer R, Sminia P. Reirradiation tolerance of the human brain. *Int J Radiat Oncol Biol Phys*. 2008;70:1350-1360.

Senft C, Bink A, Franz K, Vatter H, Gasser T, Seifert V. Intraoperative MRI guidance and extent of resection in glioma surgery: a randomised, controlled trial. *Lancet Oncol*. 2011;12:997-1003.

Stummer W, Pichlmeier U, Meinel T, et al. Fluorescence-guided surgery with 5-aminolevulinic acid for resection of malignant glioma: a randomised controlled multicentre phase III trial. *Lancet Oncol*. 2006;7:392-401.

Wallner KE, Galicich JH, Krol G, et al. Patterns of failure following treatment for glioblastoma multiforme and anaplastic astrocytoma. *Int J Radiat Oncol Biol Phys*. 1989;16:1405-1409.

Astrocytic Tumors

Balss J, Meyer J, Mueller W, Korshunov A, Hartmann C, von Deimling A. Analysis of the *IDH1* codon 132 mutation in brain tumors. *Acta Neuropathol*. 2008;116(6):597-602.

Bikowska-Opalach B, Szlufik S, Grajkowska W, et al. Pilocytic astrocytoma: a review of genetic and molecular factors, diagnostic and prognostic markers. *Histol Histopathol*. 2014;29(10):1235-1248.

Brandes AA, Franceschi E, Tosoni A, et al. MGMT promoter methylation status can predict the incidence and outcome of pseudoprogression after concomitant radiochemotherapy in newly diagnosed glioblastoma patients. *J Clin Oncol*. 2008;26:2192-2197.

Brandsma D, Stalpers L, Taal W, Sminia P, van den Bent MJ. Clinical features, mechanisms, and management of pseudoprogression in malignant gliomas. *Lancet Oncol*. 2008;9:453-461.

Brat DJ, Aldape K, Colman H, et al. cIMPACT-NOW update 3: recommended diagnostic criteria for "diffuse astrocytic glioma, IDH-wildtype, with molecular features of glioblastoma, WHO grade IV." *Acta Neuropathol*. 2018;136(5):805-810.

Brem H, Piantadosi S, Burger PC, et al. Placebo-controlled trial of safety and efficacy of intraoperative controlled delivery by biodegradable polymers of chemotherapy for recurrent gliomas. The Polymer-Brain Tumor Treatment Group. *Lancet*. 1995;345:1008-1012.

Brown TJ, Brennan MC, Li M, et al. Association of the extent of resection with survival in glioblastoma: a systematic review and meta-analysis. *JAMA Oncol*. 2016;2(11):1460-1469.

Chaichana KL, Jusue-Torres I, Navarro-Ramirez R, et al. Establishing percent resection and residual volume thresholds affecting survival and recurrence for patients with newly diagnosed intracranial glioblastoma. *Neuro Oncol*. 2014;16:113-122.

Collins VP, Jones DTW, Giannini C. Pilocytic astrocytoma: pathology, molecular mechanisms and markers. *Acta Neuropathol*. 2015;129(6):775-788.

Forsyth PA, Shaw EG, Scheithauer BW, et al. Supratentorial pilocytic astrocytomas. A clinicopathologic, prognostic, and flow cytometric study of 51 patients. *Cancer*. 1993;72:1335-1342.

Friedman HS, Prados MD, Wen PY, et al. Bevacizumab alone and in combination with irinotecan in recurrent glioblastoma. *J Clin Oncol*. 2009;27:4733-4740.

Hart MG, Garside R, Rogers G, Stein K, Grant R. Temozolomide for high grade glioma. *Cochrane Database Syst Rev*. 2013;(4):CD007415.

Herrlinger U, Tzaridis T, Mack F, et al. Lomustine-temozolomide combination therapy versus standard temozolomide therapy in patients with newly diagnosed glioblastoma with methylated MGMT promoter (CeTeG/NOA-09): a randomised, open-label, phase 3 trial. *Lancet*. 2019;393(10172):678-688.

Jones DT, Kocialkowski S, Liu L, et al. Tandem duplication producing a novel oncogenic BRAF fusion gene defines the majority of pilocytic astrocytomas. *Cancer Res*. 2008;68:8673-8677.

Körber V, Yang J, Barah P, et al. Evolutionary trajectories of IDH^{WT} glioblastomas reveal a common path of early tumorigenesis instigated years ahead of initial diagnosis. *Cancer Cell*. 2019;35(4):692-704.e12.

Quant EC, Norden AD, Drappatz J, et al. Role of a second chemotherapy in recurrent malignant glioma patients who progress on bevacizumab. *Neuro Oncol*. 2009;11:550-555.

Quinn JA, Reardon DA, Friedman AH, et al. Phase II trial of temozolomide in patients with progressive low-grade glioma. *J Clin Oncol*. 2003;21:646-651.

Sabel M, Giese A. Safety profile of carmustine wafers in malignant glioma: a review of controlled trials and a decade of clinical experience. *Curr Med Res Opin*. 2008;24:3239-3257.

Sanai N, Chang S, Berger MS. Low-grade gliomas in adults. *J Neurosurg*. 2011;115:948-965.

Smith JS, Chang EF, Lamborn KR, et al. Role of extent of resection in the long-term outcome of low-grade hemispheric gliomas. *J Clin Oncol*. 2008;26:1338-1345.

Taal W, Brandsma D, de Bruin HG, et al. Incidence of early pseudo-progression in a cohort of malignant glioma patients treated with chemoirradiation with temozolomide. *Cancer*. 2008;113:405-410.

Whittle IR. What is the place of conservative management for adult supratentorial low-grade glioma? *Adv Tech Stand Neurosurg*. 2010;35:65-79.

Yan H, Parsons DW, Jin G, et al. IDH1 and IDH2 mutations in gliomas. *N Engl J Med*. 2009;360(8):765-773.

Oligodendroglial Tumors

Baumert BG, Mason WP, Ryan G, et al. Temozolomide chemotherapy versus radiotherapy in molecularly characterized (1p loss) low-grade glioma: a randomized phase III intergroup study by the EORTC/NCIC-CTG/TROG/MRC-CTU (EORTC 22033–26033). *J Clin Oncol*. 2013;31(suppl). Abstract 2007.

Buckner JC, Gesme D Jr, O'Fallon JR, et al. Phase II trial of procarbazine, lomustine, and vincristine as initial therapy for patients with low-grade oligodendroglioma or oligoastrocytoma: efficacy and associations with chromosomal abnormalities. *J Clin Oncol*. 2003;21:251-255.

van den Bent MJ, Brandes AA, Taphoorn MJ, et al. Adjuvant procarbazine, lomustine, and vincristine chemotherapy in newly diagnosed anaplastic oligodendroglioma: long-term follow-up of EORTC Brain Tumor Group Study 26951. *J Clin Oncol*. 2013;31:344-350.

van den Bent MJ, Taphoorn MJ, Brandes AA, et al. Phase II study of first-line chemotherapy with temozolomide in recurrent oligodendroglial tumors: the European Organization for Research and Treatment of Cancer Brain Tumor Group Study 26971. *J Clin Oncol*. 2003;21:2525-2528.

Wick W, Hartmann C, Engel C, et al. NOA-04 randomized phase III trial of sequential radiochemotherapy of anaplastic glioma with procarbazine, lomustine, and vincristine or temozolomide. *J Clin Oncol*. 2009;27:5874-5880.

Metastatic Tumors 101

Rupesh Kotecha and Minesh P. Mehta

KEY POINTS

1. Brain metastasis in the modern era should be managed in a multidisciplinary approach to ensure optimal timing of local and systemic therapies.
2. Radiation therapy treatment options include whole brain radiotherapy, stereotactic radiosurgery, and hippocampal-avoidance whole brain radiotherapy.
3. Targeted agents and immunotherapies have revitalized the role of systemic therapy in patients with newly diagnosed or recurrent brain metastases.
4. Resection remains the first approach in patients with large, symptomatic metastasis but can also be performed in patients who need pathologic confirmation or re-evaluation of tumor biology or molecular profile.

INTRODUCTION

It is estimated that today, in the United States, there are over 15.5 million people living with a diagnosis of cancer, and the American Cancer Society projects that more than 1.7 million new cancer diagnoses will occur in 2019. The American Society of Clinical Oncology predicts that cancer will overtake heart disease as the most common cause of death by 2030, and it is already the leading cause of death in Americans younger than 85 years of age. Metastatic disease, that is, cancer that has spread from its site of origin (from the Greek *meta*, meaning "next," and *stasis*, meaning "placement"), is the cause of death in the vast majority of cancer patients. This chapter provides a general overview of central nervous system (CNS) metastasis followed by an extensive review of specific clinical entities, including brain metastasis, epidural spinal column metastasis, and leptomeningeal metastasis (LM).

OVERVIEW OF METASTATIC TUMORS

Epidemiology

Although the number of new cases of metastasis to the CNS diagnosed annually is estimated at over 200,000, the exact incidence remains unknown. The reason for this is that although cancer as a disease is reportable, sites of metastatic disease are not routinely recorded in any registry. Autopsy studies have reported the presence of intracranial metastases in approximately 10% to 30% of all cancer patients (15% to the brain, 5% to the leptomeninges, and 5% to the dura) as well as occult LM in approximately 20% of cancer patients. The incidence of brain metastasis has risen steadily over the last few decades, a phenomenon that is likely multifactorial: Guidelines for systemic staging of cancer have now incorporated imaging of the brain for a variety of cancers, clinical trial entry often precludes a diagnosis of brain metastasis resulting in more frequent screening, high-resolution imaging allows smaller brain metastasis to be detected, and increasingly effective treatments lead to prolonged survival and thus a longer period during which CNS metastases may develop. One conjectured reason for the very high incidence of metastatic disease to the brain is the highly selective permeability of the blood-brain barrier (BBB), which allows tumor cells sanctuary in the CNS both from immune surveillance and the cytotoxic effects of chemotherapy because most of these agents fail to penetrate the barrier adequately.

Although the brain parenchyma, especially the gray-white junction, is the location most likely to be involved (80%) with metastatic disease to the CNS, other common sites include the epidural space and leptomeninges. Less common sites include the dura, intramedullary spinal cord, optic apparatus, and other cranial and peripheral nerves. Data regarding these less common sites are generally limited to case reports and small series, and therefore, this discussion focuses on CNS metastases, primarily of the parenchymal brain.

Pathobiology

The molecular processes within cancer cells and their microenvironment that ultimately result in the development of metastatic disease are poorly understood and are the focus of much ongoing research. It is known that the spread of tumor cells into systemic circulation is an early phenomenon in the natural history of malignancy, but these circulating tumor cells do not always lead to metastasis. It is estimated that less than 0.01% of these cells are able to establish a metastatic lesion at a distant anatomic site. This could well be a consequence of immune surveillance mechanisms. It is also known that certain malignancies have a predilection to metastasize to particular organs. This may be due in part to simple anatomic considerations, such as venous drainage patterns, sites of first "entrapment", etc, but may also be dependent on specific molecular characteristics, including the secretion of specific chemotactic factors by the organ or site involved. Neurotropic growth factors in the CNS are thought to play such a role. Another possible factor is the expression of specific surface molecules on tumor cells that allow them to "home" to certain tissues. Preliminary data suggest that melanoma cells possess such molecular features, which allow them to have among the highest probabilities of metastasizing to the brain. In fact, recent emerging molecular characterization data suggest that when primary tumors, extracranial metastases, and intracranial metastases are interrogated at a molecular genetic level, metastases to the CNS are distinctly different, both from the primary tumor, as well as extracranial metastases, further lending credence to the emerging hypothesis that only cells that develop certain physiologic capabilities through unique mutations are able to metastasize to the CNS.

Possible pathways for spread of cancer include hematogenous, lymphatic, intrathecal, and perineural (Fig. 101.1). Although not technically metastatic, tumors may directly extend

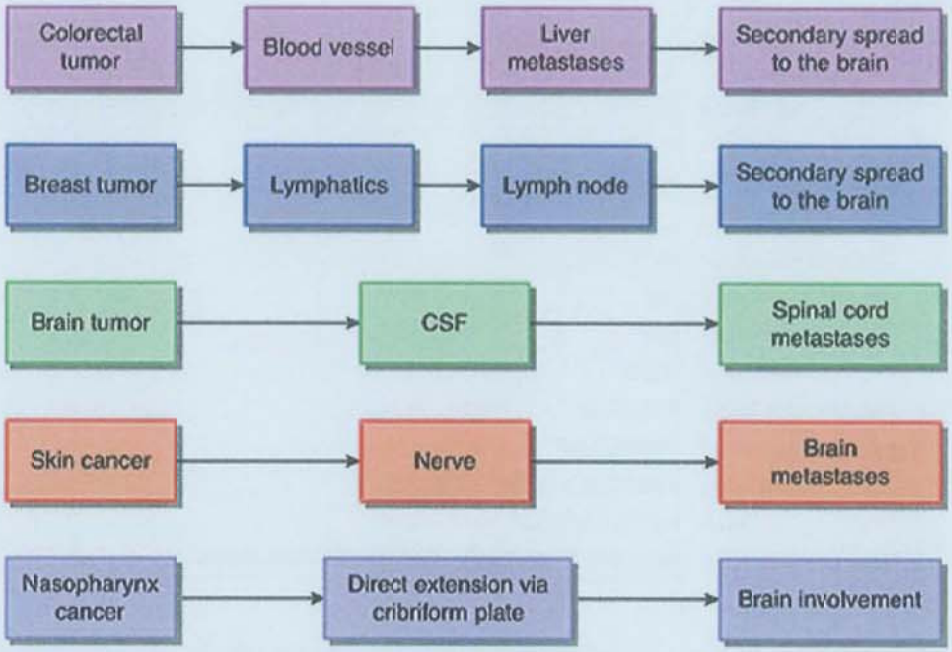

FIGURE 101.1 Routes of metastases. Abbreviation: CSF, cerebrospinal fluid.

into neighboring structures, including the CNS. For example, tumors of the head and neck may invade the brain or spinal cord by direct extension of disease through the base of skull. The intravasation of the cancer cell requires multiple signals between that cell and its surrounding microenvironment. Some data suggest that transformation of the malignant cell into a mesenchymal, or connective tissue–like, state is crucial for this, a phenomenon referred to as *epithelial-to-mesenchymal transition*.

Once intravasated and in circulation, normal anatomic organs may act as a barrier to tumor spread. Regional lymph nodes may trap tumor cells. The hepatocytes of the liver filter the blood as the venous return from abdominal organs passes through them; therefore, the liver is a frequent site of metastatic disease from gastrointestinal tract tumors. The BBB presents another obstacle for circulating tumor cells. Logically, organs with large volumes of blood flow are more prone to metastatic disease, such as the pulmonary capillary bed with its high flow. The CNS and bones receive approximately 20% of cardiac output; it is therefore not surprising that the liver, lung, CNS, and bones are the most common sites of metastatic disease.

When cancer cells arrive at a distant site, they must extravasate from circulation and establish growth at this new location, a complex process that requires multiple interactions with the new microenvironment. The nascent metastasis must also be capable of angiogenesis, the formation of new blood vessels, in order to sustain growth larger than approximately 1 mm. Despite all these required steps for the formation of distant metastases, metastatic disease from cancer is an all too real and common phenomenon, indicating that this orchestrated process of dissociation, intravasation, circulation, avoidance of immune surveillance, extravasation, and metastatic growth is efficiently coordinated by a significant number of malignancies through sophisticated genetic interplay.

Diagnosis

Metastatic disease to the CNS may present with or without symptoms, and an appropriate clinical workup is necessary to confirm the diagnosis. In asymptomatic patients, metastatic disease is often found incidentally during cancer workup and staging or while concomitant nonmalignant comorbidities are investigated. CNS metastasis is often diagnosed in the context of a known history of malignancy, but symptomatic CNS metastasis may also be the initial clinical presentation of a previously unidentified malignancy. In this situation, biopsy or resection may be required in order to pathologically confirm a diagnosis of cancer and guide treatment. The most common primary malignancy that presents with metastatic disease in the brain is lung cancer (Fig. 101.2). The most common primary malignancies that present with metastatic disease to the spine are breast and prostate cancer. In some cases, the primary malignancy responsible for the metastatic disease is never identified despite a complete and thorough evaluation.

History and Physical Examination

The clinical presentation of CNS metastasis is highly dependent on the specific neurologic structures involved and the degree to which they have been compromised. Symptoms may be of gradual or abrupt onset, which provides insight not only to the underlying pathologic processes but also to prognosis and likelihood of recovery. Clinical workup of a new neurologic deficit begins with a thorough history and physical exam, with particular focus on the elucidation of any neurologic deficits.

Laboratory Studies

Blood work has limited use in the workup of CNS metastatic disease, but one exception is tumor markers: cancer-specific or cancer-associated proteins that are measurable in the blood or cerebrospinal fluid (CSF). If these markers are elevated, especially in the CSF, then systemic metastases, including neurologic, are more likely. The converse statement, however, is not true in that normal tumor marker values do not preclude malignancy or metastatic disease. Despite this limited use, any patient with general neurologic symptoms, such as altered mental status, headaches, or seizures, should have basic testing obtained in order to rule out other etiologies such as infection, electrolyte imbalance, toxins, or blood gas abnormalities.

Imaging

Magnetic resonance imaging (MRI), with and without gadolinium contrast, is the gold standard imaging modality for patients with suspected CNS disease. Computed tomography is used in patients who cannot tolerate MRI and occasionally to further evaluate

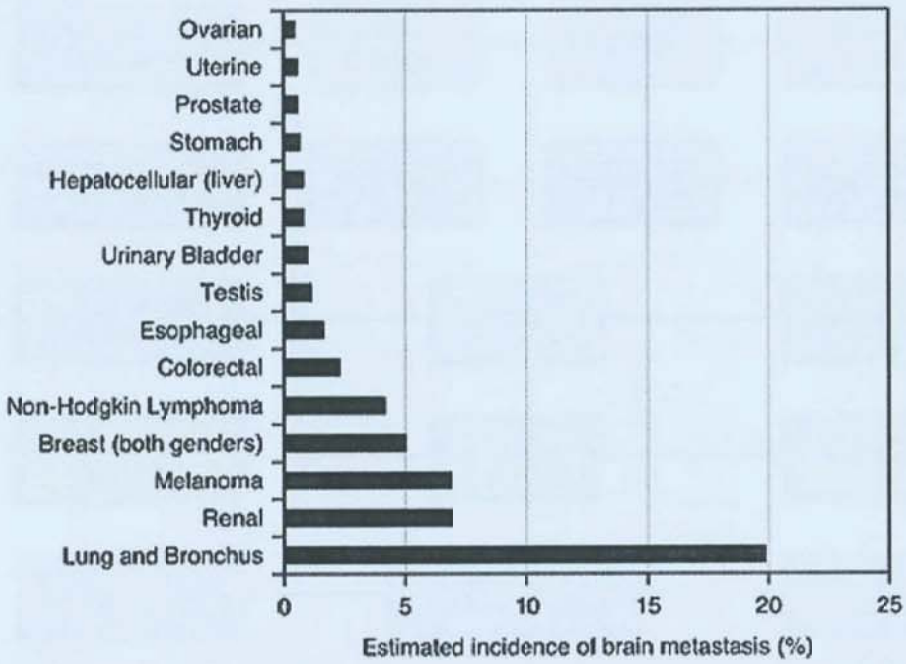

FIGURE 101.2 Estimated incidence risk of development of brain metastasis by primary tumor site.

hemorrhage; it also has value in the rare situations where the brain metastases is a consequence of a metastatic focus in the bones of the skull with direct extension intracranially. Magnetic resonance spectroscopy can suggest whether a lesion is neoplastic, inflammatory, or other. At present, positron emission tomography with ^{18}F-fluorodeoxyglucose has limited use in evaluation of brain metastases due to the high background activity of the normal brain. Novel positron emission tomography tracers are in an exploratory phase. It is important to note that none of these imaging techniques replaces histology for diagnostic accuracy.

Tissue Diagnosis

In many cases, histologic confirmation of a CNS metastasis is unnecessary, as the likelihood of metastatic disease from a known primary, especially in the setting of known metastatic disease, outweighs the likelihood of a new primary CNS tumor. This is particularly true if imaging studies demonstrate characteristic features of metastatic disease. In other cases, the diagnosis of CNS metastasis is unclear despite the history, physical exam, laboratory values, and radiographic studies. If the diagnosis of metastatic disease is in question, and if the lesion is surgically accessible with reasonable safety, biopsy, or resection should be performed to provide histopathologic diagnosis.

Another important possible method of identifying metastasis to the CNS is sampling of the CSF with a lumbar puncture (LP). LP may also rule in or out other etiologies and clarify the diagnosis of LM (also termed *leptomeningeal carcinomatosis*, *neoplastic meningitis*, or *carcinomatous meningitis*). It will not, however, diagnose parenchymal brain metastases in the absence of CSF involvement. LP is contraindicated due to the risk of brain herniation in cases where increased intracranial pressure (ICP) is suspected.

Management

Both symptomatic and definitive treatments must be addressed in a patient who presents with metastatic disease to the CNS. Symptomatic treatments include corticosteroids, medications for seizure management, and anticonvulsant prophylaxis. Definitive treatments include surgery, radiation therapy (RT), and systemic therapy (chemotherapy, targeted therapies, or immunotherapy).

Corticosteroids and Antiepileptics

Metastatic disease may cause marked edema due to extravasation of plasma from leaky tumor vasculature. Within the narrow anatomic confines of the CNS, this edema may cause increased ICP and significant compression of normal neural tissue (Fig. 101.3A). Symptoms of increased ICP include headaches and blurred vision. Corticosteroids, most commonly dexamethasone, should be given immediately to symptomatic patients and often result in rapid improvement in symptoms. One widely used dosing of corticosteroids begins with an intravenous bolus of 10 mg of dexamethasone (although the actual value of the intravenous route over oral as well as the larger 10-mg dose, in terms of symptom resolution is unclear), followed by 4 mg given every 6 hours. The dose should be rapidly titrated upward or downward as needed. Large doses can cause acute psychiatric symptoms, and chronic administration has a myriad of toxicities including candidiasis, increased risk of pneumocystis pneumonia, metabolic imbalance, sleep and mood disturbance, muscle atrophy and wasting, weight gain, osteopenia and pathologic fractures, gastrointestinal irritability, and perforation. Corticosteroids should be tapered as rapidly as tolerated once definitive therapy has been initiated.

Symptomatic patients or those with radiographic evidence of significant mass effect should be stabilized with corticosteroids as soon as possible. Corticosteroids have been shown to improve or resolve symptoms in up to two-thirds of patients and may confer a small survival benefit compared to no treatment. In select patients with an extremely poor performance status and short expected survival, symptomatic management alone with corticosteroids can be considered LEVEL 1.[1] Patients who present with seizures should be stabilized with antiepileptic medications, preferably selecting agents that do not induce cytochrome p450 hepatic enzymes because such induction could interfere with metabolism of some chemotherapies or corticosteroids. Antiepileptics are generally not indicated in patients without a prior history of seizure because they have no proven benefit when given prophylactically and may have significant adverse effects, including fatigue and decreased cognition; however, studies suggesting antiepileptics have risk outweighing benefit in seizure naïve patients were

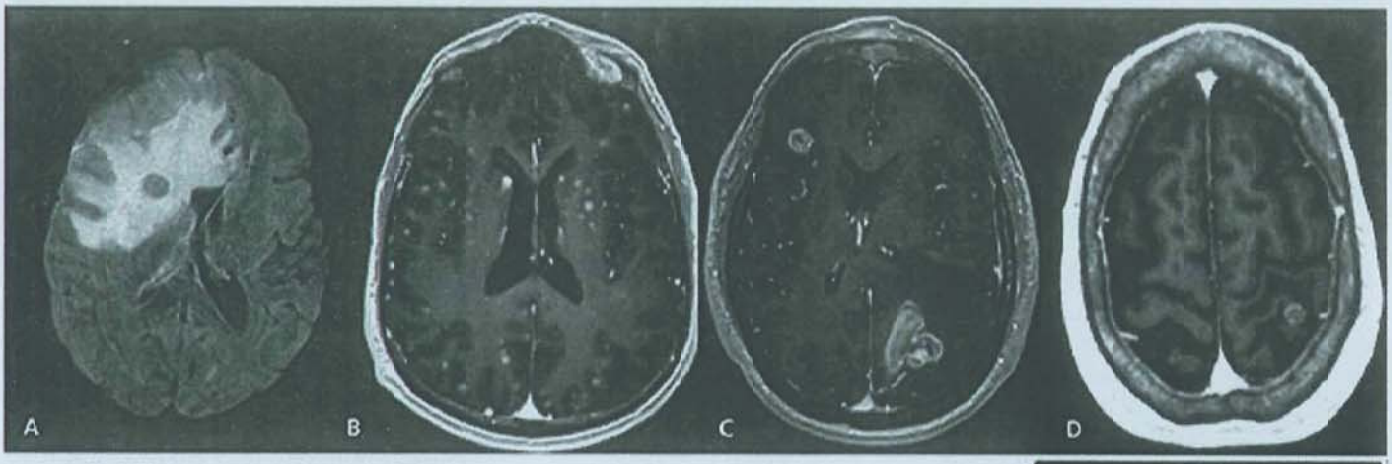

FIGURE 101.3 **A:** Edema from brain metastases causing significant mass effect and midline shift. **B:** Miliary brain metastases. **C:** Hemorrhagic brain metastasis (left parietal region). **D:** Classic appearance of brain metastases. **E:** Radiation necrosis. These are axial contrast-enhanced MR images **(B-E)** except for **(A)**, which is an axial fluid-attenuated inversion recovery magnetic resonance sequence.

conducted before some of the more modern drugs, such as levetiracetam, were developed, and definitive data are lacking in the modern era LEVEL 1.[2]

Surgery

In general, surgical management is considered for patients who are medically fit, with large tumors (>2-3 cm), one or few tumors, and/or disease associated with significant brain swelling, mass effect, and neurologic deficits. The benefits of direct tumor removal with surgery include rapid improvement in symptoms and improved local disease control. The decision for or against surgery depends on many factors, including overall clinical performance status of the patient; status and extent of systemic disease; and location, size, and number of intracranial metastases. Surgery should be followed by adjuvant RT or, less commonly, chemotherapy. Risks of surgery include bleeding, infection, CSF leak, and transient or permanent neurologic deficit.

Radiation Therapy

RT may be used in combination with surgery, typically as adjuvant therapy following maximal resection or as primary therapy for unresected disease. Tumor regression following RT is a gradual process, and the therapeutic effects lack the immediacy of resection, making RT second-line therapy in situations where immediate decompression is indicated.

For patients with known brain metastases too numerous to target individually, RT is generally delivered to the entire brain (whole brain radiation therapy [WBRT]) with the rationale that the presence of brain metastases indicates that the entire organ has been compromised. The likelihood of other tumor cells with metastatic potential elsewhere within the brain is high, and WBRT may not only treat the known lesions but may also prevent or delay the development of macroscopic disease elsewhere in the brain.

WBRT alone may reduce or eliminate symptoms from brain metastases in 60% to 80% of patients and may result in a significant radiographic response in about half of all patients. WBRT is also associated with improved median survival 4 to 6 months as opposed to 1 month without treatment. Side effects include fatigue, headaches, alopecia, neurocognitive decline, radiation necrosis, and damage related to the specific area of the brain being irradiated.

In the United States, WBRT is classically given to a total dose of 30 Gy delivered in 10 fractions, although several other fractionation schedules have been shown to have similar efficacy with no significant difference in toxicity (20 Gy in 5 fractions, 30 Gy in 15, 37.5 Gy in 15, 40 Gy in 15, and 40 Gy in 20). Doses higher than this (≥50 Gy) and hyperfractionation (more and smaller fractions) did not show a survival benefit, and larger fraction sizes were found to be detrimental, with shorter progression-free survival and higher neurologic toxicity LEVEL 1.[3-5]

Recently, clinical trials have focused on attempting to decrease the cognitive dysfunction associated with WBRT, and at least two approaches, the addition of the *N*-methyl-D-aspartate-receptor agonist, memantine, and the deliberate reduction of dose to the hippocampi have both been shown in randomized trials to produce meaningful cognitive benefit, and these techniques are now rapidly being incorporated into routine clinical practice.

Prophylactic cranial irradiation (PCI) is when WBRT is administered in the absence of known macrometastatic disease in the brain in order to decrease the likelihood of developing brain metastasis. PCI is indicated in small cell lung cancer,

which has a very high propensity for brain metastasis, and reduces the risk of subsequent intracranial failure and also improves survival LEVEL 1.[6,7] Other tumors, particularly classic pediatric brain tumors such as medulloblastoma, have a high incidence of metastatic disease to not only elsewhere in the brain but also throughout the craniospinal axis, and prophylactic craniospinal irradiation is given to the entire CNS axis in these situations.

Stereotactic radiosurgery (SRS) is a more targeted RT technique in which a much larger dose of radiation is given, generally in a single treatment. The advantages of SRS include shorter treatment time (1 d vs 2-3 wk), rapid reinitiation of systemic therapy, and decreased radiation dose to the surrounding normal brain tissue. SRS may be used safely to treat multiple brain lesions and may also be given in combination with WBRT. In certain situations, the precision of SRS is combined with the delivery of a few large fractions of radiation, as opposed to a single fraction, an approach referred to as *stereotactic radiotherapy*. This is most often performed for metastases close to sensitive structures or for those too large (>2-3 cm) for effective single fraction treatment without significant morbidity.

Chemotherapy

Chemotherapy has traditionally had a limited role in the treatment of CNS metastases because the BBB and blood-CSF barrier inhibit the ability of systemic agents to penetrate to the brain and spinal cord. Some agents with good CNS penetration include high-dose intravenous methotrexate and temozolomide. Chemotherapy may also be administered intrathecally, typically via a port placed into the ventricular system, which helps circumvent these natural anatomic barriers, but intrathecal chemotherapy (ITC) only penetrates into brain parenchyma by a few millimeters at most and is generally ineffective against most parenchymal brain metastases. Another limitation to using chemotherapy to treat neurologic metastasis is that the primary malignancy might have previously been treated with the same agent, leading to acquired resistance. Finally, mutations in the primary tumor may differ from intracranial metastases, also rendering systemic therapy less effective against these sites of metastatic disease.

Cancer histologies for which chemotherapy has shown efficacy, albeit modest, in CNS metastases include germ cell tumors (where the effect is dramatic), small cell lung cancer (where the effect can be rapid, but often of limited durability), and breast cancer. Cancers harboring specific driver mutations such as epidermal growth factor receptor (EGFR) mutations or anaplastic lymphoma kinase (ALK) rearrangements in non–small cell lung cancer (NSCLC), *BRAF* mutations in melanoma, etc, may respond well to appropriate targeted therapeutics (eg, EGFR tyrosine kinase inhibitors, ALK inhibitors, BRAF inhibitors), as newer next-generation targeted drugs do at least partially penetrate the BBB.

BRAIN METASTASIS

Epidemiology and Clinical Manifestations

The most common type of cancer of the brain is metastatic disease; brain metastases outnumber primary brain tumors by a ratio of approximately 10:1. Up to 20% to 40% of all cancer patients will develop metastatic disease to the brain at some point during the course of their systemic disease. The brain may be a site of relapse at any time in the patient's clinical course, but the median time interval between the primary cancer diagnosis and development of brain metastasis is approximately 1 year, but the interval range can exceed 10 years. NSCLC is the most common source of brain metastases. In comparison, a larger proportion of patients with diagnoses such as melanoma, small cell lung cancer, renal cell carcinoma, and specific subsets of breast cancer will develop brain metastases, but due to the lower number of patients diagnosed with these diseases, the total incidence from these primary tumors is lower than that from NSCLC.

Symptoms of CNS metastases result from both focal pressure on surrounding tissue, destruction of normal neurons, and global increases in ICP from the metastases or associated peritumoral edema. Presenting symptoms most often include headache (49%), altered mental status (32%), focal weakness (30%), ataxia (21%), and seizures (18%). Diffuse, small, miliary lesions scattered throughout the brain parenchyma are particularly associated with leukemia and small cell lung cancer and may manifest as a generalized encephalopathy (**Fig. 101.3B**).

Untreated brain metastases generally produce worsening symptoms over days to weeks. In some cases, symptoms are more acute and may mimic ischemic or hemorrhagic stroke. The more abrupt clinical course may particularly be seen with bleeding within the metastasis; hemorrhagic brain metastases are classically associated with certain histologies, including melanoma, renal carcinoma, choriocarcinoma, NSCLC, and thyroid (**Fig. 101.3C**).

Diagnosis

In the setting of a known diagnosis of cancer and new neurologic symptoms, multiple, spheroidal, enhancing brain lesions, mostly at the gray-white junction, with a disproportionate degree of edema on MRI, strongly suggest a diagnosis of brain metastases. Differential diagnosis includes primary brain tumor, lymphoma, abscess, other infectious processes, stroke, multifocal demyelination, or radiation necrosis. A seminal series of 54 patients, all with a prior history of an invasive malignancy, with a new single brain lesion seen on imaging who underwent resection or biopsy reported pathologic discordance in 11%; in other words, 1 of 10 patients with MRI findings consistent with a single metastatic lesion in the brain might not have a brain metastasis.

Brain metastases may be single or multiple. The classic appearance of metastatic disease in the brain is a round, irregular, ring-enhancing lesion at the gray-white matter interface with associated vasogenic edema (**Fig. 101.3D**). In comparison, high-grade gliomas are most commonly single and rarely present as multiple distinct lesions and may appear more infiltrative and irregularly shaped than brain metastases. Primary CNS lymphoma tends to present as periventricular, homogenously enhancing disease. Intracranial abscesses are high on the list of differentials in the setting of immunosuppression. These appear as well-circumscribed, thick-rimmed, ring-enhancing masses with central hypodensity. Stroke, both hemorrhagic and ischemic, may produce both similar symptoms and imaging findings as brain metastases. Multifocal demyelination has been reported after treatment with certain chemotherapy agents (5-fluorouracil and levamisole) and may also mimic metastases in appearance. Radiation necrosis is a known potential complication from RT, particularly SRS, and may also appear as a contrast-enhancing mass (**Fig. 101.3E**).

About 80% of brain metastases involve the cerebral hemispheres, 10% the cerebellum, and 5% the brainstem, a rate of incidence that appears consistent with the relative volume and percentage of intracranial blood flow. A high proportion of brain metastases are seen in the watershed regions. This is most likely due to smaller blood vessels and slower blood flow in these areas. For reasons that are not fully understood, different histologies may preferentially metastasize to different brain locations. For example, lung cancer tends to metastasize to the cerebrum, whereas gastrointestinal malignancies tend to metastasize to the cerebellum.

Management

Approximately 30% to 50% of patients with metastatic disease to the brain will die from progressive intracranial disease. Therefore, when considering treatment options, one must consider not only the extent of intracranial disease but also overall disease burden, clinical status, and prognosis. To predict survival in the setting of intracranial metastasis, the Radiation Therapy Oncology Group (RTOG) developed a recursive partitioning analysis classifier that stratified patients based on performance status, age, control of primary tumor, and presence of extracranial metastatic disease. Subsequently, the Graded Prognostic Assessment index was developed as a more objective prognostic scoring system and incorporated additional variables such as the number of brain metastases, with further iterations being histology specific and the most recent versions incorporating molecular markers. Based on these classification schemes, predictions may be made regarding overall survival, which may then be used to potentially guide therapy decisions.

Two clinical scenarios merit additional clarification: (1) a single brain lesion, meaning known disease elsewhere with only one lesion in the brain, and (2) a solitary brain lesion, meaning the one metastasis to the brain is the only known site of disease. (It should be noted that the literature often uses single and solitary interchangeably.) Single or solitary brain lesions generally warrant aggressive management because this may have a significant impact on survival. Several series have reported that treatment of single, synchronous brain metastases from NSCLC in addition to definitive thoracic treatment improved survival.

After medical stabilization, definitive treatment with surgery, focused RT with SRS or WBRT, chemotherapy (including targeted agents in highly selected patients), or different combinations of these modalities are considered. The only clinical trials that have ever demonstrated survival advantage from more aggressive therapy are in patients with single (inclusive of solitary) brain metastasis.

Focal Treatment

Brain metastases may be focally treated with either surgery or SRS. After resection of a brain metastasis, patients undergo either SRS or WBRT, to improve the rate of local disease control LEVEL 1.[8]

Surgery

Resection of a limited number of brain metastases, usually one, results in improved outcomes, both for locoregional recurrence and overall survival. Resection alone, however, is not adequate and results in a high risk of local failure (Fig. 101.4). For patients with solitary or single brain metastases with controlled systemic disease, resection followed by WBRT prolongs survival (median 40-50 weeks), functional independence, and improved neurologic function versus WBRT alone LEVEL 1.[9] Appropriate patient selection is crucial because resection of single metastases in patients with a greater burden of systemic disease or with poorer performance status generally does not lengthen survival. This is believed to be the reason behind the lack of survival benefit seen in the trial by Mintz et al because this study included patients with Karnofsky performance status of 50, compared to minimum Karnofsky performance status of 70 for patients enrolled in the other two trials LEVEL 1.[10] The results of this trial were also potentially confounded by a high rate of surgery following disease progression among patients randomized to WBRT alone. As an alternative to adjuvant WBRT, patients with limited brain metastases who undergo resection of one or more lesions can also undergo postoperative SRS to the resected metastases as well as definitive SRS to the remaining lesions. This approach results in similar survival rates yet reduced decline in neurocognitive function, compared to WBRT, at the cost of increased focal brain necrosis and a substantially elevated risk of failure in the rest of the brain, including the leptomeninges LEVEL 1.[11] Table 101.1 summarizes the key randomized surgical and RT trials LEVEL 1.[9,10,12-14]

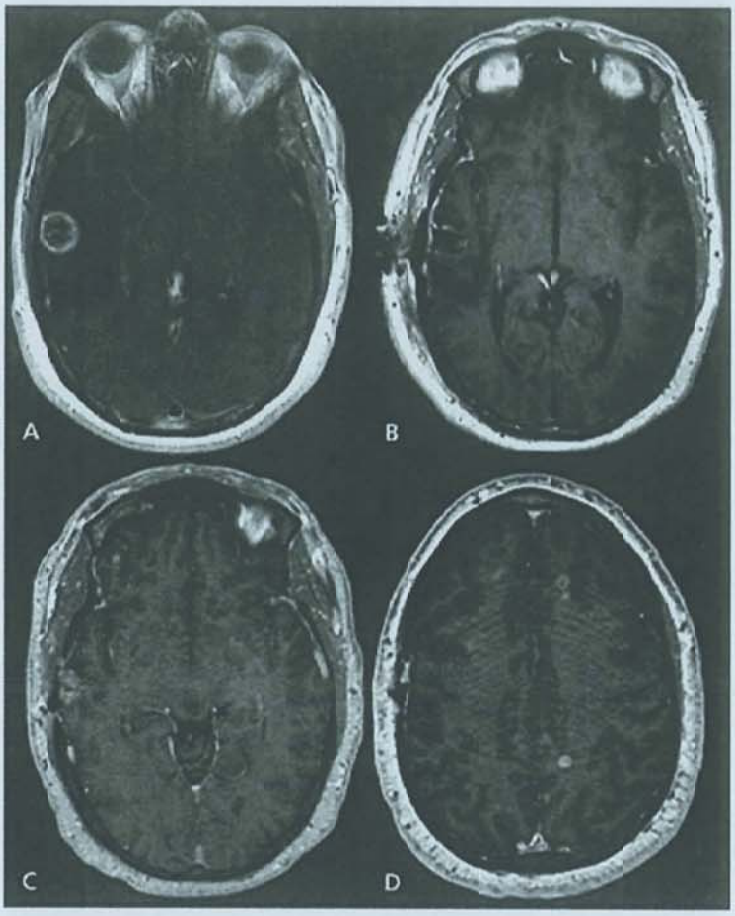

FIGURE 101.4 Patient with non–small cell lung cancer who presented with a single right temporal brain metastasis **(A)**, which underwent resection **(B)** without postoperative radiotherapy recommended. Patient ultimately experienced a local recurrence in the postoperative bed **(C)** as well as numerous intracranial metastases necessitating salvage whole brain radiotherapy **(D)**.

Surgery is preferred to radiation in the setting of extensive edema and increased ICP because it is the most efficacious therapy for immediate reduction of mass effect. Surgery is also preferred for cases in which a pathologic sample is desired to guide

TABLE 101.1 Comparison of Overall Survival for Surgery and Surgery Plus Radiotherapy Randomized Controlled Trials

Trial	N	Surgery + WBRT	WBRT Alone	*P* Value
Patchell et al	48	40 wk	15 wk	< .01
Noordijk et al	63	~40 wk	~24 wk	.04
Mintz et al	84	~22.4 wk	~25.2 wk	NS
Trial	**N**	**Surgery/ SRS + WBRT**	**Surgery or SRS Alone**	***P* Value**
Kocher et al	359	10.9 mo	10.7 mo	NS
Trial	**N**	**Surgery + SRS**	**Surgery Alone**	***P* Value**
Mahajan et al	132	17 mo	19 mo	NS

Abbreviations: NS, not significant; SRS, stereotactic radiosurgery; WBRT, whole brain radiation therapy.

treatment and for lesions larger than 4 cm. Wider application of surgery is limited by the risk of morbidity, particularly for multiple metastases for which multiple craniotomies might be necessary. Retrospective studies of resection of up to two metastases in well-selected patients suggest a possible survival advantage, but level 1 evidence to support this approach is lacking. Although no randomized trials have explored the role/value of multiple craniotomies for multiple metastases, in clinical practice, patients presenting with multiple large metastases with considerable mass effect and imminent herniation might be best served by undergoing such an approach because neurosurgical techniques, risks of anesthesia, and neurointensive care unit recovery processes have dramatically improved over the last decade, permitting safe application of such a radical approach (Fig. 101.5).

Stereotactic Radiosurgery

SRS is used to deliver a single, high-dose treatment of RT to a small, well-circumscribed target and is frequently used for metastatic disease that is not amenable to surgery due to location or to patient comorbidities. Unlike surgery, SRS may be considered in the treatment of multiple lesions. SRS results in either stability or decrease in tumor size in over 80% of patients and represents an effective means to achieve local control. With submillimetric treatment precision accomplished with increasingly sophisticated immobilization and imaging and extremely sharp dose gradients, SRS is capable of safely delivering high doses of radiation to the target with markedly reduced dose to neighboring sensitive structures. This capability for dose escalation means that metastases from radioresistant histologies, such as melanoma and renal cell carcinoma, are more likely to be controlled. The prescribed dose of RT delivered by SRS is determined by the size of the lesion, with larger lesions receiving lower doses due to the increased risk of inducing unacceptable edema and radiation necrosis. Also for this reason, the largest lesion that may be safely treated with single-fraction SRS is on the order of 3 to 4 cm, although lesions up to 5 cm in size have been treated with

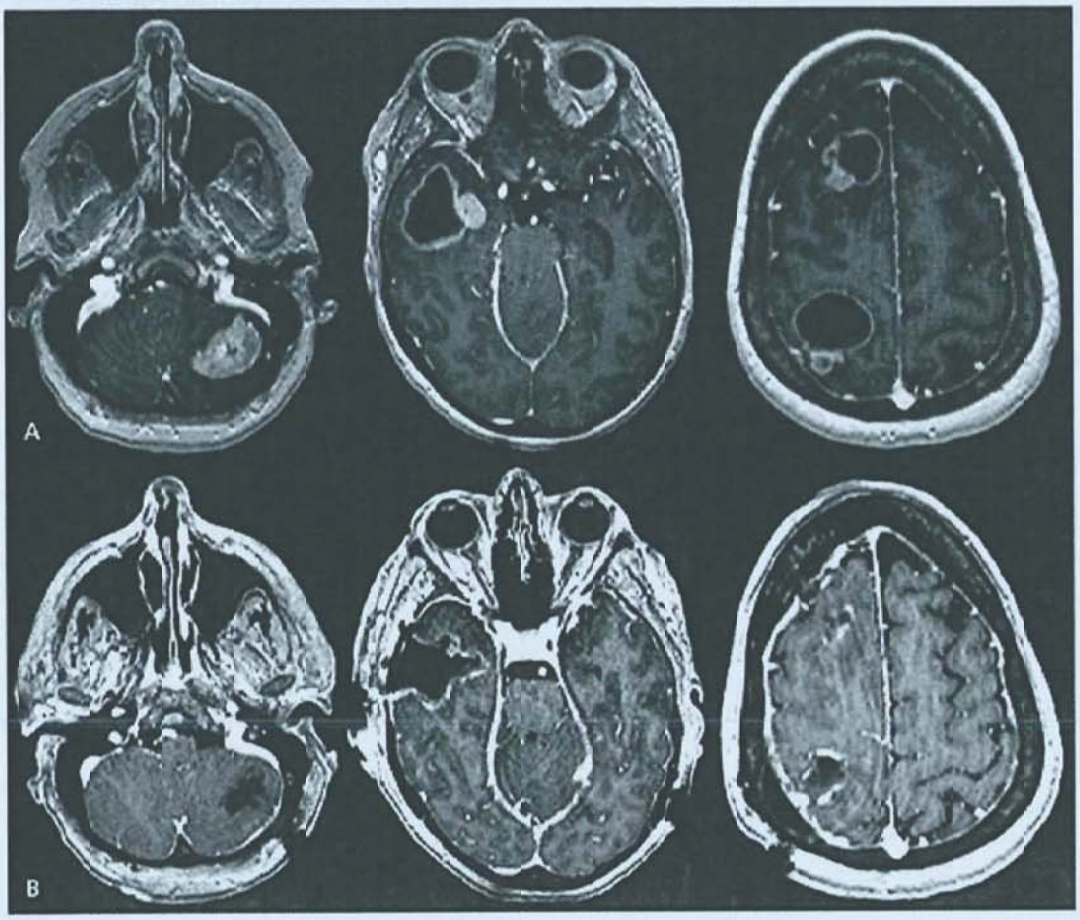

FIGURE 101.5 **A:** Patient with four large cystic brain metastases in the left cerebellar, right temporal, right frontal, and right parietal regions. **B:** Given the size and cystic nature of the lesions, all were successfully resected prior to adjuvant radiotherapy with rapid symptomatic improvement.

diminishing local control. Newer methods of delivering SRS, such as a staged approach (one dose followed by an interval of 2-4 wk followed by a boost dose) as well as the incorporation of stereotactic radiotherapy (treatment delivered over 3-5 fractions) into clinical practice have allowed for larger lesions to be treated with these high-precision RT techniques.

SRS is sometimes used in combination with WBRT. A randomized trial compared WBRT plus SRS to one to three brain metastases versus WBRT alone and found an overall survival advantage with the addition of SRS in patients with a single lesion; on post hoc analysis, other subgroups with survival benefit were identified and included patients with lung cancer with up to three lesions and RTOG recursive partitioning analysis class I patients LEVEL 1.[15]

An active area of investigation is the use of SRS to prevent local recurrence postresection. Resection bed SRS is more complex than targeting an enhancing tumor due to uncertainties regarding the interpretation of a postoperative MRI. One series reported a 1-year local control rate of 94% when a 2-mm margin was added around the defined tumor bed versus 78% when no margin was added and another suggested that most tumor bed recurrences occurred within 3 mm from the resection cavity. Consensus guidelines help to define important principles when delineating the target volume at the time of SRS planning. One concern regarding surgical bed SRS is the possibility of leptomeningeal spread secondary to the resection, especially for patients with large lesions, those that are dural based, those in patients with specific subtypes of breast cancer, and in those with posterior fossa disease. A second concern is that tumor beds "fill-up" postoperatively with normal brain tissue, and especially when margins are employed, a lot of brain parenchyma would receive high radiation doses, increasing the likelihood of necrosis. The North Central Cancer Treatment Group, in collaboration with RTOG, recently reported on a randomized study, which compared postoperative WBRT versus resection bed SRS. Patients who received postoperative SRS experienced higher rates of cognitive deterioration–free survival but no difference in overall survival, and a significantly elevated incidence of intracranial relapse LEVEL 1.[11] Some institutions use preoperative SRS to obviate the tumor bed definition challenges and contend that the leptomeningeal dissemination rate is lower, tumor control is higher, and radiation necrosis risk is lower, but no prospective evaluations of pre- versus postoperative SRS have been conducted to date.

Whole Brain Radiation Therapy in Addition to Focal Treatment

Although focal therapy, such as surgery or SRS, can effectively control the treated lesion, the rate of relapse in the rest of the brain is still approximately 30% to 70%. WBRT following resection or SRS of a single (or up to four) brain metastases yields improvement in local control, reduction in distant intracranial failure, and reduction in death from neurologic progression. The addition of WBRT to focal treatment unquestionably reduces intracranial relapse, but cognitive decline consequential to the late effects of WBRT may occur in a significant proportion of patients. Neurocognitive effects may be seen within months, and fixed deficits become pronounced years after treatment. Half or more of all patients with brain metastases die from systemic progression rather than from their intracranial disease, but certainly, some patients have prolonged survival and clinicians must therefore consider and discuss the possible late complications of WBRT. Recent data support a protective effect for the drug memantine LEVEL 1.[16] Sparing critical structures within the brain, such as the perihippocampal regenerative subgranular stem cell niche, during radiotherapy planning also reduces the development of neurocognitive deficits from WBRT. A recent randomized trial of conventional WBRT and memantine compared with hippocampal avoidance WBRT (an advanced radiotherapy treatment technique in which the entire brain parenchyma is treated to a therapeutic dose but the bilateral hippocampal regions receive reduced doses) and memantine showed a longer time to neurocognitive failure with hippocampal avoidance WBRT, supporting its role in routine clinical practice LEVEL 1.[17]

SRS is increasingly used alone, particularly in elderly patients or others with fragile baseline mentation or in those whose overall prognosis is excellent. In one small randomized trial, SRS alone actually produced neurocognitive preservation superior to WBRT plus SRS; however, the small trial size resulted in concerns regarding patient selection imbalance LEVEL 3.[18] In a larger Japanese trial, cognitive function, as measured using the Mini-Mental State Examination trended toward superiority for the SRS + WBRT arm, with a longer period to Mini-Mental State Examination decline favoring the WBRT arm LEVEL 3.[19] In a European Organisation for Research and Treatment of Cancer trial of either resection or radiosurgery, with or without WBRT, adjuvant WBRT negatively impacted some aspects of health-related quality of life, although these effects were transitory. However, compliance with health-related quality of life was only 88.3% at baseline and dropped to an abysmal low of 45% at 1 year; in trials with such large components of missing data, imputing superiority is fraught with a lot of inherent biases LEVEL 1.[13] Recently, a larger intergroup trial in 213 patients with up to three brain metastases randomized patients to SRS or SRS plus WBRT. The primary endpoint was cognitive deterioration (decline of >1 standard deviation from baseline on at least 1 cognitive test at 3 mo), and secondary endpoints included the time of intracranial failure, quality of life, functional independence, long-term cognitive status, and overall survival. Patients randomized to SRS alone experienced less cognitive deterioration at 3 months, better quality of life at 3 months, and better overall quality of life; however, the time of intracranial failure was shorter without WBRT, and there were no significant differences in functional independence or overall survival between the treatment arms LEVEL 1.[20]

Therefore, the complete omission of WBRT must be approached cautiously, especially in the context of other reports in the literature, such as the oft-forgotten study by Pirzkall et al involving 236 patients, wherein SRS plus WBRT, compared to SRS alone (not a randomized trial), yielded better tumor control and reduced intracranial relapse and a trend toward improved survival, especially in patients with no extracranial disease (15.4 vs 8.3 mo, $P = .08$), underscoring the logical expectation that WBRT added to SRS improves brain disease control, and this has the potential to translate to a survival advantage, only in patients who are less likely to succumb to extracranial progression, once again underscoring the need to perform systemic disease restaging in trials attempting to define a survival difference. This finding was most recently supported by a secondary analysis of the Japanese trial of SRS versus SRS plus WBRT, in which patients with the best prognoses appeared to have a survival benefit from the addition of WBRT in reducing subsequent brain failures.

The American Society of Radiation Oncology, in 2014, recommended against routine use of WBRT in selected patients

with limited intracranial disease treated with SRS, but if these patients have limited extracranial disease, they may well be the exact group, which might actually experience a survival benefit with WBRT, analogous to the survival benefit that accrues to small cell lung cancer patients when WBRT is used to treat presumed intracranial microscopic disease in the context of well-controlled extracranial disease (the so-called PCI, although there is nothing truly "prophylactic" about this strategy, but in reality, it is therapeutic for micrometastatic intracranial disease). The advent of systemic therapies with better BBB penetration are truly needed before a complete shift to focal therapy alone can be safely performed.

It is important to understand that recurrence of cancer in any organ frequently leads to functional deterioration within that organ, and the brain should not be expected to be an exception to this; therefore, deferring WBRT or additional SRS until relapse may have potential detrimental neurocognitive and overall survival consequences because relapse in the brain may present with potentially devastating and irreversible symptoms. Very few studies carefully analyze the mode of death in brain metastasis patients. Regine et al, in a single institution experience, reported considerably increased intracranial relapses in patients treated with SRS alone but more importantly noticed that these were most often (71%) symptomatic and associated with a neurologic deficit. Patchell et al, in their seminal trial of resection +/− WBRT, tracked cause of death and identified neurologic death as occurring far more frequently in patients not receiving WBRT, a logical outcome of increased intracranial failure LEVEL 2.[21] One option to overcome this problem is frequent monitoring with screening MRI scans after initial SRS and salvage with repeat SRS at presymptomatic recurrence. However, such an option, even if it were shown to be effective in a randomized trial, would likely be associated with increased societal costs consequential to the intense MRI surveillance and salvage with repeat SRS, usually on more than one occasion. All of these factors must be weighed for each individual patient in order to optimize treatment.

Reirradiation

Despite good initial responses, most patients will eventually experience disease progression in the brain, and so the role of reirradiation must also be considered. SRS may be used to treat recurrence after WBRT and vice versa. In some cases, WBRT may be repeated and has been reported to improve symptoms in 40% to 70% of patients. To date, there is no randomized evidence regarding the role or reirradiation for brain metastases, and clinical decisions must be made on a case-by-case basis LEVEL 2.[22]

Chemotherapy, Targeted Therapy, and Immunotherapy

The role of chemotherapy, targeted therapy, or immunotherapy is not well defined but is evolving at a rapid pace. There is no level 1 evidence favoring the use of cytotoxic chemotherapy, and therefore, no standard chemotherapy is routinely used for the treatment of brain metastases, except perhaps for germinomas. In patients with brain metastases who have failed local therapy, the same chemotherapeutic agents employed for the treatment of extracranial disease are often used. Alternatively, drugs with good CNS penetration, such as temozolomide, topotecan, irinotecan, and high-dose methotrexate may be employed, even in patients in whom chemotherapy might have at most minor efficacy against the primary tumor.

Improved understanding of tumor biology has led to the identification of specific molecular drivers of cancer development and progression. Alterations involving the *EGFR* gene and *EML4–ALK* chromosomal translocation in lung cancer, human epidermal growth factor receptor 2 (HER2) protein overexpression in breast cancer, *BRAF* mutation in melanoma, and NTRK gene fusions in adult and pediatric solid tumors are examples of distinct subsets of cancer amenable to unique treatment approaches. There have been several prospective studies in the last 5 years particularly focusing on targeted therapies or immunotherapies, which have demonstrated promising outcomes.

Epidermal Growth Factor Receptor Inhibitors in Non–Small Cell Lung Cancer

The RTOG 0320 trial did not show any additional benefit of temozolomide or erlotinib when added to WBRT and SRS in unselected patients with NSCLC with one to three brain metastases LEVEL 2.[23] One of the limitations of this study was that patients were not stratified according to *EGFR* mutational status. In a phase II study of 40 NSCLC patients with brain metastases, WBRT and erlotinib was safe, and the median survival time was 11.8 months. In the 17 patients with known *EGFR* status, the benefit of erlotinib was more pronounced in the mutant *EGFR* patients (overall survival of 19.1 mo) as compared to the wild-type *EGFR* patients (overall survival of 9.3 mo). In a large cohort of 110 patients with *EGFR* mutant lung cancer with newly diagnosed brain metastases, patients treated with WBRT (32 patients) had longer median time to intracranial progression compared to 63 patients who received erlotinib therapy upfront (24 vs 16 mo). In a retrospective multiinstitutional analysis of 35 patients with *EGFR* mutated brain metastasis, the median survivals after SRS, WBRT, and EGFR inhibitor alone were 46, 20, and 25 months ($P < .001$), despite the most favorable patients being selected for systemic therapy alone. This study demonstrates that the deferral of RT and treatment with a systemic therapy alone that has modest efficacy, may result in a survival decrement, even in patients with these favorable mutational profiles (**Fig. 101.6**). In fact, these data lend further credence to the hypothesis that if a patient is destined to live longer than just a few months, intracranial control becomes a paramount goal, and using suboptimal approaches that raise the risk of intracranial relapse might risk a decrement in overall survival.

In a phase II study of gefitinib in 41 NSCLC patients unselected for *EGFR* mutation, an objective response rate of 10% in the brain was seen. Higher response rates were reported in studies of EGFR inhibitors in enriched with patients with known *EGFR* mutations. Third-generation EGFR inhibitors, such as osimertinib, are associated with higher response rates (50%-70%) and more durable disease control. Newer agents in the pipeline for patients with these mutations also include AZD-3759 and avitinib (against the EGFR T790M-resistant mutation).

Anaplastic Lymphoma Kinase Inhibitors in Non–Small Cell Lung Cancer

The first-generation ALK inhibitor crizotinib resulted in excellent extracranial disease control, however, poor (<20%) response rates in the brain due to limited BBB permeability. Next-generation novel ALK inhibitors, such as alectinib, ceritinib, and brigatinib, show better BBB penetration and intracranial disease control (>50%) in clinical studies. New molecular-based prognostic assessments also show longer survivals in these patients, due in significant part, to the increased efficacy of these next-generation agents.

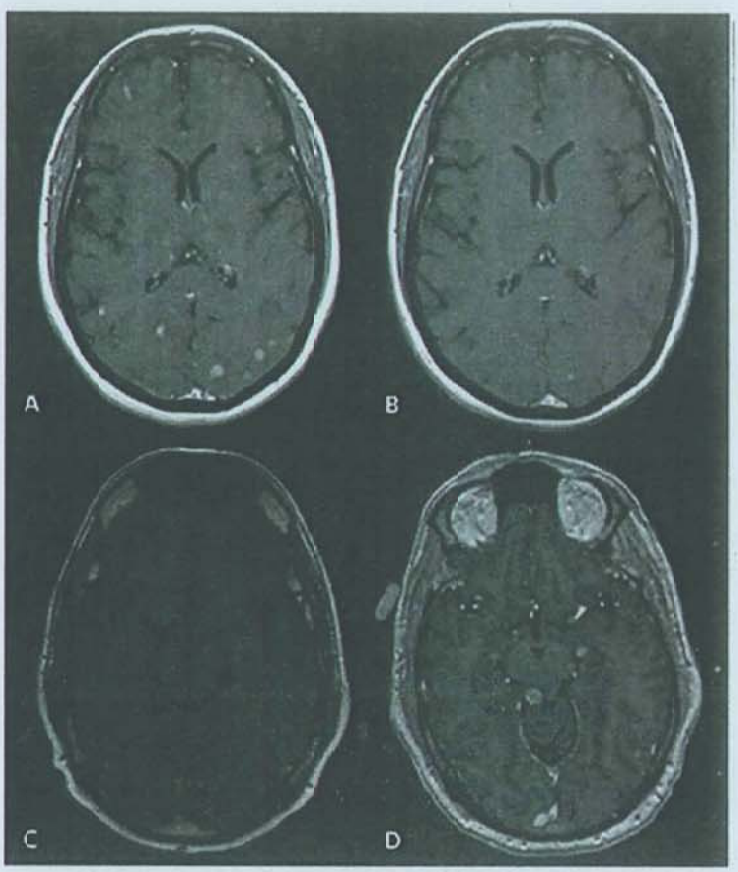

FIGURE 101.6 Differential response to epidermal growth factor receptor inhibitors in brain metastasis. One patient with innumerable brain metastases **(A)** has an excellent response to treatment with targeted therapy alone **(B)**. Contrast this with another patient with the same epidermal growth factor receptor mutation only presenting with a single brain metastasis **(C)** who is treated with the same targeted therapy but experiences symptomatic progression of disease **(D)** necessitating salvage stereotactic radiosurgery.

Human Epidermal Growth Factor Receptor 2 Inhibitors for Breast Cancer

The prototypical, first-in-class HER2 inhibitor, trastuzumab, has extremely poor BBB penetration and was initially described as yielding responses in the context of leptomeningeal carcinomatosis from breast cancer but not for parenchymal disease. Several prospective clinical trials have evaluated the role of the second-generation agent, lapatinib, single, or in combination with fluorouracil therapy in *HER2*-positive breast cancer patients with active brain metastases. In one phase II study of lapatinib in patients with *HER2*-positive breast cancer with progressive brain metastases after WBRT and/or SRS, a true CNS response rate of only 6% was seen. In a single-arm phase II study, 29 of the 45 patients with newly diagnosed, previously untreated brain metastases from *HER2*-positive breast cancer achieved an objective CNS response (66%) with the combination of lapatinib and capecitabine LEVEL 1.[24] Similarly, neratinib and capecitabine have also demonstrated favorable response rates (49%) compared to neratinib alone (8%). Newer agents such as trastuzumab emtansine, tucatinib, and tesevatinib are also being evaluated in this subset of breast cancer patients. In this context, a nearly completed NRG Oncology trial (NCT01622868) is exploring combinatorial WBRT or SRS with lapatinib, based on limited preclinical data suggesting efficacy, and results are early awaited.

Inhibitors Targeting *BRAF* in Melanoma

Activating *BRAF* mutations that result in constitutive activation of the mitogen-activated protein kinase pathway affect approximately half of cutaneous melanoma patients, and more than 95% of these are the V600E mutations (substitution of valine by glutamic acid at the 600th amino acid position). In an open-label phase II study, 172 patients with V600E or V600K mutation–positive melanoma metastatic to the brain were treated with dabrafenib. Patients in cohort A had not received any prior local therapy, and cohort B had disease progression in the brain following local therapy (surgery, WBRT, SRS). Twenty-nine of 74 patients (39%) with V600E BRAF-mutant melanoma in cohort A and 20 of 65 (31%) patients in cohort B achieved an overall intracranial response. This study provided initial evidence that dabrafenib has activity in patients with V600E *BRAF*-mutant melanoma brain metastases irrespective of prior local therapy, but the response rates of 31% to 39% have to be considered modest at best, especially given that none of these were complete responses and durability was limited.

In a prospective study, 24 patients with V600E *BRAF* mutation–positive melanoma brain metastases were treated with vemurafenib. Of 19 patients with measurable intracranial disease, 7 (37%) achieved greater than 30% intracranial tumor regression, and 3 (16%) achieved a confirmed partial response, whereas 13 out of 21 patients (62%) had extracranial responses. A phase II study of vemurafenib in 146 patients with V600 *ERAF* mutation–positive melanoma brain metastases with or without prior treatment for their brain metastases yielded a best overall intracranial response rate of 18% in each cohort.

Combinatorial systemic therapy strategies are associated with higher response rates and more durable rates of disease control as observed in a multicenter, multicohort, open-label, phase II trial of dabrafenib and trametinib in patients with V600E *BRAF* mutation–positive melanoma brain metastases.

Inhibitors Targeting *NTRK*

NTRK gene fusions are present in a variety of adult and pediatric tumors and can be detected using a variety of assays, such as DNA sequencing, RNA sequencing, and plasma cell-free DNA profiling. Targeting this oncogenic driver mutation in select patients with first-generation NTRK inhibitors has been associated with incredible response rates (>75%) regardless of the primary tumor subtype. Recent studies have also demonstrated intracranial efficacy and durable disease control using selective NTRK inhibitors for patients with solid tumors with brain metastasis or primary CNS tumors harboring NTRK gene fusions. Ongoing clinical trials will further demonstrate intracranial efficacy in larger populations of patients.

Immune-Modulating Approaches

The development of immune-modulating agents, specifically immune checkpoint inhibitors, offers an exciting opportunity for treating patients with brain metastases. Recent research has demonstrated that activated T cells can be effective in brain metastases and other intracranial tumors. In a phase II study, 72 melanoma patients with brain metastases (51 asymptomatic [cohort A], 21 symptomatic and on steroids [cohort B]) were treated with ipilimumab, a monoclonal antibody against cytotoxic T-lymphocyte–associated protein 4. Twelve of 51 patients (24%) in cohort A and 2 of 21 patients (10%) in cohort B achieved CNS disease control. Median overall survival was 7.0 months in cohort A and 3.7 months in cohort B. This study demonstrated that ipilimumab could have some activity in recurrent brain metastases.

Recent trials using antibodies against the programmed cell death protein 1 receptor of lymphocytes for patients with brain metastases have also demonstrated modest intracranial efficacy with a variety of agents, alone, and in combinatorial approaches. For example, one phase II trial using pembrolizumab showed an intracranial response rate of 22% in melanoma brain metastasis and 33% in NSCLC brain metastasis. Combination strategies of ipilimumab and nivolumab have been demonstrated to result in response rates of approximately 50% in well-selected cohorts of patients. Exuberantly, enthusiastic commentators have prematurely suggested that these data are sufficient to replace radiotherapy in melanoma patients with brain metastases, but that is, in reality, far from the case, as these patients are extremely well-selected, and the majority of patients in clinical practice would not meet the eligibility criteria of these trials.

There is considerable interest in combining these immune checkpoint inhibitors with RT. A retrospective analysis of 13 patients treated with WBRT within 30 days of ipilimumab showed that 4 out of 9 patients (44 %) experienced a partial response or stable disease. In another retrospective review, the median survival of patients with melanoma with brain metastases treated with ipilimumab and brain SRS was comparable to patients without brain metastases. In a large cohort of patients with brain metastasis treated with SRS and anti–programmed cell death ligand 1 inhibitors, we recently showed that SRS and immediate immune checkpoint inhibition resulted in high rates of durable disease control without increased risk of treatment-related toxicity. Additional research is needed to clarify the role of combinatorial immunotherapy and radiotherapy.

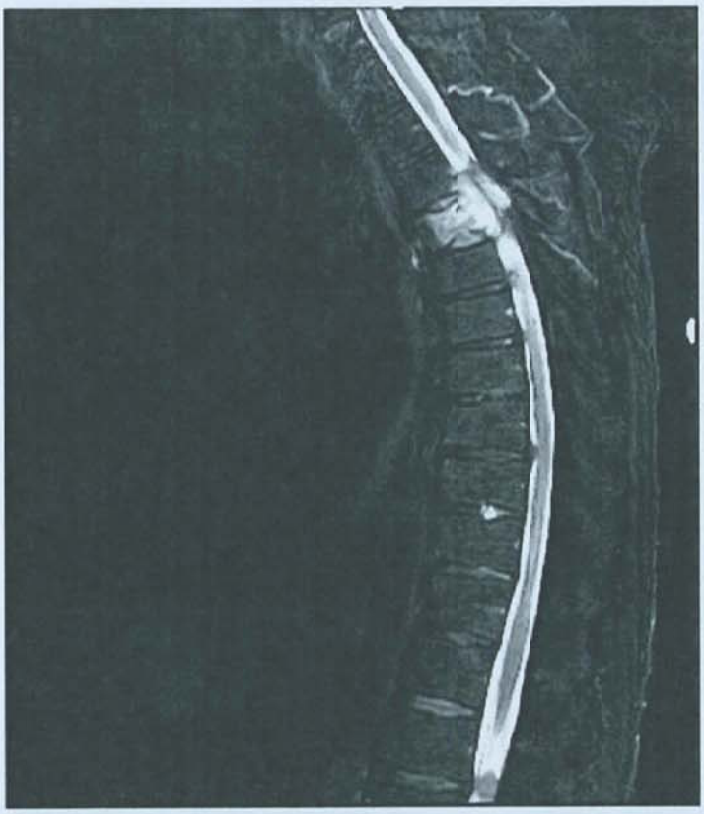

FIGURE 101.7 Spinal cord compression from metastatic disease, sagittal, T2 magnetic resonance imaging.

EPIDURAL SPINAL COLUMN METASTASIS

Epidemiology and Clinical Manifestations

Metastatic disease to the spine can be LM (discussed in the following section) or intramedullary, but by far, the most common site is epidural. Epidural spinal metastases can cause severe neurologic compromise by compressing the thecal sac and ultimately the spinal cord. The cancers that most often are responsible for epidural metastatic disease to the spine include breast, prostate, and lung cancer. This is in part due to not only the relatively high incidence of these malignancies but also their predilection for metastatic disease spread to bones; the spinal column is the most common site of bone metastasis.

Epidural spinal cord compression can be a surgical emergency that occurs in up to 15% of patients with a history of cancer. This complication typically occurs in the setting of known bone metastases but, as with brain lesions, may be the presenting symptom for a new diagnosis of primary malignancy or for new diagnosis of metastatic disease. The most common level of cord compression is the thoracic level (59%-78%), followed by lumbar (16%-33%), and cervical (4%-15%) levels (Fig. 101.7). In up to 50% of patients, disease may involve multiple levels of the vertebral column. As with bone metastases, pain is the most common presenting symptom of spinal cord compression (96%). This may be not only from the bone itself but also from spinal cord or nerve root involvement. As compression worsens, patients may also develop other signs and symptoms of spinal cord compression including gait ataxia, focal weakness (76%-86%), sensory disturbances (51%-80%), and autonomic dysfunction (40%-64%). In most cases, epidural spinal cord compression occurs due to extension of disease from the bony vertebrae, but it sometimes may be due to infiltration of the neural foramina or paravertebral spaces or from a pathologic vertebral fracture. Compression of the spinal cord and blood vessels cause mechanical nerve damage and ultimately ischemia and infarction. The longer the cord is compromised, the more likely that the damage is irreversible; it is well established that long-standing, gradually worsening neurologic symptoms are unlikely to be markedly improved following therapeutic intervention due to the chronic nature of the damage.

Diagnosis

The diagnostic test of choice for spine metastasis of any kind is a contrast-enhanced MRI scan, but if the patient's condition is rapidly deteriorating, or if the patient is unable to tolerate the length of this study, a noncontrast MRI may be partially adequate. If, however, there is clinical suspicion for either intramedullary or leptomeningeal disease, then intravenous contrast is absolutely indicated. The entire spine should be studied in order to evaluate for multilevel involvement. Patients who are unable to undergo MRI should have a computed tomography myelogram.

Management

Initial palliation of pain from spinal metastasis is often with nonsteroidal anti-inflammatory drugs, narcotics, agents to ameliorate neuropathic pain, and corticosteroids.

For spinal cord compression, the goals of care are to preserve neurologic function and to relieve pain. The early recognition and initiation of treatment, even prior to definitive diagnosis,

are critical due to the time-sensitive chance of recovery from a neurologic deficit. As soon as clinical suspicion for cord compression is raised, treatment should begin with early administration of high-dose corticosteroids to decrease swelling because this has been shown to improve outcomes in acute spinal cord injury LEVEL 1.[25]

Surgery is the primary modality for relieving spinal cord compression, particularly in the setting of limited disease because it can result in immediate decompression. The seminal prospective study comparing the addition of surgery to RT in the setting of spinal cord compression showed not only improved neurologic and functional outcomes with surgery, including ambulation, continence, and decreased steroid and narcotic requirements but also an overall survival benefit (126 vs 100 d, $P = .033$) LEVEL 1.[26] Even in the absence of spinal cord compression, surgical management should be considered in the setting of an unknown primary malignancy or new metastatic disease in order to confirm the diagnoses. For patients with vertebral fracture or spinal instability, stabilization of the spine through surgical means should be considered. Anterior epidural metastases are more challenging to access and may require thoracotomy, whereas posterior lesions are likely to be amenable to laminectomy.

Given the grave consequences of progressive disease in the spine, RT, which is a highly effective palliative treatment with up to 90% of patients experiencing a significant reduction of pain, should be considered at an early stage. This is important because pain from a compression fracture and compressive symptoms from retropulsed bony fragments are almost never adequately relieved by any modality except surgery. RT can reduce the likelihood of a pathologic fracture, as may vertebroplasty. Should a fracture occur, surgical repair is the best option when possible, and postoperative RT is the standard of care. RT in this setting decreases the likelihood of local recurrence, which may compromise the integrity of the surgical repair/stabilization. The typical time frame is 1 to 2 weeks after surgery in order to allow for adequate wound healing. In selected patients, percutaneous vertebroplasty or kyphoplasty may be effective in relieving symptoms. None of these treatments will prolong survival but may have a significant positive impact on quality of life.

RT is also a common palliative treatment for epidural spinal cord metastases, particularly for cases in which surgery is not feasible (ie, multilevel cord involvement, multiple medical comorbidities) and in the postoperative setting. As with brain metastases, the effect from radiotherapy is gradual and lacks the immediate decompression of surgery. RT alone is therefore suboptimal in the setting of spinal cord compression. The classic regimen for palliative RT is 30 Gy in 10 fractions, but other shorter schedules can be used in patients with a poorer prognosis LEVEL 1.[27] For primary malignancies involving the bone, such as multiple myeloma or sarcoma, the prescribed dose may be lower or higher and the target volume more conservative to avoid overtreating neighboring structures, particularly the spinal cord.

RT may be contraindicated in patients who have received previous RT to the same site or for relatively radioresistant tumors such as renal cell carcinoma. Reirradiation may be considered using a highly focused, intensity-modulated technique because this has been shown to stabilize or improve neurologic status in the majority of patients with minimal risk of radiation myelopathy. Stereotactic body RT, highly focal fractionated radiation with sharp dose gradients similar to SRS, may also be employed in this setting in order to minimize unnecessary dose to the spinal cord. Sahgal et al report that normalized biologically effective doses less than a point maximum of 20 to 25 Gy carry a low risk for myelopathy so long because the total effective dose does not exceed approximately 70 Gy, and the stereotactic body RT maximum dose is less than half the total normalized dose. A prospective series of 59 patients from MD Anderson who underwent reirradiation of spinal metastases demonstrated 92% freedom from neurologic deterioration from any cause at 1 year. Multiple series have also demonstrated favorable outcomes for patients treated in the upfront setting with primary spine SRS. In a cohort of 500 cases treated with spine SRS, long-term pain improvement was observed in 86%, long-term tumor control in 90%, and 84% of patients with a progressive neurologic deficit prior to treatment experienced at least some clinical improvement. These clinical series support a completed but yet to be reported RTOG phase II/III trial, which explored SRS in the up-front treatment of spine metastases and will ultimately provide insight regarding the use of this approach LEVEL 2.[28] The phase II trial supported the feasibility of single-fraction SRS for spinal metastases with no serious treatment-related toxicities. The phase III component compares SRS versus classic fractionated external beam RT with regard to pain relief and quality of life. By far, the strongest prognostic factor for neurologic outcome is the patient's neurologic status prior to treatment. The best odds for regain of function are with surgery LEVEL 2.[26] With RT, 80% of ambulatory patients remained ambulatory, but only 50% of patients with paresis and less than 10% of those with paralysis will regain the ability to walk. Pain may be relieved in over 90% of patients treated with corticosteroids and RT. Overall survival is most strongly determined by systemic disease burden.

LEPTOMENINGEAL METASTASIS

Epidemiology and Clinical Presentation

LM refers to metastasis to the pia and arachnoid. The disease may be focal or disseminated, but any involvement of the meninges with cancer indicates that the entire CSF compartment is compromised. This devastating complication occurs in up to 5% to 10% of cancer patients, with acute lymphocytic leukemia and other hematologic malignancies representing the most common sources. The most common solid tumors that spread to the leptomeninges are breast cancer, NSCLC, melanoma, and gastrointestinal tract cancers. Surgical resection of brain lesions, particularly of the posterior fossa, has been reported as a risk factor for the development of LM. Most cases of LM are diagnosed in the setting of known metastatic disease, but LM may be an isolated phenomenon, particularly for hematologic cancers.

The median survival without treatment is 4 to 6 weeks. Appropriate treatment may prolong survival to several months, particularly for lymphoma, leukemia, and to a lesser extent breast cancer. Treatment may also potentially reverse or prevent further neurologic symptoms. The presence of systemic disease, obstruction of the CSF, gross CNS metastases, and poor performance status are negative prognostic factors.

Headache is a common presenting symptom (30%-50%), as are altered mental status and signs of focal neuropathy. Patients most commonly present with multifocal neurologic symptoms from spinal cord (60%), cerebral (50%), or cranial nerve

FIGURE 101.8 Leptomeningeal metastatic disease spread, axial T1 contrast-enhanced magnetic resonance imaging.

involvement (40%). Increased ICP or hydrocephalus may develop due to obstruction of CSF flow or from disruption of the BBB. Seizures occur in up to 25% of patients.

Diagnosis

In the workup of LM, MRI of the entire CNS should be performed. Even though the sensitivity and specificity of imaging are relatively low (76% and 77%), obvious LM on imaging obviates the need for CSF sampling by lumbar or other puncture. If LM is visualized, it appears as enhancement of the leptomeninges, cranial nerves, or nerve roots or as gross tumor nodules. Visible LM is most commonly seen at the base of brain, sylvian fissures, and cauda equina, perhaps due to slower CSF flow in these regions (Fig. 101.8).

LP should be performed for CSF analysis, particularly if the clinical suspicion for LM is high and MRI is negative. LP may show a combination of malignant cells, elevated opening pressure, low glucose, high protein, and leukocytosis, typically of lymphocytes. Assessing the CSF for tumor marker levels, although not standard, may aid in diagnosis. The false-negative rate for initial LP in the diagnosis of LM is relatively high at 50%, and therefore, this procedure may need to be repeated multiple times to increase diagnostic yield if clinically indicated. In as many as 20% of patients with clinical or radiographic LM, the CSF may be nondiagnostic despite multiple samples. LP is contraindicated if there is a risk for brain herniation and should therefore follow MRI to make this assessment.

Management

LM is generally an incurable condition with a poor prognosis, and a careful balance of risks and benefits of treatment approaches must be individualized. The focus of treatment is primarily palliation of symptoms. Treatment must address the entire CSF compartment, and therefore, focal therapy with surgery and/or RT has limited use. Nevertheless, neurosurgical evaluation should be considered for CSF shunting, typically to the peritoneum, or for placement of an intrathecal reservoir. CSF shunting carries a theoretical risk of spread of tumor cells into the destination space, but this risk is generally not clinically significant in the context of such limited survival.

Symptomatic or bulky focal lesions may be treated with RT in a similar fashion to epidural metastases. Craniospinal irradiation is not routinely indicated because it does not improve outcomes and can cause significant morbidity, especially in adults (nausea, dysphagia, fatigue, and myelosuppression).

ITC is the mainstay of treatment of LM because it allows circulation to the entire CSF volume; specific agents include methotrexate, cytarabine (in both standard and depot formulations), and thiotepa. Cytarabine, especially the depot form, should be preceded and followed by 2 to 3 days of corticosteroid prophylaxis because a severe chemical meningitis can otherwise result. Combination chemotherapy may be considered, although data showing increased efficacy are sparse. ITC is less effective in patients with obstruction of the CSF and contraindicated in the setting of increased ICP. Occasionally, a combination ventriculoperitoneal shunt/Ommaya reservoir device is implanted to both reduce ICP and serve as a method for ITC delivery; however, this requires careful coordination of valve positioning and all too often becomes obstructed with CSF cells. ITC is typically administered intraventricularly using an implanted Ommaya reservoir. Administration via LP is also possible, but this method is more cumbersome, painful, and less reliable. ITC carries a risk of meningitis, myelosuppression, and encephalopathy.

Disruption in the normal flow of CSF is a common phenomenon with LM. This has important implications in the administration of ITC because it can both decrease efficacy and increase toxicity. Assessment of the CSF flow with radionuclide cisternogram prior to ITC is beneficial but not universally available. MRI-based flow studies are emerging, but the level of resolution is limited in this context. Identification of sites of obstruction may allow focal treatment with RT prior to ITC, which may improve flow even in the absence of a discrete lesion. WBRT may be considered because it is well tolerated and may improve CSF flow.

Systemic chemotherapy has limited use in the treatment of LM due to the BBB, but this is an area of ongoing investigation. Additional palliative care with analgesics, corticosteroids, antiseizure medications, and CSF shunting should be initiated as indicated.

CONCLUSIONS

Metastatic disease to the CNS axis is a widespread and clinically important scenario. The diagnosis is generally made with a combination of history, physical exam, and imaging. In some cases, blood work, biopsy, or CSF sampling may also aid in diagnosis. Management of CNS metastases is accomplished with corticosteroids, surgery, radiotherapy, systemic therapy, or a combination of these modalities. The treatment plan and clinical outcome depend on the specific factors of that individual patient, including the location and extent of metastatic lesions, duration of symptoms, and the patient's ability to tolerate treatment.

LEVEL 1 EVIDENCE

1. Mulvenna P, Nankivell M, Barton R, et al. Dexamethasone and supportive care with or without whole brain radiotherapy in treating patients with non-small cell lung cancer with brain metastases unsuitable for resection or stereotactic radiotherapy (QUARTZ): results from a phase 3, non-inferiority, randomised trial. *Lancet*. 2016;388(10055):2004-2014.
2. Glantz MJ, Cole BF, Forsyth PA, et al. Practice parameter: anticonvulsant prophylaxis in patients with newly diagnosed brain tumors. Report of the Quality Standards Subcommittee of the American Academy of Neurology. *Neurology*. 2000;54(10):1886-1893.
3. Borgelt B, Gelber R, Larson M, Hendrickson F, Griffin T, Roth R. Ultra-rapid high dose irradiation schedules for the palliation of brain metastases: final results of the first two studies by the Radiation Therapy Oncology Group. *Int J Radiat Oncol Biol Phys*. 1981;7(12):1633-1638.
4. Kurtz JM, Gelber R, Brady LW, Carella RJ, Cooper JS. The palliation of brain metastases in a favorable patient population: a randomized clinical trial by the Radiation Therapy Oncology Group. *Int J Radiat Oncol Biol Phys*. 1981;7(7):891-895.
5. Murray KJ, Scott C, Greenberg HM, et al. A randomized phase III study of accelerated hyperfractionation versus standard in patients with unresected brain metastases: a report of the Radiation Therapy Oncology Group (RTOG) 9104. *Int J Radiat Oncol Biol Phys*. 1997;39(3):571-574.
6. Aupérin A, Arriagada R, Pignon JP, et al. Prophylactic cranial irradiation for patients with small-cell lung cancer in complete remission. Prophylactic Cranial Irradiation Overview Collaborative Group. *N Engl J Med*. 1999;341(7):476-484.
7. Slotman B, Faivre-Finn C, Kramer G, et al; for EORTC Radiation Oncology Group and Lung Cancer Group. Prophylactic cranial irradiation in extensive small-cell lung cancer. *N Engl J Med*. 2007;357(7):664-672.
8. Muacevic A, Wowra B, Siefert A, et al. Microsurgery plus whole brain irradiation versus Gamma Knife surgery alone for treatment of single metastases to the brain: a randomized controlled multicentre phase III trial. *J Neurooncol*. 2008;87(3):299-307.
9. Patchell RA, Tibbs PA, Walsh JW, et al. A randomized trial of surgery in the treatment of single metastases to the brain. *N Engl J Med*. 1990;322(8):494-500.
10. Mintz AH, Kestle J, Rathbone MP, et al. A randomized trial to assess the efficacy of surgery in addition to radiotherapy in patients with a single cerebral metastasis. *Cancer*. 1996;78(7):1470-1476.
11. Brown PD, Ballman KV, Cerhan JH, et al. Postoperative stereotactic radiosurgery compared with whole brain radiotherapy for resected metastatic brain disease (North Central Cancer Treatment Group N107C/CEC·3): a multicentre, randomised, controlled, phase 3 trial. *Lancet Oncol*. 2017;18(8):1049-1060.
12. Noordijk EM, Vecht CJ, Haaxma-Reiche H, et al. The choice of treatment of single brain metastasis should be based on extracranial tumor activity and age. *Int J Radiat Oncol Biol Phys*. 1994;29(4):711-717.
13. Kocher M, Soffietti R, Abacioglu U, et al. Adjuvant whole-brain radiotherapy versus observation after radiosurgery or surgical resection of one to three cerebral metastases: results of the EORTC 22952-26001 study. *J Clin Oncol*. 2011;29(2):134-141.
14. Mahajan A, Ahmed S, McAleer MF, et al. Prospective randomized trial of post-operative stereotactic radiosurgery versus observation for completely resected brain metastases. *Lancet Oncol*. 2017;18(8):1040-1048.
15. Andrews DW, Scott CB, Sperduto PW, et al. Whole brain radiation therapy with or without stereotactic radiosurgery boost for patients with one to three brain metastases: phase III results of the RTOG 9508 randomised trial. *Lancet*. 2004;363(9422):1665-1672.
16. Brown PD, Pugh S, Laack NN, et al. Memantine for the prevention of cognitive dysfunction in patients receiving whole-brain radiotherapy: a randomized, double-blind, placebo-controlled trial. *Neuro Oncol*. 2013;15(10):1429-1437.
17. Gondi V, Pugh S, Brown PD, et al. NCOG-01. Preservation of neurocognitive function (NCF) with hippocampal avoidance during whole-brain radiotherapy (WBRT) for brain metastases: preliminary results of phase III trial NRG oncology CC001. *Neuro Oncol*. 2018;20(suppl 6):vi172.
18. Chang EL, Wefel JS, Hess KR, et al. Neurocognition in patients with brain metastases treated with radiosurgery or radiosurgery plus whole-brain irradiation: a randomised controlled trial. *Lancet Oncol*. 2009;10(11):1037-1044.
19. Aoyama H, Shirato H, Tago M, et al. Stereotactic radiosurgery plus whole-brain radiation therapy vs stereotactic radiosurgery alone for treatment of brain metastases: a randomized controlled trial. *JAMA*. 2006;295(21):2483-2491.
20. Brown PD, Jaeckle K, Ballman KV, et al. Effect of radiosurgery alone vs radiosurgery with whole brain radiation therapy on cognitive function in patients with 1 to 3 brain metastases: a randomized clinical trial. *JAMA*. 2016;316(4):401-409.
21. Patchell RA, Tibbs PA, Regine WF, et al. Postoperative radiotherapy in the treatment of single metastases to the brain: a randomized trial. *JAMA*. 1998;280(17):1485-1489.
22. Ammirati M, Cobbs CS, Linskey ME, et al. The role of retreatment in the management of recurrent/progressive brain metastases: a systematic review and evidence-based clinical practice guideline. *J Neurooncol*. 2010;96(1):85-96.
23. Sperduto PW, Wang M, Robins HI, et al. A phase 3 trial of whole brain radiation therapy and stereotactic radiosurgery alone versus WBRT and SRS with temozolomide or erlotinib for non-small cell lung cancer and 1 to 3 brain metastases: Radiation Therapy Oncology Group 0320. *Int J Radiat Oncol Biol Phys*. 2013;85(5):1312-1318.
24. Bachelot T, Romieu G, Campone M, et al. Lapatinib plus capecitabine in patients with previously untreated brain metastases from HER2-positive metastatic breast cancer (LANDSCAPE): a single-group phase 2 study. *Lancet Oncol*. 2013;14(1):64-71.
25. Sørensen S, Helweg-Larsen S, Mouridsen H, Hansen HH. Effect of high-dose dexamethasone in carcinomatous metastatic spinal cord compression treated with radiotherapy: a randomised trial. *Eur J Cancer*. 1994;30A(1):22-27.
26. Patchell RA, Tibbs PA, Regine WF, et al. Direct decompressive surgical resection in the treatment of spinal cord compression caused by metastatic cancer: a randomised trial. *Lancet*. 2005;366(9486):643-648.
27. Rades D, Šegedin B, Conde-Moreno AJ, et al. Radiotherapy with 4 Gy × 5 versus 3 Gy × 10 for metastatic epidural spinal cord compression: final results of the SCORE-2 trial (ARO 2009/01). *J Clin Oncol*. 2016;34(6):597-602.
28. Ryu S, Pugh SL, Gerszten PC, et al. RTOG 0631 phase 2/3 study of image guided stereotactic radiosurgery for localized (1-3) spine metastases: phase 2 results. *Pract Radiat Oncol*. 2014;4(2):76-81.

SUGGESTED READINGS

Abu Hejleh T, Clamon G. Advances in the systemic treatment of leptomeningeal cancer. *Clin Adv Hematol Oncol*. 2012;10(3):166-170.

American Cancer Society. Cancer facts & figures 2014. American Cancer Society Web site. https://www.cancer.org/research/cancer-facts-statistics/all-cancer-facts-figures/cancer-facts-figures-2014.html. Accessed February 15, 2015.

American Society of Clinical Oncology. The state of cancer care in America, 2014: a report by the American Society of Clinical Oncology. *J Oncol Pract*. 2014;10(2):119-142.

Auchter RM, Lamond JP, Alexander E, et al. A multiinstitutional outcome and prognostic factor analysis of radiosurgery for resectable single brain metastasis. *Int J Radiat Oncol Biol Phys*. 1996;35(1):27-35.

Barajas RF Jr, Cha S. Imaging diagnosis of brain metastasis. *Prog Neurol Surg*. 2012;25:55-73.

Bindal RK, Sawaya R, Leavens ME, Lee JJ. Surgical treatment of multiple brain metastases. *J Neurosurg*. 1993;79(2):210-216.

Ceresoli GL, Cappuzzo F, Gregorc V, Bartolini S, Crinò L, Villa E. Gefitinib in patients with brain metastases from non-small-cell lung cancer: a prospective trial. *Ann Oncol*. 2004;15(7):1042-1047.

Chamberlain MC, Kormanik P. Carcinoma meningitis secondary to non-small cell lung cancer: combined modality therapy. *Arch Neurol*. 1998;55(4):506-512.

Chin LS, Regine WF. *Principles and Practice of Stereotactic Radiosurgery*. New York, NY: Springer; 2008.

Coleman RE. Skeletal complications of malignancy. *Cancer*. 1997;80(8 suppl):1588-1594.

Cooper JS, Steinfeld AD, Lerch IA. Cerebral metastases: value of reirradiation in selected patients. *Radiology*. 1990;174(3, pt 1):883-885.

Davies H, Bignell GR, Cox C, et al. Mutations of the *BRAF* gene in human cancer. *Nature*. 2002;417(6892):949-954.

Davis PC, Hudgins PA, Peterman SB, Hoffman JC Jr. Diagnosis of cerebral metastases: double-dose delayed CT vs contrast-enhanced MR imaging. *AJNR Am J Neuroradiol*. 1991;12(2):293-300.

Delattre JY, Krol G, Thaler HT, Posner JB. Distribution of brain metastases. *Arch Neurol*. 1988;45(7):741-744.

Dummer R, Goldinger SM, Turtschi CP, et al. Vemurafenib in patients with *BRAFV600* mutation-positive melanoma with symptomatic brain metastases: final results of an open-label pilot study. *Eur J Cancer*. 2014;50(3):611-621.

Fink KR, Fink JR. Imaging of brain metastases. *Surg Neurol Int*. 2013;4(suppl 4):S209-S219.

Flannery TW, Suntharalingam M, Regine WF, et al. Long-term survival in patients with synchronous, solitary brain metastasis from non-small-cell lung cancer treated with radiosurgery. *Int J Radiat Oncol Biol Phys*. 2008;72(1):19-23.

Fuller BG, Heiss J, Oldfield EH. Spinal cord compression. In: DeVita VT Jr, Lawrence TS, Rosenburg SA, eds. *Cancer: Principles and Practice of Oncology*. Philadelphia, PA: Lippincott Williams & Wilkins; 2001:2617-2633.

Garg AK, Wang XS, Shiu AS, et al. Prospective evaluation of spinal reirradiation by using stereotactic body radiation therapy: the University of Texas MD Anderson Cancer Center experience. *Cancer*. 2011;117(15):3509-3516.

Gaspar L, Scott C, Rotman M, et al. Recursive partitioning analysis (RPA) of prognostic factors in three Radiation Therapy Oncology Group (RTOG) brain metastases trials. *Int J Radiat Oncol Biol Phys*. 1997;37(4):745-751.

Gerber NK, Yamada Y, Rimner A, et al. Erlotinib versus radiation therapy for brain metastases in patients with EGFR-mutant lung adenocarcinoma. *Int J Radiat Oncol Biol Phys*. 2014;89(2):322-329.

Gleissner B, Chamberlain MC. Neoplastic meningitis. *Lancet Neurol*. 2006;5(5):443-452.

Goblirsch MJ, Zwolak PP, Clohisy DR. Biology of bone cancer pain. *Clin Cancer Res*. 2006;12(20, pt 2):6231s-6235s.

Gondi V, Tomé WA, Mehta MP. Why avoid the hippocampus? A comprehensive review. *Radiother Oncol*. 2010;97(3):370-376.

Gondi V, Pugh SL, Tome WA, et al. Preservation of memory with conformal avoidance of the hippocampal neural stem-cell compartment during whole-brain radiotherapy for brain metastases (RTOG 0933): a phase II multi-institutional trial. *J Clin Oncol*. 2014;32(34):3810-3816.

Gutiérrez AN, Westerly DC, Tomé WA, et al. Whole brain radiotherapy with hippocampal avoidance and simultaneously integrated brain metastases boost: a planning study. *Int J Radiat Oncol Biol Phys*. 2007;69(2):589-597.

Halperin EP, Wazer DE, Perez CA. The discipline of radiation oncology. In: Halperin EP, Wazer DE, Perez CA, et al, eds. *Perez and Brady's Principles and Practice of Radiation Oncology*. Philadelphia, PA: Lippincott Williams & Wilkins; 2013:2-70.

Kim DY, Lee KW, Yun T, et al. Comparison of intrathecal chemotherapy for leptomeningeal carcinomatosis of a solid tumor: methotrexate alone versus methotrexate in combination with cytosine arabinoside and hydrocortisone. *Jpn J Clin Oncol*. 2003;33(12):608-612.

Kurup P, Reddy S, Hendrickson FR. Results of re-irradiation for cerebral metastases. *Cancer*. 1980;46(12):2587-2589.

Le Rhun E, Taillibert S, Chamberlain MC. Carcinomatous meningitis: leptomeningeal metastases in solid tumors. *Surg Neurol Int*. 2013;4(suppl 4):S265-S288.

Lin NU, Diéras V, Paul D, et al. Multicenter phase II study of lapatinib in patients with brain metastases from HER2-positive breast cancer. *Clin Cancer Res*. 2009;15(4):1452-1459.

Long GV, Trefzer U, Davies MA, et al. Dabrafenib in patients with Val600Glu or Val600Lys BRAF-mutant melanoma metastatic to the brain (BREAK-MB): a multicentre, open-label, phase 2 trial. *Lancet Oncol*. 2012;13(11):1087-1095.

Margolin K, Ernstoff MS, Hamid O, et al. Ipilimumab in patients with melanoma and brain metastases: an open-label, phase 2 trial. *Lancet Oncol*. 2012;13(5):459-465.

Mehta MP, Vogelbaum MA, Chang S, et al. Neoplasms of the central nervous system. In: DeVita VT Jr, Lawrence TS, Rosenberg SA, eds. *Cancer: Principles and Practice of Oncology*. Philadelphia, PA: Lippincott Williams & Wilkins; 2011:1700-1749.

Nichols EM, Patchell RA, Regine WF, et al. Palliation of brain and spinal cord metastases. In: Halperin EP, Wazer DE, Perez CA, et al, eds. *Perez and Brady's Principles and Practices of Radiation Oncology*. Philadelphia, PA: Lippincott Williams & Wilkins; 2013:1766.

O'Neill BP, Iturria NJ, Link MJ, Pollock BE, Ballman KV, O'Fallon JR. A comparison of surgical resection and stereotactic radiosurgery in the treatment of solitary brain metastases. *Int J Radiat Oncol Biol Phys*. 2003;55(5):1169-1176.

Park SJ, Kim HT, Lee DH, et al. Efficacy of epidermal growth factor receptor tyrosine kinase inhibitors for brain metastasis in non-small cell lung cancer patients harboring either exon 19 or 21 mutation. *Lung Cancer*. 2012;77(3):556-560.

Rades D, Stalpers LJ, Veninga T, et al. Effectiveness and toxicity of reirradiation (Re-RT) for metastatic spinal cord compression (MSCC) [in German]. *Strahlenther Onkol*. 2005;181(9):595-600.

Rades D, Stalpers LJ, Veninga T, et al. Evaluation of five radiation schedules and prognostic factors for metastatic spinal cord compression. *J Clin Oncol*. 2005;23(15):3366-3375.

Ruderman NB, Hall TC. Use of glucocorticoids in the palliative treatment of metastatic brain tumors. *Cancer*. 1965;18:298-306.

Sahgal A, Ma L, Weinberg V, et al. Reirradiation human spinal cord tolerance for stereotactic body radiotherapy. *Int J Radiat Oncol Biol Phys*. 2012;82(1):107-116.

Sawrie SM, Guthrie BL, Spencer SA, et al. Predictors of distant brain recurrence for patients with newly diagnosed brain metastases treated with stereotactic radiosurgery alone. *Int J Radiat Oncol Biol Phys*. 2008;70(1):181-186.

Schiff D, Shaw EG, Cascino TL. Outcome after spinal reirradiation for malignant epidural spinal cord compression. *Ann Neurol*. 1995;37(5):583-589.

Schöggl A, Kitz K, Reddy M, et al. Defining the role of stereotactic radiosurgery versus microsurgery in the treatment of single brain metastases. *Acta Neurochir (Wien)*. 2000;142(6):621-626.

Shaw E, Scott C, Souhami L, et al. Single dose radiosurgical treatment of recurrent previously irradiated primary brain tumors and brain metastases: final report of RTOG protocol 90-05. *Int J Radiat Oncol Biol Phys*. 2000;47(2):291-298.

Soltys SG, Adler JR, Lipani JD, et al. Stereotactic radiosurgery of the postoperative resection cavity for brain metastases. *Int J Radiat Oncol Biol Phys*. 2008;70(1):187-193.

Son CH, Jimenez R, Niemierko A, Loeffler JS, Oh KS, Shih HA. Outcomes after whole brain reirradiation in patients with brain metastases. *Int J Radiat Oncol Biol Phys*. 2012;82(2):e167-e172.

Sperduto CM, Watanabe Y, Mullan J, et al. A validation study of a new prognostic index for patients with brain metastases: the graded prognostic assessment. *J Neurosurg*. 2008;(109 suppl):87-89.

Townsend PW, Rosenthal HG, Smalley SR, Cozad SC, Hassanein RE. Impact of postoperative radiation therapy and other perioperative factors on outcome after orthopedic stabilization of impending or pathologic fractures due to metastatic disease. *J Clin Oncol*. 1994;12(11):2345-2350.

Twombly R. Cancer surpasses heart disease as leading cause of death for all but the very elderly. *J Natl Cancer Inst*. 2005;97(5):330-331.

Welsh JW, Komaki R, Amini A, et al. Phase II trial of erlotinib plus concurrent whole-brain radiation therapy for patients with brain metastases from non-small-cell lung cancer. *J Clin Oncol*. 2013;31(7):895-902.

Wen PY, Black PM, Loeffler JS. Treatment of metastatic cancer. In: DeVita VT, Heilman S, Rosenberg SA, eds. *Cancer: Principles and Practice of Oncology*. Philadelphia, PA: Lippincott Williams & Wilkins; 2001:2655-2670.

Wilson EH, Weninger W, Hunter CA. Trafficking of immune cells in the central nervous system. *J Clin Invest*. 2010;120(5):1368-1379.

Wong WW, Schild SE, Sawyer TE, Shaw EG. Analysis of outcome in patients reirradiated for brain metastases. *Int J Radiat Oncol Biol Phys*. 1996;34(3):585-590.

Wu YL, Zhou C, Cheng Y, et al. Erlotinib as second-line treatment in patients with advanced non-small-cell lung cancer and asymptomatic brain metastases: a phase II study (CTONG-0803). *Ann Oncol*. 2013;24(4):993-999.

Meningiomas 102

Thomas J. Kaley

KEY POINTS

1. Meningiomas are the most common primary brain tumor of adults and certainly the most common brain tumor most neurologists will encounter, as many are identified incidentally on imaging as computed tomography and magnetic resonance imaging are performed for many different indications.
2. The only clear risk factors for development of a meningioma are prior cranial radiation and the presence of a neurogenetic syndrome such as neurofibromatosis type 2. Meningiomas are more common in women than men, and incidence increases with advancing age.
3. Histologically, meningiomas are graded from the least aggressive World Health Organization grade I tumor to the most aggressive World Health Organization grade III tumor. The most common somatic alteration found on sequencing is an alteration leading to neurofibromatosis type 2 inactivation.
4. Typical diagnostic imaging findings are the presence of a homogenously enhancing extra-axial mass on computed tomography or magnetic resonance imaging with a characteristic dural tail.
5. Initial treatment options range from observation to surgery or radiation to combined surgery + radiation, depending on the meningioma grade, extent of resection, and clinical characteristics. Chemotherapy is usually reserved for surgery and radiation refractory meningiomas.

INTRODUCTION

Diseases of the dura are rather uncommon, except for meningiomas. Not just the most common dural disease, meningiomas are the most common intracranial primary tumor in adults. Especially in the current environment of neuroimaging with computed tomography (CT) or magnetic resonance imaging (MRI) being performed for any and every possible neurologic symptom, both symptomatic and more frequently asymptomatic meningiomas will be found. Accordingly, meningiomas will be the most common intracranial tumor neurologists, and most physicians, will encounter. Although many are benign, a meningioma may enlarge and/or cause neurologic dysfunction depending on its location within the brain. Because the cranium has only a limited capacity to accommodate an expanding mass, symptoms may occur. Surgery remains the treatment of choice, but not all meningiomas are amenable to complete resection, and some will recur and require further therapy. This chapter outlines the major dural diseases with the majority devoted to meningiomas.

MENINGIOMAS

Epidemiology

Meningiomas are the most common primary "brain" tumor in adults, although technically they are tumors of the brain covering rather than brain parenchyma. The Central Brain Tumor Registry of the United States estimates an incidence of approximately 20,000 new meningioma cases diagnosed per year. This represents 36% of all primary brain tumors. These tumors have a clear female predominance with an almost 2:1 female-to-male ratio. These tumors are quite rare in children except within a predisposing neurogenetic syndrome. They are substantially more common in adults and tend to increase in incidence with age, particularly older than the age of 65 years. Autopsy series suggest a meningioma prevalence of 2%, typically asymptomatic and discovered incidentally during life or postmortem.

The only clear risk factors for meningiomas are prior radiotherapy involving the head and neck region as well as predisposing neurogenetic syndromes, such as neurofibromatosis type 2. Ionizing radiation has also been demonstrated to be a clear risk factor for future meningioma development. Prior radiation therapy for an extracranial malignancy such as head and neck cancer or childhood leukemia is the most common. These meningiomas that develop as a result of prior radiotherapy tend to be more aggressive in their clinical course. The latency for meningioma development is inversely proportional to the dose of radiation delivered.

Although no longer performed, scalp radiation for tinea capitis, a fungal infection, has been linked to meningioma development. Similarly, older, less refined dental x-rays have been inconclusively linked to meningiomas. Currently however, radiotherapy is no longer performed for scalp infections and newer dental x-rays probably do not have significant risk, different from the older, less refined variant. Probably the most controversial potential link to meningiomas in the recent media and scientific literature has been the use of cellular phones. To date, there has been no proven definitive link between cellular phones and the development of a meningioma.

Pathobiology

Meningiomas are tumors that arise from the arachnoid coverings of the brain. Histologically, these tumors have various appearances depending on the subtype of meningioma, although most physicians frequently recall the whorling pattern of tumor cells, which is most common and calcium collections known as *psammoma bodies*. The World Health Organization (WHO) classifies meningiomas into three grades (**Table 102.1**).

The most common neurogenetic syndrome predisposing the patient to meningiomas is neurofibromatosis type 2, the less

TABLE 102.1 WHO Grading Criteria for Meningiomas

2007 WHO Criteria for Meningioma
WHO Grade I Meningioma
Angiomatous Fibrous Lymphoplasmacyte-rich Meningothelial Metaplastic Microcystic Psammomatous Secretory Transitional
WHO Grade II Meningioma
Clear cell Chordoid Atypical: ≥4 mitoses per 10 high-powered fields or at least three of the following features: • Increased cellularity • Small cells with a high nuclear to cytoplasmic ratio • Prominent nucleoli • Patternless or sheetlike growth • Necrosis
WHO Grade III Meningioma
Rhabdoid Papillary Anaplastic (malignant): ≥20 mitoses per 10 high-powered fields and/or malignant characteristics including: • Loss of typical growth patterns • Brain invasion • Abundant mitoses with atypical forms • Multifocal necrosis

Abbreviation: WHO, World Health Organization.

common form of neurofibromatosis. Neurofibromatosis type 2 is an autosomal dominant disorder with full penetrance caused by alteration of the *NF2* gene on chromosome 22, which encodes for the tumor suppressor protein Merlin (moesin-ezrin-radixin–like protein), also called *neurofibromin*. Approximately 80% of sporadic meningiomas also harbor *NF2* alterations. Some speculate that many of these are mosaics, and therefore, germline testing may be unrevealing, rather than true somatic genetic alterations. However, there is no clear selective therapy to target Merlin alterations.

Recent research efforts have focused on understanding the biology of cancer as a whole and utilizing targeted therapies that disrupt a specific biologic pathway, typically a growth factor ligand/receptor-mediated pathway. Meningiomas are highly vascular tumors with elevated expression of the vascular endothelial growth factor (VEGF) receptor and its ligand, VEGF. Other growth factor pathways such as platelet-derived growth factor, epidermal growth factor, insulin-like growth factor, and somatostatin are also expressed in meningiomas. Efforts at targeting these pathways are discussed in the chemotherapy section later in the text.

A major thrust of cancer investigation over the last decade has been whole genome sequencing to identify drugable oncogenic driver mutations. Mutations in two pathways recently were identified in approximately 20% of meningiomas: *AKT* and *SMO*. The *AKT* mutations disrupt the homeostasis that normally regulates cancer cell survival, proliferation, angiogenesis, and metabolism. The *SMO* mutations alter a key pathway responsible for controlling cancer cell self-renewal.

In the Clark et al's paper, genomic analysis revealed oncogenic mutations in *AKT1* and *SMO* in 13% and 4% of specimens, respectively. These mutated tumors tend to occur more frequently in skull base locations, which also tend to be the most surgically challenging or inaccessible areas. Patients with *AKT* mutations harbored the *E17K* mutation, a well characterized oncogenic mutation present in several other cancer types. The *E17K* mutation can be found in breast cancer, colorectal cancer, and lung cancer and results in constitutive AKT activation, which in turn stimulates downstream mammalian target of rapamycin activity, resulting in overactivity of the PI3K pathway. The PI3K pathway activation in turn stimulates multiple oncogenic processes including cell proliferation and angiogenesis. The *SMO* mutations included the L412F seen in a subset of medulloblastomas and the W535L alteration seen in basal cell carcinoma and predictive of sensitivity to U.S. Food and Drug Administration–approved therapy with vismodegib, a Hedgehog inhibitor. When the SMO protein is activated, it results in ligand-independent downstream activation of the Hedgehog pathway resulting in cell proliferation and cancer stem cell self-renewal.

In the Brastianos et al's paper, 65 meningioma specimens underwent analysis and revealed similar results identifying *AKT* and *SMO* mutations in a subset of patients. Five patients (8%) demonstrated *AKT* mutations, all E17K. Three patients (5%) demonstrated *SMO* mutations, two of which were the W535L mutation seen in basal cell carcinoma and one L412F alteration previously described in desmoplastic medulloblastoma. They then studied an additional 46 grade I tumors and 49 grade II and III tumors and found six AKT1 E17K mutated tumors (1 grade III, 5 grade I), and two SMO L412F mutated tumors (both grade I).

In summary, these two studies demonstrated that PI3K pathway activation and Hedgehog pathway activation occur in a subset of meningioma patients. The mutations seen are well characterized in other cancer types and in the case of basal cell cancer, predict therapeutic response to inhibition with an available agent. Future studies hope to define the role, if any, of these agents in the treatment of these particular molecular subtypes of meningioma. Most meningiomas that recur despite prior treatment with surgery and radiation do not harbor an *AKT* or *SMO* alteration, and the ultimate utility of finding these mutations is not yet known.

Clinical Manifestations

As with most other brain tumors, the clinical presentation of meningiomas is highly variable, depending on tumor location, size, and shape. Tumors may manifest as visual disturbances, speech dysfunction, weakness, sensory dysfunction, neurocognitive dysfunction, personality changes, or seizures. Because meningiomas are typically slow-growing neoplasms, they rarely cause acute increases in intracranial pressure resulting in symptoms like headache, nausea, vomiting, or alteration of consciousness. In fact, because they are such slow-growing tumors they can often become surprisingly large without causing any clinical neurologic dysfunction. However, even a "benign" meningioma can result in disabling neurologic dysfunction if it grows beyond the capacity of the skull to accommodate the increase in volume. Rarely, these tumors may metastasize outside the central nervous system, usually to bone. This is an exceptionally rare event, and typically only with malignant meningiomas.

Diagnosis

Meningiomas are best visualized on an MRI with contrast, which demonstrates a brightly enhancing mass arising off of the dura,

which typically has a linear continuation with the dura known as *a dural tail* (Fig. 102.1). A CT with contrast may demonstrate the same pattern of enhancement, but MRI provides a better visualization of the underlying brain. A CT may be superior for demonstrating any changes in the neighboring bone as meningiomas can trigger a reactive hyperostosis in the bone adjacent to the meningioma itself, seen in approximately 25% of patients. Without contrast, meningiomas appear on both CT and MRI as either hypo- or iso-dense/intense.

As with most tumors, neuroimaging alone cannot definitively diagnose a meningioma, which depends on tissue analysis acquired by biopsy or resection. The WHO classifies meningiomas in three grades (see Table 102.1). The WHO grade I meningiomas are classified as "benign" meningiomas and make up approximately 80% of meningiomas. They are typically slow-growing tumors that basically fail to demonstrate any of the characteristics of higher grade meningiomas. Grade I meningiomas include most of the histologic subtypes: angiomatous, fibrous, lymphoplasmacyte-rich, meningothelial, metaplastic, microcystic, psammomatous, secretory, and transitional meningiomas. The WHO grade II meningiomas include the clear cell and chordoid histologic variants as well as atypical tumors that harbor increased mitotic activity as evidenced by more than or equal to 4 mitoses per 10 high-powered fields, or at least three of the following features: increased cellularity, small cells with a high nuclear to cytoplasmic ratio, prominent nucleoli, patternless or sheetlike growth, or necrosis. Importantly, brain invasion is associated with increased rates of recurrence and is sufficient to diagnose a WHO grade II tumor regardless of the presence of other atypical features. The WHO grade III meningiomas include rhabdoid, papillary, and anaplastic (malignant). The criteria for anaplastic meningiomas include increased mitotic activity as evidenced by more than or equal to 20 mitoses per 10 high-powered fields and/or malignant characteristics resembling carcinoma, sarcoma, or melanoma, such as the loss of usual meningioma growth patterns, infiltration of underlying brain, abundant mitoses with atypical forms, and multifocal necrosis. Anaplasia is sufficient to diagnose a WHO grade III regardless of the presence of brain invasion.

Treatment

Despite advances in cancer therapy, the treatment of meningioma remains primarily surgical with the goal of maximum safe surgical resection. In patients in whom a meningioma is

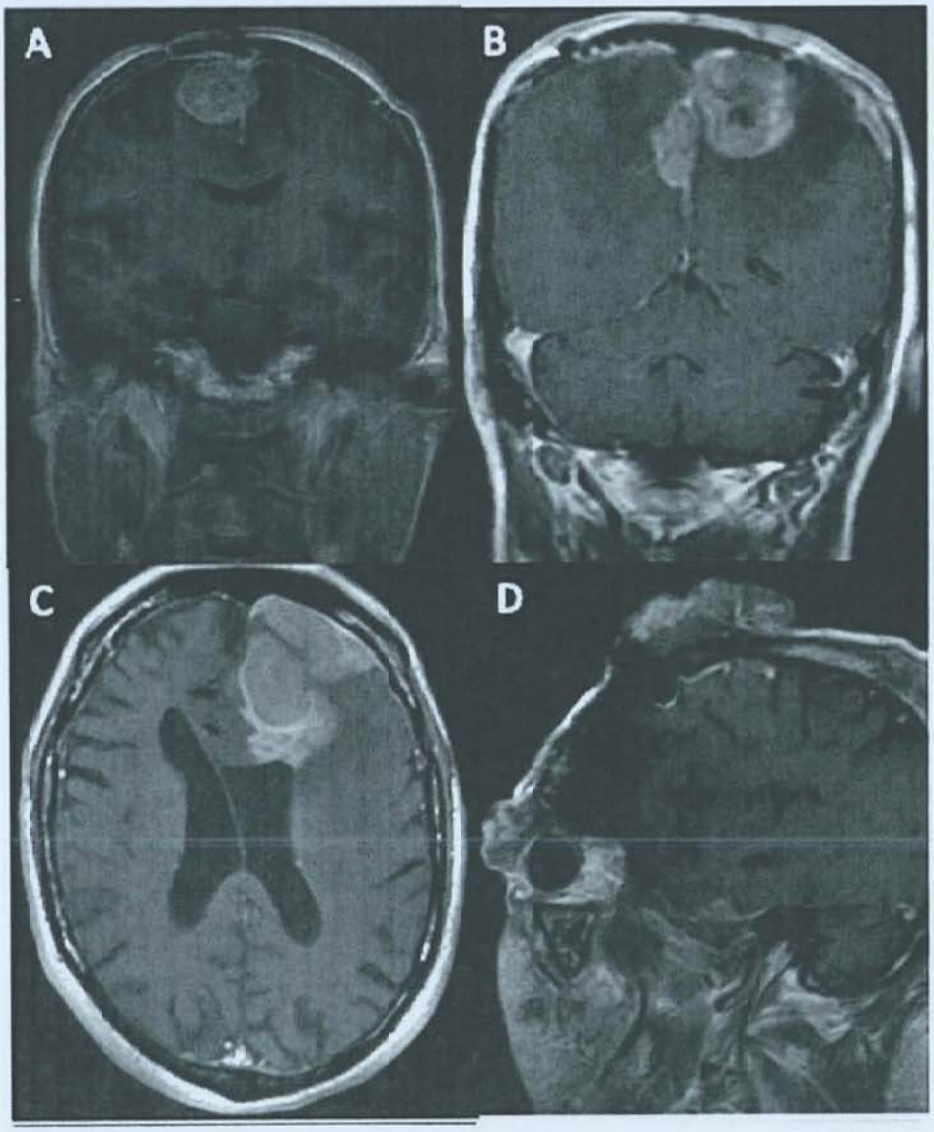

FIGURE 102.1 Magnetic resonance imaging appearance of meningiomas including coronal T1 postcontrast image demonstrating a recurrent grade I meningioma **(A)**, coronal T1 postcontrast image demonstrating an atypical meningioma noting significant peritumoral edema **(B)**, axial T1 postcontrast image demonstrating an anaplastic meningioma noting brain invasion **(C)**, and sagittal T1 postcontrast image demonstrating extracranial growth of a recurrent surgery and radiation refractory meningioma **(D)**.

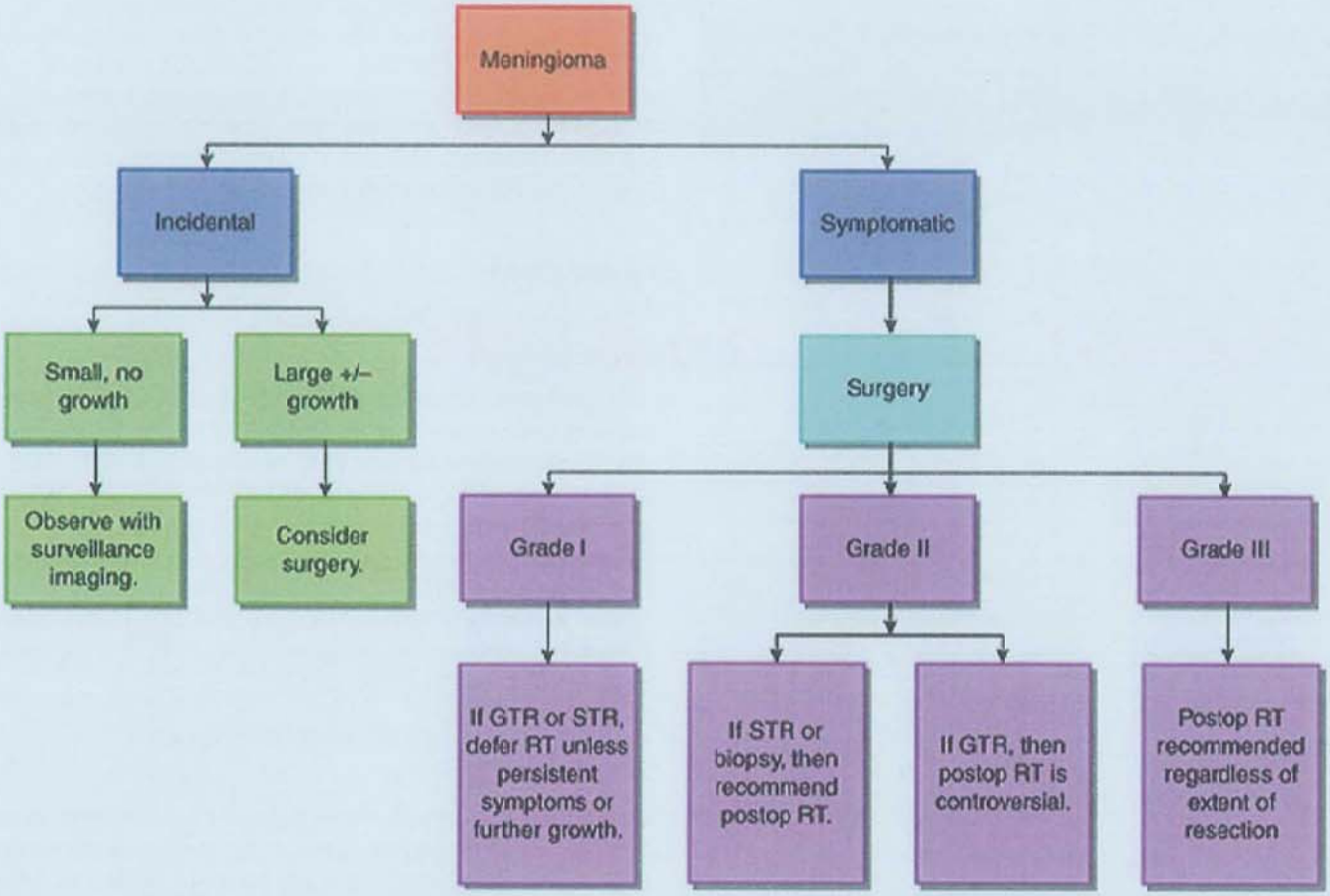

FIGURE 102.2 Algorithm for the treatment of meningiomas. Abbreviations: GTR, gross total resection; RT, radiation therapy; STR, subtotal resection.

unresectable due to location yet needs treatment, or in patients whose tumor is only amenable to a subtotal resection with persistent neurologic symptoms or dysfunction, radiation therapy is typically offered. Oftentimes, the biggest clinical question revolves around the timing of each of these therapies, which we discuss further within the individual grades of meningioma and is outlined in Figure 102.2.

Surgery

The goal of surgical resection is always maximum resection balanced against minimal neurologic surgical morbidity. The degree of surgical resection is graded on the Simpson grading scale, ranging from grade 1, which includes complete removal of not only the meningioma but also any involved dura or bone, through grade 5, which only includes decompression, with or without biopsy of the tumor. However, in clinical practice, the most commonly used terminology is *gross total resection* (removal of all visible tumor), *subtotal resection* (partial resection), or *biopsy* (only a small piece of tissue was removed for histologic diagnosis).

Radiotherapy

The two forms of radiotherapy used most often are external beam radiation therapy (EBRT) and stereotactic radiosurgery (SRS). An EBRT uses standard radiation techniques of delivering a lower dose of radiation per day over a longer course of treatment. The SRS delivers a very high dose of radiation, typically within one session. The SRS goes by many different names depending on the machine that is used, the energy source, and planning platform. The EBRT and SRS have never been compared against one another in a randomized prospective fashion. However, both EBRT and SRS of demonstrated efficacy in treating meningiomas in multiple retrospective series. Similarly, the different forms of SRS have never been compared against one another in a randomized fashion, but they are likely all comparable. The decision of whether to use EBRT or SRS is typically determined by the location of the tumor, potential complications of radiation, and expertise of the physician administering the treatment.

Chemotherapy

Unlike surgery and radiation, chemotherapy has yet to demonstrate a benefit in the treatment of meningioma. However, there is a need for effective medical or chemotherapy for certain subsets of patients with meningiomas, especially those with meningiomas refractory to surgery and radiation. In this subset, no medical therapy has yet proven effective. The other subset for which a viable chemotherapy approach is needed is patients in whom surgery and/or radiation is either technically not feasible due to tumor location or not advisable due to other circumstances.

Many chemotherapies have been studied in the treatment of meningioma; unfortunately no therapy has demonstrated clear efficacy in a randomized phase III trial (Table 102.2), and no U.S. Food and Drug Administration–approved therapies exist. Studies investigating traditional cytotoxic chemotherapies

TABLE 102.2 Medical Therapies Investigated for Meningioma

Drug	Mechanism of Action
Hydroxyurea	Ribonucleotide reductase inhibitor
Temozolomide	Alkylating chemotherapy
Irinotecan	Topoisomerase 1 inhibitor
Cyclophosphamide + Adriamycin + vincristine	Combination cytotoxic chemotherapy
Interferon-α	Immunomodulation
Mifepristone (RU486)	Antiprogesterone
Megestrol acetate	Progesterone receptor agonist
Medroxyprogesterone acetate	Synthetic progesterone
Tamoxifen	Antiestrogen
Octreotide	Somatostatin analogue
Sandostatin LAR	Somatostatin analogue
Pasireotide LAR (SOM230C)	Somatostatin analogue
Imatinib	PDGFR TKI
Erlotinib	EGFR TKI
Gefitinib	EGFR TKI
Vatalanib	VEGFR + PDGFR TKI
Sunitinib	VEGFR + PDGFR TKI
Bevacizumab	Anti-VEGF antibody
Everolimus	mTOR inhibitor
NovoTTF-100A (*external device*)	Microtubule inhibition
Pembrolizumab	Immunotherapy
Nivolumab	Immunotherapy
Abemaciclib	Cell cycle inhibitor (CDK inhibitor)

Abbreviations: CDK, cyclin-dependent kinase; EGFR, epidermal growth factor receptor; mTOR, mammalian target of rapamycin; PDGFR, platelet-derived growth factor receptor; TKI, tyrosine kinase inhibitor; VEGF, vascular endothelial growth factor; VEGFR, vascular endothelial growth factor receptor.

(temozolomide, hydroxyurea, irinotecan, and triple therapy with cyclophosphamide + doxorubicin + vincristine), hormonal therapies (progesterone and estrogen modulators), interferon α-2b, somatostatin analogues, and molecularly targeted therapies including inhibitors of platelet-derived growth factor (imatinib), epidermal growth factor receptor (gefitinib and erlotinib), have all been disappointing. The 6-month progression-free survival rates are less than 20%, similar to those for the most common and aggressive parenchymal brain tumor, glioblastomas.

Meningiomas are highly vascular, and targeting tumor vasculature may be a potentially effective strategy. Targeted therapy to disrupt tumor angiogenesis (the development of new blood vessels) such as VEGF receptor with the tyrosine kinase inhibitor sunitinib and targeting the VEGF ligand with the monoclonal antibody bevacizumab have shown some possible benefit and may represent a viable future treatment strategy. As such, both sunitinib and bevacizumab are included in the National Comprehensive Cancer Network guidelines for systemic therapy for recurrent meningiomas.

The recent discovery of oncogenic driver mutations in either AKT in the PI3K pathway or SMO in the Hedgehog pathway may provide potential therapeutic targets in a subset of patients. Inhibitors of AKT and SMO are currently in clinical trial development. However, *AKT* and *SMO* mutant tumors are a minority, and additional discoveries are desperately needed.

Outcomes

World Health Organization Grade I Meningioma

The preferred treatment of WHO grade I meningiomas remains surgical resection whenever feasible. With gross total resection, the 5-year recurrence rate is approximately 10% to 25%. With subtotal resection, it is approximately 25% to 50%. With either gross total resection or subtotal resection, postoperatively, these patients are managed with observation and surveillance imaging. Radiation is typically reserved for when patients have persistent neurologic dysfunction due to a tumor that cannot be completely resected or for patients who suffer a recurrence or progressive growth of their tumor.

World Health Organization Grade II Meningioma

As with grade 1 tumors, the initial and preferred management of WHO grade II meningiomas is also maximum safe surgical resection. If gross total resection is not achieved, absent an individual patient contraindication to radiotherapy. However, there is substantial controversy whether the benefits of immediate postoperative radiotherapy outweigh the risks for completely resected tumors. The 5-year recurrence rate after surgery alone is approximately 50%, and numerous retrospective series have demonstrated an increase in progression-free survival with the addition of postoperative radiotherapy, and some retrospective series have refuted this finding. In either body of literature, immediate postoperative radiotherapy (as opposed to radiotherapy at the time of recurrence) has yet to demonstrate an overall survival advantage and has risks. Fortunately, a large cooperative group randomized trial is ongoing, but results will take many years.

World Health Organization Grade III Meningioma

After surgery alone, the chance of recurrence at 5 years is 70% to 80% after gross total resection and 100% after subtotal resection. Therefore, postoperative radiation is nearly always offered to these patients in an attempt to increase the time before inevitable recurrence. Regardless, however, nearly all patients recur.

Incidental Meningioma

The incidental meningioma is a common yet often puzzling clinical situation. With imaging alone, there is uncertainty as to the histology, grade, and pace of growth (if any) of the incidentally found lesion. Often, the meningioma itself is asymptomatic and unrelated to the initial complaint that led to the neuroimaging. In the case of a small, asymptomatic incidentally found meningioma, the preferred treatment is one of observation. If repeat imaging demonstrates further stability then these tumors can be followed expectantly with periodic imaging and clinical evaluations. If there is growth, then typically a surgical intervention is offered to these patients.

OTHER DURAL DISEASES

Hemangiopericytomas

Hemangiopericytomas are tumors that also may arise off the dura and appear radiographically similar to meningiomas. However, they usually behave more like sarcomas with a more aggressive course, multiple recurrences, and metastases to extracranial organs (particularly bone, liver, and lung). Surgery and postoperative radiation are standard, although recurrence is nearly universal.

Dural Metastases

The radiographic appearance of metastases to the dura from extracranial malignancies (such as breast cancer) is usually very similar to that of meningiomas. However, dural metastases are more often multiple, may appear as diffuse dural thickening (below), and usually have a faster growth rate on subsequent images. These are more common in lymphoma and possibly breast cancer but should really be suspected in any patient with a systemic malignancy. The breast cancer patient is a particular challenge because these patients also have an increased incidence of meningioma. Short-interval imaging and reassessment can usually differentiate between dural metastasis and meningioma on the basis of the growth rate (faster with metastases, slower with benign meningiomas). Occasionally, these entities are mixed ("collision" tumor). Treatment is similar to metastatic disease elsewhere in the brain, considering radiation and chemotherapy, and occasionally surgery (especially if histology is in question). Dural metastases do differ from parenchymal metastases in that dural metastases are not protected by a blood-brain barrier–like parenchymal disease.

Hypertrophic Pachymeningitis

Hypertrophic pachymeningitis refers to a thickening of the dura, either focally or diffusely, that may be caused by a variety of different etiologies. In general, this is a rather rare disorder, although the differential is broad including infections (tuberculosis, fungal, syphilis), autoimmune (rheumatoid arthritis, Sjögren disease), vasculitic (Wegener, giant cell arteritis, Behçet disease), sarcoid, histiocytosis, and metastases from systemic malignancies as well as "idiopathic" hypertrophic pachymeningitis where no underlying etiology is identified.

The most common symptoms are headache, followed by visual dysfunction, then other cranial nerve dysfunction, and cerebellar dysfunction. Seizures may occur due to local irritation of underlying brain. Imaging features on MRI are typically diffuse dural enhancement, which may be either nodular or smooth. Evaluation for underlying causes should be sought, and lumbar puncture is typically necessary. In the idiopathic variety, there is typically a pleocytosis (usually lymphocytic) and elevated protein. Treatment is directed at the underlying cause or in the case of idiopathic hypertrophic pachymeningitis with immunosuppressive therapy, often starting with corticosteroids.

SUGGESTED READINGS

Black PM, Morokoff AP, Zauberman J. Surgery for extra-axial tumors of the cerebral convexity and midline. *Neurosurgery*. 2008;62(6 suppl 3):1115-1521.

Bondy M, Ligon BL. Epidemiology and etiology of intracranial meningiomas: a review. *J Neurooncol*. 1996;29:197-205.

Brastianos PK, Horowitz PM, Santagata S, et al. Genomic sequencing of meningiomas identifies oncogenic SMO and AKT1 mutations. *Nat Genet*. 2013;45:285-289.

Clark VE, Erson-Omay EZ, Serin A, et al. Genomic analysis of non-NF2 meningiomas reveals mutations in TRAF7, KLF4, AKT1, and SMO. *Science*. 2013;339:1077-1080.

Custer BS, Koepsell TD, Mueller BA. The association between breast carcinoma and meningioma in women. *Cancer*. 2002;94:1626-1635.

Grunberg SM, Rankin C, Townsend J, et al. Phase III double-blind randomized placebo-controlled study of mifepristone (RU) for the treatment of unresectable meningioma. *Proc Am Soc Clinical Oncol*. 2001;20:56a. Abstract 222.

Hatano N, Behari S, Nagatani T, et al. Idiopathic hypertrophic cranial pachymeningitis: clinicoradiological spectrum and therapeutic options. *Neurosurgery*. 1999;45:1336-1344.

Hosler MR, Turbin RE, Cho E-S, Wolansky LJ, Frohman LF. Idiopathic hypertrophic pachymeningitis mimicking lymphoplasmacyte-rich meningioma. *J Neuroophthalmol*. 2007;27:95-98.

International Agency for Research on Cancer. *WHO Classification of Tumours of the Central Nervous System*. 4th ed. Geneva, Switzerland: World Health Organization; 2007.

Kaley T, Barani I, Chamberlain M, et al. Historical benchmarks for medical therapy trials in surgery- and radiation-refractory meningioma: a RANO review. *Neuro Oncol*. 2014;16:829-840.

Kaley T, Wen P, Schiff D, et al. Phase II trial of sunitinib for recurrent and progressive atypical and anaplastic meningioma. *Neuro Oncol*. 2015;17(1):116-121.

Kupersmith MJ, Martin V, Heller G, Shah A, Mitnick HJ. Idiopathic hypertrophic pachymeningitis. *Neurology*. 2004;62:686-694.

Longstreth WT Jr, Phillips LE, Drangsholt M, et al. Dental x-rays and the risk of intracranial meningioma: a population-based case-control study. *Cancer*. 2004;100:1026-1034.

Nakamura M, Roser F, Michel J, Jacobs C, Samii M. The natural history of incidental meningiomas. *Neurosurgery*. 2003;53:62-70.

Nayak L, Iwamoto FM, Rudnick JD, et al. Atypical and anaplastic meningiomas treated with bevacizumab. *J Neurooncol*. 2012;109(1):187-193.

Norden AD, Drappatz J, Wen PY. Advances in meningioma therapy. *Curr Neurol Neurosci Rep*. 2009;9(3):231-240.

Ostrom QT, Gittleman H, Farah P, et al. CBTRUS statistical report: primary brain and central nervous system tumors diagnosed in the United States in 2006-2010. *Neuro Oncol*. 2013;15(suppl 2):ii1-ii56.

Quant EC, Wen PY. Response assessment in neuro-oncology. *Curr Oncol Rep*. 2011;13:50-56.

Rogers L, Barani I, Chamberlain M, et al. Meningiomas: knowledge base, treatment outcomes, and uncertainties. A RANO review. *J Neurosurg*. 2015;122(1):4-23.

Rudnik A, Larysz D, Gamrot J, et al. Idiopathic hypertrophic pachymeningitis—case report and literature review. *Folia Neuropathol*. 2007;45:36-42.

Sadetzki S, Flint-Richter P, Ben-Tal T, Nass D. Radiation-induced meningioma: a descriptive study of 253 cases. *J Neurosurg*. 2002;97:1078-1082.

Voller B, Vass K, Wanschitz J, et al. Hypertrophic chronic pachymeningitis as a localized immune process in the craniocervical region. *Neurology*. 2001;56:107-109.

Wen PY, Lee EQ, Reardon DA, Ligon KL, Alfred Yung WK. Current clinical development of PI3K pathway inhibitors in glioblastoma. *Neuro Oncol*. 2012;14(7):819-829.

Wen PY, Quant E, Drappatz J, Beroukhim R, Norden AD. Medical therapies for meningiomas. *J Neurooncol*. 2010;99:365-378.

103 Primary Central Nervous System Lymphoma

Lakshmi Nayak and Tracy T. Batchelor

KEY POINTS

1. The majority of primary central nervous system lymphomas are diffuse large B-cell lymphoma.
2. Primary central nervous system lymphoma is characterized on magnetic resonance imaging by homogeneous contrast enhancement and restricted diffusion.
3. A comprehensive workup and extent of disease evaluation is essential to rule out systemic lymphoma.
4. Age and performance status are the most important prognostic factors independently associated with outcome.
5. High-dose methotrexate-based chemotherapy is the standard induction treatment for newly diagnosed primary central nervous system lymphoma.
6. Intensive chemotherapy followed by autologous stem cell transplant is considered in young and healthy patients for consolidation treatment of primary central nervous system lymphoma.
7. Relapse rate is high at 50% even in patients who had a good response to initial high-dose methotrexate-based chemotherapy.
8. There is a risk of delayed neurotoxicity with whole-brain radiation therapy particularly in combination with high-dose methotrexate.

INTRODUCTION

Primary central nervous system lymphoma (PCNSL) is a rare and aggressive extranodal non-Hodgkin lymphoma (NHL) confined to the brain, leptomeninges, eyes, or spinal cord. The prognosis of PCNSL is inferior to that of other extranodal NHL subtypes. The diagnosis and management of PCNSL differs from that of other primary brain cancers and systemic NHL.

EPIDEMIOLOGY

The PCNSL is an uncommon subtype of NHL. These tumors account for 2% of all primary brain tumors and approximately 4% to 6% of all extranodal lymphomas. An estimated 7,585 cases of PCNSL were diagnosed in the United States from 2011 to 2015, and the number of cases is expected to increase further with the aging of the US population. The median age at diagnosis is 66 years, and the disease is more common in men than women (ratio 1.22:1; $P < .001$). The incidence rate for PCNSL is 0.44 per 100,000 person-years. Congenital or acquired immunodeficiency is the only established risk factor for PCNSL and individuals infected with the human immunodeficiency virus (HIV) are at greater risk for developing this tumor. However, the incidence of HIV-related PCNSL has declined significantly over time, and this chapter focuses on PCNSL in the immunocompetent host.

PATHOBIOLOGY

More than 90% of PCNSL cases are diffuse large B-cell lymphomas (DLBCL), with the remainder consisting of T-cell lymphomas, poorly characterized low-grade lymphomas, or Burkitt lymphomas. Primary central nervous system (CNS) DLBCL is composed of highly proliferative malignant tumor cells clustered in the perivascular space, with reactive lymphocytes, macrophages, and activated microglial cells intermixed with the tumor cells. Most tumors express pan–B-cell markers including CD19, CD20, CD22, and CD79a. The molecular mechanisms underlying transformation and localization to the CNS are poorly understood. Limitations in molecular studies of PCNSL include the rarity of the disease and the limited availability of tissue because the diagnosis is most often made with stereotactic needle biopsy. Like systemic DLBCL, PCNSL harbors chromosomal translocations of the *BCL6* gene, deletions in 6q, and aberrant somatic hypermutation in protooncogenes including *MYC* and *PAX5*. Inactivation of *CDKN2A* is also commonly observed in both entities. The DLBCL can be classified into three molecular subclasses by gene expression profiling: germinal center B-cell–like (GCB), activated B-cell–like (ABC), and type 3 subgroup. The non-GCB or ABC subtype is associated with an inferior prognosis versus the GCB profile. Nearly all cases of primary CNS DLBCL most closely resembles the ABC cell of origin subtype. This higher prevalence of the ABC cell of origin subtype in PCNSL may partially account for the relatively inferior prognosis of this lymphoma versus other forms of extranodal DLBCL. Moreover, recent comprehensive genomic studies have indicated certain molecular features distinguish primary CNS DLBCL from systemic DLBCL. The PCNSL exhibits B-cell receptor signaling pathway activation concurrently with toll-like receptor signaling, which is affected by recurrent *MYD88* and *CD79B* mutations. In one study, 9p24.1/*PDL1*/*PDL2* copy number gains were observed, whereas in another study, copy number gains of 9p24.1/*PDL1*/*PDL2* were not observed. The PCNSL is characterized by differential expression of genes related to adhesion and the extracellular matrix pathways, including *MUM1*, *CXCL13*, and *CHI3L1*. The ongoing somatic hypermutation with biased use of V_H gene segments that has been observed in PCNSL is suggestive of an antigen-dependent proliferation. These observations are consistent with the hypothesis that PCNSL is secondary to antigen-dependent activation of

circulating B cells, which subsequently localize to the CNS by expression of various adhesion and extracellular matrix–related genes. However, further molecular studies to investigate the transforming events and the subsequent events responsible for CNS tropism in PCNSL are needed. Insights into the molecular pathogenesis of PCNSL has led to the development of targeted therapeutic approaches for this tumor.

CLINICAL FEATURES AND DIAGNOSIS

The presenting symptoms and signs of PCNSL are variable and often depend on the location of CNS involvement. In 248 immunocompetent patients with PCNSL, 70% had focal neurologic deficits, 43% had neuropsychiatric signs, 33% had symptoms of increased intracranial pressure, 14% had seizures, and 4% had ocular symptoms. Seizures are less common than with other types of brain tumors probably because PCNSL involves predominantly subcortical white matter rather than epileptogenic gray matter. Unlike patients with systemic NHL, PCNSL patients rarely manifest B symptoms. Imaging typically demonstrates a single, homogenously enhancing lesion and less commonly multifocal enhancing brain lesions. Concurrent cerebrospinal fluid (CSF) and eye involvement can occur in up to 20% of cases. Intramedullary spinal cord lesions are rare.

The International PCNSL Collaborative Group (IPCG) has developed guidelines to determine extent of disease. A gadolinium-enhanced brain magnetic resonance imaging scan is the most sensitive radiographic study for the detection of PCNSL. The characteristic appearance of PCNSL on magnetic resonance imaging is a homogeneous contrast-enhancing lesion with perilesional T2 signal change typically related to vasogenic edema (**Fig. 103.1**). Restricted diffusion on diffusion-weighted imaging is often seen due to high cellularity and high nuclear to cytoplasmic ratio of tightly compacted malignant cells. These radiographic features may help differentiating PCNSL from other malignant tumors, inflammatory, infectious, or demyelinating conditions. Rarely, nonenhancing lesions are seen. The definitive diagnosis of PCNSL is typically made by stereotactic brain biopsy, CSF analysis, or analysis of vitreous aspirate in patients with ocular involvement. Given the possible delay in diagnosis and treatment with the latter two methods, prompt stereotactic biopsy is advised in almost all cases that are surgically accessible. A thorough diagnostic evaluation is needed to establish the extent of the lymphoma and to confirm localization to the CNS. Physical examination should consist of a lymph node examination, a testicular examination in men, and a comprehensive neurologic examination. A lumbar puncture should be performed if not contraindicated, and CSF should be assessed by flow cytometry, cytology, and immunoglobulin heavy-chain gene rearrangement. Involvement of the optic nerve, retina, or vitreous humor should be excluded with a comprehensive eye evaluation by an ophthalmologist that includes a slit lamp examination. Blood tests should include a complete blood count, a basic metabolic panel, serum lactate dehydrogenase, and HIV serology.

Because extraneural disease must be excluded to establish a diagnosis of PCNSL, computed tomography or computed tomography/positron emission tomography scans of the chest, abdomen, and pelvis and a bone marrow biopsy and aspirate should be performed to exclude occult systemic disease. Testicular ultrasound is recommended in older men to rule out primary testicular lymphoma, which has a predilection for the brain.

TREATMENT

Newly Diagnosed Primary Central Nervous System Lymphoma

Treatment for newly diagnosed PCNSL consists of induction and consolidation phases. Typically, induction consists of chemotherapy with the objective of achieving a response/remission. Once this response/remission is achieved, a different chemotherapy regimen or whole brain radiation therapy (WBRT) is administered to "consolidate" the response/remission or reduce the risk of recurrence. Defining response to treatment in PCNSL requires assessment of all sites (brain, CSF, eye) potentially involved by disease. The IPCG has established response

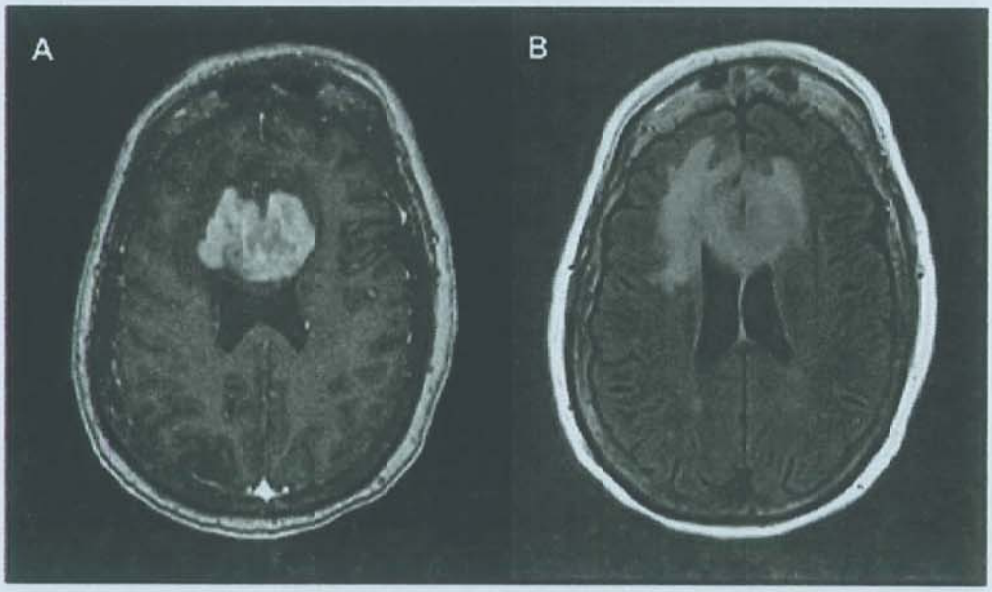

FIGURE 103.1 Magnetic resonance images from a patient with primary central nervous system lymphoma. **A:** A T1-weighted, axial, postcontrast scan demonstrates intense, homogenous enhancement of the tumor in the corpus callosum. **B:** An axial T2/fluid-attenuated inversion recovery scan at the same anatomic level demonstrates hyperintense signal surrounding the tumor, reflecting vasogenic cerebral edema.

TABLE 103.1 International Primary Central Nervous System Lymphoma Collaborative Group Consensus Guidelines for the Assessment of Response in Primary Central Nervous System Lymphoma

Response	Brain Imaging	Steroid Dose	Ophthalmologic Examination	CSF Cytology
Complete response	No contrast-enhancing disease	None	Normal	Negative
Unconfirmed complete response	No contrast-enhancing disease	Any	Normal	Negative
	Minimal enhancing disease	Any	Minor RPE abnormality	Negative
Partial response	50% decrease in enhancement[a]	NA	Normal or minor RPE abnormality	Negative
	No contrast-enhancing disease	NA	Decrease in vitreous cells or retinal infiltrate	Persistent or suspicious
Progressive disease	25% increase in enhancing disease	NA	Recurrent or new disease	Recurrent or positive
	Any new site of disease[a]			
Stable disease	All scenarios not covered by responses above			

Abbreviations: CSF, cerebrospinal fluid; NA, not applicable; RPE, retinal pigment epithelium.
[a]Based on longest single dimension of lesion.

criteria that have been adopted into most prospective clinical trials of PCNSL. Because PCNSL is a multicompartmental disease potentially involving the brain, eye, and CSF, these response criteria include assessment of each of these components (Table 103.1).

Corticosteroids decrease tumor-associated, vasogenic edema and may result in partial radiographic regression of PCNSL. An initial response to corticosteroids is associated with a favorable outcome in PCNSL. However, after an initial response to corticosteroids, almost all patients quickly progress. Corticosteroids should be avoided, if possible, prior to a biopsy, given the risk of disrupting cellular morphology, resulting in a nondiagnostic pathologic specimen.

Surgical resection is not considered part of the standard treatment approach for PCNSL given the deep, infiltrative, and multifocal nature of this tumor. Accordingly, the role of neurosurgery in PCNSL is generally to establish a diagnosis via stereotactic biopsy. Cytoreductive surgery can be considered as a lifesaving intervention in extreme cases with large lesions and impending herniation. Historic studies demonstrated that surgical resection did not add benefit to survival and in fact led to worsened outcomes due to complications from surgery. More recent studies have indicated potential survival benefit in patients undergoing surgical resection; however, these are retrospective in nature. Given that PCNSL is chemosensitive, surgical resection is to be avoided, although biopsies obtaining larger tissue samples may be considered for comprehensive genomic analysis.

Historically, PCNSL was treated with WBRT at doses ranging from 36 to 45 Gy, which resulted in a high proportion of radiographic responses but also early relapse. In a multicenter phase 2 trial, 41 patients were treated with WBRT to 40 Gy plus a 20-Gy tumor boost and achieved a median overall survival (OS) of 12 months. Given the lack of durable responses to radiation and the risk of neurotoxicity associated with this modality of therapy, WBRT alone is no longer a recommended treatment for most patients with newly diagnosed PCNSL. Moreover, because PCNSL is an infiltrative, multifocal disease, focal radiation or radiosurgery is not recommended.

An effective treatment for PCNSL is intravenous, high-dose methotrexate (HD-MTX) at variable doses (1-8 g/m^2), typically used in combination with other chemotherapeutic agents and/or WBRT. However, there is no consensus on the optimal dose of HD-MTX. Doses of methotrexate 3 g/m^2 or higher result in therapeutic concentrations in the brain parenchyma and CSF. It is now widely recognized that there is a high incidence of neurotoxicity in patients older than the age of 60 years treated with combined modality treatment that includes WBRT. This observation prompted studies using *lower doses* of WBRT. In a multicenter phase 2 study, no significant neurocognitive decline on formal neuropsychiatric testing was observed after consolidative reduced-dose WBRT (23.4 Gy) and cytarabine (AraC) in patients who had achieved a complete response to induction chemotherapy including HD-MTX. Further study and longer neuropsychological follow-up of these patients is necessary to definitively assess the safety of this regimen because numerous studies have demonstrated the delayed neurotoxic effects of WBRT in the PCNSL population.

Given the risk of clinical neurotoxicity, other studies have assessed whether WBRT can be *eliminated* from the initial management of PCNSL. In a multicenter phase 3 trial, patients were randomized to receive HD-MTX–based chemotherapy with or without WBRT LEVEL 1.[1] Five hundred fifty-one patients were enrolled, of whom 318 were treated per protocol. Intent to treat analysis revealed that patients treated in the combined modality arm (chemotherapy + WBRT) achieved improved progression-free survival (PFS), but there was no improvement in OS, demonstrating that the elimination of WBRT from the treatment regimen did not appear to compromise OS. This has led to deferral of WBRT and the application of chemotherapy-alone approaches for newly diagnosed PCNSL patients. These approaches are based on a foundation of HD-MTX. Variable doses and schedules of HD-MTX have been used, but in general, a dose of 3 g/m^2 or higher delivered as an initial bolus followed by an infusion over 3 hours administered every 10 to 21 days is recommended for optimal outcomes and adequate CSF concentrations. Multiple phase 2 studies have demonstrated the safety, efficacy, and relatively preserved cognition of HD-MTX–based chemotherapy regimens. Moreover, longer duration of induction chemotherapy with HD-MTX (more than six cycles) results in higher complete response proportions.

It has now been shown in multiple single-arm as well as randomized trials that addition of other chemotherapeutic agents to HD-MTX results in improved responses. In a phase 2 trial, 79 PCNSL patients were randomized to receive either HD-MTX *versus* HD-MTX + AraC LEVEL 1.[2] All patients underwent consolidative WBRT after induction chemotherapy. The HD-MTX + AraC arm had a higher proportion of complete radiographic responses (CR) and a superior 3-year OS.

Rituximab, a chimeric monoclonal antibody targeting the CD20 antigen on B lymphocytes, has improved survival in other forms of extranodal NHL. However, rituximab has poor penetration of the blood brain barrier. When rituximab is administered intravenously at doses of 375 to 800 mg/m^2, CSF levels from 0.1% to 4.4% of serum levels are achieved. Despite limited CSF penetration, radiographic responses were reported in relapsed PCNSL patients treated with rituximab monotherapy, and this antibody has been incorporated into contemporary regimens for PCNSL. In historical retrospective comparisons, the CR are higher with induction regimens that include rituximab versus those in which there is no rituximab. The IELSG32, a randomized phase 2 trial assessed the efficacy of addition of rituximab with or without thiotepa to HD-MTX and AraC combination. In this trial, sequential addition of rituximab (CR 30%, hazard ratio [HR] 0.74) and thiotepa (CR 49%, HR 0.46) demonstrated improved response rates compared to HD-MTX and AraC (CR 23%) LEVEL 2.[3] Conversely, in an open-label, randomized, phase 3 trial of 200 patients to assess the role of rituximab in induction chemotherapy, a benefit in the primary end point, event-free survival, was not observed. In this study, event-free survival at 1 year was 49% versus 52%, respectively, in the rituximab-containing versus no rituximab groups (HR 1.00, $P = 0.99$) LEVEL 1.[4] Given the conflicting results regarding the role of rituximab in these two randomized trials, the role of this agent in the management of newly diagnosed PCNSL is uncertain.

In the preceding studies, WBRT was employed in the consolidation phase of treatment. However, other approaches have eliminated WBRT in the treatment of newly diagnosed PCNSL. In a multicenter, phase 2 study, 44 PCNSL patients were treated with induction chemotherapy consisting of HD-MTX, rituximab, and temozolomide, all drugs with demonstrated efficacy as monotherapy in PCNSL. This induction chemotherapy was followed by consolidation chemotherapy consisting of intravenous etoposide and AraC. Sixty-six percent of these patients achieved CR; median PFS of the entire group was 2.4 years, and median OS was not reached at the time of publication. These results are comparable to regimens that include WBRT. It is noteworthy that PFS was shorter in PCNSL patients in whom chemotherapy was delayed longer than 1 month after diagnosis compared to those patients who promptly initiated chemotherapy (3-year PFS of 20% vs. 59%, $P = .05$). This observation highlights the importance of early diagnosis and prompt initiation of chemotherapy in PCNSL patients.

Given the limited durability of responses observed in many studies of PCNSL, there is interest in high-dose chemotherapy (HDT) followed by autologous stem cell transplantation (ASCT) as consolidative therapy with curative intent for newly diagnosed PCNSL. Conditioning regimens including thiotepa have demonstrated encouraging results. In a multicenter phase 2 study, 79 patients were treated with induction HD-MTX, AraC, rituximab, and thiotepa, followed by carmustine and thiotepa conditioning prior to ASCT. The overall radiographic response (ORR) was 91%, 2-year OS was 87%, and treatment-related deaths occurred in less than 10% of enrolled patients. The toxicities, mostly cytopenias, were manageable.

Encouraging results from HDT and ASCT in uncontrolled studies has led to the development of randomized studies comparing this approach as an alternative to WBRT for consolidation. The second component of the IELSG32 study evaluated 2-year PFS in patients who achieved stable disease or better and were subsequently randomized to either WBRT or ASCT. Either consolidative approach was effective in both groups; with PFS2 of 69% in the group receiving ASCT and 80% in WBRT (HR 1.50, $P = 0.17$) LEVEL 1.[5] Importantly, both strategies were well tolerated with a 3% transplant-related mortality rate. Neurocognitive function progressively improved in patients who underwent ASCT within the first 2 years of follow up, but in those who received WBRT, there was a decline in attention and executive function. In another prospective, randomized phase 2 trial, the PRECIS study, patients received induction chemotherapy with two cycles of rituximab, HD-MTX, carmustine, etoposide, prednisone (R-MBVP) and then two cycles of rituximab, AraC (R-AraC) and were then randomly assigned to receive either consolidative WBRT versus ASCT with thiotepa-busulfan-cyclophosphamide conditioning LEVEL 2.[6] Although the study was designed as a noncomparative study and both arms met predetermined efficacy thresholds, the 2-year PFS favored the ASCT arm at 87% versus 63% in the WBRT group. This study demonstrated similar neurocognitive outcomes to IELSG32, favorable for the ASCT arm. However, 11% of patients died from ASCT-related toxicity.

A next generation of randomized trials have eliminated WBRT from the consolidation and are assessing HDT/ASCT versus nonmyeloablative chemotherapy regimens (NCT01511562, NCT02531841).

Several first-generation chemotherapy regimens for PCNSL included intrathecal chemotherapy. However, a number of nonrandomized studies that included intrathecal chemotherapy did not improve outcomes in PCNSL relative to regimens that did not include intrathecal injections of chemotherapy. Moreover, the ability to consistently achieve micromolar concentrations of methotrexate in the CSF at a dose of 8 g/m^2 as well as added toxicity from intrathecal chemotherapy has led to the elimination of this approach from most of the induction chemotherapy regimens currently in use.

Treatment of Primary Central Nervous System Lymphoma in Elderly Patients

Elderly patients account for more than half of all the subjects diagnosed with PCNSL. Older age is an adverse prognostic factor, and the risk of neurotoxicity is highest in this population. In general, chemotherapy alone is the preferred option for this subgroup. The majority of PCNSL patients older than 60 years of age develop clinical neurotoxicity after treatment with a WBRT-containing regimen, and some of these patients die of treatment-related complications rather than recurrent disease. Several studies have indicated that HD-MTX at doses of 3.5 to 8 g/m^2 is well tolerated in elderly patients who have adequate renal function with manageable grade 3 or 4 renal and hematologic toxicities. In a multicenter, randomized, phase 2 trial of chemotherapy alone in elderly patients with PCNSL, 98 patients were randomized to receive three cycles of either MPV-A (HD-MTX, procarbazine, vincristine, AraC) or a more simplified, potentially less toxic regimen consisting of MT

(HD-MTX and temozolomide) LEVEL 2.[7] Although trends favored the MPV-A regimen over the MT regimen with respect to CR, PFS, and OS, none of these differences reached statistical difference. Subsequent studies suggest that the addition of rituximab to both MPV and MT could increase the radiographic response rate. The PRIMAIN multicenter study investigated the use of rituximab, HD-MTX, procarbazine, and lomustine (R-MPL) in patients 65 years of age or older. Lomustine was omitted over the course of the study due to toxicities. The 2-year PFS and OS were 37.3% and 47%, respectively. Although there was no randomization of patients to R-MPL versus R-MP (rituximab, HD-MTX, procarbazine) given lomustine was dropped during the study, R-MP was found to be more feasible and as efficacious in this patient population. Moreover, a meta-analysis of 783 elderly patients (pooled data from clinical trials and nontrial patients) showed that HD-MTX–based treatment was associated with improved survival, and there was no difference in outcomes regardless of whether oral alkylating chemotherapy or aggressive chemotherapy was added to HD-MTX. Any of the above chemotherapy regimens are reasonable options in elderly PCNSL patients.

Relapsed and Refractory Primary Central Nervous System Lymphoma

Despite high initial response rates with HD-MTX–based induction therapy, most patients with PCNSL experience relapse. Moreover, approximately 20% to 30% of newly diagnosed PCNSL patients have HD-MTX–refractory disease. The majority of relapses occur within the first 2 years from initial diagnosis, although late relapses also occur. Prognosis of relapsed or refractory PCNSL is poor with a limited number of prospective phase 2 studies and no randomized studies for guidance on management. Rechallenge with HD-MTX is effective in patients who had previously responded to this agent. In a multicenter retrospective study of 22 relapsed PCNSL patients with a history of prior response to HD-MTX, 91% had a radiographic response to the first salvage treatment with HD-MTX and 100% to second salvage. The median OS from the first salvage was 61.9 months. In patients who have not previously been treated with HDT/ASCT, this is also an option at the time of relapse. In a phase 2 trial of 43 patients with relapsed or refractory PCNSL, salvage therapy with high-dose AraC and etoposide was followed by HDT/ASCT with a conditioning regimen consisting of thiotepa, busulfan, and cyclophosphamide. Twenty-seven patients ultimately proceeded to transplantation. Twenty-six of 27 patients had a CR, and the median PFS and OS in this group were 41.1 and 58.6 months, respectively. It is noteworthy that in a small series of patients with relapsed PCNSL after initial HDT/ASCT, a second autotransplantation was successful as salvage treatment. Finally, WBRT in relapsed patients who have not received it as a part of their initial treatment can be an effective option in this setting, although the risk of neurotoxicity remains a concern. In a series of 27 relapsed or refractory PCNSL patients treated with WBRT (median dose 36 Gy), 74% achieved an ORR and the median OS was 10.6 months. Delayed neurotoxicity rates of 15% were noted at doses greater than 36 Gy even in the setting of short survival. Other agents such as temozolomide, rituximab, pemetrexed, and topotecan have been studied in the context of retrospective and prospective studies with variable ORR and poor durability typically under 6 months. Targeted agents based on the unique mutations, alterations, and dysregulated signaling pathways active in PCNSL have been studied. A multicenter phase 2 study of temsirolimus, an inhibitor of mammalian target of rapamycin, demonstrated an ORR of 54%, although median PFS was 2.1 months. Immunomodulatory drugs such as lenalidomide and pomalidomide have been studied in phase 1 dose-escalation studies in recurrent and refractory PCNSL with ORR 48% to 64% and median PFS of ≤6 months. The REVRI study, which was a multicenter phase 2 study including induction treatment with eight cycles of rituximab and lenalidomide, followed by a maintenance program of 12 monthly cycles of lenalidomide monotherapy, met its primary end point of 32% ORR at the end of induction with a median PFS of 7.8 months. Ibrutinib, which is a Bruton tyrosine kinase inhibitor, was investigated in three phase 1 studies in doses of 560 and 840 mg, by itself or in combination with other chemotherapeutic agents including HD-MTX. These studies demonstrated adequate CSF drug concentrations at higher doses with ORR of 72% to 89%. A multicenter phase 2 study of single-agent ibrutinib at 560 mg demonstrated ORR of 52% and median PFS of 4.8 months. Based on these studies, lenalidomide and ibrutinib are now included in the National Comprehensive Cancer Network guidelines as potential options for PCNSL. Checkpoint inhibitors and chimeric antigen receptor T cells are also being studied in pilot, phase 1, and phase 2 studies.

Neurotoxicity

The most frequent complication in long-term PCNSL survivors is delayed neurotoxicity. Although this risk is significant, the exact incidence of delayed neurotoxicity is unclear, as most prior studies did not systematically assess neurocognitive function with serial neuropsychological testing. The elderly patients are at highest risk for this complication, with nearly all patients older than the age of 60 years developing clinical neurotoxicity following combined modality therapy (HD-MTX and WBRT). Treatment with WBRT has been identified as the major risk factor for the development of late neurotoxicity. Common symptoms and signs include deficits in attention, memory, executive function, ataxia, and incontinence. These deficits can have a detrimental impact on quality of life. Radiographic findings include periventricular white matter changes, ventricular enlargement, and cortical atrophy (**Fig. 103.2**). Pathologic studies of patients with delayed neurotoxicity reveal demyelination, hippocampal neuronal loss, and large-vessel atherosclerosis. Although the pathophysiology is unclear and likely multifactorial, damage to neural progenitor cells has been implicated to play an important role in radiation-related neurotoxicity. Currently, there are no treatments to reverse these delayed neurotoxic effects. Neuropsychological function was maintained in one long-term follow-up study of PCNSL patients treated with chemotherapy alone. The IELSG32 and PRECIS studies that compared WBRT to HDT/ASCT indicated that neurocognitive function improved in patients on the transplant arms and deteriorated with time in the WBRT groups. It is critical that serial neuropsychological assessments are incorporated into the management of patients with PCNSL, as cognitive outcome is a critical end point. The IPCG has developed an instrument for this purpose, which is composed of quality-of-life questionnaires and standardized neuropsychological tests that include assessment of executive function, attention, memory, and psychomotor speed, the cognitive domains most sensitive to this treatment-related effect.

FIGURE 103.2 Magnetic resonance image from a patient with delayed neurotoxicity from high-dose methotrexate-based chemotherapy and whole brain radiation. An axial T2 fluid-attenuated inversion recovery scan shows periventricular white matter changes and atrophy.

OUTCOME

Two prognostic scoring systems have been developed specifically for PCNSL. In a retrospective review of 105 PCNSL patients, the International Extranodal Lymphoma Study Group (IELSG) identified age older than 60 years, Eastern Cooperative Oncology Group performance status greater than 1, elevated serum lactate dehydrogenase level, elevated CSF protein concentration, and involvement of deep regions of the brain as independent predictors of poor prognosis. In patients with zero or one factor, two or three factors, or four or five factors, the 2-year survival proportions were 80%, 48%, and 15%, respectively. In another prognostic model, PCNSL patients were divided into three groups based on age and performance status: (1) younger than 50 years old, (2) 50 years or older with a Karnofsky performance status greater than or equal to 70, and (3) 50 years or older with a Karnofsky performance status less than 70. Based on these three divisions, significant differences in overall and failure-free survival were observed. There is no "staging" system that correlates with prognosis or response to treatment in PCNSL.

As our insight into the biology of PCNSL increases and treatment improves, more patients are living longer, emphasizing the need to optimize neurocognitive function and quality of life. The IPCG recommends a schedule of follow-up neuroimaging studies and cognitive assessment in PCNSL survivors (Table 103.2).

TABLE 103.2 Recommended Follow-up Assessments for Primary Central Nervous System Lymphoma

Follow-up Schedule	Assessments	Additional Optional Assessments
Years 1-2, every 3 mo	History and physical examination Cognitive testing (MMSE) Brain MRI CSF studies and ophthalmologic evaluation if positive at baseline (until negative)	IPCG cognitive battery test at baseline and every 6 mo
Years 3-5, every 6 mo	History and physical examination Cognitive testing (MMSE) Brain MRI	IPCG cognitive battery
Years 6-10, every 12 mo	History and physical examination Cognitive testing (MMSE) Brain MRI	IPCG cognitive battery

Abbreviations: CSF, cerebrospinal fluid; IPCG, International Primary CNS Lymphoma Collaborative Group; MMSE, mini-mental status examination; MRI, magnetic resonance imaging.

LEVEL 1 EVIDENCE

1. Thiel E, Korfel A, Martus P, et al. High-dose methotrexate with or without whole brain radiotherapy for primary CNS lymphoma (G-PCNSL-SG-1): a phase 3, randomised, non-inferiority trial. *Lancet Oncol*. 2010;11(11):1036-1047.
2. Ferreri AJ, Reni M, Foppoli M, et al; for the International Extranodal Lymphoma Study Group. High-dose cytarabine plus high-dose methotrexate versus high-dose methotrexate alone in patients with primary CNS lymphoma: a randomised phase 2 trial. *Lancet*. 2009;374(9700):1512-1520.
3. Ferreri AJ, Cwynarski K, Pulczynski E, et al. Chemoimmunotherapy with methotrexate, cytarabine, thiotepa, and rituximab (MATRix regimen) in patients with primary CNS lymphoma: results of the first randomisation of the International Extranodal Lymphoma Study Group-32 (IELSG32) phase 2 trial. *Lancet Haematol*. 2016;3(5):e217-e227.
4. Bromberg JEC, Issa S, Bakunina K, et al. Rituximab in patients with primary CNS lymphoma (HOVON 105/ALLG NHL 24): a randomised, open-label, phase 3 intergroup study. *Lancet Oncol*. 2019;20(2):216-228.
5. Ferreri AJM, Cwynarski K, Pulczynski E, et al; for the International Extranodal Lymphoma Study Group. Whole-brain radiotherapy or autologous stem-cell transplantation as consolidation strategies after high-dose methotrexate-based chemoimmunotherapy in patients with primary CNS lymphoma: results of the second randomisation of the International Extranodal Lymphoma Study Group-32 phase 2 trial. *Lancet Haematol*. 2017;4(11):e510-e523.
6. Houillier C, Taillandier L, Dureau S, et al; for the Intergroupe GOELAMS–ANOCEF and the LOC Network for CNS Lymphoma. Radiotherapy or autologous stem-cell transplantation for primary CNS lymphoma in patients 60 years of age and younger: results of the intergroup ANOCEF-GOELAMS randomized phase II PRECIS study. *J Clin Oncol*. 2019;37(10):823-834.
7. Omuro A, Chinot O, Taillandier L, et al. Methotrexate and temozolomide versus methotrexate, procarbazine, vincristine, and cytarabine for primary CNS lymphoma in an elderly population: an intergroup ANOCEF-GOELAMS randomised phase 2 trial. *Lancet Haematol*. 2015;2(6):e251-e259.

SUGGESTED READINGS

Abrey LE, Batchelor TT, Ferreri AJ, et al. Report of an international workshop to standardize baseline evaluation and response criteria for primary CNS lymphoma. *J Clin Oncol*. 2005;23:5034-5043.

Abrey LE, Ben-Porat L, Panageas KS, et al. Primary central nervous system lymphoma: the Memorial Sloan-Kettering Cancer Center prognostic model. *J Clin Oncol*. 2006;24(36):5711-5715.

Bataille B, Delwail V, Menet E, et al. Primary intracerebral malignant lymphoma: report of 248 cases. *J Neurosurg*. 2000;92(2):261-266.

Batchelor T, Carson K, O'Neill A, et al. Treatment of primary CNS lymphoma with methotrexate and deferred radiotherapy: a report of NABTT 96-07. *J Clin Oncol*. 2003;21(6):1044-1049.

Batchelor TT, DeAngelis LM, eds. *Lymphoma and Leukemia of the Nervous System*. 2nd ed. New York, NY: Springer; 2013.

Batchelor TT, Giri S, Ruppert AS, et al. Myeloablative versus non-myeloablative consolidative chemotherapy for newly diagnosed primary central nervous system lymphoma: results of induction therapy in Alliance 51101. *J Clin Oncol*. 2020;38(15 suppl):8042.

Batchelor TT, Grossman SA, Mikkelsen T, Ye X, Desideri S, Lesser GJ. Rituximab monotherapy for patients with recurrent primary CNS lymphoma. *Neurology*. 2011;76(10):929-930.

Bellinzona M, Roser F, Ostertag H, Gaab RM, Saini M. Surgical removal of primary central nervous system lymphomas (PCNSL) presenting as space occupying lesions: a series of 33 cases. *Eur J Surg Oncol*. 2005;31(1):100-105.

Bromberg JEC, Issa S, Bakunina K, et al. Rituximab in patients with primary CNS lymphoma (HOVON 105/ALLG NHL 24): a randomised, open-label, phase 3 intergroup study. *Lancet Oncol*. 2019;20(2):216-228.

Chan C-C, Rubenstein JL, Coupland SE, et al. Primary vitreoretinal lymphoma: a report from an International Primary Central Nervous System Lymphoma Collaborative Group symposium. *Oncologist*. 2011;16(11):1589-1599.

Chapuy B, Roemer MG, Stewart C, et al. Targetable genetic features of primary testicular and primary central nervous system lymphomas. *Blood*. 2016;127(7):869-881.

Correa DD, Maron L, Harder H, et al. Cognitive functions in primary central nervous system lymphoma: literature review and assessment guidelines. *Ann Oncol*. 2007;18(7):1145-1151.

DeAngelis LM, Seiferheld W, Schold SC, Fisher B, Schultz CJ. Combination chemotherapy and radiotherapy for primary central nervous system lymphoma: Radiation Therapy Oncology Group Study 93-10. *J Clin Oncol*. 2002;20(24):4643-4648.

Dolecek TA, Propp JM, Stroup NE, Kruchko C. CBTRUS statistical report: primary brain and central nervous system tumors diagnosed in the United States in 2005-2009. *Neuro Oncol*. 2012;14(suppl 5):v1-v49.

Doolittle ND, Korfel A, Lubow MA, et al. Long-term cognitive function, neuroimaging and quality of life in primary CNS lymphoma. *Neurology*. 2013; 81(1):84-92.

Ferreri AJ, Blay J-Y, Reni M, et al. Prognostic scoring system for primary CNS lymphomas: the International Extranodal Lymphoma Study Group experience. *J Clin Oncol*. 2003;21(2) 266-272.

Ferreri AJ, Cwynarski K, Pulczynski E, et al; for the International Extranodal Lymphoma Study Group. Chemoimmunotherapy with methotrexate, cytarabine, thiotepa, and rituximab (MATRix regimen) in patients with primary CNS lymphoma: results of the first randomisation of the International Extranodal Lymphoma Study Group-32 (IELSG32) phase 2 trial. *Lancet Haematol*. 2016;3(5):e217-e227.

Ferreri AJM, Cwynarski K, Pulczynski E, et al; for the International Extranodal Lymphoma Study Group. Whole-brain radiotherapy or autologous stem-cell transplantation as consolidation strategies after high-dose methotrexate-based chemoimmunotherapy in patients with primary CNS lymphoma: results of the second randomisation of the International Extranodal Lymphoma Study Group-32 phase 2 trial. *Lancet Haematol*. 2017;4(11):e510-e523.

Ferreri AJM , Guerra E, Regazzi M, et al. Area under the curve of methotrexate and creatinine clearance are outcome-determining factors in primary CNS lymphomas. *Br J Cancer*. 2004;90(2):353-358.

Ferreri AJM, Reni M, Foppoli M, et al; for the International Extranodal Lymphoma Study Group. High-dose cytarabine plus high-dose methotrexate versus high-dose methotrexate alone in patients with primary CNS lymphoma: a randomised phase 2 trial. *Lancet*. 2009;374(9700):1512-1520.

Fritsch K, Kasenda B, Schorb E, et al. High-dose methotrexate-based immunochemotherapy for elderly primary CNS lymphoma patients (PRIMAIN study). *Leukemia*. 2017;31(4):846-852.

Ghesquieres H, Chevrier M, Laadhari M, et al. Lenalidomide in combination with intravenous rituximab (REVRI) in relapsed/refractory primary CNS lymphoma or primary intraocular lymphoma: a multicenter prospective 'proof of concept' phase II study of the French Oculo-Cerebral lymphoma (LOC) Network and the Lymphoma Study Association (LYSA). *Ann Oncol*. 2019;30(4):621-628.

Glantz MJ, Cole BF, Recht L, et al. High-dose intravenous methotrexate for patients with nonleukemic leptomeningeal cancer: is intrathecal chemotherapy necessary? *J Clin Oncol*. 1998;16(4):1561-1567.

Grommes C, Nayak L, Tun HW, Batchelor TT. Introduction of novel agents in the treatment of primary CNS lymphoma. *Neuro Oncol*. 2019;21(3):306-313.

Grommes C, Pastore A, Palaskas N, et al. Ibrutinib unmasks critical role of Bruton tyrosine kinase in primary CNS lymphoma. *Cancer Discov*. 2017;7(9):1018-1029.

Grommes C, Tang SS, Wolfe J, et al. Phase 1b trial of an ibrutinib-based combination therapy in recurrent/refractory CNS lymphoma. *Blood*. 2019;133(5):436-445.

Holdhoff M, Ambady P, Abdelaziz A, et al. High-dose methotrexate with or without rituximab in newly diagnosed primary CNS lymphoma. *Neurology*. 2014;83(3):235-239.

Hottinger AF, DeAngelis LM, Yahalom J, Abrey LE. Salvage whole brain radiotherapy for recurrent or refractory primary CNS lymphoma. *Neurology*. 2007;69(11):1178-1182.

Houillier C, Taillandier L, Dureau S, et al; for the Intergroupe GOELAMS–ANOCEF and the LOC Network for CNS Lymphoma. Radiotherapy or autologous stem-cell transplantation for primary CNS lymphoma in patients 60 years of age and younger: results of the intergroup ANOCEF-GOELAMS randomized phase II PRECIS study. *J Clin Oncol*. 2019;37(10):823-834.

Illerhaus G, Fritsch K, Egerer G, et al. Sequential high dose immunochemotherapy followed by autologous peripheral blood stem cell transplantation for patients with untreated primary central nervous system lymphoma—a multicentre study by the Collaborative PCNSL Study Group Freiburg. Paper presented at: 54th Annual Meeting of the American Society of Hematology; December 8-11, 2012; Atlanta, GA.

Jahnke K, Korfel A, Martus P, et al; for the German Primary Central Nervous System Lymphoma Study Group. High-dose methotrexate toxicity in elderly patients with primary central nervous system lymphoma. *Ann Oncol*. 2005;16(3):445-449.

Juergens A, Pels H, Rogowski S, et al. Long-term survival with favorable cognitive outcome after chemotherapy in primary central nervous system lymphoma. *Ann Neurol*. 2010;67(2):182-189.

Kasenda B, Ferreri AJ, Marturano E, et al. First-line treatment and outcome of elderly patients with primary central nervous system lymphoma (PCNSL)—a systematic review and individual patient data meta-analysis. *Ann Oncol*. 2015;26(7):1305-1313.

Kasenda B, Schorb E, Fritsch K, Hader, Finke J, Illerhaus G. Primary CNS lymphoma—radiation-free salvage therapy by second autologous stem cell transplantation. *Biol Blood Marrow Transplant*. 2011;17(2):281-283.

Khan RB, Shi W, Thaler HT, DeAngelis LM, Abrey LE. Is intrathecal methotrexate necessary in the treatment of primary CNS lymphoma? *J Neurooncol*. 2002;58(2):175-178.

Korfel A, Schlegel U, Herrlinger U, et al. Phase II trial of temsirolimus for relapsed/refractory primary CNS lymphoma. *J Clin Oncol*. 2016;34(15):1757-1763.

Lai R, Abrey LE, Rosenblum MK, DeAngelis LM. Treatment-induced leukoencephalopathy in primary CNS lymphoma: a clinical and autopsy study. *Neurology*. 2004;62(3):451-456.

Langner-Lemercier S, Houillier C, Soussain C, et al. Primary CNS lymphoma at first relapse/progression: characteristics, management, and outcome of 256 patients from the French LOC network. *Neuro Oncol*. 2016;18(9): 1297-1303.

Lionakis MS, Dunleavy K, Roschewski M, et al. Inhibition of B cell receptor signaling by ibrutinib in primary CNS lymphoma. *Cancer Cell*. 2017;31(6): 833-843.

Mathew BS, Carson KA, Grossman SA. Initial response to glucocorticoids. *Cancer*. 2006;15:383-387.

Mead GM, Bleehen NM, Gregor A, et al. A medical research council randomized trial in patients with primary cerebral non-Hodgkin lymphoma: cerebral radiotherapy with and without cyclophosphamide, doxorubicin, vincristine, and prednisone chemotherapy. *Cancer*. 2000;89:1359-1370.

Monje ML, Vogel H, Masek M, Ligon KL, Fisher PG, Palmer TD. Impaired hippocampal neurogenesis after treatment for central nervous system malignancies. *Ann Neurol*. 2007;62(5):515-520.

Morris PG, Correa DD, Yahalom J, et al. Rituximab, methotrexate, procarbazine and vincristine followed by consolidation reduced-dose whole-brain radiotherapy and cytarabine in newly diagnosed primary CNS lymphoma: final results and long-term outcome. *J Clin Oncol*. 2013;31(31):3971-3979.

Nayak L, Abrey LE, Drappatz J, et al; for the North American Brain Tumor Consortium. Multicenter phase II study of rituximab and temozolomide in recurrent primary central nervous system lymphoma. *Leuk Lymphoma*. 2013;54(1):58-61.

Nayak L, Batchelor TT. Recent advances in treatment of primary central nervous system lymphoma. *Curr Treat Options Oncol*. 2013;14(4):539-552.

Nelson DF, Martz KL, Bonner H, et al. Non-Hodgkin's lymphoma of the brain: can high dose, large volume radiation therapy improve survival? Report on a prospective trial by the Radiation Therapy Oncology Group (RTOG): RTOG 8315. *Int J Radiat Oncol Biol Phys*. 1992;23(1):9-17.

Nguyen PL, Chakravarti A, Finkelstein DM, Hochberg FH, Batchelor TT, Loeffler JS. Results of whole-brain radiation as salvage of methotrexate failure for immunocompetent patients with primary CNS lymphoma. *J Clin Oncol*. 2005;23(7):1507-1513.

Omuro A, Chinot O, Taillandier L, et al. Methotrexate and temozolomide versus methotrexate, procarbazine, vincristine, and cytarabine for primary CNS lymphoma in an elderly population: an intergroup ANOCEF-GOELAMS randomised phase 2 trial. *Lancet Haematol*. 2015;2(6):e251-e259.

Ostrom QT, Gittleman H, Liao P, et al. CBTRUS statistical report: primary brain and central nervous system tumors diagnosed in the United States in 2010-2014. *Neuro Oncol*. 2017;19(suppl 5):v1-v88.

Plotkin SR, Betensky RA, Hochberg FH, et al. Treatment of relapsed central nervous system lymphoma with high-dose methotrexate. *Clin Cancer Res*. 2004;10(17):5643-5646.

Ponzoni M, Issa S, Batchelor TT, Rubenstein JL. Beyond high-dose methotrexate and brain radiotherapy: novel targets and agents for primary CNS lymphoma. *Ann Oncol*. 2014;25(2):316-322.

Rae AI, Mehta A, Cloney M, et al. Craniotomy and survival for primary central nervous system lymphoma. *Neurosurgery*. 2019;84(4):935-944.

Raizer JJ, Rademaker A, Evens AM, et al. Pemetrexed in the treatment of relapsed/refractory primary central nervous system lymphoma. *Cancer*. 2012;118(15):3743-3748.

Rubenstein JL, Geng H, Fraser EJ, et al. Phase 1 investigation of lenalidomide/rituximab plus outcomes of lenalidomide maintenance in relapsed CNS lymphoma. *Blood Adv*. 2018;2(13):1595-1607.

Rubenstein JL, Hsi ED, Johnson JL, et al. Intensive chemotherapy and immunotherapy in patients with newly diagnosed primary CNS lymphoma: CALGB 50202 (Alliance 50202). *J Clin Oncol*. 2013;31:3061-3068.

Sierra Del Rio M, Ricard D, Houillier C, et al. Prophylactic intrathecal chemotherapy in primary CNS lymphoma. *J Neurooncol*. 2012;106:143-146.

Soussain C, Hoang-Xuan K, Taillandier L, et al. Intensive chemotherapy followed by hematopoietic stem-cell rescue for refractory and recurrent primary CNS and intraocular lymphoma: Societe Francaise de Greffe de Moelle Osseuse-Therapie Cellulaire. *J Clin Oncol*. 2008;26(15):2512-2518.

Swerdlow SH, Campo E, Harris NL, et al, eds. *WHO Classification of Tumours of the Haematopoietic and Lymphoid Tissues*. Lyon, France: IARC Press; 2008.

Thiel E, Korfel A, Martus P, et al. High-dose methotrexate with or without whole brain radiotherapy for primary CNS lymphoma (G-PCNSL-SG-1): a phase 3, randomised, non-inferiority trial. *Lancet Oncol*. 2010;11(11):1036-1047.

Tun HW, Johnston PB, DeAngelis LM, et al. Phase 1 study of pomalidomide and dexamethasone for relapsed/refractory primary CNS or vitreoretinal lymphoma. *Blood*. 2018;132(21):2240-2248.

Villano JL, Koshy M, Shaikh H, Dolecek TA, McCarthy BJ. Age, gender, and racial differences in incidence and survival in primary CNS lymphoma. *Br J Cancer*. 2011;105(9):1414-1418.

Zhu J-J, Gerstner ER, Engler DA, et al. High-dose methotrexate for elderly patients with primary CNS lymphoma. *Neuro Oncol*. 2009;11(2):211-215.

Tumors of the Pituitary Gland 104

Pamela U. Freda, John Ausiello, and Jeffrey N. Bruce

KEY POINTS

1. Pituitary tumors are common, benign neoplasms.
2. Most pituitary tumors present because of signs or symptoms of hormone excess or deficiency or visual disturbance due to compression of the optic chiasm.
3. All suspected pituitary adenomas require a complete endocrinologic evaluation for pituitary and target gland hormone excess or deficiency.
4. Transsphenoidal pituitary surgery using microscopic or endoscopic technique is the initial treatment of choice for hormonally inactive pituitary tumors that produce signs of mass effect, are in close proximity to the optic chiasm or exhibit significant growth, and for most endocrine-secreting tumors except prolactin-secreting tumors.
5. For tumors not cured surgically, medical therapies can be used to control excess hormone secretion and radiation therapy or radiosurgery is typically effective at controlling tumor growth.

INTRODUCTION

Pituitary tumors are a common medical problem often found incidentally on routine magnetic resonance imaging (MRI) scans. These tumors are overwhelmingly benign but may cause symptoms due to mass effect, compression of the optic chiasm, excess hormonal secretion, or hypopituitarism. As such, the diagnosis and management of these tumors involves the coordinated efforts of neurosurgeons, endocrinologists, and ophthalmologists.

EPIDEMIOLOGY

The true prevalence of pituitary adenomas is difficult to ascertain because most are asymptomatic; autopsy estimates of prevalence range from 1.7% to 24%. No sexual predilection exists, but the tumors are most common in adults, peaking in the third and fourth decades. Children and adolescents account for approximately 10% of cases. Pituitary tumors are not hereditary except for rare families with multiple endocrine neoplasia I (MEN-I), an autosomal dominant condition manifested by a high incidence of pituitary adenomas and tumors of other endocrine glands.

PATHOBIOLOGY

Pituitary tumors can be classified in four ways: by size, endocrine function, clinical findings, or histology. The first two remain the most common, as the majority of tumors are histologically benign and the clinical findings usually reflect the size or hormonal function of the tumor. With regard to size, microadenomas are less than 1 cm in diameter and macroadenomas are greater than 1 cm. Typically, when microadenomas cause symptoms, it is due to excess hormone secretion, whereas with macroadenomas, it is via compression of normal glandular or neural structures. Macroadenomas may invade the dura or bone and may infiltrate surrounding structures such as the cavernous sinus, cranial nerves, blood vessels, sphenoid bone, and brain. These locally invasive pituitary adenomas are nearly always histologically benign. In some studies, the proliferation index correlates with growth velocity and recurrence. However, their invasive character may be independent of their growth rate.

Tumors can be classified by the presence (or absence) of endocrine function, dividing tumors into secreting or nonsecreting tumors. Secreting tumors produce one or more anterior pituitary hormones, including prolactin (the most common), growth hormone, adrenocorticotropic hormone (ACTH) (causing Cushing disease), follicle-stimulating hormone, or luteinizing hormone. Mixed secretory tumors account for 10% of adenomas; interestingly, these adenomas still have a monoclonal origin. Secretion of more than one hormone has implications for medical therapy, as all excess hormone secretion must be treated. Nonfunctioning tumors do not secrete biologically active hormones or demonstrate clinical evidence of hormone excess. Immunohistochemistry for anterior lobe hormones and lineage-specific transcription factors allow for accurate cell lineage–based classification of resected tumor tissue.

In general, adenomas grow more slowly in older patients than younger patients. *Pituitary carcinomas* are rare but highly invasive, rapidly growing, and anaplastic. Unequivocal diagnosis relies on the presence of distant metastases, as certain histologic findings including pleomorphism and mitotic figures may be seen in benign adenomas.

The posterior pituitary, which contains the terminal processes of hypothalamic neurons and supporting glial cells, is a rare site of neoplasia. *Infundibulomas* are rare tumors of the neurohypophysis that are variants of pilocytic astrocytomas. *Granular cell tumors* (eg, *myoblastomas* or *choristomas*) are rare tumors of the neurohypophysis of uncertain origin.

CLINICAL MANIFESTATIONS

Clinical manifestations arise either from endocrine dysfunction or mass effect with invasion or compression of surrounding neural and vascular structures. The manifestations and management of hormonally active tumors are discussed in Chapter 122. Here, discussion is primarily limited to nonsecretory tumors, most of which are macroadenomas by the time they come to clinical attention. Macroadenomas may present with panhypopituitarism if the normal pituitary gland is destroyed. Headaches result from stretching of the diaphragma sellae and adjacent dural structures

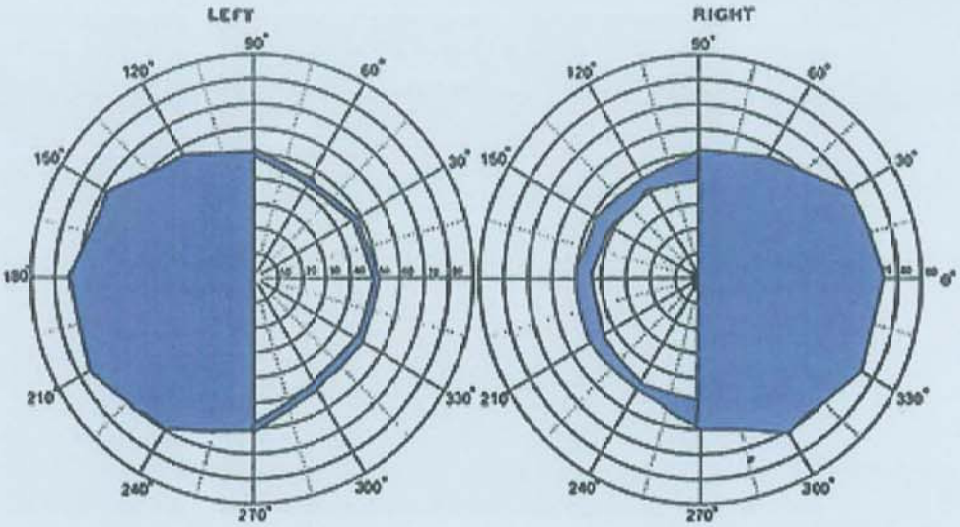

FIGURE 104.1 Pituitary macroadenoma. Bitemporal hemianopia; visual acuity *right eye* 15/200, *left eye* 15/30. The blind half-fields are black. (Courtesy of Dr. Max Chamlin.)

that transmit sensation through the first branch of the trigeminal nerve. Visual field abnormalities are caused by compression of the crossing fibers in the optic chiasm, first affecting the superior temporal quadrants and then the inferior temporal quadrants, leading to a bitemporal hemianopia. Further expansion compromises the noncrossing fibers, first affecting the lower nasal quadrants followed by the upper nasal quadrants (Fig. 104.1).

Visual loss may be accompanied by optic disc pallor and loss of central visual acuity, although papilledema is rare. Patients usually complain of blurring or dimming of vision but often are unaware of peripheral visual loss. Formal visual field testing is important because some tumors affect only the macular fibers, causing central hemianopic scotomas that may be missed on routine screening. Bitemporal hemianopia is most common, but any pattern of visual loss is possible, including unilateral or homonymous hemianopia.

Lateral extension of the tumor with compression or invasion of the cavernous sinus may compromise third, fourth, or sixth cranial nerve functions, manifesting as diplopia. The third cranial nerve is most commonly affected. Numbness may occur in the V1 or V2 distribution. Overall, however, cranial nerve dysfunction is not a common feature of adenomas and may be more suggestive of other neoplasms of the cavernous sinus.

Adenomas can become quite large before causing symptoms. Suprasellar extension may compress the foramen of Monro, causing hydrocephalus and symptoms of increased intracranial pressure. Hypothalamic dysfunction can lead to diabetes insipidus, but this condition is relatively rare. If diabetes insipidus is present, it is more suggestive of inflammation or possible tumor invasion of the pituitary stalk. Extensive subfrontal extension with compression of both frontal lobes may cause personality changes or dementia. There may be seizures or motor and sensory dysfunction. Erosion of the skull base is a risk factor for the development of cerebrospinal fluid (CSF) rhinorrhea.

In about 5% of pituitary tumors, the first symptoms are those of pituitary apoplexy caused by hemorrhage or infarction of the adenoma. Symptoms include sudden onset of severe headache, oculomotor palsies, nausea, vomiting, altered mental state, diplopia, and rapidly progressive visual loss. Apoplexy is diagnosed by computed tomography or MRI and occasionally is an indication for emergency surgery (Fig. 104.2). Histologically, the adenoma shows massive necrosis and hemorrhage. Apoplexy is almost always caused by a pituitary tumor, but it has been reported in other conditions, such as lymphocytic hypophysitis. Pituitary adenomas may enlarge during pregnancy, causing acute symptoms or even apoplexy.

DIAGNOSIS

An algorithm for the initial assessment of a pituitary mass is shown in Figure 104.3. Despite the lack of level 1 evidence, endocrine and ophthalmologic evaluations are recommended in the workup of pituitary masses.

Radiographic Features

An MRI is the best way to evaluate pituitary pathology because soft tissue is seen clearly without interference from the bony surroundings of the sella. An MRI also produces images in any plane, which helps define the relationship of the tumor to the surrounding structures. Vascular structures including the adjacent carotid artery are easily visualized by signal void. Normally, the anterior lobe of the pituitary gland has the same signal as white matter on T1-weighted imaging. With gadolinium, the normal gland enhances homogeneously. Small punctate areas of heterogeneity may be the result of local variations in vascularity, microcyst formation, or granularity within the gland. The posterior lobe shows increased signal on T1-weighted images, probably representing neurosecretory granules in the antidiuretic hormone–containing axons.

Microadenomas are sometimes difficult to see directly on MRI but may be inferred by glandular asymmetry, focal sellar erosion, asymmetric convexity of the upper margin of the gland, or displacement of the infundibulum (Fig. 104.4).

The normal gland usually shows more enhancement than a microadenoma (Fig. 104.5). In the presence of a macroadenoma, the normal gland may not be visualized and the bright signal of the posterior lobe may be absent. Areas of increased signal on the T1-weighted image may stem from hemorrhage; areas of low signal may represent cystic degeneration. An MRI alone is usually sufficient, but computed tomography may show the bony anatomy in better detail. An MRI typically excludes an aneurysm, but magnetic resonance angiography or an angiogram is indicated if aneurysm is a serious diagnostic concern.

Among the group of functional adenomas, ACTH-secreting tumors are often too small to visualize on MRI. Therefore, the diagnosis requires the presence of clinical features typical of

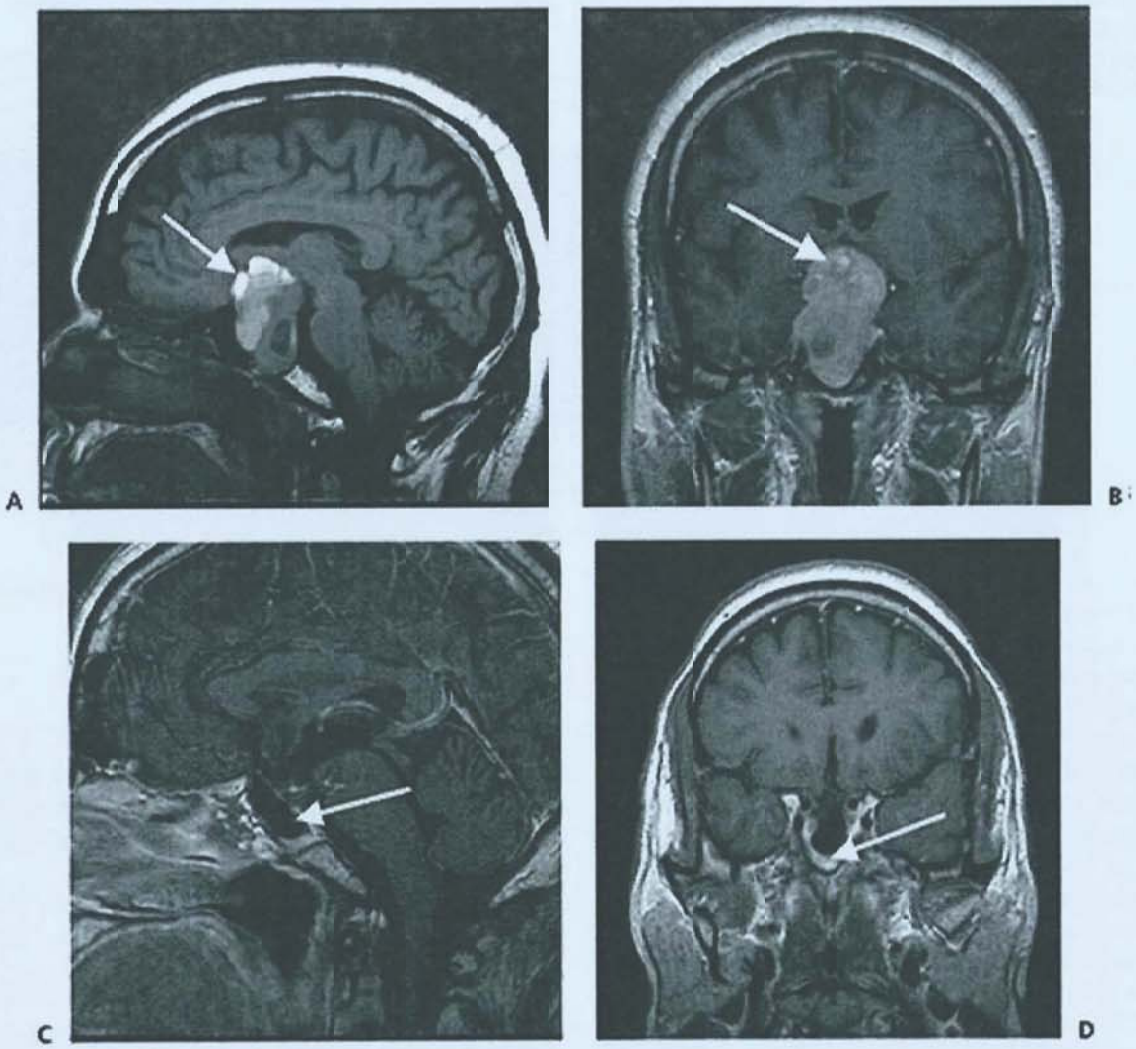

FIGURE 104.2 Pituitary apoplexy. T1-weighted sagittal (A) and coronal magnetic resonance imaging (MRI) (B) demonstrating a pituitary mass that turned out to be partially hemorrhagic in a patient with apoplexy. Hyperintensity *(arrows)* corresponds to the hemorrhagic component. C: Postoperative sagittal MRI following successful tumor resection through a standard transsphenoidal approach shows cerebrospinal fluid within the enlarged sella *(arrow)*. D: Coronal MRI shows normal gland *(arrow)* along the floor of the sella with no residual tumor.

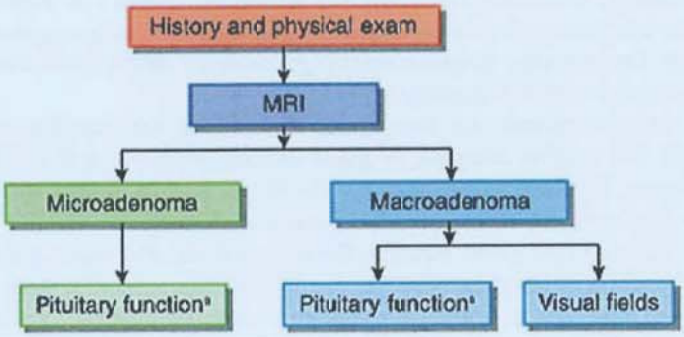

[a]Initial tests include prolactin, TSH, FT4, LH/FSH, E2, testosterone, ACTH, cortisol, GH, and IGF-1. Additional tests including dynamic studies may be needed to assess functional status.

FIGURE 104.3 Initial assessment of pituitary tumors. Abbreviations: ACTH, adrenocorticotropic hormone; E2, estradiol; FSH, follicle-stimulating hormone; FT4, free thyroxine; GH, growth hormone; IGF-1, insulin-like growth factor 1; LH, luteinizing hormone; MRI, magnetic resonance imaging; TSH, thyroid-stimulating hormone.

Cushing disease coupled with biochemical evidence of excess cortisol secretion. Typically, patients will have elevated 24-hour urinary free-cortisol levels, loss of ACTH suppression by high-dose as opposed to low-dose glucocorticoids, and elevated serum ACTH levels. However, the specific differentiation of an ACTH-secreting pituitary tumor from ectopic sources of ACTH may require measurement of ACTH peripherally and in each inferior petrosal sinus, which drains the pituitary gland.

Endocrine Evaluation

Complete endocrine evaluation is necessary for all patients with pituitary tumors, not only to establish the diagnosis of a secreting adenoma but also to determine the presence of hypopituitarism (Tables 104.1 and 104.2), which may result from compression of the normal pituitary gland.

Serum hormone levels should be obtained in all patients, and adequate hormone replacement should be administered for any deficiencies identified. Long-term follow-up monitoring is essential because hypopituitarism may develop years after diagnosis and treatment. Nonsecreting tumors may cause slight

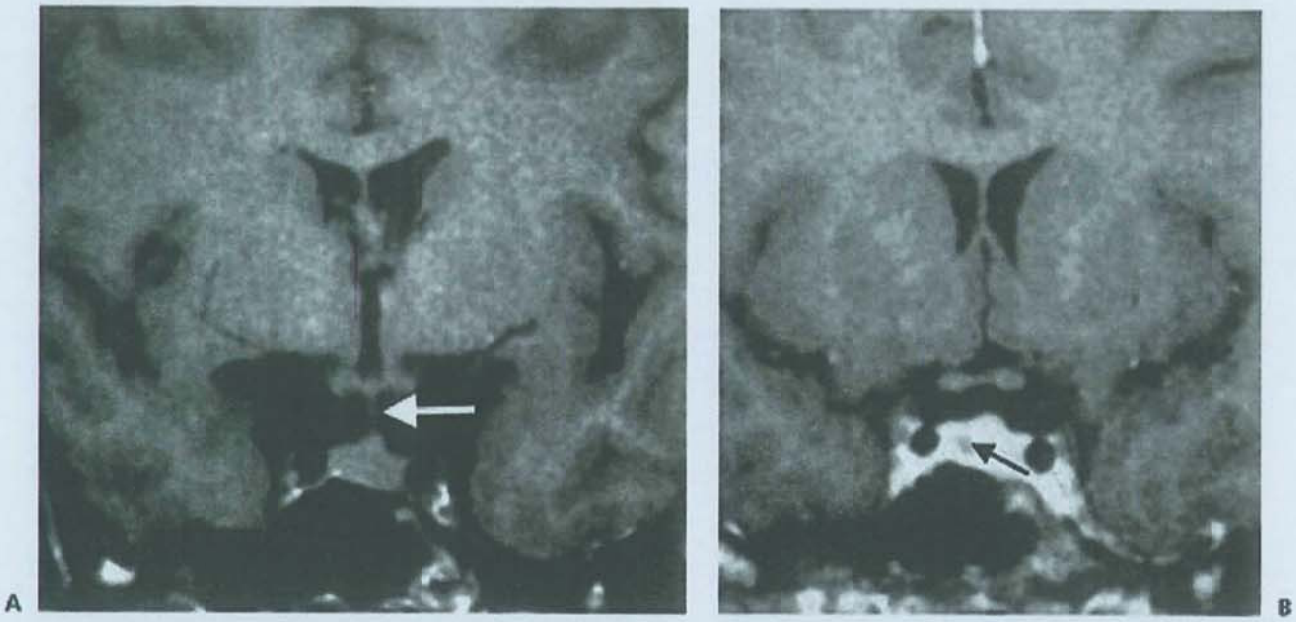

FIGURE 104.4 Pituitary microadenoma. A: T1-weighted coronal magnetic resonance imaging shows slight tilting of the pituitary stalk to the left *(arrow)*, with questionable fullness of the right pituitary gland. These are secondary signs of pituitary microadenoma but are not sufficient to establish the diagnosis radiographically. B: T1-weighted coronal scan after gadolinium enhancement demonstrates a tiny focus of relative hypointensity within the right pituitary gland *(arrow)* consistent with a microadenoma. (Courtesy of Dr. S. Chan.)

elevations of serum prolactin levels (typically <104 ng/mL) via compression of the pituitary stalk leading to interruption of dopaminergic fibers that inhibit prolactin release. Mild elevations are common and must be distinguished from prolactin-secreting macroadenomas that are more likely when prolactin levels are greater than 200 ng/mL. This distinction is important therapeutically because nonsecreting tumors do not respond to dopamine agonists (eg, cabergoline or bromocriptine).

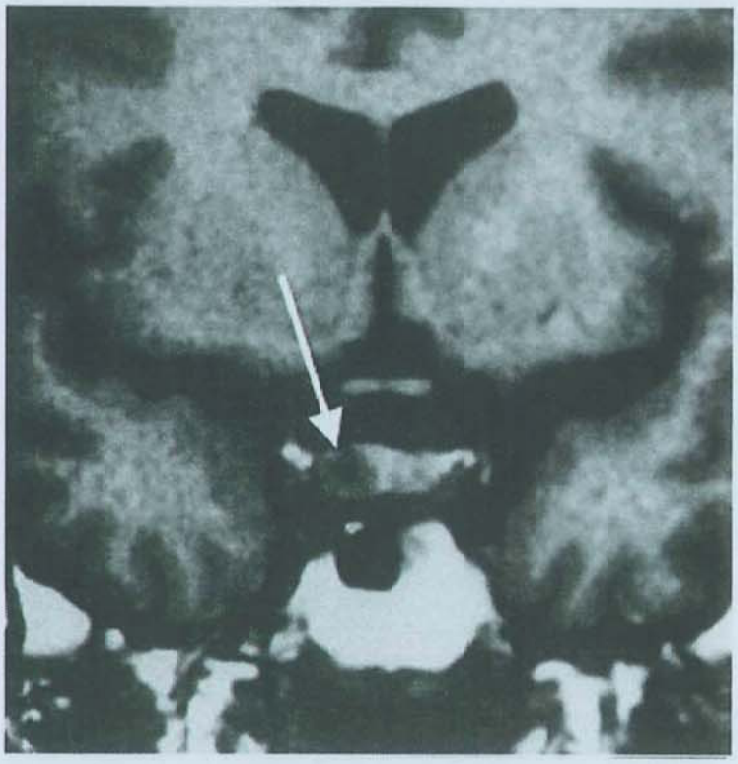

FIGURE 104.5 Pituitary adenoma. T1-weighted coronal magnetic resonance imaging after gadolinium enhancement demonstrates a discrete focus of hypointensity *(arrow)* in the right pituitary gland, most consistent with pituitary adenoma. (Courtesy of Dr. S. Chan.)

Differential Diagnosis

Most lesions in the differential diagnosis have characteristic radiographic or clinical syndromes that distinguish them from pituitary adenomas. Craniopharyngiomas have a predilection for children, are calcified, and usually include cystic areas that contain highly proteinaceous fluid with cholesterol crystals. Rathke cleft cysts are similar to craniopharyngiomas but have a cystic appearance without any solid component. Meningiomas are commonly

TABLE 104.1 Symptoms of Pituitary Failure

Gonadotroph failure
Sexual dysfunction
Amenorrhea
Infertility
Thyrotroph failure
Fatigue
Malaise
Apathy
Constipation
Weight gain
Somatotroph failure
Weight gain
Reduced bone mass
Hypercholesterolemia
Muscle weakness
Corticotroph failure
Fatigue
Weight loss
Decreased appetite
Hypoglycemia

TABLE 104.2 Symptoms of Pituitary Hypersecretion

Gonadotroph excess
Typically asymptomatic
Ovarian hyperstimulation
Thyrotroph excess
Weight loss
Heat intolerance
Palpitations
Tremors
Loose stools
Somatotroph excess
Enlargement of hands, feet, jawbone, forehead
Arthralgias, myalgias, carpal tunnel
Cardiac disease
Colonic polyps
Corticotroph excess
Increase appetite and weight gain
Hypertension
Hyperglycemia
Myopathy
Osteoporosis

found in the diaphragma sellae, planum sphenoidale, and tuberculum sellae and may be difficult to distinguish from a macroadenoma. Distinguishing characteristics of meningiomas include enhancement, visualization of a cleavage plane between the mass and the sellar contents, normally sized sella, and the presence of a dural tail of enhancement. Optic glioma, hypothalamic glioma, germinoma, dermoid tumor, metastasis, and nasopharyngeal carcinoma are less commonly seen entities that should be considered. Chordomas characteristically show extensive bony destruction of the clivus. Mucoceles of the sphenoid sinus may simulate pituitary adenoma. Visual symptoms and sellar enlargement may also result from chronic, increased intracranial pressure of any origin. Characteristic signal voids on MRI usually distinguish an aneurysm. The differential diagnosis also includes sarcoidosis, lymphoma, lymphocytic hypophysitis, and other granulomatous diseases.

Herniation of the subarachnoid space into the sella through an incompetent diaphragma sellae may produce the empty sella syndrome, with enlargement of the sella and flattening of the pituitary gland on its floor (**Fig. 104.6**). This syndrome may be associated with pseudotumor cerebri or CSF rhinorrhea. Although most are not symptomatic, an empty sella may be associated with headaches and occasionally with mild hypopituitarism, but the visual fields are usually normal. The condition is readily seen on MRI and may be a complication of previous transsphenoidal surgery.

MANAGEMENT

Pituitary tumors are histologically benign tumors but can be associated with a significant decrease in a patient's quality of life and functional capacity. Early intervention may minimize disability and must address both hormonal and neurologic function.

Treatment of pituitary adenomas begins with replacement of any deficient pituitary hormone; replacement of thyroid and adrenal hormones remains the most important. Steroid replacement must be adequate for stressful situations, including surgery on the pituitary lesion. Typically, in patients with normal adrenal function prior to surgery, dexamethasone 4 mg is administered preoperatively and tapered off by postoperative day 2 (in patients requiring a craniotomy, the starting dose may be dexamethasone 10 mg perioperatively with a more prolonged taper). A morning cortisol level can be evaluated prior to discharge. Patients with known secondary adrenal insufficiency preoperatively should be continued on replacement doses after surgery.

The goals of treatment differ according to the functional activity of the tumor. For endocrinologically active tumors, an aggressive approach aimed at reversing hypersecretion while

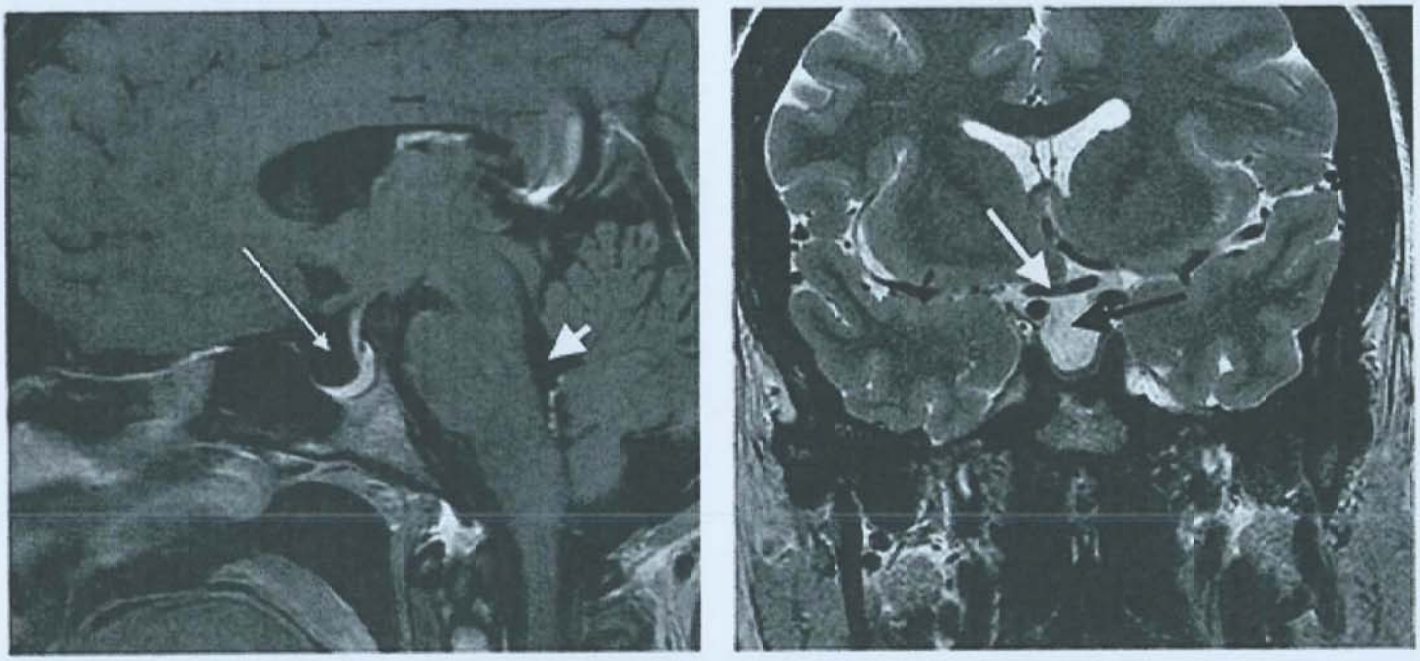

FIGURE 104.6 Empty sella. **A:** Sagittal T1-weighted magnetic resonance imaging demonstrates low-intensity intrasellar signal *(long arrow)* representing cerebrospinal fluid (compare with same signal within the fourth ventricle—*short arrow*). **B:** Coronal T2-weighted magnetic resonance imaging increased signal within the sella *(black arrow)* representing cerebrospinal fluid and normal optic chiasm *(white arrow)*. (Courtesy of Dr. Alex Khandji.)

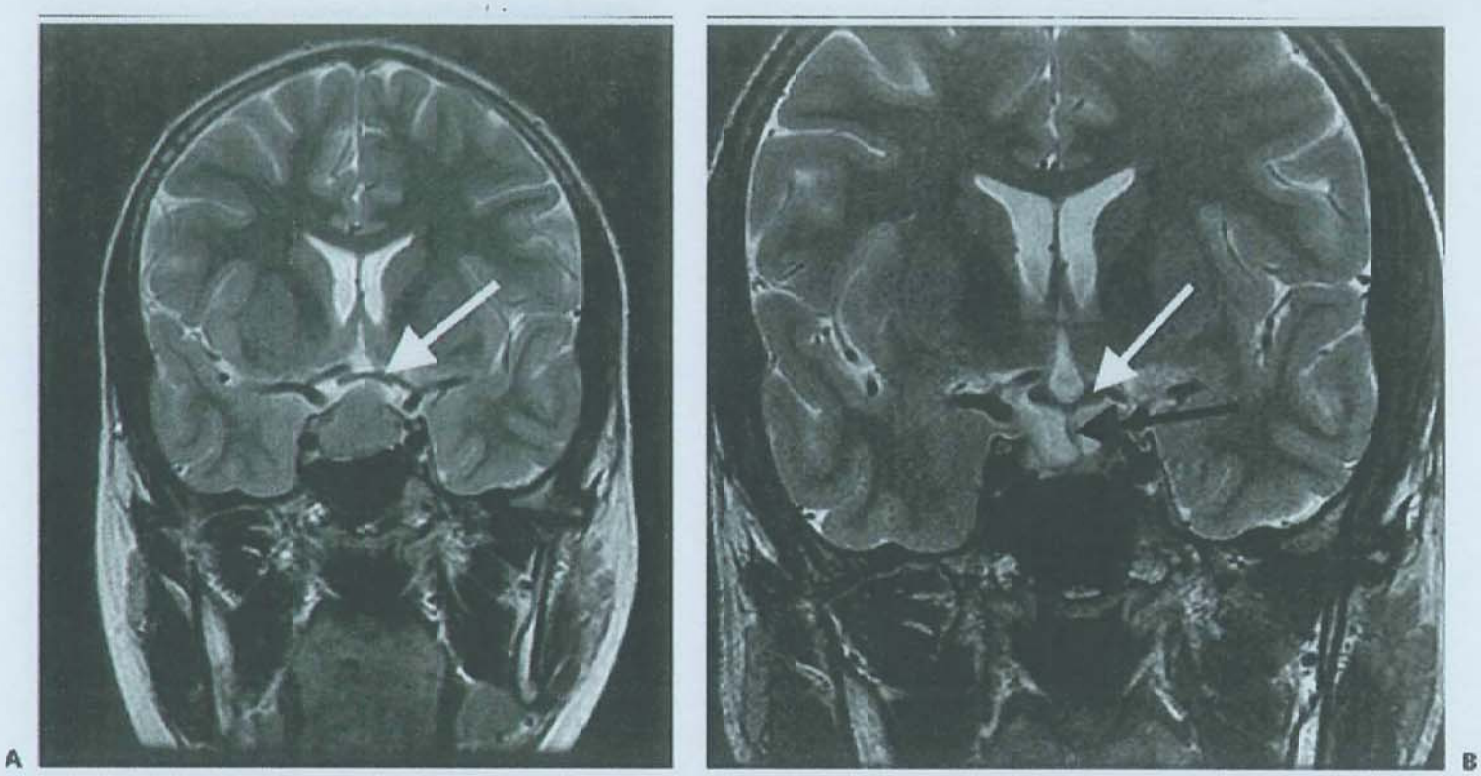

FIGURE 104.7 Prolactinoma. **A:** T2-weighted coronal magnetic resonance imaging of a 19-year-old man with a markedly elevated serum prolactin level. The tumor is partially compressing the optic chiasm *(arrow)*. **B:** Coronal magnetic resonance imaging after treatment with a dopamine agonist shows marked decrease in the tumor size such that the infundibulum *(black arrow)* and optic chiasm *(white arrow)* are decompressed.

preserving normal pituitary function is essential. This may often be achieved by surgical excision, although prolactinomas are generally better controlled by giving dopamine agonists, such as cabergoline. These medications cause tumor shrinkage and normalization of prolactin levels in almost all microadenomas and a majority of macroadenomas (Fig. 104.7). In a subset of patients with hormonally active tumors refractory to standard therapy (typically ACTH secreting), chemotherapy has been used, but further discussion of this treatment modality is beyond the scope of this chapter.

Candidates for surgical treatment also include patients with prolactinomas who fail to respond medically or those who do not tolerate the side effects of medication. The treatment strategies for secretory adenomas are covered in detail in Chapter 122.

Nonsecreting tumors are best treated by surgical reduction of the mass while maintaining pituitary function. Surgery offers the best chance for cure while providing a pathologic diagnosis of the tumor. Incidentally discovered asymptomatic adenomas require no intervention but should be followed with periodic visual field examination and MRI. Onset of symptoms or MRI documentation of growth is an indication for treatment.

Surgery

Although no level I evidence exists, the efficacy and safety of the transsphenoidal approach makes it the procedure of choice for the removal of adenomas. Both microscopic and endoscopic approaches seem to produce equivalent results. Most tumors are soft and friable; transsphenoidal access, although limited, permits complete removal even if there is suprasellar extension or the sella is not enlarged. Transsphenoidal surgery was originally developed by Cushing, but refinements in microsurgery and the availability of steroid replacement and antibiotics have dramatically improved the results.

A transcranial approach may be preferred for resection of exceptionally large tumors or those extending into the middle fossa or the suprasellar space through an intact diaphragma sellae with a waistband constriction of the tumor (Fig. 104.8). A transcranial approach may be necessary to decompress the optic structures before radiation when a transsphenoidal approach fails to adequately debulk the tumor or there is persistent major visual loss.

Radiation Therapy

Radiation therapy is complimentary to surgery in preventing progression, recurrence, and treating hormonally active tumors refractory to medical therapy. Standard radiation now uses conformal treatment planning to avoid unnecessary dosage to the temporal lobes. Doses of 4,500 to 5,000 cGy, delivered in 180 cGy fractions, are recommended. Radiation may be the only treatment for patients who are poor operative risks but in whom histologic confirmation is desired. Radiation therapy is usually not the initial treatment for hormonally active tumors because full normalization of hormone levels often does not occur for years afterwards.

Radiation therapy is indicated for patients with recurrent, medically refractory, hypersecreting tumors or administered postoperatively to patients with invasive or large, incompletely removed adenomas. It is not routinely administered after gross total resection; these patients are followed with serial MRI and visual field examination, and radiation is reserved for documented tumor regrowth.

Early complications of radiation therapy are transient and involve minor inconveniences such as epilation, dry mouth,

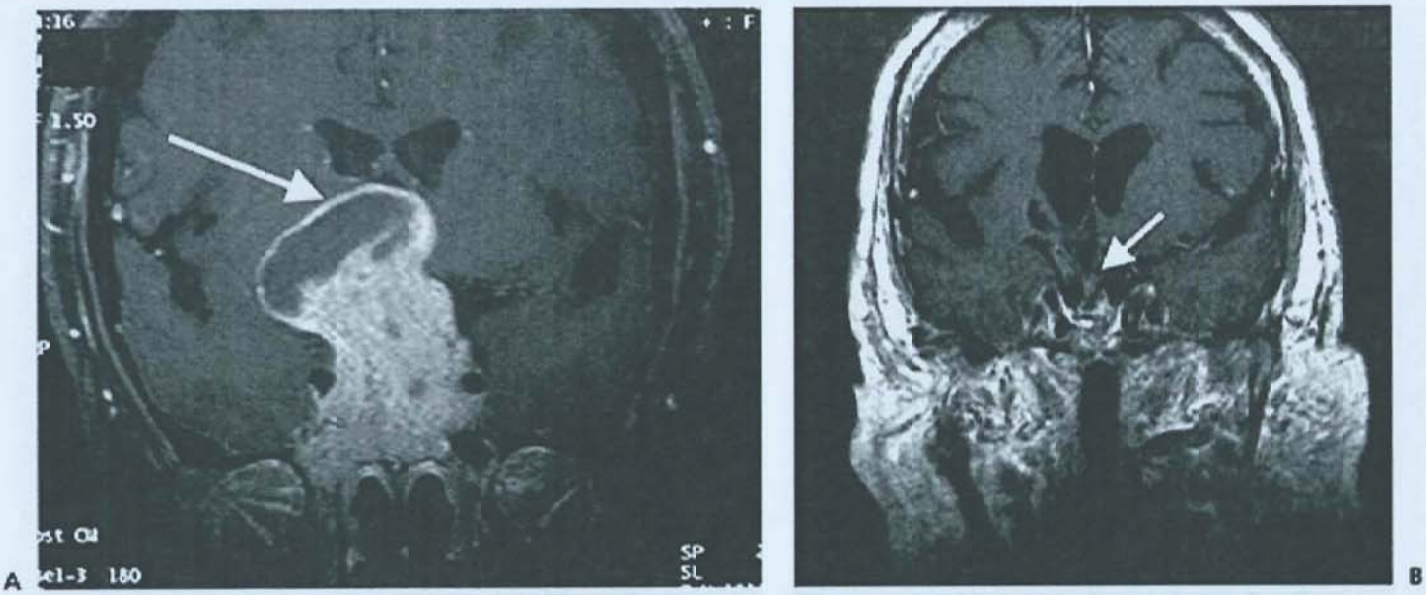

FIGURE 104.8 Giant pituitary adenoma. **A:** T1-weighted coronal magnetic resonance imaging with gadolinium showing a contrast-enhancing giant pituitary adenoma reaching up to the floor of the third ventricle with extension laterally to the right *(arrow)*. A large tumor such as this often requires a craniotomy to decompress the optic structures adequately. **B:** Coronal magnetic resonance imaging after a gross total resection of the pituitary adenoma through a craniotomy. There is no residual tumor, and the optic chiasm and a portion of the infundibulum may be seen clearly *(arrow)*.

and altered taste or smell. The most common and important delayed complication is hypopituitarism, which may occur any time from 6 months to 10 years after treatment. Annual endocrine evaluation is necessary to monitor for this complication. Other rare complications include visual loss, radiation necrosis of the temporal lobes, and radiation-induced tumors. To minimize risk of visual loss, optic structures should be decompressed before radiation therapy.

Newer techniques, such as radiosurgery using proton beam, Gamma Knife, or the linear accelerator, are effective for select patients. In these methods, a single high-dose fraction is directed to a limited volume, giving a high biologic effect. These methods may produce more rapid clinical and hormonal responses, potentially with less toxicity. However, there is concern about damage to the optic chiasm or cranial nerves. Radiosurgery is not used for large tumors or those less than 3 mm distance from the optic apparatus. This therapy may also be associated with a higher incidence of hypopituitarism.

Recurrent Tumors

Patients with recurrent tumors are difficult to manage, and treatment must be individualized. If the patient has not had prior radiation, then it would be the treatment of choice. Otherwise, repeat transsphenoidal surgery is usually indicated. Other treatment options include stereotactic radiosurgery, which may be effective and safe even in the patient who has had standard external beam radiotherapy.

OUTCOME

Given the diverse clinical spectrum seen with pituitary masses, outcomes are variable and dependent on the size and characteristics of the tumor, the therapeutic modality being assessed, and the preexisting comorbidities of the patient at the time of diagnosis.

Surgery

Transsphenoidal surgery is safe with mortality rates less than 1% and major morbidity rates less than 3.5%. Morbidity includes stroke, visual loss, meningitis, CSF leak, cranial nerve palsy, and diabetes insipidus, which is often transient.

Assessing long-term clinical outcomes in patients with nonsecreting adenomas is challenging due to the scarcity of definitive data. Total resection at time of surgery is dependent on the size of tumor and the experience of the surgeon; in selected centers, it may be as high as 75%. Rates of recurrence vary from different surgical series but have been estimated to be 20%. They are dependent on a host of clinical and nonclinical factors including tumor size, presence of symptoms on presentation, nature of the tumor (solid vs cystic), and the skill of the surgeon. The presence of a residual adenoma on postoperative MRI has been shown to correlate with increased risk of recurrence. Some improvement in visual function is estimated to occur in 80% of patients. Restoration of normal endocrine function is dependent on preoperative status in addition to the aforementioned factors. Patients with preexisting hormonal deficiencies typically will not have restoration of full pituitary function.

Regarding functional tumors, outcomes are dependent on tumor type and a full discussion is beyond the scope of this chapter. For patients with Cushing's disease and acromegaly, cure is possible if the tumor is small and symptoms are mild on presentation but risk of recurrent or residual disease increases with larger tumors or more advanced symptoms at time of diagnosis.

Radiation Therapy

Radiation therapy is highly effective in controlling tumor growth (80% or higher depending on length of follow-up). Stereotactic radiosurgery may be more effective in patients who are candidates for this modality. Some degree of hypopituitarism occurs in 30% to 50% of patients across all radiation modalities.

Medical Therapy

Dopamine agonists (cabergoline is most commonly used with starting dose of 0.25 mg once or twice a week that may be titrated based on prolactin levels and radiographic response) are highly effective in treating prolactinomas and reducing prolactin levels and tumor size in more than 90% of patients. Tumor size does impact outcomes, as macroprolactinomas have lower response rates than microprolactinomas but nonetheless, a majority will still respond to dopamine agonists.

SUGGESTED READINGS

Aghi MK, Chen CC, Fleseriu M, et al. Congress of Neurological Surgeons systematic review and evidence-based guidelines on the management of patients with nonfunctioning pituitary adenomas: executive summary. *Neurosurgery*. 2016;79(4):521-523.

Araújo C, Marques O, Almeida R, Santos MJ. Macroprolactinomas: longitudinal assessment of biochemical and imaging therapeutic responses. *Endocrine*. 2018;62(2):470-476.

Ausiello JC, Bruce JN, Freda PU. Postoperative assessment of the patient after transsphenoidal pituitary surgery. *Pituitary*. 2008;11(4):391-401.

Cámara Gómez R. Non-functioning pituitary tumors: 2012 update. *Endocrinol Nutr*. 2014;61(3):160-170.

Cappabianca P, de Divitiis E. Endoscopy and transsphenoidal surgery. *Neurosurgery*. 2004;54(5):1043-1048.

Chandler WF, Barkan AL. Treatment of pituitary tumors: a surgical perspective. *Endocrinol Metab Clin North Am*. 2008;37(1):51-66, viii.

Chen Y, Wang CD, Su ZP, et al. Natural history of postoperative nonfunctioning pituitary adenomas: a systematic review and meta-analysis. *Neuroendocrinology*. 2012;96(4):333-342.

Dekkers OM, Pereira AM, Roelfsema F, et al. Observation alone after transsphenoidal surgery for nonfunctioning pituitary macroadenoma. *J Clin Endocrinol Metab*. 2006;91(5):1796-1801.

Fernandez A, Karavitaki N, Wass JA. Prevalence of pituitary adenomas: a community-based, cross-sectional study in Banbury (Oxfordshire, UK). *Clin Endocrinol (Oxf)*. 2010;72(3):377-382.

Fernández-Balsells MM, Murad MH, Barwise A, et al. Natural history of nonfunctioning pituitary adenomas and incidentalomas: a systematic review and metaanalysis. *J Clin Endocrinol Metab*. 2011;96(4):905-912.

Fleseriu M, Bodach ME, Tumialan LM, et al. Congress of Neurological Surgeons systematic review and evidence-based guideline for pretreatment endocrine evaluation of patients with nonfunctioning pituitary adenomas. *Neurosurgery*. 2016;79(4):E527-E529.

Frank G, Pasquini E, Farneti G, et al. The endoscopic versus the traditional approach in pituitary surgery. *Neuroendocrinology*. 2006;83(3-4):240-248.

Freda PU, Beckers AM, Katznelson L, et al. Pituitary incidentaloma: an endocrine society clinical practice guideline. *J Clin Endocrinol Metab*. 2011;96(4):894-904.

Gertner ME, Kebebew E. Multiple endocrine neoplasia type 2. *Curr Treat Options Oncol*. 2004;5(4):315-325.

Goel A, Nadkarni T, Muzumdar D, Desai K, Phalke U, Sharma P. Giant pituitary tumors: a study based on surgical treatment of 118 cases. *Surg Neurol*. 2004;61(5):436-445.

Heaney AP. Pituitary carcinoma: difficult diagnosis and treatment. *J Clin Endocrinol Metab*. 2011;96(12):3649-3660.

Honegger J, Grimm F. The experience with transsphenoidal surgery and its importance to outcomes. *Pituitary*. 2018;21(5):545-555.

Honegger J, Prettin C, Feuerhake F, Petrick M, Schulte-Mönting J, Reincke M. Expression of Ki-67 antigen in nonfunctioning pituitary adenomas: correlation with growth velocity and invasiveness. *J Neurosurg*. 2003;99(4):674-679.

Huang W, Molitch ME. Management of nonfunctioning pituitary adenomas (NFAs): observation. *Pituitary*. 2018;21(2):162-167.

Ibrahim AE, Pickering RM, Gawne-Cain ML, King S, Lees PD, Ellison DW. Indices of apoptosis and proliferation as potential prognostic markers in non-functioning pituitary adenomas. *Clin Neuropathol*. 2004;23(1):8-15.

Jane JA Jr, Laws ER Jr. The surgical management of pituitary adenomas in a series of 3,093 patients. *J Am Coll Surg*. 2001;193(6):651-659.

Jho DH, Biller BM, Agarwalla PK, Swearingen B. Pituitary apoplexy: large surgical series with grading system. *World Neurosurg*. 2014;82(5):781-790.

Johnson MD, Woodburn CJ, Vance ML. Quality of life in patients with a pituitary adenoma. *Pituitary*. 2003;6(2):81-87.

Joshi SM, Cudlip S. Transsphenoidal surgery. *Pituitary*. 2008;11(4):353-360.

Komninos J, Vlassopoulou V, Protopapa D, et al. Tumors metastatic to the pituitary gland: case report and literature review. *J Clin Endocrinol Metab*. 2004;89(2):574-580.

Kreutzer J, Fahlbusch R. Diagnosis and treatment of pituitary tumors. *Curr Opin Neurol*. 2004;17(6):693-703.

Kuo JS, Barkhoudarian G, Farrell CJ, et al. Congress of Neurological Surgeons systematic review and evidence-based guideline on surgical techniques and technologies for the management of patients with nonfunctioning pituitary adenomas. *Neurosurgery*. 2016;79(4):E536-E538.

Laws ER, Sheehan JP, Sheehan JM, Jagnathan J, Jane JA Jr, Oskouian R. Stereotactic radiosurgery for pituitary adenomas: a review of the literature. *J Neurooncol*. 2004;69(1-3):257-272.

Lee MS, Pless M. Apoplectic lymphocytic hypophysitis. Case report. *J Neurosurg*. 2003;98(1):183-185.

Loeffler JS, Shih HA. Radiation therapy in the management of pituitary adenomas. *J Clin Endocrinol Metab*. 2011;96(7):1992-2003.

Lopes MBS. The 2017 World Health Organization classification of tumors of the pituitary gland: a summary. *Acta Neuropathol*. 2017;134:521-535.

Losa M, Valle M, Mortini P, et al. Gamma Knife surgery for treatment of residual nonfunctioning pituitary adenomas after surgical debulking. *J Neurosurg*. 2004;100(3):438-444.

Lucas JW, Bodach ME, Tumialan LM, et al. Congress of Neurological Surgeons systematic review and evidence-based guideline on primary management of patients with nonfunctioning pituitary adenomas. *Neurosurgery*. 2016;79(4):E533-E535.

Ma W, Ikeda H, Yoshimoto T. Clinicopathologic study of 123 cases of prolactin-secreting pituitary adenomas with special reference to multihormone production and clonality of the adenomas. *Cancer*. 2002;95(2):258-266.

Mejico LJ, Miller NR, Dong LM. Clinical features associated with lesions other than pituitary adenoma in patients with an optic chiasmal syndrome. *Am J Ophthalmol*. 2004;137(5):908-913.

Melmed S. Update in pituitary disease. *J Clin Endocrinol Metab*. 2008;93(2):331-338.

Minniti G, Flickinger J, Tolu B, Paolini S. Management of nonfunctioning pituitary tumors: radiotherapy. *Pituitary*. 2018;21(2):154-161.

Molitch ME. Management of incidentally found nonfunctional pituitary tumors. *Neurosurg Clin N Am*. 2012;23(4):543-553.

Mortini P, Losa M, Barzaghi R, Boari N, Giovanelli M. Results of transsphenoidal surgery in a large series of patients with pituitary adenoma. *Neurosurgery*. 2005;56(6):1222-1233.

Osamura RY, Lopes MBS, Grossman A, et al. Pituitary adenoma. In: Lloyd RV, Osamura RY, Klöppel G, Rosai J, eds. *WHO Classification of Tumours of Endocrine Organs*. 4th ed. Lyon, France: International Agency for Research on Cancer; 2017:14-18.

Park KJ, Kano H, Parry PV, et al. Long-term outcomes after gamma knife stereotactic radiosurgery for nonfunctional pituitary adenomas. *Neurosurgery*. 2011;69(6):1188-1199.

Pollock BE, Carpenter PC. Stereotactic radiosurgery as an alternative to fractionated radiotherapy for patients with recurrent or residual nonfunctioning pituitary adenomas. *Neurosurgery*. 2003;53(5):1086-1091.

Rajaratnam S, Seshadri MS, Chandy MJ, Rajshekhar V. Hydrocortisone dose and postoperative diabetes insipidus in patients undergoing transsphenoidal pituitary surgery: a prospective randomized controlled study. *Br J Neurosurg*. 2003;17(5):437-442.

Scheithauer BW, Kovacs KT, Laws ER Jr, Randall RV. Pathology of invasive pituitary tumors with special reference to functional classification. *J Neurosurg*. 1986;65(6):733-744.

Sheehan JP, Starke RM, Mathieu D, et al. Gamma Knife radiosurgery for the management of nonfunctioning pituitary adenomas: a multicenter study. *J Neurosurg*. 2013;119(2):446-456.

Swearingen B. Update on pituitary surgery. *J Clin Endocrinol Metab*. 2012;97(4):1073-1081.

Tanaka Y, Hongo K, Tada T, Sakai K, Kakizawa Y, Kobayashi S. Growth pattern and rate in residual nonfunctioning pituitary adenomas: correlations among tumor volume doubling time, patient age, and MIB-1 index. *J Neurosurg*. 2003;98(2):359-365.

Pineal Region Tumors 105

Jeffrey N. Bruce

KEY POINTS

1. Because of the wide histologic diversity, tissue diagnosis via surgical biopsy is essential to guide optimal management strategies.
2. If β-human chorionic gonadotropin (β-hCG) or α-fetoprotein levels are elevated, malignant germ cell elements must be present, so treatment with radiation and chemotherapy can commence without biopsy.
3. If only β-hCG is elevated (>50 IU/L) but α-fetoprotein is normal, patients should undergo surgery to distinguish a β-hCG–secreting germinoma from an immature teratoma or a choriocarcinoma, as the latter ones need more aggressive treatment.
4. Most patients present with increased intracranial pressure from obstructive hydrocephalus and usually benefit from an endoscopic third ventriculostomy.
5. Complete tumor resection is the surgical goal for benign and low-grade tumors in the pineal region. Most malignant tumors benefit from maximal safe tumor resection, but gross total resection is not recommended for localized germinomas as they are sensitive to radiation treatment.
6. Patients with malignant pineal tumors require adjuvant radiation therapy. Adjuvant chemotherapy is useful for nongerminomatous malignant germ cell tumors.
7. Patients with pineal cell or germ cell tumors require magnetic resonance imaging of the complete spine to look for spinal seeding.

INTRODUCTION

The pineal gland is composed of glandular tissue, glia, endothelial cells, and sympathetic nerve terminals. The numerous cell types that make up the normal gland and surrounding periventricular region may lead to a diverse group of tumors ranging from benign to malignant (Table 105.1), all of which may have a similar clinical presentation. Despite the common presentation, the specific histology has important implications for treatment and outcome. Optimal management of pineal region tumors therefore necessitates establishment of an accurate histologic diagnosis.

EPIDEMIOLOGY

Pineal tumors account for about 1% of all intracranial tumors in the United States. In Asia, where germ cell tumors (GCTs) are common, pineal cell tumors constitute 4% to 7% of all intracranial tumors. The GCTs are found almost exclusively during the first three decades of life, whereas pineal cell tumors have a mean age of diagnosis around 30 years of age. Although intracranial GCTs are overwhelmingly more common in men, there seems to be no strong gender preference among other pineal tumor types.

TABLE 105.1 Summary of Pathologically Verified Pineal Tumors at the New York Neurological Institute (1990-2013)

Type	Benign	Malignant	Male-to-Female Ratio	Average Age (y)
Germ cell	3	29	15:1	22
Pineal cell	16	29	1:1	41
Glial cell	18	20	1:1.5	38
Meningioma	9	2	1:2.7	46
Pineal cyst	14	0	1:2.5	36
Miscellaneous (including metastases)	3	15	1:1	40
Total	63	95	1.1:1	36

PATHOBIOLOGY

The pineal gland is an encapsulated structure situated between the velum interpositum of the posterior and the tectum of the midbrain. The gland produces melatonin in response to light-dark cycles and may play an ill-defined role in circadian rhythms. Pineocytomas and pineoblastomas arise from pineal glandular elements, astrocytomas and oligodendrogliomas from glial cells, hemangioblastomas from endothelial cells, and chemodectomas from sympathetic nerve cells. Arachnoid cells in the reflections of the tela choroidea, adjacent to the pineal gland, give rise to meningiomas. Ependymomas arise from ependymal cells that line the third ventricle. The GCTs derive from primitive germ cell rests that are retained in the pineal and other midline structures after embryologic migration.

Histologic Subtypes

Germ Cell Tumors

The GCTs account for approximately one-third of all pineal tumors and are histologically identical to gonadal GCTs. They predominate in men and usually occur in children and adolescents. Pineal GCTs occur almost exclusively in boys, but suprasellar tumors occur equally in boys and girls. The GCTs fall into two major categories: germinomas and nongerminomatous (NGGCT)

TABLE 105.2 Immunohistochemical Markers in Germ Cell Tumors[a]

Tumors	AFP	β-hCG	CD30	CD117	D-240	Glypican 3	OCT4	SOX2
Immature teratoma	+/−	−	−	−	−	+/−	−	+
Pure germinoma	−	−	−	+	+	−	+	−
Germinoma with syncytiotrophoblastic cells	−	+	−	+	+	−	+	−
Embryonal cell carcinoma	−	+/−	+	−	−	−	+	+
Choriocarcinoma	−	+	−	−	−	+	−	−
Endodermal sinus tumor (yolk sac tumor)	+	−	−	−	−	+	−	−

Abbreviations: AFP, α-fetoprotein; β-hCG, β-human chorionic gonadotropin; OCT4, octamer-binding transcription factor 4; SOX2, SRY (sex determining region Y)-box 2.
[a]Courtesy of George Zanazzi, MD.

that include choriocarcinomas, embryonal cell carcinomas, teratomas (mature and immature teratoma, teratoma with malignant transformation), and endodermal sinus tumors (also known as *yolk sac tumor*). Benign, mature teratomas may also be seen.

Germinomas arise in the midline, usually in the pineal area and suprasellar cistern and occasionally in both areas simultaneously. Rarely do they develop in the cerebral hemispheres. Germinomas account for about half of all intracranial GCTs. They are histologically identical to the testicular seminoma and ovarian dysgerminoma. Germinomas are highly malignant; pathologically, they are frequently infiltrated by lymphocytes, which may occasionally confuse the diagnosis. Pure germinomas generally are associated with absent α-fetoprotein (AFP) and β-human chorionic gonadotropin (β-hCG) levels in both cerebrospinal fluid (CSF) and serum; however, some may contain syncytiotrophoblastic elements that produce β-hCG, which confers a slightly worse prognosis in some studies (Table 105.2). Germinomas label with placental alkaline phosphatase and may occasionally seed the CSF.

The NGGCTs are highly malignant and more aggressive than germinomas; they metastasize to the CSF more frequently than germinomas. Choriocarcinoma contains cyto- and syncytiotrophoblastic cells that produce β-hCG. Endodermal sinus tumors contain yolk sac elements that produce AFP. High levels of β-hCG or AFP in the CSF or serum indicate the presence of malignant germ cell elements. When markers are elevated, a tissue diagnosis is not necessary and patients are treated with radiation and chemotherapy.

All patients with histologically confirmed GCTs, regardless of subtype, should have serum and CSF tested for β-hCG and AFP (if not done preoperatively), a complete spine magnetic resonance imaging (MRI) with gadolinium, and cytologic examination of CSF to complete staging prior to treatment.

Treatment first involves surgical resection to establish the diagnosis and debulk the tumor; if possible, gross total excision is the surgical goal. Patients with pure germinomas should be treated with radiotherapy, usually 36 to 45 Gy; the port must include 24 Gy to the whole ventricular system. If the tumor is disseminated in the CSF, craniospinal radiation is required. Chemotherapy may be useful at recurrence but is not recommended at diagnosis because most germinoma patients are cured with radiotherapy alone. The NGGCTs are relative insensitive to radiation and therefore require craniospinal radiotherapy with adjuvant chemotherapy in all cases after maximal resection. Benign GCTs such as teratomas, dermoids, and epidermoids are generally curable with surgery alone.

Pineal Cell Tumors

Primary pineal cell tumors are classified as low-grade pineocytomas (World Health Organization [WHO] grade I), pineal parenchymal tumors of intermediate differentiation (WHO grade II or III), or the highly malignant pineoblastoma (WHO grade IV). The higher grade tumors tend to occur in children and young adults, whereas pineocytomas usually occur in adults. Pineal tumors of all histologic grades may seed the leptomeninges, but pineocytomas do so only rarely. Complete resection of a pineocytoma does not require additional therapy, but incomplete resection should be followed by radiation. Intermediate-grade pineocytomas require radiotherapy, and pineoblastomas require neuraxis radiation and chemotherapy.

Gliomas

Gliomas account for one-third of pineal tumors. Most are invasive and have a prognosis comparable to astrocytomas of the upper brainstem. Some gliomas are low grade, cystic, and may be surgically curable. Anaplastic astrocytomas and glioblastomas are less common. Oligodendrogliomas and ependymomas may also occur. Treatment of these tumors is identical to the treatment of gliomas in other areas of the central nervous system.

Meningiomas

Meningiomas may arise from the velum interpositum or from the tentorial edge. They occur predominantly in middle-aged patients and in the elderly. Meningiomas make up approximately 8% of pineal region tumors but overall account for less than 1% of all meningiomas. They are amenable to surgical resection.

Metastasis and Other Miscellaneous Tumors

The pineal gland does not have a blood-brain barrier and, like the pituitary gland, may be underrecognized as a site of brain metastasis from systemic tumors. Miscellaneous tumors include sarcoma, hemangioblastoma, choroid plexus papilloma, lymphoma, and chemodectoma.

Pineal Cysts

Benign cysts of the pineal gland are often found incidentally on imaging studies, and it is important to distinguish them from cystic tumors. They are normal variants of the pineal gland and consist of a cystic structure surrounded by normal pineal parenchymal tissue (Fig. 105.1). Radiographically, they are up to 2 cm in diameter and often have some degree of peripheral enhancement as a result of the compressed normal pineal gland. Pineal cysts may be found in 4% of all MRI scans. These cysts are static, anatomic

FIGURE 105.1 Sagittal T1-weighted gadolinium-enhanced magnetic resonance imaging (MRI) of a pineal cyst. These cysts may have rim enhancement (*small arrow*) and may be up to 2 cm in diameter. They rarely cause compression of the sylvian aqueduct (*larger arrow* on patent aqueduct) and are rarely symptomatic. Histologically, they are normal variants of the pineal gland and require no treatment; they must be distinguished from cystic tumors. Growth of the cyst on serial MRIs or the development of hydrocephalus is sufficient cause to doubt the diagnosis, and surgical resection should be considered.

FIGURE 105.2 Sagittal magnetic resonance imaging with gadolinium showing multicentric germinoma involving the pineal region and infiltrating the mammillary bodies, optic chiasm, and pituitary stalk. This patient presented with diminished visual fields and diabetes insipidus.

variants and need no treatment unless they become symptomatic. The most common symptoms are headaches, followed by visual symptoms. The cysts may be sufficiently large to cause obstructive hydrocephalus. Decompression can occasionally be accomplished by third ventricular endoscopic resection of the cyst.

CLINICAL FEATURES

Pineal region tumors may become symptomatic from one of three mechanisms: increased intracranial pressure from hydrocephalus, direct compression of brainstem and cerebellum, or endocrine dysfunction. Headache, associated with hydrocephalus, is the most common symptom at onset and is caused by obstruction of third ventricular outflow at the aqueduct of Sylvius. Leptomeningeal dissemination can produce a multitude of symptoms depending on the area affected, analogous to leptomeningeal metastases from other cancers.

More advanced hydrocephalus may result in papilledema, gait disorder, nausea, vomiting, lethargy, and memory disturbance. Direct midbrain compression may cause disorders of ocular movements, such as Parinaud syndrome (paralysis of upgaze, convergence or retraction nystagmus, and light-near pupillary dissociation) or the sylvian aqueduct syndrome (paralysis of downgaze or horizontal gaze superimposed upon a Parinaud syndrome). Either lid retraction (Collier sign) or ptosis may follow dorsal midbrain compression or infiltration. Fourth nerve palsy with diplopia and head tilt may be seen. Ataxia and dysmetria may result from direct cerebellar compression.

Endocrine dysfunction is rare, usually arising from secondary effects of hydrocephalus or tumor spread to the hypothalamic region (Fig. 105.2). The symptoms may occur early, before any radiographic documentation of hypothalamic seeding.

Although precocious puberty has been linked with pineal masses, documented cases are rare. Precocious puberty is actually precocious pseudopuberty because the hypothalamic-gonadal axis is not mature. It occurs in boys with choriocarcinomas or germinomas with syncytiotrophoblastic cells and ectopic secretion of β-hCG. In boys, the luteinizing hormone–like effects of β-hCG may stimulate Leydig cells to produce androgens that induce development of secondary sexual characteristics and pseudopuberty. This phenomenon does not occur in girls with pineal region tumors because GCTs are rare in females, and both luteinizing hormone and follicle-stimulating hormone are necessary to trigger ovarian estrogen production.

DIAGNOSIS

The MRI with gadolinium is mandatory for all pineal tumors to determine the presence of hydrocephalus and evaluate tumor size, vascularity, and homogeneity. In particular, sagittal MRI reveals the relationship of the tumor to surrounding structures and also evaluates possible ventricular seeding. Angiography is not performed unless a vascular anomaly is suspected. Measurement of AFP and β-hCG in serum and CSF is required in the preoperative workup. If β-hCG or AFP levels are elevated, malignant germ cell elements must be present so a tissue diagnosis is not necessary and treatment with radiation and chemotherapy can commence. Despite improved imaging and CSF markers, a definite histologic diagnosis requires pathologic examination of tumor tissue, and all patients should undergo surgery.

MANAGEMENT

Given the rarity of pineal region tumors, studies establishing level 1 standards do not exist. Owing to the wide variety of pineal region tumor subtypes, the general approach to these tumors is to first establish a histologic diagnosis by obtaining tumor tissue through an open surgical approach or a stereotactic-guided needle biopsy (Fig. 105.3). Subsequent management is dependent on the tumor type (Fig. 105.4).

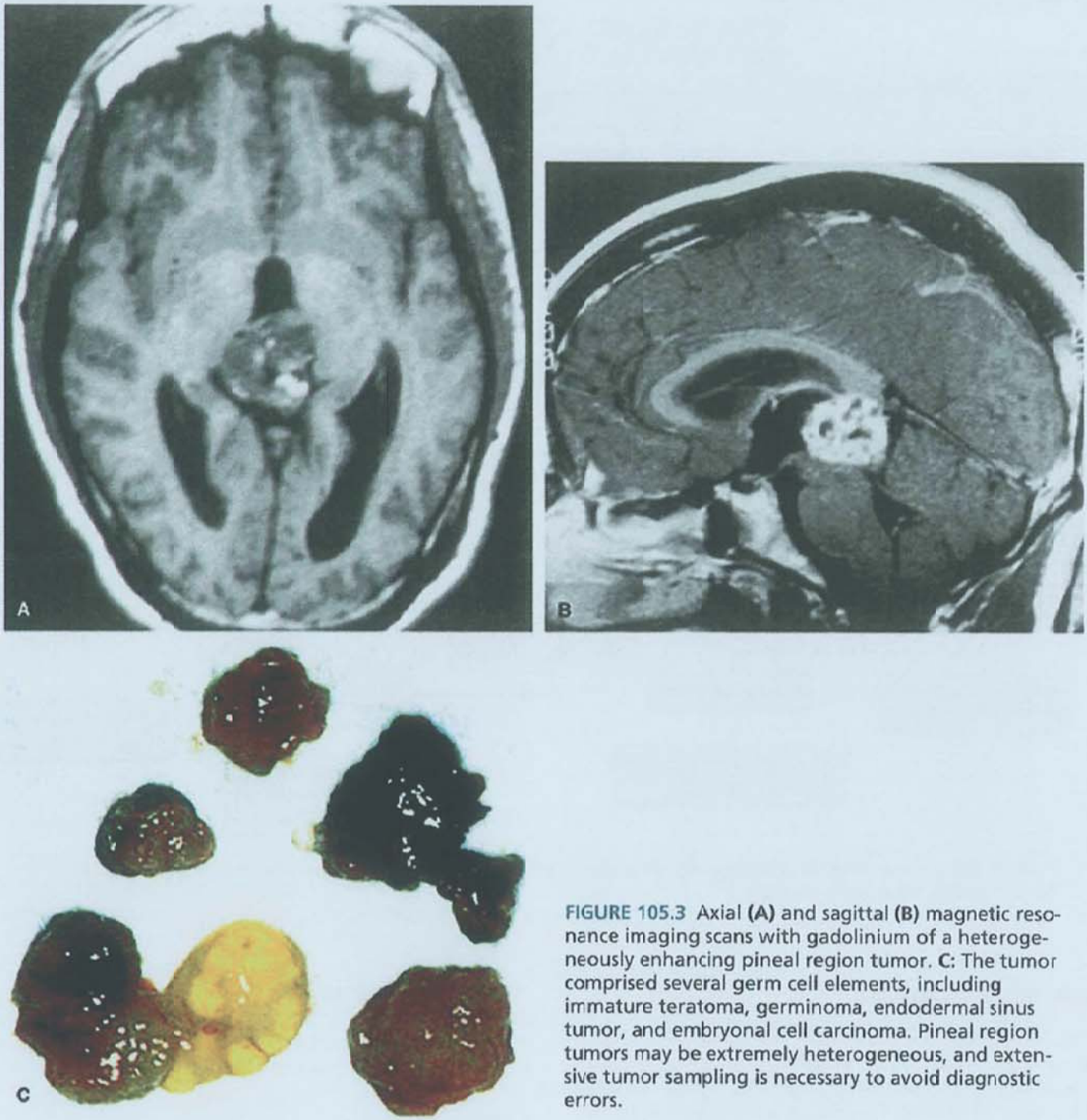

FIGURE 105.3 Axial **(A)** and sagittal **(B)** magnetic resonance imaging scans with gadolinium of a heterogeneously enhancing pineal region tumor. **C:** The tumor comprised several germ cell elements, including immature teratoma, germinoma, endodermal sinus tumor, and embryonal cell carcinoma. Pineal region tumors may be extremely heterogeneous, and extensive tumor sampling is necessary to avoid diagnostic errors.

Management of Hydrocephalus

Hydrocephalus is present in most pineal tumor patients and must be surgically addressed, preferably by an endoscopic third ventriculostomy. A ventriculoperitoneal shunt is an acceptable alternative but carries greater long-term risks including peritoneal seeding of malignant tumors.

Surgery

The pineal region may be reached surgically from one of several approaches, above or below the tentorium, depending on tumor size and coexistent hydrocephalus (**Fig. 105.5**). Complete excision is the goal for any pineal tumor. Nearly one-third of pineal tumors are benign and curable with complete resection alone. With malignant tumors, aggressive tumor resection provides the best opportunity for accurate histologic diagnosis and may increase the effectiveness of adjuvant radiotherapy or chemotherapy. The overall operative mortality is about 4%, with an additional 3% permanent major morbidity. The most serious complication of surgery is hemorrhage into a partially resected malignant tumor. The most common postoperative complications usually transient and include ocular palsies, altered mental status, and ataxia. For patients with obviously disseminated tumor or those with medical problems that pose excessive surgical risks, biopsy via a stereotactic or endoscopic approach is a reasonable alternative for obtaining diagnostic tissue. Although gaining in popularity, stereotactic biopsy is not performed routinely because of possible sampling error through insufficient tissue analysis, increased risk of hemorrhage from the adjacent deep venous system and highly vascular pineal tumors, and a better prognosis that follows aggressive resection.

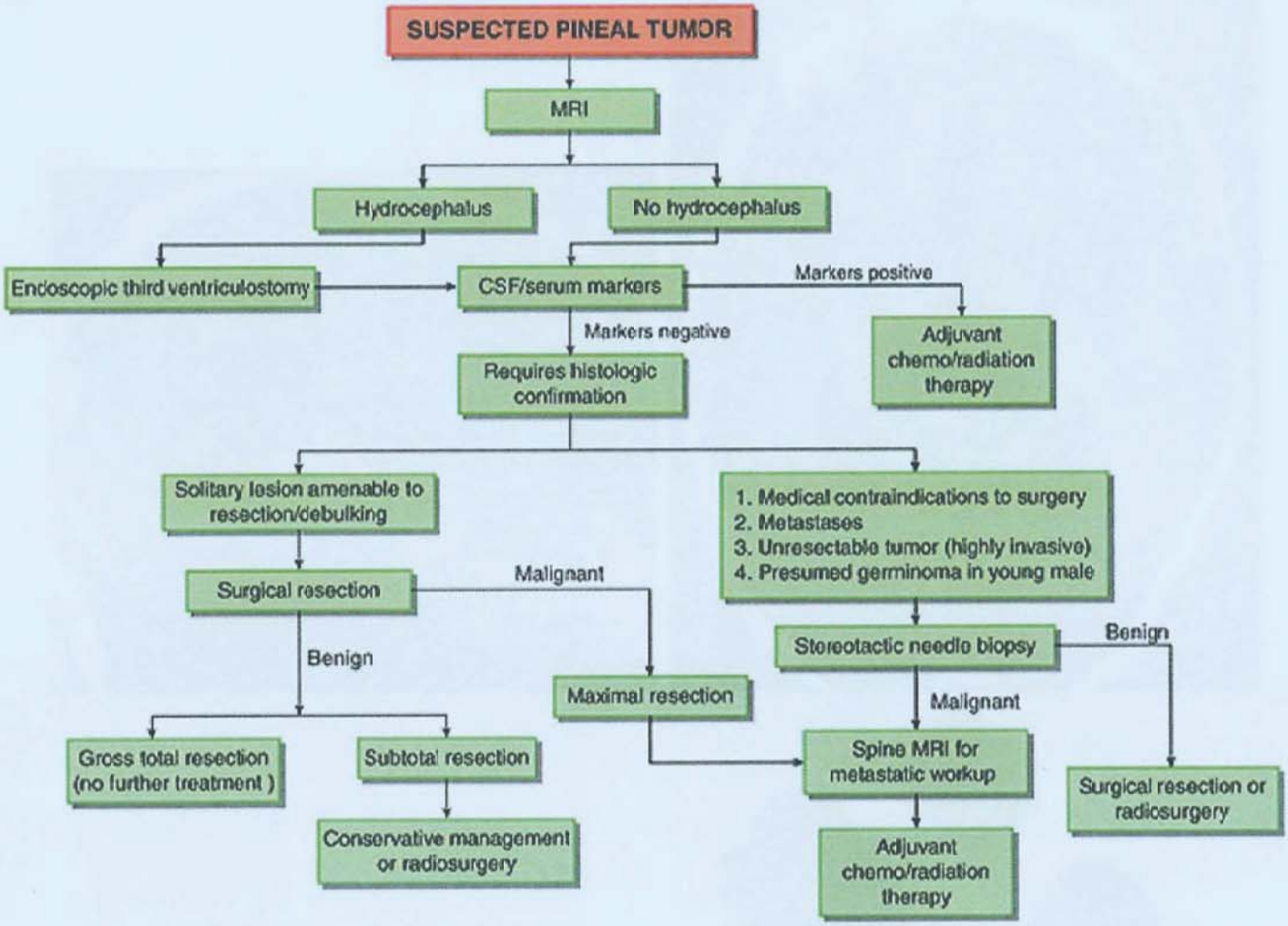

FIGURE 105.4 Algorithm for management of pineal region tumors. Abbreviations: CSF, cerebrospinal fluid; MRI, magnetic resonance imaging.

Postoperative Staging

All patients with pineal cell tumors and GCTs are evaluated for CSF seeding (**Fig. 105.6**). High-resolution gadolinium-enhanced MRI of the complete spine should be performed. Even if the spine MRI is negative, CSF analysis for cytology and markers is recommended to look for microscopic disease.

Radiotherapy

Germinomas and pineal parenchymal tumors of intermediate differentiation require radiation to a dose of 36 to 45 Gy with coverage of the ventricles. All patients with pineoblastomas, NGGCT, and disseminated germinomas require neuraxis radiotherapy, usually to a total dose of about 36 Gy, with a boost to the primary site to achieve a dose of at least 54 Gy. Gliomas are treated according to histologic subtype.

Although generally considered safe, long-term follow-up results with stereotactic radiosurgery are limited because pineal tumors are rare. There are reports of tumor control using radiosurgery as the sole treatment for some low-grade tumors such as pineocytoma, but it rarely produces complete tumor regression and is probably not optimal initial therapy unless surgery is contraindicated. The main problem with radiosurgery is not the response of the targeted mass but the potential for recurrence outside of the treatment volume. It has been used with some success for tumors less than 3 cm in diameter at recurrence, provided there is no evidence of CSF dissemination.

Chemotherapy

Chemotherapy has been of most benefit with NGGCTs and pineoblastomas. The most commonly used regimens are combinations of cisplatin, vinblastine, and bleomycin or cisplatin and VP-16 (eg, etoposide). Often a combined neoadjuvant chemotherapy with RT is used as it significantly improved outcomes in patients with NGGCT, although results remain inferior to that for patients with germinoma. In the absence of a prospective randomized study, neoadjuvant chemotherapy followed by CSI remains the standard of care for all patients with intracranial NGGCTs. Young children are treated with chemotherapy alone, and radiotherapy is deferred until they are at least 3 years or older because of the risk of severe, long-term effects on growth and cognition. Initial attempts to avoid radiation in all patients by using aggressive chemotherapy resulted in an unacceptably high incidence (50%) of recurrence at 2 years, including patients with germinoma, which is curable with radiation alone. Therefore, chemotherapy is not used as part of the initial treatment of localized germinomas.

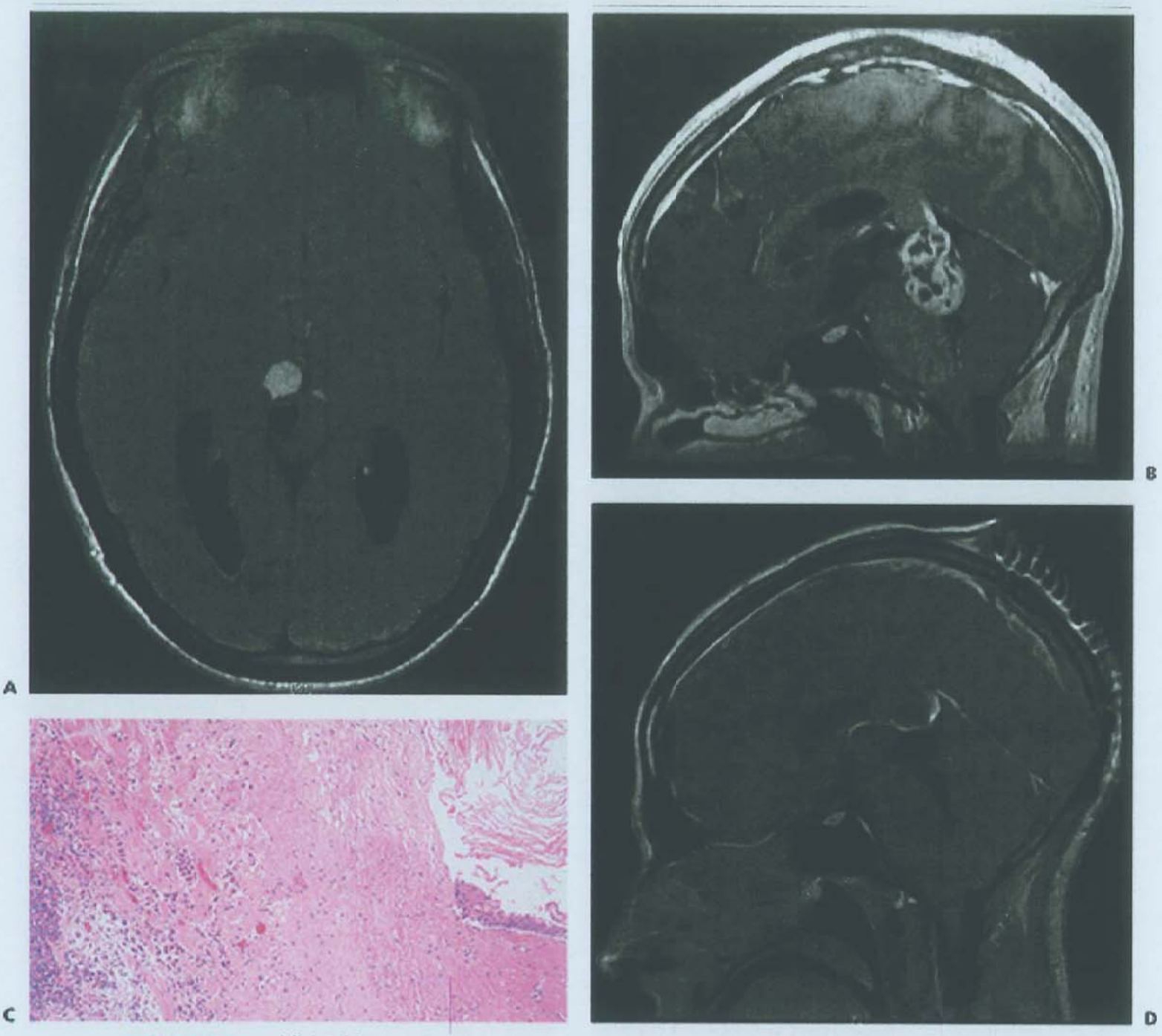

FIGURE 105.5 Axial flair without gadolinium **(A)** and sagittal T1 with gadolinium **(B)** magnetic resonance imaging scans (MRIs) of a mixed dermoid/germinoma causing hydrocephalus. **C:** Germinoma is seen on the left side of this hematoxylin- and eosin-stained section, in the form of cords and nests of large cells with round nuclei, prominent nucleoli, and abundant clear cytoplasm associated with a reactive lymphoid cell population. On the right side is a cystic area partially lined by squamous epithelium and filled with keratin, compatible with a teratomatous component. (Courtesy of Drs. George Zanazzi and Peter Canoll.) **D:** Postoperative MRI after tumor removal.

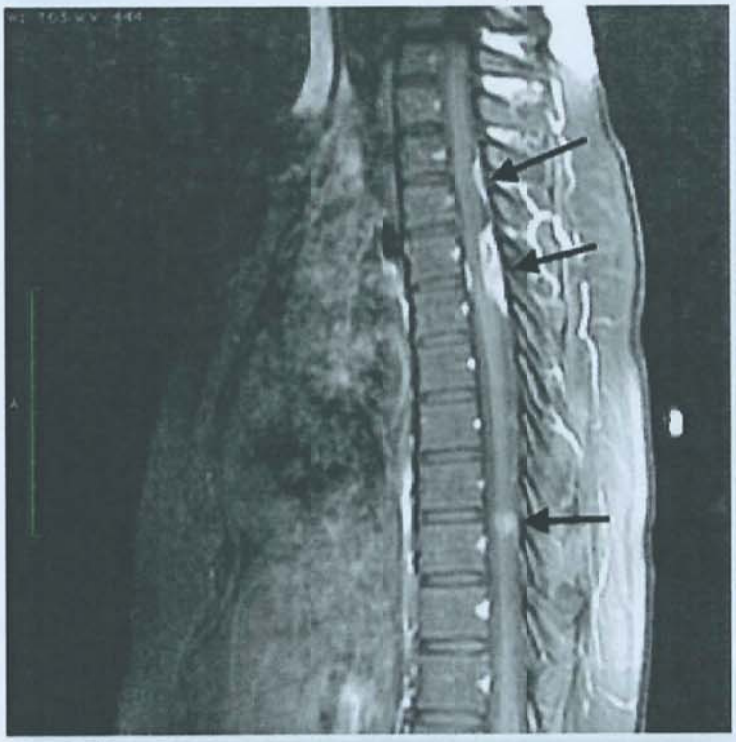

FIGURE 105.6 Intradural seeding from a pineoblastoma. Thoracic magnetic resonance imaging showing enhancing drop metastases *(arrows)* in thoracic spinal canal.

OUTCOME

Generally, benign pineal tumors and growing pineal cysts are curable with surgery alone. For malignant tumors, meta-analysis of small clinical series suggests that maximal surgical resection provides survival benefits; however, level 1 or 2 evidence is lacking. Prognosis is highly dependent on tumor histology. Germinomas have a 90% 10-year survival rate following surgery and radiotherapy, and therefore, aggressive surgical resection is not indicated. Patients with NGGCT have 5-year survival rates in the range of 50%, and the prognosis for patients with recurrent intracranial NGGCTs is generally poor. Greater than 80% of patients with pineocytomas survive 5 years particularly following aggressive surgical resection. Median survival for patients with pineoblastomas is much more variable ranging from 1 to 5 years, with prognosis influenced by extent of resection, age, and disseminated disease. The outcome for patients with glial tumors is similar to gliomas found in other regions of the brain.

SUGGESTED READINGS

Ahmed AI, Zaben MJ, Mathad NV, Sparrow OC. Endoscopic biopsy and third ventriculostomy for the management of pineal region tumors. *World Neurosurg*. 2015;83(4):543-547.

Anan M, Ishii K, Nakamura T, et al. Postoperative adjuvant treatment for pineal parenchymal tumour of intermediate differentiation. *J Clin Neurosci*. 2006;13(9):965-968.

Baehring J, Vives K, Duncan C, Piepmeier J, Bannykyh S. Tumors of the posterior third ventricle and pineal region: ependymoma and germinoma. *J Neurooncol*. 2004;70(2):273-274.

Balmaceda C, Finlay J. Current advances in the diagnosis and management of intracranial germ cell tumors. *Curr Neurol Neurosci Rep*. 2004;4(3):253-262.

Balossier A, Blond S, Touzet G, et al. Endoscopic versus stereotactic procedure for pineal tumor biopsies: comparative review of the literature and learning from a 25-year experience. *Neurochirurgie*. 2015;61(2-3):146-154.

Balossier A, Blond S, Touzet G, et al. Role of radiosurgery in the management of pineal region tumours: indications, method, outcome. *Neurochirurgie*. 2015;61(2-3):216-222.

Bruce JN. Pineal tumors. In: Winn H, ed. *Youmans Neurological Surgery*. Vol 2. 6th ed. Philadelphia, PA: Elsevier; 2011:1359-1372.

Bruce JN, Ogden AT. Surgical strategies for treating patients with pineal region tumors. *J Neurooncol*. 2004;69(1-3):221-236.

Calaminus G, Bamberg M, Jürgens H, et al. Impact of surgery, chemotherapy and irradiation on long term outcome of intracranial malignant non-germinomatous germ cell tumors: results of the German cooperative trial MAKEI 89. *Klin Padiatr*. 2004;216(3):141-149.

Chernov MF, Kamikawa S, Yamane F, et al. Neuroflberscopic biopsy of tumors of the pineal region and posterior third ventricle: indications, technique, complications, and results. *Neurosurgery*. 2006;59(2):267-277.

Choy W, Kim W, Spasic M, Voth B, Yew A, Yang I. Pineal cyst: a review of clinical and radiological features. *Neurosurg Clin N Am*. 2011;22(3):341-351, vii.

Clark AJ, Sughrue ME, Ivan ME, et al. Factors influencing overall survival rates for patients with pineocytoma. *J Neurooncol*. 2010;100(2):255-260.

Constantini S, Mohanty A, Zymberg S, et al. Safety and diagnostic accuracy of neuroendoscopic biopsies: an international multicenter study. *J Neurosurg Pediatr*. 2013;11(6):704-709.

D'Amico RS, Zanazzi G, Wu P, Canoll P, Bruce JN. Pineal region glioblastomas display features of diffuse midline and non-midline gliomas. *J Neurooncol*. 2018;140(1)63-73.

Deshmukh VR, Smith KA, Rekate HL, Coons S, Spetzler RF. Diagnosis and management of pineocytomas. *Neurosurgery*. 2004;55(2):349-357.

Echevarría ME, Fangusaro J, Goldman S. Pediatric central nervous system germ cell tumors: a review. *Oncologist*. 2008;13(6):690-699.

Fauchon F, Hasselblatt M, Jouvet A, et al. Role of surgery, radiotherapy and chemotherapy in papillary tumors of the pineal region: a multicenter study. *J Neurooncol*. 2013;112(2):223-231.

Fetell MR, Bruce JN, Burke AM, et al. Non-neoplastic pineal cysts. *Neurology*. 1991;41(7):1034-1040.

Fèvre-Montange M, Champier J, Szathmari A, et al. Microarray analysis reveals differential gene expression patterns in tumors of the pineal region. *J Neuropathol Exp Neurol*. 2006;65(7):675-684.

Fèvre-Montange M, Hasselblatt M, Figarella-Branger D, et al. Prognosis and histopathologic features in papillary tumors of the pineal region: a retrospective multicenter study of 31 cases. *J Neuropathol Exp Neurol*. 2006;65(10):1004-1011.

Hanft SJ, Isaacson SR, Bruce JN. Stereotactic radiosurgery for pineal region tumors. *Neurosurg Clin N Am*. 2011;22(3):413-420, ix.

Hasegawa T, Kondziolka D, Hadjipanayis CG, Flickinger JC, Lunsford LD. The role of radiosurgery for the treatment of pineal parenchymal tumors. *Neurosurgery*. 2002;51(4):880-889.

Hernesniemi J, Romani R, Albayrak BS, et al. Microsurgical management of pineal region lesions: personal experience with 119 patients. *Surg Neurol*. 2008;70(6):576-583.

Ito T, Kanno H, Sato K, et al. Clinicopathologic study of pineal parenchymal tumors of intermediate differentiation. *World Neurosurg*. 2014;81(5-6):783-789.

Jackson C, Jallo G, Lim M. Clinical outcomes after treatment of germ cell tumors. *Neurosurg Clin N Am*. 2011;22(3):385-394, viii.

Kellie SJ, Boyce H, Dunkel IJ, et al. Primary chemotherapy for intracranial nongerminomatous germ cell tumors: results of the second International CNS Germ Cell Study Group protocol. *J Clin Oncol*. 2004;22(5):846-853.

Kennedy BC, Bruce JN. Surgical approaches to the pineal region. *Neurosurg Clin N Am*. 2011;22(3):367-380, viii.

Knierim DS, Yamada S. Pineal tumors and associated lesions: the effect of ethnicity on tumor type and treatment. *Pediatr Neurosurg*. 2003;38(6):307-323.

Kochi M, Itoyama Y, Shiraishi S, Kitamura, Marubayashi T, Ushio Y. Successful treatment of intracranial nongerminomatous malignant germ cell tumors by administering neoadjuvant chemotherapy and radiotherapy before excision of residual tumors. *J Neurosurg*. 2003;99(1):106-114.

Korogi Y, Takahashi M, Ushio Y. MRI of pineal region tumors. *J Neurooncol*. 2001;54(3):251-261.

Kulwin C, Matsushima K, Malekpour M, Cohen-Gadol AA. Lateral supracerebellar infratentorial approach for microsurgical resection of large midline pineal region tumors: techniques to expand the operative corridor. *J Neurosurg*. 2016;124(1):269-276.

Kyritsis AP. Management of primary intracranial germ cell tumors. *J Neurooncol*. 2010;96(2):143-149.

Lassman AB, Bruce JN, Fetell MR. Metastases to the pineal gland. *Neurology*. 2006;67(7):1303-1304.

Louis DN, Ohgaki H, Wiestler OD, Cavenee WK. *WHO Classification of Tumours of the Central Nervous System*. Rev 4th ed. Geneva, Switzerland: World Health Organization; 2016.

Lutterbach J, Fauchon F, Schild SE, et al. Malignant pineal parenchymal tumors in adult patients: patterns of care and prognostic factors. *Neurosurgery*. 2002;51(1):44-56.

Mandera M, Marcol W, Bierzy ska-Macyszyn G, Kluczewska E. Pineal cysts in childhood. *Childs Nerv Syst*. 2003;19(10-11):750-755.

Matsuo S, Baydin S, Güngör A, et al. Midline and off-midline infratentorial supracerebellar approaches to the pineal gland. *J Neurosurg*. 2016:126(6): 1984-1009.

Matsutani M. Clinical management of primary central nervous system germ cell tumors. *Semin Oncol*. 2004;31(5):676-683.

Matsutani M, Sano K, Takakura K, et al. Primary intracranial germ cell tumors: a clinical analysis of 153 histologically verified cases. *J Neurosurg*. 1997; 86(3):446-455.

Michielsen G, Benoit Y, Baert E, Meire F, Caemaert J. Symptomatic pineal cysts: clinical manifestations and management. *Acta Neurochir (Wien)*. 2002; 144(3):233-242.

Morgenstern PF, Souweidane MM. Pineal region tumors: simultaneous endoscopic third ventriculostomy and tumor biopsy. *World Neurosurg*. 2013;79(2 suppl):S18.e9-S18.e13.

Ogawa K, Toita T, Nakamura K, et al. Treatment and prognosis of patients with intracranial nongerminomatous malignant germ cell tumors: a multiinstitutional retrospective analysis of 41 patients. *Cancer*. 2003;98(2):369-376.

Parwani AV, Baisden BL, Erozan YS, Burger PC, Ali SZ. Pineal gland lesions: a cytopathologic study of 20 specimens. *Cancer*. 2005;105(2):80-86.

Qi S, Fan J, Zhang X, Zhang H, Qiu B, Fang L. Radical resection of nongerminomatous pineal region tumors via the occipital transtentorial approach based on arachnoidal consideration: experience on a series of 143 patients. *Acta Neurochir (Wien)*. 2014;156(12):2253-2262.

Quick-Weller J, Lescher S, Baumgarten P, et al. Stereotactic biopsy of pineal lesions. *World Neurosurg*. 2016;96:124-128.

Regis J, Bouillot P, Rouby-Volot F, Figarella-Branger D, Dufour H, Peragut JC. Pineal region tumors and the role of stereotactic biopsy: review of the mortality, morbidity, and diagnostic rates in 370 cases. *Neurosurgery*. 1996;39(5):907-914.

Schild SE, Scheithauer BW, Haddock MG, et al. Histologically confirmed pineal tumors and other germ cell tumors of the brain. *Cancer*. 1996;78(12): 2564-2571.

Silvani A, Eoli M, Salmaggi A, et al. Combined chemotherapy and radiotherapy for intracranial germinomas in adult patients: a single-institution study. *J Neurooncol*. 2005;71(3):271-276.

Sonabend AM, Bowden S, Bruce JN. Microsurgical resection of pineal region tumors. *J Neurooncol*. 2016;130(2):351-366.

Spunt SL, Walsh MF, Krasin MJ, et al. Brain metastases of malignant germ cell tumors in children and adolescents. *Cancer*. 2004;101(3):620-626.

Villano JL, Propp JM, Porter KR, et al. Malignant pineal germ-cell tumors: an analysis of cases from three tumor registries. *Neuro Oncol*. 2008;10(2): 121-130.

Yamini B, Refai D, Rubin CM, Frim DM. Initial endoscopic management of pineal region tumors and associated hydrocephalus: clinical series and literature review. *J Neurosurg*. 2004;100(5 suppl Pediatrics): 437-441.

Yianni J, Rowe J, Khandanpour N, et al. Stereotactic radiosurgery for pineal tumours. *Br J Neurosurg*. 2012;26(3):361-366.

Zacharia BE, Bruce JN. Stereotactic biopsy considerations for pineal tumors. *Neurosurg Clin N Am*. 2011;22(3):359-366, viii.

106 Acoustic Neuroma and Other Skull Base Tumors

Randy S. D'Amico and Michael B. Sisti

KEY POINTS

1. Acoustic neuromas are benign, slow-growing tumors that are treated with a combination of observation, surgical resection, and radiosurgery with excellent outcomes in the hands of experienced practitioners.
2. Skull base pathology is variable and challenging to treat given its proximity to critical neural and vascular structures.
3. Modern treatment of skull base pathology focuses on the preservation of neurologic function.
4. Advanced radiotherapies such as stereotactic radiosurgery has improved the control of many skull base pathologies.

VESTIBULAR SCHWANNOMA (ACOUSTIC NEUROMA)

Epidemiology

Vestibular schwannomas (eg, acoustic neuroma, acoustic neurofibroma) are slow-growing, benign extra-axial tumors that originate commonly from the superior vestibular portion of the eighth cranial nerve (CN VIII). Vestibular schwannomas comprise 8% to 10% of intracranial tumors. Tumors may arise either sporadically (95%) or in association with neurofibromatosis type 2 (NF2). The incidence of sporadic cases is believed to be 1 per 100,000 person-years, with a median age of 50 years. As a result of the prevalence of magnetic resonance imaging (MRI), the incidence of vestibular schwannomas has increased recently, whereas the typical size at diagnosis has decreased.

Pathobiology

Vestibular schwannomas are histopathologically benign tumors that grow slowly from the Schwann cell sheath surrounding the vestibular branch of CN VIII. Tumors are composed of Antoni A (narrow elongated bipolar cells) and Antoni B fibers (loose reticulated pattern of cells). Verocay bodies are frequently seen and consist of acellular eosinophilic areas surrounded by parallel arrangements of spindle-shaped Schwann cells.

Vestibular schwannomas are typically unilateral lesions. Bilateral vestibular schwannomas occur in less than 5% of patients and are a defining characteristic of NF2, an autosomal dominant disorder involving the *NF2* gene located on chromosome 22 band q11-13.1. This gene normally encodes the protein merlin (schwannomin), which is thought to play a role in membrane stability through interactions with cytoskeletal and integral membrane proteins. Loss of function of merlin in Schwann cells has been associated with both sporadic and NF2-related vestibular schwannomas, and the gene is often considered a classic tumor suppressor. Cytologically, vestibular schwannomas that arise in NF2 are identical to sporadic cases but with a greater tendency to infiltrate the nerve rather than displace it. In addition to patients with bilateral lesions, any patient younger than 40 years of age with a unilateral vestibular schwannoma should also undergo evaluation for NF2.

Tumors often originate within the internal acoustic meatus (intracanalicular) and may extend into the cerebellopontine angle (extracanalicular; Fig. 106.1). Mass effect from extracanalicular tumor may compromise function of cranial nerves, brainstem nuclei, and the cerebellum. Tumors typically follow three growth patterns: (1) no or very slow growth, (2) slow growth (2 mm/y linear growth on imaging studies), or (3) fast growth (>8 mm/y) as a result of the enlargement of cystic components or rarely intratumoral hemorrhage.

Diagnosis

Vestibular schwannomas most commonly present with progressive unilateral hearing loss, characterized by difficulty with speech discrimination, especially when talking on the telephone. The next most common symptoms include tinnitus, followed by balance difficulties. This triad of symptoms is related to pressure on the eighth nerve complex in the internal auditory canal. Other presenting symptoms include facial paralysis, trigeminal neuralgia, and rarely hydrocephalus and brainstem compression in the setting of larger tumors. Although this constellation of symptoms may occur with any mass in the cerebellopontine angle, including meningiomas, cholesteatomas, or trigeminal neuromas, these lesions will rarely cause tinnitus or hearing dysfunction.

Patients with hearing loss often undergo audiometric evaluation with pure tone audiogram and speech discrimination evaluation. Those with vestibular disturbances may undergo vestibular testing. Hearing loss is typically insidious and progressive, with 70% of patients demonstrating a high-frequency loss pattern and impaired word discrimination (especially noticeable in telephone conversation). Tinnitus is usually high-pitched. Weber test lateralizes to the uninvolved side, and Rinne test will be positive on both sides if there is enough preserved hearing.

Asymmetric sensorineural hearing loss, or deficits in other cranial nerves, indicates the need for imaging. Gadolinium-enhanced MRI is the gold standard for diagnosing vestibular schwannomas. Tumors enhance brightly, and an origin within the internal auditory canal suggests vestibular schwannoma rather than meningioma. Contrast-enhanced computed tomography (CT) can also be used to diagnose vestibular

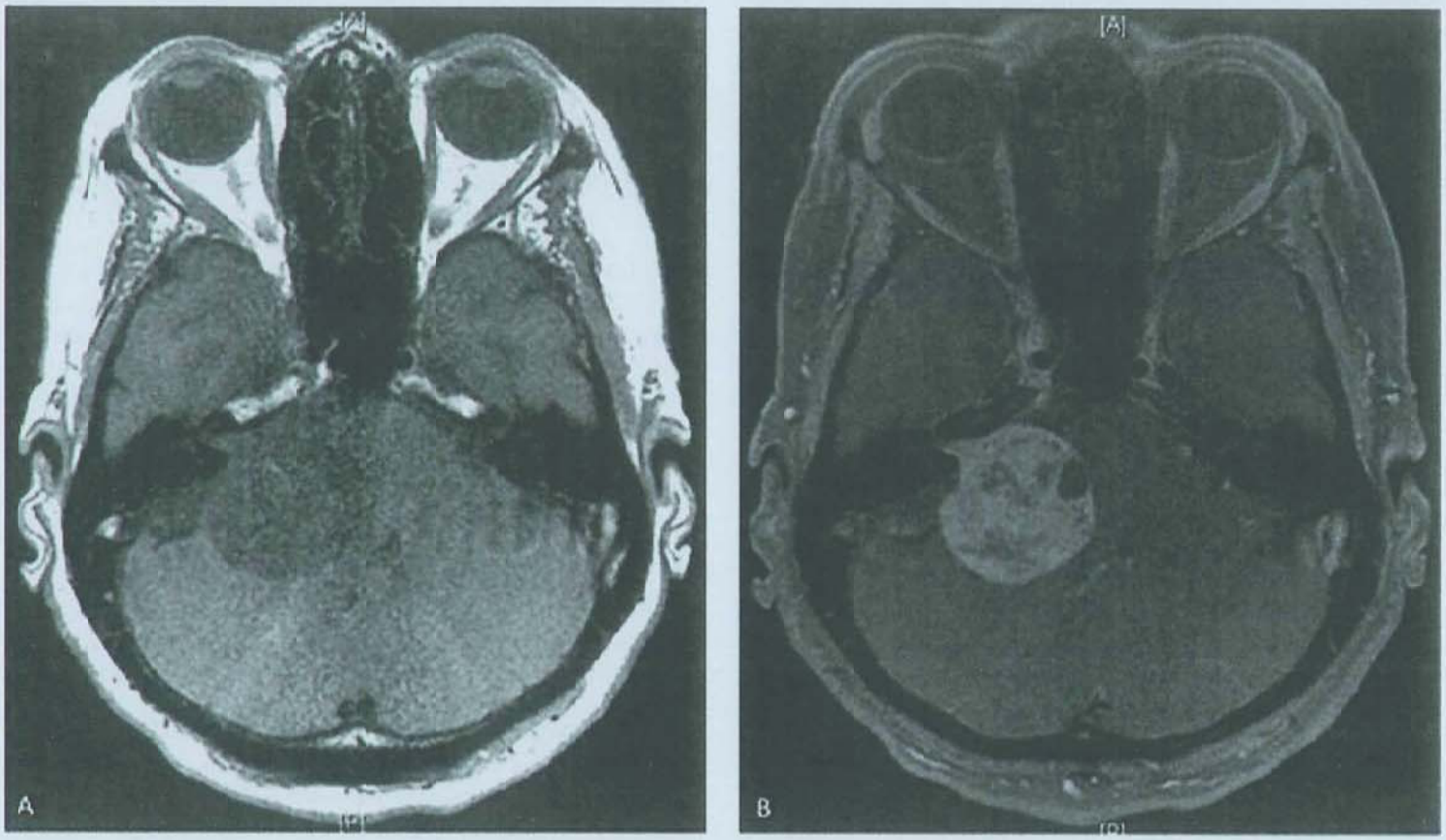

FIGURE 106.1 Vestibular schwannoma. **A:** T1-weighted axial magnetic resonance imaging before contrast shows large hypointense mass within the cerebellopontine angle exerting mass effect on the brainstem. **B:** T1-weighted axial magnetic resonance imaging postcontrast shows a vestibular schwannoma with expansion of the internal auditory meatus causing mass effect on the pons and cerebellum.

schwannomas greater than 15 mm in diameter for patients who cannot undergo MRI.

Management and Outcomes

The goal of treatment for vestibular schwannomas is to cure the tumor while preserving intact neurologic function. Following diagnosis, patients with vestibular schwannomas have several options for managing their tumor including observation with serial imaging, stereotactic radiosurgery, fractionated radiotherapy, and microsurgery. Selection of treatment modality depends on tumor size, symptoms, patient age, patient health, and patient preference. Figure 106.2 represents a decision tree following diagnosis of vestibular schwannoma. In general, noncystic, non-NF2 intracanalicular tumors or cerebellopontine tumors 20 mm or smaller may be followed with serial imaging and hearing tests. Tumors larger than 15 to 20 mm should be treated. The NF2 patients present a challenge and should be evaluated on a case-by-case basis.

Observation/Expectant Management

Observation with serial clinical assessment and follow-up MRI to monitor for signs of tumor growth is an option in the

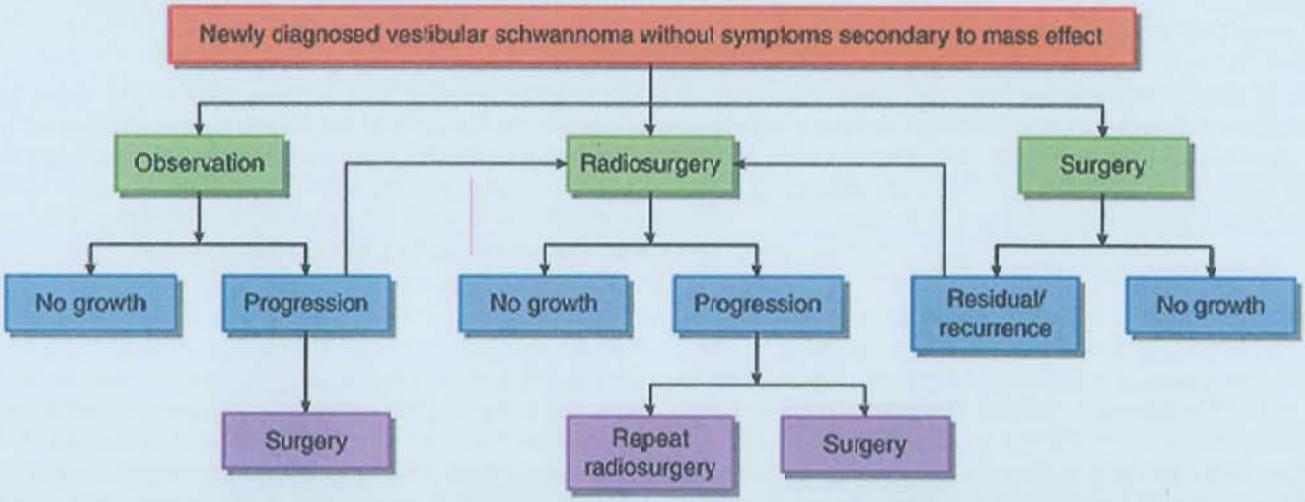

FIGURE 106.2 Treatment algorithm for vestibular schwannoma management.

management of vestibular schwannoma. Patients utilizing this approach are monitored using MRI until progression of symptoms or tumor growth warrants more invasive treatment. Imaging is recommended annually until year 5 after diagnosis with interval lengthening thereafter with tumor stability. However, observation is not without risk because tumor growth rates and progression of symptoms are not predictable. By 10 years, most clinical experience demonstrates that the majority of patients will have tumor growth and progression of symptoms. Therefore, the "wait and scan" approach should mainly be used in older patients and those whose medical comorbidities preclude other treatment options.

Stereotactic Radiosurgery

Radiosurgery is a therapeutic option that improves tumor control and hearing preservation compared with observation in patients presenting with small tumors (<30 mm diameter), serviceable hearing, or in those who wish to avoid surgery due to preference or anxiety. A dose of 12 to 13 Gy is prescribed typically and associated with improved hearing preservation. Long-term tumor control rates ranging from 91% to 98% have been reported in large series after radiosurgery, with 1.6% to 4.2% ultimately requiring resection for progressive enlargement. Individuals with sporadic vestibular schwannomas who have documented serviceable hearing in the ipsilateral ear receiving single-fraction stereotactic radiation up to 13 Gy to the tumor margin have greater than 50% to 75% chance of hearing preservation up to 5 years and a greater than 25% to 50% chance of hearing preservation at 10 years—with higher rates achievable with intracanalicular tumors. Minimizing the radiation exposure to nearby structures (ie, the cochlea, semicircular canals, and brainstem in larger tumors) minimizes morbidity rates associated with radiosurgery without sacrificing efficacy. Preservation of facial and trigeminal nerve function is also possible in the majority of patients.

For smaller tumors, hearing preservation and tumor control rates are equivalent following radiosurgery or surgical resection. However, radiosurgery is more effective than surgical resection in preserving postoperative facial function and is associated with lower rates of trigeminal neuropathy and other treatment-associated morbidity. In addition, hospital lengths of stay and management costs are less after radiosurgery and in general, postoperative functional outcomes and patient satisfaction have been found to be greater after radiosurgery when compared with microsurgery.

Advances in technology for noninvasive stereotactic radiosurgery allow using a thermoplastic mask to immobilize select patients for multisession or fractionated radiation. The opportunity to use fractionation for vestibular schwannoma patients permits lower doses to healthy brain and inner ear structures. Studies are ongoing to evaluate the long-term efficacy of this method on hearing preservation and tumor control.

Surgical Resection

Microsurgical resection remains the best cytoreductive therapy for vestibular schwannomas and is generally indicated in the setting of tumor progression after previous interventions and for those with large tumors (>30 mm diameter). In particular, microsurgery remains the preferred treatment for large lesions causing mass effect and obstructive hydrocephalus. Additional treatment is necessary in less than 2% of cases after microsurgical treatment. Facial nerve function may be preserved in more than 95% of patients with small tumors less than 20 mm, with rates of preservation dropping in the setting of tumors larger than 30 mm.

Maintenance of serviceable hearing following microsurgical resection is less probable, and patients should be counseled appropriately. Serviceable hearing, otherwise known as *useful hearing*, is assessed using the combined results of pure tone audiogram that evaluates the functionality of hearing and speech discrimination tests. Current guidelines suggest that in adults with small- to medium-sized (<20 mm) sporadic vestibular schwannomas, there is a greater than 25% to 50% chance of hearing preservation following surgical resection with improved rates in smaller tumors. Planned near-total or extensive subtotal resections, followed by radiosurgery for residual tumor, may be appropriate for large tumors, with excellent rates of facial nerve preservation and functional outcomes and no decrease in tumor control.

Chemotherapy

Patients with progressive acoustic neuromas in the setting of NF2 may derive benefit from treatment with bevacizumab, an anti–vascular endothelial growth factor monoclonal antibody. Treatment with bevacizumab may reduce the size of the tumor or prolong tumor stability in patients with NF2 without surgical options. Treatment may also improve hearing or prolong time to hearing loss in these patients with minimal associated morbidity. Additional chemotherapeutic options such as lapatinib or everolimus may also be considered.

MALIGNANT TUMORS OF THE SKULL AND SKULL BASE

Metastasis to the Skull Base

Epidemiology

The skull is a common site of metastases from systemic cancers, with skull metastases occurring in 4% of cancer patients. The most common metastatic tumors to the skull base include breast, lung, and prostate cancers. Not surprisingly, prostate carcinoma is the most frequent cause of skull metastases in men, whereas breast carcinoma is the most common in women. Colon, renal, and thyroid cancers, as well as lymphoma, melanoma, and neuroblastoma, may also metastasize to the skull base.

Diagnosis

The clinical manifestation of metastases to the skull base depends on the location of the lesion. Cranial nerves are vulnerable to compression by osseous metastases as they exit through the bony foramina of the skull. In addition, although metastases to the skull base are often painless, craniofacial pain in a patient with known cancer may be an initial symptom.

Contrast-enhanced MRI is the gold standard for detection of metastases to the skull base. A CT scan is less effective than MRI for detecting contrast-enhancing soft-tissue masses but is the best method to demonstrate lytic bone lesions. Radionuclide bone scans have great sensitivity in detecting bone metastases. Although biopsy may be difficult and hazardous, it may be necessary to establish a diagnosis. Examination of cerebrospinal fluid (CSF) may be important to evaluate meningeal carcinomatosis in select patients.

Management and Outcomes

The prognosis of skull base metastases depends on the extent of the primary disease, the location and associated extension of the tumor, and the surgical accessibility of the metastasis itself. In addition to symptomatic treatments with steroids and analgesia, specific treatments include radiotherapy, chemotherapy, and surgery. Treatment depends on the nature of the underlying tumor. Palliative radiotherapy is generally the standard treatment with a total dose of at least 30 Gy given in 3 Gy fractions with excellent symptomatic relief. Some patients benefit from chemotherapy or hormonal therapy for appropriately sensitive tumors. Stereotactic radiosurgery is useful for small tumors or tumors previously irradiated. Select patients may benefit from surgical resection. In general, the overall prognosis is poor with median survival less than 3 years for most tumors. Note that metastases to the skull are not synonymous with metastases to the brain and are not protected by the blood-brain barrier, an important consideration when choosing chemotherapeutics.

Extension of Malignant Tumors to the Skull Base

Several malignant tumors involve the skull base by direct extension (**Fig. 106.3**). These include squamous cell carcinoma (nasal sinuses and temporal bone), adenoid cystic carcinoma (salivary glands), esthesioneuroblastoma (olfactory mucosa), and nasopharyngeal carcinoma. Involvement of the skull base by these tumors may result in pain and cranial neuropathies. Erosion of the skull base and the presence of a contrast-enhancing soft-tissue mass are generally identified on CT or MRI. Biopsy of accessible lesions is diagnostic, and small tumors may be cured by wide excision prior to invasion of sensitive neural structures. Management relies on a multidisciplinary approach. However, most tumors are extensive at the time of diagnosis, and prognosis is poor despite radical excision and radiation therapy.

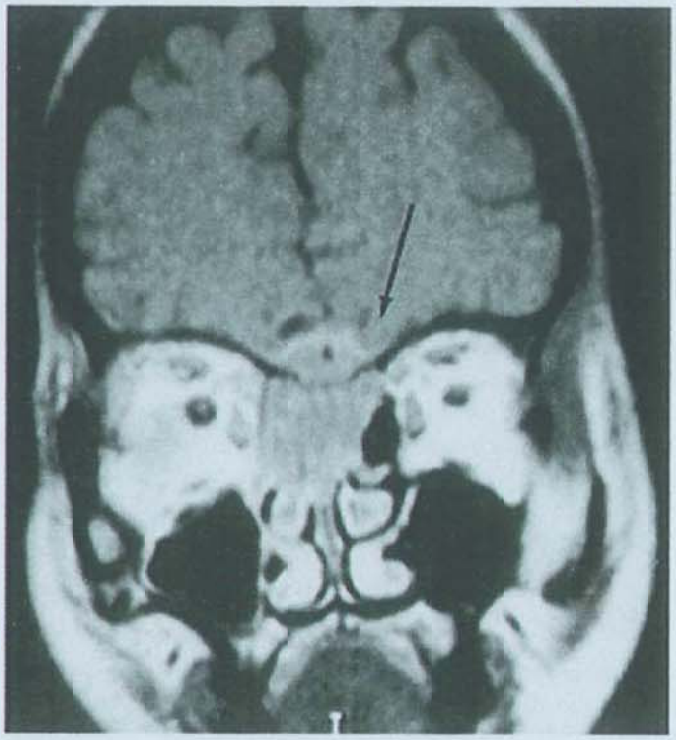

FIGURE 106.3 Esthesioneuroblastoma. Coronal magnetic resonance imaging demonstrates an esthesioneuroblastoma in the ethmoid sinus with intradural extension *(arrow)*. This tumor arises from olfactory mucosa.

Primary Malignant Tumors of the Skull and Skull Base

Chondrosarcoma

Chondrosarcoma is a malignant cartilage tumor originating in areas of endochondral ossification within the cranial base that most commonly affects men in the fourth decade. Tumors arise in the paranasal sinuses, the parasellar areas, or the cerebellopontine angle, with variable symptoms depending on location. The CT and MRI are the preferred imaging modalities. Maximal safe debulking is considered first-line therapy. Histologically, chondrosarcomas are classified into conventional, dedifferentiated clear cell, and mesenchymal subtypes and these histology-based grading systems have been shown to predict prognosis. There remains variability in the literature regarding indications for observation versus adjuvant radiotherapy following surgical management.

Chordoma

Chordoma is a rare, histologically benign, locally aggressive bone tumor associated with destruction of surrounding tissues. Derived from remnants of notochord within the axial skeleton, tumors distribute equally between the skull base, mobile spine, and sacrum with predominance in men between 50 and 60 years of age. Chordomas of the skull base often arise in the clivus and present with cranial nerve palsies. Histologically, tumors are distinguished by the presence of physaliferous cells. Treatment involves aggressive maximal safe resection followed by advanced radiotherapy such as stereotactic radiosurgery or proton beam radiation. High rates of progression and recurrence make their prognosis similar to malignant tumors.

Osteogenic Sarcoma

Osteogenic sarcoma (osteosarcoma) is the most common primary bone malignancy. Osteosarcoma primarily affects long bones with rare involvement of the skull or skull base. Lesions are the result of osteoid or immature bone production by malignant spindle cells and are associated with destruction of normal bone (**Fig. 106.4**). Patients may report a history of prior radiation, chemotherapy, Paget disease, fibrous dysplasia, or chronic osteomyelitis. Symptoms vary with location along the skull base. Treatment is maximal safe surgical resection with an emphasis on preserving neurologic function and avoiding cosmetic defects. Tumors are relatively radioresistant and chemotherapy with cisplatin, doxorubicin, and high-dose methotrexate may offer benefits.

Soft-Tissue Sarcoma

Soft-tissue sarcomas of the skull base are rare. Malignant fibrous histiocytoma, fibrosarcoma, angiosarcoma, and malignant peripheral nerve sheath tumors are the most frequently encountered lesions. The CT and MRI are essential for assessing tumor size and location. Treatment is aggressive safe resection. However, because anatomic constraints of the skull base often limit wide excision, patients will often receive adjuvant radiotherapy and chemotherapy.

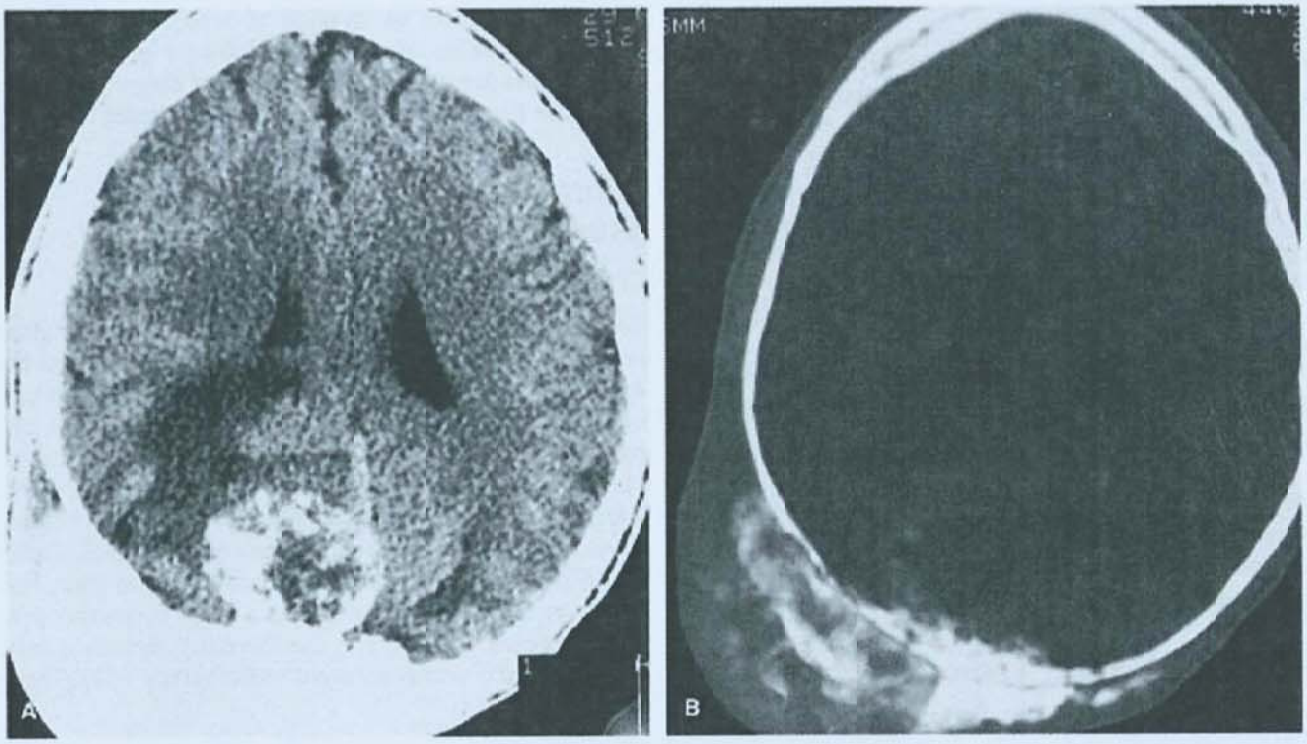

FIGURE 106.4 Osteogenic sarcoma (osteosarcoma). **A:** Noncontrast axial computed tomography shows a calcified mass within the medial right parietooccipital lobes with massive extracranial soft-tissue swelling. **B:** Corresponding bone window shows thinning and eroded calvarium with several large areas of calcification and ossification noted within the extracranial soft tissues in the right parietooccipital region. These findings are classic for osteosarcoma.

Glomus Jugulare Tumors

Jugular paragangliomas ("glomus jugulare") are the most common tumor arising within the jugular foramen. These rare, slow-growing, locally invasive, and highly vascular tumors arise from chromaffin cells in the region of the jugular bulb and course along the glossopharyngeal nerve, the tympanic branch of the glossopharyngeal nerve (Jacobson nerve), or the auricular branch of the vagus nerve (Arnold nerve). Tumors present as a result of both compression and infiltration of the adjacent temporal and occipital bone with subsequent involvement of nearby cranial nerves. Tumors may extend into the middle ear and cause conductive hearing loss, pulsatile tinnitus, and audible bruits, or may be discovered as a small vascular mass within the middle ear cavity. An MRI with contrast best visualizes tumors, and magnetic resonance angiography reveals their extensive vascularity. A CT with contrast is considered in patients who cannot undergo MRI. Digital subtraction angiography is performed for diagnosis, and embolization is essential to decrease tumor vascularity and facilitate resection. Some paragangliomas secrete catecholamines, which may be ascertained by a 24-hour urine assay and must be blocked prior to surgery. Malignant transformation of these lesions is rare.

Surgery offers the best chance of cure for glomus jugulare tumors. Gross total resection results in cessation of cardiovascular symptoms and normalization of catecholamine levels in patients symptomatic from secreting tumors. However, total removal is difficult and accompanied by significant morbidity due to the vascularity and invasiveness of the lesions. Observation is appropriate until patients become symptomatic or tumors demonstrate growth on imaging. Stereotactic radiosurgery may offer improved rates of tumor control with lower risks of morbidity compared with surgery for patients with nonsecreting tumors.

BENIGN TUMORS OF THE SKULL

Osteoma

Osteomas are rare, benign, slow-growing tumors of the skull. Histologically, tumors are composed of well-differentiated mature, compact, or cancellous bone arising from either the inner or outer table of the skull. Lesions frequently occur in the paranasal sinuses but may arise within the frontoethmoidal region, the petrous bone (mastoid sinuses), the cranial vault, and the mandible. Tumors are generally asymptomatic but may be associated with headache and recurrent sinusitis. Proptosis and orbital deformities occur secondary to orbital invasion by the tumors. Rarely, tumors present with pneumocephalus, rhinorrhea, meningitis, dural erosion, and abscess formation. Calvarial lesions are hard, painless masses with minimal intracranial extension. Diagnosis is based on the characteristic appearance of a circumscribed homogenous hyperdensity involving the skull that is best seen with CT scan (**Fig. 106.5**). Symptomatic lesions are treated with surgical resection, and reconstruction may be necessary for extensive lesions.

Chondroma

Chondromas are rare, slow-growing benign tumors arising from cartilage rests at the basilar synchondroses of the skull base. Lesions have a predilection for the sphenoethmoidal, sphenopetrosal, sphenooccipital, or petrooccipital regions. However, rare dural, intraparenchymal, and intraventricular lesions have been described. Clinical presentation varies by anatomic location and slow-growing tumors may remain asymptomatic for prolonged periods of time. Radiographically, tumors appear as lytic lesions,

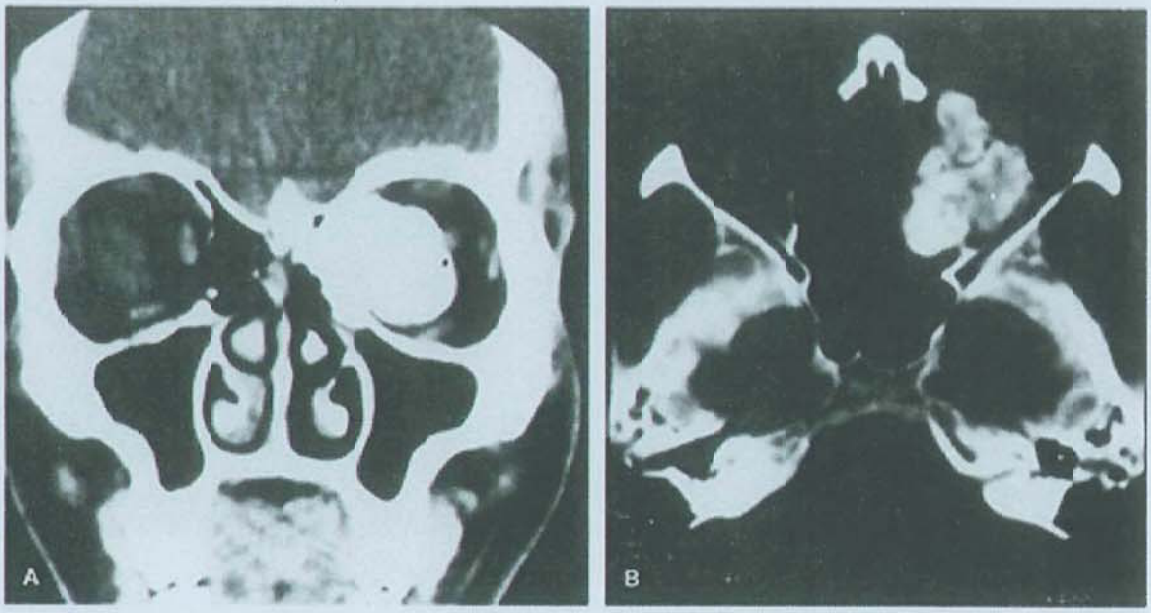

FIGURE 106.5 Orbital osteoma. Coronal (A) and axial (B) computed tomography with bone windows show an osteoma involving the orbit.

with sharp margins and erosion of surrounding bone. Stippled calcification within the lesion may be apparent and helps distinguish chondroma from metastasis or chordoma. Chondromas typically display high intensity on T2-MRI and low to intermediate intensity on T1-MRI, with a heterogeneous ring-and-arc enhancement pattern after administration of gadolinium. Treatment involves radical resection for symptomatic lesions with extension to normal bone margins to prevent recurrence. Progression to malignant chondrosarcoma is rare.

Hemangioma

Hemangiomas are benign, vascular bone tumors representing 0.2% of bony neoplasms of the skull. Lesions may involve the calvaria or the skull base (or vertebral bodies of the spine), with a predilection for the cavernous sinus. Commonly discovered incidentally after CT or MRI performed for other reasons, hemangiomas may present as a slowly enlarging lump associated with headaches that worsen with lesion expansion. However, neurologic findings are uncommon because hemangiomas rarely extend intracranially. Radiographically, tumors appear as well-circumscribed, expansive hypodense regions with a honeycomb or polka-dotted pattern on CT. An MRI demonstrates heterogeneous signal on both T1- and T2-weighted sequences and may demonstrate flow voids suggestive of a vascular lesion. However, the radiographic appearance of skull base hemangiomas is variable, and pathologic examination is often required for diagnosis. Resection is indicated for neurologic compromise, unremitting headache, mass effect, cosmetic deformity, or tissue diagnosis. Treatment is by safe maximal resection, and the use of preoperative embolization may be beneficial. The use of radiation for incompletely resected, or multiple tumors, remains controversial.

Dermoid and Epidermoid Tumors

Dermoid and epidermoid cysts are benign, extra-axial developmental lesions arising from trapped ectodermal tissue during closure of the neural tube. Cysts are lined with stratified squamous epithelium and contain keratin, cellular debris, cholesterol (epidermoids), and elements of the dermis, including hair and sebaceous glands (dermoids). Epidermoids most commonly arise in the cerebellopontine angle and the parasellar region but also occur in the middle cranial fossa and spinal canal (Fig. 106.6). Dermoids are predominantly midline lesions, arising commonly in the diploe of the fontanel extradurally and in the parasellar region intradurally.

Cysts may remain asymptomatic for years due to slow growth, with rare acute presentations due to hemorrhage or trauma. Cyst rupture is a rare complication that can cause severe chemical or aseptic meningitis. Epidermoids and dermoids typically have the appearance of hypodense areas on CT. On MRI, epidermoids present as polycystic irregular lesions with extensive growth in the CSF spaces. Epidermoids have slightly higher signal intensity than CSF on T1- and T2-weighted images and heterogeneous features on fluid-attenuated inversion recovery sequences. Diffusion-weighted imaging facilitates identification of epidermoids. Dermoids are usually hyperintense on both T1- and T2-weighted images. Radical surgical excision is the preferred treatment when possible for dermoids and epidermoids and can be curative. However, tumors are often densely adherent to cranial nerves and vascular structures. Given their slow-growing and benign nature, the primary surgical objective is then to decompress the mass by evacuating the cyst contents and removing nonadherent portions of the capsule while not manipulating cranial nerves or vascular structures to the extent that there may be permanent damage. Malignant degeneration is rare.

NEOPLASTIC-LIKE LESIONS OF THE SKULL

Hyperostosis

Hyperostosis of nonneoplastic etiology may involve either the inner or the outer table of the skull. Outer table hyperostosis is clinically insignificant aside from cosmetic concerns.

FIGURE 106.6 Epidermoid. Epidermoids are often indistinguishable from arachnoid cysts or dilated cerebrospinal fluid (CSF) spaces on magnetic resonance imaging sequences. These nonenhancing lesions are usually isointense to CSF on both postcontrast, T1-weighted images **(A)**, and T2-weighted images **(B)** with associated mass effect in larger lesions as demonstrated by this epidermoid of the cerebellopontine angle. **C:** Diffusion-weighted imaging sequences help to differentiate these lesions from CSF.

Hyperostosis of the inner table may rarely become large enough to compress intracranial contents. Hyperostosis frontalis interna is a condition occurring in postmenopausal women, characterized by increased bone deposition along the inner table of the frontal bone. Hyperostosis frontalis interna is usually an incidental finding on CT or MRI, although excessive growth can cause compression of brain tissue.

Fibrous Dysplasia

Fibrous dysplasia is a benign condition in which normal bone is replaced by poorly organized woven bone. Progressive growth of lesions may result in swelling, cosmetic deformities, and pain. Fibrous dysplasia is most commonly monostotic with involvement of a single bone. However, 25% of cases are polyostotic involving more than 50% of the skeleton and can be associated with fractures and skeletal deformities. Fibrous dysplasia may also occur as part of McCune-Albright syndrome. Lesions mostly occur in the ribs or craniofacial bones, particularly the maxilla. Localized involvement of the skull base and sphenoid wing, particularly by the sclerotic variety, may cause symptoms secondary to cranial nerve entrapment. X-rays and CT classically demonstrate a ground-glass appearance due to thin spicules of woven bone (Fig. 106.7). Chemotherapy and radiation are not effective treatments, and radiation may predispose to higher rates of malignant transformation. Neurosurgical involvement may be required for skull lesions producing refractory pain or neurologic symptoms.

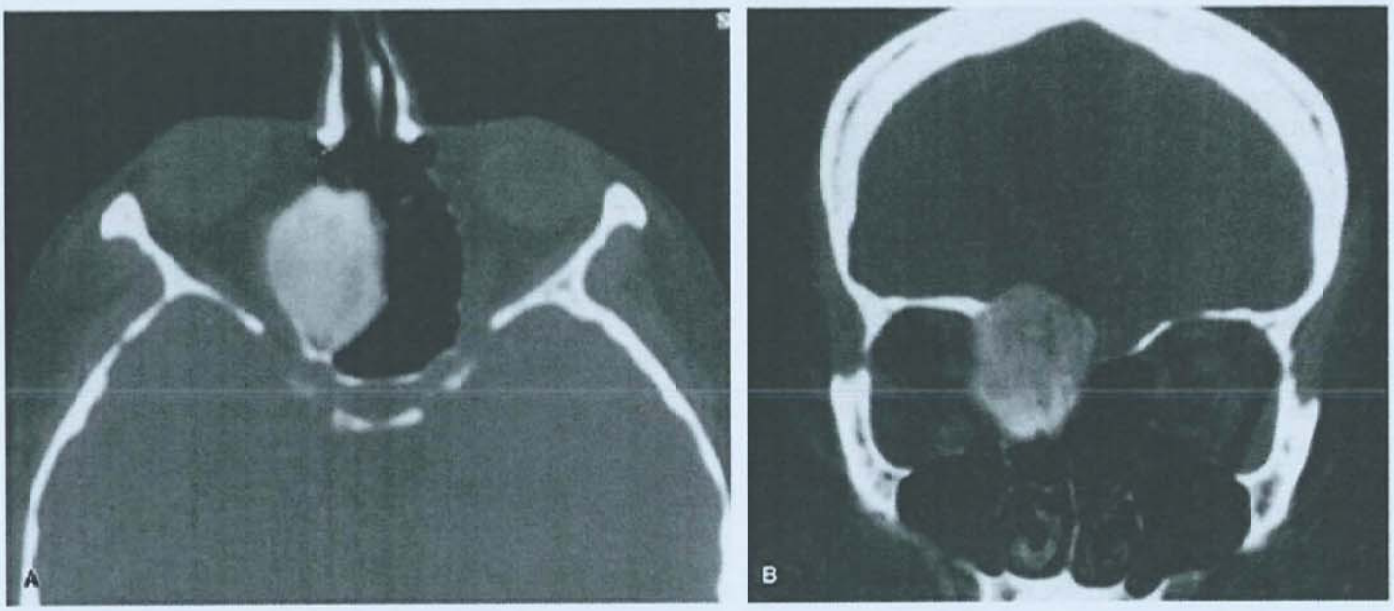

FIGURE 106.7 Fibrous dysplasia. Axial **(A)** and coronal **(B)** computed tomography with bone windows demonstrate classic ground-glass appearance of fibrous dysplasia of the orbit and ethmoid sinus.

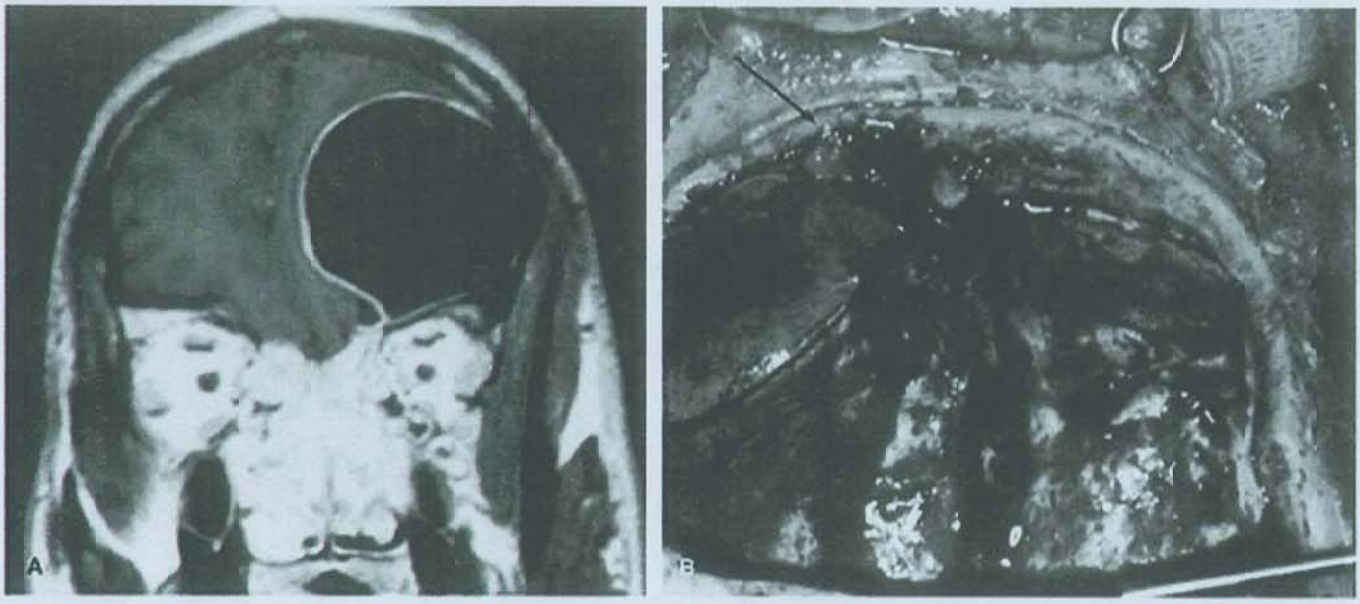

FIGURE 106.8 Mucocele. **A:** Coronal contrast-enhanced magnetic resonance imaging shows a large mucocele compressing the frontal lobe, with chronic inflammation of the nasal mucosa obstructing the nasal sinuses. **B:** Intraoperative photograph shows the mucocele before its resection and subsequent skull base reconstruction. The frontal sinus contains inflammatory tissue *(arrow)* that had caused obstruction of the sinus.

Paget Disease (Osteitis Deformans)

Paget disease is a disorder of osteoclasts causing rapid remodeling of bone. Increased bone resorption is followed by reactive osteoblastic overproduction of sclerotic, brittle woven bone that produces a characteristic mosaic pattern on x-ray. Family history is present in 15% to 30% of discovered cases and about 1% degenerate into sarcoma with the possibility of systemic metastases. Lesions commonly involve the axial skeleton, long bones, and the skull. Mostly asymptomatic or incidentally discovered, facial and skull base remodeling may result in localized pain, cranial nerve compression with deafness being the most prominent finding in most cases, or basilar invagination. Markedly elevated serum alkaline phosphatase is a constant feature. Surgical intervention should be reserved for diagnosis or relief of symptoms.

Mucocele

Occlusion of a nasal air sinus may result in an encapsulated collection of mucus or pus, known as a *mucocele*. Progressive expansion of mucoceles may result in erosion through the skull base with subsequent compression of intracranial contents. Lesions frequently enhance with intravenous contrast on MRI and CT (Fig. 106.8). Surgery with reconstruction is the treatment of choice.

Miscellaneous

A variety of systemic disease may additionally involve the skull. These include histiocytosis X (eosinophilic granuloma is the mildest form), multiple myeloma, plasmacytoma, brown tumor of hyperparathyroidism, Wegener granulomatosis, and lethal midline granuloma. Infectious lesions such as tuberculosis, syphilis, leprosy, and fungal infections (especially aspergillosis and mucormycosis) may also occur within the skull base. In addition, lesions within the nose may communicate with the intracranial cavity such as nasopharyngeal carcinoma, esthesioneuroblastoma, encephalocele, and nasal gliomas.

SUGGESTED READINGS

Arthurs BJ, Fairbanks RK, Demakas JJ, et al. A review of treatment modalities for vestibular schwannoma. *Neurosurg Rev*. 2011;34(3):265-277.

Bakkouri WE, Kania RE, Guichard JP, Lot G, Herman P, Huy PT. Conservative management of 386 cases of unilateral vestibular schwannoma: tumor growth and consequences for treatment. *J Neurosurg*. 2009;110(4):662-669.

Bowers CA, Taussky P, Couldwell WT. Surgical treatment of craniofacial fibrous dysplasia in adults. *Neurosurg Rev*. 2014;37(1):47-53.

Carlson ML, Vivas EX, McCracken DJ, et al. Congress of Neurological Surgeons systematic review and evidence-based guidelines on hearing preservation outcomes in patients with sporadic vestibular schwannomas. *Neurosurgery*. 2018;82(2):E35-E39.

Chennupati SK, Norris R, Dunham B, Kazahaya K. Osteosarcoma of the skull base: case report and review of literature. *Int J Pediatr Otorhinolaryngol*. 2008;72(1):115-119.

Combs SE, Welzel T, Schulz-Ertner D, Huber PE, Debus J. Differences in clinical results after LINAC-based single-dose radiosurgery versus fractionated stereotactic radiotherapy for patients with vestibular schwannomas. *Int J Radiat Oncol Biol Phys*. 2010;76(1):193-200.

de Bree R, van der Waal I, de Bree E, Leemans CR. Management of adult soft tissue sarcomas of the head and neck. *Oral Oncol*. 2010;46(11):786-790.

Dunn IF, Bi WL, Mukundan S, et al. Congress of Neurological Surgeons systematic review and evidence-based guidelines on the role of imaging in the diagnosis and management of patients with vestibular schwannomas. *Neurosurgery*. 2018;82(2):E32-E34.

Eversole R, Su L, ElMofty S. Benign fibro-osseous lesions of the craniofacial complex. A review. *Head Neck Pathol*. 2008;2(3):177-202.

Fayad JN, Keles B, Brackmann DE. Jugular foramen tumors: clinical characteristics and treatment outcomes. *Otol Neurotol*. 2010;31(2):299-305.

Flickinger JC, Kondziolka D, Niranjan A, Maitz A, Voynov G, Lunsford LD. Acoustic neuroma radiosurgery with marginal tumor doses of 12 to 13 Gy. *Int J Radiat Oncol Biol Phys*. 2004;60(1):225-230.

Fong B, Barkhoudarian G, Pezeshkian P, Parsa AT, Gopen Q, Yang I. The molecular biology and novel treatments of vestibular schwannomas. *J Neurosurg*. 2011;115(5):906-914.

Fountas KN, Stamatiou S, Barbanis S, Kourtopoulos H. Intracranial falx chondroma: literature review and a case report. *Clin Neurol Neurosurg*. 2008;110(1):8-13.

Germano IM, Sheehan J, Parish J, et al. Congress of Neurological Surgeons systematic review and evidence-based guidelines on the role of radiosurgery and radiation therapy in the management of patients with vestibular schwannomas. *Neurosurgery*. 2018;82(2):E49-E51.

Gologorsky Y, Shrivastava RK, Panov F, et al. Primary intraosseous cavernous hemangioma of the clivus: case report and review of the literature. *J Neurol Surg Rep*. 2013;74(1):17-22.

Gormley WB, Tomecek FJ, Qureshi N, Malik GM. Craniocerebral epidermoid and dermoid tumours: a review of 32 cases. *Acta Neurochir (Wien)*. 1994;128(1-4):115-121.

Haddad FS, Haddad GF, Zaatari G. Cranial osteomas: their classification and management. Report on a giant osteoma and review of the literature. *Surg Neurol*. 1997;48(2):143-147.

Hadjipanayis CG, Carlson ML, Link MJ, et al. Congress of Neurological Surgeons systematic review and evidence-based guidelines on surgical resection for the treatment of patients with vestibular schwannomas. *Neurosurgery*. 2018;82(2):E40-E43.

Hall FT, Perez-Ordonez B, Mackenzie RG, Gilbert RW. Does catecholamine secretion from head and neck paragangliomas respond to radiotherapy? Case report and literature review. *Skull Base*. 2003;13(4):229-234.

Haque R, Wojtasiewicz TJ, Gigante PR, et al. Efficacy of facial nerve-sparing approach in patients with vestibular schwannomas. *J Neurosurg*. 2011;115(5):917-923.

Harner SG, Laws ER Jr. Clinical findings in patients with acoustic neurinoma. *Mayo Clin Proc*. 1983;58(11):721-728.

Karpinos M, Teh BS, Zeck O, et al. Treatment of acoustic neuroma: stereotactic radiosurgery vs. microsurgery. *Int J Radiat Oncol Biol Phys*. 2002;54(5):1410-1421.

Kondziolka D, Lunsford LD, McLaughlin MR, Flickinger JC. Long-term outcomes after radiosurgery for acoustic neuromas. *N Engl J Med*. 1998;339(20):1426-1433.

Kondziolka D, Mousavi SH, Kano H, Flickinger JC, Lunsford LD. The newly diagnosed vestibular schwannoma: radiosurgery, resection, or observation? *Neurosurg Focus*. 2012;33(3):E8.

Kondziolka D, Nathoo N, Flickinger JC, Niranjan A, Maitz AH, Lunsford LD. Long-term results after radiosurgery for benign intracranial tumors. *Neurosurgery*. 2003;53(4):815-821.

Laigle-Donadey F, Taillibert S, Martin-Duverneuil N, Hildebrand J, Delattre JY. Skull-base metastases. *J Neurooncol*. 2005;75(1):63-69.

Matthies C, Samii M. Management of 1000 vestibular schwannomas (acoustic neuromas): clinical presentation. *Neurosurgery*. 1997;40(1):1-9.

Myrseth E, Møller P, Pedersen PH, Vassbotn FS, Wentzel-Larsen T, Lund-Johansen M. Vestibular schwannomas: clinical results and quality of life after microsurgery or Gamma Knife radiosurgery. *Neurosurgery*. 2005;56(5):927-935.

Neff BA, Welling DB, Akhmametyeva E, Chang LS. The molecular biology of vestibular schwannomas: dissecting the pathogenic process at the molecular level. *Otol Neurotol*. 2006;27(2):197-208.

Ostrom QT, Gittleman H, Farah P, et al. CBTRUS statistical report: primary brain and central nervous system tumors diagnosed in the United States in 2006-2010. *Neuro Oncol*. 2013;15(suppl 2):ii1-ii56.

Plotkin SR, Stemmer-Rachamimov AO, Barker FG II, et al. Hearing improvement after bevacizumab in patients with neurofibromatosis type 2. *N Engl J Med*. 2009;361(4):358-367.

Pollock BE, Driscoll CL, Foote RL, et al. Patient outcomes after vestibular schwannoma management: a prospective comparison of microsurgical resection and stereotactic radiosurgery. *Neurosurgery*. 2006;59(1):77-85.

Pollock BE, Lunsford LD, Kondziolka D, et al. Outcome analysis of acoustic neuroma management: a comparison of microsurgery and stereotactic radiosurgery. *Neurosurgery*. 1995;36(1):215-224.

Régis J, Carron R, Park MC, et al. Wait-and-see strategy compared with proactive Gamma Knife surgery in patients with intracanalicular vestibular schwannomas. *J Neurosurg*. 2010;113(suppl):105-111.

Régis J, Pellet W, Delsanti C, et al. Functional outcome after Gamma Knife surgery or microsurgery for vestibular schwannomas. *J Neurosurg*. 2002;97(5):1091-1100.

Schiefer TK, Link MJ. Epidermoids of the cerebellopontine angle: a 20-year experience. *Surg Neurol*. 2008;70(6):584-590.

Schmidinger A, Rosahl SK, Vorkapic P, Samii M. Natural history of chondroid skull base lesions—case report and review. *Neuroradiology*. 2002;44(3):268-271.

She R, Szakacs J. Hyperostosis frontalis interna: case report and review of literature. *Ann Clin Lab Sci*. 2004;34(2):206-208.

Suárez C, Rodrigo JP, Bödeker CC, et al. Jugular and vagal paragangliomas: systematic study of management with surgery and radiotherapy. *Head Neck*. 2013;35(8):1195-1204.

Sughrue ME, Yang I, Aranda D, et al. The natural history of untreated sporadic vestibular schwannomas: a comprehensive review of hearing outcomes. *J Neurosurg*. 2010;112(1):163-167.

Walcott BP, Nahed BV, Mohyeldin A, Coumans JV, Kahle KT, Ferreira MJ. Chordoma: current concepts, management, and future directions. *Lancet Oncol*. 2012;13(2):e69-e76.

Yang I, Sughrue ME, Han SJ, et al. A comprehensive analysis of hearing preservation after radiosurgery for vestibular schwannoma. *J Neurosurg*. 2010;112(4):851-859.

Yang I, Sughrue ME, Han SJ, et al. Facial nerve preservation after vestibular schwannoma Gamma Knife radiosurgery. *J Neurooncol*. 2009;93(1):41-48.

Spinal Tumors 107

David Cachia, Claudio E. Tatsui, and Mark R. Gilbert

KEY POINTS

1. Epidural tumors constitute the most frequent spinal tumors, with metastatic disease making up 95% of these lesions.
2. Spinal cord compression is a neurologic emergency. Treatment should be initiated early, as neurologic status at presentation is predictive of functional outcome.
3. In metastatic epidural disease, there is level 1 evidence that surgery followed by radiation is superior to conventional radiation alone.
4. For intramedullary tumors, the prognosis is related to tumor histology and the occurrence of a plane of surgical dissection between the lesion and the surrounding tissues.

INTRODUCTION

Tumors of the spinal cord or nerve roots are similar to intracranial tumors in cellular type. They may arise from the parenchyma of the cord, nerve roots, meninges, intraspinal blood vessels, sympathetic nerves, or vertebrae. Metastases may arise from remote tumors.

Spinal tumors are divided by location into three groups: intramedullary, extramedullary intradural, or extradural (or epidural) (Fig. 107.1). Occasionally, an extradural tumor extends through an intervertebral foramen to be partially within and partially outside the spinal canal (eg, dumbbell or hourglass tumors; Fig. 107.2).

EPIDEMIOLOGY

Spinal cord tumors are much less prevalent than intracranial tumors, in a ratio of 1:4, but this varies by histology. The intracranial-to-spinal ratio of astrocytoma is 10:1, and the ratio for ependymomas varies from 3:1 to 20:1, although spinal tumors are the most prevalent location of ependymoma in adults. Men and women are affected equally often, except that meningiomas are more common in women and ependymomas are more common in men. Spinal tumors occur predominantly in young or middle-aged adults and are less common in childhood or after age 60 years.

Spinal tumors appear most often in the thoracic region, but if the relative lengths of the divisions of the spinal cord are considered, the distribution is comparatively equal.

PATHOBIOLOGY

The histologic characteristics of primary and secondary tumors are similar to those of intracranial tumors. An analyses of data from the Surveillance, Epidemiology, and End Results and National Program of Cancer Registries that included 11,712 cases of primary spinal tumors identified over a 4-year period showed that of these, 78% were benign and 22% malignant. Histologically, the three most common tumors were meningioma, nerve sheath tumors, and ependymoma.

The most recent Central Brain Tumor Registry of the United States (CBTRUS) data on primary brain and central nervous system tumors showed that in the age group 0 to 19 years, the most common histology were ependymal tumors followed by other neuroepithelial tumors, whereas in the 20 years and older age group, tumors of the meninges predominate (Fig. 107.3).

The most frequent extradural or epidural tumors are metastasis with the most common primary sites of metastatic tumors to the spine being, in order of frequency—lung, prostate, multiple myeloma, and breast. Other common metastatic malignancies include tumors of the gastrointestinal tract, lymphomas, melanomas, kidney, sarcomas, thyroid, and plasmocytomas.

CLINICAL FEATURES

Tumors compressing the spinal cord or the cauda equina typically cause radicular pain. The slow evolution of signs of an incomplete transverse lesion of the cord or signs of compression of the conus medullaris or cauda equina usually bring patients to medical attention. In addition to cord compression, extradural tumors may obstruct the blood supply to the cord; if this occurs, the symptoms are often of sudden onset. In a patient with neurofibromatosis 1 (von Recklinghausen disease), the presence of classical signs such as café au lait spots, axillary or inguinal freckling, and Lisch nodules may focus the differential diagnosis to neurofibroma, glioma, or ependymoma.

The clinical presentation can help the physician localize the area of the spinal cord being affected even prior to any imaging studies are performed. Extramedullary tumors cause symptoms by compressing nerve roots or spinal cord or by occluding the spinal blood vessels resulting in regional ischemia and infarct. The symptoms of intramedullary tumors result from direct interference with the intrinsic structures of the spinal cord from mass effect, edema, or development of syringomyelia. Descriptions of special syndromes follow.

Extramedullary Tumors

These tumors may be either intradural or extradural (epidural). They usually involve a few spinal cord levels and cause focal signs by compressing nerve roots, particularly the dorsal roots. Extramedullary tumors may ultimately affect the spinal cord, potentially progressing to complete loss of function below the level of the lesion. The first symptoms are typically focal pain and paresthesias, arising from pressure on the dorsal

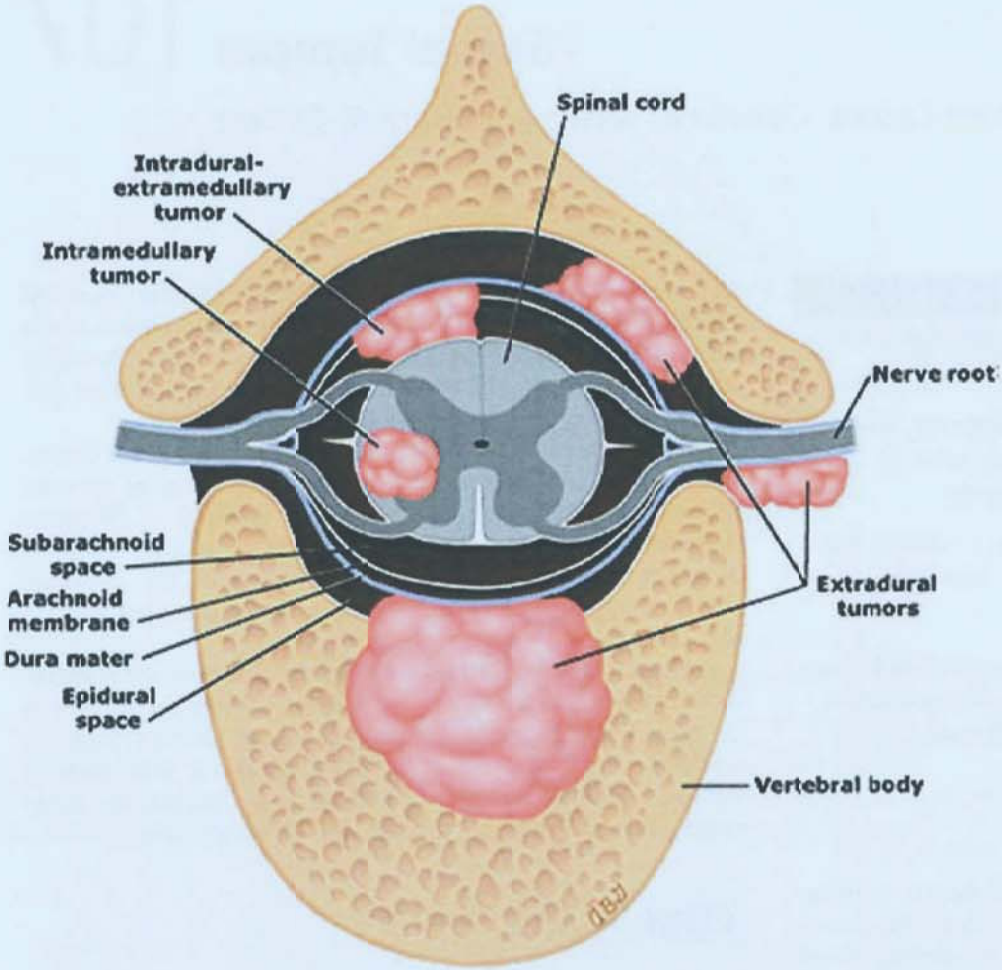

FIGURE 107.1 Location of spinal tumors in relationship to spinal anatomy. (Reproduced with permission from Welch WC, Schiff D, Gerszten PC. Spinal cord tumors. UpToDate Web site. http://www.uptodate.com/contents/spinal-cord-tumors. Accessed April 9, 2015.)

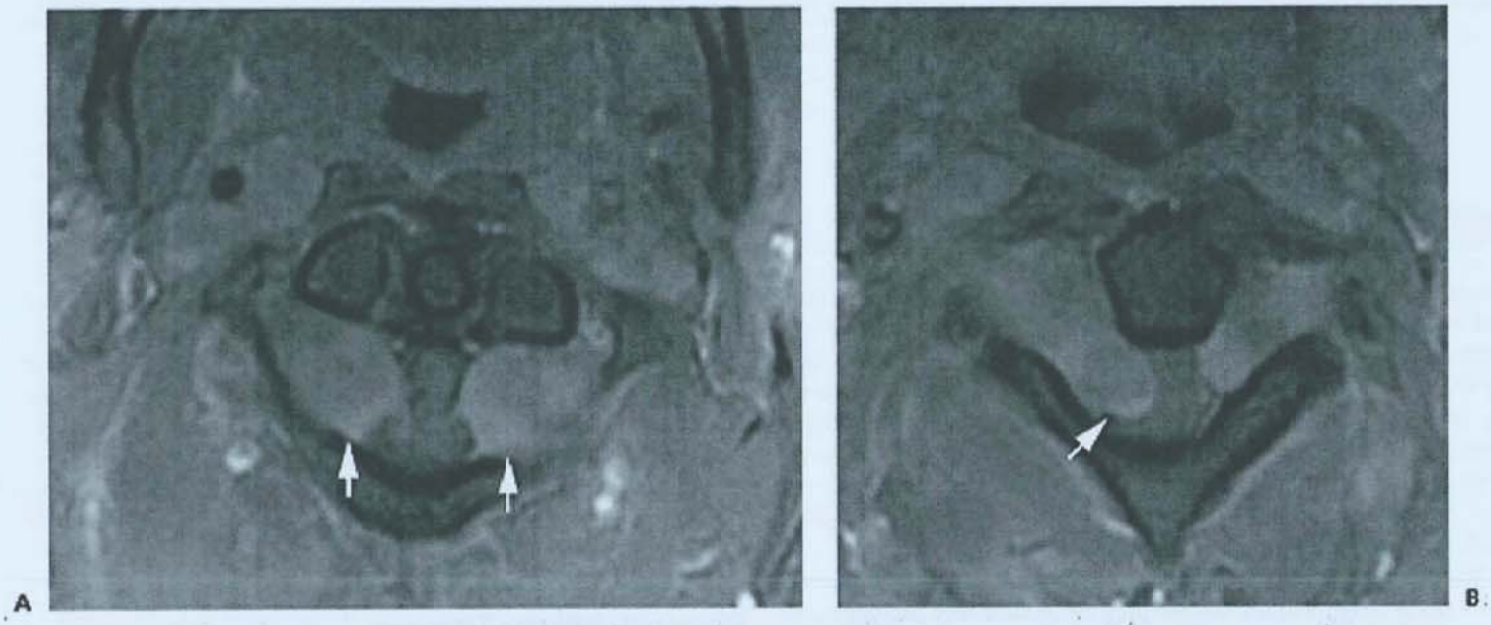

FIGURE 107.2 Neurofibromatosis. **A:** Gadolinium-enhanced T1-weighted axial magnetic resonance imaging (MRI) demonstrates bilateral neurofibromas seen at C1-C2 *(white arrowheads)*, causing severe central spinal canal stenosis. **B:** Axial contrast-enhancing MRI at C2-C3 shows a large foraminal neurofibroma extending into the canal on the right *(white arrowhead)* and causes moderate central spinal canal stenosis.

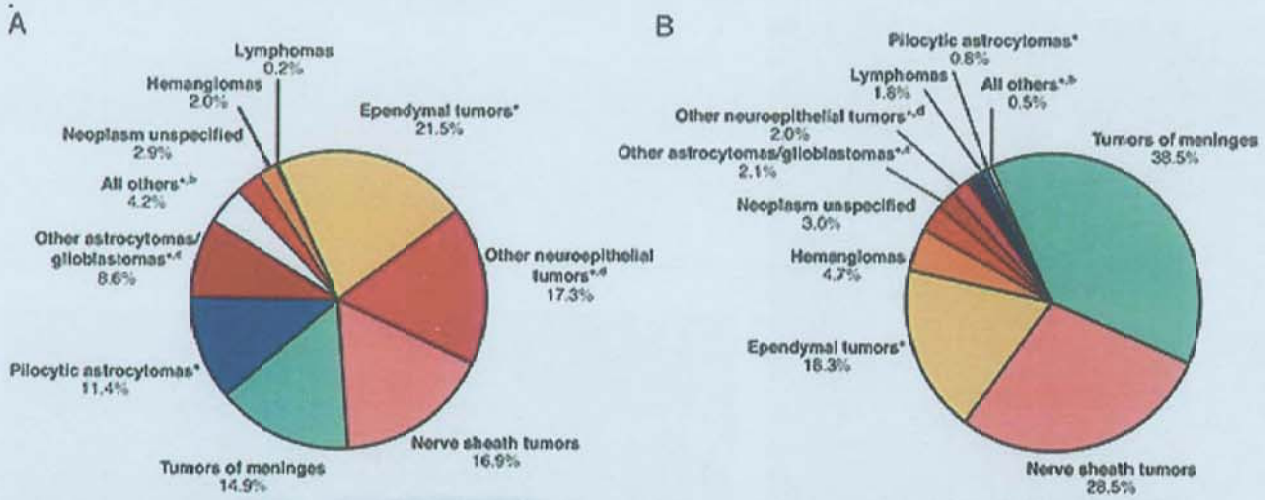

* All or some of this histology are included in the CBTRUS definition of gliomas, including ICD-O-3 histology codes 9380-9384 and 9391-9460.
a. Percentages may not add up to 100% due to rounding; b. Includes embryonal tumors, other tumors of the cranial and spinal nerves, other hematopoietic neoplasms, germ cell tumors, neoplasm unspecified; c. Includes diffuse astrocytoma, anaplastic astrocytoma and unique astrocytoma variants; d. Includes oligodendroglioma, anaplastic oligodendroglioma, oligoastrocytic tumors, glioma malignant, NOS, choroid plexus tumors, other neuroepithelial tumors and mixed neuronal-glial tumors. Abbreviatons: ICD, International Classification of Diseases; NOS, Not Otherwise Specified.

FIGURE 107.3 Distributions of primary spinal cord, spinal meninges, and cauda equina tumors by Central Brain Tumor Registry (CBTRUS) histology groupings and histology in children and adolescents (age 0-19 years, $N = 1,269$) **(A)** and adults (age 20+ years, $N = 17,479$) **(B)**, CBTRUS statistical report: National Program of Cancer Registries and Surveillance, Epidemiology, and End Results, 2011-2015. (From Ostrom QT, Gittleman H, Truitt G, Boscia A, Kruchko C, Barnholtz-Sloan JS. CBTRUS statistical report: primary brain and other central nervous system tumors diagnosed in the United States in 2011–2015. *Neuro Oncol.* 2018;20[suppl 4]:iv1-iv86.)

nerve roots. This symptom pattern is soon followed by sensory loss, weakness, and muscular wasting in the distribution of the affected roots. Compression of the spinal cord first interrupts the functions of the pathways that lie at the periphery of the spinal cord. The early signs of cord compression usually include those referable to upper motor neurons such as spastic weakness below the lesion, overactive tendon reflexes, and Babinski signs; impairment of cutaneous and proprioceptive sensation below the lesion; impaired control of the bladder and, less often, the rectum; and loss of superficial abdominal reflexes. Occasionally, symptoms may be those of lower motor neurons, such as underactive or absent reflexes with flaccid weakness, especially if the compression occurs abruptly as in spinal "shock" from trauma. If untreated, this syndrome may lead to signs and symptoms of complete transection of spinal cord, with wasting and atrophy of muscles at the level of the root lesion and, below the lesion, paraplegia or quadriplegia. The earliest and only sign can be pain, and the absence of other signs or symptoms may give the misleading impression that the cord is not compressed.

The severity and distribution of weakness and sensory loss varies, depending in part on the location of the tumor in relation to the anterior, lateral, or posterior portion of the spinal cord. Eccentrically placed tumors may cause a typical Brown-Séquard syndrome, namely, ipsilateral signs of posterior column and pyramidal tract dysfunction, with contralateral loss of pain and temperature due to involvement of the lateral spinothalamic tract. Usually, however, because of the external compression, the Brown-Séquard features are incomplete.

Spinal vessels may be occluded by extradural tumors, particularly metastatic carcinoma, lymphoma, or abscess. When the arteries destined for the spinal cord are occluded, the resulting myelomalacia causes signs and symptoms similar to those of a severe intradural process leading to necrosis of the spinal cord. Occlusion of major components of the anterior spinal artery, however, results in segmental lower motor neuron signs at the appropriate level, bilateral loss of pain and temperature sensation, and upper motor neuron signs below the lesion with preservation of dorsal column function (proprioception, discriminative tactile function, and vibration).

Extradural (Epidural) Tumors

Extradural lesions constitute the most frequent group of spinal tumors. Metastatic spinal disease accounts for 95% of those lesions, whereas primary bone tumors account for the remaining 5% of spinal lesions. In general, benign lesions within the vertebral bones are usually asymptomatic and found incidentally, whereas malignant vertebral tumors cause back pain, mechanical instability, pathologic fractures, and sometimes neurologic symptoms due to spinal cord compression. In addition to metastatic cancers, other malignant extradural tumors include multiple myeloma (Fig. 107.4), chordoma, Ewing sarcoma, and chondrosarcoma.

The most frequent benign bone lesions are hemangioma, enostosis, osteoid osteoma–osteoblastoma, aneurismal bone cyst, eosinophilic granuloma (histiocytosis), giant cell tumor, and osteochondroma. Although considered benign, these lesions can be locally aggressive associated with pain, spinal deformity, pathologic fractures, and neural elements compression. Spinal cord metastases are discussed in greater detail in the following section.

Epidural Spinal Cord Metastasis

Epidural spinal metastasis may be considered a disorder of the vertebral column; the neurologic consequences result from extension of tumor into the spinal canal. Although currently estimated to occur in about 5% to 10% of all cancer patients, as the survival of patients with systemic cancers improves, the incidence of epidural spinal cord compression has increased. Most studies have

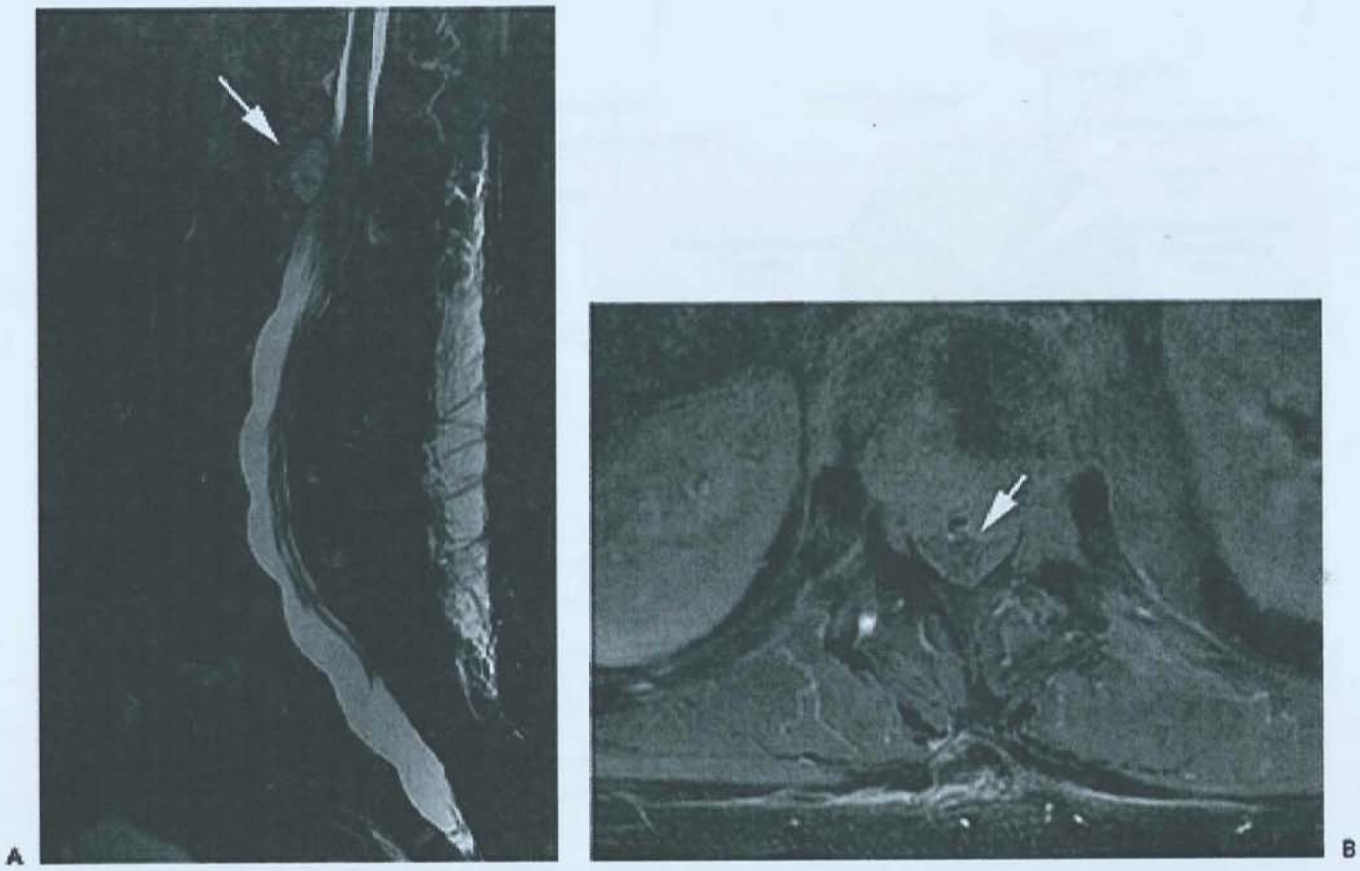

FIGURE 107.4 Epidural spinal metastases. **A:** T2-weighted sagittal magnetic resonance imaging (MRI) demonstrates destruction and mild collapse of the T12 vertebra *(arrow)* in a patient with multiple myeloma. Note the hyperintense marrow signal at multiple levels in the spine indicating additional metastatic deposits. **B:** Axial T1 with contrast MRI at T12 level shows moderate canal stenosis *(arrow)*.

demonstrated that treatment of cord compression does not prolong survival, but prompt treatment may have an important palliative role, alleviating pain and preventing neurologic disability.

Signs and symptoms of epidural spinal cord compression can be overlooked in a patient with disseminated cancer because of the presence of diffuse pain and asthenia. However, persistent neck and back pain that typically gets worse at night or at rest should prompt an investigation, not waiting for neurologic dysfunction to ensue. Limb weakness or paresthesias in the distribution of a nerve root and bowel or bladder dysfunction make this a neurooncologic emergency that commands prompt evaluation and treatment. Rarely, aside from pain, the only manifestation of cord compression may be a gait disorder, often due to sensory ataxia, without overt evidence of weakness or cutaneous sensory loss. In this situation, it may even be difficult to demonstrate impaired proprioception. The ataxia may be caused by compression of spinocerebellar pathways. The primary malignancy in more than 50% of cases of epidural cord compression is lung (Fig. 107.5) or breast cancer. Overall, more than 80% of cases arise from primary tumors in lung, breast, prostate, gastrointestinal system, melanoma, or lymphoma.

The mechanism of spread of these tumors to the epidural space includes a direct extension from a paravertebral focus through a nerve root foramen, hematogenous metastasis to the vertebrae with extension from bone into the epidural space, or retrograde spread along the venous plexus of Batson. Hematogenous spread to bone is the most common form, and computed tomography (CT) typically shows lytic or blastic changes in the vertebral bodies in 85% of those patients. Osteoblastic changes are common with prostate carcinoma and are occasionally seen with breast cancer, whereas osteolytic changes are typically seen in multiple myeloma. The CT and magnetic resonance imaging (MRI) are sensitive techniques for the detection of spinal osseous metastases. Importantly, involvement of paraspinal lymph nodes with spread to the spinal canal is common

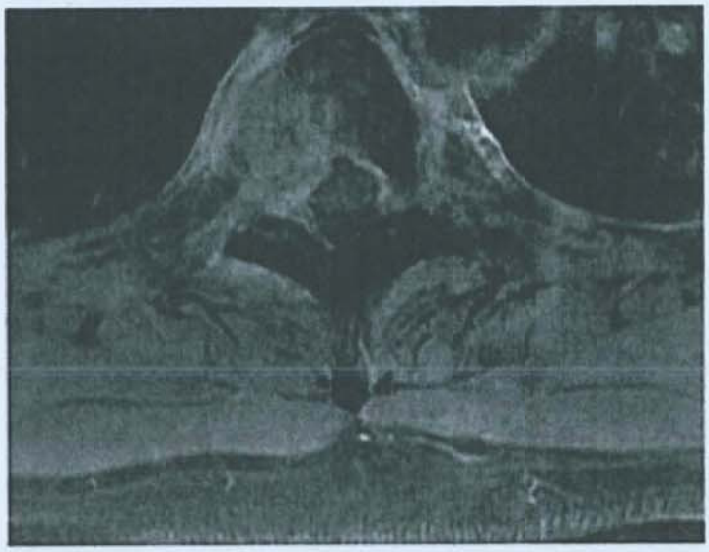

FIGURE 107.5 Epidural spinal metastases. Axial T1-weighted contrast-enhanced sequence at T5 demonstrates epidural extension of metastatic lung non–small cell carcinoma with bone destruction at this level.

with lymphoma. In this situation, the vertebral bone may be normal on imaging studies and use of screening spinal x-rays will be misleading.

Intradural Extramedullary Tumors

Neurofibromas, schwannomas, and meningiomas are the most commonly occurring primary intradural tumors of the spinal cord. On MRI with gadolinium, the lesions enhance brightly. Meningiomas may be identified by the presence of a dural tail, where the tumor attaches to the dura (Figs. 107.6 and 107.7).

A

B

FIGURE 107.6 Thoracic meningioma. **A:** T1-weighted contrast-enhanced sagittal magnetic resonance imaging (MRI) demonstrates a large intradural mass at T6-T7 with dural tail sign. **B:** Axial MRI demonstrates the large size of this lesion, probably a meningioma. Despite marked spinal cord compression, the patient had no abnormality on neurologic examination and only complained of left-sided thoracic pain.

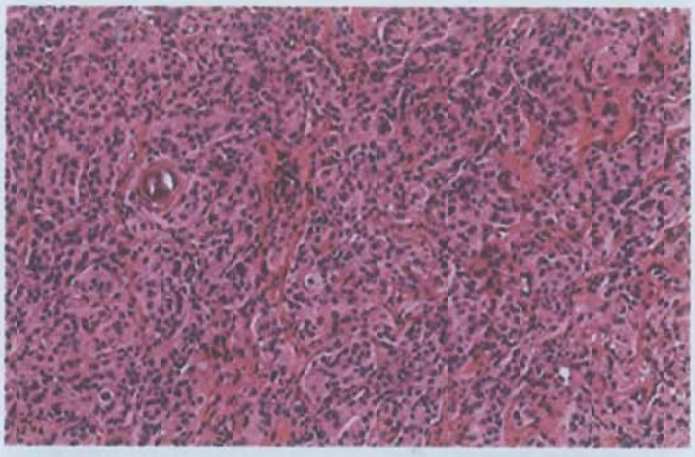

FIGURE 107.7 Meningothelial meningioma of the spinal cord. The classic variant of meningioma is composed of lobules of meningothelial cells separated by fine collagen fibers. The intercellular borders are ill-defined characteristic of a syncytial pattern. Nuclear clearing and whorl formation are frequent. Calcifications (psammoma bodies) might be present. (Courtesy of Dr. Adriana Olar, Department of Pathology, MD Anderson Cancer Center.)

Symptoms may occur slowly, and some may be asymptomatic despite large size, presumably because of slow growth allowing the spinal cord an opportunity to adapt to the mass effect.

Leptomeningeal metastasis and drop metastases of intracranial tumors also involve the intradural space, but typically, they appear as small nodules attached to the surface of the cord or cauda equina nerve roots (Fig. 107.8), although many (approximately 70%) or not visible on imaging of brain or spine and are detected only by cerebrospinal fluid (CSF) analyses.

Intramedullary Tumors

Primary Intramedullary Tumors

The most common intramedullary tumors are ependymomas and astrocytomas. A diagnosis of von Hippel-Lindau syndrome, an autosomal dominant disorder, should be considered when a spinal hemangioblastoma is present (most commonly involving the thoracic cord) because this association occurs in one-third of the cases. However, rarely, hemangioblastoma can also occur in the intradural extramedullary and extradural locations. Although a single lesion is the most common presentation, multiple lesions occur in one-fifth of cases.

Primary intramedullary tumors usually extend over many segments, causing dilatation of the spinal cord and sometimes causing syringomyelia, which can involve the whole length of the spinal cord. For this reason, the signs and symptoms of intramedullary tumors are more variable than those of extramedullary tumors (Figs. 107.9 and 107.10).

If the tumor is restricted to one or two segments, the clinical presentation can be similar to that of an extramedullary tumor. Pain may be an early manifestation if the dorsal root entry zone is affected. Compression of the crossing pain fibers in the central cord may cause loss of pain and temperature only in the affected segments. As the tumor spreads peripherally, the spinothalamic tracts may be affected; in the thoracic and cervical areas, pain and temperature fibers from the sacral area lie near the external surface of the cord and may be spared (eg, sacral sparing). Involvement of the central gray matter destroys the anterior horn

FIGURE 107.8 Leptomeningeal disease. Sagittal T1-weighted contrast-enhanced magnetic resonance imaging shows tumor deposits along the surface of the distal thoracic cord and the nerve roots of the cauda equine in a patient with breast carcinoma.

cells, with local weakness and atrophy resulting. However, pyramidal fibers may be spared. The clinical picture may be identical to that of syringomyelia with a "suspended" sensory level.

Intramedullary Metastases

Although rare, the most common tumors that cause intramedullary metastases are lung cancer or breast cancer. Intramedullary metastases typically occur with advanced metastatic disease, and at autopsy, 61% of patients with intramedullary metastases are found to have had multiple sites of cerebral or spinal lesions. Contrast-enhanced MRI is the preferred method for detection of intramedullary metastases. Reversal or stabilization of neurologic signs depends on early diagnosis, but survival is poor; 80% of patients in one series died within 3 months of diagnosis, likely a manifestation of the extent of systemic disease at the time of the spinal cord involvement.

Regional Syndromes

Foramen Magnum Tumors

Tumors in the region of the foramen magnum may extend up into the posterior fossa or down into the cervical region. The syndrome from tumor in the foramen magnum typically shows signs and symptoms of dysfunction of the lower cranial nerves, primarily those pertaining to the 11th, 12th, and rarely, the 9th and 10th. The most characteristic foramen magnum tumor, the ventrolateral meningioma, compresses the spinal cord at the cervicomedullary junction to cause long tract signs: loss of position, vibratory, and light touch perception, with more prominent symptoms in the arms than the legs. Upper motor neuron signs are seen in all four limbs. There may be cutaneous sensory loss in distribution of C2 or the occiput, with posterior cranial headaches and high cervical pain. Progression of sensory and motor symptoms may involve the limbs asymmetrically.

Cervical Tumors

Tumors of the upper cervical segments cause pain or paresthesias in the occipital or cervical region, with stiff neck, weakness, and wasting of neck muscles. Below the lesion, there may be a

FIGURE 107.9 Intramedullary glioblastoma. **A:** Sagittal T1-weighted contrast-enhanced magnetic resonance imaging (MRI) demonstrates T1-T4 intramedullary lesion with peripheral enhancement and hypointense center that expands the cord. **B:** T1-weighted MRI shows a contrast-enhancing intramedullary tumor at the T1-T2 level. At operation, a spinal glioblastoma with necrotic center was removed.

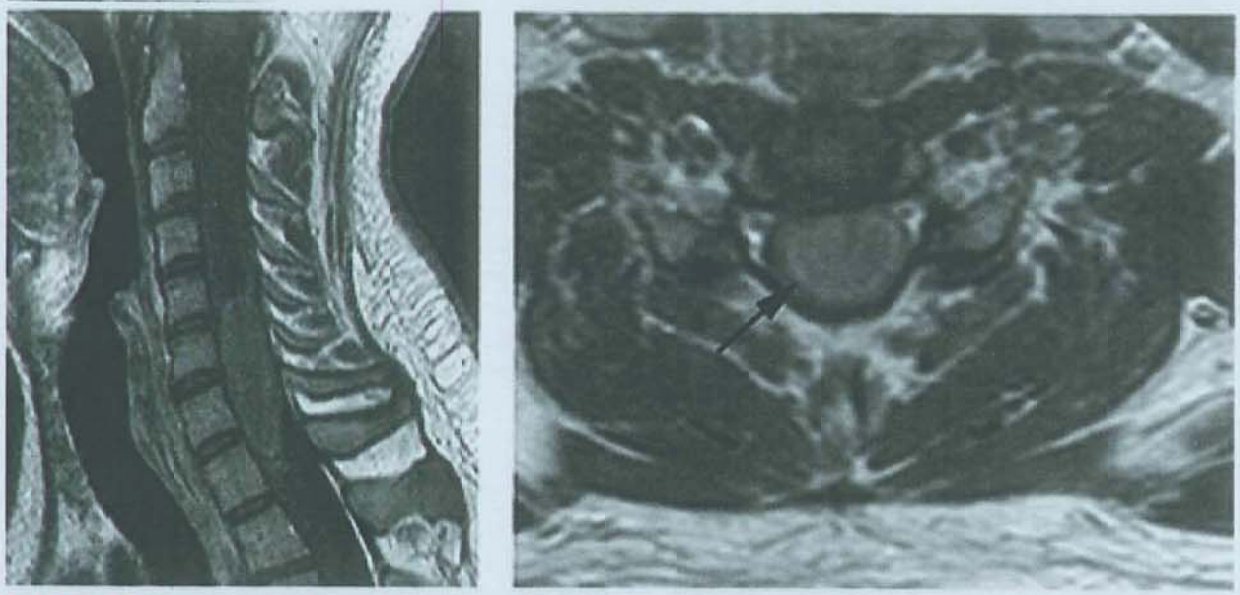

FIGURE 107.10 Intramedullary ependymoma. **A:** Sagittal T1-weighted magnetic resonance imaging shows an intramedullary enhancing mass at C5-T1. **B:** Axial T1-weighted image with contrast shows expansion and significant displacement of the cord by the tumor at C6 *(arrow)*.

spastic tetraplegia or hemiplegia. Cutaneous sensation may be affected below the lesion, and the descending trigeminal nucleus may be involved. Characteristic findings make it possible to localize the upper level of spinal tumors in the middle and lower cervical segments or T1 as shown in Table 107.1.

Other signs of cervical tumors include nystagmus, which is attributed to involvement of the descending portion of the median longitudinal fasciculus. A Horner syndrome may be found with intramedullary lesions in any portion of the cervical cord if the descending sympathetic pathways are affected.

TABLE 107.1 Localization in the Cervical and T1 Region Based on Symptomatology

C4	Paralysis of the diaphragm
C5	Atrophy and paralysis of the deltoid, biceps, supinator longus, rhomboid, and spinati muscles. The upper arms hang limp at the side. The sensory level extends to the outer surface of the arm. The biceps and supinator reflexes are lost.
C6	Paralysis of triceps and wrist extensors. The forearm is held semiflexed, and there is a partial wrist drop. The triceps reflex is lost. Sensory impairment extends to a line running down the middle of the arm slightly to the radial side.
C7	Paralysis of the flexors of the wrist and of the flexors and extensors of the fingers. Efforts to close the hands result in extension of the wrist and slight flexion of the fingers (eg, preacher's hand). The sensory level is similar to that of the sixth cervical segment but slightly more to the ulnar side of the arm.
C8	Atrophy and paralysis of the small muscles of the hand with resulting claw hand (main-en-griffe). Horner syndrome, unilateral or bilateral, results from lesions at this level and is characterized by the triad of ptosis, small pupil (ie, miosis), and loss of sweating on the face. Sensory loss extends to the inner aspect of the arm and involves the fourth and fifth fingers and the ulnar aspect of the middle finger.
T1	Lesions rarely cause motor symptoms because the T1 nerve root normally provides little functional innervation of the small hand muscles.

Thoracic Tumors

Clinical localization of tumors in the thoracic region of the cord is best made by the sensory level. It is not possible to determine the location of a lesion in the upper half of the thoracic cord by testing the strength of intercostal muscles. Lesions that affect the abdominal muscles below T10 but spare the upper ones may be localized by the Beevor sign (ie, the umbilicus moves upward when the patient, lying in the supine position, attempts to flex the neck against resistance). Abdominal skin reflexes are absent below the lesion.

Lumbar Tumors

Lesions in the lumbar region may be localized by the level of the sensory loss and motor weakness typically following a dermatome or myotome distribution. Tumors that compress only the L1 and L2 nerve roots cause loss of the cremasteric reflexes and weakness in the iliopsoas muscle. The abdominal reflexes are preserved, as are the knee and ankle jerks. Lesions affecting the L3 and L4 nerve roots may present with weakness in the quadriceps muscle, loss of patellar reflex, and pain in the anteromedial portion of the lower extremity.

The typical involvement of the L5 nerve root causes weakness of eversion, inversion, and dorsiflexion of the foot and hallux. Decreased sensation over the anterolateral calf and dorsum of the foot, with pain radiating down the leg to the hallux that can be exacerbated by the straight leg testing (Lasègue sign) is also characteristic. The presence of weakness of foot inversion in an L5 radiculopathy is an important distinguishing factor from a peroneal palsy where foot inversion strength is typically normal.

A tumor affecting the S1 root may present with weakness of the gastrocnemius and hamstring, with absent ankle jerk and decreased sensation over the lateral calf and lateral foot including the sole.

The involvement of multiple nerve roots can occur at any lumbar level, and it is usually described as cauda equina syndrome, which typically presents as flaccid paralysis of the legs with loss of knee and ankle reflexes associated with urinary retention and bowel incontinence. If both the spinal cord and cauda equina are asymmetrically affected, there may be spastic paralysis of one leg with an overactive ankle reflex on that side and flaccid paralysis with loss of reflexes on the other side.

Finally, tumors affecting the sacrum at the level of S2-S4 can cause perineal or saddle anesthesia and loss of bowel and bladder control without motor deficits observable in the lower extremities because the motor roots (L1-S1) are not affected.

Tumors of the Conus and Cauda Equina

Although a conus lesion is intramedullary involving the parenchyma of the terminal spinal cord, a cauda equina lesion is extramedullary affecting multiple exiting nerve roots. Distinguishing between the two entities is not always possible as many of the clinical features are similar. Moreover, in neoplastic processes, there is frequent involvement of both.

The first symptom of a tumor that involves the conus or cauda equina is pain in the back, rectal area, or both lower legs, often leading to the preliminary diagnosis of sciatica. Loss of bladder function and impotence are seen early especially with conus involvement. As the tumor grows, there may be flaccid paralysis of the legs, with atrophy of leg muscles, and foot drop. Fasciculation may be evident. Sensory loss may affect the perianal or saddle area and the remaining sacral and lumbar dermatomes. This loss may be slight or so severe that a trophic ulcer develops over the lumbosacral region, buttocks, hips, or heels.

DIAGNOSIS

Spinal tumors must be differentiated from other disorders of the spinal cord, including transverse myelitis, multiple sclerosis, syringomyelia, combined system disease, syphilis, amyotrophic lateral sclerosis, anomalies of the cervical spine and base of the skull, spondylosis, adhesive arachnoiditis, radiculitis of the cauda equina, hypertrophic arthritis, ruptured intervertebral disks, diastematomyelia, and vascular anomalies.

Multiple sclerosis, with a complete or an incomplete transverse lesion of the cord, may usually be differentiated from spinal cord tumors by the remitting course, signs and symptoms of more than one lesion, evoked potential studies, cranial MRI, and the presence of CSF oligoclonal bands. Acute transverse myelitis may occasionally enlarge the cord to simulate an intramedullary tumor.

Determining the differential diagnosis between spontaneous syringomyelia and intramedullary tumor-related syrinx is complicated because intramedullary cysts mimicking a syrinx are commonly associated with these tumors. Extramedullary tumors in the cervical region may give rise to localized pain and muscular atrophy in conjunction with a Brown-Séquard syndrome, producing a clinical picture similar to that of syringomyelia. The differential diagnosis may often be made by contrast-enhanced MRI that reveals a tumor nodule.

The combination of atrophy of hand muscles and spastic weakness in the legs in amyotrophic lateral sclerosis may suggest the diagnosis of a cervical cord tumor. Tumor is excluded by the lack of paresthesias, and normal sensation on examination, and by the presence of fasciculation or atrophy in leg muscles or tongue, and by imaging.

Cervical spondylosis may cause stenosis of the spinal canal and cause symptoms and signs of root irritation and/or compression of the spinal cord. Degenerative changes are extremely common, and the modality of choice for diagnosis is MRI. Clinical correlation with image findings is critical for the treatment decision because most changes on imaging studies are incidental findings or do not have a clinical correlation.

Anomalies in the cervical region or at the base of the skull, such as platybasia or Klippel-Feil syndrome, are diagnosed by CT or MRI. Occasionally, arachnoiditis may interfere with the circulation of CSF causing signs and symptoms of a transverse lesion. The CSF protein content is usually elevated. Diagnosis is made by complete or partial arrest of the contrast column on myelography or by fragmentation of the material at the site of the lesion. Slowed CSF flow will be seen using magnetic resonance flow techniques.

Epidural lipomatosis is a complication of prolonged steroid therapy but sometimes occurs without apparent cause; the fat accumulations act as an extradural mass lesion, causing low back pain and compression of the spinal cord or cauda equina.

Radiography

The diagnosis of an intraspinal tumor may be established before the operative procedure, with visualization by CT, MRI, or myelography. Vascular malformations or vascular tumors may be best visualized by spinal angiography. A CSF examination with cytologic studies may also be helpful if positive, but negative cytology does not exclude a neoplastic process.

The CT and MRI have replaced standard radiographic studies (plain x-rays). However, when conventional x-ray imaging is performed, the abnormalities (listed in the following text) are seen in about 15% of spinal neoplasms:

1. Localized destruction of the vertebrae is manifest by scalloping of the posterior margin of the vertebral body or lucency of a portion of the vertebra or pedicle.
2. Changes occur in the contour or separation of the pedicles (eg, the interpediculate distance may be measured and compared with normal values). Localized enlargement of foramina is seen with dumbbell neurofibromas. Localized enlargement of the spinal canal is usually diagnostic of an intraspinal tumor, but enlargement of many segments may be a developmental anomaly.
3. Paraspinal tissues are distorted by tumors, frequently neurofibromas that extend through the intervertebral foramen or by tumors that originate in the paraspinal structures.
4. Proliferation of bone, which is rare except in osteomas and sarcomas, is also occasionally seen in hemangiomas of bone and meninges.
5. Calcium deposits are occasionally present in meningiomas or congenital tumors.

An MRI has largely supplanted myelography for imaging both intramedullary and extramedullary processes. The MRI is the most useful test for evaluating spinal tumors. The vertebral bodies, spinal canal, and spinal cord, itself, are clearly delineated. Most spinal neoplasms display contrast enhancement. When a metastatic tumor is suspected or demonstrated, it is advisable to image the entire spinal cord because more than one lesion may be present.

The CT is the modality of choice for imaging of the bony structures but is more limited than MRI in demonstrating the soft tissues. Injection of contrast in the lumbar cistern is used for a CT myelogram, which is an alternative in cases of contraindication for MRI (ie, pacemakers or ferromagnetic implants).

A CT myelogram may demonstrate the soft-tissue changes of intraspinal tumors and is particularly useful in the diagnosis of cystic lesions in the subarachnoid space, where the contrast material may accumulate around and create a negative contrast of the cyst. It is also useful to evaluate if there is communication between the subarachnoid space and intradural cystic lesions (ie, arachnoid cysts, syringomyelia, or cystic tumors).

Cerebrospinal Fluid

When there is a complete subarachnoid block, the CSF is xanthochromic as a result of the high protein content (Froin syndrome). It may be only slightly yellow or even colorless if the subarachnoid block is incomplete. The cell count is usually normal, but a slight pleocytosis is found in about 30% of patients. Cell counts of between 25 and 100/μL are found in about 15% of patients. The protein content is increased in more than 95%. Values of over 100 mg/dL are present in 60% of the patients, and values of over 1,000 mg/dL are present in 5% and may, in rare cases, lead to communicating hydrocephalus. The glucose content is normal unless there is meningeal spread. Cytologic evaluation of the CSF is useful when malignant tumors are suspected, although, as mentioned previously, negative cytology does not exclude leptomeningeal cancer. More than one CSF sampling procedure may be required (some advocate up to five), although the remainder of the CSF profile (cells, protein, tumor markers) is usually abnormal in the setting of leptomeningeal metastases, notwithstanding the absence of malignant cells on cytologic analysis.

MANAGEMENT

Intradural Extramedullary Tumors

Once the diagnosis of an intraspinal tumor has been made, the treatment is surgical removal of the tumor whenever possible. When the neurologic disorder is severe or rapidly progressing, emergency surgery is indicated. The best results are obtained when the signs and symptoms are due solely to compression by a benign encapsulated extramedullary tumor. Some of these tumors, especially meningiomas, may lie anterior to the spinal cord, and a complete resection of the involved dura is not possible or carries a significant risk of morbidity. In these cases, a gross total resection of the mass with cauterization of the dural insertion of tumor is performed. In cases of recurrence, another surgical resection may be necessary. The functional outcome of patients harboring extramedullary tumors is predicated by the severity of the preoperative neurologic disability. Overall, surgery aiming at a gross total resection is the modality of choice for the intradural extramedullary tumors (Video 107.1) and ideally should be performed before installment of neurologic dysfunction because when this occurs, it might represent evidence of irreversible damage to the spinal cord due to compression or ischemia. Radiotherapy is typically not indicated for benign intradural extramedullary tumors. In fact, most of these lesions are low-grade tumors with no tissue separation between the lesion and the spinal cord. This increases the risk of radiation-induced myelopathy, especially in cases where preexisting damage is suspected (ie, evidence of myelomalacia or ischemia due to long-dated compression). In cases of recurrence, a second surgical procedure is usually considered a better alternative than radiation, which in general is reserved for cases where a high surgical comorbidity precludes surgery.

Intramedullary Tumors

In almost all World Health Organization (WHO) grade I (myxopapillary) and WHO grade II ependymomas, complete microsurgical resection of the tumor is the treatment of choice (Video 107.2). There is no consensus on the use of radiotherapy for WHO grade I and WHO grade II spinal cord tumors, and overall radiation is reserved for cases with incomplete resection, with bulky residual disease or symptomatic tumor recurrence when the patient is considered not to be a good surgical candidate. Radiation treatment is indicated after initial surgery for all patients with WHO grade III ependymoma. Treatment paradigms might change over the coming years with recent identification of discrete molecular ependymoma subtypes. Astrocytomas are typically infiltrating and often lack a plane of cleavage. In this case, an attempt at complete resection or extensive debulking is associated with significant risk of neurologic decline. Although radiotherapy should be given for spinal cord astrocytomas, the results particularly for WHO grade III and IV tumors are discouraging. For other less common intramedullary tumors, such as hemangioblastomas, teratomas, or dermoids, if complete removal has been achieved, typically, no further treatment is recommended aside from surveillance.

Intramedullary tumors are typically approached with multilevel laminectomies, which create disruption in the posterior tension band of the ligaments stabilizing the spine. As a result, spinal deformities that may have been present preoperatively may worsen and other deformities may develop, eventually requiring surgical correction with spinal instrumentation and fusion. If allowed to progress, these deformities may create additional functional impairment, especially in skeletally immature patients. Some surgeons have advocated replacement of the lamina after definitive surgery, rather than the standard laminectomy. However, the occurrence of postoperative kyphosis is common and the natural history of this deformity is uncertain. The additional use of radiotherapy for intraspinal tumors in younger patients may affect the growth of the spine and in adults may increase the muscle atrophy and degenerative changes leading to the development or worsening of preexisting deformities of the spine.

Epidural Disease From Metastatic Cancer

Treatment of epidural metastasis is palliative in nearly all patients. Prognostic scoring systems based on patient age, performance status, extent of spinal and extraspinal disease, tumor histology, and availability of systemic treatments are useful to predict the expected survival of patients harboring spinal metastasis. However, management has to be individualized in order to achieve the best balance between morbidity and palliation. A randomized trial LEVEL I[1] has demonstrated that surgery for spinal decompression and spinal stabilization followed by radiation is superior to conventional radiation alone in maintenance and recovery of ambulation, duration of ambulation, and maintenance of sphincter continence. Loss of bowel or bladder function is an ominous prognostic sign and is usually irreversible. Among patients diagnosed and treated early, 94% remain ambulatory until they die.

Conventional radiation therapy is the mainstay of treatment for most patients with spinal metastases, even those who had surgical decompression, with the typical treatment plan comprising 3,000 cGy divided in 10 fractions of 300 cGy each. More recently, high-dose hypofractionated radiotherapy using image-guided techniques (spinal stereotactic radiotherapy) has emerged

as an effective modality overcoming the relative radioresistance of some tumors to conventional radiation. However, in cases of symptomatic or high-degree spinal cord compression, a judicious combination of surgery to separate the tumor from the spinal cord prior to stereotactic radiation has been shown to achieve a high degree of local control with relative low morbidity.

In general, surgery provides spinal stabilization and spinal cord and nerve roots decompression, whereas radiation therapy provides local tumor control. Usually, radiation treatment is well tolerated even by patients who are seriously ill, and in most cases, palliation is often achieved with relief of pain. In general, indications for surgery include spinal cord compression due to radioresistant tumors (renal cell carcinoma, sarcomas, melanomas, etc), spinal instability, unknown tissue diagnosis, or rapid progression of neurologic dysfunction. Judicious use of surgery is critical to achieve a meaningful clinical improvement in patients with advanced systemic disease because the anticipated recovery time has to be weighed against the expected duration of survival.

OUTCOME

Epidural spinal cord compression is an emergency because without treatment, irreversible loss of neurologic function will lead to significant morbidity and mortality. It is estimated that patients who were ambulatory preoperatively were 2.3 times more likely to be able to walk postoperatively. Treatment should be initiated early, as neurologic status at presentation is predictive of functional outcome. Critical to this is the education of patients, patient families, and health care providers to recognize warning signs of cord compression early on. Recent studies do support the notion that patients with cord compression are presenting earlier. In fact, although a study published in 1998 showed that only 33% were ambulatory and 53% were catheter free at the time of initiation of therapy, in another study published in 2010, 62% of patients were ambulatory at presentation. It has also been shown that nonambulatory patients if treated surgically require more extensive surgery with consequent higher complication rates and morbidity. It is therefore of paramount importance that a careful patient selection process is pursued, always taking into consideration the patient's overall prognosis and presumed benefits balanced against the treatment-related morbidity.

For intramedullary tumors, the prognosis and outcome from surgery is strongly related to tumor histology and the occurrence of a plane of surgical dissection between the lesion and the surrounding spinal cord and nerve roots. When a plane of cleavage exists, such as in ependymomas, a complete surgical resection is potentially curative. With more diffusely infiltrating tumors such as spinal cord astrocytic tumors, the goal of surgery in most cases is diagnostic and especially in high-grade tumors, treatment is palliative with a dismal outcome irrespective of treatment.

Overall, intradural extramedullary tumors have slow progression, and usually, treatment is recommended when symptomatic or when there is a significant degree of spinal cord compression. With improved imaging, neurophysiologic monitoring, and sound microsurgical techniques, the goals of treatment for these lesions is gross total resection with curative intent. Good functional outcomes are generally observed and overall recurrence rates range between 0% and 13%.

This is in contrast to the prognosis of patients with leptomeningeal metastasis from systemic cancer where the prognosis, irrespective of the cancer of origin, is typically around 2 to 3 months, although there are exceptions, most often patients with lymphoma and occasionally breast cancer.

Videos can be found in the companion e-book edition. For a full list of video legends, please see the front matter.

LEVEL 1 EVIDENCE

1. Patchell RA, Tibbs PA, Regine WF, et al. Direct decompressive surgical resection in the treatment of spinal cord compression caused by metastatic cancer: a randomised trial. *Lancet*. 2005;366(9486):643-648.

SUGGESTED READINGS

Aghakhani N, David P, Parker F, Lacroix C, Benoudiba F, Tadie M. Intramedullary spinal ependymomas: analysis of a consecutive series of 82 adult cases with particular attention to patients with no preoperative neurological deficit. *Neurosurgery*. 2008;62:1279-1286.

Aghayev K, Vrionis F, Chamberlain MC. Adult intradural primary spinal cord tumors. *J Natl Compr Canc Netw*. 2011;9(4):434-447.

Al-Khawaja D, Seex K, Eslick GD. Spinal epidural lipomatosis—a brief review. *J Clin Neurosci*. 2008;15:1323-1326.

Aryan HE, Farin A, Nakaji P, Imbesi SG, Abshire BB. Intramedullary spinal cord metastasis of lung adenocarcinoma presenting as Brown-Sequard syndrome. *Surg Neurol*. 2004;61:72-76.

Borba LA, de Oliveira JG, Giudicissi-Filho M, Colli BO. Surgical management of foramen magnum meningiomas. *Neurosurg Rev*. 2009;32:49-58.

Chaichana KL, Woodworth GF, Sciubba DM, et al. Predictors of ambulatory function after decompressive surgery for metastatic epidural spinal cord compression. *Neurosurgery*. 2008;62:683-692.

Chamberlain MC, Tredway TL. Adult primary intradural spinal cord tumors: a review. *Curr Neurol Neurosci Rep*. 2011;11:320-328.

Cheshire WP, Santos CC, Massey EW, Howard JF Jr. Spinal cord infarction: etiology and outcome. *Neurology*. 1996;47:321-330.

Clarke JL. Leptomeningeal metastasis from systemic cancer. *Continuum*. 2012;18:328-342.

Dam-Hieu P, Seizeur R, Mineo JF, Metges JP, Meriot P, Simon H. Retrospective study of 19 patients with intramedullary spinal cord metastasis. *Clin Neurol Neurosurg*. 2009;11:10-17.

Duong LM, McCarthy BJ, McLendon RE, et al. Descriptive epidemiology of malignant and nonmalignant primary spinal cord, spinal meninges, and cauda equina tumors, United States, 2004–2007. *Cancer*. 2012;118:4220-4227.

Ebner FH, Roser F, Acioly MA, Schoeber W, Tatagiba M. Intramedullary lesions of the conus medullaris: differential diagnosis and surgical management. *Neurosurg Rev*. 2009;32:287-300.

Elsberg CA. *Surgical Diseases of the Spinal Cord, Membranes and Nerve Roots*. New York, NY: Paul B. Hoeber; 1941.

Eule JM, Erickson MA, O'Brien MF, Handler M. Chiari I malformation associated with syringomyelia and scoliosis: a twenty-year review of surgical and nonsurgical treatment in a pediatric population. *Spine (Phila Pa 1976)*. 2002;27:1451-1455.

Gerszten PC, Burton SA, Ozhasoglu C, Welch WC. Radiosurgery for spinal metastases: clinical experience in 500 cases from a single institution. *Spine (Phila Pa 1976)*. 2007;32:193-199.

Hanbali F, Fourney DR, Marmor E, et al. Spinal cord ependymoma: radical surgical resection and outcome. *Neurosurgery*. 2002;51:1162-1174.

Husband DJ. Malignant spinal cord compression: prospective study of delays in referral and treatment. *BMJ*. 1998;317(7150):18-21.

Jallo GI, Danish S, Velasquez L, Epstein F. Intramedullary low-grade astrocytomas: long-term outcome following radical surgery. *J Neurooncol*. 2001;53:61-66.

Jallo GI, Freed D, Epstein F. Intramedullary spinal cord tumors in children. *Childs Nerv Syst*. 2003;19:641-649.

Jankowski R, Nowak S, Zukiel R, Blok T, Paprzycki W, Szymaś J. Application of internal stabilisation in the surgical treatment of spinal metastases. *Neurol Neurochir Pol*. 2008;42:323-331.

King AT, Sharr MM, Gullan RW, Bartlett JR. Spinal meningiomas: a 20-year review. *Br J Neurosurg*. 1998;12:521-526.

Laufer I, Iorgulescu JB, Chapman T, et al. Local disease control for spinal metastases following "separation surgery" and adjuvant hypofractionated or high-dose single-fraction stereotactic radiosurgery: outcome analysis in 186 patients. *J Neurosurg Spine*. 2013;18:207-214.

Lonser RR, Weil RJ, Wanebo JE, DeVroom HL, Oldfield EH. Surgical management of spinal cord hemangioblastomas in patients with von Hippel-Lindau disease. *J Neurosurg*. 2003;98:106-116.

Mak KS, Lee LK, Mak RH, et al. Incidence and treatment patterns in hospitalizations for malignant spinal cord compression in the United States, 1998-2006. *Int J Radiat Oncol Biol Phys*. 2011;80(3):824.

Manzano G, Green BA, Vanni S, Levi AD. Contemporary management of adult intramedullary spinal tumors-pathology and neurological outcomes related to surgical resection. *Spinal Cord*. 2008;46:540-546.

Maranzano E, Trippa F, Chirico L, Basagni ML, Rossi R. Management of metastatic spinal cord compression. *Tumori*. 2003;89:469-475.

Mathew P, Todd NV. Intradural conus and cauda equina tumours: a retrospective review of presentation, diagnosis and early outcome. *J Neurol Neurosurg Psychiatry*. 1993;56:69-74.

Matson DD. *Neurosurgery of Infancy and Childhood*. 2nd ed. Springfield, IL: Charles C. Thomas; 1969.

McCormick PC, Stein BM. Intramedullary tumors in adults. *Neurosurg Clin North Am*. 1990;1:609-630.

McGirt MJ, Goldstein IM, Chaichana KL, Tobias ME, Kothbauer KF, Jallo GI. Extent of surgical resection of malignant astrocytomas of the spinal cord: outcome analysis of 35 patients. *Neurosurgery*. 2008;63:55-60; discussion 60-61.

Mechtler LL, Nandigam K. Spinal cord tumors: new views and future directions. *Neurol Clin*. 2013;31:241-268.

Nakamura M, Ishii K, Watanabe K, et al. Surgical treatment of intramedullary spinal cord tumors: prognosis and complications. *Spinal Cord*. 2008;46:282-286.

Ogden AT, Feldstein NA, McCormick PC. Anterior approach to cervical intramedullary pilocytic astrocytoma. Case report. *J Neurosurg Spine*. 2008;9:253-257.

Ostrom QT, Gittleman H, Truitt G, Boscia A, Kruchko C, Barnholtz-Sloan JS. CBTRUS statistical report: primary brain and other central nervous system tumors diagnosed in the United States in 2011–2015. *Neuro Oncol*. 2018;20(suppl 4):iv1-iv86.

O'Toole JE, McCormick PC. Midline ventral intradural schwannoma of the cervical spinal cord resected via anterior corpectomy with reconstruction: technical case report and review of the literature. *Neurosurgery*. 2003;52:1482-1485.

Pajtler KW, Witt H, Sill M, et al. Molecular classification of ependymal tumors across all CNS compartments, histopathological grades, and age groups. *Cancer Cell*. 2015;27(5):728-743.

Parsa AT, Chi JH, Acosta FL Jr, Ames CP, McCormick PC. Intramedullary spinal cord tumors: molecular insights and surgical innovation. *Clin Neurosurg*. 2005;52:76-84.

Putz C, Wiedenhöfer B, Gerner HJ, Fürstenberg CH. Tokuhashi prognosis score: an important tool in prediction of the neurological outcome in metastatic spinal cord compression? A retrospective clinical study. *Spine*. 2008;15;33:2669-2674.

Rades D, Huttenlocher S, Dunst J, et al. Matched pair analysis comparing surgery followed by radiotherapy and radiotherapy alone for metastatic spinal cord compression. *J Clin Oncol*. 2010;28:3597.

Ribas ES, Schiff D. Spinal cord compression. *Curr Treat Options Neurol*. 2012;14:391-401.

Robertson SC, Traynelis VC, Follett KA, et al. Idiopathic spinal epidural lipomatosis. *Neurosurgery*. 1997;41:68-74.

Sandalcioglu IE, Hunold A, Müller O, Bassiouni H, Stolke D, Asgari S. Spinal meningiomas: critical review of 131 surgically treated patients. *Eur Spine J*. 2008;17:1035-1041.

Santi M, Mena H, Wong K, Koeller K, Olsen C, Rushing EJ. Malignant astrocytomas. Clinicopathologic features in 36 cases. *Cancer*. 2003;98(3):554-561.

Schild SE, Nisi K, Scheithauer BW, et al. The results of radiotherapy for ependymomas: the Mayo Clinic experience. *Int J Radiat Oncol*. 1998;42:953-958.

Smoker WR, Khanna G. Imaging the craniocervical junction. *Childs Nerv Syst*. 2008;24:1123-1145.

Tokuhashi Y, Matsuzaki H, Oda H, Oshima M, Ryu J. A revised scoring system for preoperative evaluation of metastatic spine tumor prognosis. *Spine (Phila Pa 1976)*. 2005;30:2186-2191.

Tomita K, Kawahara N, Kobayashi T, Yoshida A, Murakami H, Akamaru T. Surgical strategy for spinal metastases. *Spine (Phila Pa 1976)*. 2001;26:298-306.

Van Goethem JW, van den Hauwe L, Ozsarlak O, De Schepper AM, Parizel PM. Spinal tumors. *Eur J Radiol*. 2004;50:159-176.

Paraneoplastic Syndromes 108

Erika Santos Horta and Tobias Walbert

KEY POINTS

1. Paraneoplastic syndromes have a broad spectrum of symptoms.
2. There is no one-to-one relation between a symptom and an antibody. Therefore, a panel of antibodies needs to be tested.
3. Paraneoplastic syndromes are treatable if quickly recognized. Usually, they are the first symptom of an undiagnosed cancer.
4. Pathogenic antibodies target a synapse protein or a membrane channel.
5. Antibodies targeting nuclear or cytoplasmic proteins are markers of the disease and highly associated with cancers.
6. Management includes diagnosis of the syndromes, the antibody or antibodies associated, a malignancy workup, and treatment.

INTRODUCTION

Paraneoplastic syndromes are a group of disorders that share common neurologic symptoms and an antibody. The neurologic manifestations are broad and include central nervous system and peripheral nervous system disorders. The spectrum of neurologic manifestations is outlined in Figure 108.1.

An association with cancer is not always confirmed but common. When associated with malignancy, paraneoplastic syndrome is called *classic* paraneoplastic syndrome. Although there is no one-to-one association among antibody, clinical manifestation and cancer, Table 108.1 summarizes the most common antibodies and paraneoplastic diseases, and the cancers most often associated with them.

FIGURE 108.1 Summary of manifestations of paraneoplastic syndromes.

In 1976, Purkinje cell cytoplasmic antibody–Tr (PCA-Tr) was found in a patient with Hodgkin lymphoma who developed acute cerebellar degeneration, this was the first instance that an antibody was associated with a neurologic symptom. Since then, the number of antibodies associated with neurologic paraneoplastic disorders has increased to over 30 recognized antibodies.

The knowledge of paraneoplastic syndromes is important because these disorders are treatable and might be the first symptom of an undiagnosed cancer.

EPIDEMIOLOGY

Paraneoplastic syndromes are seen in less than 1% of cancer patients. On the other hand, it is a diagnosis to be highly considered in some selected phenotypes. For example, paraneoplastic encephalitis is the cause of 7.5% of encephalitis cases in the United Kingdom.

Paraneoplastic syndromes affect patients of any age, from children to the elderly. Although some antibodies are highly associated with gender, like Purkinje cell cytoplasmic antibody type 1 (PCA-1) and *N*-methyl-D-aspartate (NMDA) receptor antibody with women and anti-Ta with men, paraneoplastic syndromes as an entity do not have a gender bias.

PATHOBIOLOGY

Although cancer attempts to evade the immune system, cancerous cells do express proteins, including intracellular ones. These proteins become antigens and are recognized by systemic antibodies. Paraneoplastic diseases happen when these antibodies recognize proteins that are also expressed by cells in the nervous system. Therefore, paraneoplastic syndromes are an intersection of neuroimmunology and neurooncology.

Antibodies can be pathogenic or markers of the paraneoplastic syndrome. Pathogenic antibodies such as voltage-gated potassium membrane complex (VGKC) and NMDA antibodies, usually target a synapse protein or a membrane channel. Antibodies that target nuclear or cytoplasmic proteins are usually markers of the disease and cluster of differentiation 8-T-cell receptor (CD8-T) are the cells driving the pathologic process. Examples of this class are PCA-1 and antineuronal nuclear antibody type 1 (ANNA-1).

Interestingly, cancers are more commonly associated with antibodies that target intracellular proteins than with those targeting a membrane complex or protein.

Neuroaxonal swelling, neuronal loss, chromatolysis, vacuolization of neurons, microglial proliferation, and infiltration of T cells are seen microscopically.

TABLE 108.1 Paraneoplastic Syndromes, Associated Cancers, and Antibodies

Syndrome	Frequent Associated Tumors	Frequent Associated Antibodies
Encephalitis	Lung, testicular, ovarian teratoma, thymoma, breast	ANNA-1 (Anti-Hu), NMDA, VGKC, CRMP5 (CV2), amphiphysin, Ta (Ma2), AMPA, $GABA_B$
Epilepsy	Thymoma, lung	VGKC, GAD65, CRMP5
Myelitis	Lung, breast, kidney, thyroid, ovarian endometrium, melanoma	Amphiphysin, CRMP5, PCA-1 (Anti-Yo), ANNA-1 (anti-Hu), ANNA-2, ANNA-3, AQP4, GFAP
Cerebellar degeneration	Ovarian, breast, lung, Hodgkin lymphoma	PCA-1 (Anti-Yo), PCA-2, PCA-Tr, ANNA-2, ANNA-1 (anti-Hu), CV2/CRMP5, GAD65
Peripheral neuropathy/ neuronopathy/autonomic	Lung, breast	ANNA-1, CV2/CRMP5, VGKC, peripherin, gACH, DPPX
Movement disorders	Neuroblastoma, lung, breast cancer, ovarian cancer	ANNA-1, ANNA-2, NMDA, CRMP5, Ta/Ma2
Stiff-person syndrome	SCLC, breast cancer, thymoma, Hodgkin lymphoma, adenocarcinoma	GAD65, amphiphysin, ANNA-2 (Anti-Ri), GlyR
LEMS	Thymoma, lung	VGCC, SOX1
Myasthenia Gravis	Thymoma, lung	mACHR, STR
Retinopathies	SCLC, melanoma	Antirecoverin, antiretinal bipolar cell, CV2/CRMP5

Abbreviations: AMPA, α-amino-3-hydroxy-5-methyl-4-isoxazolepropionic; ANNA, antineuronal nuclear antibody; AQP4, aquaporin-4; CRMP5, collapsin response mediator protein 5; DPPX, dipeptidyl-peptidase-like protein 6; $GABA_B$, γ-aminobutyric acid type B; gACH, ganglionic acetylcholine receptor; GAD65, glutamic acid decarboxylase 65; GFAP, glial fibrillary acidic protein; GlyR, glycine receptor; LEMS, Lambert-Eaton myasthenic syndrome; mACHR, muscarinic acetylcholine receptor; NMDA, *N*-methyl-D-aspartate receptor; PCA, Purkinje cell cytoplasmic antibody; SCLC, small cell lung cancer; SOX1, SRY-related HMG-box genes; STR, striational; VGCC, voltage-gated calcium channel; VGKC, voltage-gated potassium membrane complex.

CLINICAL MANIFESTATIONS

It is important to understand that paraneoplastic disease phenotypes are not necessarily distinct from each other. Patients with the same antibody can present with different manifestations. Furthermore, a patient with one antibody can present with a combination of symptoms like limbic encephalitis and seizures or with an encephalomyelopathy.

Encephalitis

Encephalitis is the most common central nervous system manifestation of paraneoplastic disease. The majority of antibodies have been associated with encephalitis, including ANNA-1 and γ-aminobutyric acid antibodies. Acute/subacute limbic and/or brainstem encephalitis presents with memory loss and confusion and is usually associated with other symptoms like seizures or psychiatric symptoms. This condition can antedate the diagnosis of cancer for about 6 months.

NMDA antibody is the most common antibody found in paraneoplastic encephalitis. Some characteristics of NMDA-antibody encephalitis are extreme delta brush in electroencephalogram, movement disorders symptoms like chorea and jaw dystonia, autonomic disability, and breathing instability. Ovarian teratoma is the classic tumor associated with this antibody. Recently, cases of this entity have been seen after viral infections, especially herpes simplex encephalitis.

Ta antibody, also known as *Ma2 antibody*, is usually seen in young men and associated with testicular cancer; however, Ma1 antibody can be seen in both genders. Both Ma1 and Ma2 antibodies cause encephalitis with memory and behavior alteration as well as ophthalmology features, including opsoclonus and ophthalmoplegia.

VGKC antibody includes all the antibodies against elements of the VGKC-membrane complex, like LGI1 and Caspr2. It can mimic or come with Creutzfeldt-Jakob disease. Interestingly, hyponatremia is a common finding in patients with LGI1-antibody encephalitis.

Epilepsy

Epilepsy related to paraneoplastic antibodies presents as new onset, within months of partial or secondary generalized seizures. They are difficult to treat solely with antiseizure medications. The most frequent type is temporal lobe epilepsy. Other common neurologic manifestations are encephalitis and cognition deficits as well as behavioral changes and movement disorders. The most common antibodies identified are VGKC, mainly LGI1 subtype, glutamic acid decarboxylase 65 (GAD65), and collapsin response mediator protein 5 (CRMP5) antibodies.

LGI1 antibody can have a distinct manifestation of brief dystonic movements of the face and ipsilateral arm called *faciobrachial seizures*. If not treated with immunotherapy, this progresses to encephalitis and temporal lobe epilepsy.

Myelitis

Myelitis is usually associated with encephalopathy and therefore presents as an encephalomyelopathy. The course of the disease is subacute and progressive. It can precede the diagnosis of cancer for up to 18 months. Multiple antibodies such as amphiphysin, anti–ANNA-1 and ANNA-2, CRMP5, and even aquaporin-4 (AQP4) antibodies have been associated with paraneoplastic myelitis.

A new antibody associated with myelitis is glial fibrillary acidic protein antibody. Myelitis is usually central and longitudinally extensive with contrast enhancement. Magnetic resonance imaging (MRI) of the brain can show a peculiar pattern of radial periventricular enhancement, as lines coming from the

ventricle to the cortex. Common associated symptoms are headaches, vision distortions, and tremors.

Cerebellar Ataxia

Cerebellar ataxia is caused by immunologic attack to the Purkinje cells in the cerebellum. It usually starts with gait ataxia that within weeks progresses to trunk and limbs followed by dysarthria, nystagmus, vertigo, and diplopia. It is so aggressive that patients can be bed bound over the course of months. Antibodies associated with this syndrome are PCA-1, PCA type 2, PCA-Tr, and also GAD65 and amphiphysin antibodies. The most common cancers linked with cerebellar ataxia are ovarian, breast, small cell lung cancer, and Hodgkin lymphoma.

Neuropathies

Although this chapter focuses on the association of paraneoplastic disease with antibodies, it does not cover any polyneuropathy, organomegaly, endocrinopathy, M components, and skin changes or monoclonal gammopathy of unclear significance. Paraneoplastic neuropathies, as with other paraneoplastic syndromes, usually predate a cancer diagnosis.

Sensory Neuronopathy

Sensory neuronopathy occurs due to an immunologic attack to the dorsal root ganglion. The loss of proprioception causes ataxia. This presentation is highly associated with cancer, and over 70% of patients have small cell lung cancer. It usually presents over the course of weeks, usually affecting arms first. It is asymmetrically progressive to the point that the patient becomes bedbound. The most common antibody is ANNA-1 antibody, followed by amphiphysin and CRMP5 antibodies.

Sensory-Motor Neuropathies

The neuropathies can be axonal, demyelinating, or vasculitic. The patient's history, electroneuromyography, or biopsy will not differentiate between a paraneoplastic or nonparaneoplastic neuropathy. Therefore, the only possibility of correct diagnosis is to order a paraneoplastic panel. ANNA-1 and CRMP5 are common antibodies. Pain can be a symptom of neuropathy caused by VGKC and CRMP5 antibodies. An acute form of neuropathy that resembles Guillain-Barré syndrome can be found with ANNA-1 antibody.

Autonomic Neuropathies

Autonomic neuropathies are due to immune attack to the autonomic ganglia. The spectrum of autonomic symptoms is broad, including orthostatic hypotension, sweat abnormalities, and gastric dysmotility or pseudo-obstruction. The gastric dysmotility is caused by immune attachment to the enteric neurons. The most common antibody is ganglionic acetylcholine receptor (gACH), but it can also be seen with CRMP5, peripherin, and dipeptidyl peptidase-like protein 6 antibodies. gACH-antibody positivity was identified in 16% of patients with dysautonomia, and although not found in other paraneoplastic syndromes, gACH-antibody levels correlate with severity of autonomic dysfunction.

Motor Neuropathies

These are extremely rare, and case reports are seen in patients with small cell lung cancer. Antibodies associated with motor neuropathies are ANNA-1 and CRMP5 antibodies.

Peripheral Hyperexcitability

Neuromyotonia is characterized by spontaneous and continuous muscle activity with delayed relaxation due to hyperexcitability of peripheral nerves. Clinically, muscle twitching is seen because the patient complains about muscle stiffness.

Morvan syndrome is characterized by neuromyotonia, encephalopathy as neuropsychiatric features, dysautonomia, and neuropathic pain. VGKC antibodies (specially anti-Caspr) are often associated with this syndrome, and it is linked with thymoma.

Isaac syndrome is another hyperexcitability syndrome associated with VGKC-complex antibodies and neuromyotonia. Different from Morvan syndrome, cramps are common and it does not have central nervous manifestations.

Neuromuscular Junction Disorders

Paraneoplastic neuromuscular junction disorders are Lambert-Eaton myasthenic syndrome (LEMS) and myasthenia gravis (MG).

LEMS is caused by antibody attack to the voltage-gated calcium channel (VGCC) receptor. Symptoms are muscle weakness that can be accompanied by dysautonomia. Improvement of reflexes and strength after exercise can be seen in neurologic exam. Electroneuromyography shows improvement of the compound muscle action potential with high-frequency nerve stimulation or after sustained isometric muscle contraction. Positivity for VGCC antibody plus another antibody is highly predictive of cancer. For example, lung cancer was found in 70% of patients with positivity for antibodies against VGCC N-type and p/q type channels and SOX1 antibodies.

MG is characterized by fluctuating weakness that not only affects voluntary muscles like eyes but also cause respiratory insufficiency. Electroneuromyography is the gold standard to diagnose the condition and it shows decrease of the compound muscle action potentials after high-frequency stimulation or after sustained isometric muscle contraction. It is estimated that MG will manifest in 40% of patients with thymoma (Vernino, Lennon 2004), and in this case, besides muscarinic acetylcholine receptor–antibody positivity, it demonstrates positivity for other antibodies. In patients that tested positive for muscarinic acetylcholine receptor and striational antibodies, plus CRMP5 or VGKC antibody, cancer was diagnosed in 81% and of those, 85% had thymoma.

Myopathy

Paraneoplastic myositis is largely represented by dermatomyositis and polymyositis. These conditions are beyond the scope of this chapter and are discussed in detail in Chapter 94. Autoimmune necrotizing myopathy can be seen with signal recognition particle antibody. There are rare cases of patients with ANNA-1 antibody presenting with myopathy.

Movement Disorders

Many paraneoplastic antibodies can cause hypokinetic or hyperkinetic movement disorders. Eighty percent of patients with the NMDA antibody have orobuccolingual movements and/or chorea. Chorea is also seen with CRMP5 and ANNA-1 antibodies. Myoclonus can be seen with ANNA-1 and VGKC-complex antibodies, especially with the LGI1 antibody. Jaw dystonia is associated with the ANNA-2 antibody. Parkinsonism can be seen with Ta/Ma2, ANNA-2, and LGI1 antibodies.

Stiff-person syndrome is represented by muscle rigidity and painful spasms. When combined with encephalomyelitis and dysautonomia the condition is called *progressive encephalomyelitis*. The most common antibody found in these patients is anti-GAD65, but amphiphysin and glycine receptor antibodies are also found.

Paraneoplastic Disorders Affecting the Eyes

The spectrum of eye involvement in paraneoplastic disorders is broad, including neuritis, cranial nerve neuropathies, and eye movement disorders such as nystagmus.

Paraneoplastic optic neuritis is characterized by the sudden painless onset of central scotoma. It is usually bilateral with swelling of the optic discs and altered visual-evoked potential. Paraneoplastic optic neuritis is seen with CRMP5 and ANNA-1 antibodies as in cases of paraneoplastic optic neuromyelitis with aquaporin-4 antibody

Cancer-associated retinopathy is usually also bilateral and painless. Photopsias are present, such as night blindness, constriction of the visual field, and central scotomas. On examination, arteriolar narrowing can be observed as with optic disc pallor. Electroretinography, optical coherence tomography, and fluorescein angiography do not show any alterations specific to paraneoplastic retinopathy. The most common cancer is small cell lung cancer, but cases with prostate, colon, and breast cancer have also been observed. The classic recoverin antibodies are only seen in a small number of patients, but tests should be performed for other antibodies that can damage retinal proteins. The most common is α-enolase antibody. Melanoma-associated retinopathy has rapid onset of mild loss of visual acuity and photopsias such as scotomas. In this case, antibodies are against retinal bipolar cells.

Opsoclonus-myoclonus is usually associated with ANNA antibodies. In children, neuroblastoma should be ruled out. In adults, tumors associated with this syndrome are small cell lung cancer as well as breast and other gynecologic cancers.

MANAGEMENT

The management of paraneoplastic syndromes includes the diagnosis of the syndromes, the associated antibody or antibodies, a malignancy workup, and, obviously, treatment. As the prognosis of these conditions many times depends on how quickly they've been treated, all the management arms should happen at the same time. Antibody panel results can take weeks to come back. Therefore, in the case of a suspicion of a paraneoplastic syndrome, it is better to start a treatment while the results are pending and the malignancy workup is running.

Due to the rarity of these disorders, there are no clinical trials or randomized studies, therefore all management recommendations are level C.

Diagnosis

Paraneoplastic syndromes should be suspected when acute/subacute neurologic symptoms arise. The investigation of paraneoplastic syndromes can use the same diagnostic armamentarium used in neurology. Figure 108.2 summarizes in an algorithm the necessary tests to be considered in the diagnosis of paraneoplastic disorders.

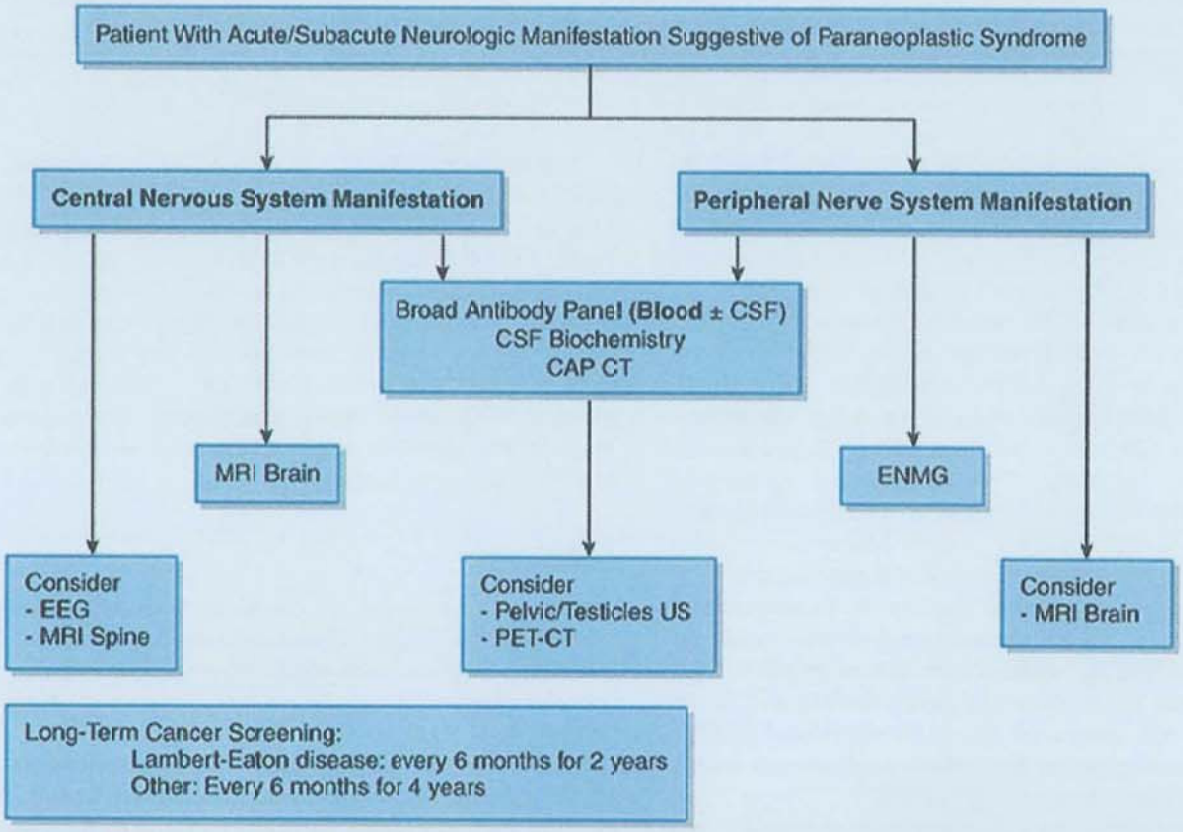

FIGURE 108.2 Algorithm for diagnosing paraneoplastic syndromes. Abbreviations: CAP CT, chest/abdomen/pelvis computed tomography; CSF, cerebrospinal fluid; EEG, electroencephalogram; ENMG, electroneuromyography; MRI, magnetic resonance imaging; PET-CT, positron emission tomography–computed tomography; US, ultrasound.

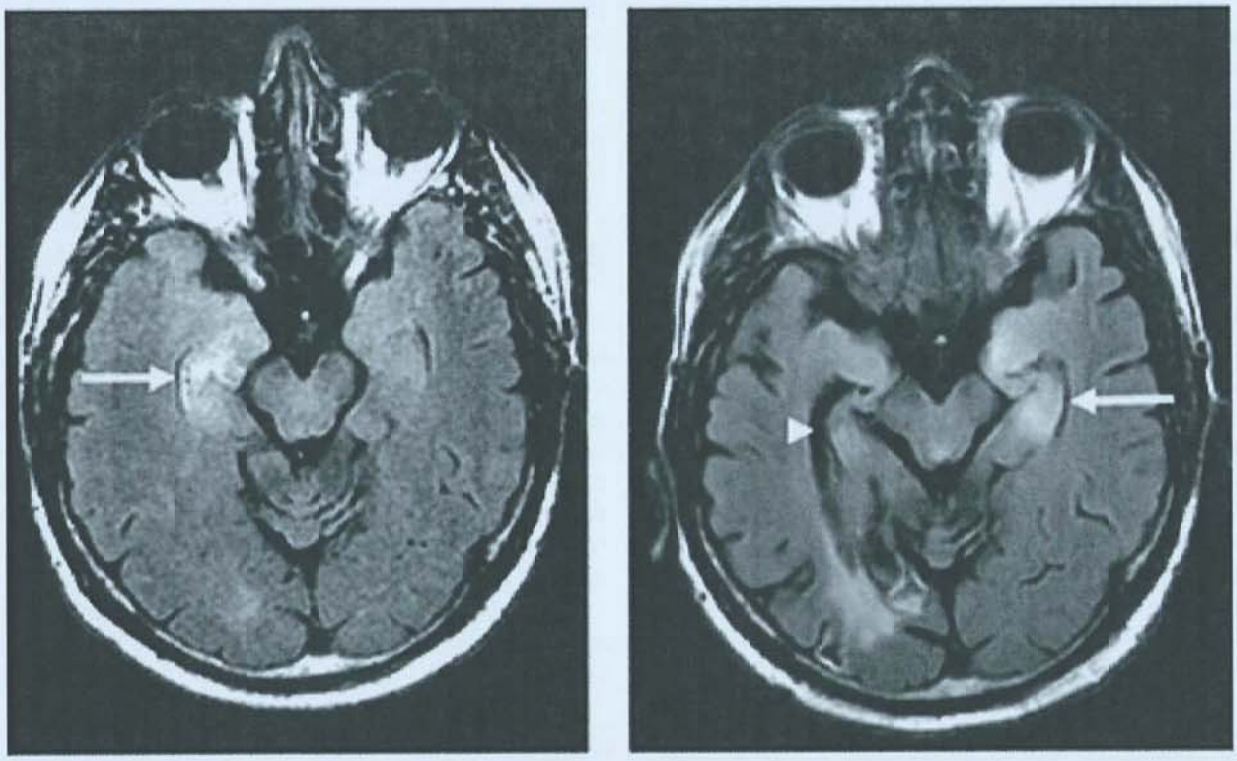

FIGURE 108.3 Anti-Hu encephalitis. A 60-year-old man presented with gradually worsening memory deficits and confusion, with subclinical seizures. Magnetic resonance imaging of the brain demonstrates T2/fluid-attenuated inversion recovery hyperintensity and mild expansion in the right medial temporal lobe *(white arrow)* **(A)**, right insular cortex (not shown), and left dorsal thalamus (not shown), without restricted diffusion (not shown) or postcontrast enhancement (not shown). The patient was in remission following treatment with intravenous immunoglobulin infusions, oral steroids, and chemotherapy, but he presented approximately 2.5 years later with worsening memory decline. Magnetic resonance imaging at that time **(B)** shows new T2/fluid-attenuated inversion recovery hyperintensity in the left medial temporal lobe *(white arrow)* with volume loss within the right medial temporal lobe *(white arrowhead)*. (Images courtesy of Dr. B. Griffith, Henry Ford Health System.)

Lumbar puncture is a resource that is commonly used because the majority of the patients will have alterations in the cerebral spinal fluid. The most common alteration is increased protein levels, but earlier in the disease, pleocytosis is more common. Increase in protein is seen in 67% to 92% of patients, oligoclonal bands in 30% to 77%, and pleocytosis in 28% to 88%.

Imaging studies are usually represented by MRIs, which are used to evaluate the neurologic symptoms LEVEL 3.[1] In limbic encephalitis, MRI of the brain can show alterations in the temporal lobes in 40% to 70% of patients (Fig. 108.3). Paraneoplastic myelitis is usually longitudinally extensive and symmetric. T2-weighted imaging is the most sensitive series, and enhancement can be seen using contrast. It usually affects the dorsolateral columns, but it can also affect the central gray matter.

Many diagnostic tests are used to look for the primary cancer. Computed tomography of the chest/abdomen/pelvis is usually the first to be performed LEVEL 3.[1] When computed tomography is negative, other exams can be added. In the case of NMDA and Ta antibodies, pelvic or test ultrasound should be considered LEVEL 3.[1] Another tool to be considered in any malignancy workup is whole-body positron emission tomography–CT LEVEL 3.[1]

Electroneuromyography is used to diagnose neuropathy, myopathy, or neuromuscular junction disorders LEVEL 3.[1] Unfortunately, it will not reveal whether the syndrome is paraneoplastic. Even muscle or nerve biopsies are unable to differentiate if a condition is paraneoplastic.

It is recommended to use a broad panel evaluating multiple antibodies rather than ordering individual antibodies LEVEL 3.[1] This is due to many reasons. A broad panel has a greater likelihood of identifying the causative antibody rather than one or two individual tests especially as antibodies can coexist, clinical manifestations may overlap, and one antibody can have multiple manifestations. Another reason is that with a broad panel, treatment can start after sample collection. A selective sequential algorithm of antibody testing would delay treatment and could result in false-negative results if antibodies were collected during or after starting immune therapy.

Treatment

Treatments are based on immune-modulator therapies and tumor removal LEVEL 3.[1] There are no clinical trials, and therefore, it is not possible to know which therapy is best. Acutely, the first line of treatment is usually with corticosteroids and/or immunoglobulin G (IgG) or plasma exchange. Second-line therapy is rituximab or cyclophosphamide. The most common doses are 1g of methylprednisone for 5 days for corticosteroids; 0.4 g/kg/d of IVIG for 5 days, five to seven sections of plasma exchange every other day, 375 mg/m^2 each week for rituximab. Long-term maintenance, when needed, is with mycophenolate mofetil, azathioprine, IVIG, cyclophosphamide, or rituximab infusions. In a noncontrolled trial of rituximab in patients with paraneoplastic

diseases associated with ANNA-1 and PCA-1 antibodies, 57% of patients improved.

Symptom management must also be addressed. In Lambert-Eaton disease, 3,4-diaminopyridine can be tried. In case of MG, pyridostigmine is the drug of choice. Benzodiazepines are used in stiff-person syndrome. Antiseizure medications are also used in paraneoplastic epilepsy.

Another question is how long should cancer screening continue for patients when a cancer is not found initially. One European task force suggested repeat oncologic workup every 6 months for 4 years, with the exception of LEMS in which screening efforts should be continued for 2 years.

OUTCOMES

The majority of paraneoplastic disorders have a good prognosis when treated quickly, and a delay in diagnosis has been associated with poor prognosis.

Prognosis is better with antibodies targeting cell surfaces such as calcium channels rather than intracellular targets.

Despite having favorable oncologic prognosis, patients with antibodies to Purkinje cells have poor neurologic prognosis, especially the PCA-1 antibody. Also, in paraneoplastic myelitis, the majority of patients will be either wheelchair dependent or need assistance with walking.

LEVEL 1 EVIDENCE

1. Vedeler CA, Antoine JC, Giometto B, et al; for Paraneoplastic Neurological Syndrome Euronetwork. Management of paraneoplastic neurological syndromes: report of an EFNS Task Force. *Eur J Neurol*. 2006;13(7):682-690.

SUGGESTED READINGS

Apiwattanakul M, Milone M, Pittock SJ, et al. Signal recognition particle immunoglobulin G detected incidentally associates with autoimmune myopathy. *Muscle Nerve*. 2016;53(6):925-932.

Celicanin M, Blaabjerg M, Maersk-Moller C, et al. Autoimmune encephalitis associated with voltage-gated potassium channels-complex and leucine-rich glioma-inactivated 1 antibodies—a national cohort study. *Eur J Neurol*. 2017;24(8):999-1005.

Chen Y, Xing XW, Zhang JT, et al. Autoimmune encephalitis mimicking sporadic Creutzfeldt-Jakob disease: a retrospective study. *J Neuroimmunol*. 2016;295:1-8.

Dalmau J, Lancaster E, Martinez-Hernandez E, Rosenfeld MR, Balice-Gordon R. Clinical experience and laboratory investigations in patients with anti-NMDAR encephalitis. *Lancet Neurol*. 2011;10(1):63-74.

Fang B, McKeon A, Hinson SR, et al. Autoimmune glial fibrillary acidic protein astrocytopathy: a novel meningoencephalomyelitis. *JAMA Neurol*. 2016;73(11):1297-1307.

Flanagan EP, McKeon A, Lennon VA, et al. Paraneoplastic isolated myelopathy: clinical course and neuroimaging clues. *Neurology*. 2011;76(24):2089-2095.

Fu JB, Raj VS, Asher A, et al. Inpatient rehabilitation performance of patients with paraneoplastic cerebellar degeneration. *Arch Phys Med Rehabil*. 2014;95(12):2496-2499.

Gordon LK. Paraneoplastic syndromes in neuro-ophthalmology. *J Neuroophthalmol*. 2015;35(3):306-314.

Granerod J, Ambrose HE, Davies NW, et al. Causes of encephalitis and differences in their clinical presentations in England: a multicentre, population-based prospective study. *Lancet Infect Dis*. 2010;10(12):835-844.

Gultekin SH, Rosenfeld MR, Voltz R, Eichen J, Posner JB, Dalmau J. Paraneoplastic limbic encephalitis: neurological symptoms, immunological findings and tumour association in 50 patients. *Brain*. 2000;123(pt 7):1481-1494.

Hoffmann LA, Jarius S, Pellkofer HL, et al. Anti-Ma and anti-Ta associated paraneoplastic neurological syndromes: 22 newly diagnosed patients and review of previous cases. *J Neurol Neurosurg Psychiatry*. 2008;79(7):767-773.

Horta ES, Lennon VA, Lachance DH, et al. Neural autoantibody clusters aid diagnosis of cancer. *Clin Cancer Res*. 2014;20(14):3862-3869.

Irani SR, Michell AW, Lang B, et al. Faciobrachial dystonic seizures precede LGI1 antibody limbic encephalitis. *Ann Neurol*. 2011;69(5):892-900.

Jones AL, Flanagan EP, Pittock SJ, et al. Responses to and outcomes of treatment of autoimmune cerebellar ataxia in adults. *JAMA Neurol*. 2015;72(11):1304-1312.

Kanikannan MA, Sirisha Y, Uppin MS, et al. Incidence and spectrum of paraneoplastic neurological syndromes: single center study. *J Neurooncol*. 2015;125(1):197-206.

Klein CJ, Lennon VA, Aston PA, McKeon A, Pittock SJ. Chronic pain as a manifestation of potassium channel-complex autoimmunity. *Neurology*. 2012;79(11):1136-1144.

López-Chiriboga AS, Clardy SL. Emerging subspecialties in neurology: autoimmune neurology. *Neurology*. 2017;89(11):e129-e133.

Marx A, Willcox N, Leite MI, et al. Thymoma and paraneoplastic myasthenia gravis. *Autoimmunity*. 2010;43(5-6):413-427.

McKeon A. Autoimmune encephalopathies and dementias. *Continuum (Minneap Minn)*. 2016;22(2):538-558.

McKeon A, Apiwattanakul M, Lachance DH, et al. Positron emission tomography-computed tomography in paraneoplastic neurologic disorders: systematic analysis and review. *Arch Neurol*. 2010;67(3):322-329.

McKeon A, Pittock SJ. Paraneoplastic encephalomyelopathies: pathology and mechanisms. *Acta Neuropathol*. 2011;122(4):381-400.

McKeon A, Tracy JA, Pittock SJ, Parisi JE, Klein CJ, Lennon VA. Purkinje cell cytoplasmic autoantibody type 1 accompaniments: the cerebellum and beyond. *Arch Neurol*. 2011;68(10):1282-1289.

Melzer N, Meuth SG, Wiendl H. Paraneoplastic and non-paraneoplastic autoimmunity to neurons in the central nervous system. *J Neurol*. 2013;260(5):1215-1233.

Newey CR, Appleby BS, Shook S, Sarwal A. Patient with voltage-gated potassium-channel (VGKC) limbic encephalitis found to have Creutzfeldt-Jakob disease (CJD) at autopsy. *J Neuropsychiatry Clin Neurosci*. 2013;25:E05-E07.

Pérez Sánchez S, Pérez Noguera R, Sánchez Sánchez V, López Domínguez JM. Anti-Hu associated paraneoplastic neuropathy simulating an axonal variant of Guillain-Barre syndrome [in Spanish]. *Neurologia*. 2020;35:346-347.

Pignolet BS, Gebauer CM, Liblau RS. Immunopathogenesis of paraneoplastic neurological syndromes associated with anti-Hu antibodies: a beneficial antitumor immune response going awry. *Oncoimmunology*. 2013;2:e27384.

Psimaras D, Carpentier AF, Rossi C. Cerebrospinal fluid study in paraneoplastic syndromes. *J Neurol Neurosurg Psychiatry*. 2010;81(1):42-45.

Quek AM, Britton JW, McKeon A, et al. Autoimmune epilepsy: clinical characteristics and response to immunotherapy. *Arch Neurol*. 2012;69(5):582-593.

Sawlani K, Katirji B. Peripheral nerve hyperexcitability syndromes. *Continuum (Minneap Minn)*. 2017;23(5):1437-1450.

Schein F, Gagneux-Brunon A, Antoine JC, et al. Anti-N-methyl-D-aspartate receptor encephalitis after herpes simplex virus-associated encephalitis: an emerging disease with diagnosis and therapeutic challenges. *Infection*. 2017;45(4):545-549.

Schmitt SE, Pargeon K, Frechette ES, Hirsch LJ, Dalmau J, Friedman D. Extreme delta brush: a unique EEG pattern in adults with anti-NMDA receptor encephalitis. *Neurology*. 2012;79(11):1094-1100.

Serafini A, Lukas RV, VanHaerents S, et al. Paraneoplastic epilepsy. *Epilepsy Behav*. 2016;61:51-58.

Shams'ili S, de Beukelaar J, Gratama JW, et al. An uncontrolled trial of rituximab for antibody associated paraneoplastic neurological syndromes. *J Neurol*. 2006;253(1):16-20.

Tobin WO, Lennon VA, Komorowski L, et al. DPPX potassium channel antibody: frequency, clinical accompaniments, and outcomes in 20 patients. *Neurology*. 2014;83(20):1797-1803.

Trotter JL, Hendin BA, Osterland CK. Cerebellar degeneration with Hodgkin disease. An immunological study. *Arch Neurol*. 1976;33(9):660-661.

Vernino S, Ermilov LG, Sha L, Szurszewski JH, Low PA, Lennon VA. Passive transfer of autoimmune autonomic neuropathy to mice. *J Neurosci*. 2004;24(32):7037-7042. doi:10.1523/JNEUROSCI.1485-04.2004.

Vernino S, Low PA, Fealey RD, Stewart JD, Farrugia G, Lennon VA. Autoantibodies to ganglionic acetylcholine receptors in autoimmune autonomic neuropathies. *N Engl J Med*. 2000;343(12):847-855.

Xu Q, Du W, Zhou H, et al. Distinct clinical characteristics of paraneoplastic optic neuropathy. *Br J Ophthalmol*. 2019;103(6):797-801.

Complications of Cancer Therapy 109

Jasmin Jo and David Schiff

KEY POINTS

1. Neurologic complications from cancer therapy may diminish patients' quality of life. Early recognition and prompt management can improve symptoms and prevent permanent deficits.
2. Complications from radiation therapy are classified into acute (<1 mo), early-delayed (1-6 mo), and late-delayed reactions (>6 mo).
3. Chemotherapy-induced peripheral neuropathy is a major dose-limiting toxicity of chemotherapy.
4. Concomitant or sequential whole-brain radiation therapy with chemotherapy such as methotrexate may cause or increase the extent of leukoencephalopathy.
5. Neurotoxicity from immunotherapy results from immune activation leading to organ-specific autoimmune-like disease.
6. Cytokine-release syndrome and chimeric antigen receptor T-cell related encephalopathy can be life-threatening, and prompt and aggressive management is essential.

INTRODUCTION

Treatment for cancer may result in neurologic complications that can adversely affect patients' functional status and outcomes. Early recognition of the clinical manifestations can assist clinicians in timely diagnosis and management. In this chapter, we discuss common complications related to radiation therapy (RT), chemotherapy, biologic agents, and immunotherapy.

NEUROLOGIC COMPLICATIONS OF RADIOTHERAPY

Introduction

RT is one of the mainstays of treatment for primary and secondary central nervous system (CNS) tumors as well as for prophylaxis in certain systemic malignancies. Complications from RT are well recognized and can have debilitating effects on quality of life. The risk for radiation injury increases with higher total dose and fractions, larger treatment volume, and co-administration of chemotherapy. Patients younger than 10 and older than 70 years old are more susceptible to neurotoxicities from RT.

Pathobiology

Complications are typically categorized according to the temporal relationship to RT: acute (>1 mo), early-delayed (1-6 mo), and late-delayed reactions (>6 mo) (**Table 109.1**). The time differentiation is important because acute and early-delayed reactions are often reversible, whereas delayed complications are irreversible. Radiation-induced capillary injury with disruption of the blood-brain barrier (BBB) leading to edema is the mechanism during acute injury. Late injury is generally associated with permanent tissue damage. The proposed mechanism for late effects is a combination of vascular injury involving the small- and medium-sized vessels, demyelination with loss of oligodendrocytes, and immunologic response to antigens released from damaged glial cells. The pathologic end state is radiation necrosis, comprising of coagulation necrosis and gross demyelination. Tissue atrophy is seen on long-term follow-up.

TABLE 109.1 Neurologic Complications of Radiotherapy

			Clinical Syndromes According to Sites			
Type	**Onset**	**Pathology**	**Brain**	**Spinal Cord**	**Cranial Nerves**	**Peripheral Nerves**
Acute	<1 mo	BBB disruption Edema	Acute encephalopathy Pseudoprogression	...	...	Paresthesia
Early-delayed	1-6 mo	Edema Demyelination	Somnolence syndrome Transient cognitive impairment Pseudoprogression	Lhermitte sign	Painless visual loss Tongue weakness Hearing loss Anosmia	Transient plexopathy Pain
Late-delayed	>6 mo	Vascular injury Demyelination Necrosis Cellular loss	Focal radionecrosis Leukoencephalopathy Cognitive impairment Dementia	Brown-Sequard syndrome Spastic paraplegia	Hearing loss Visual loss Lower CN palsies	Irreversible plexopathy Myokymia on EMG

Abbreviations: BBB, blood-brain barrier; CN, cranial nerve; EMG, electromyography.

Clinical Manifestation, Epidemiology, and Diagnosis

Acute Encephalopathy

Acute encephalopathy can develop within a few hours to days after initiation of RT. This may occur when large doses per fraction (>3 Gy) are administered to a large treatment field, especially in patients with intracranial hypertension. Patients usually present with somnolence, headache, nausea, vomiting, and exacerbation of preexisting deficits. Increased in T2/ fluid-attenuated inversion recovery (FLAIR) hyperintense signal may be seen on magnetic resonance imaging (MRI) studies, although no specific neuroimaging findings are associated with acute injury. With better understanding of safe dose fractionation schedule, this complication is rarely encountered.

Pseudoprogression or Worsening of Preexisting Symptoms

This reaction may be seen acutely or subacutely, typically manifesting as worsening or reappearance of original neurologic symptoms, headache, nausea, and lethargy. Pseudoprogression refers to contrast enhancement within the tumor bed that usually mimics tumor progression. Advance imaging techniques using perfusion or positron emission tomography studies typically reveal diminished cerebral blood volume or hypometabolism, respectively. It occurs in at least 10% to 20% of patients with glioblastoma receiving concurrent RT and temozolomide; it manifests most commonly 1 to 3 months posttreatment, but it may occur later and usually improves within a few months.

Focal Radionecrosis

Cerebral radiation necrosis develops several months to years after external beam RT and after high-dose local radiation such as stereotactic radiosurgery. The risk of developing radiation necrosis increases with larger dose per fraction, higher total dose, and treatment volume. It is reported to occur in 5% to 24% of patients with brain metastases and up to 5% with primary brain tumors. Neurologic deficits depend on the location and size of radionecrosis. An MRI does not distinguish between radiation necrosis and tumor progression. Metabolic and perfusion imaging studies may help discriminate the two entities, but surgery remains the gold standard to confirm the diagnosis.

Leukoencephalopathy and Cognitive Impairment

Cognitive dysfunction frequently develops in 6 months to several years after RT, occurring in up to 90% of patients who survives more than 6 months after whole-brain radiation therapy (WBRT). Impairment can range from mild-to-moderate deficits in short-term memory and attention to dementia in about 12% of patients. Clinical syndrome resembling normal-pressure hydrocephalus (dementia, gait ataxia, and urinary incontinence) has been observed in radiation-induced leukoencephalopathy, which may improve with ventriculoperitoneal shunting. An MRI demonstrates T2/FLAIR hyperintense signal in periventricular white matter (leukoencephalopathy) and atrophy in nearly all cases. Concomitant or sequential chemotherapy with WBRT may increase the extent of leukoencephalopathy, such as in patients with primary CNS lymphoma who received methotrexate or cytarabine.

Radiation-Induced Myelopathy

Radiation-induced damage to the spinal cord is categorized into early-delayed (6 wk to 6 mo) and late-delayed (>6 mo) myelopathy. Acute worsening of neurologic deficits should prompt investigation for intratumoral hemorrhage or tumor progression. Early-delayed myelopathy is characterized by Lhermitte sign that typically resolves spontaneously without distinctive imaging finding. Patients with late-delayed myelopathy often presents with Brown-Sequard syndrome and spastic paraplegia with impaired sensory and autonomic functions. The condition may begin abruptly or insidiously and is most often irreversible. An MRI demonstrates T2/FLAIR hyperintensity and enhancement in the affected spinal cord levels early in the course, whereas spinal cord atrophy without signal abnormality can be seen years after the onset of the disease.

Cranial Neuropathies

Any cranial nerve may be involved if included in the radiation field. The hypoglossal nerve is the most vulnerable cranial nerve followed by the vagus nerve and the recurrent laryngeal nerve, believed to be due to absorption of higher amount of energy from RT to the neck region. Optic neuropathy, the most feared complication results in painless and progressive visual loss or visual field constriction. Thus, it is important to limit the radiation dose to the optic pathway. The oculomotor, trochlear, trigeminal, abducens, and facial nerves are less vulnerable and can be affected by focal RT for skull base tumors. Permanent damage to cranial nerves is rare and usually occurs due to delayed effect.

Brachial and Lumbosacral Plexopathies

RT-induced brachial and lumbosacral plexopathies may result from treatment of breast, lung, and pelvic cancers. The usual presentation includes paresthesia and hypesthesia, followed by weakness and amyotrophy. Pain is usually relatively mild and occurs late in the course, as opposed to severe pain in patients with malignant plexopathy. Myokymia seen on electromyography, hypointensity in T1- and T2-weighted sequences, and absence of mass on MRI suggest RT-induced plexopathy.

Indirect Radiation-Induced Complications to Nervous System

RT can indirectly cause endocrine dysfunction such as hypothalamic-pituitary impairment resulting in hypothyroidism, hypogonadism, hyperprolactinemia, and panhypopituitarism; vascular damage leading to stroke, hemorrhage, vascular malformations, and rarely, stroke-like migraine attacks after radiation therapy (SMART) syndrome; and secondary tumors such as meningioma, glioma, and sarcoma.

Management and Outcome

Corticosteroid (dexamethasone, intravenous [IV] or oral, 8-16 mg/d) generally reverses symptoms from acute and early-delayed injuries but has variable benefit in radiation necrosis. Anti–vascular endothelial growth factor agents such as bevacizumab (10 mg/kg every 2 wk or 7.5 mg/kg every 3 wk, IV) have demonstrated beneficial effects in patients with cerebral radiation necrosis. In rare occasions, surgical resection of cerebral radiation necrosis is indicated, providing both therapeutic and diagnostic benefits. The use of memantine at 20 mg/day within 3 days of initiating RT for 24 weeks results in delayed time to cognitive decline, reduced rate of decline in memory executive function, and processing speed in patients with brain

metastases receiving WBRT LEVEL 1.[1] The addition of hippocampal avoidance to WBRT with memantine reduced the risk of cognitive function failure by 26%, without differences in toxicity, intracranial progression free survival, and overall survival in patients with brain metastases LEVEL 1.[2] Boswellic acids, a phytotherapeutic agent obtained by extraction from *Boswellia serrata*, has been shown to reduce RT-induced cerebral edema in patients with primary or secondary malignant brain tumors in a small prospective study LEVEL 2.[3] Larger phase III studies are warranted to confirm this finding. Pain management and physical therapy are important aspects in the management of RT-induced plexopathy.

Recovery of symptoms is typically expected in acute and early-delayed RT injuries. However, delayed complications from RT are progressive and irreversible, leading to poor outcome and quality of life for long-term survivors.

NEUROLOGIC COMPLICATIONS OF CHEMOTHERAPY

Introduction

Cytotoxic chemotherapy can affect both the central and peripheral nervous system, with the latter being the most common site of toxicity (Table 109.2). The severity depends on the treatment dose, duration, route, existing co-morbidities, and coadministration of other neurotoxic agents. These toxicities can lead to dose reduction and cessation of treatment.

TABLE 109.2 Peripheral and Central Nervous System Toxicities From Cytotoxic and Targeted Agents

Clinical Syndromes	Agents
Acute and subacute encephalopathy	Ifosfamide, high-dose methotrexate, cytarabine, docetaxel, etoposide, 5-fluorouracil, paclitaxel, procarbazine
Aseptic meningitis	IT methotrexate, liposomal cytarabine (DepoCyt)
Cerebellar dysfunction	High-dose cytarabine (AraC), 5-fluorouracil (rare)
PRES	Cisplatin, cyclophosphamide, high-dose corticosteroids, L-asparaginase, gemcitabine, bevacizumab, sorafenib, growth factors, rituximab (rare); IT methotrexate and cytarabine
Chronic leukoencephalopathy	High-dose methotrexate, 5-fluorouracil, capecitabine, fludarabine, cladribine; IT methotrexate
Acute sensory dysesthesia	Oxaliplatin, ifosfamide, cytarabine (rare)
Chronic pure sensory neuropathy	Cisplatin, oxaliplatin, carboplatin, docetaxel, procarbazine, etoposide, bortezomib, thalidomide
Chronic sensory-motor neuropathy	Vincristine, vinorelbine, nelarabine, paclitaxel, ixabepilone, etoposide, fludarabine, 5-fluorouracil, procarbazine, bortezomib, thalidomide
Chronic autonomic neuropathy	Vincristine, thalidomide, ixabepilone (rare)
Vestibulocochlear toxicity	Cisplatin

Abbreviations: IT, intrathecal; PRES, posterior reversible encephalopathy syndrome.

Pathobiology

The mechanism of chemotherapy-induced peripheral neuropathy (CIPN), which refers to generalized, relatively symmetric injury to peripheral nerves, depends on the cytotoxic agents used. Antimitotic agents, such as vinca alkaloids and taxanes, disrupt microtubule-based axonal transport leading to length-dependent axonal injury. Platinum agents such as cisplatin cause neuropathy by apoptosis of sensory neurons in dorsal root ganglion. Transient alterations of voltage-gated sodium channels leading to altered nerve excitability and refractoriness may explain neurotoxicity from oxaliplatin. Despite the presence of the BBB, the CNS remains susceptible to neurotoxicity effects. Factors leading to increased vulnerability of CNS to neurotoxicity include disruption of BBB by direct effects of tumor or by RT, direct administration of drug into the cerebral spinal fluid (CSF) by lumbar puncture or Ommaya reservoir, and intra-arterial delivery of chemotherapy. Chemotherapy can also cause damage to neural progenitor cells responsible for neurogenesis and maintenance of white matter integrity causing leukoencephalopathy.

Clinical Manifestations, Epidemiology, and Diagnosis

Acute or Subacute Encephalopathy

Chemotherapy agents such as ifosfamide, high-dose methotrexate, and procarbazine can cause acute toxicities appearing during or few days after treatment, characterized by confusion, irritability, hallucination, personality changes, seizures, and drowsiness. Ifosfamide, a nitrogen mustard alkylating agent used in the treatment of lymphoma or sarcomas, might cause encephalopathy that occurs in up to 25% of treated patients, more frequent among patients with renal dysfunction. Brain MRIs may be unremarkable or demonstrate edema. Aseptic meningitis occurs in at least 10% of patients receiving intrathecal methotrexate or liposomal cytarabine, often encountered within 24 hours of drug administration. A CSF analysis reveals pleocytosis, elevated protein, and negative cultures.

Acute Cerebellar Syndrome

Acute cerebellar syndrome may develop in 10% to 20% of patients within several days after administration of high-dose cytarabine, a pyrimidine analog frequently used in the management of leukemias and lymphomas. The main risk factor for severe neurotoxicity is renal insufficiency. Older patients (older than age 50 years) and those with hepatic insufficiency may also be at higher risk. Initial manifestations include encephalopathy, confusion, lethargy, and seizures, followed by cerebellar signs such as truncal ataxia and gait instability; however, patients may develop diffuse symptoms without cerebellar signs. With time, MRI may demonstrate cerebellar atrophy due to loss of Purkinje cells.

Posterior Reversible Encephalopathy Syndrome

Posterior reversible encephalopathy syndrome (PRES), manifesting as acute or subacute onset of headache, seizures, confusion, and visual changes, has been reported from cisplatin, cyclophosphamide, high-dose corticosteroids, and gemcitabine. The MRIs typically show bilateral areas of abnormal T2/FLAIR signals, mainly in the parieto-occipital white matter, although involvement of anterior cerebral hemispheres, basal ganglia, thalamus, cerebellum, and/or brainstem have been reported.

Chronic Leukoencephalopathy

Chronic leukoencephalopathy, characterized by progressive personality change, dementia, ataxia, and incontinence, may occur months to years following methotrexate especially when given during or soon after WBRT. When radiation is given prior to methotrexate, the RT may disrupt the BBB and cause an increased permeability of the white matter to the methotrexate. Therefore, WBRT should be administered after systemic or intrathecal methotrexate. Diffuse white matter disease, cortical-subcortical atrophy, and ventricular dilation are typical imaging findings in chronic leukoencephalopathy.

Peripheral Neuropathy

A CIPN is estimated to occur in 30% to 40% of patients treated with chemotherapy, with incidence reported to be up to 60% in those who received cisplatin, paclitaxel, docetaxel, vincristine, and oxaliplatin. Patients typically present with symmetric distal paresthesia, loss of proprioception and vibratory sense, and loss of ankle reflexes. Distal motor weakness and autonomic dysfunction may also occur with certain agents, most prominently with vincristine. Vestibulocochlear toxicity is associated with cisplatin. Acute, cold-induced dysesthesia involving the distal extremities, throat, mouth, or face occur commonly with oxaliplatin. Nerve conduction studies in CIPN may demonstrate decreased sensory nerve action potential, prolonged latencies, and delayed conduction velocities. For classic presentations of CIPN, diagnostic testing is not usually required. Identification and treatment of coexisting conditions that cause peripheral neuropathy, such as diabetes, alcohol abuse, and vitamin B_{12} deficiency, is imperative in the management of CIPN. Paraneoplastic neuropathy, such as subacute sensory paraneoplastic neuropathy associated with anti-Hu antibodies should be distinguished from CIPN as treatment involves further cancer-directed treatment.

Management and Outcome

Acute CNS toxicities usually resolve within few days with supportive treatments. Methylene blue may be effective in treatment (50 mg IV 6 times per day) or prophylaxis (50 mg, IV or oral, 4 times per day) of ifosfamide-induced encephalopathy. Discontinuation of the offending agent is indicated if a patient experiences acute myelopathy or cerebellar syndromes. Cerebellar symptoms from high-dose cytarabine usually resolves within 5 days of discontinuing the drug, but approximately 30% of patients may have permanent neurologic deficits. There are no effective treatments for neurocognitive toxicities. Chronic leukoencephalopathy is often progressive and irreversible. Erythropoietin (40,000 U weekly), methylphenidate (10 mg twice daily), modafinil (200-400 mg/d), cholinesterase inhibitors such as donepezil (5-10 mg/d), nonsteroidal anti-inflammatory agents (ie, aspirin 100 mg daily), as well as cognitive rehabilitation have been studied but no definite recommendations can be made. The CIPN most often resolves on appropriate dose reduction or discontinuation of the offending agents. However, worsening of peripheral neuropathy ("coasting") may occur for a few months after cessation of treatment (eg, cisplatin, thalidomide), preventing timely discontinuation of treatment. Antiepileptic agents, tricyclic antidepressants, serotonin-norepinephrine reuptake inhibitor, opioids, and topical local anesthetics may provide symptomatic relief of CIPN (Table 109.3) LEVEL 2.[4] Neuroprotective agents have been used to prevent or limit neurotoxicity. However, calcium and magnesium infusion (1 g of each given immediately before and after each dose of oxaliplatin) did not substantially decrease oxaliplatin-induced sensory neurotoxicity in a phase III randomized controlled trial LEVEL 2.[5] Some nutritional supplements, such as acetyl-L-carnitine, may worsen rather than improve CIPN LEVEL 2.[6]

TABLE 109.3 Therapeutic Agents Commonly Used for Chemotherapy-Induced Peripheral Neuropathy

Agents	Dose
Carbamazepine	200 mg/d; target plasma level 4-6 mg/L
Gabapentin	100-2,700 mg/d
Pregabalin	75-150 mg/d
Lamotrigine	25-300 mg/d
Duloxetine	30-60 mg/d
Amitriptyline	50 mg/d
Morphine	10-15 mg every 4-5 h
Topical gel (BAK compound)	Twice daily

Abbreviation: BAK, baclofen (10 mg), amitriptyline (40 mg), ketamine (20 mg).

NEUROLOGIC COMPLICATIONS OF BIOLOGIC AGENTS

Monoclonal Antibodies

Rituximab, a humanized monoclonal antibody directed against CD20 antigen on the surface of B cells, which is frequently used in the treatment of B-cell malignancies, may cause headaches, myalgia, paresthesia, dizziness, PRES, and rarely progressive multifocal leukoencephalopathy. Bevacizumab, a humanized antibody against vascular endothelial growth factor, increases the risk of thromboembolic stroke and intracranial hemorrhage, may cause PRES, and rarely, optic neuropathy. Management of hypertension, appropriate supportive care, and in some cases discontinuation of the drug are recommended. Women with human epidermal growth factor receptor 2 (HER-2)–expressing breast cancer treated with trastuzumab, a humanized anti–human epidermal growth factor receptor 2 monoclonal antibody, may experience headache, dizziness, and insomnia after infusion.

Small Molecule Inhibitors

Small molecule protein kinase inhibitors target both membrane-bound and intracellular molecules and interfere with corresponding enzymatic activities. These agents in general have few neurologic complications as a class. Mild visual disturbance, including diplopia, photopsia, chromatopsia, blurred vision, impaired vision, and vitreous floaters, is seen in 45% of patients receiving crizotinib (anaplastic lymphoma kinase and c-Mesenchymal-epithelial transition factor inhibitor). Trametinib, a MEK inhibitor, also causes ocular toxicities such as blurred vision and chorioretinopathy. Muscle spasm is reported in 98% of patients treated with vismodegib (SMO inhibitor). Bortezomib, a proteasome inhibitor, causes length-dependent, painful, small-fiber sensory axonal neuropathy in 40% to 64% of patients with treatment-naïve multiple myeloma and is the most common reason for treatment discontinuation. Symptoms improve with discontinuation or dose reduction of the

offending agent. Carfilzomib, a second-generation proteasome inhibitor, has significantly lower incidence (14%) of neuropathy. Thalidomide, an immunomodulatory and antiangiogenic agent used to treat multiple myeloma causes peripheral neuropathy in 70% of patients presenting with sensorimotor axonal neuropathy and dysautonomia. The incidence and severity of peripheral neuropathy is significantly less from second-generation immunomodulatory agents such as lenalidomide and pomalidomide.

NEUROLOGIC COMPLICATIONS OF IMMUNOTHERAPY

Introduction, Epidemiology, and Pathobiology

Immunotherapy comprises both active therapies, such as antitumor vaccines, cellular-based therapies (chimeric antigen receptor T cells [CAR-T cells]), and pro-inflammatory cytokines (interferon and interleukin), and passive therapies in the form of monoclonal antibodies blocking immune checkpoints, including anti-cytotoxic T-lymphocyte associated protein 4 (ipilimumab) and anti-program cell death protein 1 (pembrolizumab and nivolumab). Patients on CAR-T cell therapy sometimes develop neurologic complications due to cytokine release syndrome, which occurs in up to 40% of patients. Interleukin-2 (IL-2) crosses the BBB, causing direct toxicity to the neurons and glial cells resulting in acute/subacute neurologic symptoms in 30% to 50% of patients who receive IL-2 in an IV bolus. This incidence is reduced by constant IL-2 infusion. Immune-mediated toxicities from check point inhibitors occur as a result of immune activation leading to organ-specific autoimmune-like disease. Mild-to-moderate neurotoxicities are encountered in about 10% of patients treated with immune checkpoint inhibitors (ICI), with severe, potentially life-threatening immune-mediated neurologic complications occurring in less than 1%.

Clinical Manifestations and Diagnosis

The ICI-related neurotoxicities range from involvement of the cortex to the muscles (Table 109.4). Encephalitis and meningitis are the best described CNS adverse effects to date; other reported complications include myelitis, encephalopathy, PRES, and exacerbation of multiple sclerosis. An MRI and a CSF analysis aid in the diagnosis. The majority of patients with acute and chronic immune demyelinating polyneuropathy present with sensory and motor symptoms, sometimes associated with dysautonomia and cranial neuropathies. Cytoalbuminologic dissociation on CSF analysis and evidence of demyelination on electrophysiologic studies are usually seen. Compared to patients with idiopathic Myasthenia gravis, ICI-related MG demonstrates a higher frequency of bulbar weakness and dyspnea on presentation. Cytokine release–associated encephalopathy manifest with delirium, aphasia, tremors, myoclonus, and seizures. Neuropsychiatric symptoms, most commonly depression, encephalopathy, hallucination, and seizures, are frequently reported with interferon-α. Transient encephalopathy and neurocognitive symptoms may develop toward the end of therapy with IL-2.

Management and Outcome

Early discontinuation of immunotherapy increases the chances of complete recovery. Steroids should be initiated first (methylprednisone 125 mg IV for 3 days followed by prednisolone 1 mg/kg/d) and often are sufficient to treat symptoms. Further immunosuppressive approaches (plasmapheresis for 3-5 sessions or IV immunoglobulin 2 g/kg given over 2-5 d) are indicated for refractory cases. Anticholinergic inhibitors for MG and empiric antibiotic or antiviral agents for encephalitis are also considered. Tocilizumab (4-8 mg/kg), a monoclonal antibody that binds to interleukin-6 receptors, and methylprednisolone (1-2 mg/kg every 12 h) have been used to manage

TABLE 109.4 Neurologic Toxicities From Immune Checkpoint Inhibitors

Clinical Syndromes	Incidence	Clinical Manifestations	Diagnosis
Encephalitis	0.1%-1%	Acute or subacute onset of confusion, fever, nuchal rigidity, or seizures	MRI: normal or with T2 hyperintensity in limbic structures and subcortical regions, dural thickening and meningeal enhancement; CSF: increased protein and WBC
Meningitis	0.1%-0.2%	Fever, nuchal rigidity, somnolence	MRI: meningeal enhancement; CSF: lymphocytic pleocytosis and negative cultures
Myelitis	NA	Subacute onset of weakness, numbness, gait disturbance, sphincter dysfunction	MRI: focal T2 hyperintensities CSF: pleocytosis
Cranial neuropathies	NA	CN VII and VI are commonly affected.	MRI to rule out other causes such as stroke or mass
Meningoradiculo-neuritis	NA	Headache, radicular pain, facial palsies, sensory deficit, flaccid weakness	Brain and spine MRI may be normal or show nerve roots enhancement.
AIDP	0.1%-2%	Rapidly progressive motor and sensory deficits, areflexia, facial palsy	EMG: slowed nerve conduction velocities, conduction blocks, and absent or prolonged F and H waves; CSF: cytoalbuminologic dissociation of mild pleocytosis and high protein
CIDP	NA	Length-dependent weakness and numbness, areflexia, autonomic dysfunction	Same as AIDP
Myasthenia gravis	0.1%-0.2%	Bulbar weakness and limb weakness; pure ocular symptoms are less common	Serology: positive AchR antibody; no reported cases of positive anti-MuSK; high CK; EMG: decrement on RNS and jitter on single-fiber test

Abbreviations: AchR, acetylcholine receptor; AIDP, acute inflammatory demyelinating polyneuropathy; CIDP, chronic inflammatory demyelinating polyneuropathy; CK, creatine kinase; CN, cranial nerve; CSF, cerebral spinal fluid; EMG, electromyography; MRI, magnetic resonance imaging; NA, not available; RNS, repetitive nerve stimulation; WBC, white blood cell.

cytokine release syndrome. Neurologic symptoms usually resolve after discontinuation of proinflammatory cytokines, although permanent dementia and persistent vegetative state have been reported.

NEUROLOGIC COMPLICATIONS OF HEMATOPOIETIC STEM CELL TRANSPLANTATION

Introduction and Epidemiology

Hematopoietic stem cell transplantation (HSCT) involves IV infusion of hematopoietic progenitor cells from the patient (autologous) or a human leukocyte antigen-matched donor (allogenic) to reestablish the bone marrow function destroyed by chemotherapy or chemoirradiation given to achieve myeloablation and eradicate cancer cells. Neurologic complications from HSCT are reported to occur in 11% to 59% of patients in clinical studies and in more than 90% in autopsy reports.

Pathobiology, Clinical Manifestations, and Diagnosis

Neurologic complications can be classified according to time of onset in relation to HSCT: (1) During stem cell harvesting and conditioning, neurotoxicities develop from myeloablative doses of chemotherapy. These include seizures associated with busulfan; encephalopathy with ifosfamide, melphalan, etoposide, thiotepa; neuropathy with carboplatin, cyclophosphamide, and etoposide; severe ototoxicity with carboplatin; and rarely, pain and myeloradicular syndrome after intrathecal methotrexate. (2) During bone marrow depletion, complications are due to organ failure resulting in metabolic abnormalities, coagulopathies, infections, and drug toxicities. Focal neurologic deficits should prompt neuroimaging studies such as computed tomography and/or MRI for suspicion of subdural and intraparenchymal hemorrhages as well as infection due to bacteria (*Staphylococcus* and gram-negative organisms), viruses (adenovirus, Coxsackievirus, herpesvirus, and cytomegalovirus), and fungi (*Candida* or *Aspergillus* species). (3) After bone marrow reconstitution, complications are secondary to chronic immunosuppression and graft-versus-host disease. About 5% to 8% of patients develop opportunistic CNS infection including toxoplasmosis, human herpesvirus-6, cytomegalovirus, John Cunningham virus reactivation, nocardia, and aspergillus. Major CNS complications from calcineurin inhibitors (cyclosporine and tacrolimus) include headache, altered mental status, seizures, cortical blindness, visual and auditory hallucinations, spasticity, paresis, and ataxia. The PRES is also reported, perhaps due to direct toxicity to vascular endothelium.

Management and Outcome

For patients with CNS infection, treatment is directed toward the inciting pathogens and should be empirically started if suspicion is high as microbiologic diagnosis is often difficult. Neurologic symptoms related to calcineurin inhibitors eventually resolve after reducing or stopping the treatment.

CONCLUSION

Neurologic complications can cause significant morbidity and mortality for patients treated for cancer. These complications can result from direct toxicity to the nervous system, indirectly through toxic-metabolic effects, or from immunosuppressant effects resulting in opportunistic infection. Early recognition and differentiation from metastatic disease or paraneoplastic syndromes are imperative for proper management as well as avoidance of inappropriate discontinuation or dose-reduction of therapeutic agents.

LEVEL 1 EVIDENCE

1. Brown PD, Pugh S, Laack NN, et al. Memantine for the prevention of cognitive dysfunction in patients receiving whole-brain radiotherapy: a randomized, double-blind, placebo-controlled trial. *Neuro Oncol*. 2013;15(10):1429-1437.
2. Gondi V, Deshmukh S, Brown PD, et al. Preservation of neurocognitive function (NCF) with conformal avoidance of the hippocampus during whole-brain radiotherapy (HA-WBRT) for brain metastases: preliminary results of phase III trial NRG Oncology CC001. *Radiation Oncol*. 2018; 102:1607.
3. Kirste S, Treier M, Wehrle SJ, et al. Boswellia serrata acts on cerebral edema in patients irradiated for brain tumors: a prospective, randomized, placebo-controlled, double-blind pilot trial. *Cancer*. 2011;117(16):3788-3795.
4. Hershman DL, Lacchetti C, Dworkin RH, et al. Prevention and management of chemotherapy-induced peripheral neuropathy in survivors of adult cancers: American Society of Clinical Oncology clinical practice guideline. *J Clin Oncol*. 2014;32(18):1941-1967.
5. Loprinzi CL, Qin R, Dakhil SR, et al. Phase III randomized, placebo-controlled, double-blind study of intravenous calcium and magnesium to prevent oxaliplatin-induced sensory neurotoxicity (N08CB/Alliance). *J Clin Oncol*. 2014;32(10): 997-1005.
6. Hershman DL, Unger JM, Crew KD, et al. Randomized double-blind placebo-controlled trial of acetyl-L-carnitine for the prevention of taxane-induced neuropathy in women undergoing adjuvant breast cancer therapy. *J Clin Oncol*. 2013; 31(20):2627-2633.

SUGGESTED READINGS

Neurologic Complications of Radiotherapy

Arlt W, Hove U, Müller B, et al. Frequent and frequently overlooked: treatment-induced endocrine dysfunction in adult long-term survivors of primary brain tumors. *Neurology*. 1997;49(2):498-506.

Brandsma D, Stalpers L, Taal W, Sminia P, van den Bent M. Clinical features, mechanisms, and management of pseudoprogression in malignant gliomas. *Lancet Oncol*. 2008;9(5):453-461.

Brown PD, Pugh S, Laack NN, et al. Memantine for the prevention of cognitive dysfunction in patients receiving whole-brain radiotherapy: a randomized, double-blind, placebo-controlled trial. *Neuro Oncol*. 2013;15(10): 1429-1437.

Chi D, Behin A, Delattre JY, et al. Neurologic complications of radiation therapy. In: Schiff D, Kesari S, Wen P, eds. *Cancer Neurology in Clinical Practice. Neurologic Complications of Cancer and Its Treatment*. Totowa, NJ: Humana Press; 2008:259-286.

Crossen JR, Garwood D, Glatstein E, Neuwelt EA. Neurobehavioral sequelae of cranial irradiation in adults: a review of radiation-induced encephalopathy. *J Clin Oncol*. 1994;12(3):627-642.

Esik O, Csere T, Stefanits K, et al. A review on radiogenic Lhermitte's sign. *Pathol Oncol Res*. 2003;9(2):115-120.

Giglio P, Gilbert MR. Neurologic complications of cancer and its treatment. *Curr Oncol Rep*. 2010;12(1):50-59.

Gondi V, Deshmukh S, Brown P. Preservation of neurocognitive function with conformal avoidance of the hippocampus during whole-brain radiotherapy for brain metastases: preliminary results of phase III trial. NRG Oncology CC001. Paper presented at: ASTRO Annual Meeting; October 23, 2018; San Antonio, Texas.

Jaeckle KA. Neurologic manifestations of neoplastic and radiation-induced plexopathies. *Semin Neurol*. 2010;30(3):254-262.

Kargiotis O, Kyritsis AP. Radiation-induced peripheral nerve disorders. In: Wen P, Schiff D, Lee EQ, eds. *Neurologic Complications of Cancer Therapy*. New York, NY: Demos Medical; 2012:355-368.

Kerklaan JP, Lycklama ÀNGJ, Wiggenraad RGJ, Berghuis B, Postma TJ, Taphoorn MJB. SMART syndrome: a late reversible complication after radiation therapy for brain tumours. *J Neurol*. 2011;258(6):1098-1104.

Lee YW, Cho HJ, Lee WH, Sonntag WE. Whole brain radiation-induced cognitive impairment: pathophysiological mechanisms and therapeutic targets. *Biomol Ther (Seoul)*. 2012;20(4):357-370.

Levin VA, Bidaut L, Hou P, et al. Randomized double-blind placebo-controlled trial of bevacizumab therapy for radiation necrosis of the CNS. *Int J Radiat Oncol Biol Phys*. 2011;79(5):1487-1495.

Lin YS, Jen YM, Lin JC. Radiation-related cranial nerve palsy in patients with nasopharyngeal carcinoma. *Cancer*. 2002;95(2):404-409.

Madani O, Bompaire F, Mokhtari K, Sanson M, Ricard D. Acute demyelination secondary to radiation therapy in a patient with glioma [in French]. *Presse Med*. 2014;43:1139-1143.

Nolan CP, DeAngelis LM. Neurologic complications of chemotherapy and radiation therapy. *Continuum (Minneap Minn)*. 2015;21(2 Neuro-oncology): 429-451.

Pettorini BL, Park YS, Caldarelli M, Massimi L, Tamburrini G, Di Rocco C. Radiation-induced brain tumours after central nervous system irradiation in childhood: a review. *Childs Nerv Syst*. 2008;24(7):793-805.

Posner J. Side effects of radiation therapy. In: Posner J, ed. *Neurologic Complications of Cancer*. Philadelphia, PA: F.A. Davis Company; 1995:311-337.

Qayyum A, MacVicar AD, Padhani AR, Revell P, Husband JE. Symptomatic brachial plexopathy following treatment for breast cancer: utility of MR imaging with surface-coil techniques. *Radiology*. 2000;214(3):837-842.

Ricard D, Psimaras D, Soussain C, Martin-Duverneuil N, Delattre J-Y. Central nervous system complications of radiation therapy. In: Wen P, Schiff D, Lee EQ, eds. *Neurologic Complications of Cancer Therapy*. New York, NY: Demos Medical; 2012:301-313.

Rogers LR. Neurologic complications of radiation. *Continuum (Minneap Minn)*. 2012;18(2):343-354.

Sheline GE. Radiation therapy of brain tumors. *Cancer*. 1977;39(2 suppl): 873-881.

Thiesen B, DeAngelis LM. Hydrocephalus in radiation leukoencephalopathy: results of ventriculoperitoneal shunting. *Arch Neurol*. 1998;55(5):705-710.

Torcuator R, Zuniga R, Mohan YS, et al. Initial experience with bevacizumab treatment for biopsy confirmed cerebral radiation necrosis. *J Neurooncol*. 2009;94(1):63-68.

Young DF, Posner JB, Chu F, Nisce L. Rapid-course radiation therapy of cerebral metastases: results and complications. *Cancer*. 1974;34(4):1069-1076.

Neurologic Complications of Chemotherapy

Arrillaga-Romany IC, Dietrich J. Imaging findings in cancer therapy-associated neurotoxicity. *Semin Neurol*. 2012;32(4):476-486.

Baker WJ, Royer GL Jr, Weiss RB. Cytarabine and neurologic toxicity. *J Clin Oncol*. 1991;9(4):679-693.

Davis J, Ahlberg FM, Berk M, Ashley DM, Khasraw M. Emerging pharmacotherapy for cancer patients with cognitive dysfunction. *BMC Neurol*. 2013;13:153.

Dropcho EJ. The neurologic side effects of chemotherapeutic agents. *Continuum (Minneap Minn)*. 2011;17(1 Neurologic Complications of Systemic Disease):95-112.

Gill JS, Windebank AJ. Cisplatin-induced apoptosis in rat dorsal root ganglion neurons is associated with attempted entry into the cell cycle. *J Clin Invest*. 1998;101(2):2842-2850.

Grisold W, Cavaletti G, Windebank AJ. Peripheral neuropathies from chemotherapeutics and targeted agents: diagnosis, treatment, and prevention. *Neuro Oncol*. 2012;14 suppl 4:iv45-iv54.

Henderson RD, Rajah T, Nicol AJ, Read SJ. Posterior leukoencephalopathy following intrathecal chemotherapy with MRA-documented vasospasm. *Neurology*. 2003;60(2):326-328.

Hershman DL, Lacchetti C, Dworkin RH, et al. Prevention and management of chemotherapy-induced peripheral neuropathy in survivors of adult cancers: American Society of Clinical Oncology clinical practice guideline. *J Clin Oncol*. 2014;32(18):1941-1967.

Hershman DL, Unger JM, Crew KD, et al. Randomized double-blind placebo-controlled trial of acetyl-L-carnitine for the prevention of taxane-induced neuropathy in women undergoing adjuvant breast cancer therapy. *J Clin Oncol*. 2013;31(20):2627-2633.

Joseph EK, Chen X, Bogen O, Levine JD. Oxaliplatin acts on IB4-positive nociceptors to induce an oxidative stress-dependent acute painful peripheral neuropathy. *J Pain*. 2008;9(5):463-472.

Krishnan AV, Goldstein D, Friedlander M, Kiernan MC. Oxaliplatin-induced neurotoxicity and the development of neuropathy. *Muscle Nerve*. 2005;32(1):51-60.

Lee EQ, Arrillaga-Romany IC, Wen PY. Neurologic complications of cancer drug therapies. *Continuum (Minneap Minn)*. 2012;18(2):355-365.

Loprinzi CL, Qin R, Dakhil SR, et al. Phase III randomized, placebo-controlled, double-blind study of intravenous calcium and magnesium to prevent oxaliplatin-induced sensory neurotoxicity (N08CB/Alliance). *J Clin Oncol*. 2014;32(10):997-1005.

Menje M, Dietrich J. Cognitive side effects of cancer therapy demonstrate a functional role for adult neurogenesis. *Behav Brain Res*. 2012;227(2):376-379.

Nolan CP, DeAngelis LM. Neurologic complications of chemotherapy and radiation therapy. *Continuum (Minneap Minn)*. 2015;21(2 Neuro-oncology):429-451.

Omuro AM, Ben-Porat LS, Panagas KS, et al. Delayed neurotoxicity in primary central nervous system lymphoma. *Arch Neurol*. 2005;52(10):1595-1600.

Pelgrims J, De Vos F, Van den Brande J, Schrijvers D, Prové A, Vermorken JB. Methylene blue in the treatment and prevention of ifosfamide-induced encephalopathy: report of 12 cases and a review of the literature. *Br J Cancer*. 2000;82(2):291-294.

Rowinsky EK. Antimitotic drugs. In: Chabner BA, Longo DL, eds. *Cancer Chemotherapy and Biotherapy: Principles and Practice*. 5th ed. Philadelphia, PA: Lippincott Williams & Wilkins; 2011:216-266.

Schiff D, Wen PY, van den Bent MJ. Neurological adverse effects caused by cytotoxic and targeted therapies. *Nat Rev Clin Oncol*. 2009;6(10):596-603.

Sioka C, Kyritsis AP. Central and peripheral nervous system toxicity of common chemotherapeutic agents. *Cancer Chemother Pharmacol*. 2009;63(5):761-767.

Vargo CA, Ray LA, Newton HB. Neurological complications of chemotherapy. In: Schiff D, Arrillaga-Romany IC, Wen P, eds. *Cancer Neurology in Clinical Practice*. Cham, Switzerland: Springer Nature; 2018:275-310.

Vaughn C, Zhang L, Schiff D. Reversible posterior leukoencephalopathy syndrome in cancer. *Curr Oncol Rep*. 2008;10(1):86-91.

Velasco R, Bruna J. Chemotherapy-induced peripheral neuropathy: an unresolved issue [in Spanish]. *Neurologia*. 2010;25(2):116-131.

Neurologic Complications of Biologic Agents

Al-Tawfiq JA, Banda RW, Daabil RA, Dawamneh MF. Progressive multifocal leukoencephalopathy (PML) in a patient with lymphoma treated with rituximab: a case report and literature review. *J Infect Public Health*. 2015;8(5):493-497.

Armstrong T, Wen PY, Gilbert MR, Schiff D. Management of treatment-associated toxicities of anti-angiogenic therapy in patients with brain tumors. *Neuro Oncol*. 2012;14(10):1203-1214.

Bang YJ. The potential for crizotinib in non-small cell lung cancer: a perspective review. *Ther Adv Med Oncol*. 2011;3(6):279-291.

Basset-Séguin N, Hauschild A, Kunstfeld R, et al. Vismodegib in patients with advanced basal cell carcinoma: primary analysis of STEVIE, an international, open-label trial. *Eur J Cancer*. 2017;86:334-348.

Cobleigh MA, Vogel CL, Tripathy D, et al. Multinational study of the efficacy and safety of humanized anti-HER2 monoclonal antibody in women who have HER2-overexpressing metastatic breast cancer that has progressed after chemotherapy for metastatic disease. *J Clin Oncol*. 1999;17(9):2639-2648.

Flaherty KT, Robert C, Hersey P, et al. Improved survival with MEK inhibition in BRAF-mutated melanoma. *N Engl J Med*. 2012;367(2):107-114.

Foran JM, Rohatiner AZ, Cunningham D, et al. European phase II study of rituximab (chimeric anti-CD20 monoclonal antibody) for patients with newly diagnosed mantle-cell lymphoma and previously treated mantle-cell lymphoma, immunocytoma, and small B-cell lymphocytic lymphoma. *J Clin Oncol*. 2000;18(2):317-324.

Lane MA, Renga V, Pachner AR, Cohen JA. Late occurrence of PML in a patient treated for lymphoma with immunomodulatory chemotherapies, bendamustine, rituximab, and ibritumomab tiuxetan. *Case Rep Neurol Med*. 2015;2015:892047.

Mohty B, El-Cheikh J, Yakoub-Agha I, Moreau P, Harousseau J-L, Mohty M. Peripheral neuropathy and new treatments for multiple myeloma: background and practical recommendations. *Haematologica*. 2010;95(2):311-319.

Rampen AJ, Jongen JL, van Heuvel I, Scheltens-de Boer M, Sonneveld P, van den Bent MJ. Bortezomib-induced polyneuropathy. *Neth J Med*. 2013;71(3):128-133.

Richardson PG. Towards a better understanding of treatment-related peripheral neuropathy in multiple myeloma. *Lancet Oncol*. 2010;11(11):1014-1016.

Sherman JH, Aregawi DG, Lai A, et al. Optic neuropathy in patients with glioblastoma receiving bevacizumab. *Neurology*. 2009;73(22):1924-1926.

Siegel D, Martin T, Nooka A, et al. Integrated safety profile of single-agent carfilzomib: experience from 526 patients enrolled in 4 phase II clinical studies. *Haematologica*. 2013;98(11):1753-1761.

Neurologic Complications of Immunotherapy

Apfel SC. Neurologic complications of immunomodulatory agents. In: Wen P, Schiff D, Lee EQ, eds. *Neurologic Complications of Cancer Therapy*. New York, NY: Demos Medical Publishing; 2012:93-106.

Cuzzubbo S, Javeri F, Tissier M, et al. Neurological adverse events associated with immune checkpoint inhibitors: review of the literature. *Eur J Cancer*. 2017;73:1-8.

Hottinger AF. Neurologic complications of immune checkpoint inhibitors. *Curr Opin Neurol*. 2016;29(6):806-812.

Liao B, Shroff S, Kamiya-Matsuoka C, Tummala S. Atypical neurological complications of ipilimumab therapy in patients with metastatic melanoma. *Neuro Oncol*. 2014;16(4):589-593.

Mandel JJ, Olar A, Aldape KD, Tremont-Lukats IW. Lambrolizumab induced central nervous system (CNS) toxicity. *J Neurol Sci*. 2014;344(1-2):229-231.

Meyers CA, Scheibel RS, Forman AD. Persistent neurotoxicity of systemically administered interferon-alpha. *Neurology*. 1991;41(5):672-676.

Perrinjaquet C, Desbaillets N, Hottinger AF. Neurotoxicity associated with cancer immunotherapy: immune checkpoint inhibitors and chimeric antigen receptor T-cell therapy. *Curr Opin Neurol*. 2019;32(3):500-510.

Riegler LL, Jones GP, Lee DW. Current approaches in the grading and management of cytokine release syndrome after chimeric antigen receptor T-cell therapy. *Ther Clin Risk Manag*. 2019;15:323-335.

Rohatiner AZ, Prior PF, Burton AC, Smith AT, Balkwill FR, Lister TA. Central nervous system toxicity of interferon. *Br J Cancer*. 1983;47(3):419-422.

Schneider S, Potthast S, Komminoth P, Schwegler G, Böhm S. PD-1 checkpoint inhibitor associated autoimmune encephalitis. *Case Rep Oncol*. 2017;10(2):473-478.

Suzuki S, Ishikawa N, Konoeda F, et al. Nivolumab-related myasthenia gravis with myositis and myocarditis in Japan. *Neurology*. 2017;89:1127-1134.

Touat M, Talmasov D, Ricard D, Psimaras D. Neurological toxicities associated with immune-checkpoint inhibitors. *Curr Opin Neurol*. 2017;30(6):559-668.

Wick W, Hertenstein A, Platten M. Neurological sequelae of cancer immunotherapies and targeted therapies. *Lancet Oncol*. 2016;17(12):e529-e541.

Neurologic Complications of Hematopoietic Stem Cell Transplantation

Dulamea AO, Lupescu IG. Neurological complications of hematopoietic cell transplantation in children and adults. *Neural Regen Res*. 2018;13(6):945-954.

Hinchey J, Chaves C, Appignani B, et al. A reversible posterior leukoencephalopathy syndrome. *N Engl J Med*. 1996;334(8):494-500.

Lee EQ, Wen PY. Neurologic complications of hematopoietic stem cell transplantation. In: Schiff D, Arrillaga-Romany IC, Wen P, eds. *Cancer Neurology in Clinical Practice*. Cham, Switzerland: Springer Nature; 2018:345-357.

Rosenfeld MR, Pruitt A. Neurologic complications of bone marrow, stem cell, and organ transplantation in patients with cancer. *Semin Oncol*. 2006;33(3):352-361.

Sklar EM. Post-transplant neurotoxicity: what role do calcineurin inhibitors actually play? *AJNR Am J Neuroradiol*. 2006;27:1602-1603.

Hydrocephalus 110

Kumud Sharma and Fred Rincon

KEY POINTS

1. Hydrocephalus is characterized by an imbalance in the production, drainage, and reabsorption of cerebrospinal fluid (CSF) resulting in a dilation of the cerebral ventricles.
2. The only known cause of nonobstructive hydrocephalus is choroid plexus papilloma due to oversecretion of CSF.
3. Obstructive hydrocephalus is used to describe conditions that result near-complete blockage of CSF flow within the ventricular system.
4. *Communicating* hydrocephalus infers to CSF obstruction due to damage to the absorptive system after exiting the ventricles.
5. Normal-pressure hydrocephalus is a form of communicating hydrocephalus.

INTRODUCTION

The ventricular system of central nervous system is composed of two lateral ventricles: midline third ventricle and fourth ventricle. Ventricles and central spinal canal are lined by ependyma, which is a cuboidal epithelium. Choroid plexus, located in the floor of lateral, third, and fourth ventricles, are the main sites of cerebrospinal fluid (CSF) production. The epithelial cells of the choroid plexus secrete CSF. Choroid plexus are villous structures that project into the ventricles.

Hydrocephalus is characterized by an imbalance in the production, drainage, and reabsorption of CSF resulting in a dilation of the cerebral ventricles. The choroid plexus produces about 500 mL of CSF daily. The CSF circulates from the lateral ventricles to the third ventricle through the foramen of Monro. It then flows to the fourth ventricle via the cerebral aqueduct and exits into the subarachnoid space via the foramina of Magendie (medial) and Luschka (lateral) and moves into the subarachnoid space and spinal canal. The arachnoid villi granulations present within the superior sagittal sinus reabsorb the CSF into the venous system. At any given time, the total volume of CSF within the CNS is about 150 mL. The difference between production and quantity present is due to active absorption of CSF by arachnoid granulations.

CLASSIFICATION

Although various classifications of hydrocephalus have evolved historically, the several types are recognized (Table 110.1). Although all types of hydrocephalus are obstructive to some degree, the anatomic localization and severity of resistance to normal anterograde CSF flow can vary. *Obstructive hydrocephalus* is used to describe conditions that result to near complete blockage of CSF flow within the ventricular system. *Communicating hydrocephalus* describes conditions in which the ventricles are enlarged despite an open flow system from within the ventricles into the basal cisterns and over the convexities. Walter Dandy first described communicating hydrocephalus in 1914. He injected a tracer dye into one of the lateral ventricles. If the dye appeared in lumbar CSF, the hydrocephalus was termed *communicating*; if the dye did not appear in lumbar CSF, the hydrocephalus was termed *noncommunicating*. Because it proved useful in surgical-shunt placement, this functional classification was widely accepted. However, by this definition, *noncommunicating* hydrocephalus refers only to that caused by obstruction within the ventricular system. *Communicating* hydrocephalus infers CSF obstruction due to damage to the absorptive system after exiting the ventricles. Normal-pressure hydrocephalus (NPH) is a form of communicating hydrocephalus.

Hydrocephalus can be *acute* or *chronic*. Acute hydrocephalus can be an immediate threat to life when it develops rapidly over several hours and leads to intracranial hypertension and downward central herniation of the brain. By contrast, even massive ventriculomegaly can be minimally symptomatic if it develops gradually over weeks, months, or years and does not represent a threat to life.

Another classification of hydrocephalus is congenital versus acquired. Congenital hydrocephalus is present at birth. Acquired hydrocephalus can develop any time after birth. These forms of hydrocephalus are distinguished from *hydrocephalus ex vacuo* in which CSF volume increases without change in CSF pressure because of cerebral atrophy.

TABLE 110.1 Classification of Hydrocephalus

Obstructive hydrocephalus • Congenital malformations (ie, aqueductal stenosis) • Mass lesions causing ventricular obstruction (ie, acute intraventricular hemorrhage, third ventricular colloid cyst)
Communicating hydrocephalus • Defective reabsorption of CSF (ie, postinflammatory or posthemorrhagic) • Normal-pressure hydrocephalus • Venous insufficiency • Overproduction of CSF (ie, colloid plexus tumor) • External hydrocephalus (ie, preponderance of excess CSF over the convexities)
Hydrocephalus ex vacuo

Abbreviation: CSF, cerebrospinal fluid.

CEREBROSPINAL FLUID DIVERSION SYSTEMS

Shunt systems establish a connection between a CSF space (ventricular or lumbar) and a drainage cavity (peritoneum, pleural space, right atrium). The components of a CSF shunt include a proximal catheter, reservoir, valve, and distal catheter (Fig. 110.1). The proximal catheter is positioned intraventricularly, ideally away from choroid plexus (frontal horn of right ventricle is devoid of choroid plexus), and exits through a burr hole to connect with a reservoir in the subcutaneous tissue. The CSF may be sampled via this reservoir. A one-way valve regulates CSF flow into the distal catheter, which is subcutaneously tunneled to drain into a body cavity capable of reabsorbing fluid. All ventricular catheters are composed of silicone rubber and may vary in terms of length, internal/external diameter, shape, tip configuration, stiffness, and radiopaque markings. The valves now used include differential pressure regulators (static and programmable), flow regulators, siphon-resistive devices, and gravity-activated valves. The valves open or close based on a differential pressure, which is the pressure at the outlet (drainage cavity) minus the pressure at the inlet (intraventricular).

There are currently three different valve designs: slit, diaphragm, and spring-loaded ball-in-cone. The slit valve is an older design with a slit in the wall of the distal catheter, which opens with sufficient fluid pressure in the lumen of the catheter. The mechanical properties of the slit (silicone stiffness, wall thickness, length of slit) determine its operating pressure. Diaphragm valves have a flexible membrane, which moves in response to pressure differentials allowing CSF to flow around it. Finally, spring-loaded ball-in-cone valves contain a metallic coil or flat spring, which applies force to a ball located in a cone-shaped housing. When CSF pressure is high enough, the ball is pressed against the spring, which opens the valve. The CSF pressures change with posture (lying, sitting, or standing) and blood flow, which can alter shunt function. There are devices, which help prevent CSF siphoning during posture changes (standing up) by reacting to hydrostatic pressure across the two ends of the catheter and closing the valve. Gravitational devices use metal balls that fall into a cone-shaped seat upon standing, adding resistance to the flow in the shunt pathway equal to the height of a hydrostatic column. When the patient returns to a horizontal position, the balls move away from the fluid pathway, creating little resistance to the flow of CSF. Over drainage regulatory devices control CSF shunting during postural and vasogenic effects. Flow regulatory devices help maintain a continual flow through the valve at different pressures by varying the size of the valve opening and thus resistance to flow. Another treatment option for hydrocephalus is endoscopic fenestration.

ACUTE OBSTRUCTIVE HYDROCEPHALUS

Epidemiology

The global incidence of acute acquired obstructive hydrocephalus is unknown. Posthemorrhagic hydrocephalus occurs with an incidence of 25% to 70%, depending on the type and severity of the hemorrhage. Hydrocephalus is a frequently observed complication after recovering from aneurysmal subarachnoid hemorrhage (SAH). Despite a variable incidence of 6% to 67%, only 10% to 20% of SAH patients will require permanent CSF diversion. In pediatric populations, approximately 10% of infants with intraventricular hemorrhage (IVH) will require a shunt.

Pathobiology

In intraventricular obstructive hydrocephalus, the obstruction causes proximal dilation of the ventricles with preservation of normal ventricular size distally. Obstruction may occur at the foramen of Monro, the third ventricle, the aqueduct of Sylvius, the fourth ventricle, or the fourth ventricular outflow foramina of Luschka and Magendie. Obstructive hydrocephalus can be caused by congenital malformations, developmental lesions, mass lesions, or posthemorrhagic ventricular obstructions. According to Ayer, the ventricle closest to the obstruction enlarges

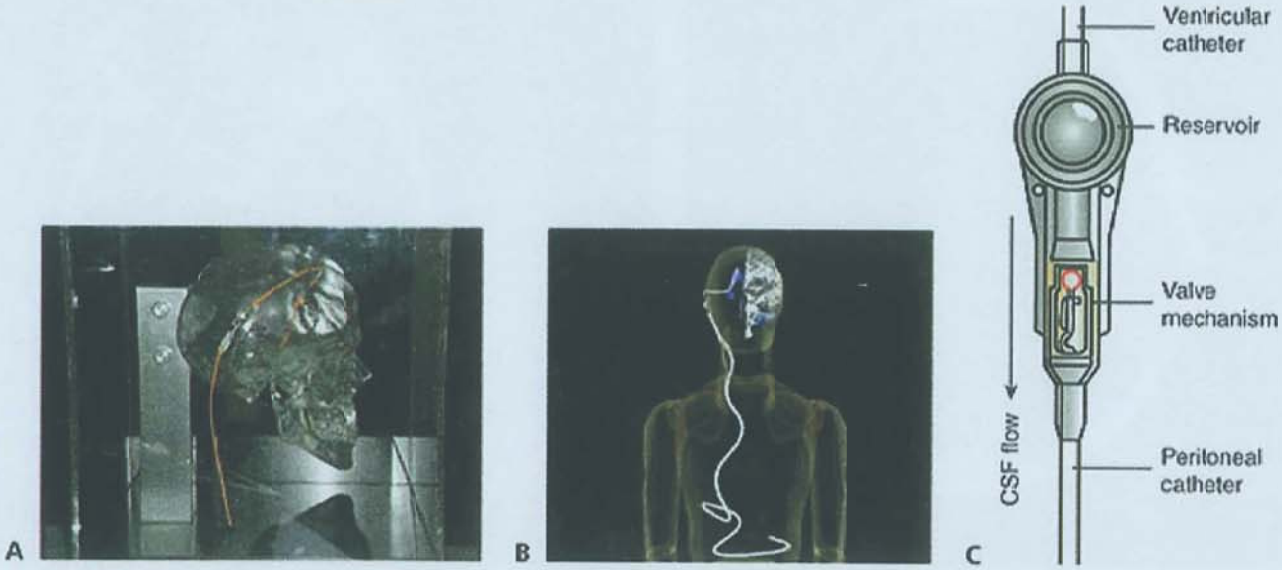

FIGURE 110.1 Cerebrospinal fluid (CSF) shunt system. **A:** Cranial segment with reservoir located behind the ear. **B:** Path of shunt tubing in the subcutaneous anterior, which ends in the peritoneal space. **C:** Cut-away view of shunt reservoir with one-way valve. Valve pictured is a Codman valve.

the most, for example, a mass in fourth ventricles leads to greater dilatation of the third compared to lateral ventricles.

Stroke and Intraventricular Hemorrhage

Ischemic stroke and intracerebral hemorrhage (ICH) complicated by IVH in adults also causes hydrocephalus (Fig. 110.2). In some patients, CSF flow obstruction is transient; therefore, intracranial pressure (ICP) increases and hydrocephalus appears but then disappears spontaneously. Other patients exhibit progressive hydrocephalus. Hydrocephalus also occurs in adults after SAH caused by head trauma or ruptured aneurysm (see Fig. 110.2). After SAH, distension of the arachnoid villi by packed red cells suggests an absorptive defect as a pathogenic mechanism for hydrocephalus.

In low birth weight infants, posthemorrhagic hydrocephalus is a major complication of IVH. Hydrocephalus results when a clot within the ventricular system obstructs CSF flow by a process of obliterative basilar arachnoiditis or by cortical arachnoiditis as a result of inflammatory response to blood products. There is an inherent predisposition to germinal matrix hemorrhage leading to periventricular hemorrhagic infarction and IVH causing hydrocephalus. Germinal matrix hemorrhage is graded by severity, as I through IV, whereby grades III and IV usually develop progressive hydrocephalus that requires shunting. Consequently, fibrotic impairment of extraventricular CSF pathways after IVH, SAH, or ICH may be complicated by dysfunction of arachnoid villi.

Tumor Related (Ball and Valve)

Intracranial neoplasms may cause obstructive hydrocephalus (Fig. 110.3). Tumors clustered about the third or fourth ventricles or the sylvian aqueduct, including pineal tumors, colloid cysts, gliomas, ependymoma, and metastases, are commonly implicated in intraventricular obstructive hydrocephalus. Prognosis, after shunting, is largely related to the type of tissue in the tumor. Other mass-like lesions, such as intraparenchymal cerebral hemorrhage, cerebellar infarction, or cerebellar hemorrhage, which assert local pressure on the ventricles, may lead to acute hydrocephalus. Basilar artery ectasia and other vascular abnormalities (eg, vein of Galen malformation) have also been associated with hydrocephalus.

Clinical Features

Patients with acute hydrocephalus clinically present with headache sometimes associated with visual obscurations, which could be followed by nausea/vomiting, subsequently leading to decreased mental status (stupor) and may lead to coma within minutes to hours depending on causation and availability of treatment. Corticospinal manifestations include lower extremity spasticity, increased deep tendon reflexes, and bilateral Babinski signs. It can progress to extensor posturing. The pupils are normal early in the process. Parinaud syndrome symptoms may appear as well. Roving eye movement, bilateral abducens palsy, and limitation of upward can be seen. If untreated, pupillary mydriasis will develop and roving eye movements will disappear. Depending on the speed of evolution, papilledema can be seen.

Diagnosis

In adults, the first test to be performed in suspected hydrocephalus is computed tomography (CT) or magnetic resonance imaging (MRI). Although CT can essentially exclude hydrocephalus, MRI is required for accurate assessment of subtle findings such as transependymal edema. The characteristic feature of hydrocephalus is ventricular enlargement out of proportion to sulcal

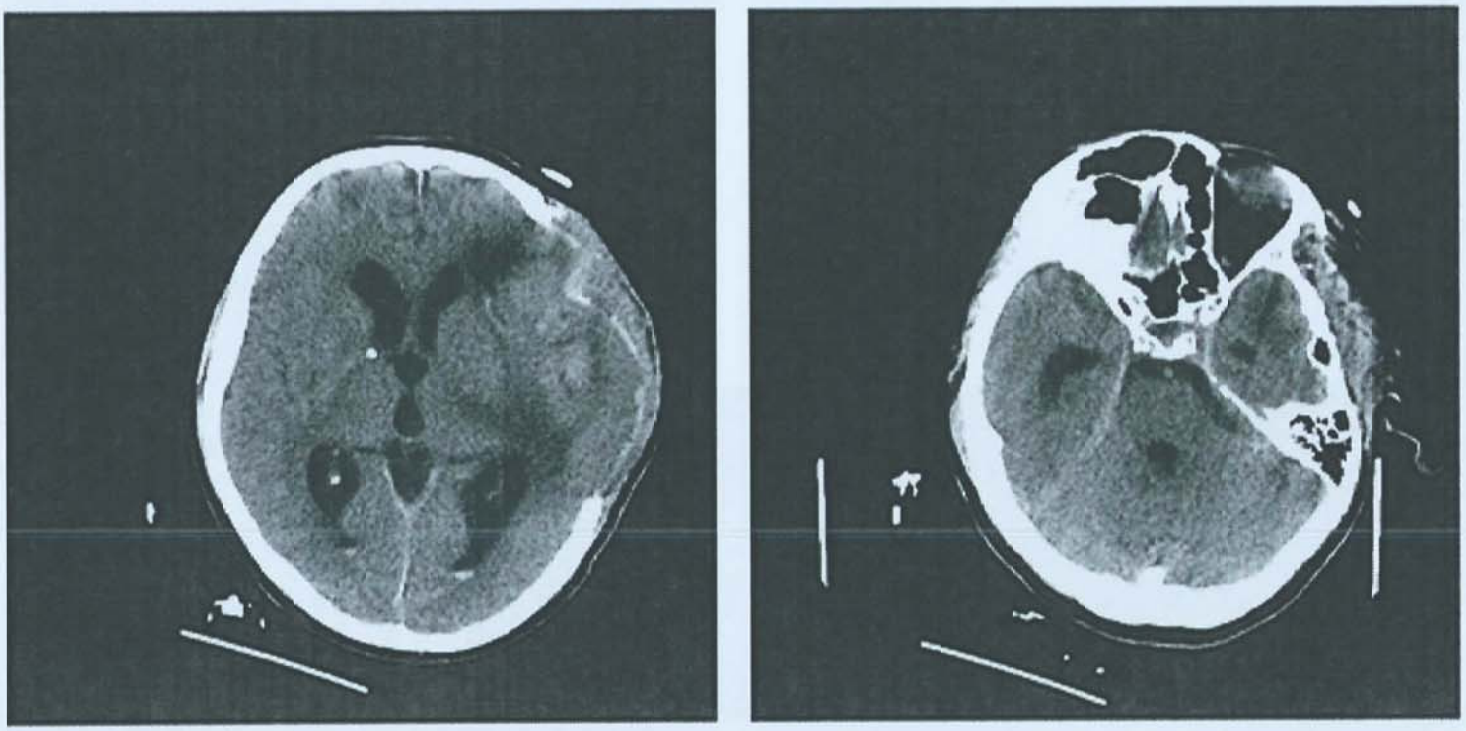

FIGURE 110.2 A 54-year-old man found unresponsive. **A:** He underwent endovascular coiling of a large left middle cerebral artery aneurysm and decompressive hemicraniectomy. **B:** The hydrocephalus persisted and he required a ventriculoperitoneal shunt after a restorative cranioplasty.

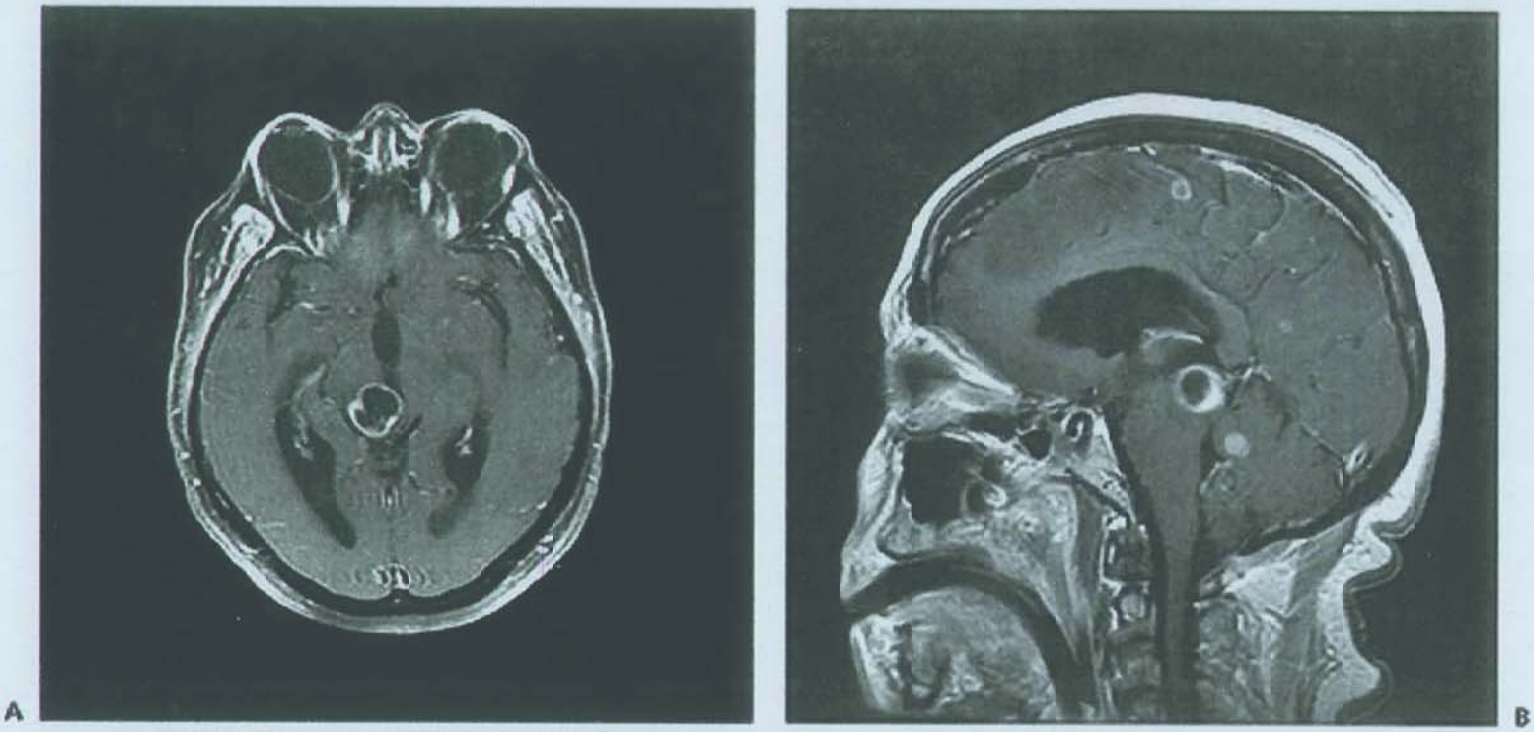

FIGURE 110.3 A,B: A 61-year-old female with a history of breast cancer presented with nausea and vomiting. She was found to have hydrocephalus secondary to brain metastasis as seen here in this T1 postcontrast magnetic resonance imaging.

enlargement. In general, brain atrophy due to degenerative disease or aging involves both "central" (ventricular) and "peripheral" (sulcal) spaces. But judging whether the ventricular enlargement is disproportionate can be difficult and is often fraught with interobserver disagreement. Thus, auxiliary features can be useful in assessing the likelihood of hydrocephalus. Abnormal periventricular white matter, with low attenuation by CT or increased T2-weighted or fluid-attenuated inversion recovery signal by MRI, suggests transependymal fluid flow, consistent with hydrocephalus, but periventricular white matter signal change is nonspecific and may arise from microvascular ischemic disease. Other allied structural changes suggesting hydrocephalus may include "ballooning" of the frontal horns of the ventricles, markedly dilated temporal horns, and bowing and thinning of the corpus callosum. Rapid longitudinal change can be diagnostically useful, but multiple CT or MRI studies over several years may not be available.

Confirmatory tests are often sought in hydrocephalus because of these uncertainties in clinical diagnosis and neuroimaging.

Treatment and Outcomes

The goal of treatment in hydrocephalic patients is to normalize CSF hydrodynamics. Treatment for every patient with hydrocephalus must be individualized. If the obstruction to flow is between the third and fourth ventricle, an endoscopic fenestration procedure can be attempted. In the case of a tumor obstructing CSF circulation, a surgical resection can be curative. If the cause of the alteration in CSF hydrodynamics is transient, the hydrocephalus may resolve during initial treatment, and temporary external ventricular drainage (EVD) or serial lumbar punctures (LPs) may be the only intervention needed. However, LP should only be employed in communicating hydrocephalus. In all forms of hydrocephalus, pharmacologic therapy is of limited value; however, there have been favorable reports of acetazolamide 500 mg orally three times a day as an adjunctive therapy to serial LP. Despite all this, most patients with symptomatic hydrocephalus will require CSF diversion through shunt insertion.

In adult-onset obstructive (noncommunicating) hydrocephalus, endoscopic third ventriculostomy (ETV) is an established treatment, with success rates of 60% to 80%. Its role in posthemorrhagic and postinflammatory hydrocephalus is debated. Common complications of this procedure include bleeding from injury to the basilar artery, intraventricular vessels, or brain parenchyma; infection; CSF leak; and hypothalamic injury. A large series published a mortality rate of 1% and permanent morbidity rate of 1.6% for ETV. Complications are more common with shunt procedures.

CONGENITAL OBSTRUCTIVE HYDROCEPHALUS

Epidemiology

Congenital hydrocephalus occurs with an incidence of 0.5 to 1.8 per 1,000 births per year and may result from either genetic or nongenetic causes.

Pathobiology

Common nongenetic causes include ICH and IVH secondary to birth trauma or prematurity and meningitis as a cause for congenital hydrocephalus. Meningitis and other inflammatory processes lead to blockage of CSF flow in the subarachnoid space especially around brainstem. This results in enlargement of entire ventricular system including fourth ventricle. Genetically, at least 43 mutants/loci linked to hereditary hydrocephalus

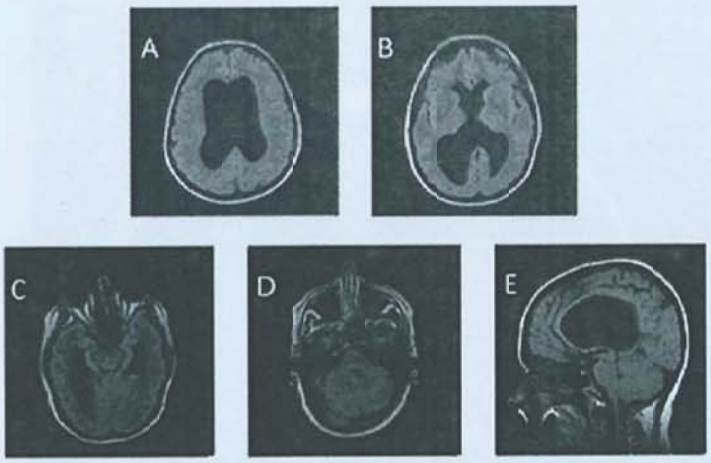

FIGURE 110.4 A 76-year-old man presented with 1-month history of gait dysfunction, memory loss, and urinary incontinence. **A, B, C,** and **D** are axial fluid-attenuated inversion recovery magnetic resonance images, and **E** is a sagittal T1 magnetic resonance image of chronic hydrocephalus secondary to aqueductal stenosis.

have been identified in animal models and humans. In some, aqueductal stenosis has been documented by MRI or at postmortem examination. It is not clear whether aqueductal lesions (eg, gliosis or fibrosis) occur developmentally or are the residue of prior viral inflammatory disease contracted in utero or in early life (Fig. 110.4). In some families, the occurrence of aqueductal stenosis, hydrocephalus of undetermined anatomic type, and the Dandy-Walker syndrome in siblings of both sexes suggests other modes of inheritance. In the Dandy-Walker syndrome, there is expansion of the fourth ventricle and the posterior fossa with obstruction of the foramina of Luschka and Magendie (Fig. 110.5). The Arnold-Chiari malformation may be associated with hydrocephalus at birth or it may develop later. Hydrocephalus could also result from congenital absence or decreased number of arachnoid villi.

FIGURE 110.5 Sagittal computed tomography scan showing a Dandy-Walker malformation.

Clinical Features

The manifestation of hydrocephalus is influenced by the patient's age. Infants will experience tension hydrocephalus if the insult occurs before the cranial sutures fuse at the end of the third year. This will cause skull enlargement and wide fontanels. If the hydrocephalus occurs recently after suture closure, it may be separated by the pressure (suture diastasis). The face will appear relatively small and with stretching of the skin of the scalp, prominent scalp veins appear. Upon percussion of the skull, a "cracked pot" sound is noted, known as *Macewen sign*. Scalp necrosis in these children can lead to CSF leakage and infections. Even mild increase in ICP molds infant's skull; radiograph of inner skull table reveals unevenly thinned appearance referred to as *beaten silver*. It leads to frontal prominence of the skull called *frontal bossing*. Head enlarges very rapidly surpassing 97th percentile. The anterior and posterior fontanels are tense. If left untreated, there is failure to thrive due to poor feeding and frequent vomiting. Parinaud syndrome eventually develops, which is caused by damage to midbrain tegmentum. The symptoms include paralysis or spasm of convergence, convergence-retraction nystagmus, visual loss and eventual optic atrophy, pseudo-Argyll Robertson pupils, eyelid retraction (Collier sign), and impaired upgaze or forced downgaze (setting-sun sign). Signs of corticospinal tract dysfunction include spasticity, increased deep tendon reflexes, positive Babinski sign, and wasting of trunk and limb muscles. The child will be developmentally delayed in motor and cognitive function.

Diagnosis

In infants, hydrocephalus must be distinguished from other forms of macrocephaly such as subdural hematoma. Sonography, described in Chapter 24, is useful in evaluating subependymal hemorrhage and IVH in high-risk premature infants and in following the infants for possible later development of progressive hydrocephalus (Fig. 110.6). Results correlate well with CT. As a bedside procedure, sonography requires minimal manipulation of critically ill infants. Plain skull radiographs and skull measurements are useful to follow the course of hydrocephalus in infants and children. Skull x-ray may also demonstrate erosion of the sella turcica or thinning of the inner table, "beaten silver cranium." Overall, CT and MRI are the best diagnostic aids for all forms of hydrocephalus. In X-linked hydrocephalus, laboratory testing for genetic analysis and counseling can be useful.

Treatment and Outcomes

Before CSF shunts were available 50 years ago, acute obstructive hydrocephalus used to be a lethal or severely disabling disease. If untreated, progressive infantile hydrocephalus carries a mortality rate as high as 50% at age 1 year and 75% at age 10 years. Treatment greatly improves these numbers. For example, with shunting, the survival rate is at least 50% after age 15 years but with a 15% incidence of mental retardation. If ICH leads to hydrocephalus in high-risk premature infants, the outcome is usually related to factors (eg, asphyxia) other than shunt responsiveness.

Endoscopic treatment of CSF pathway obstructions can effectively treat obstructive hydrocephalus, especially with aqueductal stenosis, and be used as an adjunct in treating loculated hydrocephalus. In ETV, a frontal region burr hole is made after a trajectory is chosen to provide a straight line linking the

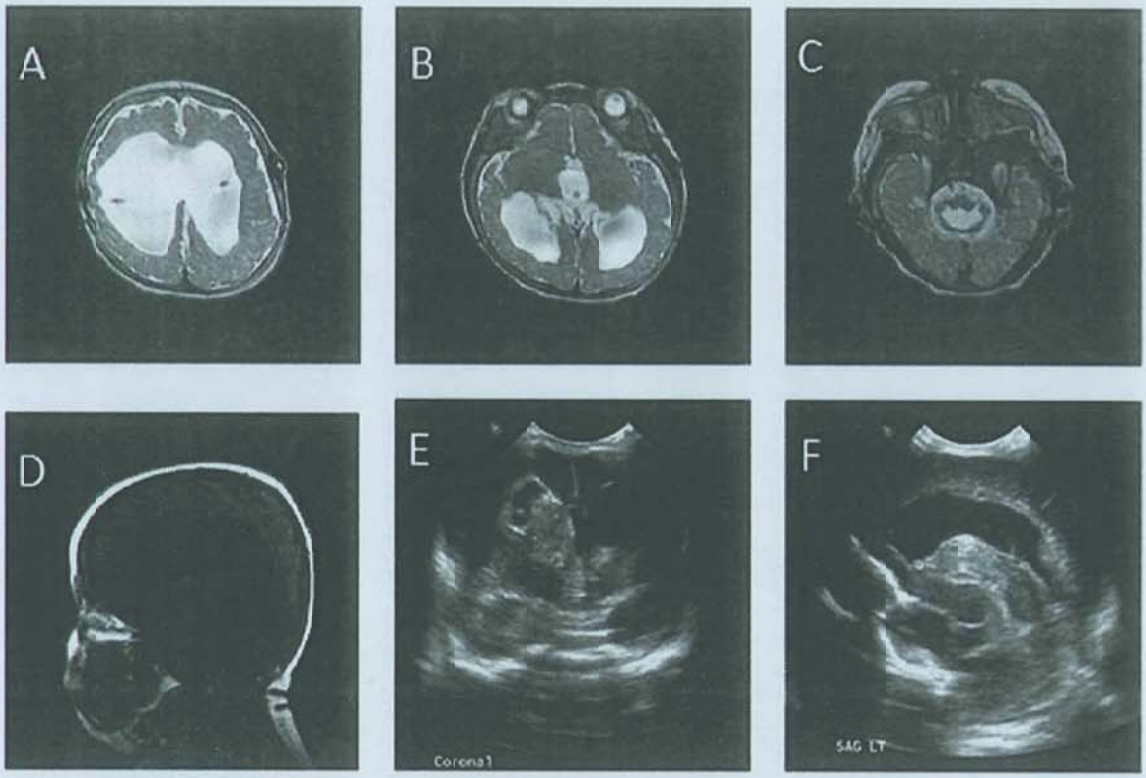

FIGURE 110.6 This former 24-week premature infant suffered grade IV intraventricular hemorrhage and subsequent posthemorrhagic hydrocephalus. A, B, and C are axial T2-weighted magnetic resonance images, and D is a sagittal T1 magnetic resonance image 3 months after hemorrhage. E and F are transcranial ultrasound images (coronal and sagittal, respectively) 1 week after birth.

foramen of Monro and the tuber cinereum, the space between the mammillary bodies posteriorly and the infundibulum of the pituitary gland anteriorly (Fig. 110.7). Stereotactic neuronavigation is commonly used for this. The endoscope is inserted and the foramen of Monro is first visualized in the lateral ventricle. The scope is advanced into the third ventricle and the tuber cinereum is identified. A probe is used to make a fenestration in the floor of the third ventricle and a balloon enlarges this hole. Endoscopic fenestration can also be performed prior to shunt insertion in cases where both foramen of Monro are obstructed. The procedure creates a connection through the septum pellucidum in these cases.

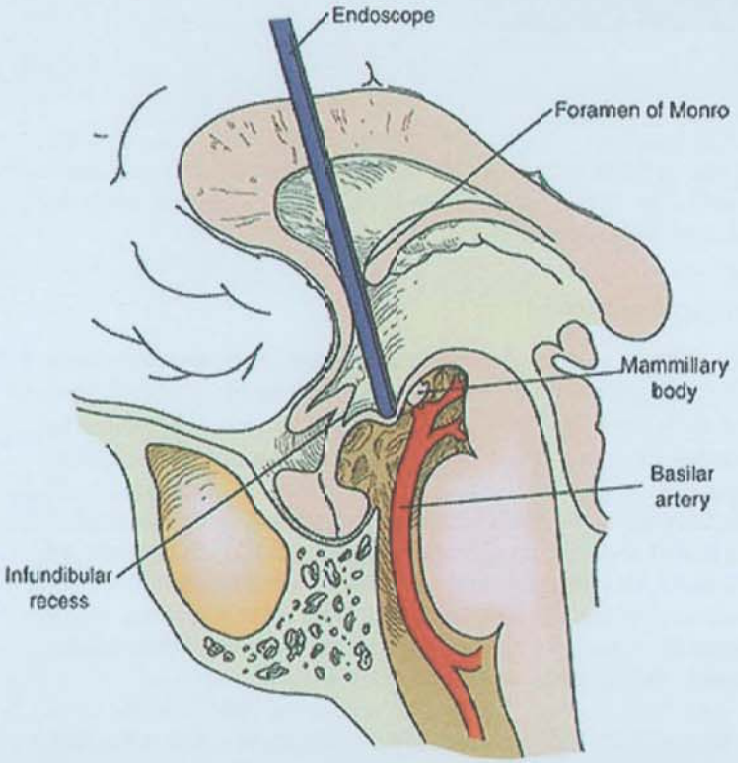

FIGURE 110.7 Endoscopic third ventriculostomy surgical approach.

COMMUNICATING HYDROCEPHALUS

When neither an intraventricular nor an extraventricular obstruction is documented, three other mechanisms may cause hydrocephalus: oversecretion of CSF, venous insufficiency, or impaired absorption of CSF by arachnoid villi. The absorptive capacity of the subarachnoid space is about 3 times the normal CSF formation rate of 0.35 mL/min (20 mL/h or 500 mL/d). Formation rates greater than 1.0 mL/min may produce hydrocephalus. Clinically, choroid plexus papilloma is the only known cause of oversecretion hydrocephalus. Absorptive capacity may be impaired in cases of inflammation in setting of infection or bleeding. Venous sinus thrombosis (especially superior sagittal sinus) leads to venous congestion and insufficiency thereby leading to decreased absorption of CSF into the venous system leading to hydrocephalus.

Among infectious diseases, bacterial, fungal, tubercular, or syphilitic meningitis may cause chronic hydrocephalus secondary to basal arachnoiditis (Fig. 110.8). Among parasitic infections, neurocysticercosis may produce both communicating and noncommunicating hydrocephalus. Otitic hydrocephalus occurs in children after chronic otitis media or mastoiditis with lateral sinus thrombosis. In these cases, the child may be febrile and listless. Eardrum perforation and purulent otic discharge usually occur. Often, ipsilateral sixth nerve paralysis and papilledema are noted. Otherwise, impaired cerebral venous drainage, for example, thrombosis of cortical veins or intracranial venous sinuses, rarely causes hydrocephalus.

Communicating hydrocephalus has been attributed to congenital agenesis of the arachnoid villi with consequent impairment of CSF absorption. Because detailed pathologic study of

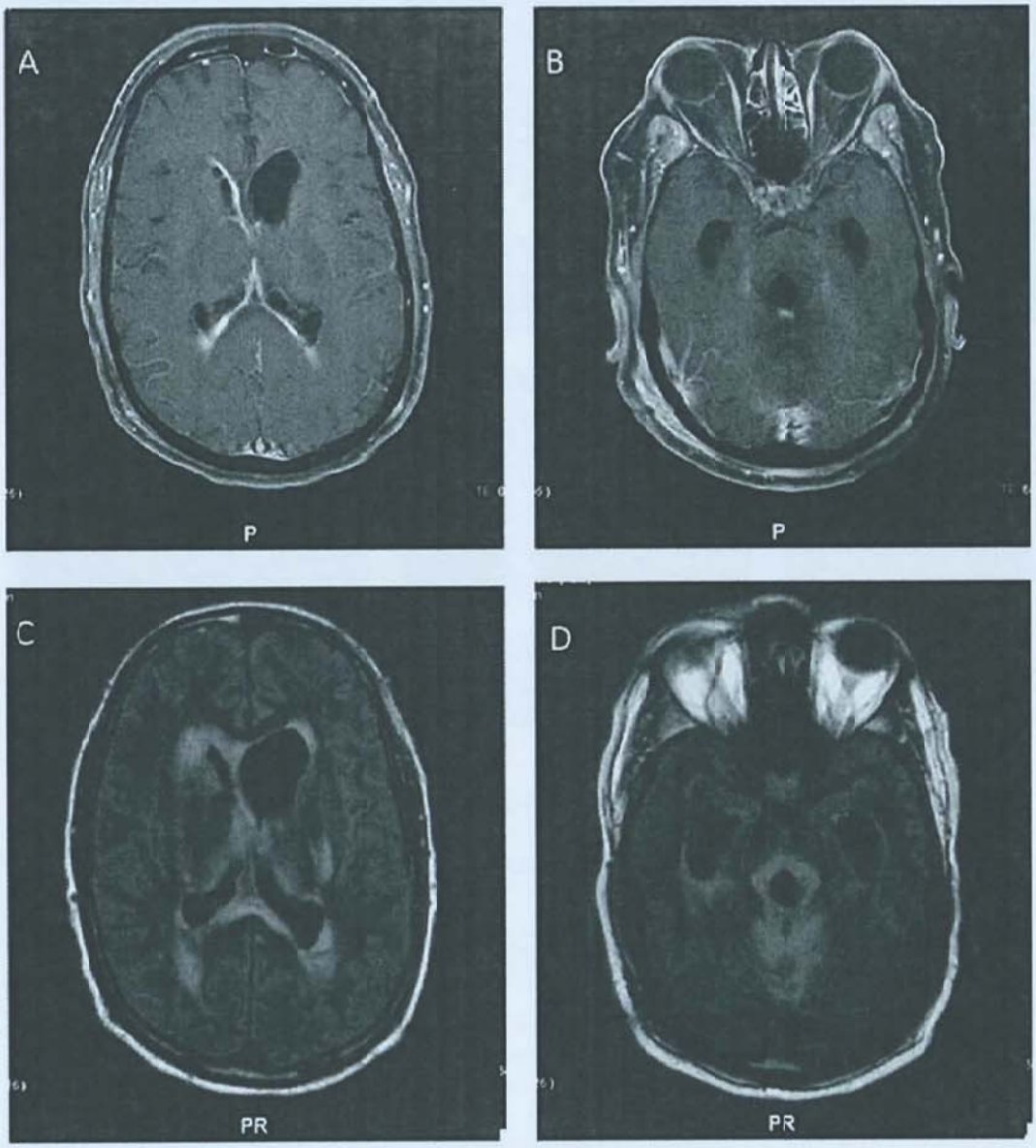

FIGURE 110.8 A 47-year-old man with ventriculitis and secondary communicating hydrocephalus. A and B are postcontrast T1 magnetic resonance images. C and D are fluid-attenuated inversion recovery magnetic resonance images.

the number of villi and their structural characteristics is difficult and rarely performed, this defect may be more common than statistics indicate. Likewise, dysfunction of arachnoid villi without obstruction of basilar or transcortical CSF pathways is not easy to assess. Hydrocephalus has also been described when lumbar CSF protein content exceeds 500 mg/dL, as in polyneuritis or spinal cord tumor. The protein may interfere with CSF absorption. Ependymoma, the most common spinal cord tumor associated with hydrocephalus, may cause tumor seeding of the arachnoid villi.

Rarely, hydrocephalus due to impairment of extracranial venous drainage follows radical neck dissection or obstruction of the superior vena cava.

NORMAL-PRESSURE HYDROCEPHALUS

Epidemiology

Recent population-based studies have estimated the prevalence of NPH to be about 0.5% in those older than 65 years, with an incidence of about 5.5 patients per 100,000 per year. This is in accordance with comparable findings stating that although NPH occurs in both men and women of any age, it is found more often in the elderly population, with a peak onset generally in the sixth to seventh decades.

Pathobiology

The NPH is a form of chronic communicating hydrocephalus with incomplete obstruction of the normal pathway of CSF flow. The NPH most likely results from a serial pattern of increased resistance to normal CSF flow at the foramen of Monro, sylvian aqueduct, fourth ventricular outflow tracts, and the arachnoid granulations. The result is a relative increase in the volume of the lateral and third ventricles, with normal ICP. Symptoms are produced by stretching and secondary dysfunction and degeneration of white matter pathways in the corona radiata, which encase the lateral ventricles, and to a lesser extent white matter tracts in the internal capsule and below.

The NPH is often "idiopathic" and may relate simply to an abnormal brain aging process, whereas in some cases, it may follow SAH from trauma or aneurysm, a resolved acute meningitis or a chronic meningitis (eg, tubercular), tumor, or surgery or

nonprogressive meningeal and ependymal diseases. Irrespective of the underlying etiology, the ventricles expand at the expense of brain volume, causing both brain compression and periventricular white matter changes. These changes are thought to arise from brain edema caused by transependymal flow of fluid (Fig. 110.9) or to ischemic demyelination caused by compression of brain tissue. There may also be neuronal dysfunction from the compression. However, the overall effect is sufficiently chronic, or compensated, so that the CSF pressure is normal.

Clinical Manifestations

A different symptom complex is seen with NPH because the hydrocephalus in this disease process is slow and insidious. Patients present with a triad of gait ataxia, dementia, and urinary incontinence. Gait change is usually the first symptom, as well as the most frequent symptom, of NPH. This change may be subacute, fluctuating, or more chronic but most often worsens over weeks or months. The gait disturbance is often inconsistent and variable

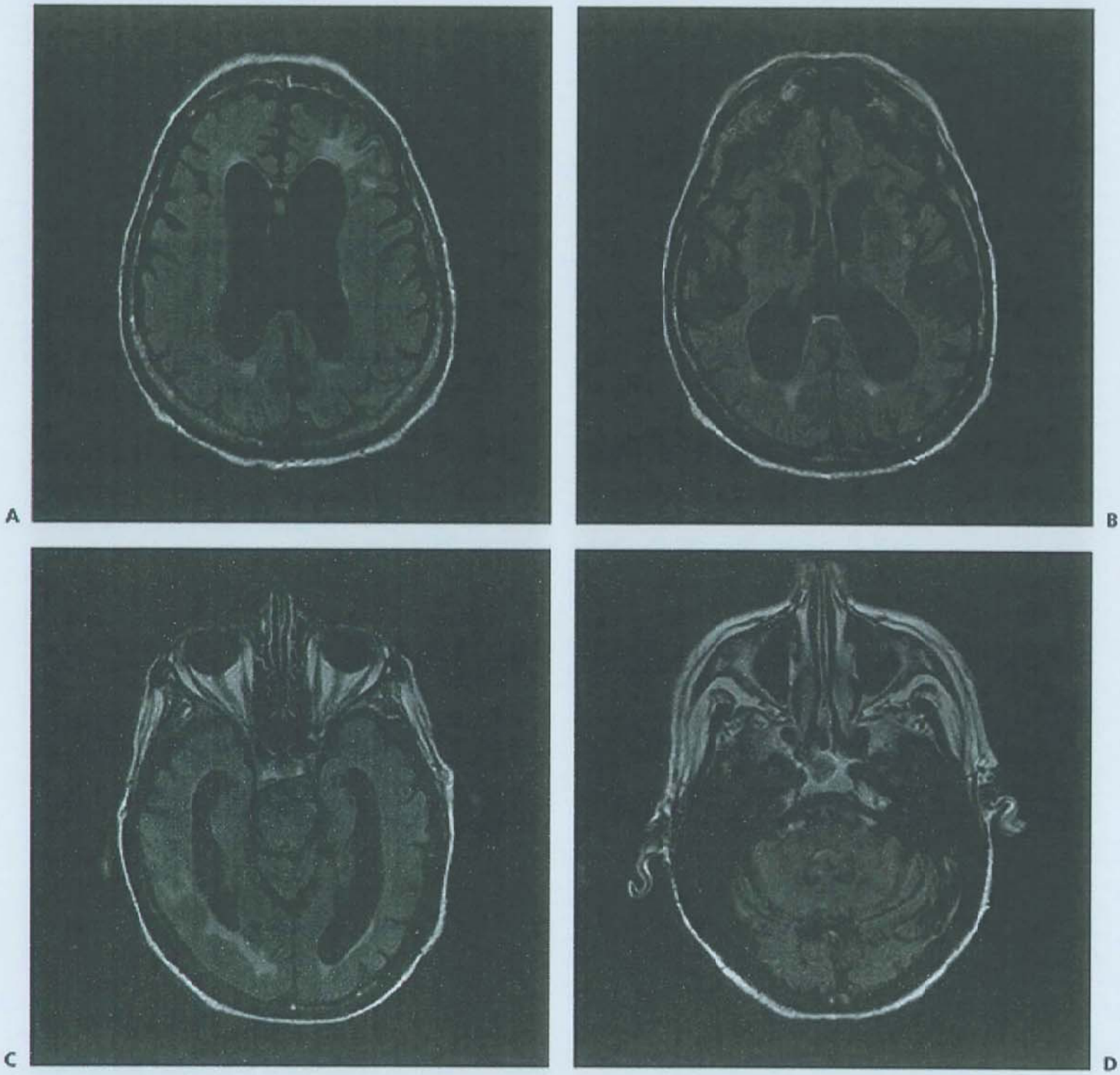

FIGURE 110.9 **A-D:** An 85-year-old man presented with gait dysfunction and urinary incontinence for 3 months. His symptoms improved after a large-volume lumbar puncture. Axial fluid-attenuated inversion recovery magnetic resonance images of a patient with normal pressure hydrocephalus. Note periventricular transependymal interstitial edema.

but has parkinsonian features, with shuffling, shortened stride length, imbalance, and often initial slowness. Frequently, the gait is wide based (not commonly a feature of Parkinson disease), often with external rotation of the legs. The gait is classically described as "magnetic," with inability to lift the feet off the floor. It is also described as a gait "apraxia" because it appears that motor program involved in starting to move the legs is impaired, without evident impairment of strength. In addition to difficulty with the initiation of gait, there may also be difficulty maintaining gait, and there may be "freezing," with problems reinitiating movement. There is no rigidity, slowness of alternating movement, or tremor. Tremor is uncommon, but falls are common. Most commonly, it presents as unsteadiness and impairment of balance with greatest difficulty bring encountered at stairs and curbs.

Urinary symptoms are also frequent in NPH and may go unrecognized, consisting only of urinary urgency or frequency. Urinary incontinence itself is common, presumably due to loss of descending control mechanisms, with consequent unsuppressed bladder contractions, together with decreased voluntary ability to control the bladder outlet. A characteristic feature is said to be incontinence in which there is little evident concern regarding the problem.

Impaired cognition, ranging from subtle to severe, occurs in NPH, usually following after the onset of gait and urinary dysfunction. The characteristics of dementia associated with hydrocephalus include "subcortical" features. Symptoms may include not only forgetfulness but also slowness in mental processing, inertia, apathy, and impaired executive function, including decision making and task switching. Memory impairment in hydrocephalus may differ from that seen in cortical dementias such as Alzheimer disease (AD). As in AD, preservation of long-term knowledge can be seen, although the memory deficits more clearly involve poor learning. Impairment in delayed recall of learned material could relate to deficits in learning but may also involve initiation and speed of retrieval. For example, recall with simple cues may be much better than free recall, indicating a dominant deficit in retrieval rather than defective encoding of learned material. Advanced hydrocephalus results in severe slowing of mentation and possibly an akinetic mute state.

Diagnosis

When NPH is suspected, additional tests may be useful for diagnosis and to determine the likelihood of response to CSF shunting. An LP is indicated to measure CSF pressure and to determine whether it contains blood or signs of chronic inflammatory or infectious disease. The opening pressure on LP in NPH may be in the upper range of normal (14-20 cm H_2O), and such relatively higher "normal" pressures may also be indicative of a greater likelihood of benefit from CSF shunting. Continuous monitoring of intraventricular pressure may reveal higher pressures than lumbar CSF pressures. Either lumbar or intraventricular monitoring may reveal the presence of Lundberg B waves, mild transient ICP elevations (<10 min in duration and generally <20 mm Hg in amplitude).

Treatment and Outcomes

When patients are properly selected, CSF diversion or shunting is a safe and effective management of idiopathic NPH with a prolonged positive outcome LEVEL 2.[1] The response of the patient with suspected NPH to CSF diversion via a ventriculoperitoneal shunt (VPS) is best evaluated with a 48- to 72-hour trial

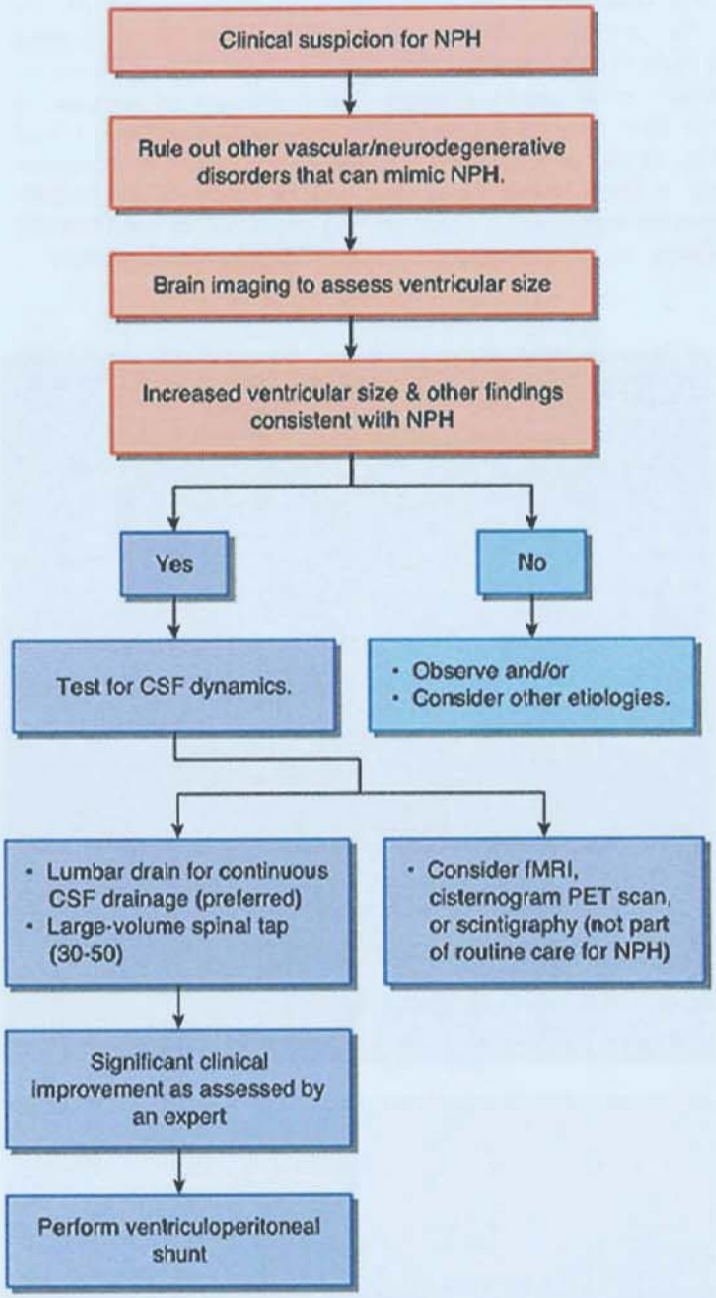

FIGURE 110.10 Suggested Algorithm for Diagnosis and Treatment of Normal-Pressure Hydrocephalus. Abbreviations: CSF, cerebrospinal fluid; fMRI, functional magnetic resonance imaging; NPH, normal-pressure hydrocephalus; PET, positron emission tomography; VPS, ventriculoperitoneal shunt.

of lumbar drainage (Fig. 110.10). This test, which requires hospital admission, essentially mimics the effect of a VPS, with the caveat that the CSF is drained out of the lumbar space (10 mL every 2 h) rather than the ventricular space. The main outcome measure of the test is subjective and objective observation of gait before, during, and after the procedure. Objective measurement is best made by videotaped recording of the patient prior to and at 24-hour intervals after the tap. In responders, gait typically improves during the first few days, with gradual loss of benefit over the next week after the lumbar drain has been removed. Cognition or urination may also improve, although this is usually less evident and more difficult to assess objectively. Lack of benefit from the tap points to likely lack of likelihood of benefit from CSF shunting. Response of symptoms to a single or

repeated large-volume (30-40 mL) LPs (the CSF "tap test") can also be attempted, but this test is not sensitive and may not detect improvement that can result from more sustained CSF diversion.

An alternative to VPS is lumboperitoneal shunting. A recent open-label randomized clinical trial (SIPHONI-2) demonstrated that lumboperitoneal shunting within 1 month of diagnosis may be beneficial in a selected cohort of NPH patients with similar long-term results as VPS LEVEL 1.[2] Radionuclide cisternogram to assess CSF flow in NPH, with a positive finding being delayed appearance of radiotracer in the lateral ventricles, does not appear to be prognostically useful for assessing the likely clinical response to VPS. An MRI evidence of an increased aqueductal CSF flow void, or an increased volume of CSF pulsing back and forth in the aqueduct ("aqueductal CSF stroke volume"), is similarly inconsistent and problematic as predictors of shunt-responsive NPH.

The decision which procedure is best for a patient should be individualized. In particular, treatment for NPH is neurosurgical and involves CSF diversion. The ETV is less likely to be a definitive management option for these patients. Shunting is most likely to be efficacious in those patients whose symptoms initially involved only gait and in those with milder cognitive dysfunction. It may also be more effective in those with a history of meningitis, SAH, or other identifiable "secondary" cause of hydrocephalus.

More successful outcomes are obtained in patients with positive spinal tap test; if the measured ICP is higher; an impaired cerebral blood flow reactivity to acetazolamide by single-photon emission computed tomography; and absence of comorbidities such as hypertension, peripheral vascular disease, stroke, and heart failure. Advanced age does not appear to be a significant predictor of poor response to shunting LEVEL 2.[1,3] No difference in outcomes after VPS placement has been observed when progressive reductions in valve opening pressures are used as compared to fixed settings LEVEL 3.[4] Patients with severe dementia, marked sulcal atrophy, or those whose first symptom is dementia, with subsequent gait and urinary involvement, are less likely to respond favorably to CSF shunting. This may relate to irreversibility of symptoms or perhaps a greater likelihood of underlying AD. Failure of shunting should be anticipated in patients with long-standing disease (dementia and incontinence) and/or who do not fit the typical syndrome of NPH. In some cases, lack of improvement can be explained by underdrainage and draining the ventricles at lower pressure can solve the problem.

LOW-PRESSURE HYDROCEPHALUS

Epidemiology

Low-pressure hydrocephalus is reported in the literature as case series, but no population statistics are known due to its uncommon occurrence.

Pathobiology

A clinical state has been described with low CSF pressures and acute symptomatic hydrocephalus in the setting of medium-pressure CSF diversion and ventriculomegaly, representing a paradoxical example of hydrocephalus with low ICP. Chronic shunting, SAH, IVH, and tumors have been associated with low-pressure hydrocephalus. It has been postulated that a decrease in cerebral elasticity coupled with the ventricular enlargement produces this syndrome. There are different viscoelastic theories that have been applied in attempts to delineate this physiologic occurrence.

Clinical Diagnosis

Pang and Altschuler (1994) described low-pressure hydrocephalus in great details. Their diagnostic criterion were (1) deterioration in neurologic status in presence of a medium pressure CSF diversion (either a shunt or EVD), (2) ventriculomegaly, (3) persistent ventriculomegaly with ICP in normal or low-normal range, (4) clinical and radiographic response to sub-zero drainage, and (5) exclusion of other causes like shunt or EVD malfunction.

Treatment and Outcome

Ultimately, this condition improves with subzero CSF drainage, which is achieved by setting the EVD height below the level of external auditory canal. These patients then eventually be treated with shunting with low pressure valves.

EXTERNAL HYDROCEPHALUS

External hydrocephalus presents as collections of subarachnoid fluid over the convexities, with or without coexisting ventriculomegaly. It can occur in both children and adults. In some cases, it can be difficult to determine whether the collection of fluid is truly in the subarachnoid or subdural space, and in some cases, both may exist. The criteria for diagnosis of benign external hydrocephalus in children is a rapidly enlarging head circumference along with a CT scan showing enlarged subarachnoid spaces, particularly in the frontal regions, and normal or only moderately enlarged ventricles. Kumar added absence of "clinicoradiological features of raised intracranial pressure," for example, ventriculomegaly without periventricular lucency and nontense fontanels as criterion for benign external hydrocephalus. The etiology in most cases is idiopathic, but it has been reported in many different conditions such as prematurity with IVH, SAH, meningitis, steroid therapy, chemotherapy, neurosurgery, and trauma. The most common theory suggests that external hydrocephalus is caused by immature arachnoid villi not being able to absorb the CSF that is produced continuously. The accumulated CSF then expands the ventricles and subarachnoid space within the compliant skull of an infant, thus avoiding marked increase in ICP. Arachnoid villi mature by age of 18 months. Why arachnoid villi are not mature in some infants is not entirely clear. Children with external hydrocephalus also have at least one close relative with macrocephaly in 40% of cases. An autosomal dominant mode of transmission is suspected. In adults, external hydrocephalus may be seen after trauma or SAH. Another cause is after surgical hemicraniectomy if the bone has not been replaced. It is important to differentiate adult external hydrocephalus from subdural hygromas because the latter will worsen if ventricular shunting is attempted.

GENERAL COMPLICATIONS AFTER SHUNT PLACEMENT

A shunt complication is any problem that requires repeat surgical intervention. This may occur due to mechanical failure causing improper device function, functional failure secondary to inadequate flow rate despite a working shunt system, or infection. The risk of shunt failure is highest in the first few months postoperatively, with a 25% to 40% failure rate at 1 year. The mean survival time for a shunt system is 5 years.

Complications can arise from any component of the shunt system. Shunt obstruction is the most frequent cause of mechanical failure in patients, with fracture of shunt tubing coming in second (Fig. 110.11). Occlusion can occur proximally at the ventricular catheter entry point, at the level of the valve, or at the end of the distal catheter. Proximal occlusions can be caused by CSF debris, a collapsed ventricle, or choroid plexus ingrowth. Proximal catheter blockage can be avoided by placing the catheter in the frontal horn of right ventricle, which lacks choroid plexus. Valve obstruction can be the consequence of debris accumulation,

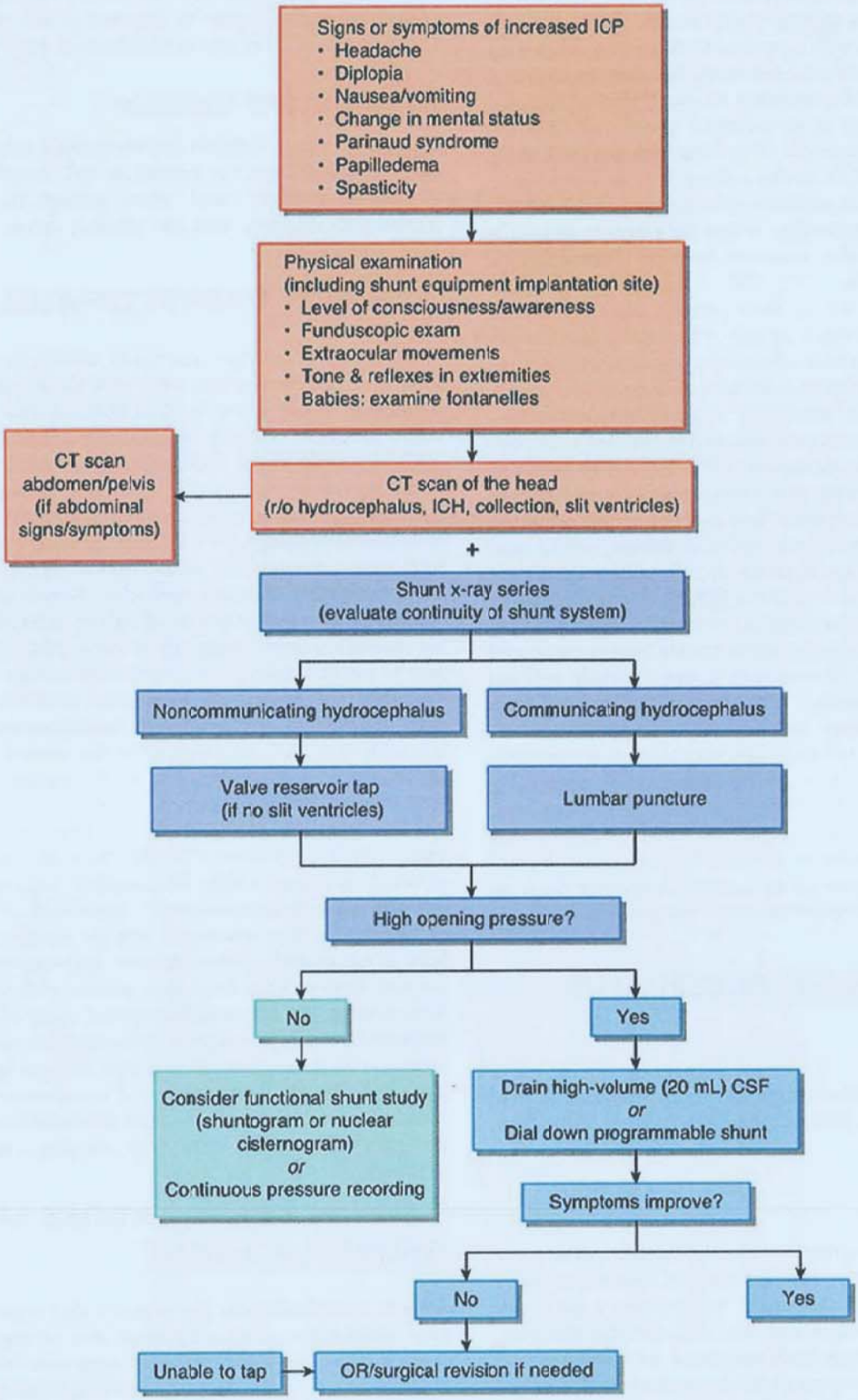

FIGURE 110.11 Approach to suspected shunt malfunction. Abbreviations: CT, computed tomography; ICH, intracranial hemorrhage; ICP, intracranial pressure; OR, operating room.

bacterial proliferation, or the development of an immune reaction. Distal occlusion is most common in distal slit catheters due to accumulation of granulomatous nodules. Disconnection or fracture can occur at any fixation point, which causes tension along the catheter course or as a host reaction to foreign material causing degradation and calcification of the catheter. The functional complication of overdrainage occurs more frequently in the older adult population. Overdrainage may cause subdural hygromas or hematomas (due to stretching and rupture of bridging veins) or slit ventricle syndrome, a state of high ICP thought to be secondary to the CSF compartment decrease removing the buffer for volume change in blood or brain tissue. Problems such as migration, misplacement, skin problems, subcutaneous CSF effusions, pediatric craniostenosis, and ventricular loculation occur less frequently. Arachnoiditis and acquired tonsillar herniation are complications unique to lumboperitoneal shunts.

Infection remains an important and potentially devastating cause of shunt failure. Although intraoperative aseptic techniques and perioperative antibiotics have reduced the incidence of shunt infection, the infection rate is still reported as high as 5% to 10%. It can be divided by site of infection: meningitis, wound infection, peritonitis, or shunt equipment infection. Symptoms correlate to the site of infection. Most shunt infections occur within 2 months of surgery. In early postoperative infections, *Staphylococcus epidermidis* and *Staphylococcus aureus* are the most common organisms, but other bacteria related to skin flora such as *Propionibacterium acnes* also occur. Gram-negative bacteria are associated with late shunt infections. Treatment requires intravenous antibiotics; ceftriaxone plus vancomycin is an acceptable empiric treatment regimen. The infected hardware must be removed and EVD performed until infection clear. Ventriculoatrial shunts may cause bacterial endocarditis as an infectious complication.

LEVEL 1 EVIDENCE

1. Halperin JJ, Kurlan R, Schwalb JM, Cusimano MD, Gronseth G, Gloss D. Practice guideline: idiopathic normal pressure hydrocephalus: response to shunting and predictors of response: report of the Guideline Development, Dissemination, and Implementation Subcommittee of the American Academy of Neurology. *Neurology*. 2015;85(23):2063-2071.
2. Kazui H, Miyajima M, Mori E, Ishikawa M; for SINPHONI-2 investigators. Lumboperitoneal shunt surgery for idiopathic normal pressure hydrocephalus (SINPHONI-2): an open-label randomised trial. *Lancet Neurol*. 2015;14(6):585-594.
3. Toma AK, Papadopoulos MC, Stapleton S, Kitchen ND, Watkins LD. Systematic review of the outcome of shunt surgery in idiopathic normal-pressure hydrocephalus. *Acta Neurochir*. 2013;155(10):1977-1980.
4. Farahmand D, Sæhle T, Eide PK, Tisell M, Hellström P, Wikkelsö C. A double-blind randomized trial on the clinical effect of different shunt valve settings in idiopathic normal pressure hydrocephalus. *J Neurosurg*. 2016;124(2):359-367.

SUGGESTED READINGS

Adams RD, Fisher CM, Hakim S, Ojemann RG, Sweet WH. Symptomatic occult hydrocephalus with "normal" cerebrospinal-fluid pressure: a treatable syndrome. *N Engl J Med*. 1965;273:117-126.

Arthur AS, Whitehead WE, Kestle JRW. Duration of antibiotic therapy for the treatment of shunt infection: a surgeon and patient survey. *Pediatr Neurosurg*. 2002;36(5):256-259.

Atkins PT, Guppy KH, Axelrod YV, Chakrabarti I, Silverthorn J, Williams AR. The genesis of low pressure hydrocephalus. *Neurocrit Care*. 2011;15:461-468.

Ayer JB. Cerebrospinal fluid pressure from the clinical point of view. *Arch NeurPsych*. 1925;14(4):440-448.

Boschert J, Hellwig D, Krauss J. Endoscopic third ventriculostomy for shunt dysfunction in occlusive hydrocephalus: long-term follow up and review. *J Neurosurg*. 2003;98:1032-1039.

Brockmeyer D. Techniques of endoscopic third ventriculostomy. *Neurosurg Clin N Am*. 2004;15:51-59.

Brodbelt A, Stoodley M. CSF pathways: a review. *Br J Neurosurg*. 2007;21(5):510-520.

Buckle C, Smith JK. Choroid plexus papilloma of the third ventricle. *Pediatr Radiol*. 2007;37(7):725.

Callen PW, Hashimoto BE, Newton TH. Sonographic evaluation of cerebral cortical mantle thickness in the fetus and neonate with hydrocephalus. *J Ultrasound Med*. 1986;5:251-255.

Carrion E, Hertzog JH, Medlock MD, Hauser GJ, Dalton HJ. Use of acetazolamide to decrease cerebrospinal fluid production in chronically ventilated patients with ventriculopleural shunts. *Arch Dis Child*. 2001;84:68-71.

Chang S, Agarwal S, Williams MA, Rigamonti D, Hillis AE. Demographic factors influence cognitive recovery after shunt for normal-pressure hydrocephalus. *Neurologist*. 2006;12:39-42.

Dalen K, Bruarøy S, Wentzel-Larsen T, Laegreid LM. Intelligence in children with hydrocephalus, aged 4–15 years: a population-based controlled study. *Neuropediatrics*. 2008;39(3):146-150.

Devito EE, Pickard JD, Salmond CH, Iddon JL, Loveday C, Sahakian BJ. The neuropsychology of normal pressure hydrocephalus (NPH). *Br J Neurosurg*. 2005;19:217-224.

Dorai Z, Hynan LS, Kopitnik TA, Samson D. Factors related to hydrocephalus after aneurysmal subarachnoid hemorrhage. *Neurosurgery*. 2003;52:763-769.

Edwards RJ, Dombrowski SM, Luciano MG, Pople IK. Chronic hydrocephalus in adults. *Brain Pathol*. 2004;14(3):325-336.

Gallia GL, Rigamonti D, Williams MA. The diagnosis and treatment of idiopathic normal pressure hydrocephalus. *Nat Clin Pract Neurol*. 2006;2:375-381.

Ginsberg HJ. Physiology of cerebrospinal fluid shunt devices. In: Winn HR, ed. *Youmans Neurological Surgery*. 5th ed. Philadelphia, PA: WB Saunders; 2004:3374-3385.

Gnanalingham KK, Lafuente J, Thompson D, Harkness W, Hayward R. The natural history of ventriculomegaly and tonsillar herniation in children with posterior fossa tumours—an MRI study. *Pediatr Neurosurg*. 2003;39(5):246-253.

Graff-Radford NR. Normal pressure hydrocephalus. *Neurol Clin*. 2007;25:809-832.

Greitz D. Radiological assessment of hydrocephalus: new theories and implications for therapy. *Neurosurg Rev*. 2004;27(3):145-165.

Jack CR Jr, Mokri B, Laws ER Jr, Houser OW, Baker HL Jr, Petersen RC. MR findings in normal-pressure hydrocephalus: significance and comparison with other forms of dementia. *J Comput Assist Tomogr*. 1987;11:923-931.

Johnston I, Teo C. Disorders of CSF hydrodynamics. *Childs Nerv Syst*. 2000;16:776-799.

Joseph VB, Rahuram L, Korah P, Chacko AG. MR ventriculography for the study of CSF flow. *AJNR Am J Neuroradiol*. 2003;24(3):373-381.

Khan A, Jabbar A, Banerjee A, Hinchley G. Cerebrospinal shunt malfunction: recognition and emergency management. *Br J Hosp Med (Lond)*. 2007;68(12):651-655.

Khoromi S, Prockop LD. Disturbances of cerebrospinal fluid circulation, including hydrocephalus and meningeal reactions. In: Greenburg JO, ed. *Neuroimaging*. 2nd ed. New York, NY: McGraw-Hill; 1999:335-374.

Kiefer M, Unterberg A. The differential diagnosis and treatment of normal-pressure hydrocephalus. *Dtsch Arztebl Int*. 2012;109(1-2):15-26.

Klinge P, Fischer J, Brinker T, et al. PET and CBF studies of chronic hydrocephalus: a contribution to surgical indication and prognosis. *J Neuroimaging*. 1998;8:205-209.

Klinge P, Marmarou A, Bergsneider M, Relkin N, Black PM. Outcome of shunting in idiopathic normal-pressure hydrocephalus and the value of outcome assessment in shunted patients. *Neurosurgery*. 2005;57(suppl 3):S40-S52.

Kuczkowski J, Narozny W, Mikaszewski B. Diagnosis and management of otitic hydrocephalus. *Am J Otolaryngol*. 2009;30(1):69.

Kumar R. External hydrocephalus in small children. *Childs Nerv Syst*. 2006;22:1237-1241.

Lan CC, Wong TT, Chen SJ, Liang ML, Tang RE. Early diagnosis of ventriculo-peritoneal shunt infections and malfunctions in children with hydrocephalus. *J Microbiol Immunol Infect*. 2003;36(1):47-50.

Luetmer PH, Huston J, Friedman JA, et al. Measurement of cerebrospinal fluid flow at the cerebral aqueduct by use of phase-contrast magnetic resonance imaging: technique validation and utility in diagnosing idiopathic normal pressure hydrocephalus. *Neurosurgery*. 2002;50(3):534-542.

Meier U, König A, Miethke C. Predictors of outcome in patients with normal-pressure hydrocephalus. *Eur Neurol*. 2004;51(2):59-67.

Našel C, Gentzsch S, Heimberger K. Diffusion-weighted magnetic resonance imaging of cerebrospinal fluid in patients with and without communicating hydrocephalus. *Acta Radiol*. 2007;48:768-773.

Oliveira LM, Nitrini R, Román GC. Normal-pressure hydrocephalus: a critical review. *Dement Neuropsychol*. 2019;13(2):133-143.

Pang D, Altschuler E. Low-pressure hydrocephalic state and viscoelastic alterations in the brain. *Neurosurgery*. 1994;35(4):643-655; discussion 655-656.

Poca MA, Sahuquillo J. Short-term medical management of hydrocephalus. *Expert Opin Pharmacother*. 2005;6(9):1525-1538.

Pratt R, Mayer SA. Normal pressure "herniation." *Neurocrit Care*. 2005;2:172-175.

Ratilal B, Costa J, Sampaio C. Antibiotic prophylaxis for surgical introduction of intracranial ventricular shunts: a systematic review. *J Neurosurg Pediatr*. 2008;1:48-56.

Rekate HL. Hydrocephalus in children. In: Winn HR, ed. *Youmans Neurological Surgery*. 5th ed. Philadelphia, PA: WB Saunders; 2004:3387-3404.

Sgouros S, John P, Walsh AR, Hockley AD. The value of colour Doppler imaging in assessing flow through ventriculo-peritoneal shunts. *Childs Nerv Syst*. 1996;12:454-459.

Vale FL, Bradley EL, Fisher WS III. The relationship of subarachnoid hemorrhage and the need for postoperative shunting. *J Neurosurg*. 1997;86:462-466.

Volpe JJ. Brain injury in the premature infant. Neuropathology, clinical aspects, pathogenesis, and prevention. *Clin Perinatol*. 1997;24(3):567-587.

Williams MA, Malm J. Diagnosis and treatment of idiopathic normal pressure hydrocephalus. *Continuum (Minneap Minn)*. 2016;22(2 Dementia):579-599.

Yasuda T, Tomita T, McLone DG, Donovan M. Measurement of cerebrospinal fluid output through external ventricular drainage in one hundred infants and children: correlation with cerebrospinal fluid production. *Pediatr Neurosurg*. 2002;36(1):22-28.

Zhang J, Williams MA, Rigamonti D. Genetics of human hydrocephalus. *J Neurol*. 2006;253(10):1255-1266.

111 Brain Edema and Increased Intracranial Pressure

Stephan A. Mayer

KEY POINTS

1. Brain edema can be classified as intracellular (cytotoxic and osmotic) or extracellular (vasogenic and interstitial).
2. Dexamethasone is useful for treating edema related to brain tumors and abscesses but has no role in the treatment of edema from stroke or trauma.
3. A stepwise tiered approach is the most effective way to treat elevated intracranial pressure (ICP).
4. Mannitol 20% at a dose of 0.5 to 1.5 g/kg or 23.4% hypertonic saline 0.5 to 2.0 mL/kg repeated as needed are the mainstay treatments for elevated ICP.
5. Decompressive hemicraniectomy is the definitive intervention for medically refractory ICP.
6. Acetazolamide 500 to 1,000 mg twice a day and if vision is threatened cerebrospinal fluid diversion are the primary treatments for idiopathic intracranial hypertension.

INTRODUCTION

Brain edema accompanies a wide variety of pathologic processes. It plays a major role in head injury, stroke, brain tumor, and cerebral infections such as brain abscess, encephalitis, and meningitis. Less common but equally devastating causes of brain edema include fulminant hepatic encephalopathy, hypertensive encephalopathy and posterior reversible encephalopathy syndrome (PRES), hydrocephalus, hypoxic-ischemic injury, hyponatremia, and other disorders associated with acute hypoosmolality (Table 111.1). Brain edema occurs in many different forms; clearly, it is not a single pathologic or clinical entity.

BRAIN EDEMA

Brain edema is defined as an increase in brain volume caused by an increase in water and sodium content. When well localized or mild in degree, brain edema is associated with little or no clinical evidence of brain dysfunction; however, when severe, it can cause massive intracranial mass effect and potentially fatal

TABLE 111.1 Conditions Characterized by Brain Edema

Intracellular Edema
Cytotoxic
• Cerebral infarction
• Hypoxic-ischemic injury
• Reye syndrome
Osmotic
• Acute hyponatremia
• Diabetic ketoacidosis
• Dialysis dysequilibrium syndrome
Extracellular Edema
Vasogenic
• Brain tumor
• Abscess
• Postendarterectomy hyperperfusion syndrome
• High-altitude cerebral edema
• Acute intermittent porphyria
• Multiple sclerosis
• Posterior reversible encephalopathy syndrome
◦ Hypertensive encephalopathy
◦ Eclampsia
Vasogenic (continued)
◦ Lead encephalopathy
◦ Immunosuppressants (tacrolimus/FK-506, cyclosporine A, interferon-α), intravenous immunoglobulin
◦ Chemotherapeutic agents (cisplatin, cytarabine)
◦ Erythropoietin
◦ End-stage renal disease
Interstitial
• Hydrocephalus
Combined Intracellular and Extracellular Edema
Vasogenic and cytotoxic
• Intracerebral hemorrhage
• Subarachnoid hemorrhage
• Dural sinus thrombosis
• Traumatic brain injury
• Encephalitis
• Meningitis
• Hepatic encephalopathy

brainstem herniation. Because the brain is encased in a rigid cranial vault, focal or generalized brain edema results in intracranial hypertension when it is severe enough to exceed the compensatory mechanisms that modulate intracranial pressure (ICP).

Brain tissue shifting or *herniation* results from the generation of compartmentalized mass effect and ICP gradients within the skull. The major forms of herniation are central, transtentorial (or uncal), subfalcine (or cingulate), and cerebellar (see Fig. 19.5).

Brain edema and vascular engorgement are different processes but can frequently coexist. *Brain engorgement* is an increase in the blood volume of the brain caused by obstruction of the cerebral veins and venous sinuses or by arterial vasodilatation, such as that caused by hypercapnia. Hypertension severe enough to overwhelm the brain's capacity to autoregulate and maintain a constant level of cerebral blood flow (CBF) is another common cause of brain engorgement. Brain engorgement is also known as *hyperemia* or *luxury perfusion*.

Pathobiology

Brain edema has conventionally been classified into three major categories: *vasogenic*, *cytotoxic*, and *interstitial*. The basic features of these three forms of cerebral edema are summarized in Table 111.2 with regard to pathogenesis, location and composition of the edema fluid, and changes in capillary permeability. A newer classification scheme focuses on the primary location of the edema fluid as *intracellular* or *extracellular*. In this scheme, the two main forms of intracellular edema are *cytotoxic* and *osmotic*, and the two main forms of extracellular edema are *vasogenic* and *interstitial* (hydrocephalic). Many causes of brain edema, including hemorrhagic stroke, venous infarction, and trauma, lead to a combination of these different forms of brain edema, and the varying contributions of each form of edema may change over time.

Vasogenic Edema

Vasogenic edema is a form of extracellular edema characterized by increased permeability of the blood-brain barrier to fluid, solutes, and macromolecules such as the plasma proteins, whose entry is normally limited by tight junctions between the capillary endothelial cells. The increase in permeability is visualized when contrast enhancement is observed with computed tomography (CT) or magnetic resonance imaging (MRI). Increased cerebrospinal fluid (CSF) protein levels are also indicative of increased endothelial permeability. MRI fluid-attenuated inversion recovery (FLAIR) sequences are more sensitive than CT for demonstrating the increases in brain tissue water content and extracellular volume that characterize vasogenic edema.

The biochemical basis of the changes in membrane integrity that underlie vasogenic edema involve the effects of free radicals (ie, superoxide ions, hydroxyl radicals, singlet oxygen, and nitric oxide) and polyunsaturated fatty acids, most notably arachidonic acid, in the peroxidation of membrane phospholipids. The ability of glucocorticoids to inhibit the release of arachidonic acid from cell membranes may explain their beneficial effects in vasogenic edema. By contrast, steroids such as dexamethasone have not been shown to be therapeutically useful in the treatment of cytotoxic or vasogenic brain edema associated with stroke or trauma.

Vasogenic edema is characteristic of clinical disorders in which a local tissue inflammatory response occurs when angiogenesis is stimulated by neoplasm, or when severe hypertension overwhelms the brain's capacity to autoregulate CBF. These disorders include brain tumor, abscess, hemorrhage, infarction with reperfusion, hypertensive encephalopathy, and traumatic contusion. Vasogenic edema related to varying degrees of vasodilation and blood-brain barrier disruption is also seen with acute demyelinating lesions in multiple sclerosis, hepatic or lead encephalopathy, Reye syndrome, and meningitis or encephalitis. Functional manifestations of vasogenic edema include focal neurologic deficits, focal electroencephalogram slowing, disturbances of consciousness, and intracranial hypertension. In patients with brain tumor, whether primary or metastatic, the clinical signs are often caused more by the surrounding edema than by the tumor mass itself.

TABLE 111.2 Classification of Brain Edema[a]

	Vasogenic	Cellular	Interstitial
Pathogenesis	Increased capillary permeability	Cellular swelling caused by energy failure or osmotic forces	Increased brain fluid due to block of CSF absorption
Location of edema	Primarily white matter	Gray and white matter	Periventricular white matter
Edema fluid composition	Plasma filtrate including plasma proteins	Increased intracellular water and sodium	CSF
Extracellular fluid volume	Increased	Early: decreased Late: increased	Increased
Capillary permeability to large molecules	Increased	Normal	Normal
Clinical disorders	Brain tumor, abscess, infarction (late), trauma, intracerebral hemorrhage, hepatic encephalopathy, high-altitude cerebral edema	Hypoxia-ischemia (early), hypo-osmolality (eg, hyponatremia), dialysis dysequilibrium syndrome	Obstructive hydrocephalus, idiopathic intracranial hypertension
Therapeutic Effects			
Steroids	Beneficial in brain tumor, abscess	Not effective	Not effective
Osmotherapy	Effectiveness limited by blood-brain barrier disruption	Effective	Rarely useful

Abbreviation: CSF, cerebrospinal fluid.
[a]Modified from Fishman RA. Brain edema. In: Fishman RA, ed. *Cerebrospinal Fluid in Diseases of the Nervous System*. 2nd ed. Philadelphia, PA: WB Saunders; 1992:116-137.

Cytotoxic Edema

Cytotoxic edema is a form of intracellular edema characterized by swelling of all the cellular elements of the brain (neurons, glia, and endothelial cells) with a concomitant reduction in the volume of the extracellular fluid space of the brain. Water accumulation related to cytotoxic edema tends to occur in three phases. In the first phase, the driving cause of cytotoxic edema is energy failure due to hypoxia, which results in adenosine triphosphate depletion and failure of active transport of sodium out of cells, resulting in intracellular sodium and water accumulation. Lactate and hydrogen ion accumulation also induces the entry of water into cells. The biologic basis of early cytotoxic brain edema, when cells are intact but metabolically challenged, involves astrocytic calcium signaling and activation of aquaporin-4 channels, which are the major influx route for water into the cell. Early in the course of cerebral ischemia, capillary permeability is usually not affected and tissue swelling is not evident.

Ionic edema is a newer term that describes a second stage in the course of cytotoxic edema due to hypoxia-ischemia. In this stage, while the blood-brain barrier remains structurally intact, additional sodium, chloride, and water accumulates within the extracellular space of the brain via upregulation of the Sur1-Trpm4 channel on the surface of endothelial cells. At this point, brain swelling begins to occur. Glyburide and other Sur1-Trom4 channel blockers targeting ionic edema formation are currently being tested in clinical trials of patients with middle cerebral artery infarction.

In the third stage of cytoxic brain edema, energy failure leads to cell death, complete disruption of cell membranes, and leakage of all intracellular contents into the extracellular space. In this final stage, tissue inflammation triggers disruption of the blood-brain barrier and the bulk flow of water, solutes, and plasma proteins into the infarcted tissue. As the process progresses to frank tissue infarction, vasogenic edema follows as the blood-brain barrier breaks down. The delay that occurs over several days in visualizing contrast enhancement with CT or magnetic resonance following an ischemic stroke illustrates that time is needed for defects in endothelial cell permeability to develop.

Osmotic Edema

Osmotic edema, like cytotoxic edema, is also caused by osmotic forces water shifting into cells but with the important difference that cellular energy failure does not play a role. Instead, the driving force is a sharp increase in the amount of free water in the extracellular fluid compartment, leading to an acute reduction in serum osmolality and movement of water into cells. Patients with pure cytotoxic edema have a normal CSF protein, and CT and MRI do not reveal contrast enhancement. As with cytotoxic edema, MRI diffusion-weighted imaging (DWI) reflects the restricted diffusion of water within swollen cells (see Chapter 22), but the process can be reversed with urgent but carefully controlled correction of the low serum osmolality.

There are several causes of osmotic edema, the most important being *acute hyponatremia* and the *osmotic dysequilibrium syndromes* that occur with hemodialysis (dialysis disequilibrium syndrome) and treatment for diabetic ketoacidosis. *Acute hyponatremia* and extracellular fluid can be caused by acute dilutional hyponatremia, syndrome of inappropriate secretion of antidiuretic hormone, or severe sodium depletion (see Chapter 125). The osmotic dysequilibrium syndromes that occur with hemodialysis or correction of diabetic ketoacidosis occur when excessive brain intracellular solutes result in excessive cellular hydration as elevated plasma osmolality is rapidly normalized. In the case of renal failure, the intracellular solutes presumably include a number of organic acids recovered in the dialysis bath. In diabetic ketoacidosis, the intracellular solutes include glucose and ketone bodies; however, there are also unidentified, osmotically active, intracellular solutes termed *idiogenic osmoles* that favor cellular swelling.

Major changes in cerebral function can result from processes that result in osmotic edema, including encephalopathy, stupor or coma, ICP elevation, brainstem herniation, asterixis, myoclonus, and focal or generalized seizures. As a general rule, intracellular edema caused by osmotic derangements is much more treatable than cytotoxic edema resulting from hypoxic-ischemic injury because cellular function remains viable. The extent of cellular swelling and neurologic dysfunction resulting from acute hypo-osmolality is directly related with how quickly it develops; chronic states of extreme hypo-osmolality that are reached gradually lead to minimal symptomatology.

Interstitial (Hydrocephalic) Edema

Interstitial edema is best characterized in obstructive hydrocephalus, in which the water and sodium content of the periventricular white matter increases because of the movement of CSF across the ventricular ependymal surface. Obstruction of the CSF outflow results in the transependymal movement of CSF and thereby an absolute increase in the volume of the extracellular fluid of the brain. Interstitial edema thus is strictly periventricular on CT and MRI, with predominance at the anterior and posterior aspects of the lateral ventricles. The composition of interstitial edema is similar to CSF. The clinical manifestations of interstitial edema (dementia, psychomotor slowing, and gait disorder) are often difficult to separate from those seen with normal pressure hydrocephalus in which there is physical traction on the periventricular white matter fiber tracts.

Selected Causes of Brain Edema

Cerebral Infarction

Most patients with arterial occlusion initially have cytotoxic edema followed by vasogenic edema, which are together termed *ischemic brain edema*. The cytotoxic phase takes place over minutes to hours and may initially be reversible. At this point, DWI may show dramatic changes well before evidence of completed tissue infarction can be demonstrated on MRI FLAIR sequences or by CT. Although osmotic or vasogenic edema can also be DWI positive, a phenomenon called *T2 shine through*, cytotoxic edema can be further differentiated from these causes on MRI because it is always associated with a reduction (low signal) in the apparent diffusion coefficient of water. The vasogenic phase of infarction takes place over hours to days as the tissue swells; in many cases, spontaneous vessel recanalization may occur and accelerate this process. A patchy and heterogenous pattern of contrast enhancement on CT or MRI at this point is characteristic.

Despite the theoretical concern that osmotic therapy with mannitol or hypertonic saline may aggravate tissue edema because these osmotically active substances may leak through disrupted endothelial cells into the infarcted brain tissue, clinical experience indicates that these treatments can effectively reverse the early stages of brainstem herniation. *Hemicraniectomy* is the definitive treatment of choice for younger patients (younger than 60 years) who are at risk for brainstem herniation due to complete infarction of the middle cerebral artery territory (see Chapter 36).

Intracerebral Hemorrhage

Perihematomal brain edema is a form of vasogenic edema that progressively increases over the first week after intracerebral hemorrhage (ICH; see Chapter 39). Symptomatic mass effect related to edema formation is the major cause of delayed neurologic deterioration after ICH. Perihematomal edema is caused by the local infiltration of plasma rich in thrombin and other coagulation proteins into the surrounding brain tissue. The thrombin then triggers a unique form of *neuro-hemo-inflammation*, stimulating the surrounding tissue to produce prostaglandins, complement, leukotrienes, and other inflammatory mediators that promote apoptotic cell death and blood-brain barrier disruption. Dexamethasone is not effective for treating perihematomal edema LEVEL 1.[1] A more recent trial of the iron chelator deferoxamine, directed at inhibiting iron-mediated inflammation, also failed to show benefit LEVEL 1.[2] A trial demonstrating worse outcomes in ICH patients on antiplatelet therapy treated with platelet transfusion suggests that inflammatory mediators included in the transfusion may aggravate perihematomal tissue injury LEVEL 1.[3]

By contrast, large doses of 20% mannitol (1.4 g/kg) have been shown to effectively reduce ICP and reverse clinical brainstem herniation in uncontrolled cohort studies. Insufficient local venous drainage, perhaps congenital or caused by local tissue compression and effacement, has been implicated in the pathogenesis of severe edema after ICH and might explain the benefits of bolus osmotherapy.

Subarachnoid Hemorrhage

Subarachnoid hemorrhage (SAH; see Chapter 40) can cause *global cerebral edema* that typically occurs at onset in poor-grade patients as well as a variety of forms of focal edema related to focal hematoma formation, cerebral infarction, brain retraction injury, and other causes. Global cerebral edema is considered the most important radiologic marker of *early brain injury* after SAH and initially is mostly vasogenic in nature (Fig. 111.1). The pathophysiology is thought to reflect transient hypoperfusion as a brief period of intracranial circulatory arrest associated with a massive surge in ICP, followed by reperfusion injury of the brain, with reflex hypertension in the setting of impaired autoregulation causing vascular engorgement. Global cerebral edema on CT affects 20% of patients and is associated with increased mortality and poor functional and cognitive outcome after SAH. Placement of an external ventricular drain is the first step in attaining ICP control; hypertonic saline and hypothermia are promising but untested potential interventions for mitigating further tissue damage.

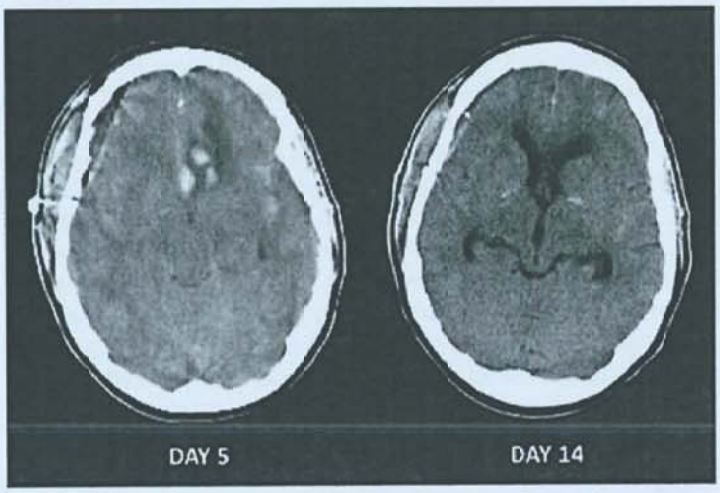

FIGURE 111.1 Global cerebral edema in a patient with subarachnoid hemorrhage. Day 5: Computed tomography shows global swelling of the brain with effacement of the quadrigeminal cisterns. A focus of hemorrhage with surrounding edema is also evident in the left inferior frontal lobe. The patient was undergoing induced hypertension, which later was felt to be exacerbating brain edema. Day 14: Resolution of global cerebral edema is evident.

Venous Infarction

Venous infarction results from occlusion of the cerebral venous and dural sinuses usually in the setting of dural sinus thrombosis (see Chapter 41) or as a complication of a neurosurgical procedure. The result is tissue hypoperfusion with congestion and engorgement of the microcirculation, which results in a combination of cytotoxic and prominent vasogenic edema. Imaging shows extensive mass effect, patchy enhancement, and secondary hemorrhagic transformation of the infarct in most cases. In addition to standard measures to control ICP, treatment is directed at preventing clot propagation within the venous system with heparin anticoagulation. Interventional approaches to restore venous flow with local thrombolytic therapy can also be attempted as a heroic measure.

Cardiac Arrest

After cardiac arrest (see Chapter 38), massive swelling of the brain that develops over the next several days is an ominous sign. Patients are usually in deep coma, and recovery is rare. Standard measures to treat brain edema at that point are usually pointless because the extent of cellular necrosis throughout the brain is very severe.

Traumatic Brain Injury

Traumatic brain injury (TBI) can result in both focal and global brain edema (see Chapter 47). The global form of edema is largely vasogenic in nature and is felt to reflect neurogenic vascular engorgement and hyperemia in the setting of autoregulatory failure and dysfunction of vasomotor centers in the brainstem. In some cases, the patients present with a lucid interval after experiencing a concussion, followed an hour later by rapid progression to coma, as the brain massively swells. *Second impact syndrome* refers to rapid and catastrophic swelling of the brain that occurs when a person experiences a second concussion before symptoms of an earlier one have resolved. Standard measures to control ICP, with emphasis on hyperventilation and blood pressure (BP) control to reduce cerebral blood volume, are effective. Focal brain edema can result from contusional injury, brain compression from epidural or subdural hematoma, thrombin-mediated perihematomal edema, or cerebral infarction when brain herniation results in compression of the anterior or posterior cerebral arteries (see Chapter 47). Steroids are not effective, and in one study, high-dose intravenous (IV) methylprednisolone (Solu-Medrol) was shown to increase mortality, which was presumably due to immunosuppression, hyperglycemia, increased muscle catabolism, and impaired wound healing LEVEL 1.[4]

Brain Tumors

Brain neoplasms (see section XIV and Chapter 150) cause a pure form of vasogenic brain edema, which is caused by the local release of cytokines, angiogenic factors, and other proinflammatory proteins that result in blood-brain barrier disruption. Malignant and highly vascular tumors as a rule cause much more local

edema of the surrounding brain tissue than do benign neoplasms such as meningiomas, although exceptions can occur. The edema characteristically tracks along the white matter pathways on MRI or CT. Vasogenic edema associated with brain neoplasm is highly responsive to glucocorticoid therapy. In addition to standard measures to control ICP, *dexamethasone* is the treatment of choice; a typical starting dose is 4 to 10 mg every 6 hours. Bevacizumab, a vascular endothelial growth factor inhibitor, is an anticancer biologic agent, which can also be used in low doses (2.5-10 mg/kg IV every 2 wk) as a steroid-sparing option to treat severe tumor-related brain edema and radiation necrosis.

Fulminant Hepatic Encephalopathy

Acute fulminant liver failure from any cause can result in hepatic encephalopathy producing clouding of consciousness with prominent asterixis (see Chapter 124). As the severity of neurologic dysfunction progresses from lethargy to stupor to coma, massive swelling of the brain can occur resulting in dangerous elevations of ICP and brainstem herniation. The cause of the brain edema is poorly understood, and its onset can be unpredictable. Initially, the edema is primarily vasogenic with a large component of vascular engorgement. Ammonia and other substances normally metabolized by the liver cross the blood-brain barrier where they cause astrocytes to swell and disrupt endothelial tight junctions. Treatment relies on standard measures to control ICP; lactulose does not control brain edema when it is present. Optimal management requires placement of an ICP monitor after meticulous correction of the coagulopathy that usually is present. Transcranial Doppler sonography and jugular venous oxygen saturation monitoring demonstrate findings consistent with excessive hyperemia and can be used as end points to ensure that hyperventilation and BP control are not excessive. Mild to moderate hypothermia (33°C) has been shown to be effective in addition to more standard measures for controlling ICP, but liver transplantation is the only known definitive treatment. If the process is uncontrolled, herniation and brain death are a common outcome.

Reye Syndrome

Reye syndrome is a form of acute hepatitis with prominent fatty changes resulting from viral infection and exposure to aspirin that can occur in children. It is often accompanied by an encephalopathy characterized by progressive stupor and coma and a combination of cytotoxic and, to a lesser extent, vasogenic brain edema. Uncontrolled intracranial hypertension can lead to fatal brainstem herniation, and the pathogenesis is obscure. The disease is rarely seen today because of restrictions of the use of aspirin in pediatric patients.

Brain Abscess

Brain abscesses (see Chapter 65) caused by localized infection with bacteria, toxoplasmosis, cysticercosis, fungal infection, or other causes result in a pure form of vasogenic edema very similar to that produced by brain tumors. Local release of various inflammatory mediators results in increased vascular permeability. As is the case with neoplasms, the edema is highly responsive to dexamethasone 6 mg every 6 hours.

Viral Encephalitis

MRI DWI sequences in patients with viral encephalitis (see Chapter 69) reveal cytotoxic edema in the limbic cortex, including the medial temporal and inferior frontal lobes, insula, and cingulate gyrus without mass effect. In milder cases, FLAIR and CT may be negative, and the lesions are only apparent on DWI. In rare cases, viral encephalitis can result in a more fulminant pattern of generalized cytotoxic and vasogenic edema that requires ICP monitoring and treatment.

Meningitis

Severe generalized brain edema can occur with acute purulent bacterial or tuberculous meningitis (see Chapter 64). Such edema is caused by the inflammatory response generated by infiltrating polymorphonuclear white blood cells and has been termed *granulocytic brain edema*. Vasogenic edema predominates, but interstitial edema may also occur as the result of communicating hydrocephalus. Dexamethasone 10 mg every 6 hours for 4 days diminishes the inflammatory response and has been shown to improve survival and reduce cranial nerve injury in adults and children with bacterial meningitis regardless of whether brain edema is evident on imaging LEVEL 1.[5] A similar steroid regimen is also commonly used to reduce the inflammatory response in patients with tuberculous meningitis. Placement of an external ventricular drain may be required in cases with a significant component of hydrocephalus and is usually sufficient to control ICP.

Posterior Reversible Encephalopathy Syndrome

PRES is a clinical syndrome characterized by neurologic dysfunction and a characteristic pattern of brain edema that predominates in the white matter of the parietal and occipital lobes (Fig. 111.2). The edema is primarily vasogenic with cerebral perfusion pressure (CPP) breakthrough and disruption of the blood-brain barrier playing a large role in the pathogenesis of the disorder (see Chapter 44). FLAIR imaging is highly sensitive and often reveals scattered microbleeds on gradient echo (T2*) sequences. A wide variety of very different pathologic entities can cause PRES, including hypertensive encephalopathy resulting from poorly controlled essential hypertension, eclampsia, a variety of immunosuppressive agents, and end-stage renal disease (see Chapter 44). Clinical manifestations start with headache, confusion, visual disturbances (including cortical blindness in some cases), and seizures and can progress to stupor or coma. Massive swelling of the brain that requires ICP monitoring and therapy is unusual but can occur. Treatment is directed at removing any possible triggering agent and BP control with treatment

FIGURE 111.2 Posterior reversible encephalopathy syndrome. Fluid-attenuated inversion recovery images show abnormally increased signal *(arrows)* in the occipital and parietal white matter.

for seizures and elevated ICP as needed. Continuous infusion antihypertensive agents that allow precise BP control, such as labetalol and nicardipine, are preferred. Magnesium sulfate 4-g bolus followed by 10 to 12 g/h has been shown to improve outcome in women with eclampsia LEVEL 1.[6]

High-Altitude Cerebral Edema

This condition is a form of global and purely vasogenic cerebral edema caused by excessive cerebral vasodilation triggered by hypoxia in high altitudes. In addition to vascular engorgement, endothelial disruption results in fluid leakage into the brain. The condition can be rapidly fatal. MRI shows posterior white matter edema with a predilection for the splenium of the corpus callosum. Immediate descent (600-1,200 m), acetazolamide 500 mg every 6 hours, and delivery of supplemental oxygen are the treatments of choice.

Postendarterectomy Hyperperfusion Syndrome

This unusual complication of carotid endarterectomy or stenting occurs in patients who have long-standing high-grade carotid stenosis. Immediately after revascularization, the cerebral circulation remains maximally dilated and is unable to recover the capacity to autoregulate. The result is a pulsatile headache; more severe cases involve focal neurologic defects related to vasogenic edema in the downstream anterior circulation. In some cases, hemorrhagic conversion occurs. Meticulous BP control can minimize the extent of injury, and the syndrome typically resolves over several days.

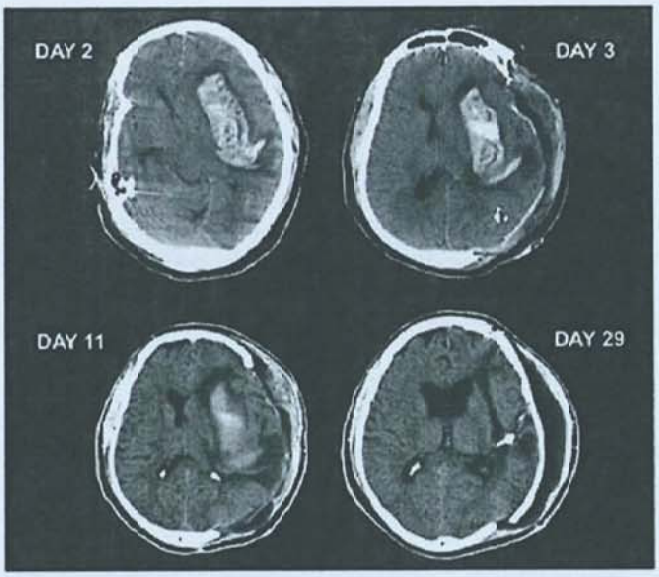

FIGURE 111.3 Decompressive hemicraniectomy in a 58-year-old man with left putamen intracerebral hemorrhage. On day 3, he experienced brainstem herniation with bilateral motor posturing and a fixed and dilated left pupil despite aggressive medical intervention. He underwent urgent hemicraniectomy and duraplasty with restoration of midline positioning of the brain evident on day 11. The day 29 image shows normalization of brain morphology after replacement of the bone flap. The patient made a near-complete recovery.

Intracranial Pressure Management

General Approach

As outlined earlier, the optimal therapy of brain edema depends on the cause. A patent airway, maintenance of an adequate BP, and the avoidance of hypoxia are fundamental requirements in the care of these patients. The administration of appropriate parenteral fluids to meet the needs of patients is also essential. Administration of salt-free hypotonic fluids to patients with cerebral edema should be strictly avoided because serum hypo-osmolality increases brain swelling. As a general rule, inflammatory processes that predominantly involve vasogenic edema respond to dexamethasone (with the exception of vasogenic edema in patients with stroke or trauma) and measures to minimize brain engorgement and cerebral blood volume, including tight BP control and hyperventilation. By contrast, cytotoxic or cellular edema resulting from fluid and solute overload on the intracellular compartment responds best to osmotic therapy.

Neurosurgical decompression of the cranial vault can be lifesaving and should always be the *first and last* consideration when patients are at risk for secondary deterioration due to compartmentalized intracranial mass effect. Surgical options include placement of an external ventricular or lumbar drain for drainage, craniotomy to remove an intracranial mass lesion, or, as a last resort, hemicraniectomy with duraplasty to definitively decompress the cranial vault (Fig. 111.3). In all comatose patients where (1) intracranial hypertension elevation is suspected, (2) imaging shows mass effect due to brain edema, and (3) aggressive intensive care unit care is indicated, placement of an ICP monitor is essential. Empiric treatment of suspected ICP should be performed in the short term but only when ICP and CPP are actually being measured can the problem be optimally treated.

Tiered Approach to Intracranial Pressure Management in a Monitored Patient

In a monitored patient for whom all first-line neurosurgical options have been exhausted, medical management of elevated ICP is best performed according to an algorithm that emphasizes the logical stepwise application of various interventions (Table 111.3). In addition to the avoidance of hypotension and hypoxia, fluid resuscitation with isotonic crystalloids, seizure prophylaxis and fever control, and head elevation to 30° lowers ICP by reducing jugular venous pressure and should be performed as a general measure in all patients (Table 111.4). Subsequent pharmacologic treatment of brain edema resulting in increased ICP should then progress through the three treatment tiers outlined in Table 111.3. In this algorithm, sedation is the fundamental first step to controlling ICP after rescue neurosurgical intervention has been performed. Sedation lowers thoracic and jugular venous pressure and can calm arterial hypertension and autonomic instability. CPP, calculated as mean arterial pressure minus ICP, can aggravate intracranial hypertension when it is either extremely low or extremely high (Fig. 111.4). Osmotherapy in the form of 0.5 to 1.5 g/kg of 20% mannitol or 23.4% hypertonic saline solution is the mainstay intervention for reducing ICP in critical "brain code" situations. Mannitol should be hung wide open, and 30 mL of 23.4% saline should be pushed through a central venous line slowly over 5 minutes. Doses can be repeated as often as every 30 minutes as needed. Hyperventilation often does not have a sustained effect and should be administered in bursts, typically in tandem with bolus osmotherapy in response to ICP crisis. When intracranial hypertension is associated with systemic acidosis, boluses of 8.4% sodium bicarbonate (50 mEq in 50 ml) or trometanol (THAM, 0.3 mol/L in 500 ml) can reduce ICP and normalize pH.

TABLE 111.3 Stepwise Management Protocol for Intracranial Pressure Crisis (>20 mm Hg for >10 min) in a Monitored Patient[a]

Tier 1
• **Early neurosurgical intervention** including ventricular drainage or craniotomy
• **Sedate** to attain a motionless, quiet state with fentanyl and propofol.
• **Optimize cerebral perfusion pressure** (generally 60-100 mm Hg) to minimize excessive vasodilation from low hypotension or perfusion pressure breakthrough.
Tier 2
• **Bolus osmotherapy** with mannitol 0.5-1.5 g/kg IV or 30 mL 23.4% hypertonic saline repeated up to every 30 min as needed.
• **Hyperventilation** to P_{CO_2} levels of 30-34 mm Hg
• **Paralyze** with a neuromuscular blocking agent such as rocuronium 0.5-1.0 mg/kg/h.
Tier 3
• **Pentobarbital infusion** titrated to ICP <25 mm Hg and EEG burst suppression (1.0-4.0 mg/kg/h)
• **Hypothermia** to a target core temperature of 33°C-35°C
• **Decompressive hemicraniectomy**

Abbreviations: EEG, electroencephalogram; ICP, intracranial pressure; IV, intravenous.
[a]See text for details.

Advanced Treatment Options for Medically Refractory Intracranial Pressure

As outlined in Figure 111.5, escalation beyond the first line of medical interventions for refractory ICP becomes more nuanced and should be tailored to the specific clinical situation and available resources and expertise. These advanced interventions for super-refractory ICP crisis are extensions of each step of first-line intervention. Decompressive hemicraniectomy should be reconsidered. CPP can be further optimized with invasive brain multimodality monitoring with the intention of normalizing CBF or brain tissue oxygen tension (see Chapter 34). After a patient is sedated with conventional agents such as propofol, paralysis or barbiturate anesthesia with pentobarbital can be considered. Bolus osmotherapy can be escalated with continued good effect on ICP to serum osmolality levels far above 320 mOsm/L. When brain hyperemia is considered an important contributing factor, aggressive hyperventilation to P_{CO_2} levels far below 30 mm Hg can be safely attained with concurrent monitoring of brain tissue oxygen tension, CBF, or jugular venous oxygen saturation (normally 70%-90%). Finally, therapeutic temperature modulation can be pushed to beyond simple fever control to lower temperature targets ranging from 35°C to 36°C.

Salvage Interventions for Super-Refractory Intracranial Pressure

Super-refractory ICP refers to the uncommon scenario when ongoing tier 2 intervention involving CPP optimization, repeated doses of bolus osmotherapy, sustained mild hyperventilation, and sedation and paralysis cannot control ICP. The process usually plays out over hours or days. At this point, consideration should be given to proceeding with decompressive hemicraniectomy. If this is not feasible or desired, the two final remaining medical options are to cool to a target temperature of 32°C to 34°C or to induce pentobarbital coma.

TABLE 111.4 Baseline Treatment Measures for Patients at Risk for Intracranial Pressure

• Avoid hypotension and hypoxia.
• Administer only isotonic fluids (avoid all sources of free water).
• Head elevation to 30°
• Control fever.
• Consider seizure prophylaxis.

Decompressive Craniectomy

The ultimate and most effective step to take when confronted with super-refractory ICP is to decompress the cranial vault. Decompression of the cranium allows the brain to swell out of the skull defect and when done properly will definitively control ICP. In severe TBI patients who have suffered ICP >25 mm Hg for 12 to 24 hours despite tier 1 and 2 therapy, craniectomy compared to continued medical therapy with escalation to pentobarbital reduces mortality from 49% to 27% LEVEL 2.[7] Decompressive craniectomy should only be used as a salvage intervention, however, because there is evidence that when performed too early, the procedure may do harm. Another trial that randomized TBI patients to surgery at the very first sign of ICP elevation resulted in increased disability, with no effect on mortality LEVEL 2.[8]

Therapeutic Hypothermia

Lowering body temperature to 33°C to 36°C can reduce ICP elevations that are refractory to standard tier 2 interventions. In general, this technique should be applied by experienced intensivists, and a detailed management protocol is required (see Chapter 38). Advanced feedback-controlled cooling technology using a surface cooling system or endovascular heat exchange catheter is generally required. Target temperature should be titrated to a level that controls ICP but no further, to minimize complications. After cooling for 24 to 72 hours, rewarming at a rate of 0.20°C to 0.33°C per hour can commence. Complications of hypothermia include cardiovascular depression and bradycardia, immunosuppression, impaired coagulation, shivering, and a variety of other metabolic derangements including hypokalemia and hyperglycemia. These complications may explain why mortality was increased in a clinical trial evaluating the use of hypothermia instituted early in the course of ICP elevation after TBI LEVEL 1.[9]

Pentobarbital Coma

High-dose barbiturate therapy, given in doses equivalent to those inducing general anesthesia, is the oldest treatment for super-refractory ICP. A lipid-soluble agent with a half life of 15 to 50 hours, which increases with the duration of infusion, pentobarbital reduces ICP due to a reduction in cerebral blood volume that is coupled to profound reductions in flow and metabolism. Complications include hypotension and cardiovascular depression, critical illness myopathy, and immunosuppression. The loading dose is 5 to 20 mg/kg/h, followed by a maintenance infusion of 1 to 4 mg/kg/h.

Specific Treatments for Brain Edema

Glucocorticoids

Glucocorticoids dramatically and rapidly (in hours) begin to reduce the focal and general signs of brain edema around tumors and abscesses but are not effective for treating the edema that results from cerebral infarction, ICH, SAH, or TBI. The major

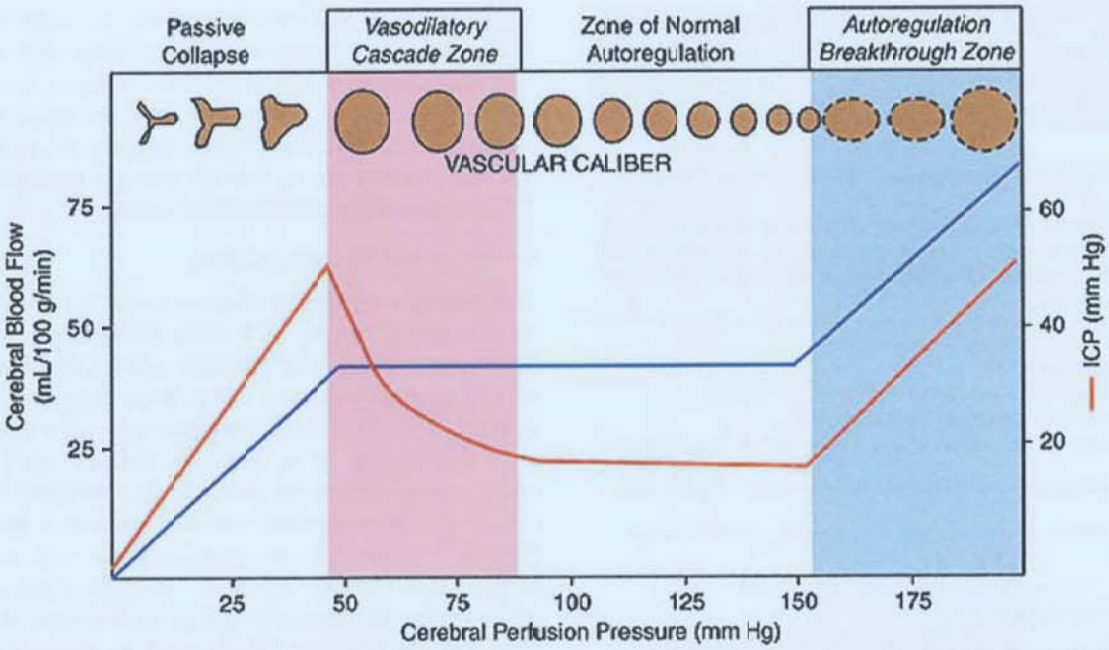

FIGURE 111.4 Cerebral autoregulation curve *(blue line)* and relationship between cerebral perfusion pressure (CPP) and intracranial pressure (ICP) in states of abnormal intracranial compliance *(red line)*. Under normal circumstances, cerebral blood flow is held constant across a wide range of CPP (50-150 mm Hg), and changes in vessel caliber have no effect on ICP. In disease states with reduced intracranial compliance, ICP can become elevated when CPP is low due to autoregulatory vasodilation and increased cerebral blood volume (vasodilatory cascade physiology) or when CPP is too high due to passive increases in cerebral blood volume due to increased hydrostatic pressure and hyperemia (autoregulation breakthrough physiology).

mechanism explaining the usefulness in vasogenic brain edema is a direct normalizing effect on endothelial cell function and permeability when the process is triggered by local release of cytokines, angiogenic factors, vascular adhesion molecules, and other inflammatory mediators.

Long-acting, high-potency glucocorticoids are most widely used for the treatment of vasogenic edema related to tumor or infection. The usual dosage of dexamethasone is a starting dose of 10 mg followed by 4 to 6 mg administered 4 times a day thereafter—a dose equivalent in potency to more than 400 mg of cortisol daily. These large doses are about 20 times the normal rate of human endogenous cortisol production. There are no convincing data, clinical or experimental, that glucocorticoids have beneficial effects for the treatment of cytotoxic or osmotic cellular edema regardless of cause. Steroids are also commonly used by neurosurgeons to enhance brain compliance and relaxation during craniotomy despite little evidence of its effectiveness. Steroids may be useful in the management of less common conditions characterized by an inflammatory CSF and brain edema, such as postinfectious acute disseminated encephalomyelitis, central nervous system vasculitis, and meningeal sarcoidosis.

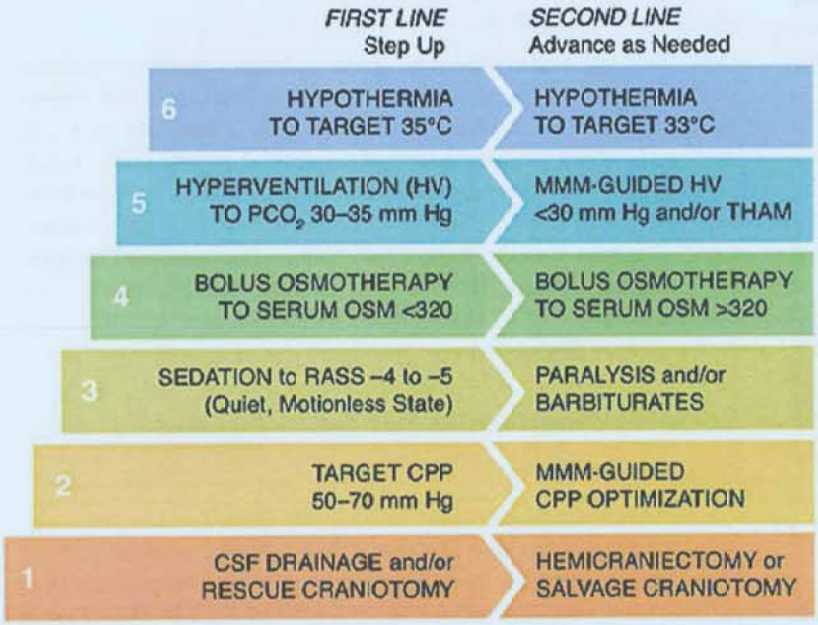

FIGURE 111.5 Stepwise intracranial pressure (ICP) management protocol. Escalation of ICP therapy should advance through first-line interventions to ensure that vital steps are not skipped. The need for repeated bolus osmotherapy, burst hyperventilation, or induction of hypothermia defines ICP crisis. At the level of super-refractory ICP crisis, second-line interventions can be added based on the clinical situation and available resources and expertise. Abbreviations: CPP, cerebral perfusion pressure; CSF, cerebrospinal fluid; MMM, multimodality monitoring; OSM, osmolality (mOsms/L); RASS, Richmond Agitation Sedation Scale; THAM, trometamol.

Mannitol

IV mannitol is the most widely used solute for the treatment of intracranial hypertension associated with brain edema. Given in a 20% solution at a dose of 0.25 to 1.5 g/kg, mannitol dehydrates brain tissue and mediates an ICP-lowering effect through several mechanisms. First, it is an osmotic diuretic that creates a concentration gradient across the blood-brain barrier and pulls free water from the brain. This decreases volume of the brain parenchyma and lowers ICP. Second, mannitol increases CPP through plasma expansion and promotes vasoconstriction and cerebral blood volume reduction by decreasing blood viscosity and improving CBF. Finally, mannitol is excreted in the urine resulting in a net clearance of free water and increased serum osmolality.

When given as a bolus infusion, mannitol can lower ICP within as little as 10 to 30 minutes. Dosing may be repeated as frequently as once an hour when ICP is elevated. As opposed to hypertonic saline, mannitol is the preferred treatment for ICP in patients with fluid overload or left ventricular failure. Complications of mannitol therapy include dehydration, electrolyte depletion, and osmotically mediated renal failure. A widened gap of more than 10 mOsm/L between the measured and calculated osmolality may indicate incomplete mannitol clearance by the kidneys and an increased risk of renal tubular necrosis. With repeated bolus dosing a "rebound effect" with successive increases in ICP may occur. Although it is sometimes stated that mannitol loses its efficacy when serum osmolality exceeds 320 mOsm/L, there is scant evidence to support this contention.

Hypertonic Saline

Hypertonic saline has an osmotic effect on the brain because of its high tonicity and ability to effectively remain outside the blood-brain barrier. Numerous animal studies have suggested that fluid resuscitation with hypertonic saline after hemorrhagic shock prevents the ICP increase that follows resuscitation with isotonic fluids. As opposed to mannitol, hypertonic saline is the treatment of choice for increased ICP in patients with hypotension or hypovolemia because it expands intravascular volume. Hypertonic saline solutions may have favorable effects on CBF by producing a boost in CPP and via local effects on the cerebral microvasculature. A clinical trial comparing hypertonic saline with isotonic crystalloid for TBI patients, however, failed to show any benefit. Infusion of a bolus dose of 3%, 7%, 10%, or 23% hypertonic saline solution results in maximal ICP reduction between 30 and 120 minutes accompanied by a surge in CPP. In the United States, use of 30-mL "bullets" of 23.4% saline has become the most popular form of hypertonic saline bolus osmotherapy. Common complications of hypertonic saline administration include volume overload, pulmonary edema, and electrolyte depletion.

IDIOPATHIC INTRACRANIAL HYPERTENSION

Idiopathic intracranial hypertension (IIH) describes a heterogeneous group of disorders characterized by increased ICP when intracranial mass lesions, obstructive hydrocephalus, intracranial infection, and hypertensive encephalopathy have been excluded. IIH is also termed *pseudotumor cerebri*. The best documented risk factors for IIH are obesity, hypervitaminosis A, steroid withdrawal, and female gender. The term *benign* has been used because spontaneous recovery is characteristic, but the condition is far from harmless: Serious threats to vision make accurate diagnosis and therapeutic intervention a necessity.

Causes of Idiopathic Intracranial Hypertension

Endocrine and Metabolic Disorders

IIH is most commonly seen in healthy women with a history of menstrual dysfunction. Frequently, the women are moderately or markedly overweight (without evidence of alveolar hypoventilation). Menstrual irregularity or amenorrhea is common; galactorrhea is an unusual symptom. The histories often emphasize excessive premenstrual weight gain. Endocrine studies have not revealed specific abnormalities of urinary gonadotropins or estrogens, and the pathogenesis is unknown. IIH has a complex relationship to adrenal hormones. Rarely, IIH is a complication of Addison disease or Cushing disease. Improvement occurs after restoration of a normal adrenal state; the mechanism in either circumstance is unknown.

IIH has also occurred in patients treated with corticosteroids for prolonged periods. Many of the patients had allergic skin disorders or asthma during childhood; IIH generally occurs when the steroid dosage is reduced but evidence of hyperadrenalism persisted. Hypoparathyroidism may also present with increased ICP; hypocalcemic seizures or cerebral calcifications may further complicate the clinical picture. IIH has also been reported in women taking oral progestational drugs.

Drugs and Toxins

IIH has been reported in otherwise healthy adolescents who are taking large doses of vitamin A for the treatment of acne. Oral doses as low as 25,000 IU daily may cause headache and papilledema with rapid improvement after cessation of the therapy. The syndrome is said to have occurred in Arctic explorers who consumed polar bear liver, a great source of vitamin A. Some cases of IIH that are manifested by bulging fontanel and papilledema have been reported in children given tetracycline. The mechanisms involved are obscure. Spontaneous, rapid recovery occurs when the drugs are stopped. Amiodarone and lithium carbonate, as well as the insecticide chlordecone, have also been reported to cause IIH.

Hematologic and Connective Tissue Disorders

Papilledema and increased ICP have been attributed to severe iron deficiency anemia with striking improvement after treatment of the anemia. Presumably, the mechanism partly reflects the marked increase in CBF that accompanies profound anemia. IIH has also been observed as a manifestation of systemic lupus erythematosus.

Pulmonary Encephalopathy

IIH may be a major complication of chronic, hypoxic hypercapnia caused by paralytic states such as muscular dystrophy and cervical myelopathy; it may also be a complication of obstructive pulmonary disease and obstructive sleep apnea. There is a chronic increase of CBF because of hypoxia and carbon dioxide retention. Patients usually appear mentally dull and encephalopathic and thus differ from most patients with IIH.

Spinal Cord Diseases

IIH rarely occurs with tumors of the spinal cord or cauda equina or with polyneuritis. Papilledema and headache disappear with treatment of the spinal lesion or regression of the polyneuropathy.

The mechanism may involve the effects of an elevated CSF protein on CSF absorption at the arachnoid villi in both cranial and spinal subarachnoid spaces. Occurrence of this syndrome, however, does not correlate with the degree of protein elevation.

Pathobiology

Several mechanisms have been considered as possible explanations for the pathophysiology of IIH. These include an increased rate of CSF formation, a sustained increase in intracranial venous pressure, a decreased rate of CSF absorption by arachnoid villi apart from venous occlusive disease, and an increase in brain volume caused by an increase in blood volume or extravascular fluid volume simulating a form of brain edema.

No data are available regarding the rate of CSF formation, and the only condition in which increased CSF formation has been demonstrated is choroid plexus papilloma. Increased CSF production might explain the pathophysiology in some of the diverse conditions associated with IIH, but this mechanism remains unproven. A sustained increase in intracranial venous pressure associated with decreased CSF absorption has similarly not been documented in IIH. The currently most favored explanation for IIH is decreased CSF absorption (in the absence of venous occlusion) resulting from altered function of the arachnoid villi. For reasons that are unclear, however, hydrocephalus does not occur in IIH. On the contrary, very often, the brain appears swollen and the ventricles are smaller than normal. It has been hypothesized that IIH might have caused by an increase in brain volume secondary to an increase in extracellular fluid volume. An increase in brain volume would be expected if the extracellular space of the brain were expanded; this is now hypothesized to be the result of impaired perivascular glymphatic drainage of interstitial fluid out of the brain.

Any theory of the pathogenesis of IIH must be consonant with the rapid therapeutic response of IIH to shunting of CSF by an implanted lumbar peritoneal shunt. Impaired CSF absorption or increased CSF formation would explain the occurrence of IIH in most cases; however, the limited data available, currently, do not allow any firm conclusions.

One of the more common forms of IIH appears in otherwise healthy persons in the absence of any of the aforementioned etiologic factors. Both genders are affected, women more than men, and occurrence is most often in patients between 10 and 50 years of age.

Clinical Features

Typically, the first symptoms are headache and impaired vision. The headache may be worse on awakening and aggravated by coughing and straining. It is often mild or may be entirely absent. In some cases, pulse-synchronous tinnitus occurs. The most common ocular complaint is visual blurring, a manifestation of papilledema. Some patients complain of brief, fleeting moments of dimming or complete loss of vision occurring many times during the day, at times accentuated or precipitated by coughing and straining. This ominous symptom indicates that vision is in jeopardy. Visual loss may be minimal despite severe chronic papilledema, including retinal hemorrhages; however, blindness occasionally develops rapidly (ie, <24 h). Visual field testing characteristically shows enlargement of the blind spots and may show constriction of the peripheral fields and central or paracentral scotoma. Diplopia caused by unilateral or bilateral sixth nerve palsy may develop as a result of increased ICP. The neurologic examination is otherwise normal. A major clinical point is that patients with IIH usually look well; their apparent well-being belies the ominous appearance of the papilledema. Although the disorder most often lasts for months, it may persist for years without serious sequelae. Remissions may be followed by one or more recurrences in 5% to 10% of cases. In some patients, IIH may be responsible for development of the *empty sella syndrome*, in which radiographic image showing enlargement of the sella turcica simulates the appearance of a pituitary tumor. CT reveals that the enlarged sella is filled with CSF flowing from a defect of its diaphragm.

Diagnosis

The patient with headache and papilledema without other neurologic signs suggest the diagnosis of IIH. Although the diagnosis of IIH may be suspected by the appearance of well-being and a history of some of the associated etiologic features listed previously, the diagnosis is essentially one of exclusion and depends on ruling out the more common structural causes of increased ICP. Brain tumor, particularly when located in relatively "silent" areas such as the frontal lobes or right temporal lobe or when obstructing the ventricular system, may be manifested only by headache and papilledema. Patients with chronic subdural hematoma, without a history of significant trauma, may have the same symptoms. Other important conditions to exclude include viral meningitis and other central nervous system infections and dural sinus thrombosis.

Diagnostic evaluation depends on MRI with venography and lumbar puncture. Lumbar puncture should be deferred until imaging indicates that the perimesencephalic cisterns are open. MRI shows no distinct pathology other than a variety of subtle findings that occur as the result of chronically increased ICP (Table 111.5). Diagnostic lumbar puncture is mandatory to establish the diagnosis of IIH. In obesity, the normal upper limit of CSF pressure is 250 mm Hg. In IIH, the CSF pressure is elevated, usually between 250 and 600 mm Hg, but the fluid is otherwise normal. The protein content is often in the lower range of normal, and lumbar CSF protein levels of 10 to 20 mg/dL are common. CSF protein content greater than 50 mg/dL, decreased CSF glucose, or increased cell count throws doubt on the diagnosis of IIH and suggests other disease conditions.

Pseudopapilledema may be a source of diagnostic confusion. In this developmental anomaly of the fundus, the ophthalmic appearance may be indistinguishable from true

TABLE 111.5 Typical Neuroimaging Features Found in Idiopathic Intracranial Hypertension

• Swollen brain
• Slit-like ventricles
• Empty sella
• Increased tortuosity of optic nerve
• Enlarged optic nerve sheath (perioptic subarachnoid space)
• Flattened posterior globe
• Intraocular protrusion of optic nerve head
• Attenuation or stenosis of the cerebrovenous sinuses

papilledema; there is elevation of the optic disc, although exudates and hemorrhages are absent. Visual acuity is normal, but visual fields may show enlargement of the blind spots. The unchanging appearance of the fundus in subsequent examinations favors the diagnosis of pseudopapilledema, as does the finding of normal CSF pressure on lumbar puncture. Optic neuritis is differentiated from IIH by visual loss and normal CSF pressure.

Treatment

The common form of IIH in patients with menstrual disorders and obesity requires individualized management. This syndrome is self-limited in most cases, and after some weeks or months, spontaneous remissions occur, making evaluation of therapy outcomes difficult. Recurrent episodes have been noted in about 5% to 10% of patients, and the illness seldom lasts for years. In the extremely obese patient (body mass index >30 kg/m^2), weight reduction is recommended. Daily lumbar puncture was used in the past to lower CSF pressure to normal levels by removing sufficient fluid; 15 to 30 mL of fluid may be removed. In many cases, short-term headache relief occurs, but as a rule, it tends to recur quickly. Because the value of serial lumbar punctures is dubious, this approach is no longer recommended LEVEL 3.[10]

An algorithm for management of established IIH is shown in Figure 111.6. A CSF shunt procedure, such as a lumboperitoneal shunt, is useful in patients with intractable headache and progressive visual impairment. It may dramatically relieve symptoms. Optic nerve sheath fenestration has its advocates as the procedure of choice to preserve vision.

Acetazolamide 500 mg 2 to 4 times a day has been used because this carbonic anhydrase inhibitor reduces CSF formation. The Neuro-Ophthalmology Research Disease Investigator Consortium trial has demonstrated that acetazolamide 1,000 mg titrated upward, along with a salt restriction and weight reduction diet, results in modest improvement in visual field function and improved quality of life in patients with mild pseudotumor cerebri LEVEL 1.[11,12] Topiramate, 25 to 50 mg twice a day, a carbonic anhydrase inhibitor and appetite suppressant as well, can be used as an alternative to acetazolamide. Hypertonic IV solutions (20% mannitol) to lower ICP may be used in acute situations when there is rapidly failing vision and surgical intervention is awaited. When the pseudotumor syndrome is a manifestation of

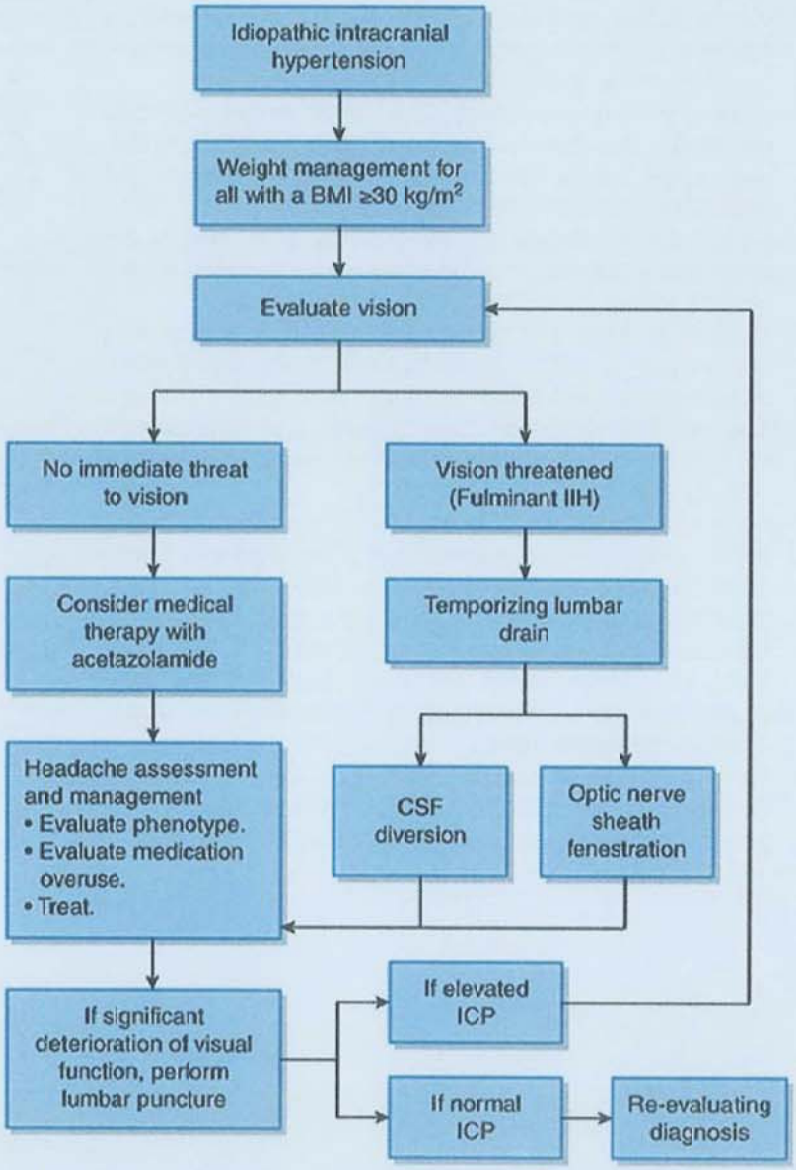

FIGURE 111.6 Management flow chart of diagnosed idiopathic intracranial hypertension (IIH). Abbreviations: BMI, body mass index; CSF, cerebrospinal fluid; ICP, intracranial pressure. (Adapted from Mollan SP, Davies B, Silver NC, et al. Idiopathic intracranial hypertension: consensus guidelines on management. *J Neurol Neurosurg Psychiatry*. 2018;89[10]:1088-1100, with permission.)

hypoadrenalism or hypoparathyroidism, replacement therapy is indicated. Vitamin A intoxication disappears when administration of the vitamin is stopped.

LEVEL 1 EVIDENCE

1. Poungvarin N, Bhoopat W, Viriyavejakul A, et al. Effects of dexamethasone in primary supratentorial intracerebral hemorrhage. *N Engl J Med*. 1987;316(20):1229-1233.
2. Selim M, Foster LD, Moy CS, et al. Deferoxamine mesylate in patients with intracerebral haemorrhage (i-DEF): a multicentre, randomised, placebo-controlled, double-blind phase 2 trial. *Lancet Neurol*. 2019;18(5):428-438.
3. Baharoglu MI, Cordonnier C, Salman RA, et al. Platelet transfusion versus standard care after acute stroke due to spontaneous cerebral haemorrhage associated with antiplatelet therapy (PATCH): a randomised, open-label, phase 3 trial. *Lancet*. 2016;387:2605-2613.
4. Roberts I, Yates D, Sandercock P, et al. Effect of intravenous corticosteroids on death within 14 days in 10008 adults with clinically significant head injury (MRC CRASH trial): randomised placebo-controlled trial. *Lancet*. 2004;364:1321-1328.
5. van de Beek D, de Gans J, McIntyre P, Prasad K. Steroids in adults with acute bacterial meningitis: a systematic review. *Lancet Infect Dis*. 2004;4(3):139-143.
6. Altman D, Carroli G, Duley L, et al. Do women with preeclampsia, and their babies, benefit from magnesium sulphate? The Magpie Trial: a randomised placebo-controlled trial. *Lancet*. 2002;359:1877-1890.
7. Hutchinson PJ, Kolias AG, Timofeev IS, et al. Trial of decompressive craniectomy for traumatic intracranial hypertension. *N Engl J Med*. 2016;375(12):1119-1130.
8. Cooper DJ, Rosenfeld JV, Murray L, et al. Decompressive craniectomy in diffuse traumatic brain injury. *N Engl J Med*. 2011;364(16):1493-1502.
9. Andrews PJD, Sinclair HL, Rodriguez A, et al. Hypothermia for intracranial hypertension after traumatic brain injury. *N Engl J Med*. 2015;373(25):2403-2412.
10. Mollan SP, Davies B, Silver NC, et al. Idiopathic intracranial hypertension: consensus guidelines on management. *J Neurol Neurosurg Psychiatry*. 2018;89(10):1088-1100.
11. Wall M, McDermott MP, Kieburtz KD, et al. Effect of acetazolamide on visual function in patients with idiopathic intracranial hypertension and mild visual loss: the Idiopathic Intracranial Hypertension Treatment Trial. *JAMA*. 2014;311(16):1641-1651.
12. Bruce BB, Digre KB, McDermott MP, Schron EB, Wall M. Quality of life at 6 months in the idiopathic intracranial hypertension treatment trial. *Neurology*. 2016;87:1871-1877.

SUGGESTED READINGS

Brain Edema

Chen L, Xu M, Yan S, Luo Z, Tong, L, Lou M. Insufficient cerebral venous drainage predicts early edema in acute intracerebral hemorrhage. *Neurology*. 2019;93:e1463-e1473.

Claassen J, Carhuapoma JR, Kreiter KT, Du EY, Connolly, Mayer SA. Global cerebral edema after subarachnoid hemorrhage: frequency, predictors, and impact on outcome. *Stroke*. 2002;33:1225-1232.

Esquenazi Y, Lo VP, Lee K. Critical care management of cerebral edema in brain tumors. *J Intensive Care Med*. 2017;32(1):15-24.

Hackett PH, Yarnell PR, Hill R, Reynard K, Heit J, McCormick J. High-altitude cerebral edema evaluated with magnetic resonance imaging: clinical correlation and pathophysiology. *JAMA*. 1998;280:1920-1925.

Halstead MR, Geocadin RG. The medical management of cerebral edema: past, present, and future therapies. *Neurotherapeutics*. 2019;16:1-6.

Ho ML, Rojas R, Eisenberg RL. Cerebral edema. *AJR Am J Roentgenol*. 2012;199(3):W258-W273.

Lee KR, Colon KP, Betz AL, Keep RF, Kim S, Hoff JT. Edema from intracerebral hemorrhage: the role of thrombin. *J Neurosurg*. 1996;84:91-96.

Liebeskind DS, Jüttler E, Shapovalov Y, Yegin A, Landen J, Jauch EC. Cerebral edema associated with large hemispheric infarction. *Stroke*. 2019;50(9):2619-2625.

Qureshi AI, Suarez JI. Use of hypertonic saline solutions in treatment of cerebral edema and intracranial hypertension. *Crit Care Med*. 2000;28:3301-3313.

Sagoo RS, Hutchinson CE, Wright A, et al. Magnetic resonance investigation into the mechanisms involved in the development of high-altitude cerebral edema. *J Cereb Blood Flow Metab*. 2017;37(1):319-331.

Schilling L, Wahl M. Mediators of cerebral edema. *Adv Exp Med Biol*. 1999;474:123-141.

Stokum JA, Gerzanich V, Simard JM. Molecular pathophysiology of cerebral edema. *J Cereb Blood Flow Metab*. 2016;36(3):513-538.

Walcott BP, Kahle KT, Simard JM. Novel treatment targets for cerebral edema. *Neurotherapeutics*. 2012;9:65-72.

Winkler EA, Minter D, Yue JK, Manley GT. Cerebral edema in traumatic brain injury: pathophysiology and prospective therapeutic targets. *Neurosurg Clin N Am*. 2016;27(4):473-488.

Idiopathic Intracranial Hypertension

Ball A, Clarke C. Idiopathic intracranial hypertension. *Lancet Neurol*. 2006;5:433-442.

Bastin ME, Sinha S, Farrall AJ, Wardlaw J, Whittle I. Diffuse brain oedema in idiopathic intracranial hypertension: a quantitative magnetic resonance imaging study. *J Neurol Neurosurg Psychiatry*. 2003;74:1693-1696.

Binder DK, Horton JC, Lawton MT, McDermott MW. Idiopathic intracranial hypertension. *Neurosurgery*. 2004;54:538-552.

Markey KA, Mollan SP, Jensen RH, Sinclair AJ. Understanding idiopathic intracranial hypertension: mechanisms, management, and future directions. *Lancet Neurol*. 2016;15(1):78-91.

Mollan SP, Ali F, Hassan-Smith G, Botfield H, Friedman DI, Sinclair AJ. Evolving evidence in adult idiopathic intracranial hypertension: pathophysiology and management. *J Neurol Neurosurg Psychiatry*. 2016;87(9):982-992.

Ridsdale L, Moseley I. Thoracolumbar intraspinal tumours presenting features of raised intracranial pressure. *J Neurol Neurosurg Psychiatry*. 1978;41:737-745.

Sinclair AJ, Woolley R, Mollan SP. Idiopathic intracranial hypertension. *JAMA*. 2014;312(10):1059-1060.

Uretsky S. Surgical interventions for idiopathic intracranial hypertension. *Curr Opin Ophthalmol*. 2009;20:451-455.

Wakerley BR, Tan MH, Ting EY. Idiopathic intracranial hypertension. *Cephalalgia*. 2015;35(3):248-261.

112 Spontaneous Intracranial Hypotension

Kevin E. Immanuel, Tiffany R. Chang, and Kiwon Lee

KEY POINTS

1. Intracranial hypotension symptoms are not restricted to postural headaches and can have more severe presentation including coma.
2. Epidural blood patch is a mainstay management for cerebrospinal leaks that could not resolve with conservative management.
3. Brain sagging should be considered in the setting of an acute deterioration in postcraniotomy patient population.

INTRODUCTION

In 1825, Magendie described a patient with symptoms of unsteadiness and vertigo resulting from hypotension of spinal fluid and ventricular collapse. A century later in 1938, Georg Schaltenbrand described a condition, which he termed *spontaneous or essential aliquorrhea*, that was marked by postural headache and low cerebrospinal fluid (CSF) pressure.

Intracranial hypotension is a condition that occurs as a result of loss of CSF volume. The loss of CSF can occur at different location of the neural axis depending on the underlying etiology. For example, CSF leaks can occur at a skull base fracture from trauma and postdural puncture CSF leaks can occur at the spinal level of needle insertion. A similar syndrome of intracranial hypotension can also be seen in patients with excessive CSF drainage by ventriculoperitoneal shunts and postcraniotomy (ie, brain sagging).

SPONTANEOUS INTRACRANIAL HYPOTENSION

Spontaneous intracranial hypotension (SIH) is the result of an idiopathic CSF leak. It is an increasingly more recognized etiology of intracranial hypotension. The SIH should be part of the differential diagnosis for any new-onset, persistent daily headache with orthostatic quality.

Epidemiology

The estimated annual incidence is 5 cases per 100,000 with an estimated prevalence of 1 case per 50,000. It is reported more in women than in men in a 2:1 ratio. Symptoms typically begin in the fourth to fifth decade of life; however, it has been reported in all age groups including in children.

Pathobiology

Most spontaneous CSF leaks occur at the cervicothoracic junction or thoracic spine; however, the underlying mechanism is not clearly defined. Some proposed mechanisms include spontaneous rupture of an arachnoid membrane and a variety of dura abnormalities such as meningeal diverticula, perineural (Tarlov) cyst, and localized absence of dura as well as spontaneous dura tears occurring where the spinal roots leave the subarachnoid space. In case reports, some spontaneous leaks have been attributed to underlying connective tissue disorders such as Marfan syndrome and Ehlers-Danlos syndrome (type II). Other predisposing etiologies include autosomal dominant polycystic kidney disease, Lehman syndrome, and neurofibromatosis type 1.

Clinical Features

Presenting symptoms are often not localized to the site of the leak and manifest in a variety of ways, making this diagnosis challenging. The symptoms are thought to be the result of loss of CSF buoyancy due to low CSF volume, resulting in downward displacement of the brain, causing traction on pain-sensitive structures such as the meninges, some cranial nerves, or compensatory engorgement of pain-sensitive intracranial venous structures, particularly in upright position.

The most common initial presentation is a new-onset, persistent daily headache with an orthostatic quality. It is usually described as a throbbing or pressure-like headache but can also be dull. The location is often holocephalic but may be localized to the frontal or occipital region. The headache is similar to postdural puncture headache, but the postural component may not be as dramatic depending on rate and volume of CSF loss. The onset of headache in SIH is minutes to hours compared to seconds as in postdural puncture headaches. The headache is alleviated by lying flat for about 15 to 30 minutes, but resolution can be delayed or incomplete. If unmanaged, SIH can lead to a chronic daily headache that may not be orthostatic or relieved by recumbency. It is important to elicit the orthostatic nature of the headache at the initial onset, as this feature may become less obvious to the patient as the headache becomes chronic.

Additional symptoms reported include visual changes, diplopia, hearing changes, neck pain and/or stiffness, convulsions, nausea, and vomiting. Atypical presentations include parkinsonism, dementia, hypopituitarism, seizures, and coma. Spinal symptoms including radicular symptoms and quadriparesis are rare. Symptoms are typically reversible with normalization of CSF pressure. The onset and exacerbation of symptoms can be associated with coughing, laughing, Valsalva maneuver, and post coitus.

TABLE 112.1 Diagnostic Criteria for Headache Attributed to Low Cerebrospinal Fluid (CSF) Pressure as Defined in International Classification of Headache Disorders, 3rd Edition (ICHD-3)[a]

A	Any new-onset, often orthostatic,[b] headache that fulfills criteria C
B	Either or both of the following: • Low CSF opening pressure (<6 cm H_2O) • Evidence of CSF leakage on imaging
C	Headache has developed in temporal relation to the low CSF pressure or CSF leakage or has led to its discovery
D	Not better accounted for by another ICHD-3 diagnosis

[a]From Headache Classification Committee of the International Headache Society. The International Classification of Headache Disorders, 3rd edition. *Cephalalgia*. 2018;38(1):102-104.
[b]Orthostatic relationship characterized by worsening in upright position and improvement in horizontal position is not relied on as a diagnostic criteria.

Diagnosis

An SIH is part of the differential diagnosis for headaches caused by intracranial hypotension. The diagnostic criteria for any headaches related to intracranial hypotension are defined in the International Classification of Headache Disorders, 3rd edition, as noted in **Table 112.1**. The diagnostic criteria for SIH are also defined in International Classification of Headache Disorders, 3rd edition, and noted in **Table 112.2**. A diagnosis of SIH cannot be made if patient had a dural puncture or another known mechanism of dural injury within a month of onset of headache.

In addition to history and physical examination, use of magnetic resonance imaging (MRI) of the brain, particularly T1-weighted images postgadolinium injection, is very helpful in making the diagnosis (Fig. 112.1). Five characteristic features seen on postgadolinium-enhanced MRI of the brain are subdural fluid collections, diffuse enhancement of pachymeninges, engorgement of venous structures, pituitary hyperemia, and sagging of the brain, which make up the mnemonic *SEEPS* (**Table 112.3**). Most observed MRI of the brain findings are a result of a compensatory change due to the loss of CSF volume. Based on the Monroe-Kellie principle, a decrease in CSF volume will result in brain sag and compensatory venous engorgement.

TABLE 112.2 Diagnostic Criteria for Headache Attributed to Spontaneous Intracranial Hypotension as Defined in International Classification of Headache Disorders, 3rd Edition (ICHD-3)[a]

A	Any new-onset headache that fulfills criteria in **Table 112.1**
B	Absence of a procedure (for at least a month) or trauma known to be able to cause CSF leakage
C	Headache has developed in temporal relation to the low CSF pressure or CSF leakage, or has led to its discovery
D	Not better accounted for by another ICHD-3 diagnosis

Abbreviation: CSF, cerebrospinal fluid.
[a]From Headache Classification Committee of the International Headache Society. The International Classification of Headache Disorders, 3rd edition. *Cephalalgia*. 2018;38(1):102-104.

There are several case reports that demonstrate improvement in MRI findings after successful treatment of CSF leak. It is important to note that in about 20% of patients diagnosed with SIH, the MRI findings will be normal; therefore, a normal MRI does not exclude the diagnosis of SIH.

Lumbar puncture (LP) can be performed to obtain opening CSF pressure. It is typically employed if there is a high suspicion of SIH, although MRI findings are normal. The LP should be performed after MRI of the brain is obtained to avoid post-LP MRI pachymeningeal enhancement, which can confound the diagnosis. A CSF opening pressure of less than 6 cm H_2O is a diagnostic criterion for SIH but not a requirement (see **Table 112.1**). In approximately 25% of patients with SIH, the CSF opening pressure is normal. In addition to low CSF opening pressure, lymphocytic pleocytosis as well as elevated protein concentration and xanthochromia have been reported.

If the MRI and CSF findings are inconclusive despite having high suspicion of SIH, computed tomographic (CT) myelography with iodinated contrast or magnetic resonance (MR) myelography with gadolinium of the spine as well as radionucleotide cisternography is advocated. Likewise, if initial treatment is ineffective and localization of the CSF leaks is desired for direct surgical intervention, these imaging modalities can accurately define the location and extent of CSF leak. The CT myelography is the most accurate study for localization of CSF leak. It can also reveal the underlying etiology of the leak, such as meningeal diverticula. It is recommended that early and delayed cuts are obtained at each spinal level to detect both fast and slow CSF leaks. The MR myelography with intrathecal gadolinium and noninvasive MR myelography have been used increasingly as a reasonable alternative. Although historically, radionucleotide cisternography has been used as an indirect indicator of CSF leak, it is seldom employed when CT or MR myelography is available, as it is less sensitive. However, simultaneous use of CT and single-photon emission computed tomography has improved the sensitivity of radionucleotide cisternography detecting the exact location of CSF leak.

Although findings from CT of the brain are not as conclusive as MRI findings, it is useful when MRI is unavailable. Nontraumatic subdural fluid collections, ventricular collapse, obliteration of subarachnoid cisterns, and displacement of pons and cerebellar tonsils below the foramen magnum all contribute to making the diagnosis (see Fig. 112.1A).

The MRI of the spine may demonstrate spinal manifestations of intracranial hypotension; however, it is not always useful in localizing the site of the CSF leak. Some imaging findings on MRI of the spine include dural enhancement, meningeal diverticula, dilated epidural or intradural veins, syringomyelia, retrospinal C1-C2 fluid, and extrathecal CSF collections. Use of MRI of the spine may be indicated if patient has neuropathic or myelopathic symptoms.

TABLE 112.3 Magnetic Resonance Imaging Features of Spontaneous Intracranial Hypotension (SEEPS)

Subdural fluid collections
Enhancement of pachymeninges
Engorgement of venous structures
Pituitary hyperemia
Sagging of the brain

Management

General Management

Most cases of SIH are self-limited, although the time course for resolution is variable. Thus, the initial treatment is usually conservative medical management with bed rest in a recumbent position, adequate oral hydration, oral or intravenous caffeine, and use of abdominal binders. Caffeine has been used to serve as a vasoconstrictor to mitigate symptoms that are attributable to compensatory venous engorgement.

For patients who do not benefit from conservative medical management and continue to have persistent and debilitating symptoms, the mainstay reported treatment is the use of epidural blood patch (EBP). It involves injection of about 10 to 20 mL of autologous blood into the spinal epidural space. It can be injected directly at the level of CSF leak if known or can be placed in the safer lower lumbar region (**Fig. 112.2**). The patient is usually placed in Trendelenburg position for up to 60 minutes after injection. The proposed mechanism is twofold: first to replace the lost CSF volume with blood volume in the spinal canal and second to serve as a sealant for any dural defect. Although there are no randomized controlled trials to evaluate the effectiveness of EBP use, it is reported to improve symptoms in 30% to 70% of patients after the first injection. Symptomatic relief is almost immediate but may not provide complete or permanent resolution of symptoms. Two or more EBPs may be required to achieve sustained relief. Thirty percent to 50% of patients may benefit from multiple administrations of EBP. After the initial one, subsequent EBP may be done with much larger volume of blood (up to 100-150 mL). It is expected that symptomatic relief should be sustained for at least a few days. Complications from EBP are rare, but they include neck and back pain, worsening of headache due to dural puncture, meningeal irritation, and rebound intracranial hypertension.

If the exact site of CSF leak is known from imaging studies and EBP does not provide sustained relief, use of percutaneous placement of fibrin sealant or directed EBP is advised. In refractory cases where the symptoms are debilitating and the site of leak is known, surgical repair using suture, aneurysm clip, muscle pledget with fibrin sealant, and Gelfoam may be considered.

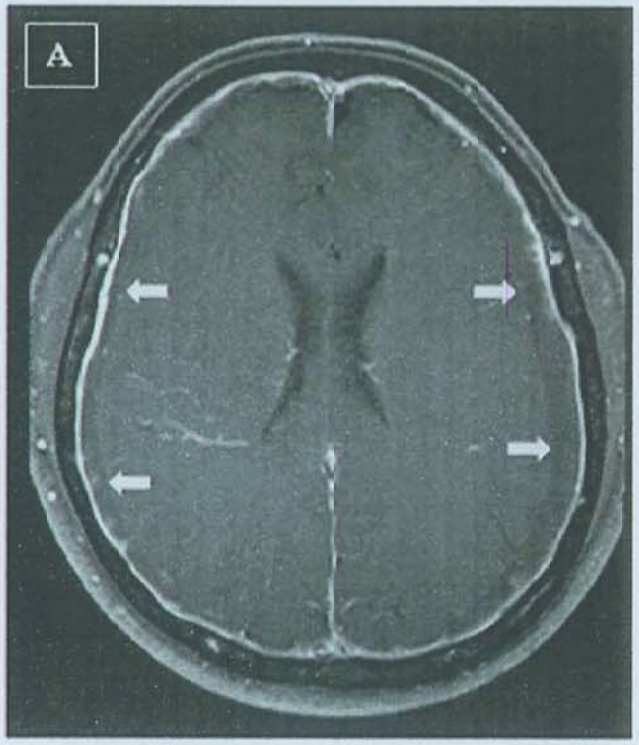

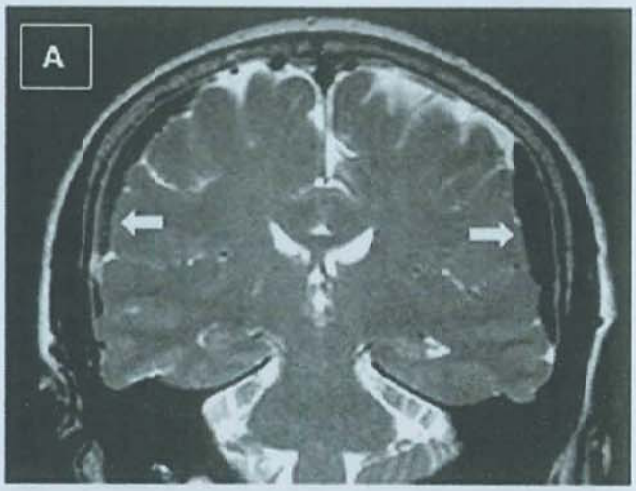

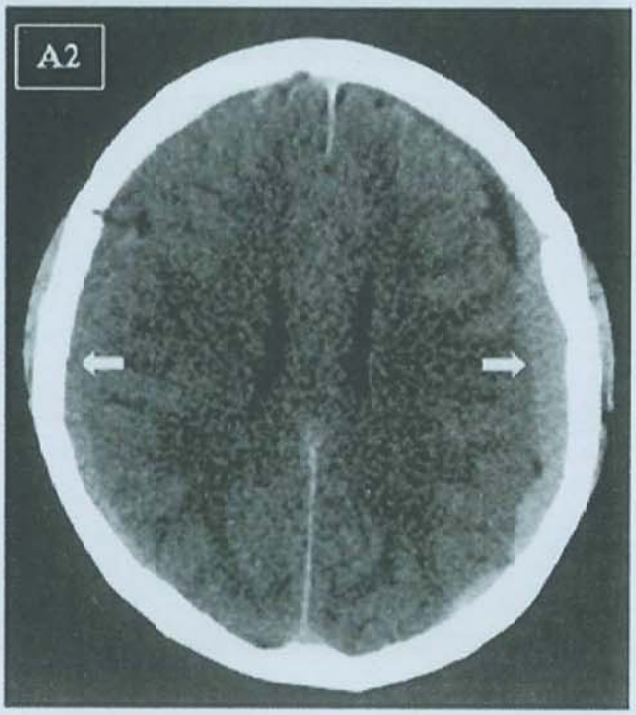

FIGURE 112.1 Cardinal magnetic resonance imaging (MRI) findings of spontaneous intracranial hypotension (mnemonic, SEEPS). **A:** Axial postcontrast T1 **(left)** and coronal T2 **(right)** MRI of the brain showing subdural fluid collections *(arrows)*, noncontrasted axial CT of the head **(bottom)** showing bilateral subdural hemorrhage. *(continued)*

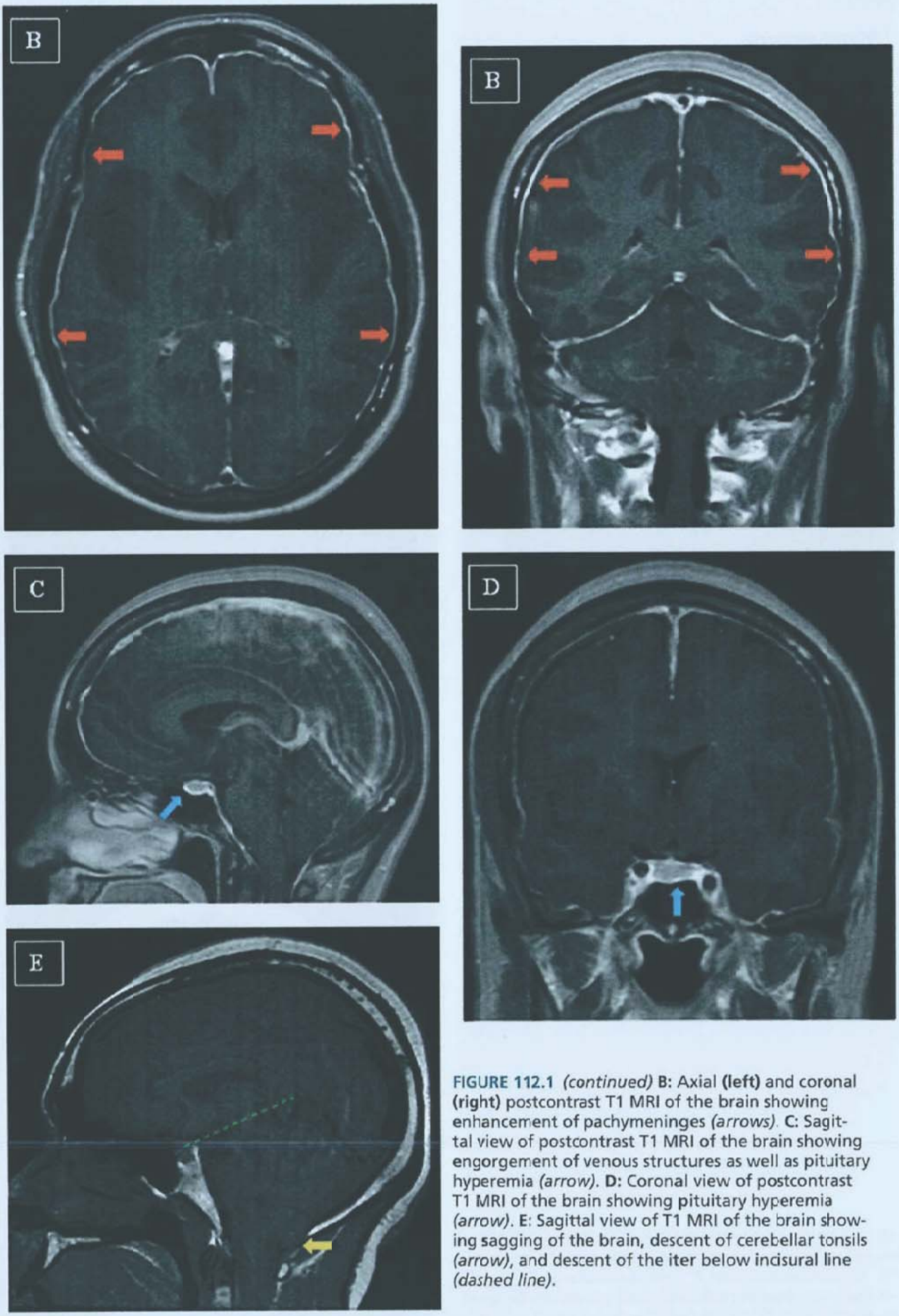

FIGURE 112.1 *(continued)* **B:** Axial **(left)** and coronal **(right)** postcontrast T1 MRI of the brain showing enhancement of pachymeninges *(arrows)*. **C:** Sagittal view of postcontrast T1 MRI of the brain showing engorgement of venous structures as well as pituitary hyperemia *(arrow)*. **D:** Coronal view of postcontrast T1 MRI of the brain showing pituitary hyperemia *(arrow)*. **E:** Sagittal view of T1 MRI of the brain showing sagging of the brain, descent of cerebellar tonsils *(arrow)*, and descent of the iter below incisural line *(dashed line)*.

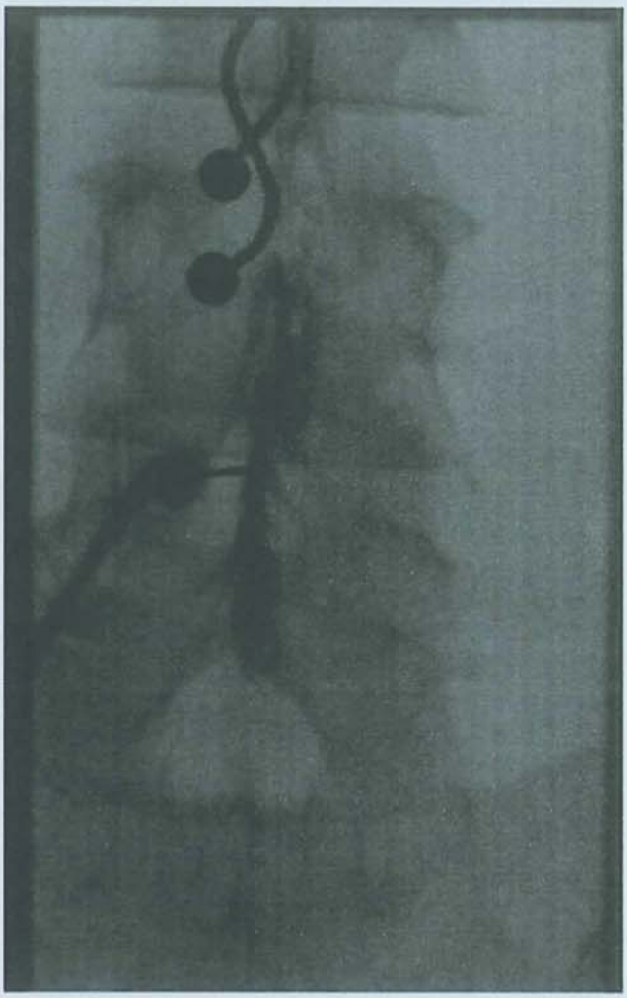

FIGURE 112.2 Epidural blood patch placement in L4/L5 level under fluoroscopy.

Outcomes

As previously stated, symptoms of SIH are often self-limited; however, timing of resolution of symptoms varies even after CSF leakage is resolved. Important complications of spontaneous CSF leaks include subdural hematoma, bibrachial amyotrophy, cerebral venous thrombosis, and, rarely, superficial siderosis. Rare but more severe complications have been reported in case reports including mental status decline, coma, and vascular infarcts from transtentorial and downward cerebellar herniation.

POSTCRANIOTOMY BRAIN SAGGING

"Brain sagging" or "sinking brain syndrome" is a serious postoperative complication. It should be part of the differential diagnosis for any patient who clinically declines after craniotomy.

Clinical Features

The syndrome typically develops as an immediate postoperative finding, or within 48 hours of surgery, often once sedation is stopped. The hallmark presentation is anisocoria with acute mental status decline. Early recognition is paramount to avoid irreversible transtentorial herniation leading to permanent damage. Reported risk factors include presurgical presence of global cerebral edema, intraoperative lumbar drain, ventriculostomy, and prolonged surgery.

TABLE 112.4 Criteria for Postcraniotomy "Brain Sagging" Syndrome

- Clinical signs of transtentorial herniation (eg, reduced level of consciousness, motor posturing, pupillary and oculomotor abnormalities)
- Radiographic signs of excess intracranial air and effacement of the basal cisterns
- Improvement of symptoms in Trendelenburg (head down) position

Diagnosis

Brain sagging may be diagnosed with three classic criteria: (1) clinical signs of transtentorial herniation, (2) excessive intracranial air with effacement of the basal cisterns (often with an oblong brain stem), and (3) improvement of symptoms when patient is placed in Trendelenburg position (**Table 112.4**).

Neuroimaging, CT or MRI of the brain, may reveal crowding of the posterior fossa as well as flattening of the optic chiasm and anterior pons, descent of the brain stem and cerebellar tonsils, and reduction of subarachnoid cisternal spaces. On imaging, patients may have a significant amount of pneumocephalus and demonstrate Mount Fuji sign, peaking of the frontal lobes with excessive intracranial air (**Fig. 112.3**). Remote hemorrhage, most often cerebellar in location, may also be seen on brain imaging following cranial or spinal surgery. This is attributed to venous bleeding secondary to intraoperative CSF loss. Remote cerebellar hemorrhage may give the appearance of a "zebra sign" on neuroimaging and can be associated with local edema and mass effect (**Fig. 112.4**).

Management

Most patients with brain sagging respond quickly when placed in Trendelenburg position. If after an hour of Trendelenburg

FIGURE 112.3 Pneumocephalus (Mount Fuji sign) after craniotomy for evacuation of subdural hemorrhage.

FIGURE 112.4 Gradient echo magnetic resonance imaging of brain showing bilateral low intensity *(white arrows)* within the cerebellar sulci consistent with chronic hemosiderin staining due to remote cerebellar hemorrhage. This pattern of irregular stripes are alternating blood and cerebellum that is sometimes referred to as the *zebra sign*. (From Paul J, Jhaveri MD, Lewis SL. Teaching neuroimages: remote cerebellar hemorrhage following resection of a supratentorial tumor. *Neurology*. 2011;77[14]:e82-e83.)

position does not improve neurologic condition, one should question the diagnosis and search for other causes of mental status deterioration. An injection of 10 to 15 mL of autologous blood (blood patch) into the lumbar space can resolve persistent symptoms of postural headache and neurologic symptoms (eg, dizziness, lethargy, dysarthria) once the herniation syndrome has been reversed. In extreme cases of brain stem herniation from CSF hypovolemia, controlled infusion of isotonic crystalloid solution via a lumbar catheter has been reported to reverse the syndrome. Conservative management with bed rest, caffeine, oral hydration, and use of an abdominal binder has also been reported as effective in less severe cases.

SUGGESTED READINGS

Albayram S, Kara B, Ipek H, Ozbayrak M, Kantarci F. Isolated cortical venous thrombosis associated with intracranial hypotension syndrome. *Headache*. 2009;49(6):916-919.

Amoozegar F, Guglielmin D, Hu W, Chan D, Becker WJ. Spontaneous intracranial hypotension: recommendations for management. *Can J Neurol Sci*. 2013;40(2):144-157.

Brockmann MA, Groden C. Remote cerebellar hemorrhage: a review. *Cerebellum*. 2006;5(1):64-68.

Chalela JA, Monroe T, Kelley M, et al. Cerebellar hemorrhage caused by remote neurological surgery. *Neurocrit Care*. 2006;5(1):30-34.

Chazen JL, Talbott JF, Lantos JE, Dillon WP. MR myelography for identification of spinal CSF leak in spontaneous intracranial hypotension. *AJNR Am J Neuroradiol*. 2014;35(10):2007-2012.

Chiapparini L, Ciceri E, Nappini S, et al. Headaches and intracranial hypotension: neuroradiological findings. *Neurol Sci*. 2004;25(suppl 3):S138-S141.

Davenport RJ, Chataway SJ, Warlow CP. Spontaneous intracranial hypotension from a CSF leak in a patient with Marfan's syndrome. *J Neurol Neurosurg Psychiatry*. 1995;59(5):516-519.

Hadizadeh DR, Kovacs A, Tschampa H, Kristof R, Schramm J, Urbach H. Postsurgical intracranial hypotension: diagnostic and prognostic imaging findings. *AJNR Am J Neuroradiol*. 2010;31(1):100-105.

Headache Classification Committee of the International Headache Society. The International Classification of Headache Disorders, 3rd edition. *Cephalalgia*. 2018;38(1):102-104.

Kelley GR, Johnson PL. Sinking brain syndrome: craniotomy can precipitate brainstem herniation in CSF hypovolemia. *Neurology*. 2004;62(1):157.

Komotar RJ, Mocco J, Ransom ER, et al. Herniation secondary to critical postcraniotomy cerebrospinal fluid hypovolemia. *Neurosurgery*. 2005;57(2):286-292.

Komotar RJ, Ransom ER, Mocco J, et al. Critical postcraniotomy cerebrospinal fluid hypovolemia: risk factors and outcome analysis. *Neurosurgery*. 2006;59(2):284-290.

Lin WC, Lirng JF, Fuh JL, et al. MR findings of spontaneous intracranial hypotension. *Acta Radiol*. 2002;43(3):249-255.

Mathew L, Komotar R. Epidural blood patch for severe postoperative intracranial hypotension. *J Neurosurg Anesthesiol*. 2008;20(1):49-52.

Mokri B. Spontaneous CSF leaks low CSF volume syndromes. *Neurol Clin*. 2014;32(2):397-422.

Mokri B, Maher CO, Sencakova D. Spontaneous CSF leaks: underlying disorder of connective tissue. *Neurology*. 2002;58(5):814-816.

Mokri B, Posner JB. Spontaneous intracranial hypotension: the broadening clinical and imaging spectrum of CSF leaks. *Neurology*. 2000;55(12):1771-1772.

Schaltenbrand G. Normal and pathological physiology of the cerebrospinal fluid circulation. *Lancet*. 1953;1(6765):805-808.

Schievink WI. Novel neuroimaging modalities in the evaluation of spontaneous cerebrospinal fluid leaks. *Curr Neurol Neurosci Rep*. 2013;13(7):358.

Schievink WI. Spontaneous spinal cerebrospinal fluid Leaks and intracranial hypotension. *JAMA*. 2006;295(19):2286-2296.

Schievink WI, Maya MM, Louy C, Moser FG, Tourje J. Diagnostic criteria for spontaneous spinal CSF leaks and intracranial hypotension. *AJNR Am J Neuroradiol*. 2008;29(5):853-856.

Schievink WI, Torres VE. Spinal meningeal diverticula in autosomal dominant polycystic kidney disease. *Lancet*. 1997;349(9060):1223-1224.

Intervertebral Disk Disease and Radiculopathy 113

Hani Malone and Peter D. Angevine

KEY POINTS

1. Back pain is ubiquitous, and radiographic evidence of degenerative disk disease is common in adults. Radiculopathy from degenerative disk disease is usually self-limited.
2. Most patients should undergo a 6-week trial of rest, pain control, and physical therapy, prior to ordering magnetic resonance imaging and referral to a surgical specialist.
3. A more urgent referral should be initiated in the presence of symptoms of cauda equina syndrome, myelopathy, or acute/progressive motor weakness.
4. Surgical treatment should be reserved for those cases in which conservative management has failed and disk disease identified on neuroimaging correlates with clinical presentation.

INTRODUCTION

Intervertebral disk disease is responsible for a range of pain syndromes that have been recognized since the time of Hippocrates. The first reported treatment of intervertebral disk pathology occurred in 1909, when Krause operated on a patient who had been diagnosed by Oppenheimer as suffering from a lesion localized to the L4 root. In surgery, Krause found an extradural mass that was described pathologically as a chondroma and the operation to remove it apparently affected a cure. In 1934, Mixter and Barr were the first to point out that these lesions were actually fragments of intervertebral disks and that they were responsible for radicular pain. They further proved the efficacy of surgical treatment in their series of 58 patients treated with laminectomy and diskectomy for lumbar disk herniation.

EPIDEMIOLOGY

In the United States, back pain is the most common reason for limiting physical activity in people younger than 45 years; it is the second most frequent cause of visits to a physician, the fifth cause of hospital admissions, and the third leading cause of surgery. In many countries, it is the most common cause of absenteeism from work, accounting for more than 12% of sick days. The aggregate economic cost in the Netherlands in 1991 was estimated to be 1.7% of gross national product. This figure likely represents the typical cost incurred by developed nations. In the United States, the aggregate cost of lower back pain is estimated to exceed $100 billion per year.

According to Andersson, "Chronic low back pain has become a diagnosis of convenience for many people who are actually disabled for socioeconomic, work-related, or psychological reasons." The complexity of the problem is measured in a lengthy literature and a long list of approaches to therapy. Medications and other therapies include nonsteroidal anti-inflammatory drugs, opiates, and antidepressants; extradural injection of steroids; decompressive surgery; physical therapy, including massage and exercise; chiropractic treatment; and acupuncture. In Finland, a third of the direct costs were spent on complementary therapies. Multidisciplinary spine centers and pain centers may be sources of the most effective approach to management.

Pathologic studies have demonstrated that almost all individuals older than the age of 30 years have some evidence of disk degeneration. As individuals age, spondylosis and osteochondrosis, the long-term sequelae of degenerative disk disease, become more and more prominent. Intervertebral disk rupture is most common in the fourth to sixth decades of life. It is relatively rare before the age of 25 years and is less common after the age of 60 years. Importantly, pathologic or radiographic findings consistent with disk disease are often asymptomatic and clinically insignificant. Although some maintain that degenerative disk disease is a byproduct of the modern human environment, there is no conclusive evidence that back pain has significantly increased over the past 50 years. Fortunately, the efficacy and morbidity associated with treating intervertebral disk disease has improved considerably.

PATHOPHYSIOLOGY

Intervertebral Disk Disease

Displaced disk material may cause signs and symptoms by bulging or protruding beneath an attenuated annulus fibrosus, or the material may extrude through a tear in the annulus and project directly into the spinal canal (**Fig. 113.1**). In either case, the encroaching disk material may irritate or compress nerve roots as they approach their exit through the neural foramina. In cervical and thoracic regions, the problem is more neurologically complex because the spinal cord itself, as well as the adjacent nerve roots, may be involved. At cervical and thoracic levels, signs and symptoms are caused either by cord compression or by a combination of cord and nerve root compression. In the lumbar region, signs and symptoms solely relate to the compression

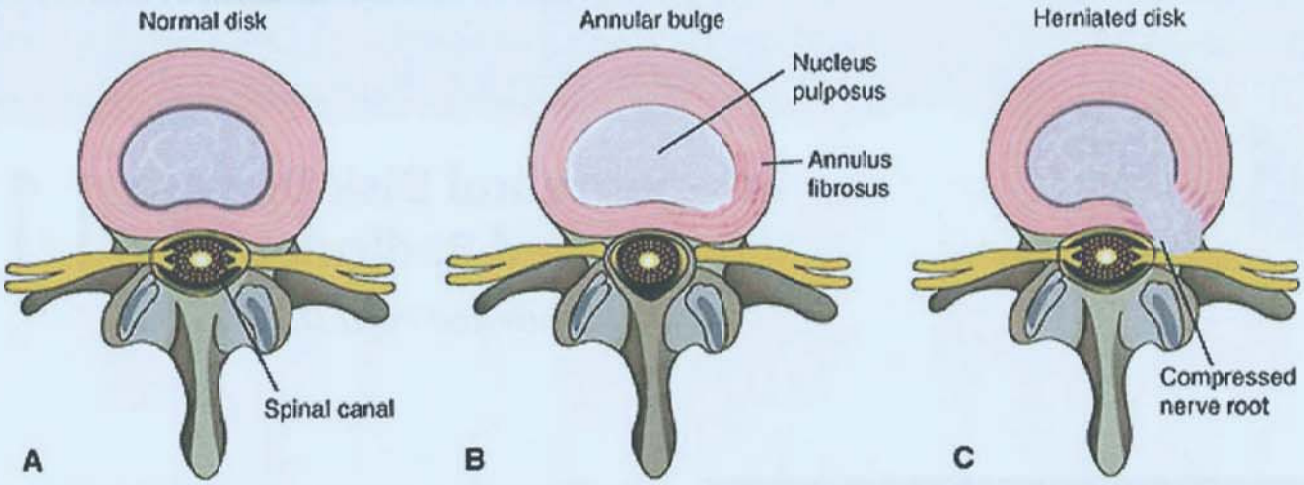

FIGURE 113.1 Anatomic illustration of the spinal canal and intervertebral disk. **A:** Demonstrating normal anatomy of the lumbar spine. **B:** An annular "disk bulge." **C:** An annular tear with herniation of the nucleus pulposus causing nerve root impingement.

of nerve roots or to compression of the cauda equina if the disk is large enough to crowd the entire spinal canal.

There are eight spinal nerve roots in the cervical spine (C1-C8), which are numbered according to vertebra below the corresponding disk space. For example, the C4 nerve root exits through the neural foramen at the C3-C4 level and the C5 nerve root exits via the C4-C5 foramen. The C8 nerve root courses through the C7-T1 intervertebral foramen, as there is no C8 vertebra. Conversely, nerve roots in the thoracic and lumbar spine are numbered according to the vertebrae above their exit through the intervertebral foramen. For example, the L5 nerve root exits the spinal canal at the level of L5-S1.

Importantly, paramedian lumbar disk herniations generally impinge on nerve roots that exit the spinal canal, a level below the site of disk herniation. For example, a paramedian herniated disk at the L4-L5 level compresses the L5 nerve root, which exits the spinal canal through the L5-S1 intervertebral foramen. This is not the case for *far lateral* disk herniations, which extend laterally to compress the rostral lumbar nerve root at the affected level. A far lateral L3-L4 lumbar disk herniation, for example, may compress the L3 nerve root either within the foramen or more distally as the root passes over the disk space (Fig. 113.2). Far lateral disk herniations account for 10% of all lumbar disk herniations, affect higher lumbar levels, and are likely to cause objective neurologic deficit. A far lateral disk herniation should be suspected with acute onset of an isolated upper lumbar radiculopathy that affects L2, L3, or L4.

In the cervical spine, degenerative disk disease most commonly affects the C5-C6 and C6-C7 levels. In the lumbar spine, most disk degeneration occurs at the L4-L5 and L5-S1 levels. This pattern suggests that the dynamics of pathologic change are partly related to wear and tear and to the repetitive trauma of motion.

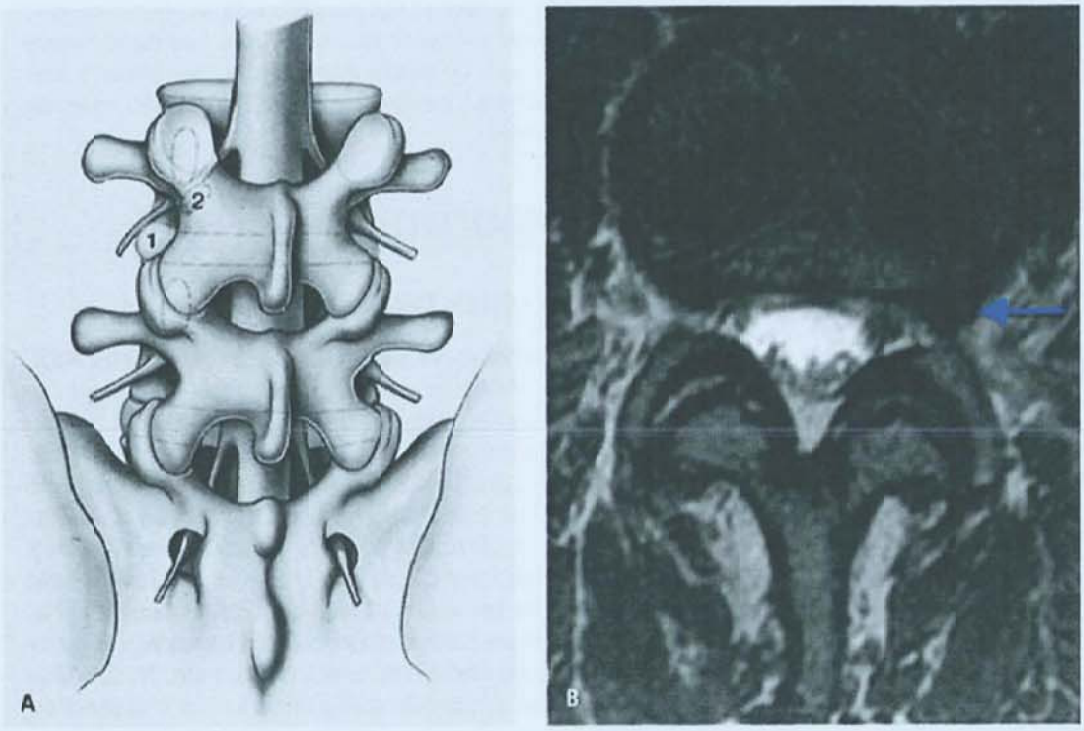

FIGURE 113.2 Far lateral disk herniation. **A:** Two sites of possible upper nerve root compression from a far lateral disk herniation. Root compression may occur at the level of the disk space (*1*) or from a rostrally migrated fragment into the foramen of the upper nerve root (*2*). **B:** Magnetic resonance imaging demonstrates a left far lateral disk herniation at the L3-L4 level (*arrow*).

TABLE 113.1 Common Root Syndromes of Intervertebral Disk Disease

Disk space	L3-L4	L4-L5	L5-S1	C4-C5	C5-C6	C6-C7	C7-T1
Root affected	L4	L5	S1	C5	C6	C7	C8
Muscles affected	Quadriceps	Peroneals, anterior tibial, extensor hallucis longus	Gluteus maximus, gastrocnemius, plantar flexors of toes	Deltoid, biceps	Biceps	Triceps, wrist extensors	Intrinsic hand muscles
Area of pain and sensory loss	Anterior thigh, medial shin	Great toe, dorsum of foot	Lateral foot, small toe	Shoulder, anterior arm	Radial forearm	Thumb, middle fingers	Index, fourth, and fifth fingers
Reflex affected	Knee jerk	Posterior tibial	Ankle jerk	Biceps	Biceps	Triceps	Triceps
Straight leg raising	Many do not increase pain	Aggravates root pain	Aggravates root pain	—	—	—	—

Thoracic disk protrusions, except at the lower thoracic levels, differ from cervical and lumbar disorders in both genesis and histopathology. Motion does not play a significant role, as thoracic vertebrae are designed for stability rather than motion, and the heavy rib cage contributes to the rigidity of this region. Ruptured thoracic disks are markedly different on gross and microscopic examination, and their consistency seldom resembles that of cervical and lumbar ruptured disks. These pathologic differences suggest a separate mechanism of injury in thoracic disk disease. Trauma has been accepted as a prime cause of thoracic disk herniation, but genetic predisposition also likely plays a role. Trauma may aggravate this susceptibility and ultimately catalyze rupture. Intervertebral disk disease is far less common in the thoracic spine compared to lumbar and cervical segments.

The signs and symptoms of herniated disks relate not only to the size and strategic location of the disk fragments but also to the size and configuration of the spinal canal. Congenital spinal stenosis, which is an abnormally narrow spinal canal, is an example of an inherited anomaly that influences the clinical impact of disk disease. Degenerative spondylosis leads to spinal stenosis and narrowing of the neural foramina through osteophyte formation and hypertrophy of the ligamentum flavum and facet joints. Degenerative spondylosis and congenital spinal stenosis are major contributors to compression syndromes of the spinal cord and cauda equina, as even small disk protrusions in these patients can further compromise an already limited canal. In a canal of normal dimensions, the severity of neural compression and the clinical impact of a protruded disk fragment depends more on the site of rupture and the volume of the extruded material.

CLINICAL FEATURES

Radicular Pain and Lumbar Disk Disease

Root syndromes of intervertebral disk disease are often episodic, so remissions are characteristic. The pain may be restricted to the back or follow a radicular distribution in one or both legs. Lumbar pain may increase after heavy lifting or twisting of the spine. It is often relieved when the patient lies down. Some patients, however, are more comfortable sitting, and many find no comfortable position.

Physical examination often reveals loss of lumbar lordosis or flattening of the lumbar spine with splinting and asymmetric prominence of the long erector muscles. Range of motion of the lumbar spine is reduced by the protective splinting of paraspinal muscles, and attempted movement in some planes induces severe back pain. There may be tenderness of the adjacent vertebrae. When the patient is erect, one gluteal fold may hang down and show added skin creases because the gluteus is wasted—evidence of involvement of the S1 root. Passive straight leg raise, when the patient is supine and the examiner lifts the patient's leg while the knee is straight, is reduced in range and increases back and leg pain. Muscle atrophy and weakness or sciatic tenderness and discomfort may occur on direct pressure at some point along the nerve from the sciatic notch to the calf. This is particularly true in older patients.

The typical syndromes of root compression at lumbar levels are described in Table 113.1. Importantly, clinical signs may not be as distinct in actual practice as the table implies. More than 80% of syndromes affect the L5 or S1 nerve roots (Table 113.2). Compression of the nerve root at these levels results in "sciatica," a sharp and burning pain that radiates down the posterior/lateral aspect of the leg to the foot or ankle (Fig. 113.3). When the lesion affects L4 or higher roots, straight leg raise does not stretch the roots above L5. Nerve root compression is often associated with numbness and tingling. Radicular pain resulting from disk disease classically intensifies with Valsalva (coughing, defecating, sneezing).

TABLE 113.2 Signs of Lumbar Disk Herniation in 97 Patients[a,b]

Disk space	L2-L3	L3-L4	L4-L5	L5-S1
Patients (n)	1	9	45	42
Weak muscles				
Anterior tibial, extensor hallucis	0	3	13	3
Gastrocnemius, plantar responses of foot	0	0	2	3
Quadriceps	0	3	0	0
Reflex affected				
Knee jerk	1	6	4	0
Ankle jerk	0	1	12	23

[a]Data are numbers of patients.
[b]From Hardy RW Jr, Plank NM. Clinical diagnosis of herniated lumbar disc. In: Hardy RW, ed. *Lumbar Disc Disease*. New York, NY: Raven Press; 1982:17-28.

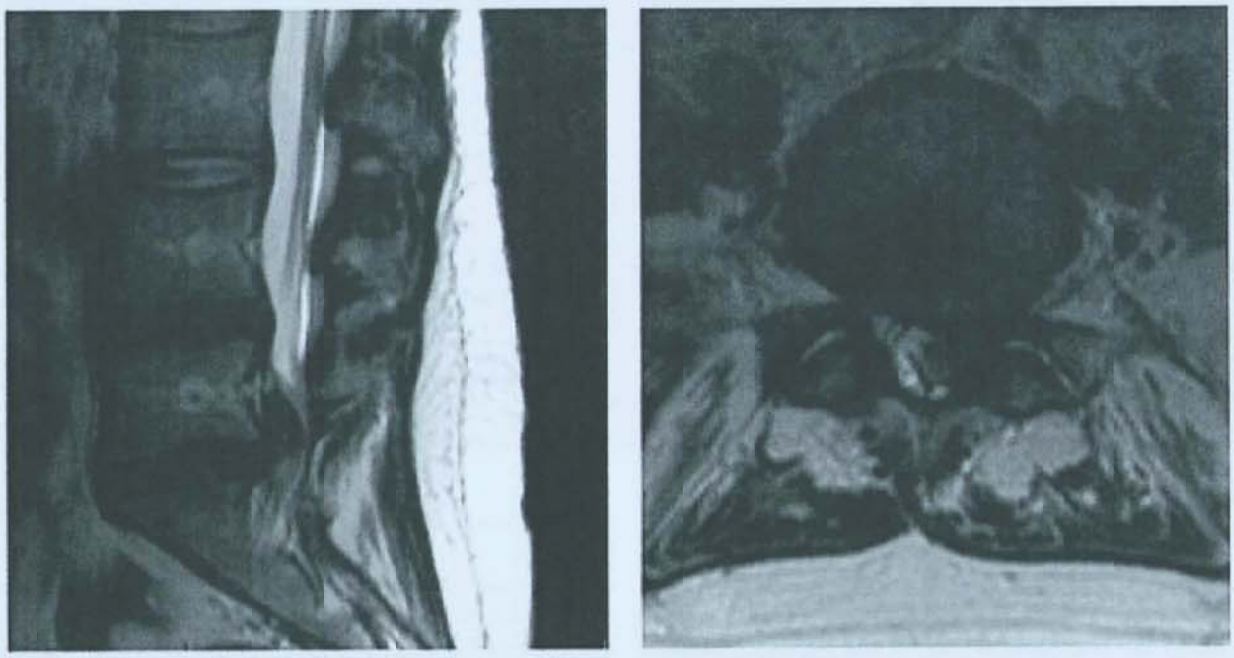

FIGURE 113.3 Magnetic resonance imaging of lumbosacral disk herniation. Sagittal **(A)** and axial **(B)** T2-weighted magnetic resonance imaging demonstrate a large L5-S1 disk herniation on the left side. Clinically, this patient had an S1 radiculopathy that did not respond to conservative therapy. Complete relief of symptoms followed lumbar diskectomy.

Thoracic Disk Rupture

The thoracic spine is designed for rigidity rather than excursion, thus wear and tear from motion and stress may not cause thoracic disk protrusion, and clinical disorders are rare. Thoracic disk disease may result from chronic vertebral changes incident to Scheuermann disease or juvenile osteochondritis with later trauma. The small capacity of the thoracic spinal canal makes this region vulnerable to cord compression from disk herniation (Fig. 113.4A). By the same token, decompressive operations are more precarious and require meticulous care to avoid damaging the spinal cord. Calcific changes are common in pathologic thoracic intervertebral disks (Fig. 113.4B), which pose additional challenges when performing diskectomy. The lower thoracic levels, however, are more capacious, and although the conus medullaris or cauda equina may be damaged by disk protrusions, surgical approaches are less hazardous compared to higher levels.

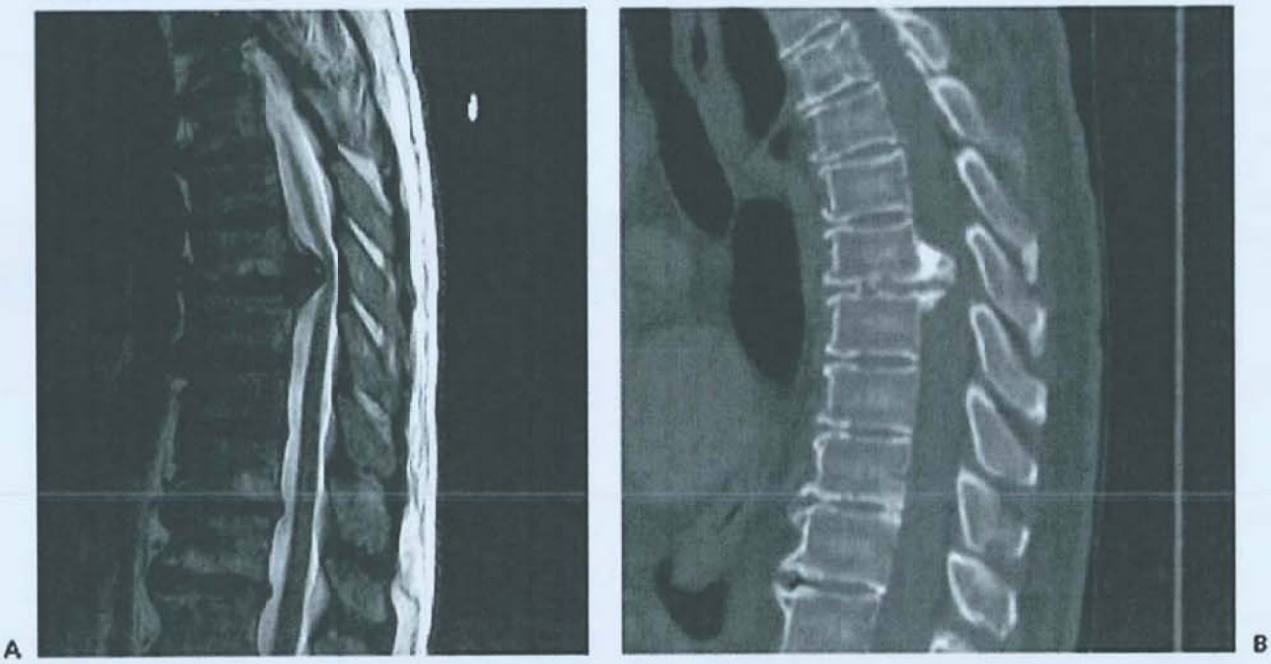

FIGURE 113.4 Calcified thoracic disk herniation. **A:** Sagittal T2-weighted magnetic resonance imaging demonstrates a large thoracic disk herniation compressing and deforming the thoracic cord. **B:** Extensive calcification of the disk-osteophyte complex is appreciable on computed tomography imaging of the thoracic spine. Calcification of a thoracic disk introduces an added degree of complexity to surgical decompression.

Cervical Disk Disease

Cervical disk herniation may involve both the nerve root and spinal cord depending on the volume of the canal and the size of the lesion. Spinal cord compression is uncommon, except with spinal stenosis or massive rupture of a disk. The sites of the most frequent disk herniations are C5-C6 and C6-C7; C4-C5 and C7-T1 are less frequently affected. Movement of the cervical spine is normally incremental and any process contributing to focal stress at individual levels adds to progressive pathologic changes in the disk and to deficits in joint mechanics (**Fig. 113.5**). Development of a new fulcrum of motion above a fusion or congenital block vertebra increases susceptibility to these changes.

The signs and symptoms of cervical disk disease usually begin with stiff neck, reactive splinting of the erector capital muscles, and discomfort at the medial border of the scapula. Radicular paresthesias and pain supervene when the root is more severely compromised. These symptoms are worsened by movements of the head and neck as well as by stretching of the dependent arm.

As compression proceeds, discrete root syndromes appear (see **Table 113.1**). C5 lesions cause pain in the shoulder and dermatomic sensory diminution with weakness and atrophy of the deltoid. C6 lesions cause paresthesias of the thumb and depression of the biceps reflex with weakness and atrophy of that muscle. In C7 lesions, paresthesias may involve the index and middle fingers, and even the thumb with atrophy and weakness in the triceps muscles, wrist extensors, and pectoral muscles as well as a parallel reflex depression. C8 subserves important intrinsic muscle functions in the hand and sensation in the fourth and fifth fingers. Because these are important in discriminatory and fine finger maneuvers, C8 damage may be disabling.

Myelopathy

Large disk protrusions in the thoracic and cervical spine, particularly with concurrent spinal stenosis, may compress the spinal cord resulting in myelopathic signs on clinical exam. Clinical signs of myelopathy reflect injury to upper motor neurons. Reflexes and tone are increased, whereas coordination and balance are diminished. Patients with cervical myelopathy often have difficulty using their hands for fine motor tasks and adopt a broad-based gait to improve balance while upright. Other signs of myelopathy on routine physical exam include Hoffman and Babinski signs, a positive Romberg test, and sustained clonus. Myelopathy is often combined with lower motor neuron weakness and may be subtle if compression of the cord is mild.

DIAGNOSIS

Initial Management and Evaluation

Radiculopathy is a clinical diagnosis based on careful history and physical examination. Immediate diagnostic testing with magnetic resonance imaging (MRI) is not necessary in patients with new-onset radicular pain that have not failed conservative measures. Patients with low back and/or radicular pain should undergo at least 6 weeks of pain control, rest, and physical therapy.

Immediate imaging should be obtained in those patients with acute and/or progressive neurologic deficits, or those in refractory severe pain. Diagnostic imaging is particularly urgent in patients with urinary retention and or saddle anesthesia, signs of cauda equina syndrome. An MRI should also not be delayed in cases with a high clinical suspicion of neoplastic or infectious systemic disease, as symptoms in these patients may be secondary to spinal metastases or epidural abscesses.

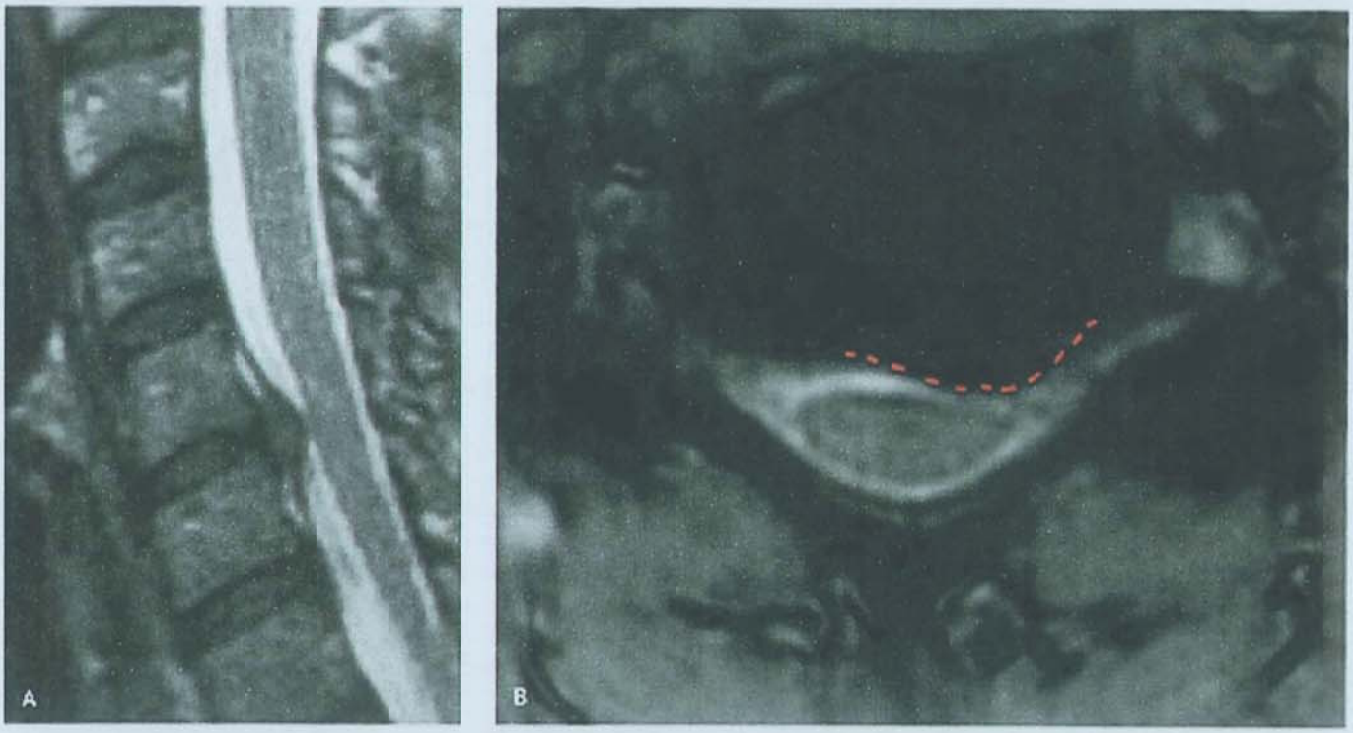

FIGURE 113.5 Cervical disk herniation. T2-weighted magnetic resonance imaging shows C5-C6 disk herniation (*dashed line* in **B**) in a patient with radiculopathy in sagittal (**A**) and axial planes (**B**).

In those patients who fail conservative management, MRI should be used to confirm a diagnosis of disk disease before considering invasive treatment. When no correlation exists between radiographic and clinical findings, electromyography and nerve conduction studies can help elucidate the etiology of presenting symptoms.

Considerations in the Cervical Spine

Lesions such as supraspinatus tendinitis, arthritic changes in the acromioclavicular joint, and rotator cuff tears may be difficult to differentiate from cervical root compression, especially because prolonged pain and lack of range of motion lead to atrophy and frozen shoulder in these syndromes. C8 and T1 lesions commonly cause a partial Horner syndrome. A diagnostic workup for syndromes of these levels must include apical lordotic views of the chest, and special care must be taken to rule out pulmonary neoplasms and abnormal cervical ribs.

Other Diagnostic Considerations

Because many disk syndromes are genetic, abnormal skeletal features throughout the spine may be sought on radiographs. These include spinal stenosis, spondylolisthesis, widespread disk disease, or Marfan syndrome. Acquired disorders, such as osteochondritis juvenilis, and metabolic states such as osteoporosis, may contribute to pathologic changes in the disk and adjacent joints, as do several forms of arthritis. Importantly, disk syndromes may be duplicated by tumors (eg, primary or metastatic), infections (eg, epidural abscess), and arachnoiditis. Epidural lipomatosis, a rare cause of low back syndromes, is a complication of steroid therapy.

Imaging and Electrodiagnostic Studies

Magnetic Resonance Imaging

An MRI is the imaging procedure of choice for disk disorders. The MRI identifies spinal cord or nerve root compression and also reveals the degree of degenerative change within the disk. It clearly delineates both intra- and extradural structures and is the ideal screening procedure for a differential diagnosis that includes structural disorders affecting the spinal cord and nerve roots.

Importantly, evidence of degenerative disk disease and even disk rupture on MRI may not correlate with clinically significant pathology that requires intervention. In studies of asymptomatic individuals, bulging and herniated disks have been identified in 50% and 27% of adults, respectively. Abnormal findings on MRI of the lumbar spine in asymptomatic adults do not appear to predict future development of low back pain. In the absence of progressive neurologic deficit or suspicion of systemic illness, such as cancer or infection, MRI should be reserved for those individuals with at least 6 weeks of persistent low back/radicular pain despite conservative therapy (see "Initial Management and Evaluation" section).

Myelography and X-ray

Computed tomography (CT) myelography is more invasive than MRI, exposing patients to the intrathecal administration of contrast as well as ionizing radiation. Accordingly, CT myelography is rarely indicated. It does effectively visualize spinal nerve roots and their trajectory through the neural foramina, particularly the anatomy of the nerve root sleeve. However, myelography is unrevealing in the evaluation of far lateral disk herniations, which occur lateral to the spinal canal and root sleeve. Myelography is useful for patients with intolerance of, or contraindications to, MRI, such as cardiac pacemakers and other implanted electrical devices. In addition, CT myelography may be preferred for patients who have surgically placed spinal implants that produce magnetic artifacts. Plain radiographs effectively depict bony anatomy but not herniated disks. Radiographs do provide valuable information related to spinal alignment and segmental stability prior to surgical intervention.

Electromyography and Nerve Conduction Studies

The primary electrodiagnostic studies used in the evaluation of radiculopathy are electromyography and nerve conduction studies. These studies can be used to accurately identify radiculopathy that has been accompanied by weakness for 3 weeks or more, but they are seldom essential. Electrodiagnostic studies are most useful when radiographic findings do not correlate with clinical presentation.

TREATMENT

Most acute attacks of back pain improve in days or weeks, and only a small minority of patients requires surgery. In one meta-analysis, 82% of patients with acute low back pain returned to work within a month of onset. In the absence of neurologic deficit, conservative treatment should be pursued so long as the patient continues to improve with analgesics and rest for lumbar and cervical disk disorders. Epidural and/or transforaminal steroid injections are a useful adjunct. These interventions reduce inflammation and thereby relieve pressure on the affected nerve root.

Expert Referral

In the acute phase, indications for referral to a treatment specialist are similar to indications for urgent MRI. Patients who present with signs/symptoms of acute or progressive neurologic deficit, including motor weakness, myelopathy, or signs of cauda equina syndrome, should be urgently evaluated by a neurosurgeon or orthopedic surgeon with experience in spine surgery. This referral should not delay MRI, which is an essential component of any potential surgical decision making. Of note, there is no evidence that early referral to a spine surgeon, in the absence of the aforementioned criteria, improves outcome. For those patients who lack acute or progressive neurologic deficit but have persistent symptoms impairing quality of life, surgery can be scheduled on an elective basis. Importantly, no randomized trial demonstrating the benefits of surgery has enrolled patients with less than 6 weeks of conservative therapy.

Lumbar Diskectomy

Lumbar diskectomy is indicated in patients with evidence of nerve root compression on neuroimaging and either corresponding radicular pain refractory to conservative therapy or corresponding acute/progressive weakness. Surgery represents an effective treatment option in properly selected patients, as diskectomy of a herniated lumbar disk fragment almost always results in long-term satisfactory relief of symptoms. Lumbar fusion is rarely required for treatment of radiculopathy from a herniated lumbar disk. Excessively prolonged physiotherapy and bed rest may cause emotional exhaustion, muscle loss, or drug dependence.

Evidence from an early randomized controlled trial by Weber comparing prolonged conservative management to diskectomy

suggests that surgery offers greater relief from radiculopathy caused by herniated lumbar disks in the short term LEVEL 1.[1] However, patients randomized to both surgical and nonsurgical groups experienced considerable symptomatic improvement over time, and the difference between groups was not statistically significant at long-term follow-up. This may be partially explained by unintended crossover between groups, as approximately one-quarter of patients randomized to nonsurgical therapy elected to have a diskectomy presumably due to persistent symptoms with conservative management.

In a large multicenter, prospective, randomized, controlled trial, researchers with the Spine Patient Outcomes Research Trial demonstrated substantial improvement with both surgical and nonsurgical treatment of lumbar disk disease with radiculopathy. Although short-term results were consistently in favor of surgery, differences in primary outcomes were not statistically different LEVEL 1.[2] At long-term follow-up (4 and 8 years), patients treated with surgery demonstrated greater improvement in secondary outcomes, including "sciatica bothersomeness," self-rated improvement, and patient satisfaction with symptoms LEVEL 1.[3] Primary outcomes (bodily pain, physical function, and disability index) also favored surgery, but these differences were not significant between groups. The results of the Spine Patient Outcomes Research Trial research effort were widely touted by the lay press, and some in the medical community, as evidence for the equivalence between modern surgical and nonsurgical treatment techniques. However, as the study authors rightly conclude, "conclusions about the superiority or equivalence of the treatments under study are not warranted based on the intent-to-treat analysis." Crossover between groups again served as a major confounder that may underestimate the relative benefit of surgery, as approximately half (49%) of patients assigned to nonoperative management ultimately elected to have surgery after a trial of conservative therapy.

Surgical techniques for lumbar diskectomy can be broadly segregated into three categories: open diskectomy, microdiskectomy, and minimally invasive diskectomy. Traditional open diskectomy involves a standard laminectomy and is performed with eyepiece magnification. Microdiskectomy is the most commonly performed procedure and typically involves a smaller incision with less bone removal in the form of a hemilaminotomy and use of the operative microscope to remove the offending disk fragment.

Minimally invasive techniques have become extremely common in modern practice. Typically, minimally invasive lumbar diskectomy includes the use of a tubular retractor system inserted through small incisions over a guidewire with fluoroscopic guidance. This technique uses muscle spitting, as opposed to the muscle cutting/detachment inherent to other methods, which its advocates suggest reduces postoperative pain and recovery time. Arts and colleagues randomized 328 patients to minimally invasive versus conventional microdiskectomy for lumbar radiculopathy. At 2-year follow-up, similar functional and clinical outcomes were reported between groups LEVEL 1.[4] A meta-analysis of randomized controlled trials comparing tubular diskectomy to conventional microdiskectomy found that both methods lead to a substantial and equivalent long-term improvement in leg pain. Total complications did not differ between study arms LEVEL 1.[5]

Cervical Diskectomy

Indications for surgery to relieve radiculopathy from disk disease in the cervical spine are similar to the indications for lumbar diskectomy. Good surgical candidates have persistent radicular pain despite at least 6 weeks of conservative treatment or acute/progressive motor weakness. Clinical evidence of myelopathy with radiographic evidence of cord compression from a herniated disk represents an additional indication for diskectomy.

Generally, spinal cord compression requires consideration of decompressive measures as soon as it is recognized. Nerve root syndromes of the cervical spine may be separated into those that require careful supervision and early operation and those that tolerate and may respond to conservative care. The muscles served by C5 may rapidly atrophy, leaving abduction paresis, poor prognosis for restoration of function, and a painful frozen shoulder. C8 is also vulnerable, and unrelieved compression may lead to irreversible atrophy with complex shoulder-arm-hand disorders that include circulatory and sweating abnormalities. C6 and C7 innervate large muscles and tolerate pressure more benignly even for long periods and may have good functional return. Cervical root syndromes are less likely to recur than lumbar disorders, and conservative therapy is worthwhile within the outlines described.

Removal of a cervical herniated disk may be performed either through a posterior laminotomy or through an anterior approach. In most case, particularly in patients with cervical kyphosis, an anterior approach is preferred. Anterior cervical diskectomy with fusion is one of the most successful and widely practiced procedures in spine surgery. By combining anterior decompression with a strut graft to promote fusion across the vacated intervertebral disk space, lordosis can be restored across the segment. Excellent results may be anticipated in appropriately selected patients.

Persson and colleagues conducted a randomized controlled trial comparing anterior cervical diskectomy to nonoperative therapy in 81 patients with clinical and radiologic signs of cervical nerve root compression lasting 12 weeks or more. Patients in the nonoperative arm were prescribed physical therapy and immobilization with a rigid cervical collar. Individuals with clinical signs of myelopathy or radiographic evidence of cord compression were excluded. Patients treated with surgery demonstrated greater improvement in both pain and motor strength at 4 months follow-up. At 1 year, no significant difference in pain remained, but patients in the surgical arm maintained a small advantage in muscle strength LEVEL 1.[6]

Prospective observational studies by Heckmann and Sampath provide further support for the efficacy of anterior cervical diskectomy in the treatment of cervical radiculopathy without myelopathy. At 2-year follow-up, patients who underwent surgery showed greater improvements in both pain and weakness compared to conservatively treated patients. Overall, approximately 75% of patients experienced significant relief from symptoms after surgery.

A primary disadvantage of anterior cervical diskectomy and fusion surgery, particularly in the young, is the development of adjacent segment disease. By fusing cervical vertebrae via the anterior cervical diskectomy with fusion procedure, a rigid segment is produced that acts as a lever arm, increasing the stress on cervical levels immediately adjacent to the fused segment. The cervical disk arthroplasty procedure, or "artificial disk," was developed to preserve motion and to obviate the potentially deleterious effects of adjacent segment stress and degeneration. This procedure is generally reserved for younger patients without significant neck pain, spondylosis, or deformity. Although it remains controversial in certain clinical scenarios, an increasing body of evidence supports the efficacy if cervical disk arthroplasty in carefully selected patients LEVEL 1.[7]

SUMMARY

Radiculopathy resulting from intervertebral disk disease is self-limited in the majority of patients. Symptoms generally improve with rest, pain control, physical therapy, and time. If symptoms persist after at least 6 weeks of conservative therapy, patients should be referred for MRI. If intervertebral disk disease identified on neuroimaging correlates with clinical presentation, patients should be referred to a spine surgeon. More urgent referral should be initiated in the presence of symptoms of cauda equina syndrome, myelopathy, or acute/progressive motor weakness. Randomized controlled trials comparing diskectomy to conservative therapy in the lumbar and cervical spine demonstrate similar long-term outcomes between groups that modestly favor surgery in appropriately selected patients. The short-term benefits of surgery have been more consistently realized across studies. Crossover between randomized arms may contribute to an underestimation of the benefit of surgery, as patients frustrated by the severity of their symptoms and the slow pace of recovery with conservative therapy commonly opt to have surgery.

LEVEL 1 EVIDENCE

1. Weber H. Lumbar disc herniation. A controlled, prospective study with ten years of observation. *Spine (Phila Pa 1976)*. 1983;8(2):131-140.
2. Weinstein JN, Tosteson TD, Lurie JD, et al. Surgical vs nonoperative treatment for lumbar disk herniation: the Spine Patient Outcomes Research Trial (SPORT): a randomized trial. *JAMA*. 2006;296(20):2441-2450.
3. Lurie JD, Tosteson TD, Tosteson ANA, et al. Surgical versus non-operative treatment for lumbar disc herniation: eight-year results for the Spine Patient Outcomes Research Trial (SPORT). *Spine (Phila Pa 1976)*. 2014;39(1):3-16.
4. Arts MP, Brand R, van den Akker ME, et al. Tubular diskectomy vs conventional microdiskectomy for the treatment of lumbar disk herniation: 2-year results of a double-blind randomized controlled trial. *Neurosurgery*. 2011;69(1):135-144.
5. Dasenbrock HH, Juraschek SP, Schultz LR, et al. The efficacy of minimally invasive discectomy compared with open discectomy: a meta-analysis of prospective randomized controlled trials. *J Neurosurg Spine*. 2012;16(5):452-462.
6. Persson LC, Moritz U, Brandt L, Carlsson CA. Cervical radiculopathy: pain, muscle weakness and sensory loss in patients with cervical radiculopathy treated with surgery, physiotherapy or cervical collar. A prospective, controlled study. *Eur Spine J*. 1997;6(4):256-266.
7. Nunley PD, Coric D, Frank KA, Stone MB. Cervical disc arthroplasty: current evidence and real-world application. *Neurosurgery*. 2018;83(6):1087-1106.

SUGGESTED READINGS

Andersson GB. Epidemiological features of chronic low-back pain. *Lancet*. 1999;354(9178):581-585.

Atlas SJ, Nardin RA. Evaluation and treatment of low back pain: an evidence-based approach to clinical care. *Muscle Nerve*. 2003;27(3):265-284.

Butterman GR. Treatment of lumbar disc herniation: epidural steroid injection compared with discectomy. A prospective, randomized study. *J Bone Joint Surg Am*. 2004;86(4):670-679.

Chou R, Fu R, Carrino JA, Deyo RA. Imaging strategies for low-back pain: systematic review and meta-analysis. *Lancet*. 2009;373:463-472.

Hansen FR, Bendix T, Skov P, et al. Intensive, dynamic back-muscle exercises, conventional physiotherapy, or placebo-control treatment of low-back pain. A randomized, observer-blind trial. *Spine (Phila Pa 1976)*. 1993;18:98-108.

Heckmann JG, Lang CJ, Zöbelein I, Laumer R, Druschky A, Neundörfer B. Herniated cervical intervertebral discs with radiculopathy: an outcome study of conservatively or surgically treated patients. *J Spinal Disord*. 1999;12(5):396-401.

Hemmilä HM. Quality of life and cost of care of back pain patients in Finnish general practice. *Spine (Phila Pa 1976)*. 2002;27(6):647-653.

Katz JN. Lumbar disc disorders and low-back pain: socioeconomic factors and consequences. *J Bone Joint Surg Am*. 2006;88(suppl 2):21-24.

Kraemer J, ed. History and terminology. In: *Intervertebral Disk Diseases: Causes, Diagnosis, Treatment, and Prophylaxis*. 3rd ed. Stuttgart, Germany: Georg Thieme Verlag; 2009:3-9.

McCormick PC. The Spine Patient Outcomes Research Trial results for lumbar disc herniation: a critical review. *J Neurosurg Spine*. 2007;6(6):513-520.

Mixter WJ, Barr JS. Rupture of the intervertebral disc with involvement of the spinal canal. *N Engl J Med*. 1934;211:210.

Peul WC, van Houwelingen HC, van den Hout WB, et al. Surgery versus prolonged conservative treatment for sciatica. *N Engl J Med*. 2007;356(22):2245-2256.

Sampath P, Bendebba M, Davis JD, Ducker T. Outcome in patients with cervical radiculopathy. Prospective, multicenter study with independent clinical review. *Spine (Phila Pa 1976)*. 1999;24(6):591-597.

Cervical and Lumbar Spinal Stenosis 114

Brian J.A. Gill and Paul C. McCormick

KEY POINTS

1. Symptoms in the setting of spinal stenosis are due to direct compression of the surrounding neural and vascular elements.
2. Cervical spondylotic myelopathy is characterized by a spastic gait, difficulty with fine motor control, and proprioceptive sensory loss.
3. Lumbar stenosis presents clinically as neurogenic claudication. This syndrome is characterized by lower extremity pain and numbness, which is exacerbated with walking or standing and relieved with sitting or leaning forward.
4. Magnetic resonance imaging is the imaging modality of choice for confirming a diagnosis of cervical or lumbar stenosis.
5. Asymptomatic patients with radiographic evidence of spinal stenosis rarely warrant surgical intervention.
6. In appropriately selected patients who have failed medical management for spinal stenosis, surgical intervention provides durable symptom relief and improves functional outcomes.

INTRODUCTION

Neck and low back pain are common causes of disability and significant socioeconomic burden.

These symptoms are the third most common cause of personal health care spending in the United States, with an estimated expenditure of 87.6 billion per year. Cervical and lumbar spinal stenosis are the most common causes of neck and low back pain, and they represent the most frequent indications for spine surgery in adults older than 65 years of age. In this chapter, we discuss the epidemiology, biology, diagnosis, and efficacy of the interventions used to manage symptomatic spinal stenosis.

EPIDEMIOLOGY

Simply defined, spinal stenosis refers to the progressive narrowing of the spaces within the spinal column where the spinal cord, nerve roots, and associated vasculature elements pass. This is primarily a radiographic diagnosis, which if clinically significant can present with pain and weakness but is commonly identified on magnetic resonance imaging (MRI) or computed tomography (CT) studies of otherwise asymptomatic patients. Furthermore, not all low back or neck pain is the result of spinal stenosis, even if present on imaging studies. As a result, it has been difficult to assess the true prevalence of radiographic and/or symptomatic spinal stenosis.

The best estimates of spinal stenosis come from the Framingham Study, which found that the prevalence of absolute and relative lumbar stenosis was 22.5% and 7.3%, respectively; this increased to 29.7% and 18.9% in the subsample of patients with clinical symptoms. A larger longitudinal study performed by the same group has shown that 50% of individuals aged 40 to 59 years have baseline degenerative changes, the prevalence of which increased two- to fourfold in those aged 60 to 69 and 70 to 89 years, respectively.

With respect to the cervical spine, Matsumoto et al has shown that degenerative changes in asymptomatic individuals are seen in up to 14% of individuals in their 20s and 87% in their 80s. In a 10-year follow-up study on this population, 81.1% of individuals demonstrated progression of their degenerative findings, and 34.1% of the patients had complaints consistent with symptomatic cervical stenosis. The major finding in all of these studies is that the frequency of degenerative changes in the cervical and lumbar spine increases linearly with age. Similar studies have shown that smoking and obesity increase the risk of the development of clinically significant spinal stenosis.

In a smaller subset of patients, acquired stenosis of the spinal canal may be due to inflammatory joint disorders, which affect the spine and sacroiliac joint known as *spondyloarthropathies*. These disorders include ankylosing spondylitis and reactive arthritis, both of which are associated with the major histocompatibility complex antigen human leukocyte antigen B27, and, unsurprisingly, their prevalence varies worldwide, clustering in areas of human leukocyte antigen B27 positivity.

Diffuse idiopathic skeletal hyperostosis and ossification of the posterior longitudinal ligament are noninflammatory disorders characterized by progressive calcification of the paravertebral ligaments which can cause stenosis, particularly in the cervical spine. Both disorders are more common in men and the elderly; ossification of the posterior longitudinal ligament also has a predilection for individuals of Asian descent.

PATHOBIOLOGY

Spondylosis

Age-related progressive arthritic degeneration of the intervertebral disks and facet joints is the most common cause of spinal stenosis. Collectively, these proliferative changes are referred to as *spondylosis*, and they occur in repetitive biomechanical stress and strain. Normal, albeit accentuated, wear and tear degenerative changes in the spine is the most common cause of spinal stenosis both in the cervical and lumbar spine. The water content of the intervertebral disk and annulus fibrosus declines progressively

with advancing age. Additionally, the intervertebral space narrows and may be obliterated, and the annulus fibrosus protrudes into the spinal canal. Osteophytes form at the margins of the vertebral body, converge on the protruded annulus, and may convert it into a bony ridge or bar. This bar may extend laterally into the intervertebral foramen. These changes all narrow the normal canal or foramina in the spinal column, and this may be exacerbated by concomitant hypertrophy of the ligamentum flavum, synovial cyst formation, overgrowth of the facets, or degenerative spondylolisthesis (anterior slippage of a vertebral body) (Fig. 114.1).

These arthritic changes can affect the central canal where they lead to compression of the spinal cord or cauda equina in the cervical and lumbar spine, respectively; the neural foramina causing compression of the exiting nerve root; or the lateral recesses of the lumbar spine where they cause compression of traveling nerve root. Spinal stenosis tends to develop at the most mobile and mechanically stressed levels. The C5-C6 and C6-C7 levels are the most commonly involved in the cervical spine, whereas L4-L5 and L3-L4 are the most commonly affected lumbar levels.

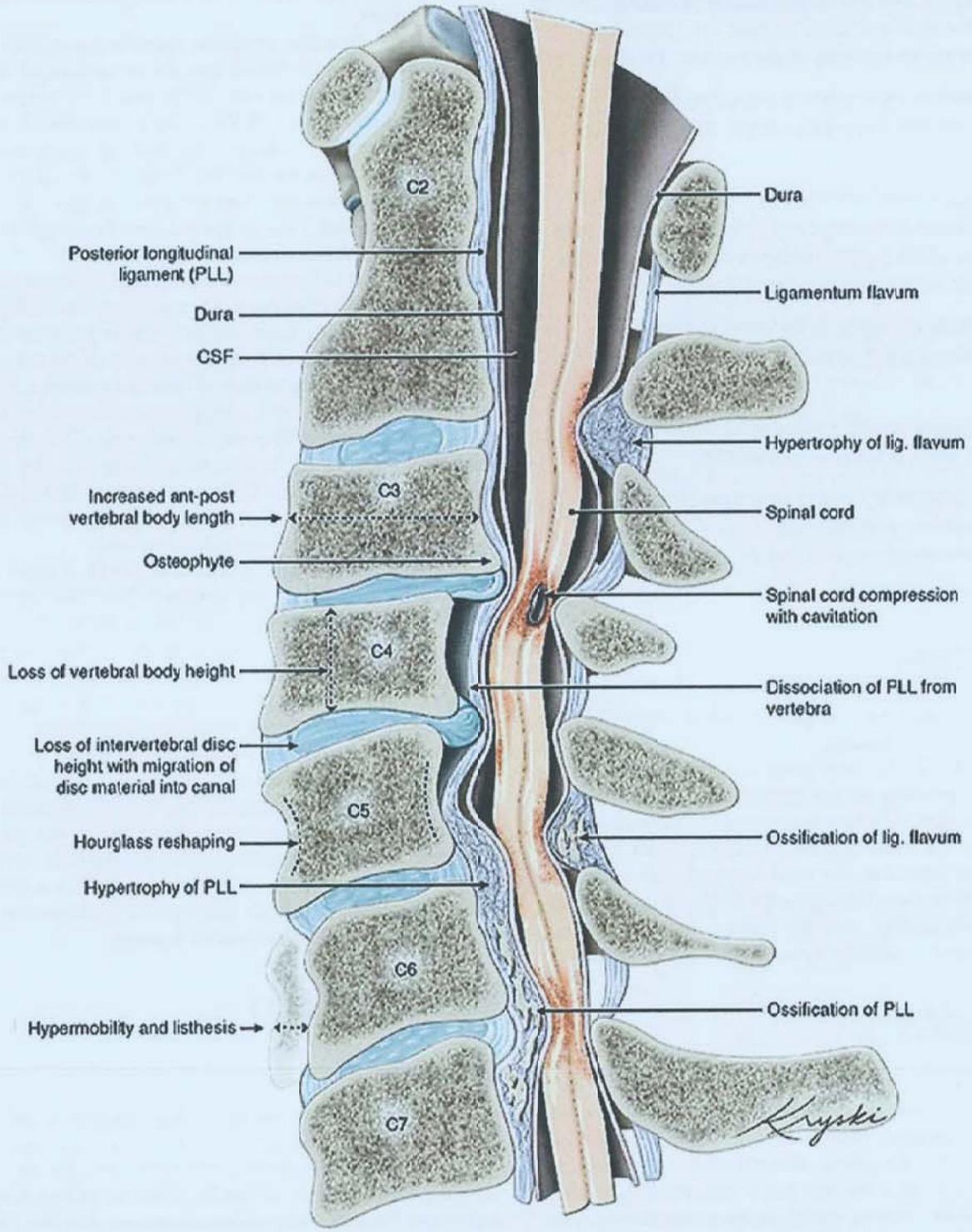

FIGURE 114.1 Artist depiction of anatomic and pathologic changes that may occur in the setting of cervical stenosis. (Reused with permission from Nouri A, Tetreault L, Singh A, Karadimas SK, Fehlings MG. Degenerative cervical myelopathy: epidemiology, genetics, and pathogenesis. *Spine [Phila Pa 1976]*. 2015;40:E675-E693.)

Congenital Stenosis

Most cases of degenerative spinal stenosis are sporadic in occurrence, although there may be a family history in some patients. The term *congenital spinal stenosis* is a bit of a misnomer because stenosis connotes an acquired narrowing. A *developmentally small spinal canal* is a more accurate term than congenital stenosis. Patients with a developmentally small canal may be more susceptible to develop symptomatic stenosis simply because they have less capacity to accommodate the proliferative degenerative changes associated with the progressive arthritic process of the spine. Patients who have either congenital fusions (ie, Klippel-Feil syndrome) may be prone to develop spinal stenosis at levels adjacent to the fused level.

Myelopathy

Progressive stenosis of the cervical spine due to the aforementioned changes can damage the spinal cord and produce a condition known as *cervical spondylotic myelopathy* (CSM). This disorder is attributed to one or more of three possible mechanisms: (1) direct compression of the spinal cord by bony or fibrous tissue overgrowth, (2) ischemia caused by compromise of the vascular supply to the cord, and (3) repeated trauma in the course of physiologic neck movement.

Pain

Pain in the setting of cervical or lumbar stenosis may be axial (confined to the neck or back) or radicular (radiate to the extremities) in nature. The mechanisms that produce myelopathy are also responsible for radiculopathy, direct compression of the nerve roots, or compression of their blood supply and subsequent ischemia can lead to radicular pain or weakness. The cervical dorsal rami, ventral rami, sympathetic trunks, and sinuvertebral nerves innervate several structures around the cervical spine. These include the synovial joints, intervertebral disks, dura, and overlying musculature. Damage to the nerve endings at any of these sites during spondylosis, or with acute events such as tears in the annulus of the intervertebral disk, can lead to specific patterns of axial neck pain including discogenic or facet joint pain syndromes. Similar mechanisms mediate axial pain syndromes in the lumbar spine.

TABLE 114.1 Clinical Manifestations of Cervical Spondylotic Myelopathy[a]

Symptoms or Signs	% of Patients
Reflexes	
Hyperreflexia	87
Babinski sign	51
Hoffmann sign	13
Spastic gait disorder	49
Bladder symptoms	49
Sensation	41
Vague sensory level	39
Proprioceptive sensory loss	33
Cervical dermatome sensory loss	
Motor functions	
Arm weakness	31
Paraparesis	21
Hemiparesis	18
Quadriparesis	10
Brown-Séquard syndrome	18
Hand atrophy	13
Fasciculation	13
Pain	
Radicular arm	41
Radicular leg	13
Neck	8

[a]Data from Lunsford LD, Bissonette DJ, Zorub DS. Anterior surgery for cervical disc disease. Part 2: treatment of cervical spondylotic myelopathy in 32 cases. *J Neurosurg*. 1980;53:12-19.

DIAGNOSIS

Clinical Manifestations

Cervical Stenosis

Patients usually present with either myelopathy or radiculopathy. A combined myeloradicular presentation is unusual but can be seen in myelopathic patients with concomitant neural foraminal stenosis. The most common symptom of myelopathy is a spastic gait disorder (Table 114.1). Axial neck pain may be prominent and chronic in nature. Clumsiness of the hands and loss of dexterity and fine motor control with tasks such as writing, typing, and buttoning are common early complaints in patients with CSM. Weakness and wasting of the hands may be seen but only as the condition becomes more advanced. Proximal arm weakness with difficulty lifting the arm over the head is the presenting complaint in a small number of patients. Bowel and bladder complaints are not common in the early stages of CSM but may be seen if it remains untreated.

The course of cervical stenosis is slowly progressive, but its natural history is not well delineated. In some patients, the condition may wax and wane with periods of relative quiescence or even improvement followed by progressive worsening. Acute worsening precipitated by a fall or other traumatic event may exacerbate existing symptoms or produce a central cord syndrome that is characterized by sudden-onset distal upper extremity numbness and weakness with relative preservation of lower extremity function. These injuries most likely occur from sudden hyperextension of the cervical spine with buckling of the ligamentum flavum causing impingement of the spinal cord. Spontaneous substantial recovery from acute central cord syndromes commonly occurs.

Lumbar Stenosis

The classic presentation of patients with lumbar stenosis is neurogenic claudication. Patients typically present with symptoms of lower extremity pain, weakness, and/or numbness with standing or walking. These symptoms are reliably relieved with sitting or leaning forward because these positions straighten the ligamentum flavum and increase the dimensions of the spinal canal. In comparison, upright positions increase the degree of lumbar stenosis by buckling of the ligamentum flavum into the spinal canal. Symptoms can vary from patient to patient in terms of the quality, distribution, severity, and duration. Most patients do not have a fixed neurologic deficit by the time of clinical presentation. Fixed deficits (eg, footdrop) or cauda equina syndrome is now rare, although they can be seen in long-standing untreated patients or acute presentations from a large central disk herniation.

Physical Examination

A thorough physical and neurologic examination should be performed when evaluating patients with complaints of neck or back pain. This includes a complete assessment of the patient's strength, sensation, reflexes, gait, and balance. Cervical spine and shoulder pathologies may have similar clinical presentations and patients frequently experience both simultaneously. A shoulder examination should be performed in patients presenting with neck pain to evaluate for a rotator cuff tear or chronic acromioclavicular joint injuries masquerading as cervical problems. Similarly, hip pain is a common mimic of low back pain, and clinical pain provocation testing can be used to differentiate the two. If present, hip pain can be reproduced by flexion, abduction, and external rotation test of the hip.

Radiographic Studies

The diagnosis of cervical or lumbar stenosis is confirmed with imaging of the spinal canal. As mentioned earlier in the chapter, it is important to appreciate that patients may have radiographic evidence of spinal stenosis without neurologic signs or symptoms. With few exceptions, these asymptomatic patients are not in need of treatment.

Plain Radiography

Formerly, the most important diagnostic tests were plain radiographs of the spine. Although other imaging modalities have largely supplanted x-rays, they still play an important role in imaging patients with spinal stenosis. Plain radiographs can demonstrate early osteophyte formation and disk space narrowing. The anteroposterior and lateral views provide information on the patient's overall alignment. Additionally, flexion and extension radiographs can be used to evaluate for any concomitant spinal instability.

Computed Tomography and Computed Tomography Myelography

Noncontrast CT scans provide complementary information to that obtained from MRI sequences and can help to differentiate an ossified disk from a soft disk herniation. This modality is also particularly useful for delineating the bony anatomy of patients prior to surgery. CT myelography is an invasive test and has been replaced by MRI for the evaluation of cervical and lumbar stenosis. However, this study may be of greater utility in patients with prior surgery where postoperative changes make MRI studies difficult to interpret. Additionally, it remains an option for symptomatic patients with contraindications to MRI (eg, due to implanted medical devices).

Magnetic Resonance Imaging

MRI is the imaging modality of choice for the evaluation of both cervical and lumbar stenosis. It is noninvasive and provides excellent resolution of the spinal cord, exiting nerve roots, and cauda equina (**Fig. 114.2**) as well as the surrounding soft tissue structures. MRI also allows the treating physician to evaluate for a range of alternative diagnoses including Chiari malformations, vascular malformations, spinal tumors, syringomyelia or demyelinating conditions such as multiple sclerosis.

Additional Tests

Electrodiagnostic studies such somatosensory-evoked potentials and electromyography (EMG) add little to aid in diagnosis of either cervical or lumbar stenosis. The diagnostic utility of transcranial magnetic stimulation remains to be ascertained, but motor-evoked potentials may be more contributory than sensory potentials. There is little role for cerebrospinal fluid (CSF) analysis. If a lumbar tap is undertaken, the CSF profile is usually normal or the protein concentration may be slightly elevated (50-100 mg/dL). Higher protein levels or CSF pleocytosis should raise the question of multiple sclerosis or tumor, including meningeal carcinomatosis.

MANAGEMENT

Cervical Stenosis

The treatment of cervical stenosis depends on many factors. As previously noted, radiographic stenosis in the absence of signs or symptoms rarely necessitates intervention. Occasionally, a patient with severe stenosis (<7 mm canal diameter) and an intramedullary signal abnormality within the spinal cord may present with little or no neurologic symptoms. In these patients, preemptive surgical decompression may be offered, but it is not clear if the benefit of surgery outweighs the risks in this patient population. Often, patients with minimal or no neurologic signs or symptoms are followed both clinically and with imaging over time. Surgical decompression is usually recommended if clinical progression is documented.

Patients with radicular symptoms from nerve root compression from foraminal stenosis are initially managed with conservative measures such as activity modulation, physical therapy, judicious use of anti-inflammatory medications, and/or steroidal spinal injections. Surgery for decompression of the nerve root either through a posterior cervical foraminotomy or an anterior cervical diskectomy and fusion (ACDF) is an option for patients with persistent radiculopathy that is not responsive to conservative management.

The natural history of CSM varies greatly and is unpredictable in individual patients. In rare instances, conservative treatment with physical therapy for gait training and neck immobilization with a firm collar may be appropriate for patients with mild myelopathy. In these cases, surgery should be considered if the myelopathy progresses despite conservative treatment. There is often no ideal surgical approach for patients with CSM, rather the chosen intervention depends on a variety of factors. Ventral compressive pathology may be better addressed with an anterior approach such as an ACDF, whereas a posterior approach may be better suited for instances of multilevel compression. Similarly, while pathology at the level of the disc space is easily addressed with an ACDF, a corpectomy (surgical removal of the vertebral body) may be needed if the site of compression lies behind the vertebral body. Patient factors also play an important role in the surgical decision making. Elderly patients or those with a history of swallowing or vocal cord disfunction are not ideal candidates for anterior procedures because they are at an increased risk for dysphagia postoperatively. All of these aspects must be considered and discussed with the patient prior to surgical intervention.

Lumbar Stenosis

Unlike cervical stenosis, most patients with lumbar stenosis do not have a neurologic deficit. As a result of this, treatment options are more variable. For patients with mild symptoms, conservative management with activity modification, physical therapy, and/or periodic epidural steroid injections may provide durable stability or even improvement from the symptoms of

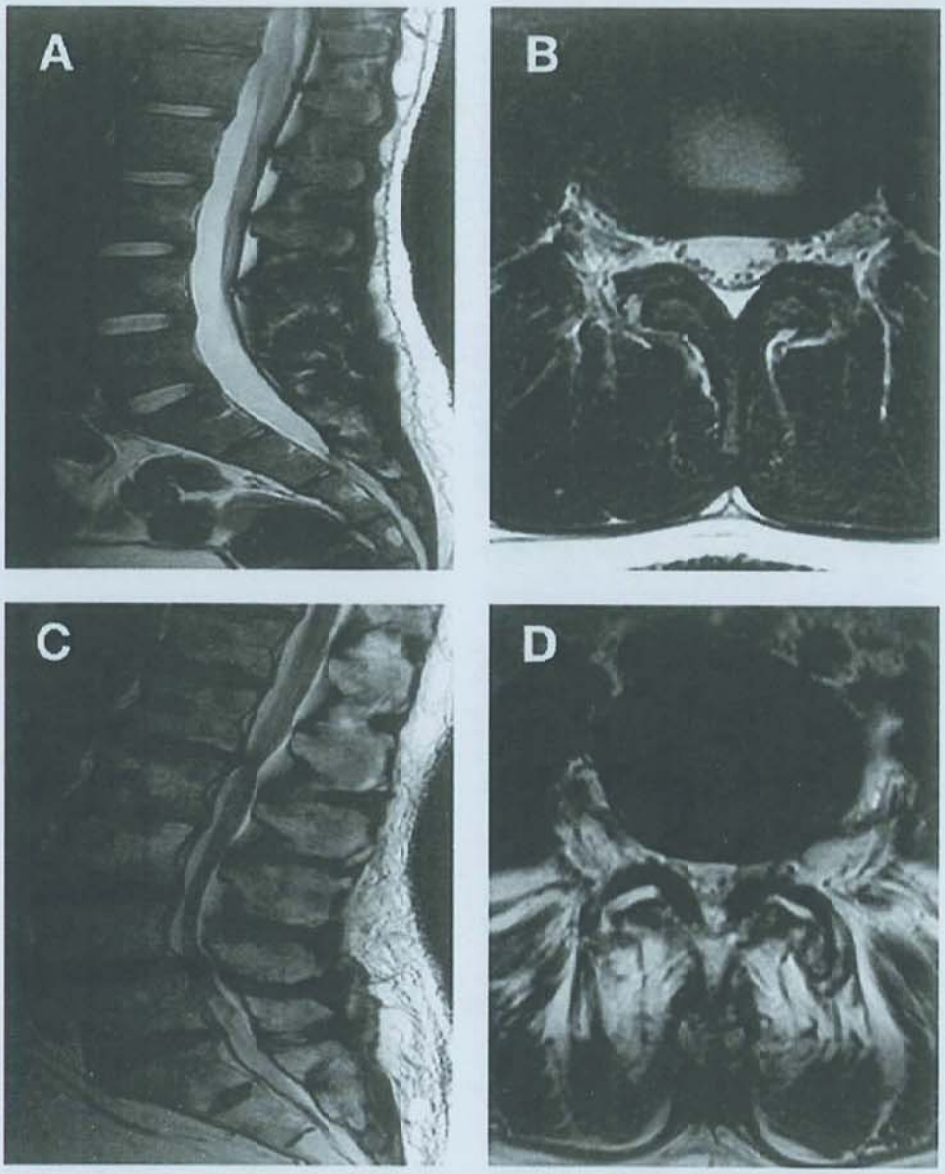

FIGURE 114.2 **A:** A normal sagittal T2-weighted magnetic resonance imaging (MRI) of the lumbar spine. **B:** A normal axial T2-weighted MRI of the lumbar spine. **C:** Sagittal T2-weighted MRI of the lumbar spine demonstrating severe lumbar stenosis at L4-L5, spondylolisthesis of L4 on L5, and multilevel loss of intervertebral disk height. **D:** Corresponding axial T2-weighted MRI of the lumbar spine at L4-L5 showing facet hypertrophy, facet joint effusion and thickening of the ligamentum flavum.

lumbar stenosis. Should the patient report worsening symptoms, function or quality of life despite a trial of conservative management, then surgical intervention for decompression may be offered.

As with cervical stenosis, a multitude of factors dictates the chosen surgical intervention for patients who have failed medical management of symptomatic lumbar stenosis. This includes location of the compressive pathology, spinal alignment, spinal stability, surgical history, and the health of the patient. Surgical options include decompressive procedures alone (laminectomy, laminectomy with diskectomy) or decompression and fusion procedures such as a transforaminal lumbar interbody fusion. The latter procedure is often preferred in patients who have severe degenerative disease with spondylolisthesis, recurrent disk herniations following surgical management, or radiculopathy caused by foraminal stenosis from loss of disk height.

OUTCOMES

A large-scale randomized trial of medical versus surgical management of cervical stenosis has yet to be performed. Despite this, there are several large noncomparative prospective studies, which demonstrate the clinical benefit of surgical intervention on patients with cervical stenosis. Fehlings et al performed a multicenter prospective study of 278 patients who underwent surgical management of CSM. At 1-year follow-up, they observed significant improvements in functional outcome, disability outcome, and health-related quality of life regardless of the underlying etiology or surgical approach. Subsequent prospective studies have yielded similar results. Thus, while the study design precludes a discussion of the absolute efficacy of surgery in comparison to medical management, the substantial variation in both the pathology addressed and the employed surgical approach would suggest that these results are generalizable.

The Spine Patient Outcomes Research Trial provides level 1 evidence of both the efficacy and durability of spinal decompression through lumbar laminectomy to relieve the symptoms of lumbar stenosis in appropriately selected patients who have failed to improve with standard nonoperative measures LEVEL 1.[1,2] Additionally, level 1 evidence provided by the Spine Patient Outcomes Research Trial also demonstrated the efficacy and durability of lumbar decompression and fusion (eg, transforaminal lumbar interbody fusion) for patients with lumbar stenosis and degenerative spondylolisthesis LEVEL 1.[3,4]

LEVEL 1 EVIDENCE

1. Weinstein JN, Tosteson TD, Lurie JD, et al. Surgical versus nonsurgical therapy for lumbar spinal stenosis. *N Engl J Med*. 2008;358(8):794-810.
2. Weinstein JN, Lurie JD, Tosteson TD, et al. Surgical versus nonsurgical treatment for lumbar degenerative spondylolisthesis. *N Engl J Med*. 2007;356(22):2257-2270.
3. Weinstein JN, Tosteson TD, Lurie JD, et al. Surgical versus non-operative treatment for lumbar spinal stenosis four-year results of the Spine Patient Outcomes Research Trial (SPORT). *Spine (Phila Pa 1976)*. 2010;35(14):1329-1338.
4. Weinstein JN, Lurie JD, Tosteson TD, et al. Surgical compared with nonoperative treatment for lumbar degenerative spondylolisthesis: four-year results in the Spine Patient Outcomes Research Trial (SPORT) randomized and observational cohorts. *J Bone Joint Surg Am*. 2009;91(6):1295-1304.

SUGGESTED READINGS

Azuma S, Seichi A, Ohnishi I, Kawaguchi H, Kitagawa T, Nakamura K. Long-term results of operative treatment for cervical spondylotic myelopathy in patients with athetoid cerebral palsy: an over 10-year follow-up study. *Spine (Phila Pa 1976)*. 2002;27(9):943-948.

Baptiste DC, Fehlings MG. Pathophysiology of cervical myelopathy. *Spine J*. 2006;6(6 suppl):190S-197S.

Bednařík J, Kadaňka Z, Voháňka S, Stejskal L, Vlach O, Schröder R. The value of somatosensory- and motor-evoked potentials in predicting and monitoring the effect of therapy in spondylotic cervical myelopathy. Prospective randomized study. *Spine (Phila Pa 1976)*. 1999;24(15):1593-1598.

Behrbalk E, Salame K, Regev GJ, Keynan O, Boszczyk B, Lidar Z. Delayed diagnosis of cervical spondylotic myelopathy by primary care physicians. *Neurosurg Focus*. 2013;35(1):E1.

Chen J, Song D, Wang X, Shen X, Li Y, Yuan W. Is ossification of posterior longitudinal ligament an enthesopathy? *Int Orthop*. 2011;35(10):1511-1516.

Ebara S, Yonenobu K, Fujiwara K, Yamashita K, Ono K. Myelopathy hand characterized by muscle wasting. A different type of myelopathy hand in patients with cervical spondylosis. *Spine (Phila Pa 1976)*. 1988;13(7):785-791.

Emery SE. Cervical spondylotic myelopathy: diagnosis and treatment. *J Am Acad Orthop Surg*. 2001;9(6):376-388.

Fehlings MG, Arvin B. Surgical management of cervical degenerative disease: the evidence related to indications, impact, and outcome. *J Neuro Surg Spine*. 2009;11(2):97-100.

Fehlings MG, Wilson JR, Kopjar B, et al. Efficacy and safety of surgical decompression in patients with cervical spondylotic myelopathy: results of the AOSpine North America prospective multi-center study. *J Bone Joint Surg Am*. 2013;95(18):1651-1658.

Försth P, Ólafsson G, Carlsson T, et al. A randomized, controlled trial of fusion surgery for lumbar spinal stenosis. *N Engl J Med*. 2016;374(15):1413-1423.

Fouyas IP, Statham PF, Sandercock PA, Lynch C. Surgery for cervical radiculomyelopathy. *Cochrane Database Syst Rev*. 2006;(2):CD001466.

Friedly JL, Comstock BA, Turner JA, et al. A randomized trial of epidural glucocorticoid injections for spinal stenosis. *N Engl J Med*. 2014;371(1):11-21.

Ghogawala Z, Benzel EC, Heary RF, et al. Cervical spondylotic myelopathy surgical (CSM-S) trial: randomized controlled trial design and rationale. *Neurosurgery*. 2014;75(4):334-346.

Ghogawala Z, Coumans JV, Benzel EC, Stabile LM, Barker FG II. Ventral versus dorsal decompression for cervical spondylotic myelopathy: surgeons' assessment of eligibility for randomization in a proposed randomized controlled trial: results of a survey of the Cervical Spine Research Society. *Spine (Phila Pa 1976)*. 2007;32(4):429-436.

Ghogawala Z, Martin B, Benzel EC, et al. Comparative effectiveness of ventral vs dorsal surgery for cervical spondylotic myelopathy. *Neurosurgery*. 2011;68(3):622-630.

Jarraya M, Guermazi A, Lorbergs AL, et al. A longitudinal study of disc height narrowing and facet joint osteoarthritis at the thoracic and lumbar spine, evaluated by computed tomography: the Framingham Study. *Spine J*. 2018;18(11):2065-2073.

Kalichman L, Cole R, Kim DH, et al. Spinal stenosis prevalence and association with symptoms: the Framingham Study. *Spine J*. 2009;9(7):545-550.

Lo YL, Chan LL, Lim W, et al. Systematic correlation of transcranial magnetic stimulation and magnetic resonance imaging in cervical spondylotic myelopathy. *Spine (Phila Pa 1976)*. 2004;29(10):1137-1145.

Lyu RK, Tang LM, Chen CJ, Chen CM, Chang HS, Wu YR. The use of evoked potentials for clinical correlation and surgical outcome in cervical spondylotic myelopathy with intramedullary high signal intensity on MRI. *J Neurol Neurosurg Psychiatry*. 2004;75(2):256-261.

Matsumoto M, Fujimura Y, Suzuki N, et al. MRI of cervical intervertebral discs in asymptomatic subjects. *J Bone Joint Surg Br*. 1998;80:19-24.

Matz PG. Does nonoperative management play a role in the treatment of cervical spondylotic myelopathy? *Spine J*. 2006;6(6 suppl):175S-181S.

Nakamura K, Kurokawa T, Hoshino Y, Saita K, Takeshita K, Kawaguchi H. Conservative treatment for cervical spondylotic myelopathy: achievement and sustainability of a level of "no disability." *J Spinal Disord*. 1998;11(2):175-179.

Nascimento FA, Gatto LAM, Lages RO, Neto HM, Demartini ZD Jr, Koppe GL. Diffuse idiopathic skeletal hyperostosis: a review. *Surgical Neurol Int*. 2014;5(suppl 3):S122-S125.

Nouri A, Tetreault L, Singh A, Karadimas SK, Fehlings MG. Degenerative cervical myelopathy: epidemiology, genetics, and pathogenesis. *Spine (Phila Pa 1976)*. 2015;40(12):E675-E693.

Nurick S. The natural history and the results of surgical treatment of the spinal cord disorder associated with cervical spondylosis. *Brain*. 1972;95(1):101-108.

Nurick S. The pathogenesis of the spinal cord disorder associated with cervical spondylosis. *Brain*. 1972;95(1):87-100.

Okada E, Matsumoto M, Ichihara D, et al. Aging of the cervical spine in healthy volunteers: a 10-year longitudinal magnetic resonance imaging study *Spine (Phila Pa 1976)*. 2009;34(7):706-712.

Persson LC, Carlsson CA, Carlsson JY. Long-lasting cervical radicular pain managed with surgery, physiotherapy, or a cervical collar. A prospective, randomized study. *Spine (Phila Pa 1976)*. 1997;22(7):751-758.

Rhee J M, Shamji MF, Erwin WM, et al. Nonoperative management of cervical myelopathy: a systematic review. *Spine (Phila Pa 1976)*. 2013;38(22, suppl 1):S55-S67.

Sampath P, Bendebba M, Davis JD, Ducker TB. Outcome of patients treated for cervical myelopathy. A prospective, multicenter study with independent clinical review. *Spine (Phila Pa 1976)*. 2000;25(6):670-676.

Shimomura T, Sumi M, Nishida K, et al. Prognostic factors for deterioration of patients with cervical spondylotic myelopathy after nonsurgical treatment. *Spine (Phila Pa 1976)*. 2007;32(22):2474-2479.

Taurog JD, Chhabra A, Colbert RA. Ankylosing spondylitis and axial spondyloarthritis. *N Engl J Med*. 2016;374(26):2563-2574.

Vu Nguyen H, Ludwig SC, Silbe J, et al. Rheumatoid arthritis of the cervical spine. *Spine J*. 2004;4(3):329-334.

115 Acquired and Hereditary Myelopathies

Natalie Weathered and Noam Y. Harel

KEY POINTS

1. The differential diagnosis of nontraumatic myelopathies is broad and requires a careful history to narrow the list and guide test selection.
2. Baseline demographics, acuity of onset, and time to nadir may be the most important historical features for narrowing the differential.
3. In cases of suspected infectious or inflammatory etiology, contrasted magnetic resonance imaging of the entire neuraxis is indicated to evaluate for asymptomatic lesions.
4. Basic lumbar puncture cell count and protein profiles in combination with extended tests provide critical information.
5. For most myelopathies, rapid diagnosis and initiation of treatment is of the utmost importance to prevent further neurologic decline.

INTRODUCTION

Myelopathy indicates pathology of the spinal cord leading to dysfunction of central motor and sensory circuits, as opposed to radiculopathy (pathology of spinal roots), which affects solely peripheral circuits. Numerous conditions may cause myelopathy (**Table 115.1**). This chapter expands on key inflammatory, infectious, vascular, metabolic, genetic, and toxic insults. We also offer clinical pearls for diagnosing the cause of acute myelopathy (**Table 115.2**) and for differentiating acute, subacute and chronic myelopathy (**Table 115.3**).

SYRINGOMYELIA

A syrinx is an intramedullary fluid-filled cavity typically found within the cervical to midthoracic spinal cord (**Fig. 115.1**), but extension down to the conus medullaris is also possible as is upward extension to the brainstem in which case it is called *syringobulbia*. The cavity is most commonly filled with cerebrospinal fluid (CSF). However, syringomyelia should be regarded as distinct from simple cystic expansion of the central canal for which the term *hydromyelia* applies.

Epidemiology

The prevalence of syringomyelia in Western countries is approximately 8.4 cases per 100,000. It typically presents either congenitally or in the third to fourth decade of life, and men are more frequently affected than women. It uncommonly presents in late-adult years.

Pathobiology

Generally speaking, primary and secondary syringomyelia arise from an impairment of normal CSF flow dynamics. Although congenital cases of isolated primary syringomyelia do exist, congenital syringomyelia more often arises associated with Chiari type 1 malformation, in which an abnormally small posterior fossa alters CSF flow.

Spinal cord tumors may also cause secondary syringomyelia by altering local CSF flow dynamics. Additionally, syringomyelia may be seen in the chronic phase after trauma, either as an ex vacuo lesion that persists after absorption of an intramedullary hematoma or due to local inflammation of the pia-arachnoid resulting in adhesions between the meninges and spinal cord. In animal models, these adhesions lead to ischemia, demyelination, and ultimately, cavitation.

Clinical Features

Cervicothoracic syringomyelia classically presents with insidious onset of a cape-like distribution of decreased pain and temperature sensation in the back, arms, and hands, which occurs due to disruption of the crossing spinothalamic tracts. Sometimes, the patient may be unaware of sensory loss until burns or abrasions on the hands are noticed after the fact. There may be varying degrees of weakness in the arms (lower motor neuron type due to involvement of cervical anterior horn cells) and legs (upper motor neuron type due to involvement of lateral corticospinal fibers). A Horner syndrome may be present if a cervicothoracic syrinx affects the intermediolateral columns. Bowel and bladder function are generally preserved unless the syrinx extends toward the sacral cord segments.

Diagnosis

Magnetic resonance imaging (MRI) allows visualization not only of the syrinx but also of any associated abnormalities such as Chiari malformation, neoplasm, arachnoid granulations, or tethered cord. Full cord imaging should be strongly considered. The MRI CSF flow studies may also be useful in guiding treatment. There are no biomarkers associated with syringomyelia. The CSF is often normal or may have a nonspecific, mild elevation in protein.

Management

Conservative observation is warranted in cases with no or only minor symptoms and in cases of Chiari malformation with tonsillar herniation less than 5 mm below the foramen magnum in the setting of normal CSF flow studies. In more severe cases of Chiari, however, posterior fossa decompression and cervical

TABLE 115.1 Differential Diagnosis of Myelopathy

Acute Myelopathy
Compressive/mechanical
• Disk herniation/subluxation
• Epidural abscess
• Epidural hematoma
• Epidural neoplasm/metastasis
• Trauma
• Vertebral compression fracture
Vascular
• Arteriovenous malformation
• Cavernous malformation
• Dural arteriovenous fistula
• Stroke
Infectious
• Bacterial
◦ Lyme
◦ *Mycoplasma pneumoniae*
◦ Syphilis
◦ Tuberculosis
• Fungal
◦ *Aspergillus* species
◦ *Blastomyces dermatitidis*
◦ *Candida* species
◦ *Coccidioides immitis*
◦ *Cryptococcus neoformans*
◦ *Histoplasma capsulatum*
◦ Zygomycetes
• Parasitic
◦ *Schistosoma* species
◦ *Taenia solium* (cysticercosis)
◦ *Toxoplasma gondii*
• Viral gray matter/acute flaccid paralysis
◦ Coxsackieviruses A and B
◦ Enterovirus
◦ Japanese encephalitis virus
◦ Poliovirus
◦ Tick-borne encephalitis virus
◦ West Nile virus
• Viral white matter/longitudinal myelitis
◦ Cytomegalovirus
◦ Epstein-Barr virus
◦ Herpes simplex virus
◦ Influenza
◦ Varicella-zoster virus
Inflammatory
• Acute disseminated encephalomyelitis
• Antiphospholipid antibody syndrome
• Behçet disease
• Mixed connective tissue disease

Acute Myelopathy *(continued)*
• Multiple sclerosis
• Neuromyelitis optica
• Paraneoplastic
• Sarcoidosis
• Sjögren syndrome
• Systemic lupus erythematosus
• Transverse myelitis
Toxic/metabolic
• Amphotericin B toxicity
• Arachnoiditis after angiographic/myelographic contrast agents
• Cytarabine toxicity
• Heroin
• Konzo
• Methotrexate toxicity
Neoplasm
Subacute Myelopathy
Inflammatory
• Acute disseminated encephalomyelitis
• Antiphospholipid antibody syndrome
• Behçet disease
• Mixed connective tissue disease
• Multiple sclerosis
• Neuromyelitis optica
• Paraneoplastic
• Sarcoidosis
• Sjögren syndrome
• Systemic lupus erythematosus
• Transverse myelitis
Vascular
• Arteriovenous malformation
• Cavernous malformation
• Dural arteriovenous fistula
Neoplasm
Postinfectious myelitis
Chronic Myelopathy
Compressive/mechanical
• Arachnoid cyst
• Disk herniation/subluxation
• Ligamentous ossification
• Paget disease
• Spinal stenosis
• Syringomyelia
Neoplasm
• Ependymoma
• Glioma (astrocytoma > oligodendroglioma)
• Hemangioblastoma
• Leukemia
• Lymphoma

TABLE 115.1 Differential Diagnosis of Myelopathy *(continued)*

Chronic Myelopathy *(continued)*	Chronic Myelopathy *(continued)*
• Meningioma	**Genetic**
• Neurofibroma	• Disorders of metabolism
Infection	◦ Abetalipoproteinemia (Bassen-Kornzweig syndrome)
• Human immunodeficiency virus	◦ Adrenomyeloneuropathy
• Human T-lymphotropic virus	◦ Arginase deficiency
• Syphilis	◦ Cobalamin C disease
• Tuberculosis	◦ Hyperornithinemia-hyperammonemia-homocitrullinuria
Toxic/metabolic	◦ Krabbe disease
• 1-Bromopropane toxicity (aerosol exposure, dry cleaning)	◦ Metachromatic leukodystrophy
• Cyanide poisoning (cassava plant ingestion)	◦ Methylene tetrahydrofolate reductase deficiency
• Fluorosis	• Distal motor-sensory axonopathy
• Hepatic myelopathy	◦ Hereditary spastic paraplegia
• Hexacarbon toxicity (glue sniffing)	• Motor neuron disease
• Lathyrism	◦ Amyotrophic lateral sclerosis
• Nitrous oxide toxicity	◦ Primary lateral sclerosis
• Nutritional deficiency	◦ Spinobulbar muscular atrophy (Kennedy syndrome)
◦ Copper	• Spinal muscular atrophy
◦ Cyanocobalamin (vitamin B_{12})	• Spinocerebellar degeneration
◦ Folate (vitamin B_9)	◦ Friedreich ataxia
◦ Thiamine (vitamin B_1)	◦ Spinocerebellar ataxia types 1-28
◦ Vitamin E	
• Organophosphate toxicity	

TABLE 115.2 Clinical Pearls for a Patient With Acute Myelopathy but Negative Magnetic Resonance Imaging

1. Initial spinal cord MRI can be negative in up to 20% of cases.
2. Did you image the right level? Sometimes, what appears to be a thoracic sensory level actually comes from a cervical lesion. Total spine MRI is warranted in any case of acute nonstructural myelopathy. Alternatively, is there any possibility the symptoms arose from a brain lesion?
3. Ensure the MRI was done with contrast as it will increase sensitivity for both active demyelination as well as vascular lesions.
4. Some lesions can radiographically resolve with time, so if the MRI is done late you may not identify the lesion.
5. Use the history to guide you.
   A. Stepwise decline? Consider an inflammatory or vascular etiology.
   B. Nadir within 12 h of onset? Consider vascular etiology.
   C. Prior bariatric surgery or denture use? Recent nitrous oxide exposure? Consider nutritional deficiency including vitamin B_{12}, folate, and copper.
   D. Prior radiation history?
   E. Pertinent family history? Consider hereditary spastic paraplegia.
   F. Travel history? Consider Lyme or HTLV.
   G. History of sexually transmitted diseases? Consider HIV or syphilis.
   H. Rheumatologic symptoms such as dry mouth, rash, history of miscarriages, or thrombosis? Consider diseases such as Sjögren syndrome, systemic lupus erythematosus, and sarcoidosis.
   I. Weight loss or smoking history? Consider a neoplastic or paraneoplastic etiology.
6. Have a low threshold to send treatable causes of myelopathy including vitamin B_{12}, folate, copper, Lyme, HIV, RPR, erythrocyte sedimentation rate, C-reactive protein, SSA (Ro), SSB (La), ANA, dsDNA, and ACE.

Abbreviations: ACE, angiotensin-converting enzyme; ANA, antinuclear antibodies; dsDNA, double-stranded DNA; HIV, human immunodeficiency virus; HTLV, human T-cell lymphotropic virus; MRI, magnetic resonance imaging; RPR, rapid plasma reagin.

TABLE 115.3 Clinical Findings of Acute, Subacute, and Chronic Nontraumatic Myelopathy

	Acute	Subacute	Chronic
Time	**Minutes to Days**	**Days to Weeks**	**Weeks to Months**
Tone	Decreased or normal	Normal or increased	Increased
Motor	Ipsilateral weakness	Ipsilateral weakness	Ipsilateral weakness
Sensory			
Pain/temperature	Contralateral loss (2 levels below)	Contralateral loss (2 levels below)	Contralateral loss (2 levels below)
Vibration/ proprioception	Ipsilateral loss	Ipsilateral loss	Ipsilateral loss
Reflexes	Decreased, normal, or increased	Increased	Increased

laminectomy with or without duraplasty is frequently pursued in hopes of restoring normal CSF flow dynamics.

In cases of syringomyelia secondary to neoplasm, if resection is not possible, then fenestration or marsupialization of the syrinx may be attempted. Lysis of adhesions and/or shunting of the syrinx to the pleural or peritoneal cavities is also performed, although the benefits have not been proven and are very difficult to predict in individual patients.

Nonoperative management includes medications to treat neuropathic pain. Occasionally, trials of diuretics are attempted in the hope of reducing syrinx size. However, this is rarely successful.

FIGURE 115.1 Syringomyelia on a T2-weighted magnetic resonance imaging. The syrinx, which appears as a high-intensity linear lesion in the central cord, extends from C4 to C7. (From Peleggi AF, Lovely TJ. Treatment of delayed Chiari malformation and syringomyelia after lumboperitoneal shunt placement: case report and treatment recommendations. *Surg Neurol Int*. 2012;3:101, with permission.)

Outcome

A study by Alfieri and Pinna found that surgical posterior fossa decompression for Chiari type 1 malformation associated with syringomyelia tends to be well tolerated with few complications. Additionally, 93.4% of patients experienced some degree of clinical improvement.

In contrast, a study of surgical treatment for posttraumatic syringomyelia showed much lower clinical success rates, with only 51% of patients reporting clinical improvement. Forty-one percent of patients experienced no clinical change, and 8% had further clinical deterioration. Notably, among those patients in whom surgery was not recommended based on lack of significant neurologic symptoms, 84% remained stable at 10 years. The high progression-free rate and the unsure evidence for surgical efficacy both argue for the clinician to take a conservative, watchful approach to posttraumatic syringomyelia if at all possible.

NEOPLASTIC MYELOPATHY

Neoplasm should be high on the differential anytime someone presents with myelopathic symptoms of unknown origin. Metastatic disease is much more common than a primary spinal tumor. In fact, an estimated 12% to 20% of patients with systemic cancer present with spinal metastasis as the initial cause of symptoms. Primary spinal cord tumors are much rarer with an estimated prevalence of 0.74 cases per 100,000.

It is important to bear in mind that not all myelopathy in the setting of neoplasm is a direct consequence of the neoplasm itself but rather may be secondary to radiation injury, chemotherapy toxicity, or a paraneoplastic disorder. Primary spinal neoplasms are discussed in Chapter 107. Further information on metastatic neoplasm may also be reviewed in Chapter 101.

Epidemiology

The cancers that most frequently metastasize to the spinal column are lung, breast, renal, hematopoietic, melanoma, prostate, and gastrointestinal. At least 95% of spinal metastases are extradural, usually to the vertebrae, where many remain asymptomatic. Autopsy studies suggest that over 30% of patients with advanced systemic cancer have pathologic evidence of vertebral metastases at the time of death. In the rostrocaudal axis, the majority of spinal metastases localize to the lumbar spine. However, due to the narrower diameter of the thoracic spinal canal, most symptomatic metastases are within the thoracic spine.

Pathobiology

Most spinal metastases travel hematologically either through the arterial system or retrogradely through Batson venous plexus. As the vertebral column comprises a large proportion of the body's bone marrow, which is rich in growth factors, the vertebrae may provide a particularly hospitable environment for metastatic cells. Leptomeningeal metastases can also result from either extension from nearby bone or spread through the CSF.

Clinical Features

In addition to the usual myelopathic symptoms of weakness, sensory loss, and urogenital dysfunction, spinal neoplasms are often marked by pain. The pain may be local (from periosteal irritation or pathologic vertebral compression deformity), or radicular, or both. It may accompany myelopathic symptoms acutely, or it may precede myelopathic symptoms by weeks to months. Although nonspecific, red flags of concern for a cancerous cause of back pain include age older than 60 years at onset, associated weight loss, worse at night, thoracic rather than lumbar pain, and tenderness to palpation. The rate of symptom progression may range from slowly progressive to an acute onset (such as a pathologic vertebral fracture secondary to intravertebral tumor). In addition, metastases may alter arterial perfusion and/or venous drainage, resulting in acute ischemia, hemorrhage, or venous compression.

Diagnosis

Although a computed tomography (CT) scan performs well at detecting bony metastases, MRI with contrast remains the test of choice, as it visualizes the extent of cord and soft-tissue involvement as well as vasogenic and cytotoxic edema. If a neoplasm is identified, full neuraxis imaging should be completed to evaluate for additional lesions, as these may alter treatment and prognosis. Additionally, if the patient is not otherwise known to have cancer, then a full assessment for the primary tumor should be initiated. If the spinal lesion is intradural, a high-volume lumbar puncture should be sent for cytology and flow cytometry although the sensitivity of these studies is not high. Ultimately, biopsy of either the spinal lesion or a suspected primary tumor source remains the diagnostic gold standard.

Management

The mainstay of treatment for spinal metastases has traditionally been glucocorticoid and radiation therapy. Radiation tends to be well tolerated, and 65% to 80% of patients report symptomatic improvement. High-dose corticosteroids such as dexamethasone 100 mg intravenous (IV) push, followed by 6 to 10 mg every 6 hours with a rapid taper over the next few days, are often used concurrently for symptom management. With improvements in technical approaches, surgical decompression has become a critical part of the spinal metastasis treatment armamentarium. A randomized trial has shown that decompressive surgical resection plus radiation therapy for acute paraplegia results in greater ability to walk (84% vs 57%) and a better chance of regaining the ability to walk (62% vs 19%), compared to radiation therapy alone LEVEL 1.[1] Other accumulated case series and studies have suggested that higher preoperative ambulatory function and shorter time between symptom onset and surgery strongly improve postsurgical prognosis.

Outcome

The prognosis after diagnosis of a spinal metastasis remains poor, with an average life expectancy of 4 to 15 months. The emphasis in management, therefore, is typically in maintaining the highest quality of life possible.

INFECTIOUS MYELOPATHY

Numerous infectious causes of myelopathy may induce symptoms through direct neuroinvasion, compression, or inflammation. Symptoms may occur at the time of the acute infection, as in the case of viral myelitis, meningoencephalitis, or abscess, or they may be delayed by days to weeks as in the case of postinfectious or postvaccination myelitis, or even years in the case of neurosyphilis or human immunodeficiency virus (HIV).

Viral Myelitis

Epidemiology

The true incidence of viral myelitis is unknown. Worldwide, the viral syndrome of acute flaccid paralysis, one form of viral myelitis, occurs in approximately 40 per 1,000,000 individuals per year. Cases of transverse myelitis number approximately 1 to 4 cases per 1,000,000 individuals per year. Viral myelitis tends to be more common in the summer and early fall with a bimodal incidence peak in adolescence and the fourth decade of life. Prior to widespread vaccination, polio accounted for the vast majority of cases of acute flaccid paralysis. More recently, West Nile virus (WNV), Japanese encephalitis, and enteroviruses A71 or D68 are the more likely culprits.

Pathobiology

Viral myelitis may occur through direct cellular toxicity or through parainfectious inflammation. In particular, anterior horn cells are often targeted by enteroviruses (including poliovirus, coxsackieviruses A and B, echovirus, enteroviruses A71 and D68) and flaviviruses (WNV, Japanese encephalitis, tick-borne encephalitis). In contrast, herpesviruses, including herpes simplex virus, varicella-zoster virus, cytomegalovirus, and Epstein-Barr virus, have a higher predilection for glial cells of the white matter and sensory neurons in the dorsal horn.

Clinical Features

Acute flaccid paralysis typically presents with fever and headache followed a few days later by the onset of flaccid paralysis of at least one extremity. Alterations in cognition may be seen, reflecting a common association between flaccid paralysis and meningitis and encephalitis. Sensory symptoms and alterations in bowel and bladder control are notably absent. In comparison, inflammatory transverse myelitis often has prominent sensory (usually symmetric) and bowel/bladder abnormalities in addition to weakness with or without cognitive symptoms that evolves over the period of hours to days.

Diagnosis

An MRI with and without contrast may show evidence of edema, demyelination, meningeal enhancement, or necrosis. In addition to cord imaging, brain MRI is warranted to evaluate for intracranial involvement—abnormalities of the deep gray matter indicate viral encephalitis, whereas white matter findings would redirect the diagnosis toward an autoimmune etiology such as postviral or parainfectious inflammation, multiple sclerosis (MS), or neuromyelitis optica (NMO) spectrum disorder.

All patients with suspected viral myelitis should undergo lumbar puncture. Typical CSF findings include pleocytosis with a lymphocytic or mononuclear predominance, normal to low-normal glucose, but elevated total protein. Additionally, many pathogenic viruses may be directly detected within CSF using

either polymerase chain reaction amplification of viral nucleic acid or specific antibody titers.

Management

In the setting of suspected viral myelitis, supportive care and prevention of complications are fundamental. Specific antiviral medications include IV acyclovir, which is typically started empirically upon presentation and may be discontinued if testing for herpes simplex virus and varicella-zoster virus are negative. If cytomegalovirus is suspected in the setting of HIV or other type of immunosuppression, then it would be reasonable to start ganciclovir and foscarnet. If the pathogen is WNV, there is mixed data supporting the use of IV immunoglobulin and interferon alfa-2b. Finally, to combat parainfectious inflammation, IV methylprednisolone is often used in parallel with these other treatments.

Outcome

Prognosis depends in no small part on whether the damage involves gray matter or white matter, with better recovery in the latter. Age, severity of abnormalities, and timing of initiation of specific treatment also affect recovery.

Human T-cell Lymphotropic Virus-Associated Myelopathy (Tropical Spastic Paraparesis)

Epidemiology

The HTLV types 1 and 2 cause insidious, progressive myelopathy in approximately 20 million people worldwide, with the highest infection rates in Japan, South America, the Caribbean, and equatorial Africa. Similar to HIV, HTLV transmission generally occurs as a result of unprotected sex, mother-to-child via breastfeeding, sharing of needles, or blood transfusions. The HTLV can result in either an aggressive T-cell leukemia affecting an estimated 3% to 5% of infected individuals, or it can cause a spastic paraparesis in approximately 0.25% to 3% of infected individuals. Among HTLV-positive individuals, women are 1.5 to 3.5 times more likely to develop HTLV-associated myelopathy/tropical spastic paraparesis (HAM/TSP) than men and may experience a faster progression of disease.

Pathobiology

Like HIV, HTLV predominantly infects $CD4^+$ T lymphocytes. As a retrovirus, it reverse transcribes its RNA genome into DNA that then integrates into the host genome as a provirus. How HTLV infection leads to chronic, inflammatory/demyelinating myelopathy is not well understood. Autopsy studies show perivascular infiltrates containing HTLV-infected lymphocytes as well as multiple inflammatory cytokines resulting in breakdown of the blood-brain barrier.

Clinical Features

The HAM/TSP is an insidious disease that begins initially with subtle weakness or stiffness of the lower extremities, followed by progression—without remission—toward spastic paraparesis and spastic bladder. Paresthesias in the lower extremities are also common, although sensory levels are not usually seen.

Diagnosis

Because individuals with HAM/TSP symptoms are generally unaware of HTLV infection, the clinician must have an appropriate index of suspicion depending on patient demographics and symptom time course.

In the early stages of the disease, MRI is often unremarkable. With progression, nonspecific subcortical and periventricular white matter demyelinating lesions appear in the brain followed eventually by spinal cord atrophy.

Lumbar puncture typically shows mild pleocytosis with elevated total protein and normal glucose. The HTLV-1 antibodies and a proviral load can be detected in the CSF. Oligoclonal bands (OCB) and evidence of intrathecal immunoglobulin G (IgG) synthesis are often present. The HTLV antibodies are present in serum as well.

Management

Several antiretroviral drugs used against HIV have been trialed against HTLV, so far without success. In the cancer literature, there are some reports of decreased HTLV-1 expression with interferon-α treatment. There are also ongoing trials in Japan investigating the benefit of an anti-C-C chemokine receptor type 4 (CCR4) monoclonal antibody, mogamulizumab, for treatment of HAM/TSP. For now, the mainstays of treatment are symptomatic, with immune-modulating medications such as corticosteroids and cyclosporine used in an attempt to improve HAM/TSP symptoms.

Outcome

The HAM/TSP remains a chronic, progressive, untreatable disease. Patients almost invariably become wheelchair bound with significant bladder and bowel dysfunction.

INFLAMMATORY MYELOPATHY

Noninfectious causes of inflammatory transverse myelitis (see Chapter 72), neuromyelitis optica (Chapter 73), myelin oligodendrocyte glycoprotein IgG (MOG-IgG)-associated disease, acute disseminated encephalomyelitis, systemic lupus erythematosus (SLE), Sjögren syndrome, mixed connective tissue disease, sarcoidosis (Chapter 75), Behçet disease, paraneoplastic syndromes (see Chapter 108), and others that remain to be identified. It is important to note that the cause remains unidentified in up to 30% of cases of spinal cord inflammation resulting in the diagnosis of idiopathic transverse myelitis.

Clinical Features

As with any other cause of myelopathy, symptoms of inflammatory myelopathy depend on the location of the lesion. Most classically, patients present with sensory symptoms, typically in the legs and often with a sensory level associated with bladder dysfunction. Symptoms may progress to include motor deficits over the course of hours to days.

Diagnosis

Brain and total spine MRI with and without contrast are essential. An MRI often reveals T2-hyperintense white matter lesions, which may have contrast enhancement (Fig. 115.2). The pattern of cord and brain MRI involvement may help narrow the differential—for example, longitudinally extensive cord lesions suggest NMO or MOG-IgG–associated disease, whereas deep brain gray matter lesions suggest acute disseminated encephalomyelitis. However, as many as 40% of cases may not show any MRI abnormality. The

FIGURE 115.2 A magnetic resonance imaging showing a transverse myelitis lesion (the lesion is the lighter, oval shape at center right). This magnetic resonance image was taken 3 months after patient recovered. (From Gaillard F. Transverse myelitis. Radiopaedia Web site. http://radiopaedia.org/cases/transversemyelitis. Accessed April 25, 2015.)

CSF studies, if done, should include testing for OCB and IgG synthesis rate. Although not highly specific, several of the most common inflammatory myelopathies are associated with characteristic CSF profiles. For example, MS tends to feature normal protein, lack of pleocytosis, and positive OCB/IgG synthesis; in contrast, NMO usually demonstrates increased protein and cell count and a lower rate of positive OCB/IgG synthesis. Specific (although not always sensitive) serum and CSF biomarkers include aquaporin-4 antibody (NMO), MOG-IgG, angiotensin-converting enzyme (sarcoidosis), antinuclear and anti–double-stranded DNA antibodies (SLE), anti-Ro/SSA (Ro) antibodies, anti-La/SSB (La) antibodies (Sjögren syndrome), anti–scl-70 antibodies (scleroderma), and paraneoplastic antibodies. Visual- and somatosensory-evoked potentials may be useful ancillary tests if MRI and CSF are unrevealing. If there is concern for a paraneoplastic process, systemic body imaging such as CT or CT–positron emission tomography is warranted. In up to 30% of cases, none of these studies are abnormal. These cases earn the diagnostic label of idiopathic transverse myelitis, a label that has steadily become less frequent due to improved diagnostic understanding.

Management

Once infection is ruled out, most cases of paraparesis related to acute inflammatory myelopathy are treated with an empirical 3- to 5-day course of IV corticosteroids, most commonly IV methylprednisolone 1,000 mg daily. More aggressive diseases such as NMO, SLE, Sjögren scleroderma, and others are often also treated with plasmapheresis or IV immunoglobulin. When the diagnosis points to a chronic inflammatory myelopathy, disease-modifying therapy is typically initiated. For example, maintenance rituximab infusions are often given for NMO. An exception is for suspected monophasic transverse myelitis, in which case it is reasonable to follow the patient clinically without initiation of a chronic medication unless a relapse occurs.

Outcome

Prognosis varies widely depending on the disease, the extent of the lesion, the rate of symptom progression, and the patient's age. Disease course may be monophasic or relapsing, with complete remission or permanent disability.

VASCULAR MYELOPATHY

Spinal Cord Infarction

Epidemiology

Compared to cerebrovascular ischemia, spinal cord infarction is quite rare, accounting for only 1% to 2% of vascular neurologic deficits and 5% to 8% of all acute myelopathies with a known diagnosis. In one small study by Cheshire and colleagues, men were almost twice as likely to experience an infarction of the spinal cord as women, but to our knowledge, this has not been studied in a larger context.

Pathobiology

The spinal cord is perfused by the anterior spinal artery and two posterior spinal arteries with the anterior spinal artery supplying the anterior two-thirds of the cord and the posterior spinal arteries supplying the remaining third. Most commonly, the anterior spinal artery forms from a merging of two branches that arise from the V4 segments of the vertebral arteries, although variations exist. However, given the length of the anterior spinal artery, it receives additional supply from feeder anterior radiculomedullary arteries that stem from branches off of the aorta. The most well-known of these feeders is the artery of Adamkiewicz. These branches are variable and typically leave portions of the spinal cord, especially the lower thoracic, vulnerable to watershed ischemia. The vast majority of spinal infarcts occur in the territory supplied by the anterior spinal artery (see Chapter 17, **Fig. 17.2**). Therefore, the most common causes of spinal cord ischemia are secondary to aortic pathology and injury, such as dissection, traumatic rupture, and surgical procedures. Additionally, traditional causes of stroke in the cerebral vasculature can also cause stroke in the spinal cord vasculature—therefore, etiologies such as cardioembolism, hypercoagulable state, atherosclerosis, and vasculitis should be considered.

Clinical Features

Symptom onset typically occurs acutely over minutes to hours, although some patients experience a slower progression of symptoms in the setting of arterial insufficiency. Back pain frequently accompanies other typical myelopathic symptoms. On acute exam, flaccid paralysis and a sensory level to pinprick and temperature below the level of the ischemic lesion will usually be present. Vibration and proprioception are relatively but not completely preserved, as the dorsal columns

are supplied by the posterior spinal arteries. Reflexes are initially reduced or absent but transition to hyperreflexia over subsequent days to weeks.

Diagnosis

When cord ischemia is suspected, special attention should be paid to diffusion-weighted and apparent diffusion coefficient MRI sequences. However, due to difficulties with resolution in the spinal canal, a negative scan does not rule out the diagnosis of ischemia, especially in the first few hours after presentation. There are no specific laboratory abnormalities to confirm the diagnosis. In fact, in the setting of acute nontraumatic myelopathy, a "nondiagnostic" CSF profile without evidence of inflammation should raise cord ischemia prominently on the differential diagnosis. Conventional digital subtraction angiography should be strongly considered under circumstances of high clinical suspicion. As part of the diagnostic workup and to guide secondary prevention, an echocardiogram, telemetry, a lipid panel, and hemoglobin A_{1c} are typically ordered, along with a hypercoagulable disease workup if the patient is younger than age 50 years or has a concerning family history.

Management

No randomized trials have looked at treatment of acute spinal cord infarction as a unique entity.

Induced hypertension with phenylephrine (20-100 μg/min) in association with spinal drainage to reduce CSF pressure (<5 cm H_2O) and increase spinal cord perfusion pressure has been described, in particular when spinal cord infarction occurs as a complication of aortic aneurysm surgery.

There are very few reports of use of tissue plasminogen activator for the treatment of acute spinal cord infarction. This is most likely a result of the broad differential diagnosis at the time of acute paraplegia (see **Table 115.1**) as well as many causes of spinal cord infarction, such as aortic surgery or aortic dissection, serving as contraindications to thrombolysis.

Outcome

The classic teaching is that prognosis for recovery of motor or sphincter function after a spinal infarct is quite poor. However, multiple small studies have shown that functional recovery of, especially, ambulation, but even bladder control, is possible.

Spinal Arteriovenous Malformations and Fistulas

Epidemiology

Arteriovenous malformations (AVMs) are inappropriate arteriovenous connections involving arteries that normally supply neural tissue. In contrast, dural arteriovenous fistulas (DAVFs) are improper connections that involve arteries serving nerve roots and meninges (**Fig 115.3**). The vast majority, approximately 70%, of all spinal vascular malformations are DAVF. The DAVF occur most frequently after the fourth decade of life and are more common in men than women. Intradural AVF are most common within the lower thoracic and lumbar spine. Extradural AVF are most common within the cervical cord. In comparison, spinal AVMs have no gender predominance and tend to present between the ages of 20 and 60 years old. Just over half of spinal AVMs are found within the thoracic cord, almost a third are cervical and the remaining are in the lumbar spine.

Pathobiology

Frank hemorrhage is not necessary to cause many of the symptoms of spinal vascular malformations. In both DAVF and AVM, the abnormal direct arterial flow into the venous system may result in myelopathy via cord compression as well as via the development of venous hypertension, which leads to intramedullary edema. Additionally, in the setting of large arteriovenous lesions, vascular steal may occur, resulting in cord ischemia. Finally, symptoms may occur when arterial pressure overwhelms the accommodation of the venous wall, leading to hemorrhage; this is more common in AVM than DAVF.

Clinical Features

Chronically progressive motor deficits, especially paraparesis, are the most common presenting symptom. The weakness may worsen with exercise. Almost half of patients will have pain, often radicular, referable to the lesion. The diagnosis often eludes detection for years, although one clinical key may be the stepwise pattern of progression. Notably, in the case of AVMs, approximately half of patients present acutely with sudden onset of myelopathic symptoms due to hemorrhage.

Diagnosis

On standard MRI sequences, signs of AVM and DAVF include cord edema and enhancement. A T2-based MRI sequences may detect characteristic abnormal flow voids with sensitivity to detect small abnormalities increased by the addition of contrast. Magnetic resonance angiography with contrast enhancement can also aid in the detection of an AVM. However, if magnetic resonance is not diagnostic and clinical suspicion remains, conventional digital subtraction angiography remains the gold standard for diagnosis. It also has the added benefit of allowing for therapeutic intervention if the diagnosis is confirmed.

Management

Treatment options for AVM and DAVF include embolization of the feeding arteries, surgical clipping or resection, and gamma knife radiosurgery. Frequently, a combination of these treatment modalities is necessary. The treatment of asymptomatic and unruptured cranial lesions, especially AVM, is quite controversial. The A Randomized Multicenter Clinical Trial of Unruptured Brain AVMs (ARUBA) was stopped prematurely due to an increased rate of adverse events in the intervention arm—including all of these options—as compared to conservative medical therapy. Although this trial excluded spinal AVMs, these results should be considered.

Outcome

Prognosis can be difficult to predict; as may be expected, the patient's age, duration, and severity of myelopathic symptoms are critical variables that influence response to treatment. Overall, complete obliteration of the vascular lesion may be difficult to attain—especially with AVMs—however, in most cases, even partial treatment can result in significant clinical improvement.

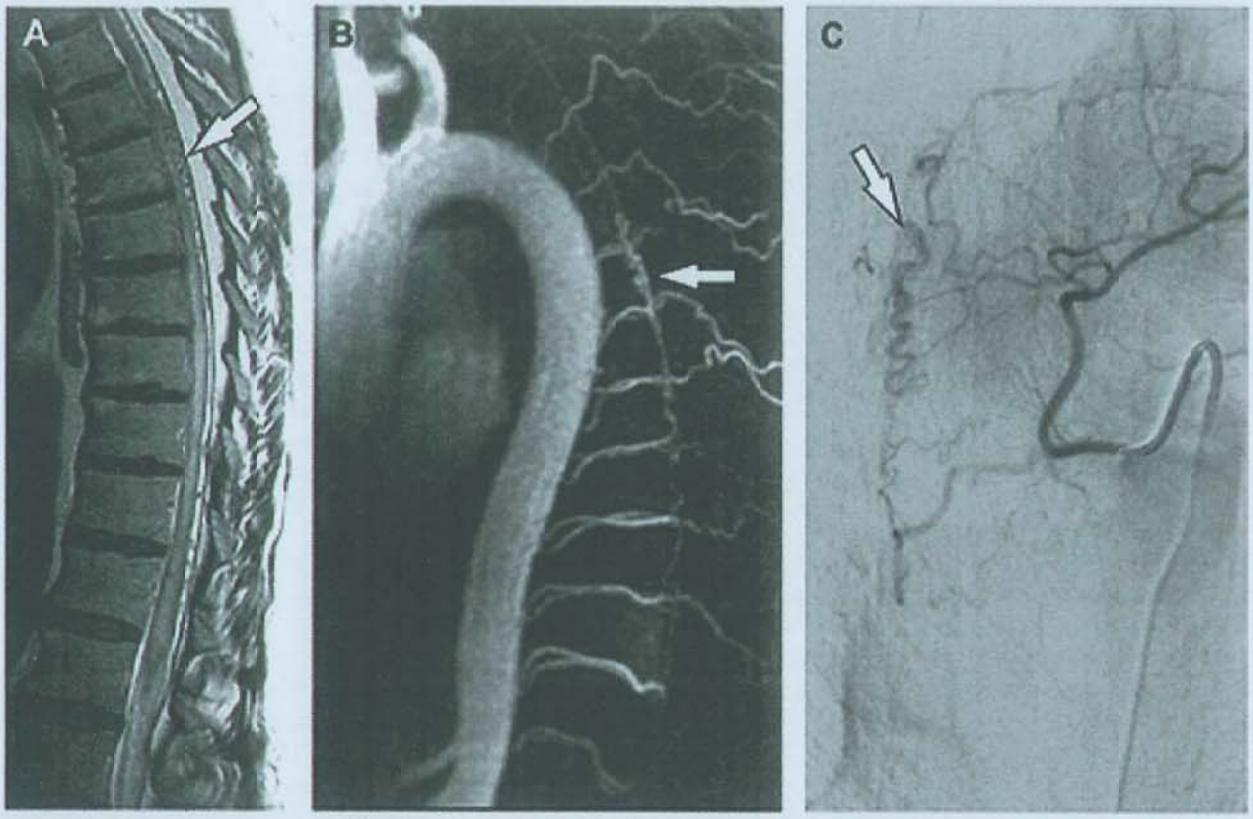

FIGURE 115.3 Dural arteriovenous fistula. **A:** Sagittal T2-weighted image of the thoracic spine shows T2 hyperintensity in the thoracic spinal cord with tortuous flow voids *(arrow)* over the dorsal aspect of the cord. **B:** Sagittal maximum-intensity projection from time-resolved magnetic resonance angiogram shows enlarged veins filling during arterial phase of imaging *(arrow)* due to shunting in the fistula. **C:** Catheter angiogram with selective injection into a spinal segmental artery shows the fistula, with the same enlarged tortuous veins *(arrow)* at the surface of the spinal cord. (From Kranz PG, Amrhein TJ. Imaging approach to myelopathy: acute, subacute, and chronic. *Radiol Clin North Am.* 2019;57[2]:257-279.)

TOXIC/METABOLIC CAUSES OF MYELOPATHY

Numerous causes of toxic or metabolic myelopathy may present with similar progressive myelopathic symptoms. The specific diagnosis derives from a combination of history of past exposures, systemic manifestations, and laboratory testing. Nutritional deficiencies, especially those of cyanocobalamin, folate, vitamin E, and copper, are discussed extensively in Chapter 128.

Myelopathy due to Radiation or Chemotherapy

Radiation therapy and a number of medications, especially chemotherapeutics, have been reported to cause myelopathy. The risk of myelopathy as a consequence of radiation therapy increases nonlinearly with the dose of radiation, with a reported prevalence of approximately 5% of patients who receive 60 cGy to the spinal cord as compared to only 1% of patients who were treated with 50 cGy. Radiation-induced myelopathy commonly presents in one of two ways. The most common is a transient myelopathy presenting with Lhermitte phenomenon approximately 6 weeks to 6 months after radiation. The MRI is typically normal, and symptoms resolve over weeks to months. There is also a delayed presentation that is a chronic and progressive form of radiation-induced myelopathy. This presents months to years after radiation. There is no consensus on treatment, but corticosteroids, hyperbaric oxygen, bevacizumab, and anticoagulation have all been tried. Of the chemotherapeutics, methotrexate and cytarabine are the most frequent offenders and are most likely to lead to a myelopathy in those treated intrathecally or with systemic doses that are high enough to penetrate the blood-brain barrier. If chemotherapy-related myelopathy occurs, it generally does so within hours to weeks after treatment and usually after the patient has received multiple doses. A number of other chemotherapeutics have been reported to cause myelopathy including fludarabine, cladribine, thiotepa, doxorubicin, and daunorubicin. In addition, amphotericin B has been reported to contribute to development of myelopathy.

Nitrous Oxide Toxicity

Nitrous oxide (NO) is an inhaled anesthetic that is used primarily for dental procedures. Therefore, occupational exposure is a risk, although NO toxicity more frequently results from recreational abuse in the form of "whippets," derived from whipped cream canisters. The NO-induced myelopathy typically results relatively rapidly after abuse and is associated with functional vitamin B_{12} deficiency due to interference with vitamin B_{12} metabolism.

Accordingly, the clinical picture, with the exception of the rate of symptom onset, which is often much more rapid in the setting of NO abuse, is identical to subacute combined degeneration including prominent proprioceptive loss in addition to spastic paraparesis. If a patient is expected to undergo a procedure with NO anesthesia and has moderately low vitamin B_{12} levels, supplementation with cyanocobalamin for a few weeks prior to the procedure can prevent this complication.

Hepatic Myelopathy

Hepatic myelopathy is an uncommon and overlooked consequence of advanced cirrhosis. It is characterized by a spastic paraparesis that almost always spares the arms and which progresses slowly over years. Sensory and autonomic symptoms are typically absent. The myelopathy is often preceded by hepatic encephalopathy and most frequently occurs in the setting of a portosystemic shunt. The MRI is often normal, especially early in the disease; however, motor-evoked potentials may confirm an abnormality. The pathobiology is unknown. There is mixed literature on improvement after liver transplantation, with some suggesting that transplantation before symptoms become too severe may allow for some degree of recovery.

GENETIC CAUSES OF MYELOPATHY

The genetic causes of myelopathy include hereditary spastic paraplegia (HSP), motor neuron disease, disorders of metabolism, and spinocerebellar degeneration. Within this section, we focus primarily on HSP.

Hereditary Spastic Paraplegia

Epidemiology

An HSP is a heterogeneous group of neurodegenerative disorders associated with mutations in any of over 50 genes with usually either autosomal dominant or autosomal recessive inheritance. The HSP has a prevalence of 5.5 cases per 100,000. Among families with autosomal dominant inheritance, the most frequent culprit mutations occur in SPG4 followed by SPG3A. Among families with autosomal recessive inheritance, mutations within SPG11 are the most common, with SPG15 and SPG5 mutations as the second and third most common anomalies. X-linked and mitochondrial causes also exist, but the epidemiology of these is not as well studied. In addition, de novo mutations can occur in the absence of family history.

Pathobiology

An HSP is classically associated with axonal degeneration at the distal ends of the lateral corticospinal tracts, often accompanied by distal degeneration within the fasciculus gracilis as well. The molecular basis for these abnormalities varies widely depending on the particular causal gene, with abnormalities involving axonal and endosomal trafficking, endoplasmic reticulum morphogenesis, lipid metabolism, and mitochondrial regulation. Further information can be found in reviews by Fink as well as Noreau and colleagues.

Clinical Features

An HSP can present at any age. It typically begins as a gait abnormality due to impaired dorsiflexion secondary to extensor spasticity. Especially early in the disease, spasticity is a more prominent finding than actual weakness and may be mildly asymmetric. As the disease progresses, more proximal leg muscles become involved leading to a scissoring gait (adductor spasticity). Abnormalities of vibratory and position sense as well as bowel and bladder control may also be seen. The arms are generally spared except for possible hyperreflexia. "Complicated" HSP refers to cases with additional symptoms such as cognitive impairment, epilepsy, parkinsonism, ataxia, peripheral neuropathy, amyotrophy, or vision or hearing loss.

Diagnosis

A presumptive diagnosis of HSP is usually made based on a combination of personal and family history and physical exam. Genetic testing finds the causative gene in only 33% to 55% of autosomal dominantly inherited cases and 18% to 29% of autosomal recessively inherited cases. The MRI is often normal but may show distal spinal cord atrophy, especially later in disease course. Sensory-evoked potentials are often abnormal, even in patients without clinical evidence of sensory abnormalities.

Management

Treatment is symptomatic. Muscle relaxants such as baclofen, tizanidine, or diazepam may aid with spasticity. Botulinum toxin injection may prove helpful in more resistant cases. Physical therapy is always encouraged to help maintain range of motion and mobility. Symptoms of spastic bladder can be treated with anticholinergic medications such as oxybutynin.

Outcome

An HSP does not typically shorten life expectancy, and many patients will experience a plateau in neurologic decline after which the degree of disability seems to stabilize. At what point this plateau will occur, however, will vary by patient and is difficult to predict.

LEVEL 1 EVIDENCE

1. Patchell RA, Tibbs PA, Regine WF, et al. Direct decompressive surgical resection in the treatment of spinal cord compression caused by metastatic cancer: a randomised trial. *Lancet*. 2005;366:643-648.

SUGGESTED READINGS

Alfieri A, Pinna G. Long-term results after posterior fossa decompression in syringomyelia with adult Chiari type 1 malformation. *J Neurosurg Spine*. 2012;17:381-387.

Cachat A, Chevalier SA, Alais S, et al. Alpha interferon restricts human T-lymphotropic virus type 1 and 2 de novo infection through PRK activation. *J Virol*. 2013;87:13386-13396.

Caldwell C, Werdiger N, Jakab S, et al. Use of model for end-stage liver disease exception points for early liver transplantation and successful reversal of hepatic myelopathy with a review of the literature. *Liver Transpl*. 2010;16:818-826.

Cheshire WP, Santos CC, Massey EW, Howard JF Jr. Spinal cord infarction: etiology and outcome. *Neurology*. 1996;47:321-330.

Cheung AT, Weiss SJ, McGarvey ML, et al. Interventions for reversing delayed-onset postoperative paraplegia after thoracic aortic reconstruction. *Ann Thorac Surg*. 2002;74:413-419.

Cho W-S, Kim K-J, Kwon O-K, et al. Clinical features and treatment outcomes of the spinal arteriovenous fistulas and malformation: clinical article. *J Neurosurg Spine*. 2013;19:207-216.

Cree BAC. Acute inflammatory myelopathies. *Handb Clin Neurol*. 2014;122:613-667.

Fink JK. Hereditary spastic paraplegia: clinico-pathologic features and emerging molecular mechanisms. *Acta Neuropathol*. 2013;126:307-328.

Fuzii HT, da Silva Dias GA, de Barros RJS, et al. Immunopathogenesis of HTLV-1-associated myelopathy/tropical spastic paraparesis (HAM/TSP). *Life Sci*. 2014;104:9-14.

Gonçalves DU, Proietti FA, Ribas JGR, et al. Epidemiology, treatment, and prevention of human T-cell leukemia virus type-1-associated diseases. *Clin Microbiol Rev*. 2010;23:577-589.

Hathout L, El-Saden S. Nitrous oxide-induced B_{12} deficiency myelopathy: perspectives on the clinical biochemistry of vitamin B_{12}. *J Neurol Sci*. 2011;301:1-8.

Heldner MR, Arnold M, Nedeltchev K, Gralla J, Beck J, Fischer U. Vascular diseases of the spinal cord: a review. *Curr Treat Options Neurol*. 2012;14:509-520.

Hrabalek L. Intramedullary spinal cord metastases: review of the literature. *Biomed Pap Med Fac Univ Palacky Olomouc Czech Repub*. 2010;154:117-122.

Irani DN. Aseptic meningitis and viral myelitis. *Neurol Clin*. 2008;26:635, viii.

Jacobs WB, Perrin RG. Evaluation and treatment of spinal metastases: an overview. *Neurosurg Focus*. 2001;11:e10.

Kim J, Losina E, Bono C, et al. Clinical outcome of metastatic spinal cord compression treated with surgical excision ± radiation versus radiation therapy alone: a systematic review of literature. *Spine (Phila Pa 1976)*. 2012;37:78-84.

Kincaid O, Lipton HL. Viral myelitis: an update. *Curr Neurol Neurosci Rep*. 2006;6:469-474.

Klekamp J. Treatment of posttraumatic syringomyelia. *J Neurosurg Spine*. 2012;17:199-211.

Koyanagi I, Houkin K. Pathogenesis of syringomyelia associated with Chiari type 1 malformation: review of evidences and proposal of a new hypothesis. *Neurosurg Rev*. 2010;33:271-285.

Krings T, Geibprasert S. Spinal dural arteriovenous fistulas. *AJNR Am J Neuroradiol*. 2009;30:639-648.

Kumar N. Metabolic and toxic myelopathies. *Semin Neurol*. 2012;32:123-136.

Lad SP, Santarelli JG, Patil CG, Steinberg GK, Boakye M. National trends in spinal arteriovenous malformations. *Neurosurg Focus*. 2009;26:1-5.

Lima M, Bica R, Araújo A. Gender influence on the progression of HTLV-I associated myelopathy/tropical spastic paraparesis. *J Neurol Neurosurg Psychiatry*. 2005;76:294-296.

Loher TJ, Bassetti CL, Lövblad KO, et al. Diffusion-weighted MRI in acute spinal cord ischaemia. *Neuroradiology*. 2003;45:557-561.

Marcus J, Schwarz J, Singh IP, et al. Spinal dural arteriovenous fistulas: a review. *Curr Atheroscler Rep*. 2013;15:335.

Martin F, Castro H, Gabriel C, et al. Ciclosporin A proof of concept study in patients with active, progressive HTLV-1 associated myelopathy/tropical spastic paraparesis. *PLoS Negl Trop Dis*. 2012;6:e1675.

Mihai C, Jubelt B. Infectious myelitis. *Curr Neurol Neurosci Rep*. 2012;12:633-641.

Nagpal S, Clarke JL. Neoplastic myelopathy. *Semin Neurol*. 2012;32:137-145.

Nardone R, Höller Y, Storti M, et al. Spinal cord involvement in patients with cirrhosis. *World J Gastroenterol*. 2014;20:2578-2585.

Newton HB. Neurological complications of chemotherapy to the central nervous system. *Handb Clin Neurol*. 2012;105:903-916.

Noreau A, Dion PA, Rouleau GA. Molecular aspects of hereditary spastic paraplegia. *Exp Cell Res*. 2014;325:18-26.

Robertson CE, Brown RD Jr, Wijdicks EF, Rabinstein AA. Recovery after spinal cord infarcts: long-term outcome in 115 patients. *Neurology*. 2012;78:114-121.

Roy AK, Slimack NP, Ganju A. Idiopathic syringomyelia: retrospective case series, comprehensive review, and update on management. *Neurosurg Focus*. 2011;31:E15.

Ruano L, Melo C, Silva MC, Coutinho P. The global epidemiology of hereditary ataxia and spastic paraplegia: a systematic review of prevalence studies. *Neuroepidemiology*. 2014;42:174-183.

Satran R. Spinal cord infarction. *Stroke*. 1988;19:529-532.

Scotti G, Gerevini S. Diagnosis and differential diagnosis of acute transverse myelopathy. The role of neuroradiological investigations and review of the literature. *Neurol Sci*. 2001;22 suppl:S69-S73.

Transverse Myelitis Consortium Working Group. Proposed diagnostic criteria and nosology of acute transverse myelitis. *Neurology*. 2002;59:499-505.

Vandertop WP. Syringomyelia. *Neuropediatrics*. 2014;45:3-9.

West TW, Hess C, Cree BAC. Acute transverse myelitis: demyelinating, inflammatory, and infectious myelopathies. *Semin Neurol*. 2012;32:97-113.

Wong SH, Boggild M, Enevoldson TP, Fletcher NA. Myelopathy but normal MRI: where next? *Pract Neurol*. 2008;8:90-102.

Zalewski NL, Rabinstein AA, Krecke KN, et al. Characteristics of spontaneous spinal cord infarction and proposed diagnostic criteria. *JAMA Neurol*. 2019;76(1):56-63.

Autonomic Failure, Autonomic Neuropathy, and Orthostatic Intolerance 116

Louis H. Weimer

KEY POINTS

1. Autonomic manifestations are common in neurologic disease but are lesser concerns in many cases.
2. Diabetes is the most common cause of autonomic neuropathy.
3. Orthostatic intolerance/postural orthostatic tachycardia syndrome is the most common cause of autonomic symptoms and autonomic center visits.
4. Many causes of severe autonomic failure and hereditary neuropathy are known but most are quite rare.
5. Parkinson disease, pure autonomic failure, and multiple system atrophy are the most important degenerative causes of autonomic failure.

INTRODUCTION

Autonomic disorders are generally considered to be uncommon conditions, but in fact, autonomic dysfunction is ubiquitous in neurologic disease, including highly prevalent processes such as seizures, strokes, mass lesions, infections, multiple sclerosis plaques, and others, but dysautonomia is often a secondary concern. A limited number of disorders produce severe or isolated dysautonomia or autonomic failure (AF). Figure 116.1 displays a representation of the most prominent or most important causes. The conditions span all anatomic and most pathologic neurologic domains. Because autonomic systems affect virtually all organ systems, symptoms produced are multiple and varied, often affecting functions not considered by most neurologists. Problems can arise from any site of autonomic control including the central cortical and subcortical autonomic network, brainstem, spinal cord, autonomic ganglia, or peripheral autonomic nerves. The range of pathogenic mechanisms is highly varied, including degenerative, hereditary, immune-mediated, paraneoplastic, aberrant reflex, and metabolic, among others. Suspicion of autonomic dysfunction rests with the clinician and can be missed if symptoms that can appear to be nonspecific are considered in isolation (Table 116.1). Early symptoms of the most characteristic finding, orthostatic hypotension (OH), may appear as postural fatigue, cognitive change, anxiety, or vertigo. This lack of certainty in many cases makes more objective assessment desirable in these instances (see Chapter 28).

EPIDEMIOLOGY

Postural hypotension (OH) is a prevalent clinical sign seen in numerous and diverse neurologic and nonneurologic conditions. Shibao et al estimated over 80,000 U.S. OH-related hospitalizations in 2004; OH was the primary diagnosis in 35%. One consensus agreement defines OH as a fall in systolic blood pressure (BP) of 20 or 10 mm Hg diastolic within 3 minutes of standing or similar orthostatic challenge, such as upright tilt, although some require a 30 mm Hg decline. OH, however, may be asymptomatic, especially in the elderly, and varies according to underlying conditions or confounding factors (Table 116.2). The sign is one marker of advanced AF caused by either diseases of central autonomic pathways or autonomic neuropathy. Some severe and important causes are discussed; a more comprehensive list is provided in Table 116.3. Acute and subacute processes are generally considered separately from more chronic conditions.

ACUTE AND SUBACUTE AUTONOMIC DISORDERS

Acute or subacute autoimmune autonomic neuropathy (AAN) or acute pandysautonomia is an unusual but distinct entity, which primarily affects peripheral autonomic nerves. Roughly, half are preceded by a viral prodrome similar to Guillain-Barré syndrome. Patients typically develop generalized AF including OH, anhidrosis, parasympathetic failure, and gastrointestinal dysfunction, although predominantly adrenergic and cholinergic variants are seen. The illness is monophasic with acute or subacute onset over several weeks. Recovery generally occurs but is often slow and incomplete. Acute signs such as ileus may develop into lesser degrees of gastrointestinal dysmotility including bloating, early satiety, nausea, vomiting, and alternating diarrhea and constipation. Antecedent viruses include herpes simplex, mononucleosis, rubella, and nondescript febrile illnesses. Roughly 25% have a restricted cholinergic form (acute cholinergic neuropathy)

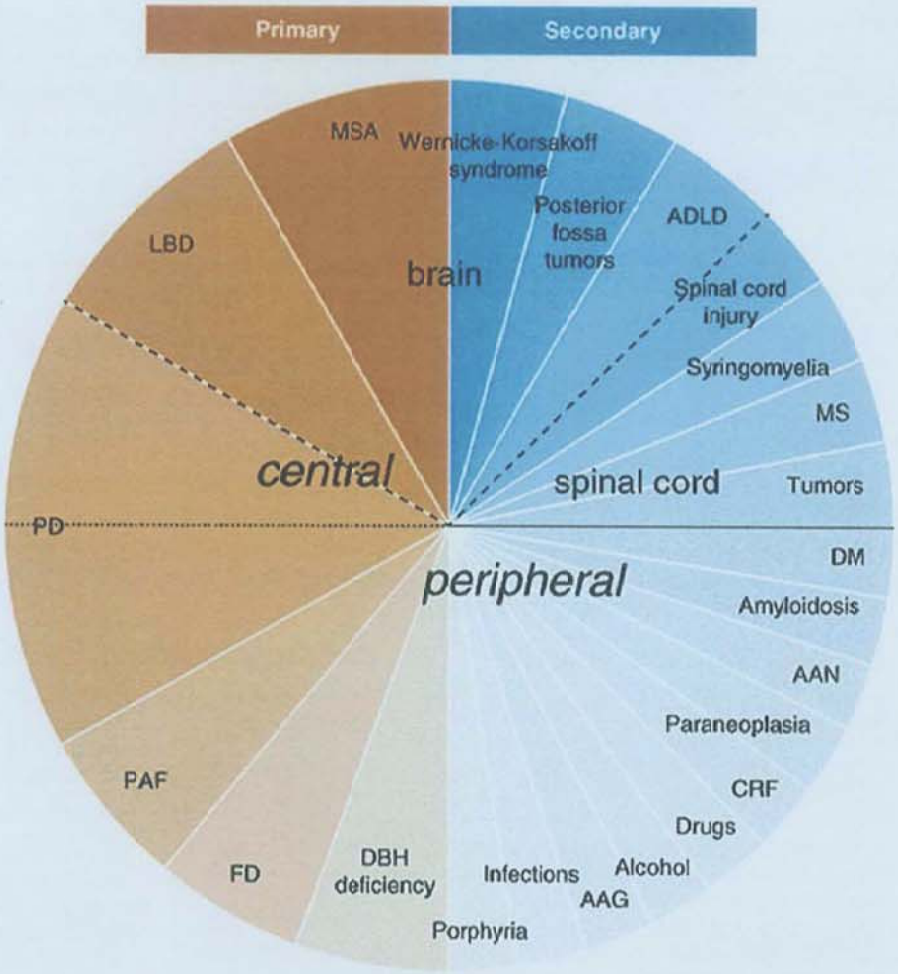

FIGURE 116.1 Schematic representation of neurogenic orthostatic hypotension causes based on disease localization. Abbreviations: AAG, autoimmune autonomic ganglionopathy; AAN, autoimmune autonomic neuropathy; ADLD, autosomal dominant leukodystrophy; CRF, chronic renal failure; DBH, dopamine-β-hydroxylase; DM, diabetes mellitus; FD, familial dysautonomia (hereditary sensory and autonomic neuropathy type III, Riley-Day syndrome); LBD, Lewy body dementia; MS, multiple sclerosis; MSA, multiple system atrophy; PAF, pure autonomic failure; PD, Parkinson disease. (From Eschlböck S, Wenning G, Fanciulli A. Evidence-based treatment of neurogenic orthostatic hypotension and related symptoms. *J Neural Transm [Vienna]*. 2017;124:1567-1605.)

TABLE 116.1 Autonomic Review of Symptoms

• Secretomotor: dry eyes and mouth, often required natural tears or frequent sips of water. Excessive saliva can also occur.
• Orthostatic: dizziness, weakness, fatigue, cognitive changes, visual disturbance, vertigo, anxiety, palpitations, pallor, nausea, syncope
• Postprandial: bloating, fullness, nausea, dizziness, sweating, orthostatic hypotension
• GI: constipation, nocturnal or intermittent diarrhea
• GU: urinary retention, difficulty with initiation, incomplete emptying, incontinence
• Sexual: erectile failure, ejaculatory dysfunction, retrograde ejaculation into bladder
• Visual: blurred vision, sensitivity to light/glare, reduced night vision
• Sudomotor: reduced loss of sweating ability (distally in polyneuropathies); excessive, paroxysmal, or inappropriate sweating; mixed pattern of loss and excessive areas, heat intolerance
• Vasomotor: distal color changes, change in skin appearance, persistently cold extremities, Raynaud phenomenon, loss of skin wrinkling in water, heat intolerance
• Other: unexplained syncope

Abbreviations: GI, gastrointestinal; GU, genitourinary.

TABLE 116.2 Factors Affecting Orthostatic Hypotension

Aggravating Factors
• Warm environment, hot bath
• Postexercise
• Prolonged motionless standing
• Large meals (carbohydrate load)
• Early morning
• Valsalva maneuver, isometric exercise
• Standing after squatting
• Volume depletion
• Rising after prolonged bed rest
• Rapid postural change
• Space flight
• Alcohol
• Medications
Beneficial Maneuvers
• Squatting, leg crossing
• Abdominal and leg compression
• Nighttime slight upright tilt
• Isotonic exercise

TABLE 116.3 Selected Disorders of Autonomic Function

Isolated Degenerative Autonomic
PAF, "Bradbury-Eggleston syndrome"
Multisystem Degenerative Disorders
MSA
Parkinson disease with autonomic failure
Central
Brain tumors (posterior fossa, third ventricle, hypothalamus), syringobulbia, MS, tetanus, Wernicke-Korsakoff syndrome, fatal familial insomnia
Spinal Cord
MS, syringomyelia, transverse myelitis, trauma, mass lesion
Peripheral
Immune mediated
Guillain-Barré syndrome (see Chapter 91), acute and subacute autonomic neuropathy, acute cholinergic neuropathy, Sjögren disease, SLE, rheumatoid arthritis, Holmes-Adie syndrome, Ross syndrome, Harlequin syndrome, acute anhidrosis
Metabolic
Diabetes, vitamin B_{12} and thiamine deficiency, uremia
Paraneoplastic
Paraneoplastic autonomic neuropathy and paraneoplastic syndromes with autonomic neuropathy (ANNA-1, α3-AchR ganglionic, CRMP5, PCA-2 antibodies), enteric neuropathy, Lambert-Eaton myasthenic syndrome (cholinergic)
Infectious
Chagas disease (cholinergic), syphilis, leprosy, HIV, Lyme disease, diphtheria
Hereditary
Familial amyloidosis, hereditary sensory and autonomic neuropathies (see Chapter 92), dopamine β-hydroxylase deficiency, porphyria, Fabry disease, norepinephrine transporter deficiency, fragile X premutation–associated tremor/ataxia syndrome, CANVAS syndrome, Hirschsprung megacolon, Ehlers-Danlos type III, myopathy, external ophthalmoplegia, neuropathy, gastrointestinal encephalopathy (MNGIE), Machado-Joseph disease, prion-induced diarrhea, and autonomic neuropathy
Toxins and Medications
Botulism, vincristine, cisplatin, taxoids, amiodarone, pyriminil (Vacor), hexacarbon, carbon disulfide, heavy metals, podophyllin, alcohol, PD-1 inhibitors
Drug and Medication Effects
Anticholinergics: tricyclic antidepressants, atropine, oxybutynin
β-Adrenergic blockers: propranolol and others
α_2-Agonists: clonidine, prazosin, α-methyl dopa, terazosin, doxazosin
α_1-Antagonists: phentolamine, phenoxybenzamine, guanabenz
Ganglionic blockers: guanethidine, hexamethonium, mecamylamine
Others: hydralazine, nitrates, diuretics, calcium channel blockers, ACE inhibitors, antihistamines, antipsychotics, Sinemet, narcotics, sildenafil, tadalafil
Reduced orthostatic tolerance
Neurocardiogenic syncope, POTS, mitral valve prolapse syndrome, prolonged bed rest or weightlessness, Chiari malformation
Others
Acquired amyloidosis, chronic idiopathic autonomic neuropathies, small-fiber neuropathy, idiopathic hyperhidrosis, idiopathic anhidrosis, Horner syndrome

Abbreviations: ACE, angiotensin-converting enzyme; AchR, acetylcholine receptor; ANNA-1, type 1 antineuronal nuclear antibodies; CANVAS, cerebellar ataxia, neuropathy, vestibular areflexia syndrome; CRMP5, collapsin response mediator protein 5; HIV, human immunodeficiency virus; MNGIE, mitochondrial neurogastrointestinal encephalomyopathy; MS, multiple sclerosis; MSA, multiple system atrophy; PAF, pure autonomic failure; PCA-2, Purkinje cell cytoplasmic antibody type 2; PD-1, programmed cell death protein 1; POTS, postural orthostatic tachycardia syndrome; SLE, systemic lupus erythematosus.

characterized by dry eyes and mouth, gastrointestinal dysmotility, bladder dysfunction, hypohidrosis, unreactive pupils, fixed heart rate, and sexual dysfunction but without significant OH. Abnormalities on formal autonomic testing are prominent in the involved systems. Nerve conduction studies are typically normal or show minor sensory abnormalities. The lack of OH in cholinergic cases complicates the diagnosis.

Demonstration of high-titer antibodies to nicotinic ganglionic acetylcholine receptor (AChR) α-3 subunits, which are similar but distinct from those at the neuromuscular junction (α-1 subunits), supports an immune-mediated basis. A paraneoplastic form, which develops in a similar time course and is indistinguishable on clinical or laboratory grounds, may appear prior to tumor discovery, most commonly thymoma. In screening patients with autonomic disorders and controls, Vernino et al found that 41% of patients with idiopathic autonomic neuropathy had high antibody titers; paraneoplastic neuropathy patients were frequently positive as well. Rarely, patients with chronic OH and AF have high antibody titers and respond to immunotherapy, such as intravenous immunoglobulin or plasma exchange. Some patients with orthostatic intolerance, discussed later, and idiopathic gastrointestinal dysmotility, but none with chronic degenerative autonomic processes, also had positive assays at lower titers. Knockout mouse models of the α-3 subunit gene, rabbits immunized against the subunit, and passive antibody transfer to other animals all induce signs of AF supporting the assertion that the antibodies are causative. Antibody titers also correlate with disease severity. Of note, low-level titers may occur in patients with other disorders or nonspecific symptoms. One-third of AAN patients recover, one-third have a partial recovery with substantial deficits, and the remainder do not improve. Gastrointestinal dysfunction and OH are usually the most debilitating manifestations. Supportive care and management of the OH and system-specific problems are the mainstays of treatment. Rare cases with AAN and myasthenia gravis have both types of AChR antibodies. Autonomic involvement is common in typical Guillain-Barré syndrome, discussed in Chapter 91, especially in more severe cases, and is a prominent cause of morbidity and mortality.

Paraneoplastic Autonomic Neuropathy

Subacute autonomic neuropathy or predominantly enteric neuropathy is also seen in isolation or with somatic sensory neuropathy and other underlying antibodies, especially type 1 antineuronal nuclear antibodies (ANNA-1; anti-Hu) usually in patients with small cell lung cancer. Paraneoplastic neuropathy is also associated with other paraneoplastic antibodies including

Purkinje cell cytoplasmic antibody type 2 (PCA-2) and collapsin response mediator protein-5. Botulism (cholinergic), acute intermittent porphyria, and toxic neuropathy are other diagnostic considerations. A rare chronic form associated with high titers to ganglionic antibodies is known that can mimic degenerative AF. Autonomic manifestations are also common in patients with Lambert-Eaton myasthenic syndrome, especially cholinergic complaints and manifestations (see Chapter 93).

Orthostatic Intolerance

Exaggerated orthostatic tachycardia may be evident in some cases without significant cardiac denervation. This led to the proposal that some patients with the common syndrome of idiopathic orthostatic intolerance without OH (postural orthostatic tachycardia syndrome), also known as *orthostatic intolerance*, may have an attenuated form of acute autonomic neuropathy. This syndrome without or without neuropathic signs is extremely common and increasingly appreciated. Orthostatic intolerance symptoms include postural light-headedness, fatigue, cognitive changes, and presyncope despite minimal changes in BP. Potential mechanisms are multiple, including excessive venous pooling, idiopathic hypovolemia, and adrenergic hypersensitivity. A minority have signs of autonomic neuropathy supported by abnormalities of sudomotor and other autonomic systems in one-third of cases and an overrepresentation of antecedent viral infection in these patients. However, the majority of cases are idiopathic. The common physiologic thread is presumed bouts of cerebral hypoperfusion, despite a seemingly adequate systemic BP, but BP is often in the low range of normal. This syndrome is the most common cause of consultation in most autonomic centers—the prevalence is estimated to be from 1 to 4 million cases in the United States. The condition is much more common in women, roughly 5:1 and commonly initially develops between ages 15 and 25 years, often after an acute illness, such as a viral syndrome. Other cases are lifelong often starting in early teen years. Postural orthostatic tachycardia syndrome/orthostatic intolerance is not associated with mortality, but sharply reduced quality life scores and increased suicide rates are reported. An association with joint hypermobility and presumed or documented Ehlers-Danlos syndrome type III is recognized. Patients with grade I Chiari malformations also typically have multiple autonomic symptoms, including orthostatic intolerance. Roughly, 40% of patients have additional vasovagal syncopal episodes. The condition must be distinguished from depression, vestibular disorders, chronic fatigue, fibromyalgia, and panic disorders but many overlap cases exist; many patients have coincident chronic and not postural fatigue, insomnia, and chronic pain. Uncommon symptomatic causes must be considered, such as adrenal insufficiency, pheochromocytoma, celiac disease, and Sjögren syndrome. Elimination of cardiac causes is also critical, notably supraventricular tachycardia. Mast cell activation disorder is a common association. The syndrome often leads to secondary deconditioning, which complicates recovery. An indistinguishable hereditary form resulting from a mutation in a norepinephrine transporter gene is known but is exceedingly rare. Similar symptoms can be seen in patients with predominantly painful small fiber neuropathy due to additional involvement of distal autonomic nerves. Treatment must be individualized based on the most prominent symptoms but is generally based on improving standing BP, increasing blood volume, minimizing anemia, and increasing activity levels. Some exercise regimens are promoted but nonupright exercise is typically best tolerated. Increased water and increased dietary salt or salt supplements are typically initially tried. If insufficient, BP raising measures can improve function; however, hypertension should be avoided. Medication options include fludrocortisone, 0.05 to 0.2 mg/d; midodrine 2.5 to 10 mg 3 times a day but not after 6 PM; and pyridostigmine, 30 to 60 mg 3 times a day. However, none of these treatments has been rigorously studied. Caffeine and stimulations help a minority, but many patients are highly intolerant to agents that increase heart rate. Beta blockade is helpful in patients with bothersome palpitations and hyperadrenergic forms but is counterproductive in other subtypes. Recovery is often very slow and incomplete. Immune-mediated treatment for this multifactorial syndrome remains controversial.

CHRONIC NEUROGENIC ORTHOSTATIC HYPOTENSION AND AUTONOMIC NEUROPATHY

Parkinsonian Syndromes and Pure Autonomic Failure

Marked AF in patients with multiple system atrophy (MSA), especially the former Shy-Drager syndrome, is frequent. Other autonomic symptoms often predate OH, including impotence, decreased sweating, and urinary incontinence. MSA is a group of disorders with overlapping neuropathology and may have autonomic, parkinsonian, or cerebellar symptoms at onset or later, as discussed in Chapter 87. Other common manifestations include sleep apnea, incontinence, impotence, dystonia, inspiratory stridor, hoarseness, lack of rest tremor, and ineffective or transient L-dopa response. Virtually all MSA patients eventually show autonomic signs or symptoms, regardless of initial manifestations. Demonstration of argyrophilic glial cytoplasmic inclusions in oligodendroglia is a characteristic but not a pathognomonic MSA hallmark. Glial cytoplasmic inclusions are prominent in sites of central autonomic control and correlate better with clinical findings than do areas of neuronal loss. Consensus diagnostic criteria first published in 1996 were simplified and refined in 2008. Increased risk of MSA has been found in families and some sporadic cases from various mutations in the gene COQ2, which is essential for the biosynthesis of coenzyme Q10. Median survival from symptom onset is approximately 10 years based on the most recent natural history studies; parkinsonism at onset and incomplete bladder emptying were the most predictive factors for faster progression.

Many patients with idiopathic Parkinson disease (IPD) also have autonomically mediated complaints, most commonly constipation and urinary dysfunction, but measurable OH is often asymptomatic. However, the prevalence of autonomic symptoms in IPD patients is well recognized. Exacerbation or inducement of OH from medications such as L-dopa is recognized and variably clinically significant.

Some patients with otherwise typical IPD have more severe AF including symptomatic OH and are designated Parkinson disease with AF. A separate disorder known as *pure autonomic failure* (PAF) or idiopathic OH, first described by Bradbury and Eggleston in 1925, is a profound, slowly progressive disorder with disabling OH, usually starting after age 50 years. By definition, no other neurologic impairment is seen, and the ultimate

diagnosis is often delayed 3 to 5 years to ensure that MSA or parkinsonism does not emerge. Autopsies show a similar pattern of classic Lewy bodies in peripheral autonomic and enteric ganglia in both Parkinson disease with AF and PAF. Similarities between these Lewy body disorders are further supported by cardiac fluorodopamine positron emission tomography studies demonstrating loss of cardiac sympathetic innervation in both conditions but not in MSA patients. The shared neurodegenerative mechanisms between IPD, diffuse Lewy body dementia, and PAF is recognized.

Dopamine β-hydroxylase deficiency is a very rare but treatable entity with severe OH, syncope, and nearly undetectable norepinephrine and epinephrine leading to a failure of BP maintenance while standing. The norepinephrine precursor (droxidopa), is beneficial for these patients and in patients with other forms of AF, was U.S. Food and Drug Administration (FDA)-approved in 2014, commonly titrated to a target dose of 100 to 600 mg three times a day.

Cerebellar ataxia, neuropathy, and vestibular areflexia syndrome is a recognized neurodegenerative ganglionopathy that commonly includes OH; in one series, 83% had evidence of autonomic dysfunction.

Numerous other common and uncommon disorders affecting the brain and spinal cord affect autonomic function but less commonly cause symptomatic OH (see **Table 116.3**). Additionally, some processes may be pathway- or organ-specific such as predominantly cholinergic, adrenergic, regional, or organ-specific disorders. Anhidrosis or hypohidrosis occurs with a variety of process, notably in length-dependent neuropathy. Regional and segmental hypohidrosis can occur; when associated with Adie pupils and hyporeflexia, the condition is known as *Ross syndrome*; some cases occur following viral infection and are presumed to be immune-mediated. Acute or subacute generalized anhidrosis also occurs. Patients, however, more commonly note increased sweating. Compensatory proximal sweating is common in patients with large areas of reduced sweating from any cause. Essential hyperhidrosis is diffuse tendency for excessive sweating and is often hereditary. Treatments directed at reducing sweating include traumatizing sweat glands with water iontophoresis, chemodenervation, or strong antiperspirants; simple anticholinergic medications are typically ineffective at tolerable dosage. Surgical endoscopic sympathectomy is an option for severe cases.

Chronic Autonomic Neuropathies

Many of the scores of different peripheral neuropathies induce autonomic dysfunction, often limited to distal sweating and vasomotor control, especially those disproportionately affecting small-diameter fibers. The consequence is dry, cool distal extremities common in many neuropathy patients. Dysfunction is generally insufficient to impair peripheral vasoconstriction or postural reflexes enough to produce symptomatic OH. A few entities, however, lead to severe or targeted autonomic dysfunction, which can produce frank AF and symptomatic OH. Particularly noteworthy causes include diabetes; familial and acquired amyloidosis; paraneoplastic neuropathies; and selected hereditary, infectious, and toxic neuropathies. Some of the more prominent examples are listed in **Table 116.3**.

Diabetic autonomic neuropathy (DAN) is the most common and important cause of autonomic neuropathy and the most extensively examined. Somatic peripheral neuropathy is usually concurrent. Much attention has focused on the impact of diabetic autonomic dysfunction on long-term survival. Ewing et al found 56% of 73 patients with DAN died within 5 years, many owing to nonautonomic complications such as renal failure. Later studies showed an increased but less ominous DAN mortality rate in diabetics without other initial complications (23% at 8 y) compared with diabetics without DAN and similar disease duration (3% at 8 y). The added autonomic dysfunction risk is independent of coronary perfusion deficits. Upper gastrointestinal dysmotility, bladder complaints, impotence, sudomotor loss, constipation, episodic diarrhea, and gustatory sweating are a few common manifestations that aid in diagnosis and may require symptomatic treatment.

Amyloidosis, including both hereditary and acquired forms, is another important consideration in patients with severe AF. Acquired forms are typically neoplastic and treated primarily by oncologists by chemotherapy and often bone marrow and stem cell transplantation. Hereditary forms are typically discovered by cardiologists or neurologists. Certain mutations in transthyretin are associated with more severe autonomic neuropathy than other mutations; approximately 130 different mutations are known. Some forms commonly cause neuropathy, whereas others rarely do; the Val30Met or common mutation is particularly significant. Patisiran, an RNA interfering molecule, and inotersen, an antisense oligonucleotide, are highly effective treatments now approved by the FDA for treatment of hereditary familial amyloid polyneuropathy. Tafamidis was approved in 2019 for familial amyloid cardiomyopathy but may help autonomic aspects as well. Other treatments remain in the pipeline. Patisiran was shown to significantly improve autonomic symptoms compared to placebo at the 18-month APOLLO trial assessment. Notably, treated patients showed stable or improved autonomic symptoms, whereas placebo patients notably declined.

Immune-mediated and paraneoplastic neuropathy are potentially treatable and often begin subacutely. A chronic form is also seen in isolation or in association with other autoimmune disorders, notably Sjögren disease. A notable report in 2005 complicated diagnosis by demonstrating a patient with presumed, very long-standing, stable AF, who demonstrated high AChR ganglionic antibodies, typically reserved for acute and subacute neuropathy, and responded markedly and repeatedly to recurrent intravenous immunoglobulin infusions.

Idiopathic painful, small-fiber neuropathy often affects distal autonomic function but rarely causes symptomatic OH or symptomatic AF. Other forms of autonomic neuropathy are listed in **Table 116.3**.

DIAGNOSIS AND MANAGEMENT OF AUTONOMIC DISORDERS

Nonautonomic conditions can cause OH and mimic AF; most important are adrenal failure and pheochromocytoma. Asymptomatic OH is a prevalent sign in the elderly, and causes are often multifactorial. Formal laboratory evaluation of autonomic disorders is discussed in Chapter 28.

Treatment of AF is directed at symptomatic relief, reduced syncope and fall risk, and improved quality of life, especially for generally the most disabling symptom—OH. Numerous pharmacologic and nonpharmacologic interventions are available

to lessen OH and improve orthostatic tolerance. Asymptomatic hypotension on standing usually requires no treatment; reasonable precautions and avoidance of precipitating factors may be adequate. An exercise reflex, which immediately but transiently lowers BP on standing may become symptomatic requiring standing slowly and in stages. However, lesser indicators of hypoperfusion such as postural "coat hanger" pattern shoulder fatigue and headache (local muscle ischemia), pure postural vertigo, postprandial fatigue, and cognitive slowing are possible indicators of OH. Supplemental water and salt intake (0.5-2 g/d) have been independently shown to be beneficial and lessen the need for medications. Raising the head of the bed 4 inches stimulates baroreceptors and decreases nocturnal diuresis. Useful postural and physical measures to attempt and others to avoid are listed in **Table 116.2**. Cumbersome compressive garments with abdominal compression are mildly effective in reducing venous pooling but are problematic for many with neurologic disorders; abdominal binders alone may help to a lesser degree. Small, frequent meals low in carbohydrates lessen postprandial hypotension. Reevaluation of the need for prescribed BP lowering and autonomically active agents should be considered. However, the evidence-based proof supporting these nonmedication efforts is weak.

If these measures are insufficient, first-line medications include fludrocortisone (starting at 0.1 mg/d) or the α-adrenergic agonist midodrine or both. Midodrine is shorter acting, and the dosage must cover vulnerable periods, especially early morning, and is not given after 6 PM; generally 2.5 to 10 mg doses 3 times a day. Droxidopa was FDA approved in 2014 and may become an additional treatment option commonly titrated to a target dose of 100 to 600 mg 3 times a day. Excessive fluid retention and heart failure are concerns, especially in the elderly. Relative anemia exacerbates OH. Pyridostigmine, which enhances autonomic ganglionic neural transmission, increases standing greater than supine BP and is a common off-label option, especially in patients with supine hypertension, which is a perennial and unresolved controversial concern with fludrocortisone, midodrine, and droxidopa. Typically, 30 or 60 mg doses are given every 6 to 8 hours. Clinical judgment is required to balance the need for adequate standing and reasonable supine pressures; this balance is challenging in severe cases. Second-line agents are numerous and are sometimes effective if earlier agents have failed. Concomitant treatment of urinary dysfunction, gastric and intestinal dysmotility, impotence, and secretomotor dysfunction is often necessary. In MSA, inspiratory stridor may lead to tracheostomy, and nocturnal positive pressure ventilation may be needed for sleep apnea.

Eschlböck and colleagues preformed an evidence-based review of neurogenic orthostatic and postprandial hypotension treatments based on the Grading of Recommendations Assessment, Development, and Evaluation methodology. Fluids, maneuvers, compression treatments, and medications were considered based on all available published studies. Efficacy, side effects, and safety are included in the recommendation that makes some conclusions controversial. The level of evidence was strong and recommendation high for midodrine. Evidence is moderate for droxidopa but recommendation was strong. These two agents are currently the only ones FDA approved to treat neurogenic OH. Partly because no dedicated modern studies are available, the evidence was weak and resultant recommendation was low for fludrocortisone. The strongest evidence for a nonmedication was for an abdominal binder.

Exacerbating factors are important considerations for both patient and physician to take appropriate precautions or avoid certain situations (see **Table 116.2**). Patients with delayed OH (3-15 min after standing) or situational triggers must anticipate potential problems. Patients with chronic, symptomatic OH may learn to recognize these conditions but often need physician instruction. Chronic OH also results in optimized cerebral autoregulation and relative tolerance of low BP but provides a narrow window between an asymptomatic state and syncope.

HEREDITARY SENSORY AND AUTONOMIC NEUROPATHY AND FAMILIAL DYSAUTONOMIA

The onset of some autonomic disorders occurs much earlier than those already discussed, including some congenital and infantile hereditary conditions. The most common and important entities are discussed.

Familial Dysautonomia (Riley-Day Syndrome)

Hereditary sensory and autonomic neuropathy type III, also known as *familial dysautonomia* (FD) and was first described by Riley et al in 1949, is a rare autosomal recessive disease with complete penetrance but variable expression. Virtually all patients are of eastern European (Ashkenazi) Jewish descent. The carrier rate may be as high as 1 in 25, and the disease prevalence was 1 in 4,100 live births. However, following the availability of genetic testing, subsequent to the gene discovery in 2001, the incidence sharply dropped. In 2009, only five new FD cases were diagnosed worldwide. There is no sex predilection in either affected individuals or carriers. The condition affects the survival and development of sensory, sympathetic, and some parasympathetic neurons. Autonomic symptoms are prominent, and general somatic growth is affected.

The causative gene is ELP1 (elongator complex protein 1), previously named IKBKAP (I kappa B kinase complex–associated protein). Two mutations in the ELP1 gene are implicated. The major FD mutation is a splice defect that displays tissue-specific expression and causes aberrant mRNA splicing. The second more infrequent mutation is a missense mutation. The end result is a nonfunctional protein and a congenital sensory and autonomic neuropathy. Specific assay for mutations of IKBKAP/ELP1 have facilitated carrier screening for FD in the Ashkenazi Jewish population. Prenatal diagnosis is available, and preimplantation genetic diagnosis is also available for at-risk couples.

The condition can be identified in the neonatal period; clinical manifestations tend to increase with age. FD is currently classified as hereditary sensory and autonomic neuropathy type III.

Clinical Manifestations

Neurologic abnormalities detected in the neonatal period include decreased muscle tone, diminished or absent deep tendon reflexes, absent corneal responses, reduced Moro reflex, and weak cry and suck. The tongue tip lacks fungiform papillae and appears smooth. Uncoordinated swallowing with resultant regurgitation may cause aspiration and pneumonia. Some infants require tube feeding, gastrostomy, and fundoplication because of gastroesophageal reflux. Absence of overflow tears, which can

be normal for the first 3 months, persists and becomes a consistent feature. Corneal ulceration can occur.

During the first 3 years of life, affected children show delayed physical and developmental milestones, episodic vomiting, excessive sweating, excessive drooling, blotchy erythema, and breath-holding spells. Up to one-third of patients have seizures during early life, usually associated with fever or hypoxia. Less than 10% of patients have subsequent epilepsy. Dysautonomic crises occur usually after age 3 years characterized by irritability, self-mutilation, negativistic behavior, diaphoresis, tachycardia, hypertension, and thermal instability; however, episodes share many characteristics of autonomic seizures and typically respond to anticonvulsants. Episodic vomiting is frequent and can be cyclic, requiring hospitalization for stabilization with parenteral hydration and sedation.

School-aged patients tend to have short stature, awkward gait, and nasal speech. School performance may be poor, frequently 20 or more intelligence points below unaffected siblings. Scoliosis is frequent. Adults older than age 20 years often have spinal deformity. Vomiting and dysautonomic crises tend to decrease during adolescence when more frequent symptoms center on decreased exercise tolerance, poor general coordination, emotional difficulties, and postural hypotension. Vasovagal syncope may occur randomly, after micturition, or during laryngeal intubation for anesthesia.

There is a high incidence of sudden death, syncope, electrocardiographic abnormalities including asystole, bradycardia, atrioventricular block, and prolonged QT interval. Pacemaker placement to protect FD patients has not been found to be protective against fatal bradyarrhythmias but may decrease syncope incidence.

Diagnosis

The diagnosis should be suspected because of the specific clinical symptoms and findings and the familial Ashkenazi Jewish background. The FD gene test provides definitive confirmation. DNA diagnoses and genetic screening of the Ashkenazi Jewish population is available. If both parents are carriers, prenatal diagnosis can be done by chorionic villus sampling (10th-11th gestational week) or by amniocentesis (14th-17th gestational week). Preimplantation diagnosis is available for at-risk couples who would not consider pregnancy termination.

The intradermal histamine phosphate test can provide additional diagnostic confirmation. An intradermal injection of 1:1,000 histamine phosphate (0.03-0.05 mL) normally produces pain and erythema. A central wheel forms within minutes and is surrounded by an axon flare that is a zone of erythema measuring 2 to 6 cm in diameter. The flare lasts for several minutes. In dysautonomic patients, the pain is greatly reduced and there is no axon flare. In infants, a saline solution of 1:10,000 histamine should be substituted.

Biochemical and Pathologic Data

The protein product is part of a six-protein elongator complex, termed *IKAP*. The mutation decreases IKAP protein production, and treatments that increase the level of the full-length IKBKAP transcript are likely to have therapeutic value. Plasma levels of both norepinephrine and dopamine are markedly elevated during dysautonomic crises.

Pathologic data reveal hypoplastic cervical sympathetic ganglia with diminished volume and neuronal counts. Sympathetic preganglionic spinal cord neurons seem reduced in number and size. Patients are deficient in nonmyelinated and small-fiber neurons. Lingual submucosal neurons and sensory axons are reduced. Taste buds are scant; circumvallate papillae are hypoplastic.

Treatment

Preventative treatment and supportive therapies include maintaining eye moisture to control absence of tearing, fundoplication with gastrostomy to control vomiting and reflux, and the use of benzodiazepine and clonidine for dysautonomic crises.

The use of epidural or deep conscious sedation forms of anesthesia have been advocated for surgical procedures to avoid intubation and the sometimes fatal complications of general anesthesia.

OH is treated similarly to adult forms. Symptomatic treatment is indicated for dysautonomic crises with parenteral fluids, diazepam, sedation, and antiemetic therapy. Growth hormone treatment in selected patients with FD may have the potential to increase growth.

Tocotrienols may elevate IKBKAP gene expression and cause increased functional cellular levels of IKAP protein and increased levels of monoamine oxidase A in cells and tissues. Phosphatidylserine, a food supplement, and pridopidine elevate IKAP levels in cells generated from FD patients and may have therapeutic value. Other agents that correct the splicing defect are under investigation to increase functional protein levels. Postnatal correction of the splicing defect in an FD mouse model, using a small molecule kinetin, improved mouse proprioceptive function.

Outcome

Long-term survival is documented; more than 40% of surviving patients are older than 20 years. Some women with FD have had pregnancies and delivered normal infants. Infant and childhood fatalities may be a result of aspiration pneumonia, gastric hemorrhage, or dehydration. A second cluster of fatalities between the ages of 14 and 24 years has been secondary to pulmonary complications, sleep deaths, and cardiopulmonary arrests. The few oldest patients are now in their fifth and sixth decades.

Other Hereditary Autonomic Disorders

A novel prion disease associated with diarrhea and hereditary sensory and autonomic neuropathy associated with a defect in the PRNP gene was described late in 2013. Other types of hereditary sensory and autonomic neuropathy or often simply hereditary sensory neuropathy typically cause more severe sensory ganglionopathy or sensory neuropathy and are often considered as a separate congenital category.

ACKNOWLEDGMENT

The author acknowledges Dr. Alan M. Aron for contributions to an earlier version of the hereditary autonomic disorder section of this chapter.

SUGGESTED READINGS

Acute and Subacute Autonomic Neuropathy

Arnold AC, Ng J, Raj SR. Postural tachycardia syndrome—diagnosis, physiology, and prognosis. *Auton Neurosci*. 2018;215:3-11.

Candessanché JP, Antoine JC, Honnorat J, et al. Paraneoplastic peripheral neuropathy associated with anti-Hu antibodies. A clinical and electrophysiological study of 20 patients. *Brain*. 2002;125(pt 1):166-175.

Etienne M, Weimer LH. Immune-mediated autonomic neuropathies. *Curr Neurol Neurosci Rep*. 2006;6(1):57-64.

Gibbons CH, Vernino SA, Freeman R. Combined immunomodulatory therapy in autoimmune autonomic ganglionopathy. *Arch Neurol*. 2008;65:213-217.

Koike H, Atsuta N, Adachi H, et al. Clinicopathological features of acute autonomic and sensory neuropathy. *Brain*. 2010;133:2881-2896.

Lei LY, Chew DS, Sheldon RS, Raj SR. Evaluating and managing postural tachycardia syndrome. *Cleve Clin J Med*. 2019;86(5):333-344.

Lennon VA, Ermilov LG, Szurszewski JH, Vernino S. Immunization with neuronal nicotinic acetylcholine receptor induces neurological autoimmune disease. *J Clin Invest*. 2003;111:907-13.

Sandroni P, Vernino S, Klein CM, et al. Idiopathic autonomic neuropathy: comparison of cases seropositive and seronegative for ganglionic acetylcholine receptor antibody. *Arch Neurol*. 2004;61:44-48.

Shannon JR, Flattem NL, Jordan J, et al. Orthostatic intolerance and tachycardia associated with norepinephrine-transporter deficiency. *N Engl J Med*. 2000;342:541-549.

Suarez GA, Fealey RD, Camilleri M, Low PA. Idiopathic autonomic neuropathy: clinical, neurophysiologic, and follow-up studies on 27 patients. *Neurology*. 1994;44:1675-1682.

Vernino S, Low PA, Fealey RD, Stewart JD, Farrugia G, Lennon VA. Autoantibodies to ganglionic acetylcholine receptors in autoimmune autonomic neuropathies. *N Engl J Med*. 2000;343:847-855.

Wallman D, Weinberg J, Hohler AD. Ehlers-Danlos syndrome and postural tachycardia syndrome: a relationship study. *J Neurol Sci*. 2014;340(1-2):99-102.

Young RR, Asbury AK, Corbett JL, Adams RB. Pure pan-dysautonomia with recovery. Description and discussion of diagnostic criteria. *Brain*. 1975;98:613-636.

Zochodne DW. Autonomic involvement in Guillain-Barré syndrome: a review. *Muscle Nerve*. 1994;17:1145-1155.

Chronic Autonomic Neuropathy, Central Autonomic Failure, and Neurogenic Orthostatic Hypotension

Benarroch EE. Postural tachycardia syndrome: a heterogeneous and multifactorial disorder. *Mayo Clin Proc*. 2012;87(12):1214-1225.

Cersosimo MG, Benarroch EE. Autonomic involvement in Parkinson's disease: pathology, pathophysiology, clinical features and possible peripheral biomarkers. *J Neurol Sci*. 2012;313:57-63.

Cruz MW. Tafamidis for autonomic neuropathy in hereditary transthyretin (ATTR) amyloidosis: a review. *Clin Auton Res*. 2019;29(suppl 1):19-24.

Eschlböck S, Wenning G, Fanciulli A. Evidence-based treatment of neurogenic orthostatic hypotension and related symptoms. *J Neural Transm (Vienna)*. 2017;124:1567-1605.

Ewing DJ, Campbell IW, Clarke BF. The natural history of diabetic autonomic neuropathy. *Q J Med*. 1980;49:95-108.

Freeman R. Clinical practice. Neurogenic orthostatic hypotension. *N Engl J Med*. 2008;358:615-624.

Freeman R, Wieling W, Axelrod FB, et al. Consensus statement on the definition of orthostatic hypotension, neurally mediated syncope and the postural tachycardia syndrome. *Auton Neurosci*. 2011;161:46-48.

Furness JB. The enteric nervous system and neurogastroenterology. *Nat Rev Gastroenterol Hepatol*. 2012;9:286-294.

Gerritsen J, Dekker JM, TenVoorde BJ, et al. Impaired autonomic function is associated with increased mortality, especially in subjects with diabetes, hypertension, or a history of cardiovascular disease: the Hoorn study. *Diabetes Care*. 2001;24:1793-1798.

Gilman S, Wenning GK, Low PA, et al. Second consensus statement on the diagnosis of multiple system atrophy. *Neurology*. 2008;71(9):670-676.

Goldstein DS, Holmes CS, Dendi R, Bruce SR, Li S-T. Orthostatic hypotension from sympathetic denervation in Parkinson's disease. *Neurology*. 2002;58:1247-1255.

González-Duarte A, Berk JL, Quan D, et al. Analysis of autonomic outcomes in APOLLO, a phase III trial of the RNAi therapeutic patisiran in patients with hereditary transthyretin-mediated amyloidosis. *J Neurol*. 2020;267(3):703-712.

Hague K, Lento P, Morgello S, Caro S, Kaufmann H. The distribution of Lewy bodies in pure autonomic failure: autopsy findings and review of the literature. *Acta Neuropathol*. 1997;94:192-196.

Kaufmann H, Freeman R, Biaggioni I, et al. Droxidopa for neurogenic orthostatic hypotension: a randomized, placebo-controlled, phase 3 trial. *Neurology*. 2014;83(4):328-335.

Klein CM, Vernino S, Lennon VA, et al. The spectrum of autoimmune autonomic neuropathies. *Ann Neurol*. 2003;53:752-758.

Magalhães M, Wenning GK, Daniel SE, Quinn NP. Autonomic dysfunction in pathologically confirmed multiple system atrophy and idiopathic Parkinson's disease—a retrospective comparison. *Acta Neurol Scand*. 1995;91:98-102.

Moon J, Kim DY, Byun JI, et al. Orthostatic intolerance symptoms are associated with depression and diminished quality of life in patients with postural tachycardia syndrome. *Health Qual Life Outcomes*. 2016;14(1):144.

Muppidi S, Vernino S. Autoimmune autonomic failure. *Handb Clin Neurol*. 2013;117:321-327.

Schroeder C, Vernino S, Birkenfeld AL, et al. Plasma exchange for primary autoimmune autonomic failure. *N Engl J Med*. 2005;353(15):1585-1590.

Shibao C, Grijalva CG, Raj SR, Biaggioni I, Griffin MR. Orthostatic hypotension-related hospitalizations in the United States. *Am J Med*. 2007;120:975-980.

Shy GM, Drager GA. A neurological syndrome associated with orthostatic hypotension: a clinical-pathologic study. *Arch Neurol*. 1960;2:511-527.

Stefanova N, Bücke P, Duerr S, Wenning K. Multiple system atrophy: an update. *Lancet Neurol*. 2009;8:1172-1178.

The Consensus Committee of the American Autonomic Society and the American Academy of Neurology. Consensus statement on the definition of orthostatic hypotension, pure autonomic failure, and multiple system atrophy. *Neurology*. 1996;46:1470.

Vagaonescu TD, Saadia D, Tuhrim S, Phillips RA, Kaufmann H. Hypertensive cardiovascular damage in patients with primary autonomic failure. *Lancet*. 2000;355:725-726.

Verbaan D, Marinus J, Visser M, van Rooden SM, Stiggelbout AM, van Hilten JJA. Patient-reported autonomic symptoms in Parkinson disease. *Neurology*. 2007;69(4):333-341.

Weimer LH, Zadeh P. Syncope and orthostatic intolerance. *Med Clin N Am*. 2009;93(2):427-449.

Wenning GK, Geser F, Krismer F, et al. The natural history of multiple system atrophy: a prospective European cohort study. *Lancet Neurol*. 2013;12:264-274.

Wu TY, Taylor JM, Kilfoyle DH, et al. Autonomic dysfunction is a major feature of cerebellar ataxia, neuropathy, vestibular areflexia 'CANVAS' syndrome. *Brain*. 2014;137(pt 10):2649-2656.

Hereditary Autonomic Neuropathies

Anderson SL, Coli R, Daly IW, et al. Familial dysautonomia is caused by mutations of the IKAP gene. *Am J Hum Genet*. 2001;68:753-758.

Anderson SL, Rubin BY. Tocotrienols reverse IKAP and monoamine oxidase deficiencies in familial dysautonomia. *Biochem Biophys Res Commun*. 2005;336(1):150-156.

Axelrod FB. Familial dysautonomia. *Muscle Nerve*. 2004;29:352-363.

Axelrod FB, Gold-von Simson G. Hereditary sensory and autonomic neuropathies: types II, III, and IV. *Orphanet J Rare Dis*. 2007;3:2-39.

Axelrod FB, Rolnitzky L, Gold von Simson G, Berlin D, Kaufmann H. A rating scale for the functional assessment of patients with familial dysautonomia (Riley Day syndrome). *J Pediatr*. 2012;161(6):1160-1165.

Blumenfeld A, Slaugenhaupt SA, Axelrod FB. Localization of the gene for familial dysautonomia on chromosome 9 and definition of DNA markers for genetic diagnosis. *Nat Genet*. 1993;4:160-164.

Couzin-Frankel J. Chasing a disease to the vanishing point. *Science*. 2010;328(5976):298-300.

Hims MM, Ibrahim EC, Leyne M, et al. Therapeutic potential and mechanism of kinetin as a treatment for the human splicing disease familial dysautonomia. *J Mol Med (Berl)*. 2007;85(2):149-161.

Mead S, Gandhi S, Beck J, et al. A novel prion disease associated with diarrhea and autonomic neuropathy. *N Engl J Med*. 2013;369:1904-1914.

Morini E, Gao D, Montgomery CM, et al. ELP1 splicing correction reverses proprioceptive sensory loss in familial dysautonomia. *Am J Hum Genet*. 2019;104(4):638-650.

Norcliffe-Kaufmann L, Slaugenhaupt SA, Kaufmann H. Familial dysautonomia: history, genotype, phenotype and translational research. *Prog Neurobiol*. 2017;152:131-148.

Rechitsky S, Verlinsky O, Kuliev A, et al. Preimplantation genetic diagnosis for familial dysautonomia. *Reprod Biomed Online*. 2003;6(4):488-493.

Riley CM, Day RL, Greely DM, et al. Central autonomic dysfunction with defective lacrimation; report of five cases. *Pediatrics*. 1949;3:468-478.

Schwartzlow C, Kazamel M. Hereditary sensory and autonomic neuropathies: adding more to the classification. *Curr Neurol Neurosci Rep*. 2019;19(8):52.

Smith AA, Dancis J. Response to intradermal histamine in familial dysautonomia—a diagnostic test. *J Pediatr*. 1963;63:889-894.

Yannai S, Zonszain J, Donyo M, Ast G. Combinatorial treatment increases IKAP levels in human cells generated from familial dysautonomia patients. *PLoS One*. 2019;14(3):e0211602.

117 Paroxysmal Sympathetic Hyperactivity After Acute Brain Injury

Sophie Samuel and Huimahn Alex Choi

KEY POINTS

1. Paroxysmal sympathetic hyperactivity (PSH) is a syndrome associated with episodes of increased sympathetic hyperactivity after acute brain injury.
2. PSH is characterized by sudden onset of transient symptoms characterized by hyperthermia, tachycardia, tachypnea, diaphoresis, and motor posturing.
3. The primary disturbance is a disconnection between inhibitory cortical pathways and autonomic nervous system centers in brainstem.
4. PSH is a diagnosis of exclusion.

INTRODUCTION

Paroxysmal sympathetic hyperactivity (PSH) is a syndrome of episodic physiologic hyperactivation manifesting in fevers, diaphoresis, tachycardia, tachypnea, hypertension, and dystonic posturing. The syndrome was first described in 1929, Wilder Penfield identified this phenomenon as diencephalic seizure because it was believed to be epileptic in nature. Since then, without a clear consensus definition, the syndrome has been described by many names: episodic autonomic instability, dysautonomia, autonomic dysregulation, central autonomic dysfunction, paroxysmal autonomic instability with dystonia, sympathetic storming, autonomic storming, dysautonomic crises. In 2014, the International Brain Injury Association developed a conceptual definition and created a census set of diagnostic criteria for this entity and proposed PSH as the name of this syndrome.

PSH is a poorly understood phenomenon, but it is widely accepted as a result of disconnection within the excitatory-to-inhibitory ratio (EIR) model. Identifying patients with these symptoms are often difficult. PSH is a diagnosis of exclusion, where other conditions with similar symptoms must first be ruled out. PSH can develop abruptly and last a short duration but can also be very challenging to manage if presenting with persistent symptoms. Delayed recognition can lead to unnecessary workup and administration of medications. This will further prolong hospitalization with potentially harmful results to patients. Additionally, uncontrolled symptoms can lead to multiorgan dysfunction secondary to brain injury.

EPIDEMIOLOGY

For decades, the absence of a unified diagnostic criterion, the unclear etiology, and the multiple different causes of PSH have hindered the study of the syndrome and resulted in widely differing estimates of prevalence of PSH from 7.7% to 33% in patients admitted to the intensive care unit, reflecting the differences in population of patients, diagnostic criteria, and time of diagnosis. The recently proposed diagnostic framework is an attempt to standardize the approach and aid in accurate and timely diagnosis of PSH.

The syndrome can manifest in both children and adults and can affect any age group and gender. The main risk factor for developing PSH after acute brain injury depends on the severity of the initial brain injury, younger age, and male gender. Few conditions predispose to the development of PSH, the most common being traumatic brain injury (79.4%), followed by hypoxic brain injury (9.7%), and stroke (5.4%). Although, traumatic brain injury may be the etiology for most cases of PSH, patients with other diseases may actually be at a higher risk for PSH. For instance, N-methyl-D-aspartate receptor–associated encephalitis is characterized by an aggressive and difficult to treat PSH-like syndrome.

PATHOBIOLOGY

The initial theory that the syndrome is epileptic in nature has been shown to be inconsistent with clinical and experimental evidence. Most believe PSH is caused by a functional disconnection leading to unbalanced activation of brainstem systems controlling the autonomic nervous system. Brain regions implicated range from the cerebral cortex to the anterior hypothalamus to the medulla and the connections in between. Regardless of the lesion location, the final common pathway is an imbalance of adrenergic outflow.

The EIR model has been used to explain the pathophysiology of PSH, and it takes into account the hypersensitive, overreactive nature of the responses to normal stimuli. Autonomic efferents at the level of the spinal cord are modulated centrally by a balance of sympathetic and parasympathetic inputs from higher brainstem nuclei. Afferents from the spinal cord can modulate this balance in response to stimuli from the environment. The EIR model proposes that the afferent stimuli from the spine have an allodynic tendency, which is normally controlled by tonic inhibitory drive from diencephalic centers. Damage to these inhibitory centers or their inhibitory processes down to the mesencephalon releases the inhibition of the allodynic tendency. Once the tonically inhibitory cycle is broken, there is a positive feedback loop that produces sympathetic overactivity to any afferent stimuli. This model explains how a normally nonnoxious stimulus can become a very noxious stimulus associated with an uncontrolled sympathetic response.

Imaging studies have shown that injury to the deep brain structures, periventricular white matter, corpus callosum, diencephalon, or brainstem may be associated with the development of PSH. PSH is associated with an increased number of lesions in the midbrain and upper pons, compared with number of lesions in cerebral cortex, subcortex, corpus callosum, and diencephalon. Bilateral diencephalic lesions have also been attributed to PSH in hypoxic ischemic encephalopathy. The evidence from imaging studies showing damage to brainstem structures emphasizes the importance of the diencephalic and mesencephalic regions to the pathophysiology of PSH.

DIAGNOSIS

Clinical Manifestations

PSH manifests abruptly in cyclic episodes, either spontaneously or in response to external stimuli. Symptoms are usually first noticed once patients are being weaned off of continuous intravenous sedation and they begin to awaken. The clinical manifestation of PSH define the syndrome: episodic increases in heart rate, blood pressure, respiratory rate, fever, diaphoresis, at times with pupillary dilatation and motor hyperactivity manifested in abnormal posturing, and dystonic movements. Duration of each episodes of exacerbation on average can be minutes to hours and can occur several times a day or in refectory cases nearly continuously. PSH can be difficult to differentiate from opiate withdrawal or agitation from mechanical ventilation. It may persist into the rehabilitation phase and lasts weeks to months after the injury. In severe cases, it may persist for a year.

The overlapping symptoms of PSH with other neurologic sequelae of acute brain injury make the diagnosis difficult and only made after excluding other causes for symptoms. Clinical suspicion and careful examination are of paramount importance in the detection of PSH. Infections, sepsis, pain, opiate withdrawal, and seizures are all diagnoses that have overlapping clinical presentations that need to be excluded in order to diagnose PSH. There are no tests available for confirming the diagnosis of PSH.

Diagnostic Criteria

Recently, a consensus diagnostic criteria has been developed. The paroxysmal sympathetic hyperactivity–assessment measure (PSH-AM) has two assessment tools: the Clinical Feature Scale (CFS) tool and the Diagnostic Likelihood Tool (DLT). The CFS consists of a scoring system from 0 to 3 for the different ranges in the categories of heart rate, respiratory rate, systolic blood pressure, temperature, severity of diaphoresis, and severity of motor posturing. The highest value of the day for each category is counted. The total CFS score can range from 0 to 18, with a score of 0 indicating no PSH-like symptoms and a score of 18 indicating that the patient is exhibiting the most severe PSH-like symptoms for that day (Table 117.1).

Previously, multiple proposed diagnostic criteria overlapped significantly in descriptive ways; consensus regarding specifics of timing, severity, number of episodes did not exist. The DLT aims to address these concerns and exclude other potential diagnoses. This tool involves 11 different criteria focused on timing of symptoms, number of episodes per day, number of consecutive days the patient has PSH-like symptoms, medication administered for sympathetic features, alternate differential diagnoses, and other presumed causes of features. The total DLT score can range from 0 to 11, with a score of 11 representing the highest diagnostic likelihood for PSH (see Table 117.1).

Characteristically, PSH tends to be triggered by minimal external stimuli, such as touching, passive movement (turning, moving limbs, and bathing), or endotracheal tube suctioning. This feature of overreactivity, allodynic response, may be a helpful characteristic for diagnostic purposes. Most of these symptoms have been incorporated into the new diagnostic criteria.

Although PSH can present early after injury, because PSH is a diagnosis of exclusion, the current recommendation is to monitor patients for a minimum of 14 days. The final PSH diagnostic likelihood score is calculated by adding the CFS and DLT score

TABLE 117.1 Paroxysmal Sympathetic Hyperactivity–Assessment Measure[a]

Clinical Feature Scale (CFS)					
	0	1	2	3	Score
Heart rate	<100	100-119	120-139	≥140	
Respiratory rate	<18	18-23	24-29	≥30	
Systolic blood pressure	<140	140-159	160-179	≥180	
Temperature	<37	37-37.9	38-38.9	≥39.0	
Sweating	Nil	Mild	Moderate	Severe	
Posturing during episodes	Nil	Mild	Moderate	Severe	
Severity of clinical features				*Nil*	*0*
				Mild	*1-6*
				Moderate	*7-12*
				Severe	*≥13*

Diagnosis Likelihood Tool (DLT)
❑ Clinical features occur simultaneously.
❑ Episodes are paroxysmal in nature.
❑ Sympathetic over reactivity to normally nonpainful stimuli.
❑ Features persist ≥3 consecutive days.
❑ Features persist ≥2 wk post brain injury.
❑ Features persist despite treatment of alternative differential diagnosis.
❑ Medication administered to decrease sympathetic features.
❑ ≥2 episodes daily
❑ Absence of parasympathetic features during episodes
❑ Absence of other presumed cause of features
❑ Antecedent acquired brain injury
DLT score: 1 point score for each feature present

PSH Diagnosis Likelihood (combined CFS and DLT score)
• *Unlikely <8*
• *Possible 8-16*
• *Probable ≥17*

Abbreviation: PSH, paroxysmal sympathetic hyperactivity.
[a]Adapted from Baguley IJ, Perkes IE, Fernandez-Ortega JF, Rabinstein AA, Dolce G, Hendricks HT; and Consensus Working Group. Paroxysmal sympathetic hyperactivity after acquired brain injury: consensus on conceptual definition, nomenclature, and diagnostic criteria. *J Neurotrauma*. 2014;31(17):1515-1520.

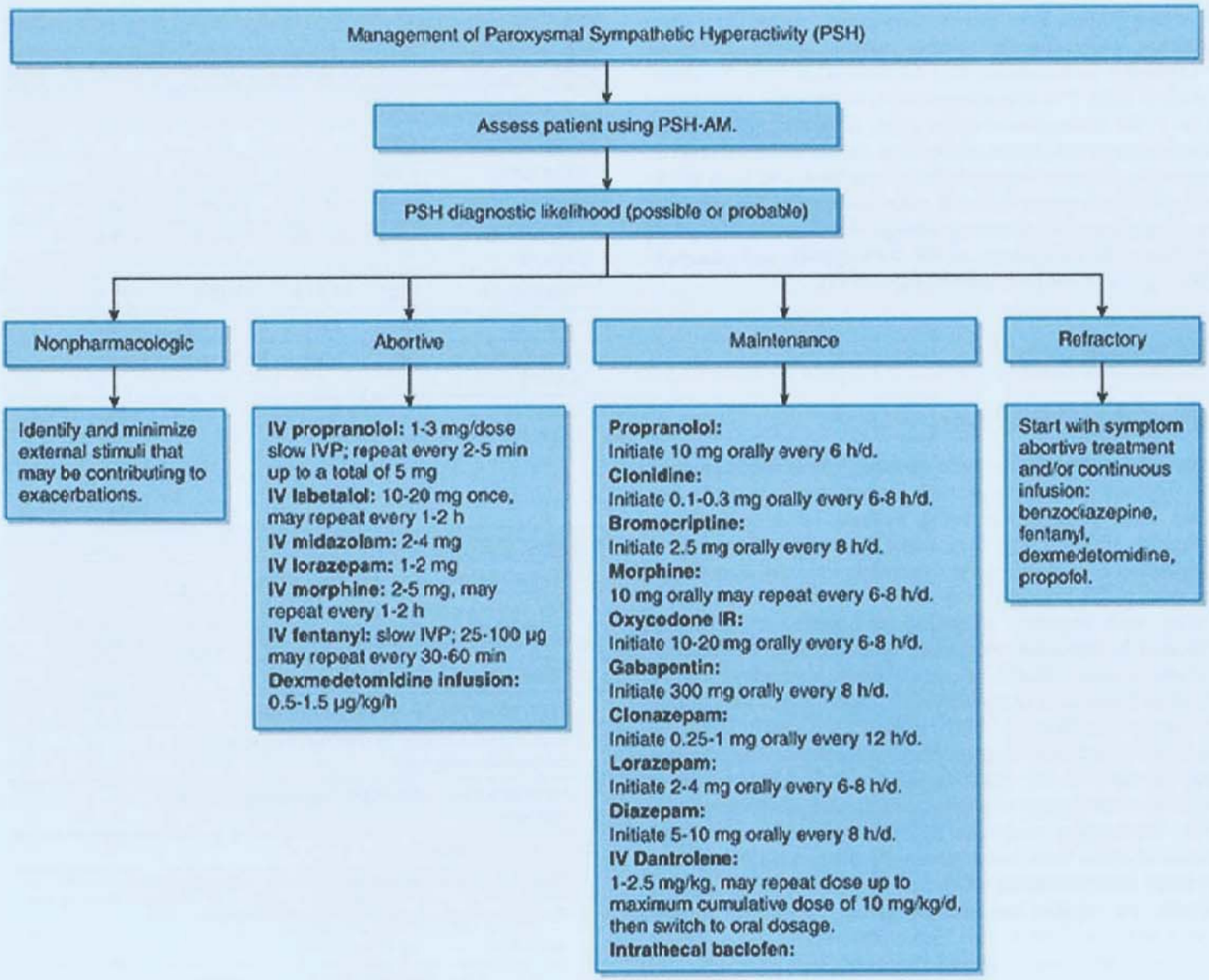

FIGURE 117.1 Combination of medications from different classes likely results in the most effective approach in managing paroxysmal sympathetic hyperactivity. Abbreviations: IV, intravenous; IVP, intravenous push; PSH-AM, paroxysmal sympathetic hyperactivity–assessment measure.

for each day. By calculating the average score for the 14 days during hospitalization, patients can be categorized under "Unlikely" (score <8), "Possible" (score 8-16) or "Probable" (score ≥17) (see Table 117.1).

Patients with high PSH-AM scores are identified as having severe PSH symptoms. However, patients presenting with mild to moderate symptoms are unlikely to be diagnosed with likelihood of PSH in the absence of the PSH-AM. A suggested treatment algorithm is presented on Figure 117.1.

MANAGEMENT

Effective clinical management of PSH requires a combination of pharmacologic as well as nonpharmacologic treatment modalities. Studies examining treatment strategies for PSH are limited, and no level 1 evidence is available to guide the management of PSH. Majority of the studies examining the management of PSH is anecdotal in nature, guided predominantly by case reports and case series. Therapy is focused on control of symptoms. Medical treatments for PSH include opioids, β-blockers, dopamine agonists, α_2-agonists, γ-aminobutyric acid (GABA)ergic agents, benzodiazepines, gabapentin, and muscle relaxants (Table 117.2). The mechanisms by which these agents improve symptoms of PSH remain speculative.

The goal of treatment is to optimize symptom control while minimizing side effects. Treatment should focus on nonpharmacologic management first. Potential stimuli, which can trigger acute episodes of exacerbation should be identified and minimized. Because patients usually are unable to communicate, this process can be difficult but an important first step. Pharmacologic management of PSH focuses on three treatment approaches: maintenance, symptom abortion, and refractory treatment (see Fig. 117.1).

When a paroxysm of hyperactivity occurs, abortive medications are indicated to control discrete breakthrough episodes. These medications have a rapid onset of action with a short half-life. The targets of the abortive medications depend on the predominant symptoms: treating hyperthermia with antipyretics, agitation with sedation, and hypertension with antihypertensive

TABLE 117.2 Medications Used for Treatment of Paroxysmal Sympathetic Hyperactivity

Medication	Location of Action	Proposed Mechanism	Symptoms Treated
Baclofen	Centrally	$GABA_B$ agonist	Pain, clonus, rigidity
Benzodiazepines	Centrally	$GABA_A$ agonist	Agitation, hypertension, tachycardia, posturing
Bromocriptine	Centrally; at hypothalamus	Dopamine agonist	Dystonia, fever, posturing
Clonidine	Centrally; decreased sympathetic outflow	α_2-Receptor agonist	Agitation, hypertension, tachycardia
Dantrolene	Peripherally	Direct-acting skeletal muscle relaxant	Muscle rigidity, posturing
Dexmedetomidine	Centrally; decreased sympathetic outflow	α_2-Receptor agonist	Agitation, hypertension, tachycardia
Gabapentin	Centrally	GABA agonist	Spasticity, allodynic response
Opioids	Centrally; medullary vagal nuclei and peripherally	μ-Opioid receptor agonist	Hypertension, tachycardia, allodynic response
Propofol	Centrally	$GABA_A$ agonist	Agitation, hypertension, tachycardia
Propranolol	Peripherally; decreasing effect of catecholamines	Nonselective β-blocker	Hypertension, tachycardia, fever

Abbreviation: GABA, γ-aminobutyric acid.

agents. Morphine, other opiates, and short-acting benzodiazepines are first-line treatment options for this indication. Dose of medication should be titrated to symptom relief and is limited by the potential side effects, mainly sedation, respiratory depression, and hypotension. Medications with a short half-life should be used for abortive treatment to minimize undesired effects. If frequency bouts of hyperactivity occur, maintenance medication should be adjusted accordingly. Importantly, once the frequency of episodes of exacerbation is controlled, maintenance medications should be aggressively tapered to maximize the alertness of patients.

First-line maintenance pharmacologic agents include medications, which are less sedating and reduce the frequency and intensity of exacerbations. These medications include nonselective β-blockers, α_2-agonists, bromocriptine, baclofen, gabapentin, opiates, and long-acting benzodiazepines such as clonazepam. Propranolol, a competitive nonselective β-blocker, is an ideal drug for controlling symptoms of PSH due to its mechanism of action and broad control of symptoms with minimum sedation. In addition to its cardiovascular effects, propranolol decreases the hyperthermic response to brain injury. Clonidine, a presynaptic α_2-receptor agonist, is a useful agent to manage hypertension and tachycardia. Because increased blood pressure due to excitation of the sympathetic nervous system is one of the major features of PSH, clonidine is often an effective medication. Morphine is a potent μ-opioid receptor agonist. In addition to morphine's analgesic properties, its cholinergic effects and histamine-releasing actions make it a good agent for the management of tachycardia and hypertension. Morphine is the most commonly used medication and can be used as maintenance as well as abortive treatment for breakthrough episodes. Bromocriptine is a synthetic dopamine agonist; the mechanism by which resolution of symptoms including hyperpyrexia and dysautonomia is achieved is unclear. Baclofen, a $GABA_B$ receptor agonist, is indicated for treatment of spasticity associated with PSH and to improve mobility. The benefit is to decrease the number and severity of spasms, thus relieving associated pain, clonus, and muscle rigidity. Benzodiazepines, $GABA_A$ receptor agonists, are useful for symptoms of motor activity, tachycardia, and hypertension. The concern with benzodiazepines is the possibility of worsening neurologic functioning in newly injured brain. A long-acting benzodiazepine, clonazepam, is helpful as a maintenance medication to reduce episodes. Gabapentin, an analog of GABA, was originally developed as an anticonvulsant. However, it may be more useful in the management of painful neuropathies, spasticity, and tremor. It is most useful as an adjunct medication, which is less sedating than benzodiazepines. Dantrolene acts directly on skeletal muscle, decreasing the force of contraction by interfering with release of calcium ion from sacroplasmic reticulum and can be used in cases when severe dystonia or posturing continues to persist. Dantrolene can possibly be effective for the amelioration of dystonic posturing, but the risk of causing hepatotoxicity can limit its use.

Finally, some develop refractory PSH, when symptoms do not respond to isolated intermittent treatment modalities and symptoms become life-threatening. In these cases, continuous intravenous medications with benzodiazepines, opioids, dexmedetomidine, or propofol drips are required. At times, antipyretics with or without temperature control devices is necessitated for aggressive temperature modulation. In addition to continuous infusions of opiates (morphine, fentanyl) and benzodiazepines, dexmedetomidine an α_2-receptor agonist can be administered as a continuous intravenous infusion predominantly for sedation. Given its favorable effects on heart rate, blood pressure, and agitation, dexmedetomidine is a useful intravenous treatment choice. If symptoms are not controlled with other medications, propofol, a general anesthetic, can be used. However, the side effects from the medication limit its use to only severe cases, and it can only be administered with close intensive care monitoring. Unlike dexmedetomidine, patients on propofol require mechanical ventilation support. If posturing persists, the use of intrathecal infusion of baclofen may be helpful. Concerns with using intrathecal infusions include an increase risk in cerebral spinal fluid leak and infection as well as mechanical problems with the catheter or pump. Dopamine antagonists such as chlorpromazine and haloperidol should be avoided because reports of exacerbation of cognitive deficits, psychosis, and neuroleptic malignant syndrome have been reported.

OUTCOME

Although the risk factors and pathobiology remain controversial, the impacts on clinical outcomes are clear. Patients who experience PSH have worse Glasgow outcome scores and worse functional independent measures compared to their counterparts.

Additionally, patients with PSH have longer intensive care unit stays, longer hospital stay, longer mechanical ventilation days, higher infectious episodes, more tracheostomy, and higher health care costs. The mechanisms as to how PSH causes worse outcomes are multifactorial. The symptoms and treatments for the symptoms cause longer period of days on the ventilator, leading to more tracheostomy and longer length of stay. PSH has a direct impact on fever burden after brain injury, which has been associated worse outcomes after brain injury. In addition, the influence of the autonomic nervous system and its effects on inflammation have been studied in other disease states and may be very active in the acutely brain injured population. The dysregulated autonomic nervous system may have an influence in causing unopposed inflammation and leading to secondary brain injury. The availability of a consensus on conceptual definition, nomenclature, and diagnostic criteria is a promising development that will pave the way to a better understanding of the disease.

SUGGESTED READINGS

Baguley IJ. The excitatory:inhibitory ratio model (EIR model): an integrative explanation of acute autonomic overactivity syndromes. *Med Hypotheses*. 2008;70:26-35.

Baguley IJ, Heriseanu RE, Gurka JA, Nordenbo A, Cameron ID. Gabapentin in the management of dysautonomia following severe traumatic brain injury: a case series. *J Neurol Neurosurg Psychiatry*. 2007;78:539-541.

Baguley IJ, Nott MT, Slewa-Younan S, Heriseanu RE, Perkes IE. Diagnosing dysautonomia after acute traumatic brain injury: evidence for overresponsiveness to afferent stimuli. *Arch Phys Med Rehabil*. 2009;90:580-586.

Baguley IJ, Perkes IE, Fernandez-Ortega JF, Rabinstein AA, Dolce G, Hendricks HT; and Consensus Working Group. Paroxysmal sympathetic hyperactivity after acquired brain injury: consensus on conceptual definition, nomenclature, and diagnostic criteria. *J Neurotrauma*. 2014;31(17):1515-1520.

Chioléro RL, Breitenstein E, Thorin D, et al. Effects of propranolol on resting metabolic rate after severe head injury. *Crit Care Med*. 1989;17:328-334.

Fernández-Ortega JF, Prieto-Palomino MA, Garcia-Caballero M, Galeas-Lopez JL, Quesada-García G, Baguley IJ. Paroxysmal sympathetic hyperactivity after traumatic brain injury: clinical and prognostic implications. *J Neurotrauma*. 2012;29:1364-1370.

Fernández-Ortega JF, Prieto-Palomino MA, Quesada-García G, Barrueco-Francioni J. Findings in the magnetic resonance of paroxysmal sympathetic hyperactivity. *J Neurotrauma*. 2011;28:1327-1328.

Hinderer SR, Lehmann JF, Price R, White O, deLateur BJ, Deitz J. Spasticity in spinal cord injured persons: quantitative effects of baclofen and placebo treatments. *Am J Phys Med Rehabil*. 1990;69:311-317.

Ko S-B, Kim CK, Lee S-H, Bae H-J, Yoon B-W. Morphine-sensitive paroxysmal sympathetic storm in pontine intracerebral hemorrhage. *Neurologist*. 2010;16:384-385.

Lv L-Q, Hou L-J, Yu M-K, et al. Prognostic influence and magnetic resonance imaging findings in paroxysmal sympathetic hyperactivity after severe traumatic brain injury. *J Neurotrauma*. 2010;27:1945-1950.

Lv L-Q, Hou L-J, Yu M-K, et al. Risk factors related to dysautonomia after severe traumatic brain injury. *J Trauma*. 2011;71:538-542.

Payen D, Quintin L, Plaisance P, Chiron B, Lhoste F. Head injury: clonidine decreases plasma catecholamines. *Crit Care Med*. 1990;18:392-395.

Penfield W. Diencephalic autonomic epilepsy. *Arch NeurPsych*. 1929;22:358-374.

Perkes I, Baguley IJ, Nott MT, Menon DK. A review of paroxysmal sympathetic hyperactivity after acquired brain injury. *Ann Neurol*. 2010;68:126-135.

Perkes IE, Menon DK, Nott MT, Baguley IJ. Paroxysmal sympathetic hyperactivity after acquired brain injury: a review of diagnostic criteria. *Brain Inj*. 2011;25:925-932.

Pranzatelli MR, Pavlakis SG, Gould RJ, De Vivo DC. Hypothalamic-midbrain dysregulation syndrome: hypertension, hyperthermia, hyperventilation, and decerebration. *J Child Neurol*. 1991;6:115-122.

Rossitch E Jr, Bullard DE. The autonomic dysfunction syndrome: aetiology and treatment. *Br J Neurosurg*. 1988;2:471-478.

Russo RN, O'Flaherty S. Bromocriptine for the management of autonomic dysfunction after severe traumatic brain injury. *J Paediatr Child Health*. 2000;36:283-285.

Samuel S, Lee M, Brown RJ, Choi HA, Baguley IJ. Incidence of paroxysmal sympathetic hyperactivity following traumatic brain injury using assessment tools. *Brain Inj*. 2018;32(9):1115-1121.

Srinivasan S, Lim CCT, Thirugnanam U. Paroxysmal autonomic instability with dystonia. *Clin Auton Res*. 2007;17:378-381.

Sleep Disorders 118

Andrew J. Westwood and Carl W. Bazil

KEY POINTS

1. Sleep is composed of four stages, N1 (5%), N2 (45%), N3 (25%), and rapid eye movement (REM) (25%), and the cycling of these stages comprise the ultradian rhythm.
2. Most REM sleep occurs in the last third of the night.
3. The ventrolateral and median preoptic nuclei are active during sleep and release γ-aminobutyric acid and galanin to inhibit neurons of the ascending arousal system.
4. Individuals with symptoms of insomnia who report daytime sleepiness should be evaluated for other causes than insomnia disorder.
5. Obstructive sleep apnea may mimic many sleep disorders and should be considered in the differential for disorders such as narcolepsy or REM behavior disorder.
6. Sleepiness or snoring are not always present in obstructive sleep apnea.
7. Individuals with narcolepsy present with sleepiness in combination with symptoms such as hypnic hallucinations, sleep paralysis, fragmented nocturnal sleep, and cataplexy. Naps are typically refreshing and vivid dreams may be present in brief naps.
8. Individuals with delayed sleep phase syndrome are often refractory to sedative-hypnotics, report being more awake at night and may fall asleep at a consistent hour later than wanted.
9. Adults experiencing non-REM parasomnias such as somnambulism may have some recall of the events during the night and misdiagnosed as dream enactment behavior.
10. The REM behavior disorder may be a prodrome of neurodegeneration, particularly synucleinopathies such as dementia with Lewy Bodies.

INTRODUCTION

Sleep and sleep disorders are frequently overlooked as a cause or exacerbating factor in neurologic dysfunction. Neuronal activity and the networks involved are different in each state of sleep (non–rapid eye movement [NREM] and rapid eye movement [REM] sleep) compared with the normal waking brain. Sleep and sleep disorders therefore offer unique opportunities to understand the physiology of the brain and its impact on daily functioning. Sleep is involved in the regulation of endocrine and autonomic output and is integral to learning and memory, areas whose complexity and relationship to sleep are only beginning to be understood.

This chapter begins with a brief description of normal sleep and its impact on functioning. An overview of sleep disorders follows with particular relation to their impact on neurologic diseases. Diagnostic testing in sleep is discussed in Chapter 30.

PHYSIOLOGY OF NORMAL SLEEP

Sleep is an active process that involves numerous distinct neuronal networks, which are ultimately expressed as altered physiologic functions. Heart rate, blood pressure, gas exchange, gastrointestinal function, hormonal secretion, and even kidney function are altered during sleep. The exact purpose(s) of sleep remains unclear, but there is considerable evidence of essential associations with immune function, memory, learning, energy conservation, and toxin clearance.

Sleep is classified into stages based on three parameters: electroencephalography (EEG), eye movement or electro-oculography, and muscle tone as assessed by electromyography (EMG) of the mentalis muscle. Arbitrary classification of 30-second recordings, or epochs, divide the process into wakefulness, three stages of NREM sleep (stages N1, N2, and N3), and one stage of REM sleep (stage R).

Wakefulness (stage W) is identified by a low-voltage fast-frequency EEG, high muscle tone, and REMs. *Stage N1* sleep is characterized by a low-voltage, mixed-frequency EEG and slow, rolling eye movements. Reactivity to outside stimuli is decreased, and mentation may proceed but is slowed. *Stage N2* consists of a moderate low-voltage background EEG with sleep spindles (bursts of 12- to 16-Hz activity lasting 0.5-2 s) and K complexes (brief high-voltage discharges with an initial negative deflection followed by a positive component). *Slow-wave sleep (stage N3)* consists of high-amplitude delta (0-2 Hz) frequencies occupying 20% or more of the epoch. During this deeper sleep, heart and respiratory rates are slowed and regular. In NREM sleep, the tonic chin EMG is of moderately high amplitude but less than that of quiet wakefulness (Fig. 118.1).

The EEG pattern during REM sleep (stage R) consists of low-voltage, mixed-frequency activity and is similar to that of stage N1 sleep. Moderately high-amplitude, 3- to 6-Hz triangular waveforms referred to as *sawtooth waves* are intermittently present and are unique to REM sleep. Intermittent bursts of rapid conjugate eye movements occur. Tonic chin EMG activity is absent or markedly reduced, and phasic muscle discharges occur in irregular bursts. The decreased EMG activity is a reflection of muscle paralysis resulting from active inhibition of muscle activity. During REM sleep, surges of parasympathetic and sympathetic activity are denoted by greater variability in heart and respiratory rates. This stage is also associated with complex vivid imagery, but visual imagery can occur in all sleep stages. When occurring in deep NREM sleep, dream images are typically fragmented and may be associated with actions such as the sensation of falling.



FIGURE 118.1 Stages of sleep. Each 30-second recording represents a different stage of sleep. Wake (*W*), non–rapid eye movement is divided into three stages (*N1*, *N2*, *N3*), and rapid eye movement (*R*). For each recording, the top two channels are electro-oculogram (LOC-A2 and ROC-A1); the following six are electroencephalography, followed by chin electromyography and leg electromyography (LAT1-LAT2), airflow, chest and abdominal movements, electrocardiogram, and oxygen saturation.

During a normal night, sleep comprises recurring cycles. Within each cycle of 90 to 120 minutes, NREM sleep alternates with REM sleep. The normal healthy adult typically falls asleep within 10 minutes and goes through the sequence of stages N1 to N3, followed by reversion to stage N2 sleep. Afterward, the first REM sleep period occurs 70 to 100 minutes into sleep. The first REM period is usually the shortest, about 10 minutes. This pattern of NREM and REM sleep is repeated 3 to 5 times during a normal night's sleep. Typically, most stage N3 sleep is seen in the first two sleep cycles, and REM sleep periods increase in duration and intensity of REM activity as the night progresses. Stage N2 sleep, however, is the most common sleep stage, typically making up half of a normal adult's night. In the normal adult, wakefulness accounts for approximately 5% of the night. The N3 and REM sleep typically account for 25% each of total sleep and N1 approximately 5% (Fig. 118.2).

NEUROANATOMY AND NEUROCHEMISTRY OF SLEEP

Evidence from lesions in animals suggest fast neurotransmitters, glutamate and γ-aminobutyric acid (GABA), form the respective core of wakefulness and sleep processes that are modulated by monoaminergic and cholinergic systems. The ascending arousal system has two main pathways: the cholinergic and the group of monoaminergic nuclei. Parabrachial and pedunculopontine glutamatergic neurons feed into the basal forebrain, which in turn sends projections to the reticular nucleus of the thalamus.

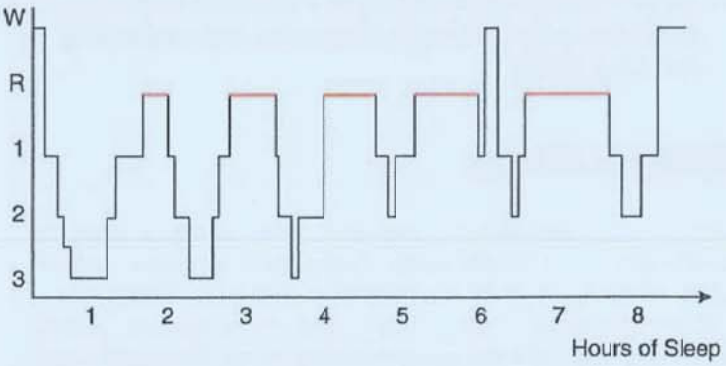

FIGURE 118.2 Hypnogram. Graphical representation of sleep stages as a function of time. This hypnogram shows normal sleep architecture with the majority of slow-wave sleep in the first third of the night, rapid eye movement sleep majority in the last third of the night, and progressive longer durations of rapid eye movement.

The monoaminergic pathways pass through the lateral hypothalamus and basal forebrain to reach the cortex by inhibiting the thalamus through GABA transmission this allows thalamocortical transmission to occur.

Wakefulness is inhibited by GABA from the ventrolateral and median preoptic nuclei. As an individual remains awake, sleep pressure builds (resulting from an accumulation of adenosine) until the transition into sleep occurs. There is reciprocal inhibition between the wake and sleep pathways, which allow one state to remain stable and avoiding a shift back and forth between wakefulness and sleep. This has been likened to a "flip-flop" switch where mutual antagonism occurs between the two.

As sleep occurs, brain waves begin to slow and form K waves and sleep spindles. During stage N3 where delta waves predominate, cortical neuronal synchrony is promoted, and this may be related to synaptic pruning. An REM sleep, however, is an activation of cholinergic neurons in the pontine dorsal tegmentum that subsequently excite neurons responsible for REM-associated atonia, rapid eye movements, increase in cortical metabolic rate, loss of thermoregulation, and other features. The REM sleep is inhibited by activation of the dorsal raphe and locus ceruleus. A network of neurons in the hypothalamus midbrain and thalamus seems to regulate REM sleep cycling.

Hypocretin—named so because it structurally resembles secretin in the gut—appears to stabilize the ability to remain awake. It is also referred to as *orexin* codiscovered by another group—named so because of its ability to stimulate food intake (from the Greek *orexis* meaning appetite).

Throughout the 24-hour day, the human body has a symphony of endocrinologic and metabolic variations that are timed to maximize performance during wakefulness and promote quality rejuvenation during sleep. Because we evolved on a planet that rotates every 24 hours, we developed a delicate neurochemistry anticipatory cycle that prepares the body for the upcoming sleep-wake state. This circadian cycle is approximately 1 day as captured in the Greek meaning of *circadian*. Many body functions, including body temperature, plasma and urine hormones, renal functions, psychological performance measures, and internal sleep-stage organization, participate in this circadian rhythm. Humans have a circadian rhythm that is approximately 24.3 hours and is driven by an intrinsic pacemaker in the suprachiasmatic nucleus. This nucleus is influenced by external time clues to synchronize the body clock with the outside world, including bright light, activity, meals, and social interactions. Evidence for the importance of circadian rhythms comes from studies of acute phase shifts, such as those that occur after jet lag or shift work. Because our internal clock is longer than 24 hours, adaptation is slower after an eastward flight (phase advance) than after a westward flight (phase delay).

SPECIFIC DISORDERS OF SLEEP

Nearly all patients with disorders of the central nervous system (CNS) are at high risk for sleep dysfunction, which may be a direct result or a secondary effect of the neurologic condition. Sleep disorders may exacerbate the symptoms of the underlying neurologic disorder and impair quality of life. In this chapter, we describe selected disorders. *Fatal familial insomnia*, a prion disease, is discussed in Chapter 55. Sleep-associated headache disorders and epilepsy syndromes are also discussed in their respective chapters.

Insomnia

Insomnia *symptoms* can consist of difficulty falling asleep (sleep-onset insomnia), difficulty staying asleep (sleep maintenance insomnia), both, early morning awakenings, or sleep that is nonrefreshing or nonrestorative. The daytime symptoms include excessive fatigue (physical tiredness), impaired performance, or emotional change. Most people have an occasional night fraught with difficulty falling asleep or trouble maintaining sleep, usually caused by an alerting response to short-term stress; this is a normal property of the brain and is not considered insomnia if it resolves quickly.

Confusion often arises from using the term *insomnia* to describe symptoms as well as a medical disorder. Insomnia *disorder* is a diagnosis of exclusion and is a subjective disorder requiring no objective evidence to support it. Generally, those with insomnia disorder do not report daytime sleepiness (although may report fatigue); in those with sleepiness, other sleep disorders should be considered.

Diagnosis

In the past, insomnia disorder has been categorized into primary or secondary types, but these were difficult to reliably ascertain. Insomnia disorder is now considered as *short-term*, *chronic*, or *other* LEVEL 2.[1]

Short-term insomnia lasting less than 3 months duration might be closely linked to the surrounding events, psychological disturbances, or sudden changes in a medical condition. Typically, there is an identifiable precipitant that an individual is able to recall. Individuals may complain of disturbances fewer than 3 times per week, but this results in a general dissatisfaction in their quality of sleep. It may also result in the individual catastrophizing that they may never sleep again. The 1-year prevalence of short-term insomnia is around 20% in the general adult population. Circadian rhythm disorders should be considered as mimickers of insomnia. In delayed sleep phase syndrome, individuals typically complain that they cannot fall asleep until later in the night and due to morning commitments have to curtail their sleep, and this results in sleep deprivation. Early morning awakening raises the possibility of advanced sleep phase if the patient falls asleep early in the evening. Alcohol also characteristically causes this symptom.

Chronic insomnia, lasting greater than 3 months on 3 or more days per week, is usually attributed to multiple factors. The factors may be divided into predisposing, precipitating, and perpetuating, which outline the formation of insomnia as an ongoing process. Characteristics that predispose an individual for insomnia are female gender, older age, psychiatric or chronic medical illness, lower socioeconomic status, poor education, obsessive-compulsive nature, poor coping strategies, and hyperalertness (Table 118.1). In general, those with insomnia disorder are not sleepy individuals—they report an inability to sleep under any circumstance.

Insomnia may be precipitated by sudden changes in environment or challenges to the body or mind. These challenges may come in the form of acute medical illness, psychological or psychiatric events, shift in schedule, or changes in medications or supplements. After the start of the insomnia, patients adopt behaviors or rituals that perpetuate the insomnia. Patients may use maladaptive habits that occur during the day or night and include heavy caffeine or alcohol use; watching television, working, or playing video games while in bed; or even eating or exercising during the usual sleep period. They may

TABLE 118.1 Principles of Good Sleep Hygiene Are the Basis for a Sound Night of Sleep

Principles of Sleep Hygiene
• Establish regular bedtimes.
• Wake regularly at a fixed time.
• Regulate the amount of sleep obtained each night.
• Exercise daily and regularly (particularly aerobic) but not in the late evening.
• Sleep in a quiet, cool, comfortable environment.
• Avoid caffeinated beverages and other stimulants (including tobacco) especially close to bedtime.
• Avoid alcohol within 3 h of bedtime.
• Avoid hypnotic drugs.
• Do something relaxing before bedtime.
• Use the bedroom only for sleep and sexual activity.

become dependent on certain somnogenic substances. Some patients develop associations of not sleeping with the bedroom and may fear going to bed. These poor associations and expectations of poor sleep promote the apprehension toward sleep. The insomnia symptom complex may indicate an underlying disorder related to primary failure of the sleep mechanism or one in which sleep disruption is a result of another disorder. Patients with obstructive sleep apnea, restless legs syndrome, and even narcolepsy may complain of insomnia. Sleep diaries, accounting bedtime and wake time, can be useful in determining potential links to schedule or circadian rhythm issues. Perception of good sleep is an important factor in evaluating the complaint of insomnia.

Some patients may embellish their symptoms, whereas other patients may not perceive they are asleep. These individuals display the normal physiologic parameters of sleep but do not recognize that they have slept. This is referred to as *sleep-state misperception* or *paradoxical insomnia*.

Insomnia symptoms may also be produced by medical or neurologic disorders. Derangement of almost any system in the body can disrupt sleep. Patients with diseases affecting the nervous system, heart, liver, kidneys, gastrointestinal tract, or lungs commonly complain of insomnia symptoms. Musculoskeletal discomfort such as in arthritis or other rheumatologic disorders may become worse with periods of rest. Pain from entrapment neuropathies such as carpal tunnel are typically worse at night, and headaches such as cluster headache or pain related to increased intracranial pressure or brain mass lesions can become more intense during sleep. Nearly all of the psychiatric illnesses have some link to poor sleep. Patients with depression or anxiety disorders may have insomnia years prior to the presentation of the affective component. Insomnia symptoms may also herald the onset of psychosis or mania. Insomnia symptoms can be triggered by many medications and sometimes adjusting the time of administration can benefit the individual.

Management

Treatment of insomnia disorder should be directed toward symptom improvement and avoidance of maladaptive behaviors. Therapy for neurologic and psychiatric disorders should be optimized, and a multipronged approach addressing the patient's behaviors, psychological attitudes, and the potential underlying neurochemistry should be constructed. Cognitive behavioral therapy for insomnia consisting of sleep restriction therapy, relaxation therapy, stimulus control, and sleep hygiene (see Table 118.1) provides a solid therapeutic foundation. Cognitive behavioral therapy for insomnia is the most effective long-term therapy for insomnia and where available should be offered first line for chronic insomnia disorder. This is becoming more readily available in self-help book formats as well as online subscription sites. The use of acupuncture for insomnia remains equivocal due to the lack of methodologic consistency in the trials LEVEL 1.[2]

There are also a number of safe, effective hypnotic substances that may be used particularly in short-term insomnia disorder to help restore normal sleep patterns and reverse negative associations with sleep time and the bedroom environment. These differ mainly in half-life, with zaleplon (5-20 mg) very short acting, zolpidem (5-10 mg) short, and eszopiclone (1-3 mg) the longest (therefore most useful in sleep maintenance insomnias). Ramelteon (8 mg) is a melatonin agonist that is also a mild hypnotic. Suvorexant (5-20 mg) is the first nonselective dual orexin antagonist and, more recently, lemborexant (5-10 mg) received U.S. Food and Drug Administration (FDA) approval. When these agents fail, benzodiazepines and sedating antidepressant drugs are alternatives. Short-acting benzodiazepines are usually preferable to avoid daytime sedation, although if anxiety is also present, longer acting compounds can be useful. Many medications are used off-label for insomnia particularly if there are concomitant symptoms that could be effectively treated at the same time, such as headaches or depression. Many medications typically used for insomnia have not received formal approval by the FDA because they have not applied for insomnia as a specific indication. Substances that promote alertness should be minimized when possible, and additional medicinal therapy should be directed toward a specific disease process. The goal of treatment with any hypnotic should be to help restore normal sleeping patterns, followed by a planned slow elimination of the drug (Table 118.2).

When an individual has less sleep than what is generally considered normal, concern may arise from those around them. Some individuals are *short sleepers* requiring less than 6 hours of sleep but do not complain of sleep/wake disturbances and therefore are not insomniacs per se—they do not have daytime impairment. Others may spend excessive amounts of time in bed. This pattern may occur, for example, from parents allocating too much time for their children to sleep, but the child functions normally. Some adult individuals are *long sleepers*, requiring 10 or more hours of sleep to function without signs of sleep deprivation. Although frustrating to patients, this condition is best treated with longer sleep times so long as no other source of ineffective sleep is found.

The Hypersomnias

Sleepiness is defined as the propensity to enter sleep. Fatigue in contrast is related to physical and/or mental exhaustion but does not result in sleep. Sleepiness is a normal feeling as one approaches a typical sleep period, but excessive sleepiness occurs when one enters sleep at an inappropriate time or setting. Excessive sleepiness can occur in degrees. In mild sleepiness, one might have only limited impairment, such as falling asleep while

TABLE 118.2 A List of Current Medications Approved by the FDA for Insomnia[a]

	FDA-Approved Pharmaceutical Treatment of Insomnia			
Class	**Agent**	**Dosage (mg)**	**Half-life (h)**	**Comments**
Nonbenzodiazepine–benzodiazepine receptor agonists	Zaleplon	5-20	1	—
	Zolpidem	5 (women) 5-10 (men)	1.4-3.6	Available as oral, oral spray, and sublingual forms
	Zolpidem ER	6.25-12.5	1.4-3.6	Women metabolize zolpidem at a lower rate than men.
	Eszopiclone	1-3	5-7	—
Orexin antagonist	Suvorexant	5-20	8-14	Do not use in patients with narcolepsy.
	Lemborexant	5-10	17-19	
Benzodiazepines	Estazolam	0.5-2	10-24	—
	Flurazepam	15-30	47-100	—
	Quazepam	7.5-15	47-100	—
	Temazepam	7.5-30	8-20	—
	Triazolam	0.0625-0.125	1.5-5.5	—
Tricyclic antidepressants	Doxepin	3-6	8-24	Approved in low-dose 3- and 6-mg formulations only
Selective melatonin receptor agonist	Ramelteon	8	8	—

Abbreviation: FDA, U.S. Food and Drug Administration.
[a]Many others are used off-label.

reading a book. Greater degrees of sleepiness, however, may be associated with bouts of irresistible sleep or sleep attacks that intrude on such activities as driving, having a conversation, or eating meals. This degree of sleepiness places the patient at significant risk for accidents and has a major impact on the person's well-being. It must occur for at least 3 months prior to diagnosis.

Clinicians should always question their patients with hypersomnia for clues of potential sleep debt, sleep disorders, or other medical or psychiatric causes. Sleep deprivation is the most common cause of sleepiness. Information regarding sleep habits, schedule during the week and weekends, and environment often discloses other important contributing factors. Excessive sleepiness may result from a wide range of medical disorders and medications. Patients with heart, kidney, or liver failure or rheumatologic or endocrinologic disorders such as hypothyroidism and diabetes may note sleepiness and fatigue. Neurologic disorders such as strokes, tumors, demyelinating diseases, epilepsy, and head trauma can evoke excessive sleepiness. Sleepiness is frequently the cardinal symptom of many sleep disorders (Table 118.3). Patients with sleep apnea, narcolepsy, restless legs syndrome–periodic limb movements, or even parasomnias may note excessive daytime sleepiness as their main complaint. Thus, the clinician should question the patient further to elucidate potential etiologies.

About 2% of men and 1.5% of women report sleeping at least 10 hours per night and are regarded as *long sleepers* (in children, it is 2 h more than the age-specific normative data). The additional sleep time is spent in REM and N2 compared to other individuals. Providing that these individuals obtain sufficient sleep prior to testing, the multiple sleep latency test (MSLT) is normal.

Narcolepsy

Narcolepsy is an incurable lifelong neurologic disorder characterized by the tetrad of (1) excessive daytime sleepiness, (2) cataplexy, (3) sleep paralysis, and (4) hypnagogic hallucinations. Patients with narcolepsy also typically have fragmentation of nocturnal sleep.

Epidemiology

Estimates of prevalence range between 2 and 10 per 10,000 individuals in North America and Europe. It is about 5 times more prevalent in Japan, and the incidence is only 1 per 500,000 in Israel. The symptoms of narcolepsy typically present between ages 10 and 30 years, although cases have been reported with onset as early as age 2 years and as late as 76 years. Men and women are equally affected. There appears to be a bimodal distribution occurring in teenage years and later around age 35 years.

TABLE 118.3 Differential Diagnosis of Excessive Daytime Sleepiness

- Insufficient sleep syndrome
- Sleep apnea syndromes
- Narcolepsy
- Idiopathic hypersomnia
- Demyelinating disease
- Infections
- Sarcoidosis
- Neurodegenerative diseases
- Tumors of the hypothalamus or rostral midbrain
- Metabolic disorders, for example, hypothyroidism, pancreatic insufficiency, renal insufficiency, hepatic encephalopathy
- Drugs, for example, antidepressants, hypnotics, and antihistamines
- Withdrawal of stimulants
- Periodic limb movement disorder
- Circadian rhythm disorders
- Depression

Clinical Features

Symptoms gradually develop over several years, but once it has fully developed, there is usually only a minor fluctuation in the severity. Sleepiness is often minimized or thought to be related to other causes, and diagnosis can be delayed for years or even decades. As weight gain and depression are common, other causes for excessive daytime sleepiness in a previously well-rested individual should be considered.

Diagnosis

Type 1 narcolepsy requires an abnormal MSLT (as described in Chapter 30) and/or cerebrospinal fluid (CSF) hypocretin-1 concentration, measured by immunoreactivity to be less than 110 pg/mL. Cataplexy does not need to be present if hypocretin-1 levels are below 110 pg/mL. Ten percent of individuals with cataplexy will not have hypocretin-1 levels below this cutoff and are now considered to be narcolepsy type 2. Narcolepsy type 2 is diagnosed if the patient has an abnormal MSLT but cataplexy is absent or CSF measurements are greater than 110 pg/mL (or not measured). In the *Diagnostic and Statistical Manual of Mental Disorders*, 5th edition, narcolepsy with the absence of cataplexy is considered *primary hypersomnia*.

Narcolepsy has been associated with several of the human leukocyte antigen (HLA) subtypes. *DQB1*0602* is found in isolation in African Americans and together with *DR2/DRB1*1501* in Caucasians and Asians. Most with narcolepsy type 1 will have the *DQB1*0602*, but it is also found in 12% to 38% of the general population. The risk of narcolepsy type 1 in first-degree relatives is approximately 1% to 2%.

Identification of the hypocretin-orexin gene and receptors in mouse models and humans revealed that narcolepsy type 1 is associated with loss of hypocretin-orexin–producing neurons in the lateral hypothalamus. Hypocretin-orexin in the CSF is found low in patients with cataplexy. Brains from narcolepsy patients show a loss of hypocretin-orexin–producing neurons. This loss of hypocretin-orexin–producing neurons is thought to permit the rapid switching between sleep and wake states.

Narcolepsy

Narcolepsy is a disorder of sleep-wake stability. Patients have bouts of irresistible sleep during wakefulness and frequent arousals during sleep. Intrusion of fragments of REM sleep into wakefulness is most evident in the presence of the symptoms of cataplexy, sleep paralysis, and hypnagogic hallucinations.

Daytime sleepiness is usually the first and most prominent symptom to appear, but hyperactivity may be seen in children as they attempt to fight off sleep. Patients often complain of attacks of irresistible sleep that occur at inappropriate times, such as during conversation, driving, and eating. Brief naps for some are refreshing. The symptom of excessive daytime sleepiness is disabling and often leads to personal, social, and economic problems.

Cataplexy

Cataplexy is the abrupt onset of paralysis or weakness of voluntary muscles without change in consciousness; it is typically precipitated by strong emotions. Events can be triggered by a joke, surprise, anger, fear, or athletic endeavors. These events last seconds to minutes, and patients have clear memory for the complete event with no postictal confusion or deficits. Longer events may proceed to the patient entering sleep. The severity of cataplexy is variable. Some patients may have as few as two or three episodes in a lifetime, whereas others may have several episodes every day. A full range of severity exists between these extremes. Cataplexy may be partial and affect only certain muscles; common examples include dysarthria; drooping of the head, face, and eyelids; and slight buckling of the knees. Severe global attacks affect all skeletal muscles except muscles of respiration and cause collapse. Onset of the attack usually takes seconds with brief moments of partial regaining of muscle tone at the beginning. Examination of the patient during the cataplectic attack will demonstrate paralysis with diffuse hypotonia, absence of deep tendon reflexes, diminished corneal reflexes, preserved pupillary responses, and phasic muscle twitching with preserved consciousness. Reflexes can be preserved in partial cataplexy. Phasic muscle twitching can occur as single jerks or repetitive muscle twitching and is most frequently seen in the face. Most episodes last only seconds to 1 minute, but severe attacks can last minutes. Sudden withdrawal of antidepressants can result in status cataplecticus. Cataplexy typically follows onset of excessive daytime somnolence, usually beginning within 5 years if present.

The combination of excessive daytime sleepiness and cataplexy is nearly always related to narcolepsy. Cataplexy can rarely be seen as an isolated symptom, suggesting an underlying neurologic disorder. Cataplexy has been reported in cases of demyelinating disease, stroke, and Niemann-Pick type C. The historical feature of clear emotional triggers differentiates cataplexy from hypotension, vertebral basilar insufficiency, and the group of neuromuscular disorders known to produce periodic paralysis. Autoimmune or paraneoplastic disorders associated with the aquaporin-4 or anti-Ma2 as well as myotonic dystrophy, parkinsonism, and severe head trauma can also present with narcolepsy.

Sleep Paralysis

Sleep paralysis is a global paralysis of voluntary muscles that occurs at the entry into or emergence from sleep. These events may include the feeling of being chased or impending danger. The terror associated with the events can be recounted by the patient years later. The events are aborted with a tactile stimulation. The paralysis associated with the event is thought to result from the same motor inhibition that occurs in REM sleep. Sleep paralysis without narcolepsy can occur in an isolated form in sleep-deprived healthy individuals but is also frequently seen in patients with depression. Prevalence of a single episode of sleep paralysis is estimated to be between 15% and 40% of the general population. Differential diagnoses for sleep paralysis should include cataplexy, atonic seizures, and familial periodic paralysis syndromes.

Hypnic Hallucinations

Hypnic hallucinations are vivid dreamlike images that occur during sleep onset (hypnogogic) or at sleep offset (hypnopompic). They may include simple to complex visual, auditory, or somatosensory hallucinations. Patients are usually aware of their surroundings and may have difficulty in discerning the hallucinations from reality. The hallucinations can be relatively pleasant or terrifying. Patients may note a feeling of weightlessness, falling, or flying or have out-of-body–like experiences that may sometimes terminate with a sudden jerk (hypnic jerk). Hypnic hallucinations are most likely the result of dissociated CNS processes involved in dreaming during REM sleep. They can be

TABLE 118.4 Comparison Between the *ICSD-3* and the *DSM-5* for the Criteria of Narcolepsy Variants

	Narcolepsy-Hypocretin Deficiency (DSM-5)	Primary Hypersomnia (DSM-5)	
	Narcolepsy Type 1 (ICSD-3)	Narcolepsy Type 2 (ICSD-3)	Idiopathic Hypersomnia (ICSD-3)
Findings on MSLT	<8 min with two or more SOREMPs	<8 min with two or more SOREMPs	<8 min and fewer than two SOREMPs[a]
Cataplexy	Present	Rarely present	Absent
CSF hypocretin	<110 pg/mL	>110 pg/mL	>110 pg/mL
Description of naps	Short and refreshing	Short and refreshing	Long and unrefreshing
Sleep efficiency	Low	Low	High (>90%)

Abbreviations: CSF, cerebrospinal fluid; *DSM-5, Diagnostic and Statistical Manual of Mental Disorders*, 5th edition; *ICSD-3, International Classification of Sleep Disorders*, 3rd edition; MSLT, multiple sleep latency test; SOREMPs, sleep-onset rapid eye movement periods.
[a]If longer than 8 min, the individual must have 11 h of sleep in a 24-h polysomnogram or averaged from 7-d wrist actigraphy.

precipitated by sleep deprivation, medications, and alcohol in normal individuals. Hallucinations typically accompany sleep paralysis in 25% to 75% of cases.

Management

The current treatment for the sleepiness of narcolepsy is the use of stimulant/wake-promoting drugs, behavioral modifications, and/or γ-hydroxybutyrate (6-9 g). The stimulants can be categorized into the amphetamine and nonamphetamines types. Modafinil (100-200 mg), armodafinil (the R-enantiomer of modafinil [150-250 mg]), and solriamfetol (75-150 mg) are wake-promoting agents chemically and pharmacologically distinct from the amphetamine stimulants LEVEL 4.[3] Pitolisant (17.8-35.6 mg) is an H3-inverse agonist and antagonist. Use of stimulant drugs should be carefully monitored; patients and physicians should cooperate in adjusting the amount and timing of doses to meet functional daytime needs and scheduling of patients' activities. Cataplexy, when present to a significant degree, is usually well controlled with the selective serotonin reuptake inhibitors (paroxetine hydrochloride [20-60 mg] or fluoxetine hydrochloride [20-60 mg]) and tricyclic compounds (imipramine hydrochloride [10-100 mg], protriptyline hydrochloride [5-60 mg], or clomipramine [10-150 mg]); however, impotence and reduced libido may occur. These medications are thought to treat cataplexy effectively because they suppress REM sleep. γ-Hydroxybutyrate (6-9 g) is given at bedtime and again during the night to improve sleep and reduce the frequency and severity of both sleepiness and cataplexy. Due to its potential for abuse, it is highly regulated and only available from a single central pharmacy. Pitolisant has evidence of anticataplectic effect in addition to its wake-promoting properties, although currently does not have FDA approval for this indication.

An important adjunctive treatment for narcolepsy is the rational scheduling of daytime naps, two 20-minute naps, for example, and the maintenance of proper sleep hygiene. The physician's role in providing the patient with a clear understanding of the nature of the symptoms and with emotional support in coping with the many adaptive difficulties cannot be overemphasized.

Outcome

Narcolepsy symptoms produce major social, familial, educational, and economic consequences for both the patient and the family. Patients often do not achieve their intellectual potential and suffer frequent failures of occupation, education, and marriage. Family members, friends, and even patients often interpret the symptoms as indicating laziness, lack of ambition, delayed maturation, or psychological defects. Because these symptoms begin during the crucial period of maturation from puberty to adulthood, misinterpretation and lack of diagnosis can greatly affect a patient's personality and feelings of self-esteem (Table 118.4).

Kleine-Levin Syndrome

Kleine-Levin syndrome (recurrent hypersomnia) consists of recurrent episodes of hypersomnia and binge eating lasting from 2 days to 5 weeks (rarely to 80 d), with intervals less than 18 months between episodes. Neurobehavioral and psychological changes, such as disorientation, automatic behavior, forgetfulness, depression, depersonalization, hallucinations, irritability, aggression, and sexual hyperactivity, often accompany the episodes of hypersomnia. During the episodes, the EEG shows general slowing with 0.5- to 2-second bursts of bisynchronous generalized moderate- to high-voltage 5- to 7-Hz waves. This resolves in between episodes. Onset is typically in early adolescent in boys and is less common in girls. Prevalence is estimated to be around one or two cases per million. Episodes decrease in frequency and severity with age and are rarely present after the fourth decade. Differential diagnosis for this condition includes encephalitis, hyperammonemic encephalopathy, demyelinating disease, head trauma, porphyria, basilar migraine, and complex partial status epilepticus as well as psychiatric conditions such as depression, seasonal affective disorder, or somatoform disorder. A menstrual variant of this condition has been reported in 18 women worldwide.

A definitive treatment for Kleine-Levin syndrome is not known, but there are reports of limited success with stimulants (especially amantadine [100-200 mg]), sodium valproate (250-60 mg/kg), carbamazepine (up to 1,200 mg/d) and antidepressant therapy (including lithium [300-1,800 mg]).

Sleep-Related Breathing Disorders

Control of respiration during sleep is an excellent model of state-dependent neuronal regulation. Respiratory patterns vary with sleep stage. Near sleep onset, occasionally, individuals will have normal pauses in breathing. Mild periodicity to breathing can be noted in light sleep, but on entrance into slow-wave sleep, breathing is very regular and response to high carbon dioxide and low oxygen levels is blunted. During REM sleep, chest musculature is paralyzed and ventilation occurs only via diaphragmatic movement. The REM sleep is also characterized by significant variation in respiratory pattern and the least response to high carbon dioxide levels and low oxygen. Each of these stages allows for the expression of dysfunction in the regulation of breathing during sleep. Some individuals with brain or

cardiac pathology may express dramatic periodic breathing or Cheyne-Stokes respiration in NREM sleep, whereas others who have impairment of ventilation owing to diaphragmatic impairment or impediment will demonstrate hypoventilation during REM sleep. More commonly, individuals may have obstruction of the upper airway during sleep.

Snoring

Snoring is created by turbulent airflow vibrating upper airway soft tissue and is more prominent during inspiration and loudest during N3 and REM sleep (the periods of greatest muscle relaxation). Snoring occurs in approximately two-thirds of adults, more commonly in men, and in over 10% of children. Persistent loud snoring is a classic symptom of obstructive sleep apnea syndrome (OSAS), but the absence of snoring does not exclude the diagnosis. Some patients' airways do not resonate to produce snoring. This is especially true in patients who have had upper airway surgical procedures that tightened tissue. Other individuals may not generate enough inspiratory force, such as those with neuromuscular disorders.

Sleep Apnea

Apnea refers to a pause in breathing, and on overnight sleep studies, the pause must persist for at least 10 seconds to be considered apnea. *Hypopneas* are defined as the partial reduction in airflow for a similar time. These respiratory events are accompanied by oxygen desaturation and/or arousals. Apneas and hypopneas are typically more prevalent during light NREM sleep and REM sleep.

Clinical Features

Historically, bed partners may describe these events as though the breathing has stopped or the patient is holding his or her breath during sleep. These events may be aborted with a loud gasp, snort, body jerks, or the quiet resumption of breathing. Some patients have hundreds of events per night and are unable to obtain quality sleep. These individuals are typically unaware of any sleep disruption but feel unrefreshed in the morning. Patients with neurologic disorders are also at higher risk for sleep apnea. Sleep apnea is more commonly seen in individuals with CNS disease such as epilepsy, strokes, and head trauma and "classical" peripheral disease such as muscular dystrophy and myotonic dystrophy. Sleep apnea is classified into two major forms: obstructive and central.

Obstructuve Apnea

Obstructive apnea is the most common form of sleep apnea. These apneas occur due to obstruction or collapse of the upper airway. The OSAS is the cluster of features including snoring, witnessed apneas, excessive daytime sleepiness, insomnia, morning headache, and impairment of daytime performance caused by the repetitive apneas. However, up to half of patients with documented obstructive sleep apnea on overnight polysomnography have no complaints of daytime symptoms. The OSAS is frequently seen in individuals with hypertension, diabetes mellitus, and vascular disease. In adults, OSAS occurs predominantly between the fourth and sixth decades and is more common in men. The prevalence of OSAS increases with age and is higher in individuals with habitual snoring and obesity. The protective effects of estrogen is lost after menopause, and the incidence in men and women becomes similar. Many patients are obese, yet some have normal body habitus. Common structural abnormalities such as narrow nasal passage, long soft palate, large tonsils, or retrognathia leading to a small airway contribute to airway obstruction. Individuals with CNS disease are found to have a higher prevalence of sleep apnea than the general population.

The OSAS is an independent risk for hypertension and the development of vascular disease. Recognized systemic complications of OSAS are systemic hypertension, pulmonary hypertension, diabetes mellitus, cardiac enlargement, myocardial infarction, stroke, elevated hematocrit, and an increased risk of sudden death during sleep.

Sleep apnea also occurs in infants and children. In infants, sleep apnea is associated with familial, congenital, and acquired dysautonomia syndromes and craniofacial disorders. Distinguishing apnea from normal periodic breathing is critical in infants, as some of these disorders are associated with either central or obstructive apneas. In children, obstructive sleep apnea is often associated with adenotonsillar hypertrophy, and daytime sequelae of hyperactivity, poor school performance, behavior problems, and limited growth have been associated.

Central Apnea

Central apnea is the absence of ventilation owing to an absence of generation of respiratory effort. Central apneas can cause complaints of frequent awakenings and restless unrefreshing sleep. These respiratory events can be caused by neurologic abnormalities involving respiratory regulatory neuronal networks. Apneas may also follow neurologic events such as nocturnal seizures or acute strokes. One form of periodic breathing, Cheyne-Stokes breathing, can be seen in individuals with heart/renal failure, neurologic lesions, and metabolic or toxic encephalopathies. Patients with central apnea need a complete cardiac and neurologic examination. Certain medications such as opiates or use of alcohol may also result in central sleep apnea.

Mixed Apnea

When a single event is a combination of the two, the term *mixed apnea* is used. The term *complex sleep apnea* has no standard definition and should be avoided. Some may use it to describe an individual who has both central and obstructive events on diagnostic testing; others use it to describe the emergence of central events when obstructive events are treated.

Management

Treatment for sleep apnea consists primarily of methods of promoting airway patency for obstructive apnea and stimulation of breathing in central apnea.

CPAP

Continuous positive airway pressure (CPAP) is the most common and effective treatment. Constant air pressure is generated by a small pump and delivered via tubing to a mask covering the nose and/or mouth. Patients may be given this treatment during polysomnography to determine the pressure required to alleviate airway obstruction during sleep. Autotitrating devices alter the pressure depending on the level of resistance; these can be prescribed for most individuals without in-laboratory titrations. In some circumstances, the positive airway pressure may need to be altered in both inspiration and expiration to maximize each breath—bilevel CPAP. In some cases of central sleep apnea, adaptive servoventilation may be required. These devices provide variable support to overcome the oscillations between hyperpneas and hypoventilation seen in this condition and

may reduce mortality in certain individuals. However, there is some evidence of increased in mortality in using this ventilatory mechanism in those with heart failure. It is unclear whether treatment is needed for individuals where central sleep apnea is related to opioid use. This breathing pattern resolves with cessation of the offending medications LEVEL 1.[4]

In those with neuromuscular disorders, volume-assured pressure support may be indicated although there is no clear benefit compared to bilevel CPAP. It can, however, adapt as the disease progresses. Typically, those with progressive neuromuscular disorders are monitored with nocturnal oximetry for evidence of sleep-related hypoventilation.

In individuals unable to tolerate any devices but have desaturations during sleep, oxygen may be prescribed. However, there is limited evidence whether sleep-related desaturations (with the absence of wake-related desaturations) are deleterious to health.

Key elements for compliance with positive airway pressure therapy include patient education of the importance of therapy, close follow-up, and addressing patient problems with the therapy. Oral appliances advancing the mandible are reasonable alternative therapies for patient with mild sleep apnea particularly if unable to tolerate positive airway pressure.

Other Treatments

The level of obstruction in obstructive sleep apnea may be found at various levels of the airway. In some patients, especially children and young adults, the removal of enlarged tonsils and adenoids relieves the obstruction. Stimulation devices of the airway have recently been developed to reduce the risk of airway collapse during sleep. The surgical procedure, uvulopalatopharyngoplasty, has been an inconsistently beneficial treatment, and selection criteria are not well established. Genioglossal and maxillary-mandibular advancements have successfully treated patients with structural abnormalities causing hypopharyngeal obstruction. Other treatments for less severe cases have been sustained weight loss and (for those with significant sleep apnea only when supine) sleeping in the lateral position. Neurostimulatory devices targeting the hypoglossal nerve can be effective in those unable to tolerate or to adequately respond to other therapies.

Hypoventilatory and Hypoxemic Disorders

Several causes of hypoventilation during sleep are known and require detection of hypercarbia (sleep-related hypoxemia requires a diagnosis of hypoxia). *Obesity hypoventilation syndrome* results in sleep as well as wake hypercarbia and requires a body mass index of 30 or to be greater than the 95th percentile for age and sex in children. *Congenital central alveolar hypoventilation syndrome*, previously called *Ondine's curse*, is a syndrome of the automatic central control of breathing due to the *PHOX2B* gene. It must be distinguished from mimickers such as Chiari malformation, obesity hypoventilation syndrome, Leigh disease, or congenital heart disease when cor pulmonale coexists. *Late-onset central hypoventilation with hypothalamic dysfunction* presents after the first few years of life with hyperphagia and respiratory failure from minor provocation. Temperature dysregulation, precocious puberty, thyroid disease, and other endocrinologic disorders may occur from inappropriately elevated or reduced levels of hypothalamic hormones.

Catathrenia

Catathrenia is the term associated with sleep-related groaning typically associated with a prolonged expiration that disturbs the bed partner or family members. It is more common in men although remains rare. There are no known long-term consequences of it and it can be treated effectively with positive airway pressure.

SLEEP-RELATED MOVEMENT DISORDERS

Restless Legs Syndrome and Periodic Limb Movement Disorder

Periodic limb movements in sleep (PLMS) are found in most patients with restless legs syndrome who are studied with polysomnography but are more commonly associated without symptoms of restless legs syndrome. Although most patients do not complain of symptoms related to the PLMS, patients or their bed partner may notice leg or arm movements during sleep. These movements may occur as periodic events or appear random. The PLMS are repetitive stereotyped movements of any of the extremities. These most commonly occur in NREM sleep and activate the lower extremities as extension of the great toe with dorsiflexion of the ankle and flexion of the knee and hip. Movements can also occur in the arms and axial muscles. The individual movements are relatively brief, lasting 0.5 to 5.0 seconds, occur at 20- to 90-second intervals, and may continue for minutes to hours. Limb movements may be accompanied by an arousal or awakening. In contrast to most movement disorders, which are diminished by sleep (eg, cerebellar and extrapyramidal tremors, chorea, dystonia, hemiballism), PLMS are initiated by sleep or drowsiness. They are also different from *hypnic jerks* (sleep starts), which are normal, nonperiodic, isolated myoclonic movements. Similar to restless legs syndrome, periodic limb movements are provoked by uremia, anemia, peripheral neuropathy, antiemetics, antidepressants, and caffeine use.

In individuals with restless legs syndrome, limb movements can be seen on the polysomnography. Periodic limb movements of sleep, however, are not necessary and are not correlative with restless legs syndrome. Eighty percent of sufferers have periodic limb movements of sleep. Periodic limb movements during wakefulness have also been noted and have been proposed as a better marker.

Restless legs syndrome is discussed in detail in Chapter 78. It is important to note that restless legs syndrome is a clinical diagnosis based on questioning the individual. It does not require a sleep study to diagnose.

In a case of hypersomnia where all medical causes, psychiatric diseases, and other sleep disorders have been excluded and the only abnormality is periodic limb movements, then *periodic limb movement disorder* is diagnosed. Periodic limb movement disorder is mutually exclusive of restless legs syndrome. There is limited literature on the treatment but is empirically treated with similar therapeutic approaches as restless legs syndrome.

Sleep-Onset Movements

Some movements occur at the transition between wake and sleep. *Sleep-related rhythmic movement disorder* involves large muscle groups moving in a stereotyped repetitive fashion that is not a tremor. It may involve the head, torso, or limbs in isolation. Sleep-related movement disorder is common in children and typically does not require treatment except protection from

injury if movements are violent. It rarely persists into adulthood, in which case it can be disruptive to bed partners and treated with low-dose clonazepam (0.25-1 mg). When smaller muscle groups are involved, other diagnoses such as bruxism, thumb sucking, or hypnagogic foot tremor, excessive fragmentary myoclonus should be considered. *Propriospinal myoclonus* results in difficulty initiating sleep and affects mainly the abdomen, trunk, and neck. When it is persistent into the daytime, a structural cause is found in 15% to 20% of cases. It typically spreads slow to rostral and caudal muscles from the axial muscles. *Sleep starts* or *hypnic jerks* involve one or more body segments in a single contraction and often asymmetrically. These may occur in association with a sensory component such as loud noise or a sensation of falling. Sleep deprivation, excessive stimulants, prior intense exercise, and emotional stress can increase frequency and severity of sleep starts. They are also prominent in heredity hyperekplexia LEVEL 1.[5]

Sleep-Related Movements

Body movements may occur during sleep such as the presentation of parasomnias or sleep-related leg cramps. *Benign sleep myoclonus of infancy* occurs only in sleep, whereas myoclonic seizures and myoclonic encephalopathy will also occur in wakefulness.

Circadian Rhythm Disorders

Disorders of the circadian sleep-wake cycle are divided into two major categories, transient and persistent. The *transient disorders* include the temporary sleep disturbance following an acute work shift change and a rapid time zone change (jet lag). Both sleep deprivation and the circadian phase shift produce symptoms including insomnia symptoms and excessive sleepiness. These disorders usually resolve as external and internal cycles become aligned. The *Diagnostic and Statistical Manual of Mental Disorders*, 5th edition, removed jet lag disorder from its list of conditions; however, the *International Classification of Sleep Disorders* still recognizes its existence.

Other disorders are more persistent. Sleep-wake cycle disorders that persist are divided into several major clinical categories. Persons who voluntarily and frequently change their sleep-wake schedule (eg, shift workers) have a mixed pattern of excessive sleepiness alternating with arousal at inappropriate times of the day or have minimal circadian pattern. Sleep is typically short and disrupted. Waking is associated with a decrease in performance and vigilance. This syndrome often disrupts social and family life.

Delayed Sleep Phase

The *delayed sleep phase type* is a specific chronobiologic sleep disorder characterized by going to bed late and waking up late in the morning. Patients are typically unable to fall asleep earlier and go to sleep between 1 and 6 AM. On weekends and vacation days, they sleep until late morning or early afternoon and feel refreshed but have great difficulty awakening at the required 7 or 8 AM for work or school. These patients have a normal sleep length and internal organization of sleep when clock time of sleep onset and sleep offset coincides with the circadian timing that controls daily sleep.

Successful treatment has been a phase shift of the time of the daily sleep episode by progressive phase delay of the sleep time. By delaying the time of going to sleep and awakening by 2 or 3 hours each day (ie, a 26- or 27-h sleep-wake cycle), the patient's sleep timing can be successfully reset to the preferred clock time. Additionally, treatment with bright light in the morning and melatonin (0.2-0.5 mg) or a melatonin agonist in the evening may help shift and lock the circadian rhythm to a desired schedule LEVEL 1.[6]

Advanced Sleep Phase

The *advanced sleep phase type* is a condition in which individuals go to bed early in the evening and wake early in the morning. Typical sleep onset is between 6 and 8 PM, with wake times between 1 and 3 AM despite efforts to delay sleep time. This pattern is more likely to occur in elderly persons. Treatment of bright light in the evening and extended-release melatonin may help the sleep-wake schedule.

Nonentrained and Irregular Sleep Phase

The rare individual with the free running type or *nonentrained type* maintains a 25- to 27-hour biologic day that does not entrain to the world's 24-hour cycle. This is more common in individuals who have prechiasmatic blindness, as light stimulus (a primary zeitgeber) does not reach the suprachiasmatic nucleus. This is in contrast to a person with an *irregular sleep-wake type* consisting of considerable irregularity without an identifiable persistent sleep-wake rhythm. There are frequent daytime naps at irregular times and a disturbed nocturnal sleep pattern. This disorder indicates dysfunction of the pacemaker, and most patients with this syndrome have congenital, developmental, or degenerative brain dysfunction, although it does occur rarely in cognitively intact patients. Treatment is difficult but should include regularly scheduled activities and time in bed based on sleep hygiene principles.

Nocturnal Behaviors

Parasomnias

Parasomnias are undesirable physical or behavioral phenomena that occur predominantly during sleep. They include disorders of arousals, such as sleepwalking or night terrors; sleep-wake transition disorders, such as sleep talking; and REM parasomnias, such as REM sleep behavior disorder (RBD). These behavioral events may mimic epileptic seizures or other psychiatric events. Key features of age of onset, time of night of the events, stereotypic behavior, memory for the events, and family history are important in historically distinguishing the etiologies. Although RBD is the only disorder requiring polysomnography for diagnosis, most patients require polysomnographic recording (with complete EEG if epilepsy is in the differential) to delineate the cause or other potential sleep disorders provoking the parasomnia.

Non–Rapid Eye Movement Parasomnias

The classic disorders of arousal occur out of slow-wave sleep and include *sleepwalking, sleep terrors*, and *confusional arousals*. These behaviors are more common in children and adolescents and are characterized as events occurring as partial arousals from the deeper stages of NREM sleep. These patients are caught in a transition of part of the brain in NREM sleep and another portion in wake. These nonstereotypic events are more common in the first half of the night (when N3 is more prevalent), and typically, patients have little to no memory for the events; recall may increase with age. Sleepwalking usually involves a series of simple motor behaviors, such as sitting up in bed, walking, opening and closing doors, or climbing stairs, however, can rarely result in jumping out of bed as well as violent behaviors.

Other automatic behaviors such as eating (sometimes of inappropriate substances) or sexual behavior can occur. Higher cognitive functions are significantly impaired, and there is reduced vigilance although motor behavior is intact. Self-injury and injury to those around them can occur.

Sleep terrors, however, start with a piercing scream or fright with significant sympathetic nervous system output. Patients have tachycardia, pupillary dilation, and sweating and appear wide eyed and inconsolable. A subgroup of patients may be harmful to themselves or others, such as fighting, throwing objects, and climbing out or walking through a window.

Confusional arousals occur following sudden awakening and may be accompanied with disorientation and the patient striking out. Other variations include sleep-related eating disorder, which is hallmarked by patients eating in a messy, haphazard manner with little or no recall. Sleep-related abnormal sexual behaviors can involve masturbatory behavior and sexual vocalizations and may have criminal consequences due to the initiation of sexual intercourse, molestation, or assault.

A small nightly dose of a benzodiazepine, such as clonazepam (0.25-4 mg) or temazepam (7.5-30 mg), is useful, especially when potential exists for the patient or bed partner to be injured. Medication such as zolpidem, phenothiazines, anticholinergics, and lithium may provoke these episodes. Hypnosis has also been used. Generally, treatment is not required, but safety is a priority especially when the individual has a tendency to leave the bed.

Rapid Eye Movement Parasomnias

RBD, a REM sleep–related parasomnia, is characterized by intermittent loss of REM sleep atonia with dream enactment. Patients usually have clear recall of the dream, and witnesses can relate the activity to the dream mentation. Events are more likely to occur in the latter half of the night (when REM is more prevalent) and do not have stereotypic behavior. Injury to self or bed partner is common. Up to 80% of middle-aged adults may develop signs of a synucleinopathy (such as Parkinson disease, dementia with Lewy bodies, or multiple system atrophy) within a decade of their RBD onset. Some studies also suggest that if individuals are monitored over several decades 100% will develop evidence of a syncleinopathy. This association is less clear when idiopathic RBD begins at a younger age. The prevalence of RBD is unknown but appears to be more common in older men. Some patients may develop RBD due to structural lesions interrupting the REM atonia pathway. Medications such as serotonin reuptake blockers and norepinephrine reuptake blockers have been cited to result in RBD-like behavior, although there is no evidence currently that these predispose to the condition.

The diagnosis is usually suggested by history and is required to be confirmed by polysomnography. Recordings show persistent muscle tone and complex behaviors during REM sleep. Most patients respond to clonazepam (0.25-4 mg) at bedtime, but success has been reported with melatonin (2-12 mg) and donepezil (10-15 mg) LEVEL 3.[7] Modifications to the sleeping environment are sometimes required to avoid self-injury and to those around them, such as bedrails, sleeping on a mattress on the floor, or placing the individual in a sleeping bag (Table 118.5).

Other REM parasomnias include painful erections, nightmares, and REM sleep–related sinus arrest, which are beyond the scope of this chapter.

Anti-IgLON5 (a neuronal cell adhesion protein) disease first described in 2014 is a heterogeneous disorder presenting with REM behavior disorder, NREM parasomnias, sleep-related breathing as well as gait abnormalities, cognitive dysfunction, and bulbar symptoms. This disease typically occurs after the age of 60 years. It is unknown if it is a primary tauopathy with a secondary immune response or a primary autoimmune disease. HLA-DRB1*10:01 and HLA-DQB1*05:01 are associated with the disorder.

TABLE 118.5 Differential Diagnosis of Dream Enactment Behavior

• REM behavior disorder
• Severe obstructive sleep apnea
• Periodic limb movement disorder
• Frontal lobe epilepsy
• Disorders of arousal
• Oneiric stupor
• Hallucinations in dementia
• Confusional awakenings in dementia
• Dissociative disorder

Abbreviation: REM, rapid eye movement.

CONCLUSION

Nearly every CNS process has been associated with disruption of sleep. The ubiquity of sleep and the brain makes this dynamic relationship even more important. Sleep may be abnormal because of involvement of brain structures that control and regulate sleep and wakefulness or because of abnormal movements or behaviors that occur during sleep. Additionally, the loss of sleep provokes further dysfunction of the brain. For example, patients with epilepsy have fewer seizures once treated for their previously unrecognized obstructive sleep apnea. Other small studies have shown patients with neuromuscular disorders improve their daytime function when their sleep-related respiratory disturbances are treated. As neurologists, we must be keenly aware that sleep provides another dimension of diagnostic and therapeutic avenues for diseases of the nervous system. More importantly, perhaps, we need to be vigilant for sleep disorders contributing to morbidity in our patients, particularly as nearly all are treatable, potentially resulting in increased quality of life.

LEVEL 1 EVIDENCE

1. American Academy of Sleep Medicine. *International Classification of Sleep Disorders*. 3rd ed. Darien, IL: American Academy of Sleep Medicine; 2014.
2. Morgenthaler T, Kramer M, Alessi C, et al. Practice parameters for the psychological and behavioral treatment of insomnia: an update. An American Academy of Sleep Medicine report. *Sleep*. 2006;29(11):1415-1419.
3. Morgenthaler TI, Kapur VK, Brown TM, et al. Practice parameters for the treatment of narcolepsy and other hypersomnias of central origin. An American Academy of Sleep Medicine report. *Sleep*. 2007;30:1705-1711.
4. Aurora N, Chowdhuri S, Ramar K, et al. The treatment of central sleep apnea syndromes in adults: practice parameters with an evidence-based literature review and meta-analyses. *Sleep*. 2012;35(1):17-40.

5. Chesson AL Jr, Wise M, Davila D, et al. Practice parameters for the treatment of restless legs syndrome and periodic limb movement disorder. An American Academy of Sleep Medicine report. Standards of Practice Committee of the American Academy of Sleep Medicine. *Sleep*. 1999;22:961-968.
6. Morgenthaler TI, Lee-Chiong T, Alessi C, et al. Practice parameters for the clinical evaluation and treatment of circadian rhythm sleep disorders. *Sleep*. 2007;30(11):1445-1459.
7. Aurora RN, Zak RS, Maganti RK, et al. Best practice guide for the treatment of REM sleep behavior disorder (RBD). *J Clin Sleep Med*. 2010;6(1):85-95.

SUGGESTED READINGS

Ackermann S, Rasch B. Differential effects of non-REM and REM sleep on memory consolidation? *Curr Neurol Neurosci Rep*. 2014;14:430.

Berry RB, Brooks R, Gamaldo CE, et al. *The AASM Manual for the Scoring of Sleep and Associated Events: Rules, Terminology and Technical Specifications. Version 2*. Westchester, IL: American Academy of Sleep Medicine; 2014.

Billiard M. Idiopathic hypersomnia. *Neurol Clin*. 1996;14:573-582.

Black J, Houghton WC. Sodium oxybate improves excessive daytime sleepiness in narcolepsy. *Sleep*. 2006;29(7):939-946.

Boeve BF. Idiopathic REM sleep behaviour disorder in the development of Parkinson's disease. *Lancet Neurol*. 2013;12(5):469-482.

Claassen DO, Josephs KA, Ahlskog JE, Silber MH, Tippmann-Peikert M, Boeve BF. REM sleep behavior disorder preceding other aspects of synucleinopathies by up to half a century. *Neurology*. 2010;75:494-499.

de Lecea L, Kilduff TS, Peyron C, et al. The hypocretins: hypothalamus-specific peptides with neuroexcitatory activity. *Proc Natl Acad Sci U S A*. 1998;95:322-327.

Drummond SP, Walker M, Almklov E, Campos M, Anderson DE, Strauss LD. Neural correlates of working memory performance in primary insomnia. *Sleep*. 2013;36(9):1307-1316.

Feber R. Childhood sleep disorders. *Neurol Clin*. 1996;14:493-511.

Giles TL, Lasserson TJ, Smith BH, White J, Wright J, Cates CJ. Continuous positive airways pressure for obstructive sleep apnoea in adults. *Cochrane Database Syst Rev*. 2006;(3):CD001106.

Greenstone M, Hack M. Obstructive sleep apnoea. *BMJ*. 2014;348:g3745.

Harris SF, Monderer RS, Thorpy M. Hypersomnias of central origin. *Neurol Clin*. 2012;30(4):1027-1044.

Heidbreder A, Philipp K. Anti-IgLON 5 disease. *Curr Treat Options Neurol*. 2018;20(8):29.

Iliff JJ, Wang M, Liao Y, et al. A paravascular pathway facilitates CSF flow through the brain parenchyma and the clearance of interstitial solutes, including amyloid β. *Sci Transl Med*. 2012;4(147):147ra111.

Kang J-E, Lim MM, Bateman RJ, et al. Amyloid-beta dynamics are regulated by orexin and the sleep-wake cycle. *Science*. 2009;326(5955):1005-1007.

Kryger MH, Roth T, Dement WC, eds. *Principles and Practice of Sleep Medicine*. 5th ed. Philadelphia, PA: WB Saunders; 2010.

Lopez R, Dauvilliers Y. Pharmacotherapy options for cataplexy. *Expert Opin Pharmacother*. 2013;14(7):895-903.

Mahowald MW, Schenck CH. NREM sleep parasomnias. *Neurol Clin*. 1996;14:675-696.

Malhotra RK, Avidan AY. Parasomnias and their mimics. *Neurol Clin*. 2012;30(4):1067-1094.

Martin TJ, Sanders MH. Chronic alveolar hypoventilation: a review for the clinician. *Sleep*. 1995;18:617-634.

Mason M, Welsh EJ, Smith I. Drug therapy for obstructive sleep apnoea in adults. *Cochrane Database Syst Rev*. 2013;(5):CD003002.

Menaker M, Murphy ZC, Sellix MT. Central control of peripheral circadian oscillators. *Curr Opin Neurobiol*. 2013;23(5):741-746.

Mignot E, Lammers GJ, Ripley B, et al. The role of cerebrospinal fluid hypocretin measurement in the diagnosis of narcolepsy and other hypersomnias. *Arch Neurol*. 2002;59(10):1553-1562.

Mignot E, Nishino S. Emerging therapies in narcolepsy-cataplexy. *Sleep*. 2005;28(6):754-763.

Newman AB, Nieto FJ, Guidry U, et al. Relation of sleep-disordered breathing to cardiovascular disease risk factors: the Sleep Heart Health Study. *Am J Epidemiol*. 2001;154(1):50-59.

Obermeyer WH, Benca RM. Effects of drugs on sleep. *Neurol Clin*. 1996;14:827-840.

Oliveira MM, Conti C, Prado GF. Pharmacological treatment for Kleine-Levin syndrome. *Cochrane Database Syst Rev*. 2013;(8):CD006685.

Postuma RB, Gagnon JF, Tuineaig M, et al. Antidepressants and REM sleep behavior disorder: isolated side effect or neurodegenerative signal? *Sleep*. 2013;36(11):1579-1585.

Prinz PN. Sleep and sleep disorders in older adults. *J Clin Neurophysiol*. 1995;12:139-145.

Rasch B, Born J. About sleep's role in memory. *Physiol Rev*. 2013;93(2):681-766.

Richardson GS, Malin HV. Circadian rhythm sleep disorders: pathophysiology and treatment. *J Clin Neurophysiol*. 1996;13:17-31.

Riemann D, Spiegelhalder K, Feige B, et al. The hyperarousal model of insomnia: a review of the concept and its evidence. *Sleep Med Rev*. 2010;14(1):19-31.

Roth T, Dauvilliers Y, Mignot E, et al. Disrupted nighttime sleep in narcolepsy. *J Clin Sleep Med*. 2013;9(9):955-965.

Sabater L, Gaig C, Gelpi E, et al. A novel non-rapid-eye movement and rapid-eye-movement parasomnia with sleep breathing disorder associated with antibodies to IgLON5: a case series, characterisation of the antigen, and post-mortem study. *Lancet Neurol*. 2014;13(6):575-586.

Sack RL, Auckley D, Auger RR, et al. Circadian rhythm sleep disorders: part I, basic principles, shift work and jet lag disorders. An American Academy of Sleep Medicine review. *Sleep*. 2007;30(11):1460-1501.

Sakurai T, Amemiya A, Ishii M, et al. Orexins and orexin receptors: a family of hypothalamic neuropeptides and G protein–coupled receptors that regulate feeding behavior. *Cell*. 1998;92:573-585.

Saper CB. The central circadian timing system. *Curr Opin Neurobiol*. 2013;23(5):747-751.

Saper CB, Fuller PM. Wake-sleep circuitry: an overview. *Curr Opin Neurobiol*. 2017;44:186-192.

Saper CB, Scammell TE, Lu J. Hypothalamic regulation of sleep and circadian rhythms. *Nature*. 2005;437(7063):1257-1263.

Schenck CH, Mahowald MW. REM sleep parasomnias. *Neurol Clin*. 1996;14:697-720.

Schmidt-Nowara W, Lowe A, Wiegand L, Cartwright R, Perez-Guerra F, Menn S. Oral appliances for the treatment of snoring and obstructive sleep apnea: a review. *Sleep*. 1995;18:501-510.

Silber MH. Sleep-related movement disorders. *Continuum (Minneap Minn)*. 2013;19(1 Sleep Disorders):170-184.

Szakacs Z, Dauvilliers Y, Mikhaylov V, et al. Safety and efficacy of pitolisant on cataplexy in patients with narcolepsy: a randomised, double-blind, placebo-controlled trial. *Lancet Neurol*. 2017;16(3):200-207.

Thorpy MJ. The clinical use of the multiple sleep latency test. The Standards of Practice Committee of the American Sleep Disorders Association. *Sleep*. 1992;15:268-276.

Thorpy MJ, Shapiro C, Mayer G, et al. A randomized study of solriamfetol for excessive sleepiness in narcolepsy. *Ann Neurol*. 2019;85(3):359-370.

Tononi G, Cirelli C. Sleep and the price of plasticity: from synaptic and cellular homeostasis to memory consolidation and integration. *Neuron*. 2014;81(1):12-34.

Vignatelli L, Billiard M, Clarenback P, et al. EFNS guidelines on management of restless legs syndrome and periodic limb movement disorder in sleep. *Eur J Neurol*. 2006;13:1049-1065.

Wise MS. Narcolepsy and other disorders of excessive sleepiness. *Med Clin North Am*. 2004;88:597-610, vii-viii.

Wozniak DR, Lasserson TJ, Smith I. Educational, supportive and behavioural interventions to improve usage of continuous positive airway pressure machines in adults with obstructive sleep apnoea. *Cochrane Database Syst Rev*. 2014;(1):CD007736.

Yaggi HK, Concato J, Kernan WN, Lichtman JH, Brass LM, Mohsenin V. Obstructive sleep apnea as a risk factor for stroke and death. *N Engl J Med*. 2005;353(19):2034-2041.

Heart-Brain Interactions 119

Shouri Lahiri and Stephan A. Mayer

KEY POINTS

1. Acute stroke after cardiac procedures can occur due to arrhythmia, hypoperfusion, thromboembolism, and coagulopathy.
2. Risks and benefits of antithrombotic medications should be considered in patients with acute stroke due to cardiac devices.
3. Reversibility is a hallmark feature of neurogenic stunned myocardium.
4. β-Blockers are a first-line treatment for paroxysmal sympathetic hyperactivity.

INTRODUCTION

The heart-brain interaction is a vital physiologic circuit often implicated in neurologic and cardiovascular injury. Cerebral complications of cardiac procedures and stroke due to atrial arrhythmias represent important causes of neurologic disability. Recent advances and complications of cardiopulmonary support with left ventricular assist device (LVAD) and extracorporeal membrane oxygenation (ECMO) have opened the door to new neurologic diagnostic and therapeutic challenges. Conversely, severe acute brain injury is being increasingly recognized as a cause of catecholamine-mediated myocardial dysfunction, an entity that is known by many names (Table 119.1) but is most accurately described as *neurogenic stunned myocardium* (NSM).

Autonomic storming is similarly caused by exaggerated sympathetic effect after brain injury and is characterized by cardiovascular abnormalities including coexistent hypertension and tachycardia. Neurogenic hypotension in the absence of cardiac dysfunction usually results from abnormal vasomotor tone and is discussed in Chapter 116.

TABLE 119.1 Synonyms for Neurogenic Stunned Myocardium

Takotsubo cardiomyopathy
Apical ballooning syndrome
Broken heart syndrome
Stress-induced cardiomyopathy
Contraction band necrosis

CEREBRAL COMPLICATIONS OF CARDIAC PROCEDURES

Epidemiology

Cerebrovascular injury is one of the most feared complications of cardiac surgery. Ischemic strokes occur in 0.8% to 5.2% of coronary artery bypass graft (CABG) surgeries, although the incidence may be decreasing with more recent publications from 2011 reporting incidence closer to 1.6%. One single-center study of more than 45,000 patients found that 40% of the strokes occurred intraoperatively with the postoperative risk for stroke peaking at 40 hours following surgery. The risk for stroke is greater for patients undergoing CABG with aortic atherosclerosis and concomitant carotid artery disease, and the risk is directly proportional to the degree of stenosis. Other risk factors for perioperative stroke with CABG include atrial fibrillation, prior stroke or transient ischemic attack, and female gender. Cognitive disability in the absence of acute infarct occurs in up to 70% of patients following CABG. The reported incidences of postoperative cognitive decline are widely variable and likely reflect variability of the cardiac procedure itself to differing neuropsychiatric testing methods and control groups.

Atrial fibrillation occurs in up to 40% of patients within a few days following CABG. It occurs in up to 50% of patients after valve surgery and up to 60% of patients following valve replacement plus CABG. Eleven percent of patients develop atrial fibrillation as a late complication of CABG. In the general population, the most common causes of atrial fibrillation are hypertension, coronary heart disease, and rheumatic heart disease, with the latter being uncommon in developed countries. The risk of ischemic stroke due to atrial fibrillation may be stratified using scoring systems such as $CHADS_2$, which incorporate additional risk factors for stroke including heart failure, advanced age, diabetes, prior stroke, female gender, etc. Refer to Chapter 45 for a detailed discussion of stroke risk due to atrial fibrillation.

LVAD and ECMO have dramatically changed the therapeutic landscape of severe, medically refractory cardiopulmonary failure. Neurologic complications are, however, common and occur in 8% to 25% of patients with LVADs. In a series from the University of Pittsburgh Medical Center, 61% of LVAD-related neurologic complications were due to embolic strokes, and 25% were intracerebral hemorrhages. In another single-center study from Columbia University, 14% of patients with LVADs developed neurologic complications of which 81% were either due to ischemic or hemorrhagic stroke. A recent review on LVAD-related bleeding and thrombosis from 2012 found that the incidence of ischemic strokes was 0.04 to 0.13 per patient-year

and 0.05 to 0.8 per patient-year and for hemorrhagic strokes. Relatively, little has been reported on the neurologic complications of adult patients on ECMO. In one series, 50% of patients receiving ECMO suffered neurologic injury of which 17% were strokes defined as either ischemic stroke, hemorrhagic stroke, or subarachnoid hemorrhage. The frequency of neurologic events was likely underestimated in this study because less than one-third of the patients underwent cerebral imaging.

Pathobiology

The majority of strokes after cardiac surgery are ischemic, although hemorrhagic conversion of ischemic infarcts is possible. Intraoperative strokes occur due to arterial emboli arising from atherosclerosis of major vessels such as the aorta or carotid arteries or due to cerebral hypoperfusion resulting from intraoperative hypotension or diminished cardiac output. Fat and air emboli may also occur. Transcranial Doppler ultrasonography monitoring of the middle cerebral artery has been used to quantify microemboli during coronary bypass surgery, which in some cases exceed 60 per operation. High-risk periods for embolization include manipulation of the heart and aorta, particularly during aortic clamping and cannulation. No causal relationship has been confirmed between number of microemboli and cognitive decline, although increased burden of new ischemic lesions has been associated with postoperative cognitive decline. Other factors that are thought to contribute to cognitive impairment after CABG include relative cerebral hypoperfusion, anesthesia, and systemic inflammatory effects.

Postoperative strokes are generally cardioembolic and related to postoperative arrhythmias such as atrial or ventricular fibrillation. Cerebral complications of atrial fibrillation occur due to embolization of thrombus from the left atrium or atrial appendage. Strokes due to atrial fibrillation are more likely to cause large-vessel occlusion and hemispheric injury than embolic sources arising from the carotid arteries. This was demonstrated in a study that showed that cardioembolic etiologies of stroke were 25 times likely to cause hemispheric events than retinal events. The presumed mechanism for this difference is the larger size of cardioembolic particles compared to emboli arising from the carotid arteries.

LVADs pose extraordinary challenges related to coagulopathy. Although anticoagulation is required to decrease risk of device thrombosis and thromboembolism, this comes at the cost of increased hemorrhagic complications. Furthermore, high-shear stress conditions related to LVADs are thought to induce an acquired von Willebrand syndrome by mechanical destruction of von Willebrand multimers. As a result, LVAD patients are at higher risk for both hemorrhagic and ischemic strokes. Hemorrhagic strokes in patients with mechanical circulatory devices should raise suspicion for endocarditis. The role of infections and inflammatory milieu on neurologic complications is an ongoing debate in patients both with and without mechanical circulatory devices. In one study of LVAD patients, 42% of cerebrovascular accidents occurred in patients with infections. An elevated white blood cell count was noted in patients with neurologic complications regardless of the presence or absence of infection, although it is unclear whether this represented a stress reaction from acute brain injury. The same study found thromboelastogram abnormalities in periods with infection than without infection suggesting that infection may activate platelet function and contribute to the risk of neurologic injury.

Similar to the LVAD, anticoagulation is required to decrease the risk of ECMO-related thrombosis and thromboembolism. Also analogous to the LVAD, increased platelet activation and consumption due to exposure to foreign surface area is common, further contributing to a bleeding diathesis. The net result is a significantly increased risk of bleeding in up to 40% of patients receiving ECMO. Thromboembolic complications are more common in venoarterial compared to venovenous ECMO because blood is infused directly to the systemic circulation with the former. Greater risk of retrograde aortic blood flow and stasis of the blood due to worsening left ventricular output also increase the risk of thrombus formation.

Diagnosis

Initial diagnosis of stroke is suggested by history and physical examination and then corroborated by neuroimaging. The clinical manifestation of stroke reflects the dysfunction of the affected neuroanatomic structures. Although hemiparesis is a common symptom of stroke, it is not an invariable finding because isolated aphasia syndromes may also be encountered. When hemiparesis is present, it may be limited to hand or fine finger movements and mistaken for a compression neuropathy. Approximately 20% of ischemic strokes involve the posterior circulation and can present with subtle eye movement abnormalities, behavioral changes, and cortical blindness—a constellation of symptoms that raise suspicion for the potentially devastating "top of the basilar" syndrome. Although there is overlap between the clinical presentations of ischemic and hemorrhagic strokes, the latter is more likely to have a more fulminant presentation with prominent impairment consciousness and rapid progression of symptoms. Neuroimaging remains an essential tool to distinguish between ischemic and hemorrhagic stroke etiologies.

The National Institute of Health Stroke Scale is a reliable 15-item scale that is validated as a measure of stroke impairment (see Chapter 16). Computed tomography of the brain is often used as an initial diagnostic test for intracranial hemorrhage because hyperacute ischemic changes may not be evident. Magnetic resonance imaging of the brain with diffusion-weighted imaging may detect ischemic abnormalities as early as within 3 minutes of symptom onset; however, it may be contraindicated in patients with metallic devices such as LVADs and certain pacemakers. Blood cultures, fungal cultures, and transesophageal echocardiograms should be obtained when there is a suspicion for endocarditis and septic emboli and particularly in patients with mechanical circulatory devices. Cerebral angiography may be indicated to diagnose mycotic aneurysms.

Management

Prevention

It is critical to employ measures to prevent neurologic complications during cardiac surgery. Preoperative evaluation involves assessment of risk factors including carotid stenosis. The risk of stroke during cardiac surgery may be lowered by performing simultaneous carotid endarterectomy. Avoiding relative hypotension during cardiac surgery may improve outcomes. This was shown in a randomized trial of 248 patients where maintaining higher pressures (mean artery pressures 80-100 vs 50-60 mm Hg) during cardiopulmonary bypass was significantly associated with lower rates of neurologic and cardiac complications or death at 6 months LEVEL 1.[1] More recent studies suggest a potential role for targeting individualized blood pressure goals based on cerebral autoregulation indices. Systemic hypothermia at 32°C for closed chamber and 28°C for open chamber procedures during cardiopulmonary bypass may reduce

cerebral metabolic rate and prevent ischemia. Transesophageal echocardiogram reduces the risk of intraoperative strokes by enhanced detection of aortic atheroma enabling the surgeon to alter technique to reduce risk of embolization. Electroencephalography can also be used to detect cerebral ischemia during cardiac surgery, although the use of this is debated.

Acute Ischemic Stroke

Thrombolytic therapy is often contraindicated for acute ischemic stroke during the postoperative period and in patients being treated with therapeutic levels of anticoagulation. Strokes occurring due to septic emboli from infected hardware also increase the risk of hemorrhage due to thrombolysis. Alternative reperfusion techniques including endovascular therapies may be considered in the appropriate circumstances. In patients with LVADs or patients receiving ECMO, the benefits of anticoagulation for thromboembolism need to be balanced with the risks of hemorrhagic conversion of ischemic infarct for a given patient based on stroke severity, size, and timeline. There are currently limited data on the optimal time frame for restarting antithrombotics; however, significant delays in restarting these medications further increase the considerable risk of thromboembolism. Other management strategies of acute ischemic stroke are discussed in Chapter 16.

Intracranial Hemorrhage

Intracranial hemorrhage is primarily a risk of LVAD and ECMO support due to the need for anticoagulation, acquired Von Willebrand factor deficiency, and concurrent risk of brain embolism. Initial management should involve discontinuation of all antiplatelet medications and anticoagulation. Anticoagulation reversal should be strongly considered for life-threatening hemorrhages with the understanding that these interventions may increase the risk of device thrombosis in patients with cardiopulmonary devices. Hemostatic therapy should be tailored to the specific anticoagulant exposure (see Table 39.3). For example, protamine sulfate may be used for heparin-related intracerebral hemorrhage, and vitamin K with prothrombin complex concentrate/fresh frozen plasma may be used for warfarin-related intracerebral hemorrhage. Targeted antidotes for factor Xa inhibitors (inactivated coagulation factor Xa), direct thrombin inhibitors, antifibrinolytics, and recombinant factor VIIa may also be considered in the appropriate clinical setting. Platelet transfusions or desmopressin (DDAVP) may be considered for selected patients. Blood pressure should be managed as per current guidelines (see Table 40.2). Endocarditis should be treated with antibiotics and surgical evaluation (see also Chapter 65). There is currently limited data on when to restart antithrombotics after intracerebral hemorrhage. A rational approach that balances the risk of hemorrhage expansion with the considerable benefits of thromboembolic prophylaxis based on the individual clinical circumstance is appropriate until further research is available.

Outcome

Perioperative stroke increases hospital mortality by up to 10-fold, and long-term survival is worse among stroke survivors. A study by Tarakji et al found that perioperative stroke decreased the likelihood of survival at 1, 10, and 20 years by 25%, 41%, and 23%, respectively.

In the Randomized Evaluation of Mechanical Assistance for the Treatment of Chronic Heart Failure trial, cerebrovascular complications were the third leading cause of death (9.8%). This finding was supported by two other publications; 1 of over 1,000 LVADs where a central nervous system event was the third leading cause of mortality accounting for 14% of deaths. Little has been reported on neurologic complications of adult ECMO patients. This may be in part due to the difficulty in knowing whether the neurologic consequences are the result of the pathology prompting ECMO or related to the ECMO process itself. In one series, 63% of subjects who underwent cerebral imaging had pathologically abnormal findings, and 90% of patients who underwent brain autopsy had evidence of intracranial pathology ranging from ischemic/hemorrhagic lesions to diffuse cerebral edema. In one study of infants receiving ECMO, major intracranial hemorrhage accounted for 55% of deaths.

CARDIOVASCULAR COMPLICATIONS OF NEUROLOGIC INJURY

Neurogenic Stunned Myocardium

Epidemiology

NSM may be defined as an acute, reversible cardiac injury commonly associated with various forms of acute brain injury including subarachnoid hemorrhage, intracerebral hemorrhage, ischemic stroke, and seizures. Electrocardiographic abnormalities are seen in up to 70% of patients with subarachnoid hemorrhage and in up to 40% of patients with intracerebral hemorrhage and ischemic stroke. Left ventricular systolic dysfunction has been found in 10% to 28% of patients with subarachnoid hemorrhage, and diastolic dysfunction is seen in up to 71% of patients.

Pathobiology

NSM is presumed to occur due to dysregulation of autonomic control, primarily of the sympathetic system. A proposed instigating mechanism is injury to the insular cortex or hypothalamus, which are important areas for autonomic control. Right cerebral hemispheric injury is more likely to be associated with sympathetic dysautonomia, whereas the left cerebral hemisphere predominantly causes parasympathetic responses. Similar neuroanatomic specialization was demonstrated in cats where lateral hypothalamic stimulation caused sympathetic responses such as tachycardia and ST-segment depressions, whereas anterior hypothalamic stimulation caused parasympathetic responses such as bradycardia. There is evidence that primary brainstem injury in the setting of transtentorial herniation can also produce a massive sympathetic discharge. All of these states are characterized by abnormal hyperactivity of the locus coeruleus, a nucleus in the pons that mediates sympathetic tone.

Catecholamine release and overload, primarily released by the cardiac sympathetic nerves, produces a state of overstimulation of myocardial cells with a characteristic histopathology termed *contraction band necrosis*. Affected myocardial cells are overloaded with calcium, remain hypercontracted, and no longer respond to β_1-receptor agonists due to uncoupling of the adenyl cyclase secondary messenger system. For this reason, attempts to improve left ventricular contractility with exogenous catecholamines such as norepinephrine in patients with cardiogenic shock tend to be ineffective.

Clinical Features

NSM tends to occur in the setting of acute severe brain injury. Subarachnoid hemorrhage is the best known and most common cause of NSM, but the condition can develop in response to any

cause of massive sympathetic outflow, including intracerebral hemorrhage, cerebral infarction with herniation; Guillain-Barré syndrome; acute hydrocephalus; traumatic brain injury; or status epilepticus, acute emotional stress, and pheochromocytoma. Mild to moderate elevations in cardiac enzymes may accompany characteristic electrocardiographic features, which include long QT intervals, widespread symmetric inverted T waves, and U waves. Left ventricular dysfunction manifests as diastolic dysfunction in mild cases. More severely affected patients develop regional left ventricular wall motion abnormalities that do not respect typical vascular territories in association with mild to moderate reduction of the left ventricular ejection fraction (20%-40%). In fulminant cases, patient can develop acute cardiogenic shock with ejection fractions of 20% or less. The level of cardiac enzyme elevation is typically low in relation to the extent of left ventricular dysfunction. A retrospective study to differentiate between acute coronary syndrome and NSM found troponin levels were 10-fold higher with infarcted heart (based on historic controls) compared to stunned myocardium (2.8 vs 0.22 ng/mL). A troponin level of less than 2.8 ng/mL and ejection fraction less than 40% in the setting of acute aneurysmal were consistent with stunned myocardium rather than acute coronary syndrome.

Acute neurogenic pulmonary edema (NPE) can occur in isolation, or in addition to, NSM. In its purest sense, NPE is thought to represent a neurally mediated noncardiogenic form of pulmonary edema characterized by disruption of the integrity of the pulmonary microvasculature (ie, "leaky lung" pulmonary edema). Acute peripheral vasoconstriction has been shown to cause a massive increase in intrathoracic blood volume, which causes a "blast effect," which then leads to increased pulmonary vascular permeability (Fig. 119.1).

Diagnosis

The takotsubo variant of NSM features characteristic echocardiographic findings of apical akinesis and ballooning with left ventricular diastolic and systolic dysfunction (▶ Video 119.1). It is important to appreciate that NSM occurs on a spectrum of variants that includes a "reverse takotsubo" pattern where the apex of the heart is normal and the base is hypokinetic (▶ Video 119.2). If clinical suspicion is high for acute coronary syndrome, coronary angiography may be required to definitively exclude underlying coronary artery disease. Serial echocardiography by definition shows progressive improvement and eventual normalization of left ventricular function over days to weeks.

Treatment and Outcome

Patients with severe acute intracranial pathology should have continuous electrocardiographic monitoring for at least 72 hours, and cardiac enzymes should be obtained. Management should be focused on treating the underlying cause of the neurogenic stunning such as securing the ruptured aneurysm. Euvolemia should be maintained using isotonic intravenous (IV) fluids as needed. There is evidence from cohort studies that NSM is less common among subarachnoid hemorrhage patients previously on β-blockers; for this reason, there may be some rationale for use of the β_1-blocker esmolol (starting at 50 μg/kg/min, titrated to attain heart rate below 100 beats/min). When cardiac function is significantly diminished, inotropic vasopressors or inotropes such as norepinephrine, dobutamine, and milrinone may be required to augment cardiac output. There is evidence that milrinone, a phosphodiesterase inhibitor, is a more effective inotrope than norepinephrine because it bypasses β_1 receptors, which are prone to receptor desensitization. NPE tends to be fragile and often responds to gentle diuresis with furosemide. Reversibility is a hallmark feature of NSM, and echocardiographic abnormalities usually improve within days.

Paroxysmal Sympathetic Storming

Synonyms for paroxysmal sympathetic storming include autonomic storming, paroxysmal dysautonomia, autonomic dysfunction syndrome, hypothalamic-midbrain dysregulation syndrome,

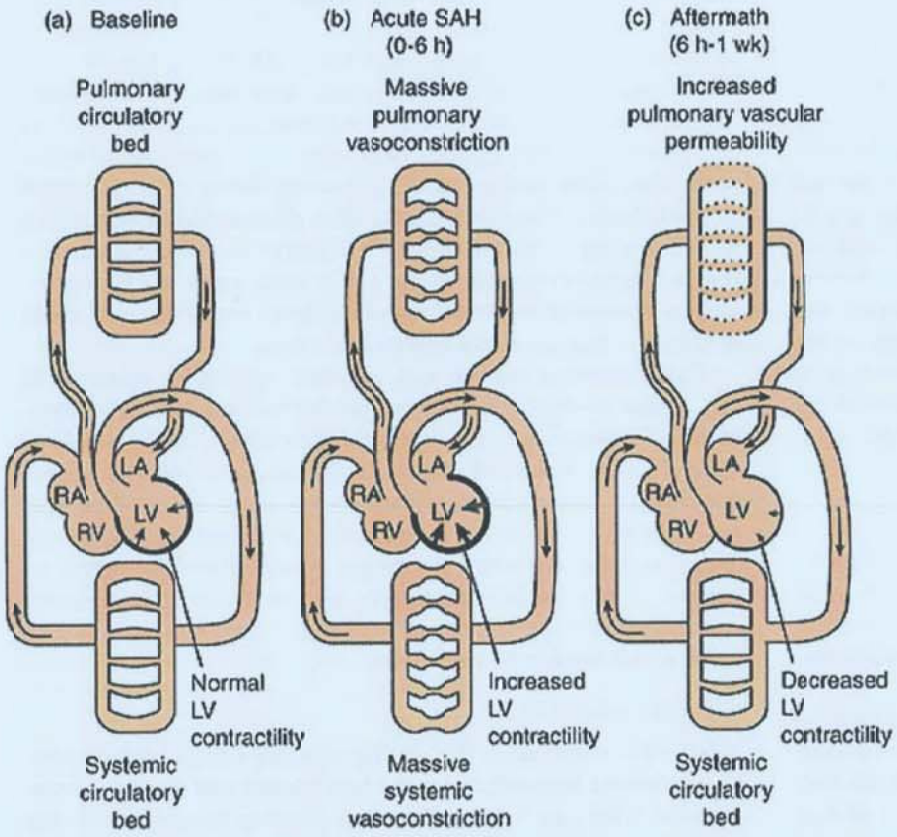

FIGURE 119.1 Diagram explaining how neurogenic stunned myocardium and pulmonary edema characterized by increased pulmonary vascular permeability can coexist after subarachnoid hemorrhage (SAH) and other forms of catastrophic brain injury. The unifying inciting event is a massive catecholamine discharge **(b)**, which leads to concomitant decreased left ventricular contractility and leaky lung pulmonary edema after the initial phase of injury **(c)**. Abbreviations: LA, left atrium; LV, left ventricle; RA, right atrium; RV, right ventricle. (Adapted from Mayer SA, Swarup R. Neurogenic cardiac injury after subarachnoid hemorrhage. *Curr Opin Anaesthesiol*. 1996;9:356-361.)

paroxysmal autonomic instability with dystonia, and neurostorming. The condition is characterized by irregular, recurrent violent sympathetic discharges in the acute or subacute phase of severe brain injury in the intensive care unit.

Epidemiology

Paroxysmal sympathetic storming occurs in up to 33% of patients with severe traumatic brain injury and severe diffuse axonal shearing injury and is also relatively common in patients with anoxic brain injury. It is less frequently seen in patients with poor-grade subarachnoid hemorrhage, coma resulting from intracerebral hemorrhage, malignant middle cerebral artery infarction syndrome, and brainstem pathology. It seems to be more common in younger patients.

Clinical Features

Autonomic storming presents with paroxysmal episodes of hypertension and tachycardia, fever, hyperventilation, diaphoresis, extensor posturing, and severe dystonia. The onset typically occurs days to weeks after the original brain injury event. The posturing and dystonia may at times resemble generalized seizures consistent with prior descriptions of autonomic storming as "diencephalic seizures."

Diagnosis

Autonomic storming is a clinical diagnosis. A diagnostic algorithm is summarized in Table 119.2. One of the easiest ways to make the diagnosis is to establish the presence of episodic parallel urges in blood pressure and heart rate when reviewing vital signs over 24 hours on a bedside monitor. Seizures may need to be excluded using continuous video electroencephalography because the episodes are often paroxysmal. Autonomic storming may need to be differentiated from the typical pressor response to elevated intracranial pressure or cerebral ischemia, which is a common compensatory sequel of acute brain injury and likely reflects efforts to maintain adequate cerebral perfusion pressure in the face of elevated intracranial pressure.

TABLE 119.2 Diagnostic Criteria for Paroxysmal Sympathetic Storming

Four of the following, occurring in episodic surges at intervals of 30 min-4 h:
• Fever (>38.3°C)
• Tachycardia (120 beats/min or 100 beats/min if on β-blockers)
• Tachypnea (respiratory rate >30 breaths/min)[a]
• Hypertension (systolic blood pressure >160 mm Hg or pulse pressure >80 mm Hg)
• Diaphoresis
• Extensor posturing or motor dystonia
• Severe dystonia

[a]In the absence of sepsis or airway obstruction.

Management

Management of sympathetic storming is focused on brain sedation, analgesics that blunt nociceptive inputs that trigger storms, agents that specifically suppress the locus coeruleus, and blunting of the peripheral manifestations of hypertension and tachycardia with β-blockers. Acute control of severe symptoms can be quickly attained with infusion of propofol (50-200 μg/kg/min), fentanyl (50-100 mg/h), or dexmedetomidine (0.7-1.4 μg/kg/h) alone or in combination (Fig. 119.2).

Pharmacotherapeutic options to control symptoms and allow weaning of analgosedative infusions in the intensive care unit

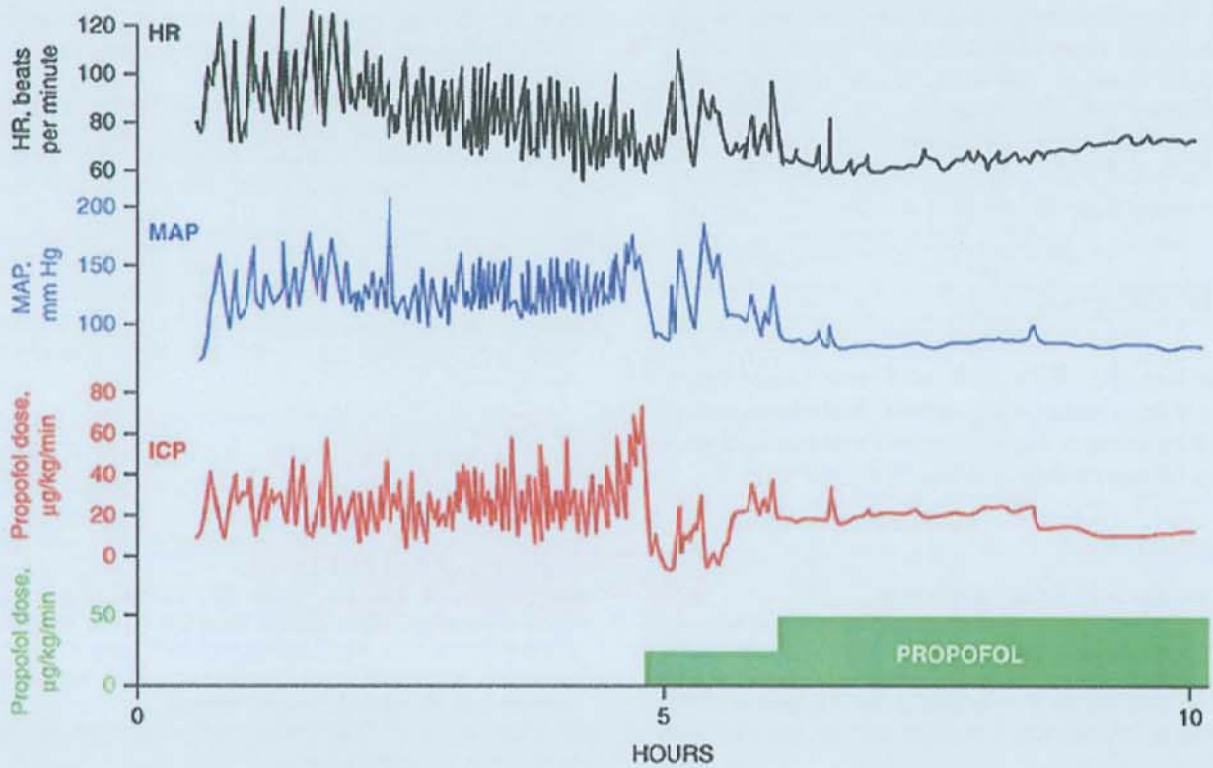

FIGURE 119.2 Suppression and stabilization of sympathetic storming with propofol infusion in a patient with paroxysmal sympathetic storming. Note the immediate stabilizing effect on intracranial pressure (ICP), which fell from levels as high as 70 mm Hg to normal at the start of the infusion. Abbreviations: HR, heart rate; MAP, mean arterial pressure.

TABLE 119.3 Pharmacotherapy for Paroxysmal Sympathetic Storming During the Subacute to Chronic Phase

Analgosedatives	• Fentanyl patch 25-300 μg/h • Morphine (Roxanol, MS Contin) 5-20 mg every 4 h • Lorazepam 2-24 mg/d • Klonopin 1-8 mg/d
β-Blockers	• Propranolol 160-640 mg/d • Labetalol 400-3,600 mg/d
Central antiadrenergic agonists	• Clonidine patch 0.1-0.9 mg/d • Bromocriptine 10-40 mg/d
Muscle relaxants	• Baclofen 10 mg 3 times a day • Dantrolene orally 25-100 mg 4 times a day
Anticonvulsants	• Gabapentin 900-3,600 mg/d

are summarized in Table 119.3. These agents should be started sequentially and evaluated during daily interruptions of continuous IV analgosedation. Concurrent use of IV antihypertensive agents such as nicardipine or labetalol is rarely needed after IV sedative agents have been administered. It is important to realize that neurogenic autohypertension is fragile and can be easily overtreated and result in impaired cerebral perfusion pressure. As such, antihypertensive medications may need to be started at lower doses and titrated up while monitoring response.

Outcome

Paroxysmal sympathetic storming typically persists for weeks to months before it resolves. Storming treated with prolonged IV infusions of analgosedatives such as propofol and fentanyl leads to increased intensive care unit length of stay and a concomitant increase in the risk of hospital-acquired infections and complications. Outcome can be improved by aggressively advancing the agents used for subacute to chronic control of symptoms in Table 119.3, which allows discontinuation of IV sedation, liberation from the ventilator, and advancement to rehabilitation.

Videos can be found in the companion e-book edition. For a full list of video legends, please see the front matter.

LEVEL 1 EVIDENCE

1. Gold JP, Charlson ME, Williams-Russo P, et al. Improvement of outcomes after coronary artery bypass. A randomized trial comparing intraoperative high versus low mean arterial pressure. *J Thorac Cardiovasc Surg*. 1995;110(5):1302-1314.

SUGGESTED READINGS

Neurologic Complications of Cardiac Interventions

Barber PA, Hach S, Tippett LJ, et al. Cerebral ischemic lesions on diffusion-weighted imaging are associated with neurocognitive decline after cardiac surgery. *Stroke*. 2008;39(5):1427-1433.

Biswas AK, Lewis L, Sommerauer JF. Aprotinin in the management of life-threatening bleeding during extracorporeal life support. *Perfusion*. 2000;15(3):211-216.

Eckman PM, John R. Bleeding and thrombosis in patients with continuous-flow ventricular assist devices. *Circulation*. 2012;19;125(24):3038-3047.

Filsoufi F, Rahmanian PB, Castillo JG, Bronster D, Adams DH. Incidence, topography, predictors and long-term survival after stroke in patients undergoing coronary artery bypass grafting. *Ann Thorac Surg*. 2008;85(3):862-870.

Kato TS, Schulze PC, Yang J, et al. Pre-operative and post-operative risk factors associated with neurologic complications in patients with advanced heart failure supported by a left ventricular assist device. *J Heart Lung Transplant*. 2012;31(1):1-8.

Maisel WH, Rawn JD, Stevenson WG. Atrial fibrillation after cardiac surgery. *Ann Intern Med*. 2001;135(12):1061-1073.

Mateen FJ, Muralicharan R, Shinohara RT, Parisi JE, Schears GJ, Wijdicks EF. Neurological injury in adults treated with extracorporeal membrane oxygenation. *Arch Neurol*. 2011;68(12):1543-1549.

McKhann GM, Grega MA, Borowicz LM Jr, Baumgartner WA, Selnes OA. Stroke and encephalopathy after cardiac surgery: an update. *Stroke*. 2006;37(2):562-571.

Selnes OA, Gottesman RF, Grega MA, Baumgartner WA, Zeger SL, McKhann GM. Cognitive and neurologic outcomes after coronary-artery bypass surgery. *N Engl J Med*. 2012;366(3):250-257.

Selnes OA, McKhann GM. Neurocognitive complications after coronary artery bypass surgery. *Ann Neurol*. 2005;57(5):615-621.

Tarakji KG, Sabik JF III, Bhudia SK, Batizy LH, Blackstone EH. Temporal onset, risk factors, and outcomes associated with stroke after coronary artery bypass grafting. *JAMA*. 2011;305(4):381-390.

Tsukui H, Abla A, Teuteberg JJ, et al. Cerebrovascular accidents in patients with a ventricular assist device. *J Thorac Cardiovasc Surg*. 2007;134(1):114-123.

Wittenstein B, Ng C, Ravn H, Goldman A. Recombinant factor VII for severe bleeding during extracorporeal membrane oxygenation following open heart surgery. *Pediatr Crit Care Med*. 2005;6(4):473-476.

Neurogenic Stunned Myocardium

Guglin M, Novotorova I. Neurogenic stunned myocardium and takotsubo cardiomyopathy are the same syndrome: a pooled analysis. *Congest Heart Fail*. 2011;17(3):127-132.

Mayer SA, Fink ME, Homma S, et al. Cardiac injury associated with neurogenic pulmonary edema following subarachnoid hemorrhage. *Neurology*. 1994;44:815-820.

Melville KI, Blum B, Shister HE, Silver MD. Cardiac ischemic changes and arrhythmias induced by hypothalamic stimulation. *Am J Cardiol*. 1963;12:781-791.

Murthy SB, Shah S, Rao CP, Bershad EM, Suarez JI. Neurogenic stunned myocardium following acute subarachnoid hemorrhage: pathophysiology and practical considerations. *J Intensive Care Med*. 2015;30(6):318-325.

Nguyen H, Zaroff JG. Neurogenic stunned myocardium. *Curr Neurol Neurosci Rep*. 2009;9(6):486-491.

Oppenheimer SM, Gelb A, Girvin JP, Hachinski VC. Cardiovascular effects of human insular cortex stimulation. *Neurology*. 1992;42(9):1727-1732.

Samuels MA. The brain-heart connection. *Circulation*. 2007;116(1):77-84.

Wittstein IS, Thiemann DR, Lima JA, et al. Neurohumoral features of myocardial stunning due to sudden emotional stress. *N Engl J Med*. 2005;352:539-548.

Sympathetic Storming

Blackman JA, Patrick PD, Buck ML, Rust RS Jr. Paroxysmal autonomic instability with dystonia after brain injury. *Arch Neurol*. 2004;61(3):321-328.

Boeve BF, Wijdicks EF, Benarroch EE, Schmidt KD. Paroxysmal sympathetic storms ("diencephalic seizures") after severe diffuse axonal head injury. *Mayo Clin Proc*. 1998;73(2):148-152.

Perkes I, Baguley IJ, Nott MT, Menon DK. A review of paroxysmal sympathetic hyperactivity after acquired brain injury. *Ann Neurol*. 2010;68(2):126-135.

Rabinstein AA. Paroxysmal sympathetic hyperactivity in the neurological intensive care unit. *Neurol Res*. 2007;29(7):680-682.

Rossitch E Jr, Bullard DE. The autonomic dysfunction syndrome: aetiology and treatment. *Br J Neurosurg*. 1988;2(4):471-478.

Sepsis-Associated Encephalopathy 120

Aurélien Mazeraud, Cássia Righy, Stephan A. Mayer, and Tarek Sharshar

KEY POINTS

1. Sepsis-associated encephalopathy (SAE) is a key manifestation of sepsis, occurring in up to 70% of patients admitted to the ICU.
2. SAE is associated with increased hospital mortality and worse long-term cognitive and functional outcomes.
3. The pathophysiology of SAE involves neurotransmitter dysfunction, inflammatory and ischemic lesions to the brain, microglial activation, brain-barrier dysfunction, and stress network activation.
4. Delirium, a common manifestation of SAE, is mostly diagnosed with validated scales in the ICU population.
5. Non-pharmacological prevention of delirium is key for managing SAE, including avoiding over-sedation (particularly with benzodiazepines), early mobilization, and sleep promotion.

INTRODUCTION

Since ancient times, physicians have recognized that the central nervous system is one of the first organs affected in sepsis. Sepsis, defined as a life-threatening organ dysfunction caused by a dysregulated host response to infection, is a leading cause of intensive care unit (ICU) admission and death worldwide. The incidence of encephalopathy in the setting of sepsis is about 50% but can vary from 8% to more than 70%. Sepsis-associated encephalopathy (SAE) is often the revealing manifestation of sepsis and alteration in mental status has been identified as one of three critical screening items for identifying high mortality risk in the patients with suspected infection (Table 120.1).

TABLE 120.1 The Quick Sequential Organ Failure Assessment Score[a]

Risk Factor	Points
Altered mental status (GCS <15)	1
Respiratory rate ≥22/min	1
Systolic blood pressure ≤100 mm Hg	1
Risk Level	**Total Points**
Low risk (<5%) for mortality	0-1
High risk (5%-20%) for mortality	2-3

Abbreviation: GCS, Glasgow Coma Scale.
[a]See also qSOFA.org.

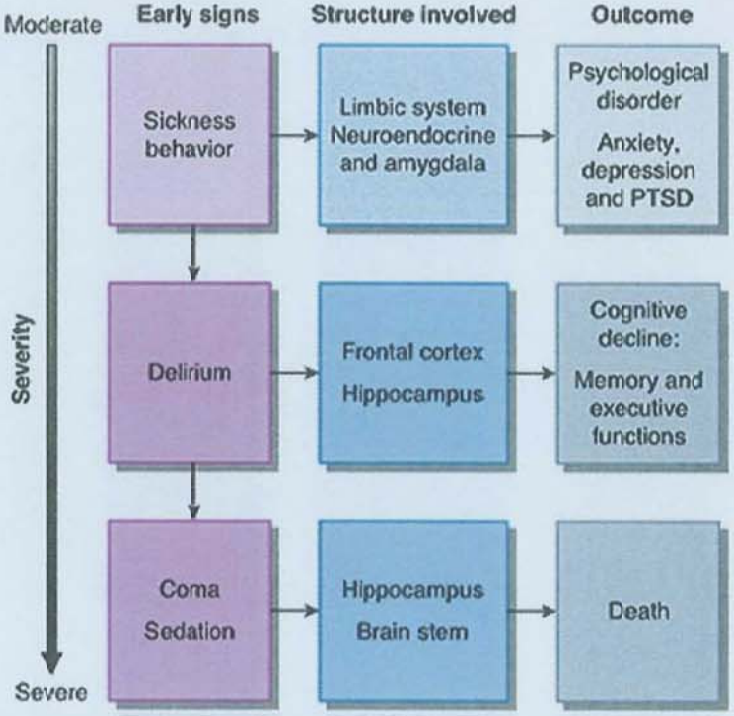

FIGURE 120.1 Early signs observed during sepsis **(left column)**, relying on specific structures **(middle column)** and associated to worst outcome **(right column)**. Whereas sickness behavior is considered as a physiologic response to systemic inflammation, delirium and consciousness disorders are clinical signs for sepsis-associated encephalopathy. PTSD, posttraumatic stress disorder.

The pathophysiology of SAE comprises neuroinflammation, vascular changes, and metabolic failure. These mechanisms are not homogeneous in the brain and may lead to region-specific focal ischemic or hemorrhagic lesions. Brain centers involved in autonomic control, arousal, awareness, and behavior are affected, accounting for the clinical features of SAE varying from sickness behavior or consciousness impairment ranging from delirium to coma (Fig. 120.1).

Early SAE is characterized by typical metabolic changes on electroencephalogram (EEG), but in more advanced cases, nonconvulsive status epilepticus can be detected in 10% to 15% of cases. Radiologic lesions such as small focal ischemic or edematous lesions can be observed in about 30% of patients with septic shock (Fig. 120.2). The SAE is associated with increased mortality and long-term cognitive impairment affecting memory, attention, verbal fluency, and psychological disorders including depression, anxiety, and posttraumatic stress disorder (see Fig. 120.1). Its management relies mainly on general ICU good practices, especially when SAE leads to coma (see Chapter 19), as specific treatment is still lacking.

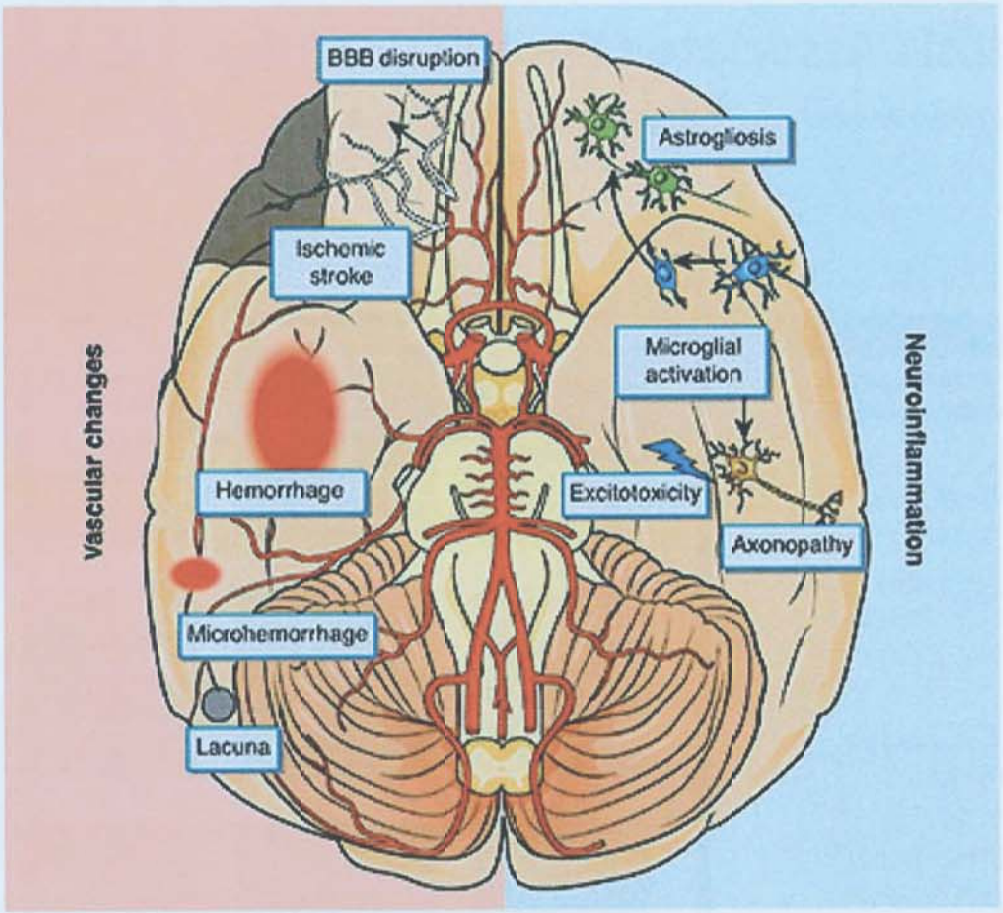

FIGURE 120.2 Schematic view of the different pathophysiologic processes observed or supposed during sepsis-associated encephalopathy. Vascular changes include blood-brain barrier (BBB) dysfunction, neurovascular uncoupling, and strokes. Neuroinflammation includes microglial and astrocytic activation enhancing excitotoxicity and metabolic imbalance inducing neuronal cell death.

In contrast to previous beliefs that the brain is an immune-privileged organ, current thinking is that the central nervous system can be profoundly affected by severe systemic infections and the inflammatory response that occurs as a consequence.

EPIDEMIOLOGY

There are 750,000 cases of sepsis per year in the United States, among whom more than 200,000 will die. Sepsis causes or contributes to one-third to one-half of all in-hospital deaths. There is an increasing incidence of sepsis, which is the result of aging and the higher prevalence of chronic diseases and immunocompromised states in the general population.

Because no consensual definition of SAE exists, the reported incidence varies widely across studies. Currently, an encephalopathy in septic patients is detected using scales for coma (ie, the Glasgow Coma Scale) or delirium (ie, the Confusion Assessment Method–Intensive Care Unit, see **Table 11.4**). Sepsis is a major risk factor for delirium and has to be sought in any critically ill patients developing confusion. Delirium and SAE have many risk factors in common, including older age, premorbid neurologic conditions (ie, dementia, Parkinson disease), need for mechanical ventilation, and acute and chronic liver and renal dysfunction. Various antibiotics are potentially neurotoxic and can induce delirium.

Overall, the incidence of SAE varies from 20% to 40% of septic patients admitted to the ICU, reaching up to 70% in elderly mechanically ventilated patients when evaluated by the Confusion Assessment Method–Intensive Care Unit. Similarly, up to 70% of patients with bacteremia have neurologic symptoms ranging from lethargy and mild inattention to coma. The EEG is abnormal in almost 80% of septic patients.

PATHOBIOLOGY

The SAE results from the deleterious effects of systemic inflammation on the brain. The inflammatory signal is mediated through specific pathways to the brain and triggers three nonexclusive processes which are ischemia, neuroinflammation, and cellular metabolic stress. Ischemia results from macro- and microcirculatory dysfunction; neuroinflammation from dysfunction of the vascular complex (ie, endothelial cells, astrocytes, and blood-brain barrier [BBB]) and microglial activation. Cellular metabolic stress is induced not only by these two processes but also other systemic factors (ie, hypoxia, drugs neurotoxicity, dysglycemia, renal or liver failure; see **Fig. 120.1**). These processes lead to mitochondrial dysfunction and oxidative stress, which compromise neuronal function and vitality. Metabolic stress early in SAE may preferentially affect specific brain regions involved in the autonomic and arousal control, behavior response to stress, and cognitive functions such as memory and attention. Experimental studies have consistently showed strong early neuronal activation in the hippocampus, the amygdala, the nucleus tractus solitarii, and the locus coeruleus in the setting of sepsis. Neuropathologic studies of patients who have died from sepsis show increased neuronal apoptosis and microglial activation in human in these specific areas. These findings provide the anatomic substrate of acute and long-term brain dysfunctions (see **Fig. 120.2**).

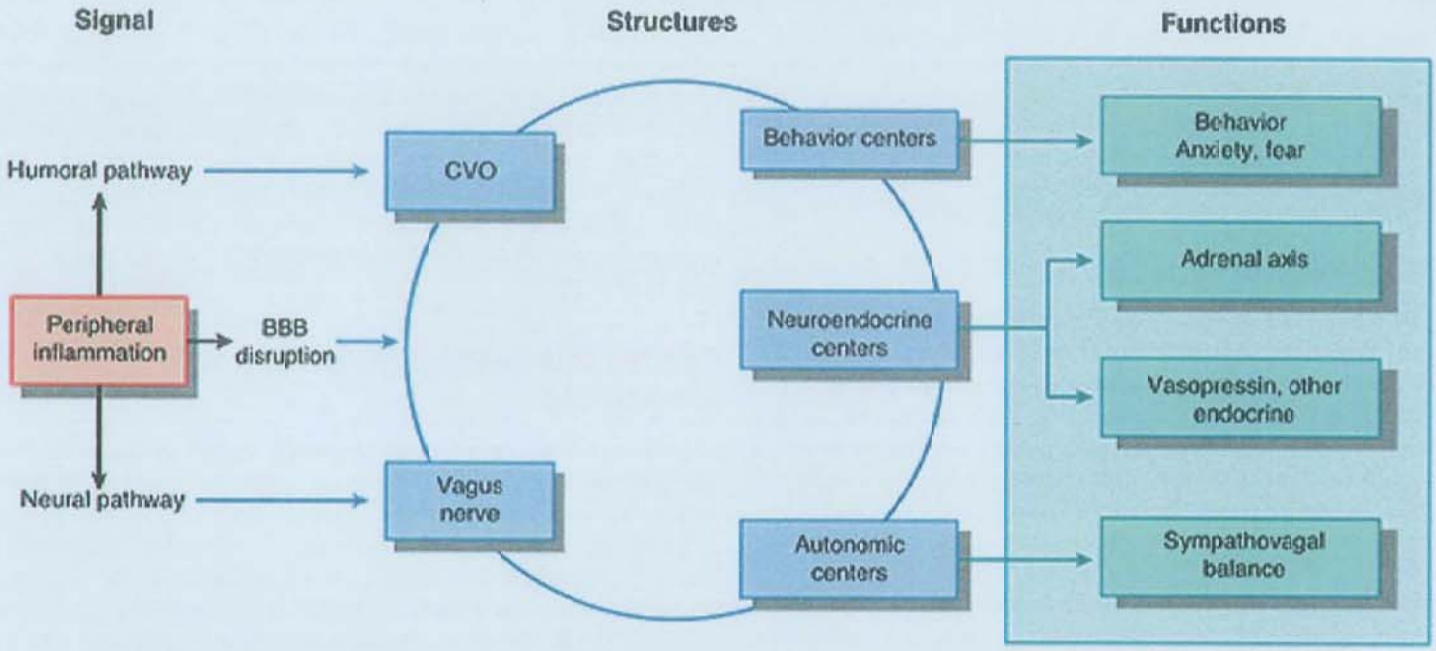

FIGURE 120.3 Scheme for the response to stress network mobilization during sepsis. The peripheral inflammation signal is transmitted to the central nervous system through three main pathways (*dark blue arrows*) activating specific structures (*light blue arrows*), the circumventricular organs (CVO) or the vagus nerve nuclei. Behavioral, neuroendocrine, and autonomic structures are interconnected and stimulated, leading to the functional response (*dark green arrows* and *rectangles*). BBB, blood-brain barrier.

Brain Signaling

Neural and humoral pathways are physiologically involved in inflammatory signaling to the brain. For instance, vagal afferents can sense intraperitoneal inflammation and convey the information to the medullary autonomic nuclei; vagal nerves are then able to modulate both local inflammation and systemic inflammation (via its splenic innervation). Owing to their connections to other autonomic centers and neuroendocrine and behavior centers, the medullary autonomic nuclei can modulate a broader response to sepsis (**Fig. 120.3**). The humoral pathway involves circumventricular organs and the *area postrema*, which lacks a BBB. They allow trafficking of inflammatory mediators toward the local neuroendocrine and autonomic centers. These two pathways are essential in the orchestration of the response to an inflammatory stress, of which *sickness behavior* is the clinical manifestation. Sickness behavior is a coordinated set of active, adaptive behaviors that help individuals cope with infection, such as sleepiness, malaise, and loss of appetite.

Neuroinflammation and Glial Cell Activation

Microglia are the mononuclear phagocytic cells of the brain and are responsible for immune defense. They are able to phagocyte, migrate, proliferate, and release various mediators. They express a wide variety of receptors, notably to cytokines and pathogen- and damage-associated molecule patterns.

SAE is considered not to be related to direct cerebral infection. Instead, sepsis appears to cause neuroinflammation as a "bystander" effect of the systemic inflammatory response. Sepsis causes microglial activation, which encompasses morphologic, immunologic, and metabolic changes. Microglial activation leads to reactive or amoeboid forms capable of free movement or phagocytosis, a process called *deramification*. These proinflammatory phenotypes are neurotoxic and contribute to pathologic neuronal activation. Through the production of cytokines, nitric oxide, gliotransmitters, and neurotoxic metabolites such as reactive oxygen species, activated microglia increase total neuronal excitability and fuel neuronal hyperactivation. Fragments of living bacteria and bacterial genomic material have been found in the brains of septic animals and humans but without evidence of infectious encephalitis. This suggests the existence of a brain microbiota in the critically ill, which is absent in healthy subjects.

Astrocytes are the most numerous cells in the brain. In addition to controlling BBB permeability and brain-water balance, astrocytes regulate cerebral blood flow via the release of nitric oxide, prostaglandins, and arachidonic acid. Astrocytes express connexins that allow bidirectional exchanges via hemichannels between astrocytes and neurons through the release of "gliotransmitters" in the extracellular milieu. It has been shown that activated microglial cells inhibit gap junction channels and activate hemichannels.

Neuroinflammation is incriminated in dementia of all causes. Indeed, it is hypothesized that a first hit primes microglial cells that will be then overreactive to a second hit. Sepsis can be the primary or the secondary hit. This hypothesis can therefore account for the relationship between the sepsis and cognitive decline as well as the deleterious impact of SAE in patients with preexisting neurodegenerative disease.

Astrocytes and Blood-Brain Barrier Dysfunction

BBB dysfunction occurs in sepsis. The BBB controls the water, molecules, and ions that flow between the blood and the brain and restrains penetration of immune cells, toxins, and pathogens into the brain. The BBB integrity is maintained by astrocytes

and pericytes. Neuropathologic and magnetic resonance imaging (MRI) studies confirm BBB impairment in patients with septic shock, notably by evidencing vasogenic edema involving the white matter. Reports of posterior reversible encephalopathy syndromes (see Chapter 44) in septic patients corroborates these findings.

Ischemic Processes

Brain ischemia can result from either macrocirculatory dysfunction, including hypotension, decreased cerebral flow, and impaired autoregulation, or microcirculatory impairment, encompassing neurovascular uncoupling, BBB disruption, and activation of the coagulation cascade. A postmortem study has shown that ischemic damages were present in all cases of fatal septic shock and were associated to disseminated intravascular coagulopathy-induced hemorrhage in about 20% of these cases. Sepsis is associated with microcirculatory dysfunction that results both in impaired cerebral vascular supply, brain metabolic crisis, and neurovascular uncoupling.

Neurotransmitter Dysfunction

Neurons in sepsis are vulnerable to mitochondrial dysfunction and oxidative stress and excitotoxicity, which is induced by enhanced release and diminished uptake of glutamate in the synaptic space. This neuroinflammatory and ischemic process may be exacerbated by systemic factors such as hypoxemia, electrolyte disorders, dysglycemia, and drug toxicity. Neurotransmitter impairment involves the dopaminergic, β-adrenergic, the γ-aminobutyric acid, and the cholinergic systems. Despite the fact that an imbalance between dopaminergic and cholinergic neurotransmission is incriminated in sepsis-associated delirium, cholinergic drugs, such as rivastigmine, as well as antidopaminergic drugs, such as haloperidol, fail to reduce its occurrence. Benzodiazepines, which are γ-aminobutyric acid agonists, increase the risk of delirium in septic patients for reasons that are unclear.

DIAGNOSIS

Clinical Features

SAE is defined by the association of a systemic infectious or inflammatory process with impairment of brain function, which can range from lethargy to delirium or coma. Focal deficits and seizures can also occur. Sepsis is more frequently associated with a hypoactive than hyperactive delirium. Abnormal movements such as myoclonus, tremor, or asterixis can also be seen. In the ICU, sepsis should be suspected in any critically ill patient who develops a change in mood, behavior, or consciousness, as delirium may be the first sign of infection, particularly in elderly patients.

Brain Imaging

Brain computed tomography (CT) is typically normal in patients with SAE. In about half of septic shock patients, brain MRI shows scattered small regions of edema or infarction, particularly in the white matter. Posterior reversible encephalopathy syndrome has also been reported in septic patients. Given the risk of transporting septic patients, brain CT imaging should be performed for relevant clinical deterioration, including focal neurologic deficit, seizures, or unexplained impaired consciousness. Brain CT scan is easier to perform and may complete a body scan used to identify a source of infection but is less specific and sensitive than MRI. A normal CT in a septic patient with clear evidence of delirium or impaired consciousness points to the diagnosis of SAE. If focal deficits are present despite normal brain imaging, continuous EEG should be performed to rule out associated seizure activity.

Continuous Electroencephalogram Monitoring

Continuous EEG monitoring can assist in the evaluation and management of SAE. Background EEG can be classified as normal or showing predominantly theta, delta, triphasic waves, or suppression. Absence of EEG reactivity to stimuli, triphasic waves, background suppression, and periodic discharges are predictors of delirium and mortality. Seizures of any type can occur in 10% to 15% of septic patients, and nonconvulsive status epilepticus occurs in a subset of these patients. Seizures in SAE almost always occur in the 25% of patients who also have periodic discharges. Nonconvulsive electrographic seizures seem to occur more frequently during periods of active delirium. Clinical tonic-clonic seizures are rare in septic patients. Continuous EEG monitoring has shown that the vast majority of epileptic events occur in the first 48 hours of monitoring. The presence of periodic discharges implies an increased likelihood of detecting electrographic seizures with additional monitoring. Sepsis slightly increases the risk of long-term epilepsy.

MANAGEMENT

The treatment of SAE is fundamentally based on the cornerstones of therapy for sepsis, including rapid diagnosis and timely antibiotic administration, fluid resuscitation directed toward clearing lactate elevation, and blood pressure and ventilatory support. Standard diagnostic studies include CT to rule out a stroke or structural abnormality and continuous EEG monitoring for the detection and treatment of seizures. Pharmacotherapy focuses for the most part on symptom control for agitated delirium or continuous intravenous sedation for ventilator dyssynchrony. There are no established neuroprotective therapies to minimize brain injury and long-term cognitive dysfunction in patients with sepsis. Fever is known to exacerbate neuronal injury and death in the setting of ischemia, making fever control an attractive neuroprotective strategy. Antipyretics have not been shown to influence the outcome of severe sepsis LEVEL 2.[1] A small randomized trial (N = 200) reported decreased vasopressor requirements and improved survival with external cooling to control fever, but the effects on neurologic outcome were not evaluated LEVEL 2.[2]

The most common and well-studied manifestation of SAE is agitated delirium (see also Chapter 11). Delirium is associated with increased mortality and ICU length of stay, and measures should be taken to avoid or minimize delirium in septic patients (Table 120.2). Standard nonpharmacologic interventions for preventing or treating delirium in the ICU include aids to orientation (ie, clock and photos in the room), adequate lighting, avoiding sleep deprivation and noise reduction, early mobilization, minimizing or discontinuing sedation (especially

TABLE 120.2 Strategies to Reduce Brain Dysfunction and Delirium in Sepsis-Associated Encephalopathy[a]

Pharmacologic Measures
• Minimize use of sedation, especially benzodiazepines.
• Perform daily sedation interruption.
• Use dexmedetomidine as the first choice for continuous intravenous sedation.
• Treat pain aggressively using nonsedating, nonsteroidal agents as first-line therapy.
• Treat metabolic disturbances such as hypoxia, hypotension, hyponatremia, and hypoglycemia.
Nonpharmacologic Measures
• Promote normal sleep with quiet times and reduced unnecessary nursing assessments.
• Frequent reorientation and cognitively stimulating activities (ie, conversation)
• Rehydration
• Use of eyeglasses and hearing aids
• Minimize physical restraints.
• Early mobilization

[a]Adapted from Sonneville R, Verdonk F, Rauturier C, et al. Understanding brain dysfunction in sepsis. *Ann Intensive Care*. 2013;3(1):15.

benzodiazepines), and management of physical and psychological discomfort LEVEL 1.[3] Regarding the pharmacologic management of delirium and seizures, no specific sedative agent is proposed by experts, except that sedation should be avoided or discontinued as soon as possible. The α-agonist dexmedetomidine has been shown to lead to more delirium-free days and lower 28-day mortality when compared sedation with lorazepam LEVEL 1.[4] Dexmedetomidine is thought to exert its beneficial effects in part through inhibition of neuronal apoptosis and reduction of the sepsis-associated inflammatory response. Antipsychotic drugs may effectively treat some symptoms of hyperactive or agitated delirium, such as agitation or hallucinations, but are poorly effective in hypoactive delirium. Prior statin use has been associated with reduced risk of delirium in cohort studies of critically ill patients, but a prospective trial of rosuvastatin in patients with sepsis-associated adult respiratory distress syndrome found no effect on the frequency of delirium of on long-term cognitive outcome LEVEL 1.[5] Rivastigmine, a cholinesterase inhibitor that was supposed to control microglial activation, has been shown to increase mortality without reducing delirium in critically ill patients, including septic patients LEVEL 1.[6]

OUTCOME

Impact of Sepsis-Associated Encephalopathy on Survival

There is a proportional relationship between the clinical or electrophysiologic severity of SAE and mortality. Indeed, mortality in sepsis increases from as low as 10% to as high as 70% as the Glasgow Coma Scale decreases from 15 (ie, normal mental status) to below 8, and as EEG progresses from a normal background rhythm to patterns showing generalized periodic discharges, lack of reactivity to stimuli, or electrographic seizures. Coma and delirium are both within the clinical spectrum of SAE, and both are associated with increased risk of death in critically ill patients.

The mechanisms underlying the relationship between SAE and increased mortality has yet to be elucidated. It may be that brain failure is a simple manifestation of generalized multisystem organ failure. It has been hypothesized that sepsis induces brain stem dysfunction that affects both arousal and attention as well as centers that regulate vital functions, such as blood pressure and heart rate, all of which can be compromised in sepsis.

Impact on Sepsis-Associated Encephalopathy on Long-term Outcome

One year after ICU discharge, 25% to 50% of critically ill patients, many who have suffered from sepsis, develop long-term cognitive impairment. Hospitalization for sepsis increases the prevalence of cognitive impairment by 10% over 8 years. Preexisting dementia increases the risk of sepsis, which in turn worsens cognitive status among those who survive. The cognitive functions preferentially impaired by sepsis are attention, verbal fluency, executive function, verbal memory, and speed of mental processing, whereas visual memory and visuoconstructive ability appear to be preserved. Psychological disorders that occur after critical illness, and sepsis in particular, include anxiety, depression, and posttraumatic stress disorder. It has been reported that sepsis increases the risk of suicide in the first 2 years after hospitalization. These psychological and cognitive disorders have a dramatic impact on quality of life and functional status.

Societal Cost of Sepsis-Associated Encephalopathy

Care for patients who develop SAE requires considerable use of ICU resources because it prolongs hospital length of stay. Subsequent long-term psychological and cognitive disorders have created a social-economic burden. Up to 40% of previously employed sepsis survivors have not returned to full-time employment 1 year after the event.

CONCLUSION

SAE is a major complication of sepsis characterized by changes in mental status ranging from sickness behavior to delirium or coma. It is associated with changes of EEG background activity and less frequently with electrographic seizures. It is associated with increased mortality and long-term emotional and neurocognitive disorders. The main mechanisms of injury include neuroinflammatory, ischemic, and excitotoxic processes. Severity of consciousness disorders and EEG changes are predictive of mortality. There is no specific treatment of SAE. Management depends on treatment of sepsis, delirium, seizures, and critical care support for coma.

LEVEL 1 EVIDENCE

1. Drewry AM, Ablordeppey EA, Murray ET, et al. Antipyretic therapy in critically ill septic patients: a systematic review and meta-analysis. *Crit Care Med*. 2017;45(5):806-813.

2. Schortgen F, Clabault K, Katsahian S, et al. Fever control using external cooling in septic shock: a randomized controlled trial. *Am J Respir Crit Care Med*. 2012;185(10): 1088-1095.
3. Inouye SK, Bogardus ST, Charpentier PA, et al. A multicomponent intervention to prevent delirium in hospitalized older patients. *N Engl J Med*. 1999;340(9):669-676.
4. Pandharipande PP, Sanders RD, Girard TD, et al. Effect of dexmedetomidine versus lorazepam on outcome in patients with sepsis: an a priori-designed analysis of the MENDS randomized controlled trial. *Crit Care*. 2010;14(2):R38.
5. Needham DM, Colantuoni E, Dinglas VD, et al. Rosuvastatin versus placebo for delirium in intensive care and subsequent cognitive impairment in patients with sepsis-associated acute respiratory distress syndrome: an ancillary study to a randomised controlled trial. *Lancet Respir Med*. 2016;4(3): 203-212.
6. van Eijk MMJ, Roes KCB, Honing MLH, et al. Effect of rivastigmine as an adjunct to usual care with haloperidol on duration of delirium and mortality in critically ill patients: a multicentre, double-blind, placebo-controlled randomised trial. *Lancet*. 2010;376(9755):1829-1837.

SUGGESTED READINGS

Angus DC, Linde-Zwirble WT, Lidicker J, Clermont G, Carcillo J, Pinsky MR. Epidemiology of severe sepsis in the United States: analysis of incidence, outcome, and associated costs of care. *Crit Care Med*. 2001;29(7): 1303-1310.

Bezzi P, Domercq M, Brambilla L, et al. CXCR4-activated astrocyte glutamate release via TNF : amplification by microglia triggers neurotoxicity. *Nat Neurosci*. 2001;4(7):702-710.

Bleck TP. Dopamine antagonists in ICU delirium. *N Engl J Med*. 2018;379(26): 2569-2570.

Cain MD, Salimi H, Diamond MS, Klein RS. Mechanisms of pathogen invasion into the central nervous system. *Neuron*. 2019;103(5):771-783.

Eidelman LA, Putterman D, Putterman C, Sprung CL. The spectrum of septic encephalopathy. Definitions, etiologies, and mortalities. *JAMA*. 1996;275(6): 470-473.

Ely EW, Inouye SK, Bernard GR, et al. Delirium in mechanically ventilated patients: validity and reliability of the confusion assessment method for the intensive care unit (CAM-ICU). *JAMA*. 2001;286(21):2703-2710.

Girard TD, Exline MC, Carson SS, et al. Haloperidol and ziprasidone for treatment of delirium in critical illness. *N Engl J Med*. 2018;379(26):2506-2516.

Hatch R, Young D, Barber V, Griffiths J, Harrison DA, Watkinson P. Anxiety, depression and post traumatic stress disorder after critical illness: a UK-wide prospective cohort study. *Crit Care*. 2018;22(1):310.

Hennessy E, Gormley S, Lopez-Rodriguez AB, Murray C, Murray C, Cunningham C. Systemic TNF-α produces acute cognitive dysfunction and exaggerated sickness behavior when superimposed upon progressive neurodegeneration. *Brain Behav Immun*. 2017;59:233-244.

Hofer S, Eisenbach C, Lukic IK, et al. Pharmacologic cholinesterase inhibition improves survival in experimental sepsis. *Crit Care Med*. 2008;36(2): 404-408.

Howarth C. The contribution of astrocytes to the regulation of cerebral blood flow. *Front Neurosci*. 2014;8:103.

Hsieh SJ, Soto GJ, Hope AA, Ponea A, Gong MN. The association between acute respiratory distress syndrome, delirium, and in-hospital mortality in intensive care unit patients. *Am J Respir Crit Care Med*. 2015;191(1):71-78.

Iwashyna TJ, Ely EW, Smith DM, Langa KM. Long-term cognitive impairment and functional disability among survivors of severe sepsis. *JAMA*. 2010;304(16):1787-1794.

Jackson JC, Hart RP, Gordon SM, et al. Six-month neuropsychological outcome of medical intensive care unit patients. *Crit Care Med*. 2003;31(4): 1226-1234.

Mazeraud A, Pascal Q, Verdonk F, Heming N, Chrétien F, Sharshar T. Neuroanatomy and physiology of brain dysfunction in sepsis. *Clin Chest Med*. 2016;37(2):333-345.

Perry VH, Holmes C. Microglial priming in neurodegenerative disease. *Nat Rev Neurol*. 2014;10(4):217-224.

Polito A, Eischwald F, Maho A-L, et al. Pattern of brain injury in the acute setting of human septic shock. *Crit Care*. 2013;17(5):R204.

Racchiusa S, Mormina E, Ax A, et al. Posterior reversible encephalopathy syndrome (PRES) and infection: a systematic review of the literature. *Neurol Sci*. 2019;40(5):915-922.

Rosengarten B, Krekel D, Kuhnert S, Schulz R. Early neurovascular uncoupling in the brain during community acquired pneumonia. *Crit Care*. 2012;16(2):R64.

Sharshar T, Gray F, Lorin de la Grandmaison G, et al. Apoptosis of neurons in cardiovascular autonomic centres triggered by inducible nitric oxide synthase after death from septic shock. *Lancet*. 2003;362(9398):1799-1805.

Shechter R, Miller O, Yovel G, et al. Recruitment of beneficial M2 macrophages to injured spinal cord is orchestrated by remote brain choroid plexus. *Immunity*. 2013;38(3):555-569.

Siew ED, Fissell WH, Tripp CM, et al. Acute kidney injury as a risk factor for delirium and coma during critical illness. *Am J Respir Crit Care Med*. 2017;195(12):1597-1607.

Singer BH, Dickson RP, Denstaedt SJ, et al. Bacterial dissemination to the brain in sepsis. *Am J Respir Crit Care Med*. 2017;197(6):747-756.

Singer M, Deutschman CS, Seymour CW, et al. The Third International Consensus Definitions for Sepsis and Septic Shock (Sepsis-3). *JAMA*. 2016;315(8): 801-810.

Skelly DT, Hennessy E, Dansereau M-A, Cunningham C. A systematic analysis of the peripheral and CNS effects of systemic LPS, IL-1β, [corrected] TNF-α and IL-6 challenges in C57BL/6 mice. *PLoS One*. 2013;8(7):e69123.

Taccone FS, Su F, Pierrakos C, et al. Cerebral microcirculation is impaired during sepsis: an experimental study. *Crit Care*. 2010;14(4):R140.

van Eijk MMJ, Roes KCB, Honing MLH, et al. Effect of rivastigmine as an adjunct to usual care with haloperidol on duration of delirium and mortality in critically ill patients: a multicentre, double-blind, placebo-controlled randomised trial. *Lancet*. 2010;376(9755):1829-1837.

Wolf SA, Boddeke HWGM, Kettenmann H. Microglia in physiology and disease. *Annu Rev Physiol*. 2017;79(1):619-643.

Young GB, Bolton CF, Archibald YM, Austin TM, Wells GA. The electroencephalogram in sepsis-associated encephalopathy. *J Clin Neurophysiol*. 1992;9(1): 145-152.

Zhang Q-H, Sheng Z-Y, Yao Y-M. Septic encephalopathy: when cytokines interact with acetylcholine in the brain. *Mil Med Res*. 2014;1:20.

121 Respiratory Support for Neurologic Diseases

David B. Seder and Stephan A. Mayer

KEY POINTS

1. When respiratory muscle strength is failing, intubation should be performed early to prevent aspiration or respiratory arrest.
2. Noninvasive ventilation is an option for patients with neuromuscular weakness and preservation of cough and airway protective reflexes.
3. Intubation and the initiation of mechanical ventilation can cause changes in cerebral blood flow and intracranial pressure and should be carefully managed.
4. Weaning from mechanical ventilation should occur as soon as possible; when prolonged intubation is anticipated, transition from endotracheal intubation to temporary tracheostomy should be considered.
5. Many patients with respiratory failure due to neurologic disease make an excellent recovery; respiratory failure itself should not be considered a reason to withdraw life-sustaining therapies.

INTRODUCTION

Much of the high morbidity and mortality from acute neurologic disorders results from abnormalities of breathing. Respiratory abnormalities can themselves worsen neurologic injury, whereas neurologic abnormalities conversely predispose to aspiration, impaired airway clearance, atelectasis, and pneumonia. In stroke, traumatic brain injury, status epilepticus, Guillain-Barré syndrome, myasthenia gravis, and many other neurologic disorders, oropharyngeal and respiratory muscle weakness predispose to aspiration of secretions into the airways, mucus plugging, hypoventilation, atelectasis, and pneumonia. Accordingly, respiratory monitoring and support are among the most common indications for the admission of neurologic patients to an intensive care unit (ICU).

EPIDEMIOLOGY

Respiratory failure requiring mechanical support complicates the care of about 10% patients with ischemic stroke and many patients with intracerebral hemorrhage, subarachnoid hemorrhage, severe traumatic brain injury, acute coma or other causes, and severe neuromuscular weakness. Outcomes of patients with respiratory failure due to neurologic disease have improved over the past three to four decades. With up-to-date management, respiratory failure should not pose an independent obstacle to recovery.

PATHOBIOLOGY

Respiratory failure in neurologic disease can be caused by cardiopulmonary failure, such as in the case of a large volume pulmonary aspiration, or more commonly by impaired airway protective reflexes, neuromuscular weakness, or impaired central ventilatory drive. It is useful to for clinicians to understand the nuances of respiratory disease because therapy varies dramatically between patients who can't breathe due to cardiopulmonary respiratory failure or a central apnea syndrome, and those who breathe well but cannot maintain a patent upper airway, which is essential for preventing lower respiratory aspiration and infection.

Pulmonary Gas Exchange

Hypoxemia is characterized by reduced oxygen content of the bloodstream. Hypoxemia is caused by five conditions: (1) a low inspired oxygen concentration, (2) alveolar hypoventilation, or impaired gas exchange within the lungs due to (3) ventilation-perfusion (V/Q) mismatching, (4) transpulmonary or intracardiac right-to-left shunting, or (5) impaired diffusion of gases between the alveoli and the capillaries. It can also be caused by low mixed venous oxygen saturation.

Impaired gas exchange can be quantified by measuring the gradient between the partial pressure of oxygen in the alveoli and the arterial blood (the A/a gradient, which is normally <20 mm Hg) or the P/F ratio, which is the partial pressure of oxygen in the arterial blood (PaO_2, normally 90-100 mm Hg) divided by the fraction of inspired oxygen (FIO_2, normally 21% in room air). Alveolar oxygen tension (PaO_2) can be calculated from the equation $PaO_2 = (FIO_2 \times 713) - (PaCO_2 / 0.8)$, where $PaCO_2$ is the arterial carbon dioxide tension.

The cause of impaired gas exchange leading to hypoxemia can be differentiated according to the response to supplemental oxygen. *Shunting*, defined as hypoxia unresponsive to oxygen supplementation, results from the direct transfer of deoxygenated venous blood into the arterial circulation through an intracardiac atrial septal defect, pulmonary arteriovenous malformation, or perfused but nonventilated lung parenchyma (ie, dense airspace consolidation due to pneumonia). With V/Q mismatching, ventilation and perfusion relationships are heterogeneously deranged, but systemic oxygenation improves in response to a higher FIO_2. Diffusion abnormalities are characterized by abnormalities of the intra-alveolar septae, which may be fibrotic (ie, interstitial lung disease), reduced in number and surface area (ie, emphysema), and inflamed or edematous (ie, acute respiratory distress syndrome, congestive heart failure). Low inhaled FIO_2 is typical of extreme altitude but can also result from equipment malfunction such as rebreathing of exhaled gases.

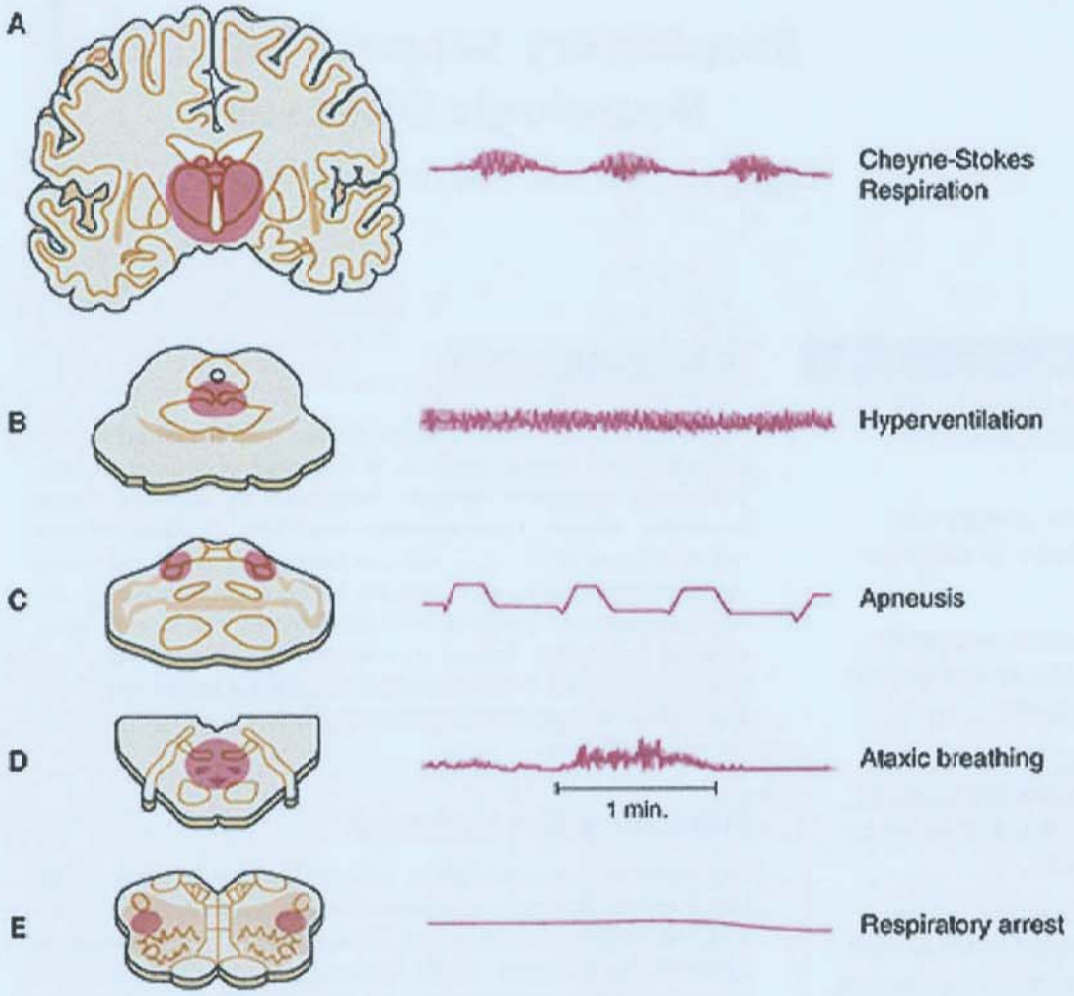

FIGURE 121.1 Neurogenic respiratory patterns. (Adapted from Plum F, Posner JB. *The Diagnosis of Stupor and Coma*. 3rd ed Philadelphia, PA: FA Davis; 1980.)

Hypercarbia results from impaired alveolar ventilation and is caused by some combination of inadequate "bellows function" of the lung (characterized by reduced minute ventilation, the product of the respiratory rate and tidal volume), increased carbon dioxide production, and impaired gas exchange. Hypoventilation can only be mechanism of hypoxia when concomitant hypercarbia is present (**Fig. 121.1**).

Respiratory Failure

The diagnosis of *respiratory failure* depends on arterial blood gas analysis and on the chronicity of the event. Three separate processes can contribute to the development of respiratory failure: (1) hypoxia, which results from impaired gas exchange in the lung; (2) ventilatory failure, which results from inadequate ability to move air into and out of the lungs; and (3) failure to protect the upper airway, which can result in airflow obstruction or aspiration of secretions, food, or gastric contents.

Chronic respiratory failure is said to be present when a patient cannot maintain adequate oxygenation (Pa_{O_2} >59 mm Hg) or ventilation (P_{CO_2} <50 mm Hg) without supplemental oxygen or ventilatory assistance. In contrast, *acute hypoxemic respiratory failure* describes a state in which adequate oxygenation cannot be maintained despite supplemental oxygen delivery. In these patients, positive pressure ventilation and supplemental oxygen administered through an endotracheal tube (ETT) or by noninvasive positive pressure ventilation (NPPV) are required to maintain normal oxygenation of arterial blood. In the hospital, hypoxemia can be easily and noninvasively diagnosed and monitored by measuring the percentage of oxygen saturation of hemoglobin in the blood (Sp_{O_2}). The clinical hallmark of hypoxemic respiratory failure is cyanosis.

Hypercarbic respiratory failure may be clinically obvious, as seen when the accessory muscles of respiration are activated and the patient appears "working hard to breathe" or can be subtle, manifest only by decreased mental acuity, myoclonus, confusion, agitation, or lethargy. Acute hypercapnia leads to acidosis and cerebral vasodilatation, which in turn can cause depressed level of consciousness ("carbon dioxide narcosis"), aggravation of elevated intracranial pressure (ICP), and blunted respiratory drive, leading to further hypoventilation. Arterial blood gas analysis is the most reliable method for diagnosing hypercarbic respiratory failure, but end-tidal carbon dioxide ($ETCO_2$) monitoring has gained popularity as a noninvasive method to monitor changes in alveolar carbon dioxide tension.

Failure of airway protection is diagnosed clinically when patients appear to be aspirating oral secretions, cannot maintain the upper airway open for gas exchange, have a rapid neurologic decline with a diminished gag and cough reflexes, or are experiencing repeated oxyhemoglobin desaturation due to intermittent plugging of the airways by secretions. Under unstable conditions, such as during a period of acute neurologic instability or during patient transport between hospitals or departments, it is advisable to intubate these patients and start mechanical ventilation to prevent sudden respiratory decompensation. Conversely, it may be safe to extubate such patients later in their hospital

course under controlled circumstances, despite significantly decreased mental status. There is no absolute measure of adequate upper airway protection, and unfortunately, such determinations remain for most part subjective.

The pathophysiology of neuromuscular respiratory failure resembles a vicious cycle. Increased mucus production and/or weak cough leads to mucus plugging and atelectasis, which in turn cause decreased efficiency of ventilation. Hypoxemia usually precedes hypercapnia because atelectasis and V/Q mismatching are an early development. As fever and infection develop, carbon dioxide production increases and ventilatory needs rise. The downward spiral of increasing carbon dioxide production, decreasing efficiency of ventilation, and progressive mucus plugging and atelectasis ultimately results in hypercarbia and respiratory failure. As ventilation fails, rapid shallow breathing and hypercapnia develop. At this stage, ventilatory reserves are exhausted, and there is the danger of sudden life-threatening hypoxemia, respiratory acidosis, or respiratory arrest.

Effects of Respiratory Compromise on Neurologic Injury

Many types of neurologic injury are exacerbated by respiratory compromise. Carbon dioxide and pH are powerful determinants of cerebral vascular tone, and the intended or unintended effects of hyperventilation (decreased cerebral blood flow, decreased intracranial blood volume, and decreased ICP) should be anticipated and monitored by clinicians. Conversely, hypoventilation and hypercapnia cause cerebral vasodilation and increased ICP. Hyperoxia is a potent exacerbant of reperfusion injury, whereas hypoxia is strongly associated with worse outcome in stroke, hypoxic-ischemic encephalopathy, and traumatic brain injury. Finally, when work of breathing is markedly increased, up to 50% of the cardiac output may be diverted to the respiratory muscles, driving metabolic stress, and potentially "stealing" blood flow from the ischemic brain or spinal cord. This metabolic stressor can be effectively managed by sedation, intubation, and initiation of full mechanical ventilatory support.

DIAGNOSIS

Diagnosis of respiratory failure in patients with neurologic disease can often be accomplished by the physical examination, although arterial blood gas analysis, chest imaging, and pulmonary function testing each have an important role to play. These modalities are discussed further below.

Examination

The initial management of the patient with impending respiratory failure is directed toward assessing the adequacy of oxygenation and ventilation, workload and stability of breathing, and assessment of the airway. In patients with fulminant respiratory failure, intubation can be lifesaving and is preferentially performed under safe, controlled circumstances well before the threat of impending cardiopulmonary arrest.

The patient's overall comfort and anxiety levels and the rate of progression of respiratory compromise should be assessed. Hypoxia is usually easy to diagnose with pulse oximetry and arterial blood gas analysis. Hypoventilation and hypercarbia may be present without distress or increased work of breathing if central respiratory drive is compromised, whereas increased respiratory effort with intact respiratory drive manifests as respiratory alkalosis. Sidestream $ETCO_2$ monitoring, less well established than oximetry but effective, is increasingly used to provide early warning of hypoventilation in patients at risk. Rapid, shallow breathing; the use of accessory muscles of the neck and the shoulder; and visible gulping or gasping with inability to generate adequate tidal volumes are signs of respiratory muscle fatigue and impending collapse, although such signs may be absent when central respiratory drive is impaired. Diaphragmatic strength can be estimated by palpating for normal outward movement of the abdomen with inspiration; with severe diaphragmatic paralysis, inspiration is associated with spontaneous inward movement of the diaphragm (abdominal paradox). Activation of respiratory muscles during the expiratory phase often indicates airflow obstruction.

When neuromuscular weakness is present, ventilatory reserves can be assessed by checking the patient's ability to count from 1 to 20 in a single breath. The strength of the patient's cough should be noted. A wet gurgled voice and pooled oropharyngeal secretions are clinical signs of dysphagia and ongoing aspiration. When severe, weakness of the glottic and oropharyngeal muscles can lead to stridor, which indicates possibly life-threatening obstruction of the upper airway.

Dysphagia is assessed by asking the patient to sip 3 oz of water; coughing is diagnostic of aspiration, and if present, oral feeding should be avoided until swallowing can be formally assessed. Patients with decreased cough and gag reflexes, however, may have aspiration without obvious clinical signs. Clinicians should have a low threshold to arrange for formal swallowing evaluation in patients with bulbar dysfunction.

Pulmonary Function Testing

Pulmonary function testing should be routinely used to monitor respiratory function in patients with neuromuscular respiratory compromise (Table 121.1). Arterial blood gases and $ETCO_2$ monitoring are helpful, but abnormalities of gas exchange usually develop later in the cycle of respiratory decompensation and are therefore insensitive for early detection of ventilatory decline. Forced vital capacity, the volume of air exhaled after maximal inspiration and exhalation, normally ranges from 40 to 70 mL/kg. Reduction in vital capacity to 30 mL/kg is associated with a weak cough, accumulation of oropharyngeal secretions, atelectasis, and nocturnal hypoxemia. Forced vital capacity below 15 mL/kg (1 L in a 70-kg person) is the level at which invasive or noninvasive ventilatory support should

TABLE 121.1 Pulmonary Function Tests in Neuromuscular Respiratory Failure[a]

	Normal	Criteria for Intubation and Weaning	Criteria for Extubation
Vital capacity (mL/kg)	40-70	15	25
Maximal inspiratory pressure (cm H_2O)	>80	20	40
Maximal expiratory pressure (cm H_2O)	>140	40	50

[a]Adapted from Mayer SA. Intensive care of the myasthenic patient. *Neurology*. 1997;48(suppl 5):S70-S75.

TABLE 121.2 Criteria[a] for Intubation and Mechanical Ventilation

- Pa_{O_2} <70 mm Hg with maximal oxygen delivery by face mask
- Pa_{CO_2} >50 mm Hg associated with acidosis (pH <7.35), which cannot be rapidly and durably reversed
- Severe oropharyngeal paresis or decreased level of arousal with inability to protect or maintain the airway
- Need for deep sedation or general anesthesia to control seizures or elevated ICP
- Maximal inspiratory pressure <25 cm H_2O or FVC <15 mL/kg
- Respiratory rate >35 breaths per minute or visibly excessive work of breathing

Abbreviations: FVC, forced vital capacity; ICP, intracranial pressure.
[a]These physiologic criteria are intended to serve only as guidelines; treatment decisions must be individualized. As a general rule, intubation in neurologic patients with impending respiratory failure should be performed *before* significant blood gas abnormalities develop.

be considered (**Table 121.2**). Maximal inspiratory pressure, normally more than 80 cm H_2O, measures the strength of the diaphragm and other muscles of inspiration and generally reflects the ability to maintain normal lung expansion and avoid atelectasis, whereas maximal expiratory pressure, normally more than 140 cm H_2O, measures the strength of the muscles of expiration and correlates with cough and the ability to clear secretions from the airway.

Blood Gas Analysis and Monitoring

Although transcutaneous monitoring of oxyhemoglobin saturation is standard, pulse oximetry alone is often inadequate to detect impending ventilatory failure because hypoxia occurs as a late event. Arterial blood gas analysis remains the gold standard for determining the partial pressure of oxygen and carbon dioxide in the blood and should be obtained when respiratory function is compromised. Thoughtful interpretation of blood gas results is also critical to reveal respiratory and metabolic acidosis or alkalosis and the extent to which these derangements have been compensated. In acute ventilatory failure, the pH is expected to drop by 0.08 units and bicarbonate to rise by 1 mEq/L for every 10 mm Hg rise in P_{CO_2}, whereas in chronic respiratory acidosis, the pH drops by 0.03 units and bicarbonate rises by 3 to 4 mEq/L for every 10-point rise in P_{CO_2}. Respiratory alkalosis can be caused by pain or anxiety but is also common in primary central nervous system injury. Central hyperventilation may suggest not only brainstem dysfunction but also elevated ICP, an unbuffered intracranial acid load, or pressure on the floor of the fourth ventricle. Arterial blood gas analysis is important in detection of carboxyhemoglobin, when carbon monoxide poisoning is suspected, and of methemoglobinemia.

Capnography ($ETCO_2$ monitoring) is useful in both intubated and nonintubated patients to monitor changes in ventilation and is particularly important for patients with elevated ICP, for whom acute changes in carbon dioxide tension can result in dramatic changes in cerebral blood flow and ICP. Capnography does not take the place of an arterial blood gas and is best interpreted in terms of its relationship to P_{CO_2}, which varies among patients and over time.

MANAGEMENT OF RESPIRATORY FAILURE

Noninvasive Positive Pressure Ventilation

Mechanical ventilatory support is the primary treatment of respiratory failure. If airway protection is adequate and the patient is relatively cooperative, NPPV administered via a snug-fitting facemask should be considered. In medical patients with an acute exacerbation or chronic obstructive pulmonary disease or congestive heart failure, NPPV has fewer complications than invasive mechanical ventilation LEVEL 1.[1] In neurologic patients, the use of NPPV is becoming increasingly common as an initial intervention for early neuromuscular respiratory failure from myasthenic exacerbation and in others with chronic neuromuscular weakness and acute respiratory disease. Its use in Guillain-Barré syndrome is controversial, however, with mixed results and some concerns about safety due to the potential for respiratory arrest.

Among patients with neuromuscular weakness, early use of NPPV maintains lung expansion, reduces the work of breathing, and minimizes the risk of severe respiratory failure requiring intubation. Only patients with adequate airway protective reflexes should be treated, and NPPV should *not* be used as a substitute for endotracheal intubation when acute respiratory failure is severe or complete elimination of the work of breathing is desirable. Noninvasive ventilation requires close observation in a monitored setting and the availability of rapid intubation in the event of respiratory decompensation. Many clinicians prefer the security of invasive mechanical ventilation with an ETT or a tracheostomy, but neurologists should be aware that in ICUs where high-quality, safe NPPV can be provided; it is often strongly preferred by patients and reduces the incidence of hospital-acquired infections, the need for sedation and analgesia, and the length of ICU stay. Noninvasive ventilation should be used in conjunction with mechanical cough assist devices to aid in airway clearance—a combination that effectively treats mucus plugging and atelectasis and keeps many patients off the ventilator.

Endotracheal Intubation and Mechanical Ventilation

Indications for endotracheal intubation due to respiratory failure may include compromised ventilation or oxygenation, the need for airway protection, or both. For patients needing endotracheal intubation, clinicians should consider the patient's comfort level as well as intracranial and arterial pressures. Intravenous (IV) access should be obtained prior to intubation and infusion because sedation and positive pressure ventilation may cause a precipitous drop in blood pressure. All patients should be preoxygenated with an F_{IO_2} of 100% prior to intubation, and in patients with elevated ICP, mild hyperventilation should be considered before lowering the head of the bed and extra efforts made to avoid hypoventilation.

Special concerns related to the intubation of neurologic patients are described in **Table 121.3**.

The administration of 50 to 100 mg of IV lidocaine immediately before intubation blunts the anticipated rise in ICP. *Rapid sequence intubation* involves administration of a combination of IV sedatives (ie, etomidate or fentanyl), amnestics (ie, midazolam), and muscle relaxants (ie, vecuronium); depolarizing

TABLE 121.3 Intubation and Respiratory Concerns Specific to Patients With Neurologic Disease

Problem	Assessment	Management
Elevated ICP	Mass lesion, cerebral edema, hydrocephalus	Preadministration of mannitol or hypertonic saline solution, minimize head-flat positioning, adequate analgesia and sedation, avoidance of hypoventilation
Brain ischemia	Acute stroke with penumbra	Administration of fluids and/or vasopressors, avoidance of vasodilators, $ETCO_2$ monitoring, avoidance of hyperventilation
Cervical spine injury or instability	Mechanism of injury suggesting cervical spine injury or radiographic injury	In-line spinal stabilization; intubation techniques to minimize anteroposterior cord displacement
Ischemia-reperfusion injury	Minimize biochemical harm	Normalize oxygenation (keep Pa_{O_2} 60-300 mm Hg) and ventilation (keep Pa_{CO_2} 30-50 mm Hg or $ETCO_2$ 30-45 mm Hg)

Abbreviations: $ETCO_2$, end-tidal carbon dioxide; ICP, intracranial pressure.

muscle relaxants such as succinylcholine should be avoided in patients suffering from immobility or paresis because of a possibly abrupt rise in serum potassium level after drug-induced muscle depolarization. The trachea may be intubated orally or nasally; a high-volume, low-pressure cuff is then inflated in the trachea to prevent leakage of air and secretions around the tube.

Modes of mechanical ventilatory support include volume- and pressure-cycled ventilation, pressure support with continuous positive airway pressure (CPAP), and many others (Table 121.4). Although no ventilatory mode is intrinsically superior to the others, in general, patients should be ventilated according to the basic principles of lung-protective ventilation to avoid ventilator-induced lung injury in the setting of acute lung injury or acute respiratory distress syndrome LEVEL 1.[2] Lung-protective ventilation endeavors to minimize barotrauma and volutrauma due to overdistention of aerated lung segments, trauma from atelectasis due to repetitive opening and closing of collapsed alveoli, and biotrauma due to inflammation. This is accomplished by minimizing peak and plateau airway pressures (goal <30 cm H_2O), providing positive end-expiratory pressure (PEEP) to prevent alveolar collapse at end-expiration and to recruit collapsed lung units, limiting exposure to toxic levels of oxygen and using small tidal volumes (4-6 mL/kg of *ideal* body weight) to prevent overdistention of vulnerable alveolar units LEVEL 1.[2] More recently, it has been shown that maintaining *driving pressure*—the plateau airway pressure minus PEEP—below 14 mm Hg is associated with reduced mortality in the setting of acute respiratory distress syndrome. In general, "permissive" hypercapnia and hypoxia—part of most lung protective ventilation protocols—should be employed cautiously and after consideration of the effects of dysventilation on neurophysiology. Unless required for control of elevated ICP, prolonged uninterrupted deep sedation and paralysis are discouraged because spontaneous respiratory efforts by the patient prevent dependent atelectasis and respiratory muscle atrophy.

TABLE 121.4 Ventilator Modes and Functions

Abbreviation	Stands for Description
SIMV	Synchronized intermittent mandatory ventilation
CMV	Continuous mandatory ventilation
PS	Pressure support
CPAP	Continuous positive airway pressure
PEEP	Positive end-expiratory pressure

Manipulation of Ventilation: Effects on Intracranial Pressure and Cerebral Blood Flow

Hyperventilation results in acute hypocarbia and respiratory alkalosis. This causes arteriolar constriction in the brain, leading immediately to decreased cerebral blood flow and lower ICP. Conversely, hypoventilation results in hypercarbia and cerebral arteriolar dilation, causing increased cerebral blood flow and ICP. These physiologic responses are frequently manipulated to treat elevations of ICP and because of the potential for harm should be carefully monitored in patients with impaired cerebral perfusion or elevated ICP.

Hyperventilation is a powerful tool to reverse critical increases in ICP and is a standard measure to reverse uncal or transtentorial herniation syndromes. The negative effects of hyperventilation on cerebral blood flow prohibit prolonged and excessive usage unless brain tissue oxygenation is concurrently monitored. Hyperventilation should not be used at all when active brain ischemia is present such as in acute large-vessel stroke or cerebral vasospasm. In addition to the danger of precipitating brain ischemia, prolonged hyperventilation is rarely effective as a treatment for elevated ICP, as compensatory mechanisms in the central nervous system rapidly buffer the pH changes in peripheral pH, and cerebral blood flow is restored. Hyperventilation below a P_{CO_2} of 20 mm Hg causes progressive hemodynamic deterioration but does not result in additional arterial constriction or reduction in ICP. It is not known whether spontaneous hyperventilation puts the brain at risk for ischemia or whether it simply reflects a physiologic compensatory mechanism at work.

$ETCO_2$ tension correlates modestly well with the partial pressure of alveolar carbon dioxide, and in-line $ETCO_2$ can be monitored as a continuous vital sign in mechanically ventilated patients, whereas sidestream $ETCO_2$ is used to monitor alveolar carbon dioxide tension in nonintubated patients. $ETCO_2$ tends to run slightly lower than arterial P_{CO_2}; differences between the two measurements reflect not only dead space ventilation but also increasing age, chronic obstructive pulmonary disease, and circumstances in which alveolar dead space increases such as hypovolemia, pulmonary embolism, and a low cardiac output state.

Prevention of Ventilator-Associated Pneumonia

Ventilator-associated pneumonia (VAP) is the most common and serious complication of endotracheal intubation. The ETT serves as a conduit for bacterial invasion of the airway and deep

TABLE 121.5 Contraindications to a Daily Spontaneous Breathing Trial

• FIO_2 >80%, PEEP >10 cm H_2O, or high risk of lung derecruitment in severe ARDS
• Deep sedation or paralysis for control of seizures, ICP, or shivering
• Active and clinically important brain or myocardial ischemia
• Severe and unstable cerebral vasospasm

Abbreviations: ARDS, acute respiratory distress syndrome; FIO_2, fraction of inspired oxygen; ICP, intracranial pressure; PEEP, positive end-expiratory pressure.

lung segments and compromises natural defenses against infection. About 20% of patients who are intubated for more than 1 week develop VAP, which adds an average of 1 week to the ICU length of stay, $40,000 to the cost of care, and carries an attributable mortality exceeding 30%. The clinical diagnosis is established by the appearance of a new pulmonary infiltrate on chest radiography more than 48 hours after intubation and the new onset of fever, leukocytosis, or purulent secretions. Neurologic patients are at particularly high risk for VAP because they are immobile and tend to aspirate.

A standardized protocol of measures that minimize bacterial colonization of the upper airway and digestive tract and the risk of aspiration can reduce the risk of VAP. These measures include 30° head elevation to minimize gastric regurgitation, mouth care with chlorhexidine-based solutions, avoidance of unnecessary antibiotics, and removal of the ETT as soon as possible by combining daily interruption of sedation with spontaneous breathing trials (SBTs) LEVEL 1.[3] Some ICUs employ selective gut decontamination or prophylactic antibiotics in patients with neurologic disease to decrease the incidence of respiratory infections, but these measures are not widely recommended and require further study.

Weaning From Mechanical Ventilation

Weaning from mechanical ventilation is a continuous process that should begin as soon as a moderate level of medical and respiratory stability is achieved. Although excessive work of breathing should be avoided as a stressor in patients with neurologic or cardiac ischemia, respiratory work is necessary to prevent muscle atrophy, and the duration of mechanical ventilation is strongly correlated with the development of VAP and other medical complications. Ventilator weaning should be delayed in only dire circumstances (**Table 121.5**). A typical weaning protocol is shown in **Figure 121.2**.

Weaning of mechanical ventilation begins with the lightening of sedation, downward titration of FIO_2 and mean airway pressure to levels consistent with spontaneous ventilation, and face mask oxygen delivery. This is typically consistent with an FIO_2 of 40% and PEEP of 5 cm H_2O. Compared to gradually reducing the respiratory rate using synchronized mandatory ventilation or the level of pressure support triggered by each breath, the best results are obtained through the use of daily SBTs. SBTs vary widely in design but reflect a measured period of breathing in which most or all of the work of breathing is performed by the patient and after which a protocolized assessment is performed to determine suitability for the discontinuation of mechanical ventilation. The most common types of SBTs involve placing the patient on CPAP with a low-level pressure support (usually 5 cm H_2O) sufficient to overcome ETT resistance and T-piece trials, in which the patient breathes spontaneously for a predetermined duration through an open tubing system with flow-by oxygen.

The ability of the patient to tolerate a T-piece or CPAP trial for 2 hours, while maintaining a ratio of respiratory rate (breaths per minute) to tidal volume (liters) less than 100, is a useful predictor of successful extubation. In patients with depressed level of consciousness or neuromuscular respiratory weakness, the ability to tolerate a T-piece or CPAP ventilation overnight offers additional reassurance that the patient has adequate stamina

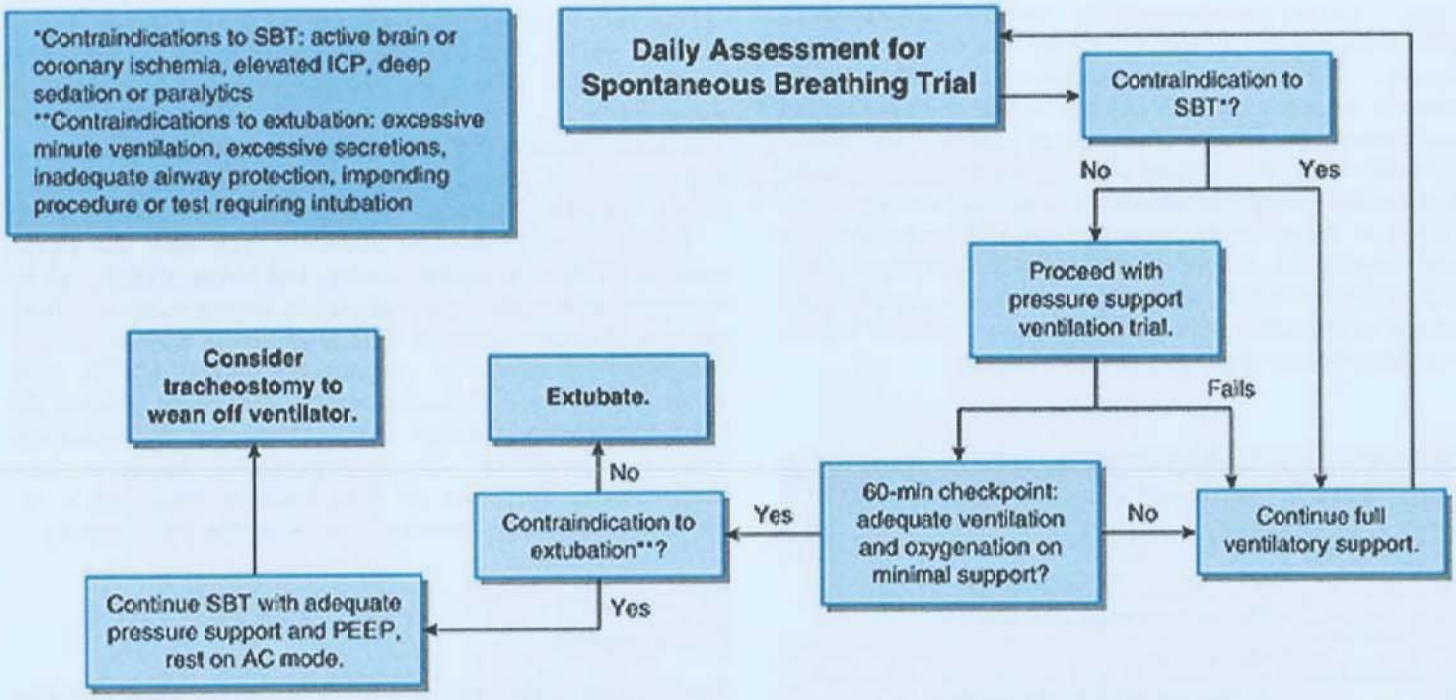

FIGURE 121.2 Ventilator weaning protocol. Abbreviations: AC, assist control; ICP, intracranial pressure; PEEP, positive end-expiratory pressure; SBT, spontaneous breathing trial.

TABLE 121.6 General Criteria for Extubation

• Successful completion of a spontaneous breathing trial
• Neurologic and medical condition is stable or improving.
• Cough and gag reflexes present, minimal pooling of secretions
• Pa_{O_2} >70 mm Hg with 40% oxygen and PEEP ≤8 cm H_2O
• Minute ventilation <12 L/min at rest
• Vital capacity >15 mL/kg and maximal inspiratory pressure >25 mm Hg
• No pending procedures, operations, or radiographic studies requiring airway protection
• Minimal secretions or moderate secretions with strong cough
• Volume status optimized, airway reactivity assessed and treated, feeds held
• Equipment, medications, and personnel necessary for reintubation readily available

Abbreviation: PEEP, positive end-expiratory pressure.

to tolerate breathing off the ventilator indefinitely. Indications of tiring during an SBT include an increasing respiratory rate with decreasing tidal volumes, a drop in arterial oxygen saturation, diaphoresis, the progressive use of accessory muscles of respiration, or hemodynamic instability. Failure of a weaning trial is a physiologic stressor, and patients with these signs should be returned to mechanical ventilation.

In patients with tracheostomy or receiving NPPV, detachment from and reconnection to the ventilator is uneventful and easy to perform. Extubation and reintubation, however, always entail risk. Before a planned extubation, the patient's volume status, airway reactivity, secretions, and cardiac function should be optimized (Table 121.6). Despite the best predictors of successful extubation, it is not possible to evaluate the airway itself prior to extubation. Even with careful patient selection and medical optimization, as many as 20% of extubated patients are reintubated within 48 hours, and patients with neurologic diseases are among the most difficult to predict.

Tracheostomy

Clinicians have traditionally performed tracheostomy when mechanical ventilation has been used for more than 14 days. Tracheostomy has several advantages over prolonged endotracheal intubation, including increased comfort, reduced risk of permanent tracheolaryngeal injury, increased ease of weaning from the ventilator (reduced dead space and less resistance to flow from the ETT), and improved ability to manage and suction secretions. In comatose patients or in those with profound neuromuscular weakness for whom a prolonged period of ventilator dependence is anticipated, early tracheostomy within 3 to 5 days of intubation extends these benefits and has been associated with reduced ICU length of stay and mortality. Most patients with significant bulbar dysfunction following an acute brain injury will require tracheostomy for secretions management, although they can often be weaned rapidly from mechanical ventilation, and many will ultimately be decannulated when cough strength and airway protective reflexes have partially recovered.

Percutaneous tracheostomy creates a temporary stoma that is easily and rapidly reversible upon decannulation, whereas surgical tracheostomy creates a more durable and permanent stoma that typically requires surgical closure. In some patients with severe persistent oropharyngeal muscle weakness, a tracheostomy is necessary to manage secretions and prevent aspiration, even though respiratory muscle function is adequate.

Long-Term Ventilation

In chronic respiratory failure, patients and clinicians should work together to determine the best interface for mechanical ventilatory support. Patients with good bulbar function and normal level of consciousness can often tolerate intermittent daytime and continuous nocturnal NPPV by nasal or face mask, whereas those at high risk for aspiration, or with a low or waxing and waning level of arousal, are more safely ventilated by tracheostomy. Patients with CRF often describe improved quality of life with NPPV and may be at lower risk of developing respiratory infections than patients with permanent tracheostomy—this has been dramatically demonstrated in patients with respiratory failure due to progressive Duchenne muscular dystrophy. Yet, patients with a tracheostomy can sometimes speak and eat; an experienced speech therapist can determine the safety of and capacity for these activities. Adjustments in tidal volume and tracheostomy size may be important in facilitating speech, and cuff deflation dramatically improves the ability to speak and swallow but leaves the airway open to aspiration.

Some patients need ventilatory support for months or years. Small suitcase- or laptop-sized ventilators are available for use at home, and battery-powered portable ventilators can allow wheelchair-bound patients to travel out of the home. For patients with respiratory failure after brainstem or high cervical cord lesions, an implantable phrenic nerve pacemaker can be used to stimulate diaphragmatic contraction, liberating the patient from connection to a machine.

OUTCOMES

At one time, neurologic and particularly cerebrovascular patients requiring mechanical ventilation had a very poor prognosis, and the usefulness of life support in the neurocritically ill was a topic of controversy. Mechanical ventilation was seen as an indicator of illness severity, and its application were rarely described. Today, with improved medical and surgical therapies for cerebrovascular disease, improved mechanical ventilation and general ICU practices, more sophisticated prevention of secondary neurologic injury, and dedicated treatment in specialized neurologic ICUs, outcomes of mechanically ventilated patients with neurologic disease have improved. As accurate prognostication can rarely be performed in the hours after presentation to the medical care system, airway and respiratory management must be initiated to prevent secondary brain injury during the stabilization phase of care, and neurologists should be prepared to provide respiratory support.

LEVEL 1 EVIDENCE

1. Rochwerg B, Brochard L, Elliott MW, et al. Official ERS/ATS clinical practice guidelines: noninvasive ventilation for acute respiratory failure. *Eur Respir J*. 2017;50(2):1602426. doi:10.1183/13993003.02426-2016.
2. Fan E, Del Sorbo L, Goligher EC, et al. An official American Thoracic Society/European Society of Intensive Care

Medicine/Society of Critical Care Medicine clinical practice guideline: mechanical ventilation in adult patients with acute respiratory distress syndrome. *Am J Respir Crit Care Med.* 2017;195(9):1253-1263.

3. Klompas M, Branson R, Eichenwald EC, et al. Strategies to prevent ventilator-associated pneumonia in acute care hospitals: 2014 update. *Infect Control Hosp Epidemiol.* 2014;35(8):915-936.

SUGGESTED READINGS

Aboussouan LS, Khan SU, Meeker DP, Stelmach K, Mitsumoto M. Effect of noninvasive positive-pressure ventilation on survival in amyotrophic lateral sclerosis. *Ann Intern Med.* 1997;127:450-453.

Bach JR. Continuous noninvasive ventilation for patients with neuromuscular disease and spinal cord injury. *Semin Respir Crit Care Med.* 2002;23(3):283-292.

Bach JR, Saporito LR, Shah HR, et al. Decanulation of patients with severe respiratory muscle insufficiency: efficacy of mechanical insufflation-exsufflation. *J Rehabil Med.* 2014;46(10):1037-1041.

Bösel J. Use and timing of tracheostomy after severe stroke. *Stroke.* 2017;48(9):2638-2643.

Bösel J, Schiller P, Hook Y, et al. Stroke-related Early Tracheostomy versus Prolonged Orotracheal Intubation in Neurocritical Care Trial (SETPOINT): a randomized pilot trial. *Stroke.* 2013;44(1):21-28.

Carrera E, Schmidt JM, Fernandez L, et al. Spontaneous hyperventilation and brain tissue hypoxia in patients with severe brain injury. *J Neurol Neurosurg Psychiatry.* 2010;81(7):793-797.

Coplin WM, Pierson DJ, Cooley KD, Newell DW, Rubenfeld GD. Implications of extubation delay in brain-injured patients meeting standard weaning criteria. *Am J Respir Crit Care Med.* 2000;161:1530-1536.

Curley G, Kavanagh BP, Laffey JG. Hypocapnia and the injured brain: more harm than benefit. *Crit Care Med.* 2010;38(5):1348-1359.

Diringer MN, Videen TO, Yundt K, et al. Regional cerebrovascular and metabolic effects of hyperventilation after severe traumatic brain injury. *J Neurosurg.* 2002;96(1):103-108.

Ely EW, Baker AM, Evans GW, Haponik EF. The prognostic significance of passing a daily screen of weaning parameters. *Intensive Care Med.* 1999;25:581.

Esteban A, Frutos F, Tobin MJ, et al. A comparison of four methods of weaning patients from mechanical ventilation. Spanish Lung Failure Collaborative Group. *N Engl J Med.* 1995;332:345.

Fan E, Brodie D, Slutsky AS. Acute respiratory distress syndrome: advances in diagnosis and treatment. *JAMA.* 2018;319(7):698-710.

Farrero E, Prats E, Povedano M, et al. Survival in amyotrophic lateral sclerosis with home mechanical ventilation. *Chest.* 2005;127:2132-2138.

Kress JP, Pohlman AS, O'Connor MF, Hall JB. Daily interruption of sedative infusions in critically ill patients undergoing mechanical ventilation. *N Engl J Med.* 2000;342:1471-1477.

Laghi F, Tobin MJ. Disorders of the respiratory muscles. *Am J Respir Crit Care Med.* 2003;168:10-48.

Levine S, Nguyen T, Taylor N, et al. Rapid disuse atrophy of diaphragm fibers in mechanically ventilated humans. *N Engl J Med.* 2008;358:1327-1335.

MacDuff A, Grant IS. Critical care management of neuromuscular disease, including long-term ventilation. *Curr Opin Crit Care.* 2003;9:106-112.

Mayer SA, Copeland DL, Bernardini GL, et al. Cost and outcome of mechanical ventilation for life-threatening stroke. *Stroke.* 2000;31:2346-2353.

Nieszkowska A, Combes A, Luyt CE, et al. Impact of tracheotomy on sedative administration, sedation level, and comfort of mechanically ventilated intensive care unit patients. *Crit Care Med.* 2005;33:2527-2533.

Perrin C, Unterborn JN, Ambrosio CD, et al. Pulmonary complications of chronic neuromuscular diseases and their management. *Muscle Nerve.* 2004;29:5-27.

Rabinstein AA, Wijdicks EF. BiPAP in acute respiratory failure due to myasthenic crisis may prevent intubation. *Neurology.* 2002;59:1647-1649.

Rabinstein AA, Wijdicks EF. Warning signs of imminent respiratory failure in neurological patients. *Semin Neurol.* 2003;23:97-104.

Rajajee V, Riggs B, Seder DB. Emergency neurological life support: airway, ventilation, and sedation. *Neurocrit Care.* 2017;27(suppl 1):4-28.

Robba C, Bonatti G, Battaglini D, Rocco PRM, Pelosi P. Mechanical ventilation in patients with acute ischaemic stroke: from pathophysiology to clinical practice. *Crit Care.* 2019;23(1):388.

Schönenberger S, Al-Suwaidan F, Kieser M, Uhlmann L, Bösel J. The SETscore to predict tracheostomy need in cerebrovascular neurocritical care patients. *Neurocrit Care.* 2016;25(1):94-104.

Schönenberger S, Hendén PL, Simonsen CZ, et al. Association of general anesthesia vs procedural sedation with functional outcome among patients with acute ischemic stroke undergoing thrombectomy: a systematic review and meta-analysis. *JAMA.* 2019;322:1283-1293.

Schönenberger S, Uhlmann L, Hacke W, et al. Effect of conscious sedation vs general anesthesia on early neurological improvement among patients with ischemic stroke undergoing endovascular thrombectomy: a randomized clinical trial. *JAMA.* 2016;316(19):1986-1996.

Seder DB, Bösel J. Airway management and mechanical ventilation in acute brain injury. *Handb Clin Neurol.* 2017;140:15-32.

Seneviratne J, Mandrekar J, Wijdicks EFM, Rabinstein AA. Noninvasive ventilation in myasthenic crisis. *Arch Neurol.* 2008;65:54-58.

Seneviratne J, Mandrekar J, Wijdicks EFM, Rabinstein AA. Predictors of extubation failure in myasthenic crisis. *Arch Neurol.* 2008;65:929-933.

Smith EE, Kent DM, Bulsara KR, et al. Effect of dysphagia screening strategies on clinical outcomes after stroke: a systematic review for the 2018 guidelines for the early management of patients with acute ischemic stroke. *Stroke.* 2018;49(3):e123-e128.

Thomas CE, Mayer SA, Gungor Y, et al. Myasthenic crisis: clinical features, mortality, complications, and risk factors for prolonged intubation. *Neurology.* 1997;48:1253-1260.

Varelas PN, Chua HC, Natterman J, et al. Ventilatory care in myasthenia gravis crisis: assessing the baseline adverse event rate. *Crit Care Med.* 2002;30:2663-2568.

Yavagal DL, Mayer SA. Respiratory complications of rapidly progressive neuromuscular syndromes: Guillain-Barré syndrome and myasthenia gravis. *Semin Respir Crit Care Med.* 2002;23:221-229.

Endocrine Diseases and the Brain 122

Spyridoula Tsetsou and Alexandra S. Reynolds

KEY POINTS

1. Pituitary disorders can cause symptoms related to lack or excess of hormones but can also result in direct compressive effects on nearby cranial nerves.
2. Obtaining thyroid-stimulating hormone and free thyroxine levels can help determine etiologies of hyperthyroidism and hypothyroidism.
3. Glycemic control is critical to minimizing occurrence or progression of neuropathy and macrovascular complications.

INTRODUCTION

Endocrine secretions and disorders of metabolism have a profound influence on the nervous system. Disturbances of consciousness and cognition along with a variety of other neurologic symptoms may accompany primary endocrine diseases (Table 122.1). This chapter considers common endocrine conditions that may cause important neurologic symptoms.

PITUITARY DISORDERS

The pituitary gland is located in the sella turcica and is divided into anterior and posterior lobes. The hypothalamus generates both the anterior and posterior lobes' hormone secretion and production (Fig. 122.1). The anterior pituitary produces and releases adrenocorticotropin or corticotropin (adrenocorticotropic hormone [ACTH]), follicle-stimulating hormone (FSH) and luteinizing hormone (LH), growth hormone (GH), prolactin, and thyroid-stimulating hormone (TSH), whereas the posterior pituitary stores and releases antidiuretic hormone (ADH) or vasopressin, and oxytocin. Stimulatory or inhibitory hormones produced by the hypothalamus (in the paraventricular and arcuate nuclei) stimulate the release of anterior pituitary hormones, which in turn stimulates hormone production at the target organ. Neurosecretory cells from the hypothalamus produce ADH and oxytocin, which are then transported and stored in the posterior pituitary.

Pituitary disorders manifest with a variety of systemic and neurologic symptoms related to either lack or excess of hormones. The pituitary's anatomic proximity with cranial nerves and the cavernous sinus (Fig. 122.2) is responsible of visual field defects (particularly bitemporal hemianopia), ophthalmoplegia, cerebrospinal fluid leak, and cavernous sinus infiltration with certain pathologies. The more common pituitary disorders are described in this chapter.

TABLE 122.1 Prevalence and Incidence of the Most Common Endocrine Diseases

Disease	Incidence	Prevalence
Hypopituitarism	4.2/100,000	45.5/100,000
Cushing disease	2-3/1,000,000	Not reported
Hypothyroidism	0.65-4.57/1,000	1-5/100
Hyperthyroidism	Not reported	0.5-1.3/100
Diabetes mellitus	6.7/1,000	9.4/100
Adrenal insufficiency	4.4-6/1,000,000	150-280/1,000,000
Cushing syndrome	0.2-5/1,000,000	40/1,000,000
Pheochromocytoma	0.005-0.1/100	1/2,500-1/6,500
Hypoparathyroidism	37/100,000	1/60,000-80,000
Hyperparathyroidism	22/100,000	1-7/1,000

Hypopituitarism

Epidemiology

Limited data are available for the epidemiology of hypopituitarism. In one population-based study from Spain, its prevalence was 45.5 cases per 100,000 with an incidence of 4.2 cases per 100,000 per year.

Pathobiology

Hypopituitarism is defined as a deficiency in one or more pituitary hormones. It can be caused by mechanical, vascular, or neural disconnection from the hypothalamus as is seen in direct damage (tumor, radiation), inflammatory processes (lymphocytic hypophysitis/infundibulitis, sarcoidosis, Langerhans cell histiocytosis, Wegener granulomatosis), infectious diseases (tuberculosis, postsurgical bacterial or fungal abscess formation, rarely syphilis or parasites), trauma, subarachnoid hemorrhage, severe hypotension or shock, empty sella syndrome, or occlusive spasm of pituitary arteries with anoxic-ischemic necrosis (apoplexy) of a pituitary gland that has hypertrophied (usually under estrogen stimulation from pregnancy, known as *Sheehan syndrome*).

Clinical Features, Diagnosis, and Treatment

ACTH Deficiency

ACTH deficiency will lead to cortisol deficiency and secondary adrenal insufficiency. Symptoms are nonspecific and include weight loss, fatigue, weakness, nausea, and orthostatic hypotension. A morning (6:00-8:00) serum cortisol greater than 18 μg/dL usually reflects an intact hypothalamic-ACTH-adrenal axis. In case of lower levels, a confirmatory test such as an ACTH stimulation test or an insulin tolerance test is required for diagnosis. However, these tests are mainly useful in chronic pathology and can falsely suggest secondary adrenal insufficiency in acute hypothalamic or pituitary injury. The gold standard treatment consists of glucocorticoid replacement, typically with hydrocortisone 15 to 25 mg/d or prednisone 4 to 7.5 mg/d. Dexamethasone should be avoided due to its long

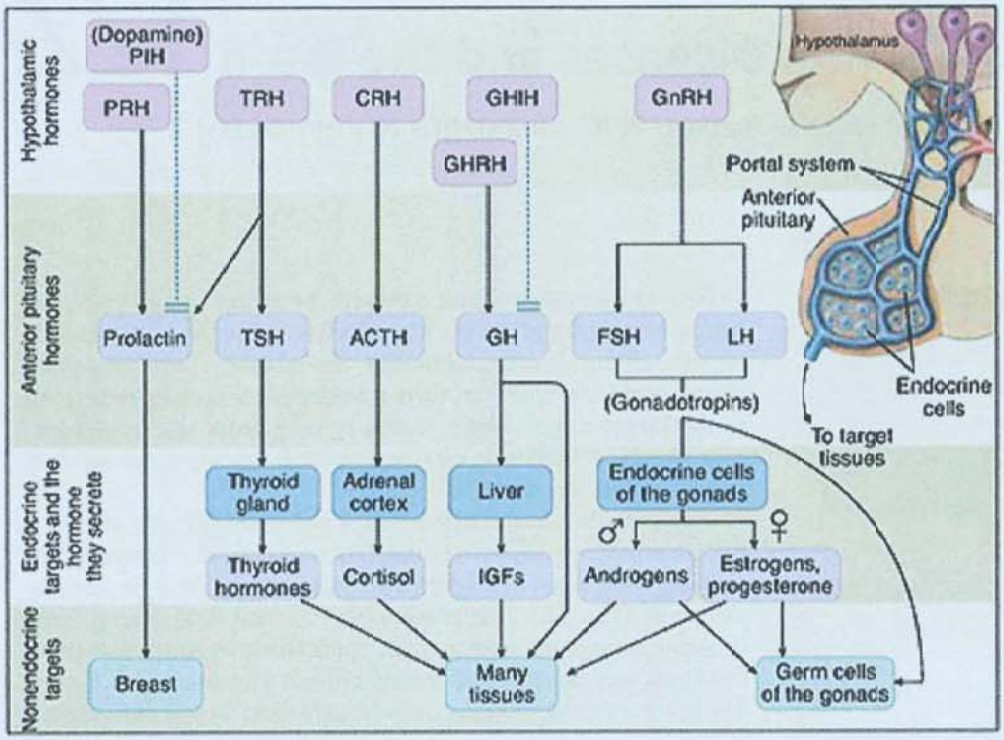

FIGURE 122.1 Hypothalamic-pituitary-target organ axis. Abbreviations: ACTH, adrenocorticotropic hormone; CRH, corticotropin-releasing hormone; FSH, follicle-stimulating hormone; GH, growth hormone; GHIH, growth hormone-inhibiting hormone (also known as somatostatin); GHRH, growth hormone–releasing hormone; GnRH, gonadotropin-releasing hormone; IGFs, insulin-like growth factors; LH, luteinizing hormone; PIH, prolactin-inhibiting factor; PRH, prolactin-releasing hormone; TRH, thyroid-releasing hormone; TSH, thyroid-stimulating hormone. (Image from Carvalho K, Grunwald T, De Luca F. Neurological complications of endocrine disease. *Semin Pediatr Neurol.* 2017;24:33-42.)

and nonphysiologic half-life; however, if it is prescribed (eg, in postneurosurgical patients), it should not be combined with prednisone or hydrocortisone.

FSH and LH Deficiency

FSH and LH deficiency will manifest as hypogonadism with oligomenorrhea or amenorrhea and impaired ovulation in females as well as decreased libido, decreased bone density, vaginal atrophy, and thin skin. In males, primary symptoms consist of decreased libido, low sperm count, erectile dysfunction, fatigue, and decreased bone density. Female hypogonadism in premenopausal women is diagnosed by low estradiol and low to normal luteinizing hormone and follicle-stimulating hormone, and is treated with estrogen and progesterone (oral, intramuscular, or transdermal). Male hypogonadism is confirmed with low morning testosterone levels and is treated with testosterone preparation (transdermal gel, patch, or intramuscular), with frequent prostate-specific antigen monitoring. Gonadotropins may be necessary for both women and men who desire fertility.

GH Deficiency

GH deficiency in adults causes thin and dry skin, weight gain (especially around the waist), muscle atrophy, fatigue, low energy, decreased exercise tolerance and strength, and mood disorders (depression, anxiety). Diagnosis requires pituitary stimulation testing (with arginine, GH-releasing hormone or insulin-induced hypoglycemia) or documented lack of three or more anterior pituitary hormones with decreased serum insulin-like growth factor 1 (IGF-1). Treatment consists of GH replacement; however, dosing is not well established in adults.

Prolactin Deficiency

Prolactin deficiency is clinically evident in cases of insufficient postpartum lactation.

TSH Deficiency

TSH deficiency will lead to a decrease in free levothyroxine (free T_4) production, with concomitant fatigue, cold intolerance, dry

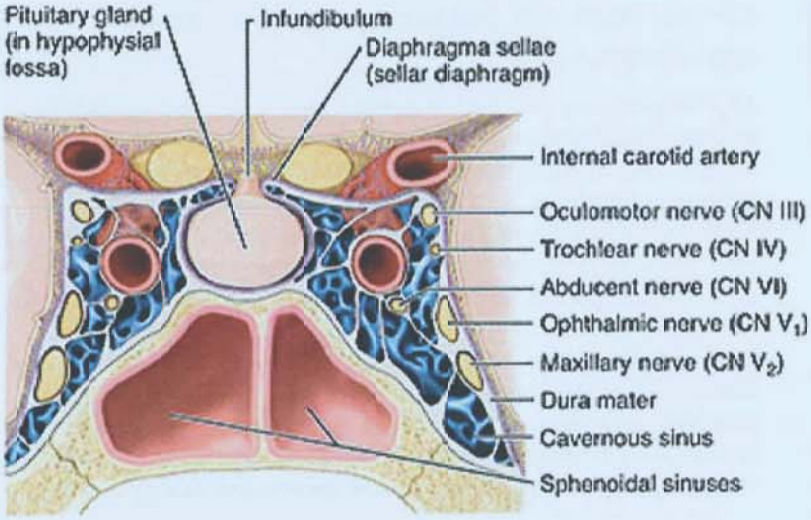

FIGURE 122.2 Pituitary sella, pituitary gland anatomy. Abbreviation: CN, cranial nerve. (Image from Utz LA, Klibanski A. Pituitary disorders. *Continuum Lifelong Learning Neurol.* 2009;15[2]:17-36.)

skin, weight gain, constipation, and mood disorders. TSH levels can sometimes be in the normal range, and free T_4 measurement is crucial for the diagnosis of central hypothyroidism when clinically suspected. Treatment consists of levothyroxine replacement.

ADH Deficiency (Diabetes Insipidus)

ADH deficiency in response to serum hyperosmolar stimuli leads to diabetes insipidus (DI). Diagnosis requires the presence of polyuria, dilute urine, and increased serum sodium level, in the setting of suspected pituitary injury. If increased water intake cannot balance the excessive fluid losses and correct the serum sodium levels, administration of desmopressin should be the next step (intravenous, intranasal, or oral).

Hyperpituitarism

Epidemiology

There is no data about the incidence of hyperpituitarism. Specific hormone excess condition incidences are referred in the following text.

Pathobiology

Excess of one or more pituitary gland hormones defines hyperpituitarism. It is usually related to primary or metastatic secretory tumors, traumatic brain injury, or specific medications. Multiple endocrine neoplasia type 1 is a syndrome consisting of pituitary adenoma with pancreatic endocrine tumors and parathyroid tumors.

Clinical Features, Diagnosis, and Treatment

Hyperprolactinemia

Hyperprolactinemia (prolactin excess) is mainly associated with prolactinomas, the most frequent functional pituitary tumor. Craniopharyngiomas and traumatic brain injury are other less frequent causes. Specific medications (antipsychotic drugs, opioids, metoclopramide, and antidepressants) as well as hypothyroidism, anorexia nervosa, polycystic ovarian syndrome, and rarely a postictal state may be associated with mild hyperprolactinemia. "Stalk effect" can also lead to mild increase in serum prolactin; this occurs as a result of any infiltrative lesion in the hypothalamus, infundibulum, or sella that impairs the inhibitory dopamine pathway. Women mainly present with galactorrhea, infertility, amenorrhea, and loss of libido. Men present with low fertility and low sperm count, impotence, loss of libido, and breast enlargement. Basal prolactin levels greater than 200 ng/mL are associated with prolactinomas and require a further workup with brain magnetic resonance imaging (MRI). Initial management consists of ergot-derived dopamine receptor agonists (bromocriptine and cabergoline), followed by surgery if there is no improvement or a progression of symptoms.

Hypercortisolism (Cushing Disease)

Cushing disease is caused by excessive ACTH production, with a reported global incidence of 2 to 3 cases per 1,000,000 inhabitants. Approximately two-thirds of cases are related to pituitary adenomas, whereas the remaining ones are due to ectopic ACTH production. Central obesity, buffalo hump, striae, muscle wasting, excessive bruising, hypertension, glucose intolerance, menstrual irregularities, and mood disorders (psychosis, depression, anxiety) are the main associated clinical symptoms. Diagnosis is based on the identification of clinical signs of hypercortisolism, establishment of hypercortisolemia (either with 24-h urine cortisol measurement, 11 PM to midnight salivary cortisol levels, or 1 mg dexamethasone suppression testing) followed by clarification of ACTH dependent/independent production. If ectopic ACTH production is suspected, the determination of the source should be the next step. Treatment consists of surgical resection.

GH Excess

GH excess in adults leads to acromegaly. This typically includes overgrowth of flat bones, and particularly, the mandible with subsequent prognathism, as well as of feet bones with increases in shoe size. Skin tags, cardiomyopathy, peripheral neuropathy, carpal tunnel syndrome, macroglossia, glucose intolerance, and fatigue are some common symptoms. Increased IGF-1 accompanies GH excess. Oral glucose suppression tests (positive if 75-g glucose load fails to suppress GH levels <2 mU/L in the following 2 h) can be useful for borderline cases. A random GH of less than 0.4 μg/L (<1 mU/L) with normal IGF-1 typically excludes active disease. Somatostatin analogues are the first choice of treatment, followed by surgical management and, rarely, radiation. Dopamine agonists and GH-receptor antagonists can also be effective.

TSH Excess

TSH excess related to a TSH-secreting pituitary adenoma is a very rare condition, with an annual incidence reported in a Swedish study of 0.15 cases per 1,000,000 inhabitants. Cosecretion of GH or prolactin is common in these cases. High serum TSH with high free and total T_4 and triiodothyronine (T_3) are diagnostic of secondary hyperthyroidism. A thyrotropin-releasing hormone (TRH) test can be used as a confirmatory study. Somatostatin analogues may be effective. Surgery is indicated for failure of improvement or symptom progression. Antithyroid drugs are contraindicated.

Syndrome of Inappropriate Antidiuretic Hormone Secretion

Syndrome of inappropriate ADH (SIADH) secretion due to excessive ADH (vasopressin) production can be related to either intracranial or extracranial pathology. Symptoms vary, from mild headaches to severe confusion, focal deficits, seizures, and death. Excess ADH release results in retention of free water causing hypotonic, euvolemic hyponatremia (sodium <135 mEq/L). Serum osmolality is usually low (<280 mOsm/kg) and urine osmolality is high (>100 mOsm). Urine sodium concentration can vary depending on sodium intake but is usually more than 40 mEq/L. Treatment consists of fluid restriction for sodium correction. Resistant cases may require administration of vasopressin-receptor antagonists. Rapid sodium correction should be avoided (except in acutely, severely symptomatic patients) due to a high risk of central pontine and extrapontine) myelinolysis.

Pituitary Tumors

Pituitary tumors can be asymptomatic or can cause symptoms related to space-occupying effects such as headaches, visual field defects, cavernous sinus infiltration, cerebrospinal fluid leak, and rarely seizures. Symptoms of hypopituitarism (through direct damage) or hyperpituitarism (due to hormone-secreting tumors) can also be present.

Pituitary Adenomas

Typically, these arise from the anterior pituitary and are the most frequent pituitary tumors. Older studies estimated that 10% to 20% of individuals have a pituitary adenoma. They are classified

on functional (if hormones are produced) or nonfunctional. Functional adenomas make up 60% to 85% of all pituitary adenomas. Adenomas are also classified according to their size; macroadenomas are greater than 1 cm in diameter, whereas microadenomas are less than 1 cm. On MRI, adenomas appear isointense on T1 sequences without gadolinium and hypointense on T1 postgadolinium (Fig. 122.3A-C). Treatment depends on symptoms and the size of the adenoma. Conservative medical management with pharmacologic agents is indicated in some types (as discussed earlier); however in case of failure, surgery should be considered. Radiation therapy can also be an option, with the risk of subsequent hypopituitarism and further tissue damage.

Prolactinoma

Prolactinomas make up 40% to 50% of anterior pituitary adenomas and of 40% of all pituitary tumors. They arise from lactotroph cells and produce prolactin excess leading to hyperprolactinemia, with symptoms as described earlier. Initial treatment consists of ergot-derived dopamine receptor agonists (bromocriptine and cabergoline) with surgery reserved in case of drug failure or for patients unable to tolerate dopamine agonists.

Corticotropin-Producing Adenoma

Corticotropin-producing adenomas result in hypercortisolism (Cushing disease). They represent 10% to 15% of pituitary adenomas. Symptoms and diagnosis are described earlier. Random cortisol levels have no value in Cushing disease diagnosis.

Growth Hormone-Secreting Adenoma

GH-secreting adenomas, which comprise 10% to 20% of pituitary adenomas, lead to acromegaly in adults, with typical symptoms as described earlier in the chapter.

Thyrotropin-Secreting Adenoma

Thyrotropin-secreting adenomas are extremely rare and represent approximately 1% of pituitary adenomas. They are the main cause of hyperthyroidism without TSH suppression.

Other Pituitary Tumors

Craniopharyngioma

Craniopharyngiomas arise from epithelial and squamous cell remnants of the craniopharyngeal duct. They are usually benign and are multicystic and calcified appearance (Fig. 122.3D-F). They tend to peak in childhood (at around the age of 9 y old) and then in adulthood (in late middle age). Symptoms result from space-occupying effects, and sometimes, DI can occur. Children may experience growth deceleration. Surgery remains the gold standard treatment. Cases of partial resection may be followed by radiation due to high risk of recurrence.

Metastatic Pituitary Tumor

Metastatic pituitary tumors are rare, with lung and breast being the most frequent primary cancers. They are characterized by rapid growth and radiologically are most often contrast enhancing. They are frequently associated with DI and cranial nerve palsies.

Other Pituitary Disorders

Pituitary Apoplexy

Pituitary apoplexy is a neurologic emergency and is caused by acute hemorrhage or infarction in pituitary sella, usually in the setting of a preexisting adenoma. Pituitary infarction is also described in peripartum or postpartum period and is associated with severe hypotension or massive blood loss.

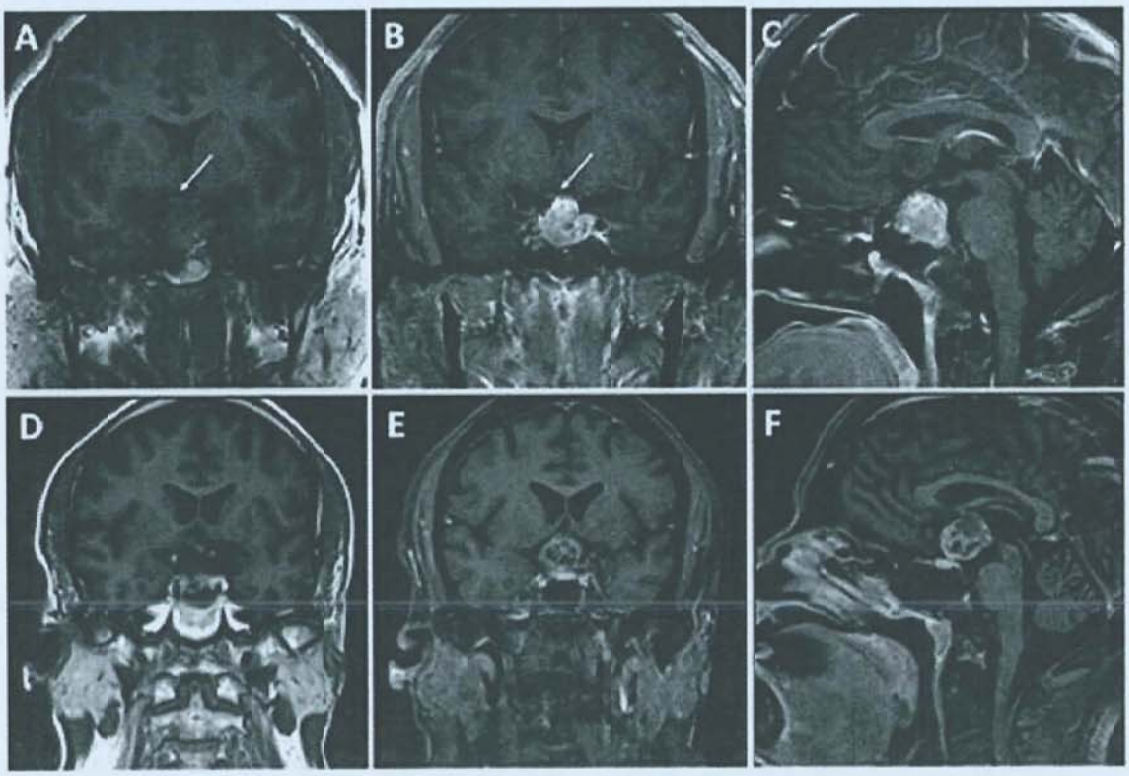

FIGURE 122.3 Magnetic resonance imaging of pituitary adenoma **(A-C)** and craniopharyngioma **(D-F)**. Coronal view, T1, without contrast **(A)** and coronal view, T1, postgadolinium showing pituitary tumor abutting the optic chiasm **(B)** *(arrows)*. C: Sagittal view, T1, postgadolinium. Coronal view, T1, without contrast **(D)** and coronal view, T1, postgadolinium showing cystic component of craniopharyngioma **(E)**. F: Sagittal view, T1, postgadolinium.

Typical symptoms include acute onset headaches, bitemporal hemianopia, ophthalmoplegia, DI or SIADH secretion, and hypopituitarism. Half of cases will not be evident on computed tomography, and diagnosis is most often confirmed by the presence of pituitary hemorrhage (high signal intensity) on MRI T1 sequences. Emergent hormonal replacement and surgical decompression are the standard treatment.

Empty Sella

Empty sella is diagnosed radiographically by the herniation of the subarachnoid space into the sella, which displaces the pituitary gland against the floor of the inferior sella. Hypopituitarism is the main symptom and hormonal replacement is indicated. Although rare, these patients should be screened for intracranial hypertension and vision abnormalities.

THYROID DISEASE

Hypothyroidism

Hypothyroidism is defined as thyroid hormone deficiency. It can be overt (or clinical), with high TSH and low free T_4 levels, or subclinical with high TSH but normal free T_4 and usually a lack of symptoms. Thyroid hormone is important in early growth and development, and the neurologic consequences of hypothyroidism depend on the age at which the deficiency begins. Severe thyroid deficiency in utero or early in life results in delayed physical and mental development, known as *cretinism*. In adults, severe thyroid hormone deficiency can result in myxedema with or without coma.

Epidemiology

Hypothyroidism is a common disorder with an estimated prevalence of 0.3% to 3.7% in the United States and 0.2% to 5.3% in Europe. Congenital hypothyroidism due to maternal iodine deficiency or dysgenesis of the thyroid occurs in 1:3,000 to 1:4,000 births.

Pathobiology

The most common cause of primary hypothyroidism in iodine-sufficient countries is autoimmune destruction (Hashimoto disease), whereas iodine deficiency is the commonest cause in iodine-deficient regions. Hypothyroidism can also result after specific drug use; most commonly this is due to amiodarone, lithium, thalidomide, interferon-α, tyrosine kinase inhibitors, monoclonal antibodies, valproate, or drugs used for multidrug-resistant tuberculosis. Radioiodine treatment, neck radiation, and thyroidectomy can also result in hypothyroidism. Other, more rare causes of primary hypothyroidism include transient thyroiditis, infiltrative diseases, or genetic disorders.

Clinical Features

Congenital Hypothyroidism

In congenital hypothyroidism, subcutaneous tissue thickens, the cry becomes hoarse; the tongue enlarges; and the infant has widely spaced eyes, a potbelly, and an umbilical hernia. Neurologically, there is mental retardation with pyramidal and extrapyramidal signs in a mainly proximal distribution. Strabismus, deafness, and preservation of primitive reflexes are common. Precocious puberty may occur. Idiopathic intracranial hypertension has been reported in hypothyroid children receiving thyroid replacement therapy.

Neurologic Manifestations

The neurologic complications of hypothyroidism include headache, disorders of the cranial and peripheral nerves, sensorimotor abnormalities, and changes in cognition and level of consciousness. Mental status changes may be prominent, with decreased attentiveness, poor concentration, lethargy, and even dementia. Psychiatric symptoms—delirium, depression, or frank psychosis (myxedema madness)—may appear, depending on the severity and duration of thyroid deficiency. Cranial nerve abnormalities, other than visual and acoustic nerve problems, are unusual. Hearing loss, vertigo, and tinnitus may be present.

Neuromuscular Manifestations

Neuromuscular findings include slowing of voluntary movements and slow relaxation of tendon reflexes, particularly the ankle jerks. Electrically silent mounding of muscles on direct percussion is called *myoedema*. There may be exercise intolerance or myopathic weakness. Enlargement of muscles with pain and stiffness in adults produces the Hoffmann syndrome.

A mild, primarily sensory neuropathy is characterized mainly by paresthesias in the hands and feet. Entrapment neuropathy of the median nerve (carpal tunnel syndrome) is attributed to the accumulation of acid mucopolysaccharides in the nerve and surrounding tissues. Cerebellar ataxia (myxedema staggers) may occur in adults, manifesting as incoordination with a slow or stiff, unstable gait. Sleep apnea may result from myxedematous changes in the upper airway and hypertrophy of the tongue.

Myxedema

Myxedema is a rare but life-threatening condition with a mortality rate as high as 40%. It is characterized by lethargy, somnolence, or impairment of attention and concentration; weakness; slowness of speech; nonpitting edema of the subcutaneous tissues; coarse, pale skin; dry, brittle hair; thick lips; macroglossia; and increased sensitivity to cold. In more severe cases, myxedema coma may occur, accompanied by hypothermia, hypotension, and respiratory and metabolic disturbances. Early recognition and management is crucial.

Nonneurologic Manifestations

Hypothyroidism manifests with a variety of symptoms; cold intolerance, weight gain, constipation, change in voice, and dry skin are the most common. Cardiovascular signs include bradycardia, dyslipidemia, increased vascular resistance, decreased cardiac output and left ventricular function, pericardial effusion, and sometimes, hypertension. Mild anemia and bleeding may occur. Rarely, it is associated with worsening kidney function.

Diagnosis

The characteristic findings of primary hypothyroidism are low circulating free T_4 and T_3, elevated TSH, and low radioiodine uptake by the thyroid. Secondary or central hypothyroidism due to hypothalamic-pituitary disease will have reduced circulating thyroid hormones with low TSH. **Table 122.2** explains the relation of thyroid test functions with the etiologies of hypothyroidism.

Management

The treatment of hypothyroidism depends on the severity of the deficiency. Myxedema coma should be treated rapidly with intravenous administration of T_4. In other patients, gradually increasing doses of oral levothyroxine (to 1.5-1.8 μg/kg/d) are recommended.

TABLE 122.2 Thyroid Function Test Abnormalities

TSH	Free Thyroxine	Differential Diagnosis
↔	↑	Overtreatment with levothyroxine TSH-secreting pituitary adenoma Thyroid hormone resistance
↔	↓	Central hypothyroidism Sick euthyroid syndrome TSH deficiencies
↑	↑	Nonadherence to therapy TSH-secreting pituitary adenoma Thyroid hormone resistance
↑	↔	Subclinical hypothyroidism Adrenal insufficiency TSH or TRH resistance syndromes
↑	↓	Autoimmune hypothyroidism Iodine deficiency Postradioiodine or thyroidectomy Medication side effect Postradiation of the head or neck Thyroid infiltration Consumptive hypothyroidism
↓	↑	Graves disease Thyroiditis Overtreatment with thyroxine Ectopic hyperthyroidism (functional thyroid cancer metastasis) Toxic multinodular goiter Toxic solitary adenoma
↓	↔	Subclinical hyperthyroidism Sick euthyroid syndrome T_3 toxicosis
↓	↓	Sick euthyroid syndrome Central hypothyroidism

Abbreviations: ↔, normal; ↑, increase; ↓, decrease; T_3, triiodothyronine; TRH, thyroid-releasing hormone; TSH, thyroid-stimulating hormone.

Older patient should be started on lower doses (25-50 μg daily). Overly rapid replacement in adults can precipitate angina pectoris or heart failure. In secondary hypothyroidism, thyroid replacement should not be started without concomitant corticosteroid replacement so as not to precipitate cortisol insufficiency. Prophylactic treatment of cretinism is important in areas with high rates of goiter, where iodine should be given to all pregnant women.

Treatment of subclinical thyroid disease (ie, normal thyroid hormone levels with elevated or depressed TSH levels) is controversial. Pregnant women with treated subclinical hypothyroidism may experience lower rates of pregnancy loss. In the general population, subclinical hypothyroidism has been reported to be associated with deficits in working memory that were reversible with T_4 replacement.

Hyperthyroidism

Thyroid hormone excess from the thyroid gland, with normal or high thyroid radioactive iodine uptake, defines hyperthyroidism. Thyrotoxicosis without hyperthyroidism can result from thyroid hormone excess from extrathyroid gland sources or release of stored hormone and it is characterized by low radioactive iodine uptake.

Epidemiology

Overt hyperthyroidism's prevalence is about 0.5% in Unites States and 0.5% to 0.8% in Europe. It affects women more commonly than men. It is more frequent in elderly and white populations as well as in iodine-deficient regions.

Pathobiology

In iodine-sufficient countries, the most common cause of thyrotoxicosis with hyperthyroidism is Graves disease, with an annual incidence of 20 to 50 cases per 100,000 inhabitants. In iodine-deficient regions, toxic multinodular goiter and toxic adenoma represent 50% of the causes. Less frequently, hyperthyroidism can result from trophoblastic tumors because TSH receptors are stimulated by human chorionic gonadotropin. Thyrotoxicosis without hyperthyroidism is much less common and usually results from thyroiditis, ingestion of thyroid hormone, or rarely from ectopic thyroid hormone production.

Clinical Features

Hyperthyroidism typically presents with an increased metabolic rate, abnormal cardiovascular and autonomic functions, tremor, and nervousness. Hyperthyroidism may be subtle in older patients with apathy, myopathy, and cardiovascular disease as the most prominent symptoms. It is associated with atrial fibrillation and cardioembolic stroke. Mental disturbances range from mild irritability to psychosis.

Thyroid Storm

Thyroid "storm" or "crisis" is usually precipitated by infection, surgery, or trauma in individuals with unrecognized hyperthyroidism. The cardinal symptom is high fever (usually greater than 39°C) accompanied by cardiac symptoms and central nervous system dysfunction. Nausea, vomiting, and abdominal discomfort are common. Affected individuals are confused or agitated and may present with psychosis. If untreated, level of consciousness may deteriorate to coma and seizures may occur. Neurologic signs such as bulbar weakness and corticospinal tract dysfunction have been described.

Ocular Symptoms

Ocular symptoms are common in hyperthyroidism. These may be seen as infrequent blinking, lid lag, or weakness of convergence and are distinct from the infiltrative ophthalmopathy known as *Graves ophthalmopathy*. The relationship of the eye disorder to thyroid status is not entirely clear. Onset of symptoms is gradual; exophthalmos is often accompanied by diplopia secondary to paresis of one or more ocular muscles. Clinically, eyelid retraction (Dalrymple sign) is first evident in 75% of cases, and pain is the most common symptom. Both eyes may be involved simultaneously, or exophthalmos in one eye may precede the other by several months. Papilledema sometimes occurs, and ulcerations of the cornea may develop secondary to failure of the lid to protect the eye. Symptoms can progress rapidly over a few months and may lead to complete ophthalmoplegia.

Neuromuscular Manifestations

Thyrotoxic myopathy is characterized by painless weakness and wasting of proximal muscles of the arms and legs. Deep tendon reflexes are normal or hyperactive, and sensation is normal. The occurrence of hyperthyroidism and periodic paralysis is more common in people of Asian ancestry and is similar to hypokalemic periodic paralysis in terms of precipitants and treatment. There is an association between hyperthyroidism and myasthenia gravis; about 5% of patients with myasthenia gravis also have hyperthyroidism.

Diagnosis

A low TSH is the best test for diagnosis. Obtaining a free T_4 should follow this. If the free T_4 is not elevated, a free T_3 measurement may be elevated, indicative of T_3 toxicosis. The radioiodine uptake by the thyroid is the next test, which is most helpful in distinguishing the different causes of hyperthyroidism. Other tests are available if the use of radioisotope studies is contraindicated or not preferred, such as thyroid ultrasound with TSH-receptor antibodies measurement. Orbital imaging will be abnormal in thyroid ophthalmopathy. Table 122.2 shows the thyroid function test abnormalities associated with hyperthyroidism.

Management

β-Adrenergic blockade (eg, propranolol 10-40 mg four times a day) is appropriate for symptomatic treatment of tremor or myopathy. Methimazole (5-120 mg daily, depending on severity) and propylthiouracil (50-300 mg three to four times a day) are antithyroid medications that inhibit thyroid hormone synthesis. Agranulocytosis is a rare but major side effect of antithyroid drugs, usually within the first 90 days of treatment. If this is suspected and confirmed, antithyroid drugs should be stopped immediately. Ablation with radioactive iodine (^{131}I) or thyroidectomy is useful in treating various etiologies of hyperthyroidism that cannot be managed with medical therapies. Thyroid storm is a medical emergency with a mortality of around 20%. Immediate goals of treatment are to inhibit thyroid hormone synthesis and release, control cardiac symptoms, and support systemic circulation. High-dose propylthiouracil is theoretically preferred because of its earlier onset of action and its capacity to inhibit peripheral T_4 conversion to T_3. Treatment of thyroid ophthalmopathy is controversial and may include immune suppression with corticosteroids, radiotherapy, or surgical decompression of the orbit. Successful treatment of hyperthyroidism results in improvement of most symptoms. Patients will need to be followed at varying intervals depending on the type of treatment that is selected.

DIABETES MELLITUS

Epidemiology

In 2015, diabetes mellitus (DM) was ranked as the sixth leading cause of disability that affects an estimated 415 million people worldwide, with the majority (approximately 90%) suffering from type 2 DM.

Etiology

Type 1 DM is characterized by pancreatic β-cell destruction leading to complete insulin deficiency. In type 2 DM, there is a pancreatic β-cell dysfunction leading to partial insulin deficiency and insulin resistance in target organs.

Clinical Features

Neurologic Complications

The primary neurologic complication of DM is peripheral neuropathy, which is the most frequent type of neuropathy in Western countries. DM neuropathy affects up to 60% of individuals with diabetes. Its incidence increases with duration of DM and with poor glycemic control. Abnormalities reported in diabetic neuropathy include axonal degeneration of nerve fibers, primary demyelination resulting from Schwann cell dysfunction, secondary segmental demyelination related to impairment of the axonal control of myelination, onion bulb formation, and hypertrophy of the basal lamina. Endoneurial capillaries often show signs of diabetic microangiopathy with marked thickening of the basal lamina. Both metabolic and ischemic mechanisms may cause diabetic neuropathies. The neuropathies include mononeuropathies (peripheral and cranial nerves), polyneuropathy, autonomic neuropathy, radiculopathies, and entrapment neuropathy (median, ulnar, and peroneal). Mononeuropathies are attributed to inflammatory and/or vascular lesions of peripheral nerves, whereas metabolic abnormalities are likely to predominate in length-dependent diabetic polyneuropathy. Genetic factors might explain why some individuals develop a more severe polyneuropathy than others with a similar diabetic status. Common cranial neuropathies involve the oculomotor and abducens nerves. Pupillary sparing is common and is related to the pattern of presumed vascular damage within the oculomotor nerve. The prognosis for recovery from mononeuropathy or radiculopathy is good.

Diabetic retinopathy is the most common cause of acquired blindness in the Western world. Later stages can be associated with severe vision deficits. Early screening is recommended at 5 years after DM diagnosis in patients 15 years and older.

Macrovascular complications (cardiovascular and stroke) represent leading causes of disability and death in patients suffering from DM.

Diagnosis

Onset of symptoms is rapid, and pain is common in both mononeuropathies and radiculopathies caused by DM. In the more common distal symmetric polyneuropathies, there is typically a gradual onset of symptoms, the character of which depends on the type(s) of peripheral nerve fibers affected. Numbness and burning are common complaints. In symptomatic diabetic neuropathy, nerve conduction studies show slowing of nerve conduction velocity owing to demyelination and loss of large myelinated fibers, and a decrease in nerve action potentials owing to loss of axons. However, if the neuropathy primarily affects small myelinated or unmyelinated fibers, nerve conduction studies may be normal.

Diabetic neuropathy is diagnosed with funduscopic exam (direct ophthalmoscopy, indirect slit lamp funduscopy, digital fundus photography, or seven-field stereoscopic fundus photography) and is characterized by the presence of microaneurysms, exudates, retinal detachment, and vitreous hemorrhages.

Management

Optimal glycemic control diminishes the risk of developing a disabling peripheral neuropathy. Attention should be paid to protection of hyposensitive areas, notably the foot. Painful diabetic polyradiculopathies often respond to antineuralgia medications such as carbamazepine, gabapentin, and pregabalin. Spontaneous improvement in focal diabetic neuropathies typically occurs. Good glycemic control is the only way to minimize occurrence and/or progression of neuropathy. Glycemic control as well as hypertension and hyperlipidemia treatment with regular exercise and weight loss will decrease risk of macrovascular complications.

Similarly, in the case of diabetic retinopathy, tight glycemic, blood pressure, and lipid control is recommended. Laser therapy is reserved for sight-threatening situations.

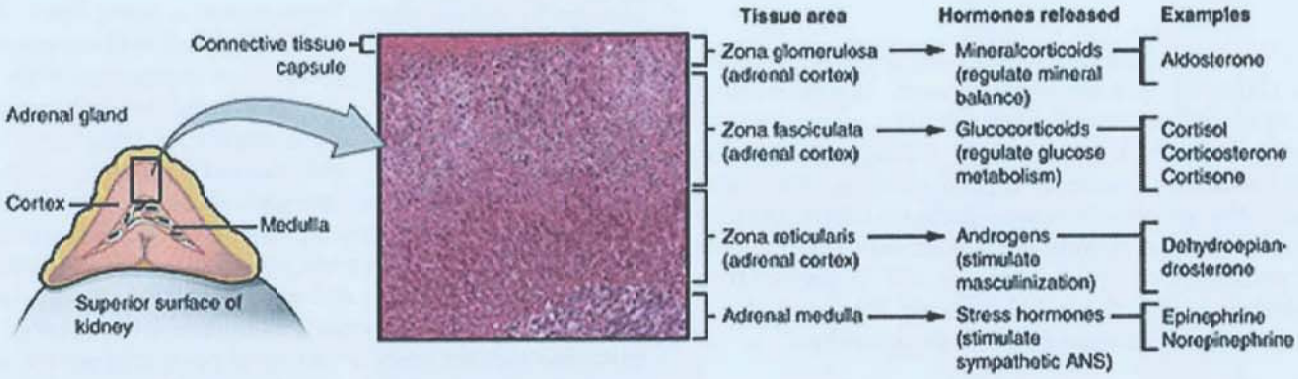

FIGURE 122.4 Adrenal glands anatomy and hormones release. Abbreviation: ANS, autonomic nervous system. (© 1999-2016, Rice University. Download for free at http://cnx.org/contents/14fb4ad7-39a1-4eee-ab6e-3ef2482e3e22@8.24.)

ADRENAL DISEASE

The adrenal glands are retroperitoneal organs located above the kidneys. They consist of the adrenal cortex and adrenal medulla. The adrenal cortex is made up, from outer to inner layers, of the zona glomerulosa, which secretes aldosterone, the zona fasciculate, which secretes cortisol, and the zona reticularis, which secrets androgens and estrogens. The adrenal medulla synthesizes and secretes catecholamines (Fig. 122.4). Adrenal gland function is under hypothalamic-pituitary axis control, with the exception of the zona glomerulosa and aldosterone production, which is regulated by renin-angiotensin pathway.

Adrenal Insufficiency

Epidemiology

Primary adrenal insufficiency, also known as *Addison disease*, has an incidence of approximately 4.4 to 6 new cases per million in Europe. Age of diagnosis peaks between third and fifth decade, with women more frequently affected than men.

Pathobiology

Autoimmune adrenalitis is the most common cause of adrenal insufficiency, followed by infectious adrenalitis (due to tuberculosis, human immunodeficiency virus, syphilis, histoplasmosis, cryptococcosis, coccidioidomycosis, or trypanosomes). More rarely, adrenal insufficiency results from bilateral adrenal hemorrhage (due to meningococcal sepsis or primary antiphospholipid syndrome), bilateral adrenal metastasis, or bilateral adrenal infiltration (by lymphoma, amyloidosis, or hemochromatosis). Iatrogenic causes include after bilateral adrenalectomy or drug-induced (by etomidate, ketoconazole, fluconazole, phenobarbital, or phenytoin). Adrenal insufficiency may also result from abrupt discontinuation of chronic glucocorticoid treatment.

Adrenal insufficiency due to mutations in the *ABCD1* gene results in abnormal metabolism of long-chain fatty acids that characterizes X-linked adrenoleukodystrophy. Congenital adrenal hyperplasia, an autosomal recessive disorder, is the most common cause of adrenal insufficiency in children.

Clinical Features

Primary Adrenal Insufficiency

In primary adrenal insufficiency, typical systemic features result from lack of all adrenocortical hormones (aldosterone, cortisol, androgens) and include fatigue, anorexia, weight loss, hypotension, skin hyperpigmentation (only in primary chronic adrenal insufficiency), and hair loss. Headache is a common complaint. Mineralocorticoid deficiency produces hyponatremia with salt cravings. Cerebral symptoms include apathy, depression, confusion, and, rarely, psychosis. Muscle pain and cramping may occur, and hyperkalemic periodic paralysis has been described.

Adrenoleukodystrophy

In adrenoleukodystrophy, there is progressive central demyelination with impairment of cognition, vision, hearing, and motor function in children. A second phenotype with onset in the late 20s, called *adrenomyeloneuropathy*, involves spastic paraparesis and sphincter disturbances.

Adrenal Crisis

Adrenal crisis may manifest as acute deterioration in patients with known adrenal insufficiency due to precipitating factors such as infection, surgery, and psychological stress. Adrenal crisis may be the first manifestation in undiagnosed adrenal insufficiency. It is a medical emergency and primary symptoms consist of profound hypotension and shock with weakness, anorexia, fever, vomiting, abdominal pain, electrolyte abnormalities (hyperkalemia, hyponatremia), confusion, or even coma.

Diagnosis

Measurement of early morning serum cortisol (6:00-8:00) and plasma ACTH generally distinguishes patients with primary adrenal insufficiency from healthy individuals and those with secondary adrenal insufficiency. The standard short corticotropin test, in which serum cortisol is measured after intravenous ACTH, demonstrates the impairment of the adrenal cortex response to ACTH. In secondary adrenal insufficiency, there may be little difference in baseline hormone measurements compared to healthy individuals. The insulin tolerance test, a powerful activator of the hypothalamic-pituitary axis, remains the gold standard for assessment of secondary adrenal insufficiency. However, this test poses a significant burden on both the patient and the physician and tests such as the short corticotropin test, which capitalizes on the relative adrenal unresponsiveness to ACTH in secondary disease, are most often used. Because hypoadrenalism may cause neurologic symptoms in adrenoleukodystrophy or adrenomyeloneuropathy, this diagnosis should be considered in young men with adrenal insufficiency.

Management

Hydrocortisone 15 to 25 mg/d is given in two or three divided doses daily, with a larger dose administered in the morning to

mimic the pattern of physiologic cortisol secretion. Presurgical dose adjustment is required as well as an increase in daily dose for the first postoperative days. Mineralocorticoid replacement (fludrocortisone 50-200 μg/d) is required only for primary adrenal insufficiency and only if daily hydrocortisone dose is less than 50 mg daily. In adrenal crisis, treatment consists of hydrocortisone 100 mg (intravenous or intramuscular) followed by 100 to 300 mg/d (as boluses or infusion) until recovery. Patients suffering from adrenal insufficiency should be educated on how to use intramuscular hydrocortisone in case of stress or infectious disease and when to seek medical attention.

Hyperadrenalism

Cushing Syndrome

Excessive secretion of glucocorticoids from the adrenal glands produces *Cushing syndrome*, or primary hypercortisolism. Cushing disease, which is ACTH-dependent and related mainly to pituitary tumors (and less frequently to ectopic ACTH production, ie, small cell lung carcinoma) has already discussed previously in this chapter (under pituitary disorders). Neurologic impairment is a devastating result; over time, global cerebral atrophy and increased muscle protein degradation will occur.

Epidemiology

The incidence of primary Cushing syndrome is 0.7 to 2.4 per million inhabitants in Europe and 0.2 to 5 per million people per year worldwide.

Pathobiology

ACTH-independent hyperadrenalism is usually due to an adrenal carcinoma or unilateral or bilateral adrenal adenoma and more rarely due to ACTH-independent macronodular adrenal hyperplasia.

Clinical Features

The physical examination in Cushing syndrome may demonstrate hypertension, plethoric facies, hirsutism, centripetal obesity, a posterior neck fat pad (buffalo hump), purple abdominal striae, and bruising. DM, gonadal dysfunction, and osteoporosis are prominent features. Cognitive changes (impaired memory, visual-spatial processing, verbal learning, and language performance) with mood disorders (particularly major depression), myopathic weakness, and headache are the most common neurologic features. Myelopathy or radiculopathy may result from epidural lipomatosis.

Diagnosis

The diagnosis of Cushing syndrome is very challenging and despite the classical clinical manifestations, the presentation can be quite nonspecific. The initial step is distinguishing Cushing syndrome from individuals with Cushing-like states where hypercortisolism is a common feature. These include obesity, depression, or alcoholism. There is no test that has absolute diagnostic accuracy. First-line screening is a 24-hour urinary free cortisol and overnight dexamethasone suppression test or late-night salivary cortisol. After Cushing syndrome has been established, plasma ACTH is measured. If ACTH is suppressed, then adrenal-dependent Cushing is suspected. There are many potential pitfalls; thus, consultation with an experienced endocrinologist is essential. Adrenal tumors or tumors as a source of ectopic ACTH will require imaging for localization.

Management

Treatment depends on the etiology. In cases where there is an adrenal tumor secreting cortisol, surgical removal of the tumor is the first-line treatment. Medical therapy includes various drugs that interfere with synthesis and secretion of cortisol. Ketoconazole (200-400 mg twice a day to three times a day), an antifungal compound that inhibits steroidogenesis, is the most widely used medication in the United States for this purpose. Evidence suggests that resolution of hypercortisolism does not completely resolve symptoms. Reduced brain volume and cognitive behavioral symptoms may only be partially reversible. Cognitive problems and psychopathology may persist even after long-term serum cortisol normalization.

Hyperaldosteronism

Epidemiology

Hyperaldosteronism is the most common disorder of the adrenal zona glomerulosa and the most common form of secondary hypertension. Table 122.3 lists indications for hyperaldosteronism screening.

Pathobiology

Aldosterone, typically produced by an adrenal adenoma or bilateral adrenal hyperplasia, is inappropriately elevated. Adrenocortical adenocarcinoma and familial hyperaldosteronism are rare causes of hyperaldosteronism.

Clinical Features

The principal clinical feature is hypertension with hypokalemia. There appears to be a higher incidence of stroke in patients with hypertension from primary aldosteronism when compared to patients with essential hypertension. Hypokalemic alkalosis can lead to muscle weakness, paresthesias, tetany, or paralysis. Recurrent attacks of muscle weakness may simulate periodic paralysis. Paresthesias may occur as a result of alkalosis. Vertigo may be caused by abrupt fluid and electrolyte shifts. Idiopathic intracranial hypertension has been reported. Many patients may suffer from mood disorders.

Diagnosis

The Endocrine Society clinical practice guidelines recommend testing for a variety of types of individuals (see Table 122.3). The aldosterone-to-renin ratio is a widely used screening test, but many antihypertensive medications, oral contraceptives, or selective serotonin reuptake inhibitors can compromise sensitivity or specificity.

TABLE 122.3 Patients in Whom to Consider Hyperaldosteronism Screening

Uncontrolled BP >140/90 mm Hg resistant to three antihypertensive medications
Controlled BP<140/90 mm Hg on four or more antihypertensive medications
Hypertension with hypokalemia (spontaneous or induced by low-dose diuretic)
Hypertension with incidental finding of adrenal abnormality
Hypertension with first-degree relative diagnosed with primary hyperaldosteronism
Hypertension and family history of early-onset hypertension or stroke prior to age 40 years

Abbreviation: BP, blood pressure.

Management

Normalization of blood pressure should be the goal. Surgical removal of adrenal tissue or tumor is recommended when appropriate. Medical therapy with spironolactone can be particularly effective.

Pheochromocytoma

Epidemiology

Pheochromocytomas are rare neuroendocrine tumors with approximately 80% arising from the chromaffin cells of the adrenal medulla. The estimated incidence is 0.005% to 0.1% of the general population. They secrete catecholamines and cause an estimated 0.1% to 0.6% of cases of secondary hypertension.

Pathobiology

Pheochromocytomas may occur sporadically or as part of a hereditary syndrome. Pheochromocytoma may be seen with neurofibromatosis, von Hippel-Lindau disease, ataxia-telangiectasia, Sturge-Weber syndrome, or multiple endocrine neoplasia type 2. It is estimated that 25% are associated with known genetic mutations.

Clinical Features

Paroxysmal or sustained hypertension is the most typical clinical symptom. It can be associated with palpitations, episodic hyperhidrosis, headaches, and other nonspecific systemic symptoms, such as nausea, emesis, or diarrhea. Anxiety attacks are common. Death may result from cerebral hemorrhage, pulmonary edema, or cardiac failure complicating an acute attack or as a result of sustained hypertension.

Diagnosis

Diagnosis is made by demonstrating increased excretion of catecholamine metabolites in urine and localization of the tumor. Measurement of fractionated plasma or urine metanephrines (or both) is recommended. Food, caffeinated beverages, strenuous physical activity, or smoking are not permitted for at least 8 to 12 hours prior to testing. A greater than fourfold elevation of plasma metanephrines is highly suggestive of the presence of a tumor. Tumors may occur in sites other than the adrenal (eg, organs of Zuckerkandl). Computed tomography, MRI, or functional imaging techniques are helpful in tumor localization.

Management

Surgical removal of the pheochromocytoma is the treatment of choice. Preoperative blockade of catecholamines, most commonly with phenoxybenzamine (10-20 mg twice a day), for 2 weeks prior to surgery is required. Calcium channel blockers and selective α_1-adrenergic blockers are alternative preoperative treatments. Volume contraction is associated with chronic vasoconstriction; thus, volume expansion is recommended to reduce postoperative hypotension. Surgery is curative for local disease and surgical debulking for more advanced disease can facilitate radiotherapy or chemotherapy. Essential hypertension may persist in up to 20% of cases. Long-term follow-up with yearly measurement of catecholamines is recommended and is especially important for patients identified with genetic mutations associated with pheochromocytoma.

PARATHYROID DISEASE

The parathyroid glands secrete parathyroid hormone (PTH), which regulates calcium with direct effects on kidney and bone and indirect effects on the gastrointestinal tract. PTH secretion, in turn, is regulated by ionized calcium concentration in extracellular fluid. Thyrocalcitonin and vitamin D also play important roles in calcium metabolism. The principal effects of PTH on the nervous system are via calcium regulation. However, PTH receptors exist in the brain and an endogenous neuropeptide is their natural ligand. Their exact function is uncertain.

Hypoparathyroidism

Epidemiology

A prevalence of 37 per 100,000 person-years is estimated in United States with approximately total of 60,000 individuals having chronic hypoparathyroidism.

Pathobiology

Hypoparathyroidism is due to deficiency of PTH or lack of peripheral response to PTH (pseudohypoparathyroidism) due to abnormal PTH receptors, defects in receptor-linked enzyme activity, or circulating antagonists. Hypoparathyroidism occurs most commonly after thyroidectomy (approximately 1%-2% with experienced endocrine surgeons) or other neck surgery. Autoimmune hypoparathyroidism is the next most common cause. Hypoparathyroidism may also be a part of inherited disorders (eg, Kearns-Sayre syndrome or DiGeorge syndrome) or glandular destruction from infiltrative processes or radiation.

Clinical Features

Tetany is the most distinctive sign that may be manifested by carpopedal spasm. Latent tetany can be demonstrated by contracture of the facial muscles on tapping the facial nerve in front of the ear (Chvostek sign) or by evoking carpal spasm by inducing ischemia in the arm with an inflated blood pressure cuff (Trousseau sign). Patients may also present with paresthesias and cramps and if hypocalcemia is acute may manifest with seizures, bronchospasm, laryngospasm, or cardiac arrhythmias. Seizures are usually generalized, tend to be frequent, and respond poorly to anticonvulsant drugs.

Intracranial calcifications are common in hypoparathyroidism. The basal ganglia are the predominant site for calcium deposition, but other regions such as the cerebellum may be affected. The calcifications are usually not associated with symptoms, but cognitive impairment and a variety of hypokinetic (parkinsonism) and hyperkinetic (choreoathetosis, hemiballismus, torticollis) movement disorders have been reported. Increased intracranial pressure may complicate hypoparathyroidism. Sensorineural hearing loss and myopathy occur rarely.

Diagnosis

Hypocalcemia with an inappropriately low intact PTH level should lead to the suspicion of hypoparathyroidism. Hypomagnesemia can lower calcium and PTH. Hypocalcemia with low PTH essentially rules out other causes of hypocalcemia, such as vitamin D deficiency, malabsorption syndrome, or renal disease. In pseudohypoparathyroidism, PTH levels will be elevated, and

there are a variety of associated physical abnormalities. In most cases, there may be a relevant prior surgery or history of some destructive process (eg, radiotherapy) involving the parathyroid glands.

Management

There are no formal guidelines for management of chronic hypoparathyroidism. Treatment options include the use of calcium, vitamin D metabolites and analogues, and thiazide diuretics to enhance renal calcium reabsorption. Antiepileptic drugs that increase metabolism of vitamin D (eg, phenytoin) should be avoided so as not to potentially interfere with calcium absorption from the gut or calcium mobilization from bone. Neuromuscular symptoms and seizures resolve with restoration of calcium to normal levels. Movement disorders may also be reversible with appropriate treatment. However, the response of cognitive behavioral symptoms is variable.

Hyperparathyroidism

Epidemiology

Primary hyperparathyroidism is the most common cause of hypercalcemia. The most recent estimated incidence was approximately 22 cases per 100,000 per year. The prevalence of primary hyperparathyroidism in the United States is estimated at 0.86% with similar rates in Europe. It predominantly affects women with an approximate female-to-male ratio of 3 to 4:1, with highest peaks in the seventh decade.

Pathobiology

Single parathyroid adenoma is the most common cause of primary hyperparathyroidism, followed by multiglandular disease. Parathyroid cancer remains a very rare cause of primary hyperparathyroidism, despite an elevating incidence the last years. Genetic syndromes that are associated with primary hyperparathyroidism include multiple endocrine neoplasia type, 1, 2A, and 4; familial hypocalciuric hypercalcemia; and familial isolated primary hyperthyroidism. Drug-induced and secondary hyperparathyroidism should also be considered.

Clinical Features

The classic syndrome of hyperparathyroidism is hypercalcemia with a combination of renal lithiasis, osteitis, and peptic ulcer disease ("stones, bones, and abdominal groans"). However, with the ease of determining serum calcium concentration by routine automated blood chemistry tests, the diagnosis is frequently made with minimal clinical symptoms, and the classic triad is rarely seen today. Currently, it is estimated that 70% to 80% of individuals have no symptoms or signs of disease at the time of diagnosis.

Common symptoms include fatigue and subjective weakness. Mental status changes include impaired memory, personality changes, affective disorders, delirium, and psychosis. Elderly patients may be particularly susceptible to the effects of hypercalcemia. Parkinsonism and a syndrome resembling motor neuron disease, reversible with parathyroid surgery, have been described. "Brown tumors" seen in osteitis fibrosa cystica may cause myelopathy. Neuromuscular symptoms include proximal weakness, muscle pain and stiffness, and paresthesias. Tendon reflexes may be normal or hyperactive.

Diagnosis

The initial diagnosis typically occurs by finding hypercalcemia with hypophosphatemia on routine laboratory screening. A PTH level should be checked and will be elevated in hyperparathyroidism. Hypercalcemia with low or undetectable PTH levels may suggest cancer-associated hypercalcemia mediated by PTH-related protein or ectopic production of PTH. Electromyography and muscle biopsy can show nonspecific evidence of myopathic or neuropathic disease. Brown tumors show variable intensities on T2-weighted images with intense enhancement on T1-weighted contrast studies. Fluid-filled cysts may be detected.

Management

Parathyroidectomy normalizes serum calcium and is the treatment of choice for patients with symptomatic primary hyperparathyroidism. Localization of a parathyroid adenoma with a variety of imaging techniques is successful in 95% of cases. In patients with mild disease or who are not surgical candidates, bisphosphonates are an option. The calcimimetic drug cinacalcet often normalizes serum calcium concentration and modestly decreases PTH levels. Although the degree of hypercalcemia does not always correlate with clinical severity, most neurologic and neuromuscular manifestations typically improve with treatment. It remains controversial as to whether symptoms such as fatigue, subjective weakness, or neuropsychiatric symptoms remit with parathyroidectomy.

SUGGESTED READINGS

Pituitary Disorders

Appleman-Dijkstra NM, Kokshoorn NE, Dekkers OM, et al. Pituitary dysfunction in adult patients after cranial radiotherapy: systemic review and meta-analysis. *J Clin Endocrinol Metab*. 2011;96(8):2330-2340.

Carvalho K, Grunwald T, De Luca F. Neurological complications of endocrine disease. *Semin Pediatr Neurol*. 2017;24:33-42.

Gounden V, Basit H, Jialal I. Hyperpituitarism. National Center for Biotechnology Information Web site. https://www.ncbi.nlm.nih.gov/books/NBK482233/. Accessed December 14, 2019.

Gounden V, Jialal I. Hypopituitarism (panhypopituitarism). National Center for Biotechnology Information Web site. https://www.ncbi.nlm.nih.gov/books/NBK470414/. Accessed December 14, 2019.

Levy A. Pituitary disease: presentation, diagnosis, and management. *J Neurol Neurosurg Psychiatry*. 2004;75(suppl 3):iii47-iii52.

Nyberg F, Halberg M. Growth hormone and cognitive function. *Nat Rev Endocrinol*. 2013;9:357-365.

Randeva HS, Schoebel J, Byrne J, Esiri M, Adams CB, Wass JA. Classical pituitary apoplexy: clinical features, management and outcome. *Clin Endocrinol (Oxf)*. 1999;51:181-188.

Schneider HJ, Aimaretti G, Kreitschmann-Andermahr I, Stalla GK, Ghigo E. Hypopituitarism. *Lancet*. 2007;369:1461-1470.

Schneider HJ, Kreitschmann-Andermahr I, Ghigo E, Stalla GK, Agha A. Hypothalamo-pituitary dysfunction following traumatic brain injury and aneurysmal subarachnoid hemorrhage: a systematic review. *JAMA*. 2007;298:1429-1438.

Tesnow AH, Wilson JD. The changing face of Sheehan's syndrome. *Am J Med Sci*. 2010;340:402-406.

Utz LA, Klibanski A. Pituitary disorders. *Continuum Lifelong Learning Neurol*. 2009;15(2):17-36.

Wiebke F, Allolio B. Clinical review: current state and future perspectives in the diagnosis of diabetes insipidus: a clinical review. *J Clin Endocrinol Metab*. 2012;97:3426-3437.

Thyroid Disease

Alix JJP, Shaw PJ. Thyroid disease and the nervous system. In: Aminoff MJ, Josephson SA, eds. *Aminoff's Neurology and General Medicine*. 5th ed. San Diego, CA: Academic Press; 2014:329-350.

Bahn RS. Graves' ophthalmopathy. *N Eng J Med*. 2010;362:726-738.

Chaker L, Bianco AC, Jonklaas J, Peeters R. Hypothyroidism. *Lancet*. 2017;390:1550-1562.
De Leo S, Lee SY, Braverman L. Hyperthyroidism. *Lancet*. 2016;388:906-918.
Feldman AZ, Shrestha RT, Hennessey JV. Neuropsychiatric manifestations of thyroid disease. *Endocrinol Metab Clin North Am*. 2013;42:453-476.
Gaitonde DY, Rowley KD, Sweeney LB. Hypothyroidism: an update. *Am Fam Physician*. 2012;86:244-251.
Halpern JF, Boyages SC, Maberly GF, Collins JK, Eastman CJ, Morris JG. The neurology of endemic cretinism. A study of two endemias. *Brain*. 1991;114:825-841.
Kwaku MP, Burman KD. Myxedema coma. *J Intensive Care Med*. 2007;22:224-231.
McDermott MT. Hyperthyroidism. *Ann Intern Med*. 2012;157:ITC1-ITC16.
Pavlu J, Carey MP, Winer JB. Hypothyroidism and nemaline myopathy in an adult. *J Neurol Neurosurg Psychiatry*. 2006;77:708-709.
Smith T, Hegedüs L. Graves' disease. *N Engl J Med*. 2016;375:1552-1565.
Squizzato A, Gerdes VE, Brandjes DPM, Büller HR, Stam J. Thyroid diseases and cerebrovascular disease. *Stroke*. 2005;36:2302-2310.
Tashko V, Davachi F, Baboci R, Drishti G, Hoxha P. Kocher-Debré-Sémélaigne syndrome. *Clin Pediatr (Phila)*. 1999;38:113-115.

Diabetes Mellitus

Awoniyi O, Rehman R, Dagogo-Jack S. Hypoglycemia in patients with type 1 diabetes: epidemiology, pathogenesis, and prevention. *Curr Diab Rep*. 2013;13:669-678.
Chatterjee S, Khunti K, Davies M. Type 2 diabetes. *Lancet*. 2017;389:2239-2251.
Cryer PE. Mechanisms of hypoglycemia-associated autonomic failure in diabetes. *N Engl J Med*. 2013;369:362-372.
Daneman D. Type 1 diabetes. *Lancet*. 2006;367:847-858.
Martin CL, Albers JW, Pop-Busui R; for DCCT/EDIC Research Group. Neuropathy and related findings in the diabetes control and complications trial/epidemiology of diabetes interventions and complications study. *Diabetes Care*. 2014;37:31-38.
Mohseni S. Hypoglycemic neuropathy. *Acta Neuropathol*. 2001;102:413-421.
Said G. Diabetic neuropathy—a review. *Nat Clin Pract Neurol*. 2007;36:331-340.
Singleton JR, Smith AG. The diabetic neuropathies: practical and rational therapy. *Semin Neurol*. 2012;32:196-203.
Strachan MWJ, Reynolds RM, Marioni RE, Price JF. Cognitive function, dementia and type 2 diabetes mellitus in the elderly. *Nat Rev Endocrinol*. 2011;7:108-114.

Adrenal Disease

Anderson NE, Chung K, Willoughby E, Croxson MS. Neurological manifestations of phaeochromocytomas and secretory paragangliomas: a reappraisal. *J Neurol Neurosurg Psychiatry*. 2013;84:452-457.
Bertorini T, Perez A. Neurologic complications of disorders of the adrenal glands. *Handb Clin Neurol*. 2014;120:749-771.
Bleicken B, Hahner S, Ventz M, Quinkler M. Delayed diagnosis of adrenal insufficiency is common: a cross-sectional study in 216 patients. *Am J Med Sci*. 2010;339:525-531.
Bourdeau I, Bard C, Noël B, et al. Loss of brain volume in endogenous Cushing's syndrome and its reversibility after correction of hypercortisolism. *J Clin Endocrinol Metab*. 2002;87:1949-1954.
Carey RM. Primary aldosteronism. *J Surg Oncol*. 2012;106:575-579.
Catena C, Colussi G, Nadalini E, et al. Cardiovascular outcomes in patients with primary aldosteronism after treatment. *Arch Intern Med*. 2008;168:80-85.
Chakera AJ, Vaidya B. Addison disease in adults: diagnosis and management. *Am J Med*. 2010;123:409-413.
Charmandari E, Nikolaides N, Chroussos G. Adrenal insufficiency. *Lancet*. 2014;383:2152-2167.
Chen H, Sippel RS, O'Dorisio MS, et al. The North American Neuroendocrine Tumor Society consensus guideline for the diagnosis and management of neuroendocrine tumors: pheochromocytoma, paraganglioma, and medullary thyroid cancer. *Pancreas*. 2010;39:775-783.
Farrugia FA, Martikos G, Tzanetis P, et al. Pheochromocytoma, diagnosis and treatment: review of the literature. *Endocr Regul*. 2017;51(3):168-181.
Funder JW, Carey RM, Fardella C, et al. Case detection, diagnosis, and treatment of patients with primary aldosteronism: an Endocrine Society clinical practice guideline. *J Clin Endocrinol Metab*. 2008;93:3266-3281.
Funder JW, Carey RM, Mantero F, et al. The management of primary aldosteronism: case detection, diagnosis, and treatment: an Endocrine Society clinical practice guideline. *J Clin Endocrinol Metab*. 2016;101(5):1889-1916.
Hirsch D, Shimon I, Manisterski Y, et al. Cushing's syndrome: comparison between Cushing's disease and adrenal Cushing's. *Endocrine*. 2018;67:712-720.
Hsieh S, White PC. Presentation of primary adrenal insufficiency in childhood. *J Clin Endocrinol Metab*. 2011;96:E925-E928.
Kiehna EN, Keil M, Lodish M, Stratakis C, Oldfield EH. Pseudotumor cerebri after surgical remission of Cushing's disease. *J Clin Endocrinol Metab*. 2010;95:1528-1532.
Krishnan AV, Colebatch JG, Kiernan MC. Hypokalemic weakness in hyperaldosteronism: activity-dependent conduction block. *Neurology*. 2005;65:1309-1312.
Lee F, Elaraj D. Evaluation and management of primary hyperaldosteronism. *Surg Clin North Am*. 2019;99:731-745.
Moser HW, Raymond GV, Dubey P. Adrenoleukodystrophy: new approaches to a neurodegenerative disease. *JAMA*. 2005;294:3131-3134.
Neiman LK, Biller BMK, Findling JW, et al. The diagnosis of Cushing's syndrome: an Endocrine Society clinical practice guideline. *J Clin Endocrinol Metab*. 2008;93:1526-1540.
Pivonello R, De Martino MC, De Leo M, Lombardi G, Colao A. Cushing's syndrome. *Endocrinol Metab Clin North Am*. 2008;37:135-149.
Puar T, Stikkelbroeck N, Smans L, Zelissen P, Hermus A. Adrenal crisis: still a deadly event in the 21st century. *Am J Med*. 2016;129:339.e1-339.e9.
Sathi N, Makkuni D, Mitchell WS, Swinson D, Chattopadhyay C. Musculoskeletal aspects of hypoadrenalism: just a load of aches and pains? *Clin Rheumatol*. 2009;28:631-638.
Starkman MN. Neuropsychiatric findings in Cushing syndrome and exogenous glucocorticoid administration. *Endocrinol Metab Clin North Am*. 2013;42:477-488.
Sukor N. Primary aldosteronism: from bench to bedside. *Endocrine*. 2012;41:31-39.
Tritos NA, Biller BMK. Advances in medical therapies for Cushing's syndrome. *Discovery Med*. 2012;13:171-179.
Tsirlin A, Oo Y, Sharma R, Kansara A, Gliwa A, Banerji MA. Pheochromocytoma: a review. *Maturitas*. 2014;77:229-238.
Valassi E, Crespo I, Santos A, Webb SM. Clinical consequences of Cushing's syndrome. *Pituitary*. 2012;15:319-329.

Parathyroid Disease

Arit W, Fremerey C, Callies F, et al. Well-being, mood and calcium homeostasis in patients with hypoparathyroidism receiving standard treatment with calcium and vitamin D. *Eur J Endocrinol*. 2002;146:215-222.
Bhadada SK, Bhansali A, Upreti V, Subbiah S, Khandelwal N. Spectrum of neurological manifestations of idiopathic hypoparathyroidism and pseudohypoparathyroidism. *Neurol India*. 2011;59:586-589.
Bilezikian JP, Bandeira L, Khan A, Cusano NE. Hyperparathyroidism. *Lancet*. 2018;391:168-178.
Bilezikian JP, Khan A, Potts JT Jr, et al. Hypoparathyroidism in the adult: epidemiology, diagnosis, pathophysiology, target-organ involvement, treatment, and challenges for future research. *J Bone Miner Res*. 2011;26:2317-2337.
Dai CL, Sun ZJ, Zhang X, et al. Elevated muscle enzymes and muscle biopsy in idiopathic hypoparathyroidism patients. *J Endocrinol Invest*. 2012;35:286-289.
De Sanctis V, Soliman A, Fiscina B. Hypoparathyroidism: from diagnosis to treatment. *Curr Opin Endocrinol Diabetes Obes*. 2012;19:435-442.
Douglas M. Neurology of endocrine disease. *Clin Med (Lond)*. 2010;10:387-390.
Fraser WD. Hyperparathyroidism. *Lancet*. 2009;374:145-158.
Marcocci C, Cetani F. Clinical practice. Primary hyperparathyroidism. *N Engl J Med*. 2011;365:2389-2397.
Powers J, Joy K, Ruscio A, Lagast H. Prevalence and incidence of hypoparathyroidism in the United States using a large claims database. *J Bone Miner Res*. 2013;28:2570-2576.
Wen HY, Schumacher HR, Zhang LY. Parathyroid disease. *Rheum Dis Clin North Am*. 2010;36:647-664.

Hematologic Diseases and the Brain 123

Andreas H. Kramer

KEY POINTS

1. Anemia is a common concern among neurocritical care patients. Optimal transfusion thresholds may differ compared with other populations but require further evaluation in clinical trials.
2. Sickle cell disease is a major cause of stroke and cognitive decline in certain populations. Optimal management involves close monitoring for neurovascular disease and transfusion to maintain the proportion of hemoglobin S below 30%.
3. Leptomeningeal and subarachnoid spread is common with high-grade systemic lymphoma. Posttransplant lymphoproliferative disorder and primary central nervous system lymphoma may be responsible for parenchymal brain lesions in immunosuppressed patients.
4. Hyperviscosity with acute leukemia or plasma cell malignancies may require emergent plasmapheresis to avoid ischemic stroke.
5. The most common neurologic complication of thrombotic thrombocytopenic purpura is posterior reversible leukoencephalopathy syndrome, but ischemic stroke may also occur. Therapy consists of emergent plasma exchange.
6. Guidelines recommend transfusion to maintain platelet concentration above 50,000/μL and 100,000/μL in patients undergoing lumbar puncture and neurosurgical procedures, respectively. Routine platelet transfusion is not recommended for patient with intracerebral hemorrhage while receiving antiplatelet therapy.
7. Anticoagulants require emergent reversal in the setting of intracranial hemorrhage. Four factor prothrombin complex concentrate should be used for warfarin reversal, and specific reversal agents are now available for direct oral anticoagulants.

RED BLOOD CELL DISORDERS

Anemia is a common condition encountered in acute, severe neurologic illnesses such as stroke and traumatic brain injury (TBI). Maturation of hematopoietic stem cells into red blood cells (RBCs) in bone marrow is regulated by the glycoprotein hormone erythropoietin (EPO), which is released by peritubular cells in the kidneys in response to reductions in oxygen (O_2) delivery. Production of RBCs is also dependent on sufficient quantities of bone marrow substrate, including iron, folate, and vitamin B_{12}. The RBCs normally have a life span of 100 to 120 days before being removed by the spleen.

Anemia

Anemia is defined as a hemoglobin (HB) concentration of less than 12 g/dL in women and 13 g/dL in men. There are numerous possible etiologies for anemia, which are presented in Figure 123.1. Measurement of the reticulocyte count helps determine whether the bone marrow is responding "appropriately" to anemia—if so, it implies that the cause is hemorrhage or hemolysis; if not, there is a problem with RBC production. The RBC indices, especially the mean cell volume (MCV), provide further information concerning the differential diagnosis. Microcytosis (MCV <80 fL) implies that there is a cytoplasmic problem with the production of HB and the maturation of RBCs. Specific causes of microcytic anemia include iron deficiency and various hemoglobinopathies. Macrocytosis (MCV >100 fL) implies that there is a nuclear defect in developing RBCs, which may be due to vitamin B_{12} and folate deficiency or drug toxicity. Normocytic anemia suggests that there is a pathologic bone marrow process or that there is reduced stimulation for RBC production. This section focuses on the neurologic implications of anemia and on sickle cell disease (SCD), which is a major cause of stroke in children and young adults.

Anemia and Transfusion in Hospitalized and Critically Ill Neurologic Patients

Anemia is one of the most common medical complications to be encountered among hospitalized patients, especially in the intensive care unit. The development of an HB concentration less than 10 g/dL has been reported in about 40% to 50% of neurocritical care patients with TBI or subarachnoid hemorrhage (SAH). The etiology of anemia in hospitalized patients is multifactorial. The RBC production is impaired during systemic inflammation, as cytokines blunt the production of EPO and prevent progenitor cells from incorporating iron. The RBC loss is accelerated by the need for frequent phlebotomy, reduced RBC survival, and (in some cases) hemorrhage. Hemodilution produced by administration of large volumes of intravenous fluids and blood loss from phlebotomy may also contribute.

Optimal care of patients with acute brain injury and various forms of stroke involves the protection of salvageable brain tissue and prevention of secondary injury. Reduced O_2 delivery to ischemic penumbra may cause increasing neurologic damage. The amount of O_2 reaching tissues is the product of local blood flow and arterial O_2 content, which is determined by the HB concentration and degree to which it is saturated with O_2.

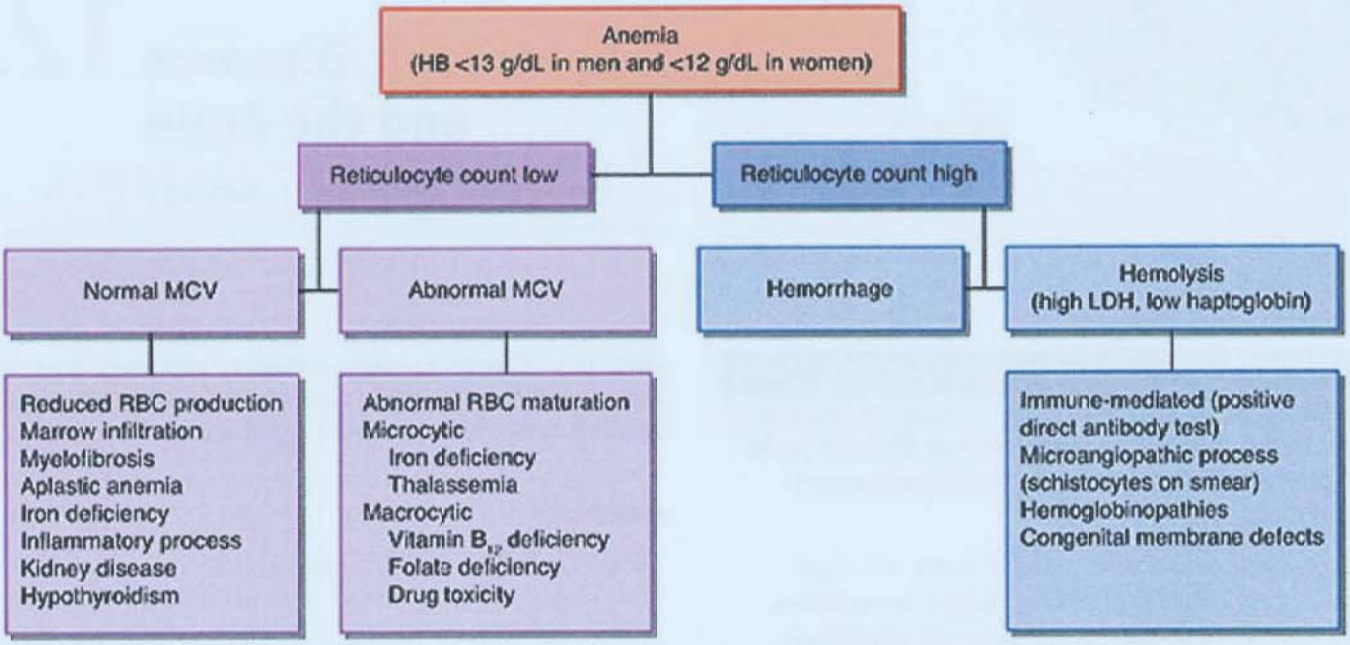

FIGURE 123.1 Approach to determining the etiology of anemia. Abbreviations: HB, hemoglobin; LDH, lactate dehydrogenase; MCV, mean cell volume; RBC, red blood cell.

Anemia is initially well tolerated by most patients for several reasons: Systemic O_2 delivery exceeds O_2 consumption by a large amount, tissues have the capacity to increase O_2 extraction, and sympathetic stimulation increases cardiac output. In the brain, the normal response to anemia is cerebral vasodilation, with a resulting increment in cerebral blood flow (CBF). Experiments in healthy volunteers demonstrate that neurocognitive impairment begins at an HB concentration below approximately 7 g/dL. It is likely that the HB threshold for neurologic deterioration is generally higher in brain-injured patients, in whom autoregulatory mechanisms may be impaired. It also seems unlikely that there is a single transfusion threshold that is optimal for all brain-injured patients.

The development of anemia is associated with worsened outcomes in patients with TBI, SAH, and intracerebral hemorrhage (ICH). Studies using invasive multimodal neurologic monitoring have found that anemia is associated with lower brain tissue O_2 tension and high cerebral lactate concentrations. Patients with SAH, in particular, are vulnerable to delayed cerebral ischemia. Administration of RBC transfusions improves O_2 delivery to the brain and increases physiologic "reserve" in regions of the brain with a high O_2 extraction fraction.

Historically, clinicians would give RBC transfusions to maintain HB concentrations greater than 9 to 10 g/dL in brain-injured patients. However, allogeneic RBC transfusions have potential adverse effects, including transfusion-related acute lung injury and immunosuppression with an increased risk of nosocomial infections. Randomized trials in general critical care patients have found no advantage, and possible harm, when RBC transfusions are used to routinely maintain HB concentrations above 10 g/dL compared with a transfusion threshold of 7 g/dL LEVEL 1.[1,2] However, there were few brain-injured patients in these studies, and HB concentrations of 7 to 9 g/dL may be too low in some brain-injured patients. There is substantial variability of practice, which will continue until definitive clinical trials are performed specifically in brain-injured patients. One moderate-sized randomized controlled trial of patients with severe TBI found that patients transfused at a threshold of 10 g/dL had higher brain tissue O_2 tension but did not have better outcomes compared with those transfused at a threshold of 7 g/dL.

Sickle Cell Disease

SCD is a group of genetic disorders characterized by the presence of "sickle hemoglobin" (HBS) caused by a mutation in the β-globin gene, whereby the sixth amino acid changes from glutamic acid to valine. The most common and severe form is sickle cell anemia, which occurs in patients homozygous for the HBS allele. There are other SCD variants where HBS is inherited from one parent and another abnormal HB from the other. Stroke is the most common neurologic complication of SCD.

Epidemiology

The global burden of SCD is increasing, especially in Africa and India. About 8% of African Americans are heterozygous for HBS and 1 in 600 are homozygous. Another 2% to 3% carry the HBC allele, which is attributable to a glutamic acid to lysine substitution. The incidence of stroke in children with SCD is increased about 300- to 400-fold, such that the chance of having a stroke by 20, 30, and 45 years of age is estimated to be about 11%, 15%, and 24%, respectively. Intracranial hemorrhage is less common but increases in incidence between 20 and 30 years of age. Stroke is a major cause of premature death and disability in patients with SCD. Untreated, stroke may recur in as many as two-thirds of patients within 2 years. By far, the strongest risk factor for stroke is a previous stroke or transient ischemic attack (TIA). Other risk factors include the degree to which HB is reduced, hypertension, frequent episodes of acute chest pain syndrome, leukocytosis, and lower pulse oximetry values.

Even in patients who have not developed overt stroke, magnetic resonance imaging (MRI) studies demonstrate that silent cerebral infarcts are common, occurring in more than a third of patients. Previous infarcts are seen especially in watershed regions and are associated with cognitive impairment and a higher subsequent risk of overt stroke. Areas of restricted diffusion,

suggestive of recent cerebral ischemia, can be detected even when patients are asymptomatic, suggesting that patients are at constant risk. Identified risk factors for silent cerebral infarcts include lower baseline HB concentration, higher systolic blood pressure, and male sex.

Pathobiology

O_2 is normally transported by adult hemoglobin (HBA) consisting of two α and β polypeptide chains that encircle a heme moiety. Unlike HBA, HBS has a tendency to polymerize when it is deoxygenated, which in turn disrupts the normal architecture and flexibility of RBCs, causing them to take on sickle-shaped morphology. Sickling of RBCs interferes with their transit through capillaries and venules, causes them to adhere to endothelium, and increases blood viscosity, all of which may produce microvascular occlusion and tissue ischemia. Increased hemolysis occurs in the spleen. Most of the clinical manifestations of sickle cell anemia are attributable either to vaso-occlusion or hemolysis.

Multiple other factors are implicated in causing cerebral ischemia. Adherence of sickled RBCs to vascular endothelium induces a cascade of events that produce leukocyte recruitment, inflammation, intimal hyperplasia, fibrosis, and thrombosis. Intravascular hemolysis and release of free HB scavenges nitric oxide, the production of which may also be impaired by endothelial damage, thereby interfering with maintenance of normal vascular tone. These factors contribute to impaired CBF autoregulation, making the brain vulnerable both to hyperemia and ischemia.

Imaging studies with digital subtraction or magnetic resonance (MR) angiography demonstrate that many patients have various forms of vasculopathy. By far, the most common cerebrovascular abnormality is stenosis of proximal intracranial vessels, especially in the anterior circulation, which may be accompanied by relative hypoperfusion if perfusion imaging is performed. Involvement of extracranial vessels is less common but does occur and may lead to cervical artery dissection and/or embolic strokes. Over time, with persistent severe intracranial stenosis, there may be development of collateral vessels resembling those of moyamoya disease. The presence of such collaterals is a marker of a greater degree of vasculopathy and has been identified as a major risk factor for future stroke. These friable vessels are also vulnerable to bleeding. Intracranial aneurysms may develop in unusual locations with a possible predilection for the posterior circulation.

Clinical Manifestations

SCD patients with cerebrovascular disease present most often with TIA or ischemic stroke. Among those with hemorrhage, SAH is more common than ICH or intraventricular hemorrhage. Repeated silent infarcts cause progressive neurologic deterioration and cognitive impairment. Neuroimaging reveals that patients with SCD have a greater degree of thinning of the frontal lobe cortex as well as reduced basal ganglia and thalamus volumes.

SCD may rarely cause complications in the spinal cord and peripheral nervous system. There have been numerous case reports of spinal cord infarction, most often involving the cervical cord and inducing quadriparesis. Ischemic injury of peripheral nerves presents as mononeuritis multiplex. Functional asplenia is a well-recognized complication of SCD. The resulting immunosuppression predisposes to bacterial infections, including meningitis, with the risk being high enough to justify prophylactic penicillin usage until at least the age of 5 years. Fever should therefore be considered a medical emergency.

Diagnosis

The diagnosis of SCD is confirmed by HB electrophoresis. Quantification of the percentage of HBS, determined by high-performance light chromatography, is important for therapeutic decision making. Ischemic strokes are rare in the absence of detectable abnormalities in the cerebral vasculature. When vasculopathy is present, the risk of stroke can be significantly ameliorated with appropriate therapy. Thus, screening of patients for cerebrovascular disease is important. Cerebral vasculature is best imaged with digital subtraction angiography, but noninvasive imaging is preferred. Both computed tomography (CT) and MR angiography can be used, although published experience is larger with the latter. Previous concerns that intravenous contrast could precipitate sickling crisis have likely been exaggerated.

In experienced hands, transcranial Doppler (TCD) ultrasonography correlates well with angiography. Increased TCD velocities in the anterior circulation are highly predictive of the risk of subsequent stroke LEVEL 3.[3] In one prospective single-center study, the sensitivity and specificity for subsequent overt stroke exceeded 85% when TCD velocity exceeded 170 cm/s. In children, when TCD velocities in either middle cerebral or intracranial internal carotid artery consistently exceed 200 cm/s, a randomized controlled trial demonstrated that a prevention strategy using RBC transfusions decreased the risk of stroke over the ensuing 2 years from 16% to 2% LEVEL 3.[4] The risk of stroke is even higher if there are elevated velocities in more than one vessel. Annual screening with TCD is recommended for children with SCD beginning at 2 years of age. Implementation of screening has been temporally associated with a reduction in the incidence of stroke in some jurisdictions. Most studies assessing the use of TCD in SCD have been in children. The TCD velocities that are associated with vascular stenosis seem to be somewhat lower in adults, and it is unclear whether TCD is as predictive of subsequent stroke risk.

Apart from imaging of the intra- and extracranial cerebral vasculature, patients with SCD who develop ischemic strokes should undergo a similar diagnostic evaluation to that of other patients, including an echocardiogram, lipid panel, and assessment for diabetes mellitus. In patients with SAH or ICH, if CT or MR angiography does not demonstrate a cause, a digital subtraction angiography should be considered to ensure that a small aneurysm or vascular abnormality is not being missed.

Management

SCD is a multisystem condition, and the management of neurologic complications occurs in the context of other concomitant treatment considerations. In the management of cerebrovascular complications, therapeutic goals are the primary and secondary prevention of strokes, including those that are silent and may contribute to cognitive decline as well as minimization of brain injury when strokes do occur. In a randomized controlled trial, antiplatelet therapy with prasugrel was ineffective in the primary prevention of TIA and stroke LEVEL 3.[5]

Transfusion Strategies and Stroke Prevention

The Stroke Prevention Trial in Sickle Cell Anemia (STOP) demonstrated that using RBC transfusions to keep the fraction of HBS less than 30% (Table 123.1) significantly reduces the risk

TABLE 123.1 Indications for Chronic Transfusion Program for the Prevention of Stroke in Patients With Sickle Cell Disease

Primary prevention (screen annually with TCDs of MCA and distal ICA between 2 and 16 y)
• If >220 cm/s, initiate transfusion program. • If 200-220 cm/s, repeat TCDs in 1-2 wk and initiate transfusion program if confirmed >200 cm/s. • If 170-200 cm/s, repeat TCDs in 3-6 mo; consider MRI scan to assess for SCI. • If <170 cm/s, repeat TCDs annually; consider MRI scan to assess for SCI.
Secondary prevention (if patient has had symptomatic stroke)
MRI evidence of silent cerebral infarction (Note: Optimal frequency of MRI screening has not yet been defined.)

Abbreviations: ICA, internal carotid artery; MCA, middle cerebral artery; MRI, magnetic resonance imaging; SCI, silent cerebral infarction; TCD, transcranial Doppler.

of stroke LEVEL 1.[4] Apart from diluting HBS with the addition of HBA, transfusions also temporarily reduce EPO production, thereby reducing the production of new HBS. The O_2 binds more efficiently to HBA than HBS, such that the O_2 saturation is temporarily increased. Although the STOP trial was a primary prevention study, chronic transfusion therapy has also been widely adopted as a secondary prevention strategy. The target HB concentration is generally greater than 9 g/dL. An HB concentration of >12.5 g/dL should likely be avoided because increasing viscosity may interfere with tissue O_2 delivery. Simple transfusions can be performed when patients are very anemic. Exchange transfusions refer to the transfusion of RBCs together with the removal of the patient's blood, which is more effective at reducing the concentration of HBS and at lowering stroke incidence.

The need for regular transfusions also has risks, most notably the development of iron overload. Over time, excess iron overwhelms the capacity of reticuloendothelial system to sequester it, and iron begins to accumulate in organs, especially the liver. The consequence of unchecked iron accumulation is hepatic fibrosis and eventually cirrhosis. Rather than performing repeated biopsies, liver iron burden can be accurately monitored noninvasively with annual quantitative MRI scans. Increasing liver iron concentration or serum ferritin (>1,500 μg/L) is an indication to initiate treatment with an iron chelator, most often deferasirox, which has similar efficacy to deferoxamine but is orally available. In an attempt to avoid long-term dependence on blood transfusions, the STOP 2 trial assessed the safety of discontinuing prophylactic transfusions in children whose TCD results had normalized over time. Unfortunately, cessation of transfusions was associated with a clear increment in TCD velocities over time as well as an increased risk of recurrent stroke LEVEL 1.[6]

Post hoc analyses of the STOP trials indicated that new silent infarcts were reduced by the use of transfusions and that discontinuation of transfusions led to an increment in the occurrence of new infarcts. However, patients treated with chronic transfusion still commonly develop progressive cerebral vasculopathy. Increased TCD velocities are not necessarily predictive of the development of silent infarcts. The MR angiography may be more predictive, but the relationship between burden of vasculopathy and risk of infarction is imperfect. Until recently, it was unclear whether performing serial MRI scans to document silent infarcts is helpful and should modify the therapeutic approach. However, the Silent Cerebral Infarct trial has demonstrated that regular transfusions to maintain HBS less than 30% and HB greater than 9 g/dL reduces the incidence of subsequent overt or silent infarcts LEVEL 1.[7] Patients should be periodically screened for silent infarcts (the optimal interval has not been defined) and enrolled in a transfusion program if they are present.

Management of Acute Stroke

There have been no randomized trials of thrombolysis or endovascular thrombectomy specifically in the treatment of pediatric stroke. The pathophysiology of acute stroke in the setting of SCD may not be the same as in other situations. Nevertheless, although the risk of iatrogenic hemorrhage may be higher, the presence of SCD is not necessarily a contraindication for the use of thrombolytics, especially if the stroke mechanism involves acute thrombotic or embolic vascular occlusion. The CT angiography, performed immediately after an initial noncontrast CT scan, can help clarify the mechanism while concomitantly identifying vascular abnormalities that may constitute a relative contraindication. Urgent transfusion to lower the HBS concentration and raise the total HB concentration to about 10 g/dL is appropriate to maximize O_2 delivery to the affected penumbra. Adequate hydration and avoidance of hypotension, hyperglycemia, and fever are other standard measures. Antiplatelet therapy is indicated in adults sustaining acute strokes in other settings, but there is no data specifically in patients with SCD. The very high risk of recurrent stroke with SCD justifies the use of chronic transfusion for secondary prevention.

Hydroxyurea as an Alternative to Chronic Transfusion

Fetal hemoglobin (HBF) consists of two gamma, rather than beta, globulins. For this reason, an increased concentration of HBF in the circulation prevents the sickling of RBCs. Hydroxyurea is thought to exert its beneficial effects in SCD by increasing the formation of HBF. A large randomized trial found hydroxyurea to reduce painful vaso-occlusive crises. Long-term follow-up demonstrated a possible mortality benefit LEVEL 1.[8] Hydroxyurea is currently recommended in patients older than 24 months with frequent pain crises, acute chest syndrome, or severe symptomatic anemia. There has been interest in using hydroxyurea as an alternative to chronic transfusion in the prevention of cerebrovascular disease. Early data suggested that hydroxyurea might be efficacious. However, among children with previous stroke, the Stroke with Transfusions Changing to Hydroxyurea trial demonstrated that discontinuing regular transfusions and instead treating patients with hydroxyurea resulted in an increased recurrent stroke risk LEVEL 1.[9] In contrast, the TCD with Transfusions Changing to Hydroxyurea trial found that among children with elevated TCD velocities, but no previous stroke, transitioning to hydroxyurea after at least 1 year of transfusions did not result in higher TCD velocities or an increased risk of stroke LEVEL 1.[10]

Intracranial Hemorrhage and Moyamoya Syndrome

Supportive care of SAH and ICH is not different compared with patients who do not have SCD. Immediate priorities with SAH are cardiopulmonary stabilization and treatment of hydrocephalus. Cerebral angiography (invasive or noninvasive) is required to identify the source of bleeding. Most aneurysms with SCD appear to be saccular and are amenable to clip ligation or coil embolization. Some aneurysms are fusiform and can be treated with endovascular stenting. Nimodipine should be used for prevention of delayed cerebral ischemia.

Moyamoya syndrome, characterized by progressive intracranial large-vessel occlusion, is a recognized and relatively common complication of sickle cell vasculopathy that is associated with an increased risk of stroke and cognitive decline (see also Chapter 44). There are no controlled studies assessing the optimal management of moyamoya syndrome specifically in the context of SCD. In the setting of an acute ischemic stroke, physiologic targets (blood pressure, P_{CO_2} and O_2, core body temperature) should be directed at optimizing cerebral perfusion and protecting vulnerable ischemic penumbra. Surgical revascularization is generally preferred for secondary prevention. Small case series have suggested a reduced risk of ischemic stroke with surgery. In adults, direct revascularization with a superficial temporal artery to middle cerebral artery bypass procedure may be possible. In children or in adults without a suitable target vessel, indirect revascularization procedures (eg, pial synangiosis) are more often performed.

Polycythemia

Polycythemia is present when the HB concentration is greater than 16.5 g/dL in women and 18.5 g/dL in men (or the hematocrit is >48% and 52%, respectively). True polycythemia should not be attributable solely to a reduction in plasma volume (hemoconcentration). "Primary" polycythemia refers to increased production of RBCs without increased release of EPO and occurs as a result of congenital or acquired mutations in RBC progenitors. "Secondary" polycythemia is an appropriate response to increased EPO production (Fig. 123.2). Management of secondary polycythemia should be directed at the underlying cause.

Polycythemia Vera

Polycythemia vera (PV) is of interest to neurologists primarily as a cause of stroke. The median age of diagnosis is about 60 years, but PV can occur across all age categories. In almost all cases, PV is associated with a mutation involving JAK2, a gene located on chromosome 9 that codes for the production of tyrosine kinase, a family of proteins that participate in the regulation of hematopoietic cell proliferation. The same mutation is present in about 50% of patients with essential thrombocythemia (ET) and primary myelofibrosis.

Pathobiology

A PV is a myeloproliferative neoplasm characterized by the clonal proliferation of RBC progenitors resulting in an elevated RBC mass. A small proportion of patients with PV will develop leukemic transformation, usually after many years. A major concern with PV and other myeloproliferative disorders is a predisposition to thrombosis. It is thought that persistently elevated viscosity produces high shear stress in blood vessels, which in turn is complicated by endothelial dysfunction, as well as platelet and leukocyte activation. Increased levels of thromboxane and other markers of platelet activation can be detected in the blood of patients with PV. High viscosity may reduce CBF to a degree that overall O_2 delivery is impaired despite the higher O_2-carrying capacity produced by a higher HB concentration. However, other factors must be at play because there is no clear evidence that secondary polycythemia increases the risk of thrombosis.

Clinical Manifestations

A PV is sometimes detected incidentally on routine blood work. However, a sizable proportion of patients have already had thrombotic events by the time they come to medical attention. Arterial thrombosis is more common than venous thrombosis. Patients may also present with transient visual disturbances, headaches, and dizziness attributable to hyperviscosity and sluggish blood flow. Other common complaints include pruritus that is exacerbated by contact with water and erythromelalgia (burning sensation in extremities with erythema or pallor). Physical examination commonly demonstrates hepato- and splenomegaly as well as facial plethora. Apart from an elevated HB concentration, other laboratory findings include thrombocytosis, leukocytosis, high lactate dehydrogenase (LDH), and low EPO levels. Major diagnostic criteria for PV include an elevated HB concentration and the presence of the JAK2 mutation. Minor criteria include characteristic findings on a bone marrow aspirate or biopsy and reduced serum EPO.

Management

The goal of treatment is to reduce symptoms and the risk of thrombosis while also minimizing long-term complications, especially leukemia. In a multicenter randomized trial involving patients with JAK2-positive PV, treatment with phlebotomy or hydroxyurea to achieve a hematocrit of less than 45% was associated with a significant reduction in thrombotic events. This target hematocrit should therefore be maintained with phlebotomy in essentially all patients LEVEL 2.[11] For patients at especially high risk for thrombosis (those older than the age of 60 y or having had previous thrombotic events), treatment with

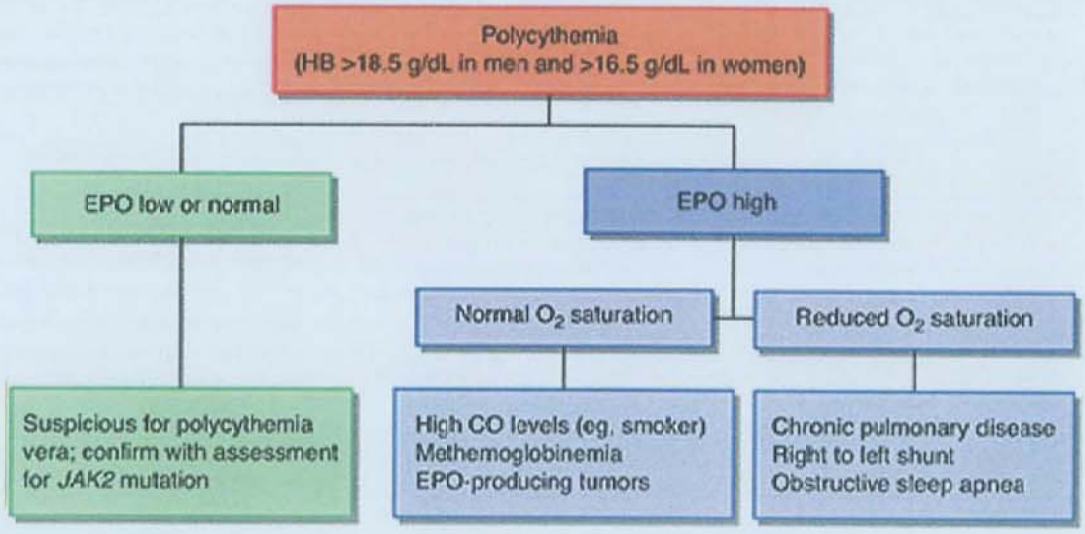

FIGURE 123.2 Approach to determining the etiology of polycythemia. Abbreviations: CO, carbon monoxide; EPO, erythropoietin; HB, hemoglobin; O_2, oxygen.

hydroxyurea is recommended, as it appears to further reduce the risk of thrombosis with a smaller increase in the risk of leukemia over time compared with other myelosuppressive drugs. The addition of low-dose aspirin (80 mg/d) can further reduce thrombotic risk LEVEL 2.[12] Use of the JAK1 and JAK2 inhibitor ruxolitinib has been demonstrated in a randomized controlled trial to reduce the hematocrit, improve splenomegaly, and improve symptoms associated with PV. There was also a possible trend toward fewer thromboembolic events, although the trial was not powered to detect a difference LEVEL 3.[13]

WHITE BLOOD CELL DISORDERS

Malignancies of Lymphoid Cells

Lymphoma, Lymphoblastic Leukemia, and Posttransplant Lymphoproliferative Disorders

Lymphoid malignancies present primarily as mass lesions, which are referred to as *lymphoma*, or with cancer cells in the blood, referred to as *leukemia*. They are most often categorized using the World Health Organization classification system. Lymphoma is divided broadly as Hodgkin and non-Hodgkin (NHL). The NHL encompasses a heterogeneous group of malignancies, arising from B lymphocytes in about 85% to 90% of cases, and T lymphocytes in about 10% to 15% of cases. B- and T-cell lymphomas are further subdivided based on whether the malignancy involves proliferation of immature precursor cells or mature cells. Neurologic involvement is rare with Hodgkin lymphoma. However, with NHL and acute lymphoblastic leukemia (ALL), neurologic complications may occur because of direct infiltration of cancer cells into the central nervous system (CNS) (Table 123.2).

Primary CNS lymphoma (PCNSL) is an extranodal variant of NHL that may involve the brain, leptomeninges, eyes, or spinal cord. It usually develops in the setting of immunosuppression. Posttransplant lymphoproliferative disorders (PTLDs) are a group of conditions involving proliferation of lymphoid or plasmacytic cells in the context of immunosuppression; involved cells usually harbor Epstein-Barr virus (EBV). The spectrum of conditions ranges from an infectious mononucleosis-like illness to malignancy that may or may not meet criteria for lymphoma.

TABLE 123.2 Classification of Most Common Subtypes of Non-Hodgkin Lymphoma and Approximate Prevalence of Central Nervous System (CNS) Involvement

Type of Lymphoma	Prevalence of CNS Involvement
Indolent lymphomas	**1%-3%**
• Follicular lymphoma (grades I and II) • Marginal zone B-cell lymphoma • Small lymphocytic lymphoma/ B-cell CLL	
Aggressive lymphomas	**3%-5%**
• Diffuse large B-cell lymphoma • Follicular lymphoma (grade III) • Mantle cell lymphoma • Peripheral T-cell lymphoma • Anaplastic large cell lymphoma	Note: Prevalence higher with certain risk factors (eg, involvement of testes, orbits, nasopharynx, breasts, multiple extranodal sites, high serum LDH).
Highly Aggressive Lymphomas	**25%-50%**
• Burkitt lymphoma • Precursor T and B lymphoblastic lymphoma • Adult T-cell lymphoma	

Abbreviations: CLL, chronic lymphocytic leukemia; LDH, lactate dehydrogenase.

Epidemiology

The distribution of NHL subtypes varies by region. In Western countries, diffuse large B-cell lymphoma and follicular lymphoma account for more than 50% of cases. The CNS involvement is most common with very high–grade lymphomas, especially Burkitt lymphoma and acute lymphoblastic lymphoma, where it may be present at the time of diagnosis in as many as a third. However, CNS involvement also occurs with intermediate- and high-grade lymphoma subtypes, including diffuse B-cell lymphoma, especially when there is lymphoma spread to testes, orbits, or the nasopharynx and when there is a high serum LDH concentration. Most cases with neurologic involvement manifest as disease relapses during or after initial treatment, even when there has been a favorable systemic response to treatment, suggesting that subclinical disease was present at the time of diagnosis. The proportion of patients developing CNS relapses may have decreased over time with the addition of rituximab to standard CHOP therapy.

More than half of cases of ALL occur in children, with a peak incidence between the ages of 2 and 5 years. The CNS infiltration is detected at diagnosis in about 5% to 10% of patients. This is likely to be an underestimate, given that identification of CNS involvement may be challenging and is not routinely pursued. Before routine use of prophylactic therapy, CNS relapses occurred in as many as 80% of cases. The CNS involvement was sometimes identified at autopsy in patients previously thought to have had more limited disease. Risk factors for CNS leukemia include younger age, high white blood cell (WBC) count, positive Philadelphia chromosome, and T-cell ALL.

PCNSL accounts for about 4% of brain tumors and may be a complication of advanced human immunodeficiency virus infection or occur following organ transplantation, although sporadic cases also occur. The EBV may be pathogenic in some cases of PCNSL as well as when more widespread PTLD involves the CNS. Following primary infection, EBV remains quiescent in some B lymphocytes. With suppression of T cell immunity, there may be polyclonal or monoclonal proliferation of these cells. The PTLD accounts for about 20% of malignancies following solid organ transplantation and occurs more frequently with more intensive immunosuppressive regimens. About a quarter of patients with PTLD have CNS involvement.

Clinical Manifestations

When diffuse lymphoma involves the CNS, the location is most often the leptomeninges and subarachnoid space. Brain parenchyma involvement is less common. This differs with PCNSL, where lesions typically arise in a periventricular distribution, with corpus callosum, basal ganglia, and thalamus involvement, although cortical lesions also occur.

The predilection of certain tumor subtypes for CNS penetration may relate to expression of various surface adhesion molecules. The most frequent manifestations of leptomeningeal involvement include headache, neck pain, and various cranial neuropathies. If there is spread to the lumbar cistern, patients

may develop low back pain and radiculopathies. The degree of subarachnoid involvement may be severe enough to interfere with cerebrospinal fluid (CSF) flow and cause hydrocephalus. With brain parenchymal involvement, there is a risk of developing seizures and focal deficits. Intramedullary spinal cord involvement is rare. In contrast, NHL and multiple myeloma (MM) are among the most common malignancies to cause extrinsic spinal cord compression (see Chapter 17).

Diagnosis

Gadolinium-enhanced MRI can identify leptomeningeal or brain parenchymal spread. There may be enhancement and thickening of the meninges or individual cranial nerves or nerve roots. There are no characteristic MRI features that definitively identify cerebral mass lesions as lymphoma rather than other tumors, although necrosis or ring enhancement would be unusual. In cases of PCNSL, stereotactic biopsy is usually required to make the diagnosis.

CSF findings include lymphocytic pleocytosis, elevated protein, normal or reduced glucose, and high opening pressure, although most patients do not have all of these. The CSF cytology and flow cytometry should both be performed, as they provide complementary information. Sampling CSF more than once may reduce false-negative rate. The CNS leukemia is defined by the presence of leukemic blasts in CSF. Blasts may occur regardless of whether or not the CSF WBC count is increased. The presence of CSF blasts predicts a worse prognosis.

CNS PTLD has different neuroimaging findings than PCNSL: It is usually multifocal, involves the cortex more than periventricular regions, has irregular margins with heterogenous enhancement, and commonly produces restricted diffusion. A diagnosis of CNS PTLD is supported by high titers of EBV in blood and CSF. However, confirmation still requires either a tissue diagnosis or identification of malignant lymphocytes in CSF.

Management

Lymphoma

When NHL is complicated by secondary CNS involvement, the usual treatment approach must be modified. Options include intensification of the chemotherapeutic regimen, with inclusion of higher doses of drugs that cross the blood-brain barrier or delivering chemotherapy directly into the CNS using either an Ommaya reservoir or repeated lumbar puncture. It is unclear which of these approaches is preferred, as they have not been compared in large clinical trials.

When systemic chemotherapy is used, the regimen usually includes high-dose methotrexate. Combining high-dose chemotherapy with autologous stem cell transplantation appears to be a promising approach. Intrathecal therapy consists of methotrexate in combination with cytarabine. Preliminary data suggest that cytarabine is more efficacious when administered as a slow-release liposomal formulation, which has the additional advantage of requiring less frequent administration. Systemic corticosteroids are effective in some patients at temporarily ameliorating neurologic symptoms and providing analgesia. Radiation therapy may be helpful in selected cases where there are radiographically visible lesions that are causing symptoms.

Because the prognosis of NHL is much worse with relapses that involve the CNS, some experts favor administration of prophylactic CNS therapy as a component of the initial chemotherapeutic regimen in patients deemed to be at high risk. The risk of CNS involvement is sufficiently high with Burkitt lymphoma and lymphoblastic lymphoma to justify CNS prophylaxis. This may also be appropriate other forms of NHL if risk factors for CNS involvement are present.

Surgical resection has a limited role, even with PCNSL, because brain involvements tend to be relatively diffuse rather than localized. As much as possible, limitation of immunosuppression is important in the treatment of PTLD. Rituximab is increasingly used in the treatment of PTLD when malignant cells express CD20.

Acute Lymphoblastic Leukemia

Phases of treatment for ALL include induction, consolidation, and maintenance. Induction therapy includes glucocorticoids, vincristine, asparaginase, and possibly an anthracycline. Philadelphia chromosome–positive patients have a worse prognosis and are also treated with tyrosine kinase inhibitors. Essentially all treatment protocols include CNS prophylaxis, which is administered during the induction phase. Consolidation and maintenance therapy involves the administration of further chemotherapy or, in some high-risk cases, hematopoietic cell transplantation (HCT).

Cranial radiotherapy used to be a standard component of CNS prophylaxis but induces CNS toxicity in a substantial proportion of patients. Radiation has been largely replaced by use of intrathecal chemotherapy LEVEL 2.[14] A variety of regimens have been used but most often include intrathecal methotrexate, cytarabine, and hydrocortisone. Neurotoxicity, with MRI evidence of leukoencephalopathy, has been described with high doses of intrathecal methotrexate.

Established CNS leukemia at the time of diagnosis is still commonly treated with the combination of whole-brain irradiation and intrathecal methotrexate. Given that the prognosis of adults with CNS leukemia is guarded, there may be a role for allogeneic HCT, but further research is required.

Plasma Cell Malignancies

Multiple Myeloma

An MM is a malignancy of marrow plasma cells characterized by the production of monoclonal immunoglobulins. It is the most prevalent hematologic malignancy after NHL and is particularly common in the elderly with a median onset age in the early 60s. MM has a higher incidence in African Americans and in men.

Plasma cell proliferation in the marrow interferes with the production of other hematopoietic cells, resulting in anemia and thrombocytopenia. Lytic bone lesions cause pain and make patients vulnerable to pathologic fractures. Increased bone metabolism precipitates hypercalcemia. Production of immunoglobulins by other plasma cells is impaired, resulting in hypogammaglobulinemia and impaired humeral immunity with increased vulnerability to bacterial infections. Renal failure may occur for a variety of reasons, including acute tubular necrosis from light-chain casts, glomerulonephropathy from amyloidosis, and the effects of hypercalcemia.

The various complications of MM (eg, hypercalcemia, infections, or uremia) may produce neurologic symptoms (eg, altered level of consciousness). Vertebral body fractures or plasmacytomas can cause spinal cord compression. Brain involvement is less common and may be due to plasmacytoma extension from the skull or the development of leptomeningeal myelomatosis with resultant cranial nerve palsies or spinal radiculopathies. The CNS involvement can generally be diagnosed with MRI

scans and assessment of CSF. There have been no prospective studies assessing optimal therapy of CNS involvement, but preliminary experience with adjunctive intrathecal chemotherapy and selective use of cranial irradiation has been favorable.

MM is the second most common cause of hyperviscosity syndrome (discussed in the following section). There have been an increasing number of case reports of hyperammonemic encephalopathy complicating MM. Although myeloma cells appear to produce significant quantities of ammonia, the pathogenesis remains unclear. As with other causes of hyperammonemia, patients develop lethargy, confusion, and seizures. In severe cases, there may be diffuse cerebral edema and coma. The relationship between serum ammonia concentration and clinical manifestations is imperfect, although most reported cases had markedly elevated levels. Clinical improvement has been reported with the initiation of chemotherapy. In several reports, hemodialysis was used successfully to lower ammonia levels more rapidly.

Waldenström Macroglobulinemia

Waldenström macroglobulinemia (WM) is a form of lymphoplasmacytic lymphoma associated with production of circulating immunoglobulin M (IgM) monoclonal antibodies. Other lymphoid malignancies (eg, chronic lymphocytic leukemia), as well as monoclonal gammopathy of undetermined significance and primary amyloidosis, may also result in increased production of IgM antibodies. The WM is a rare condition with an incidence of only 3 per million population per year.

As with MM, patients may develop clinical manifestations related to tumor infiltration in hematopoietic tissues. However, most neurologic complications are related to the effects of circulating IgM. The WM is the most common cause of the hyperviscosity syndrome, which is present in as many as one-third of patients at the time of diagnosis. Serum viscosity is generally expressed in centipoises (cP), where 1 cP is the viscosity of water. Serum usually has a viscosity of 1.4 to 1.8 cP. Clinical manifestations typically occur when viscosity exceeds 4 cP and are almost always present above 6 cP. High viscosity results in sluggish blood flow and relative hypoperfusion. Consequently, patients develop blurry vision, altered mental status, and focal neurologic deficits. In severe cases, cerebral venous thrombosis or ischemic strokes may occur. Circulating proteins also interfere with platelet aggregation, leading to prolonged bleeding time and a tendency toward mucosal hemorrhage. Funduscopy classically demonstrates segmental dilatation of retinal veins as well as retinal hemorrhages or exudates. A significant proportion of patients with WM also develop a progressive sensorimotor peripheral neuropathy. The neuropathy is usually demyelinating, affects sensation to a greater degree than motor function, and targets primarily the lower extremities. Monoclonal IgM antibodies are detected by serum protein electrophoresis and direct measurement of IgM levels. Bone marrow biopsy reveals infiltration of lymphocytes with plasma cell differentiation (>10% of cells).

Hyperviscosity syndrome is a medical emergency. The need for treatment is based primarily on the presence of clinical manifestations rather than the specific serum viscosity. Apart from fluid resuscitation, patients should undergo urgent plasmapheresis using albumin rather than plasma for fluid replacement. Each treatment reduces serum viscosity by about 20% to 30% and repeated plasmapheresis is performed until symptoms have resolved. Further therapy for WM consists of appropriate chemotherapy administered together with rituximab LEVEL 2.[15]

Acute Myeloid Leukemia

Acute myeloid leukemia (AML) is a group of hematologic malignancies involving clonal proliferation of myeloid precursor cells (destined to become granulocytes, monocytes, RBCs, or platelets). An AML may occur because of defined genetic abnormalities, as part of the natural history of myelodysplastic syndrome, or as a complication of exposure to cytotoxic drugs. An AML "not otherwise specified" is most often categorized according to the French, American, and British classification system based on the specific cell type that is implicated.

Patients with AML usually come to medical attention with manifestations attributable to pancytopenia, such as fatigue, weakness, infections, or bleeding. Leukemic infiltration of various tissues can produce additional symptoms. If the WBC is high enough, manifestations of hyperviscosity ("leukostasis") may develop, which may be severe enough to cause stupor and coma. There appears to be an increased risk of ICH for several days after the high WBC has been corrected, possibly because of reperfusion injury.

CNS leukemic involvement is uncommon at presentation and is less of a concern for AML than with ALL. It is more common with acute monocytic and myelomonocytic leukemia as well as with relapses of acute promyelocytic leukemia. In studies where lumbar puncture is routinely performed, the incidence of CNS disease approaches 20%. Additional risk factors include African American ethnicity, younger age, and a high serum LDH. Cytarabine is commonly used as part of combination chemotherapy in AML and is thought to be relatively effective at treating CNS leukemia even when clinicians are unaware that it is present. The CNS disease with AML may manifest especially with meningeal involvement and cranial neuropathies. Some patients have evidence of raised intracranial pressure with headaches, visual impairment, and papilledema. Patients may present with extramedullary granulocytic sarcomas, which sometimes develop in the brain. Other manifestations may include intracranial hemorrhage and spinal cord compression.

CNS leukemia is most often detected by lumbar puncture. There is, however, a concern that traumatic lumbar puncture could introduce leukemic cells into CSF. Traumatic lumbar puncture is more common in the presence of thrombocytopenia, such that some experts recommend only performing the procedure once the platelet count has been corrected to more than 40,000 to 50,000. Apart from the presence of blast cells, CSF protein counts are usually moderately elevated and glucose levels may be low. An MRI may be helpful in occasional patients who have intracranial mass lesions.

There have been no clinical trials to specifically direct therapy of AML involving the CNS, such that treatment strategies are largely extrapolated from experience with other malignancies. Initial intrathecal treatment usually consists of either intrathecal methotrexate or cytarabine. As with lymphoid malignancies, intrathecal therapy can be administered either by repeated lumbar puncture or an Ommaya reservoir. The dosage is reduced by about 20% when drug is delivered directly into cerebral ventricles. Treatment is usually given 2 or 3 times per week until leukemic cells have cleared and then approximately every week for 1 year. Liposomal cytarabine has the advantage that it only needs to be administered every 2 weeks initially and then monthly. Radiation therapy is reserved for refractory cases or when patients have intracranial mass lesions or cranial neuropathies.

Hematopoietic Cell Transplantation

Hematopoetic Cell Transplantation (HCT) refers to the use of high-dose preparative chemotherapy followed by the intravenous infusion of autologous or allogeneic progenitor cells. The source of transplanted cells can be bone marrow, peripheral blood, or umbilical cord blood. HCT is used primarily to treat hematologic and lymphoid cancers but occasionally also nonmalignant marrow disorders. Pretransplant preparative regimens may be myeloablative or nonmyeloablative with the goal of eradicating malignant cells. In the case of allogeneic transplantation, conditioning regimens also provide immunosuppression to prevent graft rejection. Nonmyeloablative "reduced-intensity conditioning" (RIC) regimens are used in patients who may not tolerate more intensive induction therapy. The efficacy of RIC depends in part on a graft-versus-tumor effect. Frequently used myeloablative drugs include busulfan, cyclophosphamide, and melphalan. In the treatment of lymphoma, the most common myeloablative regimen consists of combination chemotherapy with carmustine, etoposide, cytosine arabinoside, and melphalan ("BEAM"). Fludarabine is used in RIC regimens and may also be combined with lower doses of the same drugs used for myeloablation. Coadministration of total-body irradiation targets sites that may not otherwise be affected by chemotherapy. Monoclonal antibodies directed at specific antigens on bone marrow cells can be radiolabeled and used to provide directed radiation therapy, which helps avoid the adverse systemic effects of total body irradiation. Conditioning regimens are invariably complicated by the development of pancytopenia within a few days.

One of the major complications of allogeneic HCT is *graft-versus-host disease* (GVHD), which becomes more common with a greater degree of disparity in HLA matching. Calcineurin inhibitors (cyclosporine and tacrolimus), in combination with either mycophenolate or methotrexate, are used in the prevention of GVHD. T-lymphocyte depletion with antithymocyte globulin is performed in high-risk cases.

In the setting of autologous HCT, peripheral blood progenitor cells are preferred over bone marrow because this approach leads to more rapid engraftment and fewer complications. With allogeneic HCT, there seems to be little difference in survival between use of peripheral progenitor cells and bone marrow. Peripheral cells are associated with more rapid engraftment but a somewhat higher rate of GVHD. Umbilical cord blood is another widely available source of progenitor cells that is increasingly used, but it is associated with a higher rate of graft failure and delayed immune reconstitution. Engraftment typically requires between 10 days and 4 weeks, during which patients are at especially high risk for bacterial infections and require repeated RBC and platelet transfusions.

Epidemiology

Neurologic complications occur in about 15% to 20% of patients within the first 3 to 4 months after HCT. Delirium may develop at some point in as many half of patients. The risk of CNS complications is higher with allogeneic compared with autologous HCT, especially when donors are unrelated and there is a greater degree of HLA mismatch. The most common causes of CNS complications are drug toxicity and infections. Ischemic stroke and intracranial hemorrhage are relatively unusual. Some late CNS complications may be due to disease relapse.

Pathobiology

During the initial 2 to 4 weeks after HCT, before engraftment, patients are neutropenic, resulting in a relative loss of phagocytic defenses. Chemotherapy-induced mucositis enables pathogens to translocate from the gut. Patients are therefore especially vulnerable to bacterial and fungal infections, and sepsis is a common cause of nonfocal encephalopathy. Common respiratory virus (eg, influenza) and herpes simplex virus (HSV) infections may occur throughout the post-HCT course but do not usually involve the CNS. Opportunistic viruses that reactivate in the setting of impaired cell-mediated immunity, including cytomegalovirus (CMV) and varicella-zoster virus, become a concern in the postengraftment period. Patients remain vulnerable to such infections for months. Toxoplasmosis and mycobacteria are nonviral pathogens that may reactivate. During the late postengraftment period, months to years after HCT, reactivation of EBV may induce PTLD.

Because of the concerns about infection, many HCT protocols use prophylactic antimicrobials. Fluoroquinolones (eg, levofloxacin) are typically used as prophylaxis against bacteria. Acyclovir and fluconazole are the most common regimens used for prophylaxis and against HSV and fungal infections. Surveillance for CMV and *Aspergillus* species enables preemptive therapy if infection is considered to be imminent.

Clinical Manifestations, Diagnosis, and Treatment

Complications of Conditioning Drugs

Potential neurologic complications of drugs used in HCT conditioning are summarized in Table 123.3. Several drugs, especially busulfan, have been associated with development of seizures, such that some centers provide prophylaxis with antiepileptic drugs. Although data to support this practice is limited, the incidence of seizures appears to be very low with prophylaxis. Because of concerns about drug interactions, clonazepam or levetiracetam is preferred over phenytoin by some clinicians. Although less common, there have also been case reports of neurotoxicity with cyclophosphamide, melphalan, fludarabine, and cytarabine, all of which may present with encephalopathy.

Complications of Calcineurin Inhibitors

Cyclosporine and tacrolimus are widely used in the prevention of GVHD (see Table 123.3). Posterior reversible leukoencephalopathy syndrome (PRES) is the most common serious neurologic complication of calcineurin inhibitors (see also Chapter 44). This condition is characterized by vasogenic edema that preferentially (but not exclusively) involves the posterior regions of the brain. Typical manifestations of PRES include seizures, an altered or depressed level of consciousness, and visual disturbances. The diagnosis is established with MRI. Substitution with another immunosuppressive drug is generally required. Other complications that have been reported include tremors and other movement disorders, optic neuropathy, pseudotumor cerebri, akinetic mutism, plexopathy, and demyelinating lesions.

Bacterial Infections

Encephalopathy attributable to sepsis is a common neurologic complication in the early post-HCT period. However, bacterial infections specifically involving the CNS are unusual. Initial antibiotic coverage with sufficient dosing to reach the CNS needs to be broadly directed at both gram-positive and gram-negative organisms. *Listeria monocytogenes* is a pathogen that occurs particularly in immunosuppressed patients and requires additional coverage with high-dose ampicillin or, in penicillin-allergic patients, trimethoprim-sulfamethoxazole.

TABLE 123.3 Neurologic Complications of Chemotherapeutic Drugs Used in Hematopoietic Cell Transplantation

Drug	Indication	Associated Complications
Busulfan	Conditioning	Seizures
Carboplatin	Conditioning	PRES, peripheral neuropathy, ototoxicity
Carmustine	Conditioning	Delayed encephalopathy
Cyclophosphamide	Conditioning	Transient encephalopathy
Cyclosporine	GVHD prophylaxis	PRES, seizures, movement disorders, optic neuropathy, mutism, pseudotumor cerebri, polyneuropathy
Cytarabine	Systemic: conditioning Intrathecal: CNS prophylaxis	Seizures, cerebellar dysfunction, lymphocytic meningitis, cauda equine syndrome
Etoposide	Conditioning	PRES, peripheral neuropathy, acute dystonia
Fludarabine	Reduced intensity conditioning	Toxic leukoencephalopathy, PRES, retinal toxicity
Ifosfamide	Refractory lymphoma	Encephalopathy, seizures, movement disorders
Melphalan	Conditioning	Encephalopathy
Methotrexate	Systemic: conditioning Intrathecal: CNS prophylaxis, GVHD prophylaxis	PRES, necrotizing leukoencephalopathy, transient stroke-like syndrome (may have restricted diffusion), seizures, movement disorders, optic neuropathy
Sirolimus	GVHD prophylaxis	PRES, polyneuropathy
Tacrolimus	GVHD prophylaxis	PRES, seizures, movement disorders, optic neuropathy, mutism, polyneuropathy, hearing loss, demyelinating lesions

Abbreviations: CNS, central nervous system; GVHD, graft-versus-host disease; PRES, posterior reversible leukoencephalopathy syndrome.

Fungal Infections

Candida does not have a particular predilection for the CNS, but involvement may occur in the context of disseminated disease. *Candida tropicalis* is the most likely species to be implicated. It most often causes meningitis but may also produce microabscesses. The CSF WBC count is usually elevated with either a predominance of neutrophils or leukocytes. Liposomal amphotericin B is the preferred drug because it achieves relatively high CNS concentrations and has a higher rate of success compared with other agents. It can be transitioned to fluconazole after the initial 2 weeks of therapy, but a total duration of several weeks is required, depending on the clinical and radiographic course.

Severe and prolonged neutropenia, as well as GVHD, predispose patients to invasive *Aspergillus* infections, which most often appear early in the postengraftment period. The CNS involvement may occur in the context of disseminated disease or because of local spread from sinuses and has a particular predilection for the corpus callosum. Patients usually present with seizures or focal neurologic deficits. Imaging may demonstrate multiple ring-enhancing mass lesions, sometimes with concomitant infarction. The diagnosis of invasive *Aspergillus* infections can be challenging because cultures of sputum and CSF are not always positive. A positive serum galactomannan assay has a sensitivity of about 60% to 70% and specificity for invasive disease of about 90%. The sensitivity is further increased if galactomannan can be detected in a bronchoscopy sample. When feasible, histologic assessment of biopsy material can be diagnostic. The mortality associated with CNS *Aspergillus* infections is high. Voriconazole in combination with an echinocandin, as well as surgical abscess drainage when feasible, is the preferred treatment LEVEL 3.[16]

Viral Infections

Although rare, several viruses have been reported to cause encephalitis after HCT. Human herpesvirus 6 infections have been reported to occur in as many as 3% to 4% of patients undergoing allogeneic HCT, with a median posttransplant time interval of about 3 weeks. A major risk factor is the use of umbilical cord hematopoietic cells. The MRI findings, if present, are most likely to involve the temporal lobes. Other viruses tend to occur later in the course. Varicella-zoster virus reactivation is common after HCT but usually does not involve the CNS. Cases used to occur in the immediate postengraftment period. However, with use of antiviral prophylaxis, infections more often develop weeks to months later. Cases of encephalitis due to CMV, EBV, HSV, and West Nile virus have also been primarily described well after engraftment. Diagnosis of viral infections is supported by MRI findings and relevant CSF polymerase chain reaction (PCR) analysis.

Progressive multifocal leukoencephalopathy (PML) is a demyelinating condition attributable to John Cunningham (JC) virus. The PML may complicate various conditions characterized by significant immune suppression. The PML has been described after both allogeneic and autologous HCT with a median lag of about 11 months. Clinical manifestations include seizures and subacute onset of focal neurologic deficits, ataxia, and visual disturbances. The MRI shows white matter lesions, which may show contrast enhancement. The diagnosis can be made in most cases with PCR of CSF for JC virus, which has a sensitivity of about 75% to 85% and a specificity of more than 90%. Falsely negative cases can only be diagnosed definitively with brain biopsy. There is no specific therapy for JC virus. Apart from cessation of immunosuppressive agents, drugs with theoretical action against JC virus include cidofovir and mefloquine. Mirtazapine has also been administered based on the observation that JC virus uses serotonin receptors to infect cells.

Protozoal Infections

The protozoan *Toxoplasma gondii* exists in a quiescent form in some recipients of HCT and may reactivate in the postengraftment period because of impaired cell-mediated immunity.

Most patients who develop invasive disease are seropositive before undergoing transplantation. The presence of moderate to severe GVHD is a risk factor. Onset of symptoms typically occurs after about 2 to 3 months. Toxoplasmosis may present with isolated CNS involvement or as part of a disseminated infection. Clinical manifestations include fever, seizures, and a depressed level of consciousness. Extracerebral manifestations may include pneumonitis or chorioretinitis. Neuroimaging usually reveals ring-enhancing lesions. A presumptive diagnosis can be based on characteristic clinical findings in patients who have positive *Toxoplasma* serology and did not receive prophylaxis. The diagnosis can be made with CSF PCR with a high specificity but variable sensitivity. Biopsy of affected brain is usually diagnostic in patients that can safely undergo the procedure. Initial therapy consists of pyrimethamine, sulfadiazine, and leucovorin for about 6 weeks. Corticosteroids should be considered for patients with evidence of significant vasogenic edema and mass effect.

Graft-Versus-Host Disease

Acute GVHD affects primarily the gastrointestinal tract, skin, liver, eyes, and lungs; neurologic involvement is uncommon. Chronic GVHD (occurring after >100 d) involves the peripheral nervous system more often than the CNS. Conditions that have been associated with GVHD include polymyositis, immune-mediated polyneuropathy comparable to Guillain-Barré syndrome and myasthenia gravis. The CNS conditions that have been associated with GVHD include vasculitis, acute demyelinating encephalomyelitis, and aseptic meningitis. In most cases, it is unclear to what degree the GVHD is causative, and treatment does not differ from idiopathic cases.

PLATELET DISORDERS

Thrombocytopenia

After formation in the bone marrow from megakaryocytes, platelets circulate for 7 to 10 days. Thrombocytopenia is defined as a platelet count less than 150,000/μL. The risk of spontaneous hemorrhage, including intracranial hemorrhage, increases especially below 10,000 to 20,000/μL. A review of reported cases of ICH among children in the United States with immune thrombocytopenic purpura found that 90% had counts less than 20,000/μL and 75% had counts less than 10,000/μL. Excessive bleeding during surgery may be encountered below 50,000/μL. Thrombocytopenia may occur because of reduced production, increased destruction or consumption, and splenic sequestration (Figs. 123.3 and 123.4).

Prophylactic platelet transfusions are generally not recommended unless the platelet count reaches 10,000/μL. Transfusion strategies that are even more restrictive than this have been associated with a higher risk of spontaneous bleeding LEVEL 3.[17,18] The minimum platelet count required before performing lumbar puncture is not well defined but is recommended to be greater than 40,000 to 50,000/μL, particularly because the consequences of iatrogenic hemorrhage could be catastrophic. For neurosurgical procedures, counts greater than 80,000 to 100,000/μL have been suggested. A similar target seems reasonable when spontaneous ICH occurs in thrombocytopenic patients, especially in the first few hours when hematoma expansion usually occurs. The expected increment in the platelet concentration per unit transfused is about 10,000/μL. More frequent administration of lower doses may be a more efficient approach, with less overall need for allogeneic platelets compared with administration of larger doses LEVEL 1.[19] Certain causes of thrombocytopenia have other important neurologic effects and merit further discussion.

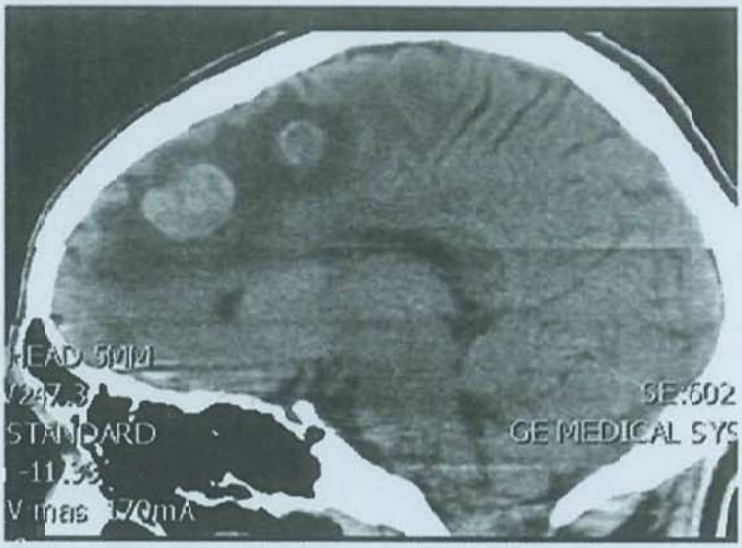

FIGURE 123.3 Computed tomography scan of a 19-year-old man who presented with acute promyelocytic leukemia, complicated by disseminated intravascular coagulation, and severe thrombocytopenia, demonstrating multiple areas of hyperdensity consistent with intracerebral hemorrhage.

Thrombotic Thrombocytopenic Purpura and Hemolytic Uremic Syndrome

Thrombotic thrombocytopenic purpura (TTP) is a clinical syndrome characterized by the presence of microangiopathic hemolytic anemia, thrombocytopenia, and various degrees of organ failure in the absence of another recognized cause (eg, malignant hypertension or scleroderma). TTP and hemolytic uremic syndrome (HUS) are likely to represent different spectrums of the same disorder, with the former classically having neurologic manifestations and the latter presenting with renal involvement. The comprehensive term *thrombotic thrombocytopenic purpura-hemolytic uremic syndrome* (TTP-HUS) reflects the overlap that occurs between these conditions. The classic "pentad" consisting of hemolysis, thrombocytopenia, fever, neurologic manifestations, and kidney failure is not required for a diagnosis of TTP-HUS and is actually not present in the majority of cases. It is possible that, over time, TTP-HUS has been recognized and treated earlier, such that progression to fulminant disease has become less common. Some patients with TTP-HUS have reduced activity of ADAMTS13, a metalloprotease responsible for cleaving von Willebrand factor (vWF). About half of patients with TTP-HUS have neurologic involvement.

Epidemiology

The incidence of TTP-HUS is about 4 to 11 cases per million population per year. About 40% of cases are idiopathic; about a third occur in the setting of various autoimmune, infectious, or malignant disorders; and the remainder is associated with various drugs, HCT, or pregnancy. A form of TTP-HUS that is particularly common in children follows diarrheal illness caused by toxin-producing enterohemorrhagic *Escherichia coli*.

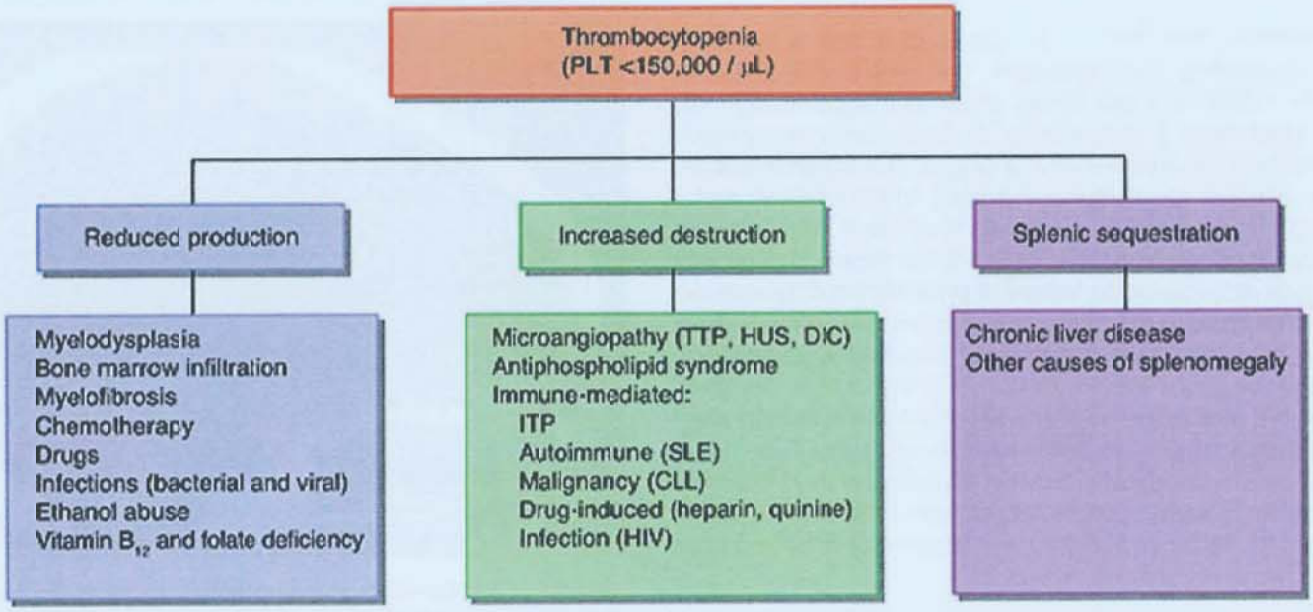

FIGURE 123.4 Causes of thrombocytopenia. Abbreviations: CLL, chronic lymphocytic leukemia; DIC, disseminated intravascular coagulation; HIV, human immunodeficiency virus; HUS, hemolytic uremic syndrome; ITP, immune thrombocytopenic purpura; PLT, platelet; SLE, systemic lupus erythematosus; TTP, thrombotic thrombocytopenic purpura.

Pathobiology

TTP is characterized pathologically by the formation of platelet-rich thrombi in arterioles and capillaries. There is also thickening of the intima, hypertrophy of underlying smooth muscle, and deposition of fibrin. Many idiopathic cases of TTP-HUS are associated with severe deficiency of ADAMTS13 activity (<10% of normal). Reduced activity is commonly related to an inhibitory antibody. The consequent accumulation of vWF multimer promotes platelet activation and aggregation. Other mechanisms that have been implicated include relative deficiency of vascular endothelial growth factor, increased amounts of plasminogen activator inhibitor type 1, and dysregulation of complement. In patients with TTP-HUS complicating enterohemorrhagic *E coli* diarrheal illness, toxins penetrate into the circulation bound to neutrophils and then target endothelial cells. Although kidney involvement is common, it is not universal, and some patients present with neurologic manifestations.

Some chemotherapeutic agents (eg, cisplatin) and immunosuppressive drugs (eg, cyclosporine) produce direct endothelial toxicity that resembles TTP-HUS. The most common drug to be implicated in causing TTP-HUS is quinine; in this case, the pathogenesis appears to be antibody mediated. The mechanism of TTP-HUS that is occasionally associated with use of the antiplatelet agent clopidogrel is not well understood. Although the pathogenesis of TTP-HUS occurring in pregnancy is not clear, it has been noted that ADAMTS13 levels decline progressively beginning in the second trimester, which may increase vulnerability.

Autopsy specimens show similar changes in cerebral microvasculature as in other organs. Some patients develop acute ischemic strokes, but these do not usually involve large vascular territories. In a series of patients with TTP who had neurologic manifestations and underwent brain MRI scans, about a third had small ischemic strokes. When angiography is performed, large-vessel occlusion is rarely observed. By far, the most common radiographic findings are those of PRES, which was present in almost half of cases. As with other causes of PRES, the mechanism likely involves vasogenic edema induced by endothelial damage and disruption of the blood-brain barrier. Thus, when clinicians observe hypodensities on CT scans, they should not necessarily conclude that they are infarcts or that they are irreversible.

Clinical Manifestations

TTP-HUS is invariably characterized by the presence of hemolysis and thrombocytopenia. Hemolysis results in increased concentrations of serum indirect bilirubin and LDH and reductions in serum haptoglobin. Levels of LDH are often very high and can be used as a surrogate for response to therapy. The RBCs become fragmented by fibrin in the microcirculation, resulting in the formation of schistocytes, which can be visualized on peripheral blood smears. Thrombocytopenia ranges from profound to relatively mild. In patients with renal involvement, there may be some hematuria and proteinuria, although it is usually not as severe as in patients with glomerulonephritis. A minority of patients requires renal replacement therapy. The most common neurologic manifestation is altered mental status, occurring in about one-third of all patients. Seizures occur in 15% to 20%, whereas coma and strokes develop in about 10%.

Diagnosis

In patients who are anemic and thrombocytopenic, crucial diagnostic tests to assess for TTP-HUS are a peripheral blood smear, serum LDH, and bilirubin. Sepsis with disseminated intravascular coagulation produces some of the same findings as TTP-HUS but usually also causes prolongation of the prothrombin time and partial thromboplastin time (PTT) and a reduction in serum fibrinogen levels. Measurement of ADAMTS13 should be performed. A low level of ADAMTS13 activity (<10%) is a specific finding that essentially confirms the diagnosis of TTP-HUS. On the other hand, patients with TTP-HUS may not have low ADAMTS13 activity, and intermediate (10% to 50%) or normal (>50%) values should not be used as criteria to stop therapy. Patients who present with higher ADAMTS13 activity do, however, appear less likely to relapse after initial therapy.

If patients have acute kidney injury that does not response readily to fluid resuscitation, a kidney biopsy can be considered and may be diagnostic. Potential causes of TTP-HUS should be sought. If there is a history of diarrhea, stool should be assessed for the presence of toxin-producing bacteria, especially *E coli* O157:H7. In women of appropriate age, pregnancy should be ruled out. Clinicians should determine whether patients have been taking various drugs that have been associated with TTP-HUS.

Management

In original descriptions of TTP-HUS, mortality was very high. Outcomes have improved markedly with use of plasma exchange (PLEX) LEVEL 1.[20] It is thought that one of the main mechanisms of PLEX is the removal of inhibitory antibodies targeting ADAMTS13 and concomitant replacement with plasma. However, the efficacy of PLEX is not necessarily limited to patients who are ADAMTS13 deficient. It is therefore reasonable to initiate PLEX even before the diagnosis is entirely certain. The benefit of PLEX is less clear in TTP-HUS associated with other conditions compared with idiopathic cases. The PLEX is usually performed daily until platelet counts have normalized and evidence of hemolysis (high LDH and presence of schistocytes) is abating. Because of the presumed autoimmune etiology of idiopathic TTP-HUS, some experts recommend treatment with corticosteroids. Preliminary data suggest rituximab may be beneficial in refractory cases. When TTP-HUS occurs in pregnancy, it may be difficult to distinguish from other obstetrical syndromes, including preeclampsia and HELLP (hemolysis, elevated liver enzymes, and low platelets) syndrome, such that early delivery should be considered. The PLEX is safe during pregnancy and should not be withheld.

Treatment of neurologic complications is largely supportive. Usual measures aimed at preventing and treating cerebral edema should be implemented. Neurologic involvement in TTP-HUS is a clear risk factor for failure to respond to therapy and worse outcomes. Longer term follow-up of patients who survive TTP-HUS reveals that many have persistent neurocognitive deficits. Strokes occur in about 10% to 15% of patients and are predicted by lower ADAMTS13 activity levels during remission. Future research should investigate whether modifications in the care of patients with TTP-HUS might prevent such deficits.

Heparin-Induced Thrombocytopenia

Heparin is one of the most common medications known to induce thrombocytopenia. Immune-mediated heparin-induced thrombocytopenia (HIT) occurs after at least 5 days of heparin exposure and is associated with a high risk of thrombotic (rather than hemorrhagic) complications, including stroke. The incidence is approximately 2% to 3% with more than 5 days of heparin exposure. The risk is higher with unfractionated rather than low molecular weight heparin. Onset beyond 2 weeks of heparin exposure is relatively uncommon.

Pathobiology and Clinical Features

The HIT is due to the formation of antibodies targeting the heparin-platelet factor 4 complex. When antibodies bind to this complex on platelet surfaces, they induce platelet activation and aggregation, which in turn promotes thrombin generation. Consumption and clearance of activated platelets causes the platelet concentration to fall. The risk of thrombosis over the 4 weeks following the diagnosis of HIT is greater than 50%. Most patients with HIT have relatively mild thrombocytopenia (rarely <20,000/μL). The development of lower extremity deep venous thrombosis is the most common complication of HIT, but arterial thrombosis can occur. Neurologic complications, primarily arterial ischemic strokes and to a lesser degree cerebral venous thrombosis, have been reported to occur in 3% to 9% of patients with established HIT.

Diagnosis

A clinical scoring system, the 4T score, can be used to assess the pretest probability that a patient could have HIT (Table 123.4). Patients are assigned 0 to 2 points for each of four variables: the degree of thrombocytopenia, the timing of the platelet drop, the development of thrombosis, and the presence of alternative causes of thrombocytopenia. A score of 0 to 3 indicates a low risk of HIT and provides justification to not pursue additional testing. A score of 4 to 5 suggests an intermediate risk and 6 to 8 indicates a high risk. Heparin-platelet factor 4 complexes can be detected with enzyme-linked immunosorbent assay with a high sensitivity but somewhat lower specificity. The gold standard test, with sensitivity and specificity greater than 95%, is the carbon 14-serotonin release assay, which is only performed at specialized centers.

Treatment

When HIT is suspected, all heparin must be discontinued, including that used for deep venous thrombosis prophylaxis or to flush venous or arterial catheters. If the suspicion for HIT is at least moderate, the risk of thrombosis is sufficiently high to justify therapeutic anticoagulation with an alternative drug that does not cross-react with heparin. Appropriate parenteral alternatives include the direct thrombin inhibitors argatroban, bivalirudin, and danaparoid as well as the pentasaccharide fondaparinux.

TABLE 123.4 The 4T Score in the Diagnosis of Heparin-Induced Thrombocytopenia[a,b]

Variable	2 Points	1 Point	0 Point
Thrombocytopenia severity	Platelet fall >50% and platelet nadir ≥20	Platelet fall 30%-50% or platelet nadir 10-19	Platelet fall <30% or platelet nadir <10
Timing of platelet count reduction	Clear onset day 5-10 or ≤1 d with prior heparin exposure past 30 d	Consistent with day 5-10 fall but not clear; onset after day 10; or fall ≤1 d with prior heparin 30-100 d ago	Platelet fall <4 d without recent exposure
Thrombosis	New thrombosis, skin necrosis	Progressive or recurrent thrombosis	None
Thrombocytopenia alternative causes	None apparent	Possible	Definite

[a]Score of 0-3: <1% chance of heparin-induced therapy (HIT); score of 4-5: 10%-15% chance of HIT; score of 6-8: >50% chance of HIT.
[b]Data from Cuker A, Gimotty PA, Crowther MA, Warkentin TE. Predictive value of the 4Ts scoring system for heparin-induced thrombocytopenia: a systematic review and meta-analysis. *Blood*. 2012;120(20):4160-4167.

Treatment with warfarin can be initiated after the platelet count has risen to more than 150,000/μL. Warfarin should overlap with parenteral anticoagulation for at least 5 days and should then be continued with a target international normalized ratio (INR) of 2 to 3 for 3 months in the setting of thrombosis and 4 to 6 weeks for HIT without thrombosis. Increasing evidence support the use of direct oral anticoagulant (DOAC) drugs (apixaban, rivaroxaban, or edoxaban) in the treatment of HIT, either after a parenteral agent or even as initial therapy.

Impaired Platelet Function

Platelet function may be impaired by numerous genetic disorders and acquired medical conditions, including uremia, plasma cell dyscrasias, advanced liver disease, and myeloproliferative disorders. More often, platelet dysfunction is iatrogenic from antiplatelet drugs used in the prevention and treatment of cardiovascular disease.

Many patients who develop spontaneous ICH or subdural hematomas are receiving antiplatelet drugs. The degree of hematoma expansion over the initial few hours after intracranial hemorrhage is a crucial predictor of outcome. Although literature is conflicting, numerous studies have suggested that the degree of expansion and the chance of poor outcome is greater among patients receiving antiplatelet drugs. Aspirin (acetylsalicylic acid [ASA]) is the most common agent and works by inhibiting the effects of cyclooxygenase-1 in converting arachidonic acid to prostaglandin H_2, thereby reducing levels of thromboxane A_2, an inducer of platelet aggregation. The antiplatelet effects of ASA are irreversible and last for the life span of the platelet. Clopidogrel is a thienopyridine drug, which works by permanently modifying platelet ADP receptors, thereby inhibiting platelet aggregation. The addition of clopidogrel to ASA is particularly important for patients who have undergone percutaneous coronary interventions. Prasugrel and ticagrelor are newer antiplatelet drugs that work on the same receptor as clopidogrel and may have a greater degree of antiplatelet effect and in turn cause a slightly higher risk of bleeding.

Newer assays enable point-of-care assessment of platelet function, thereby allowing the effects of antiplatelet drugs to be rapidly measured. This information could potentially be used in therapeutic decision making.

Platelet transfusions can improve platelet activity. However, the Platelet Transfusion in Cerebral Hemorrhage trial found that use of platelet transfusions in patients with ICH who had been using antiplatelet drugs did not attenuate hematoma expansion and appeared to, in fact, result in worse outcomes LEVEL 1.[21] Of note, few patients in the Platelet Transfusion in Cerebral Hemorrhage trial were receiving dual antiplatelet therapy or newer, more potent, antiplatelet drugs, such that further studies are justified.

Desmopressin improves platelet activity by promoting the release of vWF from endothelium. Its use among ICH, SAH, or TBI patients receiving antiplatelet drugs has been associated with less hematoma expansion, but evaluation in randomized controlled trials is needed.

Thrombocytosis

Thrombocytosis refers to an elevation in the concentration of platelets and is usually defined using a threshold of 450,000/μL. Thrombocytosis may be "reactive" in response to a systemic condition or may be a manifestation of ET or another myeloproliferative disorder ("autonomous thrombocytosis"). A reactive etiology (eg, inflammation, tissue damage, anemia) is much more common, even when thrombocytosis is extreme (>1,000,000/μL). Clinical manifestations, including vasomotor symptoms (eg, headache and visual disturbances) as well as thrombotic or hemorrhagic complications, occur with autonomous thrombocytosis and are uncommon with reactive thrombocytosis.

Essential Thrombocythemia

ET is a clonal myeloproliferative disorder characterized by an elevated platelet count. There is no specific diagnostic test for ET and excluding reactive thrombocytosis and other myeloproliferative disorders makes the diagnosis. The ET is associated with an increased risk of thrombosis, including stroke. The median age of patients diagnosed with ET is about 60 years, and it is more common in women.

Pathobiology

Numerous factors contribute an increased risk of thrombosis, including activation of platelets, resistance to the effects of endogenous coagulation inhibitors (protein C and S), increased levels of thrombomodulin, and activation of leukocytes. Risk factors for thrombosis include a previous history of thrombotic events, the presence of the JAK2 mutation, leukocytosis, and other cardiovascular risk factors.

Clinical Manifestations

Many patients are asymptomatic at the time of diagnosis. The most common complaints are vasomotor symptoms and erythromelalgia. The risk of thrombosis is not directly related to the degree of platelet elevation. The risk of thrombotic events over 15 years is about 20%, and stroke develops in about 10% to 15% of patients. A small proportion of patients eventually develop AML or myelofibrosis.

Diagnosis

Bone marrow aspirates and biopsies demonstrate hyperplasia of megakaryocytes. Cytogenetic studies reveal absence of the Philadelphia chromosome (characteristic of chronic myelogenous leukemia). About half of patients with ET will have the JAK2 mutation. To be diagnosed with ET, there should be no evidence of myelofibrosis and a normal RBC mass.

Management

Patients at low risk for thrombosis include those younger than 60 years, with no previous events and a platelet count less than 1,000,000/μL. These patients do not necessarily require treatment. Vasomotor symptoms and erythromelalgia often respond to treatment with low-dose ASA. Patients with previous thrombosis and those who are older than 60 years are generally treated with a combination of ASA and hydroxyurea, with an initial dose of 15 mg/kg/d, adjusted to achieve a target platelet count less than 600,000/μL LEVEL 2.[22] Achieving counts less than 400,000/μL may further reduce the risk of subsequent thrombosis.

COAGULATION DISTURBANCES

Coagulation disturbances develop when there is insufficient production, increased consumption, or inhibition of clotting factors. Apart from rare congenital deficiencies of specific clotting factors (eg, factor VIII with hemophilia A), reduced production of clotting factors occurs largely because of liver disease,

vitamin K deficiency, or the use of the vitamin K antagonist warfarin. Other anticoagulants work primarily by inhibiting thrombin. Consumption of clotting factors occurs with disseminated intravascular coagulation and massive hemorrhage. Coagulation disturbances are of interest to neurologists and neurosurgeons because of their association with intracranial hemorrhage.

Normal Coagulation

When endothelium is damaged, there is immediate activation and aggregation of platelets. Apart from forming an initial barrier to bleeding, the platelet plug also provides the phospholipid template upon which coagulation can proceed. Tissue factor is a membrane protein that is expressed by subendothelial cells and interacts with circulating factor VII, which in turn activates factor X. This process is further amplified by factors VIII and IX. Activated factor X, together with factor V, converts prothrombin to thrombin, which in turn promotes conversion of fibrinogen to fibrin. Thrombin also has a positive feedback effect, whereby it further activates platelets, factor VIII, and factor XI (Fig. 123.5).

To avoid unregulated clotting, there exist a number of natural anticoagulant mechanisms. Antithrombin is a protease inhibitor that blocks the activity of factor X. Thrombomodulin is a protein on the surface of endothelial cells that inhibits thrombin and activates protein C, which together with protein S inactivates factors V and VIII. The endothelial enzyme tissue plasminogen activator (tPA) stimulates the conversion of plasminogen to plasmin, which is responsible for cleaving cross-linked fibrin.

Impaired Coagulation

Warfarin-Induced Intracranial Hemorrhage

Although increasingly replaced by newer oral anticoagulants, warfarin has long been used to reduce the risk of thromboembolic complications in patients with atrial fibrillation, to prevent valve thrombosis in patients with mechanical heart valves, and as treatment of venous thromboembolism. Warfarin antagonizes the formation of vitamin K–dependent clotting factors (II, VII, IX, and X) in the liver. Its effect on clotting is measured by the prothrombin time and the measurement is standardized using the INR. For most conditions, the target INR is 2 to 3. The risk of intracranial hemorrhage with warfarin has been in the range of 1% in clinical trials but is somewhat higher in usual practice where patients may not be as carefully selected and the INR not as carefully monitored.

Hematoma expansion is more pronounced and outcomes worse among patients with warfarin-induced ICH. Although fresh frozen plasma (FFP) reverses the effects of warfarin, the time required for cross-matching, thawing, and administering 20 to 40 mL/kg of fluid results in major delays. The INR can be corrected more rapidly with the use of four-factor prothrombin complex concentrate (PCC), which contains vitamin K–dependent clotting factors in a relatively small volume of fluid that can be administered over a few minutes LEVEL 4.[23] There has been one small clinical trial specifically in patients with intracranial hemorrhage, which confirmed more rapid correction of the INR with PCC, with a suggestion also of less hematoma expansion LEVEL 2.[24] Neurocritical Care Society, American Society of Hematology, and American College of Chest Physician guidelines all recommend preferential use of four-factor PCC rather than FFP or recombinant factor VIIa. The optimal dose of PCC remains unclear but is generally recommended to include 25 to 50 IU/kg of factor IX activity. Higher doses may be preferable with more pronounced initial elevation of the INR. Repeat INR testing soon after completion of PCC administration and then every 6 to 8 hours for the next 24 to 48 hours is recommended. Intravenous vitamin K (10 mg) should also be administered to help avoid a subsequent increment in INR after initial correction.

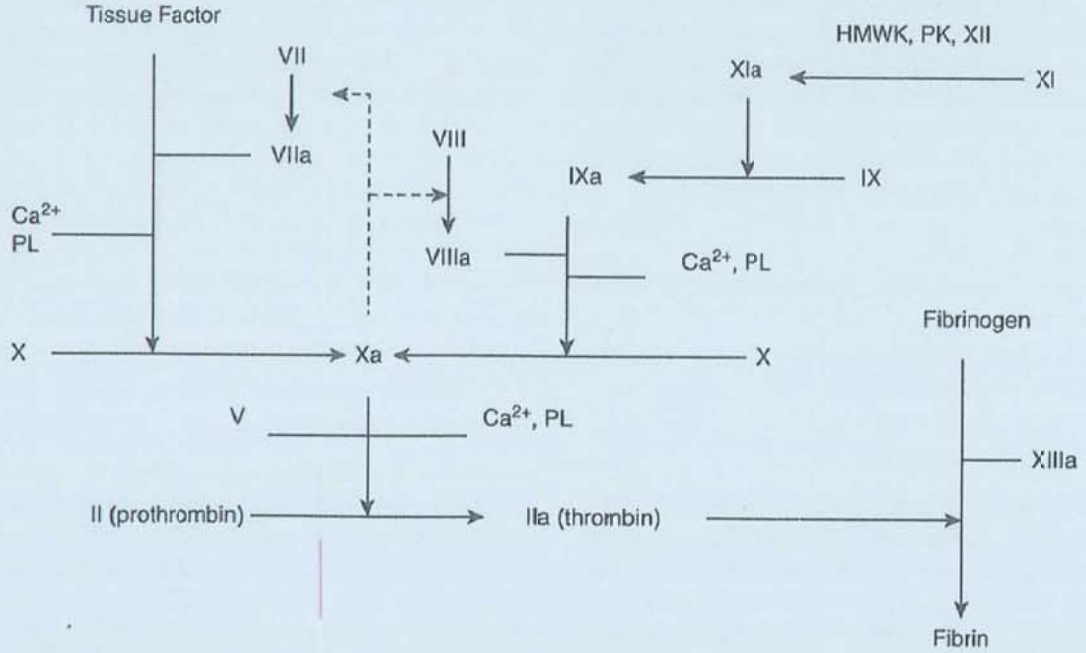

FIGURE 123.5 Traditional model of the coagulation cascade with extrinsic **(left)** and intrinsic **(right)** pathways. Although this laboratory model is useful to understand the factors, which may influence coagulation times (prothrombin time, **left**; partial thromboplastin time, **right**), it is not a physiologic model that describes exactly how coagulation functions in vivo. Abbreviations: HMWK, high molecular weight kininogen; PK, prekallikrein; PL, phospholipid.

Reversal of Novel Oral Anticoagulants

Several DOACs have been demonstrated to be equally or more efficacious than warfarin in the prevention of stroke among patients with atrial fibrillation and in the treatment of venous thromboembolism, with a comparable or lower risk of intracranial hemorrhage. Dabigatran is a direct thrombin inhibitor, whereas rivaroxaban, apixaban, and edoxaban are factor X_a inhibitors. The PTT and INR do not measure the effects of these agents. Measurement of the thrombin time or ecarin clotting time, if available, provides a better reflection of the anticoagulant effect of dabigatran. Anti–factor X_a activity can be measured to assess the anticoagulant effect of factor X_a inhibitors.

Significant early hematoma expansion and poor outcomes are common when ICU occurs in the context of DOAC use, although outcomes are generally no worse than with warfarin-associated ICH. Outcomes from DOAC-related ICH may improve with increasing availability of rapid reversal agents. Idarucizumab is a monoclonal antibody fragment that binds dabigatran with much greater affinity than thrombin, thereby neutralizing its anticoagulant effect within minutes. Andexanet alfa is a recombinant factor X_a decoy protein that binds factor X_a inhibitors. It is administered as a bolus and then subsequent 2-hour infusion and rapidly reduces anti–factor X_a activity. The degree to which these novel agents attenuate hematoma expansion has not been well studied. The PCC or activated PCC (factor VIII inhibit bypassing activity) may also have some limited efficacy for reversing the effects of both direct thrombin and factor X_a inhibitors and should be considered when reversal agents are not available.

Bleeding Associated With Thrombolytic Therapy

When tPA is administered to treat acute ischemic stroke, the risk of intracranial hemorrhage is in the range of 3% to 7%. This rate is 1% to 2% when tPA is used for other conditions, such as myocardial infarction or pulmonary embolism. Apart from discontinuation of the infusion, patients should receive 10 units of cryoprecipitate to increase fibrinogen levels because there is some evidence that hemorrhagic infarction after tPA is associated with a systemic consumption coagulopathy and fibrinogen depletion. Fibrinogen concentrate could be used instead of cryoprecipitate, but there is relatively little published experience. There is also a theoretical benefit from antifibrinolytics like tranexamic acid or ε-aminocaproic acid, and they can be administered more rapidly than cryoprecipitate or fibrinogen concentrate. Previous American Heart Association guidelines have recommended platelet transfusions because platelet aggregation may be altered by tPA, but there is little evidence to support this practice, and it is not recommended in Neurocritical Care Society guidelines.

Bleeding Associated With Unfractionated or Low Molecular Weight Heparin

Unfractionated heparin exerts its anticoagulation effect by binding the natural anticoagulant antithrombin III and inducing a conformational change that potentiates inactivation of factor X_a and thrombin. Intracranial hemorrhage is very uncommon with heparin. The effects of heparin can be reversed by protamine, which is generally administered at a dose of 1 unit for every 100 units of heparin administered in the past 2 to 3 hours, to a maximum of 50 mg. Low molecular weight heparins have a similar mechanism, but protamine is less effective as a reversal agent, although its use is still recommended in cases of intracranial hemorrhage. Preliminary experience with andexanet alfa suggests that it is effective at reversing the anti–factor X_a activity of enoxaparin.

Hypercoagulable States

Familial Thrombophilia

The possibility of thrombophilia should be considered, especially when stroke occurs in children and young adults. It should also be pursued when there are recurrent thromboembolic events or when there is a strong family history. Several familial conditions cause deficiencies or dysfunction of naturally occurring anticoagulants, including protein S, protein C, antithrombin III, and factor V. A mutation of prothrombin (factor II) has been identified as a risk factor for both ischemic strokes and cerebral venous thrombosis, especially with concomitant use of oral contraceptives.

Antiphospholipid Antibody Syndrome

The antiphospholipid syndrome (APLS) is a condition characterized by arterial or venous thrombosis and/or pregnancy morbidity, occurring in combination with persistently detectable antiphospholipid (APL) antibodies. It is of interest to neurologists primarily because it predisposes patients to ischemic stroke and cerebral venous thrombosis and is also associated with neuropsychiatric manifestations and cognitive decline.

Epidemiology

Approximately half of patients have "primary" APLS, whereas the remainder has either systemic lupus erythematosus or another connective tissue disorder. The APLS is more common in women and has a mean age at diagnosis of 40 to 45 years. Ischemic strokes occur in 10% to 20% and TIAs in about 5% to 15% of patients meeting established criteria for APLS.

Pathobiology

There are several mechanisms whereby APL antibodies may contribute to an increased risk of thrombosis, including interference with natural anticoagulant mechanisms (eg, inhibition of protein C and antithrombin III activity), activation of platelets and endothelial cells, and triggering of the complement cascade. Some cases of ischemic stroke in APLS develop because of in situ thrombosis, whereas others are cardioembolic. Valvular cardiac abnormalities that can be detected by transesophageal echocardiography range from thickening of valve leaflets to the development of frank vegetations (nonbacterial endocarditis). The mitral valve is affected more often than the aortic valve. Spontaneous echo contrast is also sometimes found in the left atrium, but a definitive association with stroke risk has not been established.

Clinical Manifestations

Prospective studies have shown that APL antibodies can be detected in a sizable proportion of patients diagnosed with ischemic strokes. However, in some cases, the antibodies are only transiently and slightly elevated and therefore not consistent with true APLS. Studies are somewhat conflicting regarding the question of whether the presence of detectable APL antibodies purports an increased risk of subsequent stroke. The association with stroke appears to be strongest and most definitive in young women and when more than one type of APL antibody is elevated.

Venous thrombosis is more common than arterial thrombosis with APLS. The possibility of APLS should always be considered

in patients presenting with idiopathic cerebral venous thrombosis. A significant proportion of patients with APLS develop cognitive deficits even without previously diagnosed strokes. The specific mechanism is not well understood, although MRI scans commonly reveal white matter disease. Apart from pregnancy loss and thrombosis, APLS can also present in some cases with microangiopathy, similar to TTP-HUS. Catastrophic APLS refers to a small subset of patients who develop multiorgan failure as a result of widespread thrombosis; this occurs in less than 1% of patients.

Diagnosis

APLS should be considered in the setting of idiopathic episodes of thrombosis, recurrent pregnancy loss, unexplained thrombocytopenia or abnormal PTT, and thrombotic microangiopathy. The APL antibody titers should not be routinely assessed in all patients with ischemic strokes. Diagnostic workup for APLS consists of enzyme-linked immunosorbent assay testing for immunoglobulin G and IgM anticardiolipin and anti–β2-glycoprotein antibodies as well as testing for a lupus anticoagulant. If positive, these assays should be repeated after at least 12 weeks for confirmation. Criteria for catastrophic APLS have been proposed and include a history of APLS, thrombosis in three or more organ systems within a week, biopsy confirmation of microthrombosis, and exclusion of other causes of thrombosis. Patients are considered to have definite catastrophic APLS if all four criteria are met. Patients have probable APLS if there are only two organs involved, if the only missing criterion is histopathology, or if the time frame of recurrent thrombosis exceeds 1 week but is less than 1 month.

Management

Optimal treatment of stroke in the context of APLS is somewhat controversial. American Stroke Association guidelines state that antiplatelet drugs remain appropriate treatment for patients with cryptogenic ischemic stroke or TIA in whom APL antibodies are detected (class 2b, level of evidence B). The rationale for this recommendation is that the largest prospective series have not demonstrated a difference in the rate of subsequent thrombotic events based on whether or not APL antibodies are present. On the other hand, the guidelines also state that oral anticoagulation is appropriate therapy for patients in whom a diagnosis of APLS is confirmed, which would be the case for any patient with stroke in whom repeat antibody testing after 12 weeks is confirmatory. In several retrospective series of confirmed APLS, treatment with aspirin had limited efficacy.

Despite availability of newer oral anticoagulants, most experience treating APLS has been with warfarin. Recent clinical trials suggest that DOACs are less effective than warfarin at treating thrombosis in the context of APLS LEVEL 1.[25,26] As in other settings, the goal INR is 2 to 3. Although some older literature advocated for more intensive anticoagulation (INR 3-4), subsequent clinical trials did not demonstrate any advantage to justify the higher risk of hemorrhage LEVEL 1.[27,28] For patients with thrombosis in the setting of APLS, indefinite anticoagulation is recommended. For patients with other reasons for a thrombotic event, in whom the elevation in APL antibody titers is mild or transient, cessation of therapy after a few months can be considered.

For patients with APL antibodies and risk factors for stroke, it is reasonable to administer antiplatelet drugs as primary prophylaxis. Antiplatelet therapy is also recommended for patients with APL antibodies and neuropsychiatric manifestations but no clear evidence of a stroke. However, identification of APL antibodies alone is likely not sufficient justification for regular use of antiplatelet therapy. There are no randomized trials specifically in patients meeting criteria for catastrophic APLS. Retrospective series suggest that mortality may be lower when patients are treated not only with anticoagulation but also with corticosteroids and PLEX.

LEVEL 1 EVIDENCE

1. Hébert PC, Wells G, Blajchman MA, et al. A multicenter randomized, controlled clinical trial of transfusion requirements in critical care. *N Engl J Med*. 1999;340(6):409-417.
2. Lacroix J, Hébert PC, Hutchison JS, et al. Transfusion strategies for patients in pediatric intensive care units. *N Engl J Med*. 2007;356(16):1609-1619.
3. Adams R, McView V, Nichols F, et al. The use of transcranial ultrasonography to predict stroke in sickle cell disease. *N Engl J Med*. 1992;326(9):605-610.
4. Adams RJ, McKie VC, Hsu L, et al. Prevention of a first stroke by transfusions in children with sickle cell anemia and abnormal results on transcranial Doppler ultrasonography. *N Engl J Med*. 1998;339(1):5-11.
5. Heeney MM, Hoppe CC, Abboud MR, et al. A multinational trial of prasugrel for sickle cell vaso-occlusive events. *N Engl J Med*. 2016;374(7):625-635.
6. Adams RJ, Brambilla D; and Optimizing Primary Stroke Prevention in Sickle Cell Anemia Trial Investigators. Discontinuing prophylactic transfusions used to prevent stroke in sickle cell disease. *N Engl J Med*. 2005;353(26):2769-2778.
7. DeBaun MR, Gordon M, McKinstry RC, et al. Controlled trial of transfusions for silent cerebral infarcts in sickle cell anemia. *N Engl J Med*. 2014;371(8):699.
8. Steinberg MH, Barton F, Castro O, et al. Effect of hydroxyurea on mortality and morbidity in adult sickle cell anemia: risks and benefits up to 9 year of treatment. *JAMA*. 2003;289(13):1645-1651.
9. National Institutes of Health. Stroke prevention study in children with sickle cell anemia, iron overload stopped early. National Institutes of Health Web site. http://www.nih.gov/news/health/jun2010;shnhlbi-03.htm. Published June 3, 2010. Accessed May 15, 2014.
10. Ware RE, Davis BR, Schultz W, et al. Hydroxycarbamide versus chronic transfusion for maintenance of transcranial Doppler flow velocities in children with sickle cell anemia—TCD with Transfusions Changing to Hydroxyurea (TWiTCH): a multicenter, open-label, phase 3, noninteriority trial. *Lancet*. 2016;387(10019):661-670.
11. Marchioli R, Finazzi G, Specchia G, et al. Cardiovascular events and intensity of treatment in polycythemia vera. *N Engl J Med*. 2013;368(1):22-33.
12. Landolfi R, Marchioli R, Kutti J, et al. Efficacy and safety of low-dose aspirin in polycythemia vera. *N Engl J Med*. 2004;350(2):114-124.
13. Vannucchi AM, Kiladjian JJ, Griesshammer M, et al. Ruxolitinib versus standard therapy for the treatment of polycythemia vera. *N Engl J Med*. 2015;372(5):426-435.

14. Pui CH, Campana D, Pei D, et al. Treating childhood acute lymphoblastic leukemia without cranial irradiation. *N Engl J Med*. 2009;360(26):2730-2741.
15. Buske C, Hoster E, Dreyling M, et al. The addition of rituximab to front-line therapy with CHOP (R-CHOP) results in a higher response rate and longer time to treatment failure in patients with lymphoplasmacytic lymphoma: results of a randomized trial of the German Low-grade Lymphoma Study Group (GLSG). *Leukemia*. 2009;23(1):153-161.
16. Herbrecht R, Denning DW, Patterson TF, et al. Voriconazole versus amphotericin B for primary therapy of invasive aspergillosis. *N Engl J Med*. 2002;347(6):408-415.
17. Rebulla P, Finazzi G, Marangoni F, et al. The threshold for prophylactic platelet transfusions in adults with acute myeloid leukemia. *N Engl J Med*. 1997;337(26):1870-1875.
18. Stanworth SJ, Estcourt LJ, Powter G, et al. A no-prophylaxis platelet-transfusion strategy for hematologic cancers. *N Engl J Med*. 2013;368(19):1771-1780.
19. Slichter SJ, Kaufman RM, Assmann SF, et al. Dose of prophylactic platelet transfusions and prevention of hemorrhage. *N Engl J Med*. 2010;362(7):600-613.
20. Michael M, Elliott EJ, Ridley GF, Hodson EM, Craig JC. Interventions for haemolytic uremic syndrome and thrombotic thrombocytopenic purpura. *Cochrane Database Syst Rev*. 2009;(1):CD003595.
21. Baharoglu MI, Cordonnier C, Salman RA, et al. Platelet transfusion versus standard care after acute stroke due to spontaneous cerebral hemorrhage associated with antiplatelet therapy (PATCH): a randomized, open-label, phase 3 trial. *Lancet*. 2016;387(10038):2605-2613.
22. Cortelazzo S, Finazzi G, Ruggeri M, et al. Hydroxyurea for patients with essential thrombocythemia and a high risk of thrombosis. *N Engl J Med*. 1995;332(17):1132-1136.
23. Sarode R, Milling TJ Jr, Refaai MA, et al. Efficacy and safety of a 4-factor prothrombin complex concentrate in patients on vitamin K antagonists presenting with major bleeding: a randomized, plasma-controlled, phase IIIb study. *Circulation*. 2013;128(11):1234-1243.
24. Steiner T, Poli S, Griebe M, et al. Fresh frozen plasma versus prothrombin complex concentrate in patients with intracranial hemorrhage related to vitamin K antagonists (INCH): a randomized trial. *Lancet Neurol*. 2016;15(6):566-573.
25. Ordi-Ros J, Sáez-Cornet L, Pérez-Conesa M, et al. Rivaroxaban versus vitamin K antagonist in antiphospholipid syndrome: a randomized noninferiority trial. *Ann Intern Med*. 2019;171(10):685-694.
26. Pengo V, Denas G, Zoppellaro G, et al. Rivaroxaban vs warfarin in high-risk patients with antiphospholipid syndrome. *Blood*. 2018;132(13):1365-1371.
27. Crowther MA, Ginsberg JS, Denburg JJ, et al. A comparison of two intensities of warfarin for the prevention of recurrent thrombosis in patients with the antiphospholipid antibody syndrome. *N Engl J Med*. 2003;349(12):1133-1138.
28. Finazzi G, Marchioli R, Brancaccio V, et al. A randomized clinical trial of high-intensity warfarin vs. conventional antithrombotic therapy for the prevention of recurrent thrombosis in patients with the antiphospholipid syndrome (WAPS). *J Thromb Haemost*. 2005;3(5):848-853.

SUGGESTED READINGS

Baehring JM, Hochberg EP, Raje N, Ulrickson M, Hochberg FH. Neurological manifestations of Waldenström macroglobulinemia. *Nat Clin Pract Neurol*. 2008;4(10):547-556.

Chaturvedi S, McCrae KR. Diagnosis and management of the antiphospholipid syndrome. *Blood Rev*. 2017; 31(6):406-417.

Connolly SJ, Crowther M, Eikelboom JW, et al. Full study report of andexanet alfa for bleeding associated with factor Xa inhibitors. *N Engl J Med*. 2019;380(14):1326-1335.

Cuker A, Gimotty PA, Crowther MA, Warkentin TE. Predictive value of the 4Ts scoring system for heparin-induced thrombocytopenia: a systematic review and meta-analysis. *Blood*. 2012;120(20):4160-4167.

Dhar R, Zazulia AR, Derdeyn CP, Diringer MN. RBC transfusion improves cerebral oxygen delivery insubarachnoid hemorrhage. *Crit Care Med*. 2017;45(4):653-659.

Frontera JA, Gordon E, Zach V, et al. Reversal of coagulopathy using prothrombin complex concentrates is associated with improved outcome compared to fresh frozen plasma in warfarin-associated intracranial hemorrhage. *Neurocrit Care*. 2014; 21(3):397-406.

Gruppo Italiano Studio Policitemia. Polycythemia vera: the natural history of 1213 patients followed for 20 years. *Ann Intern Med*. 1995;123(9): 656-664.

Inohara T, Xian Y, Liang L, et al. Association of intracerebral hemorrhage among patients taking non-vitamin K antagonist vs vitamin K antagonist organ anticoagulants with in-hospital mortality. *JAMA*. 2018;319(5):463-473.

Kramer AH, Zygun DA. Anemia and red blood cell transfusion in neurocritical care. *Crit Care*. 2009;13(3):R89.

Lamonte MP, Brown PM, Hursting MJ. Stroke in patients with heparin-induced thrombocytopenia and the effect of argatroban therapy. *Crit Care Med*. 2004;32(4):976-980.

LeRoux PD, and Participants in the International Multi-disciplinary Consensus Conference on the Critical Care Management of Subarachnoid Hemorrhage. Anemia and transfusion after subarachnoid hemorrhage. *Neurocrit Care*. 2011;15(2):342-353.

Meloni G, Proia A, Antonini G, et al. Thrombotic thrombocytopenic purpura: prospective neurologic, neuroimaging and neurophysiologic evaluation. *Haematologica*. 2011;86(11):1194-1199.

Pohl C, Harbrecht U, Greinacher A, et al. Neurologic complications of immune-mediate heparin induced thrombocytopenia. *Neurology*. 2000;54(6):1240-1245.

Pollack CV Jr, Reilly PA, van Ryn J, et al. Idarucizumab for dabigatran reversal—full cohort analysis. *N Engl J Med*. 2017;377(5):431-444.

Pósfai É, Marton I, Szoke A, et al. Stroke in essential thrombocythemia. *J Neurol Sci*. 2014;336(1-2):260-262.

Psaila B, Petrovic A, Page LK, Menell J, Schonholz M, Bussel JB. Intracranial hemorrhage (ICH) in children with immune thrombocytopenia (ITP): study of 40 cases. *Blood*. 2009;114(23):4777-4783.

Quinn CT, McKinstry RC, Dowling MM, et al. Acute silent cerebral ischemic events in children with sickle cell anemia. *JAMA Neurol*. 2013;70(1): 58-65.

Rodriguez TE. Neurologic complications of bone marrow transplantation. *Handb Clin Neurol*. 2014;121:1295-304.

Rozovski U, Ohanian M, Ravandi F, et al. Incidence of and risk factors for acute myeloid leukemia involvement of the central nervous system. *Leuk Lymphoma*. 2014;56(5):1392-1397.

Sadler JE. Pathophysiology of thrombotic thrombocytopenic purpura. *Blood*. 2017;130(10):1181-1188.

Tefferi A, Rumi E, Finazzi G, et al. Survival and prognosis among 1545 patients with contemporary polycythemia vera: an international study. *Leukemia*. 2013;27(9):1874-1881.

Thomas X, Le QH. Central nervous system involvement in adult acute lymphoblastic leukemia. *Hematology*. 2008;13(5):293-302.

Vichinsky EP, Neumayr LD, Gold JI, et al. Neuropsychological dysfunction and neuroimaging abnormalities in neurologically intact adults with sickle cell anemia. *JAMA*. 2010;303(18):1823-1831.

Ware RE, de Montalembert M, Tshilolo L, Abboud MR. Sickle cell disease. *Lancet*. 2017;390(10091):311-323.

Hepatic Disease and the Brain 124

Charles L. Francoeur and Stephan A. Mayer

KEY POINTS

1. Hepatic encephalopathy associated with chronic cirrhotic liver disease and the syndrome of encephalopathy with brain edema caused by fulminant acute liver failure are two distinct entities.
2. Cirrhotic hepatic encephalopathy is frequent, with nonspecific signs and symptoms ranging from barely perceptible to coma, and is caused by elevated levels of ammonia.
3. Lactulose and rifaximin are the only evidence-based treatments for cirrhotic hepatic encephalopathy.
4. The most frequent cause of acute liver failure leading to encephalopathy is drug toxicity, led by acetaminophen poisoning.
5. The picture of fulminant hepatic encephalopathy is dominated by cerebral edema, and intracranial pressure monitoring is sometimes required.
6. High-volume plasma exchange is the only therapy shown to improve transplant-free survival in fulminant hepatic encephalopathy, whereas orthotopic liver transplantation is the only definitive treatment when liver function does not recover.

INTRODUCTION

Neurologic manifestations of liver disease have been recognized for centuries. The liver is indispensable in its functions of synthesis, metabolism, and detoxification, and its dysfunction can cause problems ranging from subtle neuropsychiatric finding to rapid death. Tremendous advances in our understanding of the pathophysiology and in available treatments now allow for better outcomes. In this chapter, we focus on two distinct clinical presentations of hepatic disease: hepatic encephalopathy (HE) associated with chronic cirrhotic liver disease and the syndrome of encephalopathy and brain edema caused by fulminant acute liver failure (ALF).

HE associated with cirrhosis is a neuropsychiatric syndrome ranging from barely detectable changes to profound coma. It often presents in an episodic and recurrent fashion, can be precipitated by extrinsic factors, and is graded according to the West Haven scale (Table 124.1). As a general rule, the severity of the encephalopathy is proportional to the underlying severity of liver disease. ALF, on the other hand, is a less common but highly lethal entity. Core components include the acute onset of hepatocellular dysfunction, which triggers a different set of complications dominated by cerebral edema with intracranial hypertension, unregulated systemic inflammation, and multisystem organ failure.

TABLE 124.1 West Haven Hepatic Encephalopathy Grading Scale

Grade	Description
Minimal	• Psychometric or neuropsychological alterations of tests exploring psychomotor speed/executive functions or neurophysiologic alterations without clinical evidence of mental change
1	• Trivial lack of awareness • Shortened attention span • Impaired performance of addition • Euphoria or anxiety
2	• Lethargy or apathy • Minimal disorientation for time or place • Subtle personality change • Inappropriate behavior • Impaired performance of subtraction
3	• Somnolence to semistupor, responsive to verbal stimuli • Confusion • Gross disorientation, bizarre behavior
4	• Coma (unresponsive to verbal or noxious stimuli)

CIRRHOSIS AND HEPATIC ENCEPHALOPATHY

Epidemiology

In 2017, chronic liver disease was the 12th leading cause of death in the United States accounting for more than 38,000 deaths and over 100,000 hospitalizations. Those figures are probably an underestimate and the prevalence is steadily increasing. Hepatitis C patients, typically born between 1945 and 1965, are contributing to a large number of new cases, and the obesity epidemic accounts for an increase in nonalcoholic fatty liver disease.

The less severe form of neurologic impairment, minimal hepatic encephalopathy (MHE), afflicts between 60% and 80% of cirrhotic patients. Often qualified as "subclinical," MHE is nonetheless a tremendous social burden with the majority of patients being unfit to drive and half of them unable to keep a permanent job.

Overt HE occurs in 30% to 45% of cirrhotic patients. It is responsible for the bulk of hospitalization days attributed to cirrhosis and its complications. Depending on the time course, it is subdivided into episodic, recurrent (6 mo or less between episodes), or persistent (behavioral alterations that are always present).

Pathobiology

Causes of chronic liver damage are numerous (Table 124.2), and the final common pathway is cirrhosis defined by parenchymal fibrosis with hepatic architecture distortion and the formation of regenerative nodules. The associated complications are related to a loss of synthetic and metabolic functions, relative

TABLE 124.2 Causes of Cirrhosis

• Alcoholic liver disease
• α_1-Antitrypsin deficiency
• Autoimmune hepatitis
• Celiac disease
• Chronic viral hepatitis (hepatitis B and C)
• Hemochromatosis
• Infections (eg, brucellosis, syphilis, echinococcosis, schistosomiasis)
• Medication (eg, isoniazid, methotrexate)
• Nonalcoholic fatty liver disease
• Polycystic liver disease
• Primary and secondary biliary cirrhosis
• Primary sclerosing cholangitis
• Veno-occlusive disease (including Budd-Chiari syndrome)
• Wilson disease

immunosuppression, and portal hypertension often associated with portosystemic shunting.

Most of the existing evidence points to ammonia (NH_3) as the main culprit behind HE. It is generated from glutamine by the enterocytes and from catabolism of nitrogenous products (proteins and urea) by colonic bacteria. Detoxification normally takes place in the liver through the conversion of NH_3 to urea and glutamine, basically reversing what took place in the digestive tract. Cirrhosis and portosystemic shunting bypasses this process, allowing systemic levels of NH_3 to rise, which easily crosses the blood-brain barrier (BBB) by diffusion and ion channels. Once in the brain, NH_3 is taken up by astrocytes, where it triggers oxidative stress, increases intracellular calcium, induces mitochondrial dysfunction, and activates nuclear factor κB and an inflammatory response. Some data suggest that severity of HE correlates more with inflammatory indices than with NH_3 levels. Many other molecules have been implicated in the pathobiology of HE, such as neurosteroids. Synthetized by astrocytes and microglia, they appear to upmodulate the γ-aminobutyric acid type A receptors leading to the clinically obvious increased γ-aminobutyric acid-ergic tone (depression of central nervous system function) seen in HE.

Clinical Features

Cirrhosis

Compensated cirrhotic patients may be asymptomatic, but eventually, most will develop one of the myriad of possible clinical manifestations as the disease progresses (**Fig. 124.1**). They may report nonspecific symptoms like anorexia, weight loss, fatigue, and weakness. They often have a low blood pressure, and they may present with jaundice, pruritus, severe muscle cramps, or abdominal distention from ascites.

Classically, cirrhotic patients are classified according to the Child-Turcotte-Pugh score. Designed 30 years ago to predict outcome after surgery for portal hypertension (**Table 124.3**) (http://www.mdcalc.com/child-pugh-score-for-cirrhosis-mortality), it is now used to grade clinical severity and follow the evolution of most patients. Alternatively, the Model for End-Stage Liver Disease (MELD) score evaluates serum creatinine, bilirubin, and international normalized ratio (INR) to predict 3-month mortality following transjugular intrahepatic portosystemic shunt (TIPS) procedures (http://www.mdcalc.com/meld-score-model-for-end-stage-liver-disease-12-and-older/). The MELD score is also currently used to prioritize candidates for liver transplantation scaled from 6 (less ill) to 40 (gravely ill).

Minimal Hepatic Encephalopathy

Patients with MHE, by definition, have no clinically detectable abnormalities at the bedside but manifest clear deficits on psychometric testing. They usually reveal impairment of vigilance, alertness and orientation, executive functions, working memory, learning processes, visuospatial coordination, and reaction time. When looked at closely, daily functioning is usually impaired in all spheres. They have a higher risk of car accidents with less than 20% of them fit to drive. Verbal ability is characteristically unimpaired.

Overt Hepatic Encephalopathy

Overt hepatic encephalopathy (OHE) can manifest itself from subtle clinical signs to profound coma. As it sets in, one of the earliest manifestations is classically a change in the sleep pattern (usually hypersomnia). Once it progresses, behavioral changes such as apathy, anxiety, and irritability appear. Attention span diminishes and short-term memory becomes impaired.

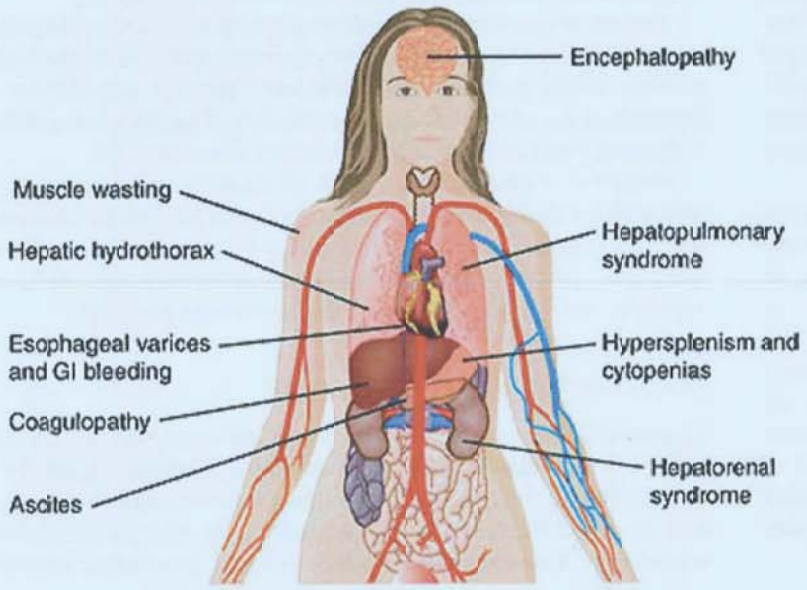

FIGURE 124.1 Common complications of cirrhosis. Abbreviation: GI, gastrointestinal.

TABLE 124.3 Child-Turcotte-Pugh Score[a]

	1	2	3
Bilirubin	<2 mg/L	2-3 mg/L	>3 mg/L
Albumin	>3.5 g/L	2.8-3.5 g/L	<2.8 g/L
INR	<1.7	1.7-2.2	>2.2
Ascites	No ascites	Ascites, medically controlled	Ascites, poorly controlled
Encephalopathy	No encephalopathy	Encephalopathy, medically controlled	Encephalopathy, poorly controlled

Abbreviation: INR, international normalized ratio.
[a]Interpretation: 5 to 6 points, child class A; 7 to 9 points, child class B; 10 to 15 points, child class C.

Patients sometimes suffer from visual perception disturbances, both as a result of cortical and retinal dysfunction, with visual agnosia, macropsia, spatial disorientation, and problems with visuospatial construction. Visual hallucinations can occur. Neuromuscular impairments include ataxia, dysarthria, hyperreflexia, and extensor plantar responses. Asterixis, although not pathognomonic, was first described in HE patients. This "flapping tremor" is a negative myoclonus characterized by brief interruptions of sustained voluntary muscle contractions causing loss of postural tone. It is usually bilateral, nonrhythmic, and with a frequency of 3 to 5 Hz. It can be elicited by hyperextension of the wrists but is also seen in the feet, tongue, or eyelids. Parkinsonian features are at times prominent with tremor, rigidity, bradykinesia, hypomimia, and slowness and monotony of speech. Focal deficits have been described but are rare. As patients deteriorate, the most striking feature is the mental status change from lethargy to stupor and coma. Unlike fulminant acute liver failure, however, brain swelling is not a feature of OHE from cirrhosis: The coma is metabolic in nature. At the point of coma, most patients are hyperventilating and have loss of deep tendon reflexes. Seizures are unusual. Mental status and motor changes do not always progress in a synchronized fashion.

Hepatic Myelopathy

Another well-described, long-term neurologic complication of cirrhosis is hepatic myelopathy. It is characterized by severe spastic paraparesis with minimal sensory involvement. Spasticity and weakness usually affect the lower limbs more severely and are progressive. It is caused by symmetric demyelination of the lateral pyramidal tracts. It does not respond to NH_3-lowering therapy, although some improvement might follow liver transplantation.

Persistent Hepatic Encephalopathy

Often preceded by multiple episodes of OHE, a chronic and largely irreversible syndrome characterized by dementia, dysarthria, gait ataxia, intention tremor, and choreoathetosis might appear. This persistent form of HE, previously referred to as *acquired hepatolenticular degeneration*, afflicts 4% of cirrhotic patients. It does not respond to standard therapies.

Diagnosis

Minimal Hepatic Encephalopathy

MHE diagnosis cannot be made at the bedside with usual examination techniques and requires neuropsychometric or neurophysiologic testing. Numerous tests have been designed but their use is limited as many are cumbersome, time consuming, and correlation is poor among them. Another issue is that they are nonspecific. For example, they cannot distinguish between neurologic abnormalities attributable to alcohol abuse and those caused by hepatic dysfunction. The reader is referred to the "Suggested Readings" section for a comprehensive description and critical analysis of available tests.

Overt Hepatic Encephalopathy

The diagnosis of OHE is made with the compatible clinical picture in the context of cirrhosis after exclusion of plausible alternative explanations. It is graded according to the West Haven criteria (see Table 124.1). The majority of OHE episodes are not spontaneous and rather precipitated by an event, and the absence of such cause in the setting of altered mental status should alert the clinician for other organ failures. Although blood NH_3 level per se does not allow staging or prognostication in chronic liver disease, a normal level puts the diagnosis of OHE in question. Brain imaging does not help in diagnosis but is used to rule out other pathologies, such as intracerebral hemorrhage, which is 5 times more prevalent in this population.

Treatment

Minimal Hepatic Encephalopathy

MHE rarely presents in clinical practice as a medical complaint and has not been widely evaluated in clinical trials. Several lines of evidence suggest a benefit on cognitive function and quality of life when MHE patients are treated with lactulose and rifaximin, as discussed in the following text.

Overt Hepatic Encephalopathy

OHE management focuses on identification and correction of the precipitating factor, exclusion of alternative causes for mental status changes, and measures to lower blood levels of NH_3 (Table 124.4), all the while supporting the patient appropriately.

Identification of the precipitating factor is paramount because its specific treatment is central to recovery. Precipitants are not always obvious and a careful history, physical examination, and appropriate laboratory tests are required. The most common causes are infection (especially spontaneous bacterial peritonitis and urinary tract infection), alcohol abuse, gastrointestinal bleeding, and iatrogenic insults such as dehydration from diuretics or lactulose, or oversedation from benzodiazepines or opiates.

The mainstay of NH_3-lowering therapy is administration of the nonabsorbable disaccharide lactulose, which has been used to treat HE since 1966. The putative mechanisms of action are multiple. The cathartic effect due to the osmolar load is thought to reduce time allowed for NH_3 absorption as well as to increase fecal nitrogen excretion. Lactulose catabolism generates

TABLE 124.4 Ammonia-Reducing Pharmacologic Therapies

Agent	Dose
Lactulose	15-45 mL orally 2-4 times a day
Sodium benzoate	5 mg orally twice a day
Rifaximin	400 mg orally 3 times a day

lactic acid, thereby acidifying colonic contents, which causes protonation of NH_3 into ammonium (NH_4^+), which is poorly absorbed, remains trapped in the lumen, and is excreted. Finally, lactulose inhibits glutaminase activity and interferes with the intestinal uptake of glutamine and its subsequent metabolism to NH_3. Lactulose is titrated to achieve two to three bowel movements per day, with a starting dose of 30 mL (20 g of lactulose) twice daily. It has been evaluated against placebo in numerous randomized controlled trials (RCTs). A recent meta-analysis concluded that lactulose is beneficial in treating both MHE and OHE. It reduces overall mortality when used for HE prevention as well as for OHE and is associated with a reduction in the risk of developing serious liver-related complications including liver failure, variceal hemorrhage, severe infections, spontaneous bacterial peritonitis, and hepatorenal syndrome. It is associated with only nonserious and mostly transient adverse events, is readily available, and inexpensive. As such, it represents the first-choice treatment for the secondary prophylaxis of OHE LEVEL 1.[1]

The other evidence-based approach is through modulation of fecal flora with rifaximin 550 mg orally 3 times a day for 14 days. Rifaximin is a minimally absorbed antibiotic with broad-spectrum activity against gram-positive, gram-negative, and anaerobic bacteria. Its site of action is the small bowel, where it lowers the bacterial load up to 1,000-fold. Trials and meta-analyses demonstrated a beneficial effect on recovery from HE, on secondary prevention of HE, and on mortality. It is usually given in addition to lactulose. LEVEL 1.[1]

Many other interventions have been studied but the evidence remains less robust, and their use is limited to use as a supplement to lactulose and rifaximin in refractory cases. They include NH_3-lowering agents such as sodium benzoate, which lowers NH_3 levels by combining with glycine to form hippurate, thereby allowing renal excretion, or the purgative laxative polyethylene glycol as well as L-ornithine L-aspartate and oral branched-chain amino acids. In the face of medically resistant HE, patients should be investigated for large portosystemic shunts because these can be treated by embolization therapy. In the presence of a TIPS, reducing caliber of the TIPS can lead to clinical improvement and should be considered in patients with severe post-TIPS HE. Liver transplantation is the only definitive treatment option.

General care measures include appropriate hydration and nutritional support with protein intake of 1.2 to 1.5 g/kg/d and correction of electrolyte abnormalities. Treatment of chronic hyponatremia must be performed carefully because cirrhotic patients are at higher risk for osmotic demyelination syndrome. Correction of hyponatremia should be performed no more quickly than 12 mmol/L per 24 hours. Correction of hypokalemia is also an essential component of therapy because it increases renal NH_3 production. After a first episode of OHE, secondary prophylaxis is recommended with lactulose and rifaximin to prevent recurrence. This therapy should be continued indefinitely.

Outcome

Even without obvious clinical manifestations, MHE patients do not fare well. After diagnosis, 50% of patients will be hospitalized within a year and 75% will die within the next 4 years. The future is even grimmer after a first episode of OHE: 40% will have a recurrent episode by the end of the year. The cumulative survival at 1 year is 42%, and, at 3 years, it is a mere 23%.

ACUTE LIVER FAILURE AND CEREBRAL EDEMA

Epidemiology

ALF is rare in developed countries, with an incidence ranging from 1 to 8 cases per million per year. There are approximately 2,000 cases annually in the United States. It is seen most commonly in previously healthy adults in their 30s, and the most prominent cause is drug-induced liver injury dominated by acetaminophen-induced hepatotoxicity (Fig. 124.2). It is of interest to the neurologist to know that other causes of ALF include carbamazepine, phenytoin, and valproic acid.

Pathobiology

Multiple Organ Failure

ALF results in a shutdown of its synthetic, metabolic, detoxification, and immunologic functions. Loss of coagulation factor synthesis leads to coagulopathy, and necrotic hepatocytes trigger an intense systemic inflammatory syndrome. This inflammatory state produces vasoparesis and is often complicated by acute renal failure and acute lung injury. Loss of neoglucogenesis may lead to hypoglycemia and reduced lactate clearance. Immunoparesis puts patients at high risk for sepsis, and bone marrow suppression manifests as cytopenia.

Encephalopathy and Cerebral Edema

The etiology of cerebral edema in ALF is not fully understood and is probably multifactorial, combining cytotoxic brain edema due to the astrocytic accumulation of glutamine and vasogenic edema characterized by increases in cerebral blood volume and cerebral blood flow [CBF], combined with disruption of the BBB.

Acute NH_3 accumulation produces different neurologic consequences than the chronic hyperammonemia seen in cirrhotic patients. The rapid transformation of NH_3 to glutamine inside the astrocytes does not allow for compensatory mechanisms such as the release of taurine or myoinositol. The osmotic effect causes astrocytes to take in water and swell, creating cytotoxic brain edema. This is why arterial NH_3 levels in ALF are highly correlated with prognosis and the extent of cerebral edema.

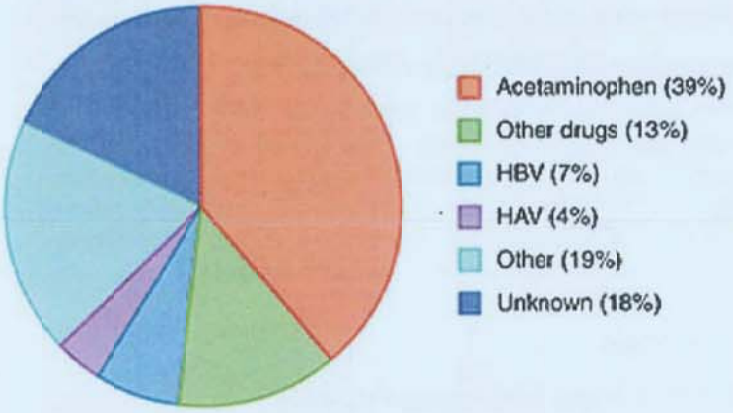

FIGURE 124.2 Common causes of acute liver failure in the United States. Abbreviations: HAV, hepatitis A virus; HBV, hepatitis B virus.

Patients with NH_3 levels less than 75 μmol/L usually do not develop encephalopathy at all, and those with NH_3 greater than 200 μmol/L have a 55% risk of developing cerebral edema with concomitant intracranial hypertension. The rapid buildup of glutamine is partially transformed to glutamate, which may explain the aggressive and agitated delirium seen in some patients and their propensity for seizures.

Numerous other causal pathways have been invoked to explain why vasogenic cerebral edema occurs with ALF. The most consistent finding implicates a variety of inflammatory mediators, including interleukin 1β, tumor necrosis factor α, interleukin 6, which are released as part of the systemic inflammatory response syndrome, triggered by acute hepatic necrosis. Excessive levels of nitric oxide, a vasodilator, have also been invoked. The result is loss of normal autoregulation, leading to vasodilation and hyperemia, and BBB disruption, leading to fluid extravasation into the brain. The vasogenic component of brain edema tends to occur prior to the onset of herniation due to global cerebral edema.

Clinical Features

The clinical picture of ALF is dominated by acute hepatic dysfunction, unregulated systemic inflammation with multiorgan dysfunction, and cerebral edema with intracranial hypertension, which is the most feared complication (Fig. 124.3).

The characteristic sleepiness and asterixis of cirrhotic patients are not reliable indicators of early encephalopathy in ALF. Instead, forewarning signs of impending cerebral edema are usually the onset of aggressive behavior and agitated delirium associated with hyperreflexia and ankle clonus. Mental status changes can quickly follow with the patient lapsing into coma in just a few hours. Hypoglycemia must be ruled out as a cause, especially with acetaminophen toxicity where it is highly prevalent (up to 55%). Multifocal myoclonus and excessive startle response are well described and later stages may reveal spasticity and extensor posturing as well extensor plantar responses. Pupillary responses are impaired only when intracranial pressure (ICP) is frankly elevated and brain herniation has occurred. Oculomotor dysfunction is uncommon, but dysconjugate gaze and periodic alternating gaze deviation are reported. The finding of systolic blood elevation and bradycardia (otherwise known as the *Cushing syndrome*) is late and unreliable. Seizures, albeit generally nonconvulsive, are also a frequent occurrence in ALF. Up to 30% of patients monitored with continuous electroencephalogram have evidence of electrographic seizures.

Diagnosis

ALF is defined as the onset of coagulopathy (INR >1.5) and encephalopathy (any degree of altered mentation) secondary to acute liver injury in a patient without preexisting liver disease. The time from the start of illness to encephalopathy is variable from hyperacute (less than a week) to subacute (up to 26 wk). Patients with Wilson disease, vertically transmitted hepatitis B virus, or autoimmune hepatitis may be included if the disease has only been recognized for less than 6 months.

When ALF is suspected, the history must be very thorough, with a focus on drug and medication ingestion, including over-the-counter medications or supplements, as well a possible viral exposure, including travel history. Although the cause of ALF remains unknown in close to 20% of cases, it is the single most important prognostic factor and might call for specific treatment, so it must be sought aggressively. In addition to laboratory testing and imaging, serial biochemical testing should be performed, including NH_3, glucose, and lactate levels; liver and renal function; electrolytes; and coagulation panels.

Treatment

General Management

Patients with a diagnosis of ALF must be hospitalized, and those developing encephalopathy should be transferred to a critical care unit because they can deteriorate in a matter of hours. Frequent neurologic assessments are mandatory in ALF patients. Special attention should be dedicated to development of delirium, mental status changes, abnormal motor tone and deep tendon reflexes, and myoclonus. Those progressing to West Haven stage III or IV (see Table 124.1), which usually corresponds to a

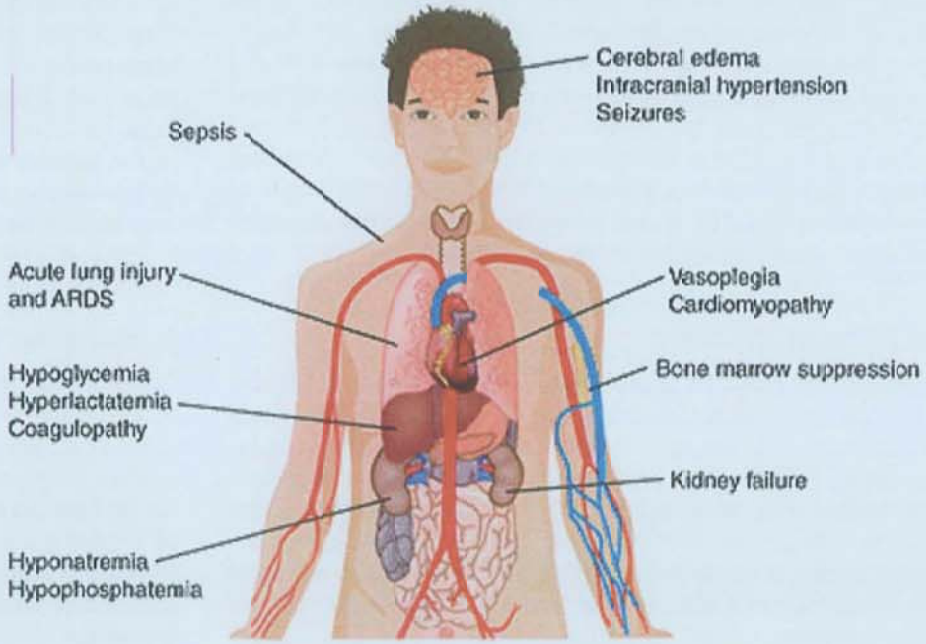

FIGURE 124.3 Multiorgan dysfunctions associated with acute liver failure. Abbreviation: ARDS, acute respiratory distress syndrome.

TABLE 124.5 Acute Liver Failure Etiologies and Specific Treatments

Etiology	Specific Treatment
Acetaminophen poisoning	IV NAC[a]
Drug-induced liver injury (non-acetaminophen)	IV NAC[a]
Mushroom poisoning (*Amanita phalloides*)	Penicillin G (1 million U/kg/d) and IV NAC[a]
HBV	Lamivudine
Herpesvirus or varicella-zoster virus	Acyclovir (10 mg/kg IV every 8 h)
Autoimmune	Prednisone (40-60 mg/d)
ALF of pregnancy or HELLP	Delivery

Abbreviations: ALF, acute liver failure; HBV, hepatitis B virus; HELLP, hemolysis, elevated liver enzymes, low platelets; IV, intravenous; NAC, *N*-acetylcysteine.

[a]Loading dose is 150 mg/kg in 5% dextrose over 15 minutes; maintenance dose is 50 mg/kg given over 4 hours followed by 100 mg/kg administered over 16 hours (or 6 mg/kg/h).

Glasgow Coma Scale score of 8 and less (see **Table 19.2**), should be intubated and strong consideration should be given to invasive ICP monitoring. Communication with a transplant center is essential and transfer criteria have to be determined very early in the evaluation process. Depending on the etiology of ALF, specific treatment should be instituted promptly, especially in the case of acetaminophen poisoning (**Table 124.5**). Hypoglycemia and hyponatremia are common, can exacerbate the severity of the neurologic insult, and must be carefully prevented.

High-Volume Plasma Exchange

Therapeutic plasma exchange (TPE) is a procedure in which a large volume of plasma is removed from a patient, through a centrifugation process, which is then replaced with 5% albumin and physiologic saline or plasma. The bulk removal and replacement of plasma removes pathologic substances and cytokines, resulting in attenuation of innate immune activation and an amelioration of multi-organ dysfunction. A recent randomized clinical trial demonstrated improvement in clinical and paraclinical variables, most importantly an increase in liver transplant-free survival in patients with ALF treated with TPE. All etiologies were included, associated with at least grade 2 HE having developed in the last 24 hours. Patient plasma was removed at a rate of 1 to 2 L/h with replacement with fresh frozen plasma in equivalent volume for a total of 15% of ideal body weight of volume exchange. TPE is now recommended in patients meeting the abovementioned inclusion criteria LEVEL 2.[2,3]

Intracranial Pressure and Transcranial Doppler Monitoring

Patients with grade III encephalopathy (see **Table 124.1**) have a risk of experiencing elevated ICP of 30%, whereas in grade IV patients, it climbs to 70%. Noncontrast head computed tomography (CT) is often performed to rule out other concomitant pathologies, such as bleeding, but the usual finding that implies a high risk of intracranial hypertension is global cerebral edema with convexity sulcal effacement, effacement of the basal cisterns and ventricles, and loss of gray-white matter differentiation.

Transcranial Doppler (TCD) is a noninvasive technique allowing indirect evaluation of both CBF and ICP (see Chapter 24). In ALF, because global cerebral edema is primarily vasogenic and caused by hyperemia and vasodilation, the rise in ICP is usually preceded by an increase in CBF and hence in TCD flow velocities. Early on, TCD flow velocities are elevated above normal values (60 cm/s in a healthy young person), and the pulsatility index (peak systolic minus diastolic flow velocity divided by mean flow velocity) is reduced below the normal value of 1.0 due to downstream vasodilation. Brain injury is highly reversible at this stage, and for this reason, the triad of coma, global cerebral edema on CT, and elevated flow velocities on TCD is the ideal time for an ICP monitor to be inserted.

After ICP has been massively elevated for a sustained period of time, the brain remains engorged but hypoperfused, CBF falls, metabolic changes in the brain cause cellular swelling, and cytotoxic brain edema ensues. At this late stage, TCD evolves toward a picture consistent with brain death: Mean flow velocities drop, the pulsatility index increases, and eventually, readings evolve to isolated systolic flow velocity spikes with diastolic flow arrest diagnostic of brain death (see Chapter 20).

As for other neurocritical care patients, invasive ICP monitoring (see Chapter 34) is the gold standard for monitoring when intracranial hypertension is the main threat to life. Although its use in ALF is still contentious, it is now recommended in patients with high-grade encephalopathy awaiting transplantation in centers with appropriate expertise. Associated with encephalopathy, the following factors are considered indications for placement of an ICP monitor.

- Global cerebral edema on CT
- Arterial NH_3 greater than 150 mmol/L
- Age younger than 50 years
- TCD indices of high CBF
- Concurrent renal or cardiovascular organ failure

The main concern of placing an invasive ICP monitor is bleeding because most patients with ALF are coagulopathic. Recent series report clinically significant bleeding in ALF patients after standard reversal procedures at the same order of magnitude as for other intracranial pathologies. Reversal of coagulopathy when placing an intracranial monitoring device should be taken seriously. Off-label usage of recombinant factor VIIa (40 μg/kg given 30 min before the procedure) is used at many liver transplant centers throughout the world to correct the coagulopathy prior to ICP monitor placement. Recombinant factor VIIa has been associated with a 5% risk of thrombotic complications, including brain and myocardial infarction.

We also recommend keeping platelets over 50,000 and to correct hypofibrinogenemia (fibrinogen <100 mg/dL) with cryoprecipitate prior to insertion. Elevated prothrombin time/INR can also be corrected with fresh frozen plasma (15 mL/kg).

Intracranial Pressure Management

Standard ICP management principles (see Chapter 111) apply to ALF patients but with some particularities. Hypertonic saline (3%) given prophylactically (at a rate of 0.5 mL/kg/h) with a sodium target of 145 to 155 mEq/L has been shown to reduce the incidence and severity of ICP crisis. Prophylactic induction of hypernatremia is thus recommended LEVEL 2[3] in high-risk patients (encephalopathy grade III or IV, NH_3 >150 μmol/L, acute renal failure or requiring vasopressors). In the event of a herniation event, mannitol boluses (20% solution at a dose of

0.5-1 g/kg) are successful in resolving ICP crisis in ALF patients and improve survival compared to placebo. Corticosteroids are not of value in cerebral edema caused by ALF and are probably harmful and should not be used LEVEL 1.[3]

The role of therapeutic hypothermia is debated. Case series show great improvement in ICP control and impressive survival rates, but an RCT and retrospective cohort studies have failed to show better outcomes with cooling, albeit showing no higher rates of bleeding or infection. Induction of hypothermia to 33°C may be considered as a rescue intervention in patients with refractory ICP crisis, refractory to sedation and paralysis, bolus osmotherapy, and hyperventilation as a bridge to liver transplantation. Indomethacin (25 mg intravenously) has been shown in a few ALF patients with ICP refractory to mannitol to dramatically reduce ICP without documented adverse effects.

Seizures

With a reported frequency of nonconvulsive seizures in up to 30% of patients, grade III or IV encephalopathy should be monitored with continuous electroencephalogram for a minimum of 48 hours. Prophylactic phenytoin failed to improve outcomes in one RCT and is thus not recommended.

Ammonia Clearance

Therapies used for HE, such as lactulose, have not been proven useful in acutely reducing blood level of NH_3 in ALF patients. Some clinical data show that hemofiltration with continuous renal replacement therapy (CRRT) might be the best way to control arterial NH_3 levels, but more convincing results have been seen with high-volume plasma exchange LEVEL 1.[2] Clearance is closely correlated with ultrafiltration rate up to 90 mL/kg/h, and glutamine is also likely to be cleared in the process. CRRT also allows for tighter control of serum sodium levels, intravascular volume, pH, and temperature.

Artificial Liver Support Systems

Numerous extracorporeal liver support systems have been developed; currently, the only U.S. Food and Drug Administration–approved device is the Molecular Adsorbent Recirculating System. This nonbiologic artificial liver support system is based on a dialysis technique using an albumin-coated membrane. It allows detoxification by removal of not only water-soluble toxins but also, in contrast to CRRT, albumin-bound substances. Among proven benefits in ALF patients, there is improvement in hemodynamic stability, reduction in ICP, and improvement of HE. The only large RCT did not show a survival benefit, although it was highly underpowered. At present, Molecular Adsorbent Recirculating System should only be considered as a "bridge to transplant" or in the context of a randomized trial.

Transplantation

Orthotopic liver transplantation is the only definitive therapy for those whose liver function does not recover. Given the usually rapid evolution toward cerebral edema, candidacy must be assessed promptly. Numerous prognostic scores have been developed trying to predict who has a poor prognosis with medical management alone and hence who will benefit most from emergent liver transplantation. None of them is universally accepted, but the most widely used are the King's College Criteria (Table 124.6). Adult patients with sudden acute- and severe-onset ALF according to the King's College Criteria have a life expectancy less than 7 days without transplant and are granted 1A status, making them the highest priority, but up to 25% will die while on the waiting list. As of 2019, more than 13,000 patients were on the liver transplant waiting list in the United States with about 10% of livers usually allocated to ALF patients.

TABLE 124.6 King's College Criteria for Acute Liver Failure

Acetaminophen-Induced ALF	
Strongly consider OLT listing.	• Arterial lactate >3.5 mmol/L after early fluid resuscitation
List for OLT.	• pH <7.3 *or* • Arterial lactate >3.0 mmol/L after adequate fluid resuscitation
List for OLT if all three occur within a 24-h period.	• Presence of grade 3 or 4 hepatic encephalopathy • INR >6.5 • Creatinine >3.4 mg/dL
Non–Acetaminophen-Induced ALF	
List for OLT.	• INR >6.5 *and* • Encephalopathy present (irrespective of grade)
List for OLT if any three of the following (and any grade of encephalopathy present).	• Age younger than 10 y or older than 40 y • Jaundice for >7 d before development of encephalopathy • INR ≥3.5 • Serum bilirubin ≥17 mg/dL • Unfavorable etiology, such as Wilson disease, idiosyncratic drug reaction, seronegative hepatitis

Abbreviations: ALF, acute liver failure; INR, international normalized ratio; OLT, orthotopic liver transplantation.

Outcome

With optimization of medical management and improved organ allocation system, the overall mortality of ALF is now between 30% and 40%. The etiology of ALF is one of the most important predictors of outcome. For example, transplant-free survival is largely over 50% for acetaminophen poisoning, hepatitis A, or pregnancy-related disease. On the contrary, survival without transplantation is less than 25% in Wilson disease, Budd-Chiari syndrome, or autoimmune hepatitis. With emergent transplantation, although the survival at 1 year is less than for elective transplantation (mainly due to infection in the first 3 months), ALF patients have a better long-term survival.

LEVEL 1 EVIDENCE

1. Sharma BC, Sharma P, Lunia MK, Srivastava S, Goyal R, Sarin SK. A randomized, double-blind, controlled trial comparing rifaximin plus lactulose with lactulose alone in treatment of overt hepatic encephalopathy. *Am J Gastroenterol.* 2013;108:1458-1463.
2. Larsen FS, Schmidt LE, Bernsmeier C, et al. High-volume plasma exchange in patients with acute liver failure: an open randomised controlled trial. *J Hepatol.* 2016;64(1):69-78.
3. Lee WM, Larson AM, Stravitz RT. *AASLD Position Paper: The Management of Acute Liver Failure: Update 2011.* Baltimore, MD: American Association for the Study of Liver Diseases; 2011.

SUGGESTED READINGS

Cirrhosis and Hepatic Encephalopathy

Gluud L, Vilstrup H, Morgan M. Nonabsorbable disaccharides for hepatic encephalopathy: a systematic review and meta-analysis. *Hepatology*. 2016; 64(3):908-922.

Hadjihambi A, Arias N, Sheikh M, Jalan R. Hepatic encephalopathy: a critical current review. *Hepatol Int*. 2018;12(suppl 1):135-147.

Prakash RK, Kanna S, Mullen KD. Evolving concepts: the negative effect of minimal hepatic encephalopathy and role for prophylaxis in patients with cirrhosis. *Clin Ther*. 2013;35(9):1458-1473.

Sharma BC, Sharma P, Lunia MK, Srivastava S, Goyal R, Sarin SK. A randomized, double-blind, controlled trial comparing rifaximin plus lactulose with lactulose alone in treatment of overt hepatic encephalopathy. *Am J Gastroenterol*. 2013;108:1458-1463.

Vilstrup H, Amodio P, Bajaj J, et al. Hepatic encephalopathy in chronic liver disease: 2014 practice guideline by the American Association for the Study of Liver Diseases and the European Association for the Study of the Liver. *Hepatology*. 2014;60(2):715-735.

Acute Liver Failure and Cerebral Edema

DellaVolpe JD, Garavaglia JM, Huang DT. Management of complications of end-stage liver disease in the intensive care unit. *J Intensive Care Med*. 2016;31:94-103.

European Association for the Study of Liver. EASL Clinical Practical Guidelines on the management of acute (fulminant) liver failure. *J Hepatol*. 2017;66(5): 1047-1081.

Karvellas CJ, Stravitz RT, Battenhouse H, Lee WM, Schilsky ML; for US Acute Liver Failure Study Group. Therapeutic hypothermia in acute liver failure: a multicenter retrospective cohort analysis. *Liver Transpl*. 2015;21:4-12.

Krisl JC, Meadows HE, Greenberg CS, Mazur JE. Clinical usefulness of recombinant activated factor VII in patients with liver failure undergoing invasive procedures. *Ann Pharmacother*. 2011;45:1433-1438.

MacDonald AJ, Karvellas C. Emerging role of extracorporeal support in acute and acute-on-chronic liver failure: recent developments. *Semin Respir Crit Care Med*. 2018;39(5):625-634.

Mohsenin V. Assessment and management of cerebral edema and intracranial hypertension in acute liver failure. *J Crit Care*. 2013;28:783-791.

Murphy N, Auzinger G, Bernel W, Wendon J. The effect of hypertonic sodium chloride on intracranial pressure in patients with acute liver failure. *Hepatology*. 2004;39:464-470.

Rabadán AT, Spaho N, Hernández D, Gadano A, de Santibañes E. Intraparenchymal intracranial pressure monitoring in patients with acute liver failure. *Arq Neuropsiquiatr*. 2008;66(2B):374-377.

Shawcross DL, Wendon JA. The neurological manifestations of acute liver failure. *Neurochem Int*. 2012;60:662-671.

Slack AJ, Auzinger G, Willars C, et al. Ammonia clearance with haemofiltration in adults with liver disease. *Liver Int*. 2014;34:42-48.

125 Renal Disease, Electrolyte Disorders, and the Nervous System

J. Kirk Roberts and Stephan A. Mayer

KEY POINTS

1. Neurologic disease in patients with renal failure may be related directly to the renal failure or may be related to an underlying condition that damages both the kidneys and the nervous system.
2. Many neurologic complications of renal failure have become less common due to earlier and more aggressive dialysis and renal transplantation. However, this has led to an increase in neurologic complications of immune suppression.
3. Sodium homeostasis is under the control of the brain and the kidneys. Hyponatremia is a common condition encountered in the neurologic intensive care unit and is most commonly related to volume depletion, the syndrome of inappropriate antidiuretic hormone secretion, and cerebral salt wasting.

INTRODUCTION

Renal disease is most commonly associated with neurologic disease when both are related to an underlying condition (eg, diabetes mellitus, hypertension) that damages both systems. However, renal disease and resultant azotemia (blood urea nitrogen elevation or uremia) can injure both the central nervous system (CNS) and the peripheral nervous system. With the increase in aggressive kidney dialysis and transplantation, the incidence of many neurologic conditions associated with chronic renal failure has declined, but a new constellation of neurologic complications associated with dialysis and transplantation has become more important.

UREMIC ENCEPHALOPATHY

The differential diagnosis of encephalopathy in a patient with renal failure is wide and includes metabolic, infectious, structural, and other causes. Fluid and electrolyte disturbances are common. Drugs that are excreted in the urine may accumulate and dosing must be adjusted.

Pathobiology

Uremia itself can cause encephalopathy. The symptoms of *uremic encephalopathy* are usually more severe in patients with more severe azotemia; they are often evident earlier and more severely in patients with acute as opposed to chronic renal failure. The specific factors that cause encephalopathy are still not identified. The earliest indicator is sensorial clouding, which progresses to delirium, obtundation, and even coma. In addition to cognitive changes, patients exhibit weakness uncoordination and are unsteady. Focal symptoms or signs may wrongly suggest a focal process. Asterixis is commonly seen, with jerking movements arising from lapses of posture holding, as of the outstretched hands. Multifocal myoclonus, involuntary twitches occurring randomly throughout the body, may become apparent, usually after stupor or coma has supervened. Tetany may be overt, with spontaneous carpopedal spasm, painful muscle contractions in hands and feet, or latent as manifest by a Trousseau sign (sustained muscle contraction and cupping of the hand, induced by arterial occlusion). Seizures are a late manifestation of uremic encephalopathy. Fluctuation of clinical symptoms and signs from day to day is characteristic.

Diagnosis

No laboratory value, including specific evaluations of renal function, correlates well with clinical symptoms and signs of uremia. Lumbar puncture may reveal elevated cerebrospinal fluid (CSF) protein, sometimes exceeding 100 mg/dL, and occasionally a mild pleocytosis but is primarily performed to exclude an infectious cause of encephalopathy. Computed tomography or magnetic resonance imaging (MRI) findings are usually nonspecific but may help to exclude ischemic stroke, intracerebral hemorrhage, subdural hematoma, or hydrocephalus. Electroencephalogram, like the clinical state, is usually more strikingly abnormal in acute renal failure than in chronic renal failure. The background activity is slow with theta and delta waves more prominent in the frontal regions. Triphasic waves may appear. Nonconvulsive status epilepticus is an important treatable cause of encephalopathy that can be identified only by electroencephalogram with dramatic improvement when appropriately managed.

Treatment

Uremic encephalopathy usually responds very well to dialysis, suggesting that one or more dialyzable substances are responsible. Sometimes, response is delayed for 1 to 2 days. A variety of metabolites acting toxically when accumulating have been postulated as the etiology of uremic encephalopathy, but no single substance has been identified as the sole or major cause. Hormonal changes, electrolyte abnormalities, altered calcium homeostasis, and imbalance of excitatory and inhibitory neurotransmission are all thought to play a role.

DIALYSIS DISEQUILIBRIUM SYNDROME

Dialysis disequilibrium syndrome describes a condition in which a variety of neurologic symptoms manifest most often, with rapid correction of uremia at the start of a dialysis program. It is

more common in those with more severe azotemia. Symptoms vary from mild headache, nausea, and muscle cramps to, rarely, delirium, obtundation, and convulsions. The syndrome is usually self-limited, subsiding in hours, but delirium may persist for several days. Although the pathogenesis is controversial, shift of water into brain is probably the cause of syndrome. The rapid reduction in blood osmoles cannot be paralleled as rapidly by a reduction in brain osmoles, resulting in an osmotic gradient between blood and brain, causing movement of water into brain and cerebral edema and encephalopathy. With improvements in dialysis, this syndrome is much less frequent now. Gradual initiation of dialysis may help prevent. Before diagnosing dialysis disequilibrium, other causes of cerebral symptoms should be excluded, including uremia, other metabolic disturbances, infection, posterior reversible encephalopathy syndrome, and others. Treatment of patients who develop dialysis disequilibrium syndrome can usually be managed by adjusting sodium in the dialysate to avoid osmotic shifts and in those with persistent or severe symptoms; mannitol or hypertonic saline can similarly be used.

DIALYSIS DEMENTIA

A subacute, progressive, usually fatal encephalopathy rarely occurs in patients who are chronically dialyzed. The first symptom is usually a stammering, hesitancy of speech and, at times, speech arrest. The speech disorder is intensified during and immediately after dialysis and at first may be seen only during these periods. As the disorder progresses, speech becomes more dysarthric and aphasic along with personality change, psychosis, myoclonus, seizures, and occasionally focal neurologic abnormalities. Brain imaging and CSF findings are usually unremarkable and, again, are most helpful in excluding other causes of encephalopathy. Increased dialysis time and renal transplantation do not seem to alter the course of the disease. Many dialysis patients are older and suffer from vascular diseases, and common causes of dementia such as Alzheimer disease and vascular dementia must be considered. However, historically, aluminum toxicity was a unique cause of dementia in those with renal disease and treated with hemodialysis. Evidence suggesting this link included the finding that aluminum content was consistently elevated in the cerebral gray matter of patients who died from this condition, and municipal water supplies heavily contaminated with aluminum were linked to the syndrome in epidemiologic studies. The frequency of the disease markedly diminished when aluminum was removed from the water used during dialysis and the use of aluminum-containing phosphate binders and antacids was reduced.

CEREBROVASCULAR DISEASE

Stroke is prevalent in patients with renal failure, mostly because of shared risk factors. However, renal failure may additionally promote atherogenesis through several mechanisms. Hypotension during dialysis may result in watershed infarction. Renal failure is associated with platelet dysfunction, and anticoagulants used during hemodialysis may contribute to intracerebral hemorrhage or subdural hematoma. Chronic subdural hematoma may present with an encephalopathic picture without focal motor or sensory symptoms and signs. Autosomal dominant polycystic kidney disease is associated with an increased risk of saccular aneurysm and subarachnoid hemorrhage (SAH).

RESTLESS LEGS SYNDROME

At least 20% of patients with chronic renal failure suffer from creeping, crawling, prickling, and pruritic sensations deep within the legs particularly when at rest and improving with movement (see Chapter 78). Periodic limb movements of sleep, an involuntary repetitive jerking of the legs while asleep, may coexist. Dialysis often does not lead to significant improvement, and treatment is similar to that in patients without renal failure.

PERIPHERAL NEUROPATHY

The most common neurologic consequence of chronic renal failure is a distal, symmetric, predominantly axonal, mixed sensorimotor neuropathy affecting the legs more than the arms. Cranial nerves, particularly vision and hearing, and the autonomic nervous system may be affected. The rate of progression, severity, prominence of motor or sensory symptoms and signs, and degree of pain varies. Decreased vibratory and temperature sense in the feet are the earliest signs, and sensory symptoms and signs usually predate motor. In general, the neuropathy evolves over several months but may be fulminant.

Pathobiology

Pathologically, uremic neuropathy is usually a primary axonal degeneration with secondary segmental demyelination; there is also a predominantly demyelinating type. Because uremic neuropathy improves with hemodialysis, it seems likely that the neuropathy results from the accumulation of dialyzable metabolites. The control of neuropathy in some patients depends on increased hours of dialysis each week. The use of erythropoietin has also been reported to improve uremic neuropathy.

Diagnosis

Other causes must always be considered given the coexistence of renal diseases and conditions that predispose to peripheral neuropathy (eg, diabetes mellitus, amyloidosis). Mononeuropathies, such as carpal tunnel syndrome caused by damage to the median nerve at the wrist or ulnar neuropathy, may occur, perhaps owing to an increased susceptibility of at-risk nerves to injury or as a vascular steal phenomenon after arteriovenous fistula. Electrophysiologic studies are often abnormal, even in those with no symptoms, with both decreased amplitudes and slowing. Among most patients who enter chronic dialysis programs, the neuropathy stabilizes or improves slowly. Patients with mild neuropathy often recover completely, but those who begin dialysis with severe neuropathy rarely recover even after several years, and some may continue to progress. However, lack of improvement or progression of symptoms while on dialysis should suggest an evaluation for an alternative diagnosis.

Management

Both dialysis and renal transplantation often have a significant beneficial effect on uremic neuropathy, with transplantation thought to be more effective. Motor nerve conduction velocities can increase within days of transplantation along with continued

improvement for several months, sometimes with complete recovery, unless there was severe axonal degeneration before transplantation.

The symptomatic treatment of painful uremic neuropathy is similar to the treatment of any painful peripheral neuropathy (see Chapter 91) but with careful attention to medication dosing, given the presence of renal failure.

MYOPATHY

In patients with renal failure, myopathy with proximal limb weakness, fatigability, and atrophy is a poorly understood condition. Muscle enzymes and electromyogram are usually normal. Muscle biopsy may reveal nonspecific alterations and sometimes type II fiber atrophy. Electrolyte abnormalities, in particular potassium, calcium, and magnesium, must be considered. If the patient has been treated with a kidney transplant and is taking steroids, a steroid myopathy may be considered.

NEUROLOGIC COMPLICATIONS OF RENAL TRANSPLANTATION

Renal transplantation is the preferred treatment of end-stage renal disease, and with advances in transplantation medicine, these patients live longer and are more at risk for the adverse consequences of long-term immunosuppression.

A femoral neuropathy may complicate renal transplant surgery caused by perioperative compression or traction. It can usually be managed with physical therapy and time. Occasionally, a compressing hematoma may need to be evacuated or nerve repair may be needed for a more severe direct nerve injury.

Transplant patients suffering systemic features of rejection may also present with encephalopathic symptoms including confusion and even seizures. Symptoms usually begin within a few months of transplant, but some occur later. Treatment of rejection usually leads to improvement.

Posterior Reversible Encephalopathy Syndrome

Several drugs are used to prevent transplant rejection, and each has adverse effects. Of particular interest to the neurologist is the *posterior reversible encephalopathy syndrome* usually seen in those patients treated with cyclosporine or tacrolimus (see Chapter 44). Posterior reversible encephalopathy syndrome may also be seen in nontransplanted patients with renal disease and hypertension. Symptoms include headache, visual disturbance, encephalopathy, and seizures. Blood pressure is usually elevated. MRI reveals changes in the white matter, most extensive in the occipital and parietal regions, that suggest vasogenic edema. Treatment involves lowering blood pressure and, whenever possible, discontinuing immunosuppressive agents. Obviously, patients with transplanted organs require immunosuppression; if medications are substituted, the patient will need continued monitoring for PRES. Patients with seizures should be treated with anticonvulsants. Late recurrence of seizures after successful treatment is low, and the anticonvulsant can usually be discontinued in the uncomplicated patient once symptoms and imaging have resolved, although some advocate continuing for 1 to 3 months.

Primary Central Nervous System Lymphoma

The risk that a lymphoma will develop after a transplant is about 35 times more than in normal people; the increased risk depends almost entirely on the increased incidence of primary CNS lymphoma. These are almost always B-cell lymphomas developing from immunosuppression-related Epstein-Barr virus infection causing lymphocyte proliferation. The tumor typically appears between 5 and 45 months after transplantation. The resulting clinical syndromes include increased intracranial pressure, rapidly evolving focal neurologic signs, or combinations of these. Convulsions are rare. The lymphoma may be multicentric and may involve the meninges. Treatment may include immunosuppression withdrawal, chemotherapy, and radiation.

Opportunistic Infections

Infections occur often in transplant patients, and a high index of suspicion must be maintained because the usual inflammatory response may be impaired diminishing the severity of symptoms. New headache or mental changes should lead the clinician to consider brain imaging and lumbar puncture. Viral infections with cytomegalovirus, herpes zoster virus, varicella-zoster virus, human herpes virus 6, Epstein-Barr virus, and John Cunningham virus can often be diagnosed on CSF with culture or polymerase chain reaction. Bacterial and tuberculous meningitis are also considerations. Systemic fungal infections are common, and secondary brain abscess formation may occur. In almost all cases, the primary source of infection is in the lung. Chest radiographs and the presence of fever aid in differentiating fungal brain abscess from brain tumor in recipients of transplants. *Aspergillus* has a unique predilection for dissemination to brain and accounts for most fungal brain abscesses; *Candida*, *Nocardia*, and *Histoplasma* are found in the others. The clinical syndrome resulting from these infections is usually delirium accompanied by seizures. Headache, stiff neck, and focal signs also occur but not commonly. The CSF is often remarkably bland, and brain biopsy may be the only reliable way to establish a diagnosis. The distinction of fungal brain abscess from possibly radiosensitive brain tumor makes it important to consider this procedure.

HYPONATREMIA

Sodium and fluid homeostasis is under the control of the brain and kidneys. The neurologist, particularly in the neurologic intensive care unit, is frequently confronted by hyponatremia (serum sodium <135 mEq/L). In this setting, the most common causes of hyponatremia are volume depletion, the syndrome of inappropriate antidiuretic hormone secretion (SIADH), and cerebral salt wasting (CSW).

Clinical Features

Hyponatremia can not only be caused by brain injury but can also further impair neurologic function and cause a vast array of clinical manifestations, ranging from mild confusion to death. The severity of symptomatology is primarily related to the speed of sodium reduction, rather than the absolute sodium level itself. Sodium is the principle osmotically active solute in

the extracellular fluid compartment. If the sodium concentration falls quickly (>1 mEq/h), free water moves into the intracellular compartment, leading to cellular swelling and edema. Unlike other organs, the CNS tolerates this process extremely poorly. Acute hyponatremia can lead to global cerebral edema and severe clinical manifestations, including seizures, coma, or death from brainstem herniation.

When sodium levels drop gradually, cells compensate by reducing the intrinsic osmolality of the intracellular compartment. This process, which involves release of intracellular electrolytes such as potassium and elimination of organic osmolytes, takes hours to days. As a result, normal cellular volume is maintained in chronic hyponatremia, but subtle neurologic dysfunction in the form of neurocognitive dysfunction, impaired reaction times, and gait instability results from these intrinsic changes in neuronal intracellular composition. Hospitalized patients with chronic hyponatremia have an increased risk of mortality and a two- to fourfold increased fall risk compared to normonatremic patients.

Diagnosis

The medical history is an important first step in the evaluation of hyponatremia and in particular includes information about fluid loss (or excess intake), low protein intake, medications, history of heart failure, cirrhosis, kidney failure, hypothyroidism, adrenal insufficiency, lung cancer, and, of course, CNS disease.

In addition to the history, physical examination should start with an assessment of *volume status* by evaluating blood pressure and heart rate, skin turgor, the mucous membranes, and jugular venous pressure. Measurement of fluid inputs and outputs typically demonstrate positive net fluid balance in patients who are hypovolemic, as the kidneys appropriately retain fluid to correct the problem. A spot urine sodium concentration is typically low in hypovolemic states (<25 mEq/L), representing avid renal sodium retention. A low central venous pressure is fairly specific for hypovolemia; otherwise, central venous pressure is a poor indicator of volume status. Advanced diagnostic methods in the intensive care unit for evaluating volume status include use of bedside ultrasound to diagnose collapsibility of the inferior vena cava with spontaneous respirations and cardiac output monitors that can measure the global end-diastolic volume index of the heart.

Essential laboratory testing in hyponatremia includes serum osmolality, urine osmolality, and urine electrolytes, in addition to standard serum chemistries. If serum osmolality is low, then true hypotonic hyponatremia is confirmed (Fig. 125.1). If serum

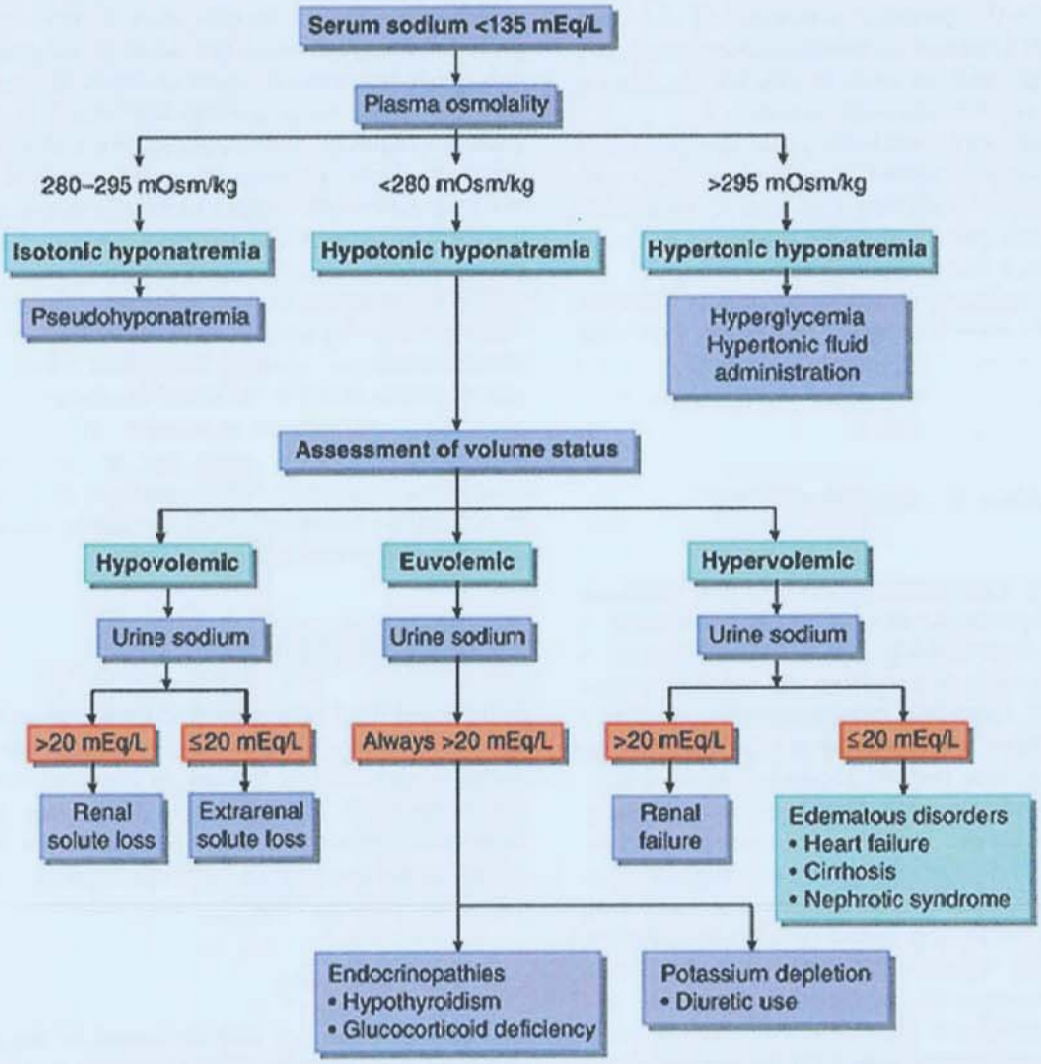

FIGURE 125.1 Diagnostic algorithm for identifying the cause of hyponatremia. Step 1 is to confirm the presence of hypotonic hyponatremia by checking serum osmolality. Step 2 is to evaluate volume status. Euvolemic hyponatremia is usually due to syndrome of inappropriate antidiuretic hormone secretion. Hypovolemia hyponatremia may be due to extrarenal sodium losses such as vomiting or diarrhea, or inappropriate renal losses, as occurs with cerebral salt wasting.

TABLE 125.1 Syndrome of Inappropriate Antidiuretic Hormone Secretion Versus Cerebral Salt Wasting

	SIADH	CSW
Serum sodium (mEq/L)	<135	<135
Serum osmolality (mOsm/kg)	<275	<275
Urine osmolality (mOsm/kg)	>100 (usually >300)	>100 (usually >300)
Urine sodium (mEq/L)	>40	>40
Volume status	Euvolemic to hypervolemic	Hypovolemic
Response to isotonic saline	No effect	Improved hyponatremia

Abbreviations: CSW, cerebral salt wasting; SIADH, syndrome of inappropriate antidiuretic hormone secretion.

sodium is low but serum osmolality is normal, elevated lipids or proteins may account for a measured pseudohyponatremia. If sodium is low and osmolality is elevated, then another substance is contributing to osmoles such as glucose, urea, alcohol, or mannitol.

When hypotonic hyponatremia is confirmed, classification of volume status as hypovolemic, euvolemic, or hypervolemic is key for identifying the cause (see **Fig. 125.1**). Analysis of urine sodium is a key ancillary test. Calculation of the fractional excretion of sodium (**Table 125.1**) is less than 1% in patients who are hypovolemic or have reduced effective circulating blood volume and normal renal function, reflecting a corrective pattern of avid sodium retention. An important exception is when fluid losses and hypovolemia are caused by excessive and inappropriate sodium excretion, as occurs with untreated CSW (**Table 125.2**).

In this setting of SIADH, patients are euvolemic, spot urine sodium is greater than 40 mEq/L, and the fractional excretion of sodium is greater than 1%. Because antidiuretic hormone (ADH) is inappropriately elevated, urine osmolality is more than a maximally dilute urine of 100 mOsm/kg and usually more than 300 mOsm/kg.

An SIADH from enhanced ADH release may occur in the setting of almost any CNS disease, including stroke, trauma, brain tumor, or encephalitis, and with acute peripheral neuropathies such as Guillain-Barré syndrome.

CSW is typically encountered in patients with SAH but can occur with other forms of acute CNS injury as well. In this condition, sympathetic nervous system activation release of circulating factors such as brain natriuretic factor drive excessive sodium excretion while suppressing the normal renin-angiotensin system response to hypovolemia. A CSW as a cause of hyponatremia is about one-tenth as common as SIADH. In some cases, most often SAH, hyponatremia can be the result of dual physiologic processes that favor the combination of excessive sodium losses and inappropriate ADH elevation.

Management

Acute Symptomatic Hyponatremia

Treatment of hyponatremia in neurologic patients, whether acute or chronic, is important. Symptomatic acute hyponatremia leading to brain edema is a medical emergency and should be treated with hypertonic saline. The mainstay of therapy is a 3% sodium chloride–acetate solution, infused at a rate of 0.25 to 1.0 mL/kg/h, depending on the severity of symptoms and sodium level. Serum sodium level should be monitored every 4 hours, with the rate of the infusion adjusted to attain a rate of correction of no more than 12 mEq/L over 24 hours (0.5 mEq/L/h). More rapid aggressive correction of hyponatremia must be avoided because of the possibility of osmotic demyelination or central pontine myelinolysis (CPM).

Chronic Hyponatremia

The mainstay of treating *hypovolemic hyponatremia*, whatever the cause, is isotonic fluid resuscitation in the form of normal (0.9%) saline. In most cases, correction of the volume deficit results in normalization of the sodium concentration.

The conventional first-line treatment for SIADH commonly involves fluid restriction, but this should more correctly be termed *free water restriction*. All sources of free water, whether oral or in the form of hypotonic intravenous fluids or enteral feeds, should be restricted in SIADH, but isotonic crystalloids can still be given to maintain intravascular volume, particularly in SAH patients who require volume expansion.

In most cases of SIADH, the usual treatment of oral free water restriction is slow; this treatment prevents more free water from being retained but does not eliminate the free water excess that currently exists. Addition of sodium tablets also does little to correct the problem because 2 g of sodium chloride is the equivalent of only 34 mEq of sodium chloride, an amount not nearly sufficient to correct the problem.

TABLE 125.2 Interpretation of Fractional Excretion of Sodium and Urinary Sodium Concentration

	Prerenal	Intrinsic Renal Disease	Postrenal Obstruction
FENa[a]	<1%	>1%	>4%
U_{Na} (mmol/L)	<20	>40	>40
Examples	Hypovolemia	Acute tubular necrosis	Bladder obstruction
	Heart failure	Glomerulonephritis	Ureteral obstruction
	Renal artery stenosis	Acute nephritis	

Abbreviations: FENa, fractional excretion of sodium; U_{Na}, urine sodium.
[a]FENa is calculated as $[(P_{Cr} \times U_{Na}) / (P_{Na} \times U_{Cr})] \times 100$.

Recently, a novel therapy of vasopressin receptor blockade has been introduced, which targets the V2 receptor in the distal collecting tubule. By causing a conformational change, aquaporin 2 allows more free water to exit ("aquaresis") leading to a significant free water clearance. *Tolvaptan* 15 mg orally daily leads to an average increase in serum sodium of 3 mEq/L over 24 hours, whereas *conivaptan* 20 mg intravenous over 1 hour, followed by a 20-mg infusion over 24 hours, results in a mean increase in sodium 6 mEq/L over 24 hours. By blocking the ADH receptor, so-called vaptan therapy targets the underlying pathophysiologic abnormality that underlies SIADH. Both agents have a U.S. Food and Drug Administration indication for patients with euvolemic or hypervolemic hyponatremia due to SIADH.

OSMOTIC DEMYELINATION SYNDROME

In 1959, Adams, Victor, and Mancall described a distinctive condition characterized by the symmetric destruction of myelin sheaths in the basis pontis in the setting of overly rapid correction of serum sodium. They coined the term *central pontine myelinolysis*.

Later recognition that the demyelination can affect white matter pathways outside of the pons let to the term *extrapontine myelinolysis (EPM)*. The term *osmotic demyelination syndrome* (ODS) is now used as a general descriptive term for the syndrome, with CPM and EPM being the two main anatomic variants.

ODS typically develops after overly rapid correction of chronic hyponatremia to normal or supranormal levels. Chronic alcoholism and undernutrition are frequently associated with this condition, but the underlying case of the hyponatremia can result from any cause, including SIADH; dehydration resulting from vomiting, diarrhea, or diuretic therapy; postoperative overhydration (seen most often due to bladder irrigation with urologic surgery); liver transplantation; or psychogenic water intoxication. Similarly, rapid correction of hyponatremia can lead to myelinolysis in uremics patient on hemodialysis. In addition to the underlying hyponatremia, profound hypophosphatemia, hypokalemia, and other electrolyte disorders may be present, and these abnormalities may play a role in producing the syndrome. Rarely, rapid increases in serum sodium level from a normal baseline can cause ODS in neurocritical care patients treated aggressively with bolus osmotherapy.

In most cases, the main causative factor in ODS appears to be rapid correction of serum sodium, but some instances occur in individuals with severe electrolyte abnormalities in the absence of overly rapid sodium correction. Similarly, correction of hyponatremia far exceeding the accepted safe rate of 0.5 mEq/L/hr can occur with no neurological consequences. Many variables other than the rate of correction of hyponatremia, such as coexisiting electrolyte and micronutrient deficiencies, seem to play a role in the pathogenesis of ODS.

Epidemiology

ODS is rare. In a 2011 study from Sweden that identified 83 affected patients, the overall incidence was 0.6 per million person-years. Most cases (87%) were hyponatremic at baseline, with a median sodium level of 104 mEq/L, and in all cases, the hyponatremia was chronic. The cause of hyponatremia was multifactorial, including drugs (57%), vomiting or diarrhea (42%), and polydipsia (32%), and the majority of patients (70%) were alcoholics. In another recent series from Massachusetts General Hospital, of 45 cases identified over 10 years, the most common comorbidities were alcoholism (43%), liver disease (26%), and kidney failure (20%).

Pathobiology

The principal pathologic change is demyelination. Within affected areas, there is degeneration with loss of oligodendrocytes but nerve cells and axon sheaths are spared, blood vessels are unaffected, and there is no inflammation. The pathophysiology seems caused by physiologic imbalance of osmoles in the brain. Apoptosis may deplete supply of energy to glial cells and Na^+/K^+ adenosine triphosphatase (ATPase) pumps, thus impairing cellular adaptation to osmotic stress. In animal studies, the initial event after administration of hypertonic saline in hypotonic rats seems to be opening of the blood-brain barrier, followed sequentially by swelling of the inner loop of the myelin sheath, oligodendrocyte degeneration, and release of macrophage-derived factors leading to the eventual breakdown of myelin. Histologically, the lesion begins in the median raphe and may involve all or part of the base of the pons (Fig. 125.2). The lesion may spread into

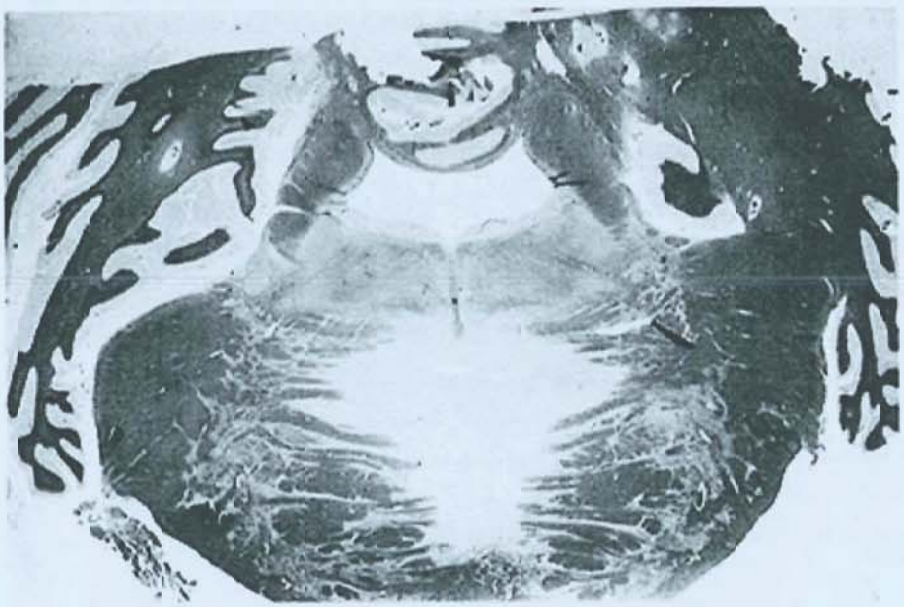

FIGURE 125.2 Central pontine myelinolysis. Histologic section through rostral pons showing characteristic lesion. (Courtesy of Dr J. Kepes.)

the pontine tegmentum or superiorly into the mesencephalon or involve bilateral extrapontine areas with or without concurrent basis pontis lesions. Microscopically, lesions resemble those of Marchiafava-Bignami disease (demyelination of corpus callosum and other commissural fibers, commonly seen in the context of chronic alcoholism and malnutrition).

The exact cause of myelinolysis is uncertain. In those with hyponatremia that has been rapidly corrected to normal or supranormal levels, it is not clear whether the low sodium, the rate of correction, or absolute change in serum sodium content is a causative factor. However, symptoms are more likely to develop with rapid correction of chronic rather than acute hyponatremia. In experimental animals, pontine myelinolysis can be produced in hyponatremic rats, rabbits, or dogs treated rapidly with hypernatremic saline. Animals left with untreated hyponatremia did not develop neuropathologic changes. Therefore, attention has focused on rate of correction of the hyponatremia as the primary inciting mechanism of myelinolysis. A recent study has suggested loss of activity of brain aquaporins (specifically aquaporins 1 and 4) affecting redistribution of water and osmolytes across various brain compartments may be seen in pontine myelinolysis.

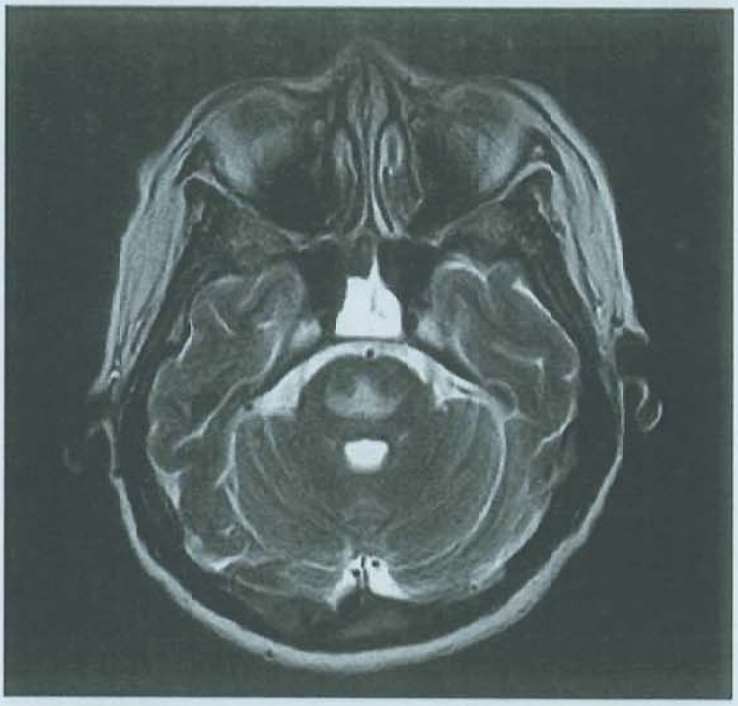

FIGURE 125.3 Magnetic resonance imaging brain T2W showing trident sign with hyperintense signal at central pons. (Reproduced with permission from Cheo SW, Low QJ, Tan YA, Chia YK. Trident sign in osmotic demyelination syndrome. *QJM*. 2020;113[2]:131-132.)

Clinical Manifestations

Patients with ODS often have a biphasic course, the first phase reflecting the underlying predisposing illness and the second phase reflecting ODS itself. Classically, neurologic signs and symptoms of myelinolysis appear within 2 to 3 days after rapid correction of sodium levels. In CPM initial symptoms of dysarthria and dysphagia progress to flaccid and then later spastic quadriplegia. Other findings may include mutism, behavioral abnormalities, frank psychosis, ophthalmoparesis, bulbar and pseudobulbar palsy, hyperreflexia, and rarely seizures or coma. In the most severe cases of CPM, the patients may be "locked in," and communication by eye blinking can sometimes be established. EPM can lead to ataxia, irregular behavior, visual field deficits, parkinsonism, choreoathetosis, dystonia, or paroxysmal kinesigenic dyskinesias. The movement disorders can appear with or without radiographic evidence of EPM. Movement disorders as result of EPM may be treatable, with some improvement noted after dopaminergic therapy.

Diagnosis

Although historically most cases were diagnosed at autopsy, the syndrome can now easily be diagnosed in life with MRI. Computed tomography scans may be normal, especially early in the course, but may reveal symmetric areas of hypodensity in the basis pontis or extrapontine regions without associated mass effect. MRI is much more sensitive and typically shows symmetric increased signal intensity in the central pons (often described as *trident-shaped*) on T2-weighted and fluid-attenuated inversion recovery images (Fig. 125.3). The lesions appear hypointense on T1-weighted images and typically do not enhance. MRI diffusion-weighted imaging may be even more sensitive because it demonstrates increased signal of restricted diffusion of water in the central pons within 24 hours of the onset of symptoms from myelinolysis. Lesions seen within the basis pontis typically spare the tegmentum and may extend to the ventral midbrain but rarely involve the medulla. In EPM, bilateral symmetric involvement may affect white matter pathways in the basal ganglia, cerebellum, thalamus, midbrain, corpus callosum, subcortical white matter, claustrum, or medial lemnisci.

Because imaging findings may lag behind clinical manifestations for up to 2 weeks, in clinically suspicious cases with initial negative neuroimaging, repeat MRI is recommended.

Other studies that can assist in diagnosing ODS include magnetic resonance spectroscopy, which can demonstrate decreased *N*-acetylaspartate/creatine ratios and increased choline/creatine ratios, and brainstem auditory–evoked responses, which may demonstrate prolonged III to V and I to V latencies. An electroencephalogram may show slowing and low voltage. CSF levels of protein and myelin basic protein may be elevated.

Prevention and Treatment

Prevention of myelinolysis includes judicious correction of hyponatremia with normal saline and free-water restriction, discontinuation of diuretic therapy, and correction of associated metabolic abnormalities and medical complications. At present, there are no clinical trials providing Level 1 evidence for the appropriate treatment of CPM. *Based on clinical guidelines, there is a very low frequency of myelinolysis if the rate of serum sodium correction is targeted at 8, and does not exceed 12, mmol/L over 24 hours.* If the serum sodium is increased faster than this rate, it by no means ensures that ODS will occur. Rather, ODS is rarely seen if the rate of correction is within these limits. Normal (0.9%) saline (154 mEq/L sodium concentration) should generally be used as the initial resuscitation fluid, although lactated Ringer solution (130 mEq/L sodium concentration) can be used as an alternative if even slower correction is desired. A variety of online calculators (https://reference.medscape.com/calculator/643/sodium-correction-rate-for-hyponatremia) exist to provide the proper fluid infusion rate to attain a 0.33 mmol/L/h correction rate (which will produce an 8 mEq increase over 24 h).

Correction of Hyponatremia Case Example

A 54-year-old 70-kg man presents to the emergency department after a witnessed seizure. He has no history of prior epilepsy, but he admits to being a long-time alcohol user who consumes approximately one pint of vodka daily. He is afebrile, vital signs are stable, and on exam, he appears dehydrated with dry mucous membranes. On neurologic testing, he is oriented to place and year but not date and appears lethargic. Laboratory testing reveals a blood alcohol content of 45 mg/dL, a serum sodium level of 119 mEq/L, and prerenal azotemia. The diagnosis is new-onset seizures provoked by alcohol use and hyponatremia. You recommend to correct his serum sodium level by 8 mEq per 24 hours, over 2 consecutive days (0.33 mEq/h). An online calculator reveals that normal saline at a rate of 405 mL/h will be sufficient to increase his sodium level from 119 to 127 mEq/L on day 1 and from 127 to 135 mEq/L on day 2.

Hyponatremic patients who are asymptomatic from brain edema or seizures may need more rapid correction, especially if the hyponatremia is more acute. The typical approach is to give 3% hypertonic saline either as 50- to 150-mL intravenous boluses, or as a continuous infusion at 0.5 to 1.0 mL/kg/h. Caution should be used in giving hypertonic saline to patients with acute symptomatic hyponatremia; frequent laboratory evaluations of serum sodium should be used as a guide to avoid overly rapid correction of low sodium levels.

Outcome

CPM was classically reported to have an extremely high mortality, ranging from 35% to 50%, and an associated high rate of permanent neurologic disability. More recently, the outcome has been found to be remarkably more upbeat. In the aforementioned Swedish national study, after 6 months of follow-up, only 7% of ODS patients had died and 60% were functionally independent. Near-complete recovery from comatose or locked-in states has been reported. Persistent disability may manifest as the late appearance of dysarthria, ataxia, tremor, dystonia, or cognitive and behavioral changes. Prognostics factors that are favorable for recovery include younger age, less severe hyponatremia, and a less severe clinical syndrome on admission and discharge.

SUGGESTED READINGS

Renal Diseases

Brouns R, De Deyn PP. Neurological complications in renal failure: a review. *Clin Neurol Neurosurg*. 2004;107:1-16.

Campistol JM. Uremic myopathy. *Kidney Int*. 2002;62:1901-1913.

Chen Y, Tian X, Wang X. Advances in dialysis encephalopathy research: a review. *Neurol Sci*. 2018;39(7):1151-1159.

Cohen JA, Raps EC. Critical neurologic illness in the immunocompromised patient. *Neurol Clin*. 1995;13:659-677.

Ellison DH, Berl T. Clinical practice. The syndrome of inappropriate antidiuresis. *N Engl J Med*. 2007;356:2064-2072.

Fugate JE, Claassen DO, Cloft HJ, Kallmes DF, Kozak OS, Rabinstein AA. Posterior reversible encephalopathy syndrome: associated clinical and radiologic findings. *Mayo Clin Proc*. 2010;85:427-432.

Giannaki CD, Hadjigeorgiou GM, Karatzaferi C, Pantzaris MC, Stefanidis I, Sakkas GK. Epidemiology, impact, and treatment options of restless legs syndrome in end-stage renal disease patients: an evidence-based review. *Kidney Int*. 2014;85:1275-1282.

Hamed SA. Neurologic conditions and disorders of uremic syndrome of chronic kidney disease: presentations, causes, and treatment strategies. *Expert Rev Clin Pharmacol*. 2019;12(1):61-90.

Johansen KL, Shubert T, Doyle J, Soher B, Sakkas GK, Kent-Braun JA. Muscle atrophy in patients receiving hemodialysis: effects on muscle strength, muscle quality, and physical function. *Kidney Int*. 2003;63:291-297.

Kim DM, Lee IH, Song CJ. Uremic encephalopathy: MR imaging findings and clinical correlation. *AJNR Am J Neuroradiol*. 2016;37(9):1604-1609.

Krishnan AV, Kiernan MC. Uremic neuropathy: clinical features and new pathophysiological insights. *Muscle Nerve*. 2007;35:273-290.

Lee JJ, Kilonzo K, Nistico A, Yeates K. Management of hyponatremia. *CMAJ*. 2014;186(8):E281-E286.

Lehrich RW, Ortiz-Melo DI, Patel MB, Greenberg A. Role of vaptans in the management of hyponatremia. *Am J Kidney Dis*. 2013;62(2):364-376.

Mistry K. Dialysis disequilibrium syndrome prevention and management. *Int J Nephrol Renovasc Dis*. 2019;12:69-77.

Rajagopal R, Swaminathan G, Nair S, Joseph M. Hyponatremia in traumatic brain injury: a practical management protocol. *World Neurosurg*. 2017;108:529-533.

Renneboog B, Musch W, Vandemergel X, Manto MU, Decaux G. Mild chronic hyponatremia is associated with falls, unsteadiness, and attention deficits. *Am J Med*. 2006;119(1):71.e1-71.e8.

Schifman RB, Luevano DR. Aluminum toxicity: evaluation of 16-year trend among 14 919 patients and 45 480 results. *Arch Pathol Lab Med*. 2018;142:742-746.

Singh S, Bohn D, Carlottti AP, Cusimano M, Rutka JT, Halperin ML. Cerebral salt wasting: truths, fallacies, theories, and challenges. *Crit Care Med*. 2002;30:2575-2579.

Sterns RH, Hix JK, Silver SM. Management of hyponatremia in the ICU. *Chest*. 2013;144(2):672-679.

Sterns RH, Silver SM. Cerebral salt wasting versus SIADH: what difference? *J Am Soc Nephrol*. 2008;19:194-196.

Yeates KE, Singer M, Morton AR. Salt and water: a simple approach to hyponatremia. *CMAJ*. 2004;170:365-369.

Zepeda-Orozco D, Quigley R. Dialysis disequilibrium syndrome. *Pediatr Nephrol*. 2012;27:2205-2211.

Osmotic Demyelination Syndrome

Adams RD, Victor M, Mancall EL. Central pontine myelinolysis: a hitherto undescribed disease occurring in alcoholic and malnourished patients. *AMA Arch Neurol Psychiatry*. 1959;81:154-172.

Adrogue HJ, Madias NE. Hyponatraemia. *N Engl J Med*. 2000;342:1581-1589.

Ashrafian H, Davey P. A review of the causes of central pontine myelinolysis: yet another apoptotic illness? *Eur J Neurol*. 2001;8:103-109.

Aegisdottir H, Cooray C, Wirdefeldt K, Piehl F, Sveinsson O. Incidence of osmotic demyelination syndrome in Sweden: a nationwide study. *Acta Neurologica Scandinavica*. 2019;140(5):342-349.

Ayus JC, Krothpalli RK, Arieff AI. Treatment of symptomatic hyponatremia and its relation to brain damage. *N Engl J Med*. 1987;317:1190-1195.

Bouchat J, Couturier B, Marneffe C, et al. Regional oligodendrocytopathy and astrocytopathy precede myelin loss and blood–brain barrier disruption in a murine model of osmotic demyelination syndrome. *Glia*. 2018;66(3):606-622.

Brunner JE, Redmond JM, Haggar AM, Kruger DF, Elias SB. Central pontine myelinolysis and pontine lesions after rapid correction of hyponatremia: a prospective magnetic resonance imaging study. *Ann Neurol*. 1990;27:61-66.

Cheo SW, Low QJ, Tan YA, Chia YK. Trident sign in osmotic demyelination syndrome. *QJM*. 2020;113(2):131-132.

Donahue SP, Kardon RH, Thompson HS. Hourglass-shaped visual fields as a sign of bilateral lateral geniculate myelinolysis. *Am J Ophthalmol*. 1995;119:378-380.

Fitts W, Vogel AC, Mateen FJ. The changing face of osmotic demyelination syndrome: a retrospective, observational cohort study [published online ahead of print August 26, 2020]. *Neurology*. 2020. doi:10.1212/CPJ.0000000000000932.

Guo Y, Hu JH, Lin W. Central pontine myelinolysis after liver transplantation: MR diffusion, spectroscopy and perfusion findings. *Magn Reson Imaging*. 2006;24:1395-1398.

Hadfield MG, Kubal WS. Extrapontine myelinolysis of the basal ganglia without central pontine myelinolysis. *Clin Neuropathol*. 1996;15:96-100.

Heng AE, Vacher P, Aublet-Cuvelier B, et al. Centropontine myelinolysis after correction of hyponatremia: role of associated hypokalemia. *Clin Nephrol*. 2007;67:345-351.

Kallakatta RN, Radhakrishnan A, Fayaz RK, Unnikrishnan JP, Kesavadas C, Sarma SP. Clinical and functional outcome and factors predicting prognosis in osmotic demyelination syndrome (central pontine and/or extrapontine myelinolysis) in 25 patients. *J Neurol Neurosurg Psychiatry*. 2011;82:326-331.

Kleinschmidt-Demasters BK, Norenberg MD. Rapid correction of hyponatremia causes demyelination: relation to central pontine myelinolysis. *Science*. 1981;211:1068-1070.

Lambeck J, Hieber M, Dreßing A, Niesen WD. Central pontine myelinosis and osmotic demyelination syndrome. *Dtsch Ärztebl Int*. 2019;116(35-36):600.

Lampl C, Yazdi K. Central pontine myelinolysis. *Eur Neurol*. 2002;47:3-10.

Lee TM, Cheung CC, Lau EY, Mak A, Li LSW. Cognitive and emotional dysfunction after central pontine myelinolysis. *Behav Neurol*. 2003;14:103-107.

Lohr JW. Osmotic demyelination syndrome following correction of hyponatremia: association of hypokalemia. *Am J Med*. 1994;96:408-413.

Martin RJ. Central pontine and extrapontine myelinolysis: the osmotic demyelination syndromes. *J Neurol Neurosurg Psychiatry*. 2004;75(suppl 3):iii22-iii28.

Mitchell AW, Burn DJ, Reading PJ. Central pontine myelinolysis temporally related to hypophosphataemia. *J Neurol Neurosurg Psychiatry*. 2003;74:820.

Popescu BF, Bunyan RF, Guo Y, Parisi JE, Lennon VA, Lucchinetti CF. Evidence of aquaporin involvement in human central pontine myelinolysis. *Acta Neuropathol Commun*. 2013;1:40.

Rojiani AM, Cho ES, Sharer L, Prineas JW. Electrolyte-induced demyelination in rats. 2. Ultrastructural evolution. *Acta Neuropathol*. 1994;88:293-299.

Ruzek KA, Campeau NG, Miller GM. Early diagnosis of central pontine myelinolysis with diffusion-weighted imaging. *AJNR Am J Neuroradiol*. 2004;25:210-213.

Salerno SM, Kurlan R, Joy SE, Shoulson I. Dystonia in central pontine myelinolysis without evidence of extrapontine myelinolysis. *J Neurol Neurosurg Psychiatry*. 1993;56:1221-1223.

Schrier RW. Treatment of hyponatremia. *N Engl J Med*. 1985;312:1121-1123.

Snell DM, Bartley C. Osmotic demyelination syndrome following rapid correction of hyponatraemia. *Anaesthesia*. 2008;63:92-95.

Uchino A, Yuzuriha T, Murakami M, et al. Magnetic resonance imaging of sequelae of central pontine myelinolysis in chronic alcohol abusers. *Neuroradiology*. 2003;45:877-880.

126 Gastric and Genitourinary Function and the Brain

Alden Doerner Rinaldi and Charles C. Esenwa

KEY POINTS

1. Gastric and genitourinary function is largely driven by autonomic outflow from the sympathetic and parasympathetic nervous systems. Their reciprocal action regulates sexual function, urinary storage, and voiding and tunes the enteric nervous system to control gut motility, secretomotor function, perfusion, fluid and nutrient absorption, and enteric immune function.
2. Injury to the nervous system at any level and by diverse mechanisms can result in myriad gastrointestinal and/or genitourinary manifestations. Identification and proper interpretation of these signs and symptoms can be helpful in both localization and diagnosis.
3. Inversely, numerous primary gastrointestinal disorders may have deleterious effects on neurologic function or lead to neurologic disease.
4. Emerging evidence links the microbiome-gut-brain axis to both neurologic health and disease, such as multiple sclerosis and stroke.

INTRODUCTION

The brain shares intricate connections with the gastrointestinal (GI) and genitourinary (GU) organ systems. Injury to the nervous system at any anatomic level and by any number of mechanisms—ischemia, trauma, inflammation, infection, toxic-metabolic insult, developmental anomaly, or degeneration—can provoke GI or GU symptoms. Inversely, primary GI disorders may have deleterious effects on neurologic function. In both cases, the human consequences in terms of quality of life, morbidity, and mortality can be enormous. Here we describe (1) the general neurologic mechanisms that lead to disruption of the healthy physiologic function of the GI and GU systems, (2) specific neurologic disorders with significant GI or GU manifestations, and (3) GI disorders frequently associated with neurologic complications.

NEUROANATOMY

The autonomic nervous system is central in the regulation of the GI and GU systems. Autonomic impulses are mediated by the cortex and hypothalamus and affect nuclei in the brainstem, thoracolumbar, and sacral spinal cord. Parasympathetic cholinergic outflow from the dorsal nucleus of the vagus nerve in the medulla promotes the vegetative functions of secretion, digestion, absorption, and gut motility, whereas sacral parasympathetics stimulate voiding, defecation, and tumescence.

Sympathetic adrenergic outflow from the thoracolumbar cord directly opposes parasympathetic function by decreasing secretions, gut motility, and splanchnic blood flow while also increasing sphincter tone to promote urinary and fecal continence. Somatic motor neurons arising from Onuf nucleus at the S2-4 segments of the sacral cord pass via the pudendal nerve to innervate muscles of the pelvic floor and sphincters at the anus and urethra maintaining volitional control over continence (Fig. 126.1).

The enteric nervous system is a quasi-independent branch of the autonomic nervous system with an estimated 400,000 to 600,000 neurons, nearly equal to that of the entire spinal cord. Its function is to (1) orchestrate gut motility, (2) control secretomotor function, (3) regulate local blood flow, (4) control fluid and nutrient absorption, and finally, (5) interact with and modulate the enteric immune system. It has two anatomically distinct subdivisions. The submucosal plexus, which includes Meissner plexus, is located in the gut wall and monitors the local epithelial environment exerting secretomotor control in response to parasympathetic stimuli, whereas the myenteric, or Auerbach, plexus located superficially in the muscular layer of the gut mediates motility through both sympathetic and parasympathetic inputs. The most proximal and distal parts of the GI tract are somatically innervated, making these areas particularly susceptible to neurologic injury.

GASTROINTESTINAL MANIFESTATIONS OF NEUROLOGIC DISEASE

Dysphagia

The process of deglutition is initiated in the cerebral cortex and overseen by the nucleus ambiguus in the medulla. Chewing, bolusing, and initiation of the swallow reflex occur in the oropharynx through a coordinated effort involving multiple cranial nerves. The swallow reflex and esophageal peristalsis are the involuntary phases and are overseen by glossopharyngeal and vagal inputs. Difficulty with swallowing, or dysphagia, can manifest as drooling, inability to effectively maneuver the food bolus, a sensation of esophageal fullness, and choking or coughing when attempting to ingest food.

A disease process affecting the primary motor cortex or supplementary motor areas, such as stroke or neurodegenerative dementia, can disrupt the preparatory and oral phases of swallowing. Direct injury to the brainstem or corticobulbar tracts by ischemia, the Parkinson-plus syndromes, or multiple sclerosis (MS) can disrupt inputs to the nucleus ambiguus, affecting the involuntary phase of swallowing. Motor neuron disorders such as amyotrophic lateral sclerosis (ALS) (Lou Gehrig disease) or spinal and bulbar muscular atrophy (Kennedy disease)

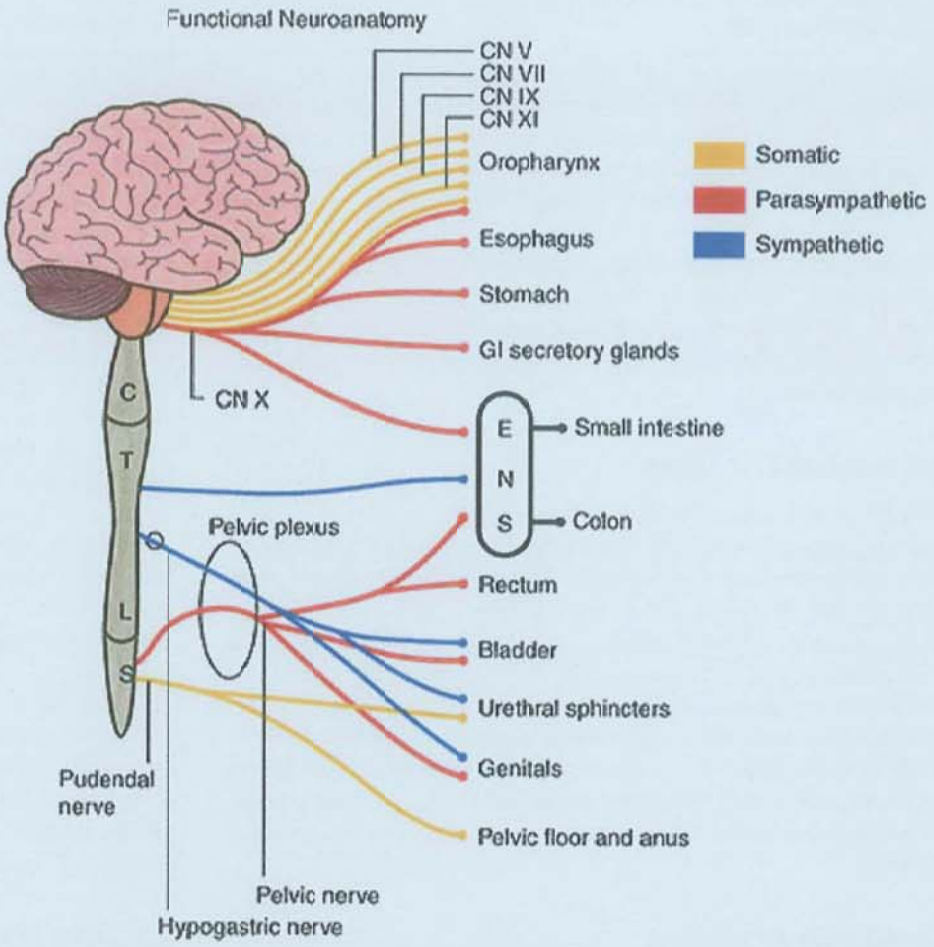

FIGURE 126.1 Peripheral neuroanatomy of the gastrointestinal (GI) and genitourinary systems. Somatic innervation predominantly by cranial nerves (CN) V, VII, IX, and XI as well as the pudendal nerves appear in yellow. Parasympathetic innervation, depicted in red, is carried rostrally from the brainstem to the oropharynx and proximal enteric nervous system by the vagus nerve (CN X). Caudal parasympathetic innervation arising from the sacral cord, instead, travels by way of the pelvic nerves. Sympathetic output, in blue, on the other hand, reaches the enteric nervous system by way of three principle ganglia—the celiac, superior, and inferior mesenteric. The pelvic organs receive their sympathetic innervation via the hypogastric nerve, which complexes with sacral parasympathetic outputs at the pelvic to richly innervate the distal colon, rectum, and genitourinary organs. Abbreviations: C, cervical; ENS, enteric nervous system; L, lumbar; S, sacral; T, thoracic.

cause prominent dysphagia by affecting the motor neurons that supply the muscles of mastication, the oropharynx, and upper esophagus. Peripherally, disorders of the neuromuscular junction, such as myasthenia gravis and botulism, and disorders of muscle, including the muscular dystrophies and inflammatory myopathies, can also have significant effects on all phases of deglutition.

Current guidelines in stroke call for dysphagia screening to be done in all patients hospitalized for acute stroke. Screening protocols vary and include cough reflex testing, bedside swallowing tests, or comprehensive assessment by a speech language pathologist LEVEL 1.[1]

Videofluoroscopy has been the gold standard in the evaluation of dysphagia, and direct visualization using videoendoscopy is now being used more commonly to objectively evaluate swallowing function in patients who have failed dysphagia screening. Although texture-modified foods and thickened liquids are often used to decrease aspiration risk, patients with severe dysphagia or those who are deemed unable to meet their free-water or nutritional requirement for more than 7 days should be considered for percutaneous endoscopic gastrostomy (PEG) placement. In stroke where deglutition is expected to recover, PEG is often temporary and primarily used as a bridge to independent swallowing LEVEL 1.[2]

Oropharyngeal dysphagia due to a degenerative disorder, although mitigated by swallow therapy, will naturally progress to malnutrition, dehydration, and ultimately carries a high risk of aspiration pneumonia. It is therefore recommended that patients with ALS or Parkinson disease (PD) participate in routine screening questionnaires to assess for dysphagia and malnutrition. Similar to stroke, dysphagia screening methods videofluoroscopy and videoendoscopy should be used to objectively evaluate swallow function. A PEG placement in patients with ALS confers a significant survival benefit of 20 months, and trade-offs should be discussed early in the disease course LEVEL 1.[3] In contrast, PEG placement in patients with dementia leads has worse outcomes when compared to both nondementia patients receiving PEG placement and dementia patients not receiving PEG placement. Factors contributing to poor outcomes include overall poor prognosis in advanced dementia, increased risk of aspiration pneumonia, increased urinary and fecal incontinence contributing to decubitus ulcers and infections, and increased use of restraints. As such, multiple guidelines recommend against PEG insertion for patients with advanced dementia LEVEL 1.[4]

Esophageal Dysmotility

The lower esophageal sphincter is controlled by the dorsal motor nucleus of the vagus nerve and is meant to serve as a one-way valve for food contents passing from the esophagus to the stomach. Achalasia is characterized by loss of esophageal peristalsis with sustained contraction of lower esophageal sphincter leading to megaesophagus and a classic "bird's beak" appearance on videofluoroscopy. Although typically a primary idiopathic disorder, there is evidence implicating an underlying inflammatory or autoimmune process affecting the ganglion cells of the myenteric plexus. Similarly, in the chronic stages of Chagas disease, achalasia can occur by infectious destruction of the myenteric plexus by the protozoa *Trypanosoma cruzi*.

Gastroparesis

Peristalsis in the stomach is controlled by independent rhythmic contractile waves paced by the interstitial cells of Cajal and overseen by vagal inputs. Gastroparesis, or delayed gastric emptying from impaired antral motility, usually presents as postprandial bloating, pain, nausea, and vomiting. Diabetic vagal neuropathy and diabetic autonomic neuropathy are common causes that can similarly affect bowel motility, causing alternating diarrhea and constipation. Prokinetic agents such as metoclopramide, cisapride, and erythromycin are used to treat acute exacerbations, whereas severe cases may require venting gastrostomy with feeding enterostomy.

Stress Gastric Ulcer

Neurologic dysfunction from traumatic brain injury, spinal cord injury, or neurologic surgery predisposes to stress-related mucosal injury and hemorrhage. Stress ulcers are particularly exacerbated by injury involving brainstem and diencephalon. Dysregulation of hypothalamic function with simultaneous overactivation of parasympathetic and sympathetic efferents both increase gastric acid production and compromise mucosal protection. Stress ulcer prophylaxis is recommended in patients with coagulopathy or those requiring mechanical ventilation but should also be considered in patients with traumatic brain or spinal cord injury. Proton pump inhibitors serve as first-line therapy.

Bowel Dysmotility

Motility of the small and large intestines is coordinated exclusively by reflex loops made up of motor neurons, interneurons, and intrinsic sensory neurons. Primary Hirschsprung disease is a condition in which this neuronal network fails to form. Failure of neural crest cells to migrate during development leaves a section of colon or rectum without functional enteric plexus. Newborns can have delay in passage of meconium and in severe instances will have massive secondary dilation of the bowel termed *megacolon*. In less severe cases, diagnosis can be delayed to late childhood and even adulthood. Patients in this subgroup come to medical attention because of chronic symptoms of constipation. Diagnosis is suggested by videofluoroscopy and is made by rectal biopsy. Surgical resection of the affected bowel is the mainstay in treatment. Destruction of the enteric plexus by *T cruzi* infection in Chagas disease is a secondary form of megacolon that has a similar diagnostic and therapeutic approach.

Incontinence

Much like the esophagus, autonomic and somatic nerves innervate the anorectum. Reflex muscle contractions and paired inhibitions drive fecal movements through the rectum and into the anal vault. Motor neurons arising from Onuf nucleus at the sacral level traverse the lower sacral plexus and pudendal nerves, ultimately exerting their effect on the external anal sphincter and muscles of the pelvic floor. Lower motor neuron injuries at this level cause sphincter dysfunction with loss of formed stool and fecal incontinence. Anorectal manometry and anal sphincter electromyography have diagnostic value in such cases.

URINARY MANIFESTATIONS OF NEUROLOGIC DISEASE

The lower urinary tract serves as both reservoir and outlet by the reciprocal action of detrusor and urethral sphincter muscles. Anatomically, the periaqueductal gray, located in the pons, integrates rostral input from the midbrain, limbic system, and cortex to promote bladder compliance and storage through a direct tonic inhibition of the pontine micturition center (PMC). This inhibition results in a *storage reflex* by which suppression of parasympathetic and activation of sympathetic pathways causes synergistic detrusor relaxation and urethral smooth muscle contraction to close the urethral outlet. A *voiding reflex* is similarly directed by the periaqueductal gray, whereby release of the PMC activates parasympathetically driven circuits throughout the thoracosacral spinal cord. Cholinergic stimulation contracts the bladder, whereas nitric oxide released from nonadrenergic noncholinergic parasympathetic fibers relaxes the internal urethral sphincter. This action is facilitated by volitional control of somatically innervated striated muscle of the external urethral sphincter to open the urethral outlet and permit micturition. These distinct reflexes may be disrupted by neurologic injury leading to symptoms that are broadly classifiable as (1) *voiding dysfunction* with hesitancy, intermittency, slow stream, straining, terminal dribble, and retention or (2) *storage dysfunction* with urgency, frequency, nocturia, incontinence, and altered bladder sensation (Fig. 126.2).

Voiding Dysfunction

Lower motor neuron lesions of the sacral roots, plexus, or peripheral nerves cause parasympathetic denervation of the detrusor muscle resulting in a large, areflexic, and underactive bladder. When occurring alone, functional voiding symptoms may be difficult to differentiate from urinary outlet obstruction, but decreased rectal tone and impaired defecation often accompany. In the extreme form, the patient will have acute urinary retention, which is a urologic emergency. Causes include spinal cord shock from traumatic injury, Guillain-Barré syndrome, conus medullaris syndrome, and cauda equina syndrome; however, additional neurologic symptoms such as sensory loss, weakness, and areflexia will typically predominate in all of these. Less commonly, acute infection of the sacral roots by varicella or herpesviruses can also cause urinary retention accompanied by unilateral sacral pain, sensory loss, and classic zoster or herpetic rash. Opiates, anticholinergic medications, α-adrenoreceptor agonists, benzodiazepines, nonsteroidal anti-inflammatory agents, and calcium channel blockers can all cause reversible voiding dysfunction.

Upper motor neuron lesions of the spinal cord can functionally uncouple the reciprocal action of the pathways responsible for bladder control. Although typically associated with storage dysfunction, it can cause detrusor sphincter dyssynergia with intermittent and simultaneous contraction of the detrusor and urethral sphincter muscles and resultant urinary retention accompanied by hesitancy and interrupted stream.

Bladder scan, postvoid residuals, urinalysis, and voiding diary will help assess degree of dysfunction, whereas spinal magnetic resonance imaging, clinical neurophysiology, and lumbar puncture can help to determine the underlying etiology. Patients with either acute or chronic voiding dysfunction are at high risk

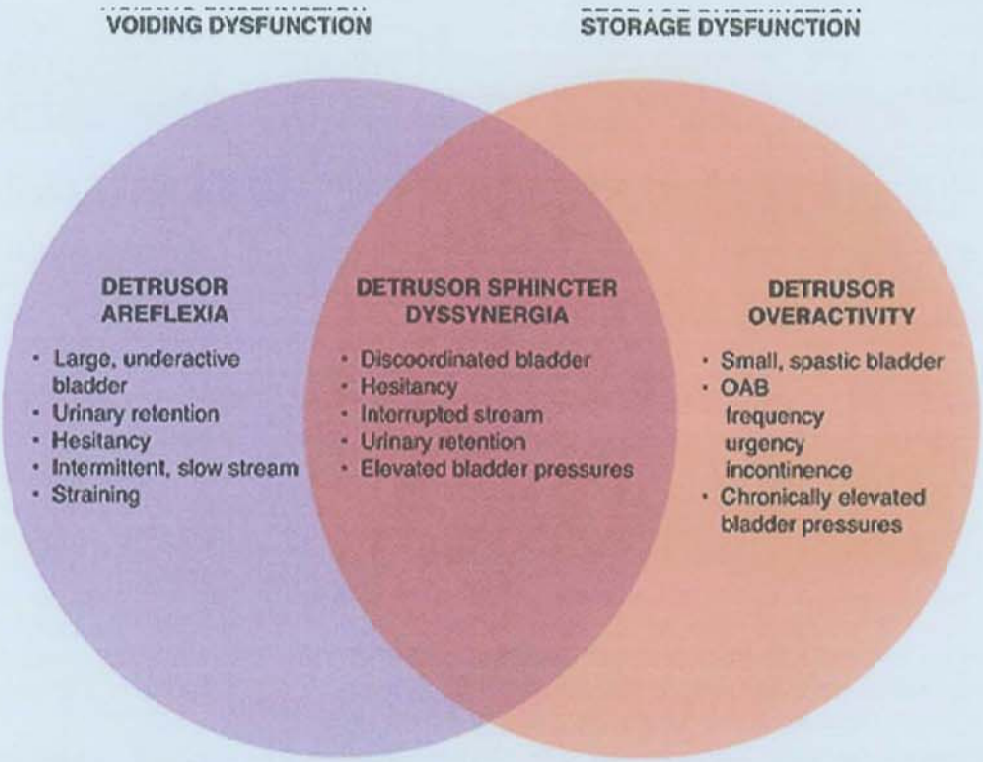

FIGURE 126.2 Symptoms of neurogenic bladder dysfunction. Particular bladder symptoms may be classified as relating to voiding dysfunction, storage dysfunction, or a mixed picture in which both occur simultaneously. Pure voiding (purple area) and storage (coral area) dysfunction are synonymous with detrusor areflexia and detrusor overactivity, respectively, whereas a combination of voiding and storage dysfunction (area of overlap) will lead to detrusor sphincter dyssynergia. Each condition leads to its own unique pattern of symptomology as listed. Abbreviation: OAB, overactive bladder.

of developing urinary tract infections and bladder stones and may require intermittent urethral catheterization or a continuous suprapubic catheter. Less definitive symptomatic management may include reflex voiding by suprapubic pressure (Credé maneuver), vibratory stimulation, or cold water applied to the genitals. Detrusor areflexia has a variable response to muscarinic receptor agonists or a parasympathomimetic agent such as bethanechol. Relaxation of the urethral sphincter by baclofen, α-adrenergic blockade, or intrasphincteric botulinum toxin injection can provide additional benefit.

Storage Dysfunction

Upper motor neuron injury, either above or below the level of the pons, can result in detrusor overactivity. Typically, the bladder is small and hyperreflexic. The patient will suffer from increased urinary frequency, urgency, and incontinence, a symptomatic triad commonly referred to as *overactive bladder (OAB) syndrome*. A chronic elevation of intravesicular pressures results and over time can lead to detrusor hypertrophy, vesicoureteric reflux, hydronephrosis, renal impairment, and even end-stage renal disease. Here too, urodynamic testing should be pursued to better assess the pathology and help plan more invasive management of refractory symptoms.

Therapeutic approaches to storage dysfunction address OAB symptoms while mitigating the long-term consequences of persistently elevated bladder pressure. Nonpharmacologic interventions such as avoiding caffeine, pelvic floor exercises, and bladder training may be efficacious for mild symptoms. Antimuscarinic agents improve bladder compliance and are considered the mainstay of pharmacotherapy. Their use is sometimes limited by adverse central nervous system (CNS) effects, constipation, and urinary retention, in which case muscarinic acetylcholine receptor M_3 specific or blood-brain barrier impermeable agents, such as darifenacin and trospium, can be employed. Desmopressin can also reduce symptoms of urinary frequency but does so by decreasing urine production. When OAB symptoms persist despite optimal pharmacotherapy, intradetrusor botulinum toxin injection may be an effective and minimally invasive treatment to reduce urinary incontinence and improve quality of life. Treatment efficacy lasts, on average, 9 to 10 months with persistent benefit using repeated treatment. Additional second-line treatment options include sacral neuromodulation and posterior tibial nerve stimulation. As an option of last resort, surgical augmentation by cystoplasty, urinary diversion, or sphincterotomy can be done to definitively reduce bladder pressures.

SEXUAL MANIFESTATIONS OF NEUROLOGIC DISEASE

The medial preoptic area of the hypothalamus mediates sexual stimuli and initiates the sexual response. Caudal projections to midbrain and brainstem nuclei—including the paraventricular nucleus of the hypothalamus, the ventral tegmental area, the raphe, and gigantocellular nuclei—drive spinal reflexes that initiate tumescence, emission, and ejaculation. Tumescence may occur by both psychogenic and reflexogenic mechanisms driven by cerebrum and spinal cord, respectively. A preponderance of parasympathetic tone transmitted via the pelvic plexus and cavernous nerves to the genital soft tissue relaxes the smooth muscle of the corpora cavernosa and helicine penile arteries. Nitric oxide released from nonadrenergic noncholinergic parasympathetic fibers further increases blood flow and intracavernosal pressure. Subsequent venous compression against the tunic albuginea restricts the outflow of blood to enhance and maintain erection. In women, tumescence occurs with increased vaginal blood flow and lubrication. Afferent signals carried by the pudendal and

hypogastric nerves are distributed rostrally throughout the CNS. As sexual stimulation increases, sympathetic tone builds with glandular emission of the various components of sperm and the formation of semen. At sexual climax, sympathetic surge through the hypogastric nerves results in a coordinated autonomic and somatic reflex. In the male, this results is simultaneous closure of the bladder neck and expulsion of semen by rhythmic contractions of striated muscle.

Female Sexual Dysfunction

Female sexual dysfunction (FSD) is a frequent, although poorly explored, comorbidity of neurologic disease, which may be categorized as disorder of sexual desire, arousal, orgasm, or sexual pain. The FSD negatively impacts quality of life, both directly and by compromising sexual relationships and, thereby, psychosocial health. The prevalence of FSD in MS is double that of the general population with more than 80% of female MS patients reporting symptoms of low desire, decreased arousal, and difficulty achieving orgasm. In MS, these symptoms of sexual dysfunction typically correlate with impaired cognitive function, depressive symptoms, bladder and bowel incontinence, Expanded Disability Status Scale scores, and MS subtype but not time since diagnosis. Similarly, FSD is overrepresented among women with epilepsy, most commonly as a lack of sexual desire and orgasmic dysfunction. Both dysregulated hypothalamic function due to ictal and interictal discharges and effects of enzyme-inducing drugs on circulating testosterone levels may contribute. Given the clear importance of sexual health on overall quality of life, a detailed sexual history should be included in any comprehensive neurologic assessment exploring any impediment to healthy sexual function, satisfaction, and relationship.

Male Sexual Dysfunction

Injury rostral to the thoracolumbar cord preserves reflexogenic erection and ejaculation but blocks the psychogenic facilitation of the human sexual response resulting in difficulty maintaining erection. Disconnecting sympathetic pathways by injury to either the thoracolumbar cord or hypogastric nerves, often by lymph node dissection or sigmoidectomy, similarly spares reflexogenic erection but frequently inhibits ejaculation. Sacral spinal cord and root injury, on the other hand, interrupts parasympathetic outflow and reflexogenic sexual response. Plasticity of thoracolumbar outputs to the pelvic plexus provides an alternative pathway by which psychogenic erection and ejaculation may reemerge.

Phosphodiesterase-5 inhibitors improve erectile function, but their use must be weighed against the cardiovascular side effects, to which neurologic patients with autonomic dysfunction are particularly prone. Apomorphine, a dopamine agonist, acts centrally to initiate erection but requires intact efferent spinal pathways to be of benefit. Intracavernous injections of prostaglandin E1, papaverine, and phentolamine as well as intraurethral alprostadil are effective second-line therapies. Ejaculatory dysfunction and sexual function in general may be treated with yohimbine, a mild monoamine oxidase inhibitor, whereas midodrine, an α_1 agonist, has been shown effective in facilitating ejaculation in men with spinal cord injury. In addition, an array of mechanical and electrostimulatory techniques for men may enable sexual function, reproduction, and improve quality of life.

NEUROLOGIC DISORDERS AND THE GASTROINTESTINAL AND GENITOURINARY SYSTEMS

Peripheral Neuropathy

Peripheral autonomic fibers are particularly susceptible to neuropathy with resultant and often concurrent cardiovascular, GI, and GU dysfunction. Acute cholinergic neuropathies are the exception, causing isolated GI and GU manifestations. The GI symptomology includes postprandial fullness, nausea, paralytic ileus, constipation, intermittent diarrhea, and bowel incontinence. The GU symptoms are also varied, but urinary retention and erectile dysfunction, a sensitive indicator of early autonomic dysfunction, predominate. Diabetes mellitus is the most common cause of autonomic neuropathy. The lower urinary tract symptoms, gastroparesis, and constipation are present in over half of diabetic patients. Pudendal compressive injury, known as *Alcock syndrome*, is classically associated with bicycle riding or labor and results in genital sensory loss, erectile dysfunction, and fecal and urinary incontinence.

Spinal Cord Injury

Spina bifida is one of the most common birth defects worldwide with an incidence of 1 or 2 per 1,000 births. In addition to lower extremity weakness and orthopedic problems, decreased bladder sensation and storage dysfunction commonly occur. This developmental anomaly or its surgical correction is also associated with tethered cord syndrome with traction of the filum terminale and displacement of the conus medullaris below the L1-2 disk space. As a consequence, flexion or extension of the spine may provoke pain, sphincter dysfunction, and incontinence.

In the acute phase of traumatic spinal cord injury, autonomic and reflex activities may be lost below the level of injury with paralytic ileus and voiding dysfunction. In the chronic phase, these disabled reflexes reemerge with exaggerated function. Hyperreflexia and loss of voluntary control increases bladder and colon wall tone and tightens the external anal sphincter leading to OAB with simultaneous constipation and mild incontinence. Chronic constipation requires attentive bowel care to help prevent stercoral rectal ulcers. With spinal cord transection at or above the level of T6, potentially fatal autonomic dysreflexia can occur after an uninhibited sympathetic surge is triggered by a noxious stimulus, such as bladder or bowel distention.

Multiple Sclerosis

Bladder dysfunction is common in MS, affecting 80% to 100% of patients over the course of their disease. Given that there are often incomplete and multilevel spinal cord lesions, patients usually give a mixed picture of urinary tract dysfunction, although storage dysfunction with OAB is most frequently encountered. In addition to conventional approaches outlined earlier, cannabis and the cannabinoid-derived nabiximol have shown modest results in increasing bladder control and improving quality of life. Sexual dysfunction affects more than half of men and women with MS. Decreased libido and arousal; dyspareunia; and inability to achieve erection, orgasm, and ejaculation may be further compounded by associated fatigue, immobility, and allodynia.

Parkinsonism

Patients with PD have been shown to develop Lewy body pathology in the enteric nervous system early in the course of the disease. Moreover, involvement of the dorsal motor nucleus of the vagus nerve causes parasympathetic dysfunction and prominent gastric symptoms. Dysphagia with pooling of saliva and drooling, postprandial fullness from delayed gastric emptying, bowel dysmotility, and constipation frequently occur. Loss of libido and erectile and ejaculatory dysfunction are also common. Pathologic hypersexuality, however, may be seen in the setting of dopamine dysregulation syndrome. Late in the disease course, there can be loss in dopamine-mediated inhibition of the PMC leading to urinary storage dysfunction and OAB.

Multiple system atrophy (MSA) is characterized by ubiquitin and α-synuclein inclusion bodies and cell loss in the brainstem, basal ganglia, cerebellum, motor cortex, and central autonomic system with subsequent autonomic failure, parkinsonism, cerebellar ataxia, and pyramidal signs. Compared to PD, urogenital dysfunction is a relatively early feature. Erectile dysfunction is the initial symptom in an estimated 41% of male patients and eventually affects almost all men with MSA. Symptoms of voiding dysfunction and urinary retention develop early in the course of the disease. As a consequence, more than half of patients with MSA suffer from recurrent urinary tract infections.

Cortical and Subcortical Disease

Urodynamic testing in patients with cortical neurodegenerative disorders such as Lewy body dementia and Alzheimer disease frequently demonstrates subclinical storage dysfunction. In normal pressure hydrocephalus, incontinence is usually the presenting symptom in the triad of gait disturbance and cognitive impairment. Detrusor overactivity is the most common form of incontinence after stroke and has a significant impact on post-stroke quality of life. Even subclinical leukoaraiosis is thought to contribute to storage dysfunction. The shared mechanism across these disparate conditions is thought to be disruption of frontal white matter tracts.

NEUROLOGIC CONSEQUENCES OF PRIMARY GASTROINTESTINAL DISEASE

Irritable bowel syndrome is a common GI syndrome that affects up to 20% of adults. It is defined by cramping abdominal pain, altered bowel habits, and changes in stool form and frequency. The underlying cause, although largely unknown, has been related to abnormally low threshold for neurogenic gut simulation by inflammatory mediators such as serotonin, histamine, and corticotropin-releasing factor resulting in dysregulated postprandial gut motility and visceral hyperalgesia.

Gluten sensitivity and celiac disease cause small bowel inflammation with dietary exposure to gluten. Diverse neurologic manifestations can occur, often before the GI symptoms are apparent. Gluten ataxia typically presents insidiously in the fifth decade of life as pure cerebellar ataxia. It can be accompanied by myoclonus, opsoclonus, palatal tremor, or chorea. A majority will have cerebellar atrophy on imaging. Nearly a quarter of patients with established celiac disease on a gluten-free diet will have electrophysiologic evidence of peripheral nerve damage. Although most commonly a sensorimotor axonal neuropathy, sensory ganglionopathy, small-fiber neuropathy, and pure motor neuropathy have been reported. Rarely, encephalopathy with headaches, diffuse or focal CNS white matter abnormalities, and cognitive deficits can be seen in association. Gradually progressive white matter disease can also occur and may be difficult to distinguish from MS. Other neurologic disorders reported in association with gluten sensitivity include stiff person syndrome, myopathy, and myelopathy. The common mechanism for these varied clinical manifestations is thought to involve perivascular inflammation, breakdown of the blood-brain barrier, and loss of the CNS immunoprivilege.

Inflammatory bowel disease (IBD) is made up of two entities: ulcerative colitis and Crohn disease. Similar to gluten sensitivity, neurologic presentations of IBD occasionally precede GI symptoms and involve both the central and peripheral nervous systems. Peripheral neuropathies, including chronic-demyelinating or large- and small-fiber axonal types, are the most common neurologic complications affecting approximately one-third of patients and are typically unresponsive to the treatment of underlying IBD.

The IBD is a hypercoagulable state with increased levels of factors V and VII, fibrinogen, and von Willebrand factor; decreased levels of protein S and antithrombin; and thrombocytosis and platelet dysfunction. Cerebral venous thrombosis is a common neurologic manifestation of ulcerative colitis. An IBD-related arterial ischemic stroke can also occur and can have multiple underlying etiologies including small-vessel disease, artery-to-artery embolism, cardioembolism with or without endocarditis, paradoxical embolism, or vasculitis. Melkersson-Rosenthal syndrome has been described in patients with IBD and is characterized by a triad of recurrent orofacial swelling, relapsing facial paralysis, and fissured tongue.

THE MICROBIOME-GUT-BRAIN AXIS AND NEUROLOGIC DISEASE

The human GI system contains a complex ecosystem of bacteria, fungi, archaea, and viruses. These far outnumber the constituent cells of the human host and inhabit specific niches across the estimated 32 m^2 of surface area lining the gut lumen. This commensal metagenome, although relatively stable across small populations, is individually unique. In addition to evolving predictably over the life course, the microbiome is altered by environmental, nutritional, host immune, and other physiologic factors. Reciprocal actions of host and microbiome are critical to normal development and global regulatory function. As such, the microbiome is increasingly viewed as a vital organ in its own right—one that is integral to host health with dysbiosis or pathologic perturbation in diversity and specific composition implicated in an array of diverse pathology including, intriguingly, neurologic disease.

The human microbiome-gut-brain axis communicates bidirectionally. Vagal stimulation of the neural plexus affects expression of antibodies, antigens, and inflammatory factors which, in turn, impact the composition and activity of the gut microbiome. The afferent vagus senses local microbial metabolites as well as the gut peptides, ghrelin and leptin, at the enormous, permeable interface of the gut with modulatory effects on the hypothalamic-pituitary axis. The blood-brain barrier and brain lymphatic vasculature serve as additional gateways to the CNS

with recirculating intestinal immune cells, microbe-associated molecular patterns, and microbially produced metabolites and neurotransmitters mediating microglial maturation and activation, neurogenesis, synaptic pruning, and brain inflammatory response.

The rise of high-throughput sequencing has allowed scientists to better characterize the metagenomic makeup of the human intestinal tract in health and disease. This bidirectional microbiome-gut-brain axis has been shown to be dysregulated across numerous psychiatric, neurodevelopmental, cerebrovascular, neuro-inflammatory, and neurodegenerative disease states. For example, differences in species diversity and redundancy occur in autism spectrum disorder and depression compared to healthy controls. Similarly, the microbiome of the frail elderly is less diverse and, therefore, more vulnerable to environmental perturbation compared to young adults. Dysbiosis also results in shifts in circulating T-cell subpopulations primed in the gut with T helper and regulatory cells conferring proinflammatory and neuroprotective effects, respectively, in both MS and stroke.

Emerging association studies have shown differences in the microbiome of patients with neuroinflammatory conditions, mainly MS and neuromyelitis optica, as well as neurodegenerative diseases including Alzheimer dementia, parkinsonism, MSA, and even mild cognitive impairment when compared to controls. In cerebrovascular disease, the microbial metabolite—trimethylamine N-oxide—has atherogenic and thrombotic properties thought to confer stroke risk. Colonic biopsies and fecal samples from patients with PD show elevated inflammatory markers. Enteroendocrine cells express α-synuclein in response to inflammation, which they can transmit to enteric neurons. According to Braak's "dual-hit hypothesis," early α-synuclein deposition in the enteric nervous system and olfactory bulb ascends the vagus to aggregate in the CNS resulting in irreversible degeneration of dopaminergic neurons in the substantia nigra and elsewhere. This is supported by neuropathologic studies showing early Lewy body accumulation in the enteric nervous system and dorsal motor nucleus of the vagus with correlation to motor and GI symptom severity.

Despite the interest and numerous studies in the field, clear casual associations are lacking. Nevertheless, the microbiome shows significant promise as a clinical biomarker of neurologic disease onset, progression, and response to medical therapy.

LEVEL 1 EVIDENCE

1. Powers WJ, Rabinstein AA, Ackerson T, et al. 2018 guidelines for the early management of patients with acute ischemic stroke: a guideline for healthcare professionals from the American Heart Association/American Stroke Association. *Stroke*. 2018;49(3):e46-e110.
2. Smith EE, Kent DM, Bulsara KR, et al. Effect of dysphagia screening strategies on clinical outcomes after stroke: a systematic review for the 2018 guidelines for the early management of patients with acute ischemic stroke. *Stroke*. 2018;49(3):e123-e128.
3. Burgos R, Breton I, Cereda E, et al. ESPEN guideline clinical nutrition in neurology. *Clin Nutr*. 2018;37(1):354-396.
4. Volkert D, Chourdakis M, Faxen-Irving G, et al. ESPEN guidelines on nutrition in dementia. *Clin Nutr*. 2015;34(6):1052-1073.

SUGGESTED READINGS

Beach TG, Adler CH, Sue LI, et al. Multi-organ distribution of phosphorylated alpha-synuclein histopathology in subjects with Lewy body disorders. *Acta Neuropathol*. 2010;119(6):689-702.

Beckel JM, Holstege G. Neuroanatomy of the lower urinary tract. In: Anderson KE, Michel MC, eds. *Urinary Tract*. Berlin, Germany: Springer-Verlag; 2011:99-116.

Beckel JM, Holstege G. Neurophysiology of the lower urinary tract. In: Anderson KE, Michel MC, eds. *Urinary Tract*. Berlin, Germany: Springer-Verlag; 2011:149-170.

Birder L, De Groat W. Autonomic control of the urinary tract. In: Robertson D, Biaggioni I, Burnstock G, Low PA, Paton JFR, eds. *Primer on the Autonomic Nervous System*. 3rd ed. London, United Kingdom: Elsevier; 2012:225-228.

Bresalier RS. The clinical significance and pathophysiology of stress-related gastric mucosal hemorrhage. *J Clin Gastroenterol*. 1991;13(suppl 2):S35-S43.

Camillieri M. Gastrointestinal function. In: Robertson D, Biaggioni I, Burnstock G, Low PA, Paton JFR, eds. *Primer on the Autonomic Nervous System*. 3rd ed. London, United Kingdom: Elsevier; 2012:205-209.

Chadwick VS, Chen W, Shu D, et al. Activation of the mucosal immune system in irritable bowel syndrome. *Gastroenterology*. 2002;122(7):1778-1783.

Chancellor MB, Patel V, Leng WW, et al. OnabotulinumtoxinA improves quality of life in patients with neurogenic detrusor overactivity. *Neurology*. 2013;81:841-848.

Chapple C. Overview of the lower urinary tract. In: Anderson KE, Michel MC, eds. *Urinary Tract*. Berlin, Germany: Springer-Verlag; 2011:1-14.

Cook DJ, Fuller HD, Guyatt GH, et al. Risk factors for gastrointestinal bleeding in critically ill patients. Canadian Critical Care Trials Group. *N Engl J Med*. 1994;330(6):377-381.

De Ridder D, Van Der Aa F, Debruyne J, et al. Consensus guidelines on the neurologist's role in the management of neurogenic lower urinary tract dysfunction in multiple sclerosis. *Clin Neurol Neurosurg*. 2013;115:2033-2040.

Drake M, Parsons B. Bladder function in health and disease. In: Robertson D, Biaggioni I, Burnstock G, Low PA, Paton JFR, eds. *Primer on the Autonomic Nervous System*. 3rd ed. London, United Kingdom: Elsevier; 2012:229-232.

Everaert K, de Waard WIQ, Van Hoof T, Kiekens C, Mulliez T, D'herde C. Neuroanatomy and neurophysiology related to sexual dysfunction in male neurogenic patients with lesions to the spinal cord or peripheral nerves. *Spinal Cord*. 2010;48:182-191.

Faaborg PM, Christensen P, Krassioukov A, Laurberg S, Frandsen E, Krogh K. Autonomic dysreflexia during bowel evacuation procedures and bladder filling in subjects with spinal cord injury. *Spinal Cord*. 2014;52(6):494-498.

Furness JB. The enteric nervous system and neurogastroenterology. *Nat Rev Gastroenterol Hepatol*. 2012;9(5):286-294.

Griffiths DJ. Use of functional imaging to monitor central control of voiding in humans. In: Anderson KE, Michel MC, eds. *Urinary Tract*. Berlin, Germany: Springer-Verlag; 2011:81-98.

Grundy D, Al-Chaer ED, Aziz Q, et al. Fundamentals of neurogastroenterology: basic science. *Gastroenterology*. 2006;130(5):1391-1411.

Hadjivassiliou M, Sanders DS, Grünewald RA, Woodroofe N, Boscolo S, Aeschlimann D. Gluten sensitivity: from gut to brain. *Lancet Neurol*. 2010;9:318-330.

Hertzler DA II, DePowell J, Stevenson CB, Mangano FT. Tethered cord syndrome: a review of the literature from embryology to adult presentation. *Neurosurg Focus*. 2010;29:E1.

Hilz M. Physiology and pathophysiology of female sexual function. In: Robertson D, Biaggioni I, Burnstock G, eds. *Primer on the Autonomic Nervous System*. 3rd ed. London, United Kingdom: Elsevier; 2012:235-238.

Kanai AJ. Afferent mechanism in the urinary tract. In: Anderson KE, Michel MC, eds. *Urinary Tract*. Berlin, Germany: Springer-Verlag; 2011:171-206.

Koppel BS, Brust JCM, Fife T, et al. Systematic review: efficacy and safety of medical marijuana in selected neurologic disorders. *Neurology*. 2014;82:1556-1563.

Linsenmeyer TA. Post-CVA voiding dysfunctions: clinical insights and literature review. *NeuroRehabilitation*. 2012;30:1-7.

McKeown SJ, Stamp L, Hao MM, Young HM. Hirschsprung disease: a developmental disorder of the enteric nervous system. *Wiley Interdiscip Rev Dev Biol*. 2013;2:113-129.

Panicker JN, Fowler CJ. The bare essentials: uro-neurology. *Pract Neurol*. 2010;10:178-185.

Papatsoris AG, Papapetropoulos S, Singer C, Deliveliotis C. Urinary and erectile dysfunction in multiple system atrophy (MSA). *Neurourol Urodyn*. 2008;27:22-27.

Perkin GD, Murray-Lyon I. Neurology and the gastrointestinal system. *J Neurol Neurosurg Psychiatry*. 1998;65(3):291-300.

Peters KM, Kandagatla P, Killinger KA, Wolfert C, Boura JA. Clinical outcomes of sacral neuromodulation in patients with neurologic conditions. *Urology*. 2013;81(4):738-743.

Pfeiffer RF. Gastrointestinal, urological, and sexual dysfunction in Parkinson's disease. *Mov Disord*. 2010;25(suppl 1):S94-S97.

Ransmayr GN, Holliger S, Schletterer K, et al. Lower urinary tract symptoms in dementia with Lewy bodies, Parkinson disease, and Alzheimer disease. *Neurology*. 2008;70:299-303.

Rossiter CD, Norman WP, Jain M, Hornby PJ, Benjamin S, Gillis RA. Control of lower esophageal sphincter pressure by two sites in dorsal motor nucleus of the vagus. *Am J Physiol*. 1990;259(6, pt 1):G899-G906.

Ruffion A, Castro-Diaz D, Patel H, et al. Systematic review of the epidemiology of urinary incontinence and detrusor overactivity among patients with neurogenic overactive bladder. *Neuroepidemiology*. 2013;41:146-155.

Sakakibara R, Kanda T, Sekido T, et al. Mechanism of bladder dysfunction in idiopathic normal pressure hydrocephalus. *Neurourol Urodyn*. 2008;27:507-510.

Schirmer CM, Kornbluth J, Heilman CB, Bhardwaj A. Gastrointestinal prophylaxis in neurocritical care. *Neurocrit Care*. 2012;16:184-193.

Siaud P, Puech R, Assenmacher I, Alonso G. Adrenergic innervation of the dorsal vagal motor nucleus: possible involvement in inhibitory control of gastric acid and pancreatic insulin secretion. *Cell Tissue Res*. 1990;259(3):535-542.

Utomo E, Groen J, Blok BFM. Surgical management of functional bladder outlet obstruction in adults with neurogenic bladder dysfunction. *Cochrane Database Syst Rev*. 2014;(5):CD004927.

127 Bone Diseases and the Central Nervous System

Roger N. Rosenberg and Alison M. Pack

KEY POINTS

1. Multiple disorders involving the skeletal system including Paget disease, fibrous dysplasia, and achondroplasia have neurologic manifestations.
2. Treatment of neurologic manifestations of disorders of skeleton is directed by treatment of underlying skeletal disease.
3. Neurologic diseases including epilepsy, stroke, Parkinson disease, and multiple sclerosis are associated with increased risk of osteoporosis and fracture.
4. Identifying and treating vitamin D deficiency, treating osteoporosis, and preventing falls may reduce risk of fracture in patients with chronic neurologic diseases.

PAGET DISEASE

Introduction

This chronic disease of the adult skeleton, formerly known as *osteitis deformans*, is characterized by bowing and irregular flattening of the bones. Any or all skeletal bones may be affected, but the tibia, skull, and pelvis are the most frequent sites. Usually, multiple bones are affected, but in 15%, only one is involved. The disease is symptomatic in 15% to 20% of affected individuals. Pain is the most common symptom. Except for the skeletal deformities and pain, the disease causes disability only when the skull or spine is involved.

Two types of neurologic symptoms appear: those owing to the abnormalities in bone and those owing to arteriosclerosis, a common accompaniment. The cerebral manifestations that occur with arteriosclerosis are identical to those seen in patients with arteriosclerosis in the absence of Paget disease.

Epidemiology

There is a postmortem incidence of 3% in patients older than 40 years of age. Men and women are equally affected. The most common age at onset is in the fourth to sixth decades; it is rare before age 30 years.

Pathobiology

Genetic and environmental factors such as paramyxovirus infection and dietary deficiency of calcium may influence the presentation. In affected bones, there is an imbalance between the formation and the resorption of bone. In most cases, there is a mixture of excessive bone formation and bone destruction. The areas of bone destruction are filled with hyperplastic vascular connective tissue. New bone formation may occur in the destroyed areas in an irregular disorganized manner. The metabolic disturbance is unknown.

The neurologic defects of osteitis deformans are usually related to pressure on the central nervous system or nerve roots by the overgrowth of bone. Convulsive seizures, generalized or neuralgic head pain, cranial nerve palsies, and paraplegia occur in a few cases. Deafness caused by pressure on the auditory nerves is the most common symptom; unilateral facial palsy is the next most common. Loss of vision in one eye, visual field defects, or exophthalmos may occur when the sphenoid bone is affected. Compression of the spinal cord is more common than compression of the brain, which is extremely rare except when there is sarcomatous degeneration of the lesions. Platybasia may occur in advanced cases. Paget disease has also been described in a patient with basilar impression and Arnold-Chiari type I malformation.

Diagnosis

The diagnosis of Paget disease is made from the patient's appearance and the characteristic radiographic changes. Involvement of the skull in advanced cases is manifested by a generalized enlargement of the calvarium, anteroflexion of the head, and depression of the chin on the chest. When the spine is involved, the patient's stature is shortened, the spine is flexed forward, and spinal mobility is greatly reduced.

Radiographically, the skull shows areas of increased bone density with loss of normal architecture, mingled with areas in which the density of the bone is decreased (**Fig. 127.1**). The margins of the bones are fuzzy and indistinct. The general appearance is that of an enormous skull with the bones of the vault covered with cotton wool. In advanced cases, there may be a flattening of the base of the skull on the cervical vertebrae (*platybasia*) with signs of damage to the lower cranial nerves, medulla, or cerebellum. Both computed tomography (CT) and magnetic resonance imaging (MRI) aid diagnosis.

The serum calcium content is normal, and the serum phosphorus is normal or only slightly increased. Serum alkaline phosphatase activity is increased; the level varies with the extent and activity of the process. It may be only slightly elevated when the disease is localized to one or two bones.

Diagnosis may be difficult if the clinical symptoms are mainly neurologic. In these instances, radiographs of the pelvis and legs or a general survey of the entire skeleton may establish the diagnosis. Rarely, it may be impossible to distinguish monophasic Paget disease of the skull from osteoblastic metastases. Search for a primary neoplasm, particularly in the prostate, or biopsy of one of the lesions in the skull may be necessary in those cases.

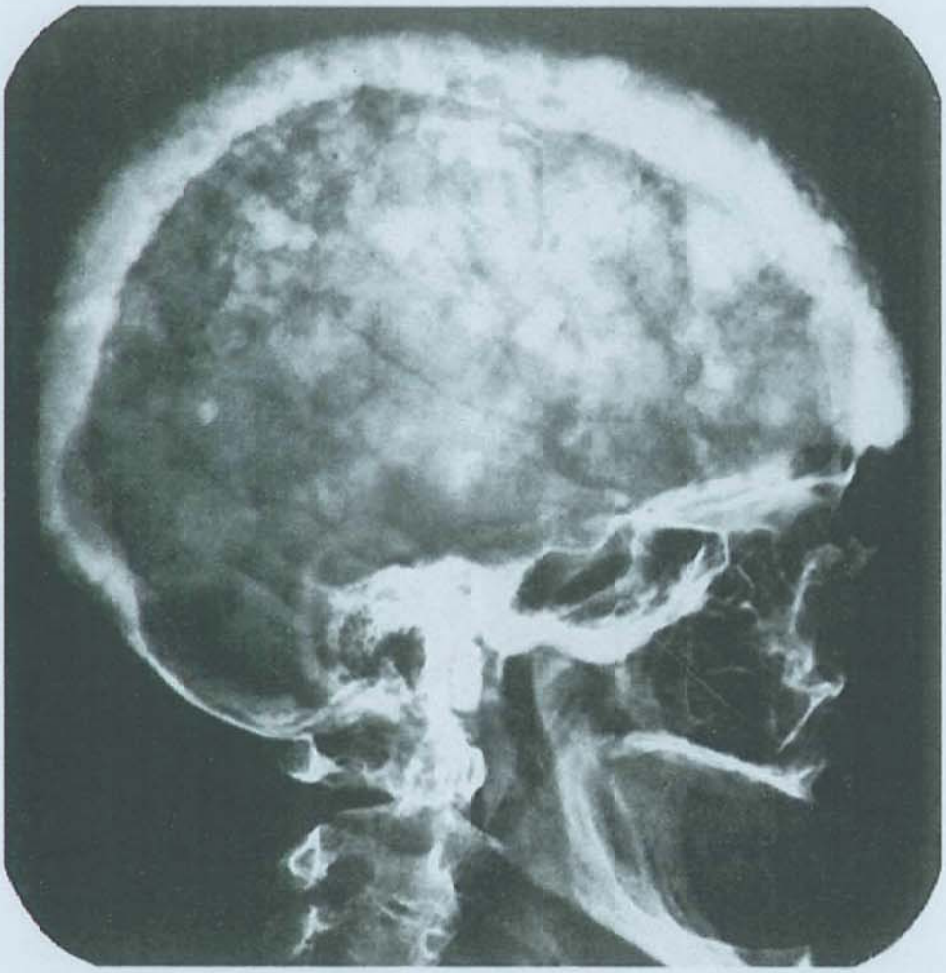

FIGURE 127.1 Osteitis deformans (Paget disease) of the skull. (Courtesy of Dr. Juan Taveras.)

Management

Bisphosphonates such as pamidronate, alendronate, risedronate, and zoledronic acid are considered the treatment of choice. These agents inhibit osteoblastic bone resorption. They have been shown to heal radiologic lesions and restore normal histology. The long-term effects of these drugs on disease progression have not been adequately studied. The most common indication is for pain. Less potent second-line choices include etidronate and tiludronate. Calcium and vitamin D repletion is necessary to avoid hypocalcemia secondary to bisphosphonates. The value of these medical therapies can be evaluated by reduction of serum levels of alkaline phosphatase measured at 4-month intervals and annual radiographs of specific lesions. Decompression of the spinal cord may be indicated for myelopathy secondary to stenosis created by the enlarged vertebrae. Similarly, platybasia may require to decompression of the posterior fossa to relieve cranial nerve dysfunction.

Calcitonin may also be given to inhibit the osteolytic process. Salmon calcitonin is given in subcutaneous injections of 50 to 100 units daily. Improvement of osteolytic lesions and reversal of neurologic manifestations have been noted with long-term therapy. About 25% of the patients develop serum antibodies to salmon calcitonin, sometimes in titers high enough to make the person resistant to the hormonal action of calcitonin; under these circumstances, human calcitonin may be effective.

Outcome

The course is variable but usually extends for decades. The neurologic lesions seldom lead to serious disability other than deafness, convulsive seizures, or compression of the spinal cord.

FIBROUS DYSPLASIA

Introduction

Fibrous dysplasia is a pathologic process characterized by small areas of bone destruction or massive sclerotic overgrowth. The skull and the bones in other parts of the body may be involved. The clinical picture of fibrous dysplasia is related to the site and extent of the bone overgrowth. Fibrous dysplasia can involve one (monostotic form) or multiple (polyostotic form) bones. Both types may be associated with hyperfunctional endocrinopathies and café au lait lesions referred to as the *McCune-Albright syndrome*.

Epidemiology

Symptoms may begin at any age, but onset usually occurs in early adult life. There is no racial or sexual predominance.

Pathobiology

Fibrous dysplasia and McCune-Albright syndrome are caused by a sporadic postzygotic missense mutation in the somatic cells of

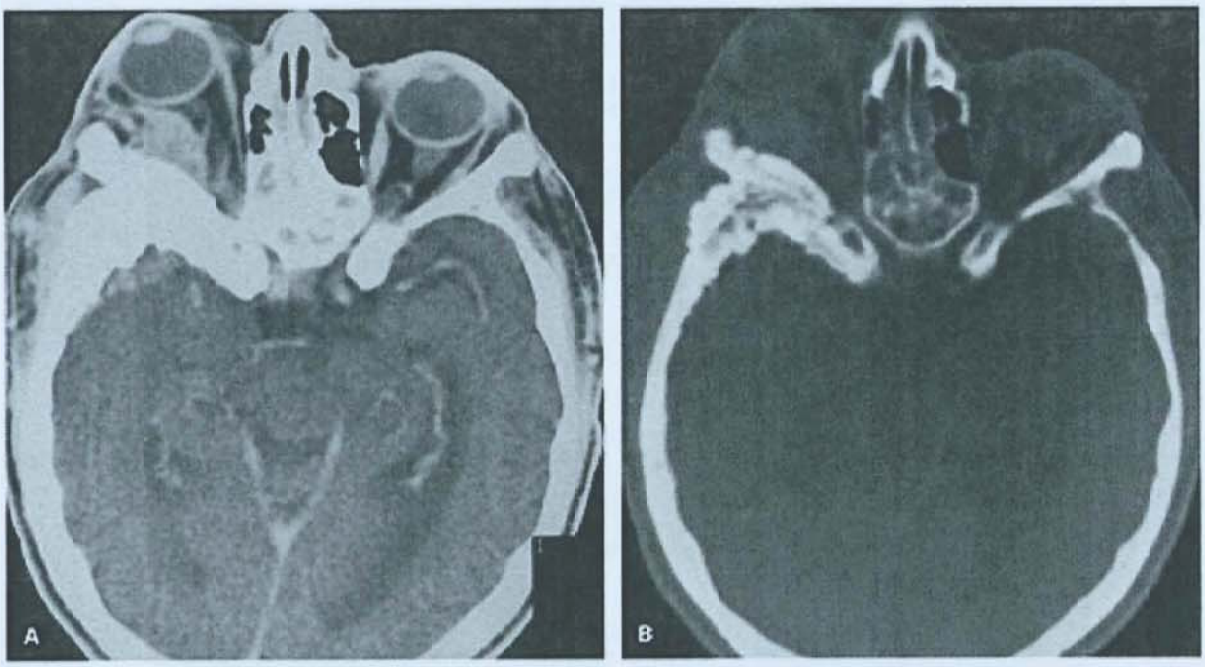

FIGURE 127.2 Fibrous dysplasia. Computed tomography. **A:** Axial contrast-enhanced scan shows proptosis on *right* with abnormal soft-tissue enhancement within orbit and middle cranial fossa. **B:** Bone window depicts pronounced thickening of sphenoid bone. (Courtesy of Dr. T. L. Chi.)

the GNAS complex locus located on chromosome 20q13. Overall, this leads to defects in osteoblast differentiation and proliferation of osteoblast progenitors leading to abnormal bone.

Diagnosis

Diagnosis is typically made clinically after complete staging of skeletal, endocrine, soft tissue, and dermatologic features. In addition to the disfiguration of the skull in the polyostotic form, symptoms of the monostotic form of the disease include headache, convulsions, exophthalmos, optic atrophy, and deafness. Most patients are, however, asymptomatic.

Radiographic features of the skull and craniofacial bones include bone expansion showing ground-glass appearance and calvarial deformity resulting in exophthalmos. The bones of the skull most often affected are the frontal (56%) and sphenoid (48%) bones. A Danish case series of 26 subjects revealed that 80% had involvement of craniofacial bones. Diffuse involvement of the entire skull produces leontiasis ossea, with exophthalmos, optic atrophy, and cranial nerve palsies (Fig. 127.2).

Management

Treatment is limited. Surgical intervention can be used to treat fracture and bony deformities. Bisphosphonates have been used to treat bone pain. A double-blind placebo-controlled trial of alendronate, an oral bisphosphonate, found no significant effect on serum osteocalcin (a marker of bone formation), pain, or functional parameters. Intravenous bisphosphonates, pamidronate and zoledronate, may be considered, but no randomized trial has been done to support an effect. Denosumab, a RANKL inhibitor, in preliminary studies is promising for patients who are refractory to bisphosphonates.

Outcome

As treatment options are limited, children and adults with fibrous dysplasia report poor physical function and pain. A small survey study did, however, find that despite functional limitations, patients with fibrous dysplasia achieved a high level of emotional and emotional function.

ACHONDROPLASIA

Introduction

Achondroplasia (*chondrodystrophy*) is the most frequent form of skeletal dysplasia causing dwarfism and is characterized by short arms and legs, lumbar lordosis, and enlargement of the head. Symptoms of nervous system involvement sometimes develop as a result of hydrocephalus, compression of the medulla and cervical cord at the level of the foramen magnum, compression of the spinal cord by ruptured intervertebral disk, and bone compression of the lower thoracic or lumbar cord. Seizures, ataxia, and paraplegia are the most common symptoms. Mental development is usually normal. Mortality rates are significantly elevated secondary to accidental, neurologic, and heart disease–related causes. Many affected infants die in the perinatal period, although a normal life span is possible for patients with less severe involvement of the bones.

Epidemiology

The disease is rare, estimated to occur in about 1 in 15,000 to 35,000 births. Males and females are affected equally. Fathers of age 35 years and older have a relatively higher risk of having an infant with de novo achondroplasia than younger fathers.

Pathobiology

Achondroplasia is caused by mutations (G1138A and G1138C) in the fibroblast growth factor receptor 3 gene. The gene product is expressed in cartilage. The mutations result in a gain of negative function, producing an inactive fibroblast growth factor receptor and resultant dwarfism. Achondroplasia is inherited as an autosomal dominant trait, although 80% of cases are sporadic.

Diagnosis

The characteristic body configuration of short arms and legs, normal-sized trunk, enlargement of the head, and changes in the radiographs of the skeleton leads to the diagnosis. Previously, CT was used to evaluate neurologic complications of achondroplasia. Currently, MRI of the brain and spine best define the presence of hydrocephalus and degree of ventricular compensation as well as whether cord compression is present. Somatosensory evoked potential may be useful for detecting cervical myelopathy.

Management

Shunting procedures may be needed for hydrocephalus caused by involvement of the bones at the base of the skull. Laminectomy is indicated for signs of cord compression.

Outcome

As no clear treatment is available for achondroplasia, patients report long-term physical and mental impairments. Studies find that adults and children with achondroplasia have lower quality of life and lower self-esteem when compared to either healthy relatives or compared to a healthy reference population.

ANKYLOSING SPONDYLITIS

Introduction

Ankylosing spondylitis is considered the prototype of the spondyloarthropathies. Neurologic symptoms have been considered to be uncommon but have only received limited study. A study investigated this question further among 24 patients recruited from an Egyptian outpatient rheumatologic clinic compared to age- and sex-matched controls. Neurologic manifestations occurred in 25% of the patients; 8.3% had myelopathy and 16.7% had radiculopathy. Subclinical neurologic complications as evident by neurophysiologic test abnormalities were common, as over 70% had at least one abnormal finding.

Epidemiology

The condition is common, affecting an estimated 1.4% of the general population. It typically occurs in younger persons, and men are affected 2 to 3 times more commonly than women.

Pathobiology

Its etiology is likely secondary to multiple genetic and environmental factors including a strong association with the gene for human leukocyte antigen B27. This inflammatory disorder affects ligamentous insertions into bones; at first, it usually affects the sacroiliac joints and lumbar spine. In some patients, the entire spine is involved, with ossification of the ligaments and fusion of the vertebra. The spine becomes rigid and susceptible to a variety of disorders that may affect the spinal cord, including fractures and dislocations, atlanto-occipital dislocation, and spinal stenosis.

A cauda equina syndrome may appear in patients with long-standing spondylitis. Signs and symptoms are symmetric, with weakness, wasting, and sensory loss in lumbosacral myotomes. Autonomic dysfunction and more specifically parasympathetic dysfunction may occur. Bladder and bowel are commonly affected, and pain may be severe. The mechanism is not clear. Although concomitant arachnoiditis has been suspected as the cause, the syndrome appears late, when there is little evidence that the underlying spondylitis is active. Moreover, there is little inflammation at postmortem examination, which is likely to show chronic fibrosis.

Diagnosis

There is erosion of posterior bone elements, and, in earlier days, myelography showed enlargement of the caudal sac and prominent diverticula of the arachnoid. The CT shows similar pathology, but MRI is more illuminating, showing nerve root thickening and sometimes enhancement of dura and nerve roots; that pattern suggests inflammation of the arachnoid structures, supporting the earlier theory.

Management

Surgery is generally ineffective and has sometimes been deleterious, although there have been rare reports of some relief. Steroid therapy has been similarly without benefit. Physical therapy may be useful. Studies suggest the use of nonsteroidal anti-inflammatory drugs or selective cyclooxygenase-2 inhibitors for symptomatic patients. Tumor necrosis factor inhibitors are useful for patients whose symptoms persist despite treatment with nonsteroidal anti-inflammatory drugs.

Outcome

Prognosis of ankylosing spondylitis depends on extraspinal manifestations, age at diagnosis, lifestyle, and treatment. Factors that affect quality of life include progressive structural and functional impairments. Cross-sectional studies and a meta-analysis of 38 studies in patients with ankylosing spondylitis found that patients with ankylosing spondylitis have significantly lower health-related quality of life when compared with either controls or the general population.

ATLANTOAXIAL DISLOCATION

Introduction

Atlantoaxial dislocation refers to loss of stability between the atlas and axis (C1-C2). The subluxation of C1 on C2 occurs in many conditions that render the odontoid process of C2 ineffective as a stabilizing post. Etiologies include cervical trauma, a congenital malformation (alone or in combination with other

anomalies of the cervical spine or cranium), or secondary to inflammatory diseases.

Epidemiology

Atlantoaxial dislocation is extremely rare in persons without any predisposing factors, can occur equally in men and women, and can present at any age. Atlantoaxial dislocation occurs with disproportionate frequency with Down syndrome (up to 30%), ankylosing spondylitis, and rheumatoid arthritis, particularly older patients (reported ranges between 25% and 80%).

Pathobiology

Pathobiology depends on etiology. Traumatic atlantoaxial dislocation is a result of disruption of the transverse, alar, or apical ligaments. Ligamentous laxity and osseous abnormalities among patients with Down syndrome leads to atlantoaxial dislocation. Among patients with inflammatory disorders such as rheumatoid arthritis, chronic inflammation causes laxity and stretching of the transverse ligament, development of granulation tissue, and erosion of the bony structures.

Diagnosis

Clinically, patients can present with mild axial neck pain, paresthesias, weakness, or signs of myelopathy on exam. In more advanced cases, patients may have lower cranial nerve dysfunction. Atlantoaxial dislocation can be diagnosed with either plain spine films, CT, or MRI.

Management

For symptomatic cases, surgical stabilization is indicated. For asymptomatic cases, there has to be consideration of the risks of surgery against uncertain risks of no surgery. A general recommendation is to consider stabilization or decompression if imaging shows deformation of the neuraxis, symptomatic, or not. A closed reduction and brace immobilization was successfully applied to a patient with traumatic bilateral rotatory dislocation of the atlantoaxial joints.

Outcome

If untreated, there is risk of cervical myelopathy or medullary compression and sudden death has been reported. Among symptomatic patients who are treated, prognosis is good.

FRACTURES AND SECONDARY OSTEOPOROSIS: NEUROLOGIC CAUSES

Introduction

Epilepsy, stroke, multiple sclerosis (MS), and Parkinson disease are all neurologic diseases associated with secondary osteoporosis resulting in increased risk of fracture. In addition, certain treatments of neurologic diseases including glucocorticosteroids, antiepileptic drugs (AEDs), and unfractionated heparin have an independent negative effect on bone. Steroid-induced osteoporosis is the most common cause of secondary osteoporosis. Enzyme-inducing AEDs such as phenytoin, phenobarbital, and carbamazepine are independently associated with lower bone mineral density (BMD). Vitamin D insufficiency is reported in all of these neurologic conditions contributing to reduced BMD and increased fracture risk.

Epidemiology

Fracture rates are increased approximately twofold in persons with epilepsy. Similarly, fractures occur 2 to 7 times more commonly in patients with stroke than in patients without stroke. Risk factors include stroke severity and living alone at time of stroke. Fracture rates are also higher in patients with MS and in persons with Parkinson disease. In Parkinson disease, the femur is the most commonly fractured bone, whereas in the community, it is the radius. Men with Parkinson disease seem to be at particular increased risk for hip fracture. A Korean population–based case control study also found increased risk of osteoporotic vertebral compression fracture in patients with Parkinson disease. Higher percentages of osteoporosis are found in persons with Parkinson disease.

Pathobiology

Among patients with epilepsy falls secondary to seizure activity, gait imbalance because of AED treatment, and potential direct effects of AED therapy on bone including secondary osteoporosis all contribute. After a stroke, fractures usually occur relatively late after stroke onset and more commonly affect the paretic side of the body. The tendency to fall as a result of poststroke hemiplegia and disuse osteoporosis increase the fracture risk. In MS patients, fracture risk is increased because of reduced BMD secondary to immobility, prolonged corticosteroid use, and vitamin D insufficiency. Similarly, vitamin D deficiency, a common finding among patients with Parkinson disease, and increased risk of falling contribute to risk of osteoporosis and fractures.

Diagnosis

Clinically, it is important to recognize that persons with neurologic diseases are at increased risk for secondary osteoporosis and fracture. Screening of patients at risk includes serologic 25-hydroxyvitamin D testing and BMD assessment using dual-energy x-ray absorptiometry.

Management

When necessary, vitamin D supplementation should be encouraged. For those with epilepsy taking enzyme-inducing AEDs, higher doses of vitamin D supplementation will be needed. Bisphosphonates are commonly used to slow progression of osteoporosis and reduce fracture risk. Randomized controlled trials have found an increase in BMD, a reduction in fracture when bisphosphonates were given to patients with epilepsy LEVEL 3[1] or Parkinson disease LEVEL 3,[2] and an open-label study found similar benefits among stroke survivors LEVEL 3.[3] A meta-analysis of eight randomized clinical trials including five stroke trials and three Parkinson disease trials found that there is efficacy against hip fracture with bisphosphonate treatment with stroke and Parkinson disease. No study has assessed their impact among MS patients.

Some reports suggest that bisphosphonates are associated with an increased risk of atrial fibrillation and may increase the risk of ischemic stroke. A Danish case control population-based study and an English case control study did not find an association between oral bisphosphonates and risk of ischemic stroke. Similarly, an analysis using a Danish nationwide cohort of over 100,000 patients with first time hospitalization for stroke found no evidence that preadmission bisphosphonate use increases 30-day mortality following stroke. A nonsignificant increased risk was found in association with an intravenous formulation (zoledronic acid) in an international multicenter randomized study. Interestingly, animal models suggest that bisphosphonates have an antiatherosclerotic effect, and in one population study, persons who received bisphosphonates had a lower risk of stroke when followed for a 2-year period. These results need to be followed up with a randomized clinical trial.

Outcome

Prognosis depends on identification and treatment of osteoporosis as well as implementing strategies to reduce fall risk. There are, however, limited well-designed studies demonstrating effects of interventions for preventing falls.

LEVEL 1 EVIDENCE

1. Lazzarri AA, Dussault PM, Thakore-James M, et al. Prevention of bone loss and vertebral fractures in patients with chronic epilepsy—antiepileptic drug and osteoporosis prevention trial. *Epilepsia*. 2013;54(11):1997-2004.
2. Sato Y, Iwamoto J, Honda Y. Once-weekly risedronate for prevention of hip fracture in women with Parkinson's disease: a randomised controlled trial. *J Neurol Neurosurg Psychiatry*. 2011;82:1390-1393.
3. Sato Y, Honda Y, Iwamoto J, Kanoko T, Satoh K. Effect of folate and mecobalamin on hip fractures in patients with stroke: a randomized controlled trial. *JAMA*. 2005;293(9):1082-1088.

SUGGESTED READINGS

Paget Disease

Chen JR, Rhee RS, Wallach S, Avramides A, Flores A. Neurologic disturbances in Paget disease of bone: response to calcitonin. *Neurology*. 1979;29:448-457.

Colina M, La Corte R, De Leonardis F, Trotta F. Paget's disease of bone: a review. *Rheumatol Int*. 2008;28(11):1069-1075.

Corey JM. Genetic disorders producing compressive radiculopathy. *Semin Neurol*. 2006;26(5):515-522.

Douglas DL, Kanis JA, Duckworth T, Beard DJ, Paterson AD, Russell RG. Paget's disease: improvement of spinal cord dysfunction with diphosphonates and calcitonin. *Metab Bone Dis Relat Res*. 1981;3:327-335.

Gruener G, Camacho P. Paget's disease of bone. *Handb Clin Neurol*. 2014;119:529-540.

Hadjipavlou A, Lander P. Paget disease of the spine. *J Bone Joint Surg Am*. 1991;73:1376-1381.

Hosking D, Lyles K, Brown JP, et al. Long-term control of bone turnover in Paget's disease with zoledronic acid and risedronate. *J Bone Miner Res*. 2007;22:142-148.

Hullar TE, Lustig LR. Paget's disease and fibrous dysplasia. *Otolaryngol Clin North Am*. 2003;36:707-732.

Iglesias-Osma C, Gómez Sánchez JC, Suquia Múgica B, Querol Prieto R, de Portugal Alvarez J. Paget's disease of bone and basilar impression associated with an Arnold–Chiari type-I malformation [in Spanish]. *An Med Interna*. 1997;14:519-522.

Langston AL, Campbell MK, Fraser WD, MacLennan GS, Selby PL, Ralston SH. Randomized trial of intensive bisphosphonate treatment versus symptomatic management in Paget's disease of bone. *J Bone Miner Res*. 2010;25:20-31.

Moiyadi AV, Praharaj SS, Pillai VS, Chandramouli BA. Hydrocephalus in Paget's disease. *Acta Neurochir (Wien)*. 2006;148(12):1297-1300.

Ralston SH, Langston AL, Reid IR. Pathogenesis and management of Paget's disease of bone. *Lancet*. 2008;372(9633):155-163.

Wallach S. Treatment of Paget's disease. *Adv Intern Neurol*. 1982;27:1-43.

Watts GD, Wymer J, Kovach MJ, et al. Inclusion body myopathy associated with Paget disease of bone and frontotemporal dementia is caused by mutant valosin-containing protein. *Nat Genet*. 2004;36:377-381.

Fibrous Dysplasia

Albright F. Polyostotic fibrous dysplasia: a defense of the entity. *J Clin Endocrinol Metab*. 1947;7:307-324.

Boyce AM, Kelly MH, Brillante BA, et al. A randomized, double blind, placebo-controlled trial of alendronate treatment for fibrous dysplasia of bone. *J Clin Endocrinol Metab*. 2014;99(11):4133-4140.

Candeliere GA, Roughley PJ, Glorieux FH. Polymerase chain reaction-based technique for the selective enrichment and analysis of mosaic Arg201 mutations in G alpha S from patients with fibrous dysplasia of bone. *Bone*. 1997;21:201-206.

Chao K, Katznelson L. Use of high-dose oral bisphosphonate therapy for symptomatic fibrous dysplasia of the skull. *J Neurosurg*. 2008;109(5):889-892.

Chapurlat RD, Orcel P. Fibrous dysplasia of bone and McCune-Albright syndrome. *Best Pract Res Clin Rheumatol*. 2008;22(1):55-69

Fitzpatrick KA, Taljanovic MS, Speer DP, et al. Imaging findings of fibrous dysplasia with histopathologic and intraoperative correlation. *AJR Am J Roentgenol*. 2004;182:1389-1398.

Javaid MK, Boyce A, Appelman-Dijkstra N, et al. Best practice management guidelines for fibrous dysplasia/McCune-Albright syndrome: a consensus statement from the FD/MAS international consortium. *Orphanet J Rare Dis*. 2019;14(1):139.

Kelly MH, Brillante B, Kushner H, Gehron Robey P, Collins MT. Physical function is impaired but quality of life preserved in patients with fibrous dysplasia of bone. *Bone*. 2005;37(3):388-394.

Leet AI, Magur E, Lee JS, Wientroub S, Robey PG, Collins MT. Fibrous dysplasia in the spine: prevalence of lesions and association with scoliosis. *J Bone Joint Surg Am*. 2004;86:531-537.

Lisle DA, Monsour PA, Maskiell CD. Imaging of craniofacial fibrous dysplasia. *J Med Imaging Radiat Oncol*. 2008;52(4):325-332.

Majoor BCJ, Papapoulos SE, Sander Dijkstra PD, Fiocco M, Hamdy NAT, Appelman-Dijkstra NM. Denosumab in patients with fibrous dysplasia previously treated with bisphosphonates. *J Clin Endocrinol Metab*. 2019;104(12):6069-6078.

Selmani Z, Aitasalo K, Ashammakhi N. Fibrous dysplasia of the sphenoid sinus and skull base presents in an adult with localized temporal headache. *J Craniofac Surg*. 2004;15:261-263.

Thomsen MD, Rejnmark L. Clinical and radiological observations in a case series of 26 patients with fibrous dysplasia. *Calcif Tissue Int*. 2014;94:384-395.

Achondroplasia

Coi A, Santoro M, Garne E, et al. Epidemiology of achondroplasia: a population-based study in Europe. *Am J Genet A*. 2019;179(9):1791-1798.

Dennis JP, Rosenberg HS, Alvord EC Jr. Megalencephaly, internal hydrocephalus and other neurological aspects of achondroplasia. *Brain*. 1961;84:427-445.

Gollust SE, Thompson RE, Gooding HC, Biesecker BB. Living with achondroplasia: attitudes toward population screening and correlation with quality of life. *Prenat Diagn*. 2003;23:1003-1008.

Hecht JT, Bodensteiner JB, Butler IJ. Neurologic manifestations of achondroplasia. *Handb Clin Neurol*. 2014;119:551-563.

Horton WA, Lunstrum GP. Fibroblast growth factor receptor 3 mutations in achondroplasia and related forms of dwarfism. *Rev Endocr Metab Disord*. 2002;3:381-385.

Richette P, Bardin T, Stheneur C. Achondroplasia: from genotype to phenotype. *Joint Bone Spine*. 2008;75(2):125-130.

Shiang R, Thompson LM, Zhu YZ, et al. Mutations in the transmembrane domain of FGFR3 cause the most common genetic form of dwarfism, achondroplasia. *Cell*. 1994;78:335-342.

Smoker WR, Khanna G. Imaging the craniocervical junction. *Childs Nerv Syst*. 2008;24(10):1123-1145.

Witt S, Kolb B, Bloemeke J, Mohnike K, Bullinger M, Quitmann J. Quality of life of children with achondroplasia and their parents—a German cross-sectional study. *Orphanet J Rare Dis*. 2019;14(1):194

Wynn J, King TM, Gambello MJ, Waller KD, Hecht JT. Mortality in achondroplasia study: a 42-year follow-up. *Am J Med Genet A*. 2007;143A(21):2502-2511.

Yamanaka Y, Ueda K, Seino Y, Tanaka H. Molecular basis for the treatment of achondroplasia. *Horm Res*. 2003;60(suppl 3):60-64.

Ankylosing Spondylitis

Borman P, Gokoglu F, Kocaoglu S, Yorgancioglu ZR. The autonomic dysfunction in patients with ankylosing spondylitis: a clinical and electrophysiological study. *Clin Rheumatol*. 2008;27:1267-1273.

Braun J, Sieper J. Biological therapies in the spondyloarthritides—the current state. *Rheumatology (Oxford)*. 2004;43:1072-1084.

Dean LE, Jones GT, MacDonald AG, Downham C, Sturrock RD, Macfarlane GJ. Global prevalence of ankylosing spondylitis. *Rheumatology (Oxford)*. 2014;53:650-657.

Haywood KL, Garratt AM, Jordan K, Dziedzic K, Dawes PT. Spinal mobility in ankylosing spondylitis: reliability, validity and responsiveness. *Rheumatology (Oxford)*. 2004;43:750-757.

Khedr EM, Rashad SM, Hamed SA, El-Zharaa F, Abdalla AKH. Neurological complications of ankylosing spondylitis: neurophysiological assessment. *Rheumatol Int*. 2009;29:1031-1040.

Law L, Beckman Rehnman J, Deminger A, Klingberg E, Jacobsson LTH, Forsblad-d'Elia H. Factors related to health-related quality of life in ankylosing spondylitis, overall and stratified by sex. *Arthritis Res Ther*. 2018;20(1):284.

Lu MC, Huang KY, Tung CH, et al. Factors associated with disease-specific quality of life in Taiwanese patients with ankylosing spondylitis: a cross-sectional study. *BMJ Open*. 2019;9(6):e028966.

Ostrowski RA, Takagishi T, Robinson J. Rheumatoid arthritis, spondyloarthropathies, and relapsing polychondritis. *Handb Clin Neurol*. 2014;119:449-461.

Sangala JR, Dakwar E, Uribe J, Vale F. Nonsurgical management of ankylosing spondylitis. *Neurosurg Focus*. 2008;24(1):E5.

Yang X, Fan D, Xia Q, et al. The health-related quality of life of ankylosing spondylitis patients assessed by SF-36: a systematic review and meta-analysis. *Qual Life Res*. 2016;25:2711-2723.

Zhou H, Buckwalter M, Boni J, et al. Population-based pharmacokinetics of the soluble TNFr etanercept: a clinical study in 43 patients with ankylosing spondylitis compared with post hoc data from patients with rheumatoid arthritis. *Int J Clin Pharmacol Ther*. 2004;42:267-276

Atlantoaxial Dislocation

Braganza SF. Atlantoaxial dislocation. *Pediatr Rev*. 2003;24(3):106-107.

Crossman JE, Thompson D, Hayward RD, Ransford AO, Crockard HA. Recurrent atlantoaxial rotatory fixation in children: a rare complication of a rare condition. Report of four cases. *J Neurosurg*. 2004;100(3 suppl Spine):307-311.

de Carvalho M, Swash M. Neurologic complications of craniovertebral dislocation. *Handb Clin Neurol*. 2014;119:435-448.

Lacy J, Bajaj J, Gillis CC. *Atlantoaxial instability*. National Center for Biotechnology Information Web site. https://www.ncbi.nlm.nih.gov/books/NBK519563/. Accessed November 4, 2019.

Ostrowski RA, Takagishi T, Robinson J. Rheumatoid arthritis, spondyloarthropathies, and relapsing polychondritis. *Handb Clin Neurol*. 2014;119:449-461.

Stevens JM, Chong WK, Barber C, Kendall BE, Crockard HA. A new appraisal of abnormalities of the odontoid process associated with atlanto-axial subluxation and neurological disability. *Brain*. 1994;117(pt 1):133-148.

Fractures and Secondary Osteoporosis: Neurologic Causes

Asghar ZB, Godoy Caballero A, Pathirannehelage S, et al. Saving bones without risking brain-bisphosphonates and risk of stroke: matched case-control study. *Osteoporosis Int*. 2019;30(9):1845-1854.

Black DM, Reid IR, Boonen SR, et al. The effect of 3 versus 6 years of zoledronic acid treatment of osteoporosis: a randomized extension to the HORIZON-Pivotal Fracture Trial (PFT). *J Bone Miner Res*. 2012;27(2):243-254.

Christensen DH, Horváth-Puhó E, Schmidt M, et al. The impact of preadmission oral bisphosphonate use on 30-day mortality following stroke: a population-based cohort study of 100,043 patients. *Clin Epidemiol*. 2015;7:381-389.

Christensen S, Mehnert F, Chapurlat RD, Baron JA, Sørensen HT. Oral bisphosphonates and risk of ischemic stroke: a case-control study. *Osteoporos Int*. 2011;22:1773-1779.

Cosman F, Nieves J, Komar L, et al. Fracture history and bone loss in patients with MS. *Neurology*. 1998;51(4):1161-1165.

Denissen S, Staring W, Kunkel D, et al. Interventions for preventing falls in people after stroke. *Cochrane Database Syst Rev*. 2019;(10):CD008728.

Jørgensen L, Engstad T, Jacobsen BK. Higher incidence of falls in long-term stroke survivors than in population controls: depressive symptoms predict falls after stroke. *Stroke*. 2002;33(2):542-547.

Kang JH, Keller JJ, Lin HC. A population-based 2-year follow-up study on the relationship between bisphosphonates and the risk of stroke. *Osteoporos Int*. 2012;23:2551-2557.

Komoroski M, Azad N, Camacho P. Disorders of bone and bone mineral metabolism. *Handb Clin Neurol*. 2014;120:865-887.

Kristensen J, Birn I, Mechlenburg I. Fractures after stroke—a Danish register-based study of 106 001 patients. *Acta Neurol Scand*. 2020;141(1):47-55.

Lee CK, Choi SK, Shin DA, et al. Parkinson's disease and the risk of osteoporotic vertebral compression fracture: a nationwide population-based study. *Osteoporos Int*. 2018;29:1117-1124.

Luan L, Li R, Wang Z, et al. Stroke increases the risk of hip fracture: a systematic review and meta-analysis. *Osteoporos Int*. 2016;27(11):3149-3154.

Mazziotti G, Angeli A, Bilezikian JP, Canalis E, Guistina A. Glucocorticoid-induced osteoporosis: an update. *Trends Endocrinol Metab*. 2006;17(4):144-149.

Ozgocmen S, Bulut S, Ilhan N, Gulkesen A, Ardicoglu O, Ozkan Y. Vitamin D deficiency and reduced bone mineral density in multiple sclerosis: effect of ambulatory status and functional capacity. *J Bone Miner Metab*. 2005;23(4):309-313.

Pack AM, Morrell MJ, Marcus R, et al. Bone mass and turnover in women with epilepsy on antiepileptic drug monotherapy. *Ann Neurol*. 2005;57(2):252-257.

Pack AM, Morrell MJ, Randall A, McMahon DJ, Shane E. Bone health in young women with epilepsy after one year of antiepileptic drug monotherapy. *Neurology*. 2008;70(18):1586-1593.

Sato Y, Honda Y, Iwamoto J. Risedronate and ergocalciferol prevent hip fracture in elderly men with Parkinson disease. *Neurology*. 2007;68(12):911-915.

Sato Y, Iwamoto J, Honda Y. An open-label trial comparing alendronate and alphacalcidol in reducing falls and hip fractures in disabled stroke patients. *J Stroke Cerebrovasc Dis*. 2011;20:41-46.

Sato Y, Iwamoto J, Kanoko T, Satoh K. Risedronate sodium therapy for prevention of hip fracture in men 65 years or older after stroke. *Arch Intern Med*. 2005;165(15):1743-1748.

Souverein PC, Webb DJ, Petri H, Weil J, Van Staa TP, Egberts T. Incidence of fractures among epilepsy patients: a population-based retrospective cohort study in the General Practice Research Database. *Epilepsia*. 2005;46(2):304-310.

Souverein PC, Webb DJ, Weil JG, Van Staa TP, Egnerts ACG. Use of antiepileptic drugs and risk of fractures: case-control study among patients with epilepsy. *Neurology*. 2006;66(9):1318-1324.

Vaserman N. Parkinson's disease and osteoporosis. *Joint Bone Spine*. 2005;72(6):484-488.

Weinstock-Guttman B, Gallagher E, Baier M, et al. Risk of bone loss in men with multiple sclerosis. *Mult Scler*. 2004;10(2):170-175.

Wood B, Walker R. Osteoporosis in Parkinson's disease. *Mov Disord*. 2005;20(12):1636-1640.

Yuan ZC, Mo H, Guan J, He JL, Wu ZJ. Risk of hip fracture following stroke, a meta-analysis of 13 cohort studies. *Osteoporos Int*. 2016;27(9):2673-2679.

Zhang W, Zhu C, Sun M, Ge Y, Yan G. Efficacy of bisphosphonates against hip fracture in elderly patients with stroke and Parkinson diseases: meta-analysis of randomized controlled trials. *J Stroke Cerebrovas Dis*. 2014;23(10):2714-2724.

128 Malnutrition, Malabsorption, and Vitamin Deficiencies

Rebecca Traub and Inna Kleyman

KEY POINTS

1. Many malnutrition or malabsorption syndromes leading to neurologic complications result from multivitamin deficiency rather than a single low vitamin level.
2. Vitamin B_{12} deficiency is one of the more common vitamin deficiency syndromes and results in subacute combined degeneration of the spinal cord.
3. Thiamine deficiency, most often seen in patients with alcohol abuse or severe malnutrition states, can cause an acute Wernicke-Korsakoff syndrome or severe sensorimotor polyneuropathy.
4. In addition to vitamin deficiency, excessive consumption of some vitamins or minerals can lead to neurologic toxicity.
5. Neurologic complications of vitamin and mineral deficiency should always be considered in patients with a history of bariatric surgery.
6. Other gastrointestinal disorders affecting absorption, including inflammatory bowel disease and celiac disease, also increase risk for vitamin deficiency syndromes.
7. Celiac disease can cause various neuropsychiatric manifestations with peripheral neuropathy and ataxia being the most common.

INTRODUCTION

Malnutrition and malabsorption lead to isolated and multiple nutritional deficiencies with neurologic manifestations that are ascribed to lack of vitamins or other essential nutrients. An excess of certain vitamins or minerals may also cause neurologic syndromes. Obesity and caloric excess also contribute directly and indirectly to neurologic health status. The wide range of neurologic complications of obesity and dietary excess including ischemic stroke, diabetic neuropathy, and degenerative disease of the spine are covered elsewhere in this text. Treatments for the epidemic of obesity have also led to nutritional disorders and neurologic disease.

Although this chapter describes typical syndromes associated with specific vitamin deficiencies, it should be noted that in clinical practice, vitamin deficiency and malnutrition are often multifactorial with multiple deficiencies occurring together to lead to clinical symptoms and signs.

CAUSES OF NUTRITIONAL DEFICIENCIES

Nutritional deficiency may occur due to inadequate dietary intake or impaired absorption related to intrinsic or iatrogenic gastrointestinal disorders. In developing countries, inadequate nutritional intake is often due to inadequate access to food and natural sources of vitamins and minerals. In developed or industrialized countries, causes of impaired intake may include alcoholism, eating disorders, or other causes of severely restricted dietary intake. Alcohol abuse is a major cause of malnutrition and is associated with numerous neurologic syndromes, the pathophysiology of which may be direct toxicity of ethanol, single or multiple vitamin deficiencies, or a combination of these factors. Another common cause of malnutrition is *anorexia nervosa*. Severely reduced caloric intake related to eating disorders often causes neuropathy, myopathy, and other syndromes related to multiple vitamin deficiencies.

Malabsorption may arise for any of several reasons, both intrinsic and iatrogenic. Bowel diseases causing malabsorption include inflammatory bowel disease, celiac disease, and disorders of pancreatic enzyme function. In patients with these disorders, neurologic abnormalities seem to be disproportionately frequent. Alone or in combination, there may be evidence of myopathy, sensorimotor peripheral neuropathy, and degeneration of corticospinal tracts, posterior columns, and cerebellum. Optic neuritis, atypical pigmentary degeneration of the retina, and dementia are less common sequelae of malabsorption.

Bariatric surgery to treat obesity and its associated complications typically involves restricting gastric volume. Neurologic complications are uncommon but may be attributed to a combination of malabsorption and hyperemesis resulting in multivitamin deficiency state. Vitamin and mineral supplementation is routinely instituted after bariatric surgery to prevent such complications. Neurologic complications of bariatric surgery are discussed in more detail later in this chapter.

VITAMIN DEFICIENCY AND EXCESS SYNDROMES

Although many presentations of neurologic disorders related to malnutrition are attributed to deficiencies of multiple vitamins and minerals occurring together, there are particular syndromes and neurologic disorders that are typically described with specific deficiencies (Tables 128.1 and 128.2). Oversupplementation of

TABLE 128.1 Neurologic Syndromes Attributed to Vitamin or Mineral Deficiency

Vitamin or Mineral	Neurologic Symptoms or Signs in Deficiency
B_1 (thiamine)	Seizures (infants), Wernicke encephalopathy, Korsakoff dementia, subacute peripheral neuropathy
B_3 (niacin)	Encephalopathy, peripheral neuropathy
B_6 (pyridoxine)	Peripheral neuropathy, ataxia, altered mental status, seizures
B_9 (folate)	Neural tube defects (prenatal deficiency)
B_{12} (cobalamin)	Myeloneuropathy, cognitive impairment, optic neuropathy
A	Xerophthalmia
D	Myopathy
E	Spinocerebellar syndrome, neuropathy, myopathy, ophthalmoplegia
Copper	Myeloneuropathy
Iron	Restless legs syndrome

some vitamins or minerals may also lead to neurologic disorders. In the following sections are descriptions of some of the more commonly seen syndromes.

Vitamin B_{12} (Cobalamin) Deficiency

Pernicious anemia, caused by vitamin B_{12} deficiency, includes the triad of anemia, neurologic symptoms, and atrophy of the epithelial surface of the tongue. The term *combined degeneration of the spinal cord* to describe the nervous system consequences of vitamin B_{12} deficiency was introduced around 1900. Replacement therapy began in the 1920s with dietary liver and parenteral liver extract in 1948, the year that vitamin B_{12} was identified. Vitamin B_{12} deficiency continues to be common, with increased risk with older age related to atrophic gastritis, decreased dietary intake, and use of medications that interfere with acid secretion.

Epidemiology

The prevalence of vitamin B_{12} deficiency varies, based on the population studied. Most studies have described a prevalence of 1% in the general population and 5% in older adults. The prevalence of pernicious anemia among older adults has been reported to be 2%, with higher rates in women than in men. Rates of vitamin B_{12} deficiency are over 10% for patients following gastric surgery.

TABLE 128.2 Neurologic Syndromes Attributed to Vitamin or Mineral Excess

Vitamin or Mineral	Neurologic Symptoms and Signs in Excess States
B_6 (pyridoxine)	Neuropathy, ganglionopathy
A	Intracranial hypertension
Manganese	Parkinsonism
Selenium	Neuropathy
Zinc	Myeloneuropathy (through copper deficiency)

Pathobiology

Cobalamin is synthesized only in specific microorganisms, and animal products are the sole dietary source. Gastric acid is needed for peptic digestion to release the vitamin from proteins. The freed vitamin B_{12} is bound by R proteins and then by gastric intrinsic factor, a glycoprotein produced by gastric parietal cells, which is needed for transport of vitamin B_{12} and which is absent in people with pernicious anemia. The combined intrinsic factor–cobalamin complex is transported across the terminal ileum and binds to transcobalamin, which then enters cells for use in metabolic processes.

About 80% of adult-onset pernicious anemia is caused by lack of gastric intrinsic factor secondary to atrophic gastritis. The disorder is thought to be autoimmune in origin because antibodies to gastric parietal cells are found in 90% and antibodies to intrinsic factor occur in up to 76% of people with pernicious anemia. Pernicious anemia also coexists with other autoimmune diseases. In those with normal intrinsic factor, the vitamin is not absorbed because of jejunal diverticulosis, tropical or celiac sprue, or loss of the stomach or ileum by surgical resection. Proton pump inhibitors and H_2-blocker medications to treat gastroesophageal reflux or peptic ulcer disease can also cause vitamin B_{12} deficiency. Chronic recreational or occupational exposure to nitrous oxide can interfere with cobalamin metabolism and cause neuropathy or combined system disease. Long-term metformin therapy for diabetes mellitus can also lead to vitamin B_{12} deficiency through interference with calcium-dependent ileal membrane function.

Pathology of Vitamin B_{12} Deficiency

In the spinal cord, white matter is affected more than gray matter. Symmetric loss of myelin sheaths occurs more often than axonal loss; changes are most prominent in the posterior and lateral columns (*combined system disease or subacute combined degeneration*; Figs. 128.1 and 128.2). The thoracic cord is affected first, and then the process extends into the cervical or lumbar spinal cord. Patchy demyelination may be seen in the frontal white matter, correlating clinically with cognitive symptoms.

Diagnosis

Today, most people with vitamin B_{12} deficiency are probably asymptomatic. If the deficiency persists, symptoms may be those of anemia, neurologic disorder, or other problems such as vitiligo, sore tongue, or prematurely gray hair. About 40% of all patients with vitamin B_{12} deficiency have some neurologic symptoms or signs, and these are often the first or most prominent manifestations of the disease. Usually, there are features of both myelopathy and peripheral neuropathy. The most common symptom is acroparesthesia—burning and painful sensations that affect the hands and feet. There may be sensory ataxia due to loss of proprioception. Memory loss, visual loss (owing to optic neuropathy), orthostatic hypotension, anosmia, impaired taste (dysgeusia), sphincter dysfunction, and impotence are other symptoms and signs that have been described. Vitamin B_{12} levels should be checked in all people undergoing evaluation of cognitive impairment, as it is a treatable cause of memory loss.

The diagnosis rests on demonstration of serum levels of vitamin B_{12} under 200 pg/mL, but low-normal values (200-350 pg/mL) may be found in people who respond to therapy. Some people with low values are not deficient, and additional tests may be useful. Both methylmalonic acid and homocysteine accumulate when there is impairment of cobalamin-dependent

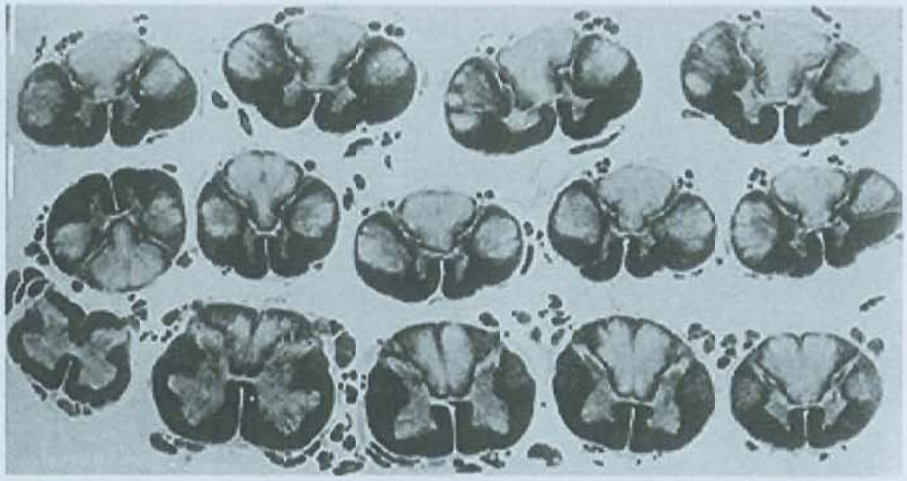

FIGURE 128.1 Subacute combined degeneration. Sections of spinal cord at various levels showing segmental loss of myelin, which is most intense in the dorsal and lateral columns.

reactions; both metabolites are abnormally increased in serum in more than 99% of patients with true cobalamin deficiency. There are limitations to these tests in certain populations, with elevated homocysteine in hereditary homocysteinemia and elevated methylmalonic acid in patients with renal failure. Pernicious anemia, which often underlies vitamin B_{12} deficiency, is best assessed with intrinsic factor antibodies. Sensitivity of these antibodies is only 50% to 70%, but specificity is nearly 100%. Antiparietal cell antibodies are more sensitive but less specific.

In patients with neurologic signs, only about 20% have severe anemia. Both the hematocrit and mean corpuscular volume may be normal, although anemia and macrocytosis are the classic abnormalities. Bone marrow biopsy reliably shows megaloblastic abnormalities.

Other testing in vitamin B_{12} deficiency may include magnetic resonance imaging (MRI) or electrodiagnostic testing. The MRI may show increased T2-weighted signal and contrast enhancement of the posterior and lateral columns of the spinal cord (Fig. 128.3), with return to normal following treatment. Nerve conduction tests may show an axonal sensorimotor neuropathy, although usually are normal. Vitamin B_{12} deficiency must be considered in any sensorimotor neuropathy, myelopathy, autonomic neuropathy, dementia, or optic neuropathy.

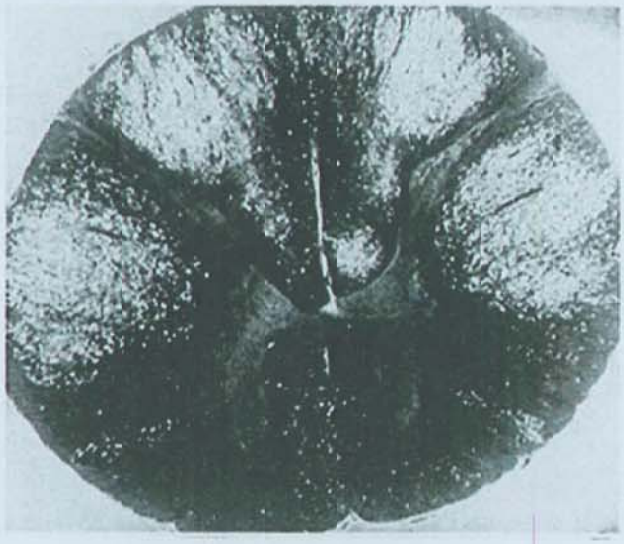

FIGURE 128.2 Subacute combined degeneration. Destruction of myelin predominating in the posterior and lateral columns. Swelling of affected myelin sheaths causes spongy appearance.

Management

Vitamin B_{12} replacement is given intramuscularly at a dosage of 1,000 μg daily for the first week, followed by weekly injections for the first month, and then monthly injections for at least a number of months. Although some patients require lifelong vitamin B_{12} injections, particularly those with pernicious anemia or surgical procedures affecting the terminal ileum, others may be transitioned to oral or sublingual formulations for maintenance therapy. There are some studies suggesting that high-dose oral vitamin B_{12} (1,000-2,000 μg daily) may even be a sufficient treatment in place of intramuscular therapy as initial treatment of deficiency.

Outcome

After injection of vitamin B_{12}, hematologic improvement may be evident within 48 hours as well as a subjective sense of general improvement. Paresthesias are often the first neurologic symptoms to improve and do so within 2 weeks; corticospinal and cognitive abnormalities are slower to respond, typically within 3 months but sometimes with continued improvement up to a year. If there is no response in 3 months, the condition is probably not from vitamin B_{12} deficiency. About half of patients are left with some neurologic abnormality on examination; the residual disability, both related to the myelopathy or cognitive injury, depends on the duration and severity of symptoms at the time that treatment is started.

Vitamin B_1 (Thiamine) Deficiency

Introduction

Thiamine is an important cofactor in the metabolism of amino acids and carbohydrates. Thiamine also plays a role in the neuromuscular junction and neurotransmission.

Epidemiology

Thiamine deficiency most often occurs as a complication of severe caloric restriction. In developing countries, this may occur as "outbreaks" in the setting of famine and among refugee populations. In developed countries, thiamine deficiency is most often seen as a complication of alcoholism, eating disorders, or after gastric surgery. The elderly may be at particular risk for thiamine deficiency due to poor absorption of the vitamin.

Pathobiology

The typical manifestations of thiamine deficiency include beriberi, both infantile and adult, and Wernicke-Korsakoff syndrome.

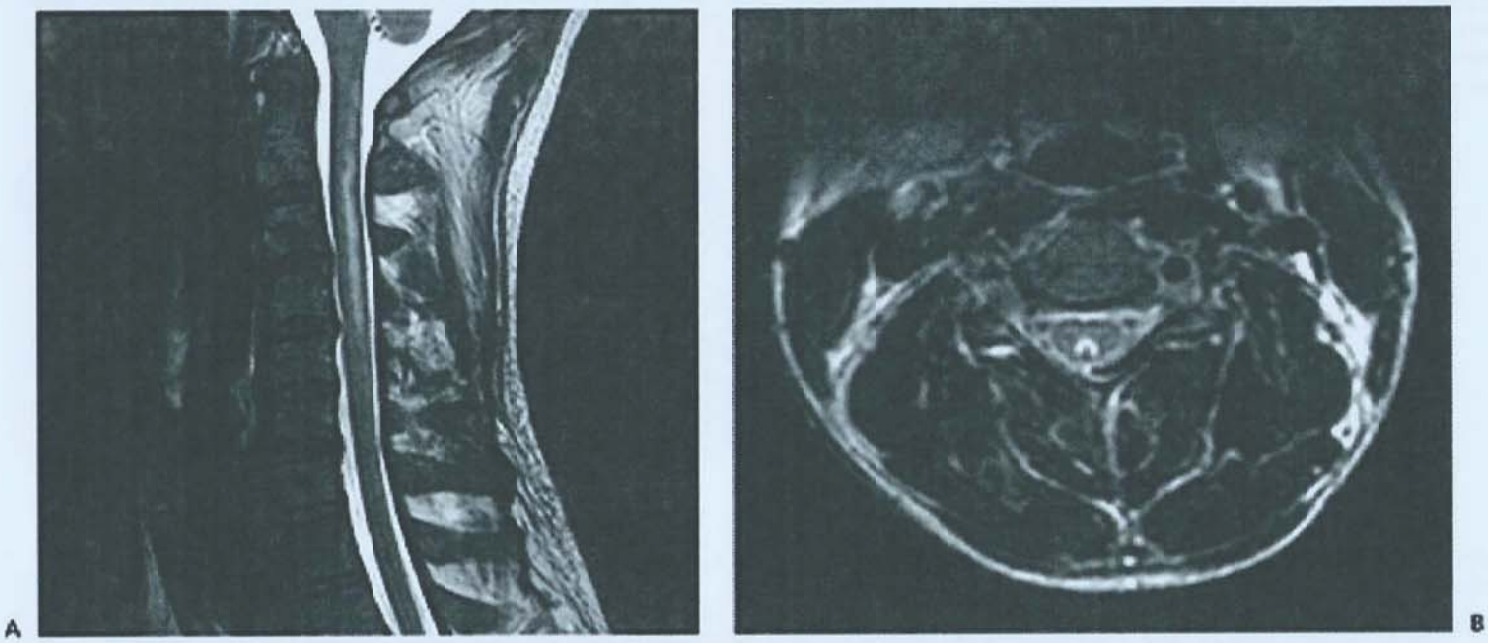

FIGURE 128.3 Increased T2 signal in the posterior columns on cervical spine magnetic resonance imaging in vitamin B_{12} deficiency. **A:** Sagittal. **B:** Axial. (Courtesy of Dr. Alexander G. Khandji, Professor of Radiology, Columbia University)

Infantile beriberi typically occurs in the first few months of life, with primarily a cardiopulmonary picture, although a neurologic syndrome of vomiting, nystagmus, and seizures may occur. Infants fed with formula deficient in thiamine have developed beriberi, with a cluster of cases seen in Israel in 2003. Adult beriberi has traditionally been divided into two subtypes. Dry beriberi refers to a sensorimotor neuropathy, which usually occurs with a subacute presentation. The neuropathy can be severe, causing near quadriplegia. Wet beriberi refers to the high-output heart failure sometimes accompanying the neuropathy of adult thiamine deficiency.

Wernicke-Korsakoff syndrome is a central nervous system (CNS) manifestation of thiamine deficiency. Wernicke encephalopathy refers to the acute presentation of altered mental status, ataxia, and ophthalmoplegia. This syndrome has traditionally been described in alcoholics although can be seen in anyone with malnutrition or malabsorption. Many do not have the full clinical triad and rather have isolated ataxia or ophthalmoplegia. *Korsakoff syndrome* refers to the more chronic manifestations of CNS injury due to thiamine deficiency: dementia with prominent or isolated memory deficits and confabulation.

Diagnosis

Thiamine can be measured in a number of ways, most often as a blood level. Supplementation, often given intravenously in the emergency department or ambulance, will usually invalidate tests for vitamin B_1 deficiency. The diagnosis is usually made based on historical and clinical grounds, unless a vitamin B_1 level is measured before supplementation. In Wernicke-Korsakoff syndrome, MRI of the brain may demonstrate typical abnormalities, including T2 hyperintense signal and restricted diffusion in the mamillary bodies and thalami (Fig. 128.4). These MRI findings are often reversible with treatment.

Management

Thiamine can be given intravenously or intramuscularly for deficiency conditions, typically 100 mg daily for 7 to 14 days, followed by oral supplementation. Acute Wernicke encephalopathy is treated with even higher doses, 500 mg intravenously three times daily for 3 days and then once daily for an additional 5 days. In any patient at risk for thiamine deficiency (eg, history of alcoholism or other risk factors for malnutrition), thiamine should be given in the emergency setting prior to glucose administration to avoid precipitation of acute Wernicke encephalopathy, as glucose metabolism increases demand for thiamine. Some advise prophylactic oral thiamine supplementation in alcoholics, elderly, or others at risk for deficiency.

FIGURE 128.4 Increased T2 signal in the mamillary bodies and midbrain tectum *(arrows)* in Wernicke encephalopathy due to thiamine deficiency.

Outcome

Prompt treatment with intravenous thiamine as described in the preceding text will often improve the clinical symptoms of thiamine deficiency, including peripheral neuropathy or Wernicke-Korsakoff syndrome, but patients will often have some residual disability that is not fully reversible.

Vitamin B_6 (Pyridoxine) Deficiency or Excess

Introduction

Vitamin B_6 has a number of critical cofactor roles, including metabolism of amino acids, lipids, and carbohydrates. It also plays a role in neurotransmitter formation, endocrine function through effects on steroid hormones, and in both the humoral and cell-mediated immune system.

Epidemiology

Vitamin B_6 deficiency typically occurs in combination with other vitamin deficiencies and is seen in any medical condition that causes malnutrition or malabsorption. Specific risk factors for pyridoxine deficiency include uremia and dialysis, alcoholism, older age, disorders of systemic inflammation, and human immunodeficiency virus. Certain medications may reduce vitamin B_6 levels in plasma.

Pathobiology

Vitamin B_6 Deficiency

Low vitamin B_6 levels have been associated with peripheral neuropathy, although isolated vitamin B_6 deficiency causing neuropathy is probably rare. Ataxia and altered mental status have also been reported with low levels of this vitamin. Severe vitamin B_6 deficiency leads to seizures, rarely seen from dietary deficiency. The genetic condition of pyridoxine-dependent seizures is a treatable cause of refractory epilepsy in neonates.

Vitamin B_6 Toxicity

Excessive supplementation with vitamin B_6 can cause sensory neuropathy and in severe cases, sensory ganglionopathy. Most cases are at doses of vitamin B_6 over 250 mg daily, although some have occurred at doses as low as 100 mg daily.

Diagnosis

Pyridoxine levels can be measured in plasma. A fasting specimen is the most accurate measure of vitamin B_6 tissue stores. In an individual person with neuropathy, it may be difficult to interpret a modestly elevated or reduced vitamin B_6 level and know whether it is responsible for clinical symptoms. The lab testing must be combined with clinical history and symptomatology to interpret values.

Management

Vitamin B_6 is orally supplemented in cases of deficiency at a dose of 50 to 100 mg daily.

Outcome

Vitamin B_6 supplementation in deficiency cases should improve or reverse neurologic symptoms. Pyridoxine-dependent seizures will also respond to treatment with supplementation. Patients with severe sensory neuropathy or ganglionopathy from pyridoxine toxicity will often have loss of the sensory dorsal root ganglion and may not show much clinical improvement, rather stabilization of deficits, with cessation of the vitamin supplementation.

Vitamin B_9 (Folic Acid) Deficiency

Folate is found in many vegetables, legumes, and animal products and in many fortified grains and foods. The primary neurologic role of folate supplementation is in women during pregnancy (or chance of pregnancy), where it plays a critical role in neural tube formation. Prenatal folic acid supplementation reduces the risk of neural tube defects by 50% to 70%. Supplements are recommended at least a month before conception, given that formation of the neural tube occurs during the first weeks of embryonic development. In women at low risk for neural tube defects, 0.4 to 0.8 mg daily is recommended. In those on antiepileptics that interfere with folate absorption or those with a prior history of pregnancy with neural tube defect, 4 mg daily is recommended.

In adults, folate deficiency has primarily hematologic manifestations, with rare, if any, neurologic symptoms. There is limited benefit to checking folate levels in patients presenting with dementia, neuropathy, or other neurologic syndromes. It should be noted that folic acid supplementation may mask vitamin B_{12} deficiency by correcting some of the associated anemia and allowing the associated neurologic syndrome to go undiagnosed. Therefore, vitamin B_{12} levels should be assessed before initiating folate replacement.

Vitamin B_3 (Niacin) Deficiency

Niacin deficiency (pellagra) is primarily seen in populations that are dependent on corn but can also be seen in the setting of alcoholism, malabsorption, chronic infection, carcinoid syndrome, secondary to vitamin B_6 deficiency, and in Hartnup syndrome, an autosomal recessive disorder that causes impaired synthesis of niacin from tryptophan. Pellagra typically affects the gastrointestinal tract, skin, and the nervous system (ranging from neuropsychiatric symptoms to encephalopathy that may progress to spasticity, ataxia, myoclonus, or coma). Deficiency can also cause a peripheral neuropathy similar to that seen with thiamine deficiency. Treatment with oral or intravenous nicotinic acid results in variable improvement of the neurologic manifestations.

Vitamin A Deficiency or Toxicity

Vitamin A is a fat-soluble vitamin found in plants (beta-carotene or provitamin A) and animal sources, particularly fish, dairy, and meat, especially liver (retinol, preformed vitamin A). Retinoids are compounds related to retinol, many with actions similar to vitamin A. Physiologically, vitamin A has critical roles in fetal eye development and maintenance of retinal photoreceptor cells. Vitamin A deficiency is uncommon in developed countries but remains one of the most common nutritional deficiencies worldwide. In developed countries, vitamin A deficiency may occur in disorders of fat absorption, as in cystic fibrosis, pancreatic disorders, and celiac disease.

Vitamin A deficiency causes *xerophthalmia*, a term used to describe the spectrum of eye diseases related to deficiency, from night blindness to complete blindness and dryness or ulceration of the conjunctiva and cornea. Diagnosis of vitamin A deficiency is typically made on clinical grounds, although serum retinol levels may be measured.

Vitamin A toxicity (hypervitaminosis A) may also cause neurologic disease, with a clinical presentation of increased cerebrospinal

fluid pressure similar to the syndrome of idiopathic intracranial hypertension. Most cases occur with ingestion of excessive amounts of supplements, although it has also been described in people consuming large amounts of dietary liver. Isotretinoin, a retinoic acid derivative used for the treatment of acne, can similarly cause pseudotumor cerebri, presumably through similar mechanism of action.

Vitamin D Deficiency

Vitamin D is a fat-soluble vitamin obtained through diet or skin exposure to ultraviolet rays in sunlight. Deficiency may occur due to inadequate dietary intake, disorders of fat absorption, and inadequate exposure to sunlight. The primary manifestations of vitamin D deficiency are related to bone development and maintenance, with rickets in children and osteomalacia in adults. However, vitamin D is implicated in a number of neurologic conditions. Severe vitamin D deficiency has been described causing myopathy but only at very low serum levels, typically in cases of malabsorption. Patients with epilepsy are at increased risk for low bone density and fracture. This increased risk is multifactorial and complex, partially related to cytochrome P450 enzyme–inducing antiepileptic medications, which increase vitamin D metabolism. Because of this risk of bone loss in many patients with epilepsy, vitamin D and calcium supplementation are generally advised. Vitamin D has effects on multiple cellular functions of the immune system, and studies have demonstrated an association between vitamin D deficiency and a number of autoimmune disorders, including multiple sclerosis. Whether supplementing vitamin D in patients already diagnosed with multiple sclerosis is beneficial from a clinical standpoint has yet to be established. Diagnosis of vitamin D deficiency is made by measuring 25-hydroxyvitamin D levels to assess vitamin D status. There is some variation in goal levels, with most recommending 30 to 40 ng/mL.

Vitamin E Deficiency

Vitamin E is a fat-soluble vitamin found in many foods, including meat, oil, eggs, and vegetables. It is an antioxidant and a component of cell membranes. Risk factors for vitamin E deficiency are disorders that impair fat absorption, including cholestasis and pancreatic deficiencies. There are genetic diseases causing deficient vitamin E absorption and resultant neurologic impairments. The typical neurologic manifestations of vitamin E deficiency include neuropathy, myopathy, and ataxia.

MINERAL DEFICIENCY AND EXCESS SYNDROMES

Copper Deficiency and Toxicity

Introduction

Copper, a trace mineral present in many foods, is absorbed in the stomach and proximal small intestine. In the liver, it becomes part of ceruloplasmin, which is transported through the body. Copper deficiency has multisystemic effects on skin and hair, liver, bone, and the nervous system. Risk factors for copper deficiency are malabsorption, including gastric surgery and celiac disease, and excessive zinc ingestion through supplements or zinc-containing denture creams.

Epidemiology

Risk of copper deficiency is greatest in patients with malabsorption syndromes or with a history of gastric surgery. A number of cases have been described associated with excessive zinc supplementation.

Pathobiology

The neurologic syndrome of copper deficiency is typically myelopathy or myeloneuropathy, often mimicking vitamin B_{12} deficiency. There is gait ataxia, sensory loss, and spasticity, with physical exam demonstrating prominent loss of vibration and joint position sense, hyperreflexia, and extensor plantar responses.

Diagnosis

Lab testing in copper deficiency will show a low serum copper and/or ceruloplasmin level. When excessive zinc ingestion is suspected as a cause of copper deficiency, serum zinc and 24-hour urinary zinc can be measured. Given the similar clinical features, vitamin B_{12} levels should always be checked in patients with suspected copper deficiency myeloneuropathy, and imaging of the spinal cord is often indicated, showing abnormal signal in the posterior columns.

Management

Copper is supplemented at a dose of 2 mg daily. Some recommend higher doses for initial treatment in the symptomatic patient. Usually, oral supplementation suffices; however, intravenous and intramuscular forms can be used if there is concern for severe impaired absorption.

Outcome

Improvement in myeloneuropathy symptoms typically occurs with copper supplementation and correction of deficiency state.

Wilson Disease

Wilson disease, which is described in detail in Chapter 139, is a hereditary, autosomal recessive disorder of excessive copper accumulation, which leads to liver disease and a characteristic neurologic syndrome of ataxia, dysarthria, dystonia, tremor, and parkinsonism.

Other Mineral Deficiencies and Toxicities

- Iron: Iron deficiency in childhood is associated with developmental delays. In adults, iron deficiency is a treatable cause of restless legs syndrome.
- Manganese: Manganese toxicity, primarily occurring through occupational exposure, although also reported in patients receiving parenteral nutrition, can cause symptoms similar to those seen in Parkinson disease.
- Selenium: Selenium toxicity, typically occurring in excessive supplementation, causes neuropathy in association with dermatologic symptoms.
- Zinc: Excessive zinc ingestion, as described earlier, causes a secondary copper deficiency and associated myeloneuropathy.

NEUROLOGIC COMPLICATIONS OF BARIATRIC SURGERY

Introduction

Surgical procedures performed to manage obesity are broadly referred to as *bariatric surgery*. These are increasingly common treatment options for weight reduction and improved management of hypertension, diabetes, sleep apnea, and metabolic disorders. The overall objective of bariatric surgery is to reduce intake or absorption of macronutrients (fats, carbohydrates, proteins) to reduce caloric intake, but the absorption of micronutrients (essential minerals and vitamins) is also affected. There are several different types of surgical options including gastric bypass (Roux-en-Y gastric bypass), sleeve gastrectomy, adjustable gastric band, and biliopancreatic diversion with duodenal switch (BPD/DS). Sleeve gastrectomy and band placement both reduce stomach volume and are considered restrictive procedures. Gastric bypass and BPD/DS are considered malabsorptive procedures because they impair normal digestion and absorption of food (in addition to having a restrictive effect). Although gastric bypass is considered the "gold standard" of weight loss surgery and is the most commonly performed procedure worldwide, sleeve gastrectomy has become the most common procedure performed in the United States.

Micronutrient deficiencies may occur days, months, or even many years following bariatric surgery. Some patients have underlying deficiency before undergoing surgery, and these deficiency states can be worsened postoperatively due to vomiting, reduced absorption, changes in diet and gut microbiome, and loss of intrinsic factor and gastric acid. Deficiency of vitamin B_{12}, folate, thiamine, and copper is most common following bariatric surgery, but absorption of vitamin E, pyridoxine, niacin, vitamin A, and vitamin D is also affected.

Various neurologic complications can arise from malabsorption and deficiency of these individual vitamins and nutrients. These are seen more frequently in bariatric procedures causing substantial malabsorption, such as gastric bypass and BPD/DS, and are less likely in restrictive procedures like sleeve gastrectomy and adjustable band placement. Complications such as compressive or stretch peripheral nerve injuries, rhabdomyolysis, Wernicke encephalopathy, and inflammatory polyradiculoneuropathies tend to occur in the early postoperative period, and peripheral neuropathy, myelopathy, myopathy, and optic neuropathy occur later.

Epidemiology

More than an estimated 250,000 bariatric surgeries were performed in the United States in 2018 (and an estimated 630,000 procedures performed worldwide in 2016). It has been reported that up to 9% of patients who have bariatric surgery experience neurologic complications related to micronutrient malabsorption. Peripheral neuropathy accounts for 70% to 80% of these complications with CNS involvement being the least common.

Pathobiology

The Roux-en-Y gastric bypass procedure is performed by dividing the upper portion of the stomach to create a small stomach pouch; the proximal small intestine is then divided and its distal end is connected to the stomach pouch. The remaining end of the proximal small intestine is connected to small intestine further down, where food mixes with digestive enzymes. With this type of bypass, less digestion occurs in the stomach and less absorption occurs in the small intestine. In the BPD/DS procedure, a small stomach pouch is created and a large portion of the small intestine is bypassed; there is a significant reduction in absorption because food and digestive enzymes do not mix until far down the small intestine.

Vitamin B_{12} deficiency is common in bypass procedures because most of the stomach and duodenum are bypassed, reducing the breakdown of vitamin B_{12} and its binding with intrinsic factor. As described previously in this chapter, vitamin B_{12} deficiency typically presents with paresthesias, weakness, loss of position and vibratory sense, and cognitive changes. This can take months to years to develop because haptic stores are usually sufficient to maintain levels. A less common, but more serious, complication after bariatric surgery is Wernicke encephalopathy due to thiamine deficiency. This can present as ataxia, nystagmus, and memory dysfunction. Thiamine deficiency can also be accompanied by a sensorimotor peripheral neuropathy or painful and rapidly progressive polyradiculoneuropathy. This can be seen within days to week postoperatively and is more frequent in patients with severe vomiting.

Other neurologic complications related to individual vitamin and mineral deficiencies affected by bariatric surgery are reviewed in more detail earlier in this chapter.

Diagnosis

Although there are guidelines for nutritional supplementation and management following bariatric surgery, deficiency states still occur due to issues with adherence, follow-up, hyperemesis, and preexisting nutrient deficiency. Patients should ideally be screened for vitamin and mineral deficiencies preoperatively and supplemented appropriately before undergoing surgery. Postoperatively, there are guidelines for regular follow-up and serum testing of various vitamins and minerals. It can be difficult to predict which patients will develop deficiencies, so close surveillance is essential.

Management

If a specific deficiency does develop, prompt recognition and treatment can help prevent irreversibly neurologic injury. It is generally accepted that lifelong multivitamin supplementation is necessary after bariatric surgery, but specific recommendations regarding supplements and dosing vary; this may depend on the type of procedure performed, the specific deficiency identified, and the clinical course postoperatively.

NEUROLOGIC COMPLICATIONS OF GLUTEN-RELATED DISORDERS

Introduction

Gluten-related disorders can broadly be divided into autoimmune (including celiac disease and gluten ataxia), allergic, and nonautoimmune nonallergic (gluten sensitivity). We will focus

specifically on the neurologic complications of the autoimmune subtype in this section.

Celiac disease is an autoimmune enteropathy involving the adaptive immune system, which can cause gastrointestinal symptoms like diarrhea, malabsorption, and weight loss as well as neurologic sequelae. Various neurologic manifestations have been described including peripheral neuropathy, epilepsy, headaches, increased intracranial pressure, neuromyelitis optica, stiff person syndrome, myopathy, myelopathy, myoclonus ataxia, chorea, paroxysmal nonkinesigenic dystonia, other movement disorders, and psychiatric conditions.

Epidemiology

The estimated prevalence of celiac disease in the United States is about 1%. Neurologic manifestations may appear in up to 22% of people with celiac disease, and individuals with celiac disease have an estimated 2.5-fold increased risk of developing peripheral neuropathy.

Pathobiology

The pathogenesis of neurologic complications seen in gluten-related disorder is not well understood but is thought to be immune mediated and related to gluten-triggered inflammatory changes. Celiac disease and gluten-related disorders can cause deficiencies of vitamin E, copper, vitamin B_{12}, folate, zinc, vitamin B_1, vitamin B_6, and vitamin D. However, nutritional deficiency secondary to malabsorption is not the only explanation for the spectrum of neurologic sequelae, and immune factors likely play a greater role.

Peripheral neuropathy in celiac disease typically presents as a chronic axonal sensorimotor neuropathy, but chronic inflammatory demyelinating polyradiculoneuropathy, autonomic neuropathy, mononeuritis multiplex, small fiber neuropathy, and sensory ganglionopathy have also been reported.

Gluten ataxia is a related immune-mediated disorder that refers to adult-onset progressive ataxia in the presence of gluten antibodies and is thought to be triggered by gluten ingestion in genetically susceptible individuals. Cerebellar atrophy and white matter abnormalities may be seen on MRI of the brain, and pathologic examination has shown Purkinje cell loss and lymphocytic infiltration within the cerebellum and posterior columns of the spinal cord. Gastrointestinal symptoms are not necessarily present.

Diagnosis

Affected individuals may have the presence of gliadin-related immunoglobulin A antibodies (antiendomysial and antitissue transglutaminase) along with histopathologic evidence of damage to the small intestinal mucosa (villous atrophy, crypt hyperplasia, increased epithelial lymphocytes) on biopsy. Human leukocyte antigen genetic testing and response to a gluten-free diet can also be used to help establish the diagnosis. Neurologic manifestations may be present without gastrointestinal symptoms, so it is important to consider this diagnostic possibility even without typical gastrointestinal complaints.

Management

Strict adherence to a gluten-free diet is generally effective in treating many of the neurologic complications described in the preceding text; however, the clinical response may be variable. Patients with long-standing symptoms may have some irreversibly injury. Some studies have shown a response to immunotherapy such as intravenous immunoglobulin and oral immunomodulatory agents, but this is not well established.

SUGGESTED READINGS

Allen RP, Auerbach S, Bahrain H, Auerbach M, Earley CJ. The prevalence and impact of restless legs syndrome on patients with iron deficiency anemia. *Am J Hematol*. 2013;88:261-264.

Bloomberg RD, Fleishman A, Nalle JE, Herron DM, Kini S. Nutritional deficiencies following bariatric surgery: what have we learned? *Obes Surg*. 2005;15:145-154.

Butler CC, Vidal-Alaball J, Cannings-John R, et al. Oral vitamin B_{12} versus intramuscular vitamin B_{12} for vitamin B_{12} deficiency: a systematic review of randomized controlled trials. *Fam Pract*. 2006;23:279-285.

Butterworth RF. Thiamin deficiency and brain disorders. *Nutr Res Rev*. 2003;16:277-284.

Castelli MC, Friedman K, Sherry J, et al. Comparing the efficacy and tolerability of a new daily oral vitamin B_{12} formulation and intermittent intramuscular vitamin B_{12} in normalizing low cobalamin levels: a randomized, open-label, parallel-group study. *Clin Ther*. 2011;33:358.e2-371.e2.

Chang CG, Adams-Huet B, Provost DA. Acute post-gastric reduction surgery (APGARS) neuropathy. *Obes Surg*. 2004;14:182-189.

Chin RL, Sander HW, Brannagan TH, et al. Celiac neuropathy. *Neurology*. 2003;60:1581-1585.

Cooke WT, Smith WT. Neurological disorders associated with adult coeliac disease. *Brain*. 1966;89(4):683-722.

Czeizel AE, Dudas I. Prevention of the first occurrence of neural-tube defects by periconceptional vitamin supplementation. *N Engl J Med*. 1992;327:1832-1835.

De Jager J, Kooy A, Lehert P, et al. Long term treatment with metformin in patients with type 2 diabetes and risk of vitamin B-12 deficiency: randomised placebo controlled trial. *BMJ*. 2010;340:c2181.

De-Regil LM, Fernández-Gaxiola AC, Dowswell T, Peña-Rosas JP. Effects and safety of periconceptional folate supplementation for preventing birth defects. *Cochrane Database Syst Rev*. 2010;(10):CD007950.

Goodman BP, Bosch EP, Ross MA, Hoffman-Snyder C, Dodick DD, Smith BE. Clinical and electrodiagnostic findings in copper deficiency myeloneuropathy. *J Neurol Neurosurg Psychiatry*. 2009;80:524-527.

Goodman JC. Neurological complications of bariatric surgery. *Curr Neurol Neurosci Rep*. 2015;15(12):79.

Green PH, Alaedini A, Sander HW, Brannagan TH III, Latov N, Chin L. Mechanisms underlying celiac disease and its neurologic manifestations. *Cell Mol Life Sci*. 2005;62:791-799.

Green R, Kinsella LJ. Current concepts in the diagnosis of cobalamin deficiency. *Neurology*. 1995;45:1435-1440.

Hack JB, Hoffman RS. Thiamine before glucose to prevent Wernicke encephalopathy: examining the conventional wisdom. *JAMA*. 1998;279:583-584.

Hadjivassiliou M, Sanders DS, Grünewald RA, Woodroofe N, Boscolo S, Aeschlimann D. Gluten sensitivity: from gut to brain. *Lancet Neurol*. 2010;9(3):318-330.

Healton EB, Savage DG, Brust JC, Garrett TJ, Lindenbaum J. Neurologic aspects of cobalamin deficiency. *Medicine (Baltimore)*. 1991;70:229-245.

Imdad A, Herzer K, Mayo-Wilson E, Yakoob MY, Bhutta ZA. Vitamin A supplementation for preventing morbidity and mortality in children from 6 months to 5 years of age. *Cochrane Database Syst Rev*. 2010;(12):CD008524.

Işikay S, Kocamaz H. The neurological face of celiac disease. *Arq Gastroenterol*. 2015;52(3):167-170.

Jaiser SR, Winston GP. Copper deficiency myelopathy. *J Neurol*. 2010;257:869-881.

Juhasz-Pocsine K, Rudnicki SA, Archer RL, Harik SA. Neurologic complications of gastric bypass surgery for morbid obesity. *Neurology*. 2007;68:1843-1850.

Kinsella LJ, Green R. "Anesthesia paresthetica": nitrous oxide-induced cobalamin deficiency. *Neurology*. 1995;45:1608-1610.

Koffman BM, Greenfield LJ, Ali II, Pirzada NA. Neurologic complications after surgery for obesity. *Muscle Nerve*. 2006;33:166-176.

Kopelman MD, Thomson AD, Guerrini I, Marshall EJ. The Korsakoff syndrome: clinical aspects, psychology and treatment. *Alcohol Alcohol*. 2009;44:148-154.

Kumar N. Neurologic complications of bariatric surgery. *Continuum (Minneap Minn)*. 2014;20(3, Neurology of Systemic Disease):580-597.

Kumar N. Nutritional neuropathies. *Neurol Clin*. 2007;25:209-255.

Kumar N, Gross JB Jr, Ahlskog JE. Copper deficiency myelopathy produces a clinical picture like subacute combined degeneration. *Neurology*. 2004;63:33-39.

MacFarquhar JK, Broussard DL, Melstrom P, et al. Acute selenium toxicity associated with a dietary supplement. *Arch Intern Med*. 2010;170:256-261.

Mayo-Smith MF. Pharmacological management of alcohol withdrawal. A meta-analysis and evidence-based practice guideline. American Society of Addiction Medicine Working Group on Pharmacological Management of Alcohol Withdrawal. *JAMA*. 1997;278:144-151.

Mayo-Wilson E, Imdad A, Herzer K, Yakoob MY, Bhutta ZB. Vitamin A supplements for preventing mortality, illness, and blindness in children aged under 5: systematic review and meta-analysis. *BMJ*. 2011;343:d5094.

Mechanick JI, Youdim A, Jones DB, et al. Clinical practice guidelines for the perioperative nutritional, metabolic, and nonsurgical support of the bariatric surgery patient—2013 update: cosponsored by American Association of Clinical Endocrinologists, the Obesity Society, and American Society for Metabolic & Bariatric Surgery. *Endocr Pract*. 2013;19:337-372.

Mikati MA, Dib L, Yamout B, Sawaya R, Rahi AC, El-Hajj Fuleihan G. Two randomized vitamin D trials in ambulatory patients on anticonvulsants: impact on bone. *Neurology*. 2006;67:2005-2014.

Nations SP, Boyer PJ, Love LA, et al. Denture cream: an unusual source of excess zinc, leading to hypocupremia and neurologic disease. *Neurology*. 2008;71:639-643.

Pack AM. Bone disease in epilepsy. *Curr Neurol Neurosci Rep*. 2004;4:329-334.

Patchell RA, Fellows HA, Humphries LL. Neurologic complications of anorexia nervosa. *Acta Neurol Scand*. 1994;89:111-116.

Penniston KL, Tanumihardjo SA. The acute and chronic toxic effects of vitamin A. *Am J Clin Nutr*. 2006;83:191-201.

Pfeiffer RF. Gastroenterology and neurology. *Continuum (Minneap Minn)*. 2017;23(3, Neurology of Systemic Disease):744-761.

Russell JSR, Batten FE, Collier J. Subacute combined degeneration of the spinal cord. *Brain*. 1900;23:39-110.

Sapone A, Bai J, Ciacci C, et al. Spectrum of gluten-related disorders: consensus on new nomenclature and classification. *BMC Med*. 2012;10:13.

Savage DG, Lindenbaum J, Stabler SP, Allen RH. Sensitivity of serum methylmalonic acid and total homocysteine determinations for diagnosing cobalamin and folate deficiencies. *Am J Med*. 1994;96:239-246.

Stabler SP. Clinical practice. Vitamin B_{12} deficiency. *N Engl J Med*. 2013;368:149-160.

Thawani SP, Brannagan TH III, Lebwohl B, Green PHR, Ludvigsson JF. Risk of neuropathy among 28,232 patients with biopsy-verified celiac disease. *JAMA Neurol*. 2015;72(7):806-811.

Victor M, Lear AA. Subacute combined degeneration of the spinal cord. *Am J Med*. 1956;20:896-911.

Wald NJ. Folic acid and the prevention of neural-tube defects. *N Engl J Med*. 2004;350:101-103.

129 Neurologic Disease During Pregnancy

Alison M. Pack

KEY POINTS

1. Pregnancy may be associated with alterations in preexisting neurologic conditions, such as epilepsy or migraine, or herald the emergence of neurologic disorders, such as peripheral nerve entrapment or a movement disorder.
2. Pregnancy rates for women with epilepsy have increased. Most women maintain good seizure control throughout pregnancy. The majority of women with epilepsy deliver healthy babies.
3. Preeclampsia can progress to eclampsia, a syndrome of diffuse multifocal brain edema that can result in posterior reversible encephalopathy syndrome.
4. Pregnancy is a risk factor for stroke, and the postpartum period is the most vulnerable time.
5. The multiple sclerosis relapse rate decreases in pregnancy, especially in the third trimester, and increases in the first 3 months postpartum.
6. The majority of migraine headaches improve during pregnancy, especially for migraines without aura.
7. Carpal tunnel syndrome is the most frequent neuropathy of pregnancy.
8. Myasthenic symptoms in pregnancy are variable and can increase in 30% to 40% of patients. Exacerbations occur more likely in the first trimester and postpartum period.
9. Restless legs syndrome is the most common movement disorder of pregnancy.

INTRODUCTION

Pregnancy and the postpartum period are times of major biologic and social changes. Pregnancy may be associated with alterations in preexisting neurologic conditions, such as epilepsy or migraine, or herald the emergence of neurologic disorders, such as peripheral nerve entrapment or a movement disorder. This chapter addresses the diagnosis, management, and treatment of neurologic disorders arising in or altered by pregnancy.

Biology of Pregnancy

Physiologic changes during pregnancy may influence the expression of neurologic disease and complicate management. Alterations in neuroactive steroid hormones may affect the phenotypic appearance of the disease. Changes in pharmacokinetics, medication compliance, and sleep patterns may make disease management more challenging.

The concentration and type of circulating steroid hormones change during pregnancy. Estrogen production increases. In the nonpregnant state, the main circulating estrogens are estradiol, which is synthesized by ovarian thecal cells, and estrone, which is produced by the extraglandular conversion of androstenedione. Estriol is a peripheral metabolite of estrone and estradiol. In pregnancy, the concentrations of all these estrogens, particularly estriol, increase. As pregnancy progresses, maternal steroids and dehydroisoandrosterone from developing fetal adrenal glands are converted principally to estriol. Progesterone production also increases dramatically. These hormonal changes may affect neurologic conditions that are hormone responsive, including migraine, epilepsy, and multiple sclerosis (MS).

Drug pharmacokinetics is affected by the physiologic changes of pregnancy (Table 129.1). Renal blood flow and glomerular filtration increase as a function of increased cardiac output. Plasma volume, extravascular fluid, and adipose tissue increase to create a larger volume of distribution. Serum albumin decreases, which reduces drug binding, increases the free fraction, and increases drug clearance. These pharmacokinetic alterations may affect drug concentrations and are most important for drugs that are highly protein bound, hepatically metabolized, or renally cleared.

Other events of pregnancy that may compromise management are hyperemesis gravidarum, sleep deprivation, and poor compliance. Hyperemesis gravidarum can make it difficult to maintain adequate concentrations of oral medications. Sleep deprivation aggravates many neurologic conditions and can be a particular problem in the third trimester. Compliance may deteriorate because of a woman's concern that taking medication might harm her baby. Women are often advised by friends, relatives, and even medical personnel to minimize fetal drug exposure.

TABLE 129.1 Physiologic Changes During Pregnancy[a]

Variable	Change
Extracellular volume	Increases 4-6 L
Plasma volume	Increases 40%
Renal blood flow	Increases 30%-50%
Glomerular filtration rate	Increases 30%-50%
Cardiac output	Increases 30%-50%
Serum albumin	Decreases 20%-30%

[a]Data from Silberstein SD. Drug treatment and trials in women. In: Kaplan PW, ed. *Neurologic Disease in Women*. New York, NY: Demos Medical Publishing; 1998:25-44.

This may lead to skipped doses, reduced doses, or even self-discontinuation of an indicated medication.

EPILEPSY

Epidemiology

Each year, 20,000 women with epilepsy become pregnant. This number has grown as marriage rates have increased for women with epilepsy because parenting has become more socially supported and because the medical management of pregnancy in women with epilepsy has improved.

Seizure Control and Monitoring Antiseizure Medication Concentrations

Although most women do maintain good seizure control throughout pregnancy, particularly if they have been seizure free for the 9 months preceding conception, seizure frequency may change. Changes responsible for this include changes in sex hormones, antiseizure medication (ASM) metabolism, sleep schedules, and medication compliance. ASM concentrations may change. The total ASM concentration falls because of an increase in volume of distribution, decreased drug absorption, and increased drug clearance. Lamotrigine (Lamictal) concentrations decrease throughout pregnancy because of markedly increased clearance mediated by estrogen-induced increased glucuronidation. Monitoring of this medication should be performed at least monthly and appropriate adjustments made. Concentrations of levetiracetam (Keppra), oxcarbazepine (Trileptal), and topiramate (Topamax) also decrease in pregnancy and doses need to be adjusted. For some ASMs that are highly protein bound, although the total concentration decreases, the proportion of unbound or free drug increases because albumin levels and protein binding decline. Therefore, it is necessary to follow the non–protein-bound drug concentrations for ASMs that are highly protein bound, including carbamazepine (Tegretol), phenytoin sodium (Dilantin), and sodium valproate (Depakene). Dose adjustments should maintain a stable non–protein-bound fraction.

Teratogenicity

The incidence of major congenital malformations (MCMs) in association with in utero ASM exposure is increased at least two- or threefold when compared to the general population. In a pooled analysis of 26 studies, MCMs occurred at a higher rate for infants born to women with epilepsy on ASMs (6.1%) compared with women with epilepsy off ASMs (2.8%) and a control population (2.1%). Current published risks are derived from data gathered from international prospective registries. A prospective U.S.-based North American registry continues to gather information about pregnancy and fetal outcome in women using ASMs. This registry should be contacted regarding any woman who becomes pregnant while taking ASMs (1-888-233-2334). A European registry includes countries throughout Europe, Asia, and the continent of Australia and prospectively records information about the effects of ASMs as monotherapy on the developing fetus. The Australian group has independently published their findings. A U.K. register is also actively following pregnant women with epilepsy. MCMs related to ASM exposure include neural tube defects, cleft lip and palate, cardiac defects (atrial septal defect, tetralogy of Fallot, ventricular septal defect, coarctation of the aorta, patent ductus arteriosus, and pulmonary stenosis), and urogenital defects.

Data is available for many of the commonly used ASMs (Table 129.2). Among the currently available ASMs, valproate is consistently associated with the highest rate of MCMs including a higher risk of neural tube defects. Results from the European Surveillance of Congenital Anomalies found that in utero valproate exposure resulted in a 12.7-fold increase (odds ratio 12.7; 95% confidence interval [CI], 7.7-20.7) of spina bifida when compared to those with no exposure. Findings suggest the risk of valproate-associated MCMs increases at doses above

TABLE 129.2 Major Congenital Malformations in Commonly Used Antiseizure Medications[a]

	Carbamazepine	Gabapentin	Lamotrigine	Levetiracetam	Oxcarbazepine	Phenobarbital	Phenytoin	Topiramate	Valproate	Zonisamide
EURAP Registry										
No. (%)	107 (5.5)	NA	74 (2.9)	17 (2.8)	10 (3.0)	19 (6.5)	8 (6.4)	6 (3.9)	142 (10.3)	NA
95% CI	(4.5-6.6)	NA	(2.3-3.7)	(1.7-4.5)	(1.4-5.4)	(4.2-9.9)	(2.8-12.2)	(1.5-8.4)	(8.8-12.0)	NA
No. of Exposures	1,957	NA	2,514	599	333	294	125	152	1,381	NA
North American Registry										
No. (%)	31 (3.0)	1 (0.7)	31 (2.0)	11 (2.4)	4 (2.2)	11 (5.5)	12 (2.9)	15 (4.2)	30 (9.3)	0
95% CI	(2.1-4.2)	(0.02-3.8)	(1.4-2.8)	(1.2-4.3)	(0.6-5.5)	(2.8-9.7)	(1.5-5.0)	(2.4-6.8)	(6.4-13.0)	(0.0-3.3)
No. of Exposures	1,033	145	1,562	450	182	199	416	359	323	90
United Kingdom and Ireland Register										
No. (%)	43 (2.6)	1 (3.2)	49 (2.3)	2 (0.7)	NA	NA	3 (3.7)	3 (4.8)	82 (6.7)	NA
95% CI	(1.9-3.5)	(0.6-16.2)	(1.8-3.1)	(0.20-2.5)	NA	NA	(1.3-10.2)	(1.7-13.3)	(5.5-8.3)	NA
No. of Exposures	1,657	31	2,098	304	NA	NA	82	70	1,220	NA

Abbreviations: EURAP, international registry of antiepileptic drugs and pregnancy; NA, not available.

[a]Reported number and percentage of major congenital malformations, 95% confidence interval (CI), and number of exposures in the EURAP Registry, North American Register, and United Kingdom and Ireland Register.

700 mg/d. Phenobarbital, which is used throughout the world, particularly in developing countries, results in a significantly increased risk of MCMs, notably cardiac malformations. First-trimester topiramate exposure is associated with an increased risk of oral clefts. Although carbamazepine has a lower total risk of MCMs than valproate, results from European Surveillance of Congenital Anomalies found a 2.6-fold increased risk of spina bifida (odds ratio, 2.6; 95% CI, 1.2-5.3) when compared to those with no exposure. Lamotrigine and levetiracetam are associated with the lowest risk. Data are limited for other commonly used ASMs including brivaracetam, eslicarbazepine, lacosamide, perampanel, and pregabalin.

Higher ASM doses are likely associated with higher risk of MCMs. The international registry of antiepileptic drugs and pregnancy (EURAP) Registry has found that the risk of MCMs increased with increasing dose at time of conception for valproate, phenobarbital, carbamazepine, and lamotrigine.

Polytherapy may an independent risk factor for teratogenicity. Rates of major malformations are elevated in children exposed to multiple ASMs. The specific ASM combination is likely a factor. For example, ASM combination therapy that includes valproate has a higher MCM rate than other ASM combinations.

Several mechanisms have been postulated to explain the teratogenicity of ASMs. Some ASMs may be teratogenic because of free radical intermediates that bind with RNA and disrupt DNA synthesis and organogenesis. Higher concentrations of oxide metabolites increase the risk of fetal malformations. Some ASMs cause folic acid deficiency, which is associated with higher occurrence and recurrence rates of neural tube defects. The American Academy of Neurology (AAN) and American Epilepsy Society recommend that all women with epilepsy of childbearing age receive at least 0.4 mg of folic acid per day. There is currently insufficient evidence to know if higher doses of folic acid offer greater benefit.

Effects of Antiseizure Medications on Cognition

In addition to the teratogenicity of ASMs, ASMs may also affect cognitive outcomes of exposed infants. Retrospective and prospective studies suggest a negative effect of valproate; children whose mothers took valproate have lower scores on neuropsychological tests and have more special needs. Early studies were limited by retrospective design, size, and inability to control for confounding variables such as maternal IQ. Data from the prospective well-controlled Neurodevelopmental Effects of Antiepileptic Drugs (NEAD) study finds that in utero, valproate exposure was associated with impaired cognitive development. Children exposed to valproate had significantly lower IQ scores at age 6 years (analyses controlled for maternal IQ, ASM dose, gestational age, and folic acid use) when compared to children whose mothers took carbamazepine, lamotrigine, or phenytoin. In addition, findings from NEAD suggest that verbal abilities may specifically be at risk from valproate as well as the other studied ASMs (carbamazepine, lamotrigine, and phenytoin). Periconceptional folic acid use resulted in improved cognitive outcomes. The mean IQs were higher in children exposed to periconceptional folic acid (mean, 108; 95% CI, 106-111) when compared to unexposed children for all ASMs (mean, 101; 95% CI, 98-104; $P = .0009$). Valproate exposure has also been reported to increase the risk of autism and autism disorders among in utero–exposed children. Cognitive outcome data is limited for other commonly used ASMs.

Management of Epilepsy During Pregnancy

Management of epilepsy in women of reproductive age should focus on maintaining effective control of seizures while minimizing fetal exposure to ASMs. This applies to dosage and number of ASMs. Medication reduction or substitution should be considered prior to conception. Altering medication during pregnancy increases the risk of breakthrough seizures and exposes the fetus to an additional ASM. The recommended ASM management in pregnancy is monotherapy at the lowest effective dose. Higher ASM doses are associated with higher risks of MCMs as well as poorer cognitive outcomes. If there is a family history of neural tube defects, an agent other than valproate and carbamazepine should be considered.

Seizures in pregnancy may result in miscarriage, preterm labor, fetal bradycardia, and injury to the mother and child. Seizures do not appear to increase the risk of MCMs. Frequent generalized tonic-clonic seizures increase risk of impaired cognitive development.

Once a woman is pregnant, prenatal diagnostic testing includes a maternal serum α-fetoprotein and an anatomic ultrasound at 14 to 18 weeks. This combination will identify more than 95% of infants with neural tube defects. In some instances, amniocentesis may be indicated.

Enzyme-inducing ASMs may result in ASM-related vitamin K deficiency, which increases the risk of early fetal hemorrhage. Although earlier AAN guidelines recommended that women taking enzyme-inducing ASMs be given supplemental vitamin K (vitamin K_1, 10 mg/d) for the last month of gestation, there is insufficient evidence to determine if prenatal vitamin K supplementation reduces neonatal hemorrhagic complications. Importantly, all neonates receive vitamin K at delivery.

For pregnant women with new-onset seizures, the diagnostic strategy is similar to that for any patient with a first-time seizure. The neurologic history and examination can be directed to signs of a specific cause, such as acute intracranial hemorrhage or central nervous system (CNS) infection. Evaluation should include screening for hypertension, proteinuria, and edema to exclude eclampsia. Follow-up studies include serologic tests for syphilis and human immunodeficiency virus, electroencephalogram (EEG), and magnetic resonance imaging (MRI), which is the preferred imaging technique for pregnant women. As in nonpregnant women with a first-time seizure, treatment depends on seizure type and cause.

Breastfeeding

The American Academy of Pediatrics recommends breastfeeding for the first 6 months of life. Although infants whose mothers take ASMs will continue to be exposed to ASMs in breast milk, findings from a prospective study, the Maternal Outcomes and Neurodevelopmental Effects of Antiepileptic Drugs supports that overall drug exposure is low. The median percentage of infant-to-mother concentration for seven commonly used ASMs (carbamazepine, levetiracetam, lamotrigine, oxcarbazepine, topiramate, valproate, and zonisamide) ranged from 0.3% to 44.2% in 164 infant-mother concentration pairs. In support of breastfeeding are findings from the NEAD study assessing and comparing cognitive outcomes in breastfed children exposed to

ASMs with nonbreastfed children (exposed to ASMs in utero). Breastfed children had a higher IQ and adjusted verbal index compared to nonbreastfed children.

PREECLAMPSIA AND ECLAMPSIA

Preeclampsia and eclampsia are most often seen in young primigravida women and in multiparous women with a change in partner. Preeclampsia is a multisystem disorder that is diagnosed clinically by hypertension, proteinuria, and edema. Modern consensus definitions define preeclampsia as pregnancy-induced hypertension beginning after 20th week with proteinuria. Women are also defined as having preeclampsia if they have pregnancy-induced hypertension without proteinuria if they have other common symptoms including cerebral symptoms, epigastric or right upper quadrant pain with nausea or vomiting, or thrombocytopenia and abnormal liver enzymes. Preeclampsia is associated with hepatic and coagulation abnormalities, hypoalbuminemia, increased urate levels, and hemoconcentration. Studies suggest that secreted antiangiogenic factors such as fms-like tyrosine kinase 1 contribute to the acute symptomatology and potential long-term effects. Women who develop preeclampsia/eclampsia should be screened for glomerular and cardiovascular disease throughout life.

Epidemiology

Preeclampsia affects 5% to 8% of pregnancies. In black women, preeclampsia has a higher prevalence and is more likely to be associated with maternal complications. Cerebrovascular disease is the leading cause of maternal mortality in women with preeclampsia. Preeclampsia can progress to eclampsia, a syndrome of diffuse multifocal brain edema that can result in posterior reversible encephalopathy syndrome. Fewer than 5% of women with preeclampsia progress to eclampsia. The incidence in Europe and other developed countries is 1 per 2,000. In developing countries, the incidence varies from 1 in 100 to 1 in 1,700. Worldwide, eclampsia probably accounts for 50,000 deaths annually.

Clinical Features

Neurologic abnormalities associated with *eclampsia* may include headaches, confusion or lethargy, seizures, cortical blindness or visual field defects, coma, brain hemorrhage, or death due to herniation from massive global cerebral edema. Seizures are most often generalized but may be focal. Common neurologic findings on exam include memory deficits, increased deep tendon reflexes, visual perception deficits, visual information–processing deficits, altered mental status, and cranial nerve deficits. Cortical blindness and visual field defects may occur because occipital lobes are preferentially involved.

Diagnosis

The differential diagnosis of eclampsia includes subarachnoid hemorrhage and cerebral venous thrombosis. The diagnosis is established by appropriate clinical features in the presence of increased blood pressure plus proteinuria, edema, or both. A significant increase in blood pressure is defined as an increase of more than 15 mm Hg diastolic or 30 mm Hg systolic above baseline measurements obtained before or early in pregnancy. If no early reading is available, a blood pressure of 140/90 mm Hg or higher in late pregnancy is significant.

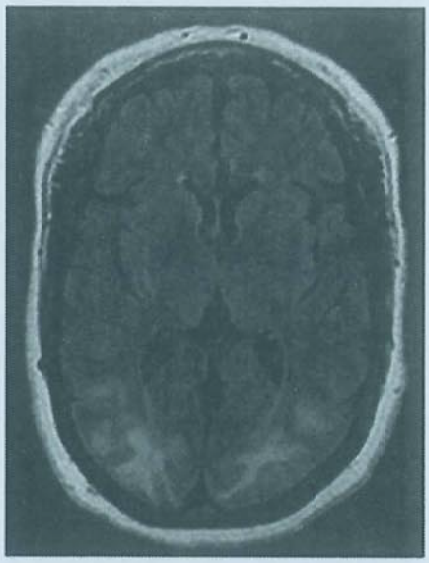

FIGURE 129.1 Symmetric posterior edema on magnetic resonance imaging T2 fluid-attenuated inversion recovery images characteristic of posterior reversible encephalopathy syndrome in a hypertensive pregnant woman who presented with visual changes (patches in her vision). (From Hosley CM, McCullough LD. Acute neurological issues in pregnancy and the peripartum. *Neurohospitalist*. 2011;1:104-116.)

Neuroimaging, EEG, cerebrospinal fluid analysis, and angiography may help in diagnosis. Computed tomography (CT) is usually normal in eclampsia but may show hypodense regions in areas of cerebral edema. MRI provides better detection of edema in the cortical mantle and is the mainstay for confirming the diagnosis. MRI characteristically shows sulcal hyperintensity and small multifocal microinfarcts and hemorrhages, with a predilection for the occipital lobes (Fig. 129.1). EEG may show spike-and-wave discharges. The cerebrospinal fluid is usually normal in preeclampsia, but the protein content may be moderately elevated, and the pressure may be increased. In some patients, angiography shows arterial spasm. A subset of patients with severe eclampsia also develop hemolysis, elevated liver enzymes, and a low platelet count (HELLP) syndrome.

Pathologic examination of eclamptic brains reveals petechial hemorrhages in cortical and subcortical patches. Microscopically, these petechial hemorrhages are ring hemorrhages about capillaries and precapillaries occluded by fibrinoid material. Areas that are predisposed include the parietooccipital and occipital regions.

Treatment

The most accepted treatment of eclampsia is delivery of the fetus, if possible. Hypertension should be treated with continuous infusion antihypertensive agents, initially directed toward attaining the patient's baseline premorbid blood pressure levels or a 20% reduction in systolic blood pressure, whichever is higher. Presently, magnesium sulfate (a 4- to 6-g loading dose, followed by an infusion of 1 to 2 g an hour, with a target serum magnesium level of 2.0-3.5 mmol/L) is the first-line treatment for the prevention and treatment of eclamptic seizures and other symptoms of eclampsia. Randomized trials have compared magnesium sulfate and other agents including phenytoin and diazepam, and the

results suggest that magnesium sulfate is the agent of choice. An international randomized placebo-controlled trial (MAGnesium sulphate for Prevention of Eclampsia [MAGPIE] trial) compared the use of magnesium sulfate and placebo for preeclampsia; magnesium sulfate halved the risk of eclampsia and reduced the risk of maternal death from 1.9% to 0.8% LEVEL 1.[1] Hypertension refractory to magnesium alone can be treated with intravenous nicardipine, clevidipine, or labetalol. There were no substantive harmful effects to mother or baby in the short term. For women at high risk for preeclampsia, the U.S. Preventive Services Task Force recommends low-dose aspirin as preventive medication after 12 weeks of gestation LEVEL 1.[2]

STROKE

Epidemiology

Pregnancy is a risk factor for stroke, and the postpartum period is the most vulnerable time. Stroke incidence as determined in a systematic review and meta-analysis is 30.0 per 100,000 pregnancies with a mean age of 22 to 33 years. When compared to nonpregnant young adult age groups, the incidence is 3 times higher. Using the National Inpatient Sample, acute stroke occurred in 1 of every 2,222 hospitalizations with no decrease in over 9 years. Factors that increase the risk (**Table 129.3**) for stroke include pregnancy-related hypertension and cesarean delivery. Certain medical conditions may also increase the risk. Data from the National Inpatient Sample of the Healthcare Cost and Utilization Project suggest that the incidence of pregnancy-associated stroke has risen since the 1990s. The analysis, which included all types of pregnancy-associated strokes, found a 47% increase when comparing the time periods 1994-1995 to 2006-2007. Concurrent hypertensive disorders and heart disease explain most of the increase. Among those with acute stroke in the National Inpatient Sample analysis, there were increases in prevalence of most stroke risk factors including obesity, smoking, hyperlipidemia, migraine, and gestational hypertension increased. Mortality is approximately 10% to 13% and is higher in black women, older women, and those with no prenatal care. Presumptive mechanisms include changes in the coagulation and fibrinolytic systems leading to a hypercoagulable state and an increase in viscosity and stasis, which can promote thrombosis. In the postpartum period, the large decrease in blood volume at childbirth, rapid changes in hormone status that alter hemodynamics and coagulation, and the strain of delivery may predispose to a stroke. The risk of thrombosis in the postpartum period persists until at least 12 weeks after delivery.

TABLE 129.3 Risk Factors for Maternal Stroke

Older age
African American race
Obesity
Hypertensive disorders of pregnancy Gestational hypertension Preeclampsia Eclampsia
Cardiac disease Preexisting chronic hypertension Preexisting valvular, congenital, or ischemic heart disease
Cesarean delivery
Infections
Migraines
Diabetes
Hematologic disorders Sickle cell disease Antiphospholipid syndrome Thrombotic thrombocytopenic purpura Hyperhomocysteinemia Mutations in prothrombin gene Deficiencies in antithrombin III, protein C, protein S, and factor V Leiden
Systemic lupus erythematosus
Smoking
Alcohol use
Recreational drug use (particularly cocaine)

Ischemic Stroke

Arterial occlusion resulting in cerebral infarction (see Chapter 36) accounts for approximately one-half of strokes in pregnant women and occurs primarily in the second and third trimesters. Arterial strokes are generally a consequence of identifiable risk factors, including premature atherosclerosis, moyamoya disease, Takayasu arteritis, fibromuscular dysplasia, and primary CNS vasculitis.

Cerebral Venous Thrombosis

Cerebral venous thrombosis (see Chapter 41) is the second most common cause of stroke in pregnant women, causing approximately one-third of strokes in pregnant women. Cerebral venous thrombosis usually occurs late in pregnancy or in the postpartum period. The pathophysiology of venous infarctions differs from strokes associated with arterial occlusion because they occur in the setting of venous thrombosis secondary to venous congestion and rise in pressure. A systematic review and pooled analysis of pregnancy-related cerebral venous thrombosis found the most frequently involved sinuses are the superior sagittal sinus (67%) and the transverse sinus (64%). Contributing factors include the underlying hypercoagulable state in pregnancy, alterations in platelet function, prothrombotic and antithrombotic proteins, as well as iron deficiency anemia and adaptive response to hemorrhage of labor and delivery. Testing for free protein S deficiency, an acquired hypercoagulable state, is positive in many patients. The clinical presentation is variable because the woman can present with headaches (the most common presenting symptom), focal neurologic deficits, depressed mental status, or seizures. Hematologic disorders can play an etiologic role in arterial and venous strokes (see **Table 129.3**). Other causes are cardiogenic and paradoxic emboli.

Diagnosis

The key to early diagnosis of stroke in pregnancy is prompt neuroimaging. As with nonpregnant patients, CT and MRI should be done to identify areas of stroke as well as study cerebral vasculature. MRI is the preferred imaging modality in pregnancy, and scanning is safe in all trimesters; no human data demonstrates increased teratogenicity. In the emergent evaluation of stroke, CT may be more readily available. The estimated fetal radiation exposure for a single maternal CT of the head is far below safety threshold for

teratogenesis or developmental disabilities. Angiography including magnetic resonance, CT, or transfemoral catheter angiography may be needed to assess stroke etiology. The current gold standard for diagnosing cerebral venous thrombosis is magnetic resonance venography in combination with MRI. Imaging of cerebral venous thrombosis reveals thrombus within cerebral vein or venous sinus either without parenchymal changes or with evidence of cerebral edema, apparent ischemic stroke, or hemorrhage. Hemorrhage occurs in almost half of those with cerebral venous thrombosis (see "Cerebral Hemorrhage" section for further discussion). Further evaluation such as cardiac ultrasound and serologic studies to evaluate for conditions associated with an increased stroke risk should be pursued. With the exception of protein C, protein S, and antithrombin III deficiency, other hypercoagulable studies can be performed. Evaluation of protein C, protein S, and antithrombin III factors should occur at least 6 weeks after delivery because they are directly affected by pregnancy itself.

Treatment

Treatment of strokes in pregnancy is directed to the specific cause.

Intravenous Thrombolysis

Thrombolysis improves outcomes after stroke. As pregnant women were excluded from the trials involving recombinant tissue plasminogen activator, no controlled studies are available. Intravenous tissue plasminogen activator has a short half-life and does not cross the placenta, and there is a shift to consider its use in pregnancy. Studies find comparable outcomes of pregnant or postpartum women when compared to nonpregnant women. Potential concern relates to maternal hemorrhage, placental hemorrhage and abruption, fetal loss, and preterm labor and not increased teratogenicity.

Mechanical Thrombectomy

Similar to intravenous thrombolysis, pregnant women were excluded from randomized thrombectomy trials. There are, however, multiple reports of pregnant women undergoing successful thrombectomy and a registry-based study found similar outcomes for pregnant women when compared to nonpregnant women.

Unfractionated and Low Molecular Weight Heparin

Anticoagulation is a treatment option for prevention of recurrent stroke in patients with stroke due to arterial dissection. Unfractionated heparin does not cross the placenta. However, long-term use (>1 mo) is associated with osteoporosis and thrombocytopenia. Use of low molecular weight heparin (LMWH) is thus considered to be a more preferable choice than unfractionated heparin because the development of osteoporosis, thrombocytopenia, as well as allergies is less likely. Indeed, LMWH is the drug of choice for treatment of venous thromboembolism from deep vein thrombosis, one of the leading causes of maternal mortality and morbidity in the developed world. Warfarin (Coumadin) crosses the placenta and is a known teratogen. It is therefore recommended only for women who cannot tolerate heparin or who have recurrent thromboembolic events. Aspirin complications in pregnancy include teratogenic effects and bleeding in the neonate. However, low-dose aspirin (<150 mg) is safe in the second and third trimesters, with no increase in maternal or neonatal adverse effects.

Anticoagulation is also the treatment of choice for cerebral venous thrombosis including those with cerebral hemorrhage. Acutely, early anticoagulation with either unfractionated heparin or LMWH is recommended. Studies find that among nonpregnant patients, patients who received heparin had lower mortality when compared to those who did not. In one study, no worsening with anticoagulation occurred in those with hemorrhage. Prolonged anticoagulation is also recommended, typically for 3 to 6 months. Warfarin can be used in the postpartum period. In those cases of cerebral venous thrombosis during pregnancy, LMWH is used and is held during labor and delivery.

CEREBRAL HEMORRHAGE

Epidemiology

The risk of cerebral hemorrhage increases in pregnancy. Cerebral hemorrhage occurs in 1 to 5 pregnancies per 10,000, with an associated mortality of 30% to 40%. Factors that predispose to hemorrhage include physiologic changes of pregnancy such as hypertension; high concentrations of estrogens causing arterial dilation; and increases in cardiac output, blood volume, and venous pressure. Pregnancy-related conditions also increase the risk of hemorrhage. These include eclampsia, metastatic choriocarcinoma, cerebral emboli, and coagulopathies.

Subarachnoid hemorrhage accounts for 50% of all intracranial bleeding in pregnancy and carries a high mortality. Cerebral aneurysms and arteriovenous malformations cause most subarachnoid hemorrhages in pregnancy. Other causes include eclampsia, cocaine use, coagulopathies, ectopic endometriosis, moyamoya disease, and choriocarcinoma. Aneurysmal bleeding usually occurs in older patients in the second and third trimesters. In contrast, hemorrhages from arteriovenous malformations occur in younger women throughout gestation, with the highest risk during labor and the puerperium. A recent large study from China did not, however, find an increased risk of hemorrhage in patients with cerebral arteriovenous malformation during pregnancy and the puerperium.

As discussed previously, cerebral venous thrombosis may also result in cerebral bleeding as a complication of venous infarction. Stasis of flow leads to infarction and secondary hemorrhage. The hemorrhage can extend to multiple areas of the brain including subarachnoid, subdural, and intraventricular spaces.

Diagnosis and Treatment

The diagnosis and treatment of subarachnoid hemorrhage and intracerebral hemorrhage in pregnant women are similar to those in nonpregnant patients. Subarachnoid hemorrhage is diagnosed by clinical manifestations and CT. If brain CT is normal and the clinical signs are consistent with intracranial hemorrhage, lumbar puncture should be performed. Once intracranial hemorrhage is detected, follow-up studies include MRI and four-vessel angiography. Noncontrast CT is also the most sensitive means of diagnosing intracerebral hemorrhage. As previously discussed, cerebral venous thrombosis is best initially diagnosed using magnetic resonance venography in combination with MRI. Digital subtraction angiography with careful venography may be necessary in equivocal cases but is less preferable due to fetal exposure to radiation. Treatment of these conditions is directed to supporting the mother and fetus and preventing complications. Blood pressure should be carefully monitored, and fetal monitoring is indicated. The specific treatment depends on the etiology of the hemorrhage and may require emergent surgery,

especially in setting of aneurysmal subarachnoid hemorrhage, when the risk of early rebleeding is high. As in nonpregnant patients, management of intracranial pressure (ICP) is important. Current practice suggests that monitoring ICP and cerebral perfusion pressure plays a role in guiding therapy in cerebral hemorrhage, particularly for patients at high risk for developing hydrocephalus.

MULTIPLE SCLEROSIS

Epidemiology

MS affects 1 in 10,000 people in Western countries, primarily women in the childbearing years between the ages of 20 and 40. MS is classified as either relapsing remitting or chronic progressive with the majority having the relapsing remitting subtype. Pregnancy is common among women with MS and the prevalence is increasing. Between approximately one-fifth and one-third of women with MS will deliver a child after disease onset. A retrospective U.S. administrative claims study using data from January 1, 2006, to June 30, 2015, found that pregnancies increased from 7.9% to 9.5% Interestingly in a similar time frame, pregnancies decreased in women without MS. Initial presentation of MS during pregnancy is unusual.

Clinical Features

Whether pregnancy affects MS onset remains inconclusive. Most published studies support either a beneficial effect or net-neutral effect, and a few studies conclude that pregnancy increases risk of developing MS. Prospective studies and other surveys found that the relapse rate decreases in pregnancy, especially in the third trimester, and increases in the first 3 months postpartum. Pregnancy, however, does not reduce relapse risk in women who stop the disease-modifying drugs fingolimod and natalizumab. Women who stop these disease-modifying drugs are at risk for severe relapse after drug cessation. Severe rebound relapses during pregnancy have been reported as early as 1 month after stopping fingolimod and 3 to 4 months after stopping natalizumab. A high relapse rate or disability before pregnancy is associated with an increased risk of postpartum attacks. Pregnancy does not increase risk of long-term disability. The outcome of the pregnancy itself is not affected by MS.

Pathobiology

The mechanisms responsible for the change in the rate of relapses include humoral and immunologic changes, as seen also in pregnant women with other autoimmune diseases such as rheumatoid arthritis or systemic lupus erythematosus. There is no correlation of relapse rate with the physical stress of childbirth and caring for the newborn, sleep deprivation, type and dose of anesthesia, breastfeeding, or socioeconomic factors.

Treatment

Treatment of MS is divided into three categories: disease-modifying, acute, and symptomatic therapies. Disease-modifying therapies include natalizumab, interferon β, glatiramer acetate, fingolimod, dimethyl fumarate, teriflunomide, ocrelizumab/rituximab, and alemtuzumab and have variable effects in pregnancy (**Table 129.4**). Although not as effective as some of the other disease-modifying agents, glatiramer acetate and interferon β are considered the safest. Teriflunomide is U.S. Food and Drug Administration (FDA) category X because it is teratogenic in animal models but there is no data to support increased teratogenicity in humans. The use of disease-modulating therapies during pregnancy should be limited to cases whereby potential benefits outweigh the risks. If a severe relapse does occur with pregnancy, a short course of corticosteroid therapy is recommended. Use in early pregnancy should be avoided if possible because it may increase the risk of oral clefts and lower birth weight. In addition, neonatal adrenal suppression may follow maternal corticosteroid use, and large prenatal doses in animals caused growth retardation and compromised development of the CNS. Symptomatic therapies should be minimized in pregnancy. Intrathecal baclofen may be safe for the treatment of severe spasticity due to MS.

TABLE 129.4 Multiple Sclerosis Disease-Modifying Therapies Effects in Pregnancy

Disease-Modifying Therapy	Effects in Pregnancy
Glatiramer acetate/ interferon β	No data of teratogenicity in animal studies Does not cross placenta No reported effects on fertility or miscarriage No reported increased teratogenicity Safe with early first trimester exposure
Dimethyl fumarate	High doses results in adverse effects in rats No increased fetal abnormalities in humans No washout period required
Teriflunomide	Increased teratogenicity in multiple animal studies No reported increased teratogenicity in human U.S. Food and Drug Administration category
Fingolimod	Probable increased teratogenicity Two-month washout period required
Natalizumab	Infant pancytopenia when given in third trimester
Rituximab/ Ocrelizumab	Infant B-cell depletion with second and third trimester exposure
Alemtuzumab	Increased embryo lethality and reduced levels of B and T lymphocytes in animal studies High risk of autoimmune thyroiditis for 4 years after stopping—may induce transient neonatal Graves disease

MIGRAINE

Epidemiology

Migraine is diagnosed in 18% of women of childbearing years. Postpartum headaches are common, occurring in approximately 30% of women typically during 3 to 6 days postpartum. They are associated with both personal and family histories of migraine headaches.

Clinical Features

Sixty percent to 70% of migraine headaches improve during pregnancy, especially for migraines without aura. Women who had migraine onset at menarche or who have had menstrual migraines are more likely to experience improvement, especially in the first or second trimester.

A Danish population-based registry study of over 22,000 pregnancies among women with migraine and over 228,000 found that women with migraine and their offspring had greater risks of several adverse pregnancy outcomes than women without migraine. Migraine was associated with an increased prevalence of low birth weight (adjusted prevalence ratio [aPR], 1.14; 95% CI, 1.06-1.23), preterm birth (aPR, 1.21; 95% CI, 1.13-1.30), and cesarean delivery (aPR, 1.20; 95% CI, 1.15-1.25) but not of small for gestational age offspring (aPR, 0.94; 95% CI, 0.88-0.99) and birth defects (aPR, 1.01; 95% CI, 0.93-1.09).

Pathobiology

Higher levels of estrogen are probably responsible for this improvement during pregnancy. The subsequent fall in estrogen levels may cause postpartum headaches.

Diagnosis

Migraines may also arise during pregnancy. Studies suggest these headaches are more likely to be with aura. If migraine arises in pregnancy, the differential diagnosis must be considered. A new-onset migraine with aura can be a symptom of vasculitis, brain tumor, or occipital arteriovenous malformation. Subarachnoid hemorrhage can cause headache any time during pregnancy or delivery. Other disorders with headache include stroke, cerebral venous thrombosis, eclampsia, pituitary tumor, and choriocarcinoma.

Treatment

Medication use during pregnancy should be limited. Nonpharmacologic approaches including biofeedback and relaxation practices have good evidence for efficacy as preventative treatments and may also be effective as an acute treatment. Acetaminophen is the analgesic of choice because studies confirm that it is safe at therapeutic doses of 4 g or less per day. If necessary, codeine or other narcotics may be used. Chronic use though can result in neonatal withdrawal. Low-dose aspirin may also be given but should be avoided toward the end of pregnancy because of increased risk of prolonged labor, postpartum hemorrhage, and neonatal bleeding. Ibuprofen is the nonsteroidal anti-inflammatory drug (NSAID) of choice during pregnancy and can be given in the first and second trimesters. Both aspirin and NSAIDs are associated with premature closure of the fetal ductus arteriosus. NSAIDs are also associated with an increased risk of oligohydramnios. Antiemetics such as metoclopramide or prochlorperazine may relieve the headache and associated nausea and vomiting. These agents are generally safe and effective. Ergotamine and dihydroergotamine mesylate (D.H.E. 45) should be avoided. The triptans are effective and widely used for the treatment of headache. Current evidence does not support adverse outcomes associated with their use in pregnancy. However, because limited information is available, their use in pregnancy is not recommended. Sumatriptan has been available the longest and is the most widely used, particularly in the first trimester. Current data suggest that first-trimester exposure of sumatriptan is not associated with any significant increase in congenital malformations or poor pregnancy outcomes. For someone with recurrent headaches, a β-adrenergic blocker, such as propranolol, may be used prophylactically. However, adverse effects including intrauterine growth retardation have been reported with β-adrenergic blockers. In addition, treatment should be stopped 2 to 3 days before delivery to reduce risk of fetal bradycardia and reduction in uterine contraction. Other agents used to prophylactically treat migraine headaches include valproate and topiramate. These agents should be discontinued prior to conception because they are both associated with higher than expected rates of MCMs. In conclusion, the choice of medication for migraine in pregnant women should balance the mother's comfort with the least fetal risk.

NEOPLASMS

Epidemiology

Brain tumors rarely become symptomatic during pregnancy. The incidence of glioma, the most common tumor in pregnancy, is 2.6 to 15 per 100,000. Systemic cancer and brain metastases are unusual in young women and rarely begin during pregnancy.

Clinical Features and Diagnosis

The types of tumors arising in pregnancy differ from those in nonpregnant women. Glioma is the most common, followed by meningioma, acoustic neuroma, and then a variety of other tumors, including pituitary tumors. Tumor growth may be exacerbated by pregnancy, especially meningioma. Possible mechanisms include increased blood volume, fluid retention, and stimulation of tumor growth by hormones.

Choriocarcinoma is the only systemic tumor specifically associated with pregnancy. Brain metastases are common in choriocarcinoma; among patients diagnosed with choriocarcinoma, 3% to 20% have brain disease at diagnosis.

Cerebral neoplasms cause headaches, seizures, focal signs, or symptoms of increased ICP. The seizures may be focal or generalized. Nausea and vomiting in the first trimester can be confused with morning sickness.

All women suspected of having a brain tumor should be examined with MRI.

Treatment

Studies suggest that pregnancy is not a contraindication to biopsy and/or resection. Radiation therapy should be avoided. Chemotherapy is definitely contraindicated. Cesarean delivery is preferable to vaginal delivery to avoid increased ICP secondary to Valsalva.

NEUROPATHIES

Women are at an increased risk for peripheral neuropathy during pregnancy and the puerperium. Backache and poorly localized paresthesias are common. At least 50% of pregnant women have back pain. Among the specific rare neuropathies that occur with a higher incidence during pregnancy are carpal tunnel syndrome, facial nerve palsy, meralgia paresthetica, and chronic inflammatory demyelinating polyneuropathy.

Carpal Tunnel Syndrome

Carpal tunnel syndrome is the most frequent neuropathy of pregnancy. Estimated prevalence ranges from 1% to 62%. A recently published prospective study reported 34% prevalence of carpal tunnel symptoms among 639 women. It usually begins in the

third trimester and disappears after delivery. It is attributed to generalized edema. Other potential hypotheses include the effect of hormones such as relaxin on ligamentous laxity, changes in sleep position, and increased adipose tissue. A prospective study found that 30% of women noted resolution of symptoms soon after delivery, 11% during lactation, and 5% after interruption of lactation. Prognosis was better for those who developed symptoms later in pregnancy.

Bell Palsy

Bell palsy appears with a slightly higher frequency during pregnancy, mostly in the third trimester. Prognosis for recovery is excellent and is similar to that in nonpregnant women. Corticosteroid use within 3 to 7 days of presentation is the current treatment recommendations for the general population. Steroids are FDA category C and are probably safe in pregnancy. The potential risks in pregnancy particularly if the woman has poorly controlled hypertension or hyperglycemia need to be considered. The AAN guidelines do not find conclusive evidence to support use of antiviral agents; they are, however, safe in pregnancy. Because studies suggest that women who develop Bell palsy have an increased incidence of hypertension and preeclampsia, these women should be monitored closely.

Meralgia Paresthetica

Meralgia paresthetica, a sensory neuropathy of the lateral femoral cutaneous nerve of the thigh, is attributed to compression of the nerve under the lateral part of the inguinal ligament. Swelling during pregnancy, increased body weight, and increased lordosis during pregnancy are possible causes. Numbness, burning, tingling, or pain in the lateral thigh suggests the diagnosis. A local anesthetic with or without steroids is usually all that is necessary. Most women improve in the postpartum period. The incidence of chronic inflammatory demyelinating polyneuropathy is slightly higher during pregnancy. As in nonpregnant women, treatment includes plasma exchange, intravenous immunoglobulin, or steroids.

MYASTHENIA GRAVIS

Epidemiology

Myasthenia gravis (MG) is 2 times more common in women than men. In women, the onset is most common in the third decade.

Clinical Features

MG symptoms are variable and reported to worsen in 30% to 40% of patients. Exacerbations occur more likely in the first trimester and postpartum period.

The total rate of pregnancy complications particularly preterm rupture of the amniotic membranes is higher among women with MG than in the general population. An association between MG and preeclampsia has been described. Pregnancy does not affect the long-term outcome of MG.

Neonatal MG affects 12% to 20% of infants born to mothers with MG. The occurrence of neonatal MG does not correlate with maternal disease severity or titer of maternal anticholinesterase receptor antibodies. The symptoms clear within a few weeks.

Treatment

Treatment of myasthenia during pregnancy includes immunosuppressant drugs, plasma exchange, and intravenous immunoglobulin. For women who develop preeclampsia and eclampsia, use of magnesium should be avoided because magnesium blocks entry at the nerve terminal and inhibits acetylcholine release. Use of prednisone in the first trimester is associated with a small increase in cleft palate, and high doses may lead to premature rupture of membrane. Use of cyclosporine is not recommended because of reported increased risk of spontaneous abortions, prematurity, and low birth weight. Rituximab is also not recommended because it is associated with B-cell lymphocytopenia. Azathioprine and mycophenolate mofetil should not be used because they can result in significant risk to the fetus and are designated by the FDA as category D, positive evidence of human fetal risk. Anticholinesterase drugs are reportedly safe. Intravenous immunoglobulin is recommended for treatment of myasthenic crisis during pregnancy. Although plasma exchange is an option for treatment of a myasthenic crisis, there is a risk of hypotension. Thymectomy is deferred until long after delivery. (Myasthenia is also discussed in Chapter 93.)

MOVEMENT DISORDERS

Movement disorders are unusual in young women, but those that specifically occur during pregnancy include the restless legs syndrome, chorea, and drug-induced movement disorders.

Restless Legs Syndrome

The restless legs syndrome is the most common movement disorder of pregnancy. It is a chronic condition that has an autosomal dominant pattern of inheritance and is characterized by a crawling, burning, or aching sensation in the calves with an irresistible urge to move the legs. It occurs in 10% to 20% of pregnant women. A systematic review and meta-analysis found a pooled overall prevalence of 21%. Symptoms can occur for the first time in pregnancy, usually in the second and third trimesters. For women with preexisting restless legs syndrome, there can be a worsening of symptoms. In a study of 606 pregnant women, 59 had preexisting restless legs syndrome and among those women, 36 reported worsening of symptoms. Iron deficiency has been found in patients with restless legs syndrome, and treatment of iron deficiency in pregnant women has been advocated, but therapeutic trials have yet not been performed. Also, lower folate levels are associated with the restless legs syndrome and treatment recommendations include folate supplementation. Other treatments include massage, flexion and extension, walking, benzodiazepines, opiates, or levodopa.

Chorea Gravidarum

Chorea gravidarum occurs in pregnancy (see Chapter 84). Treatment is reserved for those with violent and disabling chorea and includes haloperidol or benzodiazepines.

Parkinsonism and Idiopathic Parkinson Disease

Drugs that block dopamine receptors are often used to treat the nausea and vomiting of pregnancy. These drugs can cause new-onset

chorea, tremor, dystonia, or parkinsonism. Idiopathic Parkinson disease is uncommon in women younger than 40 years. More common is secondary parkinsonism caused by medication or toxins. There is no definite evidence that Parkinson disease worsens during pregnancy, and there is little information about the toxicity of antiparkinson medications. Successful pregnancies have been reported in women taking levodopa.

LEVEL 1 EVIDENCE

1. Magpie Trial Collaborative Group. Do women with preeclampsia, and their babies, benefit from magnesium sulphate? The Magpie Trial: a randomised placebo-controlled trial. *Lancet*. 2002;359:1877-1890.
2. LeFevre ML. Low-dose aspirin use for the prevention of morbidity and mortality from preeclampsia: U.S. Preventive Services Task Force recommendation statement. *Ann Intern Med*. 2014;161(11):819-826.

SUGGESTED READINGS

Biology of Pregnancy

Silberstein SD. Drug treatments and trials in women. In: Kaplan PW, ed. *Neurologic Disease in Women*. 2nd ed. New York, NY: Demos Medical Publishing; 2006:41-62.

Taylor HS, Pal L, Seli E, eds. Neuroendocrinology. In: *Speroff's Clinical Gynecologic Endocrinology and Infertility*. 9th ed. Philadelphia, PA: Wolters Kluwer; 2020:103-136.

Epilepsy

Artama M, Gissler M, Malm H, Ritvanen A; and Drug and Pregnancy Group. Effects of maternal epilepsy and antiepileptic drug use during pregnancy on perinatal health in offspring: nationwide, retrospective cohort study in Finland. *Drug Saf*. 2013;36(5):359-369.

Baxter P. Valproate and folic acid in pregnancy: associations with autism. *Dev Med Child Neurol*. 2014;56(7):604.

Bech BH, Kjaersgaard MI, Pedersen HS, et al. Use of antiepileptic drugs during pregnancy and risk of spontaneous abortion and stillbirth: population based cohort study. *BMJ*. 2014;349:g5159.

Birnbaum AK, Meador KJ, Karanam A, et al. Antiepileptic drug exposure in infants of breastfeeding mothers with epilepsy. *JAMA Neurol*. 2020;77(4):441-450.

Bromley R, Weston J, Adab N, et al. Treatment for epilepsy in pregnancy: neurodevelopmental outcomes in the child. *Cochrane Database Syst Rev*. 2014;(10):CD010236.

Campbell E, Kennedy F, Russell A, et al. Malformation risks of antiepileptic drug monotherapies in pregnancy: updated results from the UK and Ireland Epilepsy and Pregnancy Registers. *J Neurol Neurosurg Psychiatry*. 2014;85:1029-1034.

Christensen J, Grønborg TK, Sørensen MJ, et al. Prenatal valproate exposure and risk of autism spectrum disorders and childhood autism. *JAMA*. 2013;309(16):1696-1703.

Cohen MJ, Meador KJ, Browning N, et al. Fetal antiepileptic drug exposure: motor, adaptive, and emotional/behavioral functioning at age 3 years. *Epilepsy Behav*. 2011;22(2):240-246.

Hernández-Díaz S, Smith CR, Shen A, et al; for North American AED Pregnancy Registry. Comparative safety of antiepileptic drugs during pregnancy. *Neurology*. 2012;78(21):1692-1699.

Jentink J, Loane MA, Dolk H, et al; for EUROCAT Antiepileptic Study Working Group. Valproic acid monotherapy in pregnancy and major congenital malformations. *N Engl J Med*. 2010;362(23):2185-2193.

Johnson EL, Stowe ZN, Ritchie JC, et al. Carbamazepine clearance and seizure stability during pregnancy. *Epilepsy Behav*. 2014;33:49-53.

Kilic D, Pedersen H, Kjaersgaard MI, et al. Birth outcomes after prenatal exposure to antiepileptic drugs—a population-based study. *Epilepsia*. 2014;55(11):1714-1721.

Margulis AV, Mitchell AA, Gilboa SM, et al; and National Birth Defects Prevention Study. Use of topiramate in pregnancy and risk of oral clefts. *Am J Obstet Gynecol*. 2012;207(5):405.e1-405.e7.

Mawhinney E, Craig J, Morrow J, et al. Levetiracetam in pregnancy: results from the UK and Ireland epilepsy and pregnancy registers. *Neurology*. 2013;80(4):400-405.

Meador K, Baker G, Browning N, et al. Breastfeeding in children of women taking antiepileptic drugs: cognitive outcomes at age 6 years. *JAMA Pediatr*. 2014;168(8):729-736.

Meador KJ, Baker GA, Browning N, et al; for NEAD Study Group. Fetal antiepileptic drug exposure and cognitive outcomes at age 6 years (NEAD study): a prospective observational study. *Lancet Neurol*. 2013;12(3):244-252.

Morrow J, Russell A, Guthrie E, et al. Malformation risks of antiepileptic drugs in pregnancy: a prospective study from the UK Epilepsy and Pregnancy Register. *J Neurol Neurosurg Psychiatry*. 2006;77:193-198.

Pennell PB, Klein AM, Browning N, et al; for NEAD Study Group. Differential effects of antiepileptic drugs on neonatal outcomes. *Epilepsy Behav*. 2012;24(4):449-456.

Thomas SV, Syam U, Devi JS. Predictors of seizures during pregnancy in women with epilepsy. *Epilepsia*. 2012;53(5):e85-e88.

Tomson T, Battino D. Teratogenic effects of antiepileptic drugs. *Lancet Neurol*. 2012;11(9):803-813.

Tomson T, Battino D, Bonizzoni E, et al; for EURAP Study Group. Comparative risk of major congenital malformations with eight different antiepileptic drugs: a prospective cohort study of the EURAP Registry. *Lancet Neurol*. 2018;17(6):530-538.

Tomson T, Battino D, Perucca E. Teratogenicity of antiepileptic drugs. *Curr Opin Neurol*. 2019;32(2):246-252.

Tomson T, Landmark CJ, Battino D. Antiepileptic drug treatment in pregnancy: changes in drug disposition and their clinical implications. *Epilepsia*. 2013;54(3):405-414.

Werler MM, Ahrens KA, Bosco JL, et al; and National Birth Defects Prevention Study. Use of antiepileptic medications in pregnancy in relation to risks of birth defects. *Ann Epidemiol*. 2011;21(11):842-850.

Preeclampsia and Eclampsia

Burrows RF, Burrows EA. The feasibility of a control population for a randomized control trial of seizure prophylaxis in the hypertensive disorders of pregnancy. *Am J Obstet Gynecol*. 1995;173:929-935.

Lucas MJ, Leveno KJ, Cunningham FG. A comparison of magnesium sulfate with phenytoin for the prevention of eclampsia. *N Engl J Med*. 1995;333:201-205.

Miller EC. Preeclampsia and cerebrovascular disease. *Hypertension*. 2019;74:5-13.

Paternoster DM, Fantinato S, Manganelli F, Nicolini U, Milani M, Girolami A. Recent progress in the therapeutic management of pre-eclampsia. *Expert Opin Pharmacother*. 2004;5(11):2233-2239.

Postma IR, Slager S, Kremer HP, de Groot JC, Zeman GG. Long-term consequences of the posterior reversible encephalopathy syndrome in eclampsia and preeclampsia: a review of the obstetric and nonobstetric literature. *Obstet Gynecol Surv*. 2014;69(5):287-300.

Sibai BM. Etiology and management of postpartum hypertension-preeclampsia. *Am J Obstet Gynecol*. 2012;206(6):470-475.

Thadhani R, Mutter WP, Wolf M, et al. First trimester placental growth factor and soluble fms-like tyrosine kinase 1 and risk for preeclampsia. *J Clin Endocrinol Metab*. 2004;89(2):770-775.

Zambrano MD, Miller EC. Maternal stroke: an update. *Curr Atheroscler Rep*. 2019;21(9):33.

Stroke

Camargo EC, Feske SK, Singhal AB. Stroke in pregnancy: an update. *Neurol Clin*. 2019;37:131-148.

Cauldwell M, Rudd A, Nelson-Piercy C. Management of stroke and pregnancy. *Eur Stroke J*. 2018;3(3):227-236.

Elgendy IY, Gad MM, Mahmoud AN, Keeley EC, Pepine CJ. Acute stroke during pregnancy and puerperium. *J Am Coll Cardiol*. 2020;75:180-190.

Grear KE, Bushnell CD. Stroke and pregnancy: clinical presentation, evaluation, treatment and epidemiology. *Clin Obstet Gynecol*. 2013;56(2):350-359.

Guimicheva B, Czuprynska J, Arya R. The prevention of pregnancy-related venous thromboembolism. *Br J Haematol*. 2015;168(2):163-174.

Gulati D, Strbian D, Sundararajan S. Cerebral venous thrombosis: diagnosis and management. *Stroke*. 2014;45(2):e16-e18.

Hovsepian DA, Sriram N, Kamel H, Fink ME, Navi BB. Acute cerebrovascular disease occurring after hospital discharge for labor and delivery. *Stroke*. 2014;45(7):1947-1950.

Johnson DM, Kramer DC, Cohen E, Rochon M, Rosner M, Weinberger J. Thrombolytic therapy for acute stroke in late pregnancy with intra-arterial recombinant tissue plasminogen activator. *Stroke*. 2005;36(6):e53-e55.

Kamel H, Navi BB, Sriram N, Hovsepian DA, Devereux RB, Elkind MSV. Risk of a thrombotic event after the 6-week postpartum period. *N Engl J Med*. 2014;370(14):1307-1315.

Kashkoush AI, Ma H, Agarwal N, et al. Cerebral venous sinus thrombosis in pregnancy and puerperium: a pooled, systematic review. *J Clin Neurosci*. 2017;39:9-15.

Kuklina EV, Tong X, Bansil P, George MG, Callaghan WM. Trends in pregnancy hospitalizations that included a stroke in the United States from 1994 to 2007: reasons for concern? *Stroke*. 2011;42(9):2564-2570.

Leffert LR, Clancy CR, Bateman BT. Treatment patterns and short-term outcomes in ischemic stroke in pregnancy or postpartum period. *Am J Obstet Gynecol*. 2016;214(6):723.e1-723.e11.

Leonhardt G, Gaul C, Nietsch HH, Buerke M, Schleussner E. Thrombolytic therapy in pregnancy. *J Thromb Thrombolysis*. 2006;21(3):271-276.

Liang CC, Chang SD, Lai SL, Hsieh CC, Chueh HY, Lee TH. Stroke complicating pregnancy and the puerperium. *Eur J Neurol*. 2006;13(11):1256-1260.

Mantoan Ritter L, Schüler A, Gangopadhyay R, et al. Successful thrombolysis of stroke with intravenous alteplase in the third trimester of pregnancy. *J Neurol*. 2014;261(3):632-634.

Murugappan A, Coplin WM, Al-Sadat AN, et al. Thrombolytic therapy of acute ischemic stroke during pregnancy. *Neurology*. 2006;66(5):768-770.

Singhal AB, Kimberly WT, Schaefer PW, Hefley-Whyte ET. Case records of the Massachusetts General Hospital. Case 8-2009. A 36-year-old woman with headache, hypertension, and seizure 2 weeks post partum. *N Engl J Med*. 2009;360(11):1126-1137.

Star M, Flaster M. Advances and controversies in the management of cerebral venous thrombosis. *Neurol Clin*. 2013;31(3):765-783.

Starke RM, Komotar RJ, Hickman ZL, et al. Clinical features, surgical treatment, and long-term outcome in adult patients with moyamoya disease. Clinical article. *J Neurosurg*. 2009;111(5):936-942.

Swartz RH, Caykey ML, Foley N, et al. The incidence of pregnancy-related stroke: a systematic review and meta-analysis. *Int J Stroke*. 2017;12(7):687-697.

Wabnitz A, Bushnell C. Migraine, cardiovascular disease, and stroke during pregnancy: systematic review of the literature. *Cephalalgia*. 2015;35(2):132-139.

Wiese KM, Talkad A, Mathews M, Wang D. Intravenous recombinant tissue plasminogen activator in a pregnant woman with cardioembolic stroke. *Stroke*. 2006;37(8):2168-2169.

Headache

Bánhidy F, Ács N, Horváth-Puhó E, Czeizel AE. Pregnancy complications and delivery outcomes in pregnant women with severe migraine. *Eur J Obstet Gynecol Reprod Biol*. 2007;134(2):157-163.

Browne ML, Van Zutphen AR, Botto LD, Louik C, Richardson S, Druschel CM. Maternal butalbital use and selected defects in the National Birth Defects Prevention Study. *Headache*. 2014;54(1):54-66.

Burch R. Epidemiology and treatment of menstrual migraine and migraine during pregnancy and lactation: a narrative review. *Headache*. 2020;60:200-216.

Cripe SM, Frederick IO, Qiu C, Williams MA. Risk of preterm delivery and hypertensive disorders of pregnancy in relation to maternal co-morbid mood and migraine disorders during pregnancy. *Paediatr Perinat Epidemiol*. 2011;25(2):116-123.

David PS, Kling JM, Starling AJ. Migraine in pregnancy and lactation. *Curr Neurol Neurosci Rep*. 2014;14(4):439.

Frederick IO, Qiu C, Enquobahrie DA, et al. Lifetime prevalence and correlates of migraine among women in a Pacific Northwest Pregnancy Cohort Study. *Headache*. 2014;54(4):675-685.

Nezvalová-Henriksen K, Spigset O, Nordeng H. Triptan exposure during pregnancy and the risk of major congenital malformations and adverse pregnancy outcomes: results from the Norwegian Mother and Child Cohort Study. *Headache*. 2010;50(4):563-575.

Nezvalová-Henriksen K, Spigset O, Nordeng H. Triptan safety during pregnancy: a Norwegian population registry study. *Eur J Epidemiol*. 2013;28(9):759-769.

Skajaa N, Szépligeti SK, Xue F, et al. Pregnancy, birth, neonatal, and postnatal neurological outcomes after pregnancy with migraine. *Headache*. 2019;59:869-879.

Wabnitz A, Bushnell C. Migraine, cardiovascular disease, and stroke during pregnancy: systematic review of the literature. *Cephalalgia*. 2015;35(2):132-139.

Zambrano MD, Miller EC. Maternal stroke: an update. *Curr Atheroscler Rep*. 2019;21(9):33.

Cerebral Hemorrhage

Feske SK, Singhal AB. Cerebrovascular disorders complicating pregnancy. *Continuum (Minneap Minn)*. 2014;20(1 Neurology of Pregnancy):80-99.

Helbok R, Olson DM, Le Roux PD, Vespa P; and Participants in the International Multidisciplinary Consensus Conference on Multimodality Monitoring. Intracranial pressure and cerebral perfusion pressure monitoring in non-TBI patients: special considerations. *Neurocrit Care*. 2014;21(suppl 2):S85-S94.

Liu XJ, Wang S, Zhao YL, et al. Risk of cerebral arteriovenous malformation rupture during pregnancy and puerperium. *Neurology*. 2014;82(20):1798-1803.

Nasr DM, Brinjikji W, Cloft HJ, Saposnik G, Rabinstein AA. Mortality in cerebral venous thrombosis: results from the national inpatient sample database. *Cerebrovasc Dis*. 2013;35(1):40-44.

Star M, Flaster M. Advances and controversies in the management of cerebral venous thrombosis. *Neurol Clin*. 2013;31(3):765-783.

Wang J, Wang R, Zhao J. Ruptured cerebral aneurysm from choriocarcinoma. *J Clin Neurosci*. 2013;20(9):1324-1326.

Multiple Sclerosis

Coyle PK, Sinclair SM, Scheuerle AE, Thorp JM Jr, Albano JD, Rametta MJ. Final results from the Betaseron (interferon β-1b) Pregnancy registry: a prospective observational study of birth defects and pregnancy-related adverse events. *BMJ Open*. 2014;4(5):e004536.

D'hooghe MB, Haentjens P, Nagels G, D'hooghe T, De Keyser J. Menarche, oral contraceptives, pregnancy and progression of disability in relapsing onset and progressive onset multiple sclerosis. *J Neurol*. 2012;259(5):855-861.

Ebrahimi N, Herbstritt S, Gold R, Amezcua L, Koren G, Hellwig K. Pregnancy and fetal outcomes following natalizumab exposure in pregnancy. A prospective, controlled observational study. *Mult Scler*. 2014;21(2):198-205.

Fagius J, Burman J. Normal outcome of pregnancy with ongoing treatment with natalizumab. *Acta Neurol Scand*. 2014;129(6):e27-e29.

Finkelsztejn A, Brooks JB, Paschoal FM Jr, Fragoso YD. What can we really tell women with multiple sclerosis regarding pregnancy? A systematic review and meta-analysis of the literature. *BJOG*. 2011;118(7):790-797.

Fragoso YD. Glatiramer acetate to treat multiple sclerosis during pregnancy and lactation: a safety evaluation. *Expert Opin Drug Saf*. 2014;13(12):1743-1748.

Fragoso YD, Finkelsztejn A, Kaimen-Maciel DR, et al. Long-term use of glatiramer acetate by 11 pregnant women with multiple sclerosis: a retrospective, multicentre case series. *CNS Drugs*. 2010;24(11):969-976.

Haghikia A, Langer-Gould A, Rellensmann G, et al. Natalizumab use during the third trimester of pregnancy. *JAMA Neurol*. 2014;71(7):891-895.

Hellwig K, Haghikia A, Rockhoff M, Gold R. Multiple sclerosis and pregnancy: experience from a nationwide database in Germany. *Ther Adv Neurol Disord*. 2012;5(5):247-253.

Houtchens MK, Edwards NC, Schneider G, Stern K, Phillips AL. Pregnancy rates and outcomes in women with and without MS in the United States. *Neurology*. 2018;91:e1559-e1569.

Karp I, Manganas A, Sylvestre MP, Ho A, Roger E, Duquette P. Does pregnancy alter the long-term course of multiple sclerosis? *Ann Epidemiol*. 2014;24(7):504-508.e2.

Langer-Gould AM. Pregnancy and family planning in multiple sclerosis. *Continuum (Minneap Minn)*. 2019;25(3):773-792.

Lu E, Wang BW, Guimond C, Synnes A, Sadovnick D, Tremlett H. Disease-modifying drugs for multiple sclerosis in pregnancy. *Neurology*. 2012;79(11):1130-1135.

Nguyen A-L, Havrdova EK, Horakova D, et al; for MSBase Study Group. Incidence of pregnancy and disease-modifying therapy exposure trends in women with multiple sclerosis: a contemporary cohort study. *Mult Scler Relat Disord*. 2019;(28):235-243.

Peng A, Qiu X, Zhang L, et al. Natalizumab exposure during pregnancy in multiple sclerosis: a systematic review. *J Neurol Sci*. 2019;396:202-205.

Ponsonby AL, Lucas RM, van der Mei IA, et al. Offspring number, pregnancy, and risk of a first clinical demyelinating event: the Ausimmune Study. *Neurology*. 2012;78(12):867-874.

Ramagopalan S, Yee I, Byrnes J, Guimond C, Ebers G, Sadovnick D. Term pregnancies and the clinical characteristics of multiple sclerosis: a population based study. *J Neurol Neurosurg Psychiatry*. 2012;83(8):793-795.

Romero RS, Lünzmann C, Bugge JP. Pregnancy outcomes in patients exposed to interferon beta-1b. *J Neurol Neurosurg Psychiatry*. 2015;86(5):587-589.

Sandberg-Wollheim M, Alteri E, Moraga MS, Kornmann G. Pregnancy outcomes in multiple sclerosis following subcutaneous interferon beta-1a therapy. *Mult Scler*. 2011;17(4):423-430.

Sepúlveda M, Montejo C, Llufriu S, et al. Rebound of multiple sclerosis activity after fingolimod withdrawal due to planning pregnancy: analysis of predisposing factors. *Mult Scler Relat Disord*. 2020;38:101483.

van der Kop ML, Pearce MS, Dahlgren L, et al. Neonatal and delivery outcomes in women with multiple sclerosis. *Ann Neurol*. 2011;70(1):41-50.

Varytė G, Zakarevičienė J, Ramašauskaitė D, Laužikienė D, Arlauskienė A. Pregnancy and multiple sclerosis: an update on the disease modifying treatment strategy and a review of pregnancy's impact on disease activity. *Medicina (Kaunas)*. 2020;56:49.

Vukusic S, Coyle PK, Jurgensen S, et al. Pregnancy outcomes in patients with multiple sclerosis treated with teriflunomide: clinical study data and 5 years of post-marketing experience. *Mult Scler*. 2020;26(7):829-836.

Neoplasms

Bonfield CM, Engh JA. Pregnancy and brain tumors. *Neurol Clin*. 2012;30(3):937-946.

Daras M, Cone C, Peters KB. Tumor progression and transformation of low-grade glial tumors associated with pregnancy. *J Neurooncol*. 2014;116(1):113-117.

Scarrott LJ, Raina A, Madej T, Rajesh U. Recurrent glioblastoma multiforme in pregnancy. *J Obstet Gynaecol*. 2012;32(7):704-705.

van Westrhenen A, Senders JT, Martin E, DiRisio AC, Broekman MLD. Clinical challenges of glioma and pregnancy: a systematic review. *J Neurooncol*. 2018;139:1-11.

Verheecke M, Halaska MJ, Lok CA, et al; for ESGO Task Force "Cancer in Pregnancy." Primary brain tumours, meningiomas and brain metastases in pregnancy: report on 27 cases and review of literature. *Eur J Cancer*. 2014;50(8):1462-1471.

Zwinkels H, Dörr J, Kloet F, Taphoorn MJB, Vecht CJ. Pregnancy in women with gliomas: a case-series and review of the literature. *J Neurooncol*. 2013;115(2):293-301.

Peripheral Nerve Disorders

de Oliveira GAD, Bernardes JM, Santos ES, Dias A. Carpal tunnel syndrome during the third trimester of pregnancy: prevalence and risk factors. *Arch Gynecol Obstet*. 2019;300(3):623-631.

Guidon AC, Massey EW. Neuromuscular disorders in pregnancy. *Neurol Clin*. 2012;30(3):889-911.

Massey EW, Guidon AC. Peripheral neuropathies in pregnancy. *Continuum (Minneap Minn)*. 2014;20(1 Neurology of Pregnancy):100-114.

Meems M, Truijens S, Spek V, Visser LH, Pop VJ. Prevalence, course and determinants of carpal tunnel syndrome symptoms during pregnancy: a prospective study. *BJOG* 2015;122(8):1112-1118.

Mondelli M, Rossi S, Monti E, et al. Prospective study of positive factors for improvement of carpal tunnel syndrome in pregnant women. *Muscle Nerve*. 2007;36(6):778-783.

Myasthenia Gravis

Boldingh MI, Maniaol AH, Brunborg C, Weedon-Fekjær H, Verschuuren J, Tallaksen C. Increased risk for clinical onset of myasthenia gravis during the postpartum period. *Neurology*. 2016;87:2139-2145.

Ducci RD, Lorenzoni PJ, Kay CSK, Werneck LC, Scola RH. Clinical follow-up of pregnancy in myasthenia gravis patients. *Neuromuscul Disord*. 2017;27:352-357.

Guidon AC, Massey EW. Neuromuscular disorders in pregnancy. *Neurol Clin*. 2012;30(3):889-911.

Hoff JM, Daltveit AK, Gilhus NE. Myasthenia gravis in pregnancy and birth: identifying risk factors, optimising care. *Eur J Neurol*. 2007;14(1):38-43.

Massey JM, DeJusus-Acosta CD, Niks EH, et al. A transient neonatal myasthenic syndrome with anti-MUSK antibodies. *Neurology*. 2008;70(14):1215-1216.

O'Carroll P, Bertorini TE, Jacob G, Mitchell CW, Graff J. Transient neonatal myasthenia gravis in a baby born to a mother with new-onset anti-MuSK-mediated myasthenia gravis. *J Clin Neuromuscul Dis*. 2009;11(2):69-71.

Oskoui M, Jacobson L, Chung WK, et al. Fetal acetylcholine receptor inactivation syndrome and maternal myasthenia gravis. *Neurology*. 2008;71(24):2010-2012.

Waters J. Management of myasthenia gravis in pregnancy. *Neurol Clin*. 2019;37:113-120.

Wen JC, Liu TC, Chen YH, Chen SF, Lin HC, Tsai WC. No increased risk of adverse pregnancy outcomes for women with myasthenia gravis: a nationwide population-based study. *Eur J Neurol*. 2009;16(8):889-894.

Movement Disorders

Bordelon YM, Smith M. Movement disorders in pregnancy. *Semin Neurol*. 2007;27(5):467-475.

Chen SJ, Shi L, Bao YP, et al. Prevalence of restless legs syndrome during pregnancy: a systematic review and meta-analysis. *Sleep Med Rev*. 2018;40:43-54.

Earley CJ. Restless legs syndrome. *N Engl J Med*. 2003;348:2103-2109.

Golbe LI. Pregnancy and movement disorders. *Neurol Clin*. 1994;12:497-508.

Kranick S, Mowry E, Colcher A, Horn S, Golbe LI. Movement disorders and pregnancy: a review of the literature. *Mov Disord*. 2010;25(6):665-671.

Manconi M, Govoni V, De Vito A, et al. Restless legs syndrome and pregnancy. *Neurology*. 2004;63(6):1065-1069.

Miyasaki JM, Aldakheel A. Movement disorders in pregnancy. *Continuum (Minneap Minn)*. 2014;20(1 Neurology of Pregnancy):148-161.

Rogers JD, Fahn S. Movement disorders and pregnancy. In: Devinsky O, Feldmann E, Hainline B, eds. *Neurological Complications of Pregnancy*. New York, NY: Raven; 1994:163-178.

Scott M, Chowdhury M. Pregnancy in Parkinson's disease: unique case report and review of the literature. *Mov Disord*. 2005;20(8):1078-1079.

130 Neurologic Complications of Organ Transplantation

Eelco F. M. Wijdicks

KEY POINTS

1. Neurologic complications have declined but remain prevalent. Drug toxicity must be a common consideration.
2. Immunosuppressed transplant recipients have a proclivity for infections with *Listeria monocytogenes*, *Nocardia*, or *Aspergillus*.
3. Human herpes virus 6 (HHV-6B) is often reactivated in a graft-versus-host disease and may cause a serious form of encephalitis.
4. Progressive multifocal leukoencephalopathy remains a major late complication in transplant patients.

INTRODUCTION

Organ transplantation has been associated with a distinct spectrum of neurologic complications. Complications can emerge during pretransplant preparation (eg, hematopoietic stem cell transplantation and chemotherapy), perioperative support (eg, cardiac transplantation with cardiopulmonary bypass or extracorporeal membrane oxygenation), and postoperative management (eg, newly introduced immunosuppression). Some neurologic complications, particularly peripheral nerve injury, are related to the surgical procedure.

When large series are reported, neurologic complications from organ transplantation occur in approximately 5% to 10% of patients. Of course, the prevalence depends on the motivation of transplant teams to consult a neurologist and thus is a reflection of how relevant a neurologic complication is when seen in the whole of the clinical picture. Prospective incidence studies may not capture all the postoperative neurologic events if they are not systematically examined by neurologists. Moreover, over the years, there has been a continuous decline in neurologic complications in some types of organ transplantation, mostly as a result of increased experience with titrating immunosuppressive drugs (eg, renal, liver) and presence of skilled multidisciplinary teams. Many patients leave the intensive care unit soon after surgery.

Neurologic complications are major when they involve recurrent seizures, postoperative failure to awaken, immunosuppression neurotoxicity, or acute disabling neuromuscular disease. Familiarity with the administration and dosing of the main intravenous immunosuppressive drugs has reduced the risk of major neurotoxicity, and extreme cases with coma and seizures and neuroimaging showing diffuse white matter edema are now rarely seen.

This chapter does not attempt to fully discuss all neurologic complications described over the years and many involve the general risks of patients being immunocompromised patients. These are the most common considerations when asked to see these patients in consultation (Table 130.1).

TABLE 130.1 Neurologic Syndromes in Transplant Recipients and Causes

Failure to awaken or acute coma	Hypoxic-ischemic brain injury, brain edema, oversedation, acute graft failure, calcineurin neurotoxicity, cefepime toxicity, intracranial hemorrhage, fulminant CNS infection
Seizures	Calcineurin neurotoxicity, intracranial hemorrhage, new mass (abscess, tumor), posterior reversible encephalopathy syndrome
Aphasia, dysarthria	Calcineurin neurotoxicity, ischemic stroke
Hemiparesis	Brachial plexopathy, ischemic or hemorrhagic stroke, brain tumor, brain abscess
Tremors	Calcineurin neurotoxicity
Myoclonus, asterixis	Acute liver, renal, or pulmonary disease; drug toxicity

Abbreviation: CNS, central nervous system.

GENERAL CONSIDERATIONS

Generally speaking, and not surprisingly, a patient with more elaborate surgery has a higher risk of an early neurologic complication. For instance, liver transplantation carries a much higher risk of early neurologic complications than renal transplantation. Once the patient goes successfully through the first critical weeks, a later phase includes a proclivity for central nervous system (CNS) infections, and much later—although it may be only a few months—serious malignancies may appear. Dramatic is the appearance of posttransplant lymphoproliferative disease and likely explained from introducing genetic material of an Epstein-Barr virus (EBV)-seropositive donor into an EBV-seronegative recipient. It may involve the CNS.

Neurologic complications may result in an increased risk of early demise. Most instructively—when reviewed in more detail—the majority of patients with a lung transplantation were found to have a neurologic manifestation or complication with a third seriously affecting quality of life or resulting in a fatal outcome. That leaves the question of whether neurologic complications are sufficiently recognized.

There are several other considerations. First, neurologic complications may be specific to the type of transplantation. Neurologic complications associated with bone marrow transplantation are quite different than those from organ transplants such as a kidney or liver. Second, seizures are often drug related and less commonly due to a permanent structural lesion. It is a difficult

task to implicate certain drugs, but several drugs lower the seizure threshold (ie, calcineurin inhibitors and antibiotics such as imipenem). Third, any structural lesion in the brain, whether it has the appearance of a cerebritis or ring enhancing, is most often due to an infectious cause and requires immediate treatment. Fourth, major sodium abnormalities and osmotic shifts can be seen after liver transplantation causing osmotic demyelination.

Central Nervous System Infections

The threshold for cerebral fluid examination should be low even if meningitis is not suspected. Because an infectious mass lesion may be present, a computed tomography (CT) scan may need to be performed to exclude such a lesion. An acutely febrile patient with an abnormal level of consciousness should prompt an aggressive search for a CNS infection. Immunosuppressed transplant recipients have a proclivity for infections with *Listeria monocytogenes*, *Nocardia*, or *Aspergillus*. Infections with *Cryptococcus neoformans* or *Toxoplasma gondii* are rarely seen within 6 months after transplantation. All of these infections present often with meningeal enhancement on a CT or magnetic resonance imaging scan, solitary or multiple abscesses, or ring lesions. None of them are specific and can only be documented by biopsy. Disseminated viral infections have also been described with very high mortality rates, but again, no systemic studies have been reported.

A viral encephalopathy which has emerged more recently is a human herpes virus 6 (HHV-6B) and may become apparent with the development of acute graft-versus-host disease. The HHV-6B (but not HHV-6A) reactivation is frequent after transplantation and observed in 40% of patients. The encephalitis may have appeared already several weeks after transplantation and is not likely recognized or initially misdiagnosed as metabolic derangement or neurotoxicity from immunosuppressive agents. Delirium may be the only clinical sign before a patient lapses into a deeper coma. Isolation by polymerase chain reaction in cerebrospinal fluid is necessary. The mortality is high with about 80% of the patients remaining comatose. In any patient with a suspicion of encephalitis and without another clear cause, early empiric treatment for HHV-6B should be started with ganciclovir 5 mg/kg intravenously every 12 hours or foscarnet 90 mg/kg intravenously every 12 hours.

Another underrecognized infection is cytomegalovirus (CMV) encephalopathy. Approximately 80% of liver recipients have reactivation of a latent CMV that may occur several weeks after transplantation. Again, the diagnosis of CMV encephalitis is notoriously difficult with a presentation that is baffling to most clinicians. Some patients present with focal findings such as dysarthria, spasticity, and rigidity and tremor, and others only develop fever and neck stiffness. The CMV chorioretinitis may be demonstrated, but CMV encephalitis may occur without this manifestation. In all these opportunistic infections, recent availability of polymerase chain reaction technology has increased recognition, but there is yet no evidence that early treatment improves outcome.

Encephalopathy and Delirium

In actuality, there are particular syndromes that most often present to the neurologist. The most commonly encountered reason for a consultation has to do with assessment of an "altered state of consciousness." The appearance of a new encephalopathy may be due to rejection causing dysfunction of the graft or may have other causes.

Acute confusional state or delirium remains difficult to define in transplant recipients and can be considered if it lasts more than 2 to 3 consecutive days. Postoperative hyperactive delirium associated with hallucinations is common posttransplantation, and some circumstances should be recognized. If patients are seen in the immediate postoperative period, both hyperactive and hypoactive delirium after liver transplantation occurs in about a third of the patients. This is more often in patients who had a pretransplant encephalopathy and is more often seen in alcoholic liver disease.

In evaluating patients with impaired consciousness, some guidance can be provided. All potential sedative drugs should be carefully scrutinized, and the time remaining to clearance should be calculated. Physicians should consider administration of flumazenil or naloxone to eliminate the remaining effects. Neurotoxicity of immunosuppressive drugs is frequently implicated, and it continues to be a concern to be dealt with. None of these drugs do cause other structural disease other than a leukoencephalopathy, which cannot be clinically or radiographically distinguished from posterior reversible encephalopathy syndrome (see also Chapter 44).

Drug Toxicity

There are many drugs and medications that need to be considered in acute confusion. This includes the use of calcineurin inhibitors, opioid antagonists, β-adrenergic blockers, and high-dose corticosteroids. All of these drugs can be implicated. Other commonly used drugs, such as midazolam and propofol, may impact level of consciousness, particularly because they have different pharmacokinetics in transplant patients. Midazolam, for example, although relatively short acting in comparison with other sedative agents, has a prolonged activity if the liver graft is not functioning fully. It is also highly protein bound, and preexisting low protein levels may increase its sedative effects. Clearance of propofol is dependent on hepatic blood flow and cardiac output; and if both are disturbed, awakening from propofol may be markedly delayed, and the patient may not characteristically awaken as usually anticipated 10 to 15 minutes after discontinuation of infusion. Opioids may continue to linger after cardiac transplantation; typically, very large doses are used during the procedure.

Neurotoxicity associated with cyclosporine or tacrolimus is often considered but less often diagnosed. Breakdown of the blood-brain barrier is needed for cyclosporine to enter because no lipoprotein transport system exists. Cyclosporine is very lipophilic from aliphatic groups but cannot cross the blood-brain barrier because of tight junctions. How crossing occurs remains unknown, and perhaps, impairment of the blood-brain barrier is facilitated by surgery-associated ischemic insults due to hypotension. The predilection of the posterior areas of the brain may also be related to a less-developed blood-brain barrier that quickly opens when challenged. Oligodendroglia is more susceptible than astrocytes and explains largely white matter lesions on magnetic resonance imaging (Fig. 130.1).

The pathway of neurotoxicity associated with cyclosporine or tacrolimus has not been resolved at a molecular level. Both immunosuppressive drugs bind to an immunophilin, a protein with an affinity for both drugs, and consequently trigger a cascade of actions that include blockade of calcineurin. Calcineurin is involved in cell signaling and maintenance of cytoskeletal protein function, particularly in oligodendrocytes. Inhibition of

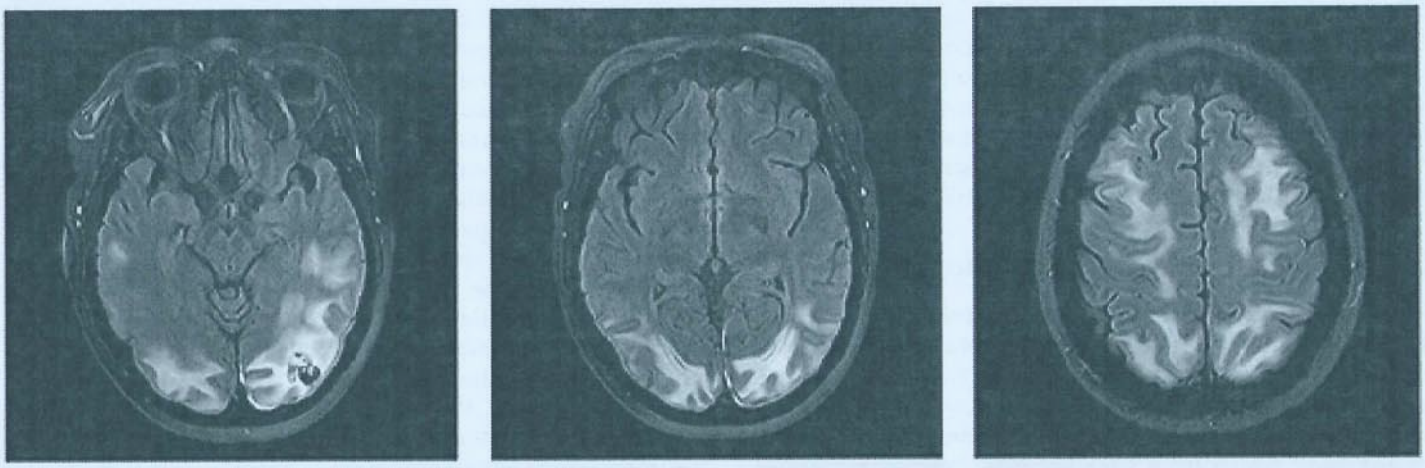

FIGURE 130.1 Magnetic resonance images of tacrolimus-associated toxicity with posterior white matter edema and an intraparenchymal hematoma following donor allogeneic stem cell transplant.

calcineurin activity, therefore, may lead to neuronal death or apoptosis. It remains very likely, however, that extremely high doses in the earlier days of transplantation due to unfamiliarity with the drugs has been the major driving factor. This possibility is also supported by the very low incidence of cyclosporine neurotoxicity using oral preparations, resulting in stable blood levels and avoidance of extreme blood levels during intravenous loading. The earliest abnormality seems to be neurotoxicity from fluid extravasation (vasogenic edema) and not cell destruction (cytotoxic edema). Very limited pathology studies are available, and some have suggested demyelination. Neurotoxicity is best considered a cerebral arterial leak syndrome.

One should obtain serum levels of cyclosporine or tacrolimus and trend the values. A marked increase in levels may indicate development of neurotoxicity, but such an association is only plausible if it is seen outside of the usual intravenous loading period that is within the first week of treatment. Many transplant surgeons titrate toward increasing plasma levels, and these levels should not be misinterpreted as indicative of neurotoxicity. Recent laboratory values should be obtained and should include electrolyte panel, liver and renal function tests, serum ammonia, arterial blood gas, and, where indicated, antiepileptic drug levels. Drug interactions are common with these drugs and may lead to sudden toxicity.

Finally, a mistake is to label postoperative encephalopathy as multifactorial, and it often does nothing to find the possible triggers. For example, a liver transplant recipient may have severe hyponatremia and rising creatinine and blood urea nitrogen and show signs of early rejection. Cefepime toxicity may be the cause of decline in consciousness and new myoclonus. Improvement can be expected when the drug is discontinued.

ORGAN-SPECIFIC COMPLICATIONS

Lung Transplantation

Lung transplant patients, due to significant challenges in oxygenation, may have severe neurologic complications in a third of the patients. Most severe complications are perioperative stroke and encephalopathy, and when neurologic complications occur, there is a higher mortality. Acute hyperammonemia—an unexpected and not completely explained metabolic derangement in lung transplant recipients—has also been described causing seizures and profound encephalopathy. Cyclosporin neurotoxicity is not a major cause of complications in lung transplant recipients.

Cardiac Transplantation

Cardiac transplantations are obviously at risk of ischemic injury as a result of embolization from aortic atheroembolism but also perioperative cardiogenic shock requiring extreme measures such as intra-aortic balloon pump support or extracorporeal membrane oxygenation. Intracerebral hemorrhage is rarely seen after cardiac transplantation, but poorly controlled hypertension may cause a lobar or basal ganglia hemorrhage.

Liver Transplantation

One relatively uncommon but dramatic clinical scenario is a patient with acute fulminant hepatic failure (FHF) followed by rapid listing for liver transplantation. This condition is very unique with many clinical uncertainties, and neurologists and neurosurgeons are often asked to be part of rapidly changing clinical decisions making. There are three immediate concerns. First, the transition of hepatic encephalopathy (basically a metabolic injury) to brain edema (now a structural injury) must be recognized. Second, intracranial pressure (ICP) may rise steeply and requires prompt treatment. Third, some patients may have already progressed to brain death, which would preclude transplantation.

The mechanism of brain edema in an FHF (see also Chapter 119) is influenced by multiple factors. Hyperosmolarity due to increased ammonia and also the development of oxidative stress may contribute. Brain edema is mostly vasogenic and is usually first confirmed by the appearance of severe brain swelling on CT. A useful method to identify the development of vasogenic brain edema in encephalopathic patients with FHF is to identify increased cerebral blood flow velocity associated with reduced waveform pulsatility on transcranial Doppler (see Chapter 24).

Once identified, brain edema requires aggressive treatment to prevent transtentorial herniation and is best guided by an ICP monitor (see Chapter 107). However, patients who have an ICP monitoring device placed and are treated aggressively

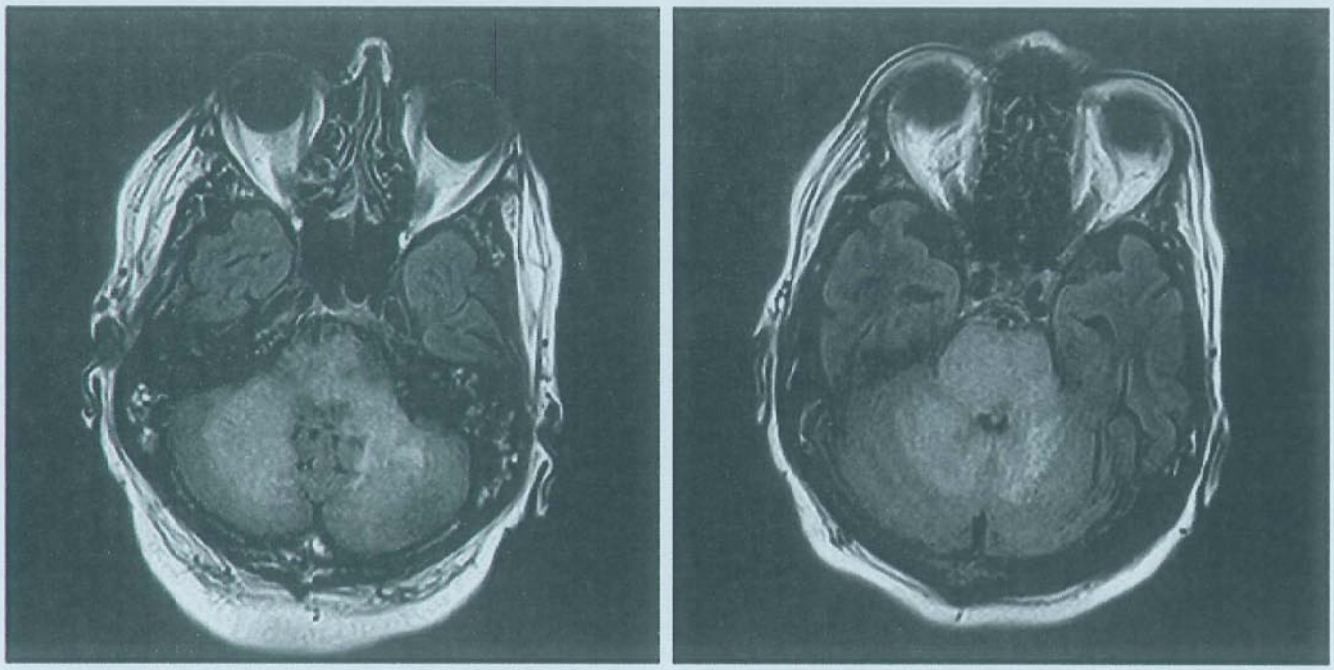

FIGURE 130.2 Magnetic resonance images of progressive multifocal leukoencephalopathy after liver transplantation.

do not have a better outcome or higher percentage of liver transplantation and that could question the role of ICP-based management. Most centers place an intraparenchymal ICP in comatose patients with evidence of cerebral edema on CT, but the situation is further complicated by the presence of coagulopathy, which invariably complicated FHF. Use of recombinant factor VII (4-mg intravenous push) or prothrombin complex concentrate (25-50 U/kg, depending on baseline international normalized ratio) is an important new development in countering coagulopathy in FHF. Their use has significantly decreased the frequency of bleeding complications, particularly related to ICP monitor insertion.

Intestinal Transplantation

Intestinal transplantation for a short bowel syndrome due to thrombosis, inflammatory bowel disease, and radiation enteritis has become another "organ" that can be transplanted, but experience is only in a few hundred patients. The initial experience is not sufficient to potentially identify specific complications, and most reported are in the known categories such as encephalopathy, CNS infection, seizures, stroke, and neuromuscular complications. Early assessment suggests rate of neurologic complications is much higher than solid organ transplants. One possible explanation is the higher immunosuppression as a result of relative lower resistance to rejection of the intestine. Moreover, later serious vitamin deficiencies may occur as a result of a short bowel syndrome.

LONG-TERM EFFECTS OF IMMUNOSUPPRESSION

Any transplant recipient is at risk of developing B-cell lymphomas or glioblastoma multiforme or progressive multifocal leukoencephalopathy. These disorders are extremely uncommon but can present within months after transplantation. Most notorious is the occurrence of CNS lymphoma several weeks after transplantation (may vary from a few weeks to more than two decades after transplantation). Most posttransplantation lymphomas are monoclonal B-cell lymphomas, but multiclonal B-cell lymphomas or T-cell lymphomas have been reported. The EBV infection has been linked to B-cell lymphoma. The CNS lymphoma debuts with both brain and spinal cord involvement, but presentation is nonspecific with new behavioral changes, visual hallucinations, or focal signs such as hemiparesis. In most patients, a change in personality may be the only key sign. Meningeal involvement may produce headache. The diagnosis can only be considered if the CT scan shows a new mass lesion in the periventricular region and with proportionally large amount of perilesional edema. A biopsy might be necessary to find the lesion followed by aggressive treatment with radiation. Outcome, however, remains very poor with ultimate demise in all patients.

Progressive multifocal leukoencephalopathy is caused by JC virus (see also Chapter 68), and the disorder is usually relentless (Fig. 130.2). Withdrawal of immunotherapy or highly active antiretroviral treatment is considered with some good outcomes reported.

CONCLUSIONS

There are early and late neurologic complications after organ transplantation. The nature of neurologic complications may change with new treatment protocols and new drug approaches. Neurotoxicity from immunosuppressive drugs remains commonly implicated but is not common except if the dosing is high or some new drug interaction occurs. Many patients remain subject to a number of CNS sedatives commonly used in intensive care settings. Other complications relate to common operative stressors (hypotension) or perioperative concerns (infections, hemorrhage). This field—neurology of organ transplantation—requires special expertise and frequent reassessment of the spectrum of complications.

SUGGESTED READINGS

Amodio P, Biancardi A, Montagnese S, et al. Neurological complications after orthotopic liver transplantation. *Dig Liver Dis*. 2007;39(8):740-747.

Buis CI, Wiesner RH, Krom RA, Kremers WK, Wijdicks EF. Acute confusional state following liver transplantation for alcoholic liver disease. *Neurology*. 2002;59(4):601-605.

Cui R, Fayek S, Rand EB, Feygin T, Khrichenko D, Shaked A. Central pontine myelinolysis: a case report and clinical-pathological review. *Pediatr Transplant*. 2012;16(6):E251-E256.

Fugate JE, Kalimullah EA, Hocker SE, Clark SL, Wijdicks EF, Rabinstein AA. Cefepime neurotoxicity in the intensive care unit: a cause of severe, underappreciated encephalopathy. *Crit Care*. 2013;17(6):R264.

Ghaus N, Bohlega S, Rezeig M. Neurological complications in liver transplantation. *J Neurol*. 2001;248(12):1042-1048.

Goldstein LS, Haug MT III, Perl J II, et al. Central nervous system complications after lung transplantation. *J Heart Lung Transplant*. 1998;17(2):185-191.

Guarino M, Benito-Leon J, Decruyenaere J, et al. EFNS guidelines on management of neurological problems in liver transplantation. *Eur J Neurol*. 2006; 13(1):2-9.

Hill JA. Human herpesvirus 6 in transplant recipients: an update on diagnostic and treatment strategies. *Curr Opin Infect Dis*. 2019;32(6)584-590.

Hocker S, Rabinstein AA, Wijdicks EFM. Pearls & oy-sters: status epilepticus from hyperammonemia after lung transplant. *Neurology*. 2011;77(10): e54-e56.

Knight JS, Tsodikov A, Cibrik DM, Ross CW, Kaminski MS, Blayney DW. Lymphoma after solid organ transplantation: risk, response to therapy, and survival at a transplantation center. *J Clin Oncol*. 2009;27(20):3354-3362.

Kromm JA, Power C, Blevins G, Larratt L, van Landeghem FKH, Rempel J. Rapid multifocal neurologic decline in an immunocompromised patient. *JAMA Neurol*. 2016;73(2):226-231.

Lewis MB, Howdle PD. Neurologic complications of liver transplantation in adults. *Neurology*. 2003;61(9):1174-1178.

Mateen FJ, Dierkhising RA, Rabinstein AA, van de Beek D, Wijdicks EFM. Neurological complications following adult lung transplantation. *Am J Transplant*. 2010;10(4):908-914.

Mateen FJ, Muralidharan R, Carone M, et al. Progressive multifocal leukoencephalopathy in transplant recipients. *Ann Neurol*. 2011;70(2):305-322.

Muñoz P, Valerio M, Palomo J, et al. Infectious and non-infectious neurologic complications in heart transplant recipients. *Medicine (Baltimore)*. 2010; 89(3):166-175.

Ogata M, Oshima K, Ikebe T, et al. Clinical characteristics and outcome of human herpesvirus-6 encephalitis after allogeneic hematopoietic stem cell transplantation. *Bone Marrow Transplant*. 2017;52(11):1563-1570.

Ohara H, Kataoka H, Nakamichi K, Saijo M, Ueno S. Favorable outcome after withdrawal of immunosuppressant therapy in progressive multifocal leukoencephalopathy after renal transplantation: case report and literature review. *J Neurol Sci*. 2014;341(1-2):144-146.

Pittock SJ, Rabinstein AA, Edwards BS, Wijdicks EFM. OKT3 neurotoxicity presenting as akinetic mutism. *Transplantation*. 2003;75(7):1058-1060.

Pruitt AA. Central nervous system infections complicating immunosuppression and transplantation. *Continuum (Minneap Minn)*. 2018;24(5, Neuroinfectious Disease):1370-1396.

Pruitt AA. Neurologic complications of transplantation. *Continuum (Minneap Minn)*. 2017;23(3, Neurology of Systemic Disease):802-821.

Schiff D, O'Neill B, Wijdicks E, Antin JH, Wen PY. Gliomas arising in organ transplant recipients: an unrecognized complication of transplantation? *Neurology*. 2001;57(8):1486-1488.

Shokes A, Wison R. Neurologic complications of kidney transplantation. *Transl Androl Urol*. 2019;8(2):164-172.

Silveira FP, Husain S, Kwak EJ, et al. Cryptococcosis in liver and kidney transplant recipients receiving anti-thymocyte globulin or alemtuzumab. *Transpl Infect Dis*. 2007;9(1):22-27.

Singh N. How I treat cryptococcosis in organ transplant recipients. *Transplantation*. 2012;93(1):17-21.

Stracciari A, Guarino M. Neurologic complications of intestinal transplantation. *Handb Clin Neurol*. 2014;121:1267-1276.

Uchida H, Sakamoto S, Sasaki K, et al. Central pontine myelinolysis following pediatric living donor liver transplantation: a case report and review of literature. *Pediatr Transplant*. 2014;18(4):E120-E123.

van de Beek D, Patel R, Daly RC, et al. Central nervous system infections in heart transplant recipients. *Arch Neurol*. 2007;64(12):1715-1720.

Weber SC, Uhlenberg B, Raile K, Querfeld U, Müller D. Polyoma virus-associated progressive multifocal leukoencephalopathy after renal transplantation: regression following withdrawal of mycophenolate mofetil. *Pediatr Transplant*. 2011;15(2):E19-E24.

Wijdicks EFM. *Neurologic Complications in Organ Transplant Recipients*. Boston, MA: Butterworth-Heinemann; 1999.

Wijdicks EFM, Hocker SE. Neurologic complications of liver transplantation. *Handb Clin Neurol*. 2014;121:1257-1266.

Wijdicks EFM, Wiesner RH, Krom RA. Neurotoxicity in liver transplant recipients with cyclosporine immunosuppression. *Neurology*. 1995;45(11): 1962-1964.

Zhao CZ, Erickson J, Dalmau J. Clinical reasoning: agitation and psychosis in a patient after renal transplantation. *Neurology*. 2012;79(5):e41-e44.

Zivkovi SA, Eidelman BH, Bond G, Costa G, Abu-Elmagd KM. The clinical spectrum of neurologic disorders after intestinal and multivisceral transplantation. *Clin Transplant*. 2010;24(2):164-168.

Alcoholism 131

John C. M. Brust

KEY POINTS

1. Neurological disorders in alcoholics can be the result of intoxication, withdrawal, or other neurological complications of heavy drinking.
2. Wernicke-Korsakoff syndrome is the result of thiamine deficiency.
3. Alcoholic polyneuropathy, cerebellar ataxia, amblyopia, and dementia are probably the result of both ethanol toxicity and nutritional deficiency.
4. Although controversial, epidemiological evidence suggests that compared to abstention, mild-to-moderate ethanol intake decreases the risk of ischemic stroke whereas heavy intake increases risk of hemorrhagic stroke.
5. No threshold of safety has been identified for alcohol intake during pregnancy and the risk of fetal alcohol spectrum disorder.

INTRODUCTION

In the United States, 7% of all adults and 19% of adolescents are "problem drinkers": psychically or physically dependent on ethanol or, even if abstinent most of the time, likely to get into trouble when they drink. Ethanol-related deaths exceed 100,000 each year, accounting for 5% of all deaths in the United States. The devastation is direct (from intoxication and withdrawal) or indirect (from nutritional deficiency or other ethanol-related diseases).

ACUTE ETHANOL SYNDROMES

Intoxication

Ethanol acts at many levels of the neuraxis. Although specific ethanol receptors comparable to opioid receptors do not appear to exist, ethanol interacts directly with membrane proteins of a number of neurotransmitter systems, and much of its actions depend on facilitation at inhibitory γ-aminobutyric acid (GABA) receptors and inhibition at excitatory glutamate receptors.

Most estimates of a "standard drink" refer to 12 oz of beer, 5 oz of wine, or 1.5 oz of 80 proof spirits, each of which contains roughly 14 g of 100% ethanol. To obtain a mildly intoxicating blood ethanol concentration (BEC) of 100 mg/dL, a 70-kg person must drink about 50 g (2 oz) of 100% ethanol. Following zero-order kinetics, ethanol is metabolized at about 70 to 150 mg/kg of body weight per hour, with a fall in BEC of 10 to 25 mg/dL/h. Thus, most adults require 6 hours to metabolize a 50-g dose, and the ingestion of only 8 g of additional ethanol per hour would maintain the BEC at 100 mg/dL.

Globally, ethanol use is the seventh leading risk factor for all-cause death and disability, and it is the leading risk factor for death and disability among men and women aged 15 to 49 years. In that age group, the three leading causes of attributable death are tuberculosis, road injuries, and self-harm. Among those aged 50 years and older, the leading attributable cause is cancer.

Symptoms and signs of acute ethanol intoxication are a result of cerebral depression, possibly at first of the reticular formation with cerebral disinhibition and later of the cerebral cortex itself. Manifestations depend not only on the BEC but also on the rate of climb and the person's tolerance, which is related less to increased metabolism than to poorly understood adaptive changes in the brain. At any BEC, intoxication is more severe when the level is rising than when it is falling, when the level is reached rapidly, and when the level has only recently been achieved. A single BEC determination therefore is not a reliable indicator of drunkenness, and the correlations of Table 131.1 are broad generalizations. Death from respiratory paralysis may occur with a BEC of 400 mg/dL, and survival may occur at 700 mg/dL; a level of 500 mg/dL would be fatal in 50% of individuals.

Low to moderate BECs cause slow saccadic eye movements and interrupted jerky pursuit movements that may impair visual acuity. Esophoria and exophoria cause diplopia. With a BEC of 150 to 250 mg/dL, there is increased electroencephalography (EEG) beta activity ("beta buzz"); higher BECs cause EEG slowing. During sleep, suppression of the rapid eye movement stage is followed by rapid eye movement rebound after a few hours.

TABLE 131.1 Correlation of Symptoms With Blood Ethanol Concentration

BEC	Symptoms
50-150 mg/dL	• Euphoria or dysphoria, shyness or expansiveness, friendliness or argumentativeness • Impaired concentration, judgment, and sexual inhibitions
150-250 mg/dL	• Slurred speech and ataxic gait, diplopia, nausea, tachycardia, drowsiness, or labile mood with sudden bursts of anger or antisocial acts
300 mg/dL	• Stupor alternating with combativeness or incoherent speech, heavy breathing, vomiting
400 mg/dL	• Coma
500 mg/dL	• Respiratory paralysis

Abbreviation: BEC, blood ethanol concentration.

The term *pathologic intoxication* refers to sudden extreme excitement with irrational or violent behavior after even small doses of ethanol. Episodes are said to last for minutes or hours, followed by sleep and, on awakening, amnesia for the events that took place. Delusions, hallucinations, and homicide may occur during bouts of pathologic intoxication. Some cases might be psychological dissociative reactions; others may be owing to the kind of paradoxic excitation that sometimes follows barbiturate administration. These syndromes are more likely to occur in younger people who have had little prior exposure to alcohol.

The term *alcoholic blackout* refers to amnesia for periods of intoxication, sometimes lasting several hours, even though consciousness at the time did not seem to be disturbed. Although sometimes considered a sign of physiologic dependence, blackouts also occur in occasional drinkers. The amnesia is a direct effect of ethanol on memory encoding.

Acute ethanol poisoning causes more than 1,000 deaths each year in the United States. In stuporous alcoholic patients, subdural hematoma, meningitis, and hypoglycemia are important diagnostic considerations, but it is equally important to remember that ethanol intoxication alone can be fatal.

Blood ethanol causes a rise of blood osmolality, about 22 mOsm/L for every 100 mg/dL of ethanol; however, there are no transmembrane shifts of water, and the hyperosmolarity does not cause symptoms. Ethanol overdose should be considered in any comatose patient whose serum osmolarity is higher than predicted by calculation of the sum of serum sodium, glucose, and urea.

Patients stuporous or comatose from ethanol intoxication are generally managed similarly to those poisoned by other depressant drugs (**Table 131.2**). Death comes from respiratory depression, and mechanical ventilation in an intensive care unit is the mainstay of treatment. Hypovolemia, acid-base or electrolyte imbalance, and abnormal temperature require attention, and if there is any uncertainty about the blood glucose level, 50% glucose is given intravenously, along with parenteral thiamine. Because ethanol is rapidly absorbed, gastric lavage does not help unless other drugs have been ingested. In obstreperous or violent patients, sedatives (including benzodiazepines and dopamine-blocking agents) should be used with caution because they may push patients into stupor and respiratory depression. Patients being addressed may appear alert but then lapse into stupor or coma when stimuli are decreased.

TABLE 131.2 Treatment of Acute Ethanol Intoxication

For Obstreperous or Violent Patients
• Isolation, calming environment, and reassurance—avoid sedatives
• Close observation
• Lorazepam 2-4 mg IVP, repeated as needed, titrated to effect (calm, cooperative)
For Stuporous or Comatose Patients
• If hypoventilation, mechanical ventilation in an intensive care unit
• If hypoglycemic, intravenous 50% glucose with parenteral thiamine 100 mg
• Careful monitoring of blood pressure; correction of hypovolemia or acid-base imbalance
• Avoid emetics or gastric lavage.
• Avoid stimulants
• Do not forget other possible causes of coma in an alcoholic.

In a nonhabitual drinker, a BEC of 400 mg/dL can take 20 hours to return to zero. The only practical agent that might accelerate ethanol metabolism and elimination is fructose, but this causes gastrointestinal upset, lactic acidosis, and osmotic diuresis. Hemodialysis or peritoneal dialysis can be used for BECs greater than 600 mg/dL; for severe acidosis; for concurrent ingestion of methanol, ethylene glycol, or other dialyzable drugs; or for severely intoxicated children. Analeptic agents such as ethamivan, caffeine, or amphetamine have no useful role and can cause seizures and cardiac arrhythmia. Although patients are often depleted of magnesium, administration of magnesium sulfate may further depress the sensorium in intoxicated patients. Anecdotal reports describe temporary reversal of ethanol intoxication with the μ-opioid antagonist naloxone.

Ethanol-Drug Interactions

The combination of ethanol with other drugs, often in suicide attempts, causes 2,500 deaths annually in the United States. Ethanol is often taken with marijuana, barbiturates, opioids, cocaine, hallucinogens, and inhalants—with varying interactions. Alcoholics often abuse barbiturates, and although ethanol and barbiturates are cross-tolerant, each lowers the lethal dose of the other when they are taken in combination.

Impaired judgment and respiratory depression are also hazards when ethanol is combined with hypnotics, such as methaqualone (Quaalude), sedating antihistamines, antipsychotic agents, and benzodiazepines. Hypnotic drugs with long half-lives may cause potentially dangerous incoordination when ethanol is consumed the following day.

The cross-tolerance of ethanol with general anesthetics raises the threshold to sleep induction, but synergistic interaction then increases the depth and length of the anesthetic stage reached. Tricyclic antidepressants do not have a consistent effect; desipramine antagonizes the effects of ethanol and amitriptyline potentiates them. Ethanol and morphine, repeatedly used, can increase each other's potency, and methadone addicts not only frequently become alcoholic but also then develop a characteristic encephalopathy. Death has followed ethanol taken with propoxyphene. A mild reaction resembling that caused by disulfiram occurs when patients combine ethanol with sulfonylureas such as tolbutamide or with some antibiotics, including chloramphenicol, griseofulvin, isoniazid, metronidazole, and quinacrine.

Ethanol Withdrawal

The term *hangover* refers to the headache, nausea, vomiting, malaise, nervousness, tremulousness, and sweating that can occur in anyone after brief but excessive drinking. Hangover does not imply ethanol dependence, but *ethanol withdrawal* does imply dependence and encompasses several disorders (**Table 131.3**), which may occur

TABLE 131.3 Ethanol Withdrawal Syndromes

Early (<48 h After Last Drink)
Tremulousness
Hallucinosis
Seizures
Late (>48 h After Last Drink)
Delirium tremens

alone or in combination after reduction or cessation of drinking. Severity depends on the length and degree of a particular binge. Withdrawal syndromes are particularly common during hospitalization and can be exacerbated by concurrent illness.

Clinical Manifestations

Tremulousness

Tremulousness, the most common ethanol withdrawal symptom, usually appears in the morning after several days of drinking. It is usually promptly relieved by ethanol, but if drinking cannot continue, tremor becomes more intense, with insomnia, easy startling, agitation, facial and conjunctival flushing, sweating, anorexia, nausea, retching, weakness, tachypnea, tachycardia, and systolic hypertension. Except for inattentiveness and inability to fully recall the events that occurred during the binge, mentation is usually intact. In some patients, tremulousness can persist for weeks or longer.

Perceptual Disturbances

Perceptual disturbances, with variable insight, occur in about 25% of ethanol-dependent patients in acute withdrawal and include nightmares, illusions, and hallucinations, which are most often visual but may be auditory, tactile, olfactory, or a combination of these. Imagery includes insects, animals, or people. Hallucinations are usually fragmentary, lasting minutes at a time for several days. Sometimes, however, auditory hallucinations of threatening content last much longer and may even progress to a persistent state of auditory hallucinosis with paranoid delusions requiring care in a mental hospital. Repeated bouts of acute auditory hallucinosis may predispose to the chronic form.

Seizures

Ethanol can precipitate *seizures* in any epileptic; seizures usually occur the morning after weekend or even single-day drinking rather than during inebriation. Alcohol-related seizures affecting alcoholics not otherwise epileptic have traditionally been considered a withdrawal phenomenon, usually occurring within 48 hours of the last drink in persons who have abused ethanol chronically or in binges for months or years. The minimal duration of drinking sufficient to cause seizures is uncertain, but the risk is dose-related, beginning at only 50-g absolute ethanol daily. Seizures usually occur singly or in a brief cluster; status epilepticus is infrequent. Focal features are present in 25% and do not consistently correlate with evidence of previous head injury or other structural cerebral pathology. Alcohol seizures sometimes accompany tremulousness or hallucinosis, but they may occur in otherwise asymptomatic individuals. Their frequent appearance during active drinking or after more than 1 week of abstinence is consistent with mechanisms other than withdrawal per se.

The diagnosis of alcohol-related seizures depends on an accurate history and exclusion of other cerebral lesions. Workup should include brain computed tomography or magnetic resonance imaging and consideration of lumbar puncture. Alcohol withdrawal can trigger new-onset seizures in patients with intracranial hemorrhage, central nervous system infection, or brain neoplasm. Fewer than 10% of patients with alcohol-related seizures have spontaneous EEG abnormalities, compared with 50% of those with idiopathic epilepsy.

Transient *parkinsonism* during alcohol withdrawal is described in older patients. Transient chorea and dystonia are described in younger patients.

Delirium Tremens

In contrast to tremor, hallucinosis, or seizures, which usually occur within 48 hours of abstinence, *delirium tremens* usually begins from 48 to 72 hours after the last drink. Patients with delirium tremens are often hospitalized for other reasons. Delirium tremens may follow withdrawal seizures either before the postictal period has cleared or after 1 or 2 asymptomatic days, but when seizures occur during a bout of delirium tremens, some other diagnosis (eg, meningitis) should be considered.

Symptoms of delirium tremens typically begin and end abruptly, lasting from hours to a few days. There may be alternating periods of confusion and lucidity. Infrequently, relapses may prolong the disorder for a few weeks. Patients are typically agitated, inattentive, and grossly tremulous, with fever, tachycardia, and profuse sweating. They pick at the bed clothes or stare wildly about and intermittently shout at or try to fend off hallucinated people or objects. Hypokinetic delirium is infrequent. Mortality is as high as 15%; death is usually owing to other diseases (eg, pneumonia or cirrhosis), but it may be attributed to unexplained shock or lack of response to therapy or have no apparent cause.

Pathobiology

The pathophysiologic basis of ethanol withdrawal in its several forms is probably a combination of glutamate receptor upregulation and GABA receptor downregulation. Neuronal excitotoxicity during withdrawal could then set the stage for a kindling pattern of repeated withdrawal episodes, further excitotoxicity, a permanently lowered seizure threshold, and the occurrence of seizures temporally independent of withdrawal.

Management

Treatment of ethanol withdrawal includes prevention or reduction of early symptoms, prevention of delirium tremens, and management of delirium tremens after it starts (Table 131.4).

TABLE 131.4 Treatment of Ethanol Withdrawal

Prevention or Reduction of Early Symptoms
• Lorazepam 1-4 mg orally or IV; diazepam 5-20 mg; or chlordiazepoxide 25-100 mg repeated hourly until sedation or mild intoxication; successive daily doses tapered with resumption of higher dose if withdrawal symptoms recur
• Thiamine 100 mg and multivitamins IM or IV
• Magnesium, potassium, and calcium replacement as needed
Delirium Tremens
• Lorazepam 2-4 mg IV or IM or diazepam 10 mg IV, repeated every 5-15 min until calming; maintenance dose every 1-4 h as needed
• If refractory to benzodiazepines, phenobarbital 260 mg IV repeated in 30 min as needed
• If refractory to phenobarbital, propofol 25-100 μg/kg/min, with endotracheal intubation and repeated doses to produce general anesthesia
• Careful attention to fluid and electrolyte balance; several liters of saline per day, or even pressors, may be needed.
• Cooling blanket for high fever
• Prevent or correct hypoglycemia.
• Thiamine and multivitamin replacement
• Consider coexisting illness (eg, liver failure, pancreatitis, meningitis, subdural hematoma).

Abbreviations: IM, intramuscularly; IV, intravenously.

Benzodiazepines

Benzodiazepines, which have cross-tolerance with ethanol, are appropriately given to recently abstinent alcoholics or those with mild early withdrawal symptoms. Lorazepam (Ativan) 2 to 4 mg every 4 hours is a reasonable starting agent and dose. It is important to adjust the dose to symptom response, level of consciousness, and respiratory status after initiating therapy. A loading dose may cause symptoms of mild intoxication (calming, dysarthria, ataxia, fine nystagmus); dosage can then be adjusted to avoid both intoxication and tremulousness, and after 1 or 2 days, it can be gradually tapered, with reinstitution should withdrawal symptoms reappear.

Compared to fixed dose schedules, symptom-triggered pharmacotherapy more effectively decreases the likelihood of progression to delirium tremens and is less likely to result in sedative accumulation. Among standard protocols for symptom-triggered therapy, the Clinical Institute for Withdrawal Assessment for Alcohol (CIWA) scale assesses at regular intervals vital signs, nausea/vomiting, tremor, paroxysmal sweating, anxiety, agitation, tactile, visual or auditory disturbances, headache, and orientation/clouding of consciousness.

Anti-Adenergic Agents

β-Adrenergic blockers such as propranolol and α_2 agonists such as clonidine or dexmedetomidine are helpful as adjunctive therapy to help control symptoms of sympathetic overdrive, but they are not cross-tolerant with alcohol and have reportedly triggered hallucinosis. Phenobarbital, which has a different GABAergic mechanism of action than benzodiazepines, has also been used as add-on treatment.

Anticonvulsants

Numerous anticonvulsants, especially those with GABAergic actions, have been subjected to randomized trials comparing them to benzodiazepine or placebo for treating acute alcohol withdrawal. A Cochrane review of 56 such trials concluded that evidence was insufficient to recommend their use. Similar conclusions were reached in Cochrane reviews of baclofen or γ-hydroxybutyric acid compared to benzodiazepines in the treatment of alcohol withdrawal.

Parenteral lorazepam given to patients following an ethanol withdrawal seizure reduces the likelihood of recurrence. Status epilepticus during ethanol withdrawal is treated as in other situations. Long-term anticonvulsants are not indicated in patients whose seizures occur only during withdrawal; abstainers do not need them, and drinkers do not take them. Alcoholics whose seizures occur independent of withdrawal and epileptics whose seizures are exacerbated by ethanol unfortunately do need anticonvulsant prophylaxis even though compliance is unlikely.

Ethanol and Antipsychotics

Intravenous parenteral ethanol solutions have been used to treat delirium tremens. Treating with parenteral ethanol has the disadvantage of a low therapeutic index, and because ethanol is directly toxic to many organs, it should be avoided during hospitalization, even though most patients resume drinking on discharge. Haloperidol and phenothiazines are less likely to prevent hallucinosis or delirium tremens than drugs cross-tolerant with ethanol, and they can lower seizure threshold, prolong the QT interval, cause hypotension, and impair thermoregulation. They are appropriately considered in patients whose only symptoms are hallucinations or in whom hallucinations have outlasted other withdrawal symptoms.

General Medical Management

Hypomagnesemia is common during early ethanol withdrawal, and although it may not be the primary cause of symptoms, magnesium sulfate should be given to hypomagnesemic patients. Hypokalemia and hypocalcemia may also be present, and the latter may respond to treatment only when hypomagnesemia is corrected. Parenteral thiamine and multivitamins are given even if there are no clinical signs of depletion.

Delirium tremens, once it appears, cannot be abruptly reversed by any agent, and the mainstay of treatment is a parenteral benzodiazepine in dosage sufficient to produce adequate sedation. The required doses might be fatal in a normal person (see Table 131.4), but one cannot predict in any individual patient how high the tolerable dose is. Liver disease decreases the metabolism of benzodiazepines, and patients with cirrhosis are more vulnerable to the depressant effects of sedatives; as delirium tremens clears, hepatic encephalopathy can take its place.

General medical management in delirium tremens is intensive. Although dehydration may be severe enough to cause shock, patients with liver damage may retain sodium and water. Hypokalemia can cause cardiac arrhythmias. Hypoglycemia may be masked, as may other serious coexisting illnesses, such as alcoholic hepatitis, pancreatitis, meningitis, or subdural hematoma.

CHRONIC ETHANOL SYNDROMES

Wernicke-Korsakoff Syndrome

Clinical Manifestations

Although they share the same pathology, Wernicke and Korsakoff syndromes are clinically distinct. Wernicke syndrome, when full-blown, consists of mental, eye movement, and gait abnormalities. Korsakoff syndrome is a mental disorder that differs qualitatively from Wernicke syndrome (Table 131.5). Both are the result of thiamine deficiency.

TABLE 131.5 Major Nutritional Disturbances in Alcoholics

Disorder	Clinical Disorder	Deficiency
Wernicke syndrome	Dementia with lethargy, inattentiveness, apathy, and amnesia Ophthalmoparesis Gait ataxia	Thiamine
Korsakoff syndrome	Dementia, mainly amnesia, with or without confabulation	Thiamine
Cerebellar degeneration	Gait ataxia; limb coordination relatively preserved	Probably thiamine plus other vitamins plus ethanol neurotoxicity
Polyneuropathy	Distal limb sensory loss and weakness; less often autonomic dysfunction	Probably thiamine plus other vitamins plus ethanol neurotoxicity
Amblyopia	Optic atrophy, decreased visual acuity, central scotomas; total blindness rare	Probably thiamine plus other vitamins plus ethanol neurotoxicity

Wernicke Syndrome

In acute Wernicke syndrome, mental symptoms most often consist of a global confusional state that appears over days or weeks; there is inattentiveness, indifference, decreased spontaneous speech, disorientation, impaired memory, and lethargy. Selective amnesia is unusual. Disordered perception is common; a patient might identify the hospital room as his or her apartment or a bar. In fewer than 10%, mentation is normal.

Abnormal eye movements include nystagmus (horizontal with or without vertical or rotatory components), lateral rectus palsy (bilateral but usually asymmetric), and conjugate gaze palsy (horizontal with or without vertical), progressing to complete external ophthalmoplegia. Although sluggishness of pupillary reaction is common, total loss of reactivity to light and ptosis are rare. Mental symptoms, including progression to coma, can occur without evident abnormal eye movements in patients with pathologically verified acute Wernicke syndrome.

Truncal ataxia, present in more than 80% of patients, may prevent standing or walking. Dysarthria and limb ataxia, especially in the arms, are infrequent. Peripheral neuropathy, which occurs to some degree in most patients, may cause weakness sufficient to mask the ataxia. Abnormalities of vestibular caloric testing are common, with gradual improvement, often incomplete, over several months.

Patients with the Wernicke syndrome frequently have signs of nutritional deficiency (eg, skin changes, tongue redness, cheilosis) or liver disease. Autonomic signs are common. Although beriberi heart disease is rare, acute tachycardia, dyspnea on exertion, and postural hypotension unexplained by hypovolemia are common, and sudden circulatory collapse may follow mild exertion. Hypothermia is less frequent; fever usually indicates infection.

In acute Wernicke syndrome, the EEG may show diffuse slowing or it may be normal. Cerebrospinal fluid is normal except for occasional mild protein elevation. Elevated blood pyruvate, falling with treatment, is not specific. Decreased blood transketolase (which requires thiamine pyrophosphate as cofactor) and serum thiamine level may be depressed, but in most centers, the diagnosis depends on history and examination (and thiamine and multivitamins should be given to any alcoholic patient, symptomatic or not).

Korsakoff Syndrome

In most patients, the more purely amnestic syndrome of Korsakoff emerges as the other mental symptoms of Wernicke syndrome respond to treatment. How often Korsakoff syndrome occurs without a background of Wernicke syndrome is disputed and bound up with the question of "alcoholic dementia" (see later in the text). Pathologic changes of Wernicke-Korsakoff are sometimes encountered unexpectedly at autopsy, suggesting the presence of subclinical or atypical forms, including unexplained coma.

The amnesia of Korsakoff syndrome is both anterograde, with inability to retain new information, and retrograde, with rather randomly lost recall for events months or years old. Alertness, attentiveness, and behavior are relatively preserved, but there tends to be a lack of spontaneous speech or activity. Confabulation is not invariable and, if initially present, tends gradually to disappear. Insight is usually impaired, and there may be flagrant anosognosia for the mental disturbance.

Pathobiology

The histopathologic lesions of Wernicke-Korsakoff syndrome consist of variable degrees of neuronal, axonal, and myelin loss; prominent blood vessels; reactive microglia, macrophages, and astrocytes; and, infrequently, small hemorrhages. Nerve cells may be relatively preserved in the presence of extensive myelin destruction and gliosis, and astrocytosis may predominate chronically.

Lesions affect the thalamus (especially the anterior and dorsomedial nuclei and the medial pulvinar), the hypothalamus (especially the mammillary bodies), the midbrain (especially the oculomotor and periaqueductal areas), and the pons and medulla (especially the abducens and medial vestibular nuclei). Such lesions sometimes produce abnormal signals on magnetic resonance imaging, including diffusion-weighted imaging. Diffusion tensor imaging reveals disruption of the fornix. In the anterior-superior vermis of the cerebellum, severe Purkinje cell loss and astrocytosis accompany lesser degrees of neuronal loss and gliosis in the molecular and granular layers.

Memory impairment in Korsakoff syndrome correlates best with lesions involving the anterior nuclei of the thalamus; other components of the so-called Papez circuit (eg, the mammillary bodies) probably contribute. The global confusion of Wernicke syndrome can occur without visible thalamic lesions and may be a biochemical disorder. Periaqueductal, oculomotor, or abducens nucleus lesions probably explain ophthalmoparesis. Both cerebellar and vestibular lesions likely contribute to ataxia.

Experimental and clinical evidence ascribes a specific role to thiamine in the Wernicke-Korsakoff syndrome. A genetic influence is implied because only a small minority of alcoholic or otherwise malnourished people are affected, and whites seem more susceptible than blacks.

Management and Outcome

Untreated Wernicke-Korsakoff syndrome can be fatal, and the mortality rate is 10% among treated patients. Concomitant liver failure, infection, or delirium tremens often makes the cause of death unclear. Postural hypotension and tachycardia call for strict bed rest; associated medical problems may require intensive care. The cornerstone of treatment is thiamine, 1,000 mg daily, until a normal diet can be taken; intramuscular or intravenous administration is preferred because thiamine absorption is impaired in chronic alcoholics. Hypomagnesemia may retard improvement after thiamine treatment; magnesium is therefore replaced, along with other vitamins. Protein intake may have to be titrated against the patient's liver status.

With thiamine treatment, the ocular abnormalities (especially abducens and gaze palsies) improve within a few hours and usually resolve within 1 week; in about 35% of patients, horizontal nystagmus persists indefinitely. Global confusion may improve in hours or days and usually resolves within 1 month, leaving Korsakoff amnesia in more than 80%. In less than 25% of these patients, there is eventual clearing of the memory deficit. Ataxia may improve in a few days, but recovery is complete in less than 50% of patients, and nearly 35% do not show improvement at all.

Nonalcoholics who develop Wernicke encephalopathy (eg, as a result of starvation or hyperemesis gravidarum) are less likely to have Korsakoff amnesia following treatment, consistent with a contributory role for alcohol itself in the pathogenesis of Wernicke-Korsakoff syndrome.

Alcoholic Cerebellar Degeneration

Cerebellar cortical degeneration may occur in nutritionally deficient alcoholics without Wernicke-Korsakoff syndrome (see Table 131.5). Instability of the trunk is the major symptom,

often with incoordination of leg movements. Arm ataxia is less prominent; nystagmus and dysarthria are rare. Symptoms evolve in weeks or months and eventually stabilize, sometimes even with continued drinking and poor nutrition. Ataxia without Wernicke disease is less likely to appear abruptly or to improve.

Pathologically, the superior vermis is invariably involved, with nerve cell loss and gliosis in the molecular, granular, and especially the Purkinje cell layers. There may be secondary degeneration of the olives and of the fastigial, emboliform, globose, and vestibular nuclei. Involvement of the cerebellar hemispheric cortex is exceptional and limited to the anterior lobes. Pathologic evidence of Wernicke disease may coexist, even though it is unsuspected clinically. Computed tomography and autopsies, moreover, have revealed cerebellar atrophy in alcoholics who were not clinically ataxic.

Although similar cerebellar lesions occur in malnourished nonalcoholics, most patients with alcoholic cerebellar degeneration do not have clinical or pathologic evidence of Wernicke disease. The disorder is probably the result of both nutritional deficiency and ethanol toxicity, perhaps involving glutamate.

Alcoholic Polyneuropathy

Alcoholic polyneuropathy is a sensorimotor disorder that stabilizes or improves with abstinence and an adequate diet (see **Table 131.5**). Neuropathy is found in most patients with Wernicke-Korsakoff syndrome but more often occurs alone. Paresthesia is usually the first symptom; there may be burning or lancinating pain and exquisite tenderness of the calves or soles. Impaired vibratory sense is usually the earliest sign; proprioception tends to be preserved until other sensory loss is substantial. Loss of ankle jerks is another early sign; eventually, there is diffuse areflexia. Weakness appears at any time and may be severe. Distal leg muscles are affected first, although proximal weakness may be marked. Radiologically demonstrable neuropathic arthropathy of the feet is common, as are skin changes (eg, thinning, glossiness, reddening, cyanosis, hyperhidrosis). Peripheral autonomic abnormalities are usually less prominent than in diabetic neuropathy but may cause urinary and fecal incontinence, hypotension, hypothermia, cardiac arrhythmia, dysphagia, dysphonia, impaired esophageal peristalsis, altered sweat patterns, or abnormal Valsalva ratio. Pupillary parasympathetic denervation is rare. The cerebrospinal fluid is usually normal except for occasional mild elevation of protein content.

Pathologically, the neuropathy is axonal, and clinical and experimental evidence suggests that it is both toxic and nutritional in origin. A clinical and pathologic study found that pure thiamine deficiency neuropathy differs from pure alcoholic neuropathy; alcoholic neuropathy is sensory dominant, slowly progressive, and painful and causes predominantly small-fiber axonal loss, whereas thiamine deficiency neuropathy is motor dominant and acutely progressive and causes predominantly large-fiber axonal loss.

Peripheral nerve pressure palsies, especially radial and peroneal, are common in alcoholics. Nutritional polyneuropathy may increase the vulnerability of peripheral nerves to compression injury in intoxicated individuals, who tend to sleep deeply in unusual locations and positions. Recovery usually takes days or weeks; splints during this period can prevent contractures.

Alcoholic Amblyopia

Alcoholic amblyopia is a visual impairment that progresses over days or weeks, with development of central or centrocecal scotomas and temporal disc pallor (see **Table 131.5**). Demyelination affects the optic nerves, chiasm, and tracts, with predilection for the maculopapular bundle. Retinal ganglion cell loss is secondary. Although amblyopia improves in patients who receive dietary supplements but continue to smoke and drink ethanol, direct toxicity from ethanol and from compounds in tobacco smoke (perhaps cyanide) could be contributory. Alcoholic amblyopia does not progress to total blindness; it may remain stable without change in drinking or eating habits. Improvement, which is often incomplete, nearly always follows abstinence and nutritional replacement.

Pellagra

Nicotinic acid deficiency in alcoholics causes pellagra, with dermatologic, gastrointestinal, and neurologic symptoms. Altered mentation progresses over hours, days, or weeks to amnesia, delusions, hallucinations, or delirium. Nicotinic acid therapy (plus other vitamins, deficiency of which can be contributory) usually results in prompt improvement.

Alcoholic Liver Disease

Alcoholic liver disease, progressing from reversible steatosis through steatohepatitis to cirrhosis, is a major cause of death among alcoholics. Altered mentation in an alcoholic always raises the possibility of hepatic encephalopathy, which may accompany intoxication, withdrawal, Wernicke syndrome, meningitis, subdural hematoma, hypoglycemia, or other alcohol states. Hepatic encephalopathy is discussed in detail in Chapter 124. Other neurologic disorders encountered in alcoholic cirrhotics include a poorly understood syndrome of altered mentation, myoclonus, and progressive myelopathy following portacaval shunting, as well as acquired chronic hepatocerebral degeneration, a characteristic syndrome of dementia, dysarthria, ataxia, intention tremor, choreoathetosis, muscular rigidity, and asterixis, which usually occurs in patients who have had repeated bouts of hepatic coma. Heavy ethanol use greatly increases the risk for acetaminophen hepatotoxicity and for cirrhosis and hepatocellular carcinoma in patients with hepatitis C infection.

Hypoglycemia

Metabolism of ethanol by alcohol dehydrogenase and of acetaldehyde by mitochondrial aldehyde dehydrogenase uses nicotinamide adenine dinucleotide (NAD). The resulting elevated NADH-to-NAD ratio impairs gluconeogenesis, and if food is not being eaten and liver glycogen is depleted, there may be severe hypoglycemia with altered behavior, seizures, coma, or focal neurologic deficit. Residual symptoms are common, including dementia. Even after appropriate treatment with intravenous 50% dextrose, these patients require close observation; blood glucose may fall again, with the return of symptoms and possibly permanent brain damage. Ethanol stimulates intestinal release of secretin, which aggravates reactive hypoglycemia, especially in children, by enhancing glucose-stimulated insulin release.

Alcoholic Ketoacidosis

In alcoholic ketoacidosis, β-hydroxybutyric acid and lactic acid accumulate in association with heavy drinking. The mechanism relates to starvation, increased lipolysis, and impaired fatty acid oxidation. Typical patients are young binge drinkers who stop drinking when they are overcome by anorexia. Vomiting, dehydration, confusion, obtundation, and hyperventilation ensue. Blood glucose may be normal, low, or moderately elevated, with little or no glycosuria. A large anion gap is accounted for by β-hydroxybutyrate, lactate, and lesser amounts of pyruvate and acetoacetate. Serum insulin levels are low, and serum levels of growth hormone, epinephrine, glucagon, and cortisol are high, but glucose intolerance usually clears without insulin and is not demonstrable on recovery. It is not unusual for patients to have repeated attacks of alcoholic ketoacidosis.

Alcoholics may have other reasons for metabolic acidosis with a large anion gap (eg, methanol or ethylene glycol poisoning). When β-hydroxybutyrate is the major ketone present, the nitroprusside test (Acetest) may be negative. Treatment includes infusion of glucose (and thiamine); correction of dehydration or hypotension; and replacement of electrolytes such as potassium, magnesium, and phosphate. Small amounts of bicarbonate may be given. Insulin is usually not needed.

Infection in Alcoholics

Alteration of white blood cell function contributes to the alcoholic's predisposition to infection (eg, bacterial and tuberculous meningitis). Infectious meningitis must always be considered in alcoholics with seizures or altered mental status, even when the clinical picture seems to be that of intoxication, withdrawal, thiamine deficiency, hepatic encephalopathy, hypoglycemia, or other alcoholic disturbances. Alcoholic intoxication is a risk factor for human immunodeficiency virus infection.

Trauma in Alcoholics

Thrombocytopenia, a direct effect of ethanol and a consequence of cirrhosis, increases the likelihood of intracranial hematomas after head injury. Abnormalities of clotting factors also increase the possibility of intracranial hematomas. Experimentally, moreover, acute ethanol enhances blood-brain barrier leakage around areas of cerebral trauma. Close observation is essential after even mild head injury in intoxicated patients; an abnormal sensorium must not be dismissed as drunkenness.

Alcohol and Cancer

Independently of tobacco, ethanol in moderate amounts increases the risk of carcinoma of the mouth, esophagus, pharynx, larynx, liver, and, probably, large bowel and breast.

Alcohol and Stroke

As with coronary artery disease, epidemiologic studies suggest that low to moderate amounts of ethanol decrease ischemic stroke risk, whereas higher amounts increase it. Meta-analysis of rigorously designed cohort and case-control studies found a J-shaped association between ethanol consumption and the risk of ischemic stroke and a linear association between ethanol consumption and the risk of hemorrhagic stroke. In the United States, the relationship holds for men and women; for blacks, whites, and Hispanics; and for spirits, beer, and wine. Whether extra risk is temporally associated with binge drinking and whether special benefit is conferred by wine (especially red wine) is less clear. In asymptomatic subjects, moderate ethanol consumption reduces the risk of both carotid atherosclerosis and leukoaraiosis. Ethanol could either prevent or cause stroke by several mechanisms. Acutely and chronically, ethanol causes hypertension. It reportedly lowers blood levels of low-density lipoproteins, raises levels of high-density lipoproteins, decreases fibrinolytic activity, increases or inhibits platelet reactivity, increases or decreases C-reactive protein, dilates or constricts cerebral vessels, and indirectly reduces cerebral blood flow through dehydration. The antioxidant properties of flavonoids in red wine might confer special protection. Alcoholic cardiomyopathy predisposes to embolic stroke.

Not all studies have found a protective effect of mild to moderate drinking on ischemic stroke, and some describe increased risk at any dose. Moreover, even if light drinking does reduce the risk of ischemic stroke (and coronary artery disease), the protection is offset by the enormous worldwide contribution of ethanol to all-cause mortality and morbidity. The Global Burden of Disease Study 2016 concluded that the only "level of consumption that minimizes health loss is zero."

Alcoholic Myopathy

Alcoholic myopathy is of two types. Chronic myopathy produces painless proximal weakness; serum creatine kinase can be elevated or normal, and, pathologically, there is atrophy affecting especially type 2 fibers (a nonspecific finding also seen with disuse or glucocorticoid toxicity). Cardiomyopathy may be present. Acute alcoholic myopathy consists of rhabdomyolysis, painful swelling, and myoglobinuria with renal injury. Both types of myopathy are attributed to direct effects of ethanol on muscle independent of malnutrition. Acute rhabdomyolysis often occurs hours or days after binge drinking. Workup includes checking for potassium or phosphate depletion, which are common in alcoholics. Treatment is supportive, and symptoms improve with abstinence.

Central Pontine Myelinolysis and Marchiafava-Bignami Disease

Central pontine myelinolysis occurs in both alcoholics and nondrinkers and is a consequence of overvigorous correction of hyponatremia. Marchiafava-Bignami disease is nearly always associated with alcoholism (including wine, beer, and whiskey). It is of unknown origin and causes symptoms, including death, that are scarcely explained by the characteristic callosal lesions. Central pontine myelinolysis is discussed in detail in Chapter 125.

Alcoholic Dementia

Whether ethanol, as a direct neurotoxin, can cause progressive mental decline in the absence of nutritional deficiency, brain trauma, or other indirect mechanisms has been controversial for decades. Properly controlled animal studies reveal dose-related impaired learning and neuropathologic changes in hippocampus and other brain regions. Brains of alcoholics without evident

nutritional deficiency have reduced volume especially affecting white matter; reports of cortical or hippocampal neuronal loss are less consistent, but neuropathologic changes appear to correlate with memory and other cognitive impairment. A plausible mechanism is inhibition of glutamate neurotransmission with receptor upregulation and rebound excitotoxicity. It is possible that ethanol neurotoxicity and thiamine deficiency are synergistic in this regard.

Numerous cohort and case-control studies addressing dose-related effects of ethanol on cognition have found that compared to nondrinking, low to moderate alcohol intake actually reduces the risk of dementia. As with ischemic stroke, in these studies, a J-shaped curve reflects ethanol's long-term effects on cognition: Compared to nondrinking, moderate intake reduces the risk of dementia and heavy intake increases it. Ethanol's protective effect is independent of its benefit on cerebrovascular disease. Wine, beer, and spirits are each protective, with some studies finding special benefit in red wine (perhaps related to antioxidant polyphenols such as resveratrol). A mechanism for ethanol's protection against nonvascular dementia is otherwise unclear.

Some studies have failed to find a protective effect of mild to moderate drinking on cognition, and some have described an increased risk at any dose compared to abstinence. The apparent risk reduction among light drinkers has been attributed to socioeconomic and educational status of light drinkers compared to never drinkers (and heavy drinkers).

Fetal Alcohol Spectrum Disorders

Ethanol ingestion during pregnancy causes congenital malformations and delayed psychomotor development. Major clinical features of the *fetal alcohol syndrome* (FAS) include cerebral dysfunction, growth deficiency, and distinctive facies (Table 131.6); less often, there are abnormalities of the heart, skeleton, urogenital organs, skin, and muscles. Neuropathologic abnormalities include absence or displacement of the corpus callosum, hydrocephalus, cerebellar dysplasia, abnormal neuronal migration, heterotopic cell clusters, and microcephaly. These changes occur independently of other potentially incriminating factors, such as maternal malnutrition, smoking, other drug use, or age. Binge drinking, which may produce high ethanol levels at a critical fetal period, may be more important than chronic ethanol exposure, and early gestation appears to be the most vulnerable period.

The face of a typical patient with FAS is distinctive and as easily recognized at birth as that of an infant with Down syndrome. Irritability and tremulousness with poor suck reflex and hyperacusis are usually present at birth and last weeks or months. Of these children, 85% perform more than two standard deviations below the mean on tests of mental performance; those who are not grossly retarded rarely have even average mental ability. Older children are often hyperactive and clumsy, and there may be hypotonia or hypertonia. Except for neonatal seizures, epilepsy is not a component of the syndrome.

Some children of alcoholic mothers have milder cognitive or behavioral features—for example, depression, anxiety, or hyperactivity. The broad continuum of ethanol's fetal effects is referred to as *fetal alcohol spectrum disorders* (FASDs), comprising mental, emotional, craniofacial, physiologic, and immunologic abnormalities that occur alone or in combination. Dysregulation of the hypothalamic-pituitary-adrenal axis, with hyperstress responses, is a major feature in many subjects.

TABLE 131.6 Clinical Features of Fetal Alcohol Syndrome

Majority	Minority
CNS	**Ears**
Mental retardation	Posteriorly rotated
Microcephaly	Poorly formed concha
Hypotonia	**Skeletal**
Poor coordination	Pectus excavatum or carinatum
Hyperactivity	Syndactyly, clinodactyly, or camptodactyly
Impaired growth	Limited joint movements
Pre- and postnatal for length and weight	Nail hypoplasia
Diminished adipose tissue	Radioulnar synostosis
Eyes	Bifid xiphoid
Short palpebral fissures	Scoliosis
Ptosis	Klippel-Feil anomaly
Strabismus	**Cardiac**
Epicanthal folds	Septal defects
Myopia	Great vessel anomalies
Microphthalmia	**Cutaneous**
Blepharophimosis	Abnormal palmar creases
Cataracts	Hemangiomas
Retinal pigmentary abnormalities	Infantile hirsutism
Nose	**Muscular**
Short, upturned	Diaphragmatic, inguinal, or umbilical hernias
Hypoplastic philtrum	Diastasis recti
Mouth	**Urogenital**
Thin vermilion lip borders	Labial hypoplasia
Retrognathia in infancy	Hypospadias
Micrognathia or prognathia in adolescence	Small rotated kidneys
Prominent lateral palatine ridges	Hydronephrosis
Cleft lip or palate	
Small teeth with faulty enamel	
Maxilla	
Hypoplastic	

Abbreviation: CNS, central nervous system.

Ethanol is directly teratogenic to many animals. Proposed mechanisms include apoptosis secondary to blockade of *N*-methyl-D-aspartate glutamate receptors during a critical period of synaptogenesis, toxicity to adhesion molecules essential for neuronal migration, and fetal vasospasm and central nervous system ischemia. Twin studies show genetic vulnerability to FASD (100% concordance in monozygotes, 63% in dizygotes), and ethanol has epigenetic effects which in animals are transgenerational. Epigenetics might explain observations that paternal drinking also carries risk for FASD.

In humans, the risk of alcohol-induced birth defects is established with more than 3 oz of absolute alcohol daily. Below that, the risk is uncertain; a threshold of safety has not been defined. As rates of ethanol use in the United States rose during the 1990s, so did the incidence of FAS. On the basis of data from the United States and France, it was estimated that the incidence of FASD is nearly 1% of all live births. The FASD may affect 1% of infants born to women who drink 1 oz of ethanol daily early in pregnancy. More than 30% of the offspring of heavy drinkers are affected by FAS, which thus may be the leading teratogenic cause of mental retardation in the Western world.

TREATMENT OF CHRONIC ALCOHOLISM

The literature on the treatment of alcoholism is voluminous, and strong opinions outweigh scientific data. Not all problem drinkers consume physically addicting quantities of ethanol, no personality type defines an alcoholic, and the relative roles of genetics and social deprivation vary from patient to patient. Of course, such variability of alcoholic populations means that no treatment modality (eg, psychotherapy, group psychotherapy, family or social network therapy, drug therapy, behavioral [aversion] therapy) or no single therapeutic setting (eg, general hospital, halfway house, vocational rehabilitation clinic, Alcoholics Anonymous) is appropriate for all. For example, the success rate of Alcoholics Anonymous has been estimated to be 34%.

Use of tranquilizing and sedating drugs is especially controversial because they may lead to switching of dependency or to drug-ethanol interactions. Some clinicians espouse short-term use of these drugs in doses high enough to reduce the psychological tensions that lead to ethanol use but low enough not to block symptoms of ethanol withdrawal.

Disulfiram inhibits aldehyde dehydrogenase and reduces the rate of oxidation of acetaldehyde, accumulation of which accounts for the symptoms that appear soon after someone taking disulfiram drinks ethanol. Within 5 to 10 minutes, there is throbbing headache, dyspnea, nausea, vomiting, sweating, chest pain, palpitations, hypotension, anxiety, and confusion. The severity and duration of these symptoms depend on the amount of ethanol drunk; severe reactions can last hours or be fatal and require hospital admission, with careful management of hypotension and cardiac arrhythmia.

Taken in the morning, when the urge to drink is least, disulfiram, 0.25 to 0.5 g daily, does not alter the taste for ethanol and helps only patients who strongly desire to abstain. Side effects of disulfiram that are unrelated to ethanol ingestion include drowsiness, psychiatric symptoms, and cardiovascular problems. Less common side effects include paranoia, impaired memory, ataxia, dysarthria, and even major motor seizures, which may be difficult to distinguish from ethanol effects. Hypersensitivity hepatitis and fulminant peripheral neuropathy can also occur.

Naltrexone and acamprosate are both U.S. Food and Drug Administration approved for treatment of alcoholism. Naltrexone might work by decreasing dopaminergic activity in reward circuits. Acamprosate might work by modulating glutamate neurotransmission and resetting a disrupted balance between GABA and glutamate systems. Placebo-controlled trials suggest that acamprosate (1,332-3,000 mg/d) is more effective than naltrexone in maintaining abstinence, whereas naltrexone (50-100 mg/d) is more effective in reducing heavy drinking and craving should drinking be resumed.

Topiramate affects both dopaminergic and glutamatergic pathways, and placebo-controlled trials demonstrate benefit (at doses ranging from 50 to 300 mg/d) both for maintaining abstinence and for reducing heavy drinking.

SUGGESTED READINGS

Amato L, Minozzi S, Davoli M. Efficacy and safety of pharmacological interventions for the treatment of the alcohol withdrawal syndrome. *Cochrane Database Syst Rev*. 2011;(6):CD008537.

Bijjal S, Subodh BN, Narayanaswamy JC, Chand P, Benegal V, Murthy P. Dystonia as a presenting feature of alcohol withdrawal. *J Neuropsychiatry Clin Neurosci*. 2012;24:E15-E16.

Blodgett JC, Del Re AC, Maisel NC, Finney JW. A meta-analysis of topiramate's effects for individuals with alcohol use disorders. *Alcohol Clin Exp Res*. 2014; 38:1481-1488.

Bråthen G, Ben-Menachem E, Brodtkorb E, et al. EFNS guideline on the diagnosis and management of alcohol-related seizures: report of an EFNS Task Force. *Eur J Neurol*. 2005;12:575-581.

Brust JCM. A 74-year-old man with memory loss and neuropathy who enjoys alcoholic beverages. *JAMA*. 2008;299:1046-1054.

Brust JCM. Acute withdrawal: diagnosis and treatment. *Handb Clin Neurol*. 2014;125:123-131.

Brust JCM. Ethanol. In: *Neurological Aspects of Substance Abuse*. 2nd ed. Boston, MA: Butterworth-Heinemann; 2004:317-425.

Brust JCM. Ethanol and cognition: indirect effects, neurotoxicity and neuroprotection: a review. *Int J Environ Res Public Health*. 2010;7:1540-1557.

Brust JCM. Stroke and substance abuse. In: Grotta J, Albers GW, Broderick JP, et al, eds. *Stroke: Pathophysiology, Diagnosis, and Management*. 6th ed. Philadelphia, PA: Elsevier; 2015:648-657.

Brust JCM. Wine, flavonoids, and the "water of life." *Neurology*. 2002;59: 1300-1301.

Carlson RW, Kumar NN, Wong-Mckinstry E, et al. Alcohol withdrawal syndrome. *Crit Care Clin*. 2012;28:549-585.

Cassidy EM, O'Sullivan I, Bradshaw P, Islam T, Onovo C. Symptom-triggered benzodiazepine therapy for alcohol withdrawal syndrome in the emergency department: a comparison with the standard fixed dose benzodiazepine regimen. *Emerg Med J*. 2012;29:802-804.

De la Monte SM, Kril JJ. Human alcohol-related neuropathology. *Acta Neuropathol*. 2014;127:71-90.

Frazee EN, Personett HA, Leung JG, Nelson S, Dierkhising RA, Bauer PR. Influence of dexmedetomidine therapy on the management of severe alcohol withdrawal syndrome in critically ill patients. *J Crit Care*. 2014;29:298-302.

GBD 2016 Alcohol Collaborators. Alcohol use and burden for 195 countries and territories, 1990-2016: a systematic analysis for the Global Burden of Disease Study 2016. *Lancet*. 2018;392:1015-1035.

Harding A, Halliday G, Caine D, Kril J. Degeneration of anterior thalamic nuclei differentiates alcoholics with amnesia. *Brain*. 2000;123(pt 1):141-154.

Heffernan M, Mather KA, Xu J, et al. Alcohol consumption and incident dementia: evidence from the Sydney Memory and Ageing Study. *J Alzheimers Dis*. 2016;52:529-538.

Hillbom M, Saloheimo P, Fujioka S, Wszolek ZK, Juvela S, Leone MA. Diagnosis and management of Marchiafava-Bignami disease: a review of CT/MRI confirmed cases. *J Neurol Neurosurg Psychiatry*. 2014;85:168-173.

Hughes JC, Cook CC. The efficacy of disulfiram: a review of outcome studies. *Addiction*. 1997;92:381-395.

Jones SB, Loehr L, Avery CL, et al. Midlife alcohol consumption and the risk of stroke in the Atherosclerosis Risk in Communities study. *Stroke*. 2015; 46:3124-3130.

Jung MK, Callaci JJ, Lauing KL, et al. Alcohol exposure and mechanisms of tissue injury and repair. *Alcohol Clin Exp Res*. 2011;35:392-399.

Koike H, Iijima M, Sugiura M, et al. Alcoholic neuropathy is clinicopathologically distinct from thiamine-deficiency neuropathy. *Ann Neurol*. 2003;54:19-29.

Kril JJ, Harper CG. Neuroanatomy and neuropathology associated with Korsakoff's syndrome. *Neuropsychol Rev*. 2012;22:72-80.

Lee H, Roh S, Kim DJ. Alcohol-induced blackout. *Int J Environ Res Public Health*. 2009;6:2783-2792.

Leone MA, Vigna-Taglianti F, Avanzi G, Brambilla R, Faggiano F. Gamma-hydroxybutyrate (GHB) for treatment of alcohol withdrawal and prevention of relapses. *Cochrane Database Syst Rev*. 2010;(2);CD0006266.

Liu J, Wang L. Baclofen for alcohol withdrawal. *Cochrane Database Syst Rev*. 2011;19(1):CD008502.

Maisel NC, Blodgett JC, Wilbourne PL, Humphreys K, Finney J. Meta-analysis of naltrexone and acamprosate for treating alcohol use disorders: when are these medications most helpful? *Addiction*. 2013;108:275-293.

Manzo G, De Gennaro A, Cozzolino A, Serino A, Fenza G, Manto A. MR imaging findings in alcoholic and nonalcoholic acute Wernicke's encephalopathy: a review. *Biomed Res Int*. 2014;2014:503596.

Mead EA, Sarkar AK. Fetal alcohol spectrum disorders and their transmission through genetic and epigenetic mechanisms. *Front Genet*. 2014;5:1-10.

Mellion M, Gilchrist JM, de la Monte S. Alcohol-related peripheral neuropathy: nutritional, toxic, or both? *Muscle Nerve*. 2011;43:309-316.

Minozzi S, Amato L, Vecchi S, Davoli M. Anticonvulsants for alcohol withdrawal. *Cochrane Database Syst Rev*. 2011;17(3):CD005064.

Mukamal KJ, Ascherio A, Mittleman MA, et al. Alcohol and risk for ischemic stroke in men: the role of drinking patterns and usual beverage. *Ann Intern Med*. 2005;142:11-19.

Mukamal KJ, Kuller LH, Fitzpatrick AL, Longstreth WT Jr, Mittleman MA, Siscovick DS. Prospective study of alcohol consumption and risk of dementia in older adults. *JAMA*. 2003;289:1405-1413.

Muzyk AJ, Fowler JA, Norwood DK, Chilipko A. Role of α_2-agonists in the treatment of acute alcohol withdrawal. *Ann Pharmacother*. 2011;45:649-657.

Nahum L, Pignat J-M, Bouzerda-Wahlen A, et al. Neural correlate of anterograde amnesia in Wernicke-Korsakoff syndrome. *Brain Topogr*. 2015;28(5):760-770.

Noble JM, Weimer LH. Neurologic complications of alcoholism. *Continuum (Minneap Minn)*. 2014;20(3 Neurology of Systemic Disease):624-641.

Ntais C, Pakos E, Kyzas P, Ioannidis JPA. Benzodiazepines for alcohol withdrawal. *Cochrane Database Syst Rev*. 2005;(3):CD005063.

Pitel AL, Segobin SH, Ritz L, Eustache F, Beaunieux H. Thalamic abnormalities are a cardinal feature of alcohol-related brain dysfunction. *Neurosci Biobehav Rev*. 2015;54:38-45.

Reynolds K, Lewis LB, Nolan JDL, Kinney GL, Sathya B, He J. Alcohol consumption and risk of stroke: a meta-analysis. *JAMA*. 2003;289:579-588.

Rosenbloom MJ, Pfefferbaum AMD. Magnetic resonance imaging of the living brain: evidence for brain degeneration among alcoholics and recovery with abstinence. *Alcohol Res Health*. 2008;31:362-376.

Rosenson J, Clements C, Simon B, et al. Phenobarbital for acute alcohol withdrawal: a prospective randomized double-blind placebo-controlled study. *J Emerg Med*. 2013;44(3):592-598.e2.

Sabia S, Elbaz A, Britton A, et al. Alcohol consumption and cognitive decline in early old age. *Neurology*. 2014;82:332-339.

Sacco RL, Elkind M, Boden-Albala B, et al. The protective effect of moderate alcohol consumption on ischemic stroke. *JAMA*. 1999;281:53-60.

Samokhvalov AV, Irving H, Mohapatra S, Rehm J. Alcohol consumption, unprovoked seizures, and epilepsy: a systematic review and meta-analysis. *Epilepsia*. 2010;51:1177-1184.

Solfrizzi V, D'Introno A, Colacicco AM, et al. Alcohol consumption, mild cognitive impairment, and progression to dementia. *Neurology*. 2007;68:1790-1799.

Topiwala A, Ebmeier KP. Effects of drinking on late-life brain and cognition. *Evid Based Mental Health*. 2018;21:12-15.

Victor M, Adams RD, Collins GH. *The Wernicke-Korsakoff Syndrome*. 2nd ed. Philadelphia, PA: FA Davis; 1989.

Xu W, Wang H, Wan Y, et al. Alcohol consumption and dementia risk: a dose-response meta-analysis of prospective studies. *Eur J Epidemiol*. 2017;32:31-42.

Drug Intoxication and Withdrawal 132

John C. M. Brust

KEY POINTS

1. Psychic dependence consists of craving and drug-seeking behavior; addiction is psychic dependence.
2. Physical dependence produces somatic withdrawal symptoms and signs.
3. A variety of agents produce psychic dependence, physical dependence, or both, and when more than one recreational drug is used, diverse symptoms of intoxication and withdrawal, as well as medical and neurologic complications, can be complicated and confusing.

INTRODUCTION

There are two kinds of drug dependence. *Psychic dependence* leads to craving and drug-seeking behavior. *Physical dependence* produces somatic withdrawal symptoms and signs. Depending on the particular drug and the circumstances of its administration, psychic and physical dependence can coexist or occur alone. *Addiction* is psychic dependence.

In the United States, dependence of one or both types is encountered with a variety of agents, licit and illicit (**Table 132.1**). Different classes of drugs produce diverse symptoms of intoxication and withdrawal as well as medical and neurologic complications.

In 2016, an epidemiologic survey of American adults reported a 9.9% lifetime prevalence of *Diagnostic and Statistical Manual of Mental Disorders* (5th edition) drug use disorder (not including tobacco or ethanol).

DRUGS OF DEPENDENCE

Opioids

Opioids include agonists, antagonists, and mixed agonist-antagonists (**Table 132.2**).

TABLE 132.1 Drugs of Dependence
Opioids
Psychostimulants
Sedatives/hypnotics
Marijuana
Hallucinogens
Inhalants
Phencyclidine
Anticholinergics
Ethanol
Tobacco

TABLE 132.2 Commonly Used Opioids
Agonist
• Camphorated tincture of opium (paregoric)
• Morphine
• Meperidine
• Methadone
• Fentanyl
• Hydromorphone
• Oxycodone
• Hydrocodone
• Propoxyphene
• Heroin
Antagonist
• Naloxone
• Naltrexone
Mixed Agonist-Antagonist
• Pentazocine
• Butorphanol
• Buprenorphine

Beginning in the 1990s, the United States and other countries experienced a steady rise in the use of prescription opioids to treat chronic noncancer pain. There soon emerged an epidemic of recreational use of these products, followed by an epidemic of illicit opioid use, including heroin, fentanyl, and "designer" fentanyl analogs and novel synthetic opioids. Of 72,306 drug overdose deaths reported in the United States during 2017, 84% were opioid-related.

Desomorphine, a reduction of codeine that is more potent but also often contains more impurities, is termed *crocodile* for the green-black skin lesions found on parenteral users.

Kratom, obtained from a Southeast Asian tree, contains mitragynine, which has opioid-like as well as serotonin-like effects. Kratom leaves can be chewed, ingested, or smoked.

At desired levels of intoxication, agonist opioids produce drowsy euphoria; analgesia; cough suppression; miosis; and often nausea, vomiting, sweating, pruritus, hypothermia, postural hypotension, constipation, and decreased libido. Taken parenterally or smoked (often in combination with alkaloidal crack cocaine), heroin produces a "rush," a brief ecstatic feeling followed by euphoria and either relaxed "nodding" or garrulous hyperactivity. Overdose causes coma, respiratory depression, and pinpoint (but reactive) pupils. For adults with respiratory depression, treatment consists of respiratory support and naloxone, 2 mg intravenously, repeated as needed up to 20 mg; for those with normal respirations, smaller doses (0.4-0.8 mg) are given to avoid precipitation of

withdrawal signs. Naloxone is short acting, and patients receiving it require close observation.

Fentanyl and fentanyl analogs, some of which are thousands of times more potent than morphine, require larger doses of naloxone to reverse respiratory depression. Escalating opioid overdose fatalities have led to nonprescription availability of naloxone as self-injection or nasal spray.

Opioid agonist withdrawal symptoms include irritability, lacrimation, rhinorrhea, sweating, yawning, mydriasis, myalgia, muscle spasms, piloerection, nausea, vomiting, abdominal cramps, fever, hot flashes, tachycardia, hypertension, and orgasm. In adults, seizures and delirium are not features of opioid withdrawal, which is rarely life threatening and can usually be prevented or treated with 20 mg of methadone taken once or twice daily. By contrast, untreated opioid withdrawal in newborns is severe and protracted, probably causes seizures, and is often fatal. Treatment is with titrated doses of methadone or paregoric; a barbiturate can be added if additional drug withdrawal is suspected or if seizures require treatment.

Effective pharmacotherapy for opioid dependence consists of substitution with oral methadone or buprenorphine. Treatment failure is usually attributable to inadequate dosage. Antagonist therapy with naltrexone proved disappointing.

Psychostimulants

Psychostimulants include amphetamine-like agents and cocaine (**Table 132.3**). 3,4-Methylenedioxymethamphetamine (MDMA; "ecstasy") appears to combine the psychostimulant properties of amphetamine with the hallucinogenic properties of lysergic acid diethylamide (LSD). An East African–Arabian shrub, khat (*Catha edulis*), is chewed for the effects of its psychoactive ingredient cathinone. Numerous "designer" analogs of cathinone, including methcathinone (ephedrone), mephedrone, and methylenedioxypyrovalerone (MDPV), are available on the Internet as "bath salts." Also available are "designer" psychostimulants chemically characterized as aminoindanes, piperazines, and pipradrol.

Desired effects of psychostimulants include alert euphoria with increased motor activity and physical endurance. Taken parenterally or smoked as alkaloidal cocaine ("crack") or methamphetamine ("ice"), psychostimulants produce a rush clearly distinguishable from that of opioids. With repeated use, there is stereotypic activity progressing to bruxism or other dyskinesias and paranoia progressing to frank hallucinatory psychosis. Overdose causes headache, chest pain, tachycardia, hypertension, flushing, sweating, fever, and excitement. There may be delirium, cardiac arrhythmia, myoclonus, seizures, myoglobinuria, shock, coma, and death. Malignant hyperthermia and disseminated intravascular coagulation are described. Treatment includes benzodiazepine sedation, oxygen, bicarbonate for acidosis, anticonvulsants, cooling, an antihypertensive (preferably an α-blocker such as phenoxybenzamine or a direct vasodilator such as sodium nitroprusside), respiratory and blood pressure support, and cardiac monitoring.

Psychostimulant withdrawal produces fatigue, depression, and increased hunger and sleep. Objective signs are few, but depression or somnolence can require treatment or even hospitalization.

An effective pharmacotherapy for psychostimulant dependence does not exist.

TABLE 132.3 Commonly Used Psychostimulants

Dextroamphetamine
Methamphetamine
Ephedrine
Pseudoephedrine
Methylphenidate
Pemoline
Phenmetrazine
Phentermine
Phenylpropanolamine (no longer produced in the United States)
3,4-Methylenedioxymethamphetamine (ecstasy)
Cocaine
Cathinone, methcathinone

Sedatives

Sedative agents include barbiturates, benzodiazepines, and miscellaneous products (**Table 132.4**). Benzodiazepines are often taken with recreational opioids, and a variety of "designer" benzodiazepines are currently available, often undetectable with standard assays. Desired effects and overdose with sedatives are similar to ethanol intoxication, although respiratory depression is much milder with benzodiazepines. Treatment is supportive; for severe benzodiazepine poisoning, there is a specific antagonist, flumazenil. Sedative withdrawal causes tremor and seizures, which can be prevented or treated with titrated doses of a barbiturate or a benzodiazepine such as lorazepam. Delirium tremens is a medical emergency requiring intensive care.

γ-Hydroxybutyric acid and two of its precursors, γ-butyrolactone and 1,4-butanediol, are notorious as "date rape" drugs. Often taken with ethanol, they cause sedation and respiratory depression. Treatment is supportive. Dependence occurs and withdrawal signs resemble those of other sedatives and ethanol, including seizures and delirium tremens.

Marijuana

Marijuana, from the hemp plant *Cannabis sativa*, contains many cannabinoid compounds, of which the principal psychoactive agent is Δ-9-tetrahydrocannabinol (THC). Hashish refers to preparations made from the plant resin, which contains high concentrations of psychoactive cannabinoids. Δ-9-THC acts at cannabinoid receptors in the brain, and the pharmaceutical development of synthetic receptor agonists was soon followed by their availability as recreational agents. Marketed as "Spice" or "K2," they are often many times more potent than Δ-9-THC.

Usually smoked, marijuana produces a relaxed dreamy euphoria, often with jocularity, disinhibition, depersonalization, subjective slowing of time, conjunctival injection, tachycardia, and postural hypotension. High doses cause auditory or visual hallucinations, confusion, and psychosis, but fatal overdose has not been documented. Withdrawal symptoms, other than craving, are minimal; there may be jitteriness, anorexia, and headache. Psychic dependence is common, however.

Synthetic cannabinoids ("K2," "Spice") frequently produce serious adverse effects, including psychosis, hallucinations, cardiac arrhythmia, myocardial infarction, vertigo, hypertension, protracted vomiting, seizures, acute kidney injury, stroke, and death. Withdrawal symptoms are more severe than with

TABLE 132.4 Sedative/Hypnotic Drugs
Barbiturates
• Phenobarbital
• Primidone
• Amobarbital
• Butalbital (only in mixtures, eg, Fioricet)
• Pentobarbital
• Secobarbital
• Methohexital
• Thiopental
Benzodiazepines
• Alprazolam
• Clorazepate
• Chlordiazepoxide
• Diazepam
• Lorazepam
• Oxazepam
• Flurazepam
• Temazepam
• Triazolam
• Clonazepam
• Midazolam
Miscellaneous Agents
• Buspirone
• Chloral hydrate
• Paraldehyde
• Diphenhydramine
• Ethchlorvynol
• Glutethimide
• Hydroxyzine
• Meprobamate
• Methaqualone (no longer produced in the United States)
• Zolpidem
• Zalepion
• γ-Hydroxybutyric acid

marijuana, and dependence liability is greater. Synthetic cannabinoids are not identified in toxicology screens, and there is no antidote for overdose.

A nonpsychoactive cannabinoid, cannabidiol (CBD), is FDA-approved for treating seizures in patients with Dravet or Lennox-Gastaut syndrome. Evidence supports the efficacy of oral cannabis extracts containing Δ-9-THC and CBD in treating spasticity, central pain, and urinary frequency in patients with multiple sclerosis. There is no evidence that smoked marijuana is of benefit in any neurologic disorder.

Hallucinogens

Hallucinogenic plants are used ritualistically or recreationally around the world. In the United States, the most popular agents are the indolealkylamines psilocybin and psilocin (from several mushroom species), the phenylalkylamine mescaline (from the peyote cactus), and the synthetic ergot compound LSD. Increasingly popular is the herb *Salvia divinorum*, which contains the kappa-opioid receptor agonist salvinorin A. Other synthetic hallucinogens carry such street names as "fly" and "dragonfly." "2-C" drugs are phenylalkylamines with hallucinogenic properties.

The acute effects of hallucinogens are perceptual (distortions or hallucinations, usually visual and elaborately formed), psychologic (depersonalization or altered mood), and somatic (dizziness, tremor, and paresthesia). Some users experience paranoia or panic and some, days to months after use, have flashbacks, the spontaneous recurrence of drug symptoms without taking the drug. High doses of LSD cause hypertension, obtundation, and seizures, but fatalities are usually the result of accidents or suicide. Treatment of overdose consists of a calm environment, reassurance, and, if necessary, a benzodiazepine. Withdrawal symptoms do not occur.

Inhalants

Recreational inhalant use is especially popular among children and adolescents, who sniff a wide variety of products, including aerosols, spot removers, glues, lighter fluid, fire-extinguishing agents, bottled fuel gas, marker pens, paints, and gasoline. Compounds include aliphatic hydrocarbons such as *n*-hexane, aromatic hydrocarbons such as toluene, and halogenated hydrocarbons such as trichloroethylene; in addition, nitrous oxide is sniffed from whipped-cream dispensers and butyl or amyl nitrite from room odorizers. Despite such chemical diversity, desired subjective effects are similar to those of ethanol intoxication. Overdose can cause hallucinations, seizures, and coma; death has resulted from cardiac arrhythmia, accidents, and aspiration of vomitus. Symptoms tend to clear within a few hours, and treatment consists of respiratory and cardiac monitoring. There is no predictable abstinence syndrome other than craving.

Phencyclidine

Developed as an anesthetic, phencyclidine (PCP or "angel dust") was withdrawn because it caused psychosis. As a recreational drug, it is usually smoked. The related agents ketamine, dextromethorphan, and methoxetamine are also used recreationally. Low doses of PCP cause euphoria or dysphoria and a feeling of numbness; with increasing intoxication, there is agitation, nystagmus, tachycardia, hypertension, fever, sweating, ataxia, paranoid or catatonic psychosis, hallucinations, myoclonus, rhabdomyolysis, seizures, coma, respiratory depression, and death. Treatment includes a calm environment with benzodiazepine sedation and restraints as needed, gastric suctioning, activated charcoal, forced diuresis, cooling, antihypertensives, anticonvulsants, and monitoring of cardiorespiratory and renal function. Neuroleptics, which can aggravate seizures, hypotension, and myoglobinuria, are best avoided. Symptoms can persist for hours or days. Psychic dependence to PCP occurs, but withdrawal signs are infrequent, usually consisting of nervousness, tremor, and upset stomach.

Anticholinergics

The recreational use of anticholinergics includes ingestion of the plant *Datura stramonium*, popular among American adolescents,

as well as use of antiparkinson drugs and the tricyclic antidepressant amitriptyline. Intoxication produces decreased sweating, fever, tachycardia, dry mouth, dilated unreactive pupils, and delirium with hallucinations. Severe poisoning causes myoclonus, seizures, coma, and death. Treatment includes intravenous (IV) physostigmine, 0.5 to 3 mg, repeated as needed every 30 minutes to 2 hours, plus gastric lavage, cooling, bladder catheterization, respiratory and cardiovascular monitoring, and, if necessary, anticonvulsants. Neuroleptics, which have anticholinergic activity, are contraindicated. There is no withdrawal syndrome.

COMPLICATIONS OF DRUG TOXIDROMES

Trauma

Trauma may be a consequence of a drug's acute effects, for example, automobile and other accidents during marijuana, inhalant, or anticholinergic intoxication; violence in psychostimulant or PCP users; and self-mutilation during hallucinogen psychosis. Trauma among users of illicit drugs, however, is most often the result of the illegal activities necessary to distribute and procure them. Overprescribing of sedatives is a major contributor to falls in the elderly.

Infection

Parenteral users of any drug are subject to an array of local and systemic infections, which in turn can affect the nervous system. Hepatitis leads to encephalopathy or hemorrhagic stroke. Cellulitis and pyogenic myositis produce more distant infection, including vertebral osteomyelitis with myelopathy or radiculopathy. Endocarditis, bacterial or fungal, leads to meningitis, cerebral infarction or abscess, and septic ("mycotic") aneurysm. Tetanus, often severe, affects drug injectors, and botulism occurs either at injection sites or, among cocaine snorters, in the nasal sinuses. Malaria affects heroin users in endemic areas. Anthrax has affected users of contaminated heroin.

Parenteral drug use is a major risk factor for human immunodeficiency virus (HIV) infection. Users are subject to the same neurologic complications that affect nondrug users, especially syphilis and tuberculosis, including drug-resistant forms. Because of promiscuity and associated sexually transmitted diseases, nonparenteral cocaine users are also at increased risk for AIDS. Heroin and cocaine are themselves immunosuppressants (heroin users were vulnerable to unusual fungal infections before the AIDS epidemic); yet, their use in HIV-seropositive individuals does not seem to accelerate the development of AIDS.

Progressive myelopathy occurs in parenteral drug users infected with either human T-lymphotropic virus (HTLV)-I or HTLV-II.

Seizures

Seizures are a feature of withdrawal from sedatives, including, infrequently, benzodiazepines. Methaqualone (no longer legally available in the United States) and glutethimide have reportedly caused seizures during intoxication. Opioids lower seizure threshold, but seizures are seldom encountered during heroin overdose. Myoclonus and seizures more often occur in meperidine users, a consequence of the active metabolite normeperidine. Seizures may occur in cocaine users without other evidence of overdose. In animals, repeated cocaine administration produces seizures in a pattern suggestive of kindling. Amphetamine and other psychostimulants are less epileptogenic than cocaine, but seizures did affect users of the no longer legal over-the-counter anorectic phenylpropanolamine. A case-control study found that marijuana was protective against the development of new-onset seizures.

Stroke

Illicit drug users frequently abuse ethanol and tobacco, increasing their risk for ischemic and hemorrhagic stroke. Parenteral drug users are subject to stroke through systemic complications such as hepatitis, endocarditis, and AIDS. Heroin users develop nephropathy with secondary hypertension, uremia, and bleeding. Heroin has also caused stroke in the absence of other evident risk factors, perhaps through immunologic mechanisms.

Amphetamine users are prone to intracerebral hemorrhage following acute hypertension and fever. They are also at risk for occlusive stroke secondary to cerebral vasculitis affecting either medium-sized arteries (resembling polyarteritis nodosa) or smaller arteries and veins (resembling hypersensitivity angiitis). Ischemic and hemorrhagic stroke is also a frequent consequence of cocaine use, regardless of route of administration. Most hemorrhagic strokes are probably consequent to acute surges of hypertension; most ischemic strokes are probably secondary to cocaine's vasoconstrictive actions on cervical and intracranial circulation. Cerebral saccular aneurysms and vascular malformations are often found in patients undergoing angiography for cocaine-related intracranial hemorrhage.

Because of their association with stroke, diet pills and decongestants containing phenylpropanolamine were banned by the U.S. Food and Drug Administration. Similar association led to a number of states banning dietary supplements containing ephedra. Intracerebral and subarachnoid hemorrhages are described in MDMA users.

Anecdotal and epidemiologic reports describe marijuana use as a risk factor for ischemic stroke. A population survey found that subjects who used marijuana at least weekly had 4.7 times the risk of stroke compared to nonusers. A proposed mechanism is reversible cerebral vasoconstriction. Stroke is also described in synthetic cannabinoid users.

LSD and PCP are vasoconstrictive, and occlusive and hemorrhagic strokes have followed their use.

Altered Mentation

Dementia in illicit drug users may be the result of concomitant ethanol abuse, malnutrition, head trauma, or infection. Parenteral drug users are at risk for HIV encephalopathy. Whether the drugs themselves cause lasting cognitive or behavioral change is more difficult to establish, for predrug mental status is nearly always uncertain and many drug users are probably self-medicating preexisting psychiatric conditions (eg, cocaine for depression).

Clinical studies describe significant impairments in working memory, verbal fluency, and "cognitive impulsivity" among users of opioids, including prescription opioids and methadone maintenance therapy. Functional imaging studies demonstrate reduced cerebral gray matter density, decreased white matter fractional anisotropy, and abnormal connectivity patterns.

Controversy exists over whether psychostimulants predispose to lasting depression or if PCP predisposes to schizophrenia.

In animals and humans, methamphetamine damages both dopaminergic and serotonergic nerve terminals, and MDMA destroys serotonin nerve terminals. Impaired memory is described in abstinent methamphetamine users, and among MDMA users followed prospectively, only a few years of use was associated with cognitive decline and abnormal fractional anisotropy in multiple brain areas.

Cocaine is not neurotoxic to axon terminals, and reports on the long-term cognitive effects of cocaine are conflicting. Studies of animals exposed to cocaine demonstrate structural brain abnormalities.

Clinical, imaging, and animal studies convincingly demonstrate that marijuana use, especially during adolescence, causes lasting behavioral and cognitive alteration. Long-term marijuana users demonstrate axonal microstructural alterations and volume reductions in brain regions rich in cannabinoid receptors. Epidemiologic studies provide persuasive evidence that marijuana is a significant risk factor for schizophrenia.

Sedatives can cause reversible dementia in the elderly and delayed learning in small children.

Lead encephalopathy is described in gasoline sniffers, and cerebral white matter lesions with dementia are described in toluene sniffers.

Fetal Effects

The effects of illicit drugs on intrauterine development are also difficult to separate from damage secondary to ethanol, tobacco, malnutrition, and inadequate prenatal care or home environment. Infants exposed in utero to heroin have reportedly been small for gestational age, at risk for respiratory distress, and cognitively impaired later in life.

Prenatal methamphetamine exposure is an independent risk factor for fetal growth restriction. A 10-year prospective study controlling for such confounders as additional drugs and environmental influences concluded that first-trimester cocaine exposure confers risk for reduced height, weight, and head circumference and for abnormal behavior. Reviews of studies addressing maternal cocaine use during pregnancy found convincing association with microcephaly, perinatal cerebral infarction, brain abnormalities on magnetic resonance diffusion tensor imaging, and reduced volumes of cortical gray matter. Animal studies demonstrate that in utero, cocaine exposure detrimentally affects learning.

Long-term cohort studies of in utero marijuana exposure have demonstrated impaired attention and memory and smaller head size. Animal studies show abnormal axonal connectivity.

Organic solvents are teratogenic in animals.

Miscellaneous Effects

Guillain-Barré–type neuropathy and *brachial* or *lumbosacral plexopathy*, probably immunologic in origin, have been associated with heroin use. (Brachial plexopathy has also resulted from septic aneurysm of the subclavian artery.) Severe sensorimotor polyneuropathy occurs in sniffers of glue containing *n*-hexane. *Myoglobinuria* and renal failure have followed use of heroin, amphetamine, cocaine, and PCP.

Myeloneuropathy, indistinguishable from cobalamin deficiency, occurs in nitrous oxide sniffers. Anemia is absent, and serum vitamin B_{12} levels are usually normal. The mechanism is inactivation of the cobalamin-dependent enzyme methionine synthetase.

Possibly vascular in origin, acute myelopathy occurs in parenteral heroin users.

Severe irreversible parkinsonism developed in Californians exposed to a meperidine analog contaminated with 1-methyl-4-phenyl-1,2,3,6-tetrahydropyridine, a metabolite of which is toxic to neurons in the substantia nigra. Symptoms responded to levodopa.

Dementia, *ataxia*, *quadriparesis*, *blindness*, and *death* occur in smokers of heroin pyrolysate ("chasing the dragon"). Autopsies show spongiform changes in the central nervous system white matter. The responsible toxin has not been identified.

Parenteral methcathinone users are subject to *extrapyramidal gait disturbance* and *hypophonia*, a consequence of hypermagnesemia following the use of potassium permanganate in the preparation of the drug.

Blindness developed in a heroin user whose mixture contained large quantities of quinine.

Chronic cocaine users experience *dystonia* and *chorea*, and cocaine can precipitate symptoms in patients with *Tourette syndrome*.

Marijuana inhibits luteinizing and follicle-stimulating hormones, causing *reversible impotence* and *sterility* in men and *menstrual irregularity* in women.

Ataxia and *cerebellar white matter* changes have occurred in toluene sniffers.

Hallucinogen users not only experience flashbacks but, in some cases, visual phenomena persist for years (*hallucinogen-persisting perception disorder*).

Cocaine is frequently adulterated with the immunomodulatory drug levamisole, complications of which include leukopenia, vasculitis, and leukoencephalopathy.

A common adulterant in the preparation of synthetic cannabinoids is the vitamin K anticoagulant brodifacoum. Intracranial hemorrhage is described in users.

SUGGESTED READINGS

Angoa-Pérez M, Annekin JH, Kuhn DM. Neurotoxicology of synthetic cathinone analogs. *Curr Top Behav Neurosci*. 2017;32:209-230.

Baldacchino A, Balfour DJK, Passetti F, Humphris G, Matthews K. Neuropsychological consequences of chronic opioid use: a quantitative review and meta-analysis. *Neurosci Biobehav Rev*. 2012;36:2056-2068.

Battistella G, Fornari E, Annoni JM, et al. Long-term effects of cannabis on brain structure. *Neuropsychopharmacology*. 2014;39(9):2041-2048.

Bolla KI, Brown K, Eldreth D, Tate K, Cadet JL. Dose-related neurocognitive effects of marijuana use. *Neurology*. 2002;59:1337-1343.

Bowen LL, McRae-Clark A. Therapeutic benefit of smoked cannabis in randomized placebo-controlled studies. *Pharmacotherapy*. 2018;38(1):80-85.

Broussard CS, Rasmussen SA, Reefhuis J, et al. Maternal treatment with opioid analgesics and risk for birth defects. *Am J Obstet Gynecol*. 2011;204:314.e1-314.e11.

Brust JCM. Cognition and cannabis: from anecdote to advanced technology. *Brain*. 2012;135(pt 7):2004-2005.

Brust JCM, ed. *Neurological Aspects of Substance Abuse*. 2nd ed. Boston, MA: Butterworth-Heinemann; 2004.

Brust JCM. Seizures, illicit drugs, and ethanol. *Curr Neurol Neurosci Rep*. 2008;8:333-338.

Brust JCM. Spice, pot, and stroke. *Neurology*. 2013;81:2064-2065.

Brust JCM. Stroke and substance abuse. In: Grotta JC, Albers GW, Broderick JP, et al, eds. *Stroke: Pathophysiology, Diagnosis, and Management*. 6th ed. Philadelphia, PA: Elsevier; 2016:648-657.

Brust JCM. Substance abuse and movement disorders. *Mov Disord*. 2010;25:2010-2020.

Buckingham-Howes S, Berger SS, Scaletti LA, Black MM. Systematic review of prenatal cocaine exposure and adolescent development. *Pediatrics*. 2013;131:e1917-e1937.

Cascio MJ, Jen K-Y. Cocaine/levamisole-associated autoimmune syndrome: a disease of neutrophil-mediated autoimmunity. *Curr Opin Hematol*. 2018;25:29-36.

Cohen K, Weinstein AM. Synthetic and non-synthetic cannabinoid drugs and their adverse effects—a review from public health prospective. *Front Public Health*. 2018;6:162.

Corazza O, Schifano F, Simonato P, et al. Phenomenon of new drugs on the internet: the case of ketamine derivative methoxetamine. *Hum Psychopharmacol*. 2012;27:145-149.

de Win MM, Jager G, Booij J, et al. Sustained effects of ecstasy on the human brain: a prospective neuroimaging study in novel users. *Brain*. 2008;131(pt 11): 2936-2945.

Dos Santos JF, Cavalcante CMB, Barbossa FT, et al. Maternal, fetal and neonatal consequences associated with the use of crack cocaine during the gestational period: a systematic review and meta-analysis: *Arch Gynecol Obstet*. 2018;298:487-503.

Frazer KM, Richards Q, Keith DR. The long-term effects of cocaine use on cognitive functioning: a systematic critical review. *Behav Brain Res*. 2018;348: 241-262.

Freeman MJ, Rose DZ, Myers MA, Gooch CL, Bozeman AC, Burgin WS. Ischemic stroke after use of the synthetic marijuana "spice." *Neurology*. 2013;81: 2090-2093.

Fried PA, Smith AM. A literature review of the consequences of prenatal marihuana exposure. An emerging theme of a deficiency in aspects of executive function. *Neurotoxicol Teratol*. 2001;23:1-11.

Gaston TE, Szaflarski JP. Cannabis for the treatment of epilepsy: an update. *Curr Neurol Neurosurg Rep*. 2018;18:73.

Grant BF, Saha TD, Ruan WJ, et al. Epidemiology of DSM-5 drug use disorder: results from the National Epidemiologic Survey on Alcohol and Related Conditions-III. *JAMA Psychiatry*. 2016;73(1):39-47.

Grant KS, Petroff R, Isoherranen N, Stella N, Burbacher TM. Cannabis use during pregnancy: pharmacokinetics and effects on child development. *Pharmacol Ther*. 2018;182:133-151.

Grund JP, Latypov A, Harris M. Breaking worse: the emergence of krokodil and excessive injuries among people who inject drugs in Eurasia. *Int J Drug Policy*. 2013;24:265-274.

Gwira Baumblatt JA, Weideman C, Dunn R, Schaffner Q, Paulozzi LJ, Jones TF. High-risk use by patients prescribed opioids for pain and its role in overdose deaths. *JAMA Intern Med*. 2014;174(5):796-801.

Hanczaruk M, Reischl U, Holzmann T, et al. Injectional anthrax in heroin users, Europe, 2000–2012. *Emerg Infect Dis*. 2014;20(2):322-323.

Hemachandra D, McKetin R, Cherbuin N, Anstey KJ. Heavy cannabis users at elevated risk of stroke: evidence from a general population survey. *Aust N Z J Public Health*. 2018;40(3):226-230.

Hermle L, Simon M, Ruchsow M, Geppert M. Hallucinogen-persisting perception disorder. *Ther Adv Psychopharmacol*. 2012;2:199-205.

Iversen L, White M, Treble R. Designer psychostimulants: pharmacology and differences. *Neuropharmacology*. 2014;87:59-65.

Johanson CE, Frey KA, Lundahl LH, et al. Cognitive function and nigrostriatal markers in abstinent methamphetamine abusers. *Psychopharmacology (Berl)*. 2006;185:327-338.

Karila L, Marillier M, Chaumette B, Billieux J, Franchitto N, Benyamina A. New synthetic opioids: part of a new addiction landscape. *Neurosci Biobehav Rev*. 2019;106:133-140.

Kaufman MJ, Levin JM, Ross MH, et al. Cocaine-induced cerebral vasoconstriction detected in humans with magnetic resonance angiography. *JAMA*. 1998;279:376-380.

Kelkar AH, Smith MA, Martial A, et al. An outbreak of synthetic cannabinoid-associated coagulopathy in Illinois. *N Engl J Med*. 2018;379:1216-1223.

Khattak S, K-Moghtader G, McMartin K, Barrera M, Koren G. Pregnancy outcome following gestational exposure to organic solvents: a prospective controlled study. *JAMA*. 1999;281:1106-1109.

Koppel B, Brust JCM, Fife T, et al. Systematic review: efficacy and safety of medical marijuana in selected neurologic disorders. Report of the Guideline Development Subcommittee of the American Academy of Neurology. *Neurology*. 2014;82:1556-1563.

Kosten TR, O'Connor PG. Management of drug and alcohol withdrawal. *N Engl J Med*. 2003;348:1786-1795.

Kriegstein AR, Shungu DC, Millar WS, et al. Leukoencephalopathy and raised brain lactate from heroin vapor inhalation ("chasing the dragon"). *Neurology*. 1999;53:1765-1773.

Larocque A, Hoffman RS. Levamisole in cocaine: unexpected news from an old acquaintance. *Clin Toxicol (Phila)*. 2012;50:231-241.

Levine SR, Brust JCM, Futrell N, et al. Cerebrovascular complications of the use of the "crack" form of alkaloidal cocaine. *N Engl J Med*. 1990;323: 699-704.

Lineberry TW, Bostwick JM. Methamphetamine abuse: a perfect storm of complications. *Mayo Clin Proc*. 2006;81:77-84.

Mattick RP, Kimber J, Breen C, Davoli M. Buprenorphine maintenance versus placebo or methadone maintenance for opioid dependence. *Cochrane Database Syst Rev*. 2014;(3):CD002207.

Meier MH, Caspi A, Ambler A, et al. Persistent cannabis users show neuropsychological decline from childhood to midlife. *Proc Natl Acad U S A*. 2012;109(40):E2657-E2664.

Murphy PN, Wareing M, Fisk JE, Montgomery C. Executive working memory deficits in abstinent ecstasy/MDMA users: a critical review. *Neuropsychobiology*. 2009;60:159-175.

Ng SKC, Brust JCM, Hauser WA, Susser M. Illicit drug use and the risk of new-onset seizures. *Am J Epidemiol*. 1990;132:47-57.

Pacher P, Steffens S, Haskó G, Schindler TH, Kunos G. Cardiovascular effects of marijuana and synthetic cannabinoids: the good, the bad, and the ugly. *Nat Rev Cardiol*. 2018;15:151-166.

Paul ABM, Simms L, Amini S, Paul AE. Teens and spice: a review of adolescent fatalities associated with synthetic cannabinoid use. *J Forensic Sci*. 2018;63:1121-1124.

Pujol J, Blanco-Hinojo L, Batalla A, et al. Functional connectivity alterations in brain networks relevant to self-awareness in chronic cannabis users. *J Psychiatric Res*. 2014;51:68-78.

Qiu Y, Jiang G, Su H, et al. Progressive white matter microstructure damage in male chronic heroin dependent individuals: a DTI and TBSS study. *PLoS One*. 2013;8(5):e63212.

Rech MA, Donahey E, Cappiello Dziedzic JM, Oh L, Greenhalgh E. New drugs of abuse. *Pharmacotherapy*. 2015;35:189-197.

Richardson GA, Goldschmidt L, Larkby C, Day NL. Effects of prenatal cocaine exposure on child behavior and growth at 10 years of age. *Neurotoxicol Teratol*. 2013;40:1-8.

Rosenbaum CD, Carreiro SP, Babu KM. Here today, gone tomorrow . . . and back again? A review of herbal marijuana alternatives (K2, Spice), synthetic cathinones (bath salts), Kratom, Salvia divinorum, methoxetamine, and piperazines. *J Med Toxicol*. 2012;8:15-32.

Smith LM, LaGrasse LL, Derauf C, et al. The infant development, environment, and lifestyle study: effects of prenatal methamphetamine exposure, polydrug exposure, and poverty on intrauterine growth. *Pediatrics*. 2006;118:1149-1156.

Spronk DB, van Wel JHP, Ramaekers JG, Verkes RJ. Characterizing the cognitive effects of cocaine: a comprehensive review. *Neurosci Biobehav Rev*. 2013;37:1838-1850.

Stepens A, Logina I, Liguts V, et al. A parkinsonian syndrome in methcathinone users and the role of manganese. *N Engl J Med*. 2008;358:1009-1017.

Tarabar AF, Nelson LS. The gamma-hydroxybutyrate withdrawal syndrome. *Toxicol Rev*. 2004;23:45-49.

Torres-Moreno MC, Papaseit E, Torrens M, Farré M. Assessment of efficacy and tolerability of medicinal cannabinoids in patients with multiple sclerosis: a systematic review and meta-analysis. *JAMA Netw Open*. 2018;1:e183485.

Tortoriello G, Morris CV, Alpar A, et al. Miswiring the brain: Δ-9-tetrahydrocannabinol disrupts cortical development by inducing an SCG10/stathmin-2 degradation pathway. *EMBO J*. 2014;33:668-685.

Vadivelu N, Kai AM, Kodumundi V, Sramcik J, Kaye AD. The opioid crisis: a comprehensive overview. *Curr Pain Headache Rep*. 2018;22:16.

van Winkel R, Kuepper R. Epidemiological, neurobiological, and genetic clues to the mechanisms linking cannabis use to risk for nonaffective psychosis. *Annu Rev Clin Psychol*. 2014;10:767-791.

Volkow ND, Baler RD, Compton WM, Weiss SRB. Adverse health effects of marijuana use. *N Engl J Med*. 2014;370:2219-2227.

Volkow ND, Benveniste H, McLellan AT. Use and misuse of opioids in chronic pain. *Annu Rev Med*. 2018;69:451-465.

Wang Y, Zhu J, Li Q, et al. Altered fronto-striatal and fronto-cerebellar circuits in heroin-dependent individuals: a resting-state FMRI study. *PLoS One*. 2013;8(3):e58098.

Weiner WJ, Rabinstein A, Levin B, Weiner C, Shulman LM. Cocaine-induced persistent dyskinesias. *Neurology*. 2001;56:964-965.

Westover AN, McBride S, Haley RW. Stroke in young adults who abuse amphetamines or cocaine: a population-based study of hospitalized patients. *Arch Gen Psychiatry*. 2007;64:495-502.

Wolff V, Armspach JP, Lauer V, et al. Cannabis-related stroke: myth or reality? *Stroke*. 2013;44:558-563.

Wolff V, Jouanjus E. Strokes are possible complications of cannabinoids use. *Epilepsy Behav*. 2017;70(pt B):355-363.

Zvosec D, Smith SW, McCutcheon JR, Spillane J, Hall BJ, Peacock EA. Adverse events, including death, associated with the use of 1,4-butanediol. *N Engl J Med*. 2001;344:87-94.

Neurotoxicology 133

Christopher Zammit and Stephan A. Mayer

KEY POINTS

1. Xenobiotics are substances within an organism that are not usually found in or produced by that organism.
2. Anticholinergic intoxication produces flushed skin, anhidrosis, delirium, and urinary retention, among other symptoms.
3. Serotonin syndrome causes tremor, ocular and extremity clonus, hyperreflexia, agitation, or diaphoresis after a serotoninergic agent is introduced.
4. Neuroleptic malignant syndrome causes mental status changes, muscular rigidity, hyperthermia, and autonomic disturbances.
5. Benzodiazepines are the preferred treatment for toxin-induced seizures.

INTRODUCTION

Xenobiotics are substances within an organism that are not normally found in or produced by that organism. *Neurotoxicology* refers to the adverse effects of xenobiotics, or poisons, on the nervous system. This is a massive field with well over 350 documented neurotoxic xenobiotics. To facilitate digestibility and clinical use of the topic, this chapter focuses on acute neurotoxicology. Chronic neurotoxic associations and syndromes are listed and briefly described. Neurotoxicology with reference to neurodevelopment, withdrawal syndromes, and psychiatric disorders, such as psychosis and mood disorders, are minimally discussed.

Xenobiotics can include medications; industrial chemicals such as heavy metals, air pollution, solvents, and vapors; substances produced by other organisms (eg, marine toxins, snake venom); food additives; herbal products and botanicals; recreational drugs; and insecticides, herbicides, rodenticides, and other household products. Acute neurotoxic events have been better described and causational links are more convincing. Neurotoxic effects from chronic exposures are more challenging to prove because the clinical symptoms may be temporally distant from the exposure or the concentration of the xenobiotic in the organism is so low that it may be difficult to detect.

EPIDEMIOLOGY

The specific incidence, prevalence, and demographics of specific neurotoxins, where available, are mentioned individually in the following sections. Age, gender, and certain comorbidities have been associated with the occurrence and severity of various toxicity syndromes.

Clinical toxicity is more commonly seen in older patients for several reasons. Age-related decrements in renal and hepatic function impair the ability to clear and eliminate xenobiotics. Reductions in neuronal quantity increase the sensitivity to the presence of xenobiotics. Finally, changes in mitochondrial function are known to occur with advanced age, increasing the possibility of excitotoxicity.

Gender has been associated with certain clinical manifestations in the setting of xenobiotics. Bruxism and dystonia are more prevalent in males, whereas tardive dyskinesia and parkinsonism are more frequently observed in females.

Comorbidities can increase the risk of neurotoxicity if they impair elimination of the xenobiotic (eg, renal insufficiency or cirrhosis) or facilitate its entry into the central nervous system (CNS) via disturbance of the blood-brain barrier (eg, meningitis, encephalitis). The presence of or prior exposure to other nonneurotoxic xenobiotics (eg, prescription medications) can influence the relative neurotoxicity of a xenobiotic by impairing its metabolism or elimination; hastening its conversion to a neurotoxic metabolite; and altering gene expression, neurotransmitter production, release, breakdown, and neurotransmitter receptor density or function. Efflux transporters on the blood-brain barrier, such as P-glycoproteins and organic acid transport proteins, are typically responsible for shuttling xenobiotics out of the CNS. Some medications and conditions are known to inhibit the function of P-glycoproteins (Table 133.1), increasing the concentration of the neurotoxic xenobiotics in the CNS. Some nutrition inadequacies, such as heavy metal deficiencies, can enhance the uptake of neurotoxic xenobiotics. Lastly, some neurologic disorders can be unmasked with the introduction of a xenobiotic (Table 133.2).

TABLE 133.1 Selected P-glycoprotein Inhibitors and Inducers

Inhibitors	Inducers
• Amiodarone	• Avasimibe
• Ceftriaxone	• Carbamazepine
• Clarithromycin, erythromycin	• Clotrimazole
• Cyclosporine	• Phenytoin
• Diltiazem	• Phenobarbital
• Hydrocortisone	• Rifampin
• Ketoconazole, itraconazole	• St. John's wort
• Nicardipine	• Tipranavir/ritonavir
• Propranolol	• Prazosin
• Ritonavir, saquinavir, nelfinavir	• Progesterone
• Tamoxifen	
• Tacrolimus	
• Verapamil	

TABLE 133.2 Neurologic Disorders Unmasked by Xenobiotics

Xenobiotic	Neurologic Disorder
Aminoglycosides	Myasthenia gravis
Vincristine	Charcot-Marie-Tooth
Antiretrovirals	Human immunodeficiency virus–related peripheral neuropathy

PATHOBIOLOGY

For neurotoxicity to occur, a xenobiotic must come into contact with the nervous system. CNS toxicity occurs when certain xenobiotics cross the blood-brain barrier via endocytosis, transport proteins, or diffusion. Lipophilic xenobiotics gain entry via diffusion, whereas hydrophilic ones must engage with one of the two other mechanisms.

Neurotoxicity occurs through a variety of mechanisms that are summarized in Table 133.3. The most elusive mechanism to associate with a xenobiotic are those that alter gene expression because the appearance of clinical toxicity may not occur until the xenobiotic has been eliminated from the system. *Excitotoxicity* is a common end point for several of the neurotoxic xenobiotics whether it is through activation of excitatory pathways or via retarded energy production, which leads to metabolic failure in the setting of neuroexcitation.

Neurotoxicity can manifest pathophysiologically as central or peripheral demyelination, neuronal death, clinical syndromes related to the activation or inhibition of neurotransmitter pathways, or impaired function due to disrupted neuronal or glial processes.

CLINICAL FEATURES

Neurotoxic presentations are protean and may include seizures or status epilepticus, ataxia, tremor, encephalopathy, movement disorders, peripheral neuropathies, lethargy, stupor, coma, cognitive impairment, neuropsychiatric behavioral disturbances, or diffuse weakness. Lateralization of neurologic deficits is uncommon unless the toxicity is unmasking a prior neurologic insult.

Seizures are a not uncommon neurotoxic presentation. Table 133.4 lists some xenobiotics known to cause seizures. A variety of movement disorders have been reported to be caused by xenobiotics, including dyskinesias, akathisia, chorea, parkinsonism, dystonias, myoclonus, and asterixis (Table 133.5). Tremors associated with xenobiotics, which can be resting, sustention, or kinetic, are summarized in Table 133.6. Medications and toxins known to cause ataxia are listed in Table 133.7. Cranial and/or peripheral neuropathies can be the result of demyelination, axonal injury, or failed transmission at the neuromuscular junction (NMJ) or of the action potential and present with diffuse weakness, autonomic dysfunction, and/or sensory disturbances. Tables 133.8 and 133.9 summarize xenobiotics associated with each of these mechanisms. Lastly, Table 133.10 lists xenobiotics associated with myopathies, which present with diffuse myalgias and weakness.

TABLE 133.3 Mechanisms of Neurotoxicity

Cellular	Membrane	Cellular Signaling
• Oxidative injury/ neuroexcitation	• Disrupted ion homeostasis	• Altered neurotransmitter production, release, metabolism, or uptake
• Disturbed energy production	• Antagonism/ agonism of ion channels	• Blunted or exaggerated neurotransmitter receptor activation
• Altered gene expression or transcription		• Mimics neurotransmitter, stimulating receptor
• Altered protein function or structure		

DIAGNOSIS

Many of the neurotoxic xenobiotics or their metabolites can be detected in the serum, urine, or other body tissues or fluids. Of note, the detection of a neurotoxic xenobiotic should not universally lead the clinician to conclude that it is the culprit for the clinical complaint or ailment. The clinical symptoms should be consistent with a well-documented neurotoxicity or syndrome in a patient with a known exposure to the toxin. Otherwise, a neurotoxin can be suspected to be the cause of the clinical symptoms, but other etiologies should be excluded. Improving symptoms in the setting of neurotoxin elimination serves to increase confidence in the diagnosis of neurotoxicity. Additional diagnostic clues can be obtained when certain odors are perceived that are suggestive of a particular xenobiotic (Table 133.11).

TREATMENT

In any acute neurotoxic presentation, the first steps are to rule out hypoglycemia and remove the victim from the exposure. If the toxin is on the patient's clothing or skin, they should be promptly decontaminated. Health care workers should employ universal precautions when approaching such patients to prevent self-exposure. Entry into an enclosed environment should be delayed until decontamination can be performed to not poison other patients or health care providers. If providing glucose, *thiamine* 100 mg intravenous (IV) should be considered prior to doing so as to not induce Korsakoff syndrome in those with a (relative) thiamine deficiency. In hypopneic or apneic patients with miotic pupils, *naloxone* 0.4 to 2.0 mg IV can be administered to reverse a potential opiate overdose.

The core components of treating any neurotoxic presentation include reducing absorption of the toxin, enhancing its elimination, provision of an antidote, and supportive care. Performing gastric lavage, administering activated charcoal, and/or providing whole bowel irrigation has the potential to reduce the absorption of an ingested xenobiotic.

Gastric lavage has largely become antiquated because it is resource intensive, often requires endotracheal intubation, and has not been objectively shown to be beneficial. However, it still has a role in the hyperacute ingestions (within 1 h) of highly toxic substances that are not effectively absorbed by activated charcoal and do not have an effective antidote. Due to the risk for inadvertent aspiration, hydrocarbons and alkaline caustics should not be lavaged.

TABLE 133.4 Xenobiotics Known to Induce Seizures[a]

Xenobiotic Category	Specific Agents
Antihistamines	**Diphenhydramine**, doxylamine
Anticholinergics	Benztropine mesylate, scopolamine
Antibiotics	**Isoniazid**, β-lactams (penicillins, cephalosporins, carbapenems), ciprofloxacin
Antivirals	Acyclovir, valacyclovir, amantadine
Antimalarials	**Chloroquine**, mefloquine, pyrimethamine
Nonsteroidal anti-inflammatories	Mefenamic acid, phenylbutazone (veterinary NSAID), ibuprofen, naproxen, salicylates
Opioids	*Meperidine*, propoxyphene, tramadol
Local anesthetics	Bupivacaine, lidocaine, procaine, tetracaine
Antiepileptics	Phenytoin, carbamazepine, valproic acid, ethosuximide
Antineoplastics	Bleomycin, busulphan, carmustine, chlorambucil, cisplatin, cytarabine, mechlorethamine, methotrexate, vinblastine, vincristine
Antidepressants	***Bupropion***, fluoxetine, maprotiline, mianserin, trazodone
Tricyclic antidepressants	All of them
Antipsychotics, mood stabilizers	All antipsychotics, especially *chlorpromazine*, *clozapine*, and *phenothiazines*, lithium
Stimulants	Methylphenidates, pemoline
Antiemetics	*Prochlorperazine*, metoclopramide, *promethazine*, droperidol
Cardiovascular drugs	Propranolol, flecainide, digoxin
Ergotamines	Dihydroergotamine, ergotamine
Methylxanthines	Caffeine, **theophylline**
Other medications	Levodopa, baclofen, levothyroxine, allopurinol, bromocriptine, colchicine, corticosteroids
Alcohols	Ethylene glycol, methanol
Recreational drugs	Cocaine, MDMA (ecstasy or molly), amphetamines, phencyclidine, nicotine
Rodenticides	**TETS**, thallium, zinc phosphide, arsenic
Pesticides/insecticides	Pyrethrins (insecticides), organochlorines (eg, lindane), organic phosphorus compounds (eg, malathion)
Botanicals	**Cicutoxin** (water hemlock), picrotoxin (*Anamirta cocculus*, plant and performance enhancers), ackee fruit, daphne, rhododendrons
Heavy metals	Thallium, arsenic, copper, lead, nickel, manganese
Household and industrial toxins	Carbon monoxide, **camphor**, cyanide, fluoride, phenols (eg, paint strippers), 1,4-dichlorobenzene (eg, mothballs), **monomethylhydrazine (rocket fuel)**, carbon disulfide, hydrogen sulfide, methyl bromide, triazine, various hydrocarbons, chlorophenoxy herbicides
Ingestion	Domoic acid (amnestic shellfish poisoning), **ciguatera** (moray eels, barracuda, red snapper), tetrodotoxin (puffer fish species, blue-ringed octopus, horseshoe crab), **gyromitrin (*Gyromitra* fungus species)**, herbals (lobelia, passion flower, periwinkle, wormwood, *Galega*, mandrake, jimson weed)
Envenomations	Pit viper, tick bite, scorpion

Abbreviations: MDMA, 3,4-methylenedioxymethamphetamine; NSAID, nonsteroidal anti-inflammatory drug; TETS, tetramethylenedisulfotetramine.
[a]The **xenobiotics** in **bold** are reported to have caused status epilepticus, and those in *italics* frequently cause seizures. **Strychnine poisoning** causes nonepileptic convulsions and is intentionally excluded from these lists.

TABLE 133.5 Movement Disorders Associated With Xenobiotics

Chorea	Myoclonus	Reversible Parkinsonism	Irreversible Parkinsonism
• Anticholinergics	• Anticholinergics	• Carbon disulfide	• Calcium channel blockers
• Antiepileptics	• Antiepileptics	• Carbon monoxide	• Chemotherapeutics (several)
• Levodopa	• Sedatives/hypnotics	• Copper	• Cyclosporine
• Amantadine	• Bismuth	• Cyanide	• Antipsychotics
• Bromocriptine	• Ethanol	• Heroin	• Antiemetics
• Carbon monoxide	• Lead	• Manganese	• Sertraline
• Corticosteroids	• Levodopa	• MPTP	• Valproate
• Dopamine antagonists	• Mercury		• Trazodone
• Toluene	• Tricyclic antidepressants		• Progesterone
• Sympathomimetics			• Kava-kava
• Oral contraceptives			
• Lithium			
Dyskinesia	**Akathisia**	**Dystonia**	
• Antidopaminergics	• Antidepressants	• Anticholinergics	
• Calcium channel blockers	• Antidopaminergics	• Dopamine antagonists	
	• Calcium channel blockers	• Levodopa	
	• Tetrabenazine		
	• AMPT		

Abbreviations: AMPT, α-methyl-p-tyrosine; MPTP, 1-methyl-4-phenyl-1,2,3,6-tetrahydropyridine.

TABLE 133.6 Xenobiotics Associated With Tremors

Resting Tremor	Sustention Tremor	Kinetic Tremor
• Hypoglycemics	• Amiodarone	• Amiodarone
• Calcium channel blockers	• Hypoglycemics	• Hypoglycemics
• Antidopaminergics	• Methylxanthines	• Sedative/hypnotics
• Carbon disulfide	• Carbon disulfide	• Carbamazepine
• Carbon monoxide	• Carbon monoxide	• Colistin
• Captopril	• Antidopaminergics	• Lithium
• Lithium	• Sympathomimetics	• Phenytoin
• Manganese	• MAOIs	• Valproic acid
• Methanol	• TCAs	
• MPTP	• Ethanol	
• Phenytoin	• Sedative/hypnotics	
• Tetrabenazine	• Phenytoin	
	• Valproic acid	
	• Phencyclidine	
	• Corticosteroids	
	• Arsenic, lead	
	• Lithium	
	• Levodopa	

Abbreviations: MAOIs, monoamine oxidase inhibitors; MPTP, 1-methyl-4-phenyl-1,2,3,6-tetrahydropyridine; TCAs, tricyclic antidepressants.

Similarly, the use of activated charcoal has decreased over the years because published evidence has failed to demonstrate appreciable efficacy. It is not to be used in those with a depressed level of consciousness, at risk for aspiration, and after some ingestions (Table 133.12). Whole bowel irrigation can be considered in those with an ingestion of a highly toxic sustained-release medication or xenobiotics that are not absorbed by activated charcoal.

Options for enhanced elimination include the provision of hemodialysis, hemoperfusion, urinary alkalinization, and rarely, exchange transfusion. The elimination of protein-bound xenobiotics is not appreciably enhanced with dialysis.

TABLE 133.7 Medications and Toxins Associated With Ataxia

- **Antiepileptics:** phenytoin, carbamazepine, oxcarbazepine, gabapentin, levetiracetam, lamotrigine, valproate sodium
- **Antineoplastic agents:** cytarabine, methotrexate, 5-fluorouracil, asparaginase
- **Heavy metals:** methylmercury, arsenic, lead, thallium, manganese
- **Lithium**
- **Hydrocarbons:** toluene, benzene, *n*-hexane, carbon tetrachloride
- **Sedatives/hypnotics:** benzodiazepines, barbiturates, ethanol
- **Amiodarone**
- **Carbon disulfide**
- **Cyclosporine**
- **Tacrolimus**
- **Metronidazole**
- **Bismuth**
- **High-dose corticosteroids**

Table 133.13 summarizes some neurotoxins and their antidotes. Benzodiazepines are the preferred treatment for neurotoxin-induced seizures. Ion channel dysfunction is a not uncommon mechanism for several of the seizure-inducing neurotoxins, which may be made worse with the administration of many of the commonly used antiepileptics (eg, phenytoin or valproic acid).

OUTCOME

Outcomes following a neurotoxin exposure are dependent on the pathophysiology of the neurotoxic insult. Mechanisms that lead to neuronal injury or death are more likely to produce permanent deficits than mechanisms that interfere with the functioning of neurotransmitters or cell signaling. In some circumstances, toxins that alter cell signaling or action potential propagation can lead to permanent changes in the structure, function, or density of neurotransmitter receptors or ion channels, increasing the possibility of lasting effects. Many of the toxicities are dependent on the peak concentration of the toxin in the patient and its concentration over time. Clinical outcomes can be worsened with delays in toxic elimination or the provision of an antidote. Reexposure tends to produce exponentially severe clinical symptoms, which are more likely to be permanent.

COMMON NEUROTOXIDROMES

Neurotoxins with similar mechanisms of action typically produce distinct syndromes that allow for their clinical recognition and commonalities in their treatment. This section summarizes several syndromes, provides lists of known culprit neurotoxins, outlines treatment options, and describes their expected clinical outcomes.

Anticholinergic Toxicity

Approximately 20,000 patients are exposed to anticholinergic xenobiotics per year. This is likely an underestimate because this only accounts for the recognized and reported cases. To be specific, these substances have antimuscarinic properties that produce their characteristic clinical symptoms. Xenobiotics with antinicotinic actions are separate and distinct from those mentioned here. Hundreds of medications have anticholinergic properties, which places many patients at risk for subtle toxicities that may manifest in mild behavioral or cognitive disturbances.

Clinical Features

Clinical symptoms of anticholinergic toxicity are summarized in Table 133.14 and are secondary to antimuscarinic actions. Patients rarely have all of the associated symptoms; tachycardia and dry mucous membranes are the most commonly seen. The most severe exposures produce hyperthermia, coma, and/or seizures. Xenobiotics with antimuscarinic activity are summarized in Table 133.15. Note that ophthalmic drops are absorbed systemically and therefore can produce anticholinergic symptoms in the setting of liberal administration. Additionally, recreational drugs have been contaminated with anticholinergic adulterants on more than one occasion (eg, heroin tainted with scopolamine).

Treatment

Treatment is largely supportive. Hyperthermia should be rapidly corrected with conductive and evaporative measures. Agitation and

TABLE 133.8 Neuropathies Associated With Xenobiotics

Xenobiotic	Acute			Subacute/Chronic			Cranial Nerve
	Sens	Motor	Aut	Sens	Motor	Aut	
5-Fluorouracil				My	My	My	
Acrylamide				Ax	Ax		
Allyl chloride				Ax	Ax		
Amiodarone				My	My		II, III
Ammonia							II
Amphotericin B				My	My	My	
Arsenic	My	My		Ax	Ax		
Buckthorn				My	Ax, My	My	
Carbon disulfide				Ax	Ax		
Cisplatin							II
Clioquinol							II
Colchicine				Ax			
Cyclosporine				My	My	My	
Dapsone					Ax		
Deferoxamine							II
Diethylene glycol				My	My	My	II, III, VI, VII, VIII
Dimethyl mercury							II
Disulfiram				Ax	Ax		
Ethambutol				Ax			
Ethanol					Ax		
Ethionamide				Ax			
Ethylene glycol							V, VII, VIII, IX, X
Ethylene oxide				Ax	Ax		
Fludarabine				My	My	My	
Glutethimide				Ax			
Gold				Ax, My	Ax, My		
Hexacarbons	Ax	Ax	Ax	Ax	Ax		
Hydralazine				Ax	Ax		
Hydrogen sulfide							I
Hydroxychloroquine				Ax	Ax	Ax	
Interferon-α				Ax, My	Ax, My	Ax, My	II, III
Isoniazid				Ax	Ax		
L-Tryptophan				My	My	My	
Levamisole				My	My	My	
Linezolid				Ax	Ax	Ax	
Lithium							VI
MDMA							VI
Mercury					Ax		
Methanol				Ax	Ax	Ax	II
Methotrexate				My	My	My	II
Methyl bromide				Ax	Ax		
Methyl iodide							II, III
Metronidazole				Ax	Ax		
Misonidazole				Ax	Ax		
Nitrofurantoin				Ax	Ax		

(table continues on page 1324)

TABLE 133.8 Neuropathies Associated With Xenobiotics *(continued)*

Xenobiotic	Acute			Subacute/Chronic			Cranial Nerve
	Sens	Motor	Aut	Sens	Motor	Aut	
Nitroglycerin							VI
Nitrous oxide				Ax, My	My	My	
Nucleoside analogs				Ax	Ax	Ax	
OPCs				Ax	Ax		
Oxaliplatin				Ax	Ax	Ax	II, V, VI
Phenytoin				Ax	Ax		
Polychlorinated biphenyls				Ax	Ax		
Procainamide				My	My	My	
Pyridoxine	Ax						
Quinine							II, VIII
Salicylates							VIII
Solvents							II, VIII
Tacrolimus				My	My	My	
Taxol				Ax			
Thallium	Ax	Ax		Ax	Ax		III, IV, VI
TNF-α inhibitors				My	My	My	
Triorthocresyl phosphate	Ax	Ax					
Vacor	Ax		Ax	My	My	My	
Vincristine				Ax, My	Ax, My	My	V
Zinc				My	My	My	

Abbreviations: Aut, autonomic; Ax, axonopathy; MDMA, 3,4-methylenedioxymethamphetamine; My, myelinopathy; OPCs, organic phosphorus compounds; Sens, sensory; TNF, tumor necrosis factor.

seizures should be controlled with benzodiazepines such as *lorazepam* 2 to 4 mg IV repeated as needed. Antipsychotics should be avoided because they lower the seizure threshold and nearly all of them have antimuscarinic actions as well (see Table 133.15). Antiepileptics are typically not effective in the treatment of anticholinergic-induced seizures and their action on ion channels may increase the risk for cardiac arrhythmias. Status epilepticus is rarely the result of antimuscarinic toxicity; if present, other etiologies should be considered.

Physostigmine is an acetylcholinesterase (AChE) inhibitor that has been used to treat anticholinergic toxicity and is the only AChE inhibitor that crosses the blood-brain barrier. A dose of 0.02 mg/kg can be given over 5 minutes and repeated every 10 to 15 minutes. It has a rapid onset and short duration of action (~1 h). Extreme caution must be exercised when using physostigmine because it may produce symptoms of cholinergic toxicity, severe bradycardia, and even asystole. Anticholinergic toxicity is quite rarely fatal with supportive therapy; therefore, the use of physostigmine is rarely justified, given its associated risks. It is contraindicated in atrioventricular and intraventricular conduction delays and in tricyclic antidepressant toxicity.

Sympathomimetic Toxicity and Acute Excited State

The clinical presentation of patients with a toxin-induced excited delirium and those with sympathomimetic toxicity is largely indistinguishable. The risk factors, patient characteristics, and management are largely the same as well, so they are discussed together. Some pertinent idiosyncrasies of some of the xenobiotics are mentioned. Table 133.16 summarizes the various agents known to cause excited delirium.

Widespread use of prescription, botanical, and recreational stimulants and hallucinogens has brought the neurotoxic effects of these substances into daily clinical conversation. There are well over 100,000 presentations to emergency departments each year in the United States related to these xenobiotics. Their neurotoxic effects are exerted through manipulation of the mechanisms carried out by the central monoamine neurotransmitters (serotonin, norepinephrine, and dopamine). This includes increased neurotransmitter release, exaggerated effects at its postsynaptic receptor, decreased neurotransmitter breakdown, and receptor agonism or antagonism, among other mechanisms. In several cases, the culprit xenobiotic's effects are not isolated to one neurotransmitter or receptor, making their clinical manifestations less predictable and reliable.

Clinical Features

Clinically, these patients will present with hypervigilance, agitation, paranoia, hallucinations, stereotyping, dyskinesias, choreoathetoid movements, tachycardia, hypertension, mydriasis, and/or diaphoresis. More severe toxicity can cause delirium, combativeness, severe hyperthermia (>40°C), and seizures. Wide complex tachycardia can be seen in the setting of cocaine- (due to its sodium channel blockade) or rhabdomyolysis-induced hyperkalemia. The patient may have a depressed level of consciousness

TABLE 133.9 Neuromuscular Junction and Peripheral Nerve Action Potential Propagation Dysfunction Related to Xenobiotics

Xenobiotic	Presynaptic	Postsynaptic	Axonal Transmission
Aminoglycosides	X	X	
Azathioprine	X		
β-Adrenergic agonists	X	X	
Chloroquine	X	X	
Ciguatera toxin			X
Clindamycin	X	X	
Corticosteroids			
Crotaline venom	X		
D-Penicillamine		X	
Elapid snake venom	X		X
Gymnothoratoxin			X
Holocyclotoxin (tick paralysis)	X		X
Latrodectus mactans venom (black widow)	X		X
Lithium	X	X	
Magnesium	X		
Nicotine alkaloids		X	X
OPCs, carbamates		X	
Phenothiazines		X	
Phenytoin	X	X	
Polymyxins	X	X	
Procainamide	X	X	
Quinidine	X	X	
Saxitoxin			X
Scorpion venom			X
Tetrodotoxin			X
Trimethaphan		X	
Verapamil	X		

Abbreviation: OPCs, organic phosphorus compounds.

due to other coingested intoxicants. Diaphoresis is absent in anticholinergic toxicity, making this finding suggestive of excited delirium. However, it can be absent in sympathomimetic toxicity if the patient is volume depleted.

Diagnosis

Diagnosis is largely based on the clinical presentation and history. When the circumstances are unknown, the provider must exclude life-threatening, treatable etiologies, such as an intracranial hemorrhage, status epilepticus, or CNS infection. Urine drug screens are frequently performed, but they are fraught with false positives and negatives. Furthermore, a positive finding on a urine drug screen may be the result of a prior exposure and is not the cause of the patient's current symptoms. A basic metabolic panel should be obtained. Hyponatremia has been known to occur in 3,4-methylenedioxymethamphetamine ingestions causing status epilepticus.

TABLE 133.10 Xenobiotics Associated With Myopathy

Xenobiotic Category	Specific Agents
Antiretrovirals	Azidothymidine, zidovudine
Antibiotics	Penicillin, D-penicillamine, rifampin, sulfonamides
Antimalarials	Chloroquine, hydroxychloroquine
Lipid-lowering medications	Clofibrate, HMG-CoA reductase inhibitors (statins), niacin
Immunosuppressives and antineoplastics	Cyclosporine, vincristine, glucocorticoids (especially when combined with a neuromuscular blocker)
Other medications	Amiodarone, cimetidine, colchicine, doxylamine, ε-aminocaproic acid, ipecac, procainamide, propylthiouracil, suxamethonium (succinylcholine)
Recreational drugs	Ethanol, heroin, phencyclidine
Envenomations	Snakes: *Bothrops asper* (pit viper), *Agkistrodon* (pit viper), *Acanthophis* (elapid snakes), other crotaline snakes Spider: *Loxosceles* species (recluse spider)

Abbreviation: HMG-CoA, hydroxymethylglutaryl-coenzyme A.

Treatment

Treatment is largely supportive. Agitation should be treated with liberal *benzodiazepine* administration with the goal of minimizing muscle activity to prevent hyperthermia. Antipsychotics are not typically used to avoid administering drugs with anticholinergic actions that may increase the risk for seizures, delirium, and hyperthermia. If they are used, the *butyrophenones* (haloperidol, droperidol) are the best option, so long as the patient's QTc interval is normal. Antiepileptics are best avoided because these patients frequently have electrolyte abnormalities and are at higher risk for complications when they are given. Benzodiazepines, propofol, or barbiturates are preferred for seizure management. Hyperthermia must be avoided or rapidly corrected. IV hydration should be provided to prevent

TABLE 133.11 Smells and Odors Suggestive of Neurotoxic Xenobiotics

Odor or Smell	Xenobiotic
Mothballs	Camphor
Garlic	Organophosphates, arsenic, thallium
Peanuts	Vacor
Carrots	Cicutoxin (water hemlock)
Wintergreen	Methyl salicylates
Fruity	Chlorinated hydrocarbons
Glue	Solvents, toluene
Rotten eggs	DMSA, hydrogen sulfide
Shoe polish	Nitrobenzene

Abbreviation: DMSA, meso-2,3-dimercaptosuccinic acid.

TABLE 133.12 Xenobiotic Ingestions That Should Not Be Treated With Activated Charcoal

- Heavy metals (eg, lead, arsenic)
- Acids
- Alkalis
- Hydrocarbons
- Alcohols
- Inorganic ions (eg, lithium, fluoride, calcium)
- Oils

rhabdomyolysis-induced kidney injury and hyperkalemia. Cocaine-induced wide complex tachycardia may be treated with sodium bicarbonate. Persistent hypertension despite adequate sedation can be treated with *phentolamine* 5 mg IV repeated as needed or nitroglycerine IV 5 to 20 μg/min. β-Blockers are best avoided given the potential for worsened vasospasm due to unopposed α-agonist activity. With optimal acute management, outcomes are typically outstanding.

TABLE 133.13 Neurotoxins and Their Antidotes/Specific Treatments

Neurotoxin/Toxidrome	Antidote/Treatment
Arsenic, lead, mercury	Dimercaprol (BAL)
TCAs	Bicarbonate
Rattlesnake envenomation	CroFab antivenin
Serotonin syndrome	Cyproheptadine
Arsenic, lead, mercury	D-Penicillamine
NMS, sympathomimetic hyperpyrexia	Dantrolene
Iron	Cefuroxime
Digoxin	Digoxin-specific Fab
Lead	DMSA, EDTA
Methanol, ethylene glycol	Ethanol
Benzodiazepines	Flumazenil
Methanol, methotrexate	Folate/folinic acid
Ethylene glycol, methanol	Fomepizole
Cyanide, hydrogen sulfide	Hydroxycobalamin, sodium thiosulfate, sodium nitrite
Local anesthetics, TCAs	Intralipid 20%
Valproic acid	L-Carnitine
Black widow spider envenomation	Lactrodectus antivenin
Opioids	Naloxone
Anticholinergics	Physostigmine
Organophosphates, carbamates	2-PAM
Isoniazid, monomethylhydrazine, ethylene glycol	Pyridoxine

Abbreviations: 2-PAM, pralidoxime; BAL, British anti-Lewesite; DMSA, meso-2,3-dimercaptosuccinic acid; EDTA, ethylenediaminetetraacetic acid; NMS, neuroleptic malignant syndrome; TCAs, tricyclic antidepressants.

Cholinergic Toxicity: Organophosphates and Carbamates

Organophosphates (OPs) and carbamates are AChE inhibitors that have been recognized and used since the mid-19th century. OPs are used as weapons of war (eg, sarin gas), insecticides, and for medicinal purposes. Carbamates have medical applications (eg, physostigmine) and are used as insecticides. Some xenobiotics that are carbamates do not inhibit AChE.

Epidemiology

Exposure to OPs and carbamates has been on the decline in the United States, falling to less than 10,000 reports per year in the mid-2000s. This is in contrast to the hundreds of thousands of deaths that occur each year in rural Asia. Chronic and delayed sequelae are subject to underreporting because the association between the exposure and clinical event may go unrecognized.

Pathobiology

OPs and carbamates are highly lipophilic xenobiotics that penetrate tissues with ease. Systemic toxicity occurs following dermal exposure via cutaneous absorption, inhalation, or less commonly, ingestion. The initial binding of AChE by OPs is reversible and then becomes irreversible, a process termed *aging*. The time to "aging" varies by OP and ranges from a few hours to a couple of days, with the weapons of war having the shortest time to aging. Once the bond is "aged," the antidote *pralidoxime* is not effective. Carbamates, on the other hand, do not age, and their effects dissipate upon their clearance.

Clinical Features

The clinical manifestations of OP or carbamate exposure are the result of increased acetylcholine in all neuronal junctions (ie, parasympathetic and sympathetic postganglionic muscarinic, parasympathetic and sympathetic preganglionic nicotinic, CNS, and NMJ nicotinic; Fig. 133.1). Symptom onset ranges from a few minutes to several hours. The high lipophilicity of the compounds causes them to be absorbed in adipose tissues; delayed effects can be seen when they diffuse into the circulation. A syndrome of OP-induced delayed axonal neuropathy is the result of inhibition of a neuronal lysophospholipase neuropathy target esterase.

Clinical full range of manifestations of OP or carbamate exposure are summarized in Table 133.15. The most common presentation includes miosis, diaphoresis, and dyspnea due to bronchorrhea. CNS manifestations range from restlessness and confusion to stupor, coma, and seizure activity. The increased acetylcholine at the NMJ leads to muscle fasciculations, weakness, and finally, paralysis. A syndrome of delayed NMJ dysfunction seen in 25% of patients 1 to 4 days after OP exposures, characterized by muscle weakness without fasciculations and respiratory insufficiency, has been called *intermediate syndrome*. Some patients experience an OP-induced delayed polyneuropathy that involves the upper and lower motor neurons days to weeks after exposure.

Diagnosis

The diagnosis of OP/carbamate toxicity is best made based on known exposure and subsequent symptoms. In cases of uncertain exposure or atypical or subtle presentations, measurement of plasma and red blood cell *cholinesterase levels* can assist in the diagnosis. There are several caveats to their interpretation that

TABLE 133.14 Clinical Findings of Neurotoxic Syndromes

Anticholinergic	• Flushed skin • Anhidrosis • Dry mucus membranes • Urinary retention • Constipation/ileus/decreased bowel sounds • Hyperthermia • Mydriasis • Blurred vision (impaired accommodation) • Agitation, confusion, delirium, psychosis • Visual hallucinations • Myoclonus, choreoathetosis, picking behavior • Stupor/coma (higher doses) • Seizures (very rarely status epilepticus)
Sympathomimetic	• Diaphoretic • Hypertensive • Tachycardic • Hyperthermia • Agitation, combativeness, psychosis • Hallucinations • Mydriasis • Seizures
Organophosphate and carbamate toxicity	• Restlessness • Diarrhea • Lacrimation • Salivation • Urination • Bronchorrhea
Organophosphate and carbamate toxicity *(continued)*	• Diaphoresis • Muscle fasciculations • Seizures/convulsions • Confusion to stupor/coma • Blurred vision/miosis[a] • Bronchospasm[a] • Bradycardia[a] • Hypotension[a]
Neuroleptic malignant syndrome	• Confusion/delirium • Catatonia/mutism • Stupor/coma • Lead pipe rigidity • Hyperthermia • Tachycardia • Hypertension • Tachypnea
Serotonin syndrome	• Agitation, hypervigilance • Confusion, delirium • Hyperthermia • Tachycardia • Hypertension • Diaphoresis • Diarrhea • Ocular clonus • Mydriasis • Akathisia • Tremor • Rigidity • Hyperreflexia[b] • Clonus[b]

[a]Cholinergic activity at the preganglionic sympathetic fibers leads to increased release of norepinephrine at the postganglionic nerve terminals in the target organs. Clinically, this results in activation of the sympathetic and parasympathetic pathways, which may lead to normocardia, tachycardia, normotension, bronchodilation, or mydriasis.
[b]More pronounced in the lower extremities.

TABLE 133.15 Xenobiotics With Anticholinergic Properties

Category	Specific Agents
Antihistamines	Cetirizine, chlorpheniramine, cimetidine, diphenhydramine, doxylamine, hydroxyzine, loratadine, ranitidine
Antipsychotics	Chlorpromazine, clozapine, olanzapine, quetiapine, risperidone, ziprasidone
Antiemetics	Doxylamine, metoclopramide, promethazine, scopolamine
Antivertigo	Meclizine, scopolamine
Tricyclic antidepressants	Amitriptyline, desipramine, doxepin, imipramine, nortriptyline
Antidepressants	Mirtazapine, paroxetine
Antiparkinsonian	Benztropine, biperiden, carbidopa/levodopa, procyclidine, selegiline, trihexyphenidyl
Ophthalmic	Atropine, cyclopentolate, homatropine, tropicamide
Bronchodilators	Ipratropium, tiotropium
Antispasmodics	Dicyclomine, hyoscyamine, loperamide, oxybutynin,[a] propantheline
Muscle relaxants	Baclofen, carisoprodol, cyclobenzaprine, methocarbamol
Others	Amantadine, glycopyrrolate,[a] trazodone
Botanicals	Deadly nightshade (atropine, *Atropa belladonna*), henbane (*Hyoscyamus niger*), jimson weed (scopolamine, *Datura stramonium*), mandrake (*Mandragora officinarum*)

[a]Does not cross blood-brain barrier.

TABLE 133.16 Xenobiotics Causing Sympathomimetic Toxicity/Acute Excited State

Category	Source	Specific Agents	Comments
Cocaine	Coca plant (*Erythroxylum coca*)	Cocaine hydrochloride, methylecgonidine, and ecgonidine ("crack")	WCT/arrhythmias and local anesthetic due to Na channel blockage
Methamphetamines	Synthetic	"Crank," "crystal," "chalk," "ice," etc	Lead toxicity can be seen due to contamination.
Designer (recreational) amphetamines	Synthetic	MDMA ("ecstasy," "XTC," or "Adam"), MDA, MDEA ("Eve"), PMA ("death"), DOM ("STP"), DOI, DOB, others	Hyponatremia not uncommonly seen that may be due to ADH-like action with MDMA; irreversible damage to serotoninergic neurons seen on MRI
Prescription amphetamines	Synthetic	Dextroamphetamine, lisdexamfetamine	
Prescription piperazine compounds	Synthetic	Methylphenidate	
NMDA receptor antagonists	Synthetic	PCP, ketamine, dextromethorphan	
Synthetic cannabinoid	Synthetic	HU-210, JWH-018, JWH-073, JWH-200, CP-47, and cannabicyclohexanol (all largely referred to as *K2* or *spice*)	New compounds rapidly cycled in as DEA adds them to controlled substances lists
Ephedrine	Ephedra (*ma-huang*)	Various recreation, herbal, and weight loss compounds	
Cathinone	Khat (*Catha edulis*)	Consumed by chewing or in teas	Manganese toxicity from contamination has produced EPS.
Cathinone derivatives	Synthetic	Mephedrone, methylone, ethylone, butylone, pyrovalerone, MDPV, methcathinone, ethcathinone, others ("bath salts" marketed under many names)	
Methylxanthines	*Coffea arabica*, many other botanicals	Caffeine	
N-substituted piperazine compounds	Synthetic	"Legal E," "legal X," BZP ("A2"), TFMPP ("Molly"), CPP, 25I-NBOMe ("N-bomb")	
Mescaline	Cacti (*Lophophora williamsii*, *Lophophora diffusa*, *Trichocereus pachanoi*)	"Peyote"	
LSD	Synthetic		
LSD-like substances	Hawaiian baby woodrose (*Argyreia nervosa*), Hawaiian woodrose (*Merremia tuberosa*), morning glory (*Ipomoea violacea*), ololiuqui (*Rivea corymbosa*)		
Hallucinogen: tryptamines (indole alkaloids)	*Psilocybe*, *Panaeolus*, and *Conocybe* mushrooms Various plants and organisms Synthetics	Psilocybin and psilocin "magic mushrooms" DMT, 5-MeO-DMT AMT, DiPT, 5-MeO-DiPT ("foxy" or "foxy-methoxy")	Drank as *ayahuasca*
Hallucinogens: botanicals	*Salvia divinorum* *Mitragyna speciosa* Korth tree African rain forest shrub (*Tabernanthe iboga*) Wormwood tree extract (*Artemisia absinthium*) Isoxazole mushrooms (*Amanita muscaria*, *Amanita pantherina*, *Amanita gemmata*, and *Amanita cothurnata*)	Salvinorin A or divinorin A Kratom, specific compound uncertain, suspect mitragynine Iboga (ibogaine) Thujone ("absinthe") Ibotenic acid and muscimol	Ion channel effects; 11 deaths reported from cardiac arrest Inhibitor of $GABA_A$ receptor→ seizures

Abbreviations: 25I-NBOMe, 2-(4-iodo-2,5-dimethoxyphenyl)-*N*-[(2-methoxyphenyl)methyl]ethanamine; 5-MeO-DiPT, 5-methoxy-tryptamine; 5-MeO-DMT, 5-methoxy-dimethyltryptamine, diisopropyl; ADH, alcohol dehydrogenase; AMT, alpha-methyltryptamine; BZP, 1-benzylpiperazine; CPP, 1-(chlorophenyl) piperazine; DEA, Drug Enforcement Administration; DiPT, diisopropyltryptamine; DMT, dimethyltryptamine; DOB, 2,5-dimethoxy-4-bromoamphetamine; DOI, 2,5-dimethoxy-4-iodoamphetamine; DOM, 4-methyl-2,5-dimethoxyamphetamine; EPS, extrapyramidal symptoms; $GABA_A$, γ-aminobutyric acid type A; LSD, lysergic acid diethylamide; MDA, 3,4-methylenedioxyamphetamine; MDEA, 3,4-methylenedioxymethamphetamine; MDMA, 3,4-methylenedioxymethamphetamine; MDPV, methylenedioxypyrovalerone; MRI, magnetic resonance imaging; Na, sodium; NMDA, *N*-methyl-D-aspartate; PCP, phencyclidine; PMA, paramethoxyamphetamine; STP, serenity, tranquility, and peace; TFMPP, 1-(trifluoromethylphenyl)piperazine; WCT, wide complex tachycardia.

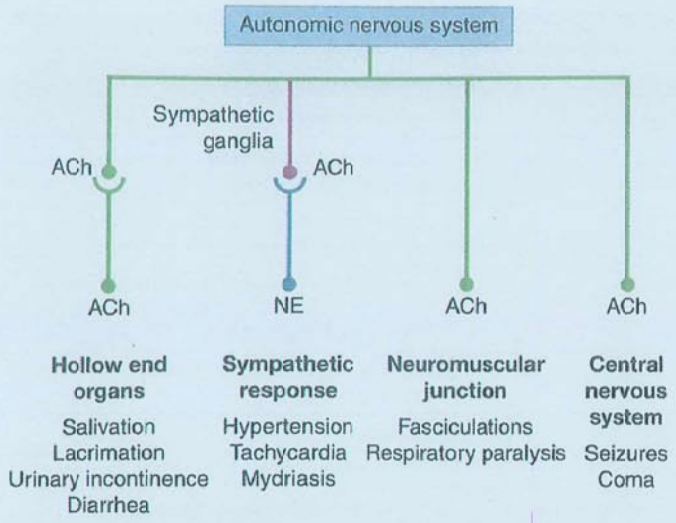

FIGURE 133.1 Sites of action of organophosphates and carbamates. Abbreviations: ACh, acetylcholine; NE, norepinephrine.

are beyond the scope of this text. Spontaneous repetitive potentials on single-nerve electromyography are a sensitive finding of AChE inhibition.

Treatment

Patients with OP exposure must be rapidly decontaminated by removing all clothing and liberally irrigating the skin. The initial treatment begins with liberal amounts of *atropine* (starting dose 1-2 mg IV doubled every 5 min until respiratory secretions are ceased). It is not uncommon for patients to require nearly 500 mg of atropine during the initial hour of care. Additionally, an oxime, typically *pralidoxime*, should be administered as soon as the syndrome is suspected (1-2 mg IV every 4 h for at least 24 h) to prevent aging and irreversible inhibition of AChE. Of note, the evidence supporting oxime use is conflicting. Benzodiazepines, particularly *diazepam* 5 to 10 mg IV every 4 to 6 hours, have been observed to decrease cerebral injury resulting from OP-induced seizures and mitigate OP-induced respiratory depression. *Ketamine* (1-4 mg/kg loading dose followed by 0.1-0.5 mg/min IV infusion) and other *N*-methyl-D-aspartate receptor antagonists have been shown to reduce OP-induced seizures and enhance survival in mice. When endotracheal intubation is being performed, succinylcholine is best avoided.

Outcome

The case fatality rate ranges from 10% to 40%. Evidence is lacking that describes neurologic outcomes with precision following acute and chronic poisoning. Residual deficits with an incomplete recovery are common in those with OPIDN. Cognitive deficits have been observed after acute OP exposure.

Neuroleptic Malignant Syndrome

Neuroleptic malignant syndrome (NMS) is an idiosyncratic life-threatening neurologic emergency seen in those on neuroleptic (antidopaminergic) agents or after withdrawal of dopaminergic medications (Table 133.17). Precise estimates of its incidence are lacking. It can occur at any age of life and is seen more often in men, but this is proportional to the increased use of neuroleptics in the male gender. NMS is frequently seen within the first 2 weeks of treatment with a neuroleptic, but it may occur at any time even in those on antipsychotics for years. The risk of NMS is higher with rapid dose escalation, parenteral administration, switching of agents, and when higher doses are used. The precise pathophysiology is not known, but it is believed to be the result of a relative dopamine deficit in the CNS. Genetic studies have identified a specific allele of the D2 receptor that results in a decreased amount and function of dopamine receptors to be a risk factor.

TABLE 133.17 Examples of Medications That Cause Neuroleptic Malignant Syndrome

Dopaminergic Agents (Discontinuation)	Antipsychotics	Antiemetics
Bromocriptine	Aripiprazole	Droperidol
Amantadine	Chlorpromazine	Metoclopramide
Rimantadine	Clozapine	Prochlorperazine
Memantine	Haloperidol	Promethazine
Levodopa	Olanzapine	
Cabergoline	Quetiapine	
Dihydroergocryptine	Risperidone	
Pergolide	Thioridazine	
	Ziprasidone	

Clinical Features

Clinical features include mental status changes, muscular rigidity, hyperthermia, and autonomic dysfunction; symptoms typically present in this sequence. Mental status changes may precede the other symptoms by 24 hours or more. Mental status changes range from confusion and delirium to catatonia, mutism, stupor, and coma. Cogwheeling, dystonia, and other dyskinesias can be seen in addition to the lead pipe rigidity. The majority of patients will have a temperature higher than 38°C, with nearly half exceeding 40°C. Autonomic dysfunction manifests as tachycardia, hypertension, and tachypnea. Laboratory abnormalities may include an elevated creatine kinase (>4 times normal), transaminitis, and leukocytosis.

Diagnosis

The diagnosis is clinical. A scoring system has been proposed, but it has not been validated. The evaluation is typically targeted toward identifying metabolic derangements that require correction and the exclusion of other differential diagnoses. Cerebral edema has been observed on magnetic resonance imaging (MRI). Seizures are not typically seen in NMS. Cerebral spinal fluid evaluation may reveal a mild protein elevation without pleocytosis or hypoglycorrhachia.

Treatment

Treatment includes aggressive supportive therapy, temperature correction, and cessation of any possible offending agent (or resumption of a discontinued one). *Dantrolene* (1-2.5 mg/kg IV), a skeletal muscle relaxant that works by inhibiting calcium release from the sarcoplasmic reticulum, maybe used to reduce rigidity and help to correct hyperthermia and rhabdomyolysis. It should not be used if there is a significant transaminitis. *Amantadine* (100 mg orally every 12 h) and *bromocriptine* (2.5 mg

orally every 6 h) are dopamine agonists that may be considered in the treatment of NMS. Summated evidence from retrospective observations and cases suggests that they may hasten recovery and reduce mortality, but this is far from conclusive. There are reports of electroconvulsive therapy being used, but its true efficacy is far from clear. In fact, several patients are reported to have gone into cardiac arrest during electroconvulsive therapy.

Outcome

Recovery typically occurs within 2 weeks of stopping the neuroleptic (or resuming the dopamine agonist), with some exceptions being reported. The mortality ranges from 5% to 20%. Relapse upon resumption of neuroleptics is very difficult to predict. If they must be resumed, lower potency agents should be selected at the lowest possible dose. Weak evidence suggests lithium therapy may increase the risk of developing NMS; therefore, it is best avoided if possible.

Serotonin Syndrome

Serotonin syndrome is a life-threatening neurologic emergency resulting from a relative serotonin excess. The death of Libby Zion at New York Hospital in 1984, which was reported in the mainstream media and eventually led to the creation of the contemporary laws that limit resident work hours, was suspected to be the result of serotonin syndrome. The syndrome can be precipitated when two or more serotonergic medications are coadministered but can occur with monotherapy as well (see **Table 133.18** for a list of serotonergic xenobiotics). There are over 25,000 reported cases of potential toxic exposure to serotonergic agents annually in the United States, with nearly 10,000 of them suspected to cause serotonin syndrome resulting in nearly 100 deaths. Serotonin syndrome occurs on a spectrum. Mild symptoms are likely to go unrecognized and are underreported.

Pathobiology

Serotonin receptors are primarily found in the CNS in the brainstem (midline raphe nuclei) and peripherally in the gastrointestinal tract, vasculature, and platelets. Rapid increases in serotonin concentration at these sites produce the symptoms of serotonin syndrome. Mild symptoms include tremor, diarrhea, and restlessness or hypervigilance. More severe symptoms result in further autonomic dysfunction, hyperthermia (>40°C), and more significant deficits in mental status (see **Table 133.14**). Clonus (ocular, spontaneous, and induced) and hyperreflexia are specific for serotonin syndrome and are more pronounced in the lower extremities. The onset is typically within minutes to hours of exposure to the serotonergic agent.

Diagnosis

Table 133.19 outlines the Hunter Serotonin Toxicity Criteria, which have a sensitivity of 84% and specificity of 97% for diagnosing serotonin syndrome. The diagnosis is completely clinical. Laboratory and imaging investigations are done to evaluate for metabolic derangements and to exclude alternative diagnoses.

Management

Symptoms resolve promptly upon the cessation of all serotonergic agents, making this the cornerstone of treatment. Unfortunately, some selective serotonin reuptake inhibitors have long half-lives (eg, fluoxetine's half-life is 1 wk). In such cases, prolonged supportive therapy is necessary. Agitation should be treated with benzodiazepines. If agitation persists or if autonomic dysfunction persists despite control of agitation, *cyproheptadine*, a histamine and serotonin antagonist, maybe used. It is only available for oral administration. The initial dose is 12 mg followed by 2 mg every 2 hours. There is little evidence beyond case reports to confirm that it has any therapeutic benefit. Outcomes can be expected to be excellent with optimal supportive care and prompt withdrawal of the serotonergic agent(s).

TABLE 133.18 Xenobiotics Known to Potentially Cause Serotonin Syndrome

Category	Specific Examples
SSRIs	Citalopram, escitalopram, fluoxetine, paroxetine, sertraline
SNRIs	Desvenlafaxine, duloxetine, milnacipran, venlafaxine
TCAs	Amitriptyline, clomipramine, desipramine, doxepin, imipramine, nortriptyline, protriptyline, trimipramine
MAOIs	Isocarboxazid, moclobemide, phenelzine, tranylcypromine
DNRIs	Bupropion
SARIs	Nefazodone, trazodone, and vilazodone
Recreational drugs	Cocaine, methamphetamine, designer amphetamines (eg, MDMA ["ecstasy"]; see Table 133.16), LSD
AEDs	Carbamazepine, valproate
Triptans	Almotriptan, eletriptan, frovatriptan, rizatriptan, sumatriptan, zolmitriptan
Ergots	Ergotamine, methylergonovine
Amphetamines	Dextroamphetamine, lisdexamfetamine
Opioids	Meperidine, tramadol, pentazocine, fentanyl
Appetite suppressants	Fenfluramine, phentermine, dexfenfluramine, sibutramine
Parkinson medications	Levodopa, carbidopa/levodopa, rasagiline, selegiline
Serotonin receptor antagonists	Dolasetron, granisetron, ondansetron, palonosetron
Antibiotics	Linezolid, tedizolid
Others	Tryptophan, St John's wort, cyclobenzaprine, dextromethorphan, buspirone, lithium, methylene blue, procarbazine

Abbreviations: AEDs, antiepileptic drugs; DNRIs, dopamine–norepinephrine uptake inhibitors; LSD, lysergic acid diethylamide; MAOIs, monoamine oxidase inhibitors; MDMA, 3,4-methylenedioxymethamphetamine; SARIs, serotonin antagonist and reuptake inhibitors; SNRIs, serotonin–norepinephrine reuptake inhibitors; SSRIs, selective serotonin reuptake inhibitors; TCAs, tricyclic antidepressants.

TABLE 133.19 Hunter Serotonin Toxicity Criteria

Any of the following are present after a serotonergic agent is introduced:
- Spontaneous clonus
- Inducible or ocular clonus with agitation or diaphoresis
- Inducible or ocular clonus with hypertonicity and fever
- Tremor with hyperreflexia

Carbon Monoxide Poisoning

Carbon monoxide (CO) intoxication is a common cause of neurotoxic damage and death. Deaths averaged 5,600 annually over a 10-year period in the United States and split between accidental and intentional. Statistics on nonfatal CO encephalopathy and the delayed CO-induced neuropsychiatric syndrome are imprecise. CO competes with oxygen for binding to hemoglobin, myoglobin, and cytochrome *c* oxidase resulting in tissue hypoxia and disordered cellular energy generation.

Clinical Features

Clinical presentations range from mild, viral syndrome–like symptoms, such as headache, malaise, dizziness, nausea, difficulty concentrating, and dyspnea, to coma, particularly in the setting of smoke inhalation. In survivors, neurologic symptoms include dementia, cerebellar dysfunction, and parkinsonism. A delayed neuropsychiatric syndrome may follow acute exposure by 3 to 240 days with cognitive and personality changes and psychotic behavior. This syndrome occurs in 10% to 30% of CO poisonings. Although up to 10% of victims show gross neurologic or psychiatric impairment, more frequently there is only a subtle, persistent neuropsychiatric deficit. Computed tomography, MRI, magnetic resonance spectroscopy, and isotopic imaging can disclose the brain damage. Postmortem findings include multifocal necrosis and myelinopathy with discrete lesions in the globus pallidus, cortex, and white matter.

Diagnosis

The diagnosis is made by measuring the serum carboxyhemoglobin (COHb) level. Normal levels are less than 5% in nonsmokers and can be as high as 12% in two-pack-per-day smokers. Although serious toxicity is often associated with levels greater than 25%, neurologic damage is not always directly related to the COHb level. Furthermore, serum levels may have fallen by the time the patient reaches the emergency department such that a normal COHb level does not rule out CO poisoning. Blood taken at the scene by emergency technicians can be used. Measurement of CO in expired air and in the exposure area's ambient air can also be useful. The U.S. government standard for CO prohibits exposure to more than 35 ppm, averaged over an 8-hour workday.

Treatment

Initial treatment is 100% oxygen by a nonrebreather face mask, which will reduce the elimination half-life of COHb from 4 to 5 hours to 1 to 2 hours. Treatment continues until the COHb levels are below 10%. Most experts advocate hyperbaric oxygen for treatment of symptomatic CO poisoning. It enhances elimination of COHb with an average half-life of 20 minutes at three atmospheres, but randomized trials have not clarified whether it hastens recovery or reduces the rate of late sequelae. Coma, ischemic symptoms, acidosis, levels over 25%, and pregnancy with levels over 20% are indications for hyperbaric oxygen.

Malignant Hyperthermia

Malignant hyperthermia is a life-threatening reaction that occurs in approximately 1/100,000 exposures to volatile anesthetics or succinylcholine. It results from the improper opening of the ryanodine receptors on the sarcoplasmic reticulum in skeletal muscle. Its presentation is on a spectrum, with the most pronounced episodes being characterized by diffuse muscle rigidity despite neuromuscular blockade. The first signs are an elevation of the end-tidal carbon dioxide and tachycardia. Fever develops later, with the temperature being prone to rapid elevations. Untreated, rhabdomyolysis and hyperthermia and their associated complications lead to death. Rapid treatment with *dantrolene* (2.5 mg/kg IV followed by 1 mg/kg IV until symptoms resolve) is the cornerstone of treatment.

Epidemiologically, malignant hyperthermia is most commonly the result of a mutation of the ryanodine receptor or dihydropyridine receptor. Additional cases are seen in those with several hereditary myopathies. Population-based screening is not justifiable. Genetic testing is specific but not sensitive. Contracture testing is much more sensitive, but it is invasive and only available at select centers. Additionally, contracture testing has a 20% false-positive rate.

Strychnine Poisoning

Strychnine, a competitive antagonist of glycine, causes involuntary tonic-clonic activity in otherwise awake individuals. It is derived from the seeds of the tree *Strychnos* nux-vomica. Contemporary poisonings are usually the result of the adulteration of recreational drugs and less commonly in herbal medications. It is absorbed through all routes, including dermal, with an onset of 10 to 20 minutes. It is largely eliminated by the liver with a half-life of approximately 12 hours. The diagnosis is clinical. Rhabdomyolysis and its associated complications are a significant threat as well as respiratory arrest from an inability to properly ventilate. Treatment is supportive with benzodiazepine or propofol use.

Methanol (Methyl Alcohol)

Methanol ingestion occurs when it is substituted for ethanol or in suicide attempts. Poisoning is related to the conversion of methanol to formaldehyde and formic acid, which results in a severe metabolic acidosis. The initial clinical presentation is similar to acute ethanol intoxication with gastrointestinal symptoms, drunkenness, and coma. The mortality rate is approximately 35%. Visual loss is common and attributed to retinal metabolism of methanol to formic acid. Cerebral imaging has demonstrated petechial hemorrhages and edema. Inhibitors of aldehyde dehydrogenase (ethanol and fomepizole) block the conversion of methanol to formaldehyde, allowing it to be excreted in the urine.

Volatile Organic Compounds

Neurologic syndromes caused by volatile organic compounds (*solvents*) occur after either occupational or deliberate exposure by inhalation abuse. The agents include aromatic and aliphatic hydrocarbons, alcohols, esters, ketones, aliphatic nitrates, anesthetic agents, halogenated solvents, and propellants. Aromatic hydrocarbons, especially *toluene*, produce cerebral and cerebellar damage. Aliphatic hydrocarbons caused outbreaks of peripheral neuropathy in industrial or recreational exposures to *n*-hexane or methyl-*n*-butyl ketone, which begin in the lower extremities and ascend, resembling Guillain-Barré syndrome. Pathophysiologically, neurofilamentous axonal swelling and distal axonal degeneration are seen.

Other organic compounds that induce axonal neuropathy by industrial exposure are acrylamide, carbon disulfide, methyl bromide, and triorthocresyl phosphate. Halogenated hydrocarbons

are toxic for the CNS by damaging nerve cell membranes and altering neurotransmission; an excitatory phase is rapidly followed by CNS depression. The compounds include chloroform, methylene chloride, and tetrachloroethane. The neurotoxic potential of one substance is sometimes facilitated by others in the same commercial product.

Nitrous Oxide Myelopathy

Nitrous oxide (NO), commonly known as *laughing gas*, is used as an inhaled anesthetic. Chronic exposure to NO, also known as *Layzer syndrome*, was described in the late 1970s in a series of dentists with occupational exposure or chronic NO abuse. It has also been described in those with a vitamin B_{12} deficiency that are exposed to NO. Because NO interferes with the action of vitamin B_{12}, symptoms mimic its deficiency and include paresthesias, Lhermitte symptoms, ataxia, leg weakness, impotence, and sphincter disturbances. Examination showed signs of sensorimotor polyneuropathy, often implicating the posterior and lateral columns of the spinal cord, which can be confirmed on MRI. Electrodiagnostic tests showed axonal polyneuropathy. Animal studies have suggested that methionine has a protective role. Improvement has been reported to occur over weeks to months after exposure ceased.

Heavy Metals

Lead

Acute lead encephalopathy in children is typically attributed to pica or ingestion of flaking lead-containing paint. Children with blood levels above 80 μg/dL are more susceptible than adults to overt lead encephalopathy with delirium, ataxia, seizure, stupor, or coma with associated cerebral edema. Adults with chronic lead exposure yielding blood lead levels of 25 to 60 μg/dL may experience irritability, headache, myalgias, anorexia, nausea, crampy abdominal pain, and depression with signs of impaired visual-motor dexterity and reaction times. Objective neuropathies that manifest in muscle weakness and atrophy occur with long-term levels of 60 μg/dL or more. Because of links between lead and cognitive dysfunction, behavioral problems, as well as stunted growth in children, the Centers for Disease Control and Prevention has declared levels exceeding blood concentration of 5 μg/dL to be abnormal and requiring case management. Periodic screening of children aged 9 to 36 months is advocated, especially because the symptoms are nonspecific, including lethargy, anorexia, intermittent abdominal pain with vomiting, or constipation. Testing blood lead levels is recommended for children with presumed autism, attention deficit disorder, pervasive development disorder, mental retardation, or language problems.

A diagnosis of lead intoxication is supported if blood zinc protoporphyrin exceeds 100 μg/dL or if urinary aminolevulinic acid excretion is more than 15 mg/L. With blood lead levels of 10 μg/dL, the activity of aminolevulinic acid dehydratase is low. At higher lead levels, the activities of coproporphyrinogen oxidase and ferrochelatase are also low. Anemia and basophilic stippling of erythrocytes are characteristic. Nerve conduction velocities are nonspecifically slow in lead and other neuropathies.

Treatment combines decontamination, supportive care, and the judicious use of chelating agents. In affected people, chelation therapy commences with levels of 40 to 45 μg/dL. Supportive care may include treatment of increased intracranial pressure by standard use of IV mannitol and glucocorticoids, the latter because the pathophysiology of lead encephalopathy involves capillary leak. In patients with lead encephalopathy, calcium disodium edetate or calcium ethylenediaminetetraacetic acid should be administered at 30 mg/kg every 24 hours. Some advocate initiating chelation with a single dose of dimercaprol (British anti-Lewisite [BAL]) 4 to 5 mg/kg deep intramuscularly. Alternatively, meso-2,3-dimercaptosuccinic acid (succimer) is advocated for treatment of moderately severe chronic lead intoxication. Childhood lead exposure carries a risk of long-lasting health impairment, especially with neurocognitive and neurobehavioral sequelae, emphasizing the need for primary prevention and for obtaining occupational and environmental information.

Mercury

The relations between elemental, inorganic, and organic forms of mercury involve transformations from one form to another. Modern epidemics include Minamata disease from fish contaminated by methyl mercury (MeHg), which affected 2,500 people in Japan, and erethism (abnormal sensitivity to stimulation of any type)—also known as the *mad hatter syndrome*—from mercuric nitrate used in the hatting industry. Acute toxicity from elemental mercury may include encephalopathy and seizures, whereas its chronic toxicity includes peripheral sensorimotor neuropathy, dysarthria, and parkinsonism. Subclinical nerve conduction and neuropsychiatric abnormalities have been documented in the modern workplace.

Organic mercury includes MeHg, the cause of Minamata disease, and ethyl mercury. Excessive MeHg intake has been reported in fish-eating communities in Greenland, the Faroe Islands, the Seychelles, the Madeira Basin of the Amazon River, and New Zealand. Symptoms of organic mercury toxicity include tremor; ataxia; dysarthria; paresthesias of the hands, feet, and mouth; visual field constriction; erethism; and spasticity. Prenatal exposure to MeHg can cause severe congenital abnormalities such as micrognathia, microcephaly, mental retardation, blindness, and motor deficits. Minamata disease produces neuropathologic abnormalities in the cerebral cortex, cerebellum, and peripheral nerves.

The 24-hour urine mercury concentration may assess both recent exposure and elimination of tissue burden. The normal blood concentration is less than 10 to 20 μg/L, and the urinary level is less than 20 μg/L. Treatment consists of decontamination and chelation with established guidelines. If the person is symptomatic, dimercaprol is given intramuscularly 3 to 5 mg/kg every 4 hours on day 1, every 12 hours on day 2, and then once a day for the next 3 days followed by a 2-day interruption. Other agents are meso-2,3-dimercaptosuccinic acid and 2,3-dimercapto-propane-1-sulfonate, a water-soluble form of BAL. All agents are somewhat effective for organic and inorganic mercury poisoning.

Arsenic

Arsenic toxicity is a global health problem. It is estimated that tens of millions of people, for example, in Bangladesh, are at risk for excessive arsenic levels from natural geologic sources leaching into aquifers, contaminated drinking water, mining, and other industrial processes. Arsenicosis can result in cancer at various sites, encephalopathy, and axonal peripheral neuropathy. The chronic version is "blackfoot disease" with

vascular changes, gangrene, and a less severe peripheral neuropathy. The use of arsenic trioxide to treat leukemia may cause arsenic neuropathy.

Vomiting, bloody diarrhea, myoglobinuria, renal failure, arrhythmias, hypotension, seizures, coma, and death characterize acute arsenic poisoning. In survivors, *Mees lines* on the fingernails and sensorimotor neuropathy appear in 7 to 14 days. Slow and incomplete recovery takes years. Cognition may be impaired in some survivors depending on the severity of the acute encephalopathy.

The diagnosis of arsenic intoxication is confirmed by urinary levels more than 75 μg/dL. Hair analysis has been used but is not reliable. BAL therapy is also used for acute arsenic poisoning. It is most effective before symptoms of neuropathy appear. BAL is considered more effective than penicillamine in treating the chronic neuropathy. Hemodialysis is another treatment for an acute episode.

Thallium

Despite the ban on manufacture of thallium rodenticides in the United States, accidental and suicidal exposures still occur because the poisons are available in other countries. After an acute exposure, gastrointestinal symptoms occur first with paresthesias occurring a few weeks later with the onset of a neuropathy. The encephalopathy presents with cognitive impairment and choreoathetosis, myoclonus, or other involuntary movements. Alopecia, which is unique to thallium toxicity, begins 1 to 3 weeks after exposure.

After acute exposure, blood tests are not useful for detecting thallium because it is rapidly taken up by the cells. Normal urinary thallium values are 0.3 to 0.8 μg/L. Levels of 200 to 300 μg/L are seen in overt poisoning. A provocative test uses potassium chloride, which is given orally in a dose of 45 mEq. Potassium displaces thallium from tissue stores, blood levels rise, and urinary content can be followed serially.

Treatment of acute poisoning depends in part on enhancing urinary and fecal excretion of thallium by giving laxatives and using Prussian blue or activated charcoal to retard absorption. Urinary excretion is enhanced by forced diuresis and administration of potassium chloride. Hemodialysis may be effective.

Manganese

Manganese intoxication, still a threat in industrial settings, reproduces the essential motor features of parkinsonism but with sufficient clinical and pathologic differences to indicate the conditions are not identical; for instance, exaggerated tendon reflexes and behavioral features occur early in manganese toxicity. The outlook is gloomy, including severe cognitive loss. Responses to levodopa and to chelation therapy are limited.

Aluminum

Dialysis dementia (see Chapter 125) has been attributed to aluminum in the dialysis water and also in ingested phosphate binders used to control blood phosphorus levels. Treatment of the water and avoidance of the binders have decreased the incidence. Encephalopathy, however, has also occurred in uremic patients dialyzed with deionized water and also in those that ingest the phosphate binders without dialysis. Paresthesias and weakness were part of "potroom palsy," a complex syndrome in workers in a smelter who were exposed to pots that had not been vented properly. Other manifestations included ataxia, tremor, and memory loss.

Plant, Animal, and Marine Neurotoxins

Ciguatera poisoning or the *marine neurotoxic syndrome* is the most common nonbacterial form of food poisoning in the United States and is endemic in subtropical regions. Toxins are found in tropical reef fish, which acquire them when they consume dinoflagellates. Initial symptoms are gastrointestinal followed by sensory symptoms, paresthesias, and pruritus. *Sensory inversion*, manifested as cold feeling hot and vice versa, dysuria, and dyspareunia are particular to this poisoning. Myalgia, fasciculations, areflexia, trismus, and carpopedal spasm are also reported. Respiratory failure is uncommon. There is no formal laboratory or clinical criteria for diagnosis. Mechanistically, most associated toxins open sodium channels. Treatment is symptomatic, with a randomized trial of mannitol showing no advantage.

Shellfish poisoning can result from contamination of mollusks by saxitoxin, which blocks sodium channels. The symptoms are similar to ciguatera but more severe, and respiratory depression is a greater risk. Cerebellar ataxia was the dominant finding and hypertension is common. Binding assays and liquid chromatography identify the toxin in serum and urine. In Japan, the agent of puffer fish poisoning is tetrodotoxin. Treatment of these conditions is symptomatic.

Amnesic shellfish poison is due to consuming domoic acid, a glutamate receptor agonist, in mussels, which can result in a transient encephalopathy. There is no specific treatment.

Many plants contain pharmacologically active substances that cross the blood-brain barrier with resulting delirium, hallucinations, seizures, and sedation. *Cicutoxin*, from *water hemlock*, produces a clinical state of agitation and confusion followed by sedation. *Andromedotoxin* from *rhododendron* is a depressant. Over 100,000 potential toxic exposures to botanicals are reported per year.

Neurolathyrism presents with spastic paraparesis in impoverished countries and is seen during times of drought when the *Lathyrus* plant is consumed. *Konzo* is a disease due to prolonged consumption of the bitter cassava *Manihot esculenta* prevalent in sub-Saharan Africa with a similar presentation. Cassava contains a cyanoglucoside linamarin, which is enzymatically converted to cyanide, which then damages neural calls. The clinical picture is a sudden, symmetric, and permanent spastic paraplegia. Males are predominately affected in both conditions. Hearing loss, visual impairment, and dysarthria may be seen in cassavaism but not neurolathyrism.

ACKNOWLEDGMENT

Leon D. Prockop, Louis H. Weimer, and Lewis P. Rowland, contributed to the content in this chapter in previous editions. Edward (Mel) J. Otten is to be thanked for his mentorship and advisement on the content of this chapter.

SUGGESTED READINGS

Aaron CK. Organophosphate poisoning–induced intermediate syndrome: can electrophysiological changes help predict outcome? *PLoS Med*. 2008;5(7):e154.

Andersen HR, Nielsen JB, Grandjean P. Toxicologic evidence of developmental neurotoxicity of environmental chemicals. *Toxicology*. 2000;144(1-3):121-127.

Arora A, Neema M, Stankiewicz J, et al. Neuroimaging of toxic and metabolic disorders. *Semin Neurol*. 2008;28:495-510.

Arseneau N, Braden K. Anticholinergic toxicity, polypharmacy, and inappropriate prescribing. *UWOMJ*. 2016;84(2):31-33.

Bouchard M, Mergler D, Baldwin ME, Panisset M. Manganese cumulative exposure and symptoms: a follow-up study of alloy workers. *Neurotoxicology*. 2008;29(4):577-583.

Buckley NA, Eddleston M, Li Y, Bevan M, Robertson J. Oximes for acute organophosphate pesticide poisoning. *Cochrane Database Syst Rev*. 2011;(2):CD005085.

Buckley NA, Juurlink DN, Isbister G, Bennett MH, Lavonas EJ. Hyperbaric oxygen for carbon monoxide poisoning. *Cochrane Database Syst Rev*. 2011; 2011(4):CD002041.

Chateau-Degat M-L, Beuter A, Vauterin G, et al. Neurologic signs of ciguatera disease: evidence of their persistence. *Am J Trop Med Hyg*. 2007;77(6):1170-1175.

Clancy C, Klein Schwarz W. Plants: central nervous system toxicity. In: Ford MD, Delaney KA, Ling LJ, Erickson T, eds. *Clinical Toxicology*. Philadelphia, PA: WB Saunders; 2001:909-921.

Costa LG. Overview of neurotoxicology. *Curr Protoc Toxicol*. 2017;74(1): 11.1.1-11.1.11.

de Carvalho M, Jacinto J, Ramos N, de Oliveira V, Pinho e Melo T, de Sá J. Paralytic shellfish poisoning: clinical and electrophysiological observations. *J Neurol*. 1998;245:551-554.

Feldman RG. *Occupational and Environmental Neurology*. Philadelphia, PA: Lippincott-Raven; 1999.

Greenburg MI, Hamilton R, Phillips SD, McCluskey GJ. *Occupational, Industrial, and Environmental Toxicology*. 2nd ed. Philadelphia, PA: Mosby; 2003.

Hadzic A, Glab K, Sanborn KV, Thys DM. Severe neurologic deficit after nitrous oxide anesthesia. *Anesthesiology*. 1995;83:863-866.

Hampson NB, Hauff NM. Risk factors for short-term mortality from carbon monoxide poisoning treated with hyperbaric oxygen. *Crit Care Med*. 2008;36(9):2523-2527.

Hoffman R, Howard MA, Lewin N, Nelson L, Goldfrank LR. *Goldfrank's Toxicologic Emergencies*. 10th ed. New York, NY: McGraw-Hill; 2015.

Hon KL, Fung CK, Leung AK. Childhood lead poisoning: an overview. *Hong Kong Med J*. 2017;23(6):616-621.

Jeffery B, Barlow T, Moizer K, Paul S, Boyle C. Amnesic shellfish poison. *Food Chem Toxicol*. 2004;42(4):545-557.

Juntunen J, Matikainen E, Antti-Poika M, Suoranta H, Valle M. Nervous system effects of long-term occupational exposure to toluene. *Acta Neurol Scand*. 1985;72:512-517.

Kim JH, Chang KH, Song IC, et al. Delayed encephalopathy of acute carbon monoxide intoxication: diffusivity of cerebral white matter lesions. *AJNR Am J Neuroradiol*. 2003;24:1592-1597.

Layzer RB. Myeloneuropathy after prolonged exposure to nitrous oxide. *Lancet*. 1978;2:1227-1230.

Lidsky TI, Schneider JS. Lead neurotoxicity in children: basic mechanisms and clinical correlates. *Brain*. 2003;126(pt 1):5-19.

Lutes JM, Borchelt JE, Janulewicz PA, Adams J. Developmental neurotoxicology of antiepileptic drugs. In: Slikker W Jr, Paule MG, Wang C, eds. *Handbook of Developmental Neurotoxicology*. 2nd ed. Cambridge, MA: Academic Press; 2018:499-508.

Meyer-Baron M, Schäper M, Knapp G, van Thriel C. Occupational aluminum exposure: evidence in support of its neurobehavioral impact. *Neurotoxicology*. 2007;28(6):1068-1078.

Modi S, Dharaiya D, Schultz L, Varelas P. Neuroleptic malignant syndrome: complications, outcomes, and mortality. *Neurocrit Care*. 2016;24(1): 97-103.

Moretto A, Lotti M. Poisoning by organophosphorus insecticides and sensory neuropathy. *J Neurol Neurosurg Psychiatry*. 1998;64:463-468.

Myers JE, teWaterNaude J, Fourie M, et al. Nervous system effects of occupational manganese exposure on South African manganese mineworkers. *Neurotoxicology*. 2003;24:649-656.

Nayak P. Aluminum: impacts and disease. *Eviron Res*. 2002;89(2):101-115.

Perkins RA, Morgan SS. Poisoning, envenomation, and trauma from marine creatures. *Am Fam Physician*. 2004;69:885-890.

Prockop LD. Carbon monoxide. In: Dobbs MR, ed. *Clinical Neurotoxicology*. Philadelphia, PA: Saunders Elsevier; 2009:500-514.

Rutchik JS, Wittman RI. Neurologic issues with solvents. *Clin Occup Environ Med*. 2004;4(4):621-656.

Schaumberg H, Albers JW. Identification of neurotoxic disease. *Continuum Lifelong Learn Neurol*. 2008;14(5):11-34.

Sethi NK, Mullin P, Torgovnick J, Capasso G. Nitrous oxide "whippit" abuse presenting with cobalamin responsive psychosis. *J Med Toxicol*. 2006;2(2):71-74.

Shrot S, Ramaty E, Biala Y, et al. Prevention of organophosphate-induced chronic epilepsy by early benzodiazepine treatment. *Toxicology*. 2014;323: 19-25.

Slavica V, Dubravko B, Milan J. Acute organophosphate poisoning: 17 years of experience of the National Poison Control Center in Serbia. *Toxicology*. 2018;409:73-79.

Steenland K, Jenkins B, Ames RG, O'Malley M, Chrislip D, Russo J. Chronic neurological sequelae to organophosphate pesticide poisoning. *Am J Public Health*. 1994;84:731-736.

Stepens A, Logina I, Liguts V, et al. A parkinsonian syndrome in methcathinone users and the role of manganese. *N Engl J Med*. 2008;358(10): 1009-1017.

Struwe G. Psychiatric and neurological symptoms in workers occupationally exposed to organic solvents—results of a differential epidemiological study. *Acta Psychiatr Scand Suppl*. 1983;303(suppl):100-104.

Sykes OT, Walker E. The neurotoxicology of carbon monoxide—historical perspective and review. *Cortex*. 2016;74:440-448.

Uddin MF, Alweis R, Shah SR, et al. Controversies in serotonin syndrome diagnosis and management: a review. *J Clin Diagn Res*. 2017;11(9):OE05-OE07.

Vahidnia A, van der Voet GB, de Wolff FA. Arsenic neurotoxicity—a review. *Hum Exp Toxicol*. 2007;26(10):823-832.

Weaver LK. Clinical practice. Carbon monoxide poisoning. *N Engl J Med*. 2009;360(12):1217-1225.

Weaver LK, Hopkins RO, Chan KJ, et al. Hyperbaric oxygen for acute carbon monoxide poisoning. *N Engl J Med*. 2002;347(14):1057-1067.

Weissman BA, Raveh L. Therapy against organophosphate poisoning: the importance of anticholinergic drugs with antiglutamatergic properties. *Toxicol Appl Pharmacol*. 2008;232(2):351-358.

Zhao G, Ding M, Zhang B, et al. Clinical manifestations and management of acute thallium poisoning. *Eur Neurol*. 2008;60(6):292-297.

Radiation Injury 134

Matthew R. Leach and Christopher Zammit

KEY POINTS

1. The clinical effects of radiation are related to individual patient susceptibility, dose absorbed, dose rate, and distribution of dose.
2. Radiation necrosis may be differentiated from brain tumor disease progression by higher apparent diffusion coefficient (ADC) values on diffusion imaging, hypermetabolism on positron emission tomography, reduction in choline levels on magnetic resonance single-photon emission computed tomography, and/or hypoperfusion on magnetic resonance perfusion imaging.
3. First-line treatment for radiation necrosis is glucocorticoids. Refractory cases may be treated with bevacizumab, hyperbaric oxygen, or surgery.
4. Late manifestations of radiation injury are generally less responsive to treatment and often permanent, such as myelopathy and delayed radiation necrosis.

INTRODUCTION

The first known description of nervous system injury by radiation was in 1930 by Fischer and Holfelder. Contemporary medicine's use of radiotherapy to treat malignancies has brought radiation injury into daily clinical discussion. The expansion of nuclear energy programs during the 1970s increased the risk for widespread radiation injury in the event of nuclear plant failure. The Three Mile Island accident in 1979 and disasters at the Chernobyl Nuclear Power Station in 1986 and the Fukushima Nuclear Power Plant following a tsunami in 2011 have provided real reminders of the ongoing risk.

Radiation injury is the result of exposure to ionizing radiation. Nonionizing radiation does not cause neurologic injury; its biologic injury is limited to thermal surface injury. Nervous system injury results from x-rays or γ rays; alpha and beta particles also produce ionizing radiation, but they do not penetrate tissue by more than 8 mm and therefore do not reach the central or peripheral nervous system. Internal injury can result when alpha or beta particles are ingested, but even in such cases, their proximity to central neurologic structures limits their ability to produce significant neurologic injury.

The amount of radiation absorbed is described in terms of *gray* (Gy), where 1 Gy is equal to 1 J of radiation absorbed per kilogram of tissue. A *radiation-absorbed dose* (rad) is equal to 100th of a Gy (ie, 100 rad = 1 Gy). One rad is also equal to one *roentgen equivalent man* (rem), that is, 1 rad = 1 rem. In contrast, the dose of radiation delivered is described in sieverts (Sv), where 1 Sv is equal to 100 rem. To provide context, we are exposed to approximately 3 millisieverts (mSv) per year from natural radioactive material and cosmic radiation. Furthermore, one head computed tomography (CT) delivers 2 mSv of radiation.

Therapeutic radiation is typically administered as whole brain radiation therapy (WBRT) or stereotactic radiosurgery (SRS). WBRT is diffuse irradiation of the entire brain (although many new protocols are "temporal" or "hippocampal sparing" to reduce cognitive side effects) and is used either prophylactically or for treatment of diffuse metastases. In contrast, SRS focuses radiation on specific lesions, converging many low-dose beams of radiation on a target with millimeter precision to deliver high-dose radiation at their intersection with relatively little effect on surrounding tissues. Radiation effects on the nervous system and other organ systems (Table 134.1) can be difficult to predict because the amount of radiation delivered is not necessarily equal to the amount absorbed, particularly when considering occupational or environmental exposures. The clinical effects of radiation are related to the individual susceptibility, dose rate, dose absorbed, and distribution of the dose.

EPIDEMIOLOGY

As mentioned earlier, the incidence of radiation injury is related to individual patient characteristics, use of concomitant therapies, the dose amount, dose rate, and distribution of the exposure (Table 134.2). In particular, patients at the extremes of age are more at risk for complications with radiotherapy and complications increase with concomitant administration of many chemotherapies. Hypertension and diabetes mellitus increase the

TABLE 134.1 Radiation Effects

- Acute constitutional symptoms: fatigue, malaise, anorexia, nausea
- Acute cerebral edema
- Early-delayed leukoencephalopathy or demyelination
- Late-delayed radiation necrosis
- Myelopathy
- Vasculopathy
- Stroke-like migraine attacks after radiation therapy (SMART) syndrome
- Plexopathy
- Neuropathy (including cranial and optic neuropathy)
- Ocular neuromyotonia
- Neuroendocrine disorders
- Radiation-induced tumors
- Neuropsychiatric, behavioral, and cognitive disturbances

TABLE 134.2 Risk Factors for Injury After Radiation Exposure

• Age <5 y or >60 y
• Use of concomitant chemotherapy
• Extent of radiation bed
• Total radiation dose
• Fractionation schedule

risk of radiation injury in adults. Radiation injury to the nervous system may occur after scalp radiation for tinea capitis, radiotherapy to the head or neck for extracranial malignancy, whole body radiation for liquid malignancies or stem cell transplant, brachytherapy, or both WBRT and SRS for intracranial malignancies. The majority of patients undergoing radiation therapy for central nervous system malignancy will experience some form of side effect, but the duration and severity of these effects vary widely.

Acute cerebral edema may occur days to weeks after radiation. It rarely occurs at doses below 2 Gy and is seen in about half of the time after doses over 7.5 Gy. Delayed leukoencephalopathy and/or demyelination typically occur between 1 and 6 months after exposure. Radiation necrosis is seen between 6 months and 7.5 years after radiotherapy, with a median onset of 14 months, and 75% of patients experience symptoms within 3 years. The cumulative dosing threshold for necrosis is reported as being 50 to 60 Gy, with a 5% incidence in those receiving a total of 50 Gy in daily doses of 2 Gy.

Myelopathy occurs 1 to 3 years after radiation, with peaks in incidence at 12 to 14 months and 24 to 28 months. Similar to radiation necrosis, 5% of patients receiving total doses of approximately 60 Gy to the spinal cord have been reported to develop myelopathy, but this is not consistent.

Intracranial and extracranial vasculopathy have been seen over 20 years after radiation exposure. Patients treated with radiotherapy incur significantly increased morbidity and mortality due to cerebrovascular disease compared to the general population with some reviews citing up to a fourfold increase. Incidence increases with increasing doses of radiation. Stroke-like migraine attacks after radiation therapy (*SMART*) syndrome has been reported many years after whole brain radiation. It is rare with risk factors that include time since irradiation, male sex, and genetic susceptibility.

Plexopathy and neuropathy (including cranial and optic neuropathy) are typically seen after radiation directed at the affected region. Brachial plexopathy after radiation for breast cancer has a median onset of 4.5 months. Transient symptoms are seen in 1% to 2% of those receiving doses of 50 Gy. Lumbosacral plexopathy is rarely seen, even at doses of up to 70 to 80 Gy. Neuropathy is rarely seen at doses under 60 Gy. Optic neuropathy is seen within 3 years of exposure when it occurs.

The radiation dose threshold associated with neuroendocrine disorders in children is less than that for the previously mentioned injuries. Growth hormone deficiency is seen in fractionated doses of less than 20 Gy. Sixty-five percent of children undergoing prophylactic cranial radiation for acute lymphocytic leukemia in a total dose of 20 to 30 Gy are observed to have a growth hormone deficit. Other neuroendocrine disorders occur at total doses over 40 to 50 Gy, including gonadotropin deficiency, thyrotropin deficiency, adrenocorticotropic hormone deficiency, and hyperprolactinemia. In total, an estimated 50% of survivors of childhood cancer will develop an endocrinopathy, with most patients needing lifelong follow-up with an endocrinologist.

Cognitive and neuropsychiatric disturbances are all too common in children receiving radiation for malignancies, with some series reporting rates of 100%. Similarly, almost all adults undergoing WBRT will experience cognitive side effects. Radiotherapy that traverses the hippocampus or frontostriatal brain circuitry is felt to increase the risk of occurrence and many contemporary protocols are "hippocampal sparing" with radiation directed away from the mesial temporal area.

Radiation-induced tumors include meningiomas, sarcomas, gliomas, and schwannomas. Meningiomas have a latency of up to 37 years at doses of 8.5 Gy and as short as 18 months after 20 Gy. Sarcomas are seen about 10 years after doses of 50 Gy with an unclear frequency. The relationship between glioma occurrence and radiation therapy is not agreed on. However, high-volume cell phone use has been associated with the occurrence of gliomas (and meningiomas) and the risk appears to be related to the "dose" of cell phone use. Peripheral nerve tumors are seen in about 10% of patients receiving radiation therapy directed through a peripheral nerve.

PATHOBIOLOGY

Ionizing radiation causes biologic injury by damaging the most basic elements that make up cellular structures and conduct cellular processes. The x-rays and/or γ rays collide with electrons, causing elements to become ionized that were not otherwise, altering their ability to conduct cellular functions. This will damage DNA, leading to mutations that contribute to the increased malignancy risk. Cells that have high rates of turnover are the most vulnerable to this damage (eg, hematopoietic, mucosal, endothelial, and gastrointestinal cells). This is one of the reasons that the hippocampus, with its neural progenitor cell population, is particularly sensitive to radiation.

The acute side effects and early cerebral edema seen after radiation are suspected to be secondary to vascular endothelial dysfunction and disruption of the blood-brain barrier, causing vasogenic edema (hence its clinical response to corticosteroids). This endothelial damage also contributes to advanced/premature hyalinization of the vessel wall more chronically. The latently observed leukoencephalopathy is thought to be the result of this edema in combination with a transient demyelination due to oligodendrocyte dysfunction, as the time frame corresponds with expected myelin turnover.

Later effects are due to cell death related to aforementioned DNA damage with subsequent cytotoxic edema. Radiation necrosis is predominately a white matter process that may occur by one or more of the following mechanisms: glial dysfunction, vasculopathy, or immunologic response. Glial dysfunction is supported by histologic changes including white matter necrosis, cystic cavitation with gliosis, and patchy demyelination suspected to be the result of oligodendrocytes injury. Alternatively, vascular injury has been observed histologically as perivascular lymphocytic infiltration, endothelial proliferation, fibrinoid degeneration, capillary occlusion, and intraluminal thrombosis of medium- and small-sized arteries. Endothelial cell injury then causes vasogenic edema. A *mineralizing microangiopathy* is seen in nearly 20% of patients at autopsy and can be appreciated clinically as calcifications at the gray-white junction

on head CT (see Fig. 134.4). Lastly, an *immunologic mechanism* is suspected to occur when irradiated glial cells release antigens that induce an autoimmune reaction. These mechanisms are all triggered by chronic oxidative stress linked to free radical generation and further contribute to advanced atherosclerosis and neurocognitive decline. White matter necrosis is seen after higher radiation doses, whereas lower doses are observed to cause vascular damage, with a more delayed presentation. Asymptomatic animals are found to have a spongy vacuolation of the spinal cord white matter. In contrast, the animals with paralysis were found to have tissue destruction and vascular changes, predominately in the posterior and lateral columns. Long-term vascular damage can lead to advanced cerebrovascular disease. Endothelial damage, subintimal fibrosis and hypertrophy, dysfunction of the elastic membrane, and thickening and fibrosis of the muscular wall all play a role in the advanced vascular disease seen in this population.

Plexopathies and neuropathies can be the result of an occlusion of an artery (eg, subclavian artery stenosis causing a brachial plexopathy) or radiation fibrosis, producing external compression around the nerve. Peripheral nerve ischemia due to radiation injury to the vasa nervorum is also suspected. Autopsies of those with radiation vasculopathy reveal myointimal proliferation, hyalinization, and occlusion.

DIAGNOSIS

The diagnosis for many of the clinical sequela of radiation therapy rests on the identification of their clinical features, time frame between radiation exposure and onset of symptoms, and exclusion of other conditions or inflictions that can produce the same symptoms. Most clinical complications can be classified as *early*, *early-delayed*, or *late* injury, and often a given complication can have different presentations at each stage depending on the dose delivered. The early onset of cerebral edema after radiotherapy can be appreciated on head CT and brain magnetic resonance imaging (MRI) (T2 or fluid-attenuated inversion recovery [FLAIR]), but the clinical diagnosis is often assumed if there is improvement in symptoms after the administration of corticosteroids. Early-delayed leukoencephalopathy is suspected by history of radiation therapy and the time between radiation exposure and symptom onset. T2 and FLAIR sequences on MRI may demonstrate hyperintensities, but these are not specific for the condition. Confidence in the diagnosis of early-delayed leukoencephalopathy is strengthened by the gradual improvement in symptoms without treatment or intervention. Radiation plexopathy due to fibrosis is favored with electromyography demonstrating myokymia. CT and MRI changes consistent with fibrosis increase the likelihood of a causational link but are not conclusive. Endocrinopathies and pituitary dysfunction are diagnosed as described elsewhere in this text. Cognitive and neurobehavioral disturbances are detected through neuropsychiatric assessment. The clinical and imaging features of the various complications of radiation injury are summarized in Table 134.3.

Acute Radiation Sickness

Acutely radiated victims of an occupational or environmental event or accident typically do not know the dose of radiation they were exposed to. Symptoms of acute radiation sickness (ARS) on presentation include nausea, vomiting, diarrhea, or headache. Alopecia and scalp erythema may also be seen. Injury to the pharyngeal mucosa may cause pharyngitis and eustachian tube dysfunction leading to otitis media. The onset, persistence, and severity of symptoms are used to gage the dose and therefore the prognosis of the victim. If neurologic symptoms are present acutely and are not the result of an injury sustained from a blast or other traumatic force, such as a decreased level of consciousness, ataxia, and seizures, the estimated radiation exposure is greater than 10 Gy and mortality is 100%. Those with a moderate radiation dose (2-6 Gy) may develop some mild transient cognitive impairment. Those with a higher dose (~6-10 Gy) will have more significant disturbances in cognition and consciousness that persist beyond 24 hours and have an expected survival of less than 5%. If the radiation dose remains uncertain due to confounders or an ambivalent presentation, the absolute lymphocyte count at 48 hours can provide further insight into the estimated radiation dose absorbed (Table134.4).

Cerebral Edema and Early Delayed Leukoencephalopathy

Symptoms of cerebral edema from radiation injury following therapeutic radiotherapy with high daily dose fractions appear within a few days to weeks and include headache, nausea, and vomiting. Local edema may cause transient worsening of prior neurologic deficits, which can mimic progression of disease (so called "pseudo-progression"). A delayed leukoencephalopathy can present 4 to 10 weeks after radiation with somnolence and headache. This is the result of blood-brain barrier breakdown and defects in the formation and maintenance of the myelin sheath. It is generally self-limited and reversible, although in the long term, advanced small vessel disease may lead to a more permanent leukoencephalopathy. A posterior fossa syndrome of ataxia, dysarthria, and nystagmus may follow radiation to the middle ear area for glomus jugulare tumors.

The early onset of cerebral edema after radiotherapy can be appreciated on head CT and MRI. The latter often demonstrates T2 or T2 FLAIR signal hyperintensity. Ultimately, the diagnosis is clinical and often assumed if there is improvement in symptoms after the administration of corticosteroids.

Radiation Necrosis

Radiation necrosis can also be classified as early, early-delayed, or late-onset but is most often a later consequence of radiation that presents between 6 months and 7.5 years after radiotherapy with clinical manifestations that may mimic the original tumor. Other presentations may include seizures, headaches, or increased intracranial pressure. Focal or lateralizing neurologic deficits can be neuroanatomically linked to the site of the treated malignancy or distant from it. Eighty-five percent of radiation necrosis cases occur within 2 years of treatment. It is more likely to occur with high doses of radiation or reirradiation of previously treated areas.

Radiation necrosis should be suspected when symptoms begin more than 6 months after radiotherapy. Neuroradiologic abnormalities range from focal mass lesions to diffuse white matter changes (Fig. 134.1). Mass lesions are typically at the site of the original tumor/malignancy or in the path of delivered radiotherapy. CT and/or MRI may demonstrate ringlike or heterogeneous enhancement mimicking the original neoplasm.

TABLE 134.3 Clinical Manifestations of Radiation Injury: Features and Risk Factors

Clinical Manifestation	Clinical Features	Imaging Features	Dose[a]	Time Frame[a]	Risk Factors
Acute radiation sickness	Nausea, vomiting, diarrhea, headache	Acute cerebral edema, loss of gray-white differentiation	>2 Gy	Minutes to hours after exposure	Environmental exposure
Nonspecific constitutional symptoms	Fatigue, headache, anorexia	None	Any	Days to weeks after exposure	Extremes of age, comorbid hypertension, and/or diabetes
Acute cerebral edema	Pseudoprogression, encephalopathy	Vasogenic and cerebral edema	>2 Gy	Days to weeks after exposure	Concurrent temozolomide or CTLA-4 agent use
Leukoencephalopathy/ neurocognitive changes	Cognitive slowing	Advanced white matter T2 signal change	>20 Gy, more common after >60 Gy	>1-6 mo after exposure	Extremes of age, comorbid hypertension, and/or diabetes
Radiation necrosis	New or worsening focal deficits	Contrast enhancement, cytotoxic cerebral edema	>50 Gy, higher risk if delivered over shorter time/fewer fractions	6 mo to 7.5 y after exposure	High doses of radiation delivered over fewer fractions
SMART syndrome	Stroke syndrome with associated headache	Heterogenous gyriform enhancement and increased perfusion	>50 Gy	15+ y	Comorbid hypertension and/or diabetes
Myelopathy	Lower extremity paresthesia, weakness, bowel/bladder dysfunction	White matter T2 signal change	>60 Gy, higher risk if delivered over shorter time	1-3 y after exposure	Younger age, high dose, wider field of radiation
Plexopathy/neuropathy	Unilimb paresthesias, pain, or weakness, myokymia on EMG	Swelling of plexus	>60 Gy	3-6 mo	High doses, overlapping fields, axillary focus of treatment, concurrent chemotherapy
Neuroendocrine effects	Growth hormone deficiency, hypogonadism, adrenal insufficiency, and/or hypothyroidism	Leukoencephalopathy, diffuse cerebral microbleeds, vacuolation of cortex and white matter	GH deficiency: >10 Gy Gonadotropin deficiency: >20 Gy Hypothyroidism: >40 Gy Adrenal failure: >45 Gy	>1 y	More common in children
Vasculopathy	Acute stroke syndromes	Advanced large vessel disease, leukoencephalopathy, or mineralizing microangiopathy	>40 Gy	10+ y	HTN, DM
Secondary tumor formation	Symptoms consistent with new/progressive mass lesion	Mass lesion on CT or MRI	>8.5 Gy	Dose-dependent, generally 10+ y	Genetic predisposition, high dose

Abbreviations: CT, computed tomography; CTLA-4, cytotoxic T-lymphocyte-associated protein 4; DM, diabetes mellitus; EMG, electromyography; GH, growth hormone; HTN, hypertension; MRI, magnetic resonance imaging; SMART, stroke-like migraine attacks after radiation therapy.

[a]Doses and time frames listed in this table are those commonly associated with various sequelae, but patients may develop complications at lower doses, especially with increasing time since exposure. Similarly, patients exposed to higher doses of radiation will often develop complications earlier in their course.

TABLE 134.4 Acute Radiation Syndrome Prognosis Based on Acute Symptoms and 48-h Absolute Lymphocyte Count

Radiation Dose (Gy)	Acute Symptoms	24-h CNS Symptoms	48-h Absolute Lymphocyte Count	Prognosis/Mortality
0-0.4	None to very mild, onset ~6 h	None to very mild headache	1,400-3,000 (normal)	Excellent, <5%
0.5-2	None to mild, onset 2-6 h	None to headache	1,000-1,399	Good, <5%
2-4	Mild to moderate, onset 1-2 h	Brief cognitive impairments	500-999	Fair, 5%-50%
4-8	Moderate to severe, onset 10-60 min	Drowsy to confused	100-499	Poor, 50%-100%
>8	Severe, onset within 10 min	Immediate lethargy, coma, seizures	100	Dismal, 100%

Abbreviation: CNS, central nervous system.

FIGURE 134.1 Radiation necrosis on magnetic resonance imaging (MRI). **A:** Coronal T1 post contrast MRI. **B:** Axial T1 post contrast MRI. **C:** Axial T2 FLAIR MRI. An 85-year-old male with history of left trigeminal schwannoma was treated with fractionated stereotactic radiosurgery (3,000 cGy in 5 fractions). Two months after treatment, he presented with worsening trigeminal neuralgia-type pain. The images here demonstrate ring-enhancing lesions with extensive surrounding T2 fluid-attenuated inversion recovery signal change, typical of radiation necrosis.

Angiography and/or perfusion imaging, however, will demonstrate that the lesion is avascular. Initially, changes are typically seen in the white matter but may progress to involve the gray matter over a period of 6 months to 2 years. Diffuse white matter changes are seen as areas of hypodensity on CT or increased signal intensity on T2/FLAIR on MRI (with MRI being more sensitive), do not necessarily correlate with clinical symptoms, and are typically not reversible. Mild or early changes are seen adjacent to the frontal and occipital horns of the lateral ventricles. More extensive or progressive changes extend to include the centrum semiovale. The most advanced show diffuse lesions with a characteristic scalloped configuration. Accompanying changes include cortical atrophy or ventricular dilatation. In all stages, mass effect is rare, and if seen, an alternative process or focal necrosis should be considered.

Distinguishing tumor recurrence from radiation necrosis may be difficult. Both may demonstrate contrast enhancement and diffusion restriction, but recurrent tumor often has lower ADC values than radiation necrosis on diffusion-weighted imaging. Single-photon emission CT and positron emission tomography may be helpful. Hypometabolic areas on positron emission tomography are suggestive of radiation necrosis. Similarly, hyperperfused areas on perfusion magnetic resonance may suggest tumor recurrence over radiation necrosis (cannot be used in the setting of hemorrhage). A reduction in choline levels on magnetic resonance spectroscopy suggests tumor necrosis (and therefore radiation necrosis), whereas an increase could suggest tumor recurrence. Lactate elevations are suggestive (but not diagnostic) of necrosis due to vasculopathy. Serial imaging may be necessary to differentiate between radiation necrosis and disease recurrence or progression. Clinicians should avoid anchoring themselves to a diagnosis based on neuroimaging alone and should have a low threshold for performing a biopsy to increase their diagnostic certainty.

Myelopathy

Radiation-induced myelopathy may also present as an early, early-delayed, or late injury. Early-onset myelopathy is generally seen with ARS and is generally fatal. Early-delayed radiation myelopathy is transient and presents within 6 months of radiotherapy. Lhermitte sign (ie, flexion of the neck causes an electric shock sensation down the spine) is common and was reported in up to 15% of those receiving radiation for Hodgkin lymphoma. Delayed radiation myelopathy presents 1 to 3 years following radiotherapy and presents with painless numbness and paresthesias, which then progress to include a spastic gait, sphincter symptoms, and limb weakness. Less commonly, acute paraplegia occurs acutely over a few hours and in this instance is thought to be the result of vascular injury causing infarction. Also worth mentioning is a syndrome that simulates motor neuron disease, which progress over 1 to 2 years and then plateaus.

Radiation myelopathy is diagnosed via exclusion of other processes and its time of onset in relation to the radiation administration (~1-3 y after radiotherapy). MRI is the preferred diagnostic test and may demonstrate cord swelling, atrophy, or complete subarachnoid block, but it also may be normal. Signal changes on TI (low intensity) or T2 (high intensity) and contrast enhancement may appear 1 month after the onset of clinical symptoms. Beginning about 1 year after onset of symptoms, cord atrophy is seen, and there is no further contrast enhancement. The diagnostic approach should seek to exclude other possible etiologies of the patient's myelopathy, such as extra- or intramedullary tumors, leptomeningeal metastases, or cord compression due to vertebral body abnormalities.

Radiation-Induced Vasculopathy and SMART Syndrome

Radiation-induced vasculopathy typically presents as a transient ischemic attack and/or ischemic stroke. The time course to onset can be short or several decades after radiotherapy. Radiation therapy is an independent risk factor for cerebrovascular disease, particularly after a posttreatment interval of over 10 years. Comorbid hypertension and diabetes mellitus increase the risk of vasculopathy after radiation therapy. Irradiation of the circle of Willis is generally the strongest predictor for stroke, with exponential increase after more than or equal to 40 Gy to these structures; however, there is significant variation in the

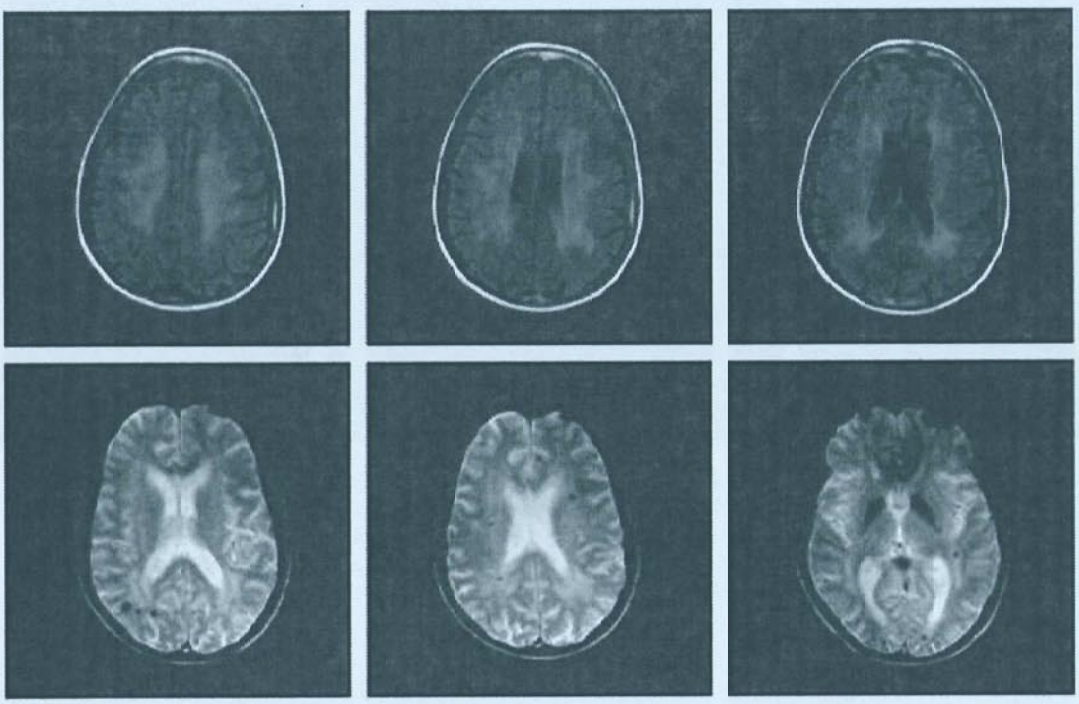

FIGURE 134.2 Whole brain radiation. A 45-year-old woman with breast cancer complicated by multiple brain metastases was treated with multiple courses of whole brain radiation. Although asymptomatic, her imaging here demonstrates diffuse leukoencephalopathy with confluence T2 fluid-attenuated inversion recovery hyperintensities **(top three images)** and scattered microbleeds on susceptibility-weighted imaging **(bottom three images)**.

dose-risk association and genetic factors have also been identified as playing a role in the development of vasculopathy after irradiation.

Radiation-induced vasculopathy may present as advanced large-vessel atherosclerotic disease, pronounced small vessel white matter disease, and/or cerebral microbleeds (Fig. 134.2). Moyamoya-like findings have been described as well. The small vessel disease seen on imaging should be distinguished from early-delayed leukoencephalopathy in that it occurs years after irradiation and is irreversible. Radiation vasculopathy is suspected based on history, location and appearance of the lesion(s), and localization to a region of prior radiotherapy. Stenotic lesions from radiation exposure tend to be more longitudinally extensive and are more prone to restenosis after intervention. Small vessel disease may present with a mineralizing microangiopathy with calcifications observable even on noncontrast CT (Fig. 134.3). More commonly, there is increased T2/FLAIR signal in the area of treatment with or without microbleeds seen on susceptibility-weighted imaging. Cerebrovascular malformations have been reported in the field of irradiated tissue as well.

One clinically distinct vascular syndrome is SMART syndrome. This relatively rare condition presents many years after radiation exposure with recurrent complex migraines with focal neurologic findings, typically in patients who have received over 50 Gy of radiation and often to lesions in the posterior fossa. Risk factors include male sex, time since radiation, and genetic susceptibility. It is typically seen in patients treated for childhood malignancies many years after treatment. Deficits are usually transient during an attack; however, recurrent or progressive cases have also been reported, and there is a presumed association with vasculopathy and increased risk for stroke in these patients.

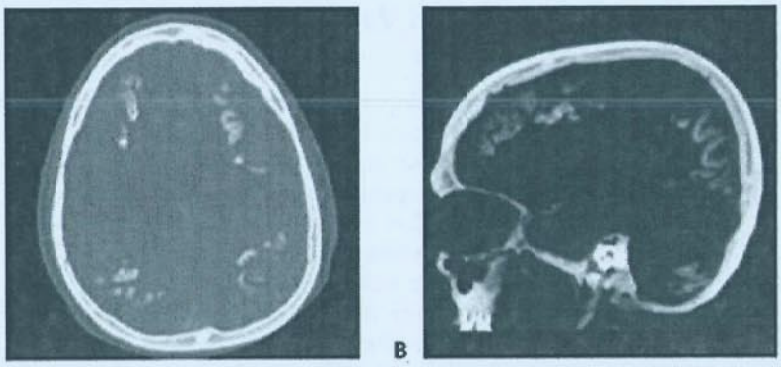

FIGURE 134.3 Mineralizing microangiopathy on noncontrast head computed tomography (CT). **A:** Axial non-contrast head CT set to bone window. **B:** Coronal non-contrast head CT. A 56-year-old male with distant history of childhood lymphoma treated with chemotherapy and radiation underwent magnetic resonance imaging of the brain for new-onset hearing loss. Whereas magnetic resonance imaging showed susceptibility changes initially concerning for hemorrhage, computed tomography shown here revealed diffuse calcifications of the gyri concerning for dystrophic calcinosis. Other than his hearing loss, the patient was asymptomatic from these lesions.

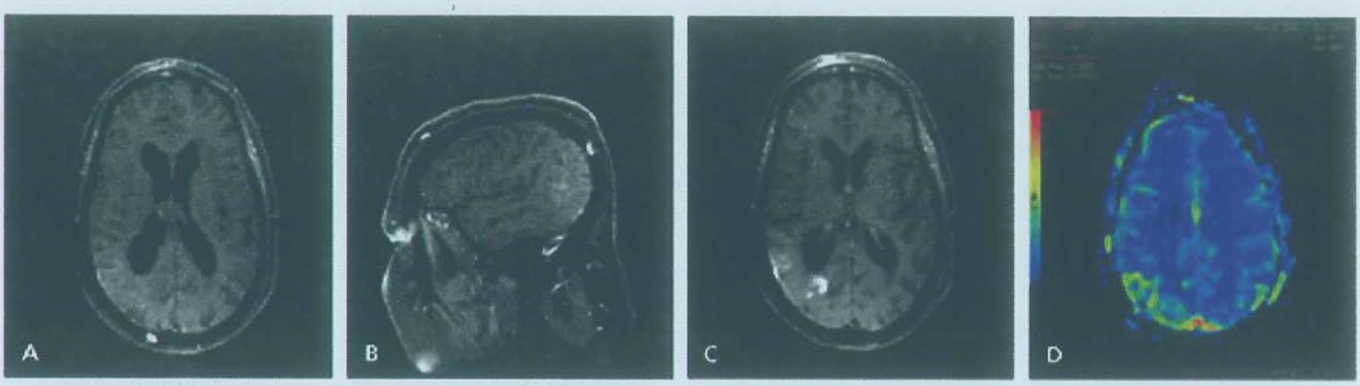

FIGURE 134.4 Stroke-like migraine attacks after radiation therapy (SMART) syndrome on MRI and MR perfusion imaging. **A:** Axial T2 FLAIR MRI. **B:** Coronal T2 FLAIR MRI. **C:** Axial T2 FLAIR MRI. **D:** Axial magnetic resonance perfusion (MRP) image. A 44-year-old male with low-grade oligodendroglioma was treated with resection and stereotactic radiosurgery. Approximately 3 years after treatment, he developed stereotyped episodes of headache; encephalopathy; and left hemibody numbness, hemiplegia, and ataxia with an accompanying left hemianopsia. Magnetic resonance imaging here shows subtle heterogenous gyriform enhancement and with loss of fluid-attenuated inversion recovery suppression and increased flow over this area on magnetic resonance perfusion consistent with stroke-like migraine attacks after radiation therapy syndrome.

Although SMART syndrome is primarily thought to be due to a migraine-like pathology with impaired vascular reactivity and radiation-induced endothelial dysfunction, some studies have suggested a possible epileptic etiology and many described cases have included electrographic seizure as part of the presentation. Thus, electroencephalogram is important to rule out seizure in these patients. Unilateral gyriform enhancement with focal or regional cortical thickening on MRI many years after radiation exposure in a patient with headaches, seizures, and/or focal neurologic findings is suggestive of SMART syndrome (Fig. 134.4). There may be loss of FLAIR suppression and increased flow over this area on perfusion imaging.

Neuropathy and Plexopathy

Radiation plexopathy is observed in three distinct clinical syndromes. A transient plexus injury presents 3 to 6 months following radiotherapy with paresthesias, pain, or weakness. Acute ischemic brachial neuropathy has an acute presentation that does not progress and is painless. Radiation fibrosis presents with painless paresthesias involving the upper (brachial) plexus +/− swelling of the arm about 4 years after radiotherapy. Tumor recurrence can also present in a delayed fashion with paresthesias, but there is typically no swelling, it is painful, and it affects the lower plexus. Electromyography is the diagnostic test of choice and reveals myokymia with the pathognomonic doublets seen on electrodiagnostic testing. Imaging may show increased T2 signal and thickening of the brachial plexus (Fig. 134.5).

Optic Neuropathy and Ocular Neuromyotonia

Similar to peripheral mononeuropathies or plexopathies, patients treated with radiation can develop cranial neuropathies as well. Optic neuropathy presents with painless visual loss, decreased visual acuity, and/ or abnormal visual fields within 3 years of radiotherapy. Exam demonstrates papilledema followed by optic atrophy and hemorrhagic exudates. Imaging may show T2/FLAIR signal hyperintensity such as with other optic neuropathies.

Ocular neuromyotonia presents with tonic spams of extraocular muscles innervated by a particular extraocular nerve that occur during sustained eccentric gaze, resulting in hyperaction of the innervated muscle(s). It most commonly occurs after radiation to the skull base (ie, the oculomotor nerves) and is thought to be due to nerve demyelination and ephaptic transmission versus a possible calcium channel dysfunction.

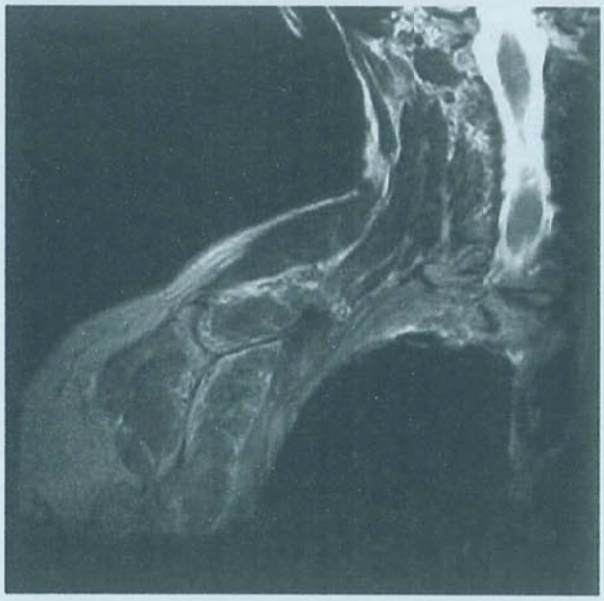

FIGURE 134.5 Plexopathy. T2 hyperintensity and swelling plexopathy. A 63-year-old female with history of breast cancer treated with local radiation presented to neurology clinic with 11 months of worsening right upper extremity monoplegia, paresthesia, and areflexia. Additional examination revealed right ptosis and miosis (concerning for proximal T1 involvement), and magnetic resonance imaging demonstrated T2 signal hyperintensity and swelling in all three (upper, middle, and lower) trunks of the brachial plexus proximal to the supraclavicular region.

Neuroendocrine Dysfunction

Endocrine dysfunction presents with abnormal growth or puberty in children, with decrease in muscle mass, increase in adipose tissue, infertility, and constitutional symptoms of endocrine dysfunction (fatigue, skin changes, heat/cold intolerance, etc) in adults. This may manifest as a growth hormone deficiency, hypogonadism, adrenal insufficiency, hypothyroidism, and/or hyperprolactinemia. Factors that affect risk in fractionated radiation therapy include total dose, fraction size, age at time of radiation, and length of time after radiation therapy. Growth hormone deficiency is the most common and often only deficiency seen after cranial irradiation, occurring after doses as low as 10 Gy. This is a frequent complication in children undergoing either prophylactic cranial radiation therapy or total body irradiation for bone marrow transplant. Gonadotropin deficiency occurs with doses above 20 Gy and manifests as a failure to enter puberty in children and with amenorrhea, infertility, sexual dysfunction, and decreased libido in adults. Thyrotropin deficiency may occur with doses above 40 Gy, and presentations may include weight gain and lethargy. Adrenocorticotropic hormone deficiency is uncommon, occurring in patients receiving doses over 45 to 50 Gy, and presenting with lethargy, fatigue, fasting hypoglycemia, and hyponatremia. Hyperprolactinemia is featured by delayed puberty, galactorrhea, and amenorrhea in women and decreased libido and impotence in men.

Neurocognitive Effects

Neuropsychological sequela of radiation is most conspicuous when it manifests with a delayed IQ decline, learning disability, or academic failure. These symptoms are seen most commonly in children or adults receiving WBRT, with some studies demonstrating cognitive decline in over 90% of patients in the latter group. So-called "hippocampal sparing" protocols have been shown to significantly reduce the risk and severity of decline LEVEL 1.[1-4] Detailed neuropsychiatric testing can reveal deficits in memory, executive function, processing speed, and verbal selective reminding. MRI will often demonstrate a leukoencephalopathy with diffuse T2 signal hyperintensity as well as scattered microbleeds on susceptibility-weighted imaging (see Fig. 134.3). The incidence and severity of neurocognitive symptoms appears to correlate with the degree of leukoencephalopathy seen on MRI. A normal pressure hydrocephalus-like syndrome of ataxia, cognitive disturbance, and urinary incontinence has been described that may improve transiently with ventriculoperitoneal shunting, although many of these patients go on to develop diffuse cerebral atrophy and dementia despite shunting.

MANAGEMENT

Few nervous system effects from ARS do not have specific therapies. The treatment of ARS is described in other texts and largely includes supportive care and granulocyte-stimulating drugs when significant lymphopenia is seen. Corticosteroids do not have a role in ARS because immunosuppression is one of the most feared and deadly consequences of high-dose ionizing radiation exposures. Treatment is generally supportive and acutely symptomatic patients have a high level of mortality.

In patients who develop constitutional symptoms such as anorexia and fatigue, steroids may be considered, but treatment is generally supportive. In a double-blind trial terminated prematurely, 68 patients with primary or metastatic brain tumors were given methylphenidate versus placebo during radiation therapy with no difference in fatigue or cognition at 8 weeks LEVEL 1.[5,6] Early and early-delayed manifestations of radiation injury in particular are often self-limited and do not require specific treatments. Early cerebral edema, early-delayed leukoencephalopathy, early or early-delayed myelopathy, plexopathies, and neuropathies are often treated with corticosteroids. Among these, only cerebral edema seems to have an appreciable clinical response and in cases of patients with significant cerebral edema before radiation therapy, prophylactic treatment with dexamethasone can be considered. Not uncommonly, there is a transient improvement with corticosteroids in myelopathy, but without alteration of the ultimate course of the disease. Steroids can again be considered in optic neuropathies, and ocular neuromyotonia in particular is treated with carbamazepine or lacosamide.

Similarly, early or early-delayed radiation necrosis is often self-limited and does not require treatment. It is important to distinguish radiation necrosis from disease progression, however, and biopsy or follow-up imaging after 1 to 2 months is generally recommended to exclude the former. In some cases, however, radiation necrosis may cause significant neurologic worsening, cerebral edema, or mass effect, leading to delayed central nervous system injury. In these cases, symptomatic patients are again treated with glucocorticoids as a first line. Refractory cases with ongoing injury from radiation necrosis may be treated with bevacizumab, hyperbaric oxygen therapy, or surgery. There is also limited evidence for use of the free radical scavenger edaravone.

In patients who fail steroids, several randomized controlled trials demonstrated beneficial effect of bevacizumab in reducing brain edema radiologic worsening LEVEL 1.[7,8] Bevacizumab is humanized monoclonal antibody against vascular endothelial growth factor, which inhibits its binding to specific surface receptors on endothelial cells to attenuate blood-brain barrier permeability. Hyperbaric oxygen serves to increase oxygen concentration in ischemic areas of radiation injury and has been shown in several case reports and smaller series to be beneficial patients with radiation necrosis. One study of prophylactic hyperbaric oxygen therapy after SRS for metastases demonstrated decreased rates of white matter injury without known benefit. Randomized controlled trials are needed to further evaluate the role of this therapy in the treatment of radiation necrosis. In rare cases, debulking surgery may be necessary to alleviate mass effect should more conservative measures fail. There is limited evidence that laser interstitial thermal therapy may provide improved outcomes over more traditional surgical techniques in these patients. Finally, one open-label randomized controlled trial demonstrated improvement in both symptoms and MRI findings after treatment with the free radical scavenger edaravone in conjunction with steroids; however, further study of this agent is needed LEVEL 1.[9] Unlike acute and early-delayed reactions, which are usually reversible, later manifestations are generally less responsive to treatment with a more malignant course. There are no known effective treatments for late-onset radiation myelopathy; although treatment with bevacizumab has shown promise in case studies, no definitive evidence exists for its use at this time. Treatments for plexopathy include the prevention of shoulder subluxation, treating lymphedema, and providing analgesia.

Vasculopathy due to radiation injury is treated similar to other nonradiation-related cerebrovascular disease. Large artery vasculopathy has been treated successfully with stenting and

some radiation oncologists recommend yearly carotid duplex screening for large vessel atherosclerosis 2 to 5 years after radiation to the neck. It is reasonable to consider antiplatelet agents for small vessel disease. Although concomitant treatment with hyperbaric oxygen during radiation treatment has been shown to reduce the incidence of white matter injury on imaging, this is of unknown clinical significance and is not regularly employed.

The SMART syndrome does not have any proven or specific treatments; patients often receive a course of corticosteroids and antiepileptics. Some authors advocate for antiplatelet agents and/or statins. It is again important to recognize seizures in this population, and all patients with suspected SMART syndrome should undergo evaluation with electroencephalogram.

Patients with suspected neuroendocrine dysfunction after radiation should have screening labs for hypothalamic and/or pituitary dysfunction and be referred to an endocrinologist. Most will require long-term endocrinology follow-up and hormone replacement therapy.

With regard to neurocognitive symptoms, the best treatment is preventative, and significant clinical evidence exists demonstrating that SRS or hippocampal sparing WBRT offers improved cognitive outcomes compared to conventional WBRT protocols LEVEL 1.[1-4] In patients who do develop symptoms, conflicting data exists on the use of neurostimulants in this population, with one randomized controlled trial showing modest benefit but two demonstrating no effect LEVEL 1.[10] The prophylactic use of acetylcholinesterase inhibitors (and in particular memantine) during radiation treatment in this population is more promising, with randomized controlled trails showing benefit in cognitive performance compared to baseline LEVEL 1.[11,12] Its use has also been linked to significant decreases in brain edema, brain infarct size, and brain vasculature changes following WBRT. A phase II study in 2004 of vitamin E provided some benefit as well; however, the study was not randomized or blinded with a small sample size and no long-term follow-up.

OUTCOME

Prognosis after radiation injury varies widely depending on the complication, timing, and degree of injury. Outcomes after acute radiation syndromes are displayed in **Table 134.2**. For patients treated with therapeutic radiation, acute side effects tend to be more benign in their course and often respond to treatment with steroids. Early cerebral edema, early delayed leukoencephalopathy/demyelination, and ocular myotonia, for example, are nearly always self-limited and reversible. In contrast, more delayed complications tend to be irreversible and are less responsive to treatment. Although acute radiation necrosis is often self-limited and/or easily treated with steroids, more delayed or aggressive cases can be progressive and fatal both with and without treatment. Symptoms of radiation myelopathy are also not expected to improve. Outcomes after vasculopathy are related to the efficacy and timing of revascularization efforts. Outcomes after SMART syndrome have only been described in case series, but up to 50% appear to have residual neurologic deficits and these patients may be at increased risk for stroke. Radiation plexopathy, neuropathy, and optic neuropathy are usually irreversible. Neuroendocrine effects are permanent in most cases, requiring lifelong hormone replacement therapy. Cognitive deficits are typically not reversible and not uncommonly progressive, resulting in death or permanent disability and dependence.

LEVEL 1 EVIDENCE

1. Brown PD, Jaeckle K, Ballman KV, et al. Effect of radiosurgery alone vs radiosurgery with whole brain radiation therapy on cognitive function in patients with 1 to 3 brain metastases: a randomized clinical trial. *JAMA*. 2016;316:401-409.
2. Brown PD, Ballman KV, Cerhan JH, et al. Postoperative stereotactic radiosurgery compared with whole brain radiotherapy for resected metastatic brain disease (NCCTG N107C/CEC·3): a multicentre, randomised, controlled, phase 3 trial. *Lancet Oncol*. 2017;18:1049-1060.
3. Gondi V, Hermann BP, Mehta MP, Tomé WA. Hippocampal dosimetry predicts neurocognitive function impairment after fractionated stereotactic radiotherapy for benign or low-grade adult brain tumors. *Int J Radiat Oncol Biol Phys*. 2013;85(2):348-354.
4. Tsai PF, Yang CC, Chuang CC, et al. Hippocampal dosimetry correlates with the change in neurocognitive function after hippocampal sparing during whole brain radiotherapy: a prospective study. *Radiat Oncol*. 2015;10:253.
5. Mulhern RK, Khan RB, Kaplan S, et al. Short-term efficacy of methylphenidate: a randomized, double-blind, placebo-controlled trial among survivors of childhood cancer. *J Clin Oncol*. 2004;22(23):4795-4803.
6. Butler JM Jr, Case LD, Atkins J, et al. A phase III, double-blind, placebo-controlled prospective randomized clinical trial of d-threo-methylphenidate HCl in brain tumor patients receiving radiation therapy. *Int J Radiat Oncol Biol Phys*. 2007;69(5):1496-1501.
7. Levin VA, Bidaut L, Hou P, et al. Randomized double-blind placebo-controlled trial of bevacizumab therapy for radiation necrosis of the CNS. *Int J Radiat Oncol Biol Phys*. 2011;79(5):1487-1495.
8. Xu Y, Rong X, Hu W, et al. Bevacizumab monotherapy reduces radiation-induced brain necrosis in nasopharyngeal carcinoma patients: a randomized controlled trial. *Int J Radiat Oncol Biol Phys*. 2018;101(5):1087-1095.
9. Tang Y, Rong X, Hu W, et al. Effect of edaravone on radiation-induced brain necrosis in patients with nasopharyngeal carcinoma after radiotherapy: a randomized controlled trial. *J Neurooncol*. 2014;120(2):441-447.
10. Page BR, Shaw EG, Lu L, et al. Phase II double-blind placebo-controlled randomized study of armodafinil for brain radiation-induced fatigue. *Neuro Oncol*. 2015;17(10):1393-1401.
11. Brown PD, Pugh S, Laack NN, et al. Memantine for the prevention of cognitive dysfunction in patients receiving whole-brain radiotherapy: a randomized, double-blind, placebo-controlled trial. *Neuro Oncol*. 2013;15:1429-1437.
12. Rapp SR, Case LD, Peiffer A, et al. Donepezil for irradiated brain tumor survivors: a phase III randomized placebo-controlled clinical trial. *J Clin Oncol*. 2015;33(15):1653-1659.

SUGGESTED READINGS

Central Nervous System Effects

Chernov MF, Ono Y, Abe K, et al. Differentiation of tumor progression and radiation-induced effects after intracranial radiosurgery. *Acta Neurochir Suppl*. 2013;116:193-210.

Coderre JA, Morris GM, Micca PL, et al. Late effects of radiation on the central nervous system: role of vascular endothelial damage and glial stem cell survival. *Radiat Res*. 2006;166:495-503.

Diaz AZ, Choi M. Radiation-associated toxicities in the treatment of high-grade gliomas. *Semin Oncol*. 2014;41(4):532-540.

Donahue B. Short- and long-term complications of radiation therapy for pediatric brain tumors. *Pediatr Neurosurg*. 1992;18:207-217.

Doyle DM, Einhorn LH. Delayed effects of whole brain radiotherapy in germ cell tumor patients with central nervous system metastases. *Int J Radiat Oncol Biol Phys*. 2008;70(5):1361-1364.

Genc M, Genc E, Genc BO, Kiresi DA. Significant response of radiation induced CNS toxicity to high dose steroid administration. *Br J Radiol*. 2006;79(948):e196-e199.

Greene-Schloesser D, Robbins ME, Peiffer AM, Shaw EG, Wheeler KT, Chan MD. Radiation-induced brain injury: a review. *Front Oncol*. 2012;2:73.

Kim JH, Brown SL, Jenrow KA, Ryu S. Mechanisms of radiation-induced brain toxicity and implications for future clinical trials. *J Neurooncol*. 2008;87(3):279-286.

Landau K, Killer HE. Radiation damage. *Neurology*. 1996;46:889.

Mayer R, Sminia P. Reirradiation tolerance of the human brain. *Int J Radiat Oncol Biol Phys*. 2008;70:1350-1360.

Mettler FA Jr, Voelz G. Major radiation exposure—what to expect and how to respond. *N Engl J Med*. 2002;346(20):1554-1561.

Moss H, Nannis E, Poplack DG. The effects of prophylactic treatment of the central nervous system on the intellectual functioning of children with acute lymphocytic leukemia. *Am J Med*. 1981;71:47-52.

Mostow EN, Byrne J, Connelly RR, Muvihill JJ. Quality of life in long-term survivors of CNS tumors of childhood and adolescence. *J Clin Oncol*. 1991;9:592-599.

Nolan CP, DeAngelis LM. Neurologic complications of chemotherapy and radiation therapy. *Continuum (Minneap Minn)*. 2015;21(2 Neuro-oncology):429-451.

Norris AM, Carrington BM, Slevin NJ. Late radiation change in the CNS: MR imaging following gadolinium enhancement. *Clin Radiol*. 1997;52:356-362.

Packer RJ, Meadows AT, Rorke LB, Goldwein JL, D'Angio G. Long-term sequelae of cancer treatment on the central nervous system in childhood. *Med Pediatr Oncol*. 1987;15:241-253.

Partap S, Russo S, Esfahani B, et al. A review of chronic leukoencephalopathy among survivors of childhood cancer. *Pediatr Neurol*. 2019;101:2-10

Schultheiss TE, Kun LE, Ang KK, Stephens LC. Radiation response of the central nervous system. *Int J Radiat Oncol Biol Phys*. 1995;31:1093-1112.

Sheline GE, Wara WM, Smith V. Therapeutic irradiation and brain injury. *Int J Radiat Oncol Biol Phys*. 1980;6:1215-1228.

Twijnstra A, Boon PJ, Lormans ACM, ten Velde GP. Neurotoxicity of prophylactic cranial irradiation in patients with small cell carcinoma of the lung. *Eur J Cancer Clin Oncol*. 1987;23:983-986.

Endocrine Dysfunction

Ben Arush MW, Elhasid R. Effects of radiotherapy on the growth of children with leukemia. *Pediatr Endocrinol Rev*. 2008;5(3):785-788.

Burstein S. Poor growth after cranial irradiation. *Pediatr Rev*. 1997;18:442-444.

Constine LS, Woolf PD, Cann D, et al. Hypothalamic-pituitary dysfunction after radiation for brain tumors. *N Engl J Med*. 1993;328:87-94.

Crowne E, Gleeson H, Benghiat H, Sanghera P, Toogood A. Effect of cancer treatment on hypothalamic-pituitary function. *Lancet Diabetes Endocrinol*. 2015;3(7):568-576.

Duffner PK, Cohen ME, Voorhess ML, et al. Long-term effects of cranial irradiation on endocrine function in children with brain tumors. A prospective study. *Cancer*. 1985;56:2189-2193.

Mechanik JI, Hochberg FH, LaRocque A. Hypothalamic dysfunction following whole-brain irradiation. *J Neurosurg*. 1986;65:490-494.

Rappaport R, Brauner R. Growth and endocrine disorders secondary to cranial irradiation. *Pediatr Res*. 1989;25:561-567.

Shalet SM. Radiation and pituitary dysfunction. *N Engl J Med*. 1993;328:131-133.

Woo E, Lam K, Yu YL, Ma J, Wang C, Yeung RT. Temporal lobe and hypothalamic-pituitary dysfunctions after radiotherapy for nasopharyngeal carcinoma: a distinct clinical syndrome. *J Neurol Neurosurg Psychiatry*. 1988;51:1302-1307.

Neurocognitive Effects

Anderson V, Godber T, Smibert E, Ekert H. Neurobehavioural sequelae following cranial irradiation and chemotherapy in children: an analysis of risk factors. *Pediatr Rehabil*. 1997;1:63-76.

Armstrong C, Ruffer J, Corn B, DeVries K, Mollman J. Biphasic patterns of memory deficits following moderate-dose partial-brain irradiation: neuropsychologic outcome and proposed mechanisms. *J Clin Oncol*. 1995;13:2263-2271.

Crossen JR, Garwood D, Glatstein E, Neuwelt EA. Neurobehavioral sequelae of cranial irradiation in adults: a review of radiation-induced encephalopathy. *J Clin Oncol*. 1994;12:627-642.

Duffey P, Chari G, Cartlidge NEF, Shaw PJ. Progressive deterioration of intellect and motor function occurring several decades after cranial irradiation. A new facet in the clinical spectrum of radiation encephalopathy. *Arch Neurol*. 1996;53:814-818.

Edelmann MN, Krull KR, Liu W, et al. Diffusion tensor imaging and neurocognition in survivors of childhood acute lymphoblastic leukaemia. *Brain*. 2014;137(pt 11):2973-2983.

Glauser TA, Packer RJ. Cognitive deficits in long-term survivors of childhood brain tumors. *Childs Nerv Syst*. 1991;7:2-12.

Hardy SJ, Krull KR, Wefel JS, Janelsins M. Cognitive changes in cancer survivors. *Am Soc Clin Oncol Educ Book*. 2018;38:795-806.

Kazda T, Jancalek R, Pospisil P, et al. Why and how to spare the hippocampus during brain radiotherapy: the developing role of hippocampal avoidance in cranial radiotherapy. *Radiat Oncol*. 2014;9:139.

Krull KR, Minoshima S, Edelmann M, et al. Regional brain glucose metabolism and neurocognitive function in adult survivors of childhood cancer treated with cranial radiation. *J Nucl Med*. 2014;55(11):1805-1810.

Meadows A, Gordon J, Massari DJ, Littman P, Fergusson J, Moss K. Declines in IQ scores and cognitive dysfunctions in children with acute lymphocytic leukemia treated with cranial irradiation. *Lancet*. 1981;2:1015-1018.

Mody R, Li S, Dover DC, et al. Twenty-five-year follow-up among survivors of childhood acute lymphoblastic leukemia: a report from the Childhood Cancer Survivor Study. *Blood*. 2008;111(12):5515-5523.

Mulhern RK, Kovnar E, Langston J, et al. Long-term survivors of leukemia treated in infancy: factors associated with neuropsychologic status. *J Clin Oncol*. 1992;10:1095-1102.

Roddy E, Mueller S. Late effects of treatment of pediatric central nervous system tumors. *J Child Neurol*. 2016;31(2):237-254.

Optic Neuropathy and Ocular Neuromyotonia

Danesh-Meyer HV. Radiation-induced optic neuropathy. *J Clin Neurosci*. 2008;15:95-100.

Eckstein D, Riechardt AI, Heufelder J, et al. Radiation-induced optic neuropathy: observation versus intravitreal treatment: can visual acuity be maintained by intravitreal treatment? *Am J Ophthalmol*. 2019;208:289-294..

Harris J, Levene M. Visual complications following irradiation for pituitary adenomas and craniopharyngiomas. *Radiology*. 1976;120:167-171.

Kountouri M, Pica A, Walser M, et al. Radiation-induced optic neuropathy after pencil beam scanning proton therapy for skull-base and head and neck tumours. *Br J Radiol*. 2020;93(1107):20190028.

Parsons J, Fitzgerald C, Hood C, Ellingwood KE, Bova FJ, Million RR. The effects of irradiation on the eye and optic nerve. *Int J Radiat Oncol Biol Phys*. 1983;9:609-622.

Pomeranz HD, Henson JW, Lessell S. Radiation-associated cerebral blindness. *Am J Ophthalmol*. 1998;126:609-611.

Soares-Dos-Reis R, Martins AI, Brás A, Matos A, Bento C, Lemos J. Ocular neuromyotonia. *Pract Neurol*. 2018;18(5):389-390.

Radiation-Induced Tumors

Abalo KD, Rage E, Leuraud K, et al. Early life ionizing radiation exposure and cancer risks: systematic review and meta-analysis [published online ahead of print September 10, 2020]. *Pediatr Radiol*. doi:10.1007/s00247-020-04803-0.

Bowers DC, Nathan PC, Constine L, et al. Subsequent neoplasms of the CNS among survivors of childhood cancer: a systematic review. *Lancet Oncol*. 2013;14(8):e321-e328.

Brenner AV, Sugiyama H, Preston DL, et al. Radiation risk of central nervous system tumors in the Life Span Study of atomic bomb survivors, 1958-2009. *Eur J Epidemiol*. 2020;35(6):591-600.

Braganza MZ, Kitahara CM, Berrington de González A, Inskip PD, Johnson KJ, Rajaraman P. Ionizing radiation and the risk of brain and central nervous system tumors: a systematic review. *Neuro Oncol*. 2012;14(11):1316-1324.

D'Elia A, Tropeano MP, Maiola V, Frati A, Salvati M. The etiology of low-grade gliomas: pathological and clinical considerations about radiation-induced low-grade gliomas. *Neurol Sci*. 2015;36(7):1091-1095.

Ecemis GC, Atmaca A, Meydan D. Radiation-associated secondary brain tumors after conventional radiotherapy and radiosurgery. *Expert Rev Neurother*. 2013;13(5):557-565.

Mehyar LS, Abu-Arja MH, Stanek JR, Elbeshlawi I, AbdelBaki MS. The risk of developing secondary central nervous system tumors after diagnostic irradiation from computed tomography in pediatrics: a literature review. *Pediatr Neurol*. 2019;98:18-24.

Ron E, Modan B, Boice JD Jr, et al. Tumors of the brain and nervous system after radiotherapy in childhood. *N Engl J Med*. 1988;319:1033-1039.
Shapiro S, Mealey J Jr, Sartorius C. Radiation-induced intracranial malignant gliomas. *J Neurosurg*. 1989;71:77-82.

Peripheral Neuropathy

Giese WL, Kinsella TJ. Radiation injury to peripheral and cranial nerves. In: Gutin PH, Leibel SA, Sheline GE, eds. *Radiation Injury to the Nervous System*. New York, NY: Raven Press; 1991:383-403.
Gillette EL, Mahler PA, Powers BE, et al. Late radiation injury to muscle and peripheral nerves. *Int J Radiat Oncol Biol Phys*. 1995;31:1309-1318.
Zheng B, Lin J, Li Y, et al. Predictors of the therapeutic effect of corticosteroids on radiation-induced optic neuropathy following nasopharyngeal carcinoma. *Support Care Cancer*. 2019;27(11):4213-4219.

Radiation-Induced Plexopathy

Bowen BC, Verma A, Brandon AH, Fiedler JA. Radiation-induced brachial plexopathy: MR and clinical findings. *AJNR Am J Neuroradiol*. 1996;17:1932-1936.
Georgiou A, Grigsby PW, Perez CA. Radiation induced lumbosacral plexopathy in gynecologic tumors: clinical findings and dosimetric analysis. *Int J Radiat Oncol Biol Phys*. 1993;26:479-482.
Harper CM Jr, Thomas J, Cascino T, Litchy WJ. Distinction between neoplastic and radiation-induced brachial plexopathy, with emphasis on the role of EMG. *Neurology*. 1989;39:502-506.
Jaeckle KA, Young DF, Foley KM. The natural history of lumbosacral plexopathy in cancer. *Neurology*. 1985;35:8-15.
Kori SH, Foley KM, Posner JB. Brachial plexus lesions in patients with cancer: 100 cases. *Neurology*. 1981;31:45-50.
Olsen NK, Pfeiffer P, Johannsen L, Schrøder H, Rose C. Radiation-induced brachial plexopathy: neurological follow-up in 161 recurrence-free breast cancer patients. *Int J Radiat Oncol Biology Phys*. 1993;26:43-49.
Thomas JE, Cascino TL, Earle JD. Differential diagnosis between radiation and tumor plexopathy of the pelvis. *Neurology*. 1985;35:1-7.
Wouter van Es H, Engelen AM, Witkamp TD, Ramos LM, Feldberg MA. Radiation-induced brachial plexopathy: MR imaging. *Skeletal Radiol*. 1997;26:284-288.

Radiation Myelopathy

Alfonso ED, De Gregorio MA, Mateo P, et al. Radiation myelopathy in over-irradiated patients: MR imaging findings. *Eur Radiol*. 1997;7:400-404.
Goldwein JW. Radiation myelopathy: a review. *Med Pediatr Oncol*. 1987;15:89-95.
Grünewald R, Chroni E, Panayiotopoulos C, Enevoldson TP. Late onset radiation-induced motor neuron syndrome. *J Neurol Neurosurg Psychiatry*. 1992;55:741-742.
Jeremic B, Djuric L, Mijatovic L. Incidence of radiation myelitis of the cervical spinal cord at doses of 5500 cGy or greater. *Cancer*. 1991;68:2138-2141.
Koehler PJ, Verbiest H, Jager J, Vecht CJ. Delayed radiation myelopathy: serial MR-imaging and pathology. *Clin Neurol Neurosurg*. 1996;98:197-201.
Komachi H, Tsuchiya K, Ikeda M, Koike R, Matsunaga T, Ikeda K. Radiation myelopathy: a clinicopathological study with special reference to correlation between MRI findings and neuropathology. *J Neurol Sci*. 1995;132:228-232.
Melki PS, Halimi P, Wibault P, Masnou P, Doyon D. MRI in chronic progressive radiation myelopathy. *J Comput Assist Tomogr*. 1994;18:1-6.
Schultheiss TE, Higgins EM, El-Mahdi AM. The latent period in clinical radiation myelopathy. *Int J Radiat Oncol Biol Phys*. 1984;10:1109-1115.
Thornton AF, Zimberg SH, Greenberg HS, Sullivan MJ. Protracted Lhermitte's sign following head and neck irradiation. *Arch Otolaryngol Head Neck Surg*. 1991;117:1300-1303.
Wang PY, Shen WC, Jan JS. Serial MRI changes in radiation myelopathy. *Neuroradiology*. 1995;37:374-377.
Wara W, Phillips T, Sheline G, Schwade JG. Radiation tolerance of the spinal cord. *Cancer*. 1975;35:1558-1562.
Wong CS, Fehlings MG, Sahgal A. Pathobiology of radiation myelopathy and strategies to mitigate injury. *Spinal Cord*. 2015;53(8):574-580.

Radiation Necrosis

Chung C, Bryant A, Brown PD. Interventions for the treatment of brain radionecrosis after radiotherapy or radiosurgery. *Cochrane Database Syst Rev*. 2018;7(7):CD011492.
Glitza IC, Guha-Thakurta N, D'Souza NM, et al. Bevacizumab as an effective treatment for radiation necrosis after radiotherapy for melanoma brain metastases. *Melanoma Res*. 2017;27(6):580-584.
Minniti G, Clarke E, Lanzetta G, et al. Stereotactic radiosurgery for brain metastases: analysis of outcome and risk of brain radionecrosis. *Radiat Oncol*. 2011;6:48.
Ohguri T, Imada H, Kohshi K, et al. Effect of prophylactic hyperbaric oxygen treatment for radiation-induced brain injury after stereotactic radiosurgery of brain metastases. *Int J Radiat Oncol Biol Phys*. 2007;67:248-255.
Ruben JD, Dally M, Bailey M, Smith R, McLean CA, Fedele P. Cerebral radiation necrosis: incidence, outcomes, and risk factors with emphasis on radiation parameters and chemotherapy. *Int J Radiat Oncol Biol Phys*. 2006;65:499-508.
Sadraei NH, Dahiya S, Chao ST, et al. Treatment of cerebral radiation necrosis with bevacizumab: the Cleveland clinic experience. *Am J Clin Oncol*. 2015;38(3):304-310.
Schüttrumpf LH, Niyazi M, Nachbichler SB, et al. Prognostic factors for survival and radiation necrosis after stereotactic radiosurgery alone or in combination with whole brain radiation therapy for 1–3 cerebral metastases. *Radiat Oncol*. 2014;9:105.
Shah R, Vattoth S, Jacob R, et al. Radiation necrosis in the brain: imaging features and differentiation from tumor recurrence. *Radiographics*. 2012;32(5):1343-1359.
Siu A, Wind JJ, Iorgulescu JB, Chan TA, Yamada Y, Sherman JH. Radiation necrosis following treatment of high grade glioma—a review of the literature and current understanding. *Acta Neurochir (Wien)*. 2012;154(2):191-201.
Telera S, Fabi A, Pace A, et al. Radionecrosis induced by stereotactic radiosurgery of brain metastases: results of surgery and outcome of disease. *J Neurooncol*. 2013;113(2):313-325.
Verma N, Cowperthwaite MC, Burnett MG, Markey MK. Differentiating tumor recurrence from treatment necrosis: a review of neuro-oncologic imaging strategies. *Neuro Oncol*. 2013;15(5):515-534.

Stroke-like Migraine Attacks After Radiation Therapy (SMART) Syndrome

Armstrong AE, Gillan E, DiMario FJ Jr. SMART syndrome (stroke-like migraine attacks after radiation therapy) in adult and pediatric patients. *J Child Neurol*. 2014;29(3):336-341.
Black DF, Morris JM, Lindell EP, et al. Stroke-like migraine attacks after radiation therapy (SMART) syndrome is not always completely reversible: a case series. *AJNR Am J Neuroradiol*. 2013;34(12):2298-2303.
Fan EP, Heiber G, Gerard EE, Schuele S. Stroke-like migraine attacks after radiation therapy: A misnomer? *Epilepsia*. 2018;59:259-268.
Olsen AL, Miller JJ, Bhattacharyya S, Voinescu PE, Klein JP. Cerebral perfusion in stroke-like migraine attacks after radiation therapy syndrome. *Neurology*. 2016;86:787-789.
Takahashi H, Kimura T, Yuki N, Yoshioka A. Stroke-like migraine attacks after radiation therapy (SMART) syndrome followed by cerebral infarction. *Intern Med*. 2018;57(13):1921-1924.
Zheng Q, Yang L, Tan LM, Qin LX, Wang CY, Zhang HN. Stroke-like migraine attacks after radiation therapy syndrome. *Chin Med J (Engl)*. 2015;128(15):2097-2101.

Vascular Complications

Aizer AA, Du R, Wen PY, Arvold ND. Radiotherapy and death from cerebrovascular disease in patients with primary brain tumors. *J Neurooncol*. 2015;124:291-297.
Benson PJ, Sung JH. Cerebral aneurysms following radiotherapy for medulloblastoma. *J Neurosurg*. 1989;70:545-550.
El-Fayech C, Haddy N, Allodji RS, et al. Cerebrovascular diseases in childhood cancer survivors: role of the radiation dose to Willis circle arteries. *Int J Radiat Oncol Biol Phys*. 2017; 97:278-286.
Houdart E, Mounayer C, Chapot R, Saint-Maurice JP, Merland JJ. Carotid stenting for radiation-induced stenosis: a report of 7 cases. *Stroke*. 2001;32:118-121.
Kralik SF, Mereniuk TR, Grignon L, et al. Radiation-induced cerebral microbleeds in pediatric patients with brain tumors treated with proton radiation therapy. *Int J Radiat Oncol Biol Phy*. 2018;102(5):1465.
Kreisl TN, Toothaker T, Karimi S, DeAngelis LM. Ischemic stroke in patients with primary brain tumors. *Neurology*. 2008;70(24):2314-2320.
Murphy ES, Xie H, Merchant TE, Yu JS, Chao ST, Suh JH. Review of cranial radiotherapy-induced vasculopathy. *J Neurooncol*.2015;122:421-429.
Nordstrom M, Felton E, Sear K, et al. Large vessel arteriopathy after cranial radiation therapy in pediatric brain tumor survivors. *J Child Neurol*. 2018;33:359-366.
Pozzati E, Giangaspero F, Marliani F, Acciarri N. Occult cerebrovascular malformations after irradiation. *Neurosurgery*. 1996;39:677-682.

Roongpiboonsopit D, Kuijf HJ, Charidimou A, et al. Evolution of cerebral microbleeds after cranial irradiation in medulloblastoma patients. *Neurology*. 2017;88:789-796.

Ullrich NJ, Robertson R, Kinnamon DD, et al. Moyamoya following cranial irradiation for primary brain tumors in children. *Neurology*. 2007;68(12):932-938.

Wahl M, Anwar M, Hess CP, Chang Sm, Lupo JM. Relationship between radiation dose and microbleed formation in patients with malignant glioma. *Radiat Oncol*. 2017;12:126.

Warrington JP, Ashpole N, Csiszar A, Lee YW, Ungvari Z, Sonntag WE. Whole brain radiation-induced vascular cognitive impairment: mechanisms and implications. *J Vasc Res*. 2013;50(6):445-457.

Werner MH, Burger PC, Heinz ER, Friedman AH, Halperin EC, Schold SC Jr. Intracranial atherosclerosis following radiotherapy. *Neurology*. 1988;38:1158-1160.

Xu J, Yongjun C. Radiation-induced carotid artery stenosis: a comprehensive review of the literature. *Interv Neurol*. 2014;2(4):183-192.

Electrical and Lightning Injury 135

Imad Khan and Christopher Zammit

KEY POINTS

1. Electrical injuries can be differentiated into low- and high-voltage electrical injuries (LVEI, HVEI).
2. LVEI severity, such as electrical wire contact, depends on the amount of current and whether current is alternating or direct.
3. High voltage electrical injuries, such as lightning strikes, lead to violent muscle contractions and burn injuries at the point of contact and along tissues of low resistance such as nerves, muscle and blood vessels.
4. Long term neurological symptoms after electrical injury may include neuropsychiatric dysfunction, Parkinsonism, progressive motor deficits, myelopathy, focal dystonia, and tics.

INTRODUCTION

Electrical injuries (EI) and lightning strikes (LS) have been reported to cause a variety of neurologic injuries. Interestingly, although some of the associated neurologic sequelae are seen acutely, others develop in a delayed fashion. Although both EI and LS produce injury via the creation of an electrical current, the neurologic complications of each can be quite different.

Low-voltage electrical injuries (LVEI) are defined as resulting from exposures of less than 1,000 V, whereas greater exposures are termed *high-voltage electrical injuries* (HVEI). They are to be further distinguished as being the result of a direct current or an alternating current (AC), with the latter producing approximately 3 times as much injury as the former. The LS are exceptionally brief, with voltages on the order of the millions, and produce a unique constellation of immediate and delayed injuries.

EPIDEMIOLOGY

The first death in the United States related to an artificial electrical source occurred in front of a crowd in Buffalo, New York, in 1881 when an intoxicated man came into contact with a generator. His death was seen as being quite painless, leading to the use of electrocution as a humane method of capital punishment. Formal reporting of electrical and lightning injuries is not required, limiting the accuracy of existing epidemiologic data.

There are an estimated 3,000 EI per year in the United States, including 1,000 deaths. Children are more likely to suffer LVEI, whereas adolescents and adults more commonly experience HVEI, which are frequently occupationally related.

Over 15,000 police departments across the United States use conducted energy weapons (CEWs), such as stun guns and TASER devices to restrain suspects. Cardiac arrests have occurred after the uses of CEW, but a causational link has been proposed in only a minority of cases. In the majority of circumstances, excited delirium and/or intoxicants ingested by the victim are blamed for causing the arrest.

Three hundred to 1,000 lightning injuries occur per year in the United States, with an estimated mortality rate of 10%. Many victims either do not seek care at the time of the injury, and half of the immediate deaths are transported directly to the coroner and never reported. Victims are usually men (4.5:1 male-to-female ratio) in their second to third decade of life and are performing outdoor recreational or occupational activities.

PATHOBIOLOGY

Electrical Injuries

The severity of LVEI is subject to the pathway of the current and proportional to the duration of exposure and amount of current (milliamperes). Low-voltage AC, in contrast to low-voltage direct current, can produce continuous involuntary muscle contractions. If the victim grips an AC electrical source with their hand, tetany of the flexors of the upper extremity prove stronger than the extensors, causing the victim's grasp of the source to be strengthened. Currents of 6 to 9 mA or greater, which can be achieved via exposure to a standard 110-V household outlet, exceed the "let-go threshold," rendering the victim incapable of dissociating himself or herself from the source. If the current flows through the thorax, tetany of the muscles of respiration can occur, causing the victim to suffocate. Currents of approximately 50 to 100 mA can cause ventricular fibrillation; the current threshold is inversely proportional to the duration of exposure.

Direct contact with a high-voltage electrical source more commonly produces diffuse, sudden, and violent muscle contractions that thrust the victim away from the source, causing traumatic insults in addition to the EI. Even with brief exposures, the high voltages convey a tremendous amount of energy, which is released via electrothermal heating at points of high resistance (eg, the skin, where full-thickness burns are seen). Internally, the current is carried along tissues of low resistance, such as the nerves, muscles, and blood vessels. Immediate effects include muscle necrosis and small-vessel thrombosis, resulting in threats to extremity viability and peripheral nerve integrity through compartment syndromes and limb ischemia.

In contrast to a direct-contact injury, a spark can jump from a highly charged source to a ground source, forming an electrical arc, where temperatures can reach 2,500°C. When a victim is caught in the path of the arc, he or she suffers cutaneous thermal burns and blast injuries when the suddenly heated air rapidly cools, in addition to a HVEI by becoming part of the conduction pathway of the current.

The CEWs are reported to be high voltage (with an initial charge of ~50,000 V). However, the victim does not experience this voltage. Instead, it allows for an arc to be created if the

barbs do not make contact with the skin, which happens about 30% of the time. Once contact is made, the voltage immediately decreases to provide a current of approximately 2 mA in brief pulses at a rate of 20 times per second, producing involuntary muscle clonus (much like an AC circuit), preventing the suspect from resisting. Because of the low current, EI is rare with CEWs, and most injuries, when they do occur, are traumatic and related to when the victim falls to the ground.

Lightning Strikes

Lightning victims can be directly struck with the discharge, receive current via an adjacent object that was directly struck (side flash), become part of the ground current when their feet are apart (step voltage), be the conduit for currents that originate from the ground and discharge toward the clouds (upward stream), and/or experience a concussive or blast injury from the rapid heating and cooling of the air (thunder). Curiously, some of the injuries typically seen with direct-contact HVEI are not found in lightning injuries, and entry and exit wounds are only seen in a minority of cases, suggesting that most, if not all, of the current flows external to the victim. This is thought to result in a powerful magnetic field being created over the victim, causing electrical currents to flow internally through low-resistance tissues (ie, nerves, muscles, blood vessels), resulting in powerful muscle contractions and medullary dysfunction leading to apnea, asystole, and a tremendous catecholamine surge.

Ball lightning is a poorly understood, spherical, mobile electrical field observed floating along power lines, down aisles of airplanes, or through the air during lightning storms. Coronal discharges are another form of lightning-related phenomenon thought to be caused by air breakdown when electric stress at a conductor's surface exceeds a certain value, causing a colored glow near the surface of the conductor. Neurologic sequelae have been reported in those that have come into contact with ball lightning and coronal discharges, including peripheral neuropathy, ataxia, and cognitive and memory deficits.

The pathophysiology of neuronal injury after EI and LS is not clear, and several plausible mechanisms have been reported. The low resistance of nerves makes them a conduit for the electrical current, causing tremendous excitatory discharges, which result in microglia activation, electroporation, and chromatolysis. Electroporation is the destabilization of neuronal cell membranes from electrical current–induced changes in cellular proteins, resulting in their dysfunction and perhaps ultimate death. Microglia activation produces an inflammatory response suspected to result in injury to neurons and oligodendrocytes. Upregulation of postsynaptic cortical γ-aminobutyric acid B receptors is also a suggested consequence of the excitatory impulse based on the results of experiments using transcranial magnetic stimulation in patients with HVEI. Axonal injury and demyelination have been observed in EI and LS victims on magnetic resonance imaging, nerve conduction studies, and autopsy.

Blood vessels similarly conduct electrical current, which has been observed to cause microvascular thrombosis and large vessel vasospasm, with some case reports of cerebral thrombosis. Endothelial cell dysfunction at the capillary level resulting in tissue ischemia is a proposed etiology for some of the delayed clinical consequences.

Muscles are also low resistance and therefore conduct a great deal of electrical current. Sarcolemmal injury is a proposed cause of the protracted fatigue reported by many victims of HVEI.

CLINICAL FEATURES

The immediately clinical presentation of EI and LS can range from a minor contact burn to cardiac arrest. In EI due to direct contact, particularly HVEI, there are often significant cutaneous burns with much more extensive internal burn injuries, particularly involving muscles, small vessels, and tendons. Limb amputation may be required, and rhabdomyolysis is frequent in HVEI. Traumatic injuries to the head and spinal cord are also common. Vasospasm and cerebral arterial thrombosis, both immediate and delayed, have been reported. Myelopathy is frequently reported and occurs at a spinal level consistent with the path of the electrical current. Contact injuries to the head and LS may cause a multiple-level myelopathy when the current exits through the foot. Myelopathy may occur in a delayed presentation, with a time period that is inversely proportional to the patient's age. Curiously, peripheral neuropathy is not commonly seen, but when it does occur, it tends to affect motor nerves more than sensory and recently has been described to be axonal.

Neuropsychiatric symptoms, cognitive and memory impairment, autonomic dysfunction, fatigue, chronic headaches, and sleep disturbances are quite common among survivors. The constellation of symptoms is similar to those seen after a traumatic brain injury.

Cherington has divided the neurologic complications of lightning injury into four categories. Category I are temporary and benign, category II are prolonged and permanent, category III includes delayed symptoms, and category IV are traumatic neurologic injuries that occur secondary to falls, sudden violent muscle contractions, or blast effects. **Table 135.1** summarizes these injuries.

Keraunoparalysis, or Charcot paralysis, is an immediate, transient paralysis seen in some LS victims. It involves the lower extremities more than the upper and is characterized by pale limbs with diminished or absent pulses, sensory symptoms, and hypertension. Strength and sensation typically improve to baseline within hours, sometimes sooner. A catecholamine surge has been suspected, but not proven, to be the cause.

Cerebellar dysfunction, including stroke and cerebellar ataxia, is a rarely reported complication of LS described in a few case reports. In the case of cerebellar stroke, posterior fossa edema can ensue, putting the patient at risk of brainstem compression.

Several case reports have attempted to suggest a link between EI/LS and amyotrophic lateral sclerosis; however, several recent reviews have summarized the available data and reports and concluded that any link is quite unlikely.

TABLE 135.1 Neurologic Complication in Victims of Lightning Strikes

Category I	Headache, numbness, weakness, depressed level of consciousness, keraunoparalysis (Charcot paralysis)
Category II	Hypoxic encephalopathy; cognitive deficits; memory and attention impairment; mood, behavioral, and sleep disturbances; fatigue; autonomic dysfunction; cold insensitivity; acute ischemic stroke; intracerebral hemorrhage (basal ganglia or brainstem); myelopathy
Category III	Parkinsonism, progressive motor disease, focal dystonia, and tics
Category IV	Traumatic intracranial hemorrhage, spinal cord injury due to fractures, or hemorrhages

DIAGNOSIS

Victims of EI or LS with an altered level of consciousness, focal deficit, or paralysis on presentation should have emergent diagnostic imaging of the head and/or spine performed to evaluate for traumatic injuries or acute ischemia, which may warrant prompt interventions. Acute cerebral ischemia many be secondary to thrombosis or vasospasm; emergent computed tomography or conventional angiography should be considered.

MANAGEMENT

Specific treatments for the neurologic sequela of electrical and lighting injuries have not been described. Intravenous thrombolytics and/or endovascular therapy (clot retrieval if thrombosis or angioplasty/intra-arterial therapy if vasospasm) should be considered in patients presenting with a sudden onset of focal neurologic deficits after an EI or LS. Victims who are resuscitated after a cardiac arrest and not following commands should be considered candidates for targeted temperature management, barring other contraindications. Similarly, if the victim remains comatose for longer than 2 hours without an alternate explanation, it may suggest he or she was transiently asystolic and/or apneic, particularly in the setting of a LS. Cardiac automaticity and ventilation may have spontaneously resumed but not without suffering a hypoxic-ischemic cerebral injury. The astute clinician should consider targeted temperature management in this setting as well because the event is the equivalent of return of spontaneous circulation in a cardiac arrest patient who received an active resuscitation. Traumatic injuries should be treated accordingly. Survivors of EI and LS may be referred to an international support group, Lightning Strike & Electric Shock Survivors International, Inc. (http://www.lightning-strike.org).

OUTCOME

The neuropsychiatric complications, cognitive deficits, and autonomic disturbances seen after EI and LS are most commonly permanent and at times progressive. Myelopathy may improve, and recovery has been seen in some victims, but most are left with persistent symptoms. Cardiopulmonary resuscitation success rates have been higher in victims of electrical and lightning injuries than from other causes even when the interval from injury has been prolonged. Outcomes after EI or LS complicated by a cerebral infarction or hypoxic-ischemic injury are only found in case reports or case series, making accurate estimations impossible.

SUGGESTED READINGS

Abhinav K, Al-Chalabi A, Hortobagyi T, Nigel Leigh P. Electrical injury and amyotrophic lateral sclerosis: a systematic review of the literature. *J Neurol Neurosurg Psychiatry*. 2007;78:450-453.

Cherington M. Neurologic manifestations of lightning strikes. *Neurology*. 2003;60:182-185.

Cherington M. Spectrum of neurologic complications of lightning injuries. *NeuroRehabilitation*. 2005;20:3-8.

Cherington M, Yarnell PR, Lane J, Anderson L, Lines G. Lightning-induced injury on an airplane: coronal discharge and ball lightning. *J Trauma*. 2002;52(3):579-581.

Critchley M. Neurological effects of lightning and electricity. *Lancet*. 1934;1:68-72.

Davidson GS, Deck JH. Delayed myelopathy following lightning strike: a demyelinating process. *Acta Neuropathol*. 1988;77:104-108.

Jain RS, Gupta P, Handa R, Nagpal K, Prakash S, Agrawal A. Vertebrobasilar territory ischemic stroke after electrical injury: delayed sequelae. *J Stroke Cerebrovasc Dis*. 2014;23(6):1721-1723.

Jost W, Schönrock L, Cherington M. Autonomic nervous system dysfunction in lightning and electrical injuries. *NeuroRehabilitation*. 2005;20:19-23.

Kashigar A, Udupa K, Fish J, Chen R. Neurophysiological assessment of fatigue in electrical injury patients. *Exp Brain Res*. 2014;232:1013-1023.

Kleinschmidt-DeMasters BK. Neuropathology of lightning-strike injuries. *Semin Neurol*. 1995;15:323-328.

Kwon KH, Kim SH, Minn YK. Electrodiagnostic study of peripheral nerves in high-voltage electrical injury. *J Burn Care Res*. 2014;35:e230-e233.

Primeau M. Neurorehabilitation of behavioral disorders following lightning and electrical trauma. *NeuroRehabilitation*. 2005;20:25-33.

Reisner A. Possible mechanisms for delayed neurological damage in lightning and electrical injury. *Brain Inj*. 2013;27(5):565-569.

Roshanzamir S, Dabbaghmanesh A, Ashraf A. Predicting post-electrical injury autonomic dysfunction symptom occurrence by a simple test. *Burns*. 2013;40:624-629.

Vilke GM, Bozeman WP, Chan TC. Emergency department evaluation after conducted energy weapon use: review of the literature for the clinician. *J Emerg Med*. 2011;40:598-604.

Decompression Illness 136

Matthew R. Leach and Christopher Zammit

KEY POINTS

1. The diagnosis of decompression illness (DCI) is clinical and characteristic symptoms upon decompression consistent with DCI should be treated as such.
2. Initial treatment for DCI is high fraction oxygen and recompression.
3. Transport to hyperbaric centers should occur at low altitude.
4. Patients with neurologic sequelae from decompression illness should wait at least 4 to 6 weeks before returning to diving.

INTRODUCTION

The symptoms of decompression illness (DCI) have been observed in underwater and caisson workers building underwater pier and bridge pilings since the early 1800s, when it was coined "caisson disease." Today, DCI refers to the sequela that result from arterial gas embolism (AGE) and decompression sickness (DCS). Both conditions are the result of rapid changes in ambient pressure that cause dissolved inert gases to emerge in the circulation as bubbles. The rapid growth in popularity of underwater diving with a self-contained underwater breathing apparatus, particularly by travelers, has made DCS a diagnostic possibility even in land-locked areas. Although this chapter focuses on DCI, other dysbaric conditions with neurologic inflictions or complaints are also briefly discussed, which include middle ear barotrauma (MEBT), inner ear barotrauma (IEBT), alternobaric vertigo (ABV), carbon monoxide poisoning, nitrogen narcosis, oxygen toxicity, and swallow water blackouts.

EPIDEMIOLOGY

DCS has been observed in those who perform submersion activities (eg, SCUBA, saturation, or breath-hold diving), high-altitude aviation (eg, U-2 pilots), and simulated altitude ascents. AGE can occur after resurfacing from depths of only 1 to 1.5 m, whereas DCS is never seen after surfacing from depths of less than 6 m and very rarely occurs after dives less than 10 m in depth. AGE can occur if the diver rapidly ascends to the surface, holds his or her breath during ascent, or has intrinsic lung disease, particularly those with blebs and asthmatics. DCS risk factors include longer submersion times, deeper submersions, high exertion and warm temperatures during the dive, cold temperatures after the dive, older age, obesity, dehydration, and male gender. Divers with a patent foramen ovale (PFO) appear to be at increased risk (odds ratios of 2.6-5.6) for neurologic DCI when compared with divers without a PFO. Dive computers and tables are available to advise whether "decompression stops" are required during ascent to mitigate the DCS risk and have significantly reduced the incidence of DCI and dysbaric conditions over the last several decades.

DCI is estimated to occur in 2 to 10 out of every 10,000 dives, with higher rates in U.S. Navy and commercial divers and the lower rates in recreational divers. The Divers Alert Network, a not-for-profit organization dedicated to improving diving safety for all divers founded at Duke University produces an annual report, which profiles diving-related complications. Statistics from the most recent report are outlined in **Table 136.1**. Although total calls to the Divers Alert Network have been increasing over the last 10 years, the majority of reports deal with barotrauma or environmentalism issues, and fatalities from DCI have been decreasing, possibly due to the advent of the aforementioned dive computers. The number of calls to the Divers Alert Network and fatalities from diving injuries are trended in **Figure 136.1**.

DCS is less commonly seen in high-altitude flying, when compared with submersion activities, and when observed, the symptoms are typically less severe and rarely include neurologic manifestations. A notable recent exception are Air Force U-2 pilots who fly at altitudes of up to 70,000 ft (21,336 m) in suits that are pressurized to approximately 30,000 ft (10,058.4 m) above sea level.

PATHOBIOLOGY

DCI is believed to result from bubbles of inert gas, particularly nitrogen, being formed in the circulation during decompression. The concentration of inert gas in plasma is directly proportional to the ambient pressure. In the case of submersion, the ambient

TABLE 136.1 2015 Diving-Related Deaths and Morbidity in the United States[a]

Condition	Confirmed	Suspected
Fatalities	43[b]	—
Disabling injury	34[b]	—
Decompression sickness (DCS)	250	599
DCS type 2[c]	106	279
Inner ear DCS	31	34
Arterial gas embolism	12	41
Middle ear barotrauma	445	—
Inner ear barotrauma	13	38
Alternobaric vertigo	3	5
Calls to Divers Alert Network emergency line	2,518	—

[a]Data from the 2017 Divers Alert Network annual report.
[b]American and Canadian residents.
[c]That is, with neurologic, inner ear, and cardiopulmonary complications.

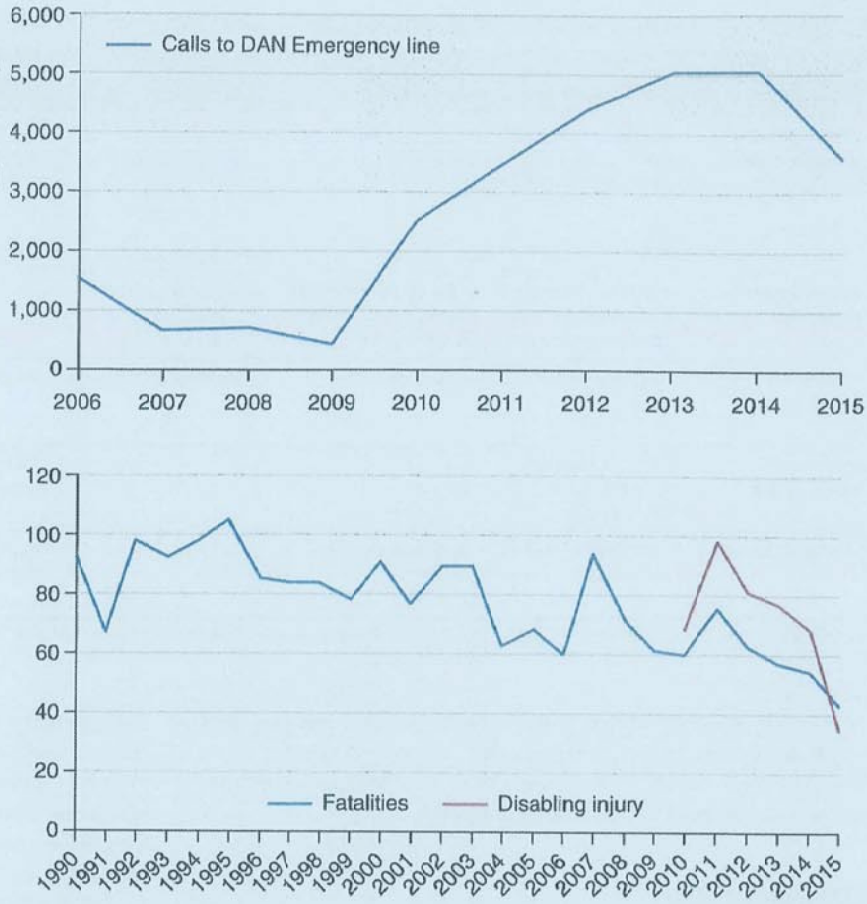

FIGURE 136.1 Incidence of calls to the Divers Alert Network (DAN) emergency hotline and diving-related fatalities. Data from the DAN annual reports from 1992-2017, available publicly at www.diversalertnetwork.org. Despite a significant increase in calls to the DAN emergency hotline, diving-related fatalities have decreased since the 1990s, likely due to a combination of increased safety awareness and improved technology. Most importantly, the advent of dive computers which can advise divers on a safe speed of ascent has likely contributed to decreased mortality. Serious injuries—tracked only since 2010—have also decreased over the last few years.

pressure is increased, causing inert gases, mostly nitrogen, to become intensely dissolved in the blood and tissues of the body. The amount dissolved also increases as the temperature rises. Upon ascent (whether that is resurfacing from a dive or ascending in elevation, as in aviation), these inert gases become supersaturated and come out of solution. Ideally, the gas is delivered to the alveoli, where it is expired. In reality, gas bubbles can be observed via ultrasound in the blood of all divers upon emergence from a dive. Typically, the pulmonary circulation filters the bubbles and the diver does not experience any symptoms. However, if the quantity of bubbles is too great, they will buildup and occlude small veins and lymphatic vessels. At high bubble loads, the pulmonary vasculature also develops occlusions, increasing right heart pressures and raising the possibility of opening an otherwise closed PFO through which bubbles can pass into the arterial circulation.

In addition to vessel occlusion, intravascular bubbles are known to irritate the endothelium, causing capillary leakage, and platelet, complement, and cytokine activation, leading to third spacing, hemoconcentration, small-vessel thrombosis, and eventually hypotension. The occlusive action in the venules combined with small-vessel thrombosis is hypothesized to be the cause of the cerebral, vestibular, and spinal cord injuries and dysfunction in neurologic DCS. Inert gases preferentially dissolve in tissue with a high lipid content, such as the central nervous system (CNS), where the emergence of nitrogenous bubbles is suspected to contribute to neurologic dysfunction and injury.

AGE has a slightly different pathophysiology. Alveolar gas that abruptly expands on decompression (as per Boyle law) and is not ventilated appropriately will force itself through the alveolar-capillary membrane and directly enter the arterial circulation, where it produces mechanical obstructions. The most notable clinical sequela occurs when the cerebral or coronary vessels are occluded, producing ischemic strokes and myocardial infarctions.

MEBT and IEBT occur during compression when the eustachian tube collapses and the middle ear cannot equalize its pressure with the ambient pressure. In MEBT, the tympanic membrane ruptures, exposing the middle ear to the water, causing vertigo and, at times, a seventh cranial nerve palsy. IEBT is the result of a sudden equalization of pressure in the inner ear, causing injury to the cochleovestibular system. In contrast, ABV occurs during ascent when gases expand in the middle ear but cannot escape to allow equalization.

Nitrogen narcosis is a result of high concentrations of dissolved nitrogen that can occur at depth of greater than 100 ft (30.48 m). CNS oxygen toxicity can occur when the partial pressure of oxygen exceeds 1.4 atm. Compressed air tanks can be contaminated with carbon monoxide or carbon dioxide if the compressor's exhaust is too close to the air intake, causing carbon monoxide poisoning. Symptoms would be expected to occur during decent or at depth, in contrast to DCI that occurs with ascent or after surfacing. Swallow water blackouts occur in divers who hyperventilate ambient air prior to a dive, driving their arterial carbon dioxide levels very low without increasing their arterial oxygen content. During the dive, carbon dioxide levels do not increase sufficiently to increase respiratory drive, whereas oxygen levels fall, causing a loss of consciousness.

TABLE 136.2 Neurologic Manifestations and Treatment of Diving-Related Maladies

Sequelae	Manifestations	Exposure	Timeframe	Treatment	Risk Factors
Decompression sickness type 2	Diverse neurologic symptoms, both focal and nonfocal	Typically dives >10 m in depth	>10 min after surfacing up to 24 h	Hyperbaric O_2 therapy	Longer submersion times, deeper submersions, high exertion and warm temperatures during the dive, cold temperatures after the dive, older age, obesity, dehydration, male gender
Arterial gas embolism	Focal neurologic deficit/acute stroke syndromes	Can occur with relatively brief, shallow dives >1 m	<10 min after surfacing		Breath holding during ascent, intrinsic lung disease
Middle ear barotrauma	Vertigo, hearing loss	Rapid descent	Develops mid-dive	Supportive care	Sinus congestion or ear infection, anatomic abnormalities, smoking, pregnancy
Inner ear barotrauma	Vertigo, hearing loss, ruptured TM, CN VII palsy			ENT consultation and surgical repair	
Nitrogen narcosis	Depressed level of alertness	Prolonged, deep dives		Hyperbaric O_2 therapy	Longer submersion times, deeper submersions, use of traditional oxygen mixtures

Abbreviations: CN, cranial nerve; ENT, ear, nose, and throat; O_2, oxygen; TM, tympanic membrane.

Of note, the use of oxygen-enriched, helium-oxygen, and helium-oxygen-nitrogen mixtures for prolonged and/or deep dives has been shown to decrease the risk of bubble formation, which may decrease the risk of DCS LEVEL 1.[1]

DIAGNOSIS

DCS has been divided into two clinical categories, type 1 (DCS1) and type 2 (DCS2). The majority of the time, DCS presents within 24 hours of decompression, but delayed presentations have been seen, particularly in those that have flown or ascended in altitude shortly after decompression. DCS1 includes signs and symptoms related to the integumentary, lymphatic, or musculoskeletal system. The patient will describe joint aches and pains, itching, or extremity edema, and a lenticular skin rash believed to be due to venous status, known as *cutis marmorata*, can be observed.

DCS2 can include features of DCS1 with additional symptoms related to the CNS, lungs, or vestibular system. The pulmonary symptoms, which include a cough, dyspnea, or chest pain, have been called the chokes. Vestibular symptoms, also known as *the staggers*, manifest as vertigo, nystagmus, nausea, or vomiting and can be difficult to differentiate from ABV because both can occur on ascent. The symptoms of cerebral DCS can include headache, diplopia, dysarthria, paresthesias, weakness, personality changes, disorientation, fatigue, ataxia, drowsiness, and even lethargy. Visual disturbances include optic neuropathy, homonymous hemianopsia, and central retinal artery occlusion. Spinal cord DCS presents with limb weakness, numbness, paresthesias, incontinence, priapism, urinary retention, or back/pelvic pain.

AGE has a dramatic and abrupt presentation, occurring during ascent or within 10 minutes of surfacing, and is commonly found to be the cause of death in diving fatalities. The presentation can include a variety of neurologic changes, including stroke syndromes, and may include pulmonary symptoms in about half of the cases. It can be difficult to distinguish AGE from DCS2 but treatment is the same, and sorting out the diagnosis is of academic interest only.

MEBT, IEBT, and ABV all have similar symptoms. MEBT will often include a ruptured tympanic membrane. IEBT should be distinguished because the symptoms will be persistent and often require referral to an otolaryngologist. IEBT and vestibular DCS may be difficult to distinguish as well. A history of a sudden symptom onset upon equalization of pressures suggests IEBT. Cerebellar infarcts have been seen as a result of DCS and should be treated the same as vestibular DCS (Table 136.2).

The diagnosis of DCS is clinical. Any symptoms upon decompression consistent with DCS should be treated as such. It is important to remember that DCS has been reported up to 24 hours after a dive, although severe neurologic complications usually appear within 10 minutes of surfacing, and 90% of patients present within the first 3 hours. There are sporadic reports of carotid artery dissection and one report of an epidural spinal hematoma in a breath-hold diver, but these cases are the exception, and recompression should not be delayed.

Magnetic resonance imaging (MRI) lesions have been seen in DCI, but they lack sensitivity because even those with incomplete recovery have been observed to have normal serial imaging. AGE findings are similar to those seen with thrombotic emboli (ie, diffusion-weighted imaging hyperintense with low ADC values acutely). Magnetic resonance findings in DCS2 include both foci of ischemia as well as T2 hyperintense lesions without diffusion restriction. The latter demonstrate a preponderance for white matter, possibly due to the high fat content of myelin and high solubility of nitrogen in fat, although lesions are commonly seen in grey matter as well. Similarly, in spinal DCI, there is predominant involvement of thoracic cord segments due to again high fat content as well as relative hypoperfusion leading to poor nitrogen "washout" during ascent. Many of these T2 signal changes seem to be reversible with timely recompression, although there is often discrepancy between clinical and radiographic outcomes and imaging findings should not influence acute treatment decision making. Divers without a history of neurologic DCS have rarely been reported to have abnormal MRIs, but there are only a handful of controlled studies to fully describe the specificity of neuroimaging. Spinal canal stenosis has been associated with the occurrence of spinal DCS and MRI lesions, but it is not associated with clinical outcomes.

MANAGEMENT

DCI is a medical emergency that calls for the immediately administration of 100% oxygen and recompression. Large-scale observational evidence suggests that timely recompression optimizes outcomes and hastens recovery. More recent publications challenge whether time to recompression impacts the rates of recovery in those with neurologic DCS, but the datasets are small and limited to observations. Therefore, expeditious recompression remains the standard of care, and DCS must be considered a medical emergency.

Hyperbaric oxygen therapy (HBT or HBOT) can be provided in monoplace or multiplace chambers, with the later allowing for hands-on treatment of the patient, if needed. HBT promotes the dissolution and elimination of gasses from tissues, increases delivery of oxygen to ischemic tissues, reduces tissue edema and blood vessel permeability, counteracts the adherence of leukocytes to brain vessels, and partially blocks lipid peroxidation in reperfused tissues. HBT recommendations for DCS and AGE can be found in the U.S. Navy Diving Manual (see "Suggested Readings"). Serial HBT dives are performed until benefit is not seen with consecutive treatments. All patients being considered for HBT should have a chest x-ray for evaluation of pneumothorax and pneumomediastium because untreated pneumothorax is a contraindication for recompression and air transport. Patients requiring air transport to HBT should be flown at the lowest safe altitude (recent recommendations are <500 ft [152.4 m] above surface level) or in a pressurized aircraft. Portable chambers that allow for partial recompression are available. For chamber locations and emergency information, U.S. physicians should contact the Divers Alert Network, at 1-919-684-9111, a 24-hour hotline. In cases where safe, timely transport to HBT is not available, in-water repressurization is a reasonable alternative, although more data is needed to determine the exact protocol for this approach LEVEL 7.[2,3]

Otherwise, treatment of DCI is supportive. Patients should be maintained normothermic because warmer temperatures hasten the absorption of dissolved inert gasses, but hyperthermia may worsen neurologic injury. Isotonic, non–dextrose-containing intravenous fluids should be administered because many of these patients are hemoconcentrated. If AGE is suspected, intravenous lidocaine is commonly provided because randomized evidence from the cardiac surgery literature, where AGE and cerebral injury are commonly seen, suggests it has neuroprotective benefits. Aspirin is considered by many, without evidence to support its use. A randomized controlled trial of tenoxicam for DCS demonstrated that it hastened recovery and reduce the number of required recompressions from 3 to 2, but clinical outcomes were no different LEVEL 7.[4] Preliminary evidence is promising for perfluorocarbons, but clinical trials are needed. A small study from the 1990s suggested that a helium-oxygen mixture might be superior to an air-oxygen mixture during recompression, but the results have not been reproduced. A recent study of PFO closure in divers suggests it reduces the incidence of DCS and the quantity of ischemic brain lesions on MRI.

OUTCOME

Cerebral DCS outcomes are similar to ischemic stroke survivors, as one series found, the National Institutes of Health Stroke Scale, to have a similar ability to predict outcomes in both conditions. Spine DCS outcomes have been found to be worse in those older than 42 years of age, with bladder symptoms, with progressive symptoms upon decompression, with initial severe symptoms, and with MRI abnormalities. One-quarter to one-third of spinal cord DCS victims will make an incomplete recovery. Although there is no data to support specific return-to-diving guidelines for recreational divers, the U.S. Navy handbook permits divers with DCS1 symptoms, which resolved on initial treatment to return to diving after 7 days, and those with DCS2 symptoms, which resolved on initial treatment to return to diving after 30 days. The Divers Alert Network recommends that patient with DCS2 symptoms wait at least 4 to 6 weeks before diving and that symptoms requiring serial treatments warrant 4 to 6 months abstinence from diving and neurologic reevaluation. Vestibular symptoms should be given extra caution and also merit 4 to 6 months delay with thorough evaluation for an intact vestibular system before return to diving. Further caution should be taken in patients with multiple medical comorbidities in all cases.

LEVEL 1 EVIDENCE

1. Brebeck AK, Deussen A, Range U, Balestra C, Cleveland S, Schipke JD. Beneficial effect of enriched air nitrox on bubble formation during scuba diving. An open-water study. *J Sports Sci*. 2018;36(6):605-612.
2. Blatteau JE, Pontier JM. Effect of in-water recompression with oxygen to 6 msw versus normobaric oxygen breathing on bubble formation in divers. *Eur J Appl Physiol*. 2009;106(5):691-695.
3. Dituri J, Sadler R, Siddiqi F, et al. Echocardiographic evaluation of intracardiac venous gas emboli following in-water recompression. *Undersea Hyperb Med*. 2016;43(2):103-112.
4. Bennett M, Mitchell S, Dominguez A. Adjunctive treatment of decompression illness with a non-steroidal anti-inflammatory drug (tenoxicam) reduces compression requirement. *Undersea Hyperb Med*. 2003;30(3):195-205.

SUGGESTED READINGS

Bennett MH, Lehm JP, Mitchell SJ, Wasiak J. Recompression and adjunctive therapy for decompression illness. *Cochrane Database Syst Rev*. 2012;(5):CD005277.

Billinger M, Zbinden R, Mordasini R, et al. Patent foramen ovale closure in recreational divers: effect on decompression illness and ischaemic brain lesions during long-term follow-up. *Heart*. 2011;97(23):1932-1937.

Blatteau JE, Gempp E, Constantin P, Louge P. Risk factors and clinical outcome in military divers with neurological decompression sickness: influence of time to recompression. *Diving Hyperb Med*. 2011;41(3):129-134.

Blatteau JE, Gempp E, Simon O, et al. Prognostic factors of spinal cord decompression sickness in recreational diving: retrospective and multicentric analysis of 279 cases. *Neurocrit Care*. 2011;15(1):120-127.

Bove AA. Diving medicine. *Am J Respir Crit Care Med*. 2014;189(12):1479-1486.

Buzzacott P. DAN annual diving report 2017 edition: a report on 2015 diving fatalities, injuries, and incidents. Divers Alert Network Web site. https://www.diversalertnetwork.org/medical/report/AnnualDivingReport-2017Edition.pdf. Accessed March 1, 2019.

Byyny RL, Shockley LW. Scuba diving and dysbarism. In: Marx J, Hockberger R, Walls R, eds. *Rosen's Emergency Medicine: Concepts and Clinical Practice*. Vol 2. 8th ed. Philadelphia, PA: Elsevier/Saunders; 2014:1915-1927.

Clark JE. Moving in extreme environments: inert gas narcosis and underwater activities. *Extrem Physiol Med*. 2015;4:1.

Gao GK, Wu D, Yang Y, et al. Cerebral magnetic resonance imaging of compressed air divers in diving accidents. *Undersea Hyperb Med*. 2009;36(1):33-41.

Gempp E, Blatteau JE. Risk factors and treatment outcome in scuba divers with spinal cord decompression sickness. *J Crit Care*. 2010;25(2):236-242.

Gempp E, Blatteau JE, Stephant E, Pontier J-M, Constantin P, Pény C. MRI findings and clinical outcome in 45 divers with spinal cord decompression sickness. *Aviat Space Environ Med*. 2008;79(12):1112-1116.

Gempp E, Louge P, Lafolie T, Demaistre S, Hugon M, Blatteau JE. Relation between cervical and thoracic spinal canal stenosis and the development of spinal cord decompression sickness in recreational scuba divers. *Spinal Cord*. 2014;52(3):236-240.

Germonpré P. Patent foramen ovale and diving. *Cardiol Clin*. 2005;23:97-104.

Holck P, Hunter RW. NIHSS applied to cerebral neurological dive injuries as a tool for dive injury severity stratification. *Undersea Hyperb Med*. 2006;33(4):271-280.

Kamtchum Tatuene J, Pignel R, Pollak P, Lovblad KO, Kleinschmidt A, Vargas MI. Neuroimaging of diving-related decompression illness: current knowledge and perspectives. *AJNR Am J Neuroradiol*. 2014;35(11):2039-2044.

Kizer KW, Van Hoesen. Diving medicine. In: Auerbach PS, ed. *Wilderness Medicine*. 6th ed. Philadelphia, PA: Elsevier/Mosby; 2012.

Kohshi K, Tamaki H, Lemaître F, Okudera T, Ishitake T, Denoble PJ. Brain damage in commercial breath-hold divers. *PLoS One*. 2014;9(8):e105006.

MacDonald RD, O'Donnell C, Allan GM, et al. Interfacility transport of patients with decompression illness: literature review and consensus statement. *Prehosp Emerg Care*. 2006;10(4):482-487.

McGuire S, Sherman P, Profenna L, et al. White matter hyperintensities on MRI in high-altitude U-2 pilots. *Neurology*. 2013;81(8):729-735.

Mitchell SJ, Bennett MH, Bryson P, et al. Consensus guideline: pre-hospital management of decompression illness: expert review of key principles and controversies. *Undersea Hyperb Med*. 2018;45(3):273-286.

Moon RE. Adjunctive therapy for decompression illness: a review and update. *Diving Hyperb Med*. 2009;39(2):81-87.

Naval Sea Systems Command. Diagnosis and treatment of decompression sickness and arterial gas embolism. In: *U.S. Navy Diving Manual*. Washington, DC: U.S. Government Publishing Office; 2016:17-1–17-52. *Diving Medicine and Recompression Chamber Operations*; vol 5, revision 7. https://www.navsea.navy.mil/Portals/103/Documents/SUPSALV/Diving/US%20DIVING%20MANUAL_REV7.pdf?ver=2017-01-11-102354-393. Accessed March 1, 2019.

Pollock NW, Buteau D. Updates in decompression illness. *Emerg Med Clin North Am*. 2017;35(2):301-319.

Ryles MT, Pilmanis AA. The initial signs and symptoms of altitude decompression sickness. *Aviat Space Environ Med*. 1996;67:983-989.

Shupak A, Melamed Y, Ramon Y, Bentur Y, Abramovich A, Kol S. Helium and oxygen treatment of severe air-diving-induced neurologic decompression sickness. *Arch Neurol*. 1997;54(3):305-311.

Vann RD, Butler FK, Mitchell SJ, Moon RE. Decompression illness. *Lancet*. 2011;377:153-164.

Winkler BE, Koch A, Schoeppenthau H, et al. Effects of FLIRT on bubble growth in man. *Int J Sports Med*. 2012;33(11):903-908.

Neonatal Neurology 137

Arthur M. Mandel

KEY POINTS

1. Premature infants are vulnerable to intraventricular hemorrhage due to the fragile vasculature in the germinal matrix. Prognosis varies, depending on the hemorrhage grade.
2. Hypoxic-ischemic encephalopathy is a major cause of morbidity in neonates, but therapeutic hypothermia is an effective treatment.
3. Seizures are more common in the newborn period because of a predisposition to neuronal excitability. There is a broad etiology, which helps determine treatment.
4. Stroke in neonates are ischemic, hemorrhagic, or due to sinus venous thrombosis. Treatment and outcome depends on cause, extent, and location of the injury.
5. Periventricular leukomalacia typically is seen in premature infants and can result in spasticity, cognitive, or visual complications.

Pediatric neurologists treat many children with brain injuries that originate in the perinatal period and cause mental retardation, cerebral palsy, and/or seizures. This chapter focuses on some of the most common disease processes affecting neonates.

GERMINAL MATRIX-INTRAVENTRICULAR HEMORRHAGE

Epidemiology

Low birth weight and prematurity increase the risk of germinal matrix hemorrhage (GMH) and intraventricular hemorrhage (IVH), and the incidence and severity of IVH increases with earlier prematurity and lower birth weight. The prevalence of periventricular IVH in newborns weighing less than 1,500 g has declined, falling from approximately 40% in 1980 to 20% since the late 1990s. Corticosteroid therapy prenatally and surfactant use after birth have contributed to the decline of IVH. However, with the increased survival rate of extremely low birth weight infants, there are more infants at highest risk, with a risk of 45% in infants less than 1,000 g. In a population-based study in Switzerland, IVH rates decreased 3.5% with each added week of gestation.

Severe IVH (defined as Papile grades III-IV, see in the following text) increases with decreasing gestational age. In a large, multicenter registry of infants of very low gestational age (22-28 wk) and birth weight (401-1,500 g), born between 2003 and 2007 in the United States, 16% overall had severe IVH, and the prevalence increased with decreasing gestational age, from 38% at 22 weeks to 7% at 28 weeks.

Antenatal glucocorticoid therapy decreases the risk of GMH-IVH. A GMH-IVH is more likely to develop in infants requiring neonatal transport. Increased risk of GMH-IVH also is associated with respiratory distress (presumably affecting cerebral blood flow and central venous pressure), rapid increases in arterial blood pressure as well as hypotension, and cardiopulmonary resuscitation.

Pathobiology

The germinal matrix is a well-vascularized and highly cellular layer between the caudate nucleus and thalamus, which gradually involutes during the fetal period. It is susceptible to hemorrhage because of the friable nature of its capillary network. The risk for hemorrhage is further exacerbated by disturbances in cerebral blood flow, through either hypotension or lower cerebral perfusion, possibly lowered further by positive pressure ventilation through endotracheal intubation, and/or through hypoperfusion-reperfusion coupled with immaturity of intrinsic cerebral vasoreactivity and autoregulatory mechanisms. Other factors potentially increasing risk of IVH during prematurity are metabolic (hypoglycemia, hypernatremia), hematologic (anemia, thrombocytopenia), and immunologic (chorioamnionitis, immaturity of antioxidant responses or other immune responses).

The Papile grading system, with some modification, is the most commonly used scale to describe the severity of the IVH (Fig. 137.1). The IVH may remain in the matrix area (grade I), or rupture into the lateral ventricles (grade II), which can result in ventricular enlargement or distension (grade III). Grade IV, now termed *periventricular hemorrhagic infarction* (PVHI), refers to extensive IVH with parenchymal involvement, likely due to terminal venous occlusion, venous infarction, and subsequent secondary hemorrhage.

Late in the course after IVH (1-3 wk after the initial hemorrhage), especially with more severe IVH, there can be posthemorrhagic hydrocephalus, or progressive ventricular dilatation, thought to result from impaired reabsorption of cerebrospinal fluid (CSF) because of inflammation of the subarachnoid villi. Usually, impaired reabsorption results in a communicating hydrocephalus, although there can also be a noncommunicating hydrocephalus due to localized obstruction or scarring.

Clinical Manifestations

Most IVH in premature infants occurs within the first 5 postnatal days, with the majority occurring on the first day of life. Late IVH is associated with low cerebral blood flow, usually from systemic processes.

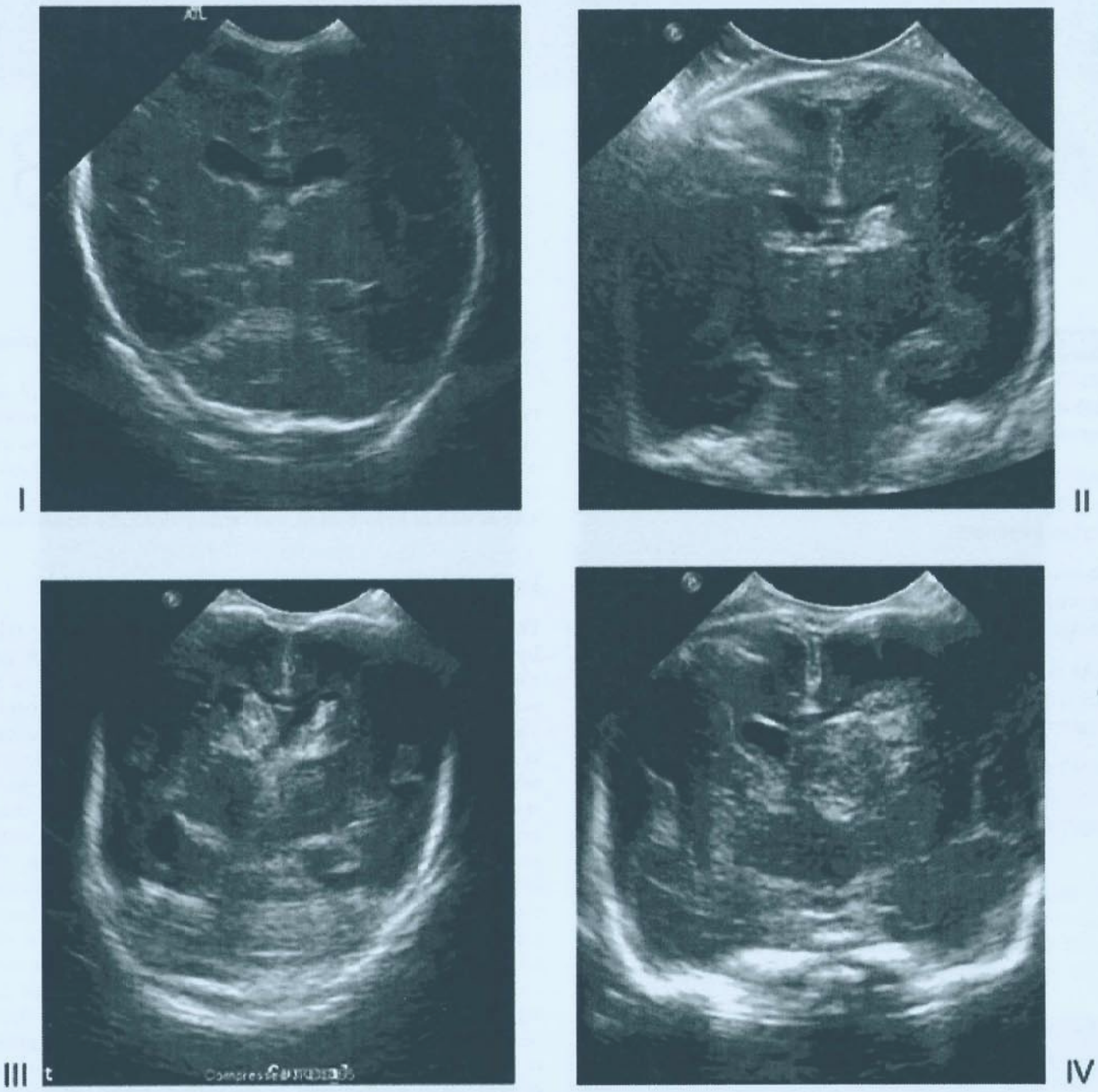

FIGURE 137.1 Papile grading system for neonatal intraventricular hemorrhage, shown by head ultrasonography. Echodensities are seen in periventricular region (A, grade I), with rupture into the lateral ventricles (B, grade II), and with ventricular enlargement (C, grade III). Periventricular hemorrhagic infarction (D, grade IV) has parenchymal involvement. (From El-Dib M, Massaro AN, Bulas D, Aly H. Neuroimaging and neurodevelopmental outcome of premature infants. *Am J Perinatol*. 2010;27[10]:803-818.)

The clinical presentation of IVH varies, depending on severity. Grade I IVH is usually asymptomatic. Many grade II and some grade III hemorrhages are clinically silent, but there may be a saltatory course evolving over hours to days, characterized by nonspecific findings of altered level of consciousness, hypotonia, eye movement changes, subtle changes in movement, decreased spontaneous movements, and disturbed respiratory function. Some grade III hemorrhages produce hydrocephalic symptoms of varying severity, and if seen in combination with PVHI, there may be signs of severe apnea, bradycardia, extensor posturing, and opisthotonus. There also may be flaccid weakness, cranial nerve abnormalities including fixed pupils to light, most likely leading to unresponsiveness and death within hours. There may be clonic limb movements, which some clinicians have labeled as seizures, although there is usually little electroencephalography (EEG) correlation. Most infants who die have other lesions, such as periventricular leukomalacia (PVL) (see section on "Periventricular Leukomalacia"), brainstem necrosis, or cerebellar necrosis.

Diagnosis

Cranial ultrasonography is the preferred imaging modality because of its portability, its ability to delineate blood in the

parenchyma and ventricles as well as ventricular size, and its lack of ionizing radiation. Routine ultrasound screening should be performed in all infants with a gestational age younger than 30 weeks, at age 7 to 14 days, and then repeated at 36 to 40 weeks gestational age. Ultrasonography should be strongly considered in infants with abnormal clinical signs such as changes in neurologic or respiratory status or with systemic conditions, which can predispose to IVH.

Computed tomography (CT) or magnetic resonance imaging (MRI) have limited usefulness as routine screening tools, because of their lack of portability, exposure to ionizing radiation (CT), and a longer examination time (MRI). However, these modalities may be helpful in documenting other lesions, such as parenchymal abnormalities or subdural or posterior fossa hemorrhages. It is best to avoid CT scanning because of the exposure to ionizing radiation, if MRI is available.

Lumbar puncture may be helpful if ultrasonography is unavailable. The red blood cell count is typically high, with a protein concentration of 250 to 1,200 mg/dL. Later, the CSF becomes xanthochromic, and there may be a low glucose concentration.

Management

Prevention

The most effective prevention strategy is avoidance of premature birth. When preterm birth is inevitable, there are some prenatal and delivery room practices associated with a lowered risk of IVH. Corticosteroids given antenatally, at a dose of two 12-mg intramuscular injections of betamethasone at 24-hour intervals, reduce risk of IVH. Delayed clamping of the umbilical cord (30-60 s) has been associated observationally with a reduction in the relative risk of IVH, although a recent large trial showed no effect of delayed clamping on death or major morbidity. Maternal transport to a perinatal center before delivery reduces risk of IVH in very low birth weight infants as compared with infant transport after delivery. Tocolytic therapy may be associated with reduced risk of severe IVH.

General measures of neonatal care are widely accepted to reduce risk of IVH in the postnatal period. Resuscitation should be prompt and hemodynamic instability, hypoxia, hypercarbia, hyperoxia, and hypocarbia should be avoided. Hypotension and hypertension should be avoided and corrected (in a gradual fashion to avoid large acute changes in blood pressure). Coagulopathies and metabolic abnormalities should be corrected. Bicarbonate therapy is associated with an increased risk of IVH and should be avoided.

Therapeutic Intervention

In general, no treatment is needed for grade I and II hemorrhages, although they should be followed for progression by regular cranial ultrasonography. For grade III hemorrhage or PVHI, ongoing monitoring should be performed, with weekly head ultrasounds, daily head circumference measurement, and frequent clinical assessment for increased intracranial pressure. If there is evidence of significant lateral ventricular dilatation or increased intracranial pressure, intervention may be needed. Serial lumbar punctures can be performed, although they should be coupled with cranial ultrasonography to ensure that there is a resultant decrease in ventricular size, and it is unclear that there is advantage over conservative management. As a temporizing measure, ventricular drainage with a direct extraventricular drain or with a subcutaneous drain to a subcutaneous reservoir or a ventriculosubgaleal shunt may be helpful. Usually, if a drain is needed, eventually a permanent ventricular shunt, usually a ventriculoperitoneal shunt, will be necessary, although a third ventriculostomy may be effective as well in some cases. Every attempt should be made to delay shunting until the newborn attains as much somatic growth as possible. There are no medical interventions that have been shown to safely reduce the long-term effects of IVH.

Outcome

Grade I and II IVH usually has a good short-term outcome, with an 80% to 90% survival rate without an obvious neurologic abnormality. However, there may be long-term disorders of learning and behavior, especially with extremely low birth weight neonates (<1,000 g).

The mortality rate of grade III IVH and PVHI is approximately 20%, with 75% of the surviving infants developing posthemorrhagic hydrocephalus. Long-term prognosis worsens with decreasing gestational age and increasing severity of IVH, with higher rates of developmental delay, cerebral palsy, bilateral deafness, and bilateral blindness associated with more severe bleeds and extreme prematurity. Some infants with PVHI survive without disability, especially when the infarctions are small.

PERINATAL ASPHYXIA/HYPOXIC-ISCHEMIC ENCEPHALOPATHY

Epidemiology

Depending on the definitions used, perinatal asphyxia in developed countries affects 3 to 8 newborns per 1,000 live births and causes moderate to severe hypoxic-ischemic encephalopathy (HIE) in 0.5 to 1 per 1,000 live births. Globally, 10% to 60% of neonates with HIE die, and 25% have long-term neurodevelopmental difficulties.

Pathobiology

Most commonly, HIE is associated with severe maternal hypotension, uterine rupture, placental abruption, and placental or umbilical cord dysfunction. In addition, there may be associated hypoxic cardiopulmonary, hepatic, or renal injury.

Brain pathology depends on the level of maturity at the time of the insult as well as the duration and location of the insult. In infants injured less than 32 weeks' gestation, PVL is commonly seen because of the vulnerability of late oligodendroglial precursors. After 36 weeks' gestation, hypoxic lesions are frequently located in the cerebral gray matter, deep gray nuclei, brainstem, and Purkinje cells of the cerebellum.

On a cellular and molecular level, hypoxia-ischemia acutely causes neuronal loss in the cerebral sulci, often with edema and infarction. Chronically, there is neuronal loss and astrocytosis, with possible atrophy, cystic encephalomalacia, ulegyria (cortical scarring resulting in deep sulcal atrophy), status marmoratus (altered myelination of the corpus striatum, giving a marble-like appearance), and cerebellar atrophy. Energy failure from hypoxia stems from loss of mitochondrial function, which can be confirmed by measuring increased lactic acid levels in the CSF or by magnetic resonance spectroscopy (MRS).

TABLE 137.1 Apgar Scores[a]

	Score of 0	Score of 1	Score of 2
Color	Blue or pale, entire body	Blue at extremities, body pink	No cyanosis
Heart rate	Absent	<100	>100
Reflex irritability	No response to stimulation	Feeble cry or grimace when stimulated	Cry or pull away when stimulated
Muscle tone	None	Some flexion	Flexed arms and legs
Respiratory effort	Absent	Weak, gasping, irregular	Strong, lusty cry

[a]Adapted from Apgar V. A proposal for a new method of evaluation of the newborn infant. *Curr Res Anesth Analg*. 1953;32(4):260-267.

There is accompanying membrane depolarization, an increase in neurotransmitter release, as well as excessive activation of glutamate receptors. Consequently, there is excitotoxic cellular injury, leading to an increase in intracellular calcium that leads to a cascade of pathologic pathways leading to secondary cell death. In addition, there is oxidative stress, which produces reactive oxygen species and subsequent reactive nitrogen radicals, also contributing to cell toxicity. After the anoxic insult, many cells undergo reoxygenation and reperfusion. Reperfusion contributes further to oxidative stress by producing more reactive oxygen species and further cellular injury.

Clinical Manifestations

The initial presentation of HIE is typically low Apgar scores, which translate into bradycardia, depressed respiration, diminished responsiveness, and decreased muscle tone (**Table 137.1**). One of three clinical patterns then evolves: (1) mild: awake, irritable, hyperalert with jitteriness, dilated pupils, increased deep tendon reflexes, and normal muscle tone; (2) moderate: lethargy with depressed deep tendon reflexes, frequently with seizures; and (3) severe: apathy, with severe hypotonia, poorly reactive pupils, an absent Moro reflex, depression or coma, and seizures. There is usually clinical improvement with the mild and moderate cases as the newborns become more alert, improve their tone, and are able to feed. Seizures or therapy for seizures may delay recovery. Newborns with severe encephalopathy will usually become stuporous, develop frequent seizures, respiratory depression, brainstem abnormalities, and may show signs of decerebration. They become unresponsive and lose sucking reflexes and the Moro response, and even with vigorous supportive and anticonvulsant therapy, 20% to 30% of these newborns die. If the neonate survives, seizures usually stop after 48 to 72 hours, and there is usually some recovery.

Diagnosis

Other causes of encephalopathy should be distinguished from HIE in the newborn period. The American College of Obstetricians and Gynecologists summarized signs that would likely result in HIE in infants greater than 35 weeks' gestation: Apgar score less than 5 at 5 and 10 minutes, cord pH less than 7.0 and/or base deficit ≥12 mmol/L, consistent brain injury seen on MRI or MRS, multisystem organ failure, as well as a sentinel hypoxic/ischemic event and nonreassuring fetal heart rate patterns LEVEL 1.[1] Multisystem organ failure consistent with HIE includes renal, hepatic, or cardiac dysfunction; hematologic abnormalities; metabolic derangements such as low serum glucose or sodium or elevated CSF lactate; and/or gastrointestinal injury. All of these criteria lie on a continuum, so, for example, worsening acidemia increases the likelihood of an intrapartum hypoxic injury.

Certain patterns of brain injury seen in neuroimaging of late preterm or term infants are commonly seen in HIE, including parasagittal injury in an arterial watershed distribution and/or injury to the deep gray nuclei (**Figs. 137.2** and **137.3**). Neuroimaging, alternatively, may reveal another cause of encephalopathy, such as a developmental brain malformation or a focal area of infarction. Brain MRI is the most sensitive imaging modality for most lesions and usually yields the most useful information, although it requires transport, monitoring, and support. If available, an MRS can be useful for diagnosis of HIE if a lactate peak is seen. Head CT is useful for detecting intracranial hemorrhage and brain calcifications but is less sensitive for detecting mild brain edema or white matter injury, which is somewhat obscured because of the high water content of the newborn white matter. The posterior fossa is not adequately imaged with CT because of bony artifact. Cranial ultrasonography can be done at the bedside but is not very sensitive for detection of white matter abnormalities or lesions in the outer cerebral cortex.

Along with revealing seizure activity that may be inapparent clinically, EEG can be helpful to indicate the degree of HIE: indications of severity include a burst-suppression pattern and/or a relatively inactive background. Amplitude-integrated EEG, while not as sensitive as standard EEG, may show low voltage in the setting of severe HIE and is able to detect some if not all seizure activity.

Management

Because multiple organ systems are involved in addition to the brain, management and therapeutic measures include maintenance of physiologic homeostasis, including providing adequate ventilation, maintenance of perfusion and metabolism, avoidance of brain edema, and seizure control. Therapeutic hypothermia for 72 hours, with a target rectal temperature of 33 to 35 degrees, has been shown in multiple randomized controlled trials to lower mortality and major neurodevelopmental disability in term and late preterm infants with moderate or severe HIE LEVEL 1.[2] There are some adverse effects of hypothermia, including an increase in sinus bradycardia and in thrombocytopenia, but generally, hypothermia is well tolerated. Hypothermia must be initiated within 6 hours after delivery, so it is essential that infants are transferred immediately to a center with expertise. In less developed countries, low-technology therapeutic hypothermia (using cooling bags or packs) has been shown to reduce neurologic morbidity and

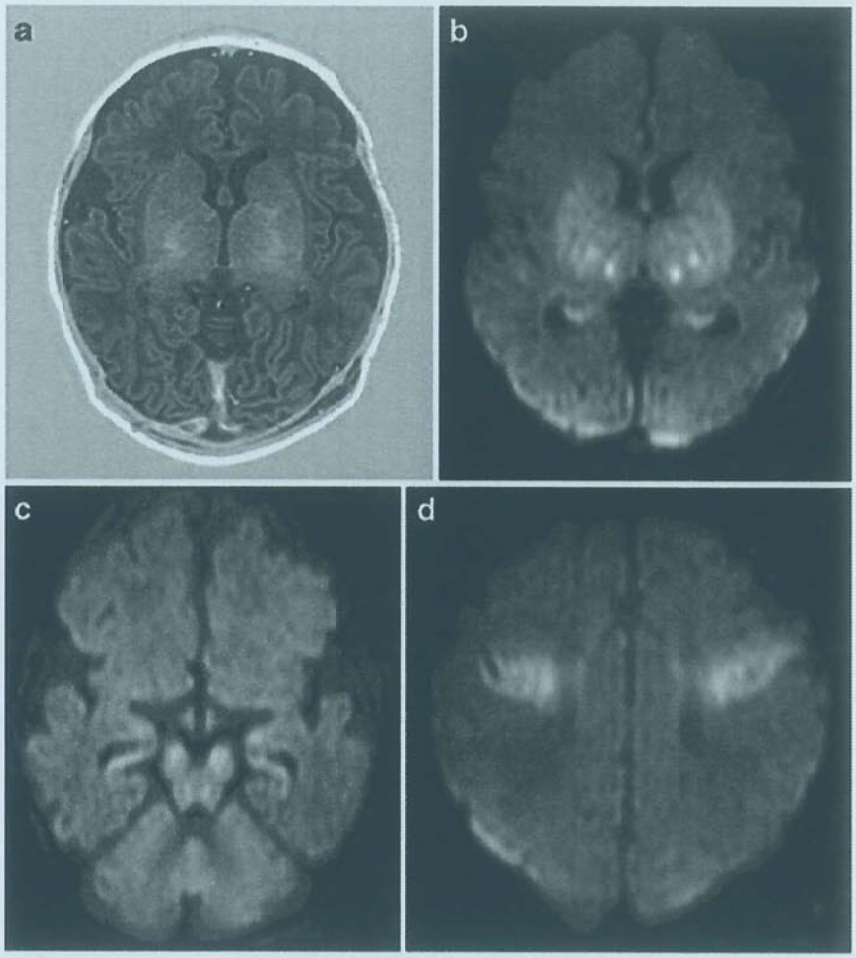

FIGURE 137.2 Magnetic resonance imaging of full-term infant with birth asphyxia (from ruptured uterus). **A:** Inversion recovery sequence shows increased intensity within thalami and basal ganglia. **B-D:** Diffusion-weighted imaging shows restricted diffusion in the ventrolateral thalami, lentiform nuclei, cerebral peduncles, and perirolandic cortex. (From de Vries LS, Groenendaal F. Patterns of neonatal hypoxic-ischaemic brain injury. *Neuroradiology*. 2010;52[6]:555-566.)

mortality, albeit with less robust evidence than with electrical cooling systems.

Outcome

Long-term prognosis of HIE depends on the extent of brain injury. Therapeutic hypothermia has improved neurologic prognosis. Most infants with mild HIE have a normal outcome. Children with severe HIE who survive the neonatal period usually have low cognitive ability and scholastic achievement, serious motor disability, and epilepsy. Children with moderate HIE form a heterogenous group, depending on how the outcomes are measured and how the degree of encephalopathy is defined.

NEONATAL SEIZURES

Epidemiology

Neonatal brains are particularly susceptible to seizures because of a relative abundance of excitatory neurotransmitters and the relative underdevelopment of inhibitory systems. Seizures occur

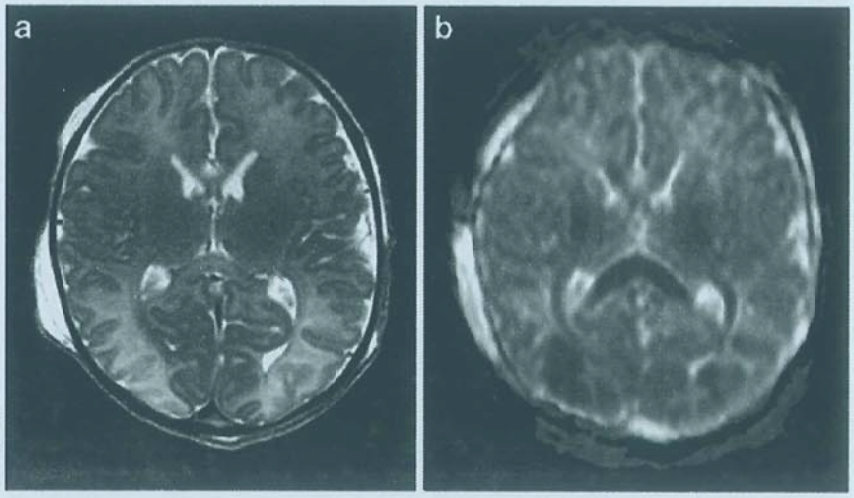

FIGURE 137.3 Magnetic resonance imaging of full-term infant born with severe anemia, showing watershed pattern of injury. **A:** T2-weighted sequence shows loss of cortical ribbon, with increased signal intensity in corpus callosum. **B:** Apparent diffusion coefficient map shows decreased signal intensity in posterior watershed areas, splenium of corpus callosum, and optic radiation. (From de Vries LS, Groenendaal F. Patterns of neonatal hypoxic-ischaemic brain injury. *Neuroradiology*. 2010;52[6]:555-566.)

in 1 to 3.8 per 1,000 newborns and are often an urgent clinical problem requiring prompt diagnosis and treatment.

Pathobiology

The vast majority of neonatal seizures are due to specific etiologic causes rather than epileptic syndromes. The most common causes are encephalopathy (often HIE) in term infants and IVH in premature babies. Other important causes include other hemorrhage (intracerebral, subdural, subarachnoid), infection (meningitis, encephalitis, or intrauterine), infarction, metabolic causes (hypoglycemia, hypocalcemia, hypomagnesemia), chromosomal anomalies, cerebral malformations, neurodegenerative disorders, inborn errors of metabolism (eg, glycine encephalopathy, urea cycle defects, phenylketonuria, maple sugar urine disease, lactic or organic acidurias), and maternal drug withdrawal or intoxication. Some seizures are responsive to vitamin treatment, including vitamin B_6, pyridoxal phosphate, and folinic acid. There has been a decrease in seizure frequency from transient metabolic causes or infection, most likely because of the advances in neonatal care over the past few decades.

On a molecular and cellular level, both animal models and human studies indicate that the developmental regulation of excitatory and inhibitory synaptic networks play a crucial role in the greater susceptibility of neonates to seizures. In particular, both α-amino-3-hydroxy-5-methyl-4-isoxazole propionic acid and *N*-methyl-D-aspartate subtypes of glutamate receptors, which are excitatory, have high expression, and are expressed with subunit composition enhancing excitability of neuronal networks in the period around birth both in humans and in animal models. Additionally, the inhibitory class of γ-aminobutyric acid receptors are underexpressed during this time period.

There are three well-recognized neonatal epilepsy syndromes as classified by the International League Against Epilepsy: benign neonatal familial convulsions (BFNS) (which may be further classified into benign familial neonatal epilepsy, benign familial neonatal-infantile epilepsy, and benign familial infantile epilepsy—refer to Chapter 143), early myoclonic encephalopathy (EME), and early infantile epileptic encephalopathy (EIEE, or Ohtahara syndrome). In addition, there are benign neonatal seizures (with multiple names including "fifth-day fits"), which frequently do not require long-term therapy. Identified genes for BFNS, a dominantly inherited condition, include *KCNQ2* and *KCNQ3*, coding for voltage-gated potassium channels, and *PRRT2*, coding for a presynaptic protein involved in neurotransmission. There is evidence that carbamazepine and oxcarbazepine are effective treatments for BFNS. There are multiple etiologies of EME and EIEE, usually a severe metabolic cause for EME or a structural lesion for EIEE.

Clinical Manifestations

Seizure semiology and EEG features of neonatal seizures differ from those of older children and adults. Consequently, classification schemes for seizures in older children and adults are not appropriate for neonates. Neonatal seizure classification schemes most often rely on dominant clinical features. Focal clonic, focal tonic, and some myoclonic seizures have associated ictal EEG discharges. Other paroxysmal movements, such as generalized tonic posturing and motor automatisms (mouthing, pedaling, and rotatory arm movements), have unreliable or inconsistent EEG equivalents and may reflect etiologies other than seizures such as HIE. Generalized tonic-clonic seizures do not occur in newborns because of the immaturity of the cerebral white matter. In addition, many neonatal seizures are only seen on EEG (are subclinical or nonconvulsive), and so EEG monitoring is important for both identification and management.

Diagnosis

As with older patients with seizures, history is essential, especially details about the pregnancy, delivery, and family history. Head circumference, the presence of congenital anomalies, neurocutaneous markings, and organomegaly are all relevant findings. The neurologic exam should also note any abnormal posturing or unusual movements.

Laboratory evaluation should focus first on common metabolic or infectious disorders that are treatable—serum should be studied for levels of glucose, calcium, magnesium, sodium, and acid-base levels as well as culture. The CSF should be evaluated for meningitis and hemorrhage. An EEG should be done promptly if there are abnormal movements or unexplained behavioral changes. Continuous EEG should be done if available, as there can be seizures without clinical manifestations. Ultrasound may identify hemorrhage and hydrocephalus. Amplitude-integrated EEG may be able to detect seizures, although localization is limited and some seizures may be missed. A CT also shows hemorrhage and hydrocephalus and, in addition, demonstrates parenchymal calcifications and major cerebral malformations. An MRI is usually necessary to detect more subtle developmental abnormalities, such as lissencephaly, polymicrogyria, or cortical dysplasia.

Timing of the first seizure may aid in the diagnosis. Seizures due to severe brain malformations, intracerebral hemorrhage, and hypoxic-ischemic injury occur within 24 to 48 hours. Seizures caused by infection and inborn errors of metabolism typically begin later in the first week of life. Seizures due to drug withdrawal usually occur in the first 3 days (eg, alcohol or short-acting barbiturates) but may not appear for 2 to 3 weeks (eg, methadone).

Seizures must be distinguished from other paroxysmal phenomena that occur in newborns, including jitteriness, which can be triggered or stopped by manipulation of a limb; benign sleep myoclonus; dyskinesias (eg, seen commonly with severe bronchopulmonary dysplasia); and the movements that occur during rapid-eye movement sleep. Brief, generalized, tonic postures that occur with poor cerebral perfusion or with resolving encephalopathies are usually not epileptic seizures, and they respond poorly or not at all to antiepileptic drugs.

Management

Etiology of seizures is a crucial determinant for choosing an appropriate treatment protocol. If there is a metabolic or infectious cause, for example, there may be specific therapies to address the seizures. Pyridoxine and pyridoxal-5′-phosphate may be effective treatments for seizures refractory to conventional antiepileptic medications. Treatment of metabolic causes of neonatal seizures is presented in Table 137.2.

First-line anticonvulsant therapy for neonatal seizures has traditionally been phenobarbital, followed by fosphenytoin (preferred over phenytoin because of fewer cardiac side effects) and short-acting benzodiazepines such as intravenous lorazepam and midazolam. Increasingly, levetiracetam is being used because of

TABLE 137.2 Treatments for Metabolic Causes of Seizures

Cause	Treatment	Maintenance
Hypoglycemia	10% glucose IV 2 mL/kg	8 mg/kg/min
Hypocalcemia	10% calcium gluconate (100 mg/kg or 1 mL/kg IV) infused over 5-10 min, checking HR and infusion site, repeated in 10 min if no response OR Calcium chloride (20 mg/kg or 0.2 mL/kg)	Add calcium gluconate to IV solution.
Hypomagnesemia (may be associated with hypocalcemia)	50% solution IM 0.25 mL/kg or 125 mg/kg; repeat every 12 h until normalized	
Pyridoxine-responsive seizures	Pyridoxine 100 mg IV or pyridoxal phosphate 30 mg/kg/d divided 3 times a day	Pyridoxine 15-18 mg/kg/d and folinic acid 3-5 mg/kg/d
Pyridoxal phosphate-responsive seizures	Pyridoxal phosphate 30 mg/kg/d divided 3 or 4 times a day for 3-5 d and folinic acid 3-5 mg/kg/d	Pyridoxal phosphate 30 mg/kg/d divided 4 times a day

Abbreviations: HR, heart rate; IM, intramuscular; IV, intravenous.

its favorable side effect profile and ease of use. Lidocaine can be used second line as long as there are no contraindications (eg, congenital heart disease or pretreatment with fosphenytoin). Midazolam can also be used second line or as a treatment for status epilepticus. Topiramate may also be helpful for refractory seizures. Recommendations are to start with one anticonvulsant, and increase levels to maximum tolerance if needed, before starting with another anticonvulsant. Treatment of acute symptomatic neonatal seizures is presented in Table 137.3.

Outcome

Prognosis usually depends on etiology, and, as discussed in the preceding text, it is essential to address and remedy the underlying cause of the seizures if possible. The HIE, severe IVH, and cerebral malformations may be associated with poor outcomes, depending on severity. An interictal EEG showing a suppression-burst pattern, a low-voltage background, and/or continuous multifocal epileptiform discharges frequently correlates with disabling brain damage.

Approximately 15% to 30% of neonates with seizures will develop epilepsy. There has been a decrease in overall mortality during the past few decades from neonatal seizures, from approximately 40% to 20%, although the prevalence of long-term neurodevelopmental sequelae has been unchanged at approximately 30%, perhaps because sicker infants are surviving the acute illness but then developing chronic manifestations. There is also some question about whether seizures directly cause brain injury, in particular when there is already an underlying defect in energy metabolism such as in HIE.

TABLE 137.3 Treatment of Acute Symptomatic Neonatal Seizures[a]

Medication	Dosage	Notes
Phenobarbital	Load: 20-30 mg/kg IV, repeated once as needed; maintenance: 4-6 mg/kg/d divided twice a day (target serum level 40-60 μg/mL)	Side effects: respiratory depression, depressed level of consciousness, hypotension, hypotonia, hepatotoxicity, blood dyscrasia, skin rash
Fosphenytoin (and phenytoin)	Load: 20 mg/kg IV; maintenance: 5-8 mg/kg/d divided twice or 3 times a day (may need four times a day) (target level 20 μg/mL); may need to check free concentration (target level 1-2 μg/mL)	Cardiovascular, CNS, cutaneous side effects, which are less often seen with fosphenytoin compared with phenytoin. Variability in pharmacokinetics may result in inconsistent serum levels.
Levetiracetam	Load: 40-60 mg/kg IV; maintenance: 40-60 mg/kg/d divided twice or three times a day	Pharmacokinetics incompletely understood for neonates
Lorazepam	Load: 0.05-0.1 mg/kg IV	Side effects: respiratory depression, depressed consciousness, hypotension; myoclonus in neonates with low birth weight
Midazolam	Load: 0.15 mg/kg IV and then continuous infusion (1 μg/kg/min, titrating to effect, maximum 2-5 μg/kg/min)	Side effects: respiratory depression, depressed consciousness, hypotension
Topiramate	Load: 10 mg/kg/d divided twice a day, increase in 2 d by 5 mg/kg/d divided twice a day; goal dose 5-6 mg/kg/d	May be helpful for refractory seizures; no intravenous form is available; may result in metabolic acidosis and/or weight loss/appetite suppression
Lidocaine	Load: 2 mg/kg over 10 min, then continuous infusion 7 mg/kg/h for 4 h, then 3.5 mg/kg/h for 12 h, then 1.75 mg/kg/h for 12 h; initial infusion 3.5 h rather than 4 h if being treated with therapeutic hypothermia	Side effect: arrhythmia; should only be given in ICU setting with continuous cardiac monitoring. Avoid concurrent treatment with proarrhythmic drugs such as phenytoin. Avoid in patient with congenital heart disease and if patient has received phenytoin or fosphenytoin (because of arrhythmia risks).

Abbreviations: CNS, central nervous system; ICU, intensive care unit; IV, intravenous.
[a]Adapted from Glass HC. Neonatal seizures: advances in mechanisms and management. *Clin Perinatol*. 2014;41(1):177-190 and Ahrens S, Ream M, Slaughter L. Status epilepticus in the neonate: updates in treatment strategies. *Curr Treat Options Neurol*. 2019;21:8.

STROKE AND SINUS VENOUS THROMBOSIS

Epidemiology

Acute symptomatic perinatal stroke can be classified into three clinical groups (with incidence): arterial-ischemic stroke (70%), sinus venous thrombosis (20%), and hemorrhagic stroke (10%). The incidence is approximately 10-fold higher than in childhood stroke in general. In retrospective studies, the prevalence of perinatal ischemic stroke has been found to be approximately 1 per 3,500, but this prevalence is undoubtedly an underestimate because it is based in part on database searches, which may not account for all cases.

Pathobiology

Pathophysiologic mechanisms leading to neonatal ischemic stroke include embolism, arteriopathy, or thrombosis. Most commonly, there is an infarction in the distribution of the middle cerebral artery, more commonly on the left. Neonates are at particular risk for thromboembolism because of multiple factors, including placental pathology or the normal thrombosis of placental vessels seen at birth; right-to-left shunts that may result from a patent foramen ovale or another congenital heart lesion; or indwelling umbilical vessel catheters, commonly used in neonatal intensive care units. Prothrombotic states, either from a systemic condition such as infection or from an inherited coagulation disorder, may also play a contributory role.

Hemorrhagic stroke may result from conversion of an ischemic infarction or may be caused by a bleeding diatheses or a vascular anomaly.

Sinus venous thrombosis may result from placental conditions resulting in a prothrombotic state, or from a prothrombotic disorder. Most thromboses occur in the superior sagittal or transverse sinus, and there is frequently infarction, which may be hemorrhagic. There may be associated dehydration and/or sepsis/meningitis.

Clinical Manifestations

Arterial ischemic stroke frequently presents with seizures, with contralateral focal seizures if there is unilateral cerebral infarction. There may also be hemiparesis, which may appear as a subtle asymmetry of spontaneous movements. There may be a normal neonatal course, however, with hemiparesis presenting only after many months. Sinus venous thrombosis usually presents with seizures and/or alteration of consciousness. Hemorrhagic stroke also presents with alteration of consciousness and seizures as well as focal weakness, apnea, or hypotonia.

Diagnosis

Head CT, or, preferably, MRI/magnetic resonance angiography, will show complete or branch infarcts, usually in the middle cerebral artery distributions. An infarct may be detected early with diffusion-weighted imaging. Magnetic resonance angiography can also be helpful if there are congenital vascular anomalies or carotid artery dissection.

In Sinus Venous Thrombosis (SVT), MRI/magnetic resonance venography or CT may show the "empty delta" sign and/or associated stroke or hemorrhage (Fig. 137.4). There may also be hemorrhagic infarction bilaterally in the parasagittal regions if there is sagittal sinus thrombosis (the most common form of SVT) or hemorrhage involving deep structures with deep venous thrombosis. There may also be seen IVHs, together with thalamic and internal capsule infarction.

If the infant presents with seizures, a thorough evaluation for systemic causes, such as infection, inborn errors of metabolism, or toxicity should be performed. The EEG may show focal attenuation, slowing, and/or epileptiform discharges. An echocardiogram should be done to evaluate for a congenital anomaly or a thrombus. Prothrombin and activated partial thromboplastin times should be measured if there is hemorrhage. The placenta can be examined to assess for clots or infarcts.

Hypercoagulability should be evaluated in the setting of ischemic stroke and sinus venous thrombosis. The workup includes maternal studies for lupus anticoagulant, anticardiolipin antibody, and antinuclear antibodies. The placenta should be examined for infarcts or clots. Protein S, protein C, and antithrombin III can be tested in the newborn period but should be retested at 3 to 4 months of age because newborns normally have low values of these proteins. Genetic analysis can be performed for factor V Leiden and prothrombin G20210A mutations. Homocystinuria, if not part of regular newborn screening, can be assessed with the maternal homocysteine concentration or methylene tetrahydrofolate reductase mutations.

Management

Supportive care for stroke includes maintenance of adequate oxygenation; treatment of acidosis, electrolyte disturbances, dehydration, and anemia; and antibiotic or anticonvulsant treatment if needed. For arterial ischemic stroke, treatment with anticoagulants or antiplatelet agents is restricted to patients with a documented cardioembolic source or recurrent arterial ischemic stroke, or patients who are at risk for recurrent stroke because of severe thrombophilic disorders.

Historically, there has been controversy regarding anticoagulation therapy for SVT, although there is now growing evidence supporting its safety, and there is also evidence that treatment reduces the occurrence of clot propagation. Current recommended guidelines from the American College of Chest Physicians (AACP) suggest anticoagulation for 6 weeks up to 3 months.

Outcome

Long-term prognosis for ischemic stroke depends on the location and extent of the ischemic injury. Hemiparesis occurs in 25% to 30% of infants with unilateral infarction and is more often seen when there is infarction of the entire middle cerebral artery territory. Milder neuromotor dysfunction occurs in another 30% with unilateral damage. Epilepsy occurs in 10% to 40% of patients with acute perinatal stroke. Cognitive impairment occurs in 20% to 25% of patients with unilateral infarction, with a worse risk if there is bilateral infarction or a large injury. The involvement of deep gray nuclei worsens cognitive outcome.

Outcome of sinus venous thrombosis varies. Most neonates (93%-97%) survive the immediate neonatal period. Motor deficit occurs in approximately 60% of survivors, with cognitive impairment in approximately 25% to 50% and epilepsy in 20% to 40%.

Hemorrhagic stroke outcomes are also quite variable. Mortality ranges from 4% to 25%, and there may be subsequent cerebral palsy, cognitive impairment, and/or epilepsy.

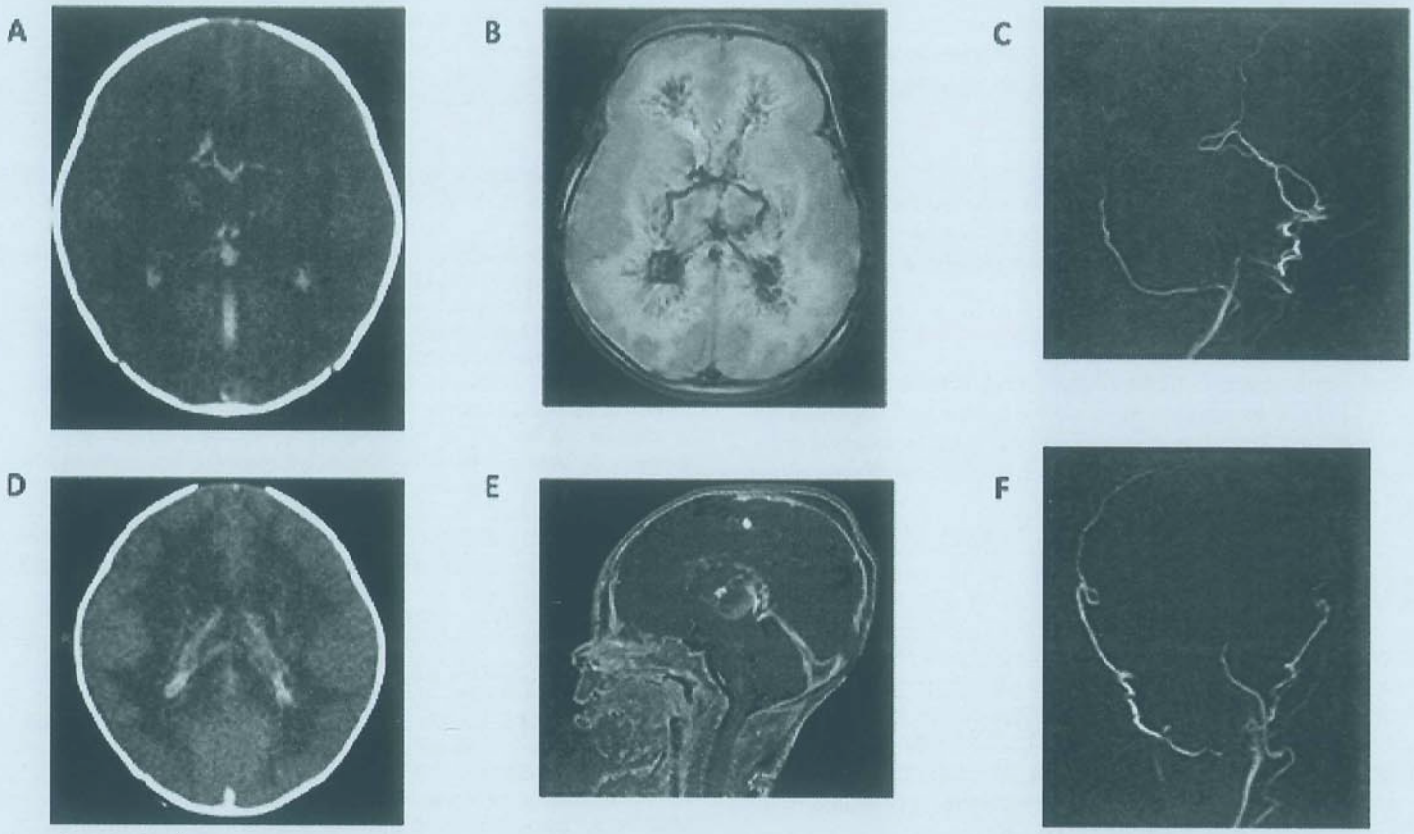

FIGURE 137.4 **A,D:** Head computed tomography, age 6 weeks. Extensive dural venous thrombosis involving the superior sagittal sinus, straight sinus, and internal cerebral veins, with hemorrhage extending intraventricularly. **B:** Magnetic resonance imaging of brain, age 6 weeks. Susceptibility-weighted consistent with hemorrhage in the periventricular, subcortical, and deep white matter. **E:** Sagittal view of postgadolinium T1 magnetic resonance imaging showing filling defect in confluence of sinuses. **C,F:** Magnetic resonance venography, age 6 weeks. Extensive dural venous sinus thrombosis with partial flow in the bilateral transverse sinuses with patency of the internal jugular veins.

PERIVENTRICULAR LEUKOMALACIA

Epidemiology

A PVL is a focal injury, usually from infection or ischemia, to the cerebral white matter, in the periventricular region; occasionally, there is more diffuse injury. It is more commonly seen in premature infants, especially in infants less than 32 weeks gestational age, although it can be seen in term infants as well. Prevalence based on ultrasound diagnosis ranges from 5% to 15% of very low birth weight infants, but the prevalence is higher when MRI, which is a more sensitive imaging modality, is used.

Pathobiology

The cerebral white matter of premature neonates is particularly vulnerable to injury because of a number of factors: (1) diminished vascularization and subsequent reduced blood flow in the periventricular area; (2) inadequate cerebral vascular autoregulation (with reduced cerebral perfusion in the setting of hypotension); and (3) the susceptibility of preoligodendrocytes (the predominant cell in white matter at early gestational ages and the precursor to normal myelin-producing cells) to injury and cell death from glutamate toxicity, which stems from hypoxia. Maternal infection, which is a risk factor for premature birth itself and lead to umbilical cord funisitis, or neonatal sepsis, is associated with PVL because of cytokines such as interleukin-1β, interleukin-6, and tumor necrosis factor α producing free radicals, which then activate astrocytes and microglia, which in turn release reactive oxygen species, toxic to the susceptible preoligodendrocytes.

Clinical Manifestations

Hypomyelination is seen in periventricular fibers descending from the frontal lobes to the peripheral neurons in the legs. Consequently, the classical presentation is spastic diplegia and cerebral palsy, which may not present in the newborn period. The involvement of the visual radiations in the posterior white matter can result in visual impairment. There may also be ex vacuo ventriculomegaly, with associated decreased gray matter volume, which may cause behavioral abnormalities and subnormal IQ scores.

Diagnosis

Ultrasonography typically reveals echodensities adjacent to the lateral ventricles, throughout the periventricular region, and usually evolves over time, with potential development of echolucent cysts within weeks and then ventriculomegaly over months.

More sensitive is MRI, which can detect more subtle diffuse white matter injuries or noncystic lesions. Diffusion-weighted imaging may allow for earlier detection of PVL or white matter injuries.

Management

Infants with PVL need to be closely monitored for development of neurologic sequelae, with the appropriate therapy provided for spasticity, cognitive, and visual complications.

Outcome

Infants with more extensive injury and ventriculomegaly are more likely to experience more severe motor and cognitive difficulties. Cyst formation is more likely to result in cerebral palsy. White matter injuries are a risk factor for cortical abnormalities and reduction in gray matter volume.

LEVEL 1 EVIDENCE

1. Executive summary: neonatal encephalopathy and neurologic outcome, second edition. Report of the American College of Obstetricians and Gynecologists' Task Force on Neonatal Encephalopathy. *Obstet Gynecol*. 2014;123(4):896-901.
2. Wassink G, Davidson JO, Dhillon SK, et al. Therapeutic hypothermia in neonatal hypoxic-ischemic encephalopathy. *Curr Neurol Neurosci Rep*. 2019;19(1):2.

SUGGESTED READINGS

Germinal Matrix-Intraventricular Hemorrhage

Amer R, Moddemann D, Seshia M, et al. Neurodevelopmental outcomes of infants born at <29 weeks of gestation admitted to Canadian neonatal intensive care units based on location of birth. *J Pediatr*. 2018;196:31-37.

Ann Wy P, Rettiganti M, Li J, et al. Impact of intraventricular hemorrhage on cognitive and behavioral outcomes at 18 years of age in low birth weight preterm infants. *J Perinatol*. 2015;35:511-515.

El-Dib M, Massaro AN, Bulas D, Aly H. Neuroimaging and neurodevelopmental outcome of premature infants. *Am J Perinatol*. 2010;27(10):803-818.

Fogarty M, Osborn DA, Askie L, et al. Delayed vs early umbilical cord clamping for preterm infants: a systematic review and meta-analysis. *Am J Obstet Gynecol*. 2018;218(1):1-18.

Hammers AL, Sanchez-Ramos L, Kaunitz AM. Antenatal exposure to indomethacin increases the risk of severe intraventricular hemorrhage, necrotizing enterocolitis, and periventricular leukomalacia: a systematic review with metaanalysis. *Am J Obstet Gynecol*. 2015;212(4):505.e1-505.e13.

Handley SC, Passarella M, Lee HC, Lorch SA. Incidence trends and risk factor variation in severe intraventricular hemorrhage across a population based cohort. *J Pediatr*. 2018;200:24-29.e3.

Kluckow M, Evans N. Low superior vena cava flow and intraventricular haemorrhage in preterm infants. *Arch Dis Child Fetal Neonatal Ed*. 2000;82(3):F188-F194.

Kuint J, Barak M, Morag I, Maayan-Metzger A. Early treated hypotension and outcome in very low birth weight infants. *Neonatology*. 2009;95(4):311-316.

Leijser LM, Miller SP, van Wezel-Meijler G, et al. Posthemorrhagic ventricular dilatation in preterm infants: when best to intervene? *Neurology*. 2018;90:e698-e706.

Levene MI, Wigglesworth JS, Dubowitz V. Hemorrhagic periventricular leukomalacia in the neonate: a real-time ultrasound study. *Pediatrics*. 1983;71(5):794-797.

McCrea HJ, Ment LR. The diagnosis, management, and postnatal prevention of intraventricular hemorrhage in the preterm neonate. *Clin Perinatol*. 2008;35(4):777-792.

Ment LR, Bada HS, Barnes P, et al. Practice parameter: neuroimaging of the neonate: report of the Quality Standards Subcommittee of the American Academy of Neurology and the Practice Committee of the Child Neurology Society. *Neurology*. 2002;58:1726-1738.

Noori S, Seri I. Hemodynamic antecedents of peri/intraventricular hemorrhage in very preterm neonates. *Semin Fetal Neonatal Med*. 2015;20(4):232-237.

Parodi A, Morana G, Severino MS, et al. Low-grade intraventricular hemorrhage: is ultrasound good enough? *J Matern Fetal Neonatal Med*. 2015;28(suppl 1):2261-2264.

Parodi A, Rossi A, Severino M, et al. Accuracy of ultrasound in assessing cerebellar haemorrhages in very low birthweight babies. *Arch Dis Child Fetal Neonatal Ed*. 2015;100(4):F289-F293.

Plaisier A, Raets MM, Ecury-Goossen GM, et al. Serial cranial ultrasonography or early MRI for detecting preterm brain injury? *Arch Dis Child Fetal Neonatal Ed*. 2015;100(4):F293-F300.

Pinto Cardoso G, Houivet E, Marchand-Martin L, et al. Association of intraventricular hemorrhage and death with tocolytic exposure in preterm infants. *JAMA Netw Open*. 2018;1(5):e182355.

Roberts D, Brown J, Medley N, Dalziel SR. Antenatal corticosteroids for accelerating fetal lung maturation for women at risk of preterm birth. *Cochrane Database Syst Rev*. 2017;(3):CD004454.

Robinson S. Neonatal posthemorrhagic hydrocephalus from prematurity: pathophysiology and current treatment concepts. *J Neurosurg Pediatr*. 2012;9(3):242-258.

Shankaran S, Lin A, Maller-Kesselman J, et al. Maternal race, demography, and health care disparities impact risk for intraventricular hemorrhage in preterm neonates. *J Pediatr*. 2014;164(5):1005-1011.

Stoll BJ, Hansen NI, Bell EF, et al. Trends in care practices, morbidity, and mortality of extremely preterm neonates, 1993-2012. *JAMA*. 2015;314(10):1039.

Tarby TJ, Volpe JJ. Intraventricular hemorrhage in the premature infant. *Pediatr Clin North Am*. 1982;29(5):1077-1104.

Vesoulis ZA, Bank RL, Lake D, et al. Early hypoxemia burden is strongly associated with severe intracranial hemorrhage in preterm infants. *J Perinatol*. 2019;39(1):48-53.

Volpe J. *Neurology of the Newborn*. 6th ed. Philadelphia, PA: Elsevier; 2018.

Whitelaw A, Lee-Kelland R. Repeated lumbar or ventricular punctures in newborns with intraventricular haemorrhage. *Cochrane Database Syst Rev*. 2017;(4):CD000216.

Zaben M, Finnigan A, Bhatti MI, Leach P. The initial neurosurgical interventions for the treatment of posthaemorrhagic hydrocephalus in preterm infants: a focused review. *Br J Neurosurg*. 2016;30(1):7-10.

Perinatal Asphyxia/Hypoxic-Ischemic Encephalopathy

Armstrong-Wells J, Bernard TJ, Boada R, Manco-Johnson M. Neurocognitive outcomes following neonatal encephalopathy. *NeuroRehabilitation*. 2010;26(1):27-33.

Awal MA, Lai MM, Azemi G, Boashash B, Colditz PB. EEG background features that predict outcome in term neonates with hypoxic ischaemic encephalopathy: a structured review. *Clin Neurophysiol*. 2016;127(1):285-296.

Azzopardi D. Clinical management of the baby with hypoxic ischaemic encephalopathy. *Early Hum Dev*. 2010;86(6):345-350.

Azzopardi D, Strohm B, Marlow N, et al. Effects of hypothermia for perinatal asphyxia on childhood outcomes. *N Engl J Med*. 2014;371(2):140-149.

Bashir RA, Vayalthrikkovil S, Espinoza L, Irvine L, Scott J, Mohammad K. Prevalence and characteristics of intracranial hemorrhages in neonates with hypoxic ischemic encephalopathy. *Am J Perinatol*. 2018;35(7):676-681.

Cashen K, Reeder RW, Shanti C, et al. Is therapeutic hypothermia during neonatal extracorporeal membrane oxygenation associated with intracranial hemorrhage? *Perfusion*. 2018;33(5):354-362.

Chandrasekaran M, Chaban B, Montaldo P, Thayyil S. Predictive value of amplitude-integrated EEG (aEEG) after rescue hypothermic neuroprotection for hypoxic ischemic encephalopathy: a meta-analysis. *J Perinatol*. 2017;37(6):684-689.

de Vries LS, Groenendaal F. Patterns of neonatal hypoxic-ischaemic brain injury. *Neuroradiology*. 2010;52(6):555-566.

Diederen CMJ, van Bel F, Groenendaal F. Complications during therapeutic hypothermia after perinatal asphyxia: a comparison with trial data. *Ther Hypothermia Temp Manag*. 2018;8(4):211-215.

Executive summary: neonatal encephalopathy and neurologic outcome, second edition. Report of the American College of Obstetricians and Gynecologists' Task Force on Neonatal Encephalopathy. *Obstet Gynecol*. 2014;123(4):896-901.

Ferriero DM. Neonatal brain injury. *N Engl J Med*. 2004;351(19):1985-1995.

Garfinkle J, Wintermark P, Shevell MI, et al. Cerebral palsy after neonatal encephalopathy: do neonates with suspected asphyxia have worse outcomes? *Dev Med Child Neurol*. 2016;58(2):189-194.

Glass HC. Hypoxic-ischemic encephalopathy and other neonatal encephalopathies. *Continuum (Minneap Minn)*. 2018;24(1):57-71.

Hakobyan M, Dijkman KP, Laroche S, et al. Outcome of infants with therapeutic hypothermia after perinatal asphyxia and early-onset sepsis. *Neonatology*. 2019;115(2):127-133.

Kurinczuk JJ, White-Koning M, Badawi N. Epidemiology of neonatal encephalopathy and hypoxic-ischaemic encephalopathy. *Early Hum Dev*. 2010;86(6):329-338.

Martinello K, Hart AR, Yap S, Mitra S, Robertson NJ. Management and investigation of neonatal encephalopathy: 2017 update. *Arch Dis Child Fetal Neonatal Ed*. 2017;102(4):F346-F358.

Martinez-Biarge M, Diez-Sebastian J, Wusthoff CJ, Mercuri E, Cowan FM. Antepartum and intrapartum factors preceding neonatal hypoxic-ischemic encephalopathy. *Pediatrics*. 2013;132(4):e952-e959.

Pappas A, Shankaran S, McDonald SA, et al. Cognitive outcomes after neonatal encephalopathy. *Pediatrics*. 2015;135(3):e624-e634.

Polglase GR, Ong T, Hillman NH. Cardiovascular alterations and multiorgan dysfunction after birth asphyxia. *Clin Perinatol*. 2016;43(3):469-483.

Rossouw G, Irlam J, Horn AR. Therapeutic hypothermia for hypoxic ischaemic encephalopathy using low-technology methods: a systematic review and meta-analysis. *Acta Paediatr*. 2015;104(12):1217-1228.

van Handel M, Swaab H, de Vries LS, Jongmans MJ. Behavioral outcome in children with a history of neonatal encephalopathy following perinatal asphyxia. *J Pediatr Psychol*. 2010;35(3):286-295.

van Laerhoven H, de Haan TR, Offringa M, Post B, van der Lee JH. Prognostic tests in term neonates with hypoxic-ischemic encephalopathy: a systematic review. *Pediatrics*. 2013;131(1):88-98.

Volpe JJ. Neonatal encephalopathy: an inadequate term for hypoxic-ischemic encephalopathy. *Ann Neurol*. 2012;72(2):156-166.

Weeke LC, Boylan GB, Pressler RM, et al. Role of EEG background activity, seizure burden and MRI in predicting neurodevelopmental outcome in full-term infants with hypoxic-ischaemic encephalopathy in the era of therapeutic hypothermia. *Eur J Paediatr Neurol*. 2016;20(6):855-864.

Wood T, Thoresen M. Physiological responses to hypothermia. *Semin Fetal Neonatal Med*. 2015;20(2):87-96.

Neonatal Seizures

Ahrens S, Ream M, Slaughter L. Status epilepticus in the neonate: updates in treatment strategies. *Curr Treat Options Neurol*. 2019;21(2):8.

Boylan GB, Stevenson NJ, Vanhatalo S. Monitoring neonatal seizures. *Semin Fetal Neonatal Med*. 2013;18(4):202-208.

Buraniqi E, Sansevere AJ, Kapur K, et al. Electrographic seizures in preterm neonates in the neonatal intensive care unit. *J Child Neurol*. 2017;32(10):880-885.

Cobo NH, Sankar R, Murata KK, Sewak SL, Kezele MA, Matsumoto JH. The ketogenic diet as broad-spectrum treatment for super-refractory pediatric status epilepticus: challenges in implementation in the pediatric and neonatal intensive care units. *J Child Neurol*. 2014;50(1):101-103.

Cowan LD. The epidemiology of the epilepsies in children. *Ment Retard Dev Disabil Res Rev*. 2002;8(3):171-181.

Fisher RS, Cross JH, French JA, et al. Operational classification of seizure types by the International League Against Epilepsy: position paper of the ILAE Commission for Classification and Terminology. *Epilepsia*. 2017;58(4):522-530.

Gillam-Krakauer M, Carter BS. Neonatal hypoxia and seizures. *Pediatr Rev*. 2012;33(9):387-396.

Glass HC. Neonatal seizures: advances in mechanisms and management. *Clin Perinatol*. 2014;41(1):177-190.

Glass HC, Shellhaas RA, Wusthoff CJ, et al. Contemporary profile of seizures in neonates: a prospective cohort study. *J Pediatr*. 2016;174:98-103.

Lloyd RO, O'Toole JM, Pavlidis E, Filan PM, Boylan GB. Electrographic seizures during the early postnatal period in preterm infants. *J Pediatr*. 2017;187:18-25.

Lundqvist M, Ågren J, Hellström-Westas L, Flink R, Wickström R. Efficacy and safety of lidocaine for treatment of neonatal seizures. *Acta Paediatr*. 2013;102(9):863-867.

Pisani F, Facini C, Bianchi E, Giussani G, Piccolo B, Beghi E. Incidence of neonatal seizures, perinatal risk factors for epilepsy and mortality after neonatal seizures in the province of Parma, Italy. *Epilepsia*. 2018;59(9):1764-1773.

Sands TT, Balestri M, Bellini G, et al. Rapid and safe response to low-dose carbamazepine in neonatal epilepsy. *Epilepsia*. 2016;57(12):2019-2030.

Shellhaas RA, Chang T, Tsuchida T, et al. The American Clinical Neurophysiology Society's guideline on continuous EEG monitoring in neonates. *J Clin Neurophysiol*. 2011;28:611-617.

Shellhaas RA, Wusthoff CJ, Tsuchida TN, et al. Profile of neonatal epilepsies: characteristics of a prospective US cohort. *Neurology*. 2017;89(9):893-899.

Silverstein FS, Jensen FE. Neonatal seizures. *Ann Neurol*. 2007;62(2):112-120.

Stockler S, Plecko B, Gospe SM Jr, et al. Pyridoxine dependent epilepsy and antiquitin deficiency: clinical and molecular characteristics and recommendations for diagnosis, treatment and follow-up. *Mol Genet Metab*. 2011;104(1-2):48-60.

Stroke and Sinus Venous Thrombosis

Bosenbark DD, Krivitzky L, Ichord R, et al. Clinical predictors of attention and executive functioning outcomes in children after perinatal arterial ischemic stroke. *Pediatr Neurol*. 2017;69:79-86.

Chabrier S, Peyric E, Drutel L, et al. Multimodal outcome at 7 years of age after neonatal arterial ischemic stroke. *J Pediatr*. 2016;172:156-161.

Cole L, Dewey D, Letourneau N, et al. Clinical characteristics, risk factors, and outcomes associated with neonatal hemorrhagic stroke: a population-based case-control study. *JAMA Pediatr*. 2017;171(3):230-238.

Martinez-Biarge M, Cheong JL, Diez-Sebastian J, Mercuri E, Dubowitz LMS, Cowan FM. Risk factors for neonatal arterial ischemic stroke: the importance of the intrapartum period. *J Pediatr*. 2016;173:62-68.

Moharir MD, Shroff M, Stephens D, et al. Anticoagulants in pediatric cerebral sinovenous thrombosis: a safety and outcome study. *Ann Neurol*. 2010;67:590-599.

Monagle P, Chan AK, Goldenberg NA, et al. Antithrombotic therapy in neonates and children: Antithrombotic Therapy and Prevention of Thrombosis, 9th ed: American College of Chest Physicians Evidence-Based Clinical Practice Guidelines. *Chest*. 2012;141(2 suppl):e737S-e801S.

Raju TN, Nelson KB, Ferriero D, Lynch JK. Ischemic perinatal stroke: summary of a workshop sponsored by the National Institute of Child Health and Human Development and the National Institute of Neurological Disorders and Stroke. *Pediatrics*. 2007;120:609-616.

Rattani A, Lim J, Mistry AM, et al. Incidence of epilepsy and associated risk factors in perinatal ischemic stroke survivors. *Pediatr Neurol*. 2019;90:44-55.

Rutherford MA, Ramenghi LA, Cowan FM. Neonatal stroke. *Arch Dis Child Fetal Neonatal Ed*. 2012;97:F377-F384.

Periventricular Leukomalacia

Folkerth RD. Periventricular leukomalacia: overview and recent findings. *Pediatr Dev Pathol*. 2006;9(1):3-13.

Gullion L, Stansell J, Moss H, Jenkins D, Aljuhani T, Coker-Bolt P. The impact of early neuroimaging and developmental assessment in a preterm infant diagnosed with cerebral palsy. *Case Rep Pediatr*. 2019;2019:9612507.

Hafström M, Källén K, Serenius F, et al. Cerebral palsy in extremely preterm infants. *Pediatrics*. 2018;141(1):e20171433.

Kinney HC. The near-term (late preterm) human brain and risk for periventricular leukomalacia: a review. *Semin Perinatol*. 2006;30(2):81-88.

Krägeloh-Mann I, Horber V. The role of magnetic resonance imaging in elucidating the pathogenesis of cerebral palsy: a systematic review. *Dev Med Child Neurol*. 2007;49(2):144-151.

Linsell L, Malouf R, Morris J, Kurinczuk JJ, Marlow N. Prognostic factors for cerebral palsy and motor impairment in children born very preterm or very low birthweight: a systematic review. *Dev Med Child Neurol*. 2016;58(6):554-569.

Persson M, Razaz N, Tedroff K, Joseph KS, Cnattingius S. Five and 10 minute Apgar scores and risks of cerebral palsy and epilepsy: population based cohort study in Sweden. *BMJ*. 2018;360:k207.

Volpe JJ. Brain injury in premature infants: a complex amalgam of destructive and developmental disturbances. *Lancet Neurol*. 2009;8(1):110-124.

138 Nervous System Formation and Malformation

Gary D. Clark

KEY POINTS

1. Nervous system development involves a series of distinct, yet overlapping phases.
2. Malformations of the nervous system can best be understood in the context of the phases have gone awry.
3. Genetic disorders give insight into the molecular processes underlying phases of nervous system development.

OVERVIEW

Induced by underlying mesodermal structures, such as the notochord, and inhibited by surrounding ectodermal tissue, the nervous system begins as a thickened layer of poorly differentiated cells in the developing ectodermal layer of a 14-day human embryo. By 21 days, ridgelike structures have formed in the lateralmost aspects of the neuroectoderm, begin to appose and to close in multiple closure sites, first in the cervical region. This forms a tubelike structure, termed the *neural tube*, and this closure is normally complete by 26 days, before most women know that they are pregnant. Errors in this process lead to myelomeningoceles (L1 and more rostral) and encephaloceles.

At the most caudal end of this tube is a mixed cell mass of ectoderm and mesoderm, termed the *caudal cell mass*, which is induced by the presence of the neural tube to form the sacrum, filum terminale, the conus medullaris, and the cauda equina. Errors in these processes lead to tethered spinal cords, caudal regression, fatty filum terminale, sacral pits and tracks, and other sacral defects.

The neural crest cells form from the extreme lateral aspects of the neuroectoderm and give rise to many of the sensory ganglia of cranial and spinal nerves in addition to the sympathetic chain and other structures.

Once the neural tube is completely formed, patterning or segmentation of this tube leads to the formation of the well-described vesicles of the developing nervous system (prosencephalon, mesencephalon, and rhombencephalon). The prosencephalon divides in the midline to two telencephalic vesicles that will become the cerebral hemispheres. Precursors lining the ventricles of the developing nervous systems become postmitotic and migrate radially to populate developing structures such as the cortex. Axons sprout and cross the midline to form the corpus callosum and thereby connect the two developing hemispheres. Neurons extend axons to connect in a very deliberate and use dependent fashion to the appropriate targets. To understand nervous system malformations, some additional genetic, molecular and basic neurobiology insight is needed.

This chapter summarizes normal and abnormal human central nervous system (CNS) formation and describes the genetic aberrations that cause congenital malformations of the CNS. Much of human CNS development is inferred from animal studies and from abnormal developmental processes. Without being exhaustive, the proteins believed to be involved in the individual components of CNS development and those involved in pathologic alterations of normal development will be listed. The functions of some of the genes responsible for abnormal development can be surmised by examining the pathologic consequences. Hence, one is able to correlate genetic abnormalities with developmental neuropathology. Other genes and molecules involved in abnormal human CNS formation have well-studied counterparts in animals that provide insight into their function in humans.

The study of the genetics of human development is a rapidly growing area, and important new genetic mechanisms are being described often. Although the information regarding human genes involved in normal and abnormal brain formation was as up-to-date as possible at the time that this chapter was written, important new insights into the genetics of human CNS development have likely been made since. Please visit Online Mendelian Inheritance in Man (OMIM) for more current information (http://www.ncbi.nlm.nih.gov/omim). As is the convention for the time that this chapter is written, terms such as *pathogenic variant* for those previously termed *mutation* are used herein.

Emphasis is placed on important information for the clinician in this chapter; space limitations and lack of current applicability to clinical neurology limit the amount of information that can be communicated. Instead, the covered pathologic entities are presented in the context of the developmental processes that are believed to have gone awry. Disorders previously categorized as migration abnormalities might, on the basis of new genetic insights, be found in the discussion of cellular differentiation or segmentation, for example. As further insights are made into human brain developmental disorders leading to neurologic disorders, the following categorization scheme will likely undergo alteration.

FORMATION OF NEUROECTODERM

The human brain is formed from the *neuroectoderm*, a placode of cells that are induced by the underlying notochord to differentiate from the ectoderm, a process beginning at 14 to 18 days of gestation. The nature of the inducible factor(s) (actually inhibiting factors because they inhibit bone morphogenic protein 4) involved in this process remain unknown. The molecular action of these molecules probably is similar to that of the retinoids, binding to a nuclear receptor to promote or suppress specific genes.

NEURAL TUBE CLOSURE

Primary Neurulation

The neuroectoderm placode develops ridges (folds) laterally and begins to approximate in the region of the future medulla at 22 days of gestation, before most women are aware they are pregnant. This closure, a process known as *neurulation*, results in a tube that continues to extend by the process of approximation of the neural folds in multiple locations rostrally and caudally until a complete neural tube is formed at 28 days of gestation, with the latter period marking the end of caudal neural tube closure (future spinal cord). The rostral neural tube, which closes at approximately 24 days gestation, serves as the foundation for further brain development; the caudal end of the tube forms the spinal cord (Fig. 138.1).

Although the specific molecules and genes involved in the processes of neural tube closure in the human are unknown, clearly a combination of genetic and environmental factors leads to disorders of these processes. Studies in mice suggest that a codeletion of *Paxl*, a gene for a *transcriptional factor* that mediates notochord signaling, and *Pdgfra*, the platelet-derived growth factor alpha gene, may lead to a spina bifida–like phenotype.

Certain ethnic groups experience a higher incidence of neural tube closure defects than do others, and genetic disorders with an apparent autosomal recessive inheritance that include neural tube defects have been described. In addition, teratogens are involved in neural tube pathology. The most notable teratogens for the neurologist are the anticonvulsants valproate and carbamazepine, each of which imposes a risk of 1% to 6% for a neural tube defect in offspring exposed in utero to these common drugs. Whereas folate supplementation appears to prevent neural tube defects in large population studies, this vitamin may or may not be protective when these disorders are associated with the aforementioned anticonvulsants. Given the likely lack of harm of short-term treatment with folate, it seems prudent to offer this vitamin (400-4,000 μg daily, depending on risk factors) to women of childbearing age who are on anticonvulsants.

Specific Neural Tube Defects

In the human, multiple genes and factors are likely involved in the pathogenesis of disorders of neural tube formation and closure. The human disorders of neural tube closure include craniorachischisis (a complete failure of neural tube closure along the entire neuraxis), anencephaly (a failure of anterior neural tube closure), myeloschisis (a failure of posterior, neural tube closure), spina bifida (myelomeningocele, a failure of closure of a portion of posterior neural tube), and encephalocele (a partial defect in anterior neural tube closure). Fetal recognition of myelomeningocele with correction in utero prior to 26 weeks' gestation can dramatically alter the need for subsequent ventriculoperitoneal shunting (reduced by 42%) and reduces the incidence of intellectual disability.The risk is to the mother, and this risk is being lowered by new relatively less invasive techniques.

Encephaloceles

Encephaloceles (brain substance outside of the skull) and meningoceles (meninges and cerebrospinal fluid only) vary in location, in the amount of brain involved, and, therefore, in the clinical manifestations of the lesions. In most cases, the neural tube is closed, and the gyral pattern of the protruding brain appears normal. Occipital encephaloceles are more common in eastern Asia and nasal encephaloceles are more common in the rest of the world. One should avoid nasogastric tube placement in the situation of a nasal mass in a newborn owing to the possibility of a nasal encephalocele; it is possible in this situation to place the tube in the brain substance.

Meckel Syndrome

Meckel syndrome, a genetic disorder that involves an occipital encephalocele, cerebellar malformations (molar tooth anomaly—see discussion below in Joubert syndrome), microcephaly, renal dysplasia (polycystic kidneys), polydactyly, retinal dystrophy, and other malformations, appears to be caused by pathogenic variants in genes involved in ciliary function. Meckel syndrome is allelic with Joubert syndrome and the same genetic aberrations are present in both disorders. Most of these disorders are

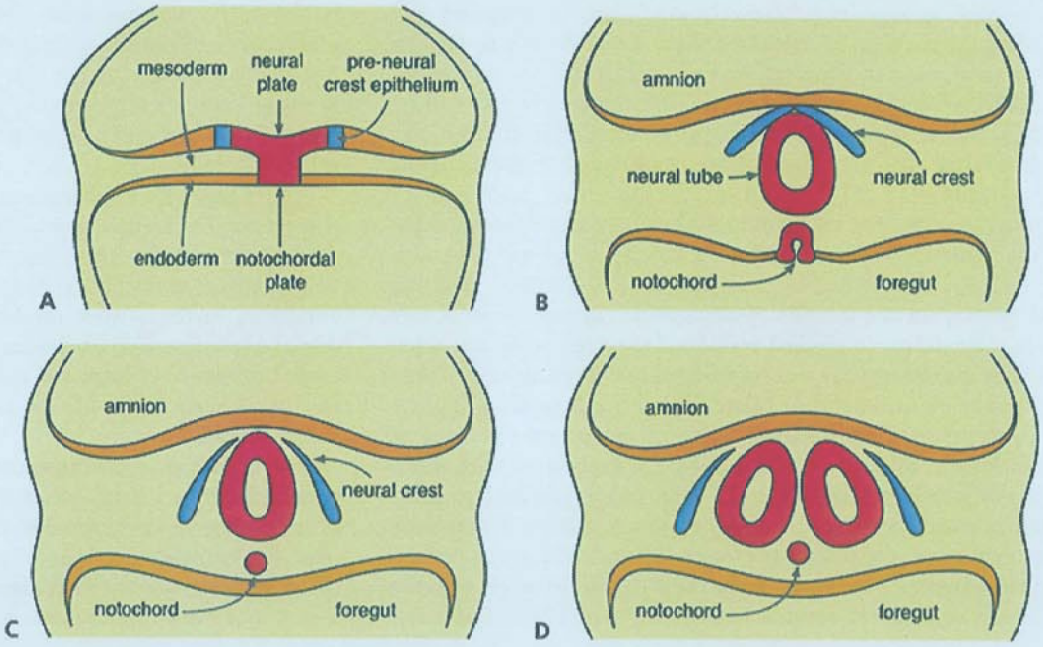

FIGURE 138.1 A: Notochord plate induces the neuroepithelium to differentiate from surrounding ectoderm. At the periphery of the neuroepithelium, neural crest forms. B: Neural tube closes. C,D: Rostral neural tube is induced by ventral notochord (Sonic Hedgehog and other factors) to split into two telencephalic vesicles that will become the cerebral hemispheres. (Drawings by Nathan Lucy.)

inherited in an autosomal recessive fashion, although some are inherited in a dominant fashion and others X-linked dominant or recessive. The genes involved are part of a ciliary complex that determines cell polarity and are important for the migration of early neurons in the posterior fossa.

EMBRYONIC NERVOUS SYSTEM SEGMENTATION

Flexures of the rostral neural tube delineate the primary vesicles of the developing nervous system; these are designated as the hindbrain (rhombencephalon), the midbrain (mesencephalon), and the forebrain (prosencephalon). These primary vesicles then further subdivide into the secondary vesicles that later will form the adult brain structures. The hindbrain consists of the metencephalon and myelencephalon; these structures will become the pons, the cerebellum, and the medulla oblongata of the adult. Rostrally, the mesencephalon will become the midbrain of the adult. The forebrain is further divided into the telencephalon and the diencephalon. The telencephalon will become the cerebral hemispheres, and the diencephalon will become the thalamus and hypothalamus of the adult.

FIGURE 138.2 Segmentation or patterning defect. Schizencephalic cleft in a developing fetus at 21 weeks' gestation. *Arrow* points to the cleft in the developing cortex.

Transcriptional Factors and Homeobox Genes

Regional specification of the developing nervous system is an important step in human CNS development and is likely under the control of a number of genes that encode transcriptional factors and of a number of molecules that influence these genes. Many of these genes were first described in the fruit fly, *Drosophila*, and are involved in the regional specification of the fly embryo. Not surprisingly, the function of the proteins encoded by the comparable genes in mammals differs considerably from that in fruit flies, but the general role of these proteins appears to be that of regional specification of clones of cells destined to form structures in the fully developed nervous system.

Transcriptional factors are proteins with distinct sequences that participate in DNA binding and thus influence DNA. In *Drosophila*, at least two transcriptional factors encoding homeobox genes, empty spiracles, have been shown to specify brain structures in humans. In the rudimentary structures of mutant flies that are devoid of *ems*, there seems to be a failure of regional specification of a clone of cells that are destined to form that structure. In humans, pathogenic variants in the comparable gene *EMX2* result in schizencephaly, a cleft in the cortical mantle. The clefts in this disorder extend from the pia to the ventricle and are lined with a polymicrogyric gray matter (see the discussion in "Polymicrogyria" section). The pia and ependyma are usually in apposition, especially in severe cases. The defect is termed *open-lip* if the cleft walls are separated by cerebrospinal and *closed-lip* if the walls appose. These clefts may be unilateral or bilateral and the prognosis appears to be dependent on location, bilateral occurrence, or extent of the lesion. Bilateral schizencephaly is associated with intellectual disability and spastic cerebral palsy; affected patients often are microcephalic. Seizures almost always accompany severe lesions, especially the open-lip and bilateral schizencephalic clefts. The exact frequency of seizures in patients with the less severe lesions is uncertain, or is the incidence of asymptomatic schizencephaly. Most patients in whom schizencephaly is diagnosed undergo neuroimaging because of seizures. Therefore, there is an ascertainment bias in favor of a universal occurrence of seizure in this disorder. Hence, patients with schizencephaly who do not have epilepsy might exist, but the malformation remains undetected because no imaging is done. With fetal imaging, asymptomatic schizencephaly has been noted (personal observation, Fig. 138.2).

Seizure type and onset may vary in this disorder. Patients may experience focal or generalized seizures. Some will present with infantile spasms. The onset varies from infancy to the early adult years. Seizures may be easily controlled or may be recalcitrant to standard anticonvulsant therapy.

Improvements in neuroimaging have enhanced the recognition of these disorders and have broadened the spectrum of the radiographic appearance of schizencephalic lesions. The lesions may occur in isolation or may be associated with other anomalies of brain development. An especially common association is made between septo-optic dysplasia and schizencephaly: As many as 50% of patients with septo-optic dysplasia also have schizencephaly.

Other genes for transcriptional factors have been described in the mouse. *Pax3*, *PaxS*, *Pax6*, *Dlxl*, *Dlx2*, *Dbx*, and the *Hox* genes are found in specific brain regions. In general, the *Pax* genes tend to be expressed in the midbrain, and the *Dlx* genes tend to be expressed in the ventral forebrain, ventral telencephalon, and dorsal telencephalon; *Dlx2* is important for the genesis of GABAergic interneurons from the median ganglionic eminence. The *Hox* genes seem to specify the neuromeres and rhombomeres of the hindbrain.

Furthermore, in an interesting link to the ventral inductive events described later, when applied to proliferating cells at critical times in development, the protein Sonic Hedgehog can alter the expression of the homeobox genes. This ties the inductive proteins to the expression of homeobox genes and gives a hint as to the mechanisms involved in inductive processes.

A gradient of retinoic acid in a rostral (less) to caudal (more) fashion seems to be important for *Hox* and other patterning gene expression patterns in the hindbrain, neck, and other structures of the head. Retinoic acid activity also decreases Sonic Hedgehog signaling (see "Ventral Induction" section). Because of their affect on Sonic Hedgehog signaling, retinoids are highly regulated and should not be given to women who may become pregnant.

Septo-Optic Dysplasia

Septo-optic dysplasia (de Morsier syndrome) is a disorder characterized by absence of the septum pellucidum, optic nerve hypoplasia, and hypothalamic dysfunction. This disorder should be considered in any patient who exhibits any of these findings, and all such patients should have hypothalamic function screening. Fifty percent of patients with septo-optic dysplasia have schizencephaly. Although this is a rare disorder, genetic syndromes with this phenotype and with some risk of recurrence have been described. For instance, pathogenic variants in homeobox gene expressed in embryonic stem (ES) cells, *HESX1*, have caused a dominantly inherited disorder in siblings. There is evidence that this disorder may result from early, nonspecific insults to the developing fetal brain. This disorder can be suspected in utero but magnetic resonance imaging (MRI) of the fetus may be necessary to assure a proper diagnosis. The prognosis for development is highly variable, with learning, intellectual, and motor impairments often described. Asymptomatic patients probably only come to medical attention if there are needs for neuroimaging. Pathogenic variants in *COL11A2* and *PAX6* have also been described as a cause of this disorder. Because most of the genes related to this phenotype are undiscovered and no genetic panels exist, it is recommended that clinicians consider exome sequencing in order to delineate the recurrence risk, if any, in a family.

VENTRAL INDUCTION

Normal Prosencephalon Division

The telencephalon is formed by medial division of a rostral single tubelike structure (prosencephalon); the two vesicles (telencephalon) formed in this division become the two cerebral hemispheres. The ventral and anterior portion of this division is induced by midline facial structures and the notochord via soluble factors. Abnormalities of this induction and division lead to midline abnormalities of the brain such as holoprosencephaly. These disruptions of normal development occur before 42 days of gestation.

Sonic Hedgehog, which was described first in *Drosophila* as a soluble factor (protein) that influences dorsoventral patterning of the developing embryo, is probably the most important of the soluble factors influencing ventral induction. Sonic Hedgehog is expressed in the notochord (also in ventral forebrain and floor plate—future facial structures), interacts through a well-defined signaling pathway that includes *PTCH*, a human homolog of *patched*, and alters the expression of transcriptional factors (homeobox and other related gene products).

Other molecules of interest in this inductive process are the retinoids (discussed previously in segmentation), which are lipids capable of crossing membranes and have been shown to exist in gradients across embryos. Retinoic acid can alter the pattern of transcriptional factors in neuroepithelial cells, and it can also downregulate Sonic Hedgehog, perhaps explaining some of the midfacial defects and holoprosencephaly seen in retinoid embryopathy. Also, cholesterol and cholesterol-derived lipids serve as a cofactor for Sonic Hedgehog, thus perhaps explaining telencephalic cleavage difficulties in Smith-Lemli-Opitz syndrome (7-dehydrocholesterol reductase deficiency).

Disorders of Ventral Induction

Holoprosencephaly

The holoprosencephaly syndromes are heterogeneous disorders of ventral induction and telencephalic cleavage that result from a failure of the prosencephalic vesicle to medially cleave normally. At least three forms of this disorder have been described: alobar, semilobar, and lobar. In the alobar form, the telencephalic vesicle completely fails to divide, producing a single horseshoe-shaped ventricle, sometimes with a dorsal cyst, fused thalami, and a malformed cortex. In the semilobar form, the interhemispheric fissure is present posteriorly, but the frontal and, sometimes, parietal lobes continue across the midline. In the lobar form, only minor changes may be seen: The anterior falx is absent, the frontal lobes and horns are hypoplastic, partial fusion of the thalamus, and the genu of the corpus callosum may occur. Holoprosencephaly is the most common human malformation leading to miscarriage.

Because Sonic Hedgehog and patched are expressed in the developing face, it is not surprising that holoprosencephaly is associated with a spectrum of midline facial defects. These include cyclopia, in which there is a single central eye and a supraorbital proboscis; ethmocephaly, in which the nose is replaced by a proboscis located above hypoteloric eyes; cebocephaly, in which hypotelorism and a nose with a single nostril are seen; and premaxillary agenesis, with hypotelorism, a flat nose, a single frontal incisor, and a midline cleft lip.

Only children who have the semilobar and lobar forms are known to survive for more than a few months. An infant affected with the severe form is microcephalic (unless aqueduct stenosis and hydrocephalus are present), hypotonic, and visually inattentive. In infants with the less severe forms of holoprosencephaly, myoclonic seizures frequently develop and, if the infant survives, autonomic dysfunction, failure to thrive, psychomotor retardation, and atonic or spastic cerebral palsy often are present. Some infants with the lobar form may be only mildly affected. Pituitary defects may be associated with these malformations and may result in neuroendocrine dysfunction.

Holoprosencephaly has been reported to be associated with maternal diabetes, retinoic acid exposure, cytomegalovirus, and rubella. Chromosomal abnormalities associated with this disorder include trisomies 13 and 18; duplications in 3p, 13q, and 18q; and deletions in 2p, 7q, 13q, and 18q. Autosomal dominant forms exist in which the pathogenic variant is in the Sonic Hedgehog gene on chromosome 7. In this form, the clinical features vary. In its mildest form, presence of a single central incisor, attention deficit disorder, or a choroid fissure coloboma may be the only clinical manifestation of autosomal dominant holoprosencephaly (Fig. 138.3).

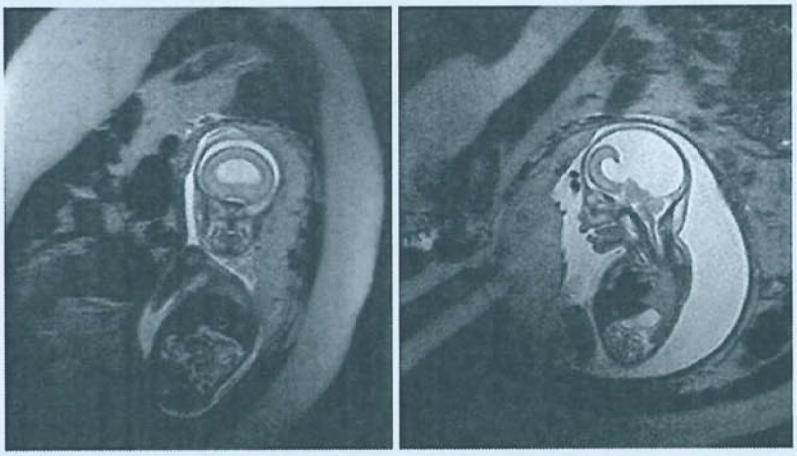

FIGURE 138.3 Failure of telencephalic cleavage. Holoprosencephaly in a fetus at 32 weeks' gestation. Note the single ventricle with no division of the cerebrum into hemispheres on a coronal view **(left panel)**. On a sagittal view **(right panel)**, a dorsal cyst is noted that is typical for alobar holoprosencephaly.

NEURONAL AND GLIAL PROLIFERATION

Normal Cell Proliferation

Lining the interior of the newly developed telencephalic vesicles is a proliferative, primitive neuroepithelium. Neuroepithelial processes extend from the ventricular surface to the pial surface, and the nuclei of the primitive neuroepithelial cells move from the cortical surface in a premitotic phase to a mitotic phase near the ventricle. Cells divide at the most ventricular aspects of the developing telencephalon and, after division, move back toward the pial surface. The pial processes of neuroepithelial cells near the ventricle often will detach from the cortical surface before a new cycle begins.

Neuroepithelial cells divide in so-called proliferative units such that each unit will undergo a specific number of divisions resulting in the appropriate number of cells for the future cortex. Abnormalities in the number of proliferative units or in the total number of divisions can lead to disorders of brain manifested by abnormal brain size and, therefore, an unusually small (microcephaly) or large head (macrocephaly). Disorders in which too many cells are generated in the proliferative phase result in megalencephaly (large brain) or, if proliferative events go awry on only one side of the developing cortex, hemimegalencephaly. Once the appropriate complement of cells is generated in the proliferative phase, the cells that will become the neurons of the cerebral cortex become postmitotic and are referred to as *neuroblasts*. Others undergo a programmed cell death, apoptosis. The genetics of apoptosis are best characterized in the simple nematode *Caenorhabditis elegans*. Approximately 10% of the cells generated during development of this worm will undergo apoptotic or programmed cell death. Pathogenic variants leading to smaller or larger numbers of surviving cells result in smaller or larger nematodes, respectively. The molecular characterization of these pathogenic variants has led to identification of a number of "death" genes and of genes that prevent apoptosis. The mammalian counterparts of the nematode death genes encode enzymes that are cysteine aspartate–specific proteases, also known as *caspases*. At least one function of such enzymes is that of an interleukin-converting enzyme, common in the inflammatory response of the body. These enzymes have been shown to promote neuronal death; in addition, when an animal is produced without caspase 3, a larger than normal brain results.

Disorders of Neuronal and Glial Proliferation

Microcephaly

Although primary familial microcephaly may be a normal variant, in the classic symptomatic form, clinical and radiologic examinations reveal a receding forehead, flat occiput, early closure of fontanelles, and hair anomalies such as multiple hair whirls and an anterior cowlick. Neuroimaging may show small frontal and occipital lobes, open opercula, and an uncovered cerebellum. The cortex may appear malformed (polymicrogyria, pachygyria, diminished white matter).

Neurologic findings also vary. Only mild psychomotor retardation may be noted, sometimes associated with pyramidal signs, or more severe intellectual disability, seizures, and a hypotonic cerebral palsy might be present. Primary microcephaly is seen in many genetic syndromes and, in its isolated form, may be autosomal recessive. Autosomal dominant and X-linked transmission has also been reported. *Microcephaly vera* is the term applied to this genetic form of microcephaly. Affected children present with a head circumference that is usually more than 2 standard deviations below the mean, hypotonia, and intellectual disability. They later show mental retardation, dyspraxias, motor incoordination, and occasionally seizures.

Destructive lesions of the forming brain, such as those caused by teratogens and by infectious agents, also may result in microcephaly. Teratogens of note are alcohol, cocaine, and hyperphenylalaninemia (maternal phenylketonuria). Intense radiation exposure in the first trimester can cause microcephaly. Microcephaly and intracranial calcifications are likely due to well-recognized in utero infections caused by cytomegalovirus, toxoplasmosis, Zika, or the human immunodeficiency virus, among others.

Although now usually recognized in utero, patients with pathologic microcephaly or pathologic macrocephaly have been, in the past, identified by their pediatricians. Neuroimaging may reveal an etiology in such patients. Because multiple genetic or teratogenic etiologies must be considered, one must use neuroimaging as a clue to possible etiologies (presence of malformations, calcifications, etc.). The prognosis varies greatly and depends on the etiology. Familial microcephaly and familial macrocephaly with benign outcomes have been described.

Megalencephaly and Hemimegalencephaly

The terms *megalencephaly* and *hemimegalencephaly* refer to disorders in which the brain volume is greater than normal (not owing to the abnormal storage of material); usually, the enlarged brain is accompanied by macrocephaly, or a large head. Although considered by some to be a migration disorder, the increase in brain size in these disorders appears to be attributable to errors in neuroepithelial proliferation, as the microscopic appearance of the brain is that of an increase in number of cells (both neurons and glia) and in cell size.

Typically, patients are noted to have large heads at birth and may manifest an accelerated head growth in the first few months of life. Children with megalencephaly or hemimegalencephaly may come to medical attention when presenting with seizures, a developmental disorder (intellectual disability), hemihypertrophy, or a hemiparesis (opposite the affected hemisphere). Seizures vary both in onset and in type and usually are the most problematic symptom, sometimes necessitating hemispherectomy or callosotomy.

Approximately 50% of patients with linear sebaceous nevus syndrome have hemimegalencephaly associated with *HRAS* or *KRAS* somatic-mosaic pathogenic variants. Many patients with hypomelanosis of Ito also have hemimegalencephaly. The neuropathologic and clinical pictures in these conditions appear to be identical to the isolated hemimegalencephalies. Interestingly, the genetic aberrations suggest an upregulation of the mammalian target of rapamycin (mTOR) pathway via a downregulation of phosphoinositol kinase 3 (PI3 kinase).

Microscopic examination of the affected brain usually reveals an increase in cellularity, large bizarre neurons, enlarged glia, cortical lamination defects, and heterotopias. The cortex usually is thickened, and malformed neurons are disturbed in polarity. Interestingly, the cytologic basis for the increase in brain size may be the abundant cytoplasm of individual cells.

NEURONAL DIFFERENTIATION

Normal Differentiation

At the time of neuronal differentiation, the neural tube consists of four contiguous layers: (1) the ventricular zone, which gives rise to neurons and all the glia of the CNS; (2) the subventricular zone, which is the more superficial layer and is the staging area from which postmitotic neurons begin to differentiate and to migrate; (3) the intermediate zone, which is the contiguous, more superficial zone and which is destined to become the cortical plate and the future cerebral cortex; and (4) the marginal zone, which is the outermost zone and is composed of the cytoplasmic extensions of ventricular neuroblasts, corticopetal fibers, and the terminal processes of radial glia (which, at this time, are completely spanning the neural tube).

Differentiation of neuroepithelial cells begins in the subventricular layer at approximately gestational day 26. Neuroepithelial cells were destined to become neurons at the time of the final mitotic division of the neuroepithelial cell precursor, before moving to the subventricular zone, the staging area for neuronal migration. At this point, these neuroblasts lack electrically polarized membranes as would commonly be seen in neurons. The fate of the neuroblast is likely determined before this final mitosis has occurred because the postmitotic neuroblast has the properties of many neuron types. The older, larger pyramidal cells are the first cells to be born and probably differentiate early in order to act as targets or barriers in the migration of the nervous system.

No disorders of solely neuronal differentiation have yet been identified, although some disorders may be found to fit into this category. For instance, premature neuroblast differentiation could result in an inability of these cells to migrate and thus could manifest as a migration abnormality. The megalencephaly and hemimegalencephaly syndromes may yet be found to be the results of disturbances in differentiation, as discussed earlier. Disorders such as tuberous sclerosis, in which both tumor development and areas of migration abnormalities are seen, seem to be a differentiation disorder due to upregulation of mTOR. The brain manifestations of this disorder include hamartomas of the subependymal layer (tubers), areas of cortical migration abnormalities (cortical dysgenesis), and the development of giant-cell astrocytomas in upward of 5% of patients. Two genes for tuberous sclerosis have been identified: *TSC1* (encodes for hamartin) has been localized to 9q34 and *TSC2* (encodes for tuberin) has been localized to 16p13.3. Both proteins suppress mTOR, and loss or dysfunction lead to overactivation of this important protein in development. The frequency of gene abnormalities in tuberous sclerosis patients has been estimated to be almost equally distributed between *TSC1* and *TSC2*. Interestingly, recently type IIb cortical dysplasias were found to harbor human papillomavirus (HPV) 16 and its oncogenic protein E6, which exerts its effect by upregulating mTOR by, in part, depressing *TSC2*. Therefore, at least some cortical dysplasias are preventable by HPV vaccination of parents prior to conception.

NEURONAL MIGRATION

Normal Migration

At the most rostral end of the neural tube in the 40-day-old fetus, the first mature neuron arrives at the developing cortical surface. These first neurons are the *Cajal-Retzius cells*, which are the major neurons of the cortex by day 43. Cajal-Retzius cells, along with corticopetal nerve fibers, form a so-called preplate. These cells will be the major cell type of the most superficial layer of the cerebral cortex, layer I. At the same time that the Cajal-Retzius cells are arriving at the most superficial layer of cortex, other pioneering neurons differentiate and form a so-called subplate. The pioneering neurons of the subplate and the preplate act as the police officers of the developing nervous system and define the limits of the developing cortical plate, which will become the six-layered cortex of the adult brain. Most of the cells of the subplate will die postnatally in a programmed cell death (see earlier discussion of apoptosis).

Near the end of the proliferative phase of neurodevelopment, billions of postmitotic neurons are poised to begin the trip to the cortical surface and to form the cortical plate. This tremendous number of neurons accomplishes this task, for the most part, by attaching to and migrating along radial glia (radially spanning from ventricle to pial surface) in a process known as *radial migration* (**Fig. 138.4**). In the process of migration, the deepest layer of the cortical plate forms before the other layers. Therefore, the first neurons to arrive at the future cortical plate are layer VI neurons. More superficial layers of cortex then are formed such that the neurons of layer V migrate and pass the neurons of layer VI; the same process occurs for layers IV, III, and II. The cortex therefore is formed in an inside-out fashion.

The molecules and the interactions between neurons and glia are extremely important in this process of neuronal migration.

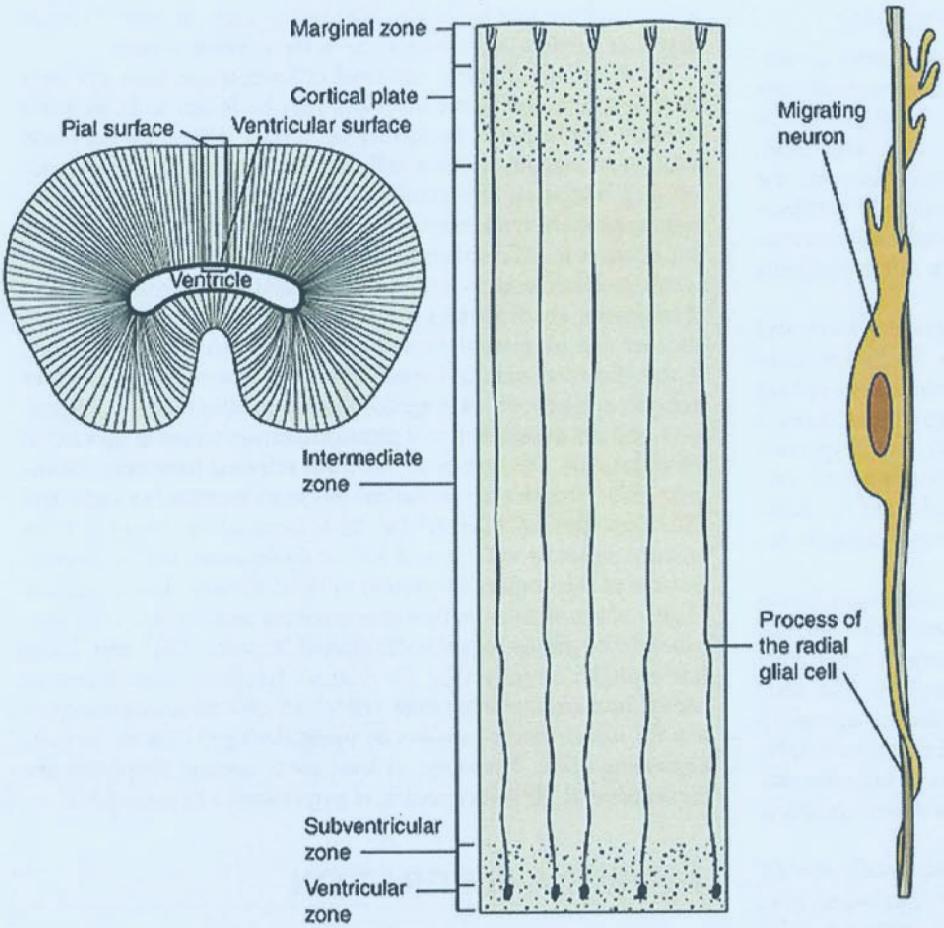

FIGURE 138.4 Neuronal radial migration in cortical development. **Upper left** depicts a single cortical vesicle stained for glia. Glia radially project from the ventricle to the cortical surface. The **right figure** depicts the apposition of the migrating neuron to a radial glial cell. Cells migrate past their predecessor to deposit in an inside out fashion.

Reelin, the protein involved in the migration mouse mutant, reeler, appears to be one such important molecule. Reelin appears to promote an attachment of neurons to glia and, when abnormal, as in the mouse mutant reeler, it leads to an inverted cortex such that the most superficial neurons are the first to arrive and the later arriving neurons are deeper. This mouse mutant cortex appears to be due to an abnormally adhesive interaction between neurons and glia. Additional molecules that appear to act in an adhesive manner are laminin, astrotactin, L1 antigen, fibronectin, neural cell adhesion molecules (NCAM), and adhesion molecule on glia.

Neuroblast movement on radial glia involves an extension of a leading process, a neural outgrowth having an orderly arrangement of microtubules. *Microtubules* are cytoskeletal elements with a polymerizing (positive) and a depolymerizing (negative) end. They serve as the major structural element that gives shape to long neural processes. When microtubules depolymerize, or slide, long neural processes are shortened. Shortening of the leading process of migrating neurons has been associated with forward movement of the soma of migrating neurons in vitro. Cytoskeletal changes in leading processes have been purported to be responsible for this shortening and somal movement.

A possible mode of movement in neuronal migration on glia would be the attachment of the neuron to a matrix secreted by either the glia or the neurons. This matrix is likely to consist of the aforementioned adhesion molecules. The attachment of the neuron is through *integrin* receptors, cytoskeletal-linking membrane-bound recognition sites for adhesion molecules. That attachment serves as a stronghold for the leading process and soma of the migrating neuron. Shortening of the leading process owing to depolymerization or shifts of microtubules results in movement of the soma relative to the attachment points. This theory of movement of neurons also includes a phase of detachment from the matrix at certain integrin receptors so that the neuroblast can navigate successfully along as much as 6 cm of developing cortex (the maximum estimated distance of radial migration of a neuroblast humans). Finally, the movement of cells must stop at the appropriate location, the boundary between layer I and the forming cortical plate. Therefore, some stop signal must be given in order for the migrating neuroblast to detach from the radial glia and begin to differentiate into a cortical neuron. This process is deficient in such disorders as cobblestone lissencephalies (discussed in the following text).

Other forms of neuronal migration occur in brain development. Some evidence exists for a tangential migration of neurons in the cortex and in the early granule cell migration in the cerebellum. A so-called chain migration of neurons on other neurons occurs in the formation of the olfactory bulbs. In this chain migration, neuroblasts from the subventricular zone of the lateral ventricle migrate to the olfactory bulb through a sheath of glial cells, but the actual migration occurs on other neurons.

Cortical Neuronal Migration Disorders

Many clinical entities are associated with neuronal migration disorders. In some, abnormalities are limited to the nervous system, but, in others, malformations involving other organs also are present. The responsible genetic mechanism has been identified in some of these disorders, and new genetic mechanisms are being identified regularly. Although the role of the gene product in producing many of these migration disorders

may not yet be entirely clear, the disorders provide important clues to mechanisms that are responsible for normal brain development.

Modern neuroimaging techniques, particularly MRI, have allowed the recognition of major migration disorders. Some of these disorders are associated with typical clinical features that might alert the clinician to the presence of such abnormalities even before imaging is obtained. In other disorders, the clinical features are so varied that a strong correlation between imaging and clinical presentation does not exist. High-field MRI and other research techniques may further refine the clinician's ability to refine diagnoses.

Lissencephaly

Although the term *lissencephaly* (smooth brain) refers to the external appearance of the cerebral cortex in those disorders in which a neuronal migration aberration leads to improper number of neurons at the surface of the cortex (Fig. 138.5), the most important observation in such cases is the thickened cortex with neurons in what should be white matter. In such deficits of migration, Gyri and sulci do not form properly because the cortical-cortical attractive forces that result from strong associations are decreased, owing to improper axon pathways (ie, the targets for synapses are malpositioned). It is important to note that the term *lissencephaly* is applied to cortical disorders in which there is a thickened cortex (migration deficit) and a cortical surface abnormality; rarely is there a completely smooth brain. At least two types of lissencephaly have been identified: type I, or classic lissencephaly, and type II, or cobblestone lissencephaly. This classification is based on both the external appearance of the brain and the underlying histology.

Type I (Classic) Lissencephaly

Type I lissencephaly most often accompanies the *Miller-Dieker syndrome*. In this disorder, an inadequate radial migration of neurons appears to have taken place. The cortex is described as being composed of a four-layer abnormal sequence, consisting of an outer molecular layer (layer 1), which is similar to normal layer I; a disorganized cellular layer of neurons near the normal location for the outer cortex (layer 2) (cells that should be in layers II-VI of the normal cortical plate); a cell-sparse zone (layer 3); and a heterotopic zone of neurons that have been arrested in neuronal migration (layer 4). The most extensive layer in this lissencephalic sequence is layer 4, the heterotopic zone. The neurons and cells of this zone have the appearance of cells that would normally be in layers II-IV of the normal cortical plate; however, these neurons are highly disorganized. Therefore, the later waves of neuronal migration that form the outer cortical plate appear to be those most affected by the migration abnormality in this disorder.

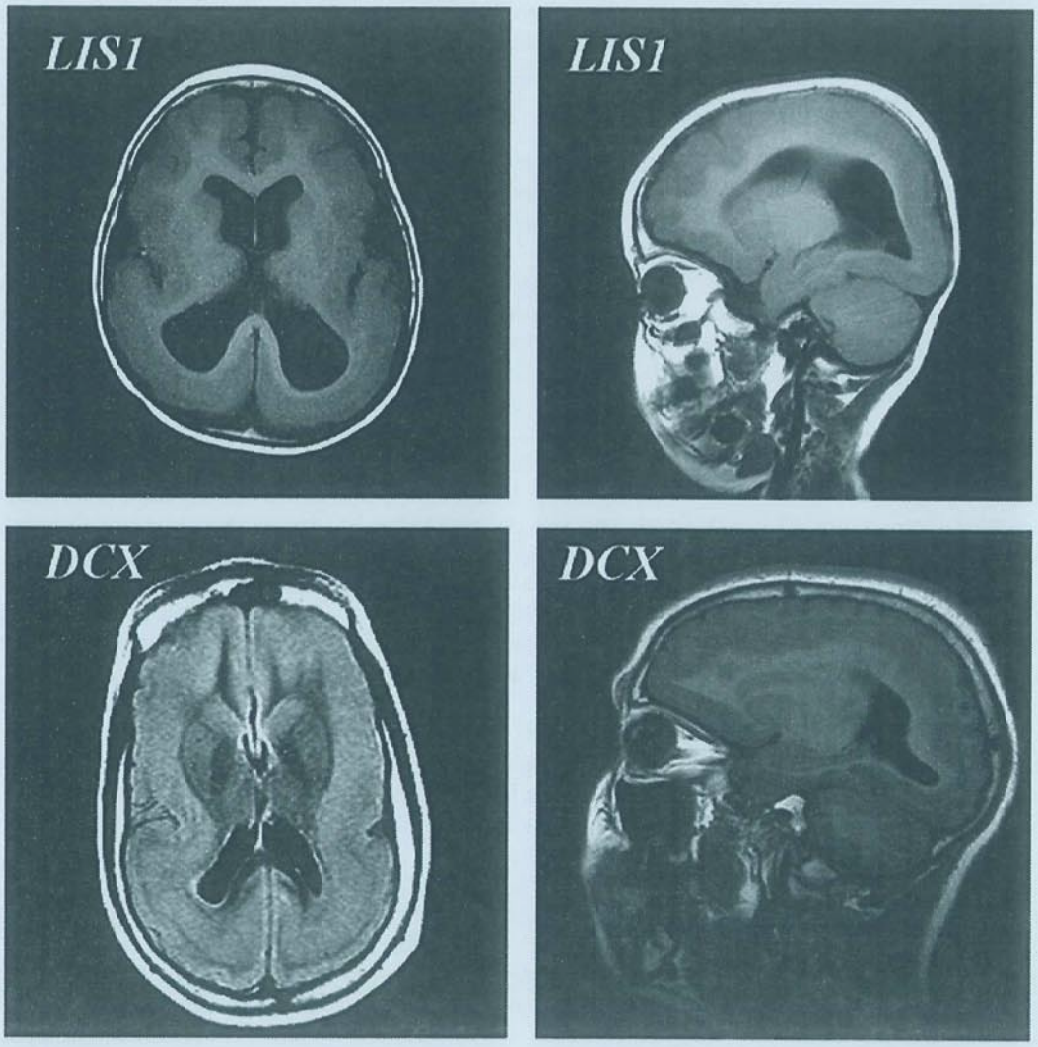

FIGURE 138.5 Lissencephaly spectrum. **Top panels** are from a patient harboring a *LIS1* deletion. To the left is an axial T1 magnetic resonance image demonstrating agyria posteriorly and pachygyria anteriorly. To the right is a lateral sagittal T1 magnetic resonance image from the same patient demonstrating the same gradient of posterior worse than anterior malformation. Bottom panels are from a female with a *DOUBLECORTIN* (*DCX*) mutation demonstrating the so-called double cortex (subcortical band heterotopia).

Hallmarks on imaging are a lack of opercularization (covering of the sylvian fissure), large ventricles with colpocephaly (fetal-like configuration of the occipital horns), and agyria or pachygyria (see Fig. 138.5). The corpus callosum is almost never absent, and the posterior fossa has a normal appearance on neuroimaging. Head size typically is in the low-normal range at birth, but most patients develop microcephaly owing to a decreased rate of brain growth over the first year of life. Nearly all patients with this disorder will develop seizures within this first year, and more than 80% of them will have infantile spasms. This seizure frequency is far greater than that seen in other neuronal migration disorders.

In the Miller-Dieker syndrome, facial dysmorphism, cardiac abnormalities (40%), sacral abnormalities (70%), deep palmar creases, and, in male patients, genital abnormalities (70%) may be seen. The sacral abnormalities include deep sacral dimples, sacral pits, and sacral tracks. Facial abnormalities include upturned nares, a short nose, a thin, "pouty" upper lip, a long philtrum, micrognathia, and bitemporal hollowing. Although the bitemporal hollowing may be the result of the underlying brain abnormality, the other facial features would be difficult to explain on the basis of the brain abnormality alone. Therefore, these abnormalities are believed to result from deficits of genes near the lissencephaly gene on the seventeenth chromosome. Larger deletions of the distal short arm of chromosome 17 appear to result in the full Miller-Dieker phenotype, whereas microdeletions of just the lissencephaly gene, *LIS1*, result in isolated lissencephaly. Therefore, a deletion in the lissencephaly gene appears to be sufficient for the brain abnormalities, but other genes (14-3-3) must be deleted for the full phenotypic manifestations of the Miller-Dieker syndrome to be seen.

Miller-Dieker lissencephaly is one of the migration disorders of brain in which the responsible genetic defect has been identified. By both molecular and cytogenetic techniques, deletions in the terminal portion of one arm of chromosome 17 can be found in approximately 90% of Miller-Dieker lissencephaly cases. These patients typically have dysmorphic features and other congenital anomalies (see earlier discussion). The deletions of the terminal part of chromosome 17 in these cases have included microdeletions, ring 17 chromosome, pericentric inversions, and a partial monosomy of 17p13.3. These genetic abnormalities often are the result of an inherited unbalanced translocation from a parent with a balanced translocation involving this region of chromosome 17; multiple mechanisms of inheritance similar to this have been described for this disorder. Of course, a parent with a balanced translocation of chromosome 17p is at a greatly increased risk of having another child with Miller-Dieker lissencephaly. In families that are affected in this manner, screening with amniocentesis can be performed in subsequent pregnancies.

Current chromosomal microarray testing will detect deletions of *LIS1* and of the neighboring *14-3-3* gene, thus genetically distinguishing Miller-Dieker syndrome from isolated lissencephaly. Some patients with isolated lissencephaly (no facial, skeletal, or cardiac abnormalities) also have small deletions of the terminal portion of the short arm of chromosome 17. Therefore, some researchers suspected that within one deleted region of chromosome 17 was a gene that, when deleted, was sufficient to result in the lissencephaly phenotype. In 1993, the human gene for this form of lissencephaly was identified as *LIS1*.

The protein encoded by *LIS1* has 99% homology to a 45-kD subunit of a bovine brain platelet-activating factor acetylhydrolase (in humans *PAFAH1B1*). Subsequently, depletion of this protein has been demonstrated in the brains of patients with Miller-Dieker syndrome and with isolated lissencephaly. Interestingly, whereas the message for *LIS1* in mice is expressed ubiquitously, the LIS1 protein product has been localized to the neuropile, Cajal-Retzius cells, and ventricular neuroepithelium at the time of human neuronal migration. However, it is not the lack of enzyme activity that leads to the brain malformation; rather it appears that the catalytic units of this enzyme complex regulate the available level of LIS1 protein.

The brain malformations in LIS1 deficiencies are usually worse posteriorly as compared with X-linked lissencephaly, which is worse anteriorly as discussed in the following text. However, in Miller-Dieker syndrome, the malformation may be equally severe anteriorly and posteriorly, thus making a distinction phenotypically difficult. This lesion can be detected in utero, but late in the pregnancy. The life expectancy is dependent on the severity of the neurologic impairment.

X-linked lissencephaly looks nearly identical to the *LIS1* deletion form of this disorder: Patients have classic lissencephaly, and the neurologic presentation is the same. However, the malformation is usually worse anteriorly, and the skeletal and other anomalies seen in the Miller-Dieker syndrome are not noted in this form of lissencephaly. In addition, X-linked lissencephaly occurs almost exclusively in boys. Girls who are heterozygous for the same gene have band heterotopia. Women with band heterotopia have been noted to give birth to boys with lissencephaly.

The *X-linked lissencephaly–band heterotopia syndrome* has been linked to Xq22.3.145,146. In female patients, the less severe phenotype is likely attributable to random X inactivation, such that in a variable percentage of cells, normal gene expression is seen and, in the remaining cells, the pathogenic variant for X-linked lissencephaly, *DOUBLECORTIN*, is expressed. Doublecortin is a microtubule associated protein that appears to stabilize the cytoskeletal structure. It appears that X-linked lissencephaly is a cell-autonomous disorder, in that the cell expressing the abnormal X chromosome manifests aberrant migration or disturbed substrate on which cells can migrate.

The band heterotopia or double-cortex syndrome is a unique form of a neuronal migration defect that almost exclusively occurs in girls and is allelic with X-linked lissencephaly in boys. In this disorder, a circumferential, thick band of tissue is isointense with cerebral gray matter located within what should be the white matter of the hemispheres (see Fig. 138.5). This band is most obvious in the frontocentroparietal regions in keeping with the anterior worse than posterior gradient in this disorder. The inner and outer margins at its interface with the adjacent white matter usually are smooth. The overlying gyral pattern may vary from normal cortex to abnormal sulcation. This anomaly represents incomplete neuronal migration. The exact mechanism is unclear, but possibilities include a lack of separation of the migrating neuron from the radial fiber or an arrest on the path to a normal cortical location.

Patients with band heterotopia typically present with seizures and a developmental disorder. The seizure type is variable, and the onset of epilepsy usually is between 2 months and 11 years of age. Patients may present with infantile spasms or, even though the migration abnormality is diffuse, with focal seizures. Control of the epilepsy varies, some patients being

controlled with monotherapy and others being entirely refractory to all agents.

Most patients with the X-linked lissencephaly–band heterotopia syndrome (double cortex) have impaired intellectual development that ranges from severe retardation to low-normal IQs; there is a report of a girl with an IQ of 91. Generally, individuals with this syndrome are less impaired than are patients with other diffuse neuronal migration defects such as lissencephaly. Patients in whom seizures are of later onset generally have less developmental impairment. Neurologic findings include mild dysarthria and mild bilateral pyramidal syndromes.

Type II (Cobblestone) Lissencephaly

In type II lissencephaly, the brain may have a smooth appearance or may exhibit polymicrogyria and pachygyria. The underlying cortical histology is that of a bizarre arrangement of neurons. Typically, in the most affected areas, normal cortical plate formation is not evident. Rather, bizarre whirls of cells are found. In addition, cells seem to penetrate the molecular layer and may spill into the subarachnoid space as if part of a volcanic eruption. This deposition of neurons in the subarachnoid space imparts a cobblestone street–like appearance to the brain surface; thus, the term *cobblestone lissencephaly* has been used to describe the cortex in these disorders. The Walker-Warburg, muscle-eye-brain, and Fukuyama muscular dystrophy syndromes are genetically distinct. Abnormalities that may or may not be seen in these disorders include muscular dystrophy, ocular anterior chamber abnormalities, retinal dysplasias (abnormal electroretinogram and visual-evoked responses), hydrocephalus (usually of an obstructive type, requiring shunting), and encephaloceles. The Walker-Warburg syndrome or muscle-eye-brain disorder might be diagnosed even if the ocular examination and muscle biopsies are normal. On MRI, an abnormal white matter signal, hypoplastic brainstem and cerebellum, and a thickened falx suggest the Walker-Warburg diagnosis (see Fig. 138.7). Neuroimaging of the muscle-eye-brain disorders might reveal focal white matter abnormalities. This disorder and other cobblestone lissencephalies have been diagnosed in utero.

In the cobblestone lissencephaly spectrum, despite the widespread cortical abnormalities, only one-third of patients develop seizures. The typical presentation is that of a child with marked hypotonia, macrocephaly (obstructive hydrocephalus), and eye abnormalities. Depending on the degree of brain and of muscle involvement, this disorder may not be compatible with life. Long-term survival is rare. Syndromes accompanying type II lissencephaly include the Walker-Warburg syndrome, hydrocephalus, agyria, retinal dysplasia, with or without eye (anterior chamber) abnormalities (HARD-±-E) syndrome, muscle-eye-brain disease, and Fukuyama muscular dystrophy. These are all the result of recessive inheritance of pathogenic variants in extracellular matrix proteins or in the cell receptors for the extracellular matrix.

Fukuyama muscular dystrophy is distinguished from the Walker-Warburg–like syndromes by the severity of the muscular dystrophy, by the cortical malformation that includes polymicrogyria and frequently by Japanese inheritance. This disorder is seen more often in Japan than in the Western hemisphere, probably because it is the result of a founder pathogenic variant (a viral transposon insertion) in a gene termed *FUKUTIN*. Patients typically present with evidence of a neuronal migration defect (cobblestone lissencephaly) with polymicrogyria, hypotonia, and depressed reflexes.

TABLE 138.1 Cobblestone Lissencephaly Disorders

Gene	Inheritance	Phenotypes
POMT1	AR	Cobblestone lissencephaly, muscular dystrophy
POMT2	AR	Intellectual disability, "mild brain malformations," muscular dystrophy
FUKUTIN	AR	Fukuyama muscular dystrophy, cobblestone lissencephaly, Walker-Warburg syndrome, limb-girdle muscular dystrophy
FKRP	AR	Walker-Warburg syndrome, muscle-eye-brain, cardiomyopathy, limb-girdle muscular dystrophy
LARGE	AR	Brain malformations, congenital muscular dystrophy
ISPD	AR	Cobblestone lissencephaly, limb-girdle muscular dystrophy

Abbreviation: AR, autosomal recessive.

Not surprisingly, patients with other pathogenic variants of *FUKUTIN* have been described to have muscle-eye-brain and even cardiac abnormal phenotypes. The protein fukutin interacts with laminin, an extracellular protein expressed in brain, muscle, and eyes, and with alpha dystroglycans on muscle membranes. There is further interaction with fukutin-related protein (FKRP), which seems to promote glycosylation of α-dystroglycans in coordination with fukutin; FKRP pathogenic variants may cause Walker-Warburg, muscle-eye-brain, HARD-±-E, muscular dystrophy, or may be asymptomatic. See Table 138.1 for known genes involved in cobblestone lissencephalies; only about 50% of patients have genetic aberrations identified, making the case for exome sequencing in these disorders.

All of these syndromes are accompanied by muscle abnormalities; the most extreme muscle involvement is in the Fukuyama muscular dystrophy patients. In the Walker-Warburg syndrome, the muscle abnormalities may or may not be clinically apparent (normal creatinine kinase, no apparent myopathy on clinical exam).

Kallmann Syndrome

Kallmann syndrome is an X-linked disorder characterized by anosmia and a defect in gonad development. Patients with this disorder may have other neurologic signs and symptoms, including cerebellar dysfunction and eye movement abnormalities. Therefore, abnormalities in other areas of brain, especially the cerebellum, have been suspected in this disorder. Gonadal dysfunction is thought to result from a deficiency in gonadotropin-releasing hormone. Because the neurons that produce gonadotropin-releasing hormone are derived from the olfactory plate and actually migrate back into the forebrain via the olfactory nerve, the abnormality of this hormone is likely due to an arrest in migration of the gonadotropin-releasing hormone neurons.

The gene for Kallmann syndrome has been localized to the X chromosome and appears to encode a fibronectin type III–like molecule. Because fibronectin type III has been proposed to be a neural adhesion molecule, the gene for Kallmann syndrome probably also encodes a neural adhesion molecule involved in olfactory and hypothalamic neuron migration.

Zellweger Syndrome

Zellweger syndrome is an autosomal recessive, peroxisomal disorder characterized by neuronal migration abnormalities, hepatomegaly, renal cysts, and stippled calcification of the patella. The neuronal migration defects include pachygyria and polymicrogyria, with underlying abnormalities best characterized as a nonlayered appearance of the cortex. Migration abnormalities are also noted in the cerebellum and in the brainstem in this disorder. Children with Zellweger syndrome present in the neonatal period with severe hypotonia, characteristic facies, hepatomegaly, and seizures. A mouse model of Zellweger syndrome has been produced; migration abnormalities were noted in the cerebellum and cortex, despite normal-appearing radial glia. Disturbed maturation of neurons and apoptotic neurons also are noted in this mouse model; perhaps similar mechanisms are operative in the comparable human disorder. More than 12 *PEX* genes have been implicated in Zellweger or Zellweger-like disorders; all are inherited in an autosomal recessive pattern.

Zellweger syndrome results from the body's inability to make peroxisomes owing to a deficiency of one of the 12 proteins encoded by the *PEX* genes. A number of peroxisomal enzymes are abnormal and lead to the accumulation of very-long-chain fatty acids. Therefore, testing for this disorder includes an assay of very-long-chain fatty acids.

Polymicrogyria

Polymicrogyria (many small gyri) is a disorder often considered to be a neuronal migration disorder; it is important to recognize that this malformation may result both genetic and destructive processes. The microscopic appearance of the lesion is that of too many small abnormal gyri. The gyri may be shallow and separated by shallow sulci, which may be associated with an apparent increased cortical thickness on neuroimaging. The multiple small convolutions may not have intervening sulci, or the sulci may be bridged by fusion of overlying molecular layer, which may give a smooth appearance to the brain's surface; alternatively, the brain may appear to have pachygyria.

Polymicrogyria takes two distinct histologic forms, four-layered and unlayered. The four-layer form consists of an outer layer, a neuronal layer, a cell-sparse layer, and a deeper neuronal layer. One theory is that the lower cell-sparse layer of the four-layer types represents a glial scar from laminar necrosis. On the basis of examination of fetuses in which the occurrence of the insult causing the malformation has been accurately timed, this pattern is believed to occur as a result of insults late in the first or early in the second trimester. Others believe that this is a postmigration insult resulting from distorted migration of cells through an injured area, the outcome of which is the cell-sparse layer. A cell-sparse layer between the upper and lower neuronal layers is absent from the unlayered form. Insults that occur early in the second trimester before migration is completed are believed to be the origin of unlayered polymicrogyria. Identical twin pregnancies discordant for polymicrogyria have been described; the theory being that global insults can lead to polymicrogyria. The common association of congenital cytomegalovirus infection with polymicrogyria supports the hypothesis that a destructive process can be involved in these disorders. Cytomegalovirus maternal infections during pregnancy is a common cause of polymicrogyria and microcephaly; Zika virus appears to cause similar malformations.

Polymicrogyria has also been associated with genetic and chromosomal disorders. It is found in disorders of peroxisomal metabolism such as Zellweger syndrome (see discussion earlier) and neonatal adrenoleukodystrophy. It has also been associated with the Bloch-Sulzberger syndrome, Meckel-Gruber syndrome, thanatophoric dysplasia, and Fukuyama congenital muscular dystrophy. Familial bilateral frontal polymicrogyria and bilateral perisylvian polymicrogyria have been reported. If no identifiable cause of the polymicrogyric malformation is found, the recurrence risk may be that of an autosomal recessive disorder (25%) or an X-linked disorder in boys. A bilateral parasagittal parieto-occipital polymicrogyria has also been described. Multiple chromosomal deletions and duplications, including X-linked potential inheritance, have been described. Multiple recessively inherited disorders have also been identified, including GPR56 and WDR62 pathogenic variants in families with recurrences of polymicrogyria with variable phenotypes.

The clinical picture varies depending on the location, extent, and etiology of the abnormality. Microcephaly with severe developmental delay and hypertonia may result when polymicrogyria is diffuse. When polymicrogyria is unilateral, focal deficits might be seen. Epilepsy often is present, characterized by partial-complex seizures or partial seizures that secondarily generalize. The age at presentation and severity of seizures depends on the extent of the associated pathology.

The lesions are most clearly recognized by MRI and are best noted on sagittal views. They often are recognized by the rough appearance of the surface of the cortex on a thin-cut T_2-weighted image. If MRI cuts are thick, these lesions may be confused with pachygyria. Because the genetic implications of pachygyria and polymicrogyria differ considerably, distinguishing between these two conditions is important.

Congenital Bilateral Perisylvian Syndrome

Advances in neuroimaging have led to the recognition of the congenital bilateral perisylvian syndrome, also known as the *Foix-Chavany-Marie syndrome*. The MRI demonstrates bilateral abnormalities in the opercular and perisylvian regions. The cortex is irregular, and the sylvian fissure may extend to the top of the convexity.

Striking clinical features include a pseudobulbar palsy with abnormal tongue movements, dysarthria, dysphasia, mental retardation, absent or hyperactive gag reflex, drooling, and pyramidal signs in more than 70% of the reported cases. These patients may be intellectually disabled, and nearly all have severe language disorders. Dysphagia can impair proper nutrition. Seizures are present in most of the affected patients. Several patients have had infantile spasms during the first year of life. Seventy percent of the patients experience seizures before the age of 10. The etiology of this syndrome is similar to other forms of polymicrogyria (deletions, duplications, insults [cytomegalovirus, twin pregnancies], Aicardi syndrome [see following text], and recessively inherited pathogenic variants in genes).

Heterotopias

Heterotopias are collections of normal-appearing neurons in an abnormal location, likely secondary to a disturbance in radial migration. The exact mechanism of the migrational aberration has not been established. Various hypotheses include damage to the radial glial fibers, premature transformation of radial glial cells into astrocytes, or a deficiency of specific molecules on the

surface of neuroblasts or of the radial glial cells (or the receptors for those molecules) that results in disruption of the normal migration process. Heterotopias often occur as isolated defects that may result in epilepsy only. However, when they are multiple, heterotopias might also be associated with a developmental disorder and cerebral palsy (usually spastic). In addition, if other migration defects such as gyral abnormalities are present, the clinical syndrome may be more profound. Usually, no cause is apparent. Occasionally, heterotopias may be found in a variety of syndromes, including neonatal adrenoleukodystrophy, glutaric aciduria type II, GM_2 gangliosidosis, neurocutaneous syndromes, multiple congenital anomaly syndromes, chromosomal abnormalities, and fetal toxic exposures.

Heterotopias may be classified by their location: subpial, within the cerebral white matter, and in the subependymal region. Leptomeningeal heterotopias often contain astrocytes mixed with ectopic neurons and may resemble a gliotic scar. They may be related to discontinuities in the external limiting membrane and often are associated with type II lissencephaly. These *subarachnoid heterotopias* are responsible for the pebbled appearance of the surface of the brain (therefore the name cobblestone lissencephaly). *White matter heterotopias* may be focal, subcortical, or diffuse. They may cause distortion of the ventricles and may be associated with diminished white matter in the surrounding area. When diffuse, they may take the form of a circumferential subcortical layer of heterotopic gray matter, which has been called *band heterotopia* or the *double-cortex syndrome* (see previous discussion in "Type I [Classic] Lissencephaly" section). Laminar heterotopia consists of sheets of ectopic gray matter that may be split into elongated islands. A central ovoid mass of white matter may be present within the band. Patients with this form of subcortical heterotopia have a high prevalence of developmental delay, hemiplegia, and seizures. Nodular subcortical heterotopias may be seen in association with subependymal heterotopias.

Subependymal heterotopias often are associated only with epilepsy. Most patients will have normal intelligence and no motor deficits. These heterotopias are located just beneath and abut the ependymal lining of the lateral ventricles. They may be either bilateral or unilateral and are located most often adjacent to the occipital horns and trigones and, less commonly, within the temporal horns and frontal horns. Seizure onset in patients with subependymal heterotopias is relatively late, often in the second decade, and more often affects women. The seizures may be partial complex, tonic-clonic, or focal motor. Subependymal heterotopias have been identified as an X-linked dominant syndrome linked to markers in the distal Xq28 locus, and pathogenic variants in *FILAMIN A* have been found to be causative. FILAMIN A, a cytoskeletal protein, must be important for the initiation of migration because cells are arrested in the ventricular zone. An increased incidence of spontaneous abortions, patent ductus arteriosus, spontaneous hemorrhage, and a much higher than expected incidence of female offspring are noted in affected women, suggesting that inheritance of *FILAMIN A* pathogenic variants may be lethal for male embryos. Some variants in this gene may result in male phenotypes. A syndrome marked by periventricular heterotopia, mental retardation, and syndactyly has recently been described in males.

Patients with diffuse gray matter heterotopias, whether subependymal or in the white matter, frequently are candidates for medical treatment of epilepsy. Occasionally, patients who are refractory to medical management may be considered for hemispherectomies or focal cortical resections. In the case of bilateral temporal lobe periventricular heterotopias, the prognosis for a surgical cure may be poor.

Cortical Dysgenesis

Cortical dysgenesis refers to disorders of cortical formation. In general, many of the disorders just discussed are considered to be within its spectrum. In this section, an emphasis on the focal macroscopic and microscopic lesions that do not fit into the preceding classifications are discussed.

The terms *cortical dysplasia* and *cortical dysgenesis* often are used synonymously for the same disorders. Included in these terms are not only the obvious malformations such as smooth gyri and clefts but also lesions classified as focal cortical dysplasias and microdysgenesis. Focal cortical dysplasia may involve a major part of a lobe and may be characterized by the congregation of large, bizarre neurons and abnormal glial cells in the subadjacent white matter. *Microdysgenesis* can be detected only histologically and is beyond the imaging capability of current MRI scans. It consists of unipolar and bipolar neurons under the pia, increased neurons in the first layer of the cortex, indistinct boundaries between the first and second layers of the cortex, neuronal glial heterotopias in the pia, persistence of columnar architecture of the cortex, and an increased number of neurons in the white matter. Patients with microdysgenesis are reported in series of patients undergoing epilepsy surgery. Microdysgenesis is not detected in patients with controlled epilepsy, and thus, the incidences of migration disorders and of microdysgenesis responsible for epilepsy are unknown.

Microdysgenesis was the most common migration disorder noted in a series of pathologic examinations of brain tissue removed from epileptic patients. Malformations of this type were found in 14% of epileptic brains; the frequency of other abnormalities in epileptic brains was microgyria, 4.7%; heterotopia, 15%; and pachygyria, 8%. In patients with microdysgenesis, seizure onset occurs between 2 and 20 years of age.

A surprisingly high incidence of microdysgenesis has been reported in brain tissue removed from adults to treat recalcitrant seizures. The lesions noted included ectopic neurons within the subcortical white matter in 42% of the specimens and neuronal clustering in 28%; in addition, bare areas were present within layers II to VI. Similar findings have been reported in epilepsy surgical specimens from children. Thus, microscopic abnormalities have been found in 20% to 40% of specimens from patients undergoing surgical therapy for intractable epilepsy, the most common lesions being microdysgenesis and cortical dysplasias.

As mentioned earlier, MRI has been useful in detecting migration abnormalities and generally has been found to be more sensitive than CT scanning. The MRI-apparent migration abnormalities have been detected in as many as 50% of patients who underwent epilepsy surgery. Of those patients with epilepsy alone, 6.7% had migration abnormalities; in those who had both mental retardation and epilepsy, such abnormalities were found in 13.7%. The abnormalities included pachygyria or polymicrogyria or both, schizencephaly, heterotopias, and hemimegalencephaly. Of 222 adults with temporal lobe epilepsy studied by MRI, 7.2% were found to have malformations of the temporal lobe. These malformations consisted of heterotopias, focal neocortical dysgenesis, hippocampal malformations, or a combination of various lesions.

Cortical dysgenesis has also been associated with hippocampal sclerosis, leading some to believe that hippocampal sclerosis is a disorder of brain formation. Raymond and colleagues studied 100 patients with hippocampal sclerosis diagnosed by histologic examination or MRI and found that 15 of the patients also had cortical dysgenesis. The most common abnormality was subependymal heterotopia. The cortical dysplasia was, at times, contralateral to the hippocampal sclerosis.

Clearly, migration aberrations need not be manifested by abnormal motor function; rather, epilepsy and intellectual disability might be the only clinical symptoms in these disorders.

The severity of the migration disorder correlates with clinical symptoms. Patients with milder forms of neuronal migration defects (ie, focal cortical dysplasias, heterotopias, microdysgenesis) may appear normal. Most often, migration disorders are diagnosed in patients with epilepsy, as neuroimaging is performed for seizure. These patients generally have partial seizures and normal life expectancies. Some patients with these disorders will have developmental delays, mild intellectual deficits, or spastic or atonic cerebral palsy. Profound defects are associated with more severe symptoms.

Children presenting with intractable epilepsy, significant intellectual disability, and neurologic signs more often have diffuse migration abnormalities on MRI scanning. Therefore, not surprisingly, the degree of abnormality on MRI scans correlates well with the degree of neurologic involvement. The age of onset of seizures varies from early childhood to young adult life. Generally, the severity of the seizures and the severity of the pathology correlate positively. Severe abnormalities are associated with seizures in the first year of life, whereas microdysgenesis may be associated with adult onset of seizures. Later onset seizures also tend to correlate with subependymal heterotopias.

Although the pathogenic mechanisms involved in focal dysgenesis remain poorly understood, mechanisms similar to those involved in global or more extensive migration disorders probably are operative. Therefore, definition of the pathogenic mechanisms causing these disorders is important. An important insight into the pathogenesis of focal developmental lesions may have come from the observation that the HPV 16 RNA and its oncogenic protein E6 are present in focal cortical dysplasia type IIb resected for epilepsy. This fascinating observation potentially ties HPV with tuberous sclerosis because the E6 protein encoded by HPV exerts its oncogenic effect via depression of TSC2 and AKT, thereby upregulating mTOR as occurs in tuberous sclerosis. In support of this hypothesis, cortical dysplasia type IIB also occurs in tuberous sclerosis. Indeed, other viruses could have similar effects on the developing nervous system and could explain microdysgenesis and other lesions of the nervous system described earlier.

POSTERIOR FOSSA FORMATION AND MALFORMATION

Posterior fossa malformations are best understood in terms of the normal developmental processes that have gone awry. At 4 weeks of human gestation, the hindbrain or rhombencephalon bends and divided into two vesicles, the metencephalon and the myelencephalon. The pons develops in the floor of the metencephalon and the lateral walls of the myelencephalon form the medulla oblongata. The cerebellum develops from the dorsal hindbrain (neuromere 1, rhombic lip) with contributions from the lower mesencephalon, which forms the vermis, and the metencephalon, which forms the cerebellar hemispheres. As this development progresses, mesenchymal tissue from the forming skull and meninges invade to form the choroid plexus. This invasion of mesenchymal tissue is caudal to the developing rhombic lip, and this invasion penetrates the developing fourth ventricle. The roof of the developing fourth ventricle is divided by this invading mesenchymal tissue in to two areas, the anterior membranous area and the posterior membranous area. The rhombic lip, the developing cerebellum, grows over the structures as it enlarges to form the cerebellum. As the cerebellum develops, the anterior membranous area involutes, and the posterior membranous area protrudes outward from the developing nervous system. This performs the so-called Blake's pouch cyst, which may persist normally until 4 months' gestation. Eventually, the foramina of Magendie form in the Blake's pouch cyst, and the protrusion normally involutes. The foramina of Luschka also develops around this time.

A proliferative zone of cells in the ventricular region of the rhombic lip give rise to future Purkinje cells, which migrate radially toward the surface of the developing cerebellum. At the tip of the rhombic lip, cerebellar granule cells are formed that migrate over the surface of the rhombic lip and then, in a reverse radial migration, penetrate the developing cerebellum, pass Purkinje cells, and deposit in the developing internal granule cell layer. This process of cerebellar granule cell formation occurs in the first year of human life. Prior to the formation of granule cells, other neurons are formed in the ventricular zone and migrate to the various nuclei of the brainstem.

For the purposes of this chapter, I will divide posterior fossa malformations into predominantly neuronal structural malformations and malformations of the foramina, ventricular, and transient cyst structures of the developing brain. This division is in all likelihood further defined by the genetic abnormalities that are involved in neuronal genesis, migration, and patterning (predominantly neuronal structural malformations) and those of mesenchymal support structures that are important in the formation of the transient cysts of the developing posterior fossa.

Joubert, Meckel-Gruber, and Other Ciliopathies

In the classic form, Joubert syndrome is a recessively inherited disorder with clinical features of variable intellectual impairment, respiratory rate dysregulation, oculomotor movement abnormalities (classically oculomotor apraxia), hypotonia, and ataxia. Kidney, liver, renal, and retinal abnormalities may accompany these symptoms and signs. Radiologically, Joubert syndrome is recognized by the molar tooth anomaly and accompanying vermian hypoplasia or aplasia. The molar tooth malformation results from thin cerebellar peduncles that extend dorsally at right angles to the brainstem and absence or hypoplasia of the vermis giving the appearance of roots of a molar tooth. Absence of the cerebellar peduncle decussation and disturbance of the cortical spinal tract decussation combined with brainstem nuclei abnormalities results in a thinning of the brainstem with a prominent isthmus giving the ventral brainstem the appearance of the crown of a molar tooth. Cerebellar foliation defects may be noted along with other brainstem abnormalities.

The Meckel-Gruber syndrome may include the above brainstem and cerebellar abnormalities but is distinguished by the presence of an occipital encephalocele that is usually located near the level of the torcula and may contain supratentorial contents or infratentorial contents or both. There may be syndactyly, renal, liver, retinal, or kidney pathology and the developmental outcomes are more severe than those of Joubert syndrome.

Genetically, Joubert and Meckel-Gruber are caused by recessive loss of function pathogenic variants in primary ciliary genes. The primary cilia are the polarity antennae of many cells, are not motile, or have motility functions other than to determine directionality in development.

Rhombencephalosynapsis

Rhombencephalosynapsis is fusion of the cerebellar hemispheres with absence of the vermis. The cause of this lesion is unknown but seems to result from a dorsal lack of division of the developing cerebellum. Clinical manifestations may be developmental, or this lesion may be seen in asymptomatic patients. To date, the genetics of this lesion is undetermined with the exception of an implication of *ZIC2* in a combination of holoprosencephaly and rhombencephalosynapsis noted in two half sisters concordant for a pathogenic variant in this gene. This lesion is also associated with the Gomez-Lopez-Hernandez syndrome.

Dandy-Walker

Possibly failure to form the foramina of Magendie or failure to involute the anterior membranous area results in an enlargement of the fourth ventricle thereby lifting, externally rotating and compressing the vermis. The cerebellar hemispheres are splayed outward and the torcula may be elevated. The posterior fossa is enlarged and in 80% of cases there is obstructive hydrocephalus requiring postnatal shunting from either failure to form the foramina and therefore outflow from the fourth ventricle or from compression of the aqueduct of Silvius. This lesion is associated with good neurologic outcomes if there are no accompanying distinct malformations of the brain and if not accompanying trisomy 9, 13, 18, 21 or other chromosomal aberrations. Some of the genes associated with this disorder are expressed in meninges and developing skull (*FOXC1*) and others in the dorsal cerebellum during development (*ZIC1*, *ZIC4*). The single gene defects thus far associated with this brain lesion are heterozygote deletions or loss of function mutations (Fig. 138.6).

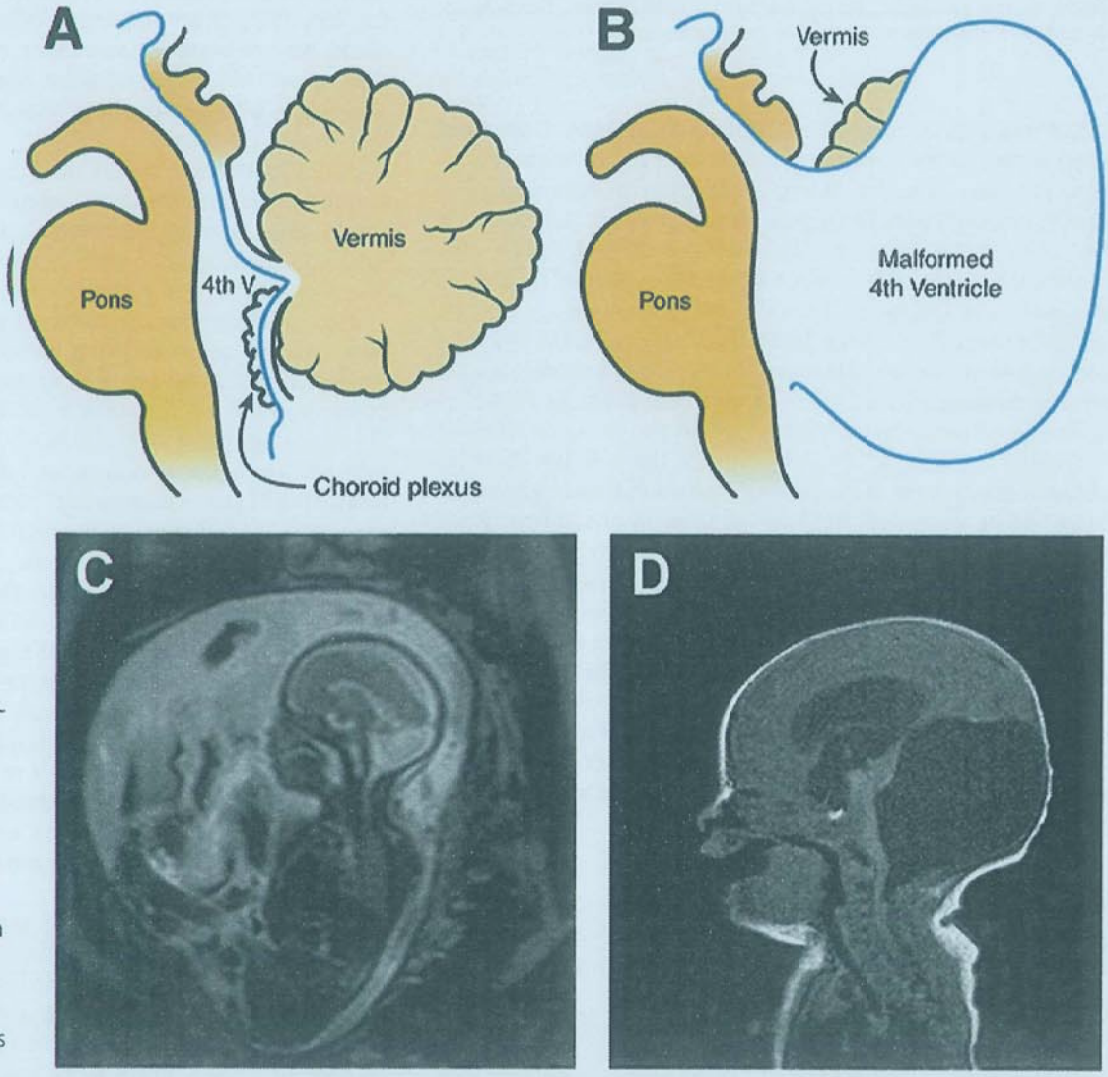

FIGURE 138.6 Dandy-Walker malformation. **A:** Midsagittal drawing of the posterior fossa with normal fourth ventricle. **B:** Midsagittal drawing of the posterior fossa in Dandy-Walker malformation. The foramina of Magendie have not opened resulting in a large fourth ventricle that rotates, compresses, and elevates the vermis and the torcula. **C:** 21-week fetus with Dandy-Walker malformation. **D:** Dandy-Walker malformation with obstructive hydrocephalus in a newborn. (Panels A and B by Nathan Lucy.)

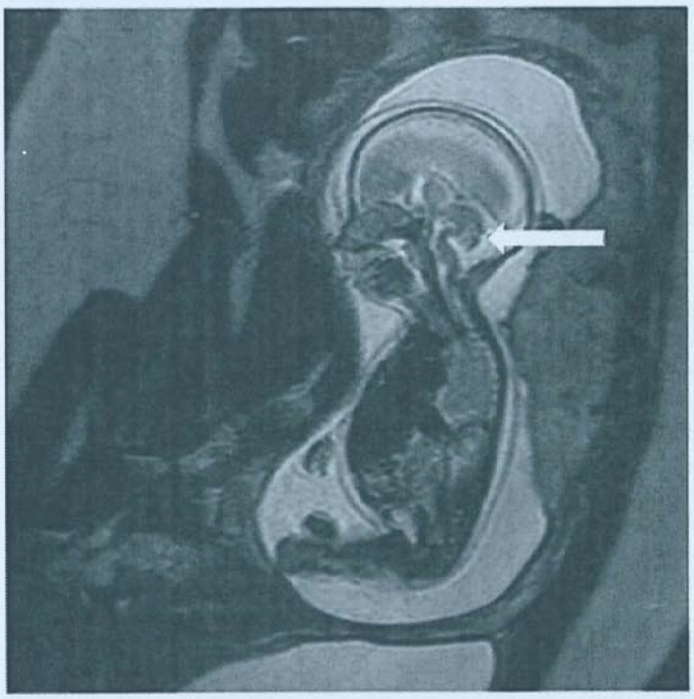

FIGURE 138.7 Walker-Warburg syndrome. Midsagittal magnetic resonance imaging of a fetus at 25 weeks' gestation. The ventricles are enlarged, but importantly (see *arrow*), there is a hypoplastic brainstem in a Z-like configuration.

Unfortunately, a rather loose use of the terms *Dandy-Walker* and *Dandy-Walker variant* have made the literature regarding these malformations very difficult to interpret and given the impression that these lesions carry poor prognoses; for the most part, they do not. It is my opinion that the terms *Dandy-Walker* and *Dandy-Walker variant* should be reserved for those malformations that solely involve enlargement of the fourth ventricle with its consequences such that in the case of Dandy-Walker variant, the lesion should include at least upward rotation of the vermis. An enlarged cisterna magna forms embryologically in a different fashion, although *FOXC1* is implicated in both enlarged cisterna magna and in Dandy-Walker. Furthermore, arachnoid cysts may form in the posterior fossa resulting in enlargement of the posterior fossa and even compression of developing structures, but because these form distinctly from the dilatation of the fourth ventricle in Dandy-Walker, the term *Dandy-Walker* should not be applied to these lesions or should the expectations be the same. Similarly, in the earlier described lesions of the posterior fossa that do not expand it, there may be hypoplasia of the brainstem, malformations of the cerebellum, or other malformations that disturb the posterior fossa. The developmental consequences of these lesions are usually dire and to use the term *Dandy-Walker* in any form to describe these is not accurate embryologically and lowers the developmental expectations for true Dandy-Walker patients (Fig. 138.7).

PROCESS OUTGROWTH AND SYNAPSE FORMATION

Corpus Callosum

Callosal formation begins early in human development; the first axons crossing from one developing hemisphere to the other side are apparent at 6 weeks' gestation. By 11 to 12 weeks, there is an identifiable corpus callosum, and by 18 to 20 weeks, all of the structures of the corpus callosum are present (rostrum, body, splenium). Errant formation of this structure can result in complete agenesis, so-called partial agenesis or dysgenesis. The corpus callosum continues to form and differences in appearance may be seen through adolescence owing to myelination and pruning of crossing fibers.

The outcome depends on the genetic disorder, and outcome data is heavily biased toward poor outcomes. There is an ascertainment bias in many brain developmental disorders, but perhaps none more than in callosal disorders. Most patients with callosal agenesis/dysgenesis have neuroimaging because they have presented to a neurologist owing to developmental or neurologic issues. Asymptomatic people with callosal agenesis or dysgenesis are therefore not recognized. However, with commonplace fetal imaging, it is possible that more accurate data regarding outcomes in these disorders will be obtained. In fact, in a French cohort of 20 patients with agenesis or dysgenesis of the corpus callosum identified in utero (without prejudice), 80% have had normal outcomes up to 10 years later.

Multiple etiologies of agenesis/dysgenesis of the corpus callosum have been described and the potential etiologies are legion. For the clinician, the division into accompanying other brain malformations, isolated, and symptomatic seems the most useful. Examples of accompanying other brain malformations include Walker-Warburg and other muscle-eye-brain disorders, ciliopathies (see posterior fossa malformations), X-linked lissencephaly with ambiguous genitalia (*ARX* pathogenic variants), and Aicardi syndrome.

Aicardi syndrome occurs mostly in females (in XXY males), is accompanied by other brain anomalies (polymicrogyria, intracranial cysts, nodular heterotopia), and is defined by chorioretinal lacunae; the genetic basis of this disorder is unknown. The prognosis is poor and epilepsy is nearly a certainty.

It is important for the clinician to recognize that structural brain disease can result from metabolic disorders. Nonketotic hyperglycinemia may result in agenesis/dysgenesis of the corpus callosum. With the structural brain disease and lack of acidosis, the neurologist and neonatologist may easily assume that the seizures, hypotonia, and depressed mental status at birth are the result of the brain malformation. Similarly, pyruvate dehydrogenase complex deficiency may result in callosal agenesis/dysgenesis with or without lactic acidosis.

An important review of the genetics of callosal dysgenesis was published as an editorial by Dobyns and nicely catalogs observations with and without other CNS malformations associated with duplications, deletions, trisomies, and point pathogenic variants (recessive, X-linked and dominant). A reasonable evaluation of a patient symptomatic from a callosal dysgenesis would include an ophthalmologic exam if female to rule out Aicardi syndrome, metabolic studies to include cerebrospinal fluid glycine to serum glycine ratios, serum amino acids, urine organic acids, chromosomal microarray, and, if these are negative, consideration for whole exome sequencing.

Fetal recognition of isolated agenesis of the corpus callosum may carry a different prognosis as discussed earlier. Eighty percent of the fetuses so identified will be normal in follow-up. When evaluating the fetus with a corpus callosum malformation, it is important to recognize that Aicardi syndrome, with its poor prognosis, needs to be considered as a possibility for females.

Normal Synapse Formation

Even as neurons are arriving in the cortical plate, important neural outgrowths and synapses are forming. The process by which neurons sprout new extensions (neurites) that grow impressive distances to make precise synaptic connections is remarkable and has been well studied, although it is still being elucidated. During development, many more synapses are made than are needed; these subsequently are pruned to improve precision of synaptic connections. Such pruning occurs while other synapses are strengthened. Pruning may be a phenomenon peculiar to the developing nervous system, but synapse strengthening probably continues throughout life.

Most early neurites will form axons. The distance and the terrain that a forming axon must negotiate to reach its target is often formidable; yet, this process occurs with little error. Neurites consist of a long shaft of dynamic cytoskeletal elements that terminate in a growth cone, a highly motile structure capable of responding to chemical cues.

The nature of the chemical cues that guide growth cones and, thus, developing axons are threefold: adhesive, chemoattractive, and chemorepulsive. Adhesive molecules, such as those in the NCAM family, line projection pathways; integrin receptors on growth cones and neurites link the internal cytoskeleton of these structures with the extracellular adhesive molecules. These adhesive molecules provide a substrate on which the motile growth cone and neurite can respond to the chemical cues that determine the final synaptic target.

Diffusible cues appear to provide a trophic influence on developing axons through a chemoaffinity mechanism. One hypothesis is that gradients of chemotactic substances, emitted at the targets for synapse formation, interact with receptors on the growth cone that steer the growth cone toward the target.

Although it appears not to play a role in the early stages of synapse formation, synaptic activity is critical for subsequent remodeling. Pathways apparently are overrepresented often in early postnatal life, and "exuberant" projections of axons must be appropriately pruned. This occurs in a use-dependent fashion such that pathways used for neural activity are retained and those not used are eliminated. The classic studies of Hubel and Wiesel have demonstrated that this process is critical in the formation of the proper synaptic connections of the visual cortex. In their studies, the eyelid of one kitten eye was closed temporarily, and the eye deprived of light was underrepresented, whereas the eye that remained open was overrepresented in the visual cortex. This phenomenon is noted in children who have significant amblyopia (so-called lazy eye). If this amblyopia is not recognized during a critical period of synapse remodeling, these children can be cortically blind in the affected eye.

Throughout life, significant synaptic plasticity persists. Memory is believed to result from a strengthening of heavily used synapses, a phenomenon known as *long-term potentiation*. Considering the lessons learned about the role neuronal activity plays in the remodeling of connectivity in sensory systems, one wonders whether early life experiences, such as seizures, could also alter local circuit remodeling for the recurrent axon collaterals of hippocampal pyramidal cells. Hence, during hippocampal development, if repeated seizures occur, the synchronous discharging of pyramidal cells might prevent axonal remodeling that normally takes place, and an excess in axonal branching present in early life could be maintained into adulthood. In turn, this consolidation could result in an imbalance between recurrent excitation and inhibition and lead to the production of a chronic epileptic focus in hippocampus.

Disorders of Process Outgrowth

The disorders of process outgrowth probably are poorly recognized, given the current limitations of neuroimaging. Many children with cerebral palsy and normal neuroimaging scans likely have disorders involving dendritic branching and axonal growth. While there are likely many synapse disorders, a number have been well characterized.

Down syndrome (trisomy 21) includes a static encephalopathy characterized by mental retardation and hypotonia. The major neuropathologic changes in Down syndrome are a reduction in both the dendritic spines and the number of synapses.

Rett syndrome is a progressive disorder that affects girls and is due to a loss of function of *MECP2*. After a normal gestation, normal birth, and normal first 6 months of development, regression in intellect and motor function is seen. Girls affected with this disorder develop a gait and a truncal apraxia, loss of purposeful hand movements, stereotypic hand movements, progressive spasticity, autism-like social withdrawal, and intellectual disability. Accompanying this decline is a deceleration in head growth, which occurs during a time that brain development mainly involves glial proliferation and neuronal process outgrowth. Although patients typically have normal head sizes at birth, they become microcephalic during the time of their decline in function.

Pathologic examinations of the brains of patients with Rett syndrome support a disturbance in neuronal process outgrowth. The size of individual neurons is reduced, which is accompanied by an increase in packing density in the cerebral cortex, thalami, and basal ganglia. Abnormal dendritic branching has been noted in affected brain; this is especially prominent in layers III and V neurons of the frontal, motor, and temporal cortices. Because dendritic branching is believed to occur in response to axonal innervation, an examination of Rett syndrome brains for axonal aberrations revealed significantly lower numbers of axons entering cortex as compared to normal.

Fragile X syndrome is the most common nonchromosomal, genetic form of mental retardation seen in boys and men. The disorder results from the disturbance of the *FMR1* gene on the long arm of the X chromosome by a triplicate repeat. The brain in this disorder appears normal, but, on microscopic examination, dendritic spine abnormalities are apparent.

Autistic spectrum disorders may turn out to be disorders of synapses. Male patients with autism may have an abnormal acceleration in head growth before age of 2. Neuroligins and other synapse-specific targeting proteins implicated in autism are on the X chromosome, perhaps explaining, in part, the increased incidence of autism in boys.

CONCLUSIONS

Exciting, new genetic and molecular understanding of nervous system development and disturbances in that development have led to this attempt to give the clinician the framework to understand malformations of the human CNS and to evaluate patients afflicted by these disorders. Obtaining an etiology in such situations is of value to the patient, the family, and potentially to society. With new technologies such as exome sequencing, ribonucleic acid sequencing, and genomic sequencing, the potential for obtaining an etiology is vastly enhanced.

SUGGESTED READINGS

Adzick NS, Thom EA, Spong CY, et al. A randomized trial of prenatal versus postnatal repair of myelomeningocele. *N Engl J Med*. 2011;364(11):993-1004.

Ackroyd MR, Whitmore C, Prior S, et al. Fukutin-related protein alters the deposition of laminin in the eye and brain. *J Neurosci*. 2011;31(36):12927-12935.

Aicardi J. Aicardi syndrome. *Brain Dev*. 2005;27(3):164-171.

Aicardi J, Goutières F. The syndrome of absence of the septum pellucidum with porencephalies and other developmental defects. *Neuropediatrics*. 1981;12:319-329.

Allendoerfer K, Shatz C. The subplate, a transient neocortical structure: its role in the development of connections between thalamus and cortex. *Annu Rev Neurosci*. 1994;17:185-218.

Amir RE, Van den Veyver IB, Wan M, Tran CQ, Francke U, Zoghbi HY. Rett syndrome is caused by mutations in X-linked MECP2, encoding methyl-CpG-binding protein 2. *Nat Genet*. 1999;23(2):185-188.

Angevine JB Jr, Sidman RL. Autoradiographic study of cell migration during histogenesis of cerebral cortex in the mouse. *Nature*. 1961;192:766-768.

Aravind L, Koonin EV. The fukutin protein family—predicted enzymes modifying cell-surface molecules. *Curr Biol*. 1999;9(22):R836-R837.

Arimura T, Hayashi YK, Murakami T, et al. Mutational analysis of fukutin gene in dilated cardiomyopathy and hypertrophic cardiomyopathy. *Circ J*. 2009;73(1):158-161.

Armstrong D, Dunn JK, Antalffy B, Trivedi R. Selective dendritic alterations in the cortex of Rett syndrome. *J Neuropathol Exp Neurol*. 1995;54(2):195-201.

Armstrong DD. Review of Rett syndrome. *J Neuropathol Exp Neurol*. 1997;56(8):843-849.

Armstrong DD. The neuropathology of temporal lobe epilepsy. *J Neuropathol Exp Neurol*. 1993;52(5):433-443.

Armstrong DD, Antalffy B, Dunn JK. Quantitative Golgi studies of dendrites in Rett syndrome and trisomy 21. Paper presented at: American Association of Neuropathologists; 1996; June 11-16, Vancouver, British Columbia, Canada.

Baes M, Gressens P, Baumgart E, et al. A mouse model for Zellweger syndrome. *Nat Genet*. 1997;17:49-57.

Bahi-Buisson N, Poirier K, Boddaert N, et al. GPR56-related bilateral frontoparietal polymicrogyria: further evidence for an overlap with the cobblestone complex. *Brain*. 2010;133(11):3194-3209.

Baker EM, Khorasgani MG, Gardner-Medwin D, Gholkar A, Griffiths PD. Arthrogryposis multiplex congenita and bilateral parietal polymicrogyria in association with the intrauterine death of a twin. *Neuropediatrics*. 1996;27(1):54-56.

Balci B, Uyanik G, Dincer P, et al. An autosomal recessive limb girdle muscular dystrophy (LGMD2) with mild mental retardation is allelic to Walker-Warburg syndrome (WWS) caused by a mutation in the POMT1 gene. *Neuromuscul Disord*. 2005;15(4):271-275.

Barkovich A, Chuang S, Norman D. MR of neuronal migration anomalies. *AJR Neuroradiol*. 1987;8:1009-1017.

Barkovich AJ, Kjos BO. Gray matter heterotopias: MR characteristics and correlation with developmental and neurologic manifestations. *Radiology*. 1992;182:493-499.

Barth P. Disorders of neuronal migration. *Can J Neurol Sci*. 1987;14:1-16.

Becker LE, Armstrong DL, Chan F. Dendritic atrophy in children with Down's syndrome. *Ann Neurol*. 1986;20:520-526.

Beedle AM, Nienaber PM, Campbell KP. Fukutin-related protein associates with the sarcolemmal dystrophin-glycoprotein complex. *J Biol Chem*. 2007;282(23):16713-16717.

Belfort MA, Whitehead WE, Shamshirsaz AA, et al. Fetoscopic open neural tube defect repair: development and refinement of a two-port, carbon dioxide insufflation technique. *Obstet Gynecol*. 2017;129(4):734-743.

Belfort MA, Whitehead WE, Shamshirsaz AA, Ruano R, Cass DL, Olutoye OO. Fetoscopic repair of meningomyelocele. *Obstet Gynecol*. 2015;126(4):881-884.

Belichenko PA, Hagberg B, Dahlström A. Morphological study of neocortical areas in Rett syndrome. *Acta Neuropathol*. 1997;93:50-61.

Belichenko PV, Oldfors A, Hagberg B, Dahlström A. Rett syndrome: 3-D confocal microscopy of cortical pyramidal dendrites and afferents. *Neuroreport*. 1994;5:1509-1513.

Brockington M, Blake DJ, Prandini P, et al. Mutations in the fukutin-related protein gene (FKRP) cause a form of congenital muscular dystrophy with secondary laminin alpha2 deficiency and abnormal glycosylation of alpha-dystroglycan. *Am J Hum Genet*. 2001;69(6):1198-1209.

Brockington M, Yuva Y, Prandini P, et al. Mutations in the fukutin-related protein gene (FKRP) identify limb girdle muscular dystrophy 2I as a milder allelic variant of congenital muscular dystrophy MDC1C. *Hum Mol Genet*. 2001;10(25):2851-2859.

Chang W, Winder TL, LeDuc CA, et al. Founder *Fukutin* mutation causes Walker-Warburg syndrome in four Ashkenazi Jewish families. *Prenat Diagn*. 2009;29(6):560-569.

Chen J, Tsai V, Parker WE, Aronica E, Baybis M, Crino PB. Detection of human papillomavirus in human focal cortical dysplasia type IIB. *Ann Neurol*. 2012;72(6):881-892.

Chong SS, Pack SD, Roschke AV, et al. A revision of the lissencephaly and Miller-Dieker syndrome critical regions in chromosome 17p13.3. *Hum Mol Genet*. 1997;6(2):147-155.

Cirak S, Foley AR, Herrmann R, et al. *ISPD* gene mutations are a common cause of congenital and limb-girdle muscular dystrophies. *Brain*. 2013;136(pt 1):269-281.

Clark GD. Brain development and the genetics of brain development. *Neurol Clin*. 2002;20(4):917-939.

Clark GD, Mizuguchi M, Antalffy B, Barnes J, Armstrong D. Predominant localization of the LIS family of gene products to Cajal-Retzius cells and ventricular neuroepithelium in the developing human cortex. *J Neuropathol Exp Neurol*. 1997;56(9):1044-1052.

Clarke NF, Maugenre S, Vandebrouck A, et al. Congenital muscular dystrophy type 1D (MDC1D) due to a large intragenic insertion/deletion, involving intron 10 of the LARGE gene. *Eur J Hum Genet*. 2011;19(4):452-457.

Constantine-Paton M, Cline HT, Debski E. Patterned activity, synaptic convergence, and the NMDA receptor in developing visual pathways. *Annu Rev Neurosci*. 1990;13:129-154.

Cotarelo RP, Valero MC, Prados B, et al. Two new patients bearing mutations in the fukutin gene confirm the relevance of this gene in Walker-Warburg syndrome. *Clin Genet*. 2008;73(2):139-145.

Courchesne E, Karns CM, Davis HR, et al. Unusual brain growth patterns in early life in patients with autistic disorder: an MRI study. *Neurology*. 2001;57(2):245-254.

D'Gama AM, Woodworth MB, Hossain AA, et al. Somatic mutations activating the mTOR pathway in dorsal telencephalic progenitors cause a continuum of cortical dysplasias. *Cell Rep*. 2017;21(13):3754-3766.

Danninger G, Feichtinger P, Haub G, Rett A, Spindler P. On the problem of sensitivity to pain in childhood [in German]. *Wien Med Wochenschr*. 1966;116(37):732-736.

Darling DL, Yingling J, Wynshaw-Boris A. Role of 14-3-3 proteins in eukaryotic signaling and development. *Curr Top Dev Biol*. 2005;68:281-315.

Daube JR, Chou SM. Lissencephaly: two cases. *Neurology*. 1966;16:179-191.

de Bernabé DB, van Bokhoven H, van Beusekom E, et al. A homozygous nonsense mutation in the fukutin gene causes a Walker-Warburg syndrome phenotype. *J Med Genet*. 2003;40(11):845-848.

de Bernabé DB, Voit T, Longman C, et al. Mutations in the FKRP gene can cause muscle-eye-brain disease and Walker-Warburg syndrome. *J Med Genet*. 2004;41(5):e61.

De Ciantis A, Barkovich AJ, Cosottini M, et al. Ultra-high-field MR imaging in polymicrogyria and epilepsy. *AJNR Am J Neuroradiol*. 2015;36(2):309-316.

de Paula F, Vieira N, Starling A, et al. Asymptomatic carriers for homozygous novel mutations in the FKRP gene: the other end of the spectrum. *Eur J Hum Genet*. 2003;11(12):923-930.

De Rosa MJ, Secor DL, Barsom M, Fisher RS, Vinters HV. Neuropathologic findings in surgically treated hemimegalencephaly: immunohistochemical, morphometric, and ultrastructural study. *Acta Neuropathol*. 1992;84:250-260.

Dieker H, Edwards RH, ZuRhein G. The lissencephaly syndrome. *Birth Defects*. 1969;5:53-64.

Dobyns WB. Absence makes the search grow longer. *Am J Hum Genet*. 1996;58(1):7-16.

Dobyns WB. Agenesis of the corpus callosum and gyral malformations are frequent manifestations of nonketotic hyperglycinemia. *Neurology*. 1989;39(6):817-820.

Dobyns WB, Andermann E, Andermann F, et al. X-linked malformations of neuronal migration. *Neurology*. 1996;47(2):331-339.

Dobyns WB, Guerrini R, Czapansky-Beilman DK, et al. Bilateral periventricular nodular heterotopia with mental retardation and syndactyly in boys: a new X-linked mental retardation syndrome. *Neurology*. 1997;49:1042-1047.

Dobyns WB, Mirzaa G, Christian SL, et al. Consistent chromosome abnormalities identify novel polymicrogyria loci in 1p36.3, 2p16.1-p23.1, 4q21.21-q22.1, 6q26-q27 and 21q2. *Am J Med Genet A*. 2008;146A(13):1637-1654.

Dobyns WB, Patton MA, Stratton RF, Mastrobattista JM, Blanton SH, Northrup H. Cobblestone lissencephaly with normal eyes and muscle. *Neuropediatrics*. 1996;27(2):70-75.

Dobyns WB, Stratton RF, Parke JT, Greenberg F, Nussbaum RL, Ledbetter DH. Miller-Dieker syndrome: lissencephaly and monosomy 17p. *J Pediatr*. 1983;102(4):552-558.

Dobyns WB, Truwit CL. Lissencephaly and other malformations of cortical development: 1995 update. *Neuropediatrics*. 1995;26:132-147.

Faust PL, Hatten ME. Targeted deletion of the PEX2 peroxisome assembly gene in mice provides a model for Zellweger syndrome, a human neuronal migration disorder. *J Cell Biol*. 1997;139(5):1293-1305.

Fox JW, Lamperti ED, Ek io lu YZ, et al. Mutations in filamin 1 prevent migration of cerebral cortical neurons in human periventricular heterotopia. *Neuron*. 1998;21(6):1315-1325.

Frosk P, Greenberg CR, Tennese AA, et al. The most common mutation in FKRP causing limb girdle muscular dystrophy type 2I (LGMD2I) may have occurred only once and is present in Hutterites and other populations. *Hum Mutat*. 2005;25(1):38-44.

Garcia C, Dunn D, Trevor T. The lissencephaly (agyria) syndrome in siblings. Computerized tomographic and neuropathologic findings. *Arch Neurol*. 1978;35:608-611.

Geranmayeh F, Clement E, Feng LH, et al. Genotype-phenotype correlation in a large population of muscular dystrophy patients with LAMA2 mutations. *Neuromuscul Disord*. 2010;20(4):241-250.

Gleeson JG, Allen KM, Fox JW, et al. Doublecortin, a brain-specific gene mutated in human X-linked lissencephaly and double cortex syndrome, encodes a putative signaling protein. *Cell*. 1998;92(1):63-72.

Gleeson JG, Lin PT, Flanagan LA, Walsh CA. Doublecortin is a microtubule-associated protein and is expressed widely by migrating neurons. *Neuron*. 1999;23(2):257-271.

Gleeson JG, Luo RF, Grant PE, et al. Genetic and neuroradiological heterogeneity of double cortex syndrome. *Ann Neurol*. 2000;47(2):265-269.

Godfrey C, Clement E, Mein R, et al. Refining genotype phenotype correlations in muscular dystrophies with defective glycosylation of dystroglycan. *Brain*. 2007;130(pt 10):2725-2735.

Goodman CS, Shatz CJ. Developmental mechanisms that generate precise patterns of neuronal activity. *Cell*. 1993;72 suppl:77-98.

Greenberg F, Stratton R, Lockhart L, Elder FF, Dobyns WB, Ledbetter DH. Familial Miller-Dieker syndrome associated with pericentric inversion of chromosome 17. *Am J Med Genet*. 1986;23(4):853-859.

Guerrini R, Dubeau F, Dulac O, et al. Bilateral parasagittal parietooccipital polymicrogyria and epilepsy. *Ann Neurol*. 1997;41:65-73.

Hardiman O, Burke T, Phillips J, et al. Microdysgenesis in resected temporal neocortex: incidence and clinical significance in focal epilepsy. *Neurology*. 1988;38:1041-1047.

Harel T, Goldberg Y, Shalev SA, Chervinski I, Ofir R, Birk OS. Limb-girdle muscular dystrophy 2I: phenotypic variability within a large consanguineous Bedouin family associated with a novel FKRP mutation. *Eur J Hum Genet*. 2004;12(1):38-43.

Hattori M, Adachi H, Tsujimoto M, Arai H, Inoue K. Miller-Dieker lissencephaly gene encodes a subunit of brain platelet-activating factor acetylhydrolase. *Nature*. 1994;370:216-218.

Hinton VJ, Brown WT, Wisniewski K, Rudelli RD. Analysis of neocortex in three males with the fragile X syndrome. *Am J Med Genet*. 1991;41:289-294.

Hopkins B, Sutton VR, Lewis RA, Van den Veyver I, Clark G. Neuroimaging aspects of Aicardi syndrome. *Am J Med Genet A*. 2008;146A(22):2871-2878.

Hopkins IJ, Humphrey I, Keith CG, Susman M, Webb GC, Turner EK. The Aicardi syndrome in a 47, XXY male. *Aust Paediatr J*. 1979;15(4):278-280.

Horesh D, Sapir T, Francis F, et al. Doublecortin, a stabilizer of microtubules. *Hum Mol Genet*. 1999;8(9):1599-1610.

Hubel DH, Wiesel TN. The period of susceptibility to the physiological effects of unilateral eye closure in kittens. *J Physiol*. 1970;206:419-436.

Ismail S, Schaffer AE, Rosti RO, Gleeson JG, Zaki MS. Novel mutation in the *fukutin* gene in an Egyptian family with Fukuyama congenital muscular dystrophy and microcephaly. *Gene*. 2014;539(2):279-282.

Jamain S, Quach H, Betancur C, et al. Mutations of the X-linked genes encoding neuroligins NLGN3 and NLGN4 are associated with autism. *Nat Genet*. 2003;34(1):27-29.

Jelinek JE, Bart RS, Schiff GM. Hypomelanosis of Ito ("incontinentia pigmenti achromians"). Report of three cases and review of the literature. *Arch Dermatol*. 1973;107:596-601.

Jones KL, Gilbert EF, Kaveggia EG, Opitz JM. The Miller-Dieker syndrome. *Pediatrics*. 1980;66:277-281.

Kallmann F, Schoenfeld W, Barrera S. The genetic aspects of primary eunuchoidism. *Am J Ment Defic*. 1944;48:203-236.

Kava M, Chitayat D, Blaser S, Ray PN, Vajsar J. Eye and brain abnormalities in congenital muscular dystrophies caused by fukutin-related protein gene (FKRP) mutations. *Pediatr Neurol*. 2013;49(5):374-378.

Ke N, Ma H, Diedrich G, et al. Biochemical characterization of genetic mutations of GPR56 in patients with bilateral frontoparietal polymicrogyria (BFPP). *Biochem Biophys Res Commun*. 2008;366(2):314-320.

Kim MH, Cierpicki T, Derewenda U, et al. The DCX-domain tandems of doublecortin and doublecortin-like kinase. *Nat Struct Biol*. 2003;10(5):324-333.

Kobayashi K, Nakahori Y, Miyake M, et al. An ancient retrotransposal insertion causes Fukuyama-type congenital muscular dystrophy. *Nature*. 1998;394(6691):388-392.

Kuzniecky R. Magnetic resonance imaging in developmental disorders of the cerebral cortex. *Epilepsia*. 1994;35(suppl 6):S44-S56.

Kuzniecky R, Andermann F. The congenital bilateral perisylvian syndrome: imaging findings in a multicenter study. *AJNR Am J Neuroradiol*. 1994;15:139-144.

Kuzniecky R, Andermann F, Guerrini R. Congenital bilateral perisylvian syndrome: study of 31 patients. *Lancet*. 1993;341:608-612.

Kuzniecky R, Berkovic S, Andermann F, Melanson D, Olivier A, Robitaille Y. Focal cortical myoclonus and Rolandic cortical dysplasia: clarification by magnetic resonance imaging. *Ann Neurol*. 1988;23:317-325.

Kuzniecky R, Garcia JH, Faught E, Morawetz RB. Cortical dysplasia in temporal lobe epilepsy: magnetic resonance imaging correlations. *Ann Neurol*. 1991;29(3):293-298.

Ledbetter SA, Kuwano A, Dobyns WB, Ledbetter DH. Microdeletions of chromosome 17p13 as a cause of isolated lissencephaly. *Am J Hum Genet*. 1992;50:182-189.

Lehéricy S, Dormont D, Sémah F, et al. Developmental abnormalities of the medial temporal lobe in patients with temporal lobe epilepsy. *AJNR Am J Neuroradiol*. 1995;16:617-626.

Liesi P, Seppälä I, Trenkner E. Neuronal migration in cerebellar microcultures is inhibited by antibodies against a neurite outgrowth domain of laminin. *J Neurosci Res*. 1992;33(1):170-176.

Lin YC, Murakami T, Hayashi YK, et al. A novel FKRP gene mutation in a Taiwanese patient with limb-girdle muscular dystrophy 2I. *Brain Dev*. 2007;29(4):234-238.

Lo Nigro C, Chong CS, Smith ACM, Dobyns WB, Carrozzo R, Ledbetter DH. Point mutations and an intragenic deletion in *LIS1*, the lissencephaly causative gene in isolated lissencephaly sequence and Miller-Dieker syndrome. *Hum Mol Genet*. 1997;6:157-164.

Longman C, Brockington M, Torelli S, et al. Mutations in the human LARGE gene cause MDC1D, a novel form of congenital muscular dystrophy with severe mental retardation and abnormal glycosylation of alpha-dystroglycan. *Hum Mol Genet*. 2003;12(21):2853-2861.

Louhichi N, Triki C, Quijano-Roy S, et al. New FKRP mutations causing congenital muscular dystrophy associated with mental retardation and central nervous system abnormalities. Identification of a founder mutation in Tunisian families. *Neurogenetics*. 2004;5(1):27-34.

MacLeod H, Pytel P, Wollmann R, et al. A novel FKRP mutation in congenital muscular dystrophy disrupts the dystrophin glycoprotein complex. *Neuromuscul Disord*. 2007;17(4):285-289.

Marin-Padilla M. Structural abnormalities of the cerebral cortex in human chromosomal aberrations: a Golgi study. *Brain Res*. 1972;44:625-629.

Matsuo N, Kawamoto S, Matsubara K, Okubo K. Cloning and developmental expression of the murine homolog of doublecortin. *Biochem Biophys Res Commun*. 1998;252(3):571-576.

McConnell S. The control of neuronal identity in the developing cerebral cortex. *Curr Opin Neurobiol*. 1992;2(1):23-27.

Meencke H-J, Veith G. Migration disturbances in epilepsy. In: Engel J Jr, Wasterlain C, Cavalheiro EA, Heinemann U, Avanzini G, eds. *Molecular Neurobiology of Epilepsy*. Amsterdam, Netherlands: Elsevier; 1992:31-40.

Mercuri E, Topaloglu H, Brockington M, et al. Spectrum of brain changes in patients with congenital muscular dystrophy and FKRP gene mutations. *Arch Neurol*. 2006;63(2):251-257.

Miller JQ. Lissencephaly in two siblings. *Neurology*. 1963;13:841-850.

Mizuguchi M, Takashima S, Kakita A, Yamada M, Ikeda K. Lissencephaly gene product. Localization in the central nervous system and loss of immunoreactivity in Miller-Dieker syndrome. *Am J Pathol*. 1995;147(4):1142-1151.

Moutard ML, Kieffer V, Feingold J, et al. Agenesis of corpus callosum: prenatal diagnosis and prognosis. *Childs Nerv Syst*. 2003;19(7-8):471-476.

Moutard ML, Kieffer V, Feingold J, et al. Isolated corpus callosum agenesis: a ten-year follow-up after prenatal diagnosis (how are the children without corpus callosum at 10 years of age?). *Prenat Diagn*. 2012;32(3):277-283.

Muntoni F, Brockington M, Godfrey C, et al. Muscular dystrophies due to defective glycosylation of dystroglycan. *Acta Myol*. 2007;26(3):129-135.

Murdock DR, Clark GD, Bainbridge MN, et al. Whole-exome sequencing identifies compound heterozygous mutations in WDR62 in siblings with recurrent polymicrogyria. *Am J Med Genet A*. 2011;155A(9):2071-2077.

Naftolin F, Harris G, Bobrow M. Effect of purified luteinizing hormone releasing factor on normal and hypogonadotrophic anosmic men. *Nature*. 1971;232:496-497.

Novarino G, Akizu N, Gleeson JG. Modeling human disease in humans: the ciliopathies. *Cell*. 2011;147(1):70-79.

Ogawa M, Miyata T, Nakajima K, et al. The reeler gene-associated antigen on Cajal-Retzius Neurons is a crucial molecule for laminar organization of cortical neurons. *Neuron*. 1995;14:899-912.

Palmini A, Andermann F, Olivier A, et al. Focal neuronal migration disorders and intractable partial epilepsy: a study of 30 patients. *Ann Neurol*. 1991;30:741-749.

Pinard JM, Motte J, Chiron C, Brian R, Andermann E, Dulac O. Subcortical laminar heterotopia and lissencephaly in two families: a single X linked dominant gene. *J Neurol Neurosurg Psychiatry*. 1994;57:914-920.

Poussaint TY, Fox JW, Dobyns WB, et al. Periventricular nodular heterotopia in patients with filamin-1 gene mutations: neuroimaging findings. *Pediatr Radiol*. 2000;30(11):748-755.

Powers JM. The pathology of peroxisomal disorders with pathogenetic considerations. *J Neuropathol Exp Neurol*. 1995;54(5):710-719.

Powers JM, Tummons RC, Caviness VS Jr, Moser AB, Moser HW. Structural and chemical alterations in the cerebral maldevelopment of fetal cerebro-hepato-renal (Zellweger) syndrome. *J Neuropathol Exp Neurol*. 1989;48(3):270-289.

Puckett RL, Moore SA, Winder TL, et al. Further evidence of Fukutin mutations as a cause of childhood onset limb-girdle muscular dystrophy without mental retardation. *Neuromuscul Disord*. 2009;19(5):352-356.

Ramocki MB, Scaglia F, Stankiewicz P, Belmont JW, Jones JY, Clark GD. Recurrent partial rhombencephalosynapsis and holoprosencephaly in siblings with a mutation of ZIC2. *Am J Med Genet A*. 2011;155A(7):1574-1580.

Raymond AA, Fish D, Sisodiya S, Alsanjari N, Stevens JM, Shorvon SD. Abnormalities of gyration, heterotopias, tuberous sclerosis, focal cortical dysplasia, microdysgenesis, dysembryoplastic neuroepithelial tumour and dysgenesis of the archicortex in epilepsy: clinical, EEG and neuroimaging features in 100 adult patients. *Brain*. 1995;118:629-660.

Raymond AA, Fish DR, Stevens JM, Cook MJ, Sisodiya SM, Shorvon SD. Association of hippocampal sclerosis with cortical dysgenesis in patients with epilepsy. *Neurology*. 1994;44:1841-1845.

Reiner O, Carrozzo R, Shen Y, et al. Isolation of a Miller-Dieker lissencephaly gene containing G protein beta-subunit-like repeats. *Nature*. 1993;364:717-721.

Rijntjes-Jacobs EG, Lopriore E, Steggerda SJ, Kant SG, Walther FJ. Discordance for Schimmelpenning-Feuerstein-Mims syndrome in monochorionic twins supports the concept of a postzygotic mutation. *Am J Med Genet A*. 2010;152A(11):2816-2819.

Rogers T, al-Rayess M, O'Shea P, Ambler MW. Dysplasia of the corpus callosum in identical twins with nonketotic hyperglycinemia. *Pediatr Pathol*. 1991;11(6):897-902.

Rugarli EI, Ballabio A. Kallmann syndrome. From genetics to neurobiology. *JAMA*. 1993;270(22):2713-2716.

Rugarli EI, Lutz B, Kuratani SC, et al. Expression pattern of the Kallmann syndrome gene in the olfactory system suggests a role in neuronal targeting. *Nat Genet*. 1993;4(1):19-26.

Sanes JR. Topographic maps and molecular gradients. *Curr Opin Neurobiol*. 1993;3:67-74.

Sanz Cortes M, Torres P, Yepez M, et al. Comparison of brain microstructure after prenatal spina bifida repair by either laparotomy-assisted fetoscopic or open approach. *Ultrasound Obstet Gynecol*. 2020;55(1):87-95.

Saredi S, Ruggieri A, Mottarelli E, et al. Fukutin gene mutations in an Italian patient with early onset muscular dystrophy but no central nervous system involvement. *Muscle Nerve*. 2009;39(6):845-848.

Sattar S, Gleeson JG. The ciliopathies in neuronal development: a clinical approach to investigation of Joubert syndrome and Joubert syndrome-related disorders. *Dev Med Child Neurol*. 2011;53(9):793-798.

Schwankhaus J, Currie J, Jaffe M, Rose SR, Sherins RJ. Neurologic findings in men with isolated hypogonadotropic hypogonadism. *Neurology*. 1989;39(2, pt 1):223-226.

Schwanzel-Fukuda M, Bick D, Pfaff D. Luteinizing hormone-releasing hormone (LHRH)-expressing cells do not migrate normally in an inherited hypogonadal (Kallmann) syndrome. *Brain Res Molec Brain Res*. 1989;6:311-326.

Sharief N, Craze J, Summers D, Butler L, Wood CB. Miller-Dieker syndrome with ring chromosome 17. *Arch Dis Child*. 1991;66:710-712.

Sheen VL, Dixon PH, Fox JW, et al. Mutations in the X-linked filamin 1 gene cause periventricular nodular heterotopia in males as well as in females. *Hum Mol Genet*. 2001;10(17):1775-1783.

Shevell MI, Matthews PM, Scriver CR, et al. Cerebral dysgenesis and lactic acidemia: an MRI/MRS phenotype associated with pyruvate dehydrogenase deficiency. *Pediatr Neurol*. 1994;11(3):224-229.

Shimozawa N, Tsukanoto T, Suzuki Y, et al. A human gene responsible for Zellweger syndrome that affects peroxisome assembly. *Science*. 1992;255:1132-1134.

Sidman R, Rakic P. Neuronal migration, with special reference to developing human brain: a review. *Brain Res*. 1973;62:1-35.

Stewart RM, Richman DP, Caviness VS Jr. Lissencephaly and pachygyria: an architectonic and topographical analysis. *Acta Neuropathol*. 1975;31:1-12.

Sugama S, Kusano K. Monozygous twin with polymicrogyria and normal cotwin. *Pediatr Neurol*. 1994;11(1):62-63.

Sunohara N, Sakuragawa N, Satoyoshi E, Tanae A, Shapiro LJ. A new syndrome of anosmia, ichthyosis, hypogonadism, and various neurological manifestations with deficiency of steroid sulfatase and arylsulfatase C. *Ann Neurol*. 1986;19:174-181.

Swann JW, Hablitz JJ. Cellular abnormalities and synaptic plasticity in seizure disorders of the immature nervous system. *Ment Retard Dev Disabil Res Rev*. 2000;6(4):258-267.

Takada K, Becker L, Chan F. Aberrant dendritic development in the human agyric cortex: a quantitative and qualitative Golgi study of two cases. *Clin Neuropathol*. 1988;7:111-119.

Takashima S, Becker LE, Chan F, Takada K. A Golgi study of the cerebral cortex in Fukuyama-type congenital muscular dystrophy, Walker-type lissencephaly and classical lissencephaly. *Brain Dev*. 1987;9:621-626.

Toda T, Chiyonobu T, Xiong H, et al. Fukutin and alpha-dystroglycanopathies. *Acta Myol*. 2005;24(2):60-63.

Topaloglu H, Brockington M, Yuva Y, et al. FKRP gene mutations cause congenital muscular dystrophy, mental retardation, and cerebellar cysts. *Neurology*. 2003;60(6):988-992.

Trovato R, Astrea G, Bartalena L, et al. Elevated serum creatine kinase and small cerebellum prompt diagnosis of congenital muscular dystrophy due to FKRP mutations. *J Child Neurol*. 2014;29(3):394-398.

Turner D, Cepko C. A common progenitor for neurons and glia persists in rat retina late in development. *Nature*. 1987;328:131-136.

van den Bosch H, Schrakamp G, Hardeman D, Zomer AWM, Wanders RJA, Schutgens RBH. Ether lipid synthesis and its deficiency in peroxisomal disorders. *Biochimie*. 1993;75:183-189.

Verkerk AJMH, Pieretti M, Sutcliffe JS, et al. Identification of a gene (FMR-1) containing a CGG repeat coincident with a breakpoint cluster region exhibiting length variation in fragile X syndrome. *Cell*. 1991;65:905-914.

Volpe J, Adams R. Cerebro-hepato-renal syndrome of Zellweger: an inherited disorder of neuronal migration. *Acta Neuropathol*. 1972;20:175-198.

Walter MC, Petersen JA, Stucka R, et al. FKRP (826C>A) frequently causes limb-girdle muscular dystrophy in German patients. *J Med Genet*. 2004;41(4):e50.

Wan M, Lee SS, Zhang X, et al. Rett syndrome and beyond: recurrent spontaneous and familial MECP2 mutations at CpG hotspots. *Am J Hum Genet*. 1999;65(6):1520-1529.

Willer T, Lee H, Lommel M, et al. *ISPD* loss-of-function mutations disrupt dystroglycan O-mannosylation and cause Walker-Warburg syndrome. *Nat Genet*. 2012;44(5):575-580.

Yamamoto LU, Velloso FJ, Lima BL, et al. Muscle protein alterations in LGMD2I patients with different mutations in the Fukutin-related protein gene. *J Histochem Cytochem*. 2008;56(11):995-1001.

Yamamoto T, Kato Y, Karita M, et al. Fukutin expression in glial cells and neurons: implication in the brain lesions of Fukuyama congenital muscular dystrophy. *Acta Neuropathol*. 2002;104(3):217-224.

Yan W, Assadi AH, Wynshaw-Boris A, Eichele G, Matzuk MM, Clark GD. Previously uncharacterized roles of platelet-activating factor acetylhydrolase 1b complex in mouse spermatogenesis. *Proc Natl Acad Sci U S A*. 2003;100(12):7189-7194.

Zutt M, Strutz F, Happle R, et al. Schimmelpenning-Feuerstein-Mims syndrome with hypophosphatemic rickets. *Dermatology*. 2003;207(1):72-76.

Inherited Metabolic Diseases 139

Marc C. Patterson

KEY POINTS

1. Inherited metabolic diseases are individually rare but collectively frequent; every neurologist will encounter such patients.
2. Small molecule disorders (amino and organic acid disorders, urea cycle disorders, oxidative phosphorylation defects) typically present most severely in neonates or in older children and adults under conditions of metabolic stress, such as intercurrent illness, pregnancy, or gastrointestinal hemorrhage.
3. Large molecule disorders (lysosomal disorders, peroxisomal disorders, glycogen storage diseases) have more insidious progression, with progressive weakness, or progressive neuro degeneration, accompanied by cognitive impairment, seizures, movement disorders, and sensory impairments.
4. The possibility of an inherited metabolic disorder should be considered in any patient with multisystem manifestations not readily explained by another mechanism (vascular, infectious, nutritional, or immunologic), although the possibility of dual diagnosis should also be considered.
5. Most patients with inherited metabolic disease have recognizable phenotypes, which can guide focused testing.
6. Next generation sequencing has revolutionized the diagnosis of inherited metabolic diseases, but owing to the difficulty in interpreting variants of undetermined significance, biochemical confirmation is always desirable, where feasible.
7. Specific therapies are available, or in prospect, for an increasing number of inherited metabolic diseases. Patients deserve an accurate and timely diagnosis to ensure implementation of specific therapy and to permit timely genetic counseling.

INTRODUCTION

There are hundreds of inherited metabolic diseases (IMDs), each individually rare, but collectively sufficiently common to constitute a significant public health burden. Most severe IMDs involve the nervous system either directly, or by producing neurologic dysfunction through intoxication with toxic substrates, energy deficiency (to which the brain is especially prone), deficiency of essential substrates or neurotransmitters, or combinations thereof. Although the complexity of these disorders defies easy classification, they may be conveniently divided into small and large molecule disorders for clinical purposes. The former group includes amino and organic acidopathies, and urea cycle disorders, among others. Most result from enzyme deficiencies that impair the body's ability to cope with substrate loads. In severe forms, they present in neonates exposed to normal substrates for the first time without their mother's metabolic machinery to compensate. Lesser degrees of impairment may present later and intermittently under conditions of unusual stress.

In contrast, large molecule disorders, which include the lysosomal, peroxisomal, and glycogen storage diseases, have a slowly but inexorably progressive course, paralleling the accumulation of macromolecules within cells. The most severe phenotypes exhibit specific patterns of neurodegeneration, reflecting the loci of storage and dysfunction in the nervous system. Thus, predominantly neuronal storage, as seen in the neuronal ceroid lipofuscinoses (NCLs) and neuroaxonal dystrophies, presents as poliodystrophies. Disorders in which white matter bears the major burden of disease are designated as leukodystrophies.

This chapter surveys some of the more prominent of these disorders but cannot be comprehensive. Indeed, the major text of inherited metabolic disease (*Metabolic and Molecular Bases of Inherited Disease*) was last published in print form in 2001, when its 4,600 pages had reached the limits of print publishing. The *Metabolic and Molecular Bases of Inherited Disease* is now only available as an electronic text Online Metabolic and Molecular Bases of Inherited Disease, and the interested reader is referred to it and the recommended reading lists in each of the following sections for more comprehensive data on disorders of interest. Other useful resources include several freely databases and applications that can be used at the bedside on a smartphone or tablet: Online Mendelian Inheritance in Man (OMIM) at https://www.ncbi.nlm.nih.gov/omim, GeneReviews at https://www.ncbi.nlm.nih.gov/books/NBK1116/, the Electronic Vademecum Metabolicum at http://www.vademetab.org/, and Treatable Intellectual Disability at http://www.treatable-id.org/ (treatable-id.net on portable devices).

SMALL MOLECULE DISORDERS

Glucose Transporter Type 1 Deficiency Syndrome

Clinical Syndrome

In 1991, De Vivo et al described two children with infantile seizures, delayed motor and behavioral development, acquired microcephaly, and ataxia. Lumbar puncture revealed low cerebrospinal fluid (CSF) glucose concentrations (hypoglycorrhachia) and low-normal to low CSF lactate concentrations.

Seizures begin in early infancy, and the seizure types vary with the age of the patient. In infancy, the dominant seizure types include behavioral arrest, pallor and cyanosis, eye deviation simulating opsoclonus, and apnea. The electroencephalogram (EEG) at this stage may be normal or show focal spikes in infancy and evolves to a generalized spike-wave pattern in childhood.

In childhood, the seizures typically include astatic seizures, atypical absence seizures, and generalized tonic-clonic seizures. The seizures are refractory to antiepileptic drugs but respond to a ketogenic diet. Other paroxysmal events often induced by exertion, including abnormal eye movements, ataxia, paralysis (with or without migraine), and dyskinesias, are frequent. Many patients exhibit static defects, of which intellectual disability, ataxia, dystonia, and spasticity are prominent.

Laboratory Data

Diagnosis requires awareness of the clinical manifestations and documentation of hypoglycorrhachia (CSF glucose <40 mg/dL or 2.2 mmol/L, in the absence of hypoglycemia). A low or low-normal CSF lactate concentration strengthens the presumptive diagnosis.

Molecular Genetics and Pathogenesis

D-Glucose is the obligate fuel for brain metabolism under virtually all circumstances. With fasting, the brain adapts to use ketone bodies (β-hydroxybutyrate and acetoacetate) in partial lieu of glucose. The transport of D-glucose across the blood-brain barrier and into brain cells is selectively mediated by glucose transporter 1 (GLUT1), a member of a multigene family of protein transporters that facilitate the diffusion of sugar molecules across tissue barriers. GLUT1 is encoded by *SLC2A1* on chromosome 1p34.1, and is present in high abundance in brain capillaries, astroglial cells, and erythrocyte membranes.

The molecular basis of the syndrome is GLUT1 haploinsufficiency; a few patients are hemizygous, but most are heterozygous with a variety of mutations. This syndrome is the first genetically determined abnormality of the blood-brain barrier; it may be familial and transmitted as an autosomal dominant trait.

Diagnosis

Lumbar puncture for measurement of glucose and lactate (with simultaneous serum assays of both) is critical in establishing the diagnosis. Confirmatory evidence is provided by sequencing of the *SLC2A1* gene; mutations are found in more than 90% of cases; severe phenotypes have been associated with microdeletions in the *SLC2A1* region.

Management

Standard treatment is the ketogenic diet, which controls the seizures, at least early in the course, but is less effective in improving cognition and behavior. More recently, anaplerotic therapy with triheptanoin has been studied, with evidence of benefit. Several trials of this agent were in progress in 2019. Antiepileptic drugs have been uniformly ineffective.

Hyperammonemia

Hyperammonemia has many genetic and acquired causes. The hepatic urea cycle is the major mammalian system for the detoxification of ammonia and defects have been described in all six urea cycle enzymes. The prevalence of these disorders is 1:35,000; two-thirds present after the newborn period. The mortality is 24% in neonates and 11% in older individuals. An additional pathway from arginine to citrulline generates the putative second messenger and neurotransmitter, nitric oxide, catalyzed by nitric oxide synthetase. The enzyme is found in many tissues, including brain. Animal studies suggest that derangement of this pathway, cerebral energy metabolism, amino acid and neurotransmitter pathways, mitochondrial permeability, signal transduction, and oxidative stress all contribute to the brain injury associated with exposure to high levels of ammonia.

Neonatal Hyperammonemia

Transient hyperammonemia is occasionally seen in otherwise well premature infants and rarely requires treatment. Hyperammonemia may reflect liver damage associated with birth asphyxia or congenital hepatic disease; the birth history usually establishes the diagnosis.

The ill neonate with hyperammonemia without other explanation often has an inborn error of metabolism that, directly or indirectly, affects the urea cycle. Marked hyperammonemia causes progressive lethargy, vomiting, poor feeding, apneic episodes, and seizures. These nonspecific symptoms occur in many disorders, such as sepsis, that can also precipitate hyperammonemia. The age at onset of these symptoms is a useful differential diagnostic point. Infants with hyperammonemia owing to urea cycle enzymopathies or organic acidurias typically are well until they have received 1 to 3 days of protein feeding. In contrast, infants with hyperammonemia secondary to impaired pyruvate metabolism are symptomatic within the first 24 hours. Pyruvate dehydrogenase and pyruvate carboxylase (type B) deficiencies feature lactic acidosis, and these diagnoses can be confirmed by an assay of enzyme activities in fibroblasts and/or direct sequencing of the relevant genes.

Organic acidurias (with the exception of maple syrup urine disease) lead to ketoacidosis, which distinguishes them from urea cycle enzymopathies. Severe deficiency of urea cycle enzymes, other than arginase, causes similar clinical syndromes. The affected child is well for the first 24 hours, but signs of hyperammonemia appear as protein feedings continue. Respiratory alkalosis with hyperventilation is classic, but not always present, and infants with sepsis or vomiting may have metabolic acidosis or alkalosis. Plasma amino acid and orotic acid assays help to distinguish different urea cycle defects (**Table 139.1**).

TABLE 139.1 Plasma Amino Acid and Urinary Orotic Acid Findings in Urea Cycle Defects

Enzymatic Deficiency	Citrulline	Argininosuccinic Acid	Orotic Acid	Arginine
Carbamyl phosphate synthetase (CPS)	0 to trace	0	↓	↓
Ornithine transcarbamylase (OTC)	0 to trace	0	↑↑	↓
Argininosuccinate synthetase (citrullinuria)	↑↑	0	↑	↓
Argininosuccinase (argininosuccinic aciduria)	↑	↑↓	nl	↓
Arginase	nl	0	↑	↑↑
Transient hyperammonemia of newborn	nl or slightly ↑	0	nl	nl

Abbreviations: ↑, increased; ↓, decreased; nl, normal.

Direct sequencing of urea cycle genes will make the diagnosis in more than 80% of cases; tissue enzyme analysis is required in the remainder. All of the urea cycle genes are autosomal recessive, except for ornithine carbamyl transferase deficiency, which is X-linked. Prenatal screening is available.

Prolonged exposure to high levels of ammonia damages the brain. Thus, acute hyperammonemic coma in the newborn is a medical emergency, and rapid reduction in ammonia levels is necessary. Peritoneal dialysis is more effective than exchange transfusion; hemodialysis may also be effective. Useful adjuncts include intravenous administration of sodium benzoate and sodium phenylbutyrate. A block in the urea cycle (other than at arginase) renders arginine an essential amino acid, which must be supplemented. Protein catabolism should be minimized by temporarily eliminating protein from the diet and by ensuring adequate caloric intake, principally as glucose. Long-term management depends on the specific enzyme defect.

Hyperammonemia in Older Children and Adults

Primary metabolic disease is much less likely a cause of hyperammonemia in an older child or adult than in neonates. Partial urea cycle defects (as seen in ornithine transcarbamylase heterozygotes—ie, women) may cause episodic hyperammonemia during periods of metabolic stress and should be considered, especially if there are affected relatives. Allopurinol loading, popular historically, has been supplanted by sequencing of urea cycle genes. Heterozygotes for ornithine transcarbamylase deficiency have impaired neuropsychological function compared to controls; impeccable metabolic control is critical in preserving neurologic function. The older child or adult with hyperammonemia usually has severe liver disease or drug-induced hyperammonemia.

Valproate-Associated Hyperammonemia

Valproate therapy is one of the most common causes of hyperammonemia in clinical neurologic practice. Malnourished patients with carnitine deficiency and those with unrecognized urea cycle and fatty acid oxidation defects seem to be at higher risk for this complication. This dose-related laboratory finding may occur without clinical symptoms. The pathogenesis is disputed but may result from inhibition of hepatic *N*-acetylglutamate synthase activity by valproyl-coenzyme A (CoA). It is unclear whether patients become symptomatic from the increased ammonia under these circumstances.

L-Carnitine supplementation can prevent the development of hyperammonemia in animals and humans receiving valproate; the clinical significance of this reduction is unclear. Some authors routinely supplement L-carnitine in patients with reduced serum carnitine levels. In severe acute valproate hepatotoxicity with hyperammonemia, a disorder with high mortality, intravenous L-carnitine has been shown to improve survival compared to oral therapy with the same agent.

Disorders of Amino Acid Metabolism

Twenty-one amino acids are required for normal human metabolism; the 21st, selenocysteine, has a unique metabolic role, differing from the other amino acids. Amino acids are the basic elements in the construction of proteins and enzymes as well as other compounds including hormones, neurotransmitters, and nucleotides.

Nine amino acids cannot be synthesized endogenously and are thus designated as "essential" (histidine, isoleucine, leucine, lysine, methionine, phenylalanine, threonine, tryptophan, and valine). The nonessential amino acids are mostly synthesized from glucose, whereas tyrosine is a product of the metabolism of phenylalanine, and cysteine is a product of the metabolism of methionine.

Mass screening for disorders of amino acid metabolism has resulted in early biochemical diagnosis of phenylketonuria (PKU) and other aminoacidopathies. In one screening program in New South Wales, Australia, the incidence of PKU was 1:10,000 live births per year; the incidence of defects of amino acid transport was about 2:10,000 live births per year; and the combined incidence of all other aminoacidopathies was less than 8:100,000 live births per year. Although these conditions are rare, they are important because neurologic damage is potentially preventable with early treatment and because they provide information about the development and functions of the brain. PKU is described in some detail as a model for this family of disorders.

Phenylketonuria

Phenylalanine hydroxylase deficiency is an autosomal recessive inborn error of metabolism manifested by impaired hepatic hydroxylation of phenylalanine to tyrosine, leading to elevated levels of phenylalanine in the blood and urine. Untreated, the disorder causes a clinical picture highlighted by intellectual disability, seizures, and imperfect hair pigmentation.

The disease has been found in all parts of the world. The incidence varies around the world, being highest in the Turkish population at approximately 1:2,500 to approximately 1:10,000 in Northern European and East Asian populations.

Pathogenesis and Pathology

The hydroxylation of phenylalanine to tyrosine is an irreversible and complex reaction that requires phenylalanine hydroxylase and five other enzymes, in addition to several nonprotein components. Phenylalanine hydroxylase is normally found in liver, kidney, and pancreas, but not in brain or skin fibroblasts.

In classic PKU, enzyme activity is generally less than 5% of normal. More than 40% of PKU subjects and more than 80% of those with mild PKU are tetrahydrobiopterin (BH_4) responsive when challenged with 20 mg/kg BH_4.

In some 1% to 3% of subjects, hyperphenylalaninemia results from a deficiency of BH_4. The BH_4-deficient hyperphenylalaninemias comprise a genetically heterogeneous group of disorders caused by mutations in the genes encoding enzymes involved in the synthesis or regeneration of the coenzyme BH_4. Three genetic defects in the synthesis of BH_4 have been described. These involve guanosine triphosphate cyclohydrolase 1, 6-pyruvoyl-tetrahydropterin synthase, and sepiapterin reductase. In addition, there are two disorders in the regeneration of the aromatic amino acid–hydroxylating system: dihydropteridine reductase and pterin-4a-carbinolamine dehydratase. All these conditions lead to hyperphenylalaninemia associated with progressive neurologic deterioration, along with a variety of dyskinesias.

Children with classic PKU are born with only slightly elevated phenylalanine blood levels, but these rise rapidly on an unrestricted diet. Phenylalanine is converted to phenylpyruvic acid, phenylacetic acid, and phenylacetylglutamine, which impart a characteristic odor to the urine.

Brain changes are nonspecific and diffuse and involve both gray and white matter; they include interference with normal maturation of the brain, defective myelination, and diminished or absent pigmentation of the substantia nigra and locus ceruleus.

Symptoms and Signs

PKU exhibits a wide range of clinical and biochemical severity. In the classic form, untreated infants appear normal at birth. Vomiting and irritability in the first few months is followed by cognitive delay; ultimate intellectual disability may be severe. Seizures, including epileptic spasms, usually present in the first 18 months.

Untreated children are fairer, with lighter irides than unaffected sibs, and may have eczema and a peculiar musty ("mousey") odor. Focal neurologic abnormalities are rare, but microcephaly, mild spastic paraparesis, and tremor may occur.

Magnetic resonance imaging (MRI) usually shows white matter signal hyperintensity on T2-weighted sequences, mainly in the posterior watershed regions.

Diagnosis

Most PKU patients are identified through newborn screening. If the diagnosis of a case of classic PKU is missed, the most likely reason is laboratory error, rather than insufficient protein intake or too early testing of the infant.

Mutation analysis facilitates carrier detection and the prenatal diagnosis of PKU in families with at least one previously affected child. Newborn screening programs have also detected conditions other than PKU with neonatal hyperphenylalaninemia. Patients with moderate and mild PKU and mild hyperphenylalaninemia, as these entities are termed, have phenylalanine levels that tend to be lower than those seen in classic PKU.

Management

All infants whose blood phenylalanine concentration is greater than 10 mg/dL (600 μM/L) and whose tyrosine concentration is low or normal (ie, 1-4 mg/dL) should be started on a low-phenylalanine diet immediately. Infants whose blood phenylalanine concentrations remain in the range of 6.6 to 10.0 mg/dL (400-600 μM/L) on an unrestricted diet are generally not treated, and on follow-up evaluations, children of this group have normal intelligence and a normal MRI.

Therapy for classic PKU is restriction of the dietary phenylalanine, using one of several low-phenylalanine formulas. Milk is added to the diet in amounts sufficient to maintain blood levels of the amino acid between 2 and 6 mg/dL (120-360 μM/L). Generally, patients tolerate this diet quite well, and within 1 to 2 weeks, the serum concentration of phenylalanine becomes normal.

Weekly serum phenylalanine determinations are essential to monitor dietary adherence for life. Strict dietary control should be maintained for life, and most centers strive to keep levels below 6 mg/dL (360 μM/L) in all patients with PKU. Dietary lapses are frequently accompanied by progressive white matter abnormalities on MRI. The addition of sapropterin (5-20 mg/kg/d), an orally active synthetic form of BH_4, permits a less restrictive diet for those patients who respond to a BH_4 challenge.

Phenylalaninemia caused by BH_4 deficiency requires diet, administration of BH_4 or a synthetic pterin, and replacement of neurotransmitter precursors (L-dopa/carbidopa and 5-hydroxytryptophan), whose synthesis is also impaired.

Early detection and dietary control of PKU has increased the number of homozygous PKU women achieving pregnancy. Maternal hyperphenylalaninemia causes intellectual disability, microcephaly, seizures, and congenital heart defects in affected children. During pregnancy, phenylalanine levels must be monitored as closely as during infancy because the fetus is exposed to even higher phenylalanine concentrations than the mother.

Prognosis

When a child with classic PKU is maintained on a low-phenylalanine diet, seizures disappear and the EEG normalizes. Abnormally blond hair regains natural color, and head growth resumes.

Cognitive effects are less clear cut. In most studies, some deficit in intellectual development has been found, even in infants who had been diagnosed and treated as neonates. This could be a consequence of prenatal brain damage induced by high phenylalanine levels in the fetus.

Although the measured IQ is normal in most, deficits have been noted in executive functioning, attention, verbal memory, verbal fluency, and expressive naming. There is no threshold below which phenylalanine has no effect on cognition. Neurologic deterioration during adult life is generally the consequence of dietary lapses.

Other Amino Acid Disorders

Several other aminoacidopathies have distinguishing features that enable the clinician to suspect the diagnosis. Maple syrup urine disease, a disorder of branched chain amino acid metabolism, produces a characteristic odor (detectable in cerumen as well as urine) and classically presents in the first week of life with acute encephalopathy and opisthotonic posturing. Isoleucine, leucine, and valine are present in excess in the urine. Emergent diagnosis and management is necessary to preserve life and neurologic function; a few patients are thiamine responsive. Later onset forms may also occur.

Homocystinuria is manifest as tall stature, dislocated lenses, and varying degrees of intellectual impairment; a subgroup of patients responds to therapy with cobalamin. Thromboembolic episodes may begin in infancy. Disorders of sulfur amino acids are summarized in **Table 139.2**.

Hartnup disease is a disorder of renal tubular transport of tryptophan and other neutral amino acids; it causes intermittent ataxia with a pellagra-like rash. The disorders of amino acid transport are summarized in **Table 139.3**.

Organic Acidurias

Progress in diagnostic techniques in the 1950s enabled the identification of a family of disorders of distal steps in intermediary metabolism marked by the accumulation of nonamino organic acids, which are preferentially excreted in the urine and are not detectable in bodily fluids by older methods. These compounds are mono-, di-, and tricarboxylic acids derived from the breakdown of amino acids through the intramitochondrial degradation of CoA-activated carbonic acids. They are separated from the amino acid disorders only because of the analytical methods employed in their diagnosis, not because of any fundamental biologic difference. The classic organic acidurias have a number of common clinical features, including precipitation of acute encephalopathy, acidosis, and hyperammonemia, and other multisystem manifestations, by an excess substrate load or metabolic stress in the form of fever or other illness that leads to a hypercatabolic state. Profound brain and systemic injury follows unless rapid and effective intervention is undertaken. This usually involves substrate restriction, suppression of aberrant pathways by providing alternate energy sources, and removal of offending metabolites by dialysis, hemofiltration, or by activating alternate pathways. The classical organic acidurias include propionic aciduria, methylmalonic aciduria, and isovaleric aciduria.

TABLE 139.2 Disorders of Sulfur Amino Acids

Disorder	Enzyme Deficiency	Neurologic Picture
Homocystinuria	Cystathionine-β-synthase	Multiple thromboembolic episodes starting in first year of life, mental retardation, ectopia lentis
Homocystinuria and mild homocysteinemia	$N^{5,10}$-methylenetetrahydrofolate reductase	Seizures, microcephaly, spastic paraparesis, ataxia
Cystathioninuria	γ-Cystathionase	Asymptomatic
Homocystinuria With Megaloblastic Anemia		
Cbl E	Methionine synthase reductase	Severe developmental delay, lethargy, staring spells, hypotonia
Cbl G	Methionine synthase	Failure to thrive, mental retardation, cerebral atrophy
Cbl C	Synthesis of methyl and adenosyl cobalamin	Marfanoid habitus, mental retardation, acute psychosis, subacute spinal cord degeneration
Cbl D	Synthesis of methyl and adenosyl cobalamin	Acute psychosis, mental retardation, subacute spinal cord degeneration, Marfanoid habitus
Cbl F	Cobalamin lysosomal release	Developmental delay, sudden death in infancy
Sulfite oxidase deficiency	Sulfite oxidase	Seizures starting in neonatal period, profound mental retardation, subluxation of lens
Molybdenum cofactor deficiency	Molybdenum cofactor deficiency	As for sulfite oxidase deficiency

Abbreviation: Cbl, cobalamin.

Propionic aciduria is associated with a poor long-term neurologic outcome, as assessed by cognitive measures and the presence of basal ganglia lesions; isovaleric aciduria is typically associated with an excellent outcome; and methylmalonic aciduria is associated with intermediate impairment of neurologic function. Early diagnosis and tight metabolic control are necessary, but not always sufficient, to achieve the best outcome in these disorders.

Most of these diseases result from deficient activity of enzymes or their cofactors and present as neonatal encephalopathies in their most severe forms; less profound defects may present intermittently in older children. Slowly progressive disorders with predominant or exclusive neurologic manifestations are designated as cerebral organic acidopathies and include glutaric aciduria type 1, L-2-hydroxyglutaric aciduria, D-2-hydroxyglutaric aciduria (D-2-HGA), succinic semialdehyde dehydrogenase deficiency, and Canavan disease.

Glutaric aciduria type 1 results from glutaryl CoA dehydrogenase deficiency and manifests as macrocephaly, hypotonia, and mild motor delay; affected children can decompensate suddenly in the face of metabolic stress and exhibit a hyperkinetic movement disorder that is refractory to most therapy. The MRI shows enlarged extra-axial spaces over the frontal and temporal convexities, with widened Sylvian fissures. Signal hyperintensity and eventual necrosis occur in the striatum in untreated cases and correlate with the presence of a hyperkinetic movement disorder. Glutaric acid and 3-methyl glutaric acid are excreted in excess in the urine, as is glutarylcarnitine. Carnitine supplementation is of proven benefit in preventing neurologic progression but must be introduced early if permanent basal ganglia injury is to be prevented.

L-2-hydroxyglutaric aciduria is associated with mutations in the L2HGDH gene and presents with progressive ataxia and intellectual disability in children; adult onset with similar, more slowly progressive symptoms, also occurs on occasion. The MRI shows a characteristic pattern that involves the basal ganglia and dentate nuclei, as well as the subcortical, but not cerebellar, white matter. Patients with this disorder have an increased risk

TABLE 139.3 Defects in Amino Acid Transport

Transport System	Condition	Biochemical Features	Clinical Features
Basic amino acids	Cystinuria (three types)	Impaired renal clearance, defective intestinal transport of lysine, arginine, ornithine, and cystine	Renal stones, no neurologic disease
	Lowe syndrome	Impaired intestinal transport of lysine and arginine, impaired tubular transport of lysine	Severe mental retardation, congenital glaucoma, cataracts, myopathy
Acidic amino acids	Dicarboxylic aminoaciduria	Increased excretion of glutamic, aspartic acids	Severe mental retardation, glaucoma, cataracts, myopathy, sex-linked transmission
Neutral amino acids	Hartnup disease	Defective intestinal and renal tubular transport of tryptophan and other neutral amino acids	Intermittent cerebellar ataxia, photosensitive rash
Proline, hydroxyproline, glycine	Iminoglycinuria	Impaired tubular transport of proline, hydroxyproline, and glycine	Harmless variant
β-Amino acids	None known	Excretion of β-aminoisobutyric acid and taurine in β-alaninemia is increased due to competition at the tubular level	Harmless variant

of primary brain tumors attributed to the putative "oncometabolite" 2-hydroxyglutarate.

D-2-hydroxyglutaric aciduria is genetically and clinically heterogeneous. Some patients who excrete D-hydroxyglutaric acid in the urine are asymptomatic; others exhibit facial dysmorphism, seizures, hypotonia, and developmental delay. About half of the patients have recessive mutations in D2HGDH, designated type 1 D-2-HGA. The remainder, designated type 2 D-2-HGA, harbor dominant mutations in IDH2, a gene which is mutated in some cases of acute myeloid leukemia and gliomas. A few patients have been described with combined D- and L-2-hydroxyglutaric aciduria resulting from mutations in the SLC25A1 gene. The phenotype is severe, with hypotonia, delay, and intractable seizures; it is important to recognize, as it may respond to therapy with citrate.

Succinic semialdehyde dehydrogenase deficiency is a disorder of γ-aminobutyric acid metabolism that results from mutations in ALDH5A1 and presents with hypotonia, developmental delay, and ataxia. Fewer than 200 patients had been described by the time of the most recent review, in 2017. Epilepsy, which may be difficult to control, occurs in more than half of affected children, along with movement disorders and behavioral disturbances. The MRI may show hyperintensities in the basal ganglia, specifically the globus pallidus, and less frequently in the dentate nuclei, brainstem, and subcortical white matter. The 4-hydroxy butyric acid is increased in urine and CSF and may be detected by magnetic resonance spectroscopy (MRS). Treatment is symptomatic; vigabatrin (50 mg/kg/d; 500-1,500 mg twice daily), which inhibits the production of succinic semialdehyde, is a logical choice as an antiepileptic drug but is not always effective. Valproate (10-60 mg/kg/d) is relatively contraindicated but can be cautiously employed if seizures are refractory to other agents. A class IV trial of taurine showed no evidence of clinically meaningful benefit.

Canavan disease is a spongiform leukodystrophy in which deficient activity of aspartoacylase leads to accumulation of *N*-acetyl aspartic acid (NAA) in bodily fluids and the brain. It is commonly manifest as hypotonia and progressive macrocephaly in infants followed by loss of milestones, spasticity, seizures, and premature death. The MRI shows diffuse white matter hyperintensity, and MRS demonstrates marked elevation of NAA. Attenuated forms of the illness may lack diffuse white matter involvement but show only hyperintense signal in the basal ganglia. The diagnosis is made by demonstrating defective aspartoacylase activity in leucocytes and corresponding mutations in the ASPA gene. Antenatal diagnosis is possible using gene sequencing. Gene therapy using an adeno-associated dependoparvovirus A, serotype 2 vector has shown reduced NAA levels and evidence of clinical stabilization in an open-label study in humans with Canavan disease. The purification of aspartoacylase has led to the identification of potential inhibitors of this enzyme as a novel treatment strategy, and one murine study has shown that knocking down the activity of the gene (*N*-acetyltransferase 8-like [NAT8L]) encoding enzyme responsible for the synthesis of NAA (NAT8L) using a short hairpin inhibitory RNA suppresses the development of spongiform leukoencephalopathy in this model. Other studies have shown that knocking out NAT8L produces neurologic abnormalities in mice, suggesting that complete absence of NAA is detrimental. Studies in two mouse models of Canavan disease have demonstrated that correction of oligodendrocytes alone reverts established disease.

Disorders of Purine and Pyrimidine Metabolism

Introduction

Purines and pyrimidines are heterocyclic compounds that participate in nucleotide synthesis, generation of energy compounds (ie, adenosine diphosphate and adenosine triphosphate [ATP]), and in signaling pathways (eg, cyclic adenosine monophosphate). Several disorders of purine and pyrimidine metabolism have been recognized (Table 139.4). Findings include anemia, immunodeficiency, hypo- or hyperuricemia (with nephrolithiasis and renal failure in severe cases), and a variety of neurologic phenotypes. The latter range through sensorineural hearing loss, developmental delays, intellectual disability, autism, seizures, and movement disorders. The archetype and most frequently recognized of these disorders is the Lesch-Nyhan syndrome, described in more detail in the following paragraphs.

Lesch-Nyhan Syndrome

In 1964, Lesch and Nyhan described two brothers with hyperuricemia, intellectual disability, choreoathetosis, and self-destructive biting of the lips and fingers. Most cases are seen in males, but at least one symptomatic female with skewed X-inactivation has been described. The trait is X-linked recessive. The basic defect is the lack of hypoxanthine-guanine phosphoribosyltransferase. The enzyme deficiency increases the rate of purine biosynthesis, and uric acid reaches high levels in blood, urine, and CSF. Urate is deposited in the kidneys and joints and may result in nephropathy and gout.

The neurologic manifestations include severe intellectual disability, spasticity, and choreoathetosis that start in the first year. The characteristic self-mutilating behavior appears in the second year. Death is usually caused by renal failure and may occur in the second or third decade of life. Sudden death may occur at any time because of acute respiratory failure, often related to the motor disorder. Milder variants are recognized, in which self-mutilation may be absent and manifestations may be restricted to cognitive impairment with mild motor symptoms, or progressive spastic paraparesis. The pathogenesis of the cerebral symptoms is not known, but these symptoms are not prevented by the administration of allopurinol.

Diagnosis depends on recognition of the clinical manifestations and may be made precisely by biochemical assay of the enzyme in erythrocyte hemolysates or cultured fibroblasts. The DNA analysis confirms the diagnosis and may be used for prenatal diagnosis and carrier detection; mutations can be detected in most affected individuals. More than 400 mutations have been described.

Gout is treated effectively with allopurinol, but the neurologic disorder is daunting. Restraints may be needed to prevent affected children from damaging themselves or others; dental extraction is often required to prevent facial mutilation. Diazepam (1-2.5 mg by mouth three to 4 times daily), carbamazepine (10-35 mg/kg/d), gabapentin (10-40 mg/kg/d), or botulinum toxin are sometimes helpful, and some patients may respond to *S*-adenosylmethionine (SAM), but physical restraint is often required in classic cases. Deep brain stimulation surgery, targeted to the globus pallidus, has improved or abolished self-mutilation in some cases. Neither enzyme replacement nor gene therapy is available for Lesch-Nyhan syndrome.

TABLE 139.4 Disorders of Purine and Pyrimidine Metabolism

Enzyme	Anemia	ID	Uric Acid	MR	SNHL	Seizures	Ataxia	MD	Other
cNT	+	+	–	+		+	+	+	Symptoms improve with uridine
Purine Pathway									
PRPS	–	–	+	+	+	–	+	–	Autism
ADSL	–	–	0	+	–	+	–	–	Autism
AMPD1	–	–	0	–	–	–	–	–	Muscle cramps, increased CK
ADA	–	+	0	+	–	–	–	+	Spasticity
NP	+	+	–	+	–	–	–	+	Spasticity
XDH	–	–	–	–	–	–	–	–	Myopathy, arthropathy
HPRT	–	–	+	+	–	+	–	+	Self-mutilation, spasticity, 6-thioguanine resistance
APRT	–	–	+	–	–	–	–	–	
Pyrimidine Pathway									
UMPS	+	–	0	+	–	–	–	–	
UMPH1	+	–	0	–	–	–	–	–	
DPYD	–	–	0	+	–	+	–	–	Microcephaly, 5-fluorouracil sensitivity, autism
DPYS	–	–	0	+	–	+	–	–	
UP	–	–	0	+	–	+	–	+	

Abbreviations: +, present (or increased for uric acid); –, absent (or decreased for uric acid); 0, phosphoribosyl pyrophosphate; ADA, adenosine deaminase deficiency; ADSL, adenylosuccinate lyase deficiency; AMPD1, muscle adenosine monophosphate deaminase deficiency; APRT, adenosine phosphoribosyltransferase deficiency; CK, creatine kinase; DPYD, dihydropyrimidine dehydrogenase deficiency; DPYS, dihydropyrimidinase deficiency; HPRT, hypoxanthine-guanine phosphoribosyltransferase deficiency (Lesch-Nyhan syndrome); ID, immunodeficiency; cNT, cytosolic 5′-nucleotidase superactivity (nucleotide depletion syndrome); MD, movement disorder; MR, developmental delay, mental retardation; NP, nucleoside phosphorylase deficiency; PRPS, phosphoribosyl pyrophosphate synthetase superactivity; SNHL, sensorineural hearing loss; UMPH1, uridine monophosphate hydrolase (pyrimidine 5′-nucleotidase) deficiency; UMPS, uridine monophosphate synthase deficiency (hereditary orotic aciduria); UP, ureidopropionase deficiency; XDH, xanthine dehydrogenase (xanthine oxidase) deficiency (xanthinuria; secondary impairment in molybdenum cofactor deficiency).

Other Purine Disorders

Neurologic abnormalities are also seen in patients who are without other enzymes of purine-nucleoside metabolism. **Adenosine-deaminase deficiency** causes severe, combined immunodeficiency in infants; some patients have extrapyramidal or pyramidal signs and psychomotor development and may be retarded. Partial exchange transfusion may be clinically beneficial. Also, a few patients lacking **purine-nucleoside phosphorylase** with impaired cellular immunity have shown a form of spastic paraparesis in childhood. 5′-Nucleotidase superactivity produces a complex phenotype with all of the features of purine and pyrimidine disorders; it responds to oral uridine therapy. These patients may have autistic features that may also be prominent in **phosphoribosyl pyrophosphate synthetase**, **adenylosuccinate lyase**, and **dihydropyrimidine dehydrogenase** deficiencies.

Porphyrias

The porphyrias are a family of disorders in which the synthesis of heme, and its precursors, is impaired. They are traditionally divided into hepatic and erythropoietic subgroups according to the major sites of gene expression. **Acute intermittent porphyria** (AIP) is the most frequent of these disorders and the most likely to present to a neurologist.

The AIP is an autosomal dominant disorder with low penetrance caused by deficiency of hydroxymethylbilane synthase (also known as *porphobilinogen deaminase*), most frequently observed in Sweden and South Africa, which typically presents as an acute encephalopathy with pronounced behavioral changes (including frank psychosis) that may be accompanied by seizures, autonomic neuropathy causing abdominal pain, tachycardia and hypertension, or a painful motor neuropathy that may progress to quadriplegia with respiratory failure in severe cases. Patients may have hyponatremia as a consequence of inappropriate antidiuretic hormone secretion. Decompensation may be provoked by fasting or by exposure to alcohol or any one of a number of drugs that interact with this pathway, including older anesthetic agents, barbiturates, and oral contraceptives; pregnancy may also precipitate an attack. Drugs appear to precipitate attacks of AIP by inducing δ-aminolevulinic acid synthase, thereby leading to hepatic heme depletion, or by inhibiting the P450 cytochrome system. Understanding these mechanisms facilitates prediction of the likely toxicity of drugs in affected individuals.

The diagnosis of AIP requires timely assay of urine porphobilinogen, with subsequent confirmation by sequencing of the hydroxymethylbilane synthase gene. Acute management, which must not be delayed for definitive diagnosis, requires the removal of precipitants, careful attention to fluid and electrolyte balance, the administration of intravenous Panhematin or heme arginate to shut down the synthetic pathway, appropriate analgesia with agents such as gabapentin (10-40 mg/kg/d), and management of seizures with safe agents such a benzodiazepines that do not exacerbate the metabolic block.

A number of atypical presentations have been reported in AIP, including posterior reversible encephalopathy syndrome, acute cortical blindness, and progressive muscular atrophy. Long-term management hinges on education of the patients and

their medical providers to recognize and avoid situations and agents that provoke decompensation. One study of two patients found that weekly administration of intravenous heme was associated with marked reduction in acute attacks and reduction in health care costs. In rare cases, liver transplantation may be indicated to manage hepatic failure or recurrent attacks when conservative management is ineffective; AIP may recur after successful transplantation if the donor has unrecognized disease.

Acute variegate porphyria, a dominant disorder associated with decreased activity of the mitochondrial enzyme protoporphyrinogen oxidase, can present in a clinically indistinguishable fashion from AIP because the typical blistering rash may be absent in as many as half of affected individuals in acute crises. It is managed in the same fashion as AIP.

Disorders of Metal Metabolism

Several inherited neurologic diseases are associated with abnormal handling of metals in the brain. These may be conveniently divided into disorders of copper and iron metabolism.

Disorders of Copper Metabolism

Wilson Disease

Kinnier Wilson described his eponymous disease in 1912 as hepatolenticular degeneration, a disorder characterized by progressive dystonia, tremor, and psychiatric disturbances, usually beginning in adolescence, and accompanied by cirrhosis. A decade earlier, Kayser and Fleischer had reported the brown corneal rings now known to represent the accumulation of copper in Descemet membrane. These have proven to be an excellent gauge of excess copper stores, which regress in the face of effective copper removal, only to reappear if treatment is discontinued.

Wilson disease is caused by mutations in the transporter, encoded by the ATP7B gene that transports copper from hepatocytes to the bile and blood; its dysfunction leads to accumulation of copper in the liver, where it provokes fibrosis and eventually cirrhosis. When this store is exhausted, copper begins to deposit in the lenticular nuclei, causing extrapyramidal dysfunction, and if untreated destruction of the nuclei.

Neurologic presentations are rare in the first decade of life; Wilson disease is more likely to present in young children with acute or chronic liver failure, hemolytic anemia, or renal tubular dysfunction, reflecting the tissues in which copper is toxic. Affected adolescents have a typical appearance, in which the upper lip is drawn back to expose the teeth, accompanied by a wing-beating tremor and dystonic posturing. Spasticity, dysphagia, and dysarthria are commonly seen, and Parkinsonian features are most prominent in some cases. Psychiatric manifestations are frequent and may dominate the clinical picture.

Laboratory tests may show elevated transaminases; low serum uric acid; and elevated urine copper, amino acids, and urate secondary to tubular dysfunction. Serum copper and ceruloplasmin are low. Apart from the demonstration of two mutations in trans in the ATP7B gene, no single test is diagnostic for Wilson disease. A diagnostic scoring system has been developed to assist the clinician; this includes presence or absence of Kayser-Fleischer rings or neurologic symptoms, serum ceruloplasmin, liver copper content, urinary copper excretion, and mutation analysis of the ATP7B gene.

Penicillamine (600-3,000 mg daily for adults; 20 mg/kg/d in children, rounded off to the nearest 250 mg, given in two or three divided doses) is the traditional chelating agent used in Wilson disease, but its adverse effect profile has led to the employment of zinc (which impairs copper absorption) (150 mg elemental zinc per day for adults; for children <50 kg in body weight, 75 mg/d, administered in three divided doses, 30 min before meals) and trientine (which increases urinary copper excretion) (900-2,700 mg/d in two or three divided doses, with 900-1,500 mg/d used for maintenance therapy; in children, the weight-based dose is not established, but the dose generally used is 20 mg/kg/d rounded off to the nearest 250 mg, given in two or three divided doses) as preferred treatments today. Vitamin E may have a role as an antioxidant, but no dosage regimen has been widely accepted. If copper stores can be removed before permanent tissue damage has occurred, the prognosis is excellent, provided that treatment is continued lifelong. Liver transplantation is an option in those with irreversible hepatic failure or who cannot tolerate other treatments.

Menkes Disease

In contrast to Wilson disease, the manifestations of Menkes disease reflect the effects of copper deficiency on the brain and other tissues. Menkes disease is caused by mutations in the X-linked ATP7A gene, which encodes the protein that facilitates transport of copper from the gut to the circulation. The resultant systemic deficiency of copper leads to dysfunction of multiple enzyme systems, including cytochrome c oxidase, lysyl oxidase, and dopamine β-hydroxylase. The disease manifests in boys in the first 2 months with developmental regression, hypotonia, seizures, twisted, sparse, fair hair (often absent through easy breakage), hypothermia, and hypoglycemia. They have a cherubic appearance secondary to abnormal collagen formation, which is also responsible for the bony anomalies (metaphyseal flaring) and dilatation of the urinary collecting system and blood vessels. The latter may rupture spontaneously, leading to intracranial hemorrhage, sometimes mistakenly attributed to child abuse. Without treatment, most boys die by 3 years, although survival into the fourth decade has been reported in one treated patient with a mild phenotype.

The diagnosis is suspected clinically and confirmed by ATP7A mutation analysis. Bypassing the impaired gut absorption by administering subcutaneous copper histidine has shown benefit in morbidity and mortality, provided that treatment is instituted before permanent damage has occurred. A combination of CSF-directed gene therapy and subcutaneous copper histidine has shown benefit in a mouse model of Menkes disease.

Females with ATP7A mutations can present when X-autosome translocation has occurred, or in theory, in cases of Turner syndrome. Their clinical manifestations resemble those in boys.

Two allelic variants have been recognized in patients with ATP7A mutations. The occipital horn syndrome manifests as calcification of the insertions of the trapezius muscles, associated with joint laxity, a dilated urinary collecting system, and tortuous blood vessels, with only mild, if any, cognitive impairment. A distal motor neuropathy resembling Charcot-Marie-Tooth syndrome has also been described in adult males; it lacks any other findings in common with Menkes disease.

Disorders of Iron Metabolism

A family of rare diseases, embraced by the acronym NBIA (neurodegeneration with brain accumulation) has been delineated in recent years. All feature varying combinations of basal ganglia dysfunction associated with neuropsychiatric symptoms. Ten of the 12 known subtypes are autosomal recessive disorders;

Beta-propeller protein-associated neurodegeneration (BPAN) is X-linked dominant, and neuroferritinopathy is autosomal dominant. The disorders have been classified into subgroups according to their proposed pathomechanisms: (1) abnormal CoA biosynthesis (pantothenate kinase–associated neurodegeneration [PKAN] and COASY protein-associated neurodegeneration), (2) abnormal lipid metabolism (PLA2G6-associated neurodegeneration [PLAN], mitochondrial-membrane protein-associated neurodegeneration, fatty acid hydroxylase-associated neurodegeneration, and leukoencephalopathy with dystonia and neuropathy), (3) autophagosome and lysosomal dysfunction (BPAN and Kufor-Rakeb syndrome), (4) iron homeostasis (neuroferritinopathy and aceruloplasminemia), and (5) those of uncertain mechanism (Woodhouse-Sakati syndrome and GTPBP2-associated NBIA). The core disorders in this family are PKAN (NBIA 1) (formerly known as *Hallervorden-Spatz disease*) and PLAN (NBIA 2).

PKAN, or NBIA 1, is a childhood-onset neurodegenerative disorder that most often presents in the first decade with intellectual delay and progressive gait and oromandibular dystonia; more subtle disturbances of cognitive function and gait may occur with later onset forms of the disease. Saccadic eye movement disorders including vertical supranuclear gaze palsy have been described. The classic phenotype also includes retinal pigmentation, acanthocytes, and deposition of iron in the globus pallidus. This causes signal hypointensity in the globus pallidus on MRI early in the course of the disease; with progression, a central area of hyperintensity appears in the medial globus pallidus, producing the "eye of the tiger" sign. Although highly suggestive of the diagnosis, the absence of this finding does not rule out the diagnosis of PKAN, which is established by sequencing of the PANK2 gene. Although there is no definitive therapy for PKAN, small studies suggest a stabilizing effect of iron chelation using deferiprone.

NBIA 2, PARK14 or PLAN, first recognized as infantile neuroaxonal dystrophy, is associated with mutations in PLA2G6, which encodes calcium-independent phospholipase A2. The key features are the combination of ataxia, truncal hypotonia, spasticity, nystagmus, and optic atrophy with peripheral neuropathy. The MRI shows cerebellar atrophy and iron deposition in the globus pallidus—without hyperintensity. Later onset forms may have a dystonia-Parkinson phenotype. Axonal spheroids are the pathologic hallmark of the disease, and their demonstration in biopsies was critical to the diagnosis before mutation analysis was available. Only symptomatic therapy is available.

Disorders Associated With Acanthocytosis

Acanthocytes are irregularly shaped red cells with spiny projections whose appearance reflects abnormal membrane structure. They are found in chorea-acanthocytosis, abetalipoproteinemia, hypobetalipoproteinemia, McLeod syndrome, PKAN (see above), and in Huntington disease-like 2, a triplet repeat disease affecting the gene encoding junctophilin-3, a protein involved in sarcoplasmic and plasma membranes.

Chorea-acanthocytosis is an autosomal recessive disorder in which patients experience the onset of a hyperkinetic movement disorder in early adulthood, which eventually evolves into parkinsonism. The movements are often drug resistant but may respond to deep brain stimulation targeted at the globus pallidus interna. A neuropsychiatric syndrome beginning with features of obsessive-compulsive disorder may evolve into dementia; some patients also have an axonal neuropathy and seizures. Death usually occurs within 15 years; there is no disease-modifying therapy. Patients have mutations in VPS13A, the human analog of the yeast vacuolar protein sorting 13 gene. The gene product, chorein, interacts with beta-adducin and beta-actin, membrane cytoskeletal proteins expressed at synapses and red cell membranes.

Two related disorders of lipid metabolism are also associated with acanthocytosis. **Abetalipoproteinemia (Bassen-Kornzweig syndrome)** is caused by mutations in the gene encoding the microsomal triglyceride transfer protein. This leads to severe diarrhea and almost complete absence of apoB-containing proteins in the blood, with very low levels of cholesterol (often less than 40 mg/dL) and other blood lipids. Fat-soluble vitamins are correspondingly low; perhaps the most significant is vitamin E, whose deficiency causes a spinocerebellar syndrome, progressive ophthalmoplegia, and pigmentary retinopathy. Vitamin K deficiency may cause serious bleeding. The presence of very low serum cholesterol and acanthocytes should suggest the diagnosis, which can be confirmed by mutation analysis. Treatment with vitamins E and K is effective if begun early. **Hypobetalipoproteinemia** results from mutations in the apoB gene itself; the phenotype is indistinguishable from abetalipoproteinemia; the treatment is the same.

McLeod syndrome is an X-linked disorder, originally recognized in asymptomatic individuals donating blood. They have abnormal expression of Kell blood group antigens secondary to mutations in the XK gene. A subgroup of people with this finding has a symptomatic neuromyopathy associated with elevated creatine kinase levels, hemolysis and involuntary movements; some also have seizures. The MRI shows caudate atrophy and increased signal in the putamen. Cardiomyopathy may occur and lead to premature death. The electromyography shows axonal degeneration, and muscle biopsy may show myopathy and denervation. Complex phenotypes likely result from contiguous gene syndromes; XK is adjacent to CYBB (causing X-linked chronic granulomatous disease), Duchenne muscular dystrophy, and RPGR (X-linked retinitis pigmentosa) on the X chromosome.

LARGE MOLECULE DISORDERS

Lysosomal and Associated Large Molecule Disorders

Lysosomal diseases are characterized by the accumulation of macromolecules within lysosomes because of genetically determined deficiency of a catabolic enzyme or related gene product. The stored materials comprise complex lipids, saccharides, or proteins, and the central nervous system (CNS) is usually affected. Both autosomal and X-linked inheritance occur. Carrier detection and prenatal diagnosis are available for most of these disorders. Specific treatment in the form of enzyme replacement therapy (ERT) for mucopolysaccharidosis (MPS) types I, II , VI, and VII and Gaucher, Fabry, Wolman, and Pompe diseases; substrate reduction therapy for Gaucher disease; and hemopoietic stem cell transplantation for several lysosomal storage diseases has now entered practice, albeit with varying evidence of efficacy.

Lipidoses

Lipid-storage diseases involve all three major lipid classes: neutral lipids (ie, cholesterol ester, fatty acid, and triglycerides), polar lipids (ie, glycolipids and phospholipids), and very polar lipids (ie, gangliosides).

GM2 Gangliosidoses

Hexosaminidase deficiency diseases result from a genetically determined deficiency of the enzyme hexosaminidase, which causes accumulation in cells (especially in neurons) of GM2 ganglioside and other glycosphingolipids.

For full activity, hexosaminidase requires two different subunits: the α-subunit, coded for by the HEXA locus on chromosome 15, and the β-subunit, coded for by the HEXB locus on chromosome 5. Three isozymes of hexosaminidase have a defined subunit structure: hexosaminidase A (αβ), hexosaminidase B (ββ), and hexosaminidase S (αα). Hexosaminidase A is required for cleavage of GM2 ganglioside, but the true substrate is the ganglioside bound to a protein activator whose deficiency also causes a GM2 gangliosidosis (the so-called "AB variant"). The GM2 gangliosidoses are classified according to the phenotype, the genetic locus, and the allele involved.

Progressive infantile encephalopathy was the most common clinical pattern in the past. The success of carrier screening in the Ashkenazi Jewish community dramatically reduced its incidence, and later onset variants are now seen more commonly. Hexosaminidase deficiencies show diverse phenotypes from infancy to adulthood. This diagnosis can be suspected with nearly any degenerative neurologic disorder, except demyelinating neuropathy or myopathy. Sensory dysfunction, ocular palsies, neurogenic bladder, and extraneural involvement are not prominent features.

The diagnosis is made by assaying hexosaminidase activity in blood serum and leukocytes and by sequencing the hexosaminidase genes.

Infantile Encephalopathy With Cherry-Red Spots

Three disorders in this group are well known: classic infantile Tay-Sachs disease (α-locus), infantile Sandhoff disease (β-locus), and the so-called "AB variant" (activator locus). Heterozygosity for α-locus mutations occurs in 1 in 30 Ashkenazi Jews (compared with 1 in 300 for the general population), accounting for the ethnic concentration of classic Tay-Sachs disease and genetic compounds containing α-locus mutations.

In all three conditions, the infants appear normal until 4 to 6 months of age. They learn to smile and reach for objects but do not sit or crawl. A myoclonic-jerk reaction to sound (traditionally, but misleadingly, termed *hyperacusis*) and the macular cherry-red spot are constant findings. The cherry-red macular spot is a funduscopic finding reflecting a combination of foveal atrophy and perifoveal lipid accumulation. The former improves visualization of the underlying choroid (whose color may range from bright red to brown in different individuals), which is contrasted with the more opaque surrounding lipid-laden retinal tissue. Cherry-red spots may be seen in GM2 and GM1 gangliosidoses, Niemann-Pick disease types A and B (but not in C), and sialidosis type 1 (cherry-red spot-myoclonus syndrome) and has been occasionally reported in Krabbe disease.

Affected infants become floppy and weak but have hyperactive reflexes, clonus, and extensor plantar responses. Visual deterioration, apathy, and loss of developmental milestones lead to a vegetative state by the second year. Seizures and myoclonus are prominent for the first 2 years. The infants eventually become decorticate. They need tube feeding, have difficulty with secretions, and are blind. Head circumference enlarges progressively to about the 90th percentile, from ages 1 to 3 years, and then stabilizes. Death is due to intercurrent infection, usually pneumonia. The disease is confined to the nervous system, apart from variable hepatosplenomegaly in Sandhoff disease.

By light microscopy, grossly ballooned neurons are found throughout the brain, cerebellum, and spinal cord. By electron microscopy, membranous cytoplasmic bodies (ie, distended lysosomes) are seen, with regularly spaced, concentric, dark, and pale lamellae.

GM2 ganglioside content is markedly increased in the brain and, to a much lesser degree, in the viscera. Other glycosphingolipids such as asialo-GM2 and globoside accumulate to a lesser degree.

The storage results from the deficiency of hexosaminidase. In classic Tay-Sachs disease, hexosaminidase A is absent and hexosaminidase B increased. Heterozygous carriers have a partial decrease of hexosaminidase A.

In infantile Sandhoff disease, hexosaminidases A and B are deficient. Carriers have partially decreased hexosaminidases A and B. In one form of the AB variant, a hexosaminidase A–activating protein is missing. Although levels of hexosaminidases A and B are increased, GM2 ganglioside cannot be cleaved. Diagnosis requires the use of the natural substrate, GM2 ganglioside, or direct testing for the activator or activator mutations. In a second form of the AB variant, the residual hexosaminidase A cleaves artificial but not sulfated artificial or natural substrate. Although this is detected as an AB variant, it is an α-locus disorder.

Late-Infantile, Juvenile, and Adult GM2 Gangliosidoses

These disorders present with dementia and ataxia with or without macular cherry-red spots. Spasticity, muscle wasting stemming from anterior horn cell disease, and seizures are frequently seen. Hexosaminidase A deficiency or hexosaminidases A and B deficiencies are found on biochemical study of serum, leukocytes, and cultured skin fibroblasts.

Other late-onset forms of GM2 gangliosidosis present as cerebellar ataxia or spinocerebellar ataxia. Hexosaminidase A or hexosaminidases A and B deficiencies are found on biochemical study.

Motor neuron disease resembling spinal muscular atrophy III may be the first evidence of late-onset GM2 gangliosidoses. Upper motor neuron findings may also be present, giving an amyotrophic lateral sclerosis-like phenotype.

Many, perhaps most, of these late-onset cases are compound heterozygotes. Diagnosis requires both enzyme assay and DNA sequencing.

A variety of therapeutic approaches to the GM2 gangliosidoses have shown disappointing results, including enzyme augmentation, hematopoietic stem cell transplantation, enzyme enhancement, and substrate reduction therapy. Gene therapy in animal models is promising, but has no proven benefit to date in humans.

GM1 Gangliosidosis

This group of disorders is characterized by the deficiency of GM1 ganglioside β-galactosidase and storage of GM1 ganglioside, asialo-GM1, keratan sulfate-like oligosaccharides, and glycoproteins. Other β-galactosidases such as those that cleave galactosylceramide and lactosylceramide are not deficient, and these compounds do not accumulate. There are at least three forms of deficiency of this enzyme: primary deficiency of β-galactosidase, causing infantile and late-infantile GM1 gangliosidosis and an adult form; combined neuraminidase and β-galactosidase deficiency; galactosialidosis; and combined deficiency of β-galactosidase and several other lysosomal enzymes in I-cell disease, mucolipidosis II (ML II). The latter two types are discussed under "Mucolipidoses" section.

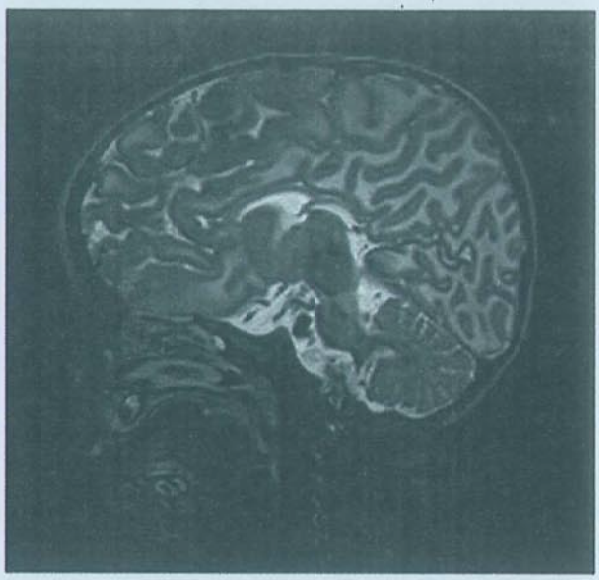

FIGURE 139.1 Sagittal T2-weighted magnetic resonance imaging of an infant with GM1 gangliosidosis, showing macrocephaly and signal hyperintensity throughout the white matter.

Infantile GM1 Gangliosidosis

Infantile GM1 gangliosidosis is earlier in onset, more severe, and more rapidly progressive than infantile Tay-Sachs disease. Soon after birth, these infants become hypotonic, with poor sucking ability and slow weight gain. They have frontal bossing, coarsened features, large low-set ears, and an elongated philtrum. Gum hypertrophy, macroglossia, peripheral edema, and, often, faint corneal haze are noted. Strabismus and nystagmus may be seen. About half the patients develop macular cherry-red spots. Development is slow, and they do not sit or crawl. By the age of 6 months, liver and spleen are enlarged; joint stiffness and claw-hand deformities may be seen, and the skin is thickened. Seizures may develop. Infants typically die before age 2 years of pneumonia or cardiac arrhythmias.

The MRI of the brain may be normal initially, but as the head grows rapidly, diffuse signal hyperintensity appears throughout the white matter (Fig. 139.1). X-rays show changes similar to those of Hurler syndrome after 6 to 12 months, with anterior beaking of vertebral bodies and a J-shaped sella turcica. Peripheral blood smears show vacuolated lymphocytes, and foamy histiocytes are found in the bone marrow.

Diagnosis is suggested by the characteristic oligosaccharide pattern in urine and confirmed by assay of GM1 ganglioside β-galactosidase in blood leukocytes or cultured skin fibroblasts and mutation analysis.

Late-Infantile GM1 Gangliosidosis

Symptoms begin between ages 1 and 3 years, with gait ataxia, hypotonia, hyperreflexia, dysarthria, and speech regression. Seizures, dementia, and spastic quadriplegia lead to death, usually by pneumonia. Optic atrophy and evidence of anterior horn cell disease may be found. Corneas are clear, organomegaly is absent, and bone changes are scanty.

Juvenile and Adult GM1 Gangliosidosis

Juvenile and adult forms of this disorder may present with skeletal deformities or neurologic manifestations. Occasional corneal clouding, angiokeratomas, and hernias are observed. Changes in the gums, facial appearance, and the macula are typically absent. The neurologic manifestations include extrapyramidal and pyramidal signs, ataxia, oculomotor abnormalities, and behavioral changes. There are no approved treatments for any form of GM1 gangliosidosis, but scattered reports suggest that miglustat may benefit some patients with later onset forms of the disease. Gene therapy has shown benefit in murine models of the disease, but there are no human trial data available.

Fabry Disease

Fabry disease is an X-linked disorder in which the skin, kidney, peripheral and autonomic nervous systems, and blood vessels store trihexosylceramide, a breakdown product of globoside. Trihexosylceramide accumulates because of a deficiency of α-galactosidase A. Female heterozygotes are frequently clinically affected, albeit less severely and later than hemizygotes.

Symptoms usually commence in childhood or adolescence, with lancinating pains in the limbs, especially the feet and hands, often brought on by temperature changes and accompanied by paresthesia or abdominal crises. Anhidrosis and unexplained fever are common.

Angiokeratomas, which become more numerous with age, are purple; macular and maculopapular; hyperkeratotic; 1 to 3 mm in size; and with a predilection for the groin, buttocks, scrotum, and umbilicus. Glycolipid storage in the renal glomeruli and tubules begins with asymptomatic proteinuria in children; it progresses to renal failure and hypertension in the third or fourth decade. Glycolipid storage in blood vessel walls may cause stroke. Edema of the limbs, whorled corneal clouding (cornea verticillata) visible by slit lamp, and myocardial involvement may occur. ERT has been demonstrated to reverse lipid storage in the kidney, heart, and blood vessels and to produce corresponding improvement or reversal of renal impairment, pain, cardiac function, and cerebral blood flow. In some cases, renal transplant may still be required when renal failure supervenes. The lancinating pains may respond to phenytoin (5-8 mg/kg/d), carbamazepine (10-35 mg/kg/d), or gabapentin (10-40 mg/kg/d).

Heterozygous women may also be affected, but manifestations are less marked. Skin lesions are few or absent. Corneal opacity is more common. If renal or cardiac involvement occurs, they are later in onset and less severe. Fabry disease is diagnosed by finding decreased β-galactosidase activity in plasma and leukocytes and a mutation in the β-galactosidase gene.

Gaucher Disease

Gaucher disease is an autosomal recessive sphingolipidosis in which glucocerebroside is stored as a result of deficiency of glucocerebroside β-glucosidase (or glucocerebrosidase). At least four forms have been described: the infantile neuronopathic form, the juvenile neuronopathic form, the adult neuronopathic form, and the adult nonneuronopathic form.

These distinctions seem to be artificial, with overlapping manifestations occurring across a broad spectrum of phenotypes. The adult (nonneuropathic) form (type I) is more common in Ashkenazi Jews than in the general population. Diagnosis of all forms is made by demonstrating reduced glucocerebroside β-glucosidase activity in cultured skin fibroblasts or blood leukocytes and is further refined by demonstrating mutations in the β-glucosidase gene.

Type II (Infantile Neuronopathic) Gaucher Disease

This disease occurs in the first year of life, often in the first 3 months. The course is rapid, with developmental regression and

death before age 2 years. Affected infants lose weight, reflecting the mechanical compression of the gut and the hypercatabolic state associated with pronounced hepatosplenomegaly. The neurologic signs reflect severe brainstem dysfunction and include stridor, difficulty in sucking and swallowing, strabismus, retrocollis, spasticity, and hyperreflexia. Bilateral esotropia is typical. Later, affected children enter a vegetative state, becoming flaccid and weak. Seizures may occur. Macular cherry-red spots and optic atrophy do not occur.

Type III (Juvenile Neuronopathic) Gaucher Disease

Outside Europe and North America, type III Gaucher is the most common form of the disease. The manifestations range from a severe form, presenting in infancy as pulmonary infiltrates, splenomegaly, and cardiorespiratory failure, to a progressive myoclonic dementia in adolescents or adults (common in the northern provinces of Norrbotten and Västerbotten in Sweden). Horizontal supranuclear gaze palsy, with characteristic looping movements, in which the inability to generate horizontal saccades is partially compensated by generating vertical saccades accompanied by a horizontal head thrust, is an important clue to the diagnosis.

Type I (Adult) Gaucher Disease

These patients have visceral (eg, liver, lymph nodes, lung) and skeletal manifestations without primary neurologic disease. Multiple myeloma may be a late complication. It is most common in Ashkenazi Jews. Type 1 Gaucher disease presents at any age from infancy to the seventh decade. Splenectomy should be avoided unless ERT is not possible or the mechanical and hematologic manifestations are not otherwise controlled. Lesions of long bones, pelvis, or vertebral bodies may be painful. Severe cases may require surgical intervention, including joint replacement. ERT, with purified modified β-glucosidase (ie, alglucerase) or recombinant β-glucosidase (ie, imiglucerase), reverses all of the manifestations of type 1 Gaucher disease, provided that treatment begins before severe tissue damage has occurred. Substrate reduction therapy with miglustat or eliglustat is also approved by the U.S. Food and Drug Administration for therapy of type 1 Gaucher disease.

Adult Neuronopathic Gaucher Disease

Parkinsonism has been found to be more frequent in several studies of adults with Gaucher disease and in heterozygotes for glucocerebrosidase mutations. The relation now appears well established; the mechanism remains uncertain, and nonspecific lysosomal dysfunction may play a role in several neurodegenerative diseases, including parkinsonism.

Niemann-Pick Disease

This group of disorders includes several diseases that were grouped together in 1958 by Crocker and Farber on the basis of the overlapping pathology (ie, visceral foam cells) and biochemistry (ie, lysosomal storage of the glycosphingolipid sphingomyelin). Crocker subsequently proposed four groups. It is now recognized that his groups A and B are primary sphingomyelinase deficiencies, whereas groups C and D are allelic disorders, whose primary defect is not deficiency of a lysosomal hydrolase, but in intracellular lipid trafficking. Patients with types A and B Niemann-Pick disease have deficient activity of the sphingomyelin-cleaving enzyme acid, acid sphingomyelinase. The diagnosis should be suspected in patients with progressive hepatosplenomegaly, with or without cerebral symptoms. The bone marrow contains characteristic mulberry storage cells (ie, distinct from Gaucher cells). Decreased sphingomyelinase activity may be shown in cultured skin fibroblasts, leukocytes, or tissue.

Infantile Niemann-Pick Disease (Type A)

This is the most severe form of Niemann-Pick disease and occurs more commonly in Ashkenazi Jews than in the general population. Transient neonatal jaundice is followed by progressive hepatosplenomegaly; developmental regression and weight loss lead to dementia, hypotonia, and death by age 2 years. About one-half of patients develop macular cherry-red spots. Seizures are uncommon. Bone involvement is mild. Skin often has a brownish-yellow tinge. Most patients have diffuse haziness or patchy infiltrates in the lungs.

Diagnosis relies on the characteristic clinical picture, plus demonstration of near-total deficiency of sphingomyelinase in leukocytes or cultured skin fibroblasts, and by demonstrating mutations in the acid sphingomyelinase gene.

Juvenile Nonneuronopathic (Type B)

This form presents with asymptomatic splenomegaly or hepatosplenomegaly without neurologic disorder in infants, children, or adults, although cherry-red spots may be found. These patients have more residual sphingomyelinase (ie, 15%-20% of normal) than those with type A (ie, up to 10%). ERT is currently in clinical trials for Niemann-Pick disease type B.

Niemann-Pick Disease Type C

Niemann-Pick disease type C (NPC) may arise at any age from fetal life (ie, with ascites) to the fifth or sixth decades. Early-onset disease is dominated by hepatic and pulmonary failure, which are usually lethal in infancy. Classic childhood-onset disease more often presents insidiously with school failure and clumsiness that evolve into a progressive syndrome of ataxia, dystonia, and dementia. Vertical supranuclear gaze palsy is characteristic and almost invariably presents early, although often unrecognized. About 50% of patients have seizures, and 20% experience gelastic cataplexy. Hepatosplenomegaly is variable, and its absence does not rule out NPC. Genetic isolates have been described in Nova Scotia (formerly Niemann-Pick disease type D) and in Hispanics in Colorado and New Mexico.

Most patients with NPC are compound heterozygotes for mutations in NPC1; the gene product is a large transmembrane protein, localized to the late endosomal-lysosomal pathway. Dysfunction of this protein is associated with impaired trafficking of large molecules in this pathway, with accumulation of glycolipids, sphingomyelin, and cholesterol in lysosomes. The diagnosis rests on demonstration of this defect. Direct DNA analysis can be used as a first-line diagnostic test, but false negatives occur owing to the size of the gene and the large number of mutations (more than 300 recognized to date). The standard biochemical test requires demonstration of accumulation of free cholesterol in lysosomes, which is identified by filipin staining. This is an indirect index of the functional defect, with a significant number of variant cases with results that may be difficult to distinguish from heterozygotes. Assay of 3-beta, 5-alpha, 6-beta-cholestane triol in blood is a sensitive and generally specific marker of NPC, and is now established as a first-line diagnostic test. There is no approved therapy for NPC in the United Sates, although miglustat has been approved for management of its neurologic manifestations in the European Union and several other countries. In 2019, clinical trials were underway for *N*-acetyl-L-leucine, intrathecal and intravenous cyclodextrin,

and oral arimoclomol in NPC. Arimoclomol was granted breakthrough therapy status for NPC by the U.S. Food and Drug Administration in 2019.

A small number of cases of NPC are associated with mutations in a second gene, NPC2, whose gene product is a soluble, lysosomal protein. The NPC2 appears to interact with NPC1 either through transfer of unesterified cholesterol, responding to oxysterol signals, or some combination of both. Hematopoietic stem cell transplantation may be helpful in this disorder, although no controlled data are available.

Farber Disease

Farber disease is caused by deficiency of acid ceramidase. Infants with this disease have profound reduction of enzyme activity and present with painful swollen joints, hoarseness, vomiting, respiratory difficulty, or limb edema in the first few months of life, sometimes as early as 2 weeks of age. Most patients die of pulmonary disease before age 2 years, but some survive into adolescence. Hematopoietic stem cell transplantation has produced improvement in several measures, but does not prevent neurologic deterioration. Children with higher residual acid ceramidase activity (>10%) may present with a spinal muscular atrophy-progressive myoclonic epilepsy phenotype, distinct from that associated with SMN1 mutations, or with a less severe phenotype that includes optic nerve and retinal involvement, including cherry-red spots.

Cerebrotendinous Xanthomatosis (Cholestanol Storage Disease)

Cerebrotendinous xanthomatosis is an autosomal recessive disorder associated with elevated blood cholestanol levels and mutations in the sterol 27-hydroxylase gene (CYP27).

Patients with cerebrotendinous xanthomatosis often have early cognitive impairment and may have unexplained diarrhea beginning in infancy, but cataracts, tendon xanthomas, and progressive spasticity, usually associated with ataxia, commonly do not begin before adolescence or young adulthood. The spasticity and ataxia are severe and progressive. Speech is affected. Neuropathy may appear with distal muscle wasting. Sensory deficits and Babinski signs are seen. Pseudobulbar palsy develops terminally. Death from neurologic disease or myocardial infarction usually occurs in the fourth to sixth decade. Some patients have apparently normal mental function.

Tendon xanthomas are almost always seen on the Achilles tendon and may occur elsewhere. The cerebellar hemispheres contain large (ie, up to 1.5 cm) granulomatous xanthomas with extensive demyelination. The brainstem and spinal cord may be involved.

Treatment with chenodeoxycholic acid may prevent or reverse neurologic manifestations if started early in life.

Mucopolysaccharidoses

The MPS are defined by a characteristic phenotype and by the tissue storage and urinary excretion of acid mucopolysaccharide. They were originally considered a single disease, but eight clinical types, and numerous subtypes, are now known. Each is caused by deficiency of a lysosomal hydrolase required for degradation of one or more of three sulfated mucopolysaccharides: dermatan sulfate, heparan sulfate, and keratan sulfate.

Diagnosis is suspected based on the clinical picture, presence of excessive amounts of one or more acid mucopolysaccharides in urine, and is confirmed by demonstrating a specific enzyme defect. Urine screening tests for excess mucopolysaccharides are useful but are subject to false-positive and false-negative results. Positive screening tests require confirmation by quantitative and qualitative determination of urinary mucopolysaccharides and demonstration of the enzyme defect. False negatives are relatively frequent in Sanfilippo and Morquio syndromes. If clinical suspicion for an MPS is high, diagnostic evaluation should be pursued despite a negative urine screening test. Prenatal diagnosis of these disorders is available.

Hurler Syndrome (Mucopolysaccharidosis Type I)

This is the most severe of the MPS and is characterized by onset in infancy, progressive disability, and death usually occurring before 10 years of age. Nearly all the features found in other types are present in Hurler syndrome. Corneal clouding and lumbar gibbus occur in the first year of life, followed by the development of stiff joints with periarticular swelling; short, stubby hands and feet; claw hands; lumbar lordosis; chest deformity; and short stature by 2 or 3 years of age. The facies are characteristic, with thickened eyelids and lips; frontal bossing; bushy eyebrows; a depressed nasal bridge; ocular hypertelorism; enlarged tongue; noisy breathing; rhinorrhea; and widely spaced, peg-like teeth. Psychomotor slowing is followed by dementia, but seizures are not typical. Deafness is frequent, and few patients develop speech. Leptomeningeal thickening, arachnoid cysts, and hydrocephalus may occur. Cardiac murmurs resulting from valvular heart disease, coronary occlusion, and cardiac enlargement may occur and cause death. Abdominal distention is common, with inguinal and umbilical hernias and hepatomegaly. Corneal clouding progresses and, with retinal degeneration, impairs vision. Cervical cord compression with quadriplegia may occur.

Radiographic changes support the diagnosis of MPS, but do not reliably distinguish the various types. Findings include ovoid or beaked lumbar vertebrae, peg-shaped metacarpals, a J-shaped sella turcica, and spatulate ribs. Peripheral leukocytes and bone marrow cells contain metachromatic granules. Clear vacuoles are seen in hepatocytes and other cells. Zebra bodies containing lipids occur in the brain. Both dermatan sulfate and heparan sulfate accumulate in excess. The diagnosis is made by demonstrating severe deficiency of α-L-iduronidase in cultured skin fibroblasts and leukocytes. Mutation analysis of the α-L-iduronidase gene confirms the diagnosis and permits prenatal diagnosis.

Scheie syndrome, a milder allelic variant of Hurler syndrome, is characterized by juvenile onset of joint stiffness with the development of claw hands and deformed feet. A phenotype intermediate between that of the Hurler and Scheie syndromes is referred to as the *Hurler-Scheie compound*.

Hunter Syndrome (Mucopolysaccharidosis Type II)

Hunter syndrome includes mild and severe forms. Both are X-linked recessive and show iduronate-2-sulfatase deficiency. A Hunter-like phenocopy in girls with iduronate-2-sulfatase deficiency occurs in the context of total sulfatase deficiency (metachromatic leukodystrophy [MLD], Austin type).

Boys with the severe form experience juvenile-onset joint stiffness, typical facial features (Fig. 139.2), dysostosis multiplex, hepatosplenomegaly, diarrhea, dwarfing, and mental deterioration. Progressive deafness is prominent. Pigmentary retinal deterioration, papilledema, and hydrocephalus may be seen. Nodular or pebbled-skin change over the scapulae and absence of corneal clouding are important features distinguishing Hunter syndrome from Hurler syndrome. Patients usually die as teenagers.

Patients with the mild form of Hunter syndrome may be asymptomatic or have only mild systemic findings.

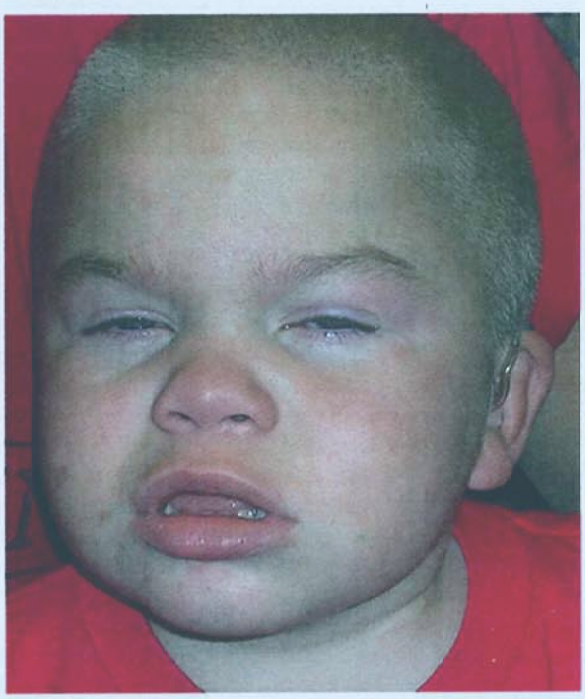

FIGURE 139.2 Mucopolysaccharidosis type II (Hunter syndrome); note periorbital fullness, increased tissue thickness of the lips and cheeks, and hearing aid.

Sanfilippo Syndrome (Mucopolysaccharidosis Type III)

Patients with this syndrome outnumber all other forms of MPS combined. They exhibit progressive cognitive impairment, mild somatic involvement, and urinary excretion of heparan sulfate alone. Four biochemically distinct forms reflect four metabolic steps required for the degradation of heparan, but not dermatan or keratan, sulfate. Sanfilippo patients have juvenile-onset dementia, with delay or deterioration of speech or school performance. Children presenting with psychiatric disorder, intellectual disability, or dementia should be carefully examined for subtle changes in facial features, hepatosplenomegaly, hirsutism, joint stiffness, and radiographic changes of dysostosis multiplex. These patients deteriorate neurologically, with progressive dementia, spastic quadriparesis, tetraballism, athetosis, incontinence, and seizures. Cardiac involvement may occur. Corneal clouding is absent. Bone changes, short stature, and organomegaly are slight. Patients may die in adolescence or survive into the third decade of life.

The diagnosis is made by the characteristic clinical picture, increased heparan sulfate in the urine, and by demonstration of the specific enzyme defect and mutations in the relevant gene. Screening tests for mucopolysacchariduria may be negative in Sanfilippo syndrome. There is currently no therapy of proven efficacy in MPS III, although ERT, substrate reduction therapy, and gene therapy have been explored in humans and animal models.

Mucolipidoses

The MLs resemble the Hurler phenotype but lack excess urinary mucopolysaccharide, having instead, excess urinary oligosaccharides or glycopeptides, most of which are fragments of more complex structures. Urinary thin-layer chromatography for oligosaccharides is a useful screening test.

Sialidosis (Mucolipidosis I)

Patients with sialidoses have deficiency of α-L-neuraminidase, also known as *sialidase* encoded by the NEU1 gene. In most forms, sialic acid–containing glycoproteins, oligosaccharides, and glycolipids accumulate in tissue, and sialyloligosaccharides are excreted in urine.

The diagnosis is based on clinical findings; the presence of abnormal sialyloligosaccharides in the urine; deficiency of the appropriate sialidase in cultured skin fibroblasts, tissue, or leukocytes; and demonstration of mutations in NEU1. There are at least two distinct lysosomal sialidases.

In addition to the isolated sialidase deficiencies, two other groups of MLs have sialidase deficiency. In one, galactosialidosis, both sialidase and β-galactosidase are deficient because a stabilizing protein they share is defective. In the second group, ML II and ML III, sialidase and several other lysosomal hydrolases are deficient owing to deficient activity of the phosphotransferase that is responsible for creating the mannose-6-phosphate motif that targets enzymes to the lysosome.

Sialidoses with isolated sialidase deficiency have a highly variable clinical picture. Neonate and infants are categorized as having sialidosis type 2. Neonates with congenital sialidoses have hydrops fetalis, hepatosplenomegaly, and short survival times. Infants with nephrosialidosis resemble the Hurler phenotype and develop macular cherry-red spots and renal disease. Children with sialidosis type 1 (also known as *ML I*), a milder disorder, are similarly affected but develop ataxia, myoclonic jerks, and seizures. The mildest form is the cherry-red spot myoclonus disorder, in which adolescents, who are usually intellectually normal, develop macular cherry-red spots, myoclonus, and myoclonic seizures. There is a predilection for individuals of Italian descent.

There is no disease-modifying therapy for any form of ML I.

Mucolipidoses II and III

ML II, or I-cell disease, and ML III, or pseudo-Hurler polydystrophy, are allelic autosomal recessive disorders associated with deficiency of the enzyme, glycoprotein *N*-acetylglucosamine-1-phosphotransferase, whose activity is required for mannose-6-phosphate targeting of glycoproteins, including many lysosomal hydrolases, from the Golgi apparatus to the lysosome. These diseases are associated with mutations in the GNPTAB and GNPTG genes, which encode the α/β and γ subunits of the enzyme, respectively. Study of a sample of more than 1,000 unrelated individuals with nonsyndromic persistent stuttering identified 164 individuals who carried rare nonsynonymous coding variants in one of these genes, without manifestations suggestive of ML.

ML II is a severe disorder that resembles Hurler syndrome without corneal clouding. Cultured fibroblasts contain coarse inclusions (I-cells). Diagnosis is made by finding excess sialooligosaccharides in the urine and deficiencies of multiple lysosomal enzymes in cultured skin fibroblasts, with elevated levels of these enzymes in plasma. In brain and viscera, only β-galactosidase is consistently deficient.

ML III is a milder clinical disorder than ML II that may present with joint stiffness, carpal tunnel syndrome, avascular necrosis of bone, or mild intellectual impairment. Pamidronate may be helpful in managing the bony lesion of ML III, particularly hip disease. There is no disease-modifying therapy for ML II or ML III.

Mucolipidosis IV

ML IV is an autosomal recessive disorder associated with severe intellectual disability, defects in motor and speech function, corneal clouding and progressive retinal degeneration leading to blindness, and a shortened life span. Corneal clouding may present as early as 6 weeks of age. The disease was initially thought to occur almost exclusively in Ashkenazi Jews, but cases have now been identified from around the world, although only a little over 100 individuals have been reported in total. Achlorhydria is universal, and measurement of elevated serum-gastrin levels is a convenient and reliable screening test for ML IV. Diagnosis may now be made by mutation analysis of the MCOLN1 gene, which codes for mucolipin, also known as *TRPML1*, a member of the transient receptor potential family of proteins. Dysfunction of TRPML1 leads to impairments in endosomal-lysosomal trafficking, autophagy, lysosomal exocytosis, mammalian target of rapamycin complex 1 signaling, and heavy metal homeostasis. Miglustat has slowed progression in the ML IV mouse, and fingolimod has been demonstrated to inhibit astrocytic inflammation in the same model, but no disease-modifying therapy is yet available for affected humans.

Neuronal Ceroid Lipofuscinoses

The NCLs are a family of lysosomal diseases characterized by varying degrees of progressive dementia, epilepsy, and visual impairment associated with retinal pigmentation and profound cortical atrophy. They were previously defined by histologic and ultrastructural features and a plethora of confusing and inconsistently applied eponyms, but are now classified according to genotypes. The common pathologic features include neurons engorged with periodic acid–Schiff (PAS)-positive and autofluorescent material on light microscopy and typical profiles, including granular osmiophilic deposits and curvilinear and fingerprint bodies (or combinations of these), on electron microscopy. Although the signs and symptoms are confined to the nervous system, the abnormal cytosomes are widely distributed in skin, muscle, peripheral nerves, leukocytes, urine sediment, and viscera.

Thirteen genes have been associated with 14 NCL loci; the gene associated with 1 locus (CLN9) has not yet been identified. All are autosomal recessive, except for the Parry form of adult NCL, which is associated with dominant mutations in DNAJC5. Some phenotypes may be associated with mutations in several genes (such as adult NCL, associated with mutations in cathepsin D [CTSD], PPT1, CLN3, CLN5, CLN6, CTSF, GRN), and some genes, such as PPT1, may cause several different phenotypes, which is associated with infantile, late-infantile, and juvenile NCL.

The diagnosis of PPT1-, TPP1-, and CTSD-deficient forms of NCL may be made by enzyme assay and confirmed by mutational analysis. A database listing NCL mutations is available online at https://www.ucl.ac.uk/ncl-disease/.

Supporting investigations include an abnormal electroretinogram in the infantile, late-infantile, and juvenile forms and electron microscopic examination of tissue (ie, skin, nerve, muscle, or rectal biopsy for autonomic neurons). Abnormal autofluorescence is seen on examination of frozen section of biopsied muscle, enabling rapid diagnosis.

The most frequent phenotypes are late infantile (NCL2) and juvenile (NCL3). The former presents between 2 and 4 years with seizures, associated with developmental regression, ataxia, myoclonus, and spasticity. Retinal degeneration occurs later in the course and eventually leads to blindness.

Juvenile NCL begins in the latter half of the first decade with progressive loss of vision and later onset of epilepsy. Patients may survive into the fourth decade.

Rapid and accurate diagnosis of NCL is essential, now that disease-modifying therapy is available, or in clinical trials. Cerliponase alfa, administered directly into the cerebral ventricles, stabilizes NCL2 and has been approved by the U.S. Food and Drug Administration for this indication. Trials of gene therapy are in progress for CLN2, CLN3, and CLN6. Recombinant human pro-CTSD is under investigation in CTSD-deficient hippocampus slice cultures in vitro, retinal cells in vivo, and in the CLN10 mouse model.

Leukodystrophies

The leukodystrophies are progressive, genetic metabolic disorders causing dysmyelination, in contrast to leukoencephalopathies that are often acquired.

Disorders such as Krabbe disease, MLD (which are lysosomal diseases), adrenoleukodystrophy (ALD) (discussed with other peroxisomal disorders), Alexander disease, and classic Pelizaeus-Merzbacher disease (PMD) were defined by traditional clinical and pathologic investigations. Careful clinical and magnetic resonance phenotyping combined with molecular biology have led to the identification of a variety of additional leukodystrophies, including childhood ataxia with central hypomyelination (also known as *vanishing white matter disease* [VWM]), megalencephalic leukoencephalopathy with subcortical cysts, hypomyelination of the basal ganglia and cerebellum, oculodentodigital dysplasia, and leukoencephalopathy involving the brainstem and spinal cord with lactate elevation. This leaves a heterogeneous, but shrinking group, of unclassified leukodystrophies, historically referred to as *orthochromatic or sudanophilic leukodystrophies*. Diffuse sclerosis (Schilder disease) is included in this chapter, although it resembles multiple sclerosis more than traditional leukodystrophies.

Metachromatic Leukodystrophy

MLD comprises a group of autosomal recessive disorders with degeneration of central and peripheral myelin, striking metachromasia of the stored substances, primarily sulfatides, and deficiency of the sulfatide-cleaving enzyme, sulfatase A, also called *arylsulfatase A* (ARSA). Late-infantile onset disease is most common.

The diagnosis of MLD is complicated by the existence of sulfatase A pseudodeficiency, an autosomal recessive condition in which sulfatase A activity is greatly diminished in enzyme assays using artificial substrates, but there is no neurologic disease. An additional complication is the requirement of sulfatase A for the sulfatide-activator protein. Patients with genetic deficiency of sulfatide-activator protein may have MLD, but the commonly used enzyme assays may fail to diagnose this condition.

Late-Infantile Metachromatic Leukodystrophy

Affected infants have onset of difficulty in walking after the first year of life, usually between ages 12 and 30 months. Flaccid paresis and diminished, or absent, tendon reflexes are typical, but occasionally, spastic paresis develops. Genu recurvatum, hyperextension of the knee, may be noted. Progressive dementia and dysarthria follow.

Peripheral neuropathy leads to loss of tendon reflexes and may be accompanied by limb pain. Later, patients become bedridden and quadriplegic, with feeding difficulties, bulbar and pseudobulbar palsies, and optic atrophy. Children so affected

usually die in the first decade of life, blind and in a vegetative state. Investigations show increased CSF protein content, impaired gallbladder function, and increased urinary-sulfatide excretion. Before the availability of enzyme assays and molecular sequencing, the diagnosis could be confirmed by the demonstration of metachromatic lipids on sural nerve biopsy,

Sulfatide accumulates in brain, peripheral nerves, and some extraneural tissues (eg, kidney). Sulfatide causes brown metachromasia, with acetic acid–cresyl violet staining in glial cells, Schwann cells, myelin lamellae, and neurons. Characteristic "tuffstone" bodies are seen by electron microscopy.

The diagnosis is based primarily on enzyme analysis, supported by ARSA gene sequencing. Trials of intrathecal ERT with recombinant human ARSA are currently in progress in subjects with late-infantile MLD.

Late-Onset Metachromatic Leukodystrophy

Juvenile metachromatic leukodystrophy patients resemble those with late-infantile MLD but for the later onset of symptoms (usually between 3 and 10 y) and slower progression of the disease. Emotional disturbance or dementia are more common presentations, although gait disorder may be the initial symptom. Nystagmus and tremor may be noted. Nerve conduction velocities are slowed and CSF protein concentrations are elevated. The diagnosis can usually be suspected from MRI or the brain, which shows diffuse, confluent signal hyperintensity in the white matter of the centra semiovale, with a striated "tigroid" appearance (Fig. 139.3).

MLD commonly starts in adults in the third or fourth decade as a psychiatric disorder (mimicking schizophrenia) or progressive dementia. Other findings may include truncal ataxia, hyperactive reflexes, and seizures. Both psychiatric and motor manifestations may coexist in association with certain mutations. The CSF protein concentration is usually not elevated. The illness runs a protracted course, averaging 15 years.

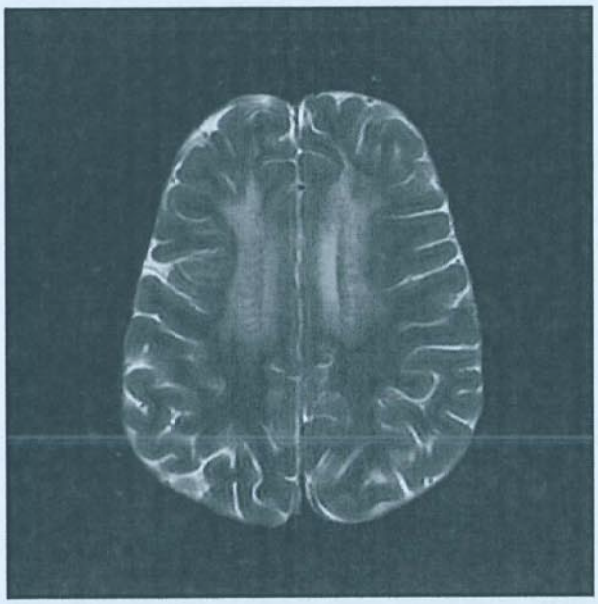

FIGURE 139.3 Axial T2-weighted magnetic resonance imaging of an 18-year-old with metachromatic leukodystrophy, illustrating the characteristic "tigroid" appearance of the white matter.

Krabbe (Globoid Cell) Leukodystrophy

Patients are normal at birth but may have subtle findings, such as fisting in the first few weeks. At 3 to 6 months, irritability, inexplicable crying, fevers, rigidity, seizures, feeding difficulty, vomiting, and slowing of cognitive and motor development become apparent. Later, psychomotor regression occurs, accompanied by increasing tone and extensor posturing. Reflexes may be increased before being lost. Optic atrophy is frequent. Patients may develop flaccidity or flexor postures before death, at about 2 years of age. Most children have acquired microcephaly, but macrocephaly with hydrocephalus is occasionally observed.

The CSF protein is increased, and nerve conduction velocities are slowed. Galactocerebrosidase activity is deficient in serum, leukocytes, and cultured skin fibroblasts; the enzyme is encoded by GALC. Psychosine, a substrate for this enzyme, is increased at least 200-fold over levels in the normal brain. Psychosine toxicity is probably the cause of the disease based on studies showing its ability to produce characteristic lesions in animal models.

A few patients with juvenile onset and slower progression of dementia, optic atrophy, and pyramidal tract signs, without neuropathy, have had galactocerebrosidase deficiency. An adult-onset disorder with a similar but more slowly progressive course resembling a spinocerebellar ataxia has been described.

Hematopoietic stem cell transplantation in the first 3 weeks of life is effective in prolonging life in infants with early infantile Krabbe disease, although many such children have significant residual neurologic disabilities. The availability of this therapy has led to the implementation of newborn screening for Krabbe disease in several states in the United States. The effectiveness of hematopoietic stem cell transplantation in older patients with Krabbe disease is controversial.

Alexander Disease

Alexander disease is an autosomal dominant progressive leukodystrophy associated with gain-of-function mutations in the GFAP gene that encodes glial fibrillary acidic protein. As such, it is a primary disorder of astrocytes, in contrast to other leukodystrophies, in which the major affected cell type is the oligodendrocyte. The classic presentation occurs in infants, who manifest macrocephaly, developmental regression, seizures, and progressive spasticity. The MRI shows a pattern of frontally predominant white matter hyperintensity, sometimes with cavitation, with periventricular hyperintensity with or without enhancement and "garlands," and increased signal intensity in the medulla, middle cerebellar peduncles, and long tracts, with or without atrophy (particularly in later onset cases) (Figs. 139.4 and 139.5). Some patients develop hydrocephalus secondary to compression of the aqueduct of Sylvius by swollen midbrain astrocytes. Cases in which tumor-like lesions occur have been reported. The affected areas show accumulation of Rosenthal fibers.

In adolescents and adults, Alexander disease is much less likely to be associated with macrocephaly and may be manifest as cognitive and emotional disturbance, with relatively mild long tract signs or ataxia; persistent vomiting may be prominent. Oculopalatal myoclonus has been described as a classical finding in such patients but is often absent. The anatomic and clinical patterns overlap with neuromyelitis optica, which is an acquired disorder of astrocytes, in which antibodies are directed at aquaporin, expressed in water channels in astrocytes.

There is no disease-modifying therapy available for Alexander disease, but given its prolonged course, particularly in later onset forms, vigorous supportive treatment is strongly encouraged.

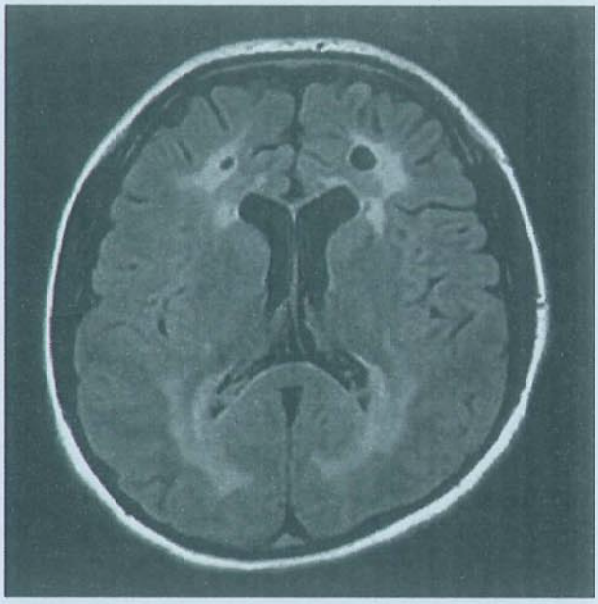

FIGURE 139.4 Axial T2 fluid-attenuated inversion recovery magnetic resonance imaging of a 12-year-old with Alexander disease, showing frontal predominant white matter hyperintensity with cavitation and periventricular hyperintensity.

Antisense suppression of GFAP expression in mouse models of Alexander disease has produced positive effects pathologically and in the clinical phenotype of the affected animals.

Pelizaeus-Merzbacher Disease

PMD is an X-linked hypomyelinating disorder associated with duplications, deletions, and point mutations in the gene encoding central proteolipid protein (PLP1). Infantile forms of the disease present with profound hypotonia and unusual pendular nystagmus with gray optic disks. The most severely affected infants do not develop further and succumb to their illness in the first few years of life, but some boys make developmental gains and survive into the second decade, although they rarely walk or talk. In those who survive into childhood, intellectual disability, progressive ataxia, spasticity, and choreoathetosis are often observed. The MRI in PMD shows profound hypomyelination, with reduced white matter volume. Some patients with mild mutations in PLP1 have a slowly progressive spastic paraplegia, classified as spastic paraplegia 2. There is no established therapy for PMD, but a trial of human CNS stem cells implanted into the cerebral hemispheres in four boys reported that subjects were alive at the end of the study period; two of these subjects developed specific alloantibodies against the donor cells. The clinical responses were variable, but the subjects were generally stable. A study of the ketogenic diet in the mouse model of PMD showed evidence of benefit, in contrast to cholesterol supplementation, which was not of benefit in two patients.

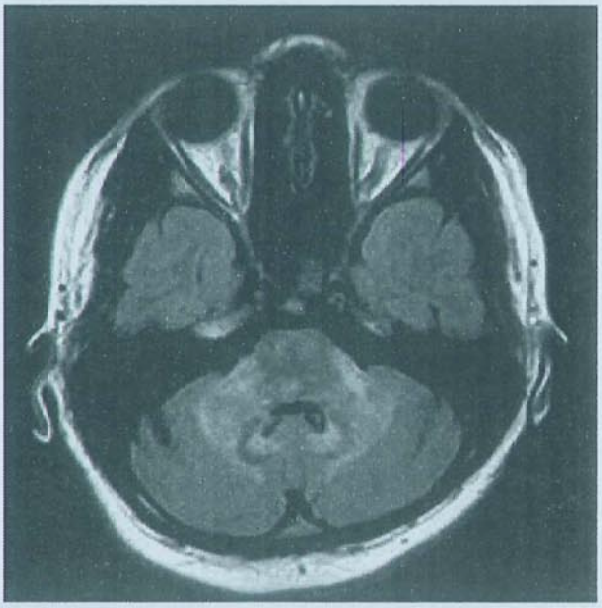

FIGURE 139.5 Axial T2 fluid-attenuated inversion recovery magnetic resonance imaging of a 12-year-old with Alexander disease, showing increased signal in the medulla, middle cerebellar peduncles, and long tracts.

A number of families, who lack mutations in PLP1, have been recognized with a PMD-like illness. Recessive mutations in GJA12/GJC2, which encodes a protein essential in gap junction formation in myelin, have been identified in some such families; TUBB4A mutations have been identified in another case mimicking PMD.

Vanishing White Matter Disease

In 1994, Schiffmann and colleagues described four girls with progressive ataxic diplegia, whose imaging studies showed confluent white matter disease early in the course of the illness; the peripheral nerves and intellect were spared, and extensive investigation for previously described leukodystrophies was uninformative. Biopsy specimens showed hypomyelination, demyelination, gliosis, and reduced quantities but qualitatively normal lipids. The MRS showed reduced *N*-acetylaspartic acid, choline, and creatine restricted to the white matter. They named this disorder *childhood ataxia with central hypomyelination*. A year earlier, Hanefeld et al had described three children with identical features, whose disease they named *myelinopathia centralis diffusa*.

In 1997, van der Knaap's group described nine more patients with this phenotype. They emphasized the unusual combination of slowly progressive ataxia with episodic decompensation in the face of minor trauma (motor change) or intercurrent infection (coma). They also recognized that the white matter signal eventually disappeared, to be replaced by CSF intensity signal. The latter was found to correspond to extensive cystic degeneration of the cerebral white matter with preserved cortex in an autopsied case. Subsequent studies have emphasized the relative preservation of oligodendrocytes with abundant foamy cytoplasm and scarcity of astrocytes as the specific neuropathologic hallmark of the disease.

Van der Knaap's descriptive term, vanishing white matter disease, *VWM*, which emphasizes the most dramatic aspect of this illness, has subsequently dominated the literature. Myelinopathia centralis diffusa was never widely accepted, but childhood ataxia with central hypomyelination is still encountered, most often in tandem with VWM.

VWM is caused by mutations in any one the genes coding for the subunits of the eukaryotic translation initiation factor 2 b (eIF2B); VWM is the first disease recognized that is associated with mutations in a translation factor. The eIF2B protein is the major regulator of protein synthesis under conditions of mild stress, such as temperatures up to 41°C. The gene is expressed in all tissues, yet VWM is restricted to the cranial white matter. In vitro studies of VWM brain have shown that all three pathways of the unfolded protein response are inappropriately activated

but only in white matter. This remarkable specificity remains unexplained, as is the case for other disorders involving mutations of DNA housekeeping machinery that are expressed in specific regions of the nervous systems, such as spinal muscular atrophy.

As has proven to be the case in other inborn errors of metabolism, the appearance and use of a diagnostic test for VWM has been followed by the recognition of a broader range of phenotypes than those originally described. Thus, Cree leukoencephalopathy and ovarioleukodystrophy have both been shown to be associated with mutations in eIF2B. The former is an autosomal recessive leukodystrophy, lethal in the first 2 years, that is observed in the native North American Cree and Chippewayan population where high rates of consanguinity prevail. Death in the context of a common viral infection may be the presenting feature. The latter phenotype can be associated with either primary or secondary amenorrhea and a more indolent neurologic course, with variable dementia, gait ataxia, sphincter dysfunction, optic atrophy, and episodic decompensation. Other unusual features have been reported, including marked macrocephaly in a child with survival into the third decade, adult presentation with psychosis, and precipitation of symptoms after being frightened by a horse.

Despite the availability of DNA diagnostic testing, confirmation of the diagnosis may be technically difficult because VWM can result from mutations in any of the five genes coding for subunits of eIF2B and because there is a high frequency of private and low-frequency mutations in the cases described to date.

There is, as yet, no specific treatment for VWM. Avoidance of the precipitating factors is obviously advisable, but difficult to accomplish in practice, given the propensity of children to bump their heads and catch colds. A small molecule (integrated stress response inhibitor [ISRIB]) that specifically activates eIF2b has shown promise in cellular models of this disease, although this has not yet been reproduced in whole animal models. In contrast, transplantation of murine glial progenitor cells has shown promise in mouse models of VWM.

Diffuse Sclerosis

Schilder described new syndromes of diffuse demyelination of the brain in 1912, 1913, and 1924. Later advances identified the 1913 description as one of ALD, and the 1924 patient had subacute sclerosing panencephalitis. Nevertheless, the 1912 case delineated a clinical and pathologic syndrome that is still seen, even though cases of uncomplicated diffuse sclerosis are so few that each encounter results in a case report. In 1994, a review counted 12 cases since 1912; a subsequent review added 16 more between 1998 and 2008.

Schilder disease was and is regarded as a variant of multiple sclerosis, but the etiology and pathogenesis are not known.

At autopsy, there are large areas of demyelination in the centrum ovale, with relative preservation of axons. Subcortical U-fibers are often spared. In acute lesions, there is perivascular infiltration by $CD45^+$ lymphocytes and giant cells; there may be necrosis. The lesions are similar to those of multiple sclerosis. In fact, in most cases that include large areas of demyelination, there are also smaller, more typical lesions of multiple sclerosis. For these cases, the term *transitional sclerosis* has been used. It is assumed that the small lesions coalesce to form the large ones. The demyelinating lesions contain $CD68^+$ macrophages and GFAP-positive astrocytes with long processes.

The clinical syndrome is a leukoencephalopathy, with progressive dementia, psychosis, corticospinal signs, and loss of vision caused by either optic neuritis with papilledema or cerebral blindness. Brainstem signs may include nystagmus and internuclear ophthalmoplegia. The disease is relentlessly progressive, with average survival of about 6 years but sometimes as long as 45 years.

Diagnosis depends on imaging; MRI shows gadolinium enhancement of large white matter lesions. There may be CSF pleocytosis with evidence of intrathecal synthesis of gamma globulin and oligoclonal bands. Brain biopsy may be needed to identify the few cases that simulate mass lesions. A retrospective analysis of the CSF profile of all patients reported in the literature between 1960 and 2018 found a substantial lack of oligoclonal bands, as well as a lack of EBV serum antibodies, and the so called measles/rubella/zoster reaction. The authors concluded that diffuse sclerosis is immunologically distinct from multiple sclerosis and that the features are more similar to those reported in patients with myelin oligodendrocyte glycoprotein-positive encephalitis, neuromyelitis optica spectrum disorders, or Baló concentric sclerosis.

Steroid therapy was followed by complete resolution of lesions or only minor sequelae in 10 of 16 cases reported in the decade up to 2008; 9 cases subsequently recurred. Intravenous immunoglobulin has been used successfully; surgical resection is occasionally required to manage herniation complicating a large lesion. Recurrent disease following steroid therapy has been reported in one affected teenager.

Disorders of Carbohydrate Metabolism

Glycogen Storage Diseases

Abnormal metabolism of glycogen and glucose may occur in a series of genetically determined disorders, each representing a specific enzyme deficiency (Table 139.5). The signs and symptoms of each disease are largely determined by the tissues in which the enzyme defect is expressed. Virtually all enzymes of glycogen metabolism, including tissue-specific isoforms or subunits, have been assigned to chromosomal loci, and the corresponding genes have been cloned and sequenced. Numerous mutations have been identified and genotype: Phenotype correlation is taking shape.

Severe fasting hypoglycemia may result in periodic episodes of lethargy, coma, convulsions, and anoxic brain damage in glucose-6-phosphatase deficiency (glycogenosis type I) or in glycogen synthetase deficiency. The liver is enlarged in both diseases. Clinical manifestations tend to become milder in patients who survive the first few years of life.

The CNS is directly affected by the enzyme defect in generalized glycogen storage diseases, even though neurologic symptoms are lacking in some disorders, and in others, it may be ascribed to liver rather than to brain dysfunction. The following enzyme defects seem to be generalized: acid maltase (type II), debrancher (type III), brancher (type IV), and phosphoglycerate kinase (type IX).

Acid alpha glucosidase (acid maltase; acid α-1,4 and α-1,6 glucosidase) deficiency is a lysosomal disorder due to mutations in the GAA gene on chromosome 17. In the infantile form of acid maltase deficiency, first described by Johannes Pompe in 1932 (Pompe disease), pathologic involvement of the CNS has been documented, with accumulation of both free and intralysosomal glycogen in all cells, especially spinal motor neurons and neurons of the brain stem nuclei. Peripheral nerve biopsy specimens show accumulation of glycogen in Schwann cells. The profound generalized weakness of infants with Pompe disease is probably due to combined effects of glycogen storage in muscle,

TABLE 139.5 Classification of Glycogen Storage Disease

Type	Affected Tissues	Clinical Presentation	Glycogen Structure	Enzyme Defect	Mode of Transmission
I	Liver and kidney	Severe hypoglycemia; hepatomegaly	Normal	Glucose-6-phosphatase	AR
II	—	—	—	—	—
Infancy	Generalized	Cardiomegaly; weakness; hypotonia; death <1 y	Normal	—	AR
Childhood	Generalized	Myopathy simulating Duchenne dystrophy; respiratory insufficiency	Normal	Acid maltase	AR
Adult	Generalized	Myopathy simulating limb-girdle dystrophy or polymyositis; respiratory insufficiency	Normal	—	AR
III	Generalized	Hepatomegaly; fasting hypoglycemia; progressive weakness	PLD	Debrancher	AR
IV	Generalized	Hepatosplenomegaly; cirrhosis of liver; neuromuscular disease; APBD	Polyglucosan	Brancher	AR
V	Skeletal muscle	Intolerance to intense exercise; cramps; myoglobinuria	Normal	Muscle phosphorylase	AR
VI	Liver; RBC	Mild hypoglycemia; hepatomegaly	Normal	Liver phosphorylase	AR
VII	Skeletal muscle; RBC	Intolerance to intense exercise; cramps; myoglobinuria	Normal (± polyglucosan)	PFK-M	AR
VIII	Liver	Asymptomatic hepatomegaly	Normal	Phosphorylase kinase	XR
	Liver and skeletal muscle	Hepatomegaly; growth retardation; hypotonia	Normal	Phosphorylase kinase	AR
	Skeletal muscle	Exercise intolerance; myoglobinuria	Normal	Phosphorylase kinase	XR; AR (?)
	Heart	Fatal infantile cardiomyopathy	Normal	Phosphorylase kinase	AR
IX	Generalized	Hemolytic anemia; seizures; mental retardation	Normal (?)	PKG	XR
		Intolerance to intense exercise; myoglobinuria			
X	Skeletal muscle	Intolerance to intense exercise; myoglobinuria	Normal (?)	PGAM-M	AR
XI	Skeletal muscle	Intolerance to intense exercise; myoglobinuria	Normal (?)	LDH-M	AR
XII	Skeletal muscle; RBC	Exercise intolerance	Normal (?)	Aldolase A	AR
XIII	Skeletal muscle	Exercise intolerance	Normal (?)	β-Enolase	AR
	Generalized	Myoclonus epilepsy (Lafora disease)	Polyglucosan	Laforin	AR
XIV	Generalized	Hepatopathy, myopathy, cardiomyopathy, malignant hyperthermia, bifid uvula	Normal	PGM1	AR
XV	Skeletal muscle, heart	Myopathy, cardiac arrhythmias	Glycogen depletion	GYG1	AR
0	Muscle	Cardiomyopathy; exercise intolerance	Glycogen deficiency	Glycogen synthetase	AR

Abbreviations: ?, not yet definitively documented; APBD, adult polyglucosan body disease; AR, autosomal recessive; GYG1, glycogenin 1; LDH-M, muscle lactate dehydrogenase; PFK-M, muscle phosphofructokinase; PGAM-M, muscle phosphoglycerate mutase; PGM1, phosphoglucomutase 1; PKG, phosphoglycerate kinase; PLD, phosphorylase-limit dextrin; RBC, red blood cell; XR, X-linked recessive.

anterior horn cells, and peripheral nerves. In four patients with the childhood form of acid maltase deficiency, increased glycogen deposition in neurons of the brain stem was related to fatal intractable hyperpyrexia. No morphologic changes were seen in the CNS of a patient with adult-onset acid maltase deficiency despite marked decrease of enzyme activity. However, the enzyme defect predisposes to dilated arteriopathy and cerebral aneurysm formation, sometimes leading to stroke. ERT is now standard of care for Pompe disease and has been shown to diminish the number of infants requiring ventilator support and generally extend lifespan, without completely reversing the manifestations of the disease. The incomplete response to ERT is attributed to its inability to correct the impaired autophagy, which is characteristic of this disorder. Owing to these shortcomings, additional approaches to treatment, including the use of antisense oligonucleotides to modify splice sites, stop codon readthrough therapy, enzyme enhancement/chaperone therapy, and gene transfer therapy, are under active study in Pompe disease.

Patients with **debrancher deficiency** (glycogenosis type III, due to mutations in the AGL gene on chromosome 1, have hepatomegaly, fasting hypoglycemia, and seizures in infancy and childhood, which usually remit around puberty. Muscle biopsy shows a vacuolar myopathy, with evidence of impaired autophagy. Although overt signs of peripheral neuropathy are rare, abnormal deposits of glycogen have been documented both in axons and in Schwann cells and may explain, in part at least, the distal wasting and mixed EMG pattern observed in adult patients with neuromuscular involvement. Historically, type III glycogen storage disease patients have been treated with cornstarch, which provides a continuous source of glucose to prevent

hypoglycemia, and minimize ketosis, which may have detrimental effects in growing children. Case reports have suggested benefit from a modified ketogenic diet in adults, for whom ketosis poses fewer problems than in children.

In **branching enzyme deficiency** (glycogenosis type IV, due to mutations in the GBE1 gene on chromosome 3), the clinical picture is typically dominated by liver disease, with progressive cirrhosis and chronic hepatic failure causing death in childhood. However, the neuromuscular system is involved more often than it was previously realized, with fetal, congenital, juvenile, or adult presentations. The severe congenital myopathy, sometime associated with cardiomyopathy, may simulate spinal muscular atrophy type I (Werdnig-Hoffmann disease). Deposits of a basophilic, intensely PAS-positive material that is partially resistant to β-amylase digestion (polyglucosan) have been found in all tissues; in the CNS, spheroids composed of branched filaments were present in astrocytic processes, particularly in the spinal cord and medulla. Ultrastructurally, the storage material was composed of aggregates of branched osmiophilic filaments, 6 nm in diameter often surrounded by normal glycogen particles.

In **phosphoglycerate kinase deficiency** (glycogenosis type IX, due to mutations in the PGK1 on the X chromosome), the type and severity of clinical manifestations vary in different genetic variants of the disease and are probably related to the severity of the enzyme defect in different tissues. In several families, the clinical picture was characterized by the association of severe hemolytic anemia with intellectual disability and seizures.

Lafora Disease and Other Polyglucosan Storage Diseases

Several diseases are associated with the accumulation of an unusual form of glycogen referred to as *polyglucosan*. Polyglucosan differs from glycogen in having very long strands (which confer insolubility), fewer branching points, and similarities to the plant carbohydrate, amylopectin.

The most prominent of these disorders include Lafora disease and adult polyglucosan body disease (APBD), but polyglucosan storage also occurs in glycogen storage diseases types 4, 7, and 15; polyglucosan body myopathies types I and II; and hypertrophic cardiomyopathy type 6.

Myoclonus epilepsy with Lafora bodies (Lafora disease) is an autosomal recessive disease that is characterized by the triad of epilepsy, myoclonus, and dementia. Inconstant other neurologic manifestations include ataxia, dysarthria, spasticity, and rigidity. Classically, onset is in adolescence, and the course progresses rapidly to death, which occurs between 17 and 24 years in 90% of patients. Negative criteria or manifestations that imply some other disease include onset before 6 or after age 20 years, optic atrophy, macular degeneration, prolonged course, or normal intelligence. Epilepsy, with predominantly occipital seizures, is the first manifestation in most patients; status epilepticus is common in terminal stages. Myoclonus usually appears 2 or 3 years after the onset of epilepsy, may affect any area of the body, is sensitive to startle, and is absent during sleep. Intellectual deterioration generally follows the appearance of seizures by 2 or 3 years and progresses rapidly to severe dementia. Therapy is symptomatic and is designed to suppress seizures and reduce the severity of myoclonus; some control of myoclonus is achieved with benzodiazepines.

Laboratory findings are normal except for EEG changes; bilaterally synchronous spike-wave discharges of are commonly seen in association with myoclonic jerks. The EEG abnormalities may be found in asymptomatic relatives. The pathologic hallmark of the disease is the presence in the CNS of the bodies first described by Lafora in 1911: round, basophilic, strongly PAS-positive intracellular inclusions that vary in size from dust-like bodies less than 3 nm in diameter to large bodies up to 30 nm in diameter. The medium and large bodies often show a dense core and a lighter periphery. Lafora bodies are seen only in neuronal perikarya and processes and are most numerous in cerebral cortex, substantia nigra, thalamus, globus pallidus, and dentate nucleus.

Ultrastructurally, Lafora bodies are not membrane bound. They consist of two components in various proportions: amorphous, electron-dense granules and irregular filaments. The filaments, which are about 6 nm in diameter, are often branched and frequently continuous with the granular material.

Irregular accumulations of a material similar to that of the Lafora bodies is found in liver, heart, skeletal muscle, skin, and retina, suggesting that Lafora disease is a generalized storage disease. Both histochemical and biochemical criteria indicate that the storage material is a branched polysaccharide composed of glucose (polyglucosan) similar to the amylopectin-like polysaccharide that accumulates in branching enzyme deficiency. The activity of branching enzyme, however, is normal in several tissues, including brain, of patients with Lafora disease. About half of the cases of Lafora disease are due to mutations in the EPM2A gene, which encodes laforin, a member of the dual-specificity protein phosphatase family that additionally contains a glycogen-binding domain. Lafora disease is genetically heterogeneous, and pathogenic mutations have been identified in a second gene, EPM2B, which encodes an E3 ubiquitin ligase called *malin*. Laforin and malin act cooperatively to mediate polyglucosan degradation; the laforin-malin complex also protects against endoplasmic reticulum stress-induced apoptosis. The third gene associated with Lafora body disease is PRDM8, recognized in 2012. This gene encodes PR domain containing protein 8 and is associated with early-onset Lafora disease. The PRDM8 moves laforin and malin to the nucleus; gain-of-function mutations in the gene lead to excessive sequestration of these proteins in the nucleus, and thus, loss of their function in the cytosol.

Metformin showed a neuroprotective effect in a murine model of Lafora disease. A small study in humans identified a few responders, but the role of metformin in human Lafora disease remains unproven.

A clinically distinct form of polyglucosan body disease (APBD) occurs in patients with a complex but stereotyped chronic neurologic disorder characterized by progressive upper and lower motor neuron involvement, sensory loss, sphincter problems, neurogenic bladder, and, in about half of the cases, dementia; there is no myoclonus or epilepsy. Onset is in the fifth or sixth decade of life, and the course ranges from 3 to 20 years. Electrophysiologic studies show axonal neuropathy. In some cases, the clinical picture simulates amyotrophic lateral sclerosis. Throughout the CNS, polyglucosan bodies are present in processes of neurons and astrocytes but not in perikarya. There are also polyglucosan accumulations in peripheral nerve and in other tissues, including liver, heart, and skeletal and smooth muscle. As in debranching enzyme deficiency and Lafora disease, the abnormal polysaccharide in APBD seems to have longer peripheral chains than normal glycogen. Branching enzyme activity was significantly decreased in leukocytes from Israeli patients, and this finding was confirmed in both leukocytes and peripheral nerve specimens from American Ashkenazi Jewish patients. Mutations in the gene encoding the branching enzyme (GBE1) have been found in both Ashkenazi Jewish families with APBD and in non-Jewish patients, confirming that

APBD is a clinical variant of branching deficiency. The observation that APBD is often associated with "mild" GBE1 mutations or even heterozygous mutations may explain the late onset of symptoms. There is no established disease modifying therapy for APBD; a clinical trial of triheptanoin in APBD found no clear evidence of benefit, although the agent was well tolerated.

Another form of polyglucosan is in corpora amylacea, first described by Purkinje in 1837, which accumulate progressively and nonspecifically with age. They are more commonly seen within astrocytic processes in the hippocampus and in subpial and subependymal regions; however, they also occur in intramuscular nerves in patients older than 40 years. The term *Bielschowsky bodies* refers to polyglucosan bodies found in the perikarya of neurons in the globus pallidus of asphyxiated infants with dystonia.

Peroxisomal Diseases: Adrenoleukodystrophy, Zellweger Syndrome, and Refsum Disease

Peroxisomes are ubiquitous cellular organelles that participate in a variety of essential biochemical functions. Peroxisomes are enclosed by a single membrane and contain no DNA, implying that all peroxisomal-associated proteins are encoded by nuclear genes. A complex shuttle system transports peroxisomal enzymes and structural proteins from the cytosolic polyribosomes (where they are made) to the peroxisome. This system involves at least two recognition sequences (peroxisomal targeting sequences) that are embedded in the protein products themselves, and several receptors or transporters; the system is ATP dependent. Peroxisomes participate in both anabolic and catabolic cellular functions, especially in the metabolism of lipids. For example, peroxisomes contain a complete series of enzymes for the β-oxidation of fatty acids. These enzymes are distinct from the mitochondrial enzymes of β-oxidation in both genetic coding and substrate specificity. Because mitochondrial enzymes of β-oxidation cannot metabolize carbon chain lengths greater than 24, the peroxisomal system is required for the degradation of endogenous and exogenous very long-chain fatty acids (VLCFA). The peroxisome is also the site of the initial and rate-limiting steps of the synthesis of plasmalogens, ether-linked lipids that constitute the major portion of the myelin sheath. Other key functions include cholesterol and bile acid biosynthesis, degradation of pipecolic and phytanic acids, and transamination of glyoxylate.

Human diseases caused by disruption of peroxisome function are divided into two broad categories (Table 139.6). The first category is characterized by abnormalities in more than one metabolic pathway, often accompanied by morphologic changes of the peroxisome. The prototype of this class is the Zellweger syndrome, discussed in the following paragraphs. Milder phenotypes in the Zellweger spectrum include neonatal ALD, infantile Refsum disease, and hyperpipecolic acidemia. A second phenotype, distinct from the Zellweger spectrum and termed *rhizomelic chondrodysplasia punctata* (RCDP), is associated with severe growth failure, profound developmental delay, cataracts, rhizomelia (disproportionate length of proximal limbs, such as short limbs of achondroplasia), epiphyseal calcifications, and ichthyosis. Patients with RCDP have decreased plasmalogen levels and elevated phytanic acid, but unlike the Zellweger spectrum, the β-oxidation pathway and VLCFA levels are normal. In recognition of the similar cellular pathophysiology in these phenotypes, *peroxisome biogenesis disorder* (PBD) is now the preferred term for all Zellweger spectrum and RCDP conditions.

TABLE 139.6 Human Genetic Diseases Due to Peroxisomal Dysfunction

Peroxisomal Biogenesis Disorders	Single Peroxisomal Enzyme Disorders
Zellweger syndrome	X-linked adrenoleukodystrophy
Neonatal adrenoleukodystrophy	Oxidase deficiency (pseudoneonatal adrenoleukodystrophy)
Infantile Refsum disease	Bifunctional enzyme deficiency
Hyperpipecolic acidemia	Thiolase deficiency (pseudo-Zellweger)
Rhizomelic chondrodysplasia punctate	DHAP acyl transferase deficiency
	Alky1 DHAP synthase deficiency
	Glutaric aciduria type III (one case only)
	Refsum disease
	Hyperoxaluria type 1
	Acatalasia

Abbreviation: DHAP, dihydroxyacetone phosphate.

The second class of human peroxisomal diseases shows the genetic and biochemical features of single enzyme defects. In addition to X-linked ALD and Refsum disease, discussed later in this chapter, this category includes defects in the β-oxidation pathway of VLCFA, which cause a Zellweger-like phenotype, and defects in plasmalogen synthesis, which result in an RCDP-like phenotype.

Zellweger Spectrum Disorder

Zellweger spectrum disorder has replaced the term *Zellweger syndrome* (cerebrohepatorenal syndrome) and describes a family of disorders, all of which have mutations in a PEX gene. These are autosomal recessive disorders with no ethnic or racial predilection. The PEX genes (pexins) encode gene products that are required for normal peroxisome assembly. Affected newborns are strikingly floppy and inactive and lack neonatal reflexes. The characteristic facies includes a high narrow forehead, round cheeks, flat root of the nose, wide-set eyes with shallow orbits, puffy eyelids, pursed lips, narrow high-arched palate, and small chin. The head circumference is normal, but the fontanels and sutures are wide open. Eye findings include pigmentary retinopathy, retinal arteriolar attenuation, and optic atrophy. The pinnas may be abnormal and posteriorly rotated. Affected infants suck and swallow poorly and often require tube feeding. Some have congenital heart disease, notably patent ductus arteriosus or septal defects. The liver is cirrhotic and either enlarged or shrunken; some children are jaundiced, and some develop splenomegaly and a bleeding diathesis. Cystic dysplasia of the kidneys may be palpable and may cause mild renal failure. Genital anomalies include an enlarged clitoris, hypospadias, and cryptorchidism. Minor skeletal anomalies include contractures of large and small joints, polydactyly, low-set rotated thumbs, and clubfeet; there are also stippled calcifications of the patella and epiphyseal cartilage. The children are apathetic, poorly responsive to environmental stimuli, and limp. Tendon reflexes are absent or hypoactive. Many children have seizures and fail to thrive or develop; most succumb within the first few months of life.

Typical but nonspecific laboratory findings include elevated bilirubin levels, abnormal liver enzymes, elevated serum iron, saturated iron-binding capacity, and transferrin. The CSF protein content may be elevated. The EEG is abnormal, and MRI shows poor myelination, brain atrophy, pachygyria, polymicrogyria, and

neuronal heterotopias. Diffusion-weighted and tensor-diffusion MRIs identify regions of injury in patients with PBD that are not apparent with conventional MRI.

The hallmark of Zellweger spectrum disorders is dysfunction in multiple enzymatic pathways, including the following:

1. Levels of VLCFA—those with 24 or more carbons—are increased in plasma, fibroblasts, and chorionic villus.
2. In plasma and urine, increased content of intermediates of bile acid metabolism includes trihydroxycholestanoic acid and dihydroxycholestanoic acid.
3. Levels of pipecolic and phytanic acids increase.
4. Plasmalogen levels decrease.

Pathologically, the absence of functional peroxisomes in hepatocytes is a pathognomonic feature of Zellweger spectrum disorders and one that helps distinguish it from other PBDs and from single enzyme disorders such as pseudo-Zellweger disease. Membrane proteins may assemble with membrane lipids to form rudimentary "ghosts" of peroxisomes that seem unable to import enzymes. Secondary abnormalities are also seen in mitochondria that show an abnormally dense matrix and distorted cristae.

Therapy for Zellweger spectrum disorders is primarily supportive and limited because of the multisystem impairment already present at birth. Reliable prenatal diagnosis is available by mutation analysis when the genotype has been established in the proband. Living-donor hepatic transplantation has been reported in three patients before the onset of severe complications. One subject succumbed to complications of the procedure, but the other two have shown evidence of clinical and biochemical improvement at 9 months and 17 years follow-up, respectively.

Adrenoleukodystrophy

ALD is an X-linked recessive disorder with variable expressivity; it is well defined genetically, clinically, and pathologically. The ALD gene encodes a member of the ATP-binding cassette transporter class of proteins (ABCD1). The most common phenotype is the childhood cerebral form. Affected boys have normal early development. Behavioral change is the most common initial feature, with abnormal withdrawal, aggression, poor memory, or difficulties in school, ultimately evolving into progressive dementia. Visual loss with optic atrophy reflects demyelination along the entire visual pathway. The outer retina is notably spared. Progressive gait disturbance with pyramidal tract signs is an important feature. Dysphagia and deafness may occur. Seizures are common late in the disease, but are occasionally the first manifestation. Some patients have overt signs of adrenal failure, including fatigue, vomiting, salt craving, and hyperpigmentation that is most prominent in skinfolds. The course is relentlessly progressive. Patients enter a vegetative state and die from adrenal crisis or other causes 1 to 10 years after onset.

Several other clinical phenotypes have been described. Adrenomyeloneuropathy (AMN) is the most common of the variant phenotypes. Typical features are spastic paraparesis, peripheral neuropathy, and adrenal insufficiency, beginning in the second decade. Hypogonadism, impotence, and sphincter disturbance are also seen. Cerebellar dysfunction and dementia have been reported. A similar syndrome is found in about 15% of women who are heterozygous for mutation at the ALD gene. The MRI frequently reveals cortical demyelinating lesions in AMN patients, even in those without signs or symptoms of cortical involvement. Pathologic findings in AMN include demyelination and dying-back changes in the cord, and lamellar cytoplasmic inclusions in brain, adrenal gland, and testis; the findings are similar to those of ALD.

An adolescent cerebral form of ALD is similar to the childhood form but for its onset. In adults, X-linked ALD may present as dementia, schizophrenia, or focal cerebral syndromes such as aphasia, Klüver-Bucy syndrome, or hemianopia; adrenal insufficiency is usually present. Adult ALD includes spastic paraparesis, frontal lobe syndromes, cerebellar dysfunction, or olivopontocerebellar atrophy. Female heterozygotes may be symptomatic with adult ALD. Adrenal insufficiency can be seen without neurologic disorder; ALD should be considered in any boy with unexplained Addison disease. Finally, children and adults with the biochemical defect may be asymptomatic or presymptomatic. Phenotypic heterogeneity is the rule within families with multiple affected individuals; the disparate manifestations are probably the result of modifying genetic loci or environmental factors.

Laboratory evaluation of the patient with ALD reveals elevated CSF protein and posteriorly predominant white matter signal hyperintensity with marginal enhancement. Occasionally, the onset is frontal or cerebellar. The corticotropin stimulation test usually shows adrenal insufficiency, even in the absence of clinical signs. Characteristic inclusions, accumulations of lamellar lipid profiles, may be seen in the brain, adrenal glands, sural nerve biopsy, or testis. The primary finding in the brain is extensive diffuse demyelination, sparing U-fibers in the centrum semiovale and elsewhere. In involved areas of white matter, perivascular infiltration of lymphocytes and plasma cells is prominent.

Diagnosis is suggested by the characteristic clinical findings of neurologic deterioration, demonstration of adrenal hypofunction, and MRI abnormalities. The demonstration of elevated VLCFA levels in plasma and cultured skin fibroblasts without disruption of other peroxisomal functions should be followed by ABCD1 mutation analysis.

Several approaches have been taken to treat ALD. Ideally, cases would be detected at birth, which would allow immediate treatment and genetic counseling for parents. A method for newborn screening is under investigation.

Steroid replacement therapy is given during stressful periods, such as intercurrent illness, or if there is evidence of adrenal insufficiency. Dietary avoidance of VLCFA alone does not lead to biochemical change because of endogenous synthesis. Efforts to lower endogenous synthesis using glycerol trierucate oil and glycerol trioleate oil (Lorenzo oil), in conjunction with dietary restriction, do produce a fall in VLCFA levels, in both affected individuals and female carriers. Unfortunately, this striking biochemical change does not have an equally striking clinical correlate; its use is most likely limited to presymptomatic boys.

Hematopoietic stem cell transplantation has shown benefit in early-stage ALD, in a number of studies since the initial report in 1990, but is accompanied by significant risk, and lesions will typically progress for 12 to 18 months following the procedure until arresting. This delay in response likely reflects gradual replacement of host glial cells by their transplanted counterparts. Several trials of ex vivo gene therapy using lentiviral vectors have shown promising results, which are at least comparable, if not superior, to hematopoietic stem cell transplantation.

Refsum Disease

This autosomal recessive disease (also known as *heredopathia atactica polyneuritiformis*) is unique among the lipidoses because

the stored lipid (phytanic acid) is not synthesized in the body but is exclusively dietary in origin. This has enabled successful therapy by dietary management. Symptoms begin in early childhood in some patients, but may be delayed until the fifth decade in others. Progressive night blindness usually appears in the first or second decade, followed by limb weakness and gait ataxia. Symptoms are progressive, but abrupt exacerbations and gradual remissions may occur with intercurrent illness or pregnancy. There are no seizures, but some patients have psychiatric symptoms. Peripheral neuropathy is manifest by loss of tendon reflexes, weakness and wasting, and distal sensory loss. Ataxia may be seen. A granular pigmentary retinopathy is universally present. Other findings include ichthyosis, nerve deafness (often severe), cataracts, miosis and pupillary asymmetry, pes cavus, and bone deformities with shortening of the metatarsal bones, epiphyseal dysplasia, and, in some, kyphoscoliosis. The CSF protein content is elevated. Nerve conduction velocities are slowed. The ECG changes include conduction abnormalities. Peripheral nerves may feel thickened and, on histologic study, may show hypertrophic interstitial changes and onion-bulb formation. The course is generally progressive with exacerbations and remissions. Peripheral visual fields may ultimately be lost, with resulting telescopic vision. Sudden death may result from cardiac arrhythmia.

The biochemical defect in Refsum disease has been identified as phytanoyl-CoA hydroxylase deficiency; the responsible gene in most cases is PAHX. Several kindreds with typical Refsum disease have lacked PAHX mutations or linkage to chromosome 10; they proved to be heterozygous for mutations in PEX7. The PEX7 gene encodes the receptor for the type 2 peroxisomal targeting signal, whose normal function is essential for phytanoyl-CoA hydroxylase import to peroxisomes. Diagnosis is made by the characteristic clinical picture and elevation of phytanic acid levels in the plasma. Studies in rat brain suggest that phytanic acid exerts direct neurotoxic effects by binding to the inner mitochondrial membrane, impairing mitochondrial ATP supply and membrane permeability.

Therapy limits dietary phytanic acid and its precursor, phytol, a branched-chain fatty alcohol, which is abundantly present in nature as part of the chlorophyll molecule. When dairy products, ruminant fat, and chlorophyll-containing foods are eliminated, plasma phytanic acid levels are reduced and tissue stores are mobilized, with improvement of symptoms. Paradoxically, symptoms may worsen and plasma phytanic acid levels may rise shortly after institution of dietary therapy, especially if patients reduce caloric intake and lose weight. Increased plasma phytanic acid causes anorexia, increased weight loss, and still more severe symptoms. Adequate caloric intake helps prevent weight loss and abrupt fat mobilization. Plasmapheresis helps to prevent or treat exacerbations. Induction of phytanic acid ω-oxidation might be helpful. Cochlear implantation has been successful in a few patients with Refsum disease. Cataract surgery improves visual outcomes in patients with Refsum disease, and other disorders in which both cataracts and retinal dystrophy occur, but is associated with an increased risk of complications. Liver transplantation has led to biochemical improvement, but no clinical benefit, and is not currently recommended.

Another rare peroxisomal phenotype can be confused with Refsum disease. Patients with α-methylacyl-CoA racemase deficiency may have retinopathy and peripheral neuropathy plus a variety of cerebral findings, including seizures, progressive cognitive decline, and relapsing encephalopathy.

SUGGESTED READINGS

Glucose Transporter Type 1 Deficiency Syndrome

Cappuccio G, Pinelli M, Alagia M, et al. Biochemical phenotyping unravels novel metabolic abnormalities and potential biomarkers associated with treatment of GLUT1 deficiency with ketogenic diet. *PLoS One*. 2017;12(9):e0184022.

Daci A, Bozalija A, Jashari F, Krasniqi S. Individualizing treatment approaches for epileptic patients with glucose transporter type 1 (GLUT-1) deficiency. *Int J Mol Sci*. 2018;19(1):122.

De Vivo DC, Trifiletti RR, Jacobson RI, Ronen GM, Behmand RA, Harik SI. Defective glucose transport across the blood–brain barrier as a cause of persistent hypoglycorrhachia, seizures, and developmental delay. *N Engl J Med*. 1991;325(10):703-709.

Pascual JM, Liu P, Mao D, et al. Triheptanoin for glucose transporter type I deficiency (G1D): modulation of human ictogenesis, cerebral metabolic rate, and cognitive indices by a food supplement. *JAMA Neurol*. 2014;71(10):1255-1265.

Pascual JM, Ronen GM. Glucose transporter type I deficiency (G1D) at 25 (1990-2015): presumptions, facts, and the lives of persons with this rare disease. *Pediatr Neurol*. 2015;53(5):379-393.

Hyperammonemia

Bennett EE, Hummel K, Smith AG, Longo N. Acute presentation and management of the encephalopathic child with an undiagnosed inborn error of metabolism. *J Emerg Med*. 2019;56(1):e5-e8.

Chandra SR, Christopher R, Ramanujam CN, Harikrishna GV. Hyperargininemia experiences over last 7 years from a tertiary care center. *J Pediatr Neurosci*. 2019;14(1):2-6.

Sirrs S, Hannah-Shmouni F, Nantel S, Neuberger J, Yoshida EM. Transplantation as disease modifying therapy in adults with inherited metabolic disorders. *J Inherit Metab Dis*. 2018;41(5):885-896.

Tchan M. Hyperammonemia and lactic acidosis in adults: differential diagnoses with a focus on inborn errors of metabolism. *Rev Endocr Metab Disord*. 2018;19(1):69-79.

Disorders of Amino Acid Metabolism and Organic Acidurias

Blackburn PR, Gass JM, Vairo FPE, et al. Maple syrup urine disease: mechanisms and management. *Appl Clin Genet*. 2017;10:57-66.

Bouchereau J, Leduc-Leballeur J, Pichard S, et al. Neurocognitive profiles in MSUD school-age patients. *J Inherit Metab Dis*. 2017;40(3):377-383.

Gelfand AA, Gallagher RC. Cyclic vomiting syndrome versus inborn errors of metabolism: a review with clinical recommendations. *Headache*. 2016;56(1):215-221.

Schillaci LP, DeBrosse SD, McCandless SE. Inborn errors of metabolism with acidosis: organic acidemias and defects of pyruvate and ketone body metabolism. *Pediatr Clin North Am*. 2018;65(2):209-230.

Yang H, Zhao C, Wang Y, Wang SP, Mitchell GA. Hereditary diseases of coenzyme A thioester metabolism. *Biochem Soc Trans*. 2019;47(1):149-155.

Purine and Pyrimidine Disorders

Kaur P, Neethukrishna K, Kumble A, Girisha KM, Shukla A. Identification of a novel homozygous variant confirms ITPA as a developmental and epileptic encephalopathy gene. *Am J Med Genet A*. 2019;179(5):857-861.

Nyhan WL, O'Neill JP, Jinnah HA, et al. Lesch-Nyhan syndrome. In: Adam MP, Ardinger HH, Pagon RA, et al, eds. *GeneReviews*. Seattle, WA: University of Washington, Seattle; 1993-2019. https://www.ncbi.nlm.nih.gov/books/NBK1149/.

Schretlen DJ, Varvaris M, Vannorsdall TD, Gordon B, Harris JC, Jinnah HA. Brain white matter volume abnormalities in Lesch-Nyhan disease and its variants. *Neurology*. 2015;84(2):190-196.

Sklirou E, Lichter-Konecki U. Inborn errors of metabolism with cognitive impairment: metabolism defects of phenylalanine, homocysteine and methionine, purine and pyrimidine, and creatine. *Pediatr Clin North Am*. 2018;65(2):267-277.

Tewari N, Mathur VP, Sardana D, Bansal K. Lesch-Nyhan syndrome: the saga of metabolic abnormalities and self-injurious behavior. *Intractable Rare Dis Res*. 2017;6(1):65-68.

Wevers RA, Christensen M, Engelke UFH, et al. Functional disruption of pyrimidine nucleoside transporter CNT1 results in a novel inborn error of metabolism with high excretion of uridine and cytidine. *J Inherit Metab Dis*. 2019;42(3):494-500.

Porphyria

Hudgins K. Porphyria: a rare, complicated, and misdiagnosed disease. *Crit Care Nurs Q*. 2019;42(2):192-197.

Suh Y, Gandhi J, Seyam O, et al. Neurological and neuropsychiatric manifestations of porphyria. *Int J Neurosci*. 2019;129(12):1226-1233.

Yarra P, Faust D, Bennett M, Rudnick S, Bonkovsky HL. Benefits of prophylactic heme therapy in severe acute intermittent porphyria. *Mol Genet Metab Rep*. 2019;19:100450.

Disorders of Metal Metabolism

Akinseye ON, Yazdani R, Tornow KA, Reeder KN, Clarke RL, Pfeifer CM. Imaging findings of Menkes disease, a radiographic mimic of abusive trauma. *Radiol Case Rep*. 2019;14(8):993-996.

Beyens A, Van Meensel K, Pottie L, et al. Defining the clinical, molecular and ultrastructural characteristics in occipital horn syndrome: two new cases and review of the literature. *Genes (Basel)*. 2019;10(7):528.

Carecchio M. Parkinsonism in neurometabolic diseases. *Int Rev Neurobiol*. 2019;149:355-376.

Cleymaet S, Nagayoshi K, Gettings E, Faden J. A review and update on the diagnosis and treatment of neuropsychiatric Wilson disease. *Expert Rev Neurother*. 2019;19(11):1117-1126.

Cochen De Cock V, Woimant F, Poujois A. Sleep disorders in Wilson's disease. *CurrNeurol Neurosci Rep*. 2019;19(11):84.

Darling A, Aguilera-Albesa S, Tello CA, et al. PLA2G6-associated neurodegeneration: new insights into brain abnormalities and disease progression. *Parkinsonism Relat Disord*. 2019;61:179-186.

Di Fonzo A, Franco G, Barone P, Erro R. Parkinsonism in diseases predominantly presenting with dystonia. *Int Rev Neurobiol*. 2019;149:307-326.

Di Meo I, Carecchio M, Tiranti V. Inborn errors of coenzyme A metabolism and neurodegeneration. *J Inherit Metab Dis*. 2019;42(1):49-56.

Di Meo I, Tiranti V. Classification and molecular pathogenesis of NBIA syndromes. *Eur J Paediatr Neurol*. 2018;22(2):272-284.

Droms RJ, Rork JF, McLean R, Martin M, Belazarian L, Wiss K. Menkes disease mimicking child abuse. *Pediatr Dermatol*. 2017;34(3):e132-e134.

Durairaj J, Shanbhag ER, Veena P, Gowda M, Keepanasseril A. Wilson's disease presenting during pregnancy: a diagnostic and therapeutic dilemma. *Obstet Med*. 2018;11(3):148-150.

Dusek P, Schneider SA, Aaseth J. Iron chelation in the treatment of neurodegenerative diseases. *J Trace Elem Med Biol*. 2016;38:81-92.

Garoufalia Z, Prodromidou A, Machairas N, et al. Liver transplantation for Wilson's disease in non-adult patients: a systematic review. *Transplant Proc*. 2019;51(2):443-445.

Levi S, Cozzi A, Santambrogio P. Iron pathophysiology in neurodegeneration with brain iron accumulation. *Adv Exp Med Biol*. 2019;1173:153-177.

Lutsenko S, Washington-Hughes C, Ralle M, Schmidt K. Copper and the brain noradrenergic system. *J Biol Inorg Chem*. 2019;24(8):1179-1188.

Marshall RD, Collins A, Escolar ML, et al. Diagnostic and clinical experience of patients with pantothenate kinase-associated neurodegeneration. *Orphanet J Rare Dis*. 2019;14(1):174.

Ogata R, Chong PF, Maeda K, et al. Long surviving classical Menkes disease treated with weekly intravenous copper therapy. *J Trace Elem Med Biol*. 2019;54:172-174.

Ryan A, Nevitt SJ, Tuohy O, Cook P. Biomarkers for diagnosis of Wilson's disease. *Cochrane Database Syst Rev*. 2019;(11):CD012267.

Sandahl TD, Laursen TL, Munk DE, Vilstrup H, Weiss KH, Ott P. The prevalence of Wilson disease: an update. *Hepatology*. 2020;71(2):722-732.

Saroli Palumbo C, Schilsky ML. Clinical practice guidelines in Wilson disease. *Ann Transl Med*. 2019;7(suppl 2):S65.

Vairo FPE, Chwal BC, Perini S, Ferreira MAP, de Freitas Lopes AC, Saute JAM. A systematic review and evidence-based guideline for diagnosis and treatment of Menkes disease. *Mol Genet Metab*. 2019;126(1):6-13.

Disorders Associated With Acanthocytosis

Liu Z, Liu Y, Wan X, et al. Pallidal deep brain stimulation in patients with chorea-acanthocytosis. *Neuromodulation*. 2018;21(8):741-747.

Peikert K, Danek A, Hermann A. Current state of knowledge in chorea-acanthocytosis as core neuroacanthocytosis syndrome. *Eur J Med Genet*. 2018;61(11):699-705.

Termsarasab P, Frucht SJ. The "stutter-step": a peculiar gait feature in advanced Huntington's disease and chorea-acanthocytosis. *Mov Disord Clin Pract*. 2018;5(2):223-224.

Walker RH, Miranda M, Jung HH, Danek A. Life expectancy and mortality in chorea-acanthocytosis and McLeod syndrome. *Parkinsonism Relat Disord*. 2019;60:158-161.

Yeshaw WM, van der Zwaag M, Pinto F, et al. Human VPS13A is associated with multiple organelles and influences mitochondrial morphology and lipid droplet motility. *Elife*. 2019;8:e43561.

Lysosomal and Associated Large Molecule Disorders

Bonnot O, Gama CS, Mengel E, et al. Psychiatric and neurological symptoms in patients with Niemann-Pick disease type C (NP-C): findings from the international NPC Registry. *World J Biol Psychiatry*. 2019;20(4):310-319.

Breiden B, Sandhoff K. Lysosomal glycosphingolipid storage diseases. *Annu Rev Biochem*. 2019;88:461-485.

Colella P, Mingozzi F. Gene therapy for Pompe disease: the time is now. *Hum Gene Ther*. 2019;30(10):1245-1262.

Dunn-Pirio AM, Eckstein C. Recurrent Schilder's disease. *Mult Scler Relat Disord*. 2018;26:8-10.

Geberhiwot T, Moro A, Dardis A, et al. Consensus clinical management guidelines for Niemann-Pick disease type C. *Orphanet J Rare Dis*. 2018;13(1):50.

Hanefeld F, Holzbach U, Kruse B, Wilichowski E, Christen HJ, Frahm J. Diffuse white matter disease in three children: an encephalopathy with unique features on magnetic resonance imaging and proton magnetic resonance spectroscopy. *Neuropediatrics*. 1993;24(5):244-248.

Jarius S, Haas J, Paul F, Wildemann B. Myelinoclastic diffuse sclerosis (Schilder's disease) is immunologically distinct from multiple sclerosis: results from retrospective analysis of 92 lumbar punctures. *J Neuroinflammation*. 2019;16(1):51.

Kwon JM, Matern D, Kurtzberg J, et al. Consensus guidelines for newborn screening, diagnosis and treatment of infantile Krabbe disease. *Orphanet J Rare Dis*. 2018;13(1):30.

Marco S, Haurigot V, Bosch F. In vivo gene therapy for mucopolysaccharidosis type III (Sanfilippo syndrome): a new treatment horizon. *Hum Gene Ther*. 2019;30(10):1211-1221.

Marques ARA, Di Spiezio A, Thiessen N, et al. Enzyme replacement therapy with recombinant pro-CTSD (cathepsin D) corrects defective proteolysis and autophagy in neuronal ceroid lipofuscinosis. *Autophagy*. 2019;16(5):811-825.

Mole SE, Anderson G, Band HA, et al. Clinical challenges and future therapeutic approaches for neuronal ceroid lipofuscinosis. *Lancet Neurol*. 2019;18(1):107-116.

Page KM, Stenger EO, Connelly JA, et al. Hematopoietic stem cell transplantation to treat leukodystrophies: clinical practice guidelines from the Hunter's Hope Leukodystrophy Care Network. *Biol Blood Marrow Transplant*. 2019;25(12):e363-374.

Pant DC, Dorboz I, Schluter A, et al. Loss of the sphingolipid desaturase DEGS1 causes hypomyelinating leukodystrophy. *J Clin Invest*. 2019;129(3):1240-1256.

Patterson M. Niemann-Pick disease type C. In: Adam MP, Ardinger HH, Pagon RA, et al, eds. *GeneReviews*. Seattle, WA: University of Washington, Seattle; 1993-2019. https://www.ncbi.nlm.nih.gov/books/NBK1296/.

Pena SA, Iyengar R, Eshraghi RS, et al. Gene therapy for neurological disorders: challenges and recent advancements. *J Drug Target*. 2019;28(2):111-128.

Platt FM, d'Azzo A, Davidson BL, Neufeld EF, Tifft CJ. Lysosomal storage diseases. *Nat Rev Dis Primers*. 2018;4(1):27.

Pleasure D, Guo F, Chechneva O, et al. Pathophysiology and treatment of Canavan disease. *Neurochem Res*. 2020;45(3):561-565.

Poletti V, Biffi A. Gene-based approaches to inherited neurometabolic diseases. *Hum Gene Ther*. 2019;30(10):1222-1235.

Schiller S, Henneke M, Gärtner J. Opening new horizons in the treatment of childhood onset leukodystrophies. *Neuropediatrics*. 2019;50(4):211-218.

Schiffmann R, Moller JR, Trapp BD, et al. Childhood ataxia with diffuse central nervous system hypomyelination. *Ann Neurol*. 1994;35(3):331-340.

Selvanathan A, Ellaway C, Wilson C, Owens P, Shaw PJ, Bhattacharya K. Effectiveness of early hematopoietic stem cell transplantation in preventing neurocognitive decline in mucopolysaccharidosis type II: a case series. *JIMD Rep*. 2018;41:81-89.

Stone WL, Basit H, Master SR. Gaucher disease. In: *StatPearls*. Treasure Island, FL: StatPearls Publishing; 2020. https://www.ncbi.nlm.nih.gov/books/NBK448080/.

Thomas A, Thomas AK. POLR3-related leukodystrophy. *J Clin Imaging Sci*. 2019;9:45.

van der Knaap MS, Barth PG, Gabreels FJ, et al. A new leukoencephalopathy with vanishing white matter. *Neurology*. 1997;48(4):845-855.

Velho RV, Harms FL, Danyukova T, et al. The lysosomal storage disorders mucolipidosis type II, type III alpha/beta, and type III gamma: update on GNPTAB and GNPTG mutations. *Hum Mutat*. 2019;40(7):842-864.

Waldman AT. Leukodystrophies. *Continuum (Minneap Minn)*. 2018;24(1, Child Neurology):130-149.

Yu FPS, Amintas S, Levade T, Medin JA. Acid ceramidase deficiency: Farber disease and SMA-PME. *Orphanet J Rare Dis*. 2018;13(1):121.

Disorders of Carbohydrate Metabolism

Cenacchi G, Papa V, Costa R, et al. Update on polyglucosan storage diseases. *Virchows Arch*. 2019;475(6):671-686.

Colella P, Mingozzi F. Gene therapy for Pompe disease: the time is now. *Hum Gene Ther*. 2019;30(10):1245-1262.

Ebbink BJ, Poelman E, Aarsen FK, et al. Classic infantile Pompe patients approaching adulthood: a cohort study on consequences for the brain. *Dev Med Child Neurol*. 2018;60(6):579-586.

Francini-Pesenti F, Tresso S, Vitturi N. Modified Atkins ketogenic diet improves heart and skeletal muscle function in glycogen storage disease type III. *Acta Myol*. 2019;38(1):17-20.

Gentry MS, Guinovart JJ, Minassian BA, Roach PJ, Serratosa JM. Lafora disease offers a unique window into neuronal glycogen metabolism. *J Biol Chem*. 2018;293(19):7117-7125.

Kanungo S, Wells K, Tribett T, El-Gharbawy A. Glycogen metabolism and glycogen storage disorders. *Ann Transl Med*. 2018;6(24):474.

Kishnani PS, Koeberl DD. Liver depot gene therapy for Pompe disease. *Ann Transl Med*. 2019;7(13):288.

Kohler L, Puertollano R, Raben N. Pompe disease: from basic science to therapy. *Neurotherapeutics*. 2018;15(4):928-942.

Llavero F, Arrazola Sastre A, Luque Montoro M, et al. McArdle disease: new insights into its underlying molecular mechanisms. *Int J Mol Sci*. 2019;20(23):5919.

Martin MA, Lucia A, Arenas J, Andreu AL. Glycogen storage disease type V. In: Adam MP, Ardinger HH, Pagon RA, et al, eds. *GeneReviews*. Seattle, WA; 1993. https://www.ncbi.nlm.nih.gov/books/NBK1344/.

Peeks F, Boonstra WF, de Baere L, et al. Research priorities for liver glycogen storage disease: an international priority setting partnership with the James Lind Alliance. *J Inherit Metab Dis*. 2020;43(2):279-289.

Ross KM, Ferrecchia IA, Dahlberg KR, Dambska M, Ryan PT, Weinstein DA. Dietary management of the glycogen storage diseases: evolution of treatment and ongoing controversies. *Adv Nutr*. 2020;11(2):439-446.

Weinstein DA, Steuerwald U, De Souza CFM, Derks TGJ. Inborn errors of metabolism with hypoglycemia: glycogen storage diseases and inherited disorders of gluconeogenesis. *Pediatr Clin North Am*. 2018;65(2):247-265.

Peroxisomal Diseases: Adrenoleukodystrophy, Zellweger Syndrome, and Refsum Disease

Steinberg SJ, Raymond GV, Braverman NE, Moser AB. Zellweger spectrum disorder. In: Adam MP, Ardinger HH, Pagon RA, et al, eds. *GeneReviews*. Seattle, WA; 1993. https://www.ncbi.nlm.nih.gov/books/NBK1448/.

Turk BR, Theda C, Fatemi A, Moser AB. X-linked adrenoleukodystrophy: pathology, pathophysiology, diagnostic testing, newborn screening, and therapies [published online ahead of print November 25, 2019]. *Int J Dev Neurosci*. doi:10.1016/j.ijdevneu.2019.11.002.

Wanders RJA. Peroxisomal disorders: improved laboratory diagnosis, new defects and the complicated route to treatment. *Mol Cell Probes*. 2018;40:60-69.

Wanders RJA, Klouwer FC, Ferdinandusse S, Waterham HR, Poll-Thé BT. Clinical and laboratory diagnosis of peroxisomal disorders. *Methods Mol Biol*. 2017;1595:329-342.

Chromosomal Disorders and Disorders of DNA 140

Marc C. Patterson

KEY POINTS

1. Chromosomal disorders are associated with a substantial number of neurodevelopmental diseases; these are often, but not invariably, associated with abnormal development of other organ systems.
2. They range from addition or subtraction of entire chromosomes (aneuploidy) to copy number variations associated with microdeletions and duplications.
3. In some cases, the DNA sequence is intact, but gene expression has been silenced by abnormal methylation (imprinting).
4. Disorders of DNA maintenance, transcription, and translation are commonly associated with varying combinations of premature aging, neurodegeneration, light sensitivity, immunodeficiency, and susceptibility to malignancy.

INTRODUCTION

Rearrangements of the human genome, ranging from grossly disordered chromosome number to submicroscopic variations in copy numbers can profoundly affect development and function of the nervous system. Likewise, defects in the machinery that maintain the integrity and duplication fidelity of DNA lead to a family of rare disorders characterized by varying combinations of neurodegeneration, premature aging, light sensitivity, immunodeficiency, and susceptibility to malignancy.

CHROMOSOMAL DISORDERS

Human chromosomal anomalies are manifested as change in the total number of chromosomes, structural rearrangements, imprinting abnormalities, or variations in copy number. Examples of abnormal chromosome number (ie, aneuploidy) are sex-chromosomal aneuploidy, such as 45,X (Turner syndrome), and autosomal aneuploidy, such as 47,XX +21 (trisomy 21, Down syndrome). Structural abnormalities include regional deletions or insertions, segmental translocations (ie, reciprocal or Robertsonian) or inversions (ie, pericentric or paracentric), duplications, and ring chromosomes. There are many chromosomal syndromes, which result primarily from these numeric or segmental anomalies, producing a functional change of gene dosage; gene imprinting is also recognized as a critical modifier of expression. The most common manifestation of chromosomal anomalies is intellectual disability. Congenital malformations occur with variable frequency and differences in severity. In the sex-chromosome disorders, infertility is the most common feature. In Table **140.1**, I summarize the features of several classic chromosome disorders as examples: trisomy 21, Prader-Willi syndrome (PWS), Angelman syndrome (AS), and a common idiopathic intellectual disability syndrome caused by subtelomeric anomalies of chromosomes. A variety of mechanisms underlie these disorders. Trisomy 21 results from chromosomal nondisjunction (maternal 80%, paternal 20%), an age-related phenomenon in most cases, and unbalanced translocation in the remainder. The PWS and AS result from loss of paternally or maternally imprinted alleles in the same chromosomal

TABLE 140.1 Common Chromosomal Disorders

Genetic Abnormality/Eponym	Key Clinical Features	Diagnosis
Trisomy 21; chromosome 14/21 translocation; Down syndrome	Intellectual disability, hypotonia, atlantoaxial instability, short stature. Characteristic round facies with epicanthal folds. Early-onset dementia; congenital heart disease, increased risk of leukemia	Chromosome analysis
Prader-Willi syndrome; 15q11-13 deletion	Neonatal hypotonia and failure to thrive, followed by uncontrolled appetite with obesity (hypothalamic dysfunction); characteristic facial features, intellectual disability and behavior (obsessiveness, mood swings, skin picking)	DNA methylation analysis (loss of paternal allele at *SNRPN* locus: includes 15q11-13 deletion, uniparental disomy and imprinting defects—detects 99% of cases)
Angelman syndrome; 15q11-13 deletion	Characteristic facies, microbrachycephaly, protruding tongue, jerky limb movements (features may not be apparent until after 1 y); developmental delays and intellectual disability	DNA methylation analysis (loss of maternal allele: includes 15q11-13 deletion, uniparental disomy and imprinting defects—78% of cases); UBE3A mutation analysis (11% of cases); chromosome analysis (translocations, inversions—1% of cases); no diagnostic test findings—10% of cases
22q11 deletion syndrome (CATCH-22; DiGeorge; velocardiofacial syndrome)	Cardiac malformations, facial clefts, other cranial and brachial arch anomalies, dysmorphism, intellectual disability and psychiatric disorders (schizophrenia, OCD, ASD, and ADHD)	FISH, MLPA, chromosomal microarray (detects 95+% of cases)

Abbreviations: ADHD, attention deficit hyperactivity disorder; FISH, fluorescent in situ hybridization; MLPA, multiplex ligation-dependent probe amplification; OCD, obsessive-compulsive disorder; ASD, autism spectrum disorder.

region (15 q11-13); such loss may reflect abnormal imprinting (methylation—see in the following text), chromosomal deletion, translocation or inversion, or point mutations in a specific gene (UBE3A for AS). CATCH-22 is a deletion syndrome—the manifestations are at least in part a reflection of the amount of genetic material that is lost.

Genomic Imprinting

Genomic imprinting is an epigenetic phenomenon that permits non-Mendelian inheritance in the mammalian genome. Several autosomal genes are inherited, in a silent state, on one parental allele, and in an active state on the other parental allele. This parent-of-origin–specific gene expression is called *genomic imprinting*. The diseases that arise from these genes are mostly caused by mutation of the active allele, duplication of the nonactive allele, or imprinting errors resulting in silencing of the active allele. Over 20 imprinted genes have now been identified in the mouse genome; many of them have human homologs. For example, the *IGF-2* gene is paternally active, and only when the gene defect is inherited from the father do the offspring express the dwarfing phenotype. In PWS and AS, deletions in the PWS critical region on the paternal chromosome, or maternal uniparental disomy, result in silencing the paternally active allele and the PWS phenotype, whereas deletion of the AS critical region on the maternal chromosome, or paternal uniparental disomy, results in the silencing of the maternal allele and the AS phenotype.

The molecular mechanism of genomic imprinting is incompletely understood. The isolation of a *cis*-acting imprinting center, located upstream to the promoter region of the *SNRPN* gene, has helped us understand the molecular basis of genomic imprinting. Deletions or mutations in this imprinting center have been shown to associate with PWS or AS, depending on the origin of parental germ lines. It is postulated that the imprinting center confers a male or female imprint by use of an imprinting switch during gametogenesis. In the female germ line, the imprinting switch is needed to reset the male chromosome from the maternal grandfather, to confer the characteristics of a female chromosome. In the male germ line, the same process is needed to reset the female chromosome from the paternal grandmother to confer the characteristics of a male chromosome. This epigenetic mark is thought to be achieved by DNA methylation. In the case of PWS, the inactive allele on the maternal chromosome is hypermethylated, which suppresses gene transcription. The hypermethylated cytosine residues on the DNA sequences may repel the transcription factors needed for the activation of gene transcription. In other imprinted genes such as the insulin-like growth factor 2 (IGF-2) receptor, DNA methylation is associated with the active allele on the maternal chromosome. Therefore, other factors in addition to DNA methylation may be involved in genomic imprinting.

Autism Spectrum Disorder and Genomic Imprinting

Autism is a neurodevelopmental disorder characterized by language and social impairments and prominent repetitive, stereotypic behaviors. Interstitial duplication of maternal chromosome 15q11-13 region is one of the more common chromosomal anomalies in autism. Clinically, there are some phenotypic overlaps between autism spectrum disorders and PWS. Interestingly, among the children with PWS, those who express two maternally imprinted alleles are twice more likely to have autism spectrum disorder than those with PWS caused by deletion of paternally imprinted alleles. The identification of mutations in the methyl CpG-binding protein 2 gene as the major cause of Rett syndrome suggested that DNA methylation (and hence genomic imprinting) may play important roles in other neurodevelopment disorders.

Subtle chromosomal anomalies such as subtelomeric and submicroscopic deletion or duplication frequently give rise to neurologic phenotypes, without necessarily causing somatic manifestations. Techniques using subtelomeric probes led the way in improving cytogenetic diagnosis but have been largely supplanted by array comparative genomic hybridization (CGH) in the investigation of idiopathic intellectual disability and cancers.

Intellectual Disability Associated With Subtelomeric Chromosomal Deletion

Telomeres are the chromosome ends that contain complex DNA protein structures. The DNA sequence is a repetitive-hexanucleotide motif, TTAGGG, ranging from 2 to 15 kb in length. This repetitive sequence and its specific DNA-binding proteins form a cap structure at the chromosome ends. This cap structure enables cells to distinguish chromosome ends, prevents fusion or degradation of chromosomes, and facilitates chromosomal segregations during cellular divisions. A reverse transcriptase named telomerase recognizes this terminal repetitive-DNA sequence and works to maintain the chromosomal integrity by adding telomeric DNA onto chromosome ends, when a lagging strand is created during replication. Anomalies of these DNA protein structures change the chromosomal length. Shortening of telomeric length is seen in normal aging of somatic cells, whereas unchecked telomerase activation results in chromosomal fusion, as is often seen in cancer cells.

Intellectual disability is a common developmental disorder. The etiology of about 30% to 40% of moderate-to-severe intellectual disability (IQ < 50) remains unknown, despite extensive diagnostic testing, and these patients have a normal karyotype using routine- or high-resolution chromosomal-banding techniques.

Since the early 1990s, researchers have developed DNA probes to detect subtle subtelomeric-chromosomal anomalies in humans. At least 5% of children with idiopathic intellectual disability harbor subtelomeric-chromosomal rearrangements, detected by a set of subtelomeric probes in different fluorescent in situ hybridization studies. These rearrangements include subtelomeric deletions, duplications, or derivative chromosomes resulting in partial monosomy–trisomy states. The positive detection rate increases when screening criteria include severe intellectual disability, positive family history of intellectual disability, and at least one physical dysmorphism. In selected cases, fluorescent in situ hybridization study remains a useful tool for identifying the etiology of the disorders of patients with idiopathic intellectual disability and is often used to refine or confirm findings from chromosomal microarray studies.

Chromosomal Microarray

The general term *chromosomal microarray* refers to at least two different techniques, which detect copy number variations using microchips.

Single nucleotide polymorphism arrays rely on recognition of changes of single nucleotides, specifically those that would be

predicted to alter the amino acid sequence of the protein encoded by that stretch of DNA. In addition, they have the potential to detect uniparental disomy, which is important in a number of chromosomal disorders, including PWS and AS. Single nucleotide polymorphism arrays have been recommended as an efficient screening test in populations with intellectual disability, with a diagnostic yield greater than 10% in one study.

Array Comparative Genomic Hybridization

Chromosomal disorders arising from segmental deletion or duplication contribute to variations of copy numbers of DNA fragments. These fragments are often not visualized by current high-resolution chromosomal banding. This submicroscopic genomic copy number variation is thought to be the most common cause of idiopathic developmental delay, including intellectual disability. In CGH, the patient's DNA is hybridized to arrayed genomic DNA targets (genomic clones or oligonucleotides) on a glass slide or gene chip. The signal intensities of each hybridized genomic target are compared with those of the control standards (or the parents). Variation of copy numbers can be readily detected. This genetic diagnostic tool has led to the identification of an evergrowing family of novel microdeletion syndromes. The repetitive observation of microscopic chromosomal anomalies and their correlation with certain clinical phenotypes is likely to identify the genetic causes of many idiopathic neurodevelopmental disorders whose cause is currently unknown. Investigators have reported relatively high yields of CGH in cohorts with intellectual disability and autism, in both children and adults.

DISORDERS OF DNA MAINTENANCE, TRANSCRIPTION, AND TRANSLATION

Except for components of the respiratory chain encoded by mitochondrial DNA, the DNA of the nucleus is responsible for the production of the molecules essential to the cellular economy. Disorders that impair the maintenance of the integrity of DNA, or its timely and accurate transcription and translation, frequently lead to neurodegeneration, impaired growth, premature aging, and a propensity to develop malignancies. The brain is particularly vulnerable to these disorders because cerebral neurons are, for practical purposes, irreplaceable, and their high metabolic rate mandates high levels of oxygen consumption; both of these factors render the central nervous system (CNS) more susceptible to damage by reactive oxygen species and other metabolites than less richly endowed tissues.

This section provides an introduction to the processes involved and the rare diseases resulting from derangement of these controls. It is likely that the number of these disorders will continue to grow in parallel with the relevant basic science. Neurologists in the 21st century must have a firm grasp of the essential principles to diagnose and manage people affected by these diseases.

DNA Maintenance and Transcription

The DNA is subject to errors in its duplication during cell division and during the process of repair following exposure to a variety of mutagens (environmental, toxic, and therapeutic). The elaborate machinery includes helicases that unwind the strands of DNA in preparation for transcription into RNA,.RNA polymerase, which directs the formation of messenger RNA (mRNA) on the DNA template, and DNA polymerase, which catalyzes the duplication of DNA. The process is fine-tuned by a large family of transcription factors; investigators are constantly adding to their number. This process is highly dependent on sites of replication origin, which change during development and in the face of disease.

A complex system has evolved to correct errors in nucleic acid duplication. When single bases are incorrectly inserted into the new DNA molecules, they are removed by the process of base excision repair, mediated by specific DNA glycolyases and endonucleases and DNA polymerases and ligases. Longer segments of 25 to 32 bases are frequently damaged by exposure to ultraviolet radiation and are removed by nucleotide excision repair, which requires its own family of proteins. Breaks of double-stranded DNA activate a mechanism that requires the participation of DNA protein kinase and recombination proteins. The processes are even more complex than is implied by this brief overview because many of the involved proteins play multiple, mutually modifying roles in repair and transcription.

Precursor-mRNA (pre-mRNA) is transcribed from the genomic DNA template and includes the sequences of both expressed sequences (exons) and intervening sequences (introns). Introns are removed from pre-mRNA by RNA splicing to produce the mRNA used in translation of the message into protein. This process requires the participation of five additional RNA molecules (small nuclear RNAs) and more than 50 proteins. The small nuclear RNAs are added to multiprotein complexes known as *spliceosomes*. The steps involved in pre-mRNA processing into mRNA occur in the nucleus and conclude with export of the mRNA to the cytoplasm via the nuclear pore complex.

DNA Translation and Modification

Translation of mRNA requires intact ribosomal function, factors to control the initiation and duration of translation, and machinery to modify the nascent polypeptide chains by the addition of smaller molecules, particularly oligosaccharides. This modification amplifies the ability of the organism to respond to changing needs at different stages of development (such as differing proportions of enzyme or structural protein isoforms) or in response to external stimuli (as in the modification of T-cell receptor populations and other elements of the immune system to target invading microorganisms). The most important such processes are *N*- and *O*-linked glycosylation.

Cell Cycle Control

The activity of the systems responsible for DNA transcription, maintenance, and translation is related to the phase of the cell cycle, which is regulated by a highly conserved family of protein kinases known as *cyclin-dependent kinases*. Cyclin-dependent kinases are themselves regulated by inhibitory phosphorylation (Wee1), dephosphorylation (Cdc25), the binding of inhibitor proteins (CKIs), and through cyclical proteolysis (ubiquitin ligases and activators—SCF, APC, Cdc20, Hct1) and gene regulatory proteins (E2F, p53).

Specific Disorders

Table 140.2 summarizes selected monogenic DNA disorders. The categorization of specific disorders in one category is an arbitrary oversimplification because the gene products have multiple actions in many cases.

TABLE 140.2 Selected Disorders of DNA Synthesis, Maintenance, Transcription, and Translation

Disorder	Inheritance	Gene and Protein	Mechanism (Known or Putative)	Specific Features
DNA Maintenance and Transcription				
Cockayne syndrome type 1 (CSA) MIM 216400	AR	*CSA* ERCC8	CSA/ERCC8 interacts with p44, CSB, and TFIIH. Mutations thus lead to RNA polymerase II dysfunction and impaired nucleotide excision repair.	Intellectual disability, accelerated aging, pigmentary retinal degeneration, optic atrophy, deafness, marble epiphyses, photosensitivity, and basal ganglia/cerebellar calcification
COFS MIM 214150	AR	*CSB* ERCC6	Abnormal nucleotide excision repair resulting from disturbed RNA polymerase I–TFIIH interaction within the CSBIP/150 complex, of which CSB/ERCC6 is a component	Microcephaly, microphthalmia, cataracts, dysmorphism, failure to thrive, recurrent pneumonias, axial hypotonia, appendicular hypertonia, hyperreflexia, and progressive contractures; calcifications in the periventricular frontal white matter and basal ganglia
Progeria MIM 176670	AR	*LMNA* Lamin A	Lamins are structural components of the nuclear membrane. Mutations in *LMNA* are associated with both defective nuclear mechanics and impaired transcriptional activation.	Postnatal onset of short stature, failure to thrive and accelerated aging, loss of scalp hair, subcutaneous fat, joint stiffness and early atherosclerosis leading to strokes and myocardial infarcts, and premature death. Elevated prothrombin time, platelets, phosphorous; conductive hearing loss is also reported. Cognition is spared.
XP (de Sanctis-Cacchione syndrome—most commonly complementation group D—XPD) MIM 278730	AR	*ERCC2* ERCC2	Abnormal nucleotide excision repair: *XPD* (*ERCC2*) interacts with the p44 subunit of TFIIH stimulating 5′-3′ helicase activity. Mutations in the *XPD* prevent the interaction with p44, leading to decreased *XPD* helicase activity.	Intellectual disability, short stature, facial freckling, spasticity, hypogonadism, and olivopontocerebellar atrophy
Trichothiodystrophy (TTD 1) MIM 601675	AR	*ERCC2* ERCC2	As for XP; TFIIH also stabilizes thyroid hormone receptors in TTD mouse brain.	Intellectual disability, hair shaft abnormalities, ichthyosis, immature sexual development, short stature, and facial dysmorphism
Rett syndrome MIM 312750	X linked	*MECP2* MeCP2	Regulation of gene expression, chromatin composition, and chromosomal architecture through binding to methylated DNA. The MeCP2 is expressed ubiquitously by neurons; levels of MeCP2 expression increase during neuronal differentiation and remain at high levels in the adult brain.	Classic phenotype restricted to females; normal development for first 6 mo, followed by acquired microcephaly, loss of hand skills and replacement by stereotypies, regression of skills, seizures, spasticity, and scoliosis
Spinal muscular atrophy 1, 2, and 3 MIM 253300, 253550, 253400	AR	*SMN1* SMN	*SMN1* is a key component of the spliceosome complex; selective vulnerability of anterior horn cells is not yet understood.	Loss of anterior horn cells (and neurons of brainstem and thalami in severe cases)

(table continues on page 1414)

TABLE 140.2 Selected Disorders of DNA Synthesis, Maintenance, Transcription, and Translation *(continued)*

Disorder	Inheritance	Gene and Protein	Mechanism (Known or Putative)	Specific Features
DNA Translation and Translational Modification				
CACH, Cree leukoencephalopathy, ovarioleukodystrophy **MIM 603896**	AR	*EIF2B1* *EIF2B2* *EIF2B3* *EIF2B4* *EIF2B5* eIF2B	Translation initiation factor 2B catalyzes exchange of GDP for GTP, an essential stage in recycling of eIF2; GEF activity. Mutations in any of the five genes coding for subunits of eIF2B cause loss of normal downregulation of protein translation under stress, resulting in protein denaturation and accumulation of aggregates producing cellular toxicity.	Slowly progressive ataxia with diffuse loss of white matter; episodes of coma with fever and motor impairment with minor trauma
CDG-1a **MIM 212065**	AR	*PMM2* PMM2	PMM2 is one of a family of enzymes catalyzing the assembly of the LLO precursor that is attached to the nascent polypeptide chain during cotranslational modification by *N*-linked glycosylation.	Intellectual disability, short stature, progressive ataxia, peripheral neuropathy, stroke-like episodes, seizures, immune dysfunction, intermittent hepatic failure, coagulopathies
Cell Cycle Regulation				
Angelman syndrome **MIM 105830**	Multiple mechanisms, including maternal deletion of 15q11-13, paternal uniparental disomy, imprinting defects, and point mutations or small *UBE3A* intragenic deletions. Some patients have *MECP2* mutations.	*UBE3A* Ubiquitin-protein ligase E3A	The *UBE3A* gene encodes sense and antisense RNA transcripts in the brain with neuron-specific imprinting of *UBE3A* in primary brain cell cultures. The maternal *UBE3A* allele is preferentially expressed in the neuronal nucleus and at synapses; absence of this allele is associated with abnormal dendritic spine morphology.	Psychomotor retardation, ataxia, hypotonia, epilepsy, absence of speech, large mandible, and tongue thrusting; optic atrophy and albinism in some
Ataxia-telangiectasia **MIM 208900**	AR	*ATM* ATM	The ATM protein is a PI3K that phosphorylates key substrates involved in DNA repair and/or cell cycle control.	Progressive ataxia, choreoathetosis, anterior horn cell loss, immune deficiency, scleral telangiectasia
Seckel syndrome 1 **MIM 210600**	AR	*ATR* ATR *CEP152* Centrosomal protein 152	ATR is a PI3K involved in cell cycle progression, DNA recombination, and the detection of DNA damage; *CEP152* regulates genomic integrity and cellular response to DNA damage.	Short stature, dysmorphism ("bird-headed dwarf"), congenital microcephaly, intellectual disability; no immune deficiency or cancers

Abbreviations: AR, autosomal recessive; ATM, ataxia-telangiectasia mutated; ATR, ataxia-telangiectasia and Rad3-related; CACH, childhood ataxia with central nervous system hypomyelination; CDG-1a, congenital disorder of glycosylation 1a; COFS, cerebro-oculo-facio-skeletal syndrome; CSA, Cockayne syndrome group A; CSB, Cockayne syndrome group B; CSBIP, CSB IP/150, CSB immunoprecipitated fraction; eIF2, eukaryotic initiation factor 2; eIF2B, eukaryotic translation initiation factor 2B; ERCC2, excision repair cross-complementing rodent repair deficiency 2; ERCC6, excision repair cross-complementing rodent repair deficiency 6; ERCC8, excision repair cross-complementing rodent repair deficiency 8; GEF, guanine nucleotide exchange factor; LLO, lipid-linked oligosaccharide; MeCP2, methyl CpG-binding protein 2; PI3K, phosphatidylinositol 3-kinase; PMM2, phosphomannomutase 2; TFIIH, transcription factor II H; TTD, trichothiodystrophy; XP, xeroderma pigmentosum.

SUGGESTED READINGS

Chromosomal Disorders

Aygun D, Bjornsson HT. Clinical epigenetics: a primer for the practitioner. *Dev Med Child Neurol*. 2020;62(2):192-200.

Bindels-de Heus K, Mous SE, Ten Hooven-Radstaake M, et al. An overview of health issues and development in a large clinical cohort of children with Angelman syndrome. *Am J Med Genet A*. 2020;182(1):53-63.

Chandrasekhar T, Copeland JN, Spanos M, Sikich L. Autism, psychosis, or both? Unraveling complex patient presentations. *Child Adolesc Psychiatr Clin N Am*. 2020;29(1):103-113.

Cipriani G, Danti S, Carlesi C, Di Fiorino M. Aging with Down syndrome: the dual diagnosis: Alzheimer's disease and Down syndrome. *Am J Alzheimers Dis Other Demen*. 2018;33(4):253-262.

Dagli AI, Mueller J, Williams CA. Angelman syndrome. National Center for Biotechnology Information Web site. https://www.ncbi.nlm.nih.gov/books/NBK1144/. Accessed July 6, 2020.

Eaton CB, Thomas RH, Hamandi K, et al. Epilepsy and seizures in young people with 22q11.2 deletion syndrome: prevalence and links with other neurodevelopmental disorders. *Epilepsia*. 2019;60(5):818-829.

Hamner T, Udhnani MD, Osipowicz KZ, Lee NR. Pediatric brain development in Down syndrome: a field in its infancy. *J Int Neuropsychol Soc*. 2018;24(9):966-976.

Ishii A, Ihara H, Ogata H, et al. Autistic, aberrant, and food-related behaviors in adolescents and young adults with Prader-Willi syndrome: the effects of age and genotype. *Behav Neurol*. 2017;2017:4615451.

Kasinathan A, Dhawan S, Suthar R, Sankhyan N. Pseudo hypsarrhythmia: an early marker of Angelman syndrome. *Ann Indian Acad Neurol*. 2019;22(3):359-361.

Kaur S, Christodoulou J. MECP2 disorders. National Center for Biotechnology Information Web site. https://www.ncbi.nlm.nih.gov/books/NBK1497/. Accessed July 6, 2020.

Kim Y, Wang SE, Jiang YH. Epigenetic therapy of Prader-Willi syndrome. *Transl Res*. 2019;208:105-118.

Kimonis VE, Tamura R, Gold JA, et al. Early diagnosis in Prader-Willi syndrome reduces obesity and associated co-morbidities. *Genes (Basel)*. 2019;10(11):E898.

Lopez SJ, Segal DJ, LaSalle JM. UBE3A: an E3 ubiquitin ligase with genome-wide impact in neurodevelopmental disease. *Front Mol Neurosci*. 2018;11:476.

Nixon DW. Down syndrome, obesity, Alzheimer's disease, and cancer: a brief review and hypothesis. *Brain Sci*. 2018;8(4):E53.

Potter H, Chial HJ, Caneus J, et al. Chromosome instability and mosaic aneuploidy in neurodegenerative and neurodevelopmental disorders. *Front Genet*. 2019;10:1092.

Shay JW, Wright WE. Telomeres and telomerase: three decades of progress. *Nat Rev Genet*. 2019;20(5):299-309.

Vacca RA, Bawari S, Valenti D, et al. Down syndrome: neurobiological alterations and therapeutic targets. *Neurosci Biobehav Rev*. 2019;98:234-255.

Van L, Heung T, Graffi J, et al. All-cause mortality and survival in adults with 22q11.2 deletion syndrome. *Genet Med*. 2019;21(10):2328-2335.

Vickers RR, Gibson JS. A review of the genomic analysis of children presenting with developmental delay/intellectual disability and associated dysmorphic features. *Cureus*. 2019;11(1):e3873.

Disorders of DNA Maintenance, Transcription, and Translation

Agathangelou K, Apostolou Z, Garinis GA. Nuclear DNA damage and ageing. *Subcell Biochem*. 2018;90:309-322.

Ahmed A, Almohanna H, Griggs J, Tosti A. Genetic hair disorders: a review. *Dermatol Ther (Heidelb)*. 2019;9(3):421-448.

Altassan R, Péanne R, Jaeken J, et al. International clinical guidelines for the management of phosphomannomutase 2-congenital disorders of glycosylation: diagnosis, treatment and follow up. *J Inherit Metab Dis*. 2019;42(1):5-28.

Araújo SJ, Kuraoka I. Nucleotide excision repair genes shaping embryonic development. *Open Biol*. 2019;9(10):190166.

Ashapkin VV, Kutueva LI, Kurchashova SY, Kireev II. Are there common mechanisms between the Hutchinson-Gilford progeria syndrome and natural aging? *Front Genet*. 2019;10:455.

Burger K, Ketley RF, Gullerova M. Beyond the trinity of ATM, ATR, and DNA-PK: multiple kinases shape the DNA damage response in concert with RNA metabolism. *Front Mol Biosci*. 2019;6:61.

Fang X, Sun Y. Whole-exome sequencing enables the diagnosis of variant-type xeroderma pigmentosum. *Front Genet*. 2019;10:495.

Ferreira CR, Altassan R, Marques-Da-Silva D, Francisco R, Jaeken J, Morava E. Recognizable phenotypes in CDG. *J Inherit Metab Dis*. 2018;41(3):541-553.

Ferri D, Orioli D, Botta E. Heterogeneity and overlaps in nucleotide excision repair disorders. *Clin Genet*. 2020;97(1):12-24.

Foo MXR, Ong PF, Dreesen O. Premature aging syndromes: from patients to mechanism. *J Dermatol Sci*. 2019;96:58-65.

Gamez A, Yuste-Checa P, Brasil S, et al. Protein misfolding diseases: prospects of pharmacological treatment. *Clin Genet*. 2018;93(3):450-458.

Gordon LB, Brown WT, Collins FS. Hutchinson-Gilford progeria syndrome. National Center for Biotechnology Information Web site. https://www.ncbi.nlm.nih.gov/books/NBK1121/. Accessed July 6, 2020.

Güngör G, Güngör O, Çakmakli S, et al. Vanishing white matter disease with different faces. *Childs Nerv Syst*. 2020;36(2):353-361.

Hamilton EMC, van der Lei HDW, Vermeulen G, et al. Natural history of vanishing white matter. *Ann Neurol*. 2018;84(2):274-288.

Herrero M, Mandelboum S, Elroy-Stein O. eIF2B mutations cause mitochondrial malfunction in oligodendrocytes. *Neuromolecular Med*. 2019;21(3):303-313.

Jin S, Cordes N. ATM controls DNA repair and mitochondria transfer between neighboring cells. *Cell Commun Signal*. 2019;17(1):144.

Kaseb H, Hozayen S. Chromosome instability syndromes. National Center for Biotechnology Information Web site. https://www.ncbi.nlm.nih.gov/books/NBK537198/. Accessed July 6, 2020.

Kemp MG. Damage removal and gap filling in nucleotide excision repair. *Enzymes*. 2019;45:59-97.

Köhler W, Curiel J, Vanderver A. Adulthood leukodystrophies. *Nat Rev Neurol*. 2018;14(2):94-105.

Kokic G, Chernev A, Tegunov D, Dienemann C, Urlaub H, Cramer P. Structural basis of TFIIH activation for nucleotide excision repair. *Nat Commun*. 2019;10(1):2885.

Kreienkamp R, Gonzalo S. Hutchinson-Gilford progeria syndrome: challenges at bench and bedside. *Subcell Biochem*. 2019;91:435-451.

Laugel V. Cockayne syndrome. National Center for Biotechnology Information Web site. https://www.ncbi.nlm.nih.gov/books/NBK1116/. Accessed July 6, 2020.

Levy A, Lang AE. Ataxia-telangiectasia: a review of movement disorders, clinical features, and genotype correlations. *Mov Disord*. 2018;33(8):1238-1247.

Li Y, Zhou G, Bruno IG, et al. Transient introduction of human telomerase mRNA improves hallmarks of progeria cells. *Aging Cell*. 2019;18(4):e12979.

Llorens-Agost M, Luessing J, van Beneden A, et al. Analysis of novel missense ATR mutations reveals new splicing defects underlying Seckel syndrome. *Hum Mutat*. 2018;39(12):1847-1853.

Martínez-Monseny AF, Bolasell M, Callejón-Poo L, et al. AZATAX: acetazolamide safety and efficacy in cerebellar syndrome in PMM2 congenital disorder of glycosylation (PMM2-CDG). *Ann Neurol*. 2019;85(5):740-751.

Maynard S, Keijzers G, Akbari M, et al. Lamin A/C promotes DNA base excision repair. *Nucleic Acids Res*. 2019;47(22):11709-11728.

Moreira MC, Koenig M. Ataxia with oculomotor apraxia type 2. National Center for Biotechnology Information Web site. https://www.ncbi.nlm.nih.gov/books/NBK1116/. Accessed July 6, 2020.

Moriwaki S, Kanda F, Hayashi M, et al. Xeroderma pigmentosum clinical practice guidelines. *J Dermatol*. 2017;44(10):1087-1096.

Nano M, Basto R. Consequences of centrosome dysfunction during brain development. *Adv Exp Med Biol*. 2017;1002:19-45.

Prates Mori M, de Souza-Pinto NC. Role of mitochondrial dysfunction in the pathophysiology of DNA repair disorders. *Cell Biol Int*. 2018;42(6):643-650.

Qian M, Liu Z, Peng L, et al. Boosting ATM activity alleviates aging and extends lifespan in a mouse model of progeria. *Elife*. 2018;7:e34836.

Schoenaker MHD, Van Os NJH, Van der Flier M, et al. Telangiectasias in ataxia telangiectasia: clinical significance, role of ATM deficiency and potential pathophysiological mechanisms. *Eur J Med Genet*. 2018;61(5):284-287.

Stowe RC, Jimenez-Gomez A, Balasa A, Clark GD. Cockayne syndrome complicated by moyamoya vasculopathy and stroke. *Pediatr Neurol*. 2018;86:73-74.

Tillotson R, Bird A. The molecular basis of MeCP2 function in the brain. *J Mol Biol*. 2019;S0022-2836(19):30595-30599.

van der Knaap MS, Abbink TEM. Ovarioleukodystrophy: vanishing white matter versus AARS2-related ovarioleukodystrophy. *Clin Neurol Neurosurg*. 2018;171:195.

van der Knaap MS, Fogli A, Boespflug-Tanguy O, Abbink TEM, Schiffmann R. Childhood ataxia with central nervous system hypomyelination/vanishing white matter. National Center for Biotechnology Information Web site. https://www.ncbi.nlm.nih.gov/books/NBK1258/. Accessed July 6, 2020.

van Os NJH, van Deuren M, Weemaes CMR, et al. Classic ataxia-telangiectasia: the phenotype of long-term survivors. *J Neurol*. 2020;267:830-837.

Vidal S, Brandi N, Pacheco P, et al. The most recurrent monogenic disorders that overlap with the phenotype of Rett syndrome. *Eur J Paediatr Neurol*. 2019;23(4):609-620.

Wang S, Min Z, Ji Q, et al. Rescue of premature aging defects in Cockayne syndrome stem cells by CRISPR/Cas9-mediated gene correction. *Protein Cell*. 2020;11:1-22.

Wong LC, Singh S, Wang HP, Hsu CJ, Hu SC, Lee WT. FOXG1-related syndrome: from clinical to molecular genetics and pathogenic mechanisms. *Int J Mol Sci*. 2019;20(17):4176.

Xu J, Lahiri I, Wang W, et al. Structural basis for the initiation of eukaryotic transcription-coupled DNA repair. *Nature*. 2017;551(7682):653-657.

Zhu YC, Xiong ZQ. Molecular and synaptic bases of CDKL5 disorder. *Dev Neurobiol*. 2019;79(1):8-19.

The Floppy Infant 141

Maryam Oskoui, Laurent Servais, and Darryl C. De Vivo

KEY POINTS

1. Central causes of congenital hypotonia are more common than peripheral causes.
2. Polyhydramnios, fetal akinesia, and perinatal malpresentation are frequently recognized in infants with neuromuscular disorders.
3. Hypoxic-ischemic encephalopathy is the most common cause of hypotonia in the newborn period.
4. Acute-onset constipation and cranial nerve involvement should suggest infantile botulism.
5. The triad of infantile hypotonia, areflexia, and tongue fasciculations should suggest 5q spinal muscular atrophy caused by homozygous *SMN1* deletions, a medical emergency demanding immediate disease-modifying therapy to achieve optimal outcome.
6. Infants of mothers with myasthenia gravis or myotonic dystrophy should be monitored for neuromuscular signs in the newborn period.
7. Early-onset neuropathies are more often hypomyelinating than axonal and can be associated with central nervous system involvement.
8. The presence in infancy of cardiomyopathy and elevated creatine kinase should suggest Pompe disease and early treatment with enzyme replacement therapy.

INTRODUCTION

Tone opposes gravity and maintains postural attitude. The term *hypotonia* refers to a state of low muscle tone. When held by an examiner in prone position in horizontal suspension, a full-term infant maintains a straight back and neck with flexed limbs. A hypotonic infant will drape over the examiner's hand with limbs and head hanging limply, thus the origin of the term *floppy infant*. Low neck tone can be observed when pulling the infant to a sitting position if it offers little or no resistance and the head remains in extension or falls forward once seated upright. In vertical suspension, the hypotonic infant's torso slips through the examiner's hands because of low tone in shoulder girdle muscles instead of adduction of the arms and fixing at the shoulders. Decreased limb recoil and a scarf sign are observed with appendicular hypotonia in addition to diminished resistance to passive limb movement when examined. The floppy infant seems to be weak, but the examiner may find it difficult to distinguish between true weakness and apparent weakness due to hypotonia and/or hyperlaxity.

The hypotonic infant represents a diagnostic challenge with a seemingly limitless differential diagnosis. Clues on history and examination can help narrow the list of possible etiologies (Fig. 141.1). Family history may reveal an inherited risk for hypercoagulability (including prior maternal spontaneous abortions), immune-mediated conditions, genetic syndromes (premature death may suggest a metabolic syndrome), neuropathies, myasthenia gravis, or myopathies/muscular dystrophies (developmental delay and weakness). Maternal neuromuscular disorders such as myotonic dystrophy or myasthenia gravis may have been previously undiagnosed with milder symptoms, and a high clinical suspicion is needed. The pregnancy history should highlight possible decreased fetal movements (akinesia), polyhydramnios (decreased fetal swallowing), in utero toxin exposure (alcohol, narcotics, antiepileptic drugs), and intrauterine infections (herpes simplex, cytomegalovirus, toxoplasmosis, rubella). The perinatal history includes gestational age (prematurity), difficult delivery (sentinel event, perinatal depression, or shoulder dystocia), and breech presentation. It should also be noted whether the infant had low tone, limb contractures, difficulty breathing, poor suck, feeding difficulties, or a weak cry at birth. Potential exposures to *Clostridium botulinum* (via honey, corn syrup or home-canned goods consumption, or dirt) should be considered. The temporal pattern of the hypotonia itself is informative, whether it is present prenatally, at birth, or after birth and whether it improves, worsens, or transforms to spasticity over time.

The aforementioned history will complement a careful neurologic exam designed to identify (1) unique dysmorphic features; (2) a highly arched palate or tenting of the mouth (suggestive of congenital tongue weakness); (3) respiratory distress with paradoxical breathing; (4) cardiomyopathy (seen in carnitine deficiency, fatty acid oxidation disorders); (5) organomegaly (seen in acid maltase deficiency, Zellweger syndrome, and other storage disorders); (6) genitourinary abnormalities such as hypogonadism and hypospadias (Prader-Willi syndrome, Smith-Lemli-Opitz syndrome); (7) skin changes (birthmarks seen in neurocutaneous syndromes, doughy quality); (8) musculoskeletal abnormalities (congenital scoliosis, kyphosis, contractures seen in arthrogryposis, hip dysplasia, torticollis, hyperextensibility of joints); (9) level of alertness (encephalopathy); (10) quality of cry; (11) cranial nerve dysfunction such as facial weakness, ptosis, limited extraocular movements, tongue fasciculations, tongue atrophy, strength of suck; (12) focal or diffuse weakness; (13) evidence of hypertonicity (increased jitteriness and rigidity of the limbs) or hypotonicity (frog-legged posture while supine, lack of spontaneous movement, scarf sign, tendency to keep the trunk flexed while held in horizontal suspension, slip through); and (14) tendon reflex responses. The pertinent findings on examination in conjunction with a thorough history will guide the clinician to whether the infant's presentation is related to a nonneurologic (metabolic, systemic or genetic syndrome)

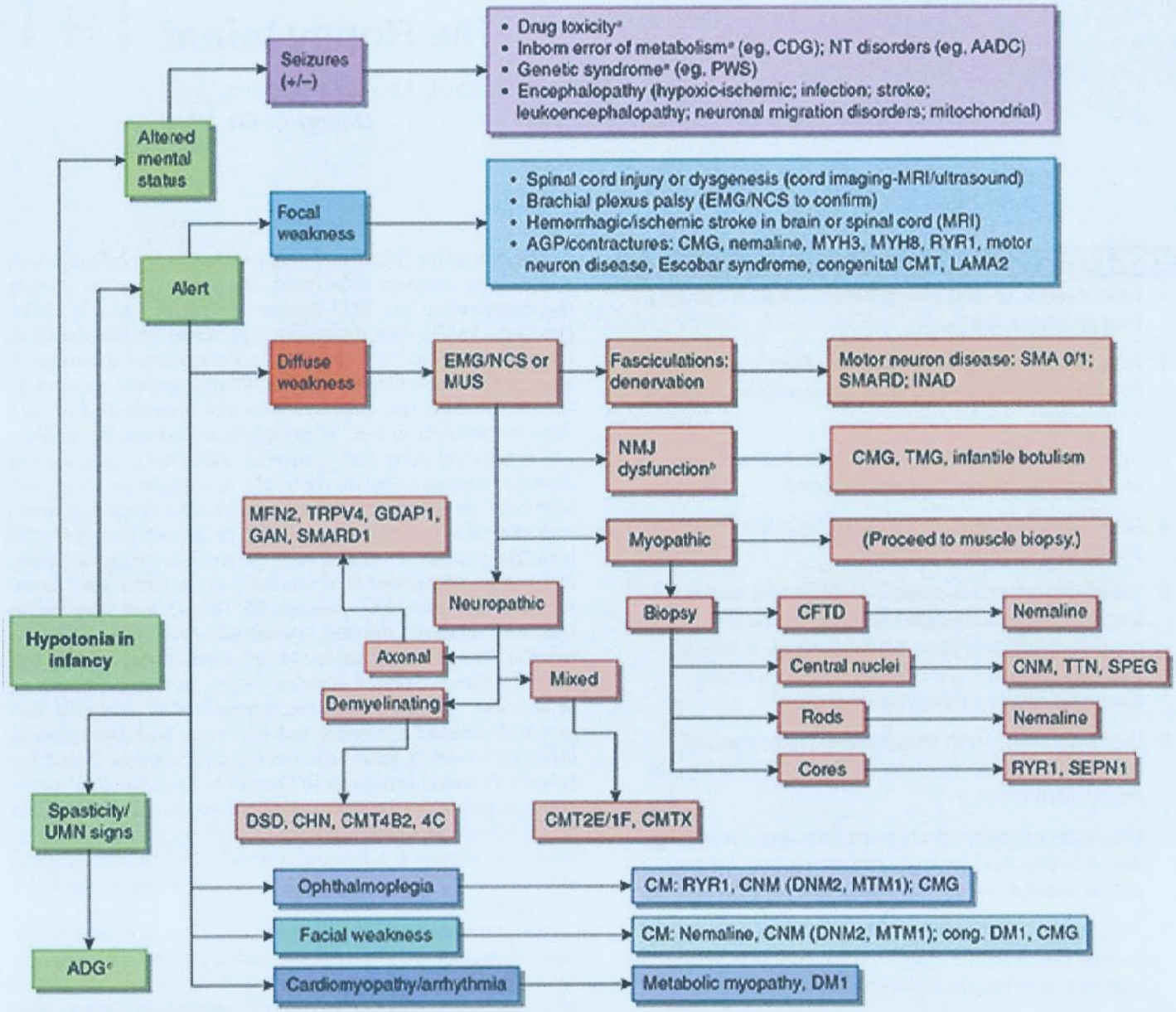

FIGURE 141.1 Differential diagnosis for hypotonia in infants. [a]May be associated with pathognomonic dysmorphic features. [b]Muscle ultrasound (MUS) is not diagnostic for neuromuscular junction dysfunction but can visualize fasciculations and fibrofatty replacement in muscle either due to myopathy, neuropathy, or motor neuron disease. [c]May also present with seizures. Abbreviations: AADC, aromatic l-amino acid decarboxylase deficiency; ADG, α-dystroglycanopathy; AGP, arthrogryposis; CDG, congenital disorder of glycosylation; CFTD, congenital fiber-type disproportion; CHN, congenital hypomyelinating neuropathy; CM, congenital myopathy; CMG, congenital myasthenia gravis; CMT, Charcot-Marie-Tooth; CNM, centronuclear myopathy; CMTX, Charcot-Marie-Tooth disease type X; DM1, myotonic dystrophy; DNM2, dynamin 2 gene; DSD, Dejerine-Sottas disease; EMG, electromyography; GAN, giant axonal neuropathy; GDAP1, ganglioside induced differentiation associated protein 1; INAD, infantile neuroaxonal dystrophy; LAMA2, laminin α_2 gene; MFN2, mitofusin 2 gene; MRI, magnetic resonance imaging; MTM1, myotubularin 1 gene; MYH3, myosin heavy chain 3 gene; MYH8, myosin heavy chain 8 gene; NCS, nerve conduction studies; NMJ, neuromuscular junction; NT, neurotransmitter; PWS, Prader-Willi syndrome; RYR1, ryanodine receptor 1 gene; SEPN1, selenoprotein 1 gene; SMA, spinal muscular atrophy; SMARD, spinal muscular atrophy and respiratory distress; SMARD1, spinal muscular atrophy and respiratory distress type 1; SPEG, striated muscle preferentially expressed protein kinase; TMG, transient myasthenia gravis; TRPV4, transient receptor potential cation channel, subfamily V, member 4; TTN, titin gene; UMN, upper motor neuron.

or neurologic etiology that may be primarily central (brain and spinal cord), peripheral (anterior horn cell, peripheral nerve, neuromuscular junction, or muscle), or both.

CENTRAL HYPOTONIA

Central hypotonia is due to lesions above the anterior horn cells of the spinal cord. Central hypotonia is often symmetric and affects the upper and lower limbs equally as well as the trunk. It may also present with additional features of central nervous system (CNS) involvement such as early developmental impairment, seizures, encephalopathy, or brisk tendon reflexes.

Vascular Causes

Hypoxic-ischemic encephalopathy develops in the setting of perinatal hypoxia and is by far the most common cause of hypotonia seen in newborns. The initial presentation of hypoxic-ischemic encephalopathy in the newborn period may be hypotonia and hyporeflexia in addition to seizures, decreased level of alertness, and irritability. There may be a history of a sentinel event, and signs of perinatal distress may be observed. Over time, the initial presentation of hypotonia usually gives way to hypertonia with increased tendon reflexes and spasticity (refer to Chapter 137). Other vascular etiologies include intraventricular hemorrhage seen in premature newborns (see Chapter 137) and ischemic or hemorrhagic stroke (see Chapter 149). Investigations for these etiologies include brain imaging (magnetic resonance imaging [MRI]) and electroencephalography, and examination of the placental pathology can provide further etiologic clues.

Structural Causes

Neuronal migration disorders include holoprosencephaly, anencephaly, lissencephaly, pachygyria, polymicrogyria, and/or heterotopias (refer to Chapter 138). Microcephaly, dysmorphic features, and seizures can be observed. It should be noted that neuronal migration disorders might be part of a larger syndrome that can also present with peripheral hypotonia, for example, congenital muscular dystrophies such as Fukuyama congenital muscular dystrophy, Walker-Warburg syndrome, or muscle-eye-brain disease (refer to Chapter 147). Several forms of cerebral palsy (CP) can present with truncal hypotonia in infancy, such as ataxic or dyskinetic subtypes. The CP is an umbrella term including a heterogenous group of conditions involving nonprogressive central motor impairment due to abnormalities of the developing fetal or infant brain. Cerebral maldevelopment, deep gray matter or cerebellar abnormalities, and nonspecific neuroimaging can be seen in CP. Intracranial neoplasms presenting in infancy should also be considered in the context of macrocephaly, vomiting, or cranial nerve involvement (refer to Chapter 150). Investigations to consider include brain imaging, electroencephalography in the context of encephalopathy or seizures, creatine kinase if a congenital muscular dystrophy is suspected, ophthalmologic evaluation, and genetic testing such as chromosomal microarray and targeted gene sequencing.

Metabolic Causes

Inborn errors of metabolism include toxic accumulation of metabolites such as aminoacidopathies, organic acidurias and urea cycle defects, disorders of energy metabolism such as fatty acid oxidation defects and other mitochondrial disorders, glycogen storage disorders, and disorders affecting intracellular processing of small molecules such as peroxisomal disorders including Zellweger syndrome, neonatal adrenoleukodystrophy, and infantile Refsum disease (refer to Chapter 139). Some inborn errors of metabolism may also cause peripheral neuropathy. Other clinical features can include lethargy, apnea or tachypnea, poor feeding, seizures, vomiting, organomegaly, or ambiguous genitalia. The temporal pattern of symptoms such as cyclical symptoms, worsening with systemic stress, or development of symptoms with the introduction of feedings can lend further clues. Investigations to consider when a metabolic etiology is considered would include serum glucose, electrolytes, plasma amino acids, urine organic acids, acylcarnitines, ammonia, liver function, thyroid profile, lactate, pyruvate, calcium, magnesium, uric acid, isoimmune electrophoresis for transferrin, carnitine profile, very long chain fatty acids, and cerebrospinal fluid (CSF) studies for glucose, protein, amino acids, lactate, pyruvate, neurotransmitters, pterins, and 5-methyltetrahydrofolate.

Systemic Causes

Systemic causes include infections, electrolyte or hormonal imbalance, and toxin exposure. Congenital infections include toxoplasmosis, *Treponema pallidum*, rubella, cytomegalovirus, herpesvirus, hepatitis B and C viruses, human immunodeficiency virus, varicella, and parvovirus B19. These may present with hypotonia in addition to other features of intracranial calcifications or cysts, abnormal liver function, skin rash, hearing loss, encephalopathy, seizures, and/or retinitis or optic nerve atrophy. Over time, the exam can evolve to spasticity and increased tendon reflexes. Acute sepsis and CNS infection in infants can also present with hypotonia, hypo- or hyperthermia, and encephalopathy. Infants of diabetic mothers, premature newborns, or those born with intrauterine growth restriction are at higher risk for hypoglycemia at birth. Congenital hypothyroidism is now included in most newborn screening programs. Intrauterine exposure to drugs such as lamotrigine, lithium, narcotics, and benzodiazepines has been associated with hypotonia. Antepartum or peripartum maternal exposure to high levels of magnesium sulfate for the treatment of eclampsia and prevention of cerebral palsy has also been associated with congenital hypotonia. Investigations to consider include blood, urine, and CSF bacterial and viral studies; urine and blood toxin screens; and serum glucose, electrolytes, and thyroid-stimulating hormone level.

Chromosomal Disorders

Genetic syndromes that most commonly present with hypotonia include Down syndrome (distinct facial features and higher risk of associated cardiac anomalies and duodenal atresia), Prader-Willi syndrome (distinctive facial features, genital hypoplasia, initial failure to thrive followed by hyperphagia, and obesity after age 1 year), fragile X syndrome, Cohen syndrome, trisomy 18, 1p36 deletion, 22q13 deletion syndrome, 22q11.2 deletion syndrome, DiGeorge/velocardiofacial syndrome, Williams syndrome, trisomy 13, Smith-Magenis syndrome, Sotos syndrome (macrocephaly), Lowe syndrome, Smith-Lemli-Opitz syndrome, Wolf-Hirschhorn syndrome, Kabuki syndrome, Cri-du-chat syndrome (refer to Chapter 140). Investigations include specific

genetic studies such as FMR1, array comparative genomic hybridization, 7-dehydrocholesterol, and cardiac evaluation.

Spinal Cord

For discussion of spinal dysraphism/spina bifida, refer to Chapter 138. Spinal cord injury may be secondary to intrauterine mispositioning or trauma/severe asphyxia during birth (via hypoperfusion between the anterior spinal artery and paired spinal arteries) that subsequently damages the lower motor neurons of the spinal cord. Autopsy studies of fatally asphyxiated neonates demonstrate prominent, ischemic necrosis of anterior spinal cord gray matter. Infants with spinal cord injury often present with hypotonia, weakness, and absent tendon reflexes only in the regions distal to the site of injury. Ultrasound/MRI of the spine also may be used to identify cord ischemia or spinal dysraphism.

PERIPHERAL HYPOTONIA

Peripheral hypotonia refers to disorders of the motor unit (anterior horn cell, peripheral nerve, neuromuscular junction, and muscle). The distribution of the muscle weakness can help with diagnosing its etiology. Investigations to identify the underlying etiology can include electromyography and nerve conduction studies (EMG/NCS), serum creatine kinase, muscle imaging, genetic testing and muscle or nerve biopsy.

Anterior Horn Cell Disorders

The quintessential anterior horn cell disease in infancy is 5q spinal muscular atrophy, an autosomal recessive disorder affecting the survival of motor neuron (*SMN*) gene. Genetically affected infants can present at birth or at any time after the newborn period. The severe phenotype presents with paradoxical breathing, tongue fasciculations, areflexia, and generalized weakness more evident in the proximal muscle groups (refer to Chapter 146). Infants with later onset symptoms can have preserved reflexes at the time of presentation with mild increase in creatine kinase level. The diagnosis is confirmed by genetic testing. Other diagnostic tests such as EMG/NCS and muscle biopsy are rarely indicated. On EMG/NCS, fasciculations and reduced compound motor action potential amplitude are observed in affected muscles. Consensus statements for standard of care emphasize interdisciplinary care. Prompt diagnosis and initiation of disease-modifying treatment is necessary to affect the optimal outcome. Spinal muscular atrophy with respiratory distress type 1 (SMARD1) or *infantile axonal neuropathy with respiratory failure* is due to mutation in the *IGHMBP2* gene. A similar phenotype has also been described in a patient with *REEP1* (the gene involved in *SPG3*) mutation but with clinical signs of upper motor neuron involvement. Children with SMARD1 present with respiratory failure and progressive distal weakness. Nerve conduction studies usually show absent responses. Nerve biopsy demonstrates decreased myelinated fibers, active axonal degeneration or active evidence of regeneration, and no onion bulb formations.

Poliomyelitis is an infectious cause of anterior horn cell dysfunction, with asymmetric limb weakness, respiratory insufficiency, and meningeal irritation. The CSF studies show pleocytosis and elevated protein. Treatment is mostly supportive. An effective vaccine has significantly reduced the global incidence. Acute flaccid myelitis is a polio-like illness. The involvement of anterior horn cell and spinal cord gray matter results in asymmetric weakness, areflexia, urinary retention, and respiratory failure. The CSF shows pleocytosis and elevated protein. The Centers for Disease Control and Prevention (CDC) reports a seasonal increase in incidence between August and October, associated with enterovirus infection, especially enterovirus D68. Testing for poliovirus has been negative in affected children. In 2018, the CDC reported 233 cases of acute flaccid myelitis in 41 states, with the average age of affected patients being 5 years. Treatment is supportive and rehabilitation services facilitate long-term outcomes.

Brachial Plexus Palsy

Obstetrical brachial plexus palsy (BPP) is the most common cause in the newborn. However, other causes include familial congenital BPP and structural causes such as uterine malformation or lesions involving the proximal head of the humerus, the cervical vertebrae, or the first rib. Risk factors for obstetrical BPP include shoulder dystocia, large birth weight, vaginal deliveries associated with vacuum extraction, or direct compression of the fetal neck during delivery by forceps, as these maneuvers can cause stretching of the cervical nerve roots (via misdirected traction or hyperextension of the arms).

The BPP are divided into four categories based on location of injury: (1) upper (Erb palsy, C5-C7, most common palsy presenting with adducted arm that is internally rotated at the shoulder; wrist is flexed and fingers are extended in a "waiter's tip" posture), (2) intermediate (C7 and sometimes C8 and T1), (3) lower (Klumpke paralysis—C8, T1—poor hand grasp with more intact proximal muscles), and (4) total plexus palsy (C5-C8 and sometimes T1—second most common and the most devastating—claw hand and flaccid arm with no sensation). An additional finding that may be associated with a poor prognosis is Horner syndrome.

Investigations include x-rays of the chest, spine, and upper limbs to screen for associated lesions (fracture of ribs, transverse process, clavicle, humerus, or phrenic nerve injury). An MRI of the upper limb/shoulder and spinal MRI also is helpful to rule out nerve root evulsion. Computed tomography myelography may be used if MRI is not possible. An EMG/NCS supports documentation of the severity of the neural lesion and detects signs of reinnervation. Serial EMG/NCSs within the first 48 hours after birth will distinguish between prenatal and obstetric causes of BPP. Sensory-evoked potentials can be used to assess the integrity of sensory conduction.

Supportive therapy to maintain passive range of motion and muscle strength is recommended. The majority (70%-95%) of patients with BPP make complete spontaneous recovery, but both the extent (upper, lower, total) and the severity (avulsion, rupture) of the injury influence the prognosis (lower plexopathies tend to be more severe). A small proportion of infants, managed conservatively, have severe permanent disability. The optimal timing of surgical exploration remains controversial, but most recommendations are for intervention in the first 6 months of life if there is no evidence of meaningful clinical recovery such as bicep flexion overcoming gravity.

Peripheral Neuropathy

Peripheral neuropathies in early infancy are rare and can present with hypotonia, weakness, sensory alteration, areflexia,

contractures, ataxia, congenital hip dysplasia, and predominantly distal muscle wasting. These conditions may be described according to neurophysiologic findings (via EMG/NCS) and findings on nerve biopsy. With advances in genetic testing, nerve biopsy is often not indicated. We describe here only the forms that can manifest at birth or in early infancy. Forms with later onset and the rare acquired causes are described in Chapters 91 and 92. Neuropathies that manifest early in life are more often demyelinating than axonal.

Demyelinating Neuropathies

Early-onset demyelinating neuropathies may occur in isolation or with central hypomyelination or other CNS abnormalities (**Table 141.1**). The investigation of early-onset demyelinating neuropathy should include a workup of potential central nervous involvement.

Early-onset demyelinating neuropathies confined to the peripheral system include congenital hypomyelinating neuropathy or Dejerine-Sottas disease. Severe cases of congenital hypomyelinating neuropathy present at birth with profound weakness, hypotonia, arthrogryposis, and respiratory insufficiency. Tongue fasciculations may be present. Dejerine-Sottas disease describes a clinical phenotype characterized by symptom onset in the first 2 years of life, delayed motor development, hypotonia that predominates in the distal muscles, and ataxia. An NCS show significantly slow conduction velocity (median motor nerve conduction velocity of 12 m/s or less) and even conduction blocks in the most severe forms. An EMG can show signs of active denervation.

Several genes are associated, with additional phenotypic features such as *PMP22* point mutations (sensorineural hearing loss, facial weakness, nystagmus, vestibular dysfunction, ptosis, limited extraocular movements, and bladder symptoms), *MPZ* (Adie pupil), *EGR2* (cranial nerve involvement including tongue fasciculations), and *CNTNAP1*. Patients with SH3TC2 or KIAA1985, also referred to as *CMT4C*, may present with early-onset severe spinal deformities, often as the presenting symptom. Foot deformity is common and may precede weakness. Hearing loss is the most common form of cranial nerve involvement, although facial weakness, nystagmus, and tongue atrophy/fasciculations are also reported. Respiratory insufficiency or hypoventilation may also occur.

Axonal Neuropathies

In addition to hypotonia, infants with axonal neuropathy can have pyramidal tract involvement or optic atrophy in *MFN2*; congenital foot deformities (often talipes equinovarus), early contractures, congenital hip dysplasia, scoliosis, vocal cord paresis presenting as stridor or respiratory distress due to diaphragmatic involvement in *TRPV4*; and vocal cord paresis, diaphragmatic dysfunction with restrictive lung disease, and optic atrophy in *GDAP1*. The NCSs show a mixed axonal sensory neuropathy with abnormal velocities. Motor and sensory responses may be unrecordable. Nerve biopsy shows severe loss of large, myelinated fibers and abnormal aggregations of small, round mitochondria on electron microscopy. Autosomal dominant axonal neuropathy can be caused by mutations in several genes like *KIF1B* and *MFN2* (CMT2A), *RAB7* (CMT2B), *TRPV4* (CMT2C), *GARS* (CMT2D), *NEFL* (CMT2E), *HSPB1* (CMT2F), *MPZ* (CMT2I), *GDAP1* (CMT2K), *HSPB8* (CMT2L), and *AARS* (CMT2N). Associated CNS involvement is seen in infantile neuroaxonal dystrophy (*PLA2G6*) or with *Twinkle* mutations with severe encephalopathy, abnormal eye, and limb movements and deafness.

TABLE 141.1 Differential Diagnosis Hypotonic Infant

Central causes:
1. *Vascular*
   A. Hypoxic-ischemic encephalopathy
   B. Intraventricular hemorrhage
   C. Ischemic or hemorrhagic stroke
2. *Structural*
   A. Brain malformations
   B. Cerebral palsy
   C. Intracranial neoplasms
3. *Metabolic*
   A. Toxic metabolites
   B. Energy metabolism
   C. Intracellular small molecules
4. *Systemic*
   A. Congenital infections
   B. Sepsis/CNS infection
   C. Endocrine disorders
   D. Electrolyte disturbance
5. *Chromosomal disorders*
   A. Prader-Willi syndrome
   B. Trisomy 21
   C. DiGeorge syndrome
6. *Spinal cord*
   A. Dysraphism/spina bifida
   B. Ischemic injury

Peripheral causes:
1. *Anterior horn cell*
   A. Spinal muscular atrophy 5q
   B. SMARD1
   C. Poliomyelitis
   D. Acute flaccid myelitis
2. *Brachial plexus injury*
   A. Erb palsy
   B. Klumpke palsy
3. *Peripheral nerve*
   A. Demyelinating neuropathies
      i. Early-onset demyelinating neuropathies with CNS involvement
         a. Waardenburg syndrome and Hirschsprung disease: *SOX10*
         b. Severe forms of Cockayne syndrome: *ERCC6* and *ERCC8*
         c. Krabbe disease: *GALC*
         d. Merosin-deficient congenital muscular dystrophy: *LAMA2*
         e. Navajo neurohepatopathy: *MPV17*
         f. Congenital disorders of glycosylation: multiple genes
         g. Congenital cataracts, facial dysmorphism, and neuropathy: *CTP1*
         h. POLG-related hepatocerebral mtDNA depletion syndromes: *POLG1*
         i. Leigh syndrome: multiple genes
         j. *PRUNE1*
         k. *PTRH2*
   B. Axonal neuropathies
      i. Early-onset axonal neuropathy with CNS involvement
         a. Infantile neuroaxonal dystrophy (INAD): *PLA2G6*
         b. *Twinkle* mutations with severe encephalopathy, abnormal movements, and deafness
   C. Mixed neuropathies
4. *Neuromuscular junction*
   A. Transient neonatal myasthenia gravis
   B. Fetal acetylcholine receptor inactivation syndrome (FARIS)
   C. Congenital myasthenic syndromes
   D. Infantile botulism
5. *Muscle*
   A. Congenital muscular dystrophies
      i. Merosin deficient
      ii. Congenital disorders of glycosylation
      iii. Congenital myotonic dystrophy
   B. Congenital myopathies
      i. Nemaline myopathy
      ii. Central core myopathy
      iii. Myotubular myopathy
   C. Metabolic myopathies
      i. Acid maltase deficiency (Pompe disease)
      ii. Mitochondrial myopathy

Abbreviations: CNS, central nervous system; mtDNA, mitchondrial DNA; POLG, DNA polymerase subunit gamma; SMARD1, spinal muscular atrophy with respiratory distress type 1.

Mixed Axonal and Demyelinating Neuropathy

Severe, early-onset cases can be caused by dominant or recessive mutations in *NEFL*. Pes cavus is frequent. Additional features include intellectual disability, pyramidal signs, hearing loss, ataxia, and tremor. The NCSs show mixed axonal and demyelinating features. Compound motor action potentials are usually moderately to severely reduced, and distal motor latencies may be significantly prolonged. *SPTBN4* mutation has been found in more complex and severe syndromes starting at birth and associated with CNS involvement and including a mainly axonal neuropathy

Neuromuscular Junction Disorders

Infant Botulism

In 2016, the CDC reported 205 confirmed cases of botulism of which 150 (73%) were in infants. The 150 cases of infant botulism were reported from 29 states and the District of Columbia, with California reporting the most (n = 47; 32%). The median age of patients was 4 months (range: 0-10 mo) with no reported deaths.

Infant botulism results from the ingestion of *C botulinum* spores. This bacterium is a gram-positive spore that produces seven different toxins (A → G), and only types A, B, E, and F are known to cause disease in humans. Upon ingestion of *C botulinum* spores, colonization occurs in the infant's intestinal tract, which lacks the competitive microbial flora that normally inhibits growth of ingested spores. The spores then produce neurotoxins that are absorbed into the blood and eventually bind to the presynaptic nerve terminals. This prevents the binding, fusion, and release of acetylcholine and causes a symmetric, descending motor weakness, and flaccid paralysis with autonomic dysfunction.

Botulinum toxicity often presents with acute manifestations of pupillary dilation and paralysis, ophthalmoplegia, feeding difficulties, decreased gag, bulbar palsy, ileus, constipation, hypotonia, weakness, decreased tendon reflexes, and apneic spells. Hypotension, neurogenic bladder, and other signs of autonomic dysfunction can occur early in the course of the disease. Diagnostic triad on EMG/NCS include compound muscle action potentials of decreased amplitude in at least two muscle groups, tetanic and posttetanic facilitation defined by an amplitude of more than 120% of baseline, and prolonged posttetanic facilitation of more than 120 seconds and absence of posttetanic exhaustion. The diagnosis is confirmed by the recovery of the bacterium and the exotoxin in the feces. Stool samples should be collected carefully, as the botulinum toxin is poisonous.

Prompt recognition and diagnosis is imperative for treatment. Supportive care is the mainstay of treatment, with inpatient observation and management of respiratory and feeding complications. Baby botulinum immune globulin is available only to infants who are diagnosed with suspected botulism within 7 days of hospital admission and after consultation with an Infant Botulism Treatment and Prevention Program physician. The use of botulinum immune globulin shortens hospital stay and reduces the need for mechanical ventilation and tube feeding. Infants are expected to make a complete recovery if spared any secondary complications.

Myasthenia

Infants born to myasthenic mothers are at risk for transient neonatal symptoms from passive transfer of maternal acetylcholine receptor antibodies across the placenta. Symptoms include hypotonia and generalized weakness, weak cry, facial palsy, respiratory insufficiency, and feeding difficulties with a weak gag. Other clues to prenatal onset of symptoms include polyhydramnios (poor fetal swallowing) and arthrogryposis (reduced fetal movements). Diagnosis is confirmed by detection of circulating serum acetylcholine receptor antibodies and demonstration of decremental response on repetitive nerve stimulation at 3 to 5 Hz. Supportive care is the mainstay of treatment, with more severe symptoms benefiting from acetylcholinesterase inhibition. Symptoms improve over days to weeks. Rarely, mothers who have antibodies to the fetal subunit of the acetylcholine receptor (γ subunit) have more severely affected infants, either with recurrent miscarriages or infants with transient neonatal myasthenic symptoms that maintain a static facial diplegia and velopharyngeal insufficiency (fetal acetylcholine receptor inactivation syndrome). Prevention for future effected pregnancies include more intensive immunomodulatory treatment of the mother.

Congenital myasthenic syndromes include a number of genetic disorders affecting presynaptic, synaptic, or postsynaptic components of the neuromuscular junction. These conditions are described more completely in Chapter 93. Neonatal or early infancy presentation include hypotonia and muscle weakness, arthrogryposis, facial diplegia, ptosis, ophthalmoplegia, delayed pupillary light reflex, bulbar weakness, weak cry, poor suck, feeding difficulty, episodic decompensation, and episodic apnea. Progressive improvement can be seen in several forms (Dok-7, Rapsyn, CHaT). Treatment is specific to underlying etiology, and options include acetylcholinesterase inhibition, 3,4-diaminopyridine, salbutamol, and fluoxetine.

Muscle Disorders

Myopathies and muscular dystrophies are described more completely in Chapter 147. For metabolic myopathies, refer to Chapters 99, 139, 144, and 147. Congenital myopathies presenting in infancy with hypotonia and weakness include central core disease (*RYR1*), X-linked myotubular myopathy (*MTM1*), and nemaline rod myopathy. Other clinical features include ophthalmoplegia, facial diplegia, respiratory muscle weakness, and bulbar weakness. Congenital muscular dystrophies associated with central abnormalities include those associated with congenital disorders of glycosylation as well as merosin-deficient congenital muscular dystrophy. Infants born to mothers with myotonic dystrophy are typically more severely affected than their mothers due to anticipation in this triplet repeat disorder. Characteristic facial diplegia, tented upper lip, and temporal hollowing is observed, with respiratory distress and feeding difficulties in infants who have over 1,500 repeats (congenital myotonic dystrophy). Screening for cardiac arrhythmia, cataracts, and endocrine disorders is needed, and these children can have significant impairment across developmental domains. Diagnosis is confirmed by genetic testing; clinical myotonia is absent in infancy but observed later in childhood. Myotonia, however, can be readily detected in the mother when the diagnosis is suspected in the newborn infant.

Metabolic myopathies associated with glycogen storage disorders such as acid maltase deficiency (Pompe disease) can have neonatal presentation and should be suspected with cardiomyopathy. Early diagnosis of Pompe disease allows early institution of enzyme replacement therapy, which minimizes morbidity and prolongs survival. Mitochondrial myopathies can also present

with infant hypotonia, such as cytochrome c oxidase deficiency. Investigations to consider are serum creatine kinase, brain imaging, EMG/NCS, isoimmune electrophoresis for transferrin, and genetic testing. A normal creatine kinase level can be observed with several congenital myopathies.

SUGGESTED READINGS

Abbassi-Ghanavati M, Alexander JM, McIntire DD, Savani RC, Leveno KJ. Neonatal effects of magnesium sulfate given to the mother. *Am J Perinatol*. 2012;29:795-799.

Baets J, Deconinck T, De Vriendt E, et al. Genetic spectrum of hereditary neuropathies with onset in the first year of life. *Brain*. 2011;134(pt 9): 2664-2676.

Berardo A, DiMauro S, Hirano M. A diagnostic algorithm for metabolic myopathies. *Curr Neurol Neurosci Rep*. 2010;10(2):118-126.

Bönnemann CG, Wang CH, Quijano-Roy S, et al. Diagnostic approach to the congenital muscular dystrophies. *Neuromuscul Disord*. 2014;24:289-311.

Brun L, Ngu LH, Keng WT, et al. Clinical and biochemical features of aromatic L-amino acid decarboxylase deficiency. *Neurology*. 2010;75(1):64-71.

Chien YH, Hwu WL, Lee NC. Pompe disease: early diagnosis and early treatment make a difference. *Pediatr Neonatol*. 2013;54:219-227.

Darras BT, Jones HR Jr, Ryan MM, De Vivo DC, eds. *Neuromuscular Disorders of Infancy, Childhood, and Adolescence*. 2nd ed. London, United Kingdom: Academic Press; 2015.

Dubowitz V. *The Floppy Infant*. Cambridge, United Kingdom: Cambridge University Press; 1993.

Engel AG, Shen XM, Selcen D, Sine SM. Congenital myasthenic syndromes: pathogenesis, diagnosis, and treatment. *Lancet Neurol*. 2015;14(4): 420-434.

Johnson NE, Butterfield R, Berggren K, et al. Disease burden and functional outcomes in congenital myotonic dystrophy: a cross-sectional study. *Neurology*. 2016;87(2):160-167.

Kamboj M. Clinical approach to the diagnoses of inborn errors of metabolism. *Pediatr Clin North Am*. 2008;55(5):1113-1127.

Kozma C. Neonatal toxicity and transient neurodevelopmental deficits following prenatal exposure to lithium: another clinical report and a review of the literature. *Am J Med Genet A*. 2005;132A:441-444.

Lehman LL, Rivkin MJ. Perinatal arterial ischemic stroke: presentation, risk factors, evaluation, and outcome. *Pediatr Neurol*. 2014;51:760-768.

Leonard JV, Morris AA. Inborn errors of metabolism around time of birth. *Lancet*. 2000;356(9229):583-587.

Leyenaar J, Camfield P, Camfield C. A schematic approach to hypotonia in infancy. *Paediatr Child Health*. 2005;10(7):397-400.

Lott IT. Neurological phenotypes for Down syndrome across the life span. *Prog Brain Res*. 2012;197:101-121.

Menezes MP, North K. Inherited neuromuscular disorders: pathway to diagnosis. *J Paediatr Child Health*. 2012;48:458-465.

Michelson DJ, Ciafaloni E, Ashwal S, et al. Evidence in focus: nusinersen use in spinal muscular atrophy: report of the guideline development, dissemination, and implementation subcommittee of the American Academy of Neurology. *Neurology*. 2018;91(20):923-933.

Neu N, Duchon J, Zachariah P. TORCH infections. *Clin Perinatol*. 2015;42(1): 77-103, viii.

North KN, Wang CH, Clarke N, et al. Approach to the diagnosis of congenital myopathies. *Neuromuscul Disord*. 2014;24:97-116.

Oskoui M, Darras B, De Vivo D. Spinal muscular atrophy: 125 years later and on the verge of a cure. In: Sumner C, Paushkin S, Ko CP, eds. *Spinal Muscular Atrophy: Disease Mechanisms and Therapy*. London, United Kingdom: Elsevier Science; 2016:3-20.

Oskoui M, Jacobson L, Chung WK, et al. Fetal acetylcholine receptor inactivation syndrome and maternal myasthenia gravis. *Neurology*. 2008;71(24): 2010-2012.

Parikh S, Bernard G, Leventer RJ, et al. A clinical approach to the diagnosis of patients with leukodystrophies and genetic leukoencephelopathies. *Mol Genet Metab*. 2015;114(4):501-515.

Pearl PL, Taylor JL, Trzcinski S, Sokohl A. The pediatric neurotransmitter disorders. *J Child Neurol*. 2007;22(5):606-616.

Pifko E, Price A, Sterner S. Infant botulism and indications for administration of botulism immune globulin. *Pediatr Emerg Care*. 2014;30:120-127.

Prasad AN, Prasad C. Genetic evaluation of the floppy infant. *Semin Fetal Neonatal Med*. 2011;16:99-108.

Scott K, Gadomski T, Kozicz T, Morava E. Congenital disorders of glycosylation: new defects and still counting. *J Inherit Metab Dis*. 2014;37(4): 609-617.

Takcı Ş, Bayhan C, Çelik T, Yiğit S. Hypotonia and poor feeding in an infant exposed to lamotrigine and valproic acid in utero. *Turk J Pediatr*. 2013;55:546-548.

Tuysuz B, Kartal N, Erener-Ercan T, et al. Prevalence of Prader-Willi syndrome among infants with hypotonia. *J Pediatr*. 2014;164:1064-1067.

Uzun S, Kozumplik O, Jakovljević M, Sedić B. Side effects of treatment with benzodiazepines. *Psychiatr Danub*. 2010;22(1):90-93.

Wilmshurst JM, Ouvrier R. Hereditary peripheral neuropathies of childhood: an overview for clinicians. *Neuromuscul Disord*. 2011;21:763-775.

Wilmshurst JM, Pollard JD, Nicholson G, Antony J, Ouvrier R. Peripheral neuropathies of infancy. *Dev Med Child Neurol*. 2003;45:408-411.

Yiu EM, Ryan MM. Demyelinating prenatal and infantile developmental neuropathies. *J Peripher Nerv Syst*. 2012;17:32-52.

Yiu EM, Ryan MM. Genetic axonal neuropathies and neuronopathies of pre-natal and infantile onset. *J Peripher Nerv Syst*. 2012;17:285-300.

Zuarez-Easton S, Zafran N, Garmi G, Hasanein J, Edelstein S, Salim R. Risk factors for persistent disability in children with obstetric brachial plexus palsy. *J Perinatol*. 2017;37(2):168-171.

142 Disorders of Motor and Cognitive Development

Jason B. Carmel, Toni S. Pearson, and Reet Sidhu

KEY POINTS

1. Childhood is not only a time of increased brain plasticity but also a time of increased vulnerability.
2. Malformation or injury of the developing brain can result in deficits of several neurologic functions.
3. If there is impaired movement, then the condition is called *cerebral palsy*, which often affects other nervous system functions, including sensation and cognition.
4. If the impairment is cognitive and affects overall intelligence, then the condition is called *intellectual disability*.
5. Autism spectrum disorder is a developmental disorder that primarily affects social and language function.
6. If multiple neurologic functions are affected, the impairment is known as *global developmental delay*.

INTRODUCTION

Infancy and early childhood are marked by rapid brain growth and development. A wide variety of genetic and environmental factors may affect the immature brain during this period and manifest as a delay in the acquisition of milestones in one or more developmental domains: motor (gross and fine), speech/language, social, and cognitive. The delay may be isolated to one domain. When development in more than one domain is significantly delayed in children younger than the age of 5 years, the term *global developmental delay* (GDD) applies.

Developmental delay is a common reason for referral to a child neurologist. The aims of the initial neurologic evaluation of a child with developmental delay are, first, to confirm the nature and severity of the suspected delay and, second, to characterize any specific findings that may provide a clue to the underlying diagnosis. A detailed history is the key starting point. Items of particular importance include the family history (presence of neurologic or developmental disorders in the siblings, parents, grandparents, aunts, or uncles), perinatal history (complications during pregnancy, birth, or the neonatal period, including prematurity), and history of any coexisting medical problems. With regard to the presenting problem (eg, motor delay), important items include the age at which the initial concern arose, the child's developmental progress over time, and whether or not there has been developmental regression. On general examination, the child's head circumference, height and weight, and the presence of any dysmorphic features should be noted. The eyes and optic fundi should be thoroughly examined, and skin should be checked for stigmata of neurocutaneous syndromes. Specific features of interest in the neurologic examination will be outlined in the relevant sections in the following text.

DISORDERS OF MOTOR DEVELOPMENT

The acquisition of motor skills features prominently in the first year of life (Table 142.1). As a result, conditions that affect the motor system often present during infancy with motor developmental delay. Motor delay may also be the first manifestation of a condition that affects development globally because impaired motor function becomes apparent earlier than impairments in other domains, such as cognition and language. Motor delay may be accompanied by specific motor symptoms such as increased appendicular tone ("stiff"), decreased axial tone ("floppy"), and involuntary movements.

TABLE 142.1 Motor Developmental Milestones in the First 5 Years[a]

Gross Motor	Age Range
Hold head steady	2-4 mo
Roll over	2-5 mo
Sit without support	5½-7 mo
Pull to stand	8-10 mo
Walk	11-15 mo
Run	14-20 mo
Jump	21-28 mo
Hop	3-4 y
Balance on one foot for 4 s	3½-5 y
Fine Motor	**Age Range**
Grasp rattle	3-4 mo
Reach	4-6 mo
Transfer objects	5-8 mo
Pincer grasp	7-10 mo
Scribble	12-17 mo
Feed self with spoon	13-18 mo
Stack two blocks	13-21 mo
Hold crayon using fingers (not fist)	2-3 y
Copy a circle	3-4 y
Refined tripod pencil grip, print own name, copy a square	4-5 y

[a]Age range indicates approximately the 25th to 90th percentile for each milestone according to the Denver II Developmental Screening Tool.

Approach to the Child With Motor Delay

The neurologic examination begins with observation, particularly in the infant or toddler. Observe the child's spontaneous posture and movements for asymmetry, paucity of movement that may hint at weakness, abnormal postures, and excessive or involuntary movements. On cranial nerve examination, look for eye movement abnormalities including restricted range of movement and nystagmus. If the child can speak, note whether speech is clear or dysarthric. Turning attention to the body, assess muscle tone in the trunk and limbs. Low truncal tone is common to many disorders that present with motor delay in infancy. Are the limbs hypotonic or spastic (a rate-dependent increase in tone)? Check whether tendon reflexes are abnormally brisk, suggesting an upper motor neuron lesion, or reduced, suggesting an abnormality of the lower motor neuron, nerve, or muscle. Assess coordination on targeted reaching movements (looking for dysmetria) and, in an older child, rapid alternating movements such as repetitive hand tapping. If the child is able, ask them to rise to standing from the floor (looking for a Gowers sign, which indicates proximal leg weakness). Note whether the gait is narrow or wide-based and steady or unsteady. If involuntary movements are present, note their body distribution, their quality (eg, sustained, writhing, or jerky), whether they are random or repetitive and stereotyped, and in what contexts they appear (eg, at rest, during movement).

Following the clinical evaluation, neuroimaging may be considered and directed by the history and examination. Magnetic resonance imaging of the brain is indicated if there is a history of developmental regression, marked micro- or macrocephaly (>2 standard deviations from the mean), abnormal rate of head growth, or any abnormalities on neurologic examination including cranial nerve dysfunction, focal weakness, spasticity, abnormally brisk reflexes, or involuntary movements. Other investigations, such as genetic testing, may be indicated by the clinical syndrome or brain imaging results. In all cases, the aim is to determine a specific etiologic diagnosis whenever possible in order to guide the most appropriate management strategy. If the clinical syndrome and brain imaging findings are compatible with a developmental malformation or acquired brain lesion, then symptomatic management will be the most important consideration (see "Cerebral Palsy" section in the following text). On the other hand, several individually rare genetic and metabolic disorders may present with motor delay and mimic cerebral palsy (CP). It is vital that the child neurologist be alert to signs that may indicate one of these conditions (Table 142.2).

TABLE 142.2 Features That Should Prompt Evaluation for a Possible Genetic or Metabolic Disorder in a Child Presenting With Symptoms of Cerebral Palsy

- Parent or sibling with a neurologic disorder
- Absent history of perinatal complications
- Normal brain imaging
- Developmental regression
- Progressive neurologic symptoms
- Ataxia or involuntary movements
- Signs of peripheral neuromuscular disease (reduced or absent reflexes, sensory loss)
- Fluctuating motor symptoms, for example, diurnal variation, worsening during fasting or exercise (may be symptoms of a treatable condition, eg, a neurotransmitter disorder or GLUT1 deficiency syndrome)

Abbreviation: GLUT1, glucose transporter 1.

Making the correct diagnosis in these cases has important implications for management. In some cases, there is a disease-specific treatment that may dramatically improve the clinical course. Even if no disease-specific treatment yet exists, accurate diagnosis makes it possible to provide prognostic information and genetic counseling regarding recurrence risk in future pregnancies to the family.

Cerebral Palsy

CP is defined as an insult to the developing brain that impairs movement or posture. CP is an umbrella term that describes a group of disorders (the cerebral palsies) characterized by motor impairment due to a developmental anomaly or nonprogressive brain lesion that arose in the developing fetal or infant brain. The term *cerebral palsy* remains useful if considered not as a diagnosis in itself, but rather as a descriptive term that has widespread familiarity and conveys a recognized set of clinical characteristics and medical needs.

CP is common, with a birth prevalence of 2 or 3 per 1,000 live births in developed countries. Risk factors include a history of prematurity, intrauterine growth retardation, multiple gestation, intrauterine infection, and antepartum hemorrhage. One common misconception is that CP is usually caused by birth asphyxia. Although ascribing etiology has challenges, the rate of perinatal asphyxia is likely less than 20%. Other causes of CP include periventricular leukomalacia (the most common form of brain injury in very preterm infants), cerebral malformations, stroke, and infection. The etiology is usually, but not always, evident on brain imaging.

CP may be classified according to the predominant motor abnormality: spasticity, dyskinesia (involuntary movements including dystonia, chorea, or athetosis), or ataxia. In most cases, there is a mixture of more than one motor feature, such as spasticity and dystonia. CP may be further classified according to the body regions that are primarily affected: diplegia (both legs), quadriplegia (all four limbs), and hemiplegia (one side of the body). An accurate characterization of the motor syndrome is important for two reasons. First, it assists the interpretation of the clinical history and brain imaging findings in establishing the etiology of a child's CP. Second, it guides management decisions.

Spastic Diplegia

Approximately, one-third of children with CP have spastic diplegia (or diparesis), in which spasticity is predominantly found in the legs. The arms may be mildly affected or unaffected. Parents may notice leg stiffness and a tendency for the legs to cross ("scissoring") due to increased tone in the hip adductor muscles. The increased lower limb tone may lead an infant to roll over or bear weight through the legs at an atypically early age. An older child with mild to moderate symptoms may have a narrow-based, scissoring gait and toe walking. On examination, there is increased tone in the legs, particularly hip adductors, hamstrings, and calves. Tendon reflexes are brisk, and plantar responses are extensor. The most commonly associated brain imaging abnormality is bilateral periventricular white matter lesions, particularly in children with a history of prematurity. The white matter lesions may be periventricular leukomalacia, consequences of intraventricular hemorrhage, or both.

Spastic Quadriplegia

Spastic quadriplegia (found in 20%-25% of children with CP) is often the most severe form. Quadriplegia is frequently associated with diffuse brain injury or dysgenesis, but one side may be more

affected than the other. Brain imaging may demonstrate abnormalities in both gray and white matter. The most common alteration in tone is axial hypotonia (weak neck and trunk) and limb hypertonia (spasticity). A subset of patients has lesions in the deep gray nuclei (basal ganglia or thalamus) and may have a coexisting movement disorder. Most children with spastic quadriplegia are unable to walk and are dependent on a wheelchair for mobility and on support from caregivers for daily activities. Due to the diffuse nature of the brain injury, a number of comorbidities are often present, including seizures, cognitive impairment, sensory impairments, and speech/swallowing difficulties. If swallowing is impaired, a feeding gastrostomy may be required to ensure adequate nutrition. For children who have both the inability to speak and limited voluntary control of hand movements, communication can be very challenging. Effective use of a communication device such as a board or tablet to which the child can point, or devices with eye tracking capability, may vastly improve the quality of life for both the child and his/her caregivers.

Spastic Hemiparesis

Spastic hemiparesis is found in about one-third of children with CP and results from a unilateral brain lesion, such as a cerebral infarct (often in the territory of the middle cerebral artery), focal malformation (eg, schizencephaly, cortical dysplasia), or periventricular hemorrhagic infarction. Such lesions may have been acquired prenatally or perinatally, but symptoms tend to manifest around age 6 months, when parents notice that the child exhibits a strong preference to use one hand over the other. Handedness normally develops at age 2 to 3 years, and so an obvious hand preference younger than 12 months of age should prompt clinical evaluation for a hemiparesis.

The hemiparesis usually affects the arm and hand more than the leg. Children with spastic hemiplegic CP are able to walk, although walking may be delayed, and an asymmetric gait pattern with toe walking and circumduction of the affected leg is observed. In mild cases, upper limb weakness may only be evident as a subtle loss of hand dexterity or abnormal arm posturing during running. On the other hand, large lesions that involve both the white matter and the cortex can be associated with pronounced weakness as well as cortical sensory loss, leading to little or no functional hand use. Speech and language development is often delayed in the setting of a unilateral lesion of either hemisphere, but most children develop age-appropriate spoken language by the time they enter school. Longitudinal follow-up studies describe the emergence of subtle cognitive weaknesses in school-aged children with a history of perinatal stroke. Seizures are an additional factor that may adversely impact long-term cognitive outcome.

Dyskinetic Cerebral Palsy

Involuntary movements are the predominant motor finding in 5% to 10% of children with CP. The majority of children with dyskinetic CP have a history of term birth. Several types of involuntary movements may occur either alone or in combination. *Dystonia* describes stereotyped, abnormal twisting postures that may be fixed or intermittent. When severe dystonia causes fixed postures that make the limb appear hypertonic, it may be difficult to distinguish from severe spasticity. *Athetosis* refers to continuous writhing or wriggly movements, whereas *chorea* appears as discrete, random-appearing, jerky movements. Children with dyskinetic CP often have low tone that develops during infancy. A key feature of the involuntary movements is their tendency to worsen with increased activity or attempts to initiate voluntary movement. Often, muscles of the face and neck are involved in addition to the trunk and limbs.

Basal ganglia lesions are the most common abnormality seen on brain imaging in children with dyskinetic CP. These lesions may result from hypoxic-ischemic injury (in which cortical injury is also often seen) or neonatal hyperbilirubinemia (*kernicterus*, usually caused by maternal-fetal blood group incompatibility and now rare in developed countries). In instances where the cortex is spared, children may have good cognitive function despite severe motor disability and speech impairment.

Ataxic Cerebral Palsy

Ataxic CP is the least common form of CP (<5%) and is characterized by hypotonia, trunk and gait ataxia, and limb ataxia (intention tremor, dysmetria). If speech is affected, dysarthria with a slow and scanning quality is typical. Brain imaging may demonstrate a cerebellar malformation or lesion, although it is often normal. Both dyskinetic and ataxic CP are associated with normal brain imaging in a significant proportion of children (approximately one-third and one-half, respectively). In these cases, it is important to consider further investigation for an underlying treatable or neurodegenerative condition (**Table 142.3**).

TABLE 142.3 Selected Genetic Conditions That May Mimic Dyskinetic and Ataxic Cerebral Palsy

Condition	Features
Neurotransmitter disorders	Hypotonia, dystonia with diurnal variation (better in morning and after sleep), oculogyric crises. Diagnosed by CSF neurotransmitter metabolite assay, genetic testing. Many forms respond to levodopa treatment.
GLUT1 deficiency syndrome	Seizures, acquired microcephaly, ataxia, spasticity, dystonia, paroxysmal dyskinesia (may be triggered by exercise, fasting); treatment: ketogenic diet
Creatine deficiency	Intellectual disability, seizures, autism, progressive dystonia in GAMT deficiency; treated with creatine monohydrate supplementation.
Benign hereditary chorea	Hypotonia, chorea, dystonia, myoclonus; may be associated with hypothyroidism, neonatal respiratory distress, or asthma
Lesch-Nyhan syndrome	Hypotonia, dystonia, self-injurious behavior, elevated plasma urate
Ataxia-telangiectasia	Slowly progressive ataxia; chorea; dystonia (involuntary movements may precede onset of ataxia); oculocutaneous telangiectasia; immunodeficiency; elevated serum α-fetoprotein; reduced levels of serum IgA, IgE, IgG_2
Pelizaeus-Merzbacher disease	Initial hypotonia then spastic quadriparesis, ataxia, ± dystonia and chorea, nystagmus (in classic form)
Niemann-Pick disease type C	Initial hypotonia followed by vertical supranuclear gaze palsy, slowly progressive ataxia, dystonia; ± hepatosplenomegaly

Abbreviations: CSF, cerebrospinal fluid; GAMT, guanidinoacetate methyltransferase; GLUT1, glucose transporter 1; Ig, immunoglobulin.

Management of Cerebral Palsy

Children with CP should be referred to a multidisciplinary specialty center and to an early intervention program for therapy services as soon as they are identified. Hearing and vision should both be assessed early. Interventions are directed toward (1) spasticity management; (2) management of involuntary movements; and (3) improvement of strength, motor abilities, function, and self-care. Effective management requires regular follow-up as the child grows and develops so that realistic expectations and achievable goals can be set and periodically reevaluated.

Spasticity management aims to reduce hypertonia in order to maximize the child's ability to gain muscle strength and range of movement through physical therapy and to prevent long-term complications such as joint contractures and deformity. Functional goals depend on the severity of the child's impairment. For example, the goal for a child with moderate spastic diparesis may be to achieve independent ambulation. In a child with severe spastic quadriplegia, seizures, and intellectual disability (ID), the goal may be to improve patient comfort and ease care during daily activities such as dressing and bathing. The effect of spasticity on a child's posture and motor function can change over time, often increasing noticeably during periods of rapid growth. Thus, although CP is caused by a nonprogressive brain lesion, the signs and symptoms change with time.

Botulinum toxin injections are an effective tool for reducing spasticity, particularly when targeted toward a limited number of muscle groups. The toxin's effect lasts approximately 3 to 4 months, so injections typically need to be repeated up to 3 times per year. Short-term efficacy must be weighed against emerging evidence for injections causing muscle fibrosis. Sometimes, injections may be combined with serial casting to treat mild contractures. Oral medications such as baclofen (starting dose: 2.5-5 mg/d) and diazepam (starting dose: 1-5 mg/d depending on age and size) are useful when symptoms are generalized and offer modest benefit, but side effects such as sedation often limit the dose and efficacy.

Neurosurgical options for the management of spasticity include placement of an intrathecal baclofen pump and selective dorsal rhizotomy. Compared to oral baclofen, intrathecal baclofen may achieve a greater reduction in spasticity and dystonia, particularly in the legs, with fewer side effects. However, this potential benefit must be weighed against the long-term effort needed to maintain the pump and risk of complications. Rhizotomy aims to produce a permanent reduction in tone and is a good treatment option for some patients. Traditionally, the "ideal" rhizotomy candidate has been an ambulating child aged 3 to 8 years with spastic diparesis, in whom the goal of surgery is to optimize gait and independent function. Rhizotomy may also be appropriate in selected patients with spastic quadriparesis in order to ease caregivers' burden of care and reduce the need for future botulinum toxin injections and orthopedic procedures. If musculoskeletal complications such as joint contractures develop despite medical and surgical attempts to control spasticity, orthopedic surgery (such as tendon release procedures) may be indicated. Orthopedic realignment may be important for achieving functional goals.

Children with dyskinetic CP often benefit from symptomatic treatment of their involuntary movements. For dystonia, trihexyphenidyl, starting at a low dose (1-2 mg/d) and titrated gradually to the point of tolerance (with common side effects being sedation, constipation, and urinary retention), may reduce abnormal posturing. Levodopa (starting dose: 25-50 mg/d) is beneficial in some children with dystonic CP. Hyperkinetic movements, such as chorea or athetosis, may respond to tetrabenazine (starting dose: 6.25-12.5 mg/d). Deep brain stimulation, with electrodes placed in the globus pallidus pars interna, may be a surgical option in severe, treatment-refractory cases of dyskinetic CP, although experience regarding efficacy and long-term outcome remains limited.

The rehabilitation team, composed of a physiatrist; orthotist; and physical, occupational, and speech/language therapists, plays an essential role in the care of a child with CP. Physical therapy aims to improve strength and quality of movement, train function, and maintain range of motion. Occupational therapy focuses on arm and hand movement control and building independence in daily activities. Speech and language therapy focuses on communication. It is important to assess the child's home and school environments and determine equipment to facilitate mobility, independence, and functional communication.

Although diagnosed during childhood, CP is a lifelong condition, and there are more adults living with CP than children. Interventions made early in life must consider the long-term consequences of the intervention. Children with severe motor and ID will require lifelong care, either from a parent or relative or in a nursing home setting. Less affected children need a school and therapy program targeted to their abilities, aiming to maximize their potential for future independence and well-being.

Developmental Coordination Disorder

Developmental coordination disorder (DCD) affects about 5% to 6% of children and is characterized by subtle impairments in gross and fine motor skills that typically manifest as difficulties in daily activities such as dressing, writing, or learning to ride a bike. Affected children are often described as "clumsy." In contrast to CP, the neurologic examination in DCD is normal apart from subtle signs such as mild hypotonia and dysdiadochokinesia. The underlying neurophysiologic basis remains poorly understood. DCD often co-occurs with other developmental disorders including attention deficit hyperactivity disorder (ADHD), learning disabilities, and speech/language impairment.

DISORDERS OF HIGHER CEREBRAL FUNCTIONS

Assessment of speech and language, cognitive, academic, and reciprocal social abilities is an essential component of the evaluation of a child with developmental delay. The disorders that affect these domains of development are all defined behaviorally, lacking a single biologic marker or gold standard diagnostic instrument. Consequently, thorough assessment is crucial for proper diagnosis and effective management. The groups of developmental disorders of higher cerebral development under consideration are listed in Table 142.4.

Approach to the Child With Language, Cognitive, or Academic Delays

The age and manner in which children acquire speech and language varies considerably. Knowledge of normal developmental language milestones is essential in order to properly assess

TABLE 142.4 Developmental Disorders of Higher Cerebral Functions

Disorder	Function Affected	Location of Brain Dysfunction
Intellectual disability	Cognition	Diffuse or multifocal
Dysphasia (developmental language disorder)	Oral language	Language systems
Dyslexia (reading disability)	Written language (phonologic processing)	Language systems (left perisylvian)
Dyscalculia (math disability)	Math (spatial cognition)	Posterior right hemisphere
Nonverbal learning disability (NVLD)	Visuospatial, math, social cognition	Right parietal
Attention deficit hyperactivity disorder (ADHD)	Focused attention (executive functioning)	Prefrontal
Autism spectrum disorders (ASDs)	Social cognition	Connectivity

a child (Table 142.5). Speech and/or language delays are one of the most common presenting complaints to a child neurologist, especially in toddlers and preschool children. Hearing impairment must be excluded in all children with speech and language delays. The main diagnostic considerations in toddlers/preschoolers are developmental language disorders, autism spectrum disorders (ASDs), ID, and ADHD, although a definitive diagnosis of the latter may be postponed until a child is older if symptoms are not severe.

The mental status examination is the most informative part of the neurologic examination in the evaluation of a developmental disability involving cognitive function. The mental status exam in the toddler/preschooler relies heavily on observation. Watch the child play with representational toys (eg, tiny dolls in a dollhouse, cars and trucks at a fire station, people and animals at a farm), assess his or her ability to talk to and play with the examiner or parent, and observe his or her interest and ability to focus on an activity introduced by another person (playing ball,

TABLE 142.5 Language and Social/Emotional Milestones

Age	Receptive Skills	Expressive Skills	Social/Emotional
0-2 mo	Startle, eye widening to sound	Range of cries (from hunger to pain)	Smiles spontaneously
2-4 mo	Quiets to voice, eye blinking to sound	Coos in response to voice	Smiles responsively
4-9 mo	Head turns to sound, responds with raised arms when mom says "up" and reaches for child, responds appropriately to friendly or angry voices	Babbling, repeats self-initiated sounds	Laughs to social attentions
9-12 mo	Listens selectively to familiar words, begins to respond to "no" and to one-step commands (usually accompanied by gesture), understands 10 words	Repeats parent-initiated sounds, symbolic gestures, jargoning, says "mama/dada" nonspecifically	Responds and plays social games: pat-a-cake, peek-a-boo. Joint attention emerges.
12-18 mo	Points to three body parts, understands up to 50 words, recognizes common objects by name, follows one-step commands accompanied by gestures	Uses words to express needs, 10 words by 18 mo, word usage may be inconsistent and mixed with jargon	Responds to name, joint attention established, functional play
18 mo-2 y	Points to pictures when asked "show me," begins to distinguish "you" from "me"	Telegraphic two-word phrases "go bye-bye," "mama up," "baby go"; 2 y: vocabulary of at least 50 words and 50% intelligible by strangers	Symbolic play (feed baby, mix food in bowls)
2 ½ y	Follows two-step commands, can identify actions in pictures and objects by use	Two- to three-word sentences develop, adjectives and adverbs appear, begins to ask questions	Imaginative play
3 y	Knows several colors; knows what to do when we are hungry, thirsty, or sleepy; aware of past and future, understands "today" and "not today"	Uses pronouns and plurals, sentence length increases to three to five words, can tell stories that begin to be understood; uses negatives "I can't" and "I won't"; verbalizes toileting needs; tells full name, age, and gender	Starts to join in play with other children, begins dramatic play
3 ½ y	Answers questions as "do you have a doll?" and "what toys do you have?"	Can relate experiences in sequential order, asks for permission	More independent in play with other children, shares toys and takes turns with assistance
4 y	Understands same versus different, can follow three-step commands, understands why we have houses, umbrellas . . .	Can tell a story, uses past tense, names primary colors, asks many questions, nearly all speech understood by strangers	Fully plays and interacts with other children, improving in turn taking and cooperation, very imaginative with self and others
5 y	Understands what we do with eyes and ears; understands "if," "because," "when," "why"; understands differences and comparisons; begins to understand left and right	Asks definition of specific words, makes serious inquiries ("how does this work?" "what does it mean?"), language is now complete in structure and form, all parts of speech are used as well as all types of sentences and clauses	Respects reasonable authority, wants to do what is expected, plays games with rules

looking at pictures, drawing). Particular attention should be paid to the child's ability to engage in creative/imaginative play, imitation, behavioral flexibility (ability to switch activities), attention span, and joint attention (the ability to draw another person's attention to an object of interest through the use of eye gaze and gestures, such as pointing).

Speech and/or language disorders can be subdivided based on the area of deficit: expressive or receptive. Expressive disorders can exist in isolation, but receptive disorders always coexist with expressive deficits. Speech and language skills should be assessed in the following areas: (1) production: amount of speech and its intelligibility, fluency, length and syntactic complexity of sentences, and richness of vocabulary; (2) pragmatics: knowing how to engage another person in conversation, turn taking, topic maintenance, appropriate eye gaze, awareness of tone of voice, facial expression, gestures, and body postures; (3) comprehension: following commands, answering simple questions (eg, what's that? where is _?), answering complex, open-ended questions (eg, why? when? how?); and (4) abnormal features: immediate echolalia, delayed echolalia (overlearned scripts), perseveration, abnormal prosody, and narrow range of topics.

In school-age children, school failure or underachievement is a common presenting complaint. In this age group, the differential diagnosis includes those disorders under consideration in the toddler/preschool years but expands to include disorders affecting academic achievement, for example, learning disabilities. Thus, the evaluation of the older child must include an assessment of academics in the areas of reading, writing, spelling, and mathematics. An assessment of cognitive ability is the first step, as the diagnosis of learning disability implies at least average intelligence. Attention should also be evaluated, as ADHD can now be diagnosed more reliably than in the toddler/preschooler. Language screening in the office is best done through a combination of informal assessment (as described for the preschooler) and standardized measures to assess vocabulary, word retrieval, word fluency, and automaticity of retrieval. General fund of knowledge, reading, spelling, writing, arithmetic, drawing (visuospatial skills), attention, and social reciprocity should also be evaluated. These skills can be assessed qualitatively; however, standardized screening tests are advisable to increase reliability.

Many children will come to the office with a detailed quantitative report generated by a psychologist or neuropsychologist detailing the strengths and weaknesses in cognitive, linguistic, and academic domains. It is important to be knowledgeable in the interpretation of these tests and their scores as parents rely on neurologists to synthesize the findings for diagnostic clarification and developing an effective management plan. If a child has not had a formal assessment, it is advisable to have a comprehensive evaluation by a psychologist (preferably a neuropsychologist) and speech language pathologist to assess the child's cognitive and linguistic strengths and weaknesses. This should include a report of school achievement tests when learning disabilities are suspected. Attention disorders (with or without hyperactivity) frequently co-occur with learning disability; therefore, it is essential to diagnose these conditions accurately, as management strategies are quite different (ie, educational vs pharmacologic).

Developmental Language Disorders

Developmental language disorders (DLD), often lumped under the umbrella term *specific language impairment* or *developmental dysphasias*, are a heterogeneous group of disorders characterized by inadequate language acquisition at the expected age despite otherwise normal development. The diagnostic criteria remain controversial, but DLD is usually ascribed when there is evidence that expressive and/or receptive language deficit is not attributable to inadequate hearing, ID, extreme and prolonged social deprivation (not simply social impoverishment), or a known brain lesion. Dysphasias can affect phonology (speech sounds) and syntax (word order, grammar) or higher order language processing skills, for example, semantic (word meaning) and pragmatics (communicative and conversational use of language). Genetics is the major cause of the developmental dysphasias, which occur more frequently in boys than girls.

Autism spectrum disorder is an important diagnostic consideration in any child with a speech and/or language delays. Children with ASDs differ from children with DLD in their lack of drive to communicate. Unlike ASD, children with DLD use gestures, such as pointing and head nodding, which are usually well coordinated with eye gaze and facial expressions. Children with ASD have abnormal features such as echolalia, overlearned scripts, and perseverative language, in addition to the hallmark of impaired social reciprocity (see Chapter 143).

The occurrence of language regression in a child raises alarm in most families and sets off a cascade of neurodiagnostic testing that usually involves performing electroencephalography (EEG). The exceptionally rare acquired epileptic aphasia or *Landau-Kleffner syndrome* (LKS) refers to previously normal children who lose their language skills, usually due to word deafness (ie, auditory verbal agnosia), in the setting of clinical seizures or an epileptiform EEG that is activated in sleep. Electrical status epilepticus during slow-wave sleep (ESES) is the EEG pattern seen in LKS. Similarly, approximately one-third of children with ASDs experience regression during the first 1 to 3 years of life, commonly referred to as *autistic regression*. The EEGs in these children can be epileptiform. Children with autistic regression, however, undergo a more global loss of skills involving language, nonverbal communication, and sociability, unlike those with LKS who tend to maintain nonverbal communication skills and reciprocal social capabilities. The degree of overlap between LKS, ESES, and autistic regression with epileptiform EEG is currently poorly understood, although it is known that ESES is rarely seen in children with a more global autistic regression.

Intellectual Disability

Intellectual disability, also known as *intellectual developmental disorder*, requires limitations in both intellectual ability and deficits in adaptive skills relative to the child's age, experience, and environment. The onset of both deficits must occur during childhood. Deficits in intellectual functioning must be confirmed through clinical evaluation and standardized IQ testing. The IQ definition of ID uses 100 as the mean and 15 as the standard deviation. An IQ score of 65 to 75 (2 standard deviations below the mean, with a variation of +/− 5 points) is the demarcation point. The level and severity of ID (mild, moderate, severe, and profound) is defined on the basis of adaptive skills rather than the IQ score. The definition links the severity of ID to the degree of community support required to achieve optimal independence. Mild ID indicates the need for intermittent support, moderate ID for limited support, severe ID for extensive support, and profound ID for pervasive support. Although both intellectual and adaptive functioning are pertinent in defining ID,

impairment of adaptive function is more likely to be the presenting feature than low IQ; however, it is expected that there is an association between intellectual functioning and adaptive skills.

The term *global developmental delay* is used to describe children younger than the age of 5 years with significant delays in developmental milestones in several areas of functioning. GDD can be diagnosed using a standardized test, which shows performance at least 2 standard deviations below the mean in at least two developmental domains: motor, speech and language, cognition, personal-social, and/or adaptive (daily living). The diagnosis of ID is not used for children younger than age 5 years old because IQ scores are not reliable until after 5 years and because some children with GDD will not meet criteria for ID as they get older.

The prevalence of ID varies due to differences in diagnostic approach, population characteristics, and study design but is generally considered to be 1%. Mild ID represents the majority (85%) and severe ID the minority (0.5%-1%). Those with severe ID are more likely to have a definable etiology, whereas those with mild ID tend to come from socially disadvantaged backgrounds, often with a family history of mild ID or borderline intellectual function. The prevalence of GDD (in children younger than 5 y) is estimated at 1% to 3%.

The yield of diagnostic testing in determining a cause for GDD/ID is quite variable. The diagnostic evaluation should focus on clues for a genetic versus acquired etiology for ID. Recent years have seen important progress in identifying the genes involved in ID and currently, genetic defects are found in approximately 25% to 50%. A history of consanguinity, pregnancy losses/stillbirths, postnatal deaths of prior offspring, or birth defects should raise suspicion for a genetic etiology. If there is a family member known to have GDD/ID, testing specific to the known disorder should be performed, and if not known, a comprehensive genetics evaluation should be initiated. Observed dysmorphic features may prompt specific testing (eg, Down syndrome, fragile X syndrome).

Other neurodiagnostic investigations should be undertaken based on the clinical picture. Inherited metabolic diseases are responsible for 1% to 5% of unspecified ID, and testing should be undertaken if clinical indicators are present. An EEG is appropriate if an underlying epilepsy syndrome is suspected or when there are paroxysmal behaviors concerning for seizures. Neuroimaging is recommended as part of the diagnostic evaluation of a child with GDD. Magnetic resonance imaging is more sensitive than computed tomography (CT), with abnormalities found in approximately one-half to one-third of children with global delay. The chance of detecting an abnormality increases if movement abnormalities, particularly CP, are present.

The management of children with ID focuses on finding the appropriate educational setting for children with mild ID, vocational training for those with moderate ID, and determining home or institutional placement for those with severe and profound ID. Available evidence demonstrates the benefits of early intervention through a variety of programs, at least with respect to short-term outcomes, and suggests that early diagnosis of a child with global delay may improve long-term outcome.

Learning Disabilities

Learning disabilities occur in approximately 10% to 15% of school-aged children and can affect one or more academic skills. Learning disabilities involve reading (dyslexia), spelling (dysorthographia), writing (dysgraphia), mathematics (dyscalculia), and visuospatial skills (nonverbal learning disability [NVLD]). Executive functioning deficits are seen in learning disabilities and also in disorders of attention, for example, ADHD. Specific learning disabilities do not refer to those children whose learning problems result from visual, hearing, or motor handicaps or are a consequence of emotional disturbance, environmental, cultural, or economic disadvantage. The term *learning disability* implies at least average intelligence.

Dyslexia

Developmental dyslexia is the most widely recognized and most common learning disabilities. It occurs in as many as 10% of school-aged children and comprises 80% of learning disabilities. Boys are more often affected than girls. Dyslexia is characterized by an unexpected difficulty learning to read despite at least average intelligence, adequate instruction, and sociocultural opportunity. Major sensory functions must be normal. Dyslexia has a significant genetic component with heritability estimated at 54% to 84%. Dyslexia susceptibility 1 candidate 1 was the first gene reported to be associated with dyslexia. Numerous candidate dyslexia susceptibility genes have subsequently been identified including several that affect neuronal migration.

There are different subtypes of dyslexia but the most common involves impaired phonologic processing. Children with dyslexia have difficulties with accurate and/or fluent word recognition, poor spelling, and decoding abilities. They have problems segmenting and sequencing speech into phonemes (ie, speech sounds). Measures that assess phonologic functioning (eg, segmenting words [say *cowboy* without the *boy*, say *smack* without the *m*], word and nonword blending, sound matching of first and last syllables) best differentiate dyslexic from normal readers.

A history of language delay and/or a family history of reading disabilities are often found in those with dyslexia. The elemental neurologic examination is normal. Routine imaging is normal and unnecessary, except perhaps in children with abnormalities on neurologic examination, seizures, or large discrepancies between verbal and spatial skills. All children with dyslexia should have a formal neuropsychological evaluation to determine their cognitive abilities (strengths and weaknesses) and to determine if there are co-occurring conditions that might affect treatment (eg, ADHD).

Dyslexia is a lifelong disorder; however, most children with early reading problems learn to read at grade level if they are diagnosed by age 8 to 9 years (third or fourth grade) and evidence-based reading instruction is provided. Early diagnosis is essential, as children diagnosed late are likely to continue to have reading problems, even if remediated. Large population studies suggest that some degree of reading disability persists into adulthood in most, and occupational attainment may be lower in some.

Nonverbal Learning Disabilities

Mycklebust and Johnson coined the term *nonverbal learning disabilities* in 1967. It described a predominantly social emotional disorder that in many ways resembled the current concepts of the ASDs but included some spatial difficulties as well. The distinction between NVLDs and high-functioning ASD is widely debated. Some differentiate NVLD from ASD based on the lack of restrictive behaviors and the presence of greater verbal than performance IQ in NVLD. Subtypes of NVLD were subsequently described that involved varying degrees of social cognitive

impairments, visuoperceptual skills, math difficulties, attention, and executive functioning relative to average or above-average reading (decoding) and spelling. NVLD does not appear in the *Diagnostic and Statistical Manual of Mental Disorders*, 5th edition (*DSM-5*), but is referred to by various other names, including *right hemisphere syndrome* and *visuospatial learning disability*. The exact prevalence is unknown largely due to varying definitions but it is generally thought to account for approximately 10% of all learning disabilities.

The basis for the identification of children with NVLDs is usually their higher verbal as compared with performance IQ scores on neuropsychological assessment batteries. This is an indicator of their visuospatial and visuomotor difficulties, which are a core feature of the disorder. A complete neuropsychological evaluation is required for diagnosis. Suggested management for NVLDs often trades on developing verbal strengths to compensate for the nonverbal deficits.

Dyscalculia

Developmental dyscalculia involves any or all aspects of mathematics from difficulties representing and manipulating numeric information to learning and remembering arithmetic facts to executing arithmetic procedures. The prevalence of dyscalculia is approximately 3% to 6%, affecting both genders equally. A developmental Gerstmann syndrome (right/left disorientation, finger agnosia, dysgraphia, dyscalculia, and sometimes constructional apraxia) occurs in as many as 2% of school-aged children. ADHD co-occurs in one-fourth of individuals, and approximately one-fifth have dyslexia.

Comprehensive neuropsychological evaluations are recommended in individuals suspected of having dyscalculia. Children with neuropsychological signs of both left and right hemisphere dysfunction can have dyscalculia. Both groups have similar problems on arithmetic batteries, but those with left hemisphere dysfunction seem to perform significantly worse in addition, subtraction, complex multiplication, and division and also make more visuospatial errors. Math remediation is appropriate for the child with isolated difficulties or with mathematics difficulties in combination with other learning difficulties.

Attention Deficit Hyperactivity Disorder

ADHD begins in childhood with symptoms of hyperactivity, impulsivity, and/or inattention. For children younger than 17 years of age, the *DSM-5* diagnosis requires six or more symptoms of hyperactivity and impulsivity and six or more symptoms of inattention. For individuals 17 years and older, five or more symptoms per category are required. Depending on the predominance of symptoms, ADHD is divided into three subtypes: predominantly inattentive, predominantly hyperactive-impulsive, and combined type. Symptoms of hyperactivity/impulsivity and inattention must occur often; be present in more than one setting, such as school or work and home; persist for at least 6 months; be present before age 12 years; impair academic, social, or occupational functioning; and be excessive for the developmental level of the child.

The reported prevalence of ADHD in school-aged children ranges from 1% to 20%. The *DSM-5* conservatively estimates the prevalence of ADHD as about 5% of children and 2.5% of adults in most cultures. The variation in prevalence is secondary to differing techniques of ascertainment and invariably reflects the lack of a biologic marker for the disorder. ADHD occurs approximately twice as often in males. Affected females are more likely to present primarily with inattentive features.

ADHD occurs and can be diagnosed in the toddler (although the false-positive rate is relatively high). The diagnosis is more reliably made when a child reaches 4 years old. Hyperactive and impulsive symptoms typically increase during the next 3 to 4 years, peaking at age 7 to 8 years. By adolescence, hyperactivity symptoms diminish, although symptoms of impulsivity and feelings of restlessness persist. Symptoms of inattention usually are not obvious until the child is 8 to 9 years old. ADHD persists into adulthood in two-thirds to three-fourths of people diagnosed with ADHD in childhood.

Attention disorders (with or without hyperactivity) are diagnosed based on history obtained from parents, observations of the child, questionnaires from parents and teachers, and in some instances, computerized tests of attention. As the disorder must affect functioning in at least two settings (school, after school, or home), it is advisable to obtain some written or verbal report from the child's teacher or school personnel. Given the high rate of psychiatric comorbidities in ADHD (eg, anxiety and mood disorders, oppositional defiant disorder, conduct disorder), both narrowband questionnaires that specifically assess for ADHD and broadband questionnaires that assess for ADHD as well as other psychiatric comorbidities should be used. The elemental neurologic examination is generally normal, although minor findings are common (eg, synkinesis during repetitive finger tapping and sequencing tasks). Neuropsychological testing is not absolutely necessary unless comorbid learning disabilities are suspected. The neuropsychological profile usually reveals average intelligence, but low scores are common on the Wechsler IQ subtests that demand attention or rapid processing (eg, digit span, coding, arithmetic, symbol search) and intratest scatter often is found, reflecting variability in attention. Executive frontal lobe functioning—the ability to initiate, inhibit, sustain, and shift attention; working memory; and organizational skills—is often impaired.

ADHD has a substantial genetic component. Reported concordance of ADHD in identical twins ranges from 0.70 to 0.88. ADHD frequently co-occurs with other neurobehavioral disorders such as Tourette syndrome, obsessive-compulsive disorder, anxiety, and learning disabilities, raising the question of possible shared susceptibility genes.

Dopamine appears to be the primary neurotransmitter involved in ADHD. Medications that increase levels of dopamine, in particular psychostimulants, are the mainstay of treatment. The National Institutes of Health–sponsored Multimodal Treatment Study of ADHD has shown both behaviorally and by neuropsychological testing that stimulants work and that they work better than behavioral modification LEVEL 1.[1] Approximately, 75% of children respond to stimulants initially. Side effects may limit treatment (eg, weight loss, rebound depression or irritability, flat affect) in 5% to 10%. Many different formulations of the stimulants exist, with different durations of action. Tics are not a contraindication to stimulant use in ADHD, although they may affect medication choices. Comorbid mood or anxiety disorders also influence medication choice. Medications other than stimulants can also be used to treat ADHD. Atomoxetine (starting dose: 0.5 mg/kg every day) and α-agonists clonidine (starting dose: 0.05-0.1 mg every day), guanfacine (starting dose: 0.5-1 mg every day), Intuniv (starting dose: 1 mg every day), and Kapvay (starting dose: 0.1 mg at bedtime) are accepted nonstimulant medication choices. Tricyclic antidepressants, selective

serotonin reuptake inhibitors, serotonin-norepinephrine reuptake inhibitors, bupropion, and modafinil have all been used but generally only in those who failed to respond to stimulants. In addition to medication, treatment should focus on parent skills training, educational accommodations (preferential seating, extended time/separate testing site for testing, organizational supports), and behavioral modification.

LEVEL 1 EVIDENCE

1. The Multimodal Treatment Study of Children with Attention-Deficit/Hyperactivity Disorder Cooperative Group. A 14-month randomized clinical trial of treatment strategies for attention-deficit/hyperactivity disorder. *Arch Gen Psychiatry*. 1999;56(12): 1073-1086.

SUGGESTED READINGS

Disorders of Motor Development

Bax M, Tydeman C, Flodmark O. Clinical and MRI correlates of cerebral palsy: the European Cerebral Palsy Study. *JAMA*. 2006;296(13):1602-1608.

Delgado MR, Hirtz D, Aisen M, et al. Practice parameter: pharmacologic treatment of spasticity in children and adolescents with cerebral palsy (an evidence-based review): report of the quality standards subcommittee of the American Academy of Neurology and the Practice Committee of the Child Neurology Society. *Neurology*. 2010;74(4):336-343.

Ellenberg JH, Nelson KB. The association of cerebral palsy with birth asphyxia: a definitional quagmire. *Dev Med Child Neurol*. 2013;55(3):210-216.

Gupta R, Appleton RE. Cerebral palsy: not always what it seems. *Arch Dis Child*. 2001;85(5):356-360.

Himmelmann K, McManus V, Hagberg G, et al. Dyskinetic cerebral palsy in Europe: trends in prevalence and severity. *Arch Dis Child*. 2009;94(12): 921-926.

Kan P, Gooch J, Amini A, et al. Surgical treatment of spasticity in children: comparison of selective dorsal rhizotomy and intrathecal baclofen pump implantation. *Childs Nerv Syst*. 2008;24(2):239-243.

Krägeloh-Mann I, Cans C. Cerebral palsy update. *Brain Dev*. 2009;31(7):537-544.

Krägeloh-Mann I, Horber V. The role of magnetic resonance imaging in elucidating the pathogenesis of cerebral palsy: a systematic review. *Dev Med Child Neurol*. 2007;49(2):144-151.

McIntyre S, Morgan C, Walker K, Novak I. Cerebral palsy—don't delay. *Dev Disabil Res Rev*. 2011;17(2):114-129.

Nelson KB. Causative factors in cerebral palsy. *Clin Obstet Gynecol*. 2008;51(4): 749-762.

Olaya JE, Christian E, Ferman D, et al. Deep brain stimulation in children and young adults with secondary dystonia: the Children's Hospital Los Angeles experience. *Neurosurg Focus*. 2013;35(5):E7.

Schaefer GB. Genetics considerations in cerebral palsy. *Semin Pediatr Neurol*. 2008;15(1):21-26.

Steinbok P. Selective dorsal rhizotomy for spastic cerebral palsy: a review. *Childs Nerv Syst*. 2007;23(9):981-990.

Tilton A. Management of spasticity in children with cerebral palsy. *Semin Pediatr Neurol*. 2009;16(2):82-89.

Vidailhet M, Yelnik J, Lagrange C, et al. Bilateral pallidal deep brain stimulation for the treatment of patients with dystonia-choreoathetosis cerebral palsy: a prospective pilot study. *Lancet Neurol*. 2009;8(8):709-717.

Westmacott R, MacGregor D, Askalan R, deVeber G. Late emergence of cognitive deficits after unilateral neonatal stroke. *Stroke*. 2009;40(6):2012-2019.

Zwicker JG, Missiuna C, Harris SR, Boyd LA. Developmental coordination disorder: a review and update. *Eur J Paediatr Neurol*. 2012;16(6):573-581.

Disorders of Higher Cerebral Functions

Baron IS. *Neuropsychological Evaluation of the Child*. New York, NY: Oxford University Press; 2004.

Bates E, Thal D, Finlay B, et al. Early language development and its neural correlates. In: Segalowitz SJ, Rapin I, eds. *Handbook of Neuropsychology*. 2nd ed. Amsterdam, Netherlands: Elsevier Science; 2003. *Child Neuropsychology, Part II*; vol 8.

Cortese S. The neurobiology and genetics of attention-deficit/hyperactivity disorder (ADHD): what every clinician should know. *Eur J Paediatr Neurol*. 2012;16:422-433.

Cortese S, Holtmann M, Banaschewski T, et al. Practitioner review: current best practice in the management of adverse events during treatment with ADHD medications in children and adolescents. *J Child Psychol Psychiatry*. 2013;54(3):227-246.

Flore LA, Milunsky JM. Updates in the genetic evaluation of the child with global developmental delay or intellectual disability. *Semin Pediatr Neurol*. 2012;19:173-180.

Gibson CJ, Gruen JR. The human lexinome: genes of language and reading. *J Commun Disord*. 2008;41(5):409-420.

Kaminsky EB, Kaul V, Paschall J, et al. An evidence-based approach to establish the functional and clinical significance of CNVs in intellectual and developmental disabilities. *Genet Med*. 2011;13(9):777-784.

Michelson DJ, Shevell MI, Sherr EH, Moeschler JB, Gropman AL, Ashwal S. Evidence report: genetic and metabolic testing on children with global developmental delay: report of the quality standards subcommittee of the American Academy of Neurology and the Practice Committee of the Child Neurology Society. *Neurology*. 2011;77:1629-1635.

Miller DT, Adam MP, Aradhya S. Consensus statement: chromosomal microarray is a first-tier clinical diagnostic test for individuals with developmental disabilities or congenital anomalies. *Am J Hum Genet*. 2010;86: 759-764.

Peterson RL, Pennington BF. Developmental dyslexia. *Lancet*. 2012;379: 1997-2007.

Rapin I, Dunn M, Allen DA. Developmental language disorders. In: Segalowitz SJ, Rapin I, eds. *Handbook of Neuropsychology*. 2nd ed. Amsterdam, Netherlands: Elsevier Science; 2003:593-630. *Clinical Neuropsychology, Part II*; vol 8.

Rudel RG, Holmes J, Pardes J. *Assessment of Developmental Learning Disorders: A Neuropsychological Approach*. New York, NY: Basic Books; 1988.

Scerri TS, Schulte-Körne G. Genetics of developmental dyslexia. *Eur Child Adolesc Psychiatry*. 2010;19:179-197.

Schubiner H, Katragadda S. Overview of epidemiology, clinical features, genetics, neurobiology, and prognosis of adolescent attention-deficit/hyperactivity disorder. *Adolesc Med State Art Rev*. 2008;19(2):209-215.

Shalev RS. Developmental dyscalculia. In: Segalowitz SJ, Rapin I, eds. *Handbook of Neuropsychology*. 2nd ed. Amsterdam, Netherlands: Elsevier Science; 2003. *Child Neuropsychology, Part II*; vol 8.

Sharp SI, McQuillin A, Gurling H. Genetics of attention-deficit hyperactivity disorder (ADHD). *Neuropharmacology*. 2009;57:590-600.

Shaywitz SE, Shaywitz BA. Paying attention to reading: the neurobiology of reading and dyslexia. *Dev Psychopathol*. 2008;20(4):1329-1349.

Shevell M. Global developmental delay and mental retardation or intellectual disability: conceptualization, evaluation, and etiology. *Pediatr Clin North Am*. 2008;55(5):1071-1084, xi.

Shevell M, Ashwal S, Donley D, et al. Practice parameter: evaluation of the child with global developmental delay: report of the quality standards subcommittee of the American Academy of Neurology and The Practice Committee of the Child Neurology Society. *Neurology*. 2003;60:367-380.

Spencer TJ, Brown A, Seidman LJ, et al. Effect of psychostimulants on brain structure and function in ADHD: a qualitative literature review of magnetic resonance imaging-based neuroimaging studies. *J Clin Psychiatry*. 2013;74(9):902-917.

Whitmore K, Hart H, Willems G, eds. *A Neurodevelopmental Approach to Specific Learning Disorders*. London, United Kingdom: Mac Keith Press; 1999.

Autism Spectrum Disorders 143

Sylvie Goldman and Jennifer M. Bain

KEY POINTS

1. Autism spectrum disorders (ASD) are a common neurodevelopmental disorder, behaviorally defined by deficits in social interaction and communication and the presence of restricted and repetitive patterns of behavior, interests, and activities and sensory atypicalities.
2. Genetics plays a large role in the pathophysiology of ASD and should be included in the workup of an individual with ASD.
3. Seizures are more common in ASD than the general population; therefore, there should be a low threshold to use electroencephalogram monitoring.
4. There is no indication for brain imaging or metabolic workup in most cases of autism.
5. Medical comorbidities are common in ASD and should be screened routinely especially when behavioral changes emerge.

INTRODUCTION

Autism spectrum disorders (ASDs) are a heterogeneous group of biologically based, behaviorally defined, neurodevelopmental disorders characterized by core symptoms of impairments in (1) social communication and social interactions and (2) restricted and repetitive patterns of behavior, interests, and activities and sensory atypicalities. The term *autism* (originating from the Greek word *autos* meaning *self*) was adopted for the first time in 1911 by Eugen Bleuler, a Swiss psychiatrist, to refer to a group of symptoms related to schizophrenia. Leo Kanner later used the term *autism* in 1943 to describe children whose behavior was "governed rigidly and consistently by the powerful desire for aloneness and sameness."

The ASDs have been defined in the *Diagnostic and Statistical Manual of Mental Disorders* (*DSM*) of the American Psychiatric Association. The initial diagnosis of *classic autism* or *early infantile autism* was described in the *DSM-II* (1968) as a form of childhood schizophrenia marked by a detachment from reality, whereas *DSM-III* broadened the concept by adding a diagnosis at the mild end of the spectrum referred to as *pervasive developmental disorder–not otherwise specified* (PDD-NOS). The *DSM-IV* and *DSM-IV-TR* further broadened this spectrum by adding the higher functioning Asperger disorder and regressive phenotype of childhood disintegrative disorder. The most recent revision in 2013 is *DSM-5* where ASD combines the separate diagnostic categories of autistic disorder, PDD-NOS, and Asperger syndrome. These changes are based on research results, which have failed to document these categories as separate biologic entities. Recent meta-analyses have confirmed stability or even decreased rates of diagnoses with this single diagnostic entity as compared to the individual diagnoses under *DSM-IV-TR*.

Under the *DSM-5*, ASD diagnosis requires three deficits in social communication and at least two symptoms in the category of restricted range of activities/repetitive behaviors that have been identified from an early age. Deficits in language have been removed as a separate criterion and are now included in the social and communication diagnostic criteria. Another important change in the *DSM-5* is the additional category of abnormal sensory symptoms. The *DSM-5* specifies three levels of severity (mild, moderate, severe), rated separately for each domain. In addition to the diagnosis, individuals are also described in terms of level of language and intellectual disability, any known genetic cause (eg, fragile X syndrome, Rett syndrome) and presence of medical conditions such as seizures, psychiatric disorders (eg, anxiety, depression), and/or gastrointestinal disorders. The variability in severity and range of disabilities seen in children with ASD cannot be overemphasized.

EPIDEMIOLOGY

The prevalence of ASD has increased significantly particularly since the late 1990s when the estimated frequency was about 1 per 1,000 for autism and 2.8 per 1,000 for all ASD subtypes (autistic disorder, Asperger syndrome, and PDD-NOS). Since 2000, the Centers for Disease Control and Prevention supports ASD surveillance via the Autism and Developmental Disabilities Monitoring Network by identifying ASD through screening and review of health and education records and documents behaviors associated with ASD at various U.S. sites. The most recently reported prevalence rate of 16.8 per 1,000 (1 in 59) among 8-year-olds, with prevalence estimates varying from 13.1 to 29.3 per 1,000 across the different sites (2014). Early monitoring of 4-year-olds in the early Autism and Developmental Disabilities Monitoring cohort has shown that a diagnosis of autism at age 2 years can be reliable, valid, and stable and encourages providers to make earlier diagnoses for referral for treatment. Non-Hispanic white children were approximately 30% more likely to be identified with ASD than non-Hispanic black children and almost 50% more than Hispanic children. The ASDs are diagnosed 4 times more likely in males than in females; however, studies report that many girls have been missed or diagnosed later due to the clinical male-biased approach and male-based instruments. The recent emphasis and recognition of a female phenotype for ASD is helping to lower the age of diagnosis for girls.

The overall increase of ASD prevalence may be related to several factors, most notably changes in diagnostic criteria, broadening of the definition with an emphasis on heterogeneity, co-morbidity, and inclusion of mildly affected individuals. There is also increased awareness among parents and professionals, especially with increased media attention. Changes in legislation and insurance mandates have also transformed the negatively stigmatizing

diagnosis of ASD into a somewhat more favorable diagnosis providing robust, comprehensive interventions. There remains variability between states in level and comprehensiveness of services.

PATHOBIOLOGY

Genetics

The ASDs are clinically and etiologically heterogeneous; genetic identification may provide stratification for anticipatory guidance and clinical trials. Twin and family studies provide evidence for ASD as a genetically based disorder with heritability estimates of 85% to 92%. Genetic heterogeneity is suspected. Using currently available technology, a genetic cause can be identified in up to 30% to 40% of children with ASD, whereas some studies argue the percentage is much higher. The proportion of cases with genetic etiology increases with additional comorbidities such as intellectual disability and epilepsy.

Known genetic causes of ASD include cytogenetic visible chromosomal abnormalities, copy number variants (CNVs) (eg, submicroscopic deletions and duplications), and single-gene disorders in which neurologic findings are associated with ASD. For both chromosomal microarrays (CMAs) and whole exome sequencing, it continues to be difficult to establish whether variants are pathogenic or benign; therefore, continued research is essential for newly identified variants. Parental testing is frequently performed to assist in interpretation of abnormal findings. Informed genetic counseling is critical in this process, and children identified with variants of unclear significance should be followed periodically by the geneticist to identify any new information that be shared with them.

The CMA is rapidly replacing high-resolution chromosomes as the initial test of choice to evaluate children with ASD. The CMA has identified clinically relevant de novo genetic imbalances in up to 20% of individuals with autism of unknown cause. The most common autism-related CNVs are the 15q11.2-11.3 duplications, reciprocal 16p11.2 microdeletions and duplications, and the 7q11.23 duplication (**Table 143.1**). Recent estimates are that CNVs that contain multiple contiguous genes may confer susceptibility to ASD in up to 8% to 9% of individuals. It should be noted that CMA will not detect balanced translocations or low-level mosaicism; a karyotype should be done when there is a family history of multiple miscarriages or there is high suspicion of mosaic aneuploidy.

Fragile X DNA testing remains essential in the evaluation of ASD because it is the most common single gene cause of autism. Approximately 1% to 3% of patients with ASD will have a mutation in the fragile X mental retardation 1 gene while approximately 60% of males and 20% of females with fragile X syndrome also meet criteria for ASD.

Identification of single-gene disorders as potential etiologies continues to grow. The list of autism "risk genes" continues to grow into the hundreds (see **Table 143.1**). Methods used include both large genome-wide association studies and whole exome sequencing of large autism databases. Instead of identifying specific genes, grouping based on function is currently used to better categorize these single genes. For example, neuroligin 3 and 4, neurexin 1, contactin 4, contactin-associated protein-like 2, and SHANK3 all play roles in synapse formation and function. The mammalian target of rapamycin (mTOR) signaling pathway also contains many ASD risk genes including *TSC1*, *TSC2*, *PTEN*, and *NF1*. Other genes have roles in splicing and posttranscriptional regulation, DNA methylation and chromatin remodeling, and other transcription factors. This area is rapidly evolving especially as large remote access autism databases grow such as SPARK for Autism (Simons Foundation) and Google's MSSNG.

Genetic stratification provides more insight into the pathophysiology of autism, establishes homogenous cohorts for precision medicine clinical trials, and provides targeted information about anticipatory guidance and information for family planning. Lastly, identification of ASD as related to an overarching genetic syndrome can allow clinicians to screen for potential medical comorbidities associated with this syndrome such as those associated with higher incidences of epilepsy, which would warrant electroencephalogram (EEG) monitoring.

The strong evidence that supports a genetic etiology for ASD has led researchers to develop the high-risk sibling cohorts referred as *Baby Siblings Research Consortium (BSRC) studies*, defined as groups of children who have an older sibling with a confirmed diagnosis of ASD. These studies provide insights into the very early presentation of ASD. For example, the Baby Siblings Research Consortium follows infants from high familial risk for autism and focuses on specific skills or traits to identify biomarkers for earlier autism diagnosis. For example, early motor skills and language development, especially receptive language and specific EEG patterns as early as 3 months of age, were strong predictors of later ASD diagnosis.

Lastly, while the genetics in autism research is expanding exponentially, studies examining environmental influences continue to be investigated as additional factors, which may influence and trigger the development of ASD. Established environmental risk factors for ASD include prematurity, advanced parental age, maternal infections (such as rubella), gestational diabetes, and maternal medication use (notably valproic acid). Mounting evidence suggests that airborne toxins, including air pollution increased the risk of having a child with autism. However, it is important to note that the interactions between genetics and environment are still largely unknown. There is no scientific evidence that any vaccine, including measles-mumps-rubella cause autism.

TABLE 143.1 Genetic Testing for Autism Spectrum Disorder (ASD)

Chromosomal karyotype
Comparative genomic hybridization array for copy number variants
Fragile X DNA testing
Single nucleotide polymorphism arrays
Gene panel testing—sequencing high-risk genes for ASD (such as *TSC1* and *TSC2*, *SHANK3*, *MECP2*, *CACNA1C*)
Whole-exome sequencing
Whole-genome sequencing

Neuropathology

Studies of brain structure have implicated abnormalities in prenatal and postnatal brain development, particularly neuronal sequences and maturation. Prenatal imaging and postmortem study supports a prenatal onset of ASD, occurring during the second and third trimesters of pregnancy. The generalized enlargement of the brain resulting from premature overgrowth attests to the broadness of the involvement of the brain, precluding focal brain theories and single primary deficit theories. The occurrence of mutations in genes that

act on molecular signaling pathways involved in the development and maintenance of neuronal and synaptic connections, notably with pruning, have reinforced the centrality of disruption of cortical growth and connectivity in ASD.

The most consistent abnormality seen on neuroimaging studies and in postmortem examination is increased brain weight and volume in children with ASDs compared to controls. Very young children with ASD (18 mo to 4 y) have a 5% to 10% increase in brain volume, especially in the frontal lobes, which parallels the increasing head circumference during this period. By adolescence and adulthood, however, brain volumes seem to be lower than in controls, suggesting brain overgrowth within the first few years of life is followed by potential neurodegeneration. Imaging studies also highlight other anatomic abnormalities noted in other brain regions, including the cerebellum, hippocampus, and basal ganglia. Increased brain volume in childhood is attributed primarily to enlargement of white matter, specifically the corona radiata and U-fibers, whereas the size of the corpus callosum is reduced, perhaps resulting in decreased interhemispheric communication. These white matter and connectivity abnormalities are still largely under investigation. Magnetic resonance spectroscopy studies suggest that gray matter is abnormal and dendritic arborization and synaptosome density reduced with lower levels of neuronal *N*-acetylaspartate and alterations in choline and creatinine metabolism. Emerging research supports abnormal gyrification patterns in individuals with ASDs at various time points of development. Other brain imaging techniques under investigation are positron emission tomography and single-photon emission computed tomography, which suggest reduced brain perfusion and neurotransmitter abnormalities. Functional imaging studies (functional magnetic resonance imaging) have shown atypical patterns of brain activation during tasks of face processing, language, and emotional understanding. Activation of the mirror neuron system—a network within the inferior frontal gyrus and posterior parietal lobe that is thought to subserve imitation and understanding of intentions of other people—is reduced in individuals with ASDs, suggesting a role for this network in autism. Focal patches of abnormal laminar cytoarchitecture and cortical disorganization of neurons, but not glia, have suggested a dysregulation of layer formation and neuronal differentiation prenatally. Efforts by organizations such as the *Autism Brain Net* brain bank hope to safely secure more postmortem tissue for future studies.

DIAGNOSIS

With no biomarkers available, the diagnosis of ASD relies solely on detailed clinical observation and developmental history (Fig. 143.1). Even though most symptoms of ASD can be identified reliably between 18 and 24 months, most children are diagnosed around age 4 years and many are still misdiagnosed with language delays or anxiety. Consequently, a major emphasis has been on early diagnosis using a cohort of high-risk siblings (BSRC) described earlier. Infants with an older sibling who carries a diagnosis of ASD are enrolled in longitudinal studies starting in early infancy before traits can be confirmed. Specific target behaviors, called *predictors*, include facial recognition, eye gaze, and motor milestones.

Social communication dysfunction, the hallmark of ASDs, can take many forms from avoidance and aloofness to excessive friendliness. Early signs of social impairments include failure to respond to name, reduced initiation, abnormal eye gaze (gaze aversion, staring), paucity of communicative gestures, lack of reciprocity, poor imitation, and impairment of joint attention defined as the ability to draw another person's attention to an object of interest through coordinated eye gaze and gestures such as pointing. Children with ASD interact with others to fulfill their own needs (self-directed) rather than to share their interests, enjoyment, and achievements.

Another cardinal feature of ASD is a restricted range of interests and activities that take the form of repetitive, patterned, and often rhythmic behaviors. These include sound or word repetition and motor stereotypies such as hand flapping, finger flicking, spinning, throwing, or body rocking. These repetitive behaviors may also involve specific sensory modalities such as smelling, licking, or looking from the corner of the eyes. This category also encompasses unusual preoccupations and play interests such as a focus on details rather than the use of the whole toy for functional purpose (eg, spinning the plate rather than using it to pretend to feed the doll). Children with ASD may line up toys, flick doll's eyes, or play with unusual objects (eg, a piece of string) instead of engaging in imaginative play. Many children develop routines or rituals and a need for sameness or resistance to changes, which make transitions very difficult. Adults with ASD may be preoccupied by timetables, routes, or movies.

In addition to the previously revised diagnostic criteria for ASD, the *DSM-5* provides a new diagnostic category namely "Social Communication Disorder" intended to identify individuals who have significant problems in using verbal and nonverbal communication in social interactions and who do not exhibit repetitive, stereotyped behaviors, restricted interests or sensory anomalies.

Evaluation

The evaluation of a child with autism includes a detailed clinical history and observation of free and structured activities as well as a battery of parent questionnaires and standardized verbal, nonverbal, and motor tests. When feasible, a multidisciplinary team is the best approach. Indeed, experts argue that no single tool should be used to make a diagnosis of ASD. By age 2 years, a qualified professional should reliably be able to make the diagnosis. The American Academy of Pediatrics recommends screening all children at well-child visits at 18 months and at 24 months of age. A number of questionnaires and observation measures are available to screen for ASD such as the Modified Checklist for Autism in Toddlers-Revised between 18 and 36 months of age and the Social Communication Questionnaire or the Social Responsiveness Scale, 2nd edition, for older children. The Autism Diagnostic Observation Schedule-2 (ADOS-2) is considered the "gold standard" diagnostic instrument for ASD. It consists of a semistructured, standardized assessment of social interaction, play, and imaginative use of material for toddlers through adults using different modules. The ADOS-2 is often used in conjunction with the Autism Diagnostic Interview-Revised (ADI-R), a clinical diagnostic interview focusing on early social and repetitive behaviors. Both the ADOS-2 and ADI-R require special training to administer and score. Other well-known assessments include the Childhood Autism Rating Scale, 2nd edition, and the Gilliam Autism Rating Scale, 3rd edition, for which teachers, parents, and clinicians provide a rating of specific diagnostic behaviors.

Neurologic Examination

Observations of the child are the key components of the neurologic examination. Head circumference should be measured because macrocephaly, defined as greater than 2.5 standard deviations above the mean or 98% for age, has been observed in some children

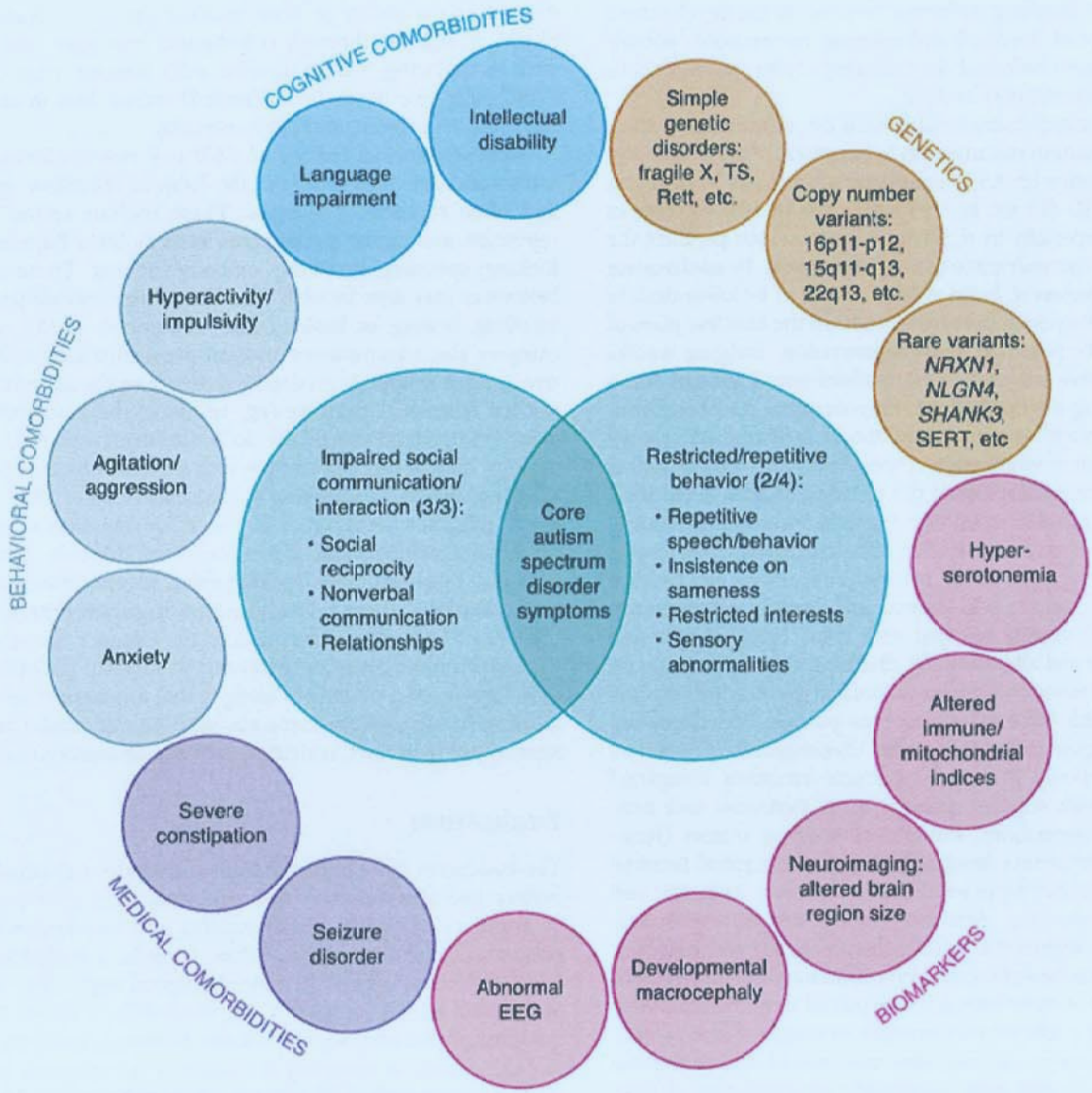

FIGURE 143.1 *Diagnostic and Statistical Manual of Mental Disorders*, 5th edition, criteria of autism spectrum disorder and associated comorbidities.

with ASD. Microcephaly may be more suggestive of a developmental brain injury such as hypoxic ischemic encephalopathy, in utero infection such as TORCH infection or a specific genetic disorder. The skin examination requires careful attention, especially given the high co-occurrence with tuberous sclerosis and other neurocutaneous syndromes. Identification of dysmorphic features is important for making genetic diagnoses (eg, fragile X, velocardiofacial syndrome, and Smith-Magenis syndrome). Facial recognition software may provide clues for syndromic diagnoses. Motor findings may include mild hypotonia and/or motor apraxia. Toe walking and motor stereotypies are very common. Abnormal motor features are not considered as diagnostic criteria but are observed in more than 85% of individuals with ASD and are the earliest reliable predictor of a later ASD diagnosis among high-risk siblings of children with ASD. Early motor delays in head lag and postural control within the first 18 months, and delayed emergence of advanced postures such as kneeling or standing in high-risk children between 6 and 14 months of age are noted in children who later receive an autism diagnosis. With the advent of wearable technologies, gait analysis, in particular, has proven useful to measure these motor abnormalities.

Many children have a constellation of symptoms that are referred to as *sensory deficits*; however, the neurologic basis for this is unclear. These include a preoccupation with sensory features of objects, over- or underresponsiveness to environmental stimuli, or paradoxical responses to sensory stimuli (eg, excessive sniffing or licking, oral aversions, intolerant to loud noises, or tactile contact).

Cognition and Language

Large variations in intellectual functioning contribute to the challenge of diagnosing and treating ASD. Although intelligence is not a defining feature of ASD, it strongly influences prognosis and treatment response (children with IQs in the moderately to severely delayed range have poorer outcomes). Current estimates report intellectual disability (IQ <70) in approximately 31% of individuals with ASD. Savant skills can be seen in visuospatial ability, rote memory, calculation, or music ability but remain rare. Attention deficit hyperactivity disorder (ADHD) is a common comorbidity with ASD. In addition to overall cognitive disabilities and scattered skills, executive functions (eg, organization, planning, inhibition,

and working memory) and attention control (eg, hyper focus and lack of shifting) are commonly affected, whereas sustained attention is relatively spared.

Three unresolved issues need to be mentioned: (1) diagnosing ASD in individuals with very low IQ, (2) evaluation of IQ in severely affected individuals, and (3) cognitive/behavioral regression. Autism diagnostic tools are not designed for individuals with a mental age below 12 months, and thus, the controversy remains as to what extent an ASD diagnosis is applicable in very cognitively impaired individuals. Similarly, individuals severely affected by ASD symptoms with significant mood dysregulation, absence of language, and rigid behaviors may not perform to the full extent of their true cognitive abilities and may be wrongly classified. For example, techniques using eye tracking instead of verbal responses in individuals with Rett syndrome (with and without ASD) may be a promising alternative techniques to common IQ tests. Developmental regression or loss of previously acquired skills during the first 1 to 3 years of life has been reported in approximately one-third of children with ASD. There is an ongoing debate as to whether children experienced a true loss of skills versus a decline in premorbid developmentally delayed children. Regressions are difficult to capture and to document in a timely and reliable way, so ancillary sources such as home videos may be used as objective evidence. Clinical studies report that, overall, children who present a history of loss of skills have poorer outcome compared to children who did not.

Although no longer a criterion for a diagnosis of ASD, language disorder is highly prevalent and may include expressive, receptive, and pragmatic deficits. Language skills are often considered as outcome predictor especially for children who do not develop any language (minimally verbal or nonverbal). In fact, the most common parental concern in ASD clinics is language delay; an estimated 30% of individuals with ASD are minimally verbal or nonverbal. As opposed to children with language disorder without ASD, children with ASD do not compensate for their language impairment through nonverbal strategies such as gestures, facial expressions, or imitation. Their expressive language is characterized by immediate and delayed echolalia with repetitive and stereotyped phrases. Some children will use scripts from television or videos. Other abnormalities include syntax (word order, gender errors, rules of grammar), semantics (word meaning), and pragmatics skills (use of language for communication). Low and higher functioning individuals are extremely literal and concrete and often have difficulties understanding jokes, humor, or sarcasm. Speech prosody (melody of language) is impaired, as evidenced by mechanical, monotonous, excessively rapid, high-pitched, or dysregulated volume speech. Children with ASD often express more than what they can understand (receptive language), which differentiates them from language-impaired children without ASD. In the past, many children with ASD were misdiagnosed with deafness before it could be established that their hearing was normal. A small proportion of children with severe ASD, despite normal hearing, present with a significant auditory language processing disorder, which prevents them from decoding language into meaningful words (verbal auditory agnosia). Some children have a fascination with letters and numbers in the early toddler years, and some may learn to read without instruction, for example, hyperlexia, although overall comprehension is often limited. As children age, narrative skills become impaired with difficulty interpreting and reciprocating social and emotional cues. These individuals may use pedantic speech to tell simple events and usually talk only about topics of their own interest while being oblivious of the listener's interest, need for clarification, or even presence. Their conversations sound more like a monologue with a fixed intonation rather than a true dialogue. They often fail to maintain appropriate interpersonal distance and are unthinkingly intrusive or persistent. They also have poor nonverbal communication such as particular difficulty reading facial expressions, body language, social cues, and change of tone of voice.

Medical and Psychiatric Comorbidities

Medical comorbidities frequently exist in ASD. Examples of commonly associated medical conditions include, but are not limited to, pain (due to migraine headaches, dental caries, ear infection, fractures, constipation, etc), gastrointestinal disorders (eg, gastroesophageal reflux disease, constipation), genitourinary conditions (eg, urinary tract infection), hormonal imbalance/endocrine dysfunction (eg, menstruation), and sleep disturbance (eg, sleep apnea). Other neuropsychiatric disorders are more highly prevalent in ASD, including epilepsy, sleep disorders, and psychiatric conditions anxiety, depression, obsessive-compulsive disorder, ADHD, and self-injurious behaviors. It is important to consider medical causes for any change in behavior, especially in those individuals who are nonverbal or with limited language capability.

Epilepsy

Individuals with ASD have a higher risk of epilepsy compared with the general population. Epilepsy occurs in up to one-third of individuals with ASD with reports ranging from 5% to 50%. Variation in estimates is likely related to multiple factors such as sample ascertainment, degree of intellectual disability, age, gender, and type of ASD (idiopathic vs syndromic). Some of the most widely recognized syndromes associated with ASD and epilepsy include tuberous sclerosis, fragile X syndrome, Rett syndrome, Angelman syndrome, and 15q duplication syndrome. Intellectual disability and motor impairments (eg, cerebral palsy) have been identified most commonly as significant risk factors for epilepsy in ASD. Rates are higher in those with more severe cognitive impairments.

Age of onset of epilepsy in ASD generally appears in two peaks, one in early childhood (0-5 y) and the other in adolescence (10-15 y). The peak before age 5 years, however, includes those children with ASD secondary to epileptic spasms, tuberous sclerosis, and other epileptic encephalopathies.

Given the prevalence of epilepsy in autism, it is important to consider the possibility of seizures when evaluating an individual with autism. Currently, there is inadequate evidence to recommend EEG in all individuals with autism; however, the physician should have a low threshold for ordering an EEG. Although all seizure types can occur in ASD, the most commonly observed are complex partial seizures (85%) and generalized tonic-clonic seizures (7%). Absence and myoclonic seizures occur less commonly (1%-4%). The assessment for medical comorbidities that mimic seizures should include sleep disorders, gastroesophageal reflux and other gastrointestinal disorders, and behavioral disorders including ADHD.

Epileptiform EEG abnormalities are frequently seen in children with ASD, with or without epilepsy. Because these background or epileptiform EEG abnormalities can occur in ASD individuals without a clinical history of seizures, they are not to be considered evidence for epilepsy. The significance of these abnormalities, especially in the absence of clinical seizures, remains unclear. At present, there are no data to support the use of

antiepileptic drugs or epilepsy surgery in the treatment of EEG abnormalities in the absence of clinical seizures.

The relationship of autistic regression to epilepsy and epileptiform EEG abnormalities is also unclear. The literature is inconsistent with some studies reporting higher rates of epilepsy in children with ASD and regression and others showing no relationship. However, language regression is a hallmark of Landau-Kleffner syndrome (LKS), a rare childhood-onset epileptic encephalopathy in which loss of previously acquired language skills occurs in the context of an epileptiform EEG, activated in sleep. Electrical status epilepticus during slow-wave sleep (ESES) is the electroencephalographic pattern seen in LKS. The degree of overlap between LKS, ESES, and autistic regression with epileptiform EEG is currently poorly understood, although ESES is rarely seen in children with a more global autistic regression. At the current time, there are no data to support the use of LKS- or ESES-specific treatment regimens in those with more classic autistic regression and epileptiform EEG without clinical seizures.

Neurodiagnostic Testing

All children with ASD should have a comprehensive medical/pediatric history and examination. Neurodiagnostic testing can potentially identify any diagnosable or treatable condition. Hearing impairment must be excluded by a formal audiology assessment. Clinical practice guidelines recommend genetic testing but other diagnostic investigations such as neuroimaging, EEGs, or metabolic laboratory investigations follow "best practice" evidence-based guidelines when available. As mentioned earlier, CMA and fragile X are considered first-tier testing in the diagnostic workup of ASD (Table 143.1). The MECP2 sequencing for Rett syndrome and phosphatase and tensin homolog testing for those with head circumferences greater than 2.5 standard deviation above the mean are recommended second-tier testing. See Table 143.2 for genetic disorders associated with an ASD phenotype. The EEG, including a sleep record or overnight video-EEG monitoring, is appropriate when seizures occur or if developmental regression has occurred (see "Epilepsy" section).

TABLE 143.2 Genetic Disorders Associated With Autism Spectrum Disorders

Single-Gene Disorders	Cytogenetically Visible Chromosomal Abnormalities	Copy Number Variants (CNVs)
Fragile X	15q duplication syndrome	15q11.2-11.3 duplications
PTEN macrocephaly syndrome	Trisomy 21	Reciprocal 16p11.2 microdeletions and duplications
Rett syndrome	Turner syndrome (45,X)	7q11.23 duplication
Tuberous sclerosis complex (TSC)		PTEN, phosphatase, and tensin homolog
Angelman syndrome		
Sotos syndrome		
Timothy syndrome		
Joubert syndrome		
Williams syndrome		
Sanfilippo syndrome		
Cohen syndrome		
Cornelia de Lange syndrome		
22q11.1 deletion syndrome		
Duchenne muscular dystrophy		
Neurofibromatosis, type 1		

Abbreviation: PTEN, phosphatase and tensin homolog.

TABLE 143.3 Red Flags That Might Indicate a Metabolic Etiology for Autism Spectrum Disorders[a]

History or *Symptoms*	*Physical* or *Laboratory* Findings
• Active or recurrent regression • Profound intellectual disability or global developmental delay • Severe growth retardation • Deafness • Unexplained intractable seizures • Fatigue with daily activities or exercise • Recurrent or relapsing history of decompensation with illness • Family history suggestive of metabolic disease	• Objective neurologic abnormalities (eg, significant hypotonia with gross motor delay, muscle weakness, microcephaly, macrocephaly, dystonia/chorea) • Multiple organ system involvement • Unrelated signs suggesting an inborn error of metabolism (eg, hypoglycemia, metabolic acidemia) • MRI abnormality suggestive of metabolic disease

Abbreviation: MRI, magnetic resonance imaging.
[a]List is not meant to be exhaustive.

Only 1% of patients with autism have an underlying metabolic disorder. There are multiple metabolic causes of ASD, many of which are not usually associated with any dysmorphology. A careful history and examination often identifies "red flags" that increases a concern for an inborn error of metabolism (Tables 143.3 and 143.4). Treatable conditions include phenylketonuria, hyperammonemia/urea cycle defects, and creatine synthesis/creatine transporter defects. Primary mitochondrial disease and ASD is a subject of much debate. Some investigators report a significant incidence of mitochondrial DNA changes or functional disturbances in children with ASD. Whether these are the primary cause of ASD remains to be defined. The extent of the evaluation for an underlying metabolic disorder depends on clinical suspicion and the relevance to family counseling.

The clinical rationale for neuroimaging in children with ASD is an attempt to determine a specific etiopathologic diagnosis for an individual. In a minority of cases, the detection of an abnormality of the brain may lead to determination of a specific cause for the child's ASD. This is true especially if the lesion is pathognomonic for a given disorder, for example, a neurocutaneous syndrome such as tuberous sclerosis complex. However, in many cases, the etiology of the brain abnormality is still unknown and the relationship to the ASD unclear. Nonetheless, the magnetic resonance imaging may help guide more focused etiologic investigations that could further lead to specific diagnoses in a limited number of cases. Sedation for

TABLE 143.4 Metabolic Disorders Associated With Autism Spectrum Disorders

Phenylketonuria
Mitochondrial disorders
Mucopolysaccharidosis, including Sanfilippo
Smith-Lemli-Opitz syndrome
Urea cycle disorders
Adenylosuccinate lyase deficiency
Cerebral folate deficiency
Disorders of creatine transport or metabolism
Succinic semialdehyde dehydrogenase deficiency
Dihydropyrimidinase deficiency
Cystathionine β-synthase deficiency
Homocysteine
Biotinidase deficiency

TABLE 143.5 Clinical Indicators That Might Prompt Neuroimaging With Brain Magnetic Resonance Imaging

• Seizures or history of focal EEG
• Microcephaly
• Extreme (>3 SD above mean) or progressive macrocephaly
• Neurocutaneous lesions
• Suspicion of CNS structural abnormality
• Focal motor findings or a change in motor examination
• Active or recurrent regression

Abbreviations: CNS, central nervous system; EEG, electroencephalogram; SD, standard deviation.

this procedure must be carefully weighed by the clinician. For these reasons, imaging is not a routine part of the evaluation of individuals with ASD in the absence of "red flags" (**Table 143.5**).

MANAGEMENT

There are no known cures for ASDs; however, early intensive behavioral and educational interventions are the most effective evidence-based intervention for treating ASD core symptoms in ASD. Children with ASD often require many hours of multiple therapies along with parent support.

Behavioral interventions may include applied behavior analysis based on response reinforcement and the Treatment and Education of Autistic and Related Communication-Handicapped Children method using structured teaching. Functional behavioral analysis is an important evaluation tool to identify the antecedents, consequences, and functions of behaviors. So far, applied behavior analysis therapy remains the only evidence-based treatment and shows best results to alleviate maladaptive and challenging behaviors such avoidance, aggression, and self-injurious behaviors. These behaviors may require psychopharmacologic treatment and exclusion of medical causes.

After many years of damaging irrational theories about the mother's role in ASD, the field has finally recognized parental involvement as a central part of the treatment program. Thus, newer approaches include Developmental, Individual Difference, Relationship approach (DIR/Floortime) based on social relationships; the Early Start Denver Model a combination of developmental and relationship-based interventions; Parent-mediated social Communication Therapy; and Joint Attention, Symbolic Play, Engagement and Regulation treatment and approach. Social skills training is also important for older and higher functioning individuals with ASD. Caregiver and family involvement continues to be integral in most behavioral programs.

A combined approach of pharmacotherapy and behavioral modification therapy is often necessary. The only U.S. Food and Drug Administration–approved medications specifically indicated for autism-related concerns are aripiprazole and risperidone for ASD-associated irritability and aggression. However, other medications are commonly used to treat comorbid symptoms/conditions such as inattention, hyperactivity/impulsivity, obsessive-compulsive disorder, anxiety, depression, sleep disturbance, and seizures. The effects of pharmacologic interventions are enhanced by behaviorally based programs. Clinical investigations continue to study the efficacy of medications on social deficits.

OUTCOME

The ASD is a lifelong disorder and symptoms often change with age. Families must be supported during transitions to adolescence and adulthood. Decisions about guardianship should be made prior to running 18 years of age. Support groups and advocacy groups may provide guidance during these transition periods.

Outcome studies of children diagnosed with ASD suggest that although 40% show overall improvement during adolescence, as many as a third may deteriorate. The onset of seizures may contribute to this decline. Approximately, two-thirds of adults with autism show poor social adjustment (limited independence in social relations) and half require institutionalization. In addition, psychiatric comorbidities commonly develop in adolescence and adulthood: depression, anxiety, catatonia, and schizophrenia.

Although ASD are considered lifelong, recent literature suggests that a minority of individuals with ASD may not fulfill diagnostic criteria after middle childhood and are considered "optimal outcome." These older children may be functioning within the nonautistic range of social interaction and communication with subtle social and communication difficulties (such as personal narratives) and mild residual restricted and repetitive behaviors. Early motor skills may be predictive of optimal outcome.

SUGGESTED READINGS

American Psychiatric Association. *Diagnostic and Statistical Manual of Mental Disorders*. 5th ed. Washington, DC: American Psychiatric Association; 2013.

Aylward EH, Minshew NJ, Field K, Sparks BF, Singh N. Effects of age on brain volume and head circumference in autism. *Neurology*. 2002;59:175-183.

Bai D, Yip BHK, Windham GC, et al. Association of genetic and environmental factors with autism in a 5-country cohort. *JAMA Psychiatry*. 2019;76(10):1035-1043.

Baio J, Wiggins L, Christensen DL, et al. Prevalence of autism spectrum disorder among children aged 8 years—autism and developmental disabilities monitoring network, 11 sites, United States, 2014. *MMWR Surveill Summ*. 2018;67(6):1-23.

Ballaban-Gil K, Tuchman R. Epilepsy and epileptiform EEG: association with autism and language disorders. *Ment Retard Dev Disabil Res Rev*. 2000;6:300-308.

Bauman ML, Kemper TL, eds. Neuroanatomic observations of the brain in autism. In: *The Neurobiology of Autism*. Baltimore, MD: Johns Hopkins University Press; 1994:119-145.

Baumer N, Spence SJ. Evaluation and management of the child with autism spectrum disorder. *Continuum (Minneap Minn)*. 2018;24(1, Child Neurology):248-275.

Bowman LC, Varcin KJ. The promise of electroencephalography for advancing diagnosis and treatment in neurodevelopmental disorders. *Biol Psychiatry Cogn Neurosci Neuroimaging*. 2018;3(1):7-9.

Casanova MF, Buxhoeveden DP, Switala AE, Roy E. Minicolumnar pathology in autism. *Neurology*. 2002;58:428-432.

Chita-Tegmark M, Arunachalam S, Nelson CA, Tager-Flusberg H. Eye-tracking measurements of language processing: developmental differences in children at high risk for ASD. *J Autism Dev Disord*. 2015;45(10):3327-3338.

Chugani DC, Muzik O, Behen M, et al. Developmental changes in brain serotonin synthesis capacity in autistic and nonautistic children. *Ann Neurol*. 1999;45:287-295.

Davignon MN, Qian Y, Massolo M, Croen LA. Psychiatric and medical conditions in transition-aged individuals with ASD. *Pediatrics*. 2018;141(suppl 4):S335-S345.

Dementieva YA, Vance DD, Donnelly SL, et al. Accelerated head growth in early development of individuals with autism. *Pediatr Neurol*. 2005;32:102-108.

Fein D, Barton M, Eigsti IM, et al. Optimal outcome in individuals with a history of autism. *J Child Psychol Psychiatry*. 2013;54(2):195-205.

Filipek PA, Accardo PJ, Ashwal S, et al. Practice parameter: screening and diagnosis of autism: report of the Quality Standards Subcommittee of the American Academy of Neurology and the Child Neurology Society. *Neurology*. 2000;55:468-479.

Fombonne E. Epidemiology of autistic disorder and other pervasive developmental disorders. *J Clin Psychiatry*. 2005;66(suppl):3-8.

Friedman SD, Shaw DW, Artru AA, et al. Regional brain chemical alterations in young children with autism spectrum disorder. *Neurology*. 2003;60:100-107.

Gandal MJ, Haney JR, Parikshak NN, et al. Shared molecular neuropathology across major psychiatric disorders parallels polygenic overlap. *Science*. 2018;359(6376):693-697.

Gaugler T, Klei L, Sanders S, et al. Most genetic risk for autism resides with common variation. *Nat Genet*. 2014;46:881-885.

Hazlett HC, Gu H, Munsell BC, et al. Early brain development in infants at high risk for autism spectrum disorder. *Nature*. 2017;542(7641):348-351.

Herbert MR, Ziegler DA, Deutsch CK, et al. Dissociations of cerebral cortex, subcortical and cerebral white matter volumes in autistic boys. *Brain*. 2003;126(pt 5):1182-1192.

Hollander E, Anagnostou E, Chaplin W, et al. Striatal volume on magnetic resonance imaging and repetitive behaviors in autism. *Biol Psychiatry*. 2005;58:226-232.

Jeste SS. The neurology of autism spectrum disorders. *Curr Opin Neurol*. 2011;24(2):132-139.

Kanner L. Autistic disturbances of affective contact. *Nerv Child*. 1943;2:217-250.

Kindregan D, Gallagher L, Gormley J. Gait deviations in children with autism spectrum disorders: a review. *Autism Res Treat*. 2015;2015:741480.

Kulage KM, Goldberg J, Usseglio J, Romero D, Bain JM, Smaldone AM. How has DSM-5 affected autism diagnosis? A 5-year follow-up systematic literature review and meta-analysis. *J Autism Dev Disord*. 2020;50(6):2102-2127.

Lovaas OI, Smith T. A comprehensive behavioral theory of autistic children: paradigm for research and treatment. *J Behav Ther Exp Psychiatry*. 1989;20(1):17-29.

MacDonald R, Parry-Cruwys D, Dupere S, Ahearn W. Assessing progress and outcome of early intensive behavioral intervention for toddlers with autism. *Res Dev Disabil*. 2014;35(12):3632-3644.

Maski KP, Jeste SS, Spence SJ. Common neurological co-morbidities in autism spectrum disorders. *Curr Opin Pediatr*. 2011;23(6):609-615.

McGuire K, Fung L, Hagopian L, et al. Irritability and problem behavior in autism spectrum disorder: a practice pathway for pediatric primary care. *Pediatrics*. 2016;137(suppl 2):S136-S148.

Naigles LR. Input and language development in children with autism. *Semin Speech Lang*. 2013;34(4):237-248.

Niemi MEK, Martin HC, Rice DL, et al. Common genetic variants contribute to risk of rare severe neurodevelopmental disorders. *Nature*. 2018;562(7726):268-271.

O'Roak BJ, State MW. Autism genetics: strategies, challenges, and opportunities. *Autism Res*. 2008;1:4-17.

Ozonoff S, Young GS, Landa RJ, et al. Diagnostic stability in young children at risk for autism spectrum disorder: a baby siblings research consortium study. *J Child Psychol Psychiatry*. 2015;56(9):988-998.

Ramocki MB, Zoghbi HY. Failure of neuronal homeostasis results in common neuropsychiatric phenotypes. *Nature*. 2008;455:912-918.

Rapin I, Tuchman RF. Autism: definition, neurobiology, screening, diagnosis. *Pediatr Clin North Am*. 2008;55(5):1129-1146, viii.

Redcay E, Courchesne E. When is the brain enlarged in autism? A meta-analysis of all brain size reports. *Biol Psychiatry*. 2005;58:1-9.

Sacrey LR, Zwaigenbaum L, Bryson S, et al. Developmental trajectories of adaptive behavior in autism spectrum disorder: a high-risk sibling cohort. *J Child Psychol Psychiatry*. 2019;60(6):697-706.

Schaefer GB, Mendelsohn NJ. Clinical genetics evaluation in identifying the etiology of autism spectrum disorders: 2013 guideline revisions. *Genet Med*. 2013;15(5):399-407.

Sebat J, Lakshmi B, Malhotra D, et al. Strong association of de novo copy number mutations with autism. *Science*. 2007;316(5823):445-449.

South M, Rodgers J, Van Hecke A. Anxiety and ASD: current progress and ongoing challenges. *J Autism Dev Disord*. 2017;47(12):3679-3681.

Stoner R, Chow ML, Boyle MP, et al. Patches of disorganization in the neocortex of children with autism. *N Engl J Med*. 2014;370:1209-1219.

Tang O, Gudsnuk K, Kuo S, et al. Loss of mTOR-dependent macroautophagy causes autistic-like synaptic pruning deficits. *Neuron*. 2014;83(5):1131-1143.

Tuchman RF, Rapin I, Shinnar S. Autistic and dysphasic children. II: epilepsy. *Pediatrics*. 1991;88:1219-1225.

Veatch OV, Maxwell-Horn AC, Malow BA. Sleep in autism spectrum disorders. *Curr Sleep Med Rep*. 2015;1(2):131-140.

Volkmar FR, Siegel M, Woodbury-Smith M, et al. Practice parameter for the assessment and treatment of children and adolescents with autism spectrum disorder. *J Am Acad Child Adolesc Psychiatry*. 2014:53(2):237-257.

Zwaigenbaum L, Penner M. Autism spectrum disorder: advances in diagnosis and evaluation. *BMJ*. 2018;361:k1674.

144 Mitochondrial Encephalomyopathies

Salvatore DiMauro, Emanuele Barca, and Michio Hirano

KEY POINTS

1. In addition to generation of adenosine triphosphate energy via oxidative phosphorylation, mitochondria perform multiple additional functions, which can be disrupted and cause a variety of human diseases.
2. Common clinical features of mitochondrial disease include multisystemic involvement (eg, three or more affected organs), encephalomyopathies, chronic progressive external ophthalmoplegia, and Leigh syndrome.
3. The key principles of mitochondrial point mutations are (1) maternal inheritance, (2) mitochondrial DNA (mtDNA) heteroplasmy, (3) threshold effect, and (4) tissue distribution. These factors affect the clinical phenotypes of mtDNA mutations.
4. In addition to maternally inherited mitochondrial diseases, there are sporadic disorders (eg, Kearns-Sayre syndrome typically caused by spontaneous single large-scale mtDNA deletions) as well as autosomal dominant, autosomal recessive, and X-linked diseases.
5. Mitochondrial diseases can affect individuals at any age from birth through late adulthood.

TABLE 144.1 Genetic Classification of Mitochondrial Diseases With Representative Clinical Syndromes

1. **Defects of mitochondrial DNA**
   - A. Single deletions (usually sporadic)
     - i. Kearns-Sayre syndrome
     - ii. Chronic progressive external ophthalmoplegia (CPEO) and CPEO-plus
     - iii. Pearson syndrome
   - B. Point mutations (maternal transmission)
     - i. Mitochondrial encephalomyopathy, lactic acidosis, and stroke-like episodes
     - ii. Myoclonus epilepsy with ragged red fibers
     - iii. Leber hereditary optic neuropathy
     - iv. Neuropathy, ataxia, and retinitis pigmentosa
2. **Defects of nuclear DNA (mendelian or X-linked transmission)**
   - A. "Direct hits": mutations in genes encoding subunits of the respiratory chain enzyme complexes with biochemical defects of complex I, II, III, or IV presenting as Leigh syndrome or a multisystemic disorder
   - B. "Indirect hits": defects of respiratory chain enzyme complex assembly factors with biochemical defects of complex I, II, III, or IV presenting as Leigh syndrome or a multisystemic disorder
   - C. Defects of mitochondrial transcription
   - D. Defects of mitochondrial translation
   - E. Defects of mitochondrial lipid composition
   - F. Defects of mitochondrial dynamics (fusion, fission, movement)
   - G. Defects of mitochondrial DNA maintenance
   - H. Defects of mitochondrial importation
   - I. Defects of mitochondrial metal metabolism

INTRODUCTION

Mitochondria are uniquely intriguing organelles not only for the variety of biologic functions that they perform but also because of their regulation by two genomes—their own DNA (mitochondrial DNA [mtDNA]) and that of the nucleus (nDNA). Accordingly, mitochondrial diseases can be due to mutations in either genome (Table 144.1). The main function of mitochondria is aerobic production of adenosine triphosphate (ATP) energy through oxidative phosphorylation (OxPhos). Because brain and muscle have high-energy requirements, mitochondrial disorders frequently manifest as encephalomyopathies. Advances in this rapidly expanding field have been covered extensively in recent reviews, but here we provide general overview of the genetically and clinically heterogeneous mitochondrial diseases.

In 1962, the first human disease attributed to mitochondrial dysfunction was described as a hypermetabolic state in a patient with normal thyroid function and excessive number of abnormally large mitochondria in skeletal muscle. Biochemical studies showed "loose coupling" of OxPhos. This syndrome was named after the endocrinologist Rolf Luft. Since then, however, there has been only one other known case of Luft syndrome and its etiology remains unknown.

Later in the 1960s, mitochondrial diseases were brought to prominence by Milton Shy and Nicholas Gonatas, who defined this new organellar disorder by the electron microscopic appearance of overabundant or enlarged mitochondria with paracrystalline inclusions. Soon thereafter, W. King Engel noted that abnormal proliferation of mitochondria could be identified under the light microscope as *ragged red fibers* (RRF) with a modified Gomori trichrome stain. For the next two decades, this histologic hallmark was the basis for recognition of mitochondrial diseases based on an initial biochemical classification.

The molecular era of mitochondrial disease began in 1988 when the first two pathogenic mutations in mtDNA were described: a point mutation in Leber hereditary optic neuropathy (LHON) patients and single large deletions causing mitochondrial myopathy.

EPIDEMIOLOGY

Although mitochondrial diseases have been detected worldwide, epidemiologic data are limited. The prevalence of mitochondrial disease in the pediatric population (younger than 18 y old) has

been estimated to be 5 to 15 per 100,000 across various regions of Europe, Australia, and Japan. In the North East of England, the prevalence of mitochondrial disease in adults (older than 16 y old) has been estimated to be 12.5 per 100,000.

PATHOBIOLOGY

We consider separately the pathobiology associated with mtDNA mutations and with nDNA mutations.

Pathobiology of mtDNA Mutations: Mitochondrial Genetics Versus Mendelian Inheritance

Human mtDNA is a small (16.6 kb) circle of double-stranded DNA (Fig. 144.1) comprising only 37 genes. Of these, 13 encode polypeptides, all subunits of the OxPhos pathway: 7 subunits of complex I (nicotinamide adenine dinucleotide hydride [NADH]-ubiquinone oxidoreductase), 1 subunit of complex III (ubiquinone–cytochrome *c* oxidoreductase), 3 subunits of complex IV (cytochrome *c* oxidase [COX]), and 2 subunits of complex V (ATP synthase). The other 24 genes encode 22 transfer RNAs (tRNAs) and 2 ribosomal RNAs (rRNAs) that are required for translation of messenger RNAs on mitochondrial ribosomes (mitoribosomes). The subunits of complex II (succinate dehydrogenase [SDH]-ubiquinone oxidoreductase) and the enzymes required for synthesis of small electron carriers (coenzyme Q_{10} [CoQ_{10}] [ubiquinone] and cytochrome *c*) are encoded exclusively by nDNA.

The following main principles distinguish mitochondrial genetics from mendelian genetics and help explain many of the clinical peculiarities of mtDNA-related disorders.

1. *Polyplasmy*. Most cells contain multiple mitochondria and each mitochondrion contains multiple copies of mtDNA so that there are thousands of mitochondrial genomes in each cell.
2. *Heteroplasmy*. When an mtDNA pathogenic mutation affects some but not all genomes, a cell, a tissue, indeed a whole individual will harbor two populations of mtDNA, normal (or wild-type) and mutant, a condition known as *heteroplasmy*; in normal tissues, all mtDNA were considered identical, a situation called *homoplasmy*. However, highly sensitive next-generation sequencing has revealed the coexistence of mutated mtDNA variants (0.2%-2.0% heteroplasmy) and

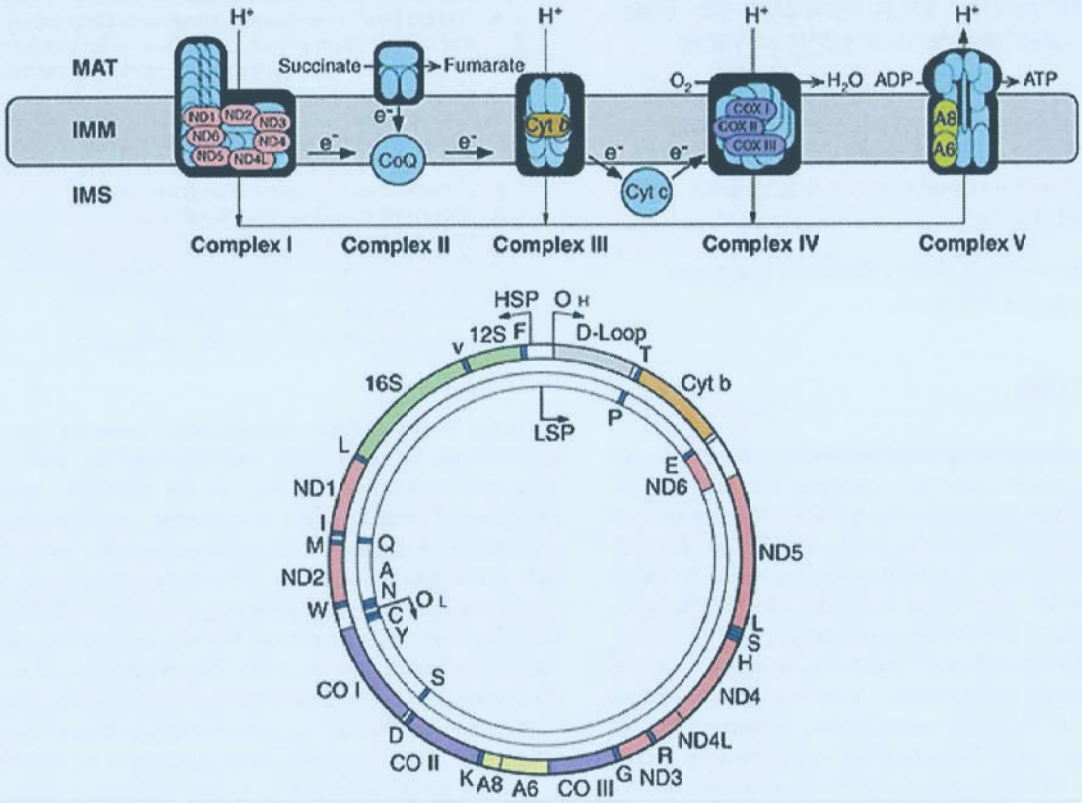

FIGURE 144.1 The oxidative phosphorylation pathway **(top)** and mitochondrial DNA **(bottom)**. Genes and corresponding gene products are similarly color-coded. ND denotes the subunits of NADH-coenzyme Q (CoQ) oxidoreductase (complex I); cyt *b*, cytochrome *b*; subunits of cytochrome *c* oxidase (COX) are labeled CO in the mitochondrial DNA scheme and COX in the respiratory chain rendition; *A6* and *A8* indicate subunits 6 and 8 of adenosine triphosphate (ATP) synthase. The 22 transfer RNA genes are denoted by one-letter amino acid nomenclature, whereas *12S* and *16S* denote ribosomal RNAs. O_H and O_L are the origin of heavy- and light-strand replication; heavy strand promoter (HSP) and light strand promoter (LSP) are the promoters of heavy- and light-strand transcription. Abbreviations: ADP, adenosine diphosphate; cyt *c*, cytochrome *c*; H_2O, water; IMM, inner mitochondrial membrane; IMS, intermembrane space; MAT, matrix.

wild-type mtDNA within a cell in blood and skeletal muscle of clinically unaffected individuals (a phenomenon termed *universal heteroplasmy*).

3. *Threshold effect*. The functional impairment associated with a pathogenic mtDNA mutation is largely determined by the degree of heteroplasmy, and a minimal critical number of mutant genomes (the mutation load) is required before tissue dysfunction becomes evident (and related clinical signs become manifest), a concept aptly termed *threshold effect*. This is, however, a relative concept: Tissues with high metabolic demands, such as brain, heart, and muscle, tend to have lower tolerance for mtDNA mutations than do metabolically less active tissues.
4. *Mitotic segregation*. Both organellar division and mtDNA replication are apparently stochastic events unrelated to cell division: Thus, the number of mitochondria (and mtDNA) can vary not only in space (ie, among cells and tissues) but also in time (ie, during development or aging). Moreover, at cell division, the proportion of mutant mtDNAs in daughter cells may drift, allowing for relatively rapid changes in genotype; therefore, if and when the threshold is exceeded, a clinical phenotype may manifest.
5. *Maternal inheritance*. At fertilization, all mitochondria (and all mtDNA) in the zygote are derived from the oocyte. Therefore, a mother carrying an mtDNA pathogenic mutation will pass it on to all her children, males and females, but only her daughters will transmit to their progeny, in a vertical matrilineal line. There are, however, a few exceptional cases of paternal leakage of mtDNA into zygotes leading to biparental inheritance. When maternal inheritance is evident in a clinical setting, it provides strong evidence that an mtDNA mutation must underlie the disease in question. However, the other features of mitochondrial genetics (eg, heteroplasmy degree and the threshold effect) often mask maternal inheritance by causing striking intrafamilial clinical heterogeneity. Thus, when suspecting an mtDNA-related disorder, it is crucial to collect the family history meticulously, paying special attention to "soft signs" (such as short stature, hearing loss, or migraine headache) in potentially oligosymptomatic maternal relatives.

More than 270 point mutations of mtDNA have been identified (**Fig. 144.2**). Ten pathogenic mutations in mtDNA have been observed frequently in neonatal cord blood of over 3,000 well babies, and a surprisingly high frequency, 1 in 200, harbored a pathogenic mtDNA mutation. The frequent occurrence of mtDNA mutations leads to a correspondingly high prevalence of mtDNA-related diseases: In the northeast of England, for example, 1 in 10,000 people are clinically affected by mtDNA-related disorders, and 1 in 6,000 individuals are considered at risk.

Mendelian Inheritance

The identification of nDNA mutations for mitochondrial diseases has accelerated rapidly since the discovery in 1995 of the first "direct hit" mutation in an nDNA-encoded gene for one of four subunits of complex II, exclusively controlled by nuclear genetics. These advances have been made possible by rapidly evolving molecular genetic technologies, including next-generation genome-wide (whole exome) sequencing and mitochondrial disease panels encompassing subsets of the nDNA genes required for mitochondrial functions. The advantages of high-throughput DNA sequencing are eminently practical, enabling rapid diagnosis of puzzling cases and informing genetic counseling.

Direct Hits Mutations

"Direct hits" refer to pathogenic mutations that directly affect nDNA-encoded respiratory chain subunits in all five complexes but most commonly affecting the 22 of the 45 structural subunits of the gigantic complex I. A growing number of direct hits affect complex II, complex III, complex IV (COX), and complex V (ATP synthase). In keeping with the all-or-none effect of mostly recessive mendelian mutations, as opposed to the variegated effect of heteroplasmic mtDNA mutations, disorders to direct hits to the mitochondrial respiratory chain generally manifest at or soon after birth and are severe, often being lethal in infancy, most often associated with Leigh syndrome (LS).

Indirect Hits Mutations

Even when all nDNA-encoded subunits of the various complexes are expressed correctly, they must be translated, imported into mitochondria, and directed to the inner mitochondrial membrane (IMM). At this site, they assemble with their mtDNA-encoded counterparts, acquire prosthetic groups, if necessary multimerize, and further assemble into supercomplexes (respirasomes). Mutations in these pathways are referred to as *indirect hits*, as they indirectly affect the mitochondrial respiratory chain.

In 1998, the search for the molecular basis of COX-deficient LS led to simultaneous discovery by two groups of the first mutant mitochondrial assembly gene, *SURF1*. Mutations in SURF1 are among the most common causes of LS. Mutations in at least 14 more COX assembly factors have been associated with various human diseases, predominantly encephalopathy, but cardiopathy often occurs with some mutations (*SCO2*, *COX10*, *COX15*, and *COA5*), whereas hepatopathy is associated with the *SCO1* mutations.

In patients with complex I deficiencies that are difficult to define molecularly, mutant assembly factors have been identified through next-generation sequencing of DNA. The clinical manifestations of these indirect hits tend to be more clinically heterogeneous than those associated with direct hits; all described patients have had encephalopathy resembling LS, but many have had leukodystrophy rather than gray matter involvement. Cardiomyopathy is often the dominating feature, presenting in infancy or in early childhood and early death.

The first assembly defect in complex III was identified in 2002 in Finnish infants with an extremely severe syndrome named GRACILE, an acronym aptly summarizing the symptoms and signs: growth retardation, aminoaciduria, cholestasis, iron overload, and early death. The mutated protein was the mitochondrial chaperone BCSL1, needed for insertion of the iron-sulfur (Fe-S) subunit into complex III.

A new group of disorders attributed to deficiency of CoQ_{10} can be related to indirect hits that consist of mutations in a cascade of biosynthetic enzymes. They result in deficiency of this relatively simple component, CoQ_{10}, which is an integral part of the respirosome, where it shuttles electrons from complexes I and II to complex III, acts as an antioxidant, and modulates apoptosis. Molecular defects in genes encoding CoQ_{10} biosynthetic enzymes (*PDSS2* and *COQ2*) were initially discovered in 2006, but mutations in other biosynthetic genes (*PDSS1*, *COQ4*, *COQ5*, *COQ6*, *COQ7*, *ADCK3* [*COQ8A*], *COQ8B*, and *COQ9*) followed. Five clinical syndromes are attributed to CoQ_{10} deficiency, and they are considered in the following section.

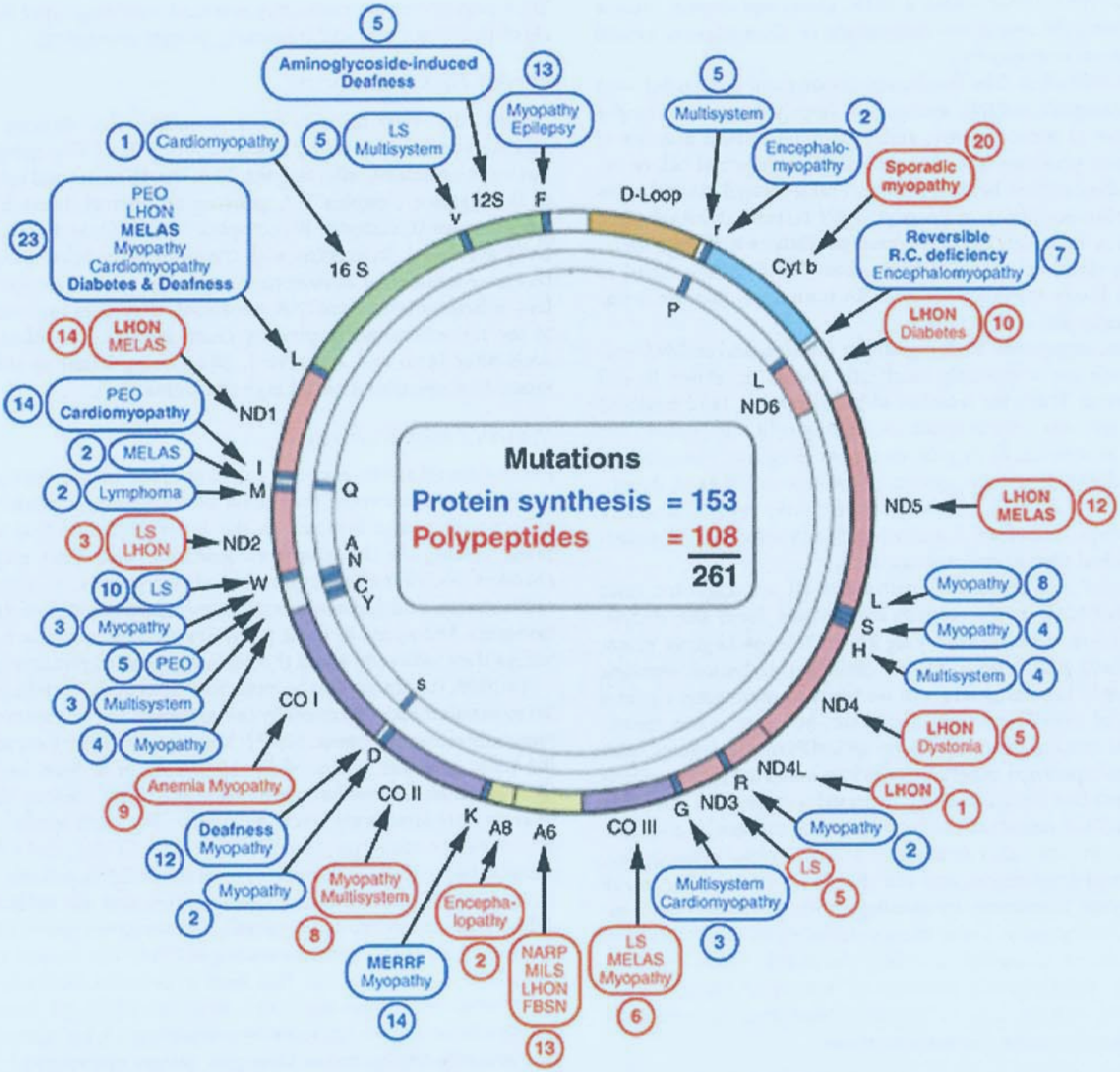

FIGURE 144.2 Morbidity map of human mitochondrial DNA. Disorders caused by mutations in protein-coding genes are shown in *red*. Disorders caused by mutations in gene controlling protein synthesis are shown in *blue*. Abbreviations: CO, cytochrome oxidase; cyt *b*, cytochrome *b*; FBSN, familial bilateral striatal necrosis; LHON, Leber hereditary optic neuropathy; LS, Leigh syndrome; MELAS, mitochondrial encephalomyopathy, lactic acidosis, and stroke-like episodes; MERRF, myoclonus epilepsy with ragged red fibers; MILS, maternally inherited Leigh syndrome; NARP, neuropathy, ataxia, and retinitis pigmentosa; ND, NADH dehydrogenase; PEO, progressive external ophthalmoplegia.

Defects of Mitochondrial Ribonucleic Acid (mtRNA) Translation

The mitochondrial genome is transcribed into 13 mRNAs, which are translated by mitoribosomes into the 13 mtDNA-encoded OxPhos subunits. As described in a comprehensive review, this process can be divided into two phases: a posttranscriptional phase (involving tRNA modifications, aminoacyl-tRNA synthetases, and processing of ribosomal proteins) and mtRNA translation (initiation, elongation, termination, and recycling). Representative examples of defects of each step of the mitochondrial translation process are briefly highlighted.

Abnormal Transfer RNA Modifications

Pseudouridylation modification is thought to promote stability and conformation of mitochondrial and nuclear tRNAs. Mutations in pseudouridine synthase 1 (*PUS1*) differentially impair nuclear and mitochondrial tRNA maturation causing mitochondrial myopathy, lactic acidosis, and sideroblastic anemia; in addition, psychiatric symptoms and facial dysmorphism are likely due to abnormal cytosolic protein synthesis.

The conundrum of spontaneous improvement in *infantile reversible COX-deficient myopathy* (more accurately designated reversible infantile respiratory chain deficiency [RIRCD]) was

resolved by elucidation of the tRNA modification processes in this disorder. RIRCD is due to homoplasmic mutations in *MT-TE*, which encodes mt-tRNA^{Glu}. Pathogenesis of the disease became more complex when patients in two families were found to harbor mutations in the *TRMU* gene, which modifies a wobble uridine base in mt-tRNA^{Glu}. Skeletal muscle from infants in the initial symptomatic phase showed significantly decreased 2-thiouridylation due to defective TRMU activity, which exacerbated the effect of the mtRNA^{Glu} mutation and triggered the mitochondrial translation defect, thus demonstrating an nDNA-modifying effect on the mtDNA mutation.

Mutations in 17 highly specialized aminoacyl-tRNA synthetases (ARs), which covalently link an amino acid to its cognate tRNA (tRNA charging), are associated with multiple specific clinical syndromes. Mitoribosomes consist of two mRNA components (12S and 16S rRNAS) and of novel about 30 and 50 nDNA-encoded proteins. Of the roughly 80 ribosomal proteins, 6 have been firmly linked to mitochondrial diseases: MRPL3, MRPS16, MRPS22, MRPL44, MRPL12, and MRPS34. Patients with defects of mitochondrial elongation factor genes (*GFM1* encoding EFG1; *TUFM*, EF-Tu$_{mt}$; and *TSFM*, EF-TS$_{mt}$) typically present with infantile-onset multisystemic diseases. Of the three known mitochondrial translation termination factors, which catalyze release of fully synthesized polypeptides, mutations have only been identified in a poorly characterized ribosome-recycling factor encoded by *C12orf65* in two unrelated families with LS, optic atrophy, and ophthalmoplegia. Mutations in two mitochondrial translation activators, both required for COX, have been linked to human diseases. Mutations in the gene *TACO1* (encoding translational activator for COX I), cause late-onset LS and COX deficiency, whereas mutations in *LRPPRC* (which encodes a leucine-rich pentatricopeptide repeat–containing protein) have been identified as the cause of a distinctive LS prevalent in French Canadians. Mutations of *RMND1* cause mitochondrial translational defects affecting multiple organs; however, the function of the encoded protein, which contains a domain of unknown function (DUF 155), remains a mystery.

Defects of the Inner Mitochondrial Membrane Lipid Milieu

The respiratory chain resides in the phospholipid component of the IMM and alterations in the lipid milieu are increasingly associated with mitochondrial encephalomyopathy. Cardiolipin, a dimeric molecule composed of two phosphatidylglycerol moieties connected by a glycerol group, is the signature mitochondrial phospholipid and a major component of the IMM, where it is synthesized. Cardiolipin deficiency was first documented—together with mutations in the gene encoding tafazzin (*TAZ*)—in patients with Barth syndrome, an X-linked mitochondrial myopathy and cardiomyopathy, with neutropenia and stunted growth.

Similar to Barth syndrome, Sengers syndrome affects primarily heart and muscle, with the distinctive additional clinical feature of congenital cataracts. Whole exome sequencing revealed mutations in the acylglycerol kinase (*AGK*) gene. Notably, lack of phosphatidic acid is a precursor of cardiolipin, thus providing a point of convergence in Sengers syndrome and Barth syndrome, which could account for the clinical similarities between the two disorders.

The mitochondrial-associated endoplasmic reticulum (ER) membrane (MAM) is the close physical and functional association between ER and mitochondria. MAMs are involved in multiple functions, including lipid transport, cholesterol metabolism, calcium signaling, energy metabolism, apoptosis, and mitochondrial dynamics.

New diseases have been associated with MAM dysfunction, including the 3-methylglutaconic aciduria (MEG), Deafness (D), Encephalopathy (E), and Leigh-like disease (L) (MEGDEL) syndrome, in which the SERAC protein is located in the MAM and controls exchange of phospholipids between the ER and mitochondria. Interestingly, a central role of MAM in the pathogenesis of Alzheimer disease has been well documented.

Defects of Mitochondrial Dynamics

Mitochondria are highly dynamic organelles that move around the cell on microtubular tracks and, similar to their bacterial precursors, they fuse and divide, thus forming tubular networks that favor a balanced distribution of energy throughout the cell. Impairment of mitochondrial motility, fusion, or fission causes the nervous system particularly susceptible, as it is highly dependent on oxidative energy, and mitochondria must travel long distances along central axons and peripheral nerves.

Mitochondrial fusion requires coordinated action of multiple guanosine triphosphatases (GTPases) in the outer mitochondrial membrane (OMM), namely mitofusins MFN1 and MFN2, and in the IMM, namely OPA1.

Mitochondrial fission requires cytosolic dynamin-related protein 1 (DRP1; also a guanosine triphosphatase), which is recruited to the OMM together with two partners, mitochondrial fission (FIS1) and mitochondrial fission factor (MFF). Once recruited to the OMM, DRP1 forms a spiral that wraps around the mitochondrion like a noose and severs the mitochondrial membrane using guanosine triphosphate hydrolysis.

Defects of Mitochondrial DNA Maintenance

These disorders have been traditionally subdivided into two groups (1) mtDNA depletion syndromes (MDS) manifesting early in life and presenting as myopathy, hepatocerebral disease, or encephalomyopathy and (2) multiple mtDNA deletions, usually associated with chronic progressive external ophthalmoplegia (CPEO) with other manifestations that are predominantly neurologic (PEO-plus).

The disorders of mtDNA maintenance are usually caused either by defects of mtDNA replication that are catalyzed by polymerase (POLG; genes *POLG* and *POLG2*) and by the helicase Twinkle (*PEO1*) or by altered homeostasis of the intramitochondrial deoxynucleoside triphosphates pool that is controlled by multiple genes including *TK2* (encoding thymidine kinase 2), *DGUOK* (encoding deoxyguanosine kinase), and *TYMP* (encoding thymidine phosphorylase). In addition, the gene encoding adenine nucleotide translocase 1 (*ANT1*) causes autosomal dominant PEO. Another mutant gene (*OPA1*), which is required mitochondrial fusion, has curiously been associated with autosomal dominant PEO-plus.

It has become increasingly evident that both mtDNA depletion and multiple mtDNA deletions often coexist in the same patient and are often caused by the same genes that cause either isolated depletion or multiple deletions of mtDNA (Table 144.2). A peculiarity of these disorders is that—although they are unequivocally mendelian—they share many features of mitochondrial genetics, including heteroplasmy and the threshold effect.

TABLE 144.2 Paradigms of Mitochondrial DNA-Mutation Disorders[a]

		mtDNA Single Deletions		tRNA		ATPase6	
Tissue	Symptom/Sign	KSS	Pearson	MERRF	MELAS	NARP	MILS
CNS	Seizures	−	−	+	+	−	+
	Ataxia	+	−	+	+	+	±
	Myoclonus	−	−	+	±	−	−
	Psychomotor retardation	−	−	−	−	−	+
	Psychomotor regression	+	−	±	+	−	−
	Hemiparesis/hemianopia	−	−	−	+	−	−
	Cortical blindness	−	−	−	+	−	−
	Migraine-like headaches	−	−	−	+	−	−
	Dystonia	−	−	−	+	−	+
PNS	Peripheral neuropathy	±	−	±	±	+	−
Muscle	Weakness	+	−	+	+	+	+
	Ophthalmoplegia	+	±	−	−	−	−
	Ptosis	+	−	−	−	−	−
Eye	Pigmentary retinopathy	+	−	−	−	+	±
	Optic atrophy	−	−	−	−	±	±
	Cataracts	−	−	−	−	−	−
Blood	Sideroblastic anemia	±	+	−	−	−	−
Endocrine	Diabetes mellitus	±	−	−	±	−	−
	Short stature	+	−	+	+	−	−
	Hypoparathyroidism	±	−	−	−	−	−
Heart	Conduction block	+	−	−	±	−	−
	Cardiomyopathy	±	−	−	±	−	±
GI	Exocrine pancreas dysfunction	±	+	−	−	−	−
	Intestinal pseudo-obstruction	−	−	−	−	−	−

Abbreviations: −, absent; +, present; ±, variably present; CNS, central nervous system; GI, gastrointestinal; KSS, Kearns-Sayre syndrome; MELAS, mitochondrial encephalomyopathy, lactic acidosis, and stroke-like episodes; MERRF, myoclonus epilepsy with ragged red fibers; MILS, maternally inherited Leigh syndrome; mtDNA, mitochondrial DNA; NARP, neuropathy, ataxia, and retinitis pigmentosa; PNS, peripheral nervous system; tRNA, transfer RNA.
[a]Typical features are highlighted in red for each disorder except MILS, which is diagnosed neuropathologically.

Disorders of Mitochondrial Protein Importation

A prerequisite for the assembly of any OxPhos complex is the import of nDNA-encoded subunits from the cytoplasm into mitochondria, thus adding one more category to the indirect hits, namely defects in the mitochondrial importation machinery.

DIAGNOSIS

Mitochondrial DNA-Related Diseases

Mitochondria and mtDNA are ubiquitous, which explains why every tissue in the body can be affected by mtDNA mutations. This is illustrated in Figure 144.2 depicting mtDNA as a veritable Pandora box (abbreviated morbidity map). Table 144.2 is a compilation of symptoms and signs reported in patients with three different types of mtDNA mutations, including single deletions, point mutations in two distinct tRNA genes, and point mutations in a protein-coding gene. As shown by the boxes, certain constellations of symptoms and signs are sufficiently characteristic to make the diagnosis relatively easy in typical patients. On the other hand, because of the peculiar rules of mitochondrial genetics, different tissues harboring the same mtDNA mutation may be affected to different degrees or not at all, which explains the sometimes puzzling variety of syndromes associated with carriers of mtDNA mutations, even within a single pedigree.

Among the maternally inherited encephalomyopathies, four syndromes are more frequent. The first is MELAS (mitochondrial encephalomyopathy, lactic acidosis, and stroke-like episodes), which usually presents in children or young adults after normal early development. Symptoms include seizures, migraine-like headache, and stroke-like episodes causing cortical blindness, hemiparesis, or hemianopia. Magnetic resonance imaging (MRI) of the brain shows "infarcts" that do not correspond to the distribution of major vessels, raising the question of whether the strokes are vascular due to mitochondrial microangiopathy (Fig. 144.3). The most common cause of MELAS is *m3243A>G* in the *tRNA*Leu(UUR) gene, but more than 20 other mutations have been associated with this disorder.

The second syndrome is *MERRF* (myoclonus *epilepsy with ragged red fibers*), characterized by myoclonus, seizures, myopathy, and cerebellar ataxia. Less common signs include dementia, hearing loss, peripheral neuropathy, and multiple lipomas. The typical mtDNA mutation in MERRF is the m.8344A>G in the *tRNA*Lys gene, but other mutations in the same gene have been reported.

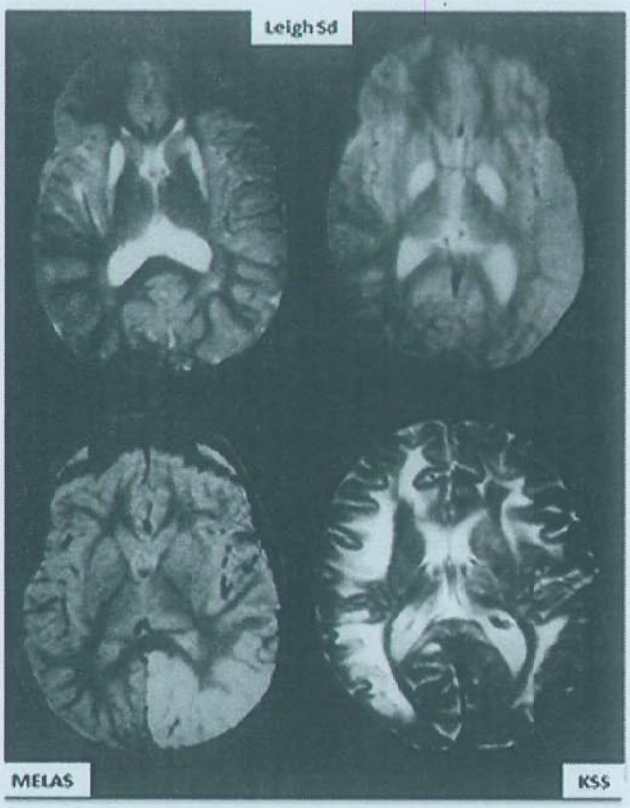

FIGURE 144.3 Characteristic brain magnetic resonance imaging abnormalities in mitochondrial encephalomyopathies. These T2-weighted images show bilateral putaminal hyperintensities in a child with cytochrome c oxidase–associated Leigh syndrome **(top left panel)**, bilateral globus pallidus hyperintensities in a child with a familial Leigh syndrome phenotype **(top right)**, a left posterior cerebral hyperintense stroke-like lesion in a child with mitochondrial encephalomyopathy, lactic acidosis, and stroke-like episodes (MELAS) **(bottom left)**, and bilateral white matter hyperintensities in a child with Kearns-Sayre syndrome (KSS) **(bottom right)**.

The third syndrome has two clinical presentations. The first is NARP (neuropathy, ataxia, and retinitis pigmentosa), which usually affects young adults and causes retinitis pigmentosa, dementia, seizures, ataxia, proximal weakness, and sensory neuropathy. The second is maternally inherited LS (*MILS*), a more severe infantile encephalopathy with characteristic symmetric lesions in the basal ganglia and the brainstem (see Fig. 144.3). As noted by the late Anita Harding in her original description of this syndrome, the two major causative mutations (m.8993G>T or m.8993C>T, both affecting the same gene *MTATP6*) affect maternal relatives in the same family with those afflicted with MILS having higher mutation loads than individuals with NARP.

The fourth syndrome, LHON, is characterized by acute or subacute loss of vision in young adults, more frequently males, due to bilateral optic atrophy. Mutations in three genes of complex I (ND genes) account for more than 90% of LHON, *m.11778G>A* in *ND4*, *m.3460G>A* in *ND1*, and *m.14484T>C* in *ND6*. Epidemiologic studies have shown that LHON is the most common mtDNA-related disorder in adults. Epigenetic factors contribute to disease expression in homoplasmic patients by virtue of increased penetrance due to the European mtDNA haplogroup J and a protective effect of estrogens in women who are less frequently affected than men.

Three sporadic conditions are associated with mtDNA single deletions, Kearns-Sayre syndrome (KSS), CPEO, and *Pearson syndrome*. All three conditions are typically sporadic; however, a few cases of maternal transmission have been reported. A multicenter retrospective study of 226 families has confirmed that women carrying single mtDNA deletions have a low risk of having affected children (1 in 24).

KSS is a multisystem disorder with the obligate triad of impaired eye movements (PEO and ptosis), pigmentary retinopathy and heart block (often requiring installment of an automatic implantable cardioverter defibrillator-pacemaker), plus ataxia, or markedly elevated cerebrospinal fluid (CSF) protein (>100 mg/dL). Frequent additional signs include dementia, endocrinopathies (diabetes mellitus, growth hormone deficiency, and hypoparathyroidism), and lactic acidosis.

CPEO is a relatively benign disorder characterized by ptosis, PEO, and proximal myopathy. In addition, patients often develop dysphagia.

Pearson syndrome, characterized by sideroblastic anemia and exocrine pancreatic dysfunction, is usually a fatal disorder of infancy. Due to *mitotic segregation* of deleted mtDNAs resulting in loss of the mutant mtDNA from blood cells but increased mutation burden in muscle and other postmitotic cells, the phenotype often evolves into CPEO or KSS in some surviving babies.

It is often stated that any patient having multiple organ involvement and evidence of maternal inheritance should be suspected of harboring a pathogenic mtDNA point mutation until proven otherwise. Although this "rule of thumb" has some practical value, it is also important to keep in mind that patients with involvement of a single tissue can still have pathogenic point mutations of mtDNA. This is especially true for skeletal muscle. As described earlier, isolated myopathy with PEO can be due to single large-scale mtDNA deletions, but isolated myopathy without PEO has been associated with point mutations in several tRNA genes, which can be due to generalized but skewed heteroplasmy in muscle. However, a simple nonmaternal inherited rule can be applied to pure mitochondrial myopathies due to somatic mutations in protein-coding mtDNA genes, including subunits of complex I, complex III (including cytochrome *b*, *MTCYB*), or complex IV, accompanied by severe exercise intolerance, myalgia, and myoglobinuria.

Mendelian Inheritance

LS is the most frequent mitochondrial disorder affecting infants and children and reflecting the ravages of energy shortage on the developing nervous system; LS is a defined neuropathologically or neuroradiologically entity by bilateral symmetric lesions all along the neuraxis but especially in the basal ganglia, thalami, brainstem, and cerebellar roof nuclei. Microscopically, there is neuronal loss, proportionate loss of myelin, reactive astrocytosis, and proliferation of cerebral microvessels. Clinically, these children manifest psychomotor retardation or regression, respiratory abnormalities, hypotonia, failure to thrive, seizures, and optic atrophy. Although we have highlighted mtDNA mutations in complex V genes causing LS (NARP/MILS), several other defects in mtDNA-encoded complex I (NADH dehydrogenase [ND]) genes as well as mutations in nuclear encoded subunits of complexes I, II, and IV frequently cause LS.

Besides LS, four distinct presentations have been attributed to direct hits in complex I deficiency: fatal infantile lactic acidosis, neonatal cardiomyopathy with lactic acidosis, leukodystrophy with macrocephaly, and hepatopathy with renal tubulopathy. Likely, these disorders represent variations of the common LS theme rather than separate clinical entities: Usually, these children appear healthy at birth or early in life, but disease progression is rapid and relentless, leading to death often before 1 year of age.

It has long been known that complex IV deficiency is a common cause of LS, but years went by before a mutated gene (*SURF1*) was associated with LS, the first example of an "indirect hit." Mutations in the COX assembly gene *SCO2* cause a severe combination of neonatal cardiomyopathy with encephalopathy, which is fatal in the first weeks or months of life. Importantly, SCO2 mutations can simulate spinal muscular atrophy (SMA); therefore, it is important to consider *SCO2* mutations in patients with the clinical picture of SMA but without mutations in the SMN gene and with cardiomyopathy and COX-deficiency in muscle histology. Mutations in several other genes encoding COX assembly proteins have been associated with encephalopathy resembling LS together with involvement of other tissues. However, mutations in *SCO1* cause encephalohepatopathy, mutations in *COX10* cause encephalonephropathy, and mutations in *COX15* cause encephalocardiopathy as do mutations in *C2orf64*. Additional disorders due to indirect hits and resulting in generalized COX deficiency, including an unusual "toxic" mechanism of COX inhibition, have been reported. Indirect hits in complex V are rather frequently associated with mutations in the gene *TMEM70*, resulting in defective assembly of ATP synthase. Most patients harboring *TMEM70* mutations were severely affected with neonatal hypotonia, apneic spells, psychomotor delay, hypertrophic cardiomyopathy, and profound lactic acidosis, whereas a minority presented with additional infantile-onset cataracts, early-onset gastrointestinal dysfunction, and multiple joint contractures.

Indirect hits include heterogeneous diseases with five major phenotypes due to CoQ_{10} deficiency (Fig. 144.4). These disorders are important to diagnose because they often respond to CoQ_{10} supplementation. The first patients reported in 1989 were a pair of sisters, ages 12 and 14 years old with a mitochondrial disorder characterized by encephalopathy (mental retardation, seizures, and mild ataxia) and myopathy with recurrent myoglobinuria. The triad of mitochondrial myopathy, myoglobinuria, and encephalopathy has been reported in a few other patients. The second syndrome is childhood-onset cerebellar atrophy and ataxia, with variable additional symptoms, including neuropathy, seizures, mental retardation, and muscle weakness. The molecular basis of this phenotype was identified in some but not all patients, and the mutated gene was *ADCK3/COQ8A*. The third syndrome was an infantile multisystemic disease, which typically manifests as encephalopathy and nephropathy (particularly steroid-resistant nephrotic syndrome). This syndrome was initially associated with mutations in COQ2 and PDSS and subsequently in additional genes required for CoQ_{10} biosynthesis including *PDSS1*, *PDSS2*, *COQ4*, and *COQ9*. The fourth syndrome, dominated by severe nephropathy and typically leading to end-stage renal disease, was originally attributed to *COQ2* gene mutations, whereas steroid-resistant nephrosis and end-stage renal failure associated with sensorineural deafness was linked to *COQ6* mutations. The fifth syndrome is isolated myopathy and, in a few cases, has been due to multiple acyl-coenzyme A (CoA) dehydrogenases deficiency causing secondary CoQ_{10} deficiency.

Defects of the Inner Mitochondrial Membrane Lipid Milieu

Phospholipid metabolism and the lipid composition of the IMM were relatively neglected in the study of mitochondrial diseases, but there was a recent awakening of this subject and several new disorders were discovered, thanks in part to whole exome sequencing.

Barth syndrome is an X-linked disorder characterized by mitochondrial cardiac and skeletal myopathy, cyclic neutropenia,

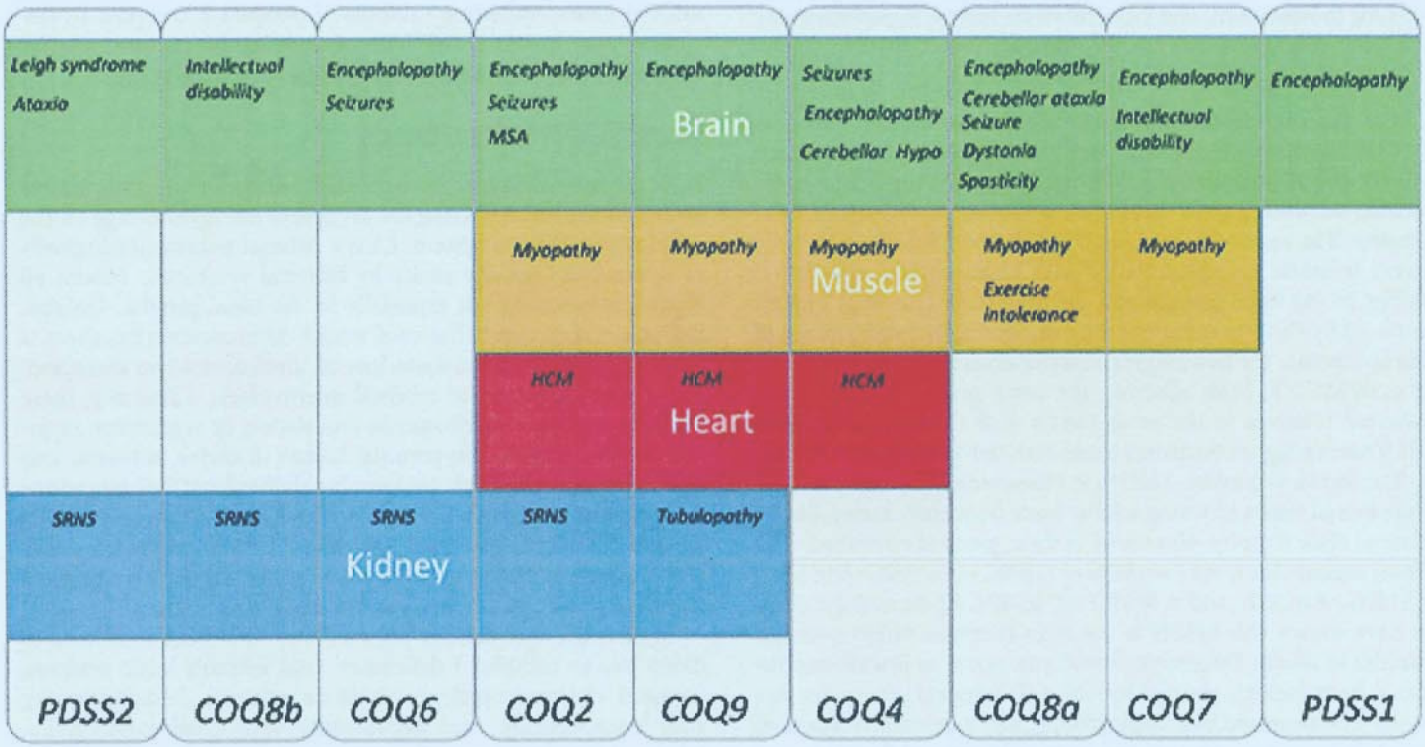

FIGURE 144.4 Schematic representation of the clinical spectrum associated with primary coenzyme Q_{10} deficiencies. Hypertrophic cardiomyopathy (HCM), steroid-resistant nephrotic syndrome (SRNS), multiple system atrophy (MSA), and cerebellar hypoplasia (cerebellar hypo).

and growth retardation and, as previously noted, is due to *TAZ* mutations that alter cardiolipin, the most abundant phospholipid component of the IMM.

Sengers syndrome, an autosomal recessive disorder, was described in 1975 and consisted of congenital cataracts, hypertrophic cardiomyopathy, skeletal myopathy, exercise intolerance, and lactic acidosis. This syndrome was ultimately attributed through exome sequencing to mutations in the gene (*AGK*) encoding acylglycerol kinase.

A third disorder of the mitochondrial lipid milieu was identified in 15 patients with a *congenital myopathy* characterized by early-onset muscle weakness and mental retardation with protracted course (most patients were alive at the time of publication and only four had died between the ages of 2½ and 28 y). The hallmark of the disease was the presence in muscle of greatly enlarged mitochondria (megaconial disease) displaced at the periphery of the fibers and the genetic cause was due to mutations in the gene (*CHKB*) encoding choline kinase beta.

A genetic alteration of phospholipid metabolism explained a syndrome characterized by 3-methylglutaconic aciduria (3-methylglutaconic aciduria type IV, deafness, and encephalopathy, Leigh-like which was dubbed *MEGDEL*). This syndrome was caused by mutations in the phospholipid remodeling gene *SERAC1*, a key player in intracellular cholesterol trafficking and a member of the MAMs.

Defects of Mitochondrial Translation

Mitochondrial translation is a complex mechanism that requires the cooperation of almost 100 different proteins needed to form the mitoribosome, elongation factors, and aminoacyl-tRNA synthases. It is not surprising that mitochondrial translational defects typically present with diverse clinical phenotypes, often infantile onset and severe manifestations with multisystemic disease and LS being the most prevalent. However, a few distinct phenotypes have emerged in this group of heterogeneous disorders. As previously noted, mitochondrial myopathy, lactic acidosis, and sideroblastic anemia can be caused not only by *PUS1* mutations but also by *YARS* mutations. RIRCD to a homoplasmic $tRNA^{Glu}$ is particularly important to diagnose because, with proper supportive care, children typically improve spontaneously and eventually become clinically normal. Pathogenic mutations in the gene *DARS* (encoding aspartyl-tRNA synthethase) cause brainstem and spinal cord involvement and lactate elevation (*LBSL*) in affected children with cerebellar ataxia, spasticity, dorsal column dysfunction, and mild cognitive decline. Equally severe mutations in the gene *RARS2* (encoding arginyl-tRNA synthetase) have been identified in three patients with severe infantile encephalopathy with *pontocerebellar hypoplasia*. Mutations in *EARS2*, encoding glutamyl-tRNA synthetase, were identified by whole exome sequencing in a cohort of 11 unrelated cases with symmetric cerebral white matter abnormalities and signal abnormalities of the thalami, midbrain, pons, medulla oblongata, and cerebellar white matter. All patients share an infantile-onset and rapidly progressive disease with severe lactic acidosis. Mutations in *MARS2*, encoding the methionyl-tRNA synthetase, were found to be responsible for *autosomal recessive spastic ataxia with leukoencephalopathy*.

Defects of mitoribosomes have been associated with complex multisystemic disorders sometimes presenting with congenital abnormalities (dysmorphism and heart defects); however, in one family with *MPRL3* mutations, four siblings manifested fatal infantile-onset hypertrophic cardiomyopathy and psychomotor retardation. Similarly, patients with abnormal mitochondrial translational elongation factors typically present with fatal infantile diseases with early hepatoencephalopathy with *GFM1* (EFG1) mutations and macrocystic leukodystrophy and micropolygyria due to *TUFM* (EF-Tu_{mt}) defects.

Defects of Mitochondrial Dynamics

There is a group of disorders due to numerous mutations in mitochondrial fusion proteins and, less commonly, in fission proteins. Mutations in fusion proteins, such as OPA1, result in a dominant optic atrophy (DOA or Kjer disease), the nDNA blindness corresponding to the mtDNA disorder LHON. Other mutations in fusion proteins, such as MFN2 or GADP1, result in Charcot-Marie-Tooth neuropathies (types 2A and 4A).

Two infants with distinct mutations in fission genes (*DRP1* and *MFF*) showed both mitochondrial and peroxisomal abnormalities, and they were severely affected with rapidly fatal encephalopathy and lactic acidosis.

Defects of Mitochondrial DNA Maintenance

Here, we consider the main clinical phenotypes associated with MDS, with multiple mtDNA syndromes (PEO-plus), and, finally, with combined appearance of mtDNA depletion and of multiple mtDNA deletions.

Mitochondrial DNA Depletion Syndromes

Myopathic Mitochondrial DNA Depletion Syndromes

Patients usually present in the first year of life with failure to thrive, hypotonia, weakness, and sometimes PEO. They usually die in childhood from pulmonary insufficiency but severity of weakness and survival vary considerably. The myopathic MDS is most commonly due to mutations in the gene (*TK2*) encoding mitochondrial thymidine kinase 2. More than 90 patients have been reported in the literature with a range of more than 45 different mutations. Notably, mutations in *TK2* can also cause a phenocopy of SMA; therefore, it is of practical importance to screen for *TK2* mutations in patients with SMA but without mutations in the *SMN1* gene.

Encephalomyopathic Mitochondrial DNA Depletion Syndromes

Two variants of this condition are both due to a defect of succinyl-CoA lyase activity in the Krebs cycle. Mutations in the gene (*SUCLA2*) encoding the ATP-dependent succinyl-CoA lyase SUCLA2 cause severe psychomotor retardation, muscle hypotonia, hearing loss, generalized seizures, knee and hip contractures, mild ptosis, lactic acidosis, and methylmalonic aciduria. There is only moderate mtDNA depletion (about 30%) in muscle, whereas MRI of the brain is suggestive of LS. Mutations in the gene (*SUCLG1*) encoding the guanosine triphosphate-dependent isoform SUCLG1 cause a much more severe and rapidly fatal phenotype with mtDNA depletion in both muscle and liver, characterized clinically by dysmorphic features, congenital lactic acidosis, and methylmalonic aciduria. A less dismal course, more like the SUCLA2 phenotype, is correlated to the degree of residual activity.

Patients with mtDNA depletion are due to mutations in RRM2B (encoding the small subunit, p53R2, of the p53-inducible ribonucleotide reductase protein). Infants are hypotonic and children are weak but may also manifest nephropathy and central

nervous system involvement with microcephaly, seizures, and developmental delay.

Hepatocerebral Mitochondrial DNA Depletion Syndromes

Mutations in three other genes, *DGUOK*, *MPV17*, and *POLG*, also cause liver and brain involvement. Mutations in *DGUOK*, encoding the mitochondrial deoxyguanosine kinase, were first reported in 2001. Severe mutations cause fatal infantile hepatopathy and brain involvement, whereas milder mutations cause isolated liver disease and are compatible with longer survival.

Mutations in *MPV17*, which encodes a small mitochondrial membrane protein of unknown function, cause a rather typical hepatocerebral syndrome in Caucasian children but is associated with a peculiar neurohepatopathy that is prevalent in the Navajo population due to a founder *MPV17* mutation. The clinical features of Navajo neurohepatopathy (NNH) include peripheral and central nervous system involvement, acral mutilation, corneal scarring or ulceration, liver failure, and immunologic derangement.

Alpers-Huttenlocher syndrome is the most important form of hepatocerebral MDS, and it has been attributed to mutations in *POLG*. Alpers-Huttenlocher syndrome is defined as a disorder of childhood by the tetrad of refractory seizures, episodic psychomotor regression, cortical blindness, and hepatopathy with micronodular cirrhosis. It is crucially important not to expose these children to valproate, which often precipitates fulminant hepatic failure.

Syndromes due to Multiple Mitochondrial DNA Deletions

Mutations in ANT1

Mutations in the gene for one isoform of the adenine nucleotide translocator (*ANT1*) have been identified in patients with autosomal dominant PEO, sometime associated with psychiatric disorders. In a seminal paper, multiple mtDNA deletions were most abundant in brain, followed by cardiac and skeletal muscle. Sporadic PEO may also infrequently be due to mutations in *ANT1* and the association of mitochondrial myopathy and cardiomyopathy, even in patients with recessive inheritance and without PEO, should raise the question of *ANT1* mutations.

Mutations in PEO1

In 2001, autosomal dominant PEO with multiple mtDNA deletions was associated with mutations in the gene (*PEO1*), encoding a mitochondrial helicase called *Twinkle*, an essential factor for mtDNA maintenance and for the regulation of mtDNA copy number. A review of 33 patients from 26 families showed that the most common symptoms were ptosis (97%) and ophthalmoparesis (94%), followed by exercise intolerance (52%) and mild proximal weakness (33%). Central nervous system involvement was infrequent and included visual impairment, migraine, lethargy, hearing loss, and epilepsy. Cardiac problems were noted in 24% of the patients. A relatively benign long-term progression was noted in a large family with autosomal dominant isolated PEO.

Mutations in POLG

Mutations in the gene encoding the only mitochondrial polymerase, *POLG*, have emerged as major causes of a vast array of mitochondrial disorders. More than 150 mutations have been described in all three domains of the gene, exonuclease, linker, and polymerase and may cause either autosomal dominant or autosomal recessive PEO, a syndrome comprising autosomal recessive sensory ataxic neuropathy, dysarthria, and ophthalmoparesis; mitochondrial recessive ataxia syndrome; or parkinsonism with or without PEO.

Mutations in OPA1

One unexpected gene was recently added to those described earlier and associated with myopathy and PEO, *OPA1*. This was unexpected because mutations in *OPA1* had been initially associated with a purely ophthalmologic condition, DOA or Kjer disease, and because the gene product is a mechanoenzyme associated with mitochondrial fusion rather than with mitochondrial maintenance.

However, a syndromic disorder, often dubbed DOA-plus, has emerged, which is characterized more or less sequentially by optic atrophy with visual failure, sensorineural deafness, ataxia, myopathy, axonal sensory motor polyneuropathy, and PEO. Muscle biopsy in these patients shows scattered ragged blue, COX-negative fibers and multiple mtDNA deletions. The relationship between this defect of mitochondrial dynamics and altered mitochondrial maintenance is intriguing. Two explanations have been proposed: decreased ability by the organelles to repair stress-induced mtDNA damage or accelerated accumulation of preexisting age-associated somatic mtDNA mutations.

Coexistence of Mitochondrial DNA Depletion and Mitochondrial DNA Multiple Deletions

Mitochondrial Neurogastrointestinal Encephalomyopathy

One of the disorders in which the coexistence of multiple mtDNA deletions and mtDNA depletion was first recognized is mitochondrial neurogastrointestinal encephalomyopathy (MNGIE). This autosomal recessive multisystemic syndrome is characterized by mitochondrial myopathy with ptosis and PEO, peripheral neuropathy, gastrointestinal dysmotility causing severe cachexia, and leukoencephalopathy without cognitive impairment. MNGIE is due to mutations in the gene (*TYMP*) encoding thymidine phosphorylase, resulting in elevated levels of thymidine and deoxyuridine in plasma and tissues. The disease usually starts in the late teens and is relentlessly progressive, with an average age of death at 37 years. Molecular analysis has shown over 50 *TYMP* mutations resulting in mtDNA multiple deletions, depletion, and site-specific somatic mtDNA point mutations in multiple tissues. A mouse model has demonstrated that increased levels of thymidine and deoxyuridine imbalance mitochondrial deoxynucleotide triphosphate pools, resulting in mtDNA instability.

Infantile-onset spinocerebellar ataxia was described in the 1970s in Finland. Between 9 and 18 months, children develop acute or subacute ataxia, hypotonia, athetosis, and areflexia, and by teenage years, they lose independent ambulation. Additional symptoms include PEO, optic atrophy, sensorineural hearing loss, cognitive impairment, sensory neuropathy, and autonomic nervous system dysfunction. In 2005, this autosomal recessive disorder was attributed to mutations in *PEO1*. Both brain and liver showed mtDNA depletion.

In addition to causing early childhood-onset myopathic mtDNA depletion, mutations in *TK2* can also cause adult-onset myopathy with mtDNA depletion and even late-onset PEO with multiple mtDNA deletions rather than mtDNA depletion.

Mutations in *RRM2B* can also be associated with autosomal dominant or recessive PEO and multiple mtDNA deletions.

Exome sequencing revealed *DGUOK* mutations in five adult patients with PEO and mitochondrial myopathy with multiple mtDNA deletions: Only one of these patients had had liver problems in childhood. Mutations in *MPV17*, in addition to causing juvenile-onset mtDNA depletion, can also cause adult-onset PEO-plus with multiple mtDNA deletions in muscle.

DIAGNOSTIC WORKUP

Laboratory

Lactic acidosis is a common finding in OxPhos disorders, and the lactate-to-pyruvate ratio is often elevated (>20:1). Information about CSF lactate and pyruvate is important because CSF values can be increased in children with encephalopathy and normal blood lactate. However, lack of lactic acidosis does not exclude the diagnosis. For example, in patients with NARP or MILS, blood lactate and pyruvate can be normal or only mildly elevated. Serum creatine kinase levels are usually normal or modestly increased except, of course, in patients with myopathy during episodes of myoglobinuria. As another exception to this rule, and a useful diagnostic clue, serum creatine kinase values can be markedly elevated in children with the myopathic form of mtDNA depletion, such as those with mutations in the gene (*TK2*) encoding mitochondrial thymidine kinase. Another important laboratory test is plasma thymidine, which is greatly increased in patients with MNGIE, an autosomal recessive disease due to mutations in *TYMP* encoding thymidine phosphorylase.

Neuroradiology

Bilateral MRI T2 signal hyperintensities in basal ganglia and brainstem are indicative of LS. Stroke-like lesions predominantly affecting the cortex, often in the posterior cerebral hemispheres, are typically seen in patients with MELAS. Increased MRI T2 signal abnormality of the central white matter is sometimes observed in KSS, whereas basal ganglia calcifications are common in both MELAS and KSS syndrome (see **Fig. 144.3**). White matter signal abnormalities are distinctively seen in patients with complex I deficiency or in children with mtDNA translation defects or in several patients with problems of mtDNA maintenance. Proton magnetic resonance spectroscopy reveals lactate accumulation in the CSF and in specific areas of the brain, where lactate concentration can be compared to the concentration of *N*-acetylaspartate, an indicator of cell viability.

Exercise Physiology

Impaired oxygen extraction by exercising muscle can be detected by near-infrared spectroscopy, which measures the degree of deoxygenation of hemoglobin. A simpler test is based on the measurement of the P_{O_2} in cubital venous blood after forearm aerobic exercise. P_{O_2} rises paradoxically in patients with mitochondrial myopathy or PEO, and the degree of rise reflects the severity of oxidative impairment. By phosphorus 31 magnetic resonance spectroscopy, the ratio of phosphocreatine to inorganic phosphate can be measured in muscle at rest, during exercise, and during recovery. In patients with mitochondrial dysfunction, phosphocreatine to inorganic phosphate ratios are lower than normal at rest, decrease excessively during exercise, and return to baseline more slowly than normal.

PATHOLOGY

Skeletal Muscle

Muscle biopsy has a central role in the diagnosis of primary mtDNA-related disorders but is equally important in diagnosing patients with defects of mtDNA maintenance, who have strictly mendelian inheritance and secondary mtDNA alterations. In both types of disorders, abnormal mitochondrial proliferation, a hallmark of mitochondrial dysfunction, can be revealed with the modified Gomori trichrome stain (RRF) or better with the SDH reaction (ragged blue fibers) (**Fig. 144.5**). RRF are present in muscle biopsies from patients with most disorders due to mtDNA mutations although rare exceptions include NARP/MILS and LHON. Most cases of mendelian inheritance rarely are diagnosable by the presence of RRF or ragged blue fibers, but these types of fibers are exceptionally detectable in patients with either mtDNA depletion or mtDNA multiple deletions.

The COX histochemical reaction typically reveals scattered COX-negative and COX-deficient fibers, which usually correspond to—but are not confined to—RRF. RRF are COX-positive in two main conditions: (1) typical MELAS syndrome and (2) mutations in mtDNA genes encoding cytochrome *b* or complex I subunits. To confirm the pathogenicity of an mtDNA mutation, single fibers can be dissected out of thick cross-sections of muscle and used to determine the levels of a given mutation by polymerase chain reaction. Finding higher levels of the

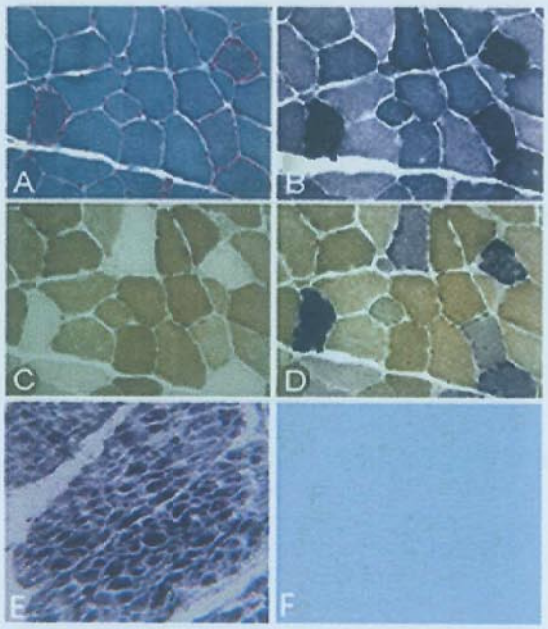

FIGURE 144.5 Serial sections from the muscle biopsy of a patient with myoclonus epilepsy with ragged red fibers syndrome. With the modified Gomori trichrome stain **(A)**, two ragged red fibers are evident. The same fibers appear *ragged-blue* with the succinate dehydrogenase (SDH) stain **(B)**, are pale with the cytochrome *c* oxidase (COX) stain **(C)**, and appear more or less intensely blue with the combined COX/SDH stain **(D)**. In contrast to the checkerboard appearance of the muscle biopsy in an mitochondrial DNA-related disease, the biopsy from a patient with mutations in *SCO2*, an nDNA assembly gene of COX, shows normal fiber type–related variability in SDH staining intensity **(E)** but uniform lack of COX activity **(F)**.

mutation in affected (ragged red or COX-negative fibers) than in unaffected (non–ragged red, COX-positive fibers) is strong evidence that the mutation in question is pathogenic.

Electron microscopy has lost much of its historical diagnostic value, but it can reveal focal accumulations of mitochondria or mitochondria with paracrystalline inclusions in cases in which histochemical results are equivocal.

Neuropathology

The major neuropathologic findings in mitochondrial encephalomyopathies consist of four histologic lesions: spongy degeneration, neuronal loss, gliosis, and demyelination. Although these lesions are nonspecific, their distribution patterns vary in patients with different mtDNA-related disorders. Thus, the neuropathology of KSS is characterized by spongiform degeneration, which is usually generalized and affects both gray and white matter. In MELAS, multifocal necrosis predominates, affecting not only the cerebral cortex or the subcortical white matter but also the cerebellum, thalamus, and basal ganglia. Calcification of basal ganglia is also common. In MERRF, neuronal degeneration, astrocytosis, and demyelination affect preferentially the cerebellum (especially the dentate nucleus), the brainstem (especially the olivary nucleus), and the spinal cord. In LS, due to either mtDNA-related diseases or mendelian conditions, there are symmetric, bilateral foci of necrosis in the basal ganglia, thalamus, midbrain, and pons. Microscopically, the lesions show vascular proliferation, gliosis, neuronal loss, demyelination, and cystic cavitation.

BIOCHEMICAL FINDINGS

All 37 mtDNA-encoded genes are required for synthesis of the mitochondrial OxPhos pathway (see **Fig. 144.1**); therefore, disorders due to mutations of mtDNA are usually associated with biochemical defects of OxPhos. Skeletal muscle is the preferred tissue for biochemical analysis because it is rich in mitochondria, it is invariably affected in multisystem disorders (mitochondrial encephalomyopathies), and it is the most common tissue affected in isolation (mitochondrial myopathies). Because mitochondrial proliferation in muscle (RRF) is a common occurrence, activities of respiratory chain complexes should be referred to the activity of citrate synthase, a nuclear-encoded enzyme of the mitochondrial matrix that is a good marker of mitochondrial abundance.

Biochemical studies in muscle extract from patients with mtDNA-related disorders yield two main types of results. The first pattern consists of partial defects in the activities of multiple complexes containing mtDNA-encoded subunits (I, III, and IV) contrasting with normal or increased activities of SDH (complex II) and citrate synthase. The second pattern is a severe deficiency in the activity of one specific respiratory complex. As a rule, the first pattern is found in patients with single mtDNA deletions (eg, KSS) or mutations in tRNA genes (eg, MELAS, MERRF) because these genetic errors impair mitochondrial protein synthesis in toto. The second pattern is typical of mutations in mtDNA protein-coding genes. For example, mutations in the cytochrome *b* gene cause isolated complex III deficiency. However, mutations in ND genes, which are encountered with increasing frequency in patients with MELAS, LS, LHON, or overlap syndromes, cause inconsistent and often modest impairment of complex I activity.

Specific enzyme defects are documentable in mendelian conditions, especially clear in "direct" and "indirect" hits of complex I and complex IV. However, universal decrease of all respiratory chain enzymes (except for complex II) typically appears in conditions of MDS and—equally devastating—it typically also characterizes most disorders due to mtDNA translation syndromes. Occasionally, defects in Fe-S assembly proteins show biochemical decreases of three specific respiratory chain enzymes (complex I, complex II, complex III) and of one specific enzyme of the Krebs cycle (aconitase) of which Fe-S are components.

MANAGEMENT

No panacea for respiratory chain dysfunction and no universal therapy for mitochondrial disorders currently exist. Nevertheless, symptomatic pharmacologic treatments (eg, antiepileptic drugs) and surgical remedies (such as blepharoplasty) are useful in prolonging and improving the lives of patients with mitochondrial disease. Exercise therapy has been demonstrated to improve exercise tolerance and quality of life in patients with mitochondrial diseases. Several strategies aimed at curing (or even preventing) mitochondrial diseases have shown promise in vitro or in animals or have produced encouraging preliminary results in humans and are briefly reviewed in the following sections.

Mitochondrial Transfer

For mtDNA-related diseases, many of which are devastating and undiagnosable prenatally, the ultimate goal is to prevent their occurrence altogether via mitochondrial replacement. In this approach, the nucleus of an in vitro–fertilized oocyte from an mtDNA mutation carrier is transferred to an enucleated oocyte from a normal donor: The embryo will have the nDNA of the biologic parents but the mtDNA of a normal mitochondrial donor. In nonhuman primate experiments using oocyte spindle-chromosomal complex transfer, the infants were healthy and devoid of original maternal mtDNA. The same technique was applied to fertilized and unfertilized but parthenogenically activated human oocytes, and the cells were found to develop into normal blastocysts and contain virtually exclusively donor mtDNA. Moreover, only donor mtDNA was detected after stem cell lines from blastocysts were differentiated into neurons, cardiomyocytes, and β cells. Similar results were obtained in the United Kingdom after pronuclear transfer in abnormally fertilized human oocytes developed to the blastocyst stage. Despite ethical concerns, in 2016, the Human Fertilisation and Embryology Authority authorized the use of this technology on a case-by-case basis. The first oocyte mitochondrial replacement procedure with in vitro fertilization has been already performed in a woman carrier who gave birth to a healthy boy with low neonatal mtDNA mutation loads.

Shifting Heteroplasmy

For mtDNA-related disorders, an obvious but challenging goal is to shift heteroplasmy in patients, thereby lowering the mutation load to subthreshold levels. When deprived of glucose and exposed to ketogenic media, cybrids harboring single mtDNA deletions shifted their heteroplasmy level and recovered mitochondrial function, probably through selective mitochondrial autophagy (mitophagy). A genetic approach to heteroplasmic

shifting involves use of restriction endonucleases to eliminate specific pathogenic mutations.

Enhancement of Oxidative Phosphorylation Function

The most obvious therapeutic approach to mitochondrial disorders is to enhance OxPhos function, thereby mitigating both energy crisis (ATP deficit) and oxidative stress (toxic buildup of reactive oxygen species). The compound used almost universally in patients with mitochondrial disease is CoQ_{10}, given the pivotal role of this molecule in electron transport, its antioxidant properties, and its safety even at high doses. Two synthetic analogs of CoQ_{10}—idebenone and parabenzoquinone—seem more promising. Idebenone, a short-chain benzoquinone, has shown mild positive results at 900 mg daily in two studies of patients with LHON. The second compound, a parabenzoquinone labelled EPI-743, has so far been tested only in open studies: This compound at 100 to 400 mg 3 times daily reversed vision loss in four of five patients with LHON, produced clinical improvement in 12 children with various mitochondrial disorders, and arrested or reversed disease progression in 13 children with genetically proven LS.

Elimination of Noxious Compounds

The second logical therapeutic approach to mitochondrial disease is to eliminate the noxious compounds that accumulate in these disorders. To decrease brain lactate in patients with MELAS, we used dichloroacetate, which keeps pyruvate dehydrogenase in the active form and favors lactate oxidation. Unfortunately, this agent had unacceptable neurotoxicity and treatment had to be discontinued. A more promising "detoxifying therapy" seems to be allogeneic hematopoietic stem cell transplantation (AHSCT) aimed at restoring sufficient thymidine phosphorylase activity in patients with MNGIE to normalize the circulating toxic levels of thymidine and deoxyuridine. As of 2012, 9 of 24 patients with MNGIE who had undergone AHSCT were alive and had normal blood thymidine phosphorylase activity, virtually undetectable levels of thymidine and deoxyuridine, and mild clinical improvements; however, transplant-related mortality was unacceptably high. A safety study in a subset of AHSCT in patients with MNGIE is under way to assess if transplants can be performed with low morbidity in mildly to moderately affected individuals.

Small Molecule Therapies

Compassionate use of deoxynucleosides (thymidine and deoxycytidine) has shown promising results in patients with defects of mtDNA maintenance due to TK2 deficiency. A follow-up clinical trial is in progress.

Alteration of Mitochondrial Dynamics

Mitochondrial dynamics could be exploited therapeutically in two opposing ways. Enhancing mitochondrial fission can favor mitophagy, a natural "quality control" function that sequesters and eliminates dysfunctional mitochondria, perhaps through sensing their abnormally low membrane potential. Alternatively, enhancement of mitochondrial fusion and "networking" would allow complementation of "bad" and "good" mitochondria and normalization of overall mitochondrial function.

Although natural mitochondrial proliferation (eg, RRF) is a futile compensatory mechanism, preliminary studies indicate that it may be possible to improve on natural processes by enhancing mitochondrial biogenesis through activation of the transcriptional coactivator PGC-1α AMPK pathway or sirtuin 1. The advantage over disease-induced mitochondrial proliferation, which appears to favor mutated mtDNAs, is that upregulation of mitochondrial biosynthesis increases numbers of all mtDNAs, allowing wild-type genomes to compensate for mutated ones. Encouraging results have been obtained in four mouse models of COX deficiency.

SUGGESTED READINGS

General Reviews

DiMauro S. Mitochondrial encephalomyopathies—fifty years on: the Robert Wartenberg Lecture. *Neurology*. 2013;81:281-291.

DiMauro S, Schon EA, Carelli V, Hirano M. The clinical maze of mitochondrial neurology. *Nat Rev Neurol*. 2013;9:429-444.

Gorman GS, Chinnery PF, DiMauro S, et al. Mitochondrial diseases. *Nat Rev Dis Primers*. 2016;2:16080.

Rahman J, Rahman S. Mitochondrial medicine in the omics era. *Lancet*. 2018;391:2560-2574.

History

DiMauro S, Bonilla E, Lee CP, et al. Luft's disease. Further biochemical and ultrastructural studies of skeletal muscle in the second case. *J Neurol Sci*. 1976;27:217-232.

Engel WK, Cunningham CG. Rapid examination of muscle tissue. An improved trichrome method for fresh-frozen biopsy sections. *Neurology*. 1963;13:919-923.

Holt IJ, Harding AE, Morgan-Hughes JA. Deletions of muscle mitochondrial DNA in patients with mitochondrial myopathies. *Nature*. 1988;331:717-719.

Luft R, Ikkos D, Palmieri G, Ernster L, Afzelius B. A case of severe hypermetabolism of nonthyroid origin with a defect in the maintenance of mitochondrial respiratory control: a correlated clinical, biochemical, and morphological study. *J Clin Invest*. 1962;41:1776-1804.

Shy GM, Gonatas NK, Perez M. Two childhood myopathies with abnormal mitochondria. I. Megaconial myopathy. II. Pleoconial myopathy. *Brain*. 1966;89:133-158.

Wallace DC, Singh G, Lott MT, et al. Mitochondrial DNA mutation associated with Leber's hereditary optic neuropathy. *Science*. 1988;242:1427-1430.

Pathobiology

Alexander C, Votruba M, Pesch UE, et al. OPA1, encoding a dynamin-related GTPase, is mutated in autosomal dominant optic atrophy linked to chromosome 3q28. *Nat Genet*. 2000;26:211-215.

Area-Gomez E, de Groof A, Bonilla E, et al. A key role for MAM in mediating mitochondrial dysfunction in Alzheimer disease. *Cell Death Dis*. 2018;9:335.

Bione S, D'Adamo P, Maestrini E, Gedeon AK, Bolhuis PA, Toniolo D. A novel X-linked gene, G4.5. is responsible for Barth syndrome. *Nat Genet*. 1996;12:385-389.

Boczonadi V, Ricci G, Horvath R. Mitochondrial DNA transcription and translation: clinical syndromes. *Essays Biochem*. 2018;62:321-340.

Bourdon A, Minai L, Serre V, et al. Mutation of RRM2B, encoding p53-controlled ribonucleotide reductase (p53R2), causes severe mitochondrial DNA depletion. *Nat Genet*. 2007;39:776-780.

Bourgeron T, Rustin P, Chretien D, et al. Mutation of a nuclear succinate dehydrogenase gene results in mitochondrial respiratory chain deficiency. *Nat Genet*. 1995;11:144-149.

Bykhovskaya Y, Casas K, Mengesha E, Inbal A, Fischel-Ghodsian N. Missense mutation in pseudouridine synthase 1 (PUS1) causes mitochondrial myopathy and sideroblastic anemia (MLASA). *Am J Hum Genet*. 2004;74:1303-1308.

Calvo SE, Compton AG, Hershman SG, et al. Molecular diagnosis of infantile mitochondrial disease with targeted next-generation sequencing. *Sci Transl Med*. 2012;4:118ra110.

Calvo SE, Tucker EJ, Compton AG, et al. High-throughput, pooled sequencing identifies mutations in NUBPL and FOXRED1 in human complex I deficiency. *Nat Genet*. 2010;42:851-858.

Chen H, Chan DC. Mitochondrial dynamics—fusion, fission, movement, and mitophagy—in neurodegenerative diseases. *Hum Mol Genet*. 2009;18(R2): R169-R176.

Cuesta A, Pedrola L, Sevilla T, et al. The gene encoding ganglioside-induced differentiation-associated protein 1 is mutated in axonal Charcot-Marie-Tooth type 4A disease. *Nat Genet*. 2002;30:22-25.

Delettre C, Lenaers G, Griffoin JM, et al. Nuclear gene OPA1, encoding a mitochondrial dynamin-related protein, is mutated in dominant optic atrophy. *Nat Genet*. 2000;26:207-210.

DiMauro S, Tanji K, Schon EA. The many clinical faces of cytochrome c oxidase deficiency. *Adv Exp Med Biol*. 2012;748:341-357.

Elpeleg O, Miller C, Hershkovitz E, et al. Deficiency of the ADP-forming succinyl-CoA synthase activity is associated with encephalomyopathy and mitochondrial DNA depletion. *Am J Hum Genet*. 2005;76:1081-1086.

Fernandez-Vizarra E, Berardinelli A, Valente L, Tiranti V, Zeviani M. Nonsense mutation in pseudouridylate synthase 1 (PUS1) in two brothers affected by myopathy, lactic acidosis and sideroblastic anaemia (MLASA). *J Med Genet*. 2007;44:173-180.

Garcia-Diaz B, Barros MH, Sanna-Cherchi S, et al. Infantile encephaloneuromyopathy and defective mitochondrial translation are due to a homozygous RMND1 mutation. *Am J Hum Genet*. 2012;91:729-736.

Gempel K, Topaloglu H, Talim B, et al. The myopathic form of coenzyme Q_{10} deficiency is caused by mutations in the electron-transferring-flavoprotein dehydrogenase (ETFDH) gene. *Brain*. 2007;130:2037-2044.

Gorman GS, Schaefer AM, Ng Y, et al. Prevalence of nuclear and mitochondrial DNA mutations related to adult mitochondrial disease. *Ann Neurol*. 2015;77:753-759.

Hakonen AH, Goffart S, Marjavaara S, et al. Infantile-onset spinocerebellar ataxia and mitochondrial recessive ataxia syndrome are associated with neuronal complex I defect and mtDNA depletion. *Hum Mol Genet*. 2008;17:3822-3835.

Heeringa SF, Chernin G, Chaki M, et al. COQ6 mutations in human patients produce nephrotic syndrome with sensorineural deafness. *J Clin Invest*. 2011;121:2013-2024.

Holt IJ, Harding AE, Petty RK, Morgan-Hughes JA. A new mitochondrial disease associated with mitochondrial DNA heteroplasmy. *Am J Hum Genet*. 1990;46:428-433.

Horvath R, Kemp JP, Tuppen HA, et al. Molecular basis of infantile reversible cytochrome c oxidase deficiency myopathy. *Brain*. 2009;132:3165-3174.

Indrieri A, van Rahden VA, Tiranti V, et al. Mutations in *COX7B* cause microphthalmia with linear skin lesions, an unconventional mitochondrial disease. *Am J Hum Genet*. 2012;91:942-949.

Janer A, Antonicka H, Lalonde E, et al. An *RMND1* mutation causes encephalopathy associated with multiple oxidative phosphorylation complex deficiencies and a mitochondrial translation defect. *Am J Hum Genet*. 2012;91:737-743.

Lagier-Tourenne C, Tazir M, López LC, et al. ADCK3, an ancestral kinase, is mutated in a form of recessive ataxia associated with coenzyme Q_{10} deficiency. *Am J Hum Genet*. 2008;82:661-672.

López LC, Schuelke M, Quinzii C, et al. Leigh syndrome with nephropathy and CoQ_{10} deficiency due to *decaprenyl diphosphate synthase subunit 2 (PDSS2)* mutations. *Am J Hum Genet*. 2006;79:1125-1129.

Luo S, Valencia CA, Zhang J, et al. Biparental inheritance of mitochondrial DNA in humans. *Proc Natl Acad Sci U S A*. 2018;115:13039-13044.

Mandel H, Szargel R, Labay V, et al. The deoxyguanosine kinase gene is mutated in individuals with depleted hepatocerebral mitochondrial DNA. *Nat Genet*. 2001;29:337-341.

Massa V, Fernandez-Vizarra E, Alshahwan S, et al. Severe infantile encephalomyopathy caused by a mutation in COX6B1, a nucleus-encoded subunit of cytochrome c oxidase. *Am J Hum Genet*. 2008;82:1281-1289.

McShane MA, Hammans SR, Sweeney M, et al. Pearson syndrome and mitochondrial encephalomyopathy in a patient with a deletion of mtDNA. *Am J Hum Genet*. 1991;48:39-42.

Mimaki M, Hatakeyama H, Komaki H, et al. Reversible infantile respiratory chain deficiency: a clinical and molecular study. *Ann Neurol*. 2010;68:845-854.

Mitsuhashi S, Ohkuma A, Talim B, et al. A congenital muscular dystrophy with mitochondrial structural abnormalities caused by defective de novo phosphatidylcholine biosynthesis. *Am J Hum Genet*. 2011;88:845-851.

Mollet J, Giurgea I, Schlemmer D, et al. Prenyldiphosphate synthase, subunit 1 (PDSS1) and OH-benzoate polyprenyltransferase (COQ2) mutations in ubiquinone deficiency and oxidative phosphorylation disorders. *J Clin Invest*. 2007;117:765-772.

Mootha VK, Lepage P, Miller K, et al. Identification of a gene causing human cytochrome c oxidase deficiency by integrative genomics. *Proc Natl Acad Sci U S A*. 2003;100:605-610.

Naviaux RK, Nguyen KV. POLG mutations associated with Alpers' syndrome and mitochondrial DNA depletion. *Ann Neurol*. 2004;55:706-712.

Ogasahara S, Engel AG, Frens D, Mack D. Muscle coenzyme Q deficiency in familial mitochondrial encephalomyopathy. *Proc Nat Acad Sci U S A*. 1989;86:2379-2382.

Ostergaard E, Christensen E, Kristensen E, et al. Deficiency of the α subunit of succinate–coenzyme A ligase causes fatal infantile lactic acidosis with mitochondrial DNA depletion. *Am J Hum Genet*. 2007;81:383-387.

Ostergaard E, Schwartz M, Batbayli M, et al. A novel missense mutation in SUCLG1 associated with mitochondrial DNA depletion, encephalomyopathic form, with methylmalonic aciduria. *Eur J Pediatr*. 2010;169:201-205.

Payne BA, Wilson IJ, Yu-Wai-Man P, et al. Universal heteroplasmy of human mitochondrial DNA. *Hum Mol Genet*. 2013;22:384-390.

Quinzii C, Naini A, Salviati L, et al. A mutation in para-hydroxybenzoate-polyprenyl transferase (COQ2) causes primary coenzyme Q_{10} deficiency. *Am J Hum Genet*. 2006;78:345-349.

Scheper GC, van der Klok T, van Andel RJ, et al. Mitochondrial aspartyl-tRNA synthetase deficiency causes leukoencephalopathy with brain stem and spinal cord involvement and lactate elevation. *Nat Genet*. 2007;39:534-539.

Schlame M, Towbin JA, Heerdt PM, Jehle R, DiMauro S, Blank TJJ. Deficiency of tetralinoleoyl-cardiolipin in Barth syndrome. *Ann Neurol*. 2002;51:634-637.

Schon EA, Area-Gomez E. Mitochondria-associated ER membranes in Alzheimer disease. *Mol Cell Neurosci*. 2013;55:26-36.

Spelbrink JN, Li FY, Tiranti V, et al. Human mitochondrial DNA deletions associated with mutations in the gene encoding Twinkle, a phage T7 gene 4-like protein localized in mitochondria. *Nat Genet*. 2001;28:223-231.

Spinazzola A, Viscomi C, Fernandez-Vizarra E, et al. MPV17 encodes an inner mitochondrial membrane protein and is mutated in infantile hepatic mitochondrial DNA depletion. *Nat Genet*. 2006;38(5):570-575.

Steenweg ME, Ghezzi D, Haack T, et al. Leukoencephalopathy with thalamus and brainstem involvement and high lactate 'LTBL' caused by EARS2 mutations. *Brain*. 2012;135(pt 5):1387-1394.

Tatuch Y, Christodoulou J, Feigenbaum A, et al. Heteroplasmic mtDNA mutation (T->G) at 8993 can cause Leigh disease when the percentage of abnormal mtDNA is high. *Am J Hum Genet*. 1992;50:852-858.

Tiranti V, Hoertnagel K, Carrozzo R, et al. Mutations of SURF-1 in Leigh disease associated with cytochrome *c* oxidase deficiency. *Am J Hum Genet*. 1998;63:1609-1621.

Tiranti V, Viscomi C, Hildebrandt T, et al. Loss of ETHE1, a mitochondrial dioxygenase, causes fatal sulfide toxicity in ethylmalonic encephalopathy. *Nat Med*. 2009;15:200-205.

Visapää I, Fellman V, Vesa J, et al. GRACILE syndrome, a lethal metabolic disorder with iron overload, is caused by a point mutation in *BCS1L*. *Am J Hum Genet*. 2002;71:863-876.

Waterham HR, Koster J, van Roermund CW, Mooyer PAW, Wanders RJA, Leonard JV. A lethal defect of mitochondrial and peroxisomal fission. *N Engl J Med*. 2007;356:1736-1741.

Wortmann SB, Vaz FM, Gardeitchik T, et al. Mutations in the phospholipid remodeling gene SERAC1 impair mitochondrial function and intracellular cholesterol trafficking and cause dystonia and deafness. *Nat Genet*. 2012;44:797-802

Zhu Z, Yao J, Johns T, et al. SURF1, encoding a factor involved in the biogenesis of cytochrome c oxidase, is mutated in Leigh syndrome. *Nat Genet*. 1998;20:337-343.

Züchner S, Mersiyanova IV, Muglia M, et al. Mutations in the mitochondrial GTPase mitofusin 2 cause Charcot-Marie-Tooth neuropathy type 2A. *Nat Genet*. 2004;36:449-451.

Clinical Features

Amati-Bonneau P, Valentino ML, Reynier P, et al. OPA1 mutations induce mitochondrial DNA instability and optic atrophy 'plus' phenotypes. *Brain*. 2008;131(pt 2):338-351.

Andreu AL, Hanna MG, Reichmann H, et al. Exercise intolerance due to mutations in the cytochrome *b* gene of mitochondrial DNA. *N Engl J Med*. 1999;341:1037-1044.

Béhin A, Jardel C, Claeys KG, et al. Adult cases of mitochondrial DNA depletion due to TK2 defect: an expanding spectrum. *Neurology*. 2012;78:644-648.

Carelli V, Barboni P, Sadun AA. Mitochondrial ophthalmology. In: DiMauro S, Hirano M, Schon EA, eds. *Mitochondrial Medicine*. Oxon, United Kingdom: Informa Healthcare; 2006:105-142.

Carrozzo R, Dionisi-Vici C, Steuerwald U, et al. SUCLA2 mutations are associated with mild methylmalonic aciduria, Leigh-like encephalomyopathy, dystonia and deafness. *Brain*. 2007;130(pt 3):862-874.

Chinnery PF, DiMauro S, Shanske S, et al. Risk of developing a mitochondrial DNA deletion disorder. *Lancet*. 2004;364:592-596.

DiMauro S, Nicholson JF, Hays AP, et al. Benign infantile mitochondrial myopathy due to reversible cytochrome c oxidase deficiency. *Ann Neurol*. 1983;14:226-234.

Elliott HR, Samuels DC, Eden JA, Relton CL, Chinnery PF. Pathogenic mitochondrial DNA mutations are common in the general population. *Am J Hum Genet*. 2008;83:254-260.

Emmanuele V, López LC, Berardo A, et al. Heterogeneity of coenzyme Q_{10} deficiency: patient study and literature review. *Arch Neurol*. 2012;69:978-983.

Fratter C, Gorman GS, Stewart JD, et al. The clinical, histochemical, and molecular spectrum of PEO1 (Twinkle)-linked adPEO. *Neurology*. 2010;74:1619-1626.

Fratter C, Raman P, Alston CL, et al. RRM2B mutations are frequent in familial PEO with multiple mtDNA deletions. *Neurology*. 2011;76:2032-2034.

Garone C, Rubio JC, Calvo SE, et al. MPV17 mutations causing adult-onset multisystemic disorder with multiple mitochondrial DNA deletions. *Arch Neurol*. 2012;69:1648-1651.

Garone C, Taylor RW, Nascimento A, et al. Retrospective natural history of thymidine kinase 2 deficiency. *J Med Genet*. 2018;55:515-521.

Hirano M, Kaufmann P, De Vivo DC, et al. Mitochondrial neurology I: encephalopathies. In: DiMauro S, Hirano M, Schon EA, eds. *Mitochondrial Medicine*. Oxon, United Kingdom: Informa Healthcare; 2006:27-44.

Hudson G, Amati-Bonneau P, Blakely EL, et al. Mutation of OPA1 causes dominant optic atrophy with external ophthalmoplegia, ataxia, deafness and multiple mitochondrial DNA deletions: a novel disorder of mtDNA maintenance. *Brain*. 2008;131(pt 2):329-337.

Hudson G, Schaefer AM, Taylor RW, et al. Mutation of the linker region of the polymerase gamma-1 (POLG1) gene associated with progressive external ophthalmoplegia and Parkinsonism. *Arch Neurol*. 2007;64:553-557.

Karadimas CL, Vu TH, Holve SA, et al. Navajo neurohepatopathy is caused by a mutation in the *MPV17* gene. *Am J Hum Genet*. 2006;79:544-548.

Koene S, Rodenburg RJ, van der Knaap MS, et al. Natural disease course and genotype-phenotype correlations in complex I deficiency caused by nuclear gene defects: what we learned from 130 cases. *J Inherit Metab Dis*. 2012;35:737-747.

Luoma P, Melberg A, Rinne JO, et al. Parkinsonism, premature menopause, and mitochondrial DNA polymerase gamma mutations: clinical and molecular genetic study. *Lancet*. 2004;364:875-882.

Mancuso M, Orsucci D, Angelini C, et al. Phenotypic heterogeneity of the 8344A>G mtDNA "MERRF" mutation. *Neurology*. 2013;80:2049-2054.

Paradas C, Gutiérrez Rios P, Rivas E, Carbonell P, Hirano M, DiMauro S. *TK2* mutation presenting as indolent myopathy. *Neurology*. 2013;80:504-506.

Ronchi D, Garone C, Bordoni A, et al. Next-generation sequencing reveals DGUOK mutations in adult patients with mitochondrial DNA multiple deletions. *Brain*. 2012;135(pt 11):3404-3415.

Rötig A, Appelkvist EL, Geromel V, et al. Quinone-responsive multiple respiratory-chain dysfunction due to widespread coenzyme Q_{10} deficiency. *Lancet*. 2000;356:391-395.

Saneto RP, Naviaux RK. Polymerase gamma disease through the ages. *Dev Disabil Res Rev*. 2010;16:163-174.

Sengers RC, Trijbels JM, Willems JL, Daniels O, Stadhouders AM. Congenital cataract and mitochondrial myopathy of skeletal and heart muscle associated with lactic acidosis after exercise. *J Pediatr*. 1975;86:873-880.

Tyynismaa H, Sun R, Ahola-Erkkilä S, et al. Thymidine kinase 2 mutations in autosomal recessive progressive external ophthalmoplegia with multiple mitochondrial DNA deletions. *Hum Mol Genet*. 2012;21:66-75.

Tyynismaa H, Ylikallio E, Patel M, Molnar MJ, Haller RG, Suomalainen A. A heterozygous truncating mutation in RRM2B causes autosomal-dominant progressive external ophthalmoplegia with multiple mtDNA deletions. *Am J Hum Genet*. 2009;85:290-295.

Yu-Wai-Man P, Griffiths PG, Gorman GS, et al. Multi-system neurological disease is common in patients with OPA1 mutations. *Brain*. 2010;133:771-786.

Pathology

Hays AP, Oskoui M, Tanji K, et al. Mitochondrial neurology II: myopathies and peripheral neuropathies. In: DiMauro S, Hirano M, Schon EA, eds. *Mitochondrial Medicine*. Oxon, United Kingdom: Informa Healthcare; 2006:27-44.

Tanji K, Kunimatsu T, Vu TH, Bonilla E. Neuropathological features of mitochondrial disorders. *Semin Cell Dev Biol*. 2001;12:429-439.

Therapy

Cerutti R, Pirinen E, Lamperti C, et al. NAD^+-dependent activation of Sirt1 corrects the phenotype in a mouse model of mitochondrial disease. *Cell Metab*. 2014;19:1042-1049.

Craven L, Elson JL, Irving L, et al. Mitochondrial DNA disease: new options for prevention. *Hum Mol Genet*. 2011;20(R2):R168-R174.

Craven L, Tuppen HA, Greggains GD, et al. Pronuclear transfer in human embryos to prevent transmission of mitochondrial DNA disease. *Nature*. 2010;465:82-85.

Domínguez-González C, Madruga-Garrido M, Mavillard F, et al. Deoxynucleoside therapy for thymidine kinase 2-deficient myopathy. *Ann Neurol*. 2019;86:293-303.

Enns GM, Kinsman SL, Perlman SL, et al. Initial experience in the treatment of inherited mitochondrial disease with EPI-743. *Mol Genet Metab*. 2012;105:91-102.

Gilkerson RW, De Vries RL, Lebot P, et al. Mitochondrial autophagy in cells with mtDNA mutations results from synergistic loss of transmembrane potential and mTORC1 inhibition. *Hum Mol Genet*. 2012;21:978-990.

Hirano M, Garone C, Quinzii CM. CoQ_{10} deficiencies and MNGIE: two treatable mitochondrial disorders. *Biochim Biophys Acta*. 2012;1820:625-631.

Karaa A, Haas R, Goldstein A, Vockley J, Weaver WD, Cohen BH. Randomized dose-escalation trial of elamipretide in adults with primary mitochondrial myopathy. *Neurology*. 2018;90:e1212-e1221.

Kaufmann P, Engelstad K, Wei Y, et al. Dichloroacetate causes toxic neuropathy in MELAS: a randomized, controlled clinical trial. *Neurology*. 2006;66:324-330.

Klopstock T, Yu-Wai-Man P, Dimitriadis K, et al. A randomized placebo-controlled trial of idebenone in Leber's hereditary optic neuropathy. *Brain*. 2011;134(pt 9):2677-2686.

Martinelli D, Catteruccia M, Piemonte F, et al. EPI-743 reverses the progression of the pediatric mitochondrial disease—genetically defined Leigh syndrome. *Mol Genet Metab*. 2012;107:383-388.

Paull D, Emmanuele V, Weiss KA, et al. Nuclear genome transfer in human oocytes eliminates mitochondrial DNA variants. *Nature*. 2013;493:632-637.

Sadun AA, Chicani CF, Ross-Cisneros FN, et al. Effect of EPI-743 on the clinical course of the mitochondrial disease Leber hereditary optic neuropathy. *Arch Neurol*. 2012;69:331-338.

Tachibana M, Amato P, Sparman M, et al. Towards germline gene therapy of inherited mitochondrial diseases. *Nature*. 2013;493:627-631.

Tachibana M, Sparman M, Sritanaudomchai H, et al. Mitochondrial gene replacement in primate offspring and embryonic stem cells. *Nature*. 2009;461:367-372.

Taivassalo T, Haller RG. Exercise and training in mitochondrial myopathies. *Med Sci Sports Exerc*. 2005;37:2094-2101.

Tanaka M, Borgeld HJ, Zhang J, et al. Gene therapy for mitochondrial disease by delivering restriction endonuclease SmaI into mitochondria. *J Biomed Sci*. 2002;9(6, pt 1):534-541.

Viscomi C, Bottani E, Civiletto G, et al. In vivo correction of COX deficiency by activation of the AMPK/PGC-1 axis. *Cell Metab*. 2011;14:80-90.

Wenz T, Diaz F, Spiegelman BM, Moraes CT. Activation of the PPAR/PGC-1 pathway prevents a bioenergetic deficit and effectively improves a mitochondrial myopathy phenotype. *Cell Metab*. 2008;8:249-256.

Neurocutaneous Syndromes 145

Marc C. Patterson

KEY POINTS

1. The integument and nervous system both develop from the ectoderm of the fetus. As a result, many developmental disorders of the central nervous system are accompanied by characteristic cutaneous manifestations. These disorders are known as *neurocutaneous syndromes.*
2. Two overlapping subclassifications of neurocutaneous disorders have been proposed: neurocristopathies, which embrace disorders in which cells of neural crest origin develop abnormally or undergo neoplastic transformation, and RASopathies, including disorders associated with mutations of genes in the rat sarcoma/mitogen-activated protein kinase pathway.
3. The diagnosis of neurocutaneous syndromes is based on clinical criteria. Genetic testing is supportive, but owing to the large size of many of these genes, as well as tissue mosaicism, mutations cannot be defined in all patients who clearly have such syndromes.
4. Most of the neurocutaneous syndromes are dominantly inherited and have variable penetrance and highly variable expressivity. Clinicians must be alert to the possibility of such syndromes and thoroughly evaluate potentially affected individuals, in whom manifestations may be subtle.

INTRODUCTION

Several genetic diseases involve both the skin and nervous system. These are called *neurocutaneous disorders* or *neuroectodermatoses.* In the past, they were referred to as the *phakomatoses* (*phakos* is the Greek word for lentil, flat plate, or spot). Many neurocutaneous syndromes are included in other pathologic or genetic groupings. For example, neurofibromatosis (NF) 1 and 2, tuberous sclerosis complex (TSC), Sturge-Weber syndrome, von Hippel-Lindau syndrome, and Waardenburg syndrome are included in the family of neurocristopathies. Neurocristopathies are defined as genetic disorders in which cells derived from the neural crest manifest abnormal development, undergo neoplastic transformation, or both.

The term *RASopathy* refers to disorders in which genes expressed in the rat sarcoma (RAS)/mitogen-activated protein kinase (MAPK) pathway are mutated, resulting in abnormal cell numbers, morphology, location, or ageing. This group includes NF-1, as well as the overlapping phenotypes of Noonan syndrome, Noonan syndrome with multiple lentigines (LEOPARD syndrome), and Legius syndrome. Any part of the central nervous system (CNS) or peripheral nervous system can be affected by these hereditary diseases; their expressivity is quite variable both between and within kindreds.

NEUROFIBROMATOSIS

Introduction

Although NF was first described at least as early as the 17th century and a comprehensive clinical review was published in 1849, the clinical and pathologic phenotypes were first linked by von Recklinghausen in 1882. NF is one of the most common single-gene disorders of the CNS. Cardinal features include multiple cutaneous hyperpigmented marks (*café au lait spots*), multiple neurofibromas and lesions in bone, CNS, peripheral nervous system, or other organs. The best characterized forms are neurofibromatosis type 1 (NF-1; *von Recklinghausen disease* or *peripheral NF* (MIM 162200) and neurofibromatosis type 2 (NF-2; *central NF* or the *bilateral acoustic neuroma syndrome* [MIM 101000]) and schwannomatosis, a phenotype characterized by the presence of multiple schwannomas, associated with intractable pain, without vestibular involvement. The three conditions differ in genetics, pathogenesis, and clinically.

Epidemiology

Both sexes are affected equally, and the condition is found worldwide in all racial and ethnic groups. Incidence figures must be a minimal estimate, because mild cases are often unrecognized.

Molecular Genetics and Pathogenesis

NF-1, NF-2, and schwannomatosis are autosomal dominant conditions; penetrance of NF-1 is almost 100%, but expressivity varies. Mutations account for 50% of new cases. The *NF-1* gene has been mapped to chromosome 17q11.2. The gene product is called *neurofibromin*, a tumor-suppressor gene that acts through the RAS/MAPK pathway. Translocations, large megabase deletions, large internal deletions, small rearrangements, and point mutations all occur in the *NF-1* gene. Although the genotypes differ, the phenotypes are indistinguishable. The marked clinical variability within families having an identical *NF-1* gene mutation equals the variability among families with different *NF-1* gene mutations. The exception occurs with large megabase deletions, associated with cognitive dysfunction and more severe clinical manifestations generally. Mutation inactivates the gene, and, by analogy with other oncogenes, loss of the allelic gene later in life could result in tumor formation. It is not known how the other manifestations of the disease arise. Several potential genetic modifiers in associated signaling pathways have been identified in screening studies.

The *NF-2* gene maps to chromosome 22q12. The gene product is similar to that of the moesin-ezrin-radixin–like protein gene; for this reason, it is called *merlin.* Deletions of the gene have been found in schwannoma and meningioma cells, the major tumors in NF-2 patients. Merlin inhibits the Rac/CDC42-dependent Ser/Thr p21 activated kinase (PAK1), which activates

both Ras transformation and NF-1, through two separate domains. Specific inhibitors of PAK1 selectively inhibit the growth of NF-2–deficient cancer cells, suggesting that PAK1 is essential for the malignant growth of NF-2–deficient cells. Inhibitors of PAK1 might have a future role as therapies for these tumors.

Schwannomatosis has been linked to mutations in three genes: *SMARCB1*, *LZTR1*, and *COQ6*. The *SMARCB1* gene product is a subunit of the SWI/hSHNF chromatin remodeling complex. Mutations in this gene account for about half of familial schwannomatosis but only about 10% of sporadic cases. The *LZTR1* encodes a protein that acts as a tumor suppressor; COQ6 mutations impair the synthesis of coenzyme Q10.

Neuropathology

Dysplasia, hyperplasia, and neoplasia of neural-supporting tissues involve the central, peripheral, and autonomic nervous systems. Visceral manifestations result from hyperplasia of the autonomic ganglia and nerves within the organ. Dysplastic and neoplastic changes also affect skin, bone, endocrine glands, and blood vessels. Developmental anomalies include thoracic meningocele and syringomyelia. Patients affected by NF-1 are more likely than others to have neoplastic disorders, including neuroblastoma, Wilms tumor, leukemia, pheochromocytoma, and sarcomas.

Neoplasms involving the peripheral nervous system and spinal nerve roots include schwannomas and neurofibromas. Intramedullary spinal cord tumors include ependymomas (especially of the conus medullaris and filum terminale) and astrocytomas (although some of these may actually be ependymomas when electron microscopy is used); gangliogliomas are rare. The most common intracranial tumors are hemispheric astrocytomas of any histologic grade from benign to highly malignant; posterior fossa tumors are rare. Pilocytic astrocytic gliomas of the optic nerve and optic chiasm are also characteristic and generally progress very slowly. Bilateral acoustic neuromas and solitary or multicentric meningiomas occur in adults with NF-2.

Symptoms and Signs

There are at least four forms of NF. *Peripheral NF (NF-1)* as described by von Recklinghausen is most common. *Central NF (NF-2)* is manifested by bilateral acoustic neuromas with mild cutaneous changes. *Segmental NF* arises from mosaic-type microdeletions in NF-1; it is characterized by café au lait spots and neurofibromas that are limited, usually affecting an upper body segment. The lesions extend to the midline and include the ipsilateral arm but spare the head and neck. *Cutaneous NF* is limited to pigmentary changes; there are numerous café au lait spots but no other clinical manifestations. One percent to 4% of patients with a mild NF phenotype (café au lait spots only) have a related disorder, Legius syndrome, which is associated with mutations in the *SPRED1* gene in 90% of cases.

The NF-1–Noonan syndrome has the clinical manifestations of NF-1 coupled with a Noonan syndrome phenotype. The clinical features of the Noonan syndrome include ocular hypertelorism, downward-slanting palpebral fissures, webbed neck, low-set ears, and pulmonic stenosis.

NF-1 has protean and progressive manifestations. Families and physicians often anticipate a fate like that of Joseph Merrick (the Elephant Man, who almost certainly had the Proteus syndrome, not NF-1). In reality, many patients with the disease are functionally indistinguishable from normal. Often, they have only cutaneous lesions and are not diagnosed until they see a physician because of a learning disability, scoliosis, or another problem.

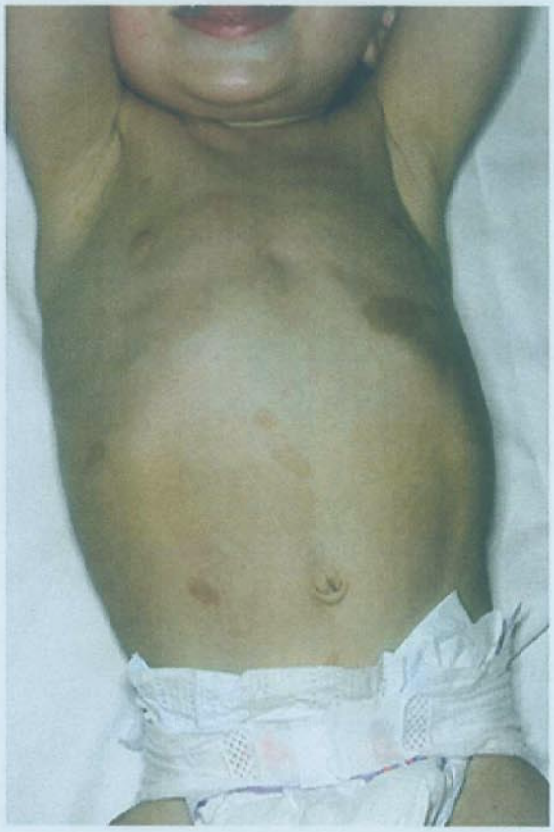

FIGURE 145.1 Café au lait macules on the trunk of an infant with neurofibromatosis type 1.

Cutaneous Manifestations

The café au lait macule is the pathognomonic lesion, being present in almost all patients (Fig. 145.1). Six or more café au lait spots larger than 5 mm in diameter before puberty and greater than 15 mm in diameter after puberty are diagnostic. The spots are usually present at birth but may not appear until age 1 or 2 years. Increasing in both size and number during the first decade of life, the macules tend to be less evident after the second decade because they blend into the surrounding hyperpigmented skin. These discrete, tan macules involve the trunk and limbs in a random fashion but tend to spare the face.

Other cutaneous manifestations may include freckles over the entire body, but freckles usually involve the axilla and other intertriginous areas. Larger, darker hyperpigmented lesions are often associated with an underlying plexiform neurofibroma; if this involves the midline, it may indicate the presence of a spinal cord tumor.

Ocular Findings

Pigmented iris hamartomas (Lisch nodules) are pathognomonic and consist of small translucent yellow or brown elevations on slit lamp examination (Fig. 145.2). The nodules increase in number with age and are present in almost all patients older than 20 years.

FIGURE 145.2 Lisch nodules in a patient with neurofibromatosis type 1.

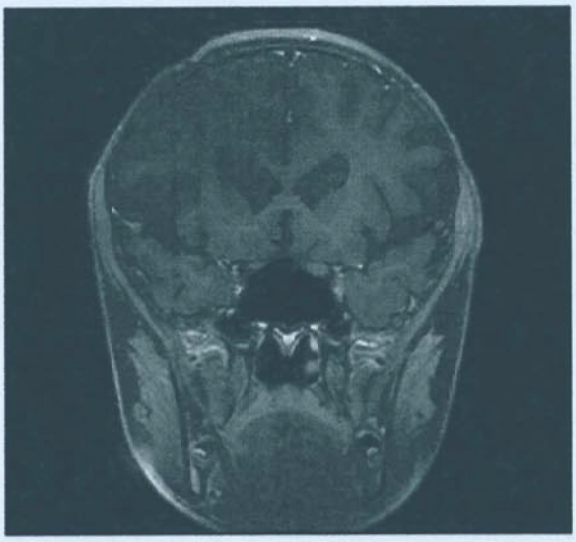

FIGURE 145.3 Left optic nerve glioma on coronal magnetic resonance imaging of the brain.

Neurologic Symptoms

Neurofibromas are highly characteristic lesions and usually become clinically evident at age 10 to 15 years. They always involve the skin, ultimately developing into sessile, pedunculated lesions. The nodules are found on deep peripheral nerves or nerve roots and on the autonomic nerves that innervate the viscera and blood vessels. The lesions increase in size and number during the second and third decades. There may be a few or many thousands. These benign tumors consist of neurons, Schwann cells, fibroblasts, blood vessels, and mast cells. They rarely give rise to any symptoms other than pain as a result of pressure on nerves or nerve roots; however, they may undergo sarcomatous degeneration in the third and fourth decades of life. Neurofibromas involving the terminal distribution of peripheral nerves form vascular plexiform neurofibromas that result in localized overgrowth of tissues or segmental hypertrophy of a limb. Spinal root or cauda equina neurofibromas are often asymptomatic when they are small, but large tumors may cause myelopathy. The number and size of neurofibromas may increase during pregnancy.

Optic gliomas, astrocytomas, acoustic neuromas, neurilemmomas, and meningiomas have a combined frequency of 5% to 10% in all patients with NF. Optic nerve gliomas and other intracranial neoplasms are often evident before age 10 years; acoustic neuromas become symptomatic at about age 20 years. When optic glioma is associated with NF, it commonly involves the optic nerve (Fig. 145.3) or is multicentric; less frequently, it involves the chiasm. Optic nerve glioma must be distinguished from the commonly observed nonneoplastic optic nerve hyperplasia. The optic glioma of NF is slowly progressive and has a better prognosis than similar tumors without this association.

NF-2 is clinically evident at about age 20 years; symptoms include hearing loss, tinnitus, imbalance, and headache. Only a few café au lait spots and neurofibromas are seen. Intracranial and intraspinal neoplasms include meningiomas, schwannomas, and gliomas.

The CNS involvement in NF is highly variable. Macrocephaly, a common clinical manifestation of postnatal origin, is an incidental finding, not related to academic performance, seizures, or neurologic function. Specific learning disabilities or attention deficit disorder, with or without impaired speech, is the most common neurologic complication of NF. Intellectual disability or convulsive disorders each occur in about 5% of the patients. Brainstem tumors associated with NF-1 have a more indolent course than those without NF.

Occlusive cerebrovascular disease is rare but is sometimes seen in children, resulting in acute hemiplegia and convulsions. Magnetic resonance angiography or conventional angiography may demonstrate tapering occlusion of the supraclinoid portion of the internal carotid artery at the origin of the anterior and middle cerebral arteries with associated collaterals in the adjacent basal ganglia (moyamoya disease).

A more severe form of NF-1, often clinically apparent in young children, is due to a contiguous gene deletion on chromosome 17q11 that includes neurofibromin. In addition to the clinical features of NF-1, there are dysmorphic features, major malformations, and intellectual disability.

Skeletal and Limb Manifestations

Skeletal anomalies characteristic of NF include (1) unilateral defects in the posterosuperior wall of the orbit, with pulsating exophthalmos, usually associated with dural ectasia; (2) a defect in the lambdoid with underdevelopment of the ipsilateral mastoid; (3) dural ectasia with enlargement of the spinal canal and scalloping of the posterior portions of the vertebral bodies (also seen in connective tissue disorders such as Marfan and Ehlers-Danlos syndromes); (4) scoliosis, affecting between 21% and 49% of patients with NF-1; (5) pseudarthrosis, especially involving the tibia (5% of cases) and radius; (6) "twisted ribbon" rib deformities; and (7) enlargement of long bones.

Miscellaneous Manifestations

Pheochromocytomas occur in 0.1% to 5.7% of patients with NF-1; they are rare in children. Hypertension may be due to a pheochromocytoma (20%-50% of cases) or a neurofibroma of a renal artery. A population-based study from Finland found a standardized incidence ratio for all forms of cancer of 5.03 in their cohort of NF-1 patients; in addition to intracranial gliomas

and malignant peripheral nerve sheath tumors, these included breast cancer, gastrointestinal stromal tumor, and thyroid cancer. Precocious puberty and, less commonly, sexual infantilism result from involvement of the hypothalamus by glioma or hamartoma. Cystic lesions, malignancy, and interstitial pneumonia are pulmonary complications.

Diagnosis

Diagnosis of NF-1 or NF-2 is based on clinical, radiologic, and pathologic findings as well as the family history. Diagnostic criteria were established by a National Institutes of Health Consensus Conference (**Table 145.1**). Some investigators have suggested updating the criteria to account for new knowledge regarding "anaemic nevi, unidentified bright objects, choroidal hamartomas, and a typical neuropsychological phenotype" in NF-1.

Laboratory Data

Diagnosis is usually made by clinical presentation and family history. Molecular genetic studies are available, but many subjects who meet consensus diagnostic criteria do not have detectable mutations in the NF-1 gene. Most affected individuals have de novo mutations.

All patients and those at risk should receive a tailored evaluation to confirm the diagnosis and assess the extent of disease. A comprehensive evaluation may include psychoeducational and psychometric testing; electroencephalogram; ophthalmologic and audiologic testing; cranial computed tomography (CT), including orbital views; CT of the spine and internal auditory foramina; magnetic resonance imaging (MRI) of brain and spine; and quantitative measurement of 24-hour urinary catecholamines. The MRI of the brain frequently demonstrates areas of signal hyperintensity that may represent areas of abnormal myelination (**Fig. 145.4**); some such lesions reveal themselves as low-grade gliomas over time, mandating periodic surveillance.

TABLE 145.1 Diagnostic Criteria for Neurofibromatosis

Neurofibromatosis Type 1 (Any Two or More)
Six or more café au lait macules Before puberty >5 mm diameter After puberty >15 mm diameter
Freckling in the axillary or inguinal areas
Two or more neurofibromas or one plexiform neurofibroma
A first-degree relative with NF-1
Two or more Lisch nodules (iris hamartomas)
Bone lesion
Sphenoid dysplasia
Thinning of the cortex of long bones with or without pseudarthrosis
Neurofibromatosis Type 2
Bilateral eighth nerve tumor (MRI, CT, or histologic confirmation)
A first-degree relative with NF-2 and a unilateral eighth nerve tumor
A first-degree relative with NF-2 and any two of the following: neurofibroma, meningioma, schwannoma, glioma, or juvenile posterior subcapsular lenticular opacity

Abbreviations: CT, computed tomography; MRI, magnetic resonance imaging; NF-1, neurofibromatosis type 1; NF-2, neurofibromatosis type 2.

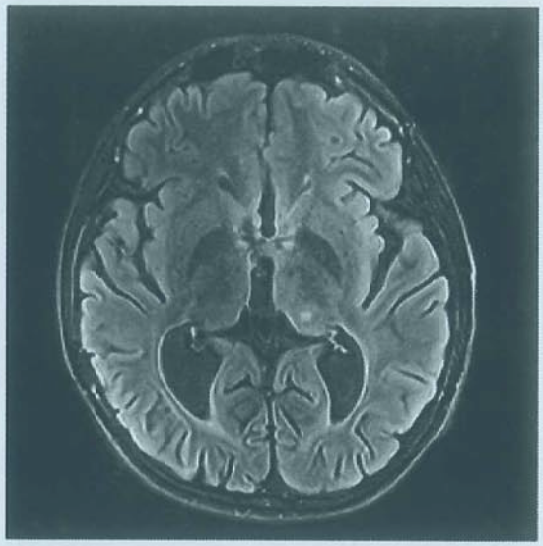

FIGURE 145.4 Area of signal hyperintensity on axial magnetic resonance imaging of the brain in a patient with neurofibromatosis type 1.

Management

There is no specific treatment for NF, but its manifestations may be ameliorated with early recognition and prompt therapeutic intervention. Learning disabilities should be considered in all children with NF-1 and may be complicated by comorbid conditions (such as attention deficit hyperactivity disorder) that warrant educational therapy or behavioral modification, psychotherapy, and pharmacotherapy. Speech problems require a language evaluation and formal speech therapy, and seizures should be managed with appropriate antiepileptic drugs. Progressive kyphoscoliosis usually requires surgical intervention. Surgery may be necessary for removal of pheochromocytomas and intracranial or spinal neoplasms; cutaneous neurofibromas require extirpation when they compromise function or are disfiguring. Preliminary data suggest that thalidomide might have a role in treating neurofibromas. Radiation therapy is reserved for some CNS neoplasms, including optic glioma. Genetic counseling by a qualified geneticist or genetic counselor is essential, and psychotherapy with family counseling is often indicated.

TUBEROUS SCLEROSIS COMPLEX

Introduction

TSC was first described by von Recklinghausen in 1863. In 1880, Bourneville coined the term *sclérose tubéreuse* for the potato-like lesions in the brain. In 1890, Pringle described the facial nevi, or *adenoma sebaceum*. Vogt later emphasized the classic triad of seizures, intellectual disability, and adenoma sebaceum. TSC (MIM 191440) is a progressive genetic disorder characterized by the development in early life of hamartomas; malformations; and congenital tumors of the CNS, skin, and viscera.

Epidemiology

The incidence of TSC is 1 in 6,000 to 10,000 live births. Clinical surveys suggest a prevalence between 1 in 10,000 and 1 in 170,000. Pulmonary lymphangioleiomyomatosis, progressive and often fatal, occurs almost exclusively in young women.

Genetics

Tuberous sclerosis is an autosomal dominant trait, with a high incidence of sporadic cases and protean clinical expression. This variability is attributed to modifier genes. The defective genes map to chromosome 9q34 (TSC1) and chromosome 16p13.3 (TSC2). TSC1 or TSC2 is mutated in 75% to 85% of TSC patients; no mutation is found in 15%. *Hamartin* is the gene product for TSC1, and *tuberin* is the gene product for TSC2. Hamartin and tuberin form heterodimers that inhibit the mammalian target of rapamycin; phosphorylation is an important aspect of this complex process, which involves over 50 interacting proteins.

Pathology and Pathogenesis

The pathologic changes are widespread and include lesions in the nervous system, skin, bones, retina, kidney, lungs, and other viscera. Multiple small nodules often line the ventricles.

TSC is characterized by the presence of hamartias and hamartomas. Hamartias (from the Greek for "flaw") are malformations in which cells native to a tissue display abnormal architecture and morphology. These lesions do not grow disproportionately for the tissue or organ in which they are found. Hamartomas have the same characteristics but grow excessively for their site of origin. This old concept is valuable in recognizing the proliferative potential of lesions found in TSC. Thus, cortical tubers are hamartias and do not grow excessively, whereas angiomyolipomas are hamartomas that grow disproportionately and may produce symptoms as a consequence.

The brain is usually normal in size, but variable numbers of hard nodules occur on the surface of the cortex. These nodules are smooth, round, or polygonal and project slightly above the surface of the neighboring cortex. They are white, firm to the touch, and of various sizes. Some involve only a small portion of one convolution; others encompass the convolutions of one whole lobe or a major portion of a hemisphere. In addition, there may be developmental anomalies of the cortical convolutions in the form of pachygyria or microgyria. On sectioning of the hemispheres, sclerotic nodules may be found in the subcortical gray matter, the white matter, and the basal ganglia. The lining of the lateral ventricles is frequently the site of numerous small nodules that project into the ventricular cavity. Sclerotic nodules are less frequently found in the cerebellum. The brainstem and spinal cord are rarely involved.

Histologically, the nodules are characterized by a cluster of atypical glial cells in the center and giant cells in the periphery. Calcifications are relatively frequent. Other features include heterotopia, vascular hyperplasia (sometimes with actual angiomatous malformations), disturbances in the cortical architecture, and, occasionally, development of subependymal giant cell astrocytomas (SEGAs). Intracranial giant aneurysm and arterial ectasia are uncommon findings.

The skin lesions are multiform and include the characteristic facial angiofibromas and fibrous plaques, typically localized to the frontal area. The facial lesions are not adenomas of the sebaceous glands (a commonly used misnomer) but rather small hamartomas arising from nerve elements of the skin combined with hyperplasia of connective tissue and blood vessels (angiofibromas). In late childhood, lesions similar to those on the face are found around or underneath the nails (*periungual or subungual fibromas*). Circumscribed areas of hypomelanosis or depigmented nevi (Fig. 145.5) are common in tuberous sclerosis and are often found in infants. Although these depigmented nevi are less specific than the angiofibromas, they are important indications of the diagnosis in infants with seizures. Histologically, the skin appears normal except for the loss of melanin, but ultrastructural studies show that melanosomes are small and have reduced content of melanin.

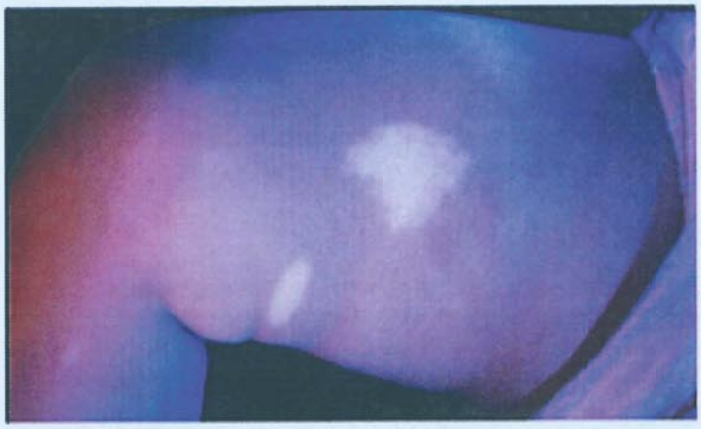

FIGURE 145.5 Hypopigmented lesions on the thigh of an infant with TSC1, highlighted with ultraviolet light (Woods lamp).

The retinal lesions are small, congenital tumors composed of glia, ganglion cells, or fibroblasts. Glioma of the optic nerve has been reported.

Other lesions include cardiac rhabdomyoma; renal angiomyolipoma, renal cysts, and, rarely, renal carcinoma; cystic disease of the lungs and pulmonary lymphangioleiomyomatosis; hepatic angiomas and hamartomas; skeletal abnormalities with localized areas of osteosclerosis in the calvarium, spine, pelvis, and limbs; cystic defects involving the phalanges; and periosteal new bone formation confined to the metacarpals and metatarsals.

Symptoms and Signs

The cardinal features of tuberous sclerosis are skin lesions, convulsive seizures, and disability. The disease is characterized by variable expressivity of the clinical manifestations and is often age related: the symptomatic neonate with cardiac rhabdomyoma and heart failure; the infant with hypomelanotic macules and infantile spasms; preschool and school-age children with angiofibromas, developmental delay, learning disability or intellectual disability, and seizures; and adults with migrational dermatologic lesions, subungual fibromas, seizures, and often intellectual disability.

Cutaneous Findings

Depigmented or hypomelanotic macules are the earliest skin lesion. They are present at birth, persist through life, and may be found only with a Wood lamp examination. The diagnosis is suggested if there are three or more macules measuring 1 cm or more in length. Numerous small macules sometimes resemble confetti or depigmented freckles. Most macules are leaf shaped, resembling the leaf of the European mountain ash tree and sometimes following a dermatomal distribution. Facial angiofibromas never present at birth, but are clinically evident in more than 90% of affected children by age 4 years. At first, the facial lesion is the size of a pinhead and red because of the angiomatous component. It is distributed symmetrically on the nose and cheeks in a butterfly distribution. The lesions may involve the forehead and chin but rarely involve the upper lip. They gradually

increase in size and become yellowish and glistening. *Shagreen patches*, connective tissue hamartomas, are also characteristic. Rarely present in infancy, the patches become evident after age 10 years. Usually found in the lumbosacral region, shagreen patches are yellowish-brown elevated plaques that have the texture of pigskin (from which the name originated in French). Other skin lesions include café au lait spots, small fibromas that may be tiny and resemble coarse gooseflesh, and ungual and periungual fibromas that appear after puberty.

Neurologic Findings

Epileptic spasms are the characteristic seizures in young infants and, when associated with hypopigmented macules, are diagnostic of tuberous sclerosis. The older child or adult has generalized tonic-clonic or focal seizures. There is a close relationship between the onset of seizures at a young age and intellectual disability. Intellectual disability rarely occurs without clinical seizures, but intellect may be normal, despite seizures. Other than delayed acquisition of developmental milestones, intellectual impairment, or nonspecific language or coordinative deficiencies, the formal neurologic examination is typically nonfocal. TSC is strongly associated with autism spectrum disorder.

Ophthalmic Findings

Hamartomas of the retina or optic nerve are observed in about 50% of patients. Two types of retinal lesions are seen on funduscopy: first, the easily recognized calcified hamartoma near or at the disc with an elevated multinodular lesion that resembles mulberries, grains of tapioca, or salmon eggs, and second, the less distinct, relatively flat, smooth-surfaced, white or salmon-colored, circular or oval lesion located peripherally in the retina. Nonretinal lesions may range from the specific depigmented lesion of the iris, to nonspecific, nonparalytic strabismus; optic atrophy; visual-field defects; or cataracts.

Visceral and Skeletal Findings

Renal lesions include hamartomas (angiomyolipomas) and hamartias (renal cysts). Typically, both are multiple, bilateral, and usually innocuous and silent. Renal angiomyolipomas grow and occasionally bleed, but most can simply be followed with annual CT scans. Renal cell carcinoma is a rare complication in the older child or adult. In one series, 50% of patients with cardiac rhabdomyoma had tuberous sclerosis. Often asymptomatic, this cardiac tumor may be symptomatic at any age and in infancy can (rarely) result in death.

Pulmonary hamartomas consisting of multifocal alveolar hyperplasia associated with cystic lymphangioleiomyomatosis occur in fewer than 1% of patients. These become symptomatic (often with a spontaneous pneumothorax) in women in the third or fourth decade and are progressive and often lethal. Hamartomatous hemangiomas of the spleen and racemose angiomas of the liver are rare and usually asymptomatic. Sclerotic lesions of the calvarium and cystic lesions of the metacarpals and phalanges are asymptomatic. Enamel pitting of the deciduous teeth and gingival fibromas may aid in diagnosis.

Laboratory Data

An MRI of the brain is the cornerstone of diagnosis of TSC. Cortical tubers may be hypo- or isointense on T1-weighted images and show varying patterns of hyperintensity on T2 and fluid-attenuated inversion recovery sequences; calcification may occur over time (Fig. 145.6). Subependymal nodules are common and most calcify over time; radial bands of hyperintense signal from the ventricles to the cortex are characteristic of TSC. SEGAs arise from the caudothalamic groove and may obstruct the ipsilateral foramen of Monro; these tumors most often present in the second decade. Positron emission tomography often reveals hypometabolic regions that are not obviously abnormal on MRI, indicating a more extensive disturbance of cerebral function.

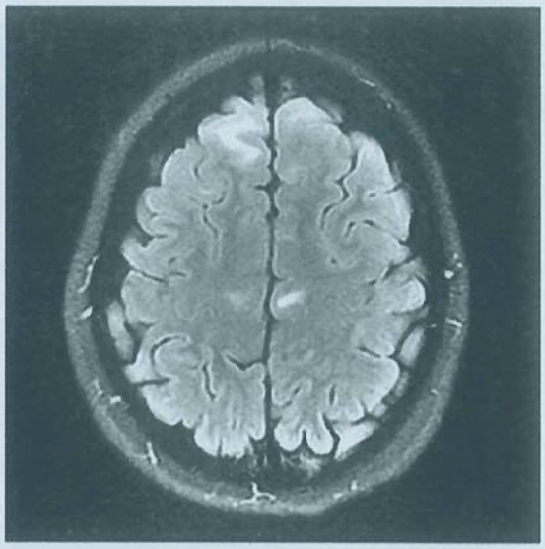

FIGURE 145.6 Multiple cortical tubers in an 18-year-old with TSC1.

Visceral lesions are best assessed with imaging studies. Cardiac rhabdomyomas, easily visualized on echocardiography, are frequent in neonates and typically regress over time, whereas renal angiomyolipomas may gradually enlarge and produce symptoms by obstructing the collecting system or bleeding. They are best monitored with ultrasound or CT.

Pulmonary lymphangioleiomyomatosis may be detected on routine chest x-rays, but chest CT is more sensitive.

The electroencephalogram (EEG) is often abnormal, especially in patients with clinical seizures. Abnormalities include slow-wave activity and epileptiform discharges such as hypsarrhythmia, focal or multifocal spike or sharp-wave discharges, and generalized spike-and-wave discharges. Routine laboratory tests of blood and urine are usually normal, except if there is renal dysfunction, including bleeding from angiolipomas.

Diagnosis

Clinical diagnosis is possible at most ages. In infancy, three or more characteristic depigmented cutaneous lesions suggest the diagnosis, which is reinforced by the presence of epileptic spasms. In the older child or adults, the diagnosis is made by the triad of tuberous sclerosis: facial angiofibromas, epilepsy, and intellectual disability. Retinal or visceral lesions may be diagnostic. The disease, however, is noted for its protean manifestations, and the family history may be invaluable in establishing the diagnosis, which is often reinforced by CT or MRI lesions. Antenatal diagnosis of TSC by fetal ultrasound and MRI is suggested by the presence of a cardiac rhabdomyoma and cortical tubers. Prenatal molecular diagnosis is available for both TSC1 and TSC2.

TABLE 145.2 Diagnostic Criteria for Tuberous Sclerosis Complex

A. Genetic Diagnostic Criteria
The identification of either a TSC1 or TSC2 pathogenic mutation in DNA from normal tissue is sufficient to make a definite diagnosis of tuberous sclerosis complex (TSC). A pathogenic mutation is defined as a mutation that clearly inactivates the function of the TSC1 or TSC2 proteins (eg, out-of-frame indel or nonsense mutation), prevents protein synthesis (eg, large genomic deletion), or is a missense mutation whose effect on protein function has been established by functional assessment (www.lovd.nl/TSC1, www.lovd/TSC2). Other TSC1 or TSC2 variants whose effect on function is less certain do not meet these criteria and are not sufficient to make a definite diagnosis of TSC. Note that 10%-25% of TSC patients have no mutation identified by conventional genetic testing, and a normal result does not exclude TSC or have any effect on the use of clinical diagnostic criteria to diagnose TSC.
B. Clinical Diagnostic Criteria
Major Features
1. Hypomelanotic macules (≥3, at least 5-mm diameter)
2. Angiofibromas (≥3) or fibrous cephalic plaque
3. Ungual fibromas (≥2)
4. Shagreen patch
5. Multiple retinal hamartomas
6. Cortical dysplasias[a]
7. Subependymal nodules
8. Subependymal giant cell astrocytoma
9. Cardiac rhabdomyoma
10. Lymphangioleiomyomatosis (LAM)[b]
11. Angiomyolipomas (≥2)[b]
Minor Features
1. "Confetti" skin lesions
2. Dental enamel pits (>3)
3. Intraoral fibromas (≥2)
4. Retinal achromic patch
5. Multiple renal cysts
6. Nonrenal hamartomas
Definite diagnosis: two major features or one major feature with ≥2 minor features
Possible diagnosis: either one major feature or ≥2 minor features

[a]Includes tubers and cerebral white matter radial migration lines.
[b]A combination of the two major clinical features (LAM and angiomyolipomas) without other features does not meet criteria for a definite diagnosis.

The differential diagnosis includes other neurocutaneous syndromes that are differentiated by their characteristic skin lesions. Multisystem involvement may complicate the diagnosis of tuberous sclerosis. The Tuberous Sclerosis Complex Consensus Conference has published diagnostic criteria (Table 145.2).

Course and Prognosis

Mild or solely cutaneous involvement often follows a static course, whereas patients with the full-blown syndrome have a progressive course with increasingly frequent and intense seizures and cognitive impairment. The child with epileptic spasms that are not promptly controlled is at great risk for intellectual disability. Brain tumor, status epilepticus, renal insufficiency, cardiac failure, or progressive pulmonary impairment can lead to premature death.

Management

Everolimus, a derivative of rapamycin, has been approved for the treatment of SEGAs that are not suitable for surgery. The initial dose is based on body surface area as follows: 2.5 mg once daily for body surface area 0.5 to 1.2 m^2; 5 mg once daily for 1.3 to 2.1 m^2; 7.5 mg once daily for greater than or equal to 2.2 m^2 and is subsequently adjusted based on serum levels, aiming for a trough concentration of 5 to 10 ng/mL. The drug is also being used for off-label indications, including topical application for angiofibromas and for adjunctive treatment of intractable epilepsy. The efficacy of the agent for these purposes has not yet been established in clinical trials. Everolimus has a number of adverse effects related to its immunosuppressive actions and should be administered with careful monitoring. The cutaneous lesions do not compromise function, but cosmetic surgery may be indicated for facial angiofibromas or large shagreen patches. Epileptic spasms respond to corticosteroid or corticotropin therapy; currently, vigabatrin (25 mg/kg/dose twice a day initially, maximum 75 mg/kg/dose twice a day) is the drug of choice. Focal and generalized seizures are treated with appropriate antiseizure drugs. Patients with focal seizures and minimal developmental delay may experience long-term seizure control following surgical resection of epileptogenic tubers. Progressive cystic renal disease often responds to surgical decompression, but with renal failure, dialysis or renal transplantation may be necessary. Cardiac rhabdomyomas are rarely symptomatic but may be managed medically with standard therapy for arrhythmias or cardiac failure. Surgery is rarely required. Progressive pulmonary involvement is an indication for respiratory therapy, but response is poor and most patients die a few years after the onset of this complication without lung transplantation.

ENCEPHALOTRIGEMINAL ANGIOMATOSIS

Introduction

Encephalotrigeminal angiomatosis (*Sturge-Weber-Dimitri syndrome*; MIM 185300) is manifested by a cutaneous vascular port-wine nevus of the face, contralateral hemiparesis and hemiatrophy, glaucoma, seizures, and intellectual disability. The condition is attributed to partial persistence of a primitive embryonic vascular plexus that develops around the cephalic portion of the neural tube 6 weeks after conception and under the ectoderm in the region destined to become facial skin. In encephalotrigeminal angiomatosis, the vascular plexus persists beyond the ninth week, when it normally regresses. Variability in this process accounts for unilateral or bilateral involvement and also for an incomplete syndrome characterized by leptomeningeal angiomatosis without facial involvement.

Epidemiology

The syndrome occurs in 1:20,000 to 1:50,000 live births.

Genetics

Almost all patients with encephalotrigeminal angiomatosis, and with nonsyndromic port wine stains, carry somatic mosaic activating mutations in the *GNAQ* gene. Mutations in this gene lead to abnormal signaling between G-protein–coupled receptors and downstream effectors. Similar mechanisms have been described in the Proteus and McCune-Albright syndromes.

Neuropathology

The occipital lobe is most often affected, but lesions may involve the temporal and parietal lobes or the entire cerebral hemisphere. Atrophy is characteristically unilateral and ipsilateral to the facial nevus. Leptomeningeal angiomatosis with small venules fills the subarachnoid space. Calcification of the arteries on the surface of the brain and intracerebral calcifications of small vessels are seen. Recent studies have associated focal cortical dysplasia with medically intractable epilepsy in encephalotrigeminal angiomatosis, with important implications for early surgical intervention.

Symptoms and Signs

Facial nevus and a neurologic syndrome of seizures, hemiplegia, intellectual disability, and glaucoma are characteristic. Typically, other than the facial nevus, the child has normal function for months or years. The subsequent clinical course is highly variable.

Cutaneous Manifestations

The port-wine facial stain, or nevus flammeus, involves variable portions of the face and neck. Most commonly involving the forehead, the nevus may involve one-half of the face and may extend to the neck. The nevus may cross or fall short of the midline. Bilateral facial lesions are seen in about 15% of cases (**Fig. 145.7**). Recent studies have suggested that the distribution of the nevus flammeus conforms more closely to the embryonic circulation rather than the divisions of the trigeminal nerve, as previously thought; a nevus involving any part of the forehead is the best clinical indicator of adverse outcome, including glaucoma, seizures, and abnormal development.

Neurologic Manifestations

Epilepsy is the most common neurologic manifestation, usually starting in the first year of life with focal or generalized motor or focal dyscognitive seizures. Often refractory to antiseizure medications, the focal motor seizures, hemiparesis, and hemiatrophy are contralateral to the facial nevus. Onset of seizures before age 2 years and refractory epilepsy has prognostic significance; these patients are more likely to be intellectually impaired. Intellectual disability often becomes more apparent over time.

Ophthalmologic Manifestations

Raised intraocular pressure with glaucoma and buphthalmos occurs in approximately 30% of patients. Buphthalmos, congenital enlargement of the eye, is more common than glaucoma and results from antenatal intraocular hypertension. Homonymous hemianopia, a common visual-field complication, is typically associated with occipital lobe involvement. Other congenital anomalies include coloboma of the iris and deformity of the lens.

Laboratory Data

An MRI with contrast-enhanced fluid-attenuated inversion recovery sequences is the most sensitive noninvasive technique to identify leptomeningeal involvement and cortical atrophy (**Fig. 145.8**). Fluorodeoxyglucose–positron emission tomography may be helpful in predicting seizure control and cognitive outcome: In a study of 13 children, patients with mild asymmetry of glucose uptake had worse cognitive function than those with marked asymmetry, suggesting that functional reorganization

FIGURE 145.7 Bilateral port-wine stain in an infant with Sturge-Weber syndrome.

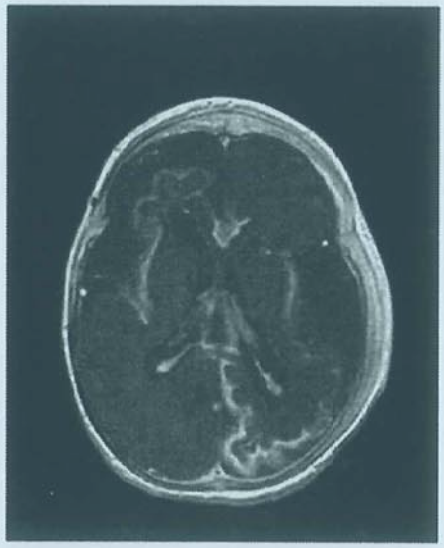

FIGURE 145.8 Gadolinium-enhanced axial magnetic resonance imaging of the brain (patient shown in **Fig. 145.7**), demonstrating meningeal enhancement, and bilateral, asymmetric, cortical atrophy.

of the cortex more readily occurs with more severe injury. The capillaries over the affected hemisphere are homogeneously increased, the superficial cortical veins are markedly decreased, and the superior sagittal sinus may be diminished or not seen.

The EEG shows low amplitude over the affected areas, and this electrical suppression correlates with the degree of intracranial calcification. The remainder of the hemisphere may show epileptiform activity. The EEG evolves over time, with increasing epileptiform activity, but these electrical changes do not correlate with clinical or seizure severity.

Diagnosis

The diagnosis is based on the facial vascular port-wine nevus flammeus and one or more of the following: seizures, contralateral hemiparesis and hemiatrophy, intellectual disability, and ocular findings of glaucoma or buphthalmos. Meningeal involvement is usually obvious on MRI. Rarely, Sturge-Weber-Dimitri syndrome may occur with the neurologic syndrome and the typical meningeal involvement, absent the facial nevus. Encephalotrigeminal angiomatosis must be distinguished from other vascular malformation syndromes, including Klippel-Trenaunay and Parkes Weber syndromes, both of which feature combined vascular malformations, in contrast to the pure capillary lesions of encephalotrigeminal angiomatosis. The identification of GNAQ mutations provides a means of molecular confirmation in biopsies of affected tissue.

Management

The facial nevus rarely requires early cosmetic therapy. Later, this blemish can be covered with cosmetics or permanently treated with laser therapy. Seizures may be difficult to control with antiseizure medications. Children with medically intractable seizures often respond to hemispherectomy, even when hemiplegia is present. Physical and occupational therapies are indicated for the hemiparesis. Educational therapy and placement in special education are important for learning-disabled or intellectually impaired patients; vocational training is essential in affected older children and young adults. Behavioral problems are common and include mood disorder, disruptive behavior disorder, and adjustment disorder in children, and substance-related disorder in adults. Prophylactic daily low-dose aspirin to prevent venous thrombosis is controversial but can be considered if there are recurrent transient ischemic episodes. Yearly monitoring for glaucoma is recommended for all patients and, if present, should be treated aggressively.

INCONTINENTIA PIGMENTI

Introduction

Incontinentia pigmenti (IP; MIM 308300), described by Bloch and Sulzberger, is a genetic disorder affecting the skin in a characteristic manner and also involving the brain, eyes, nails, and hair.

Genetics

IP is an X-linked dominant condition that is lethal in males. Mutations in the *NEMO/IKKγ* gene at Xq28 cause the disease. The *NEMO/IKKγ* is an essential component of the newly discovered nuclear factor kappa B (NF-κB) signaling pathway. When activated, NF-κB controls the expression of multiple genes, including cytokines and chemokines, and protects cells against apoptosis. The *NEMO/IKKγ* deficiency causes the phenotypic expression of the disease via the NF-κB pathway.

Sporadic disease has also appeared in girls with no family history of the disease. In these cases, there is a translocation with a breakpoint at Xp11.21. Some patients and some families do not map to either site, implying *locus heterogeneity*, with still more gene loci to be discovered.

Incontinentia pigmenti achromians (IPA, or hypomelanosis of Ito; MIM 146150) resembles IP in that the pigmentary changes respect the lines of Blaschko, but it is otherwise an unrelated syndrome. Blaschko lines are not ordinarily visible, but several cutaneous disorders follow parallel linear streaks. A pregnant woman with IP runs a 25% risk of a spontaneous miscarriage (the affected son); 50% of her infant daughters will be affected and will have the disease. Daughters are likely to be more severely affected than their mothers.

Neuropathology

The neuropathologic findings are nonspecific and include cerebral atrophy with microgyria, focal necrosis with formation of small cavities in the central white matter, and focal areas of neuronal loss in the cerebellar cortex.

Cutaneous Findings

One-half of affected infants have the initial linear vesicobullous lesions at birth, and most of the remaining children show the lesions in the first 2 weeks of life. The lesions may be confused with those of neonatal herpes simplex. About 10% are delayed, appearing as late as age 1 year. The skin lesions can recur and ultimately may undergo a characteristic change to linear verrucous and dyskeratotic growth, usually between the second and sixth weeks of life (Fig. 145.9); pigmentary changes appear between 12 and 26 weeks. Some infants may show the pigmentary lesions at birth without further cutaneous progression. The pigmentation involves the trunk and limbs, is slate gray-blue or brown, and is distributed in irregular marbled or wavy lines (Fig. 145.10). With age, the pigmentary lesions fade and become depigmented with atrophic skin changes.

FIGURE 145.9 Linear, verrucous/dyskeratotic skin lesions in an infant with incontinentia pigmenti.

FIGURE 145.10 Pigmented lesions of the trunk in an infant with incontinentia pigmenti.

Neurologic, Ophthalmic, and Other Symptoms

About 20% of affected children have a neurologic syndrome that may include slow motor development; pyramidal tract dysfunction with spastic hemiparesis, quadriparesis, or diplegia; intellectual disability; and seizures. Infants may present with epileptic spasms.

Strabismus, cataracts, and severe visual loss occur in about 20% of affected children. Retinal vascular changes may result in blindness with ectasia, microhemorrhages, avascularity, and later, retinal pigmentation and atrophy.

Partial or total anodontia and peg-shaped teeth are characteristic of IP. Partial or complete diffuse alopecia with scarring and nail dystrophy may also occur.

Laboratory Data

Eosinophilia, as high as 65%, is often seen in infants younger than age 1 year, together with an associated leukocytosis. Eosinophils are also found in the vesicobullous lesions and in affected dermis.

Management

There is no specific treatment for IP, and management is directed at complications, such as anticonvulsants for seizures. One report suggested that steroid therapy improved neurologic manifestations in a neonate with multiple cerebral infarctions complicating IP, but there are no controlled data to substantiate this effect. Awareness of the ocular manifestations is essential, because laser coagulation of avascular retina prevents blindness.

INCONTINENTIA PIGMENTI ACHROMIANS (HYPOMELANOSIS OF ITO)

Introduction

IPA is a syndrome of regions of cutaneous hypopigmentation that conform to the lines of Blaschko, first described by the German dermatologist in 1901, which define the cutaneous distribution of many hereditary dermatoses and acquired inflammatory disorders. The pattern is believed to result from functional autosomal mosaicism transmittable through the action of retrotransposons. IPA is associated with variable involvement of other body systems, particularly the nervous system. It is perhaps best considered a phenotype, rather than a disease, because there are many potential etiologies.

Epidemiology and Genetics

IPA is found in all races and sexes and is a syndrome with multiple etiologies.

Cases of IPA with an identifiable cause are associated with somatic mosaicism for chromosomal trisomies; as many as 90% of affected individuals have neurologic manifestations, including developmental delay, intellectual disability, seizures, and autism spectrum disorder.

Pathogenesis and Pathology

The pathogenesis of this disease is similar to that of other neurocutaneous disorders. Migration of neural cells to the brain and melanoblasts to the skin from the neural crest occurs between 3 and 6 months' gestational age. A disturbance of this migration results in both brain and cutaneous pigmentary disease.

The hypopigmented skin lesions are characterized by a decrease in the number of dopa-positive melanocytes and decreased pigment production in the basal layer of the epidermis.

Clinical Manifestations

In infancy, hypopigmented skin lesions appear as whorls or streaks that follow the lines of Blaschko. This lesion is the negative image of IP. In later childhood, affected areas tend to return to normal skin color. The cutaneous lesion is often associated with developmental and neurologic abnormalities with hypotonia, pyramidal tract dysfunction, intellectual disability (approximately 80%), and seizures. Ophthalmologic disorders, including strabismus, optic atrophy, microphthalmia, tessellated fundus (a normal fundus with a pigmented choroid that creates the appearance of dark polygonal areas between choroidal blood vessels), eyelid ptosis, and heterochromia iridis, are also present. Hair, teeth, and the musculoskeletal system may also be affected.

Diagnosis and Laboratory Data

Because there is no pathognomonic laboratory test, diagnosis is clinical. Investigation for chromosomal mosaicism, with karyotyping of blood, fibroblasts, and hair bulbs, should be considered in all cases.

Management

The whorled, marble-cake hypopigmented skin lesions do not require any treatment. Therapy is directed toward the associated complications, such as antiseizure drugs, and specialized educational facilities for the learning- or intellectually-disabled child.

SUGGESTED READINGS

General

Barros FS, Marussi VHR, Amaral LLF, et al. The rare neurocutaneous disorders: update on clinical, molecular, and neuroimaging features. *Top Magn Reson Imaging*. 2018;27(6):433-462.

Becker B, Strowd RE III. Phakomatoses. *Dermatol Clin*. 2019;37(4):583-606.

Gürsoy S, Erçal D. Genetic evaluation of common neurocutaneous syndromes. *Pediatr Neurol*. 2018;89:3-10.

Kang M, Lee YS. The impact of RASopathy-associated mutations on CNS development in mice and humans. *Mol Brain*. 2019;12(1):96.

Korf BR, Bebin EM. Neurocutaneous disorders in children. *Pediatr Rev*. 2017;38(3):119-128.

Marjanska A, Jatczak-Gaca A, Wojtkiewicz A, Wysocki M, Styczynski J. Demographical profile and spectrum of multiple malignancies in children and adults with neurocutaneous disorders. *Anticancer Res*. 2018;38(9):5453-5457.

Pevec U, Rozman N, Gorsek B, Kunej T. RASopathies: presentation at the genome, interactome, and phenome levels. *Mol Syndromol*. 2016;7(2):72-79.

Rosser T. Neurocutaneous disorders. *Continuum (Minneap Minn)*. 2018;24 (1, Child Neurology):96-129.

Sato TS, Handa A, Priya S, Watal P, Becker RM, Sato Y. Neurocristopathies: enigmatic appearances of neural crest cell-derived abnormalities. *Radiographics*. 2019;39(7):2085-2102.

Stafstrom CE, Staedtke V, Comi AM. Epilepsy mechanisms in neurocutaneous disorders: tuberous sclerosis complex, neurofibromatosis type 1, and Sturge-Weber syndrome. *Front Neurol*. 2017;8:87.

Tajan M, Paccoud R, Branka S, Edouard T, Yart A. The RASopathy family: consequences of germline activation of the RAS/MAPK pathway. *Endocr Rev*. 2018;39(5):676-700.

Tidyman WE, Rauen KA. Expansion of the RASopathies. *Curr Genet Med Rep*. 2016;4(3):57-64.

Troullioud Lucas AG, Mendez MD. Neurocutaneous syndromes. National Center for Biotechnology Information Web site. http://www.ncbi.nlm.nih.gov/books/NBK537001/. Accessed July 26, 2020.

van Steensel MA. Neurocutaneous manifestations of genetic mosaicism. *J Pediatr Genet*. 2015;4(3):144-153.

Neurofibromatosis

Armand ML, Taieb C, Bourgeois A, et al. Burden of adult neurofibromatosis 1: development and validation of a burden assessment tool. *Orphanet J Rare Dis*. 2019;14(1):94.

Cassina M, Frizziero L, Opocher E, et al. Optic pathway glioma in type 1 neurofibromatosis: review of its pathogenesis, diagnostic assessment, and treatment recommendations. *Cancers (Basel)*. 2019;11(11):1790.

Coy S, Rashid R, Stemmer-Rachamimov A, Santagata S. An update on the CNS manifestations of neurofibromatosis type 2. *Acta Neuropathol*. 2020;139(4):643-665.

Eoli M, Saletti V, Finocchiaro G. Neurological malignancies in neurofibromatosis type 1. *Curr Opin Oncol*. 2019;31(6):554-561.

Evans DG, Hartley CL, Smith PT, et al. Incidence of mosaicism in 1055 de novo NF2 cases: much higher than previous estimates with high utility of next-generation sequencing. *Genet Med*. 2020;22(1):53-59.

Farazdaghi MK, Katowitz WR, Avery RA. Current treatment of optic nerve gliomas. *Curr Opin Ophthalmol*. 2019;30(5):356-363.

Friedman JM. Neurofibromatosis 1. National Center for Biotechnology Information Web site. http://www.ncbi.nlm.nih.gov/books/NBK1109/. Accessed July 26, 2020.

Halliday D, Parry A, Evans DG. Neurofibromatosis type 2 and related disorders. *Curr Opin Oncol*. 2019;31(6):562-567.

Kang E, Kim YM, Seo GH, et al. Phenotype categorization of neurofibromatosis type I and correlation to NF1 mutation types. *J Hum Genet*. 2020;65:79-89.

Karaconji T, Whist E, Jamieson RV, Flaherty MP, Grigg JRB. Neurofibromatosis type 1: review and update on emerging therapies. *Asia Pac J Ophthalmol (Phila)*. 2019;8(1):62-72.

Pegat A, Ducray F, Jeannin-Mayer S, Jouanneau E, Pinson S, Petiot P. Charcot-Marie-Tooth (CMT)-like polyneuropathy revealing neurofibromatosis type 2: a case report and review of the literature. *Rev Neurol (Paris)*. 2019;175(7-8):486-489.

Taddei M, Erbetta A, Esposito S, Saletti V, Bulgheroni S, Riva D. Brain tumors in NF1 children: influence on neurocognitive and behavioral outcome. *Cancers (Basel)*. 2019;11(11):1772.

Uusitalo E, Rantanen M, Kallionpää RA, et al. Distinctive cancer associations in patients with neurofibromatosis type 1. *J Clin Oncol*. 2016;34(17):1978-1986

Ylä-Outinen H, Loponen N, Kallionpää RA, Peltonen S, Peltonen J. Intestinal tumors in neurofibromatosis 1 with special reference to fatal gastrointestinal stromal tumors (GIST). *Mol Genet Genomic Med*. 2019;7(9):e927.

Tuberous Sclerosis Complex

Byers HM, Jensen DM, Glass IA, Bennett JT. Minimal mosaicism, maximal phenotype: Discordance between clinical and molecular findings in two patients with tuberous sclerosis. *Am J Med Genet C Semin Med Genet*. 2018;178(3):374-378.

Canevini MP, Kotulska-Jozwiak K, Curatolo P, et al. Current concepts on epilepsy management in tuberous sclerosis complex. *Am J Med Genet C Semin Med Genet*. 2018;178(3):299-308.

Curatolo P, Bombardieri R. Tuberous sclerosis. *Handb Clin Neurol*. 2008;87: 129-151.

Davis PE, Filip-Dhima R, Sideridis G, et al. Presentation and diagnosis of tuberous sclerosis complex in infants. *Pediatrics*. 2017;140:e20164040.

Hallett L, Foster T, Liu Z, Blieden M, Valentim J. Burden of disease and unmet needs in tuberous sclerosis complex with neurological manifestations: systematic review. *Curr Med Res Opin*. 2011;27:1571-1583.

Lu DS, Karas PJ, Krueger DA, Weiner HL. Central nervous system manifestations of tuberous sclerosis complex. *Am J Med Genet C Semin Med Genet*. 2018;178(3):291-298.

Randle SC. Tuberous sclerosis complex: a review. *Pediatr Ann*. 2017;46(4): e166-e171.

Encephalotrigeminal Angiomatosis

De la Torre AJ, Luat AF, Juhász C, et al. A multidisciplinary consensus for clinical care and research needs for Sturge-Weber syndrome. *Pediatr Neurol*. 2018;84:11-20.

Gittins S, Steel D, Brunklaus A, Newsom-Davis I, Hawkins C, Aylett SE. Autism spectrum disorder, social communication difficulties, and developmental comorbidities in Sturge-Weber syndrome. *Epilepsy Behav*. 2018;88:1-4.

Nguyen V, Hochman M, Mihm MC Jr, Nelson JS, Tan W. The pathogenesis of port wine stain and Sturge Weber syndrome: complex interactions between genetic alterations and aberrant MAPK and PI3K activation. *Int J Mol Sci*. 2019;20(9):2243.

Su WW. Acute primary angle-closure in Sturge-Weber syndrome. *Am J Ophthalmol Case Rep*. 2018;10:101-104.

Tian Y, Wang Y, Gao X, Zhang Y, Ju Y. Eye and appearance characteristics of encephalocraniocutaneous lipomatosis. *Eye (Lond)*. 2019;33(2):328-331.

Incontinentia Pigmenti

Abdollahimajd F, Fallahi M, Kazemian M, Nilipour Y, Radfar M, Tehranchi ST. Incontinentia pigmenti misdiagnosed as neonatal herpes simplex virus infection. *Case Rep Pediatr*. 2018;2018:1376910.

Seo MY, You SJ, Kim SH, Cho WH, Chae JH. A 6-month-old girl with incontinentia pigmenti presenting as status epilepticus. *J Epilepsy Res*. 2017;7(2):118-120.

Sharawat IK, Saini L, De D, Sankhyan N. Nature's canvas: an infant with stripes and whorls. *Pediatr Neurol*. 2019;92:76-77.

Tomotaki S, Shibasaki J, Yunoki Y, et al. Effectiveness of corticosteroid therapy for acute neurological symptoms in incontinentia pigmenti. *Pediatr Neurol*. 2016;56:55-58.

Incontinentia Pigmenti Achromians (Hypomelanosis of Ito)

Albuja AC, Shrivastava A, Khan GQ. Manifestations of hypomelanosis of Ito. *Pediatr Neonatol*. 2018;59(5):536-537.

Chamli A, Litaiem N. Hypomelanosis of Ito. National Center for Biotechnology Information Web site. https://www.ncbi.nlm.nih.gov/books/NBK538268/. Accessed July 26, 2020.

Dawson MZ, Ghosh D. Chasing zebras: a child with skin stripes and whorls. *Pediatr Neurol*. 2018;79:74-75.

Kromann AB, Ousager LB, Ali IKM, Aydemir N, Bygum A. Pigmentary mosaicism: a review of original literature and recommendations for future handling. *Orphanet J Rare Dis*. 2018;13(1):39.

146 Spinal Muscular Atrophies of Childhood

Basil T. Darras, Richard S. Finkel, and Darryl C. De Vivo

KEY POINTS

1. Clinical subtypes of spinal muscular atrophy (SMA) classified by maximal functional status achieved are type I ("nonsitters"), type II ("sitters"), and type III ("walkers").
2. Type IV SMA is a mild phenotype with onset during early adult or middle age. All SMA types show a spectrum of severity within each subgroup.
3. Non–5q13-associated SMA is a heterogeneous group of motor neuron diseases with clinical characteristics usually distinct from classic SMA.
4. Ninety-five percent to 98% of SMA patients have deletions of the *SMN1* gene. The remainder are compound heterozygotes or have undergone gene conversions from *SMN1* to *SMN2*.
5. Correlation between *SMN2* copy number and phenotype severity cannot predict clinical severity, especially with the intermediate forms of the disease.
6. The justification of adding newborn screening for the genetic identification of presymptomatic individuals with SMA has been demonstrated.
7. Recent data suggest the pathologic effects of reduced survival motor neuron protein are also observed distally, at the neuromuscular junctions.
8. Therapeutic efforts include *SMN1* gene replacement and pharmaceuticals to upregulate *SMN2* expression.
9. New treatments for symptomatic patients with SMA provide some degree of rescue, with improved survival and motor function, but are not a cure.

INTRODUCTION

In the early 1890s, the Austrian clinician Guido Werdnig at the University of Graz, Austria, and the German clinician Johann Hoffmann in Heidelberg, Germany, described an infantile onset neuromuscular disorder causing progressive muscular weakness associated with loss of anterior horn cells in the spinal cord and early death. The spinal muscular atrophies (SMAs) have since been defined as a group of genetic disorders characterized by progressive muscle weakness and atrophy, associated with degeneration of spinal and, in the most severely affected patients, lower bulbar motor neurons. The most common of these disorders, and the leading cause of infant mortality, is classic proximal SMA, which is found in all populations and diagnosed more frequently in infants and children than in adults.

Classic SMA results from homozygous deletions or mutations involving the "survival motor neuron" (*SMN*) gene. Two *SMN* genes, designated *SMN1* and *SMN2*, are present on each chromosome 5, as the result of an inverted duplication at locus 5q13 (**Fig. 146.1**). The duplicated *SMN2* gene is differentiated from *SMN1* by 5-13 nucleotide changes, one of which is essential in creating an exonic splicing silencer in exon 7, leading to exclusion of exon 7 in most transcripts and diminished production (5%-10%) of full-length functional SMN protein. Most patients with 5q proximal SMA harbor homozygous deletions involving exon 7 of the *SMN1* gene, and all patients have at least one *SMN2* copy.

The role of the SMN protein is still under active investigation, but there is a rough correlation between *SMN2* gene copy number, which varies normally in the population, the level of SMN protein, and severity of disease. Abnormalities of the neuromuscular junction have been noted in animal models, and abnormal muscle development in the most severely affected patients.

EPIDEMIOLOGY

The incidence of SMA has been estimated at 1 in 6,000 to 11,000 live births or about 7.8 to 10 per 100,000 live births and at 4.1 per 100,000 live births for SMA type I. The estimated pan-ethnic disease frequency is approximately 1 in 11,000. The carrier frequency for mutations in the *SMN1* gene has been estimated to be highest in Caucasians (1:47) and lowest in African Americans (1:72). Ashkenazi Jews (1:67), Asians (1:59), and Hispanics (1:68) are of intermediate frequency.

CLINICAL CHARACTERISTICS

Although most patients with SMA have deletions or mutations involving the *SMN1* gene, there is a range of phenotypic severity that permits division into four broad clinical subtypes. It is recognized that the subtypes represent a phenotypic continuum extending from the very severe, with onset in utero, to the very mild, with onset during adulthood; there is also a spectrum of severity within each of these subgroups (**Table 146.1**). For the purposes of clinical classification, or of guidelines developed for standards of care, the "maximal functional status achieved" approach, which classifies type I patients as "nonsitters," type II patients as "sitters," and type III patients as "walkers," has been used. Patients with a mild phenotype and onset during middle or late age are classified as type IV. The age at onset is also considered in the classification, but because of potential overlap between subtypes and the difficulty in accurately determining the onset of symptoms, it has not been considered as the sole determinant of disease subtype.

Type I Spinal Muscular Atrophy

Patients with type I SMA, also known as *Werdnig-Hoffmann disease*, present within the first 6 months of life. SMA type I has

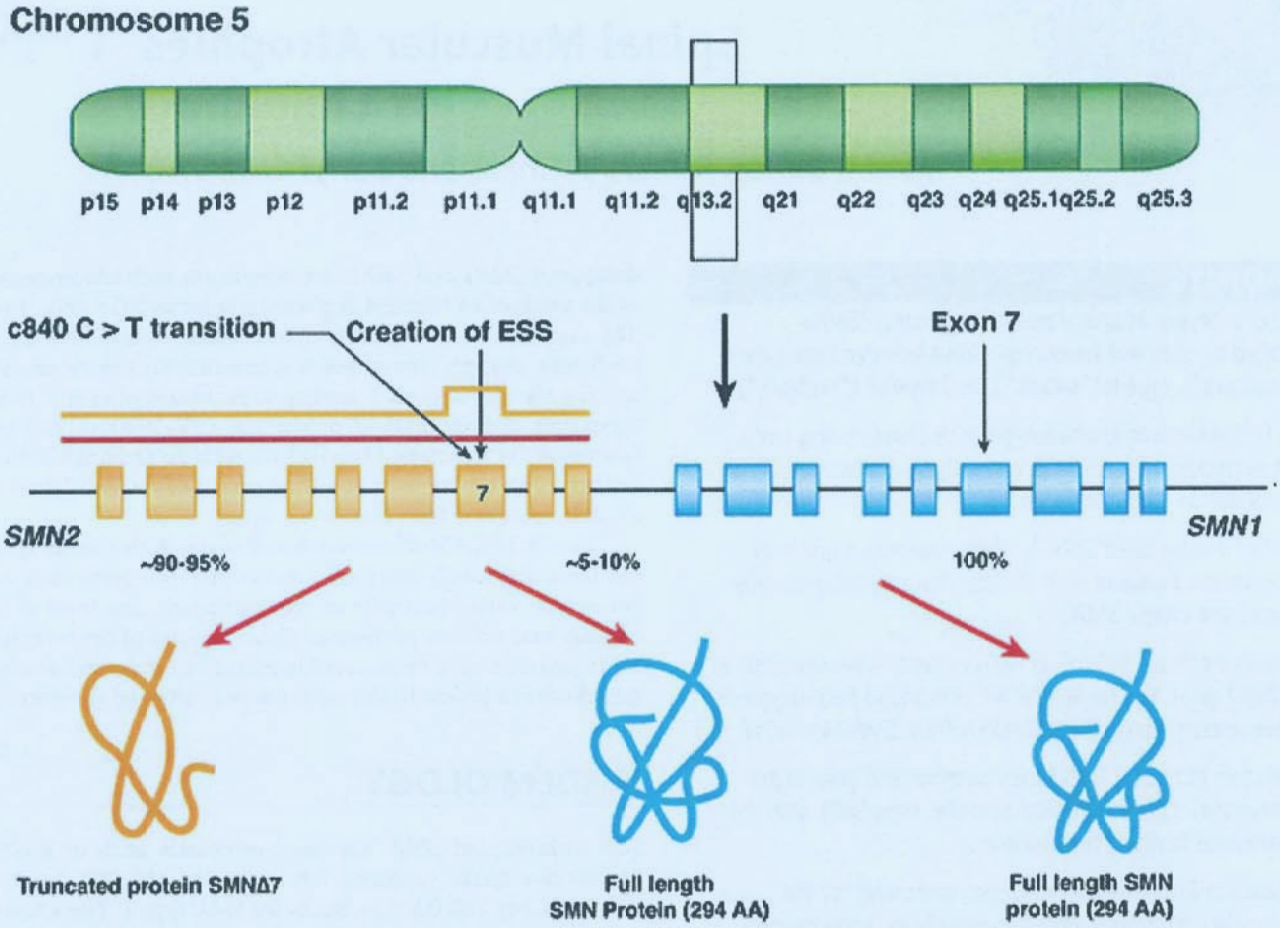

FIGURE 146.1 Schematic diagram of human *SMN1* and *SMN2* genes on chromosome 5. Patients with spinal muscular atrophy have deletions or mutations in both copies of *SMN1*. A C-to-T transition at position 6 of *SMN2* creates an exonic splicing suppressor (ESS) that leads to skipping of exon 7 during transcription and production of truncated, nonfunctional SMN protein. However, a small amount (5%-10%) of full-length messenger RNA is produced from the *SMN2* gene, resulting in functional, full-length SMN protein. AA, amino acids. (Reprinted with permission from Darras BT, Markowitz JA, Monani UR, De Vivo DC. Spinal muscular atrophies. In: Darras B, Jones HR Jr, Ryan M, De Vivo DC. *Neuromuscular Disorders of Infancy, Childhood, and Adolescence: A Clinician's Approach*. San Diego, CA: Academic Press: 2015;117-145: Fig 1, p. 118.)

been further subdivided into three groups: type IA with symptoms of hypotonia at birth or onset within the neonatal period, type IB with onset of symptoms prior to age 3 months, and type IC with onset between ages 3 and 6 months. Infants with SMA type I have progressive proximal weakness that affects the legs more than the arms. They have poor head control, hypotonia that causes them to assume a "frog-leg" and "jug-handle" arm posture when lying and to "slip through" on vertical suspension, and areflexia. They are never able to sit ("nonsitters") (see **Table 146.1**). There is also weakness of the intercostal muscles with relative sparing of the diaphragm, producing a bell-shaped chest and a pattern of paradoxical or "belly" breathing. Infants with type I SMA also exhibit tongue fasciculations, difficulty swallowing, risk of aspiration, and failure to thrive. Other cranial nerves are not as affected, although facial weakness does occur at later stages of the disease. Cognition is normal, and they are often noted at diagnosis to have a bright, alert expression that contrasts with their generalized weakness. Sensation is preserved. Infants with type I SMA usually develop respiratory failure by age 2 years, or much earlier, and in the past, most did not survive past age 2 years. Improvement in pulmonary and nutritional support and orthopedic management over the past three decades has significantly improved survival of type I patients but has not changed the progressive decline in motor function. Until the advent of the new therapeutics, these patients failed to improve in motor or respiratory function from the day of diagnosis even with maximal supportive care. Multidisciplinary standard of care initiatives were convened in 2006 and 2017, resulting in published guidelines. These efforts reflect more expert opinion than data from the literature and need to be individualized based on the specifics of the patient, the resources available, and the parents' preferences. There has been a growing trend to provide such supportive care in a proactive way rather than a reactive one. For example, the use of a cough-assist device is often recommended shortly following diagnosis and not waiting for an ineffective cough to evolve.

Type II Spinal Muscular Atrophy

This intermediate form of SMA was first reported in 1893 at the University of Edinburgh, United Kingdom, and described again by Byers and Banker in 1961 and in detail by Dubowitz

TABLE 146.1 Clinical Classification of Spinal Muscular Atrophy[a]

SMA Type	Other Names	Age at Onset	Life Span	Highest Motor Milestone Achieved	Other Features	Proportion of Total SMA (%)
Type IA	Prenatal, congenital SMA, Werdnig-Hoffmann disease	Prenatal	<6 mo	Mostly unable to achieve motor milestones	• Severe weakness at birth • Profound hypotonia • Facial diplegia • Areflexia • Early respiratory failure • Joint contractures	60[b]
Type IB, type IC	Werdnig-Hoffmann disease, severe SMA ("nonsitters")	Type IB (0-3 mo) Type IC (3-6 mo)	<2 y without respiratory support	Never sits supported	• Weakness • "Frog leg" posture, hypotonia • Tongue fasciculations • Hyporeflexia, areflexia • Suck and swallow difficulties • Respiratory failure	60
Type II	Intermediate SMA ("sitters"), Dubowitz disease	6-18 mo	>2 y ~70% alive at 25 y of age	Sits independently, never stands or walks	• Proximal weakness, hypotonia • Postural hand tremor • Hyporeflexia • Average or above average intellectual skills by adolescence • Scoliosis	27
Type III	Kugelberg-Welander disease, mild SMA ("walkers")	>18 mo Type IIIA (prior to 3 y) Type IIIB (after 3 y)	Almost normal	Stands and walks	• May have hand tremor • Resembles muscular dystrophy	12
Type IV	Adult SMA	>21 y	Normal	Normal		1

Abbreviation: SMA, spinal muscular atrophy.
[a]Modified with permission from Markowitz JA, Singh P, Darras BT. Spinal muscular atrophy: a clinical and research update. *Pediatr Neurol*. 2012;46:1-12.
[b]SMA types IA, IB, and IC collectively have a 60% proportion of total incidence of SMA.

in 1964. Patients with type II SMA, also known as *intermediate SMA* or *Dubowitz disease*, are able to sit unsupported at some point ("sitters") but are never able to stand alone or walk (see Table 146.1). Symptom onset is typically between ages 6 and 18 months. They have progressive proximal weakness affecting legs more than arms, hypotonia, and areflexia. Tongue fasciculations are seen in about half of patients. Nearly all type II patients develop progressive scoliosis that, in combination with intercostal muscle weakness, results in significant restrictive lung disease as they grow older. They develop joint contractures and can have ankylosis of the mandible. They exhibit tremor, or polyminimyoclonus, of the hands. Although their body mass index may be low (at the 3rd percentile or less when compared with normal children), the high-functioning, nonambulatory patients have a higher relative fat mass index and are at risk for becoming overweight. Cognition is normal, and verbal intelligence may be above average. In a study done on 240 type II patients, survival rates were found to be 98.5% at 5 years and 68.5% at 25 years. Patients may live into the third decade, but life expectancy is shortened due to the risk of respiratory compromise.

Type III Spinal Muscular Atrophy

In 1956, Kugelberg and Welander described a much milder form of SMA characterized by prolonged ambulation. Patients with type III SMA, also known as *Kugelberg-Welander disease*, are able to stand alone and walk at some point ("walkers"). The onset of symptoms occurs after age 18 months; it has further been subdivided into type IIIA (onset between ages 18 months and 3 years) and type IIIB (onset after age 3 years). They have progressive proximal weakness affecting legs more than arms and may ultimately need to use a wheelchair, but they generally develop little to no respiratory muscle weakness or severe scoliosis. Loss of ambulation increases the risk of these complications. They may have tremor or polyminimyoclonus of the hands. Sometimes, the calves of these patients can be prominent, and hence, type III SMA can be confused with Becker muscular dystrophy. Life expectancy is not significantly different compared with the normal population (see Table 146.1).

Outliers

The most severe form of SMA, type 0 in certain reports, presents with onset in utero and with severe weakness, joint contracture, and need for respiratory and feeding support at birth. At the other end of the spectrum, milder adult-onset SMA, or type IV SMA, has also been described with onset of symptoms after age 21 years and essentially normal life span. Most patients with the SMA type IA and IV phenotypes have homozygous deletions of exon 7 in *SMN1*, but as it is discussed in the "Genetics" section, the *SMN2* copy number is usually only one in SMA type IA and four to five in adult SMA type IV.

Other "Spinal Muscular Atrophies"

The non–5q13-associated SMAs are a heterogeneous group of motor neuron diseases associated with mutations in several different genes (eg, X-linked and autosomal dominant or recessive SMAs), distal or segmental SMAs, or distal hereditary motor neuropathies. Patients with these disorders generally have some clinical characteristics that differentiate them from those with 5q13-associated or classic SMA. The differential diagnosis of SMA is detailed in Table 146.2.

TABLE 146.2 Differential Diagnosis of 5q Spinal Muscular Atrophy[a]

Spinal Cord Disorders
Neoplasms (SMA types I, II, III)
Other myelopathies (SMA types I, II, III)
Other Motor Neuron Disorders
SMARD1 (SMA type I)
Juvenile muscular atrophy of distal upper extremity (Hirayama disease)
Fazio-Londe disease, Brown-Vialetto-van Laere syndrome
Other non-5q SMAs (SMA types I, II, III)
Juvenile ALS (SMA type III)
Neuropathies
Congenital hypomyelinating or axonal neuropathies (SMA types I, II)
Hereditary motor and sensory neuropathies (SMA types II, III)
CIDP (SMA types II, III)
Neuromuscular Junction Disorders
Botulism (SMA type I)
Congenital myasthenic syndromes (SMA types I, II, III)
Lambert-Eaton myasthenic syndrome (SMA type III)
Autoimmune myasthenia gravis (SMA types II, III)
Myopathies
Congenital myopathies (SMA types I, II, III)
Congenital myotonic dystrophy (SMA type I)
Congenital muscular dystrophies (SMA types I, II)
Muscular dystrophies (DMD/BMD, LGMD) (SMA type III)
Inflammatory myopathies (SMA type III)
Channelopathies (SMA type III)
Metabolic Disorders
Mitochondrial myopathies (SMA types I, II, III)
Acid maltase/Pompe disease (SMA types I, II, III)
Other metabolic myopathies (SMA types I, II, III)
Hexosaminidase A deficiency (SMA types III, IV)
Acid ceramidase deficiency (SMA type III)
Other Disorders
Chromosomal abnormalities (SMA types I, II, III)
Prader-Willi syndrome (SMA types I, II)
Central nervous system abnormalities (SMA types I, II, III)
Hexosaminidase A deficiency (SMA types III, IV)

Abbreviations: ALS, amyotrophic lateral sclerosis; BMD, Becker muscular dystrophy; CIDP, chronic inflammatory polyneuropathy; DMD, Duchenne muscular dystrophy; LGMD, limb-girdle muscular dystrophy; SMA, spinal muscular atrophy; SMARD1, spinal muscular atrophy with respiratory distress 1.
[a]Modified with permission from Markowitz JA, Singh P, Darras BT. Spinal muscular atrophy: a clinical and research update. *Pediatr Neurol*. 2012;46:1-12.

GENETICS

The *SMN* Gene

About 95% to 98% of patients with SMA harbor deletions of the *SMN1* gene. The remainders are compound heterozygotes with an *SMN1* deletion in one allele and a small-scale intragenic mutation in the other *SMN1* allele or have undergone gene conversions from *SMN1* to *SMN2*. De novo mutations occur at a rate of about 2%, which is relatively high, and explained by the fact that this region of chromosome 5 is unstable, containing not only the inverted repeat of *SMN1* and *SMN2* but also other surrounding low copy number repeats. This leads to a high rate of unequal crossover and de novo mutations (especially paternally derived), which could explain the relatively high carrier frequency despite the mortality rate for the severe forms of the disease.

The number of copies of *SMN2* per chromosome 5 varies among normal individuals, and 10% to 15% of the population possess no copies of *SMN2*. Among patients with SMA, a clear inverse correlation has been established between *SMN2* copy number and phenotypic severity. Feldkotter et al in 2002 found that in their series, 80% of patients with type I SMA had one or two copies of *SMN2*, 82% of patients with type II had three copies of *SMN2*, and 96% of patients with type III had three or four *SMN2* copies (**Fig. 146.2**). However, this correlation is not so perfect as to predict the clinical severity in an individual patient based on *SMN2* copy number, especially with the intermediate forms of the disease where there is some overlap (patients with three or four copies of *SMN2* have been described with all three phenotypes). One reason for the overlap is that not all *SMN2* gene copies are equal; because of genetic modifiers, some copies probably produce less and some more than 10% functional protein. In general, though, it can be said that a patient with one or two copies of *SMN2* is highly likely to present with SMA type IA, IB, or IC. Current laboratory testing for the determination of *SMN2* copy number uses several techniques. The multiplex ligation-dependent probe amplification (MLPA) technique is felt to be the most accurate, especially when attempting to distinguish three from four from five copies.

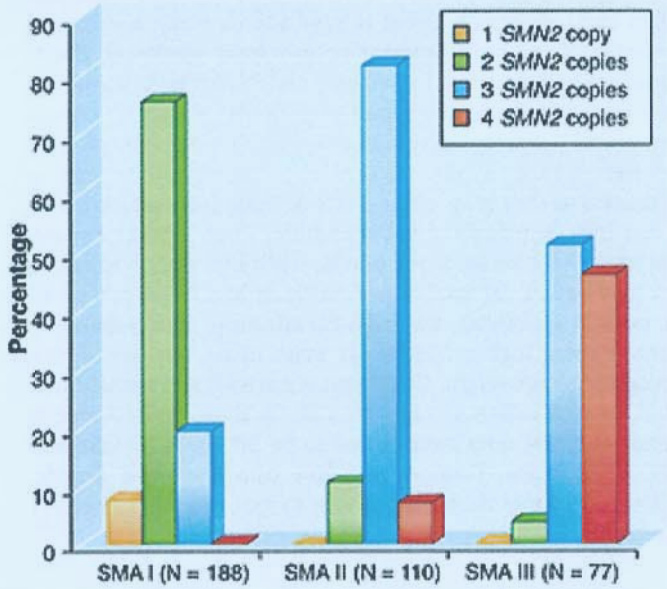

FIGURE 146.2 Frequency of patients with spinal muscular atrophy (SMA) types I, II, and III and *SMN2* copy numbers. In spinal muscular atrophy type I, 80% of patients had one or two copies of *SMN2*, 82% of patients with type II had three copies of *SMN2*, and 96% of patients with type III carried three or four *SMN2* copies. (Modified with permission from Feldkotter MV, Schwarzer V, Wirth R, Wienker TF, Wirth B. Quantitative analyses of *SMN1* and *SMN2* based on real-time lightCycler PCR: fast and highly reliable carrier testing and prediction of severity of spinal muscular atrophy. *Am J Hum Genet*. 2002;70:358-368, Fig 3.)

Newborn Screening

The potential for newborn screening for SMA has been of great interest as the ideal time to initiate therapy would be prior to when the subclinical degeneration of motor neurons becomes symptomatic and there is the best opportunity to rescue the largest number of motor neurons. Swoboda et al performed a prospective study in prenatally diagnosed infants with type I SMA and found that, associated with the initial onset of symptoms or decline in function in these young infants, there was electrophysiologic evidence of precipitous denervation (assessed with serial measurements of compound motor action potential amplitude and motor unit number estimation), suggesting that motor neuron loss occurs very early. These observations reinforce the importance of newborn screening to identify genetically affected infants prior to the period of greatest motor neuron loss now that effective disease modifying treatments are available. The justification of adding newborn screening for the genetic identification of presymptomatic individuals with SMA has been demonstrated. SMA was added to the U.S. Department of Health and Human Services Recommended Uniform Screening Panel in 2018 and, as of late 2019, 20 states in the United States have implemented statewide or pilot newborn screening programs. Additional efforts are underway in Europe, especially Germany.

Regarding the issue of routine preconception and prenatal screening for SMA, the American College of Obstetricians and Gynecologists Committee on Genetics reaffirmed in 2019 their recommendation of preconception and prenatal screening for SMA in the general population.

PATHOBIOLOGY

SMA is characterized by spinal motor neuron loss and skeletal muscle atrophy. However, a precise understanding of how the cellular pathology of the disease evolves over its course continues to be handicapped by a paucity of suitable patient material. Our current appreciation of SMA pathophysiology stems largely from analyses of autopsy material, reflecting pathology at the end of the disease. Analyses of early disease pathology have relied mostly on murine models. Still, from the current studies, certain key findings emerge. These, almost invariably, include a profound loss of the large anterior horn cells of the spinal cord. Less frequently, motor neurons are found mispositioned. Surviving anterior horn motor neurons often appear swollen or chromatolytic, containing phosphorylated neurofilaments, ribosomes, and vesicles. In fewer instances, such pathology has also been observed in dorsal root neurons, cells comprising Clarke's column, and the thalamus of the brain. Intramuscular nerves in SMA patients sometimes appear beaded or are reported to undergo wallerian degeneration.

Considering the degeneration of the spinal motor neurons, an expected pathologic characteristic is neurogenic atrophy of the skeletal muscles. Muscle from severely (type I) affected patients typically consists of a sea of small, rounded, atrophic fibers within which are sometimes seen islands of one or more large hypertrophic cells. In some instances, the atrophic fibers also appear immature with centrally rather than peripherally located nuclei, giving the appearance of a myopathic condition or possibly that of early developmental arrest at the myotube stage.

Although SMA has historically been described as a disease characterized by motor neuron cell body loss, more recent data suggest the earliest pathologic effects of reduced SMN protein are observed distally, at the neuromuscular junctions. This early pathology that affects the pre- as well as postsynapse was first observed in mouse models of the disease and has now been confirmed in human samples as well (Fig. 146.3). Patients with SMA often describe significant fatigue, and repetitive nerve stimulation testing has demonstrated an increased incidence of a decremental response, adding electrophysiologic support to a myasthenic-like component to SMA.

MANAGEMENT

SMA is a unique "translational" disease because of the presence of the *SMN2* gene, which is a well-validated target for therapeutic interventions. Besides *SMN1* gene replacement using viral vectors, the effort on therapeutics has aimed at finding pharmaceutical compounds that can upregulate *SMN2* expression or affect other modifying genes to produce more functional SMN protein.

Agents That Upregulate *SMN2* Gene Expression and Promote Exon 7 Inclusion

Small Molecules

A class of drugs known as *histone deacetylase inhibitors* has been investigated extensively as potential therapeutic agents in SMA.

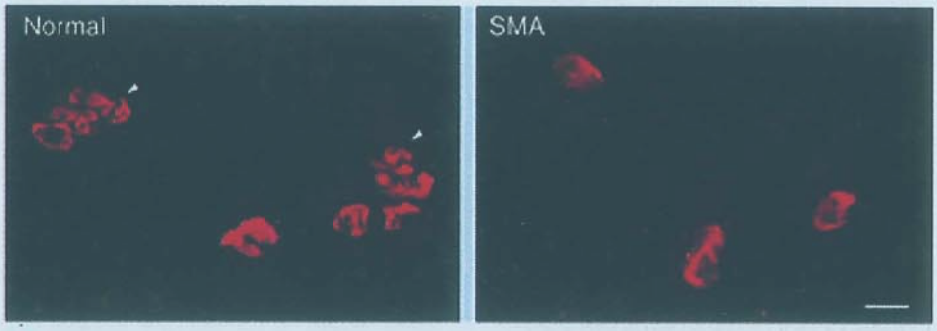

FIGURE 146.3 The neuromuscular junction defects in spinal muscular atrophy (SMA). The postsynaptic motor endplates are smaller and less complex compared to those of a control normal individual *(arrowheads)*. Tissue was obtained from autopsy and stained as a whole mount preparation with fluorescently labeled α-bungarotoxin. Scale bar: 30 μM. (Reprinted with permission from Monani UR, De Vivo DC. Neurodegeneration in spinal muscular atrophy: from disease phenotype and animal models to therapeutic strategies and beyond. *Future Neurol.* 2014;9[1]:49-65, Fig 2.)

Histones, which are core proteins in chromatin, play a role in epigenetic regulation of gene expression via their acetylation status. Several compounds that are histone deacetylase inhibitors, such as phenylbutyrate and valproic acid, have been shown to increase full-length *SMN2* transcript levels in cell lines from patients, usually by activating the human *SMN2* promoter, enhancing transcription, and correcting the splicing pattern; however, in clinical trials they failed to show efficacy.

Albuterol, a β-adrenergic agonist, was evaluated in a pilot open label study of 13 SMA type II and III patients due to its reported positive effect on muscle strength in healthy individuals. At 6 months, a significant improvement was noted in myometry, forced vital capacity, and dual-energy X-ray absorptiometry scores, but there was no significant change in Medical Research Council strength score. Another study of 23 SMA type II patients treated with salbutamol (a form of albuterol) for 12 months showed improved functional scores on the Hammersmith Functional Motor Scale (HFMS) after 6 and 12 months, but this was not a placebo-controlled study and must be interpreted with caution. Despite the lack of conclusive evidence, albuterol/salbutamol is sometimes prescribed to enhance endurance and diminish fatigue in SMA patients. Tremor may increase, and this can be problematic for SMA patients.

Other Approaches

Antisense Oligonucleotides

Antisense oligonucleotides (ASOs) have been developed that block an intronic splicing suppressor element, which in turn prevents skipping of exon 7. Periodic intracerebroventricular deliveries of ASOs in SMA mice models had been found to improve the motor phenotype. Based on the promise of preclinical studies and phase I/II clinical trials, randomized, double-blind, sham procedure-controlled phase III trials were developed by Ionis and Biogen. Pharmaceuticals were conducted to assess the safety, tolerability, and clinical efficacy of multiple doses of an ASO (ISIS-SMNRx), or nusinersen (Spinraza), which was delivered intrathecally into the subarachnoid space of patients with infantile or later onset SMA. The studies were successful LEVEL 1,[1] and nusinersen was approved broadly in 2016 by U.S. Food and Drug Administration, and later by European Medicines Agency (EMA) and other regulatory agencies as treatment for SMA. Long-term extension studies and postmarketing reports describe continued improvement for most patients treated with nusinersen; the safety profile remains favorable and the lumbar punctures generally well tolerated. There are challenges in delivering nusinersen intrathecally to patients who have undergone spinal fusion for correction of scoliosis or in patients with complex spines. Interventional radiologists have had success in most of these patients. The development of catheters and ports to deliver the drug is being explored currently.

Gene Therapy

Among other therapeutic targets, gene therapy has shown potential in animal models. Foust et al demonstrated that self-complementary adeno-associated virus 9 crossed the blood-brain barrier and infected approximately 60% of motor neurons when injected intravenously into neonatal mice. Remarkable therapeutic benefit resulted, with mice surviving 12 months or more with no evidence of muscle weakness. An *SMN1* gene replacement clinical trial (START) to treat SMA type I was conducted at Nationwide Children's Hospital, Columbus, Ohio, United States. The initial (START) trial with AVXS-101 showed positive results and has been followed by ongoing studies in the United States and Europe (STR1VE) LEVEL 1.[2] In 2019, the U.S. Food and Drug Administration approved AVXS-101 (onasemnogene) under the name Zolgensma for the treatment of SMA (symptomatic or presymptomatic) patients under age 2 years.

CARE OF THE PATIENT WITH SPINAL MUSCULAR ATROPHY

Patients with SMA and their families benefit greatly from a multidisciplinary approach to care. This approach involves members from neurology/neuromuscular medicine, orthopedics, physical and occupational therapy and rehabilitation medicine, pulmonology, nutrition, and gastroenterology. Genetic counseling remains important. For severely affected patients with type I SMA, early involvement of the pediatric advanced care or palliative care team can provide parents with support and assistance in making decisions that are consonant with their values and help to maximize their child's quality of life. In 2007 and 2018, Consensus Statements for Standard of Care in Spinal Muscular Atrophy were released by a multidisciplinary team regarding the current best recommendations for management of patients with SMA.

SUMMARY

Classic 5q-SMA is no longer a progressive neurodegenerative disease with a dismal prognosis. New treatments for symptomatic patients with SMA now provide some degree of rescue, with improved survival and motor function, but are not a cure. Early diagnosis and treatment after symptom onset offer the best opportunity for an optimal response to these drugs. Presymptomatic identification and treatment has resulted in normal motor development in many of these infants. The durability of these treatments, especially in growing children, remains to be determined. Combinatorial treatment may offer an enhanced response and will need to be addressed in future clinical investigations.

LEVEL 1 EVIDENCE

1. Finkel RS, Mercuri E, Darras BT, et al; for ENDEAR Study Group. Nusinersen versus sham control in infantile-onset spinal muscular atrophy. *N Eng J Med*. 2017;377(18):1723-1732.
2. Mendell JR, Al-Zaidy S, Shell R, et al. Single-dose gene-replacement therapy for spinal muscular atrophy. *N Eng J Med*. 2017;377(18):1713-1722.

SUGGESTED READINGS

American College of Obstetricians and Gynecologists. Committee Opinion No. 691 summary: carrier screening for genetic conditions. *Obstet Gynecol*. 2017;129(3):597-599.

Bennett CF, Krainer AR, Cleveland DW. Antisense oligonucleotide therapies for neurodegenerative diseases. *Annu Rev Neurosci*. 2019;42:385-406.

Burghes AH, McGovern VL. Antisense oligonucleotides and spinal muscular atrophy: skipping along. *Genes Dev*. 2010;24(15):1574-1579.

Darras BT. Non-5q spinal muscular atrophies: the alphanumeric soup thickens. *Neurology*. 2011;77(4):312-314.

Darras BT, Kang PB. Clinical trials in spinal muscular atrophy. *Curr Opin Pediatr*. 2007;19(6):675-679.

Darras BT, Markowitz JA, Monani UR, De Vivo DC. Spinal muscular atrophies. In: Darras BT, Jones HR Jr, Ryan MM, De Vivo DC, eds. *Neuromuscular Disorders of Infancy, Childhood, and Adolescence: A Clinician's Approach*. San Diego, CA: Academic Press; 2015:117-145.

De Vivo DC, Bertini E, Swoboda KJ, et al. Nusinersen initiated in infants during the presymptomatic stage of spinal muscular atrophy: interim efficacy and safety results from the Phase 2 NURTURE study. *Neuromuscul Disord*. 2019;29(11):842-856.

Dubowitz V. Chaos in the classification of SMA: a possible resolution. *Neuromuscul Disord*. 1995;5(1):3-5.

Dubowitz V. Very severe spinal muscular atrophy (SMA type 0): an expanding clinical phenotype. *Eur J Paediatr Neurol*. 1999;3(2):49-51.

Feldkötter MV, Schwarzer V, Wirth R, Wienker TF, Wirth B. Quantitative analyses of SMN1 and SMN2 based on real-time lightCycler PCR: fast and highly reliable carrier testing and prediction of severity of spinal muscular atrophy. *Am J Hum Genet*. 2002;70(2):358-368.

Finkel RS, Mercuri E, Meyer OH, et al. Diagnosis and management of spinal muscular atrophy: part 2: pulmonary and acute care; medications, supplements and immunizations; other organ systems; and ethics. *Neuromuscul Disord*. 2018;28(3):197-207.

Foust KD, Wang X, McGovern VL, et al. Rescue of the spinal muscular atrophy phenotype in a mouse model by early postnatal delivery of SMN. *Nat Biotechnol*. 2010;28(3):271-274.

Gan JJ, Garcia V, Tian J, et al. Acid ceramidase deficiency associated with spinal muscular atrophy with progressive myoclonic epilepsy. *Neuromuscul Disord*. 2015;25(12):959-963.

Hoffmann J. Ueber chronische spinale Muskelatrophie im Kindesalter, auf familiärer Basis. *Deutsch Z Nervenheilk*. 1893;3:427-470.

Hua Y, Sahashi K, Hung G, et al. Antisense correction of SMN2 splicing in the CNS rescues necrosis in a type III SMA mouse model. *Genes Dev*. 2010; 24(15):1634-1644.

Kariya S, Park GH, Maeno-Hikichi Y, et al. Reduced SMN protein impairs maturation of the neuromuscular junctions in mouse models of spinal muscular atrophy. *Hum Mol Genet*. 2008;17(16):2552-2569.

Kinali M, Mercuri E, Main M, et al. Pilot trial of albuterol in spinal muscular atrophy. *Neurology*. 2002;59(4):609-610.

Mercuri E, Finkel RS, Muntoni F, et al. Diagnosis and management of spinal muscular atrophy: part 1: recommendations for diagnosis, rehabilitation, orthopedic and nutritional care. *Neuromuscul Disord*. 2018;28(2):103-115.

Monani UR, De Vivo DC. Neurodegeneration in spinal muscular atrophy: from disease phenotype and animal models to therapeutic strategies and beyond. *Future Neurol*. 2014;9(1):49-65.

Monani UR, Lorson CL, Parsons DW, et al. A single nucleotide difference that alters splicing patterns distinguishes the SMA gene SMN1 from the copy gene SMN2. *Hum Mol Genet*. 1999;8(7):1177-1183.

Oskoui M, Levy G, Garland CJ, et al. The changing natural history of spinal muscular atrophy type 1. *Neurology*. 2007;69(20):1931-1936.

Pane M, Staccioli S, Messina S, et al. Daily salbutamol in young patients with SMA type II. *Neuromuscul Disord*. 2008;18(7):536-540.

Prior TW, Snyder PJ, Rink BD, et al. Newborn and carrier screening for spinal muscular atrophy. *Am J Med Genet A*. 2010;152A(7):1608-1616.

Rudnik-Schöneborn S, Berg C, Zerres K, et al. Genotype-phenotype studies in infantile spinal muscular atrophy (SMA) type I in Germany: implications for clinical trials and genetic counselling. *Clin Genet*. 2009;76(2): 168-178.

Singh P, Liew KM, Darras BT. Current advances in drug development in spinal muscular atrophy. *Curr Opin Pediatr*. 2013;25(6):682-688.

Sugarman EA, Nagan N, Zhu H, et al. Pan-ethnic carrier screening and prenatal diagnosis for spinal muscular atrophy: clinical laboratory analysis of >72,400 specimens. *Eur J Hum Genet*. 2012;20(1):27-32.

Swoboda KJ, Prior TW, Scott CB, et al. Natural history of denervation in SMA: relation to age, SMN2 copy number, and function. *Ann Neurol*. 2005;57(5): 704-712.

Wang CH, Finkel RS, Bertini ES, et al. Consensus statement for standard of care in spinal muscular atrophy. *J Child Neurol*. 2007;22(8):1027-1049.

Werdnig G. Zwei fruihnfantile hereditare Falle von progressive Muskelatrophie unter dem Bilde der Dystrophie, aber auf neurotischer Grundlage. *Arch Psychiat Neurol*. 1891;22:437-481.

Zerres K, Rudnik-Schöneborn S, Forrest E, Lusakowska A, Borkowska J, Hausmanowa-Petrusewicz I. A collaborative study on the natural history of childhood and juvenile onset proximal spinal muscular atrophy (type II and III SMA): 569 patients. *J Neurol Sci*. 1997;146(1):67-72.

147 Muscular Dystrophies and Congenital Myopathies

James J. Dowling, Hernan D. Gonorazky, Dimah N. Saade, Michael W. Lawlor, and Darryl C. De Vivo

KEY POINTS

1. Muscular dystrophies and congenital myopathies are clinically defined by functional impairment of the skeletal muscle.
2. Key features include static weakness or dynamic changes including myalgias, cramping, myotonia, or rhabdomyolysis.
3. An elevated creatine kinase is found in most cases of muscular dystrophy.
4. Genetics provide a refined diagnosis beyond clinical features and muscle biopsy.
5. Clinical, histopathologic, and genetic features define the major subcategories of muscular dystrophies and congenital myopathies.
6. The age of onset of muscular dystrophies can vary widely and may also depend on genetic factors.
7. Treatment strategies are specific to each disorder, including supportive care in progressive disease.

INTRODUCTION

Muscular dystrophies and congenital myopathies encompass a spectrum of primary muscle disorders caused by mutations in genes that encode aspects of muscle structure and/or function. Onset is most typically in childhood, although there is tremendous variability (usually dictated by genetic subtype), and patients with genetic muscle disease may present at essentially any age. The definition of these conditions is evolving in the era of genomics. Whereas muscle biopsy findings were historically the driving factor for diagnosis, currently, genetics have primacy in most cases. In other words, most muscular dystrophies and congenital myopathies are defined by their underlying genetic cause.

DEFINITIONS

An operational definition of muscular dystrophy may include the following:

- Functional impairment of the skeletal muscle (either "static" resulting in weakness and the sequelae of that weakness or "dynamic" resulting in episodic symptoms such as myalgias, cramping, myotonia, or rhabdomyolysis)
- Dystrophic pattern on muscle biopsy (recent and older myofiber degeneration and regeneration, inflammation, and fibrofatty replacement) (Fig. 147.1)
- Elevated creatine kinase (CK) (typically > 800 U/L)
- Demonstration of pathogenic mutation(s) in a gene associated with muscular dystrophy

An operational definition of congenital/structural myopathy may include the following:

- Functional impairment of the skeletal muscle (typically non- or slowly progressive; static and/or dynamic as above)
- Suggestive findings on muscle biopsy, particularly including pathognomonic changes seen with subtypes such as nemaline myopathy (NM) (nemaline rods), core myopathy (either central cores or multiminicores), centronuclear myopathy (CNM) (central nuclei surrounded by haloes of oxidase positive organelles), and fiber-type disproportion (selective type I fiber hypotrophy, usually with type I fiber predominance) (Fig. 147.2)
- Normal to mildly elevated CK
- Demonstration of pathogenic mutation(s) in a gene association with myopathy

Muscular Dystrophy Classification

The classification of muscular dystrophies is based on clinical and genetic characteristics and fall into five broad categories: congenital muscular dystrophies (CMD), dystrophinopathies, limb-girdle muscular dystrophies (LGMD), scapuloperoneal myopathies (including Emery-Dreifuss muscular dystrophy [EDMD]), and other unique conditions (facioscapulohumeral muscular dystrophy or FSHD, myotonic dystrophy, and oculopharyngeal muscular dystrophy or OPMD) (Table 147.1).

Congenital Myopathy Classification

The classification of congenital myopathies has historically been dictated by muscle biopsy features. However, evolution in the field has mirrored the advances in genetics and genomics, and classification now represents a hybrid of clinical, biopsy, and genetic features. Congenital myopathies can be subdivided into the following categories based on their pathologic features: NM, core myopathy, CNM, and congenital fiber-type disproportion. In some cases, it is preferable to use terminology more reflective of the genetic changes to encompass a common genetic cause occurring across a range of morphologic patterns (as is seen in *RYR1*-related myopathies). Additional myopathies fitting more under a broader umbrella of "structural" myopathies include distal myopathies and myofibrillar myopathies.

Laboratory Diagnosis

Genetic testing via DNA extracted from blood is now the gold standard of laboratory diagnostics for muscular dystrophies and

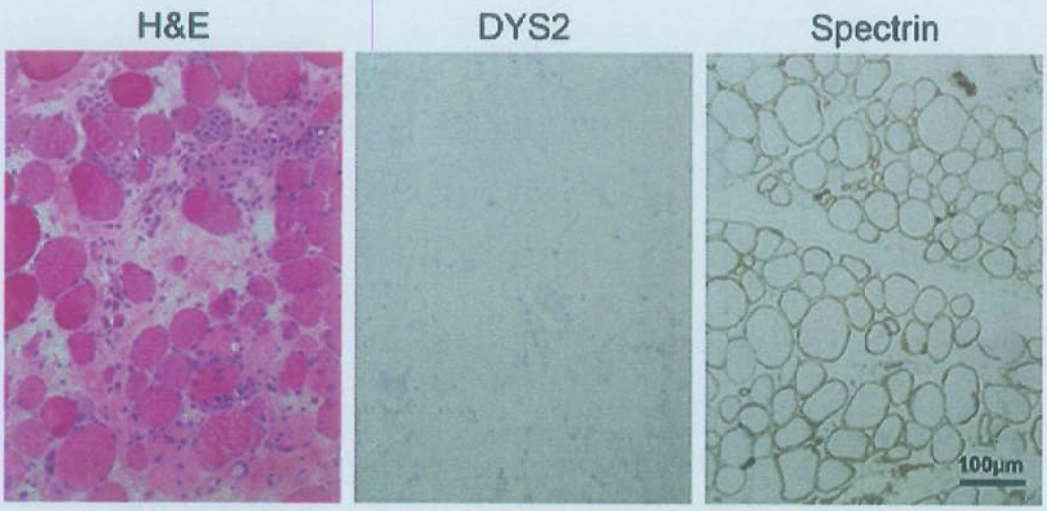

FIGURE 147.1 Typical muscle biopsy findings in a muscular dystrophy. Hematoxylin and eosin staining displays evidence of recent myofiber degeneration and regeneration, including myonecrosis, myophagocytosis, inflammation, and basophilic fibers (indicative of recent regeneration), in addition to evidence of older myofiber degeneration and regeneration including internally nucleated fibers, endomysial fibrosis, and fatty infiltration (not shown in this image). Immunostaining for dystrophin (DYS2 antibody shown here) shows a complete loss of dystrophin in most or all fibers, possibly with a very small number of fibers that retain dystrophin expression. Expression of proteins that are not associated with the dystrophin glycoprotein complex (such as spectrin) will be retained at the sarcolemma, confirming that the tissue was sufficient in quality for the detection of dystrophin if it was present. Bar = 200 µm.

congenital myopathies, and a positive genetic test is considered the definitive diagnostic study. There are multiple technical approaches for genetic testing that include single gene tests (such as deletion/duplication analysis followed by Sanger sequencing for the *DMD* gene and Southern blot for the repeat expansion of *DMPK* 3′UTR in myotonic dystrophy type 1 [DM1]), multigene panels (encompassing sets of genes such as all LGMD genes or all congenital myopathy genes, performed on a "next-generation sequencing" platform), and whole exome sequencing. These approaches are all available on a commercial basis, with multiple providers offering various platforms. Of note, whole genome sequencing is not currently available on a clinical basis but is likely to be a front-line genetic testing strategy in the near future.

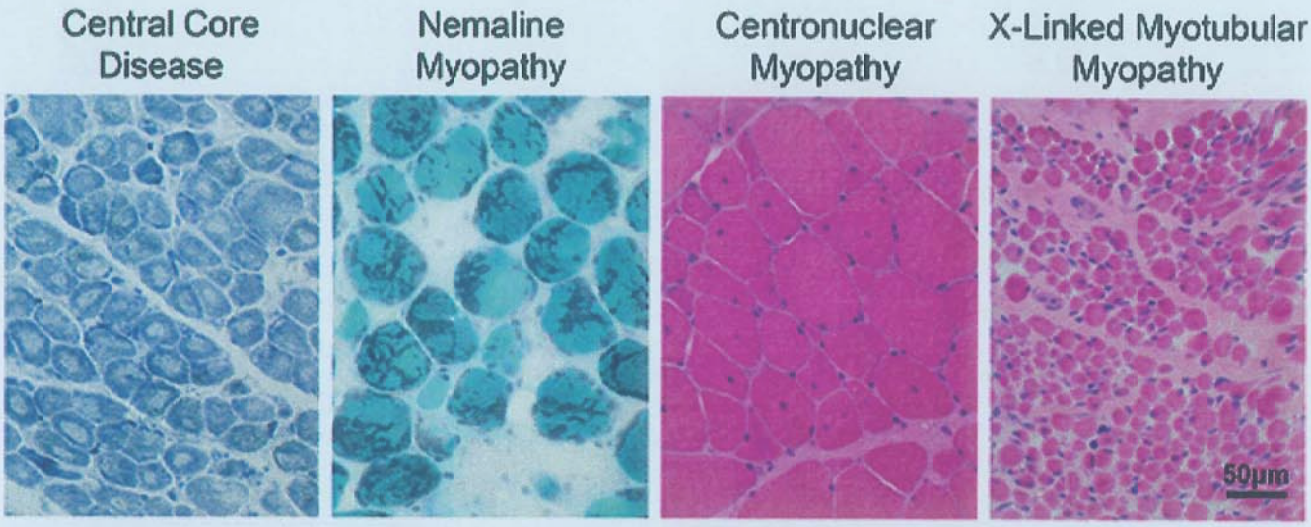

FIGURE 147.2 Muscle biopsy pathology in congenital myopathies. Representative images of muscle biopsies characteristic for central core disease (nicotinamide adenine dinucleotide stain shown), nemaline myopathy (Gomori trichrome stain shown), centronuclear myopathy (hematoxylin and eosin stain shown), and X-linked myotubular myopathy (hematoxylin and eosin stain shown). Central core disease, nemaline myopathy, and centronuclear myopathy are diagnosed by the presence of abnormal structures or distributions of organelles in the sarcoplasm. The differentiation of X-linked myotubular myopathy and centronuclear myopathies due to other genetic causes can often be made on the basis of very small fiber size and characteristically abnormal organelle distributions in X-linked myotubular myopathy. However, biopsies from the most severely affected patients with centronuclear myopathies related to other genes can display a similar appearance. Bar = 200 µm.

TABLE 147.1 Features of the Most Common Muscular Dystrophies

Disorder	Duchenne (DMD)	Facioscapulohumeral (FSHD)	Myotonic Dystrophy (DM1)	Emery Dreifuss	LGMD
MIM number	310200	158900	16090	EDMD1 310300; EDM2 181350; EDMD3 616516; EDMD4 612998; EDMD5 612999; EDMD6 300696; EDMD7 614302	Refer to Table 147.2
Incidence estimates	1 in 3,500 live male births	1 in 20,000 births	1 in 8,000 births	Variable depending on the genotype	Variable depending on the genotype
Mode of inheritance	X-linked recessive	Autosomal dominant	Autosomal dominant	EDMD1, EDMD6 X-linked; EDMD2, EDMD4, EDMD5, EDMD7 autosomal dominant, EDMD3 autosomal recessive	Please refer to Table 147.2
Gene defect	Deletion and duplication in 70% of the cases in dystrophin gene	FSHD1: reduced number of tandem repeats in D4Z4: 1-8 repeats (normal 10 to >100 repeats)	DM1: CTG expansion in protein kinase gene; 50 to >2,000 repeats (normal 5-37 repeats)	EDMD1 EMD; EDMD2 and EDMD3 *LMNA*; EDMD4 *SYNE1*; EDMD5 *SYNE2*; EDMD6 *FHL1*; EDMD7 *TMEM43*	Refer to Table 147.2
		FSHD2: mutations in chromatin modifier *SMCHD1* causing chromatin relaxation at D4Z4			
Expressivity	Complete	Variable	Variable	Variable	Variable
Age of onset	Childhood	Adolescence, rarely childhood	Broad range (infancy to adult life)	Variable, from neonatal to third decade	From toddler to adulthood
Weakness distribution					
Calf hypertrophy	Common	Never	Never	Never	Some, depending on the genotype
Rate of progression	Relatively rapid	Slow	Variable	Variable depending on the genotype	Variable depending on the genotype
Facial weakness	Rare and mild	Common	Common	None	None
Contractures	Common	Rare	Rare	Common	Common
Cardiac disease	typical onset in adolescence (cardiomyopathy)	None	Common (conduction defect AV block)	Common in EDMD1, EDMD2, EDMD3 (conduction defect, ventricular fibrillation)	Some, depending on the genotype
Other clinical features	Respiratory insufficiency, scoliosis, variable cognitive and neurobehavioral impairment	High-frequency hearing loss and retinal vasculopathy (rare)	Cataracts, endocrine dysfunction	Lipodistrophy in *LMNA*, scoliosis, rigid spine syndrome	Variable depending on the genotype

Abbreviations: DM1, myotonic dystrophy type 1; DMD, Duchenne muscular dystrophy; EDMD, Emery-Dreifuss muscular dystrophy; FSHD, facioscapulohumeral muscular dystrophy; LGMD, limb-girdle muscular dystrophy.

The specific genetic test to use for a patient is dictated by the clinical history, physical exam, and any available ancillary test results (such as creatine phosphokinase [CPK] levels, muscle biopsy findings, electromyography [EMG]/nerve conduction velocity results, and muscle and/or brain imaging). For example, first-line testing for a 3-year-old boy with frequent falls, a positive Gowers' sign, and large calves with a CPK >800 U/L would be focused exclusively on analysis of the *DMD* gene. Genetic evaluation for a 2-month-old female with neonatal hypotonia, diffuse weakness that includes prominent facial weakness, and respiratory difficulties and with a normal CPK would start with DM1 genetic testing and then (either concurrently or after a negative DM1 result) would utilize either a multigene panel that includes congenital muscle disease genes (congenital myopathies and congenital myasthenic syndromes) or whole exome sequencing. More details about genetic testing strategies are included in the individual disease subsections.

The use and application of nongenetic diagnostic tests is changing with the widespread availability of comprehensive genetic testing, and currently published diagnostic practice parameters in many cases require updating to reflect this evolving landscape. CPK levels are typically obtained on most/all patients with suspected muscle disease because they are inexpensive, minimally invasive to collect, and can provide important discrimination of subcategories of genetic muscle disease. EMG is no longer considered a first-line test, with the rare exception of the suspicion of a myotonic condition (noting that myotonia is not observed in myotonic dystrophy until after approximately age 6 y). EMG/nerve conduction velocity can be helpful when congenital myasthenic syndrome is in the differential diagnosis, although congenital myasthenic syndrome genes are well represented on relevant multigene panels.

If/when to perform a muscle biopsy is context dependent, and increasingly, muscle biopsy has become a second-line diagnostic test. This is because of the invasive nature of biopsy versus blood testing and the fact that genetic testing may provide a definitive diagnosis in the absence of a biopsy. Biopsy remains an excellent methodology for classification of patients with muscle disease, providing discrimination of dystrophy versus myopathy and enabling precise subtyping in many cases. For example, in individuals with CMD, muscle biopsy can delineate whether the cause is merosin deficiency, collagen 6 mutation, or dystroglycanopathy. Moving forward, biopsy will be most likely positioned as a test used to add validation to ambiguous genetic testing results (such as clarifying whether a novel variant of unknown significance in a gene is, in fact, pathogenic) and to aid in diagnostics when genetic testing does not establish a diagnosis. Muscle biopsy is also an ideal source material for advanced "omics" strategies such as RNA sequencing, which has been recently shown to be useful for identifying gene mutations in panel and/or exome negative cases.

Muscle ultrasound and magnetic resonance imaging (MRI) of skeletal muscle are increasingly used in the diagnostic evaluation. Muscle imaging can show the selective pattern of muscle involvement associated with some muscular dystrophies and congenital myopathies. For example, there is selective involvement of sartorius and adductor longus in selenoprotein N1 (*SEPN1*) myopathy with sparing of the gracilis. MRI offers good delineation between fatty infiltration and skeletal muscle and may guide the choice of the muscle to biopsy. It is somewhat limited by cost and by the fact that children younger than 5 years typically need sedation in order to tolerate the test. Muscle ultrasound is painless, is less expensive compared to MRI, and offers dynamic images. However, it requires a user familiar with muscle analysis. Overall, as with biopsy, muscle imaging is largely positioned as a second-line diagnostic modality useful for helping clarify uncertain genetic testing results and for providing ancillary data when genetic testing is not informative.

CONGENITAL MUSCULAR DYSTROPHIES

Definitions

CMD are generally defined by the following criteria: onset before 18 months of age, elevated CPK, and dystrophic features on muscle biopsy. In the genomics era, confirmatory gene mutation(s) in the setting of symptom onset in the preambulant aged child is sufficient for diagnosis. There are three major subtypes of CMD—merosin-deficient CMD (MDC1A, also called *LAMA2*-related CMD), COL6-related dystrophies (COL6-RDs), and dystroglycanopathy. They each account for approximately 30% of CMD cases, although there is variation between different regions and ethnic groups. The remaining 10% of CMD includes diagnoses such as rigid spine muscular dystrophy (which is discussed in the context of *SEPN1*-related congenital myopathies), Marinesco-Sjögren syndrome (an ultrarare condition featuring cataracts, brain abnormalities, and a mild muscle disease), and *LMNA*-related CMD (discussed in the context of EDMD) and *CHKB*-related CMD.

Epidemiology

The global incidence and prevalence of CMDs has not been rigorously established. A population study in Italy defined the prevalence as 0.563 per 100,000, whereas a population study in New Zealand established it as 0.64 per 100,000.

Diagnosis

CPK levels are typically elevated and can be as high as 10 times normal. Some individuals will have normal CPK, however, and a normal CPK cannot be used to exclude a CMD. Muscle biopsy usually shows classic features of a muscular dystrophy (degenerating/regenerating fibers, inflammation, fibrous, and fatty tissue replacement). Immunostaining of biopsies can be quite informative, as there are good antibodies to merosin/LAMA2, glycosylated dystroglycan, and to collagen 6. Diagnostic confirmation relies on identification of a causative gene mutation. Biallelic mutations in *LAMA2* are the only known cause of MDC1A. Mutations, either recessive or dominant, in 1 of the 3 COL6 genes (*COL6A1*, *COL6A2*, *COL6A3*) cause Ullrich congenital muscular dystrophy (UCMD). Dystroglycanopathies are caused by biallelic/recessive mutations in 1 of >20 genes. CMD genes are all included on commercially available multigene panels, and panel testing or whole exome sequencing is now typically pursued in infants with a consistent clinical picture prior to muscle biopsy. Important conditions to consider in the differential diagnosis of CMDs include congenital myopathies, congenital myasthenic syndromes, and spinal muscular atrophy.

Merosin-Deficient Congenital Muscular Dystrophy

MDC1A typically presents at or around the time of birth with hypotonia and diffuse extremity weakness. Infants with MDC1A also commonly have joint contractures, respiratory failure, and feeding difficulties. The disease is relatively nonprogressive throughout childhood, although there is a failure to meet most motor milestones, and individuals typically do not achieve the ability to stand or walk. Important comorbidities include scoliosis, which is usually severe, requiring of surgical correction and is often therapeutically recalcitrant, and respiratory difficulties, which often are progressive in the teen years and adulthood requiring noninvasive ventilation.

Historically, the diagnosis of MDC1A was made based on muscle biopsy, where the observation of absent merosin staining by immunohistochemistry establishes a diagnosis. Many patients are now diagnosed first by genetic testing, where biallelic *LAMA2* mutations provide a diagnosis in the appropriate clinical context. Care should be taken with interpretation of "negative" gene testing, as up to 30% of patients will not have an *LAMA2* coding sequence mutation of one or both alleles. Most likely, these represent cases with intronic *LAMA2* mutations or structural rearrangements of the *LAMA2*, as at present, *LAMA2* remains the only known cause of MDC1A. Of note, CPK levels in MDC1A patients are typically elevated, often 5 to 50 times of normal.

In addition, to muscle disease, individuals with MDC1A have abnormal brain MRI scans. The most typical pattern is diffuse white matter change seen on T2/fluid-attenuated inversion recovery that is similar in appearance to other leukoencephalopathies. The clinical consequences of these changes have been hard to precisely define, as most MDC1A patients do not have delays in cognitive development and have normal intelligence. There is an increased risk of epilepsy (up to 30%) and also infrequently observed malformations of cortical development. MDC1A patients also manifest demyelinating peripheral neuropathy. As with the brain MRI changes, the clinical symptoms associated with neuropathy in this patient subgroup are not well established.

LAMA2 encodes laminin-alpha2 (also known as merosin and laminin-211), a protein that forms part of heterotrimeric laminin-2/merosin protein in the extracellular matrix. Loss of LAMA2 results in failure to produce laminin-211, which in turn impairs the binding of myofibers (via integrin and dystroglycan receptors) to the basement membrane. This lost adhesion causes muscle membrane fragility and alters signaling pathways within the muscle cell. The sequelae of impaired signaling includes increased myofiber cell death; based on this concept, therapies aimed at blocking apoptosis have been successfully tested in preclinical models of MDC1A. One compound, a GAPDH inhibitor called Omigapil (NCT01805024), has been evaluated in a phase 1 clinical trial for MDC1A and UCMD (see below). Other therapeutic strategies include ones aiming at restoring adhesion to the basement membrane (e.g. synthetic laminin or mini agrin) and gene editing based therapies using CRISPR/Cas9.

COL6-Related Dystrophies

COL6-RDs are a clinically distinctive subtype of CMD. UCMD is the severe form of CL6-RD; it features the unusual combination of muscle weakness, joint hyperlaxity, and joint contractures. UCMD exists in a continuum with the allelic condition Bethlem myopathy, a later onset myopathy also characterized by joint laxity and contractures (Fig. 147.3). There are also some patients with features intermediate between UCMD and Bethlem myopathy. Other clinical features include keratosis pilaris, hyperextensible skin, and keloid scar formation. The disease is associated with progression including worsening joint contractures, the early development of scoliosis, and progressive respiratory decline (which often precedes loss of ambulation in Bethlem myopathy). Many UCMD patients fail to develop independent ambulation, whereas others lose motor skills over time.

FIGURE 147.3 Bethlem sign in COL6-related dystrophies. Depiction of the Bethlem sign or "prayer sign" in a patient with Bethlem myopathy. Long finger flexor contractures prevent full extension of the fingers when the palms are placed together with dorsiflexed wrists.

Diagnosis is usually suspected based on clinical phenotype. CPK levels can be normal or mild/moderately elevated. Mutations in one of three collagen 6 genes (*COL6A1*, *COL6A2*, and *COL6A3*) are the underlying cause of UCMD/Bethlem myopathy. Mutations can be dominant or recessive. Dominant mutations can be associated with mild or severe symptoms depending on how severely they disrupt the processing of the resulting collagen 6 protein. Recessive mutations, particularly ones that result in loss of expression of collagen 6, are most often seen in patients with a UCMD phenotype.

Collagen 6 is a heteropolymer formed from the three COL6 subunits (COL6A1/COL6A2/COL6A3). It is synthesized in fibro/adipogenic progenitors where it goes the first stages of oligomerization. Subsequent stages occur in the extracellular matrix, where the mature collagen 6 resides. Collagen 6 potentially interacts with several receptors on the muscle membrane. Loss of collagen 6 in the matrix impacts second messenger pathways within the muscle cell. As with MDC1A, increased apoptosis is proposed as one important pathomechanism, and drugs (such as omigapil) that block programmed cell death are under consideration as potential therapeutics. Due to the nature of the mutations that cause UCMD (particularly splice site and deep intronic alleles), UCMD is an excellent candidate disease for antisense oligonucleotide therapy (to alter/modify gene splicing), as supported by preclinical data including from patient cell lines.

Dystroglycanopathies

The dystroglycanopathies are a clinically and genetically heterogeneous subtype of CMD. The classic clinical phenotype is the Walker-Warburg syndrome, which features a constellation of features including ocular defects, cobblestone lissencephaly, intractable epilepsy, profound global developmental delay, and muscular dystrophy. It is one of the most severe neurogenetic disorders of infancy and often is associated with death in the first 18 months of life. However, dystroglycanopathies exist on a continuum, from Walker-Warburg syndrome to isolated LGMD without CNS involvement. Phenotypes along this spectrum include muscle-eye-brain disease, CMD with cognitive impairment, CMD without brain involvement, and LGMD. The clinical

picture is often dictated by the extent of central nervous system impairment and the severity of seizures.

There are >20 genes associated with dystroglycanopathy (DGopathy). The unifying element among these genes is that their gene products impact, in some way, the processing and glycosylation of dystroglycan. Dystroglycan is a transmembrane receptor that links the basement membrane (via binding to merosin) to the actin cytoskeleton (via association with dystrophin). Rare mutations in dystroglycan itself have been reported. The classic DGopathy genes are ones that encode Golgi apparatus glycosylation enzymes responsible for adding the unique O-mannose sugar modification to dystroglycan. Other DGopathy genes impact dystroglycan processing less directly, although result in similar phenotypes (ie, affecting brain structure and muscle integrity). The most commonly encountered DGopathy genes include *POMT1*, *POMT2*, *FKRP*, *FKTN*, and ISPD. A range of phenotypes can be seen with mutations in each of these, although there are some rough genotype-phenotype correlations. For example, *POMT1* and *POMT2* mutations more commonly cause Walker-Warburg syndrome, whereas fukutin-related protein (*FKRP*) mutations are most commonly associated with LGMD. Mutations in some of the genes are associated with unique clinical entities. For example, *GPPMB* mutations cause CMD with overlapping symptoms of congenital myasthenic syndrome.

While muscle biopsies are obtained in CMD patients at an ever-decreasing frequency, they often provide a critical clue for an underlying DGopathy. Specifically, they manifest abnormal immunostaining with an antibody specific for the glycosylated form of dystroglycan. This aberrant staining is not exclusive to DGopathies, but it enables successful subcategorization (particularly in the setting of CNS involvement) in many cases and has been used to subclassify patients as having DGopathy. With the classical DGopathy cases, CPK levels are usually highly elevated. In some of the more newly described genetic subtypes, CPK levels have been normal or only modestly elevated.

At present, therapy for DGopathies has been exclusively supportive in nature. DGopathies are excellent target diseases for gene replacement therapy as they (1) are typically caused by recessive loss of expression mutations and (2) are caused by small genes that can fit into most gene therapy vectors. Another strategy is to try and rescue the glycosylation defect on dystroglycan, and small molecular modulators have been identified in preclinical models. One open and important question is whether (and to what extent) individuals with severe presentations (such as Walker-Warburg syndrome) will respond to any disease-specific modulatory therapies.

Management

At present, care for all CMD subtypes is supportive in nature. There are no specific disease-modifying therapies or cures. Management is focused in several domains, including respiratory care, physio- and occupational therapy, and orthopedic management of contractures and scoliosis. Seizure management is important particularly in some subtypes of dystroglycanopathy and in some cases of MDC1A. Episodes of hypoglycemia, likely due to reduced muscle mass (and thus smaller gluconeogenic stores), have been reported, primarily in MDC1A patients, and require a high index of suspicion for their detection and treatment. A standard of care document, based primarily on best care practices, was released in 2010. Subsequently, subtype specific natural history studies have been completed, and these have enabled more precise clinical care.

DYSTROPHINOPATHIES

Definitions

Duchenne muscular dystrophy (DMD) and Becker muscular dystrophy (BMD) (MIM 310200, also referred to as *dystrophinopathies*) are allelic disorders caused by mutations in the dystrophin gene located at Xp21. Out-of-frame deletion or duplication mutations result in the absence of dystrophin protein leading to a severe clinical phenotype (Duchenne), whereas in-frame deletion or duplication mutations in which some dystrophin protein remains result in a milder clinical phenotype (Becker) (see **Table 147.1**). Point mutations can cause either DMD or BMD; nonsense mutations are most typically seen in DMD. There can be overlap in the clinical phenotype, and such cases are often classified as having an "intermediate" phenotype. DMD/BMD is considered X-linked recessive conditions, with males manifesting symptoms and females presenting as asymptomatic carriers. Female carriers can display symptoms and rarely have a severe childhood onset disease.

Epidemiology

The incidence of DMD is about 1 in 5,000 male births, with no clear geographic or ethnic variation. Approximately one-third of cases are caused by de novo mutations; the others are more clearly familial. A small percentage of cases are caused by gonadal mosaicism. Because the life span of patients with DMD is shortened, the prevalence is less—about 1 in 18,000 males. BMD is much less common, with an incidence estimated at 1:18,000 to 1:30,000 live male births, although the overall lifetime prevalence is 1:16,000 to 1:18,000 and is similar to DMD (due to the fact that BMD patient live significantly longer).

Duchenne and Becker Muscular Dystrophies

Duchenne Muscular Dystrophy

The condition may be presymptomatically detected in infancy if serum enzymes (such as alanine aminotransferase, aspartate transaminase, or CPK) are coincidentally measured. A positive family history may also alert an astute physician to the early recognition of motor delay. Symptom onset is classically described as occurring between ages 2 and 4 years, although this may reflect the challenge of evaluating weakness in young children. It is true, however, that symptoms are not present at birth. That said, young children with DMD score lower on scales that evaluate gross motor function. Walking is often delayed, and running is usually never normal; toe walking and waddling gait may also be evident. The condition is progressive, with worsening difficulties in walking, climbing stairs, and rising from chairs. An exaggerated lordosis is assumed to maintain balance. Patients tend to fall easily if jostled and have difficulty rising from the ground. In doing so, they use a characteristic maneuver called the *Gowers sign* (see **Fig. 147.2**). They roll over to kneel, push down on the ground with extended forearms to raise the rump and straighten the legs, then move the hands to the knees, and push up to a standing position. The Gowers sign is also seen in other conditions that include proximal limb and trunk weakness, such as most LGMD and spinal muscular atrophy (**Fig. 147.4**). Tendon reflexes (particularly in the lower extremities) may be diminished or absent, and calf hypertrophy is typically present.

As the disease progresses, the upper extremity becomes affected. Slight facial weakness may be seen, but speech, swallowing, and ocular movements are typically spared. Iliotibial contractures limit hip extension; heel cord contractures are partly responsible for toe walking. Loss of ambulation occurs between ages 9 and 12 years or later (12-14 y) when treated with glucocorticoids, after which patients become wheelchair dependent. Scoliosis may then become serious and may compromise limb and respiratory function. Elbow and knee contractures contribute to disability. Respiratory muscle weakness causes progressive decline in lung capacity beginning at about age 8 years. Nocturnal hypoventilation may occur and cause morning headaches and daytime fatigue if untreated. By about age 20 years, respiration is often compromised to the point that respiratory support is needed. Life expectancy in DMD has improved greatly in the last three decades, related to better coordinated medical and respiratory care combined with glucocorticoid therapy.

The heart is usually spared clinically until late in the disease when congestive heart failure and arrhythmias may develop. The electrocardiogram (ECG) is abnormal in most patients, with increased QRS amplitude in lead V_1 and deep, narrow Q waves in left precordial leads. Echocardiography shows progressively diminished contractility. Signs of cardiomyopathy may not be apparent because of the inability to exercise but may supervene in some cases. Early subclinical cardiac involvement is becoming increasingly recognized, as modalities such as cardiac MRI (which can detect more subtle changes than echocardiography) are more frequently employed in DMD patient care.

Constipation is common, but more severe gastrointestinal symptoms, such as intestinal hypomotility and acute gastric dilatation, are rare. Osteoporosis begins in the ambulatory years, is more severe in the legs, and may contribute to fractures. Intellectual impairment with predominantly verbal difficulties is seen in one-third of boys with DMD, and the average IQ is shifted approximately 1 standard deviation below normal. There is also an increased prevalence of neurobehavioral challenges in DMD boys, including attention deficit hyperactivity disorder and autism.

Anesthetic catastrophes may occur with hyperkalemia, extremely high CK levels (even more than 20 times the normal maximum), acidosis, cardiac failure, hyperthermia, and rigidity. The risk can be decreased by avoiding depolarizing muscle relaxants, particularly succinylcholine, and using care with volatile anesthetics. This vulnerability is distinct from malignant hyperthermia (MH).

Becker Muscular Dystrophy

This condition is defined by milder skeletal muscle weakness compared to DMD. Calf hypertrophy is present, weakness is greatest proximally, and serum CPK levels are high. EMG is myopathic and muscle biopsy reveals some staining of dystrophin. The two clinical features that distinguish it from DMD are differences in age at onset (typically after age 10 y) and rate of progression (still walking after age 16 y, often later). A differential exam feature compared with DMD is the absence of weakness of the neck flexors. Cognitive impairment is less common than in DMD. Cardiomyopathy usually develops later and may overshadow limb weakness. Cardiac complications contribute to 50% of BMD deaths compared with 20% with DMD, and some patients have severe cardiomyopathy with only mild muscle weakness. Another allelic disorder, X-linked dilated cardiomyopathy, demonstrates little to no skeletal muscle weakness. Some individuals with dystrophinopathy may only present dynamic symptoms, and DMD mutations are a leading cause of exertional rhabdomyolysis. In some instances, the only manifestation is elevated CPK levels (ie, hyperCKemia).

FIGURE 147.4 Gowers sign. Two panels showing a positive Gowers sign. In these pictures, the affected individual utilizes her hands to "walk up" her thighs from a squatting position to rise from the floor to standing. While a positive Gowers sign is most commonly associated with Duchenne muscular dystrophy, it may be present in any patient who has lower extremity proximal muscle weakness.

Intermediate Phenotype

Some patients show an intermediate phenotype that can be considered either severe BMD or mild DMD. Onset is shifted as compared to DMD, and such individuals remain ambulatory after age 12 years but use wheelchairs before age 16 years. They have preserved antigravity strength in the neck flexors longer than typical DMD patients.

Manifesting Carriers

DMD is an X-linked recessive condition. Female mutation carriers are usually asymptomatic, but "manifesting carriers" can have limb weakness, calf hypertrophy, cardiomyopathy, or high serum CPK levels. Cardiac screening is recommended in all carrier females.

Diagnosis

The diagnosis of Duchenne dystrophy is suggested in boys by typical clinical features (waddling gait, positive Gowers sign, calf/shoulder hypertrophy) in the setting of high CPK. Despite the recognizable features of DMD, there remains a diagnostic gap of approximately 2 years from average symptom onset to average age of diagnosis. Several international efforts have focused on increasing awareness in primary physicians of the presenting symptoms of DMD. Newborn screening (using serum CPK) is also feasible and may soon be available.

High CPK values are sometimes encountered in screening blood chemistry analysis done for other purposes; regardless of the clinical findings, and underlying dystrophinopathy should be considered. Similarly, screening liver function studies (alanine aminotransferase/aspartate transaminase), which are elevated in DMD, may be performed routinely when a child has an infection. If unexplained increased serum liver enzyme values are detected, serum CPK should then be assayed, and if elevated, a muscular dystrophy (of which DMD is most common) should be suspected, not a liver disease. Appropriate genetic testing should then be pursued (see as below and in subsequent sections). Of note, in DMD, serum CPK levels are highest in the presymptomatic years and then gradually decrease with age.

Increased CPK levels are also seen in girls and women who carry dystrophin mutations, in most/all forms of muscular dystrophy, in inflammatory myopathies such as dermatomyositis and anti-HMGCR necrotizing myopathy, in some patients with spinal muscular atrophy, and, for unknown reasons, in some otherwise asymptomatic individuals (idiopathic or asymptomatic hyperCKemia). Even before myopathic symptoms begin, high CPK values are seen in many muscular dystrophies, including DMD, the dysferlinopathies (LGMD2B or Miyoshi myopathy), and caveolin-3 mutations (LGMD1C). Clinical monitoring, combined with understanding of genotype-phenotype correlations, is required to determine the future impact and prognosis in cases of elevated CPK without overt clinical involvement.

Molecular Genetics

The dystrophin (*DMD*) gene is mutated in both Duchenne and Becker dystrophies, which are allelic diseases. Dystrophin encodes a cytoskeletal protein located at the plasma membrane. Brain and other organs contain slightly different isoforms. In muscle, dystrophin is associated with membrane glycoproteins that link the cytoskeleton with membrane proteins and then to laminin and the extracellular matrix (see Fig. 147.1). The protein plays an essential role in maintaining muscle fiber integrity. If dystrophin is absent, as in Duchenne dystrophy, or is abnormal, as in Becker dystrophy, the sarcolemma becomes unstable in contraction and relaxation, and the damage results in excessive calcium influx, thereby leading to muscle cell necrosis. If specific glycoproteins that associate with dystrophin are abnormal or missing, the same problems arise, as in some LGMDs (described later in the chapter).

Genetic testing, in the form of deletion/duplication analysis and direct DNA sequencing, is the primary method of establishing the diagnosis of DMD/BMD. Single or multiexon deletions or duplications account for about 65% of DMD and 85% of BMD patients. Patients with DMD typically have "frameshift" deletions/duplications that alter the DNA reading frame and consequently change amino acids downstream of the mutation, whereas individuals with BMD have milder "in-frame" rearrangements that maintain the sequence of amino acids flanking the mutation. Point mutations or small rearrangements account for the remainder and can be detected by gene sequencing. Carriers can be similarly identified, and the test can also be used for prenatal diagnosis. Genetic counseling is critical both before and after testing, and the diagnosis of DMD/BMD has important implications for family planning and potentially for those related to the affected individual.

The initial evaluation of a boy suspected to have dystrophinopathy includes a serum CPK followed by genetic screening for *DMD* mutations performed on peripheral blood leukocytes. Mutations that interfere with the expression of dystrophin cause DMD and those that lead to abnormal quality or quantity of dystrophin cause BMD. Muscle biopsy is typically only pursued in cases where the diagnosis is highly suspected but the genetic testing is unrevealing, in atypically presenting cases, and in the setting of variants of unknown significance in the *DMD* gene. Immunocytochemistry for dystrophin and Western blot for quantitative dystrophin analysis can confirm and refine the diagnosis in these questionable cases. In DMD, dystrophin staining is absent by both immunocytochemistry and Western blot. In BMD, immunocytochemistry may show an interrupted pattern of staining on the surface membrane or negative staining with a subset of antidystrophin antibodies (with preservation of dystrophin signal using other antibodies), and the Western blot shows decreased dystrophin levels or abnormal protein size. Of note, approximately 5% of cases are due to deep intronic mutations, which can be uncovered through analysis of RNA from muscle biopsies.

Management

Standard of care guidelines for Duchenne muscular dystrophy, based on both clinical trial evidence and expert opinion, are published and widely available LEVEL 1.[1] These include recommendations for multidisciplinary team composition, appropriate respiratory, orthopedic and cardiac care, and specific pharmacologic interventions. Adherence to these care practices has led to improvements in the clinical course of DMD and an increase in overall survival of 5 to 10 years.

Oral corticosteroids are effective, standard of care therapy for DMD. Prednisone (0.75 mg/kg/d) or deflazacort (0.9-1.2 mg/kg/d) can be used. Prednisone therapy improved function and strength in placebo-controlled trials, but the side effects of chronic administration—in particular, weight gain, growth retardation, osteoporosis, cataracts, and behavioral changes—can limit their long-term use. If not prohibited by side effects, prednisone is usually offered to ambulatory patients older than 5 years of age and should be continued until side effects outweigh benefits, which typically occurs after ambulation is lost. Data on the use of prednisone before

age 5 years is lacking, and the extent of continued benefit after a child becomes wheelchair dependent not fully known. Of note, several alternative dosing strategies are being considered (such as alternate day or weekend only high dose). These strategies offer fewer side effects and seem to have equivalent benefits to daily dosing in the short term. However, further study is needed to know if they provide the same long-term impact. Also, new analogs designed to have the positive effects of steroids without the side effects are currently in clinical testing and may ultimately replace glucocorticoid treatment.

Although current therapy has improved the lives of boys and men with DMD, new and additional therapies are still greatly needed, as life expectancy still only reaches the early 30s. Several exciting therapeutic approaches are currently being investigated. These include antisense oligonucleotide-based exon skipping, a strategy designed to restore reading frame in patients with suitable deletions by removing additional exons. One such drug, eteplirsen, has been granted provisional U.S. Food and Drug Administration approval, but confirmatory phase III data is still lacking. Another strategy is gene replacement therapy or gene therapy. Because dystrophin is too large to fit into conventional viral vectors (such as AAV8/9), micro- or minidystrophins have been designed and tested. Currently, at least four different microdystrophin-based gene therapies are being evaluated in clinical trials. A third gene-based approach is premature stop codon "read through," a strategy whereby a drug prevents the stopping of translation at premature nonsense codons and limits nonsense mediated decay of the RNA. Ataluren is a "read-through" drug that has provisional U.S. Food and Drug Administration approval for patients with DMD and nonsense mutations. Its true efficacy is still under investigation. One final exciting technology is CRISPR/Cas9 gene editing, which offers the potential of correcting mutations at the genomic DNA level. Based on suggestive preclinical data, the first clinical trials of CRISPR for DMD are in the planning stages.

Supportive management in DMD is aimed at maintaining function and independence, avoiding complications, and improving quality of life. *Orthopedic and rehabilitation measures* include stretching exercises and ankle-foot orthoses during sleep to prevent contractures. Later, standing and walking can be maintained with ankle-foot orthoses or knee-ankle-foot orthoses combined with standing devices or walkers. Surgical release of contractures is only occasionally used for functional reasons, such as maintaining standing or ambulation. During the wheelchair years, surgical scoliosis stabilization can help maintain a comfortable sitting position and may reduce the risk of atelectasis and pneumonia.

Pulmonary function should be monitored regularly in patients with respiratory symptoms and in those who are nonambulatory to detect declines in respiratory muscle strength or ability to cough. Reduced cough strength increases the risk of atelectasis and respiratory infections. Therefore, chest physical therapy and mechanical insufflators/exsufflators are useful. When symptoms of sleep-disordered breathing are suspected, overnight in-home oximetry or laboratory-based sleep studies can confirm nocturnal hypoventilation. Noninvasive nighttime mechanical ventilation should then be considered. Later in the disease when respiratory muscle weakness progresses, continuous noninvasive ventilation is often needed, and sometimes the difficult decision whether to do a tracheostomy arises.

Cardiac function should be assessed prior to any major surgery in those with respiratory insufficiency or cardiac symptoms and, at least annually beginning at approximately 8 years of age. Current screening involves ECG and echocardiogram; cardiac MRI is increasingly being used, as it detects changes before they are apparent on echo. Perindopril (2-4 mg/d) has been shown to improve cardiac function in DMD and likely slows the progression of cardiac disease. Interventions including implantable cardioverter defibrillator placement and cardiac transplantation has been performed in select BMD patients. *Other measures* include precautions with general anesthesia, influenza and pneumococcal vaccinations, weight control, maintenance of bone health, neuropsychological evaluation to guide in educational issues, and social support to aid emotionally and financially. Genetic counseling for families is crucial.

SCAPULOPERONEAL MYOPATHIES

Emery-Dreifuss Muscular Dystrophy

EDMD is a clinically and genetically heterogeneous muscular dystrophy subtype united by a triad of signs/symptoms (Fig. 147.5):

1. A characteristic humeroperoneal distribution of weakness. That is, the biceps and triceps are affected rather than shoulder girdle muscles, and distal muscles are affected more than proximal muscles in the legs. The limb weakness may be mild or severe.
2. The presence of contractures that are disproportionately severe and are evident before much weakness is noted. The contractures affect the elbows, knees, ankles, fingers, and spine. A rigid spine often develops, and neck flexion can be limited.
3. Important cardiac disease: Heart block, atrial paralysis, and atrial fibrillation are found in 95% of patients by age 30 years and lead to placement of a pacemaker. Dilated cardiomyopathy occurs in about 35% of all cases.

FIGURE 147.5 Clinical features of Emery-Dreifuss muscular dystrophy (EDMD). Individual with EDMD due to dominant mutation in FHL1 gene with two of the classical aspects of the triad of signs/symptoms seen in EDMD: wasting of the humeral musculature and elbow flexion contractures.

EDMD has been associated with mutations in six genes, with variants in *LMNA* and *EMD* accounting for the vast majority of cases. Dominant mutations in the lamin A/C gene (*LMNA*) are the most common cause and present a spectrum of phenotypes from congenital onset muscular dystrophy, to the EDMD phenotype (MIM 181350), to a limb girdle presentation. Next most common is the X-linked form (MIM 310300) caused by mutations in emerin (*EMD*). Of note, *LMNA*-related EDMD tends to present earlier and with more severe symptoms than disease due to *EMD* mutations. Other causes include mutations in the X-linked gene *FHL1* encoding four-and-a-half LIM protein 1, and rarely autosomal dominant mutations in *SYNE1* (MIM 612998), *SYNE2* (MIM 612999), and *TMEM43* (MIM 614302). The overall prevalence is approximately 1:100,000. A proportion of cases remain genetically unresolved.

Symptoms of EDMD often start before age 5 years with difficulty walking. Examination typically shows symmetric contractures and weakness without pseudohypertrophy. Tendon reflexes are hypoactive or absent, and there may be mild facial weakness. Head drop may be present, particularly with early-onset forms of *LMNA* mutation. Serum CK activity can be mildly elevated to levels less than 10 times normal. The diagnosis is usually confirmed by DNA testing. Absence of emerin can be demonstrated by immunocytochemical study of a muscle biopsy. Emerin staining is absent not only in muscle nuclei but also in circulating white blood cells and skin. As a result, skin biopsy, leukocytes, or inner cheek swabs for exfoliated mucosal cells can be examined diagnostically instead of muscle biopsy. However, given that other EDMD subtypes (including *LMNA*) cannot be reliably discerned by immunostaining, DNA or gene product analysis is preferred to establish accurate diagnosis. Cardiac surveillance (including 24-h ECG and echocardiography) is crucial.

EDMD must be distinguished from other conditions. The rigid spine syndrome includes vertebral and limb contractures but not cardiomyopathy or muscle wasting. Because the cardiac abnormality may not be evident in childhood, some patients with a rigid spine might be expected to have EDMD. As discussed in the CMD section, collagen 6–related disorders (Bethlem myopathy/Ullrich CMD-MIM 158810/254090).

Management is symptomatic and may include physical therapy and surgical tendon release for contractures. Pacemaker/cardioverter-defibrillator (implantable cardioverter defibrillator) implantation and treatment of cardiomyopathy is often crucial. Female carriers are at risk for arrhythmias and should have regular cardiac evaluations.

LMNA-Related Myopathies

Mutations in *LMNA* represent the commonest cause of EDMD but are also seen in a spectrum of muscle diseases including CMD and LGMD. There are also rare patients reported with Charcot-Marie-Tooth and mutations in *LMNA*, and a distinctive premature aging condition (progeria) associated with specific mutations in the C-terminus of the gene. Patients with myopathic presentations have a range of severe manifestations. All are unified by the presence of early-onset and progressive contractures. The congenital form of the disease is particularly aggressive, with progressive neck flexors contractures, scoliosis, and respiratory failure, leading to the need for early ventilatory support and scoliosis surgery. Such patients often do not survive into adulthood. Note that all myopathic patients with *LMNA* mutations have elevated CPK values. Muscle biopsy findings are nonspecific and may show focal areas of inflammation and necrosis, and there is no antibody currently available that allows the reliable demonstration of LMNA loss. Diagnosis therefore rests on identification of causative mutations in the appropriate clinical setting.

LMNA encodes the nuclear envelope intermediate filament protein lamin A/C. Taken with the fact that several of the other causes of EDMD are associated with nuclear envelope proteins, the disorder in general is considered to have its root pathology with the abnormal structure and function of the nuclear membrane. While pathomechanisms are still being worked out, the predominant theory is that this disturbance of the nuclear envelope leads to mechanical instability of the myofiber and to alterations in gene expression.

Presently, management for *LMNA*-related myopathies focuses on anticipatory respiratory care, physiotherapy and surgical intervention for contractures and scoliosis, and treatment for cardiac arrhythmias. Arrhythmias are a leading cause of death in this disorder and must be proactively monitored upon clinical suspicion of the disease. Implantable defibrillators have been shown to reduce severity of arrhythmias and to improve survival.

At present, there are no experimental therapies in clinical trial for *LMNA* muscle disease. Given the inflammation seen on muscle biopsy, steroid therapy has been considered, and anecdotal cases support its further study. A systematic investigation of this is underway. Other considerations include gene therapy using a trans-splicing approach and allele-specific silencing using antisense oligonucleotides targeted to specific mutations, although this strategy requires careful consideration as haploinsufficiency of *LMNA* may lead to cardiomyopathy.

FACIOSCAPULOHUMERAL MUSCULAR DYSTROPHY

Definition

FSHD (MIM 158900) is defined by characteristic clinical features that include facial weakness (affecting primarily eyelid closure and lower facial movement), weakness of the scapular stabilizers (leading to the characteristic appearance of scapular winging) (Fig. 147.6), and prominent involvement of humeral muscles

FIGURE 147.6 Asymmetric scapular winging in facioscapulohumeral muscular dystrophy. Asymmetric scapular winging, a classical feature of facioscapulohumeral muscular dystrophy, may also be observed in other forms of muscular dystrophy. It results from weakness of the scapular stabilizing muscles.

in the upper extremity, abdominal and truncal muscles, and distal muscles in the lower extremity. Ultimately, the condition is defined by the presence of a positive genetic test. There are two forms of FSHD, FSHD1 and FSHD2, that share similar clinical symptoms but differ based on underlying genetic change.

Molecular Genetics

The disease is autosomal dominant with nearly complete penetrance. Almost all FSHD patients have deletion/contraction of a 3.3-kilobase repeat element, termed *D4Z4*, on the subtelomeric end of chromosome 4q35. Normal individuals have 11 to 150 repeats; FSHD1 patients usually have fewer than 11. The deletion results in inappropriate expression of the double homeobox–containing gene *DUX4* in muscle cells. Of note, the deletion must occur on a permissive 4q allele (4qA) in order to cause disease. Also, there is correlation between repeat number and clinical severity, with fewer repeats equating to earlier onset and increased severity. About 5% of FSHD patients have chromatin relaxation at D4Z4 without D4Z4 contraction resulting from dominant mutation in the chromatin modifier gene *SMCHD1*. This rare form is referred to as *FSHD2*.

Clinical Manifestations

The following features are characteristics of FSHD:

1. Facial weakness is evident not only by limitation of lip movements but also in the slightly everted lips and wide palpebral fissures. Patients may state that they have never been able to whistle or blow up a balloon. Some are said by relatives to sleep with eyes open.
2. Scapular winging is prominent. Protrusion of the scapula is more evident when the patient tries to push against a wall with elbows extended and hands at shoulder level. The winging becomes more evident when the patient tries to raise the arms laterally. The patient cannot raise the arms to shoulder level even though there is no weakness of the deltoids on manual testing. This limitation is caused by inadequate fixation of the scapula to the chest wall.
3. The shoulder girdle has a characteristic appearance. Viewed from the front, the clavicles seem to sag and the tips of the scapulae project above the supraclavicular fossa. This abnormality becomes more marked when the subject tries to raise the arms laterally to shoulder level. Smallness of the pectoral muscles affects the anterior axillary fold, which is ordinarily diagonal but assumes a vertical position. Abdominal muscle weakness may cause abdominal protrusion and exaggerated lumbar lordosis. The lower abdominal muscles are weaker than the upper causing a positive "Beevor" sign with the navel moving toward the head upon neck flexion in a supine position. The limb muscle weakness is often asymmetric. It is important to remark that weakness and atrophy in most patients is asymmetric if one compares one hemibody with the other. This feature is not commonly found with other muscular dystrophies making it a key feature in order to arrive to a diagnosis.
4. Leg weakness may affect proximal muscles or, more often, the tibialis anterior and peroneals, resulting in foot drop.

Within a single family, the condition may vary markedly. Progression is slow, however, and the condition may not shorten longevity. About 20% of patients eventually use a wheelchair. Respiratory insufficiency is rare. Men may be more severely affected than women. The disease may present in the first 2 years of life in individuals with large deletions (congenital FSHD).

Associated Disorders

Occasion additional features include mild sensorineural hearing loss, vascular retinopathy, Coats disease (exudative telangiectasia of the retina), and, rarely, intellectual disability in congenital onset cases. Cardiac involvement is rare in FSHD. On the other hand, pain is common, with frequent sites including, in descending order, lower back, lower limbs, shoulders, and neck.

Differential Diagnosis

The differential diagnosis includes myogenic and neurogenic scapuloperoneal syndromes and some forms of LGMD (such as LGMDR1), especially when facial weakness is absent. Additionally, EDMD is sometimes confused with FSHD, but the essential clinical features are different. The increasing availability of genetic testing for FSHD, LGMD, and EDMD typically provides diagnostic clarity in these settings. Infantile onset of FSHD is rare, but facial weakness may be severe enough to simulate the Möbius syndrome of congenital facial diplegia.

Laboratory Studies

The diagnosis is established by leukocyte DNA testing for a contraction of the subtelomeric repeat array on 4q35. Presymptomatic diagnosis is possible in families with more than one affected member, but testing should be done only with appropriate counseling. EMG and muscle biopsy, by definition, should show a myopathic pattern. Muscle biopsy changes are usually mild and nonspecific. Inflammatory cells are found in some patients, raising the question of polymyositis, but immunosuppressive therapy is not effective. Rarely, patients with typical manifestations do not have a causative mutation for FSHD1/FSHD2, which may imply additional locus heterogeneity or potentially limits of sensitivity of current tests for the known mutation loci.

Management

Currently, there are no disease-modifying treatments for FSHD. Scapular weakness becomes progressively disabling, and some interventions are commonly tried despite lack of compelling evidence. These include taping and vests for scapular stabilization, and wiring of the scapula to the chest wall to facilitate use of the arms. Additional supportive treatments include physical therapy, analgesics for joint pain, and ankle-foot orthosis for foot drop. Albuterol, a β_2-agonist sympathomimetic drug, was evaluated in a placebo-controlled phase 3 clinical trial. The primary end point, a difference in global strength, was not reached, but the drug did improve two secondary end points: grip strength and muscle mass.

Therapeutic development is focused primarily on strategies to reduce DUX4 expression or DUX4-related toxicity. A small molecule p38 inhibitor is currently being evaluated in clinical trial, having been shown to reduce DUX4 expression in patient cells. Gene-based knockdown strategies, either using antisense oligonucleotides to DUX4 or viral-based gene therapy, are attractive approaches that have been tested in preclinical models and are likely to soon enter clinical trial.

MYOTONIC MUSCULAR DYSTROPHY AND PROXIMAL MYOTONIC MYOPATHY

Definitions

Myotonic dystrophy (DM1; MIM 160900) is an autosomal dominant, multisystem disease with unique symptomatology that includes muscular dystrophy, myotonia, cardiomyopathy, cataracts, and endocrinopathies. *Proximal myotonic myopathy* (PROMM, DM2; MIM 602668) shares many characteristics with DM1 but differs based on age of onset and underlying genetic cause.

Epidemiology

DM1 is typically not life limiting (with some exceptions), and penetrance is almost 100%. Because of this, DM1 is a disease of high prevalence, about 5 per 100,000 throughout the world, and is likely the most common adult form of muscular dystrophy. The incidence is about 13.5 per 100,000 live births. The disease is found throughout the world, although there are areas with founder mutations and very high prevalence, such as the Charlevoix-Saguenay region of Northeastern Quebec.

FIGURE 147.7 The myopathic facial appearance typical of myotonic dystrophy. Individual with congenital myotonic dystrophy (>1,000 CTG repeats in DMPK 3′UTR). Note the classic features of bitemporal wasting, bilateral ptosis, and lower facial weakness (resulting in the C-shaped appearance of the mouth).

Diagnosis

Clinical Features

The clinical features of DM1 are characteristic and the diagnosis is often evident by clinical inspection. Early foot drop may lead to confusion with Charcot-Marie-Tooth disease, but EMG patterns distinguish the two. The congenital form (congenital myotonic dystrophy [cDM1]) may resemble a congenital muscle disease, particularly X-linked myotubular myopathy (XLMTM) (which shares many clinical features with cDM1 and may manifest similar changes on muscle biopsy), or instead a syndrome with global developmental delay.

The myopathy of DM1 is distinctive in distribution and appearance. Unlike most other forms of muscular dystrophy, it affects facial musculature in addition to the extremities. Ptosis is common, and dysarthria and dysphagia may occur. The temporal, lower facial, and sternocleidomastoid muscles are weak and atrophic, resulting in a distinct facial gestalt (Fig. 147.7). In men, frontal baldness contributes to this impression. Limb weakness is most pronounced distally and affects the hands and feet equally. Distal leg weakness may cause a foot drop or steppage gait. The rate of progression is slow, and longevity may not be affected, but variation is evident; some people are almost asymptomatic, some experience progressive disability, and some are born with a more severe subtype called cDM1.

Electrodiagnostic Features

Myotonia is a core feature of the disease. Clinical myotonia is a phenomenon of impaired relaxation. It is most evident in the hands as failure of hand opening. It may impair skilled movements and complicate actions such as shaking hands or turning a doorknob. As a sign on examination, the slow relaxation can be elicited by tapping the thenar eminence or, in the forearm, the bellies of the extensors of the fingers. Myotonia can also be evoked by asking the patient to grasp forcefully and then relax, which an unaffected person can do rapidly. Of note, the myotonic phenomenon is due to a secondary involvement of the *CLC1* gene encoding the chlorine channel.

Interestingly, myotonia typically is not seen until age 7 years at the earliest; thus, EMG is not useful before this age. Electrical myotonia is a distinctive pattern of waxing and waning high-frequency discharges observed on EMG. Myotonic discharges are seen in other disorders as well, such as "nondystrophic myotonias," which are described in other chapters: hyperkalemic periodic paralysis and paramyotonia congenita in Chapter 97 and myotonia congenita and the Schwartz-Jampel syndrome in Chapter 98. "Pseudomyotonia," or impaired relaxation without true myotonic discharges, is seen in the Isaac syndrome or neuromyotonia (see Chapter 98). Myotonic-like discharges, but not clinical myotonia, are seen in patients with acid maltase deficiency. Inclusion body myopathy with both Paget disease and frontotemporal dementia can be associated with electrical-myotonia. However, none of these other myotonic syndromes has the characteristic myopathy and multisystem involvement of DM1 and therefore rarely cause diagnostic confusion. *Muscle biopsy* may show a dystrophic pattern with an increased percentage of internalized nuclei. Serum CK level may be normal or slightly increased.

Other Clinical Features

Cataracts are almost universal but take years to appear. Early findings include characteristic iridescent opacities and posterior opacities called "Christmas tree cataracts." Cataracts are related to the decreased expression in the gene *SIX5*.

Endocrinopathy is most readily seen in men. Frontal baldness is almost universal, and hypogonadism (testicular atrophy, tubular degeneration, reduce testosterone, and oligospermia) is common; fertility in males, however, is not clearly diminished.

In females, menstrual irregularities and ovarian failure are observed but only rarely; difficulties during pregnancy may occur due to uterine muscle hypercontraction. Diabetes mellitus and insulin resistance may be more common than in the general population, and therefore, annual measurements of glucose and glycosylated hemoglobin should be considered. Hypothyroidism is rare but should be considered so that untreated hypothyroidism does not contribute to muscle weakness.

Cardiac involvement is manifested as conduction disturbances, including atrial fibrillation and ventricular tachyarrhythmias, in more than half of the adult patients with DM1. The most frequent finding is AV conduction block (between 28% and 58%). Fatal arrhythmias are an important problem. It is therefore recommended that patients have cardiac screening at diagnosis and annually thereafter. The workup should include 12-lead ECG and, if suspicion of arrhythmia, should also include 24-hour Holter monitoring and echocardiogram. Permanent pacing is recommended if/when abnormal rhythms are detected. Cardiac involvement is due to the involvement of several genes including the mis-splicing of *SCN5A*.

Involvement of the gastrointestinal tract is frequent. Most patients will have difficulties swallowing and may experience dysphagia, dyspepsia, and reflux. Diarrhea with abdominal cramping is also a common complaint. Other complications are pseudoobstruction or megacolon. Although the abnormalities on the skeletal muscle are well-defined, histologic evidence of smooth muscle abnormalities are confounding. Thus, the pathophysiologic explanation for the gastrointestinal manifestation remains evasive.

Cognitive impairment is common in cDM1, and intellectual disability is rare in patients with later onset. However, mild cognitive and neuropsychiatric impairment may be evident. cDM1 usually presents with a global cognitive involvement, whereas classic DM1 only involves executive function. Juvenile forms of DM1 present with a higher involvement of all memory domains compared with the adult forms. There is also documented a progressive decline of the frontal and temporal functions in adult forms of DM1.

Excessive daytime somnolence is most frequently attributed to nocturnal hypoventilation, but there are other explanations as well. Several studies have described a central rapid eye movement sleep dysregulation that may contribute to the somnolence frequently reported in this population. The incidence of diurnal somnolence, as measured through the Daytime Sleepiness Scale, was significantly higher in DM1 patients (50%) than in DM2 patients (27%). These symptoms may be helped by treatment with modafinil or methylphenidate. *Respiratory difficulties* may occur due to diaphragmatic and intercostal muscle weakness as well as impaired respiratory drive.

Genetics

Ultimately, DM1 is a genetic diagnosis. It is caused by expansion of a CTG repeat in the 3′UTR of one allele of the *DMPK* gene located on 19q13.2. Unaffected people have 5 to 30 CTG repeats; affected individuals have more than 50. Infants with cDM1 have more than 800 repeats and typically have >2,000. It is an autosomal dominant disease, and each successive generation has more repeats and is more severely impacted. In general, the larger the repeat, the younger the age at onset and the more severe the syndrome, which is a phenomenon referred to as *anticipation*. Of note, there is rapid anticipation of repeats from maternal alleles, and the cDM1 form only results when the mother has a pathogenic repeat. Genetic counseling is critical in this disorder and should be provided both before testing is initiated and upon return of the results, as there are almost always important implications for additional family members (including parents and their siblings).

Myotonia Variants

Congenital Myotonic Dystrophy

About 5% of children born to a person with DM1 have symptoms at birth, a condition termed *congenital myotonic dystrophy*. It affects children of either sex who are born to a woman with the usual adult form of the disease, which is often so mild that the woman may be asymptomatic at the time of diagnosis in the child. cDM1 infants have difficulty feeding and breathing in the newborn period, develop slowly, present with global cognitive delay, and show developmental anomalies of the face and jaws as well as severe limb weakness and clubfeet. Importantly, symptoms improve after the first year of life: Nearly every child with cDM1 eventually walks. The disease process tends to go through four phases: severe neonatal symptoms, progressive improvements in developmental milestones, plateau of progress and of symptomatology, and lastly progression as typically seen in patients with classic disease.

Proximal Myotonic Myopathy

When the mutation causing DM1 was discovered in 1992, it became evident that some patients did not carry the mutation. Their symptoms and signs are similar to those of DM1 in many respects, including autosomal dominant myopathy, myotonia, cataracts, and weakness of the sternocleidomastoids. The distribution of limb weakness is different: DM1 is primarily a distal myopathy, whereas DM2 presents weakness of pelvic girdle muscles. Other differences are less conspicuous. For instance, myotonia is more difficult to elicit, symptoms are less severe, and there may be calf hypertrophy. Congenital and pediatric presentations have not been reported in DM2 families, and anticipation is not prominently observed. Most important, the syndrome does not map to chromosome 19 but maps to chromosome 3q and is caused by a CCTG expansion in the *CNBP* gene.

Management

Myotonia can be ameliorated with mexiletine (150-1,000 mg/d, class 1 evidence), phenytoin sodium (Dilantin) (300-400 mg/d), or other anticonvulsant drugs. Rehabilitation measures are helpful for muscle function and in assisting the patient in the activities of daily living. Orthoses help with foot drop. Ocular and cardiac symptoms are treated as in any patient. An ECG should be recorded annually for adults, and slit lamp examination is also carried out periodically. Glucose metabolism, thyroid function, and, in symptomatic males, testosterone levels should be periodically monitored and when abnormal, treated. Fatigue is common and often responds to pharmacologic treatment such as modafinil (200-400 mg/d). Pain is a frequent symptom and should be managed with pharmacologic and other approaches. General anesthesia should be avoided if possible because of increased postoperative pulmonary complications. In cDM1, respiratory support and feeding tubes are often needed in infancy, and feeding support may be required at all phases of the disease. Early intervention with physical, occupational, and speech therapy and special education are indicated to address the problems associated with global developmental delay. Families should be educated about the nature of the disease, inheritance, and the availability of DNA diagnosis for adults and for prenatal testing.

The primary pathomechanism underlying the disease is alteration of RNA splicing as a result of the toxic RNA produced from the *DMPK* locus. The expanded repeat in the 3′UTR forms a hairpin that then sequesters factors (muscle-blind proteins) that are critical for regulating splicing. The result is mis-splicing of hundreds of genes in the affected tissues, resulting in the stereotyped multiorgan involvement of the disorder. Several of these mis-splicing events are tied to specific phenotypes, such as the mis-splicing of *CLC1* that results in myotonia. The main experimental therapeutic strategies are aimed at either reducing the toxic RNA species or else replenishing muscleblind proteins. For example, an antisense oligonucleotide-based approach that promotes degradation of the repeating containing DMPK is currently under development.

LIMB-GIRDLE MUSCULAR DYSTROPHY

Definition

Limb-girdle muscular dystrophy is a term originally conceived to separate progressive muscular dystrophies that were not X-linked (DMD/BMD) or otherwise clinically distinct dystrophies, such as FSHD or DM1. The group comprises a heterogeneous collection of progressive muscular dystrophies primarily involving shoulder and pelvic girdle muscles, with either autosomal dominant or recessive inheritance, and a normal dystrophin gene product. There are >30 distinct genetic subtypes of LGMD (**Table 147.2**). The subtypes are usually not clinically distinguishable due to marked variability in severity and age onset within and between the different causes. However, some characteristic features are seen with specific defects (see **Table 147.2**). The identification of new gene defects has led not only to refinement of this category but has also advanced the understanding of basic muscle cellular biology (**Fig. 147.8**). The newly identified proteins include many not previously known to play a role in normal muscle function.

Epidemiology

Prevalence estimates range from 1:50,000 to 1:100,000. The most common subtypes are LGMDR1 (calpainopathy), LGMDR2 (dysferlinopathy), LGMDR9 (*FKRP*-related LGMD), LGMDR12 (*ANO5*-related LGMD). The most common LGMDs to present before adolescence and adulthood are LGMDR9 and the sarcoglycanopathies (LGMDR3-6).

Diagnosis

Historically, the diagnosis of LGMD was considered based on elevated CPK and suggestive muscle biopsy. Biopsy findings include degenerative/regeneration, inflammation, and fibrosis. Antibodies to several of the known causes exist and can help suggest a specific diagnosis, particularly for some of the recessive subtypes. Currently, genetic testing is considered the definitive test and is often pursued prior to biopsy. There are >30 genetic subtypes of LGMD, which can be tested using multigene panels or whole exome sequencing. The diagnostic rate is between 30% and 50%, suggesting the presence of a large unsolved pool of patients with LGMD phenotype.

In the old nomenclature, an alphanumeric system was used (229th European Neuromuscular Center International Workshop), and subtypes are subclassified into autosomal dominant (type 1) and autosomal recessive (type 2) groups. A letter was assigned based on the order of discovery. Individual protein defects were given an additional letter designation in order of discovery. The 229th European Neuromuscular Center International Workshop proposed a new classification based on mode of inheritance, numbered based on the order of discovery and finally linked to the gene which is related (eg, LGMD2A would be LGMDR1 calpain-3–related).

Many of the entities, especially dominant ones, have one or more allelic disorders, in some cases with identical gene defects with multiple manifestations (see **Table 147.3**). Allelic disorders include several with isolated hyperCKemia without muscular weakness (caveolin-3, calpain-3, dysferlin, *ANO5*), some with neurogenic weakness (lamin A/C), and others with other muscle disorders such as rippling muscle disease (*CAV3*; MIM 606072), autosomal dominant EDMD (lamin A/C), and distal myopathy (dysferlin, *ANO5*; MIM 254130; 613319).

Clinical Manifestations

In general, recessive forms are more common, more severe, and have an earlier onset. Some have characteristic manifestations, but none can be conclusively diagnosed on clinical grounds alone. All of the disorders are characterized by proximal weakness of the pelvic or shoulder girdle muscles and dystrophic signs on muscle biopsy; some include cardiomyopathy. Disorders with primarily distal myopathic weakness are now grouped separately as *distal myopathies* (*eg, LGMD1E and LGMD1A now are classified exclusively as myofibrillar myopathies, which cause a primary distal phenotype*). Severity may vary between and within families. Proximal muscle weakness manifesting as difficulty climbing stairs or arising from a deep-seated chair are common early symptoms. A waddling gait then develops. Difficulty raising the arms and scapular winging may be seen. Patellar reflexes tend to be lost before ankle jerks. Cranial muscles are usually spared. The progression of disease is slow in most cases, but some of the childhood forms progress in a manner similar to DMD.

Autosomal Recessive Limb-Girdle Muscular Dystrophy

Lgmdr1/Lgmdd4 (Lgmd2a)

Recessive mutations in the calpain-3 (*CAPN3*; MIM 253600) gene on chromosome 15q are among the most common causes of LGMD, and over 130 distinct mutations spanning numerous countries are known. In some populations, these mutations account for 28% to 50% of LGMD cases if sarcoglycanopathies and dystrophinopathies are excluded. There has been described a less common variant with dominant inheritance (LGMDD4; MIM 618129) due to a 21-bp in-frame deletion (c.643_663del21) that produces a milder, late-onset phenotype. Calpain-3 encodes a calcium-sensitive protease that is a muscle cytoskeletal regulator through its ability to cleave titin and filamin C. Disease severity varies from asymptomatic hyperCKemia (usually considered a presymptomatic stage of calpainopathy most frequently observed in children or in young adults) to severe weakness with either classical LGMD (Leyden-Moebius LGMD) or a milder scapulohumeral LGMD (Erb LGMD) variant. Onset ranges from 2 to 45 years. The disease is progressive, and loss of ambulation

TABLE 147.2 Genetic Subtypes of Limb-Girdle Muscular Dystrophies

MIM	Name	Map Position	Gene	Clinical Features
603511	LGMDD1	7q	*DNAJB6*	Pelvic girdle greater than shoulder girdle weakness, onset second to sixth decade
608423	LGMDD2	7q32.1-q32.2	*TNPO3*	Spanish, pelvic girdle affected before shoulder girdle, juvenile (15 y) or adult (third or fourth decade), rimmed vacuoles
609115	LGMDD3	4q21	*HNRNPDL*	Onset 15-50 y, slow progression, mild disease course, flexion limitation of fingers, progressive permanent, decreased movement range in interphalangeal joints, flexion limitations of toes
613530	LGMDD4	3p25.1-p23	*CAPN3*	Adult onset, myalgia, hyperlordosis, back pain, scapula winging
158810	LGMDD5	2q431.4; 21q22.3; 21q22.3	*COL6A1, COL6A2, COL6A3*	Onset variable, slow progression, approximately half of patients need ambulatory support after faith decade, normal to slightly increase CK
253600	LGMDR1	15q15	*CAPN3*	Elevated CK, proximal weakness, scapular winging, onset 20-40 y
253601	LGMDR2	2p13	*DYSF*	Highly elevated CK, distal and/or pelvic girdle weakness, rare calf hypertrophy, onset 17-23 y
608099	LGMDR3	17q12-21	*SGCA*	Childhood onset, variable severity, progressive, calf muscle hypertrophy, highly elevated CK, contractures
604286	LGMDR4	4q12	*SGCB*	Childhood onset, most patients loss ambulation in the second to fourth decade, highly elevated CK
253700	LGMDR5	13q12	*SGCG*	Proximal weakness, calf hypertrophy, onset 3-15 y
601287	LGMDR6	5q33-34	*SGCD*	Childhood onset, most patients loss ambulation in the second to fourth decade, highly elevated CK
601954	LGMDR7	17q11-12	*TCAP*	Proximal and distal leg weakness, proximal arm weakness, onset 9-15 y, rimmed vacuoles
254110	LGMDR8	9q31-34	*TRIM32*	Manitoba Hutterites, facial weakness possible, proximal leg and neck weakness, onset 1-9 y
607155	LGMDR9	19q13.3	*FKRP*	Proximal arm greater than leg weakness, onset 1.5-27 y
608807	LGMDR10	2q24.3	*TTN*	Finnish, proximal weakness, tibial muscular dystrophy
609308	LGMDR11	9q34.1	*POMT1*	Turkish, mild proximal greater than distal weakness, hypertrophy, cognitive and language delay, onset 1-3 y
611307	LGMDR12	11p13-p12	*ANO5*	French Canadian, proximal weakness, quadriceps atrophy, muscle pain, onset 11-50 y
611588	LGMDR13	9q31	*FKTN*	Hypotonia, proximal weakness, normal cognitive development, onset in infancy
613158	LGMDR14	14q24	*POMT2*	Hypotonia, delayed motor milestones, scapular winging
613157	LGMDR15	1p32	*POMGnT1*	Onset by age 12 y; scapular winging; proximal greater than distal weakness; ankle contractures
613818	LGMDR16	3p21	*DAG1*	Childhood onset; cognitive delay; ankle contractures; proximal greater than distal weakness
613723	LGMDR17	8q24	*PLEC1*	Motor delay, especially ambulation
615356	LGMDR18	4q35.1	*TRAPPC11*	Facial, proximal muscle weakness; cognitive delay
615352	LGMDR19	3p21	*GMPPB*	Onset usually in first decade; variable phenotype; some patients with microcephaly, seizures, cognitive delay, respiratory insufficiency, and cardiomyopathy
616052	LGMDR20	7p21	*ISPD*	Childhood onset, slowly progressive lower limbs more severely affected, loss of independent ambulation in adulthood, scapular winging
617232	LGMDR21	3q13	*POGLUT1*	Onset in early to mid-20s, slowly progressive, mild increment of CK scapular winging and respiratory impairment
254090	LGMDR22	21q22	*COL6A1-COL6A2-COL6A3*	Onset in infancy, progressive, normal intelligence, generalize muscle weakness, hyperhidrosis, follicular hyperkeratosis, calcaneal protrusion, increase laxity, scoliosis
618138	LGMDR23	6q22	*LAMA2*	Onset ranges from childhood to adult, slowly progressive, variable penetrance, patients remain ambulatory, muscle cramps, calf hypertrophy in some patients with seizures and executive deficits, white matter abnormalities seen on brain imaging
618135	LGMDR24	3p22	*POMGNT2*	Childhood onset, highly variable phenotype penetrance, calf hypertrophy
616812	LGMDR25	6q21	*BVES*	Variable onset most frequent associated with cardiac arrhythmias
618848	LGMDR26	6q21	*POPDC3*	Adult onset (teenage to 40 y old), slowly progressive, calf hypertrophy, no respiratory insufficiency or cardiac involvement

Abbreviation: CK, creatine kinase.

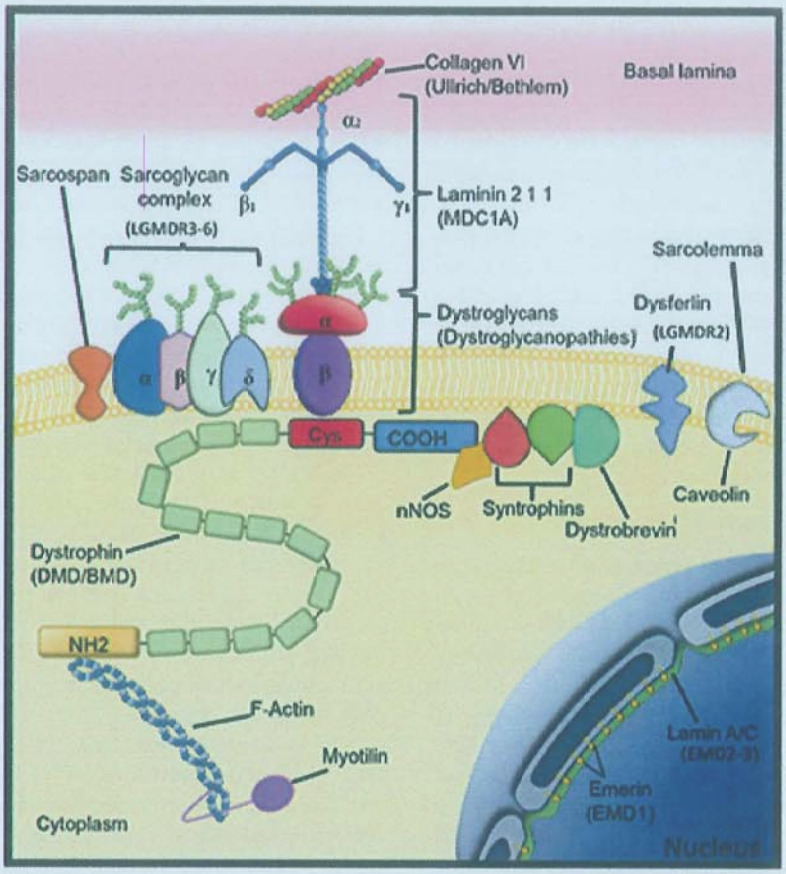

FIGURE 147.8 Skeletal muscle proteins and muscular dystrophies. Organization of the dystrophin-glycoprotein complex and related proteins in the sarcolemma. α-Dystroglycan links to the extracellular components with β-dystroglycan, which are two subunits of a transmembrane glycoprotein anchoring the cell to the extracellular matrix. Dystroglycan binds not only to dystrophin, a cytoskeletal protein, but also to the sarcoglycan complex. The dystrophin attaches to cytoskeletal actin at its N-terminus and to syntrophins and α-dystrobrevin at its C-terminus (where a neuronal nitric oxide synthase [nNOS] binding domain is also present). Dysferlin and caveolin-3 are believed to help in membrane repair. Lamin A/C and emerin are located in the nuclear membrane and help aid its anchoring to the cytoskeleton. The subtypes of muscular dystrophy associated with mutations in the various sarcolemmal proteins are present in brackets. Abbreviations: BMD, Becker muscular dystrophy; DMD, Duchenne muscular dystrophy; EMD, Emery-Dreifuss muscular dystrophy; LGMD, limb-girdle muscle dystrophies; MDC1A, congenital muscular dystrophy type 1A. (Adapted by permission from Dowling JJ, Gonorazky HD, Cohn RD, Campbell C. Treating pediatric neuromuscular disorders: the future is now. *Am J Med Genet A*. 2018;176[4]:804-841.)

occurs around 10 to 30 years after the onset. Some have predominantly distal myopathy. Pelvic weakness initially sparing hip adductors and extensors, scapular winging, abdominal laxity, and early contractures are characteristic especially over the Achilles tendon. There is absence of cardiomyopathy, intellectual disability and usually the neck extensors or flexors muscles are not involved.

LGMDR1 is ultimately a genetic diagnosis, although many suspected individuals only have one identified *CAPN3* variant. In such cases, complex rearrangements or noncoding mutations are suspected. In terms of other diagnostic studies, CPK levels are often elevated (range 190-11,000 IU/L ~5,000). Biopsy findings are nonspecific; immunostaining of calpain-3 is not reliable, and therefore, Western blot is needed for a biopsy-based diagnosis. Western blot analysis needs to be interpreted with caution because it is neither completely specific or 100% sensitive, and calpain-3 levels can be partially reduced in other muscular dystrophies such as dysferlinopathies or titinopathies, or lowered due to artificial degradation. Moreover, 20% to 30% of patients diagnosed with LGMDR1 present a normal quantitative expression of the protein with a loss of its function.

Lgmdr2 (Lgmd2b)

The prevalence of LGMDR2 (MIM 253601) in the general population is not known. In Libyan Jews, the prevalence estimate is 1 every 1,300 due to a founder phenomenon. There has also been described a founder variant in the Spanish population (Arg1905Ter). Most pathogenic variants introduce a stop codon or premature truncation of the protein. Dysferlin mutations are the cause of LGMDR2 and are allelic with distal Miyoshi myopathy. These two phenotypes can be observed within a single family and likely represent a single clinical entity. LGMDR2 can also present as asymptomatic hyperCKemia. Disease predominantly affects the gastrocnemius and soleus muscles, but the LGMDR2 phenotype progresses proximally, with involvement of the pelvic and shoulder girdles, but typically not with scapular

winging or neck involvement. Most of the patients complain of muscle cramps or myalgia before weakness. These features along with the age of onset and very high levels of CPK are key clues for the diagnosis. Onset is later than most recessive LGMDs, usually after age 15 years and occasionally much later. Progression is slow and patients tend to be wheelchair-bound two decades after the onset. Cardiac involvement, although reported, is rare. Respiratory involvement with forced vital capacity <50% predicted is seen only late in the progression of the disease in severely affected patients. CPK is usually in the high end of the spectrum, comparable with levels seen in DMD, likely because dysferlin appears to play an important role in muscle membrane repair. Biopsy is typically dystrophic and may include considerable inflammation. Because there are individuals with partial dysferlin deficiency detected by immunostaining, Western blot is generally considered the more specific method.

Lgmdr3-6 (Sarcoglycanopathies) (Lgmd2c-F)

Sarcoglycans are dystrophin-associated glycoproteins integral to sarcolemmal stability. The four primary protein subunits (α, β, γ, and δ) form a complex that provides support and signaling functions for the muscle membrane. Recessive loss of expression/function mutations in one of the four subunits result in in LGMD with a "Duchenne-like" picture. Genetic testing is now the gold standard for diagnosis. Muscle biopsies show characteristic loss of expression by immunostaining of all four subunits regardless of which specific sarcoglycan is mutated. When affecting males, this group of disorders is the main differential diagnosis with DMD due to their clinical similarities, age of onset and high CPK. Overall, sarcoglycanopathies represent up to 68% of pediatric onset cases of LGMD but only 10% of adult-onset cases. LGMDR3 (MIM 608099) (α-sarcoglycanopathy) is most common, followed by β, γ, then δ. There are founder mutations present in specific communities, such as two mutations in β-sarcoglycan observed in the Amish population in North America.

The typical age of onset is between 2 and 4 years with waddling gait, difficulties with stairs, and a positive Gowers' sign. The disease is relentlessly progressive, with loss of ambulation typically by age 15 years, and with prominent scoliosis and respiratory failure that occurs after wheelchair dependence. Cardiomyopathy is seen in a fraction of patients, more in β (LGMDR4; MIM 604286) and γ (LGMDR5; MIM 253700) than in the other two subtypes. Onset may occur later (up to age 15 y); cases with complete complex loss manifest from 3 to 15 years of age and are typically wheelchair users by age 15 years. Partial loss delays onset until the teens or early adulthood. γ-Subunit defects are more severe, often with congenital onset.

Unlike DMD, glucocorticoids are not known to be effective for the treatment of sarcoglycanopathy, although there is anecdotal evidence that they may have utility in the setting of sudden decline. Treatment is focused on preventing and treating contractures and scoliosis, management of cardiac disease if/when it develops, and monitoring and intervention related to respiratory failure. Gene replacement therapy is under consideration, and phase 1 trials with intramuscular injection have been completed for LGMDR4 and LGMDR5.

Lgmdr9

LGMDR9 (LGMD2I; MIM 607155) is one of a growing number of dystrophies caused by abnormal α-dystroglycan glycosylation and disruption of the link between dystroglycan and laminin (ie, dystroglycanopathies). LGMDR9 results from mutations in *FKRP*, which encodes an enzymatic regulator of dystroglycan glycosylation. Approximately 100 different *FKRP* mutations have been identified, of which more than half of them cause LGMDR9. LGMDR9 exists on a continuum with CMD due to *FKRP* mutation. In fact, mutations in most dystroglycanopathy genes more commonly present as CMD and not LGMD, with *FKRP* and *ISPD* being important exceptions.

Accurate prevalence data are not yet known, but this form is relatively common in some populations. The c.826C>A variant (p.Leu276Ile) is usually found in patients from Northern Europe, either in homozygosity or compound heterozygosity. When homozygous, it usually causes a milder phenotype, and when in compound heterozygosity, it presents an intermediate phenotype. There are other founder mutations, including one in Mexican communities that causes CMD.

LGMDR9 is a clinically complex disorder. Many patients present with pediatric onset and progressive symptoms that include eventual loss of ambulation. Others may present with fulminant, rapid onset of weakness resembling a myositis. Triggers for this can be infection or local injury (such as a bone fracture). In such patients, symptoms may rapidly improve after a period of time, although they may remain severe. Cardiomyopathy occurs in a subset of patients; respiratory involvement is typically mild if/when it occurs.

The current management strategies revolve around anticipatory care and interventions for secondary complications (such as scoliosis and cardiomyopathy). Glucocorticoids have been considered in anecdotal cases but have not been formally studied. Gene replacement therapy is feasible given the small size of *FKRP*. One challenge to clinical trials for this disorder is the variability of disease natural history, with a range of clinical presentations and disease course.

Lgmdr12

LGMDR12 (LGMD2L; MIM 611307) is due to pathogenic variants in *ANO5*, which presents with late-onset leg weakness, with a mean age of onset of approximately 35 years. It should be suspected in individuals with late adult-onset proximal lower limb weakness, prominent asymmetry, calf myalgias or burning sensation, and markedly elevated CPK levels, typically 10 to 50 times the upper limit of normal. Muscle imaging usually presents with fatty replacement of the gastrocnemius medialis, soleus, and the posterior thigh muscles. Other phenotypes include a distal presentation (Miyoshi-like) and asymptomatic hyperCKemia with exercise induced myalgias. Cardiac involvement occurs in some individuals and usually manifests as cardiomyopathy, although in some cases, arrhythmias have been also reported. It is estimated to be one of the most common causes of LGMD. In the U.K. population, about 25% of LGMD cases are due to *ANO5* mutations. In the United States, LGMDR12 is the fourth most prevalent LGMD subtype.

Other Recessive Limb-Girdle Muscular Dystrophies

The remaining known recessive forms are considerably rarer.

LGMDR7 (LGMD2G; MIM 601954) is a very rare disorder linked to defects in *telethonin*, which is a muscle-specific protein localized to the Z-disc, associated with *titin*, and likely affecting sarcomere structure. LGMDR8 (LGMD2H; MIM 254110) is a relatively mild LGMD seen in Canadian Hutterites owing to a defect in *TRIM32*, which is likely involved in targeting proteins for proteasome degradation.

LGMDR10 (LGMD2J; MIM 608807) is a rare form of LGMD also known as *tibial muscular dystrophy*; it is caused by defects in the very large *TTN* gene. This sarcomeric protein has multiple proposed roles and directly interacts with numerous other proteins discussed in this section. Myofibrillar myopathy with respiratory failure and familial dilated cardiomyopathy 1G (MIM 603689; 604145) are other titinopathies. The recessive mutation can also produce forms of congenital myopathies or congenital titinopathies. Clinical features may include neck, and limb weakness, associated with joint contractures and spinal and chest wall deformities as well as early-onset respiratory insufficiency, and mild facial weakness. CPK levels varied within normal range to elevated. Interestingly, the muscle biopsy can show a variety of features, such as central nuclei, minicores, and/or dystrophic features. Due to the large size of this protein, depending on the differential splicing there are alternative isoforms of different length that will be expressed differently depending of the functional properties of each specific skeletal muscles. It also plays a key role in cardiac muscles where there are multiple mature isoforms. Several *TTN* mutations are associated with cardiomyopathy, including in particular truncating variants. The risk of cardiomyopathy in LGMDR10 is unclear.

LGMDR11, LGMDR13, LGMDR14, LGMDR15 and LGMDR24 (LGMD2K, LGMD2M, LGMD2N, LGMD2O; *POMGNT2*-related muscular dystrophy; MIM 609308; 611568; 613158; 613157) have defects of alpha-dystroglycan glycosylation due to mutations in *POMT1*, *FKTN*, *POMT2*, *POMGNT1* and *POMGNT2*, respectively. The LGMD presentation for these dystroglycanopathies includes early-onset limb girdle weakness, variable cognitive involvement with global developmental delay, and CPK levels 20 to 40 times normal. Most commonly, mutations in these genes present as CMD.

In the Turkish population, an ancestral founder mutation in *PLEC* causes LGMDR16 (LGMD2Q), which presents in early childhood as muscle weakness. Other *PLEC* mutations, however, cause epidermal bullosa simplex with late-onset muscular dystrophy or myasthenic syndrome with late-onset myopathy. *PLEC* encodes a scaffold protein critical for myofiber structure.

Previously named LGMD2R, *DES*-related muscular dystrophy is now considered part of the subgroup of distal myopathies, more specifically myofibrillar myopathy group. This reclassification also includes LGMD2V caused by pathogenic variants in *GAA* that caused Pompe disease, LGMD2W, and LGMD2Y. Currently, they have been reclassified to specific entities (*PINCH-2*–related myopathy and *TOR1AIP1*-related myopathy, respectively).

LGMDR21 (LGMD2Z) is associated with recessive mutation of *POGLUT1*. More than 20 patients have now been reported with this LGMD subtype. Onset ranges from congenital and early-onset symptoms to presentation in the fourth decade with primary respiratory complaints. All patients thus far have presented with limb girdle pattern of weakness. CK is mildly increased, muscle biopsy shows a moderate to severe dystrophic pattern, and muscle MRI is distinctive, with an "inside to outside" pattern of fatty degeneration that resembles the pattern seen with COL6-RD.

LGMDR22 and LGMDD5 are caused by mutations in three genes: *COL6A1*, *COL6A2*, *COL6A3*. They are most commonly known to produce a CMD form with a dominant or recessive inheritance pattern. LGMDR23 is due to recessive mutations in *LAMA2*, which more commonly cause MDC1A. The spectrum of LGMDR23 is quite wide, ranging from childhood onset resembling DMD or sarcoglycanopathies to milder phenotypes beginning in adolescence or adulthood. *LAMA2* encodes the laminin alpha-2 protein, and there is a direct correlation with residual laminin alpha-2 expression and the severity of the disease. COL6-RD and MDC1A are presented in detail in the section on CMDs.

LGMDR25 (LGMD2X) is caused by loss of function variants in *BVES*, encoding the Popeye domain containing protein 1 (POPDC1). This is a mild LGMD with onset between the second and the third decade associated with frequent episodes of syncope due to AV block requiring pacemaker placement in most cases. Other features include elevated CK (within 1,000-3,000 IU/L) and exercise induced myalgias.

Autosomal Dominant Limb-Girdle Muscular Dystrophy

Dominant forms are less common (10% of LGMD), are typically milder in clinical severity, and are associated with substantial clinical heterogeneity. As described as below and in subsequent sections, several subtypes previously considered as forms of dominant LGMD have now been reclassified into other muscle disease categories.

Limb-Girdle Muscular Dystrophy 1A

LGMD1A is rare and linked to defects in myotilin localized to the Z-disc near telethonin. Affected members are described as having a distinctive, dysarthric speech pattern. This disorder has now been reclassified as a myofibrillar myopathy within the distal myopathies.

Limb-Girdle Muscular Dystrophy 1B

LGMD1B is a result of mutations in the *LMNA* gene that encodes both lamin A and lamin C, which are alternative splice forms. Currently, it has been reclassified as autosomal dominant EDMD. *LMNA* mutations are also seen in hypertrophic cardiomyopathy, familial partial lipodystrophy, CMT2C, mandibuloacral dysplasia, and Hutchinson-Gilford progeria. The LGMD phenotype is relatively mild but often has significant cardiomyopathy and cardiac conduction disease similar to EDMD; some also have contractures but less severely than in EDMD.

Limb-Girdle Muscular Dystrophy 1C

Mutations in caveolin-3 (*CAV3*) cause LGMD1C. This disorder has been reclassified as rippling muscle disease. In addition, *CAV3* mutations can cause asymptomatic hyperCKemia and a form of distal myopathy. The dystrophic form of the disease often begins around age 5 years with cramping, mild weakness, and calf hypertrophy, but mild cases without clinical weakness are also seen. Caveolin-3 is a component of plasma membrane vesicular invagination structures important for cellular trafficking and signaling. CAV3 interacts with dysferlin, and in some patients with dysferlinopathy, there is a secondary reduction in CAV3 levels.

Limb Girdle Muscular Dystrophy 1D

LGMDD1 (MIM 611332) previously known as LGMD1E is caused by pathogenic variants in *DNAJ6B*. The initial phenotype encompassed an adult onset LGMD with slow progression. This phenotype is usually caused by mutations in the C-terminal. N-terminal variants produce a different phenotype

with earlier onset and distal involvement with more severe compromise of the respiratory and bulbar muscles. Muscle biopsy shows autophagic vacuoles on the center of the fiber or over the subsarcolemmal region, associated with internalized nuclei and variability on the fiber size. CPK is typically normal or slightly elevated but may be increased up to 3,000 IU/L.

Limb-Girdle Muscular Dystrophy D2

LGMDD2 (MIM 610032) is associated with mutations in *TNPO3*, found in a large Spanish family with variable juvenile to adult-onset muscular dystrophy. *TNPO3* encodes Transportin 3, a nuclear protein that is a member of the importin-beta/transportin family. Muscle biopsies in the Spanish patients showed abnormally enlarged nuclei increased mitochondria and filamentous structures observed in electron microscopy. Several other reports have described a similar phenotype.

LGMDD3 (MIM 607137) is caused by mutations in *HNRPDL*. It was identified in a Brazilian family with 12 individuals affected with slowly progressive proximal muscle weakness of variable onset (late teens to early adulthood). All patients developed type 2 diabetes after the fourth decade. Another feature present was weakness of toes and finger flexors. CPK usually is elevated (up to 10-fold above the upper normal limit). A later report contributed an additional Uruguayan family where some members developed early cataracts.

Limb-Girdle Muscular Dystrophy 1G Through Limb-Girdle Muscular Dystrophy 1H

These disorders are chromosomally mapped forms awaiting gene identification.

Differential Diagnosis

The differential diagnosis for LGMDs requires important consideration of age and clinical presentation plus any ancillary diagnostic data. For the "Duchenne-like" LGMDs (sarcoglycanopathies and dystroglycanopathies), which present with symptoms in the first decade and have a relentlessly progressive course like DMD/BMD, the key disorders to consider are DMD, type 3 SMA, and late infantile Pompe disease. Other considerations (particularly when the CPK is normal or only mildly elevated) are certain subtypes of congenital myopathy and congenital myasthenic syndrome. Lastly, inflammatory myopathies (especially anti HMGCR myopathy in pediatric cases) provide an important, and potentially treatable, differential diagnosis.

Management

Treatment presently is supportive in nature for essentially all subtypes, as meaningful disease-modifying therapies have yet to enter the clinic. As with other types of muscular dystrophy, key management considerations relate to support of motor function (mobility assistance ranging from canes to wheelchairs), respiratory care (bilevel positive airway pressure, for example, when nocturnal hypoventilation or sleep apnea develop), cardiac care (cardiomyopathy occurs in some subtypes), and orthopedic management (for scoliosis). Lifespan is not impacted in many of the subtypes. Important exceptions include the sarcoglycanopathies, which have progressive symptomatology leading respiratory failure, and, in some cases, fatal cardiac disease.

OCULOPHARYNGEAL MUSCULAR DYSTROPHY

OPMD is a late-onset autosomal dominant disorder with progressive ptosis, dysphagia, and late-onset proximal limb weakness. Autosomal recessive forms are known. Although originally recognized in French Canadian families, cases have been recognized worldwide. The bulbar onset, is usually confused with myasthenia gravis rather than other myopathies. Muscle filamentous intranuclear inclusions are a pathologic hallmark, but rimmed vacuoles are also prominent. The CPK is normal or mildly elevated. The disease maps to 14q11.2-q13 and is caused by an expanded GCG repeat in the polyadenylation-binding protein 2 (*PABP2*). The disease-producing repeat number is unusually short. The normal repeat length is 6, and disease results from lengths of 7 to 13, most commonly 9 and 10 repeats. A more severe autosomal recessive phenotype with earlier onset is described in homozygous patients. *Oculodistal muscular dystrophy* is even less common than OPMD and differs in the distribution of limb weakness, the genetic locus has not yet been mapped.

OTHER RARE DYSTROPHIES

Several forms of scapuloperoneal weakness with dystrophic muscle pathology are not linked to the FSHD site. Some show hyaline bodies. Autosomal dominant and recessive and X-linked–dominant inheritance patterns are described. A similar phenotype is neurogenic (scapuloperoneal muscular atrophy). Mutations in the *FHL1* gene cause reducing body myopathy, and a milder phenotype called X-linked dominant scapuloperoneal myopathy. Desmin and myosin heavy-chain 7 gene mutations have been identified in autosomal dominant cases. Other rare discrete entities include epidermolysis bullosa simplex with late-onset muscular dystrophy linked to plectin gene mutations and desmin-related myopathy, one with a defect in the α-β crystalline gene on 11q as well as dominant and recessive forms linked to the desmin gene on 2q. Despite all of the identified genetic defects, additional forms of LGMD will be linked to yet unidentified chromosomal loci and novel pathogenic genes.

Distal Myopathies (Distal Muscular Dystrophies)

Distal myopathies (distal muscular dystrophies) are defined by clinical manifestations in the feet and hands preceding proximal limb weakness. As heritable diseases with features of myopathy and slow progression, they are properly considered muscular dystrophies. The distinction from hereditary neuropathies is supported by spared sensation and histologic and electrodiagnostic features of myopathy. Most distal myopathies have been assigned to different chromosomal positions, confirming the clinical differences in patterns of inheritance, onset in leg or hands, predominant leg weakness in anterior or posterior compartments, presence or absence of vacuoles on muscle biopsy, and serum CPK levels.

The most common form is *Welander distal* myopathy (MIM 604454), which was first described in Sweden; inheritance is autosomal dominant. Symptoms begin in adolescence or adult years and progress slowly. The legs are affected before the hands.

Histologic changes are mild, but filamentous inclusions may resemble those seen in OPMD or inclusion body myositis. Serum CPK is only slightly elevated.

In the autosomal recessive *Nonaka* variant (MIM 605820), a vacuolar myopathy is seen, the gastrocnemius muscles are spared, and serum CPK values are only slightly increased. Nonaka distal myopathy and hereditary inclusion body myopathy share clinical and morphologic similarities; both conditions are a result of defects in the UDP-*N*-acetylglucosamine 2-epimerase/*N*-acetylmannosamine kinase (*GNE*) gene. *Miyoshi* (MIM 254130) distal myopathy is also autosomal recessive but differs from Nonaka in that the histologic changes are nonspecific (without vacuoles), the gastrocnemius muscles are affected first, and serum CPK values are notably elevated; hyperCKemia may be noted before symptomatic weakness. Miyoshi myopathy and LGMDR2 (proximal limb weakness) are allelic, map to 2p17, and are associated with mutations in *DYSF* (see Fig. 147.1). Miyoshi type 3 is due to *ANO5* mutations. Some Miyoshi families do not have mutations in either gene, which implies further locus heterogeneity. Other variants of distal myopathies have been described and more are likely to be identified.

NONDYSTROPHIC MYOPATHIES—CONGENITAL MYOPATHIES

Definitions

Congenital myopathies are a clinically and genetically heterogeneous group of conditions that have historically been identified and defined by features on muscle biopsy in the context of clinically apparent muscle disease (see Fig. 147.2). The general histopathologic definition encompasses both a lack of dystrophic findings on muscle biopsy and instead the observation of one of a range of nondystrophic changes. Such changes include the presence of excessive central nuclei (when >25% and seen in the absence of other pathology, termed *centronuclear myopathy*), the observation of nemaline rods or bodies (best seen on Gomori trichrome and verified with electron microscopy and suggestive of a diagnosis of NM), the existence of cores or core-like lesions (best appreciated with oxidative stains and often categorized as central core disease (CCD) or minicore myopathy depending on the specific appearance), and the finding of selective type I myofiber smallness in the absence of other features defining a specific congenital myopathy called congenital fiber-type disproportion. Additional abnormalities have been described, such as caps and zebra bodies, and in all, there are dozens of different categorizations of congenital myopathies derived from these biopsy observations. Additionally, it should be noted that some congenital myopathy patients show muscle replacement with fibrous and fatty tissue with increasing age, despite the lack of active muscle degeneration on muscle biopsy.

With the broad application of genetic testing, the definition of congenital myopathy is shifting. It now includes consideration of not only biopsy findings but also clinical features and genetic testing results. In many cases, patients no longer require muscle biopsy data to support their diagnosis, and the condition is instead defined based on gene mutation in the context of clinical symptoms. For example, a severely weak male infant with an underlying causative mutation in *MTM1* would be considered to have XLMTM even if he has not had a muscle biopsy or if a muscle biopsy did not show the classic features of XLMTM. Of note, mutations in more than 20 genes have been identified to cause congenital myopathy (Table 147.3) (Fig. 147.9).

Epidemiology

Establishing the true incidence and prevalence of congenital myopathies has been a challenging undertaking because it requires population-based assessment and must take into account the possibility of missed diagnoses and the fact that patients may present outside of the early childhood period. That said, there have been attempts to define these numbers, with one comprehensive study from a single U.S. state documenting a point prevalence of 1:26,000. This number is likely an underestimate due to underascertainment, and the true prevalence is probably closer to 1:10,000 (based on fraction of patients seen in typical pediatric neuromuscular clinic when compared to disorders with known prevalence such as DMD and SMA). In terms of subtype prevalence based on genetics, *RYR1*-related myopathies (ie, myopathies due to *RYR1* mutations) are by far the most common. In one study examining a large U.K. cohort, *RYR1* mutations were found in more than half the genetically solved cases. Other frequently encountered genetic subtypes include *TTN*, *ACTA1*, *SEPN1*, *NEB*, and *MTM1*. *TTN* mutations in particular are emerging as being nearly as common as *RYR1*. In terms of prevalence based on histopathology, core myopathies are the most common, reflecting the association between *RYR1* mutations and core-like lesions. NM is the next most common, followed closely by CNM.

Diagnosis

Given the setting of a suggestive clinical picture, the establishment of a definitive diagnosis of congenital myopathy comes from either a positive genetic test for a known myopathy gene or a muscle biopsy with one of the recognized histopathologic patterns (eg, centronuclear, nemaline, core). Although not systematically examined, based on available literature and anecdotal experience, genetic testing (via multigene panel or whole exome sequencing) identifies an etiology in approximately two-thirds of cases. Other supportive diagnostic studies include laboratory investigations, EMG, and muscle MRI. CPK values are typically normal, although elevated CPKs have been found in some cases (eg, some *RYR1* and *SEPN1* cases), and a high CPK cannot be used to exclude a diagnosis of congenital myopathy. Other laboratory studies have little value in terms of providing a positive diagnosis; screening metabolic laboratories, for example, have essentially no diagnostic yield. Muscle biopsy, the historic standard for congenital myopathies, is now considered second line after genetic testing in most situations. Biopsy can be essential to clarify cases when genetic testing is ambiguous (such as when a variant of unknown significance is found) or to help establish a diagnosis when genetic testing in not revealing. In critically ill neonates, a biopsy can be obtained rapidly and thus help clarify diagnosis before genetic testing results are reported. Muscle MRI is an emerging modality that has been looked at for several subtypes, and there are important patterns associated with specific genetic causes. MRI therefore can provide a useful adjunct to clarify cases where variants of unknown significance are identified or when a specific mutation eludes diagnosis on next-generation sequencing panels or whole exome sequencing. Important differential diagnoses include congenital myasthenic syndrome, CMD (and LGMDs in older children), mitochondrial disease, and spinal muscular atrophy.

TABLE 147.3 Genetic Subtypes of Congenital Myopathies[a]

Gene	Subtype	Inheritance Pattern	Protein	Primary Subcellular Involvement	Possible Pathogenesis
ACTA 1	• NM	AD, AR	Actin, α_1, skeletal muscle	Thin filament involvement	Abnormal thin filament structure
	• Cap disease (NM variant)	AD			
	• Zebra body myopathy (NM variant)	AD			
	• Congenital fiber-type disproportion	AD			
TPM3	• NM variant	AD, AR	Tropomyosin 3		
	• Cap disease (NM variant)	AD			
	• Congenital fiber-type disproportion	AD			
TPM2	• NM	AD	Tropomyosin 2 (β)		
	• Cap disease (NM variant)	AD			
TNNT1	• NM	AR	Troponin T type 1 (skeletal, slow)		
NEB	• NM	AR	Nebulin		Thin filament remodeling +/– stability
	• Core-rode myopathy	AR			
LMOD3	• NM	AR	Leiomodin 3		
KBTBD13	• NM	AD	Kelch repeat and BTB (POZ) domain containing protein 13		
CFL2	• NM	AR	Cofilin 2 (muscle)		
KLHL40	• NM	AR	Kelch-like family member 40		
KLHL41	• NM	AR	Kelch-like family member 41		
MYO18B	• NM	AR	Myosin 18B	Unknown	Unknown
RYR1	• Central core myopathy	AD, AR	Ryanodine receptor 1	Triad involvement	Abnormal EC coupling
	• Multiminicore myopathy	AR			
	• Core rod myopathy	AD, AR			
	• NM	AR			
	• Congenital fiber-type disproportion	AR			
	• Centronuclear myopathy	AR			
	• Congenital neuromuscular disease with uniform type 1 fiber	AD			
CACNAS1	• Congenital fiber-type disproportion	AR	DHPR		
STAC3	• Native American myopathy	AR	SH3 and cysteine-rich domain-containing protein 3		
ORAI1	• Tubular aggregate myopathy	AD	Transmembrane protein 142A		Abnormal SOCE
STIM1	• Tubular aggregate myopathy	AD	Stromal interaction molecule 1		
SEPN1	• Multiminicore myopathy	AR	Selenoprotein N1		Oxidative defects
	• Congenital fiber-type disproportion	AR			
CCDC78	• Centronuclear myopathy	AD	Coiled coil domain containing protein 78		Abnormal EC coupling
BIN 1	• Centronuclear myopathy	AR, AD	Amphiphysin		Membrane remodeling +/– stability
DNM2	• Centronuclear myopathy	AD	Dynamin 2		
MTM1	• Myotubular myopathy	XR	myotubularin		
SPEG	• Centronuclear myopathy with dilated cardiomyopathy	AR	SPEG complex locus		
PTPLA (HACD1)	• Congenital myopathy related to PTPLA	AR	Protein tyrosine phosphatase-like A (3-hydroxyacyl-CoA dehydratase 1)		
TTN	• Centronuclear myopathy	AR	Titin		
	• Congenital myopathy with fatal cardiomyopathy	AR			

TABLE 147.3 Genetic Subtypes of Congenital Myopathies[a] *(continued)*

Gene	Subtype	Inheritance Pattern	Protein	Primary Subcellular Involvement	Possible Pathogenesis
MYH7	• Myosin storage myopathy	AD	Myosin, heavy chain 7, cardiac muscle		Abnormal ATPase and actin-binding properties; structural abnormalities
	• Myosin storage myopathy with cardiomyopathy	AR			
	• Congenital fiber-type disproportion	AD			
MYH2	• Myosin IIa myopathy	AD, AR	Myosin, heavy chain 2, skeletal muscle	Heavy chain	Abnormal ATPase and actin-binding properties
CNTN1	• Compton-North congenital myopathy	AR	Contactin 1	NJ	Structural abnormalities; aberrant NJ adhesion
MEGF10	• Early-onset myopathy, areflexia, respiratory distress, and dysphagia	AR	Multiple EGF-like domains 10	Satellite cells	Abnormal regulation of satellite cells
	• Minicores	AR			
ZAK	• Congenital fiber-type disproportion	AR	Sterile alpha motif and leucine zipper containing kinase AZK	Unknown	Mitogen-activated protein kinase signaling pathway

Abbreviations: AD, autosomal dominant; AR, autosomal recessive; ATPase, adenosine triphosphatase; CoA, coenzyme A; DHPR, dihydropyridine receptor; EC, excitation contraction; EGF, epidermal growth factor; NJ, neuromuscular junction; NM, nemaline myopathy; SOCE, store-operated calcium entry; XR, X-linked recessive.

[a]Adapted by permission from Gonorazky HD, Bönnemann CG, Dowling JJ. The genetics of congenital myopathies. *Handb Clin Neurol*. 2018;148:549-564.

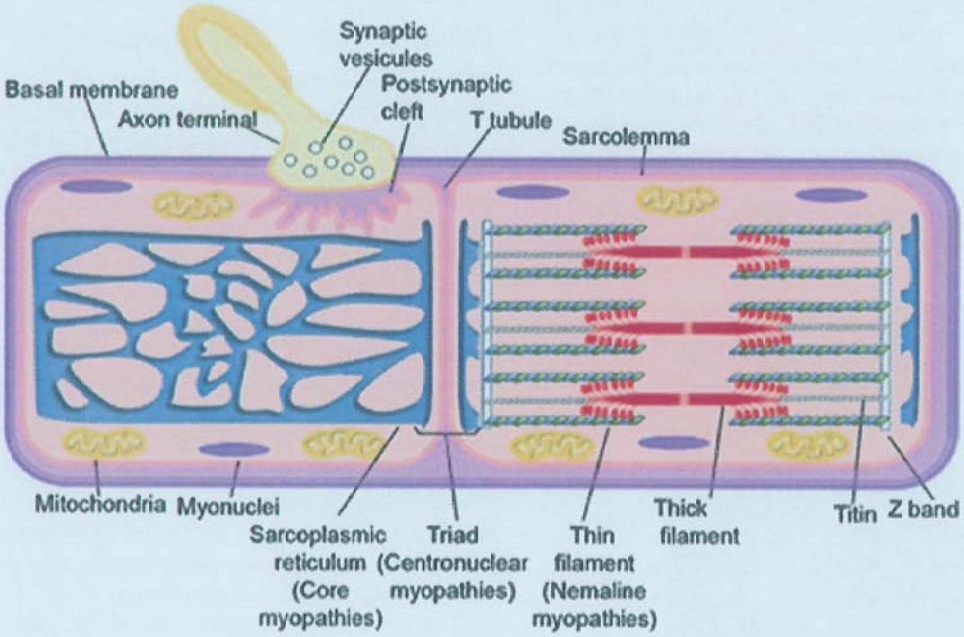

FIGURE 147.9 Skeletal muscle proteins and congenital myopathies. The triad is a structure formed by the apposition of the T tubule and the sarcoplasmic reticulum (SR). Prompted by signals from the neuromuscular junction, its depolarization allows the release of calcium from the SR (via the ryanodine receptor, RyR1) into the cytoskeleton (a process called excitation contraction coupling). The thin filaments are composed primarily of skeletal muscle actin as well as the accessory proteins nebulin, troponin, and tropomyosin. Each actin molecule has a binding site with the myosin head (which compose the thick filament). Each troponin molecule has a binding site for calcium. In the presence of calcium release from the SR during excitation contraction coupling, the troponin binds calcium and moves tropomyosin to allow the cross-bridge binding of actin with the myosin head to produce a muscle contraction. The energy for the contraction is provided by adenosine triphosphate generated from the mitochondria. The thin filaments are anchored to the Z band in part by titin, which also serves a molecular spring for the myofiber, which enables it to provide passive resistance to contraction of the sarcomere. Within brackets are the congenital myopathies that result from mutations of the proteins that function at the various muscle substructures. (Adapted by permission from Dowling JJ, Gonorazky HD, Cohn RD, Campbell C. Treating pediatric neuromuscular disorders: the future is now. *Am J Med Genet A*. 2018;176[4]:804-841.)

X-Linked Myotubular Myopathy

XLMTM is caused by a pathogenic mutation in the *MTM1* gene. The typical clinical presentation is one of severe neonatal hypotonia and weakness, including respiratory failure and challenges with oral feeding. Boys with XLMTM additionally have prominent facial weakness and ophthalmoparesis (which may be hard to detect in affected infants). Some patients will have a distinctive overall appearance that includes prominent eyes, elongated facies, dolichocephaly, long tapered fingers, and increased growth parameters (particularly when compared to other congenital myopathy patients) (Fig. 147.10). About 25% of XLMTM patients die in the first year of life. Survivors have significant support needs, with the majority requiring tracheostomy and mechanical ventilation, G-tube feeding, and wheelchair assistance for mobility. After the age of 2 years, the mortality rate is approximately 10% per year; few patients with classic XLMTM reach adulthood. The main cause of death is respiratory failure (acute on chronic), although rarely, patients experience sudden and fatal liver hemorrhage due to a condition called hepatic peliosis. Of note, XLMTM does not affect the heart directly. It is also not thought to cause cognitive impairment, but this has not been adequately studied, and recent comprehensive natural history studies suggest learning impairment may manifest in some patients.

Historically, XLMTM was defined based on suggestive muscle biopsy findings, with a pattern typical of CNM. These include myofiber hypotrophy, increased central nuclei, and a distinctive alteration of oxidative stains, with accumulation in the center of the fiber. On electron microscopy, there is depletion of triads, and triad pathology is considered a main driver of disease pathogenesis. A definitive diagnosis is considered only in cases where an *MTM1* mutation is identified. Myotubularin is a lipid phosphatase that acts in the endosome to dephosphorylate phosphoinositides. Mutations are most commonly loss of function, including nonsense, frameshift, and rearrangements (deletions and duplications). Missense mutations are also found, with some missense and splice site changes resulting in a milder phenotypic presentation. This milder phenotype accounts for about 10% to 15% of cases, and affected individuals usually achieve the ability to ambulate and do not require daytime ventilatory support. The *MTM1* gene is located on the X chromosome; as such, most patients are males. There are rarely severely manifesting carrier females who present in infancy or early childhood. There are also underrecognized clinical manifestations in "healthy" carrier females, including exercise intolerance, mild progressive weakness, myalgias, facial weakness, and ophthalmoparesis. Weakness in affected females is often asymmetric.

FIGURE 147.10 X-linked myotubular myopathy. Individual with X-linked myotubular myopathy due to mutation in the *MTM1* gene. This photo presents classical features of the disease, including ptosis, fixed eye positioning (indicative of ophthalmoparesis), facial weakness, reduced muscle bulk, and respiratory insufficiency requiring tracheostomy and invasive ventilation.

Management of XLMTM currently centers on supportive care, with critical attention to respiratory function and preservation of respiratory reserve. Pyridostigmine has been shown in preclinical models and in case reports to improve the XLMTM phenotype, although its impact on patients has not been systematically examined. Several therapies are on the cusp of clinical care, having been shown to be effective in improving muscle structure and function and animal survival in animal models of the disease. Gene replacement therapy is currently being tested in clinical trial, and preliminary data from the trial have been extremely promising. Other potential therapeutic strategies include lowering dynamin-2 (either with tamoxifen or via antisense oligonucleotide) and inhibition of the partnering lipid kinase.

Other Centronuclear Myopathies

CNM is an umbrella diagnosis that includes all myopathies with muscle biopsy findings that include >25% central/internal nuclei in the absence of dystrophic changes. In addition to XLMTM, mutations in five other genes have been found in conjunction with CNM pathology (*RYR1*, *DNM2*, *BIN1*, *SPEG*, and *TTN*). Mutations in *RYR1* and *TTN* are common causes of congenital myopathy in general, and CNM pathology is found in only a fraction of the overall cohort. Heterozygous *DNM2* mutations are the most common cause of autosomal dominant CNM. In addition to the classic features of CNM on biopsy, *DNM2* patients also have a distinctive "spoke on wheel" pattern with oxidative stains. Recessive causes include mutations in *RYR1*, *TTN*, *BIN1*, and *SPEG*. Histopathology in *RYR1* CNM may resemble XLMTM, whereas pathology in *BIN1* may look like that seen with *DNM2* CNM, with the additional feature of clumps of several internal nuclei in individual fibers. Of note, all of the CNM genes are included on multigene congenital myopathy panels, and thus, many patients are now diagnosed based on genetics alone.

There is a broad range of clinical symptomatology associated with non-XLMTM CNM. Although the spectrum of severity spans from neonatal lethality to adult onset, an overall distinguishing clinical feature of CNM as compared to other congenital myopathies is ophthalmoparesis. This is seen in all subtypes except for titinopathies. Patients with *RYR1*-related CNM tend to have severe weakness that can phenocopy XLMTM. *BIN1* and *SPEG* mutations are rare and also may be seen with neonatal onset disease; patients with *SPEG*-related CNM may have severe cardiomyopathy, and it is the only subtype documented to manifest primary heart disease. *TTN*-related CNM is typically milder with childhood onset and the ability to achieve ambulation. *DNM2*-related CNM is bimodal in distribution, with a neonatal onset form (less severe than XLMTM) and a milder form that presents in adolescence and early adulthood. There are clear genotype-phenotype correlations that account for this.

Currently, there are no dedicated therapies for the non–X-linked forms of CNM, and management is strictly supportive. As with XLMTM, and supported by preclinical data and patient case reports, pyridostigmine is used off-label by many patients with CNM. Unlike XLMTM, the therapeutic pipeline contains fewer potential therapies. In addition, the natural history is poorly defined, and suitable outcome measures have yet to be defined.

Nemaline Myopathy

NM encompasses a group of genetically heterogeneous muscle diseases unified by the observation of nemaline rods or nemaline bodies on muscle biopsy. Rods are best visualized with modified Gomori trichrome and have a distinctive appearance on electron microscopy. Clinically, NM can be broken down into categories based on clinical severity. These include severe congenital (16%), intermediate congenital (20%), typical congenital (46%), childhood onset (13%), and late onset (4%). The most striking clinical feature in NM regardless of subtype is usually lower facial and bulbar weakness, resulting in a distinctive myopathic facial appearance and impairments with speech and swallowing. Weakness tends to be more axial than appendicular and is associated with scoliosis (often severe) and respiratory failure (most typically nocturnal hypoventilation and sleep apnea). Mutations in at least 14 genes have been associated with NM. As with other myopathy subtypes, genetic testing is often pursued before muscle biopsy, and the evolving definition of NM includes cases with consistent gene mutations without a supporting muscle biopsy.

The severe congenital form often results in neonatal lethality and is on the differential for fetal akinesia syndrome. This is the only NM category with significant associated mortality. Heterozygous mutations in *ACTA1* are the most likely to result in the severe form, although *ACTA1* mutations present a wide range of clinical phenotypes. Biallelic/recessive mutations in *KLHL40*, *KLHL41*, and *LMOD3* are rare but nearly always are associated with severe or intermediate congenital forms. *LMOD3* NM is the only subtype with frequent ophthalmoparesis. Typical congenital myopathy presents with neonatal hypotonia and weakness. Extremity weakness is largely nonprogressive, and individuals typically achieve ambulation and may even show gains in strength after infancy. Persistent disability relates mainly to bulbar dysfunction and axial symptoms (neck flexor contractures, scoliosis, nocturnal respiratory failure). Biallelic/recessive mutations in *NEB* are the most common cause of typical congenital NM and overall the most common cause of NM, accounting for approximately 50% of cases. Other genetic causes for typical congenital NM include heterozygous mutations in *ACTA1*, *TPM2*, and *TPM3*. Of note, the adult-onset form of NM refers primarily to sporadic late-onset NM, an autoimmune disease that will not be discussed further in this section.

ACTA1 mutations are the second most common cause of NM. Mutations are almost always dominant missense variants, although recessive actinopathies have been reported. Mutations are found throughout the gene, and the ACTA1 protein is extremely intolerant to changes in its amino acid sequence. There is an extremely broad range of clinical severity associated with *ACTA1* mutations including notable intra- and interfamilial variation for similar mutations. The explanation for this variability is not clear but may relate either to the ratio of mutant to wild type protein or to the level of expression of the highly homologous cardiac actin isoform. Recessive actinopathies are compatible with life due to the predominant expression of the cardiac isoform during early fetal development and disease severity is inversely correlated with the postnatal level of expression of cardiac actin. Mutations can also be seen with several different histopathologic subtypes, including rods, cores, cores and rods, and fiber-type disproportion as well as rare findings such as caps and zebra bodies.

ACTA1 encodes filamentous skeletal muscle actin, the core component of the sarcomeric thin filament. *NEB* encodes nebulin, a giant protein that associates with actin, and has been shown to dictate thin filament length. *TPM2* and *TPM3* encode tropomyosins that function at the actin-myosin cross bridge; *LMOD3* is also part of this structure. Other NM genes, such as *KLHL40* and *KLHL41*, which are involved in protein ubiquitination, serve to modulate thin filament stability. In total, based on the known function of these genes and the impact of mutations, the unifying pathomechanism underlying NM is dysfunction of the structure/function of the thin filament, with a resulting consequence being reduced force generation and muscle weakness.

At present, there are no disease-modifying therapies for any NM subtype. Supportive care is as with other congenital myopathies, with an emphasis on targeted management of the severe bulbar dysfunction observed in many individuals. L-tyrosine has been reported in a case series to reduce salivation and improve speech and swallowing in some patients but results in the broad NM population are mixed at best. There are a limited number of therapeutic candidates in the development pipeline for NM, perhaps owing to the fundamental function of the thin filament and the challenge in finding modifiers for alterations in its structure and activity. There is also a need for systematic examination of disease natural history and identification of outcome measures suitable for interventional clinical trials.

Core Myopathies—RYR1-Related Myopathies

RYR1-related myopathies are the most common subtype of congenital myopathy. In some populations, the prevalence of pathogenic *RYR1* variants is thought to be as high as 1:10,000. Mutations in *RYR1* manifest an extremely broad range of clinical presentations and histopathologic features. The classic disorder associated with heterozygous missense mutations is CCD, named for the characteristic absence of staining seen with oxidative stains on muscle biopsy. Patients with CCD tend to have mild/moderate extremity weakness that is nonprogressive, although occasionally, individuals can present with severe symptoms starting at birth that can result in respiratory failure and even early death (**Fig. 147.11**). Another classic disorder associated with heterozygous *RYR1* variants is MH, a pharmacogenetic condition precipitated by volatile anesthetics and that is characterized by fever, muscle rigidity, and fulminant muscle breakdown. Some patients will have both CCD and MH. Other clinical conditions linked to heterozygous variants are exertional rhabdomyolysis, myalgias with exercise intolerance, periodic paralysis, and heat stroke.

An approximately equal proportion of cases are caused by recessive/biallelic mutations in *RYR1*. Patients with recessive *RYR1*-related myopathy tend to have an overall more severe clinical picture as compared to patients with heterozygous/dominant mutations. The recessive *RYR1*-myopathy phenotype often includes diffuse weakness with extraocular and facial muscle weakness. All motor domains are usually impacted, and affected individuals are often wheelchair and ventilator

FIGURE 147.11 Central core disease. Photograph of an individual with central core disease (as established by muscle biopsy) and a de novo heterozygous mutation in the *RYR1* gene. Key features of the disease illustrated in this picture include mild lower facial weakness, respiratory muscle weakness (as evidenced by the presence of a tracheostomy), muscle hypotrophy, and chest wall skeletal deformity.

dependent, although there is a range of severity that is correlated in many cases with the type of *RYR1* mutations. Specifically, patients with nonsense or frameshift mutations tend to have a more severe disease compared to individuals with two missense variants. In terms of histopathology, central cores are only rarely encountered in recessive cases; instead, biopsies are characterized by a range of findings including multiminicores, core-like lesions, central nuclei, and/or fiber-type disproportion. Correlations between histotype and phenotype are not fully defined, nor is the relationship between histotype and genotype.

RYR1 is a large gene with 106 exons that encodes the ryanodine type I receptor (RyR1). RyR1 is a calcium channel located at the terminal sarcoplasmic reticulum. It is a key component of the excitation contraction apparatus and an important contributor to intracellular calcium homeostasis in skeletal muscle. Mutations are located throughout the gene. There are three "hotspots" for missense mutations where the majority of the mutations associated with either CCD or MH or their combination are found. Mutation consequence falls into four broad categories: leading to reduced levels of RyR1 protein, resulting in impaired release of calcium from the sarcoplasmic reticulum, causing chronic calcium leak, and leading to hyperexcitability to various stimuli (such as volatile anesthetics or heat).

Clinical management is dictated by disease severity and the presence of dynamic symptoms. For example, individuals with mutations with expected MH susceptibility should be given appropriate anesthetic precautions, although in practice, most/all patients with *RYR1* mutations are considered as MH susceptible. MH reactions are treated intraoperatively with dantrolene. Individuals with exercise intolerance, exertional rhabdomyolysis, and heat illness are cautioned to avoid certain conditions (such as avoiding exertion on hot days); there is some case study evidence for use of dantrolene to improve exercise tolerance and reduce myalgias. For patients with static symptoms, care is anticipatory and related to maintenance of respiratory function and support for extremity muscle weakness. Skeletal problems are common, including chest wall deformities and progressive scoliosis, and scoliosis surgery is often required. Importantly, other organ systems are not affected in *RYR1* myopathy; there is no evidence of cardiac involvement, and cognitive function is intact.

Currently, there are no disease-modifying treatments other than dantrolene for MH. Aberrant oxidative stress has been found in both preclinical models and in patients. However, a clinical trial evaluating the antioxidant N-acetyl cysteine did not show clinical benefit. Additional therapeutic strategies, such as drugs (eg, Rycals) that improve RyR1 calcium release, are in development; in parallel, work to establish a better understanding of disease natural history is ongoing. Of note, RyR1 interacts with the dihydropyridine receptor to help regulate excitation contraction coupling in the muscle. Mutations in a subunit of this receptor, *CACNA1S*, cause muscle diseases with substantial phenotypic overlap to *RYR1*-related myopathies. These include MH susceptibility (with heterozygous *CACNA1S* mutations) and a severe myopathy with core like lesions due to recessive mutations.

Core Myopathies—SELENON-Related Myopathy

The other major cause of core myopathy is recessive mutations in the *SELN* gene, previously known as *SEPN1*. *SELN*-related myopathy is associated with several histotypes including minicore myopathy (most common), Mallory body myopathy, congenital fiber-type disproportion, and rigid spine muscular dystrophy. Despite these range of pathologic changes, the phenotype is generally uniform and is characterized by axial weakness with severe neck flexion weakness, contractures, rigid spine, and progressive scoliosis, with relative sparing of the extremity muscles, fitting overall with so-called rigid spine syndrome. Respiratory insufficiency is severe and progressive with patients often requiring nocturnal and eventually daytime noninvasive ventilatory support while remaining ambulant.

SELN encodes the SELENON protein, a selenocysteine containing cytoplasmic protein that has an important role in regulating oxidative stress in skeletal muscle fiber. Disease pathogenesis is likely related to impaired ability of the myofiber to buffer pro-oxidants and free radicals, which cause subsequent damage. A logical potential therapeutic strategy therefore for *SELN*-related myopathy is antioxidant therapy; preclinical studies (in mice and patient cells) support this approach. A clinical trial of *N*-acetylcysteine is in progress.

Management at present in *SELN*-related myopathy focuses on optimization of respiratory function, monitoring of scoliosis, and eventual scoliosis surgery. Respiratory insufficiency and scoliosis are progressive and can often worsen rapidly. Despite these severe comorbidities, and the recognizable nature of the condition, there appears to be substantial underdiagnosis of *SELN*-related myopathy. This assertion is backed by estimations based on mutational frequency in the general population.

TTNopathies

An emerging group of myopathies are due to mutations in *TTN*, one of the largest genes in the genome. Heterozygous (typically truncating) mutations in *TTN* are known to be a common cause of dilated cardiomyopathy. *TTN*-related skeletal myopathy (or TTNopathy) has only recently come to the fore, largely due to improvements in sequencing technology and the ability to comprehensively and accurately examine the whole *TTN* gene in a cost-effective manner. TTNopathy is likely to be the second most common form of congenital myopathy after *RYR1*-related myopathy.

The clinical spectrum of TTNopathy is continually expanding and unifying phenotypes or histotypes have yet to emerge. Recessive TTNopathy is perhaps the most prevalent subtype. Patients typically have diffuse extremity weakness with onset in infancy or early childhood, with a relatively nonprogressive course. Facial muscles are largely spared, and no cases have yet been identified with ophthalmoparesis. There is an increased risk of cardiomyopathy, the extent of which is uncertain and difficult to predict. An additional obstacle to accurately diagnosing a titinopathy is the large number of *TTN* variants of unknown significance (mostly missense variants) and the risk of improperly attributing pathogenicity to polymorphic changes that do not contribute to a patient's underlying disease. Variants require careful clinical correlation; lower extremity muscle MRI may reveal a pattern of selective involvement of the semitendinosus muscle that can aid in the diagnostic clarification of *TTN*-related myopathy.

TTN encodes the giant protein Titin. Titin spans the length of the sarcomere and is thought to act as a molecular spring to provide mechanical support and stability to the myofiber during muscle contraction. Titin likely also participates in signaling processes within the myofiber. At present, there are no clear disease-modifying therapies. One challenge is that the large size of TTN makes it somewhat difficult to model, and its myriad functions make it difficult to elucidate specific impairments associated with *TTN* mutations.

Management

There are currently no approved therapies for any subtype of congenital myopathy. Care is therefore supportive in nature. Key management considerations are related to respiratory care, feeding assistance, and neuromotor support. Most individuals with congenital myopathy will experience respiratory failure, ranging from severe symptomatology present from birth (requiring mechanical ventilation) to nocturnal hypoventilation with onset in the teen or adult years (managed with noninvasive ventilatory strategies). Feeding difficulties are also common, as facial weakness is a relatively specific clinical feature of congenital myopathies and can often result in an inability to chew/swallow food. A feeding tube is required in more than a quarter of cases. In terms of motor function, approximately 25% of patients with congenital myopathy will fail to independently ambulate, and about 10% of those who walk eventually lose the ability to do so. Musculoskeletal problems, including joint contractures and scoliosis, are common and can be progressive, and scoliosis surgery is commonly required.

Outcomes

The majority of patients have relatively nonprogressive disease and are able to live into adulthood. A fraction of patients present with extremely severe neonatal disease, resulting either in death in infancy or during childhood. Disease outcomes in adults with congenital myopathy are poorly defined, although it is likely that there is progressive disability that is currently under appreciated.

LEVEL 1 EVIDENCE

1. Moxley RT III, Ashwal S, Pandya S, et al; for Quality Standards Subcommittee of the American Academy of Neurology, Practice Committee of the Child Neurology Society. Practice parameter: corticosteroid treatment of Duchenne dystrophy: report of the Quality Standards Subcommittee of the American Academy of Neurology and the Practice Committee of the Child Neurology Society. *Neurology*. 2005;64(1):13-20.

SUGGESTED READINGS

General

Crudele JM, Chamberlain JS. AAV-based gene therapies for the muscular dystrophies. *Hum Mol Genet*. 2019;28(R1):R102-R107. doi:10.1093/hmg/ddz128.

Dowling JJ, Gonorazky HD, Cohn RD, Campbell C. Treating pediatric neuromuscular disorders: the future is now. *Am J Med Genet A*. 2018;176(4):804-841.

Emery AE. The muscular dystrophies. *Lancet*. 2002;359(9307):687-695. doi:10.1016/S0140-6736(02)07815-7.

Hoffman EP, McNally EM. Exon-skipping therapy: a roadblock, detour, or bump in the road? *Sci Transl Med*. 2014;6:230.

Congenital Muscular Dystrophies

Bönnemann CG. The collagen VI-related myopathies: muscle meets its matrix. *Nat Rev Neurol*. 2011;7(7):379-390. doi:10.1038/nrneurol.2011.81.

Bönnemann CG, Wang CH, Quijano-Roy S, et al. Diagnostic approach to the congenital muscular dystrophies. *Neuromuscul Disord*. 2014;24(4):289-311.

Godfrey C, Foley AR, Clement E, Muntoni F. Dystroglycanopathies: coming into focus. *Curr Opin Genet Dev*. 2011;21(3):278-285. doi:10.1016/j.gde.2011.02.001.

Jain MS, Meilleur K, Kim E, et al. Longitudinal changes in clinical outcome measures in COL6-related dystrophies and LAMA2-related dystrophies. *Neurology*. 2019;93(21):e1932-e1943. doi:10.1212/WNL.0000000000008517.

Kang PB, Morrison L, Iannaccone ST, et al. Evidence-based guideline summary: evaluation, diagnosis, and management of congenital muscular dystrophy: report of the Guideline Development Subcommittee of the American Academy of Neurology and the Practice Issues Review Panel of the American Association of Neuromuscular & Electrodiagnostic Medicine. *Neurology*. 2015;84(13):1369-1378.

Kemaladewi DU, Maino E, Hyatt E, et al. Correction of a splicing defect in a mouse model of congenital muscular dystrophy type 1A using a homology-directed-repair-independent mechanism. *Nat Med*. 2017;23(8):984-989.

Oliveira J, Gruber A, Cardoso M, et al. LAMA2 gene mutation update: toward a more comprehensive picture of the laminin-α2 variome and its related phenotypes. *Hum Mutat*. 2018;39(10):1314-1337. doi:10.1002/humu.23599.

Sframeli M, Sarkozy A, Bertoli M, et al. Congenital muscular dystrophies in the UK population: clinical and molecular spectrum of a large cohort diagnosed over a 12-year period. *Neuromuscul Disord*. 2017;27(9):793-803.

Wang CH, Bonnemann CG, Rutkowski A, et al. Consensus statement on standard of care for congenital muscular dystrophies. *J Child Neurol*. 2010;25(12):1559-1581.

Yurchenco PD, McKee KK, Reinhard JR, Rüegg MA. Laminin-deficient muscular dystrophy: molecular pathogenesis and structural repair strategies. *Matrix Biol*. 2018;71-72:174-187. doi:10.1016/j.matbio.2017.11.009.

Congenital Myopathies

Amburgey K, McNamara N, Bennett LR, McCormick ME, Acsadi G, Dowling JJ. Prevalence of congenital myopathies in a representative pediatric united states population. *Ann Neurol*. 2011;70(4):662-665. doi:10.1002/ana.22510.

Carlier RY, Quijano-Roy S. Myoimaging in congenital myopathies. *Semin Pediatr Neurol*. 2019;29:30-43. doi:10.1016/j.spen.2019.03.019.

Childers MK, Joubert R, Poulard K, et al. Gene therapy prolongs survival and restores function in murine and canine models of myotubular myopathy. *Sci Transl Med*. 2014;6(220):220ra10.

Colombo I, Scoto M, Manzur AY, et al. Congenital myopathies: natural history of a large pediatric cohort. *Neurology*. 2015;84(1):28-35. doi:10.1212/WNL.0000000000001110.

Gonorazky HD, Bönnemann CG, Dowling JJ. The genetics of congenital myopathies. *Handb Clin Neurol*. 2018;148:549-564.

Jungbluth H, Treves S, Zorzato F, et al. Congenital myopathies: disorders of excitation-contraction coupling and muscle contraction. *Nat Rev Neurol*. 2018;14(3):151-167.

Lawal TA, Todd JJ, Meilleur KG. Ryanodine receptor 1-related myopathies: diagnostic and therapeutic approaches. *Neurotherapeutics*. 2018;15(4):885-899. doi:10.1007/s13311-018-00677-1.

Oates EC, Jones KJ, Donkervoort S, et al. Congenital titinopathy: comprehensive characterization and pathogenic insights. *Ann Neurol*. 2018;83(6):1105-1124. doi:10.1002/ana.25241.

Ravenscroft G, Laing NG, Bönnemann CG. Pathophysiological concepts in the congenital myopathies: blurring the boundaries, sharpening the focus. *Brain*. 2015:138;246-268. doi:10.1093/brain/awu368.

Saade DN, Neuhaus SB, Foley AR, Bönnemann CG. The use of muscle ultrasound in the diagnosis and differential diagnosis of congenital disorders of muscle in the age of next generation genetics. *Semin Pediatr Neurol*. 2019;29:44-54. doi:10.1016/j.spen.2019.01.001.

Sewry CA, Laitila JM, Wallgren-Pettersson C. Nemaline myopathies: a current view. *J Muscle Res Cell Motil*. 2019;40(2):111-126. doi:10.1007/s10974-019-09519-9.

Tasfaout H, Cowling BS, Laporte J. Centronuclear myopathies under attack: a plethora of therapeutic targets. *J Neuromuscul Dis*. 2018;5(4):387-406. doi:10.3233/JND-180309.

Todd JJ, Lawal TA, Witherspoon JW, et al. Randomized controlled trial of *N*-acetylcysteine therapy for *RYR1*-related myopathies. *Neurology*. 2020;94(13):e1434-e1444. doi:10.1212/WNL.0000000000008872.

Wang CH, Dowling JJ, North K, et al. Consensus statement on standard of care for congenital myopathies. *J Child Neurol*. 2012;27(3):363-382.

Duchenne Muscular Dystrophy

Amoasii L, Hildyard JCW, Li H, et al. Gene editing restores dystrophin expression in a canine model of Duchenne muscular dystrophy. *Science*. 2018;362(6410):86-91. doi:10.1126/science.aau1549.

Birnkrant DJ, Bushby K, Bann CM, et al. Diagnosis and management of Duchenne muscular dystrophy, part 1: diagnosis, and neuromuscular, rehabilitation, endocrine, and gastrointestinal and nutritional management. *Lancet Neurol*. 2018;17(3):251-267.

Birnkrant DJ, Bushby K, Bann CM, et al. Diagnosis and management of Duchenne muscular dystrophy, part 2: respiratory, cardiac, bone health, and orthopaedic management. *Lancet Neurol*. 2018;17(4):347-361. doi:10.1016/S1474-4422(18)30025-5.

Birnkrant DJ, Bushby K, Bann CM, et al. Diagnosis and management of Duchenne muscular dystrophy, part 3: primary care, emergency management, psychosocial care, and transitions of care across the lifespan. *Lancet Neurol*. 2018;17(5):445-455.

Charleston JS, Schnell FJ, Dworzak J, et al. Eteplirsen treatment for Duchenne muscular dystrophy: exon skipping and dystrophin production [published correction appears in *Neurology*. 2018;91(13):637]. *Neurology*. 2018;90(24):e2146-e2154. doi:10.1212/WNL.0000000000005680. (class II evidence of exon skipping)

Crone M, Mah JK. Current and emerging therapies for Duchenne muscular dystrophy. *Curr Treat Options Neurol*. 2018;20(8):31.

Flanigan KM, Ceco E, Lamar KM, et al. LTBP4 genotype predicts age of ambulatory loss in Duchenne muscular dystrophy. *Ann Neurol*. 2013;73(4):481-488. doi:10.1002/ana.23819.

Frank DE, Schnell FJ, Akana C, et al. Increased dystrophin production with golodirsen in patients with Duchenne muscular dystrophy. *Neurology*. 2020;94(21):e2270-e2282. doi:10.1212/WNL.0000000000009233.

Griggs RC, Miller JP, Greenberg CR, et al. Efficacy and safety of deflazacort vs prednisone and placebo for Duchenne muscular dystrophy. *Neurology*. 2016;87(20):2123-2131. doi:10.1212/WNL.0000000000003217. (class I evidence for efficacy for either deflazacort or prednisone)

McDonald CM, Campbell C, Torricelli RE, et al. Ataluren in patients with nonsense mutation Duchenne muscular dystrophy (ACT DMD): a multicentre, randomised, double-blind, placebo-controlled, phase 3 trial. *Lancet*. 2017;390(10101):1489-1498. doi:10.1016/S0140-6736(17)31611-2.

Mendell JR, Sahenk Z, Lehman K, et al. Assessment of systemic delivery of rAAVrh74.MHCK7.micro-dystrophin in children with Duchenne muscular dystrophy: a nonrandomized controlled trial [published online ahead of print June 15, 2020]. *JAMA Neurol*. 2020;e201484. doi:10.1001/jamaneurol.2020.1484.

Facioscapulohumeral Muscular Dystrophy

Goselink RJM, Schreuder THA, van Alfen N, et al. Facioscapulohumeral dystrophy in childhood: a nationwide natural history study. *Ann Neurol*. 2018;84(5):627-637. doi:10.1002/ana.25326.

Hamel J, Tawil R. Facioscapulohumeral muscular dystrophy: update on pathogenesis and future treatments. *Neurotherapeutics*. 2018;15(4):863-871. doi:10.1007/s13311-018-00675-3.

Kissel JT, McDermott MP, Mendell JR, et al; for FSH-DY Group. Randomized, double-blind, placebo-controlled trial of albuterol in facioscapulohumeral dystrophy. *Neurology*. 2001;57:1434-1440. (albuterol not effective; first clinical trial for FSHD)

Lek A, Zhang Y, Woodman KG, et al. Applying genome-wide CRISPR-Cas9 screens for therapeutic discovery in facioscapulohumeral muscular dystrophy. *Sci Transl Med*. 2020;12(536):eaay0271. doi:10.1126/scitranslmed.aay0271.

Lemmers RJ, Tawil R, Petek LM, et al. Digenic inheritance of an SMCHD1 mutation and an FSHD-permissive D4Z4 allele causes facioscapulohumeral muscular dystrophy type 2. *Nat Genet*. 2012;44(12):1370-1374. doi:10.1038/ng.2454.

Lemmers RJ, van der Vliet PJ, Klooster R, et al. A unifying genetic model for facioscapulohumeral muscular dystrophy. *Science*. 2010;329(5999):1650-1653. doi:10.1126/science.1189044.

LoRusso S, Johnson NE, McDermott MP, et al. Clinical trial readiness to solve barriers to drug development in FSHD (ReSolve): protocol of a large, international, multi-center prospective study. *BMC Neurol*. 2019;19(1):224. doi:10.1186/s12883-019-1452-x.

Sacconi S, Briand-Suleau A, Gros M, et al. $FSHD_1$ and $FSHD_2$ form a disease continuum. *Neurology*. 2019;92(19):e2273-e2285. doi:10.1212/WNL.0000000000007456.

Tawil R, Kissel JT, Heatwole C, et al. Evidence-based guideline summary: evaluation, diagnosis, and management of facioscapulohumeral muscular dystrophy: report of the Guideline Development, Dissemination, and Implementation Subcommittee of the American Academy of Neurology and the Practice Issues Review Panel of the American Association of Neuromuscular & Electrodiagnostic Medicine. *Neurology*. 2015;85(4):357-364.

Tawil R, Van Der Maarel SM, Tapscott SJ. Facioscapulohumeral muscular dystrophy. The path to consensus on pathophysiology. *Skelet Muscle*. 2014;4:12.

Emery-Dreifuss Muscular Dystrophy

Bonne G, Di Barletta MR, Varnous S, et al. Mutations in the gene encoding lamin A/C cause autosomal dominant Emery-Dreifuss muscular dystrophy. *Nat Genet*. 1999;21(3):285-288.

Bonne G, Quijano-Roy S. Emery-Dreifuss muscular dystrophy, laminopathies, and other nuclear envelopathies. *Handb Clin Neurol*. 2013;113:1367-1376.

Fatkin D, MacRae C, Sasaki T, et al. Missense mutations in the rod domain of the lamin A/C gene as causes of dilated cardiomyopathy and conduction-system disease. *N Engl J Med*. 1999;341:1715-1724.

Heller SA, Shih R, Kalra R, Kang PB. Emery-Dreifuss muscular dystrophy. *Muscle Nerve*. 2020;61(4):436-448. doi:10.1002/mus.26782.

Liang WC, Mitsuhashi H, Keduka E, et al. TMEM43 mutations in Emery-Dreifuss muscular dystrophy-related myopathy. *Ann Neurol*. 2011;69(6):1005-1013.

Mercuri E, Poppe M, Quinlivan R, et al. Extreme variability of phenotype in patients with an identical missense mutation in the lamin A/C gene: from congenital onset with severe phenotype to milder classic Emery-Dreifuss variant. *Arch Neurol*. 2004;61:690-694.

Muchir A, Worman HJ. Emery-Dreifuss muscular dystrophy: focal point nuclear envelope. *Curr Opin Neurol*. 2019;32(5):728-734. doi:10.1097/WCO.0000000000000741.

Quijano-Roy S, Mbieleu B, Bönnemann CG, et al. De novo LMNA mutations cause a new form of congenital muscular dystrophy. *Ann Neurol*. 2008;64(2):177-186. doi:10.1002/ana.21417.

Quinzii C, Vu TH, Min C, et al. X-linked dominant scapuloperoneal myopathy is due to a mutation in the gene encoding four-and-a-half LIM protein 1. *Am J Hum Genet*. 2008;82:208-213.

Zhang Q, Bethmann C, Worth NF, et al. Nesprin-1 and -2 are involved in the pathogenesis of Emery Dreifuss muscular dystrophy and are critical for nuclear envelope integrity. *Hum Mol Genet*. 2007;16(23):2816-2833. doi:10.1093/hmg/ddm238.

Limb-Girdle Dystrophies

Angelini C, Giaretta L, Marozzo R. An update on diagnostic options and considerations in limb-girdle dystrophies. *Expert Rev Neurother*. 2018;18(9):693-703.

Ghaoui R, Cooper ST, Lek M, et al. Use of whole-exome sequencing for diagnosis of limb-girdle muscular dystrophy: outcomes and lessons learned. *JAMA Neurol*. 2015;72(12):1424-1432. doi:10.1001/jamaneurol.2015.2274.

Liu J, Harper SQ. RNAi-based gene therapy for dominant limb girdle muscular dystrophies. *Curr Gene Ther*. 2012;12(4):307-314. doi:10.2174/156652312802083585.

Mendell JR, Chicoine LG, Al-Zaidy SA, et al. Gene delivery for limb-girdle muscular dystrophy type 2D by isolated limb infusion. *Hum Gene Ther*. 2019;30(7):794-801. doi:10.1089/hum.2019.006.

Narayanaswami P, Weiss M, Selcen D, et al. Evidence-based guideline summary: diagnosis and treatment of limb-girdle and distal dystrophies: report of the Guideline Development Subcommittee of the American Academy of Neurology and the Practice Issues Review Panel of the American Association of Neuromuscular & Electrodiagnostic Medicine. *Neurology*. 2014;83(16):1453-1463.

Straub V, Murphy A, Udd B; for LGMD Workshop Study Group. 229th ENMC International Workshop: limb girdle muscular dystrophies—nomenclature and reformed classification Naarden, the Netherlands, 17-19 March 2017. *Neuromuscul Disord*. 2018;28(8):702-710. doi:10.1016/j.nmd.2018.05.007.

Vissing J. Limb girdle muscular dystrophies: classification, clinical spectrum and emerging therapies. *Curr Opin Neurol*. 2016;29(5):635-641. doi:10.1097/WCO.0000000000000375.

Walter MC, Reilich P, Thiele S, et al. Treatment of dysferlinopathy with deflazacort: a double-blind, placebo-controlled clinical trial. *Orphanet J Rare Dis*. 2013;8:26. doi:10.1186/1750-1172-8-26.

Warman Chardon J, Díaz-Manera J, Tasca G, et al. MYO-MRI diagnostic protocols in genetic myopathies. *Neuromuscul Disord*. 2019;29(11):827-841. doi:10.1016/j.nmd.2019.08.011.

Wicklund MP, Kissel JT. The limb-girdle muscular dystrophies. *Neurol Clin*. 2014;32(3):729-ix. doi:10.1016/j.ncl.2014.04.005.

Myotonic Dystrophy

Ashizawa T, Gagnon C, Groh WJ, et al. Consensus-based care recommendations for adults with myotonic dystrophy type 1. *Neurol Clin Pract*. 2018;8(6):507-520.

Gao Z, Cooper TA. Antisense oligonucleotides: rising stars in eliminating RNA toxicity in myotonic dystrophy. *Hum Gene Ther*. 2013;24(5):499-507.

Johnson NE, Aldana EZ, Angeard N, et al. Consensus-based care recommendations for congenital and childhood-onset myotonic dystrophy type 1. *Neurol Clin Pract*. 2019;9(5):443-454. doi:10.1212/CPJ.0000000000000646.

Johnson NE, Butterfield R, Berggren K, et al. Disease burden and functional outcomes in congenital myotonic dystrophy: a cross-sectional study. *Neurology*. 2016;87(2):160-167. doi:10.1212/WNL.0000000000002845.

Lanni S, Pearson CE. Molecular genetics of congenital myotonic dystrophy. *Neurobiol Dis*. 2019;132:104533. doi:10.1016/j.nbd.2019.104533.

Liquori CL, Ricker K, Moseley ML, et al. Myotonic dystrophy type 2 caused by a CCTG expansion in intron 1 of ZNF9. *Science*. 2001;293(5531):864-867. doi:10.1126/science.1062125.

Logigian EL, Martens WB, Moxley RT IV, et al. Mexiletine is an effective antimyotonia treatment in myotonic dystrophy type 1. *Neurology*. 2010;74(18):1441-1448. doi:10.1212/WNL.0b013e3181dc1a3a. (class I evidence)

McNally EM, Mann DL, Pinto Y, et al. Clinical care recommendations for cardiologists treating adults with myotonic dystrophy. *J Am Heart Assoc*. 2020;9(4):e014006. doi:10.1161/JAHA.119.014006.

Schoser B, Montagnese F, Bassez G, et al. Consensus-based care recommendations for adults with myotonic dystrophy type 2. *Neurol Clin Pract*. 2019;9(4):343-353.

Thornton CA, Wang E, Carrell EM. Myotonic dystrophy: approach to therapy. *Curr Opin Genet Dev*. 2017;44:135-140. doi:10.1016/j.gde.2017.03.007.

Wheeler TM, Leger AJ, Pandey SK, et al. Targeting nuclear RNA for in vivo correction of myotonic dystrophy. *Nature*. 2012;488(7409):111-115. doi:10.1038/nature11362.

Yum K, Wang ET, Kalsotra A. Myotonic dystrophy: disease repeat range, penetrance, age of onset, and relationship between repeat size and phenotypes. *Curr Opin Genet Dev*. 2017;44:30-37. doi:10.1016/j.gde.2017.01.007.

Other Dystrophies

Brais B. Oculopharyngeal muscular dystrophy. *Handb Clin Neurol*. 2011;101:181-192.

Brockington M, Yuva Y, Prandini P, et al. Mutations in fukutin-related protein gene (FKRP) identify limb-girdle muscular dystrophy 2I as a milder allelic variant of congenital muscular dystrophy MDC1C. *Hum Mol Genet*. 2001;10:2851-2859.

Dowling JJ, Moore SA, Kalimo H, Minassian BA. X-linked myopathy with excessive autophagy: a failure of self-eating. *Acta Neuropathol*. 2015;129(3):383-390. doi:10.1007/s00401-015-1393-4.

Hackman P, Sarparanta J, Lehtinen S, et al. Welander distal myopathy is caused by a mutation in the RNA-binding protein TIA1. *Ann Neurol*. 2013;73(4):500-509.

Kayman-Kurekci G, Talim B, Korkusuz P, et al. Mutation in TOR1AIP1 encoding LAP1B in a form of muscular dystrophy: a novel gene related to nuclear envelopathies. *Neuromuscul Disord*. 2014;24(7):624-633.

Milone M, Liewluck T. The unfolding spectrum of inherited distal myopathies. *Muscle Nerve*. 2019;59(3):283-294. doi:10.1002/mus.26332.

Savarese M, Johari M, Johnson K, et al. Improved criteria for the classification of titin variants in inherited skeletal myopathies. *J Neuromuscul Dis*. 2020;7(2):153-166. doi:10.3233/JND-190423.

Schessl J, Zou Y, McGrath MJ, et al. Proteomic identification of FHL1 as the protein mutated in human reducing body myopathy. *J Clin Invest*. 2008;118(3):904-912. doi:10.1172/JCI34450.

Udd B. Molecular biology of distal muscular dystrophies—sarcomeric proteins on top. *Biochim Biophys Acta*. 2007;1772:145-158.

148 Seizures and Epilepsies in Neonates and Children

Tristan T. Sands and M. Roberta Cilio

KEY POINTS

1. A child's age affects the risk for seizures and epilepsies; in turn, epileptic activity has the potential to negatively impact neurodevelopment.
2. Seizure and epilepsy incidences are high in neonates; distinguishing epilepsy from acute symptomatic seizures is critical for appropriate management.
3. Febrile seizures affect 2% to 5% of children, most presenting between 6 months and 3 years; only 2% to 5% of children with febrile seizures have epilepsy.
4. Epilepsy syndromes, defined by age of onset, clinical context, seizure type(s), and findings on electroencephalography, have implications for treatment and prognosis.
5. Single gene causes of epilepsy in children are increasingly identified and precision medicine approaches are actively being pursued.
6. Children with refractory epilepsy may be surgical candidates; cortical dysplasia is a common cause of epilepsy leading to neurosurgical intervention.

INTRODUCTION

Incidence of seizures and epilepsy peaks in the first years of life, stabilizes after adolescence, and rises again in old age. A child's age in part determines the risk for seizures and how epilepsy may manifest and, in turn, seizures and epilepsy have the potential to negatively impact neurodevelopment. The age-dependent expression of epilepsy gives rise to particular conditions, each characterized by the age of onset, clinical context, seizure type(s), electroencephalography (EEG) findings, associated etiologies, and prognosis (Fig. 148.1).

The evaluation of unprovoked seizures relies not only on history and examination but also crucially on EEG monitoring for characterization of the brain activity, accurate seizure identification, and clarification of seizure type. This initial workup determines subsequent investigations into etiology, selection of antiseizure medication, and family counseling.

Epilepsy in children may be acquired, following brain injury or associated with cerebral malformations, genetic syndromes (eg, trisomy 21), inborn errors of metabolism, and pathogenic variants in a growing number of genes identified as monogenic causes of neurodevelopmental disability and/or epilepsy. In many cases, the cause of epilepsy remains undetermined, but the number of patients with unknown etiology is progressively decreasing thanks to the advances in EEG monitoring, neuroimaging, and genetics.

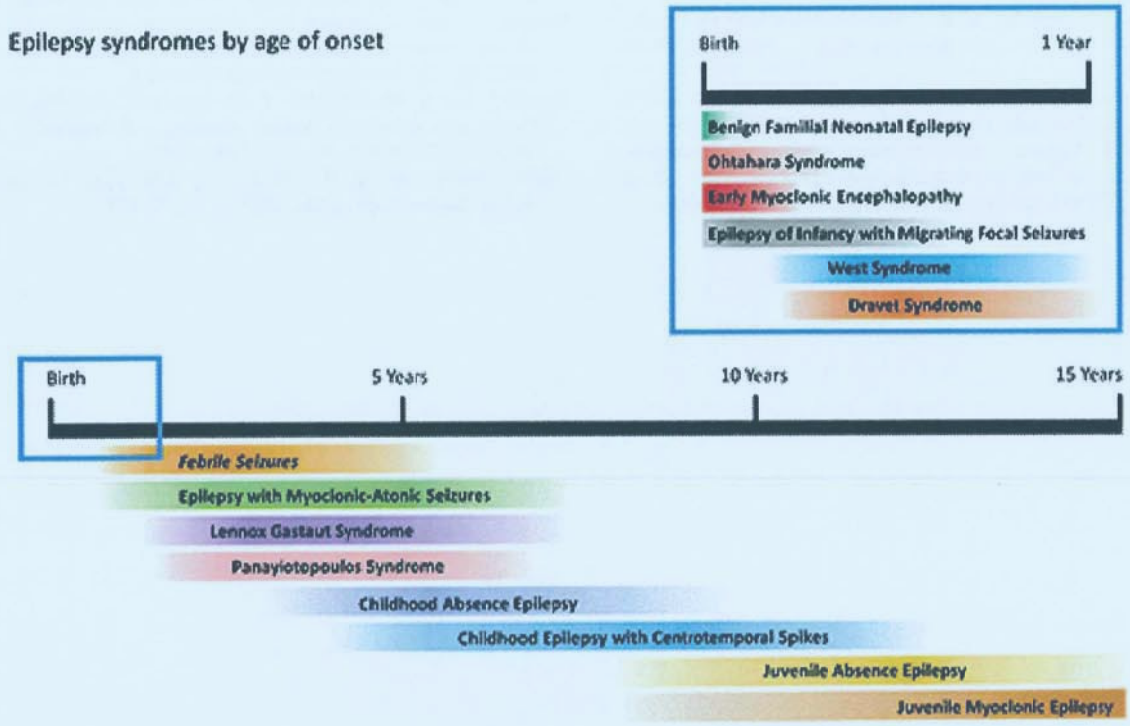

FIGURE 148.1 Epilepsy syndromes by age of onset. "Febrile seizures" is italicized as an age-dependent condition not traditionally diagnosed as epilepsy.

AGE-DEPENDENT SEIZURES NOT TRADITIONALLY DIAGNOSED AS EPILEPSY

In the following section, we discuss seizures in neonates because of particularities related to the expression of seizures in the setting of early brain development. We then discuss seizures provoked by fever in the absence of central nervous system (CNS) infection in infants and toddlers, which is one of the most common neurologic complaints in the pediatric emergency department.

Neonatal Seizures

Seizure incidence is high in the neonatal period, affecting 1 to 3.8 per 1,000 term neonates. Most cases are due to acute brain insults, occur in their immediate aftermath, and resolve after the acute period passes. The most common etiologies of seizures in neonates include hypoxic ischemic encephalopathy (38%), ischemic stroke (18%), and intracranial hemorrhage (12%). Not all seizures in neonates are acute symptomatic "neonatal seizures," however, as neonatal-onset epilepsies account for about 13% of newborns with seizures. These neonatal epilepsies (discussed in a subsequent section) must be identified early, as the workup and management are different from that of acute symptomatic seizures.

Long-term polygraphic EEG recording is essential for accurate detection of seizures in neonates, as most of these seizures have no reliable clinical correlate. Conversely, many abnormal behaviors that raise concern for seizures do not have any electrographic correlate and therefore do not need to be treated with antiseizure medications. In general, suspected seizures, unexplained recurrent abnormal paroxysmal events, encephalopathy, or risk for brain injury are all appropriate indications for prolonged EEG monitoring.

Acute symptomatic seizure burden is often high and status epilepticus is common, with or without clinical manifestations. Seizures are often difficult to control and the two treatments with the highest level of evidence, phenobarbital and phenytoin, are effective in less than half of cases LEVEL 1.[1] Guidelines recommended by the American Clinical Neurophysiology Society suggest at least a 24-hour long EEG monitoring after the last recorded seizure. While the optimal duration of treatment is unknown, it is probably safe to discontinue antiseizure medications as early as 72 hours of seizure freedom in neonates with acute symptomatic seizures, and it has become common practice at some centers to stop treatment prior to discharge.

Febrile Seizures

Febrile seizures (FS) are seizures associated with a fever, in the absence of a CNS infection or other acute symptomatic etiology in children without prior unprovoked seizures. Thorough evaluation to exclude these causes is of the utmost importance, and there are published guidelines from the American Academy of Pediatrics that include indications for lumbar puncture LEVEL 1.[2] FS are the most common cause of seizures in the pediatric population, affecting an estimated 2% to 5% of children. Initial FS usually (90%) occur prior to 3 years of age. Peak incidence is between 18 and 24 months and only 6% occur prior to 6 months. The nature of the underlying predisposition to FS in these children is usually unknown, but genetic factors likely play a role, as 25% to 40% of affected children have a positive family history.

About two-thirds of FS occur within the first 24 hours of illness, mainly as the patient's temperature is rising. Indeed, in some children, the seizure is the first indication of illness. FS can be divided into simple and complex types. FS are simple when they are isolated, brief, and generalized clonic or tonic-clonic. Complex FS have focal features or are followed by a postictal focal neurologic deficit (Todd paresis), last more than 15 minutes, or occur more than once within 24 hours. About one-third of children with FS have more than one episode, but greater than three occur in less than 5%. Risk factors for recurrence include age at the time of the first FS (higher if prior to 18 mo and especially if before 12 mo), first-degree relatives with a history of FS, low peak temperature, and a short duration of fever before the seizure (sometimes before recognition). Whether the seizure type is complex or simple is not predictive of recurrence.

Despite risk of recurrence, FS per se do not imply a diagnosis of epilepsy and patients are usually not started on antiseizure medication. Antipyretics, given early in the illness, are recommended for treating the fever, although it is unclear that they reduce the risk of FS. Acute management of prolonged FS demands the same urgency and approach as other prolonged seizures, as they entail risk of long-term sequelae. Indeed, febrile status epilepticus has been shown, in the prospective FEBSTAT study, to lead to acute hippocampal injury, subsequently progressing to mesial temporal sclerosis in some cases. As having had a prolonged FS increases risk of future prolonged FS, such patients should have a rescue medication for use at home

The relative risk of epilepsy is increased by a history of an FS on the order of two to three times that of the general population, but the absolute risk remains low (2%-5%). It is likely that children with very early or late onset and with more than three FS are at higher risk.

AGE-DEPENDENT EPILEPSIES AND EPILEPSY SYNDROMES IN NEONATES AND CHILDREN

Epilepsy syndromes are characterized by age at onset, clinical context, seizure type(s), and findings on EEG. Each is associated with a particular set of etiologies and prognosis. The term *benign* is used in relation to prognosis in a relative sense, as in many ways none of these conditions are truly benign. There is an effort to shift to terminology such as "self-limited" if the seizures remit with time or "pharmacoresponsive" if the seizures respond well to medications, but these features are neither necessary nor sufficient for generally good outcomes and we retain the term. Similarly, the term *idiopathic* is used to describe epilepsy syndromes in which the cause is unknown and there are no aspects suggesting a hidden structural etiology. There has been a tendency to abandon the term, for example, replace idiopathic generalized epilepsy with genetic generalized epilepsy, but this overstates our understanding of the causes of these epilepsies and again we have retained the term *idiopathic*. Finally, some epilepsy syndromes are *epileptic encephalopathies*,

a term defined by the International League Against Epilepsy as a condition in which

> *The epileptic activity itself may contribute to severe cognitive and behavioral impairments, above and beyond what might be expected from the underlying pathology alone (such as a cortical malformation), and that these may worsen over time. Certain syndromes may be referred to as epileptic encephalopathies, but the encephalopathic effects of seizures and epilepsy may potentially occur in association with any form of epilepsy* LEVEL 1.[3]

Benign Epilepsies in Neonates and Infants

Benign epilepsies presenting in the first year of life occur in otherwise well neonates and infants with normal development, neuroimaging and interictal EEG. Genetic investigations for benign epilepsy in infancy should include *KCNQ2*, *KCNQ3*, *SCN2A* and, with onset beyond the neonatal period, *PRRT2*. These benign epilepsies with onset in the first year of life all tend to respond well to carbamazepine (CBZ), regardless of the gene, allowing for early treatment based on clinical presentation.

Benign Familial Neonatal Epilepsy

Benign familial neonatal epilepsy (BFNE) is a dominantly inherited epilepsy caused by pathogenic variants in *KCNQ2* and *KCNQ3* genes, encoding voltage-gated potassium channels responsible for a subthreshold current important in limiting neuronal excitability. Seizures begin in the first few days of life and tend to remit after weeks to months. In between seizures, the exam is normal and the EEG shows only mild abnormalities. Seizures are focal with shifting laterality, characterized by asymmetric tonic posturing often accompanied by apnea, evolving to unilateral or bilateral asynchronous clonic jerking. Seizures last 1 to 2 minutes but may be frequent, as many as 20 to 30 times a day. The seizures are highly responsive to CBZ. Up to 25% of patients develop epilepsy later in life, particularly those who have experienced a higher number of seizures in the neonatal period. Of note, *KCNQ2* and *KCNQ3* can rarely cause infantile epilepsy with onset outside of the neonatal period as well.

Benign Familial Neonatal-Infantile Epilepsy

Benign familial neonatal-infantile epilepsy is a dominantly inherited epilepsy with seizures resembling those of BFNE but with onset from 2 days to 6 months (mean 3 mo). It is associated with pathogenic mutations in the *SCN2A* gene, encoding a voltage-gated sodium channel localized to the axon initial segments, where it plays a role in regulating the generation and propagation of action potentials.

Benign Familial Infantile Epilepsy

Benign familial infantile epilepsy is a dominantly inherited epilepsy with onset of seizures in otherwise healthy infants between 4 and 20 months of age (peak around 6 mo) caused by pathogenic variants in *PRRT2*, which encodes a presynaptic protein implicated in neurotransmitter release. Seizures last 1 to 4 minutes and are focal in onset with initial head and eye deviation followed by uni- or bilateral tonic-clonic activity. Laterality of the initial semiology varies for the same patient, and seizures can occur in clusters. Seizures typically respond to CBZ. The interictal EEG is normal, and the seizures resolve by 2 years. A sporadic form of benign infantile epilepsy occurs that is indistinguishable from BFIE except with respect to family history. Patients with pathogenic *PRRT2* variants may also develop paroxysmal dyskinesia with brief attacks of dystonia or choreoathetosis, referred to as *infantile convulsions with choreoathetosis*.

Epileptic Encephalopathy Syndromes in Neonates and Infants

Age-dependent epileptic encephalopathies are epilepsy syndromes that present at certain developmental stages, each defined by frequent seizures of a particular type, distinctive abnormal EEG findings, and neurodevelopmental impairment. Each age-dependent epileptic encephalopathy syndrome may be caused by a variety of innate and acquired etiologies, a given etiology may present with different syndromes in different patients, and a given individual may transition from one syndrome to another over time, suggesting that each condition represents a common final expression of epileptic brain dysfunction determined by developmental period.

Ohtahara Syndrome and Early Myoclonic Encephalopathy

Two electroclinical syndromes, Ohtahara syndrome (OS) and early myoclonic encephalopathy (EME), represent the earliest of the age-dependent epileptic encephalopathies, with onset in the neonatal period. The syndromes share encephalopathy and a neonatal suppression-burst EEG pattern but differ principally in the main seizure type, either epileptic spasms or multifocal myoclonic seizures. The main seizure type in OS is tonic-spasms, but focal seizures may be seen in one-third of cases. An EEG shows a suppression-burst pattern, invariant in wakefulness and sleep. OS mainly results from structural lesions (eg, large malformations of cortical development [MCDs]) and/or de novo variants in intolerant genes important for brain function. Focal lesions may be betrayed by asymmetry of the EEG or by consistent lateralizing seizure semiology. The condition is often refractory to treatment and associated with high mortality and poor neurodevelopmental outcomes. Subsequent evolution to West syndrome (WS) is common in both OS and EME.

Myoclonic seizures are the main seizure type in EME. They are multifocal, low in amplitude, random in timing and location, and can be present during wakefulness and sleep. Focal seizures, usually subclinical, may also occur. The suppression-burst pattern may be limited to, or most pronounced in sleep and has very long interburst intervals in comparison to OS. EME is associated with high morbidity and mortality. The most important associated etiologies are inborn errors of metabolism, usually autosomal recessive disorders, resulting from variants in genes encoding enzymes or metabolite transporters. The most common reported specific etiology is glycine encephalopathy (previously known as *nonketotic hyperglycinemia*).

Over the last decade, long-term video-EEG monitoring in the nursery, advances in neuroimaging, and metabolic testing together with readily available sophisticated genetic analysis has allowed for the identification of an increasing number of specific etiologies of neonatal epilepsy in newborns diagnosed with OS and EME, including KCNQ2 encephalopathy, SCN2A encephalopathy, glycine encephalopathy, and pyridoxine-dependent epilepsy. Increasingly, labeling neonatal epileptic encephalopathy as OS or EME is less helpful for prognosis and treatment than knowing whether there is a responsible brain malformation and/or identifying the underlying genetic cause.

West Syndrome

WS is an age-dependent infantile epileptic encephalopathy with onset typically at 4 to 7 months of age, characterized by a triad of epileptic spasms, an EEG pattern of chaotic high-voltage slow waves and multifocal spikes termed *hypsarrhythmia* (Fig. 148.2A), and neurodevelopmental regression or stagnation. The initial clinical manifestation of epileptic spasms may be subtle and easily misdiagnosed as episodes of colic or reflux or as startles. A high index of suspicion is important in infants presenting with recurrent stereotyped episodes, most often in clusters, as early treatment is important for outcomes. Clusters of spasms commonly occur during transitions to and from sleep. Ictal EEG shows a diffuse or lateralized slow wave usually associated with an electrodecrement and/or fast activity. As with OS

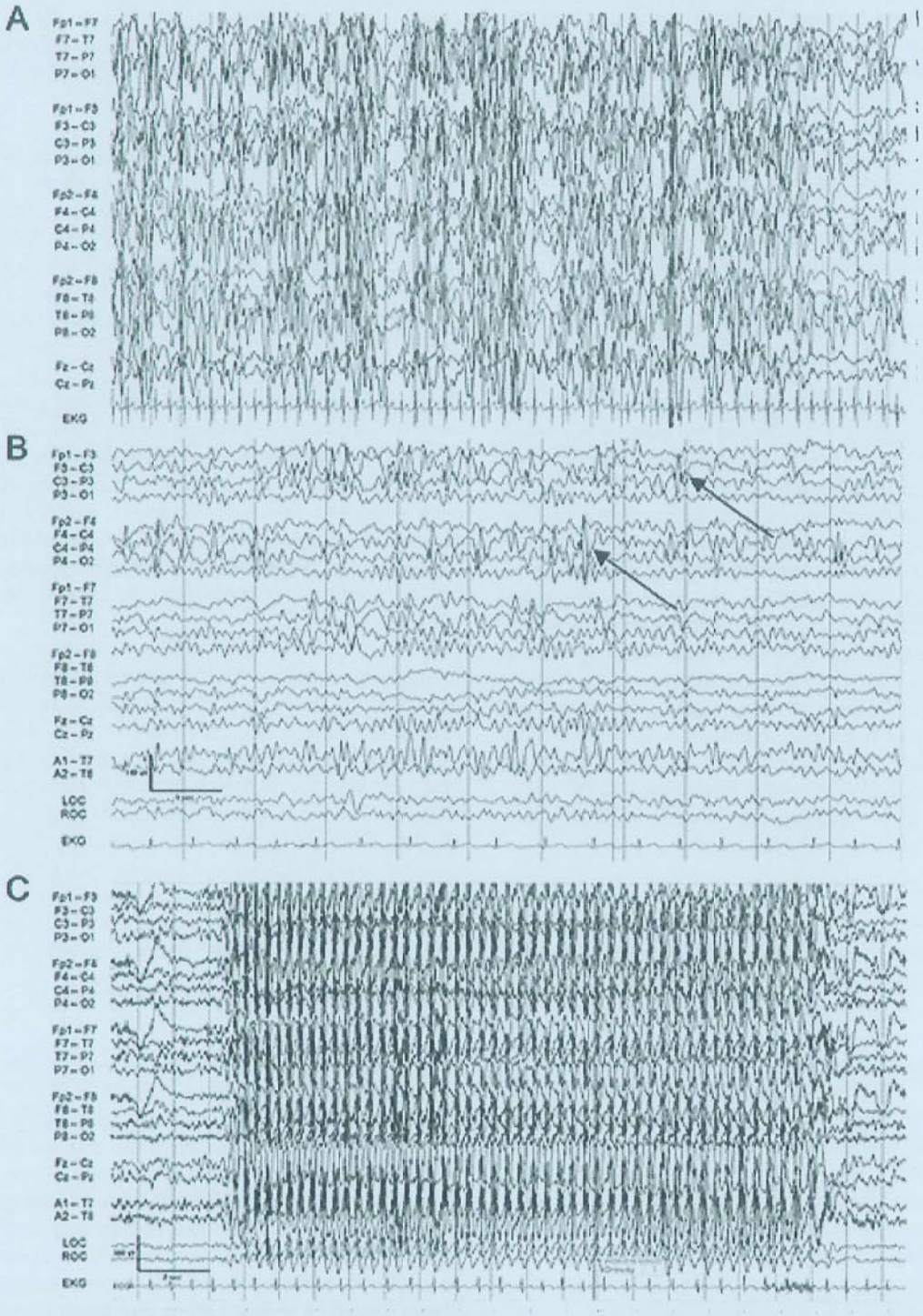

FIGURE 148.2 Hallmark electroencephalography findings in selected epilepsy syndromes. **A:** Hypsarrhythmia in a drowsy 6-month-old infant with West syndrome and previously normal development prior to successful treatment with adrenocorticotropin hormone. **B:** Centrotemporal spikes *(arrows)* in a 4-year-old boy with childhood epilepsy with centrotemporal spikes. **C:** Typical absence seizure provoked by hyperventilation in an 8-year-old girl with childhood absence epilepsy.

and EME, the etiology of WS is variable and can result from acquired brain injury (eg, hypoxic-ischemic brain injury), pathogenic genetic variants, and/or MCD. Many infants subsequently progress to Lennox-Gastaut syndrome (LGS).

The American Academy of Neurology and Child Neurology Society practice parameter on treatment of WS in 2012 concluded that (1) low-dose adrenocorticotropin hormone (ACTH) should be considered; (2) ACTH or vigabatrin (VGB) may be offered for short-term treatment, with ACTH preferred over VGB unless the cause is tuberous sclerosis complex (TSC); (3) hormonal therapy may be considered for use in preference to VGB in previously normal infants with WS of unknown cause to possibly improve developmental outcome; and that (4) a shorter lag time to treatment with either hormonal therapy or VGB possibly improves long-term developmental outcomes LEVEL 1.[4] For WS in the setting of TSC, level C evidence supports a higher response rate with VGB. Recently, there has been interest in using both hormonal therapy and VGB simultaneously as first-line treatment, based on an open-label study that suggested improved outcomes.

Genetic Developmental and Epileptic Encephalopathies in Neonates and Infants

Many severe genetic epilepsies have developmental consequences arising directly from the effect of the genetic mutation in addition to the effect of the frequent epileptic activity on development. In order to acknowledge that both the developmental and the epileptic component may be playing a role in the clinical presentation, it has been recently suggested to include the word "developmental" to define many genetic epileptic encephalopathy, hence "developmental and epileptic encephalopathy" (DEE) LEVEL 1.[5] In the following text, we review a selection of DEEs. As a rule, each gene is associated with a spectrum of conditions. The list of genes is not exhaustive and continues to grow (**Table 148.1**). We have focused on genes that cause epileptic encephalopathy in the heterozygous or hemizygous state (ie, autosomal dominant or X-linked genes). Of note, there are a number of genetic syndromes resulting from copy number variants that frequently cause epilepsy (eg, Wolf-Hirschhorn syndrome, trisomy 21) that are not discussed.

KCNQ2 Encephalopathy

De novo missense variants in *KCNQ2* cause a neonatal-onset epilepsy with seizures starting in the first days of life, encephalopathy, and a suppression-burst or multifocal epileptiform interictal EEG pattern. Whereas the variants in *KCNQ2* associated with BFNE result in a partial loss of function, variants associated with DEE have more profound consequences on channel function (eg, dominant negative effects). The seizure semiology is the same as that for BFNE and they also respond well to CBZ. Outcome tends to remain poor despite seizure control, arguing for additional developmental roles for *KCNQ2*. Both a common cause of neonatal epileptic encephalopathy (identified in over one-third of cases) and responsible for the majority of benign neonatal epilepsy, *KCNQ2* is arguably the most important epilepsy gene in the nursery.

STXBP1 Encephalopathy

Heterozygous de novo variants in *STXBP1*, encoding a regulator of synaptic exocytosis, cause a spectrum of DEE most commonly with onset in the neonatal or infantile period and epileptic spasms or tonic seizures as main seizure type. Approximately 20% of cases present with OS, and others present with nonsyndromic early-onset epilepsy and developmental encephalopathy (approximately 50%) or WS (approximately 10%).

GNAO1 Encephalopathy

Heterozygous de novo missense variants in the GTP-binding domain of *GNAO1*, encoding the α subunit of a heterotrimeric guanine-binding protein (G-protein), a signaling molecule with a role in calcium current inhibition, are associated with a phenotype characterized by hypotonia, developmental delay and seizures, and/or a hyperkinetic movement disorder with onset in the first 3 months of life. Deep brain stimulation may be helpful in treating the movement disorder in these patients.

ARX Disorders

ARX variants are associated with a spectrum of X-linked conditions ranging from OS, lissencephaly with abnormal genitalia, to intellectual disability with focal dystonia. There is a great deal of pleiotropy within families sharing the same mutation. Expansion in either of two polyalanine tracts in the gene product of *ARX* are an important cause of early-onset DEE and may be missed by next generation sequencing diagnostic approaches.

SCN2A Encephalopathies

De novo variants in *SCN2A* are associated with a staggering variety of phenotypes, ranging from OS, to refractory WS with comorbid hyperkinetic movement disorder, to intellectual disability with autism in patients with or without epilepsy. It has been suggested that early infantile, sodium channel blocker–responsive epilepsy results from gain-of-function missense variants (as with BFNIE), whereas other phenotypes result from loss-of-function or mixed effects on the channel.

CDKL5 Encephalopathy

Pathogenic variants in *CDKL5* cause a unique X-linked condition principally seen in girls (12:1 female to male ratio) that presents in the first 3 months of life. A three-stage electroclinical course has been described with an early period of developmental delay and seizures, followed by epileptic spasms, typically with a "hypermotor-tonic-spasms" seizure sequence and developmental stagnation with or without hypsarrhythmia. Subsequently, patients develop refractory epilepsy with multiple seizure types and high amplitude slowing and bursts of spikes and polyspikes on EEG. Developmentally, only about a third of females with the condition learn to walk and males acquire minimal motor skills.

Epilepsy of Infancy With Migrating Focal Seizures

Epilepsy of infancy with migrating focal seizures (EIMFS) associated with de novo missense variants in *KCNT1*, is a severe electroclinical syndrome that presents within the first 6 months of life with many patients presenting in the neonatal period. Previously well infants suffer developmental deterioration in the setting of medically intractable multifocal seizures that grow increasingly frequent till they become nearly continuous. Other genes have been reported in association with an EIMFS phenotype, but only in EIMFS associated with *KCNT1* variants have the seizures been demonstrated to migrate from one focus to another. Interictal EEG rapidly deteriorates from normal to multifocal epileptiform activity. Developmental impairment is severe to profound and mortality rates are high. The *KCNT1* encodes a sodium-activated potassium channel that mediates slow hyperpolarization that accompanies repetitive neuronal firing. The pathologic mutations

TABLE 148.1 Prominent Monogenic Causes of Epilepsies and Epilepsy-Related Conditions

Gene	Locus	Disorders	Gene Product	Function	Mechanism
AKT3	1q43-q44	MPPH2, HME, FCD type IIb	Protein kinase B gamma	MTOR signaling pathway repressor	LoF
ALDH7A1	5q23.2	Pyridoxine-dependent epilepsy	Antiquitin	α-Aminoadipic semialdehyde dehydrogenase in the pipecolic acid pathway of lysine catabolism	LoF (recessive)
ARX	Xp21.3	X-linked infantile spasms, WS, OS, lissencephaly with abnormal genitalia	Aristaless-related homeobox	Transcriptional regulator critical for cortical interneuronal fate	LoF
CDKL5	Xp22.13	CDKL5 deficiency disorder	Cyclin-dependent kinase-like 5	Serine-threonine kinase; role in transcriptional regulation and neuronal development	LoF
CHD2	15q26.1	MAE	Chromodomain helicase DNA-binding protein 2	Chromatin remodeling with effects on gene expression	LoF
CHRNs (A2, A4, B2)	8p21.2 20q13.33 1q21.3	ADNFLE	Cholinergic receptor; nicotinic α_2, α_4, and β_2 subunits	Nicotinic acetylcholine receptor; excitatory ligand-gated ion channel	GoF
CSTB (EPM1)	21q22.3	Unverricht-Lundborg disease	Cystatin B	Regulator of cathepsins, lysosomal enzymes involved in protein breakdown	LoF (recessive)
DCX	Xq23	Lissencephaly, SBH ("double cortex")	Doublecortin	MAP	LoF
DEPDC5	22q11.2-q11.3	FFEVF, ADNFLE, sporadic focal epilepsy, FCD type IIb	Disheveled, Egl-10 and pleckstrin domain-containing protein 5	Component of GATOR (GAP for Rag GTPases that regulate MTOR activity)	LoF
DNM1	9q34.11	WS	Dynamin-1	GTPase specific to brain with role in presynaptic endocytosis	LoF
EPM2A	6q24.3	Lafora disease	Laforin	Regulation of glycogen formation	LoF (recessive)
FLNA	Xq28	PVNH	Filamin A	Actin-binding protein important in cross-linking and anchoring to the cell membrane	LoF
FOXG1	14q12	WS	Forkhead box g1	Transcriptional repressor implicated in neuronogenesis	GoF/LoF
GLI3	7p14.1	Hypothalamic hamartoma	GLI-Kruppel family member 3	Zinc finger transcription factor that functions in the sonic hedgehog signaling pathway	LoF
GNAO1	16q13	OS	Guanine nucleotide-binding protein, alpha activating activity polypeptide O	G protein–coupled receptor component; regulates calcium current inhibition	LoF
GNAQ	9q21.2	Sturge-Weber syndrome	Guanine nucleotide–binding protein, Q polypeptide	α subunit of a heterotrimeric GTP-binding protein that mediates stimulation of phospholipase C-β during blood vessel development	LoF (somatic only)
GRIN2A	16p13.2	Epilepsy-aphasia spectrum syndromes	Glutamate receptor, ionotropic, NMDA 2A	NMDA α_2 receptor, a ligand-gated ion channel involving in learning and memory	LoF/GoF
KCNQ2	20q13.33	BFNE, sporadic benign neonatal epilepsy, KCNQ2 encephalopathy	Kv7.2	Voltage-gated ion channel; regulates subthreshold potassium currents	LoF
KCNQ3	8q24.22	BFNE	Kv7.3	Voltage-gated ion channel; regulates subthreshold potassium currents	LoF
KCNT1	9q34.3	EIMFS, ADNFLE	Potassium channel, sodium-activated subfamily T, member 1	Sodium-activated potassium ion channel; mediates slow hyperpolarization accompanying repetitive neuronal firing	GoF
LGI1	10q23.33	ADFEAF	Leucine-rich glioma inactivated 1	Interacts with ligand-gated and voltage-gated ion channels in the pre- and postsynaptic membrane	LoF

(table continues on page 1508)

TABLE 148.1 Prominent Monogenic Causes of Epilepsies and Epilepsy-Related Conditions *(continued)*

Gene	Locus	Disorders	Gene Product	Function	Mechanism
MECP2	Xq28	Rett syndrome, MECP2 duplication syndrome	Methyl-CpG binding protein 2	Transcriptional repressor	LoF/GoF
MEF2C	5q14.3	WS	Myocyte enhancer factor 2c	Transcription factor important in synapse elimination during forebrain development	LoF
MT-TK	Mitochondrial	MERRF	Transfer RNA, mitochondrial, lysine	Mitochondrial tRNA for lysine	LoF
MTOR	1p36.22	HME	Mechanistic target of rapamycin	Key kinase in the MTOR signaling pathway	GoF
NBEA	13q13.3	MAE	Neurobeachin	Regulates synaptic structure and function through targeted trafficking of postsynaptic proteins	LoF
PAFAH1B1 (LIS1)	17p13.3	Lissencephaly, SBH	Platelet-activating factor acetylhydrolase, isoform 1B, α subunit	Regulator of the motor protein dynein	LoF
PCDH19	Xq22.1	PCDH19 epilepsy	Protocadherin 19	Cell-cell adhesion and signaling	LoF
PIK3CA	3q26.32	MCAP, HME, FCD type IIb	Phosphatidylinositol 3-kinase catalytic subunit α	MTOR signaling pathway repressor	LoF
POLG	15q26.1	Alpers syndrome	Polymerase, DNA, gamma	Replication of mitochondrial DNA	LoF (recessive)
PRRT2	16p11.2	BFIE, sporadic benign infantile epilepsy, PKD, ICCA	Proline-rich transmembrane protein 2	Regulation of presynaptic neurotransmitter release	LoF
SCN1A	2q24.3	DS, GEFS+	Nav1.1	Voltage-gated sodium channel; regulates excitability of inhibitory cortical interneurons	LoF
SCN2A	2q24.3	BFNIE, SCN2A encephalopathy	Nav1.2	Voltage-gated sodium channel; critical role in regulating neuronal action potential during first several months of life	GoF/LoF
SCN8A	12q13.13	EOEE	Nav1.6	Voltage-gated sodium channel; critical role in regulating neuronal action potential	GoF/LoF
SLC2A1	1p34.2	Glut1 deficiency syndrome	Solute carrier family 2, member 1	Glucose transporter	LoF
SLC6A1	3p25.3	MAE	Solute carrier family 6, member 1	GABA transporter	LoF
STXBP1	9q34.11	OS, WS	Syntaxin-BFNIE-binding protein 1	SM (Sec1p/Munc18) family member; regulates SNARE complexes during exocytosis	LoF
SYNGAP1	6p21.32	EMA, MAE	Synaptic Ras GAP 1	GAP, negative regulator of signaling interactions in the postsynaptic terminal	LoF
TPP1 (CLN2)	11p15.4	NCL type II	Tripeptidyl peptidase I	Lysosomal serine protease involved in breakdown of certain peptides	LoF (recessive)
TSC1, TSC2	9q34.13 16p13.3	TSC	Hamartin; Tuberin	GAP, negative regulator of MTOR signaling	LoF
TUBA1A	12q13.12	Microlissencephaly	Tubulin alpha-1a	Tubulin subunit, component of microtubules	LoF

Abbreviations: ADFEAF, autosomal dominant focal epilepsy with auditory features; ADNFLE, autosomal dominant nocturnal frontal lobe epilepsy; BFIE, benign familial infantile epilepsy; BFNE, benign familial neonatal epilepsy; BFNIE, benign familial neonatal-infantile epilepsy; CDKL5, cyclin-dependent kinase-like 5; DS, Dravet syndrome; EIMFS, epilepsy of infancy with migrating focal seizures; EMA, epilepsy with myoclonic-absences; EOEE, early-onset epileptic encephalopathy; FCD, focal cortical dysplasia; FFEVF, familial focal epilepsy with variable foci; GABA, γ-aminobutyric acid; GAP, GTPase activating protein; GEFS+; genetic epilepsy with febrile seizures plus; GoF; gain of function; HME, hemimegalencephaly; ICCA, infantile convulsions with choreoathetosis; LoF, loss of function; MAE, epilepsy with myoclonic-atonic seizures; MAP, microtubule-associated protein; MCAP, megalencephaly-capillary malformation syndrome; MERRF, myoclonic epilepsy with ragged-red fibers; MPPH2, megalencephaly-polymicrogyria-polydactyly-hydrocephalus syndrome 2; MTOR, mechanistic target of rapamycin; NCL, neuronal ceroid lipofuscinosis; NMDA, *N*-methyl-D-aspartate 2A; OS, Ohtahara syndrome; PKD, paroxysmal kinesigenic dyskinesia; PVNH, periventricular nodular heterotopia; SBH, subcortical band heterotopia; SNARE, soluble NSF-attachment protein receptor; TSC, tuberous sclerosis complex; WS, West syndrome.

increase the current amplitude through increased cooperativity between individual channels. The *KCNT1* can cause a spectrum of epilepsies, including a form of autosomal dominant nocturnal frontal lobe epilepsy. Although quinidine can reverse the increased conductance imparted by some pathologic gain-of-function mutations in vitro, therapeutic trials in patients have been disappointing.

SCN8A Encephalopathy

De novo missense variants in *SCN8A*, encoding a voltage-gated sodium channel causes a spectrum of epilepsies, including an early-onset epileptic encephalopathy, presenting with multiple seizure types during infancy with onset around 4 to 5 months of age. Ataxia or a hyperkinetic movement disorder are common. A high rate of sudden unexpected death in epilepsy has been observed in patients. Similar to *SCN2A*, gain-of-function effects, including impaired channel inactivation or shifted voltage dependence, account for some conditions while loss-of-function variants are responsible for others.

Genetic Epilepsy With Febrile Seizures Plus

Genetic epilepsy with febrile seizures plus (GEFS+) is an autosomal dominant epilepsy syndrome with incomplete penetrance, in which at least two family members have febrile and/or afebrile seizures. Several genes have been implicated, including *SCN1A*.

Dravet Syndrome

Variants in *SCN1A* were originally identified in GEFS+ families, but *SCN1A* was subsequently discovered to be the major gene for Dravet syndrome (DS), accounting for >85% of cases. *SCN1A* encodes a voltage-gated sodium channel important for inhibitory interneuron function. DS has an onset between 3 and 8 months (peak at 6 mo) and presents with bouts of status epilepticus with hemiclonic or generalized clonic or tonic-clonic seizures most often triggered by increased temperature. Typically, even a mild increase in body temperature due to fever, hot weather, or hot bath can be a triggering factor. These episodes become frequent over time and, between 1 and 4 years, other seizure types appear, including myoclonic jerks, atypical absences, and focal impaired awareness seizures. The EEG is usually normal at onset but progresses to generalized, focal, and multifocal abnormalities. Photosensitivity is present early in approximately 40% of patients. The occurrence of sudden unexplained death in epilepsy is relatively high. From the second year of life, children demonstrate variable neurologic impairment, such as ataxia and corticospinal tract dysfunction, as well as behavioral disturbances, and learning disabilities. Seizure frequency tends to stabilize or decrease after 5 years, but developmental outcomes remain severe. CBZ and other sodium channel blocking agents should be avoided as they may worsen seizures. Valproate (VPA) and clobazam are considered first-line antiseizure medications but rarely result in seizure freedom. Stiripentol has demonstrated efficacy as add-on therapy to these agents. Ketogenic diet, a dietary therapy with a high-fat, low carbohydrate diet, can be considered a second-line therapy in DS with a classical ketogenic diet for children under 2 years of age, a modified Atkins diet for children older than 12 years, and either form of the diet for the ages in-between, based on the child's and family's preferences.

Among the new and emerging therapies, a relevant role is played by pharmaceutical-grade cannabidiol (CBD) and fenfluramine (FEN). CBD has shown efficacy in the treatment of seizure in DS in a randomized controlled trial (RCT) LEVEL 1,[6] and it has recently been approved for use by the U.S. Food and Drug Administration. FEN, which was originally developed as an appetite suppressant, has been reported effective in DS in short and long term retrospective and prospective studies. A multicenter RCT with FEN in add-on in DS has been completed and has shown a high rate of responders (70% with more than 50% reduction in convulsive seizure in the FEN group vs 7.5% in the placebo group). The FEN RCT is still unpublished.

PCDH19 Girls Clustering Epilepsy

PCDH19 encodes a protocadherin, involved in cell-cell adhesion. Variants in *PCDH19* cause epilepsy with an unusual X-linked inheritance pattern that spares males in the carrier state. Onset is usually later than DS, between 6 and 36 months with a median age of 10 months. Seizures are triggered or exacerbated by mild/moderate elevations in temperature and often present initially as FS. There is a characteristic "stormy" ictal pattern with clusters of seizures recurring for several days with variable intervening periods of quiescence, lasting months to years. Seizures are most commonly focal with fearful screaming, apnea, or tonic stiffening. The interictal EEG may be normal or show slowing and/or focal or multifocal epileptiform discharges. Cognitive outcome varies from typical to severe intellectual disability. Behavioral or psychiatric disturbances including autism and schizophrenia may become the most clinically problematic symptoms, especially over time, as the seizures tend to become tractable or diminish in adolescence or adulthood.

Toddler-Onset Epilepsy Syndromes

Lennox-Gastaut Syndrome

The term *Lennox-Gastaut syndrome* is often improperly used as a synonym for symptomatic generalized epilepsy, but like other age-dependent epileptic encephalopathies, such as WS, LGS is defined by the presence of specific seizure types and EEG features. The etiology is variable. LGS can occur in the context of acquired brain injury, pathogenic genetic variants, and/or MCD.

Age of onset is between 3 and 5 years of age. The core seizure types include tonic seizures (the hallmark of LGS), especially arising out of sleep, atonic seizures (drop attacks), and atypical absences. The EEG is poorly organized and shows diffuse, usually frontally predominant, slow (2-2.5 Hz) spike and wave during wakefulness and bursts of generalized paroxysmal fast activity during non–rapid eye movement sleep. Ictal EEG of the atypical absences is characterized by a prolonged runs of the slow spike-and-wave complex described earlier. Atonic seizures associated with a generalized spike- or polyspike-wave and tonic seizures manifest with diffuse fast activity (10-20 Hz) accompanying electrodecrement. In patients who evolve to LGS from WS (approximately 20% of LGS), the tonic component and corresponding electrodecrement of epileptic spasms may become progressively prolonged, morphing into tonic seizures over time. Felbamate, lamotrigine (LTG), topiramate, rufinamide, and CBD all have demonstrated efficacy in treating seizures in LGS in randomized controlled studies. VPA, benzodiazepines, and zonisamide are considered also effective based on clinical experience. As in DS, pharmaceutical-grade CBD has shown efficacy in an RTC LEVEL 1,[7] and it has recently been approved by U.S. Food and Drug Administration for use in this syndrome. FEN has also shown to be effective in this syndrome in open-label studies. The results in RTCs are also very promising but still unpublished.

Epilepsy With Myoclonic-Atonic Seizures

Epilepsy with myoclonic-atonic seizures (MAE), or Doose syndrome, is a rare epilepsy syndrome with peak age of onset between 2 and 6 years. The primary seizure types are myoclonic and myoclonic-atonic with a myoclonic jerk preceding a sudden loss of muscle tone. Ictal EEG shows discharges of generalized spikes or polyspike-and-wave complexes with a prominent subsequent slow wave. Patients usually have other generalized seizure types including atypical absences and generalized tonic-clonic seizures (GTCs). Clinically, there is regression associated with the onset of seizures. Outcomes can be good if patients were previously developmentally normal and seizures are controlled. Variants in a number of genes can present with predominantly generalized seizures in infants and toddlers, some with a MAE-like presentation (eg, *CHD2*, *SLC2A1*, *SLC6A1*, *NBEA*), although in these cases, children are typically impaired prior to onset of the epilepsy and seizure control does not alter disability arising from the genetic etiology. VPA is frequently used as first-line, but ketogenic diet and modified Atkins are effective alternative treatments.

Landau-Kleffner Syndrome and Continuous Spikes and Waves During Slow Sleep

The Landau-Kleffner syndrome (LKS) and continuous spikes and waves during slow sleep (CSWS) are epileptic encephalopathies associated with electrical status epilepticus during slow sleep (ESES). The ESES is the term used to describe an extreme form of sleep-activated EEG activity, quantified by spike-wave index, the number of spikes/the number of seconds of non–rapid eye movement sleep. The exact spike-wave index needed to qualify as ESES varies by author but ranges from over 50% to 85%. The hallmark of the associated clinical syndromes is developmental stagnation or regression. LKS manifests affects previously normal children in early childhood with regression in the domain of language, typically starting with a receptive aphasia. CSWS is a condition of more global regression and, in half of cases, there is premorbid delay. Pathogenic variants in *GRIN2A*, encoding the NMDA receptor α_2 subunit, have been reported to account for up to 20% of children with LKS, raising the possibility for novel therapeutic approaches.

Idiopathic Focal Epilepsies of Childhood

The idiopathic focal epilepsies of childhood represent a set of relatively common, age-dependent, self-limited, and pharmacoresponsive epilepsies characterized by focal seizures in typically developing children with relatively good outcome with regard to seizures and development. Diagnosis relies on recognition of seizure semiology and presence of appropriate (and absence of inappropriate) interictal findings in the correct clinical setting (eg, typical development, absence of focal brain lesions).

Childhood Epilepsy With Centrotemporal Spikes

Childhood epilepsy with centrotemporal spikes (CECTS), previously known as *benign rolandic epilepsy*, is one of the most common epilepsy syndromes and usually presents in typically developing school-aged children (peak at 7-10 y) with focal seizures out of sleep referable to primary sensorimotor regions. Hemifacial and/or unilateral oropharyngeal tingling or numbness is followed by hemifacial jerking, drooling, and often speech arrest. Awareness may or may not be impaired. Seizures are typically brief, lasting 1 to 3 minutes and tend to occur shortly after falling asleep or just before awakening but can occur during wakefulness less commonly. Postictal dysarthria is frequent. A Todd paresis may also be observed after prolonged seizures. Secondary generalization occurs in about half of cases. Interictal EEG shows hallmark bilaterally independent spike and wave discharges, maximal in the central and temporal leads (Fig. 148.2B), and forming a characteristic dipole with the frontal regions. Of note, such centrotemporal spikes may be observed in individuals who never develop seizures, especially relatives of those with a history of CECTS. Moreover, epileptiform abnormalities with a similar appearance may occur in other epilepsies (eg, bilateral polymicrogyria). Therefore, magnetic resonance imaging (MRI) is usually performed early in the course as for other focal epilepsies.

Seizures usually remit within 4 years of onset and prior to 16 years of age. There is a spectrum with regard to seizure frequency with 10% to 20% having only one and 10% to 20% having frequent seizures, but the vast majority have several. Some children with CECTS may not require medication. The decision to initiate antiseizure medications ultimately must take into consideration risks and benefits of everyday medication. When treated, the seizures tend to be responsive (eg, to CBZ or levetiracetam).

Panayiotopoulos Syndrome

Panayiotopoulos syndrome starts on average earlier than CECTS (peak 3-6 y) with focal seizures with autonomic semiology, which may be prolonged. The child typically complains of not feeling well, having nausea, looking pale, and retching or vomiting. There is often unilateral eye deviation, which may recur intermittently throughout the seizure. Initially, awareness is preserved, but, over time, it is usually impaired. The seizure may progress to uni- or bilateral tonic-clonic seizures. Seizures are notable for their long duration, up to 1 hour or more, with status epilepticus being common. Interictal EEG is variable but most often shows focal spike and wave discharges that morphologically resemble those of CECTS, usually including occipital location but extraoccipital spikes are common. Patients usually have one to a few seizures before resolution within 1 to 2 years of onset and there is limited evidence for treatment.

Gastaut Syndrome

Gastaut syndrome presents with a peak age of 8 to 9 years with occipital seizures characterized by elementary visual hallucinations commonly followed by eye deviation, motor features, impaired awareness, etc. Other patients have seizures that manifest with ictal blindness. Half of patients have a postictal headache, and the main differential diagnosis is migraine with aura. Seizures are frequent, commonly daily, but resolve in 2 to 4 years.

Idiopathic Generalized Epilepsies of Childhood

The idiopathic generalized epilepsies of childhood represent a set of age-dependent epilepsies with generalized seizure types (eg, GTCs, myoclonic seizures, and typical absence seizures) with characteristic EEG findings in typically developing children. Although strong genetic influences exist, as indicated by twin studies and population studies, they are not determinative (eg, monozygotic twins can be discordant for epilepsy) and the nature of this influence in most cases appears polygenic.

Childhood Absence Epilepsy

Childhood absence epilepsy (CAE) presents in typically developing school-aged children (4-10 y; peak 5-7 y) with absence seizures. It is relatively common, accounting for 10% to 20% of pediatric-onset epilepsy. Absence seizures are brief, lasting under 20 seconds, but frequent, occurring many times per day. They are characterized by an abrupt loss of awareness and cessation of voluntary behavior, during which automatisms or simple motor phenomena may occur, and are associated with a 3 Hz spike-and-wave discharge time-locked with the psychomotor arrest (Fig. 148.2C). The termination of the seizure is similarly abrupt without a postictal period. Absence seizures can be induced by hyperventilation in over three-fourths of cases, helpful in making the initial diagnosis and subsequently determining seizure control. GTCs can rarely occur.

During absence seizures, thalamocortical projections become synchronized through inhibitory input from the reticular thalamus, resulting in rebound bursting via T-type voltage-gated calcium channels. Feedback to the reticular nucleus perpetuates the synchronization. Ethosuximide, which acts primarily at these T-type calcium channels, as well as VPA, are considered first-line antiseizure medications LEVEL 1.[8] VPA is particularly useful in presence of GTCs in addition to absences. LTG also has demonstrated efficacy and is considered second line. In CAE, seizures usually remit by the end of the second decade.

Jeavons Syndrome

Jeavons syndrome or epilepsy with eyelid myoclonia usually starts in early childhood and is characterized by very brief seizures consisting of eyelid myoclonia with or without associated absences triggered by eyelid closure. Electrographically, there is abnormal fast activity and generalized 3 to 6 Hz polyspikes-and-waves with photosensitivity. Usually, there are infrequent GTCs as well. This epilepsy syndrome is often difficult to treat and usually persists throughout life.

Epilepsy with Myoclonic Absences

Epilepsy with myoclonic absences (EMA) is a rare epilepsy syndrome with mean onset at 7 years of age (although onset can occur from early infancy) characterized by seizures lasting up to 1 minute with 3 Hz generalized spike-and-wave like typical absence seizures. During the absence, there are myoclonic jerks of the upper limbs time-locked with the spikes causing progressive elevation of the upper extremities. Typical absences and GTCs may also occur. The prognosis of EMA remains variable. Therapeutic combinations, such as VPA and ethosuximide, or VPA and LTG, are usually effective; however, in a proportion of patients, seizures are resistant to drug treatment. These patients may experience cognitive deterioration and, in some cases, evolution toward a more severe form of epilepsy, including LGS. The more benign cases usually present with myoclonic absences as the only seizure type, whereas patients who experience other seizures, especially GTCs, in association with myoclonic absences may have a less favorable outcome. Pathogenic variants in *SYNGAP1* cause an epilepsy spectrum overlapping EMA with typical onset in the toddler years.

Juvenile myoclonic epilepsy

Juvenile myoclonic epilepsy (JME) is relatively common, accounting for up to 10% of epilepsy. It usually presents during adolescence (peak from 14-15 y) with myoclonic jerks of the upper limbs most abundant in the first half-hour after waking. Amplitude and clinical symmetry vary depending on the patient's activity. The vast majority of patients also have GTCs, which may start with a cluster of myoclonic seizures evolving to clonic then tonic-clonic motor features. Typical absences are less commonly seen and when present are short, infrequent, and not a major aspect of the presentation. An EEG shows generalized polyspike-and-wave discharges and photosensitivity is common. JME is usually pharmacoresponsive but rarely remits with age. VPA is considered first-line therapy, but it should be avoided if possible in reproductive age women given substantial teratogenic risk. Zonisamide seems to be a good alternative.

Juvenile Absence Epilepsy

Juvenile absence epilepsy is less common than CAE or JME and has a mean onset of 10 to 12 years. Typical absence seizures occur with a lower frequency, but the seizures are often longer. Most patients also have GTCs and may even have myoclonic seizures, making the distinction between juvenile absence epilepsy and JME challenging. As with JME, seizures are usually pharmacoresponsive, but continued treatment is often needed to maintain lifelong seizure freedom.

Epilepsy with Generalized Tonic-Clonic Seizures Alone

Epilepsy with generalized tonic-clonic seizures alone may first present in the first, second, or third decade of life with GTCs occurring most often shortly after awakening from sleep and triggered by sleep deprivation.

Rasmussen Encephalitis

Rasmussen encephalitis (RE) is a chronic hemispheric encephalitis that affects previously healthy school-aged children (median age of 6 y) with relentless medically refractory focal seizures. Multiple seizures commonly emerge over time, including *epilepsia partialis continua*, a rare seizure type described by the International League Against Epilepsy as "recurrent focal motor seizures (typically affecting hand and face, although other body parts may be affected) that occur every few seconds or minutes for extended periods (days or years)." RE causes progressive lateralized atrophy of cerebral gray matter, manifesting as progressive enlargement of sulci and ex vacuo expansion of the lateral ventricle as well as progressive functional deficits referable to the affected hemisphere (cognitive, contralateral motor, contralateral visual hemifield). The inflammation in RE is T-cell mediated, but it is unknown whether the inciting antigens are endogenous or some undiscovered pathogen. Hemispherotomy provides seizure control in the majority of cases and, if performed early, may circumvent deleterious effects of uncontrolled epileptic activity on the unaffected hemisphere.

INBORN ERRORS OF METABOLISM CAUSING SEIZURES AND EPILEPSY IN NEONATES AND CHILDREN

Inborn errors of metabolism associated with seizures include sulfite oxidase and molybdenum cofactor deficiencies, glycine encephalopathy, ornithine transcarbamylase deficiency, Menkes syndrome, disorders of glycosylation, creatine deficiency syndromes, biotinidase deficiency, and many others. These conditions

are rare but important to consider given that they are frequently progressive and may entail specific targeted management. In the following text, we review some selected examples.

Pyridoxine-dependent Epilepsy

Pyridoxine-dependent epilepsy is a rare autosomal recessive condition that presents with frequent seizures, mainly myoclonic and clonic, in the first days of life or even in utero. Neonates with pyridoxine-dependent epilepsy usually present with irritability, restlessness, crying, and vomiting preceding the seizures. *ALDH7A1* encodes antiquitin, an enzyme critical for lysine catabolism. Accumulation of the metabolic intermediate, α-aminoadipic semialdehyde, causes the pyridoxine deficiency. If the condition is suspected, intravenous pyridoxine can be administered empirically, ideally under EEG monitoring and in the neonatal intensive care unit. Immediate clinical response (classically accompanied by an episode of apnea) neither confirms nor rules out the diagnosis. Diagnosis is made through detection of α-aminoadipic semialdehyde in the urine and confirmed through genetic testing. Folinic acid-responsive epilepsy is the same condition.

Glut1 Deficiency Syndrome

Glut1 deficiency syndrome is caused by insufficient transport of glucose from the blood to the brain due to heterozygous variants in the glucose transporter encoded by *SLC2A1*. Most patients present in the first months to years of life. Paroxysmal events, including abnormal eye movements and seizures, are the most common presenting symptoms. Other clinical features emerge over time and include deceleration of head growth, spasticity, ataxia, movement disorder, and intellectual disability. Diagnosis is made through identification of hypoglycorrhachia. Seizures are usually generalized, including absences, GTCs, and myoclonic seizures and patients may present with MAE or early-onset (younger than 3 years of age) CAE. Treatment with ketogenic diet is first-line for seizure control and, if the condition is diagnosed and treated early, may improve the neurodevelopmental outcome.

Progressive Myoclonic Epilepsies

Progressive myoclonic epilepsies (PMEs) are a heterogeneous collection of recessive disorders characterized by myoclonic jerks and seizures with progressive neurologic deterioration. Unverricht-Lundborg disease and Lafora disease are PMEs with onset in previously normal children during late childhood and adolescence. The sialidoses and neuronal ceroid lipofuscinoses are groups of neurodegenerative lysosomal storage diseases that cause PME. Recently, intraventricular treatment with cerliponase alfa as enzyme replacement therapy has been approved for neuronal ceroid lipofuscinoses due to *CLN2*. Alpers syndrome presents with seizures, neurodevelopmental regression, and hepatic degeneration due to mitochondrial DNA depletion, most often resulting from variants in *POLG*, which encodes the mitochondrial DNA polymerase-γ. Frequent focal seizures from the occipital lobes and epilepsia partialis continua are characteristic. Myoclonic epilepsy with ragged red fibers is a PME caused by mutation in the gene for mitochondrial tRNA, *MT-TK*, which is encoded by maternally inherited mitochondrial DNA.

EPILEPSIES ASSOCIATED WITH BRAIN MALFORMATIONS

Epilepsy may result from brain lesions acquired at or after birth (eg, hypoxic-ischemic encephalopathy, stroke), malformations (eg, polymicrogyria) due to in utero injury (eg, due to TORCH infections, such as cytomegalovirus or Zika virus, fetal alcohol exposure), or from MCDs caused by variants in particular genes. MCDs may present with epilepsy at any age but often start in the first years of life. MCDs account for about 15% of pediatric epilepsy with onset before 3 years of age, including almost 40% of cases of neonatal-onset epilepsy. Moreover, MCDs, and particularly focal cortical dysplasias (FCD), represent the most common cause of medically intractable epilepsy leading to epilepsy surgery in the pediatric population.

MCDs reflect the result of abnormal developmental processes during corticogenesis, including cell proliferation, migration, and differentiation. They are generally the result of constitutional or somatic genetic mutations, which arise during development and affect a variable portion of the CNS. Somatic variants in the same gene may cause lesions of different sizes depending on the extent of the affected tissue. As only the affected tissue harbors the mutation, somatic variants may not be detectable in blood. Genes mutated in MCDs encode cytoskeletal-associated proteins and members of the mechanistic target of rapamycin (MTOR) growth signaling pathway.

Cortical Dysgenesis

Cortical dysplasia, ranging in extent from FCD to dysplastic megalencephaly (DMEG) affecting the entire brain, is often the result of pathogenic variants in components of the MTOR pathway. Patients with regions of dysplastic cortex may begin having focal seizures at any age, but onset in the first few years of life is common and there is a risk for developing age-dependent epileptic encephalopathies with the associated seizure types (eg, WS with epileptic spasms in patients with TSC). Identification of the responsible pathway has led to interest in repurposing MTOR inhibitors for epilepsy associated with these "MTORopathies" and a benefit has been demonstrated in a randomized trial of in patients with TSC LEVEL 1.[9]

Focal Cortical Dysplasia

Focal cortical dysplasia is characterized by the presence of an abnormal arrangement of cortical neurons with (type II) or without (type I) the presence of abnormal cellular features, such as dysmorphic neurons with (type IIb), or without (type IIa), balloon cells. Type II FCD (eg, resulting from dominantly inherited or de novo mutation of *DEPDC5*) may reveal itself on MRI as a blurring of the gray-white junction, and/or as T2 hyperintensity, which may extend through the subcortical white matter to the lateral ventricle ("transmantle sign"), be limited to the bottom of a sulcus ("bottom of sulcus sign"), or may appear similar to cortical tubers (see subsequent section). In early infancy, these signal changes on MRI are very different (eg, T1 hyperintensity). Subsequently, between 12 and 30 months, the sensitivity of detection on MRI becomes poor due to incomplete myelination. Given that FCD is a relatively common cause of focal epilepsy with onset in toddlers, that the rate of medical intractability is high with additional risk for epileptic encephalopathy, and that these patients have high rates of seizure freedom following epilepsy surgery, a high degree of suspicion for FCD is warranted in this population even if a lesion cannot be detected on initial MRI.

Tuberous Sclerosis Complex

Tuberous sclerosis complex is a multisystem disorder (brain, skin, lung, kidney, and heart) caused by dominantly inherited pathogenic variants in *TSC1* or *TSC2*. TSC has a great deal of phenotypic variability, as the associated lesions are considered to arise from somatic "second-hits." CNS manifestations include epilepsy, autism, intellectual disability, and dysregulated behavior and sleep. Obstructive hydrocephalus may result from growth of subependymal giant-cell astrocytomas. Epilepsy affects over 90% of individuals and is associated with cortical tubers, regions of cortical dysplasia manifesting as thickened, T2 hyperintense, cortical gyri. Histologically, tubers have dysmorphic neurons and balloon cells like FCD type IIb. VBG is the drug of choice. However, patients with TSC may be excellent surgical candidates if a tuber responsible for the epileptic focus can be identified.

Hemimegalencephaly and Dysplastic Megalencephaly

Hemimegalencephaly (HME) and dysplastic megalencephaly (DMEG) affect one and both cerebral hemispheres, respectively. HME and DMEG exist on a spectrum of lesion size with small FCD type II, sharing histopathology and genetic alteration affecting the MTOR pathway (eg, *PIK3CA*, *AKT3*, *MTOR*). Affected cortex often shows abnormal gyral patterns, and macrocephaly from brain enlargement is common. HME and DMEG may affect the CNS in isolation or occur as part of more general overgrowth syndromes. For HME as for FCD, surgical disconnection (ie, hemispherotomy) is indicated for intractable epilepsy.

Periventricular Nodular Heterotopias

Periventricular nodular heterotopias are abnormal nodular collections of gray matter adjacent to the lateral ventricles, thought to arise during development, as a result of disrupted neuroepithelium. Therefore, they can occur in association with other cerebral malformations, which determine the extent of associated neurodevelopmental disability. Pathogenic variants in *FLNA*, which encodes a protein with a role in cross-linking and anchoring actin filaments to the cell membrane, are a cause of familial periventricular nodular heterotopia with an X-linked recessive mode of inheritance. Seizures may be generated by the heterotopia itself and/or overlying cortex and are often amenable to surgical management.

Lissencephaly

Lissencephaly, "smooth brain," refers to an absent (agyria) or reduced (pachygria) cerebral convolutions. The malformation reflects arrest of neuronal migration after the first trimester. The cortical neurons are actually in a heterotopic collection deep to their appropriate location. Indeed, pathogenic variants in *DCX* on the X chromosome cause lissencephaly in males but cause a subcortical band heterotopia (ie, a "double cortex") in females, for whom lyonization results in two populations of neurons. Pathogenic variants in certain cytoskeletal elements are responsible for lissencephaly, and somatic mutation of these same genes can cause subcortical band heterotopia. Pathogenic variants in *LIS1*, encoding a dynein regulator, cause a posterior predominant lissencephaly, whereas mutation of *DCX*, encoding a microtubule-associated protein, causes an anterior predominant lissencephaly. *TUBA1A* variants can cause microcephaly with lissencephaly and hypoplasia of the cerebellum and white matter tracts (eg, anterior limb of the internal capsule, corpus callosum). Severe to profound intellectual disability is typical in patients with lissencephaly. Seizures usually start in the first months of life and evolution to age-dependent epileptic encephalopathies (eg, WS) is common.

Hypothalamic Hamartomas

Hypothalamic hamartomas (HH) are dysplastic malformations of the hypothalamus that cause epilepsy typically with onset in the first year of life with characteristic gelastic (laughing) seizures and/or dacrystic (crying) seizures. Over time, patients develop other seizure types often with evolution to epileptic encephalopathy. Intellectual disability and severe behavioral dysregulation are common features. Patients may develop central precocious puberty, which can occur independently of epilepsy. Seizures are typically medically refractory and surgical management is the treatment of choice with the goal of disconnecting the HH from the mamillothalamic tracts. Somatic variants of the sonic hedgehog signaling pathway (eg, *GLI3*) have been implicated in the pathogenesis of HH.

Sturge-Weber Syndrome

Sturge-Weber syndrome (SWS) is a neurocutaneous syndrome characterized by angiomatosis of leptomeninges and/or choroid of the eye, usually accompanied by a facial *nevus flammeus* (port-wine stain). Leptomeningeal angiomas cause impaired venous drainage leading to chronic ischemic injury to the adjacent cerebral cortex with associated atrophy and calcifications (tram-track sign). The SWS is caused by somatic variants in *GNAQ*, a signaling molecule important in blood vessel development. The SWS is usually characterized by focal epilepsy, with prolonged focal seizure, with or without secondary generalization, often severe and refractory, leading to epileptic encephalopathy. Patients may develop intellectual disability, hemianopia and progressive hemiparesis, manifesting as a Todd paresis of increasing duration over time, correlated with frequent seizures and recurrent episodes of status epilepticus. Therefore, in refractory patients, resective surgery or hemispherotomy should be considered early.

LEVEL 1 EVIDENCE

1. Painter MJ, Scher MS, Stein AD, et al. Phenobarbital compared with phenytoin for the treatment of neonatal seizures. *N Engl J Med*. 1999;341:485-489.
2. Subcommittee on Febrile Seizures. Febrile seizures: guideline for the neurodiagnostic evaluation of the child with a simple febrile seizure. *Pediatrics*. 2011;127:389-394.
3. Berg AT, Berkovic SF, Brodie MJ, et al. Revised terminology and concepts for organization of seizures and epilepsies: report of the ILAE Commission on Classification and Terminology, 2005-2009. *Epilepsia*. 2010;51:676-685.
4. Go CY, Mackay MT, Weiss SK, et al. Evidence-based guideline update: medical treatment of infantile spasms. Report of the Guideline Development Subcommittee of the American Academy of Neurology and the Practice Committee of the Child Neurology Society. *Neurology*. 2012;78(24):1974-1984.

5. Scheffer IE, Berkovic S, Capovilla G, et al. ILAE classification of the epilepsies: position paper of the ILAE Commission for Classification and Terminology. *Epilepsia*. 2017;58:512-521.
6. Devinsky O, Cross JH, Laux L, et al. Trial of cannabidiol for drug-resistant seizures in the Dravet syndrome. *N Engl J Med*. 2017;376:2011-2020.
7. Thiele EA, Marsh ED, French JA, et al. Cannabidiol in patients with seizures associated with Lennox-Gastaut syndrome (GWPCARE4): a randomised, double-blind, placebo-controlled phase 3 trial. *Lancet*. 2018;391:1085-1096.
8. Glauser TA, Cnaan A, Shinnar S, et al. Ethosuximide, valproic acid, and lamotrigine in childhood absence epilepsy. *N Engl J Med*. 2010;362:790-799.
9. French JA, Lawson JA, Yapici Z, et al. Adjunctive everolimus therapy for treatment-resistant focal-onset seizures associated with tuberous sclerosis (EXIST-3): a phase 3, randomised, double-blind, placebo-controlled study. *Lancet*. 2016;388:2153-2163.

SUGGESTED READINGS

Bahi-Buisson N, Kaminska A, Boddaert N, et al. The three stages of epilepsy in patients with CDKL5 mutations. *Epilepsia*. 2008;49:1027-1037.

Barkovich AJ, Raybaud C, eds. *Pediatric Neuroimaging*. 6th ed. Philadelphia, PA: Wolters Kluwer; 2018.

Berg AT, Coryell J, Saneto RP, et al. Early-life epilepsies and the emerging role of genetic testing. *JAMA Pediatr*. 2017;171(9):863-871.

Cay-Martinez KC, Hickman RA, McKhann Ii GM, Provenzano F, Sands TT. Rasmussen encephalitis: an update. *Semin Neurol*. 2020;40(2):201-210.

Cornet MC, Sands TT, Cilio MR. Neonatal epilepsies: clinical management. *Semin Fetal Neonatal Med*. 2018;23:204-212.

Glass HC, Shellhaas RA, Wusthoff CJ, et al. Contemporary profile of seizures in neonates: a prospective cohort study. *J Pediatr*. 2016;174:98-103.e1.

Grinton BE, Heron SE, Pelekanos JT, et al. Familial neonatal seizures in 36 families: clinical and genetic features correlate with outcome. *Epilepsia*. 2015;56:1071-1080.

Kelly M, Park M, Mihalek I, et al. Spectrum of neurodevelopmental disease associated with the GNAO1 guanosine triphosphate-binding region. *Epilepsia*. 2019;60:406-418.

Knupp KG, Wirrell EC. Treatment strategies for Dravet syndrome. *CNS Drugs*. 2018;32:335-350.

Lewis DV, Shinnar S, Hesdorffer DC, et al. Hippocampal sclerosis after febrile status epilepticus: the FEBSTAT study. *Ann Neurol*. 2014;75:178-185.

Meisler MH, Helman G, Hammer MF, et al. SCN8A encephalopathy: research progress and prospects. *Epilepsia*. 2016;57:1027-1035.

Numis AL, Angriman M, Sullivan JE, et al. KCNQ2 encephalopathy: delineation of the electroclinical phenotype and treatment response. *Neurology*. 2014;82:368-370.

Numis AL, Nair U, Datta AN, et al. Lack of response to quinidine in KCNT1-related neonatal epilepsy. *Epilepsia*. 2018;59:1889-1898.

Pearl PL, ed. *Inherited Metabolic Epilepsies*. 2nd ed. New York, NY: Demos; 2018.

Pisano T, Numis AL, Heavin SB, et al. Early and effective treatment of KCNQ2 encephalopathy. *Epilepsia*. 2015;56:685-691.

Sanders SJ, Campbell AJ, Cottrell JR, et al. Progress in understanding and treating SCN2A-mediated disorders. *Trends Neurosci*. 2018;41:442-456.

Sands TT, Balestri M, Bellini G, et al. Rapid and safe response to low-dose carbamazepine in neonatal epilepsy. *Epilepsia*. 2016;57:2019-2030.

Shellhaas RA, Wusthoff CJ, Tsuchida TN, et al. Profile of neonatal epilepsies: characteristics of a prospective US cohort. *Neurology*. 2017;89:893-899.

Stamberger H, Nikanorova M, Willemsen MH, et al. STXBP1 encephalopathy: a neurodevelopmental disorder including epilepsy. *Neurology*. 2016;86:954-962.

Weckhuysen S, Ivanovic V, Hendrickx R, et al. Extending the KCNQ2 encephalopathy spectrum: clinical and neuroimaging findings in 17 patients. *Neurology*. 2013;81:1697-1703

Wolff M, Johannesen KM, Hedrich UB, et al. Genetic and phenotypic heterogeneity suggest therapeutic implications in SCN2A-related disorders. *Brain*. 2017;140:1316-1336.

Pediatric Stroke 149

Sally M. Sultan and Robert H. Fryer

KEY POINTS

1. The highest incidence of stroke in childhood occurs in the neonatal period.
2. Arteriopathies, both transient and progressive, are the most common cause of stroke in childhood.
3. In both neonatal stroke and cerebral venous thrombosis, evaluation for clotting disorders are a key part of the workup.
4. Moyamoya disease/syndrome is a progressive vasculopathy with collateral blood vessel formation that occurs by itself or as part of an underlying genetic disorder.
5. The role of patent foramen ovale closure in childhood stroke remains uncertain.
6. Strokes are common in sickle cell anemia and can be prevented by transfusion (and hydroxyurea).

INTRODUCTION

Stroke incidence peaks at the extreme ends of the age continuum, in both the newborn period and in the elderly, forming a U-shaped curve over the lifespan. After an initial spike in the first week of life, the stroke incidence precipitously drops in childhood and remains low throughout adolescence. There is a steady rise in stroke incidence throughout adulthood, reaching its highest levels in the elderly. Arterial ischemic stroke (AIS) is the most common cause of stroke in the pediatric population, followed by cerebral sinovenous thrombosis (CSVT) and intracranial hemorrhage (ICH). This chapter starts with a discussion of perinatal stroke (<29 d old) followed by stroke in infants, children, and adolescents (29 d old to <18 y of age). Sickle cell anemia (SCA), which carries a very high risk of stroke in childhood and adolescence, is also discussed. The last part of this chapter addresses the growing role of genetics in pediatric stroke disorders.

PERINATAL STROKE

Perinatal stroke is defined as signs and symptoms referable to a vascular event with radiologic or pathologic confirmation of the vascular event. Perinatal stroke most often affects term infants, but it includes strokes that occur from 20 weeks of gestation through 28 postnatal days and can affect preterm infants. A *presumed perinatal stroke* is diagnosed in an older child when neuroimaging shows a chronic stroke with or without delayed focal neurologic signs referable to the vascular lesion. One relatively common presentation of presumed perinatal stroke is the appearance of hemiparesis or early hand preference in an infant between 4 and 8 months of age with imaging showing a chronic infarct.

Epidemiology

Perinatal Arterial Ischemic Stroke

Assessment of data regarding the incidence of neonatal stroke is confounded by difficulties including those patients whose stroke is not identified in the days or weeks after birth. In the National Hospital Discharge Survey (1980-1998), the rate of neonatal ischemic stroke was 17.8/100,000 and hemorrhagic stroke was 6.7/100,000. The overall incidence of neonatal stroke was 26.4/100,000 or 1/4,000 live births per year. This high incidence does not account for infants who present after the first few days of life, children who are diagnosed with a presumed perinatal stroke, and undiagnosed hemiplegic cerebral palsy. Other studies that have attempted to capture strokes identified in the neonatal period along with presumed perinatal stroke and perinatal intracerebral hemorrhage suggest an incidence as high as 1 in 2,200 live births.

The incidence of stroke during the newborn period is at least 10-fold higher than the incidence of stroke in childhood. Some studies have shown a higher rate of perinatal stroke in males than females.

Perinatal Cerebral Sinovenous Thrombosis

The incidence of CSVT in neonates is approximately 2 to 3 per 100,000. CSVT typically occurs in term or near-term infants. In one study, the mean gestational age was 37 weeks, and 19% of the neonates were preterm. The mean birth weight was 2,720 g.

Perinatal Intracranial Hemorrhage

A study of population prevalence of perinatal ICH in Northern California identified approximately 6.2 cases per 100,000 live births for an incidence of approximately 1 in 6,300 live births.

Pathobiology

Perinatal Arterial Ischemic Stroke

The majority of perinatal strokes likely occur in the few days before and after delivery. AIS is most common in the anterior circulation and on the left, specifically involving the middle cerebral artery (MCA). This preference for the left MCA is presumably due to the more direct course of blood flow from the heart and aorta into the left common carotid artery. Approximately one-quarter of perinatal AIS involves both cerebral hemispheres. Despite a recent expansion of research in this field, there are no strong predictors of perinatal stroke. Placental factors, including thrombi formation and inflammation, combined with the presence of transitory right to left circulatory shunts in the newborn circulatory system may contribute to the high incidence of stroke in the perinatal period.

Peripartum Factors

Risk factors for perinatal stroke are incompletely understood but can be divided into those present before the onset of labor

TABLE 149.1 Risk Factors for Perinatal Stroke

Before Labor and Delivery
Primiparity
Preeclampsia
Oligohydramnios
History of infertility
During and After Labor and Delivery
Fetal heart rate abnormality
Emergency caesarean delivery
Chorioamnionitis
Prolonged rupture of membranes
Prolonged second stage of labor
Vacuum extraction
Cord abnormality
Sepsis and meningitis

and those present during or shortly after labor and delivery (Table 149.1). The risk of stroke increases dramatically with each additional risk factor present.

Prothrombotic Factors

The role of prothrombotic factors in perinatal stroke remains unclear. A large meta-analysis that included many observational studies showed a possible association between thrombophilic states and perinatal stroke, but a more recent prospective case-control study showed at best a minimal association between inherited thrombophilic states and perinatal stroke. Furthermore, the levels of many coagulation and anticoagulation factors in the newborn are much lower than in the adult, and laboratory measurements are less reliable.

Infection

Sepsis and meningitis have long been associated with large-artery ischemic strokes and CSVT. In an international series of neonates, 23% had a systemic illness around the time of stroke.

Congenital Heart Disease

Intracardiac thrombi due to congenital heart disease are a source of embolic stroke in the newborn. Approximately one-fifth of neonates have a cardiac risk factor most often in the form of congenital heart disease. Aside from inherited heart disease, there is limited data on other cardiac causes of perinatal stroke. In two series of neonates without known congenital heart disease, echocardiography was not informative.

Perinatal Cerebral Sinovenous Thrombosis

The cerebral sinuses may be subject to injury during the birth process and, as seen in perinatal AIS, inflammation of the placenta may lead to a prothrombotic state. The deep venous system is more prone to thrombosis in the neonatal period compared with childhood. In one study, the involvement of the straight sinus, the vein of Galen, or internal cerebral veins was seen in more than two-thirds of neonates with CSVT.

In neonates with CSVT, concurrent hemorrhagic infarcts are seen in 35% to 50%. Intraventricular hemorrhage (IVH) is found in 19% to 38% of neonates. Concurrent AIS has been reported in 10% and subarachnoid hemorrhage (SAH) in 5%.

Perinatal Intracranial Hemorrhage

In most cases of perinatal ICH, a cause cannot be identified. Occasional cases may be due to hemorrhagic conversion of an arterial or venous infarct. Hemorrhagic disease of the newborn, due to low vitamin K, along with other acquired or congenital coagulopathies are important causes of perinatal ICH.

Clinical Features

Perinatal Arterial Ischemic Stroke

Neonatal seizures are the most common presenting sign of a stroke. In one international series on ischemic stroke, 72% of neonates presented with seizures. Other common presenting signs are changes in tone and level of consciousness. Those that do not present in the perinatal period with seizure come to clinical attention later in life due to focal neurologic deficits or seizures, and a chronic infarct is found on imaging.

Perinatal Cerebral Sinovenous Thrombosis

Neonates are more likely to present with seizures and generalized encephalopathy compared with children with CSVT. Typical neonatal diffuse signs are a depressed level of consciousness, jitteriness, irritability, apnea, poor feeding, and low tone.

Perinatal Intracranial Hemorrhage

More than 50% of neonates with ICH also present with seizures. Neonates are more likely than children to present with signs of encephalopathy such as lethargy, hypotonia, feeding difficulties, and apnea.

Diagnosis and Imaging

Perinatal Arterial Ischemic Stroke

Ultrasound is safe, widely available, and does not require transport of the neonate to an imaging suite. It is sensitive for intraventricular and periventricular blood and chronic infarction, but sensitivity is low for AIS. In one study, only 30% of perinatal AIS was detected on ultrasound. Computed tomography (CT) scan is often avoided in the neonate because of the availability of ultrasound and to prevent exposure to radiation, but where indicated, CT will accurately show superficial ischemic and hemorrhagic lesions. Magnetic resonance imaging (MRI) is safe, more sensitive for early ischemic strokes and superficial lesions, and can often be done without anesthesia in newborns.

Perinatal Cerebral Sinovenous Thrombosis

Symptoms may begin around the time of birth, but diagnosis may be delayed. In one study, the mean age at diagnosis was 9 days of age. Doppler ultrasound is portable and well tolerated, but in one neonatal study, only 48% of CSVT was detected.

Perinatal Intracranial Hemorrhage

Ultrasound is useful in identifying hemorrhage in the neonatal brain; however, it is not as useful in identifying the etiology of the hemorrhage. Magnetic resonance angiography (MRA) can typically show large vascular malformations but may miss small malformations. Conventional angiography can be used to identify smaller malformations.

Management

Perinatal Arterial Ischemic Stroke

Where there is no cardiac indication for aspirin or anticoagulation, there is a recommendation against its use after a first perinatal AIS. For recurrent AIS, aspirin or anticoagulation is suggested. After a stroke, if there is delayed acquisition of milestones, hypotonia, spasticity, or focal deficits, it is reasonable to institute multispecialty therapy. If an *MTHFR* mutation with elevated homocysteine levels is discovered, it is reasonable to give folate and B vitamins to normalize homocysteine levels for secondary stroke prevention. Anticoagulation with low molecular weight heparin (LMWH) and unfractionated heparin (UFH) can be considered in selected neonates with severe thrombophilic disorders and multiple cerebral or systemic emboli. Thrombolytic agents are not recommended in neonates until more information about safety and effectiveness is known.

Perinatal Cerebral Sinovenous Thrombosis

In the large single-center retrospective analysis, 25% of the neonates with CSVT were anticoagulated only after thrombus propagation. Within 2 weeks of diagnosis, thrombus propagation occurred in 4% of treated neonates and 28% of untreated neonates. Propagation was asymptomatic but was associated with new venous infarcts in 10%. Anticoagulant-related ICH occurred in 8% and only happened when there was pretreatment ICH.

Anticoagulation can be considered in neonates with clinical or radiologic evidence of propagating CSVT despite supportive therapy. There is insufficient evidence to recommend the initial routine use of anticoagulation in neonates with CSVT. Despite this recommendation, at many stroke centers, anticoagulation is started with an initial CSVT diagnosis unless there is a significant hemorrhage.

Perinatal Intracranial Hemorrhage

Neonates with ICH resulting from coagulation factor deficiency require replacement of the deficient coagulation factors. Neonates born to mothers exposed to warfarin, phenytoin, or barbiturates may require higher doses of vitamin K. Supportive measures such as treatment of dehydration and anemia should be considered.

Outcome

Perinatal Arterial Ischemic Stroke

Neurologic Deficits

Perinatal stroke is presumed to be the most common cause of hemiplegic cerebral palsy. Initial imaging can be used to predict neurodevelopmental outcomes in perinatal AIS. Strokes that involved the main branch of the MCA, where the entire MCA territory is infarcted, have a poor outcome, with 100% developing hemiplegic cerebral palsy in one study. Other predictors of poor outcome include involvement of the basal ganglia, thalamus, and the middle third of the cerebral peduncle. However, newborns whose strokes do not involve the basal ganglia, thalamus, and cerebral peduncle fare much better, with about 43% to 71% or greater having a normal neurodevelopmental outcome (Fig. 149.1).

Cognitive and Behavioral Deficits

Involvement of the basal ganglia and thalamus is a predictor of cognitive deficits and behavior problems. However, in most other types of unilateral infarction, IQ is generally preserved. Despite the predominance of left-sided MCA infarcts in perinatal AIS, many children will have intact language acquisition.

Seizures and Epilepsy

Although seizures are common in the acute setting of a perinatal AIS, a smaller percentage of patients will go on to develop

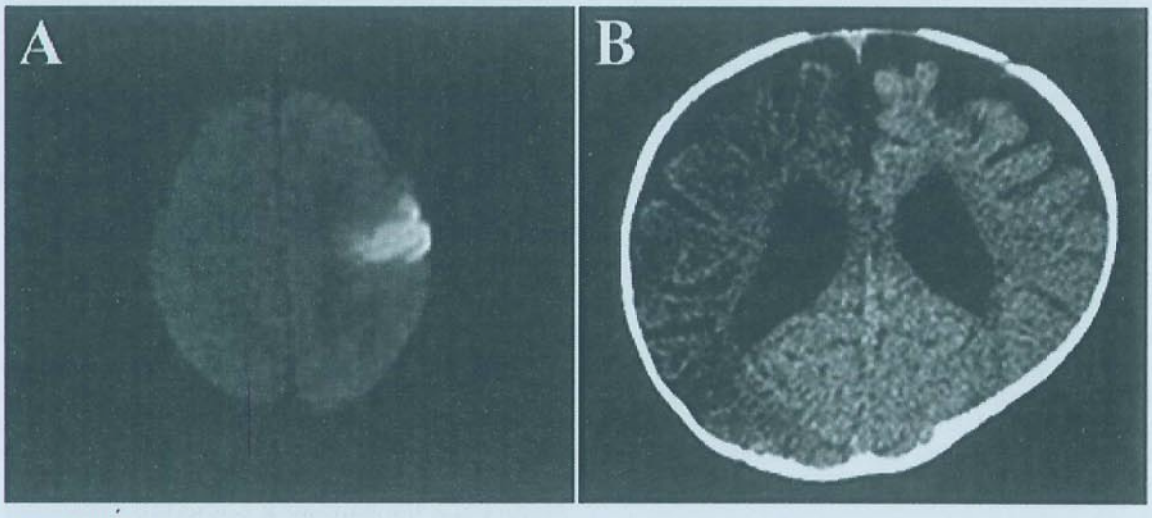

FIGURE 149.1 Perinatal arterial ischemic stroke. **A:** Diffusion-weighted imaging image showing a left-sided cortical infarct in a term newborn presenting on the second day of life with seizures. This infant was last seen at 32 months of age off of antiseizure medications and with normal development. **B:** Head computed tomography showing a large right middle cerebral artery/anterior cerebral artery infarct in an infant with hypoplastic left heart syndrome, postoperative from a Fontan procedure, with numerous deep venous thromboses. This infant has a poor prognosis.

epilepsy. One study found that 47% of survivors of perinatal AIS had epilepsy, but other studies have shown a lower rate. Large infarct size seems to be a risk factor for the development of epilepsy after a perinatal AIS.

Recurrence

Recurrent stroke is extremely rare in perinatal stroke except in those newborns with congenital heart disease. In northern California, the 5-year cumulative recurrence rate was only 1.2%. However, newborns with perinatal stroke and cardiac disease have a higher recurrence rate.

Perinatal Cerebral Sinovenous Thrombosis

Anticoagulation for CSVT may be safe even in neonates. In the large single-center review, there were no deaths related to anticoagulation in neonates. Recurrence is seen in 8% of neonates. Recanalization may be better in neonates than in older children. In one study at 3 months, 85% of neonates had complete recanalization.

Outcome is more likely to be normal in neonates without parenchymal involvement due to CSVT. In neonates with infarction, the outcome was normal in only 41% to 43%, and 29% had severe disability at follow-up. The risk of an unfavorable outcome was similar even among neonates with major anticoagulant-related hemorrhage.

Poor outcome includes epilepsy (38% in one series), spastic hemiplegia or tetraplegia, and intellectual disability or developmental delay. A predictor of poor neonatal outcome was the absence of anticoagulant treatment.

Perinatal Intracranial Hemorrhage

Epilepsy occurs in a small proportion of patients with perinatal ICH. Elevated intracranial pressure that requires intervention is a risk factor for the development of epilepsy in patients with perinatal ICH.

Epidemiology

Childhood Arterial Ischemic Stroke

The annual incidence for childhood AIS is 1 to 2 per 100,000 children and peaks among school-aged children. From the first 676 patients in the International Pediatric Stroke Study registry, the largest registry of all pediatric stroke, the median age at first AIS presentation was 5.7 years.

For all childhood stroke, there is a predominance of affected males with an estimated ratio of 3:2 boys:girls. In the California discharge database, the relative risk (RR) for ischemic and hemorrhagic stroke was higher among boys than girls: for AIS, RR 1.25; SAH, RR 1.24; and ICH, RR 1.34. Mortality after AIS was also higher among boys (17% vs 12%).

Studies in the United States have identified racial and ethnic disparities in childhood stroke where black children are at higher risk for ischemic and hemorrhagic stroke than white children. Pediatric stroke mortality was found to be higher in stroke belt states (southeastern United States), compared with other US states.

Childhood Cerebral Sinovenous Thrombosis

Population-based incidence studies report that less than 1 per 100,000 children per year are diagnosed with CSVT (see Chapter 41). Many stroke providers believe true incidence is significantly higher and diagnoses are missed. Among patients with a presumed diagnosis of idiopathic intracranial hypertension, routine imaging discloses CSVT in as many as 26%. CSVT also peaks in school-aged children. The mean age of children at the time of diagnosis is 5 to 9 years.

Childhood Intracranial Hemorrhage

Hemorrhagic stroke can be further broken down into intracerebral hemorrhage, IVH, and SAH. In children, approximately half of all strokes are hemorrhagic. The annual incidence rate ranges from 0.63 to 5.11 per 100,000 children without SCA. ICH affects school-aged children. The median age of affected children is 7 to 10 years. Arteriovenous malformations (AVMs) are the most common cause of ICH in childhood and approximately 10% of nontraumatic childhood ICH remain idiopathic.

Pathobiology

Childhood Arterial Ischemic Stroke

Arteriopathy (50% of Arterial Ischemic Stroke)

Arteriopathy in pediatric stroke is presumed to be nonatheromatous and instead due to inflammation, infection, and inherited disorders of tissue stability and repair. Arteriopathy is found in approximately 50% of childhood AIS, and discrete radiographic and clinical subtypes have begun to be described. Two reported predictors of arteriopathy are a recent upper respiratory infection and SCA. The traditional nomenclature for AIS arteriopathy subtypes are *focal cerebral arteriopathy, moyamoya, intracranial and extracranial arterial dissection, vasculitis, sickle cell arteriopathy, postvaricella arteriopathy*, and other unspecified forms of arteriopathy. Frequencies of arteriopathy subtypes are as reported in the International Pediatric Stroke Study registry.

Focal Cerebral Arteriopathy (25%)

This entity is typically characterized by unilateral mainstem arterial disease with lenticulostriate infarction. An East Asian study found that FCA was reversible in 68%, progressive in 20%, and stable in 12%. Of the patients with reversible arteriopathy, 53% had early worsening. In European cohorts, the course of unilateral arteriopathy was progressive in only 6%, stabilized in 32%, improved in 45%, and completely normalized in 23%. Among patients with a nonprogressive arteriopathy, 44% had an antecedent varicella infection, and 18% had a recurrent stroke or transient ischemic attack (TIA).

Moyamoya (22%)

Moyamoya arteriopathy (see also Chapter 44) is the progressive development of bilateral occlusive disease of the terminal internal carotid arteries (ICAs) with basal collaterals (Fig. 149.2). There may also be involvement of the mainstem branches of the terminal ICA. The term *moyamoya syndrome* is used when there is an accompanying condition (Table 149.2) known to be associated with moyamoya arteriopathy and the term *moyamoya disease* when the disorder is idiopathic. Moyamoya disease is more common in Asian populations, and about half of Asian patients with moyamoya have a mutation in the gene RNF213. Moyamoya arteriopathy is commonly progressive. In a single-center series, progression developed in 45% over 5 years. Stroke recurrence is also high from 20% over 4 years to 38% over 10 years.

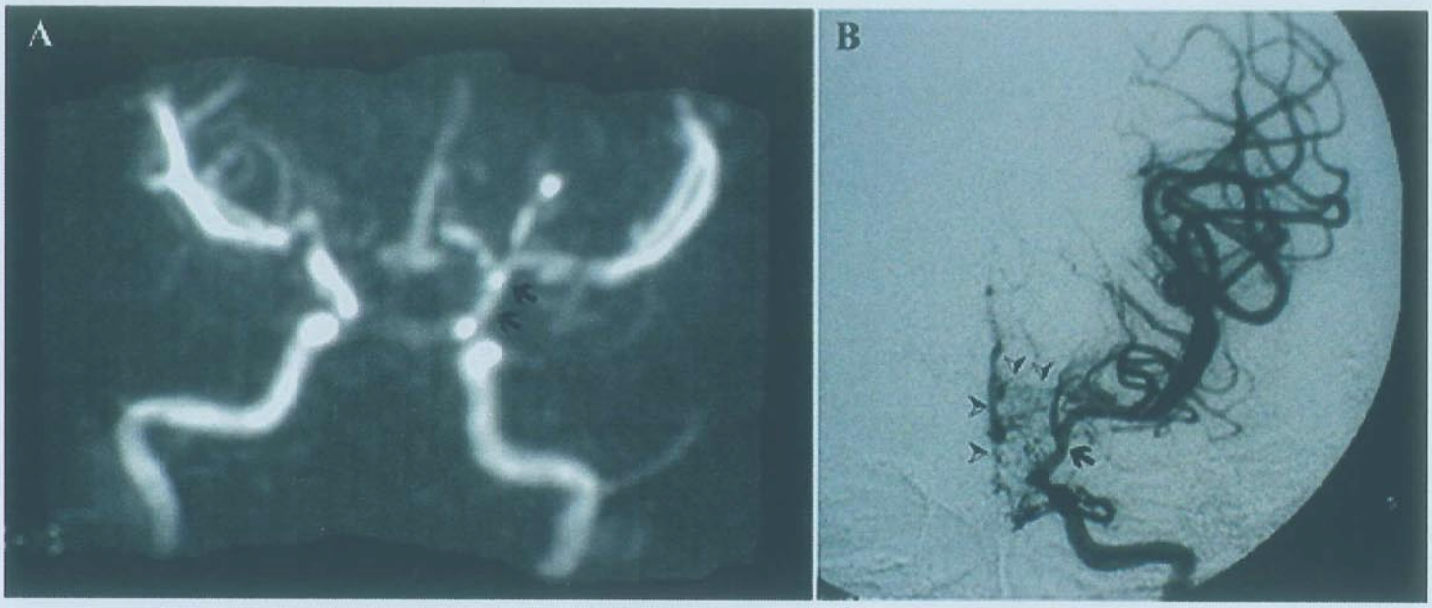

FIGURE 149.2 Moyamoya syndrome in a 7-year-old boy with sickle cell anemia who had a seizure and a stroke. **A:** Magnetic resonance angiography of the anterior circulation showing occlusion of bilateral A1 segments and narrowing of both the left *(arrows)* and right terminal internal carotid arteries (ICAs) and middle cerebral arteries. **B:** In the same patient, cerebral angiogram of the left ICA injection showing narrowing of the terminal ICA *(arrow)* extending into middle cerebral artery, along with the fine moyamoya collateral vessels that form at the base of the brain *(arrowheads)*. This child had a bilateral encephaloduroarteriosynangiosis procedure and has done well with no further strokes or seizures.

Craniocervical Arterial Dissection (20% of Arteriopathy)

Arterial dissection in childhood includes intracranial and extracranial dissections. In a meta-analysis of arterial dissection in children younger than 18 years, males were affected considerably more than females: 74% male in anterior circulation dissections and 87% male in posterior circulation dissections. This predominance persisted even for nontraumatic dissections. Of dissection involving the anterior circulation, 40% were extracranial and of dissections involving the posterior circulation, 79% were extracranial. One-third of dissections are spontaneous, but less than a fifth are associated with significant trauma. The mean age of presentation is older than all AIS at 8 to 10 years. Common presenting symptoms are hemiparesis and headache. Neck pain was less common in children. Follow-up after an average of 5 years showed moderate or severe deficits in 14%, recurrent strokes in 9%, and recurrent dissections only after anterior circulation dissection and in 10% of those patients.

TABLE 149.2 Diseases Associated With Moyamoya Syndrome

Autosomal Dominant Inheritance
Neurofibromatosis type I
Alagille syndrome
Noonan syndrome
Costello syndrome
Autosomal Recessive Inheritance
Sickle cell anemia
GUCY1A3 mutation
SAMHD1 mutation
Microcephalic osteodysplastic primordial dwarfism
Seckel syndrome
Recessive X-linked Inheritance
BRCC3/MTCP1 deletion
Aneuploidy Disorder
Down syndrome
Turner syndrome
Other
PHACE syndrome

Vasculitis (12% of Arteriopathy)

Cerebral vasculitis is rare and can be difficult to diagnose in children (see Chapter 43). Vasculitis due to systemic inflammatory conditions, viral, fungal, mycobacterial, and even parasitic infections is more likely than primary central nervous system angiitis. Consider vasculitis where there are infarcts in multiple vascular territories with microhemorrhages.

Sickle Cell Arteriopathy (8% of Arteriopathy)

See later detailed discussion of sickle-cell arteriopathy.

Post–varicella Angiopathy (7% of Arteriopathy)

This entity traditionally results in stenosis of the distal internal carotid and mainstem branches with lenticulostriate infarction. (See later discussion on "Risk Factors, Infection.")

Cardiogenic (30% of Arterial Ischemic Stroke)

Cardiogenic causes of stroke include congenital heart disease, valvular heart disease, arrhythmias, cardiomyopathy, cardiac surgery and catheterization, extracorporeal membrane oxygenation, left ventricular assist device, and Kawasaki disease.

Congenital heart disease is the most common cardiac risk factor, reported in 59% of those with a cardiogenic stroke.

An isolated patent foramen ovale (PFO) was reported in 15% and cardiac catheterization in 8%.

Thromboembolic (15% of Arterial Ischemic Stroke)

Thromboembolic stroke may be due to an indwelling catheter, infection, or a hypercoagulable state that is inherited or acquired.

Cryptogenic Stroke (5% of Arterial Ischemic Stroke)

Cryptogenic stroke, where the etiology of the stroke is unknown despite a comprehensive workup, is reported in approximately one-fifth of children.

Childhood Cerebral Sinovenous Thrombosis

The cerebral veins and sinuses are thin-walled and without valves. Cerebral veins drain into the sinuses that form from dural pockets around the brain. Unlike arterial vascular territories, thrombosis of particular veins does not present with well-defined clinical syndromes. The venous system has considerable anatomic variability, flow can be reversed, and there may be collateral drainage pathways such as through occipital sinuses.

The cerebral veins and sinuses are positioned for thrombotic complications. Venous drainage is slow; it follows a tortuous route and the walls easily distend. A combination of local inflammation in the vessel wall, systemic thrombophilia, hyperosmolality, reduced blood flow, and injury to the vessel wall all work to tip the balance toward cerebral thrombosis. When a thrombus obstructs venous outflow, the pressure becomes high in the venous system. Edema and hemorrhage can develop from high pressure in the capillaries with plasma and red blood cell diapedesis or frank rupture, and the high pressure can exceed arterial perfusion pressure resulting in ischemic infarction. Hydrocephalus with intracranial hypertension will occur when cerebrospinal fluid reabsorption through arachnoid villi and pacchionian body granulations in the dural sinuses becomes impaired. A large thrombus in the superior sagittal sinus, the sinus where most of the reabsorption occurs, will generally lead to a communicating hydrocephalus.

In children, the superior sagittal and lateral sinuses are most often affected, and two or more sinuses or veins are involved. Sinus occlusion may present with intracranial hypertension, whereas an isolated cerebral vein thrombosis may present with focal neurologic signs.

CSVT is a complication of many chronic inflammatory, infectious, and prothrombotic states (Table 149.3).

Prothrombotic tendencies may be present in half of children tested, and more than one abnormality is not uncommon. The meta-analysis of prothrombotic traits in childhood stroke also found a positive association for all of the thrombophilia traits studied with CSVT: antithrombin deficiency, protein C deficiency, protein S deficiency, factor V G1691A mutation, and prothrombin G20210A mutation. An antithrombin deficiency was 18-fold higher in children with CSVT compared to a control population and protein C or S were 6 and 5 times higher in a cohort of children with CSVT.

Childhood Intracranial Hemorrhage

ICH in children is most often intraparenchymal hemorrhage or intraparenchymal hemorrhage with IVH extension. Isolated IVH is rare. Hematoma expansion may occur in one-third of children, and the expansion may be significant, requiring urgent evacuation.

Causes of ICH from three pediatric tertiary care centers in the United States are AVMs (37%), unknown (17%), cavernous malformations (13%), coagulopathy (11%), anticoagulation (9%), aneurysm (9%), developmental venous anomaly (2%), and moyamoya (2%). In the Baltimore-Washington Cooperative Young Stroke Study, ICH was due to AVMs (29%), hematologic causes (23%), vasculopathy (18%), surgical complications (12%), coagulopathy (6%), and indeterminate causes (12%).

TABLE 149.3 Diseases Associated With Cerebral Sinovenous Thrombosis

Chronic Inflammatory and Hypercoagulable Diseases
Inflammatory bowel disease
Systemic lupus erythematosus
Behçet disease
Celiac disease
Multiple sclerosis
Head injury
Brain neoplasm
Hematologic malignancy
Infectious
Mastoiditis
Otitis
Sinusitis
Meningitis
Prothrombotic States
Nephrotic syndrome
Homocystinuria
Oral contraceptive use
Pregnancy
Asparaginase treatment
Thrombophilia Traits
Antithrombin deficiency
Protein C deficiency
Protein S deficiency
Factor V mutation
Prothrombin mutation
Other
Anemia
Hydrocephalus
Dehydration
Hypoxia
Postoperative period
Postcatheterization

Diagnosis

Childhood Arterial Ischemic Stroke

Patients who present with new focal neurologic deficits should undergo an urgent CT scan of the head to rule out acute hemorrhage. Early ischemic stroke may not be seen on head CT and should be confirmed with MRI. In children with moyamoya disease, transcranial Doppler (TCD) may be useful to follow for

stability or progression of vascular disease. (class IIb, level of evidence C). Arteriopathies are a common causes of childhood stroke, so an MRA should be performed as part of the evaluation of a child with a stroke. Cerebral angiography should be considered in cases where the MRA is not informative.

Childhood Cerebral Sinovenous Thrombosis

Presenting symptoms are often diffuse and nonspecific. In series of children with CSVT, the most common presenting symptoms are headache, vomiting, and visual symptoms. Presenting symptoms may overlap with traditional symptoms of idiopathic intracranial hypertension. Other presenting symptoms are lethargy, malaise, irritability, poor appetite, limb weakness, unsteady gait, and seizures.

Common clinical signs on presentation are papilledema, seizure, fever, sixth nerve palsy, and hemiparesis (Fig. 149.3). Other signs include a decreased level of consciousness, visual field defects, cranial nerve palsies, ataxia, speech impairment, and hemisensory loss.

The diagnosis is often delayed. A retrospective chart review of 21 children treated from 1997 to 2005 found that there was a mean of 6 days from onset of symptoms to hospital presentation, and from hospital presentation to diagnosis, there was a mean of 3 days.

There are pathognomonic imaging signs for CSVT. The cord sign is due to dense cortical veins or thrombosed sinuses. The dense-triangle sign due to acutely congealed blood is a very early and transient sign. The delta- or empty-triangle sign is a late finding and is the result of venous flow in the collateral veins in the walls of the sinus compared with absent flow within the sinus.

CT scan is widely available and can be obtained rapidly. At many centers, good quality images can now be obtained with low radiation. In one study, unenhanced CT scan was 73% sensitive for CSVT, and there were no false-positive results. CT venogram increases the sensitivity of the study to detect thrombus in the vein and may be superior to magnetic resonance venogram in visualization of cerebral veins but requires skilled technicians for appropriate timing of the contrast bolus to avoid arterial contamination. It is also affected by poor cardiac output and conditions associated with increased circulation time.

MRI is superior for the evaluation of parenchymal abnormalities. MRI and magnetic resonance venogram do not require contrast, but contrast can be helpful to distinguish between a hypoplastic sinus and thrombosis in the lumen. Flow voids can be mistaken for thrombosis where there is slow cerebral flow.

In children with CSVT, approximately one-quarter have no parenchymal involvement, one-third have ischemic infarcts, and one-third have ICH. Intraventricular and SAHs are seen in less than 10%.

Childhood Intracranial Hemorrhage

Children with nontraumatic brain hemorrhage should undergo a thorough risk factor evaluation. When noninvasive imaging does not demonstrate a nidus, conventional cerebral angiography should be performed. For a patient who presents with symptoms that could be explained by an aneurysm, computed tomography angiography or conventional angiography may be considered even if the patient's MRA fails to show evidence of an aneurysm.

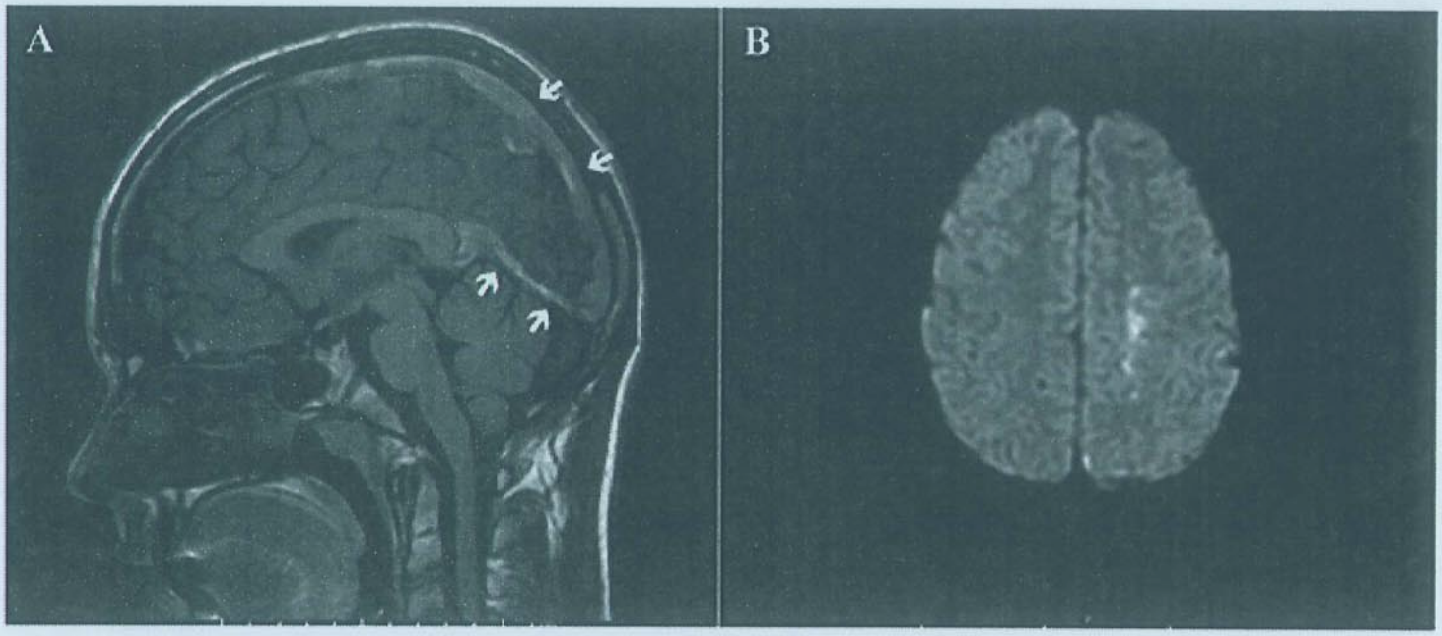

FIGURE 149.3 Cerebral sinovenous thrombosis in a 14-year-old boy with a history of migraine headaches. His headaches markedly worsened over a 3-week period, and he presented to the emergency room with right hand weakness and papilledema. **A:** Sagittal T1 weighted noncontrast magnetic resonance imaging of the brain shows thrombus in the superior sagittal sinus and straight sinus *(arrows)*. **B:** Diffusion-weighted imaging showing diffusion restriction in the left centrum semiovale. His father had a history of deep venous thrombosis, but no clear hypercoagulable state was identified. He was treated with anticoagulation for a year with complete resolution of symptoms.

Management

Childhood Arterial Ischemic Stroke

Acute care after AIS begins with maintenance of normal oxygenation, normothermia, normoglycemia, and control of systemic hypertension. It is reasonable to treat dehydration and anemia. There is no evidence that in children with normal oxygenation, supplemental oxygen provides benefit, and in children without clinical or electrographic seizures, prophylactic administration of antiepileptic medications is not necessary. There is no data confirming the safety and efficacy of hypothermia as an acute treatment for stroke.

Initial therapy in children without SCA should be UFH or LMWH or aspirin (1-5 mg/kg/d) until dissection and embolic causes have been excluded. Once excluded, daily aspirin prophylaxis (1-5 mg/kg/d) for a minimum of 2 years should be continued. In children receiving aspirin who have recurrent AIS or TIAs, consider changing to clopidogrel or an anticoagulant.

Hyperacute stroke therapies include intravenous tissue plasminogen activator (tPA), and endovascular thrombectomy remain controversial in children. The 2015 American Heart Association stroke guidelines support the use of mechanical thrombectomy in select patients younger than 18 years of age up to 6 hours after stroke onset. In 2018, the American Heart Association stroke guidelines extended the window of mechanical thrombectomy in suitable adults up to 24 hours from stroke onset based on the DAWN and DEFUSE-3 trials but did not extend the window in children with stroke. A review of 29 pediatric patients who underwent mechanical thrombectomy with an average age of 10 years showed a significant improvement in National Institutes of Health Stroke Scale scores with no major complications. Despite the lack of evidence, it is not unreasonable to consider mechanical thrombectomy in a child younger than 18 years old up to 24 hours after the stroke onset. Intravenous tPA is an established and effective treatment for adults with stroke if treated within 4.5 hours. A recent consensus statement from the American Heart Association/American Stroke Association recommended consideration of hyperacute therapies such as intravenous tPA and endovascular thrombectomy in children meeting the following criteria: (1) persistent disabling neurologic deficits (pediatric National Institutes of Health Stroke Scale ≥6), (2) radiographically confirmed large-artery occlusion, (3) larger children (due to the size of catheters relative to the size of arteries), (4) treatment decisions made by neurologists with expertise in the treatment of childhood stroke, and (5) interventions by endovascular surgeons also with expertise in the treatment of pediatric stroke.

A child who has suffered a stroke should be enrolled in age-appropriate rehabilitation and therapy program. Cognitive and behavioral performance is especially important in school-aged children. Neuropsychological assessment is useful for planning therapy and educational programs and monitoring cognitive, behavioral, and language deficits after a stroke.

Craniocervical Arterial Dissection

The American Heart Association Stroke Council recommends beginning treatment of an extracranial CCAD with UFH or LMWH and to continue subcutaneous LMWH or bridge to warfarin for 3 to 6 months of treatment. The American College of Chest Physicians recommends anticoagulant therapy for at least 6 weeks, with ongoing treatment dependent on radiologic assessment. One can also consider using an antiplatelet agent instead of LMWH or warfarin. Beyond 6 months, for recurrent symptoms, it is reasonable to continue anticoagulation or an antiplatelet agent. If symptoms have resolved but there is residual abnormality of the dissected artery on imaging, it is also reasonable to continue an antiplatelet agent beyond 6 months. Surgical procedures may be considered for symptoms due to CCAD despite optimal medical therapy. For an intracranial dissection and for SAH resulting from CCAD, anticoagulation is not recommended.

Moyamoya Arteriopathy

With moyamoya disease, surgical revascularization can effectively reduce the risk of stroke. Children with moyamoya should be referred to an appropriate center for consideration of revascularization. There is less literature to recommend one surgical procedure over another, but indirect revascularization may be preferred in younger children whose small-caliber vessels make direct anastomosis difficult, and direct bypass techniques may be preferable in older individuals. Indications for revascularization surgery include progressive ischemic symptoms, evidence of inadequate perfusion, or collateral reserve. After revascularization surgery or in asymptomatic individuals with moyamoya disease, aspirin may be considered. In general, anticoagulants are not recommended with moyamoya disease because of the risk of hemorrhage and the difficulty of maintaining therapeutic levels in children.

Supportive care in children with moyamoya disease includes techniques to reduce anxiety and pain that could lead to hyperventilation-induced vasoconstriction. Preoperative and perioperative hydration is often used with revascularization surgery. Perioperative and intraoperative avoidance of hypotension, hypovolemia, hyperthermia, and hypocarbia may reduce the risk of perioperative stroke.

Cardiogenic Stroke

Treatment for congestive heart failure and congenital heart lesions is recommended and may reduce the likelihood of cardiogenic embolism. This includes resection of an atrial myxoma and does not yet apply to PFOs. It is reasonable to begin anticoagulation following a cardiac embolism in children who are judged to have a high risk for recurrence. UFH or LMWH can be introduced as a bridge to warfarin. LMWH can be continued instead of warfarin, and it is reasonable to continue either LMWH or warfarin for at least 1 year or until the lesion responsible for the risk has been corrected. For a suspected cardiac embolism with an unknown or lower risk of stroke and that is unrelated to a PFO, it is reasonable to treat with aspirin for at least 1 year. It is reasonable to close large atrial septal defects (excludes PFOs) to prevent stroke.

In patients with endocarditis of a prosthetic valve, it may be reasonable to continue long-term anticoagulation. Anticoagulation should not be used for native valve endocarditis, and it is not necessary to remove a cardiac rhabdomyoma in an individual who has been asymptomatic.

Inherited Thrombophilic State

In children with AIS or CSVT, it is reasonable to measure the serum homocysteine level and to introduce therapies such as diet and supplementation of folate, vitamin B_6, or vitamin B_{12} to lower elevated homocysteine values. In an adolescent with AIS or CSVT, it is reasonable to discontinue oral contraceptives.

Other Causes

Children with Fabry disease should receive a-galactosidase replacement therapy.

Childhood Cerebral Sinovenous Thrombosis

Recommendations on anticoagulant use are based on retrospective analysis. While we await a prospective study on anticoagulant use in neonates, a large single-center retrospective analysis of 162 neonates and children from 1992 to 2005 suggests benefit for anticoagulant use even with preexisting hemorrhage. The study was conducted at an institution where a protocol was initiated in 1995 and was practiced. All neonates and children without significant ICH received anticoagulation. If anticoagulation was not started because of significant ICH, a follow-up study was done at 5 to 7 days for clot stability. If the follow-up imaging showed clot propagation, these patients were treated with anticoagulation despite significant ICH. Within 2 weeks of diagnosis, the thrombus propagated in 7% of treated children and 37% of untreated children. Propagation was symptomatic in 60% of children and associated with more severe deficits at discharge. Anticoagulant-related ICH occurred in 5% of treated children and 98% of ICH with anticoagulation occurred in patients with pretreatment ICH. ICH as a complication of anticoagulation was most commonly a subdural hemorrhage and almost all bleeds occurred with additional factors such as supratherapeutic anticoagulation, hypertension, thrombocytopenia, ventriculoperitoneal shunt surgery, and cerebral atrophy.

The acute management of children with CSVT should include hydration, control of clinical and subclinical seizures, and treatment of elevated intracranial pressure. With severe or longstanding increased intracranial pressure, there is a risk for vision loss. Visual fields and visual acuity should be periodically assessed and appropriate measures to control elevated intracranial pressure should be instituted. Monitoring the intracranial pressure may be considered during the acute phase of CSVT.

Bacterial infection and anemia are treatable causes of CSVT, so children with a suspected bacterial infection should receive appropriate antibiotics and a complete blood count should be performed. There may be benefit to diagnostic testing for underlying infections with blood cultures and sinus radiographs. Performing a thorough thrombophilic screen may be beneficial, and its results could affect the risk of rethrombosis and influence therapeutic decisions. In children who have an impaired mental status and are paralyzed or sedated, subclinical seizures are not uncommon. Continuous electroencephalography monitoring may be considered for these patients.

The American Heart Association Stroke Council suggests that it is reasonable to institute either UFH or LMWH whether or not there is secondary hemorrhage, followed by warfarin therapy for 3 to 6 months. Follow-up neuroimaging studies in children with CSVT to confirm vessel recanalization or recurrence of the thrombus may be beneficial. The American College of Chest Physicians recommends initial anticoagulation with UFH or LMWH only in children without significant ICH, followed by LMWH or a vitamin K antagonist for a minimum of 3 months. If after 3 months of therapy, there is incomplete radiologic recanalization of CSVT or ongoing symptoms, anticoagulation should be continued for an additional 3 months. In children with significant hemorrhage, there is a suggestion to repeat the radiologic evaluation at 5 to 7 days and if there is propagation of thrombus, institute anticoagulation.

There are case series describing local cerebral thrombolysis for CSVT. Reported cases suggest that there may be benefit in the hands of experienced interventionalists, but there may also be a considerable risk for hemorrhagic complications. The American Heart Association Stroke Council suggests that in selected children, administration of a thrombolytic agent can be considered. The American College of Chest Physicians suggests thrombolysis, thrombectomy, or surgical decompression only in children with severe CSVT in whom there is no improvement with initial UFH therapy. In children with CSVT and ongoing risk factors for thrombosis, such as nephrotic syndrome, or l-asparaginase therapy, prophylactic anticoagulation is suggested.

Childhood Intracranial Hemorrhage

Children with a severe coagulation factor deficiency should receive appropriate factor replacement therapy, and children with less severe factor deficiency should receive factor replacement after trauma. There is a recommendation to identify and correct, where clinically feasible, congenital vascular anomalies. Recently, a randomized trial of uUnruptured brain arteriovenous malformations in adults found that medical management alone was superior to interventional therapy for patients with unruptured AVMs. This study is changing treatment practice for unruptured AVMs.

The child with an acute brain hemorrhage requires urgent care. Attention should be toward assessment of respiratory effort, control of systemic hypertension, control of clinical and subclinical seizures, and managing increased intracranial pressure. In general, surgical evacuation of a supratentorial intracerebral hematoma is not recommended. Surgery is reasonable in selected patients at risk for cerebral herniation or who have extremely elevated intracranial pressure; however, it is not clear whether this improves the outcome. Acute hydrocephalus with an ICH requires ventricular drainage. If hydrocephalus persists beyond the acute period, shunting may be indicated. Low platelet counts should be corrected, and vitamin K should be administered for vitamin K–dependent coagulation disorders. In the ongoing acute care of patients with SAH, measures to control cerebral vasospasm may be beneficial.

It is reasonable to follow-up asymptomatic individuals who have a condition that predisposes them to intracranial aneurysms with a cranial MRA every 1 to 5 years, depending on the perceived level of risk posed by an underlying condition. Given the possible need for repeated studies over a period of years, computed tomography angiography may be preferable to conventional angiogram for screening individuals at risk for aneurysm.

Outcome

Childhood Arterial Ischemic Stroke

Neurologic Deficits

A child who has suffered a stroke should be enrolled in age-appropriate rehabilitation and therapy program. Cognitive and behavioral performance is especially important in school-aged children. The pediatric stroke outcome measure is based on a detailed age-appropriate, neurologic exam and scored for four domains: sensorimotor deficit, language deficit—production (excludes dysarthria), language deficit—comprehension, and cognitive or behavioral deficit. The weight of language and cognitive and behavioral deficits is considerably greater, and motor deficits are less weighty compared with similar adult stroke

outcome measures. Neuropsychological assessment is useful for planning therapy and educational programs and monitoring cognitive, behavioral, and language deficits after a stroke.

In one single-center series of 90 children followed for a mean of 2 years after an AIS, 49% were either normal or mildly impaired on the pediatric stroke outcome measure.

Recurrence

In northern California, the 5-year cumulative recurrence rate was 19% after childhood AIS. All of the recurrences occurred among children with a vascular abnormality. In a large single-center series, 37% of children had a recurrent AIS or TIA at a median of 267 days (range 1 d to 11.5 y). Of the 84% of patients who had reimaging, 11% had clinically silent recurrent ischemia. Among children with arteriopathy in northern California, the 5-year cumulative recurrence rate was 66%. Factors associated with silent reinfarction and clinical recurrences were moyamoya, low birth weight, genetic thrombophilia, previous TIA, bilateral infarction, preexisting condition, and leukocytosis.

Epilepsy

Poststroke seizures and epilepsy is considerable in children. A number of different studies from different continents show that the frequency of poststroke epilepsy in childhood stroke is between 7% and 29.2%. The rate of poststroke seizure is higher.

Childhood Cerebral Sinovenous Thrombosis

In large-center series, anticoagulation is not associated with increased mortality or severe neurologic outcomes.

Recanalization

At 3 months, more than half of children have recanalization of thrombosed vein. A prothrombotic disorder is associated with no recanalization.

Recurrence

Recurrence occurs in 5% to 17% of children. This may depend on the course of the underlying risk factors and residual patency of the cerebral venous system.

Neurologic Deficits

Poor neurologic outcomes after CSVT include chronic intracranial hypertension, frequent headaches, cognitive difficulties, hemiparesis, reduced visual acuity, isolated sixth nerve palsy, and epilepsy in 5% to 8%. Predictors for good outcome are anticoagulation treatment, older age, no parenchymal abnormality on imaging, and lateral sinus involvement.

In a small cohort of children followed for a mean of 2.1 years after a CSVT, 79% were either normal or mildly impaired. In a larger series of children, outcome was unfavorable in 37%.

Mortality

Mortality is reported between 5% and 12%. In one series of children, most of whom were not treated with anticoagulation, early mortality was 18%.

Childhood Intracranial Hemorrhage

Neurologic Deficits

Disability is more prevalent after childhood ICH than other forms of stroke. In a single-center prospective cohort study at a median follow-up of 3.5 months, 71% of survivors had neurologic deficits, and 55% had clinically significant disability. A prospective cohort from three centers found severe disability in 12%, moderate disability in one-half, and good recovery in only one-third.

Recurrence

In a population-based study from northern California, the 5-year cumulative recurrence rate was 10%. Sixty-four percent of recurrences were within the first 6 months. Children with idiopathic hemorrhage had no recurrences, compared with children with a structural lesion such as a vascular malformation or tumor who had a 5-year cumulative recurrence rate of 13%.

Epilepsy

In one study, at 2 years, epilepsy developed in less than 15%. A risk factor for late seizures and epilepsy was elevated intracranial pressure requiring acute intervention.

Mortality

Childhood ICH confers mortality in approximately 5%.

SICKLE CELL ANEMIA

The process of neurologic injury that confers long-term cognitive and focal impairment in SCA begins in childhood. Neurologic complications of sickle cell disease include cognitive deficit, ischemic and hemorrhagic stroke due to arterial and venous thrombus, sickle cell arteriopathy, and white matter T2 hyperintensity on brain imaging.

Epidemiology

The Cooperative Study of Sickle Cell Disease, the largest series of stroke in SCA, showed that by the age of 20 years, the risk of stroke was 11%, and peak incidence was from 2 to 5 years. There were no gender differences in stroke incidence. In SCA, the annual incidence of stroke is orders of magnitude greater than other childhood stroke. The Baltimore-Washington Cooperative Young Stroke Study found an annual incidence of 285 per 100,000.

Pathobiology

At low oxygen tension, sickle cell hemoglobin polymerizes to form an elongated and rigid sickle shape. This translates to high blood viscosity and the potential for endothelial damage. Sickle cell arteriopathy may be the most important determinant of stroke risk. Over time, arteriopathy tends to progress. Children with a history of stroke were more likely to have progressive vasculopathy than children with abnormal TCDs but no history of stroke. Silent ischemia is twice as common as clinical strokes and confers a high risk for recurrent stroke. Sickle-related arteriopathy more often takes the form of moyamoya arteriopathy with high-grade internal carotid and proximal circle of Willis artery occlusive disease and collateral formation. Older children and adults are at risk for aneurysms, dolichoectasia, and SAH.

The combination of risk factors that result in vascular disease and stroke are still not fully understood. Risk factors such as infection, elevated leukocyte count, acute chest syndrome, inflammation, low hemoglobin concentration, and nocturnal desaturations may all contribute to the risk for stroke in SCA.

Single-nucleotide polymorphisms in genes for a tumor necrosis factor promoter, interleukin-4 receptor, β_2-adrenoceptor, leukotriene C4 synthase, vascular cell adhesion molecule 1, and low-density lipoprotein receptor are all reported in association with stroke in children with SCA. These genes are involved in inflammatory pathways.

Diagnosis

The American Heart Association/American Stroke Association guidelines (2011) recommend TCD for selection of children for primary stroke prevention LEVEL 1.[1] MRI and MRA are not similarly established.

Management

The only class I recommendations for primary pediatric stroke prevention is in SCA. The recommendations largely derive from the STOP I and II randomized controlled trials. The STOP I trial enrolled children with SCA, mean TCD velocity in the ICA or MCA of 200 cm/s or greater, and no history of stroke. Patients were randomized to periodic blood transfusions versus standard of care. The study was terminated prior to completion because the results were highly significant. In the standard of care arm, there were 10 ischemic and 1 hemorrhagic strokes, compared with the transfusion arm where there was 1 ischemic stroke. Periodic transfusions reduced the risk of stroke by 92%. There is a recommendation to begin TCD screening at 2 years LEVEL 1.[1] TCD should be performed annually, and abnormal studies should be repeated in 1 month. Borderline and mildly abnormal TCD studies may be repeated in 3 to 6 months. For TCD velocity greater than 200 cm/s, even in children without a clinical stroke, regular transfusions are recommended to reduce the risk of stroke in children 2 to 16 years of age LEVEL 2.[1] Children with a confirmed infarction should also receive regular red cell transfusion in conjunction with measures to prevent iron overload. Prior to undergoing a cerebral angiogram, all children with SCA should be treated with a red blood cell transfusion to reduce red blood cell sickling precipitated by the procedure.

When routine transfusions became accepted clinical practice for abnormal TCDs or history of a stroke, the question of when one could safely stop transfusions became widely relevant. Seven years after STOP I, STOP II published its findings. Patients with greater than 30 months on transfusion therapy, no history of a clinical stroke, and reversion to a low-risk TCD (<170 cm/s) were randomly assigned to continuation or discontinuation of transfusions. Again, the trial was stopped early. Of 41 patients in the discontinuation group, 14 developed a high-risk TCD over a mean of 4.5 months, and 2 had a stroke. Neither outcome occurred in the continuation group. A long-term transfusion program is currently recommended LEVEL 3.[2]

There is ongoing research on hydroxyurea as an alternative to routine transfusions. Hydroxyurea increases fetal hemoglobin and mean corpuscular volume, and it decreases reticulocytes, white blood cells, and platelets. In the TCDs with transfusions changing to hydroxyurea trial, hydroxyurea was found to be noninferior compared to the transfusion protocol.

Myeloablative stem cell transplantation if successful could reverse high TCD velocities and almost eliminate the risk of stroke in children. Transplantation requires a matched donor, and even if one is identified, rejection and morbidity are considerable. In children at high risk for stroke, particularly those who are not candidates for transfusion, it might be reasonable to consider bone marrow transplantation, but this should be done in a clinical trial setting.

In children without SCA and moyamoya arteriopathy, revascularization is an effective treatment for prevention of recurrent stroke. The data in children with SCA and moyamoya arteriopathy is more limited but suggests benefit. The American Heart Association/American Stroke Association recommendation is to consider surgical revascularization as a last resort in cases where there is cerebrovascular dysfunction despite optimal medical management.

Acute management of ischemic stroke should include hydration, correction of hypoxemia, and correction of systemic hypotension. An exchange transfusion to reduce sickle hemoglobin to less than 30% of the total hemoglobin is reasonable. A vascular lesion should be considered when there is an ICH. There are no data to indicate that periodic transfusions reduce the risk of ICH caused by sickle cell disease.

Outcome

Neurologic Deficits

Compared with healthy children, children with SCA have deficits in working memory and processing speed on neurocognitive testing.

Recurrence

Untreated, the risk of recurrent stroke may be 50%.

Mortality

Overall stroke-related mortality is approximately 10%, and in the 2 weeks after a hemorrhagic stroke, mortality is as high as one-quarter.

GENETICS OF STROKE IN CHILDREN

Stroke genetics is a rapidly expanding field because several genetic pathways have been identified in the last decade that provide insight into angiogenesis and blood vessel function. These disorders can be categorized as follows:

Disorders with Abnormal Angiogenesis

Mutations in these genes leading to AVMs, aneurysms, and cerebral cavernous malformations (CCMs). RASA1 mutation can cause cerebral AVMs. Hereditary hemorrhagic telangiectasias, particularly the ENG and ACVRL1 mutations, can also lead to brain AVMs. Several disorders cause CCM1, CCM2, and CCM3. Rupture of CCMs can lead to spontaneous ICHs and stroke.

Disorders of Vessel Wall Stenosis

These disorders typically lead to moyamoya arteriopathy. In these cases, there is proliferation of components of the blood vessel wall, causing gradual stenosis of the vessel, ischemia in the region of the brain supplied by the blood vessel, and formation of moyamoya collaterals. These disorders are described above in the section on moyamoya syndrome (see Table 149.2).

Connective Tissue Disorders

In these disorders, the blood vessels form appropriately but the connective tissue supporting the vessel is unusually weak and prone to dissection. Ehlers-Danlos type IV and osteogenesis imperfecta type I are the best-known examples, but there are several similar connective tissue disorders that can present with spontaneous cerebral arterial dissection. COL4A1 mutation, which affects type IV collagen, falls into this category and can present in neonates with intrauterine stroke and porencephaly.

Thrombophilic Disorders

These hematologic conditions disrupt the normal balance between clot formation and clot breakdown and predispose children to AIS, CSVT, and ICH. Examples include PTG20210, factor V Leiden, MTHR, and protein C deficiency.

Genetic or Metabolic Stroke or Stroke-like Episodes

Some examples include PHACE syndrome, Fabry disease, mitochondrial encephalomyopathy, lactic acidosis, and stroke-like episodes, and POLG1 gene mutations. Stroke has also been described in organic acidurias (methylmalonic, propionic, isovaleric, and glutaric aciduria type II) and congenital disorder of glycosylation type Ia. It sometimes can be unclear in these disorders whether the stroke is due to the metabolic condition affecting the brain vasculature directly, the brain parenchyma directly, or both.

Family members with clotting disorders or strokes at a young age may clue the clinician into considering one of these genetic disorders. On physical examination, skin telangiectasias or hyperextensible joints are also highly suggestive of a genetic condition leading to stroke. If any of these factors are present, the clinician should pursue a genetic evaluation.

LEVEL 1 EVIDENCE

1. Adams RJ, McKie VC, Hsu L, et al. Prevention of a first stroke by transfusions in children with sickle cell anemia and abnormal results on transcranial Doppler ultrasonography. *N Engl J Med*. 1998;339(1):5-11.
2. Adams RJ, Brambilla D; for the Optimizing Primary Stroke Prevention in Sickle Cell Anemia (STOP 2) Trial Investigators. Discontinuing prophylactic transfusions used to prevent stroke in sickle cell disease. *N Engl J Med*. 2005;353(26):2769-2778.

SUGGESTED READINGS

Albers GW, Lansberg MG, Kemp S, et al. A multicenter randomized controlled trial of endovascular therapy following imaging evaluation for ischemic stroke (DEFUSE 3). *Int J Stroke*. 2017;12(8):896-905.

Amlie-Lefond C, Bernard TJ, Sébire G, et al. Predictors of cerebral arteriopathy in children with arterial ischemic stroke: results of the International Pediatric Stroke Study. *Circulation*. 2009;119(10):1417-1423.

Amlei-Lefond C, Gilden D. Varicella zoster virus: a not uncommon cause of stroke in children and adults. *J Stroke Cerebrovasc Dis*. 2016;25(7):1561-1569.

Aygun B, Wruck LM, Schultz WH, et al. Chronic transfusion practices for prevention of primary stroke in children with sickle cell anemia and abnormal TCD velocities. *Am J Hematol*. 2012;87(4):428-430.

Barry M, Hallam, D, Bernard TH, Amlie-Lefond C. What is the role of mechanical thrombectomy in childhood stroke? *Pediatr Neurol*. 2019;95:19-25.

Benders M, Groenendaal F, Uiterwaal C, et al. Maternal and infant characteristics associated with perinatal arterial stroke in the preterm infant. *Stroke*. 2007;38:1759-1765.

Bernard TJ, Manco-Johnson MJ, Lo W, et al. Towards a consensus-based classification of childhood arterial ischemic stroke. *Stroke*. 2012;43(2):371-377.

Bernaudin F, Socie G, Kuentz M, et al. Long-term results of related myeloablative stem-cell transplantation to cure sickle cell disease. *Blood*. 2007;110(7):2749-2756.

Beslow LA, Abend NS, Gindville MC, et al. Pediatric intracerebral hemorrhage: acute symptomatic seizures and epilepsy. *JAMA Neurol*. 2013;70(4):448-454.

Beslow LA, Licht DJ, Smith SE, et al. Predictors of outcome in childhood intracerebral hemorrhage: a prospective consecutive cohort study. *Stroke*. 2010;41(2):313-318.

Bishop S, Matheus MG, Abboud MR, et al. Effect of chronic transfusion therapy on progression of neurovascular pathology in pediatric patients with sickle cell anemia. *Blood Cells Mol Dis*. 2011;47(2):125-128.

Braun KP, Bulder MM, Chabrier S, et al. The course and outcome of unilateral intracranial arteriopathy in 79 children with ischaemic stroke. *Brain*. 2009;132(pt 2):544-557.

Cole L, Dewey D, Letourneau N, et al. Clinical characteristics, risk factors, and outcomes associated with neonatal hemorrhagic stroke: a population-based case-control study. *JAMA Pediatr*. 2017;171(3):230-238.

deVeber G, Andrew M, Adams C, et al. Cerebral sinovenous thrombosis in children. *N Engl J Med*. 2001;345(6):417-423.

deVeber GA, MacGregor D, Curtis R, Mayank S. Neurologic outcome in survivors of childhood arterial ischemic stroke and sinovenous thrombosis. *J Child Neurol*. 2000;15(5):316-324.

Earley CJ, Kittner SJ, Feeser BR, et al. Stroke in children and sickle-cell disease: Baltimore-Washington Cooperative Young Stroke Study. *Neurology*. 1998;51(1):169-176.

Ferriero DM, Fullerton HJ, Bernard TJ, et al. Management of stroke in neonates and children: a scientific statement from the American Heart Association/American Stroke Association. *Stroke*. 2019;50(3):e51-e96.

Fox CK, Glass HC, Sidney S, Lowenstein DH, Fullerton HJ. Acute seizures predict epilepsy after childhood stroke. *Ann Neurol*. 2013;74(2):249-256.

Fullerton HJ, Elkins JS, Johnston SC. Pediatric stroke belt: geographic variation in stroke mortality in US children. *Stroke*. 2004;35(7):1570-1573.

Fullerton HJ, Wu YW, Sidney S, Johnston SC. Recurrent hemorrhagic stroke in children: a population-based cohort study. *Stroke*. 2007;38(10):2658-2662.

Fullerton HJ, Wu YW, Sidney S, Johnston SC. Risk of recurrent childhood arterial ischemic stroke in a population-based cohort: the importance of cerebrovascular imaging. *Pediatrics*. 2007;119(3):495-501.

Fullerton HJ, Wu YW, Zhao S, Johnston SC. Risk of stroke in children: ethnic and gender disparities. *Neurology*. 2003;61(2):189-194.

Ganesan V, Prengler M, Wade A, Kirkham FJ. Clinical and radiological recurrence after childhood arterial ischemic stroke. *Circulation*. 2006;114(20):2170-2177.

Golomb MR, MacGregor DL, Domi T, et al. Presumed pre- or perinatal arterial ischemic stroke: risk factors and outcomes. *Ann Neurol*. 2001;50(2):163-168.

Grelli KN, Gindville MC, Walker CH, Jordan LC. Association of blood pressure, blood glucose, and temperature with neurological outcome after childhood stroke. *JAMA Neurol*. 2016;73(7):829-835.

Guey S, Tournier-Lasserve E, Hervé D, Kossorotoff M. Moyamoya disease and syndromes: from genetics to clinical management. *Appl Clin Genet*. 2015;8:49-68.

Hankinson TC, Bohman LE, Heyer G, et al. Surgical treatment of moyamoya syndrome in patients with sickle cell anemia: outcome following encephaloduroarteriosynangiosis. *J Neurosurg Pediatr*. 2008;1(3):211–216.

Hills NK, Johnston SC, Sidney S, Zielinski BA, Fullerton HJ. Recent trauma and acute infection as risk factors for childhood arterial ischemic stroke. *Ann Neurol*. 2012;72(6):850-858.

Kenet G, Lütkhoff LK, Albisetti M, et al. Impact of thrombophilia on risk of arterial ischemic stroke or cerebral venous thrombosis in neonates and children: a systematic review and meta-analysis of observational studies. *Circulation*. 2010;121(16):1838-1847.

Kirton A, Armstrong-Wells J, Chang T, et al. Symptomatic neonatal arterial ischemic stroke: the International Pediatric Stroke Study. *Pediatrics*. 2011;128(6):e1402-e1410.

Kurnik K, Kosch A, Sträter R, Schobess R, Heller C, Nowak-Göttl U; for the Childhood Stroke Study Group. Recurrent thromboembolism in infants and children suffering from symptomatic neonatal arterial stroke: a prospective follow-up study. *Stroke*. 2003;34(12):2887-2892.

Laugesaar R, Kolk A, Tomberg T, et al. Acutely and retrospectively diagnosed perinatal stroke: a population-based study. *Stroke*. 2007;38(8):2234-2240.

Lee J, Croen LA, Backstrand KH, et al. Maternal and infant characteristics associated with perinatal arterial stroke in the infant. *JAMA*. 2005;293(7):723-729.

Lynch JK. Epidemiology and classification of perinatal stroke. *Semin Fetal Neonatal Med*. 2009;14(5):245-249.

Lynch JK, Hirtz DG, DeVeber G, Nelson KB. Report of the National Institute of Neurological Disorders and Stroke workshop on perinatal and childhood stroke. *Pediatrics*. 2002;109(1):116-123.

Mackay MT, Wiznitzer M, Benedict SL, et al. Arterial ischemic stroke risk factors: the International Pediatric Stroke Study. *Ann Neurol*. 2011;69(1):130-140.

Ment LR, Ehrenkranz RA, Duncan CC. Bacterial meningitis as an etiology of perinatal cerebral infarction. *Pediatr Neurol*. 1986;2(5):276-279.

Miller ST, Macklin EA, Pegelow CH, et al. Silent infarction as a risk factor for overt stroke in children with sickle cell anemia: a report from the Cooperative Study of Sickle Cell Disease. *J Pediatr*. 2001;139(3):385-390.

Moharir MD, Shroff M, Stephens D, et al. Anticoagulants in pediatric cerebral sinovenous thrombosis: a safety and outcome study. *Ann Neurol*. 2010;67(5):590-599.

Monagle P, Chalmers E, Chan A, et al. Antithrombotic therapy in neonates and children: American College of Chest Physicians Evidence-Based Clinical Practice Guidelines (8th Edition). *Chest*. 2008;133(6 suppl):887S-968S.

Munot P, Crow YJ, Ganesan V. Paediatric stroke: genetic insights into disease mechanisms and treatment targets. *Lancet Neurol*. 2011;10(3):264-274.

Nash M, Rafay MF. Craniocervical arterial dissection in children: pathophysiology and management. *Pediatr Neurol*. 2019;95:9-18.

Nogueira RG, Jadhav AP, Haussen DC, et al. Thrombectomy 6 to 24 hours after stroke with a mismatch between deficit and infarct (DAWN trial). *N Engl J Med*. 2018;378(1):11-21.

Ohene-Frempong K, Weiner SJ, Sleeper LA, et al. Cerebrovascular accidents in sickle cell disease: rates and risk factors. *Blood*. 1998;91:288-294.

Pegelow CH, Macklin EA, Moser FG, et al. Longitudinal changes in brain magnetic resonance imaging findings in children with sickle cell disease. *Blood*. 2002;99(8):3014-3018.

Powars D, Wilson B, Imbus C, Pegelow C, Allen J. The natural history of stroke in sickle cell disease. *Am J Med*. 1978;65(3):461-471.

Ricci D, Mercuri E, Barnett A, et al. Cognitive outcome at early school age in term-born children with perinatally acquired middle cerebral artery territory infarction. *Stroke*. 2008;39(2):403-410.

Rodan L, McCrindle BW, Manlhiot C, et al. Stroke recurrence in children with congenital heart disease. *Ann Neurol*. 2012;72(1):103-111.

Schoenberg BS, Mellinger JF, Schoenberg DG. Cerebrovascular disease in infants and children: a study of incidence, clinical features, and survival. *Neurology*. 1978;28(8):763-768.

Sébire G, Meyer L, Chabrier S. Varicella as a risk factor for cerebral infarction in childhood: a case-control study. *Ann Neurol*. 1999;45(5):679-680.

Sébire G, Tabarki B, Saunders DE, et al. Cerebral venous thrombosis in children: risk factors, presentation, diagnosis and outcome. *Brain*. 2005;128(pt 3):477-489.

Simchen MJ, Goldstein G, Lubetsky A, Strauss T, Schiff E, Kenet G. Factor v Leiden and antiphospholipid antibodies in either mothers or infants increase the risk for perinatal arterial ischemic stroke. *Stroke*. 2009;40(1):65-70.

Wagenaar N, Martinez-Biarge M, van der Aa NE, et al. Neurodevelopment after perinatal arterial ischemic stroke. *Pediatrics*. 2018;142(3):e20174164.

Wu YW, March WM, Croen LA, Grether JK, Escobar GJ, Newman TB. Perinatal stroke in children with motor impairment: a population-based study. *Pediatrics*. 2004;114(3):612-619.

Wusthoff CJ, Kessler SK, Vossough A, et al. Risk of later seizure after perinatal arterial ischemic stroke: a prospective cohort study. *Pediatrics*. 2011;127(6):e1550-e1557.

Zimmerman SA, Schultz WH, Burgett S, Mortier NA, Ware RE. Hydroxyurea therapy lowers transcranial Doppler flow velocities in children with sickle cell anemia. *Blood*. 2007;110(3):1043-1047.

Brain Tumors in Children 150

James H. Garvin, Jr

KEY POINTS

1. Primary brain tumors are the second commonest childhood cancer (after leukemia) and the leading cause of cancer-related death.
2. Low-grade astrocytomas are the largest group of primary brain tumors in children, followed by medulloblastoma, high-grade astrocytoma, and ependymoma. The risk is increased in syndromes such as neurofibromatosis.
3. The diagnostic classification of childhood brain tumors was revised substantially in 2016 to integrate emerging molecular findings.
4. Survival of children with brain tumors is approximately 70% overall and has improved substantially for medulloblastoma but remains poor for high-grade astrocytoma and especially diffuse intrinsic pontine glioma.
5. Current research focuses on identification of molecular targets for novel therapies, improved drug delivery, radiation-sparing treatment strategies, and quality of survival.

INTRODUCTION

Childhood brain tumors range from benign congenital lesions to aggressive, infiltrative cancers. Malignant brain tumors are the most common solid tumor cancers of childhood, the second most common cancer overall (after leukemia), and the leading cause of death. Limitations to cure include tumor resectability, brain tolerance of radiation therapy, and limited chemotherapy penetration of the blood-brain barrier. Treatment sequelae may seriously compromise quality of survival. Nonetheless, research advances and refinement of treatment techniques continue to give a sense of cautious optimism. Current research focuses on radiation-sparing treatment strategies, improved drug delivery, and identification of molecular targets for novel therapies. A prevailing concept is that malignant brain tumors are propagated from stemlike progenitor cells, with transcriptional programs mirroring those of normal neuronal and other lineages but stalled in development. These tumor progenitor cells may be intrinsically resistant to standard radiation and chemotherapy but could be eliminated by targeted therapy with agents, which disrupt critical signaling pathways or induce differentiation.

EPIDEMIOLOGY

Incidence

Malignant and nonmalignant central nervous system (CNS) tumors may arise at any time in infancy and childhood. Most pediatric brain tumors occur in the first decade of life. Location is predominantly cerebral/ventricular in infants, cerebellar/brainstem in young children, and midbrain/cerebral in older children and adolescents (**Fig. 150.1A,B**). Incidence rates are tracked by the Central Brain Tumor Registry of the United States. The incidence rate of primary malignant and nonmalignant CNS tumors in the United States in children ages 0 to 14 years is 5.65 cases per 100,000 (approximately 3,500 per year). For adolescents and young adults ages 15 to 39 years, the corresponding incidence rate is 11.2 cases per 100,000 (approximately 12,000 per year). Malignant CNS tumors account for about 25% of all cancer diagnoses in children ages 0 to 14 years, and 17% of cancer cases in adolescents ages 15 to 19 years (about 20% of childhood cancer overall).

The incidence of childhood brain tumors worldwide is highest in the United States. Here, the incidence is higher in non-Hispanic whites and Asian-Pacific islanders than blacks, Hispanics, and American Indian/Alaskan natives. The annual incidence of childhood brain tumors in the United States increased by 35% between 1973 and 1994, led mainly by supratentorial low-grade astrocytomas and brainstem tumors diagnosable by magnetic resonance imaging (MRI), which became widely available in the mid-1980s, displacing computed tomography (CT). Data for 1998-2013 show stable incidence rates for children ages 0 to 19 years, with modest trends toward increased pilocytic astrocytomas and decreased CNS embryonal tumors. A separate analysis showed increased incidence of malignant CNS tumors in children from 2000 to 2010 and in adolescents from 2000 to 2008. However, these findings may be attributable to changes in identification, reporting, and classification, rather than true changes in incidence.

Childhood brain tumor survival rates vary widely, from highly curable cerebellar pilocytic astrocytomas to lethal diffuse intrinsic pontine gliomas (DIPGs). (Note that *glioma* is an umbrella term used to describe the different types of tumors arising from the glial or supporting tissue of the brain, including astrocytoma, oligodendroglioma, and glioblastoma.) Brain tumors vary in their clinical aggressiveness. Some are slow-growing and are likely to be curable. Others are rapidly growing, invasive, difficult to treat, and likely to recur. Categorization of primary brain tumors as malignant or benign does not always reflect clinical behavior. Certain histologically benign lesions such as craniopharyngioma may cause extensive brain damage and endocrine dysfunction, whereas low-grade astrocytomas are rarely life-threatening but can progress to high-grade gliomas, at least in adults. Moreover, tumorigenesis of high-grade astrocytomas in children differs from adult glioblastoma, as deduced from comparative genomic hybridization studies.

Histologies

Astrocytomas are the largest group of primary CNS tumors in children age 0 to 14 years, mostly of low-grade histology (World Health Organization [WHO] grades I and II) (**Fig. 150.2A**). Next in frequency are medulloblastomas, the most common

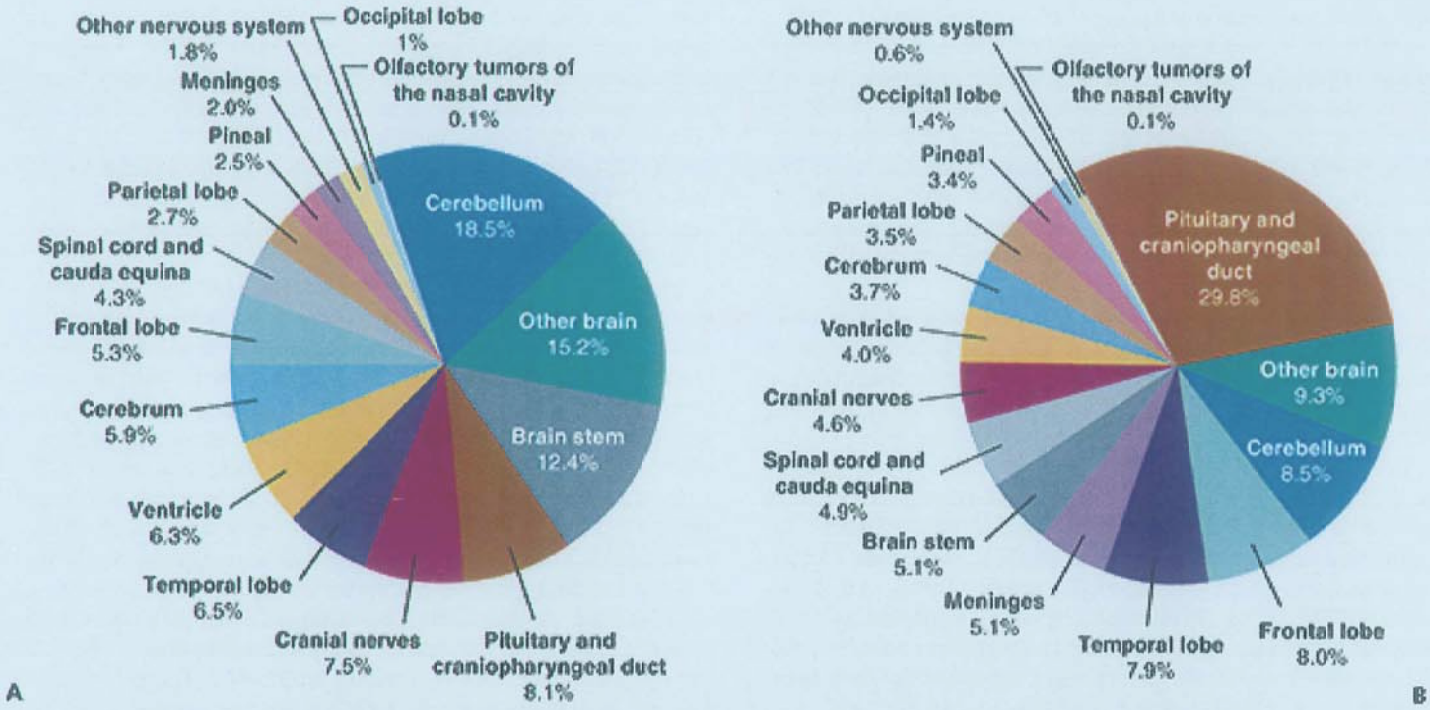

FIGURE 150.1 A: Distribution in children (age 0-14 y) of primary brain and central nervous system tumors by site (N = 16,366), CBTRUS Statistical Report: NPCR and SEER, 2008-2012. B: Distribution in adolescents (age 15-19 y) of primary brain and central nervous system tumors by site (N = 6,747), CBTRUS Statistical Report: NPCR and SEER, 2008-2012. Percentages may not add up to 100 due to rounding. (Source: Ostrum QT, Gittleman H, Fulop J, et al. CBTRUS statistical report: primary brain and central nervous system tumors diagnosed in the United States in 2008-2012. *Neuro Oncol.* 2015;17[suppl 4]:iv1-iv62.)

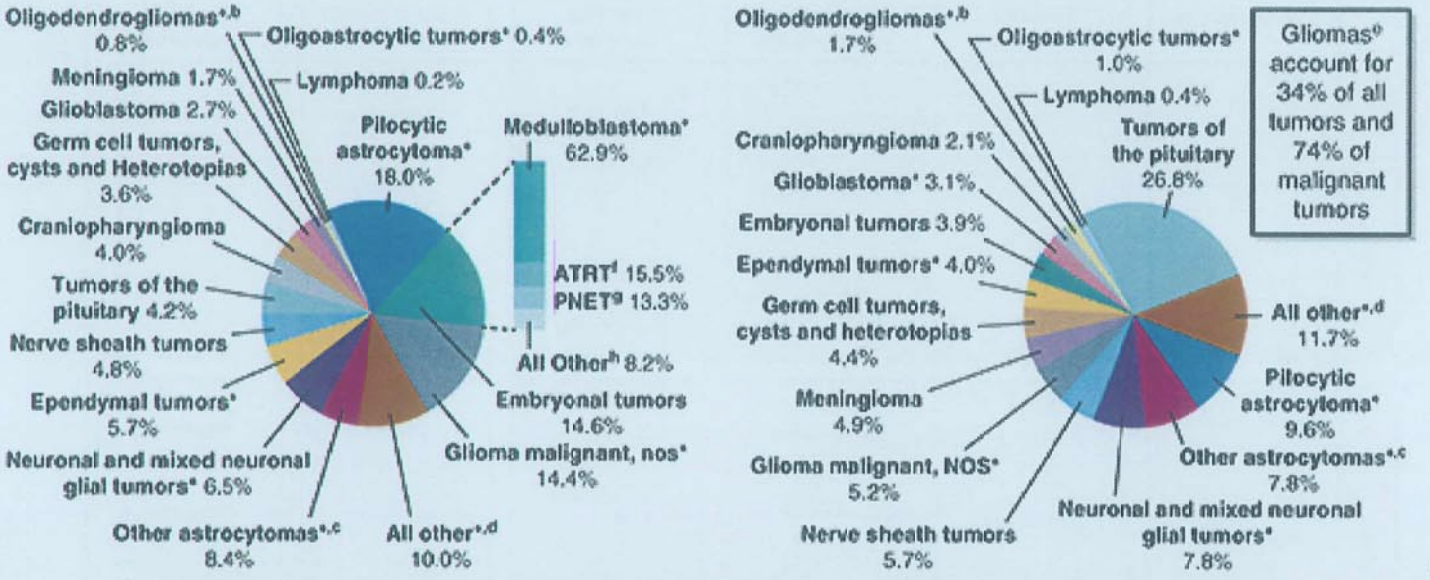

FIGURE 150.2 A: Distribution in children (age 0-14 y) of primary brain and central nervous system tumors by Central Brain Tumor Registry of the United States (CBTRUS) histology groupings and histology (N = 16,366), CBTRUS Statistical Report: NPCR and SEER, 2008-2012. B: Distribution in adolescents (age 15-19 y) of primary brain and central nervous system tumors by histology (N = 6,747), CBTRUS Statistical Report: NPCR and SEER, 2008-2012. Abbreviations: ATRT, atypical teratoid/rhabdoid tumor; NOS, not otherwise specified; PNET, primitive neuroectodermal tumor. [a]Percentages may not add up to 100 due to rounding. [b]Includes oligodendrogliomas and anaplastic oligodendrogliomas. [c]Includes diffuse astrocytoma, anaplastic astrocytoma, and unique astrocytoma variants. [d]Includes choroid plexus tumors, other neuroepithelial tumors, tumors of the pineal region, other tumors of cranial and spinal nerves, mesenchymal tumors, primary melanocytic lesions, other neoplasms related to the meninges, other hematopoietic neoplasms, hemangioma, neoplasm unspecified, and all other. [e]ICD-O-3 histology codes 9380-9384, 9391-9460, and 9480.

high-grade malignant tumor (reported as an embryonal tumor in Central Brain Tumor Registry of the United States), with atypical teratoid/rhabdoid tumors (AT/RTs) and other embryonal tumors previously termed *primitive neuroectodermal tumors* (PNETs). After these are a diverse group of congenital and acquired lesions, including high-grade astrocytomas, ependymomas, craniopharyngiomas, germ cell tumors, and choroid plexus tumors. Neuronal tumors (gangliocytoma) and mixed glioneuronal tumors (ganglioglioma, dysembryoplastic neuroepithelial tumor [DNT]) are relatively uncommon.

The distribution of histologies changes somewhat in older adolescents (age 15-19 y) (**Fig. 150.2B**). The principal primary brain tumors of adults (glioblastoma multiforme, meningioma, oligodendroglioma, pituitary adenoma) are uncommon in young children but begin to emerge in later adolescence.

CNS metastases from solid tumors are also uncommon in children, unlike in adults. Cerebral metastases may occur as late events in pediatric germ cell tumors (13.5% incidence), osteosarcoma (6.5%), neuroblastoma (4.4%), melanoma (3.6%), Ewing sarcoma (3.3%), rhabdomyosarcoma (1.9%), and Wilms tumor (1.3%). CNS involvement by acute leukemia or non–Hodgkin lymphoma can be present at diagnosis and/or relapse, and treatment protocols incorporate prophylactic intrathecal chemotherapy. Primary spinal cord tumors are uncommon in children; the predominant histologies (age 0-19 y) are astrocytomas, ependymal tumors, and neuroepithelial tumors.

Risk Factors

The causes of congenital and childhood CNS tumors remain unknown. ("Congenital" refers to lesions detected prenatally or within the first 60 d of life.) A meta-analysis from 16 international surveys revealed a male-to-female ratio of 1.29. Increased head circumference at birth is positively associated with brain cancer in childhood, with a relative risk of 1.27 per 1-cm increase after adjustment for birth weight, gestational age, and gender, suggesting brain pathology may originate in fetal development. The most common CNS tumors diagnosed in the first year of life are low-grade astrocytoma, medulloblastoma, ependymoma, and choroid plexus tumors.

Most CNS tumors are sporadic, but CNS tumors occur with increased frequency in certain inherited disorders, and other risk-modifying factors have been identified or proposed in nonsyndromic children (**Fig. 150. 3**). Individuals with *neurofibromatosis type 1 (NF-1)* have a 10% chance of developing an intracranial tumor, including optic pathway gliomas and astrocytomas elsewhere in the brain and spinal cord. The incidence of NF-1 is approximately 1 in 3,000 individuals; half of cases are inherited, and the remainder are sporadic. The *NF-1 gene* maps to chromosome 17q11.2, and loss of one NF-1 allele is evident in nearly all NF-1–associated pilocytic astrocytomas but only rarely in sporadic pilocytic astrocytomas, suggesting different mechanisms of tumor formation. In the less common neurofibromatosis type 2 (NF-2) (incidence approximately 1 in 37,000), there is a predisposition to bilateral vestibular schwannomas (acoustic neuromas), with chromosome 22q deletions and *NF-2 gene* mutations in at least half of cases. NF-2 also predisposes to ependymomas, which commonly show a chromosome 22q deletion, but analysis of the *NF-2 gene* in ependymomas has revealed only a single mutation in a tumor that had lost the remaining wild-type allele.

Children with tuberous sclerosis complex (incidence 1 in 5,000-10,000) have benign hamartomas of the brain and are at

	Demographics	Growth/ development	Germline susceptibility	Immune function	Environmental exposures	Somatic alterations
Reduced risk			Common SNPs Epimutations Maternal genetic effects	**Allergic/ atopic conditions** **Early life exposure to infections**	*In utero* folic acid	
Increased risk	**Race/ethnicity** **Male gender** **Parental age**	Intrauterine growth rate High birthweight Head circumference Congenital anomalies	**Cancer syndromes:** ***NF1*** ***TSC*** ***PTCH*** ***APC*** Common SNPs Maternal genetic effects		**Ionizing radiation** Hazardous air pollutants Pesticides Dietary nitroso compounds	Somatic mutations Epigenetic alterations Tumor micro-environment

FIGURE 150.3 Summary of established and suspected risk factors related to childhood brain tumors. More established risk factors are listed in bold type. Suggested risk factors that are high priority for validation are listed in nonbold type. Abbreviation: SNPs, single nucleotide polymorphisms). (Source: Johnson KJ, Cullen J, Barnholtz-Sloan JS, et al. Childhood brain tumor epidemiology: a brain tumor epidemiology consortium review. *Cancer Epidemiol Biomarkers Prev.* 2014;23[12]:2715-2736.)

risk during childhood for subependymal giant cell astrocytoma (SEGA) or ependymoma. The tuberous sclerosis genes map to chromosomes 9q and 16p, and allelic loss at these loci has been found in some SEGAs, suggesting a tumor suppressor function.

Sturge-Weber syndrome is the third most common neurocutaneous disclusively sporadically due to an activating mutation in GNAQ. Neurologic abnormalities include leptomeningeal angiomas, with case reports of angiomatous meningioma and hypothalamic low-grade astrocytoma.

Hemangioblastomas of the cerebellum, medulla, and spinal cord are associated with von Hippel-Lindau disease, and choroid plexus tumors have occasionally been reported. Loss of chromosome 3p sequences has been described in one choroid plexus tumor, suggesting involvement of the *VHL gene*.

There is an increased risk of brain tumors in the Li-Fraumeni syndrome, particularly choroid plexus carcinoma (CPC) but also astrocytoma. Li-Fraumeni syndrome involves germ line mutations in the p53 tumor suppressor gene on chromosome 17 and predisposes to many other cancers.

Gorlin syndrome (nevoid basal cell carcinoma syndrome), resulting from *PTCH1 gene* mutation, predisposes to medulloblastoma, specifically Sonic Hedgehog (SHH) subtype (see the following discussion). Turcot syndrome describes the association of primary CNS tumors with colorectal polyps, either familial adenomatous polyposis or hereditary nonpolyposis colorectal cancer, due to mutations in the adenomatous polyposis coli (APC) and DNA mismatch repair genes. Familial adenomatous polyposis is associated with medulloblastoma (Turcot syndrome type 2) in childhood, whereas hereditary nonpolyposis colorectal cancer is associated with glioblastoma in young adults (Turcot syndrome type 1).

Cowden syndrome (multiple hamartoma syndrome with germ line phosphatase and tensin homolog [PTEN] tumor suppressor mutation) is associated with dysplastic gangliocytoma of the cerebellum (Lhermitte-Duclos disease), whereas Rubinstein-Taybi syndrome (germ line mutation in CREBBP involved in sonic hedgehog regulation) is associated with meningioma, medulloblastoma, and oligodendroglioma. Ataxia telangiectasia features progressive cerebellar atrophy and has been associated with meningioma in addition to lymphoma and leukemia.

There is a predisposition to pineoblastoma in hereditary retinoblastoma (Rb) ("trilateral retinoblastoma") and also in DICER1 syndrome, which involves mutation in an endoribonuclease responsible for the production of mature microRNAs, small single-stranded RNA molecules that target messenger RNAs (mRNAs) and repress protein synthesis. DICER syndrome also predisposes to pleuropulmonary blastoma and multiple adult-onset cancers. Pituitary adenomas are seen in multiple endocrine neoplasia type 1.

Common genetic variation may also influence tumor susceptibility. Studies investigating birth order, birth weight, presence of congenital anomalies, advanced parental age, maternal diet and prenatal vitamin consumption, familial allergic conditions, and childhood infectious exposures have yielded mixed results or borderline evidence for a positive association, but brain tumor risk is increased in the presence of congenital anomalies of the CNS.

Combined cytogenetic and molecular studies of the common sporadic childhood brain tumors have revealed nonsyndromic genomic alterations potentially contributing to tumorigenesis. Isochromosome 17q is found in half of all medulloblastomas, implicating a tumor suppressor gene. Clinical outcome is now predictable by gene expression profiles. Somatic TP53 mutation in medulloblastoma and overexpression of p53 in high-grade astrocytoma of childhood are associated with adverse outcome. In medulloblastoma, low MYC oncogene mRNA expression and high Trk C neurotrophin-3 receptor mRNA expression identify better prognosis.

The desmoplastic subtype of medulloblastoma is specifically associated with the nevoid basal cell carcinoma syndrome, caused by mutations in the *PTCH1 gene*, a tumor suppressor gene normally encoding patched-1, which blocks cell proliferation unless missing or bound by the Sonic Hedgehog protein, the ligand for the patched-1 receptor. Desmoplastic medulloblastoma in infants from affected families is reported to have a good prognosis. Conversely, the large cell, anaplastic variant of medulloblastoma, and the AT/RT have an unfavorable prognosis. Diagnosis of these variants is based on light microscopic and immunohistochemical findings, and AT/RT is further distinguished by chromosome 22q11 deletion with inactivation of the hSNF5/INI1 gene.

Environmental risk factors for CNS tumors include ionizing radiation, which in the distant past was given even for benign conditions such as tinea capitis. In children treated for acute lymphoblastic leukemia, there is a 1.39% cumulative incidence of secondary brain tumors (gliomas and meningiomas) at 20 years, and cranial irradiation is a dose-dependent predisposing factor, with a latency of 7 to 9 years. Another study with 30-year follow-up found a 3.0% cumulative incidence of brain tumors (excluding meningioma) following acute lymphoblastic leukemia treatment. Radiation therapy in medulloblastoma is also associated with an increased incidence of secondary malignant brain tumors, as high as 4%. Regarding radiation exposure from diagnostic procedures, a retrospective cohort study concluded that although the absolute risk is small, use of CT scans in children with doses of about 60 mGy could triple the risk of brain cancer (estimated 1 excess case per 10,000 head CT scans). There is no conclusive evidence of risk from exposure to electromagnetic fields (from electric blankets, microwave ovens, or cell phones).

Studies have shown an association between farm and animal exposures and childhood brain tumors and a weak association with toxic exposures occurring in the household. Although not implicated in retrospective studies, maternal smoking during pregnancy was associated with slightly increased risk of brain tumors in offspring in a prospective study linking birth and cancer registries. The incidence of medulloblastoma in England declined after 1984 when multivitamin supplementation in pregnancy became widespread following reports that folate reduced the risk of neural tube defects. Maternal intake of folic acid in pregnancy was reported to be protective against medulloblastoma, but this association could not be confirmed in a subsequent study. A seasonal variation in medulloblastoma (but not other brain tumors) was noted in the United States between 1995 and 2001, peaking in October, and a separate study found increased risk of medulloblastoma associated with paternal exposure to any heat source in the 3 months prior to the index pregnancy, redirecting attention to electric blankets. Established and suspected risk factors for childhood brain tumors are summarized in **Figure 150.3**.

Survival

Survival of children with brain tumors is approximately 70% overall and substantially higher for nonmalignant lesions and low-grade tumors but distinctly worse for high grade glioma and especially DIPG (**Table 150.1**).

TABLE 150.1 One-, Two-, Five-, and Ten-Year Relative Survival Rates for Selected Malignant Brain and Central Nervous System Tumors by Age Groups[a]

Diagnosis	Age Group	1 y	2 y	5 y	10 y
Pilocytic astrocytoma	0-14 y	98.7%	98.5%	97.2%	94.9%
	0-19 y	98.5%	98.3%	96.8%	96.2%
Diffuse astrocytoma	0-14 y	91.2%	87.0%	82.7%	80.7%
	0-19 y	92.4%	87.3%	82.7%	80.4%
Anaplastic astrocytoma	0-14 y	58.7%	39.7%	30.4%	25.9%
	0-19 y	62.9%	41.9%	31.0%	26.5%
Glioblastoma multiforme	0-14 y	50.9%	29.1%	22.2	15.2%
	0-19 y	57.2%	32.5%	19.2%	12.6%
Oligodendroglioma	0-14 y	95.8%	95.1%	92.7%	90.1%
	0-19 y	96.8%	94.6%	92.2%	90.1%
Anaplastic oligodendroglioma	0-19 y	84.5%	62.3%	31.0%	26.5%
Ependymoma	0-14 y	93.6%	86.0%	72.2%	62.8%
	0-19 y	94.0%	86.9%	74.7%	64.9%
Oligoastrocytoma	0-14 y	94.6%	86.5%	78.7%	72.5%
	0-19 y	93.4%	86.8%	81.2%	76.1%
Neuronal/neuronal-glial	0-14 y	97.1%	90.6%	87.2%	87.2%
	0-19 y	96.3%	86.3%	84.1%	72.4%
Embryonal	0-14 y	79.9%	70.3%	62.1%	55.5%
	0-19 y	80.9%	71.0%	61.9%	55.8%
All CNS	0-14 y	85.2%	78.0%	72.3%	68.2%
	0-19 y	86.4%	79.1%	73.0%	69.0%

Abbreviation: CNS, central nervous system.
[a]Source: Ostrom QT, Gittleman H, Farah P, et al. CBRTUS statistical report: primary brain and central nervous system tumors diagnosed in the United States in 2006-2010. *Neuro Oncol.* 2013;15(suppl 2):ii1-ii56.

Survival for certain tumors has improved substantially. The best example is medulloblastoma, where survival improved from essentially zero percent to over 50% with the introduction of postoperative craniospinal irradiation in the 1950s, and further improvement has been achieved with the introduction of adjuvant chemotherapy. Postoperative irradiation affords improved survival in ependymoma, and there may be a benefit of neoadjuvant or maintenance chemotherapy (ie, before or after radiation therapy). Combined modality therapy incorporating radiotherapy and high-dose chemotherapy with autologous peripheral blood stem cell rescue has led to improved survival in AT/RT, and intensive chemotherapy with peripheral blood stem cell rescue allows deferral or avoidance of craniospinal irradiation in responding infants with medulloblastoma.

PATHOBIOLOGY

Current research on CNS tumorigenesis is based on the molecular genetics of tumor-associated syndromes, rodent models of pediatric brain tumors, and technologic advances in efforts to identify genes that regulate normal and neoplastic cells in the developing CNS. Although the names of individual brain tumors imply that they originate from normal brain cells (eg, astrocytoma from astrocytes), the primitive embryonal tumors of childhood that arise during brain development more likely result from aberrant regulation of neurodevelopment genes. Recently, it has been postulated that brain tumors, like hematologic malignancies, contain small numbers of stem cells (identified as $CD133^+$), which have marked capacity for proliferation and self-renewal. These stem cells can not only differentiate to phenotypically recognizable brain tumor cells but also maintain clonal proliferation and may be highly resistant to conventional anticancer treatment such as radiation and cytotoxic chemotherapy. Candidate stem cells have been proposed for medulloblastoma, ependymoma, and malignant astrocytomas. Further characterization of brain tumor stem cells may offer new insights into mechanisms of tumorigenesis and lead to novel treatment strategies based on preferential targeting of tumor stem cells.

Sonic Hedgehog, Wnt Signaling, Cerebellar Development, and Medulloblastoma

In the 19th century, Obersteiner described the cells of the external granular layer in the developing cerebellum. Based on morphologic similarity, granule cell precursors (GCPs) were considered the cells of origin in medulloblastoma. Now, gene chip analysis and mouse models have linked medulloblastoma to molecular markers of GCPs. The cerebellum matures through a complex interplay of genes of general CNS development and specifically cerebellar genes. For instance, SHH is a glycoprotein involved in the development of the CNS. In cerebellar development, Purkinje cells secrete SHH to activate genes in GCPs and stimulate proliferation of these cells. Activating mutations of the SHH pathway account for desmoplastic medulloblastoma in the nevoid basal cell carcinoma syndrome (Gorlin syndrome), 10% to 20% of sporadic medulloblastomas, and histologically similar tumors in mice that are heterozygous for the equivalent genes. Genome sequencing of SHH-driven medulloblastomas reveals pathway mutations involving PTCH1 (across all age groups), SUFU (infants, including cases of germ line mutation), and SMO

(in adults). Functional assays in different SHH-driven medulloblastoma xenografts demonstrated that tumors harboring PTCH mutation were responsive to SMO inhibition, whereas tumors with SUFU mutation or MYCN amplification were resistant.

Wnt proteins also play a role in CNS development and have been linked to medulloblastoma. Patients with Turcot syndrome, which involves defects in the APC gene, are susceptible to colorectal and brain tumors, notably medulloblastoma. APC is an element of the Wnt signaling pathway, and up to 30% of spontaneous medulloblastomas show mutations in APC and other components of this neurodevelopmental signaling cascade. Cell nuclear accumulation of β-catenin protein is also associated with activation of Wnt/Wg signaling, and positive immunostain for β-catenin in medulloblastoma has been associated with favorable treatment outcome even with metastatic disease at presentation.

Wnt proteins bind to receptors and modulate C-myc, a transcription factor that promotes cell cycle progression. Activation of C-myc and N-myc leads to proliferation, cell growth, and maintenance of an undifferentiated cellular phenotype; these genes are amplified in some medulloblastomas and are associated with a poor clinical outcome. The same genes are amplified by the SHH pathway. Wnt1 is required for mesencephalon/metencephalon patterning early in development. Cerebellar primordia fail to develop in mice lacking Wnt1, and mutations in other Wnt pathway components have been implicated not only in medulloblastoma but also in colon cancer, hepatocellular carcinoma, and prostate and ovarian cancers.

Deletion of chromosome 17p, the most frequently detected genetic lesion in medulloblastoma, has been identified as a cause of unrestrained hedgehog signaling. This deletion results in loss of REN(KCTD11), a suppressor of hedgehog signaling, thus removing a checkpoint of hedgehog-dependent events during cerebellar development and tumorigenesis. Inactivation of the tumor suppressor p53, also a resident of chromosome 17, may contribute to the growth of tumors resembling medulloblastoma in mice, but there is neither an increased incidence of medulloblastoma in humans lacking p53 nor a change in p53 within the medulloblastoma cells, although somatic p53 mutation confers poor prognosis clinically.

The gene *Bmi1*, which induces leukemia through repression of tumor suppressors, is overexpressed in many medulloblastomas and promotes cerebellar GCP proliferation. Linked overexpression of *Bmi1* and patched (*PTCH*) in primary human medulloblastomas, together with rapid induction of BIM expression on addition of SHH or overexpression of the SHH target Gli1 in cerebellar granule cell culture, implicates Bmi1 overexpression as an alternative or additive mechanism in medulloblastoma pathogenesis.

CD133 identifies medulloblastoma stem cells, and in a mouse model enrichment of CD133 in group 3 medulloblastoma is associated with increased metastasis and poor outcome. The signal transducers and activators of transcription-3 pathway are selectively activated in $CD133^+$ medulloblastoma stem cells and promote tumorigenesis through regulation of c-MYC. Treatment with signal transducers and activators of transcription-3 inhibitors resulted in tumor regression and could represent a potential therapeutic strategy for recurrent group 3 medulloblastoma.

"Classic" medulloblastoma has the histologic appearance of a small, round, blue cell tumor with a diffuse pattern of poorly differentiated cells. Neuroblastic ("Homer-Wright") rosettes may be present, and immunohistochemical staining is usually positive for synaptophysin and occasionally for neurofilament protein or glial fibrillary acidic protein (GFAP), although the latter usually represents reactive intratumoral astrocytes. Desmoplastic/nodular medulloblastoma typically arises in cerebellar hemispheres and is characterized by nodular islands of differentiating neuroblasts; an "extensively nodular" variant is recognized in infants. Large cell/anaplastic medulloblastoma comprises large neoplastic cells with vesicular nuclei and prominent nucleoli. About one-quarter exhibit at least moderate anaplasia and show aggressive clinical behavior.

A specific chromosome abnormality, isochromosome 17q (ie, duplication of the long arm or deletion of the short arm of chromosome 17), is seen in half of cases of medulloblastoma. This could result in inactivation of a tumor suppressor gene located on chromosome 17 but is distinct from p53. It is unclear whether chromosome 17p deletions impart poor prognosis, but diploid tumors have worse outcome than aneuploid or hyperdiploid tumors.

The 2016 revision of the WHO classification of CNS tumors now incorporates the molecular subgroups of medulloblastoma as distinct entities (**Fig. 150.4**): (1) Wnt tumors (named for drosophila wingless) with classic histology and very good prognosis; (2) SHH tumors (named for Sonic Hedgehog), relatively more common in infants and adults, with desmoplastic/nodular histology and intermediate prognosis (good in infants); (3) "group 3" tumors with overrepresentation of large cell/anaplastic (LC/A) histology, MYC amplification, very frequent metastasis, and poor prognosis; and (4) "group 4" tumors with classic histology but tendency for metastasis, occasional MYCN amplification, and intermediate prognosis.

Immunohistochemical correlations are nuclear positivity for β-catenin in Wnt tumors, GAB1 positivity in SHH tumors, and filamin A and YAP1 positivity in both. Correlation with cytogenetic findings shows isochromosome 17q to be typical of group 3 and 4 tumors, monosomy 6 associated with Wnt tumors, and 9q and 10q deletion in SHH tumors. Profiling six fluorescent in situ hybridization biomarkers (GLI2; MYC; and chromosomes 11, 14, 17p, and 17q) reliably identifies very low-risk and very high-risk patients within SHH, group 3, and group 4 medulloblastomas. Exam sequencing has revealed subtype-specific somatic mutations in known medulloblastoma-related genes (CTNNB1, PTCH1, MLL2, SMARCA4) and genes not previously considered medulloblastoma-related (DDX3X, CTDNEP1, KDM6A, TBR1).

Wnt-activated medulloblastomas occur mainly in older children, represent 10% of all medulloblastomas, and have the best prognosis. Expected findings are β-catenin nuclear staining, 6q loss, and/or CTNNB1 mutation. APC mutation should prompt germ line testing for Turcot syndrome.

SHH-activated medulloblastomas have bimodal age distribution (younger than age 3 y and adolescent), represent 30% of medulloblastomas, and have good prognosis in infants but intermediate in adolescents. Expected findings are desmoplastic/nodular histology, 9q deletions, and mutations in SHH pathway genes (PTCH1, PTCH2, SMO, SUFU, and GLI2). Infant SHH includes two subtypes, one with focal amplifications and frequently metastasizing and a second with distinctive histology (medulloblastoma with extensive nodularity) and good prognosis. SHH-activated tumors in children age 3 to 16 years are enriched for MYCN and GLI2 amplification and TP53 mutation and have worse prognosis (<50% survival).

Non-Wnt/non-SHH medulloblastoma includes two subgroups. Group 3 medulloblastoma (20% of all cases) shows male preponderance, infant and childhood age, frequent metastatic presentation, large cell/anaplastic histology, isochromosome 17, MYC amplification, and poor prognosis (<50% survival).

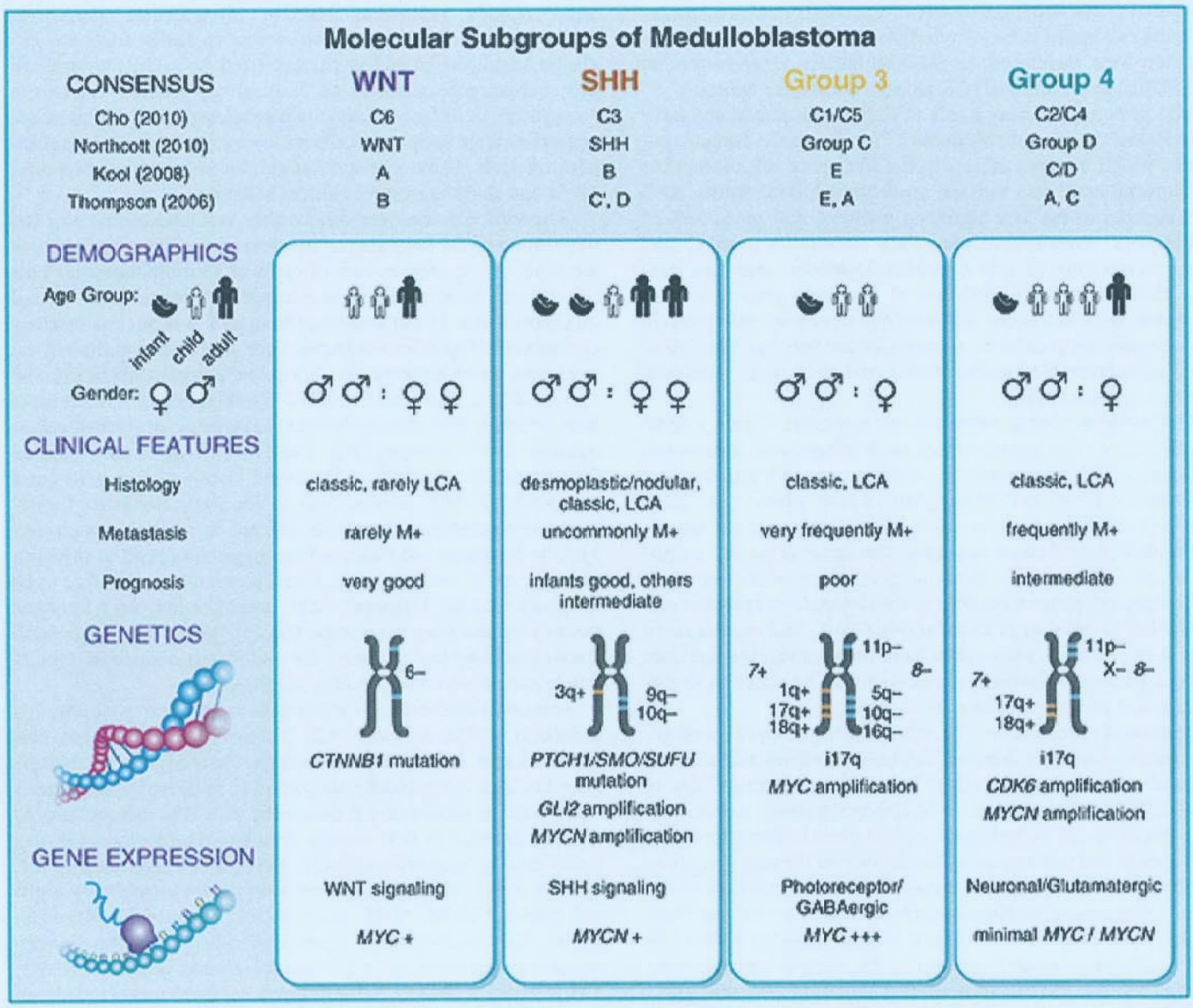

FIGURE 150.4 Molecular subgroups of medulloblastoma. (Source: Kool M, Korshunov A, Remke M, et al. Molecular subgroups of medulloblastoma: an international meta-analysis of transcriptome, genetic aberrations, and clinical data of WNT, SHH, group 3, and group 4 medulloblastomas. *Acta Neuropathol.* 2012;123:473-484.)

Patients whose tumors show large cell/anaplastic histology without MYC amplification have better prognosis (70% survival). Group 4 medulloblastoma (40% of cases) shows male preponderance, infant to adolescent age, metastatic presentation, classic or large cell/anaplastic histology, MYCN or CDK6 amplification, and intermediate prognosis.

The term *supratentorial primitive neuroectodermal tumor* (sPNET), implying a histologic counterpart of medulloblastoma occurring outside the posterior fossa and tending to disseminate via cerebrospinal fluid (CSF) pathways, was eliminated in the 2016 WHO Classification of CNS tumors, which emphasizes integrated phenotypic and genotypic diagnosis. Fully 31% of PNETs were reclassified as high-grade gliomas, based on shared genetic and epigenetic mutations or copy number alterations. Meanwhile, a molecularly distinct group was created: embryonal tumor with multilayered rosettes (ETMR), chr19q13.41 microRNA cluster (C19MC)-altered, and histologically similar tumors without C19MC alteration. This group of aggressive lesions arising mainly in toddlers includes embryonal tumor with abundant neuropil and true rosettes, ependymoblastoma, and medulloepithelioma (collectively 11% of the total). Pineoblastoma is now categorized as a pineal parenchymal tumor, which can be associated with germ line mutations in RB1 ("trilateral retinoblastoma") or DICER1.

Four new distinct entities were introduced in WHO 2016, accounting for 24% of the total: CNS neuroblastoma with FOXR2 activation, CNS Ewing sarcoma family tumor with CIC alteration, CNS high-grade neuroepithelial tumor with MN1 alteration, and CNS high-grade neuroepithelial tumor with BCOR alteration (**Fig. 150.5**).

Three molecular subgroups were proposed based on differential expression of cell lineage markers LIN28 and OLIG2: (1) primitive neural (younger females with poorest survival), (2) oligoneural (older males with best survival), and (3) mesenchymal (older males with highest incidence of metastatic disease and intermedi-

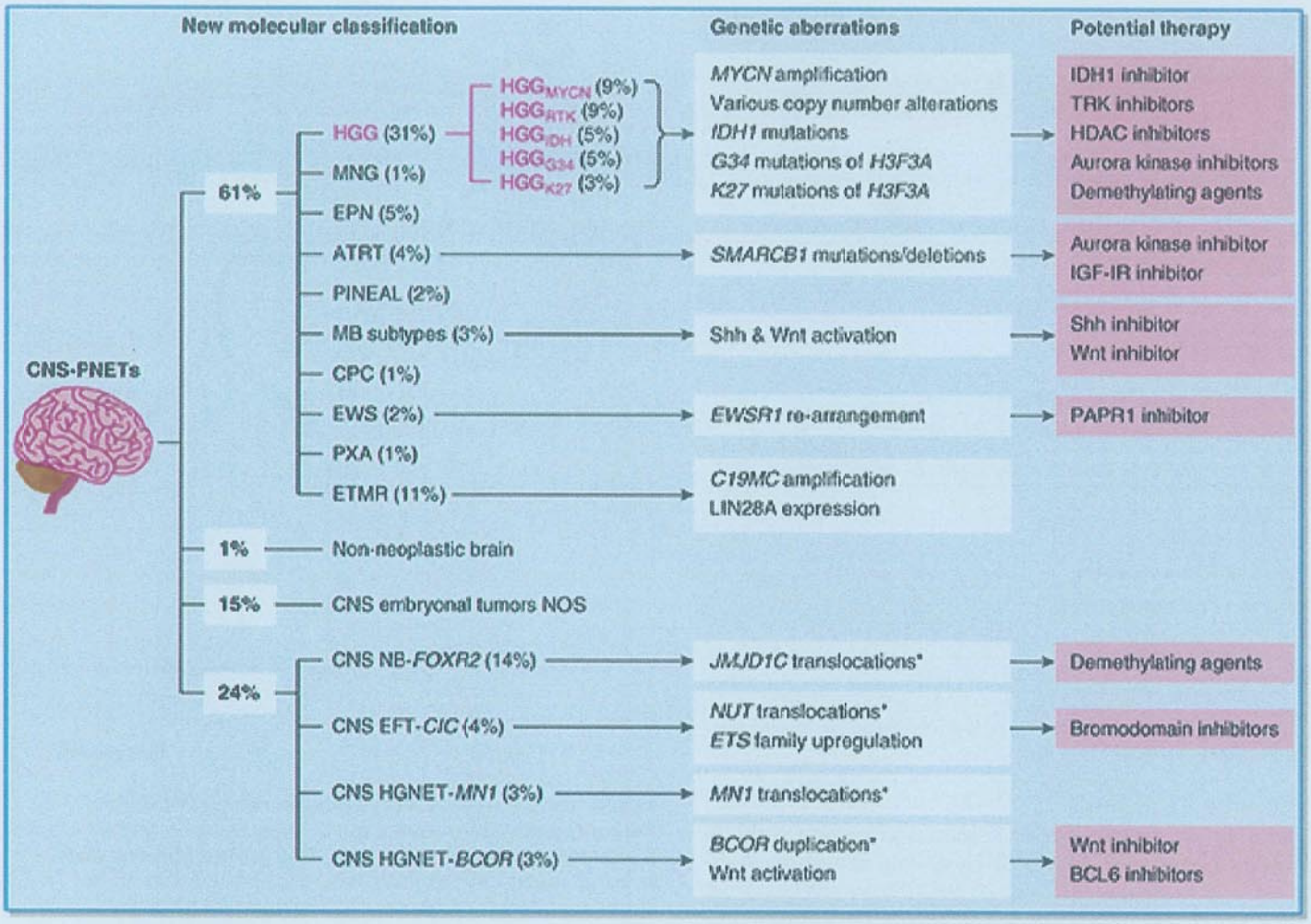

FIGURE 150.5 Revised molecular classification of supratentorial embryonal tumors. Abbreviations: ATRT, atypical teratoid/rhabdoid tumor; BCL6, B-cell lymphoma 6; CNS, central nervous system; CPC, choroid plexus carcinomas; EFT, Ewing sarcoma family tumor; EPN, ependymoma; ETMR, embryonal tumor with multilayered rosettes; EWS, Ewing sarcoma; HDAC, histone deacetylase; HGG, high grade glioma or high-grade glioma; HGNET, high grade neuroepithelial tumor; IDH1, isocitrate dehydrogenase 1; IGF-IR, insulin like growth factor 1 receptor; MB, medulloblastoma; MNG, meningioma; NB, neuroblastoma; NOS, not otherwise specified; PARP1, poly(ADP-ribose) polymerase 1; PNET, primitive neuroectodermal tumor; PXA, pleomorphic xanthoastrocytoma; TRK, tropomyosin receptor kinase. (Source: Zaky W. Revisiting management of pediatric brain tumors with new molecular insights. *Cell.* 2016;164:844-846.)

ate survival). A high-level amplicon involving the C19MC identifies an aggressive subgroup of CNS PNET with distinct gene expression profiles and poor survival. ATRTs have monosomy or deletion of chromosome 22, and inactivating mutations of the hSNF5/INI-1 gene at 22q11.2 are considered fundamental to pathogenesis. Loss of chromosome 19 has been reported in AT/RT.

The resulting new classification of CNS embryonal tumors in WHO 2016 is shown in **Table 150.2**.

Astrocytes, Growth Factors, Tumor Suppressors, and Astrocytoma

Astrocytes develop later than neurons and continue to do so long after neurogenesis stops. Astrocytes retain the capacity for division throughout life and are more susceptible to transformation. Control over astrocyte proliferation and differentiation may be divided into two main categories: cell signaling and cell cycle arrest pathways. During glial development, precursor cells respond to growth factors such as epidermal growth factor (EGF) or platelet-derived growth factor (PDGF). Their receptors (EGF receptor [EGFR] and PDGF receptor [PDGFR]) are activated to stimulate tyrosine kinase activity and intracellular pathways that control proliferation and differentiation, programmed cell death, migration, cellular shape, and metabolism.

Amplification and mutation of EGFR are among the most common genetic abnormalities found in adult glioblastomas, particularly those arising de novo (as opposed to lesions progressing from fibrillary astrocytomas). These tumors contain ligands that may activate the receptor, stimulating a pathway that results in tumor progression. In addition, the receptor may be mutated to a constitutively activated form, unable to bind ligand but generating unregulated tyrosine kinase activity. Mice lacking EGFR have fewer GFAP-positive cells, and massive neuronal degeneration is attributed to a lack of trophic support from the missing glial cells. Amplification of EGFR is uncommon in pediatric high-grade astrocytomas, but significant differential expression of the EGFR/

TABLE 150.2 Classification of Central Nervous System (CNS) Embryonal Tumor Classification, WHO 2016[a]

Medulloblastoma, genetically defined
- Medulloblastoma, Wnt-activated
- Medulloblastoma, sonic hedgehog (SHH)-activated, TP53 mutant
- Medulloblastoma, SHH-activated, TP53 wild type
- Medulloblastoma, non-Wnt/non-SHH
  - Medulloblastoma, group 3
  - Medulloblastoma, group 4

Medulloblastoma, histologically defined - Medulloblastoma, classic - Medulloblastoma, desmoplastic/nodular - Medulloblastoma with extensive modularity - Medulloblastoma, large cell/anapestic
Medulloblastoma, not otherwise specified (NOS)
Embryonal tumor with multilayered rosettes (ETMR), C19MC-altered
ETMR, NOS
CNS neuroblastoma
CNS ganglioneuroblastoma
CNS embryonal tumor, NOS
CNS atypical teratoid/rhabdoid tumor
CNS embryonal tumor with rhabdoid features

[a]Source: Louis DN, Perry A, Reifenerger G, et al. The 2016 World Health Organization classification of tumors of the central nervous system: a summary. *Acta Neuropathol*. 2016;131:803-820.

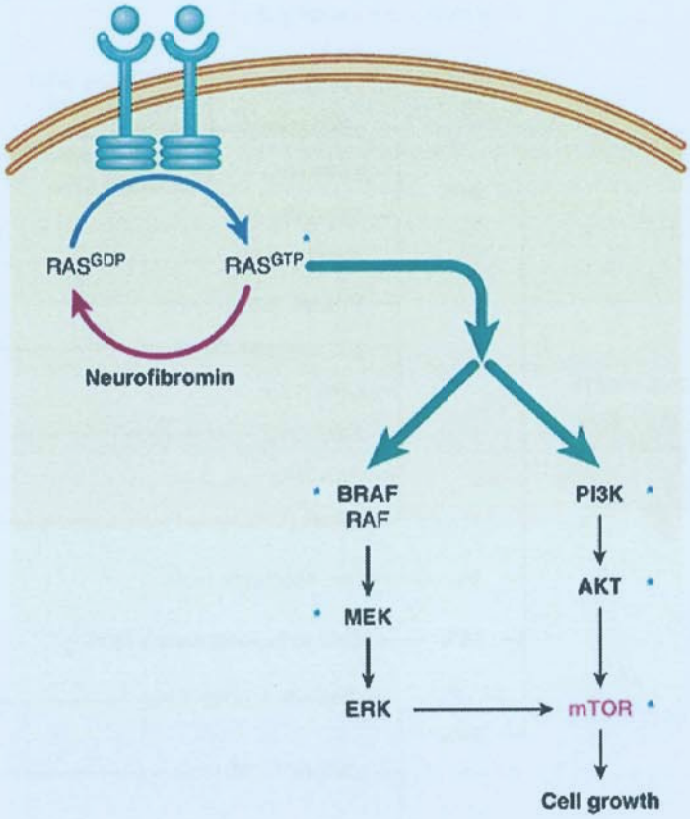

FIGURE 150.6 Regulation of neuroglial cell proliferation. Neurofibromin operates as a tumor suppressor protein by accelerating the conversion of the RAS proto-oncogene from its active, guanosine triphosphate (GTP)-bound state to its inactive, guanosine diphosphate (GDP)-bound state. Loss of neurofibromin expression, as seen in neurofibromatosis type 1–associated gliomas, results in increased RAS-GTP levels and hyperactivation of downstream RAS signaling pathways, to result in increased cell growth. RAS activation following neurofibromin loss leads to high levels of mitogen-activated extracellular signal-regulated kinase (MEK)/extracellular-signal-regulated kinase (ERK) and phosphoinositide 3-kinase (PI3K)/protein kinase B (AKT)/mammalian target of rapamycin activity. Deregulated BRAF kinase activity leads to increased MEK/ERK signaling to result in high levels of mammalian target of rapamycin activation and increased cell growth. The *asterisks* denote the molecular targets for which clinically available pharmacologic inhibitors exist for the potential treatment of pilocytic astrocytomas in children. (Source: Chen Y-H, Gutmann DH. The molecular and cell biology of pediatric low-grade gliomas. *Oncogene*. 2014;33:2019-2026.)

FKBP12/HIF-2α growth- and angiogenesis-promoting pathway has been demonstrated. High PDGFR protein expression is associated with malignant histology in pediatric glioma but is not an independent prognostic factor. Attempts to block glioma progression through disruption of the EGFR pathway have led to development of drugs targeting EGFR or PDGFR.

Ras is a downstream effector of several growth factor receptors, signaling through both mitogenic and antiapoptotic pathways. It is under control of the *NF-1 gene* neurofibromin, and loss of function mutations in neurofibromin underlie the NF-1 syndrome, with predisposition to optic nerve glioma, astrocytoma, and glioblastoma. Neurofibromin functions as a Ras-guanosine triphosphatase-activating protein, but it had been unclear how Ras deregulation was involved in NF-1 pathogenesis. It has now been demonstrated that neurofibromin tightly regulates the mammalian target of rapamycin (mTOR) pathway. mTOR is a highly conserved serine/threonine protein kinase that regulates many steps in cell growth and proliferation, including ribosome biogenesis and protein translation. mTOR is constitutively activated in NF-1–deficient cells and tumors; aberrant mTOR activation depends on Ras and is mediated by the phosphorylation and inactivation of the tuberous sclerosis complex-2–encoded protein tuberin. Tumor cell lines from NF-1 patients are highly sensitive to the mTOR inhibitor rapamycin, which has therapeutic implications.

BRAF alterations (in particular tandem duplication and fusion KIAA1549-BRAF on chromosome 7q34) are now widely accepted as molecular markers for pilocytic astrocytoma, in particular for the differential diagnosis of supratentorial pediatric gliomas. Besides their diagnostic use, the evidence of mitogen activated protein kinase (MAPK) pathway–activating BRAF fusions and mutations in brain tumors has moreover drawn the attention of neurooncologists to the potential use of MEK1/2 and RAF inhibitors in the therapy of high- and low-grade gliomas (Fig. 150.6).

Molecular profiling of pediatric glioblastomas identifies at least two subsets. One group is associated with *Ras* and *Akt* pathway activation and exhibits increased expression of genes related to proliferation and a neural stem cell phenotype; this subset has very poor prognosis. A second group with better prognosis is not associated with activation of *Ras* and *Akt* pathways and may originate from astroglial progenitors. Both subsets show overexpression of Y-box-binding protein (YB-1), which may promote oncogenesis.

The tumor suppressor phosphatase with homology to tensin (PTEN) is mutated or lost in some pediatric high-grade astrocytomas, as in adult glioblastoma. PTEN is expressed throughout the embryo and is critical in CNS development. PTEN mutations are thought to cause Lhermitte-Duclos disease (dysplastic

gangliocytoma of the cerebellum) characterized by enlarged cerebellar folia, distorted cerebellar cortex, abnormally myelinated axon bundles, and dysplastic neurons. Conditional inactivation of the gene in the cerebellum of developing mice has generated a mammalian model of that disease. Loss of PTEN promotes astrocytic growth and survival because it would otherwise act as a repressor of antiapoptotic signaling pathways. PTEN is also thought to regulate astrocyte migration and invasion by effects on cell shape and movement. When PTEN is overexpressed, it inhibits tumor cell movement; conversely, reduction of PTEN activity promotes cell movement, invasiveness, and perhaps metastasis. Loss of PTEN has been associated with inferior survival in childhood gliomas. PTEN is a component gene in the mTOR pathway; immunohistochemical analysis of Lhermitte-Duclos disease lesions showed high levels of phospho-AKT and phospho-S6 in the large ganglionic cells, indicating activation of the PTEN/AKT/mTOR pathway and suggesting a central role for mTOR in Lhermitte-Duclos disease (LDD) pathogenesis as well as potential therapeutic intervention through pharmacologic inhibition of mTOR.

The tumor suppressors Rb protein and p53 are also regulators of cell survival and programmed cell death and are intimately involved with astrocytoma. Rb mutations in children lead to tumors in the retina, whereas mice null for Rb do not survive because of lethally abnormal patterns of neuronal development with pronounced CNS programmed cell death. Rb encodes a phosphoprotein important in cell cycle regulation, blocking transcription factors that promote proliferation. In the developing CNS, Rb is found in the ventricular zone where neuroblasts proliferate.

Rb is also involved in the regulation of apoptosis through interactions with the tumor suppressor p53, a transcription factor upregulated in response to cellular stress to facilitate arrest of the cell cycle for either DNA repair or cell death. Humans with the Li-Fraumeni syndrome lack p53 and show marked susceptibility to gliomas. p53 mutant mice develop tumors early in life.

Under conditions of Rb inactivation, many cells enter the cell cycle inappropriately and subsequently undergo apoptosis. However, Rb loss may synergize with the loss of apoptotic regulators, such as p53 to promote tumor formation. With the loss of Rb, transcription factors go unchecked, which then promotes cell proliferation. Loss of Rb might normally lead to apoptosis, but if p53 is also missing, apoptosis is impaired and tumorigenesis is enhanced. In fact, approximately 75% of adult glioblastomas show impaired apoptotic mechanisms and p53 pathway defects. Mutations in p53 were detected in one-third of childhood high-grade astrocytomas and nearly half overexpressed the p53 protein. This finding was strongly associated with adverse outcome.

Epigenetic mutations in histone and chromatin remodeling genes appear to be uniquely important in pediatric glioblastoma multiforme. Exome sequencing revealed H3.3 or H3.1 K27M mainly in brainstem HGA and K27M-H3.3 mainly in thalamic HGA (70%-80% of all glioblastoma in these locations). This mutated H3.3 (encoded by H3F3A) is inconsistently associated with ATRX mutations. G34R/V-H3.3 mutations occur mainly in cerebral hemispheric glioblastoma, similar to isocitrate dehydrogenase (IDH) mutations, which have a predilection for the frontal cortex. Both H3.3 mutations are significantly associated with ATRX mutations and TP53 mutations, mainly in older children and young adults with cerebral cortical glioblastoma. H3F3A mutations are also associated with alternative telomere lengthening. Increased TERC (telomerase RNA template) and human telomere reverse transcriptase (hTERT) mRNA (encoding telomerase catalytic component) have been associated with worse overall survival (OS) in children with non-brainstem high-grade glioma after controlling for tumor grade and extent of resection.

Investigation of molecular aberrations in DIPG has lagged because most cases are diagnosed clinically without pathologic confirmation. However, high-resolution single-nucleotide polymorphism–based DNA analysis of a series of DIPGs using postmortem samples revealed recurrent changes distinct from supratentorial high-grade astrocytomas, specifically expression (and gains) of platelet-derived growth factor receptor α (PDGFRA) and occasional low-level gains in poly(ADP-ribose) polymerase (PARP)-1. Mutations in H3F3A (encoding histone H3.3) or HIST1H3B (encoding histone H3.1) are common in DIPG. Whole-genome sequencing has identified three molecular subgroups of DIPG (H3 K27M, silent, and MYCN) and recurrent activating mutations involving the activin receptor gene ACVR1 in some cases.

H3.3K27M expression synergizes with p53 loss and PDGFRA activation in neural progenitor cells derived from human embryonic stem cells, resulting in neoplastic transformation. Genome-wide analyses indicate a resetting of the transformed precursors to a developmentally more primitive stem cell state, with evidence of major modifications of histone marks at several master regulator genes. Drug screening assays identified a compound targeting the protein menin as an inhibitor of tumor cell growth in vitro and in mice.

Another study of in vitro and xenograft models using postmortem DIPG tumor tissue found that the hedgehog signaling pathway is active in DIPG tumor cells, modulating self-renewal in neurosphere culture and promoting hypertrophy of the ventral pons. Thus, the Hedgehog pathway represents a potential therapeutic target in DIPG.

The anatomic location and age specificity of histone mutations and IDH mutations in childhood and adolescent high-grade astrocytoma are represented in Figure 150.7. More detailed information is summarized in Figure 150.8.

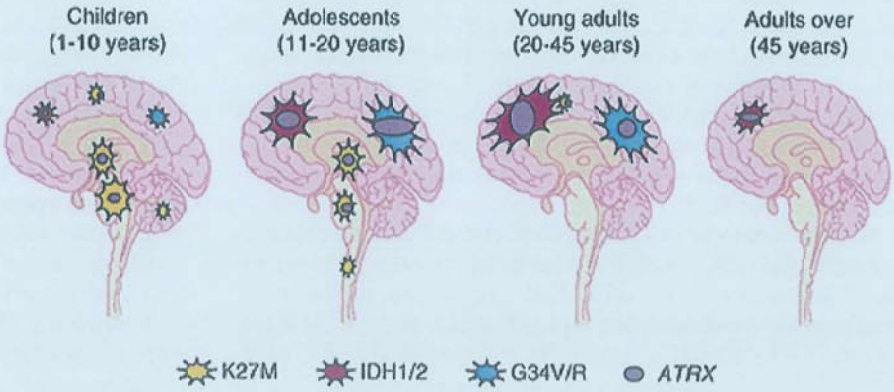

FIGURE 150.7 Neuroanatomic and age specificity of isocitrate dehydrogenase, K27M-H3.3 and G34R/V-H3.3 mutations in high-grade astrocytomas. Note: The size of the shape illustrating each mutation is approximately proportional to the percentage identified. (Source: Fontebasso AM, Liu X-Y, Sturm D, Jabado N. Chromatin remodeling defects in pediatric and young adult glioblastoma: a tale of a variant histone 3 tail. *Brain Pathol*, 2013;23:210-216.)

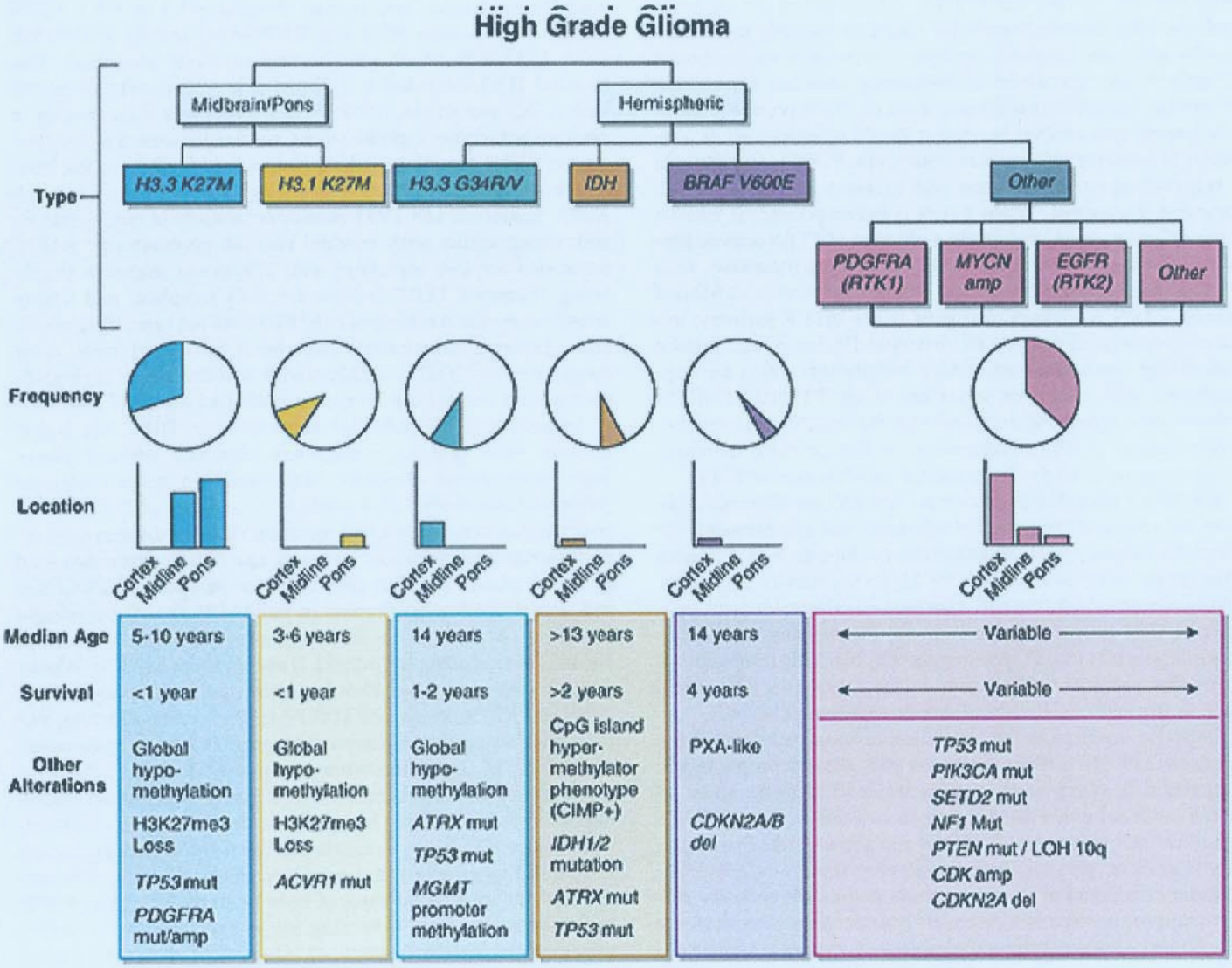

FIGURE 150.8 Clinical and molecular features of pediatric high grade gliomas. Abbreviations: IDH, isocitrate dehydrogenase; PXA, pleomorphic xanthoastrocytoma. (Source: Pollack IF, Agnihotri S, Broniscer A. Childhood brain tumors: current management, biological insights, and future directions. *J Neurosurg Pediatr*. 2019;23:261-273.)

Ependymal Cells, RELA Fusions, and Ependymoma

Ependymomas arise from CSF-producing ependymal cells lining the ventricular system of the brain and spinal cord. Simian virus 40–related DNA sequences have been demonstrated in ependymomas and CPCs suggesting a viral etiology. Cytogenetic and molecular studies of childhood ependymomas have revealed isochromosome 1q as an early genetic event as well as rearrangements or deletions of chromosomes 6, 17, and 22. hTERT expression predicts tumor progression. Tumor-derived stem cells show a radial glia phenotype with gene expression patterns corresponding to radial glia cells from anatomically distinct compartments of the CNS.

Both supratentorial and infratentorial ependymomas are derived from radial glial cells, although supratentorial tumors may show neuronal differentiation. In the WHO 2016 classification, supratentorial ependymomas are divided into C11orf95-RELA positive (ST-EPN-RELA) or C11orf95-RELA negative/YAP1 fusion positive (ST-EPN-YAP1). ST-EPN-RELA tumors account for approximately 70% of supratentorial ependymomas in children. In ST-EPN-RELA tumors, the novel oncogenic fusion involving C11orf95 and RELA genes results from chromothripsis involving chromosome 11q13.1 and leads to aberrant activation of the nuclear factor-kappa B signaling pathway. ST-EPN-RELA tumors may also have homozygous deletion of CDKN2 or gain of chromosome 1q, both poor prognosis factors.

Infratentorial ependymomas are divided into two groups, A and B. Tumors in the first group (posterior fossa ependymoma A [PF-EPN-A]) exhibit a balanced genome with CpG island methylator phenotype; CpG methylation drives transcriptional silencing of differentiation genes. About 25% of PF-EPN-A tumors have gain of chromosome 1q, independently associated with poor prognosis. Tumors in the less common second group (posterior fossa ependymoma B [PF-EPN-B]) have a higher degree of genomic instability and cytogenetic aberrations but mainly involving gain or loss of whole chromosomes, without CpG island methylator phenotype; at least five subtypes are recognized.

A summary of clinical, histologic, and molecular characteristics of ependymomas across anatomic compartments is shown in Figure 150.9.

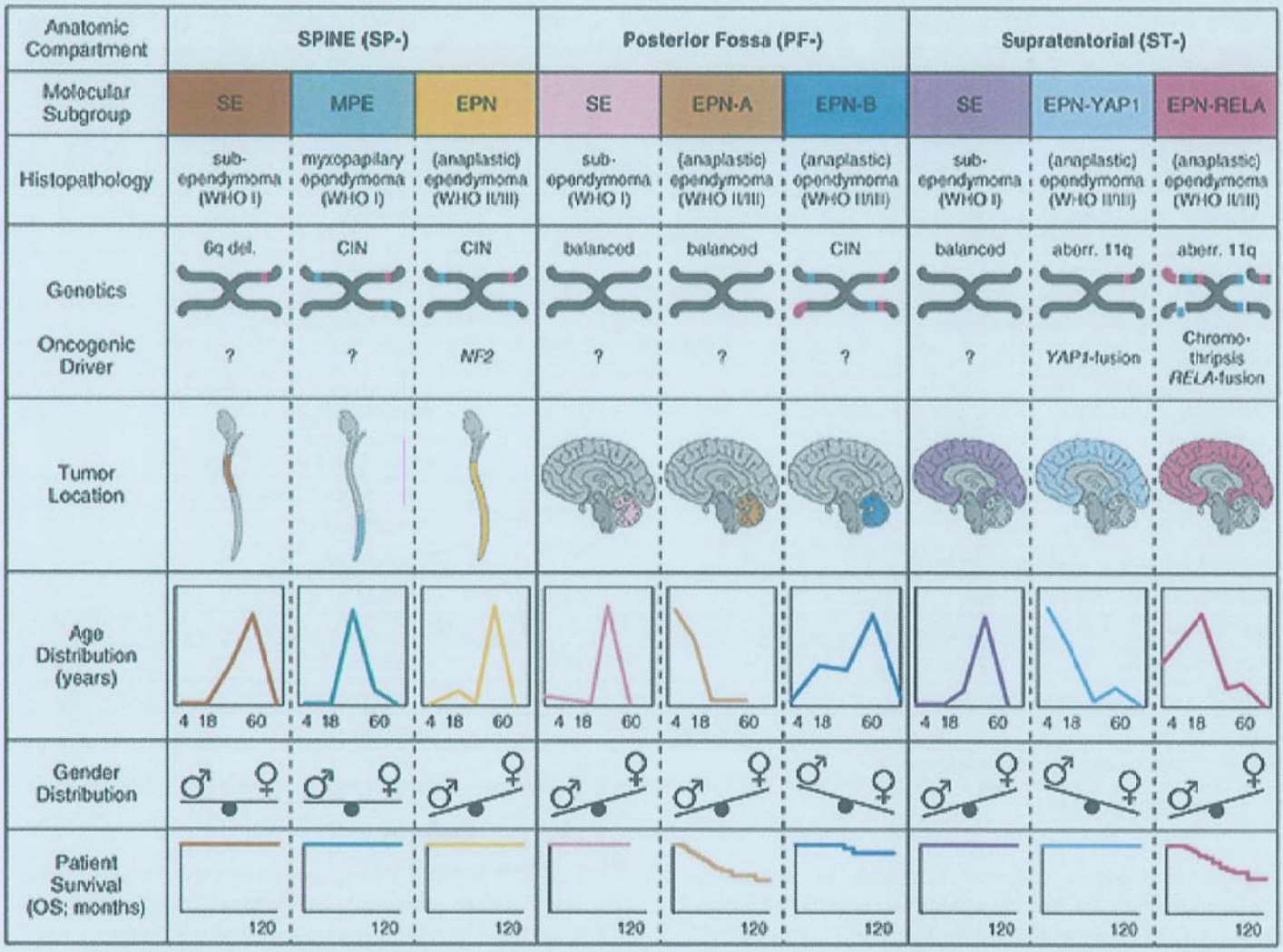

FIGURE 150.9 Ependymal tumors across central nervous system compartments, histopathologic grades, and age groups. (Source: Pajtler KW, Witt H, Sill M, et al. Molecular classification of ependymal tumors across all CNS compartments, histopathological grades, and age groups. *Cancer Cell*. 2015;27:728-743.)

Integrated Classification of Central Nervous System Tumors

Pathologic diagnosis is based on the WHO classification, which distinguishes astrocytic tumors, oligodendroglial tumors and mixed gliomas, ependymal tumors, choroid plexus tumors, and neuronal and mixed neuronal–glial tumors. Among entities newly incorporated in the 2007 revised classification were angiocentric glioma, papillary glioneuronal tumor, rosette-forming glioneuronal tumor of the fourth ventricle, papillary tumor of the pineal region, pituicytoma, and spindle cell oncocytoma of the adenohypophysis. Newly described histologic variants of pediatric tumors included pilomyxoid astrocytoma, anaplastic medulloblastoma, and medulloblastoma with extensive nodularity. In addition, the rhabdoid tumor predisposition syndrome was added to the list of familial cancer syndromes.

Some childhood brain tumors, such as supratentorial astrocytomas, have been difficult to characterize in the WHO classification. A proposed pediatric classification divides tumors into glial, mixed glial–neuronal, neural, embryonal, and pineal categories. Glial tumors include astrocytoma, ependymoma, oligodendroglioma, and choroid plexus tumor. Mixed glial–neuronal tumors include ganglioglioma and subependymal giant cell tumor. Neural tumors include gangliocytoma. Embryonal tumors are PNET, ATRT, and medulloepithelioma. Pineal tumors are represented by pineocytoma.

The 2016 revision of the WHO classification features many changes that are relevant to clinicians and researchers. The 2016 CNS WHO introduces diagnostic terms that "integrate" histologic and molecular information and suggests presenting diagnoses in a four-layered reporting format. In addition, it uses a "not otherwise specified" designation to identify diagnostic categories that are not precisely defined. A better understanding of the biology of specific entities led to changes in tumor nosology, such as diffuse gliomas based on IDH gene status, and diffuse midline gliomas H3 H27M mutant (Table 150.3).

For embryonal tumors and related entities, molecular subgroups were identified, including medulloblastoma Wnt-activated and SHH-activated, ETMR C19MC-altered, and RELA fusion–positive ependymomas. There will likely be additional practical advances that emerge over the next few years. A new initiative entitled Consortium to Inform Molecular and Practical Approaches to CNS Tumor Taxonomy will formulate recommendations between WHO updates.

TABLE 150.3 2016 World Health Organization Classification and Histologic Grade of Astrocytic Tumors[a]

Tumor Type	Grade	Common Locations
Diffuse Astrocytic Tumors		
Diffuse astrocytoma, IDH mutant Diffuse astrocytoma, IDH wild type	II	Cerebrum
Anaplastic astrocytoma, IDH mutant Anaplastic astrocytoma, IDH wild type	III	Cerebrum
Glioblastoma, IDH mutant Glioblastoma, IDH wild type	IV	Cerebrum
Diffuse midline glioma, H3K27M mutant	IV	Thalamus, brainstem
Other Astrocytic Tumors		
Pilocytic astrocytoma	I	Optic nerve, chiasm/hypothalamus Thalamus, basal ganglia Cerebral hemispheres Cerebellum, brainstem, spinal cord
Pilomyxoid astrocytoma	Uncertain	Third ventricle, midbrain
Pleomorphic xanthoastrocytoma	II	Temporal lobe
Anaplastic pleomorphic xanthoastrocytoma	III	Temporal lobe
Subependymal giant cell astrocytoma	I	Ventricle
Other Gliomas		
Angiocentric glioma	I	Cerebrum
Chordoid glioma of the third ventricle	II	Third ventricle
Astroblastoma	Uncertain	Cerebrum

Abbreviation: IDH, isocitrate dehydrogenase.
[a]Source: Louis DN, Perry A, Reifenberger G, et al. The 2016 World Health Organization classification of tumors of the central nervous system: a summary. *Acta Neuropathol*. 2016;131:803-820.

Pathologic diagnosis is greatly facilitated by immunohistochemical staining for specific markers such as GFAP in glial tumors, epithelial membrane antigen in ependymoma, and synaptophysin or neurofilament in medulloblastoma and gangliogliomas. Additional serum and immunohistochemical markers include α-fetoprotein (AFP) and human chorionic gonadotropin (HCG) for germ cell tumors, S100 for neural tumors, smooth muscle actin for AT/RT, and cytokeratin for CPC. An important trend in tumor pathology is the application of cytogenetic and DNA approaches. Examples are isochromosome 17q in medulloblastoma, chromosome 1p and 19q deletions in oligodendroglioma, and monosomy or deletion of chromosome 22 (hSNF/INI-1 locus) in ATRT. Molecular characterization is now incorporated into the integrated final diagnosis, and tumor tissue immunostaining is now available for certain mutations such as H3 K27M and BRAF V600E. Moreover, histone H3 mutations have been shown to be detectable in CSF-derived tumor DNA from children with diffuse midline glioma. A consensus recommendation is that next generation sequencing should be routinely included in the workup of most pediatric gliomas.

CLINICAL FEATURES

Symptoms

Children with brain tumors often present with symptoms and signs of increased intracranial pressure (ICP). Many pediatric tumors arise in ventricular or periventricular locations (including medulloblastoma, ependymoma, and choroid plexus tumors). Tumor-associated mass effect may result in obstruction of normal CSF pathways, with ventriculomegaly. Characteristic signs are headache, vomiting, and diplopia, but the onset may be gradual and nonfocal. Fatigue, personality change, or worsening school performance may be described. Symptoms in infants are nonspecific and include irritability, anorexia, persistent vomiting, and developmental delay or regression, with macrocephaly and seemingly forced-downward deviation of the eyes ("sunset sign"). Beyond infancy, symptoms tend to be more specific to anatomic location (**Fig. 150.10**). The median duration of symptoms before diagnosis was 2 months in two series; only one-third of the patients were diagnosed in the first month after onset of symptoms, but diagnostic delay is less important than tumor aggressiveness in determining survival outcome. Persistent vomiting, recurrent headache (awakening the child from sleep), neurologic findings (ataxia, head tilt, weakness, vision loss, papilledema), endocrine disturbance (growth deceleration, diabetes insipidus, precocious puberty), and stigmata of neurofibromatosis should all prompt evaluation for the presence of a CNS tumor.

Symptoms of CNS tumors generally correlate with tumor location (see **Fig. 150.10**). Supratentorial tumors, which predominate in infants and toddlers and also occur in older children, cause headache, limb weakness, sensory loss, and occasionally seizures, deteriorating school performance, or personality change. Seizures are a presenting symptom in 10% to 15% of children with brain tumors and may be generalized, focal motor, or psychomotor; electroencephalogram is almost always abnormal. Most tumors associated with seizures are located in the temporal lobe; frontal lobe tumors more often affect personality and movement. The incidence of underlying neoplasm in children with intractable epilepsy approaches 20%, and the increased risk

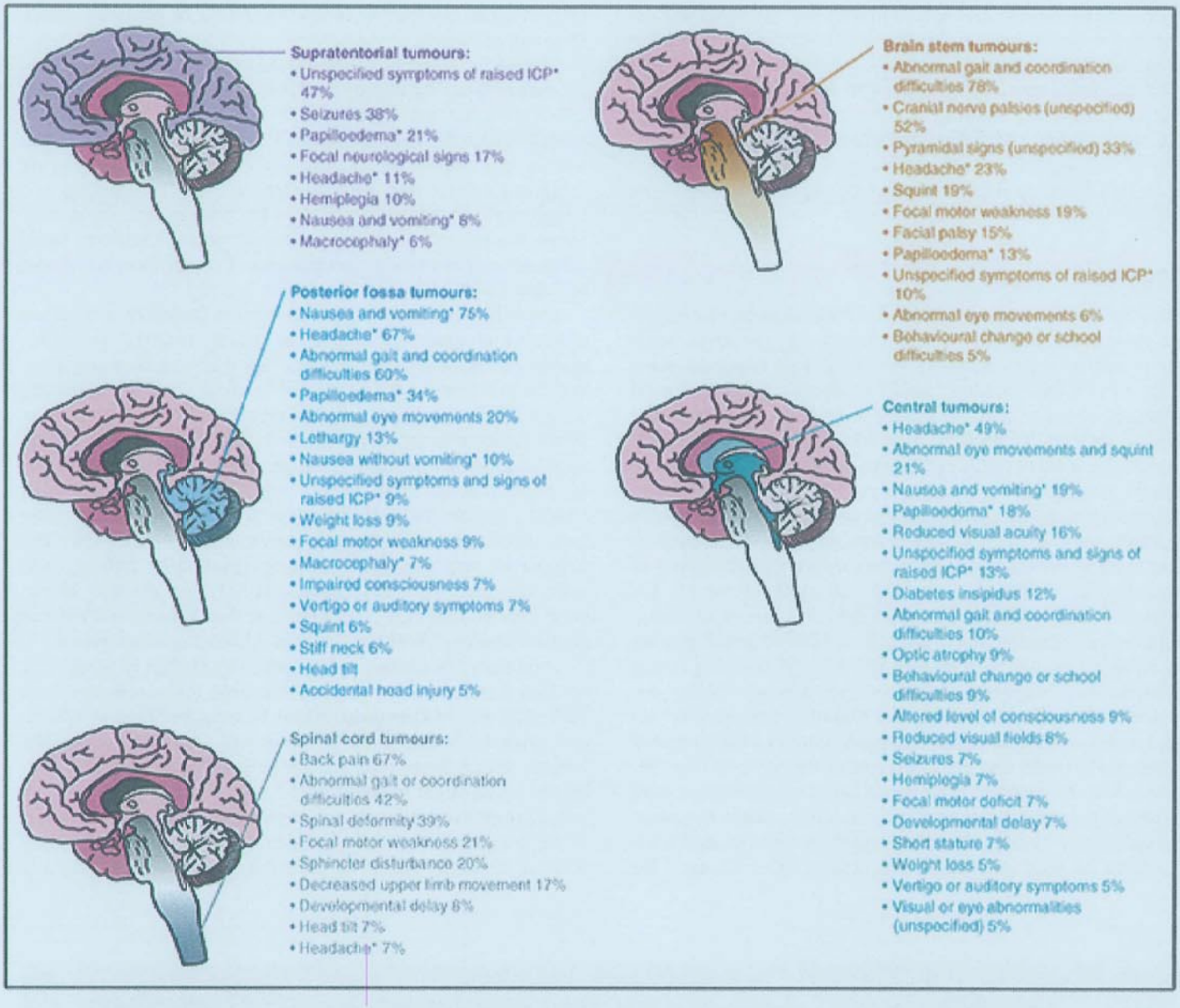

FIGURE 150.10 Symptoms of central nervous system tumors according to location. Abbreviation: ICP, intracranial pressure. (Source: Wilne S, Collier J, Kennedy C, Koller K, Grundy R, Walker D. Presentation of childhood CNS tumours: a systematic review and meta-analysis. *Lancet Oncol.* 2007;8:685-695.)

of having a brain tumor persists even 10 or more years after a clinical diagnosis of epilepsy.

Parietal lobe tumors affect reading ability and awareness of contralateral extremities (hemineglect). Occipital lobe tumors cause visual field disturbance and occasionally hallucinations. Suprasellar lesions may cause both visual field defects and endocrine dysfunction. The Parinaud syndrome (upgaze paresis and mild pupil dilatation with better reaction to accommodation than light, retraction or convergence nystagmus, and lid retraction) is found in pineal region tumors.

Infratentorial tumors, which predominate from ages 4 to 11 years, typically cause headache, vomiting, diplopia, and imbalance. Bilateral sixth cranial nerve palsy is a frequent sign of increased ICP. Brainstem tumors cause facial and extraocular muscle palsies, ataxia, and hemiparesis. Leptomeningeal spread occurs at diagnosis or recurrence in up to 15% of children with CNS tumors (more often in medulloblastoma or occasionally ependymoma) and may be asymptomatic or may cause pain, irritability, weakness, or bowel and bladder dysfunction.

Children with confirmed diagnosis of NF-1 have approximately 15% to 20% incidence of optic pathway gliomas, and require surveillance ophthalmologic examinations at least annually. Most optic pathway gliomas develop by age 6 years, when reliable ophthalmologic evaluation may be difficult, but MRI screening remains controversial. Indications for neuroimaging include vision change, new or worsening symptoms, and accelerated growth or precocious puberty. MRI screening of unselected NF-1 patients detected optic pathway gliomas in 18% at a median age of 3 years, of whom 15% had progression requiring therapy, particularly those with schismatic and postchiasmatic tumors. Patients with vision deficits at diagnosis were more likely to experience visual decline despite therapy when compared to presymptomatic

patients diagnosed by MRI. Children with negative brain and orbital MRI screening at age 15 months or later did not develop symptomatic optic pathway gliomas.

Brain tumors may also be discovered as incidental findings in children undergoing imaging for other reasons, without specific CNS signs. When radiologic characteristics suggest the possibility of a low-grade tumor, the accepted approach is interval follow-up. Further intervention may be required in about 10% of cases.

Diagnosis

MRI is the preferred imaging modality for evaluation of children with symptoms suggestive of brain tumor (eg, persistent headache of recent onset, morning vomiting) and abnormal signs on neurologic examination (head tilt, ataxia) or other clinical predictors of brain tumor (diabetes insipidus). CT may be the initial evaluation (especially if hydrocephalus or intracranial hemorrhage is suspected), but compared with CT, MRI is more sensitive (especially for nonenhancing, infiltrative tumors and leptomeningeal involvement), may generate images in any plane (eg, axial, coronal, sagittal), and is not compromised in the posterior fossa by bone artifact. Brain tumors are typically hypo- or isointense on T1-weighted imaging and hyperintense on T2-weighted imaging. Contrast enhancement is a feature of malignant tumors, reflecting blood-brain barrier disruption. Perfusion and diffusion sequences may also be useful in assessing tumor aggressiveness. Magnetic resonance spectroscopy (MRS) can provide additional information; for example, compared to benign tumors or normal brain, malignant tumors have increased choline peaks (reflecting increased membrane turnover) and decreased *N*-acetylaspartate (absence of functional neurons). MRI is repeated postoperatively to confirm extent of tumor resection, although it may be difficult to distinguish tumor from surrounding edema or residual tumor from postoperative changes; for these reasons, postoperative studies should be obtained within 48 hours of surgery.

MRI of the spine has replaced myelography as the standard procedure for evaluation of spinal cord tumors, drop metastases, and leptomeningeal disease. Spine MRI is required in cases of medulloblastoma, ependymoma, CPC, AT/RT, and pineal region tumors and should be obtained preoperatively if one of these diagnoses is suspected. Lumbar puncture for CSF cytology and tumor markers should also be done in children with these diagnoses. Recommended baseline and surveillance studies, based on tumor aggressiveness and patterns of recurrence, are shown in Table 150.4.

Guidelines for brain tumor assessment (based on evaluation of adult high grade gliomas) were updated in 2010 by the Response Assessment in Neuro-Oncology Working Group, replacing the previously used Macdonald criteria, and incorporating T2 and fluid-attenuated inversion recover (FLAIR) sequences to assess nonenhancing tumor growth. This partly addressed the issue of treatment-related tumor pseudoprogression in the first 12 weeks postradiation therapy, typically with new T2/FLAIR intensity within the high-dose treatment region (80% isodose line). Application of Response Assessment in Neuro-Oncology Criteria to pediatric neuro-radiology must take into account brain development, tumor heterogeneity, and variable blood-brain barrier integrity. The Response Assessment in Pediatric Neuro-Oncology Working Group is addressing these issues.

Treatment responses are determined by change in tumor size on MRI based on the most reproducible measurements from T2/FLAIR-weighted or postcontrast T1-weighted images, whichever gives the best estimate of tumor size. Measurements of the longest tumor dimension and its perpendicular should be recorded for all target lesions (up to 5) and any new lesions. In assessing response, lesions less than twice the combined thickness of the image slice and interslice gap are discounted, and cystic/necrotic elements and/or leptomeningeal disease are generally

TABLE 150.4 Baseline and Surveillance Studies in Children With Central Nervous System Tumors[a]

Diagnosis	Baseline Evaluation	Surveillance (Months From End of Treatment)
Medulloblastoma/PNET Posterior fossa ependymoma Germ cell tumor Atypical teratoid rhabdoid tumor Choroid plexus carcinoma	Brain/spine MRI Lumbar CSF	Brain MRI 3, 6, 9, 12, 16, 20, 24, 30, 36, 48, 60, and annually Spine MRI 12, 24,[a] 36, 48[a]
Brainstem glioma Supratentorial ependymoma	Brain/spine MRI Lumbar CSF (for ependymoma)	Brain MRI 4, 8, 12, 16, 20, 24, 30, 36, 48, 60, and annually Spine MRI 18,[a] 48[a]
Cerebellar low-grade astrocytoma Hypothalamic/optic glioma Cerebral low-grade glioma Oligodendroglioma Craniopharyngioma Choroid plexus papilloma	Brain MRI	Brain MRI 6, 12, 18, 24, 36, 48, 60, and annually
Cerebellar or cerebral high-grade astrocytoma	Brain MRI Spine MRI[b] Lumbar CSF[b]	Brain MRI 3, 6, 9, 12, 18, 24, 30, 36, 42, 48, 60, and annually Spine MRI 12,[a] 24,[a] 36,[a] 48[a]

Abbreviations: CSF, cerebrospinal fluid; MRI, magnetic resonance imaging; PNET, primitive neuroectodermal tumor.

[a]Source: Data from Kramer ED, Vezine LG, Packer RJ, Fitz CR, Zimmerman RA, Cohen MD. Staging and surveillance of children with central nervous system neoplasms: recommendations of the Neurology and Tumor Imaging Committees of the Children's Cancer Group. *Pediatr Neurosurg.* 1994;20:254-263.

[b]If residual or dissemination.

[c]If symptoms.

not measured. Enlargement or reduction of existing lesions should correlate with increase or decrease in two-dimensional measurement, but increased enhancement on T1 without increase in disease bulk on T2/FLAIR is not considered tumor progression, and decreased enhancement without decreased bulk on T2/FLAIR may represent altered contrast permeability rather than regression. Thus, complete or partial response requires disappearance or greater than 50% reduction of all target lesions, respectively, whereas 25% increase or the appearance of new lesions or newly positive CSF cytology indicates progressive disease. Imaging may be supplemented by positron emission tomography (PET), which characterizes metabolic abnormalities that distinguish high grade from low grade and residual or recurrent tumor from cerebral necrosis. Thallium 201 single-photon emission CT is sensitive for recurrent tumors, although MRS offers similar capability and is more widely available.

TREATMENT

Surgery

The mainstay of therapy for childhood brain tumors is surgery, which may be curative by itself in congenital, benign, and low-grade tumors. For example, pilocytic astrocytoma arising in the cerebellum can be completely or nearly completely resected in nearly all patients, and cerebral hemispheric low-grade tumors are often completely resectable. Gross total resection (no visible tumor at completion of surgery) or radical subtotal resection (95%-99% tumor removal) is generally attempted in malignant tumors and contributes to the cure rates of ependymoma and medulloblastoma (Fig. 150.11). Resection of a high-grade astrocytoma improves the otherwise guarded prognosis. Aggressive resection of low-grade astrocytomas in midline structures (hypothalamus, thalamus, brainstem, and spinal cord) can provide long-term disease control but with risk of neurologic sequelae.

The introduction of the operating microscope and ultrasonic aspirator has improved both the safety and effectiveness of surgery. Adoption of intraoperative MRI can improve the rate of tumor resection and may alter surgical strategy. The extent of resection should be confirmed by postoperative MRI. Radical resection is generally not attempted for infiltrative lesions deep in the thalamus, intrinsic to the brainstem, or in functionally eloquent areas; in these sites, surgery is typically limited to open or closed biopsy (<1% resection) or partial or subtotal resection (10%-49% and 50%-95% tumor removal, respectively). Advanced neuroimaging techniques, which may be useful for mapping eloquent regions include magnetoencephalography, diffusion tensor imaging, and functional MRI. Multiple biopsies may be useful in lesions appearing heterogeneous on MRI when major resection is not attempted. Some lesions can be approached using minimally invasive procedures, such as endoscopic third ventriculostomy. Stereotactic (eg, CT- or MRI-guided) techniques are used for biopsy or subtotal resection in difficult-to-reach areas such as the basal ganglia. However, even a 99% resection of a lesion that is 10 cm^3 in size will leave 10^8 tumor cells behind, and additional postoperative treatment will be necessary to prevent the lesion from regrowing.

Some lesions respond well to radiotherapy and/or chemotherapy, such that confirmatory biopsy is sufficient. For example, pineal region germinoma is highly sensitive to both radiation and chemotherapy, so radical resection should not be attempted, whereas choriocarcinoma (recognized by serum and CSF HCG elevation) and pineoblastoma require more substantial resection.

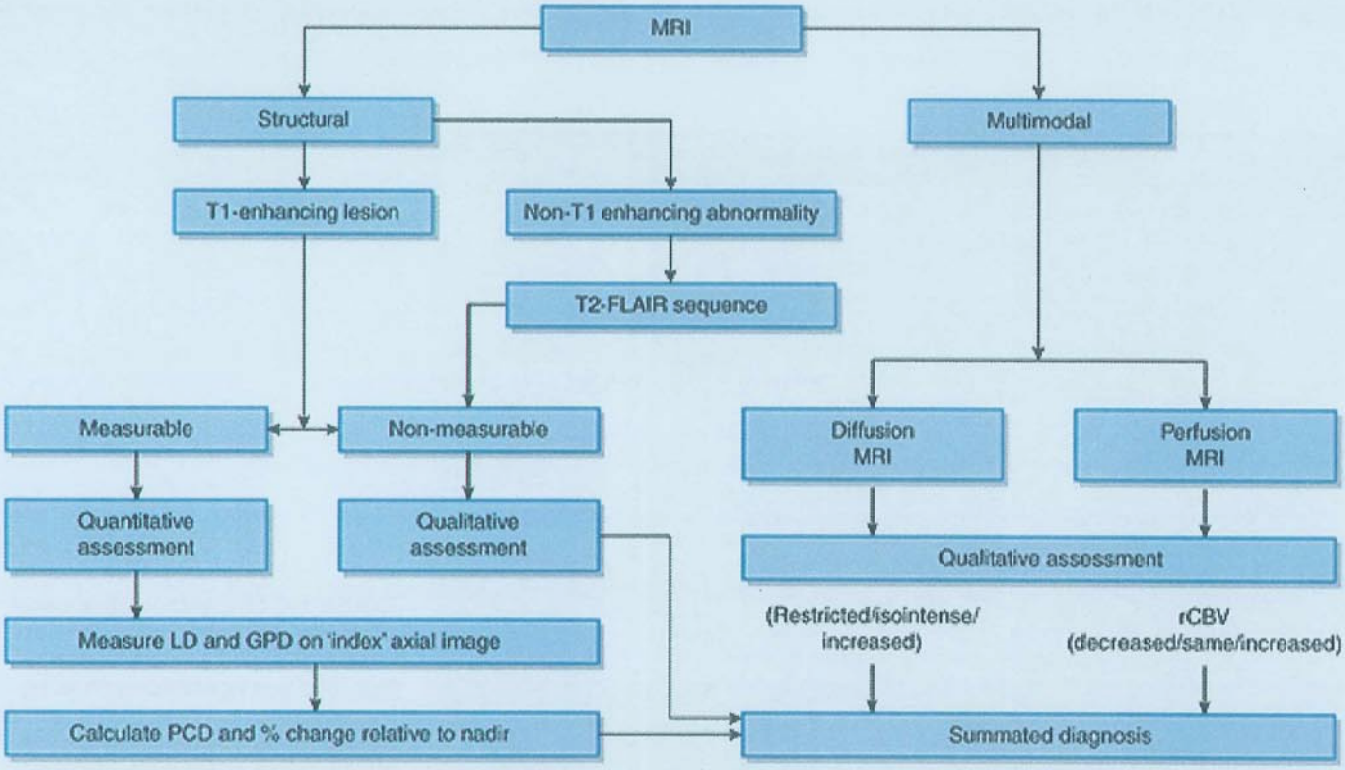

FIGURE 150.11 Tumor evaluation by magnetic resonance imaging (MRI). Abbreviations: FLAIR, fluid-attenuated inversion recovery; GPD, greatest perpendicular diameter; LD, longest diameter; PCD, product of cross-sectional enhancing diameters; rCBV, relative cerebral blood volume.

In addition to establishing a tissue diagnosis, surgery may be necessary for relief of obstructive hydrocephalus. With temporary placement of an external drain or endoscopic third ventriculostomy, followed by tumor resection, it may be possible to avoid the need for a permanent ventriculoperitoneal shunt in most patients.

Operative mortality is generally no more than 1%, but morbidity varies according to the site and extent of surgery and the condition of the child. A unique and increasingly recognized complication of midline posterior fossa tumor resection is the cerebellar mutism syndrome, consisting of diminished speech progressing to mutism, emotional lability, hypotonia, and ataxia. In two prospective trials for standard and high-risk medulloblastoma, cerebellar mutism was reported in 24% of children. In both cohorts, brainstem invasion by tumor was the only predictive feature. At 1 year from diagnosis, nonmotor speech/language deficits, neurocognitive deficits, and/or ataxia persisted in a substantial proportion of patients.

Surgery is facilitated by real-time neuronavigation, in which preoperative imaging is updated during surgery to account for anatomic shifts in the brain (Fig. 150.12). Surgery may also be facilitated by intraoperative monitoring of sensory and other evoked potentials.

Adjunctive measures include the use of corticosteroids, which counteract tumor edema and are often used in the perioperative period but should be tapered within 1 to 2 weeks, if possible. Patients undergoing surgery for supratentorial tumors are placed on anticonvulsants if they have had seizures or if the surgical approach is likely to cause seizures. Prophylactic anticonvulsants are generally continued for 1 week to 12 months.

Patients may be referred for second look surgery following subtotal resection and interim chemotherapy. This approach is incorporated into protocols for newly diagnosed ependymoma. Patients with symptomatic recurrence are also referred for reoperation, particularly with the possibility of clonal evolution (as in medulloblastoma) or to provide tissue for molecular testing to identify potential therapeutic targets.

Radiation Therapy

Radiation therapy is used for nearly all malignant CNS tumors and for some low-grade lesions as well, particularly at recurrence or progression. Based on standard x-ray (photon) therapy, doses typically administered to achieve local control range from 45 to 55 Gy, in divided fractions of 150 to 200 cGy, to the tumor as localized on MRI plus 1- to 2-cm margin. Higher doses may be given, often in smaller twice-daily doses (eg, hyperfractionated technique), but with high total doses, there is increased risk of injuring normal brain tissue. The volume irradiated depends on tumor histology and may include an involved field or whole brain and spine. Presymptomatic craniospinal irradiation is almost always given for medulloblastoma because of its propensity to disseminate throughout the neuraxis. Doses of 36 Gy have been used conventionally, but lower doses (23.4 Gy and possibly 18 Gy) are adequate in standard-risk patients if supplemented with adjuvant chemotherapy.

Newer radiotherapy techniques may increase the effective tumor dose and limit toxicity to the surrounding brain. *Three-dimensional conformal radiation therapy* allows tailoring of treatment to the actual tumor volume rather than arbitrary compartments such as the whole posterior fossa. *Stereotactic irradiation* techniques with arc photons, in conjunction with rigid head fixation systems, permit single high-dose delivery (eg, radiosurgery), which may be useful for management of recurrent lesions in previously irradiated patients. *Intensity-modulated radiation therapy* uses combinations of variable intensity fields from different beam directions to maximize tumor dose while minimizing dose to adjacent normal tissues. *Proton therapy* takes advantage of the superior physical properties of protons compared to

FIGURE 150.12 Intraoperative panel of images in 13-year-old male with left occipital pilocytic astrocytoma. This child was operated upon using frameless stereotaxy and intraoperative neuronavigation to ensure complete removal of his lesion. (Source: Nejat F, El Khashab M, Rutka JT. Initial management of childhood brain tumors: neurosurgical considerations. *J Child Neurol*. 2008;23:1136-1148.)

photons, with limited penetration of particles beyond the tumor target, less tissue scatter, and little lateral dispersion. Early applications of proton therapy included ocular melanoma and skull base tumors, but the possibility of comparable tumor control with substantially decreased dose to adjacent normal tissues makes the technique potentially advantageous for many pediatric indications. *Interstitial radioactive implants (brachytherapy)* may be appropriate in some cases. Use of *radiation sensitizers*, including chemotherapy agents (carboplatin, capecitabine, tipifarnib) and gadolinium derivatives, is currently under study.

Acute side effects of radiation therapy include headache, nausea, alopecia, skin hyperpigmentation and desquamation, and a transient "somnolence syndrome," occurring 4 to 8 weeks after treatment. Radiation-associated imaging changes such as pseudoprogression and radiation necrosis must be distinguished from true tumor progression with convincing 25% volume increase and/or appearance of disease in previously uninvolved locations. Radiation therapy to large volumes is problematic in infants and toddlers because of increased neurocognitive sequelae. Dose-intensive chemotherapy may be used to defer irradiation, or involved field treatment with supplemental chemotherapy may be substituted for whole-brain irradiation (as in medulloblastoma). Radiation therapy is deferred in patients with NF-1 in favor of chemotherapy because these patients may have increased susceptibility to radiation toxicity and second malignancies.

Chemotherapy

Chemotherapy is used as an adjunct to radiotherapy and as postradiation maintenance therapy in medulloblastoma and high-grade astrocytomas as neoadjuvant therapy in chemotherapy-sensitive tumors (eg, CNS germ cell tumors), as primary postsurgical treatment in infants, and in recurrent tumors. Effective agents include the nitrosoureas (eg, carmustine, lomustine), vincristine, cisplatin, carboplatin, etoposide, and cyclophosphamide. Temozolomide appears promising, although response rates in phase II trials have been relatively low. Chemotherapy is generally given systemically and in combination because of complementary mechanisms of action of different agents and to subvert potential tumor resistance. The effectiveness of systemically administered chemotherapy is limited by the blood-brain barrier. Regional delivery of drugs (eg, intra-arterial, intrathecal, intratumor) potentially circumvents this problem, and responses to intra-arterial carboplatin- or methotrexate-based chemotherapy with osmotic blood-brain barrier disruption are reported for germ cell tumors and primary CNS lymphoma. The dose intensity of conventional, systemic chemotherapy may be increased with the use of hematopoietic growth factors, which shorten the period of myelosuppression and permit the use of higher doses or shorter intervals between treatments. A related approach is the use of extremely high doses of chemotherapy, supported by autologous hematopoietic stem cell rescue, and this approach has been used for chemotherapy-sensitive recurrent tumors or as an intensive consolidation therapy for infants.

The role of adjuvant cisplatin-based chemotherapy following radiation is well established for childhood medulloblastoma and pineoblastoma. For standard-risk medulloblastoma, use of chemotherapy permits reduction in the dose of radiotherapy. Dose-intensive cyclophosphamide-based chemotherapy has been used following radiation therapy for standard- and high-risk medulloblastoma with the goal of reducing exposure to cisplatin. For high-grade astrocytomas, temozolomide is used routinely with and following radiation therapy, as in adults. Preirradiation chemotherapy is being tested in CNS germ cell tumors ependymoma but has been generally ineffective in medulloblastoma and high-grade astrocytomas, including brainstem tumors, presumably because of delaying definitive radiation therapy.

In very young patients (infants and toddlers younger than age 3-4 y) with malignant brain tumors, dose-intensive chemotherapy is commonly used postoperatively with the goal of deferring or avoiding radiation therapy. This approach appears effective in medulloblastoma and AT/RT. Intrathecal therapy (intraventricular and intralumbar methotrexate) has also been advocated for medulloblastoma in a protocol designed to avoid radiation therapy.

Chemotherapy is commonly used for recurrent CNS tumors, and patients may receive additional irradiation as well. High-dose chemotherapy with stem cell rescue may offer effective salvage therapy for recurrent medulloblastoma at least when combined with radiation therapy in younger previously unirradiated patients. Established and newer chemotherapy agents can be tested against panels of childhood brain tumor xenografts. Doses of certain chemotherapy agents such as irinotecan may require adjustment if patients are also receiving hepatic enzyme–inducing anticonvulsant drugs such as phenytoin, phenobarbital, carbamazepine, and Mysoline (primidone).

Biologic agents in clinical trials for recurrent CNS tumors include differentiation agents (retinoic acid), agents targeting tumor growth factor receptors (erlotinib, gefitinib, imatinib, lapatinib), farnesyltransferase inhibitors (tipifarnib), agents interfering with angiogenesis (bevacizumab, cilengitide, lenalidomide), histone deacetylase inhibitors (suberoylanilide hydroxamic acid, valproic acid), heat shock protein inhibitors (17-allylaminogeldanamycin), and DNA repair enzyme inhibitors (O^6-benzylguanine).

With detailed identification of gene mutations and fusions by DNA tumor whole exome sequencing and RNA methylation array, it is possible to tailor "targeted" therapy to entire molecular pathways, taking into account downstream targets. For example, vemurafenib targets *BRAF V600E* mutation in ganglioglioma, but not *KIAA1549-BRAF* fusion, which is more frequent in pilocytic astrocytoma; in the latter situation, an alternative treatment strategy is downstream inhibition of MEK by trametinib.

Immunotherapy would be an attractive option for treatment of pediatric CNS tumors but remains an elusive goal. Convection-enhanced delivery of chemotherapy and immunotoxin conjugates are currently being evaluated. Certain glioma-associated antigens are overexpressed on pediatric brainstem and nonbrainstem gliomas and could be suitable targets for vaccine strategies.

SPECIFIC TYPES OF PEDIATRIC CENTRAL NERVOUS SYSTEM TUMORS

Congenital Tumors

Craniopharyngioma

Craniopharyngioma originates from embryonic tissue rests located in the Rathke pouch, which later forms the anterior pituitary gland. Craniopharyngioma may appear clinically at any age, even later adulthood, and constitutes 6% to 10% of intracranial tumors in children. Craniopharyngiomas vary from small,

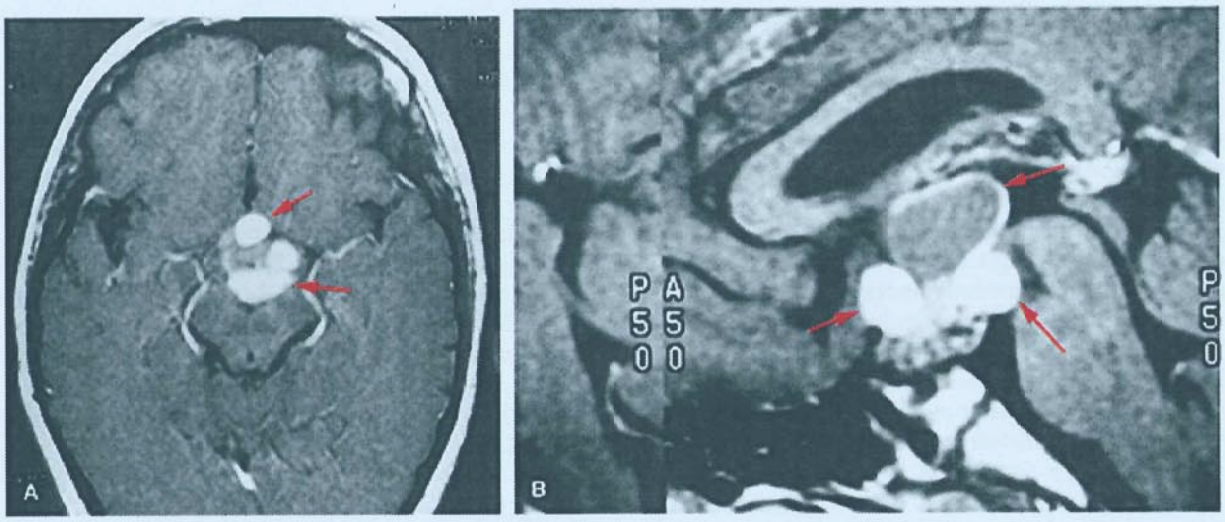

FIGURE 150.13 Axial (A) and sagittal (B) magnetic resonance imaging of a craniopharyngioma.

well-circumscribed, solid nodules to huge, multilocular cysts invading the sella turcica. The cysts are filled with turbid fluid that may contain cholesterol crystals. Clinical manifestations include short stature, hypothyroidism, and diabetes insipidus, with vision loss and signs of increased ICP. CT is useful for demonstrating calcification and bony expansion of the sella, but MRI is preferred for better definition of the relationship of the tumor to neighboring vessels, optic chiasm and nerves, and the hypothalamus (Fig. 150.13).

Craniopharyngiomas are histologically benign and may be categorized as mucoid epithelial cysts, squamous epitheliomas, or adamantinomas; the latter is the most frequent in children. Activating β-catenin (CTNNB1) gene mutations are found in most adamantinomatous tumors. Total surgical removal may be difficult because the tumor can invade the hypothalamus or third ventricle and adhere to optic nerves or blood vessels. A conservative approach is to drain the cyst and resect nonadherent tumor and then administer radiation therapy to the involved area. For children younger than 3 years, it may be preferable to defer resection by implanting an intracystic catheter with subcutaneous reservoir for serial cyst fluid drainage. Definitive treatment options are complete resection or subtotal resection with radiation therapy. In addition to the standard transsphenoidal approach for small tumors, there is renewed interest in the endonasal approach with endoscopic visualization as an alternative to craniotomy. Recurrence rates at 5 years after complete resection or subtotal resection with irradiation are similar in pediatric series (10%-20%). Radical surgery is likely to be accompanied by panhypopituitarism, necessitating lifelong hormonal replacement therapy, whereas irradiation has lesser hormonal sequelae but causes cognitive deficits, especially in younger children. Focused treatment by stereotactic radiosurgery (eg, Gamma Knife), especially at recurrence, may be advantageous in this regard. Interferon alfa-2a and pegylated interferon alfa-2b have been used in recurrent craniopharyngiomas.

The other type of pituitary tumor is adenoma, which is rare in childhood but increasingly frequent in adolescents and common in adults (up to 5% incidence in autopsy series). Adenomas may be associated with Cushing disease, hyperprolactinemia, and acromegaly. Functioning adenomas in childhood are most often ACTH-producing, whereas prolactinomas are most frequent in adolescents. Pituitary adenomas are usually sporadic but may be manifestations of genetic conditions such as multiple endocrine neoplasia type 1, Carney complex, familial isolated pituitary adenoma, and McCune-Albright syndrome. Initial treatment is with dopamine agonists such as bromocriptine, whereas surgery is reserved for symptomatic tumors causing hydrocephalus or vision loss. Surgery is indicated for asymptomatic arachnoid cysts causing obstructive hydrocephalus or seizures; options include cystectomy, fenestration, or cyst-peritoneal shunting.

Epidermoid Cysts

Epidermoid cysts (cholesteatomas) account for about 2% of all intracranial tumors. They arise within skull tables or adjacent to the dura usually in the suprasellar region, skull base, brainstem or cerebellopontine angle, or within a ventricle. They arise from epithelial cells retained during neural tube closure, have a pearly appearance, and may contain cyst fluid with cholesterol crystals. Clinical onset is usually in young adulthood, with hearing loss, hemifacial spasm, or trigeminal neuralgia. MRI demonstrates a lesion with low T1- and high T2-weighted signal intensity (Fig. 150.14); involvement of multiple cranial nerves and the internal carotid artery is common. Treatment is surgical resection with radical removal of the tumor capsule.

Dermoid tumors are also cystic, and sebaceous gland secretions impart a dark yellow color to the cyst fluid. Intracranial dermoids are associated with Goldenhar syndrome (ie, oculo-auriculo-vertebral dysplasia). Treatment is surgical resection. Epidermoid and dermoid cysts occasionally undergo malignant transformation into squamous cell carcinoma.

Arachnoid cysts are also in the differential of extra-axial cystic lesions. Arachnoid cysts result from focally impaired CSF flow and cystic dilatation of subarachnoid spaces, typically in the sylvian fissure, presenting with headache and occasionally seizures. MRI can be helpful in distinguishing arachnoid cysts from epidermoid cysts. CSF signal is seen in both; gut epidermoid cysts show hyperintense FLAIR signal and reduced diffusion on diffusion-weighted imaging, whereas arachnoid cysts have low signal on FLAIR and diffusion-weighted imaging (unless containing proteinaceous fluid or blood). A large cisterns magna (either a normal variant or associated with Dandy-Walker

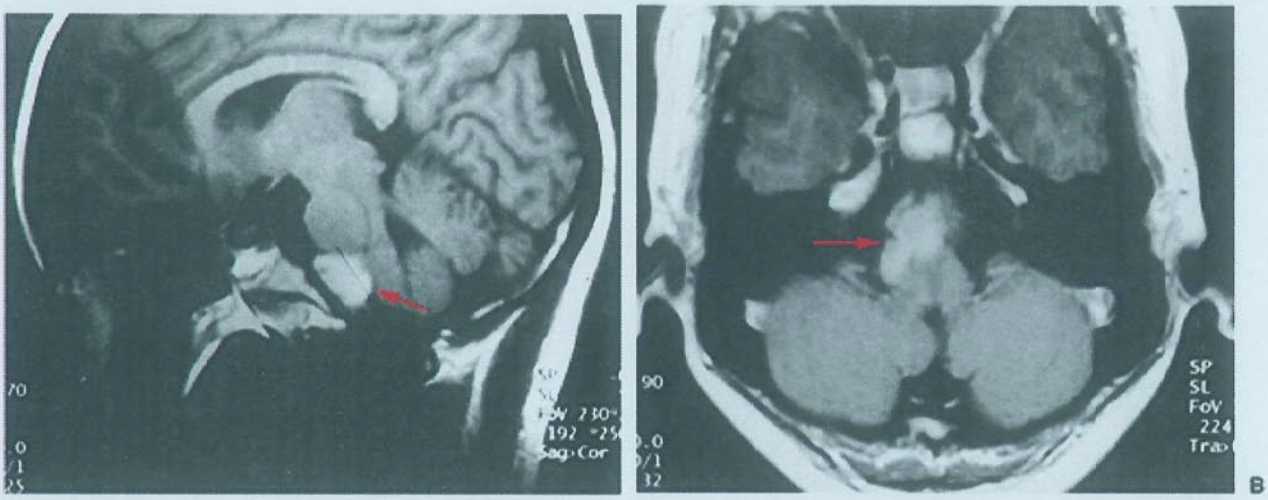

FIGURE 150.14 Sagittal **(A)** and axial **(B)** magnetic resonance imaging of a pontomedullary epidermoid cyst.

syndrome) may resemble an arachnoid cyst but does not cause mass effect on the cerebellum and vermis. Surgery is indicated for asymptomatic arachnoid cysts causing obstructive hydrocephalus or seizures; options include cystectomy, fenestration, or cyst-peritoneal shunting.

Teratoma and Chordoma

Teratomas are composed of cells originating from at least two and usually all three embryonic layers: ectoderm, mesoderm, and endoderm. Extragonadal teratomas occur in infants as sacrococcygeal tumors. Intracranial teratomas have also been reported in infants, usually supratentorial or intraventricular, presenting with macrocephaly. Posterior fossa immature teratoma in an infant with trisomy 21 has been reported. Although rare, teratoma is the most frequently intracranial tumor encountered at birth and may be detected on fetal ultrasound. Infant MRI reveals a large cystic and solid contrast-enhancing mass, which may contain fat and calcifications. Extra-axial teratomas may arise in the pineal or suprasellar region in older children. Teratomas may be classified as mature, immature, or mature with malignant transformation. Treatment is surgical resection, but prognosis for immature and transformed teratomas is guarded, and adjuvant chemotherapy may be considered.

Chordomas develop from remnants of the embryonic notochord. Half are in the sacrococcygeal region, one-third at the sphenoid-occipital junction, and the remainder elsewhere along the spinal column. They are rare, accounting for less than 1% of CNS tumors, and usually remain asymptomatic until adulthood. These tumors are locally invasive and cause vision loss or cranial nerve dysfunction. They may invade the nasopharynx or intracranial sinuses and may extend into the neck causing torticollis. Childhood chordoma can be associated with tuberous sclerosis.

Chordomas have a smooth, nodular surface that resembles cartilage; the characteristic histologic feature is the presence of large masses of physaliferous cells and round or polygonal cells arranged in cords and having large cytoplasmic vacuoles containing mucin. Chordomas grow slowly but may recur after excision. A malignant variant is distinguished by mitotic spindle cells and may metastasize to the lung. Chordoma should be suspected in a patient presenting with multiple cranial nerve palsies or erosion of the skull base. Treatment is surgical resection, although gross total resection is rarely achieved. Radiation therapy may be used postoperatively or at recurrence. Proton radiotherapy is advocated because it may confer effective local control and possibly better cosmetic outcome than with conventional irradiation. There has been no defined role for chemotherapy in chordoma, but loss of SMARCB1/INI1 protein in poorly differentiated chordomas has been reported, associated not with point mutations but with SMARCB1/INI1 gene deletions instead, potentially targetable by the EZH inhibitor tazemetostat.

Choroid Plexus Tumors

Choroid plexus tumors are rare congenital tumors arising in the choroid plexus of the lateral or fourth ventricles. They may cause symptoms shortly after birth, and most are diagnosed before age 2 years. The first manifestation is likely to be macrocephaly resulting from hydrocephalus, with bulging fontanelle and split sutures noted in infants. Excess CSF production arising from the tumor may approach 2,000 mL/d.

The majority are choroid plexus papillomas (CPPs; WHO grade I), slowly growing hamartomatous lesions that extend into a ventricle and tend not to be invasive. CPPs may arise in Aicardi syndrome, Down syndrome, von Hippel-Lindau disease, and NF-2. Papillomas are often calcified on CT scan and enhance with contrast; they must be distinguished in the infant age group from ependymomas, which lack calcification. Atypical papillomas (WHO grade II) have a higher growth fraction (mitotic rate by MIB-1 >2%). Total excision of localized lesions may be curative and stops the excessive CSF production, but malignant transformation of incompletely resected papillomas has been reported.

CPCs (WHO grade III) typically arise in a lateral ventricle and invade the brain parenchyma with development of hydrocephalus (Fig. 150.15). Hydrocephalus may result from obstruction of normal CSF flow, overproduction of CSF by the tumor itself, local expansion of the ventricles, or spontaneous hemorrhage. CPCs are more heterogeneous than CPPs on imaging due to focal necrosis and surrounding vasogenic edema; in nearly half of cases, there is dissemination in the leptomeninges.

According to the 2016 WHO criteria, CPC must harbor at least four of the five following characteristics: elevated mitotic activity (generally >5 mitoses per 10 HPF), hypercellularity,

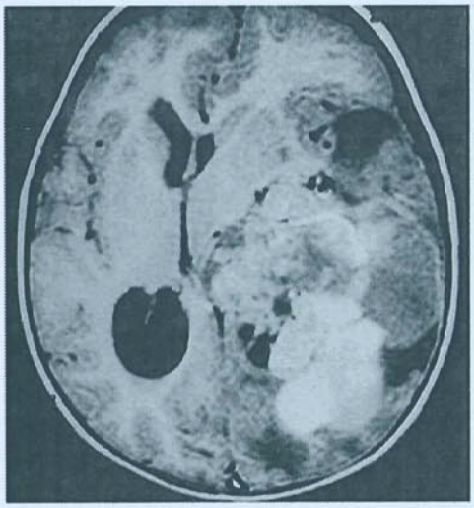

FIGURE 150.15 Magnetic resonance imaging of a choroid plexus carcinoma of the lateral ventricle with parenchymal invasion.

nuclear pleomorphism, solid growth with sheets of tumor cells, and necrosis. Extensive invasion into the surrounding brain parenchyma is a frequent finding.

Immunohistochemistry of CPP and CPC shows positivity for pancytokeratin, with variable positivity for S-100, GFAP, and synaptophysin. E-cadherin is positive in most choroid plexus tumors, distinguishing them from ependymomas, which are typically negative. Platelet-derived growth factor (PDGF) receptors may be overexpressed or amplified in some CPCs. CPC may be a manifestation of Li-Fraumeni syndrome or rhabdoid predisposition syndrome, and evidence should be sought for germ line mutation in TP53 or hSNF5/INI1/SMARCB1, respectively. Cells with a rhabdoid morphology are not uncommon in CPCs, and such tumors need to be differentiated from AT/RT, for example, by p53 positivity and retained nuclear INI-1 (BAF-47) reactivity. Differences in gene copy number, gene expression, and DNA methylation signatures distinguish CPCs from CPPs and atypical CPP; however, molecular similarities among the papillomas suggest that these two histologic subgroups are indeed a single molecular entity. A greater number of copies of mutated TP53 were significantly associated with increased tumor aggressiveness and a worse survival outcome in CPCs.

CPPs may be cured by surgery alone, with 5-year survival of 80% to 100% following gross total resection and 60% to 70% following subtotal resection. Atypical CPP has increased risk of local recurrence, and, in the CPT-SIOP-2000 study, infants with incompletely resected atypical CPP were given adjuvant chemotherapy with 97% survival at 5 years.

CPCs behave aggressively with a tendency for leptomeningeal dissemination and local recurrence. Adjuvant chemotherapy and/or irradiation is generally given, even following apparent gross total resection, owing to their invasiveness and guarded prognosis (median survival 6 mo in one series). For patients undergoing subtotal resection of CPCs, or with leptomeningeal dissemination at presentation, both carboplatin-based chemotherapy and focal or craniospinal irradiation are recommended as per the CPC-SIOP-2000 study. The benefit of chemotherapy was shown in a meta-analysis demonstrating superior survival with addition of chemotherapy, even in nonirradiated patients and patients with incomplete tumor resection (2-y OS 54% vs 24% without chemotherapy). A more recent single institution experience demonstrated 71% 5-year survival at 5 years in CPC patients treated with the chemotherapy and irradiation following maximal surgery, and the improved outcome with combined modality treatment was confirmed in another meta-analysis. PDGF receptor signaling has been suggested as a potential therapeutic target.

Colloid Cysts

Colloid cysts arise presumptively from the anlage of the paraphysis. These lesions grow in the anterior superior portion of the third ventricle as small, white cysts filled with homogeneous, gelatinous material. They do not usually cause symptoms until adulthood when there may be intermittent hydrocephalus causing unexplained headache. Although quite rare in children, colloid cysts should be considered in the differential diagnosis of persistent headache. Disturbance of the limbic system may cause emotional and behavioral changes in some instances. Colloid cyst of the third ventricle may be identified at autopsy in cases of unexplained death, including in adolescents and young adults. Colloid cysts are T2 hyperintense on MRI without enhancement. The treatment of choice is radical removal by open or stereotypically guided microsurgery. Other options are stereotactic cyst aspiration, ventriculoperitoneal shunting, transcortical/transcallosal resection, and endoscopic removal and marsupialization.

Ganglioglioma and Related Glioneuronal Tumors

Gangliogliomas are rare, glioneural tumors that account for 2.5% of pediatric brain tumors. The peak age incidence is 10 to 20 years. They arise mainly in the temporal lobe but also in other cerebral lobes or spinal cord. The usual prodrome is a long history of refractory epilepsy. Imaging reveals a solid to cystic lesion with calcification on CT and hypometabolic activity on PET. The majority harbor BRAF V600E mutation, novel variants, or BRAF fusions, occasionally with CDKN2A homozygous deletion.

Total surgical resection is recommended, and prognosis for long-term seizure control is excellent. Malignant transformation to glioblastoma may follow incomplete resection. Radiation therapy and chemotherapy are of uncertain benefit. Vemurafenib has been used in BRAF-mutant ganglioglioma, with addition of cobimetinib to overcome resistance.

Desmoplastic infantile ganglioglioma (DIG) is a rare cerebral glioneural tumor of early childhood. DIGs are large hemispheric tumors that are generally benign, but deep lesions may be aggressive. Treatment is resection. Related glioneural tumors include desmoplastic astrocytoma of infancy and pleomorphic xanthoastrocytoma (PXA), which usually occur in the temporal lobe in adolescents and young adults. PXA (grade II) and anaplastic PXA (grade III, with requirement for more than 5 mitoses per 10 HPF) typically present with seizures and headache. These tumors enhance on MRI, are GFAP and S100 positive, and variably express neuronal markers such as synaptophysin. They may contain BRAF fusions. Treatment is surgical resection. Response to targeted therapy has been reported in DIG with BRAF alteration.

Dysplastic Gangliocytoma

Dysplastic gangliocytoma of the cerebellum (Lhermitte-Duclos disease) is a rare, benign hamartomatous entity characterized by

loss of normal cerebellar cortical architecture and may be associated with macrocephaly and mental retardation. The tumor may present in children or young adults, with cerebellar signs such as dysmetria and ataxia. MRI appearance is a well-circumscribed lesion with characteristic laminar pattern of alternating high and low T2 signal. Pathologically there is diffuse enlargement of the internal granular layer and molecular layers of the cerebellum, with replacement of the internal granular layer by dysplastic ganglion cells and axonal hypermyelination of the molecular layer. The dysplastic ganglion cells are synaptophysin positive with loss of PTEN protein expression and AKT and S6 phosphorylation, indicative of AKT/mTOR pathway activation. The lesions are generally incompletely resectable, so patients with worsening symptoms may be considered for mTOR inhibitors. The disorder has been linked with Cowden disease (autosomal dominant familial hamartoma syndrome, with increased risk of breast, uterine, and thyroid cancer). Cowden disease is characterized by germ line abnormalities in the PTEN/AKT pathway, specifically in the PTEN tumor suppressor gene. Adult-onset Lhermitte-Duclos disease is a major diagnostic criterion for Cowden disease. Successful treatment with rapamycin has been reported in an infant with Lhermitte-Duclos disease.

Dysembryoplastic Neuroepithelial Tumor

DNT is a rare, low-grade (WHO grade I), mixed neuronal and glial tumor often associated with intractable seizures in children and young adults. DNTs comprise up to 17% of underlying diagnoses in epilepsy surgery series. Cortical dysplasia is found in 30% of cases. Enhancement on MRI is patchy and multifocal; perfusion-weighted MRI and MRS may aid in diagnosis. Unlike other epilepsy-associated glioneuronal tumors, where seizures arise within the lesion, seizures associated with DNT are considered to arise from the surrounding dysplastic brain; thus, extended resection is preferred over lesionectomy alone. Risk factors for recurrent seizures include age older than 10 years and epilepsy duration more than 2 years prior to diagnosis.

Schwannoma (Neurilemmoma)

These tumors arise in Schwann cells that surround and insulate nerves, particularly the eighth cranial nerve (vestibular schwannoma or acoustic neuroma), thereby affecting balance and hearing. Schwannomas may also develop on exiting spinal nerves, resulting in cord compression. Schwannomas are rare in children and especially if bilateral should prompt investigation for NF-2. Treatment options include surgery and stereotactic irradiation.

Hearing loss is a serious complication of NF-2, and there is a need for medical treatments. Based on vascular endothelial growth factor (VEGF) expression in vestibular schwannomas, VEGF blockade with bevacizumab was shown to improve hearing in some patients associated with volume reduction in growing schwannomas. A follow-up study (including adolescents) showed durable responses in one-third of patients, and a VEGF receptor (VEGFR) peptide-directed vaccine capable of inducing VEGFR-specific cytotoxic T lymphocytes is in clinical trials.

Astrocytoma

Low-Grade Astrocytoma

Low-grade astrocytomas (WHO grades I and II) include superficial lesions in the cerebral or cerebellar cortex and deeper infiltrative lesions of the optic pathways and midbrain. Cerebellar astrocytomas constitute about one-third of posterior fossa tumors. The peak incidence is early in the second decade. These tumors arise most often in the lateral cerebellar hemispheres rather than in the vermis. Symptoms of clumsiness and unsteadiness may be present for months and eventually are accompanied by intermittent morning headache and vomiting. Midline lesions have a shorter symptom interval. Truncal ataxia, dysmetria, and papilledema are usually present at diagnosis. Head tilt may be present, but other cranial nerve palsies or long-tract signs are infrequent and suggest brainstem invasion. Cerebellar astrocytomas may be primarily cystic or solid, and cystic lesions may have a nodule (Fig. 150.16).

The typical juvenile pilocytic astrocytoma (WHO grade I) contains areas of compact fibrillated cells with microcysts and eosinophilic structures called *Rosenthal fibers*. These lesions have greater than 90% survival with surgery alone. The tumor and associated cyst should be removed completely, and if residual tumor is identified postoperatively, re-resection should be considered because irradiation will not delay tumor progression. Diffuse astrocytomas (WHO grade II) may infiltrate the brainstem and be more difficult to resect entirely, with more guarded prognosis for survival.

Cerebral hemisphere low-grade gliomas have a peak incidence between ages 2 and 4 years and again in early adolescence. In toddlers, there may be symptoms of increased ICP, developmental delay, and growth retardation and specific signs such as weakness, sensory loss, or vision deficit. These slow-growing pediatric tumors are far less likely than adult gliomas to undergo malignant degeneration. They are infiltrating, however, and may cause seizures, either generalized or focal, the latter particularly suggestive of an occult brain tumor such as a ganglioglioma.

CT often reveals a relatively homogeneous, low-density, variably enhancing lesion with indistinct margins. MRI is more sensitive, showing decreased T1- and increased T2-weighted signal and providing better resolution of tumor and edema. Fibrillary astrocytomas (WHO grade II) are the most frequent histologic variant; protoplasmic and gemistocytic variants are less common. Gross total resection often affords long-term disease control but may not be curative. Five-year survival rates are 75% to 85%. Radiation therapy at doses of 50 to 55 Gy may be given

FIGURE 150.16 Magnetic resonance imaging showing lateral location of a partly cystic partly solid cerebellar astrocytoma.

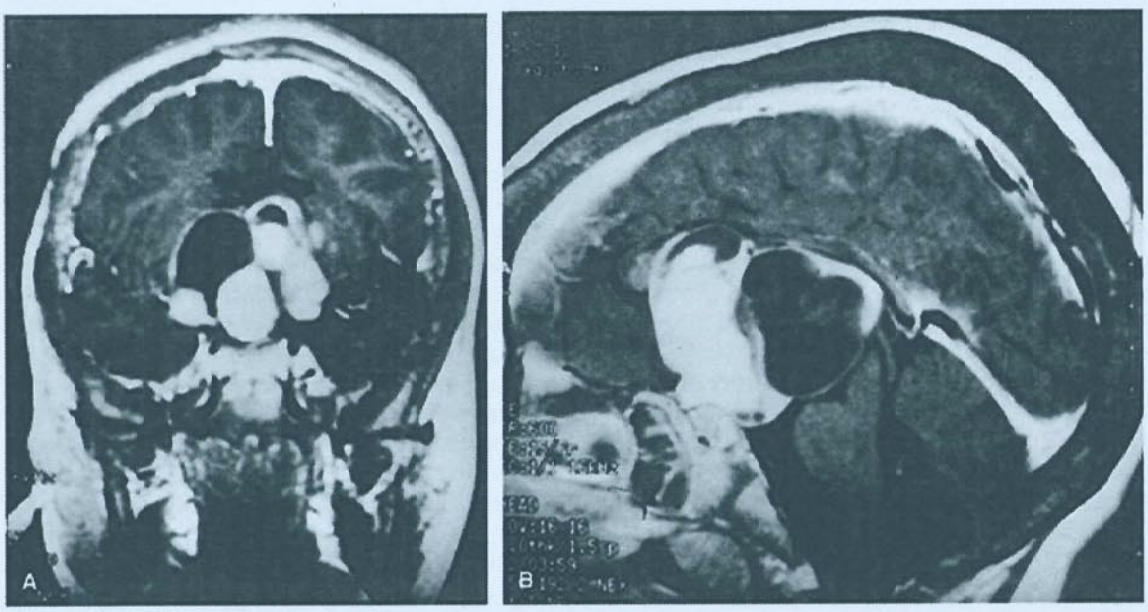

FIGURE 150.17 Coronal (A) and sagittal (B) magnetic resonance imaging of a large hypothalamic glioma.

postoperatively following incomplete resection or at progression at least in older children but reoperation should also be considered. For younger children with residual or recurrent tumor, chemotherapy (eg, vincristine and carboplatin) has been used in an attempt to defer radiotherapy, and prospective trials evaluating this approach are in progress.

Diencephalic and optic pathway gliomas constitute up to 5% of childhood CNS tumors. Unilateral optic nerve tumors are generally diagnosed in the first decade of life, and optic chiasm tumors tend to present either in infancy or the second decade. An association with NF-1 is present in 50% to 70% of patients with isolated optic nerve tumors and 10% to 20% of patients with optic chasm tumors. Adolescents are more likely to complain of slowly progressive vision loss. Infants are more likely to be evaluated because of strabismus, nystagmus, or developmental delay. Patients with contiguous optic nerve involvement usually present with proptosis and optic pallor or atrophy. Intraorbital lesions usually cause decrease in central vision, whereas chiasmatic tumors produce bitemporal hemianopic field cuts. Nystagmus may be present in the more involved eye, and amblyopia is common. With routine MRI of NF-1 patients, lesions may be detected before onset of symptoms. There may be endocrine disturbances, such as growth deceleration, precocious puberty, and diencephalic emaciation.

Thalamic lesions may cause acute hemiparesis or hemisensory loss, signs of increased ICP, seizures, or involuntary movements. Infants tend to have macrocephaly, psychomotor delay, and vision deficits. Hypothalamic tumors have insidious onset and may be associated with altered mental status, endocrine dysfunction, and focal neurologic deficits.

On CT or MRI, diencephalic gliomas are hypo- or isodense lesions with variable contrast enhancement. Larger lesions may be cystic (Fig. 150.17). Visual pathway tumors may be confined to the optic chiasm (Fig. 150.18) or may show abnormal enhancement along the optic tracts and radiations. This streaking phenomenon is best appreciated on MRI, particularly with FLAIR sequence. Most diencephalic tumors are low-grade pilocytic astrocytomas.

An increasingly recognized variant in infants and young children is pilomyxoid astrocytoma, a locally aggressive tumor

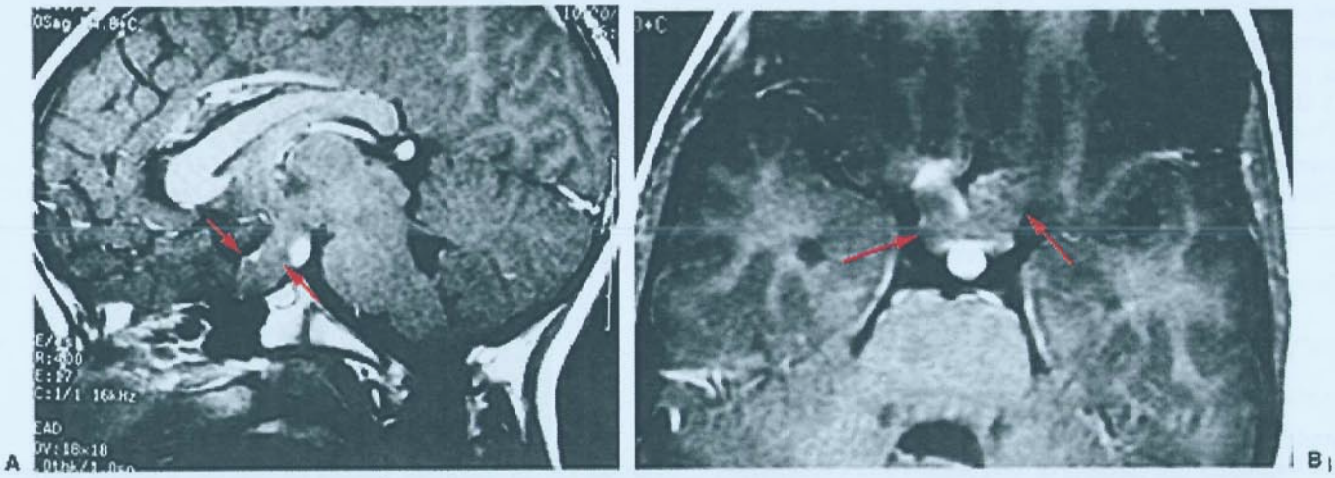

FIGURE 150.18 Sagittal (A) and coronal (B) magnetic resonance imaging of an optic pathway tumor.

(WHO grade II in WHO 2007 but subsequently not graded in WHO 2016). Thalamic tumors are often fibrillary astrocytomas, which can also be locally aggressive. The natural history of these lesions is unpredictable. Spontaneous regression has been noted. An increased MIB-1 labeling index identifies the more aggressive pilocytic astrocytomas. Visual pathway tumors have a particular tendency to spread to contiguous structures. The role of surgery is unclear.

Low-grade astrocytomas of the optic pathway, thalamus, and hypothalamus are generally unresectable. In patients with diffusely infiltrating lesions, especially with NF-1, diagnosis may be confirmed with near certainty on neuroimaging alone, and surgery may be deemed of little benefit.

Radiation therapy is an effective treatment for progressive unresectable low-grade astrocytomas. In the Children's Oncology Group (COG) ACNS0221 trial, 85 patients age 3 to 21 years with unresectable progressive, recurrent, or residual low-grade astrocytoma (predominantly pilocytic astrocytoma) were treated with 54 Gy three-dimensional conformal or intensity-modulated radiation therapy with a 5-mm CT venography margin. No patient received proton therapy. Children younger than 10 years were required to have received at least one chemotherapy course, and patients with NF-1 were ineligible. Five-year progression-free survival (PFS) and OS were 71% and 93%, respectively. Inferior outcome was associated with tumor size over 5 cm and nonpilocytic histology. The study did not include neurocognitive assessment. Proton therapy potentially reduces the radiation dose to developing brain tissue. A study of 174 children (median age 10 y) treated at a single center for nonmetastatic low-grade astrocytoma (predominantly pilocytic astrocytoma) found 5-year rates of local control, PFS, and OS of 85%, 84%, and 92%; brainstem or spinal location and dose less than 54 GyRBE were associated with inferior local control. The major disadvantages of radiotherapy are adverse endocrine and neurocognitive effects, especially in younger children. There is a need for studies comparing long-term outcomes following photon and proton therapy.

The major disadvantages of radiotherapy are adverse endocrine and neurocognitive effects, especially in younger children. Chemotherapy (based on vincristine and carboplatin) has been beneficial as initial treatment in younger children who have progressive optic pathway and hypothalamic/schismatic gliomas, delaying the need for radiotherapy by a median of 4 years; most eventually relapse, however, except for NF-1 patients who tend to have indolent disease. The same chemotherapy regimen has been advocated as initial treatment for infants with tumor-associated diencephalic syndrome of emaciation. OS for optic pathway gliomas exceeds 85% at 10 years but is less than 50% for thalamic low-grade gliomas and considerably worse for high-grade (especially bithalamic) astrocytomas.

Several chemotherapy regimens are active in pediatric low-grade astrocytomas. Two regimens were compared in a COG study for recurrent/progressive or symptomatic chiasmatic/hypothalamic tumors: carboplatin + vincristine (CV) and thioguanine + procarbazine + lomustine (CCNU) + vincristine (TPCV). Five-year event-free and OS rates across all tumor locations were 45% and 86%, respectively, with slightly better event-free survival (EFS) with TPCV and inferior survival with tumor location in the thalamus. A regimen of weekly vinblastine shows comparable activity, even in patients previously treated with CV or TPCV, and temozolomide also has single agent activity with the advantage of oral administration. A regimen of cisplatin + etoposide is also widely used, although a multicenter, prospective, randomized trial that comparing CV with CV + etoposide failed to demonstrate a difference in PFS and OS between the two regimens.

The best example of successful targeted therapy is SEGA, a low-grade glioma typically arising in individuals with tuberous sclerosis. SEGAs bear mutations in *TSC1* and *TSC2* genes and have dysregulated activation of mTOR signaling. An mTOR inhibitor, everolimus, shows substantial activity in patients with unresectable SEGAs; in a multicenter, phase III, placebo-controlled trial, 35% in the everolimus group had at least a 50% reduction in the size of the SEGA versus no reduction in the placebo group. Everolimus has also been reported effective in progressive NF-1–associated low-grade gliomas.

Because of histologic evidence of vascular proliferation in recurrent low-grade astrocytomas, treatment with antiangiogenic agents such as bevacizumab and lenalidomide has been explored. Single-agent bevacizumab produced clinical and radiologic responses in recurrent low-grade glioma, including improved visual fields in suprasellar cases, and some patients responded to rechallenge.

In separate studies, treatment of children with optic pathway gliomas with bevacizumab produced marked recovery of vision in addition to response on MRI, and bevacizumab was effective at reducing the size of prominent cystic components of low-grade astrocytomas.

Based on frequent occurrence of BRAF mutations and alterations in pilocytic astrocytomas, BRAF inhibitors are being tested in children with tumor progression. A large survey suggests that tumor progression may be more likely in tumors with BRAF single nucleotide variation compared to tumors with BRAF rearrangement. Case reports have documented activity for BRAF inhibitors (vemurafenib, dabrafenib) singly or in combination with MEK inhibitors (selumetinib, trametinib) for children, adolescents, and young adults with BRAF V600–mutated or KIAA1549-BRAF fused low-grade astrocytomas. Selumetinib has produced sustained responses in recurrent or progressive pilocytic astrocytoma and NF-1–associated low-grade astrocytomas and may become an alternative to standard chemotherapy in newly diagnosed patients. Selumetinib is also effective in unresectable plexiform neurofibromas in children with NF-1, producing durable tumor shrinkage with improved quality of life. Single-agent trametinib is also moderately effective in progressive low-grade pediatric astrocytomas.

Potentially actionable mutations in FGFR1, PTPN11, and in NTRK2 fusion genes have been identified in noncerebellar pilocytic astrocytomas, whereas rearrangements in the MYB family of transcription factors are frequent in pediatric grade II diffuse and anglocentric astrocytomas. Experience with sorafenib, a multikinase inhibitor of BRAF, VEGFR, PDGFR, and c-kit, provides a cautionary note, however, because treatment with sorafenib produced unexpected acceleration of tumor growth, perhaps by paradoxical ERK activation.

High-Grade Astrocytoma

High-grade astrocytomas account for about 10% of brain tumors in children and include anaplastic astrocytoma, oligodendroglioma, and oligoastrocytoma (WHO grade III) and glioblastoma multiforme and gliosarcoma (WHO grade IV). The WHO classification emphasizes degree of cellularity, nuclear and cellular pleomorphism, mitosis, endothelial proliferation, and necrosis. The 2016 revision of the WHO classification integrates molecular information and introduces distinct entities such as diffuse midline glioma H3K27M mutant (grade IV).

High-grade astrocytomas in children are aggressive tumors with high morbidity and mortality. Pediatric high-grade astrocytomas tend to arise de novo rather than from malignant transformation of a low-grade astrocytoma as may occur in adults. The majority of pediatric high-grade astrocytomas occur in the cerebral cortex or brainstem, less often in the midbrain and infrequently in the spinal cord. Common symptoms of cerebral cortical high-grade astrocytomas include headache, vomiting, seizures, motor weakness, and behavioral abnormalities. Cerebellar lesions may present with ataxia. Symptom duration is generally less than 3 months. Head CT is highly sensitive for the detection of high-grade astrocytoma, demonstrating heterogeneous density and diffuse contrast enhancement. MRI is necessary to confirm the anatomic origin and extent of the tumor. MRI findings include indistinct borders, mass effect, T1 hypointensity, T2 hyperintensity, and edema on FLAIR sequences. Leptomeningeal spread and distant metastases are uncommon.

Histologic criteria are the same in children as in adult high-grade astrocytoma.

Anaplastic astrocytomas (WHO grade III) are composed of astrocytes with increased cellularity, pleomorphism, and numbers of mitoses. There may be focal necrosis, but it may not be so extensive as to form pseudopalisades. In contrast to low-grade pilocytic tumors, anaplastic astrocytomas have an unstable vasculature, with a predominance of immature vessels distinguished by negative immunostaining for α-smooth muscle actin, and exhibit VEGF and anti–flt-1/VEGFR-1 immunoreactivity. Glioblastoma multiforme (WHO grade IV) has prominent vascular proliferation and a pseudopalisading pattern of necrosis.

Genetic changes in pediatric high-grade astrocytomas differ from adult tumors. EGFR amplification is uncommon, p53 pathway mutations are more common, and there tend to be fewer DNA copy number alterations. The most common focal alteration is PDGFRA amplification, sometimes associated with BRAF-V600E mutation.

Glioblastoma is subclassified as IDH wild-type, IDH mutant, or diffuse midline glioma H3K27M mutant (with histone H3.3 [H3F3A], H3.1 [HIST1H3B], or rarely HIST2H3C mutation at K27). IDH1-mutated cases are uncommon in pediatrics but have more favorable outcome than IDH wild-type cases (5-y OS 60% vs 20%).

The H3.3 K27M cases occur throughout the midbrain and pons between age 5 and 10 years and had have particularly poor prognosis (median survival 11 mo). H3.1 cases occur mainly in the pons at median age 5 years, with slightly longer median survival of 15 months; a high proportion have mutations in ACVR1. Another subtype with H3.3 (H3F3A) mutation at G34 presents in older children and young adults arising exclusively in the cerebral cortex (commonly with TP53 and ATRX mutations).

About 40% of pediatric glioblastoma multiform tumors lack histone and IDH1 mutations. Prognosis is intermediate between IDH1 mutant and H3K27M mutant cases, approximately 30% 3-year survival. This is the group characterized by gene amplification of PDGFRA, EGFR, CCND/CDK, and MYC/MYCN. Patients whose tumors have TP53 gene mutation or p53 overexpression and/or O^6-methylguanine-methyltransferase (MGMT) overexpression have inferior outcome.

Infant tumors appear to lack HOXA9/HOXA10, a tumor-promoting gene, possibly accounting for the better outcome of high-grade astrocytomas below age 3 to 4 years. Genomic subtypes are receptor tyrosine kinase–driven high-grade tumors, RAS/MAPK-driven hemispheric low-grade tumors, and RAS/MAPK-driven optic pathway/hypothalamic low-grade tumors.

Astroblastoma, previously defined histologically as a WHO grade III glial neoplasm with astroblastic pseudorosettes occurring in older adolescents and young adults, has been reassessed as encompassing distinct genetically defined entities, most often MN1 gene fusions or rearrangements.

Common symptoms of cerebral cortical high-grade astrocytomas include headache, vomiting, seizures, motor weakness, and behavioral abnormalities. Cerebellar lesions may present with ataxia. Symptom duration is generally less than 3 months. Surgery is important for diagnosis and for removing or debunking tumor and alleviating increased ICP; moreover, major resection improves survival. In children on Children's Cancer Group (CCG)-945 (involved field irradiation with adjuvant CCNU-based chemotherapy), 5-year PFS was 19% overall, but 40% of children with GTR were surviving. However, these infiltrative tumors may disseminate in the CSF and will almost certainly recur without further therapy.

Postoperative involved-field irradiation (59-60 Gy) and adjuvant chemotherapy both increase survival. The CCG Study-943 demonstrated a superior 5-year progression free survival with adjuvant vincristine, prednisone, and lomustine compared to radiation alone (44% vs 19%). The CCG-945 study compared that chemotherapy to a multiagent combination with comparable 5-year PFS (26% and 33%). Subsequent pathology review showed that a proportion of cases in these studies were actually low-grade astrocytomas, although the statistical benefit of chemotherapy for glioblastoma was upheld. Meanwhile, the addition of temozolomide to radiation was shown to improve survival in adults with glioblastoma, and this strategy was adopted in the COG protocol ACNS0126. Three-year EFS and OS were only 11% and 22%, however, with particularly poor outcome in cases with overexpression of the DNA repair enzyme MGMT, implicating temozolomide resistance. This possibility was addressed by coadministration of O^6-benzylguanine, which inactivates and depletes MGMT, in a Pediatric Brain Tumor Consortium; there was no improvement in the response rate. A subsequent COG study, ACNS0423, lomustine was added to maintenance temozolomide, with improved outcome compared to ACNS0126. Three-year EFS and OS were 22% and 28%; the difference was most pronounced for incompletely resected glioblastoma and cases with MGMT overexpression.

Adjuvant bevacizumab is approved for recurrent/progressive glioblastoma in adults, and bevacizumab with irinotecan (PBTC-022) was minimally effective for recurrent high grade glioma or high-grade glioma (HGG) in children. However, bevacizumab given during radiotherapy in newly diagnosed pediatric high-grade astrocytoma was no better than temozolomide (COG ACNS0822); the histone deacetylase inhibitor vorinostat given during radiotherapy was also not superior to temozolomide in that trial. Similarly, in the HERBY trial, addition of bevacizumab to temozolomide during radiotherapy did not improve progression-free survival, although there was a survival benefit for patients with hypermutator tumors (mismatch repair deficiency and somatic POLE/POLD1 mutations) and those biologically resembling PXA-like, driven by BRAF V600E or NF-1 mutation.

In patients with recurrent BRAF V600E–mutated high-grade astrocytomas (which may represent malignant transformation from a low-grade tumor), complete responses to vemurafenib or dabrafenib have been reported. Other targeted therapies are being investigated, including receptor tyrosine kinase inhibitors and PARP inhibitors. Alternative pharmacologic strategies such as convection-enhanced drug delivery are currently in clinical trials.

Irradiation-avoiding strategies have been used in young children with high-grade glioma. In Head Start II and III, 5-year EFS and OS were 25% and 36%, respectively. Children younger than 36 months old had improved 5-year EFS and OS of 44% and 63%.

High-dose chemotherapy with autologous stem cell rescue afforded occasional long-term survival in recurrent patients with minimal residual tumor following surgical debulking. Immune checkpoint inhibition has been effective in children with balletic mismatch repair deficiency, who are susceptible to leukemia and gastrointestinal cancers as well as brain tumors. Immunomodulating agents, oncolytic virotherapy, dendritic cell vaccines, and chimeric antigen receptor T cells are all being investigated as potential therapies.

Brainstem Glioma

Brainstem gliomas are a heterogeneous group. Small intrinsic tectal gliomas are indolent and may be managed conservatively. But the typical diffuse, intrinsic pontine lesions carry the worst prognosis of any childhood brain tumor. Brainstem tumors constitute 10% to 20% of posterior fossa tumors, with a peak incidence at ages 5 to 8 years. Most arise in the pons, and there may be contiguous spread to the medulla or midbrain. Despite the clinical aggressiveness of these tumors, the histologic appearance at initial diagnosis is quite variable, but at autopsy, most show anaplastic features. This may reflect sampling error at initial biopsy or subsequent malignant transformation. These tumors infiltrate the brainstem and compress normal structures while extending superiorly and inferiorly to produce diffuse enlargement of the brainstem. DIPGs are nearly uniformly fatal within 18 to 24 months. Some tumors extend ventrally, laterally, or posteriorly, and the primarily exophytic tumors tend to be more accessible to surgical resection and carry a better prognosis as do focal midbrain lesions.

The course is insidious with slowly progressive cranial neuropathy, motor symptoms and disturbance of gait, swallowing, and speech. Vomiting and headache indicate the presence of hydrocephalus, which is generally a late finding. Children with dorsal exophytic lesions may have more unsteadiness and less evidence of cranial nerve dysfunction. CT shows a low-density lesion in the brainstem, with compression and obliteration of surrounding cisterns but little if any contrast enhancement. Uncommonly, brainstem tumors may be isodense or hyperdense with cystic areas. MRI is preferred because of the detail appreciated on sagittal images typically revealing more extensive disease than appreciated on CT. The magnetic resonance appearance is of decreased signal intensity on T1-weighted images (**Fig. 150.19A**) and increased T2-weighted signal. Ring enhancement with contrast administration is prognostically unfavorable. MRI may also demonstrate infiltration of the medulla (**Fig. 150.19B**) or thalamus.

Given the accuracy of magnetic resonance diagnosis, the morbidity of surgery, and the variable prognostic impact of biopsy, it has been accepted that surgery is not warranted for most patients with diffuse intrinsic pontine lesions, in whom major resection when attempted has not improved survival. Biopsy may be offered in the context of research protocols accruing tissue samples for molecular studies or to guide selection of targeted therapies. Patients with exophytic, cervicomedullary tumors are more likely to benefit from surgery as are patients with atypical clinical courses or magnetic resonance findings (eg, symptom duration exceeding 6 mo, absence of cranial nerve findings primarily exophytic or focal ring-enhancing lesions). Children younger than age 3 years may fare better. Standard treatment is field-radiation therapy except for completely resected focal lesions. Most children with brainstem gliomas benefit at least transiently from radiation therapy to a dose of 54 to 56 Gy. Although leptomeningeal dissemination may occur, the main risk is for local recurrence. Median survival is only 9 to 12 months with 3-year survival of 13%.

Chemotherapy (including temozolomide and topotecan) and immunotherapy (such as β-interferon) have been unsuccessful in this condition, although new agents continue to be studied. Because about 80% of DIPG have histone H3.1 or H3.3 mutations, the histone deacetylase inhibitor vorinostat or the prodrug capecitabine have been tried with and following radiation therapy. Veliparib, a PARP inhibitor, added to radiation and maintenance temozolomide did not improve survival. An Akt/era and dopamine D_2 receptor inhibitor ONC201 is in clinical trials for H3K27M-mutated tumors. "Personalized treatment" adds

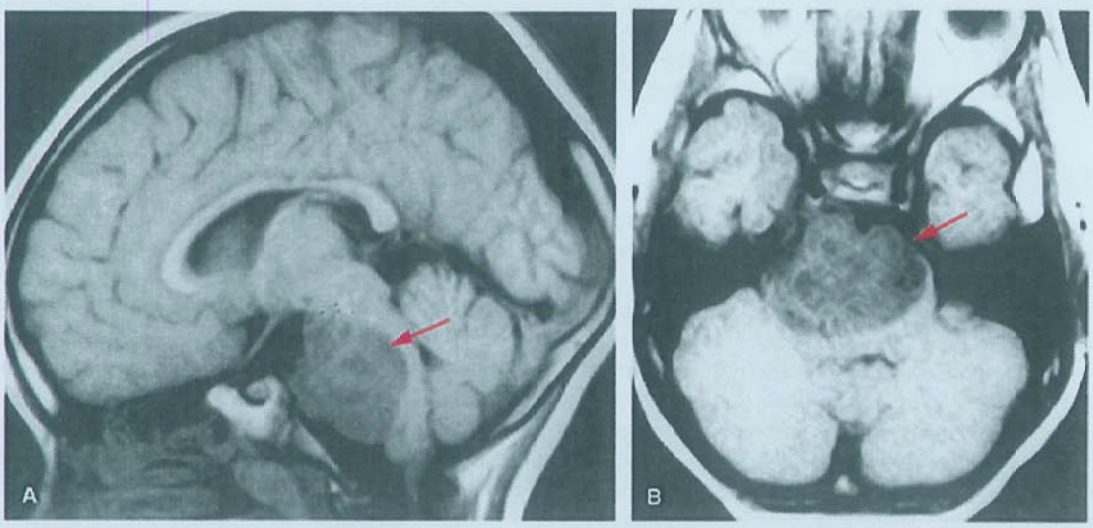

FIGURE 150.19 **A:** Sagittal magnetic resonance imaging of a diffuse brainstem glioma. **B:** Axial image showing infiltration.

individualized targeted therapies to a backbone of radiation and a combination of nimotuzumab, vinorelbine, and valproate. High-throughput drug screening with candidate validation in patient-derived xenografts and transcriptional and metabolic testing may identify drug combinations which are cytotoxic but also exploit key metabolic dependencies.

Another approach is regional tumor treatment by convection-enhanced delivery of drugs and immunotoxins. Determination of responses is complicated by interobserver variability in tumor measurement; the most consistent results are derived from FLAIR images. It has been suggested that clinical trials should incorporate other objective endpoints, such as survival, rather than radiologic response alone. Children with brainstem tumors should also be monitored for signs of hydrocephalus because CSF diversion by shunting or third ventriculostomy can improve quality of life.

Brainstem tumors in children with NF-1 are a distinct entity, occurring more often in the medulla than in the pons and associated with less aggressive behavior. The majority of such patients will survive without adjuvant treatment.

Spinal Cord Astrocytoma

Spinal cord astrocytomas account for about 4% of childhood CNS neoplasms. Other primary spinal cord tumors in children include gangliogliomas and ependymomas. Spinal high-grade astrocytomas are uncommon. Astrocytomas may occur in any part of the cord but are seen most often in the cervical region, with the solid component extending an average of five spinal segments. Most have benign histologic appearance and grow slowly. Symptoms and signs may include pain (ie, localized or radicular), weakness or spasticity, gait disturbance, and bowel or bladder dysfunction. Gadolinium-enhanced MRI is preferred for demonstrating the location of the solid tumor, associated cysts, and edema. Treatment may be attempted gross-total or near-total resection or partial resection with decompression of cysts with postoperative radiotherapy.

The degree of neurologic recovery depends on the preoperative condition of the patient. A potential complication is spinal deformity, resulting from laminectomy, radiotherapy, or both. About one-third of patients require a spine stabilization procedure. For children with low-grade tumors, survival rates of 55% at 10 years have been reported after partial resection and radiotherapy. Chemotherapy has been substituted for radiotherapy in very young children. The prognosis for children with high-grade tumors is worse, although 5-year PFS of 46% was reported in a study using combined radiation therapy and chemotherapy.

Oligodendroglioma

Oligodendrogliomas are a type of glioma originating presumably from oligodendrocytes or a glial precursor cell. They are more common in adults but account for about 1% of primary CNS tumors in children. The majority of patients present with seizures and finding of a tumor in the frontal lobe. Other symptoms are headache, vision change, and motor weakness. Oligodendrogliomas grow slowly but infiltrate nearby brain tissue and are divided into low- and high-grade variants according to degree of hypercellularity and pleomorphism (WHO grades II and III). Tumor cells have a distinctive monotonous round cell ("fried egg") appearance. A consistent finding is deletion or codeletion of chromosomal arms 1p and/or 19q. This finding correlates with chemosensitivity and improved prognosis, at least in anaplastic oligodendrogliomas and mixed oligoastrocytomas. Active regimens include procarbazine + lomustine + vincristine and single agent temozolomide (either standard 5-d cycles or low-dose extended dosing).

Medulloblastoma and Embryonal Tumors

Medulloblastoma

Medulloblastoma and supratentorial embryonal tumors (formerly supratentorial primitive neuroectodermal tumors) are collectively the most common malignant CNS tumors of childhood. The presumed cell of origin of medulloblastoma is derived from fetal external granular cells of the cerebellum or rests in the posterior medullary velum. These tumors account for about 30% of infratentorial tumors in children but are uncommon in adults.

Medulloblastomas typically involve the cerebellar vermis, grow to fill the fourth ventricle, and may infiltrate the floor of the ventricle and adjacent structures. The tumor may arise more laterally, especially in older children and adolescents. *Nonmedulloblastoma embryonal tumors* generally arise in the cerebral cortex. These lesions appear to originate from the germinal matrix of the primitive neural tube. A distinct entity is *ETMR*, characterized by C19MC amplification. Most are diagnosed before age 10 years. *Pineoblastoma* is a related lesion not included in the embryonal classification but treated similarly to medulloblastoma.

Children with medulloblastoma typically present with ataxia, diplopia, and symptoms of increased ICP (morning headache, vomiting, lethargy). Median age is 5 years, and symptom duration is often less than 3 months, and occasionally emergent if there is spontaneous in tumoral hemorrhage. Older children with laterally situated medulloblastomas may present with ipsilateral dysmetria and cranial neuropathies without hydrocephalus. Children with nonmedulloblastoma embryonal tumors present with headache and vomiting due to increased ICP; infants may have lethargy, irritability, and an enlarging head circumference. Supratentorial tumors may present with hemiparesis, seizures, and visual field defects. Upgaze paresis may be noted in pineoblastoma or with compression of the tectum of the midbrain.

These tumors appear isodense or hyperdense on CT and usually enhance homogeneously. Hydrocephalus is seen in more than 80% of patients. Other CT features include small cysts, calcification, and hemorrhage. MRI may give better indication of tumor extent (**Fig. 150.20A**) and possible leptomeningeal dissemination (**Fig. 150.20B,C**). MRI is also preferred over CT to facilitate evaluation of disseminated spinal tumor, which is found in up to one-third of patients with medulloblastomas.

Aggressive surgical resection is recommended for medulloblastoma and supratentorial embryonal tumors. The goal is complete or near-complete resection. In medulloblastoma, this is limited mainly by tumor infiltration of the fourth ventricle, the brainstem, or one of the cerebellar peduncles. Morbidity may include the posterior fossa syndrome of aseptic meningitis or (less commonly) mutism, pharyngeal dysfunction, and ataxia, with possible long-term sequelae. Placement of an external ventricular drain may be required, but preoperative ventriculoperitoneal shunting is not usually recommended due to the risk of upward herniation and because hydrocephalus will be relieved by tumor removal in most patients. Up to 30% of patients may require permanent shunting.

Postoperative MRI should be obtained within 48 hours to confirm the extent of resection. Spine MRI should be obtained if

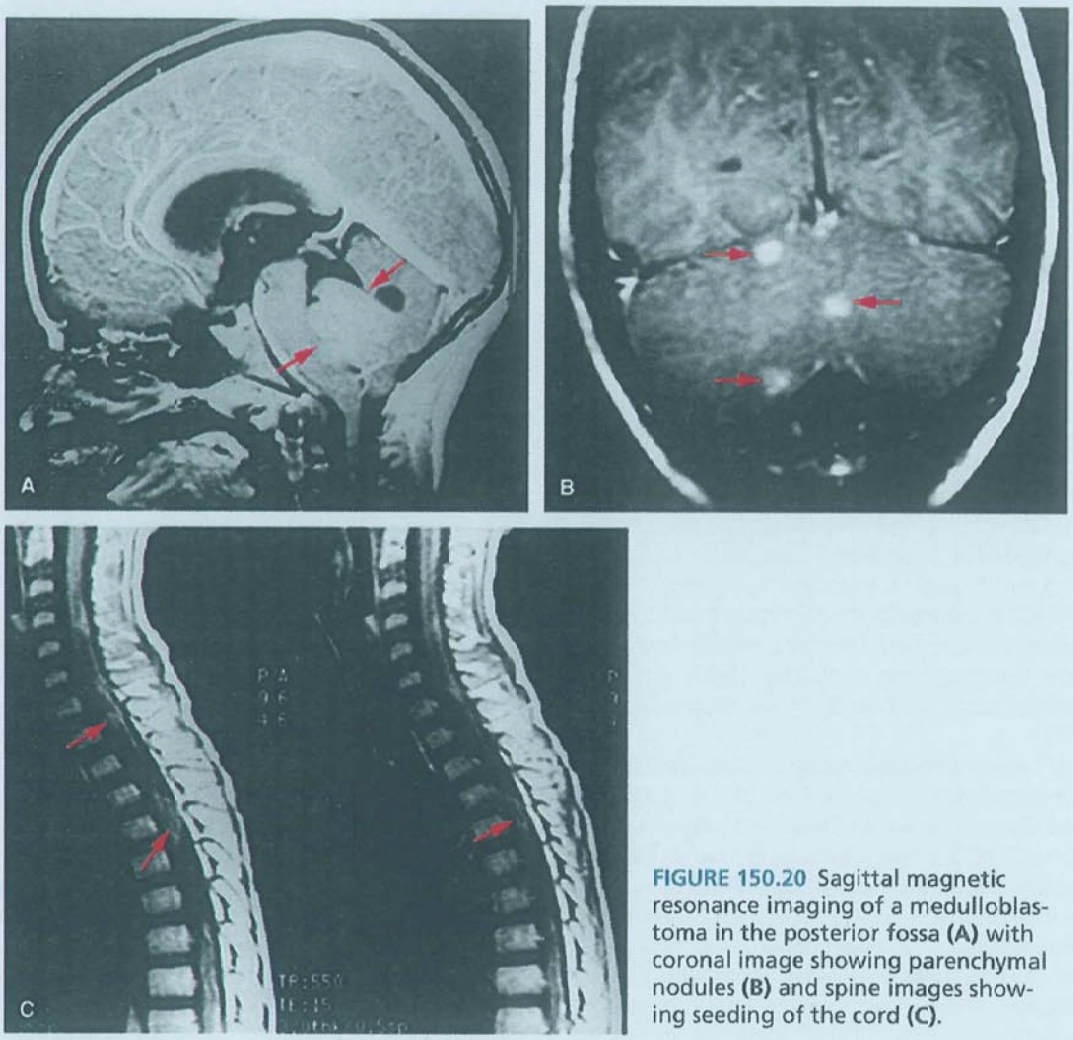

FIGURE 150.20 Sagittal magnetic resonance imaging of a medulloblastoma in the posterior fossa **(A)** with coronal image showing parenchymal nodules **(B)** and spine images showing seeding of the cord **(C)**.

not already done preoperatively. Lumbar puncture for CSF cytology is also required at a safe interval after surgery, usually after 10 days to avoid false-positive results. Patients with medulloblastoma are stratified clinically as *average risk* (ie, localized posterior fossa medulloblastoma with no more than 1.5 cm^2 postoperative residual tumor) and *high risk* (ie, more than 1.5 cm^2 residual or dissemination outside the posterior fossa, including positive CSF cytology). Up to 40% of children will present with dissemination of medulloblastoma. The staging system for tumor extent is as follows:

- M0: no dissemination
- M1: positive CSF cytology only
- M2: gross nodular seeding in cerebellar/cerebral subarachnoid space and/or lateral or third ventricle
- M3: gross nodular seeding in spinal subarachnoid space
- M4: extraneural metastasis

It is now apparent that medulloblastomas comprise at least four distinct subtypes based on aberrant activation of signaling pathways regulating cerebellar development or oncogene amplification: (1) *Wnt tumors* (named for drosophila wingless) with classic histology and very good prognosis. Also termed *classic medulloblastoma*, this subtype has the histologic appearance of a small, round, blue cell tumor with a diffuse pattern of poorly differentiated cells. Neuroblastic ("Homer-Wright") rosettes may be present but are not required for diagnosis. Immunohistochemical staining is typically positive for synaptophysin and occasionally for neurofilament protein or GFAP, although the latter usually represents reactive intratumoral astrocytes. (2) *SHH tumors* (named for sonic hedgehog), relatively more common in infants and adults, with desmoplastic/nodular histology and intermediate prognosis (good in infants). This subtype arises in cerebellar hemispheres and is characterized by nodular islands of differentiating neuroblasts. An "extensively nodular" variant is recognized in infants. (3) *"Group 3" tumors* with overrepresentation of large cell/anaplastic histology, MYC amplification, very frequent metastasis, and poor prognosis. Large cell/anaplastic medulloblastoma vaguely resembles large cell lymphoma, with large neoplastic cells having vesicular nuclei and prominent nucleoli. Most group 3 medulloblastomas fall between these histologic extremes, but one-quarter exhibit at least moderate anaplasia. The presence of more than 50% large cell/anaplastic histology is considered a high-risk criterion, even if the tumor is localized and completely resected, because of more aggressive behavior. (4) *"Group 4" tumors* with classic histology but tendency for metastasis, occasional MYCN amplification, and intermediate prognosis.

Immunohistochemical correlations are nuclear positivity for β-catenin in Wnt tumors, GAB1 positivity in SHH tumors, and filamin A and YAP1 positivity in both. Correlation with cytogenetic

findings shows isochromosome 17q to be typical of group 3 and 4 tumors, monosomy 6 associated with Wnt tumors, and 9q and 10q deletion in SHH tumors. Profiling six fluorescent in situ hybridization biomarkers (GLI2; MYC; and chromosomes 11, 14, 17p, and 17q) reliably identifies very low-risk and very high-risk patients within SHH, group 3, and group 4 medulloblastomas.

In infants, medulloblastoma must be distinguished from AT/RT, which has not only a small cell component resembling medulloblastoma but also cords of cells in a mucinous background that resemble chordoma, with a rhabdoid appearance of the cytoplasm of the larger cells.

Exome sequencing has revealed subtype-specific somatic mutations in known medulloblastoma-related genes (CTNNB1, PTCH1, MLL2, SMARCA4) and genes not previously considered medulloblastoma-related (DDX3X, CTDNEP1, KDM6A, TBR1). In particular, mutant DDX3X potentiates transactivation of a TCF promoter and enhances cell viability in combination with mutant β-catenin. Growth factor–independent 1 family proto-oncogenes GFI1 and GFI1B have been identified as oncogenic drivers for groups 3 and 4 tumors, an example of "enhancer hijacking" wherein coding sequences are juxtaposed proximal to active enhancer elements. Epigenetic alterations also contribute to medulloblastoma tumorigenesis, including highly prevalent regions of hypomethylation correlating with increased gene expression.

Relatively less is known about the cytogenetic and molecular features of supratentorial embryonal tumors, but gene expression analysis shows distinct patterns of gene activation that differ from those of medulloblastoma. Three molecular subgroups have been proposed based on differential expression of cell lineage markers LIN28 and OLIG2: (1) primitive neural (younger females with poorest survival), (2) oligoneural (older males with best survival), and (3) mesenchymal (older males with highest incidence of metastatic disease and intermediate survival). A high-level amplicon involving the C19MC identifies an aggressive subgroup of embryonal tumors with distinct gene expression profiles and poor survival.

Children with average-risk medulloblastoma have approximately 80% 5-year disease-free survival, whereas high-risk children have approximately 65% 5-year survival. Infants younger than age 3 years have inferior outcome and are considered high-risk patients even with localized tumors; an exception appears to be SHH tumors in infants for whom de-escalation of therapy may be considered.

Radiation therapy is the standard postoperative treatment for medulloblastoma and nonmedulloblastoma embryonal tumors. Craniospinal irradiation is given because the entire neuraxis is at risk for tumor recurrence. Conventional doses are 23.4 (average-risk patient) to 36 Gy (high-risk patient) to the brain and spine, with a boost to the local tumor site to a dose of 54 to 55.8 Gy. Radiotherapy should be initiated within 4 to 6 weeks. Proton therapy may be advantageous because during spine treatment there will be lesser dose scatter to the anterior chest and abdomen. Intellectual outcome is reported to be better after proton therapy compared to radiotherapy.

Historically, adjuvant (postirradiation) chemotherapy with vincristine and lomustine was introduced for high-risk medulloblastoma and shown to improve survival; the addition of cisplatin afforded a remarkable 5-year PFS rate of 85% in one series. Preirradiation chemotherapy did not improve survival. Accordingly, adjuvant chemotherapy was introduced for average-risk patients, and the combination of reduced dose neuraxis irradiation with weekly vincristine, followed by vincristine + lomustine + cisplatin chemotherapy (COG A9961), resulted in a 5-year PFS rate of 79%. Other successful regimens include alternating vincristine + lomustine + cisplatin and vincristine + cyclophosphamide or higher dose cyclophosphamide (with peripheral stem cell support) allowing reduction of vincristine and cisplatin. Treatment regimens for high-risk medulloblastoma generally incorporate dose-intensified vincristine + cisplatin + cyclophosphamide, affording 50% to 70% survival, including patients with metastatic disease. Side effects include high-frequency hearing loss and renal insufficiency with cisplatin and myelosuppression with lomustine and cyclophosphamide. Vincristine side effects include alopecia, constipation, and occasional syndrome of inappropriate antidiuretic secretion. Vincristine can cause dose-limiting peripheral neuropathy; substitution of vinblastine appears to be safe.

Radiation therapy is deferred in infants, in favor of dose-intensive chemotherapy. Addition of high-dose methotrexate to a cisplatin/cyclophosphamide-based infant protocol resulted in 49% 3-year EFS. Best results were in infants with nondisseminated totally resected tumors with desmoplasia histology. A series of trials using higher dose, marrow-ablative chemotherapeutic regimens supported by autologous peripheral blood stem cell rescue have shown that infants younger than 3 years at diagnosis of medulloblastoma can be treated successfully with deferred or no radiotherapy (3-y EFS 67% for M0 and 49% for M+0). Based on favorable results, the upper age for this approach has been extended to 6 years. Early tumor progression on chemotherapy has remained a major problem. Addition of high-dose methotrexate to cisplatin-based chemotherapy for young children with newly diagnosed disseminated medulloblastoma (including autotransplant consolidation) resulted in a high response rate and 49% 3-year EFS.

Some protocols for older infants combine local tumor irradiation (ie, using confocal techniques) and chemotherapy, either conventional or high dose (with autologous stem cell rescue). Another strategy has been to incorporate intraventricular methotrexate with systemic chemotherapy, as in the HIT 2000 trial, with the goal of avoiding irradiation. In that study, children younger than age 4 years with desmoplastic/nodular histology had 93% progression-free and craniospinal radiation-free survival at 5 years, without excessive neurotoxicity.

With recognition of the four subtypes of medulloblastoma, it may be possible through preclinical testing to identify chemotherapeutic agents with selective effectiveness against particular subtypes. For example, screening murine group 3 medulloblastomas against a library of 7,000 compounds in a high-throughput cell-based assay revealed synergistic antitumor activity of pemetrexed and gemcitabine as combination therapy in group 3 tumors overexpressing MYC.

For recurrent medulloblastoma, the combination of temozolomide + irinotecan appears active, as does temozolomide + topotecan or single-agent oral etoposide. Recurrence tends to be local in SHH medulloblastoma and metastatic in group 3 and 4 tumors. Overall prognosis following recurrence is guarded. Targeted therapy with agents such as SHH inhibitors is under investigation. High-dose chemotherapy with hematopoietic stem cell rescue has been used for selected patients with recurrent medulloblastoma who remain chemotherapy-sensitive. Increasing pursuit of targeted therapy may be anticipated following successful treatment of a young adult with SHH-driven medulloblastoma with the hedgehog pathway inhibitor GDC-0449 and demonstration of antitumor activity of

vismodegib in a child with SHH medulloblastoma. Newer approaches include radioimmunotherapy with monoclonal antibody conjugates (as used in neuroblastoma), and preclinical studies of direct infusion of drugs into the fourth ventricle or infusion of autologous ex vivo expanded natural killer cells or chimeric antigen receptor T cells into CSF.

Nonmedulloblastoma Embryonal Tumors

For nonmedulloblastoma embryonal tumors, the same treatment approach of maximal resection, craniospinal irradiation, and adjuvant chemotherapy has been pursued. Prognosis is worse compared to medulloblastoma, generally less than 40% 5-year survival even for localized tumors. Moreover, there is no histologic or molecular system of tumor subclassifications to guide therapy. Hyperfractionated radiotherapy with cisplatin-based maintenance chemotherapy (HIT 2000) afforded 58% 5-year survival. Preirradiation chemotherapy was not helpful for older patients. Radiation may be deferred in the youngest patients, in whom dose-intensive chemotherapy can offer similar outcomes; radiotherapy can then be tailored to chemotherapy response.

ETMR includes three histologic variants with identical molecular findings (LIN28A positive, C19MC mRNA amplification, and trisomy 2) all arising in infants and young children in supratentorial cortical or paraventricular sites. *Ependymoblastoma* was previously considered to be a variant of ependymoma, whereas *embryonal tumor with abundant neuropil and true rosettes* was originally described as a primitive neuroectodermal tumor. The third variant, *medulloepithelioma*, is also an aggressive cerebral hemispheric tumor of infants and young children but shows a range of differentiation from embryonal primitive neuroepithelioma to variants exhibiting maturation. A review of the French experience with this group of tumors managed with multimodality therapy showed 1-year EFS and OS of 36% and 45%, respectively. Better survival was associated with radical resection, tandem high-dose chemotherapy, and risk-adapted radiation. Localized medulloepithelioma in the eye or orbit may be curable by radical surgical resection.

Central neurocytoma is a WHO grade II neuroepithelial intraventricular tumor typically presenting in older children or young adults with hydrocephalus and occasionally seizures. Variants include cerebral (extraventricular) neurocytoma and ganglioneurocytoma (with ganglion cell differentiation). Histologic appearance may resemble oligodendroglioma. Surgical resection is curative, with radiotherapy, stereotactic radiosurgery, and/or chemotherapy for incompletely resected or recurrent tumors.

Recurrent CNS embryonal tumors have guarded prognosis, generally less than 25% survival. Biopsy or surgical resection may be necessary to distinguish recurrent embryonal tumor from radiation necrosis or a new primary tumor such as meningioma or high-grade astrocytoma. Molecular studies may reveal emergent targetable mutations at the subclonal level. Children managed initially with deferral of radiation may benefit from local or craniospinal irradiation at tumor progression; this should be particularly considered in patients with recurrent medulloblastoma who can undergo complete resection of tumor. Other patients may be offered reirradiation at primary or metastatic sites, including the option of stereotactic irradiation. Recurrent CNS embryonal tumors may respond at least transiently to chemotherapy, with single-agent etoposide, topotecan, or temozolomide; combined temozolomide/irinotecan; and multiagent metronomic protocols containing bevacizumab. High-dose chemotherapy with autologous peripheral blood stem cell rescue has been used with variable results; interpretation of results is confounded by whether transplant outcomes are reported on an intent to treat basis. New agents may be efficacious in particular disease subtypes, such as vismodegib in recurrent sonic hedgehog medulloblastoma.

Pineoblastoma and Trilateral Retinoblastoma

Pineoblastomas are excluded from the revised embryonal tumor group classification and fall into distinct molecular subgroups with homozygous loss of function alteration in microRNA biogenesis genes (DICER1, DROSHA, DGCR8) or recurrent alteration in MYC–miR-17/92-RB1 pathway genes. Pineoblastoma has generally been treated similarly to medulloblastoma with similar 70% 5-year EFS following craniospinal irradiation and multiagent chemotherapy. Prognosis has been consistently worse in infants, including in the Head Start series of protocols, with early disease progression during induction chemotherapy. Pineoblastomas must be distinguished from pineal germ cell tumors (discussed separately) and pineocytomas (benign pineal parenchymal tumors treated by surgery alone or with radiotherapy).

Rb is an uncommon eye tumor of very young children, accounting for 3% of childhood cancers. Rb arises in the retina and may extend to the vitreous (with leukocoria), macula (with strabismus), optic nerve, and choroid, with risk of CNS and systemic dissemination. In 25% to 30% of cases, Rb is heritable (due to germ line RB1 mutation), including 15% of children with unilateral disease and all cases of bilateral disease. Rarely, children with bilateral Rb develop an intracranial neuroblastic tumor, resulting in "trilateral" Rb. The intracranial lesion most often occurs as pinealoblastoma and may initially be interpreted as a benign pineal cyst. Because most deaths from Rb have been due to trilateral Rb, MRI screening of infants with heritable Rb for pineal involvement has been advocated up to age 3 years.

Atypical Teratoid/Rhabdoid Tumor

CNS AT/RT is a rare, highly aggressive embryonal tumor of infants and young children accounting for up to 20% of infant cases in some series. About half present at supratentorial sites and half in the posterior fossa. Symptom duration is typically quite brief, with disease dissemination in about 20%. ATRTs have monosomy or deletion of chromosome 22. Fundamental to pathogenesis are somatic and germ line inactivating mutations of SMARCB1 (previously INI1/hSNF5) and SMARCA4 tumor suppressor genes, which are also mutated in renal rhabdoid tumors. The 2016 WHO classification defines AT/RT by the presence of either *SMARCB1* or *SMARCA4* alterations. Tumors with histologic features of AT/RT that lack these genomic alterations are termed *CNS embryonal tumor with rhabdoid features*. Three biologically distinct subsets of AT/RT have been described: AT/RT TYR (a melanosomal gene encoding tyrosinase, seen in infants), AT/RT SHH (with increased expression of sonic hedgehog pathway genes, seen in toddlers), and AT/RT MYC (with elevated MYC expression, in slightly older children). Reported median survivals are 37 months, 16 months, and 13 months, respectively.

Outcome for AT/RT with conventional chemotherapy has been poor (median survival <12 mo), but 2-year PFS of 53% was achieved with surgery, radiation therapy, and parenteral and intrathecal chemotherapy based on the Intergroup Rhabdomyosarcoma Study III. Better outcome has been associated with older age, localized presentation, and gross total resection. Radiation therapy

and intensive chemotherapy both contribute to survival. Protocols combining surgery, intensive chemotherapy with autologous peripheral blood stem cell rescue, and response-based irradiation have improved outcome for older children with AT/RT and are being evaluated in infants. In the COG ACNS0333 trial, 4-year EFS was 37% and OS 43%, uninfluenced by timing of radiation (pre- or posthigh-dose chemotherapy consolidation). Nearly all relapses occurred within 2 years and were predominantly local. Development of new agents is focussed on EZH2 inhibitors, targeting an obligatory dependence of cells with *SMARCB1 or SMARCA4* loss.

Ependymoma and Other Tumors

Ependymoma

Ependymomas constitute 5% to 10% of all primary childhood brain tumors and also occur in adults. Most ependymomas appear to be histologically mature (WHO grade II). Subtypes include papillary clear cell and tanycytic ependymoma (all WHO grade II). Variants include anaplastic ependymoma (WHO grade III, with increased cellularity and mitotic activity, microvascular proliferation and necrosis), which carries a worse outcome in some series, and the clinically indolent subependymoma and myxopapillary ependymoma (WHO grade I). "Ependymoblastoma" is no longer retained and is reclassified as an ETMR.

The 2016 WHO classification of supratentorial ependymomas includes RELA-positive and RELA-negative/YAP1-positive tumors. ST-EPN-RELA ependymoma presents at a median age of 8 years and has poor prognosis (5-y PFS 29%), although outcome is better in the clear cell ependymoma subset. ST-EPN-YAP1 tumors are less common, occurring mainly in infants. These tumors exhibit gene fusions involving YAP1, usually with MAMLD1. Prognosis is better that for ST-EPN-RELA (5-y PFS 66%). Both ST-EPN-RELA and ST-EPN-YAP1 may have anaplastic or nonanaplastic histology.

Transcriptional profiling of infratentorial ependymomas reveals two demographically, genetically, and clinically distinct groups: (1) younger patients (median age 2.5 y) with laterally located tumors with tendency for metastatic recurrence and poor PFS (18% at 5 y) versus (2) older patients (median age 20 y) with much better EFS (91% at 5 y). Both PF-EPN-A and PF-EPN-B may have anaplastic or non anaplastic histology.

Ependymoma and subependymoma may occur as primary spinal cord tumors, usually in adults. Myxopapillary ependymoma may be seen in children, typically arising in the distal spinal cord, with a tendency to disseminate early to the upper cord or brain.

Clinical symptoms depend on tumor location. About two-thirds of ependymomas occur in the posterior fossa. Tumors filling or compressing the fourth ventricle produce obstructive hydrocephalus with nausea, vomiting, and morning headaches. Tumors arising low in the fourth ventricle and extending into the lower medulla may cause neck pain, whereas cranial nerve palsies may result from brainstem invasion or compression of cranial nerves. In patients with supratentorial lesions, seizures and focal deficits are seen. Features on CT include calcification and variable enhancement. MRI will better demonstrate invasion by posterior fossa lesions into the brainstem (Fig. 150.21) or upper cervical spinal cord. Diagnostic evaluation includes spine MRI and lumbar puncture for CSF cytology.

FIGURE 150.21 Magnetic resonance appearance of an ependymoma showing tumor extension through the foramen of Luschka *(arrow)* and invasion of the brainstem.

Treatment of newly diagnosed intracranial ependymoma includes maximal surgical resection, involved field irradiation (conformal, intensity-modulated radiation therapy, or proton, 54-59.4 Gy), and chemotherapy. Postoperative residual disease may be managed by chemotherapy and second-look surgery prior to radiation therapy. Disseminated disease is typically managed with craniospinal irradiation with or without chemotherapy. Completely resected localized supratentorial nonanapestic ependymoma has been managed recently without radiation therapy, with progression-free survival in about two-thirds of cases. Infants with ependymoma may be given chemotherapy postoperatively with the goal of deferring radiation therapy, although involved field irradiation does improve survival outcome and is generally offered by age 12 to 18 months.

The most important predictor of outcome is the extent of surgical resection as confirmed by postoperative imaging. Successive clinical trials for ependymoma show that the rate of complete resection has increased from 50% to 75%. Resectability of posterior fossa lesions may be limited by brainstem infiltration, extension into the cerebellar pontine angle, or involvement of cranial nerve nuclei. Supratentorial lesions may also be infiltrative and difficult to remove. Gross total resection of ependymomas followed by involved-field irradiation to 55 Gy (tumor bed with 1-cm margin) affords up to 75% survival, whereas local recurrence is more likely following subtotal resection, and survival rates drop below 30%.

Patients with tumor dissemination at diagnosis (fewer than 10% of cases) do poorly. Additional poor prognosis factors include younger age at diagnosis, anaplastic histology, and tumor expression of the enzymatic subunit of telomerase (hTERT) and expression of the neural stem cell marker Nestin.

Adjuvant chemotherapy may improve outcome based on the responses of recurrent ependymomas to cisplatin and other agents and responses in infants. Preirradiation cisplatin-based chemotherapy for patients with postoperative residual tumor (CCG-9942) produced objective responses in 57% of patients, and 5-year EFS of patients receiving chemotherapy for incompletely resected tumors equaled that of patients with complete resection and no chemotherapy (55% vs 58%). The

COG ACNS0121 trial introduced observation for classic supratentorial ependymoma after gross total resection, and for the remaining patients gave conformal radiation after gross total or near-total resection, and for subtotal resection preirradiation chemotherapy with second-look surgery. The 5-year EFS rates were 61%, 37%, and 68% for observation, subtotal resection and GTR/near-total resection groups, respectively. A successor study (ACNS-0831) randomizes patients to postradiation chemotherapy versus radiation alone.

Primary postoperative chemotherapy with irradiation at progression has been reported in children younger than age 5 years with 59% 4-year survival (23% without irradiation). A similar study in children younger than age 3 years found 61% survival at 3 years leading to a larger study (POG-9233/34) demonstrating that with prolonged dose-intensive chemotherapy, 40% of infants with ependymoma could survive without radiotherapy. Infants younger than 3 years on the SJYC07 protocol received postoperative chemotherapy and consolidate focal conformal radiation, with 4-year PFS 75% and OS 92%. Based on Head Start protocol experience, there is no benefit of myeloablative chemotherapy with autologous stem cell rescue, although one report suggests a survival advantage in the group with anaplastic ependymoma.

Treatment of myxopapillary ependymoma is surgery, with increasing use of adjuvant irradiation.

Recurrent ependymomas are managed by resection, possible reirradiation of stereotactic radiosurgery, and chemotherapy. Active agents include cisplatin and carboplatin, etoposide, temozolomide, vincristine, and cyclophosphamide.

Prospects for targeted therapy focus on histone deacetylase inhibitors, γ-secretase inhibitors (blocking notch signaling pathway activation), telomerase inhibitors (in hTERT-positive ependymoma), and lapatinib (a dual EGFR antagonist). Potential predictive biomarkers were analyzed prospectively in an Italian cooperative group trial; better outcome was associated with lower hTERT mRNA expression and nucleoli protein expression; mRNA expression levels of EGFR and prominin 1/CD133 were not significant on multivariate analysis, although the prominin 1/CD133 cancer stem cell marker was strongly expressed in a substantial fraction of cases and appeared to be associated with more indolent disease.

Central Nervous System Germ Cell Tumors

CNS germ cell tumors tend to arise in the pineal and suprasellar regions (infundibulum and pituitary stalk). Germ cell tumors account for 3% to 4% of brain tumors in Western countries, but up to 15% in Japan and other parts of Asia. They account for about half of all pineal tumors and 5% to 10% of parasellar lesions. Pineal germ cell tumors account for half of all pineal tumors and have a male preponderance, presenting in adolescence. Suprasellar germ cell tumors predominate in younger females. Rarely, patients may present with synchronous suprasellar and pineal tumors.

CNS germ cell tumors are classified as germinoma, embryonal carcinoma, yolk sac tumor, choriocarcinoma, teratoma (mature or immature), teratoma with malignant transformation, and mixed germ cell tumor. About 50% to 65% of germ cell tumors are germinomas, histologically primitive lesions resembling gonadal germ cell tumors and presumably derived from embryonic migration of totipotent germ cells. Among nongerminomatous germ cell tumors, teratomas and mixed germ cell tumors are variously composed of mature, immature, and malignant elements. Choriocarcinomas are rare but highly malignant.

Chromosomal comparative genomic hybridization analysis of CNS germ cell tumors suggests that genomic alterations are essentially indistinguishable from those found in extracranial germ cell tumors. Mutations in the KIT/RAS signaling pathway are found frequently, or in the AKT/mTOR pathway, with global hypomethylation and chromosomal instability.

Symptoms and signs of pineal region germ cell tumors most often include headaches and Parinaud syndrome of upgaze paresis, convergence nystagmus, and light-near pupillary response dissociation. With extension to the overlying thalamus, there may be hemiparesis, incoordination, vision disturbances, or movement disorders. Suprasellar germ cell tumors produce pituitary and hypothalamic dysfunctions (notably diabetes insipidus) but usually not vision loss. CT appearance is of an irregular lesion of mixed density, occasionally with calcification and with variable enhancement.

MRI is more sensitive for purposes of follow-up evaluation. MRI may reveal a pineal cyst in otherwise healthy children being evaluated for headache; lack of hydrocephalus and Parinaud syndrome should lead one away from the diagnosis of a pineal tumor. Diagnosis may be aided by measurement of AFP and β-subunit of HCG, which are secreted by germ cell tumors but not pineal parenchymal cell tumors or cysts and are detectable in serum and CSF. Pure germinomas and mature teratomas are negative for AFP and HCG; germinomas with syncytiotrophoblastic elements may have low levels of HCG. AFP is elevated in endodermal sinus tumors and some immature teratomas; HCG is elevated in choriocarcinoma and embryonal carcinomas. Elevations of both indicate the presence of mixed malignant elements. Even with tumor marker elevation, however, histologic confirmation is recommended.

Surgery for pineal region germ cell tumors is technically difficult, but major resections may be achieved with acceptable morbidity rates by the use of supratentorial suboccipital or infratentorial supracerebellar approaches. Most patients require CSF shunting. There may be transient visual migraines caused by occipital lobe contusions. Teratomas may be encapsulated and are therefore easier to remove. Germ cell tumors may disseminate throughout the neuraxis in up to 10% of cases. Extracranial spread to lung and bone has also been reported.

Radiotherapy is the standard treatment for pure germinomas, given in the past as 35 to 45 Gy to the brain and spine with a 10- to 15-Gy boost to the area of the tumor, affording 90% survival at 5 years. More recently, craniospinal doses were reduced to 24 to 36 Gy (with tumor boost to 40-50 Gy) with comparable survival outcome. Addition of neoadjuvant carboplatin/etoposide chemotherapy may allow further reductions in the dose and extent of irradiation, potentially lessening the considerable endocrine, neuro-ophthalmologic, and neuropsychological sequelae of treatment.

Survival rates for mixed malignant germ cell tumors have been considerably lower, especially with radiotherapy alone, but have improved with the addition of chemotherapy. Current protocols are based on cisplatin- or carboplatin-containing regimens active in gonadal germ cell tumors; following chemotherapy, patients receive response-based radiation to protocol-defined fields (craniospinal or whole ventricular). For incomplete responders, second look surgery is an option. With craniospinal irradiation, 5-year EFS exceeds 80%, and a current protocol is investigating whether this result can be maintained

with radiation limited to the whole ventricular system. High-dose chemotherapy with autologous stem cell rescue is an effective strategy in recurrent germ cell tumors and has also been added for tumors refractory to initial therapy. Patients with germinoma recurrence following chemotherapy alone should be referred for radiation therapy, and reirradiation may also been offered.

Central Nervous System Lymphoma

Primary CNS lymphomas are rare both in children and adults, constituting fewer than 1% of intracranial tumors. They may occur at any age and are generally of B-lymphocyte origin, including Burkitt type, and can be a manifestation of congenital or acquired immunodeficiency, particularly HIV-associated. The tumor location is usually the cerebral cortex. CNS lymphomas appear isodense or hyperdense on CT with enhancement. MRI shows an iso- to hypointense lesion on T1-weighted images and iso-, hypo-, or slightly hyperintense lesion on T2-weighted images with variable enhancement. Whole-body ^{18}F-fluorodeoxyglucose PET may reveal extracranial sites of disease not seen on other imaging such as CT scan. An unusual presentation was progressive panhypopituitarism in a 15-year-old immunocompetent adolescent male on growth hormone for 3 years for growth deceleration; baseline MRI had been normal, but repeat MRI revealed a lesion in the pituitary stalk, which was a high grade B-cell lymphoma. Whole-brain irradiation has produced survival rates of only 20% to 30% in adults. A prospective trial in immunocompetent adults with primary CNS lymphoma showed that preirradiation high-dose methotrexate chemotherapy improved survival rates over whole-brain irradiation alone but with additive life-threatening neurologic toxicity. For these reasons, methotrexate- and cytarabine-based chemotherapy without irradiation is now the preferred treatment in both adults and children. The addition of rituximab was advantageous in an adult study in non-HIV patients. Intrathecal chemotherapy may be added in the event of positive CSF cytology. Consolidative high-dose thiotepa-based chemotherapy with autologous peripheral blood stem cell rescue has been used in responding younger patients. Newer agents used at recurrence in adults include ibrutinib and lenalidomide. Salvage irradiation is also an option. There is a case report of response to rituximab (intravenous and intraventricular) in a child with refractory primary CNS lymphoma.

Meningioma and Mesenchymal Tumors

Meningiomas are rare in childhood, accounting for 2.5% of pediatric brain tumors. Meningiomas can be associated with NF-2, and this diagnosis should be sought in any child with meningioma. Meningiomas may also occur in previously irradiated sites. These tumors usually arise on the meningeal surface but (in contrast to adults) may grow as parenchymal lesions presumably from meningeal cell rests. CT and MRI show an isointense or hyperintense lesion enhancing with contrast (Fig. 150.22).

Most lesions are clinically benign (grade I), although 10% of pediatric or NF-2–associated tumors show anaplasia (grade III) and 50% have atypical features (grade II). Overall prognosis is worse than in adults. High mitotic index, MIB-1 labeling index, and variant histology (eg, papillary, clear cell) are associated with invasiveness and adverse outcome. Deletions of NF-2, DAL-1, and chromosome 1p and 14q are common. Surgery is the primary treatment. Radiotherapy is of uncertain value but has been used for recurrent tumors, especially after unsuccessful

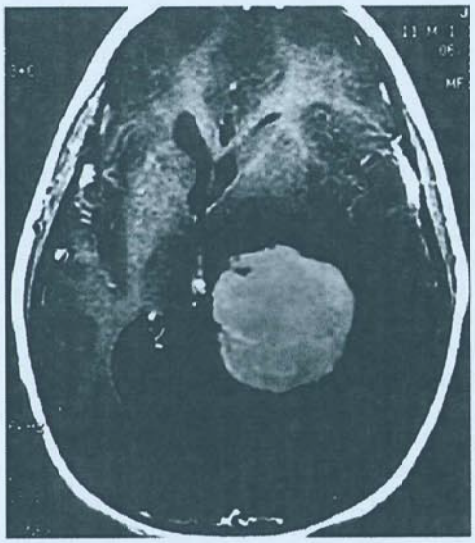

FIGURE 150.22 Axial magnetic resonance imaging of a meningioma.

reresection. Meningiomas may occasionally involve the leptomeninges, primarily, and these tumors (ie, meningeal sarcomas) tend to behave aggressively. Treatment has been combined radiation and chemotherapy.

Meningeal sarcomas may extend intracranially from the skull or arise directly from the dura or develop within meningiomas. Treatment includes surgery, radiotherapy, and chemotherapy guided by the particular histologic subtype. *Fibrous histiocytomas* arise from the dura or grow in brain parenchyma. Benign variants are curable by surgical resection, but malignant fibrous histiocytoma has guarded prognosis despite multimodality therapy. Solitary fibrous tumors arise from the dura and grow slowly; they are distinguished from fibrous meningioma by immunohistochemical positivity for CD34, vimentin, and BCL2. Surgical resection is curative.

Hemangiopericytomas occur mainly in adults, grow rapidly, and may present with seizures. Local recurrence is a problem as well as neuraxis spread and extracranial metastasis; radiotherapy and chemotherapy (including antiangiogenic agents) may be useful.

Malignant Melanoma

Primary malignant melanomas arise in children as well as adults, usually associated with the meninges (whereas metastatic lesions more commonly involve the brain parenchyma), with gadolinium enhancement on MRI and possible leptomeningeal spread. Most lesions contain melanosomes, and electron microscopy can confirm the diagnosis. Prognosis is poor, and tumors are radioresistant, although newer targeted therapies may supplement surgery. *Meningeal melanocytomas* occur mainly in adults and arise in the posterior fossa or spinal cord. Without complete resection, these lesions may transform to malignant melanoma.

LATE EFFECTS OF TREATMENT AND QUALITY OF LIFE

The health of children surviving brain tumors is generally worse than that of survivors of other childhood cancers. Children with supratentorial astrocytomas or craniopharyngioma have a

lower health status index than children with other types of brain tumors. A survey of health-related quality of life in childhood brain tumor survivors found cognitive impairment in two-thirds of the children and pain in almost one-third. Global health status was lowest in children given radiation therapy before age 5 years and in those with residual disease. Even among survivors of pediatric low-grade glioma who continue to have excellent long-term survival into adulthood, the greatest risk factor for death in multivariate analysis was administration of radiation.

Another survey of residual physical handicap in survivors found motor impairment in 56% of patients, cognitive impairment (ie, IQ score <80) in 30%, visual impairment in 24%, and epilepsy in 21%.

A study of psychological outcomes in long-term survivors found that the prevalence of psychological distress (11%) exceeded that in siblings (5%) and was not a direct result of cancer treatment but rather was associated with diminished social functioning and vocational skills. Another report found increased risk of hospital admission was the focus for psychiatric disorders among patients with brain tumors who had survived at least 3 years from diagnosis compared to other childhood cancer survivors, in whom there was no increased risk.

Radiation Effects

Radiation effects include a transient somnolence syndrome of sleepiness, irritability, anorexia, and headaches lasting about a week. Radiation necrosis develops in 0.1% to 5.0% of patients after conventional treatment at 50 to 60 Gy in daily fractions of 180 to 200 cGy. The onset may be within 3 months and is usually seen by 3 years, although occasionally not until much later; the symptoms and signs are those of a recurrent intracranial mass with possible seizures and progressive neuropsychological impairment. Surgical resection may be considered, but the disease may be multifocal following craniospinal irradiation. Medical management includes corticosteroids and usually a trial of bevacizumab.

Cavernous hemangiomas (cavernomas) developed in 3.4% of children at a median of 37 months following radiotherapy for brain tumors. Median age at treatment was 7 years. These rare benign complications of radiation therapy occurs between 2 and 30 years after cranial irradiation. The relative risk of stroke for 5-year survivors of brain tumors was 29.0 compared to sibling controls with dose-dependent increased risk following cranial irradiation exceeding 30 Gy. Treatment is symptomatic.

Endocrine Dysfunction

Endocrine dysfunction may follow irradiation to the hypothalamus and pituitary. Doses as low as 18 Gy may produce growth hormone deficiency, and doses above 36 Gy may cause hypothyroidism and gonadal dysfunction in more than half of patients. Nearly 40% of brain cancer survivors in the Childhood Cancer Survivor Study were below the 10th percentile for height. Risk factors included age younger than 5 years at diagnosis and radiation therapy to the hypothalamic-pituitary axis. Growth hormone deficiency in the absence of other anterior pituitary hormone deficiencies in children receiving cranial irradiation for posterior fossa tumors suggests growth hormone is the hormone most sensitive to radiation injury.

The next most common pituitary hormone abnormality is gonadotropin deficiency. There is an increased risk for delayed puberty and infertility as well as precocious puberty, which can be managed with gonadotropin-releasing hormone antagonists. Frank adrenal insufficiency is uncommon. Hypothalamic obesity, a syndrome of intractable weight gain, is an uncommon but serious complication of hypothalamic irradiation at doses exceeding 50 Gy.

Hypothyroidism is relatively common, particularly in children receiving craniospinal irradiation, because the thyroid gland is in the treatment field. Central hypothyroidism is rare. Hypothyroidism contributes to poor growth and impaired school performance, so thyroid supplementation should be provided. There is also an up to 15-fold increased risk of subsequent primary carcinoma of the thyroid, particularly in females, and most commonly papillary carcinoma.

Children should be followed for measurement of linear growth, periodic thyroid function studies, and additional endocrine evaluation if there is precocious or delayed-onset puberty. Growth hormone treatment improves final height in children with growth hormone deficiency after brain tumor therapy. Growth hormone response depends on adequate thyroid function, and thyroid supplementation may be required. In the subset of patients in whom growth was further limited by early puberty, the combination of gonadotrophin-releasing hormone analogs and growth hormone is reported to improve prospects for attainment of target height. A survey of growth hormone replacement therapy in patients with medulloblastoma suggests a trend toward underutilization, despite ample evidence that there is no increased risk of brain tumor recurrence associated with growth hormone therapy. There is evidence of an increase in the already existing risk for second malignant neoplasms in patients previously treated with radiation therapy. This increased risk of second neoplasms in growth hormone–treated childhood cancer survivors is now listed in the United States labeling for recombinant human growth hormone products.

Cardiovascular and Pulmonary Effects

Cardiovascular late effects in children treated for brain tumors include increased risk of stroke, blood clots, and angina-like symptoms. Late effects are common in those treated with surgery and radiation and higher still in those treated with surgery, radiation, and chemotherapy.

Large-vessel arteriopathy was identified by magnetic resonance angiography in 8.7% of brain tumor survivors following cranial radiation (given at a median age of 6.3 y). These arteriopathies were considered radiation-induced based on localization to the radiation field and absence of other etiologies. One patient had a middle cerebral artery ischemic stroke 2.4 years postradiation, and another had symptoms concerning for transient ischemic attack. The remainder were asymptomatic, and arteriopathy was detected by screening magnetic resonance angiography; these individuals may be candidates for primary stroke prevention strategies.

Cardiovascular problems may be compounded by restrictive lung disease and cardiotoxicity in recipients of craniospinal irradiation or intensive chemotherapy. Among survivors of childhood brain cancer whose mean age was 26 years and mean posttreatment interval was 16 years, systolic blood pressures and waist-to-hip ratios were higher than controls, as were blood lipid abnormalities. These findings identify dyslipidemia, central obesity, and hypertension as controllable risk factors for cardiovascular disease.

Compared to siblings, survivors are at increased risk for chronic cough, need for supplemental oxygen, and pulmonary fibrosis. Survivors treated with craniospinal irradiation were 10 times more likely to report chest wall deformity. These patients should be monitored for scoliosis, which can interfere with lung function.

Neurologic Sequelae

Neurologic and neurosensory sequelae in adult survivors of childhood brain tumors include hearing loss, blindness, cataracts, and diplopia. Nearly half of the survivors have coordination problems, and one-quarter have motor control problems after radiation doses of 50 Gy to frontal brain regions. Seizures are reported in one-quarter of patients, especially after radiation doses of 30 Gy or more. Atonic seizures in particular are difficult to control and are associated with pervasive cognitive impairments. Patients treated with surgery alone generally have no more than minor neurologic impairment that does not interfere with activities of daily living.

Radiation therapy is a principal cause of neurocognitive disorders in children with CNS tumors. Other factors include acute or chronic increased ICP, tumor mass effect, poorly controlled seizure disorders, hormonal deficits, and complications of surgery and chemotherapy. A neurologic predictor scale has been developed to quantify the influence of the various tumor- and treatment-related risks for neurocognitive problems. Radiologic evaluation of patients treated for medulloblastoma with craniospinal irradiation, with or without chemotherapy, showed reduced volumes of normal white matter, which correlated with full-scale IQ. Neurocognitive problems are more likely in children treated at a young age or with high doses of radiation, especially when applied to cerebral-cortical areas associated with higher functions. The effects may be progressive for years and may include attention deficit, impaired memory, and lowering IQ. In one series, mean observed full-scale IQ was 97.1 for nonirradiated patients and 78.8 for irradiated patients. For children with standard-risk medulloblastoma, hyperfractionated radiotherapy was associated with better executive function than standard radiotherapy without any difference in behavior or quality of life. These children generally require psychological intervention and special education programs.

Chronic neurotoxicity of chemotherapy used in treating CNS tumors includes hearing loss (eg, especially after cisplatin therapy) and peripheral neuropathy (eg, with vincristine or occasionally cisplatin and etoposide). Renal impairment and hypertension are associated with cisplatin therapy. Osteopenia is found in half of the children surviving brain tumors, and bone pain may limit physical activity. Chemotherapy may potentiate the deleterious effect of craniospinal irradiation on growth.

Secondary Malignancies

There is an increased risk (3%-5%) of second tumors, including meningiomas and sarcomas arising 10 to 20 years after cranial irradiation. Secondary leukemia has been reported after chemotherapy with alkylating agents and etoposide. In a cohort of patients surviving 5 years from diagnosis of a CNS tumor, survival estimates were 91% at 10 years and 86% at 15 years; causes of late mortality were disease progression (58%), second malignant tumor (21%), and medical complications (18%). Among 5-year survivors treated between 1973 and 1998, the risk of second malignant neoplasms was higher for patients treated after 1985, even controlling for radiotherapy, possibly consistent with increased use of intensive chemotherapy in recent years. A subsequent report refuted this conclusion, showing that the risk of second neoplasm was no higher following radiotherapy plus chemotherapy than following radiotherapy alone (12.0% vs 11.3%, respectively, at 20 years in medulloblastoma patients).

SUGGESTED READINGS

Epidemiology

Agha MM, Williams JI, Marrett L, To T, Zipursky A, Dodds L. Congenital abnormalities and childhood cancer. *Cancer*. 2005;103:1939-1948.

Amlashi SF, Riffaud L, Brassier G, Morandi X. Nevoid basal cell carcinoma syndrome: relation with desmoplastic medulloblastoma in infancy. A population-based study and review of the literature. *Cancer*. 2003;98:618-624.

Bergsagel DJ, Finegold MJ, Butel JS, Kupsky WJ, Garcea RL. DNA sequences similar to those of simian virus 40 in ependymomas and choroid plexus tumors of childhood. *N Engl J Med*. 1992;326:988-993.

Bishop AJ, McDonald MW, Chang AL, Esiashvili N. Infant brain tumors: incidence, survival, and the role of radiation based on Surveillance, Epidemiology, and End Results (SEER) data. *Int J Radiat Oncol Biol Phys*. 2012;82:341-347.

Curless RG, Toledano SR, Ragheb J, Cleveland WW, Falcone S. Hematogenous brain metastasis in children. *Pediatr Neurol*. 2002;26:219-221.

Dubuc AM, Northcott PA, Mack S, Witt H, Pfister S, Taylor MD. The genetics of pediatric brain tumors. *Curr Neurol Neurosci Rep*. 2010;10:215-223.

Girardi F, Allemani C, Coleman MP. Worldwide trends in survival from common childhood brain tumors: a systematic review. *J Glob Oncol*. 2019;5:1-25.

Gittleman HR, Ostrom QT, Rouse CD, et al. Trends in central nervous system tumor incidence relative to other common cancers in adults, adolescents, and children in the United States, 2000 to 2010. *Cancer*. 2015;121:102-112.

Gold DR, Cohen BH. Brain tumors in neurofibromatosis. *Curr Treat Options Neurol*. 2003;5:199-206.

Gururangan S, Robinson G, Ellison DW, et al. Gorlin syndrome and desmoplastic medulloblastoma: report of 3 cases with unfavorable clinical course and novel mutations. *Pediatr Blood Cancer*. 2015;62:1855-1858.

Johnson KJ, Cullen J, Barnholtz-Sloan JS, et al. Childhood brain tumor epidemiology: a brain tumor epidemiology consortium review. *Cancer Epidemiol Biomarkers Prev*. 2014;23(12):2716-2736.

Larouche V, Huang A, Bartels U, Bouffet E. Tumors of the central nervous system in the first year of life. *Pediatr Blood Cancer*. 2007;49(7 suppl): 1074-1082.

Mody R, Li S, Dover DC, et al. Twenty-five-year follow-up among survivors of childhood acute lymphoblastic leukemia: a report from the Childhood Cancer Survivor Study. *Blood*. 2008;111:5515-1523.

Ostrom QT, de Blank PM, Kruchko C, et al. Alex's Lemonade Stand Foundation infant and childhood primary brain and central nervous system tumors diagnosed in the United States in 2007-2011. *Neuro Oncol*. 2015;16(suppl 10):x1-x36.

Ostrom QT, Gittleman H, Truitt G, Boscia A, Kruchko C, Sloan J. CBTRUS statistical report: primary brain and other central nervous system tumors diagnosed in the United States in 2011-2015. *Neuro Oncol*. 2018;20(suppl 4):iv1-iv86.

Packer RJ, Zhou T, Holmes E, et al. Survival and secondary tumors in children with medulloblastoma receiving radiotherapy and adjuvant chemotherapy: results of Children's Oncology Group trial A9961. *Neuro Oncol*. 2013;1:97-103.

Pearce MS, Salotti JA, Little MP, et al. Radiation exposure from CT scans in childhood and subsequent risk of leukaemia and brain tumours: a retrospective cohort study. *Lancet*. 2012;380:499-505.

Vijapura C, Saad Aldin E, Capizzano AA, Piliceni B, Sato Yutaka, Miritani TT. Genetic syndromes associated with central nervous system tumors. *Radiographics*. 2017;37:258-280.

Withrow D, de Gonzalez AB, Lam CJK, Warren KE, Shiels MS. Trends in pediatric central nervous system tumor incidence in US, 1998-2013. *Cancer Epidemiol Biomarkers Prev*. 2019;28:522-530.

Zumel-Marne A, Kundi M, Castaño-Vinyals G, et al. Clinical presentation of young people (10-24 years old) with brain tumors: results from the international MOBI-Kids study. *J Neurooncol*. 2020;147:427-440.

Pathobiology

Bao S, Wu Q, McLendon R, et al. Glioma stem cells promote radioresistance by preferential activation of the DNA damage response. *Nature*. 2006;444:756-760.

Biegel JA, Tan L, Zhang F, Wainright L, Russo P, Rorke LB. Alterations of the hSNF5/INI1 gene in central nervous system atypical teratoid/rhabdoid tumors and renal and extrarenal rhabdoid tumors. *Clin Cancer Res*. 2002;8:3461-3467.

Buczkowicz P, Hoeman C, Rakopoulos P, et al. Genomic analysis of diffuse intrinsic pontine gliomas identifies three molecular subgroups and recurrent activating ACVR1 mutations. *Nat Genet*. 2014;46:451-456.

Chen YH, Gutmann DH. The molecular and cell biology of pediatric low-grade gliomas. *Oncogene*. 2014;33:2019-2026.

Dorris K, Sobo M, Onar-Thomas A, et al. Prognostic significance of telomere maintenance mechanisms in pediatric high-grade gliomas. *J Neurooncol*. 2014;117:67-76.

Fontebasso AM, Liu XY, Sturm D, Jabado N. Chromatin remodeling defects in pediatric and young adult glioblastoma: a tale of a variant histone 3 tail. *Brain Pathol*. 2013;23:210-216.

Garg N, Bakhshinyan D, Venugopal C, et al. CD133^{+} brain tumor-initiating cells are dependent on STAT3 signaling to drive medulloblastoma recurrence. *Oncogene*. 2017;36:606-617.

Garzia L, Kijima N, Morrissy AS, et al. A hematogenous route for medulloblastoma leptomeningeal metastases. *Cell*. 2018;173:1549.

Geoerger B, Gaspar N, Opolon P, et al. EGFR tyrosine kinase inhibition radiosensitizes and induces apoptosis in malignant glioma and childhood ependymoma xenografts. *Int J Cancer*. 2008;123:209-216.

Gesundheit B, Klement G, Senger C, et al. Differences in vasculature between pilocytic and anaplastic astrocytomas of childhood. *Med Pediatr Oncol*. 2003;41:516-526.

Gibson P, Tong Y, Robinson G, et al. Subtypes of medulloblastoma have distinct developmental origins. *Nature*. 2010;468:1095-1099.

Gupta T, Maitre M, Sastri GJ, et al. Outcomes of salvage re-irradiation in recurrent medulloblastoma correlate with age at initial diagnosis, primary risk-stratification, and molecular subgrouping. *J Neurooncol*. 2019;144:283-291.

Holland EC, Celestino J, Dai C, Schaefer L, Sawaya RE, Fuller GN. Combined activation of RAS and AKT in neural progenitors induces glioblastoma formation in mice. *Nat Genet*. 2000;25:55-57.

Hovestadt V, Jones DT, Picelli S, et al. Decoding the regulatory landscape of medulloblastoma using DNA methylation sequencing. *Nature*. 2014;510:537-541.

Hovestadt V, Smith KS, Bihannic L, et al. Resolving medulloblastoma cellular architecture by single-cell genomics. *Nature*. 2019;572:74-79.

Jacobs JFM, Grauer OM, Brasseur F, et al. Selective cancer-germline gene expression in pediatric brain tumors. *J Neurooncol*. 2008;88:273-280.

Jessa S, Blanchet-Cohen A, Krug B, et al. Stalled developmental programs at the root of pediatric brain tumors. *Nat Genet*. 2019;51:1702-1723.

Johnson RA, Wright KD, Poppleton H, et al. Cross-species genomics matches driver mutations and cell compartments to model ependymoma. *Nature*. 2010;466:632-636.

Jones DT, Jäger N, Kool M, et al. Dissecting the genomic complexity underlying medulloblastoma. *Nature*. 2012;488:100-105.

Judkins AR, Mauger J, Rorke LB, Ht A, Rorke LB, Biegel JA. Immunohistochemical analysis of hSNF5/INI1 in pediatric CNS neoplasms. *Am J Surg Pathol*. 2004;28:644-650.

Kameda-Smith MM, Wang A, Abdulhadi N. Salvage therapy for childhood medulloblastoma: a single center experience. *Can J Neurol Sci*. 2019;46:403-414.

Kool M, Jones DT, Jäger N, et al. Genome sequencing of SHH medulloblastoma predicts genotype-related response to smoothened inhibition. *Cancer Cell*. 2014;25:393-405.

Korshunov A, Schrimpf D, Ryzhova M, et al. H3-/IDH-wild type pediatric glioblastoma is comprised of molecularly and prognostically distinct subtypes with associated oncogenic drivers. *Acta Neuropathol*. 2017;134:507-516.

Lassaletta A, Zapotocky M, Mistry M, et al. Therapeutic and prognostic implications of BRAF V600E in pediatric low-grade gliomas. *J Clin Oncol*. 2017;35:2934-2941.

Leung C, Lingbeek M, Shakhova O, et al. Bmi1 is essential for cerebellar development and is overexpressed in human medulloblastomas. *Nature*. 2004;428:337-341.

Li M, Lee KE, Lu Y, et al. Frequent amplification of a chr19q13.41 microRNA polycistron in aggressive primitive neuroectodermal brain tumors. *Cancer Cell*. 2009;16:533-546.

Louis DN, Wesseling P, Aldape K, et al. cIMPACT-NOW update 6: new entity and diagnostic principle recommendations of the cIMPACT-Utrecht meeting on future CNS tumor classification and grading. *Brain Pathol*. 2020;30(4):844-856.

Lusher ME, Lindsey JC, Latif F, Pearson A, Ellison P, Clifford SC. Biallelic epigenetic inactivation of the RASSF1A tumor suppressor gene in medulloblastoma development. *Cancer Res*. 2002;62:5906-5911.

Miklja Z, Pasternak A, Stallard S, et al. Molecular profiling and targeted therapy in pediatric gliomas: review and consensus recommendations. *Neuro Oncol*. 2019;21:968-980.

Miller S, Rogers HA, Lyon P, et al. Genome-wide molecular characterization of central nervous system primitive neuroectodermal tumor and pineoblastoma. *Neuro Oncol*. 2011;13:866-879.

Monje M, Mitra SS, Freret ME, et al. Hedgehog-responsive candidate cell of origin for diffuse intrinsic pontine glioma. *Proc Natl Acad Sci U S A*. 2011;108:4453-4458.

Morrissy AS, Garzia L, Shih DJ. Divergent clonal selection dominates medulloblastoma at recurrence. *Nature*. 2016:529:351-357.

Nobre L, Pauck D, Golbourn B, et al. Effective and safe tumor inhibition using vinblastine in medulloblastoma. *Pediatr Blood Cancer*. 2019;66:e27694.

Northcott PA, Lee C, Zichner T, et al. Enhancer hijacking activates GFI1 family oncogenes in medulloblastoma. *Nature*. 2014;511:428-434.

Northcott PA, Shih DJ, Peacock J, et al. Subgroup-specific structural variation across 1,000 medulloblastoma genomes. *Nature*. 2012;488:49-56.

Pajtler KW, Witt H, Sill M, et al. Molecular classification of ependymal tumors across all CNS compartments, histopathological grades, and age groups. *Cancer Cell*. 2015;27:728-743.

Pickles JC, Fairchild AR, Stone TJ, et al. DNA methylation-based profiling for paediatric CNS tumour diagnosis and treatment: a population-based study. *Lancet Child Adolesc Health*. 2020;4:121-130.

Pollack IF, Finkelstein SD, Woods J, et al. Expression of p53 and prognosis in children with malignant gliomas. *N Engl J Med*. 2002;346:420-427.

Pomeroy SL, Tamayo P, Gaasenbeek M, et al. Prediction of central nervous system embryonal tumour outcome based on gene expression. *Nature*. 2002;415:436-442.

Pugh TJ, Weeraratne SD, Archer TC, et al. Medulloblastoma exome sequencing uncovers subtype-specific somatic mutations. *Nature*. 2012;488:106-110.

Rodriguez FJ, Lim KS, Bowers D, Eberhart CG. Pathological and molecular advances in pediatric low grade astrocytoma. *Annu Rev Pathol*. 2013;8:361-379.

Rubin JB, Rowitch DH. Medulloblastoma: a problem of developmental biology. *Cancer Cell*. 2002;2:7-8.

Schneider DT, Zahn S, Sievers S, et al. Molecular genetic analysis of central nervous system germ cell tumors with comparative genomic hybridization. *Mol Pathol*. 2006;19:864-873.

Schwartzentruber J, Korshunov A, Liu XY, et al. Driver mutations in histone H3.3 and chromatin remodelling genes in paediatric glioblastoma. *Nature*. 2012;482:226-231.

Shih DJ, Northcott PA, Remke M, et al. Cytogenetic prognostication within medulloblastoma subgroups. *J Clin Oncol*. 2014;32:886-896.

Stupp R, Hegi ME. Targeting brain-tumor stem cells. *Nat Biotechnol*. 2007;25:193-194.

Sturm D, Orr BA, Toprak UH, et al. New brain tumor entities emerge from molecular classification of CNS-PNETs. *Cell*. 2016;164:1060-1072.

Taylor MD, Northcott PA, Korshunov A, et al. Molecular subgroups of medulloblastoma: the current consensus. *Acta Neuropathol*. 2012;123:465-472.

Taylor MD, Poppleton H, Fuller C, et al. Radial glia cells are candidate stem cells of ependymoma. *Cancer Cell*. 2005;8:323-335.

Thirant C, Bessette B, Varlet P, et al. Clinical relevance of tumor cells with stem-like properties in pediatric brain tumors. *PLoS One*. 2011;6:e16375.

Witt H, Mack SC, Ryzhova M, et al. Delineation of two clinically and molecularly distinct subgroups of posterior fossa ependymoma. *Cancer Cell*. 2011;20:143-157.

Wu G, Broniscer A, McEachron TA, et al. Somatic histone H3 alterations in pediatric diffuse intrinsic pontine gliomas and non-brainstem glioblastomas. *Nat Genet*. 2012;44:251-253.

Yang RR, Aibaidula A, Wang WW, et al. Pediatric low-grade gliomas can be molecularly stratified for risk. *Acta Neuropathol*. 2018;136:641-655.

Zaky W. Revisiting management of pediatric brain tumors with new molecular insights. *Cell*. 2016;164:844-846.

Zarghooni M, Bartels U, Lee E, et al. Whole-genome profiling of pediatric diffuse intrinsic pontine gliomas highlights platelet-derived growth factor receptor alpha and poly (ADP-ribose) polymerase as potential therapeutic targets. *J Clin Oncol*. 2010;28:1337-1344.

Symptoms, Diagnosis, and Initial Management

Beccaria K, Canney M, Bouchoux G, Puget S, Grill J, Carpentier A. Blood-brain barrier disruption with low-intensity pulsed ultrasound for the treatment of pediatric brain tumors: a review and perspectives. *Neurosurg Focus*. 2020;48:E10.

Bénit CP, Vecht CJ. Seizures and cancer: drug interactions of anticonvulsants with chemotherapeutic agents, tyrosine kinase inhibitors, and glucocorticoids. *Neurooncol Pract*. 2016;3:245-260.

Borgwardt L, Højgaard L, Carstensen H, et al. Increased fluorine-18 2-fluoro-2-deoxy-D-glucose (FDG) uptake in childhood CNS tumors is correlated with malignancy grade: a study with FDG positron emission tomography/magnetic resonance imaging coregistration and image fusion. *J Clin Oncol*. 2005;23:3030-3037.

Capper D, Jones DTW, Sill M, et al. DNA methylation-based classification of central nervous system tumours. *Nature*. 2018;555:469-474.

Caruso DA, Orme LM, Neale AM, et al. Results of a phase 1 study utilizing monocyte-derived dendritic cells pulsed with tumor RNA in children and young adults with brain cancer. *Neuro Oncol*. 2004;6:236-246.

Dobrovoljac M, Hengartner H, Boltshauser E, Grotzer MA. Delay in the diagnosis of paediatric brain tumours. *Eur J Pediatr*. 2002;161:663-667.

Goethe EA, Gadgil N, Stormes K, Wassef A, Lopresti M, Lam S. Predicting dysphagia in children undergoing surgery for posterior fossa tumors. *Childs Nerv Syst*. 2020;36:925-931.

Gorsi HS, Malicki DM, Barsan V, et al. Nivolumab in the treatment of recurrent or refractory pediatric brain tumors: a single institutional experience. *J Pediatr Hematol Oncol*. 2019;41:e235-e241.

Guerra JA, Dhall G, Marachelian A, et al. Marrow-ablative chemotherapy followed by tandem autologous hematopoietic cell transplantation in pediatric patients with malignant brain tumors. *Bone Marrow Transplant*. 2017;52:1543-1548.

Habrand JL, De Crevoisier R. Radiation therapy in the management of childhood brain tumors. *Childs Nerv Syst*. 2001;17:121-133.

Huang TY, Piunti A, Lulla, et al. Detection of histone H3 mutations in cerebrospinal fluid-derived tumor DNA from children with diffuse midline glioma. *Acta Neuropathol Commun*. 2017;5:28.

Jaspan T, Morgan PS, Warmuth-Metz M, et al. Response assessment in pediatric neuro-oncology: implementation and expansion of the RANO criteria in a randomized phase II trial of pediatric patients with newly diagnosed high-grade gliomas. *AJNR Am J Neuroradiol*. 2016;37:1581-1587.

Kestle JR. Pediatric hydrocephalus: current management. *Neurol Clin*. 2003;21:883-895.

Kirsch DG, Tarbell NJ. New technologies in radiation therapy for pediatric brain tumors: the rationale for proton radiation therapy. *Pediatr Blood Cancer*. 2004;42:461-464.

Korshunov A, Meyer J, Capper D, et al. Combined molecular analysis of BRAF and IDH1 distinguishes pilocytic astrocytoma from diffuse astrocytoma. *Acta Neuropathol*. 2009;118:401-405.

Kramer ED, Vezina LG, Packer RJ, Fitz CR, Zimmerman RA, Cohen MD. Staging and surveillance of children with central nervous system neoplasms: recommendations of the Neurology and Tumor Imaging Committees of the Children's Cancer Group. *Pediatr Neurosurg*. 1994;20:254-263.

Kremer P, Tronnier V, Steiner HH, et al. Intraoperative MRI for interventional neurosurgical procedures and tumor resection control in children. *Childs Nerv Syst*. 2006;22:674-678.

Kukal K, Dobrovoljac M, Boltshauser E, Ammann RA, Grotzer MA. Does diagnostic delay result in decreased survival in paediatric brain tumours? *Eur J Pediatr*. 2009;168(3):303-310.

Levisohn L, Cronin-Golomb A, Schmahmann JD. Neuropsychological consequences of cerebellar tumour resection in children: cerebellar cognitive affective syndrome in a paediatric population. *Brain*. 2000;123(pt 5):1041-1050.

Lian H, Daniels C, Han YP, et al. Incidence of metastatic disease and survival among patients with newly diagnosed primary CNS tumors in the United States from 2004-2013. *J Cancer*. 2019;10:3037-3045.

Lin CT, Riva-Cambrin JK. Management of posterior fossa tumors and hydrocephalus in children: a review. *Childs Nerv Syst*. 2015;31:1781-1789.

Louis DN, Perry A, Reifenberger G, et al. The 2016 World Health Organization classification of tumors of the central nervous system: a summary. *Acta Neuropathol*. 2016;131:803-820.

Main C, Stevens SP, Bailey S, et al. The impact of routine surveillance screening with magnetic resonance imaging (MRI) to detect tumour recurrence in children with central nervous system (CNS) tumours: protocol for a systematic review and meta-analysis. *Syst Rev*. 2016;5:143.

Medina LS, Kuntz KM, Pomeroy S. Children with headache suspected of having a brain tumor: a cost-effectiveness analysis of diagnostic strategies. *Pediatrics*. 2001;108:255-263.

Merchant TE, Hua C-H, Shukla H, Ying X, Nill S, Oelfke U. Proton versus photon radiotherapy for common pediatric brain tumors: comparison of models of dose characteristics and their relationship to cognitive function. *Pediatr Blood Cancer*. 2008;51:110-117.

Minn AY, Pollock BH, Garzarella L, et al. Surveillance neuroimaging to detect relapse in childhood brain tumors: a Pediatric Oncology Group study. *J Clin Oncol*. 2001;19:4135-4140.

Pfister S, Hartmann C, Korshunov A. Histology and molecular pathology of pediatric brain tumors. *J Child Neurol*. 2009;24:1375-1386.

Pollack IF, Keating R. New delivery approaches for pediatric brain tumors. *J Neurooncol*. 2005;75:315-326.

Qayed M, Cash T, Tighiouart M, et al. A phase I study of sirolimus in combination with metronomic therapy (CHOAnome) in children with recurrent or refractory solid and brain tumors. *Pediatric Blood Cancer*. 2000;67:e28134.

Rodriguez D, Chambers T, Warmuth-Metz M, et al. Evaluation of the implementation of the Response Assessment in Neuro-Oncology Criteria in the HERBY trial of pediatric patients with newly diagnosed high-grade gliomas. *AJNR Am J Neuroradiol*. 2019;40:568-575.

Roth J, Beni-Adani L, Biyani N, Constantini S. Classical and real-time neuronavigation in pediatric neurosurgery. *Childs Nerv Syst*. 2006;22:1065-1071.

Roth J, Bercovich O, Roach A, et al. Seizures following surgery for supratentorial extratemporal low-grade tumors in children: a multicenter retrospective study [published online ahead of print April 3, 2020]. *J Neurosurg Pediatr*. doi:10.3171/2020.2.PEDS19673.

Roth J, Fischer N, Limbrick DD, CreveCoeur T, Ben-Sira L, Constantini S. The role of screening spinal MRI in children with solitary posterior fossa low-grade glial tumors [published online ahead of print November 15, 2019]. *J Neurosurg Pediatr*. doi:10.3171/2019.9.PEDS19358.

Sandberg DI. Endoscopic management of hydrocephalus in pediatric patients: a review of indications, techniques, and outcomes. *J Child Neurol*. 2008;23:550-560.

Soleman J, Kozyrev DA, Ben-Sira L, Constantini S, Roth J. Management of incidental brain tumors in children: a systematic review. *Childs Nerv Syst*. 2020;36:1607-1619.

Steinbok P, Cochrane DD, Perrin R, Price A. Mutism after posterior fossa tumour resection in children: incomplete recovery on long-term follow-up. *Pediatr Neurosurg*. 2003;39:179-183.

Tabori U, Hansford JR, Achatz MI, et al. Clinical management and tumor surveillance recommendations of inherited mismatch repair deficiency in childhood. *Clin Cancer Res*. 2017;23:e32-e37.

Taylor JS, Langston JW, Reddick WE, et al. Clinical value of proton magnetic resonance spectroscopy for differentiating recurrent or residual brain tumor from delayed cerebral necrosis. *Int J Radiat Oncol Biol Phys*. 1996;36:1251-1261.

Utriainen M, Metsähonkala L, Salmi TT, et al. Metabolic characterization of childhood brain tumors: comparison of ^{18}F-fluorodeoxyglucose and ^{11}C-methionine positron emission tomography. *Cancer*. 2002;95:1376-1386.

Walker D, Wilne S, Grundy R, et al. A new clinical guideline from the Royal College of Pediatrics and Child Health with a national awareness campaign accelerates brain tumor diagnosis in UK children—"HeadSmart: Be Brain Tumor Aware." *Neuro Oncol*. 2016;18:445-454.

Warren KE. NMR spectroscopy and pediatric brain tumors. *Oncologist*. 2004;9:312-318.

Warren KE, Patronas N, Aikin AA, Albert PS, Balis FM. Comparison of one-, two-, and three-dimensional measurements of childhood brain tumors. *J Natl Cancer Inst*. 2001;93:1401-1405.

Warren KE, Poussaint TY, Vezina G, et al. Challenges with defining response to antitumor agents in pediatric neuro-oncology: a report from the Response Assessment in Pediatric Neuro-Oncology (RAPNO) Working Group. *Pediatr Blood Cancer*. 2013;60:1397-1401.

Warren KE, Vezina G, Poussaint TY, et al. Response assessment in medulloblastoma and leptomeningeal seeding tumors: recommendations from the Response Assessment in Pediatric Neuro-Oncology Committee. *Neuro Oncol*. 2018;20:13-23.

Wen PY, Macdonald DR, Reardon DA, et al. Updated response assessment criteria for high-grade gliomas: Response Assessment in Neuro-Oncology Working Group. *J Clin Oncol*. 2010;28:1963-1972.

Wilne S, Collier J, Kennedy C, Kohler K, Grunfy R, Walker D. Presentation of childhood CNS tumours: a systematic review and meta-analysis. *Lancet Oncol*. 2007;8 685-695.

Wilne S, Koller K, Collier J, Kennedy C, Frundy G, Walker . The diagnosis of brain tumours in children: a guideline to assist healthcare professionals in the assessment of children who may have a brain tumour. *Arch Dis Child*. 2010;95:534-539.

Yousaf J, Avula S, Abernethy LJ, et al. Importance of intraoperative magnetic resonance imaging for pediatric brain tumor surgery. *Surg Neurol Int*. 2012;3(suppl 2):S65-S72.

Congenital Tumors

Abel TW, Baker SJ, Fraser MM, et al. Lhermitte-Duclos disease: a report of 31 cases with immunohistochemical analysis of the PTEN/AKT/mTOR pathway. *J Neuropathol Exp Neurol*. 2005;64(4):341-349.

Antonelli M, Raso A, Mascelli S, et al. SMARCB1/INI1 involvement in pediatric chordoma: a mutational and immunohistochemical analysis. *Am J Surg Pathol*. 2017;41:56-61.

Bächli H, Avoledo P, Gratzl O, et al. Therapeutic strategies and management of desmoplastic infantile ganglioglioma: two case reports and literature review. *Childs Nerv Syst*. 2003;19:359-366.

Bakhtiar Y, Yonezawa H, Bohara M, et al. Posterior fossa immature teratoma in an infant with trisomy 21: a case report and review of the literature. *Surg Neurol Int*. 2012;3:100.

Bettegowda C, Adogwa O, Mehta V, et al. Treatment of choroid plexus tumors; a 20-year single institutional experience. *J Neurosurg Pediatr*. 2012;10: 398-405.

Blakeley JO, Ye X, Duda DG. Efficacy and biomarker study of bevacizumab for hearing loss resulting from neurofibromatosis type 2-associated vestibular schwannomas. *J Clin Oncol*. 2016;34:1669-1675.

Blessing MM, Blackburn PR, Balcom JR, et al. Novel *BRAF* alteration in desmoplastic infantile ganglioglioma with response to targeted therapy. *Acta Neuropathol Commun*. 2018;6:118.

Elliott RE, Hsieh K, Hochm T, Belitskaya-Levy I, Wisoff J, Wisoff JH. Efficacy and safety of radical resection of primary and recurrent craniopharyngiomas in 86 children. *J Neurosurg Pediatr*. 2010;5:30-48.

Fornari M, Solero C, Lasio G, et al. Surgical treatment of intracranial dermoid and epidermoid cysts in children. *Childs Nerv Syst*. 1990;6:66-70.

Fouladi M, Jenkins J, Burger P, et al. Pleomorphic xanthoastrocytoma: favorable outcome after complete surgical resection. *Neuro Oncol*. 2001;3:184-192.

Gardner PA, Prevedello DM, Kassam AB, Snyderman CH, Carrau R, Mintz AH. The evolution of the endonasal approach for craniopharyngioma. *J Neurosurg*. 2008;108:1043-1047.

Hamlat A, Hua ZF, Saikali S, et al. Malignant transformation of intra-cranial epithelial cysts: systematic article review. *J Neurooncol*. 2005;74:187-194.

Hellwig D, Bauer BL, Schulte M, Gatscher S, Riegel T, Bertalanffy H. Neuroendoscopic treatment for colloid cysts of the third ventricle: the experience of a decade. *Neurosurgery*. 2003;52:525-533.

Im SH, Chung CK, Cho BK, et al. Intracranial ganglioglioma: preoperative characteristics and oncologic outcome after surgery. *J Neurooncol*. 2002;59:173-183.

Jeibmann A, Wrede B, Peters O, Wolff JE, Paulus W, Hasselblatt M. Malignant progression in choroid plexus papillomas. *J Neurosurg*. 2007;107(3 suppl):199-202.

Kaylie DM, Warren FM III, Haynes DS, Jackson CG. Neurotologic management of intracranial epidermoid tumors. *Laryngoscope*. 2005;115:1082-1086.

Keil MF, Stratakis CA. Pituitary tumors in childhood: update of diagnosis, treatment and molecular genetics. *Expert Rev Neurother*. 2008;8:563-574.

Kobayashi T. Long-term results of gamma knife radio surgery for 100 consecutive cases of craniopharyngioma and a treatment strategy. *Prog Neurol Surg*. 2009;22:63-76.

Mallick S, Benson R, Melgandi W, Rath GK. Effect of surgery, adjuvant therapy, and other prognostic factors on choroid plexus carcinoma: a systematic review and individual patient data analysis. *Int J Radiat Oncol Biol Phys*. 2017;99:1199-1206.

Mallucci C, Lellouch-Tubiana A, Salazar C, et al. The management of desmoplastic neuroepithelial tumours in childhood. *Childs Nerv Syst*. 2000;16: 8-14.

Marks AM, Bindra RS, DiLuna ML, et al. Response to the BRAF/MEK inhibitors dabrafenib/trametinib in an adolescent with a BRAF V600E mutated anaplastic ganglioglioma intolerant to vemurafenib. *Pediatr Blood Cancer*. 2018;65:e26969.

Merchant TE, Kun LE, Hua CH, et al. Disease control after reduced volume conformal and intensity-modulated radiation therapy for childhood craniopharyngioma. *Int J Radiat Oncol Biol Phys*. 2013;85:e187-e192.

Merino DM, Shlien A, Villani A, et al. Molecular characterization of choroid plexus tumors reveals novel clinically relevant subgroups. *Clin Cancer Res*. 2015;21:184-192.

Mortini P, Losa M, Pozzobon G, et al. Neurosurgical treatment of craniopharyngioma in adults and children: early and long-term results in a large case series. *J Neurosurg*. 2011;114:1350-1359.

Nolan MA, Sakuta R, Chuang N, et al. Dysembryoplastic neuroepithelial tumors in childhood: long-term outcome and prognostic features. *Neurology*. 2004;62:2270-2276.

O'Brien DF, Farrell M, Delanty N, et al. The Children's Cancer and Leukaemia Group guidelines for the diagnosis and management of dysembryoplastic neuroepithelial tumours. *Br J Neurosurg*. 2007;21:539-549.

Pekmezci M, Villanueva-Meyer JE, Goode B, et al. The genetic landscape of ganglioglioma. *Acta Neuropathol Commun*. 2018;6:47.

Phi JH, Kim SK, Park SH, Hong SH, Wang KC, Cho BK. Immature teratomas of the central nervous system: is adjuvant therapy mandatory? *J Neurosurg*. 2005;103(6 suppl):524-530.

Rades D, Zwick L, Leppert J, et al. The role of postoperative radiotherapy for the treatment of gangliogliomas. *Cancer*. 2010;116:432-442.

Sagers JE, Beauchamp RL, Zhang Y, et al. Combination therapy with mTOR kinase inhibitor and dasatinib as a novel therapeutic strategy for vestibular schwannoma. *Sci Rep*. 2020;10:4211.

Shaktawat S, Salman WD, Twaij Z, Al-Dawoud A. Unexpected death after headache due to a colloid cyst of the third ventricle. *World J Surg Oncol*. 2006;4:47.

Tabori U, Shlien A, Baskin B, et al. TP53 alterations determine clinical subgroups and survival of patients with choroid plexus tumors. *J Clin Oncol*. 2010;28:1995-2001.

Tamburrini G, Colosimo C Jr, Giangaspero F, Riccardi R, Di Rocco C. Desmoplastic infantile ganglioglioma. *Childs Nerv Syst*. 2003;19:292-297.

Tamura R, Fujioka M, Morimoto Y, et al. A VEGF receptor vaccine demonstrates preliminary efficacy in neurofibromatosis type 2. *Nat Commun*. 2019;10:5758.

Thomas C, Sill M, Ruland V, et al. Methylation profiling of choroid plexus tumors reveals 3 clinically distinct subgroups. *Neuro Oncol*. 2016;18:790-796.

Touat M, Gratieux J, Condette Auliac S, et al. Vemurafenib and cobimetinib overcome resistance to vemurafenib in *BRAF*-mutant ganglioglioma. *Neurology*. 2018;91:523-525.

Uliel-Sibony S, Kramer U, Fried I, Fattal-Valevski A, Constantini S. Pediatric temporal low-grade glial tumors: epilepsy outcome following resection in 48 children. *Childs Nerv Syst*. 2011;27:1413-1418.

Vinchon M, Dhellemmes P. Craniopharyngiomas in children: recurrence, reoperation and outcome. *Childs Nerv Syst*. 2008;24:211-217.

Wrede B, Hasselblatt M, Peters O, et al. Atypical choroid plexus papilloma: clinical experience in the CPT-SIOP-2000 study. *J Neurooncol*. 2009;95: 383-392.

Wrede B, Liu P, Wolff JE. Chemotherapy improves the survival of patients with choroid plexus carcinoma: a meta-analysis of individual cases with choroid plexus tumors. *J Neurooncol*. 2007;85:345-351.

Yang I, Sughrue ME, Rutkowski MJ, et al. Craniopharyngioma: a comparison of tumor control with various treatment strategies. *Neurosurg Focus*. 2010;28:E5.

Yao L, Alahmari M, Temel Y, Hovinga K. Therapy of sporadic and NF2-related vestibular schwannoma. *Cancers (Basel)*. 2020;12:835.

Yasuda M, Bresson D, Chibbaro S, et al. Chordomas of the skull base and cervical spine: clinical outcomes associated with a multimodal surgical resection combined with proton-beam radiation in 40 patients. *Neurosurg Rev*. 2012;35:171-182.

Yeung JT, Pollack IF, Panigrahy A, Jakacki RI. Pegylated interferon-α-2b for children with recurrent craniopharyngioma. *J Neurosurg Pediat*. 2012;10: 498-503.

Zacharia BE, Bruce SS, Goldstein H, Malone HR, Neugut AI, Bruce JN. Incidence, treatment and survival of patients with craniopharyngioma in the surveillance, epidemiology and end results program. *Neuro Oncol*. 2012;14:1070-1078.

Zak M, Ledbetter M, Maertens P. Infantile Lhermitte-Duclos disease treated successfully with rapamycin. *J Child Neurol*. 2017;32:322-326.

Zaky W, Finlay JL. Pediatric choroid plexus carcinoma: Biologically and clinically in need of new perspectives. *Pediatr Blood Cancer*. 2018;65:e27031.

Astrocytoma

Armstrong GT, Phillips PC, Rorke-Adams LB, Judkins AR, Localio AR, Fisher MJ. Gliomatosis cerebri: 20 years of experience at the Children's Hospital of Philadelphia. *Cancer*. 2006;107:1597-1606.

Ater JL, Zhou T, Holmes E, et al. Randomized study of two chemotherapy regimens for treatment of low-grade glioma in young children: a report from the Children's Oncology Group. *J Clin Oncol*. 2012;30:2641-2647.

Avery RA, Hwang EI, Jakacki RI, Packer RJ. Marked recovery of vision in children with optic pathway gliomas treated with bevacizumab. *JAMA Ophthalmol*. 2014;132:111-114.

Bander ED, Tizi K, Wembacher-Schroeder E, et al. Deformational changes after convection-enhanced delivery in the pediatric brainstem. *Neurosurg Focus*. 2020;48:E3.

Banerjee A, Jakacki RI, Onar-Thomas A, et al. A phase I trial of the MEK inhibitor selumetinib (AZD6244) in pediatric patients with recurrent or refractory low-grade glioma: a Pediatric Brain Tumor Consortium (PBTC) study. *Neuro Oncol*. 2017;19:1135-1144.

Benesch M, Eder HG, Sovinz P, et al. Residual or recurrent cerebellar low-grade glioma in children after tumor resection: is re-treatment needed? A single center experience from 1983 to 2003. *Pediatr Neurosurg*. 2006;42:159-164.

Bouffet E, Jakacki R, Goldman S, et al. Phase II study of weekly vinblastine in recurrent or refractory pediatric low-grade glioma. *J Clin Oncol*. 2012;30:1358-1363.

Bouffet E, Larouche V, Campbell BB, et al. Immune checkpoint inhibition for hypermutant glioblastoma multiforme resulting from germline biallelic mismatch repair deficiency. *J Clin Oncol*. 2016;34:2206-2211.

Bowers DC, Gargan L, Kapur P, et al. Study of the MIB-1 labeling index as a predictor of tumor progression in pilocytic astrocytomas in children and adolescents. *J Clin Oncol*. 2003;21:2968-2973.

Bowers DC, Krause TP, Aronson LJ, et al. Second surgery for recurrent pilocytic astrocytoma in children. *Pediatr Neurosurg*. 2001;34:229-234.

Bronisder A, Laningham FH, Sanders RP, Kun LE, Ellison DW, Gajjar A. Young age may predict a better outcome for children with diffuse pontine glioma. *Cancer*. 2008;113(3):566-572.

Cherlow JM, Shaw DWW, Margraf LR, et al. Conformal radiation therapy for pediatric patients with low-grade glioma: results from the Children's Oncology Group phase 2 study ACNS0221. *Int J Radiat Oncol Biol Phys*. 2018;103:861-868.

Chi AS, Tarapore RS, Hall MD, et al. Pediatric and adult H3 K27M-mutant diffuse midline glioma treated with the selective DRD2 antagonist ONC201. *J Neurooncol*. 2019;145:97-106.

Cohen KJ, Pollack IF, Zhou T, et al. Temozolomide in the treatment of high-grade gliomas in children: a report from the Children's Oncology Group. *Neuro Oncol*. 2011;13:317-323.

Daglioglu E, Cataltepe O, Akalan N. Tectal gliomas in children: the implications for natural history and management strategy. *Pediatr Neurosurg*. 2003;38:223-231.

Dunkel IJ, Garvin JH Jr, Goldman S, et al. High dose chemotherapy with autologous bone marrow rescue for children with diffuse pontine brain stem tumors. Children's Cancer Group. *J Neurooncol*. 1998;37:67-73.

Espinoza JC, Haley K, Patel N, et al. Outcome of young children with high-grade glioma treated with irradiation-avoiding intensive chemotherapy regimens: final report of the Head Start II and III trials. *Pediatr Blood Cancer*. 2016;63:1805-1813.

Fangusaro JR, Onar-Thomas A, Young Poussaint T, et al. Selumetinib in paediatric patients with BRAF-aberrant or neurofibromatosis type 1-associated recurrent, refractory, or progressive low-grade glioma: a multicentre, phase 2 trial. *Lancet Oncol*. 2019;20:1011-1022.

Finlay JL, Boyett JM, Yates AJ, et al. Randomized phase III trial in childhood high-grade astrocytoma comparing vincristine, lomustine, and prednisone with the eight-drugs-in-1-day regimen. Childrens Cancer Group. *J Clin Oncol*. 1995;13:112-123.

Finlay JL, Dhall G, Boyett JM, et al. Myeloablative chemotherapy with autologous bone marrow rescue in children and adolescents with recurrent malignant astrocytoma: outcome compared with conventional chemotherapy: a report from the Children's Oncology Group. *Pediatr Blood Cancer*. 2008;51:806-811.

Finlay JL, Zacharoulis S. The treatment of high grade gliomas and diffuse intrinsic pontine tumors of childhood and adolescence: a historical—and futuristic—perspective. *J Neurooncol*. 2005;75:253-266.

Fisher PG, Tihan T, Goldthwaite PT, et al. Outcome analysis of childhood low-grade astrocytomas. *Pediatr Blood Cancer*. 2008;51:245-250.

Franz DN, Belousova E, Sparagana S, et al. Efficacy and safety of everolimus for subependymal giant cell astrocytomas associated with tuberous sclerosis complex (EXIST-1): a multicentre, randomised, placebo-controlled phase 3 trial. *Lancet*. 2013;381:125-132.

Franz DN, Weiss BD. Molecular therapies for tuberous sclerosis and neurofibromatosis. *Curr Neurol Neurosci Rep*. 2012;12:294-301.

Fukuoka K, Mamatjan Y, Tatevossian R, et al. Clinical impact of combined epigenetic and molecular analysis of pediatric low grade gliomas [published online ahead of print April 3, 2020]. *Neuro Oncol*. doi:10.1093/neuonc/noaa077.

Gnekow AK, Kandels D, Tilburg CV, et al. SIOP-E-BTG and GPOH guidelines for diagnosis and treatment of children and adolescents with low grade glioma. *Klin Padiatr*. 2019;231:107-135.

Gnekow AK, Kortmann RD, Pietsch T, Emser A. Low grade chiasmatic-hypothalamic glioma-carboplatin and vincristin chemotherapy effectively defers radiotherapy within a comprehensive treatment strategy—report from the multicenter treatment study for children and adolescents with a low grade glioma—HIT-LGG 1996—of the Society of Pediatric Oncology and Hematology (GPOH). *Klin Padiatr*. 2004;216:331-342.

Gnekow AK, Walker DA, Kandels D, et al. A European randomised controlled trial of the addition of etoposide to standard vincristine and carboplatin induction as part of an 18-month treatment programme for childhood (≤16 years) low grade glioma—a final report. *Eur J Cancer*. 2017;81:206-225.

Gojo J, Pavelka Z, Zapletalova D, et al. Personalized treatment of H3K27M-mutant pediatric diffuse gliomas provides improved therapeutic opportunities. *Front Oncol*. 2020;9:1436.

Gorsi HS, Khanna PC, Tumblin M, et al. Single-agent bevacizumab in the treatment of recurrent or refractory pediatric low-grade glioma: a single institutional experience. *Pediatric Blood Cancer*. 2018;65:e27234.

Greenberger BA, Pulsifer MB, Ebb DH, et al. Clinical outcomes and late endocrine, neurocognitive, and visual profiles of proton radiation for pediatric low-grade gliomas. *Int J Radiat Oncol Biol Phys*. 2014;89:1060-1068.

Grill J, Massimino M, Bouffet E, et al. Phase II, open-label, randomized, multicenter trial (HERBY) of bevacizumab in pediatric patients with newly diagnosed high-grade glioma. *J Clin Oncol*. 2018;36:951-958.

Gropman AL, Packer RJ, Nicholson HS, et al. Treatment of diencephalic syndrome with chemotherapy: growth, tumor response, and long term control. *Cancer*. 1998;83:166-172.

Gross AM, Wolters PL, Dombi E, et al. Selumetinib in children with inoperable plexiform neurofibromas. *N Engl J Med*. 2020;382:1430-1442.

Gururangan S, Fangusaro J, Poussaint TY, et al. Efficacy of bevacizumab plus irinotecan in children with recurrent low-grade gliomas—a Pediatric Brain Tumor Consortium study. *Neuro Oncol*. 2014;16:310-317.

Haas-Kogan DA, Banerjee A, Kocak M, et al. Phase I trial of tipifarnib in children with newly diagnosed intrinsic diffuse brainstem glioma. *Neuro Oncol*. 2008;10(3):341-347.

Hargrave D, Bartels U, Bouffet E. Diffuse brainstem glioma in children: critical review of clinical trials. *Lancet Oncol*. 2006;7:241-248.

Hargrave DR, Bouffet E, Tabori U, et al. Efficacy and safety of dabrafenib in pediatric patients with *BRAF* V600 mutation-positive relapsed or refractory low-grade glioma: results from a phase I/IIa study. *Clin Cancer Res*. 2019;25:7303-7311.

Hawkins C, Walker E, Mohamed N, et al. BRAF-KIAA1549 fusion predicts better clinical outcome in pediatric low-grade astrocytoma. *Clin Cancer Res*. 2011;17:4790-4798.

Hayward RM, Patronas N, Baker EH, Vézina G, Albert PS, Warren KE. Interobserver variability in the measurement of diffuse intrinsic pontine gliomas. *J Neurooncol*. 2008;90(1):57-61.

Hoffman LM, Geller J, Leach J, et al. A feasibility and randomized phase II study of vorinostat, bevacizumab, or temozolomide during radiation followed by maintenance chemotherapy in newly-diagnosed pediatric high-grade glioma: Children's Oncology Group study ACNS0822. *Neuro Oncol*. 2015;17(suppl 3):iii39-iii40.

Huang EI, Jakacki RI, Fisher MJ, et al. Long-term efficacy and toxicity of bevacizumab-based therapy in children with recurrent low-grade gliomas. *Pediatr Blood Cancer*. 2013;60:776-781.

Indelicato DJ, Rotondo RL, Uezono H, et al. Outcomes following proton therapy for pediatric low-grade glioma. *Int J Radiat Oncol Biol Phys*. 2019;104:149-156.

Jakacki RI, Cohen KJ, Buxton A, et al. Phase 2 study of concurrent radiotherapy and temozolomide followed by temozolomide and lomustine in the treatment of children with high-grade glioma: a report of the Children's Oncology Group ACNS0423 study. *Neuro Oncol*. 2016;18:1442-1450.

Jallo GI, Freed D, Epstein F. Intramedullary spinal cord tumors in children. *Childs Nerv Syst*. 2003;19:641-649.

Jansen MH, Veldhuijzen van Zanten SE, Sanchez Aliaga E, et al. Survival prediction model of children with diffuse intrinsic pontine glioma based on clinical and radiological criteria. *Neuro Oncol*. 2015;17(1):160-166.

Jennings MT, Sposto R, Boyett JM, et al. Preradiation chemotherapy in primary high-risk brainstem tumors: phase II study CCG-9941 of the Children's Cancer Group. *J Clin Oncol*. 2002;20:3431-3437.

Karajannis MA, Legault G, Fisher MJ, et al. Phase II study of sorafenib in children with recurrent or progressive low-grade astrocytomas. *Neuro Oncol*. 2014;16(10):1408-1416.

Kieran MW, Turner CD, Rubin JB, et al. A feasibility trial of antiangiogenic (metronomic) chemotherapy in pediatric patients with recurrent or progressive cancer. *J Pediatr Hematol Oncol*. 2005;27:573-581.

Komotar RJ, Burger PC, Carson BS, et al. Pilocytic and pilomyxoid hypothalamic/chiasmatic astrocytomas. *Neurosurgery*. 2004;54:72-79.

Kondyli M, Larouche V, Saint-Martin C, et al. Trametinib for progressive pediatric low-grade gliomas. *J Neurooncol*. 2018;140:435-444.

Krueger DA, Care MM, Holland K, et al. Everolimus for subependymal giant-cell astrocytomas in tuberous sclerosis. *N Engl J Med*. 2010;363:1801-1811.

Laithier V, Grill J, Le Deley M-C, et al. Progression-free survival in children with optic pathway tumors: dependence on age and the quality of the response to chemotherapy—results of the first French prospective study for the French Society of Pediatric Oncology. *J Clin Oncol*. 2003;21:4572-4578.

Lashford LS, Thiesse P, Jouvet A, et al. Temozolomide in malignant gliomas of childhood: a United Kingdom Children's Cancer Study Group and French Society for Pediatric Oncology Intergroup Study. *J Clin Oncol*. 2002;20:4684-4691.

Lassaletta A, Zapotocky M, Mistry M, et al. Therapeutic and prognostic implications of BRAF V600E in pediatric low-grade gliomas. *J Clin Oncol*. 2017;35(25):2934-2941.

Levenbaum E, Ellika S, Korones DN. Bevacizumab in treating the cystic components of pediatric low-grade gliomas: a report of four patients. *Pediatric Blood Cancer*. 2019;66:e27917.

Lin GL, Wilson KM, Ceribelli M, et al. Therapeutic strategies for diffuse midline glioma from high-throughput combination drug screening. *Sci Transl Med*. 2019;11(519):eaaw0064.

Listernick R, Louis DN, Packer RJ, Gutmann DH. Optic pathway gliomas in children with neurofibromatosis 1: consensus statement from the NF1 Optic Pathway Glioma Task Force. *Ann Neurol*. 1997;41:143-149.

Martínez-Lage JF, Pérez-Espejo MA, Esteban JA, Poza M. Thalamic tumors: clinical presentation. *Childs Nerv Syst*. 2002;18:405-411.

Massimino M, Spreafico F, Cefalo G, et al. High response rate to cisplatin/etoposide regimen in childhood low-grade glioma. *J Clin Oncol*. 2002;20:4209-4216.

Merchant TE, Kun LE, Wu S, Xiong X, Sanford RA, Boop FA. Phase II trial of conformal radiation therapy for pediatric low-grade glioma. *J Clin Oncol*. 2009;27:3598-3604.

Nicholson HS, Kretschmar CS, Krailo M, et al. Phase 2 study of temozolomide in children and adolescents with recurrent central nervous system tumors: a report from the Children's Oncology Group. *Cancer*. 2007;110:1542-1550.

Packer RJ, Ater J, Allen J, et al. Carboplatin and vincristine chemotherapy for children with newly diagnosed progressive low-grade gliomas. *J Neurosurg*. 1997;86:747-754.

Packer RJ, Prados M, Phillips P, et al. Treatment of children with newly diagnosed brain stem gliomas with intravenous recombinant beta-interferon and hyperfractionated radiation therapy: a Children's Cancer Group phase I/II study. *Cancer*. 1996;77:2150-2156.

Paulino AC, Mazloom A, Terashima K, et al. Intensity-modulated radiotherapy (IMRT) in pediatric low-grade glioma. *Cancer*. 2013;119:2654-2659.

Pfaff E, El Damaty A, Balasubramanian GP, et al. Brainstem biopsy in pediatric diffuse intrinsic pontine glioma in the era of precision medicine: the INFORM study experience. *Eur J Cancer*. 2019;114:27-35.

Phillips JJ, Gong H, Chen K, et al. The genetic landscape of anaplastic pleomorphic xanthoastrocytoma. *Brain Pathol*. 2019;29:85-96.

Pollack IF, Finkelstein SD, Woods J, et al. Expression of p53 and prognosis in children with malignant gliomas. *N Engl J Med*. 2002;346:420-427.

Pollack IF, Hamilton RL, Burnham J, et al. Impact of proliferation index on outcome in childhood malignant gliomas: results in a multi-institutional cohort. *Neurosurgery*. 2002;50:1238-1244.

Pollack IF, Hamilton RL, Sobol RW, et al. O6-methylguanine-DNA methyltransferase expression strongly correlates with outcome in childhood malignant gliomas: results from the CCG-945 cohort. *J Clin Oncol*. 2006;24:3431-3437.

Robinson GW, Orr BA, Gajjar A. Complete clinical regression of a BRAF V600E-mutant pediatric glioblastoma multiforme after BRAF inhibitor therapy. *BMC Cancer*. 2014:14:258.

Roth JJ, Fierst TM, Waanders AJ, Yimei L, Biegel JA, Santi M. Whole chromosome 7 gain predicts higher risk of recurrence in pediatric pilocytic astrocytomas independently from KIAA1549-BRAF fusion status. *J Neuropathol Exp Neurol*. 2016;75:306-315.

Ryall S, Zapotocky M, Fukuoka K, et al. Integrated molecular and clinical analysis of 1,000 pediatric low-grade gliomas. *Cancer Cell*. 2020;37:569-583.

Sanghavi SN, Needle MN, Krailo MD, Geyer JR, Ater J, Mehta MP. A phase I study of topotecan as a radiosensitizer for brainstem glioma of childhood: first report of the Children's Cancer Group-0952. *Neuro Oncol*. 2003;5:8-13.

Saran FH, Baumert BG, Khoo VS, et al. Stereotactically guided conformal radiotherapy for progressive low-grade gliomas of childhood. *Int J Radiat Oncol Biol Phys*. 2002;53:43-51.

Schmandt SM, Packer RJ, Vezina LG, Jane J. Spontaneous regression of low-grade astrocytomas in childhood. *Pediatr Neurosurg*. 2000;32:132-136.

Stupp R, Mason WP, van den Bent MJ, et al. Radiotherapy plus concomitant and adjuvant temozolomide for glioblastoma. *N Engl J Med*. 2005;352:987-996.

Thorarinsdottir HK, Santi M, McCarter R, et al. Protein expression of platelet-derived growth factor receptor correlates with malignant histology and PTEN with survival in childhood gliomas. *Clin Cancer Res*. 2008;14:3386-3394.

Ullrich NJ, Prabhu SP, Reddy AT et al. A phase II study of continuous oral mTOR inhibitor everolimus for recurrent, radiographic-progressive neurofibromatosis type 1-associated pediatric low-grade glioma: a Neurofibromatosis Clinical Trials Consortium Study [published online ahead of print April 1, 2020]. *Neuro Oncol*. doi:10.1093/neuonc/noaa071.

Warren KE, Goldman S, Pollack IF, et al. Phase I trial of lenalidomide in pediatric patients with recurrent, refractory, or progressive primary CNS tumors: Pediatric Brain Tumor Consortium study PBTC-018. *J Clin Oncol*. 2011;29:324-329.

Warren KE, Gururangan S, Geyer JR, et al. A phase II study of O6-benzylguanine and temozolomide in pediatric patients with recurrent or progressive high-grade gliomas and brainstem gliomas: a Pediatric Brain Tumor Consortium Study. *J Neurooncol*. 2012;106:643-649.

Wisoff JH, Sanford RA, Heier LA, et al. Primary neurosurgery for pediatric low-grade gliomas: a prospective multi-institutional study from the Children's Oncology Group. *Neurosurgery*. 2011;68:1548-1554.

Wolff JE, Driever PH, Erdlenbruch B, et al. Intensive chemotherapy improves survival in pediatric high-grade glioma after gross total resection: results of the HIT-GBM-C protocol. *Cancer*. 2010;116:705-712.

Yang RR, Aibaidula A, Wang WW, et al. Pediatric low-grade gliomas can be molecularly stratified for risk. *Acta Neuropathol*. 2018;136:641-655.

Ependymoma

Andreiuolo F, Le Teuff G, Bayar MA, et al. Integrating Tenascin-C protein expression and 1q25 copy number status in pediatric intracranial ependymoma prognostication: a new model for risk stratification. *PLoS One*. 2017;12:e0178351.

Atkinson JM, Shelat AA, Carcaboso AM, et al. An integrated *in vitro* and *in vivo* high throughput screen identifies treatment leads for ependymoma. *Cancer Cell*. 2011;20:384-399.

Benesch M, Mynarek M, Witt H, et al. Newly diagnosed metastatic intracranial ependymoma in children: frequency, molecular characteristics, treatment, and outcome in the prospective HIT series. *Oncologist*. 2019;24(9):e921-e929.

Bouffet E, Hawkins CE, Ballourah W, et al. Survival benefit for pediatric patients with recurrent ependymoma treated with reirradiation. *Int J Radiat Oncol Biol Phys*. 2012;83:1541-1548.

Byer L, Kline CN, Coleman C, Allen IE, Whitaker E, Mueller S. A systematic review and meta-analysis of outcomes in pediatric, recurrent ependymoma. *J Neurooncol*. 2019;144:445-452.

Garvin JH Jr, Selch MT, Holmes E, et al. Phase II study of pre-irradiation chemotherapy for childhood intracranial ependymoma. Children's Cancer Group protocol 9942: a report from the Children's Oncology Group. *Pediatr Blood Cancer*. 2012;59:1183-1189.

Ghasemi DR, Sill M, Okonechnikov K, et al. MYCN amplification drives an aggressive form of spinal ependymoma. *Acta Neuropathol*. 2019;138:1075-1089.

Ghia AJ, Mahajan A, Allen PK, et al. Supratentorial gross-totally resected non-anaplastic ependymoma: population based patterns of care and outcomes analysis. *J Neurooncol*. 2013;115:513-520.

Good CD, Wade AM, Hayward RD, et al. Surveillance neuroimaging in childhood intracranial ependymoma: how effective, how often, and for how long? *J Neurosurg*. 2001;94:27-32.

Grundy RG, Wilne SA, Weston CL, et al. Primary postoperative chemotherapy without radiotherapy for intracranial ependymoma in children: the UKCCSG/SIOP prospective study. *Lancet Oncol*. 2007;8:696-705.

Khatua S, Ramaswamy V, Bouffet E. Current therapy and the evolving molecular landscape of paediatric ependymoma. *Eur J Cancer*. 2017;70:34-41.

Korshunov A, Golanov A, Sycheva R, Timirgaz V. The histologic grade is a main prognostic factor for patients with intracranial ependymomas treated in the microneurosurgical era: an analysis of 258 patients. *Cancer*. 2004;100:1230-1237.

Lee JW, Lim DH, Sung KW, et al. Multimodal treatment including tandem high-dose chemotherapy and autologous stem cell transplantation in children with anaplastic ependymomas. *Pediatric Transplant*. 2018;22:e13127.

Mack SC, Pajtler KW, Chavez L, et al. Therapeutic targeting of ependymoma as informed by oncogenic enhancer profiling. *Nature*. 2018;553:101-105.

Massimino M, Miceli R, Giangaspero F, et al. Final results of the second prospective AIEOP protocol for pediatric intracranial ependymoma. *Neuro Oncol*. 2016;18:1451-1460.

Merchant TE, Bendel AE, Sabin ND, et al. Conformal radiation therapy for pediatric ependymoma, chemotherapy for incompletely resected ependymoma, and observation for completely resected, supratentorial ependymoma. *J Clin Oncol*. 2019;37:974-983.

Modena P, Buttarelli FR, Miceli R, et al. Predictors of outcome in an AIEOP series of childhood ependymomas: a multifactorial analysis. *Neuro Oncol*. 2012;14:1346-1356.

Needle MN, Goldwein JW, Grass J, et al. Adjuvant chemotherapy for the treatment of intracranial ependymoma of childhood. *Cancer*. 1997;80:341-347.

Pajtler KW, Mack SC, Ramaswamy V, et al. The current consensus on the clinical management of intracranial ependymoma and its distinct molecular variants. *Acta Neuropathol*. 2017;133:5-12.

Pica A, Miller R, Villà S, et al. The results of surgery, with or without radiotherapy, for primary spinal myxopapillary ependymoma: a retrospective study from the rare cancer network. *Int J Radiat Oncol Biol Phys*. 2009;74:1114-1120.

Strother DR, Lafay-Cousin L, Boyett JM, et al. Benefit from prolonged dose-intensive chemotherapy for infants with malignant brain tumors is restricted to patients with ependymoma: a report of the Pediatric Oncology Group randomized controlled trial 9233/34. *Neuro Oncol*. 2014;16(3):457-465.

Tabori U, Ma J, Carter M, et al. Human telomere reverse transcriptase expression predicts progression and survival in pediatric intracranial ependymoma. *J Clin Oncol*. 2006;24:1522-1528.

Timmermann B, Kortmann RD, Kühl J, et al. Combined postoperative irradiation and chemotherapy for anaplastic ependymomas in childhood: results of the German prospective trials HIT 88/89 and HIT 91. *Int J Radiat Oncol Biol Phys*. 2000;46:287-295.

Upadhyaya SA, Robinson GW, Onar-Thomas A, et al. Molecular grouping and outcomes of young children with newly diagnosed ependymoma treated on the multi-institutional SJYC07 trial. *Neuro Oncol*. 2019;21:1319-1330.

Venkatramani R, Ji L, Lasky J, et al. Outcome of infants and young children with newly diagnosed ependymoma treated on the "Head Start" III prospective clinical trial. *J Neurooncol*. 2013;113:285-291.

Zacharoulis S, Ashley S, Moreno L, Gentet JC, Massimino M, Frappaz D. Treatment and outcome of children with relapsed ependymoma: a multi-institutional retrospective analysis. *Childs Nerv Syst*. 2010;26:905-911.

Medulloblastoma and Other Embryonal Tumors

Abdelbaki MS, Abu-Arja MH, Davidson TB, et al. Pineoblastoma in children less than six years of age: the Head Start I, II, and III experience. *Pediatr Blood Cancer*. 2020;67:e28252.

Abe M, Tokumaru S, Tabuchi K, Kida Y, Takagi M, Imamura J. Stereotactic radiation therapy with chemotherapy in the management of recurrent medulloblastomas. *Pediatr Neurosurg*. 2006;42:81-88.

Aldosari N, Bigner SH, Burger PC, et al. MYCC and MYCN oncogene amplification in medulloblastoma. A fluorescence in situ hybridization study on paraffin sections from the Children's Oncology Group. *Arch Pathol Lab Med*. 2002;126:540-544.

Bartelheim K, Nemes K, Seeringer A, et al. Improved 6-year overall survival in AT/RT—results of the registry study Rhabdoid 2007. *Cancer Med*. 2016;5:1765-1775.

Bergthold G, El Kababri M, Varlet P, et al. High-dose busulfan-thiotepa with autologous stem cell transplantation followed by posterior fossa irradiation in young children with classical or incompletely resected medulloblastoma. *Pediatr Blood Cancer*. 2014;61:907-912.

Blach LE, McCormick B, Abramson DH, Ellsworth RM. Trilateral retinoblastoma—incidence and outcome: a decade of experience. *Int J Radiat Oncol Biol Phys*. 1994;29:729-733.

Butturini AM, Jacob M, Aquajo J, et al. High-dose chemotherapy and autologous hematopoietic progenitor cell rescue in children with recurrent medulloblastoma and supratentorial primitive neuroectodermal tumors: the impact of prior radiotherapy on outcome. *Cancer*. 2009;115(13):2956-2963.

Chi SN, Gardner SL, Levy AS, et al. Feasibility and response to induction chemotherapy intensified with high-dose methotrexate for young children with newly diagnosed high-risk disseminated medulloblastoma. *J Clin Oncol*. 2004;22:4881-4887.

Chi SN, Zimmerman MA, Yao X, et al. Intensive multimodality treatment for children with newly diagnosed CNS atypical teratoid rhabdoid tumor. *J Clin Oncol*. 2009;27:385-389.

Cohen BH, Geyer JR, Miller DC, et al. Pilot study of intensive chemotherapy with peripheral hematopoietic cell support for children less than 3 years of age with malignant brain tumors, the CCG-99703 phase I/II study. A report from the Children's Oncology Group. *Pediatr Neurol*. 2015;53:31-46.

de Kock L, Sabbaghian N, Druker H, et al. Germ-line and somatic DICER1 mutations in pineoblastoma. *Acta Neuropathol*. 2014;128:583-595.

Dhall G, Grodman H, Ji L, et al. Outcome of children less than three years old at diagnosis with non-metastatic medulloblastoma treated with chemotherapy on the "Head Start" I and II protocols. *Pediatr Blood Cancer*. 2008;50:1169-1175.

Dhall G, O'Neil SH, Ji L, et al. Excellent outcome of young children with nodular desmoplastic medulloblastoma treated on "Head Start" III: a multi-institutional, prospective clinical trial [published online ahead of print April 18, 2020]. *Neuro Oncol*. doi:10.1093/neuonc/noaa102.

Donovan LK, Delaidelli A, Joseph SK, et al. Locoregional delivery of CAR T cells to the cerebrospinal fluid for treatment of metastatic medulloblastoma and ependymoma. *Nat Med*. 2020;26(5):720-731.

Dunkel IJ, Gardner SL, Garvin JH Jr, Goldman S, Shi W, Finlay JL. High-dose carboplatin, thiotepa, and etoposide with autologous stem cell rescue for patients with previously irradiated recurrent medulloblastoma. *Neuro Oncol*. 2010;12:297-303.

Dufour C, Kieffer V, Varlet P, et al. Tandem high-dose chemotherapy and autologous stem cell rescue in children with newly diagnosed high-risk medulloblastoma or supratentorial primitive neuro-ectodermic tumors. *Pediatr Blood Cancer*. 2014;61(8):1398-1402.

Ellison DW, Dalton J, Kocak M, et al. Medulloblastoma: clinicopathological correlates of SHH, WNT, and non-SHH/WNT molecular subgroups. *Acta Neuropathol*. 2011;121:381-396.

Fangusaro J, Finlay J, Sposto R, et al. Intensive chemotherapy followed by consolidative myeloablative chemotherapy with autologous hematopoietic cell rescue (AuHCR) in young children with newly diagnosed supratentorial primitive neuroectodermal tumors (sPNETs): report of the Head Start I and II experience. *Pediatr Blood Cancer*. 2008;50:312-318.

Gajjar A, Chintagumpala M, Ashley D, et al. Risk-adapted craniospinal radiotherapy followed by high-dose chemotherapy and stem-cell rescue in children with newly diagnosed medulloblastoma (St Jude Medulloblastoma-96): long-term results from a prospective, multicentre trial. *Lancet Oncol*. 2006;7:813-820.

Gajjar A, Stewart CF, Ellison DW, et al. Phase I study of vismodegib in children with recurrent or refractory medulloblastoma: a pediatric brain tumor consortium study. *Clin Cancer Res*. 2013;19:6305-6312.

Gerber NU, von Hoff K, Resch A, et al. Treatment of children with central nervous system primitive neuroectodermal tumors/pinealoblastomas in the prospective multicentric trial HIT 2000 using hyperfractionated radiation therapy followed by maintenance chemotherapy. *Int J Radiat Oncol Biol Phys*. 2014;89:863-871.

Gerber NU, von Hoff K, von Bueren AO, et al. Outcome of 11 children with ependymoblastoma treated within the prospective HIT-trials between 1991 and 2006. *J Neurooncol*. 2011;102:459-469.

Geyer JR, Sposto R, Jennings M, et al. Multiagent chemotherapy and deferred radiotherapy in infants with malignant brain tumors: a report from the Children's Cancer Group. *J Clin Oncol*. 2005;23:7621-7631.

Gilheeney SW, Saad A, Chi S, et al. Outcome of pediatric pineoblastoma after surgery, radiation and chemotherapy. *J Neuroncol*. 2008;89:89-95.

Gilman AL, Jacobsen C, Bunin N, et al. Phase I study of tandem high-dose chemotherapy with autologous peripheral blood stem cell rescue for children with recurrent brain tumors: a Pediatric Blood and Marrow Transplant Consortium study. *Pediatr Blood Cancer*. 2011;57:506-513.

Grill J, Lellouch-Tubiana A, Elouahdani S, et al. Preoperative chemotherapy in children with high-risk medulloblastomas: a feasibility study. *J Neurosurg*. 2005;103(4 suppl):312-318.

Grill J, Sainte-Rose C, Jouver A, et al. Treatment of medulloblastoma with postoperative chemotherapy alone: an SFOP prospective trial in young children. *Lancet Oncol*. 2005;6:573-580.

Horwitz M, Dufour C, Leblond P, et al. Embryonal tumors with multilayered rosettes in children: the SFCE experience. *Childs Nerv Syst*. 2016;32:299-305.

Hwang EI, Kool M, Burger PC, et al. Extensive molecular and clinical heterogeneity in patients with histologically diagnosed CNS-PNET treated as a single entity: a report from the Children's Oncology Group randomized ACNS0332 trial [published online ahead of print October 17, 2018]. *J Clin Oncol*. doi:10.1200/JCO.2017.76.4720.

Jakacki RI, Burger PC, Zhou T, et al. Outcome of children with metastatic medulloblastoma treated with carboplatin during craniospinal radiotherapy: a Children's Oncology Group Phase I/II study. *J Clin Oncol*. 2012;30:2648-2653.

Jaju A, Hwang EI, Kool M, et al. MRI features of histologically diagnosed supratentorial primitive neuroectodermal tumors and pineoblastomas in correlation with molecular diagnoses and outcomes: a report from the Children's Oncology Group ACNS0332 trial. *AJNR Am J Neuroradiol*. 2019;40:1796-1803.

Johann PD, Hovestadt V, Thomas C, et al. Cribriform neuroepithelial tumor: molecular characterization of a SMARCB1-deficient non-rhabdoid tumor with favorable long-term outcome. *Brain Pathol*. 2017;27:411-418.

Kahalley LS, Peterson R, Ris MD, et al. Superior intellectual outcomes after proton radiotherapy compared with photon radiotherapy for pediatric medulloblastoma. *J Clin Oncol*. 2020;38:454-461.

Karthigeyan M, Gupta K, Salunke P. Pediatric central neurocytoma. *J Child Neurol*. 2017;32:53-59.

Kieran MW, Turner CD, Rubin JB, et al. A feasibility trial of antiangiogenic (metronomic) chemotherapy in pediatric patients with recurrent or progressive cancer. *J Pediatr Hematol Oncol*. 2005;27:573-581.

Komori T, Scheithauer BW, Anthony DC, et al. Papillary glioneuronal tumor: a new variant of mixed neuronal-glial neoplasm. *Am J Surg Pathol*. 1998;22:1171-1183.

Kool M, Korshunov A, Remke M, et al. Molecular subgroups of medulloblastoma: an international meta-analysis of transcriptome, genetic aberrations, and clinical data of WNT, SHH, group 3, and group 4 medulloblastomas. *Acta Neuropathol*. 2012;123:473-484.

Korshunov A, Sturm D, Ryzhova M, et al. Embryonal tumor with abundant neuropil and true rosettes (ETANTR), ependymoblastoma, and medulloepithelioma share molecular similarity and comprise a single clinicopathological entity. *Acta Neuropathol*. 2014;128(2):279-289.

Kortmann RD, Kühl J, Timmermann B, et al. Postoperative neoadjuvant chemotherapy before radiotherapy as compared to immediate radiotherapy followed by maintenance chemotherapy in the treatment of medulloblastoma in childhood: results of the German prospective randomized trial HIT '91. *Int J Radiat Oncol Biol Phys*. 2000;46:269-279.

Kurmasheva RT, Sammons M, Favours E, et al. Initial testing (stage 1) of tazemetostat (EPZ-6438), a novel EZH2 inhibitor, by the Pediatric Preclinical Testing Program. *Pediatr Blood Cancer*. 2017;64:10.1002/pbc.26218.

Lafay-Cousin L, Bouffet E, Strother D, et al. Phase II study of nonmetastatic desmoplastic medulloblastoma in children younger than 4 years of age: a report of the Children's Oncology Group (ACNS1221). *J Clin Oncol*. 2020;38:223-231.

Lambo S, Gröbner SN, Rausch T, et al. The molecular landscape of ETMR at diagnosis and relapse. *Nature*. 2019;576:274-280.

Le Teuff G, Castaneda-Heredia A, Dufour C, et al. Phase II study of temozolomide and topotecan (TOTEM) in children with relapsed or refractory extracranial and central nervous system tumors including medulloblastoma with post hoc Bayesian analysis: a European ITCC study. *Pediatr Blood Cancer*. 2020;67:e28032.

Li BK, Vasiljevic A, Dufour C, et al. Pineoblastoma segregates into molecular sub-groups with distinct clinico-pathologic features: a Rare Brain Tumor Consortium registry study. *Acta Neuropathol*. 2020;139:223-241.

Morfouace M, Shelat A, Jacus M, et al. Pemetrexed and gemcitabine as combination therapy for the treatment of group 3 medulloblastoma. *Cancer Cell*. 2014;25:516-529.

Mynarek M, von Hoff K, Pietsch T, et al. Nonmetastatic medulloblastoma of early childhood: results from the prospective clinical trial HIT-2000 and an extended validation cohort. *J Clin Oncol*. 2020;38(18):2028-2040.

Nageswara Rao AA, Wallace DJ, Billups C, et al. Cumulative cisplatin dose is not associated with event-free or overall survival in children with newly diagnosed average-risk medulloblastoma treated with cisplatin based adjuvant chemotherapy: report from the Children's Oncology Group. *Pediatr Blood Cancer*. 2014;61:102-106.

Nobusawa S, Yokoo H, Hirato J, et al. Analysis of chromosome 19q13.42 amplification in embryonal brain tumors with ependymoblastic multilayered rosettes. *Brain Pathol*. 2012;22:689-697.

Northcott PA, Shih DJ, Remke M, et al. Rapid, reliable, and reproducible molecular sub-grouping of clinical medulloblastoma samples. *Acta Neuropathol*. 2012;123:615-626.

Oyharcabal-Bourden V, Kalifa C, Gentet JC, et al. Standard-risk medulloblastoma treated by adjuvant chemotherapy followed by reduced-dose craniospinal radiation therapy: a French Society of Pediatric Oncology Study. *J Clin Oncol*. 2005;23:4726-4734.

Peyrl A, Chocholous M, Kieran MW, et al. Antiangiogenic metronomic therapy for children with recurrent embryonal brain tumors. *Pediatr Blood Cancer*. 2012;59:511-517.

Pham TT, Siebert E, Asbach P, Willerding G, Erb-Eigner K. Magnetic resonance imaging based morphologic evaluation of the pineal gland for suspected pineoblastoma in retinoblastoma patients and age-matched controls. *J Neurol Sci*. 2015;359:185-192.

Picard D, Miller S, Hawkins CE, et al. Markers of survival and metastatic potential in childhood CNS primitive neuro-ectodermal brain tumours: an integrative genomic analysis. *Lancet Oncol*. 2012;13:836-848.

Ramaswamy V, Remke M, Bouffet E, et al. Recurrence patterns across medulloblastoma subgroups: an integrated clinical and molecular analysis. *Lancet Oncol*. 2013;14:1200-1207.

Reddy AT, Strother DR, Judkins AR, et al. Efficacy of high-dose chemotherapy and three-dimensional conformal radiation for atypical teratoid/rhabdoid tumor: a report from the Children's Oncology Group trial ACNS0333. *J Clin Oncol*. 2020;38:1175-1185.

Ridola V, Grill J, Doz F, et al. High-dose chemotherapy with autologous stem cell rescue followed by posterior fossa irradiation for local medulloblastoma recurrence or progression after conventional chemotherapy. *Cancer*. 2007;110:156-163.

Rudin CM, Hann CL, Laterra J, et al. Treatment of medulloblastoma with hedgehog pathway inhibitor GDC-0449. *N Engl J Med*. 2009;361:1173-1178.

Rutkowski S, Bode U, Deinlein F, et al. Treatment of early childhood medulloblastoma by postoperative chemotherapy alone. *N Engl J Med*. 2005;352:978-986.

Rutkowski S, von Hoff K, Emser A, et al. Survival and prognostic factors of early childhood medulloblastoma: an international meta-analysis. *J Clin Oncol*. 2010;28:4961-4968.

Sandberg DI, Kharas N, Yu B, et al. High-dose MTX110 (soluble panobinostat) safely administered into the fourth ventricle in a nonhuman primate model [published online ahead of print May 1, 2020]. *J Neurosurg Pediatr*. doi:10.3171/2020.2.PEDS19786.

Shih DJ, Northcott PA, Remke M, et al. Cytogenetic prognostication within medulloblastoma subgroups. *J Clin Oncol*. 2014;32:886-896.

Vincent S, Dhellemmes P, Maurage CA, Soto-Ares G, Hassoun J, Ruchoux MM. Intracerebral medulloepithelioma with a long survival. *Clin Neuropathol*. 2002;21:197-205.

von Bueren AO, Kortmann RD, von Hoff K, et al. Treatment of children and adolescents with metastatic medulloblastoma and prognostic relevance of clinical and biologic parameters. *J Clin Oncol*. 2016;34:4151-4160.

von Bueren AO, von Hoff K, Pietsch T, et al. Treatment of young children with localized medulloblastoma by chemotherapy alone: results of the prospective, multicenter trial HIT 2000 confirming the prognostic impact of histology. *Neuro Oncol*. 2011;13:669-679.

Tekautz TM, Fuller CE, Blaney S, et al. Atypical teratoid/rhabdoid tumors (ATRT): improved survival in children 3 years of age and older with radiation therapy and high-dose alkylator-based chemotherapy. *J Clin Oncol*. 2005;23:1491-1499.

Torchia J, Picard D, Lafay-Cousin L, et al. Molecular subgroups of atypical teratoid rhabdoid tumours in children: an integrated genomic and clinicopathological analysis. *Lancer Oncol*. 2015;16:569-582.

Zacharoulis S, Morales La Madrid A, Bandopadhayay P, et al. Central versus extraventricular neurocytoma in children: a clinicopathologic comparison and review of the literature. *J Pediatr Hematol Oncol*. 2016;38:479-485.

Zaky W, Dhall G, Ji L, et al. Intensive induction chemotherapy followed by myeloablative chemotherapy with autologous hematopoietic progenitor cell rescue for young children newly-diagnosed with central nervous system atypical teratoid/rhabdoid tumors: the Head Start III experience. *Pediatr Blood Cancer*. 2014;61:95-101.

Germ Cell Tumors

Calaminus G, Kortmann R, Worch J, et al. SIOP CNS GCT 96: final report of outcome of a prospective, multinational nonrandomized trial for children and adults with intracranial germinoma, comparing craniospinal irradiation alone with chemotherapy followed by focal primary site irradiation for patients with localized disease. *Neuro Oncol*. 2013;15:788-796.

Fangusaro J, Wu S, MacDonald S, et al. Phase II trial of response-based radiation therapy for patients with localized CNS nongerminomatous germ cell tumors: a Children's Oncology Group Study. *J Clin Oncol*. 2019;37:3283-3290.

Goldman S, Bouffet E, Fisher PG, et al. Phase II trial assessing the ability of neoadjuvant chemotherapy with or without second-look surgery to eliminate measurable disease for nongerminomatous germ cell tumors: a Children's Oncology Group study. *J Clin Oncol*. 2015;33:2464-2471.

Kellie SJ, Boyce H, Dunkel IJ, et al. Primary chemotherapy for intracranial nongerminomatous germ cell tumors: results of the second international CNS germ cell study group protocol. *J Clin Oncol*. 2004;22:846-853.

Kretschmar C, Kleinberg L, Greenberg M, Burger P, Holmes E, Wharam M. Preradiation chemotherapy with response-based radiation therapy in children with central nervous system germ cell tumors: a report from the Children's Oncology Group. *Pediatr Blood Cancer*. 2007;48:285-291.

Modak S, Gardner S, Dunkel IJ, et al. Thiotepa-based high-dose chemotherapy with autologous stem-cell rescue in patients with recurrent or progressive CNS germ cell tumors. *J Clin Oncol*. 2004;22:1934-1943.

Roberge D, Kun LE, Freeman CR. Intracranial germinoma: on whole-ventricular irradiation. *Pediatr Blood Cancer*. 2005;44:358-362.

Schulte SL, Waha A, Steiger B, et al. CNS germinomas are characterized by global demethylation, chromosomal instability and mutational activation of the Kit-, Ras/Raf/Erk- and AKT-pathways. *Oncotarget*. 2016;7:55026-55042.

Meningioma and Mesenchymal Tumors

Amirjamshidi A, Mehrazin M, Abbassioun K. Meningiomas of the central nervous system occurring below the age of 17: report of 24 cases not associated with neurofibromatosis and review of literature. *Childs Nerv Syst*. 2000;16:406-416.

Liu Y, Li F, Zhu S, Lui M, Wu C. Clinical features and treatment of meningiomas in children: report of 12 cases and literature review. *Pediatr Neurosurg*. 2008;44:112-117.

Pedersen M, Küsters-Vandevelde HV, Viros A, et al. Primary melanoma of the CNS in children is driven by congenital expression of oncogenic NRAS in melanocytes. *Cancer Discov*. 2013;3:458-459.

Reddy AK, Ryoo JS, Denyer S, McGuire S, Mehta AI. Determining the role of adjuvant radiotherapy in the management of meningioma: a Surveillance, Epidemiology, and End Results analysis. *Neurosurg Focus*. 2019;46:E3.

Schiariti M, Goetz P, El-Maghraby H, Tailor J, Kitchen N. Hemangiopericytoma: long-term outcome revisited. Clinical article. *J Neurosurg*. 2011;114:747-755.

Central Nervous System Lymphoma

Abla O, Sandlund JT, Sung L, et al. A case series of pediatric primary central nervous system lymphoma: favorable outcome without cranial irradiation. *Pediatr Blood Cancer*. 2006;47:880-885.

Abla O, Weitzman S, Blay JY, et al. Primary CNS lymphoma in children and adolescents: a descriptive analysis from the International Primary CNS Lymphoma Collaborative Group (IPCG). *Clin Cancer Res*. 2011;17:346-352.

Alyuz C, Aydin GB, Cila A, et al. Successful use of intraventricular and intravenous rituximab therapy for refractory primary CNS lymphoma in a child. *Leuk Lymphoma*. 2007;48:1253-1255.

Ferreri AJ, Cwynarski K, Pulczynski E, et al. Chemoimmunotherapy with methotrexate, cytarabine, thiotepa, and rituximab (MATRix regimen) in patients with primary CNS lymphoma: results of the first randomisation of the International Extranodal Lymphoma Study Group-32 (IELSG32) phase 2 trial. *Lancet Haematol*. 2016;3:e217-e227.

Ferreri AJ, Illerhaus G. The role of autologous stem cell transplantation in primary central nervous system lymphoma. *Blood*. 2016;127:1642-1649.

Mohile NA, DeAngelis LM, Abrey LE. The utility of body FDG PET in staging primary central nervous system lymphoma. *Neuro Oncol*. 2008;10:223-228.

Silfen ME, Garvin JH Jr, Hays AP, et al. Primary central nervous system lymphoma in childhood presenting as progressive panhypopituitarism. *J Pediatr Hematol Oncol*. 2001;23:130-133.

Somers KE, Almast J, Biemiller RA, Silberstein HJ, Johnson MD, Mohile NA. Diagnosis of primary CNS melanoma with neuroimaging. *J Clin Oncol*. 2013;31:e9-e11.

Late Effects of Treatment and Quality of Life

Acharya S, Wu S, Ashford JM, et al. Association between hippocampal dose and memory in survivors of childhood or adolescent low-grade glioma: a 10-year neurocognitive longitudinal study [published online ahead of print April 12, 2019]. *Neuro Oncol*. doi:10.1093/neuonc/noz068.

Bandopadhayay P, Bergthold G, London WB, et al. Long-term outcome of 4,040 children diagnosed with pediatric low-grade gliomas: an analysis of the Surveillance Epidemiology and End Results (SEER) database. *Pediatr Blood Cancer*. 2014;61:1173-1179.

Bell J, Parker KL, Swinford RD, Hoffman AR, Maneatis T, Lippe B. Long-term safety of recombinant human growth hormone in children. *J Clin Endocrinol Metab*. 2010;95:167-177.

Bhat SR, Goodwin TL, Burwinkle TM, et al. Profile of daily life in children with brain tumors: an assessment of health-related quality of life. *J Clin Oncol*. 2005;23:5493-5500.

Brière M-E, Scott JG, McNall-Knapp RY, Adams RL. Cognitive outcome in pediatric brain tumor survivors: delayed attention deficit at long-term follow-up. *Pediatr Blood Cancer*. 2008;50:337-340.

Cardarelli C, Cereda C, Masiero L, et al. Evaluation of health status and health-related quality of life in a cohort of Italian children following treatment for a primary brain tumor. *Pediatr Blood Cancer*. 2006;46:647-644.

Gleeson HK, Stoeter R, Ogilvy-Stuart AL, Gattamaneni HR, Brennan BM, Shalet SM. Improvements in final height over 25 years in growth hormone (GH)-deficient childhood survivors of brain tumors receiving GH replacement. *J Clin Endocrinol Metab*. 2003;88:3682-3689.

Grill J, Kieffer V, Kalifa C. Measuring the neuro-cognitive side-effects of irradiation in children with brain tumors. *Pediatr Blood Cancer*. 2004;42:452-456.

Huang TT, Chen Y, Dietz AC, et al. Pulmonary outcomes in survivors of childhood central nervous system malignancies: a report from the Childhood Cancer Survivor Study. *Pediatr Blood Cancer*. 2014;61:319-325.

Kahalley LS, Peterson R, Ris MD, et al. Superior intellectual outcomes after proton radiotherapy compared with photon radiotherapy for pediatric medulloblastoma. *J Clin Oncol*. 2020;38:454-461.

Kennedy C, Bull K, Chevignard M, et al. Quality of survival and growth in children and young adults in the PNET4 European controlled trial of hyperfractionated versus conventional radiation therapy for standard-risk medulloblastoma. *Int J Radiat Oncol Biol Phys*. 2014;88:292-300.

Laughton SJ, Merchant TE, Sklar CA, et al. Endocrine outcomes for children with embryonal brain tumors after risk-adapted craniospinal and conformal primary-site irradiation and high-dose chemotherapy with stem-cell rescue on the SJMB-96 trial. *J Clin Oncol*. 2008;26:1112-1118.

Maule M, Scélo G, Pastore G, et al. Risk of second malignant neoplasms after childhood central nervous system malignant tumours: an international study. *Eur J Cancer*. 2008;44:830-839.

Micklewright JL, King TZ, Morris RD, Krawiecki N. Quantifying pediatric neuro-oncology risk factors: development of the neurological predictor scale. *J Child Neurol*. 2008;23:455-458.

Morris EB, Gajjar A, Okuma JO, et al. Survival and late mortality in long-term survivors of pediatric CNS tumors. *J Clin Oncol*. 2007;25:1532-1538.

Nathan PC, Patel SK, Dilley K, et al. Guidelines for identification of, advocacy for, and intervention in neurocognitive problems in survivors of childhood cancer: a report from the Children's Oncology Group. *Arch Pediatr Adolesc Med*. 2007;161:798-806.

Nordstrom M, Felton E, Sear K, et al. Large vessel arteriopathy after cranial radiation therapy in pediatric brain tumor survivors. *J Child Neurol*. 2018;33:359-366.

Oberfield SE, Chin D, Uli N, David R, Sklar C. Endocrine late effects of childhood cancers. *J Pediatr*. 1997;131(1, pt 2):S37-S41.

Odame I, Duckworth J, Talsma D, et al. Osteopenia, physical activity and health-related quality of life in survivors of brain tumors treated in childhood. *Pediatr Blood Cancer*. 2005;46:357-362.

Ottensmeier H, Schlegel PG, Eyrich M, et al. Treatment of children under 4 years of age with medulloblastoma and ependymoma in the HIT2000/HIT-REZ 2005 trials: neuropsychological outcome 5 years after treatment. *PLoS One*. 2020;15:e0227693.

Packer RJ, Gurney JG, Punyko JA, et al. Long-term neurologic and neurosensory sequelae in adult survivors of a childhood brain tumor: Childhood Cancer Survivor Study. *J Clin Oncol*. 2003;21:3255-3261.

Patterson BC, Chen Y, Sklar CA, et al. Growth hormone exposure as a risk factor for the development of subsequent neoplasms of the central nervous system: a report from the Childhood Cancer Survivor Study. *J Clin Endocrinol Metab*. 2014;99:2030-2037.

Pietilä S, Ala-Houhala M, Lenko HL, et al. Renal impairment and hypertension in brain tumor patients treated in childhood are mainly associated with cisplatin treatment. *Pediatr Blood Cancer*. 2005;44:363-369.

Ris MD, Leisenring WM, Goodman P, et al. Neuropsychological and socioeconomic outcomes in adult survivors of pediatric low-grade glioma. *Cancer*. 2019;125:3050-3058.

Roddy E, Mueller S. Late effects of treatment of pediatric central nervous system tumors. *J Child Neurol*. 2016;31:237-254.

Ross L, Johansen C, Dalton SO, et al. Psychiatric hospitalizations among survivors of cancer in childhood or adolescence. *N Engl J Med*. 2003;349:650-657.

Sabin ND, Santucci AK, Klimo P Jr, et al. Incidental detection of late subsequent intracranial neoplasms with magnetic resonance imaging among adult survivors of childhood cancer. *J Cancer Surviv*. 2014;8:329-335.

Shabason EK, Brodsky C, Baran J, et al. Clinical diagnosis of attention-deficit/hyperactivity disorder in survivors of pediatric brain tumors. *J Neurooncol*. 2019;143:305-312.

Sklar CA, Mertens AC, Mitby P, et al. Risk of disease recurrence and second neoplasms in survivors of childhood cancer treated with growth hormone: a report from the Childhood Cancer Survivor Study. *J Clin Endocrinol Metab*. 2002;87:3136-3141.

Tsui K, Gajjar A, Li C, et al. Subsequent neoplasms in survivors of childhood central nervous system tumors: risk after modern multimodal therapy. *Neuro Oncol*. 2015;17:448-456.

Willard VW, Berlin KS, Conklin HM, Merchant TE. Trajectories of psychosocial and cognitive functioning in pediatric patients with brain tumors treated with radiation therapy. *Neuro Oncol*. 2019;21:678-685.

Wolfe-Christensen C, Mullins LL, Scott JG, McNall-Knapp RY. Persistent psychosocial problems in children who develop posterior fossa syndrome after medulloblastoma resection. *Pediatr Blood Cancer*. 2007;49:723-726.

Zapotocky M, Beera K, Adamski J, et al. Survival and functional outcomes of molecularly defined childhood posterior fossa ependymoma: cure at a cost. *Cancer*. 2019;125:1867-1876.

Zebrack BJ, Gurney JG, Oeffinger K, et al. Psychological outcomes in long-term survivors of childhood brain cancer: a report from the Childhood Cancer Survivor Study. *J Clin Oncol*. 2004;22:999-1006.

151 Pediatric Brain Injury and Shaken Baby Syndrome

Joshua Cappell and Steven G. Kernie

KEY POINTS

1. Pediatric brain injury includes a broad array of clinical presentations, which further vary within the childhood age spectrum.
2. Causes are socially influenced and include child abuse, self or mutual violence, vehicular, firearm use, and high-risk behaviors of adolescence.
3. Primary brain injuries reflect velocity, mechanism, biomechanical factors, and compartment involved.
4. Secondary brain injuries reflect macroscopic/structural and microscopic/metabolic sequelae of the initial injury.
5. Imaging criteria for traumatic brain injury (TBI) have meaningfully reduced unnecessary exposure to ionizing radiation, particularly in mild TBI.
6. Medical management is directed toward secondary prevention; few modalities are available to promote reversal of injury.
7. Prognostication in pediatric TBI remains challenging across the spectrum of disease.
8. Long-term management often includes neurologic care given risk of seizures as well as comprehensive academic planning.

INTRODUCTION

The still-developing nervous system holds the potential for greater recovery from traumatic brain injury (TBI) while also carrying the risk of disordered development, dysplasia, and other adverse sequelae. At the same time, mechanical factors may differentiate pediatric from adult injury such as the unfused or less mineralized calvarium and the narrower subarachnoid and sulcal spaces. Pediatric head trauma also differs not only from adult but also within the childhood age spectrum. The mechanisms, including not only the velocity but also the *intentionality*—whether the injury was accidental—strongly affect the severity distribution. Greater impact force, as seen in vehicular (especially unrestrained)-induced injury or nonaccidental injury, skews the distribution toward more severe presentation and worse outcomes.

Data gleaned from the large American ADAPT (Approaches and Decisions in Acute Pediatric TBI) trial, an interinstitutional comparative effectiveness study, has confirmed that seizures and apneas are more common in the abusive head trauma patients when compared with other mechanisms.

EPIDEMIOLOGY

Trauma is the major cause of morbidity and mortality in childhood, and nervous system involvement is the biggest determinant of severity. Children account for about one-half million incidents of TBI per year in the United States, a rate disproportionately high for their part of the overall population. Although the mechanisms and circumstances vary across the pediatric age range—with child abuse dominant in infancy and self- or mutual violence, vehicular, firearm use, and other high-risk behaviors prevalent in adolescence—it remains true across the pediatric age range that the causes are to a great extent socially influenced rather than purely sporadic and therefore often at least potentially preventable. As such, the reduction of the immense toll of brain injury relies on two distinct approaches: prevention of primary injury and of secondary injury.

The former is an educational and legal as much as medical task. Initiatives such as infant car seats, bike helmets, and statewide abuse recognition and reporting systems are critical components. Although recent public attention to cumulative and late effects of concussion was largely generated by cases of prominent adult athletes, much of the response has been to change practice from middle school through college, the duration of the athletic careers of most of the public.

PATHOBIOLOGY

Primary Brain Injury

The pathophysiology of primary and secondary brain injury is distinct (Fig. 151.1). The primary injury depends on linear and angular velocity, mechanism (penetrating or closed), biomechanical factors (contrecoup injury), trajectory, and compartment. The consequences can be considered based on the tissue impacted. Epidural and subdural bleeds (Fig. 151.2) contribute to injury largely due to the pressure they cause by stealing intracranial space. Gray matter architecture can be disrupted in concussion, contusion, or abrasion. Cortical projections and corticocortical connections can be interrupted by penetrating foreign bodies or bone fragments. Less obvious on initial computed tomography (CT) imaging but highly influential on outcome is the diffuse axonal injury, the shearing of fiber tracts from torsional forces. Cerebral ischemia due to vascular dissection, occlusion, and thrombosis can be as injurious as force to the parenchyma directly. In intentionally inflicted trauma, multiple mechanisms may have contributed. The injuries of the "shaken baby" can be compounded by impact, partial strangulation, or carotid compression.

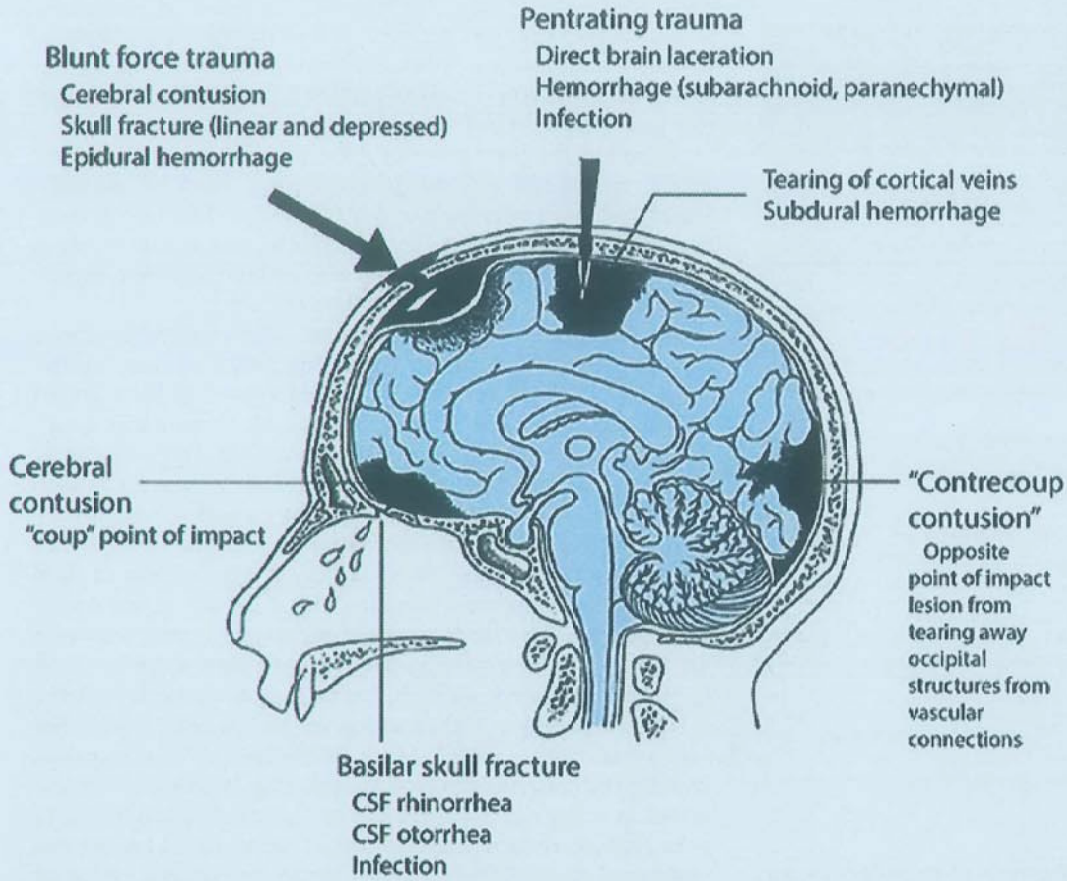

FIGURE 151.1 Mechanisms of craniocerebral injury related to trauma. (Adapted from Chandrasoma P, Taylor CR. *Concise Pathology*. 3rd ed. Stamford, CN: Appleton & Lange; 1997. www.accessmedicine.com.)

FIGURE 151.2 Noncontrast head CT demonstrating a right-sided subdural hematoma *(short black arrow)* and intracerebral hemorrhage *(long white arrow)* with subarachnoid blood in the overlying sulci *(long black arrow)*, and left-sided epidural hematoma *(short white arrow)*. (From Mattiello JA, Munz M. Four types of acute post-traumatic intracranial hemorrhage. *N Engl J Med*. 2001;344[8]:580.)

Secondary Brain Injury

Secondary injury encompasses all subsequent deleterious processes at various levels of organization (Table 151.1).

Macroscopic Secondary Injury

On a macroscopic scale, the pediatric brain is at high risk from loss of volume. Because brain growth drives skull growth in childhood and the atrophy of adulthood is not yet present, accommodation of hematoma and cerebral edema (which evolves largely over the first 3 days postinjury) is poor. Although the dura and unfused calvarium of the neonate and infant flexibly allows reshaping (as required during parturition), it maintains intracranial volume nearly constant as it is inelastic to outward stretch. Consequently, babies too are subject to severe restriction of the intracranial vault. Pressure can cause herniation, compromise cerebral perfusion pressure globally, or compress adjacent cerebral vessels exacerbating tissue compromise.

Multiple factors threaten the already wounded cortical tissue. Cerebral autoregulation is less robust after injury, increasing the risk that cerebral perfusion pressure will fall beneath the compensated range. Injury to the normally well-sealed and precisely regulated blood-brain barrier implies loss of control of the neuronal microenvironment.

Microscopic Secondary Injury

At the cellular level, excitotoxicity due to excessive glutamate release, calcium entry, and hyperactivated intrinsic membrane conductances place increased metabolic demands and interfere with cell volume regulation. At the same time, mitochondrial dysfunction and impaired perfusion make the cells less able to meet these increased demands, leading to cell death.

TABLE 151.1 Example Mechanisms of Secondary Brain Injury after Trauma

Systemic
Hypoperfusion due to the following:
• Respiratory cause: hypoventilation, airway obstruction, lung injury
• Cardiac causes: commotio cordis, stunned myocardium, arrhythmia
• Vascular cause: hypotension due to hemorrhagic hypovolemia, spinal shock, adrenal injury or insufficiency, dysautonomia, especially associated with delirium
• Electrolyte abnormalities of central cause but with systemic effect (salt wasting, diabetes insipidus, syndrome of inappropriate antidiuretic hormone secretion)
Intracranial
• Hypoperfusion due to expanding mass
• Subdural, epidural, parenchymal hematoma (which can be due to loss of clotting factors to systemic injury), hydrocephalus, or swelling of diffuse axonal injury
• Excitotoxicity and energy exhaustion due to seizures
Injury to Intervening and Adjacent Structures
• Carotid occlusion or dissection, poor jugular drainage
• Infection due to penetrating injury, of particular concern with injury to the sinuses

Although overlapping with mechanisms of secondary injury in the adult, the distribution of injury may differ in the child because of incomplete myelination and selective expression of transmitter and voltage-dependent conductance in specific developmental windows.

DIAGNOSIS AND MANAGEMENT

Medical management is directed toward secondary prevention, providing, through optimized care, the best possible outcome obtainable given that an injury has already occurred. This is the medical challenge commonly faced by practitioners in a chain from the first responder to the emergency room and the pediatric intensive care unit. To date, few modalities are available to promote reversal of injury, and neuroprotection in the strictest sense, of physiologically isolating the brain from systemic changes, remains largely experimental. Consequently, the focus of management in the acute period is on preventing additional injury so that the body may gradually heal itself to the maximum extent to which it is intrinsically capable rather than extrinsically promoting healing.

The mechanisms of potential secondary injury to be intercepted are several: Head trauma is often accompanied by systemic trauma. This in turn can cause brain hypoperfusion at the very moment that the brain is most susceptible to hypoperfusion due to impairment of the usual protective reflexes that ordinarily prioritize the maintenance of cerebral blood flow. Consequently, the highest priority in the acute management of pediatric brain injury is on stabilizing perfusion: providing adequate oxygenation, ventilation, and blood pressure. Hypotension in particular is common due to many mechanisms (see Table 151.1) and has been shown to be quite deleterious, independent of other factors. It should be combatted aggressively by fluid resuscitation and, as needed, by pressor support and transfusion.

Differences between pediatric and adult TBI are emphasized by improved outcomes when children are treated at pediatric-experienced centers. Direct admission to such a center is superior to secondary transfer.

Although the perception of some practitioners may be that highly specialized elective procedures or workups mandate tertiary care, whereas trauma is the "bread and butter" of community hospitals, studies show to the contrary that not only is trauma experience important but also pediatric-specific experience in particular matters in childhood injury.

As in all cases of pediatric trauma, clinicians must always consider whether the child presenting with TBI has injuries consistent—in both severity and wound age—with the reported mechanism. Infants are most vulnerable both because they are affected at higher rates and because they are unable to recount events. Difficult legal and ethical questions arise often because many traumas result from poor supervision, raising concern for negligence even when there was no intent to harm. In inadequately explained trauma, a social or home safety screening, involvement of child protection specialist, and discussion with the jurisdictional agency are imperative. Screenings are mandated whenever even a concern has been raised by a presentation not only when there is a high suspicion or certainty. As such, it is most constructive for parents to regard reporting as a chance to assess and mitigate risks rather than an accusation, much less a determination, of criminality. Workup is directed both toward uncovering other signs of abuse as well as ruling out disorders that may actually present similarly or be claimed as such. Although recent work argued against von Willebrand disease being a mimic of abuse, for example, excluding a bleeding diathesis can still be of medicolegal importance

Factors to be considered are shown in Table 151.2.

Minor Traumatic Brain Injury

Patients presenting with a Glasgow Coma Scale (GCS) score of 8 or less (see Table 47.3) are defined by most studies as having severe head trauma. Patients with a GCS of 14 or 15 are generally regarded as having minor head trauma. This category often overlaps with concussion, defined as a head injury causing transient loss or alteration of consciousness or loss of memory. Increasing evidence that lasting encephalopathy can result from the cumulative effects of even minor head trauma in professional sports has made this a source of greater societal and parental concern. American Academy of Neurology guidelines recommend refraining from activities with recurrent injury risk (practice or play) until resolution of concussion and associated symptoms such as headache. American Academy of Pediatrics guidelines also recommend "cognitive rest"

TABLE 151.2 Considerations in Evaluation of Possible or Suspected Nonaccidental Trauma

• Establish age of injury or injuries and determination of consistency with reported history.
• Social work screen; discuss with child protective services, police, or district attorney's office
• Ophthalmology consult with dilated examination
• Skeletal survey and/or radionucleotide study for reactive changes of older, healing bone injury
• Exclude (by clinical findings or lab test) other causes such as coagulopathy, osteogenesis imperfecta, or glutaric aciduria.

including reducing academic activities to prevent exacerbation of symptoms. However, there is no evidence supporting this as either necessary or beneficial for recovery.

Indications for Head Computed Tomography Imaging in Minor Traumatic Brain Injury

Several studies have established criteria mandating a head CT in infants and children presenting with injury, aiming to eliminate unnecessary scans while assuring that no potentially actionable findings are missed by not scanning. The Canadian Assessment of Tomography for Childhood Head Injury or "CATCH" rule is to scan any child with any of the following: GCS less than 14, suspected open or depressed skull fracture, worsening headaches, or irritability on exam. Application of this rule identified 98% of patients with CT findings of injury and all patients requiring surgical intervention among the 2,043 CTs performed.

The Pediatric Emergency Care Applied Research Network (PECARN) conducted a large study across 25 centers to identify and validate a decision rule to determine necessity of head CT for children (younger than 18 years) presenting with a GCS of 14 or 15 LEVEL 1.[1] Among children younger than 2 years of age, criteria with predictive value were alteration of mental status per examiner *or* not at baseline per parent, presence of nonfrontal scalp hematoma, loss of consciousness longer than 5 seconds, severe mechanism (vehicular, hit by high-velocity object or >3 ft fall), or palpable fracture. Absence of these elements had a predictive value approaching 100% for excluding clinically important injury warranting CT scanning (**Fig. 151.3**). In the children 2 years or older, validated criteria were any alteration of mental status, *any* loss of consciousness (even <5 s), emesis, severe injury (in these meaning vehicular, high-velocity object or >5 ft fall), signs of basilar skull fracture (Battle or "raccoon" sign, hematotympanum, or cerebrospinal fluid oto- or rhinorrhea), and severe headache. Absence of these factors was greater than 99% predictive for the absence of a clinically significant injury to be found on imaging, providing a level I evidence basis for decision making. A recent survey by the Pediatric Emergency Care Applied Research Network found that adherence to the clinical decision rule can indeed modestly reduce the number of CTs while detecting clinically important TBIs.

Depending on the mechanism of injury, imaging of the neck may be warranted as well and stabilization kept in place until concurrent cervical trauma is excluded. Particularly in cases where there may have been strain or torsion between head and torso, consideration should be given to the possibility of C-spine fractures, subluxations, ligamentous injury, and vessel damage such as carotid or vertebral dissection.

Severe Traumatic Brain Injury

In an effort to improve and standardize the management of severe pediatric TBI, a collaborative literature review was undertaken to assemble evidence-based guidelines. These have recently been updated and are the basis of **Table 151.3**. Regarding some interventions, large, well-designed trials have been performed, for example, showing that cooling did not show a demonstrable neuroprotective benefit in children, or did steroids in a large adult trial. In **Table 151.4**, the order in which interventions are implemented is presented with higher "tiers" offering more aggressive measures for the circumstance that the prior, less invasive tier has failed to adequately control intracranial pressure (ICP). Particular management considerations and evidence are described in the text below.

Intracranial Pressure in Children

Normal ICP in children ranges up to 28 cm H_2O corresponding to 20 mm Hg. Elevations of ICP after trauma have been associated with higher mortality in observational studies, especially if elevated ICP has been unresponsive to interventions. Although ICP monitors have not been directly demonstrated to improve outcomes, they do allow the titration of therapies that reduce ICP. Lower ICP, even when achieved by intervention, correlates with better outcome. Consequently, the latest pediatric TBI guidelines include a level III recommendation for the consideration of ICP monitoring in severe TBI. A recent trial in Bolivia and Ecuador directly comparing management with and without the use of ICP monitoring included some adolescents (age older than 13 years). However, the study was not powered to analyze teenagers separately.

Analysis of data on over 3,000 children treated at 30 hospitals did not find any difference in outcome depending on whether an ICP monitor was placed. However, the monitored group may have been higher risk to begin with in ways inadequately captured by retrospective analysis so that it was benefit of their monitor that brought their outcomes down to that of the unmonitored group.

Hypothermia Following Severe Traumatic Brain Injury

Hypothermia as a treatment modality after TBI was carefully evaluated by the Canadian Critical Care Trials Group in the Hypothermia Pediatric Head Injury Trial LEVEL 2.[2] Two hundred twenty-five children were randomly assigned to either hypothermic therapy 90.5°F, initiated within 8 hours of the injury and maintained for 24 hours, or normothermia. No advantage was found for hypothermia, a level I evidence finding (this and other level I designations in the present chapter are based on criteria comparable to the original version of the pediatric severe TBI guidelines, generally corresponding to level II in the second edition). In fact, more hypotension was seen in the hypothermia group with a possible trend toward greater mortality. Whether there exist individual subgroups, such as refractory elevated ICP awaiting decompression, who may benefit, remains uncertain. Meanwhile, routine use of hypothermia cannot be recommended for pediatric TBI.

Seizure Prophylaxis

The original Temkin et al. study in 1990 established a benefit to the short-term use of phenytoin in patients older than 16 years of age to reduce seizures in the week after injury. Indications for prophylaxis were the presence of intracranial blood and/or a depressed skull fracture LEVEL 1.[3] In a retrospective analysis of pediatric cases, low GCS scores were most predictive of early seizures, and treatment with phenytoin was associated with a lower seizure rate. In one prospective trial, no benefit for rate of seizures within 48 hours was seen in children receiving phenytoin within 1 hour of arrival LEVEL 1.[4] However, benzodiazepines given for elevated ICP or intubation may have masked the effect. The current pediatric TBI guidelines include a level II recommendation for consideration of phenytoin prophylaxis. Since the introduction of intravenous levetiracetam, this is an increasingly chosen option because of a perceived high degree of efficacy and a favorable side effect profile. The feasibility of this was demonstrated by a phase II trial in 2013 in which levetiracetam 55 mg/kg/d, divided twice a day, was administered to children ages 6 to 17 years for 30 days. A prospective trial will be needed to confirm benefit.

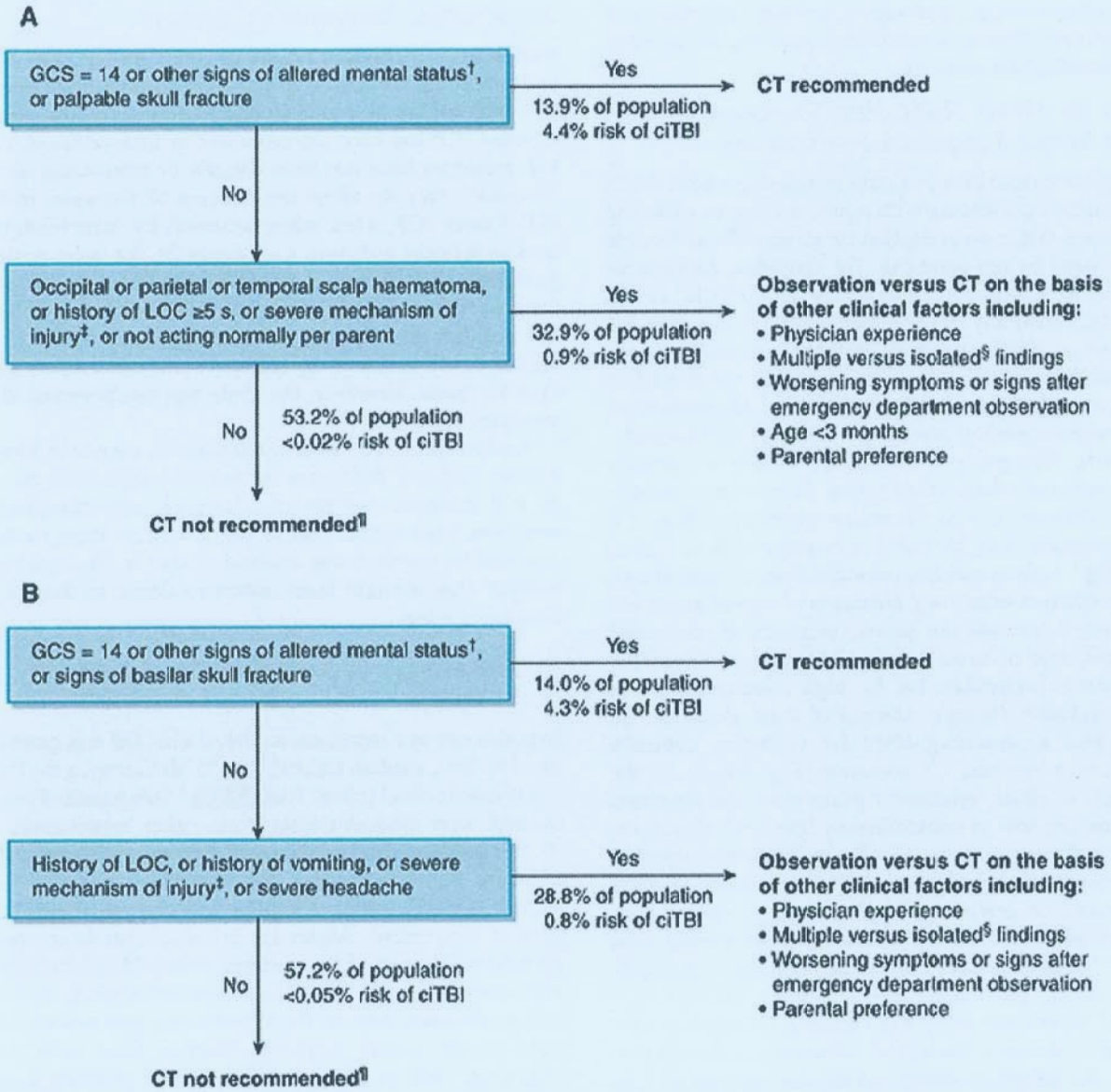

FIGURE 151.3 Suggested computed time (CT) algorithm for children younger than 2 years **(A)** and for those aged 2 years and older **(B)** with Glasgow Coma Scale (GCS) scores of 14 to 15 after head trauma. Abbreviations: ciTBI, clinically important traumatic brain injury; LOC, loss of consciousness. *Data are from the combined derivation and validation populations. †Other signs of altered mental status: agitation, somnolence, repetitive questioning, or slow response to verbal communication. ‡Severe mechanism of injury: motor vehicle crash with patient ejection, death of another passenger, or rollover; pedestrian or bicyclist without helmet struck by a motorized vehicle; falls of more than 0.9 m (3 ft) (or more than 1.5 m [5 ft] for panel B); or head struck by a high-impact object. §Patients with certain isolated findings (ie, with no other findings suggestive of traumatic brain injury), such as isolated LOC, isolated headache, isolated vomiting, and certain types of isolated scalp hematomas in infants older than 3 months, have a risk of ciTBI substantially lower than 1%. ¶Risk of ciTBI exceedingly low, generally lower than risk of CT-induced malignancies. Therefore, CT scans are not indicated for most patients in this group.

Repeat Imaging

Criteria for repetition of imaging in pediatric TBI are not well established. In one analysis, worsening was found in 13% of follow-up scans. However, among these, all requiring surgical intervention had clinical indications of worsening neurologic status. Consequently, the pediatric TBI guidelines include a level II recommendation suggesting that repeat imaging may not be warranted in the absence of clinical change or increasing ICP. On the other hand, in a separate large retrospective case series, 27% of patients showed worsening, of whom less than a fifth had accompanying clinical signs. Furthermore, among those whose CTs led to surgical intervention, two-thirds did not have clinical signs. This would suggest that high clinical concern based on initial findings or clinical picture in addition to worsening or rising ICP is sufficient justification for repeat CT.

TABLE 151.3 Best Evidence Management for Severe Traumatic Brain Injury[a,b]

Invasive Pressure Monitoring
Use of ICP monitoring is suggested in infants with severe TBI (level III).
Intracranial Pressure
Treatment of ICP is suggested at targeting a threshold of <20 mm Hg (level III).
Cerebral Perfusion Pressure
A CPP threshold of 40-50 mm Hg is suggested to ensure that the minimum value of 40 mm Hg not be breached. There may be age-specific thresholds with infants at the lower end and adolescents at the higher end of this range (level III).
Advanced Neuromonitoring
If brain oxygenation monitoring is used, maintenance of a partial pressure of brain tissue oxygen >10 mm Hg is suggested (level III).
Hypothermia
Prophylactic moderate (32°C-33°C) is not recommended over normothermia to improve overall outcomes (level II). Moderate hypothermia (32°C-33°C) is suggested for ICP control (level III).
Ventilation
Prophylactic severe hypoventilation to a $Paco_2$<30 mm Hg in the initial 48 h after injury is not suggested (level III). If hyperventilation is used in the management of refractory intracranial hypertension, advanced neuromonitoring for evaluation of cerebral ischemia is suggested.
Seizure Prophylaxis
Prophylactic treatment is suggested to reduce the occurrence of posttraumatic epilepsy (level III).
Use of Steroids
The use of steroids is not suggested to improve outcome or reduce ICP (level III).
Sedatives
With use of multiple ICP-related therapies as well as appropriate use of analgesia and sedation in routine ICU care, avoiding bolus administration of midazolam and/or fentanyl during ICP crises is suggested due to risks of cerebral hypoperfusion (level III).
Reimaging
Excluding the possibility of elevated ICP on the basis of a normal initial (0-6 h after injury) CT examination of the brain is not suggested in comatose pediatric patients (level III). Routinely obtaining a repeat CT scan >24 h after admission and initial follow-up is not suggested for decisions about neurosurgical intervention, unless there is either evidence of neurologic deterioration or increasing ICP.
Hyperosmolar Therapy
Bolus hypertonic saline (3%) is recommended in patients with intracranial hypertension. Recommended doses for acute use range between 2 and 5 mL/kg over 10-20 min (level II). Continuous infusion of hypertonic saline is suggested in patients with intracranial hypertension. Suggested effective doses as a continuous infusion of 3% saline range between 0.1 and 1.0 mL/kg of body weight per hour, administered on a sliding scale. The minimum dose needed to maintain ICP <20 mm Hg is suggested (level III). Bolus of 23.4% hypertonic saline is suggested for refractory ICP. The suggested dose is 0.5 mL/kg with a maximum of 30 mL (level III).

Abbreviations: CPP, cerebral perfusion pressure; CT, computed tomography; ICP, intracranial pressure; TBI, traumatic brain injury.
[a]Levels shown here are their strength-of-recommendation designations.
[b]Based on Kochanek P, Tasker RC, Carney N, et al. Guidelines for the management of pediatric severe traumatic brain injury, third edition: update of the Brain Trauma Foundation guidelines, executive summary. *Pediatr Crit Care Med.* 2019;20:S1-S82.

TABLE 151.4 Stepwise Approach to Management of Elevated Intracranial Pressure

Tier 1
• Head of bed elevation • Sedation and neuromuscular blockade • Mechanical ventilation to normal arterial carbon dioxide pressure • Active normothermia • Hyperosmolar therapy • External ventricular drainage
Tier 2
• Moderate hyperventilation • Mild hypothermia (to 35°C) • Thiopental infusion
Tier 3
• Decompressive craniectomy

Decompressive Craniectomy

The recent DEcompressive CRAniectomy (DECRA) trial, which did not show a survival benefit to decompressive craniectomy as a rescue therapy, did not include children. A prospective but small, early pediatric trial found a trend toward benefit of decompressive bitemporal craniectomy in patients with medically refractory ICP. However, the decompression in this study was performed without duraplasty, different from the techniques more commonly employed. A larger study in children including duraplasty has yet to be done, and the use of decompressive craniectomy including duraplasty is regarded as a level III option in the pediatric TBI guidelines.

OUTCOME

Except in the most severe of cases, the degree of injury, whether by clinical criteria or imaging, incompletely predicts ultimate outcome. Consequently, prognostic prediction during the acute treatment should be cautious. In children, recovery may continue long after the injury. Diffusion tensor imaging is emerging as the best predictor, especially for the extent of white matter damage in diffuse axonal injury. There is less clinical experience with the use of serum markers for gradation in trauma.

Patients with moderate and severe injuries typically will require inpatient rehabilitation after their stabilization. Impairments of gross and fine motor skills are easily identified and readily justify the need for physical and occupational therapy. However, parents should be forewarned of the possibility of more subtle deficits that may even be unapparent on screening neurologic exam but can impose large burdens as the patient attempts to resume activities of daily living and education. Posttraumatic changes in memory, attention, motivation, as well as migraine or tension-like headaches can all interfere with return to school. Neuropsychological testing can be helpful in identifying cognitive disabilities. Schools can be asked to structure an individualized education plan or supplemental services and accommodation (commonly known as a *504 plan*, referring to Section 504 of Federal Disability Law) to smooth the transition.

Neurologic follow-up may be warranted to treat sequela such as headaches or chronic posttraumatic seizures. Also, in infants, screening may be needed to identify failure of proper skull healing. The incompletely fused or partially mineralized pediatric skull can undergo aberrant healing. Pressure on a fracture or diastasis

of an existing suture can lead to a "growing fracture." Over a period of weeks to months, this can allow formation of so-called leptomeningeal cysts, a misnomer used to describe what is actually a dural herniation through the skull defect. This entity, extremely rare in adults, can be ruled out in young children with severe TBI by a follow-up skull film 6 weeks to 3 months after injury.

LEVEL 1 EVIDENCE

1. Kuppermann N, Holmes JF, Dayan P, et al. Identification of children at very low risk of clinically-important brain injuries after head trauma: a prospective cohort study. *Lancet*. 2009;374:1160-1170.
2. Hutchison JS, Ward RE, Lacroix J, et al. Hypothermia therapy after traumatic brain injury in children. *N Engl J Med*. 2008;358:2447-2456.
3. Temkin NR, Dikmen SS, Wilensky AJ, Keihm J, Chabal S, Winn HR. A randomized, double-blind study of phenytoin for the prevention of post-traumatic seizures. *N Engl J Med*. 1990;323:497-502.
4. Young KD, Okada PJ, Sokolove PE, et al. A randomized, double-blinded, placebo-controlled trial of phenytoin for the prevention of early posttraumatic seizures in children with moderate to severe blunt head injury. *Ann Emerg Med*. 2004;43(4):435-446.

SUGGESTED READINGS

Chesnut RM, Temkin N, Carney N, et al; for Global Neurotrauma Research Group. A trial of intracranial-pressure monitoring in traumatic brain injury. *N Engl J Med*. 2012;367:2471-2481.

Cooper DJ, Rosenfeld JV, Murray L, et al; for DECRA Trial Investigators and the Australian and New Zealand Intensive Care Society Clinical Trials Group. Decompressive craniectomy in diffuse traumatic brain injury. *N Engl J Med*. 2011;364:1493-1502.

Duhaime AC, Christian CW, Rorke LB, Zimmerman RA. Nonaccidental head injury in infants—the "shaken-baby syndrome." *N Engl J Med*. 1998;338:1822-1829.

Figg RE, Stouffer CW, Vander Kolk WE, Connors RH. Clinical efficacy of serial computed tomographic scanning in pediatric severe traumatic brain injury. *Pediatr Surg Int*. 2006;22(3):215-218.

Giza CC, Kutcher JS, Ashwal S, et al. Summary of evidence-based guideline update: evaluation and management of concussion in sports. *Neurology*. 2013;80(24):2250-2257.

Halstead ME, Walter KD; and Council on Sports Medicine and Fitness. Sport-related concussion in children and adolescents. *Pediatrics*. 2010;126(3):597-615.

Hollingworth W, Vavilala MS, Jarvik JG, et al. The use of repeated head computed tomography in pediatric blunt head trauma: factors predicting new and worsening brain injury. *Pediatr Crit Care Med*. 2007;8(4):348-356.

Kochanek P, Carney N, Adelson PD, et al. Guidelines for the acute medical management of severe traumatic brain injury in infants, children, and adolescents—second edition. *Pediatr Crit Care Med*. 2012;13(suppl):S1-S82.

Lewis RJ, Yee L, Inkelis SH, Gilmore D. Clinical predictors of post-traumatic seizures in children with head trauma. *Ann Emerg Med*. 1993;22:1114-1118.

Pearl PL, McCarter R, McGavin CL, et al. Results of phase II levetiracetam trial following acute head injury in children at risk for posttraumatic epilepsy. *Epilepsia*. 2013;54(9):e135-e137.

Pinto PS, Meoded A, Poretti A, Tekes A, Huisman TAGM. The unique features of traumatic brain injury in children. Review of the characteristics of the pediatric skull and brain, mechanisms of trauma, patterns of injury, complications and their imaging findings—part 2. *J Neuroimaging*. 2012;22(2):e18-e41.

Pinto PS, Poretti A, Meoded A, Tekes A, Huisman TAGM. The unique features of traumatic brain injury in children. Review of the characteristics of the pediatric skull and brain, mechanisms of trauma, patterns of injury, complications and their imaging findings—part 1. *J Neuroimaging*. 2012;22(2):e1-e17.

Taylor A, Butt W, Rosenfeld J, et al. A randomized trial of very early decompressive craniectomy in children with traumatic brain injury and sustained intracranial hypertension. *Childs Nerv Syst*. 2001;17:154-162.

152 Human Immunodeficiency Virus, Fetal Alcohol Syndrome, and Drug Effects

Claudia A. Chiriboga

KEY POINTS

1. Although rare in the United States, pediatric human immunodeficiency virus (HIV) affects nearly 1.8 million children ages 0 to 14 years worldwide.
2. Pediatric HIV/AIDS manifestations are broad; depend on severity of underlying HIV and immune response; and can include HIV encephalopathy, stroke, and opportunistic infections.
3. Fetal alcohol exposure is associated with a range of neurologic complications, with a spectrum of severities and phenotypes.
4. The four main neurologic phenotypes following fetal alcohol exposure are fetal alcohol syndrome, partial fetal alcohol syndrome, alcohol-related neurodevelopmental disorder, and alcohol-related birth defects.
5. Prenatal cocaine exposure is associated with neurobehavioral and developmental outcomes, strokes, and malformations.
6. Prenatal opiate exposure is associated with lower intelligence and withdrawal.

PEDIATRIC AIDS AND HUMAN IMMUNODEFICIENCY VIRUS INFECTION

Introduction

With the advent of effective therapy, there have been marked declines in pediatric human immunodeficiency virus (HIV) in some but not all populations. Similar to adult populations, manifestations of HIV infection are broad and relate to the burden of viral load and immune response. Pediatric neurologic sequelae of HIV also relate to severity of illness and can reflect diffuse or focal brain disease, with or without opportunistic infections (OIs).

Epidemiology

Pediatric HIV in the United States continues to decline in children under age 13 years. Unfortunately, worldwide, there are about 1.8 million HIV-infected children aged 0 to 14 years. Most of these children live in Africa, primarily Eastern and Southern Africa, and are infected perinatally. In the United States intravenous drug abuse and sexual contact with HIV-infected partners are the maternal risk factors in nearly all perinatal cases. Mother-to-child HIV transmission rates have dropped dramatically in the United States with the increase in surveillance efforts to identify HIV infection among pregnant women and the use of highly active antiretroviral drugs treatment (HAART) during pregnancy. Perinatal transmission rates in the United States dropped from about 25% prior to prophylaxis to less than 2% with HAART. In 2016, 73 children younger than the age of 13 years were diagnosed with HIV in the United States, a decrease from 166 children diagnosed in 2009. Rates of perinatally acquired HIV in 2015 decreased to less than 1 in 100,000 births in some ethnic/racial groups (white and Hispanic) but remained elevated among African Americans (5.4 per 100,000).

Most HIV transmission from mother to infant occurs in the last trimester of pregnancy and at the time of delivery. Risk factors for vertical transmission are HIV identification at delivery, recent maternal HIV seroconversion, high viral burden, and maternal AIDS LEVEL 1.[1] Premature infants are also at increased risk of infection. Infection may result from exposure to blood and other body fluids at delivery. Breastfeeding is, thus, not recommended in the United States; cesarean section is not routinely recommended unless maternal viral burden is high. Youths (older than age 13 y and younger than age 24 y) are the fastest growing group of HIV-infected individuals and in 2017 accounted for 21% of new HIV diagnoses most increase occurred in the 21 to 24 years age range. HIV infection predominantly affected adolescent and young men (87%) and were mostly the result of male-to-male sexual transmission. Heterosexual contact is the main risk factor for adolescent girls and young women.

Determining transmission of HIV infection to offspring based on detection of HIV antibody has been replaced by infant HIV polymerase chain reaction (PCR). Furthermore, maternal HIV infection status is no longer required to determine infant HIV infection status. The Centers for Disease Control and Prevention surveillance definition states a child is considered definitively infected if he or she has positive virologic results on two separate specimens or is aged older than 18 months and has either a positive virologic test or a positive confirmed HIV antibody test. HIV-seropositive children who do not meet these criteria are considered perinatally exposed and later seroreverters when antibodies turn negative. Since 1994, clinical classification system for confirmed cases of HIV infection in children has been replaced by a five staging system that applies to both adults and children: 0, 1, 2, 3, or unknown. Stage 0 corresponds to early infection as noted by a negative HIV test within 6 months of HIV diagnosis. Stages 1 to 3 are classified immunologically (absolute CD4 count or percent CD4 count) depending on the child's age (younger than 12 mo, 1-5 y, and older than 6 y): stage 1, no evidence of immune suppression; stage 2, moderate immune suppression; and stage 3, severe immune suppression (either a low CD4 count or whether an

TABLE 152.1 Infection Stage Based on Age-Specific CD4⁺ T-lymphocytes Count or Age-Specific CD4⁺ T-lymphocyte Percentage of Total Lymphocytes[a]

		<12 mo		1-5 y		>6 y	
Stage	Immunologic Category	Cells/μL	(%)	Cells/μL	(%)	Cells/μL	(%)
1	No evidence of suppression	≥1,500	(≥34)	≥1,000	(≥30)	≥500	(>26)
2	Moderate suppression	750-1,499	(26-33)	500-999	(22-29)	200-499	(14-25)
3	Severe suppression	<750	(<26)	<500	(<22)	<200	(<14)

[a]Adapted from Selik RM, Mokotoff ED, Branson B, Owen SM, Whitmore S, Irene Hall H. Revised surveillance case definition for HIV infection—United States, 2014. *MMWR Morb Mortal Wkly Rep*. 2014;63:1-10.

opportunistic illness was diagnosed) (Table 152.1). T-cell counts in infants and toddlers are higher for a specific immune category and reach adult levels after age 6 years.

Pathobiology

HIV infection is maintained by viral persistence in helper T lymphocytes and macrophages. HIV strains with tropism for monocyte-derived macrophages have a predilection to infect cerebral vascular endothelium and the central nervous system (CNS). Infected macrophages traverse the blood-brain barrier and infect microglial cells; astrocytes are infected nonproductively, whereas neurons are spared from direct infestation. Neuronal dropout is seen as the disease advances, but it is not known how HIV induces neural damage. Postulated mechanisms include release of soluble neurotoxins by HIV-infected macrophages and lymphocytes (eg, cytokines, quinolinic acid, viral antigens, or undefined viral products), neurotoxin amplification by astrocyte-macrophage interaction, and impaired blood-brain barrier function secondary to HIV-related endothelial damage. Nonproductive infection of a portion of astrocytes is reportedly amplified bystander neurotoxicity. These neurotoxins are believed to produce a reversible metabolic encephalopathy that may disappear with effective antiretroviral treatment.

Glial nodules and endothelial hyperplasia with calcification, dystrophic calcification, and perivascular mononuclear inflammation are common pathologic findings of subacute encephalitis in HIV-infected brains. The glial nodule comprises a cluster of chronic inflammatory cells in the neuropil and is often associated with multinucleated giant cells, which presumably arise from coalescent microglia.

Clinical Manifestations

Mild HIV infection includes diarrhea, unexplained persistent fever, lymphadenopathy, and parotitis. Lymphoid interstitial pneumonitis and recurrent bacterial infections are seen in HIV-infected children but not in infected adults. Prior to the advent of antiretroviral therapy, severe manifestations in early infancy, such as progressive encephalopathy or OIs (eg, *Pneumocystis jiroveci*, formerly known as *Pneumocystis carinii*), carried a poor prognosis for survival, but with effective antiretroviral therapy, these disorders are compatible with survival to adulthood.

Human Immunodeficiency Virus Encephalopathy

Two types of encephalopathy are seen in children: progressive and static. The evolution of the progressive encephalopathy may be fulminant, inexorably progressive, or stepwise. Progressive encephalopathy is characterized by loss of developmental milestones, progressive pyramidal tract dysfunction, and acquired microcephaly or impaired brain growth. The static encephalopathy is less well defined, and all cases may not be related to direct HIV CNS disease.

The neurologic abnormalities commonly include abnormalities of muscle tone, hyperreflexia, clonus, and impaired head growth. Hypotonia with corticospinal tract dysfunction may be seen in infants early in the course of the encephalopathy and evolves into a spastic diparesis; with newer antiretroviral treatments, progression to a spastic tetraparesis, with or without pseudobulbar palsy, is seldom seen in the United States. In Jamaica, 23% of HIV-infected children presenting between 2002 and 2009 had a diagnosis of HIV encephalopathy, a third of whom had a spastic tetraparesis. Ataxia and rigidity are uncommon. Prior to HAART, progressive neurologic dysfunction was the first evidence of progression to AIDS in 10% of infected children. In young children, early presentation may mimic a leukodystrophy. At the time of neurologic symptom onset, there is always evidence of underlying HIV infection, such as immunologic compromise (low CD4 counts) or high viral load. Many infected children exhibit global developmental delay or cognitive impairment of varying degree regardless of neurologic findings.

The rate of neurologic abnormalities reported in HIV-infected cohorts before the advent of antiretroviral treatments was 15% to 30%. The incidence of progressive HIV encephalopathy in 2000 was less than 2% in the U.S. cohort followed. Children most at risk are those who have recovered from HIV encephalopathy. Older HIV-infected children may show problems in visual-spatial processing functions and expressive language and may develop AIDS dementia complex indistinguishable from that described in adults. Children with HIV encephalopathy who respond to antiretroviral therapy may show reversal of microcephaly and cognitive impairments. The most frequent sequelae of "arrested" HIV encephalopathy are learning difficulty and nonprogressive mild spastic diparesis.

Primary Central Nervous System Lymphoma

HIV is associated primary CNS lymphoma (non-Hodgkin), which is an AIDS-defining condition. The rate of this mostly B-cell lymphoma is 2% to 6%, 1,000 times higher than in the general population and mostly linked to Epstein-Barr virus infection. The incidence of CNS lymphoma has decreased because the advent of HAART from an incidence ratio (HIV-infected children/uninfected children) of 1,994 down to an incidence ratio of 1,088. CNS lymphoma is still the most common cause of focal cerebral signs in symptomatic HIV-infected children (see also Chapter 103). It is often multifocal, and seizures are reported

TABLE 152.2 Distinguishing Features Between Central Nervous System Lymphoma and Toxoplasmosis Abscess

	Lymphoma	Toxoplasmosis
Distribution of lesion	Often solitary, subependymal spread	Typically multifocal, basal ganglia or cortico-medullary junction
Enhancement	Typically homogenous	Often ring or nodular
MR perfusion	Increased rCBV	Decreased rCBV
SPECT	Increased uptake	Decreased uptake
MRS	Increased choline peak	Decreased choline peak

Abbreviations: MR, magnetic resonance; MRS, magnetic resonance spectroscopy; rCBV, relative cerebral blood volume; SPECT, single-photon emission computed tomography (thallium).

in about 33% of patients. It may be difficult to differentiate this tumor from a toxoplasmic brain abscess by neuroimaging, but a positive PCR for Epstein-Barr virus in cerebrospinal fluid (CSF) is highly suggestive of CNS lymphoma. Thallium single-photon emission computed tomography and magnetic resonance (MR) spectroscopy may prove helpful in distinguishing CNS toxoplasmosis from lymphoma (Table 152.2). Diagnostic confirmation may require brain biopsy.

Stroke

Untreated HIV infection produces inflammation of cerebral vessels, increasing the risk of stroke, which occurred at a rate of 1.3% a year in symptomatic HIV-infected children. More than 50% of strokes were hemorrhagic and occurred with thrombocytopenia (especially immune thrombocytopenic purpura) or CNS neoplasia. Nonhemorrhagic stroke and subarachnoid hemorrhage are attributed to an arteriopathy of large vessels in the circle of Willis (fusiform aneurysms) or meninges (Fig. 152.1). HIV-related strokes may be clinically silent, so the true incidence is probably higher. In cases of stroke, varicella-zoster virus (VZV) should be excluded as the etiologic agent by CSF PCR, especially when small intracranial vessels are involved. Ocular involvement should be excluded by pupillary dilatation for ophthalmologic assessment. Any vasculopathy in an HIV-infected patient is presumed to be infectious (from either HIV or VZV) and should be treated with appropriate antiretroviral and antiviral medication.

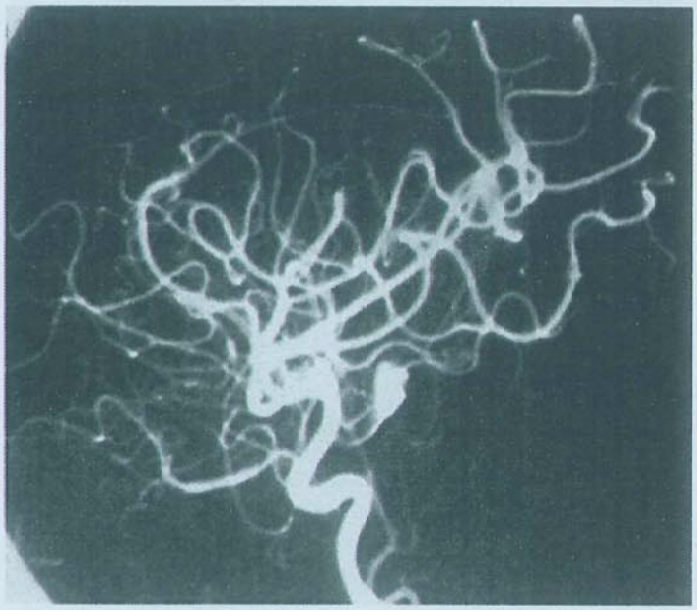

FIGURE 152.1 Fusiform aneurysm in a child with advanced human immunodeficiency virus encephalopathy presenting with intraventricular hemorrhage and stroke.

Opportunistic Central Nervous System Infection

As opposed to adults, OIs in children involve primary infections rather than reactivation. Exposure rates to OI pathogens are cumulative and approximate adult rates by adolescence. Hence, rates of CNS OI occur less frequently in HIV-infected young children. Presentation and treatment of OIs are akin to what is described among HIV-infected adults (see Chapter 70). For instance, the seroprevalence of the John Cunningham virus that causes progressive multifocal leukoencephalopathy (PML) rises from about 16% in children 1 to 5 years of age to 34% by age 21 to 50 years. Prior to HAART, the PML event rate was 0.06 per 100 person years, with affected children identified at a median age of 10.8 years and median CD4 count of 6 cells/mm^3. Survival of children with PML has increased with antiretroviral treatment and effective antiretroviral combination therapy.

Less Common Manifestations

HIV-associated myelopathy, polyneuropathy, and myopathy are rare in children. Spinal cord pathology may show demyelinating changes of the corticospinal tracts, vacuolar changes, or myelitis attributable to HIV or other virus. Acute inflammatory demyelinating polyneuropathy is a rare complication in pediatric HIV.

HIV brain infection is nonfocal and subcortical. Seizures are not common. Focal signs or seizures raise the possibility of neoplasm, strokes, or, less likely, OIs.

Diagnostic Testing

Human Immunodeficiency Virus Testing

Because of early testing, most HIV-positive children in the United States are identified soon after birth, especially in states with universal perinatal screening. HIV DNA PCR is the preferred diagnostic method, whereas quantitative HIV RNA PCR is more sensitive in determining plasma concentration (copies per mL) of HIV RNA, commonly referred to as *plasma viral load*. By age 6 months, 100% of HIV-infected children are identified by a positive PCR. In newborns, a negative PCR test for HIV does not exclude infection but decreases the risk of HIV infection to 3%. Viral load runs higher in asymptomatic children than in asymptomatic adults. Sustained high viral load and low CD4 count predict progression to AIDS. High viral loads in early infancy predict early onset of symptomatic HIV disease but with prophylactic treatment (during pregnancy and for up to 6 wk to newborn postnatally) rates can be lowered to 1%. In industrialized countries, most progression to AIDS in the post-HAART era, is related to nonadherence to HAART of any cause (ie, medical or social), which in turn facilitates development of drug resistance. HIV-1 syncytial-inducing phenotypes that are linked to aggressive early symptomatic disease.

Neuroimaging

In children with HIV encephalopathy, brain atrophy (cortical and subcortical) is the most common imaging abnormality (Fig. 152.2). Periventricular or parietooccipital demyelination can be observed on magnetic resonance imaging (MRI) (Fig. 152.3). Frontal lobe

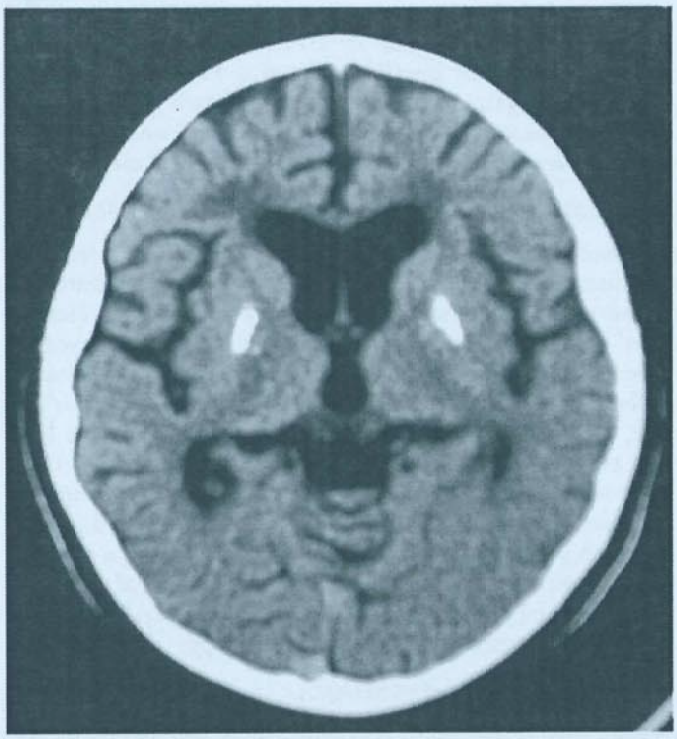

FIGURE 152.2 Computed tomography scan of an infant with human immunodeficiency virus encephalopathy showing cortical and subcortical atrophy, basal ganglia, and frontal lobe calcifications. (Courtesy of Dr. Ram Kairam.)

or basal ganglia enhancement and calcifications are late manifestations of HIV encephalopathy, best seen on computed tomography (CT), and occur primarily in symptomatic infants (see Fig. 152.2). Imaging findings may be indistinguishable from Aicardi-Goutières syndrome. HIV myelopathy may show a high signal on spinal MRI but is usually normal. Bilateral cerebral lesions may mimic myelopathy and must be excluded with MRI or CT. Lesions of PML are commonly located in the parietooccipital or frontal regions, affecting both periventricular and subcortical white matter. These lesions may be difficult to distinguish from HIV demyelination.

Cerebrospinal Fluid

CSF findings are commonly normal in children with HIV infection. In the absence of OI, CSF analysis in children with progressive encephalopathy may show nonspecific changes of lymphocytic pleocytosis and elevated protein content. Intra–blood-brain barrier synthesis of HIV-specific antibody or antigen detection in CSF has not been useful in predicting encephalopathy. CSF viral load, although not routinely available, may prove useful in determining HIV encephalopathy in children, especially in cases of compartmentalization (ie, a sequestered HIV reservoir in the CNS), in which systemic measures of viral load do not parallel the CNS level of viral replication.

Management

Antiretroviral Therapy

HAART, consisting of a protease inhibitor or a nonnucleoside reverse transcriptase inhibitor administered in combination with nucleoside reverse transcriptase inhibitors, has been reported to suppress viral replication, improve immune function, and decrease AIDS-related death as well as diminish rates of HIV encephalopathy. High systemic viral load tends to predict the development of HIV encephalopathy, whereas CD4 counts tend to predict HIV disease progression primarily from OIs. Children younger than 1 year tend to be at greatest risk for progression and should be treated regardless of symptomatology LEVEL 1.[2] After 12 months, treatment is not indicated if child is asymptomatic or minimally symptomatic. Most antiretroviral agents

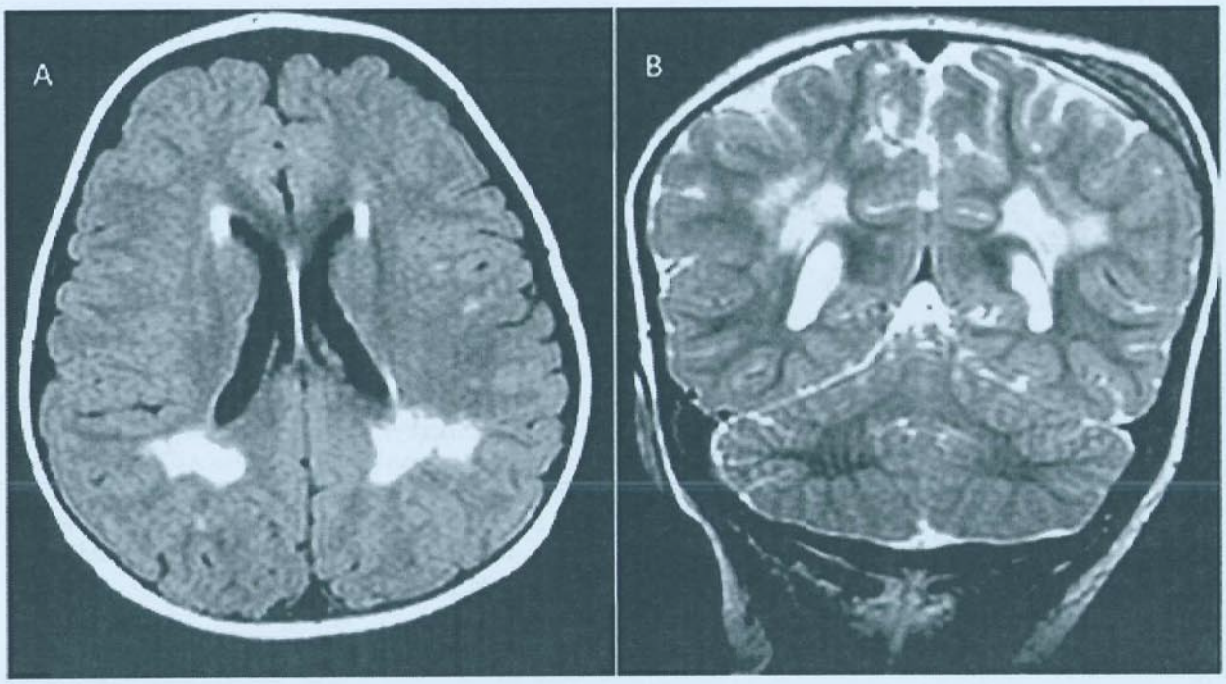

FIGURE 152.3 Parietal occipital demyelination on axial fluid-attenuated inversion recovery (A) and coronal T2 (B) images in a child with advanced human immunodeficiency virus encephalopathy and high viral load (RNA human immunodeficiency virus = 1.5 million copies/mL).

have poor CNS penetrance with the exception of zidovudine, nevirapine, stavudine, and abacavir. However, antiretroviral CNS penetration did not impact the treatment response in AIDS dementia complex. Hence, a change in HAART regimen is not recommended based on CNS involvement.

Antiretroviral Therapy Side Effects

Treatment with nucleoside inhibitors of viral reverse transcriptase can alter mitochondrial (mt) function by inhibiting mtDNA polymerase-γ, which is responsible for the replication of mtDNA. Inhibition of mtDNA results in diminished synthesis of respiratory chain enzymes, causing the syndrome of mt depletion. Antiretroviral-induced mt dysfunction in turn is responsible for diverse adverse effects frequently observed in HIV-infected patients. Nonneurologic side effects include hepatic steatosis, lactic acidemia (>2 mmol/L), and lipodystrophy, a disorder characterized by the accumulation of visceral fat, breast adiposity, cervical fat pads, hyperlipidemia, insulin resistance, and fat wasting in face and limbs. Neurologic side effects include myopathy, peripheral neuropathy, and parkinsonism. mt depletion myopathy can be seen in children treated with combination therapy, especially with nucleoside reverse transcriptase inhibitor that has a high affinity to mt polymerase-γ. Low-dose treatment with didanosine causes a painful sensory neuropathy in less than 10% of patients treated. The neuropathy is dose related and usually clears with cessation of treatment. Didanosine, stavudine, and zalcitabine have a high affinity for binding polymerase-γ, whereas zidovudine, abacavir, tenofovir, and lamivudine have a lower affinity for that enzyme. Changing antiretroviral agents usually relieves the symptoms.

Outcome

Many children treated for HIV experience good response and recovery, with HIV becoming a manageable chronic illness because it can be in adults. Immune reconstitution inflammatory syndrome (IRIS) can occur after introduction of HAART and most often is due to worsening or de novo manifestations of OI (clinically or radiographically) or less often of HIV. The syndrome coincides with improving CD4 count and is not caused by treatment failure or a new infection. In a Johns Hopkins cohort, the independent predictors of IRIS in adults were boosted (with ritonavir) protease inhibitor and rapid decline of viral load (>2.5 log). The infection most commonly reported in adult IRIS is cryptococcal meningitis, but PML and HIV dementia have also been reported. PML-IRIS may be distinguished from PML on MRI because of transient enhancement with contrast. In immune-suppressed (ie, CD4 <15%) Thai children, the incidence of IRIS following HAART was 19%, the median time of onset was 4 weeks, and the primary pathogens involved were VZV and tuberculosis. Most cases of IRIS occur within the first 3 months of treatment, although delayed cases are reported.

FETAL ALCOHOL SPECTRUM DISORDERS

Introduction

The term *fetal alcohol spectrum disorder* was coined to describe the continuum of alcohol effects on the fetus. Ranging from severe to mild, the expanded phenotype associated with prenatal alcohol exposure is composed of four diagnostic categories: fetal alcohol syndrome (FAS), partial fetal alcohol syndrome, alcohol-related neurodevelopmental disorder, and alcohol-related birth defects (Table 152.3). Current definition of documented prenatal alcohol exposure includes greater than or equal to 6 drinks a week or greater than or equal to 3 drinks per occasion greater than or equal to 2 occasions during pregnancy, social or legal alcohol-related problems, acute intoxication, or positive alcohol biomarker during pregnancy. Fetal susceptibility to the effects of alcohol is greatest during the first trimester of pregnancy, but there is no safe trimester to drink alcohol.

TABLE 152.3 Criteria for Diagnosing Fetal Alcohol Spectrum Disorder[a]

Clinical Finding	FAS	PFAS	ARND	ARBD
Dysmorphic features ≥2 of the following: 1. Microphthalmia, short palpebral fissures, or both 2. Poorly developed philtrum 3. Thin upper lip	✓	✓		
Prenatal and postnatal growth impairment (weight or length <10th percentile)	✓	✓[b]		
Structural: head circumference <10th percentile or abnormal brain structure on neuroimaging, unprovoked seizures	✓			
Neurobehavioral deficits • Cognitive impairments >1.5 SD above the norm (>3 y); developmental delay (<3 y) Or • Impaired self-regulation (impaired mood or behavioral or impulse control or ADHD)	✓	✓	✓	
Birth defects associated with prenatal alcohol exposure (clinical or experimental)				✓
Documented prenatal alcohol exposure	NR	NR	✓	✓

Abbreviations: ADHD, attention deficit hyperactivity disorder; ARBD, alcohol-related birth defects; ARND, alcohol-related neurodevelopmental disorder; FAS, fetal alcohol syndrome; NR, not required; PFAS, partial fetal alcohol syndrome; SD, standard deviation.

[a]Adapted from Hoyme HE, Kalberg WO, Elliott AJ, et al. Updated clinical guidelines for diagnosing fetal alcohol spectrum disorders. *Pediatrics*. 2016;138(2):e20154256.

[b]Either one (central nervous system or somatic growth impairment) required when diagnosing without documented prenatal alcohol exposure.

Epidemiology

FAS rates ascertained in a middle-class U.S. community ranged from 6 to 9 per 1,000 children (midpoint, 7.5). The partial fetal alcohol syndrome rate in one community ranged from 11 to 17 per 1,000 children (midpoint, 14). Risk factors for FAS include poverty, poor maternal nutrition, and advanced maternal age.

Pathobiology

Despite extensive study, the specific underlying mechanisms of FAS remain uncertain and suggest a complex process. Risk of FAS is modulated by genetic factors: certain enzyme polymorphisms confer protection (eg, alcohol dehydrogenase enzyme and cytochrome P450 2E1), whereas others increase risk (absence of acetaldehyde dehydrogenase 2 [ADH_2]). Differential diagnosis includes several genetic disorders (eg, velocardiofacial syndrome, William syndrome) and thus warrants genetic testing.

Diagnosis

FAS diagnoses requires two of the three cardinal dysmorphic features affecting (short palpebral fissures [<10th percentile], smooth philtrum, and thin vermilion border of the upper lip), cognitive impairments greater than or equal to 1.5 standard deviation above the mean and growth impairments including small head size or abnormal brain morphogenesis LEVEL 3.[3] Most children with FAS are mildly or moderately retarded, with mean IQ scores of 65 to 70, but intellectual ability varies widely. In families with several affected siblings, the youngest child is usually the most cognitively impaired. Prenatal alcohol exposure has been linked to lower IQ scores, hyperactive behavior, attention problems, learning difficulty (especially with arithmetic), and speech disorders. Neuroimaging abnormalities are common among alcohol-exposed infants and commonly include volume loss/microcephaly and developmental anomalies of cerebellum or corpus callosum (agenesis, hypoplasia). Neuroimaging abnormalities correlate with neurocognitive impairments.

Partial Fetal Alcohol Syndrome

Partial fetal alcohol syndrome is defined based on facial dysmorphology and neuropsychological scores seen in FAS but can be diagnosed with only one of the two growth parameters, either small head circumference or impaired somatic growth.

Alcohol-Related Neurodevelopmental Disorder

Alcohol-related neurodevelopmental disorder requires documented prenatal alcohol exposure and neurobehavioral deficits (either cognitive impairment <1.5 standard deviation above mean in children older than age 3 y), developmental delay (children younger than age 3 y), or impairments of self-regulation (mood or behavioral regulation impairment, attention deficit, or impulse control).

Alcohol-Related Birth Defects and Other Outcomes

Alcohol is a well-established teratogen, and birth defects are common. *Alcohol-related birth defects* refer to isolated birth defects that occurs with documented prenatal alcohol exposure. Anomalies must be linked to alcohol exposure in clinical or experimental settings. Congenital anomalies occur in about a third of infants born to heavy drinkers, compared with 9% of minor anomalies in infants of women who abstain from alcohol (see Table 152.3). Decreasing alcohol intake during pregnancy is beneficial to offspring, reducing the frequency of growth retardation and dysmorphic features.

Maternal alcohol abuse increases the risk of spontaneous abortions, infant mortality, intrauterine growth retardation, and prematurity.

Postnatal Alcohol Exposure

Alcohol transferred through breast milk impairs motor development but not mental development at age 1 year. Ingestion of alcohol by children may lead to hypoglycemic seizures.

Alcohol Withdrawal Syndrome

Infants born to women who drink large amounts of alcohol during pregnancy may rarely exhibit signs of withdrawal. Restlessness, agitation, tremulousness, opisthotonus, and seizures are seen shortly after birth and disappear within a few days.

Management and Outcome

Treatment of FAS is largely supportive, focused on the neurodevelopmental and behavioral challenges these children and their families may face. A comprehensive and supportive approach toward alcohol cessation in the family is important to address other lasting psychosocial impacts of alcoholism on children into young adulthood.

PRENATAL AND PERINATAL EFFECTS OF SUBSTANCE ABUSE

Cocaine

Although the cocaine epidemic has abated, cocaine is still one of the most frequent hard drugs of abuse in urban centers, whereas methamphetamine is the preferred substance of abuse in rural settings (with effects similar to those of cocaine). Cocaine use during pregnancy has been linked to spontaneous abortion, abruptio placentae, stillbirth, and premature delivery. These events may immediately follow a large intake of cocaine and are attributed to drug-induced vasoconstriction of intrauterine vessels. Women who use cocaine tend to resort to prostitution, increasing risks for syphilis and HIV. They also tend to lack prenatal care, adding to the risks of infant death, low birth weight, and prematurity.

Low birth weight and intrauterine growth retardation are common among cocaine-exposed infants. Fetal brain growth is impaired independently of birth weight or gestational age. Sudden infant death syndrome has also been linked to cocaine exposure in utero. In addition to any specific cocaine-related effects, offspring are at increased risk because of polydrug exposure, as cocaine is rarely the only drug used.

Neurobehavior

State regulation difficulties are well described among cocaine-exposed newborns. Findings vary from irritability and excitability to decreased organizational response and interactive behavior, even if the exposure to cocaine was limited to the first trimester of pregnancy. Modulation of attention is impaired among cocaine-exposed infants who, unlike unexposed infants, prefer higher rates of stimuli when in a high level of arousal.

Infant processing abilities, as reflected by looking time at novel stimuli, are also affected by prenatal cocaine exposure. Exposed infants show motor and movement abnormalities, including excessive tremor and hypertonia. Dose-response effects of cocaine on state regulation and neurologic findings that tend to be transient are reported in newborns and infants. Some studies show no neurobehavioral effects, however.

Strokes

Experimentally, cocaine and its main metabolite, benzoylecgonine, cause vasoconstriction of fetal cerebral vessels. Neonatal stroke and porencephaly have been associated with prenatal cocaine exposure. Some cases may be related to other neonatal stroke risk factors that accompany fetal cocaine exposure, such as abruptio placentae or birth asphyxia. Intraventricular hemorrhage is observed among infants more heavily exposed to cocaine.

Seizures

Focal seizures may occur in cocaine-exposed newborns with strokes. Electroencephalograms in cocaine-exposed infants show bursts of sharp waves and spikes that are often multifocal. These findings do not correlate with clinical seizures or neurologic abnormalities and may disappear in 3 to 12 months. Cocaine-exposed premature infants are at increased risk of neonatal seizures. Seizures are rare if there is no stroke.

Malformations

Prenatal cocaine exposure has been linked with urogenital malformations, limb reduction deformities, and intestinal atresia and infarction. Agenesis of the corpus callosum and septo-optic dysplasia has also been noted. These teratogenic effects may result from cocaine-induced vasoconstriction and fetal vascular disruption in early organogenesis.

Neurodevelopmental Impact

In experiment models, prenatal cocaine has been reported to affect serotonin, norepinephrine, dopaminergic, and γ-aminobutyric acid systems. Lower CSF levels of homovanillic acid found in human newborns exposed to cocaine suggest dopaminergic involvement. In infancy, there may be a high incidence of global hypertonia that resolves prior to age 24 months (**Table 152.4**). Many studies in toddlers and school-aged children have failed to show that prenatal cocaine exposure adversely affects cognition, except as mediated through cocaine effects on brain growth. Cocaine-exposed children seem to suffer from language delays and an excess of neurobehavioral abnormalities, including irritability, impaired attention, inhibitory control, impulsivity, and aggressive behavior. Early neurobehavior involving orientation and irritability tend to improve over the first 2 years of life. Heavy prenatal cocaine exposure has been associated with delinquent behavior in both genders at older ages. In children followed through adolescence, low to moderate effects on cognitive, language and behavior (attention, externalizing behaviors, and poor executive function), as well risk for substance misuse are reported.

Cocaine Exposure in Childhood

Passive intoxication with cocaine may be caused by breastfeeding or passive inhalation of free-base cocaine (crack). Seizures are the chief manifestation of symptomatic intoxication but intoxication may be unsuspected. Urine toxicology screening is used to detect illicit substances in evaluating seizures in infants and children, regardless of socioeconomic status.

TABLE 152.4 Neurologic Fetal Cocaine Effects and Associations

Neonatal Period
Microcephaly
Vascular abnormalities
Stroke
Porencephaly
Intraventricular hemorrhage
Seizures
Symptomatic (secondary to vascular complications)
Primary (owing to cocaine or its metabolites)
Brain malformations
Agenesis of corpus callosum
Septo-optic dysplasia
Skull defects
Encephalocele
Abnormal neurobehavior
Impaired organizational state
Depressed sensorium
Hypertonia
Coarse tremor
Irritability/excitable state
Infancy and Childhood
Neurologic
Hypertonia in infancy
Developmental
Language delays
Semantic delays
Behavioral
Inattentiveness
Temperamental differences
Impulsivity
Aggressive or delinquent behavior

Withdrawal Symptoms

There is no evidence of a cocaine-induced withdrawal syndrome. Even with remote prenatal cocaine exposure, cocaine-exposed infants may show hypertonicity and tremor, which are probably manifestations of a transient embryopathy resulting from cocaine-related perturbations of neurotransmitter levels.

Opiates

Cheap and abundant supplies of heroin are fueling a nationwide epidemic of late, especially in urban centers. Prospective studies, however, on the developmental impact of prenatal heroin exposure are sparse. Methadone, on account of its controlled administration, has been more extensively studied. The main risk factor linked to developmental effects and lower IQ scores is the presence of neonatal withdrawal syndrome.

TABLE 152.5 Opiate Withdrawal Syndrome
Central Nervous System
• Jitteriness/tremors
• Irritability
• Hypertonia
• High-pitch cry
• Generalized convulsions
Autonomic
• Fever
• Nasal stuffiness
• Mottling of skin
• Sweating
• Tachypnea
Gastrointestinal
• Vomiting
• Diarrhea
• Poor feeding

Withdrawal Symptoms

Infants born to opiate-dependent mothers (**Table 152.5**) are at risk for neonatal withdrawal syndrome characterized by signs and symptoms of CNS hyperirritability, gastrointestinal dysfunction, respiratory distress, and autonomic disturbances. CNS signs and symptoms consist of hypertonicity, tremor, hyperreflexia, irritability, sleep disturbances, feeding difficulties, and occasionally seizures LEVEL 1.[4] Onset of neonatal withdrawal from heroin usually begins within 24 hours of birth, withdrawal from methadone usually starts around 24 to 72 hours of age, and withdrawal to buprenorphine starts at around 40 hours and peaks in severity at 70 hours of age. The neonatal withdrawal syndrome associated with methadone is more severe and occurs more often (84%) than that described with buprenorphine (60%). For both opioids, signs of withdrawal may be delayed in onset until 5 to 7 days of age or later. Genetic factors may influence onset or severity of withdrawal symptoms. For instance, infants treated for withdrawal were more likely to carry a homozygous allele of the CYP2B6 gene that encodes a cytochrome P450 mono-oxygenase enzyme, whereas certain catechol-o-methyltransferase and μ-opioid receptor single-nucleotide polymorphisms have been linked to more severe withdrawal symptoms. Among neonates acutely withdrawing from opioids, seizures are observed in 2% to 11% and electroencephalogram abnormalities without evidence of seizures in over 30%. Mild withdrawal does not require treatment, other than swaddling and a quiet room, but symptomatic infants are likely to require pharmacologic intervention. The two most popular agents used to treat withdrawal are paregoric (camphorated tincture of opium) and phenobarbital. Of the two, paregoric is more physiologic because it substitutes for the substance causing withdrawal but is only effective for opiate withdrawal. Other opiates studied include morphine and buprenorphine. For suspected polydrug exposure, phenobarbital may be preferable.

The most widespread scale in use to assess the severity of withdrawal syndrome is that developed by Finnegan LEVEL 3.[5]: It assesses 21 signs in three domains: CNS, gastrointestinal, and autonomic/sleep/respiratory. Assessments are recommended every 2 to 4 hours after birth, and treatment is suggested for withdrawal scores 8 or higher. Paregoric or phenobarbital is then titrated according to the severity of withdrawal score. There is no agreed on standard treatment protocol to manage neonatal abstinence. When using phenobarbital, one can choose to load (15 mg/kg) prior to titrating maintenance (5-8 mg/kg) dose. Paregoric doses may start at 0.2 mL every 3 hours and titrate by 0.05 mL according to withdrawal score. Tapering of the dose may commence by the end of the second week as tolerated.

LEVEL 1 EVIDENCE

1. Centers for Disease Control and Prevention. HIV Surveillance Report: diagnoses of HIV infection in the United States and dependent areas, 2017; vol. 29. Centers for Disease Control and Prevention Web site. https://www.cdc.gov/hiv/pdf/library/reports/surveillance/cdc-hiv-surveillance-report-2017-vol-29.pdf. Published 2018. Accessed December 9, 2020.
2. Siberry GK, Abzug MJ, Nachman S, et al; and Panel on Opportunistic Infections in HIV-Exposed and HIV-Infected Children. Guidelines for the prevention and treatment of opportunistic infections in HIV-exposed and HIV-infected children: recommendations from the National Institutes of Health, Centers for Disease Control and Prevention, the HIV Medicine Association of the Infectious Diseases Society of America, the Pediatric Infectious Diseases Society, and the American Academy of Pediatrics. *Pediatr Infect Dis J*. 2013;32(suppl 2):i-KK4.
3. Hoyme HE, Kalberg WO, Elliott AJ, et al. Updated clinical guidelines for diagnosing fetal alcohol spectrum disorders. *Pediatrics*. 2016;138(2):e20154256.
4. Behnke M, Smith VC; for Committee on Substance Abuse, Committee on Fetus and Newborn. Prenatal substance abuse: short- and long-term effects on the exposed fetus. *Pediatrics*. 2013;131:e1009-e1024.
5. Devlin LA, Breeze JL, Terrin N, et al. Association of a simplified Finnegan neonatal abstinence scoring tool with the need for pharmacologic treatment for neonatal abstinence syndrome. *JAMA Netw Open*. 2020;3(4):e202275.

SUGGESTED READINGS

Chiriboga CA, Fleishman S, Champion S, Gaye-Robinson L, Abrams EJ. Incidence and prevalence of HIV encephalopathy in children with HIV infection receiving highly active anti-retroviral treatment (HAART). *J Pediatr*. 2005;146(3):402-407.

Donald KA, Eastman E, Howells FM, et al. Neuroimaging effects of prenatal alcohol exposure on the developing human brain: a magnetic resonance imaging review. *Acta Neuropsychiatr*. 2015;27(5):251-269.

Evers S, Rahmann A, Schwaag S, Frese A, Reichelt D, Husstedt IW. Prevention of AIDS dementia by HAART does not depend on cerebrospinal fluid drug penetrance. *AIDS Res Hum Retroviruses*. 2004;20(5):483-491.

Kaminen-Ahola, N. Fetal alcohol spectrum disorders: genetic and epigenetic mechanisms [published online ahead of print May 9, 2020]. *Prenat Diagn*. doi:10.1002/pd.5731.

Manabe YC, Campbell JD, Sydnor E, Moore RD. Immune reconstitution inflammatory syndrome: risk factors and treatment implications. *J Acquir Immune Defic Syndr*. 2007;46(4):456-462.

Mazzoni P, Chiriboga CA, Millar WS, Rogers A. Intracerebral aneurysms in human immunodeficiency virus infection: case report and literature review. *Pediatr Neurol*. 2000;23:252-255.

Sanlorenzo LA, Stark AR, Patrick SW. Neonatal abstinence syndrome: an update. *Curr Opin Pediatr*. 2018;30(2):182-186.

Schwenk H, Ramirez-Avila L, Sheu SH, et al. Progressive multifocal leukoencephalopathy in pediatric patients: case report and literature review. *Pediatr Infect Dis J*. 2014;33(4):e99-e105.

Selik RM, Mokotoff ED, Branson B, Owen SM, Whitmore S, Irene Hall H. Revised surveillance case definition for HIV infection—United States, 2014. *MMWR Morb Mortal Wkly Rep*. 2014;63:1-10.

Walker SY, Pierre RB, Christie CD, Chang SM. Neurocognitive function in HIV-positive children in a developing country. *Int J Infect Dis*. 2013;17(10):e862-e867.

Psychosis 153

Jacob S. Ballon and T. Scott Stroup

KEY POINTS

1. New-onset psychosis requires medical workup to determine possible reversible causes.
2. Delirium is a common cause of psychosis, especially in the elderly or medically compromised.
3. In addition to schizophrenia, psychosis is associated with bipolar disorder, major depression, posttraumatic stress disorder, and delusional disorder.
4. Antipsychotic medications are effective symptomatic treatment of psychosis but are associated with significant adverse effects and should be used judiciously.
5. Clozapine is the only evidence-based medication for treatment-resistant schizophrenia; any decision to discontinue it should be carefully considered.

INTRODUCTION

Psychosis is characterized as a detachment from reality, often including hallucinations or delusions. Psychotic symptoms are a core feature of schizophrenia but may also be seen in other serious psychiatric disorders including bipolar disorder, major depressive disorder, and posttraumatic stress disorder. Importantly, psychosis may also be a prominent symptom in many neurologic disorders, other medical conditions, substance intoxications, and withdrawal syndromes. New-onset psychosis should prompt a thorough workup to determine the etiology of such symptoms.

Psychotic experiences can be characterized as phenomena in which sensory experiences are generated by aberrant brain stimuli rather than external inputs. Hallucinations can be auditory (eg, hearing voices), visual (eg, seeing objects that are not there), or can occur in other sensory domains, although olfactory, tactile, and gustatory hallucinations are less typical of psychiatric illness. Hallucinations can be differentiated from illusions by having no basis in reality, whereas illusions are misperceptions of natural sensations. Delusions are fixed, false beliefs that persist in spite of contradictory evidence. Often, delusions are paranoid (eg, a feeling of being watched or followed) or grandiose (eg, possessing special powers or relationships with powerful people). Hallucinations and delusions must be assessed within the relevant cultural context.

The lifetime prevalence of psychosis is between 3% and 5% in the general population. Most cases of psychosis are due to causes other than schizophrenia. The main causes of nonschizophrenia psychoses are drug-induced psychosis, mood disorders, and general medical conditions.

SCHIZOPHRENIA AND OTHER PSYCHOTIC DISORDERS

Epidemiology

Globally, estimates suggest that almost 1% of the population will develop schizophrenia in their lifetime. The typical age of onset of schizophrenia is the late teens or early 20s, with men diagnosed on average a few years younger than women. Most people who develop schizophrenia have a prodromal period of illness before they meet the threshold for diagnosis. The prodrome is commonly characterized by subthreshold psychotic symptoms in conjunction with declines in social and occupational functioning. Schizophrenia typically follows a relapsing and remitting course characterized by periods of stability with episodic exacerbations of symptoms. Although antipsychotic medications are efficacious in reducing psychotic symptoms, many individuals may still have symptoms despite usual treatment.

Pathobiology

Scientists debate whether schizophrenia is a degenerative brain disease, neurodevelopmental disease, or a combination of both. Several studies have shown that there are neuroanatomic differences in ventricle size, cortical thickness, gray and white matter, and overall brain volume in people with schizophrenia. Supporting neurodevelopmental hypotheses, neuroanatomic differences are seen before the onset of psychosis. However, favoring degenerative hypotheses, these differences increase over the course of illness. Furthermore, although many studies have shown that cognitive decline predates the onset of psychosis, there is some evidence that cognitive deficits worsen over time. It is difficult to isolate a specific degenerative process of schizophrenia itself apart from other environmental factors such as chronic exposure to antipsychotic drugs.

Much work has been done to identify the specific neurotransmitter systems responsible for psychosis and schizophrenia. Although no single system is responsible for the overall psychotic phenotype, several have been shown to contribute to the development of symptoms. Dopamine is often most closely associated with psychosis, and all currently marketed antipsychotic drugs are dopamine D_2 antagonists, but those drugs do not address all facets of the illness. Other neurotransmitters implicated include serotonin, glutamate, and acetylcholine.

Diagnosis

Schizophrenia is a serious mental illness responsible for significant morbidity, diminished quality of life, loss of productivity,

and premature mortality. There is a 5% to 10% risk of suicide, and schizophrenia is a leading cause of disability throughout the world. Symptoms of schizophrenia can be categorized into positive, negative, and cognitive domains. Positive symptoms refer to delusions, hallucinations, and disorganized speech or behavior. Negative symptoms include apathy and avolition and generally refer to deficits in functioning. Cognitive symptoms affect multiple domains including primarily executive functioning, verbal learning, and working memory.

Although schizophrenia cannot be diagnosed until psychosis has been present for at least 1 month, nonspecific symptoms have been seen from early childhood in people who later develop schizophrenia. For example, young children who go on to develop schizophrenia have increased incidence of deficits in motor skills compared to children who do not develop schizophrenia or other psychiatric disorders.

The *Diagnostic and Statistical Manual of Mental Disorders*, 5th edition (*DSM-5*), which was released in 2013, modified the criteria for psychotic disorders (**Fig. 153.1**). A schizophrenia diagnosis requires at least two out of five symptoms including hallucinations, delusions, disorganized speech, disorganized behavior, or negative symptoms for at least 1 month and with an overall duration of illness of at least 6 months. *DSM-5* requires hallucinations, delusions, or disorganized speech; only having disorganized behavior and negative symptoms does not meet the new criteria. When mood symptoms are prominent, a timeline is essential to determining the correct diagnosis. If there are concurrent mood symptoms along with the hallucinations or delusions, the criteria for schizoaffective disorder are met if the psychotic symptoms persist for at least 2 weeks in the absence of mood symptoms and if the mood symptoms are present for the majority of the entire illness. If the psychotic symptoms occur only in the context of a mood disorder (bipolar disorder or major depressive disorder), then the diagnosis is bipolar disorder or major depressive disorder with psychotic features. If the only psychotic symptom is a delusion, then the diagnosis may be delusional disorder, particularly if there is limited functional impairment. Catatonia is a constellation of psychomotor features that may include stupor, posturing, mutism, stereotypy, and other odd mannerisms. Catatonia is often associated with schizophrenia but can be present in most other serious mental illnesses. Catatonia is included in the *DSM-5* as a specifier for several mental disorders and is seen in approximately 10% of patients hospitalized with schizophrenia.

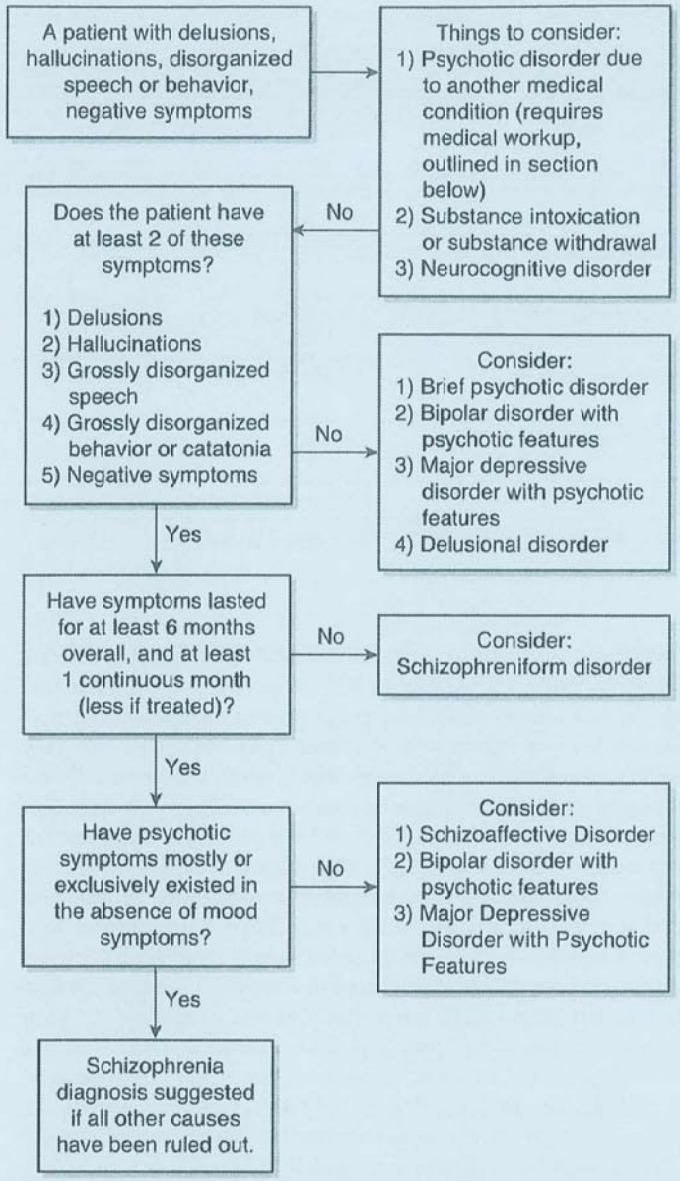

FIGURE 153.1 Diagnostic algorithm for a patient with psychotic symptoms. (Based on American Psychiatric Association. *Diagnostic and Statistical Manual of Mental Disorders*. 5th ed. Washington, DC: American Psychiatric Association; 2013.)

Bipolar Disorder, Manic With Psychotic Features Case

A 27-year-old recent business-school graduate returned from a trip to Europe and was noted by friends and family to be abnormally active and needing little sleep. In a manner that was distinctly out of character, she purchased a flashy new car and numerous new outfits, the latter usually bought online in the early morning hours. She talked rapidly and extensively about her "unique" entrepreneurial "gifts," and about how she was a "special consultant" to famous e-commerce billionaires. Others were perplexed by her conviction that recent newspaper headlines were intended to communicate her importance. She denied needing to sleep and spent frantic hours trying to "return the calls" of various chief executive officers. When speaking, she spoke rapidly rhymed words and had difficulty getting directly to her point. Despite saying she was in a "fantastic mood" she was often irritable, loud, and angry when confronted about her behavior by friends and colleagues if she didn't get what she wanted immediately. She had no history of delusions or hallucinations.

Major Depressive Disorder With Psychotic Features Case

An 87-year-old woman was admitted to the psychiatric unit with several weeks of depressed mood, social withdrawal from peers, and weight loss of 12 lb. She stated repeatedly that "something is wrong with me" and that her liver was rotting. She was unable to be dissuaded from this belief and perseverated that "everything is hopeless." Once in the hospital, she stayed in her bed all day long and stared at the ceiling. Electroconvulsive therapy was offered and initiated via court order. After four treatments, she began to engage with other patients on the unit for brief periods and to attend group therapy. She continued her course of electroconvulsive therapy along with antidepressant medication and within a month was much improved and seen smiling with her husband.

TABLE 153.1 Distinguishing Characteristics of Illnesses Commonly Associated With Psychosis

Condition	Typical Age of Onset	Distinguishing Characteristics
Schizophrenia	Late teens, 20s; later for women than men	Hallucinations, delusions, disorganized thinking/behavior, and functional impairment
Schizoaffective disorder	Late teens, 20s; later for women than men	Psychotic symptoms are present even in the absence of mood symptoms; mood symptoms are present for the majority of the illness.
Bipolar disorder	20s	Psychosis only in the context of mood episode; typically in context of severe manic episode
Major depressive disorder with psychotic features	Throughout life; peaks 20s and 30s	Psychosis relatively rare; only in the context of depressive episode
Alzheimer disease	Elderly	Present in up to 50% of patients; nonbizarre delusions; visual hallucinations common
Dementia with Lewy bodies	Elderly	Often visual hallucinations; associated with motor symptoms and sensitivity to antipsychotic side effects
Delirium	Throughout lifespan, especially in elderly	Resolves when underlying disturbance has resolved
Posttraumatic stress disorder	Any age; increased risk in veterans	History of severe trauma; predominantly associated with hallucinations, may be associated dissociative symptoms

Psychotic symptoms frequently occur in other psychiatric disorders (Table 153.1). Up to 60% of people with bipolar disorder have a history of at least one psychotic symptom, and psychosis is seen in up to 50% of manic episodes. Psychosis may also be present in depression, especially when it is severe. Overall, people with depression are 3 times more likely to have hallucinations and 9 times more likely to have delusions compared to those without depression. Up to 15% of people with schizophrenia have comorbid obsessive-compulsive symptoms. People with social phobia and general anxiety also have an increased incidence of psychosis. Data from the National Comorbidity Survey suggests that psychosis should lead to a separate subtype categorization of posttraumatic stress disorder and a subtype of "with dissociative symptoms" was added to *DSM-5*. Substance abuse and schizophrenia frequently co-occur, with rates of substance use disorders as high as 70% in people with schizophrenia. In a large European study of first-episode schizophrenia, already 31.1% of patients reported a comorbid substance use disorder, including 22.2% who used marijuana. Comorbid substance use is associated with poorer medication adherence, more hospitalizations, and overall worse functional outcomes, with the worst effects seen in heavy substance users.

Schizophrenia-Spectrum Case

A 21-year-old male college student was brought to the student health service by his resident advisor. The resident advisor noted that over the past several months, the student withdrew from fellow students and stopped participating in dormitory activities. His grades suffered, and he was caught smoking marijuana in his room. He recently began putting tape over the cameras in the computer lab and foil over the windows of his room. When asked about these behaviors, the student said that the Central Intelligence Agency (CIA) was tracking his movements through a vast network of computers. He spent several nights sleeping in the library or in a local 24-hour coffee shop to avoid detection. He believed that the CIA considered him to have special knowledge of operations within the government. The student believed that everyone knew about him because the CIA had put up a Web site about him. He said that he could hear agents and other people talking to him through the walls of his room, commenting on his behaviors, and telling him that he was stupid. His sleep was poor, and he was using marijuana to help sleep and to manage his anxiety.

Management and Outcome

Antipsychotic Medication

The mainstay of treatment for schizophrenia and other psychotic disorders is antipsychotic medication. Antipsychotics reduce psychotic symptoms and reduce relapse rates LEVEL 1.[1] All currently available antipsychotic medications antagonize dopamine D_2 receptors in the brain, which is thought to be their primary mechanism of action. Historically, antipsychotic medications have been categorized based on their potency at the D_2 receptor into high-potency and low-potency categories. Antipsychotics also affect other neurotransmitters including serotonergic, histaminergic, and adrenergic receptors. Effects on the various neurotransmitters determine therapeutic and adverse effects.

All antipsychotic drugs are capable of inducing neurologic side effects including abnormal involuntary movements known as *tardive dyskinesia* (TD), *akathisia* (restlessness), *dystonia*, and *pseudoparkinsonism* (tremor, rigidity, and bradykinesia) (Table 153.2). By definition, TD is associated with prolonged (at least 3 mo) exposure to an antipsychotic agent. Increased age, female gender, and duration of exposure are the greatest risk factors for TD. Newer (or second-generation) antipsychotics tend to have lower risk of TD, but risk varies according to individual drug characteristics as well as dose and duration of exposure. Drugs with lower potency at the D_2 receptor tend to be associated with more adverse metabolic side effects (weight gain, diabetes, dyslipidemia), whereas those with higher potency are more likely to cause neurologic side effects. Severe dystonias, especially those involving laryngeal or extraocular muscles, require emergency treatment with intramuscular diphenhydramine (50 mg) or benztropine (2 mg). Oral benztropine (1-4 mg daily) is effective for treatment of antipsychotic-induced tremors, and propranolol (30-90 mg daily) is often used for treatment of akathisia.

Metabolic side effects are closely associated with many antipsychotic treatments, in particular clozapine, olanzapine, quetiapine, and risperidone. The mechanism by which antipsychotics cause these effects is not conclusively known. Schizophrenia has long been associated, even before the introduction of antipsychotic medications, with increased rates of diabetes and obesity compared to the general population. Clozapine, olanzapine, and

TABLE 153.2 Selected Information on Commonly Used Antipsychotics[a]

Antipsychotic Medication	Typical Daily Dose Range for Schizophrenia (mg)	Metabolic Side Effects/Weight	Akathisia/ Pseudoparkinsonism	Prolactin Elevation	Sedation	Anticholinergic Side Effects	Orthostatic Hypotension
Aripiprazole	10-30	−	+	−	+	−	−
Asenapine	10-20	++	++	++	++	−	+
Brexpiprazole	2-4	+	+	−	+	−	−
Cariprazine	1.5-6	+	++	−	+	−	−
Chlorpromazine	300-1,000	+++	+	++	+++	+++	+++
Clozapine	150-600	+++	−	−	+++	+++	+++
Haloperidol	5-20	+	+++	+++	++	−	−
Iloperidone	12-24	++	−	+	+	+	+++
Lurasidone	40-160	−	++	−	++	−	+
Olanzapine	10-30	+++	+	+	++	++	−
Paliperidone	6-12	++	++	+++	+	−	+
Perphenazine	12-48	++	++	++	++	−	−
Quetiapine	300-750	++	−	−	++	−	++
Risperidone	2-8	++	++	+++	+	−	++
Ziprasidone	120-160	−	+	+	+	−	+

Abbreviations: +, low risk/mild effects; ++, medium risk/moderate effects; +++, high risk/severe effects; −, minimal risk.

[a]Data from Lawrence RE, Stroup TS, Lieberman JA. Schizophrenia spectrum disorders. In: Roberts LW, ed. *The American Psychiatric Publishing Textbook of Psychiatry*. 7th ed. Washington, DC: American Psychiatric Association; 2019:257-278; and Buchanan RW, Kreyenbuhl J, Kelly DL, et al. The 2009 schizophrenia PORT psychopharmacological treatment recommendations and summary statements. *Schizophr Bull*. 2010;36(1):71-93.

quetiapine are potent antihistaminergic agents and thus are associated with drowsiness and central histamine H_1 receptor activity, which may contribute to their risk of weight gain. Other theories regarding the metabolic effects focus on shared signaling pathways between insulin regulation and psychosis involving the kinase *AKT1* in the brain, pancreas, and liver. Peripheral response to antipsychotic drugs may feedback to the brain in a way that alters insulin secretion, which may have effects on weight. Although diabetes may often result from the central adiposity associated with antipsychotics, there are likely multiple pathways responsible for these metabolic effects because people may develop insulin resistance and diabetes in the absence of weight gain and vice versa.

A dangerous but rare side effect of antipsychotic drugs is neuroleptic malignant syndrome (NMS). NMS is characterized by tremors, muscle rigidity and myalgias, extreme fever, other autonomic instability, and altered mental status. The muscle rigidity ultimately leads to rhabdomyolysis, with increased creatine kinase and white blood cell counts. The resultant muscle breakdown products can lead to acute renal failure. Without rapid and intensive intervention, NMS can be fatal and is in nearly 10% of cases. Treatment of NMS focuses on stopping the antipsychotic immediately, cooling the hyperthermia rapidly, and protecting the kidneys from myoglobinemia through aggressive hydration.

Antipsychotics differ mainly in side effects, but some small to moderate differences in efficacy have also been detected. All three of the medicines with better efficacy that are available in the United States (clozapine, olanzapine, and risperidone) are associated with adverse metabolic effects. This finding leads to a clinical dilemma in which clinicians and patients must balance the opportunity for maximum symptom improvement with significant metabolic risk.

Clozapine has a special role because it is more efficacious than other antipsychotics in patients with treatment-resistant schizophrenia and has been shown to decrease suicidality and to cause the fewest abnormal involuntary movements. However, in addition to weight gain and significant metabolic side effects, clozapine is also associated with agranulocytosis and subsequent risk of death due to infection. Therefore, patients taking clozapine must be enrolled in a clozapine registry (www.clozapinerems.com) and monitored carefully for decreases in granulocyte counts. Other risks of clozapine include myocarditis and seizures. However, with close clinical monitoring, clozapine can be highly effective for many patients.

TABLE 153.3 Medical Conditions That Can Present With Psychosis

Delirium
Dementia/neurodegenerative disorders
Neoplasms
Seizures
Intoxications/medications
HIV/AIDS/other infections
Autoimmune/limbic encephalitis
Systemic lupus erythematosus
Neurovascular events
Leukodystrophies
Endocrine disorders
Mitochondrial disorders

Abbreviation: HIV, human immunodeficiency virus.

Nonpharmacologic Treatment

Nonpharmacologic treatments for schizophrenia that are supported by some evidence include repetitive transcranial magnetic stimulation for auditory hallucinations that do not respond to antipsychotic medications LEVEL 1.[1] Several psychosocial treatments are effective for specific problems associated with persistent psychotic illnesses. For example, multidisciplinary teams known as *Assertive Community Treatment* teams provide outreach and comprehensive care, which reduces rates of hospitalization LEVEL 1.[2] Supported employment programs are effective in helping people with schizophrenia obtain jobs LEVEL 1.[2]

OTHER CAUSES OF PSYCHOSIS

When a patient presents with psychosis for the first time, it is important to remember that psychotic symptoms are associated with numerous brain conditions, and the cause may not always be identifiable (**Table 153.3**). A thorough workup should be conducted to make sure that potentially reversible causes of psychosis are ruled out.

The workup for reversible causes of psychosis should start broadly and then focus more narrowly according to the specific presentation (**Table 153.4**). Laboratory tests are used to investigate possible metabolic or nutritional abnormalities, signs of infection/inflammation, and autoimmune processes. Neuroimaging may be indicated, particularly if there are focal neurologic

TABLE 153.4 Suggested Medical Workup for Psychosis[a]

In all patients
• Complete blood count
• Glucose, chemistries, liver function tests
• Thyroid-stimulating hormone
• Vitamin B_{12} and folate
• Urinalysis
• Urine drug screen
• HIV test
Secondary testing to be done as clinically indicated
• Brain imaging with CT or MRI
• Electroencephalogram
• Lumbar puncture
• Chest radiography
• Blood and urine cultures
• Arterial blood gases
• Serum cortisol levels
• Antinuclear antibodies (to test for autoimmune disorders such as systemic lupus erythematosus)
• Ceruloplasmin (to test for Wilson disease)
• Rapid plasma reagin (to test for syphilis)
• Toxin search/drug levels

Abbreviations: CT, computed tomography; HIV, human immunodeficiency virus; MRI, magnetic resonance imaging.

[a]Based on Freudenreich O, Schulz SC, Goff DC. Initial medical work-up of first-episode psychosis: a conceptual review. *Early Interv Psychiatry*. 2009;3(1):10-18.

deficits or an acute personality change. Lumbar puncture and electroencephalogram may also be part of a workup when associated symptoms suggest the possibility of infection.

Delirium is a common cause of psychosis and should be suspected in any patient with acute psychosis, particularly those who are older than typical first-episode psychosis patients. Although the definitive intervention for delirium is treatment of the underlying medical condition, there are important steps to take while the underlying cause is sought and treated. The first step is to ensure the patient's physical safety. Efforts to normalize the sleep-wake cycle should be a priority. Frequent reminders of location, time, and situation are helpful to reorient patients to their surroundings. Medications that cause or exacerbate delirium, including anticholinergic agents, should be avoided as much as possible. Benzodiazepines should also be avoided in nonalcoholic delirium. Antipsychotic medications can be useful in symptomatic treatment of delirium and associated psychosis. Antipsychotics have been shown to shorten the duration of delirium episodes with similar efficacy seen across multiple agents.

Psychosis frequently occurs in the setting of drug intoxication and withdrawal states. In severe alcohol and benzodiazepine withdrawal, patients may experience delirium tremens, which is fatal in approximately 1% of cases. This is characterized by autonomic instability, hallucinations, and agitation. Benzodiazepines (eg, lorazepam 2 mg every 2 h as needed) are the mainstay of treatment for significant alcohol withdrawal and delirium tremens LEVEL 1.[3] Many forms of drug intoxications can yield psychotic symptoms. Cannabis, particularly because it has become more potent in recent years, often causes a transient psychotic state characterized mostly by paranoia. Sympathomimetic drugs, such as amphetamine or methamphetamine, can cause paranoia and hallucinations with acute and chronic use. *N*-methyl-D-aspartate (NMDA) antagonists such as primary care provider and ketamine are also associated with auditory hallucinations, paranoia, and negative symptoms. These drugs, as well as amphetamines, are often used in animal models of schizophrenia because of the similarity in presentation to schizophrenia. Tactile hallucinations are often seen with amphetamines and cocaine.

Psychosis is also common in major neurocognitive disorders such as dementias. Patients with dementia often report paranoid delusions or feelings that people are stealing from them. In dementia with Lewy bodies (DLB), many patients report delusions and visual hallucinations (including "lilliputian hallucinations" of little people/animals) and develop pseudoparkinsonism even with low doses of antipsychotics. Antipsychotics can be helpful in treating these psychotic symptoms and can help reduce dementia-related agitation but should be used with caution and in low dosages. In many circumstances, cholinesterase inhibitors are effective and should be considered first in DLB. If using antipsychotics in treating patients with DLB, quetiapine, at low doses (eg, 25-50 mg daily), is a good first choice. Clozapine (eg, 25-50 mg daily) is a second choice if quetiapine is not effective; it has substantial anticholinergic effects and requires close monitoring of white blood cell counts because of a risk of agranulocytosis. Dementia is not a U.S. Food and Drug Administration–approved indication for antipsychotics, and all antipsychotics carry a black box warning for this use because of an increased risk of mortality for elderly dementia patients. The possible benefits of antipsychotics in reducing psychosis or agitation must be weighed against the small but significant risk of increased mortality as well as the other adverse effects of antipsychotics. Importantly, if an antipsychotic is used for a patient with dementia, it should be discontinued unless there are clear benefits.

Dementia With Lewy Bodies Case

A 70-year-old woman who lives alone and has demonstrated increasing problems with self-care was brought for evaluation by her two grown sons, she reports she has become frightened by strange people coming in to her yard; the sons believe that she was "seeing things." Upon questioning, it became clear that the strangers, because of their reported tiny size, were in fact visual hallucinations. Her Mini-Mental State Examination score was 24 of 30. Although further evaluation was pending, she began symptomatic treatment with low-dose risperidone. She experienced severe "stiffness." On exam, she was rigid and had minimal facial expression. In retrospect, it became clear that she had experienced significant bradykinesia over several months. When risperidone was switched to quetiapine her rigidity and bradykinesia improved but persisted.

Because brain tumors can have many psychiatric manifestations, including psychosis, the workup for new-onset psychotic symptoms should include neuroimaging. The presence of other focal neurologic findings should raise the index of suspicion for psychosis secondary to a brain lesion. Peripheral tumors including small cell lung cancer (and resultant paraneoplastic syndrome), steroid-producing hormones such as adrenal tumors (Cushing disease), and pheochromocytoma may also cause psychosis. Another rare cause of psychosis is autoantibodies to the NMDA receptor. These antibodies, most often seen in young women, often derive from ovarian teratomas or other tumors; surgical removal of the tumors may resolve the symptoms. Immunotherapy (eg, steroids, intravenous immunoglobulins, and plasmapheresis) can also be used to treat the psychosis and associated symptoms with good effect.

Seizures may also cause psychotic symptoms, and the presence of other seizure sequelae, such as auras or postictal periods, should prompt testing in that domain including electroencephalogram. Psychosis may occur intraictally or postictally. Temporal lobe epilepsy is classically associated with psychotic symptoms including déjà vu (a sense of reexperiencing something that is novel), fear without identifiable cause, or olfactory hallucinations. Treatment of epileptic-related psychosis can be complicated because antipsychotic medications can lower the seizure threshold. However, this effect is generally not clinically significant except in the case of clozapine (eg, at doses ≥600 mg daily or when blood levels rise rapidly). Some antiepileptic drugs including levetiracetam, vigabatrin, and topiramate can worsen psychosis. In addition, carbamazepine induces antipsychotic drug metabolism and may lead to decreased blood levels, resulting in the emergence of psychotic symptoms. On the other hand, valproic acid (eg, 500-1,500 mg daily) is commonly used off-label as adjunctive agent to potentiate the initial efficacy of antipsychotic drugs in the treatment of schizophrenia, although the efficacy of this strategy is uncertain. Ultimately, if antipsychotics are indicated in someone with a seizure disorder, then the choice of drug depends largely on tolerance for side effects and drug-drug interactions.

A number of infections are known to cause psychosis. Infections that yield brain lesions, such as neurocysticercosis or other fungal infections, seen as ring-enhancing lesions on magnetic resonance imaging, can cause both seizure activity and associated psychosis. Up to 15% of human immunodeficiency virus (HIV) patients may experience psychotic symptoms generally through opportunistic infections, HIV-associated neoplasms, or HIV-associated delirium/dementia. More commonly, HIV is associated with psychotic symptoms, both through progression of the illness or through drug interactions with antiretroviral

therapy or from highly active antiretroviral therapy medications themselves. Other infections sometimes associated with psychosis include Lyme disease, herpes, and neurosyphilis. Herpes encephalitis, the most common sporadic viral encephalitis in the United States, requires immediate attention because there is a high risk of mortality if not treated promptly. Acyclovir (30 mg/kg/d) should be started while waiting for the results of lumbar puncture and imaging studies.

Many medications are associated with psychosis. Steroids are most commonly implicated in causing psychotic symptoms and can also cause other significant emotional side effects including depression and anxiety. Treatment of Parkinson disease is often complicated by psychosis when using prodopaminergic agents. Low doses of quetiapine (25-50 mg daily) or clozapine (25-50 mg daily), which have a relatively low risk of pseudoparkinsonism, are recommended for treating psychotic symptoms in patients with Parkinson disease. Psychoactive medications including sympathomimetic agents, opioids, and benzodiazepines can cause psychosis, particularly in high dosages. Psychosis has also been reported to be associated with antibiotics, antimalarials (particularly mefloquine), antituberculous drugs, and muscle relaxants.

Delirium With Psychosis Case

A 73-year-old man is admitted to orthopedic surgery for surgical repair of his left hip. On postoperative day 2, nurses report that he is agitated and complaining that he sees a "crippled equestrian" near the air conditioning vent. Nurses also report that he was awake much of the night and sleeping during the day. He was given lorazepam last night to help him sleep, but the report from nursing staff is that it made him agitated, and he needed to be placed on 1:1 observation because he did not sleep and tried to get out of bed unsafely. He's been picking at his bed sheets and nearly pulled out his intravenous line. When you see him at the bedside, he says that the year is 1968, and he is at a racetrack. His vital signs show a low-grade fever and tachycardia, and his complete blood count shows a mildly elevated white count.

CONCLUSION

Psychosis presents in many psychiatric and other medical conditions and is generally a sign of a severe underlying problem. Not all cases of psychosis are due to a primary psychotic disorder such as schizophrenia, and many represent urgent medical problems. This is particularly important in older patients and in cases that do not otherwise fit the typical pattern of schizophrenia onset. A broad differential should be considered to identify reversible and potentially progressive causes of psychosis. Prompt, appropriate treatment should lead to improved outcomes.

LEVEL 1 EVIDENCE

1. Buchanan RW, Kreyenbuhl J, Kelly DL, et al. The 2009 schizophrenia PORT psychopharmacological treatment recommendations and summary statements. *Schizophr Bull*. 2010;36(1):71-93.
2. Dixon LB, Dickerson F, Bellack AS, et al. The 2009 schizophrenia PORT psychosocial treatment recommendations and summary statements. *Schizophr Bull*. 2010;36(1):48-70.
3. Awissi DK, Lebrun G, Coursin DB, Riker RR, Skrobik Y. Alcohol withdrawal and delirium tremens in the critically ill: a systematic review and commentary. *Intensive Care Med*. 2013; 39(1):16-30.

SUGGESTED READINGS

Achim AM, Maziade M, Raymond E, Olivier D, Mérette C, Roy MA. How prevalent are anxiety disorders in schizophrenia? A meta-analysis and critical review on a significant association. *Schizophr Bull*. 2011;37(4):811-821.

Adachi N, Kanemoto K, Toffol B, et al. Basic treatment principles for psychotic disorders in patients with epilepsy. *Epilepsia*. 2013;54(suppl 1):19-33.

Addington J, Heinssen R. Prediction and prevention of psychosis in youth at clinical high risk. *Annu Rev Clin Psychol*. 2012;8(1):269-289.

Allison DB, Mentore JL, Heo M, et al. Antipsychotic-induced weight gain: a comprehensive research synthesis. *Am J Psychiatry*. 1999;156(11):1686-1696.

American Psychiatric Association. *Diagnostic and Statistical Manual of Mental Disorders*. 5th ed. Washington, DC: American Psychiatric Association; 2013.

American Psychiatric Association. Practice guideline for the treatment of patients with HIV/AIDS. Work Group on HIV/AIDS. American Psychiatric Association. *Am J Psychiatry*. 2000;157(11 suppl):1-62.

Awissi DK, Lebrun G, Coursin DB, Riker RR, Skrobik Y. Alcohol withdrawal and delirium tremens in the critically ill: a systematic review and commentary. *Intensive Care Med*. 2013;39(1):16-30.

Ballard C, Aarsland D, Francis P, Corbett A. Neuropsychiatric symptoms in patients with dementias associated with cortical Lewy bodies: pathophysiology, clinical features, and pharmacological management. *Drugs Aging*. 2013;30(8):603-611.

Ballon J, Stroup TS. Polypharmacy for schizophrenia. *Curr Opin Psychiatry*. 2013;26(2):208-213.

Bartolommei N, Lattanzi L, Callari A, et al. Catatonia: a critical review and therapeutic recommendations. *J Psychopathol*. 2012;18:234-246.

Bleakley S. Identifying and reducing the risk of antipsychotic drug interactions. *Prog Neurol Psychiatry*. 2012;16(2):20-24.

Bousman CA, Glatt SJ, Everall IP, et al. Methamphetamine-associated psychosis: a model for biomarker discovery in schizophrenia. In: Ritsner MS, ed. *Handbook of Schizophrenia Spectrum Disorders*. Vol 1. Dordrecht, The Netherlands: Springer Science and Business Media BV; 2011:327-343.

Buchanan RW, Kreyenbuhl J, Kelly DL, et al. The 2009 schizophrenia PORT psychopharmacological treatment recommendations and summary statements. *Schizophr Bull*. 2010;36(1):71-93.

Clegg A, Young JB. Which medications to avoid in people at risk of delirium: a systematic review. *Age Ageing*. 2011;40(1):23-29.

Dixon LB, Dickerson F, Bellack AS, et al. The 2009 schizophrenia PORT psychosocial treatment recommendations and summary statements. *Schizophr Bull*. 2010;36(1):48-70.

Fallon BA, Levin ES, Schweitzer PJ, Hardesty D. Inflammation and central nervous system Lyme disease. *Neurobiol Dis*. 2010;37(3):534-541.

Foster R, Olajide D, Everall IP. Antiretroviral therapy-induced psychosis: case report and brief review of the literature. *HIV Med*. 2003;4(2):139-144.

Freudenreich O, Schulz SC, Goff DC. Initial medical work-up of first-episode psychosis: a conceptual review. *Early Interv Psychiatry*. 2009;3(1):10-18.

Gutierrez B, Heiber G, Torres-Gonzalez F, Cervilla JA. The role of microbial agents in the etiology of schizophrenia: an infectious hypothesis for psychosis? *Curr Immunol Rev*. 2011;7(1):57-63.

Hor K, Taylor M. Suicide and schizophrenia: a systematic review of rates and risk factors. *J Psychopharmacol*. 2010;24(4 suppl):81-90.

Kahn RS, Keefe RE. Schizophrenia is a cognitive illness: time for a change in focus. *JAMA Psychiatry*. 2013;70(10):1107-1112.

Karam CS, Ballon JS, Bivens NM, et al. Signaling pathways in schizophrenia: emerging targets and therapeutic strategies. *Trends Pharmacol Sci*. 2010;31(8):381-390.

Keck PE Jr, McElroy SL, Havens JR, et al. Psychosis in bipolar disorder: phenomenology and impact on morbidity and course of illness. *Compr Psychiatry*. 2003;44(4):263-269.

Kerfoot KE, Rosenheck RA, Petrakis IL, et al; for CATIE Investigators. Substance use and schizophrenia: adverse correlates in the CATIE study sample. *Schizophr Res*. 2011;132(2-3):177-182.

Kessler RC, Birnbaum H, Demler O, et al. The prevalence and correlates of nonaffective psychosis in the National Comorbidity Survey Replication (NCS-R). *Biol Psychiatry*. 2005;58(8):668-676.

Kohen D. Diabetes mellitus and schizophrenia: historical perspective. *Br J Psychiatry Suppl*. 2004;184(47):s64-s66.

Kroeze WK, Hufeisen SJ, Popadak BA, et al. H_1-histamine receptor affinity predicts short-term weight gain for typical and atypical antipsychotic drugs. *Neuropsychopharmacology*. 2003;28(3):519-526.

Krystal JH, Karper LP, Seibyl JP, et al. Subanesthetic effects of the noncompetitive NMDA antagonist, ketamine, in humans. Psychotomimetic, perceptual,

cognitive, and neuroendocrine responses. *Arch Gen Psychiatry*. 1994;51(3): 199-214.

Kuepper R, van Os J, Lieb R, Wittchen HU, Höfler M, Henquet C. Continued cannabis use and risk of incidence and persistence of psychotic symptoms: 10 year follow-up cohort study. *BMJ*. 2011;342:d738.

Lee KC, Ladizinski B. Mucocutaneous manifestations of illicit drug use. *Int J Dermatol*. 2014;53(8):1048-1051.

Leucht S, Cipriani A, Spineli L, et al. Comparative efficacy and tolerability of 15 antipsychotic drugs in schizophrenia: a multiple-treatments meta-analysis. *Lancet*. 2013;382(9896):951-962.

Lonergan E, Britton AM, Luxenberg J, Wyller T. Antipsychotics for delirium. *Cochrane Database Syst Rev*. 2007;(2):CD005594.

Mahajan SK, Machhan PC, Sood BR, et al. Neurocysticercosis presenting with psychosis. *J Assoc Physician India*. 2004;52:663-665.

Meltzer HY, Alphs L, Green AI, et al; for International Suicide Prevention Trial Study Group. Clozapine treatment for suicidality in schizophrenia: International Suicide Prevention Trial (InterSePT). *Arch Gen Psychiatry*. 2003;60(1):82-91.

Murray CJ, Vos T, Lozano R, et al. Disability-adjusted life years (DALYs) for 291 diseases and injuries in 21 regions, 1990–2010: a systematic analysis for the Global Burden of Disease Study 2010. *Lancet*. 2012;380(9859): 2197-2223.

Ohayon MM, Schatzberg AF. Prevalence of depressive episodes with psychotic features in the general population. *Am J Psychiatry*. 2002;159(11):1855-1861.

Olabi B, Ellison-Wright I, McIntosh AM, Wood SJ, Bullmore E, Lawrie SM. Are there progressive brain changes in schizophrenia? A meta-analysis of structural magnetic resonance imaging studies. *Biol Psychiatry*. 2011;70(1):88-96.

Ondo WG, Tintner R, Voung KD, Lai D, Ringholz G. Double-blind, placebo-controlled, unforced titration parallel trial of quetiapine for dopaminergic-induced hallucinations in Parkinson's disease. *Mov Disord*. 2005;20(8):958-963.

Perälä J, Suvisaari J, Saarni SI, et al. Lifetime prevalence of psychotic and bipolar I disorders in a general population. *Arch Gen Psychiatry*. 2007;64(1):19-28.

Rolinski M, Fox C, Maidment I, et al. Cholinesterase inhibitors for dementia with Lewy bodies, Parkinson's disease dementia and cognitive impairment in Parkinson's disease. *Cochrane Database Syst Rev*. 2012;(3):CD006504.

Saha S, Chant D, Welham J, McGrath J. A systematic review of the prevalence of schizophrenia. *PLoS Med*. 2005;2(5):e141.

Schmitz B. Effects of antiepileptic drugs on mood and behavior. *Epilepsia*. 2006;47(suppl 2):28-33.

Schneider LS, Tariot PN, Dagerman KS, et al; for CATIE-AD Study Group. Effectiveness of atypical antipsychotic drugs in patients with Alzheimer's disease. *N Engl J Med*. 2006;355(15):1525-1538.

Schwarz C, Volz A, Li C, Leucht S. Valproate for schizophrenia. *Cochrane Database Syst Rev*. 2008;(3):CD004028.

Sellner J, Trinka E. Seizures and epilepsy in herpes simplex virus encephalitis: current concepts and future directions of pathogenesis and management. *J Neurol*. 2012;259(10):2019-2030.

Shevlin M, Armour C, Murphy J, Houston E, Adamson G. Evidence for a psychotic posttraumatic stress disorder subtype based on the National Comorbidity Survey. *Soc Psychiatry Psychiatr Epidemiol*. 2011;46(11):1069-1078.

Smith MJ, Thirthalli J, Abdallah AB, Murray RM, Cottler LB. Prevalence of psychotic symptoms in substance users: a comparison across substances. *Compr Psychiatry*. 2009;50(3):245-250.

Stevens JR, Jarrahzadeh T, Brendel RW, Stern TA. Strategies for the prescription of psychotropic drugs with black box warnings. *Psychosomatics*. 2014;55(2):123-133.

Strawn JR, Keck PE Jr, Caroff SN. Neuroleptic malignant syndrome. *Am J Psychiatry*. 2007;164(6):870-876.

Stroup TS, Lawrence R, Abbas AI, Miller BR, Perkins DO, Lieberman JA. Schizophrenia spectrum and other psychotic disorders. In: Hales RE, Yudofsky SC, Roberts LW, eds. *The American Psychiatric Publishing Textbook of Psychiatry*. 6th ed. Arlington, VA: American Psychiatric Association; 2014:273-310.

Titulaer MJ, McCracken L, Gabilondo I, et al. Treatment and prognostic factors for long-term outcome in patients with anti-NMDA receptor encephalitis: an observational cohort study. *Lancet Neurol*. 2013;12(2):157-165.

Wahab S, Md Rani SA, Sharis Othman S. Neurosyphilis and psychosis. *Asia Pac Psychiatry*. 2013;5(suppl 1):90-94.

Walker EF, Savoie T, Davis D. Neuromotor precursors of schizophrenia. *Schizophr Bull*. 1994;20(3):441-451.

Wobrock T, Falkai P, Schneider-Axmann T, et al; for EUFEST Study Group. Comorbid substance abuse in first-episode schizophrenia: effects on cognition and psychopathology in the EUFEST study. *Schizophr Res*. 2013;147(1): 132-139.

Zipursky RB, Reilly TJ, Murray RM. The myth of schizophrenia as a progressive brain disease. *Schizophr Bull*. 2013;39(6):1363-1372.

Mood Disorders 154

Andrés Barrera, Licínia Ganança, Alejandro S. Cazzulino, and Maria A. Oquendo

KEY POINTS

1. Major depressive episodes can occur in both bipolar and unipolar syndromes with a minimum duration of 2 weeks.
2. Major depressive disorder has a 12-month prevalence of 13.4% for women and 7.2% for men.
3. Major depressive disorder somatic therapies include antidepressants, transcranial magnetic stimulation, and electroconvulsive therapy.
4. Bipolar disorders have a lifetime prevalence of 0.3% to 1.5% and a female-to-male ratio of 1:1.
5. Bipolar disorder pharmacotherapy includes lithium, valproate, lamotrigine, carbamazepine, dopamine blockers, and electroconvulsive therapy.

INTRODUCTION

Mood disorders are defined by the presence of a distinct period of persistently altered mood, specifically, depressed, manic, or hypomanic states. These states may signal the presence of depressive or bipolar disorders depending on the presenting symptoms and the longitudinal course of the illness. It is fundamental to differentiate between major depressive disorder (MDD) and bipolar disorder because they have different clinical presentations, prognoses, etiologies, genetic factors, and importantly treatments. Moreover, treating bipolar disorder with antidepressants alone may precipitate hypomanic or manic episodes.

Comorbidity between mood and neurologic disorders occurs frequently. Mood, especially depressive, symptoms may be part of or precede the clinical presentation of some neurologic disorders (eg, Huntington disease [HD]). They may also increase the risk for cerebrovascular disorders, and possibly some dementias, and therefore have a considerable impact in the prognosis and quality of life of primary neurologic disorders.

EPIDEMIOLOGY

It is estimated that 300 million people worldwide are affected by depression. Major depression is one of the leading causes of disability in the United States and worldwide; it ranked 11th in terms of disability-adjusted life years in a study of 291 diseases and injuries conducted in 21 regions. Moreover, according to the National Mental Health Association, depression affects 1 in every 33 children and 1 in every 10 adolescents (13.3%.) In any given year, about 21 million people in the United States will suffer from major depression (https://www.nimh.nih.gov/health/statistics/major-depression.shtml).

The incidence of depression is nearly twice as high in women as it is in men, and suicide attempts are more numerous in women. However, death from suicide is far more common in men. Additionally, postpartum depression occurs after as many as 10% of all deliveries. The 12-month prevalence of depression in the U.S. population is estimated to be around 8.7% for women and 5.3% for men.

Bipolar disorder has a lifetime risk of 0.3% to 1.5%, with equal prevalence among men and women. It is estimated that around 22.5% of depressed patients may in fact be bipolar but have yet to be diagnosed.

PATHOBIOLOGY

Mood disorders result from the interaction between biologic (genetic) and environment factors. Genetic factors are thought to be relevant due to the high heritability of mood disorders, estimated at about 30% to 40%. The data from twin studies indicates that environmental factors also play an important role in the expression of mood disorders. Nonetheless, the risk of becoming ill increases two- to threefold for first-degree family members of patients with mood disorders. It is for this reason that interest in epigenetic studies in mood disorder—which concurrently take into account both explanatory factors—is increasing. Of note, despite early suggestions that bipolar disorder is more heritable than depressive disorders, the evidence that genetic vulnerability or heritability of mood disorders differs between bipolar and unipolar conditions is mixed and far from definitive.

Pathophysiology of Major Depressive Disorder

With the growing availability of functional and structural brain magnetic resonance imaging and of treatments like transcranial magnetic stimulation (TMS), which targets specific brain circuits, there is a better understanding of the significant changes in the structure and function of the brain in unipolar depression. Findings indicate that the core pathologic dysfunction in unipolar depression appears to be in the prefrontal/limbic network. At the same time, this network influences and is highly influenced and modulated by at least three other systems: hypothalamic-pituitary-adrenal (HPA) axis, the basal ganglia network, and the mesolimbic network.

Prefrontal/limbic dysregulation is characterized by a decrease in activity and/or volume in several dorsal structures: the dorsolateral prefrontal cortex (PFC), dorsomedial PFC, dorsal anterior cingulate cortex (ACC), and rostral ACC. In contrast, there is increased activity in ventral structures, the amygdala, the subgenual ACC, the ventrolateral PFC, and orbital PFC. The hippocampus plays a special role, although medial and deep in

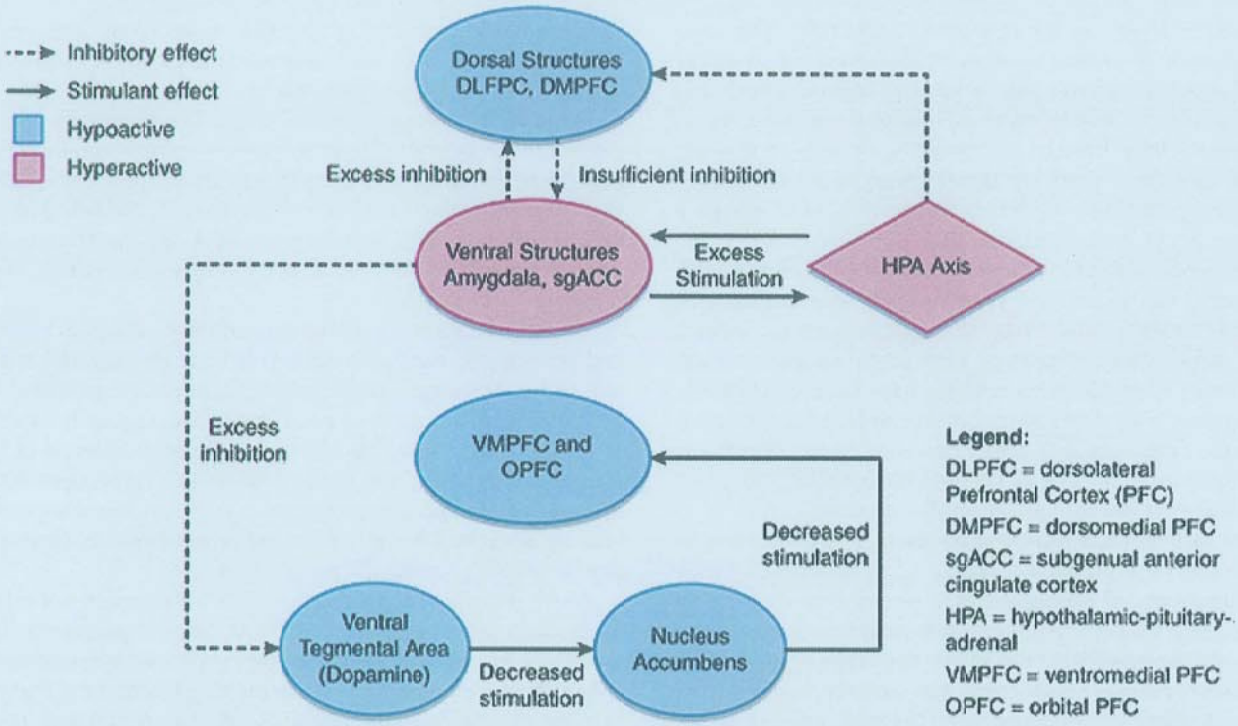

FIGURE 154.1 Neurocircuitry of major depressive disorder.

the temporal lobe, showing marked hypoactivity and significant volume loss. Simply stated, the prefrontal network, which under normal circumstances controls and regulates the limbic system and thus mood, is overpowered by the limbic system. In a depressed state, the limbic network "controls" the prefrontal network, yielding a state in which unregulated mood can take over.

The HPA axis—part of the stress system—is central in depressive disorders and may provide a "gateway" for a new mood episode. Stress has been implicated in the pathophysiology of depression not only as mediated through glutamatergic changes in response to stress but also as exemplified by prominent changes to the neuroendocrine system. Under normal conditions, stress prompts the HPA axis to secrete serum cortisol. In mood disorders, the HPA axis may become unresponsive to the normal negative feedback loop, leading to a failure to restore cortisol to normal levels once the stressor is removed. These changes may be accompanied by the loss of normal diurnal variation in cortisol levels. Whether these changes are linked to negative early life experiences, leading to enduring changes in the HPA axis thereby increasing the probability of developing a mood disorder later in life, is not known. Chronic increases in cortisol levels have been implicated in the activation of the amygdala and possibly the subgenual ACC as well as in a decrease in activity and volume of the hippocampus and rostral anterior cingulated cortex.

The relation between the basal ganglia and the prefrontal/limbic network is highly complex. There are at least four circuits between the basal ganglia and the prefrontal/limbic network, some of which are implicated in the control of goal directed behavior (rewards and punishments) and rumination, two activities central to the manifestation of mood disorders. Finally, the mesolimbic network, specially the dysregulation of the dopaminergic projections from the ventral tegmental area to the nucleus accumbens and PFC are keys to understanding anhedonia, a core symptom of depression. The decrease in dopaminergic tone mediates the lack of motivation, interest, and incapacity for joy in depression (Fig. 154.1).

The neurotransmitter systems involved in the dysfunction of these circuits in MDD include the serotonergic, glutamatergic, noradrenergic, and dopaminergic systems. The serotonergic system plays a key role in depression, with studies demonstrating an overall decrease in serotonin (5-HT) function. Brain imaging studies demonstrate increased 5-HT_{1A} receptor binding, with 5-HT_{1A} upregulated in response to low serotonergic tone and fewer brain 5-HT reuptake sites. Tryptophan (5-HT precursor) depletion has been shown to produce rapid depressive relapses in patients with a history of depression, but no change in subjects with no personal or familial history of mood disorders. This suggests that low levels of 5-HT in the brain are not sufficient to cause depression but may act in concert with other factors in vulnerable individuals to cause symptoms. Indeed, many antidepressants exert their action through modulation of 5-HT transmission.

Dopamine also has a fundamental role in mood disorder. It is involved in motivation, incentivized behavior, and reward and therefore is key to understanding anhedonia—perhaps the most characteristic symptom of depression. Low cerebrospinal fluid levels of the dopamine metabolite, homovanillic acid, have been documented in depressed patients, and exposure to dopamine-depleting drugs such as reserpine is known to precipitate depression. On the other hand, some antidepressants like bupropion and sertraline and stimulants like amphetamines and methylphenidate increase dopaminergic tone in the ventral tegmental area–nucleus accumbens circuit improving motivation, activity, attention, and energy in depressed patients.

Changes in other neurotransmitters such as norepinephrine and glutamate have also been identified. Norepinephrine is linked to the pathophysiology of severe depression; studies have shown decreased norepinephrine turnover, increased metabolites of norepinephrine, and induced depressive episodes with

norepinephrine depletion by reserpine. Glutamate, the main excitatory neurotransmitter appears to be increased in major limbic and cortical systems, possibly in response to stress, and may exert pathogenic effects either by limiting neurogenesis or dendritic remodeling directly, enhancing apoptosis or may act in concert with other factors having effects on neuroplasticity.

Other neuropathologic aspects of depressive disorders have received significant attention. For example, depression is associated with neuroinflammatory processes, comporting with the observation that depressive symptoms (fatigue, anhedonia, anorexia, etc) could be viewed as "sickness behaviors." Indeed, changes in inflammatory markers, such as increased interleukin 6 and tumor necrosis factor α levels have been consistently found in patients with depression. Furthermore, administration of therapeutic cytokines has been shown to cause significant depressive symptoms in 50% of exposed individuals, providing further evidence for the role of neuroinflammation.

As noted earlier, neuroplastic changes in the hippocampus have been linked to depression. Chronic stress is associated with decreased hippocampal neurogenesis, a phenomenon observed in animal models of depression and postmortem tissue. Treatments with antidepressants seem to reverse these hippocampal deficits in neurogenesis. Both stress and antidepressants have been shown to affect levels of brain-derived neurotrophic factor (BDNF), which is normally highly expressed in hippocampus and PFC and plays a major role in neuronal growth, survival, and maturation. BDNF also seems to have antidepressant-like actions and can induce molecular transcription in several key pathways.

Some psychosocial models focus on loss as the cause of depression in vulnerable, or less resilient, individuals. Exogenous factors may include social rejection or loss (interpersonal, financial, or health-related). Certainly, loss of income, job, social status, or the failure to achieve a life goal may produce profound mourning. Regardless, clinical symptoms that develop in response to these stressors are ultimately mediated through brain circuitry and neurochemistry.

Pathophysiology of Bipolar Disorder

The pathophysiology of bipolar disorder is still being clarified; it needs to address not only very different states: depressive and manic or hypomanic episodes but also a dynamic dysfunction between them: the change across episodes, from the extreme energy and expansive mood of mania to the lack of energy and depressed mood of depressive episodes. As in MDD, the core pathologic dysfunction in bipolar disorder is in the mood regulation in the prefrontal/limbic network; specially decreased control of the ventral PFC over the amygdala and the nucleus accumbens. Functional neuroimaging has shown hyperactive amygdala as well as ventral striatum and hypoactive ventral PFC. Structural evidence from brain imaging studies shows a reduction of volume, presumably neurons and glial cells, in areas such as the PFC, amygdala, and striatal regions, as well as white matter hyperintensities. As is the case in major depression, positron emission tomography studies suggest serotonergic abnormalities including fewer 5-HT transporters and more 5-HT_{1A} receptors. Other relevant neurotransmitters include dopamine and glutamate. For instance, drugs that increase dopamine release, such as amphetamines, can induce manic-like symptoms. Similarly, decreased dopamine reuptake and reductions in dopamine transporter availability are linked to bipolar disorder. In addition, increased cortical glutamate levels and vesicular glutamate transporter gene expression are also implicated in the neurobiology of bipolar disorder.

As with depression, bipolar disorder can be viewed as a disorder related to synaptic plasticity involving dysfunction of neuroprotective pathways and impaired neuronal resilience. Multiple pathways related to plasticity are implicated, including impaired regulation of calcium signaling cascades, associated with oxidative stress, and mitochondrial and endoplasmic reticulum stress response dysfunction.

Several intracellular molecular pathways affected by lithium and pertinent to neuroplasticity have been investigated as potential pathophysiologic contributors. The phosphoinositol pathway, involved in protein kinase C activation, regulates expression of several genes including BDNF. In fact, altered levels of BDNF are posited to contribute to the polarity switch process. Another lithium target, glycogen synthase kinase 3, is a key component of Wnt signaling and has effects on neurotransmission, neuroplasticity, neuronal growth, and metabolism.

As we describe in this chapter, bipolar disorder is a different illness than MDD, with distinct treatment and prognosis. Therefore, to clarify differences in pathologic processes is essential not only to define etiology but also to identify biomarkers that might help in the differential diagnosis. Recent functional imaging studies show differences in the connectivity within the insula and the parietal lobe differentiating bipolar depressed patient from unipolar depressed patient and healthy subjects.

CLINICAL MANIFESTATIONS

Depressive Disorders

A depressive episode is distinct from the normal emotional feelings of sadness or loss or a passing state of these emotions. Functional impairment and significant distress are key criteria, and indeed, depression encompasses dysfunction in affective, cognitive, behavioral, and psychomotor domains.

In order to make the diagnosis, at least one of two gateway symptoms must be present for a minimum of 2 weeks: depressed mood and/or substantial decrease in interest or pleasure. Interestingly, depressed mood can manifest in a variety of ways, and patients may report feeling down, sad, depressed, anxious, angry, or irritable. Of note, males may be more likely to present with irritability or anger, sometimes making the diagnosis more challenging to identify. Women more often present with "classic" sadness or depression. Anhedonia, or inability to feel pleasure, manifests as a reduction or loss of interest in things, people, or activities. As "gateway symptoms," the diagnosis of depression cannot be made in the absence of at least one of them.

Cognitively, patients may experience difficulty concentrating or making decisions, a decrease in productivity, forgetfulness, and slowed thoughts. In addition, patients often report distorted thoughts that are negative and pessimistic, including feelings of worthlessness, loss of self-esteem, and unreasonable self-blame or guilt. The future is regarded with a sense of dread and hopelessness. Moreover, negative memories from the past may be preferentially recalled. At times, such cognitive distortions may be of delusional intensity. For example, patients may become convinced they are gravely ill or impoverished and unable to process or "believe" results from medical tests or bank reports. Other delusions typical of depression with psychotic features

focus on pessimism or deserved punishment. Auditory hallucinations are usually simple and mood congruent, for example, patients may hear a single word or short phrases with guilt, punishment, illness, death, or worthlessness content.

The behavioral symptoms of depression include changes in appetite and weight and disruptions of sleep patterns. Sleep disturbances include difficulty falling asleep (early insomnia), waking up in the middle of the night (middle insomnia), and waking up earlier than usual (terminal insomnia). Middle and terminal insomnias are more specific to depression than early insomnia, which is more common in the absence of a mood disorder. However, some patients experience hypersomnia rather than insomnia. Similarly, patients often report poor appetite and weight loss, although increased appetite and weight are sometimes observed, too. Other behavioral symptoms include loss of libido.

Psychomotor activity is usually diminished in depression and low energy and physical fatigue are often present. Patients may experience difficulty completing day-to-day activities and self-care or find that these activities require greater effort. In extreme cases, patients may become virtually immobile and mute, and this condition combined with loss of appetite and overall self-neglect can result in a medical emergency due to dehydration or poor nutrition. In contrast, some patients exhibit psychomotor agitation, which is often accompanied by intense anxiety. Agitation can often not only be seen in depressed patients but may also result from the side effects of antidepressant medications.

Perhaps, the most worrisome symptom of depression is suicidal thinking or behavior. Suicidal ideation may range from passing thoughts that life is not worth living to well-defined plans with intent to kill oneself. About 15% of patients with depression acknowledge a suicide attempt at some point in their lives and between 2% and 12% of patients with depression die by suicide. This is another way in which depression can lead to morbidity and mortality.

On examination, depressed patients characteristically exhibit a dejected posture, with bent shoulders, frowning, and a downcast gaze. Gestural movements and facial expressions are reduced, and grooming may be neglected. Patients usually take more time to start answering questions and speak slowly and softly.

Bipolar Disorders

The distinguishing feature of bipolar disorder is the presence of a manic episode that lasts at least 1 week or longer or a hypomanic episode that lasts at least 4 days or longer. Beside duration, hypomania is characterized by the same symptoms seen in mania, but of less severity. Generally, impairment in hypomania is less pronounced than in mania. This distinction between mania and hypomania allows the classification between bipolar I (manic episodes) and bipolar II (hypomanic episodes). Bipolar disorder also is characterized for dysfunctions in affective, cognitive, psychomotor, and behavioral domains. There are other subtypes of bipolar disorder; cyclothymic disorders (hypomanic and depressive symptoms not enough to meet full criteria), substance/medications induced bipolar disorder, and bipolar disorder related to another medical condition.

As described before, mania, lasting a minimum of 1 week, is characterized by abnormally elevated or euphoric feelings. As with depression, there can be significant irritability and anger, especially when the patient is frustrated, but patients often appear exaggeratedly cheerful and happy. By definition, mania causes severe impairment.

Cognitive abnormalities include rapid or even racing thoughts, which may translate into rapid, pressured speech that can, as the severity of mania progresses, become increasingly disorganized. As thoughts become disorganized, speech can exhibit flight of ideas or loosening of associations. In addition, patients are easily distracted and have difficulty focusing on tasks that require concentration. Patients also frequently exhibit impaired judgment and engage in activities they would normally eschew if well. Patients may go on spending sprees, engage in promiscuous sexual behaviors, or make risky business decisions. Cognitive distortions in mania often include inflated self-esteem and grandiose ideas such as a sense of being special, capable of anything, or possessing special powers. As in depression, the cognitive distortions can cross the line into delusional or psychotic thinking. Grandiose delusions are a common psychotic feature in mania.

Behaviorally, manic patients are usually overactive with increased energy levels and engage in multiple activities. Typically, the number of hours of sleep is reduced, without the sensation of fatigue or sleepiness. In fact, insomnia is often the first recognizable symptom of a manic episode. Appetite is usually reduced and combined with increased activity can lead to significant weight loss. Manic patients classically dress with bright colors, use excess make up, or wear extravagant clothing. Movements are exaggerated or theatrical, and patients may express excessive familiarity toward strangers.

From a psychomotor vantage, manic patients frequently have increased psychomotor activity. They may both engage in goal-oriented activities at an accelerated pace or be overactive in a general way, with pacing or fidgeting.

Interviewing can be very difficult because manic psychopathology tends to block communication. It is usually counterproductive for the physician to spend time arguing with or countering the illogical thinking of the patient. Insight is absent in virtually all cases and, therefore, patients typically object to treatment.

Hypomania has a similar clinical presentation but may be briefer, cause less functional impairment, and has no psychotic symptoms.

Although the presence of manic or hypomanic episodes differentiates bipolar from depressive disorders, depression is prominent in bipolar disorder. In fact, over the course of the disorder, most bipolar patients spend significantly more time depressed than manic or hypomanic. Bipolar depression usually has an earlier onset, greater risk of suicidal behavior, likely linked to the greater time spent depressed, and more episodes of illness.

Seasonal Affective Disorder

Seasonal affective disorder is characterized by episodes that regularly occur in a specific season. The most notorious is MDD occurring during winter, also known as *winter depression*. It typically starts in the fall and extends until the spring. In addition to other symptoms of depression, specially anhedonia, low energy and inactivity, seasonal affective disorder is characterized by increased sleep, increased appetite, and weight gain. As many as 15% of patients with MDD have a seasonal presentation. The pathogenesis, although not known, has been associated with disturbance in the circadian rhythms in the context of decreased daylight during the winter.

DIAGNOSIS

There is no pathognomonic sign or symptom and, as of yet, no biologic or neuroimaging markers that can establish the diagnosis of a mood disorder. Therefore, mood disorder diagnoses are established according to their clinical features. Each category has specific criteria, which are defined by consensus and described in manuals such as the *Diagnostic and Statistical Manual of Mental Disorders* (fifth edition, *DSM-5*). It is likely that these diagnoses will ultimately be understood as a grouping of multiple distinct disorders and more specific entities within the current disorders will be defined using genetics, epigenetics, brain imaging, and other methods.

MDD is diagnosed by the presence of at least one major depressive episode. Episodes can occur a single time but, more often, they are recurrent. Additionally, episodes can occur with mixed symptoms of hypomania but without meeting the full criteria for hypomania (or mania). If full criteria for manic or hypomanic episode and full criteria for major depressive episode are present at the same time, the diagnosis is bipolar disorder with mixed features.

DSM-5 criteria for MDD requires a least five of the following symptoms: (1) depressed mood, (2) anhedonia (loss of interest, motivation, or pleasure), (3) weight loss or gain, (4) insomnia or hypersomnia, (5) psychomotor agitation or retardation, (6) loss of energy, (7) low self-esteem or inappropriate guilt, (8) decreased capacity to think or concentrate or indecisiveness, (9) death or suicidal ideation or behavior. The duration of the episode needs to be at least 2 weeks. Recall that depressed mood and anhedonia are gateway symptoms and at least one of them must be present to make the diagnosis of major depression.

Persistent depressive disorder is a form of depression that has less than five symptoms, as required in MDD, but lasting for at least 2 years, with little or no remission during that time. Typical symptoms include low mood, lack of energy and interest, low self-esteem, and irritability. Chronic forms of depressive disorders are associated with poorer response to treatment, slower rate of improvement over time, younger age of onset, longer episodes, greater disease burden, higher rates of medical and psychiatric comorbidity, and higher rates of suicidal ideation.

Mood and associated physical symptoms may occur in relation to the menstrual cycle. **Premenstrual dysphoric disorder** is diagnosed if symptoms are present during the last week of the luteal phase, remit within a few days of the follicular phase, and are absent in the week following menses. A prospectively documented cyclical pattern over at least 2 consecutive months must be present to confirm the diagnosis.

Mood disorders in children and adolescents bring specific diagnostic challenges. Behavioral problems are common and include withdrawal, sullenness, truancy, poor grades, and tantrums. Children and adolescents showing persistent irritability, which manifests as frequent temper outbursts and angry, irritable mood in between outbursts, may be eligible for the diagnosis of **disruptive mood dysregulation disorder**. To meet the criteria, the temper outburst need to be frequent, three or more per week, and the symptoms must be present for at least 1 year.

The presence of at least one manic episode is required to diagnose a **bipolar I disorder**. In contrast, a **bipolar II disorder** diagnosis requires a history of both depressive and hypomanic episodes. Recurrence of episodes, interspersed with periods of normal mood (euthymia), is the norm, although single episodes are possible. In some cases, patients never fully recover and continue on a chronic course.

TABLE 154.1 Neurologic Disorders Commonly Associated With Mood Symptoms

Depressive Symptoms	Manic Symptoms
• Stroke (depression as both risk factor and sequelae) • Parkinson disease • Huntington disease • Essential tremor • Multiple sclerosis • Epilepsy • Dementia	• Focal strokes in right basotemporal and inferofrontal region • Stroke/tumor in perihypothalamic region • Huntington disease • Multiple sclerosis • Head trauma • Neurosyphilis • Creutzfeldt-Jakob disease • Frontotemporal dementia

Patients with **cyclothymia** alternate between mild, short-lived depressions and hypomania. The cycles may be continuous and last for several weeks to several months. Rarely do these patients complain specifically about the highs they experience. More commonly, patients will complain only of being depressed at times, not realizing that they have been hypomanic at other times. Cyclothymia is sometimes a precursor to the more classic form of bipolar disorder.

Substance/medication-induced bipolar or depressive disorders can occur when mood episodes develop during or soon after substance intoxication or withdrawal or alternatively after exposure to a medication. Note that in cases where mania or hypomania ensues after treatment with an antidepressant, the diagnosis of bipolar disorder is warranted if the manic/hypomanic symptoms do not remit on withdrawal of the antidepressant (considering the time needed for metabolic elimination of the compound). Similarly, **bipolar or depressive disorders due to another medical condition** occur when there is evidence from the history, medical examination, or laboratory findings that the mood episode is a direct pathophysiologic consequence of another medical condition. See **Table 154.1** for a list of common neurologic disorders associated with mood symptoms.

When patients present with the characteristic symptoms of a depressive or bipolar disorder, but do not meet full criteria, a diagnosis of **other specified bipolar or depressive disorders** can be established if the condition causes clinically significant distress or impairment (**Fig. 154.2**).

Differential Diagnosis

Sadness is a normal reaction to life adversity and is characterized by an adequate response in proportion to the provoking stimulus, relatively brief duration, and lack of a major impact on psychosocial functioning. In normal bereavement and adjustment disorders, there is typically a reduction in depressive symptoms after the removal of provoking stressors.

Some medical conditions cause prominent mood symptoms. In addition to the history and physical examination, laboratory testing should include hepatic and thyroid function, studies of electrolytes, calcium, blood urea nitrogen, creatinine, a complete blood count, urinalysis, and a urine drug screen.

Differential Diagnosis With Neurologic Disorders

Twenty-five percent to 40% of patients with neurologic conditions, including Parkinson disease (PD) and HD, as well as Alzheimer disease, develop a marked depressive syndrome at

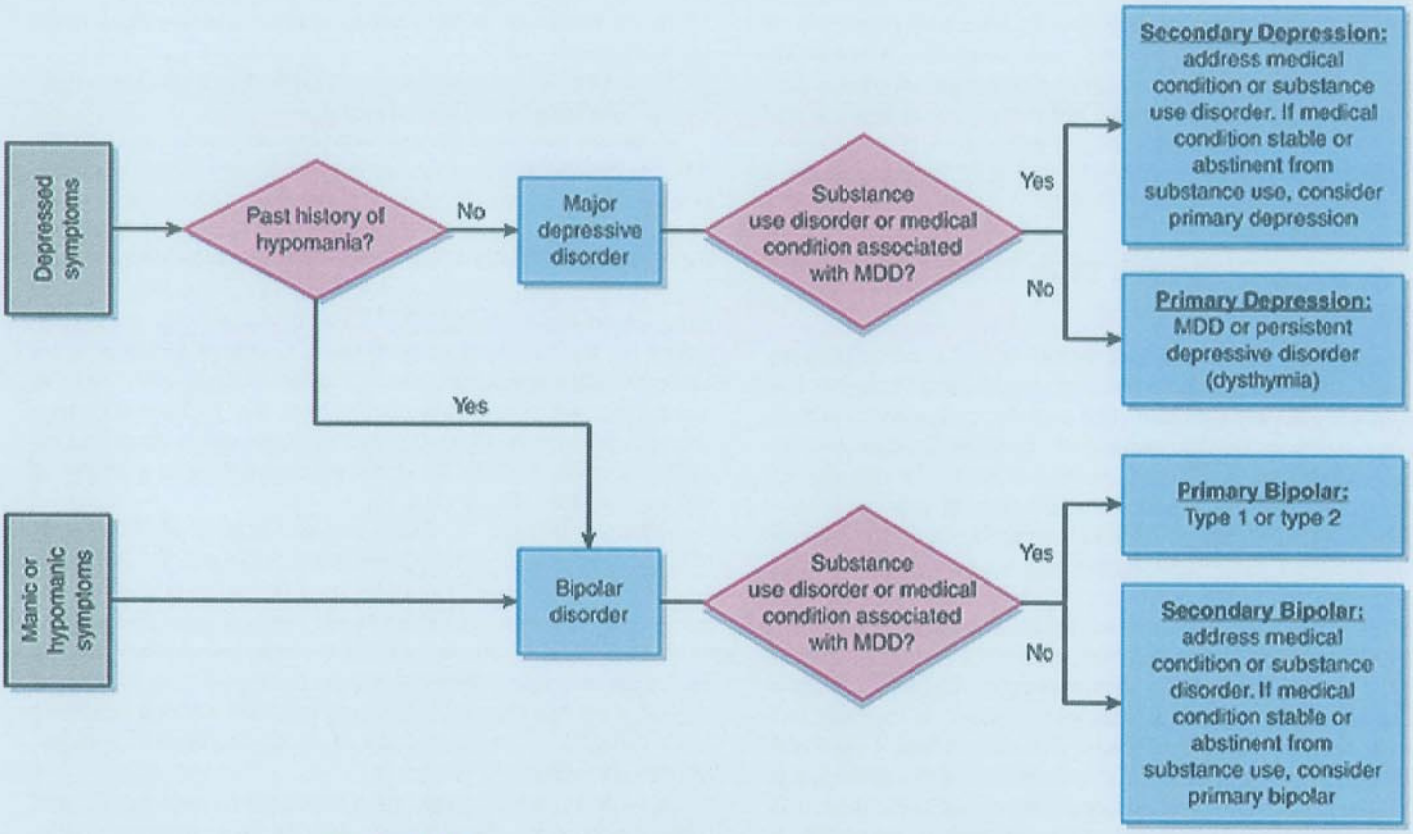

FIGURE 154.2 Algorithm for major depressive disorder (MDD) diagnosis.

some point over the course of the illness. Mood symptoms may precede neurologic manifestations in the cases of PD, HD, and essential tremor (ET). Critically, PD shares some symptoms with major depression, such as bradykinesia, decreased or even expressionless faces, bradyphrenia, stooped posture, loss of interest and concentration, and reduced libido. Comorbidity between the two disorders is highly prevalent, around 40%. Bromocriptine treatment is also associated with depressive symptoms. Features that facilitate the diagnosis of depression in these patients include the presence of a pervasive low mood (sometimes with diurnal variation), early morning awakening, pessimism (not proportional to the level of neurologic disability), and suicidal ideation. Of note, some psychiatric drugs directly affect dopaminergic transmission, such as first- and second-generation antipsychotics, and can cause or worsen parkinsonian symptoms or cause tardive dyskinesias.

Depressive symptoms can occur in patients with ET with prevalences as high as 49%. Not only do these symptoms result from the functional impairment associated with a disabling tremor but also may be a part of the pathophysiologic process and in some cases precede the onset of motor symptoms. A recent study revealed lower scores on items such as "reported sadness," "inability to feel," and "pessimistic thoughts" in depressed patients with ET. Euphoria can also be seen in neuropathologic states. Frontal lobe lesions can manifest with euphoria, often in the form of silliness and lack of foresight. Extreme social disinhibition, in the absence of other features of mania, strongly suggests frontal lobe pathology.

Patients suffering from dementia may present with manic-like agitation or depression. Cognitive and behavioral changes mimicking depression, such as apathy and loss of concentration, are more common than those that mimic mania, such as restlessness and combativeness. The medical evaluation is most important in elderly patients because they are at the greatest risk for having another illness comorbid with depression. They may also have a different medical condition presenting as depression. Although "pseudodementia" may be a sign of depression in the elderly, this assumption should be regarded as a diagnosis of exclusion. The appearance of a late-life affective disorder, especially in patients with no family history of such a condition, suggests a medical etiology.

Psychiatric symptoms, such as irritability, impulsivity, anxiety, and depressed mood, are almost ubiquitous in HD, which may initially present as a depressive illness. Depression may predate the neurologic diagnosis by 4 to 10 years. Apathy is a symptom that typically worsens as the disease progresses and may be related to the disorder itself. Suicide and suicide attempts are common. Manic symptoms can occur but are not as common. Family history is indicative of HD, and the definitive diagnosis is made through genetic testing.

Mood disorders are very common in epilepsy, 55% of individuals with epilepsy report depression, and they tend to have a pleomorphic presentation, sometimes not meeting full *DSM-5* criteria. Depressed mood, irritability, and anxiety are common. Mood disorders are classified according to their temporal relation to the occurrence of seizures as ictal (during the seizure), peri-ictal (preceding or following the seizure), or interictal (independently of the seizure).

In some situations, as in the so-called masked depression, patients fail to report feeling sad or depressed and can present with pain, fatigue, and other vague medical complaints. The presence of at least five of the necessary symptoms establishes the correct

diagnosis. The differential diagnosis is especially important in neurology because these patients often complain of headaches or backaches that are not amenable to conventional treatments.

Sleep apnea can cause fatigue, diminished concentration, and other symptoms similar to those of depression. A polysomnographic study may be warranted, especially in obese patients presenting with depressive symptoms.

Differential Diagnosis With Other Psychiatric Disorders

The distinction between mood disorders and other psychiatric disorders can be difficult and further complicated by the fact that comorbidity is very common. The negative symptoms of schizophrenia, such as apathy, anhedonia, decreased motor activity, social withdrawal, and cognitive decline, can resemble depression. On the other hand, patients with schizophrenia can present with grandiose delusions and florid agitation similar to mania. In mood disorders, delusional themes tend to be congruent with the main presenting mood. A history of periodic psychotic illnesses with a return to proper functioning between episodes is more suggestive of an affective disorder, whereas a history of chronic or deteriorating functioning is more suggestive of schizophrenia. A diagnosis based on a longitudinal evaluation is the most reliable. In the case of schizoaffective disorder, in which psychotic and mood symptoms coexist, the persistence of psychotic symptoms after resolution of mood symptoms validates the diagnosis.

Comorbidity with substance abuse disorders is prominent. In community samples, over 50% of individuals with mood disorders meet criteria for alcohol and/or substance abuse disorders. Patients may view substance abuse as a form of "self-medication," but often, symptoms are in fact caused or exacerbated by the substance. Such changes may be limited to the period of intoxication or occur after intoxication. If intoxication occurs frequently, it may produce diagnostic uncertainty, and prolonged abstinence may be necessary to make an accurate diagnosis. Patients with mood disorders who abuse both alcohol and drugs are more difficult to treat and have a higher rate of suicide attempts and suicide. Alcohol is often used in suicide attempts and may be the factor that triggers impulsive, self-destructive behavior or that intensifies the effects of an overdose.

Depressed patients often have severe anxiety and sometimes experience panic attacks as part of their illness. Predominance of either anxiety or depressive symptoms usually helps to establish the correct diagnosis. Nevertheless, there is a high rate of comorbidity with depression and all forms of anxiety disorders.

In the case of personality disorders, especially borderline personality disorder, the differential diagnosis is made if characteristic personality features, such as feelings of emptiness, extreme rejection sensitivity, and frantic efforts to avoid perceived abandonment, exist outside mood episodes. Borderline personality disorder is often comorbid with mood disorders.

TREATMENT

Treatment of Depressive Disorders

Depression can be treated with either pharmacotherapy or manualized therapies such as cognitive behavioral therapy or interpersonal therapy LEVEL 1.[1] More severe depression may require both medication and psychotherapy. Hospitalization may be necessary, especially for actively suicidal patients or for those whose personal care is so impaired that around the clock nursing is essential.

Antidepressant medications are classified by molecular structure or by effects on neurotransmitters.

There are five main groups: selective serotonin reuptake inhibitors (SSRIs) (fluoxetine, escitalopram, etc), serotonin norepinephrine reuptake inhibitors (venlafaxine, duloxetine, etc), tricyclic antidepressants (TCAs) (imipramine, nortriptyline, etc), and monoamine oxidase inhibitors (MAOIs) (phenelzine, tranylcypromine), and atypical antidepressants (mirtazapine, bupropion, vortioxetine, etc) LEVEL 1.[2-7] Any of these drugs are a good choice for the treatment of depression. Common side effects include gastrointestinal disturbance, agitation (especially early in treatment), and sexual dysfunction. Note that patients with psychotic depression rarely respond to antidepressants alone and require either the addition of an antipsychotic drug or a course of electroconvulsive therapy (ECT).

Although in general, SSRIs are as effective as TCAs and MAOIs in mild to moderate depression, TCAs and MAOIs introduced in the 1960s are often still used for patients who do not respond to one or more of the newer medications. The relative reluctance to use TCAs and MAOIs is due to issues of tolerability and/or serious side effects as well as their potential lethality if used in a suicide attempt. The most common adverse reactions when using TCAs are mainly due to cardiovascular and anticholinergic side effects.

As with any medication, drug interactions may occur, and cross-checking for these is key. MAOIs have important, life-threatening interactions with several drugs as well as interactions with food and, therefore, dietary precautions are essential.

A family history of effective drug response or previous response to a medication may be used to inform treatment selection. It is best with most medications to start with a low dose and increase slowly. Full benefit may take up to 4 to 6 weeks. After an initial episode, treatment should continue for 6 to 9 months at full dosage after the acute phase in order to prevent relapse.

Symptomatic relief with treatment may not result in immediate improvement of psychosocial function, which may be delayed. Relapses occur in up to 20% of patients in 6 months and over 30% in 1 year according to Keller. The risk of recurrence increases by 16% with each recurrent episode. The high rates of relapse have led to recommendations of maintenance treatment with drug therapy and prophylactic psychotherapy for patients with at least two episodes of depression LEVEL 1.[8,9]

Fifty percent to 60% of patients respond (50% improvement or better) to an initial course of antidepressant. However, remission (return to baseline or near baseline) is harder to attain and only about a third of patients remit after a first antidepressant treatment, requiring use of a different medication or augmentation strategies (see the following text).

Depression is often resistant to treatment. Several strategies have been developed to overcome this issue, such as combining antidepressants or augmenting antidepressant efficacy by adding other drugs such as lithium, stimulants (eg, dextroamphetamine or methylphenidate), antipsychotics, buspirone, or thyroid hormone. Empirical data driving decision making around intervention selection for treatment-resistant depression is still lacking. Studies comparing outcomes have not shown an advantage for any of the augmentation or second-tier strategies described thus far.

The past two decades have seen a growing or renewed interest in neuromodulation treatments, TMS and ECT LEVEL 1.[10-12]

TMS has been approved for the treatment of resistant depression, with response rates of around 60%.

It is a very safe and well-tolerated treatment, with less than 5% discontinuation. The most common side effect is mild temporary headache and discomfort in the application site. Its most serious side effect is seizures occurring during the sessions. Seizures are very uncommon; less than 0.1% during the complete treatment course. Unlike with ECT, there is no cognitive or memory loss, and it does not require general anesthesia for its application. At this point, there is no maintenance regimen approved by the U.S. Food and Drug Administration, and there are no clear guidelines.

Electroconvulsive treatment is indicated for patients with the following characteristics:

1. Failure to respond to adequate antidepressant pharmacotherapy trials
2. Depression with psychotic or catatonic features
3. Actively suicidal patients or manic patients so severely agitated that they must be rapidly controlled
4. Intolerance of side effects, as can happen in patients with PD, or allergies to multiple antidepressants
5. Inability to participate in pharmacotherapy or psychotherapy due to refusal to eat or drink or markedly slowed speech and cognition

ECT is a safe treatment and generally well tolerated. The most common side effect is mild, temporary memory loss. Because it is administered under general anesthesia, risks associated with anesthesia are also present. With proper medical preparation and screening, treatments may be administered even in the presence of neurologic or cardiovascular conditions. At the end of the course of treatment, a maintenance regimen must be instituted to prevent relapse. This can take the form of antidepressant medications, usually in combination, or "maintenance" ECT, generally administered monthly.

Treatment of Bipolar Disorders

Mood stabilization treatment is the gold standard for bipolar disorders LEVEL 1.[13-16] It serves to both control acute phases of the disease and prevent future episodes. Lithium is a potent antimanic. Remission is achieved in about 60% to 70% of cases, especially for patients with euphoric mania and infrequent episodes, although it takes several weeks to fully exert its therapeutic benefits. Lithium therapy requires regular blood level monitoring to prevent toxicity, which manifests at higher levels and can be life-threatening. Agitated and medically ill patients are at increased risk for toxicity. Lithium can cause hypothyroidism in 10% to 20% of patients and is relatively contraindicated in renal disease. Tremor is a common side effect.

Anticonvulsants such as valproate or carbamazepine can be used with good results in dysphoric mania or rapid cycling. They are often combined with lithium. Mood stabilization with second-generation antipsychotics (olanzapine, quetiapine, risperidone, or lurasidone) LEVEL 1,[17,18] is usually quicker and may also be more effective when psychotic symptoms are present. Sedating agents can also be used as adjunctive therapy for rapid control of agitation. The anticonvulsant lamotrigine has been shown to prevent recurrence of depression, but the data on its ability to control manic or hypomanic phases is weak.

In the case of bipolar depression, treating a depressive episode with antidepressants alone carries the risk of inducing to mania or hypomania. Nonetheless, aggressive treatment of depression is essential in bipolar disorder because it is in this phase that suicidal behavior occurs. Thus, although less dramatic than mania, it is certainly just as dangerous, if not more. Using mood stabilizers alone is only effective in a few cases. Most commonly, bipolar depression is treated with a combination of antidepressants and mood stabilizers. Quetiapine and lurasidone both have antidepressant effects and are U.S. Food and Drug Administration approved for monotherapy in bipolar depression.

Manic relapse may be spontaneous, induced by therapeutic drugs, or induced by substances. With continued use of a mood stabilizer, the risk of antidepressant-induced mania is about 10%. Data suggest that newer antidepressants are less likely than tricyclics or MAOIs to precipitate manic "switches."

After the second bipolar episode, regardless of polarity, patients should be treated indefinitely because relapse is almost certain. The treatment goal is to maintain euthymia and prevent either depression or manic episodes. Lithium has been the prophylactic drug of choice for decades, but the antipsychotic mood stabilizers are also approved for long-term prophylaxis. Consideration of side effect profiles as well as therapeutic benefits is essential when considering treatment selection.

Treatment of Mood Disorders Comorbid With Neurologic Disorders

Patients with dementia frequently develop psychiatric symptoms, including depression, elation, delusions, hallucinations, and periods of extreme irritability, agitation, or disinhibition. Dementia may be accompanied by full-blown psychiatric syndromes. These episodes are often brief. Nevertheless, modest doses of antidepressants may be of use. Side effects may be minimal with low doses. Antipsychotic medications must be used with extreme care but may be useful to treat agitation. They may induce extrapyramidal symptoms, especially the conventional ones.

Significant clinical depression occurs in 40% to 50 % patients with PD. The depressive symptoms respond well to low doses of antidepressants including the SSRIs. Occasionally, SSRI therapy increases parkinsonism, especially sertraline at higher doses, wherein the drug's selective affinity for 5-HT transporters is obviated. ECT is safe and effective and may improve both the depression and the motor symptoms of PD. In the case of HD, manic symptoms should be treated with the usual medications but often require smaller (one-third to one-half) doses. At times, ECT may be lifesaving. Treatment of mood disorders associated with epilepsy depends on whether the episode in question is ictal, peri-ictal, or interictal. When the mood disorder is ictal or peri-ictal, the focus of the treatment is the epileptic disorder with antiepileptic medications, and when it is interictal, the focus of the treatment is the depressive disorder with antidepressants. Drugs used to treat mood disorders, including for example, lithium or valproic acid may cause or exacerbate tremor. See **Table 154.2** for a list of neurologic adverse effects of common drugs used to treat mood disorders.

OUTCOME

Mood disorders are a major cause of disability and are highly associated with poor psychosocial functioning, mainly due to depressive episodes, which are much more common and longer lasting.

First-onset MDD typically peaks from ages 14 to 19 years, although first depressive episodes can appear at any age. If untreated, an episode lasts on average 6 to 9 months. Fifty percent to 70% of patients with major depression have recurrent episodes in their lifetimes. Young age, presence of a severe preceding episode,

TABLE 154.2 Neurologic Side Effects Associated With Drugs Used for Mood Disorders Treatment

Side Effect	Drug
Seizures	(All antidepressants and antipsychotics can potentially induce seizures.)
	Bupropion
	Maprotiline
	Amoxapine
	Imipramine
	Escitalopram
	Clozapine
	Selegiline
Tremor	Bupropion
	Lamotrigine
	SSRIs
	Antipsychotics (especially first generation)
	Phenelzine
	Trazodone
	Lithium
	Valproic acid
Akathisia	Aripiprazole and other antipsychotics
	SSRIs
Dyskinesia	Selegiline
Tardive dyskinesia	Antipsychotics
Cerebrovascular events	Increased risk with second-generation antipsychotics in elderly
Headaches	Trazodone
	Venlafaxine
Ataxia	Lamotrigine
	Nefazodone
Aseptic meningitis	Lamotrigine (rare)

Abbreviation: SSRIs, selective serotonin reuptake inhibitors.

persistence of even mild depressive symptoms, and a history of multiple episodes increase the likelihood of recurrence. Symptom profiles can often change from one episode to another. Around 12% to 20% of patients will present a chronic course. Risk factors for chronicity include a strong family history of depression, older age, longer duration of illness before treatment is sought, alcoholism, medical illness, disability of spouse, or multiple recent deaths of family members.

Bipolar disorder usually has an earlier age of onset than major depression. The first episode is more frequently depressive, with a peak incidence at age 17 years. Late-onset bipolar disorder is rare and is usually associated with organic disease. Mania typically ensues within 5 years of the first depressive episode.

In terms of the polarity of episodes, very few patients present only recurrent manic episodes with little or no depression. Rather, depressive episodes and symptoms tend to dominate the longitudinal course of bipolar disorder. Bipolar disorder can also vary in terms of the frequency of episodes. Almost all patients with bipolar disorder have recurrent episodes, and episodes are more frequent and numerous than in depressive disorders. In some cases, patients may experience four or more mood episodes in a year, termed *rapid cycling*. Once thought to be a characteristic of the patient, rapid cycling can occur and later resolve itself with a return to less frequent episodes.

Bipolar patients usually function well when medicated. Nevertheless, although many patients are able to resume normal activities within several weeks to months after recovery, approximately 40% of patients have significant social dysfunction for up to 2 years after an episode. Persistent cognitive deficits are documented as well. Neurobiologic deterioration from repeated episodes may play a role in this phenomenon.

Suicide is the most dreaded outcome of mood disorders. The suicide rate in bipolar illness is higher than in any other psychiatric illness, responsible for the death of 8% to 15% of patients, and patients with bipolar disorder carry a 15-fold greater risk of suicide than the general population. Risk is even greater in the case of comorbidity with substance abuse disorders. Specific interventions for suicidal behavior such as Safety Planning Intervention and Cognitive Therapy for Suicidal Behavior are potential options to address risk and mood stabilization and aggressive management of depression can be lifesaving.

LEVEL 1 EVIDENCE

1. Cuijpers P, Dekker J, Hollon SD, Andersson G. Adding psychotherapy to pharmacotherapy in the treatment of depressive disorders in adults: a meta-analysis. *J Clin Psychiatry*. 2009;70(9):1219.
2. Anderson IM. Selective serotonin reuptake inhibitors versus tricyclic antidepressants: a meta-analysis of efficacy and tolerability. *J Affect Disord*. 2000;58:19-36.
3. Papakostas GI, Thase ME, Fava M, Nelson JC, Shelton RC. Are antidepressant drugs that combine serotonergic and noradrenergic mechanisms of action more effective than the selective serotonin reuptake inhibitors in treating major depressive disorder? A meta-analysis of studies of newer agents. *Biol Psychiatry*. 2007;62:1217-1227.
4. Arroll B, Macgillivray S, Ogston S, et al. Efficacy and tolerability of tricyclic antidepressants and SSRIs compared with placebo for treatment of depression in primary care: a meta-analysis. *Ann Fam Med*. 2005;3:449-456.
5. Kasper S. Clinical efficacy of mirtazapine: a review of meta-analyses of pooled data. *Int Clin Psychopharmacol*. 1995; 10(suppl 4):25-35; correction, 1996;11:153.
6. Thase ME, Haight BR, Richard N, et al. Remission rates following antidepressant therapy with bupropion or selective serotonin reuptake inhibitors: a meta-analysis of original data from 7 randomized controlled trials. *J Clin Psychiatry*. 2005;66:974-981.
7. Papakostas GI, Montgomery SA, Thase ME, Katz JR, Krishen A, Tucker VL. Comparing the rapidity of response during treatment of major depressive disorder with bupropion and the SSRIs: a pooled survival analysis of 7 double-blind, randomized clinical trials. *J Clin Psychiatry*. 2007;68:1907-1912.
8. Hansen R, Gaynes B, Thieda P, et al. Meta-analysis of major depressive disorder relapse and recurrence with second-generation antidepressants. *Psychiatr Serv*. 2008;59:1121-1130.
9. Kupfer DJ, Frank E, Perel JM, et al. Five-year outcome for maintenance therapies in recurrent depression. *Arch Gen Psychiatry*. 1992;49:769-773.
10. Husain MM, Rush AJ, Fink M, et al. Speed of response and remission in major depressive disorder with acute electroconvulsive therapy (ECT): a Consortium for Research in ECT (CORE) report. *J Clin Psychiatry*. 2004;65:485-491.

11. Petrides G, Fink M, Husain MM, et al. ECT remission rates in psychotic versus nonpsychotic depressed patients: a report from CORE. J ECT. 2001;17:244-253.
12. Lam RW, Chan P, Wilkins-Ho M, Yatham LN. Repetitive transcranial magnetic stimulation for treatment-resistant depression: a systematic review and metaanalysis. *Can J Psychiatry*. 2008;53:621-631.
13. Severus E, Taylor M, Sauer C, Pfennig A, Bauer M, Geddes J. Efficacy of lithium in the long-term treatment of bipolar disorders: a new meta-analysis. *Bipolar Disord*. 2014;16:96.
14. Miura T, Noma H, Furukawa TA, et al. Comparative efficacy and tolerability of pharmacological treatments in the maintenance treatment of bipolar disorder: a systematic review and network meta-analysis. *Lancet Psychiatry*. 2014;1:351-359.
15. Calabrese JR, Huffman RF, White RL, et al. Lamotrigine in the acute treatment of bipolar depression: results of five double-blind, placebo-controlled clinical trials. *Bipolar Disord*. 2008;10:323-333.
16. Cipriani A, Reid K, Young AH, Macritchie K, Geddes J. Valproic acid, valproate and divalproex in the maintenance treatment of bipolar disorder. *Cochrane Database Syst Rev*. 2013;(10):CD003196.
17. Suppes T, Vieta E, Liu S, Brecher M, Paulsson B; and Trial 127 Investigators. Maintenance treatment for patients with bipolar I disorder: results from a North American study of quetiapine in combination with lithium or divalproex (Trial 127). *Am J Psychiatry*. 2009;166:476-488.
18. Ogawa Y, Tajika A, Takeshima N, Hayasaka Y, Furukawa T. Mood stabilizers and antipsychotics for acute mania: a systematic review and meta-analysis of combination/augmentation therapy versus monotherapy. *CNS Drugs*. 2014;28:989-1003.

SUGGESTED READINGS

Andreazza AC, Young LT. The neurobiology of bipolar disorder: identifying targets for specific agents and synergies for combination treatment. *Int J Neuropsychopharmacol*. 2014;17(7):1039-1052. doi:10.1017/S1461145713000096.

Aprahamian I, Nunes PV, Forlenza OV. Cognitive impairment and dementia in late-life bipolar disorder. *Curr Opin Psychiatry*. 2013;26(1):120-123.

Bauer M, Adli M, Ricken R, Severus E, Pilhatsch M. Role of lithium augmentation in the management of major depressive disorder. *CNS Drugs*. 2014;28(4):331-342.

Berent D, Zboralski K, Orzechowska A, Galecki P. Thyroid hormones association with depression severity and clinical outcome in patients with major depressive disorder. *Mol Biol Rep*. 2014;41(4):2419-2425.

Borgelt L, Strakowski SM, DelBello MP, et al. Neurophysiological effects of multiple mood episodes in bipolar disorder. *Bipolar Disord*. 2019;21(6):503-513.

Cardamone L, Salzberg MR, O'Brien TJ, Jones NC. Antidepressant therapy in epilepsy: can treating the comorbidities affect the underlying disorder? *Br J Pharmacol*. 2013;168(7):1531-1554.

Cipriani A, Hawton K, Stockton S, Geddes JR. Lithium in the prevention of suicide in mood disorders: updated systematic review and meta-analysis. *BMJ*. 2013;346:f3646.

Coplan J, Gugger JJ, Tasleem H. Tardive dyskinesia from atypical antipsychotic agents in patients with mood disorders in a clinical setting. *J Affect Disord*. 2013;150(3):868-871.

Ellard KK, Zimmerman JP, Kaur N, et al. Functional connectivity between anterior insula and key nodes of frontoparietal executive control and salience networks distinguish bipolar depression from unipolar depression and healthy control subjects. *Biol Psychiatry Cogn Neurosci Neuroimaging*. 2018;3(5):473-484.

Hasin DS, Sarvet AL, Meyers JL, et al. Epidemiology of adult *DSM-5* major depressive disorder and its specifiers in the United States. *JAMA Psychiatry*. 2018;75(4):336-346.

Heim C, Binder EB. Current research trends in early life stress and depression: review of human studies on sensitive periods, gene-environment interactions, and epigenetics. *Exp Neurol*. 2012;233(1):102-111.

Hellmann-Regen J, Piber D, Hinkelmann K, et al. Depressive syndromes in neurological disorders. *Eur Arch Psychiatry Clin Neurosci*. 2013;263(suppl 2):S123-S136.

Kessler RC, Petukhova M, Sampson NA, et al. Twelve-month and lifetime prevalence and lifetime morbid risk of anxiety and mood disorders in the United States. *Int J Methods Psychiatr Res*. 2012;21(3):169-184.

Kudlow PA, Cha DS, Lam RW, McIntyre RS. Sleep architecture variation: a mediator of metabolic disturbance in individuals with major depressive disorder. *Sleep Med*. 2013;14(10):943-949.

Kupfer DJ, Frank E, Phillips ML. Major depressive disorder: new clinical, neurobiological, and treatment perspectives. *Lancet*. 2012;379(9820):1045-1055.

Mann JJ. The serotonergic system in mood disorders and suicidal behaviour. *Philos Trans R Soc Lond B Biol Sci*. 2013;368(1615):20120537.

Marsh L. Depression and Parkinson's disease: current knowledge. *Curr Neurol Neurosci Rep*. 2013;13(12):409.

McGrath CL, Kelley ME, Holtzheimer PE, et al. Toward a neuroimaging treatment selection biomarker for major depressive disorder. *JAMA Psychiatry*. 2013;70(8):821-829.

Miller JM, Hesselgrave N, Ogden RT, et al. Brain serotonin 1A receptor binding as a predictor of treatment outcome in major depressive disorder. *Biol Psychiatry*. 2013;74(10):760-767.

Oquendo MA, Ellis SP, Chesin MS, et al. Familial transmission of parental mood disorders: unipolar and bipolar disorders in offspring. *Bipolar Disord*. 2013;15(7):764-773.

Perera TD, Thirumangalakudi L, Glennon E, et al. Role of hippocampal neurogenesis in mnemonic segregation: implications for human mood disorders. *World J Biol Psychiatry*. 2013;14(8):602-610.

Perlis RH, Dennehy EB, Miklowitz DJ, et al. Retrospective age at onset of bipolar disorder and outcome during two-year follow-up: results from the STEP-BD study. *Bipolar Disord*. 2009;11(4):391-400.

Proudfoot J, Whitton A, Parker G, Doran J, Manicavasagar V, Delmas K. Triggers of mania and depression in young adults with bipolar disorder. *J Affect Disord*. 2012;143(1-3):196-202.

Ratheesh A, Davey C, Hetrick S, et al. A systematic review and meta-analysis of prospective transition from major depression to bipolar disorder. *Acta Psychiatr Scand*. 2017;135(4):273-284.

Rist PM, Schürks M, Buring JE, Kurth T. Migraine, headache, and the risk of depression: prospective cohort study. *Cephalalgia*. 2013;33(12):1017-1025.

Robillard R, Naismith SL, Hickie IB. Recent advances in sleep-wake cycle and biological rhythms in bipolar disorder. *Curr Psychiatry Rep*. 2013;15(10):402.

Rosenblat JD, Cha DS, Mansur RB, McIntyre RS. Inflamed moods: a review of the interactions between inflammation and mood disorders. *Prog Neuropsychopharmacol Biol Psychiatry*. 2014;53:23-34.

Sagna A, Gallo JJ, Pontone GM. Systematic review of factors associated with depression and anxiety disorders among older adults with Parkinson's disease. *Parkinsonism Relat Disord*. 2014;20(7):708-715.

Salvadore G, Quiroz JA, Machado-Vieira R, Henter ID, Manji HK, Zarate CA Jr. The neurobiology of the switch process in bipolar disorder: a review. *J Clin Psychiatry*. 2010;71(11):1488-1501.

Sanacora G, Banasr M. From pathophysiology to novel antidepressant drugs: glial contributions to the pathology and treatment of mood disorders. *Biol Psychiatry*. 2013;73(12):1172-1179.

Sanacora G, Treccani G, Popoli M. Towards a glutamate hypothesis of depression: an emerging frontier of neuropsychopharmacology for mood disorders. *Neuropharmacology*. 2012;62(1):63-77.

Strakowski SM, Adler CM, Almeida J, et al. The functional neuroanatomy of bipolar disorder: a consensus model. *Bipolar Disord*. 2012;14(4):313-325.

Vázquez GH, Tondo L, Undurraga J, Baldessarini RJ. Overview of antidepressant treatment of bipolar depression. *Int J Neuropsychopharmacol*. 2013;16(7):1673-1685.

Verdelho A, Madureira S, Moleiro C, et al; for LADIS Study. Depressive symptoms predict cognitive decline and dementia in older people independently of cerebral white matter changes: the LADIS study. *J Neurol Neurosurg Psychiatry*. 2013;84(11):1250-1254.

Vieta E, Popovic D, Rosa AR, et al. The clinical implications of cognitive impairment and allostatic load in bipolar disorder. *Eur Psychiatry*. 2013;28(1):21-29.

Vilalta-Franch J, López-Pousa S, Llinàs-Reglà J, et al. Depression subtypes and 5-year risk of dementia and Alzheimer disease in patients aged 70 years. *Int J Geriatr Psychiatry*. 2013;28(4):341-350.

Wu KY, Chang CM, Liang HY, et al. Increased risk of developing dementia in patients with bipolar disorder: a nested matched case-control study. *Bipolar Disord*. 2013;15(7):787-794.

Zahodne LB, Marsiske M, Okun MS, Bowers D. Components of depression in Parkinson disease. *J Geriatr Psychiatry Neurol*. 2012;25(3):131-137.

155 Anxiety Disorders, Posttraumatic Stress Disorder, and Obsessive-Compulsive Disorder

Franklin R. Schneier

KEY POINTS

1. Anxiety disorder features take the form of fearful thoughts, physical symptoms of anxiety, and phobic avoidance behaviors.
2. Within neurologic disorders, comorbid anxiety disorders are associated with greater distress and impairment in functioning.
3. Posttraumatic stress disorder commonly co-occurs with traumatic brain injuries.
4. Obsessive-compulsive disorder commonly co-occurs with tic disorders.
5. The best established treatments for anxiety disorders, posttraumatic stress disorder, and obsessive-compulsive disorder are cognitive behavioral therapies and serotonin reuptake inhibitor medications.

INTRODUCTION

Anxiety is an adaptive emotional state related to anticipation of threat; it can encompass fearful thoughts, symptoms of physiologic arousal, and preparation for fight or flight. *Anxiety disorders* are characteristic syndromes of maladaptation to various types of anticipated threat. Examples include dangers from predators, interpersonal conflicts, germs, and other hazards. Anxiety disorders are distinguished from mild episodes of anxiety by their persistence and intensity and also by the diagnostic requirement that they cause marked distress or impairment in functioning.

Anxiety disorders have historically included panic disorder, agoraphobia, specific phobias, social anxiety disorder, generalized anxiety disorder, obsessive-compulsive disorder (OCD), acute stress disorder, and posttraumatic stress disorder (PTSD). The *Diagnostic and Statistical Manual of Mental Disorders* (5th edition, *DSM-5*), places OCD in a separate category of obsessive-compulsive and related disorders and PTSD in a separate category of trauma- and stressor-related disorders, in recognition of their unique features. Two disorders previously categorized as childhood disorders, separation anxiety disorder and selective mutism, are now also recognized as anxiety disorders that can persist into adulthood.

Anxiety and anxiety disorders may co-occur with neurologic disease through a variety of mechanisms. Neurologic disease processes may cause anxiety symptoms directly by dysregulating function of brain circuits that subserve anxiety. Alternatively, primary neurologic illnesses may lead to anxiety via psychological mechanisms as when visible signs of a movement disorder lead to embarrassment and social anxiety or when an uncertain or poor prognosis leads to anticipatory anxiety. A primary anxiety disorder or its treatment may generate neurologic manifestations, such as syncope secondary to hyperventilation in panic disorder, or a seizure due to abrupt discontinuation of a benzodiazepine. Neurologic and psychiatric conditions may also co-occur secondary to another causal agent as when combat trauma leads to both traumatic brain injury (TBI) and PTSD.

EPIDEMIOLOGY

The broad category of anxiety disorders constitutes the most common type of psychiatric disorder with a lifetime prevalence of over 25%. Anxiety disorders are more common in women by a 2:1 ratio, have an age of onset before 30 years in most cases, and tend to be chronic. Community prevalence rates for individual anxiety disorders range from 5% to 12% for social anxiety disorder and specific phobias to 1% to 2% for panic disorder and OCD, with intermediate rates for PTSD and generalized anxiety disorder.

PATHOBIOLOGY

The neural circuits, neurochemistry, and behaviors mediating human anxiety share features with neural systems that mediate withdrawal responses to aversive stimuli across species. In humans, these responses incorporate higher cortical functions such as anxious anticipation and adaptations based on life experiences and culture. Twin studies show heritability of specific anxiety disorders in the range of 10% to 60%, but findings for individual genes explain only very small proportions of the overall risk. Environmental risk factors for anxiety disorders include early childhood trauma and acute stressors, such as interpersonal loss.

Studies in rodents and humans have implicated dysregulation of central nervous system fear circuitry, including the amygdala, hippocampus, and prefrontal cortex, in the development and maintenance of conditioned fear; this circuitry is activated when persons with social anxiety disorder, specific phobias, or PTSD are exposed to fear-inducing stimuli. Related processes include fear memory consolidation, generalization, and extinction. PTSD has been associated with dysfunction across salience, executive, and default mode networks (Fig. 155.1). Anxiety disorders also have been shown to be associated with a proinflammatory milieu and with dysfunction of several neurotransmitter systems, including serotonin, norepinephrine, γ-aminobutyric acid, and

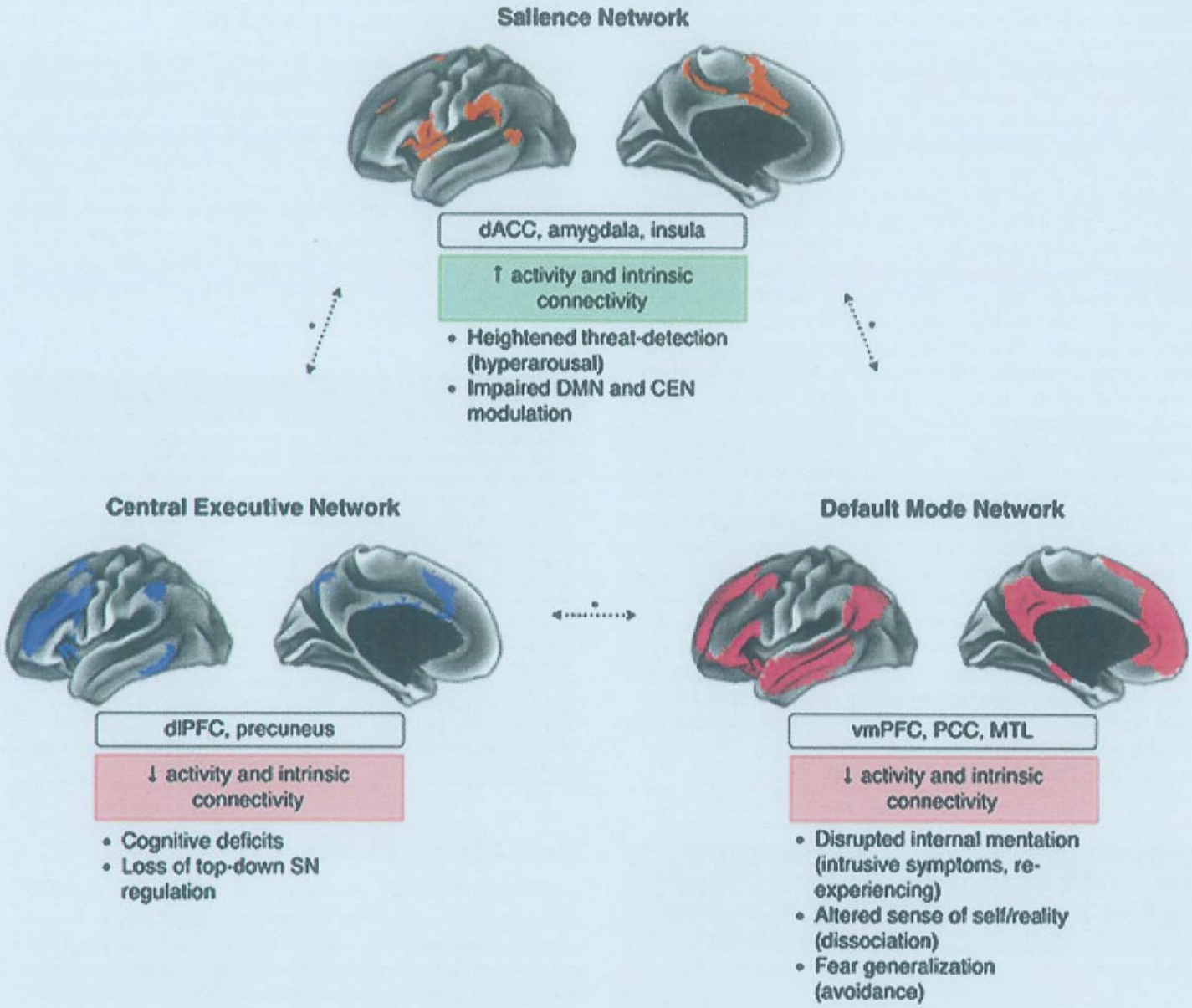

FIGURE 155.1 Network-based neurobiologic model of posttraumatic stress disorder. The figure shows the cortical representations of the salience network (SN; *orange*), default mode network (DMN; *red*), and central executive network (CEN; *blue*) in healthy individuals; notable region of interests within these networks; the changes in posttraumatic stress disorder predicted by the model; and the putative resulting phenotypic abnormalities. Abbreviations: dACC, dorsal anterior cingulate cortex; dlPFC, dorsolateral prefrontal cortex; MTL, medial temporal lobe; PCC, posterior cingulate cortex; vmPFC, ventromedial prefrontal cortex. The *asterisk* denotes altered between-network connectivity. (From Akiki TJ, Averill CL, Abdallah CG. A network-based neurobiological model of PTSD: evidence from structural and functional neuroimaging studies. *Curr Psychiatry Rep.* 2017;19:81.)

glutamate. Dopamine dysfunction has also been reported, and elevated rates of panic disorder, generalized anxiety disorder, and social anxiety disorder have been reported in Parkinson disease. Sympathetic nervous system and hypothalamic-pituitary axis abnormalities have been found across anxiety disorders. Panic disorder has been associated with hyperventilation, hypocapnia, and disordered carbon dioxide regulation.

The pathobiology of OCD shows some differences from other anxiety disorders. Anatomic and brain imaging evidence suggest hyperactivity in a circuit involving the orbitofrontal cortex, basal ganglia, and thalamus. Acquired lesions in the cortico-striato-thalamic circuit, parietal and temporal cortex, cerebellum, and brainstem have been reported to induce compulsivity. OCD has been associated with other neurologic conditions involving the basal ganglia, such as Tourette syndrome, Huntington disease, and Sydenham chorea.

DIAGNOSIS

Clinical Features Across Anxiety Disorders

Anxiety disorder patients may present with anxiety, avoidance, physical symptoms, secondary depression, or substance abuse. Complaints of anxiety should be assessed with respect to symptoms and cognitions, frequency and intensity, environmental

precipitants, avoidance, and interference with functioning. Some anxiety disorder features can occur across these disorders. *Anticipatory anxiety* refers to apprehension in anticipation of a feared situation and may include worry, difficulty concentrating, or physical symptoms. Anxiety disorders are often marked by a failure of the habituation that normally occurs during continuing exposure to a feared situation. A *panic attack* is defined by intense fear that reaches a peak in minutes and includes a group of physical anxiety symptoms, often with feelings of unreality, dizziness, paresthesias, dyspnea, and fear of dying. *Phobic avoidance* involves excessive avoidance of circumscribed feared situations, and it is often the most directly disabling of anxiety disorder features.

Anxiety often leads to symptoms of depression, so anxious patients should be evaluated for depressed mood, loss of pleasure, change in weight, sleep disturbance, fatigue, poor concentration, and suicidal ideation. Substance abuse is also common in anxiety disorder patients and may be either a precipitant of anxiety or a response to it. People with anxiety disorders are usually aware that the symptoms are related to an excessive or unrealistic reaction on their part, and in this way, they differ from patients with psychotic disorders with delusional fears.

Anxiety disorders may interact with other medical conditions so that patients with asthma may also experience dyspnea related to panic attacks, and individuals with disorders that attract unwanted attention (eg, essential tremor) may be impaired by excessive fear of embarrassment as in social anxiety disorder. Medical conditions that can directly mimic anxiety symptoms include hyperthyroidism; hyperparathyroidism; cardiac arrhythmias; reactions to caffeine, cocaine, or marijuana; pheochromocytoma; and vestibular dysfunction.

See **Table 155.1** for key diagnostic features.

TABLE 155.1 Key Diagnostic Features of Anxiety Disorders

Diagnosis	Key Diagnostic Features
Panic disorder	Recurrent unexpected panic attacks
Agoraphobia	Avoidance of situations where escape might be difficult in the event of experiencing panic-like symptoms
Social anxiety disorder	Persistent and excessive fears of negative evaluation in social or performance situations
PTSD and acute stress disorder	After a traumatic event, persistent intrusive thoughts, avoidance of reminders, dysphoria, and hyperarousal
Obsessive-compulsive disorder	Obsessive thoughts and repetitive compulsive behaviors
Generalized anxiety disorder	Excessive anxiety and worry about multiple issues
Specific phobia	Persistent and excessive fear of a specific object or situation
Separation anxiety disorder	Persistent and excessive fear of separation from an attachment figure
Selective mutism	Persistent failure to speak in specific social situations (eg, school); usually seen in young children

Abbreviation: PTSD, posttraumatic stress disorder.

Panic Disorder and Agoraphobia

The essential feature of panic disorder, as described in *DSM-5*, is recurrent unexpected panic attacks followed by persistent concerns or significant changes in behavior related to fear of another attack. Patients with panic disorder are often first seen medically because of fears that they are having a heart attack or stroke. Panic attacks may become cued by specific situations most commonly involving situations in which the person anticipates difficulty escaping or getting help in the event of an attack, such as traveling away from home, being in a crowd, or being alone. When people fear and avoid such situations, the diagnosis of agoraphobia is made.

Panic Disorder Case Example

A 23-year-old woman presented to the emergency department complaining of 1-hour duration of light-headedness, weak legs, difficulty breathing, tingling sensations in her hands, and fear that she was having a stroke. Symptoms came on suddenly with no specific trigger, although she was feeling stressed after having had an argument with her boyfriend yesterday. Medical and neurologic evaluation was unremarkable. The patient was told that her symptoms were due to anxiety, and they subsequently resolved over a couple of hours. However, the patient developed daily recurrences of attacks over the next week, with fear that the symptoms would be persistent and disabling, even if they were not life-threatening. She called in sick to work and asked a family member to stay with her. Following 8 weeks of treatment with a selective serotonin reuptake inhibitor (SSRI) medication and cognitive behavioral therapy (CBT), her panic attacks remitted, although she continued to experience occasional brief surges of mild anxiety.

Social Anxiety Disorder (Social Phobia)

Social anxiety disorder, also known as *social phobia*, is characterized by an excessive fear of social situations due to fears of negative evaluation. The person may avoid social or performance situations or endure them with great distress. Physical symptoms, such as sweating, tremor, and blushing, may be present, but they are not necessary for the diagnosis as per *DSM-5*. The scope of feared situations may encompass most situations and appear similar to extreme shyness or may be limited to performance situations, such as public speaking. Social anxiety disorder is distinguished from normal shyness by its greater persistence and severity and its associated distress or impairment. Persons with social anxiety disorder often have difficulty participating in classroom settings or work meetings, dating, or engaging in social gatherings.

Posttraumatic Stress Disorder and Acute Stress Disorder

Stress disorders occur in persons exposed to a traumatic event in which the person experienced, witnessed, or was confronted with actual or threatened death, serious injury, or sexual violence to self or others. PTSD features according to *DSM-5* include more than 1 month of (1) intrusive memories, dreams, or flashbacks or intense psychological and physiologic distress at exposure to reminders of the trauma; (2) avoidance of stimuli associated with the trauma; (3) alterations in cognition or mood, such as self-blame or inability to experience positive emotions; and (4) symptoms of increased arousal, such as hypervigilance,

insomnia, poor concentration, irritability, or reckless behavior. Acute stress disorder is diagnosed when a similar syndrome is present in the month after trauma exposure, and it may progress to PTSD. Only a minority of serious traumatic events, however, result in development of PTSD. Trauma-related disorders are more likely to occur following stressors of an interpersonal nature (eg, physical or sexual assault) relative to noninterpersonal trauma (motor vehicle accident or natural disaster), and after repeated stressors.

PTSD Case Example

A 26-year-old woman army veteran was referred to treatment by her family after they observed that since return from deployment she seemed detached and unmotivated to pursue work or social activities. During her initial evaluation, she reported intrusive recollections of a sexual assault that had occurred 1 year ago during her service but that she had never reported or discussed with anyone. She had continued to function well until leaving the military, at which time she began to feel detached from her friends and family, and fearful in situations around unfamiliar men. She startled easily to noises and slept poorly. She felt "damaged" and saw no future for herself, but she did not have any active suicidal ideation. She began trauma-focused CBT, in which she recounted details of her trauma, and discussed its meanings for how she viewed herself and the safety of social situations. She experienced high anxiety during the first several therapy sessions but soon reported diminished symptoms, and she gradually was able to resume social activities and pursue employment.

Obsessive-Compulsive Disorder

OCD is defined in *DSM-5* by recurrent obsessions or compulsions that are time-consuming (more than 1 h/d) or cause significant distress and impairment. Obsessions are recurrent and persistent thoughts, urges, or images that are experienced as intrusive and unwanted and cause marked anxiety or distress. The individual attempts to ignore or suppress the obsessions or to neutralize them with some other thought or action. Insight into the truth of obsessive beliefs may vary. Compulsions are repetitive behaviors, such as washing or checking, or mental acts, such as counting, that an individual feels driven to perform in response to an obsession or according to rigid rules. The individual may have ideas that the behaviors prevent distress or that they somehow prevent a dreaded event (eg, death of a loved one). However, these behaviors are not realistically connected with what they are intended to prevent, or they are clearly excessive. Up to 30% of individuals with OCD have a lifetime tic disorder, and in such cases, the diagnosis should be specified as *tic related*.

Generalized Anxiety Disorder

Generalized anxiety disorder is characterized, according to *DSM-5*, by excessive anxiety and worry about a number of events or activities occurring more days than not for at least 6 months. The individual finds it difficult to control the worry, which is associated with three or more of (1) restlessness or feeling keyed up, (2) fatigue, (3) difficulty concentrating, (4) irritability, (5) muscle tension, and (6) sleep disturbance. Generalized anxiety disorder is highly comorbid with depression.

Specific Phobias

Persons with a specific phobia exhibit persistent fear of a specific object or situation, exposure to which evokes a fear response out of proportion to the actual danger. As specified in *DSM-5*, common types are the following: animal (eg, spiders or dogs), natural environment (eg, storms, heights), situational (eg, airplanes, enclosed places), and blood-injection-injury (eg, needles, dentist). A vasovagal response has been specifically associated with blood-injection-injury phobia.

Separation Anxiety Disorder

Separation anxiety disorder is characterized in *DSM-5* by an excessive fear of separation from an attachment figure as evidenced by at least three of the following: excessive distress related to separation, excessive worry about harm to an attachment figure, excessive worry about an untoward event that results in separation, reluctance to go out (eg, to work), reluctance to be alone, reluctance to sleep away from an attachment figure, nightmares about separation, and physical symptoms when separated. Adults often worry about a significant other or a child.

Selective Mutism

Selective mutism is generally diagnosed in young children but may persist into adulthood. As described in *DSM-5*, the diagnosis is based on observation that an individual manifests a persistent failure to speak in specific social situations (eg, school) despite speaking in other situations. The behavior interferes with functioning and is not due to a lack of knowledge of the spoken language or a communication disorder (eg, childhood-onset fluency disorder). A child with selective mutism may be unable to offer an explanation for his or her silence, although high levels of social anxiety often appear to be associated with this reticent behavior.

Anxiety and Neurologic Disease: Comorbidity and Differential Diagnosis

Anxiety disorder symptoms can overlap greatly with symptoms of a variety of neurologic disorders, including movement disorders, epilepsy, or cerebrovascular disease. For example, tremor is a common manifestation of anxiety, and it is particularly common in performance situations for individuals with social anxiety disorder. Light-headedness, occasionally even leading to syncope, is common during panic attacks. Panic-related light-headedness is usually of short duration and accompanied by dyspnea, hyperventilation, and intense fear. Paresthesias, tinnitus, vertigo, impaired concentration, derealization, and depersonalization may also occur during panic attacks or other periods of high anxiety. Importantly, the presence of psychopathology does not rule out the presence of concurrent neurologic disorder, and symptoms of a primary neurologic disorder, such as tremor or vertigo, may be exacerbated by situational anxiety. When a comorbid anxiety disorder complicates a neurologic disorder, treatments targeted at each condition may be necessary.

PTSD in veterans has been associated with neurologic and cognitive problems, as in Gulf War illness. Mild TBI in civilians was associated with an approximately twofold increased risk of PTSD 3 to 6 months later compared to a group with nonhead injuries. When a TBI co-occurs, PTSD symptoms may overlap TBI-related neurocognitive symptoms.

Obsessive-compulsive symptoms have been specifically associated with several neurologic disorders sharing dysfunction of frontostriatal circuitry, including Huntington disease, Sydenham chorea, and Gilles de la Tourette syndrome. OCD shares genetic heritability with Tourette syndrome. In patients with

Huntington disease, obsessive-compulsive symptoms, particularly obsessive checking, pathologic impulses, and compulsive rituals, have been reported in 15% to 50% of cases. OCD symptoms are also elevated in persons with the genetic mutation for Huntington but who have not yet met criteria for the diagnosis.

Tics have a compulsive quality, and like compulsions, if resisted, they result in internal tension that is relieved by performance of the behavior. The compulsions of OCD, however, are often accompanied by a complex thought process (eg, need to relieve a sense of contamination) that seems to motivate the compulsive behavior. Compulsions that are present in patients with Tourette syndrome tend to be related to symmetry, counting, or "just right" thoughts and less likely to relate to fears of contamination or harm to others. Pediatric autoimmune neuropsychiatric disorders associated with streptococcal infections and more recently the broader category of pediatric acute neuropsychiatric syndrome are controversial variants of childhood-onset OCD and neurologic disorders such as tics disorders, in which both conditions may be associated with the development of an immune response against group A β-hemolytic *Streptococcus*, or other triggers.

In epilepsy, and particularly refractory focal epilepsy, there is an increased rate of anxiety disorders, impacting quality of life. Interictal anxiety symptoms may include anticipatory anxiety about having a seizure, phobic avoidance of situations in which seizures have occurred, and fears of being seen by others during a seizure. Panic disorder symptoms are the anxiety symptoms most likely to be generated directly by a seizure and may be challenging to distinguish from primary panic attacks. Patients with primary panic attacks are less likely than seizure patients to experience automatisms, impaired consciousness, or déjà vu experiences and more likely to have accompanying phobias, depression, and anticipatory anxiety.

Dementia is accompanied by rates of anxiety as high as 75%, often in the form of generalized anxiety disorder symptoms. Rates of anxiety symptoms may be particularly greater in vascular dementia and frontotemporal dementia. The presence of anxiety in dementia is associated with a variety of worse outcomes, including more impairment in quality of life, activities of daily living, nighttime awakenings, and neuropsychological performance. Additionally, PTSD has been associated with increased risk for dementia.

Males with the genetic syndrome fragile X commonly experience symptoms of multiple anxiety disorders, particularly social anxiety symptoms of poor eye contact and excessive shyness. They also have elevated rates of separation anxiety, panic attacks, and agoraphobia. Compulsive behaviors are present in most patients, but these often involve pleasurable activities rather than the unwanted compulsions characteristic of OCD.

In patients with multiple sclerosis, anxiety disorders occur at three times the rate of the general population. Generalized anxiety disorder, OCD, panic disorder, and social anxiety disorder have been found to be elevated in some studies. Anxiety is associated with confirmed exacerbations and pseudoexacerbations of multiple sclerosis and with greater impairment and lower quality of life, although it has not been specifically linked to progression of brain lesions.

Anxiety symptoms are common during a stroke, and in the first year poststroke the prevalence of anxiety disorders is greater than 25%, with anxiety often related to fear of stroke recurrence.

Neurologic symptoms that attract unwanted attention, such as tremor or dystonia, may result in elevated fears of embarrassment. For some patients, the social anxiety may lead to avoidance and greater impairment than that of the underlying disorder. When social anxiety is out of proportion to the severity of the underlying condition, diagnosis and treatment of social anxiety disorder may be warranted.

MANAGEMENT

General Approaches to Anxiety Disorders

Psychological and pharmacologic treatments (Table 155.2) have well-established efficacy for anxiety disorders. The two best established first-line treatments for most of the anxiety disorders are CBT and SSRI medications, based on dozens of controlled trials in specific anxiety disorders. Other psychotherapies, such as short-term psychodynamic therapies, and other medications, such as benzodiazepines, have been demonstrated efficacious in certain anxiety disorders. This section describes the general features of CBT and classes of medication used for anxiety disorders as well as their unique adaptations for specific anxiety disorders.

CBTs for anxiety disorders are short-term psychotherapies based on the observation that patients manifest cognitive distortions (irrational negative thoughts) that maintain anxiety and avoidance behaviors, and that deny them opportunities to disprove those fears or to experience habituation of anxiety symptoms. Components of this therapy may include cognitive restructuring, exposure, and relaxation techniques. Typically, an active therapist helps the patient identify his or her cognitive distortions and avoidance behaviors and introduces alternative approaches for coping with feared situations. Therapist and patient collaborate to conduct exposures to the feared situations in the presence of the therapist and through homework assignments. As the patient uses new coping skills to manage the anxiety induced by the exposure without resorting to avoidance or rituals, new learning takes place and the habitual cycle of fear and avoidance recedes. A far smaller body of evidence exists for efficacy of other psychotherapy approaches to anxiety, including psychodynamic therapy. Disorder-specific features of CBT and other psychotherapies are discussed in the following text under specific anxiety disorder sections.

SSRIs and serotonin-norepinephrine reuptake inhibitors (SNRIs) have emerged as first-line treatments for each of the anxiety disorders (with the exception of specific phobias) based on efficacy and acceptability. No single SSRI has been shown to be superior to others, although individuals often have different responses to different agents. Dosages are similar to those recommended for treatment of depression. Responses typically become apparent after 2 to 4 weeks of treatment, but an adequate acute trial may require 8 to 12 weeks of treatment, and nonresponders should have the dosage gradually increased to the maximum as tolerated. Common side effects include nausea, insomnia, fatigue, weight gain, and sexual dysfunction. Treatment guidelines tend to recommend that responders to an acute trial of medication be maintained on the effective dose for 6 to 12 months, and when medication is discontinued, it should be tapered to minimize risk of withdrawal symptoms and relapse.

Medication is commonly combined with CBT, although evidence for additive efficacy is limited. Other medications, including some classified as benzodiazepines, tricyclic antidepressants, monoamine oxidase inhibitors, anticonvulsants, and antipsychotics, have also been shown to be effective for some of the anxiety disorders. These are discussed where relevant in the following text under specific anxiety disorder sections.

TABLE 155.2 Medications Used in the Treatment of Anxiety Disorders

Medication	Initial Dose (mg/d)	Target Dose (mg/d)	Indication LEVEL 1
Selective Serotonin Reuptake Inhibitors			
Sertraline	50[a]	50-200	OCD,[1] PD,[2] SAD,[3] PTSD,[4] GAD[5]
Paroxetine	10[a]	10-60	OCD,[1] PD,[2] SAD,[3] PTSD,[4] GAD[6]
Paroxetine CR	12.5[a]	12.5-75	SAD[3]
Citalopram	10[a]	20-40	PD,[2] OCD[1]
Escitalopram	5[a]	5-20	GAD[6]
Fluvoxamine	50[a]	50-300	OCD,[1] PD,[2] SAD[3]
Fluoxetine	20	20-80	OCD,[1] SAD,[3] PTSD[4]
Serotonin-Norepinephrine Reuptake Inhibitors			
Venlafaxine XR	75[a]	75-375	SAD,[3] PD,[2] PTSD,[4] GAD[6]
Duloxetine	30[a]	30-60	GAD[6]
Other Antidepressants			
Nefazodone	200	200-600	PTSD[4]
Mirtazapine	15	30-60	SAD,[3] PD[2]
Clomipramine	25	50-250	OCD,[7] PD[8]
Imipramine	25	50-300	PD[9]
Phenelzine	15	30-90	SAD[3]
Benzodiazepines			
Clonazepam	0.25	0.5-4	SAD,[3] PD[10]
Alprazolam	0.25	0.5-6	PD,[10] GAD[11]
Lorazepam	0.5	1-2	GAD[11]
Diazepam	5	20	GAD[11]
Other Classes			
Buspirone	10	30-60	GAD[12]
Hydroxyzine	25	50	GAD[6]
Gabapentin	600	900-3,600	SAD[3]
Pregabalin	300	600	SAD,[3] GAD[6]
Prazosin	1	2-6	PTSD[13]
Risperidone	0.5	0.5-6	PTSD[4]
Quetiapine ER	50	50-300	GAD[14]

Abbreviations: CR, controlled release; ER, extended release; GAD, generalized anxiety disorder; OCD, obsessive-compulsive disorder; PD, panic disorder; PTSD, posttraumatic stress disorder; SAD, social anxiety disorder; XR, extended release.
[a]For PD, antidepressants are commonly initiated at half the usual initial dose.

Panic Disorder and Agoraphobia

CBT for panic and agoraphobia has been shown efficacious in multiple randomized controlled trials (RCTs) LEVEL 1.[15] It helps patients decatastrophize their beliefs about physical symptoms through cognitive restructuring and interoceptive exposure, which involves purposefully inducing feared physical symptoms (eg, by exercise or hyperventilation). Patients with agoraphobia purposefully approach their feared situations. Among pharmacologic treatments for panic disorder, SSRIs LEVEL 1[2] and SNRIs LEVEL 1[2] are first-line treatments. Benzodiazepines LEVEL 1,[10] the antidepressant mirtazapine LEVEL 1,[2] and the older class of tricyclics (eg, imipramine) LEVEL 1[9] and clomipramine LEVEL 1[8] have also been shown to be efficacious. Antidepressants are typically started at half of the usual starting dose because some panic disorder patients will report excessive stimulation with initial dosing. Benzodiazepines are often prescribed on an as-needed basis for intermittent anxiety, but for panic disorder and social anxiety disorder (see the following section), they are most effectively used with standing doses. Alprazolam and clonazepam are the benzodiazepines that have been best studied in panic disorder. Benzodiazepines have rapid onset of effect and a relatively low rate of side effects other than sedation. They are sometimes used in combination with SSRIs. Disadvantages include potential for abuse, cognitive and motor impairment, risk of severe withdrawal symptoms if discontinued abruptly, and lack of efficacy for comorbid depressive symptoms.

Social Anxiety Disorder

CBT LEVEL 1[15] is effective in either individual or group formats, incorporating role-playing techniques to practice exposure to feared social scenarios. SSRIs and the SNRI venlafaxine are first-line treatments based on numerous RCTs LEVEL 1.[3] A smaller number of RCTs support use of the benzodiazepine clonazepam; the antidepressant

mirtazapine, gabapentin, and pregabalin, which act at calcium channels; and the older antidepressant class of monoamine oxidase inhibitors (eg, phenelzine) LEVEL 2.[3] β-Adrenergic blockers (eg, propranolol), taken on an as-needed basis, are commonly used for anxiety that is limited to predictable performance situations.

Posttraumatic Stress Disorder and Acute Stress Disorder

Efficacy of CBT for acute stress disorder and PTSD has been established by more than two-dozen controlled trials LEVEL 2.[15] Goals of psychotherapy for acute stress disorder are to reestablish a sense of safety, build a therapeutic alliance, provide information, and allow ventilation of emotion only after the perceived threat ends. Treatment of PTSD involves education about the normal course of stress response, relaxation techniques, cognitive therapy to address pathogenic beliefs, and exposure to trauma-related stimuli through imaginal techniques, such as reviewing a script of the trauma, and through in vivo exposure.

Pharmacologic treatments for PTSD are used primarily as an adjunct to psychotherapy. The SSRIs paroxetine, fluoxetine, and sertraline and the SNRI venlafaxine, each have a few RCTs supporting efficacy LEVEL 2.[4] Benzodiazepines, however, have not been shown to be effective. Single controlled trials have supported efficacy for the serotonergic antidepressant nefazodone LEVEL 2.[4] The α_1-antagonist prazosin has appeared efficacious in small trials, with specific benefit for nightmares LEVEL 2,[13] but a large trial in veterans failed to replicate these effects. Two very small RCTs have suggested efficacy for the atypical antipsychotic risperidone LEVEL 2.[4] Several RCTs suggest that transcranial magnetic stimulation may also be effective for PTSD LEVEL 2.[16]

Obsessive-Compulsive Disorder

Exposure and response prevention is the most effective treatment of OCD based on many controlled trials including comparisons to medication treatment LEVEL 2.[15] This CBT involves systematically exposing a patient to feared situations and preventing ritualizing (eg, touching dirt without washing, leaving home without checking the lock). Clinical trials report high response rates in patients who participate in this therapy.

SSRIs LEVEL 2[1] and the serotonergic tricyclic antidepressant clomipramine LEVEL 2[7] are the only established pharmacologic monotherapies for OCD. Patients may require maximal dosage and a 12-week trial to assess efficacy, and most patients achieve only partial benefit from these medications. The only pharmacologic augmentation strategy shown to be effective for partial responders to SSRIs, on the basis of several small RCTs, is the use of antipsychotic agents, such as haloperidol or risperidone LEVEL 2.[5] One small RCT has suggested efficacy for transcranial magnetic stimulation of the medial prefrontal and anterior cingulate cortices in treatment-refractory patients LEVEL 2.[6] Other small RCTs have suggested efficacy for deep brain stimulation to the ventral capsule/ventral striatum or the anteromedial subthalamic nucleus in treatment-refractory patients LEVEL 2.[12] Refractory OCD has also occasionally been treated neurosurgically by anterior cingulotomy, subcaudate tractotomy, or anterior capsulotomy.

Generalized Anxiety Disorder

CBT for generalized anxiety disorder has established efficacy LEVEL 2[15] and often incorporates self-monitoring of symptoms and their triggers, and relaxation techniques. In addition to SSRIs and SNRIs, which have established efficacy in multiple RCTs LEVEL 2,[11] other drugs with evidence for efficacy from RCTs include pregabalin LEVEL 2,[11] the serotonin 1A receptor agonist–antagonist buspirone LEVEL 2,[14] and antihistamines (eg, hydroxyzine) LEVEL 2.[11] Although benzodiazepines were once a mainstay for generalized anxiety, recent studies have questioned the quality of the early trials in generalized anxiety disorder that established efficacy of these medications LEVEL 2.[17] The antipsychotic quetiapine has appeared efficacious in several controlled trials but carries a risk of serious adverse effects, such as tardive dyskinesia LEVEL 2.[18] Several small RCTs have also suggested at least short-term efficacy of transcranial magnetic stimulation to the right dorsolateral prefrontal cortex or right parietal cortex LEVEL 2.[19]

Specific Phobias

Desensitization by exposure is the preferred treatment for specific phobias, and it is highly effective. Medications have received little study, but benzodiazepines, taken as needed, are useful for feared situations that are encountered only occasionally.

Separation Anxiety Disorder and Selective Mutism

There have been no controlled studies of treatment of either of these disorders in adults. Controlled trials in children suggest that both SSRIs and CBT are beneficial for separation anxiety disorder. Studies of selective mutism similarly suggest a role for SSRIs and CBT.

Treatment of Anxiety Disorders Comorbid With Neurologic Disorders

Although there is little data to guide approaches to these patients, existing studies suggest that standard treatments for the comorbid anxiety disorder can be effective in reducing anxiety symptoms and impairment. For example, CBT has been shown to reduce anxiety symptoms and social adjustment in epilepsy patients with mixed psychiatric problems even in the absence of reduction in seizure frequency. γ-Aminobutyric acid–ergic anticonvulsants such as benzodiazepines and pregabalin often benefit comorbid anxiety, and SSRIs can be used with only small effects on seizure threshold. In dementia, psychosocial interventions are preferred for anxiety because benzodiazepines and antipsychotics carry increased risks for the elderly and cognitively impaired. In Tourette syndrome, CBT and SSRIs, sometimes augmented with antipsychotics, should be considered for patients with comorbid OCD. In multiple sclerosis, self-management interventions incorporating CBT techniques have shown promise in reducing anxiety LEVEL 2.[20] Open trials for poststroke anxiety have suggested possible benefit for buspirone and for SSRIs plus psychotherapy, and a small RCT suggested benefit for self-help relaxation.

OUTCOME

Efficacious psychological and pharmacologic treatments have been well established for most of the anxiety disorders. CBTs have yielded response rates upward of 80% in some studies for those patients able to complete a course of treatment.

Response rates to an initial trial of SSRI medication typically range from 50% to 70%, but less than half of these responders attain remission. These same approaches appear to be useful for anxiety disorders that are comorbid with neurologic disorders. Research is ongoing into exploring anxiety disorder treatments with novel mechanisms, improving treatment selection through personalized medicine, and developing alternative strategies for patients who do not respond fully to first-line treatments.

LEVEL 1 EVIDENCE

1. Grassi G, Pallanti S. Current and up-and-coming pharmacotherapy for obsessive-compulsive disorder in adults. *Expert Opin Pharmacother*. 2018;19:1541-1550.
2. Andrisano C, Chiesa A, Serretti A. Newer antidepressants and panic disorder: a meta-analysis. *Int Clin Psychopharmacol*. 2013;28:33-45.
3. Schneier FR. Pharmacotherapy of social anxiety disorder. *Expert Opin Pharmacother*. 2011;12:615-625.
4. Ipser JC, Stein DJ. Evidence-based pharmacotherapy of post-traumatic stress disorder (PTSD). *Int J Neuropsychopharmacol*. 2012;15:825-840.
5. Fineberg NA, Reghunandanan S, Brown A, Pampaloni I. Pharmacotherapy of obsessive-compulsive disorder: evidence-based treatment and beyond. *Aust N Z J Psychiatry*. 2013;47:121-141.
6. Hawken ER, Dilkov D, Kaludiev E, Simek S, Zhang F, Milev R. Transcranial magnetic stimulation of the supplementary motor area in the treatment of obsessive-compulsive disorder: a multi-site study. *Int J Mol Sci*. 2016;17:420.
7. Foa EB, Liebowitz MR, Kozak MJ, et al. Randomized, placebo-controlled trial of exposure and ritual prevention, clomipramine, and their combination in the treatment of obsessive-compulsive disorder. *Am J Psychiatry*. 2005;162:151-161.
8. Bakker A, van Dyck R, Spinhoven P, van Balkom AJ. Paroxetine, clomipramine, and cognitive therapy in the treatment of panic disorder. *J Clin Psychiatry*. 1999;60:831-838.
9. Barlow DH, Gorman JM, Shear MK, Woods SW. Cognitive-behavioral therapy, imipramine, or their combination for panic disorder: a randomized controlled trial. *JAMA*. 2000;283:2529-2536.
10. Stein M, Steckler T, Lightfoot JD, Hay E, Goddard AW. Pharmacologic treatment of panic disorder. *Curr Top Behav Neurosci*. 2010;2:469-485.
11. Strawn JR, Geracioti L, Rajdev N, Clemenza K, Levine A. Pharmacotherapy for generalized anxiety disorder in adult and pediatric patients: an evidence-based treatment review. *Expert Opin Pharmacother*. 2018;19:1057-1070.
12. Luyten L, Hendrickx S, Raymaekers S, Gabriëls L, Nuttin B. Electrical stimulation in the bed nucleus of the stria terminalis alleviates severe obsessive-compulsive disorder. *Mol Psychiatry*. 2016;21:1272-1280.
13. Raskind MA, Peterson K, Williams T, et al. A trial of prazosin for combat trauma PTSD with nightmares in active-duty soldiers returned from Iraq and Afghanistan. *Am J Psychiatry*. 2013;170:1003-1010.
14. Chessick CA, Allen MH, Thase M, et al. Azapirones for generalized anxiety disorder. *Cochrane Database Syst Rev*. 2006;(3):CD006115.
15. Carpenter JK, Andrews LA, Witcraft SM, Powers MB, Smits JAJ, Hofmann SG. Cognitive behavioral therapy for anxiety and related disorders: a meta-analysis of randomized placebo-controlled trials. *Depress Anxiety*. 2018;35(6):502-514.
16. Yan T, Xie Q, Zheng Z, Zou K, Wang L. Different frequency repetitive transcranial magnetic stimulation (rTMS) for posttraumatic stress disorder (PTSD): a systematic review and meta-analysis. *J Psychiatr Res*. 2017;89:125-135.
17. Martin JL, Sainz-Pardo M, Furukawa TA, Martín-Sánchez E, Seoane T, Galán C. Benzodiazepines in generalized anxiety disorder: heterogeneity of outcomes based on a systematic review and meta-analysis of clinical trials. *J Psychopharmacol*. 2007;21:774-782.
18. Maher AR, Maglione M, Bagley S, et al. Efficacy and comparative effectiveness of atypical antipsychotic medications for off-label uses in adults: a systematic review and meta-analysis. *JAMA*. 2011;306:1359-1369.
19. Dilkov D, Hawken ER, Kaludiev E, et al. Repetitive transcranial magnetic stimulation of the right dorsal lateral prefrontal cortex in the treatment of generalized anxiety disorder: a randomized, double-blind sham controlled clinical trial. *Prog Neuropsychopharmacol Biol Psychiatry*. 2017;78:61-65.
20. Kidd T, Carey N, Mold F, et al. A systematic review of the effectiveness of self-management interventions in people with multiple sclerosis at improving depression, anxiety and quality of life. *PLoS One*. 2017;12(10):e0185931.

SUGGESTED READINGS

American Psychiatric Association. *Diagnostic and Statistical Manual of Mental Disorders*. 5th ed. Washington, DC: American Psychiatric Association; 2013.

Dissanayaka NN, Sellbach A, Matheson S, et al. Anxiety disorders in Parkinson's disease: prevalence and risk factors. *Mov Disord*. 2010;25:838-845.

Engdahl BE, James LM, Miller RD, et al. Brain function in Gulf War illness (GWI) and associated mental health comorbidities. *J Neurol Neuromedicine*. 2018;3:24-34.

Etkin A, Wager TD. Functional neuroimaging of anxiety: a meta-analysis of emotional processing in PTSD, social anxiety disorder, and specific phobia. *Am J Psychiatry*. 2007;164:1476-1488.

Fibbe LA, Cath DC, van den Heuvel OA, Veltman DJ, Tijssen MA, van Balkom AJ. Relationship between movement disorders and obsessive-compulsive disorder: beyond the obsessive-compulsive-tic phenotype. A systematic review. *J Neurol Neurosurg Psychiatry*. 2012;83:646-654.

Figee M, Wielaard I, Mazaheri A, Denys D. Neurosurgical targets for compulsivity: what can we learn from acquired brain lesions? *Neurosci Biobehav Rev*. 2013;37:328-339.

Goodarzi Z, Mele B, Guo S, et al. Guidelines for dementia or Parkinson's disease with depression or anxiety: a systematic review. *BMC Neurol*. 2016;16:244.

Goodman WK, Alterman RL. Deep brain stimulation for intractable psychiatric disorders. *Annu Rev Med*. 2012;63:511-524.

Hingray C, McGonigal A, Kotwas I, Micoulaud-Franchi JA. The relationship between epilepsy and anxiety disorders. *Curr Psychiatry Rep*. 2019;21:40. doi:10.1007/s11920-019-1029-9.

Jenike MA. Clinical practice. Obsessive–compulsive disorder. *N Engl J Med*. 2004;350:259-265.

Leahy RL, Holland SJF, McGinn LK. *Treatment Plans and Interventions for Depression and Anxiety Disorders*. 2nd ed. New York, NY: The Guilford Press; 2012.

Leonardo E, Hen R. Anxiety as a developmental disorder. *Neuropsychopharmacology*. 2008;33:134-140.

Liberzon I, Sripada CS. The functional neuroanatomy of PTSD: a critical review. *Prog Brain Res*. 2008;167:151-169.

Martino D, Defazio G, Giovannoni G. The PANDAS subgroup of tic disorders and childhood-onset obsessive-compulsive disorder. *J Psychosom Res*. 2009;67:547-557.

Perugi G, Frare F, Toni C. Diagnosis and treatment of agoraphobia with panic disorder. *CNS Drugs*. 2007;21:741-764.

Schneier FR. Clinical practice. Social anxiety disorder. *N Engl J Med*. 2006;355:1029-1036.

Simpson HB, Neria Y, Lewis-Fernández R, Schneier F, eds. *Anxiety Disorders: Theory, Research and Clinical Perspectives*. Cambridge, United Kingdom: Cambridge University Press; 2010.

Stein DJ, Hollander E, Rothbaum BO, eds. *Textbook of Anxiety Disorders*. 2nd ed. Washington, DC: American Psychiatric Publishing; 2010.

Stein MB, Jain S, Giacino JT, et al. Risk of posttraumatic stress disorder and major depression in civilian patients after mild traumatic brain injury: a TRACK-TBI study. *JAMA Psychiatry*. 2019;76(3):249-258. doi:10.1001/jamapsychiatry.2018.4288.

Tay KW, Subramaniam P, Oei TP. Cognitive behavioural therapy can be effective in treating anxiety and depression in persons with dementia: a systematic review. *Psychogeriatrics*. 2019;19:264-275.

Somatic Symptom Disorders 156

Anna L. Dickerman, Philip R. Muskin, and Vivian Liu

KEY POINTS

1. Somatic symptom disorder occurs when physical symptoms distressing to the patient are also associated with maladaptive thoughts, feelings, and behaviors.
2. Evidence-based treatments exist for somatic symptom and related disorders. Psychotherapy is the mainstay of treatment; early recognition and appropriate management may significantly improve prognosis.
3. Somatic symptom disorders are complex; an interdisciplinary team approach that integrates the neurological symptoms and the psychological distress may improve outcomes.

INTRODUCTION

Somatic symptom and related disorders are a group of psychiatric illnesses in which patients experience bodily symptoms along with associated abnormal thoughts, feelings, and behaviors that cause clinically significant distress and functional impairment. Patients with somatic symptom disorders initially present in medical or neurologic settings. These disorders may worsen medical and psychiatric morbidity among patients by increasing health care utilization and costs due to greater chronicity of symptoms and contribute to higher rates of disability. Patients with somatic symptom disorders can be among the most challenging for both psychiatric and nonpsychiatric clinicians. Some patients may have verified symptoms, but their emotional response is disproportionately distressing and maladaptive, and this adversely impacts physical function and well-being. Other patients may have notable anxiety or distress due to neurologic deficits, whereas there are no findings elicited during examination or on imaging. Evidence-based treatments exist for these illnesses, and timely recognition and appropriate management may significantly improve prognosis. Somatic symptom disorders are complex, and patients with these conditions often present to neurologists before they see or are referred to psychiatrists. Familiarity with somatic symptom disorders can be helpful to recognize when psychiatric consultation or referral is appropriate. This chapter provides an overview of the different types of somatic symptom disorders, epidemiology and pathobiology, management strategies, and outcome.

Somatic Symptom Disorders in *Diagnostic and Statistical Manual of Mental Disorders* (Fifth Edition)

The somatic symptom disorders are a group of disorders that have undergone significant diagnostic criteria revision in *Diagnostic and Statistical Manual of Mental Disorders* (Fifth Edition, *DSM-5*) (Table 156.1).

The diagnostic criteria for somatic symptom disorders (referred to as *somatoform disorders* in *Diagnostic and Statistical Manual of Mental Disorders* [Fourth Edition, *DSM-IV*]) gave rise to confusion about terminology and underdiagnosis by clinicians. The hallmark of somatoform disorders in *DSM-IV* was the absence of a medical explanation for somatic symptoms. This is problematic because conditions that are medically "unexplained" are not necessarily psychogenic in origin, that is, fibromyalgia and chronic fatigue syndrome are not considered psychiatric illnesses. The mere absence of a clear medical explanation for physical symptoms is not sufficient to make a psychiatric diagnosis; conversely, it is possible to have a documented medical condition and still have an abnormal psychological response to the physical symptoms. Patients with somatic symptom disorders *may or may not have a co-occurring and diagnosable medical condition*. The distinctive characteristic of these disorders has been shifted away from the somatic symptoms or their underlying etiology per se and focused on the maladaptive way in which the patient presents and interprets symptoms.

The terminology of somatic symptom disorders in *DSM-5* reduces the number of disorders and subcategories to minimize problematic overlap and diagnostic confusion. Somatic symptom disorders are defined on the basis of *positive* psychiatric symptoms rather than the *absence* of medical explanation for symptoms. The *DSM-5* criteria thus focus more on the psychological impact, particularly the distress caused by somatic symptoms and the patient's maladaptive response, and less on the definitive physiologic origin of the somatic symptoms. A *DSM-5* diagnosis of somatic symptom disorder does not require an exhaustive workup necessitating that the clinician rule-out any physiologically based medical condition. The notable

TABLE 156.1 *DSM-IV* Somatoform Disorders and *DSM-5* Somatic Symptom Disorders

DSM-IV Somatoform Disorders	*DSM-5* Somatic Symptom Disorders
Somatization disorder	Somatic symptom disorder
Hypochondriasis	Illness anxiety disorder
Conversion disorder	Conversion disorder (functional neurologic symptom disorder)
Pain disorder	Factitious disorder
Body dysmorphic disorder	Psychological factors affecting other medical conditions
Undifferentiated somatoform disorder	Other specified somatic symptom and related disorder
Somatoform disorder NOS	Unspecified somatic symptom and related disorder

Abbreviations: *DSM-IV, Diagnostic and Statistical Manual of Mental Disorders* (Fourth Edition); *DSM-5, Diagnostic and Statistical Manual of Mental Disorders* (Fifth Edition); NOS, not otherwise specified.

American Psychiatric Association. *Diagnostic and Statistical Manual of Mental Disorders*. 5th ed. Washington, DC: American Psychiatric Association; 2013.

exceptions to this new rule are conversion disorder (functional neurologic symptom disorder) and pseudocyesis. *DSM-5* also eliminates the use of arbitrarily high-symptom requirements that were in the *DSM-IV* diagnostic criteria for somatoform disorders. A large body of research has shown that the relationship between somatic symptoms and psychopathology exists along a spectrum that was not adequately reflected by prior *DSM-IV* symptom count prerequisites.

The *DSM-IV* diagnosis of body dysmorphic disorder has been moved to the chapter on obsessive-compulsive disorder and related illnesses in *DSM-5* because there is a large body of research establishing pathophysiologic connections between obsessive-compulsive illness and body dysmorphia. Body dysmorphic disorder is thus no longer considered a somatic symptom disorder. This research has considerable treatment implications. Somatization disorder, hypochondriasis, pain disorder, and undifferentiated somatoform disorder (all diagnoses in *DSM-IV*) have been removed and incorporated into two central diagnoses in *DSM-5*: somatic symptom disorder and illness anxiety disorder. Factitious disorder is now considered a somatic symptom disorder in *DSM-5* because these patients often present with somatic symptoms. Psychological factors affecting other medical condition (PFAOMC) is now a psychiatric diagnosis in *DSM-5*. The diagnosis is quite prevalent in medical and surgical patients. The revised *DSM-5* criteria should reduce stigmatization of patients and improve diagnostic reliability across various medical disciplines.

Refer to the chapter on somatic symptom disorders in the *DSM-5* for more information.

SOMATIC SYMPTOM DISORDER

Introduction

Somatic symptom disorder is defined as an illness in which patients experience at least 6 months of one or more distressing somatic symptoms in addition to maladaptive thoughts, feelings, and behaviors related to these symptoms. This may include disproportionate or persistent thoughts about symptoms, an abnormally high level of anxiety about symptoms, and/or excessive time and energy devoted to the symptoms.

Somatic Symptom Disorder Case Example

A 60-year-old woman experiences rare palpitations and has been told she has a soft murmur of no hemodynamic significance. Her medical evaluation includes an echo stress test, numerous electrocardiograms, and a cardiac catheterization. She has been given the diagnosis of mitral valve prolapse, and told there is no need for treatment. She consistently makes appointments with her cardiologist driven by her fear of a "cardiac event" and severely limits her activities to not "stress her heart." The woman has somatic symptom disorder as her response to an insignificant medical finding is distressing and her maladaptive behavior of limiting her activity is not in keeping with the reality of her murmur.

Epidemiology

The prevalence of somatic symptom disorder is approximately 5% to 7% in the general adult population, approximately 15% in primary care, and over 50% in secondary care. The diagnosis of somatic symptom disorder may be applicable to more people, because diagnostic criteria in *DSM-5* emphasizes the adverse psychological burden of symptoms, and no longer requires that symptoms lack a medical explanation. Females report distressing somatic symptoms more frequently than males. Initial symptoms can begin at any age and usually appear by early adulthood.

Certain demographic factors are associated with a more severe clinical course, including female gender and older age. In elderly individuals, somatic symptom disorder is more likely to go unrecognized because of comorbid medical illness. The physical complaints of older patients may also be misattributed to "normal aging" or "understandable" concern.

Somatic symptom disorder occurs more frequently in individuals with lower educational/socioeconomic status, which is associated with more severe illness and worse outcome. Demographic factors that adversely impact the clinical course include unemployment, history of childhood physical or sexual abuse or other adversity, medical and psychiatric comorbidity, and external factors that reinforce the illness (eg, disability payments).

Pathobiology

Biologic, psychological, and social factors contribute to the development of somatic symptom disorder as is the case for most psychiatric illnesses. Biologic risk factors include genetic vulnerability to increased sensitivity to pain and other physical sensations. There is also an emerging literature to suggest a potential role for psychoneuroimmune mechanisms of somatic symptom amplification. Proinflammatory cytokines are known to be involved in the production of illness behavior. Chronic activation or sensitization of this system may result in nonspecific somatic symptoms and chronic pain. It has been hypothesized that immunologic mechanisms in the setting of infectious triggers may contribute to the development of somatic symptom disorders. Functional neuroimaging studies have demonstrated aberrant cortical and limbic activity in regions involved with emotion, self-referential processing, and motor planning; alterations in these regions may impact conscious processing and the experience of mild or chronically painful stimuli. Furthermore, beliefs and expectations also exert strong influence on how patients perceive symptoms, which may contribute to reports of functional abnormalities inconsistent with neuroanatomy and physiology.

Psychosocial risk factors for somatic symptom disorder include early childhood trauma such as physical, sexual, or emotional abuse and/or neglect. Social learning mechanisms such as the attention gained from physical illness or lack of reinforcement of nonsomatic (eg, emotional) expressions of distress may also contribute to the occurrence of somatic symptom disorder. Intrinsic temperamental factors may correlate with a higher risk of developing somatic symptom disorder, including alexithymia (difficulty identifying inner emotional states), and neuroticism (high levels of negative affect). Difficulties in communication—from intellectual, emotional, or social limitations—can predispose to bodily expression of distress.

Diagnosis

Patients with psychiatric illness often present with somatic symptoms, which are not diagnostic of somatic symptom disorder. The hallmark of somatic symptom disorder is that symptoms are prominent in the chief complaint; distressing; and

associated with maladaptive thoughts, feelings, and behaviors related to the symptoms. Patients with major depressive disorder may experience notable fatigue, whereas patients with anxiety disorders may experience tachycardia or abdominal pain. Usually, the cardinal feature of these other illnesses is a pronounced mood disturbance accompanied by numerous other physical and mental symptoms, whereas the distress in somatic symptom disorders emanates predominantly from the physical symptoms themselves. Mood and anxiety disorders frequently co-occur with somatic symptom disorders. Depressive disorders are common in patients with somatic symptom disorder, particularly in the elderly. Patients with somatic symptom disorder are at increased risk for developing secondary substance use disorders, with studies showing rates of opioid use disorders up to twice as high as seen in the general population.

Medical comorbidity is common among patients with somatic symptom disorder, which may complicate the diagnosis. Objectively corroborated problems should be judiciously investigated; however, unnecessary exhaustive diagnostic testing should be avoided because this may inadvertently reinforce the development of new somatic symptoms or even cause iatrogenic harm. Iatrogenic creation of symptoms may be subsequently mislabeled as psychogenic. Common complications of somatic symptom disorder include iatrogenic harm from invasive procedures or dependence on habit-forming substances such as opiates. Greater medical and psychiatric comorbidity is typically associated with greater severity of illness, degree of distress, and functional impairment.

Cultural factors are crucial when considering the diagnosis of somatic symptom disorder; many culture-bound syndromes present with prominent physical symptoms (eg, listlessness, diarrhea, and fever in Susto among the indigenous peoples of Latin America, or tremor and rapid heart rate in Taijin Kyofusho seen in Japan). Differences in medical care across cultures can also affect the presentation and course of somatic symptom disorders. The ways in which individuals recognize and respond to bodily sensations is influenced by numerous interacting factors that occur within a given social and cultural context, which effects the way in which the patient perceives illness and seeks medical attention.

Management

Somatic symptom disorder is difficult to treat, and the literature does not suggest a single superior treatment approach. An interdisciplinary "team" approach with collaboration between medical and mental health specialists is crucial to promote consistency, so the patient is less likely to feel dismissed or abandoned and to help minimize errors of diagnostic omission in either domain. It is recommended that one primary physician endeavor to form a stable relationship with the patient and arrange regular and reliable follow-up appointments on a predetermined scheduled basis.

When discussing the diagnosis of somatic symptom disorder with a patient, a thorough and empathic approach is most likely to put the patient at ease and facilitate successful psychiatric referral and follow-up. A discussion that somatic symptoms often have multifactorial causes may help patients understand that stress can generate physical symptoms without the patient's awareness. Clinicians should be mindful that some patients may be resistant to considering the relevance of psychological factors or may feel that the physician implies the problem is "in all in your head." Providing education about somatic symptom disorder and giving patients a list of psychiatric diagnostic criteria is helpful in legitimizing and validating their complaints by giving them a "genuine" diagnosis. Developing a relationship with the patient's family may also be helpful for understanding and managing the greater social context in which somatic symptoms tend to occur.

Various treatments are successful for somatic symptom disorders. The therapeutic focus shifts from "cure" toward symptom management. Psychotherapy is the mainstay of treatment for somatizing patients; such approaches include cognitive behavioral therapy (CBT) LEVEL 2[1,2] and psychodynamic psychotherapy LEVEL 2.[3] A meta-analysis of 15 randomized controlled trials of CBT for patients with somatoform disorders or medically unexplained symptoms showed that CBT significantly alleviated somatic symptoms, depressive symptoms, and improved physical functioning with efficacy maintained for up to 1 year of follow-up LEVEL 2.[4] Another meta-analysis found that psychotherapy, including forms other than CBT, can be effective for improving physical symptoms and functional impairment in patients with severe somatoform disorder and that improvements were maintained for 1 year after treatment LEVEL 2.[5] A limitation to existing evidence is that most trials evaluated patients using *DSM-IV* diagnostic criteria for somatoform disorder, and thus, further investigation is warranted using *DSM-5* diagnostic criteria for somatic symptom disorder.

Data suggests that pharmacotherapy can be helpful in the management of somatic symptom disorder. Serotonergic antidepressants are moderately effective in reducing intensity of functional somatic symptoms. Medications are helpful in treating the comorbid depressive and anxiety disorders. Agents commonly used for neuropathic pain such as mixed noradrenergic/serotonergic antidepressants, tricyclic antidepressants, and certain anticonvulsants may be helpful. The mechanism of action for these agents remains to be fully elucidated, but recent research findings suggest potential modulation of the psychoneuroimmune pathobiology described earlier discussion. In the case of somatic symptom disorder with predominant pain, use of addictive substances should be avoided.

Outcome

Early psychiatric intervention is likely to improve outcomes for patients with somatic symptom disorder; greater chronicity of undiagnosed somatization is correlated with worse outcomes and makes subsequent mental health treatment more challenging. A systematic review found that a majority of patients with medically unexplained symptoms, across all clinical settings, improved during follow-up, although 10% to 30% deteriorate. A possible explanation for improvement of symptoms may be partially due to regression to the mean because symptoms are at their worst when selecting patient during clinic visits. Without intervention, symptoms are likely to recur and may worsen in severity. When treating patients with somatic symptom disorder, consider the reinforcing role of secondary gain in maintaining symptoms. Although patients with somatic symptom clearly suffer, they may also obtain relief from certain societal, personal, and professional responsibilities as a result of their illness. Any successful treatment of somatic symptom disorder will seek as much as possible to eradicate these reinforcing agents and help reduce the possibility of further iatrogenic harm.

ILLNESS ANXIETY DISORDER

Introduction

Illness anxiety disorder was formerly termed *hypochondriasis* in *DSM-IV*. In *DSM-5*, illness anxiety disorder is characterized by a preoccupation with having or acquiring a serious medical illness that leads to clinically significant distress and dysfunction in social and/or occupational function, but bodily complaints and symptoms are absent or mild. The hallmark of illness anxiety disorder is distress and preoccupation related to the individual's *anxiety about the meaning or significance* of the somatic complaint rather than the actual symptoms. Patients with illness anxiety disorder have a high level of health anxiety that is disproportionate to their actual physical illness or risk of illness. They may engage in excessive health-related behaviors, including frequently checking their body or researching diseases on the Internet. Medical reassurance or negative diagnostic tests are unlikely to alleviate these patients' excessive concerns.

Illness Anxiety Disorder Case Example

A 35-year-old woman feels a lump in her breast. She has a strong family history of breast cancer and has a history of seeing doctors frequently for a variety of complaints that do not lead to a medical diagnosis. She requests an "emergency appointment" with a surgeon who tells her that she does not feel a mass. Imaging of the woman's breast shows no pathology. The woman continues to fear she has breast cancer, self-examines her breast repeatedly, and calls her gynecologist's office weekly with concerns that she might have breast cancer. The patient has no physical symptoms, that is, there is no lump in her breast. Her anxiety is unrelated to any pathology and is of an intensity to interfere with her life.

Epidemiology

Estimates of the prevalence of illness anxiety disorder are based on epidemiologic studies on the *DSM-IV* diagnosis of hypochondriasis. These community surveys and population-based samples demonstrate a 1- to 2-year prevalence of health anxiety and/or disease conviction ranging from 1.3% to 10%. In ambulatory medical populations, the 6-month/1-year prevalence rates are between 3% and 8%. Illness anxiety disorder is equally prevalent in males and females. A recent population-based study found 8.3% of those surveyed had high health anxiety alone, with no reported somatic symptom burden, which differentiates illness anxiety disorder from somatic symptom disorder.

Illness anxiety disorder is a chronic and often relapsing condition that typically begins in early to middle adulthood. In medical settings, no significant age differences have been found between those with low versus those with high levels of illness anxiety. In the general population, health-related anxiety increases with age, often focusing on cognitive deficits. The pathologic distress caused by health-related anxiety is distinct from whether or not there is a comorbid medical condition or cognitive impairment. Patients with health anxiety who develop disproportionate and dysfunctional distress about memory or cognitive function may have a family history or personal exposure to dementia, or due to health anxiety, interpret age-appropriate memory failure as pathologic. Particularly for older patients, it is important to differentiate between the irreversible progression of dementia and consider whether anxiety or functional memory impairment may be a contributing factor to the clinical presentation. Patients with functional memory problems have been reported as more likely to attend clinic alone and give extended, detailed descriptions of reported memory lapses; dementia patients often look to companions to help provide information and often have difficulty giving structured answers with confidence.

Pathobiology

There are biologic and psychosocial components to the development of illness anxiety disorder. A history of childhood abuse/neglect or serious childhood illness may be a potential risk factor for the development of illness anxiety disorder in adulthood (*DSM-5*). Major life stressors or illnesses are factors that may trigger the development of illness anxiety disorder.

Diagnosis

In order to make a diagnosis of illness anxiety disorder, the degree of worry or preoccupation must be *disproportionate* to the severity or significance of the physical symptom. The patient must have severe and continuous anxiety that causes significant distress for a minimum of 6 months. Even with a diagnosis of illness anxiety disorder, as with other somatic symptom disorders, it is important to evaluate the patient for the presence of an underlying or co-occurring medical or neurologic disease. Of course, anxiety related to health and well-being is a normal response to being diagnosed with a major medical illness.

Major mood and other anxiety disorders are other differential diagnostic considerations. Depressed patients can become preoccupied with concerns about their body and health. What distinguishes illness anxiety disorder from depressive and anxiety disorders is the patient's narrowed and persistent focus on health-related anxiety. Patients with illness anxiety disorder may develop depression; this may make it difficult to tease apart, which of the two is the primary psychiatric diagnosis. Patients with mood disorders and psychotic disorders may develop somatic delusions. Delusions are fixed, false beliefs that are held with a degree of conviction and intensity that is not typically seen in illness anxiety disorder. Patients with delusions believe their ideas are real in spite of evidence to the contrary (ie, distinguish between subjective internal experiences and the objective external world), whereas patients with illness anxiety disorder are usually able to accept the possibility that they may not be ill at all. Somatic delusions are often more bizarre or striking than the fears associated with illness anxiety disorder (eg, delusions of complete bodily decay). Patients who are psychotic and have somatic delusions typically have other symptoms of psychosis.

Illness anxiety disorder is a relatively new diagnosis, and therefore, exact rates of comorbidities are not yet known. Prior research on hypochondriasis suggests that comorbidity is high in these patients. As many as two-thirds of illness anxiety disorder, patients are likely to have at least one other major mental illness. Patients with significant illness anxiety are particularly likely to have comorbid depressive and anxiety disorders. Other common comorbid syndromes include somatic symptom disorder and personality disorders.

Management

The treatment of illness anxiety disorder has not been thoroughly researched. Evidence suggests that serotonergic antidepressants

may be effective for somatic symptom disorders characterized by predominant illness anxiety LEVEL 1.[6,7] Therapeutic dosages of selective serotonin reuptake inhibitors (SSRIs) may be higher than those for depressive and anxiety disorders. CBT may be a particularly effective form of psychotherapy LEVEL 1,[7,8] with the majority of patients responding with improved physical functioning quality of life, decreased pain, better function despite pain, and less sleep difficulty and maintaining these improvements at 12 months. Additional results found that the effect of both CBT and SSRI increased over a follow-up period of 18 months and were both effective at improving hypochondriacal complaints and comorbid symptoms of depression and anxiety LEVEL 1.[9]

A recent randomized controlled study showed systematic exposure and education about the role of avoidance as a maintaining factor in health anxiety produced clinically significant improvement in health anxiety among patients diagnosed with somatic symptom disorder or illness anxiety disorder, and this effect was observed when treatment was delivered through an internet-based platform with or without therapist support and also when provided in the form of a printed booklet. Further research is needed in this area, although these results suggest increased accessibility to treatment may help patients access effective therapeutic resources.

A randomized controlled trial in patients with *DSM-IV* hypochondriasis showed a greater response rate to a serotonergic antidepressant (fluoxetine) than to CBT and a small incremental advantage with joint treatment LEVEL 1.[10] Fluoxetine also significantly reduced anxiety and improved quality of life. Results from this trial are likely applicable to individuals with *DSM-5* diagnosis of illness anxiety disorder and somatic symptom disorder because anxiety and fears/beliefs related to illness remain prominent features of the condition. Other studies suggest greater remission and long-term maintenance of remission (over a mean of 8.6 y, range 4-16 y) in patients who continue treatment with SSRIs, as compared to patients who discontinued SSRIs.

Outcome

Patients referred early for psychiatric evaluation tend to have a better prognosis compared to those who receive only medical assessment and treatment. Psychiatric referral should be presented as a supplement, rather than an alternative to or replacement for ongoing medical care and evaluation. Continued treatment with SSRIs may maintain long-term remission and clinical improvement. Regularly scheduled, supportive treatment visits with a consistent primary care physician are helpful.

CONVERSION DISORDER (FUNCTIONAL NEUROLOGIC SYMPTOM DISORDER)

Introduction

Patients with conversion disorder or functional neurologic symptom disorder exhibit one or more symptoms of altered voluntary motor or sensory functions that cause significant distress or functional impairment. *DSM-5* specifies that *conversion disorder symptoms must be incompatible with recognized medical or neurologic conditions*. It may be difficult to determine clinically if a neurologic symptom is of so-called functional (no corresponding neurologic lesion (inconsistent with known neuroanatomy) or organic (with correlative neurologic findings) etiology, so the diagnosis should not be made simply because diagnostic tests are normal or because the symptom is "bizarre." Functional neurologic symptoms may be acute or chronic and may affect various or multiple sensory or motor modalities. The diagnosis of conversion disorder in *DSM-5* does *not* require that a psychological stressor precede the development of symptoms. This criterion was dropped because it is not always possible to immediately identify an antecedent stressor with the onset of functional neurologic symptoms. Nevertheless, it is important to make the diagnosis quickly in order to minimize morbidity or iatrogenic complications. The change in the diagnostic criteria does not imply that psychological factors are absent or not important for the patient and the symptoms.

In the most recent version of the International Classification of Diseases, ICD-10 updated in 2016, conversion and dissociative disorders are grouped together. A proposal for ICD-11 suggests moving conversion to the neurology section of ICD as functional neurologic disorder, which reflects a rationale similar to the changes in diagnostic criteria in *DSM-5*. Functional neurologic disorders and conversion symptoms should be described empirically based on observations and diagnosed based on positive features, with less emphasis on the potential psychological factors underlying the presentation.

The conventional psychodynamic model of conversion is that patients unconsciously transmute their psychic distress into physical symptoms. It can be difficult to definitively eliminate the possibility of conscious feigning when initially encountering a patient with conversion disorder. Therefore, the assessment of conscious versus unconscious production of symptoms is unreliable. Thus, the new diagnostic criteria for conversion disorder no longer require a definitive judgment that the symptoms are unconsciously produced.

Conversion Disorder Case Example

A 39-year-old woman is admitted to the hospital after sudden loss of function in her right arm. She is obese, is a cigarette smoker, and takes an oral contraceptive. She reports that she suddenly lost the ability to move or feel her arm during an argument with her teenage son whom she "felt like smacking." When hypnotized by the psychiatric consultant, she is able to lift her right arm while in the trance; however, the arm becomes limp when she is out of the trance state. To not shame or embarrass the patient, the psychiatrist tells the patient she will recover with physical therapy. She recommends psychotherapy to talk about her anger and to explore her relationship with her son.

Epidemiology

Methodologic differences in epidemiologic studies of conversion disorder have led to great variability in the reported rates of prevalence. Lifetime prevalence rates in the general population range from 11 in 100,000 to 500 in 100,000. In the general hospital setting and the outpatient neurologic setting, lifetime prevalence rates are 4% to 15%. Neurologic dysfunction of psychogenic origin occurs in 1% to 9% of neurologic diagnoses, and abnormal movements are among the most common symptoms; patients with psychogenic movement disorders are estimated to account for 2% to 3% of those in movement disorder clinics. Conversely, 10% to 15% of patients with psychogenic movement disorders also have associated organic neurologic disorders.

Conversion disorder usually presents in early adult life and is approximately 2 to 3 times more likely to occur in females. Conversion disorder is also more frequently seen in patients of lower socioeconomic status and those with relatively less education. As with the other somatic symptom disorders, psychiatric comorbidity is high, for example, depressive and anxiety disorders and posttraumatic stress disorder as well as personality disorders and impairment of psychosocial functioning. To date, there is no strong data showing any association between psychotic illnesses, such as bipolar disorder or schizophrenia, and conversion disorder or functional neurologic symptoms.

Functional neurologic disorders in children are similar to those in adults. Patients are often girls, age 10 to 14 years, presenting most commonly with motor loss and pain and lethargy. Two surveillance reports of conversion disorder in children reported approximately 70% of patients were female, and similar 12-month incidence of 3 to 4 per 100,000; incidence in children younger than 10 years of age was 0.26 to 0.8 per 100,000. Antecedent stressors were reported by approximately 60% to 80% of children with FND, most commonly bullying at school. Long-term data is limited to date.

Pathobiology

Functional neurologic symptoms are likely caused by a combination of biologic, psychological, and social factors; how these factors interact may vary in each patient. A growing evidence base, which includes neuroimaging studies, is improving the understanding of abnormal brain function and connectivity in patients with conversion or functional neurologic symptoms. Conversion disorder can present with almost any neurologic symptom, commonly abnormal movements or seizures, which appear to have a voluntary quality but are perceived by the patient as involuntary. Genetics and epigenetics, social and environmental influences, altered neural connectivity, abnormal cognitive processing, learning, and expectations may all play a role in the development of functional neurologic symptom disorder.

Biologically, an underlying personal or family history of organic neurologic disease is a risk factor for the development of functional neurologic symptoms. For example, patients with epilepsy are more likely to develop psychogenic nonepileptic seizures (PNESs) than the general population; the estimated comorbidity of PNES in epilepsy patients is approximately 10%. Maladaptive coping style and personality traits as well as difficulty identifying and expressing emotion (alexithymia) may predispose an individual to development of conversion symptoms.

Epigenetic changes that affect brain development and cognitive function may suggest a pathobiologic mechanism for the association between environmental factors, such as a history of abuse or trauma, and the development of conversion disorder. Studies comparing patients with PNES to healthy volunteers have found that PNES patients have higher basal cortisol levels, a marker of overall greater stress level that is unrelated to seizure frequency, physical activity, or acute psychological stress. Other studies comparing patients with PNES to patients with complex partial seizures have found that PNES patients have statistically significant pre-ictal heart rate increases and postictal heart rate reductions normalized to baseline and decreased resting vagal tone. Neuroimaging of PNES patients have shown alterations with and across sensorimotor, emotional regulation/processing, cognitive control, and multimodal integration brain systems (see **Table 156.2** which summarizes neuroimaging findings in patients with functional movement disorders).

Neuroimaging studies show different patterns of brain activation and deactivation in patients with conversion disorder as compared to patients who consciously feign symptoms. Although there is no commonly accepted theory about the functional neuroanatomy of conversion disorder, available evidence suggests that symptoms may represent a "functional unawareness syndrome" involving abnormal limbic-motor connectivity and networks involved in the processing of emotion and affect. Functional imaging studies have shown hypoactivity in the supplementary motor area (SMA, an area associated with action planning and selection) and abnormally strong connectivity between the SMA and amygdala, which is enhanced by emotional stimuli. This may suggest a mechanism to explain why patients with functional hyperkinetic movements may experience symptoms as involuntary, if SMA hypoactivity limits the ability to suppress an action. Other functional neuroimaging studies in patients with functional tremor have observed abnormal activation patterns in the cingulate cortex, ventromedial prefrontal cortex, precuneus cortex—brain regions involved with self-awareness and the affective and sensory component of memories. Increased regional cerebral blood flow has been observed in subcortical structures of patients with functional movement disorders, more so than in patients with essential tremor and organic dystonia.

Higher order cognitive processes that integrate and interpret sensory and motor stimuli are also implicated in functional disorders because perception and control of both movement and sensation are dynamically influenced by data from and interactions with the environment. A study examining sensory attenuation (ie, the effect that a touch generated by one's own movement is perceived with reduced intensity as compared to an identical touch by an externally generated force) found that patients with functional dystonia did not show the sensory attenuation seen in healthy controls and that the functional patients were also more accurate in perceiving forces caused by their own actions. The loss of sensory attenuation in patients with functional disorders may be related to an increased focus on somatic sensations, which combined with decreased inhibition of motor movements suggested by SMA hypoactivity, may increase the likelihood of perceiving actions as involuntary and reinforce these expectations in some patients.

Environmental factors such as childhood abuse/neglect and other stressful or traumatic life events can be associated with the development of conversion disorder. Although not all individuals who experience early adverse life events will develop conversion disorder, a controlled study found that patients with a "clinically definite" functional movement disorder reported significantly higher rates of childhood trauma and traumatic events as compared to healthy volunteers. Dissociation, a commonly seen psychological response to trauma, has also been described in patients with conversion disorder, particularly those with PNES. Researchers have hypothesized similar psychological processes underlying conversion and dissociative disorders despite the descriptive differences between the two conditions, likely with disturbances in higher level integrative cognitive functions affecting awareness, consciousness, identity, and memory. A history of trauma may increase vulnerability to later life stressors such as later trauma, illness, or injury. Functional movement disorders such as tremor and dystonia have been described, often developing with variable timing after a peripheral injury. There is a hypothesis suggesting that trauma or physical injury may unmask or exacerbate a preexisting vulnerability to develop abnormal movements, as reported in patients with genetic conditions such as mitochondrial disorders.

TABLE 156.2 Areas of Abnormal Activation Observed in Patients With Functional Movement Disorders[a]

Regions of Altered Activation	Observed Abnormalities in Patients With Somatization
Anterior insula	• Increased activity • Anterior insular cortex is associated with awareness of sensations and movement. • Inverse association between left anterior insular volume observed in patients with functional neurologic disorder and childhood abuse burden
Inferior frontal cortex	• Increased activation • Right inferior frontal cortex implicated in active inhibition of motor actions for speech
Ventromedial prefrontal cortex	• Increased activity • Implicated in internal self-representations and integrating memory and imagery with emotional components
Anterior cingulate cortex	• Increased activity • Observed with functional tremor and functional dystonia
Posterior cingulate cortex	• Increased activity • Seen in patients with functional disorders at rest or in response to emotional stimuli
Amygdala	• Increased activity • Increased and prolonged activation in response to positive and negative stimuli
Precuneus	• Increased activity • Hyperactivity observed with conversion disorders • Implicated in internal self-representations and integrating memory and imagery with sensory components
Cerebellum	• Increased activity • Higher regional cerebral blood flow • Enhanced activation in functional tremor compared to essential tremor
Right temporoparietal junction (rTPJ)	• Decreased activity • rTPJ detects discrepancies between internal motor intentions and actual motor effects.
Sensory and motor cortex	• Decreased activity
Dorsolateral prefrontal cortex (dlPFC)	• Decreased activity • dlPFC has functions in motor planning and regulation.
Presupplementary motor area (pre-SMA), supplementary motor area (SMA)	• Decreased activity, although increased activity seen to sad or fearful stimuli • SMA is involved in preparation and suppression of motor plans.
Abnormal Connectivity	**Possible Role in Pathogenesis of Somatization**
Hyperconnectivity between ventromedial prefrontal cortex and posterior cingulate cortex and precuneus	• Abnormal activation may affect internal self-representations and integration of memory with emotional or sensory components.
Hyperconnectivity between amygdala and SMA and PaGM	• Abnormally increased connectivity between limbic and motor regions in functional disorders • Periaqueductal gray matter, which is involved in freeze response to fear, has increased activity.
Decreased connectivity between rTPJ and several motor areas	• Implications for perceiving discrepancies between motor intentions and consequences
Decreased connectivity between dlPFC and SMA	• Abnormal top-down control by dlPFC may allow expression of previously learned patterned movements.

Abbreviation: PaGM, periaqueductal gray matter.
[a]Adapted from Baizabal-Carvallo J, Hallett M, Jankovic J. Pathogenesis and pathophysiology of functional (psychogenic) movement disorders. *Neurobiol Dis.* 2019;127:32-44 and Voon V, Cavanna AE, Coburn K, Sampson S, Reeve A, LaFrance WC Jr. Functional neuroanatomy and neurophysiology of functional neurological disorders (conversion disorder). *J Neuropsychiatry Clin Neurosci*. 2016;28(3):168-190.

Diagnosis

A diagnosis of conversion disorder should only be made following a thorough neurologic assessment, including detailed history and examination and relevant imaging or other studies. A thorough physical examination is essential to assess any neurologic symptom, no matter what the etiology. This conveys to patients that their physical presentation is being given due attention. The history may also provide information that suggests a functional component; patients may report a physical injury or illness as a trigger associated with the sudden onset of weakness, abnormal movements, or altered sensations (Table 156.3).

Conversion disorder and functional neurologic symptoms can be differentiated from organic illness by its incompatibility with known features of neurologic disease or inconsistency observed during physical examination. Functional abnormal movements may display characteristics that imply an element of voluntary control (eg, enhanced by attention, alleviated by distraction, entrainment of tremor); yet, the hallmark of functional symptoms is that patients perceive them as involuntary. These inconsistencies or incongruities are positive signs that point toward a diagnosis of conversion disorder; however, as with the other somatic symptom disorders, conversion disorder (or other apparent functional overlay) is not mutually exclusive with organic physical or neurologic illness. In fact, deficits due to neurologic disease are a risk factor for developing functional symptoms, as suggested by patients with both neurologic and functional diagnoses

TABLE 156.3 Factors Contributing to Functional Neurologic Disorders

Factors	Contribution to Functional Neurologic Disorders	Examples
Predisposing	Preexisting psychiatric conditions (mood or anxiety disorders, PTSD, excessive vigilance) or certain cognitive styles (eg, obsessive or rigid patterns of thinking) can make individuals more vulnerable to somatization. Trauma, abuse, or distressing experiences from the present, recent past, formative years, or childhood can be a risk for somatic symptom disorders. There may be mild genetic risk and other risk factors that are not yet known or well understood.	Excessive stress Emotional difficulties Heightened threat vigilance Cognitive style
Precipitating	Beliefs and expectations about health contribute to disordered sensorimotor processing to distort or amplify an unpleasant somatosensory experience. Misdirected or excessive attention, anxiety, and dissociation can facilitate aberrant processing or perception. Somatic symptoms offer a plausible "explanation" for confusing or conflicting experiences. Patients may be conscious of this, or their participation may be preconscious and out of their awareness.	Health beliefs Expectations Attentional processes Anxiety Dissociation
Perpetuating	Maladaptive behavioral responses can be reinforced by learning, social, and external factors. CNS plasticity and remodeling may contribute.	Behavioral responses Cognitive remodeling Social context External factors

Abbreviations: CNS, central nervous system; PTSD, posttraumatic stress disorder.

(eg, epilepsy and PNES, multiple sclerosis and functional weakness, idiopathic intracranial hypertension, and functional visual deficits). As noted by Pierre Janet, Charcot's assistant, "the fact that a system is psychological should not cause us to conclude that it is not at the same time anatomical. On the contrary, the one involves the other."

PNES, also called *psychogenic nonepileptic attacks* are among the most common functional neurologic disorder. The gold standard for diagnosis of PNES video-electroencephalogram (EEG) capture of episodes, with lack of ictal EEG discharges before, during, and after typical episodes of seizure-like activity. Evaluation with video-EEG is important because most patients with PNES are misdiagnosed with epilepsy and treated unnecessarily with antiepileptic medications, which provide no benefit to these patients and instead expose them to potential adverse effects. Subjective patient reports may also be helpful in differentiating between PNES and epilepsy, and some self-report questionnaires have been shown to accurately distinguish between PNES and epilepsy with sensitivity and specificity of 85%. Patients with PNES are more likely to describe their seizures as a "state or place" they enter passively, whereas patients with epilepsy describe their seizures as an external active force that independently acts on their body. Patients with PNES are more likely to emphasize their loss of consciousness as complete and absolute, even though some studies show a greater portion of PNES patients demonstrate some responsiveness or ability to follow simple commands during seizure events, as compared to patients with epilepsy. How patients experience and report PNES symptoms may aid in diagnosis and suggests aspects that may lead to better understanding of functional symptoms.

Conversion disorder should not be diagnosed simply based on the presence of psychiatric symptoms; depression and anxiety are common comorbidities with both organic and functional neurologic illness, whereas patients with psychotic illness are unlikely to have functional complaints. Depression and anxiety are often comorbid with functional neurologic symptoms. Assessing for psychiatric symptoms requires skillful tact because patients may feel extensive questioning to be dismissive of or detracting from what they perceive as the most bothersome aspect of their complaints. Patients often perceive low mood, anxiety, and stress as predictable responses to their somatosensory symptoms and may minimize low mood, anxiety, or stress, sometimes, intentionally, if they believe their problems are neurologic and perceive any discussion of psychiatric symptoms as distracting. In fact, some studies have shown that patients with functional disorders are less likely to attribute their symptoms to stress than patients with organic neurologic disease.

Overt evidence of deliberate feigning or exaggeration of symptoms should guide one away from a diagnosis of conversion disorder and more toward factitious disorder or malingering.

Management

Effective treatment of conversion disorder begins with empathic and positive communication of the diagnosis. It is generally best to avoid any comments that suggest to the patient that there is nothing "biologically" wrong in order to prevent embarrassment. It is helpful to inform, the patient that he or she is clearly suffering from real symptoms that are concerning and disruptive, but the expectation is that he or she will ultimately recover. The patient should be told that there is no need to be exposed to unnecessary medication or studies, which may be invasive and potentially cause harm, but that treatment focusing on managing the emotional issues and distress associated with the symptoms is very important for ultimate improvement. This type of phrasing can help engage the patient in a dialogue about any stress associated with the symptoms.

Any clinician treating patients with conversion disorder should be aware of the potential role of past trauma in this illness and should be sensitive to therapeutic implications in the management of a traumatized patient (particularly as it relates to forming a stable treatment alliance). Although the psychological conflict producing the symptoms may seem obvious to the physician, delicacy is required in presenting an interpretation of the proposed etiology to the patient. The most common "precipitants" are aggressive and sexual thoughts that are unacceptable to the patient; however, if the patient could adaptively cope with such thoughts then the symptoms would not be manifested.

Despite the illness burden of conversion disorder and the therapeutic challenges inherent in its management, there is a lack of empirical data on effective treatment strategies. The majority of evidence for the treatment of conversion disorder is in the form of uncontrolled case series and reports. In general, the cornerstone of management for conversion disorder has been

psychotherapy. There is little clinical evidence to support the use of pharmacotherapy in the absence of other comorbid psychiatric conditions such as depressive or anxiety disorders. Antiepileptic medication and surgical procedures have no efficacy for PNES and can cause significant harmful effects. Some success has been reported with antidepressants LEVEL 1,[11] mood stabilizers, and antipsychotics. Treatment with the antipsychotics is problematic given the potential for neuroleptic-induced movement disorder in patients who may already have psychogenic movement disorders.

Psychotherapy for conversion disorder should aim to help the individual develop more adaptive coping strategies to deal with emotional conflicts and more effective ways of communicating distress. CBT is one such therapeutic modality LEVEL 1.[12] Psychoanalytic and psychodynamic approaches to conversion can also be quite effective LEVEL 1.[13]

In addition to psychotherapy, there are studies of small sample sizes with preliminary findings suggesting possible efficacy for hypnosis LEVEL 1,[14,15] behavioral therapy and rehabilitation, physical therapy, and paradoxical intention. Incorporating hypnosis as an adjunctive technique has support from current theories about the role of suggestion and expectation in the development of functional symptoms. These treatments can be potentially "face-saving" and more readily acceptable for the patient, as they are based on a physical model of recovery, and may be particularly helpful for patients who have difficulty engaging in psychotherapy.

Outcome

There is great variation in the degree of symptom severity among patients with conversion disorder. Although conversion symptoms can be short-lived, it is not unusual for symptoms to recur in the same individual; 1-year relapse rates can be as high as 20% to 25%. Good prognostic factors include acute onset and short duration of symptoms, presence of an identifiable stressor at the onset of illness, short interval between onset and referral to treatment, higher intelligence, and willingness to accept a psychological component to the illness. Underlying personality disorder is a poor prognostic indicator, as is comorbid somatic symptom disorder. The more long-standing the conversion symptoms, the more difficult it becomes to treat the disorder. This may be because of the accumulation of associated benefits over time (eg, secondary gain). Comorbid psychiatric and medical illness is also associated with worse outcome.

FACTITIOUS DISORDER

Introduction

Unlike the other somatic symptom disorders, factitious disorder involves *intentional falsification of* physical and/or psychological symptoms, or induction of injury or disease. The individual is aware of the deception and presents him or herself as ill, injured, or impaired. A subtype of factitious disorder involves the presentation of someone else close to the patient as ill, injured, or impaired. This was previously called *factitious disorder by proxy* in *DSM-IV* and is now referred to in *DSM-5* as *factitious disorder imposed on another*. Patients with factitious disorder may present with single or recurrent episodes. Münchhausen syndrome is a particularly chronic and intractable form of factitious disorder.

Unlike the malingering patient, those with factitious disorder exhibit deceptive behavior *in the absence of any obvious external reward*. The traditional model of this illness rests on the idea that patients seek secondary gain via assumption of the sick role; however, *DSM-5* does not specifically list this as a diagnostic criterion because it is often not possible to reliably infer this early on in the disease course. The deceptive behavior is not always about medical symptoms. Factitious mourning has been reported in which individuals relate a history of traumatic loss of a loved one.

Common clinical characteristics often include a history of numerous prior medical evaluations and treatments, particularly hospitalizations, surgeries, and other invasive procedures. Other features that suggest the diagnosis include a dramatic or inconsistent history that is vague or variable in its detail, inexplicable laboratory results, inconsistent physical examination findings, use of highly medicalized jargon, minimization of the presence of scars from prior invasive procedures, or confabulation of details when attempts are made to corroborate history. Patients may also demonstrate remission of neurologic deficits when they believe no one is observing. The classic example of a patient with factitious disorder is someone who migrates to different treatment settings in order to avoid discovery of the psychopathology.

Factitious Disorder Case Example

A 48-year-old woman is admitted for evaluation of an inoperable brain tumor. Neuroimaging results from extensive prior hospitalization records reveal no evidence of central nervous system pathology. When confronted by the medical team, the patient reveals that she falsified her medical records. She also disclosed that she planned to commit suicide and wanted her family to think she had an incurable cancer and would understand it when she took her life.

Epidemiology

Because of the level of deception in patients with factitious disorder, exact estimates of prevalence are unknown. In the general hospital setting, approximately 1% of individuals meet criteria for the disorder, but rates may be higher in specialized treatment settings. Factitious disorder is likely significantly underdiagnosed by physicians who are reluctant to confront deceptive patients and also due to the fact that patients rarely participate in psychiatric evaluation and treatment, and many often flee or abruptly elope from care when confronted about their deception. The typical course of factitious disorder is recurrent, intermittent episodes that last over the course of the lifespan. Patients usually present during adulthood, often before age 30 years, although there may be earlier evidence of unexpectedly numerous illnesses and procedures during childhood. Factitious disorder is more common in women, but its course is often more severe and refractory in men. Medical child abuse, a form of factitious disorder imposed on another, has an estimated prevalence ranging from 1% to 13% in studies conducted in specialist settings.

Pathobiology

Risk factors for factitious disorder include a history of childhood abuse, disturbed parental relationships/emotional deprivation, early life illness or extended hospitalizations, and exposure to or employment in the medical setting. There are

several psychodynamic as well as cognitive, social learning, and behavioral theories that have been posited for the development of factitious disorder. Behaviors leading to factitious disorder may begin at a young age when an individual experiences envy from observing the attention received by someone else who is ill or receives positive attention during their own illness or loss and then associates the pleasant experience of attention with the role of being sick. An interesting study of an online community of self-reported sufferers of factitious disorder revealed that members claimed to be aware of their motivations, were upset by their behavior and wanted to recover, and were deterred by fear from seeking treatment. Neurobiologic findings of functional imaging studies have been inconsistent.

Although little is known definitively about the motivations of patients with factitious disorder, their behavior may be a maladaptive attempt to seek care for perceived or genuine distress. Patients with factitious disorder have variable awareness of their deception, although it has been reported by observers and patients that there is often a compulsive element to the deceptive behavior, such that patients are conflicted between not wanting to engage in deceptive behavior and the simultaneous urge to occupy the sick role. Similarities between addiction and factitious disorder have been suggested, particularly the reinforcement from the emotional reward of attention and sympathy gained from occupying the sick role.

Diagnosis

A presentation inconsistent with the known natural history of a medical condition, and investigative studies that are normal or inconclusive, often lead to the diagnosis of factitious disorder. Other factors that may suggest this diagnosis include prior extensive health care use (often at multiple locations) or with symptoms predominantly manifesting when the patient is not observed. Corroborating information and past treatment records are difficult to obtain, and the patient may be inconsistent, evasive, or confrontational when asked for additional details. Patients with factitious disorder have been reported to display an unusual degree medical knowledge or use of medical terminology, appear eager for medical procedures and surgical interventions while resisting psychiatric involvement.

The major differential diagnostic consideration in factitious disorder is malingering (which is not a psychiatric diagnosis). Malingering patients fabricate medical problems to gain clear external rewards (eg, disability benefits, evading legal or military obligations), whereas patients with factitious disorder also intentionally fabricate medical needs, although not for obvious tangible gains. Most often, patients with factitious disorder are motivated by seeking the attention they receive while occupying the sick role. Malingering and factitious disorder patients may engage in a similar array of behavior when they intentionally falsify information, which ranges from exaggerating symptoms, deliberately concealment of information that would account for their presentation, feigning, inventing symptoms, misattributing cause, or self-inflicting illness or injury. Patients may have features or elements of both conditions, that is, a patient may be subconsciously motivated complain of pain while enjoying access to opiates. Many clinicians have difficulty differentiating between the somatic symptoms of factitious disorder and those of conversion disorder. The hallmark of factitious disorder is *deliberate* deception or fabrication of symptoms. In conversion disorder, patients do not intentionally produce symptoms.

Patients with factitious disorder who injure themselves do so specifically in order to assume the sick role. Factitious disorder often presents following a hospitalization for a medical condition or mental disorder. In factitious disorder imposed on another, it is following the child or dependent party's hospitalization. A systematic review of 796 published cases of medical child abuse found that nearly all abusers were female (97.6%), almost all were the victim's mother (95.6%), most were married (75.8%), and many reported to have health care–related professions (45.6%). From upon reviewed cases, the most common psychiatric diagnoses were factitious disorder imposed on self (30.9%), personality disorder (18.6%), and depression (14.2%). Seizures are reportedly the most common presentation of fabricated or induced illness in children (published cases include factitious reports by the caregiver and children administered drugs that cause seizures); examination of medical records for the child's caretaker (usually the mother) frequently include reports of nonepileptic seizures.

Patients with factitious disorder are not attempting to kill themselves or to obtain affective or emotional release from the self-injury. This distinguishes their self-harming behavior from those of patients with mood or personality disorders. Patients with factitious disorder may have comorbid mood and personality disorders and have frequent comorbid substance use disorders.

Management

Factitious disorder is one of the most difficult psychiatric illnesses to treat. Early identification of factitious disorder is important to limit unnecessary health care interventions, prevent potential iatrogenic harm to the patient, and manage the psychological impact on providers. A review of 455 published cases of factitious disorder found that 59% of patients self-induced injury or illness, whereas only 19% simulated and 22% falsely reported a medical problem. In this case series review, 14% of patients reported current suicidal ideation or past suicide attempt. Although patients with factitious disorder may appear medically knowledgeable, and often, use this to induce the circumstances for their presentation, their capacity to appreciate the harmful consequences of their behavior is impaired and their actions can lead to serious, permanent damage or potentially death. Whatever the motivation, patients with factitious disorder should be considered to be at high risk for self-harm and managed accordingly.

If a diagnosis of factitious disorder is suspected, it is often helpful to confer with hospital administrative and legal services. A strategy of supportive confrontation has been recommended by some experts, which always involves more than one member of staff, and emphasizes the patient is sick and in need of help. Other suggestions include face-saving options that might allow patients to claim to others that they "recovered" without revealing they fabricated their symptoms.

Not surprisingly, clinicians often have strong negative emotional reactions to patients who falsify symptoms. Care providers may feel exploited, humiliated, or angered. Clinicians report feeling guilty or ashamed for not recognizing false information sooner and concern that their emotional reaction might affect care for that patient or others. It is important to remember when treating the patient with factitious disorder that he or she is in fact quite ill but not in the way he or she presents.

An additional therapeutic challenge is the fact that patients often abruptly flee from care once they are confronted about the

false nature of their symptoms; other responses include denial or threats of litigation. Patients with factitious disorder are reluctant to seek treatment, and although precise reasons for this are not fully known, many of the perceived barriers may be fears similar to those faced by people reluctant to seek help for addiction including fear of disclosure, abandonment and rejection, losing a coping mechanism, and the difficulties of overcoming defense mechanisms.

Outcome

There is a dearth of comparative literature examining the efficacy of various treatment approaches. In general, it is recommended that treatment be collaborative, involving interdisciplinary team meetings and communication among providers to coordinate efforts and manage negative emotions. Psychodynamic and behavioral approaches have been used to treat the disorder. Pharmacotherapy has a role in treating specific comorbid symptoms, such as mood or psychotic disorders, if present. The ultimate goal is to redirect the patient to seek psychiatric care in an appropriate setting and support the patient in developing more adaptive behaviors.

PSYCHOLOGICAL FACTORS AFFECTING OTHER MEDICAL CONDITIONS

Introduction

Psychological or behavioral factors that adversely affect other medical conditions (PFAOMC) are very common. This diagnosis is included in the group of somatic symptom disorders because of its usual appearance in primary care and other medical settings. The essential feature of PFAOMC is clinically significant psychological or behavior factors that adversely affect a medical condition by increasing the risk for suffering, disability, or death. Psychological or behavioral symptoms may include psychological distress, patterns of interpersonal interaction, coping styles, and maladaptive coping strategies such as denial or poor adherence. A common example is denial of the significance of physical symptoms, which may in turn lead to delayed medical intervention. Clinically significant psychological factors can affect any medical condition, including those with clear pathophysiology (eg, epilepsy), functional syndromes (eg, fibromyalgia, chronic fatigue syndrome), or idiopathic medical symptoms (eg, pain, fatigue, dizziness).

There may be a temporal relationship between psychological factors and development or exacerbation of a medical condition, as in the example of a depressed patient with diabetes mellitus who neglects glucose control. Psychological factors may also interfere with treatment of a medical condition. Patients with a history of trauma may be particularly sensitive to certain invasive procedures and become resistant to medical workups. Psychological factors can constitute additional health risks or adversely influence underlying pathobiology. A hypoxic patient with pulmonary disease who subsequently develops anxiety will experience vasoconstriction secondary to release of catecholamines, resulting in further reduction of oxygen delivery to tissues and a positive feedback loop contributing to exacerbation of both hypoxia and anxiety.

PFAOMC Case Example

A patient with a well-documented history of epilepsy is brought to the emergency department in *status epilepticus*. When he recovers, he states that he has taken all of his medications as prescribed; however, serum levels of the anticonvulsants are not detectable. When confronted with this information, he admits that it is not "strong" to take medication and he stopped his medication. During his meeting with the psychiatric consultant, he elaborates further that he stopped taking medications as they were constant reminders of his illness and that having to rely on medication made him feel "weak." The psychiatrist notes that even the "best of the best" get help such as progolfers having a swing coach, something with which the patient could identify. Over the next week in the hospital, the patient and psychiatrist explored strategies for seeing the medications as allowing the patient to really be himself, not someone with seizures.

Epidemiology

The exact prevalence of PFAOMC is unknown; however, private insurance billing data from the United States indicates that this diagnosis is made more commonly than somatic symptom disorder. Denial of medical illness is not currently a diagnosable disorder in *DSM-5* but is commonly seen in clinical settings.

Pathobiology

Psychological factors may impact a medical illness at any point during the life cycle. Older individuals may be at greater risk for their own health to be adversely impacted by the stress associated with providing care for an ill partner. Clinicians should be mindful that greater age, greater prevalence and severity of comorbidities, and social factors can combine to increase the risk for elderly patients to develop psychological factors that then adversely affect other medical conditions.

Diagnosis

By definition, the diagnosis of PFAOMC necessitates the presence of a comorbid medical illness along with a psychological symptom or behavior. The hallmark of PFAOMC is the directionality of psychological factors adversely affecting underlying medical or neurologic disease. Conversely, when psychiatric symptoms develop predominantly in response to the stressor of medical illness, a diagnosis of adjustment disorder is more appropriate. In actual clinical practice, psychological syndromes often co-occur with medical illness in a mutually exacerbating fashion, making it difficult to determine the exact direction of causality. If the symptoms leading to aggravation of medical illness are best explained by another major mental illness such as major depressive disorder, then it is this condition that should be noted rather than PFAOMC.

Management

These patients should be managed by both their neurologist and a psychiatrist with full acknowledgement that the patient has a neurologic illness as well as clinically significant psychological distress that impacts the illness. Some patients will benefit from education about the interaction between stress and the body. The use of relaxation techniques, hypnosis, breath training, and meditation are all useful to engage the patient in taking control over what feels out of control.

Outcome

The outcome in these cases depends on a compassionate approach to the exacerbation of the neurologic symptoms.

CONCLUSIONS

Somatic symptom disorders are a complex group of psychiatric illnesses that cause much suffering for the patient and are frequently frustrating for the clinician as well. This chapter has reviewed major recent findings on epidemiology and what is known about the pathobiology specific to each of the somatic symptom disorders. Fortunately, a variety of evidence-based therapeutic modalities are available for some of these disabling disorders. Management should focus on understanding and treating dysfunctional thoughts, feelings, and behaviors related to the somatic symptoms, as opposed to attempting to complete eliminating the symptoms themselves. Invasive workups should be initiated with caution. Early recognition and appropriate referral by general medical and neurologic practitioners remain the initial crucial step in facilitating treatment and may significantly improve outcomes. Neurologic follow-up is important to prevent feelings of abandonment and ensure that relevant medical or neurologic illness is not missed.

LEVEL 1 EVIDENCE

1. Allen L, Woolfolk R. Cognitive behavioral therapy for somatoform disorders. *Psychiatr Clin North Am*. 2010;33:579-593.
2. Kroenke K. Efficacy of treatment for somatoform disorders: a review of randomized controlled trials. *Psychosom Med*. 2007;69:881-888.
3. Abbass A, Kisely S, Kroenke K. Short-term psychodynamic psychotherapy for somatic disorders. Systematic review and meta-analysis of clinical trials. *Psychother Psychosom*. 2009; 78(5):265-274.
4. Liu J, Gill N, Teodorczuk A, Li Z, Sun J. The efficacy of cognitive behavioural therapy in somatoform disorders and medically unexplained physical symptoms: a meta-analysis of randomized controlled trials. *J Affect Disord*. 2019;245:98-112.
5. Koelen JA, Houtveen JH, Abbass A, et al. Effectiveness of psychotherapy for severe somatoform disorder: meta-analysis. *Br J Psychiatry*. 2014;204(1):12-19.
6. Fallon BA, Petkova E, Skritskaya N, et al. A double-masked, placebo-controlled study of fluoxetine for hypochondriasis. *J Clin Psychopharmacol*. 2008;28:638-645.
7. Greeven A, van Balkom AJLM, Visser S, et al. Cognitive behavior therapy and paroxetine in the treatment of hypochondriasis: a randomized controlled trial. *Am J Psychiatry*. 2007;164:91-99.
8. Barsky AJ, Ahern DK. Cognitive behavior therapy for hypochondriasis: a randomized controlled trial. *JAMA*. 2004;291:1464-1470.
9. Greeven A, van Balkom AJ, van der Leeden R, Merkelbach JW, van den Heuvel OA, Spinhoven P. Cognitive behavioral therapy versus paroxetine in the treatment of hypochondriasis: an 18-month naturalistic follow-up. *J Behav Ther Exp Psychiatry*. 2009;40(3):487-496.
10. Fallon BA, Ahern DK, Pavlicova M, Slavov I, Skritskya N, Barsky AJ. A randomized controlled trial of medication and cognitive-behavioral therapy for hypochondriasis. *Am J Psychiatry*. 2017;174(8):756-764.
11. LaFrance WC Jr, Keitner GI, Papandonatos GD, et al. Pilot pharmacologic randomized controlled trial for psychogenic nonepileptic seizures. *Neurology*. 2010;75(13):1166-1173.
12. Speckens AE, van Hemert AM, Spinhoven P, et al. Cognitive behavioural therapy for medically unexplained physical symptoms: a randomized controlled trial. *BMJ*. 1995;311:1328-1332.
13. Hinson VK, Weinstein S, Bernard B, Leurgans SE, Goetz CG. Single-blind clinical trial of psychotherapy for treatment of psychogenic movement disorders. *Parkinsonism Relat Disord*. 2006;12:177-180.
14. Moene FC, Spindhoven P, Hoogduin KA, van Dyck R. A randomized controlled clinical trial on the additional effect of hypnosis in a comprehensive treatment program for inpatients with conversion disorder of the motor type. *Psychother Psychosom*. 2002;71:66-76.
15. Moene FC, Spindhoven P, Hoogduin KA, et al. A randomized controlled clinical trial of a hypnosis-based treatment for patients with conversion disorder, motor type. *Int J Clin Exp Hypn*. 2003;51:29-50.

SUGGESTED READINGS

Allin M, Streeruwitz A, Curtis V. Progress in understanding conversion disorder. *Neuropsychiatr Dis Treat*. 2005;1(3):205-209.

American Psychiatric Association. *Diagnostic and Statistical Manual of Mental Disorders*. 5th ed. Washington, DC: American Psychiatric Association; 2013.

Andrade C, Bhakta SG, Singh NM. Systematic enhancement of functioning as a therapeutic technique in conversion disorder. *Indian J Psychiatry*. 2009; 51(2):134-136.

Ani C, Reading R, Lynn R, Forlee S, Garralda E. Incidence and 12-month outcome of non-transient childhood conversion disorder in the U.K. and Ireland. *Br J Psychiatry*. 2013;202:413-418.

Ataoglu A, Ozcetin A, Icmeli C, Ozbulut O. Paradoxical therapy in conversion reaction. *J Korean Med Sci*. 2003;18:581-584.

Baizabal-Carvallo J, Hallett M, Jankovic J. Pathogenesis and pathophysiology of functional (psychogenic) movement disorders. *Neurobiol Dis*. 2019;127:32-44.

Bakvis P, Spinhoven P, Giltav EJ, et al. Basal hypercortisolism and trauma in patients with psychogenic nonepileptic seizures. *Epilepsia*. 2010;51(5):752-759.

Bakvis P, Spinhoven P, Roelofs K. Basal cortisol is positively correlated to threat vigilance in patients with psychogenic nonepileptic seizures. *Epilepsy Behav*. 2009;16:558-560.

Ballmaier M, Schmidt R. Conversion disorder revisited. *Funct Neurol*. 2005;20(3): 105-113.

Barsky AJ. Assessing the new *DSM-5* diagnosis of somatic symptom disorder. *Psychosom Med*. 2016;78:2-4.

Barsky AJ, Orav EJ, Bates DW. Somatization increases medical utilization and costs independent of psychiatric and medical comorbidity. *Arch Gen Psychiatry*. 2005;62:903-910.

Bass C, Halligan P. Factitious disorders and malingering in relation to functional neurologic disorders. *Handb Clin Neurol*. 2016;139:509-520.

Binzer M, Andersen PM, Kullgren G. Clinical characteristics of patients with motor disability due to conversion disorder: a prospective control group study. *J Neurol Neurosurg Psychiatry*. 1997;63(1):83-88.

Bodde NM, Brooks JL, Baker GA, et al. Psychogenic non-epileptic seizures—diagnostic issues: a critical review. *Clin Neurol Neurosurg*. 2009;111:1-9.

Boeckle M, Liegl G, Jank R, Pieh C. Neural correlates of conversion disorder: overview and meta-analysis of neuroimaging studies on motor conversion disorder. *BMC Psychiatry*. 2015;16:195.

Bourgeois JA, Chang CH, Hilty DM, Servis ME. Clinical manifestations and management of conversion disorders. *Curr Treat Options Neurol*. 2002;4:487-497.

Bowman ES. Why conversion seizures should be classified as a dissociative disorder. *Psychiatr Clin North Am*. 2006;29:185-211.

Brown RJ, Cardeña E, Nijenhuis E, van der Hart O. Should conversion disorder be reclassified as a dissociative disorder in DSM V? *Psychosomatics*. 2007;48:369-378.

Burke MJ, Ghaffar O, Staines WR, Downar J, Feinstein A. Functional neuroimaging of conversion disorder: the role of ancillary activation. *Neuroimage Clin*. 2014;6:333-339.

Carlier I, Wiltens D, van Rood Y, van Veen T, Dekker J, van Hemert AM. Treatment course and its predictors in patients with somatoform disorders: a routine outcome monitoring study in secondary psychiatric care. *Clin Psychol Psychother*. 2018;25:550-564.

Carson A, Hallett M, Stone J. Assessment of patients with functional neurologic disorders. *Handb Clin Neurol*. 2016;139:169-188.

Carson AJ, Ringbauer B, Stone J, McKenzie L, Warlow C, Sharpe M. Do medically unexplained symptoms matter? A prospective cohort study of 300 new referrals to neurology outpatient clinics. *J Neurol Neurosurg Psychiatry*. 2000;68:207-210.

Cloninger CR. Somatoform and dissociative disorders. In: Winokur G, Clayton P, eds. *The Medical Basis of Psychiatry*. 2nd ed. Philadelphia, PA: WB Saunders; 1994:169-192.

Creed FH, Barsky AJ. A systematic review of the epidemiology of somatisation disorder and hypochondriasis. *J Psychosom Res*. 2004;56:391-408.

Creed FH, Davies I, Jackson I, et al. The epidemiology of multiple somatic symptoms. *J Psychosom Res*. 2012;72:311-317.

Deeley Q. Hypnosis as therapy for functional neurologic disorders. *Handb Clin Neurol*. 2016;139:585-595.

Dehoust MC, Schulz H, Härter M, et al. Prevalence and correlates of somatoform disorders in the elderly: results of a European study. *Int J Methods Psychiatr Res*. 2017;26(1):e1550.

Deka K, Chaudhury PK, Bora K, Kalita P. A study of clinical correlates and sociodemographic profile in conversion disorder. *Indian J Psychiatry*. 2007;49(3):205-207.

Delvecchio G, Rossetti MG, Caletti E, et al. The neuroanatomy of somatoform disorders: a magnetic resonance imaging study. *Psychosomatics*. 2019;60:278-288.

Dickinson P, Looper KJ. Psychogenic nonepileptic seizures: a current overview. *Epilepsia*. 2012;53:1679-1689.

Dikel TN, Fennel EB, Gilmore RL. Posttraumatic stress disorder, dissociation, and sexual abuse history in epileptic and nonepileptic seizure patients. *Epilepsy Behav*. 2003;4:644-650.

Eisendrath SJ, Feder A. Management of factitious disorders. In: Feldman MD, Eisendrath SJ, eds. *The Spectrum of Factitious Disorders*. Washington, DC: American Psychiatric Press; 1996:195-213.

Eisendrath S, McNiel D. Factitious physical disorders, litigation, and mortality. *Psychosomatics*. 2004;45:350-353.

Ejareh Dar M, Kanaan RA. Uncovering the etiology of conversion disorder: insights from functional neuroimaging. *Neuropsychiatr Dis Treat*. 2016;12:143-153.

Espay AJ, Aybek S, Carson A. Current concepts in diagnosis and treatment of functional neurological disorders. *JAMA Neurol*. 2018;75(9):1132-1141.

Evren C, Can S. Clinical correlates of dissociative tendencies in male soldiers with conversion disorder. *Isr J Psychiatry Relat Sci*. 2007;44(1):33-39.

Feinstein A. Conversion disorder: advances in our understanding. *CMAJ*. 2011;183(8):915-920.

Feldman M, Feldman J. Tangled in the web: countertransference in the therapy of factitious disorders. *Int J Psychiatry Med*. 1995;25:389-399.

Feldman MD, Hamilton JC, Deemer HN. Factitious disorders. In: Phillips K, ed. *Somatoform and Factitious Disorders*. Washington, DC: American Psychiatric Publishing; 2001:129-166.

Ford CV. *Lies! Lies!! Lies!!! The Psychology of Deceit*. Washington, DC: American Psychiatric Press; 1996.

Ford CV, Folks DG. Conversion disorders: an overview. *Psychosomatics*. 1985;26:371-374, 380-383.

Ganos C, Edwards MJ, Bhatia KP. Posttraumatic functional movement disorders. *Handb Clin Neurol*. 2016;139:499-507.

García-Campayo J, Fayed N, Serrano-Blanco A, Roca M. Brain dysfunction behind functional symptoms: neuroimaging and somatoform, conversive, and dissociative disorders. *Curr Opin Psychiatry*. 2009;22:224-231.

Goldstein LH, Deale AC, Michell-O'Malley SJ, Toone BK, Mellers JDC. An evaluation of cognitive behavioral therapy as a treatment for dissociative seizures: a pilot study. *Cogn Behav Neurol*. 2004;17:41-49.

Goldstein LH, Drew C, Mellers J, Mitchell-O'Malley S, Oakley DA. Dissociation, hypnotizability, coping styles and health locus of control: characteristics of pseudoseizure patients. *Seizure*. 2000;9:314-322.

Goldstein LH, Mellers JDC. Ictal symptoms of anxiety, avoidance behaviour, and dissociation in patients with dissociative seizures. *J Neurol Neurosurg Psychiatry*. 2006;77:616-621.

Griem J, Stone J, Carson A, Kopelman M. Psychologic/functional forms of memory disorder. *Handb Clin Neurol*. 2016;139:407-417.

Harden CL. Pseudoseizures and dissociative disorders: a common mechanism involving traumatic experiences. *Seizure*. 1997;6:151-155.

Hedman E, Axelsson E, Andersson E, Lekander M, Ljótsson B. Exposure-based cognitive-behavioural therapy via the Internet and as bibliotherapy for somatic symptom disorder and illness anxiety disorder: randomised controlled trial. *Br J Psychiatry*. 2016;209:407-413.

Hinson VK, Haren WB. Psychogenic movement disorders. *Lancet Neurol*. 2006;5:695-700.

Hirsch M. The body as a transitional object. *Psychother Psychosom*. 1994;62:78-81.

Hurtwitz TA. Somatization and conversion disorder. *Can J Psychiatry*. 2004;49:172-178.

Kanaan RAA, Craig TKJ, Wessely SC, David AS. Imaging repressed memories in motor conversion disorder. *Psychosom Med*. 2007;69:202-205.

Kleinstäuber M, Witthöft M, Steffanowski A, et al. Pharmacological interventions for somatoform disorders in adults. *Cochrane Database Syst Rev*. 2014;(11):CD010628.

Kozlowska K, Nunn KP, Rose D, Morris A, Ouvrier RA, Varghese J. Conversion disorder in Australian pediatric practice. *J Am Acad Child Adolesc Psychiatry*. 2007;46(1):68-75.

Krahn L, Li H, O'Connor MK. Patients who strive to be ill: factitious disorder with physical symptoms. *Am J Psychiatry*. 2003;160:1163-1168.

Kranick S, Gorrindo T, Hallett M. Psychogenic movement disorders and motor conversion: a roadmap for collaboration between neurology and psychiatry. *Psychosomatics*. 2011;52(2):109-116.

Kroenke K. Efficacy of treatment for somatoform disorders: a review of randomized controlled trials. *Psychosom Med*. 2007;69(9):881-888.

Lacourt TE, Houtveen JH, Smeets HM, Lipovsky MM, van Doornen LJ. Infection load as a predisposing factor for somatoform disorders: evidence from a Dutch General Practice Registry. *Psychosom Med*. 2013;75(8):759-764.

Lawlor A, Kirakowski J. When the lie is the truth: grounded theory analysis of an online support group for factitious disorder. *Psychiatry Res*. 2014;218(1-2):209-218.

Leary PM. Conversion disorder in childhood—diagnosed too late, investigated too much? *J R Soc Med*. 2003;96:436-438.

Lee S, Creed F, Ma Y, Leung C. Somatic symptom burden and health anxiety in the population and their correlates. *J Psychosom Res*. 2015;78:71-76.

Levenson JL, Sharpe M. The classification of conversion disorder (functional neurologic symptom disorder) in ICD and DSM. *Handb Clin Neurol*. 2016;139:189-192.

Li Q, Xiao Y, Li Y, et al. Altered regional brain function in the treatment-naive patients with somatic symptom disorder: a resting-state fMRI study. *Brain Behav*. 2016;6(10):e00521. doi:10.1002/brb3.521.

Mace CJ, Trimble MR. Ten-year prognosis of conversion disorder. *Br J Psychiatry*. 1996;169:282-288.

Manchikanti L, Giordano J, Boswell MV, Fellows B, Machukonda R, Pampati V. Psychological factors as predictors of opioid abuse and illicit drug use in chronic pain patients. *J Opioid Manag*. 2007;3(2):89-100.

Masuda D, Hayashi Y. A case of dissociative (conversion) disorder treated effectively with haloperidol: an adolescent boy who stopped talking. *Seishin Igaku (Clinical Psychiatry)*. 2003;45:663-665.

Messina A, Fogliana AM. Valproate in conversion disorder: a case report. *Case Rep Med*. 2010;2010:205702.

Milrod B. A 9-year-old with conversion disorder, successfully treated with psychoanalysis. *Int J Psychoanal*. 2002;83:623-631.

Muskin PR, Feldhammer T, Gelfand JL, Strauss DH. Maladaptive denial of physical illness: a useful new diagnosis. *Int J Psychiatry Med*. 1998;28:503-517.

Nash SS, Kent LK, Muskin PR. Psychodynamics in medically ill patients. *Harv Rev Psychiatry*. 2009;17(6):389-397.

Ness D. Physical therapy management for conversion disorder: case series. *J Neurol Phys Ther*. 2007;31:30-39.

North CS. The classification of hysteria and related disorders: historical and phenomenological considerations. *Behav Sci (Basel)*. 2015;5(4):496-517.

Noyes R, Carney CP, Hillis SL, Jones LE, Langbehn DR. Prevalence and correlates of illness worry in the general population. *Psychosomatics*. 2005;46:529-539.

olde Hartman T, Borguis M, Lucassen P, van de Laar F, Speckens A, van Weel C. Medically unexplained symptoms, somatisation disorder and hypochondriasis: course and prognosis. A systematic review. *J Psychosom Res*. 2009;66:363-377.

Oulis P, Kokras N, Papadimitriou GN, Masdrakis VG. Adjunctive low-dose amisulpride in motor conversion disorder. *Clin Neuropharmacol*. 2009;32(6):342-343.

Pareés I, Brown H, Nuruki A, et al. Loss of sensory attenuation in patients with functional (psychogenic) movement disorders. *Brain*. 2014;137:2916-2921.

Perez DL, LaFrance WC Jr. Nonepileptic seizures: an updated review. *CNS Spectr*. 2016;21(3):239-246.

Perez DP, Barsky A, Daffner K, Silbersweig D. Motor and somatosensory conversion disorder: a functional unawareness syndrome? *J Neuropsychiatry Clin Neurosci*. 2012;24:141-151.

Phillips M, Ward N, Ries R. Factitious mourning: painless patienthood. *Am J Psychiatry*. 1983;140(4):420-425.

Plassman R. Inpatient and outpatient long-term psychotherapy of patients suffering from factitious diseases. *Psychother Psychosom*. 1994;62:96-107.

Plassman R. Münchhausen syndromes and factitious diseases. *Psychother Psychosom*. 1994;62:7-26.

Plassman R. Structural disturbances in the body self. *Psychother Psychosom*. 1994;62:91-95.

Plug L, Sharrack B, Reuber M. Seizure metaphors differ in patients' accounts of epileptic and psychogenic nonepileptic seizures. *Epilepsia*. 2009;50(5):994-1000.

Reinsberger C, Perez DL, Murphy MM, Dworetzky BA. Pre- and postictal, not ictal, heart rate distinguishes complex partial and psychogenic nonepileptic seizures. *Epilepsy Behav*. 2012;23(1):68-70.

Reuber M, Rawlings GH. Nonepileptic seizures—subjective phenomena. *Handb Clin Neurol*. 2016;139:283-296.

Roelofs K, Keijsers GP, Hoogduin KA, Näring GW, Moene FC. Childhood abuse in patients with conversion disorder. *Am J Psychiatry*. 2002;159:1908-1913.

Rosebush PI, Mazurek MF. Treatment of conversion disorder in the 21st century: have we moved beyond the couch? *Curr Treat Options Neurol*. 2011;13(3):255-266.

Scher LM, Knudsen P, Leamon M. Somatic symptom and related disorders. In: Hales RE, Yudofsky SC, Roberts LW, eds. *The American Psychiatric Publishing Textbook of Psychiatry*. 6th ed. Arlington, VA: American Psychiatric Publishing; 2014:531-556.

Schrader H, Bøhmer T, Aasly J. The incidence of diagnosis of Munchausen syndrome, other factitious disorders, and malingering. *Behav Neurol*. 2019;2019:3891809.

Schweitzer J, Zafar U, Pavlicova M, Fallon BA. Long-term follow-up of hypochondriasis after selective serotonin reuptake inhibitor treatment. *J Clin Psychopharmacol*. 2011;31:365-368.

Shapiro AP, Teasell RW. Behavioral interventions in the rehabilitation of acute v. chronic non-organic (conversion/factitious) motor disorders. *Br J Psychiatry*. 2004;185:140-146.

Spence SA, Crimlisk HL, Cope H, et al. Discrete neurophysiological correlates in prefrontal cortex during hysterical and feigned disorder of movement. *Lancet*. 2000;355:1243-1244.

Spitzer C, Barnow S, Gau K, Freyberger HJ, Grabe HJ. Childhood maltreatment in patients with somatization disorder. *Aust N Z J Psychiatry*. 2008;42:335-341.

Steinhausen HC, von Aster M, Pfeiffer E, Göbel D. Comparative studies of conversion disorders in childhood and adolescence. *J Child Psychol Psychiatry*. 1989;30:615-621.

Stenner MP, Haggard P. Voluntary or involuntary? A neurophysiologic approach to functional movement disorders. *Handb Clin Neurol*. 2016;139:121-129.

Stone J. Functional neurological disorder (FND): a patient's guide. Neurosymptoms.org Web site. https://www.neurosymptoms.org. Accessed December 02, 2020.

Stone J, Aybek S. Functional limb weakness and paralysis. *Handb Clin Neurol*. 2016;139:213-228.

Stone J, Warlow C, Sharpe M. The symptom of functional weakness: a controlled study of 107 patients. *Brain*. 2010;133:1537-1551.

Stone J, Zeman A, Simonotto E, et al. FMRI in patients with motor conversion symptoms and controls with simulated weakness. *Psychosom Med*. 2007;69(9):961-969.

Strauss DH, Spitzer RL, Muskin PR. Maladaptive denial of physical illness: a proposal for DSM-IV. *Am J Psychiatry*. 1990;147:1168-1172.

Sutherland A, Rodin G. Factitious disorders in a general hospital setting: clinical features and a review of the literature. *Psychosomatics*. 1990;31:392-399.

Syed TU, Arozullah AM, Loparo KL, et al. A self-administered screening instrument for psychogenic nonepileptic seizures. *Neurology*. 2009;72(19):1646-1652.

Teasell RW, Shapiro AP. Strategic-behavioral intervention in the treatment of chronic nonorganic motor disorders. *Am J Phys Med Rehabil*. 1994;73:44-50.

Tolchin B, Martino S, Hirsch LJ. Treatment of patients with psychogenic nonepileptic attacks. *JAMA*. 2019;321(20):1967-1968.

van Beilen M, de Jong BM, Gieteling EW, Renken R, Leenders KL. Abnormal parietal function in conversion paresis. *PLoS One*. 2011;6(10):e25918. doi:10.1371/journal.pone.0025918.

Viederman M. Metaphor and meaning in conversion disorder: a brief active therapy. *Psychosom Med*. 1995;57:403-409.

Voon V, Cavanna AE, Coburn K, Sampson S, Reeve A, LaFrance WC Jr. Functional neuroanatomy and neurophysiology of functional neurological disorders (conversion disorder). *J Neuropsychiatry Clin Neurosci*. 2016;28(3):168-190.

Voon V, Lang AE. Antidepressant treatment outcomes of psychogenic movement disorders. *J Clin Psychiatry*. 2005;66:1529-1534.

Vuilleumier P. Chicherio C, Assal F, Schwartz S, Slosman D, Landis T. Functional neuroanatomical correlates of hysterical sensorimotor loss. *Brain*. 2001;124:1077-1090.

Ward NS, Oakley DA, Frackowiak RS, Halligan PW. Differential brain activations during intentionally simulated and subjectively experienced paralysis. *Cogn Neuropsychiatry*. 2003;8:295-312.

Williams DT, Harding KJ, Fallon BA. Somatoform disorders. In: Rowland LP, Pedley TA, eds. *Merritt's Neurology*. 12th ed. Philadelphia, PA: Lippincott Williams & Wilkins; 2010:1069-1075.

Wise MG, Rundell JR. *Clinical Manual of Psychosomatic Medicine: A Guide to Consultation-Liaison Psychiatry*. Washington, DC: American Psychiatric Publishing; 2005.

Yates G, Bass C. The perpetrators of medical child abuse (Munchausen syndrome by proxy)—a systematic review of 796 cases. *Child Abuse Negl*. 2017;72:45-53.

Yates G, Feldman M. Factitious disorder: a systematic review of 455 cases in the professional literature. *Gen Hosp Psychiatry*. 2016;41:20-28.

Zonneveld LN, van Rood YR, Timman R, Kooiman CG, Van't Spijker A, Busschbach JVJ. Effective group training for patients with unexplained physical symptoms: a randomized controlled trial with a non-randomized one-year follow-up. *PLoS One*. 2012;7(8):e42629.

Neurologic Rehabilitation 157

Joel Stein and Heidi Schambra

KEY POINTS

1. Rehabilitation is a key component of management for many neurologic disorders, such as stroke, brain injury, spinal cord injury, multiple sclerosis, and brain tumors.
2. Central nervous system plasticity underlies recovery of neurologic impairments and may be facilitated through goal-directed activity.
3. Compensatory approaches are often needed to restore maximum functional independence when neurologic recovery proves insufficient alone.
4. Rehabilitation commonly requires a team approach. Physician leadership and advocacy is important to coordinate care and make certain patients receive appropriate rehabilitation services.

INTRODUCTION

Neurologic disorders commonly cause impairments that impede intellectual and physical activities. Neurologists, physiatrists, and other physicians play an important dual role: (1) prescribing and monitoring rehabilitation therapies to maximize functional recovery and (2) optimizing patient health to maximize engagement in these therapies. The type and timing of these therapies substantially contribute to the quality of life for patient and family. However, access to rehabilitation services can vary significantly, and many individuals with acute and chronic neurologic conditions do not receive adequate rehabilitation therapy. With proper training and equipment, these individuals may improve in their independence, their access to the community, and the ease with which caregivers assist them. The medical and neurologic management of patients with neurologic injury begins in the acute setting and continues throughout the course of care, through varied institutional and home settings. Understanding the scope of neurorehabilitation is thus essential in the management continuum of acute to chronic neurologic disorders.

The World Health Organization's *International Classification of Functioning, Disability and Health* defines limitations caused by disease in three broad categories: bodily functions, activity participation, and societal participation. These definitions provide a framework for understanding the impact of disease on personal independence and integration into society and can furthermore help identify patients who may benefit from rehabilitation. The planning and prescription of a rehabilitation program for a neurologically impaired individual requires characterization of the neurologic disorder in terms of natural history, localization, and extent of nervous system involvement; determination of cognitive and physical impairments and their resulting activity limitations; and understanding these disabilities in the context of the patient's physical and social environment. Combining this information with knowledge of available resources for postacute care, the type and intensity of rehabilitation therapies can be planned.

Impairments caused by neurologic disease or injury frequently affect an individual's ability to perform functions, such as activities of daily living (ADLs) and instrumental ADLs. The ADLs include the basic activities an individual performs daily, including feeding, grooming, dressing, toileting, bathing, and mobility. Instrumental activities of daily living are activities beyond basic self-care that allow a patient to participate in the home and community, such as meal preparation, housekeeping, laundry, shopping, using a telephone/technology, driving a car/using transportation, and money management.

A broad range of neurologic disorders may benefit from rehabilitation interventions. These include acute neurologic disorders, such as stroke, traumatic brain injury, and spinal cord injury; fluctuating disorders, such as multiple sclerosis and neurooncology; and progressive disorders, such as Parkinson disease, neuropathies, amyotrophic lateral sclerosis, and others. For individuals with acute neurologic events, a postacute period of rehabilitation, either in an inpatient rehabilitation facility (IRF) or hospital or in a skilled nursing facility (SNF), is commonly necessary and can be an important component of the patient's overall recovery. For chronic or progressive conditions, inpatient rehabilitation is unusual, and most care is provided in an outpatient setting. Limitations in the duration and amount of rehabilitation services covered by insurance are common and may result in suboptimal care for individuals whose needs exceed the covered services. Novel technologies, such as telemedicine, wearable robotics, and others, may provide an opportunity to move more rehabilitation into the home and serve as extenders of rehabilitation therapies at lower cost.

COMPENSATION AND RECOVERY

Two principal approaches are used in neurorehabilitation programs: compensating for impairment and reducing impairment by enhancing neurologic recovery. *Compensation* teaches techniques that leverage preserved neurologic function to adapt to and manage neurologic impairment. Often, equipment of various types (eg, a brace, walker, tablet computer) is a component of a compensatory strategy. For example, a person with a paralyzed arm can be trained in one-handed techniques using the nonparetic arm, a patient unable to walk can learn to use a cane and a leg

brace, or a patient with severe dysarthria can communicate with a tablet computer using speech synthesis. Although compensation yields faster results and improves functional independence by reducing disability at activity level, it does little to diminish the original neurologic impairment. Troublingly, rodent models suggest that training compensation after stroke (eg, using the nonparetic limb to grasp a food pellet) impedes the beneficial effects of training to reduce impairment in the paretic limb.

Enhancing neurologic *recovery* entails the augmentation of endogenous neuroplastic processes and the facilitation of functional return. A mainstay of this approach is the practice of functional, task-specific activities. For example, a patient can practice reaching and grasping with a paretic arm to improve motor control, a patient with gait dysfunction can practice locomotion, or a patient with visuospatial neglect can practice shifting attention to the neglected space. This approach requires intensive training for weeks to months and contributes to the biologic restoration of function. Other strategies to enhance neurologic recovery include noninvasive brain stimulation with repetitive transcranial magnetic stimulation or transcranial electrical stimulation, neuropharmacology, peripheral and vagal nerve stimulation, and potentially stem cells and/or growth factors. Because these strategies are often insufficient to restore neurologic function, many patients require compensatory approaches to achieve adequate function in daily life.

Some combination of compensatory and recovery training is commonly used in neurorehabilitation programs. However, given the short lengths of stay in postacute rehabilitation facilities and the cost-benefit considerations of compensatory and impairment training, a personalized selection of rehabilitation approaches is warranted. Tailoring the rehabilitative approach based on recovery potential is an area of current clinical research. Knowing a patient's potential would enable clinicians to set realistic rehabilitation goals and could steer the rehabilitation team toward the most appropriate therapeutic approach. For example, a recently developed algorithm uses a patient's early motor function and corticospinal tract integrity (as determined by transcranial magnetic stimulation) to both predict motor recovery and guide rehabilitation approaches, including the incorporation of compensatory strategies.

In addition to these strategies to promote recovery of motor dysfunction, a variety of novel methods have been developed to facilitate motor training. These include robot-aided rehabilitation, which has been found to be modestly effective compared with conventional clinical rehabilitation. However, superiority has not been convincingly demonstrated relative to dose-matched upper limb exercise or gait training for stroke patients. Virtual reality, mirror therapy, and mental imagery practice are also under study as methods to either augment conventional movement training or to enhance engagement in treatment.

Exercises to increase the strength of muscle groups are also commonly used for stroke survivors and individuals with brain injuries. Of note, cortical map reorganization in animal models does not result from resistance training, and there is insufficient evidence from clinical trials to support the use of resistance training to aid in recovery LEVEL 3.[1]

Most patients who have marked neurologic injury, particularly those with stroke, are deconditioned and have limited exercise capacity and aerobic reserve. Rehabilitation therapy with mobilization and exercise helps to increase general conditioning and tolerance for exercise. In animal models, aerobic exercise increases production of brain-derived neurotrophic factor, which supports synaptogenesis and synapse stabilization. A meta-analysis of human stroke rehabilitation trials showed improvement in disability with aerobic cardiorespiratory training, largely attributed to improved gait and balance metrics LEVEL 1.[1]

For some conditions, such as complete spinal cord injury or amyotrophic lateral sclerosis, recovery may not a realistic goal. Novel compensatory devices may provide a path toward restored function. For individuals with paraplegia, exoskeletal robotic systems for the lower limbs allow resumption of walking in a limited fashion for some individuals. Neuroprostheses remain experimental at present but hold the potential to bypass damaged parts of the nervous system to restore a portion of lost abilities. Some of these use electroencephalography or other noninvasive systems, whereas others use cortical electrodes and computational systems to detect and decode motor intent and to convey commands to a patient's arm, a robotic arm, or a computer or other device.

NEUROPLASTICITY AND RECOVERY

Following focal injury, the central nervous system (CNS) undergoes long-lasting structural and functional changes. Neuroplasticity is upregulated after injury, and this enhanced state can be engaged to maximize the activity-dependent plasticity that results from rehabilitation training. Injury-induced plasticity after CNS injury and activity-dependent plasticity share many common mechanisms and substrates. Importantly, it is the interaction of both that produces maximal recovery gains.

Injury-Induced Plasticity

Injury to the CNS activates biologic recovery processes. Elucidating the mechanisms of neurorecovery is a rapidly evolving field. Animal models of CNS injury, particularly ischemic stroke, have helped build our understanding of the complex molecular and cellular aspects of recovery in the brain and spinal cord. Rapid, significant changes in gene expression and protein production occur after ischemic injury and may help or hinder plasticity in perilesional and remote interconnected areas.

At the cellular level, processes that promote plasticity include neurogenesis and angiogenesis, axonal sprouting, dendritic arborization, synaptogenesis and silent synapse unmasking, changes in synaptic strength, and changes in glutamatergic and GABAergic tone. Processes that limit plasticity include excitotoxicity, delayed neuronal death, edema, inflammation, expression of growth inhibitors, and glial scar formation. Free radical formation, astrocyte activation, and slow synchronized depolarizations have both helpful and harmful effects. Importantly, these processes peak and fade within the first weeks to early months after injury, underscoring the limited time window for pairing with rehabilitation training.

Studies targeting these plasticity modifiers, either by upregulating or downregulating their effects, are actively underway. For example, in animal models, selective serotonin reuptake inhibitors increase expression of brain-derived neurotrophic factor and synaptogenesis and prolong the window of recovery. Although some preliminary evidence in humans suggested fluoxetine might enhance motor recovery, recent larger clinical trials have failed to confirm effects on disability.

In traumatic brain injury, amantadine has been shown to accelerate recovery but not to alter ultimate outcome LEVEL 2.[2]

Other medications continue to be evaluated as potential recovery agents in preclinical and clinical trials, but none are currently considered standard care.

Activity-Dependent Plasticity

Using training to capitalize on neuroplasticity after brain injury is a key objective of neurorehabilitation. The optimal type, timing, and dose of training required to maximize activity-dependent plasticity after CNS injury is an active area of basic and clinical research. Some direction about best practices can be gleaned from animal stroke studies in the motor system. One clear principle that has emerged from animal models is that injury-induced plasticity needs to interact with paretic limb training in order to promote recovery. For example, in a nonhuman primate model of stroke, untrained animals achieved only half of the behavioral function of their trained counterparts, even when given twice as long to recover—in other words, injury-induced plasticity alone is insufficient to restore function. In a rodent model of stroke, trained rats show both increased perilesional synapse formation and improved behavioral function compared to their untrained counterparts. These results suggest that physical training, eliciting activity-dependent plasticity in its own right, engages with injury-induced plasticity to produce better functional gains.

How early to begin therapy is a point of debate, given concerns about glutamate excitotoxicity after CNS injury. In rodent models of stroke, paretic limb training started 5 days after stroke results in greater functional gains than the same amount of training started 30 days after stroke. However, there is some concern that too much therapy very early after injury may have adverse consequences. A large multicenter pragmatic randomized controlled trial (RCT) of early mobilization after stroke, the a very early rehabilitation trial after stroke (AVERT) trial, found that more aggressive mobilization within the first 24 hours poststroke resulted in poorer long-term outcomes LEVEL 1.[3] Even outside of the 24-hour window poststroke, optimal dosing and timing of therapy remains unclear, as demonstrated in a randomized, single-blind phase II trial that found that a higher dose of constraint-induced movement therapy initiated within 2 weeks poststroke resulted in less motor improvement.

The dose of therapy is also an issue of exploration. From animal and human motor learning studies, it is clear that high doses of repetitive, goal-directed practice are required for long-term skill gains. Yet, an RCT of varying levels of upper limb task-oriented training poststroke failed to demonstrate any advantage for higher doses LEVEL 1,[4] and an RCT of high-dose training delivered 6 months or more poststroke showed little effect on function LEVEL 1.[5] Overall, these studies demonstrate that we do not yet know the optimal dose, timing, or duration of rehabilitation after stroke or other neurologic injuries.

LEVELS OF CARE

Rehabilitation services are provided in a variety of settings and at varied levels of intensity and duration. Postacute care can occur in IRFs, in SNFs, from home health agencies, or at outpatient facilities. At IRFs, patients receive 3 hours of therapy 5 to 7 days per week for usually less than 1 month. There is daily physician (typically physiatrist or neurologist) oversight. At SNFs, patients receive 0.5 to 2 hours of therapy 5 to 6 days per week for usually less than 2 months. There is weekly to monthly physician oversight, usually by a general practitioner, internist, or geriatrician. In outpatient therapy, be it in-home or at a facility, patients receive 0.5 to 1 hour of therapy 2 to 3 times per week, durations average 1 month, and physician oversight is typically very limited.

In an IRF, the most common neurologic diagnoses are stroke, traumatic and nontraumatic brain injuries, and spinal cord injury; also seen are brain neoplasms, multiple sclerosis, Parkinson disease, and peripheral neuropathies (particularly critical illness neuromyopathy and acute inflammatory polyneuropathy). For patients hospitalized with acute neurologic injury, functional outcome is improved by an experienced, coordinated interdisciplinary team providing a comprehensive rehabilitation program. Stroke patients who receive rehabilitation therapies on a stroke rehabilitation unit have better functional outcomes and shorter hospital stays than those treated on a general neurology ward, and benefits persist over time. Similarly, stroke patients admitted to hospital-based intensive rehabilitation programs have better functional recovery and are more likely to return home than those treated in a low-intensity rehabilitation program at an SNF. For these reasons, the American Heart Association's Stroke Rehabilitation Guidelines recommend that "stroke survivors who qualify for and have access to IRF care receive treatment in an IRF in preference to a SNF."

Multiple considerations go into determining the best placement for the medically stable neurologic patient. For admission to an IRF, the patient must have impairments that necessitate at least two therapy types (see the following text), must tolerate at least 3 hours of therapy daily, and must have 24-hour medical and nursing needs. Placement at an SNF typically occurs when the patient is unable to tolerate a high intensity of rehabilitation or has low capacity for functional improvement and has reduced medical and nursing needs. Outpatient therapy is appropriate for patients with mild and limited deficits or follows a course of inpatient rehabilitation to extend functional training at home or in the community. Interestingly, availability of postacute care has been demonstrated to be an important predictor of its use. Nonclinical factors that strongly influence placement include availability, convenience, distance to provider, demographic factors (age, race, and marital status), insurance status, local practice patterns, and characteristics of the discharging hospital (size, ownership, status as a teaching hospital, etc).

THE DISCIPLINES

A comprehensive inpatient neurorehabilitation program requires an interdisciplinary team composed of the physician, physical therapist, rehabilitation nurse, occupational therapist, speech language pathologist, neuropsychologist, social worker, and recreational therapist. All team members participate in formulating a treatment and discharge plan, working together to attain collective goals of reducing patient disability and in educating and training the patient and family in preparation for return home. Importantly, patients must also shift from being passive recipients of medical treatment in the acute setting to being active participants in their own therapy to maximize their neurologic recovery.

Physician

The physician, as team leader, defines the type and prognosis of the neurologic disorder, sets realistic treatment goals, and coordinates the rehabilitation services. A major role of the physician is to optimize patient engagement in therapy through management

of medical issues (eg, orthostatic hypotension, depression, pain, constipation or incontinence, infection, nutrition, and hydration). With the team, the physician reviews progress toward attaining functional goals that allow the patient to return home. Roadblocks, alternative strategies, and discharge dispositions are discussed at weekly team rounds. Postdischarge plans for home care and outpatient therapy are coordinated with the patient and family.

Rehabilitation Nursing

Rehabilitation nurses provide general medical and more targeted nursing for patients with neurologic dysfunction. A major nursing focus for the neurologically impaired patient is prevention of pressure ulcers due to immobility and management of bowel and bladder incontinence (see the following section). In the inpatient setting, the nurse helps incorporate skills learned in therapy into the patient's daily routines. The nurse also educates the patient and family in medication administration, self-catheterization, and skin care.

Physical Therapy

Physical therapy focuses on bed mobility, transferring to chair or toilet, ambulating and/or wheelchair mobility, and stair climbing. Techniques and orthotics are chosen to maximize safe and independent mobility; to optimize energy efficiency; to prevent decubitus skin ulcers, tendon contractures, and falls; and to enhance motor recovery. Limitations in mobility and sensorimotor function are addressed by strengthening exercises, gait and balance training, and stretching. The PTs also concentrate on musculoskeletal and orthopedic injuries. Typical problems associated with neurologic injury include musculoskeletal pain, muscle spasm, joint pain, heterotopic ossification, and contractures.

Leg and trunk weakness, impaired postural reflexes, ataxia, proprioceptive loss, and visuospatial neglect may all interfere with ambulation and are actively managed. Bracing, assistive devices (eg, cane, walker), and a wheelchair are used as compensatory strategies for safe completion of ADLs. The feasibility of restoring ambulation depends on diagnosis, severity of neurologic impairment, and comorbid conditions (eg, sarcopenia in elderly patients). For example, for most stroke survivors, ambulation is usually ultimately achievable through rehabilitation even if nonambulatory in the acute phase, often with the use of an ambulatory aid such as a cane and/or a brace for the ankle. When ambulation is not possible, such as for many individuals with spinal cord injury, mobility is attained through training in the use of a wheelchair of the correct size and height, occasionally employing a special seat to prevent skin breakdown or cushions for trunk support. For individuals who cannot self-propel a manual wheelchair, a power wheelchair can often be used for independent mobility. Exoskeletal-powered leg braces have been developed, which can provide limited walking ability for individuals with paraplegia (Fig. 157.1), although cost and device limitations remain barriers to widespread adoption at present.

FIGURE 157.1 Exoskeletal robotic leg braces for individuals with paraplegia. (Courtesy of ReWalk.)

Occupational Therapy

Occupational therapy (OT) focuses on restoring ability to perform ADLs and addressing limitations in the patient's occupational and social role caused by neurologic injury. The OTs treat patients with the goal of enabling patients to return to home, community, and work. Typically, OTs concentrate on impairments affecting the use of the arms and hands, such as weakness, sensory loss, ataxia, and abnormal tone. Improving motor skills is only one of the important components in enhancing performance of ADLs. The OTs also address impaired attention, judgment, cognition, and memory; visuospatial neglect; and apraxia. Training focuses on restoring upper extremity functional skills that are important for self-care at home and autonomy in the community. If necessary, adaptive aids are used to increase the use of the impaired arm and hand, such as hand and wrist orthoses, reachers, Velcro closures, and built-up utensils. When the impairment is unilateral and severe, an occupational therapist may select adaptive equipment and train the patient and family to compensate. Advanced programs may include learning special one-sided techniques, such as driving with the left hand and foot.

The OTs also optimize safety and functionality in the home environment by training the patient and the family in use of adaptive equipment (eg, tub benches, elevated toilet seats, ramps, grab bars, safety rails).

Speech, Language, and Cognitive Therapy

The speech-language pathologist (SLP) focuses on dysphagia (see the following section), dysarthria, aphasia, and cognitive dysfunction in the neurologically impaired patient.

Treatment of dysarthria aims to improve intelligibility and includes methods such as slowing and exaggerating articulation, increasing breath support, and pacing speech rate. For aphasia, the SLP identifies areas of strength and weakness in receptive and expressive language. Areas of strength may then be used for compensatory purposes, such as using better preserved written expression in lieu of verbal expression. Therapeutic approaches vary widely but can employ visual and verbal cueing, melodic intonation (using preserved singing ability to facilitate speech), and constraint-induced language therapy (limiting the use of compensatory actions by the patient, such as pointing at objects, "forcing" the patient to verbally express themselves). For example, use of visual imagery as an internal cue may help to overcome the word blocking of expressive aphasia.

For cognitive rehabilitation, speech and occupational therapists collaborate on program development and implementation, and all members of the rehabilitation team contribute. Neurobehavioral impairments and how they interfere with function are first identified. Diffuse brain injury may affect several cognitive domains, and the therapeutic approach is tailored to the nature and complexity of the symptoms. For example, inattention and distractibility may preclude participation in group activities such as business meetings, or memory impairment may lead to failure at school. In diffuse or multifocal brain injury that impairs attention, behavior, cognition, and language, it is necessary to provide a structured program that minimizes distractions by controlling the noise and activity in the environment. Strategies are used to help compensate for impairments across multiple cognitive domains. For example, memory cues help to improve retention of techniques learned in physical therapy or OT; breaking a task into individual steps and then teaching one step at a time helps to overcome attentional and constructional problems. Finally, the SLP educates the patient and family about aphasia and other cognitive problems. This is essential to reduce frustration with impaired communication, memory, and abnormal behavior.

Psychology and Neuropsychology

Psychologist and neuropsychologists concentrate on the mood, behavioral, and cognitive problems that occur after injury to the brain. Neuropsychologists may perform detailed neuropsychological testing of the patient to identify cognitive and affective disorders and make therapeutic recommendations to the team. Psychologists and neuropsychologists may also counsel the patient and family in the management of their disorders.

Social Work

Social workers identify concrete resources that will enable the patient to succeed at home, such as finances, availability of caregivers, and community services. They provide counseling, support, and education to the family, who often take on a caregiving role for the patient. Social workers or case managers may directly interact with the patient's insurance provider, supplying medical updates and obtaining authorizations. They also coordinate home services and delivery of adaptive equipment and facilitate discharge planning.

Recreational Therapy

Recreational therapy focuses on the patient's social and emotional health through use of enjoyable recreation, with a goal of reintegration into the community. Group activities such as games, karaoke, gardening, and arts and crafts encourage socialization and engage patients physically and cognitively.

SPECIALIZED NEUROLOGIC AND MEDICAL MANAGEMENT

Dysphagia

Swallowing is a complex act involving voluntary and involuntary muscles including facial, lingual, masticatory, pharyngeal, esophageal, and respiratory muscles. Neurologic disorders that disturb coordinated contraction and interaction of these muscles can cause dysphagia and, secondarily, dehydration, malnutrition, aspiration pneumonia, and airway obstruction. Dysphagia evaluation is indicated for patients who have any of these complications; who report coughing, choking, or nasal regurgitation while eating; who are dysarthric; or who have a disease commonly associated with dysphagia, such as motor neuron disease, myasthenia gravis, or brainstem stroke. Dysphagia is identified with bedside testing and with video fluoroscopic or fiberoptic endoscopic evaluations of swallowing. Therapeutic approaches include altering the consistency of foods and thickening liquids, using head repositioning strategies such as a chin-tuck technique, and reducing the rate and amount of intake.

Bladder and Bowel Dysfunction

Loss of control of bladder or bowel emptying is commonly associated with several neurologic disorders and should be addressed by comprehensive neurorehabilitation programs. The cause of impaired bladder emptying or sphincter incompetence, and therefore the treatment, depends on the site of the neural injury. Evaluation includes clinical observations about incontinence and retention; addressing communication and mobility contributors (eg, difficulty in communicating toileting needs or reaching the bathroom); search for nonneurologic factors, such as infection or mechanical problems, particularly urethral obstruction by prostatic enlargement; and cystometrographic measurements of bladder and sphincter functions. The neurorehabilitation nurse plays a crucial role in the treatment of bladder and bowel disorders, including implementation of voiding programs and training patient and family to use urethral catheters.

The goal of bladder rehabilitation is to allow the bladder to fill under low pressure to a volume of 200 to 300 mL, then empty, whether volitionally or mechanically and without incontinence between emptying. Incontinence characterized by bladder hyperreflexia, in which the bladder contracts at low urine volumes and voluntary inhibition of bladder contraction and sphincter relaxation fails, commonly complicates cerebral, particularly frontal lobe, injury. Lack of awareness or indifference may impede achievement of continence, but neurologic recovery usually reduces incontinence. Prompted voiding at 2-hour intervals contributes to regaining continence. Detrusor-sphincter dyssynergia, in which dissociated bladder contraction and sphincter relaxation results in the bladder contracting against a closed sphincter, is usually a consequence of lower brainstem or spinal cord lesions. Bladder emptying, if it occurs at all, is incomplete and occurs at high vesicular pressure. Treatment includes bladder antispasmodic drugs and intermittent catheterization at 4- to 6-hour intervals. Hydronephrosis, renal failure, and bladder wall hypertrophy with consequent volume loss are potential complications of a chronically high-pressure bladder. Conversely, peripheral nerve diseases involving the nerves innervating the bladder may cause bladder flaccidity. Bladder emptying, at low pressures, is incomplete, and incontinence occurs between voluntary voiding. Cholinergic agents (e.g. Urecholine) may improve emptying, but intermittent catheterization is often necessary.

Neurologic disorders leading to immobility, decreased fluid access and intake, and loss of cortical control over rectal sphincters may cause severe constipation or impaction. Prevention combines a high-fiber diet; adequate hydration; stool softeners; and regularly scheduled evacuation using suppositories, enemas, and/or digital rectal stimulation. Bowel incontinence can also be lessened by scheduled toileting, providing regular clearance of the rectal vault.

TABLE 157.1 Morbidity in Rehabilitation

Preventable Morbidities	Common Preexisting Comorbidities Requiring Regulation	Secondary Effects
• Deep vein thrombosis • Recurrent or progression of stroke • Aspiration pneumonia • Urinary tract infections • Fecal impaction • Pressure ulcers • Falls • Dehydration • Malnutrition • Influenza or pneumococcus infection • Accelerated osteoporosis	• Hypertension • Diabetes • Osteoarthritis • Coronary artery disease • COPD • Peripheral vascular disease • Substance abuse • Impairments of hearing and vision • Poor dentition • Sleep apnea	• Partial or generalized seizures • Depression • Cognitive impairment • Intracerebral bleeding • Hydrocephalus • CSF leakage • Autonomic dysreflexia • Heterotopic ossification • Surgical site complications • Infection • Fever • Pain • Musculoskeletal injury

Abbreviations: COPD, chronic obstructive pulmonary disease; CSF, cerebrospinal fluid.

Medical Care

An important component of rehabilitation neurology is the prevention of secondary complications, the optimized management of existing comorbidities, and the early recognition and treatment of known complications or effects of injury (Table 157.1). Comorbidities are extremely common and are often dysregulated or exacerbated by the changes in activity, diet, and medications that occur after sudden neurologic injury. For example, poststroke rehabilitation has goals of gradual control of elevated blood pressure, proper control of diabetes, dyslipidemia management, appropriate administration of anticoagulation or antiplatelet agents, and counseling on lifestyle changes (eg, cessation or reduction of alcohol and tobacco use, increase in exercise) LEVEL 1.[6] Low molecular weight heparins are used to prevent deep vein thrombosis; appropriate oral consistencies are chosen to minimize the risk of aspiration and to maximize nutrition and hydration; and preventative measures are put in place to minimize the risk of falls. Poststroke depression is common and can be effectively treated with antidepressant medications such as citalopram or other selective serotonin reuptake inhibitors.

The goal of the physician is to optimize the medical management and lifestyle changes that will reduce comorbidities and secondary effects of brain injury and to coordinate with the patient's primary physician for continuation of optimum outpatient care.

LEVEL 1 EVIDENCE

1. Saunders DH, Sanderson M, Brazzelli M, Greig CA, Mead GE. Physical fitness training for stroke patients. *Cochrane Database Syst Rev*. 2013;(10):CD003316.
2. Giacino JT, Whyte J, Bagiella E, et al. Placebo-controlled trial of amantadine for severe traumatic brain injury. *N Eng J Med*. 2012;366(9):819-826.
3. Bernhardt J, Langhorne P, Lindley RI, et al. Efficacy and safety of very early mobilisation within 24 h of stroke onset (AVERT): a randomised controlled trial. *Lancet*. 2015;386(9988):46-55.
4. Winstein CJ, Wolf SL, Dromerick AW, et al. Effect of a task-oriented rehabilitation program on upper extremity recovery following motor stroke: the ICARE randomized clinical trial. *JAMA*. 2016;315(6):571-581.
5. Lang CE, Strube MJ, Bland MD, et al. Dose response of task-specific upper limb training in people at least 6 months post-stroke: a phase II, single-blind, randomized, controlled trial. *Ann Neurol*. 2016;80(3):342-354.
6. Kernan WN, Ovbiagele B, Black HR, et al. Guidelines for the prevention of stroke in patients with stroke and transient ischemic attack: a guideline for healthcare professionals from the American Heart Association/American Stroke Association. *Stroke*. 2014;45(7):2160-2236.

SUGGESTED READINGS

Ajiboye AB, Willett FR, Young DR, et al. Restoration of reaching and grasping movements through brain-controlled muscle stimulation in a person with tetraplegia: a proof-of-concept demonstration. *Lancet*. 2017;389(10081):1821-1830.

Allred RP, Maldonado MA, Hsu And JE, Jones TA. Training the "less-affected" forelimb after unilateral cortical infarcts interferes with functional recovery of the impaired forelimb in rats. *Restor Neurol Neurosci*. 2005;23(5-6):297-302.

Buntin MB, Garten AD, Paddock S, Saliba D, Totten M, Escarce JJ. How much is postacute care use affected by its availability? *Health Serv Res*. 2005;40(2):413-434.

Cooke EV, Mares K, Clark A, Tallis RC, Pomeroy VM. The effects of increased dose of exercise-based therapies to enhance motor recovery after stroke: a systematic review and meta-analysis. *BMC Med*. 2010;8:60.

Cramer SC. Repairing the human brain after stroke: I. Mechanisms of spontaneous recovery. *Ann Neurol*. 2008;63(3):272-287.

Cramer SC. Repairing the human brain after stroke. II. Restorative therapies. *Ann Neurol*. 2008;63(5):549-560.

Cumming TB, Thrift AG, Collier JM, et al. Very early mobilization after stroke fast-tracks return to walking: further results from the phase II AVERT randomized controlled trial. *Stroke*. 2011;42(1):153-158.

Deutsch A, Granger CV, Heinemann AW, et al. Poststroke rehabilitation: outcomes and reimbursement of inpatient rehabilitation facilities and subacute rehabilitation programs. *Stroke*. 2006;37(6):1477-1482.

Dromerick AW, Lang CE, Birkenmeier RL, et al. Very Early Constraint-Induced Movement during Stroke Rehabilitation (VECTORS): a single-center RCT. *Neurology*. 2009;73(3):195-201.

Duncan PW, Sullivan KJ, Behrman AL, et al. Body-weight–supported treadmill rehabilitation after stroke. *N Eng J Med*. 2011;364(21):2026-2036.

FOCUS Trial Collaboration. Effects of fluoxetine on functional outcomes after acute stroke (FOCUS): a pragmatic, double-blind, randomised, controlled trial. *Lancet*. 2019;393(10168):265-274.

Foley N, Teasell R, Salter K, Kruger E, Martino R. Dysphagia treatment post stroke: a systematic review of randomised controlled trials. *Age Ageing*. 2008;37(3):258-264.

Kim SY, Hsu JE, Husbands LC, Kleim JA, Jones TA. Coordinated plasticity of synapses and astrocytes underlies practice-driven functional vicariation in peri-infarct motor cortex. *J Neurosci*. 2018;38(1):93-107.

Kraglund KL, Mortensen JK, Damsbo AG, et al. Neuroregeneration and vascular protection by citalopram in acute ischemic stroke (TALOS). A randomized controlled study. *Stroke*. 2018;49:2568-2576.

Kwakkel G, van Peppen R, Wagenaar RC, et al. Effects of augmented exercise therapy time after stroke: a meta-analysis. *Stroke*. 2004;35(11):2529-2539.

Lang CE, Macdonald JR, Reisman DS, et al. Observation of amounts of movement practice provided during stroke rehabilitation. *Arch Phys Med Rehabil*. 2009;90(10):1692-1698.

Mead GE, Hsieh CF, Lee R, et al. Selective serotonin reuptake inhibitors (SSRIs) for stroke recovery. *Cochrane Database Syst Rev*. 2012;(11):CD009286.

Miller EL, Murray L, Richards L, et al. Comprehensive overview of nursing and interdisciplinary rehabilitation care of the stroke patient: a scientific statement from the American Heart Association. *Stroke*. 2010;41(10):2402-2448.

Nudo RJ. Recovery after brain injury: mechanisms and principles. *Front Hum Neurosci*. 2013;7:887.

Overman JJ, Carmichael ST. Plasticity in the injured brain: more than molecules matter. *Neuroscientist*. 2014;20(1):15-28.

Stinear CM, Barber PA, Petoe M, Anwar S, Byblow WD. The PREP algorithm predicts potential for upper limb recovery after stroke. *Brain*. 2012;135(pt 8): 2527-2535.

Stroke Unit Trialists' Collaboration. Organised inpatient (stroke unit) care for stroke. *Cochrane Database Syst Rev*. 2013;(9):CD000197.

Winstein CJ, Stein J, Arena R, et al. Guidelines for adult stroke rehabilitation and recovery: a guideline for healthcare professionals from the American Heart Association/American Stroke Association. *Stroke*. 2016;47(6): e98-e169.

World Health Organization. *International Classification of Functioning, Disability and Health*. Geneva, Switzerland: World Health Organization; 2001. http://www.who.int/classifications/icf/en/. Accessed April 25, 2015.

158 End-of-Life and Palliative Care in Neurology

Tobias Walbert, Fred Rincon, and James M. Noble

KEY POINTS

1. Neurologic disease trajectories, ranging from rapid to slowly progressive, and the diseases themselves, often dictate urgent treatment decisions and involve end-of-life care.
2. Palliative care focuses on the alleviation of suffering of any kind and is relevant to all stages of neurologic disease.
3. Advance directives and related orders formalize a group of key discussions held by neurologic patients, families, and their physicians and help shape the course of neurologic care when patients cannot make decisions on their own any longer.
4. Conversations about end-of-life care should happen early in the course of neurologic disease and complement other discussions involving advance directives.
5. Some neurologic diseases prevent patients from engaging in advance directive discussions and introduce potential challenges related to surrogate decision making.
6. Decisions to withdraw or withhold life support may be triggered by the need to perform a tracheostomy and gastrostomy if continued aggressive support is pursued.
7. Hospice services permit the transition of care from being focused on control of neurologic disease to the alleviation of patient suffering and quality end-of-life care.

INTRODUCTION

Disease trajectories and survival in neurologic disorders are highly variable person to person and make overall predictions challenging. The recent development of disease-modifying therapies has been life changing for many persons with some chronic neurologic diseases. For example, most forms of multiple sclerosis have effective therapies, which slow or even stop progression, and some young children with spinal muscular atrophy are now able to achieve major motor milestones previously thought impossible. But unfortunately, many neurologic diseases have not yet benefitted from major breakthrough therapies.

Although neurogenic causes of death are central to this text, with newer treatment options/technologies, patients may live longer with chronic neurologic diseases and thus die of nonneurologic causes such as coronary disease or nonneurologic malignancies, etc. Conversely, increasingly effective therapies for nonneurologic diseases, particularly cardiac and oncologic innovations, have prolonged life and permitted patients to age into periods of life more prone to be impacted by neurologic disease. With new treatments, new clinical conundra have emerged, such as definitively treating a critical medical problem, which in turn leads to longer lifespan but potentially mostly during periods of lower quality of life such as late and terminal stages of neurodegenerative disease. As discussed throughout this text, supportive care for current needs and advance care planning are essential parts of providing effective neurologic care.

Neurologic diseases occur over a wide range of timeframes, ranging from sudden life-changing illness to chronic or even life-long disease. Some diseases are chronically progressive, some are static, and some precipitously worsen. Because neurologic diseases present with a wide array of clinically localized presentations, how a patient progresses and dies is also highly variable. For example, persons with central brain diseases tend to face complications following focal or diffuse cerebral problems including hemiparesis, seizures, parkinsonism, or complications of dementia. Persons with parkinsonian, spinal cord, and neuromuscular diseases face challenges with mobility. Both central and peripheral diseases are often affected by a common final pathway of complications stemming from becoming immobile and bedbound, including deep vein thrombosis, decubitus ulcers, recurrent dysphagia and aspiration, failure to thrive with critical dehydration, and recurrent infections. Many persons with severe brain disease will be unable to direct others who provide care to make the right decisions for them. Early engagement in advance care planning and anticipatory support are necessary for all persons facing neurologic disease and are necessarily tailored to each person's specific needs.

Disease Trajectories

Four illness trajectories are seen across neurologic diseases, and often, they co-occur within diseases. These can be broadly categorized as the following:

- *Immediate decline* occurs over the course of minutes to hours such as in acute ischemic stroke and intracranial hemorrhage leading to intensive care unit level care and sometimes herniation and brain death (covered in Chapter 20).
- *Subacute decline* occurs over the course of days to weeks. Examples of subacute decline include rapid tumor expansion or persons with amyotrophic lateral sclerosis (ALS) nearing a critically impaired level of functional breathing capacity.
- *Chronic progressive decline* is seen in diseases occurring over years. Examples include neurodegenerative dementias and

movement disorders, childhood neuromuscular disease, and progressive leukoencephalopathies. Even within chronic diseases, the pace of change may differ over periods of time and may accelerate in later stages.

- *Episodic decline* is marked by exacerbations of illness over time and can be superimposed on those facing ongoing subacute or chronic progressive decline. Episodic decline may be seen in patients facing a precipitous course but may not be as clinically obvious. Episodic declines can be seen in multiple sclerosis whereby a new inflammatory flare leaves a new and sometimes critical neurologic deficit. Other examples include treatment refractory seizures complicating a brain tumor course or a fall with hip fracture complicating a more chronic disease such as dementia.

All of the above presenting or dominant trajectories may enter some period of stasis or even recovery, depending what therapies may be available to treat the underlying or most acute problem. Based on the variability of disease progression, different approaches to palliative care and end-of-life planning might be necessary. The underlying considerations on how to approach these issues are discussed in this chapter.

PALLIATIVE CARE

Palliative care is defined by the World Health Organization as "an approach that improves the quality of life of patients and their families, facing the problem associated with life threatening illness, through the prevention and relief of suffering by means of early identification and impeccable assessment and treatment of pain and other problems, physical, psychosocial and spiritual." Palliative care can begin at any phase of disease but may be increasingly engaged in later stages of a disease course. Palliative care is often delivered simultaneously to disease-modifying therapies in neurologic disease. For example, in multiple sclerosis, immunomodulatory treatments alter the course of disease, preventing or minimizing the risks of additional attacks. Simultaneously, palliative therapies may be used to improve symptoms of spasticity, pain, or urinary dysfunction and alleviate suffering.

Palliative care delivery is based on a multidisciplinary team of physicians, nurses, and other specialists who work together with the neurologist to help with symptom management and advance care planning for patients facing a life-threatening neurologic disease. As such, multidisciplinary neuropalliative care is dynamic. Although traditionally thought of as being provided in the inpatient setting, neuropalliative care is central to treatment in ambulatory settings. Over the recent years, the subspecialty of neuropalliative care has been evolving. Whereas hospice care focuses on end-of-life care, palliative care can be initiated at any stage of the disease trajectory and is provided concurrently to neurologic treatment. This palliative approach in neurology can accommodate the evolving needs of the patient and caregivers. Although needs may differ patient to patient and between specialties, regardless of the underlying disease, advance care planning and engagement in palliative care should be initiated as early as possible, including prior to crisis episodes and well before end of life. Traditional models of palliative care delivery tended to involve palliative care when acute needs arose, whereas current approaches and guidelines encourage the early integration of palliative care along with episodic engagement as needs arise (Fig. 158.1).

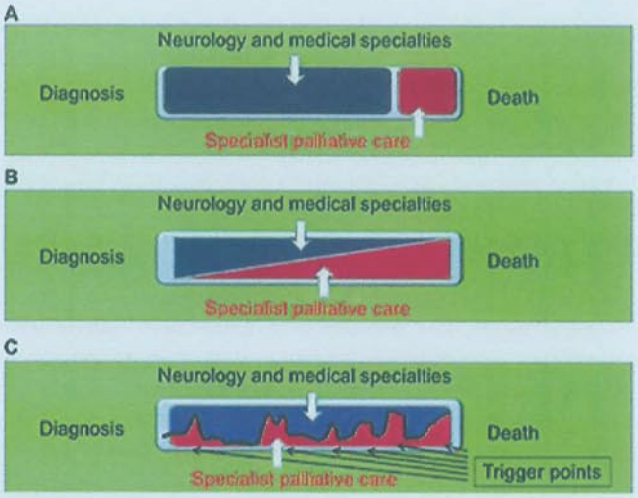

FIGURE 158.1 **A:** Historic and least favorable model of late involvement of palliative care services. **B:** Model showing early and progressively increasing involvement of palliative care services. **C:** Model of dynamic involvement of palliative care services following specific trigger points. A combination of models **B** and **C** are most often associated with favorable outcomes. This graphic itself was reproduced from Bede P, Hardiman O, O'Brannagain D. An integrated framework of early intervention palliative care in motor neurone disease as a model to progressive neurodegenerative diseases. (From Hogden A, Foley G, Henderson RD, James N, Aoun SM. *J Multidiscip Healthc*. 2017;10:205-215.)

ADVANCE DIRECTIVES AND CARE PLANNING

Advance directives (also known as *living wills*) are legal documents that patients complete to express their wishes and guide their designated health care decision makers to direct care in the event they are no longer capable of making their own health care decisions. These documents appoint a surrogate decision maker (health care proxy or medical power of attorney) to make decisions at some future time and also specify the individual's health care preferences. The process of creating such a care plan is called *advance care planning* and is considered an ongoing conversation between the patient, care givers, and health care providers with the goal of extending patient autonomy. The content of advance directives can be narrowly focused on decisions around code status or decisions focused on do not resuscitate (DNR), do not intubate (DNI), combined DNR/DNI, or determination to allow natural death. Also included in advance care planning are decisions regarding artificial support of nutrition and hydration, including surgical placement of enteral tubes for feeding in the form of a percutaneous endoscopic gastrostomy or percutaneous endoscopic jejunostomy feeding tube. More recently advance directives have embraced a holistic approach, supporting how the patient would like to die, including aesthetic preferences and measures aimed at personalized comfort. How practical these measures may be is highly dependent on the location and context in which a person becomes ill, available resources, and availability of others to enact certain components of the plan.

Shortcomings of advance directives might be that (1) the health care provider may not find instructions that clearly guide

certain treatment decisions and (2) the ethical argument that a person may not be able to predict his or her own reaction if faced with a disability. However, advance care planning and completion of an advance directive are associated with care closer to patient preference, greater use of hospice, less intensive care use at the end of life, and bereaved family members reporting fewer concerns with communications.

Neurologic disease introduces unique challenges to advance care planning, particularly when meaningful cognitive or behavioral changes are a central part of the disease or in pediatric neurologic diseases. For persons with neurologic disease with recognized progressive cerebral disease, such as neurodegenerative disorders and brain tumors, advance care planning should engage the patient as early as possible due to expected future impairment in decision making. Doing so can allow the patient to provide meaningful input, which provides guidance to family members. Even when documentation is not completed by the time decisions need to be made, discussions held between patients and family can provide important guidance both through progression and at critical times.

Some persons may never engage in advance care planning discussions, which may only be introduced at a time after the person with neurologic disease can help guide treatment decisions. This may be the case when there is a delay in seeking care or when a neurologic disease is suddenly declared such as in major stroke or a patient with unrecognized metastatic cancer presenting with status epilepticus. Whether a patient is obviously unable to engage in important medical decisions such as in critical illness, or when facing a moderate degree of cognitive decline, concerns may be raised about the ability for a patient to participate in such discussions.

TABLE 158.1 The Informed Consent Process

Components	Example
Verifying that the patient has decision-making capacity	This component verifies that the patient has insight into the proposed procedure or research. A bedside evaluation assessing if the patient can (1) understand the information; (2) understand the current situation and its consequences; (3) rationally consider information in light of one individual's values; and (4) retain the information given, analyze it, and make an informed decision.
Full disclosure	This component is designed to explain the risks and benefits, ratio, complications, and alternatives of the procedure or research. Without disclosure, voluntary choice and competence cannot be properly exercised.
Understanding	In this component, the agent verifies that the patient understands fully the risks and benefits, specifically if the ratio (risk/benefit) is in favor or not.
Voluntary choice	In this component, the agent verifies that there is deliberate informed consent. The informed consent process should be guided by the freedom to act voluntarily without coercive forces or due influence.
Formal authorization	In some jurisdictions, a written document is necessary to fully execute the procedure or research for which the subject has been asked to consent. This should include a statement of risk/benefit and potential complications and alternatives and the signatures of the health care provider, patient or surrogate, and in some instances, a witness.

Orders for Life-Sustaining Treatment

Several recent efforts have worked toward standardizing how advance care plans are enacted, particularly in the final stages of illness and life, and across multiple care settings, recognizing that critical treatment decisions are made outside of a hospital, where traditionally DNR/DNI plans were enacted. Started in 1991, the Physician Orders for Life-Sustaining Treatment (POLST) began as an initiative to translate goals for care at the end of life into medical orders that follow the patient across care settings with one of the goals being to create legal certainty. POLST programs have been encouraged in most states and become an enduring part of a patient's medical record. Related programs and initiatives, or simply renaming of POLST in certain areas, include Medical Orders for Life-Sustaining Treatment (MOLST; regionally in Northeastern United States and focused on out of hospital DNR/DNI), Medical Orders for Scope of Treatment (MOST; several states), Physician Order for Scope of Treatment (POST; several states), Do Not Resuscitate Order/Clinician Orders for Life-Sustaining Treatment (DNR/COLST; Vermont), and Transportable Physician Orders for Patient Preferences (TPOPP; Kansas and Missouri).

Informed Consent and Decision Making

The concept of informed consent originates from the notion that individuals are autonomous. Rational individuals with decisional capacity, or competency in legal terms, are uniquely qualified to decide what is best for them. It also means that people should be allowed to do what they want, even if doing so involves considerable risk or would be considered foolish by others. This of course is supported only if the individual's decision does not infringe on the autonomy or welfare of another individual (**Table 158.1**). When a patient is found not to have decision-making capacity, the health care provider needs to identify an alternate means to guide treatment decisions. For patients facing treatment decisions, this also means that the clinician must identify an alternate means to obtain consent, such as when considering invasive procedures. The options in these cases are (1) to use guidance provided in a written advance directive or (2) in the absence of an advance directive, the physician must seek the substituted judgment of a proxy or surrogate authorized by the jurisdictional law.

Several principles provide guidance for care in the absence or surrogate decision makers or a patient not providing such direction. The first, *substituted judgment*, is the principle of making a decision for the patient that they would have made themselves if able to make decisions. Authorized surrogate decision makers help in decision making as the patient cannot themselves. These persons can be appointees by advance directive or durable power of attorney (for health care decisions), or as a health care proxy or an appropriate surrogate permissible by jurisdictional law. They are expected to make the same decisions as the patient would if the patient's capacity were intact and usually based on knowledge of the patient's general values and preferences. There are inherent flaws in this approach related to the poor accuracy of the proxy's ability to predict the patient's wishes, the inherent difficulty of making serious decisions for other persons may also

make proxies reluctant to participate in the consent process on any level. This can lead to increased reliance on the physician's expertise without fully considering the risks and benefits associated with an intervention.

Secondly, the *best interest standard* may be applied when other sources for care planning and consent are lacking. This is a legal exception invoked in emergency situations, in which the consent of a reasonable person to appropriate treatment is implied. The emergency doctrine of "implied consent" allows providers to deliver certain interventions that if not performed in a timely and typically urgent or emergent basis could potentially lead to increase morbidity and mortality. The requirements to meet the best interest standard for emergency situations are as follows: (1) The treatment in question represents the usual and customary standard of care for the condition being treated, (2) it would be clearly harmful to the patient to delay treatment awaiting explicit consent, and (3) patients ordinarily would be expected to consent for the treatment in question if they had the capacity to do so. This principle is also applicable in those cases when the burden of a therapy outweighs the benefits and the pain of interventions, which would make them inhumane. Despite widely held beliefs to the contrary, it is not necessary to obtain legal counsel before withdrawing life-sustaining therapy, although engaging a local ethics resource (such as a hospital consultative service) can be very helpful in some situations, particularly if there is any ambiguity raised in the case or concerns expressed by family. One of the shortcomings of using the *best interest standard* is the possibility of the health care provider being judged as paternalistic based on that person's inherent role to prevent evil or harm by promoting good and welfare for others.

END-OF-LIFE CARE

Neurologic diseases have been at the center of discussions on issues at the end of life. To this end, end-of-life conversations should be routine between health care providers and patients suffering progressive neurologic diseases. The American Academy of Neurology has set standards for the determination of death based on neurologic criteria, prediction of outcome in comatose survivors of cardiac arrest, and for the persistent vegetative state. Additional diseases such as ALS and Alzheimer disease have been the focus of debates about physician-assisted suicide (PAS). Health care providers practicing in neuro–intensive care units also face end-of-life discussions when withholding or withdrawing life-sustaining therapies.

Life-Sustaining Therapies

Aside from disease-modifying or life-extending pharmacotherapies, two treatments should be universally considered in the context of end-of-life therapies for neurologic patients. These include (1) mechanical ventilation and (2) artificial nutrition and hydration through enteral feeding. These therapies may be used with varying degrees of encouragement by physicians and acceptance by patients, depending on neurologic disease. For example, young children facing severe neuromuscular diseases are very likely to be offered these therapies due to age, intact cognitive abilities, and obvious emotional strain of forgoing life-sustaining therapies in a young person. Given the emergence of life-changing therapies in some neuromuscular diseases and previously untreatable or incurable diseases, hope for new disease-modifying therapies may encourage use further.

At the other end of the age spectrum, life-sustaining therapies are most often considered in the context of neurodegenerative disease. In the context of dementia, surgically placed enteral tube feeding as a life-sustaining measure has fallen out of favor by many but not all persons—physicians, patients, and caregivers alike. Given that in most cases, enteral feeds are introduced in the most advanced stages of disease, most but not all families recognize that enteral feeding at best extends time spent in advanced state without necessarily improving quality of life. Enteral feeding was historically offered at a point when aspiration risks had emerged, and it is now recognized that risks of oropharyngeal microaspirations and aspiration pneumonia are not substantively mitigated by placement of enteral feeding tubes. Moreover, once surgically placed, enteral feeding tubes are not without risk, including surgical complications, pain, and risk of accidental removal, either by an agitated patient or in the process of moving a patient. The concept of "comfort feeding" in end-stage dementia has emerged, whereby very small quantities of food are hand-fed so long as it is not obviously distressing. This approach serves an alternative to tube feeding and provides comfort to alleviate perceived hunger when the patient is attempted to be fed and further addresses a potential family perception that providing no artificial hydration or nutrition is equivalent to "no care" being delivered. Video-based decision support tools have proven useful in discussions with dementia patients and caregivers. Even in dementia, mechanical ventilation is rarely necessary unless a complication of another illness has occurred.

In other neurodegenerative diseases such as ALS, or other progressive neuromuscular disorders in which cognitive abilities are preserved, there may be a greater tendency to offer both mechanical ventilation and enteral feeding as life-sustaining measures. With the advent of assistive communication devices and importance of treating mood disorders associated with end-of-life care, in these diseases there is a recognition of potential for additional time spent with a measurably good quality of life and not just an extension of life.

Ineffective, Inappropriate, and Futile Therapies

Health care providers may often encounter clinical situations in which therapies may be ineffective at achieving certain goals. Health care providers may not know whether a therapy, in a particular neurologic condition, will be effective unless the therapy is trialed. In this case, it is always better to attempt a "trial of intervention" by setting up reasonable goals of care. This hypothetical action plan, devised as a decision tree with multiple iterative outcomes, can help in determining whether those goals can be achieved by ongoing reassessment and allowing the health care provider to find if the therapy is ineffective while maintaining good communication with a patient's families, friends, and surrogates. This approach allows the health care team to withdraw an ineffective therapy rather than withhold a potentially beneficial treatment, limiting the chance for undertreatment and avoiding ethical dilemmas. It also allows for consideration of some scenarios whereby treatments may be capped. For example, in a patient who has already failed multiple chemotherapeutic agents and is facing more frequent, serious, and irrecoverable complications of disease, a plan can be implemented to offer no new therapies but permitting ongoing treatments to continue if they do not negatively affect the patient's quality of life.

Some other treatments may be considered inappropriate or inadvisable. Such treatments are characterized by extremely low likelihood of achieving the intended goal, minimally or potentially beneficial but extremely expensive, and of uncertain or controversial benefit. Finally, some other treatments may be labeled as futile. There is still controversy about the medical definition of futility, but in general, futile medical interventions serve no meaningful purpose no matter how often they are repeated. Therefore, a futile medical intervention is that for which there is de facto knowledge that it will not accomplish its intended goal. Characteristics of a futile therapy are that the intervention has no pathophysiologic rationale, that the intervention has already failed in the patient, and that the unintended effect occurs despite maximal treatment. Futile, inappropriate, or inadvisable cases are fortunately rare but very complicated from the ethical perspective, as they bring the values of the patient, surrogates, health care providers, and the society at odds. For this reason, resolution of these conflicts requires conscientious ethical analysis and a fair process that usually involves a multidisciplinary team and a bilateral or shared conflict resolution.

Withholding and Withdrawing

When facing withholding or withdrawal of medical interventions, ethical questions cannot be addressed successfully unless the probability of various outcomes is considered. To attain a balanced view of the impact of therapeutic decisions and the expected disability to the patient, the effort requires understanding of disease in question and a multidisciplinary team approach. Morally, there may be no difference between withholding and withdrawing life-sustaining therapies. However, patients, families, and health care providers have strong and divergent views. Some may feel comfortable with both situations, some may feel comfortable only when deciding not to start a therapy, but some may feel uncomfortable deciding when to stop that therapy. According to Miller and Truog, "What distinguishes withdrawing from withholding, is that in the former, the agent initiates the fatal consequence, as distinct from merely permitting it to continue without intervention to stop it." The distinction between withdrawing and withholding may cause feelings of reluctance but is morally irrelevant and can be dangerous. From the legal standpoint, the courts in the United States have upheld the concept that there is no difference between withdrawing and withholding. Both are medical decisions that entail a duty to inform the patient and his or her representative.

Death, Dying, and Hospice Care

According to the World Health Organization, health in its broader sense is defined as "a state of complete physical, mental, and social well-being and not merely the absence of disease or infirmity." Because this "state" is sometimes hard to achieve at the end of life, patients suffering terminal neurologic diseases should also have access to therapies that carry a different goal in mind: the relief of pain and suffering.

Hospice care is considered as palliative care in the last months to weeks of life, and patients may not be eligible for services unless there is a reasonable estimate that death will occur within the next 6 months. Clinical predictors have been developed for neurologic diseases with potentially long and sometimes unpredictable duration spent in severe phases of disease, including dementia and ALS. The primary goals are to relieve patients from suffering and focus on quality of life. Hospice care can be delivered in a variety of places, such as a hospital, free standing hospice unit, a nursing home, or increasingly at home. Although most Americans express their desire to die at home, relatively few actually die there, and many die in hospitals or nursing homes instead.

Although patients with neurologic disease and their families increasingly engage in hospice services, its use remains incomplete. Factors associated with hospice referral include physician comfort with discussing terminal events long enough in advance, difficulty in determining prognosis, and resource availability including financial and personnel (eg, family members' capacity to serve in a caregiver role if continuous care is not available). Several initiatives have encouraged advance care planning, including broad acceptance of free or low-cost legal documents around advance care planning.

Pain management is an important aspect of palliation. Some actions during palliative care aimed at controlling pain are morally and ethically acceptable and may have foreseeable but unintended and undesirable outcomes; the morality of the action depends on the morality of the intended outcome, not the unintended one. Several conditions must be met: (1) The action to be carried out must be morally or ethically acceptable or at least neutral, (2) the good effect must not depend on the undesired or bad effect, and (3) the good effect must be sufficient to justify the risk of the unintended outcome. Although it is not the intent of hospice care to hasten death, this principle makes it possible to administer sufficient analgesic and sedative medication to keep a patient comfortable even though the treatment will not prolong life. The principle of *double effect* is the basis of the hospice program (**Table 158.2**).

In certain circumstances, the burden of a neurologic disease at the end of life may be higher than expected. Certain patients may not achieve adequate relief of symptoms even with palliative care measures that usually include the titration of opioids. As defined by Broeckaert and Nunez-Olarte, "palliative sedation is the intentional administration of sedative drugs in dosages and in combinations required to reduce the consciousness of a terminal patient as much as necessary to adequately relieve one or more refractory symptoms." This is usually achieved by the use of benzodiazepines, propofol, and barbiturates. It is intended to achieve the relief of overwhelming symptoms when other conventional palliative care strategies have failed. The American Medical Association's Council on Ethical and Judicial Affairs has provided support for the use of palliative sedation at the end of life when (1) patients are in the final stages of their disease and are expected to die shortly, (2) conventional treatments have failed to control the symptoms, (3) consent has been obtained from the patient or surrogates, (4) a multidisciplinary team of experts have already assessed the patients' symptoms, (5) palliative sedation will not be used to solely existential experiences (anxiety, depression, feelings of isolation, etc), and (6) it will not be used to intentionally cause a patient's death.

Palliative sedation is usually reserved for the intensive care unit environment or for units designed to fulfill that purpose. Some ethicists have argued about the difference between palliative sedation and euthanasia. The difference lies in the concept of intent and the timing of the procedure. Palliative sedation is used to achieve a control of symptoms during the process of death (last resort), when other measures have failed, and exclusively in actively dying patients.

TABLE 158.2 Palliative Care Protocol During Withdrawal of Life Support

Steps	Procedures
Prewithdrawal of LST	• Meet with surrogates and family to discuss withdrawal of LSTs. • If patient is conscious, involve him or her in the discussion. • Prepare to discuss other issues such as organ donation. • Establish a time frame and additional needs: pastoral care, etc. • Document plan and discussion in the chart. • Discuss with clinical team. • Review LSTs to be withdrawn (ventilator, medications,[a] IV or enteral fluids, parenteral or enteral nutrition, pacemakers, IABPs, RRT, blood draws, etc).
Sedation/analgesia	
• Lorazepam	• If any, continue current infusion if patient is comfortable, then bolus same as hourly dose; may increase by 25%-50% OR • Begin with a bolus of 2.5-10 mg IV; may repeat boluses every 15 min as needed OR • Begin continuous infusion at 2.5-5.0 mg/h.
• Morphine	• If any, continue current infusion if patient is comfortable, then bolus same as hourly dose for signs of distress; may increase by 25% OR • Begin with a bolus of 10 mg IV and begin infusion at 5-7 mg/h. If discomfort, repeat boluses equal to hourly infusion dose and increase rate by 25%-50%.
• Fentanyl	• If any, continue current infusion if patient is comfortable, then bolus 25%-50% of the hourly dose and increase by 25%. OR • Begin with a bolus of 25-100 μg IV and begin infusion at 25-100 μg/h. If discomfort, repeat boluses 50% of hourly infusion dose and increase rate by 25%-50%.
Withdrawal of LST	• Adjust analgesia and sedation to achieve no distress before withdrawal of LST (see above). • Reduce or eliminate alarm settings and monitors. • Disconnect cardiac monitors. • Disconnect other monitoring devices (arterial lines, ICP lines, etc). • Disconnect supplemental oxygen. • Remove lines and enteral feeding tubes, if any. • Suction and control secretions if needed.
After death	• Inform family and surrogates about official time of death. • Allow family and staff to surround the patient. • Allow family to visit patient postmortem if they choose to. • Assist with postmortem decisions and complete pertinent paperwork. • Document a death note in the chart.

Abbreviations: IABP, intra-aortic balloon pump; ICP, intracranial pressure; IV, intravenous; LST, life-sustaining therapy; RRT, renal replacement therapy.
[a]Medications that can be continued to provide comfort are, for example, antiepileptics (seizures), antiemetics (rare), and skin or local oral care (glycerine creams, etc).

Refusal of Therapy, Physician-Assisted Suicide, and Euthanasia

A competent patient's refusal of therapy should be interpreted in the broader context of care and is increasingly recognized as not necessarily being suicidal. In 1983, the President's Commission for the Study of Ethical Problems in Medicine and Biomedical and Behavioral Research published its report entitled *Deciding to Forego Life-Sustaining Treatment*. The conclusion from the President's Commission was that decisions regarding health care, including the refusal or withdrawal of life-sustaining treatment, rest ultimately with the competent patient and should be exercised through the country's long tradition of procedures for informed consent. On the other hand, refusal or withdrawal of therapies by surrogates on behalf of incompetent patients that remain conscious are ethically and legally permissible as long as there are written statements or in accordance with the patient's "wishes to the extent known." In the absence of these, the decision-making process is based on the patient's best interest.

Several countries as well as some states in the United States have legalized PAS. Although not universal, many locations which have permitted PAS, require patients to be at least 18 years of age, have the ability to communicate regarding health care issues, and be diagnosed with a terminal disease with 6 months or less of life expectancy (confirmed by two independent physicians). In the setting of PAS, a physician may prescribe medications to be used by a patient for the purpose of suicide. However, at least in the United States, the physician may not actually administer the drug. Neurologic diseases generate problems for PAS. Patients may be incompetent and unable to give consent at the time of intended drug administration, even if they were competent when forming previously expressed wishes. Other patients may lose the use of their hands from motor neuron diseases such as ALS. Under these circumstances, the patients themselves cannot fill the prescription and take the drug; someone else must assist them physically, which would be considered as euthanasia and is unlawful in the United States. PAS continues to be a highly debated topic with increasing public acceptance.

If in compliance with a patient's request a physician administers a lethal drug by injection or other means, the act is euthanasia, which is illegal in the United States. In euthanasia, the health care provider intends the death of the patient. In doing so, the health care provider selects the type of drugs and doses that are lethal by all objective measures. In the process, the health care provider administers the drug and causes unconsciousness and cardiac arrest. Only if the outcome is achieved, the health care provider can conclude that the intervention was successful. These contrast with the objective of palliative sedation and palliative care, where the intent is to relieve otherwise unmanageable symptoms (principle of double effect, as detailed earlier in this chapter).

The public, physicians, and courts have had difficulty separating refusal or discontinuation of therapy, which are legal, from assisted suicide and euthanasia, which are not, at least in the United Sates. The distinction between PAS and euthanasia is the most controversial of all. At present in the United States, palliative care and palliative sedation are permissible but PAS at the discretion of the states. In some areas where euthanasia is legal, further studies have suggested its use may at least in part be related to inadequate palliative care.

Other Neurologic Issues With Death

Neurologic diseases are often underrecognized as being immediate contributors to death, or even when recognized, may not be counted as such. The accuracy of neurologic causes of death is highly variable as captured by death certificates, with dementia being the most undercounted. Across multiple American studies, these discrepancies may be more apparent among race-ethnic minority groups, and likely reflect myriad issues in health care, ranging from available accurate information to appropriate access to care to stigma of certain diseases.

Processes involving organ and tissue donation are often standardized in health care settings and remain relevant to many persons with nontransmissible neurologic disease. Complementing donation programs are tissue research programs, but these are seldom discussed in advance of or at the time of death. Although autopsies have become increasingly uncommon over the past century, major research initiatives have grown and are underway to better understand neurologic disease as well as normal neurologic aging. Brain and spinal cord autopsy repositories have proven invaluable for insights into neurodegenerative disease and further tissue-based research initiatives are underway in the United States to cover a broader age and disease spectrum. Research referral networks have been implemented in the United States, supporting multiple neurologic disease groups, and have helped reduced geographic barriers to engaging in research, including after death. Discussions of neurologic tissue donation for research should be encouraged as part of advance care planning discussions, particularly if patients have experience or expressed interest in research or other organ donation programs.

CONCLUSION

The issues discussed here are among the most controversial in modern life. Consensus is not easy to achieve, views are changing, and current practices are likely to change as well. Already, pain control and palliative care have come to the fore and provide effective alternatives to assisted suicide. Documenting the preventive value of palliative care is a challenge for all concerned. Legal changes may be anticipated but do not seem imminent.

SUGGESTED READINGS

Bar B, Creutzfeldt CJ, Rubin MA. Palliative care in the neuro-ICU: perceptions, practice patterns, and preferences of neurointensivists. *Neurocrit Care*. 2020;32(1):302-305.

Beauchamp TL, Childress JF. *Principles of Biomedical Ethics*. New York, NY: Oxford University Press; 2009.

Bernat JL. *Ethical Practice. Ethical Issues in Neurology*. 3rd ed. Philadelphia, PA: Lippincott Williams & Wilkins; 2008:24-48.

Billings JA, Block SD. Slow euthanasia. *J Palliat Care*. 1996;12:21-30.

Bomba PA, Kemp M, Black JS. POLST: an improvement over traditional advance directives. *Cleve Clin J Med*. 2012;79(7):457-464.

Broeckaert B. Palliative sedation, physician-assisted suicide, and euthanasia: "same, same but different"? *Am J Bioeth*. 2011;11:62-64.

Broeckaert B, Nuñez Olarte JM. Sedation in palliative care: facts and concepts. In: Ten Have H, Clark D, eds. *The Ethics of Palliative Care: European Perspectives*. Buckingham, United Kingdom: Open University Press; 2002: 166-180.

Commission on Aging With Dignity. *"Five Wishes:" An Easy Advance Directive Promotes Dialogue on End-of-Life Care*. Tampa, FL: Commission on Aging With Dignity; 1997.

Creutzfeldt CJ, Kluger B, Kelly AG, et al. Neuropalliative care: priorities to move the field forward. *Neurology*. 2018;91(5):217-226.

Creutzfeldt CJ, Longstreth WT, Holloway RG. Predicting decline and survival in severe acute brain injury: the fourth trajectory. *BMJ*. 2015;351:h3904.

Detering KM, Hancock AD, Reade MC, Silvester W. The impact of advance care planning on end of life care in elderly patients: randomised controlled trial. *BMJ*. 2010;340:c1345.

Enck RE. Drug-induced terminal sedation for symptom control. *Am J Hosp Palliat Care*. 1991;8:3-5.

Enck RE. Terminal sedation. *Am J Hosp Palliat Care*. 2000;17:148-149.

Fins JJ, Bernat JL. Ethical, palliative, and policy considerations in disorders of consciousness. *Neurology*. 2018;91(10):471-475.

Fleck LM, Hayes OW. Ethics and consent to treat issues in acute stroke therapy. *Emerg Med Clin North Am*. 2002;20:703-715, vii-viii.

Ganzini L, Block S. Physician-assisted death—a last resort? *N Engl J Med*. 2002;346:1663-1665.

Gostin LO. Deciding life and death in the courtroom. From Quinlan to Cruzan, Glucksberg, and Vacco—a brief history and analysis of constitutional protection of the 'right to die.' *JAMA*. 1997;278:1523-1528.

Hogden A, Foley G, Henderson RD, James N, Aoun SM. Amyotrophic lateral sclerosis: improving care with a multidisciplinary approach. *J Multidiscip Healthc*. 2017;10:205-215.

Howland J. Questions about palliative sedation: an act of mercy or mercy killing? *Ethics Medics*. 2005;30:1-2.

Integrating palliative care into neurological practice. *Lancet Neurol*. 2017;16(7):489.

Kluger BM, Vaughan CL, Robinson MT, Creutzfeldt C, Subramanian I, Holloway RG. Neuropalliative care essentials for the COVID-19 crisis. *Neurology*. 2020;95(9):394-398.

Kottow M. The battering of informed consent. *J Med Ethics*. 2004;30:565-569.

Kummer HB, Thompson DR. *Critical Care Ethics*. Mount Prospect, IL: Society of Critical Care Medicine; 2009.

Louw SJ, Keeble JA. Stroke medicine-ethical and legal considerations. *Age Ageing*. 2002;31(suppl 3):31-35.

Luchins DJ, Hanrahan P, Murphy K. Criteria for enrolling dementia patients in hospice. *J Am Geriatr Soc*. 1997;45(9):1054-1059.

Lyons-Warren AM. Update on palliative care for pediatric neurology. *Am J Hosp Palliat Care*. 2019;36(2):154-157.

Martello J, Buchhalter J, Das RR, Dubinsky R, Lee E, Anderson W. Quality improvement in neurology: universal neurology quality measurement set: executive summary. *Neurology*. 2019;92(9):418-426.

Miller FG, Truog RD. Withdrawing life-sustaining therapy: allowing to die or causing death? In: Miller FG, Truog RD, eds. *Death, Dying, and Organ Transplantation*. New York, NY: Oxford Press; 2012:1-25.

Miller RG, Jackson CE, Kasarskis EJ, et al. Practice parameter update: the care of the patient with amyotrophic lateral sclerosis: drug, nutritional, and respiratory therapies (an evidence-based review): report of the Quality Standards Subcommittee of the American Academy of Neurology. *Neurology*. 2009;73(15):1218-1226.

Mitchell SL, Kiely DK, Hamel MB, Park PS, Morris JN, Fries BE. Estimating prognosis for nursing home residents with advanced dementia. *JAMA*. 2004;291(22):2734-2740.

Mitchell SL, Mor V, Gozalo PL, Servadio JL, Teno JM. Tube-feeding in US nursing home residents with advanced dementia, 2000–2014. *JAMA*. 2016;316(7): 769-770.

National Commission for the Protection of Human Subjects of Biomedical and Behavioral Research. The Belmont Report: ethical principles and guidelines for the protection of human subjects of research. U.S. Department of Health and Human Services Web site. http://www.hhs.gov/ohrp/humansubjects/guidance/belmont.html. Accessed July 20, 2011.

Oliver DJ, Borasio GD, Caraceni A, et al. A consensus review on the development of palliative care for patients with chronic and progressive neurological disease. *Eur J Neurol*. 2016;23(1):30-38.

Pace A, Dirven L, Koekkoek JAF, et al; for European Association of Neuro-Oncology palliative care task force. European Association for Neuro-Oncology (EANO) guidelines for palliative care in adults with glioma. *Lancet Oncol*. 2017;18(6):e330-e340.

Palecek EJ, Teno JM, Casarett DJ, Hanson LC, Rhodes RL, Mitchell SL. Comfort feeding only: a proposal to bring clarity to decision-making regarding difficulty with eating for persons with advanced dementia. *J Am Geriatr Soc*. 2010;58(3):580-584.

Phillips J, Wendler D. Clarifying substituted judgement: the endorsed life approach. *J Med Ethics*. 2015;41(9):723-730.

President's Commission for the Study of Ethical Problems in Medicine and Biomedical and Behavioral Research. *Deciding to Forego Life-Sustaining*

Treatment: A Report on the Ethical, Medical, and Legal Issues in Treatment Decisions. Washington, DC: U.S. Government Printing Office; 1983.

Pritchard RS, Fisher ES, Teno JM, et al. Influence of patient preferences and local health system characteristics on the place of death. SUPPORT Investigators. Study to understand prognoses and preferences for risks and outcomes of treatment. *J Am Geriatr Soc*. 1998;46:1242-1250.

Rabkin JG, Albert SM, Tider T, et al. Predictors and course of elective long-term mechanical ventilation: a prospective study of ALS patients. *Amyotroph Lateral Scler*. 2006;7(2):86-95.

Robinson MT, Holloway RG. Palliative care in neurology. *Mayo Clin Proc*. 2017;92(10):1592-1601.

Sokol LL, Young MJ, Paparian J, et al. Advance care planning in Parkinson's disease: ethical challenges and future directions. *NPJ Parkinsons Dis*. 2019;5:24.

Stavroulakis T, McDermott CJ. Enteral feeding in neurological disorders. *Pract Neurol*. 2016;16(5):352-361.

Stein J. The ethics of advance directives: a rehabilitation perspective. *Am J Phys Med Rehabil*. 2003;82:152-157.

Sudore RL, Lum HD, You JJ, et al. Defining advance care planning for adults: a consensus definition from a multidisciplinary Delphi panel. *J Pain Symptom Manage*. 2017;53(5):821-832.e1

ten Have H, Welie JV. Palliative sedation versus euthanasia: an ethical assessment. *J Pain Symptom Manage*. 2014;47:123-136.

van der Steen JT, Lennaerts H, Hommel D, et al. Dementia and Parkinson's disease: similar and divergent challenges in providing palliative care. *Front Neurol*. 2019;10:54.

Veldink JH, Wokke JH, van der Wal G, Vianney de Jong JMB, van den Berg LH. Euthanasia and physician-assisted suicide among patients with amyotrophic lateral sclerosis in the Netherlands. *N Engl J Med*. 2002;346:1638-1644.

Volandes AE, Paasche-Orlow MK, Barry MJ, et al. Video decision support tool for advance care planning in dementia: randomised controlled trial. *BMJ*. 2009;338:b2159.

World Health Organization. *Constitution of the World Health Organization. Basic Documents*. 45th ed. Geneva, Switzerland: World Health Organization; 2006.

Worldwide Hospice Palliative Care Alliance. *Global Atlas of Palliative Care at the End of Life*. London, United Kingdom: Worldwide Hospice Palliative Care Alliance; 2014.

Wright AA, Zhang B, Ray A, et al. Associations between end-of-life discussions, patient mental health, medical care near death, and caregiver bereavement adjustment. *JAMA*. 2008;300(14):1665-1673.

Index

Page references followed by *b*, *f*, or *t* indicate boxes, figures, or tables, respectively.

A
Abacavir, 707*t*, 1582–1583
Abatacept, for dermatomyositis, 981
ABC (airway, breathing, and circulation) assessment
  in acute spinal cord syndromes, 148, 150
  in coma, 168–169
  in seizures, 60
ABCDEF bundle, for delirium, 93
ABCD score, 322, 322*t*
Abdominal reflexes, 39*t*
Abducens nerve (CN VI), 77, 78*f*
  examination of, 34, 34*f*
  injury of, 454*t*, 455
  palsy or dysfunction of, 86
Abemaciclib, for meningiomas, 1054*t*
Abetalipoproteinemia, 844*t*, 845, 1393
ABGs. *See* Arterial blood gases
ABRA. *See* Amyloid β-related angiitis
Abscess(es)
  brain. *See* Brain abscess
  spinal epidural, 619–620, 620*f*
Absence epilepsy, 568, 571
  childhood, 574, 1505*f*, 1511
  EEG of, 237*f*, 1505*f*
  juvenile, 574, 1511
Absorption rate, in MRI, 190
Abulia, 306
Academic delay, 1427–1429, 1428*t*
Acamprosate, for alcoholism, 1311
Acanthamoeba, 162*t*, 654*t*, 656
Acanthocytosis, 856, 857*f*, 881, 1393
Accessible/cell-surface antigens, ataxias due to, 838
Accessory nerve (CN XI), examination of, 36
Access site complications, in angiography, 220
Access to care, 9–14
  approaches and strategies for improving, 11
  challenges in, 10–13
  collaborative partnerships and coordinated action on, 11–12
  components required for, 9–10
  global disparities in, 5–6, 6*f*, 9, 9*f*, 11
  health-seeking behavior and, 10–13, 10*b*
  policies and guidelines affecting, 11, 11*b*
  primary care workforce and, 12–13
  stigma related to neurologic disorders and, 10, 10*b*
  telemedicine/communication technology and, 13
  training to build capacity and, 13
Accommodation, visual, 77
ACDF. *See* Anterior cervical diskectomy and fusion
ACE inhibitors. *See* Angiotensin-converting enzyme (ACE) inhibitors
Acetaminophen
  hepatotoxicity of, 1248–1251, 1248*f*, 1251*t*, 1260*t*
  for migraine in pregnancy, 1293
  for rhinosinusitis, 540
  for tension-type headache, 530
Acetazolamide
  for hyperkalemic periodic paralysis, 1001
  for hypokalemic periodic paralysis, 999–1000
  for idiopathic intracranial hypertension, 73, 1137
  for nondystrophic myotonias, 1002
Acetylcholine
  and delirium, 89
  in schizophrenia, 1588
  in sepsis-associated encephalopathy, 1204
Acetylcholine receptors
  defects, in congenital myasthenic syndromes, 974–975
  in myasthenia gravis, 963–965, 967–968, 968*t*
Acetylsalicylic acid. *See* Aspirin (acetylsalicylic acid)
Achalasia, 1263
Achilles reflex, 38, 39*t*
Achondroplasia, 1272–1273
Acid alpha glucosidase deficiency, 1011, 1015, 1017, 1402–1403
Acid ceramidase deficiency, 1397
Acidopathies, 1385
Acidurias, organic, 1388–1390
Acne treatment, and intracranial hypertension, 1135
Acoustic neuroma, 48*t*, 152, 1080–1082
  bilateral syndrome, 1456–1459
  chemotherapy for, 1082
  diagnosis of, 1080–1081
  epidemiology of, 1080
  management and outcomes of, 1081–1082
  MRI of, 1080, 1081*f*
  pathobiology of, 1080, 1081*f*
  stereotactic radiosurgery for, 1082
  surgical resection of, 1082
  treatment algorithm for, 1081*f*
Acquired hepatolenticular degeneration, 1247
Acquired immunodeficiency syndrome (AIDS), 690–710. *See also* Human immunodeficiency virus (HIV) infection
  classification of disease in, 690–691, 690*t*
  defining illnesses of, 690
  dementia in, 695–697
  historical perspective on, 690
  progression of HIV infection to, 692–693
Acquired neuromyotonia, 1007–1008
Acrodermatitis chronica atrophicans, 649
Acromegaly, 1217
  myopathy in, 994*t*
  neuropathy in, 944
Acrylamide monomer, 948
ACTH. *See* Adrenocorticotropic hormone
Actigraphy, 264, 267–268, 268*f*
Action dystonia, 106, 800
Action potential
  compound motor, 244–245, 244*f*
  electromyography of, 246–249
  sensory nerve, 243, 244*f*
Action tremors, 107, 107*f*
Activated charcoal
  for anticoagulation reversal, 139*t*
  contraindications to, 1322, 1326*t*
  for neurotoxicity, 1322
Active standing test, 54–55
Activities of daily living (ADLs), 1629, 1632
Activity-dependent plasticity, 1631
Acupuncture
  for Bell's palsy, 921
  for complex regional pain syndrome, 552*t*
  for tic disorders, 789
Acute bacterial meningitis, 604–611
  antibiotic doses for, 608, 609*t*
    clinical manifestations of, 605–607
  complications of, 604, 605, 606*f*, 609
  CSF analysis in, 607–608, 609*t*
  CT in, 607
  dexamethasone for, 608–609, 610*f*
  diagnosis of, 607–608
  differential diagnosis of, 608
  empiric antibiotic therapy for, 607, 607*t*
  etiology of, 604, 605*t*
  level 1 evidence on, 611
  pathobiology of, 605, 606*f*
  practice guidelines for, 607, 608–609
  treatment of, 608–609
  viral meningitis *versus*, 604, 608
Acute cerebellar syndrome, chemotherapy-induced, 1108, 1108*t*
Acute disseminated encephalomyelitis (ADEM)
  dengue and, 666
  Epstein-Barr virus and, 682
  multiple sclerosis *versus*, 722
  Susac syndrome *versus*, 394, 395
Acute dystonic reaction, 109*t*, 849–841, 849*t*, 850, 1590
Acute excited state, 1324–1326
Acute flaccid myelitis, 1420
Acute hypoxemic respiratory failure, 1208
Acute intermittent porphyria (AIP), 1391–1392

Acute ischemic stroke (AIS), 301–319
acute treatment of, 132–144, 307–314
aspirin in, 142
door-to-CT time in, 132
endovascular, 132, 142–143, 142*f*, 224, 224*f*, 312–314
hospital disposition in, 143
initial history in, 133
initial hospital evaluation in, 307
initial management and imaging in, 132–137
initial survey and vital signs in, 133–134
intravenous access and admission labs in, 133
priorities in, 132
thrombolysis complications in, 312, 312*t*
tPA in, 132–133, 133*f*, 140–142, 311–312, 312*t*
cardioembolic, 303*f*, 304, 403, 407–408, 407*t*
cerebral blood flow reduction in, 301–303, 302*f*
cerebral perfusion pressure in, 301–302
childhood, 1519–1524
classification and subtypes of, 303–304, 303*f*
clinical manifestations of, 304–307
completed infarction in, 302–303
complications of, 316–317
COVID-19 and, 304
critical care in, 315–317
CT of, 135–137, 138*f*, 309, 309*f*–310*f*
definition of, 301
diagnosis of, 307–311
differential diagnosis of, 133, 135*t*
epidemiology of, 301
etiology of, 301, 303–304
hypertension in, 316
infarct core and penumbra in, 302, 303*f*
infection with, 316–317
large-artery atherosclerosis causing, 303–304, 303*f*
level 1 evidence on, 317–318
management strategy for, 301
MRI of, 309–310, 310*f*
neonatal, 1362
neurologic deterioration in, 316
"other" causes of, 303*f*, 304
outcomes of, 317, 317*t*
pathobiology of, 301
perfusion imaging in, 310–311, 310*f*
postoperative, 1197
prehospital scales for, 307–308, 308*t*
prevention of. *See* Stroke prevention
small-vessel infarction causing, 303*f*, 304
symptom recognition in, 307–308
time to reperfusion in, 302
tissue-based *versus* time-based approach in, 314, 314*f*
undetermined cause of (cryptogenic), 303*f*, 304
vascular imaging in, 309*f*–310*f*, 310
vascular supply/territories in, 304, 304*f*
Acute lead encephalopathy, 1332
Acute liver failure, 1245, 1248–1251
causes of, 1248, 1248*f*
clinical features of, 1249
diagnosis of, 1249
drug-induced, 1248, 1248*f*
epidemiology of, 1248
general management of, 1249–1250
King's College Criteria for, 1251, 1251*t*
multiorgan dysfunctions associated with, 1249, 1249*f*
outcome of, 1251
pathobiology of, 1248–1249
seizures in, 1251
treatment of, 1249–1251, 1250*t*
Acute lymphoblastic leukemia (ALL), 1232–1233, 1531
Acute motor and sensory axonal neuropathy (AMSAN), 937, 939
Acute motor axonal neuropathy (AMAN), 937, 939
Acute myeloid leukemia (AML), 1234
Acute neurogenic pulmonary edema, 1198, 1198*f*
Acute promyelocytic leukemia, 1237
Acute radiation sickness (ARS), 1337, 1338*t*, 1342
Acute spinal cord syndromes, 145–151. *See also* Transverse myelitis (TM)
cardiovascular management in, 150
classic, 149*t*
compressive, 147, 148*t*, 150
diagnosis of, 147–148
differential diagnosis of, 147–148, 148*t*
epidemiology of, 145
etiology of, 148
etiology-specific treatment of, 150
focused examination in, 148–150
focused history on, 148
HIV-associated, 700*t*
ICU admission for, 150
imaging in, 149
infectious, 147, 148*t*, 150
inflammatory, 147, 148*t*, 150
initial stabilization in, 150
ischemic, 147, 150
laboratory evaluation in, 149–150, 150*t*
localization in, 148
management of, 150
outcome of, 151
pathobiology of, 145–147, 146*f*
pathology of, 147
pulmonary management in, 150
time course of, 148
Acute stress disorder, 1606, 1612
Acute symptomatic seizure, 59, 567, 578
Acute variegate porphyria, 1392
Acyclovir
for Bell's palsy, 921
for herpesvirus infections, 679*t*, 680, 681, 702, 946, 1594
for herpesvirus prophylaxis, 679*t*, 680
for viral meningitis, 607
Adalimumab, for sarcoidosis, 777*t*
Adamkiewicz, artery of, 147
Adaptive optics, 260
Adaptive plasticity, 806, 1381, 1598, 1630–1631
ADC. *See* Apparent diffusion coefficient
Addison disease, 98, 1135, 1215*t*, 1222–1223
ADEM. *See* Acute disseminated encephalomyelitis
Adenoma, pituitary. *See* Pituitary tumors
Adenosine A_{2A} antagonists, for Parkinson disease, 888
Adenosine-deaminase deficiency, 1391
Adenosine receptors, in Huntington disease, 864
Adenosine triphosphate (ATP)
in cerebral microdialysis, 293–294, 294*f*
in metabolic myopathies, 1011–1012, 1012*f*
in mitochondrial disorders, 1441
Adenovirus, 678, 678*f*
Adenylosuccinate lyase deficiency, 1391
ADHD. *See* Attention deficit hyperactivity disorder
ADLs. *See* Activities of daily living
Adrenal crisis, 1222
Adrenal disease, 1222–1224
Adrenal gland, anatomy and physiology of, 1222, 1222*f*
Adrenal insufficiency, 1215*t*, 1222–1223
dementia in, 98
intracranial hypertension in, 1135
myopathy in, 994*t*
Adrenergic function, testing of, 255–257, 256*t*
Adrenocorticotropic hormone (ACTH), 1215, 1216*f*
deficiency of, 1215–1216, 1342
excess of, 1217. *See also* Cushing disease
radiation and, 1342
for West syndrome, 1506
Adrenocorticotropic hormone (ACTH)-secreting tumors, 1064, 1065–1066, 1218
Adrenoleukodystrophy, 1222, 1399, 1405, 1405*t*, 1406, 1419
Adrenomyeloneuropathy, 1406
Adult neuronopathic Gaucher disease, 1396
Adult polyglucosan body disease (APBD), 1015, 1404–1405
Advance care planning, 1637–1639
Advance directives, 1637–1639
Advanced sleep phase, 1192
Adventitious movements, 116
AF. See Atrial fibrillation
Afferent visual pathway, 77, 77*f*
common patterns of disease in, 84–85
African trypanosomiasis, 654*t*, 655, 705
Age-associated memory impairment, 95–96
Age-dependent penetrance, genetic, 298
Age-related cognitive change, 95–96
Ageusia, COVID-19 and, 673
Aggravating factors, 18
Agitation
Alzheimer disease and, 480–481
assessment of, 89–90, 89*t*
prion diseases and, 519*t*
sepsis-associated encephalopathy and, 1204–1205
sympathomimetic toxicity and, 1324–1326
traumatic brain injury and, 436–437
Agnosia, in corticobasal degeneration, 897
Agoraphobia, 1608, 1608*t*, 1611
Agraphesthesia, cerebral infarction and, 305
Aicardi syndrome, 1380
AIDS. *See* Acquired immunodeficiency syndrome
AIP. *See* Acute intermittent porphyria
Airway protection, failure of, 1208–1209
AIS. *See* Acute ischemic stroke
Akathisia, 106*t*, 107
acute, 849*t*, 850, 851
in Parkinson disease, 880
tardive, 849–852, 849*t*, 852*f*, 853*t*, 1590, 1591*t*
xenobiotic-induced, 1320, 1321*t*
Akinesia, 104, 893–894
Akinetic mutism, 306, 508

Alanine, in magnetic resonance spectroscopy, 200
Albendazole, for neurocysticercosis, 656, 705
Alberta Stroke Programme Early CT Score (ASPECTS), 137, 138*f*, 140, 309
Albuterol
  for congenital myasthenic syndromes, 975, 975*t*
  for spinal muscular atrophies, 1472
Alcock syndrome, 1266
Alcohol–drug interactions, 1304
Alcoholic amblyopia, 1306*t*, 1308
Alcoholic blackout, 1304
Alcoholic cerebellar degeneration, 1306*t*, 1307–1308
Alcoholic dementia, 1309–1310
Alcoholic ketoacidosis, 1309
Alcoholic liver disease, 1308
Alcoholic myopathy, 1309
Alcoholic neuropathy, 949, 1306*t*, 1308
Alcohol intoxication, 1303–1304, 1303*t*, 1304*t*
Alcoholism, 1303–1312
  acute syndromes, 1303–1306
  chronic syndromes, 1306–1310
  epidemiology of, 1303
  infections in, 1309
  nutritional disturbances in, 1306–1308, 1306*t*
  trauma in, 1309
  treatment of, 1311
Alcohol myopathy, 995*t*
Alcohol-related birth defect (ARBD), 1310, 1310*t*, 1583*t*, 1584
Alcohol-related neurodevelopment disorder (ARND), 1583*t*, 1584
Alcohol use. *See also* Alcoholism; *specific related disorders*
  and cancer, 1309
  fetal effects of, 1310, 1310*t*, 1583–1584
  and intracerebral hemorrhage, 333
  and mood disorders, 1602
  and nutritional deficiencies, 1277
  and restless legs syndrome, 795
  and stroke, 409, 1309
Alcohol withdrawal, 1304–1306, 1304*t*, 1593
  clinical manifestations of, 1305
  infant, 1584
  management of, 1305–1306, 1305*t*
  pathobiology of, 1305
Aldosterone
  deficiency of, 1222–1223
  excess of, 1223–1224, 1223*t*
Alectinib, for metastatic lung cancer, 1042
Alemtuzumab
  for multiple sclerosis, 723, 724*t*
  for multiple sclerosis in pregnancy, 1292, 1292*t*
Alendronate, for complex regional pain syndrome, 553
Alertness, 28
Alexander disease, 1399, 1400–1401, 1401*f*
Alexia, 307
ALF. See Acute liver failure
Algodystrophy. *See* Complex regional pain syndrome (CRPS)
Aliasing artifacts, 196
Alien hand syndrome, 306
Alien limb phenomenon, 897
ALL. *See* Acute lymphoblastic leukemia
Alleviating factors, 18
Alleviating maneuver, 800
Allochiria, cerebral infarction and, 305–306
Allodynia, 65, 549, 557*t*, 715
Almotriptan, for migraine, 525–527, 526*t*
Alobar holoprosencephaly, 1369, 1370*f*
Alpers-Huttenlocher syndrome, 1450
α-Adrenergic agonists
  for ADHD, 1431
  for alcohol withdrawal, 1306
  for autonomic dysfunction, 1175
  for paroxysmal sympathetic hyperactivity, 1180–1181
  for tic disorders, 789, 790*t*
Alpha-lipoic acid, for neuropathic pain, 563
Alpha rhythm, 230, 231*f*
Alphavirus, 670–671
Alprazolam
  for anxiety disorders, 1611, 1611*t*
  for dystonia, 814–815
  for essential tremor, 782
  for Parkinson disease, 889
  for vertigo, 49*t*
ALS. *See* Amyotrophic lateral sclerosis
Alteplase. *See* Tissue plasminogen activator (tPA)
Alteplase Thrombolysis for Acute Noninterventional Therapy in Ischemic Stroke, 311
Alternobaric vertigo, 1350
Altitude
  and brain edema, 1132
  and decompression illness, 1350–1354
Aluminum toxicity, 1333
Alzheimer disease, 96–97, 97*t*, 476–485
  behavioral dysfunction in, 480–481
  biomarkers in, 472–473, 477–479, 478*f*, 482–483
  clinical features of, 480–481
  comorbid with Lewy body dementia, 492–493
  CT in, 481, 482
  depression in, 96, 1600–1601
  diagnosis of, 98–101, 479–483
  diagnostic criteria for, 479–480
  diagnostic phases of, 470, 470*t*
  diagnostic testing for, 481–483
  epidemiology of, 96, 476
  functional decline in, 481
  functional imaging in, 482–483, 482*f*
  gait disorder in, 129*t*
  genetics of, 300, 476–477, 477*f*
  GI/genitourinary effects of, 1267
  intracerebral hemorrhage and, 333
  laboratory testing in, 481–482
  language in, 480, 480*f*
  level 1 evidence on, 484
  Lewy body dementias *versus*, 497
  MCI as precursor of, 470–471
  MCI conversion to, delaying, 473–474
  MRI in, 481–483, 481*f*
  myoclonus in, 827
  neurodegenerative spectrum of, 470, 470*t*, 471*f*
  neurologic signs and symptoms of, 99, 99*t*
  neuropsychological testing in, 481
  outcome of, 484
  pathobiology of, 477–479, 478*f*, 478*t*
  positron emission tomography (PET) in, 101, 203*f*, 204*t*, 205–206, 205*f*–207*f*, 479–480, 482–483, 482*f*
  psychosis in, 481, 1590*t*
  SPECT in, 101, 482–483
  structural imaging in, 481*f*, 482
  treatment of, 101, 483–484, 483*t*
  visuospatial function in, 480, 480*f*
  warning signs of, 98*t*
AMAN. *See* Acute motor axonal neuropathy
Amantadine
  for ataxia, 847
  for drug-induced parkinsonism, 851
  for Huntington disease, 867
  for Kleine-Levin syndrome, 1189
  for MS patients, 727*t*
  for neuroleptic malignant syndrome, 1329–1330
  for Parkinson disease, 881, 886
  for rabies, 677
  for tardive dyskinesia, 852*f*, 853*t*
  for vegetative/minimally conscious state, 177
Amaurosis fugax, 303–304, 320
Ambenonium, for myasthenia gravis, 969, 970*t*
Amblyopia, alcoholic, 1306*t*, 1308
Amebic meningoencephalitis, 655–656
  granulomatous, 654*t*, 656
  primary, 654*t*, 655–656
American Academy of Neurology, on neuropathy testing, 937, 939*t*
American College of Radiology, appropriateness criteria of, 196, 197*t*
American Epilepsy Society, 568
American Spinal Injury Association Impairment Scale, 445, 446*t*
American trypanosomiasis, 654*t*, 655, 655*f*, 705, 1263, 1264
Amifampridine, for Lambert-Eaton myasthenic syndrome, 976
Amino acids
  essential, 1387
  in magnetic resonance spectroscopy, 200
  metabolism, disorders of, 1385, 1387–1388, 1419
  nonessential, 1387
  transport disorders, 1388, 1389*t*
4-Aminopyridine, for ataxia, 847
Amiodarone
  intracranial hypertension induced by, 1135
  myotoxicity of, 995*t*
  neuropathy induced by, 949
Amitriptyline
  for chemotherapy-induced neuropathy, 1109*t*
  for migraine prevention, 528, 529*t*
  for MS patients, 726, 727*t*
  for neuropathic pain, 562, 562*t*
  for nummular headache, 534
  for persistent idiopathic facial pain, 547
AML. *See* Acute myeloid leukemia
Ammonia
  in acute liver failure, 1248–1249, 1251
  in hepatic encephalopathy, 1246, 1247–1248, 1247*t*
  high levels of (hyperammonemia), 1386–1387
Amnesia
  alcoholic blackout, 1304
  anterograde, 602
  mild cognitive impairment and, 469–470, 470*t*
  posttraumatic, 437
  pretraumatic, 437
  transient global, 97–98, 602–603
Amnesic shellfish poison, 1333

Amphetamines
abuse/intoxication, 1314, 1316–1317
CNS vasculitis induced by, 381
for narcolepsy (excessive sleepiness), 1189
psychosis with, 1593
Amphotericin B
for aspergillosis, 646, 704
for blastomycosis, 646
for brain abscess, 617
for candidiasis, 1236
for coccidioidomycosis, 645, 703
for cryptococcal meningitis, 644
for histoplasmosis, 646
for malignant otitis externa, 621, 621*t*
Ampicillin, for bacterial meningitis, 607, 607*t*, 609*t*
Amplitude, in nerve conduction studies, 244–245
Amprenavir, 707*t*
AMSAN. *See* Acute motor and sensory axonal neuropathy
Amsler grid, 79
Amyloid angiopathy, cerebral, 401
Boston criteria for, 333, 334*t*
and intracerebral hemorrhage, 332, 333, 333*f*, 334*t*, 409
and stroke, 409
Amyloid neuropathy, 936–937, 943, 943*f*
Amyloidopathy, 97. *See also* Alzheimer disease
and intracerebral hemorrhage, 332, 333, 333*f*
Amyloidosis
autonomic dysfunction in, 1174
dominantly inherited PrP cerebral, 514
Amyloid plaque, 477–479, 478*f*, 478*t*
PET imaging of, 204*t*, 206, 206*f*, 496
Amyloid precursor protein (*APP*) gene, 477–479, 477*f*
Amyloid-related imaging abnormality (ARIA), 479
Amyloid β biomarker, 473, 477–479, 478*f*, 482–483
Amyloid β-related angiitis (ABRA), 374
Amyotrophic lateral sclerosis (ALS), 904–914, 904*t*
bulbar onset, 907, 910
clinical manifestations of, 907–909, 908*f*, 909*f*, 909*t*
dementia in, 97, 486–487, 904, 906, 908*f*
diagnosis of, 904–905, 909–912
diagnostic criteria for, 909, 909*t*, 910*t*
differential diagnosis of, 911–912, 912*t*
dysphagia in, 908, 913, 1262–1263
electrodiagnostic testing in, 911
epidemiology of, 905
familial, 905
genetics of, 487, 905, 906*f*, 907*t*
HIV-associated, 699
laboratory testing in, 911
level 1 evidence on, 913
management of, 912–913, 913*t*
multidisciplinary supportive care for, 912–913
multiple system atrophy *versus*, 896
neuroimaging in, 911
neurologic rehabilitation in, 1630
neuropathology of, 905–906, 908*f*
outcome of, 913
pathobiology of, 905–906
pathology of, 904, 905*f*
pharmacotherapy for, 912
pseudopolyneuritic variant of, 910
spinal onset, 907
spinal tumor *versus*, 1096
vagus nerve injury in, 924
Amyvid. *See* Florbetapir
Anakinra, for autoimmune encephalitis and meningitis, 770
Analgosedation, in traumatic brain injury, 434
Anal reflex, 39*t*
Anal sphincter tone, 43
Anaplasma phagocytophilum, 627, 628*f*
Anaplasmosis, 624, 624*t*, 627–628
Anaplastic astrocytoma, 152, 154, 157*t*, 1026–1029, 1532*t*, 1552
Anaplastic lymphoma kinase inhibitors, for metastatic lung cancer, 1042
Anaplastic oligodendrogliomas, 1031, 1532*t*
ANCA-positive vasculitides, 376–378
Andersen-Tawil syndrome, 998, 1001
Andexanet alfa, anticoagulation reversal with, 139*t*, 336, 409
Andromedotoxin, 1333
Anemia, 1227–1231
definition of, 1227
etiologies of, 1227, 1228*f*
in hospitalized and critically ill neurologic patients, 1227–1228
in intracerebral hemorrhage, 1228
pernicious, 1278–1279
sickle cell. *See* Sickle cell disease
in subarachnoid hemorrhage, 347, 1227–1228
in traumatic brain injury, 1227–1228
Anencephaly, 1367
Anesthesia, for endovascular therapy, 143
Anesthetic agents, for third-line seizure treatment, 61–62, 61*f*, 62*t*
Aneuploidy, 1410
Aneurysms
intracranial. *See* Intracranial (cerebral) aneurysms
MRA of, 195, 195*f*
Angelman syndrome, 1410–1411, 1410*t*, 1414*t*
Angiitis. *See also specific types*
amyloid β-related, 374
primary, of CNS, 370–374
Angioblastic meningioma, 368
Angioedema, tPA and, 312
Angiogenesis disorders, and childhood stroke, 1525
Angiography, cerebral, 217–229. *See also specific modalities*
of arteriovenous malformations, 225*f*, 363, 363*f*
carotid artery views in, 219, 220*f*
complications of, 220–221
of dural arteriovenous fistulas, 365, 365*f*
equipment for, 218, 219*f*
in fibromuscular dysplasia, 389–390, 390*f*
history of, 217–218
in moyamoya disease, 391–392, 392*f*
patient positioning for, 219
postprocedural care in, 219–220
preprocedural considerations, 218
in primary angiitis of CNS, 372, 373*f*
procedural outline and considerations, 218–220
in reversible cerebral vasoconstriction syndrome, 388, 388*f*
in subarachnoid hemorrhage, 223, 344–345, 345*f*
vertebral artery views in, 219, 221*f*
Angiokeratomas, 1395
Angiomas, cavernous. *See* Cavernous malformations
Angiomatosis, encephalotrigeminal. *See* Encephalotrigeminal angiomatosis
Angioplasty, for stroke prevention, 406–407
Angiostrongyliasis, 658, 658*t*
Angiostrongylus cantonensis, 658, 658*t*
Angiostrongylus costaricensis, 658*t*
Angiotensin-converting enzyme (ACE) inhibitors, for stroke prevention, 402, 408
Angiotensin II receptor blockers (ARBs), for stroke prevention, 402, 408
Anhedonia, 1598, 1599, 1602
Anhidrosis, 1174
Animal neurotoxins, 1333
Anisocoria, 81–82, 171
Ankle (Achilles) reflex, 38, 39*t*
Ankylosing spondylitis, 1273
Anosmia
COVID-19 and, 673
olfactory neuropathy and, 915–917
Anosognosia, 305–306, 866
ANT1 mutations, 1450
Antalgic gait, 130*t*
Antebrachial cutaneous nerve, 931
Antebrachial cutaneous nerve graft, 467
Anterior cerebral artery infarction, 305*t*, 306
Anterior cervical diskectomy and fusion (ACDF), 1156
Anterior cingulate cortex, in depression, 1596–1597, 1597*f*
Anterior cord syndrome, 149*t*, 325, 447
Anterior horn cell disorders, 1420. *See also* Spinal muscular atrophy with respiratory distress type 1 (SMARD1)
Anterior interosseous nerve, 932–933
Anterior spinal artery, 147, 147*f*
Anterior spinal artery syndrome, 147
Anterior temporal lobe resection, for epilepsy, 589–590, 589*t*
Anterograde amnesia, 602
Anthrax, 630*t*, 633–634, 634*f*
Antibiotics
for anthrax, 634
for bacterial meningitis
doses, 608, 609*t*
empiric therapy, 607, 607*t*
for brain abscess, 617, 617*t*
for brucellosis, 632
for cat-scratch disease, 633
for diphtheria, 637
for Lyme disease, 650
for malignant otitis externa, 621, 621*t*
for mycoplasmal (walking) pneumonia, 635
for osteomyelitis of skull base, 622
prophylactic
for marantic endocarditis, 398
for TBI patients, 434
for Q fever, 631
for rhinosinusitis, 540
for scrub typhus, 629
for septic thrombosis, 359
for spinal epidural abscess, 620

for spotted fever rickettsiosis, 626–627
for subdural empyema, 618
for typhus group rickettsiae, 629
for Whipple disease, 635
Antibody Prevalence in Epilepsy and Encephalopathy (APE2) score, 770, 771*t*
Anticholinergics
abuse of, 1315–1316
for acute dystonic reaction, 851
for drug-induced parkinsonism, 851
for dystonia, 814, 814*t*
for Ménière disease, 598
for Parkinson disease, 881, 886–887
for Parkinson-plus syndromes, 899
for tardive dystonia, 852, 852*f*
toxicity of, 1322–1324
clinical features of, 1322, 1327*t*
treatment of, 1322–1324
for vertigo, 48, 49*t*
xenobiotics with properties of, 1322, 1327*t*
Anticipation, genetic, 298
Anticipatory anxiety, 1608
Anticoagulation. *See also specific agents*
for atrial fibrillation, 403
for cerebral venous thrombosis, 353, 358, 1523
for childhood stroke, 1522
for ICH secondary prevention, 339–340
intracerebral hemorrhage with, 409, 1241
for marantic endocarditis, 398
for perinatal stroke, 1517
reversal, for ICH, 132, 137–138, 139*t*, 335*t*, 336, 1242
for sinus venous thrombosis, neonatal, 1362
for Sneddon syndrome, 397
for spinal cord injury, 448, 449
for stroke in neonates, 1362
for stroke in pregnant patients, 1291
in stroke patients, 317
for stroke prevention, 406
for TBI patients, 434, 435
Anticonvulsants. *See* Antiepileptic drugs (AEDs)
Antidepressants. *See also specific agents*
for ADHD, 1431–1432
adverse effects of, 1602
for anxiety disorders, 1610, 1611–1612, 1611*t*
for bipolar disorder, 1603
for burning mouth syndrome, 547
for cataplexy, 1189
for depression, 1602
for frontotemporal dementia, 490
for herpes zoster neuropathy, 946
for illness anxiety disorder, 1618–1619
for insomnia, 1186, 1187*t*
for Kleine-Levin syndrome, 1189
for migraine prevention, 528, 529*t*
for MS patients, 726
for neuropathic pain, 561–562, 562*t*, 563
for new daily persistent headache, 534
for nummular headache, 534
for obsessive-compulsive disorder, 1612
for Parkinson disease, 889
for Parkinson-plus syndromes, 899
for persistent idiopathic facial pain, 547
and restless legs syndrome, 795
for somatic symptom disorder, 1617
for stroke patients, 411
for temporomandibular disorder, 542
Antidiuretic hormone (ADH), 1215
deficiency of, 1217. *See also* Diabetes insipidus
inappropriate secretion of, 1217, 1255–1258, 1257*t*
Antidromic impulse, 245
Antiemetics
for migraine in pregnancy, 1293
for vertigo, 48, 49*t*
Antiepileptic drugs (AEDs). *See also specific drugs*
for alcohol withdrawal, 1306
for anxiety disorders, 1610, 1611–1612
for bipolar disorder, 1603
for cerebral venous thrombosis, 358, 359
for chemotherapy-induced neuropathy, 1109, 1109*t*
for cluster headache prevention, 531*t*
for complex regional pain syndrome, 552*t*, 553
for cranial neuralgias, 543, 544*t*
emergent first-line, 59–60, 59*t*
for epilepsy, 581–589
adverse effects of, 583, 583*t*
bone effects of, 589
in breastfeeding patients, 1288–1289
cognitive effects on exposed infants, 1288
combination therapy, 585
compliance with, 593, 594
discontinuation of, 587–588
dosing and pharmacokinetic data of, 584, 584*t*
generic equivalents of, 587
goals of therapy, 581
idiosyncratic reactions to, 583–584, 584*t*
pediatric, 582
pharmacology of, 584–585
psychosocial and psychiatric issues with, 593–595
remission with, 569
reproductive health issues with, 588–589, 1287–1289
selection of, 581–583, 582*t*
therapeutic monitoring of, 585
for essential tremor, 782
for focal mass lesions, 167
for glossopharyngeal neuralgia, 924
for herpes zoster neuropathy, 946
for HIV-associated seizures, 698
for ICH patients, 140, 338
for Lennox-Gastaut syndrome, 1509
for metastatic disease, 1036–1037
for migraine prevention, 528, 529*t*
for myoclonus, 829, 829*t*
for neonatal seizures, 1360–1361, 1361*t*, 1503
for neuropathic pain, 561, 562*t*, 563
for new daily persistent headache, 534
for nondystrophic myotonias, 1002
for nummular headache, 534
osteoporosis and fractures with, 1274–1275
for paroxysmal sympathetic storming, 1200*t*
for persistent idiopathic facial pain, 547
for posterior reversible encephalopathy syndrome, 387
for preeclampsia/eclampsia, 1289–1290
for pregnant patients, 1287–1289
seizure control and monitoring with, 1287
teratogenicity of, 589, 1287–1288, 1287*t*
psychosis with, 1593
for restless legs syndrome, 797*t*
for SAH patients, 347
second-line, 60–61, 61*f*
for somatic symptom disorder, 1617
for subdural empyema, 618
for SUNCT/SUNA headaches, 532
for temporomandibular disorder, 542
third-line (anesthetic), 61–62, 61*f*, 62*t*
for tic disorders, 789, 790*t*
for traumatic brain injury, 434, 578
for traumatic brain injury in children, 1575
for trigeminal neuralgia, 918
Antifungal agents. *See also specific agents*
for aspergillosis, 646
for blastomycosis, 646
for brain abscess, 617, 617*t*
for coccidioidomycosis, 645, 703
for cryptococcal meningitis, 644, 703
for histoplasmosis, 646
for malignant otitis externa, 621, 621*t*
for osteomyelitis of skull base, 622
for trypanosomiasis, 655
Antihistamines. *See also specific drugs*
for acute dystonic reaction, 851
for anxiety disorders, 1612
and restless legs syndrome, 795
for vertigo, 48, 49*t*
Antihypertensive agents. *See also specific agents*
for ICH, 138–139, 337, 337*t*
for ICH secondary prevention, 339
for preeclampsia/eclampsia, 1289–1290
for stroke prevention, 402, 408
Anti-myelin oligodendrocyte glycoprotein, 711, 732, 747, 749–750. *See also* Myelin oligodendrocyte glycoprotein (MOG) spectrum disease
Antineutrophil cytoplasmic antibody (ANCA)-positive vasculitides, 376–378
Antiphospholipid antibody syndrome (APLS), 1242–1243
chorea in, 856
multiple sclerosis *versus*, 722
Antiplatelet agents. *See also specific agents*
for antiphospholipid antibody syndrome, 1242–1243
for CADASIL, 399
in endovascular treatment, 223
for fibromuscular dysplasia, 390
and ICH, 138, 1240
for marantic endocarditis, 398
reversal, for ICH, 137–138, 139*t*, 336
for Sneddon syndrome, 397
for stroke prevention, 321–322, 405–406
for transient ischemic attacks, 321–322, 405
Antipsychotic agents. *See also specific agents*
for alcohol withdrawal, 1306
for anxiety disorders, 1610
atypical, 849
for bipolar disorder, 1603
for chorea, 859, 866–867
commonly used, 1591*t*
for delirium, 91, 92–93, 92*t*, 1205
for delirium prevention, 92
dystonia induced by, 809
for frontotemporal dementia, 490
for Huntington disease, 866–867
for Lewy body dementia, 498, 1593
malignant syndrome with. *See* Neuroleptic malignant syndrome (NMS)
metabolic side effects of, 1590–1592

Antipsychotic agents *(Continued)*
movement disorders induced by, 849–853, 849*t*. *See also* Tardive dyskinesia
for obsessive-compulsive disorder, 1612
for Parkinson disease, 888
and restless legs syndrome, 795
for schizophrenia, 1590–1592, 1591*t*
side effects of, 1590–1592, 1591*t*
for tic disorders, 789, 790*t*
Antiretroviral therapy, for HIV/AIDS, 693, 706–708
adverse neurologic effects of, 706–708, 949, 1583
categories, agents, and combination drugs in, 707*t*
in dementia, 697
pediatric, 1582–1583
Antisense oligonucleotides (ASOs), 519
for Duchenne muscular dystrophy, 1482
for Huntington disease, 868
for myotonic dystrophy, 1487
for spinal muscular atrophies, 1472
for X-linked myotubular myopathy, 1496
Antisynthetase syndrome, 979, 982, 982*t*, 983*t*, 984*t*, 986
Antiviral agents, 662. *See also specific agents and therapies*
for Bell's palsy, 921
for CMV infection, 683
for herpesviruses, 679*t*, 680, 946
for herpesviruses prophylaxis, 679*t*, 680
myotoxicity of, 994
for Ramsay Hunt syndrome, 922
for viral myelitis, 1164
Anton syndrome, 307
Anxiety, 1606–1614
ADHD and, 1431
anticipatory, 1608
burning mouth syndrome and, 546
definition of, 1606
dementia and, 498, 1610, 1612
depression with/*versus*, 1602
epilepsy and, 593, 1610, 1612
essential tremor and, 780
mild cognitive impairment and, 474
multiple sclerosis and, 716, 1610
Parkinson disease and, 880, 889
prion diseases and, 519*t*
Tourette syndrome and, 784, 787
Anxiety disorders, 1606–1614
clinical features across, 1607–1608, 1608*t*
definition of, 1606
diagnosis of, 1607–1610
epidemiology of, 1606
level 1 evidence on, 1613
management of, 1610–1612
medications for, 1610–1612, 1611*t*
neurologic diseases comorbid with, 1606, 1609–1610, 1612
neurologic diseases *versus*, 1609–1610
outcome of, 1612–1613
pathobiology of, 1606–1607, 1607*f*
Aortic arch atheromatous plaque, 408
Apathy
depression *versus*, 1601
in Huntington disease, 865–866, 1601
in Parkinson disease, 880
APE2 (Antibody Prevalence in Epilepsy and Encephalopathy) score, 770, 771*t*
Apgar scores, 1358, 1358*t*
Aphasia
brain abscess and, 614
cerebral infarction and, 305, 306
corticobasal degeneration and, 897
gliomas and, 1019
primary progressive. *See* Primary progressive aphasia (PPA)
progressive nonfluent, 893, 894
testing in, 29, 29*t*, 274
thalamic infarction and, 307
transplantation-related, 1298*t*
treatment (therapy) for, 1632
Apixaban, reversal of, 139*t*, 336, 1242
APLS. *See* Antiphospholipid antibody syndrome
Apnea
coma and, 171
definition of, 1190
sleep. *See* Central sleep apnea; Obstructive sleep apnea
Apnea testing, in brain death, 181
Apneustic breathing, 171, 1208*f*
Apolipoprotein E *(APOE)*
in Alzheimer disease, 477, 477*f*, 482
in Lewy body dementias, 493
in mild cognitive impairment, 473–474, 473*t*
Apomorphine
for Parkinson disease, 887
for restless legs syndrome, 797*t*
Apparent diffusion coefficient (ADC), 191–192, 193*t*
Apraxia
buccolingual, 305
cerebral infarction and, 305–307
constructional, 306
in corticobasal degeneration, 897
eyelid opening, 802*t*, 878–879, 894, 899, 901*t*
gait, 306
ideational, 305
ideomotor, 305
oculomotor, 307, 844*t*, 845
optic, 307
Aprosody, 878
Aquaporin 4 (AQP4)
in autoimmune disorders, 757
in neuromyelitis optica spectrum disorders, 729–731, 745–747, 746*f*
Aqueous humor, 77
Arachnoid cysts, 1546–1547
Arboviruses, 665–672. *See also specific viruses*
ARBs. *See* Angiotensin II receptor blockers
Area postrema syndrome, 730, 730*t*, 748, 1203
Arenaviruses, 677–678
Argatroban, for heparin-induced thrombocytopenia, 1239
Arginase deficiency, 1386–1387, 1386*t*
Arginine vasopressin, for hypotension in brain death, 182
Argininosuccinic acid, 1386–1387, 1386*t*
Argyrophilic grain disease, 97
ARIA (amyloid-related imaging abnormality), 479
Arimoclomol
for inclusion body myositis, 984
for Niemann-Pick disease, 1396–1397
Aripiprazole
for autism spectrum disorders, 1439
for schizophrenia, 1591*t*
side effects of, 1591*t*
for tic disorders, 789, 790*t*
Arm muscles, innervation of, 928*t*
Armodafinil
for MS patients, 727*t*
for narcolepsy (excessive sleepiness), 1189
Arm rolling, 117
ARND. *See* Alcohol-related neurodevelopment disorder
Arnold-Chiari malformation, hydrocephalus with, 1118
Arousal
and delirium, 89–90
and EEG, 230–231, 231*f*
without awareness, 168
Array comparative genomic hybridization, 1412
Arrhythmia
spinal cord injury and, 448
syncope with, 52–53
ARS. *See* Acute radiation sickness
Arsenic poisoning, 939, 947–948, 1332–1333
ART. *See* Antiretroviral therapy, for HIV/AIDS
ARTAG (primary age-related tauopathy), 479
Arteether, for malaria, 654
Artemether, for malaria, 654
Artemisinin derivatives, for malaria, 654
Arterial blood gases (ABGs)
in coma, 175
in respiratory failure, 1210
Arterial gas embolism (AGE), 1350–1354, 1352*t*
Arterial spin labeling (ASL), 200–201
Arteriopathy, in pediatric stroke, 1518–1519
Arteriosclerosis, TIAs caused by, 320
Arteriovenous malformations (AVMs), 361–364
acquired, 361
angiography of, 225*f*, 363, 363*f*
clinical features of, 361–362
congenital, 361
definition of, 225
diagnosis of, 362–363
endovascular treatment of, 225–226, 364
epidemiology of, 361
ICH with, 225, 409–410
location and size of, 361
MRI of, 362–363, 362*f*, 1166
outcome of, 364
pathobiology of, 361
ruptured, 364
SAH with, 351, 362
schizencephalic, 361
Spetzler-Martin grading scale for, 225, 225*f*, 364, 364*t*
spinal, 1166
supratentorial, 361
treatment of, 363–364
ultrasound detection of, 213–214
unruptured, 363
Artesunate, for malaria, 654
Arthropathy, 936
Artifacts, in MRI, 195–196, 196*f*
Artificial liver support systems, 1251
ARUBA (A Randomized trial of Unruptured Brain AVMs), 364, 409–410, 1166
ARX disorders, 1506
Ascaris, 162*t*, 654*t*, 658, 658*t*
ASDs. *See* Autism spectrum disorders
Asenapine, 1591*t*
Aseptic meningitis, medication-induced, 608

ASIA Impairment Scale, 445, 446*t*
ASL. *See* Arterial spin labeling
Asomatognosia, cerebral infarction and, 305–306
ASOs. *See* Antisense oligonucleotides
ASPECTS. *See* Alberta Stroke Programme Early CT Score
Asperger disorder, 1433
Aspergillosis, 153, 161*t*, 162*f*, 646
  brain abscess in, 617
  chronic meningitis in, 641*t*–643*t*, 646
  clinical presentation of, 641*t*, 646
  CSF analysis and serum diagnostics in, 642*t*, 646
  diagnosis of, 646
  epidemiology and pathobiology of, 646
  hematopoietic cell transplantation and, 1236
  HIV-associated, 703–704
  imaging in, 641*t*, 646
  invasive, 646
  malignant otitis externa in, 621, 621*t*
  osteomyelitis in, 622
  transplantation-related, 1255, 1299
  treatment of, 643*t*, 646, 704
Aspergillus, 646
Aspergillus fumigatus, 703–704
Asphyxia, perinatal, 1357–1359
  clinical manifestations of, 1358, 1358*t*
  diagnosis of, 1358
  epidemiology of, 1357
  management of, 1358–1359
  neuroimaging in, 1358, 1359*f*
  outcome of, 1359
  pathobiology of, 1357–1358
Aspiration pneumonia, stroke and, 316–317
Aspirin (acetylsalicylic acid)
  for antiphospholipid antibody syndrome, 1243
  for CADASIL, 399
  for childhood stroke, 1522
  in endovascular treatment, 223
  for essential thrombocythemia, 1240
  for giant cell arteritis, 375
  and ICH, 138, 1240
  for Kawasaki disease, 376
  for migraine, 526*t*
  for migraine in pregnancy, 1293
  for perinatal stroke, 1517
  for polycythemia, 1232
  for Sneddon syndrome, 397
  for stroke (AIS), 142
  for stroke prevention, 321–322, 405–406
  for Susac syndrome, 395
  for tension-type headache, 530
Astereognosia, cerebral infarction and, 305
Asterixis, 824, 829
  in hepatic encephalopathy, 1247
  transplantation-related, 1298*t*
  in uremic encephalopathy, 1253
Asthma, in eosinophilic granulomatosis with polyangiitis, 377–378
Astroblastoma, 1552
Astrocytes, 1535–1537
Astrocytic plaques, 896, 896*f*
Astrocytomas, 1019, 1023–1029
  anaplastic, 152, 154, 157*t*, 1026–1029, 1532*t*, 1552
  CT of, 1549–1550
  diffuse, 1024–1026, 1025*f*, 1532*t*
  diffuse fibrillary, 158*t*
  intramedullary spinal, 1093–1094
  molecular features of, 1020–1021, 1020*t*, 1023, 1024
  MRI of, 198–199, 1024, 1025*f*, 1027, 1027*f*, 1549, 1549*f*, 1550*f*
  neurofibromatosis and, 1457, 1458
  pediatric, 1549–1554
    cerebellar, 1549, 1549*f*
    chemotherapy for, 1551, 1552–1553
    classification of, 1539–1540, 1540*t*
    epidemiology of, 1528–1532, 1529*f*
    high-grade, 1551–1553
    IDH mutations in, 1537, 1537*f*
    low-grade, 1549–1551
    pathobiology of, 1535–1537, 1536*f*
    radiation therapy for, 1549–1553
    spinal cord, 1554
  pilocytic, 153–154, 158*t*, 159*f*, 1020*t*, 1023–1024, 1024*f*, 1551
  pineal, 1072
  recurrent, 1029
  subependymal giant cell, 1020*t*, 1530–1531, 1551
Asynergia, 107
Ataxia, 107, 831–848
  acquired, 837–838, 837*t*
  acute, 833, 833*t*
  alcoholic cerebellar degeneration and, 1307–1308
  autoimmune, 838
  autonomic testing in, 837
  autosomal recessive, 844–845, 844*t*, 845*f*
  brain abscess and, 614
  in Charcot-Marie-Tooth disease, 959
  childhood, with central hypomyelination, 1399, 1401–1402, 1414*t*
  chronic, 833, 833*t*
  clinical approach to, 832–837
  degenerative, 846–847
  differential diagnosis of, 833, 833*t*
  dystonia in, 804
  epidemiology of, 832
  episodic, 833, 833*t*, 846
  flowsheet for diagnosis, 835*f*
  future developments in, 847
  gait. *See* Gait ataxia
  gliomas and, 1019
  gluten, 838, 847, 1267, 1283–1284
  in Guillain-Barré syndrome, 939
  hemangioblastoma and, 368
  idiopathic late-onset, 846–847
  illicit drug use and, 1317
  inherited, 838–847
  laboratory testing in, 834
  lateral medullary infarction and, 307
  limb, 107
  management of, 847
  mitochondrial, 845–846
  multiple sclerosis and, 716
  myoclonus with, 827
  neuroanatomy of, 108
  neuroimaging in, 835–837, 836*f*, 839*f*
  neurologic examination in, 833–834
  without neuropathy, 844*t*, 845
  paraneoplastic, 838, 1101*t*, 1102
  posttraumatic, 437–438
  with predominant sensorimotor axonal neuropathy, 844*t*, 845
  with predominant sensory neuropathy, 844–845, 844*t*, 845*f*
  progressive, with palatal tremor, 827
  psychogenic, 847
  in sarcoidosis, 838, 839*f*
  signs and symptoms of, 832–833, 833*t*
  spinocerebellar, 838–844
    assessment in, 834
    associated with noncoding repeats, 843
    CAG repeat polyglutamine, 839–843
    chorea in, 857–858
    essential tremor *versus*, 781
    genetics of, 299, 838–844, 840*t*–842*t*
    genetic testing in, 843–844
    GM2 gangliosidosis and, 1394
    infantile-onset, 1450
    signs and symptoms of, 838, 840*t*–842*t*, 842*f*
    treatment of, 847
  subacute, 833, 833*t*
  thalamic infarction and, 307
  varicella-zoster virus and, 681
  visual problems in, 833, 833*t*
  Wernicke syndrome and, 1307
  xenobiotic-induced, 1320, 1322*t*
Ataxia-telangiectasia, 844*t*, 845, 1414*t*, 1531
Ataxic breathing, 171, 1208*f*
Ataxic cerebral palsy, 1425, 1426, 1426*t*
Atazanavir, 707*t*
Atelectasis, 1207, 1209–1210
Atenolol, for migraine prevention, 529*t*
Atherosclerosis
  aneurysms with, 343
  aortic arch, 408
  dementia with, 500–503, 503*f*. *See also* Vascular dementia
  intracranial stenting in, 226–227
  large-artery, ischemic stroke with, 303–304, 303*f*
Athetosis, 36, 106, 106*f*, 106*t*
  cerebral palsy and, 1425, 1426, 1427
  in dyskinetic cerebral palsy, 858
  dystonia *versus*, 802*t*
  HIV-associated, 698
Athetotic dystonia, 106
Atlantoaxial dislocation, 1273–1274
Atomoxetine, for ADHD, 1431
Atonic seizures, 571
Atorvastatin
  myotoxicity of, 993–995, 995*t*, 996*f*, 996*t*
  for stroke prevention, 408
Atovaquone, for toxoplasmosis, 167, 704
ATP. *See* Adenosine triphosphate
Atrial appendage closure, 409, 410*f*
Atrial fibrillation (AF)
  intracerebral hemorrhage risk in, 409, 410*f*
  stroke in, 133, 304
    postoperative, 1195–1197
    prevention of, 403, 406
Atropine, 1329
AT/RTs. *See* Atypical teratoid/rhabdoid tumors
Attention
  Lewy body dementias and, 494
  testing of, 30, 275
  traumatic brain injury and, 436–437

Attention deficit hyperactivity disorder (ADHD), 1428, 1428*t*, 1431–1432
diagnosis of, 1431
diagnostic criteria for, 1431
epidemiology of, 1431
neurofibromatosis and, 1458
subtypes of, 1431
Tourette syndrome with, 784, 787, 789, 1431
Atypical antipsychotics, 849
Atypical teratoid/rhabdoid tumors (AT/RTs), 1530, 1557–1558
Audiogram, 262
Audiometry, 50, 262
in Ménière disease, 598
Auditory-evoked potentials. *See* Brainstem auditory evoked potentials (BAERs)
Aura, migraine with and without, 524–525, 524*t*
Aural fullness, 521
Autism Diagnostic Interview-Revised (ADI–R), 1435
Autism Diagnostic Observation Schedule-2 (ADOS-2), 1435
Autism spectrum disorders (ASDs), 1381, 1428*t*, 1433–1440
cognition and language in, 1436–1437
core symptoms of, 1433, 1435
diagnosis of, 1435–1439
diagnostic criteria for, 1433, 1435, 1436*f*
epidemiology of, 1433–1434
epilepsy with, 1437–1438
evaluation for, 1435
genetic disorders associated with, 1438, 1438*t*
genetics of, 1434, 1434*t*
genomic imprinting and, 1411
management of, 1439
medical and psychiatric comorbidities with, 1437
metabolic disorders associated with, 1438, 1438*t*
neurodiagnostic testing in, 1438–1439
neuroimaging in, 1435, 1438–1439, 1439*t*
neurologic examination in, 1435–1436
neuropathology of, 1434–1435
outcome of, 1439
pathobiology of, 1434–1435
speech/language delays in, 1428, 1429
Tourette syndrome with, 784
Autistic regression, 1429
Autoimmune adrenalitis, 1222
Autoimmune ataxia, 838
Autoimmune autonomic neuropathy (AAN), 1170–1172
Autoimmune choreas, 854–856
Autoimmune dementia, 759
Autoimmune encephalitis and meningitis, 755–772
acute therapy for, 767, 768*t*–770*t*
antibody testing in, 763–764, 763*t*, 764*t*, 765*f*
biomarkers of, 755, 763–764, 763*t*, 764*t*, 765*f*
cancer workup in, 764–765, 766*t*–767*t*
chronic (maintenance) therapy for, 767–770, 768*t*–770*t*
clinical manifestations of, 757–760
diagnosis of, 757–765
diagnostic clues to, 759*t*
EEG findings in, 762–763, 762*f*
epidemiology of, 755–756
imaging in, 760–762, 761*f*
immunobiology of, 756–757, 756*f*
immunopathology of, 757, 758*f*
management of, 765–770
outcome of, 771
paraneoplastic, 755, 757, 764–765, 766*t*–767*t*, 767, 1101, 1101*t*, 1104*f*
pathobiology of, 756–757
postinfectious, 757
predictive scores in, 770–771, 771*t*
therapeutic drug monitoring in, 770
Autoimmune epilepsy, 759
Autoimmune GFAP astrocytopathy, 760, 761*f*, 762, 771
Autoimmune myopathy, 979–988. *See also specific types*
Autoinduction, 586
Autonomic disorders, 1170–1177, 1172*t*
acute and subacute, 1170–1173
causes of, 1170, 1171*f*
diagnosis and management of, 1174–1175
paraneoplastic, 1172–1173, 1172*t*
symptoms of, 1170, 1171*t*
Autonomic dysfunction. *See also* Autonomic disorders
in Guillain-Barré syndrome, 939
in Lewy body dementias, 494, 498
in multiple system atrophy, 495, 896, 1173–1174, 1175
in nerve injury, 453
in neuroleptic malignant syndrome, 1329
in neuropathy, 936–937
in Parkinson disease, 880–881, 1173–1174
in spinal cord injury, 447–448
Autonomic dysreflexia, 148, 449
Autonomic failure, 1170, 1173–1175
Autonomic neuropathy, 938*t*, 941, 1170–1176
Autonomic storming, 1195, 1198–1200, 1199*f*, 1199*t*, 1200*t*
Autonomic symptoms, cranial, 521
Autonomic testing, 255–258
in ataxia, 837
in clinical practice, 258
goal of, 255
heart rate variability in, 255
in Lewy body dementias, 496
reflex loops in, 255
standing and 30:15 ratio in, 256
sympathetic measures in, 255–256
techniques for, 255, 256*t*
tilt table studies in, 256–257, 257*f*
Autonomy, 1638–1639
Autosomal dominant ataxias, 838–844, 840*t*–842*t*
Autosomal dominant chorea, 857–858
Autosomal dominant limb-girdle muscular dystrophy, 1491–1492
Autosomal recessive ataxia, 844–845, 844*t*, 845*f*
Autosomal recessive chorea, 856
Autosomal recessive limb-girdle muscular dystrophy, 1487–1491
AVMs. *See* Arteriovenous malformations
Awaji ALS criteria, 909, 910*t*
Axillary nerve
anatomy of, 928, 928*f*, 928*t*, 931
injury of, 459–460, 931
transfer of radial nerve to, 467–468
Axonal injury, EMG findings in, 247
Axonal neuropathies, infant hypotonia (floppy infant) in, 1421–1422
Axonal regeneration, 453
Axonal-shearing injury, 421, 422*f*, 423*f*
Axonotmesis, 452, 452*t*, 463, 468
Azathioprine
for autoimmune encephalitis and meningitis, 767, 769*t*, 770
for Behçet syndrome, 379
for CNS vasculitis in rheumatoid arthritis, 380
for dermatomyositis, 981
for eosinophilic granulomatosis with polyangiitis, 378
for inclusion body myositis, 984
for myasthenia gravis, 970–971, 970*t*
for myelin oligodendrocyte glycoprotein spectrum disease, 732
for neuromyelitis optica spectrum disorders, 731, 752, 752*t*
for paraneoplastic syndromes, 1104
for polyarteritis nodosa, 376
for sarcoidosis, 776, 777*t*
Azithromycin
for cat-scratch disease, 633
for mycoplasmal (walking) pneumonia, 635
for scrub typhus, 629
for toxoplasmosis, 167
AZT. *See* Zidovudine

B

B_0 field, in MRI, 190
Babinski sign, 38, 908, 1091, 1149, 1397
Baby Siblings Research Consortium (BSRC) studies, 1434
Bacillus anthracis, 630*t*, 633–634
Back-averaged electroencephalography, 825
Back pain
focused history on, 67
intervertebral disk disease and, 1145
neurologic history in, 20*t*
spinal epidural abscess and, 619
spinal stenosis and, 1153
Baclofen
for ataxia, 847
for complex regional pain syndrome, 552*t*
for cramps, 1009
for cranial neuralgias, 543, 544*t*
for dystonia, 815, 853*t*
for hemifacial spasm, 822
for hereditary spastic paraplegia, 1168
for paroxysmal sympathetic hyperactivity, 1180*f*, 1181, 1181*t*
for paroxysmal sympathetic storming, 1200*t*
for spasticity in MS, 726, 727*t*
for stiff person syndrome, 1006
for tardive dystonia, 852*f*, 853*t*
for tic disorders, 789, 790*t*
for trigeminal neuralgia, 918
Bacterial cerebral vasculitis, 381
Bacterial infections. *See also specific infections*
brain, 153, 161*t*
HIV-associated, 700*t*, 705
Bacterial meningitis
acute, 604–611. *See also* Acute bacterial meningitis
meningococcal, 604–605
pneumococcal, 604–605
BAERs. *See* Brainstem auditory-evoked potentials

BAL. *See* British anti-Lewisite
Balamuthia mandrillaris, 656
Balance. *See also* Vestibular system, testing of
  assessment of, 126–127, 126*t*
  testing of, 262–263
Balint syndrome, 307
Ballism, 36, 106, 106*f*, 106*t*, 856
Balloon-assisted coiling, 222
Band heterotopia, 1374–1375, 1377
Barbiturates
  abuse/dependence, 1314
  coma induced by, 1133
  for ICP management, 432
  for sympathomimetic toxicity, 1325
Bariatric surgery
  neurologic complications of, 1283
  nutritional deficiencies with, 1277, 1283
Baroreflex index, 255–256
Barotrauma, 1350–1353, 1352*t*
Barth syndrome, 1445, 1448–1449
Bartonella henselae, 630*t*, 632–633
Basal ganglia
  abscess of, 160*f*
  in depression, 1596–1597
  focal mass lesions of, 153*f*
  gait control by, 123, 124, 124*f*, 124*t*
Basal ganglia intracerebral hemorrhage, 332, 332*f*
Basilar artery infarction, 137, 316
Basilar artery stenosis, TIAs with, 321
Basilar migraine, 54, 525
Basilar skull fractures, 420–421, 435
Bassen-Kornzweig syndrome. *See* Abetalipoproteinemia
Bath salts, 1314
Baylisascaria procyonis, 654*t*, 658, 658*t*
Baylisascariasis, 654*t*, 658, 658*t*
B cells
  autoimmune disorders and, 756–757, 756*f*
  multiple sclerosis and, 711–712
  neuromyelitis optica spectrum disorders and, 747
BDNF, in depression. *See* Brain-derived neurotrophic factor, in depression
Beaten silver, 1118
Becker muscular dystrophy, 1479–1482
  clinical features of, 1480–1481
  definition of, 1479
  diagnosis of, 1481
  epidemiology of, 1479
  intermediate phenotype of, 1481
  management of, 1481–1482
  molecular genetics of, 1481
Beck syndrome, 325
Bedside Shivering Assessment Scale, 328, 329*t*
Behavioral impairment, mild, 472
Behçet syndrome, 165*t*, 371*t*, 378–379, 722, 738
Bell, Charles, 920
Bell's palsy, 35, 915, 920–922
  diagnosis of, 920–922
  epidemiology and pathobiology of, 920
  hemifacial spasm with, 820–821
  pregnancy and, 1294
  treatment and outcome of, 921
Benign adult familial myoclonic epilepsy, 826
Benign epilepsy with centrotemporal spikes, 575
Benign epileptiform variants, 232
Benign familial infantile epilepsy, 1504
Benign familial neonatal epilepsy (BFNE), 1504
Benign familial neonatal-infantile epilepsy, 1504
Benign fasciculations, 912, 912*t*, 1009
Benign neonatal familial convulsions (BFNS), 1360
Benign paroxysmal positional vertigo (BPPV), 46–48, 48*t*, 597, 600
  Ménière disease *versus*, 597–598
  provocative positional maneuvers in, 41–42, 41*f*, 47, 600, 600*f*
  treatment of, 48, 600
Benign recurrent lymphocytic meningitis, 680–681
Benign rolandic epilepsy, 1505*f*, 1510
Benign sleep myoclonus of infancy, 1192
Benton Judgment of Line Orientation test, 274
Benznidazole, for American trypanosomiasis, 655
Benzodiazepines. *See also specific drugs*
  abuse/dependence, 1314, 1316, 1593
  for alcohol withdrawal, 1305*t*, 1306, 1593
  for anticholinergic toxicity, 1322–1324
  for anxiety disorders, 1610, 1611–1612, 1611*t*
  for cholinergic toxicity, 1329
  for chorea, 855
  for cramps, 1009
  and delirium, 91
  for dystonia, 814–815
  for essential tremor, 782
  for insomnia, 1186, 1187*t*
  for Ménière disease, 598
  for neonatal seizures, 1360–1361, 1361*t*
  for parasomnias, 1193
  for Parkinson disease, 889
  for paroxysmal sympathetic hyperactivity, 1180–1181, 1180*f*, 1181*t*
  for pediatric TBI, 1575
  for rabies, 677
  for seizures
    first-line, 59–61, 59*t*
    third-line, 61–62, 62*t*
  for serotonin syndrome, 1330
  for spasticity in MS, 726, 727*t*
  for stiff person syndrome, 1006, 1105
  for sympathomimetic toxicity, 1325
  for temporomandibular disorder, 542
  for vertigo, 48, 49*t*
Benztropine
  for acute dystonic reaction, 851, 1590
  for Parkinson disease, 886–887
  for tardive tremors, 1590
Beriberi, 947. *See also* Vitamin B_1 (thiamine)
Best interest standard, 1639
Beta activity, in EEG, 230–231, 232*f*
β-Adrenergic agonists, for congenital myasthenic syndromes, 975, 975*t*
β-Adrenergic antagonists. *See* β-Blockers
β-Blockers
  for acute akathisia, 851
  for alcohol withdrawal, 1306
  for essential tremor, 781–782
  for hyperthyroidism, 1221
  for ICH, 139, 337, 337*t*
  for migraine prevention, 528, 529*t*, 1293
  neurotoxicity of, 1299
  for orthostatic intolerance, 1173
  for paroxysmal sympathetic hyperactivity, 1180–1181, 1180*f*
  for paroxysmal sympathetic storming, 1200*t*
  for pregnant patients, 1293
  for stroke prevention, 402
  for tardive akathisia, 851
β-Galactosidase deficiency, 1394–1395
Betamethasone, for IV/GM hemorrhage prevention, 1357
Beta-propeller protein-associated neurodegeneration (BPAN), 1393
Bethlem sign, as seen in Bethlem myopathy, 1478, 1478*f*
Bevacizumab
  for acoustic neuroma, 1082
  for brain edema, 1131
  for gliomas, 1022, 1023*t*
  for meningiomas, 1054, 1054*t*
  neurologic complications of, 1109
  for pediatric astrocytoma, 1552
  for pilocytic astrocytomas, 1024
  for radiation complications, 1107, 1342
  for recurrent astrocytoma, 1029
Bibrachial amyotrophy, 904*t*, 910
Biceps brachialis reflex, 38, 39*t*
Bilateral acoustic neuroma syndrome, 1456–1459
Bilharziasis, 654*t*, 658–659, 659*t*
BinaxNOW rapid test, 654
Binswanger disease (BD), 97, 393–394
  clinical features of, 393
  diagnosis of, 393–394
  epidemiology of, 393
  level 1 evidence on, 399–400
  management of, 394
  MRI of, 502*f*
  outcome of, 394
  pathobiology of, 393
Biologic agents. *See also specific agents*
  neurologic complications of, 1109–1110
  for pediatric brain tumors, 1545
Biomarkers
  in Alzheimer disease, 472–473, 477–479, 478*f*, 482–483
  in ataxia, 834
  in autoimmune encephalitis and meningitis, 755, 763–764, 763*t*, 764*t*, 765*f*
  in cerebral microdialysis, 294, 294*t*
  in circadian rhythm disorders, 268
  in coma, 177
  in Creutzfeldt-Jakob disease, 510
  in dementia, 101
  in frontotemporal dementia, 101, 489
  in Huntington disease, 866
  in Lewy body dementias, 101, 495*t*, 496
  in mild cognitive impairment, 472–473, 473*t*
  in multiple sclerosis, 719–721
  in neuromyelitis optica spectrum disorders, 730–731
  in Parkinson disease, 871
  in survivors of cardiac arrest, 329–330
  in transverse myelitis, 740–741
Biopsy, 283–287. *See also specific biopsies*
  brain, 166, 283–284
  muscle, 121, 284–285
  nerve, 69, 121, 285–286
  skin, 69, 286–287

Bipolar disorder, 1596–1605
clinical manifestations of, 1599
diagnosis of, 1600–1602
epidemiology of, 1596
level 1 evidence on, 1604–1605
neurologic disorders associated with, 1600, 1600*t*
other specified, 1600
outcome of, 1603–1604
pathobiology of, 1596, 1598
with psychotic features, 1589–1590, 1590*t*
substance/medication-induced, 1600
treatment of, 1603
type I (manic episodes), 1599, 1600
type II (hypomanic episodes), 1599, 1600
Bisphosphonates
for complex regional pain syndrome, 552*t*, 553
for fibrous dysplasia, 1272
for osteoporosis, 1274–1275
for Paget disease, 1271
Bithermal caloric testing, 262
Bivalirudin, for heparin-induced thrombocytopenia, 1239
Blackfoot disease, 1332–1333
Blackout
alcoholic, 1304
swallow water, 1350, 1351
Blackwater fever, 654
Bladder dysfunction, 1264–1267, 1265*f*
in acute spinal cord syndromes, 148, 149
in cortical and subcortical disease, 1267
in hereditary spastic paraplegia, 1168
in multiple sclerosis, 716, 726, 727*t*, 1266
in multiple system atrophy, 896, 1267
in neuropathy, 1266
in normal-pressure hydrocephalus, 1122
in Parkinson disease, 880–881
rehabilitative therapy for, 1633
in spinal cord injury, 449, 1266
in stroke patients, 1267
in transverse myelitis, 738
Blast injuries, 438
Blastomyces dermatitidis, 645–646
Blastomycosis, 153, 161*t*, 645–646
chronic meningitis in, 641*t*–643*t*, 645–646
clinical presentation of, 641*t*, 645
CSF analysis and serum diagnostics in, 642*t*, 645–646
diagnosis of, 645–646
epidemiology of, 645
imaging in, 641*t*
pathobiology of, 645
treatment of, 643*t*, 646
Bleomycin, for pineal region tumors, 1076
Blepharophimosis, 1007
Blepharospasm, 106, 802, 807–808, 808*f*, 815
Bleuler, Eugen, 1433
Blindness, heroin and, 1317
Blinking
coma and, 171, 173*f*
in Parkinson disease, 881
Blink reflex, 246
Blister aneurysm, 344, 348
Bloch-Sulzberger syndrome, 1376
Block Design subtest, 274
Blocking, in EMG, 968
Blood-brain barrier
dysfunction, sepsis and, 1203–1204
and metastatic disease, 1034–1035
radiopharmaceuticals and, 204
Blood ethanol (alcohol) level, 1303–1304, 1303*t*
Blood flow, cerebral. *See* Cerebral blood flow (CBF)
Blood glucose levels, as contraindication to tPA, 141–142
Blood pressure
in autonomic testing, 255–257
elevated. *See* Hypertension
low. *See* Hypotension
response to standing, 256
spinal cord injury and, 447–448
in traumatic brain injury, 433
Blood transfusions
for anemia, 1227–1228
for sickle cell disease, 1229–1230, 1230*t*
Blunt nerve injury, 464–465
Blurred vision, in multiple sclerosis, 715, 715*t*
BMD. *See* Becker muscular dystrophy; Bone mineral density
B mode ultrasound, 208–209, 208*t*
BMS. *See* Burning mouth syndrome
Body dysmorphic disorder, *DSM-IV* classification and criteria for, 1615*t*, 1616
Body hemianesthesia, 44, 44*f*
Bolus-tracking, in MRI, 200
Bone disease, 1270–1276. *See also specific diseases*
Bone metabolism/health
epilepsy treatment and, 589
spinal cord injury and, 450
Bone mineral density (BMD), 1274–1275
Bone scintigraphy
in complex regional pain syndrome, 551, 551*t*
in osteomyelitis of skull base, 622
Bone windows, in CT, 185–186, 186*f*
Borden classification system, for DAVFs, 364, 365*t*
Border zone (watershed) infarction, 306, 306*f*, 325, 502*f*
Borrelia burgdorferi, 649. *See also* Borreliosis
Borreliosis (Lyme disease)
acute disseminated infection in, 649
chronic meningitis in, 641*t*–643*t*, 649–650
clinical presentation of, 641*t*, 649
CSF analysis and serum diagnostics in, 642*t*, 649–650
dementia in, 98
diagnosis of, 649–650, 938*t*
epidemiology of, 649
multiple sclerosis *versus*, 721
neuropathy in, 938*t*, 946
pathobiology of, 649
psychosis with, 1594
treatment of, 643*t*, 650
Bortezomib
for autoimmune encephalitis and meningitis, 769*t*, 770
for myasthenia gravis, 972
neurologic complications of, 1109–1110
neuropathy induced by, 949
Boston criteria, for cerebral amyloid angiopathy, 333, 334*t*
Boston Diagnostic Aphasia battery, 274
Boswellic acids, 1108
Botulinum immune globulin, 977
Botulinum toxins
for ALS patients, 913
commonly used, 817*t*
contraindications to, 815
for cranial neuralgias, 543, 544*t*
for dystonia, 813, 815–817, 852*f*, 853*t*, 867, 899
for essential tremor, 782
for hemifacial spasms, 822–823, 822*t*, 829*t*
for hereditary spastic paraplegia, 1168
for migraine prevention, 528, 529*t*
for neuropathic pain, 564
for Parkinson-plus syndromes, 899
for persistent idiopathic facial pain, 547
side effects of, 815–817, 823
for spasticity in cerebral palsy, 1427
for spasticity in MS, 726, 727*t*
for temporomandibular disorder, 542
for tic disorders, 791, 791*t*
for trigeminal neuralgia, 918
Botulism, 636*t*, 637, 976–977
clinical features of, 977
diagnosis of, 977
epidemiology and pathobiology of, 976–977
Guillain-Barré syndrome *versus*, 939–940
infant, 637, 1417, 1422
management of, 977
repetitive nerve stimulation in, 250, 251, 977
Botulism antitoxin, 977
Botulism immunoglobulin, 637
Bouncing gait, 824
Bovine spongiform encephalopathy (BSE), 517
Bowel dysfunction, 1264, 1266–1267
in multiple sclerosis, 716, 726, 727*t*
in neuropathy, 1266
rehabilitative therapy for, 1633
in spinal cord injury, 449, 1266
in transverse myelitis, 738
Bowel dysmotility, 1264. *See also* Bowel dysfunction
Bowlus and Currier test, 44, 44*f*
BPAN. *See* Beta-propeller protein-associated neurodegeneration
BPP theory of relaxation, 189–190
BPPV. *See* Benign paroxysmal positional vertigo
Brachial amyotrophic diplegia, 306, 325, 910
Brachial cutaneous nerve, 931
Brachial plexitis, idiopathic, 929
Brachial plexitis, idiopathic (Parsonage-Turner syndrome), 458, 925, 929
Brachial plexus
anatomy of, 112, 112*f*, 927–928, 928*f*
heroin and damage to, 1317
injuries of, 66, 457–458, 457*t*, 927–930
muscle weakness localized to, 112
obstetrical palsy, 1420
radiation damage to, 931, 1107, 1336, 1337, 1338*t*, 1341, 1341*f*
sensory patterns and loss, 65*t*, 66
Brachioradialis reflex, 38, 39*t*
Brachytherapy, 1545
Bradykinesia, 104
in corticobasal degeneration, 897
in Huntington disease, 865
in Parkinson disease, 877–878
Bradyphrenia, 880
BRAF
in astrocytomas, 1551, 1552
in ganglioglioma, 1548

in melanoma, 1043
in pediatric astrocytoma, 1536, 1536*f*
Brain
extracellular, 1128
focal mass lesions of, 152–167. *See also specific lesions*
gut microbiome and, 713, 1267–1268
health, global disparities in policies and guidelines for, 11, 11*b*
heart interaction with, 1195–1200
cardiovascular complications of neurologic injury, 1195, 1197–1200
cerebral complications of cardiac procedures, 1195–1197
physiology of, 1195
intracellular, 1128
Brain abscess, 153–154, 161*t*–162*t*, 612–618
antimicrobials for, 617, 617*t*
bacterial, 153, 160*f*, 612, 613, 613*t*, 617, 617*t*
brain edema with, 1131
causative organisms of, 613, 613*t*
clinical manifestations of, 614–615
definition of, 612
diagnosis of, 164–166, 615–617
epidemiology of, 612–613
focused examination for, 159
focused history on, 154–159
fungal, 153, 161*t*, 162*f*–163*f*, 612, 613, 613*t*, 617, 617*t*
imaging of, 160*f*, 162*f*–164*f*, 164–166, 612–618, 614*f*–616*f*
infection source in, 612–613
management of, 617–618
odontogenic, 612
outcome of, 618
parasitic, 153, 162*t*, 163*f*–164*f*, 612, 613, 613*t*
pathobiology of, 613–614, 613*f*
review of systems for, 159
surgical treatment of, 617
time course of, 156
viral, 153–154, 161*t*, 164*f*
Brain aneurysms. *See* Intracranial (cerebral) aneurysms
Brain biopsy, 166, 283–284
indications for, 283–284
interdisciplinary approach for, 284
neuropathologic interpretation of, 284
in primary angiitis, 372
risks associated with, 283
Brain death, 177, 179–183
ancillary tests in, 181–182, 181*t*
apnea testing, 181
checklist for, 180*t*
clinical diagnosis of, 180–182
clinical examination in, 181
cranial nerve examination in, 181
determining cause of, 180
diagnostic challenges and pitfalls in, 182, 182*t*
ethical issues in, 183
ICU management of potential organ donors in, 182
imaging confirmation of, 180–181
motor responses to pain in, 181
pediatric, 182
supratentorial lesions and, 179, 179*f*
traumatic brain injury and, 435
Brain-derived neurotrophic factor (BDNF), in depression, 1598
Brain edema, 1127–1138
bacterial meningitis and, 609
brain abscess and, 614, 1131
cardiac arrest and, 1130
cerebral infarction and, 1129
classification of, 1128, 1128*t*
conditions characterized by, 1127, 1127*t*
cytotoxic, 302, 443, 1128, 1128*t*, 1129
definition of, 1127
focal mass lesions and, 166
glucocorticoids for, 1133–1134
granulocytic, 1131
hepatic disease and, 1131, 1248–1251
high-altitude, 1132
hypertonic saline for, 1135
ICH and, 135, 138–139, 334, 1130
ICP management in, 1132–1133
interstitial (hydrocephalic), 1128, 1128*t*, 1129
ionic, 1129
level 1 evidence on, 1138
meningitis and, 1131
metastatic disease and, 1036, 1037*f*, 1038
MRI appearance of, 193*t*
osmotic, 1128, 1129
pathobiology of, 1128–1129
perihematomal, 334, 1130
postendarterectomy, 1132
posttransplant, 1300–1301
preeclampsia/eclampsia and, 1289–1290, 1289*f*
radiation injury and, 1336, 1337, 1338*t*
Reye syndrome and, 1131
specific treatments for, 1133–1135
subarachnoid hemorrhage and, 346–347, 346*f*, 1130, 1130*f*
traumatic brain injury and, 423, 1130
tumor-related, 1130–1131
vasogenic, 443, 1128, 1128*t*, 1133–1134
venous infarction and, 1130
viral encephalitis and, 1131
Brain engorgement, 1128
Brain fog, in parasarcoidosis, 776
Brain herniation, 1128. *See also* Herniation syndromes
Brain injury
acute, paroxysmal sympathetic hyperactivity after, 1178–1182
brain death in, 179–183
cardiovascular complications of, 1195, 1197–1200
early, SAH and, 346–347
traumatic. *See* Traumatic brain injury (TBI)
Brain-lung-thyroid *(NKX2-1)* syndrome, 858
Brain metastases, 1034–1049
chemotherapy for, 1038, 1042–1044
clinical manifestations of, 1038
diagnosis of, 1038–1039
differential diagnosis of, 1038
epidemiology of, 1034, 1038
focal treatment for, 1038–1041
history and physical examination in, 1035
imaging of, 1035–1036, 1038
incidence risk by primary tumor site, 1035, 1036*f*
laboratory studies in, 1035
level 1 evidence on, 1047–1048
management of, 1036–1038, 1038–1044
pathobiology of, 1034–1035, 1035*f*
pediatric, 1530
in pregnancy, 1293
radiation therapy for, 1037, 1041–1042
stereotactic radiosurgery for, 1038, 1040–1041
steroids and AEDs for, 1036–1037
surgery for, 1037, 1039–1040, 1039*f*, 1040*f*, 1040*t*
targeted therapy and immunotherapy for, 1042–1044
tissue diagnosis of, 1036
Brain oxygenation
monitoring of, 291–293
physiologic principles of, 291–292
Brain resection, for epilepsy, 589–590, 589*t*
Brain sagging, 1139, 1143–1144
clinical features of, 1143
diagnosis of, 1143
diagnostic criteria for, 1143, 1143*t*
imaging of, 1142*f*, 1143, 1143*f*, 1144*f*
management of, 1143–1144
postcraniotomy, 1139, 1143–1144, 1143*t*
Brainstem
brain death and, 179–183, 179*f*
focal mass lesions of, 153*f*
gait control by, 123, 124–125, 124*f*
sensory patterns and loss, 65*t*, 66
Brainstem abscess, 614–615
Brainstem auditory-evoked potentials (BAERs), 238, 239–240, 240*f*, 262
Brainstem aura, migraine with, 524*t*, 525
Brainstem encephalitis, 759
Brainstem gliomas, 1553–1554, 1553*f*
Brainstem infarction, syndromes of, 307, 308*t*
Brainstem myoclonus, 826*t*, 827–828
Brainstem syndromes, in multiple sclerosis, 715
Brainstem tumors, pediatric, symptoms of, 1541*f*
Brain tissue oxygen partial pressure ($PbtO_2$), 291–292, 292*t*
Brain tumors, 152–153, 157*t*–158*t*. *See also specific tumors*
biopsy of, 166, 283–284
brain edema with, 1130–1131
dementia with, 97
diagnosis of, 164–166
DNA sequencing of, 284
focused examination for, 159
headache caused by, 72, 523
history on (focused and neurologic), 21*t*, 154–159
hydrocephalus with, 1116, 1117*f*
imaging of, 152, 153*f*–156*f*, 159*f*, 164–166, 198, 198*f*
initial management of, 166–167, 166*f*
magnetic resonance spectroscopy of, 200, 201*f*
metastatic, 152, 153*f*, 156, 157*t*
neuroendovascular treatment of, 227
past medical history and, 156
in pregnancy, 1293
psychosis with, 1593
radiation-induced, 1050, 1336
review of systems for, 159
social history and, 156
stroke *versus*, 135*t*
time course of, 156
vascular, 368

Brain tumors, pediatric, 138, 153, 154, 158*t*, 159*f*, 1528–1571
chemotherapy for, 1545
classification of, 1533–1535, 1535*f*, 1539–1540, 1540*t*
clinical features of, 1540–1543
congenital, 1530, 1545–1549
diagnosis of, 1542–1543
environmental factors and, 1531
epidemiology of, 1528–1532, 1529*f*
histologies of, 1528–1530, 1529*f*
imaging (baseline and surveillance) of, 1542–1543, 1542*t*, 1543*f*
incidence of, 1528
inherited syndromes and, 1530–1531
late effects of treatment and quality of life, 1560–1562
cardiovascular and pulmonary effects, 1561–1562
endocrine dysfunction, 1561
neurologic sequelae of, 1562
radiation effects, 1561–1562
secondary malignancies, 1562
pathobiology of, 1532–1540
radiation therapy for, 1544–1545
risk factors for, 1530–1531
surgery for, 1543–1544
adjunctive therapy with, 1544
neuronavigation for, 1544, 1544*f*
resection techniques in, 1543–1544
second look, 1544
survival rates for, 1531, 1532*t*
symptoms of, 1540–1542, 1541*f*
treatment of, 1543–1545
Brain window, in CT, 185, 186*f*
Branching enzyme deficiency, 1404
Branch retinal artery occlusion (BRAO), in Susac syndrome, 394–396, 395*f*
Breast cancer
brain metastases from, 152, 156, 157*t*, 1043
skull base metastases from, 1082
spinal metastases from, 1035, 1044, 1089, 1092, 1162
Breastfeeding
alcohol use and, 1584
cocaine and, 1585
epilepsy and, 1288–1289
multiple sclerosis and, 728
Breathing, in stroke (AIS), 133
Breathing disorders, sleep-related, 1189–1191
Brexpiprazole, 1591*t*
Brigatinib, for metastatic lung cancer, 1042
Brightness (B) mode, ultrasound, 208–209, 208*t*
Brincidofovir, 679*t*
British anti-Lewisite (BAL), 1332–1333
British familial dementia, 97
Brivaracetam
for epilepsy, 582, 584*t*, 586
in pregnant patients, 1288
for myoclonus, 829*t*
Bromocriptine
depressive symptoms with, 1601
for neuroleptic malignant syndrome, 1329–1330
for Parkinson disease, 887, 1601
for paroxysmal sympathetic hyperactivity, 1180*f*, 1181, 1181*t*
for paroxysmal sympathetic storming, 1200*t*
for restless legs syndrome, 797*t*
Brownell-Oppenheimer variants, of Creutzfeldt-Jakob disease, 508
Brown-Séquard syndrome, 66, 149*t*, 445–446
Brucella abortus, 630*t*, 631
Brucella melitensis, 630*t*, 631
Brucella suis, 630*t*, 631
Brucellosis, 630*t*, 631–632
Brudzinski sign, 71, 605
BSE. *See* Bovine spongiform encephalopathy
BSRC studies. *See* Baby Siblings Research Consortium (BSRC) studies
Buccolingual apraxia, 305
Bulbocavernous reflex, 43
Bumetanide, for hypokalemic periodic paralysis, 1000
Bunina bodies, 905
Bunyaviruses, 670
Buphthalmos, 1463
Buprenorphine
for opioid dependence, 1314
for restless legs syndrome, 797*t*
Bupropion
for ADHD, 1431–1432
for depression, 1602
for neuropathic pain, 562*t*, 563
Burkitt lymphoma, 1232, 1233
Burned out Ménière disease, 598
Burning mouth syndrome (BMS), 546–547
Burr-hole
for brain abscess, 617
for traumatic brain injury, 430
Buspirone, for anxiety disorders, 1611*t*, 1612
Busulfan
for HCT conditioning, 1235
for primary CNS lymphoma, 1060
Butalbital, for migraine, 528
Butterbur, for migraine prevention, 529*t*
Butyrophenones, neurologic effects of, 849
Bystander suppression, 726

C

C9orf72 disease, 857, 864, 905
CAA. *See* Cerebral amyloid angiopathy
Cabergoline
for pituitary tumors, 1071
for restless legs syndrome, 797*t*
CADASIL. *See* Cerebral autosomal dominant arteriopathy with subcortical infarcts and leukoencephalopathy
Café au lait spots, 1456, 1457, 1457*f*
Caffeine
for hypnic headache, 534
for intracranial hypotension, 73
for orthostatic intolerance, 1173
and Parkinson disease, 874
for Parkinson patients, 889
and restless legs syndrome, 795
CAG repeat polyglutamine ataxias, 839–843
Calcineurin inhibitors. *See also* Cyclosporine; Tacrolimus
for autoimmune encephalitis and meningitis, 770*t*
for transplant patients, neurotoxicity of, 1299–1300
Calcitonin
for complex regional pain syndrome, 552*t*
for Paget disease, 1271
Calcium
in muscle cramps, 1008–1009
in neonatal seizures, 1361*t*
parathyroid disorders and, 1224–1225
in tetany, 1008
Calcium channel(s), in neuropathic pain, 559
Calcium channel blockers
for ICH, 139, 337, 337*t*
for pheochromocytoma, 1224
for reversible cerebral vasoconstriction syndrome, 388–389
for SAH patients, 349, 350
for stroke prevention, 402
Calculation, 30
Call-Fleming syndrome. *See* Reversible cerebral vasoconstriction syndrome (RCVS)
Caloric testing, 262, 598
Camptocormia, 802*t*, 809, 878
CAMs, for tic disorders. *See* Complementary and alternative medicines, for tic disorders
Canadian C-Spine Rule, 444
Canadian CT Head Rule, 428, 429*t*
Canadian Pain Society (CPS), 561, 561*t*, 564
Canavan disease, 1390
Cancer. *See also specific tumors and diseases*
alcohol and, 1309
complications of therapy, 1106–1113
paraneoplastic syndromes with, 1100–1105, 1101*t*
Candesartan, for migraine prevention, 528, 529*t*
Candidiasis
hematopoietic cell transplantation and, 1236
HIV-associated, 703
transplantation-related, 1255
Cannabidiol, for epilepsy, 582, 584*t*, 587, 1315
Cannabinoid receptors, in Huntington disease, 864
Cannabinoids
for cramps, 1009
for Lennox-Gastaut syndrome, 1509
marijuana and synthetic use, 1314–1315, 1317, 1593
for neuropathic pain, 563
for tic disorders, 791, 791*t*
Capnography, 1210
Capsaicin
for burning mouth syndrome, 547
for neuropathic pain, 562*t*, 563
Capsular warning syndrome, 321, 322–323
Carbamate toxicity, 1326–1329
Carbamazepine, 586
adverse effects of, 583, 586, 1248, 1274
for bipolar disorder, 1603
for chemotherapy-induced neuropathy, 1109*t*
for chorea, 855
for complex regional pain syndrome, 553
for cramps, 1009
for cranial neuralgias, 543, 544*t*
for diabetic neuropathy, 1221
dosage and pharmacokinetics of, 584*t*, 586
for epilepsy, 581–585, 586
in breastfeeding patients, 1288–1289
in pregnant patients, 1287–1288
teratogenicity of, 1287*t*, 1288
for hemifacial spasm, 822
for hyperexcitability disorders, 1008
for Kleine-Levin syndrome, 1189

for neonatal seizures, 1360
for neuroleptic malignant syndrome, 852
for neuropathic pain, 563
for nondystrophic myotonias, 1002
for SUNCT/SUNA headaches, 532
for trigeminal neuralgia, 918
Carbohydrate metabolism disorders, 1402–1405. *See also specific disorders*
Carbon-11, 203
Carbon-11 (^{11}C) Pittsburgh, 206, 483
Carbon-11 (^{11}C) UCB-J, 206
Carbon monoxide poisoning, 325, 1331, 1350, 1351
Carboplatin
neuropathy induced by, 949
for pediatric brain tumors, 1551, 1559
Cardiac arrest
brain edema in, 1130
hypoxic-ischemic encephalopathy in, 324–331
management of, 327–328
prognosis in survivors of, 329–330, 329*f*
therapeutic hypothermia for neuroprotection in, 324, 325*t*, 328–330
Cardiac arrhythmia
spinal cord injury and, 448
syncope with, 52–53
Cardiac output, reduced, and syncope, 51
Cardiac procedures, cerebral complications of, 1195–1197
Cardiac syncope, 51, 52–53, 52*f*, 52*t*, 55, 55*t*
Cardiac transplantation, 1300
Cardioembolic stroke, 303*f*, 304, 403, 407–408, 407*t*
Cardiogenic shock, 447
Cardiogenic stroke, in children, 1519–1520, 1522
Cardiomyopathy, with muscle weakness, 115*t*, 116
Cardiopulmonary resuscitation (CPR), in traumatic brain injury, 427
Cardiovagal function, testing of, 255–257, 256*t*
Cardiovascular complications, of neurologic injury, 1197–1200
Cardiovascular examination, in acute spinal cord injury, 148
Care planning, advance, 1637–1639
Carfilzomib, 1110
Cariprazine, 1591*t*
Carmustine/BCNU
for glioblastoma, 1028
for gliomas, 1023*t*
for HCT conditioning, 1235
for primary CNS lymphoma, 1059–1060
Carmustine wafers
for glioblastoma, 1028
for gliomas, 1023*t*
Carnitine palmitoyltransferase II (CPT II) deficiency, 1011–1013, 1015, 1017
Carotid angiography, 194–195, 219, 220*f*
Carotid artery disease, extracranial, endovascular treatment of, 224–225
Carotid artery stenting (CAS), 403, 406–407
Carotid-cavernous fistula, 434–435
Carotid dissection, 435
Carotid endarterectomy (CEA), 224–225, 403, 406–407, 1132
Carotid plaques
echodense, 210
echolucent, 210
ulceration of, 210
ultrasound of, 210–211
Carotid puncture, for angiography, 217
Carotid sinus massage, 54
Carotid sinus syndrome, 51–52
Carotid stenosis
extracranial, endovascular treatment of, 224–225
moyamoya disease and, 390–393
MRA of, 194–195
stroke prevention in, 403, 406–407
stroke with, 303–304
ultrasound of, 208–211, 209–211*f*
Carotid ultrasound, 208–212
detection criteria in, 209, 209*t*
after endarterectomy and stenting, 209, 210*f*
grayscale median index in, 210
indications for, 211–212
multiparametric, 211
normal findings in, 209, 209*f*
of plaque size, morphology, and intima-media thickness, 210–211, 211*f*
sensitivity and specificity of, 209
Carpal tunnel syndrome, 459, 933
in pregnancy, 1293–1294
testing for, 42–43, 42*f*
ultrasound of, 250
Carswell, Robert, 711
CAS. *See* Carotid artery stenting
Case fatality, 1–2
Cassava, 1333
Catamenial seizures, 588
Cataplexy, 1187–1189, 1189*t*
Cataracts
in cerebrotendinous xanthomatosis, 1397
in Duchenne muscular dystrophy, 1481
in incontinentia pigmenti, 1465
in limb-girdle muscular dystrophy, 1492
in Marinesco-Sjögren syndrome, 1477
in myotonic dystrophy, 300, 1422, 1485
in proximal myotonic myopathy, 1486
in Refsum disease, 1407
in rhizomelic chondrodysplasia punctata, 1405
in Sengers syndrome, 1445, 1449
in sequelae of pediatric brain tumors, 1562
in tuberous sclerosis complex, 1461
Catathrenia, 1191
Catatonia, 175, 1589
CATCH-22, 1410*t*, 1411
Catecholamine-O-methyltransferase (COMT) inhibitors, for Parkinson disease, 885–886
Catecholamines, plasma levels of, 257
Cat-scratch disease, 630*t*, 632–633, 633*f*
Cauda equina syndrome, 149*t*, 447
Cauda equina tumors, 1096
Caudal cell mass, 1366
Causalgia, 453, 549. *See also* Complex regional pain syndrome (CRPS)
Cavernomas. *See* Cavernous malformations
Cavernous malformations, 366–367
clinical features of, 366–367
diagnosis of, 366
familial, 366
management of, 367
MRI of, 366, 366*f*, 367*f*
pathobiology of, 366, 366*f*
radiation therapy in children and, 1561
SAH with, 351
sporadic, 366
Cavernous sinus fistulas, 364–365
Cavernous sinus syndrome, 86
Cavernous sinus thrombosis, 355, 355*t*
CBD. *See* Corticobasal degeneration
CBF. *See* Cerebral blood flow
CBIT. *See* Comprehensive behavioral intervention for tics
CBS. *See* Corticobasal syndrome
CBT. *See* Cognitive behavioral therapy
CCD. *See* Central core disease
CCMs. *See* Cerebral cavernous malformations
CDKL5 encephalopathy, 1506
CEA. *See* Carotid endarterectomy
Cebocephaly, 1369
CECTS. *See* Childhood epilepsy with centrotemporal spikes
cEEG. *See* Continuous electroencephalography
Cefepime
for bacterial meningitis, 609*t*
for brain abscess, 617, 617*t*
for malignant otitis externa, 621, 621*t*
Cefotaxime
for bacterial meningitis, 607*t*, 609*t*
for brain abscess, 617, 617*t*
for Lyme disease, 650
Ceftazidime
for bacterial meningitis, 607*t*, 609*t*
for brain abscess, 617, 617*t*
for malignant otitis externa, 621, 621*t*
for osteomyelitis of skull base, 622
Ceftriaxone
for bacterial meningitis, 609*t*
for brain abscess, 617, 617*t*
for brucellosis, 632
for Lyme disease, 650
for Whipple disease, 635
Cefuroxime, for traumatic brain injury, 427
Celiac disease, 1283–1284
ataxia in, 838, 1267, 1283–1284
neuropathy in, 938*t*, 944
Cell cycle control, 1412, 1414*t*
Cell-surface antigens, ataxias due to, 838
Cenobamate, for epilepsy, 582, 584*t*, 587
Centers for Disease Control and Prevention (CDC), classification of HIV infection, 690, 690*t*
Central cord syndrome, 149*t*, 446–447
Central core disease (CCD), 1493, 1497–1498, 1498*f*
Central neurocytoma, 1557
Central neurofibromatosis, 1456–1459
Central nystagmus, 46, 46*t*, 47*t*
Central pain, 65*f*
Central pontine myelinolysis, 1258–1260, 1258*f*, 1259*f*, 1309
Central retinal artery, TIAs affecting, 320
Central sensitization, 559–560
Central sensory syndromes, 64–66, 65*t*
Central sleep apnea, 264, 1190–1191
Central transtentorial herniation, 172, 174*t*
Central vertigo, 46
causes of, 48*t*
peripheral vertigo *versus*, 46, 46*t*
Central vision, 78–79, 79*t*
Central (upper motor neuron) weakness, 111–112
Centronuclear myopathy, 1493–1497

Cephalosporins
for bacterial meningitis, 607, 607*t*, 609*t*
for brain abscess, 617, 617*t*
for Lyme disease, 650
for malignant otitis externa, 621, 621*t*
for osteomyelitis of skull base, 622
for spinal epidural abscess, 620
for subdural empyema, 618
Cerebellar ataxia. *See* Ataxia
Cerebellar ataxia, neuropathy and vestibular areflexia syndrome, 833, 833*t*, 846
Cerebellar circuits, 832
Cerebellar cognitive affective syndrome, 835
Cerebellar degeneration, alcoholic, 1306*t*, 1307–1308
Cerebellar dysarthria, 834
Cerebellar hemorrhage, 334
Cerebellar infarction, 315–316
Cerebellar stroke, 837–838
Cerebellum
focal mass lesions of, 153*f*
gait control by, 123, 124–125, 124*f*, 124*t*
movement control by, 832
neuroanatomy of, 831–832, 831*f*
neurophysiology of, 832
vascular anatomy of, 838*f*
Cerebral amyloid angiopathy (CAA), 401
Boston criteria for, 333, 334*t*
and intracerebral hemorrhage, 332, 333, 333*f*, 334*t*, 409
and stroke, 409
Cerebral amyloidosis, dominantly inherited PrP, 514
Cerebral aneurysms. *See* Intracranial (cerebral) aneurysms
Cerebral angiography, 217–229. *See also specific modalities*
carotid artery views in, 219, 220*f*
complications of, 220–221
diagnostic, additional applications of, 226
emerging considerations in, 226–227
equipment for, 218, 219*f*
history of, 217–218
patient positioning for, 219
postprocedural care in, 219–220
preprocedural considerations, 218
procedural outline and considerations, 218–220
vertebral artery views in, 219, 221*f*
Cerebral autosomal dominant arteriopathy with subcortical infarcts and leukoencephalopathy (CADASIL), 398–399, 400, 503
Cerebral blood flow (CBF)
and brain oxygenation, 291–292
CT perfusion studies of, 187
in HIV-associated dementia, 696
magnetic resonance perfusion imaging of, 200–201, 201*f*
monitoring, regional, thermal diffusion flowmetry for, 293
monitoring of, 293
continuous, 293
in moyamoya disease, 392
physiologic principles of, 290*f*, 293
in posterior reversible encephalopathy syndrome, 384
reduction, in ischemic stroke, 301–303, 302*f*
ventilation manipulation and, 1211
Cerebral blood volume (CBV), 187, 200
Cerebral cavernous malformations (CCMs). *See* Cavernous malformations
Cerebral contusions, 423–424, 424*f*
Cerebral edema. *See* Brain edema
Cerebral gaze paresis, 171
Cerebral infarction. *See also* Acute ischemic stroke (AIS)
in acute ischemic stroke, 301–303, 302*f*, 303*f*
brain edema with, 1129
dementia with, 500–503, 502*t*, 503*f*. *See also* Vascular dementia
etiology of, 303–304
hypoxic-ischemic encephalopathy with, 325
MRI in, 191–192, 193*t*, 194*f*, 1129
pathophysiology of, 301–304, 302*f*, 303*f*
in pregnancy, 1290–1291
in SAH, 350
sickle cell disease and, 1228–1231
subcortical, in CADASIL, 398–399
syndromes of, 304–307, 305*t*
topographic patterns of, 306*f*
traumatic brain injury and, 435
Cerebral lobe hemorrhage, 334
Cerebral mean transit time (MTT), 187, 200
Cerebral microdialysis, 293–294
clinical use of, 294
monitoring with, 294
physiologic principles of, 293–294, 294*f*
threshold values and biomarkers in, 294, 294*t*
Cerebral oximetry, 292–293
Cerebral palsy (CP), 1355, 1425–1427
ataxic, 1425, 1426, 1426*t*
classification of, 1425
definition of, 1425
dyskinetic, 858, 859*f*, 1425, 1426, 1426*t*, 1427
dystonia in, 801, 804
epidemiology of, 1425
hypotonia in (floppy infant), 1419
intraventricular hemorrhage and, 1357
management of, 1427
mimics of, 1425, 1425*t*, 1426*t*
perinatal stroke and, 1362, 1517
periventricular leukomalacia and, 1363–1364
spastic diplegic, 1425
spastic quadriplegic, 1425–1426
Cerebral perfusion imaging, 203, 203*f*, 204*t*, 205–206
in dementia, 101
in moyamoya disease, 392
in stroke, 310–311, 310*f*
Cerebral perfusion pressure (CPP), 289–290
in acute ischemic stroke, 301–302
bacterial meningitis and, 609
definition of, 289
ICH and, 337–338
ICP and, 430, 432*f*, 1132, 1134*f*
monitoring of, 288–291
reactivity and autoregulation of, 289–290, 290*f*
in traumatic brain injury, 430–432
Cerebral salt wasting (CSW), 1255–1258
Cerebral sinus thrombosis, 73, 353, 355, 355*t*. *See also* Cerebral venous thrombosis (CVT)
Cerebral vasoconstriction syndrome, reversible, 73
Cerebral vasomotor reactivity testing, 214–215
Cerebral venous thrombosis (CVT), 353–360
AHA/ASA statement on, 356–357
anatomy and, 353*f*
anticoagulation therapy for, 353, 358
childhood, 1518–1524, 1521*f*
clinical features of, 353, 354–355
common causes of, 354, 354*t*
comorbid conditions with, treatment of, 359
CT of, 356–357, 357*f*
CT venography of, 355–357
diagnosis of, 355–358
digital subtraction angiography of, 356*t*, 357*f*, 359
diseases associated with, 1520, 1520*t*
endovascular therapy for, 358–359
epidemiology of, 353–354
headache caused by, 73, 353, 354
laboratory workup for, 357–358, 358*t*
level 1 evidence on, 360
management of, 353, 358–359, 1523
MR venography of, 355–356, 356*f*, 356*t*, 357*f*
outcome of, 353, 359–360
pathobiology of, 354
pediatric treatment of, 359
perinatal, 1362, 1363*f*, 1515–1518
in pregnancy, 1290
trimodal treatment of, 358
Cerebritis, 153–154
Cerebro-oculo-facio-skeletal syndrome (COFS), 1413*t*
Cerebrospinal fluid
circulation of, 1114
diversion systems (shunts) for, 1115, 1115*f*, 1122–1125
algorithm for malfunctioning, 1124*f*
complications of, 1123–1125
for idiopathic intracranial hypertension, 1137
infection, 1125
for neonatal IVH, 1357
imbalance. *See* Hydrocephalus
intracranial, 288–291. *See also* Intracranial pressure (ICP)
loss, in spontaneous intracranial hypotension, 1139–1144
in metastatic disease, 1035, 1036
MRI appearance of, 191, 193*t*
production of, 1114
Cerebrospinal fluid analysis, 277–282
in acute spinal cord syndromes, 149–150, 150*t*
in Alzheimer disease, 479–480, 481–482
in arboviral infections, 666
in ataxia, 834
in autoimmune encephalitis, 756
in brucellosis, 631
in cat-scratch disease, 633
in coma, 172
in COVID-19, 673
in Creutzfeldt-Jakob disease, 510
in dementia, 100
in dengue, 666
in diphtheria, 637
in ehrlichiosis and anaplasmosis, 628
in focal mass lesion evaluation, 166
in frontotemporal dementia, 489

in glucose transporter type 1 deficiency syndrome, 1386
in Guillain-Barré syndrome, 939–940
in herpes simplex encephalitis, 679–680
in HIV, 694
in HIV, pediatric, 1582
in HIV-associated dementia, 696
in Huntington disease, 866
hypoglycorrhachia in, 280, 280*t*
in idiopathic intracranial hypertension, 1136
in inflammatory and demyelinating disorders, 280–281
in inflammatory myelopathy, 1165
in intraventricular hemorrhage, neonatal, 1357
in leptospirosis, 632
in Lewy body dementias, 496
in lymphoma, 1233
in medulloblastoma, 1555
in meningitis, 278–280, 281*t*
in meningitis, acute bacterial meningitis, 607–608, 609*t*
in meningitis, chronic, 640, 642*t*
fungal, 642*t*, 643–646
Lyme disease, 642*t*, 649–650
syphilitic, 642*t*, 649
tuberculous, 642*t*, 647–648
in mild cognitive impairment, 472, 473*t*
in motor neuron disease, 911
in multiple sclerosis, 719–721
in mycoplasmal (walking) pneumonia, 635
in neonatal seizures, 1360
in neuromyelitis optica spectrum disorders, 748
in paraneoplastic syndromes, 1104
in pineal tumor diagnosis, 1074
pleocytosis in, 278–280
in poliomyelitis, 663
in posttransplant lymphoproliferative disorder, 1233
in Q fever, 631
in restless legs syndrome, 794
in reversible cerebral vasoconstriction syndrome, 388
in sarcoidosis, 775
in scrub typhus, 629
in sensory symptom evaluation, 69
in sleep disorders, 1188
in spinal stenosis, 1156
in spinal tumor diagnosis, 1097
in spotted fever rickettsiosis, 625
in subarachnoid hemorrhage, 344
tests in, 278, 278*t*
in tickborne encephalitis virus, 666–668
in transverse myelitis, 740
in traumatic brain injury, 429
in typhus group rickettsiae, 629
in vasculitis, 371, 373*t*
in viral infections, 661
in viral myelitis, 1163–1164
Cerebrospinal fluid cytology, 281, 281*t*
Cerebrospinal fluid fistula, 434
Cerebrospinal fluid leaks
epidural blood patch for, 1141, 1143*f*
fibrin sealant for, 1141
management of, 1141–1143
pathobiology of, 1139
spontaneous intracranial hypotension from, 1139–1144
Cerebrotendinous xanthomatosis, 844*t*, 845, 847, 1397
Cerebrovascular syndromes, 384–400. *See also specific syndromes*
Ceritinib, for metastatic lung cancer, 1042
Cerivastatin, withdrawal from market, 993–994
Ceroid lipofuscinosis, 97
Cervical artery dissection, 72–73, 316
Cervical disk disease, 1146, 1149, 1149*f*, 1150, 1151
Cervical diskectomy, 1151, 1156
Cervical dystonia, 106, 802, 807
animal models of, 806*f*
botulinum toxins for, 815
clinical manifestations of, 807, 807*f*
epidemiology of, 807
Cervical radiculopathy, EMG findings in, 247*f*
Cervical spondylotic myelopathy (CSM), 1155, 1155*t*
Cervical stenosis, 1153–1158
clinical manifestations of, 1155, 1155*t*
diagnosis of, 1155–1156
management of, 1156
outcomes of, 1157
pain in, 1155
pathobiology of, 1153–1155, 1154*f*
physical examination in, 1156
radiographic studies of, 1156
Cervical tumors, 1094–1095, 1095*t*
Cervical x-rays, in spinal cord injury, 444
Cestodes, 653, 654*t*
ChAc. *See* Chorea-acanthocytosis
Chagas disease, 654*t*, 655, 655*f*, 705, 1263, 1264
Channelopathies, 998–1003
Charcoal. *See* Activated charcoal
Charcot, Jean Marie, 711, 904
Charcot-Bouchard microaneurysms, 333
Charcot joints, 936
Charcot-Marie-Tooth (CMT) disease, 67, 936, 955–962
age of onset and progression of, 959
associated symptoms and signs in, 959
at-risk populations, 960
cellular reprogramming and high-throughput therapeutic screening in, 961
clinical presentation of, 957, 957*f*
cramps in, 1008
diagnosis of, 938*t*, 957–960
drug-induced neuropathy in, 949
epidemiology of, 955
etiology and diagnosis of, 937
gene therapy for, 960–961
genetics of, 955–959, 958*t*
genetic testing in, 957–959
inheritance pattern of, 959
management of, 960–961, 960*t*
neurophysiologic pattern of, 959
neurotrophic support in, 960–961
pathobiology of, 955–956, 956*f*
reduction of neurotoxic aggregates/misfolded proteins in, 961
related disorders, 955
targeting transport defects in, 961
Charles Bonnet syndrome, 307
Chemotherapy
for acoustic neuroma, 1082
for acute lymphoblastic leukemia, 1233
for acute myeloid leukemia, 1234
for diffuse astrocytomas, 1026
for glioblastoma, 1028
for gliomas, 1021–1022, 1023*t*
for hematopoietic cell transplantation, 1235
intrathecal, 1038, 1046
for meningiomas, 1053–1054, 1054*t*
for metastatic disease, 1038, 1042–1044, 1046
myasthenia gravis induced by, 975
myelopathy due to, 1167
neurologic complications of, 1108–1109, 1108*t*
neuropathy caused by, 949
for non-Hodgkin lymphoma, 1233
for oligodendrogliomas, 1031
for pediatric brain tumors, 1545
astrocytomas, 1551
AT/RTs, 1557–1558
brainstem gliomas, 1553–1554
effects and sequelae of, 1560–1562
ependymomas, 1558–1559
germ cell tumors, 1559
medulloblastomas, 1556–1557
for pilocytic astrocytomas, 1024
for pineal region tumors, 1073, 1076, 1559
for pituitary tumors, 1071
for primary CNS lymphoma, 1058–1060
for skull base tumors, 1083
for Waldenström macroglobulinemia, 1234
Chemotherapy-induced peripheral neuropathy (CIPN), 1108–1109, 1108*t*, 1109*t*
Cherry-red-spot-myoclonus syndrome, 1394
Cherry-red spots, infantile encephalopathy with, 1394
Cheyne-Stokes respiration (CSR), 171, 1189–1190, 1208*f*
Chiari malformation
orthostatic intolerance with, 1173
syringomyelia with, 1159–1162
Chickenpox, 681, 702
Child abuse
factitious disorder and, 1623–1625
pediatric TBI in, 1572–1578
Childhood absence epilepsy, 574, 1505*f*, 1511
Childhood ataxia with central hypomyelination, 1399, 1401–1402, 1414*t*
Childhood Autism Rating Scale, 1435
Childhood epilepsy with centrotemporal spikes (CECTS), 1505*f*, 1510
Children. *See also specific disorders*
brain death in, 182
brain injury in, 438, 1572–1578
brain tumors in, 138, 153, 154, 158*t*, 159*f*, 1528–1571
cerebral venous thrombosis in, 354, 355, 358, 359, 360
HIV infection in, 691–692, 1579–1583
Huntington disease in, 865
intracranial aneurysms/SAH in, 342
multiple sclerosis in, 728
schizophrenic symptoms in, 1589
seizures and epilepsies in, 1502–1514
stroke in, 1518–1526
Child-Turcotte-Pugh score, 1246, 1247*t*
Chloramphenicol
for brain abscess, 617
for spotted fever rickettsiosis, 626
Chlordiazepoxide, for alcohol withdrawal, 1305*t*

Chloroquine, myotoxicity of, 995*t*
Chloroxazone, for ataxia, 847
Chlorpromazine
for migraine, 526*t*, 528
for schizophrenia, 1591*t*
side effects of, 1591*t*
chokes, 1352
Cholestanol storage disease. *See* Cerebrotendinous xanthomatosis
Cholesterol
and intracerebral hemorrhage, 333
and stroke prevention, 402–403, 408
Choline, in magnetic resonance spectroscopy, 200, 201*f*
Cholinergic toxicity, 1326–1329
Cholinesterase inhibitors
for acetylcholine toxicity, 1324
for Alzheimer disease, 483, 483*t*
for congenital myasthenic syndromes, 975, 975*t*
for Huntington disease, 868
for Lewy body dementias, 497, 1593
for mild cognitive impairment, 473
for myasthenia gravis, 969, 970*t*
for primary progressive aphasia, 490
for vascular dementia, 504, 504*t*
Chondrodystrophy, 1272–1273
Chondroma, skull, 1084–1085
Chondrosarcoma, skull base, 1083
Chordoma
pediatric, 1547
skull base, 1083
Chorea(s), 36, 106, 106*f*, 106*t*, 854–860
autoimmune, 854–856
camouflaging of, 854
causes of, 854–858
cerebral palsy and, 1425, 1426, 1427
cocaine and, 1317
definition of, 106, 854
developmental, 855*t*
diagnosis of, 858–859
differential diagnosis of, 854, 855*t*, 864
drug-induced, 855*t*
dystonia *versus*, 800, 802*t*
epidemiology of, 854
flow diagram for evaluating, 104*f*
focused examination of, 104
focused history on, 103–104, 103*t*
genetic causes of, 856–858
hereditary, 855*t*
HIV-associated, 698
Huntington disease, 106, 854, 864–865, 865*t*, 866–867
idiopathic, 855*t*
immunologic, 855*t*
infectious and postinfectious causes of, 855*t*
level 1 evidence on, 859
management of, 859
neurometabolic, 855*t*
outcome of, 859
paraneoplastic, 1102
pathobiology of, 854
secondary, 855*t*
Sydenham, 106, 108, 109*t*, 854–855
vascular/structural causes of, 855*t*, 856
xenobiotic-induced, 1320, 1321*t*
Chorea-acanthocytosis (ChAc), 856, 857*f*, 1393
Chorea gravidarum, 855, 1294
Choreiform dyskinesias, 107
Choreoathetosis, 106, 856
Choriocarcinoma, 1072–1073, 1073*t*, 1293
Choristomas, 1064
Choroid plexus carcinoma, 1531, 1547–1548, 1548*f*
Choroid plexus papilloma, 1547–1548
Choroid plexus tumors, 1547–1548
Chromosomal disorders, 1410–1412, 1410*t*. *See also specific disorders*
Chromosomal microarray, 1411–1412, 1434
Chronic inflammatory demyelinating polyneuropathy (CIDP), 694, 699, 912*t*, 940–941, 941*f*
Chronic meningitis, 640–651. *See also specific types and etiologies*
clinical presentation of, 640, 641*t*
CSF analysis and serum diagnostics in, 640, 642*t*
definition of, 640
etiologies of, 640
fungal, 641–646, 641*t*–643*t*
general diagnostic approach in, 640
hypothesis-free investigations in, 650
imaging in, 640, 641*t*
level 1 evidence on, 650
Lyme disease, 641*t*–643*t*, 649–650
syphilitic, 641*t*–643*t*, 648–649
treatment of, 643*t*
tuberculous, 641*t*–643*t*, 647–648
Chronic motor or vocal tic disorder, 786, 786*t*
Chronic neurologic diseases, global disparities in, 5
Chronic progressive decline, in neurologic disease, 1636–1637
Chronic progressive external ophthalmoplegia (CPEO), 1016, 1017, 1447
Chronic traumatic encephalopathy (CTE), 416–418
diagnosis of, 417–418
epidemiology of, 416–417
management of, 418
outcome of, 418
pathobiology of, 417, 417*f*
Churg-Strauss syndrome. *See* Eosinophilic granulomatosis with polyangiitis (EGPA)
Chvostek sign, 1008, 1224
Cicutoxin, 1333
Cidofovir
for CMV infection, 683
for herpesvirus infections, 679*t*
for JC virus infection, 1236
CIDP. *See* Chronic inflammatory demyelinating polyneuropathy
Ciguatera poisoning, 948, 1333
Ciliopathies, 1378–1379
Cilostazol, for stroke prevention, 405
CIM. *See* Critical illness myopathy
Cincinnati Prehospital Stroke Scale, 307
Cinnarizine, neurologic effects of, 850
CIP. *See* Critical illness polyneuropathy
CIPN. *See* Chemotherapy-induced peripheral neuropathy
Ciprofloxacin
for anthrax, 634
for malignant otitis externa, 621*t*
for osteomyelitis of skull base, 622
Circadian rhythm, 1185
Circadian rhythm disorders, 267–268, 1192, 1599
Cirrhosis, 1245–1248
causes of, 1245, 1246*t*
Child-Turcotte-Pugh score in, 1246, 1247*t*
clinical features of, 1246, 1246*f*
diagnosis of, 1247
epidemiology of, 1245
outcome of, 1248
pathobiology of, 1245–1246
treatment of, 1247–1248
Cisplatin
adverse effects of, 1108, 1109
for pediatric brain tumors, 1551, 1556, 1558–1559
for pineal region tumors, 1076
Citalopram
for anxiety disorders, 1611*t*
for Huntington disease, 868
Citrulline, 1386–1387, 1386*t*
CJD. *See* Creutzfeldt-Jakob disease (CJD)
Cladribine, for multiple sclerosis, 723, 724*t*, 725
Clarithromycin, for Q fever, 631
Clark electrode, for brain oxygenation monitoring, 292, 292*t*
Clevidipine
for ICH, 139, 337, 337*t*
for preeclampsia/eclampsia, 1290
Clindamycin, for toxoplasmosis, 167, 704
Clinical diagnostic reasoning, 15
Clinically isolated syndrome (CIS), 714, 714*f*, 729
Clinical observation, 275
Clipping, aneurysm, 222
Clobazam, 582, 584*t*, 587
Clodronate, for complex regional pain syndrome, 553
Clomipramine, for anxiety disorders, 1611, 1611*t*
Clonazepam
for anxiety disorders, 1611–1612, 1611*t*
for burning mouth syndrome, 547
for dystonia, 814–815
for essential tremor, 782
for hemifacial spasm, 822
for myoclonus, 829, 829*t*
for parasomnias, 1193
for paroxysmal sympathetic hyperactivity, 1180*f*, 1181
for sleep disorders in dementia, 498
for tardive dyskinesia, 852*f*, 853*t*
for tic disorders, 789, 790*t*
for vertigo, 49*t*
Clonic phase, 570
Clonidine
for ADHD, 1431
for paroxysmal sympathetic hyperactivity, 1180*f*, 1181, 1181*t*
for paroxysmal sympathetic storming, 1200*t*
for tic disorders, 789, 790*t*
Clopidogrel
for CADASIL, 399
for childhood stroke, 1522
in endovascular treatment, 223
and ICH, 138, 1240
and platelet disorders, 1238, 1240
for stroke prevention, 321, 405–406
for transient ischemic attacks, 321, 405
Closed-lip schizencephaly, 1368
Closed nerve injury, 464, 465*f*
Clostridium botulinum, 636*t*, 637, 977
Clostridium perfringens, 618

Clostridium tetani, 636*t*, 638, 1006
Clozapine
for chorea, 859
for Lewy body dementias, 498, 1593
neurologic effects of, 850
for Parkinson disease, 888
for schizophrenia, 1590–1592, 1591*t*
side effects of, 1590–1592, 1591*t*
Cluster breathing, 171
Cluster headache, 74, 523, 530–532
clinical features of, 530, 531*t*
pathophysiology of, 530–531
prevention of, 531–532, 531*t*
treatment of, 531
CMAP. *See* Compound motor action potential
C mode ultrasound, 208–209, 208*t*
CMS. *See* Congenital myasthenic syndromes
CMT disease. *See* Charcot-Marie-Tooth (CMT) disease
CMV. *See* Continuous mandatory ventilation; Cytomegalovirus
Coagulation
disturbances in, 1240–1243
hypercoagulable states, 1242–1243
ICH and, 137–138, 139*t*, 1240–1241
impaired, 1241–1242
neonatal disorders of, 1362
normal, 1241, 1241*f*
Coasting, in drug-induced neuropathy, 949
COASY protein-associated neurodegeneration, 1393
Coats disease, 1484
Cobblestone lissencephaly, 1375, 1375*t*, 1377
Cobicistat, 707*t*
Cocaine, 381, 1314, 1316, 1317, 1326
prenatal and perinatal effects of, 1584–1585, 1585*t*
Coccidioides, 153, 161*t*
Coccidioides immitis, 644–646
Coccidioidomycosis, 644–646
chronic meningitis in, 641*t*–643*t*, 644–646
clinical presentation of, 641*t*, 644
CSF analysis and serum diagnostics in, 642*t*, 644–645
diagnosis of, 644–645
epidemiology and pathobiology of, 644
HIV-associated, 703
imaging in, 641*t*
outcomes of, 645
treatment of, 643*t*, 645, 703
Cochlear implants, 50
Cochlear Ménière disease, 598
Cockayne syndrome, 1413*t*
Cocoon therapy, for concussion, 415
Coding and Symbol Search subtests, 272
Coenurosis, 162*t*
Coenzyme Q_{10} deficiency, 1016, 1448, 1448*f*
COFS (cerebro-oculo-facio-skeletal syndrome), 1413*t*
Cogan syndrome, 48*t*, 355, 371*t*, 379
Cognition, higher order, 31
Cognitive behavioral therapy (CBT)
for anxiety disorders, 1610, 1612
for epilepsy, 1612
for generalized anxiety disorder, 1612
for illness anxiety disorder, 1619
for insomnia, 1186
for neuropathic pain, 563–564
for obsessive-compulsive disorder, 1612
for somatic symptom disorder, 1617
Cognitive development, disorders of, 1424, 1427–1432, 1428*t*
Cognitive impairment. *See also* Dementia; *specific dementia types*
age-related, 95–96
in bipolar disorder, 1599
chemotherapy and, 1109
in chromosomal disorders, 1410–1411
in dementia. *See* Dementia
in depression, 1598–1599
electrical/lightning injuries and, 1348–1349
essential tremor and, 780
in Huntington disease, 864–865, 865*t*, 868
mild. *See* Mild cognitive impairment (MCI)
in multiple sclerosis, 716–717, 726, 727*t*
in multiple system atrophy, 896
with muscle weakness, 114, 115*t*
in myotonic dystrophy, 1486
neurologic rehabilitation for, 1632–1633
in normal-pressure hydrocephalus, 1122
in Parkinson disease, 880, 888–889, 902
phenylketonuria and, 1387–1388
in progressive supranuclear palsy, 893–894
radiation-induced, 1107–1108, 1336, 1342, 1343
traumatic brain injury and, 436–437
vascular, 500. *See also* Vascular dementia
Cognitive motor dissociation, 177
Cognitive rest, for pediatric TBI, 1574–1575
Cognitive testing, 271–275
Cogwheeling, 170, 508, 800, 878, 1329
Coiling, aneurysm, 222, 223*f*, 348
Coil technology, 218
COL6-related dystrophies, 1477, 1478, 1478*f*
Colchicine
myotoxicity of, 995*t*
neuropathy induced by, 949
Cold pressor test, 257
Cold-stimulus headache, 524*t*, 533
Cold tolerance, 257
Collagen 6 (COL6), in congenital muscular dystrophies, 1477, 1478, 1478*f*
Collateral reinnervation, 247
Collier sign, 1074, 1118
Colloid cysts, 1548
Color Doppler ultrasound, 208–212
Colorectal cancer, brain metastases from, 157*t*
Color (C) mode ultrasound, 208–209, 208*t*
Color vision testing, 79, 259–260
Coma, 168–178
in cardiac arrest survivors, 329–330, 329*f*
in cerebral venous thrombosis, 353, 359
continuous EEG monitoring in, 294, 295
definition of, 168
diagnostic tests in, 172
diffuse axonal injury and, 421
EEG findings in, 168, 172
eyelids and eye movements in, 171–172, 171*f*, 173*f*
focused neurologic examination in, 169–172
FOUR score in, 172, 173*f*
future directions for study, 177
history in, 22*t*, 169
hydrocephalus and, 1116
induced, for ICP management, 1133
from infratentorial structural lesions, 174
initial resuscitation for, 168–169
level 1 evidence on, 177
management algorithm for, 169*f*
management strategy for, 168–175
from metabolic or diffuse brain disease, 175, 176*t*
motor responses in, 169–170
myxedema, 1219
neuroanatomy of, 168, 169*f*
physical examination in, 169, 170*t*
posterior cerebral artery infarction and, 307
presentations and treatment of, 172–175
respiration in, 171
in subarachnoid hemorrhage, 347
from supratentorial herniation syndromes, 172–174
transplantation-related, 1298*t*
in traumatic brain injury, 427*t*, 428, 428*t*, 435–436
Coma Recovery Scale-Revised, 172, 436
Combination antiretroviral therapy (cART). *See* Antiretroviral therapy
Combined degeneration of spinal cord, 1278
Combined generalized and focal epilepsy, 571
Common fibular (peroneal) nerve, 460*t*, 462, 931, 934
Communicating hydrocephalus, 1114, 1114*t*, 1119–1120, 1120*f*
Communication technology, 13
Community engagement, 13
Comparative visual field testing, 80
Compensation, in rehabilitation, 1629–1630
Complementary and alternative medicines (CAMs), for tic disorders, 789
Complement inhibition, for myasthenia gravis, 971–972
Complex MUPs, 247
Complex partial seizures. *See* Focal impaired awareness seizures
Complex regional pain syndrome (CRPS), 65, 453, 549–556
clinical features and pathology of, 549–550
continuous infusion therapy for, 553
diagnostic criteria for, 550–551
diagnostic tests for, 551, 551*t*
epidemiology of, 549
future research in, 554
intravenous therapies and intravenous regional blockade for, 552*t*, 553
management of, 552–554, 552*t*
neuromodulation for, 552*t*, 554
nonopioid pharmacotherapy for, 552–553, 552*t*
opioids for, 553
pain prevention in, 554
pathobiology of, 550
physical therapy for, 552, 552*t*
potential mechanisms of, 554, 554*t*
stages of, 551
sympathetic blocks and sympathectomy for, 552*t*, 553–554
terminology for, 549
topical agents for, 552*t*, 553
Complex repetitive discharges, in EMG, 247
Complex sleep apnea, 1190
Complex tics, 106
Compound motor action potential (CMAP), 244–245, 244*f*, 250–251, 250*f*
in axonotmesis, 463
in neurapraxia, 463

Compound skull fractures, 420, 430
Comprehension, testing of, 29, 29*t*
Comprehensive behavioral intervention for tics (CBIT), 789
Compressed sensing, in MRI, 201
Computed tomography (CT), 184–188
of acoustic neuroma, 1080–1081
in acute spinal cord syndromes, 149
in Alzheimer disease, 481, 482
appropriateness criteria for, 197*t*
of arteriovenous malformations, 363
of astrocytomas, 1549
in bacterial meningitis, 607
in Binswanger disease, 394
of brain abscess, 615–618
in brain death, 180–181
of brain edema
infarction-related, 1129
interstitial (hydrocephalic), 1129
SAH-related, 1130, 1130*f*
vasogenic, 1128
of brain sagging, 1143
of brain tumors, pediatric, 1542–1543, 1542*t*
Canadian CT Head Rule for, 428, 429*t*
of cerebral venous thrombosis, 355–357, 357*f*
cervical, in spinal cord injury, 444–445, 445*f*
in coma, 172
contrast-enhanced, 187–188
nephrotoxicity of, 187–188, 188*t*
premedication strategies for, 187, 187*t*
in cryptococcal meningitis, 643
in dementia, 101
HIV-associated, 696
description of, 184–185
of dural arteriovenous fistulas, 365
emergency, indications for, 186, 186*t*
of epidural hematoma, 426, 426*f*
in epilepsy, 580
of fibrous dysplasia, 1086, 1086*f*, 1272*f*
of focal mass lesions in brain, 164–166
in headache evaluation, 71, 73, 186
in head trauma, 186
in HIV infection, pediatric, 1581–1582, 1582*f*
Hounsfield units in, 184, 184*t*
of hydrocephalus, 1116–1117, 1118
in hypoxic-ischemic encephalopathy, 326, 326*f*
in ICH, 134–135, 137*f*, 334–335, 335*f*
in intervertebral disk disease, 1150
of intracranial aneurysms, 343
in intraventricular hemorrhage, 135, 137*f*
limitation in posterior fossa, 185
in malignant otitis externa, 621
of medulloblastoma, 1554
of meningiomas, 1050, 1052
in metastatic disease, 1035–1036, 1092–1093
in moyamoya disease, 392
in muscle weakness, 119
in myelopathy, 1163
in neurofibromatosis, 1459
noncontrast, 185, 185*f*, 186*f*
in osteomyelitis of skull base, 622
in paraneoplastic syndromes, 1104
in perinatal stroke, 1516, 1517*f*
in preeclampsia/eclampsia, 1289
in radiation injury, 1337, 1340*f*
role of, 186–187
in sarcoidosis, 775
in sepsis-associated encephalopathy, 1204
in sinus venous thrombosis, neonatal, 1362, 1363*f*
of skull base tumors, 1083–1085, 1084*f*, 1085*f*, 1086*f*
in spinal stenosis, 1153, 1156
of spinal tumors, 1096–1097
spiral, 187
in spontaneous intracranial hypotension, 1140
in stroke, 132–137, 186–187, 309, 309*f*–310*f*
door-to-CT time for, 132
initial survey and vital signs prior to, 133–134
neonatal, 1362
in pregnancy, 1290–1291
in subarachnoid hemorrhage, 71, 135, 137*f*, 186
of subarachnoid hemorrhage, 343, 344, 344*f*, 346, 346*f*, 346*t*
of subdural empyema, 618–619
of subdural hematoma, 424, 425*f*
in supratentorial herniation syndromes, 172, 174
in temporomandibular disorder, 542
in thrombocytopenia, 1237*f*
in tinnitus evaluation, 48
in toxoplasmosis, 704
in traumatic brain injury, 428–429, 429*t*, 435
in traumatic brain injury, pediatric, 1572, 1573*f*, 1575, 1576, 1576*f*
in trigeminal neuralgia, 918
in tuberculous meningitis, 647
in vertigo evaluation, 48
windows and levels in, 185–186, 186*f*
Computed tomography angiography (CTA), 185, 187, 208
in brain death, 181*t*
of dural arteriovenous fistulas, 365, 365*f*
in ICH, 334
in stroke, 134, 142, 142*f*, 309, 309*f*, 310
in subarachnoid hemorrhage, 186
Computed tomography myelography, 69, 119
in acute spinal cord syndromes, 149
in brachial plexus palsy, 1420
in intervertebral disk disease, 1150
in spinal cord injury, 445
in spinal metastasis evaluation, 1044
in spinal stenosis, 1156
in spinal tumor evaluation, 1096
in spontaneous intracranial hypotension, 73, 1140
Computed tomography perfusion (CTP) studies, 185, 187
Computed tomography venography (CTV), of cerebral venous thrombosis, 355–357
Computerized dynamic posturography, 263
COMT inhibitors. *See* Catecholamine-O-methyltransferase (COMT) inhibitors
Concentration
Lewy body dementias and, 494
traumatic brain injury and, 436–437
Concentration tests, 30
Concentric electrodes, 246
Concept formation, 275
Concussion, 413–416, 421
cumulative head impact index for, 418
definition of, 413–414
diagnosis of, 415
epidemiology of, 414
management of, 415–416
medical retirement/disqualification due to, 416
MRI in, 413–414
outcome of, 416, 418
pathobiology of, 414, 414*f*
postconcussion syndrome in, 437
repetitive, chronic traumatic encephalopathy from, 416–418
second impact syndrome with, 416
sport-related, 413
Conducted energy weapons (CEWs), 1347–1348
Conduction aphasia, 29*t*
Conduction block, 245, 245*f*
Conduction velocity, 245
Conductive hearing loss, 49–50, 50*t*
Confrontation visual field testing, 80, 80*f*
Confusional arousals, 1192–1193
Confusional state, 168
Confusion Assessment Method (CAM), 90, 90*t*, 93
Confusion Assessment Method for the ICU (CAM-ICU), 90–91, 90*t*, 93, 1202
Congenital bilateral perisylvian syndrome, 1376
Congenital central alveolar hypoventilation syndrome (Ondine's curse), 171, 1191
Congenital disorder of glycosylation 1a (CDG-1a), 1414*t*
Congenital heart disease
childhood stroke in, 1519–1520
perinatal stroke in, 1516
Congenital hydrocephalus, 1114, 1117–1119
clinical features of, 1118
diagnosis of, 1118
epidemiology of, 1117
MRI of, 1118, 1118*f*, 1119*f*
pathobiology of, 1117–1118, 1118*f*
treatment and outcomes of, 1118–1119
Congenital hypothyroidism, 1219
Congenital malformations, 1366–1384. *See also specific malformations*
alcohol use and, 1310, 1310*t*, 1583–1584
antiepileptic drugs and, 589, 1287–1288, 1287*t*
chromosomal disorders and, 1410
cocaine and, 1585
epilepsies associated with, 1512–1513
genetics of, 1366, 1368–1369
neural tube, 1367–1368
neuronal and glial proliferation disorders, 1370–1371
neuronal migration, 1372–1378
posterior fossa, 1378–1380
process outgrowth and synaptic, 1380–1381
segmentation, 1368–1369, 1369*f*
ventral induction, 1369
Congenital muscular dystrophies, 1422, 1474, 1476*t*, 1477–1479
COL6-related, 1477, 1478
definitions of, 1477
diagnosis of, 1477–1479
epidemiology of, 1477
management of, 1479
merosin-deficient, 1477, 1478
Congenital myasthenic syndromes (CMS), 974–975, 975*t*, 1422

Congenital myopathies, 1449, 1474–1477, 1493–1499
centronuclear, 1493–1497
definitions of, 1474, 1493
diagnosis of, 1493–1499
differential diagnosis of, 1493
epidemiology of, 1493
genetic subtypes of, 1493, 1494*t*–1495*t*
laboratory findings in, 1474–1477
LMNA-related, 1483
management of, 1499
muscle biopsy in, 1474, 1475*f*, 1477, 1493
muscle imaging in, 1477
outcomes of, 1499
pathophysiology of, 1495*f*
scapuloperoneal, 1482–1483, 1482*f*
Congenital myotonic dystrophy, 1486
Congenital rubella syndrome, 671
Congenital spinal stenosis, 1155
Congenital tumors, 1530, 1545–1549
Conivaptan, for SIADH, 1258
Conjunctival injection, 521
Consciousness, 168. *See also* Coma; Seizure; Syncope
assessing level of, 133
definition of, 168
disorders of, guidelines for, 435
induced altered states of, 168
meningitis and, 605–607
neuroanatomy of, 168, 169*f*
recovery of, 436
sudden alteration in, 51
Consent
implied, 1639
informed, 1638–1639, 1638*t*
Constructional apraxia, 306
Construction tests, 274
Continuous electroencephalography (cEEG), 294–295
in cerebral ischemia monitoring after SAH, 295
in coma prognosis, 295
indications for, 294, 294*t*
limitations of, 295
seizure detection in, 294–295, 295*t*
in titration of status epilepticus therapy, 295
Continuous infusion therapy, for complex regional pain syndrome, 553
Continuous intravenous (cIV) anesthetic agents, for seizures, 61–62, 61*f*, 62*t*
Continuous mandatory ventilation, 1211*t*
Continuous performance tests, 275
Continuous positive airway pressure (CPAP), 1190–1191, 1211, 1211*t*, 1212–1213
Continuous spikes and waves during slow sleep (CSWS), 1510
Contraction band necrosis, 1197
Contrast
iodinated, for CT, 187–188
leakage of, 200
nephrotoxicity of, 187–188, 188*t*, 190, 194
premedication strategies for, 187, 187*t*, 188*t*
Contrast allergy, 220–221
Contrast-enhanced computed tomography, 187–188, 194, 194*f*
Contrast-enhanced magnetic resonance angiography, 194–195
Contrast-enhanced MRI, 190
Contrast-enhanced ultrasound, 211
Contrast-induced nephropathy, 187–188, 188*t*, 221
Contrecoup lesions, 423–424
Contusions, cerebral, 423–424, 424*f*
Contusions, spinal cord, 442–443
Conus medullaris syndrome, 149*t*, 447
Conus tumors, 1096
Convergence insufficiency, 85
Conversion disorder, 135*t*, 810, 1619–1623
case example of, 1619
diagnosis of, 1621–1622
DSM-IV classification and criteria for, 1615–1616, 1615*t*, 1619
epidemiology of, 1619–1620
ICD-10 classification of, 1619
management of, 1622–1623
outcome of, 1623
pathobiology of, 1620
Coordination tests, 38, 117
Copper deficiency, 947, 1278*t*, 1282
Copper metabolism disorders, 1392
Copper toxicity, 1282
Coprolalia, 106
Copropraxia, 106
Cori-Forbes disease, 1015
Corkscrew thrombectomy devices, 313
Cornea, 77, 77*f*
Coronary artery bypass graft (CABG) surgery, cerebral complications of, 1195–1197
Coronary artery disease, as complication of spinal cord injury, 449
Coronavirus(es), 672–673, 672*f*
Coronavirus 2019. *See* COVID-19
Corpora amylacea, 1405
Corpus callosotomy, for epilepsy, 589*t*, 590
Corpus callosum
agenesis/dysgenesis of, 1380
formation of, 1380
Cortex
gait control by, 123, 124*f*, 124*t*
muscle weakness localized to, 111, 120*t*
sensory patterns and loss, 64–66, 65*t*
Cortical-basal-ganglionic degeneration. *See* Corticobasal degeneration (CBD)
Cortical dysgenesis, 1377–1378, 1512
Cortical dysplasia, 1377
Cortical electrodes, EEG with (ECoG), 236, 238
Cortical Lewy bodies, 492, 493*f*
Cortical myoclonus, 825–827, 825*t*, 826*t*
Cortical neuronal migration disorders, 1372–1378
Cortical resections, nonlesional, for epilepsy, 589*t*, 590
Cortical ribboning, 510
Cortical spikes, in EEG, 825
Cortical vein thrombosis, 353, 355*t*. *See also* Cerebral venous thrombosis (CVT)
Corticobasal degeneration (CBD), 97, 99, 486, 497, 893, 896–897
diagnosis of, 897
diagnostic criteria for, 897, 900*t*
epidemiology of, 897
historical perspective on, 896
pathobiology of, 896, 896*f*
signs and symptoms of, 897
treatment of, 897–899, 901*t*
Cortico-basal ganglia-thalamo-cortical (CBGTC) pathways, in tic disorders, 784–785
Corticobasal syndrome (CBS), 480, 827, 896
Corticospinal tract, 111, 145, 146*f*
Corticosteroids. *See* Steroid(s)
Cortisol, 1222–1224
Corynebacterium diphtheriae, 636–637, 636*t*, 945
Cough headache, primary, 524*t*, 533
Coup lesions, 423
COVID-19, 672–673
clinical spectrum of, 672
CSF analysis in, 673
encephalitis with, 757
epidemiology of, 672–673
histopathologic findings in, 673, 674*f*
neuroimaging in, 673, 674*f*
neurologic clinical features associated with, 673, 673*f*
smell and taste disturbances in, 673
stroke with, 304, 673
Cowden syndrome, 1531, 1549
Coxiella burnetii, 630–631
Coxsackievirus, 665, 1163
CP. *See* Cerebral palsy
CPAP. *See* Continuous positive airway pressure
CPEO. *See* Chronic progressive external ophthalmoplegia
CPK. *See* Creatine phosphokinase
CPP. *See* Cerebral perfusion pressure
CPR, in traumatic brain injury. *See* Cardiopulmonary resuscitation, in traumatic brain injury
CPT II deficiency. *See* Carnitine palmitoyltransferase II (CPT II) deficiency
Cramps. *See* Muscle cramps
Cranial nerve(s)
ALS and, 908
examination of, 26*t*, 32–36, 915
in brain death, 181
in muscle weakness, 116
in sensory symptom evaluation, 68
HIV and, 700*t*
injury of. *See* Cranial neuropathies
nuclei of, 915, 916*f*
pain. *See* Cranial neuralgias
pituitary disorders and, 1215, 1216*f*
radiation therapy and, 1107
sarcoidosis and, 773–774, 774*f*, 776, 923
Cranial neuralgias, 538, 542–546
diagnostic criteria for, 538
etiologies of, 539*t*
medications for, 543, 544*t*
Cranial neuropathies, 435, 451–457, 454*t*, 915–926
gliomas and, 1019–1020
isolated, 915
multiple, 915
Craniectomy
hemicraniectomy
in brain edema, 1129, 1132, 1132*f*
in ICH, 338, 339*f*
in malignant MCA infarction, 315
precautions for lumbar puncture with, 281
for traumatic brain injury, 430
for traumatic brain injury, pediatric, 1577
Craniocervical arterial dissection, 1519, 1522
Craniofacial dystonia, 106, 802, 807–808, 808*f*, 815
Craniofacial pain, 74–75

Craniopharyngiomas, 1067, 1218, 1218*f*
hyperprolactinemia with, 1217
pediatric, 1067, 1545–1546, 1546*f*
Craniorachischisis, 1367
Craniotomy
brain sagging after, 1139, 1143–1144, 1143*t*
for ICH, 338, 339*f*
for subdural hematoma, 425–426, 430
for traumatic brain injury, 430
C-reactive protein
in bacterial meningitis, 607–608
in brain abscess, 617
in malignant otitis externa, 621
in spinal epidural abscess, 619
Creatine phosphokinase (CPK)
in congenital myopathies, 1493
in muscular dystrophy, 1477, 1478, 1479, 1480, 1481
Cree leukoencephalopathy, 1414*t*
C-reflex, in myoclonus, 825, 825*t*
Cremasteric reflexes, 43
Crescendo TIAs, 322–323
Creutzfeldt, Hans Gerhard, 506
Creutzfeldt-Jakob disease (CJD), 506–520
acquired, 507, 507*t*
biomarkers in, 510
clinical presentation of, 508
CSF analysis in, 510
definite, probable, or possible, 510, 511*t*
dementia in, 96–97, 98
EEG findings in, 236, 510, 512*f*
epidemiology of, 508
familial (genetic), 299, 507, 507*t*, 511*t*, 513–514
familial Creutzfeldt-Jakob disease (fCJD), 299, 507, 507*t*, 511*t*, 513–514
as great mimicker, 508
history and nomenclature of, 506–507
iatrogenic Creutzfeldt-Jakob disease (iCJD), 507, 507*t*, 511*t*, 516, 517–518
investigational treatments for, 518–519
level 1 evidence on, 519
management and outcomes of, 518–519, 519*t*
myoclonus in, 827
neuroimaging in, 101, 192, 510–512, 513*f*, 518, 518*f*
Sporadic Creutzfeldt-Jakob disease (sCJD), 506, 507, 507*t*, 508–512
affective, 508
Brownell-Oppenheimer variants, 508
classic, 508
clinical presentation of, 508
cognitive, 508
diagnosis of, 510–512
diagnostic criteria for, 510, 511*t*
epidemiology of, 508
as great mimicker, 508
Heidenhain, 508
molecular classification of, 508–510
neuropathologic findings of, 508, 509*f*
visual variant, 508
symptomatic treatments for, 518, 519*t*
variant, 507, 507*t*, 511*t*, 516–517, 518*f*
Critical care
delirium in, 88, 90–93, 90*t*, 91*t*
EEG monitoring in, 238
ICH management in, 335
induced altered states of consciousness in, 168
monitoring in, 288–296
SAH management in, 349–350, 349*t*
sepsis management in, 1201, 1204–1205
in spinal cord injury, 448
stroke care in, 315–317
TBI management in, 433–434, 433*f*
Critical illness myopathy (CIM), 989–991, 990*t*
Critical illness polyneuropathy (CIP), 947, 989–991, 990*t*
Crizotinib
for metastatic lung cancer, 1042
neurologic complications of, 1109
"Crocodile" (desomorphine), 1313
Crohn disease, 1267
Crossed hemiparesis, 114
Crow-Fukase syndrome, 942
CRPS. *See* Complex regional pain syndrome
Cryoglobulinemic neuropathy, 941–942
Cryoglobulinemic vasculitis, 371*t*, 378
Cryptococcal meningitis, 641–644
clinical presentation of, 641–643, 641*t*
CSF analysis and serum diagnostics in, 642*t*, 643–644
diagnosis of, 643–644
epidemiology and pathobiology of, 641
HIV-associated, 703
imaging in, 641*t*, 643, 643*f*
outcomes of, 644
treatment of, 643*t*, 644
Cryptococcosis, 153, 161*t*, 163*f*
HIV-associated, 698, 703
meningitis in. *See* Cryptococcal meningitis
movement disorders with, 698
Cryptococcus gattii, 641–644
Cryptococcus neoformans, 641, 643–644
Cryptogenic stroke, 303*f*, 304, 1520
CSW. *See* Cerebral salt wasting
CSWS. *See* Continuous spikes and waves during slow sleep
CT. *See* Computed tomography
CTA. *See* Computed tomography angiography
CTE. *See* Chronic traumatic encephalopathy
Cultural factors
in global burden of neurologic disease, 7
in health-seeking behavior, 10–11, 10*b*
in somatic symptom disorder, 1617
Cushing disease, 1215*t*, 1217
ACTH-secreting tumors and, 1064, 1065–1066
dementia in, 98
intracranial hypertension in, 1135
myopathies in, 993, 994*t*
Cushing reflex, 152
Cushing syndrome, 1215*t*, 1223, 1249
Cutaneous anthrax, 633–634, 634*f*
Cutis marmorata, 396, 1352
CVT. *See* Cerebral venous thrombosis
Cyanide poisoning, 325
Cyclin-dependent kinases, 1412
Cyclophosphamide
for amyloid β-related angiitis, 374
for autoimmune encephalitis and meningitis, 767, 769*t*
for Behçet syndrome, 379
for CNS vasculitis in rheumatoid arthritis, 380
for dermatomyositis, 981
for diffuse astrocytomas, 1026
for eosinophilic granulomatosis with polyangiitis, 378
for giant cell arteritis, 375
for granulomatosis with polyangiitis, 377
for HCT conditioning, 1235
for myasthenia gravis, 970*t*
for neuromyelitis optica spectrum disorders, 752
for paraneoplastic syndromes, 1104
for pediatric brain tumors, 1556
for polyarteritis nodosa, 376
for primary angiitis of CNS, 372–373
for primary CNS lymphoma, 1060
for sarcoidosis, 776, 777*t*
for Susac syndrome, 395
Cyclophosphamide + doxorubicin + vincristine, for meningiomas, 1053–1054, 1054*t*
Cyclopia, 1369
Cyclosporine
for Behçet syndrome, 379
for dermatomyositis, 981–982
for GVHD prevention, 1235
for myasthenia gravis, 970*t*, 971
for transplant patients, toxicity of, 1299–1300
Cyclothymia, 1600
Cyproheptadine
for migraine prevention, 528
or serotonin syndrome, 1330
Cyst(s)
arachnoid, 1546–1547
colloid, 1548
pineal, 1073–1074, 1074*f*
skull, 1085, 1086*f*
in spinal cord injury, 443
Cysticercosis, 153–154, 162*t*, 164*f*, 654*t*, 656, 657*f*, 705, 1593
racemose cysticercosis , 656
Cystinuria, 1389*t*
Cytarabine
for acute myeloid leukemia, 1234
adverse effects of, 1109
for metastatic disease, 1046
for non-Hodgkin lymphoma, 1233
for primary CNS lymphoma, 1059
Cytology, CSF, 281, 281*t*
Cytomegalovirus (CMV), 683
congenital, 683, 1369, 1376
HIV-associated, 683, 693, 702, 1164
myelitis with, 1163–1164
neuropathology of, 662
neuropathy with, 938*t*, 945
transplantation-related, 1255, 1299
treatment for, 662, 679*t*, 683, 702
Cytosine arabinoside, for HCT conditioning, 1235
Cytotoxic edema, 302, 443, 1128, 1128*t*, 1129

D

D-2-hydroxyglutaric aciduria, 1390
d4T. *See* Stavudine
Dabigatran, reversal of, 139*t*, 336, 1242
Dabrafenib
for metastatic melanoma, 1043
for pediatric astrocytoma, 1552
DAI. *See* Diffuse axonal injury
Dalfampridine, for multiple sclerosis, 726, 727*t*
Dalteparin, reversal of, 139*t*
DALYs. *See* Disability-adjusted life years
DAN. *See* Diabetic autonomic neuropathy
Danaparoid, for heparin-induced thrombocytopenia, 1239
Dancing-eyes, dancing-feet syndrome, 759
Dandy, Walter, 1114

Dandy-Walker syndrome, 1118, 1118*f*, 1379–1380, 1379*f*
Dantrolene
for neuroleptic malignant syndrome, 852, 1329
for paroxysmal sympathetic hyperactivity, 1180*f*, 1181, 1181*t*
for paroxysmal sympathetic storming, 1200*t*
for stiff person syndrome, 1006
Darunavir, 707*t*
DASH. *See* Dietary Approach to Stop Hypertension
Date rape drugs, 1314
DaTscan. *See* Ioflupane
DAVFs. *See* Dural arteriovenous fistulas
DCI. *See* Decompression illness; Delayed cerebral ischemia, from vasospasm in SAH
DDAVP, antiplatelet reversal with, 139*t*
ddC. *See* Zalcitabine
ddI. *See* Didanosine
D-dimer, in cerebral venous thrombosis, 358
Death
brain, 177, 179–183, 435
end-of-life care in, 1636–1643
Debrancher deficiency, 1015, 1017, 1403–1404
Decerebrate posturing, 170, 170*f*
Decerebrate rigidity, 170
Decision making, 1638–1639
Decompression illness (DCI), 1350–1354
diagnosis of, 1352
epidemiology of, 1350, 1350*t*, 1351*f*
level 1 evidence on, 1353
management of, 1352*t*, 1353
neurologic manifestations of, 1352, 1352*t*
outcome of, 1353
pathobiology of, 1350–1351
Decompression sickness (DCS), 1350
Decorticate posturing, 170, 170*f*
Decorticate rigidity, 170
Decrementing, 877
DEE. *See* Developmental and epileptic encephalopathy
Deep brain stimulation, 276
for chorea, 859
for cluster headache prevention, 532
for dystonia, 817–818
for epilepsy, 592
for myoclonus, 829*t*
for obsessive-compulsive disorder, 1612
for Parkinson disease, 872, 879, 885, 889–890
for tardive dyskinesia, 852, 852*f*, 853*t*
for tic disorders, 791
Deep tendon reflexes, testing of, 38–39, 39*t*, 40*t*
Deep vein thrombosis (DVT)
prophylaxis
in ICH, 335*t*
in spinal cord injury, 448, 449
in traumatic brain injury, 434
stroke and, 317
Deep venous anomalies. *See* Venous malformations
Degenerative ataxia, 846–847
Déjà vu, 53*t*, 54, 570, 579, 1593, 1610
Dejerine-Roussy syndrome, 67, 307
Dejerine-Sottas neuropathy, 937, 955, 1421
Delavirdine, 707*t*
Delayed cerebral ischemia (DCI), from vasospasm in SAH, 345–346
Delayed posthypoxic leukoencephalopathy (DPHL), 326
Delayed sleep phase, 1192
Delirium, 88–94, 168
arousal level in, 89–90
assessment of, 90–91
causes of, 88
dementia *versus*, 91, 96
diagnosis of, 89
EEG findings in, 91
environmental optimization for, 91, 93
epidemiology of, 88–89
excited, in sympathomimetic toxicity, 1324–1326
focused exam in, 89
focused history in, 89
hematopoietic cell transplantation and, 1235
hyperactive, 88, 91
hypoactive, 88, 90
ICU-associated, 88, 90–93, 90*t*, 91*t*
initial laboratory workup in, 89
level 1 evidence on, 93
management of, 91–93, 93*t*, 1204–1205
mixed subtype of, 90
neurologic injury and, 91
pathobiology of, 89
patient and staff safety in, 91
pharmacologic prevention of, 92
pharmacologic symptom management for, 91
pharmacologic therapy for, 91–93, 92*t*
psychosis in, 1590*t*, 1593, 1594
risk factors for, 88, 88*t*
sepsis and, 1202, 1204–1205, 1205*t*
symptoms of, 88
transplantation-related, 1299
Delirium tremens, 1305–1306, 1305*t*, 1593
Delta activity, in EEG, 231
generalized rhythmic, 233–236
Delta sign
empty, 357
filled, 357
Delusions, 1588
in Alzheimer disease, 481
in depression, 1598–1599
in illness anxiety disorder, 1618
in Lewy body dementias, 498
in schizophrenia, 1589
Dementia, 95–102
alcoholic, 1309–1310
Alzheimer. *See* Alzheimer disease
anxiety in, 498, 1610, 1612
autoimmune, 759
biomarker imaging in, 101
brain biopsy in, 283–284
CADASIL and, 398
CSF testing in, 100
delirium *versus*, 91, 96
depression *versus*, 96, 1601
diagnosis of, 98–101
diagnostic criteria for, 95, 99, 100*t*
diagnostic testing in, 99–101
dialysis, 1254, 1333
differential diagnosis of, 98
endocrine dysfunction causing, 98
epidemiology of, 96, 97*t*
essential tremor and, 780
focused examination in, 98–99
frontotemporal. *See* Frontotemporal dementia (FTD)
general neurologic examination in, 99, 99*t*
global action on, 12, 12*f*
history in (focused and neurologic), 20*t*, 98
HIV-associated, 98, 694–697
CSF examination in, 696
differential diagnosis of, 697
imaging in, 696, 696*f*
management of, 697
in older children, 1580
pathology of, 696–697
illicit drug use and, 1316–1317
infectious causes of, 98
inflammatory causes of, 98
laboratory blood testing in, 100
language impairment in, 99
level 1 evidence on, 101
Lewy body. *See* Lewy body dementias (LBDs)
metabolic causes of, 97–98
mild cognitive impairment *versus*, 95–96, 470
mood disorders comorbid with, 1603
in multiple system atrophy, 896
myoclonus associated with, 827
neurodegenerative, 96–97
neuroimaging in, 97, 101
neurophysiologic testing in, 100–101
neuropsychological testing in, 99, 275
outcome of, 101
in Parkinson disease. *See* Parkinson disease dementia
pathobiology of, 96–98
pathoetiologic basis of, 95, 96*t*
posttraumatic stress disorder and, 1610
in progressive supranuclear palsy, 893–894
protein pathologies in, 100, 100*t*
psychosis with, 481, 1590*t*, 1593
questions to ask in, 98
structural causes of, 97
terminology and classification of, 95, 96*t*
treatment of, 101
vascular. *See* Vascular dementia
visuospatial impairment in, 99
Dementia pugilistica, 416
Dementia Rating Scale, 494
Dementia with Lewy bodies (DLB), 492–499
Alzheimer disease comorbid with, 492–493
autonomic dysfunction in, 494, 498
autonomic testing in, 496
clinical manifestations of, 494
cognitive impairment in, 494
CSF analysis in, 496
diagnosis of, 495–497
diagnostic criteria for, 495, 495*t*
differential diagnosis of, 497
epidemiology of, 492
fluctuating attention and concentration in, 494
functional brain imaging in, 496
future directions in, 498
genetic risks factors for, 493–494
level 1 evidence on, 499
lifestyle modifications for, 498
neuropathology of, 492–493, 493*f*
neuropsychological testing in, 495
neurotransmitter systems in, 493
outcome of, 499
Parkinson disease dementia *versus*, 492, 493, 495
parkinsonism in, 492, 494
pathologic features of, 492, 492*t*
psychiatric symptoms in, 494
psychosis in, 494, 498, 1590*t*, 1593
sleep disorders in, 494, 498

Dementia with Lewy bodies (DLB) *(Continued)*
SPECT in, 101, 496, 496*f*
spongiform change/microvacuolation in, 493
structural brain imaging in, 495–496
treatment of, 497–498
for cognitive symptoms, 497
for mood disorders, 498
for motor symptoms, 497–498
for psychosis, 498
de Morsier syndrome (septo-optic dysplasia), 1368, 1369
Demyelinating disorders, 711–735. *See also* Multiple sclerosis (MS)
cerebrospinal fluid analysis in, 280–281
infant hypotonia (floppy infant) in, 1421–1422, 1421*t*
level 1 evidence on, 732–733
MRI of, 197–198, 197*f*
nerve biopsy in, 286
nerve conduction studies in, 245, 245*f*
neurologic history in, 20*t*
osmotic, 1258–1260
Dengue, 666, 667*t*
Denosumab, for fibrous dysplasia, 1272
Dense MCA sign, 309, 309*f*
Dental pain, 75
Dentatorubral-pallidoluysian atrophy, 827, 858
Deoxyribonucleic acid. *See* DNA
Dependence, drug, 1313–1316, 1313*t*
Depressed skull fractures, 420
Depression
Alzheimer disease and, 96, 1600–1601
anxiety disorders and, 1608
burning mouth syndrome and, 546
dementia *versus*, 96, 1601
electroconvulsive therapy for, 498, 1602–1603
epilepsy and, 593, 1601, 1603
essential tremor and, 780
Huntington disease and, 865–866, 868, 1600–1601
illness anxiety in, 1618
level 1 evidence on, 1604–1605
Lewy body dementias and, 498
masked, 1601–1602
mild cognitive impairment and, 474
multiple sclerosis and, 716, 726
neurologic disorders associated with, 1600, 1600*t*, 1603
other psychiatric disorders *versus*, 1602
other specified, 1600
Parkinson disease and, 879*t*, 880, 889, 1600–1601, 1603
Parkinson-plus syndromes and, 899, 901*t*
prion diseases and, 519*t*
psychotic features with, 1589–1590, 1590*t*, 1598–1599
spinal cord injury and, 450
stroke and, 411
substance/medication-induced, 1600
Tourette syndrome and, 784, 787
traumatic brain injury and, 437
traumatic encephalopathy syndrome and, 417
Dermatomes, 39–40, 40*f*, 66, 67
of head and neck, 34, 34*f*
Dermatomyositis, 979, 980–982
antibodies in, 981, 981*t*
clinical features of, 980–981, 980*f*
diagnosis of, 981
differential diagnosis of, 981, 983*t*
EMG findings in, 247
epidemiology of, 980
management of, 981–982
muscle pathology in, 986, 986*f*
pathobiology of, 980
Dermoid cysts, of skull, 1085
Dermoid tumors, 1546
de Sanctis-Cacchione syndrome, 1413*t*
Desensitization therapy, 1612
Desmoplastic medulloblastoma, 1531
Desmopressin, for ICH, 138, 336
Desomorphine, 1313
Deutetrabenazine
for chorea, 859, 866
for dystonia, 814
for Huntington disease, 866
for tardive dyskinesia, 852, 852*f*, 853*t*
for tic disorders, 789, 790*t*
Developmental, Individual Difference, Relationship approach (DIR/Floortime), 1439
Developmental and epileptic encephalopathy (DEE), 1506–1509, 1507*t*–1508*t*
Developmental coordination disorder (DCD), 1427
Developmental delay, 1424
Developmental disorders. *See also specific disorders*
higher order cerebral, 1424, 1427–1432, 1428*t*
motor, 1424–1427
Developmental language disorders (DLDs), 1429
Developmentally small spinal canal, 1155
Devic, Eugène, 744
Devic disease. *See* Neuromyelitis optica spectrum disorders
Dexamethasone
for bacterial meningitis, 607, 608–609, 610*f*
for brain edema, 1131, 1133–1134
for focal mass lesions in brain, 166
for Ménière disease, 599
for metastatic disease, 1036
for migraine, 74
for neoplastic myelopathy, 1163
for neurocysticercosis, 656
for pituitary tumors, 1068
for radiation complications, 1107
Dexmedetomidine
for delirium, 91, 92–93, 92*t*, 1205
for delirium prevention, 92
for paroxysmal sympathetic hyperactivity, 1180*f*, 1181, 1181*t*
for paroxysmal sympathetic storming, 1199
Dextromethorphan
for MS patients, 726, 727*t*
for neuropathic pain, 563
for pseudobulbar symptoms, 913
Diabetes insipidus, 1217
craniopharyngiomas and, 1546
pineal region tumors and, 1074, 1074*f*
pituitary tumors and, 1065
Diabetes mellitus, 1221
cranial neuropathies in, 923
dementia in, 98
epidemiology of, 1215*t*, 1221
management, for stroke prevention, 402, 408
Diabetic amyotrophy, 949–950
Diabetic autonomic neuropathy (DAN), 1174
Diabetic lumbosacral radiculoplexus neuropathy, 949–950
Diabetic neuropathy, 949–950, 1221, 1266
diagnosis of, 938*t*, 950, 950*f*
mononeuropathies, 935, 949
polyneuropathy, 936–937, 949–950
Diabetic retinopathy, 1221
Diagnostic reasoning, 15
Diagnostics, global disparities in access to, 11
Diagnostic synthesis, 23
Dialysis dementia, 1254, 1333
Dialysis disequilibrium syndrome, 1253–1254
Diaschisis, 172
Diazepam
for acute dystonic reaction, 851
for alcohol withdrawal, 1305*t*
for anxiety disorders, 1611*t*
for ataxia, 847
for cholinergic toxicity, 1329
for hereditary spastic paraplegia, 1168
for Ménière disease, 598
for Parkinson disease, 889
for paroxysmal sympathetic hyperactivity, 1180*f*
for seizures, 59–60, 59*t*
for vertigo, 49*t*
Dicarboxylic aminoaciduria, 1389*t*
DICER1 syndrome, 1531
Dichlorphenamide
for hyperkalemic periodic paralysis, 1001
for hypokalemic periodic paralysis, 1000
Diclofenac potassium, for migraine, 526*t*
Didanosine, 706, 707*t*, 949, 1583
Diencephalic syndrome, 172, 748
Diet
and ataxia, 838, 847
ketogenic, 569, 1386, 1510
and Ménière disease, 598
and multiple sclerosis, 713
and muscle cramps, 1009
and Parkinson disease, 874
and phenylketonuria, 1388
and polyneuropathy, 947
and restless legs syndrome, 795
and stroke prevention, 401–402
Dietary Approach to Stop Hypertension (DASH), 401–402
Dietary history, 22–23
Diet pills, 1316
Diffuse astrocytoma, 1024–1026, 1025*f*, 1532*t*
Diffuse axonal injury (DAI), 421, 421*t*, 429
Diffuse brain dysfunction or injury
coma from, 175
EEG findings in, 233–236, 235*f*, 236*f*
Diffuse fibrillary astrocytoma, 158*t*
Diffuse intrinsic pontine gliomas (DIPGs), 1528, 1537, 1553
Diffuse large B-cell lymphoma (DLBCL), 1056–1057
Diffuse oligodendrogliomas, 1031
Diffuse sclerosis (Schilder disease), 728, 1399, 1402
Diffusion tensor imaging (DTI), 199–200, 199*f*
Diffusion-weighted imaging (DWI), 191–192, 193*t*, 194*f*
DiGeorge syndrome, 1410*t*, 1419
Digital subtraction angiography
in cerebral venous thrombosis, 356*t*, 357*f*, 359
in reversible cerebral vasoconstriction syndrome, 388, 388*f*

Digit Span Forward, 275
Digit Symbol Coding, 271
Dihydroergotamine
avoidance in pregnancy, 1293
for migraine, 525, 526*t*, 527
for primary exertional headache, 533
Dihydropyrimidine dehydrogenase deficiency, 1391
Diltiazem, for primary sex headache, 533
Dimenhydrinate, for vertigo, 49*t*
Dimercaprol, 1332
Dimethylaminoethanol, for hemifacial spasm, 822
Dimethylaminopropionitrile, 948
Dimethyl fumarate
for multiple sclerosis, 723, 725, 725*t*
for multiple sclerosis in pregnancy, 1292, 1292*t*
Dimethyl sulfoxide, for complex regional pain syndrome, 553
Dim light melatonin onset (DLMO), 268
DIPGs. *See* Diffuse intrinsic pontine gliomas
Diphenhydramine
for acute dystonic reaction, 851, 1590
for migraine, 74
and restless legs syndrome, 795
for vertigo, 49*t*
Diphtheria, 636–637, 636*t*
Diphtheritic neuropathy, 945
Diplegia, in cerebral palsy, 1425
Diplopia
in ataxia, 833, 833*t*
efferent pathway dysfunction and, 85–87
monocular *versus* binocular, 84
in multiple sclerosis, 715, 715*t*
supranuclear causes of, 85
transient, 83–84
Dipyridamole, for stroke prevention, 405–406
Direct hits, mutations in, 1443
Direct muscle percussion, 38–39
Disability-adjusted life years (DALYs), 2, 2*f*, 3*f*, 4*f*
disparities in, 4–6, 4*f*, 5*f*
stroke and, 5
Discrete recruitment, in EMG, 249, 249*f*
Disease trajectories, 1636–1637
Disk disease. *See* Intervertebral disk disease
Disorders of consciousness (DoC) guidelines, 435
Disparities, in neurologic disorders, 4–6, 4*f*
access to care and, 5–6, 6*f*, 9, 9*f*, 11
chronic diseases and, 5
health-seeking behavior and, 10–13, 10*b*
policies and guidelines affecting, 11, 11*b*
stroke, 5
stroke and, 5
Disruptive mood dysregulation disorder, 1600
Distal latency, in nerve conduction studies, 244
Distal myopathies, 1487, 1492–1493
Distal sensory polyneuropathy (DSPN), 699
Disulfiram, 949, 1311
Ditans, for migraine, 526*t*, 528
Diuretics
for hyperkalemic periodic paralysis, 1001
for hypokalemic periodic paralysis, 999–1000
for idiopathic intracranial hypertension, 1137
for Ménière disease, 598
for nondystrophic myotonias, 1002
for stroke prevention, 402, 408
Diurnally fluctuating dystonia, 871
Dix-Hallpike maneuver, 36, 41–42, 41*f*, 47, 262, 600
Dizziness, 45, 45*t*. *See also* Vertigo
cranial nerve assessment in, 35–36
neurologic history in, 20*t*
DLB. *See* Dementia with Lewy bodies
DMD. *See* Duchenne muscular dystrophy
D mode ultrasound, 208–209, 208*t*
DNA
maintenance and transcription of, 1412, 1413*t*–1414*t*
mitochondrial. *See* Mitochondrial DNA
translation and modification of, 1412, 1444–1445, 1449
DNA analysis, 297–300
DNA damage, from radiation, 1336
DNA disorders, 1410, 1412–1416. *See also specific disorders*
DNA sequencing
in bacterial meningitis, 608
of brain tumors, 284
in chronic meningitis, 650
next-generation, 300
Sanger method of, 300
DNI (do not intubate), 1637–1638
DNR (do not resuscitate), 1637–1638
Docetaxel
adverse effects of, 1109
neuropathy induced by, 949
Dolichoectatic aneurysms, 350
Doll's eye maneuver, 171, 171*f*
Dolutegravir, 707*t*
Dominantly inherited PrP cerebral amyloidosis, 514
Dominant optic atrophy (DOA), 1449, 1450
Domoic acid, 1333
Donepezil
for Alzheimer disease, 483, 483*t*
for Huntington disease, 868
for Lewy body dementias, 497
for mild cognitive impairment, 473
for vascular dementia, 504, 504*t*
Do not intubate (DNI), 1637–1638
Do not resuscitate (DNR), 1637–1638
Doose syndrome, 1510
Dopamine
in ADHD, 1431
in anxiety disorders, 1607
in ataxia, 837
in bipolar disorder, 1598
in dementia with Lewy bodies, 493, 496
in depression, 1597
in Huntington disease, 863–864, 866
in migraine, 524
in Parkinson disease, 871–873
in parkinsonism, 871–872
in Parkinson-plus syndromes, 893–903
plasma levels of, 257
in restless legs syndrome, 794
in schizophrenia, 1588
in sepsis-associated encephalopathy, 1204
in tic disorders, 785
Dopamine agonists
adverse effects of, 887–888
for dystonia, 814, 814*t*
for Parkinson disease, 881–883, 887–888
for paroxysmal sympathetic hyperactivity, 1180–1181
for restless legs syndrome, 795–798, 797*t*
Dopamine imaging, 204*t*, 205, 205*f*, 496, 881
Dopamine receptor antagonists. *See also specific drugs*
for chorea, 859, 866–867
for Huntington disease, 866–867
for migraine, 74, 526*t*, 527–528
neurologic effects of, 849–853, 849*t*
parkinsonism induced by, 899, 901*t*
for Sydenham disease, 855
for tic disorders, 789
Dopamine β-hydroxylase deficiency, 257
Dopa-responsive dystonia, 803, 804, 811*t*, 812, 813–814, 871
Doppler (D) mode, 208–209, 208*t*
Doppler ultrasound, transcranial, 208, 212–215
in acute liver failure monitoring, 1250
in AVM detection, 213–214
in cerebral microemboli detection, 214
in cerebral vasomotor reactivity testing, 214–215
in childhood stroke, 1520–1521
indications for, 212, 213*t*
in intracranial stenosis and occlusion, 213, 214*f*
limitations of, 215
in moyamoya disease, 392
pulsatility index in, 212, 212*f*
resistance index in, 212, 212*f*
sensitivity and specificity of, 213
in sickle cell disease, 213, 1229–1230
in sonothrombolysis, 215
in vasospasm detection in subarachnoid hemorrhage, 214, 349
Dorsal columns, 66
Dorsal root ganglion, sensory patterns and loss, 65*t*, 66
Dorsal scapular nerve, 927, 928*f*, 928*t*
Double burden of disease, 4
Double-cortex syndrome, 1374–1375, 1377
Double effect, hospice care, 1640
Down syndrome, 477, 1381, 1410, 1410*t*, 1419
Doxepin
for insomnia, 1187*t*
for migraine prevention, 529*t*
Doxycycline
for anthrax, 634
for brucellosis, 632
for Lyme disease, 650
for mycoplasmal (walking) pneumonia, 635
for prion diseases, 518
for Q fever, 631
for scrub typhus, 629
for spotted fever rickettsiosis, 626–627
for typhus group rickettsiae, 629
for Whipple disease, 635
DPHL. *See* Delayed posthypoxic leukoencephalopathy
Dravet syndrome, 571, 1509
Dream enactment behavior, 1193, 1193*t*
Drift testing, 37–38
Drop attacks, 571
Droperidol, for Ménière disease, 599
Droxidopa, for autonomic dysfunction, 1175
Drug dependence, 1313–1316, 1313*t*
Drug intoxication and withdrawal, 1313–1318. *See also specific drugs*
altered mentation in, 1316–1317
infection risk in, 1316
mood disorders with, 1602

Drug intoxication and withdrawal (*Continued*)
prenatal and perinatal effects of, 1317, 1584–1586
psychosis with, 1590, 1593
seizures in, 1316
stroke in, 1316
trauma in, 1316
DSPN. *See* Distal sensory polyneuropathy
Dual antiplatelet therapy, for stroke prevention, 405–406
Dual-task walk, in gait assessment, 127
Dubowitz disease, 1469, 1469*t*. *See also* Spinal muscular atrophies (SMAs)
Duchenne muscular dystrophy, 1476*t*, 1479–1482
cardiac function in, 1482
clinical features of, 1479–1480, 1480*f*
definition of, 1479
diagnosis of, 1481
epidemiology of, 1479
gait disorder in, 130*t*, 1479, 1481
gene therapy for, 1482
genetics of, 299, 1481
Gowers sign in, 1479, 1480*f*, 1481
intermediate phenotype of, 1481
level 1 evidence on, 1499
management of, 1481–1482
manifesting carriers of, 1481
respiratory compromise in, 1480, 1482
Duloxetine
for anxiety disorders, 1611*t*
for chemotherapy-induced neuropathy, 1109*t*
for depression, 1602
for glossopharyngeal neuralgia, 924
for neuropathic pain, 561, 562*t*
Dumbbell tumors, spinal, 1089
Duplex ultrasound, 208–212
Dural arteriovenous fistulas (DAVFs), 364–366
angiography of, 365, 365*f*
Borden classification system for, 364, 365*t*
clinical features of, 364–365
CT of, 365
definition of, 225, 364
diagnosis of, 365
endovascular treatment of, 225–226, 365–366
management and outcome of, 365–366
MRI of, 365, 1166, 1167*f*
pathobiology of, 364
SAH with, 351
spinal, 1166, 1167*f*
Dural disease, 1050, 1055. *See also* Meningiomas
Dural metastases, 1055
Dural tail, 1051–1052, 1052*f*, 1093
Duration, in neurologic history, 17
Duret hemorrhage, 436*f*
DVT. *See* Deep vein thrombosis
Dwarfism, 1272–1273
DWI. *See* Diffusion-weighted imaging
Dying, end-of-life care in, 1636–1643
Dynamic susceptibility contrast images, 200
Dysarthria
ALS and, 908, 913
ataxia with, 834, 844–845, 844*t*, 847
in Guillain-Barré syndrome, 939
with muscle weakness, 114
in myasthenia gravis, 966*t*
Parkinson disease and, 878
testing for, 36, 36*t*
transplantation-related, 1298*t*
treatment (therapy) for, 1632–1633
Dyscalculia, 1428*t*, 1430, 1431
Dysdiadochokinesia, 107
Dysembryoplastic neuroepithelial tumors (DNT), 1020*t*, 1549
Dysequilibrium, 45, 45*t*
Dysesthesia, 65, 557*t*, 715
Dysgraphia, 1430
Dyskinesia(s), 107
definition of, 107, 801, 802*t*
focused examination of, 104
focused history on, 103–104, 103*t*
HIV-associated, 698
levodopa-induced, 801, 858, 884–885
tardive. *See* Tardive dyskinesia
xenobiotic-induced, 1320, 1321*t*
Dyskinetic cerebral palsy, 858, 859*f*, 1425, 1426, 1426*t*, 1427
Dyslexia, 1428*t*, 1430
Dysmetria, 107
Dysorthographia, 1430
Dysphagia, 1262–1263
in ALS, 908, 913, 1262–1263
assessment of, 1209
in congenital bilateral perisylvian syndrome, 1376
in Guillain-Barré syndrome, 939
in Huntington disease, 865, 867
in myasthenia gravis, 966*t*, 1263
in Parkinson disease, 878, 879*t*, 891, 1262–1263, 1267
in prion diseases, 519*t*
rehabilitative therapy for, 1632, 1633
screening protocols for, 1263
in stroke patients, 316–316, 1263
Dysphasia, 1428*t*, 1429
Dysplastic gangliocytoma, 1548–1549
Dysplastic megalencephaly (DMEG), 1512, 1513
Dystonia(s), 37, 105, 106*f*, 106*t*, 800–819
acquired, 803, 803*f*, 804*t*, 809–810
action, 106
age at onset, 802, 803*f*
anatomic underpinnings of, 804–805, 805*f*
animal models of, 805–806, 806*f*
anxiety with, 1610
athetotic, 106
axis I, 802–803, 803*f*
axis II, 803, 803*f*
body distribution of, 802, 803*f*
botulinum toxins for, 813, 815–817, 852*f*, 853*t*, 867, 899
in cerebral palsy, 801, 804
cerebral palsy and, 1426, 1427
classification of subtypes, 802–803, 803*f*
clinical evaluation of, 811–812
clinical manifestations of, 802–803
cocaine and, 1317
combined syndromes, 810, 811*t*
in corticobasal degeneration, 896, 897
counseling in, 814
defining features of, 800
definition of, 106, 800
developmental or degenerative processes in, 806
diagnosis of, 811–813
differential diagnosis of, 800–802, 802*t*
diurnally fluctuating, 871
dopa-responsive, 803, 804, 811*t*, 812, 813–814, 871
emergencies in, 108, 109*t*
epidemiology of, 803–804
essential tremor *versus*, 781, 782*t*
etiologies of, 803, 803*f*, 804*t*, 806–811
focal, 802
focused examination of, 104
focused history on, 103–104, 103*t*
functional or psychogenic, 802*t*, 810, 810*t*
generalized, 802
genetics of, 298–299, 805, 810–811, 811*t*
genetic testing in, 812–813
in Huntington disease, 864–865, 865*t*, 867
idiopathic, 806–809
imaging in, 812
inherited, 803, 803*f*, 810–811, 811*t*
inherited, treatable, 815, 816*t*
isolated, 803
laboratory investigations in, 812
level 1 evidence on, 813–814
levodopa-induced, 804
management of, 813–814, 813*f*
multifocal, 802, 809
in multiple system atrophy, 896
muscle activity in, 805
myoclonic, 801, 802*t*
network physiology in, 806
neuroleptic-induced, 849, 849*t*
in neuroleptic malignant syndrome, 1329
neuronal physiology in, 805–806
neuropathology of, 803, 803*f*
oral medications for, 814–815, 814*t*
outcomes of, 818–819
in Parkinson disease, 803–804, 878, 879*t*, 881
pathobiology of, 804–806
peripheral, 809
physical and occupational therapy for, 818
physiologic underpinnings of, 805–806, 806*f*
pregnancy and, 1294–1295
in progressive supranuclear palsy, 893–894
segmental, 802, 809
spasmodic (laryngeal), 106, 802, 808–809, 815
spastic, 801, 802*t*
surgical treatments for, 817–818
syndromes with, 803–804
tardive, 802*t*, 804, 809, 849–852, 849*t*, 852*f*, 853*t*, 1590
task-specific, 106, 800, 802*t*, 808, 808*f*, 809, 809*t*
temporal features of, 802–803, 803*f*
terminology in, 801–802, 802*t*
treatment in special populations, 815
two-hit hypothesis of, 804
xenobiotic-induced, 1320, 1321*t*
Dystonic reaction, acute, 109*t*, 849–841, 849*t*, 850, 1590
Dystonic seizures, 801, 802*t*
Dystonic storm, 108, 109*t*
Dystonic tics, 106, 801, 802*t*
Dystonic tremor, 105, 802*t*
Dystroglycanopathies, 1375, 1419, 1477, 1478–1479
Dystrophin (*DMD*) gene, 1481, 1482
Dystrophinopathies, 1474, 1479–1482. *See also* Becker muscular dystrophy; Duchenne muscular dystrophy

E
Ear(s)
hearing function of. *See* Hearing loss
pain (otalgia), 540–541, 545–546
sensory innervation of, 540–541, 541*f*
Ear infection. *See* Otitis externa; Otitis media
Early infantile epileptic encephalopathy (EIEE), 1360
Early myoclonic encephalopathy (EME), 1360, 1504
Early recruitment, motor unit, 248
Early Start Denver Model, 1439
Eastern equine encephalitis (EEE), 665, 670–671, 670*f*, 671*f*
EBV. *See* Epstein-Barr virus
Echinococcus, 654*t*
Echinococcus granulosus, 162*t*
Echocardiography (ECG), transesophageal, in marantic endocarditis, 398
Echolalia, 106
Echoviruses, 665
E-cigarettes (vaping), 402
Eclampsia, 384–387, 1289–1290, 1289*f*
ECMO. *See* Extracorporeal membrane oxygenation
ECoG. *See* Cortical electrodes, EEG with
Ecopipam, for tic disorders, 789
Ecstasy (MDMA), 1314, 1316–1317
ECT. *See* Electroconvulsive therapy
Ectopic discharges, 558
Eculizumab
for myasthenia gravis, 971–972
for neuromyelitis optica spectrum disorders, 731, 752, 752*t*
Edaravone, for ALS, 912
Edema. *See* Brain edema; Pulmonary edema
Edoxaban, reversal of, 139*t*, 336, 1242
Edrophonium, in myasthenia gravis testing, 966–967
EEE. *See* Eastern equine encephalitis
EEG. *See* Electroencephalography
Efavirenz, 706, 707*t*
Efferent visual pathway, 77, 78*f*
common patterns of dysfunction, 85–87
Efgartigimod, for myasthenia gravis, 972
Eflornithine, for African trypanosomiasis, 655
EGF. *See* Epidermal growth factor receptor
EGFR. *See* Epidermal growth factor receptor (EGFR) inhibitors
EGPA. *See* Eosinophilic granulomatosis with polyangiitis
Ehlers-Danlos syndrome, 1173
Ehrlichia chaffeensis, 627, 628*f*
Ehrlichia ewingii, 627
Ehrlichiosis, 624, 624*t*, 627–628
EIMFS. *See* Epilepsy of infancy with migrating focal seizures
EIR. *See* Excitatory-to-inhibitory ratio (EIR) model
Elderly
cognitive impairment and memory loss in, 95–96
delirium in, 89
dementia in, 96, 97*t*. *See also* Dementia
depression *versus* neurologic disorders in, 1601
epilepsy treatment in, 582
falls in, 125–126
primary CNS lymphoma in, 1059–1060
Electrical injuries, 1347–1349
Electrical neuromyotonia, 1007–1008
Electrical status epilepticus during slow sleep (ESES), 1510
Electroconvulsive therapy (ECT)
for depression, 1602–1603
for depression in dementia, 498
for depression in Parkinson disease, 1603
Electroencephalography (EEG), 230–238
abnormal, 231–236
age and, 231
alpha rhythm in, 230, 231*f*
arousal state and, 230–231, 231*f*
in autism spectrum disorders, 1437–1438
in autoimmune encephalitis and meningitis, 762–763, 762*f*
beta activity in, 230–231, 232*f*
in brain death, 181*t*
in catatonia, 175
in chorea, 859
in coma, 168, 169, 172
continuous, 294–295
in cerebral ischemia monitoring after SAH, 295
in coma prognosis, 295
indications for, 294, 294*t*
limitations of, 295
seizure detection in, 294–295, 295*t*
in titration of status epilepticus therapy, 295
in Creutzfeldt-Jakob disease, 236, 510, 512*f*
in critical care monitoring, 238
in delirium, 91
delta activity in, 231
in dementia, 100–101
in diffuse brain dysfunction or injury, 233–236, 235*f*, 236*f*
in encephalotrigeminal angiomatosis, 1464
in epilepsy, 231–232, 233*t*, 567, 568–569, 579–580
focal, 572–574, 573*f*
generalized, 572, 572*f*
in epilepsy monitoring, 236–238, 237*f*, 581
in epilepsy surgery evaluation, 590–591, 591*f*, 592*f*
in epileptic encephalopathy, 1504–1506, 1505*f*
in focal brain lesion or dysfunction, 232–233, 234*f*, 235*f*
in hypoxic-ischemic encephalopathy, 327
in hysteria, 175
International 10-20 system for, 230, 230*f*
in intraoperative monitoring, 238
in Lennox-Gastaut syndrome, 1509
in limbic encephalitis, 759
long-term monitoring with, 236–238
in mild cognitive impairment, 472
in minimally conscious state, 177
in myoclonus, 825, 826
normal, 230–231, 231*f*, 232*f*, 233*f*
in seizure, 59
in seizure, neonatal, 1360, 1361
in sepsis-associated encephalopathy, 1201, 1202, 1204, 1205
in sleep, 231, 233*f*, 1183–1184, 1184*f*, 1185
in sleep studies (PSG), 264–265
in status epilepticus monitoring, 62–63
in subacute sclerosing panencephalitis, 676
in tuberous sclerosis complex, 1461
in vegetative state, 177
Electrolyte disturbance, in subarachnoid hemorrhage, 347
Electromyography (EMG), 69, 246–249
applications of, 249–250
in ataxia, 837
basic concepts of, 246
in chorea, 859
in congenital myopathies, 1477
in cramps, 1009
in dementia, 101
in dermatomyositis, 981
in dystonia, 805
fibrillations in, 246, 247*f*
in HIV-associated myelopathy, 694
in inclusion body myositis, 984
insertional activity in, 246–247
interference pattern in, 246, 248–249, 249*f*
in intervertebral disk disease, 1150
in involuntary movement diagnosis, 108
in motor neuron disease/ALS, 911
motor unit configuration in, 246, 247–248, 248*f*
motor unit recruitment in, 246, 248–249
in muscle weakness, 121
in muscular dystrophies, 1477
in myasthenia gravis, 968, 968*t*
in myoclonus, 824*f*, 825–826, 825*t*
in myotonic dystrophy, 1485
needle, 246–249
in nerve injury, 463–464
in neuromyotonia, 1007–1008
in neuropathic pain, 560
positive sharp waves in, 246, 247*f*
single-fiber, 251–252, 251*f*
in sleep studies, 264, 1183, 1184*f*
in spinal stenosis, 1156
spontaneous activity in, 246–247, 247*f*
in stiff person syndrome, 1006, 1006*f*
in tetany, 1008
in thoracic outlet syndrome, 930
Electroneuromyography, 1104
Electronystagmography (ENG), 262
Electrooculography (EOG), 264
Electroretinogram, 83, 260
El Escorial criteria, for ALS, 909, 909*t*
Eletriptan, for migraine, 525, 526*t*
Elsberg syndrome, 738, 742*t*
EMA. *See* Epilepsy with myoclonic absences
Embolic stroke of unknown source, 304
Embolism. *See also specific disorders*
atherosclerotic, and stroke, 303–304
cardiac, and stroke, 303*f*, 304, 403, 407–408, 407*t*
TIA caused by, 320
Embryonal cell carcinoma, pineal, 1072–1073, 1073*t*
Embryonal tumors, 153, 159*f*, 1554–1558. *See also specific types*
classification of, 1533–1535, 1535*f*, 1536*t*, 1539–1540, 1540*f*, 1540*t*
nonmedulloblastoma, 1554, 1557
recurrent, 1557
with rhabdoid features, 1557
Emery-Dreifuss muscular dystrophy (EDMD), 1474, 1476*t*, 1482–1483, 1482*f*

EMG. *See* Electromyography
Emotional status tests, 275
Empty delta sign, 357, 1362, 1363*f*
Empty sella syndrome, 1068, 1068*f*, 1136, 1219
Empyema, subdural, 618–619, 619*f*
Emtricitabine, 707*t*
Enalaprilat, for ICH (neurologic emergencies), 337*t*
Encephalitis. *See also specific types and disorders causing*
  adenovirus, 678, 678*f*
  autoimmune, 755–772
    acute therapy for, 767, 768*t*–770*t*
    antibody testing in, 763–764, 763*t*, 764*t*, 765*f*
    biomarkers in, 755, 763–764, 763*t*, 764*t*, 765*f*
    cancer workup in, 764–765, 766*t*–767*t*
    chronic (maintenance) therapy for, 767–770, 768*t*–770*t*
    classical syndromes, 759
    clinically restricted forms, 759
    clinical manifestations of, 757–760
    diagnosis of, 757–765
    diagnostic clues to, 759*t*
    EEG findings in, 762–763, 762*f*
    epidemiology of, 755–756
    general features of, 757–759
    imaging in, 760–762, 761*f*
    immunobiology of, 756–757, 756*f*
    immunopathology of, 757, 758*f*
    management of, 765–770
    movement disorders with, 757
    nonlimbic (serologically defined), 760
    outcome of, 771
    paraneoplastic, 757, 764–765, 765*t*–767*t*, 767, 1101, 1101*t*, 1104*f*
    pathobiology of, 756–757
    postinfectious, 757
    predictive scores in, 770–771, 771*t*
    therapeutic drug monitoring in, 770
  COVID-19 and, 757
  EEG findings in, 233–236
  herpes simplex, 153–154, 161*t*, 164*f*, 679–680
  HIV-associated, 700*t*
  immunobiology of, 756–757, 756*f*
  measles, 671–672, 675–676
  parkinsonism after, 875, 902
  rubella, 671–672
  toxoplasmosis, 153, 162*t*, 163*f*, 167, 167*t*
  viral, 153–154, 161*t*, 164*f*, 661–689, 667*t*
Encephalitis lethargica, 875, 902
Encephaloceles, 1367
Encephalomyopathic mitochondrial DNA depletion syndromes, 1449–1450
Encephalomyopathies, mitochondrial, 1441–1454
  biochemical findings in, 1452
  diagnosis of, 1445–1451
  diagnostic workup in, 1451
  epidemiology of, 1441–1442
  exercise physiology in, 1451
  historical perspective on, 1441
  management of, 1452–1453
  mendelian inheritance in, 1447–1449
  mtDNA-related, 1446–1447
  neuropathology of, 1452
  neuroradiology in, 1447*f*, 1451
  pathobiology of, 1442–1446
  pathology of, 1451–1452, 1451*f*
Encephalopathy. *See also specific types*
  chemotherapy-induced, 1108, 1108*t*
  chronic traumatic, 416–418
  EEG findings in, 233–236, 235*f*, 236*f*
  epileptic, 1503–1504
  hepatic, 1245–1248
  HIV-associated, 700*t*
  hypoxic-ischemic, 324–331
  lead, 1332
  pulmonary, and intracranial hypertension, 1135
  radiation therapy and, 1107
  sepsis-associated, 1201–1206
  transplantation-related, 1299
  uremic, 1253
Encephalotrigeminal angiomatosis, 1462–1464
  cutaneous manifestations of, 1463, 1463*f*
  diagnosis of, 1464
  epidemiology of, 1462
  genetics of, 1463
  laboratory data in, 1463–1464
  management of, 1464
  neuroimaging in, 1463–1464, 1463*f*
  neuropathology of, 1463
  ophthalmologic manifestations of, 1463
  signs and symptoms of, 1463–1464
Endocarditis
  Libman-Sacks, 397–398
  marantic (nonbacterial thrombotic), 397–398, 400
  meningitis complicating, 604, 605*t*
Endocrine disease, 1215–1226. *See also* Diabetes mellitus; *specific types*
  dementia in, 98
  epidemiology of, 1215*t*
  intracranial hypertension in, 1135
  myopathies with, 992–993, 993*t*, 994*t*
  myotonic dystrophy with, 1485–1486
  pediatric brain tumors and, 1561
  radiation-induced, 1107, 1336, 1338*t*, 1342, 1343
Endodermal sinus tumor, 1072–1073, 1073*t*
End-of-life care, 1636–1643
  death, dying, and hospice care in, 1640
  disease trajectories and, 1636–1637
  double effect in, 1640
  ineffective, inappropriate, and futile therapies in, 1639–1640
  issues after death, 1641*t*, 1642
  life-sustaining therapies in, 1639
  refusal of therapy in, 1641
  sedation in, 1640, 1641*t*
  withholding and withdrawing in, 1640, 1641*t*
Endolymphatic shunt, for Ménière disease, 599
Endoscopic third ventriculostomy (ETV), 1117, 1118–1119
Endotracheal intubation, 1210–1213
  criteria for, 1209–1210, 1210*t*
  extubation from, 1213, 1213*t*
  pneumonia associated with, 1211–1212
  rapid sequence, 1210–1211
  special concerns for neurologic patients, 1211*t*
Endovascular neurosurgery. *See* Neuroendovascular surgery (NES)
Endovascular therapy
  anesthesia for, 143
  for arteriovenous malformations, 225–226, 364
  for cerebral venous thrombosis, 358–359
  complications of, 314
  for dural arteriovenous fistulas, 365–366
  for stroke (AIS), 132, 142–143, 142*f*, 224, 224*f*, 312–314
  for subarachnoid hemorrhage, 223, 342, 348, 348*f*
Endplate noise, in EMG, 246
Endplate spikes, in EMG, 246
End-to-end neurorrhaphy, 466*t*, 467
Enfuvirtide, 707*t*
ENG. *See* Electronystagmography
Enhanced windup, in central sensitization, 559
Enoxaparin
  reversal of, 139*t*
  for TBI patients, 434
Entacapone, for Parkinson disease, 885–886
Entamoeba histolytica, 153, 162*t*, 613, 654*t*
Enterovirus(es), 662–665, 1163
Enterovirus 70 and 71, 664–665
Enterovirus D68, 664
Entry inhibitors, for HIV, 707*t*
Envelope amplitude, of MUPs, 248
Environmental assessment, for falls, 126*t*
Environmental optimization, for delirium, 91, 93
Enzyme deficiencies, 1385, 1386–1387, 1386*t*. *See also specific deficiencies*
EOG. *See* Electrooculography
Eosinophilic granulomatosis with polyangiitis (EGPA), 371*t*, 376, 377–378
  clinical manifestations of, 377
  diagnosis of, 378
  epidemiology of, 377
  management of, 378
  multiple sclerosis *versus*, 722
  neuropathy in, 942
  outcome of, 378
  pathobiology of, 377
Eosinophilic meningitis, 658, 658*t*
EPC. *See* Epilepsia partialis continua
Ependymal cells, 1538
Ependymoma, 153, 154, 158*t*
  infratentorial, 1538
  intramedullary spinal, 1093–1094, 1095*f*, 1097
  molecular features of, 1020*t*
  MRI of, 198–199, 1558, 1558*f*
  neurofibromatosis and, 1457
  pathobiology of, 1538, 1539*f*
  pediatric, 1538, 1539*f*, 1558–1559, 1559*f*
  pineal, 1072
  posterior fossa, 1538, 1539*f*
  spinal, 1539*f*
  supratentorial, 1538, 1539*f*
  survival rates for, 1532*t*
  tuberous sclerosis and, 1530–1531
Ephaptic transmission, 558
Ephedrine, for congenital myasthenic syndromes, 975
Epicrania fugax, 534
Epidemic typhus, 624, 625*t*, 629
Epidemiologic transition, 3–4
Epidemiology, 1–8. *See also specific disorders*
  changes over time, 3
  disease burden estimation, 1–2
  disparities of, 4–6, 4*f*, 5*f*, 6*f*
  sociocultural differences affecting, 7
  staging in, 3–4

E
Ear(s)
hearing function of. *See* Hearing loss
pain (otalgia), 540–541, 545–546
sensory innervation of, 540–541, 541*f*
Ear infection. *See* Otitis externa; Otitis media
Early infantile epileptic encephalopathy (EIEE), 1360
Early myoclonic encephalopathy (EME), 1360, 1504
Early recruitment, motor unit, 248
Early Start Denver Model, 1439
Eastern equine encephalitis (EEE), 665, 670–671, 670*f*, 671*f*
EBV. *See* Epstein-Barr virus
Echinococcus, 654*t*
Echinococcus granulosus, 162*t*
Echocardiography (ECG), transesophageal, in marantic endocarditis, 398
Echolalia, 106
Echoviruses, 665
E-cigarettes (vaping), 402
Eclampsia, 384–387, 1289–1290, 1289*f*
ECMO. *See* Extracorporeal membrane oxygenation
ECoG. *See* Cortical electrodes, EEG with
Ecopipam, for tic disorders, 789
Ecstasy (MDMA), 1314, 1316–1317
ECT. *See* Electroconvulsive therapy
Ectopic discharges, 558
Eculizumab
for myasthenia gravis, 971–972
for neuromyelitis optica spectrum disorders, 731, 752, 752*t*
Edaravone, for ALS, 912
Edema. *See* Brain edema; Pulmonary edema
Edoxaban, reversal of, 139*t*, 336, 1242
Edrophonium, in myasthenia gravis testing, 966–967
EEE. *See* Eastern equine encephalitis
EEG. *See* Electroencephalography
Efavirenz, 706, 707*t*
Efferent visual pathway, 77, 78*f*
common patterns of dysfunction, 85–87
Efgartigimod, for myasthenia gravis, 972
Eflornithine, for African trypanosomiasis, 655
EGF. *See* Epidermal growth factor receptor
EGFR. *See* Epidermal growth factor receptor (EGFR) inhibitors
EGPA. *See* Eosinophilic granulomatosis with polyangiitis
Ehlers-Danlos syndrome, 1173
Ehrlichia chaffeensis, 627, 628*f*
Ehrlichia ewingii, 627
Ehrlichiosis, 624, 624*t*, 627–628
EIMFS. *See* Epilepsy of infancy with migrating focal seizures
EIR. *See* Excitatory-to-inhibitory ratio (EIR) model
Elderly
cognitive impairment and memory loss in, 95–96
delirium in, 89
dementia in, 96, 97*t*. *See also* Dementia
depression *versus* neurologic disorders in, 1601
epilepsy treatment in, 582
falls in, 125–126
primary CNS lymphoma in, 1059–1060
Electrical injuries, 1347–1349
Electrical neuromyotonia, 1007–1008
Electrical status epilepticus during slow sleep (ESES), 1510
Electroconvulsive therapy (ECT)
for depression, 1602–1603
for depression in dementia, 498
for depression in Parkinson disease, 1603
Electroencephalography (EEG), 230–238
abnormal, 231–236
age and, 231
alpha rhythm in, 230, 231*f*
arousal state and, 230–231, 231*f*
in autism spectrum disorders, 1437–1438
in autoimmune encephalitis and meningitis, 762–763, 762*f*
beta activity in, 230–231, 232*f*
in brain death, 181*t*
in catatonia, 175
in chorea, 859
in coma, 168, 169, 172
continuous, 294–295
in cerebral ischemia monitoring after SAH, 295
in coma prognosis, 295
indications for, 294, 294*t*
limitations of, 295
seizure detection in, 294–295, 295*t*
in titration of status epilepticus therapy, 295
in Creutzfeldt-Jakob disease, 236, 510, 512*f*
in critical care monitoring, 238
in delirium, 91
delta activity in, 231
in dementia, 100–101
in diffuse brain dysfunction or injury, 233–236, 235*f*, 236*f*
in encephalotrigeminal angiomatosis, 1464
in epilepsy, 231–232, 233*t*, 567, 568–569, 579–580
focal, 572–574, 573*f*
generalized, 572, 572*f*
in epilepsy monitoring, 236–238, 237*f*, 581
in epilepsy surgery evaluation, 590–591, 591*f*, 592*f*
in epileptic encephalopathy, 1504–1506, 1505*f*
in focal brain lesion or dysfunction, 232–233, 234*f*, 235*f*
in hypoxic-ischemic encephalopathy, 327
in hysteria, 175
International 10-20 system for, 230, 230*f*
in intraoperative monitoring, 238
in Lennox-Gastaut syndrome, 1509
in limbic encephalitis, 759
long-term monitoring with, 236–238
in mild cognitive impairment, 472
in minimally conscious state, 177
in myoclonus, 825, 826
normal, 230–231, 231*f*, 232*f*, 233*f*
in seizure, 59
in seizure, neonatal, 1360, 1361
in sepsis-associated encephalopathy, 1201, 1202, 1204, 1205
in sleep, 231, 233*f*, 1183–1184, 1184*f*, 1185
in sleep studies (PSG), 264–265
in status epilepticus monitoring, 62–63
in subacute sclerosing panencephalitis, 676
in tuberous sclerosis complex, 1461
in vegetative state, 177
Electrolyte disturbance, in subarachnoid hemorrhage, 347
Electromyography (EMG), 69, 246–249
applications of, 249–250
in ataxia, 837
basic concepts of, 246
in chorea, 859
in congenital myopathies, 1477
in cramps, 1009
in dementia, 101
in dermatomyositis, 981
in dystonia, 805
fibrillations in, 246, 247*f*
in HIV-associated myelopathy, 694
in inclusion body myositis, 984
insertional activity in, 246–247
interference pattern in, 246, 248–249, 249*f*
in intervertebral disk disease, 1150
in involuntary movement diagnosis, 108
in motor neuron disease/ALS, 911
motor unit configuration in, 246, 247–248, 248*f*
motor unit recruitment in, 246, 248–249
in muscle weakness, 121
in muscular dystrophies, 1477
in myasthenia gravis, 968, 968*t*
in myoclonus, 824*f*, 825–826, 825*t*
in myotonic dystrophy, 1485
needle, 246–249
in nerve injury, 463–464
in neuromyotonia, 1007–1008
in neuropathic pain, 560
positive sharp waves in, 246, 247*f*
single-fiber, 251–252, 251*f*
in sleep studies, 264, 1183, 1184*f*
in spinal stenosis, 1156
spontaneous activity in, 246–247, 247*f*
in stiff person syndrome, 1006, 1006*f*
in tetany, 1008
in thoracic outlet syndrome, 930
Electroneuromyography, 1104
Electronystagmography (ENG), 262
Electrooculography (EOG), 264
Electroretinogram, 83, 260
El Escorial criteria, for ALS, 909, 909*t*
Eletriptan, for migraine, 525, 526*t*
Elsberg syndrome, 738, 742*t*
EMA. *See* Epilepsy with myoclonic absences
Embolic stroke of unknown source, 304
Embolism. *See also specific disorders*
atherosclerotic, and stroke, 303–304
cardiac, and stroke, 303*f*, 304, 403, 407–408, 407*t*
TIA caused by, 320
Embryonal cell carcinoma, pineal, 1072–1073, 1073*t*
Embryonal tumors, 153, 159*f*, 1554–1558. *See also specific types*
classification of, 1533–1535, 1535*f*, 1536*t*, 1539–1540, 1540*f*, 1540*t*
nonmedulloblastoma, 1554, 1557
recurrent, 1557
with rhabdoid features, 1557
Emery-Dreifuss muscular dystrophy (EDMD), 1474, 1476*t*, 1482–1483, 1482*f*

EMG. *See* Electromyography
Emotional status tests, 275
Empty delta sign, 357, 1362, 1363*f*
Empty sella syndrome, 1068, 1068*f*, 1136, 1219
Empyema, subdural, 618–619, 619*f*
Emtricitabine, 707*t*
Enalaprilat, for ICH (neurologic emergencies), 337*t*
Encephalitis. *See also specific types and disorders causing*
  adenovirus, 678, 678*f*
  autoimmune, 755–772
    acute therapy for, 767, 768*t*–770*t*
    antibody testing in, 763–764, 763*t*, 764*t*, 765*f*
    biomarkers in, 755, 763–764, 763*t*, 764*t*, 765*f*
    cancer workup in, 764–765, 766*t*–767*t*
    chronic (maintenance) therapy for, 767–770, 768*t*–770*t*
    classical syndromes, 759
    clinically restricted forms, 759
    clinical manifestations of, 757–760
    diagnosis of, 757–765
    diagnostic clues to, 759*t*
    EEG findings in, 762–763, 762*f*
    epidemiology of, 755–756
    general features of, 757–759
    imaging in, 760–762, 761*f*
    immunobiology of, 756–757, 756*f*
    immunopathology of, 757, 758*f*
    management of, 765–770
    movement disorders with, 757
    nonlimbic (serologically defined), 760
    outcome of, 771
    paraneoplastic, 757, 764–765, 766*t*–767*t*, 767, 1101, 1101*t*, 1104*f*
    pathobiology of, 756–757
    postinfectious, 757
    predictive scores in, 770–771, 771*t*
    therapeutic drug monitoring in, 770
  COVID-19 and, 757
  EEG findings in, 233–236
  herpes simplex, 153–154, 161*t*, 164*f*, 679–680
  HIV-associated, 700*t*
  immunobiology of, 756–757, 756*f*
  measles, 671–672, 675–676
  parkinsonism after, 875, 902
  rubella, 671–672
  toxoplasmosis, 153, 162*t*, 163*f*, 167, 167*t*
  viral, 153–154, 161*t*, 164*f*, 661–689, 667*t*
Encephalitis lethargica, 875, 902
Encephaloceles, 1367
Encephalomyopathic mitochondrial DNA depletion syndromes, 1449–1450
Encephalomyopathies, mitochondrial, 1441–1454
  biochemical findings in, 1452
  diagnosis of, 1445–1451
  diagnostic workup in, 1451
  epidemiology of, 1441–1442
  exercise physiology in, 1451
  historical perspective on, 1441
  management of, 1452–1453
  mendelian inheritance in, 1447–1449
  mtDNA-related, 1446–1447
  neuropathology of, 1452
  neuroradiology in, 1447*f*, 1451
  pathobiology of, 1442–1446
  pathology of, 1451–1452, 1451*f*
Encephalopathy. *See also specific types*
  chemotherapy-induced, 1108, 1108*t*
  chronic traumatic, 416–418
  EEG findings in, 233–236, 235*f*, 236*f*
  epileptic, 1503–1504
  hepatic, 1245–1248
  HIV-associated, 700*t*
  hypoxic-ischemic, 324–331
  lead, 1332
  pulmonary, and intracranial hypertension, 1135
  radiation therapy and, 1107
  sepsis-associated, 1201–1206
  transplantation-related, 1299
  uremic, 1253
Encephalotrigeminal angiomatosis, 1462–1464
  cutaneous manifestations of, 1463, 1463*f*
  diagnosis of, 1464
  epidemiology of, 1462
  genetics of, 1463
  laboratory data in, 1463–1464
  management of, 1464
  neuroimaging in, 1463–1464, 1463*f*
  neuropathology of, 1463
  ophthalmologic manifestations of, 1463
  signs and symptoms of, 1463–1464
Endocarditis
  Libman-Sacks, 397–398
  marantic (nonbacterial thrombotic), 397–398, 400
  meningitis complicating, 604, 605*t*
Endocrine disease, 1215–1226. *See also* Diabetes mellitus; *specific types*
  dementia in, 98
  epidemiology of, 1215*t*
  intracranial hypertension in, 1135
  myopathies with, 992–993, 993*t*, 994*t*
  myotonic dystrophy with, 1485–1486
  pediatric brain tumors and, 1561
  radiation-induced, 1107, 1336, 1338*t*, 1342, 1343
Endodermal sinus tumor, 1072–1073, 1073*t*
End-of-life care, 1636–1643
  death, dying, and hospice care in, 1640
  disease trajectories and, 1636–1637
  double effect in, 1640
  ineffective, inappropriate, and futile therapies in, 1639–1640
  issues after death, 1641*t*, 1642
  life-sustaining therapies in, 1639
  refusal of therapy in, 1641
  sedation in, 1640, 1641*t*
  withholding and withdrawing in, 1640, 1641*t*
Endolymphatic shunt, for Ménière disease, 599
Endoscopic third ventriculostomy (ETV), 1117, 1118–1119
Endotracheal intubation, 1210–1213
  criteria for, 1209–1210, 1210*t*
  extubation from, 1213, 1213*t*
  pneumonia associated with, 1211–1212
  rapid sequence, 1210–1211
  special concerns for neurologic patients, 1211*t*
Endovascular neurosurgery. *See* Neuroendovascular surgery (NES)
Endovascular therapy
  anesthesia for, 143
  for arteriovenous malformations, 225–226, 364
  for cerebral venous thrombosis, 358–359
  complications of, 314
  for dural arteriovenous fistulas, 365–366
  for stroke (AIS), 132, 142–143, 142*f*, 224, 224*f*, 312–314
  for subarachnoid hemorrhage, 223, 342, 348, 348*f*
Endplate noise, in EMG, 246
Endplate spikes, in EMG, 246
End-to-end neurorrhaphy, 466*t*, 467
Enfuvirtide, 707*t*
ENG. *See* Electronystagmography
Enhanced windup, in central sensitization, 559
Enoxaparin
  reversal of, 139*t*
  for TBI patients, 434
Entacapone, for Parkinson disease, 885–886
Entamoeba histolytica, 153, 162*t*, 613, 654*t*
Enterovirus(es), 662–665, 1163
Enterovirus 70 and 71, 664–665
Enterovirus D68, 664
Entry inhibitors, for HIV, 707*t*
Envelope amplitude, of MUPs, 248
Environmental assessment, for falls, 126*t*
Environmental optimization, for delirium, 91, 93
Enzyme deficiencies, 1385, 1386–1387, 1386*t*. *See also specific deficiencies*
EOG. *See* Electrooculography
Eosinophilic granulomatosis with polyangiitis (EGPA), 371*t*, 376, 377–378
  clinical manifestations of, 377
  diagnosis of, 378
  epidemiology of, 377
  management of, 378
  multiple sclerosis *versus*, 722
  neuropathy in, 942
  outcome of, 378
  pathobiology of, 377
Eosinophilic meningitis, 658, 658*t*
EPC. *See* Epilepsia partialis continua
Ependymal cells, 1538
Ependymoma, 153, 154, 158*t*
  infratentorial, 1538
  intramedullary spinal, 1093–1094, 1095*f*, 1097
  molecular features of, 1020*t*
  MRI of, 198–199, 1558, 1558*f*
  neurofibromatosis and, 1457
  pathobiology of, 1538, 1539*f*
  pediatric, 1538, 1539*f*, 1558–1559, 1559*f*
  pineal, 1072
  posterior fossa, 1538, 1539*f*
  spinal, 1539*f*
  supratentorial, 1538, 1539*f*
  survival rates for, 1532*t*
  tuberous sclerosis and, 1530–1531
Ephaptic transmission, 558
Ephedrine, for congenital myasthenic syndromes, 975
Epicrania fugax, 534
Epidemic typhus, 624, 625*t*, 629
Epidemiologic transition, 3–4
Epidemiology, 1–8. *See also specific disorders*
  changes over time, 3
  disease burden estimation, 1–2
  disparities of, 4–6, 4*f*, 5*f*, 6*f*
  sociocultural differences affecting, 7
  staging in, 3–4

Epidermal growth factor receptor (EGF), in pediatric astrocytoma, 1535–1536
Epidermal growth factor receptor (EGFR) inhibitors
for meningiomas, 1054, 1054*t*
for metastatic lung cancer, 1042, 1043*f*
Epidermoid cysts
pediatric, 1546–1547, 1547*f*
of skull, 1085, 1086*f*
Epidural abscess, 619–620, 620*f*
Epidural blood patch (EBP), 1141, 1143*f*
Epidural hematoma, 426
cerebral infarction with, 435
CT of, 426, 426*f*
surgical management of, 430
Epidural lipomatosis, 1096
Epidural spinal metastases, 1044–1045, 1091–1093
clinical manifestations of, 1044, 1092
diagnosis of, 1044
epidemiology of, 1044, 1091
management of, 1044–1045, 1097–1098
MRI of, 1044, 1044*f*, 1092–1093, 1092*f*
Epidural spinal tumors, 1089, 1090*f*, 1091–1093, 1098
Epilepsia partialis continua (EPC), 576, 826, 1511
Epilepsy, 567–596
age on onset, 1502, 1502*f*
age-specific incidence of, 567, 568*f*
anxiety in, 593, 1610, 1612
autism spectrum disorders and, 1437–1438
autoimmune, 759
in breastfeeding patients, 1288–1289
classification of, 570–576, 572*f*
combined generalized and focal, 571
cortical migration disorders and, 1378
CT in, 580
definition of, 567
drug-resistant, 569, 591–593
EEG findings in, 231–232, 233*t*, 567, 568–569, 572–574, 572*f*, 573*f*, 579–580
EEG monitoring in, 236–238, 237*f*, 581
encephalotrigeminal angiomatosis and, 1463, 1464
epidemiology of, 567–569
focal, 571, 572–574, 572*f*, 573*f*
generalized, 571–572, 572*f*
genetics of, 568, 569
global action on, 12, 12*b*
heterotopias and, 580, 580*f*, 1376–1377
history and examination in, 579
HIV-associated, 698
initial diagnostic evaluation of, 579
intractable, predictors of, 569, 569*t*
ketogenic diet for, 569
laboratory testing in, 580–581
level 1 evidence on, 575
magnetoencephalography in, 240–241
management of, 578–596
medical treatment of, 581–589
adverse effects of AEDs in, 583, 583*t*
bone health in, 589
combination therapy, 585
compliance with, 593, 594
discontinuation of AEDs in, 587–588
dosing and pharmacokinetic data of, 584, 584*t*
generic equivalents in, 587
goals of, 581
idiosyncratic reactions to AEDs in, 583–584, 584*t*
pharmacology of AEDs in, 584–585
reproductive health issues in, 588–589, 1287–1289
selection of AEDs for, 581–583, 582*t*
therapeutic drug monitoring in, 585
mood disorders in, 593, 1601, 1603
mortality in, 569
MRI in, 572–573, 573*f*, 580, 580*f*
myoclonus, with ragged red fibers, 845–846, 1446, 1446*t*, 1451–1452, 1451*f*
neonatal seizures and development of, 1361, 1517–1518
neonatal stroke/SVT and, 1362
neuropsychological testing in, 276
neurostimulation for, 591–593
newly diagnosed
etiology of, 568, 569*f*
seizure types in, 568, 568*f*
osteoporosis and fracture in, 1274–1275
paraneoplastic, 1101, 1101*t*, 1105
positron emission tomography in, 205, 580
posttraumatic, 437, 576
in pregnancy, 588–589, 1287–1289
AED cognitive effects on exposed infants, 1288
AED teratogenicity in, 589, 1287–1288, 1287*t*
epidemiology of, 1287
management strategy for, 1288
seizure control and monitoring in, 1287
psychosis with, 1593
psychosocial and psychiatric issues in, 593–595
reflex, 567
risk factors for, 579, 579*f*
seizure threshold in, factors lowering, 593, 593*t*
single/first seizure in
management of, 578–579
outcome after, 568–569, 569*t*
SPECT in, 580
stigma related to, 10, 10*b*
sudden unexpected death in, 594
surgical treatment of, 589–593
corpus callosotomy for, 589*t*, 590
hemispherectomy for, 589*t*, 590
lesionectomy for, 589*t*, 590
nonlesional cortical resections for, 589*t*, 590
outcome after, 589, 589*t*
preoperative evaluation in, 590–591, 591*f*, 592*f*
resective procedures in, 589–590, 589*t*
transient visual symptoms in, 83
unknown, 571, 572*f*
Epilepsy, pediatric, 1502–1514
benign neonatal and infant, 1504
brain malformations and, 1512–1513
brain tumors and, 1540–1541
childhood intracranial hemorrhage and, 1524
childhood stroke and, 1524
idiopathic focal, 1510
idiopathic generalized, 1510–1511
inborn errors of metabolism and, 1511–1512
neonatal and infantile encephalopathies, 1504–1509
neonatal seizures and development of, 1361
neonatal stroke/SVT and, 1362
toddler-onset, 1509–1510
Epilepsy of infancy with migrating focal seizures (EIMFS), 1506–1509
Epilepsy syndromes, 574–576. *See also specific syndromes*
focal, 574–575
idiopathic generalized, 574
neonatal and infantile, 1504–1506
self-limited focal of childhood, 575
Epilepsy with generalized tonic-clonic seizures alone, 1511
Epilepsy with myoclonic absences (EMA), 1511
Epileptic cry, 570
Epileptic encephalopathies, 1503–1509
definition of, 1503–1504
neonatal and infantile, 1504–1509
EEG findings in, 1504–1506, 1505*f*
genetic developmental, 1506–1509, 1507*t*–1508*t*
syndromes, 1504–1506
Epileptic myoclonus, 825, 825*t*, 826, 826*t*
Epileptic prodrome, 570
Epileptic spasms, 571, 1461, 1462
Epileptiform discharges (EDs), 231–232, 579–580
periodic lateralized, 231–232, 235*f*
Epinephrine, plasma levels of, 257
Epineurium, 451
Episodic ataxia, 846
Episodic decline, in neurologic disease, 1637
Episodic memory, 274*t*
Epithelial-to-mesenchymal transition, 1035
Epley maneuver, 600, 600*f*
EPs. *See* Evoked potentials
Epstein-Barr virus (EBV), 682–683
CSF analysis for, 661, 683
hematopoietic cell transplantation and, 1236
and multiple sclerosis, 713
myelitis with, 1163
posttransplant lymphoproliferative disorders with, 1232
transplantation-related, 1255, 1298
treatment for, 679*t*
Eptinezumab, for migraine prevention, 528, 529*t*
Epworth Sleepiness Scale, 269
Equine encephalitis, 665, 670–671, 670*f*, 671*f*
Erb palsy, 458, 929, 1420
Erectile dysfunction, 1265–1266
Erenumab, for migraine prevention, 529*t*
Ergoline pergolide, 887
Ergotamine
avoidance in pregnancy, 1293
for migraine, 525
for primary exertional headache, 533
for primary sex headache, 533
Ergots
avoidance in pregnancy, 1293
for migraine, 525–527, 526*t*
for primary exertional headache, 533
for primary sex headache, 533
Erlotinib
for meningiomas, 1054, 1054*t*
for metastatic disease, 1042
Erythema migrans, 649

Erythrocyte sedimentation rate (ESR), 73, 375
in brain abscess, 617
in malignant otitis externa, 621
in osteomyelitis of skull base, 622
in spinal epidural abscess, 619
Erythromycin, for diphtheria, 637
Escherichia coli
enterohemorrhagic, 1237
meningitis, 604, 605*t*
subdural empyema, 618
Escitalopram
for anxiety disorders, 1611*t*
for depression, 1602
for neuropathic pain, 563
ESES. *See* Electrical status epilepticus during slow sleep
Eslicarbazepine, for epilepsy, 582, 584*t*
in pregnant patients, 1288
Esophageal dysmotility, 1263
ESR. *See* Erythrocyte sedimentation rate
Essential amino acids, 1387
Essential myoclonus, 825, 825*t*, 827
Essential thrombocythemia, 1240
Essential tremor (ET), 778–783
cerebellar model of, 778–779, 780*f*
clinical manifestations of, 779–781
depressive symptoms with, 1601
diagnosis of, 781
dystonia *versus*, 781, 782*t*
epidemiology of, 778
etiology of, 778
eye movement abnormalities with, 780
gait disorder with, 130*t*, 780
hallmark motor feature of, 778, 779, 779*f*
level I evidence on, 782
morbidity and mortality associated with, 781
natural history of, 780–781, 781*f*
nonmotor features of, 780
olivary model of, 778
outcome of, 782
Parkinson disease *versus*, 781, 781*t*, 877, 881
pathobiology of, 778–779, 780*f*
treatment of, 781–782
Essential tremor–Parkinson disease (ET-PD), 781
Estazolam, for insomnia, 1187*t*
Esthesioneuroblastoma, 1083, 1083*f*
Estrogen modulators, for meningiomas, 1054, 1054*t*
Eszopiclone, 1186, 1187*t*
ET. *See* Essential tremor
Eteplirsen, for Duchenne muscular dystrophy, 1482
Ethambutol, for tuberculosis, 648
Ethanol. *See* Alcoholism; Alcohol use
Ethical issues, in brain death, 183
Ethmocephaly, 1369
Ethosuximide, dosage and pharmacokinetics of, 584*t*
Etoposide
for HCT conditioning, 1235
for pediatric brain tumors, 1551, 1559
for pineal region tumors, 1076
for primary CNS lymphoma, 1059–1060
Etravirine, 707*t*
ETV. *See* Endoscopic third ventriculostomy
Eulenburg disease. *See* Paramyotonia congenita
European Cooperative Acute Stroke Study trials, 140, 311
European Federation of Neurological Societies (EFNS), 561, 561*t*, 607, 608–609
European Neuromuscular Center workshop, 984, 984*t*
Euthanasia, 1641
Everolimus
for acoustic neuroma, 1082
for gliomas, 1022
for meningiomas, 1054*t*
for tuberous sclerosis complex, 1462
Evoked potentials (EPs), 230, 238–240. *See also specific types*
brainstem auditory, 238, 239–240, 240*f*, 262
motor, 240, 241*f*
in transcranial magnetic stimulation, 252–253, 253*f*
somatosensory, 238–239, 239*f*
visual, 83, 238, 239, 240*f*, 260
Ewing sarcoma, epidemiology of, 1530
Exacerbations, 17
Excitatory-to-inhibitory ratio (EIR) model, 1178
Excited state, acute, 1324–1326
Executive function, 30–31, 274
Exercise
for ataxic patients, 847
for Huntington disease, 868
for inflammatory myopathies, 981
metabolic myopathies and intolerance of, 1012–1013, 1015
mitochondrial disease and, 1451
for neurologic rehabilitation, 1630
primary headache associated with, 524*t*, 533
and stroke prevention, 402, 409
Exertional headache, primary, 524*t*, 533
Exome sequencing, 300
Exoskeletal leg braces, 1632, 1632*f*
Exposure response prevention (ERP), 789
Expressive aphasia
cerebral infarction and, 305, 306
testing for, 29, 29*t*
Expressive language
in autism spectrum disorders, 1437
development of, 1428*t*
disorders of, 1429
External hydrocephalus, 1123
External neurolysis, 466, 466*f*, 466*t*
External-pressure headache, 524*t*, 533
External ventricular drain, 290–291
CSF obtained from, 279–280
for hydrocephalus, 1117
for ICH, 139–140, 338
for SAH, 349
Extracellular edema, 1128
Extracorporeal membrane oxygenation (ECMO), neurologic complications of, 1195–1197
Extracranial ultrasound, 208–212
carotid, 208–212, 209–211*f*, 209*t*
imaging modalities of, 208–209, 208*t*
indications for, 211–212
multiparametric, 211
vertebral artery, 208, 211
Extradural spinal tumors. *See* Epidural spinal tumors
Extramedullary spinal tumors, 1089–1094
extradural. *See* Epidural spinal tumors
intradural, 198–199, 1089–1091, 1090*f*, 1097, 1098
Extraocular movements. *See* Eye movements
Extrapontine myelinolysis (EPM), 1258–1260
Extrapyramidal symptoms, in Huntington disease, 864–865, 865*t*
Extrapyramidal system, 111
Extreme delta brush, in EEG, 236
Extubation, 1213, 1213*t*
Eye(s). *See also* Vision; Visual disturbances
neuroanatomy of, 77–78, 77*f*, 78*f*
working together, 78, 81
Eye alignment, 81
Eyelid
anatomy of, 77–78
coma and, 171–172
Eyelid opening, apraxia of, 802*t*, 878–879, 894, 899, 901*t*
Eye movements
alcohol intoxication and, 1303
in cerebellar (ataxia) examination, 834
coma and, 171–172, 173*f*
concussion and, 415
disturbances in, 85–87
essential tremor and, 780
extra, characterization of, 81
in Huntington disease, 865
neuroanatomy of, 77, 78*f*
in progressive supranuclear palsy, 894
testing of, 34, 34*f*, 79*t*, 81, 262–263
in traumatic brain injury, 429
weakness of, 113, 116
Wernicke syndrome and, 1307

F

Fabry disease, 936, 1395, 1523, 1526
Face, Arm, Speech Test, 307
Facial defects, midline, 1369
Facial masking, in Parkinson disease, 878, 879*t*
Facial migraine, 547
Facial nerve (CN VII), 78
anatomy of, 919–920, 919*f*
compression
hemifacial spasm with, 820–823, 820*f*, 923
microvascular decompression for, 822, 823
dysfunction or palsy of, 35
examination of, 35
injury (neuropathy) of, 454*t*, 456, 919–923
Bell's palsy in, 35, 820–821, 915, 920–922, 1294
clinical manifestations of, 920, 921*t*
peripheral *versus* central, 920, 921*f*
pregnancy and, 1294
in Ramsay Hunt syndrome, 921
muscles innervated by, 820, 821*f*
sarcoidosis and, 773, 776
surgical repair of, 923
Facial nerve neuralgia, 545–546
Facial neuralgia, 539*t*
Facial pain/pain disorders, 74–75, 538–548. *See also* Headache
atypical, 75
diagnostic criteria for, 538
due to intranasal mucosal contact points, 540
due to sinuses, nose, and ears, 538–541
due to TMJ disorders, 541–542
etiologies of, 539*t*
idiopathic, 546–547

level 1 evidence on, 547–548
primary headache disorders presenting as, 547
Facial sensation, testing of, 34–35, 34*f*
Facial weakness, 113, 116
Facioscapulohumeral muscular dystrophy (FSHD), 300, 1474, 1476*t*, 1483–1484, 1483*f*
Factitious disorder, 1616, 1623–1625
case example of, 1623
diagnosis of, 1624
epidemiology of, 1623
imposed on another, 1623
malingering *versus*, 1623
management of, 1624–1625
outcome of, 1625
pathobiology of, 1623–1624
Factor VIIa, recombinant, for noncoagulopathic ICH, 335, 336
Falls
assessment for, 126–128, 126*t*, 128*t*
definition of, 125
in elderly, 125–126
in Huntington disease, 865
in muscular dystrophy, 1477, 1479
in Parkinson disease, 878, 879, 891
in progressive supranuclear palsy, 893–894
risk factors for, 125
Famciclovir
for herpesvirus prophylaxis, 679*t*
for VZV, 702
Familial cortical myoclonic tremor with epilepsy, 826
Familial dysautonomia, 1175–1176
Familial hemiplegic migraine (FHM), 524, 524*t*
Familial thrombophilia, 1242
Family history, 23, 297, 298*t*
Farber disease, 1397
Farmer's lung, 646
FAS. *See* Fetal alcohol syndrome
Fasciculations, 116, 247
in ALS, 908, 909*f*
benign, 912, 912*t*, 1009
in muscle cramps, 1008–1009
FASDs. *See* Fetal alcohol spectrum disorders
FAST mnemonic, for stroke symptoms, 307
Fatal familial insomnia (FFI), 507, 507*t*, 513, 515–516
Fatigue
in depression, 1599
in multiple sclerosis, 716, 727*t*
in myasthenia gravis, 966
in myotonic dystrophy, 1486
in Parkinson disease, 878, 879*t*
Fatty acid oxidation, disorders of, 1011–1012, 1014*t*, 1015–1016, 1405–1407
fCJD. *See* Familial Creutzfeldt-Jakob disease
Fc receptor inhibition, for myasthenia gravis, 972
FDG. *See* Fluorodeoxyglucose
Febrile Infection Related Epilepsy Syndrome (FIRES), 578
Febrile seizures, 1503, 1509
Fecal incontinence, 1264
Felbamate, 587
dosage and pharmacokinetics of, 584*t*
for hemifacial spasm, 822
for Lennox-Gastaut syndrome, 1509
Female sexual dysfunction (FSD), 1266
Femoral access, for angiography, 217–218
Femoral nerve
anatomy of, 930, 934
injury of, 460*t*, 461–462, 934
Fentanyl
abuse/dependence, 1313–1314
for palliative (end-of-life) sedation, 1641*t*
for paroxysmal sympathetic hyperactivity, 1180*f*, 1181
for paroxysmal sympathetic storming, 1199, 1200*t*
Ferritin, in restless legs syndrome, 794, 795, 798
Fetal alcohol spectrum disorders (FASDs), 1310, 1583–1584, 1583*t*
Fetal alcohol syndrome (FAS), 1310, 1310*t*, 1583–1584, 1583*t*
Fever
in meningitis, 605
seizures with, 1503, 1509
in spinal epidural abscess, 619
in subarachnoid hemorrhage, 347
in subdural empyema, 618
in traumatic brain injury, 434
Feverfew, for migraine prevention, 529*t*
Fever-induced refractory epileptic encephalopathy syndrome, 759
Fexinidazole, for African trypanosomiasis, 655
FFI. *See* Fatal familial insomnia
FHM. *See* Familial hemiplegic migraine
Fibrillations, in EMG, 246, 247*f*
Fibrin sealant, for CSF leaks, 1141
Fibromuscular dysplasia (FMD), 382, 389–390
angiography in, 389–390, 390*f*
clinical features of, 389
diagnosis of, 389–390
epidemiology of, 389
level 1 evidence on, 399
management of, 390
outcome of, 390
pathobiology of, 389
Fibromyalgia, 983*t*
Fibrous dysplasia, 1086, 1086*f*, 1271–1272, 1272*f*
Fifth-day fits, 1360
Filled delta sign, 357
Finger chase, 834
Finger-nose testing, 834
Fingolimod
for multiple sclerosis, 723, 724*t*, 725
for multiple sclerosis in pregnancy, 1292, 1292*t*
FIRES. *See* Febrile Infection Related Epilepsy Syndrome
Firing ratio, of MUPs, 248
First-pass, in MRI, 200
Fisher computed tomography rating scale, in SAH, 346*t*
Fish-mouthing, 171
504 plan, in pediatric TBI, 1577
Flail leg syndrome, 910
FLAIR imaging, in MRI, 191, 193*f*, 193*t*
Flaviviruses, 666–670, 667*t*, 1163. *See also specific infections*
Flip angle, in MRI, 189
Floppy infant, 1417–1423
anterior horn cell disorders and, 1420
brachial plexus palsy and, 1420
central hypotonia in, 1419–1420, 1421*t*
chromosomal disorders and, 1419–1420, 1421*t*
differential diagnosis of, 1417, 1418*f*, 1421*t*
HIV and, 1580
hypoxic-ischemic encephalopathy and, 1358, 1419
maternal myasthenia and, 1422
metabolic causes of, 1419, 1421*t*
muscle disorders and, 1422–1423
neurologic examination of, 1417–1419
perinatal stroke and, 1362
peripheral hypotonia in, 1420–1423, 1421*t*
peripheral neuropathy and, 1420–1422
spinal cord disorders and, 1420, 1421*t*
structural causes of, 1419, 1421*t*
systemic causes of, 1419, 1421*t*
vascular causes of, 1419, 1421*t*
Florbetaben, 101, 204*t*, 206, 473, 473*t*
Florbetapir, 101, 204*t*, 206, 473, 473*t*, 482*f*, 483
Flortaucipir, 101, 204*t*, 206, 473, 483
Flow-diverting stents, 222–223, 223*f*
Flow phenomenon, as MRI artifact, 195, 196*f*
Fluconazole
for blastomycosis, 646
for coccidioidomycosis, 645
for cryptococcal meningitis, 644, 703
for histoplasmosis, 646
Flucytosine
for aspergillosis, 704
for cryptococcal meningitis, 644
Fludarabine, for HCT conditioning, 1235
Fludrocortisone, for autonomic dysfunction, 1175
Fluency, 29, 29*t*, 274
Fluent variant/agrammatic PPA, 486, 488
Fluid-attenuated inversion recovery (FLAIR) imaging, 191, 193*f*, 193*t*
Fluid disturbance, in subarachnoid hemorrhage, 347
Fluid management
in hyponatremia, 1256–1258
for subarachnoid hemorrhage, 349, 349*t*
for traumatic brain injury, 427, 433
Flukes, 653, 654*t*, 658–659
Flumazenil, 1314
Flunarizine
for hypnic headache, 534
for migraine prevention, 528, 529*t*
neurologic effects of, 850
Fluorescent treponemal antibody (FTA), 705
Fluorine-18, 203, 204*t*, 205
Fluorine-18 (^{18}F) SDM-8, 206
Fluorodeoxyglucose (FDG), 204*t*, 205
in Alzheimer disease, 480, 482*f*, 483
in mild cognitive impairment, 472–473, 473*t*
Fluoroquinolones, for malignant otitis externa, 621, 621*t*
Fluoxetine
for anxiety disorders, 1611*t*, 1612
for cataplexy, 1189
for congenital myasthenic syndromes, 975, 975*t*
for depression, 1602
for illness anxiety disorder, 1619
for persistent idiopathic facial pain, 547
Fluphenazine
for Huntington disease, 867
for tic disorders, 789, 790*t*
Flupirtine, for prion diseases, 518

Flurazepam, for insomnia, 1187*t*
Flutemetamol, 101, 204*t*, 206
Fluvoxamine, for anxiety disorders, 1611*t*
FMD. *See* Fibromuscular dysplasia
fMRI. *See* Functional MRI
Focal ablation, for dystonia, 818
Focal aware seizures, 570, 571*f*
Focal cortical dysplasia, 1512
Focal dystonia, 802
Focal epilepsy, 571, 572–574, 572*f*, 573*f*
Focal epilepsy syndromes, 574–575
Focal impaired awareness seizures, 236, 568, 568*f*, 570, 571*f*
Focal mass lesions, brain, 152–167. *See also specific lesions*
  biopsy of, 166
  causes of, 152–154, 153*f*
  demographics of, 154
  diagnosis of, 164–166, 166*f*
  differential diagnosis of, 152
  EEG findings with, 232–233, 234*f*, 235*f*
  emergent management of, 152
  focused examination for, 159
  focused history on, 154–159
  imaging of, 164–166
  increased ICP with, 152
  infectious, 153–154, 161*t*–162*t*
  inflammatory, 154, 165*t*
  initial management of, 166–167, 166*f*
  lumbar puncture for, 166
  past medical history and, 156
  review of systems for, 159
  signs of mass effect with, 152
  social history and, 156
  time course of, 156
Focal neurologic deficits, sudden, 132. *See also* Acute ischemic stroke (AIS); Intracerebral hemorrhage (ICH)
Focal radionecrosis, 1107
Focal seizures, 57, 57*f*, 570, 571*f*
Focal to bilateral tonic-clonic seizure, 570
Focused examination
  in acute spinal cord syndromes, 148–150
  in dementia, 98–99
  in focal mass lesions, 159
  in involuntary movements, 104
  in muscle weakness, 116–117
  in pain, 67–68
  in sensory symptoms, 67–68
  in syncope, 54–55
  in vertigo, 46–47
Focused history
  on acute spinal cord syndromes, 148
  in delirium, 89
  on focal mass lesions of brain, 154–159
  on involuntary movements, 103–104, 103*t*
  on muscle weakness, 113–116
  on sensory symptoms, 67
  on vertigo, 46
Foix-Chavany-Marie syndrome, 1376
Folic acid
  deficiency, 1278*t*, 1281
  for medulloblastoma prevention, 1531
  for neonatal seizures, 1360
  for pregnant patients with epilepsy, 1288
Folinic acid, for toxoplasmosis, 167
Follicle-stimulating hormone (FSH), 1215, 1216*f*
  deficiency of, 1216
Fondaparinux
  for heparin-induced thrombocytopenia, 1239
  reversal of, 139*t*
Foodborne botulism, 637
Foot drop, 907–908, 937, 1485
Foot surgery, for Charcot-Marie-Tooth disease, 960, 960*t*
Foramen magnum tumors, 1094
Forced vital capacity, 1209–1210
Forearm muscles, innervation of, 928*t*
Forward-flexed posture, 878
Fosamprenavir, 707*t*
Foscarnet
  for CMV infection, 683, 702
  for herpesvirus infections, 679*t*
Foster-Kennedy syndrome, 916
FOUR. *See* Full Outline of UnResponsiveness
Fourth (trochlear) nerve palsy, 86
Fractures, neurologic disorders and, 1274–1275
Fragile X–associated tremor and ataxia syndrome (FXTAS), 97, 299, 845, 846*f*
Fragile X syndrome, 1381, 1419
  anxiety disorders in, 1610
Free water restriction, 1257
Freezing
  in normal-pressure hydrocephalus, 1122
  in Parkinson disease, 878–879, 890
  in progressive supranuclear palsy, 893–894
Freezing phenomenon, 104
Fremanezumab, for migraine prevention, 528, 529*t*
Frequency dimension, in MRI, 190
Friedrich ataxia, 834, 835, 844–845, 844*t*, 845*f*, 847
Froment sign, 878
Frontal bossing, 1118
Frontal lobe epilepsy, 574
Frontotemporal dementia (FTD), 96–97, 97*t*, 486–491
  ALS and, 97, 486–487, 904, 906, 908*f*
  behavioral variant, 486, 487–488
  biomarker imaging in, 101, 489
  clinical manifestations of, 487–488
  diagnosis of, 488–489
  epidemiology of, 486
  gait disorder in, 129*t*
  genetics of, 487, 487*f*
  level 1 evidence on, 490
  management of, 490
  MCI as precursor of, 471
  MRI in, 488, 489*f*
  outcome of, 490
  pathobiology of, 486–487, 487*f*
  phenotypes of, 486
  positron emission tomography in, 205, 205*f*, 488–489, 489*f*
  PPA variant. *See* Primary progressive aphasia
Frontotemporal lobar degeneration (FTLD), 486
Frovatriptan
  for migraine, 525, 526*t*
  for primary exertional headache, 533
  for primary sex headache, 533
Frozen section, 284
FSH. *See* Follicle-stimulating hormone
FSHD. *See* Facioscapulohumeral muscular dystrophy
FTA. *See* Fluorescent treponemal antibody
FTD. *See* Frontotemporal dementia
FTLD. *See* Frontotemporal lobar degeneration
Fukuyama muscular dystrophy, 1375, 1376, 1419
Full interference patterns, in EMG, 249
Full Outline of UnResponsiveness (FOUR) Score , 172, 173*f*
Fulminant hepatic encephalopathy, 1131, 1245
Functional dystonia, 802*t*, 809–810, 810*t*
Functional gait disorder, 129*t*
Functional involuntary movements, 108, 108*t*
Functional movement disorders, 1620–1623, 1621*t*
Functional MRI (fMRI), 199, 199*f*
  in Alzheimer disease, 482–483
  resting state, 199
  task paradigms with, 199, 199*f*
Functional neurologic disorder, 1619–1623, 1622*t*
Functional neurologic symptom disorder. *See* Conversion disorder
Fundoscopic examination, 32–33, 33*f*, 79*t*, 80–81, 81*f*
  in Susac syndrome, 395, 395*f*
Fundus photography, 82
Fungal infections. *See also specific infections*
  brain, 153, 161*t*, 162*f*–163*f*
  hematopoietic cell transplantation and, 1236
  HIV-associated, 700*t*, 703–704
  social history and, 156
  transplantation-related, 1255, 1299
Fungal meningitis, 640–646. *See also specific types*
Fungi, 640–641
Fusiform aneurysms, 350
Fusion inhibitors, for HIV, 707*t*
Futile therapies, in end-of-life care, 1639–1640
F wave, in nerve conduction studies, 245, 246*f*
F-wave minimal latency, 245
FXTAS. *See* Fragile X–associated tremor and ataxia syndrome

G

GABA
  in alcohol withdrawal, 1305, 1306
  in chorea, 854
  in hepatic encephalopathy, 1246
  in Huntington disease, 862–864, 866
  in sepsis-associated encephalopathy, 1204
  in sleep, 1184–1185
  in stiff person syndrome, 1005–1006, 1005*f*
  in tic disorders, 785
$GABA_A$ receptor encephalitis, 760, 761*f*, 771
GABAergic drugs, for dystonia, 814–815, 814*t*
Gabapentin, 586
  adverse effects of, 583–584, 586
  for anxiety disorders, 1611–1612, 1611*t*
  for chemotherapy-induced neuropathy, 1109*t*
  for cluster headache prevention, 531*t*
  for complex regional pain syndrome, 553
  for cramps, 1009
  for cranial neuralgias, 543, 544*t*
  for diabetic neuropathy, 1221
  dosage and pharmacokinetics of, 584*t*, 586
  for epilepsy, 581–585, 586
    teratogenicity of, 1287*t*
  for essential tremor, 782
  for glossopharyngeal neuralgia, 924
  for hemifacial spasm, 822
  for migraine prevention, 528, 529*t*
  for neuropathic pain, 561, 562*t*

for nummular headache, 534
for paroxysmal sympathetic hyperactivity, 1180–1181, 1180*f*, 1181*t*
for paroxysmal sympathetic storming, 1200*t*
for persistent idiopathic facial pain, 547
for restless legs syndrome, 797–798, 797*t*
for spasticity in MS, 727*t*
for stiff person syndrome, 1006
for SUNCT/SUNA headaches, 532
for trigeminal neuralgia, 918
Gabapentinoids. *See also* Gabapentin; Pregabalin
for neuropathic pain, 561
Gadolinium-enhanced MRI, 190, 194, 194*f*
Gait
activation and visual guidance of, 123–124
assessment of, 38, 68, 117, 126–128, 126*t*, 263, 834
clinical measures for, 123, 123*t*
focused questions for, 127–128
history in, 126, 126*t*
medication review in, 126
physical examination in, 126
standardized, 127, 128*t*
bouncing, 824
CADASIL and, 398
execution of, 125
neural control of, 123–125, 124*f*, 124*t*
regulation of, 124–125
spatial characteristics of, 123, 123*f*
traumatic brain injury and, 429
Gait apraxia, 306
Gait ataxia, 107
essential tremor and, 780
multiple sclerosis and, 716
neurologic examination in, 834
signs and symptoms of, 832–833, 833*t*
treatment of, 847
Gait cycle, 122–123, 122*f*
Gait disorders, 122–131
in ALS, 907–908
in cerebral palsy, 1426
classification of, 128, 129*t*–130*t*
conditions with, 126, 127*f*
epidemiology of, 125
essential tremor and, 130*t*, 780
falls in elderly from, 125–126
high-level, 129*t*
in Huntington disease, 130*t*, 865, 867
illicit drug use and, 1317
low-level, 130*t*
midlevel, 129*t*–130*t*
in multiple sclerosis, 726
in multiple system atrophy, 896
in muscular dystrophy, 130*t*, 1477, 1479, 1481, 1487
neurologic causes of, 125
in normal-pressure hydrocephalus, 129*t*, 902, 1121–1122
in Parkinson disease, 877–878, 879*t*, 890–891
in progressive supranuclear palsy, 893–894
timeline of onset, 126, 127*f*
Galantamine
for Alzheimer disease, 483, 483*t*
for mild cognitive impairment, 473
for vascular dementia, 504, 504*t*
Galcanezumab, 529*t*
for cluster headache prevention, 531*t*, 532
for migraine prevention, 528
γ-Aminobutyric acid. *See* GABA
γ-Hydroxybutyrate, for sleepiness and cataplexy, 1189
Gamma Knife surgery. *See* Stereotactic radiosurgery (SRS)
Ganciclovir
for CMV infection, 683, 702
for herpesvirus infections, 679*t*
for herpesvirus prophylaxis, 679*t*
Gangliocytoma, dysplastic, 1548–1549
Ganglioglioma, 1020*t*, 1457, 1548
Ganglion cell complex (GCC), of retina, 82, 82*f*
Ganglioneuritis, 941
HIV-associated, 699
paraneoplastic, 936
Gangliosidoses
GM1, 1394–1395, 1395*f*
GM2, 844*t*, 845, 1394
Garin-Bujadoux-Bannwarth syndrome, 649
Gas exchange, pulmonary, 1207–1208
Gastaut syndrome, 1510
Gastaut-type idiopathic occipital epilepsy of childhood, 575
Gastric bypass surgery, neuropathy after, 947
Gastric lavage, 1320
Gastric ulcers
prophylaxis, for TBI patients, 434
stress, 1264
Gastrointestinal cancers, brain metastases from, 152
Gastrointestinal system
manifestations of neurologic disease in, 1262–1264
neuroanatomy of, 1262, 1263*f*
neurologic consequences of primary disease of, 1267
neurologic disorders and, 1266–1267
Gastroparesis, 1264
Gaucher disease, 1395–1396
Gault, Fernand, 744
GBA1 gene, in Lewy body dementias, 494
GCA. *See* Giant cell arteritis
GCC. *See* Ganglion cell complex (GCC), of retina
GCS. *See* Glasgow Coma Scale
GCTs. *See* Germ cell tumors
GDD. *See* Global developmental delay
Gefitinib, for meningiomas, 1054, 1054*t*
Gegenhalten, 37, 169, 175
Gender specificity, 18
Generalized anxiety disorder, 1606
clinical features of, 1608*t*, 1609
treatment of, 1612
Generalized dystonia, 802
Generalized epilepsy, 571–572, 572*f*
Generalized periodic discharges, in EEG, 236, 236*f*
Generalized polymorphic slowing, in EEG, 233
Generalized rhythmic delta activity, in EEG, 233–236
Generalized seizures, 57, 57*f*, 570–571, 571*f*
Generalized tonic-clonic seizures, 570
General medical examination, 27–28
Genetic anticipation, 861–862, 1486
Genetic counseling, 297, 300
obtaining family history for, 297, 298*t*
process (discussion) in, 297, 299*t*
Genetic epilepsy with febrile seizures plus (GEFS+), 1509
Genetic heterogeneity, 299
Genetic prion disease (gPrD), 507, 507*t*, 511*t*, 512–516
Genetic testing, 19, 297–300
in autism spectrum disorders, 1434, 1434*t*
in Charcot-Marie-Tooth disease, 957–959
chromosomal microarray for, 1411–1412
in congenital myopathy, 1493
in dystonia, 812–813
in epilepsy, 569
in muscle weakness, 119
in muscular dystrophies, 1481
phenomenology in, 298–300
pretest counseling for, 297, 299*t*, 300
in spinocerebellar ataxia, 843–844
strategy for, 300
types of tests in, 300
Genitofemoral nerve
anatomy of, 934
injury of, 461, 934
Genitourinary system. *See also* Bladder dysfunction; Sexual dysfunction
manifestations of neurologic disease in, 1262, 1264–1265
neuroanatomy of, 1262, 1263*f*
neurologic disorders and, 1266–1267
Genome sequencing, 19, 300
Genomic hybridization, array comparative, 1412
Genomic imprinting, 1411
Gentamicin
for bacterial meningitis, 607, 607*t*, 609*t*
intratympanic, for Ménière disease, 599–600
Gepants
for migraine, 526*t*, 528
for migraine prevention, 530
German measles (rubella), 671–672
Germ cell tumors (GCTs)
pediatric, 1559–1560
pineal, 1072–1073, 1073*t*, 1559–1560
Germinal matrix hemorrhage (GMH), neonatal, 1355–1357
clinical manifestations of, 1355–1356
diagnosis of, 1356–1357
epidemiology of, 1355
grading of, 1116, 1355, 1356*f*, 1357
hydrocephalus with, 1116, 1355
management of, 1357
outcome of, 1357
pathobiology of, 1355
prevention of, 1355, 1357
ultrasound of, 1356–1357, 1356*f*
Germinomas, 1072–1073, 1073*t*
Gerstmann-Straüssler-Scheinker (GSS) disease, 507, 507*t*, 513, 514–515, 514*f*
Gerstmann syndrome, 305
Geste antagoniste, 106, 800, 802*t*
GFAP astrocytopathy, autoimmune, 760, 761*f*, 762, 771
GH. *See* Growth hormone
Ghosting artifacts, in MRI, 195–196
Giant cell arteritis (GCA), 371*t*, 374–375
clinical manifestations of, 374–375
diagnosis of, 375
epidemiology of, 374
headache caused by, 73, 523

Giant cell arteritis (GCA) *(Continued)*
management of, 375
outcome of, 375
pathobiology of, 374
Giant cell astrocytoma, subependymal, 1020*t*, 1530–1531, 1551
Giant somatosensory-evoked potentials, in myoclonus, 825, 825*t*
Gibbs, Clarence J., 506
Gilles de la Tourette syndrome Health-Related Quality of Life Scale, 787
Gilliam Autism Rating Scale, 1435
Ginkgo biloba, for tardive dyskinesia, 853*t*
Glabellar reflex, 881
Glasgow Coma Scale, 89, 172, 174*t*, 427*t*, 428, 428*t*, 435, 453, 1574
Glatiramer acetate
for multiple sclerosis, 725*t*, 726
for multiple sclerosis in pregnancy, 1292, 1292*t*
Glaucoma, 84, 523, 1397, 1463
Glial proliferation, 1370–1371
disorders of, 1370–1371
normal, 1370
Glioblastoma, 157*t*, 1026–1029, 1552
chemotherapy for, 1028
demographics of, 154
diagnosis of, 1027
epidemiology of, 1026
intramedullary spinal, 1094*f*
management of, 1027–1029
MRI of, 198, 198*f*, 1027, 1027*f*
outcome of, 1029
pathobiology of, 1026–1027
pseudoprogression of, 1028
radiation therapy for, 1028
recurrent, 1029
surgery for, 1028
time course of, 156
tumor-treating fields of, 1028–1029
Glioblastoma multiforme, 152, 154*f*, 1552
epigenetic mutations in, 1537
survival rates for, 1532*t*
Gliomas, 152–153, 154*f*, 157*t*, 1019–1033. *See also* Astrocytomas; Oligodendrogliomas
chemotherapy for, 1021–1022, 1023*t*
classification of, 1019
definition of, 1019
diagnosis of, 1021
diffuse midline, 1020*t*
epidemiology of, 1019
focused history on, 154–159
high-grade, 1019, 1021
level 1 evidence on, 1031–1032
low-grade, 1019, 1021
management of, 1021–1022
metastatic, 1019
metastatic disease *versus*, 1038
molecular features of, 1020–1021, 1020*t*
neurofibromatosis and, 1457–1459, 1458*f*
outcome of, 1022–1023
pathobiology of, 1019–1021
pediatric, 153, 154, 158*t*; 1019
brainstem, 1553–1554, 1553*f*
classification of, 1539–1540, 1540*t*
epidemiology of, 1528–1532, 1529*f*
IDH mutations in, 1537, 1537*f*
molecular features of, 1536–1537, 1538*f*
survival rates for, 1531–1532, 1532*t*
pineal, 1073
in pregnancy, 1293
radiation-induced, 1336
radiation therapy for, 1021–1022
surgery for, 1022
tuberous sclerosis complex and, 1460
Glioneural tumors, pediatric, 1548
Global aphasia, 29*t*
Global burden, of neurologic disease, 1–8
challenge of quantifying, 1
changes over time in, 3
disparities in, 4–6, 4*f*, 5*f*, 6*f*
epidemiologic transition in, 3–4
measures for estimating, 1–2
sociocultural differences affecting, 7
Global Campaign Against Epilepsy, 12
Global cerebral edema, 1130, 1130*f*
Global delivery of care, 9–14
approaches and strategies for improving, 11
challenges in, 10–13
collaborative partnerships and coordinated action on, 11–12
components required for, 9–10
disparities in, 5–6, 6*f*, 9, 9*f*, 11
health-seeking behavior and, 10–13, 10*b*
limited access to diagnostics and therapeutics in, 11
policies and guidelines affecting, 11, 11*b*
primary care workforce and, 12–13
stigma related to neurologic disorders and, 10, 10*b*
telemedicine/communication technology and, 13
training to build capacity and, 13
Global Dementia Observatory, 12, 12*f*
Global developmental delay (GDD), 1424, 1430
Global Stroke Services Action Plan, 11*b*
Globus pallidus, gait control by, 124
Glomus jugulare tumors, 1084
Glossopharyngeal nerve (CN IX)
examination of, 36
injury (neuropathy) of, 454*t*, 456, 923–924
pain. *See* Glossopharyngeal neuralgia
Glossopharyngeal neuralgia, 539*t*, 545, 923–924
anatomy of, 923
Glucocerebrosidase
in Gaucher disease, 1395–1396
in Lewy body dementias, 494
in Parkinson disease, 876
Glucocorticoids. *See also* Steroid(s)
for ACTH deficiency, 1215–1216
for Behçet syndrome, 379
for brain edema, 1133–1134
for CNS vasculitis in rheumatoid arthritis, 380
for giant cell arteritis, 375
for IV/GM hemorrhage prevention, 1355
for myasthenia gravis, 969–970, 970*t*, 971
osteoporosis and fractures with, 1274–1275
for primary angiitis of CNS, 372–373
for Takayasu vasculitis, 375
for traumatic brain injury, 434
Glucose
in alcoholism, 1308
in alcohol withdrawal, 1306
in bacterial meningitis, 607–608
in cerebral microdialysis, 293–294, 294*f*, 294*t*
reduced CSF level of, 280, 280*t*
stored. *See* Glycogen
in traumatic brain injury, 434
Glucose imaging, 101, 204*t*, 205
Glucose transporter type 1 deficiency syndrome, 1385–1386
Glut1 deficiency syndrome, 1512
Glutamate
in bipolar disorder, 1598
in cerebral microdialysis, 293–294, 294*t*
in depression, 1597–1598
in Huntington disease, 863–864, 867
in magnetic resonance spectroscopy, 200
in schizophrenia, 1588
in sleep, 1184–1185
in tic disorders, 785
Glutamine
in hepatic encephalopathy, 1246
in magnetic resonance spectroscopy, 200
in spinocerebellar ataxia, 838–843
Glutaric aciduria type I, 1389
Glutaric aciduria type II, 1015–1016
Gluteal nerves
anatomy of, 931
injuries of, 461
Gluten-related disorders, 1283–1284
ataxia, 838, 847, 1267, 1283–1284
neuropathy, 938*t*, 944
Glycerol, in cerebral microdialysis, 293–294
Glycine, in magnetic resonance spectroscopy, 200
Glycine encephalopathy, 1504
Glycogen, 1011
Glycogen metabolism
disorders of, 1011, 1013–1015, 1014*t*, 1385, 1402–1405, 1403*t*
diagnostic testing in, 1016–1017
epidemiology of, 1011
infant hypotonia (floppy infant) in, 1422–1423
management of, 1017
outcome of, 1017
scheme of, 1011, 1012*f*
Glycogenoses. *See* Glycogen metabolism
Glycogen storage diseases. *See* Glycogen metabolism
Glycopyrrolate, for Ménière disease, 598
Glycosylation defects, in congenital myasthenic syndromes, 974–975
GM1 gangliosidosis, 1394–1395, 1395*f*
GM2 gangliosidosis, 844*t*, 845, 1394
GMH. *See* Germinal matrix hemorrhage (GMH), neonatal
GNAO1 encephalopathy, 1506
Gnathostoma spinigerum, 654*t*, 658, 658*t*
Gnathostomiasis, 654*t*, 658, 658*t*
Goiter, 1220
Goldman kinetic perimetry, 260
Gorlin syndrome, 1531
Gowers sign, 1477, 1480, 1480*f*, 1481, 1490
GPA. *See* Granulomatosis with polyangiitis
gPrD. *See* Genetic prion disease
Gradenigo syndrome, 355
Gradient-recalled echo (GRE) imaging, 192–194, 193*t*
Graft repair of nerve, 466*t*, 467
Graft-versus-host disease, in hematopoietic cell transplantation, 1235
Gram stain, in bacterial meningitis, 607–608
Granular cell tumors, 1064
Granulocytic anaplasmosis, 624, 624*t*

Granulocytic brain edema, 1131
Granulomatosis with polyangiitis (GPA), 371*t*, 376–377
clinical manifestations of, 377
diagnosis of, 377
epidemiology of, 376
hallmarks of, 376
management of, 377
multiple sclerosis *versus*, 722
outcome of, 377
pathobiology of, 377
Granulomatosis with polyangiitis, neuropathy in, 938*t*, 942
Granulomatous amebic meningoencephalitis, 654*t*, 656
Graves disease, 1220–1221
Graves ophthalmopathy, 1220
Gray (Gy), 1335
Gray matter, MRI appearance of, 191, 193*t*
Gray matter heterotopias, 1377
Grayscale median index, in carotid ultrasound, 210
GRE imaging. *See* Gradient-recalled echo (GRE) imaging
Greater occipital nerve injection, for headache prevention, 531*t*, 532
Green flags, in headaches, 71, 73
Growth factors, and pediatric astrocytomas, 1535–1537
Growth hormone, 1215, 1216*f*
deficiency of, 1216, 1336, 1342
excess of, 1217. *See also* Acromegaly
pediatric brain tumors and, 1561
radiation and, 1336, 1342
Growth hormone–producing tumor, 158
Growth hormone-secreting tumors, 1218
GSS disease. *See* Gerstmann-Straüssler-Scheinker disease
Guanfacine
for ADHD, 1431
for tic disorders, 789, 790*t*
Guanidine, for botulism, 977
Guglielmi detachable coils, 218, 222
Guidance of gait, 123–124
Guillain-Barré syndrome, 67, 69, 937–940
clinical features of, 939
dengue and, 666
diagnosis of, 938*t*, 939–940
differential diagnosis of, 939–940
electrophysiology of, 940
epidemiology of, 937–938
Epstein-Barr virus and, 682
histology of, 940, 940*f*
HIV-associated, 695
laboratory data in, 940
muscle weakness in, 117
outcome of, 940
pathobiology of, 938–939
polyneuropathy in, 936, 937–940
treatment of, 937, 940
variants of, 937, 939
Guillain-Barré-type neuropathy, 1317
Guillain-Mollaret triangle, 827, 828*f*
Gummatous neurosyphilis, 153, 161*t*
Gunshot wounds, nerve injuries from, 465
Gut microbiome, 713, 1267–1268
GVHD, in hematopoietic cell transplantation. *See* Graft-versus-host disease in hematopoietic cell transplantation

H
Habit reversal training (HRT), 788
Haemophilus influenzae, meningitis, 604, 605*t*
Haller sign, in exercise-induced muscle spasms, 1012
Hallervorden-Spatz disease, 1393
Hallucinations, 1588
in alcohol/drug withdrawal, 1305, 1306, 1593
in Alzheimer disease, 481
hypnic, 1187–1189
in Lewy body dementias, 494, 498, 1593
olfactory, 917
in Parkinson disease, 888–889
in schizophrenia, 1589
Hallucinogen-persisting perception disorder, 1317
Hallucinogens, 1315
Haloperidol
for alcohol withdrawal, 1306
for delirium, 91, 92–93, 92*t*
for delirium prevention, 92
for Huntington disease, 867
for obsessive-compulsive disorder, 1612
for schizophrenia, 1591*t*
side effects of, 1591*t*
for tic disorders, 789, 790*t*
Hamartoma
in Cowden syndrome, 1531
hypothalamic, 1513
iris, in neurofibromatosis, 1457, 1458*f*
in tuberous sclerosis, 1460–1461, 1530–1531
Hammersmith Functional Motor Scale (HFMS), 1472
HAND. *See* HIV-associated neurocognitive disorder
Hand atrophy, in ALS, 907, 908*f*
Hand dexterity, in ataxia, 834
Hand dystonia (writer's cramp), 106, 802, 808, 808*f*, 809
Handedness, 17
Handgrip test, sustained, 257
Hand-shoulder syndrome. *See* Complex regional pain syndrome (CRPS)
Hangover, 1304
Hardy-Rand-Rittler color plates, 79
Hartnup disease, 1388, 1389*t*
Hashimoto disease, 1219
Hashimoto encephalopathy, 98, 760
Haw River syndrome, 827
HCT. *See* Hematopoietic cell transplantation
HD. *See* Huntington disease
Headache, 70–74, 521–537. *See also specific disorders causing*
anatomy and physiology of, 521, 522*f*
arteriovenous malformations and, 361, 362
autonomic symptoms in, 521
brain abscess and, 614
CADASIL and, 398
cavernous malformations and, 366
cerebral venous thrombosis and, 73, 353
classification of, 70, 522
clinical evaluation of, 521–522
cluster. *See* Cluster headache
concussion and, 413
CT in, 71, 73, 186
diagnosis of, 70–71
diagnostic evaluation of, 73–74
emergency department evaluation and management of, 71, 72*f*, 73–74
facial pain with, 547
giant cell arteritis and, 374
green flags in, 71, 73
hemangioblastoma and, 368
history in, 70
level 1 evidence on, 534–537
life-threatening, 70
meningitis and, 605, 641
migraine. *See* Migraine
moyamoya disease and, 391
neurologic history in, 20*t*
new-onset *versus* chronic, 521–522
osteomyelitis of skull base and, 622
physical examination in, 71
polyarteritis nodosa and, 376
posttraumatic, 534
primary, 70, 71, 522, 523–534, 524*t*, 547
rebound, 528
red flags in, 71, 71*t*, 73, 522
reversible cerebral vasoconstriction syndrome and, 387
secondary, 70, 71–73, 522–523
sentinel, 343
sinus, 538–540
subarachnoid hemorrhage and, 71–72, 343, 344, 344*t*
subdural empyema and, 618
tension-type. *See* Tension-type headache (TTH)
vasculitis and, 371
Head impulse test, 42, 42*f*, 46–47, 47*f*, 263
Head movements, in cervical dystonia, 807, 807*f*
Head trauma. *See also* Traumatic brain injury (TBI)
CT in, 186
dystonia in, 809
electrical/lightning injuries and, 1348
gait disorder with, 129*t*
Head vibratory hemianesthesia, 43
Health-seeking behavior, challenges in, 10–13, 10*b*
Hearing loss, 49–50
acoustic neuroma and, 1080–1082
causes of, 50*t*
diagnosis of, 49–50
in facioscapulohumeral dystrophy, 300
in Ménière disease, 597–600
physical examination in, 50
in sarcoidosis, 774
sudden, 49–50
treatment of, 50
Hearing testing, 35–36, 35*f*, 262
Heart-brain interaction, 1195–1200
cardiovascular complications of neurologic injury, 1195, 1197–1200
cerebral complications of cardiac procedures, 1195–1197
physiology of, 1195
Heart disease, congenital
childhood stroke in, 1519–1520
perinatal stroke in, 1516
Heart rate
in autonomic testing, 255–257
response to standing, 256
in stroke (AIS), 133
Heart rate variability, 255
Heart transplantation, 1300
Heat tolerance, 257
Heavy metal toxicity, 938*t*, 947–948, 1332–1333
Heidenhain variant, of Creutzfeldt-Jakob disease, 508

HELLP syndrome, 1289
Helminthic infections, 153, 162*t*, 653, 654*t*
Helsinki model, of stroke care, 132
Hemangioblastomas, 368, 1093, 1097, 1531
Hemangiomas
cavernous. *See* Cavernous malformations
skull, 1085
Hemangiopericytoma, 368, 1055, 1560
Hematologic diseases, 1227–1244. *See also specific diseases*
coagulation, 1240–1243
level 1 evidence on, 1243–1244
platelet, 1237–1240
red blood cell, 1227–1232
white blood cell, 1232–1237
Hematoma
in intracerebral hemorrhage, 140, 334, 335*f*, 338–339
in subarachnoid hemorrhage, 343
subdural. *See* Subdural hematoma
in traumatic brain injury, 424, 424*f*
Hematopoietic cell transplantation (HCT), 1235–1237
for adrenoleukodystrophy, 1406
conditioning drugs for, 1235, 1236*t*
graft-versus-host disease in, 1235, 1237
neurologic complications of, 1111, 1235–1237, 1236*t*
for primary CNS lymphoma, 1059–1060
Hemianesthesia
body, 44, 44*f*
head vibratory, 43
psychogenic, 43–44
Hemianopia, 80, 80*f*, 260*f*
brain abscess and, 614
cerebral infarction and, 305, 307
encephalotrigeminal angiomatosis and, 1463
pituitary tumors and, 1065, 1065*f*
Hemiballismus, 109*t*, 854, 856
Hemichorea, 854, 856
Hemicrania, paroxysmal, 74, 531*t*, 532
Hemicrania continua, 74, 533
Hemicraniectomy
in brain edema, 1129, 1132, 1132*f*
in ICH, 338, 339*f*
in malignant MCA infarction, 315
precautions for lumbar puncture with, 281
Hemidystonia, 802
Hemifacial spasm (HFS), 820–823, 828, 923
botulinum toxins for, 822–823, 822*t*, 829*t*
clinical features of, 821
diagnosis of, 821
differential diagnosis of, 821, 822*t*
epidemiology of, 820
facial nerve compression and, 820, 820*f*
level 1 evidence on, 823
management of, 821–822
microvascular decompression for, 822, 823
outcome of, 822–823
pathobiology of, 820–821
Hemimegalencephaly, 1371, 1513
Hemineglect, 307
Hemiparesis, 114, 129*t*
brain abscess and, 614
cerebral infarction and, 305–307
gliomas and, 1019
ICH and, 334
neonatal stroke and, 1362
posterior reversible encephalopathy syndrome and, 385
spastic, in cerebral palsy, 1426
TIAs and, 321
transplantation-related, 1298*t*
Hemiparkinsonism-hemiatrophy syndrome, 902
Hemiplegia, in cerebral palsy, 1425
Hemiplegic migraine, 524, 524*t*
Hemispherectomy, for epilepsy, 589*t*, 590
Hemodialysis, anticoagulation reversal with, 139*t*
Hemoglobin, 1227. *See also* Anemia; Polycythemia
Hemolytic uremic syndrome (HUS), 1237–1239
Hemorrhage
intracerebral. *See* Intracerebral hemorrhage (ICH)
intraventricular. *See* Intraventricular hemorrhage (IVH)
subarachnoid. *See* Subarachnoid hemorrhage
Hemorrhagic conversion, tPA and, 312, 312*t*
Hemorrhagic stroke, 401, 409–410
COVID-19 and, 673
HIV-associated, in children, 1581, 1581*f*
neonatal, 1362
varicella-zoster virus and, 682
Hendra virus, 675
Henipaviruses, 675
Henoch-Schönlein purpura, 371*t*, 378
Heparin. *See* Low-molecular-weight heparin; Unfractionated heparin (UFH)
Heparin-induced thrombocytopenia (HIT), 1239–1240, 1239*t*
Hepatic disease, 1245–1252. *See also specific diseases*
alcoholic, 1308
brain edema in, 1131, 1258–1261
level 1 evidence on, 1251
neurologic manifestations of, 1245
neuropathy associated with, 945
Hepatic encephalopathy, 1245–1248
acute liver failure and, 1248–1251
clinical features of, 1246–1247
diagnosis of, 1247
epidemiology of, 1245
fulminant, 1131, 1245
minimal, 1245–1248
outcome of, 1248
overt, 1246–1248
pathobiology of, 1245–1246
persistent, 1247
treatment of, 1247–1248, 1247*t*
West Haven scale for, 1245, 1245*t*, 1247
Hepatic failure. *See* Acute liver failure
Hepatic myelopathy, 1168, 1247
Hepatitis A, acute liver failure with, 1248*f*
Hepatitis B
acute liver failure with, 1248*f*
HIV-associated, 693, 695, 703
Hepatitis C
CNS vasculitis in, 381
epidemiology of, 1245
HIV-associated, 693, 695, 703
neuropathy with, 938*t*, 945
Hepatocerebral mitochondrial DNA depletion syndromes, 1450
Hepatolenticular degeneration, acquired, 1247
Hepatoviruses, 663
HER2 inhibitors. *See* Human epidermal growth factor receptor 2 (HER2) inhibitors
Hereditary sensory and autonomic neuropathy, 1175–1176
Hereditary spastic paraplegia (HSP), 1168
Heredopathia atactica polyneuritiformis. *See* Refsum disease
Herniated disks. *See* Intervertebral disk disease
Herniation syndromes, 1128
acute liver failure and, 1249
in cerebral venous thrombosis, 359–360
subfalcine, 172, 174*t*, 175*f*
supratentorial, 172–174
tonsillar, 174, 174*t*, 175*f*
transtentorial, 172–174, 174*t*, 175*f*, 1143
traumatic brain injury and, 436*f*
types of, 172, 174*t*, 175*f*
uncal, 172, 174*t*
upward, 174, 174*t*
Heroin, 1313–1314, 1316, 1317, 1585–1586
Herpes simplex encephalitis (HSE), 153–154, 161*t*, 164*f*, 679–680
clinical manifestations of, 679
diagnosis of, 679–680
imaging of, 679–680, 680*f*
neonatal, 680
outcome of, 680
psychosis with, 1594
treatment of, 680
Herpes simplex virus (HSV), 679–681. *See also* Herpes simplex encephalitis
benign recurrent lymphocytic meningitis with, 680–681
hematopoietic cell transplantation and, 1236
HIV-associated infection, 693, 702
HSV-1, 679–681
HSV-2, 679–681
myelitis with, 1163–1164
neonatal infection, 680
treatment for, 662, 679*t*, 680, 681
Herpesviruses, 679–683, 679*t*. *See also specific viruses*
Herpes zoster, 681–682
Herpes zoster neuropathy, 938*t*, 946
Herpes zoster oticus. *See* Ramsay Hunt syndrome
Heterogeneity, genetic, 299
Heteroplasmy, 1442–1443, 1452–1453
Heterotopias, 580, 580*f*, 1376–1377, 1513
Heterotopic ossification, 450
Heubner, artery of, occlusion of, 306
Hexosaminidase deficiency, 1394
HGA. *See* Human granulocytic anaplasmosis
HHV-6. *See* Human herpesvirus-6
HHV-7. *See* Human herpesvirus-7
HIE. *See* Hypoxic-ischemic encephalopathy
High-altitude edema, 1132
Higher cerebral functions, disorders of, 1424, 1427–1432, 1428*t*
Higher order cognition, 31
High field, in MRI, 190, 201
High-grade gliomas, 1019, 1021
High-grade oligodendrogliomas, 1029
High-voltage electrical injury (HVEI), 1347
Hippocampal sclerosis, 1378
Hirayama syndrome. *See* Monomelic muscular amyotrophy
Hirschsprung disease, 1264
Histone deacetylase inhibitors, for spinal muscular atrophies, 1471–1472

Histoplasma capsulatum, 645–646, 703
Histoplasmosis, 153, 161*t*, 645–646
chronic meningitis in, 641*t*–643*t*, 645–646
clinical presentation of, 641*t*, 645
CSF analysis and serum diagnostics in, 642*t*, 645–646
diagnosis of, 645–646
HIV-associated, 703
imaging in, 641*t*
pathobiology of, 645
transplantation-related, 1255
treatment of, 643*t*, 646
History. *See* Neurologic history; *specific disorders*
HIT. *See* Heparin-induced thrombocytopenia
HIV. *See* Human immunodeficiency virus (HIV) infection
HIV-associated neurocognitive disorder (HAND), 693, 695–697
HME. *See* Human monocytic ehrlichiosis
Hodgkin lymphoma, 1232–1234
paraneoplastic syndrome with, 1100
Hoehn and Yahr clinical staging scale, for Parkinson disease, 879, 880*t*
Hoffmann sign, 908, 1149
Hoffmann syndrome, 1219
Holoprosencephaly, 1369, 1370*f*
Homeobox genes, 1368–1369
Home run sign, 1012
Homocystinuria, 1388
Hoover sign, 43
Horizontal nystagmus, 46, 47*t*
Horner syndrome, 78, 81–82, 86, 307, 458, 1150, 1159
Hospice care, 1640
Hot cross bun sign, 835–837, 836*f*
Hounsfield units, 184, 184*t*
Hourglass tumors, spinal, 1089
H reflex, 245–246
HRT. *See* Habit reversal training
HSE. *See* Herpes simplex encephalitis
HSP. *See* Hereditary spastic paraplegia
HSV. *See* Herpes simplex virus
HTLV-1. *See* Human T-lymphotropic virus 1
HTT. *See* Huntingtin protein
Human epidermal growth factor receptor 2 (HER2) inhibitors
for metastatic breast cancer, 1043
neurologic complications of, 1109
Human ewingii ehrlichiosis (HEE), 624, 624*t*, 627–628
Human granulocytic anaplasmosis (HGA), 627–628
Human herpesvirus-6 (HHV-6), 679*t*, 683, 693, 702, 1299
Human herpesvirus-7 (HHV-7), 702
Human immunodeficiency virus (HIV) infection, 690–710
AIDS-defining illnesses in, 690
antiretroviral therapy for, 693, 697, 706–708
adverse neurologic effects of, 706–708, 949, 1583
categories, agents, and combination drugs in, 707*t*
pediatric, 1582–1583
brain abscess in, 613
classification of disease in, 690–691, 690*t*
CNS pathogenesis in, 693–694
cytomegalovirus in, 683, 693, 702, 1164
dementia in, 98, 694–697
CSF examination in, 696
differential diagnosis of, 697
imaging in, 696, 696*f*
management of, 697
in older children, 1580
pathology of, 696–697
diagnosis of, 938*t*, 1581–1582
infections, 699–706
initial approach in, 694
neurological HIV-related syndromes, 694–699
epidemiology in adults, 691, 691*t*
epidemiology in children, 691–692
eradication strategies ("shock and kill") for, 697, 708
etiology of, 692
focal mass lesions in, 156, 166–167, 166*f*, 167*t*
historical perspective on, 690
John Cunningham (JC) virus in, 684–685, 701–702, 1581
leukoencephalopathy in, 698
lymphoma in, 693, 706, 1056, 1580–1581, 1581*t*
management of, 706–708
meningitis in
bacterial, 608
fungal, 641–646
tuberculous and, 647–648
motor neuron disease in, 699
movement disorders in, 698, 700*t*
multiple sclerosis *versus*, 721–722
myelopathy in, 694, 698–699
myopathy in, 699
neoplasms in, 700*t*, 706
neurologic syndromes in, 694–695, 694*t*, 695*t*, 700*t*
neuropathy in, 938*t*, 945–946
neurosyphilis in, 648
nutritional and metabolic consequences in, 706
opportunistic infections in, 699–706, 700*t*, 1581
bacterial, 700*t*, 705
fungal, 700*t*, 703–704
mycobacterial, 705–706
parasitic, 704–705
viral, 700*t*, 701–703
outcomes of, 708
parenteral drug use and, 1316
pathobiology of, 692–694, 1580
pediatric, 691–692, 1579–1583
clinical manifestations of, 1580–1581
diagnostic testing in, 1579, 1581–1582
encephalopathy in, 1580
epidemiology of, 1579–1580
level 1 evidence on, 1586
management of, 1582–1583
neuroimaging in, 1581–1582, 1582*f*
opportunistic infections in, 1581
outcome of, 1583
primary CNS lymphoma in, 1580–1581, 1581*t*
staging system for, 1579–1580, 1580*t*
stroke in, 1581, 1581*f*
treatment side effects in, 1583
peripheral neuropathy in, 699, 700*t*
precautions for clinical and laboratory services in, 708
primary, 692
progression to AIDS, 692–693
psychosis with, 1593–1594
screening for, 691
seizures in, 698
stroke in, 697
test and treat for, 706
treatment of, 662, 693
Human monocytic ehrlichiosis (HME), 624, 624*t*, 627–628
Human T-cell lymphotropic virus-associated myelopathy, 1164
Human T-lymphotropic virus 1 (HTLV-1), 693, 702, 721–722, 1164
Human-to-human transmission, diseases of, 634–636. *See also specific diseases and infections*
Hummingbird sign, in progressive supranuclear palsy, 879
Hunt and Hess grading scale, for SAH, 343, 343*t*
Hunter Serotonin Toxicity Criteria, 1330, 1330*t*
Hunter syndrome, 1397, 1398*f*
Huntingtin protein (HTT), 863, 863*f*, 866, 868
Huntington disease (HD), 97, 861–870
behavioral (psychiatric) signs in, 864–866, 865*t*, 868
chorea of, 106, 854, 864–865, 865*t*, 866–867
clinical manifestations of, 864–865, 865*t*
cognitive impairment in, 864–865, 865*t*, 868
diagnosis of, 864–866
differential diagnosis of, 864
dystonia in, 804, 867
epidemiology of, 861
fluid biomarkers in, 866
gait disorder in, 130*t*, 865, 867
genetics of, 299, 861–862, 862*t*
genetic testing/counseling for, 297, 299*t*
gradations of, 862, 862*f*
histopathology of, 863, 863*f*
immunotherapy for, 868
juvenile, 865
level 1 evidence on, 869
management of, 866–867
measures of progression in, 866
mitochondrial function and oxidative stress in, 868
motor signs in, 864–865, 865*t*
neurochemistry of, 863–864
neuropathology of, 862–863, 862*f*
nonpharmacologic treatments for, 868
obsessive-compulsive symptoms with, 1609–1610
outcome of, 869
phenoconversion in, 864–865
structural and molecular imaging in, 864, 864*f*, 866, 867*f*
swallowing (choking) in, 865, 867
weight loss in, 867–868
Huntington disease–like 1, 858
Huntington disease–like 2, 858
Hurler syndrome, 1397
HUS. *See* Hemolytic uremic syndrome
Hutchinson sign, 681
Hydatid cysts, 654*t*
Hydralazine, for ICH (neurologic emergencies), 337*t*

Hydrocephalic (interstitial) edema, 1128, 1128*t*, 1129
Hydrocephalus, 1114–1126
acute, 1114
cerebral venous thrombosis and, 355
choroid plexus tumors and, 1547–1548
chronic, 1114
classification of, 1114, 1114*t*
communicating, 1114, 1114*t*, 1119–1120, 1120*f*
congenital *versus* acquired, 1114
dementia with, 97
diversion systems (shunts) for, 1115, 1115*f*, 1122–1125
algorithm for malfunctioning, 1124*f*
complications of, 1123–1125
infection, 1125
external, 1123
intraventricular hemorrhage and, 1115–1118, 1119*f*, 1123, 1355
level 1 evidence on, 1125
low-pressure, 1123
medulloblastoma and, 1554
normal-pressure. *See* Normal-pressure hydrocephalus (NPH)
obstructive, 139–140, 288, 1114, 1114*t*
obstructive, acute, 1115–1117
clinical features of, 1116
diagnosis of, 1116–1117
epidemiology of, 1115
pathobiology of, 1115–1116
stroke/IVH and, 1116, 1116*f*
treatment and outcomes of, 1117
tumor-related, 1116, 1117*f*
obstructive, congenital, 1117–1119
diagnosis of, 1118
MRI of, 1118, 1118*f*, 1119*f*
pathobiology of, 1117–1118, 1118*f*
treatment and outcomes of, 1118–1119
pineal region tumors and, 1074–1075
subarachnoid hemorrhage and, 346, 1115–1116, 1116*f*
tumor-related (ball and valve), 1116, 1117*f*
Hydrocephalus ex vacuo, 1114, 1114*t*
Hydrochlorothiazide
for Ménière disease, 598
for nondystrophic myotonias, 1002
Hydrocortisone
for ACTH deficiency, 1215
for adrenal insufficiency, 1222–1223
Hydroxychloroquine
myotoxicity of, 995*t*
for Q fever, 631
for Whipple disease, 635
2-Hydroxyglutarate, in magnetic resonance spectroscopy, 200
5-Hydroxytrytophan, for myoclonus, 829*t*
Hydroxyurea
for essential thrombocythemia, 1240
for meningiomas, 1053–1054, 1054*t*
for polycythemia, 1231–1232
for sickle cell disease, 1230
Hydroxyzine, for anxiety disorders, 1611*t*, 1612
Hygroma, 425
Hyperactive delirium, 88, 90
Hyperacusis, 1394
Hyperadrenalism, 1223–1224
Hyperaldosteronism, 1223–1224, 1223*t*
Hyperalgesia, 65, 557*t*
Hyperammonemia, 1386–1387
neonatal, 1386–1387
in older children and adults, 1387
valproate-associated, 1387
Hyperbaric oxygen
for decompression illness, 1353
for hearing loss, 50
for malignant otitis externa, 621–622
for radiation injury, 1342
Hypercalcemia, parathyroid disorders and, 1225
Hypercarbia, 1208–1210
Hypercarbic respiratory failure, 1208
Hypercholesterolemia, management, for stroke prevention, 402–403, 408
Hypercoagulable states, 1242–1243
Hypercortisolism, 1217. *See also* Cushing disease
Hyperekplexia, 107–108, 824, 825*t*, 826*t*, 827, 1005
Hyperemesis gravidarum, 1286
Hyperemia, 1128
Hyperesthesia, 65
Hyperexcitability, disorders of, 1004, 1004*t*, 1007–1009, 1102. *See also specific disorders*
Hyperexcitability, muscle, 1004, 1004*t*
Hyperglycemia, as contraindication to tPA, 141–142
Hyperkalemic periodic paralysis, 998, 999*t*, 1000–1001, 1000*t*
Hyperkinetic movements, 104–108, 106*t*
amplitude continuum for, 106*f*
speed continuum for, 106*f*
Hyperlipidemia, management, for stroke prevention, 402–403, 408
Hyperopia, 259
Hyperostosis, 1085–1086
Hyperoxia, 1208–1210
Hyperparathyroidism, 994*t*, 1215*t*, 1225
Hyperpathia, 307
Hyperpituitarism, 1217
Hyperpolarization, in MRI, 201–202
Hyperprolactinemia, 1217, 1342
Hypersensitivity, microglia-mediated, 560
Hypersomnias, 1186–1189
Hypertension
control of
for ICH, 132, 133, 138–139, 336–337
for stroke (AIS), 133
dietary intervention for, 401–402
induced, for spinal cord infarction, 1166
intracerebral hemorrhage with, 332–333, 409
intracranial. *See* Idiopathic intracranial hypertension (IIH); Intracranial pressure (ICP)
management, for stroke prevention, 402, 408
in pregnancy, 384–387, 1289–1290
severe, as contraindication to tPA, 141, 141*t*
stroke and, 316, 409
subarachnoid hemorrhage and, 347
traumatic brain injury and, 433
vascular parkinsonism in, 902
Hypertensive encephalopathy, 135*t*, 384–387
Hypertensive-hypervolemic-hemodilution (triple-H therapy), 349–350
Hyperthermia, malignant, 1004*t*, 1008, 1331
Hyperthyroidism, 1215*t*, 1220–1221
myopathies in, 992–993, 993*t*, 1220
neuropathy in, 944
Hypertonia
differential diagnosis of, 800–802, 802*t*
infant, cocaine and, 1585
Hypertonic saline
for brain edema, 1135
for ICP management, 139, 338, 430–431, 1132–1133, 1250
Hypertrophic pachymeningitis, 1055
Hyperventilation, 1209–1211
coma and, 171, 175, 176*t*
for ICP management, 139, 432, 1132–1133, 1211
neurogenic, 1208*f*
neurologic effects of, 1209
for traumatic brain injury, 427
Hyperviscosity syndrome, 1234
Hypnic hallucinations, 1187–1189
Hypnic headache, 524*t*, 534
Hypnic jerk, 1188, 1192
Hypoactive delirium, 88, 90
Hypocalcemia
neonatal seizures in, 1361*t*
parathyroid disorders and, 1224–1225
Hypocalcemic tetany, 1008
Hypochondriasis, 1615*t*, 1616, 1618–1619
Hypocretin, 1185, 1188, 1189*t*
Hypoglossal nerve (CN XII)
anatomy of, 925
examination of, 36
injury (neuropathy) of, 454*t*, 457, 925, 925*f*
Hypoglycemia
in alcoholism, 1308
in alcohol withdrawal, 1306
profound, hypoxic-ischemic encephalopathy in, 325
seizures with, 60
syncope with, 54
Hypoglycorrhachia, 280, 280*t*
Hypohidrosis, 976, 977, 1174
Hypokalemic periodic paralysis, 998–1000, 999*t*, 1000*t*
Hypokinesia, 104
Hypokinetic movements, 104
Hypomania, 1599
Hypomelanosis of Ito, 1465–1466
Hyponatremia, 1255–1258
acute, osmotic edema with, 1129
acute symptomatic, 1257
chronic, 1257–1258
clinical features of, 1255–1256
diagnosis of, 1256–1257, 1256*f*, 1257*t*
management of, 1257–1258, 1259–1260
myelinolysis in, 1258–1260, 1258*f*, 1259*f*
in subarachnoid hemorrhage, 347
Hypoparathyroidism, 1215*t*, 1224–1225
Hypophonia, 878, 1317
Hypopituitarism, 1215–1217, 1215*t*
Hypopnea, 1190
Hyposomia, 916
Hypotelorism, 1369
Hypotension
intracranial, spontaneous, headache caused by, 73
orthostatic. *See* Orthostatic hypotension
in potential organ donors, 182
prolonged, hypoxic-ischemic encephalopathy in, 324–325
spinal cord injury and, 444, 447–448
traumatic brain injury and, 427, 433

Hypothalamic hamartomas, 1513
Hypothalamic-pituitary-adrenal (HPA) axis, 1596–1597, 1597*f*
Hypothalamus
focal mass lesions of, 153*f*
hormones produced by, 1215
Hypothermia, in pediatric TBI, 1575
Hypothermia, therapeutic
checklist/protocol for, 328, 328*t*
for ICP management, 432, 1133, 1251
for malignant MCA infarction, 315
monitoring of, 328, 329*t*
for neuroprotection/HIE prevention, 324, 325*t*, 328–330
prognosis in, 329–330, 329*f*, 330*t*
for status epilepticus, 62
Hypothyroidism, 1215*t*, 1219–1220
congenital, 1219
dementia in, 97, 98, 100
myopathies in, 992–993, 993*t*, 1219
neuropathy in, 938*t*, 944, 1219
pediatric brain tumors and, 1561
Hypotonia
definition of, 1417
infant, 1417–1423. *See also* Floppy infant
Hypotonia-cystinuria syndrome, 975
Hypoventilation, 1207–1210
assessment of, 1209
coma and, 175, 176*t*
neurologic effects of, 1209
Hypoventilatory disorders, sleep-related, 1191
Hypovolemia
spinal cord injury and, 447
in subarachnoid hemorrhage, 347
Hypovolemic hyponatremia, 1257
Hypoxemia, 1207–1210
Hypoxemic disorders, sleep-related, 1191
Hypoxemic respiratory failure, acute, 1208
Hypoxia, 1208–1210
assessment of, 1209
brain, 291–293
hypoxic-ischemic encephalopathy in, 325
myoclonus after, 824, 826
neurologic effects of, 1209
spinal cord injury and, 444
traumatic brain injury and, 427
Hypoxic-ischemic encephalopathy (HIE)
adult, 324–331, 1209
clinical features of, 325–326
definition of, 324
diagnosis of, 326–327
EEG findings in, 327
epidemiology of, 324
imaging of, 326–327, 326*f*
level 1 evidence on, 330
outcome of, 329–330, 329*f*
pathobiology of, 324–325
somatosensory evoked potentials in, 327, 327*f*
therapeutic hypothermia for preventing, 324, 325*t*, 328–330
treatment of, 327–328
perinatal, 1357–1359
clinical manifestations of, 1358, 1358*t*
diagnosis of, 1358
epidemiology of, 1357
hypotonia in (floppy infant), 1358, 1419
management of, 1358–1359
neuroimaging in, 1358, 1359*f*
outcome of, 1359
pathobiology of, 1357–1358
seizures with, 1360, 1361
Hypsarrhythmia, 575
Hysteria, 175

I

IBM. *See* Inclusion body myositis
Ibrutinib, for primary CNS lymphoma, 1060
Ibuprofen, for migraine, 526*t*
Ice-cream headache, 533
Ice test, in myasthenia gravis, 966
ICH. *See* Intracerebral hemorrhage
iCJD. *See* Iatrogenic Creutzfeldt-Jakob disease
ICP. *See* Intracranial pressure
Idarucizumab, anticoagulation reversal with, 139*t*, 336
Ideational apraxia, 305
Ideomotor apraxia, 305
Idiogenic osmoles, 1129
Idiopathic focal epilepsies of childhood, 1510
Idiopathic generalized epilepsy syndromes, 574
Idiopathic inflammatory myopathies (IIMs), 979–988. *See also specific types*
classification/criteria, 979, 979*t*
subtypes of, 979
Idiopathic intracranial hypertension (IIH), 73, 226, 1135–1138
causes of, 1135–1136
clinical features of, 1136
diagnosis of, 1136–1137
drug- and toxin-induced, 1135
neuroimaging in, 73, 1136, 1136*t*
pathobiology of, 1136
risk factors for, 1135
treatment of, 1137–1138, 1137*f*
vitamin A and, 1135, 1138, 1281–1282
Idiopathic neuropathy, 950
ID Migraine, 71
IEBT. *See* Inner ear barotrauma
IENFD. *See* Intraepidermal nerve fiber density
IgA. *See* Immunoglobulin A
IgG. *See* Immunoglobulin G
IgM. *See* Immunoglobulin M
IIH. *See* Idiopathic intracranial hypertension
ILAE. *See* International League Against Epilepsy
Iliohypogastric nerve
anatomy of, 933
injury of, 460*t*, 461, 933
Ilioinguinal nerve
anatomy of, 934
injury of, 460*t*, 461, 934
Illness anxiety disorder, 1615*t*, 1616, 1618–1619
Iloperidone, 1591*t*
Imaging. *See specific modalities and disorders*
Imatinib, for meningiomas, 1054, 1054*t*
IMDs. *See* Inherited metabolic disorders
Iminoglycinuria, 1389*t*
Imipramine
for anxiety disorders, 1611*t*
for cataplexy, 1189
for depression, 1602
Imitation behavior, 306
Immediate decline, in neurologic disease, 1636
Immune checkpoint inhibitors
for brain metastases, 1043–1044
myasthenia gravis induced by, 975
myotoxicity of, 994–995
neurologic complications of, 1110–1111, 1110*t*
for primary CNS lymphoma, 1060
Immune-mediated necrotizing myopathy (IMNM), 979, 983*t*, 985–986, 985*t*, 987, 987*f*
Immune reconstitution inflammatory syndrome (IRIS), 684–685, 697, 701
Immune-related adverse events (irAEs), 975
Immunofluorescent study, nerve, 286
Immunoglobulin, intravenous. *See* Intravenous immunoglobulin
Immunoglobulin A (IgA), neuropathy associated with, 942
Immunoglobulin A (IgA) vasculitis, 371*t*, 378
Immunoglobulin G (IgG)
in arboviral infections, 666
in autoimmune encephalitis and meningitis, 755, 756–759, 763–764, 763*t*, 764*t*, 765*f*
in multiple sclerosis, 719–721
in viral diagnostics, 661–662
Immunoglobulin G (IgG)-related disease, 757
Immunoglobulin M (IgM)
in arboviral infections, 666
neuropathy associated with, 938*t*, 941, 942, 943*f*
in viral diagnostics, 661
Immunosuppressive measles encephalitis, 675
Immunosuppressive therapy. *See also* Steroid(s); *specific drugs*
for amyloid β-related angiitis, 374
for autoimmune encephalitis and meningitis, 767, 768*t*–770*t*
for Behçet syndrome, 379
for chorea, 855–856
for CNS vasculitis in rheumatoid arthritis, 380
for dermatomyositis, 981–982
for eosinophilic granulomatosis with polyangiitis, 378
for giant cell arteritis, 375
for granulomatosis with polyangiitis, 377
for inclusion body myositis, 984
long-term effects of, 1301
for myasthenia gravis, 969–972
neurotoxicity of, 1299–1300, 1300*f*
for polyarteritis nodosa, 376
for primary angiitis of CNS, 372–373
for sarcoidosis, 776, 777*t*
for Sneddon syndrome, 397
for Susac syndrome, 395
for transplantation, neurologic complications of, 1298–1302
Immunotherapy. *See also specific therapies*
neurologic complications of, 1110–1111
for pediatric brain tumors, 1545, 1553, 1557
Impact seizures, 575
Impedance audiometry, 262
Implied consent, 1639
Impulse control disorders (ICDs), 887–888
Inactivated polio vaccine (IPV), 663, 664
Inappropriate therapies, in end-of-life care, 1639–1640
Incidence, 1–2
Inclusion body myositis (IBM), 911, 912*t*, 979, 983–985
clinical features of, 983
diagnosis of, 983–984
diagnostic criteria for, 984, 984*t*
differential diagnosis of, 983*t*, 984, 984*t*
epidemiology of, 983

Inclusion body myositis (IBM) *(Continued)*
management of, 984–985
muscle pathology in, 986–987, 987*f*
pathobiology of, 983
sporadic, 983–985
Incomplete interference pattern, in EMG, 249, 249*f*
Incomplete penetrance, genetic, 298
Incomplete white matter infarction, 393
Incontinence
fecal, 1264
urinary, 1264–1265, 1265*f*. *See also* Bladder dysfunction
Incontinentia pigmenti, 1464–1465, 1464*f*, 1465*f*
Incontinentia pigmenti achromians, 1465–1466
Indapamide, for stroke prevention, 408
Indinavir, 707*t*
Indirect hits mutations, 1443
Indomethacin
for hemicrania, 75, 532, 533
for primary cough headache, 533
for primary exertional headache, 533
for primary sex headache, 533
for primary stabbing headache, 534
Inebilizumab
for autoimmune encephalitis and meningitis, 770
for neuromyelitis optica spectrum disorders, 731, 752, 752*t*
Ineffective therapies, in end-of-life care, 1639–1640
Infant botulism, 637, 1417, 1422
Infantile encephalopathy with cherry-red spots, 1394
Infantile epilepsy, 1502–1514
Infantile GM1 gangliosidosis, 1395, 1395*f*
Infantile GM2 gangliosidosis, 1394
Infantile metachromatic leukodystrophy, 1399–1400
Infantile neuronopathic Gaucher disease, 1395–1396
Infantile Niemann-Pick disease, 1396
Infantile-onset spinocerebellar ataxia, 1450
Infantile reversible COX-deficient myopathy, 1444–1445
Infantile spasms (West syndrome), 575
Infection. *See also specific infections*
in alcoholics, 1309
cerebral venous thrombosis in, 354, 355
CNS vasculitis in, 381
congenital, floppy infant in, 1419
hematopoietic cell transplantation and, 1235–1237
myelopathy in, 1160*t*–1161*t*, 1163–1164
neurologic history in, 21*t*
neuropathy associated with, 938*t*, 945–946
opportunistic
in HIV, 699–706, 700*t*
in HIV, pediatric, 1581
in organ transplantation, 1255, 1299
psychosis with, 1593–1594
traumatic brain injury and, 435
Infectious Diseases Society of America, 607, 608–609, 647
Inferior gluteal nerve
anatomy of, 931
injury of, 461
Inflammation, neurogenic, 558
Inflammatory bowel disease, 1267
Inflammatory disorders. *See also specific disorders*
cerebrospinal fluid analysis in, 280–281
Inflammatory myelopathy, 147, 150, 1160*t*, 1164–1165, 1165*f*
Inflammatory myopathy, 979–988. *See also specific types*
classification/criteria, 979, 979*t*
differential diagnosis of, 981, 983*t*, 984, 984*t*
EMG findings in, 247
level 1 evidence on, 987
muscle pathology in, 986–988, 986*f*, 987*f*
Inflammatory soup, 558
Infliximab, for sarcoidosis, 776, 777*t*
Influenza, 675
neurologic complications of, 675
treatment of, 662, 675
Informed consent, 1638–1639, 1638*t*
Infratentorial structural lesions, coma from, 174
Infratentorial tumors, pediatric, symptoms of, 1541
Infundibulomas, 1064
Ingestion anthrax, 633–634
Inhalant use/abuse, 1315
Inhalation anthrax, 634
Inherited disorders. *See specific disorders*
Inherited metabolic disorders (IMDs), 1385–1409
classification of, 1385
large molecule, 1385, 1393–1407
small molecule, 1385–1393
Inhibition, 274
loss, in central sensitization, 560
Injection anthrax, 633–634
Injury-induced plasticity, 1630–1631
Inner ear barotrauma (IEBT), 1350–1353, 1352*t*
Inner mitochondrial membrane (IMM)
defects in lipid milieu of, 1445, 1448–1449
indirect hits mutations and, 1443
INO. *See* Internuclear ophthalmoplegia
Inositol/myoinositol, in magnetic resonance spectroscopy, 200
Inotersen, for amyloid neuropathy, 943, 1174
Insertional activity, in electromyography, 246–247
Insomnia, 1185–1186
chronic, 1185
depression and, 1599
diagnosis of, 1185–1186
fatal familial, 507, 507*t*, 514, 515–516
management of, 1186
medications for, 1186, 1187*t*
paradoxical, 1186
short-term, 1185
Inspection, in motor examination, 36
Insulin therapy
for hyperkalemic periodic paralysis, 1001
for traumatic brain injury, 434
Integrase inhibitors, 707*t*
Integrated diagnoses, of gliomas, 1019, 1021
Intellectual ability, tests of, 271–275
Intellectual disability, 1428*t*, 1429–1430
autism spectrum disorders and, 1436–1437
chromosomal disorders and, 1410–1411
definition and classification of, 1429
Intensity-modulated radiation therapy, 1544
Intensive Care Delirium Screening Checklist (ICDSC), 90, 91*t*
Intensive care unit (ICU)
delirium in, 88, 90–93, 90*t*, 91*t*
ICH management in, 335
induced altered states of consciousness in, 168
monitoring in, 288–296
SAH management in, 349–350, 349*t*
sepsis management in, 1201, 1204–1205
stroke care in, 315–317
TBI management in, 433–434, 433*f*
Intentional falsification, 1623
Intentionality, in pediatric brain injury, 1572
Intention tremor, 107, 107*f*, 108
Intercostal nerve, transfer to musculocutaneous nerve, 467
Interference pattern, in EMG, 246, 248–249, 249*f*
Interferon α
for Behçet syndrome, 379
for meningiomas, 1054*t*
Interferon β
for multiple sclerosis, 725*t*, 726
for multiple sclerosis in pregnancy, 1292, 1292*t*
Interleukin-6 inhibitors, for neuromyelitis optica spectrum disorders, 752–753, 752*t*
Internal border zone infarction, 306, 306*f*
Internal carotid artery aneurysm, 344
Internal carotid artery infarction, 305*t*, 306
Internal neurolysis, 466–467, 466*t*, 467*f*
International 10-20 system, for EEG, 230, 230*f*
International Association for the Study of Pain (IASP), 549–551, 553, 561, 561*t*
International Chapel Hill Consensus Conference, 370, 371*t*
International Classification of Functioning, Disability and Health (WHO), 1629
International Classification of Sleep Disorders, 794, 794*t*
International Headache Society, 70, 522
International HIV Dementia Scale, 695
International League Against Epilepsy (ILAE), 567, 569, 578–579, 1503–1504
International PCNSL Collaborative Group (IPCG), 1057–1058, 1058*t*, 1060
International Standards for Neurological and Functional Classification of Spinal Cord Injury, 445, 446*t*
Internuclear ophthalmoplegia (INO), 81, 85, 171
Interstitial (hydrocephalic) edema, 1128, 1128*t*, 1129
Interstitial radiation implants, 1545
Interventional neurology. *See* Neuroendovascular surgery (NES)
Intervertebral disk disease, 1145–1152
CT in, 1150
diagnosis of, 1149–1150
electrodiagnostic studies in, 1150
epidemiology of, 1145
expert referral for, 1150
historical perspective on, 1145
lateral herniation, 1146, 1146*f*
level 1 evidence on, 1152
MRI of, 1146*f*, 1148*f*, 1149–1150, 1149*f*
myelography in, 1150
myelopathy with, 1149
pathophysiology of, 1145–1147, 1146*f*
treatment of, 1150–1151
Intestinal transplantation, 1301
Intima-media thickness, carotid, 210–211, 211*f*

Intoxication
alcohol, 1303–1304, 1303*t*, 1304*t*
drug, 1313–1318
pathologic, 1304
Intra-arterial thrombolysis, 312
Intracellular edema, 1128
Intracerebral hemorrhage (ICH), 332–341
advanced imaging in, 140
anemia in, 1228
anticoagulation-associated, 409, 1241
anticonvulsant therapy in, 140, 335*t*, 338
arteriovenous malformations and, 362, 409–410
atrial fibrillation and, 409, 410*f*
AVMs and, 225
bacterial meningitis and, 609
brain edema with, 135, 138–139, 334, 1130
cavernous malformations and, 366–367
cerebral amyloid angiopathy and, 332, 333, 333*f*, 334*t*, 409
cerebral venous thrombosis and, 355
clinical manifestations of, 334
craniotomy for, 338, 339*f*
CT of, 134–135, 137*f*, 334–335, 335*f*
definition of, 332, 332*f*
diagnosis of, 334–335
differential diagnosis of, 133, 135*t*, 333, 333*t*
dural arteriovenous fistulas and, 364–365
endovascular therapy and, 314
epidemiology of, 332
external ventricular drainage in, 139–140, 338
first hour after, 132–144
hydrocephalus with, 1116
ICU disposition for, 140
level 1 evidence on, 340
medical management of, 335–338
blood pressure control, 132, 138–139, 335*t*, 336–337
checklist for, 335*t*
hemostatic therapy, 336
ICP control, 132, 139–140, 335*t*, 337–338
reversal of anticoagulation, 132, 137–138, 139*t*, 335*t*, 336, 1242
medical support in, 338
minimally invasive surgery in, 338–339, 339*f*
moyamoya disease and, 391
MRI of, 191, 193*t*, 333*f*, 334–335
pathobiology of, 333–334
pediatric, 1572, 1573*f*
perinatal, 1515–1518
platelet dysfunction in, 137–138, 139*t*, 1240
post-CT management of, 137–140
postoperative, in cardiac procedures, 1197
pre-CT assessment and management of, 133–134
initial history in, 133
initial survey and vital signs in, 133–134
intravenous access and admission labs in, 133
in pregnancy, 1291–1292
prehospital care of, 335
primary, 332, 333*t*
prognosis in, 340, 340*t*
risk factors for, 332–333, 333*t*
risk of, issues related to, 409
secondary, 332, 333*t*
secondary prevention of, 339–340
sickle cell disease and, 1230
stroke with, 401, 409–410
surgical hematoma evacuation in, 140, 338–339
surgical management of, 338–339
symptoms and signs of, 132, 132*t*
thrombocytopenia and, 1237, 1237*f*
thrombolysis for, 338
traumatic brain injury and, 423–424, 424*f*
Intracerebral hemorrhage (ICH) score, 340, 340*t*
Intracranial (cerebral) aneurysms
arteriovenous malformations and, 362
CT of, 343
endovascular treatment of, 221–224
coiling for, 222, 223*f*
flow-diverting stents for, 222–223, 223*f*
intraluminal support device (PulseRider) for, 223
in SAH patients, 348, 348*t*
stent-assisted and balloon-assisted coiling for, 222
strategies for, 222–223
surgical treatment *versus*, 222
for unruptured aneurysms, 221–222
Woven EndoBridge (WEB) device for, 223, 223*f*
headache caused by, 71–72
MRA of, 195, 195*f*, 343
pathology and epidemiology of, 342–343
rebleeding of, 345, 345*f*
renal disease and, 1254
subarachnoid hemorrhage with, 223, 342–343, 343*t*, 410. *See also* Subarachnoid hemorrhage
Intracranial hypertension. *See also* Intracranial pressure (ICP)
idiopathic, 73, 226, 1135–1138. *See also* Idiopathic intracranial hypertension (IIH)
Intracranial hypotension, spontaneous. *See* Spontaneous intracranial hypotension (SIH)
Intracranial pressure (ICP), 288–291
CPP and, 1132, 1134*f*
increased
acute liver failure and, 1249–1251
bacterial meningitis and, 609
brain abscess and, 614, 618
cardiac arrest and, 327
cerebral venous thrombosis and, 354–355, 359
chronic meningitis and, 640
and CPP, 430, 432*f*
cryptococcal meningitis and, 641, 644
focal mass lesions causing, 152, 159, 167
ICH causing, 132, 139–140, 337–338
IIH causing, 73
mass effect with, 139, 337
metastatic disease and, 1036, 1038
papilledema with, 84, 87
pathophysiology of, 288, 288*f*
pediatric brain tumors and, 1540
secondary neurologic injury with, 288
signs and symptoms of, 288
traumatic brain injury and, 427, 430–432
traumatic brain injury in children and, 1575, 1577*t*
treatment thresholds for, 288–289
low. *See* Spontaneous intracranial hypotension (SIH)
management of, 337, 430–432, 1132–1133
in acute liver failure, 1250–1251
advanced, for refractory pressure, 1133
barbiturates for, 432
hypertonic saline for, 139, 338, 430–432, 1132–1133, 1250
hyperventilation for, 139, 432, 1132–1133, 1211
mannitol for, 139, 338, 430–432, 1132–1133, 1137, 1250–1251
pentobarbital coma for, 1133
SIBICC protocol for, 430, 431*f*
therapeutic hypothermia for, 432, 1133, 1251
tiered (stepwise), 1132, 1133*t*, 1134*t*
monitoring of, 139–140
external ventricular drainage for, 290–291
indications for, 291, 291*t*
intraparenchymal, 291
normal, 288
physiologic principles of, 288–290
super-refractory, salvage interventions for, 1133
ventilation manipulation and, 1211
Intracranial pressure waveform, 289, 289*f*
Intracranial stenosis, ultrasound of, 213
Intracranial stenting, 226–227
Intracranial ultrasound, 208, 212–215
in acute liver failure monitoring, 1250
in AVM detection, 213–214
in cerebral microemboli detection, 214
in cerebral vasomotor reactivity testing, 214–215
in childhood stroke, 1520–1521
indications for, 212, 213*t*
in intracranial stenosis and occlusion, 213, 214*f*
limitations of, 215
in moyamoya disease, 392
pulsatility index in, 212, 212*f*
resistance index in, 212, 212*f*
sensitivity and specificity of, 213
in sickle cell disease, 213, 1229–1230
in sonothrombolysis, 215
in vasospasm detection in subarachnoid hemorrhage, 214, 349
Intradural spinal tumors, 198–199, 1089–1091, 1090*f*, 1093, 1093*f*, 1097, 1098
Intraepidermal nerve fiber density (IENFD), 286–287
Intramedullary spinal tumors, 1089, 1090*f*, 1093–1094, 1097, 1098
metastatic, 1094
primary, 1093–1094, 1094*f*, 1095*f*
Intranasal mucosal contact points, facial pain attributed to, 540
Intraoperative monitoring, EEG in, 238
Intraparenchymal ICP monitors, 291
Intrathecal chemotherapy (ITC), 1038, 1046, 1545
Intrathrombus retrievable stent devices, 312–313
Intravascular large cell lymphoma, 380–381
Intravascular low-intensity ultrasound, 215
Intravenous immunoglobulin (IVIG)
for autoimmune encephalitis and meningitis, 767, 768*t*
for complex regional pain syndrome, 552*t*, 553
for dengue, 666
for dermatomyositis, 981
for Guillain-Barré syndrome, 937
for inclusion body myositis, 984
for multifocal motor neuropathy, 941
for myasthenia gravis, 970*t*, 971

Intravenous immunoglobulin (IVIG) *(Continued)*
for myelin oligodendrocyte glycoprotein spectrum disease, 732
for paraneoplastic syndromes, 1104
for stiff person syndrome, 1006
for West Nile virus infection, 668
Intravenous regional blockade (IVRB), for complex regional pain syndrome, 552*t*
Intraventricular hemorrhage (IVH)
CT of, 135, 137*f*
HIV-associated, in children, 1581, 1581*f*
hydrocephalus with, 1115–1118, 1119*f*, 1123
neonatal
clinical manifestations of, 1355–1356
epidemiology of, 1355
grading of, 1116, 1355, 1356*f*, 1357
hydrocephalus with, 1115–1118, 1119*f*, 1123
management of, 1357
MRI of, 1119*f*, 1357
outcome of, 1357
prevention of, 1355, 1357
seizures with, 1360, 1361
ultrasound of, 1356–1357, 1356*f*
Intubation
criteria for, 1209–1210, 1210*t*
extubation from, 1213, 1213*t*
pneumonia associated with, 1211–1212
rapid sequence, 1210–1211
Intuniv, for ADHD, 1431
Invasive aspergillosis, 646
Involuntary movements, 103–109
chorea. *See* Chorea
description of, 104, 105*t*
diagnosis of, 108
dystonia. *See* Dystonia
emergencies, 108, 109*t*
flow diagram for evaluating, 104*f*
focused examination of, 104
focused history on, 103–104, 103*t*
functional, 108, 108*t*
hyperkinetic, 104–108, 106*t*
hypokinetic, 104
motor examination for, 36–37
neuroanatomy of, 108
paroxysmal, 103
RLS. *See* Restless legs syndrome
treatment of, 108
tremor. *See* Tremor
Iodinated contrast
for CT, 187–188
nephrotoxicity of, 187–188, 188*t*
premedication strategies for, 187, 187*t*, 188*t*
Iodine-123 (^{123}I), 203
Ioflupane (DaTscan), 204*t*, 205, 205*f*, 473*t*, 496, 496*f*, 837
Ion channel(s)
disorders of (channelopathies), 998–1003
in neuropathic pain, 559
Ion channel antibodies, ataxias resulting from, 838, 843
Ionic edema, 1129
Ionizing radiation, injury from. *See* Radiation injury
Ipilimumab
for brain metastases, 1043
neurologic complications of, 1110
IQ, 271–272, 1429–1430
Irinotecan
for meningiomas, 1053–1054, 1054*t*
for metastatic disease, 1042
for pediatric tumors, 1552, 1556
for pilocytic astrocytomas, 1024
IRIS. *See* Immune reconstitution inflammatory syndrome
Iris hamartoma, 1457, 1458*f*
Iron deficiency, 1278*t*, 1282
in intracranial hypertension, 1135
in restless legs syndrome, 794, 795
Iron metabolism disorders, 1392–1393
Iron therapy, for restless legs syndrome, 795, 797*t*, 798
Irregular sleep-wake type of circadian rhythm disorder, 1192
Irritability, in Huntington disease, 865–866, 868
Irritable bowel syndrome, 1267
Isaac syndrome, 1004*t*, 1007–1008, 1102
Ischemia, in acute spinal cord syndromes, 147, 150
Ischemic brain edema, 1129
Ischemic penumbra, 133, 140
Ischemic stroke, acute. *See* Acute ischemic stroke (AIS)
Ishihara color plates, 79
Isocitrate dehydrogenase (*IDH1* and *IDH2*) mutations, and gliomas, 1020–1021, 1020*t*, 1024–1031, 1537, 1537*f*, 1538*f*
Isolated dystonia, 803
Isometric tremor, 107, 107*f*
Isoniazid
neuropathy induced by, 949
for tuberculosis, 648
Isovaleric aciduria, 1388–1389
Istradefylline, for Parkinson disease, 888
Itraconazole
for American trypanosomiasis, 655
for blastomycosis, 646
for coccidioidomycosis, 645
for histoplasmosis, 646
IVH. *See* Intraventricular hemorrhage
IVRB. *See* Intravenous regional blockade
Ixabepilone, neuropathy induced by, 949

J

JAE. *See* Juvenile absence epilepsy
Jakob disease. *See* Creutzfeldt-Jakob disease
Jamestown Canyon virus, 665, 670
Japanese encephalitis virus, 667*t*, 668, 1163
JCV. *See* John Cunningham (JC) virus
Jeavons syndrome, 571, 1511
Jerk
hypnic, 1188, 1192
myoclonic. *See* Myoclonus
Jerk-locked back-averaging technique, 825
Jerk nystagmus, 46, 47*t*, 81
Jet lag, 1192
Jitter, in EMG, 968
JME. *See* Juvenile myoclonic epilepsy
John Cunningham (JC) virus, 506, 683–686
clinical features of infection, 684–685
diagnosis of, 685
hematopoietic cell transplantation and, 1236
HIV-associated, 684–685, 701–702, 1581
MRI in infection, 685, 685*f*
neuropathology of, 662, 685, 686*f*
pathobiology of, 684
transplantation-related, 1255
treatment and prognosis for, 685–686
Joint position sensation, 41, 41*f*
Joubert syndrome, 1367, 1378–1379
Jugular paragangliomas, 1084
Jugular venous oxygen saturation ($SjvO_2$), 291–292
Juvenile absence epilepsy (JAE), 574, 1511
Juvenile metachromatic leukodystrophy, 1400, 1400*f*
Juvenile myoclonic epilepsy (JME), 572, 574, 1511
Juvenile neuronopathic Gaucher disease, 1396
Juvenile nonneuronopathic Niemann-Pick disease, 1396

K

Kallmann syndrome, 1375
Kaposi sarcoma, 706
Kawasaki disease, 371*t*, 376
KCNQ2 encephalopathy, 1506
Kearns-Sayre syndrome (KSS), 845–846, 1016–1017, 1446*t*, 1447, 1447*f*, 1451–1452
Kennedy disease, 912, 1262
Keraunoparalysis, 1348
Kernicterus, 859*f*, 1426
Kernig sign, 71, 343, 605
Kernohan notch, 172, 425
Ketamine
for cholinergic toxicity, 1329
for neuropathic pain, 563
for NMDA receptor encephalitis, 760
and psychosis, 1593
for rabies, 677
for refractory status epilepticus, 62, 62*t*
Ketoacidosis, alcoholic, 1309
Ketoconazole, for Cushing syndrome, 1223
Ketogenic diet, 1386, 1510
for epilepsy, 569
Ketorolac, for migraine, 74
Kidney (renal) disease, 1253–1261. *See also specific diseases*
Kinesia paradoxica, 879
Kinetic tremor, 107, 107*f*
King's College Criteria, for acute liver failure, 1251, 1251*t*
Kinsbourne disease, 828
Kjer disease, 1449, 1450
Kleine-Levin syndrome, 1189
Klein-Lisak-Andersen syndrome. *See* Andersen-Tawil syndrome
Klippel-Trenaunay syndrome, 1464
Klumpke palsy, 929, 1420
Konzo, 1333
Korsakoff syndrome, 1306–1307, 1306*t*
Krabbe disease, 1394, 1399, 1400
Krabbe-Weber-Dimitri disease, 368
Kraepelin, Emil, 476
Kratom, 1313
Krebs cycle, 1011–1012
k-space, in MRI, 190, 192*f*
KSS. *See* Kearns-Sayre syndrome
k-trans, 200
Kufor-Rakeb syndrome, 1393
Kufs disease, 97
Kugelberg-Welander disease, 1469, 1469*t*. *See also* Spinal muscular atrophies (SMAs)
Kunjin virus, 667*t*
Kuru, 506, 507, 507*t*, 516

L
L-2-hydroxyglutaric aciduria, 1389–1390
Labetalol
for ICH, 139, 337, 337*t*
for paroxysmal sympathetic hyperactivity, 1180*f*
for paroxysmal sympathetic storming, 1200*t*
for preeclampsia/eclampsia, 1290
Laboratory testing. *See specific tests and disorders*
Labyrinthectomy, for Ménière disease, 599
Lacerations, cerebral, 423
Lacerations, spinal cord, 442–443
Lacosamide, 587
adverse effects of, 583–584
dosage and pharmacokinetics of, 584*t*, 587
for epilepsy, 582–585, 587
in pregnant patients, 1288
for neuropathic pain, 562*t*, 563
for seizures, 61
Lacrimation, 521
Lacrosse virus, 665, 670
Lactate
in bacterial meningitis, 608
in cerebral microdialysis, 293–294, 294*t*
in magnetic resonance spectroscopy, 200, 201*f*
Lactulose, for hepatic encephalopathy, 1247–1248, 1247*t*
Lacunar stroke, 303*f*, 304
Lacunar TIAs, 321
Lafora disease, 1404
Lambert-Eaton myasthenic syndrome, 637, 964, 976
paraneoplastic, 976, 1101*t*, 1102, 1105
repetitive nerve stimulation studies in, 250, 251
visual/extraocular effects of, 86
Laminar heterotopia, 1377
Lamivudine, 707*t*, 1583
Lamotrigine, 586
adverse effects of, 583, 586
for bipolar disorder, 1603
for chemotherapy-induced neuropathy, 1109*t*
for cranial neuralgias, 543, 544*t*
dosage and pharmacokinetics of, 584*t*, 586
for epilepsy, 581–585, 586
in breastfeeding patients, 1288–1289
in pregnant patients, 1287–1288
teratogenicity of, 1287*t*, 1288
for glossopharyngeal neuralgia, 924
for Lennox-Gastaut syndrome, 1509
for neuropathic pain, 562*t*, 563
for SUNCT/SUNA headaches, 532
for trigeminal neuralgia, 918
Lance-Adams syndrome, 325, 824
Landau-Kleffner syndrome (LKS), 1429, 1510
Language deficits. *See also* Aphasia; *specific disorders*
in Alzheimer disease, 480, 480*f*
in autism spectrum disorders, 1436–1437
in dementia, 99
in multiple sclerosis, 717
with muscle weakness, 114, 115*t*
Language delay, 1424, 1427–1429, 1428*t*
Language disorders, developmental, 1429
Language milestones, 1427–1428, 1428*t*
Language regression, 1429
Language testing, 29, 29*t*, 274
Lapatinib, for acoustic neuroma, 1082
Laquinomod, for Huntington disease, 868
Large-artery atherosclerosis, ischemic stroke with, 303–304, 303*f*
Large cell lymphoma, intravascular, 380–381
Large-fiber neuropathy, 936
Large-molecule metabolic disorders, 1385, 1393–1407. *See also specific disorders*
Large-vessel vasculitis, 371*t*, 374–375. *See also specific types*
Larva migrans, 654*t*, 658
Laryngeal (spasmodic) dystonia, 106, 802, 808–809, 815
Lasmiditan, for migraine, 526*t*, 528
Lassa and Luho virus, 677
Latah, 827
LATE. *See* Limbic-predominant age-related TAR DNA-binding protein 43 (TDP-43) encephalopathy
Latency, in nerve conduction studies, 244–245
Late-onset central hypoventilation with hypothalamic dysfunction, 1191
Lateral brainstem infarction syndromes, 308*t*
Lateral femoral cutaneous nerve
anatomy of, 934
injury of, 460*t*, 461, 934
Lateral geniculate nucleus, 77*f*, 85
Lateralized periodic discharges (LPDs), 232–233, 235*f*
Lateral medullary infarction, 307
Lateral pectoral nerve, 928, 928*f*, 928*t*
Lateral plantar nerve, 931
Late responses, in nerve conduction studies, 245–246, 246*f*
Latrepirdine, for Huntington disease, 868
LBDs. *See* Lewy body dementias
Lead toxicity, 936, 948, 1332
Leakage, contrast, 200
Learning disabilities, 1428*t*, 1430–1431
neurofibromatosis and, 1458, 1459
neuropsychological testing in, 276
Leber hereditary optic neuropathy (LHON), 1441, 1447
Lee Silverman Voice Therapy (LSVT)–BIG, 885
Leflunomide, for eosinophilic granulomatosis with polyangiitis, 378
Left ventricular assist device (LVAD), neurologic complications of, 1195–1197
Leg braces, exoskeletal, 1632, 1632*f*
Legius syndrome, 1456
Leigh syndrome (LS), 1447–1448
maternally inherited, 1446*t*, 1447
MRI in, 1447*f*
Lemborexant, 1186, 1187*t*
Lenalidomide, for primary CNS lymphoma, 1060
Lennox-Gastaut syndrome, 571, 575, 582, 1506, 1509
Lens, 77
LEOPARD syndrome, 1456
Leprosy, neuropathy in, 936, 945, 945*f*
Leptomeningeal heterotopias, 1377
Leptomeningeal metastases, 1045–1046, 1046*f*, 1093, 1094*f*, 1098, 1162
Leptospira, 630*t*, 632
Leptospirosis, 630*t*, 632
Lesch-Nyhan syndrome, 1390
Lesionectomy, for epilepsy, 589*t*, 590
Lethargy, 168
Letter fluency, 274
Leucine-rich glioma-inactivated protein (LGI1) encephalitis, 757, 763, 771
Leucovorin, for toxoplasmosis, 1237
Leukemia
acute lymphoblastic, 1232–1233, 1531
acute myeloid, 1234
acute promyelocytic, 1237
lymphoblastic, 1232–1234
Leukodystrophies, 1385, 1399–1402
globoid cell (Krabbe disease), 1394, 1399, 1400
metachromatic, 1397, 1399–1400, 1400*f*
Leukoencephalopathy
in CADASIL, 398–399
chronic, chemotherapy-induced, 1108*t*, 1109
delayed posthypoxic, 326
HIV-associated, 698
progressive multifocal, 684–686, 685*f*, 686*f*
radiation injury and, 1336, 1337, 1338*t*, 1340*f*
radiation therapy and, 1107–1108
Leukomalacia, periventricular, 1363–1364
Levator palpebrae, 78, 78*f*
Levetiracetam, 586
adverse effects of, 583–584, 586
for cranial neuralgias, 543, 544*t*
dosage and pharmacokinetics of, 584*t*, 586
for epilepsy, 581–585, 586
in breastfeeding patients, 1288–1289
in pregnant patients, 1287–1288
teratogenicity of, 1287*t*, 1288
for ICH patients, 140
for myoclonus, 829, 829*t*
for neonatal seizures, 1360–1361, 1361*t*
for neuropathic pain, 563
for SAH patients, 347
for seizures, 61
for stiff person syndrome, 1006
for traumatic brain injury, 434, 578
for traumatic brain injury in children, 1575
for trigeminal neuralgia, 918
Levodopa
for drug-induced parkinsonism, 851
for dystonia, 813–814
improving pharmacokinetics of, 884
for Lewy body dementias, 497–498
for neuroleptic malignant syndrome, 852
for Parkinson disease, 875*f*, 879, 881–885, 890
adjunctive therapies with, 885
adverse effects of, 884–885
long-duration response to, 884
short-duration response to, 884
for Parkinson-plus syndromes, 895, 897
for progressive supranuclear palsy, 894
for restless legs syndrome, 795–797, 797*t*
Levodopa-carbidopa gel, 884
Levodopa-induced dyskinesia, 107, 801, 804, 858, 884–885
Levofloxacin, for malignant otitis externa, 621*t*
Levorphanol, for neuropathic pain, 563
Levothyroxine, for hypothyroidism, 1219
Lewis-Sumner syndrome, 937
Lewy bodies, 479, 492, 493*f*
cortical, 492, 493*f*
in Parkinson disease, 873–874, 874*f*, 880
prodromal dementia with, 495

Lewy body dementias (LBDs), 96–97, 97*t*, 492–499, 880
  Alzheimer disease comorbid with, 492–493
  autonomic dysfunction in, 494, 498
  autonomic testing in, 496
  biomarkers in, 101, 495*t*, 496
  clinical manifestations of, 494
  cognitive impairment in, 494
  CSF analysis in, 496
  diagnosis of, 98–101, 495–497
  differential diagnosis of, 497
  DLB *versus* PDD, 492, 493, 495
  epidemiology of, 96, 492
  fluctuating attention and concentration in, 494
  functional brain imaging in, 496
  future directions in, 498
  gait disorder in, 129*t*
  genetic risks factors for, 493–494
  GI/genitourinary effects of, 1267
  level 1 evidence on, 499
  lifestyle modifications for, 498
  multiple system atrophy *versus*, 497, 897
  neuropathology of, 492–493, 493*f*
  neuropsychological testing in, 495
  neurotransmitter systems in, 493
  1-year rule in, 492, 495
  outcome of, 499
  parkinsonism in, 492, 494
  pathobiology of, 492–493
  pathologic features of, 492, 492*t*
  prodromal phases of, 471
  psychiatric symptoms in, 494
  psychosis in, 494, 498, 1590*t*, 1593
  sleep disorders in, 494, 498
  SPECT in, 101, 496, 496*f*
  spongiform change/microvacuolation in, 493
  structural brain imaging in, 495–496
  treatment of, 497–498
    for cognitive symptoms, 497
    for mood disorders, 498
    for motor symptoms, 497–498
    for psychosis, 498
Lewy neurites, 479, 492, 493*f*, 873–874, 874*f*
LGI1. *See* Leucine-rich glioma-inactivated protein (LGI1) encephalitis
LGMD. *See* Limb-girdle muscular dystrophy
LH. *See* Luteinizing hormone
Lhermitte-Duclos disease, 1531, 1536–1537, 1548–1549
Lhermitte phenomenon, 715–716, 715*t*, 738, 1167
Lhermitte sign, 67–68
LHON. *See* Leber hereditary optic neuropathy
Libman-Sacks endocarditis (LSE), 397–398
Lidocaine
  for complex regional pain syndrome, 553
  for headache, 75
  for herpes zoster neuropathy, 946
  for neonatal seizures, 1361, 1361*t*
  for neuropathic pain, 562–563, 562*t*
  for SUNCT/SUNA headaches, 533
  for trigeminal neuralgia, 918
Life expectancy, 2
Life-sustaining treatment, 1637–1641
  orders for, 1637, 1638
  refusal of, 1641
  withdrawal of, 1640, 1641*t*
Li-Fraumeni syndrome, 1531
Lightning strikes, 1347–1349, 1348*t*
Limb ataxia, 107
Limb dystonias, 808, 808*f*
Limb-girdle muscular dystrophy (LGMD), 1474, 1476*t*, 1487–1492
  autosomal dominant, 1491–1492
  autosomal recessive, 1487–1491
  clinical manifestations of, 1487
  definition of, 1487
  diagnosis of, 1487
  differential diagnosis of, 1492
  epidemiology of, 1487
  genetic subtypes of, 1487, 1488*t*, 1489*f*
  management of, 1492
Limbic encephalitis, 759
Limbic-predominant age-related TAR DNA-binding protein 43 (TDP-43) encephalopathy (LATE), 97, 479
Limbic system, gait control by, 124*f*, 124*t*
Limb-shaking TIAs, 321
Limb temperature, and electrodiagnostic studies, 245
Lindau syndrome, 368
Linear skull fractures, 420
Lipid metabolism disorders, 1011–1012, 1014*t*, 1015–1016, 1393–1397, 1405–1407
Lipidoses (lipid-storage diseases), 1393–1397
Lipohyalinosis, 304, 320, 332
Lisch nodules, 1457, 1458*f*
Lissencephaly, 1373–1375, 1513
  MRI of, 1373*f*
  type I (classic), 1373–1375, 1373*f*
  type II (cobblestone), 1375, 1375*t*, 1377
Lissencephaly–band heterotopia syndrome, X-linked, 1374–1375, 1377
Listeria monocytogenes meningitis, 605, 605*t*, 607
Lithium
  for bipolar disorder, 1603
  for cluster headache prevention, 531*t*, 532
  for hypnic headache, 534
  intracranial hypertension induced by, 1135
  for Kleine-Levin syndrome, 1189
Livedo reticularis, in Sneddon syndrome, 396–397, 396*f*
Liver disease. *See* Hepatic disease
Liver failure, acute. *See* Acute liver failure
Liver transplantation, 1251, 1298, 1300–1301, 1301*f*
Living wills, 1637–1639
LKS. *See* Landau-Kleffner syndrome
LMNA-related myopathies, 1483
LMV. *See* Lymphocytic choriomeningitis virus
Lobar holoprosencephaly, 1369
Localization, 16–17, 16*t*
Location, localization *versus*, 16–17
Locked-in syndrome, 172, 175
  basilar artery occlusion and, 316
  vertebrobasilar territory infarction and, 307
Logopenic variant PPA, 480, 486, 488
Lomustine/CCNU
  for gliomas, 1023*t*
  for pediatric brain tumors, 1551, 1556
  for primary CNS lymphoma, 1060
  for recurrent astrocytoma, 1029
Long-latency reflex, 245
Long sleepers, 1187
Long-term memory, 29–30
Long-term potentiation, 1381
Long thoracic nerve
  anatomy of, 927, 928*f*, 931
  injury of, 458, 931, 931*f*
Lorazepam
  for alcohol withdrawal, 1305*t*, 1306
  for anticholinergic toxicity, 1322–1324
  for anxiety disorders, 1611*t*
  for delirium prevention, 92
  for neonatal seizures, 1360, 1361*t*
  for palliative (end-of-life) sedation, 1641*t*
  for paroxysmal sympathetic hyperactivity, 1180*f*
  for paroxysmal sympathetic storming, 1200*t*
  for seizures, 59–60, 59*t*
  for vertigo, 49*t*
Lorenzo oil, 1406
Los Angeles Motor Scale, 307
Lou Gehrig disease. *See* Amyotrophic lateral sclerosis (ALS)
Lower abdominal reflexes, 39*t*
Lower extremity nerve lesions, 460–462, 460*t*
Lower half headache, 547
Lower motor neuron disease, 904. *See also* Spinal muscular atrophy with respiratory distress type 1 (SMARD1)
Lower motor neuron weakness, 112–113
Lower radicular syndrome, 929
Lowe syndrome, 1389*t*, 1419
Low-flow TIAs, 321
Low-grade gliomas, 1019, 1021
Low-grade oligodendrogliomas, 1029
Low-molecular-weight heparin
  bleeding associated with, 1242
  for cerebral venous thrombosis, 358, 1523
  for childhood stroke, 1522
  for perinatal stroke, 1517
  reversal of, 139*t*, 336
  for spinal cord injury, 448, 449
  for stroke in pregnant patients, 1291
Low-pressure hydrocephalus, 1123
Low-voltage electrical injury (LVEI), 1347
LPDs. *See* Lateralized periodic discharges
LSD. *See* Lysergic acid diethylamide
Lumbar disk disease, 1146*f*, 1147, 1147*t*, 1148*f*, 1150–1151
Lumbar diskectomy, 1150–1151
Lumbar plexus. *See* Lumbosacral plexus
Lumbar puncture, 277–282. *See also* Cerebrospinal fluid analysis
  for idiopathic intracranial hypertension, 1137
  inadvertent trauma in, 279–280
  as key neurological skill, 277
  patient positioning for, 277, 277*f*
  precaution for patients hemicraniectomy, 281
  serial, for hydrocephalus, 1117
  for spontaneous intracranial hypotension, 1140
  techniques of, 277
  ultrasound guidance for, 277–278, 278*f*
Lumbar stenosis, 1153–1158
  clinical manifestations of, 1155
  diagnosis of, 1155–1156
  level 1 evidence on, 1158
  management of, 1156–1157
  outcomes of, 1157
  pain in, 1155
  pathobiology of, 1153–1155
  physical examination in, 1156
  radiographic studies of, 1156

Lumbar tumors, 1095–1096
Lumboperitoneal shunt
for idiopathic intracranial hypertension, 1137
for normal-pressure hydrocephalus, 1123
Lumbosacral plexus, 112, 930–931
heroin and damage to, 1317
injury of, 460–461, 460*t*, 930–931
radiation damage to, 931, 1107, 1336, 1337, 1338*t*, 1341
sensory patterns and loss, 66
Lundberg waves, 289, 289*f*
Lung cancer
brain metastases from, 152, 153*f*, 156, 157*t*, 1035, 1038, 1039*f*, 1042
skull base metastases from, 1082
spinal metastases from, 1044, 1089, 1092, 1092*f*, 1162
Lung transplantation, 1300
Lupus. *See* Systemic lupus erythematosus
Lurasidone, 1591*t*, 1603
Luteinizing hormone (LH), 1215, 1216*f*
deficiency of, 1216
Luxury perfusion, 1128
LVAD. *See* Left ventricular assist device
Lyme carditis, 649
Lyme disease (borreliosis), 649–650
acute disseminated infection in, 649
chronic meningitis in, 641*t*–643*t*, 649–650
clinical presentation of, 641*t*, 649
CSF analysis and serum diagnostics in, 642*t*, 649–650
dementia in, 98, 100
diagnosis of, 649–650, 938*t*
epidemiology of, 649
multiple sclerosis *versus*, 721
neuropathy in, 938*t*, 946
pathobiology of, 649
psychosis with, 1594
treatment of, 643*t*, 650
Lymphoblastic leukemia, acute, 1232–1233
Lymphocytic choriomeningitis virus (LMV), 677–678
Lymphoid cell malignancies, 1232–1234
Lymphoma, 1232–1233
classification of, 1232, 1232*t*
clinical manifestations of, 1232–1233
diagnosis of, 1233
epidemiology of, 1232
HIV-associated, 693, 706, 1056
HIV-associated, in children, 1580–1581, 1581*t*
intravascular large cell, 380–381
management of, 1233
paraneoplastic syndrome with, 1100
primary central nervous system. *See* Primary central nervous system lymphoma
Lymphoproliferative disorders, posttransplant, 1232–1234
Lysergic acid diethylamide (LSD), 1314, 1315, 1316
Lysosomal diseases, 1385, 1393–1402
Lyssavirus, 676
Lytico-Bodig, 900–902

M

Macewen sign, 1118
Macrocytosis, 1227
Macular star, 633, 633*f*
Mad cow disease, 517
MADD. *See* Multiple acyl-CoA dehydrogenation deficiency
Magnesium
for alcohol withdrawal, 1306
for cramps, 1009
for migraine, 74
for migraine prevention, 529*t*
for preeclampsia/eclampsia, 387, 1289–1290
in tetany, 1008
Magnesium sulfate, for reversible cerebral vasoconstriction syndrome, 388–389
Magnetic resonance angiography (MRA), 194–195, 195*f*, 208
of intracranial aneurysms, 195, 195*f*, 343
in moyamoya disease, 391–392, 392*f*, 1519*f*
in sickle cell disease, 1229–1230
in stroke, 310
Magnetic resonance imaging (MRI), 189–202
of acoustic neuroma, 1080, 1081*f*
in acute spinal cord syndromes, 149
advanced methods of, 199–201
in Alzheimer disease, 479, 481–483, 481*f*
appropriateness criteria for, 196, 197*t*
of arachnoid cyst, 1546
of arteriovenous malformations, 362–363, 362*f*, 1166
artifacts in, 195–196, 196*f*
of astrocytomas, 198–199, 1024, 1025*f*, 1027, 1027*f*, 1549–1550, 1549*f*, 1550*f*
in ataxia, 835–837, 836*f*, 839*f*
in autoimmune encephalitis and meningitis, 760–762, 761*f*
B_0 field of, 190
basic sequences in, 191–195
in Binswanger disease, 394
of brain abscess, 612–618, 614*f*–616*f*
of brain edema
cytotoxic, 1129
infarction-related, 1129
vasogenic, 1128
of brain sagging, 1142*f*, 1143, 1144*f*
of brainstem encephalitis, 759
of brain tumors, 152, 153*f*–156*f*, 164–166, 198, 198*f*
of brain tumors, pediatric, 1542–1543, 1542*t*, 1543*f*
in CADASIL, 398
of cavernous malformations, 366, 366*f*, 367*f*
in chorea evaluation, 858–859, 859*f*
in chronic meningitis, 640
clinical systems, 190
clinical use of, 196–199
in coma, 172
in complex regional pain syndrome, 551, 551*t*
in concussion, 413–414
in congenital myopathies, 1477
contrast-enhanced, 190, 194, 194*f*
of cortical dysgenesis, 1377–1378
in COVID-19, 673, 674*f*
of craniopharyngioma, 1546, 1546*f*
in Creutzfeldt-Jakob disease, 192, 510–512, 513*f*, 518, 518*f*
in cryptococcal meningitis, 643, 643*f*
in cytomegalovirus infection, 683
in decompression illness, 1352
in dementia, 101
frontotemporal, 488, 489*f*
HIV-associated, 696, 696*f*
Lewy body, 495–496
vascular, 502*f*
in depression, 1596
diffusion-weighted, 191–192, 193*t*, 194*f*
of dural arteriovenous fistulas, 365, 1166, 1167*f*
of dysembryoplastic neuroepithelial tumor, 1549
of dysplastic gangliocytoma, 1549
in eastern equine encephalitis, 670, 670*f*
emerging methods in, 201–202
in encephalotrigeminal angiomatosis, 1463, 1463*f*
of ependymoma, 198–199, 1558, 1558*f*
of epidermoid, 1085, 1086*f*, 1546, 1547*f*
in epilepsy, 572–573, 573*f*, 580, 580*f*
FLAIR, 191, 193*f*, 193*t*
of focal mass lesions of brain, 164–166
in Gerstmann-Straüssler-Scheinker disease, 515, 515*f*
of glioblastoma, 198, 198*f*, 1027, 1027*f*
of gliomas, 1021
of gliomas, brainstem, 1553, 1553*f*
in GM1 gangliosidosis, 1395, 1395*f*
gradient-recalled echo, 192–194, 193*t*
in granulomatosis with polyangiitis, 377
in headache evaluation, 71, 73
for hearing loss evaluation, 50
of hemangioblastoma, 368
in herpes simplex encephalitis, 679–680, 680*f*
high field of, 190, 201
in HIV infection, pediatric, 1581–1582, 1582*f*
in Huntington disease, 864, 864*f*, 866
of hydrocephalus, 1116–1117, 1118, 1118*f*, 1119*f*, 1121*f*
hyperpolarization in, 201–202
in hypoxic-ischemic encephalopathy, 326–327, 326*f*
in ICH, 191, 193*t*, 333*f*, 334–335
in idiopathic intracranial hypertension, 73, 1136
image creation in, 190
in inclusion body myositis, 984
in inflammatory myelopathy, 1164, 1165*f*
in intervertebral disk disease, 1146*f*, 1148*f*, 1149–1150, 1149*f*
in intracranial hypotension, 73
of intramedullary spinal tumors, 1094*f*, 1095*f*
of intraventricular hemorrhage, neonatal, 1119*f*, 1357
in leukodystrophies, 1400, 1400*f*, 1401, 1401*f*
in limbic encephalitis, 759
of lissencephaly, 1373*f*
in lymphoma, 1057, 1057*f*, 1233
in malignant otitis externa, 621
management of, 1459
of medulloblastoma, 1554–1555, 1555*f*
in Ménière disease, 598
of meningiomas, 1050, 1051–1052, 1052*f*, 1093, 1094*f*, 1560, 1560*f*
in metastatic disease
brain, 1035–1036, 1037*f*, 1038
leptomeningeal, 1046, 1046*f*, 1094*f*
spinal, 1044, 1044*f*, 1092–1093, 1092*f*
in mild cognitive impairment, 472–473, 473*t*
in minimally conscious state, 177
in mitochondrial encephalomyopathies, 1447*f*, 1451
in motor neuron disease/ALS, 911

Magnetic resonance imaging (MRI) *(Continued)*
in moyamoya disease, 391–392
of mucocele, 1087, 1087*f*
in multiple sclerosis, 191, 197–198, 197*f*, 717*t*, 718–719, 718*t*, 719*f*–722*f*, 729
in multiple system atrophy, 879
of muscle, 250
in muscle weakness, 119
in muscular dystrophy, 1477
in myelopathy, 1163
of nerve (MRI neurography), 250
in nervus intermedius neuralgia, 545
in neurofibromatosis, 1458*f*, 1459, 1459*f*
in neuromyelitis optica spectrum disorders, 730, 731*f*, 750*f*–751*f*
in neuropathic pain, 561
of oligodendrogliomas, 1030, 1030*f*
in osmotic demyelination syndrome, 1259, 1259*f*
in osteomyelitis of skull base, 622
in paraneoplastic syndromes, 1104, 1104*f*
in perinatal asphyxia/HIE, 1358, 1359*f*
in perinatal stroke, 1516, 1517*f*
in periventricular leukomalacia, 1363
physics of, 189–190
of pineal cysts, 1073–1074, 1074*f*
of pineal region tumors, 1074, 1074*f*, 1075*f*, 1077*f*, 1078*f*
in pituitary apoplexy, 1065, 1066*f*
of pituitary tumor, 155*f*, 1065–1066, 1066*f*–1070*f*, 1218, 1218*f*
in posterior reversible encephalopathy syndrome, 385, 385*f*, 386*f*, 1131, 1131*f*
in posttransplant lymphoproliferative disorder, 1233
in Powassan virus infection, 669, 669*f*
in preeclampsia/eclampsia, 1289, 1289*f*
in primary angiitis of CNS, 371–372, 373–374, 373*f*
in progressive multifocal leukoencephalopathy, 685, 685*f*, 701, 701*f*
in progressive supranuclear palsy, 879
quantitative image processing in, 202
in rabies, 676, 677*f*
in radiation injury, 1337, 1339*f*, 1340*f*, 1341*f*
safety of, 190
in sarcoidosis, 774*f*, 775, 839*f*
in seizure, 59, 60
in sensory symptom evaluation, 69
in sepsis-associated encephalopathy, 1204
in sickle cell disease, 1228–1230
in sinus venous thrombosis, neonatal, 1362, 1363*f*
of skull base tumors, 1083–1085, 1083*f*
in Sneddon syndrome, 396*f*, 397
specific absorption rate in, 190
of spinal cord infarction, 1166
in spinal cord injury, 445, 445*f*, 446*f*
of spinal epidural abscess, 619, 620*f*
in spinal stenosis, 1153, 1156, 1157*f*
of spinal tumors, 1090*f*, 1093*f*, 1094*f*, 1095*f*, 1096–1097
in spontaneous intracranial hypotension, 1140, 1140*t*, 1141*f*–1142*f*
in spotted fever rickettsiosis, 625–626, 627*f*
in stiff person syndrome, 1006
strengths and limitations of, 189
of stroke, 191–192, 194*f*, 196–197, 309–310, 310*f*
neonatal, 1362
during pregnancy, 1290–1291
in subarachnoid hemorrhage, 71
of subdural empyema, 618, 619*f*
in supratentorial herniation syndromes, 174
in Susac syndrome, 394–395, 395*f*
susceptibility-weighed, 192–194, 193*t*
in syringomyelia, 1159, 1162*f*
T1 and T2 times in, quantification of, 191
T1- and T2-weighted, 191, 192*f*, 193*f*, 193*t*
in thoracic outlet syndrome, 930
for tinnitus evaluation, 48
in toxoplasmosis, 704, 704*f*
in transient global amnesia, 603, 603*f*
in transient ischemic attacks, 321, 322, 322*t*
in transverse myelitis, 199, 738, 740*f*, 742*t*
in traumatic brain injury, 429
in trigeminal neuralgia, 543, 918
in tuberculous meningitis, 647, 647*f*
in tuberous sclerosis complex, 1461, 1461*f*
usual appearance of normal structures in, 191, 193*t*
in vegetative state, 177
of venous malformations, 367
for vertigo evaluation, 48
in viral myelitis, 1163
in vitamin B_1 deficiency, 1280, 1280*f*
in vitamin B_{12} deficiency, 1279, 1280*f*
in white matter disease, 197–198, 197*f*
Magnetic resonance perfusion imaging, 198, 200–201, 201*f*
Magnetic resonance spectroscopy (MRS), 200, 200*f*, 201*f*
in autism spectrum disorders, 1435
of brain tumors, 198, 200, 201*f*
of brain tumors, pediatric, 1542
in metastatic disease, 1036
in phenylketonuria, 1388
in stiff person syndrome, 1006
Magnetic resonance venography (MRV), 194–195, 195*f*
of cerebral venous thrombosis, 355–356, 356*f*, 356*t*, 357*f*
Magnetic source imaging, 240
Magnetic stimulation, transcranial. *See* Transcranial magnetic stimulation
Magnetoencephalography (MEG), 230, 240–241
Maintenance of wakefulness test (MWT), 264, 267
Major depressive disorder (MDD), 1596–1605
clinical manifestations of, 1598–1599
diagnosis of, 1600–1602, 1601*f*
differential diagnosis of, 1600–1602
epidemiology of, 1596
gateway symptoms of, 1598
medication side effects in, 1604*t*
neurologic disorders *versus*, 1600–1602
other psychiatric disorders *versus*, 1602
outcome of, 1603–1604
pathobiology of, 1596–1597, 1597*f*
psychotic features with, 1589–1590, 1590*t*, 1598–1599
seasonal, 1599
treatment of, 1602–1603
Major neurocognitive disorder, 95. *See also* Dementia
Malabsorption, 1277–1285
Malaria
cerebral, 653–655, 654*t*
clinical features of, 653–654
diagnosis of, 653–654
epidemiology of, 653
HIV-associated, 705
management of, 654–655
pathobiology of, 653
prevention of, 655, 705
Male sexual dysfunction, 1266
Malformations of cortical development (MCD), 1377–1378
epilepsy with, 1504, 1506, 1509, 1512
Malignant hyperthermia, 1004*t*, 1008, 1331
Malignant MCA infarction, 315
Malignant otitis externa, 621–622, 622*t*
Malingering
dystonia *versus*, 809–810
factitious disorder *versus*, 1623
tests for, 43–44
Malnutrition, 1277–1285. *See also specific deficiencies*
Mammarenavirus, 677
MAM. *See* Mitochondrial-associated endoplasmic reticulum membrane
Manganese toxicity, 1278*t*, 1282, 1333
Manic episode, 1599. *See also* Bipolar disorder
Man-in-the-barrel syndrome, 306, 325, 910
Mannitol
for brain edema, 1130, 1135
for ICP management, 139, 338, 430–431, 1132–1133, 1137, 1250–1251
MAO inhibitors. *See* Monoamine oxidase inhibitors
Maple syrup urine disease, 1388
Marantic endocarditis, 397–398, 400
Maraviroc, 707*t*
Marburg variant, 154, 165*f*, 729
Marchiafava-Bignami disease, 1259, 1309
Maribavir, 679*t*
Marijuana, 1314–1315, 1317, 1593
Marine neurotoxins, 948, 1333
Marinesco-Sjögren syndrome, 1477
Masked depression, 1601–1602
Mass effect
with focal mass lesions, 152
with ICH, 139
Mastoiditis
and brain abscess, 612, 614*f*, 615
and meningitis, 604, 605*t*
Maternal inheritance, 1443
Maternally inherited Leigh syndrome (MILS), 1446*t*, 1447, 1447*f*
Maximal expiratory pressure, 1209–1210, 1209*t*
Maximal inspiratory pressure, 1209–1210, 1209*t*
McArdle disease, 1009, 1011, 1012, 1013–1015
McArdle sign, 738
McCune-Albright syndrome, 1086, 1271–1272
McDonald criteria, for multiple sclerosis, 717–718, 717*t*, 718*t*
MCI. *See* Mild cognitive impairment
McLeod syndrome, 856–857, 1393
MCS. *See* Minimally conscious state
MDD. *See* Major depressive disorder
MDMA (ecstasy), 1314, 1316–1317
Mean transit team (MTT), 187, 200
Measles encephalitis, 671–672, 675–676

Measles inclusion body encephalitis (MIBE), 675
Measles vaccine, 671
MEBT. *See* Middle ear barotrauma
Mechanical thrombectomy, 224, 224*f*, 312–314, 313*t*, 1291, 1522
Mechanical ventilation, 1210–1213
criteria for, 1209–1210, 1210*t*
life-sustaining, 1639
long-term, 1213
modes and functions in, 1211, 1211*t*
outcomes of, 1213
pneumonia associated with, 1211–1212
weaning from, 1212–1213, 1212*f*
Meckel-Gruber syndrome, 1376, 1378–1379
Meckel syndrome, 1367–1368
Meclizine
for Ménière disease, 598
for vertigo, 49*t*
Medial brainstem infarction syndromes, 308*t*
Medial lemniscus, 66
Medial longitudinal fasciculus (MLF), 85
Medial pectoral nerve, 928, 928*f*, 928*t*
Medial plantar nerve, 931
Median nerve, 932–933
anatomy of, 928, 928*f*, 928*t*, 932
injury of, 459, 932–933
muscles innervated by, 928*t*, 932, 932*t*
pregnancy and, 1293–1294
Medical examination, general, 27–28
Medical Research Council scale of muscle power, 117
Medical retirement, concussion and, 416
Medication effects, testing for, 276
Mediterranean diet, 401–402
Medium-vessel vasculitis, 371*t*, 375–376. *See also specific types*
Medroxyprogesterone acetate, for meningiomas, 1054*t*
Medullary hemorrhage, 334
Medulloblastoma, 153, 154, 159*f*, 164, 1554–1558
chemotherapy for, 1556–1557
classification of, 1534–1535, 1536*t*
clinical manifestations of, 1554
desmoplastic, 1531
epidemiology of, 1528–1530
folic acid and prevention of, 1531
histology of, 1533
imaging of, 1554, 1555*f*
inherited syndromes and, 1531
molecular subgroups of, 1533–1535, 1534*f*, 1556
pathobiology of, 1532–1535, 1534*f*, 1555–1556
radiation therapy for, 1531, 1556
risk stratification of, 1555
staging of, 1555
surgical resection of, 1554
survival rates for, 1532
MEG. *See* Magnetoencephalography
Megacolon, 1264
Megalencephaly, 1371, 1512, 1513
MEGDEL syndrome, 1445
Megestrol acetate, for meningiomas, 1054*t*
Meige syndrome, 106, 802
Melanoma
brain metastases from, 152, 156, 157*t*, 1043
pediatric, 1530, 1560
spinal metastases from, 1162
MELAS. *See* Mitochondrial encephalopathy, lactic acidosis, and stroke-like episodes
Melatonin, 268
for circadian rhythm disorders, 1192
for cluster headache prevention, 531*t*
for hypnic headache, 534
for Parkinson patients, 889
pineal production of, 1072
for sleep disorders in dementia, 498
Melatonin receptor agonist, for insomnia, 1186, 1187*t*
MELD. *See* Model for End-Stage Liver Disease
Melkersson-Rosenthal syndrome, 923
Melphalan, for HCT conditioning, 1235
Memantine
for Alzheimer disease, 483, 483*t*
for Lewy body dementias, 497
for neuropathic pain, 563
for radiation complications, 1107–1108
for vascular dementia, 504, 504*t*
Memory
Alzheimer disease and, 480
Lewy body dementias and, 494
mild cognitive impairment and, 469
multiple sclerosis and, 717
subclassifications of, 29–30, 272, 274*t*
traumatic brain injury and, 436–437
working, 29–30, 274
Memory loss. *See also* Amnesia; Dementia
age-associated, 95–96
Memory testing, 29–30, 272, 274*t*
Mendelian inheritance, 1442–1445, 1447–1449
Ménière syndrome, 48*t*, 50*t*, 597–600
BPPV *versus*, 597–598
burned out, 598
causes of, 597*t*
clinical features of, 597, 597*t*
cochlear, 598
definitions of, 597–598
diagnosis of, 598
end-stage, streptomycin for, 600
idiopathic, 597
intratympanic and oral steroids for, 598, 599
intratympanic gentamicin for, 599–600
medical treatment of, 598–599, 598*t*
Meniett device for, 600
surgical management of, 599, 599*t*
Meniett device, 600
Meningeal biopsy, 640
Meningeal melanocytomas, 1560
Meningeal sarcomas, 1560
Meningiomas, 152, 157*t*, 1050–1055
angioblastic, 368
chemotherapy for, 1053–1054, 1054*t*
clinical manifestations of, 1051
demographics of, 154
diagnosis of, 1051–1052
epidemiology of, 1050
imaging of, 154*f*, 164, 1050–1052, 1052*f*, 1093, 1094*f*, 1560, 1560*f*
incidental, 1054
intradural spinal, 1093, 1093*f*
molecular features of, 1051
outcome of, 1054
pathobiology of, 1050–1051
pediatric, 1560, 1560*f*
pineal, 1073
pituitary tumors *versus*, 1067–1068
radiation-induced, 1050, 1336
radiation therapy for, 1053
surgery for, 1053
time course of, 156
treatment of, 1052–1054, 1053*f*
WHO grading criteria for, 1050, 1051*t*, 1052, 1054
Meningismus, 605
Meningitis/Encephalitis panel, 608
Meningitis
acute bacterial, 604–611
antibiotic doses for, 608, 609*t*
clinical manifestations of, 605–607
complications of, 604, 605, 606*f*, 609
CSF analysis in, 607–608, 609*t*
CT in, 607
dexamethasone for, 608–609, 610*f*
diagnosis of, 607–608
differential diagnosis of, 608
empiric antibiotic therapy for, 607, 607*t*
etiology of, 604, 605*t*
level 1 evidence on, 611
pathobiology of, 605, 606*f*
practice guidelines for, 607, 608–609
treatment of, 608–609
viral meningitis *versus*, 604, 608
in alcoholics, 1309
autoimmune, 755
acute therapy for, 767, 768*t*–770*t*
chronic (maintenance) therapy for, 767–770, 768*t*–770*t*
clinical manifestations of, 757
diagnosis of, 757
epidemiology of, 755–756
imaging in, 760–762
management of, 765–770
outcome of, 771
pathobiology of, 756–757
brain edema in, 1131
cerebrospinal fluid analysis in, 278–280, 281*t*, 607–608, 609*t*, 642*t*
chemotherapy-induced, 1108*t*
chronic, 640–651
clinical presentation of, 640, 641*t*
CSF analysis and serum diagnostics in, 640, 642*t*
definition of, 640
etiologies of, 640
fungal, 641–646, 641*t*–643*t*
general diagnostic approach in, 640
hypothesis-free investigations in, 650
imaging in, 640, 641*t*
level 1 evidence on, 650
Lyme disease, 641*t*–643*t*, 649–650
syphilitic, 641*t*–643*t*, 648–649
treatment of, 643*t*
tuberculous, 641*t*–643*t*, 647–648
classic triad of, 605
eosinophilic, 658, 658*t*
headache in, 71, 523
HIV-associated, 699–701
hypoglycorrhachia in, 280
meningococcal, 604–605
Mollaret, 680–681, 757
pleocytosis in, 278–280
pneumococcal, 604–605
postneurosurgical, 604–605–605*t*
sarcoidosis, 774, 774*f*, 776
viral, 661–689. *See also specific viral infections*

Meningitis vaccines, 604
Meningococcal meningitis, 604–605
Menkes disease, 1392, 1511
Menstruation
  and epilepsy, 588
  and intracranial hypertension, 1135, 1137
Mental status examination, 26*t*, 28–32, 68, 89–90, 98–99, 116, 275
  caveats to interpreting, 28
  conceptual framework for, 28, 28*f*
  in developmental disorders, 1428–1429
Meralgia paresthetica, 1294
Merci device, 312
Mercury toxicity, 948, 1332
MERFF. *See* Myoclonus epilepsy with ragged red fibers
Meropenem
  for bacterial meningitis, 607*t*, 609*t*
  for Whipple disease, 635
Merosin-deficient congenital muscular dystrophy, 1477, 1478
Mesencephalon, formation of, 1366, 1368
Mesencephalon hemorrhage, 334
Mesenchymal scarring, in spinal cord injury, 443
Mesenchymal tumors, pediatric, 1560
Mesial temporal lobe sclerosis, EEG of, 237*f*
Mesoderm, structures formed from, 1366
Messenger RNA (mRNA), 1412
Metabolic acidosis, and coma, 176*t*
Metabolic alkalosis, and coma, 175, 176*t*
Metabolic coma, 175, 176*t*
Metabolic disorders. *See also specific disorders*
  autism spectrum disorders with, 1438, 1438*t*
  childhood stroke in, 1526
  inherited, 1385–1409
    classification of, 1385
    large molecule, 1385, 1393–1407
    small molecule, 1385–1393
  intracranial hypertension in, 1135
  neonatal seizures with, 1360, 1361*t*
  pediatric seizures and epilepsy with, 1511–1512
Metabolic myelopathy, 1160*t*–1161*t*
Metabolic myopathy, 983*t*, 1004*t*, 1011–1018
  approach to diagnostic testing in, 1016–1017
  diagnosis of, 1012–1017
  epidemiology of, 1011
  management of, 1017
  outcome of, 1017
  pathobiology of, 1011–1012, 1012*f*
  triggering factors in, 1012
Metabolic neuropathy, 938*t*
Metachromatic leukodystrophy (MLD), 1397, 1399–1400, 1400*f*
Metagenomic next-generation sequencing (mNGS)
  in bacterial meningitis, 608
  in chronic meningitis, 650
Metal(s)
  heavy metal toxicity, 938*t*, 947–948, 1332–1333
  metabolism, disorders of, 1392–1393
Metastatic tumors, 1034–1049. *See also* Brain metastases; Spinal metastases
  brain, 10*f*, 152, 156
  diagnosis of, 1035–1036
  epidemiology of, 1034
  history and physical examination in, 1035
  imaging of, 1035–1036, 1037*f*
  incidence risk by primary tumor site, 1035, 1036*f*
  laboratory studies in, 1035
  level 1 evidence on, 1047
  management of, 1036–1038
  overview of, 1034–1038
  pathobiology of, 1034–1035, 1035*f*
  pineal, 1073
  pituitary, 1218
  in pregnancy, 1293
  radiation therapy for, 1037–1038
  skull base, 1082–1083
  steroids and AEDs for, 1036–1037
  surgery for, 1037
  tissue diagnosis of, 1036
Metazoan infections, 653, 654*t*. *See also specific infections*
Methadone
  for neuropathic pain, 562*t*, 563
  for opioid dependence, 1314
  prenatal and perinatal effects of, 1585–1586
  for restless legs syndrome, 797*t*, 798
Methanol (methyl alcohol) poisoning, 1331
Methimazole, for hyperthyroidism, 1221
Methotrexate
  for acute lymphoblastic leukemia, 1233
  for acute myeloid leukemia, 1234
  for autoimmune encephalitis and meningitis, 770*t*
  for Behçet syndrome, 379
  for dermatomyositis, 981–982
  for eosinophilic granulomatosis with polyangiitis, 378
  for giant cell arteritis, 375
  for granulomatosis with polyangiitis, 377
  for inclusion body myositis, 984
  for metastatic disease, 1042, 1046
  for myasthenia gravis, 971
  for neuromyelitis optica spectrum disorders, 752, 752*t*
  neurotoxicity of, 1060, 1061*f*
  for non-Hodgkin lymphoma, 1233
  for pediatric brain tumors, 1556
  for polyarteritis nodosa, 376
  for primary CNS lymphoma, 1058–1060
  for sarcoidosis, 776, 777*t*
1-Methyl-4-phenyl-1, 2, 3, 6-tetrahydropyridine (MPTP)
  and Parkinson disease, 874–875
  and Parkinson-plus syndromes, 899–900
Methylene blue, for chemotherapy complications, 1109
3,4-Methylenedioxymethamphetamine (MDMA), 1314, 1316–1317
O^6-methylguanine-DNA methyltransferase (MGMT), and gliomas, 1021
Methylmalonic aciduria, 1388–1389
Methylphenidate, for MS patients, 727*t*
Methylprednisolone
  for autoimmune encephalitis and meningitis, 767, 768*t*
  for complex regional pain syndrome, 553
  for giant cell arteritis, 375
  for immunotherapy complications, 1110–1111
  for inflammatory myelopathy, 1165
  for multiple sclerosis, 722–723
  for neuromyelitis optica spectrum disorders, 731, 751
  for primary angiitis of CNS, 372
  for Ramsay Hunt syndrome, 922
  for sarcoidosis, 776, 777*t*
  for spinal cord injury, 447
  for Susac syndrome, 395
  for transverse myelitis, 742
Metoclopramide
  dystonia induced by, 809
  for migraine, 74, 526*t*, 527–528
  for migraine in pregnancy, 1293
  neurologic effects of, 849
  for vertigo, 49*t*
Metoprolol, for migraine prevention, 529*t*
Metronidazole
  for bacterial meningitis, 607, 607*t*, 609*t*
  for brain abscess, 617, 617*t*
  neuropathy induced by, 949
  for subdural empyema, 618
  for tetanus, 638
Mexiletine
  for hyperexcitability disorders, 1008
  for hyperkalemic periodic paralysis, 1001
  for myotonic dystrophy, 1486
  for neuropathic pain, 562*t*, 563
  for nondystrophic myotonias, 1002
MG. *See* Myasthenia gravis
MIBE. *See* Measles inclusion body encephalitis
Microaneurysms, Charcot-Bouchard, 333
Microarray, 300
Microbiome-gut-brain axis, 713, 1267–1268
Microcephaly, 1369, 1370, 1376
Microcephaly vera, 1370
Microcytosis, 1227
Microdialysis, cerebral, 293–294
Microdysgenesis, 1377
Microemboli, cerebral, ultrasound of, 214
Microglia, hypersensitivity mediated by, 560
Microneurography, 257
Microscopic polyangiitis, 371*t*, 376, 378
Microtubules, 1372
Midazolam
  for delirium prevention, 92
  for ICH patients, 338
  for neonatal seizures, 1360–1361, 1361*t*
  neurotoxicity of, 1299
  for paroxysmal sympathetic hyperactivity, 1180*f*
  for seizures
    first-line, 59–61, 59*t*
    third-line, 62, 62*t*
Midbrain locomotor region (MLR), 124–125, 124*f*, 124*t*
Middle cerebral artery (MCA)
  MRI of, 194*f*
  TIAs with stenosis of, 321
Middle cerebral artery (MCA) infarction, 137, 138*f*, 142, 142*f*, 304, 305–306, 305*t*
  malignant, 315
Middle ear barotrauma (MEBT), 1350–1353, 1352*t*
Middle East respiratory syndrome-related coronavirus, 672, 672*f*
Middle radicular syndrome, 929
Midline facial defects, 1369
Midodrine, for autonomic dysfunction, 1175
Mifepristone, for meningiomas, 1054*t*

Migraine, 70, 524–530, 524*t*
with and without aura, 524–525, 524*t*
basilar, 54, 525
CADASIL and, 398
chronic, 524*t*
complications of, 524*t*
diagnosis of, 524–525
diagnostic criteria for, 524, 525*t*
epidemiology of, 523
episodic syndromes associated with, 524*t*
facial, 547
familial hemiplegic, 524, 524*t*
genetics of, 524
inpatient admission for, 75
mnemonics for evaluating, 71, 71*t*
opioids for, 75
parenteral therapies for, 74, 75*f*
pathophysiology of, 521, 522*f*, 523–524
pregnancy and, 1292–1293
prevention of, 528–530, 529*t*
stroke-like, after radiation therapy, 1336, 1338*t*, 1341*f*, 1343
stroke *versus*, 135*t*
transient visual symptoms in, 83
treatment of, 525–530
acute therapies for, 525–528, 526*t*–527*t*
butalbital compounds for, 528
clinical stratification of, 527*t*
ditans for, 526*t*, 528
dopamine receptor antagonists for, 74, 526*t*, 527–528
emergency department, 74, 75*f*
ergots for, 525–527, 526*t*
gepants for, 526*t*, 528
neuromodulation for, 527*t*, 528
NSAIDs for, 525, 526*t*, 527
opioids for, 74, 528
trigger and lifestyle approaches for, 525
triptans for, 524, 525–527, 526*t*
Migraine Disability Assessment Score, 525
Mild behavioral impairment, 472
Mild cognitive impairment (MCI), 469–475
biomarker-based assessments in, 472–473, 473*t*
classification of types, 469, 470*t*
clinical features of, 469*t*, 472
conversion to Alzheimer disease, delaying, 473
definition of, 469, 469*t*
dementia *versus*, 95–96, 470
diagnosis of, 471–473
diagnostic criteria for, 470, 471
diagnostic testing for, 472–473
epidemiology of, 470–471
gait disorder in, 129*t*
in Huntington disease, 865, 868
laboratory testing and neuroimaging in, 472
level 1 evidence on, 474
on neurodegenerative spectrum, 470, 470*t*, 471*f*
neuropsychological testing for, 472
outcomes of, 474
pathobiology of, 471
risk factors for, 471
terminology for, 469
treatment of, 473–474
Milkmaid grip, 865
Miller-Dieker syndrome, 1373–1375, 1373*f*
Miller-Fisher syndrome, 637, 937, 939
Milrinone, for SAH patients, 350
MILS. *See* Maternally inherited Leigh syndrome
Milwaukee protocol, for rabies, 677
Mineral(s)
deficiencies of, 1277, 1278*t*, 1282
excess of, 1278*t*, 1282
Mineralizing microangiopathy, 1336–1337, 1340*f*
Minimal hepatic encephalopathy (MHE), 1245–1248
Minimally conscious state (MCS), 168, 175–177, 436
Mini-Mental State Examination (MMSE), 99, 272, 275
in Lewy body dementias, 494
Ministroke, 320. *See also* Transient ischemic attack
Minor neurocognitive disorder, 95, 96
Mirror movements, 802*t*
Mirtazapine
for anxiety disorders, 1611–1612, 1611*t*
for depression, 1602
for JC virus infection, 1236
Misonidazole, neuropathy induced by, 949
Missile-related cerebral blast injury, 438
Mitchell, Silas Weir, 549
Mitochondria
dynamics
alteration of, 1453
defects of, 1445, 1449
function in Huntington disease, 868
metabolism of, 1011, 1013*f*
Mitochondrial-associated endoplasmic reticulum membrane (MAM), 1445
Mitochondrial ataxia, 845–846
Mitochondrial disease. *See also specific diseases*
DNA maintenance defects, 1445, 1449–1451
dynamics defects, 1445, 1449
encephalomyopathies, 1441–1454
biochemical findings in, 1452
diagnosis of, 1445–1451
diagnostic workup in, 1451
epidemiology of, 1441–1442
exercise physiology in, 1451
historical perspective on, 1441
management of, 1452–1453
mendelian inheritance in, 1447–1449
mtDNA-related, 1446–1447
neuropathology of, 1452
neuroradiology in, 1447*f*, 1451
pathobiology of, 1442–1446
pathology of, 1451–1452, 1451*f*
metabolic, 1011, 1014*t*, 1016, 1441
protein importation, 1446
translation defects, 1444–1445, 1449
Mitochondrial DNA
diseases related to, 1446–1448
genetics, *versus* mendelian genetics, 1442–1443
maintenance defects of, 1445, 1449–1451
map of mutations, 1443, 1444*f*
paradigm of mutations, 1446, 1446*t*
pathobiology of mutations, 1442–1443
structure and composition of, 1442, 1442*f*
threshold effect of, 1443
translation defects of, 1444–1445, 1449
Mitochondrial DNA depletion syndromes, 1445, 1446*t*, 1449–1451
Mitochondrial encephalopathy, lactic acidosis, and stroke-like episodes (MELAS), 845–846, 1446, 1446*t*, 1447*f*, 1451–1452
Mitochondrial neurogastrointestinal encephalomyopathy (MNGIE), 1450–1451, 1453
Mitochondrial transfer, 1452
Mitotic segregation, 1443
Mitoxantrone
for multiple sclerosis, 726
for myelin oligodendrocyte glycoprotein spectrum disease, 732
Mixed apnea, 1190
Mixed PPA, 486
Miyoshi distal myopathy, 1493
MLF. *See* Medial longitudinal fasciculus
MLR. *See* Midbrain locomotor region
MMN. *See* Multifocal motor neuropathy
M mode ultrasound, 208–209, 208*t*
MMR (measles-mumps-rubella) vaccine, 671
MMSE. *See* Mini-Mental State Examination
MNGIE. *See* Mitochondrial neurogastrointestinal encephalomyopathy
Möbius syndrome, 923
MoCA. *See* Montreal Cognitive Assessment
Modafinil
for ADHD, 1431–1432
for MS patients, 727*t*
for myotonic dystrophy, 1486
for narcolepsy, 1189
for Parkinson patients, 889
Model for End-Stage Liver Disease (MELD), 1246
Modified Checklist for Autism in Toddlers–Revised, 1435
Modified Rush Video-Based Rating Scale, 787
MOG spectrum disease. *See* Myelin oligodendrocyte glycoprotein (MOG) spectrum disease
Mogamulizumab, for HTLV-1 infection, 1164
Molds, 640
Molecular Adsorbent Recirculating System, 1251
Molecular imaging, 203–207. *See also* Positron emission tomography; Single-photon emission computed tomography
Mollaret meningitis, 680–681, 757
Monitored anesthesia care, for endovascular therapy, 143
Monoamine oxidase (MAO) inhibitors
for anxiety disorders, 1610
for bipolar disorder, 1603
for depression, 1602
for Parkinson disease, 881, 885, 886
serotonin syndrome with, 1330, 1330*t*
Monoclonal antibodies. *See also specific antibodies*
for migraine prevention, 528–530, 529*t*
for multiple sclerosis, 723, 724*t*
neurologic complications of, 1109
for neuromyelitis optica spectrum disorders, 731, 752–753, 752*t*
Monoclonal gammopathy, 938*t*, 942
Monomelic muscular amyotrophy, 904, 904*t*, 910
Mononeuritis, 65*t*
Mononeuritis multiplex, 66, 113, 699
Mononeuropathy, 65*t*, 66, 112–113, 560, 560*t*, 927–935, 936
clinical features of, 927
diabetic, 935, 949
epidemiology of, 927
etiology and diagnosis of, 927
HIV-associated, 699
outcome of, 927

Mononeuropathy multiplex, 560, 560*t*, 927, 936, 937
in HIV infection, 946
in leprosy, 945
Monoparesis, 114
Monopolar electrodes, 246
Monro-Kellie model, 288
Montreal Cognitive Assessment (MoCA), 99, 272, 273*f*, 275, 494
Mood disorders, 1596–1605. *See also* Bipolar disorder; Depression
ADHD and, 1431
Alzheimer disease and, 96, 1600–1601
clinical manifestations of, 1598–1599
diagnosis of, 1600–1602, 1601*f*
differential diagnosis of, 1600–1602
epidemiology of, 1596
epilepsy and, 593, 1601, 1603
essential tremor and, 780
Huntington disease and, 865–866, 868, 1600–1601
illness anxiety in, 1618
level 1 evidence on, 1604–1605
Lewy body dementias and, 498
medication side effects in, 1604*t*
multiple sclerosis and, 716, 726
neurologic disorders associated with, 1600, 1600*t*, 1603
neurologic disorders *versus*, 1600–1602
other psychiatric disorders *versus*, 1602
other specified, 1600
outcome of, 1603–1604
Parkinson disease and, 879*t*, 880, 889, 1600–1601, 1603
pathobiology of, 1596–1598, 1597*f*
psychotic features with, 1589–1590
substance/medication-induced, 1600
Tourette syndrome and, 784, 787
treatment of, 1602–1603
Mood rating scales, 275
Morphine
for chemotherapy-induced neuropathy, 1109*t*
for complex regional pain syndrome, 553
for palliative (end-of-life) sedation, 1641*t*
for paroxysmal sympathetic hyperactivity, 1180*f*, 1181
for paroxysmal sympathetic storming, 1200*t*
Morphologic diagnosis, in muscle biopsy, 285
Mortality, 1–2
Morvan syndrome, 759, 1007, 1102
Motion (M) mode ultrasound, 208–209, 208*t*
Motor action potential
in axonotmesis, 463
compound, 244–245, 244*f*
in neurapraxia, 463
Motor development
disorders of, 1424–1427
approach to child with motor delay, 1425
genetic or metabolic evaluation in, 1425, 1425*t*
milestones of, 1424, 1424*t*
Motor-evoked potentials (MEPs), 240, 241*f*
in transcranial magnetic stimulation, 252–253, 253*f*
Motor examination, 26*t*, 36–38, 68, 116–117, 274–275
in ataxia, 834
in brain death, 181
in coma, 169–170
in Huntington disease, 865
in traumatic brain injury, 429
Motoric cognitive risk syndrome, 472
Motor impersistence, 865
Motor neglect, 306
Motor nerve conduction studies, 243–245, 244*f*
Motor neuron disease, 904–914. *See also* Amyotrophic lateral sclerosis (ALS)
diagnosis of, 909–912
differential diagnosis of, 904, 911–912, 912*t*
HIV-associated, 699
level 1 evidence on, 913
management of, 912–913, 913*t*
outcome of, 913
terminology in, 904
variants of, 904, 904*t*, 909–910
Motor neuron disease with dementia, 97
Motor tic, Obsessions and compulsions, Vocal tic Evaluation Survey, 787
Motor tics, 786, 786*t*. *See also* Tic(s)
Motor unit
definition of, 246
electromyography of, 246–249
Motor unit configuration, 246, 247–248, 248*f*
Motor unit potential (MUP), 247–249, 248*f*
in axonotmesis, 463
firing ratio of, 248
interference pattern of, 248–249, 249*f*
in neurapraxia, 463
Motor unit recruitment, 246, 248–249
Motor vehicle accidents
peripheral nerve injury in, 451
spinal cord injury in, 441
Mount Fuji sign, 1143, 1143*f*
Movement disorders. *See also specific disorders*
differential diagnosis of, 800–802, 802*t*
functional, 1620–1623, 1621*t*
HIV-associated, 698, 700*t*
neuroleptic-induced, 849–853. *See also* Tardive dyskinesia
neurologic history in, 21*t*
null point in, 800
paraneoplastic, 1101*t*, 1102–1103
posttraumatic, 437–438
in pregnancy, 855, 1294–1295
sleep-related, 1191–1193. *See also* Restless legs syndrome (RLS)
xenobiotic-induced, 1320, 1321*t*
Movements
assessment of, 38. *See also* Motor examination
coma and, 169
involuntary. *See* Involuntary movements
as surrogate measurement for sleep (actigram), 264, 267–268, 268*f*
Moxifloxacin, for Q fever, 631
Moyamoya disease (MMD), 390–393, 1231, 1458, 1518
clinical features of, 391
diagnosis of, 391–392
diseases associated with, 1519*t*
epidemiology of, 391, 1518
level 1 evidence on, 399
management of, 392–393, 1522
MRI/MRA in, 391–392, 392*f*, 1519*f*
outcome of, 393
pathobiology of, 391
perfusion imaging in, 392
probable, 391
secondary causes and mimics of, 390*t*
SPECT in, 392
Suzuki severity scale for, 391, 392*t*
transcranial Doppler ultrasound in, 392
Moyamoya syndrome, 390, 1518
MPS. *See* Mucopolysaccharidoses
MPTP. *See* 1-Methyl-4-phenyl-1, 2, 3, 6-tetrahydropyridine
MRA. *See* Magnetic resonance angiography
MRI. *See* Magnetic resonance imaging
MRS. *See* Magnetic resonance spectroscopy
MS. *See* Multiple sclerosis
MSA. *See* Multiple system atrophy
MSLT. *See* Multiple sleep latency test
Mucocele, 1087, 1087*f*
Mucolipidoses, 1398–1399
Mucopolysaccharidoses, 1397–1398, 1398*f*
Mucormycosis, 153, 161*t*
Müller muscle, 78
Multifocal dystonia, 802, 809
Multifocal motor neuropathy (MMN), 911, 912*t*, 936, 937, 941
Multimodality monitoring, 295–296
Multiple acyl-CoA dehydrogenation deficiency (MADD), 1015–1016
Multiple infarct dementia, 97
Multiple myeloma, 1233–1234
hyperviscosity syndrome in, 1234
spinal metastases from, 1089, 1091, 1092*f*
Multiple organ failure, 1248
Multiple sclerosis (MS), 711–729
acute optic neuritis in, 715, 715*t*
anxiety in, 716, 1610
benign, 729
biomarkers in, 719–721
bladder, bowel, and sexual dysfunction in, 716, 726, 727*t*, 1266
cerebellar signs/symptoms in, 716
clinical manifestations of, 714–717, 715*t*
cognitive impairment in, 716–717, 726, 727*t*
diagnosis of, 713–722
diagnostic criteria for, 717–718, 717*t*, 718*t*
differential diagnosis of, 721–722
disease course in, 713–714, 714*f*
disease-modifying medications for, 722, 723–726, 724*t*–725*t*
dissemination in space, 717–718, 717*t*
dissemination in time, 717–718, 718*t*
dysphagia in, 1262
environmental influences in, 713
epidemiology of, 711
fatigue in, 716, 727*t*
focal mass lesions with, 154, 165*f*, 165*t*
gait disturbance in, 726
genetic risk factors for, 713
gut microbiome and, 713, 1268
hallmark demyelination in, 712, 712*f*
histopathology of, 712, 712*f*
historical perspective on, 711
IgG index in, 719–721
immunobiology of, 711–712
level 1 evidence on, 732–733
Lhermitte phenomenon in, 715–716, 715*t*
management of, 722–728
Marburg variant of, 729
mood disorders in, 716, 726

MRI in, 191, 197–198, 197*f*, 717*t*, 718–719, 718*t*, 719*f*–722*f*, 729
muscle weakness in, 111
NMOSD *versus*, 722, 744, 749
nonspecific signs/symptoms in, 716–717
optical coherence tomography in, 721
osteoporosis and fracture in, 1274–1275
outcomes of, 728–729
pain in, 717, 727–728, 727*t*
paroxysmal signs/symptoms in, 716, 727*t*
pathobiology of, 711–713
pathology of, 712–713, 712*f*
pediatric, 728
pregnancy and breastfeeding in, 728, 1292, 1292*t*
primary progressive, 714, 714*f*, 717–718
progressive, 713–714, 714*f*
pseudobulbar affect in, 715*t*, 716, 727*t*
pseudoexacerbation in, 723
pyramidal signs/symptoms in, 715
relapsing, 713–714, 714*f*, 715*t*
relapsing-remitting, 713, 714, 714*f*, 717, 718, 720*f*–721*f*
secondary progressive, 713, 714, 714*f*, 718, 722*f*
sensory signs/symptoms in, 715–716
spasticity in, 715, 726, 727*t*
spinal imaging in, 198, 718, 721*f*
spinal tumor *versus*, 1096
stroke *versus*, 135*t*
Susac syndrome *versus*, 394, 395, 715, 722
symptom management in, 726–728, 727*t*
transverse myelitis in, 716, 738, 742*t*, 743
treatment of acute exacerbations, 722–723
tremors in, 716, 726–727, 727*t*
Uhthoff phenomenon in, 715*t*, 716
vaccination in, 728
visual-evoked potentials in, 721
Multiple sleep latency test (MSLT), 264, 265–266, 1188, 1189*t*
Multiple system atrophy (MSA), 893, 894–896
autonomic dysfunction in, 495, 1173–1174, 1175
cognitive impairment in, 896
degenerative ataxia in, 846
diagnosis of, 897
diagnostic criteria for, 897, 899*t*
epidemiology of, 897
gait disorder in, 130*t*
GI/genitourinary effects of, 1267
historical perspective on, 894–895
Lewy body dementias *versus*, 497, 897
MRI in, 879
Parkinson disease *versus*, 879, 881, 890
pathobiology of, 895, 895*t*
signs and symptoms of, 895–896
treatment of, 897–899, 901*t*
Munchausen syndrome, 1623
MUP. *See* Motor unit potential
Murine typhus, 624, 625*t*, 629
Murray valley encephalitis virus, 667*t*, 668–669
Muscle(s)
collateral reinnervation, 247
electrodiagnostic testing of. *See* Needle electromyography
MRI of, 250
Muscle biopsy, 121, 284–285
in antisynthetase syndrome, 986
in congenital myopathies, 1474, 1475*f*, 1477, 1493
in dermatomyositis, 986, 986*f*
in inclusion body myositis, 986–987, 987*f*
in mitochondrial disease, 1451–1452, 1451*f*
in motor neuron disease/ALS, 911
in muscular dystrophies, 1474, 1475*f*, 1477, 1478, 1479, 1487
in myotonic dystrophy, 1485
in polymyositis, 986–987, 987*f*
Muscle cramps, 1004, 1004*t*, 1008–1009
clinical manifestations of, 1009
diagnosis of, 1009
epidemiology of, 1008
in metabolic myopathies, 1012–1013
with muscle weakness, 114, 115*t*
outcome of, 1009
pathobiology of, 1008–1009
treatment of, 1009
Muscle crises, 1015
Muscle hyperexcitability, 1004, 1004*t*, 1007–1009, 1102
Muscle percussion, direct, 38–39
Muscle power (strength), 37, 37*f*, 37*t*, 117
Muscle relaxants. *See also specific drugs*
for dystonia, 814*t*, 815
for hereditary spastic paraplegia, 1168
for intubation, 1210–1211
for paroxysmal sympathetic hyperactivity, 1180–1181
for paroxysmal sympathetic storming, 1200*t*
Muscle stiffness
definition of, 1004
disorders of, 1004–1007, 1004*t*. *See also specific disorders*
Muscle testing, 36–38, 116–117, 118–119*t*
Muscle tone, 37, 116–117
coma and, 169–170
deficit in dystonia. *See* Dystonia(s)
differential diagnosis of, 800–801, 802*t*
infant, 1417–1423. *See also* Floppy infant
Muscle weakness, 110–121
in acute spinal cord syndromes, 148, 149
autonomic symptoms with, 115*t*, 116
cardiac symptoms with, 115*t*
central (upper motor neuron), 111–112
cognitive or language deficits with, 114, 115*t*
common causes of, 120*t*–121*t*
demographics of, 113
diagnosis of, 117–121
differentiating concept of, 110
distal *versus* proximal, 114
distribution of, 114
emergent situations in, recognition of, 117–119
focused examination in, 116–117
focused history on, 113–116
imaging studies in, 119
laboratory testing in, 119
lumbar puncture in, 119–121
management strategy for, 110, 111*t*
in myasthenia gravis, 966, 966*t*, 967*f*
neuroanatomy and localization of, 111–112
in neuropathy, 936–937
pain with, 114, 115*t*
past medical history and, 113
pattern-matching in, 111, 111*t*
red flags in, 110, 110*t*
respiratory symptoms with, 115*t*, 116
sensory symptoms with, 114, 115*t*
stiffness and cramps with, 114, 115*t*
tempo of, 111*t*, 113–114
urinary complaints with, 115*t*
variability of, 114
visual and speech disturbances with, 114, 115*t*
Muscular atrophy, postpolio progressive, 664
Muscular dystrophies, 1474–1482
Becker. *See* Becker muscular dystrophy
classification of, 1474, 1476*t*
clinical features of, 1476*t*
congenital, 1422, 1474, 1476*t*, 1477–1479
COL6-related, 1477, 1478
definitions of, 1477
diagnosis of, 1477–1479
epidemiology of, 1477
management of, 1479
merosin-deficient, 1477, 1478
definitions of, 1474
differential diagnosis of, 983*t*
Duchenne. *See* Duchenne muscular dystrophy
Emery-Dreifuss, 1474, 1476*t*, 1482–1483, 1482*f*
facioscapulohumeral, 300, 1474, 1476*t*, 1483–1484, 1483*f*
Fukuyama, 1375, 1376, 1419
functional impairment in, 1474
infant hypotonia (floppy infant) in, 1422
laboratory findings in, 1474–1477
level 1 evidence on, 1499
limb-girdle, 1474, 1476*t*, 1487–1492
management of, 1479
muscle biopsy in, 1474, 1475*f*, 1477, 1478, 1479, 1487
muscle imaging in, 1477
myotonic, 300, 1474, 1476*t*, 1485–1487
oculopharyngeal, 1474, 1476*t*, 1492
rare, 1492–1493
Musculocutaneous nerve, 928
anatomy of, 928, 928*f*, 928*t*, 933
injury of, 933
transfer of intercostal nerve to, 467
Mutations, genetic, 298–300, 1366
direct hits, 1443
indirect hits, 1443
mendelian, 1443–1445
mitochondrial, 1442–1443, 1444*f*
Mutism
akinetic, 306, 508
selective, 1608*t*, 1609, 1612
MWT. *See* Maintenance of wakefulness test
Myalgias, 113
in metabolic myopathies, 1012–1013
Myasthenia gravis (MG), 963–978
autoimmune antibodies in, 964–965
botulism *versus*, 637
cholinesterase inhibitors for, 969, 970*t*
clinical features of, 966–967, 966*t*, 967*f*
congenital syndromes, 974–975
diagnosis of, 965–966
differential diagnosis of, 968, 984*t*
drug-induced, 975
drugs that exacerbate, 973, 973*t*, 975
dysphagia in, 966*t*, 1263
electrodiagnostic testing in, 968, 968*t*
EMG findings in, 248
epidemiology of, 963
excessive fatigability in, 966
familial, 963

Myasthenia gravis (MG) *(Continued)*
genetics of, 963
immunomodulatory therapy for, 969–972
intravenous immunoglobulin for, 970*t*, 971
laboratory testing in, 967–968, 968*t*
level 1 evidence on, 977–978
management of, 968–973
maternal, and infant hypotonia, 1422
motor neuron disease/ALS *versus*, 911, 912*t*
neonatal, 974
new insights on, 965
outcome of, 973
paraneoplastic, 1101*t*, 1102, 1105
pathobiology of, 963–965, 964*f*
plasma exchange for, 970*t*, 971
pregnancy and, 973, 1294
remissions or exacerbations in, 966
repetitive nerve stimulation in, 250–251, 250*f*, 968, 968*f*
SFEMG findings in, 251–252, 251*f*
steroids for, 969–970, 970*t*, 971
steroid-sparing agents for, 970–971
subgroups of, 963, 963*t*
T-cell autoimmunity in, 965
Tensilon test in, 966–967
thymectomy for, 972
treatment algorithm for, 969*f*
vaccination in, 973
visual/extraocular effects of, 86, 966, 966*t*, 967*f*, 969–970
Myasthenic crisis, 966, 972–973, 973*t*
Mycobacterial infections, HIV-associated, 705–706
Mycobacterium avium-intracellulare, 705
Mycobacterium tuberculosis, 647–648. *See also* Tuberculosis
Mycophenolate mofetil
for autoimmune encephalitis and meningitis, 767, 770*t*
for dermatomyositis, 981
for myasthenia gravis, 970*t*, 971
for myelin oligodendrocyte glycoprotein spectrum disease, 732
for neuromyelitis optica spectrum disorders, 731, 752, 752*t*
for paraneoplastic syndromes, 1104
for sarcoidosis, 776, 777*t*
for Susac syndrome, 395
Mycoplasma pneumoniae, 635–636
Mycotic aneurysms, 350–351
Myelin oligodendrocyte glycoprotein (MOG) spectrum disease, 711, 732
clinical manifestations of, 732
diagnosis of, 732
epidemiology of, 732
maintenance therapy for, 753
NMOSD *versus*, 749–750, 749*t*, 750*f*–751*f*
pathobiology of, 732
transverse myelitis in, 732, 738, 740–741, 742*t*, 743, 744
Myelinolysis, osmotic, 1258–1260, 1258*f*, 1259*f*
Myelinopathia centralis diffusa, 1401
Myelitis
acute flaccid, 1420
encephalitis with, 760
in neuromyelitis optica spectrum disorders, 730, 730*t*
paraneoplastic, 1101–1102, 1101*t*
transverse. *See* Transverse myelitis (TM)
varicella-zoster virus and, 682
viral, 1163–1164
Myeloablation, 1235
Myelography
CT. *See* Computed tomography myelography
in intervertebral disk disease, 1150
in spinal stenosis, 1156
Myeloid leukemia, acute, 1234
Myeloma
multiple. *See* Multiple myeloma
neuropathies associated with, 942
Myelomeningocele, 1367
Myeloneuropathy, illicit drug use and, 1317
Myelopathy, 1159–1169
acute, 1160*t*
clinical findings of, 1162*t*
negative MRI in, clinical pearls on, 1161*t*
acute nontraumatic. *See* Acute spinal cord syndromes
cervical spondylotic, 1155, 1155*t*
chronic, 1160*t*–1161*t*, 1162*t*
compressive/mechanical, 1160*t*
differential diagnosis of, 1159, 1160*t*–1161*t*
disk disease and, 1149
electrical/lightning injuries and, 1348–1349
genetic, 1161*t*, 1168
hepatic, 1168, 1247
HIV-associated, 694, 698–699
infectious, 1160*t*–1161*t*, 1163–1164
inflammatory, 147, 150, 1160*t*, 1164–1165, 1165*f*
neoplastic, 1160*t*–1161*t*, 1162–1163
radiation-induced, 1097, 1107, 1336, 1338*t*, 1339
subacute, 1160*t*, 1162*t*
toxic/metabolic, 1160*t*–1161*t*, 1167–1168
varicella-zoster, 681, 682*f*
vascular, 1160*t*, 1165–1166
Myeloschisis, 1367
Myerson sign, 881
Myoadenylate deaminase deficiency, 1009
Myoblastomas, 1064
Myocardium, stunned, neurogenic, 1195, 1195*t*, 1197–1198, 1198*f*
Myoclonic-atonic seizures, 571
Myoclonic dystonia, 801, 802*t*
Myoclonic epilepsy, juvenile, 572, 574
Myoclonic seizures, 568, 570
Myoclonus, 36–37, 105, 106*f*, 106*t*, 824–830
action-induced, 824
acute liver failure and, 1249
anatomic location of, 824–825, 825*t*, 826*t*
benign sleep, of infancy, 1192
classification of, 824–825, 825*t*
clinical manifestations of, 826, 827, 828
coma and, 169
cortical, 825–827, 825*t*, 826*t*
dementia and, 827
diagnosis of, 826–829, 828
differential diagnosis of, 826, 826*t*
dystonia *versus*, 802*t*
EEG findings in, 825, 825*t*, 826, 827
electrophysiologic features of, 825–826, 825*t*
EMG findings in, 824*f*, 825–826, 825*t*
epidemiology of, 824
epileptic, 825, 825*t*, 826, 826*t*
essential, 825, 825*t*, 827
etiology of, 825, 825*t*
HIV-associated, 698
management of, 829, 829*t*
negative, 824, 824*f*
neuroanatomy of, 108
outcome of, 829
paraneoplastic, 1102
pathobiology of, 825–826, 827, 828
peripheral, 826*t*, 828–829
phenomenologic characterization of, 824–825
physiologic, 825, 825*t*
positive, 824, 824*f*
posthypoxic action, 325
posttraumatic, 437–438
prion diseases and, 519*t*
progressive encephalomyelitis with, 759
propriospinal, 825*t*, 826*t*, 828, 1192
reflex-induced, 824
spinal, 825*t*, 826*t*, 828
spontaneous, 824
stimulation-induced, 824
subcortical, 825*t*, 826*t*, 827–828
symptomatic, 825, 825*t*, 826–827, 826*t*
tardive, 849*t*, 851
transplantation-related, 1298*t*
xenobiotic-induced, 1320, 1321*t*
Myoclonus-dystonia, 801, 802*t*, 815, 827
genetics of, 298
Myoclonus epilepsy with ragged red fibers, 845–846, 1446, 1446*t*, 1451–1452, 1451*f*
Myoedema, 1219
Myoglobinuria
classification of, 1013, 1014*t*
definition of, 1013
illicit drug use and, 1317
in metabolic myopathies, 1012–1017
muscle biopsy in, 285
Myokymia, 116
Myokymic discharges, 247
Myopathic features, in muscle biopsy, 285
Myopathic mitochondrial DNA depletion syndromes, 1449
Myopathic MUPs, 247, 248*f*
Myopathy. *See also specific types and disorders*
alcoholic, 1309
congenital, 1449, 1474
definition of, 979
distal, 1487, 1492–1493
drug-induced, 984*t*
EMG findings in, 247–249, 248*f*
endocrine, 992–993, 993*t*, 994*t*
HIV-associated, 699
infant hypotonia (floppy infant) in, 1422–1423
inflammatory and autoimmune, 979–988
classification/criteria, 979, 979*t*
differential diagnosis of, 981, 983*t*, 984, 984*t*
EMG findings in, 247
level 1 evidence on, 987
muscle pathology in, 986–988, 986*f*, 987*f*
metabolic, 983*t*, 1004*t*, 1011–1018
diagnosis of, 1012–1017
epidemiology of, 1011
management of, 1017
outcome of, 1017
pathobiology of, 1011–1012, 1012*f*
triggering factors in, 1012

motor neuron disease/ALS *versus*, 911
muscle weakness caused by, 113
paraneoplastic, 1102
renal disease and, 938*t*, 1255
toxic, 992, 993–996
visual/extraocular effects of, 86–87
xenobiotic-associated, 1320, 1325*t*
Myophosphorylase deficiency. *See* McArdle disease
Myopia, 259
Myorhythmia, 105
Myositis, 979–988. *See also specific types*
Bohan and Peter criteria for, 979, 979*t*
HIV-associated, 700*t*
paraneoplastic, 1102
Myostatin inhibition, for inclusion body myositis, 984–985
Myotonia, 114, 116–117
nondystrophic, 998, 999*t*, 1001–1002
Myotonia congenita (MC), 998, 1001–1002
Myotonic-atonic seizures, epilepsy with, 1510
Myotonic discharges, 247
Myotonic dystrophy, 1422, 1474, 1476*t*, 1485–1487
cataracts in, 300, 1485
clinical features of, 1485–1486, 1485*f*
congenital, 1486
definition of, 1485
diagnosis of, 1485–1486
electrodiagnostic features of, 1485
epidemiology of, 1485
genetics of, 300, 1486
management of, 1486–1487
Myriachit, 827
Myxedema, 1219
Myxoma, 407

N

N/2 ghosts, in MRI, 196
N-acetylaspartate, in magnetic resonance spectroscopy, 200, 200*f*, 201*f*
N-acetylcysteine, for complex regional pain syndrome, 552*t*, 553
Nadolol, for migraine prevention, 529*t*
Naegleria, 654*t*
Naegleria fowleri, 655–656
Nafcillin, for bacterial meningitis, 609*t*
Naftidrofuryl, for cramps, 1009
Naloxone, 169, 1313–1314, 1320
Naltrexone, for alcoholism, 1311
Naming, in language testing, 29
Naproxen
for cold-stimulus headache, 533
for migraine, 526*t*, 527
Naratriptan, for migraine, 525, 526*t*
Narcolepsy, 264, 1187–1189
actigraphy for, 264, 267, 268–269, 269*f*
clinical features of, 1188
diagnosis of, 1188–1189
epidemiology of, 1187
imaging in, 270
laboratory testing in, 269
management of, 1189
outcome of, 1189
variants of, 1189*t*
NARP. *See* Neuropathy, ataxia, and retinitis pigmentosa
Nasal congestion, 521
Natalizumab
for multiple sclerosis, 723, 724*t*
for multiple sclerosis in pregnancy, 1292, 1292*t*
for myelin oligodendrocyte glycoprotein spectrum disease, 732
National Emergency X-Radiography Utilization Study, 444, 444*t*
National Institute of Neurological Disorders and Stroke (NINDS) trial, 224, 311
National Institutes of Health Stroke Scale, 132, 133, 136*t*, 307–308, 1196
Nausea, in migraine, 71
Nausea and vomiting, in Ménière disease, 599
Navajo neurohepatopathy (NNH), 1450
NBIA. *See* Neurodegeneration with brain accumulation
NBTE. *See* Nonbacterial thrombotic endocarditis
NCLs. *See* Neuronal ceroid lipofuscinoses
Near-infrared spectroscopy, 292–293
Neck pain, spinal stenosis and, 1153
Necrotizing (malignant) otitis externa, 621–622, 622*t*
Needle electromyography, 246–249. *See also* Electromyography (EMG)
applications of, 249–250
basic concepts of, 246
fibrillations in, 246, 247*f*
insertional activity in, 246–247
interference pattern in, 246, 248–249, 249*f*
motor unit configuration in, 246, 247–248, 248*f*
motor unit recruitment in, 246, 248–249
positive sharp waves in, 246, 247*f*
single-fiber, 251–252, 251*f*
spontaneous activity in, 246–247, 247*f*
Nefazodone, for anxiety disorders, 1611*t*, 1612
Negative effect, in TMS, 253
Negative myoclonus, 824, 824*f*
Neisseria meningitidis, 604–605, 609*t*
Nelfinavir, 707*t*
Nemaline myopathy, 1497
Nematodes, 653, 654*t*, 658, 658*t*
Neonatal adrenoleukodystrophy, 1405, 1405*t*, 1406, 1419
Neonatal epilepsy, 1502–1514
Neonatal Fc receptor inhibition, for myasthenia gravis, 972
Neonatal herpes simplex 2 encephalitis, 680
Neonatal hyperammonemia, 1386–1387
Neonatal myasthenia gravis, 974
Neonatal neurology, 1355–1365. *See also specific neonatal disorders*
congenital malformations, 1366–1384
germinal matrix-intraventricular hemorrhage in, 1355–1357
level 1 evidence on, 1364
periventricular leukomalacia, 1363–1364
seizures, 1359–1361
stroke and sinus venous thrombosis, 1362
Neonatal stroke. *See* Perinatal stroke
Neonatal (perinatal) stroke, 1362, 1515–1518
Neostigmine, for myasthenia gravis, 966, 969
Nephrogenic system fibrosis, 190
Nephropathy, contrast-induced, 187–188, 188*t*, 221
Nerve(s)
anatomy and physiology of, 451
MRI of, 250
ultrasound of, 250
Nerve biopsy, 69, 121, 285–286
in neuropathic pain, 560–561
in sarcoidosis, 946, 947*f*
Nerve conduction studies, 69, 243–246
applications of, 249–250
in Charcot-Marie-Tooth disease, 959
in chorea, 859
in congenital myopathies, 1477
in Guillain-Barré syndrome, 940
in HIV-associated myelopathy, 694
in intervertebral disk disease, 1150
late responses in, 245–246, 246*f*
motor, 243–245, 244*f*, 245*f*
in motor neuron disease/ALS, 911
in muscle weakness, 121
in muscular dystrophies, 1477
in myasthenia gravis, 968, 968*t*
in nerve injury, 463–464
in neuropathic pain, 560
sensory, 243, 243*f*, 244*f*
Nerve conduction velocity, 244–245
Nerve fiber density, intraepidermal, 286–287
Nerve injury, 451–468, 927–935. *See also specific nerves*
acute, 451
blunt, 464–465
chronic, 451
classification of, 452, 452*t*
clinical features of, 453
closed, 464, 465*f*
in complex regional pain syndrome, 453, 549
cranial nerve, 435, 451–457
diagnosis of, 462–464
electrodiagnostic findings in, 463
end-to-end neurorrhaphy for, 466*t*, 467
epidemiology of, 451
graft repair of, 466*t*, 467
indications for early operative repair of, 465
initial evaluation of, 464, 464*f*, 465*f*
mechanisms of, 451
nerve transfer for, 466*t*, 467–468
neurolysis for, 466–467, 466*f*, 466*t*, 467*f*
open, 464, 464*f*
outcomes of, 468
peripheral sensitization in, 558–559
prognosis of, 452, 452*t*
proximal, 458–459, 931–932
repair and regeneration in, 453
sharp, 464
split repair of, 466*t*, 467
surgical planning for, 464
surgical techniques for, 466, 466*t*
tendon transfer for, 466*t*, 468
timing of studies in, 463–464
treatment of, 464–468
Nerve roots
brachial plexus, 927–930
intervertebral disk disease and, 1145–1147, 1146*f*, 1147*t*
lumbar and sacral plexuses, 930–931
sensory patterns and loss, 65*t*, 66
Nerve sheath tumors, 152
Nerve transfer, 466*t*, 467–468
Nervous system
formation of, 1366–1384
neural tube closure, 1367–1368, 1367*f*
neuronal and glial proliferation, 1370–1371
neuronal differentiation, 1371

Nervous system *(Continued)*
neuronal migration, 1371–1378, 1372*f*
process outgrowth and synapse formation, 1380–1381
segmentation, 1366, 1368–1369, 1368*f*
ventral induction, 1369
malformations of. *See* Congenital malformations
Nervus intermedius neuralgia (NIN), 545
Neural crest cells, 1366
Neuralgia. *See also specific nerves and disorders*
cranial nerve, 538, 542–546
craniofacial pain in, 74
definition of, 74, 557*t*
postherpetic, 681
Neural IgG seronegative autoimmune encephalopathy, 760
Neural tube
closure of, 1367–1368, 1367*f*
defects of, 1367–1368
formation of, 1366–1369, 1367*f*
segmentation of, 1366
Neuraminidase deficiency, 1394–1395
Neurapraxia, 452, 452*t*, 463, 468
Neurilemmoma. *See* Schwannoma
Neuroaxonal dystrophy, 97, 1385
Neuroblastoma, epidemiology of, 1530
Neurobrucellosis, 631–632
Neurocognitive disorders
major, 95. *See also* Dementia
minor, 95, 96
Neurocristopathies, 1456
Neurocritical care monitoring, 288–296. *See also specific parameters and procedures*
brain oxygenation, 291–293
cerebral blood flow, 293
cerebral microdialysis, 293–294
cerebral perfusion, 288–291
continuous EEG, 294–295
intracranial pressure, 288–291
multimodality, 295–296
Neurocutaneous syndromes, 1456–1466. *See also specific syndromes*
Neurocysticercosis, 153–154, 162*t*, 164*f*, 654*t*, 656, 705, 1593
Neurocytoma, central, 1557
Neurodegeneration with brain accumulation (NBIA), 1392–1393
Neurodegenerative dementias, 96–97
Neurodegenerative disorders, EEG findings in, 236
Neuroectoderm
formation of, 1366, 1367*f*
structures formed from, 1366–1369
Neuroectodermatoses, 1456–1466
Neuroendovascular surgery (NES), 217–229. *See also specific disorders and procedures*
angiography as foundation of, 217
angiography complications in, 220–221
angiography process in, 218–220
emerging considerations in, 226–227
history of, 217–218
level 1 evidence on, 227
procedural outline and considerations, 218–220
selected conditions diagnosed and treated with, 221–226
terminology for, 217
Neuroepithelial tumor, dysembryoplastic, 1020*t*, 1549
Neuroepithelium, 1370
Neurofibrillary tangles, 479, 893, 894*f*, 902
Neurofibroma, 1090*f*, 1093, 1457
Neurofibromatosis, 1456–1459
central, 1456–1459
cutaneous manifestations of, 1457, 1457*f*
diagnosis of, 1459
diagnostic criteria for, 1459, 1459*t*
epidemiology of, 1456
historical perspective on, 1456
laboratory data in, 1459
meningiomas with, 1050–1051
molecular genetics and pathogenesis of, 1456–1457
neurologic symptoms in, 1458
neuropathology of, 1457
ocular findings in, 1457, 1458*f*
optic nerve glioma in, 1457, 1458, 1458*f*, 1459
peripheral, 937, 1456–1459
peripheral (von Recklinghausen disease), 19, 937, 1089, 1456–1459
signs and symptoms of, 1457–1458, 1457*f*
skeletal and limb manifestations of, 1458
type 1, 1456–1459, 1457*f*, 1459*f*, 1530, 1541–1542
type 2, 1050–1051, 1456–1459, 1549
Neurofibromin, 1051, 1536, 1536*f*
Neurofilament light (NfL), 866
Neurogenic bladder, 449
Neurogenic inflammation, 558
Neurogenic MUPs, 247, 248*f*
Neurogenic pulmonary edema, 1198, 1198*f*
Neurogenic shock, 148, 447
Neurogenic stunned myocardium (NSM), 1195, 1195*t*, 1197–1198, 1198*f*
Neuro-hemo-inflammation, 1130
Neuroimaging. *See specific modalities and disorders*
Neurolathyrism, 1333
Neuroleptic-induced syndromes, 849–853, 849*t*. *See also* Tardive dyskinesia
diagnosis of, 850–851
epidemiology of, 849–850
level 1 evidence on, 853
management of, 851–852, 852*f*
outcome of, 852
pathobiology of, 850
Neuroleptic malignant syndrome (NMS), 849*t*, 1004*t*, 1008, 1329–1330, 1592
clinical features of, 1329
diagnosis of, 108, 109*t*, 850, 1329
management of, 851–852, 1329–1330
medications causing, 1329, 1329*t*
outcome of, 1330
Neurolite. *See* Technetium 99m-hexamethylpropylene amine oxide
Neurologic care
alleviating and aggravating factors in, 18
challenges in providing, 10–13
collaborative partnerships and coordinated action on, 11–12
components required for, 9–10
global delivery of, 9–14
global disparities in, 5–6, 6*f*, 9, 9*f*, 11
health-seeking behavior and, 10–13, 10*b*
improved delivery of, approaches and strategies for, 11
policies and guidelines affecting, 11, 11*b*
primary care workforce and, 12–13
stigma related to neurologic disorders and, 10, 10*b*
telemedicine/communication technology and, 13
training to build capacity of, 13
Neurologic disease. *See also specific diseases*
classification of, 1
double burden of, 4
global burden of, 1–8
challenge of quantifying, 1
changes over time in, 3
disparities in, 4–6, 4*f*, 5*f*, 6*f*
epidemiologic transition in, 3–4
measures for estimating, 1–2
sociocultural differences affecting, 7
primary, 1
secondary, 1
stigma related to, 10, 10*b*
Neurologic examination, 25–44, 68, 99, 99*t*. *See also specific elements*
in acute spinal cord syndromes, 149
in ataxia, 833–834
in autism spectrum disorders, 1435–1436
in coma, 169–172
comprehensive and screening, elements of, 25, 26*t*
descriptions *versus* impressions in, 27
in developmental disorders, 1428–1429
in floppy infant, 1417–1419
general medical examination in, 27–28
helping patient through, 26–27
in motor delay, 1425
observation and interpretation in, 27
patient and examiner positioning in, 27
in seizure diagnosis, 58
setting goals of, neurologic tests *versus*, 25
soft *versus* hard findings in, 27
top-down approach in, 25–26
visual assessment in, 82
Neurologic history, 15–24
approach to taking, 16
behaviors only observable by others, 18
gender specificity in, 18
genetic variants/testing and, 19
history of present illness, 16–19
intentional exploration of, 15–16
level 1 evidence on, 23
localizing features in, 16–17, 16*t*
neurologic symptoms in nonneurologic disease, 19
past medical, psychiatric, and surgical histories, 19
patient age in, 18
primary components of, 16–18
problem-based, 19, 20*t*–22*t*
quality of subjective experiences in, 17–18
questions addressed in, 15
review of symptoms, 19, 20*t*–22*t*
social history and, 19–23
sources of information, 16
technology as assistive tool in, 18–19
timing, onset, tempo, and duration in, 17
Neurologic rehabilitation, 1629–1635
for bladder and bowel dysfunction, 1633
compensation in, 1629–1630
disciplines involved in, 1631–1632

for dysphagia, 1632, 1633
level 1 evidence on, 1634
levels of care in, 1631
medical care in, 1634
morbidity in, 1634, 1634*t*
plasticity in, 1630–1631
recovery in, 1629–1631
for stroke patients, 410–411, 1630
vestibular, 48
Neurolysis, 466–467
external, 466, 466*f*, 466*t*
internal, 466–467, 466*t*, 467*f*
Neuroma, acoustic. *See* Acoustic neuroma
Neuromodulation
for cluster headache prevention, 532
for complex regional pain syndrome, 552*t*, 554
for epilepsy, 591–593
for migraine, 527*t*
for migraine prevention, 529*t*, 530
for tic disorders, 791
Neuromuscular disorders, neurologic history in, 21*t*
Neuromuscular junction
anatomy of, 113, 963–964, 964*f*
disorders of, 963–978. *See also* Myasthenia gravis
EMG findings in, 248
infant hypotonia (floppy infant) in, 1422
level 1 evidence on, 977–978
paraneoplastic, 1101*t*, 1102
postsynaptic, 250–251, 250*f*
presynaptic, 251
repetitive nerve stimulation in, 250–251
SFEMG findings in, 251–252, 251*f*
visual/extraocular effects of, 86
xenobiotic-associated, 1320, 1325*t*
muscle weakness localized to, 113, 120*t*
Neuromuscular respiratory failure, 1209
Neuromuscular transmission, tests of, 250–252
Neuromyelitis optica spectrum disorders (NMOSD), 711, 729–732, 744–754
B-cell recognition in, 747
biomarkers in, 730–731
clinical manifestations of, 730, 730*t*, 747
comorbid conditions with, 748–749
diagnosis of, 730–731, 747–750
diagnostic criteria for, 748, 748*t*
differential diagnosis of, 748–750, 749*t*, 750*f*–751*f*
disability in, 753
encephalitis with, 760
epidemiology of, 729, 745, 745*t*
familial occurrence of, 745
historical perspective on, 744
immunotherapy for, 731–732, 752–753, 752*t*
level 1 evidence on, 753
maintenance therapy for, 752
management of, 731–732, 751–753
MOG pathogenicity in, 747
MOG spectrum disease *versus*, 749–750, 749*t*, 750*f*–751*f*
mortality in, 753
multiple sclerosis *versus*, 722, 744, 749
outcomes of, 732, 753
pathobiology of, 729–730, 745–747, 746*f*
radiologic manifestations of, 730, 731*f*
red flags in, 744, 748, 749*t*
risk factors for, 745
serologic testing and CSF analysis in, 748
T-cell activation and polarization in, 747
transverse myelitis in, 729, 738, 740, 743, 744, 748
treatment of acute attacks in, 751–752
"upstream" pathogenesis in, 747
Neuromyotonia
acquired, 1007–1008, 1102
electrical, 1007–1008
ocular, radiation-induced, 1341
paraneoplastic, 1102
Neuromyotonic discharges, 247
Neuronal ceroid lipofuscinoses (NCLs), 1385, 1399
Neuronal differentiation, 1371
Neuronal migration, 1371–1378
cortical disorders of, 1372–1378
normal, 1371–1372, 1372*f*
Neuronal proliferation, 1370–1371
disorders of, 1370–1371
normal, 1370
Neuron loss, in Alzheimer disease, 479
NeuroPace device, 592–593
Neuropathic pain, 64–69, 65*f*, 557–566
causes by anatomic distribution, 560, 560*t*
central sensitization in, 559–560
cognitive behavioral and physical therapy for, 563–564
in complex regional pain syndrome, 549
definition of, 557, 557*t*
diagnosis of, 68–69, 560–561
eligibility criteria for trials on, 564
epidemiology of, 557
focused history in, 67
focused physical examination in, 67–68
general treatment principles for, 561
HIV-associated, 699
initial management of, 69
level 1 evidence on, 564, 950–951
management of, 561–564
mechanism underlying, 558–560
neuroanatomy and localization of, 65*f*, 65*t*, 66
outcome of, 564
pathobiology of, 557–560
peripheral sensitization in, 558–559
pharmacologic therapy for, 561–563, 561*t*, 562*t*
procedural interventions for, 564
symptomatic treatment of, 69
Neuropathy. *See also specific nerves and types*
acquired peripheral, 936–955
alcoholic, 949, 1306*t*, 1308
amyloid, 936–937, 943, 943*f*
anatomic patterns of, 560, 560*t*
ataxias with, 844–845, 844*t*, 845*f*
autonomic, 938*t*, 941, 1170–1176, 1172*t*
chemotherapy-induced, 1108–1109, 1108*t*, 1109*t*
cranial, 435, 451–457, 454*t*, 915–926
critical illness, 947, 990*t*
definition of, 557*t*
diabetic, 935, 936–937, 938*t*, 949–950, 1221, 1266
diagnosis of, 937, 938*t*
diet-associated, 947
drug-induced, 948–949
eosinophilic granulomatosis with polyangiitis and, 377
etiology of, 937, 938*t*
GI/genitourinary effects of, 1266
granulomatosis with polyangiitis and, 377
HIV-associated, 699, 700*t*
idiopathic, 950
illicit drug use and, 1317
immune-mediated, 938*t*
infant hypotonia (floppy infant) in, 1420–1422
infection-associated, 938*t*, 945–946
inherited, 955–962. *See also* Charcot-Marie-Tooth disease
large-fiber, 936
nerve biopsy in, 285–286
neurologic history in, 21*t*
outcome of, 937
pain in. *See* Neuropathic pain
paraneoplastic, 938*t*, 943–944, 1101*t*, 1102
polyarteritis nodosa and, 376
in pregnancy, 1293–1294
radiation-induced, 1336, 1337, 1341
renal disease and, 1254–1255
sensory, 941
small-fiber, 936
treatment of, 937
vasculitic, 938*t*, 941–942, 942*f*
xenobiotic-associated, 1320, 1323*t*–1325*t*
Neuropathy, ataxia, and retinitis pigmentosa (NARP), 1446*t*, 1447
Neuroplasticity, 806, 1381, 1598, 1630–1631
Neuropsychological testing, 271–276. *See also specific tests and applications*
clinical observation in, 275
diagnosis-specific issues in, 275–276
expectations from, 276
intellectual ability tests in, 271–275
normative values in, 271
performance patterns in, 271
referring for, 276
strategy of, 271
test selection in, 271
tests used in, 271–275
Neuropsychologists, rehabilitation role of, 1633
Neuroretinitis, 633, 633*f*
Neurorrhaphy, end-to-end, 466*t*, 467
Neurosarcoidosis, 773–777. *See also* Sarcoidosis
Neurosyphilis, 98, 100, 153, 161*t*, 648–649
clinical presentation of, 641*t*, 648
CSF analysis and serum diagnostics in, 642*t*, 649
diagnosis of, 649
epidemiology and pathobiology of, 648
historical perspective on, 648
HIV-associated, 705
imaging in, 641*t*
multiple sclerosis *versus*, 721
psychosis with, 1594
treatment of, 643*t*, 649
Neurotization, 466*t*, 467
Neurotmesis, 452, 452*t*, 463, 468
Neurotoxicology, 1319–1334. *See also specific toxins and toxicities*
ataxia in, 1320, 1322*t*
clinical features in, 1320, 1321*t*–1322*t*, 1327*t*
common neurotoxidromes in, 1322–1333
definition of, 1319
diagnosis in, 1320
epidemiology in, 1319
movement disorders in, 1320, 1321*t*
myopathies in, 992, 993–996, 1320, 1325*t*
neuropathies in, 1320, 1323*t*–1325*t*

Neurotoxicology *(Continued)*
pathobiology in, 1320, 1320*t*
seizures in, 1320, 1321*t*
smells and odors in, 1320, 1325*t*
treatment in, 1320–1322, 1326*t*
tremors in, 1320, 1322*t*
Neurotropic virus, HIV as, 693–694
Neurulation, 1367, 1367*f*
Neutral lipid storage disease (NLSD), 1016
Nevirapine, 707*t*, 1582–1583
Nevoid basal cell carcinoma syndrome, 1531
Nevus flammeus, 1463, 1463*f*, 1464
New daily persistent headache (NDPH), 524*t*, 534
New-onset refractory status epilepticus, 759
New Onset Refractory Status Epilepticus (NORSE), 578
New Orleans/Charity Head Trauma/Injury Rule, 429, 429*t*
Next-generation sequencing (Next-Gen), 300
in bacterial meningitis, 608
in chronic meningitis, 650
NfL. *See* Neurofilament light
Niacin (nicotinic acid) deficiency, 947, 1278*t*, 1281, 1308
Nicardipine
for ICH, 139, 337, 337*t*
for paroxysmal sympathetic storming, 1200*t*
for preeclampsia/eclampsia, 1290
for SAH patients, 350
Niemann-Pick disease, 1396–1397
type A, 1394, 1396
type B, 1394, 1396
type C, 844*t*, 845, 847, 1396–1397
Nifurtimox
for African trypanosomiasis, 655
for American trypanosomiasis, 655
Night terrors, 264, 265, 1192–1193
Nimodipine
for reversible cerebral vasoconstriction syndrome, 388–389
for SAH patients, 349
Nimotuzumab, for pediatric brain tumors, 1554
Nipah virus, 675
Nitrofurantoin, neuropathy induced by, 949
Nitrogen-13, 203
Nitrogen narcosis, 1350–1353, 1352*t*
Nitroprusside, for ICH, 337, 337*t*
Nitrous oxide toxicity, 1167–1168, 1332
Nivolumab
for brain metastases, 1043
for meningiomas, 1054*t*
neurologic complications of, 1110
NKX2-1 (brain-lung-thyroid) syndrome, 858
NLSD. *See* Neutral lipid storage disease
NMDA receptor. *See N*-methyl-D-aspartate (NMDA) receptor
NMDAR Encephalitis One-Year Functional Status, 771
N-methyl-D-aspartate (NMDA) receptor
in Huntington disease, 863–864
in neuropathic pain, 559, 563
in paraneoplastic syndromes, 1100, 1101, 1101*t*, 1102, 1104
in refractory status epilepticus, 61–62
N-methyl-D-aspartate (NMDA) receptor antagonists. *See* Dextromethorphan; Galantamine; Ketamine; Memantine; Phencyclidine (PCP)
N-methyl-D-aspartate (NMDA) receptor encephalitis, 755, 760
chorea in, 856
EEG findings in, 762–763, 762*f*
epidemiology of, 755–756
immunobiology of, 757
movement disorders in, 760, 856, 1101, 1102
outcome of, 771
paraneoplastic, 1101, 1102
predictive scoring in, 771
treatment of, 760, 767, 770, 771
NMOSD. *See* Neuromyelitis optica spectrum disorders
NMS. *See* Neuroleptic malignant syndrome
Nocardia, 153, 161*t*
Nociceptive pain, 557–558
definition of, 557, 557*t*
normal processing of, 557–558
Nociplastic pain, 549, 552–554
Nocturnal behaviors, 264, 265, 1192–1193
Nocturnal seizures, 264
Nodding syndrome, barriers to care for patients with, 10–11, 10*b*
Nonaka distal myopathy, 1493
Nonbacterial thrombotic endocarditis (NBTE), 397–398, 400
Noncoding repeats, ataxias associated with, 843
Noncommunicating hydrocephalus, 1114
Noncontrast computed tomography (NCCT), 185, 185*f*, 186*f*. *See also* Computed tomography
Nondystrophic myotonias, 998, 999*t*, 1001–1002
Nonentrained circadian rhythm disorder, 1192
Nonessential amino acids, 1387
Nongerminatous germ cell tumors, 1072–1073, 1073*t*
Non-Hodgkin lymphoma, 1232–1234
classification of, 1232, 1232*t*
clinical manifestations of, 1232–1233
diagnosis of, 1233
epidemiology of, 1232
extranodal, 1056–1062. *See also* Primary central nervous system lymphoma
management of, 1233
Noninvasive positive pressure ventilation (NPPV), 1208, 1210
Nonketotic hyperglycinemia, 1504
Nonnucleoside reverse transcriptase inhibitors, 706, 707*t*, 1582
Non-rapid eye movement (NREM) sleep, 1183–1184, 1184*f*, 1190
Nonsteroidal anti-inflammatory drugs (NSAIDs)
for cold-stimulus headache, 533
for hemicrania, 75, 532, 533
for migraine, 525, 526*t*, 527
for migraine in pregnancy, 1293
for primary cough headache, 533
for primary exertional headache, 533
for primary sex headache, 533
for primary stabbing headache, 534
for rhinosinusitis, 540
for temporomandibular disorder, 542
for tension-type headache, 530
Nonverbal learning disability (NVLD), 1428*t*, 1430–1431
Nonverbal memory, 30, 274*t*
Noonan syndrome, 1456
Noonan syndrome with multiple lentigines, 1456
Norepinephrine
in depression, 1597–1598
plasma levels of, 257
Normal-pressure hydrocephalus (NPH), 902, 1114, 1120–1123
algorithm for, 1122*f*
bladder dysfunction with, 1267
clinical manifestations of, 1121–1122
diagnosis of, 1122
epidemiology of, 1120
gait disorder in, 129*t*, 902, 1121–1122
pathobiology of, 1120–1121, 1121*f*
treatment and outcomes of, 1122–1123
NORSE. *See* New Onset Refractory Status Epilepticus
Nortriptyline
for depression, 1602
for migraine prevention, 528, 529*t*
for neuropathic pain, 562*t*
NovoTTF-1001, for meningiomas, 1054*t*
NPH. *See* Normal-pressure hydrocephalus
NPPV. *See* Noninvasive positive pressure ventilation
N-propylaporphine, for Parkinson disease, 887
NREM. *See* Non-rapid eye movement (NREM) sleep
NSAIDs. *See* Nonsteroidal anti-inflammatory drugs
NSM. *See* Neurogenic stunned myocardium
NTRK inhibitors, for brain metastases, 1043
Nuchal rigidity, 605, 614
Nucleoside reverse transcriptase inhibitors, 706, 707*t*, 1582–1583
Nucleotide reverse transcriptase inhibitors, 706, 707*t*
Null point, in movement disorders, 800
Numb chin syndrome, 917
Numbness, 64–69
in acute spinal cord syndromes, 148
anatomic distribution of, 67
diagnostic evaluation of, 68–69
focused history in, 67
focused physical examination in, 67–68
initial management of, 69
loss of sensation *versus* abnormal sensation in, 64
management strategy for, 64
neuroanatomy and localization of, 64–66, 65*t*
Nummular headache, 524*t*, 534
Nursing, rehabilitation, 1632
Nutrition
in alcoholism, 1306–1308, 1306*t*
in ALS, 908, 913
in ataxia, 834, 835, 845, 847
deficiencies in, 1277–1285. *See also specific deficiencies*
in HIV infection, 706
in Huntington disease, 867–868
life-sustaining, 1639
in myelopathy, 1167
in neuropathy, 947
in prion diseases, 518, 519*t*
in spinal cord injury, 448
in traumatic brain injury, 433–434
Nutritional history, 22–23
Nystagmoid movements, 81

Nystagmus, 46, 46*t*, 47*t*
in BPPV, 600
brain abscess and, 614
coma and, 172
concussion and, 415
in Ménière disease, 598
in progressive supranuclear palsy, 894
testing for, 81, 262–263, 262*f*

O

Oberlin procedure, 467
Obesity
antipsychotics and, 1590–1592
and intracranial hypertension, 1135, 1137
surgery for
neurologic complications of, 1283
nutritional deficiencies with, 1277
Obesity hypoventilation syndrome, 1191
Observation, clinical, 275
Obsessive-compulsive behaviors
in Huntington disease, 865–866, 868
in Sydenham disease, 854–855
in Tourette syndrome, 784, 787, 1609–1610, 1612
Obsessive-compulsive disorder (OCD), 1606
classification of, 1606, 1609
clinical features of, 1608*t*, 1609
epidemiology of, 1606
neurologic disorders comorbid with, 1609–1610, 1612
pathobiology of, 1607
tic-related, 1609
treatment of, 1612
Obstetrical brachial plexus palsy, 1420
Obstructive hydrocephalus, 288, 1114, 1114*t*
acute, 1115–1117
clinical features of, 1116
diagnosis of, 1116–1117
epidemiology of, 1115
pathobiology of, 1115–1116
stroke/IVH and, 1116, 1116*f*
treatment and outcomes of, 1117
tumor-related, 1116, 1117*f*
congenital, 1117–1119
diagnosis of, 1118
MRI of, 1118, 1118*f*, 1119*f*
pathobiology of, 1117–1118, 1118*f*
treatment and outcomes of, 1118–1119
ICH causing, 139–140
Obstructive sleep apnea, 1190–1191
clinical features of, 1190
home test for, 265
management of, 1190–1191
sleep testing in, 264–267
snoring in, 1190
symptoms of, 264
Obtundation, 168
Obturator nerve
anatomy of, 930
injury of, 460*t*, 461, 933
Occipital lobe, dysfunction, vision loss with, 85
Occipital nerve block, 546, 546*f*
Occipital nerve stimulation, for SUNCT/SUNA headaches, 532–533
Occipital neuralgia, 546
Occupational history, 22
for neurologic rehabilitation, 1632
Occupational therapy
for Charcot-Marie-Tooth disease, 960, 960*t*
for dystonia, 818
for inflammatory myopathies, 981
OCD. *See* Obsessive-compulsive disorder
Ocrelizumab
for multiple sclerosis, 723, 724*t*
for multiple sclerosis in pregnancy, 1292, 1292*t*
OCT. *See* Optical coherence tomography
Octapeptide repeat insertions (OPRIs), 507, 507*t*, 513, 516
Octreotide, for meningiomas, 1054*t*
Ocular bobbing, 172
Ocular motility, 81
Ocular motor testing, 262
Ocular neuromyotonia, radiation-induced, 1341
Oculogyric crisis, 109*t*, 802*t*, 809, 850
Oculomotor apraxia, 307, 844*t*, 845
Oculomotor nerve (CN III), 77, 78, 78*f*
examination of, 34, 34*f*
injury of, 454*t*, 455
palsy or dysfunction of, 82, 85–86
Oculopharyngeal muscular dystrophy (OPMD), 1474, 1476*t*, 1492
ODD. *See* Obsessive-compulsive disorder (OCD)
Odontogenic brain abscess, 612
ODS. *See* Osmotic demyelination syndrome
Ofatumumab, for myasthenia gravis, 972
Ohtahara syndrome, 1360, 1504
Olanzapine
for bipolar disorder, 1603
for delirium, 91, 92, 92*t*
for delirium prevention, 92
for Huntington disease, 867
for schizophrenia, 1590–1592, 1591*t*
side effects of, 1590–1592, 1591*t*
for tic disorders, 790*t*
Olfactory nerve (CN I)
anatomy of, 915
examination of, 32
injury (neuropathy) of, 453–455, 454*t*, 915–917, 916*t*
Oligoastrocytoma, survival rates for, 1532*t*
Oligodendrogliomas, 152, 154, 155*f*, 157*t*, 1019, 1029–1031
anaplastic, 1031, 1532*t*
diagnosis of, 1030
diffuse, 1031
epidemiology of, 1029
histology of, 1030, 1030*f*
management of, 1031
molecular features of, 1020–1021, 1020*t*, 1029–1030
MRI of, 1030, 1030*f*
outcome of, 1031
pathobiology of, 1029–1030
pediatric, 1554
pineal, 1072
survival rates for, 1532*t*
Olivopontocerebellar atrophy (OPCA), 894–896
OMIM. *See* Online Mendelian Inheritance in Man
Onabotulinum toxin type A. *See* Botulinum toxins
Onconeural antigens, 756*f*, 757
Ondansetron, for vertigo, 49*t*
Ondine's curse, 171, 1191
Online Mendelian Inheritance in Man (OMIM), 1366, 1385
Onset, in neurologic history, 17
OPA1 mutations, 1450
OPCA. *See* Olivopontocerebellar atrophy
Open-lip schizencephaly, 1368
Open nerve injury, 464, 464*f*
Ophthalmic examination, 80–81. *See also* Vision testing
Ophthalmoscopy, 79*t*, 80–81, 81*f*
Opicapone, for Parkinson disease, 885–886
Opioids. *See also specific drugs*
abuse/dependence, 1313–1314, 1313*t*, 1316–1317
for complex regional pain syndrome, 553
for migraine, 74, 528
for neuropathic pain, 563
neurotoxicity of, 1299
overdose of, 169
for palliative (end-of-life) sedation, 1640, 1641*t*
for paroxysmal sympathetic hyperactivity, 1180–1181, 1180*f*, 1181*t*
prenatal and perinatal effects of, 1585–1586
for restless legs syndrome, 797*t*, 798
Opisthotonus, 802*t*, 809
Opportunistic infections
in HIV, 699–706, 700*t*. *See also specific infections*
in HIV, pediatric, 1581
in organ transplantation, 1255, 1299
OPRIs. *See* Octapeptide repeat insertions
Opsoclonus-myoclonus, 1103
Opsoclonus-myoclonus-ataxia syndrome, 828
Opsoclonus-myoclonus syndrome, 759
Optical coherence tomography (OCT), 82, 82*f*, 260, 261*f*, 721
Optic apraxia, 307
Optic atrophy, dominant, 84
Optic chiasm, 77, 77*f*
pathologies of, 84–85
Optic nerve (CN II), 77, 77*f*
comparing, using pupil, 82
examination of, 32–34
injury of, 454*t*, 455. *See also* Optic neuropathy
OCT studies of, 82, 82*f*, 260, 261*f*
transient visual symptoms caused by, 83
Optic nerve glioma
in neurofibromatosis, 1457, 1458, 1458*f*, 1459
in tuberous sclerosis complex, 1460
Optic nerve tumors, 84
Optic neuritis
acute, in multiple sclerosis, 715, 715*t*
encephalitis with, 760
in neuromyelitis optica spectrum disorders, 730, 730*t*, 744, 748
paraneoplastic, 1103
Optic neuropathy, 84
acute, 84
differential diagnosis of, 84
papilledema with, 84, 87
progressive, 84
radiation-induced, 1341
sarcoidosis and, 773, 774*f*, 776
Optic radiations, 77, 77*f*, 85
Optic tract
anatomy of, 77
pathologies of, 85
Optokinetic nystagmus, 262

Oral appliances, for temporomandibular disorder, 542
Oral contraceptives, and cerebral venous thrombosis, 354
Oral polio vaccine (OPV), 663, 664
Orbicularis oculi, 78
Orbital apex syndrome, 87
Organ donation, 182, 1642
Organ failure, multiple, 1248
Organic acidopathies, 1385
Organic acidurias, 1388–1390, 1419
Organophosphate toxicity, 250, 948, 1326–1329
Organ transplantation. *See also specific organs*
  drug toxicity in, 1299–1300, 1300*f*
  encephalopathy and delirium in, 1299
  infections in, 1255, 1299
  long-term effects of immunosuppressive therapy in, 1301
  neurologic complications of, 1298–1302, 1298*t*
  posttransplant lymphoproliferative disorders in, 1232–1234, 1301
Orientia tsutsugamushi, 628
Oromandibular dystonia, 809
Oropharyngeal anthrax, 633
Oropharyngeal dysphagia, 1263
Orotic acid, 1386–1387, 1386*t*
Orphenadrine, for hemifacial spasm, 822
Orthochromatic leukodystrophies, 1399
Orthodromic flow, 245
Orthomyxoviruses, 675
Orthostatic challenge, 256–257
Orthostatic hypotension, 1170–1177
  antipsychotics and, 1591*t*
  causes of, 53, 1170, 1171*f*
  chronic neurogenic, 1173–1174
  epidemiology of, 51
  factors affecting, 1170, 1171*t*, 1175
  in Guillain-Barré syndrome, 939
  management of, 1174–1175
  in multiple system atrophy, 896, 897
  in Parkinson disease, 872, 879, 881, 889
  pathophysiology of, 52*f*
  syncope due to, 51, 52*f*, 52*t*, 53–55
  testing for, 54–55, 256–257
Orthostatic intolerance, 1173
Orthotics, for Charcot-Marie-Tooth disease, 960, 960*t*
Osimertinib, for metastatic disease, 1042
Osmotic demyelination syndrome (ODS), 1258–1260, 1258*f*, 1259*f*
Osmotic dysequilibrium syndromes, 1129
Osmotic edema, 1128, 1129
Osteitis deformans. *See* Paget disease of bone
Osteogenic sarcoma, skull base, 1083, 1084*f*
Osteoma, skull, 1084, 1085*f*
Osteomalacia, myopathy in, 994*t*
Osteomyelitis, of skull base, 622
Osteoporosis
  secondary, 1274–1275
  spinal cord injury and, 450
Osteosarcoma, epidemiology of, 1530
Otalgia, 540–541, 545–546
Other specified mood disorders, 1600
Other specified tic disorder, 786, 786*t*
Otitis externa, malignant, 621–622, 622*t*
Otitis media
  acute, 541
  and brain abscess, 612
  and meningitis, 604, 605*t*
  and transverse sinus thrombosis, 615
Otoconia, 600
Ottawa SAH Rule, 344, 344*t*
Ovarioleukodystrophy, 1414*t*
Overflow, 802*t*
Overlap myositis, 979, 982, 982*t*, 983*t*, 984*t*
Overt hepatic encephalopathy (OHE), 1246–1248
Oxaliplatin
  adverse effects of, 1109
  neuropathy induced by, 949
Oxcarbazepine, 586
  adverse effects of, 584, 586
  for cramps, 1009
  for cranial neuralgias, 543, 544*t*
  dosage and pharmacokinetics of, 584*t*, 586
  for epilepsy, 581–585, 586
    in breastfeeding patients, 1288–1289
    in pregnant patients, 1287
    teratogenicity of, 1287*t*
  for neonatal seizures, 1360
  for neuropathic pain, 562*t*, 563
Oxidative phosphorylation, enhancement of, 1453
Oxidative stress
  in Huntington disease, 868
  in Parkinson disease, 876–877
Oxycodone
  for neuropathic pain, 562*t*, 563
  for paroxysmal sympathetic hyperactivity, 1180*f*
  for restless legs syndrome, 797*t*, 798
Oxygen-15, 203, 203*f*
Oxygenation, brain. *See* Brain oxygenation
Oxygen therapy, for cluster headache, 74
Oxygen toxicity, 1350, 1351
Oxytocin, 1215

P

p53 tumor suppressor, 1537
Pachymeningitis, hypertrophic, 1055
Paclitaxel
  adverse effects of, 1109
  neuropathy induced by, 949
PACNS. *See* Primary angiitis of CNS
Paget disease of bone, 1087, 1270–1281, 1281*f*
Pain, 64–69. *See also specific causes and disorders*
  in acute spinal cord syndromes, 148
  central, 65*f*
  chronic, 557
  definition of, 557
  diagnostic evaluation of, 68–69
  focused history in, 67
  focused physical examination in, 67–68
  headache, 521. *See also* Headache
  identifying potential serious conditions, 69
  initial management of, 69
  key terminology in, 557, 557*t*
  management strategy for, 64
  modulation and perception of, 558
  motor response to, brain death and, 181
  with muscle weakness, 114
  neuroanatomy and localization of, 64–66, 65*f*, 65*t*
  neuropathic. *See* Neuropathic pain
  nociceptive, 557–558, 557*t*
  nociplastic, 549, 552–554
  normal processing of, 557–558
  radicular, 1147
  somatic, 65
  in spinal cord injury, 448–449
  symptomatic treatment of, 69
  tardive, 849*t*, 851
  transduction and transmission of, 558
Pain control, and delirium, 88, 91
painDETECT questionnaire, 557, 560
Pain disorder, 1615*t*, 1616
Pain management, in palliative care, 1640
Paired-pulse transcranial magnetic stimulation, 252
Palatal myoclonus, 827
Palilalia, 106
Paliperidone, 1591*t*
Palliative care, 1636–1643
  definition of, 1637
  disease trajectories and, 1636–1637
  double effect in, 1640
  hospice, 1640
  models of, 1637, 1637*f*
  pain management in, 1640
  sedation in, 1640, 1641*t*
Palpation, in motor examination, 36
PAN. *See* Polyarteritis nodosa
Panayiotopoulos syndrome, 575, 1510
PANDAS, 785
Panencephalitis
  progressive rubella, 671–672
  subacute sclerosing, 671–672, 675–676
Panic attack, 1608
Panic disorder, 1606
  clinical features of, 1608, 1608*t*
  treatment of, 1611, 1611*t*
Pantothenate kinase-associated neurodegeneration (PKAN), 1393
Papile grading system, for IVH, 1116, 1355, 1356*f*
Papilledema, 84, 87
  brain abscess and, 614
  chronic meningitis and, 640
  in Guillain-Barré syndrome, 939
  hemangioblastoma and, 368
  intracranial hypertension and, 1136
Paradoxical insomnia, 1186
Paragangliomas, jugular, 1084
Paragonimiasis, 654*t*
Paragonimus, 162*t*
Parakinesia, 854
Paralysis, periodic, 998–1003
Paramyotonia congenita (PC), 998, 1001–1002
Paramyxoviruses, 675–676
Paraneoplastic ataxia, 838, 1101*t*, 1102
Paraneoplastic autonomic neuropathy, 1172–1173, 1172*t*
Paraneoplastic encephalitis, 757, 764–765, 766*t*–767*t*, 767, 1101, 1101*t*, 1104*f*
Paraneoplastic epilepsy, 1101, 1101*t*, 1105
Paraneoplastic ganglioneuritis, 936
Paraneoplastic Lambert-Eaton myasthenic syndrome, 976, 1101*t*, 1102, 1105
Paraneoplastic movement disorders, 1101*t*, 1102–1103
Paraneoplastic myelitis, 1101–1102, 1101*t*
Paraneoplastic neuropathy, 938*t*, 943–944, 1101*t*, 1102

Paraneoplastic syndromes, 1100–1105, 1101*t*. *See also specific manifestations*
autoimmune disorders with, 755, 757, 764–765, 766*t*–767*t*, 767
classic, 1100
clinical manifestations of, 1101–1103
diagnosis of, 1103–1104, 1103*f*
epidemiology of, 1100
imaging in, 1104, 1104*f*
level 1 evidence on, 1105
management of, 1103–1105
outcomes of, 1105
pathobiology of, 1100
spectrum of manifestations, 1100, 1100*f*
treatment of, 1104–1105
Paraparesis, 114, 129*t*
Paraplegia, 441
Parasarcoidosis, 775–776
Parasitic infections, 653–660. *See also specific infections*
brain, 153, 162*t*, 163*f*–164*f*
HIV-associated, 704–705
neurologic (CNS), 654, 654*t*
public health burden of, 654
Parasomnias, 264, 265, 1192–1193
Parathyroid disease, 1224–1225
Parathyroid hormone (PTH), 994*t*, 1224–1225
Paratonia, 37, 169, 800–801, 802*t*
Parechoviruses, 662–663
Parenchymal hematoma, 430
Parenchymal hemorrhage, MRI appearance of, 191
Parenchymal sarcoidosis, 774, 774*f*, 776
Paresthesias, 64–69
in acute spinal cord syndromes, 148
anatomic distribution of, 67
definition of, 64, 557*t*
diagnostic evaluation of, 68–69
focused history in, 67
focused physical examination in, 67–68
in Guillain-Barré syndrome, 939
identifying potential serious conditions, 69
initial management of, 69
in multiple sclerosis, 715
neuroanatomy and localization of, 64–66, 65*t*
in Parkinson disease, 879*t*
in polyneuropathy, 936
symptomatic treatment of, 69
Parietal lobe tumors, pediatric, symptoms of, 1541
Parinaud syndrome, 172, 307, 1074, 1118
Parkes Weber syndrome, 1464
Parkinson-dementia-amyotrophic lateral sclerosis complex of Guam, 900–902
Parkinson disease (PD), 871–892
autonomic dysfunction in, 880–881, 1173–1174
biomarkers in, 871
clinical course of, 875*f*, 879–880
clinical manifestations of, 871, 877–881
clinical staging scale for, 879, 880*t*
cognitive impairment in, 880, 888–889, 902
deep brain stimulation for, 872, 879, 885, 889–890
diagnostic criteria for, 871
differential diagnosis of, 881, 882*t*
dopamine in, 871–873
dysphagia in, 878, 879*t*, 891, 1262–1263, 1267
dystonia in, 803–804, 878, 879*t*, 881
epidemiology of, 872–873
essential tremor (ET-PD), 781
essential tremor *versus*, 781, 781*t*, 877, 881
etiology of, 874–875
gait disorder in, 129*t*, 890–891
genetics of, 298, 300, 872, 873*t*, 874–876
GI/genitourinary effects of, 1267
historical perspective on, 871
idiopathic, 871
level 1 evidence on, 891
mimics of, 879
mood disorders in, 879*t*, 880, 889, 1600–1601, 1603
motor features of, 871, 877–879, 879*t*
neuroanatomy of, 108
nonmotor features of, 871, 880–881, 888–889
osteoporosis and fracture in, 1274–1275
outcome of, 890–891
pathobiology of, 873–877
pathogenesis of, 876–877
pathology of, 873–874, 874*f*
pregnancy and, 1294–1295
psychosis in, 108, 109*t*, 888–889, 1594
sensory symptoms in, 880, 916
single-sided presentation of, 879, 881
sleep problems in, 880, 889
symptomatic without evidence of dopaminergic deficits, 871
treatment of, 881–890
adenosine A_{2A} antagonists for, 888
adjunctive therapies in, 885
amantadine for, 881, 886
anticholinergic drugs for, 881, 886–887
COMT inhibitors for, 885–886
dopamine agonists for, 881–883, 887–888
general principles in, 881–882
levodopa for, 875*f*, 879, 881–885, 890
long-duration response in, 884
MAO inhibitors for, 881, 885, 886
myths about, 881
for nonmotor problems, 888–889
overview, 881–888, 883*t*
short-duration response in, 884
surgical, 883*t*, 889–890
Parkinson Disease-Cognitive Rating Scale, 494
Parkinson disease dementia (PDD), 492, 880, 902. *See also* Lewy body dementia
cognitive testing in, 494
dementia with Lewy bodies *versus*, 492, 493, 495
treatment of, 497–498, 888–889
Parkinsonian hyperpyrexia, 109*t*
Parkinsonian syndrome. *See* Parkinsonism
Parkinsonism, 104, 871–872
in alcohol withdrawal, 1305
classification of syndromes, 871, 872*t*
differential diagnosis of, 497, 881, 882*t*
drug-induced, 849–851, 849*t*, 899–900, 901*t*
in Gaucher disease, 1396
genetics of, 875–876
GI/genitourinary effects of, 1267
in Lewy body dementias, 492, 494
paraneoplastic, 1102
in Parkinson-plus syndromes, 893–903
postencephalitic, 902
posttraumatic, 438
pregnancy and, 1294–1295
primary, 871. *See also* Parkinson disease
secondary, 871, 872*t*
severe irreversible, illicit drug use and, 1317
vascular, 902
xenobiotic-induced, 1320, 1321*t*
Parkinson-plus syndromes, 871, 872*t*, 893–903. *See also* Corticobasal degeneration (CBD); Multiple system atrophy (MSA); Progressive supranuclear palsy
epidemiology of, 897
treatment of, 897–899, 901*t*
Parkinson Progression Markers Initiative, 871
Parosmia, 915–917
Paroxetine
for anxiety disorders, 1611*t*, 1612
for cataplexy, 1189
Paroxysmal dystonia, 715*t*, 727*t*
Paroxysmal hemicrania, 74, 531*t*, 532
Paroxysmal hemicrania-tic syndrome, 532
Paroxysmal sympathetic hyperactivity (PSH), 1178–1182, 1199*f*, 1199*t*
clinical manifestations of, 1179
diagnosis of, 1179–1180
diagnostic criteria for, 1179–1180, 1179*t*
epidemiology of, 1178
management of, 1180–1181, 1180*f*
medications for, 1180–1181, 1180*f*, 1181*t*
outcomes of, 1181–1182
pathobiology of, 1178
treatment algorithm for, 1180*f*
Paroxysmal sympathetic storming, 1195, 1198–1200, 1200*t*
Parsonage-Turner syndrome, 458, 925, 929
PART (primary age-related tauopathy), 479
Partial fetal alcohol syndrome (PFAS), 1583*t*, 1584
Pasireotide LAR, for meningiomas, 1054*t*
Past histories, 19
Patellar reflex, 38, 39*t*
Patent foramen ovale (PFO)
childhood stroke in, 1520
decompression illness with, 1350, 1351
Risk of Paradoxical Embolism scoring system in, 407, 407*t*
stroke with, 301, 304
stroke prevention in, 407
Pathogenic variant, 1366
Pathologic intoxication, 1304
Patient history. *See* Neurologic history; *specific disorders*
Patisiran, for amyloid neuropathy, 943, 1174
Paucity of movement, 877
PBD. *See* Peroxisome biogenesis disorder
$PbtO_2$ (brain tissue oxygen partial pressure), 291–292, 292*t*
PCDH19 girls clustering epilepsy, 1509
PCI. *See* Prophylactic cranial irradiation
PCNSL. *See* Primary central nervous system lymphoma
PCOS. *See* Polycystic ovary syndrome
PCP. *See* Phencyclidine
PCR. *See* Polymerase chain reaction
PCSK9 inhibitors. *See* Proprotein convertase subtilisin-kexin type 9 inhibitors
PD. *See* Parkinson disease
PDD. *See* Parkinson disease dementia
PDD-NOS. *See* Pervasive development disorder–not otherwise specified
Peak latency, in nerve conduction studies, 244–245

Pearson syndrome, 1446*t*, 1447
Pectoral nerves, 928, 928*f*, 928*t*
Pediatric autoimmune neuropsychiatric disorder associated with streptococcal infection (PANDAS), 785
Pedunculopontine nucleus (PPN), 124–125, 124*f*, 124*t*
PEEP. *See* Positive end-expiratory pressure
PEH. *See* Primary exertional headache
Pelizaeus-Merzbacher disease (PMD), 1399, 1401
Pellagra, 947, 1281, 1308
Pembrolizumab
  for brain metastases, 1043
  for gliomas, 1022
  for meningiomas, 1054*t*
  neurologic complications of, 1110
Pemetrexed, for primary CNS lymphoma, 1060
Pendular nystagmus, 46, 47*t*, 81
Penetrance, genetic, 298
Penicillamine, myasthenia gravis induced by, 975
Penicillin(s)
  for brain abscess, 617
  for diphtheria, 637
  for osteomyelitis of skull base, 622
  for syphilis, 648, 649
Penicillin G
  for bacterial meningitis, 609*t*
  for Lyme disease, 650
  for tetanus, 638
Pentobarbital
  for ICP management, 432
  for refractory status epilepticus, 62, 62*t*
Pentobarbital coma, 1133
Pentosan polysulfate (PPS), for prion diseases, 518–519
Penumbra device, 312
PEO. *See* Progressive external ophthalmoplegia
PEO1 mutations, 1450
Perampanel, 582, 584*t*, 587
  for epilepsy in pregnant patients, 1288
  for myoclonus, 829*t*
Perception, testing of, 272–274
Perceptual disturbances, in alcohol withdrawal, 1305
Perceptual reasoning, 275
Percheron, artery of, 307
Perfusion imaging, cerebral, 203, 203*f*, 204*t*, 205–206. *See also specific modalities and applications*
  computed tomography, 185, 187
  magnetic resonance, 200–201, 201*f*
Perfusion pressure, cerebral. *See* Cerebral perfusion pressure
Perfusion-weighted images, 200
Pergolide, for restless legs syndrome, 797*t*
Perihematomal edema, 334, 1130
Perimesencephalic SAH, 344
Perimetry, 83, 260
Perinatal asphyxia/hypoxic-ischemic encephalopathy, 1357–1359
  clinical manifestations of, 1358, 1358*t*
  diagnosis of, 1358
  epidemiology of, 1357
  management of, 1358–1359
  neuroimaging in, 1358, 1359*f*
  outcome of, 1359
  pathobiology of, 1357–1358
Perinatal stroke, 1362, 1515–1518
  arterial ischemic, 1515
  clinical features of, 1516
  cognitive and behavioral deficits with, 1517
  definition of, 1515
  diagnosis and imaging of, 1516, 1517*f*
  epidemiology of, 1515
  management of, 1517
  outcome of, 1517–1518
  pathobiology of, 1515–1516
  presumed, 1515
  recurrence of, 1518
  risk factors for, 1515–1516, 1516*t*
  seizures and epilepsy with, 1517–1518
Perindopril
  for cardiac function in Duchenne muscular dystrophy, 1482
  for ICH secondary prevention, 339
  for stroke prevention, 408
Periodic alternating gaze, 171
Periodic lateralized epileptiform discharges, 231–232, 235*f*
Periodic limb movement in sleep (PLMS), 793, 1191
Periodic paralysis, 998–1003
  hyperkalemic, 998, 999*t*, 1000–1001, 1000*t*
  hypokalemic, 998–1000, 999*t*, 1000*t*
Periorbital swelling, 521
Peripheral dystonia, 809
Peripheral myoclonus, 826*t*, 828–829
Peripheral nerves. *See also specific nerves*
  anatomy and physiology of, 451
  hyperexcitability, disorders of, 1004, 1004*t*, 1007–1009, 1102
  injury of, 451–468, 932–934. *See also* Peripheral neuropathy
    acute, 451
    blunt, 464–465
    chronic, 451
    classification of, 452, 452*t*
    clinical features of, 453
    closed, 464, 465*f*
    diagnosis of, 462–464
    electrodiagnostic findings in, 463
    end-to-end neurorrhaphy for, 466*t*, 467
    epidemiology of, 451
    graft repair of, 466*t*, 467
    indications for early operative repair of, 465
    initial evaluation of, 464, 464*f*, 465*f*
    lower extremity, 460–462, 460*t*
    mechanisms of, 451
    nerve transfer for, 466*t*, 467–468
    neurolysis for, 466–467, 466*f*, 466*t*, 467*f*
    open, 464, 464*f*
    outcomes of, 468
    prognosis of, 452, 452*t*
    repair and regeneration in, 453
    sensitization in, 558–559
    sharp, 464
    split repair of, 466*t*, 467
    surgical planning for, 464
    surgical techniques for, 466, 466*t*
    tendon transfer for, 466*t*, 468
    timing of studies in, 463–464
    treatment of, 464–468
    upper extremity, 457–460
  muscle weakness localized to, 112–113, 113*f*, 120*t*
  sensory patterns and loss, 65*t*, 66
Peripheral nervous system, anatomy of, 936
Peripheral neurofibromatosis (von Recklinghausen disease), 19, 937, 1089, 1456–1459
Peripheral neuropathy. *See also specific nerves and types*
  acquired, 936–955
  alcoholic, 949, 1306*t*, 1308
  amyloid, 936–937, 943, 943*f*
  autonomic, 938*t*, 941, 1170–1176, 1172*t*
  chemotherapy-induced, 1108–1109, 1108*t*, 1109*t*
  critical illness, 947
  definition of, 936
  diabetic, 935, 936–937, 938*t*, 949–950, 1221, 1266
  diagnosis of, 937, 938*t*
  diet-associated, 947
  eosinophilic granulomatosis with polyangiitis and, 377
  epidemiology of, 936
  etiology of, 937, 938*t*
  GI/genitourinary effects of, 1266
  granulomatosis with polyangiitis and, 377
  HIV-associated, 699, 700*t*
  idiopathic, 950
  illicit drug use and, 1317
  immune-mediated, 938*t*
  infant hypotonia (floppy infant) in, 1420–1422
  inherited, 955–962. *See also* Charcot-Marie-Tooth (CMT) disease
  large-fiber, 936
  level 1 evidence on, 950–951
  neurologic history in, 21*t*
  outcome of, 937
  paraneoplastic, 938*t*, 943–944, 1101*t*, 1102
  polyarteritis nodosa and, 376
  in pregnancy, 1293–1294
  radiation-induced, 1336, 1337, 1341
  renal disease and, 1254–1255
  small-fiber, 936
  treatment of, 937
  vasculitic, 938*t*, 941–942, 942*f*
  xenobiotic-associated, 1320, 1323*t*–1325*t*
Peripheral nystagmus, 46, 46*t*, 47*t*
Peripheral sensitization, 558–559
Peripheral sensory syndromes, 65*t*, 66
Peripheral vertigo, 46, 597–601
  causes of, 48*t*
  central vertigo *versus*, 46, 46*t*
  stroke *versus*, 135*t*
Peripheral vision, 79–80, 79*t*
Peripheral (lower motor neuron) weakness, 112–113
Perisylvian syndrome, congenital bilateral, 1376
Periungual fibromas, 1460
Periventricular hemorrhagic infarction (PVHI), 1355, 1357
Periventricular leukomalacia (PVL), 1363–1364
Periventricular nodular heterotopias, 1513
PERM. *See* Progressive encephalomyelitis with rigidity and myoclonus
Pernicious anemia, 1278–1279
Peroxisomal diseases, 1385, 1405–1407, 1405*t*

Peroxisome biogenesis disorder (PBD), 1405
Perphenazine, 1591*t*
Persistent depressive disorder, 1600
Persistent hepatic encephalopathy, 1247
Persistent idiopathic facial pain (PIFP), 547
Personality disorders, mood disorders *versus*, 1602
Personality tests, 275
Pervasive development disorder–not otherwise specified (PDD-NOS), 1433
PET. *See* Positron emission tomography
Petasites, for migraine prevention, 529*t*
PFAOMC. *See* Psychological factors affecting other medical condition
PFAS. *See* Partial fetal alcohol syndrome
PFO. *See* Patent foramen ovale
P-glycoprotein inhibitors and inducers, 1319, 1319*t*
PHACE syndrome, 1526
Phalen sign, 42–43, 42*f*, 68
Phase dimensions, in MRI, 190
Phencyclidine (PCP)
  abuse of, 1315, 1316–1317
  for NMDA receptor encephalitis, 760
Phenelzine
  for anxiety disorders, 1611*t*
  for depression, 1602
  for migraine prevention, 528
Phenobarbital
  adverse effects of, 583, 1274
  for alcohol withdrawal, 1306
  dosage and pharmacokinetics of, 584*t*
  for epilepsy, 581
  for neonatal seizures, 1360, 1361*t*
  for seizures, 61
  teratogenicity of, 1287*t*, 1288
Phenoconversion, in Huntington disease, 864–865
Phenocopies, 300, 864
Phenothiazines
  for alcohol withdrawal, 1306
  neurologic effects of, 849
Phenotypic variability, 299
Phenoxybenzamine, for pheochromocytoma, 1224
Phentolamine test, 551*t*
Phenylephrine, for spinal cord infarction, 1166
Phenylketonuria, 1387–1388
Phenylpropanolamine, CNS vasculitis induced by, 381
Phenytoin/fosphenytoin, 585
  adverse effects of, 583, 585, 1248, 1274
  for cranial neuralgias, 543, 544*t*
  dosage and pharmacokinetics of, 584*t*, 585
  dose concentration curves for, 585, 585*f*
  for epilepsy, 581–585
    in pregnant patients, 1287
    teratogenicity of, 1287*t*
  for myotonic dystrophy, 1486
  for neonatal seizures, 1360, 1361*t*
  for neuropathic pain, 563
  neuropathy induced by, 949
  for nondystrophic myotonias, 1002
  for seizures, 61
  for traumatic brain injury, 434, 578
  for traumatic brain injury in children, 1575
  for trigeminal neuralgia, 918
Pheochromocytoma, 1215*t*, 1224
  neurofibromatosis and, 1457, 1458–1459
PHN. *See* Postherpetic neuralgia
Phobia(s)
  social. *See* Social anxiety disorder
  specific, 1606
    clinical features of, 1608*t*, 1609
    treatment of, 1612
Phobic avoidance, 1608
Phonation, 104
Phonic tics, 106, 786, 786*t*
Phosphatase with homology to tensin (PTEN), 1536–1537
Phosphodiesterase, in Huntington disease, 866
Phosphofructokinase (PFK) deficiency, 1015, 1016–1017
Phosphoglucomutase 1 deficiency, 1015, 1017
Phosphoglycerate kinase deficiency, 1404
Phosphoglycerate mutase (PGAM) deficiency, 1015, 1017
Phosphoribosyl pyrophosphate synthetase deficiency, 1391
Phosphorylase *b* kinase deficiency, 1015, 1016–1017
Photophobia
  in migraine, 71
  in trigeminal autonomic cephalalgias, 530
Photoreceptors, 77
Physical dependence, 1313
Physical therapy
  for ALS, 913
  for Charcot-Marie-Tooth disease, 960, 960*t*
  for complex regional pain syndrome, 552, 552*t*
  for dystonia, 818
  for inflammatory myopathies, 981, 985
  for neurologic rehabilitation, 1632, 1632*f*
  for neuropathic pain, 563–564
  for Parkinson disease, 885
Physician, rehabilitation role of, 1631–1632
Physician-assisted suicide, 1641
Physiologic akathisia, 107
Physostigmine, 1324
Pial synangiosis, 393, 1231
Pick disease, 97, 486–487
Picket-fence pattern, in EMG, 249, 249*f*
Picornaviruses, 662–665
PIFP. *See* Persistent idiopathic facial pain
"Pill-rolling" tremor, 877
Pilocytic astrocytoma, 153–154, 158*t*, 159*f*, 1020*t*, 1023–1024, 1024*f*, 1532*t*, 1551
Pimavanserin
  for Lewy body dementias, 498
  for Parkinson disease, 888
Pimozide
  for Huntington disease, 867
  for tic disorders, 789, 790*t*
  for trigeminal neuralgia, 918
Pineal cell tumors, 1073
Pineal cysts, 1073–1074, 1074*f*
Pineal gland, anatomy of, 1072
Pineal metastases, 1073
Pineal region tumors, 1072–1079
  chemotherapy for, 1073, 1076
  clinical features of, 1074
  diagnosis of, 1074
  epidemiology of, 1072
  histologic subtypes of, 1072–1074, 1076*f*
  management of, 1074–1077, 1076*f*
  MRI of, 1074, 1074*f*, 1075*f*, 1077*f*, 1078*f*
  needle biopsy of, 1074, 1075*f*
  outcome of, 1078
  pathobiology of, 1072–1074
  pathology of, 1072, 1072*t*
  pediatric, 1554, 1557, 1559–1560
  postoperative staging of, 1076, 1078*f*
  radiation therapy for, 1073, 1076
  surgery for, 1075, 1077*f*
Pineoblastomas, 1072, 1073, 1076, 1078*f*, 1554, 1557
Pineocytomas, 1072, 1073
Ping-pong gaze, 171
PIN mnemonic, in migraine, 71
"Pins and needles," 453
Pipeline Embolization Device, 218, 222
Piperacillin, for malignant otitis externa, 621
Piperacillin-tazobactam, for malignant otitis externa, 621
Piracetam, for myoclonus, 829*t*
Pisa syndrome, 802*t*, 809, 878
Pitolisant, for narcolepsy (excessive sleepiness), 1189
Pittsburgh compound B, 206, 483
Pituitary adenomas. *See* Pituitary tumors
Pituitary apoplexy, 1065, 1066*f*, 1218–1219
Pituitary carcinomas, 1064
Pituitary disorders, 1215–1219. *See also specific disorders*
  holoprosencephaly and, 1369
  pediatric brain tumors and, 1561
Pituitary gland, anatomy and physiology of, 1215, 1216*f*
Pituitary tumors, 152, 153*f*, 157*t*–158*t*, 1064–1071, 1217–1218
  algorithm for initial assessment of, 1066*f*
  clinical manifestations of, 1064–1065, 1065*f*
  diagnosis of, 1065–1068
  differential diagnosis of, 1067–1068
  endocrine evaluation of, 1066–1067, 1067*t*, 1068*t*
  epidemiology of, 154, 1064
  focused exam for, 159
  management of, 1068–1070
  medical therapy for, 1071
  metastatic, 1218
  MRI of, 155*f*, 1064, 1065–1066, 1066*f*–1070*f*, 1218, 1218*f*
  outcome of, 1070–1071
  past medical history and, 156, 159
  pathobiology of, 1064
  pediatric, 1067, 1545–1546
  radiation therapy for, 1069–1070
  recurrent, 1070
  surgery for, 1069, 1070, 1070*f*
Pizotifen, for migraine prevention, 529*t*
PKAN. *See* Pantothenate kinase-associated neurodegeneration
PLA2G6-associated neurodegeneration (PLAN), 1393
PLAN. *See* PLA2G6-associated neurodegeneration
Plantar scratch, 38, 39*t*
Plant neurotoxins, 1333
Plasma cell malignancies, 1233–1234. *See also* Multiple myeloma
Plasma exchange/plasmapheresis, 69, 150
  for acute liver failure, 1250
  for anti-MOG disorders, 732
  for antiphospholipid antibody syndrome, 856, 1243

Plasma exchange/plasmapheresis *(Continued)*
for ataxia, 847
for autoimmune encephalitis and meningitis, 755, 764, 767, 768*t*, 771
for autonomic disorders, 1172
for CIDP, 940
for CNS vasculitis, 376, 377
for cryoglobulinemia, 942
for Guillain-Barré syndrome, 695, 937, 940
for hepatic disease, 1255, 1260, 1261
for HIV-related disorders, 695, 699, 945
for hyperexcitability disorders, 1008
for hyperviscosity syndrome, 1234
for IgG- and IgA-associated neuropathies, 942
for IgM-associated neuropathies, 942
for immunotherapy complications, 1110
for inflammatory myelopathy, 1165
for meralgia paresthetica, 1304
for multiple sclerosis, 723
for myasthenia gravis, 967, 968, 970*t*, 971, 1304
for mycoplasma pneumonia, 635
for neuromyelitis optica spectrum disorders, 731, 744, 751–752
for paraneoplastic syndromes, 1104
for Refsum disease, 1407
for Susac syndrome, 395
for Sydenham disease, 855
for thrombotic thrombocytopenic purpura, 1227, 1239
for transverse myelitis, 736, 742
for TTP-HUS, 1239
for tumor-related psychosis, 1593
for viral infections, 665, 683, 685–686
Plasmodium falciparum, 653–655, 654*t*. *See also* Malaria
Plasticity, 806, 1381, 1598, 1630–1631
Platelet-derived growth factor (PDGF), in pediatric astrocytoma, 1535–1536
Platelet disorders, 1237–1240
in ICH, 137–138, 139*t*, 1240
Platelet function, impaired, 1240
Platelet transfusion, 1237, 1240
Platybasia, 1270
Plegia, 114
Pleiotropy, 300
Pleocytosis, cerebrospinal fluid, 278–280
Pleomorphic xanthoastrocytoma, 1020*t*
PLEX. *See* Plasma exchange
Plexuses. *See also* Brachial plexus; Lumbosacral plexus
definition of, 112
muscle weakness localized to, 112, 120*t*
sensory patterns and loss, 65*t*, 66
PLMS. *See* Periodic limb movement in sleep
PLS. *See* Primary lateral sclerosis
PMA. *See* Progressive muscular atrophy
PME. *See* Post-measles encephalomyelitis
PMEs. *See* Progressive myoclonic epilepsies
PML. *See* Progressive multifocal leukoencephalopathy
P mode ultrasound, 208–209, 208*t*
PNES. *See* Psychogenic nonepileptic seizures
PNETs. *See* Primitive neuroectodermal tumors
Pneumocephalus, 434, 1143, 1143*f*
Pneumococcal meningitis, 604–605
Pneumocystis jirovecii, 693
Pneumonia
aspiration, stroke and, 316–317
mycoplasmal (walking), 635–636
ventilator-associated, 1211–1212
PNFA. *See* Progressive nonfluent aphasia
Podophyllotoxin resin, neuropathy induced by, 949
POEMS syndrome, 942
POLG ataxia, 835
POLG mutations, 1450
Poliodystrophies, 1385
Poliomyelitis, 662–664
clinical manifestations of, 663
diagnosis of, 663–664
eradication of, 663
infant hypotonia in, 1420
outcome of, 664
pathobiology of, 661, 663
syndrome after, 664, 912, 912*t*
treatment of, 664
vaccine-derived, 663, 664
Polio vaccines, 663, 664
Poliovirus, 661, 662–664
Polyarteritis nodosa (PAN), 371*t*, 375–376
clinical manifestations of, 375–376
diagnosis of, 376
epidemiology of, 375
laboratory findings in, 376
management of, 376
neuropathy in, 942
outcome of, 376
pathobiology of, 375
Polycystic ovary syndrome (PCOS), epilepsy and, 589
Polycythemia, 1231–1232, 1231*f*
Polycythemia vera, 1231–1232
Polyglucosan storage diseases, 1015, 1404–1405
Polymerase chain reaction (PCR), 300
in arboviral infections, 666
in bacterial meningitis, 608, 609*t*
in botulism, 637
in brucellosis, 631
in cat-scratch disease, 633
in chronic meningitis, 640, 650
in diphtheria, 637
in ehrlichiosis and anaplasmosis, 628
in HIV, 691, 694, 1579, 1581
in leptospirosis, 632
in mycoplasmal (walking) pneumonia, 635
in poliomyelitis, 663–664
in Q fever, 631
in spotted fever rickettsiosis, 626
in typhus group rickettsiae, 629
in viral infections, 661
in Whipple disease, 635
Polymicrogyria, 1376
Polymorphonuclear (PMN) cells, in cerebrospinal fluid, 278–280
Polymyalgia rheumatica, 983*t*
giant cell arteritis and, 374
Polymyositis, 979, 986
differential diagnosis of, 984*t*
EMG findings in, 247
HIV-associated, 699
muscle pathology in, 986–987, 987*f*
Polyneuropathy, 65*t*, 66, 112–113, 560, 560*t*, 936
acquired, 936–954
alcoholic, 949, 1306*t*, 1308
clinical features of, 936–937
critical illness, 947, 989–991, 990*t*
diagnosis of, 937, 938*t*
diet-associated, 947
distal sensory, in HIV infection, 699
distal symmetric, AAN testing recommendations for, 937, 939*t*
drug-induced, 948–949
epidemiology of, 936
etiology of, 937
outcome of, 937
treatment of, 937
Polynucleotide repeat expansion, 299, 300
Polyphasic MUPs, 247
Polyplasmy, 1442
Polysomnography (PSG), 264–265
indications for, 264, 265*t*
recordings in, 265, 266*f*
in restless legs syndrome, 795
Pomalidomide, for primary CNS lymphoma, 1060
Pompe disease, 1011, 1015, 1017, 1402–1403, 1422–1423
Pontine hemorrhage, 334
Porphobilinogen deaminase, 1391
Porphyrias, 936, 939, 1391–1392
Port-wine stain, 1463, 1463*f*, 1464
Positive end-expiratory pressure (PEEP), 1211, 1211*t*
Positive myoclonus, 824, 824*f*
Positive sharp waves, in EMG, 246, 247*f*
Positron emission tomography (PET), 203–207
in Alzheimer disease, 101, 203*f*, 204*t*, 205–206, 205*f*–207*f*, 479–480, 482–483, 482*f*
in autism spectrum disorders, 1435
in autoimmune encephalitis and meningitis, 761*f*, 762
basic principles of, 203
of brain tumors, pediatric, 1543
clinical applications of, 204–206, 204*t*
in dementia, 101
detection, acquisition, and signal display in, 204
in encephalotrigeminal angiomatosis, 1463–1464
in epilepsy, 205, 580
in fatal familial insomnia, 516
of focal mass lesions in brain, 166
in frontotemporal dementia, 101, 205, 205*f*, 488–489, 489*f*
glucose imaging in, 204*t*, 205
in Huntington disease, 866, 867*f*
in Lewy body dementias, 496
in mild cognitive impairment, 472–473, 473*t*
oxygen-15 water scan, 203, 203*f*
in Parkinson disease, 881, 897
in Parkinson-plus syndromes, 897
perfusion imaging, 203, 203*f*, 204*t*
radiopharmaceuticals for, 203–204
sensitivity and selectivity of, 203
Postconcussion syndrome, 437
Postendarterectomy hyperperfusion syndrome, 1132
Posterior cerebral artery infarction, 305*t*, 307
Posterior communicating artery aneurysm, 344
Posterior cord syndrome, 149*t*, 447
Posterior cortical atrophy, 480

Posterior fossa
formation of, 1378
limitation of CT in, 185
malformations of, 1378–1380
Posterior fossa tumors, pediatric
ependymoma, 1538, 1539*f*
symptoms of, 1541*f*
Posterior interosseous nerve, 932
Posterior reversible encephalopathy syndrome (PRES), 384–387
brain edema in, 1131–1132, 1131*f*
calcineurin inhibitors and, 1235
clinical features of, 384–385, 384*t*
diagnosis of, 385
differential diagnosis of, 385
epidemiology of, 384
etiologies of, 385, 386*t*
level 1 evidence on, 399
management of, 385–386
MRI in, 385, 385*f*, 386*f*, 1131, 1131*f*, 1289*f*
outcome of, 387
paraneoplastic, 1108, 1108*t*, 1109
pathobiology of, 384
posttransplant, 1255
sepsis and, 1204
Posterior spinal artery, 147, 147*f*
Postherpetic neuralgia (PHN), 681
Posthypoxic myoclonus, 824, 826
Post-Lyme syndrome, 649
Post-measles encephalomyelitis (PME), 675
Postoperative stroke, 1195–1197
Postpolio progressive muscular atrophy, 664
Postpolio syndrome, 664, 912, 912*t*
Postsynaptic neuromuscular junction dysfunction, 250–251, 250*f*
Posttransplant lymphoproliferative disorders (PTLD), 1232–1234, 1298, 1301
Posttraumatic amnesia, 437
Posttraumatic headache, 534
Posttraumatic seizures, 576
Posttraumatic stress disorder (PTSD), 1606
classification of, 1606
clinical features of, 1608–1609, 1608*t*
dementia risk in, 1610
epidemiology of, 1606
pathobiology of, 1606–1607, 1607*f*
psychosis in, 1590, 1590*t*
traumatic brain injury and, 1609
treatment of, 1612
Postural hypotension. *See* Orthostatic hypotension
Postural instability, in Parkinson disease, 878
Postural orthostatic hypotension syndrome, 53
Postural orthostatic tachycardia syndrome, 256
Postural reflex loss
in Parkinson disease, 878
in progressive supranuclear palsy, 893–894
Postural tremor, 107, 107*f*, 781
Posturing, coma and, 170
Posturography, computerized dynamic, 263
Potassium
and alcohol withdrawal, 1306
and nondystrophic myotonias, 998
and osmotic edema, 1129
and periodic paralysis, 998–1001, 999*t*, 1000*t*
Potassium channels
in acquired neuromyotonia, 1007
in neuropathic pain, 559
POUND mnemonic, in migraine, 71, 71*t*
Powassan virus, 665, 667*t*, 669–670, 669*f*
Power, muscle, 37, 37*f*, 37*t*, 117
Power (P) mode ultrasound, 208–209, 208*t*
PPA. *See* Primary progressive aphasia
PPMS. *See* Primary progressive multiple sclerosis
PPN. *See* Pedunculopontine nucleus
Prader-Willi syndrome, 1410–1411, 1410*t*, 1419
Pralidoxime, 1326, 1329
Pramipexole
for Parkinson disease, 887
for restless legs syndrome, 795–798, 797*t*
Prasugrel, 138, 1240
Pravastatin, myotoxicity of, 993–995, 995*t*, 996*f*, 996*t*
Praxis, testing of, 274–275
Praziquantel, for neurocysticercosis, 656, 705
Prazosin, for anxiety disorders, 1611*t*
Precocious puberty
neurofibromatosis and, 1459
pineal tumors and, 1074
Prednisone
for ACTH deficiency, 1215
for autoimmune encephalitis and meningitis, 767, 770*t*
for cluster headache prevention, 531*t*, 532
for complex regional pain syndrome, 553
for dermatomyositis, 981
for Duchenne muscular dystrophy, 1481–1482
for eosinophilic granulomatosis with polyangiitis, 378
for giant cell arteritis, 375
for inclusion body myositis, 984
for multiple sclerosis, 723
for myasthenia gravis, 969–970, 970*t*, 971
for neuromyelitis optica spectrum disorders, 752
for primary CNS lymphoma, 1059
for sarcoidosis, 776
for Susac syndrome, 395
Prefrontal cortex
in bipolar disorder, 1598
in depression, 1596–1598, 1597*f*
Pregabalin, 586
adverse effects of, 583–584
for anxiety disorders, 1611–1612, 1611*t*
for chemotherapy-induced neuropathy, 1109*t*
for complex regional pain syndrome, 553
for cranial neuralgias, 543, 544*t*
for diabetic neuropathy, 1221
dosage and pharmacokinetics of, 584*t*
for epilepsy, 582–585, 586
in pregnant patients, 1288
for herpes zoster neuropathy, 946
for neuropathic pain, 561, 562*t*
for restless legs syndrome, 797*t*, 798
for stiff person syndrome, 1006
for trigeminal neuralgia, 918
Pregnancy, 1286–1297
alcohol effects in, 1310, 1310*t*, 1583–1584
biology of, 1286–1287
cerebral hemorrhage in, 1291–1292
cerebral venous thrombosis in, 354, 1290
epilepsy in, 588–589, 1287–1289
AED cognitive effects on exposed infants, 1288
AED teratogenicity in, 589, 1287–1288, 1287*t*
epidemiology of, 1287
folic acid supplementation for, 1288
management strategy for, 1288
seizure control and monitoring in, 1287
level 1 evidence on, 1295
migraine in, 1292–1293
movement disorders in, 855, 1294–1295
multiple sclerosis and, 728, 1292, 1292*t*
myasthenia gravis and, 973, 1294
neoplasms in, 1293
neuropathies in, 1293–1294
physiologic changes and pharmacokinetics in, 1286, 1286*t*
preeclampsia and eclampsia in, 384–387, 1289–1290
stroke in, 1290–1291, 1290*t*
substance abuse in, 1584–1586
TTP-HUS in, 1239
Premaxillary agenesis, 1369
Premenstrual dysphoric disorder, 1600
Premonitory Urge for Tics Scale, 787
PREPL deletion syndrome, 975
Preretinal hemorrhage, 343
PRES. *See* Posterior reversible encephalopathy syndrome
Presbyopia, 259
Presenilin 1 (*PSEN1*) gene, 477–479, 477*f*
Presenilin 2 (*PSEN2*) gene, 477–479, 477*f*
Pressure reactivity index, 289–290, 290*f*
Pressure support (PS), 1211*t*
Presynaptic congenital myasthenic syndromes, 974
Presynaptic neuromuscular junction dysfunction, 251
Presyncope, 45, 45*t*
Pretraumatic amnesia, 437
Prevalence, 1–2
Pridopidine, for Huntington disease, 866
Primary adrenal insufficiency. *See* Addison disease
Primary afferent fiber, 246
Primary age-related tauopathy (PART), 479
Primary amebic meningoencephalitis, 654*t*, 655–656
Primary angiitis of CNS (PACNS), 370–374
brain biopsy in, 372
clinical features of, 370–371
diagnosis of, 371–372
diagnostic criteria for, 371, 372*t*
epidemiology of, 370
imaging in, 371–372, 373*f*
laboratory findings in, 371, 373*t*
management of, 372–374
outcome of, 374
pathobiology of, 370
reversible cerebral vasoconstriction syndrome *versus*, 372, 380, 380*t*, 387–388
Primary care, improving neurologic care in, 12–13
Primary central nervous system lymphoma (PCNSL), 152–153, 156*f*, 158*t*, 1056–1062, 1232–1234
clinical features and diagnosis of, 1057
diagnosis and management of, 166–167, 166*f*
epidemiology of, 1056, 1232
follow-up assessments in, 1061, 1061*t*
HIV-associated, in children, 1580–1581, 1581*t*
level 1 evidence on, 1061

Primary central nervous system lymphoma (PCNSL) *(Continued)*
metastatic disease *versus*, 1038
MRI of, 1057, 1057*f*
outcome of, 1061
past medical history and, 156
pathobiology of, 1056–1057
pediatric, 1560
posttransplant, 1255
relapsed and refractory, 1060
toxoplasmosis *versus*, 167, 167*t*
treatment of, 1057–1060, 1233
chemotherapy for, 1058–1060
for elderly patients, 1059–1060
neurotoxicity of, 1060, 1061*f*
for newly diagnosed patients, 1057–1059
radiation therapy for, 1058–1060
response guidelines in, 1057–1058, 1058*t*
stem cell transplantation for, 1059–1060
Primary cough headache, 524*t*, 533
Primary (isolated) dystonia, 803
Primary exertional headache (PEH), 524*t*, 533
Primary headache associated with sexual activity, 524*t*, 533
Primary headaches, 70, 71, 522, 523–534, 524*t*, 547. *See also* Cluster headache; Migraine; Tension-type headache (TTH)
Primary lateral sclerosis (PLS), 904, 904*t*, 910
Primary neurologic disease, 1
Primary progressive aphasia (PPA), 486–491, 894
clinical manifestations of, 488
diagnosis of, 488–489
epidemiology of, 486
logopenic variant of, 480, 486, 488
management of, 490
outcome of, 490
Primary progressive multiple sclerosis (PPMS), 714, 714*f*, 717–718
Primary stabbing headache, 534
Primidone
for epilepsy, 581
for essential tremor, 781–782
for myoclonus, 829*t*
Primitive neuroectodermal tumors (PNETs)
classification of, 1534–1535, 1535*f*
epidemiology of, 1530
supratentorial, 1534
Prion(s), 506
Prion diseases, 506–520
acquired, 507, 507*t*, 516–518
classification of, 507, 507*t*
genetic, 507, 507*t*, 511*t*, 512–516
history and nomenclature of, 506–507
investigational treatments for, 518–519
level I evidence on, 519
management and outcomes of, 518–519, 519*t*
MRI in, 192
pathobiology of, 507–508
sporadic, 506, 507, 507*t*, 508–512
symptomatic treatments for, 518, 519*t*
Prion protein gene *(PRNP)*, 506, 507–508, 507*t*, 512–516
Prion-related protein (PrP), 506, 507–508, 510
Problem-based history, 19, 20*t*–22*t*
Problem Behavior Assessment Scale, 866
Procalcitonin, in bacterial meningitis, 607–608
Procarbazine
for diffuse astrocytomas, 1026
for gliomas, 1023*t*
for pediatric brain tumors, astrocytomas, 1551
for primary CNS lymphoma, 1059–1060
Procerus sign, 894
Processing speed, 272
Process outgrowth, 1380–1381
Prochlorperazine
dystonia induced by, 809
for migraine, 74, 526*t*, 528
for migraine in pregnancy, 1293
for vertigo, 49*t*
Prodromal dementia with Lewy bodies, 495
Progeria, 1413*t*
Progesterone modulators, for meningiomas, 1054, 1054*t*
Progressive ataxia with palatal tremor, 827
Progressive bulbar palsy, 904, 904*t*, 910
Progressive encephalomyelitis, 1103
Progressive encephalomyelitis with rigidity and myoclonus (PERM), 759, 1004*t*, 1005
Progressive external ophthalmoplegia (PEO), 1445, 1447, 1449–1451
Progressive inflammatory neuropathy, 942–943
Progressive multifocal leukoencephalopathy (PML), 684–686, 1236, 1301, 1301*f*
diagnosis of, 685
HIV-associated, 693, 701–702, 701*f*
HIV-associated, pediatric, 1581
MRI of, 685, 685*f*, 701, 701*f*
multiple sclerosis *versus*, 721
neuropathology of, 685, 686*f*
pathobiology of, 684
predisposing factors for, 684*f*
treatment and prognosis for, 685–686
Progressive muscular atrophy (PMA), 904, 904*t*, 909–910
Progressive myoclonic epilepsies (PMEs), 1512
Progressive nonfluent aphasia, 893, 894
Progressive rubella panencephalitis, 671–672
Progressive supranuclear palsy (PSP), 97, 99, 486, 893–894
clinical forms of, 893, 895*t*
diagnosis of, 897
diagnostic criteria for, 897, 898*t*
epidemiology of, 897
gait disorder in, 130*t*
historical perspective on, 893
Lewy body dementias *versus*, 497
MRI in, 879
Parkinson disease *versus*, 879, 881, 890
pathobiology of, 893, 894*f*
symptoms and signs in, 893–894
treatment of, 897–899, 901*t*
Prolactin, 1215, 1216*f*
antipsychotics and, 1591*t*
deficiency of, 1216
excess of, 1217, 1342
radiation and, 1342
Prolactinoma, 157*t*, 1067, 1069, 1069*f*, 1071, 1218
Promethazine
for Ménière disease, 599
for migraine, 526*t*, 528
PROMM. *See* Proximal myotonic myopathy
Pronator drift, 37–38, 117
Prophylactic cranial irradiation (PCI), 1037–1038
Propionic aciduria, 1388–1389
Propofol
neurotoxicity of, 1299
for paroxysmal sympathetic hyperactivity, 1181, 1181*t*
for paroxysmal sympathetic storming, 1199
for refractory status epilepticus, 62, 62*t*
for sympathomimetic toxicity, 1325
Propranolol
for acute akathisia, 851
for alcohol withdrawal, 1306
for essential tremor, 781–782
for hyperthyroidism, 1221
for migraine prevention, 528, 529*t*, 1293
for paroxysmal sympathetic hyperactivity, 1180*f*, 1181, 1181*t*
for paroxysmal sympathetic storming, 1200*t*
for primary exertional headache, 533
for primary sex headache, 533
for tardive akathisia, 852*f*, 853*t*, 1590
Propriospinal myoclonus, 825*t*, 826*t*, 828, 1192
Proprotein convertase subtilisin-kexin type 9 (PCSK9) inhibitors, 403, 408
Propylthiouracil, for hyperthyroidism, 1221
Prosencephalon
disorders (malformations) of, 1369, 1370*f*
formation of, 1366, 1368, 1369
normal division of, 1369
Prosody, 29, 1437
Prostate cancer
skull base metastases from, 1082
spinal metastases from, 1035, 1044, 1089, 1162
Protamine sulfate, anticoagulation reversal with, 139*t*, 336
Protease inhibitors, 706, 707*t*, 1582
Proteinaceous infectious particle, 506. *See also* Prion diseases
Protein importation, disorders of, 1446
Prothrombin complex concentrate (PCC), for intracerebral hemorrhage, 139*t*
Proton therapy, 1544–1545
Protozoan infections, 153, 162*t*, 163*f*, 653, 654*t*. *See also specific infections*
hematopoietic cell transplantation and, 1236–1237
Protriptyline, for cataplexy, 1189
Provisional tic disorder, 786, 786*t*
Provoked seizure, 59, 59*t*
Proximal myotonic myopathy (PROMM), 1485–1487
definition of, 1485
diagnosis of, 1485–1486
epidemiology of, 1485
Proximal nerve injuries, 458–459, 931–932
PrP. *See* Prion-related protein
PS. *See* Pressure support
Psammoma bodies, 1050
Pseudoaneurysm, 351
Pseudobulbar affect, 908–909
in multiple sclerosis, 715*t*, 716, 727*t*
treatment of, 727*t*
Pseudochoreoathetosis, 854
Pseudodelta sign, 358
Pseudodementia, 1601

Pseudodystonia, 801, 802*t*
Pseudoexacerbation, in MS, 723
Pseudo-Hurler polydystrophy, 1398
Pseudomonas aeruginosa, 618, 621
Pseudomyotonia, 1485
Pseudopapilledema, 1136–1137
Pseudoparkinsonism, 1590, 1593, 1594
Pseudotumor cerebri. *See* Idiopathic intracranial hypertension (IIH)
PSG. *See* Polysomnography
PSH. *See* Paroxysmal sympathetic hyperactivity
Psilocin, 1315
Psilocybin, 1315
PSP. *See* Progressive supranuclear palsy
Psychiatric disorders. *See also specific disorders*
  testing in, 276
Psychiatric examination, 31–32
Psychiatric history, 19
Psychic dependence, 1313
Psychogenic ataxia, 847
Psychogenic dystonia, 802*t*, 809–810, 810*t*
Psychogenic gait disorder, 129*t*
Psychogenic involuntary movements, 108, 108*t*
Psychogenic nonepileptic seizures (PNES), 594–595, 1620, 1622–1623
Psychological factors affecting other medical condition (PFAOMC), 1616, 1625–1626
Psychologists, rehabilitation role of, 1633
Psychosis, 1588–1595. *See also* Schizophrenia
  characterization of, 1588
  dementia with, 481, 494, 498, 1590*t*, 1593
  in depression, 1589–1590, 1590*t*, 1598–1599
  differential diagnosis of, 1589–1590, 1590*t*
  epilepsy and, 593–594
  level 1 evidence on, 1594
  lifetime prevalence of, 1588
  medical conditions presenting with, 1592–1594, 1592*t*
  medication-induced, 1594
  mood disorders with, 1589–1590
  in Parkinson disease, 108, 109*t*, 888–889, 1594
  in substance abuse/withdrawal, 1305, 1306, 1593
  workup for, 1588, 1592–1593, 1592*t*
Psychostimulants. *See* Stimulants
Psychotic experiences, 1588
PTEN. *See* Phosphatase with homology to tensin
PTH. *See* Parathyroid hormone
PTLD. *See* Posttransplant lymphoproliferative disorders
Ptosis, 521, 966, 966*t*, 967*f*
PTSD. *See* Posttraumatic stress disorder
Puberty, precocious
  neurofibromatosis and, 1459
  pineal tumors and, 1074
Public awareness, raising, 13
Pudendal compressive injury, 1266
Pulmonary disease, spinal cord injury and, 449
Pulmonary edema
  acute neurogenic, 1198, 1198*f*
  in subarachnoid hemorrhage, 347, 1198, 1198*f*
Pulmonary encephalopathy, and intracranial hypertension, 1135
Pulmonary function testing, 1209–1210, 1209*t*
Pulmonary gas exchange, 1207–1208
Pulsatility index, in ultrasound, 212, 212*f*
Pulseless disease (Takayasu vasculitis), 371*t*, 375
PulseRider device, 223
Pulse sequence, in MRI, 190
Punch drunk, 416
Pupil(s)
  anatomy of, 77–78
  "blown," 288
  coma and, 171
  comparing to each other, 81–82
  constriction of, 78, 81–82
  dilation of, 78, 81–82
  herniation syndromes and, 172
  size and function of, 81–82
  testing for, 33–34, 33*f*, 79*t*, 81–82
  in traumatic brain injury, 429
Pupillary light response, 33–34, 33*f*
Pure autonomic failure, 1173–1174
Purine metabolism disorders, 1390–1391, 1391*t*
Purine-nucleoside phosphorylase deficiency, 1391
Putamen hemorrhage, 334
PVHI. *See* Periventricular hemorrhagic infarction
Pyrazinamide, for tuberculosis, 648
Pyridostigmine
  for autonomic dysfunction, 1175
  for congenital myasthenic syndromes, 975, 975*t*
  for myasthenia gravis, 969, 970*t*
  for X-linked myotubular myopathy, 1496
Pyridoxine. *See* Vitamin B_6
Pyrimethamine, for toxoplasmosis, 167, 704, 1237
Pyrimidine metabolism disorders, 1390, 1391*t*
Pyriminil poisoning, 948
Pyruvate, in cerebral microdialysis, 293–294, 294*t*

Q

Q fever, 630–631, 630*t*
Quadriparesis, illicit drug use and, 1317
Quadriplegia, in cerebral palsy, 1425–1426
Quality of subjective experiences, 17–18
Quantitative imaging processing, in MRI, 202
Quantitative sensory testing, 69
Quantitative sudomotor axon reflex test, 257
Quazepam, for insomnia, 1187*t*
Quetiapine
  for anxiety disorders, 1611*t*, 1612
  for bipolar disorder, 1603
  for chorea, 859, 867
  for delirium, 91, 92, 92*t*
  for Huntington disease, 867
  for Lewy body dementias, 498, 1593
  for Parkinson disease, 888
  for schizophrenia, 1590–1592, 1591*t*
  side effects of, 1590–1592, 1591*t*
  for tic disorders, 790*t*
Quinacrine, for prion diseases, 518
Quinidine
  for congenital myasthenic syndromes, 975, 975*t*
  for MS patients, 726
  for pseudobulbar symptoms, 913
Quinine
  for malaria, 654
  for muscle cramps, 1009
  TTP-HUS induced by, 1238

R

Rabies, 676–677, 677*f*
Rabies vaccine, 677
Radial access, for angiography, 218–219
Radial nerve, 932
  anatomy of, 928, 928*f*, 928*t*, 932
  injury of, 459, 932
  muscles innervated by, 928*t*, 932, 932*f*
  transfer to axillary nerve, 467–468
Radial nerve graft, 467
Radiation
  effects of, 1335, 1335*t*
  measures of, 1335
Radiation-absorbed dose (rad), 1335
Radiation injury, 1335–1346
  acute side effects of, 1545
  clinical manifestations of, 1338*t*
  CT of, 1337, 1340*f*
  diagnosis of, 1337–1342
  early, early-delayed, or late, 1337
  epidemiology of, 1335–1336
  immunologic mechanism in, 1337
  level 1 evidence on, 1343
  management of, 1342–1343
  MRI of, 1337, 1339*f*, 1340*f*, 1341*f*
  outcome of, 1343
  pathobiology of, 1336–1337
  risk factors for, 1335, 1336*t*
Radiation necrosis, 154, 1038, 1107, 1336, 1337–1339, 1338*t*, 1339*f*, 1342
Radiation plexopathy, 931, 1107, 1336, 1337, 1338*t*, 1341, 1341*f*
Radiation sensitizers, 1545
Radiation sickness, acute, 1337, 1338*t*, 1342
Radiation therapy
  for acute myeloid leukemia, 1234
  for diffuse astrocytomas, 1026
  for gliomas, 1021–1022
  for meningiomas, 1053
  for metastatic disease, 1037, 1041–1042
  myelopathy due to, 1167
  neurologic complications of, 1106–1108, 1106*t*. *See also* Radiation injury
  for oligodendrogliomas, 1031
  for pediatric brain tumors, 1544–1545
    astrocytomas, 1549–1553
    AT/RTs, 1557–1558
    effects and sequelae of, 1560–1562
    ependymomas, 1558
    germ cell tumors, 1559
    medulloblastoma, 1531, 1556
    nonmedulloblastoma embryonal tumors, 1557
  for pilocytic astrocytomas, 1024
  for pineal region tumors, 1073, 1076, 1559
  for pituitary tumors, 1069–1070
  for primary CNS lymphoma, 1058–1060
  for skull base tumors, 1083
  for spinal metastases, 1045, 1046, 1097–1098, 1163
  for spinal tumors, 1097
  whole brain, 1037, 1041–1042, 1058–1060, 1107–1108

Radicular pain, 1147
Radicular syndromes, 929
Radiculoneuropathies, 113
Radiculopathy, 927
  diagnosis of, 1149–1150
  intervertebral disk disease and, 1145–1152
  treatment of, 1150–1151
Radioactive iodine, for hyperthyroidism, 1221
Radiogenomics, 202
Radioligand, 203
Radiologically isolated syndrome (RIS), 714, 714*f*
Radionuclides, 203–204
Radiopharmaceuticals, 203–207
  clinical applications of, 204–206, 204*t*
  currently in development, 206
  detection, acquisition, and signal display, 204
Radiotracer, 203
Ragged red fibers (RRF), 845–846, 1441, 1446, 1446*t*, 1451–1452, 1451*f*
Ragin' Cajun, 827
Raltegravir, 707*t*, 708
Ramelteon, 1186, 1187*t*
Ramsay Hunt syndrome, 48*t*, 545, 681, 921, 922*f*
Rapid Arterial oCclusion Evaluation (RACE) scale, 307
Rapid eye movement (REM) behavior disorder, 264, 265, 267*f*, 1192–1193
  in Creutzfeldt-Jakob disease, 508, 510
  in Lewy body dementias, 494, 495, 497, 498
Rapid eye movement (REM) sleep, 1183–1184, 1184*f*, 1189–1190
  EEG in, 231
  studies of, 264–267
Rapid finger taps, 117
Rapid plasma reagin (RPR) assay, 649
Rapid sequence intubation, 1210–1211
Ras, in pediatric astrocytoma, 1536, 1536*f*
Rasagiline, for Parkinson disease, 886
Rasmussen syndrome, 576, 1511
RASopathy, 1456
Rathke cleft cysts, 1067
RBCs. *See* Red blood cells
Rb tumor suppressor, 1537
rCBF. *See* Regional cerebral blood flow
RCDP. *See* Rhizomelic chondrodysplasia punctata
RCVS. *See* Reversible cerebral vasoconstriction syndrome
Reactivity to external stimuli, in EEG, 233
Reading testing, 29
Reasoning, testing of, 275
Rebound headache, 528
Receptive aphasia
  cerebral infarction and, 305, 306
  testing for, 29, 29*t*
Receptive field, altered, in neuropathic pain, 559
Receptive language
  development of, 1428*t*
  disorders of, 1429
Recombinant factor VIIa (rFVIIa), for noncoagulopathic ICH, 335, 336
Recovery, in rehabilitation, 1629–1631
Recreational therapy, 1633
Recruitment, motor unit, 246, 248–249
Red blood cells (RBCs)
  in cerebrospinal fluid, 278–280
  disorders of, 1227–1232
  production and life cycle of, 1227
Red flags
  in autism spectrum disorder, 1438–1439, 1438*t*
  for functional/psychogenic movements, 108*t*
  in headaches, 71, 71*t*, 73, 522
  in muscle weakness, 110, 110*t*
  in neuromyelitis optica spectrum disorders, 744, 748, 749*t*
  in syncope, 55, 55*t*
Reduced intensity conditioning (RIC), 1235
Reduced interference pattern, in EMG, 249, 249*f*
Reemergent tremor, 781
Reflex(es)
  blink, 246
  examination of
    in acute spinal cord syndromes, 149
    for muscle weakness, 117
    for pain, numbness, and paresthesias, 68
  spinal, in male patients, 43
  testing of, 26*t*, 38–39, 39*t*, 40*t*
Reflex epilepsy, 567
Reflex-induced myoclonus, 824
Reflex sympathetic dystrophy. *See* Complex regional pain syndrome (CRPS)
Reflex syncope, 51, 52*f*
Reflex tests, specialized, 246
Refractory status epilepticus (RSE), 60, 61–62, 61*f*, 62*t*
Refsum disease, 916, 937, 1405, 1405*t*, 1406–1407, 1419
Refusal of therapy, 1641
Regional cerebral blood flow (rCBF), 293
Rehabilitation. *See* Neurologic rehabilitation
Relapsing-remitting multiple sclerosis (RRMS), 713, 714, 714*f*, 717, 718, 719*f*, 720*f*–721*f*
Related symptoms, 18
Relaxation, in MRI, 189–190, 191
REM. *See* Rapid eye movement (REM) behavior disorder; Rapid eye movement (REM) sleep
REM sleep behavior disorder. *See* Rapid eye movement (REM) behavior disorder
rem (roentgen equivalent man), 1335
Remissions, 17
Renal cancer
  brain metastases from, 152, 157*t*
  spinal metastases from, 1162
Renal disease, 1253–1261. *See also specific diseases*
  neuropathy in, 938*t*, 1255
  sodium imbalance in, 1255–1260
Renal-limited vasculitis, 376
Renal transplantation, 1298
  neurologic complications of, 1255
Rendu-Osler-Weber syndrome, 368
Reperfusion therapy. *See* Tissue plasminogen activator (tPA)
Repetition, in language testing, 29, 29*t*
Repetition time, in MRI, 191
Repetitive movements, 104
Repetitive nerve stimulation (RNS), 250–251, 250*f*
  in botulism, 250, 251, 977
  in myasthenia gravis, 250–251, 250*f*, 968, 968*f*
  in postsynaptic neuromuscular junction dysfunction, 250–251, 250*f*
  in presynaptic neuromuscular junction dysfunction, 251
Repetitive transcranial magnetic stimulation (rTMS), 252, 253, 791
Resective procedures
  for epilepsy, 589–590, 589*t*
  for tumors. *See specific tumors*
Reserpine
  neurologic effects of, 850
  for tardive dyskinesia, 853*t*
Resistance index, in ultrasound, 212, 212*f*
Respiration
  acute spinal cord syndromes and, 149, 150
  coma and, 171
  compromised, neurologic effects of, 1209
  gas exchange in, 1207–1208
  neurogenic patterns in, 1208, 1208*f*
  sleep-related disorders of, 1189–1191
  spinal cord injury and, 449
  stroke (AIS) and, 133
Respiratory acidosis, and coma, 176*t*
Respiratory alkalosis, and coma, 176*t*
Respiratory arrest, 1208*f*
Respiratory failure, 1207–1214
  acute hypoxemic, 1208
  blood gas analysis and monitoring in, 1210
  chronic, 1208
  diagnosis of, 1208, 1209–1210
  epidemiology of, 1207
  hypercarbic, 1208
  level 1 evidence on, 1213–1214
  neuromuscular, 1209
  outcomes of, 1213
  pathobiology of, 1207–1209
  pulmonary function testing in, 1209–1210, 1209*t*
Respiratory support, 1207–1214
  extubation in, 1213, 1213*t*
  ICP and CBF effects of, 1211
  invasive, 1210–1211
    criteria for, 1209–1210, 1210*t*
  level 1 evidence on, 1213–1214
  life-sustaining, 1639
  long-term, 1213
  methods of, 1210–1213
  noninvasive, 1208, 1210
  outcomes of, 1213
  pneumonia associated with, 1211–1212
  tracheostomy in, 1213
  ventilator weaning in, 1212–1213, 1212*f*
Respiratory symptoms, with muscle weakness, 115*t*, 116
Response to Immunotherapy in Epilepsy and Encephalopathy (RITE2) score, 770–771, 771*t*
Responsive neurostimulation, for epilepsy, 592–593
Resting state functional MRI, 199
Resting sweat output, in complex regional pain syndrome, 551*t*
Resting tremor, 107, 107*f*, 877, 881, 894
Restless legs syndrome (RLS), 269–270, 793–799, 1191
  diagnosis of, 794–795
  diagnostic criteria for, 793, 794, 794*t*
  early- and late-onset, 795, 795*t*
  epidemiology of, 793
  focused examination of, 104
  focused history on, 103–104, 103*t*
  laboratory testing in, 269–270
  level 1 evidence on, 798
  management of, 795–798

medications aggravating, 795
outcome of, 798
in Parkinson disease, 880
pathobiology of, 793–794
in pregnancy, 1294
primary, 793, 794–795, 795*t*
rating scales for, 795
renal disease and, 1254
secondary, 793, 794–795, 795*t*
treatment algorithm for, 796*f*
Rest tremors, 107, 107*f*
Reticular reflex myoclonus, 825*t*, 827
Retina
neuroanatomy of, 77
OCT studies of, 82, 82*f*, 260, 261*f*
testing of, 32–33, 33*f*, 78–83, 259–260
Retinal arteriolar occlusion, 84
Retinal ischemia, 83
Retinal nerve fiber layer (RNFL), 82, 82*f*
Retinoblastoma, trilateral, 1557
Retinocochleocerebral vasculopathy. *See* Susac syndrome
Retinopathy
diabetic, 1221
paraneoplastic, 1101*t*, 1103
Retropulsion, 878
Rett syndrome, 1381, 1413*t*
Reversible cerebral vasoconstriction syndrome (RCVS), 73, 380, 387–389
angiography in, 388, 388*f*
clinical features of, 387
diagnosis of, 387–388, 388*t*
epidemiology of, 387
level 1 evidence on, 399
management of, 388–389
outcome of, 389
pathobiology of, 387, 388*f*
precipitants of, 387, 388*t*
primary angiitis *versus*, 372, 380, 380*t*, 387–388
Reversible posterior leukoencephalopathy syndrome. *See* Posterior reversible encephalopathy syndrome (PRES)
Review of symptoms, neurologic, 19, 20*t*–22*t*
Rexed laminae, 558
Reye syndrome, 675, 1131
Rey-Osterrieth Complex Figure, 274
Rhabdomyolysis
HIV-associated, 699
muscle biopsy in, 285
myoglobinuria *versus*, 1013
Rhabdomyomas, in tuberous sclerosis complex, 1461, 1462
Rhabdomyosarcoma, 1530
Rhabdovirus, 676–677
Rheumatoid arthritis, CNS vasculitis in, 379–380
Rheumatologic disease, neuropathy in, 938*t*
Rhinorrhea, 521
Rhinosinusitis, 538–540
definition of, 538
diagnosis of, 538–540
epidemiology and pathobiology of, 538
management and outcome of, 540
Rhinoviruses, 662–663
Rhizomelic chondrodysplasia punctata (RCDP), 1405, 1405*t*
Rhizotomy
for glossopharyngeal neuralgia, 545
for trigeminal neuralgia, 543–545, 544*f*, 918
Rhododendron, 1333
Rhombencephalon
formation of, 1366, 1368, 1378
malformations of, 1378–1380
Rhombencephalosynapsis, 1379
Rhythmic movement disorder, 264
Ribavirin
for rabies, 677
for West Nile virus infection, 668
Riboflavin. *See* Vitamin B_2
Ribonucleic acid. *See* RNA
RIC. *See* Reduced intensity conditioning
Richardson syndrome, 893
Richmond Agitation-Sedation Scale, 89–90, 89*t*
Rickettsia 364D, 624
Rickettsial infections, 624–629, 624*t*
tickborne, 624–628, 624*t*
typhus group, 624, 625*t*, 629
Rickettsia parkeri, 624
Rickettsia prowazekii, 629
Rickettsia rickettsii, 624
Rickettsia typhi, 629
Rifampicin
for scrub typhus, 629
for tuberculosis, 648
Rifampin
for bacterial meningitis, 609*t*
for brucellosis, 632
for Q fever, 631
Rifaximin, for hepatic encephalopathy, 1247*t*, 1248
Rigidity, 37, 116
in coma, 169–170
in corticobasal degeneration, 897
dystonia *versus*, 800, 802*t*
in Huntington disease, 865
in neuroleptic malignant syndrome, 1329
in Parkinson disease, 878
in progressive encephalomyelitis, 759
in progressive supranuclear palsy, 893–894
Riker Sedation-Agitation Scale, 89–90, 89*t*
Riley-Day syndrome, 1175–1176
Rilpivirine, 707*t*
Riluzole
for ALS, 912, 913*t*
for ataxia, 847
for Huntington disease, 867
Rimegepant
for migraine, 526*t*, 528
for migraine prevention, 530
Rinne test, 35, 35*f*, 50
RIS. *See* Radiologically isolated syndrome
Risk of Paradoxical Embolism scoring system (RoPE), 407, 407*t*
Risperidone
for anxiety disorders, 1611*t*
for bipolar disorder, 1603
for delirium prevention, 92
for Huntington disease, 867
for obsessive-compulsive disorder, 1612
for schizophrenia, 1590–1592, 1591*t*
side effects of, 1590–1592, 1591*t*
for tic disorders, 789, 790*t*
RITE2 (Response to Immunotherapy in Epilepsy and Encephalopathy) score, 770–771, 771*t*
Ritonavir, 707*t*
Rituximab
for autoimmune encephalitis and meningitis, 767–770, 768*t*
for dermatomyositis, 981
for multiple sclerosis, 723, 724*t*
for multiple sclerosis in pregnancy, 1292, 1292*t*
for myasthenia gravis, 971
for myelin oligodendrocyte glycoprotein spectrum disease, 732
neurologic complications of, 1109
for neuromyelitis optica spectrum disorders, 731, 752, 752*t*
for paraneoplastic syndromes, 1104–1105
for posttransplant lymphoproliferative disorder, 1233
for primary CNS lymphoma, 1059–1060
for sarcoidosis, 776, 777*t*
for Waldenström macroglobulinemia, 1234
Rivaroxaban, reversal of, 139*t*, 336, 1242
Rivastigmine
for Alzheimer disease, 483, 483*t*
for Huntington disease, 868
for Lewy body dementias, 497
for mild cognitive impairment, 473
for vascular dementia, 504, 504*t*
Rizatriptan, for migraine, 525, 526*t*
RLS. *See* Restless legs syndrome
RMSF. *See* Rocky Mountain spotted fever
RNA
abnormal modifications of, 1444–1445
DNA transcription to, 1412, 1413*t*–1414*t*
translation of, 1412, 1444–1445, 1449
RNA interference compounds, for Huntington disease, 868
RNFL. *See* Retinal nerve fiber layer
RNS. *See* Repetitive nerve stimulation
Rocky Mountain spotted fever (RMSF), 624–627
clinical manifestations of, 625, 626*f*
diagnosis of, 625–626
epidemiology of, 625, 626*f*
MRI in, 625–626, 627*f*
pathophysiology of, 625
prevention of, 627
treatment and outcome of, 626–627
Roentgen equivalent man (rem), 1335
Romberg test, 68
RoPE scoring system. *See* Risk of Paradoxical Embolism (RoPE) scoring system
Ropinirole
for Parkinson disease, 887
for restless legs syndrome, 795–798, 797*t*
Rosenthal fibers, 1549
Ross syndrome, 1174
Rotary chair, 262–263
Rotigotine, for restless legs syndrome, 795–798, 797*t*
Roundworms, 653, 654*t*, 658, 658*t*
Rozanolixizumab, for myasthenia gravis, 972
RPR. *See* Rapid plasma reagin (RPR) assay
RRF. *See* Ragged red fibers
RRMS. *See* Relapsing-remitting multiple sclerosis
RSE. *See* Refractory status epilepticus
rTMS. *See* Repetitive transcranial magnetic stimulation

RT-QuIC, 510
Rubella, 671–672
Rubinstein-Taybi syndrome, 1531
Rubivirus, 671–672
Rufinamide, 584*t*, 587, 1509
RYR1-related myopathies, 1497–1498, 1498*f*

S

Saccadic motion, testing for, 81, 262–263
Saccular aneurysms, 342
Sacral plexus. *See* Lumbosacral plexus
SAE. *See* Sepsis-associated encephalopathy
Safety, in MRI, 190
Safinamide, for Parkinson disease, 886
SAH. *See* Subarachnoid hemorrhage
St. Louis encephalitis, 665, 667*t*, 669
Salbutamol, for congenital myasthenic syndromes, 975, 975*t*
Salt wasting, cerebral, 1255–1258
Sandhoff disease, 1394
SANDO. *See* Sensory ataxic neuropathy with dysarthria and ophthalmoplegia
Sandostatin LAR, for meningiomas, 1054*t*
Sanfilippo syndrome, 1398
Sanger sequencing, 300
Saquinavir, 707*t*
Sarcoglycanopathies, 1490
Sarcoidosis, 154, 156, 165*t*, 773–777
  ataxia in, 838, 839*f*
  clinical manifestations of, 773–775
  cranial nerve involvement in, 773–774, 774*f*, 776, 923
  CSF findings in, 775
  CT in, 775
  diagnosis of, 775–776, 938*t*
  diagnostic criteria for, 775, 775*t*
  differential diagnosis of, 775, 776*t*
  epidemiology of, 773
  management of, 776, 777*t*
  meningeal, 774, 774*f*, 776
  MRI in, 774*f*, 775
  muscle presentations of, 775–776
  nerve biopsy in, 946, 947*f*
  neuropathy in, 938*t*, 946
  outcomes of, 776
  parenchymal, 774, 774*f*, 776
  pathobiology of, 773
  PNS, 775–776
  spinal, 774*f*, 775
  transverse myelitis in, 738, 740, 742*t*
SARS. *See* COVID-19; Severe acute respiratory syndrome
Satellite potential, 247
Satralizumab, for neuromyelitis optica spectrum disorders, 731, 752*t*, 753
Saturday night palsy, 459
Sawtooth waves, in EEG, 1183
SBMA. *See* Spinobulbar muscular atrophy
SBTs. *See* Spontaneous breathing trials
SCA. *See* Spinocerebellar ataxia
Scale for Assessment and Rating of Ataxia, 834
Scalp potentials, 238
Scanning speech, 834
Scapuloperoneal myopathies, 1474, 1476*t*, 1482–1483, 1482*f*
Scheie syndrome, 1397
Schilder disease, 728, 1399, 1402
Schistosoma, 654*t*, 658–659
  Schistosoma guineensis, 659*t*
  Schistosoma haematobium, 659*t*
  Schistosoma intercalatum, 659*t*
  Schistosoma japonicum, 162*t*, 659, 659*t*
  Schistosoma mansoni, 659, 659*t*
  Schistosoma mekongi, 659*t*
Schistosomiasis, 654*t*, 658–659, 659*t*
Schizencephalic AVMs, 361
Schizencephaly, 1368, 1368*f*
Schizoaffective disorder, 1590*t*
Schizophrenia, 1588–1592
  antipsychotic medication for, 1590–1592, 1591*t*
  diagnosis of, 1588–1590
  diagnostic criteria/algorithm for, 1589, 1589*f*
  differential diagnosis of, 1589–1590, 1590*t*
  epidemiology of, 1588
  management and outcome of, 1590–1592
  mood disorders *versus*, 1602
  nonpharmacologic treatment of, 1592
  pathobiology of, 1588
  positive, negative, and cognitive symptoms in, 1589
Schizophrenia spectrum, 1590
Schwannoma, 1549
  intradural spinal, 1093
  radiation-induced, 1336
  vestibular. *See* Acoustic neuroma
Schwannomatosis, 1456–1459
Schwannosis, 443
Schwartz-Jampel syndrome, 1004*t*, 1007
SCI. *See* Spinal cord injury
Sciatica, 43, 43*f*, 1147
Sciatic nerve
  anatomy of, 931, 934
  injury of, 460*t*, 461, 462, 934
sCJD. *See* Sporadic Creutzfeldt-Jakob disease
SCN2A encephalopathies, 1506
SCN8A encephalopathies, 1509
Scopolamine, for vertigo, 49*t*
Scrapie, 506
Scrub typhus, 624, 625*t*, 628–629
Scuba diving, and decompression illness, 1350–1354
SD. *See* Sydenham disease
SE. *See* Status epilepticus
Seasonal affective disorder, 1599
Seattle International Severe Traumatic Brain Injury Consensus Conference (SIBICC), 430, 431*f*
Seckel syndrome 1, 1414*t*
Secondary headaches, 70, 71–73, 522–523
Secondary malignancies, pediatric, 1562
Secondary neurologic disease, 1
Secondary progressive multiple sclerosis (SPMS), 713, 714, 714*f*, 718, 722*f*
Second impact syndrome, 416
"Second wind," in metabolic myopathies, 1015, 1016
Sedation
  altered consciousness with, 168
  for delirium prevention, 92
  for intubation, 1210–1211
  palliative (end-of-life), 1640, 1641*t*
Sedation scales, 89–90, 89*t*
Sedative abuse/dependence, 1314, 1315*t*
Seddon nerve injury classification, 452, 452*t*
SEEPs mnemonic, for spontaneous intracranial hypotension, 1140, 1140*t*
Segmental dystonia, 802, 809
Segmentation, of nervous system, 1366, 1368–1369, 1368*f*
Seizures, 57–63
  acute liver failure and, 1251
  acute symptomatic, 59, 567, 578
  alcohol withdrawal and, 1305
  anticholinergic toxicity and, 1322–1324
  arteriovenous malformations and, 361, 362
  AVMs and, 225
  brain abscess and, 614, 618
  causes of, 59
  cavernous malformations and, 366
  cerebral venous thrombosis and, 355, 359
  classification of, 57, 57*f*, 570–576, 571*f*
  clinical features of, 54
  coma and, 169, 172
  congenital bilateral perisylvian syndrome and, 1376
  continuous EEG monitoring in, 294–295, 294*t*, 295*t*
  as contraindication to tPA, 141
  definition of, 57
  differential diagnosis of, 58–59
  drug abuse/withdrawal and, 1316
  dystonic, 801, 802*t*
  EEG findings in, 59, 567, 568
  emergent first-line drugs for, 59–60, 59*t*
  emergent management of, 59–60
  encephalotrigeminal angiomatosis and, 1463, 1464
  epidemiology of, 57
  epileptic, 567–596. *See also* Epilepsy
  failure to stop. *See* Status epilepticus
  focal, 57, 57*f*, 570, 571*f*
  generalized, 57, 57*f*, 570–571, 571*f*
  gliomas and, 1020
  glucose transporter type 1 deficiency syndrome and, 1385–1386
  history taking for, 22*t*, 58, 58*t*
  HIV-associated, 698
  hospital stabilization and treatment for, 60
  indications for hospital admission, 60
  initial diagnosis of, 58–59
  initial workup in, 60, 60*t*
  level 1 evidence on, 63
  lowered threshold for, 59, 59*t*
  management strategy for, 57, 58*t*
  MRI in, 59, 60
  negative symptoms of, 58
  neurologic examination in, 58
  neuroprotection/HIE prevention in, 328
  nocturnal, 264
  physical examination in, 58
  positive symptoms of, 58
  posterior reversible encephalopathy syndrome and, 387
  posttraumatic, 576
  preeclampsia/eclampsia and, 1289–1290
  prehospital stabilization and treatment for, 59–60
  prevention of
    with focal mass lesions, 167
    in ICH patients, 140, 335*t*, 338
  prion diseases and, 519*t*
  provoked, 59, 59*t*

psychogenic, 594–595, 1620, 1622–1623
psychosis with, 1593
schizencephaly and, 1368
second-line therapy for, 60–61, 61*f*
sensory symptoms in, 64
sepsis-associated encephalopathy and, 1204–1205
single/first
management of, 578–579
outcome after, 568–569, 569*t*
stroke *versus*, 135*t*
subarachnoid hemorrhage and, 347
subdural empyema and, 618
sympathomimetic toxicity and, 1324–1326
syncope *versus*, 53–54, 53*t*
third-line (anesthetic) treatment of, 61–62, 61*f*, 62*t*
transplantation-related, 1298–1299, 1298*t*
traumatic brain injury and, 434, 437
tuberous sclerosis complex and, 1461, 1462, 1513
unknown onset, 571, 571*f*
unprovoked, 59
vasculitis and, 371
xenobiotic-induced, 1320, 1321*t*
Seizures, pediatric, 1502–1514
brain tumors and, 1540–1541
epileptic, 1503–1511
febrile, 1503, 1509
inborn errors of metabolism and, 1511–1512
neonatal, 1359–1361, 1503
antiepileptic drugs for, 1360–1361, 1361*t*
clinical manifestations of, 1360
cocaine and, 1585
diagnosis of, 1360
EEG findings in, 1360, 1361, 1503
epidemiology of, 1359–1360, 1503
management of, 1360–1361, 1503
metabolic causes of, 1360, 1361*t*
outcome of, 1361
pathobiology of, 1360
stroke/sinus venous thrombosis and, 1362, 1517–1518
nonepileptic, 1503
traumatic brain injury and, 1575
Selective mutism, 1608*t*, 1609, 1612
Selective serotonin reuptake inhibitors (SSRIs)
for ADHD, 1431–1432
for anxiety disorders, 1610–1613, 1611*t*
for cataplexy, 1189
for depression, 1602
for illness anxiety disorder, 1618–1619
for neuropathic pain, 563
for obsessive-compulsive disorder, 1612
for Parkinson disease, 889, 1603
serotonin syndrome with, 1330, 1330*t*
for somatic symptom disorder, 1617
Selegiline, for Parkinson disease, 886
Selenium toxicity, 1278*t*, 1282
SELENON-related myopathy, 1498
Self-limited focal epilepsy syndromes of childhood, 575
Self-medication, 1602
Sellar pathology, 87
Semantic fluency, 274
Semantic memory, 274*t*
Semantic variant PPA, 486, 488
Semilobar holoprosencephaly, 1369
Semiology, 58
Sengers syndrome, 1445, 1449
Sensitization, 557*t*
central, 559–560
peripheral, 558–559
Sensorimotor axonal neuropathy, ataxia with, 844*t*, 845
Sensorineural hearing loss, 49–50, 50*t*
Sensory ataxic gait, 130*t*
Sensory ataxic neuropathy with dysarthria and ophthalmoplegia (SANDO), 844–845, 844*t*, 1016, 1017
Sensory examination, 26*t*, 39–41, 68, 68*t*
in acute spinal cord syndromes, 149
in muscle weakness, 117
Sensory gangliopathy, 66
Sensory inversion, 1333
Sensory nerve action potential (SNAP), 243, 244*f*
in axonotmesis, 463
in neurapraxia, 463
Sensory nerve conduction studies, 243, 243*f*, 244*f*
Sensory neuronopathy, 941, 1102
Sensory neuropathy, 941
ataxia with, 844–845, 844*t*, 845*f*
Sensory symptoms, 64–69. *See also* Numbness; Pain; Paresthesias
diagnostic evaluation of, 68–69
focused history of, 67
focused physical examination in, 67–68
initial management of, 69
management strategy for, 64
with muscle weakness, 114, 115*t*
neuroanatomy and localization of, 65*f*, 65*t*, CH64–66
types of, 64
Sensory testing, quantitative, 69
Sensory trick, 800
Sentinel headaches, 343
Separation anxiety disorder, 1608*t*, 1609, 1612
Sepsis
assessment in, 1201, 1201*t*
definition of, 1201
Sepsis-associated encephalopathy (SAE), 1201–1206
astrocytes and BBB dysfunction in, 1203–1204
brain signaling in, 1203, 1203*f*
diagnosis of, 1204
EEG in, 1201, 1202, 1204, 1205
epidemiology of, 1201, 1202
imaging in, 1204
impact on long-term impairment, 1205
impact on survival, 1205
ischemic processes in, 1204
level 1 evidence on, 1205–1206
management of, 1201, 1204–1205, 1205*t*
neuroinflammation and glial cell activation in, 1203
neurotransmitter dysfunction in, 1204
outcome of, 1205
pathobiology of, 1202–1204
pathophysiology of, 1200*f*, 1201–1202, 1202*f*
societal cost of, 1205
Septo-optic dysplasia, 1368, 1369
Serotonin
in bipolar disorder, 1598
in depression, 1597
in migraine, 524, 525–527
in schizophrenia, 1588
Serotonin-norepinephrine reuptake inhibitors (SNRIs)
for ADHD, 1431–1432
for anxiety disorders, 1610, 1611–1612, 1611*t*
for depression, 1602
for neuropathic pain, 561, 563
serotonin syndrome with, 1330, 1330*t*
Serotonin syndrome, 1330, 1330*t*
Sertraline, for anxiety disorders, 1611*t*, 1612
Set shifting, 274
Severe acute respiratory syndrome (SARS), 672–673. *See also* COVID-19
Severity of symptoms, 17–18
Sexual activity, primary headache associated with, 524*t*, 533
Sexual dysfunction, 1265–1266
antidepressants and, 1602
in epilepsy, 588
in multiple sclerosis, 716, 727*t*, 1266
in multiple system atrophy, 896, 1267
in neuropathy, 1266
in Parkinson disease, 880–881, 1267
in spinal cord injury and, 449, 1266
in transverse myelitis, 738
SFEMG. *See* Single-fiber electromyography
SFR. *See* Spotted fever rickettsiosis
Shagreen patches, 1461
Shaken baby syndrome, 438, 1572
Sharp injury to nerve, 464
Shellfish poisoning, 948, 1333
Shine through, in MRI, 1129
Shingles, 681–682, 702, 946
Shingrix, 682
Shivering, in therapeutic hypothermia, 328, 329*t*
Shock
cardiogenic, 447
neurogenic, 148, 447
spinal, 150, 427, 444, 447, 1091
Short sleepers, 1186
Short-term memory, 29–30
Shoulder girdle, innervation of, 928*t*
Shoulson-Fahn Total Functional Capacity scale, 862, 862*f*
Shunting, pulmonary, 1207
Shunts, for CSF, 1115, 1115*f*, 1122–1125
algorithm for malfunctioning, 1124*f*
complications of, 1123–1125
for idiopathic intracranial hypertension, 1137
infection, 1125
for neonatal IVH, 1357
Shunts, transjugular portosystemic, 1246
Shy-Drager syndrome (SDS), 894–896
SIADH. *See* Syndrome of inappropriate ADH secretion
Sialidosis, 1394, 1398
Sialorrhea
in ALS, 913
in Parkinson disease, 889
Sickle cell disease, 1228–1231
childhood stroke in, 1524–1525
clinical manifestations of, 1229
diagnosis of, 1229, 1525
epidemiology of, 1228–1229, 1524
hydroxyurea for, 1230
intracranial ultrasound in, 213, 1229–1230
management of, 1229–1231, 1525
pathobiology of, 1229, 1524–1525

Sickle cell disease *(Continued)*
stroke management in, 1230
transfusion strategies and stroke prevention in, 1229–1230, 1230*t*
Sickle hemoglobin, 1228
Sickness behavior, 1203, 1598
Sievert (Sv), 1335
SIH. *See* Spontaneous intracranial hypotension
Similarities subtest, 275
Simple partial seizures, EEG of, 236
Simultanagnosia, 307
SIMV. *See* Synchronized intermittent mandatory ventilation
Simvastatin
myotoxicity of, 993–995, 995*t*, 996*f*, 996*t*
for stroke prevention, 403
Single-fiber electromyography (SFEMG), 251–252, 251*f*
stimulated SFEMG, 251
Single nucleotide polymorphism arrays, 1411–1412
Single-photon emission computed tomography (SPECT), 203–207
in Alzheimer disease, 101, 482–483
basic principles of, 203
in brain death, 181*t*
clinical applications of, 204–206, 204*t*
in dementia
HIV-associated, 696
Lewy body, 101, 496, 496*f*
detection, acquisition, and signal display in, 204
dopamine imaging in, 204*t*, 205, 205*f*
in epilepsy, 580
in mild cognitive impairment, 473, 473*t*
in moyamoya disease, 392
in Parkinson disease, 881
perfusion imaging in, 204*t*, 205–206
radiopharmaceuticals for, 203–204
sensitivity and selectivity of, 203
in toxoplasmosis, 704
Single-pulse transcranial magnetic stimulation, 252, 253*f*, 527*t*, 528
Sinking brain syndrome. *See* Brain sagging
Sinusitis, and meningitis, 604, 605*t*
Sinus pain, 538–540
Sinus pericranii, 368
Sinus thrombosis, 73, 353, 355, 355*t*. *See also* Cerebral venous thrombosis (CVT)
Siponimod, for multiple sclerosis, 723, 725, 725*t*
Sixth (abducens) nerve palsy, 86
Sjögren syndrome
multiple sclerosis *versus*, 722
neuropathy in, 938*t*, 942
$SjvO_2$ (jugular venous oxygen saturation), 291–292
Skew deviation, 85
Skin biopsy, 286–287
in diabetic neuropathy, 950, 950*f*
in neuropathic pain, 560
in sensory symptom evaluation, 69
in Sneddon syndrome, 396, 397
Skull base (skull) lesions, neoplastic-like, 1085–1087
Skull base osteomyelitis, 622
Skull base (skull) tumors, 1080–1088
benign, 1084–1085, 1085*f*
malignant, 1082–1084
extension of malignant tumors, 1083, 1083*f*
metastatic, 1082–1083
primary, 1083, 1084*f*
Skull fractures, 420–421, 430, 435
SLE. *See* Systemic lupus erythematosus
Sleep
delirium and, 88
disorders of. *See* Sleep problems/disorders
EEG in, 231, 233*f*, 1183–1184, 1184*f*, 1185
EMG in, 264, 1183, 1184*f*
neuroanatomy and neurochemistry in, 1184–1185
physiology of, 1183–1184
stages of, 1183, 1184*f*
studies of. *See* Sleep studies
subjective reporting of, 268–269, 269*f*
Sleep apnea, 1190–1191
central, 264
clinical features of, 1190
depression *versus*, 1602
management of, 1190–1191
obstructive. *See* Obstructive sleep apnea
Sleep deprivation, 1187
Sleep diary/log, 264, 265, 268–269, 269*f*
Sleep hygiene, 1186, 1186*t*, 1189
Sleepiness
definition of, 1186
excessive, 1186–1189, 1187*t*, 1486. *See also specific disorders*
Sleeping sickness, 654*t*, 655, 705
Sleep latency, 264, 265–266, 1188, 1189*t*
Sleep onset, 265–267
Sleep-onset movements, 1191–1192
Sleep-onset rapid eye movement periods (SOREMPs), 267
Sleep paralysis, 1187–1189
Sleep position
laboratory testing in, 269–270
and syncope, 55
Sleep problems/disorders, 264–270, 1183–1194
in ALS, 913
biomarkers in, 268
breathing disorders, 1189–1191
circadian rhythm disturbances and, 267–268
in Creutzfeldt-Jakob disease, 508
in depression, 1599
epidemiology of, 264
imaging in, 270
level 1 evidence on, 1193–1194
in Lewy body dementias, 494, 495, 498
in multiple system atrophy, 896
in Parkinson disease, 880, 888, 889
in pediatric epilepsy, 1510
periodic limb movement, 793
in pregnancy, 1286, 1294
restless legs. *See* Restless legs syndrome (RLS)
Tourette syndrome and, 787
Sleep-related rhythmic movement disorders, 1191–1192
Sleep spindles, 231, 233*f*
Sleep starts (hypnic jerks), 1188, 1192
Sleep-state misperception, 1186
Sleep studies, 264–270. *See also specific sleep disorders*
in ataxia, 837
indications for, 264–267
Sleep (night) terrors, 264, 265, 1192–1193
Sleepwalking, 264, 265, 1192–1193
Small-artery TIAs, 320, 321
Small-fiber neuropathy, 936
Small molecule inhibitors. *See also specific drugs*
neurologic complications of, 1109–1110
Small-molecule metabolic disorders, 1385–1393. *See also specific disorders*
Small molecule splicing molecules, for Huntington disease, 868
Small-vessel infarction, ischemic stroke with, 303*f*, 304
Small-vessel vasculitis, 371*t*, 376–378. *See also specific types*
Small-vessel vasculopathy, and intracerebral hemorrhage, 332–333
SMARD1. *See* Spinal muscular atrophy with respiratory distress type 1
SMART. *See* Stroke-like migraine attacks after radiation therapy
SMAs. *See* Spinal muscular atrophies
Smell, sense of
COVID-19 and, 673
essential tremor and, 780
olfactory neuropathy and, 915–917, 916*t*
Parkinson disease and, 881, 888, 916
testing of, 262
and xenobiotic detection, 1320, 1325*t*
SMN gene, 1467, 1468*f*, 1470–1472, 1470*f*
Smoking
and multiple sclerosis, 713
and Parkinson disease, 874
and stroke, 402, 408–409
Smoking cessation, 402, 408–409
SNAP. *See* Sensory nerve action potential
SNCA gene
in Lewy body dementias, 494
in Parkinson disease, 875–876
SND. *See* Striatonigral degeneration
Sneddon syndrome, 396–397
clinical features of, 397
diagnosis of, 397
epidemiology of, 396
level 1 evidence on, 400
management of, 397
MRI in, 396*f*, 397
outcome of, 397
pathobiology of, 396
physiologic, 396
secondary, 396
Snellen chart, 32, 259, 259*f*
SNOOP mnemonic, for headaches, 71, 71*t*
Snoring, 1190
SNRIs. *See* Serotonin-norepinephrine reuptake inhibitors
Social anxiety disorder, 1606
clinical features of, 1608, 1608*t*
treatment of, 1611–1612
Social/emotional milestones, 1427–1428, 1428*t*
Social history, 19–23
Social workers, 1633
Sociocultural factors
in global burden of neurologic disease, 7
in health-seeking behavior, 10–11, 10*b*
in somatic symptom disorder, 1617
Sodium benzoate, for hepatic encephalopathy, 1247*t*, 1248
Sodium bicarbonate, for ICP management, 1132
Sodium channel(s), in neuropathic pain, 559
Sodium channel antagonists, for neuropathic pain, 562–563
Sodium imbalance, 1255–1260. *See also* Hyponatremia
Sodium intake, restricted, for Ménière disease, 598

Sodium oxybate, for myoclonus, 829*t*
Soft-tissue sarcoma, skull base, 1083
Solid cord injury, 442
Solitaire intrathrombus "stentriever" device, 313
Solriamfetol, for narcolepsy (excessive sleepiness), 1189
Solvent toxicity, 1331–1332
Somatic mosaicism, 300
Somatic pain, 65
Somatic symptom disorder(s), 810, 1615–1628. *See also specific disorders*
  case example of, 1616
  clinical challenge of, 1615
  cultural factors in, 1617
  diagnosis of, 1616–1617
  DSM-IV classification and criteria for, 1615–1616, 1615*t*
  epidemiology of, 1616
  evidence-based treatments for, 1615
  level 1 evidence on, 1626
  management of, 1617
  medical comorbidity with, 1617
  outcome of, 1617
  pathobiology of, 1616
Somatization disorder, 810, 1615*t*, 1616
Somatoform disorder, 810
  not otherwise specified, 1615*t*
  undifferentiated, 1615*t*, 1616
Somatosensory evoked potentials (SSEPs), 238–239, 239*f*
  giant, in myoclonus, 825, 825*t*
  in hypoxic-ischemic encephalopathy, 327, 327*f*
  in spinal stenosis, 1156
Somnolence syndrome, 1545, 1561
Sonic hedgehog (SHH)
  in medulloblastoma, 1532–1535, 1534*f*, 1555–1557
  in ventral induction, 1368–1369
Sonothrombolysis, 215
SOREMPs (sleep-onset rapid eye movement periods), 267
Sparganosis, 654*t*
Spasmodic (laryngeal) dystonia, 106, 802, 808–809, 815
Spastic diplegia, 1425
Spastic dystonia, 801, 802*t*
Spastic hemiparesis, 1426
Spasticity, 37, 116
  ALS and, 908, 909*t*
  cerebral palsy and, 1425–1426, 1427
  coma and, 170
  dystonia *versus*, 800, 802*t*
  multiple sclerosis and, 715, 726, 727*t*
  spinal cord injury and, 450
  treatment of, 726, 727*t*
Spastic paraparesis, 1007, 1164
Spastic paraplegia, hereditary, 1168
Spastic quadriplegia, 1425–1426
Special senses. *See also* Hearing; Smell, sense of; Vestibular system, testing of; Vision
  evaluation of, 259–263
Specific absorption rate, in MRI, 190
Specific language impairment, 1429
SPECT. *See* Single-photon emission computed tomography
Speech. *See also* Language deficits; Language testing
  ALS and, 908, 913
  ataxia and, 834, 844–845, 844*t*, 847
  autism spectrum disorders and, 1437
  corticobasal degeneration and, 897
  cranial nerve assessment in, 36, 36*f*, 36*t*
  disorganized, in schizophrenia, 1589
  Guillain-Barré syndrome and, 939
  muscle weakness and, 114, 115*t*
  myasthenia gravis and, 966*t*
  Parkinson disease and, 878–879, 880, 885
  progressive supranuclear palsy and, 893–894
Speech delay, 1424, 1427–1429, 1428*t*
Speech-language pathologist (SLP), 1632–1633
Speech prosody, 29, 1437
Speech therapy (rehabilitation), 410, 1632–1633
Spetzler-Martin grading scale, for AVMs, 225, 225*f*, 364, 364*t*
Sphingomyelinase deficiency, 1396
Spina bifida, 1266, 1367
Spinal accessory nerve (CN XI)
  anatomy of, 924
  injury (neuropathy) of, 454*t*, 456–457, 924–925
  transfer to suprascapular nerve, 467
Spinal cord
  anatomy of, 145–147, 146*f*
    autonomic system, 145–147
    motor system, 145, 146*f*
    sensory system, 145
    vascular, 147, 147*f*
  gait control by, 123, 124*f*
  muscle weakness localized to, 111–112, 120*t*
  sensory patterns and loss, 65*t*, 66
  tumors of. *See* Spinal tumors
Spinal cord compression
  disk disease and, 1149, 1150–1151
  lymphoma/myeloma causing, 1233
  spinal metastases and, 1044–1045, 1044*f*, 1092
  spinal stenosis and, 1152–1158
  spinal tumors and, 1091, 1098
Spinal cord disease. *See also specific disorders*
  intracranial hypertension in, 1135–1136
  neurologic history in, 21*t*
Spinal cord infarction, 1165–1166
Spinal cord injury (SCI), 441–450
  acute medical management of, 447–448
  acute phase of, 443
  autonomic dysfunction and blood pressure in, 447–448
  autonomic dysreflexia in, 449
  bone metabolism (osteoporosis) in, 450
  chronic medical management of, 448–450
  clinical evaluation of, 444
  coronary artery disease with, 449
  critical care in, 448
  definition of, 441
  diagnosis of, 444–445
  etiology and epidemiology of, 441–442
  floppy infant in, 1420
  gastrointestinal dysfunction with, 449
  general trauma care for, 447
  genitourinary complications of, 449
  GI/genitourinary effects of, 1266
  gross pathology of, 442–443
  histopathology of, 443–444
  imaging studies of, 444–445, 444*t*, 445*f*, 446*f*
  immediate phase of, 443
  intermediate phase of, 443
  late phase of, 443–444
  level 1 evidence on, 450
  life expectancy after, 441, 442*t*
  mechanism of, 442
  neurologic assessment and classification of, 445–447, 446*t*
  neurologic rehabilitation in, 1630, 1632, 1632*f*
  nontraumatic, 442
  pain after, 448–449
  pathobiology of, 442–444
  prehospital trauma protocols for, 444
  primary, 442
  psychiatric complications of, 450
  pulmonary disease with, 449
  risk stratification in, 444, 444*t*
  secondary, 442
  sociologic and economic effects from, 441–442
  spasticity with, 450
  steroids for, 447
  surgical treatment of, 448
Spinal cord syndromes. *See* Acute spinal cord syndromes
Spinal epidural abscess, 619–620
Spinal metastases, 1044–1046, 1089
  cord compression from, 1044–1045, 1044*f*
  epidural, 1044–1045, 1044*f*, 1091–1093, 1092–1093, 1092*f*, 1097–1098
  incidence risk by primary tumor site, 1035
  intramedullary, 1094
  leptomeningeal, 1045–1046, 1046*f*
  level 1 evidence on, 1047–1048
  myelopathy from, 1162–1163
Spinal muscular atrophies (SMAs), 904, 1413*t*
  adult (type IV), 1469*t*
  antisense oligonucleotides for, 1472
  care of patient with, 1472
  childhood, 904, 1467–1473
    epidemiology of, 1467
    infant hypotonia (floppy infant) in, 1420
    management of, 1471–1472
    maximal functional status achieved in, 1467
    outliers in, 1469
    pathobiology of, 1471, 1471*f*
    type I, 1467–1468, 1469*t*
    type II, 1468–1469, 1469*t*
    type III, 1469*t*
  clinical characteristics/classification of, 1467–1469, 1469*t*
  differential diagnosis of, 1470*t*
  dysphagia in, 1262–1263
  gait disorder in, 130*t*
  gene therapy for, 1472
  genetics of, 299, 1413*t*, 1467, 1468*f*, 1470–1471, 1470*f*
  historical perspective on, 1467, 1468–1469
  level 1 evidence on, 1472
  newborn screening for, 1471
  small molecules for, 1471–1472
  of unilateral upper extremity. *See* Monomelic muscular amyotrophy
Spinal muscular atrophy with respiratory distress type 1 (SMARD1), 1420
Spinal myoclonus, 825*t*, 826*t*, 828
Spinal reflexes, 43
Spinal roots
  brachial plexus, 927–930
  intervertebral disk disease and, 1145–1147, 1146*f*, 1147*t*
  lumbar and sacral plexuses, 930–931
Spinal sarcoidosis, 774*f*, 775

Spinal segmental myoclonus, 825*t*, 826*t*, 828
Spinal shock, 150, 427, 444, 447, 1091
Spinal stenosis, 1153–1158
congenital, 1155
diagnosis of, 1155–1156
electrodiagnostic studies in, 1156
epidemiology of, 1153
level 1 evidence on, 1158
management of, 1156–1157
motor neuron disease/ALS *versus*, 911, 912*t*
outcomes of, 1157
pain in, 1155
pathobiology of, 1153–1155, 1154*f*
physical examination in, 1156
radiographic studies of, 1153, 1156, 1157*f*
Spinal tumors, 1089–1099
clinical features of, 1089–1096
CSF analysis for, 1097
diagnosis of, 1096–1097
differential diagnosis of, 1096
epidemiology of, 1089
level 1 evidence on, 1098
location of, 1089, 1090*f*, 1091*f*
management of, 1097–1098
outcome of, 1098
pathobiology of, 1089, 1090*f*
pediatric, 1530, 1554
radiography of, 198–199, 1090*f*, 1093*f*, 1094*f*, 1095*f*, 1096–1097
regional syndromes, 1094–1096
Spinobulbar muscular atrophy (SBMA), 912
Spinocerebellar ataxia (SCA), 97, 838–844, 840*t*–842*t*
assessment in, 834
associated with noncoding repeats, 843
CAG repeat polyglutamine, 839–843
chorea in, 857–858
essential tremor *versus*, 781
genetics of, 299, 838–844, 840*t*–842*t*
genetic testing in, 843–844
GM2 gangliosidosis and, 1394
infantile-onset, 1450
signs and symptoms of, 838, 840*t*–842*t*, 842*f*
treatment of, 847
Spinothalamic tract, 66
Spirometra, 162*t*
Spirometra mansoni, 654*t*
Spironolactone, for hypokalemic periodic paralysis, 1000
Split repair of nerve, 466*t*, 467
SPMS. *See* Secondary progressive multiple sclerosis
Spoiled gradient-echo image, 194
Spondyloarthropathies, 1153
Spondylosis, 1153–1154
cervical tumor *versus*, 1096
definition of, 1153
Spongiform changes. *See* Vacuolation
Spongiform encephalopathies, 506. *See also* Prion diseases
Spontaneous activity, in electromyography, 246–247, 247*f*
Spontaneous aliquorrhea, 1139
Spontaneous breathing trials (SBTs), 1212, 1212*t*
Spontaneous intracranial hypotension (SIH), 1139–1144
clinical feature of, 1139
diagnosis of, 1140
diagnostic criteria for, 1140, 1140*t*
epidemiology of, 1139
headache caused by, 73, 1139
management of, 1141–1143
MRI in, 1140, 1140*t*, 1141*f*–1142*f*
outcomes of, 1143
pathobiology of, 1139
Sport-related concussion (SRC), 413–416. *See also* Concussion
Spotted fever rickettsiosis (SFR), 624–627, 624*t*
clinical manifestations of, 625, 626*f*
diagnosis of, 625–626
epidemiology of, 625, 626*f*
MRI in, 625–626, 627*f*
pathophysiology of, 625
prevention of, 627
treatment and outcome of, 626–627
SRC. *See* Sport-related concussion
SRNS. *See* Steroid-resistant nephrotic syndrome
SRS. *See* Stereotactic radiosurgery
SSEPs. *See* Somatosensory evoked potentials
SSPE. *See* Subacute sclerosing panencephalitis
SSRIs. *See* Selective serotonin reuptake inhibitors
Stabbing headache, 534
The staggers, 1352
Stance, 122, 122*f*
assessment of, 126–128, 128*t*, 834
lower extremities in, 127
upper extremities in, 127
Standing, autonomic testing during, 256
Standing test, active, 54–55
Staphylococcus aureus, 613, 618, 621
meningitis, 604–605, 605*t*
Startle disease, 827, 1005. *See also* Hyperekplexia
Statins
for delirium prevention, 92, 1205
myotoxicity of, 993–995, 995*t*, 996*f*, 996*t*
neuropathy induced by, 949
for stroke prevention, 403, 408
for TIA management, 322
Station, assessment of, 38, 68
Status epilepticus, 57, 60–62
definition of, 57
EEG in, 232
EEG monitoring in, 62–63
EEG monitoring in, continuous, 294–295, 294*t*, 295*t*
hypothermia for, 62
indications for hospital admission, 60
initial diagnosis in, 58–59
management strategy for, 57, 58*t*
refractory, 60, 61–62, 61*f*, 62*t*
refractory, new-onset, 759
second-line therapy for, 60–61, 61*f*
superrefractory, 62
third-line (anesthetic) treatment for, 61–62, 61*f*, 62*t*
traumatic brain injury and, 434
Stavudine, 706, 707*t*, 1582–1583
Steal phenomenon, arteriovenous malformations and, 361–362
Steele-Richardson-Olszewski syndrome, 893. *See also* Progressive supranuclear palsy (PSP)
Stem cell transplantation, 1235–1237
for adrenoleukodystrophy, 1406
neurologic complications of, 1111, 1235–1237, 1236*t*
for primary CNS lymphoma, 1059–1060
Stent(s). *See also specific procedures*
flow-diverting, 222–223, 223*f*
intracranial, 226–227
Stent-assisted coiling, 222
"Stentriever" devices, 313–314
Stereo-EEG, 236
Stereotactic radiosurgery (SRS), 1335
for acoustic neuroma, 1082
for glossopharyngeal neuralgia, 545
for meningiomas, 1053
for metastatic disease, 1038, 1040–1041, 1045
for Parkinson disease, 889–890
for pediatric brain tumors, 1544
for pituitary tumors, 1070
for skull base tumors, 1083
for trigeminal neuralgia, 544–545, 544*f*, 918
Stereotypies, 106, 106*t*
Steroid(s)
for ACTH deficiency, 1215–1216
for adrenal insufficiency, 1222–1223
for adrenoleukodystrophy, 1406
for amyloid β-related angiitis, 374
for antiphospholipid antibody syndrome, 1243
for antisynthetase syndrome, 982
for autoimmune encephalitis and meningitis, 767, 768*t*, 770, 770*t*
for bacterial meningitis, 608–609, 610*f*
for Behçet syndrome, 379
for Bell's palsy, 921
for brain abscess, 618
for brain edema, 1131, 1133–1134
for brucellosis, 632
for chorea, 855
for chronic inflammatory demyelinating polyneuropathy, 940
for cluster headache prevention, 531*t*, 532
for CNS vasculitis in rheumatoid arthritis, 380
for complex regional pain syndrome, 552*t*, 553
critical illness myopathy/neuropathy induced by, 989
for delirium prevention, 92
for dermatomyositis, 981
for Duchenne muscular dystrophy, 1481–1482
for eosinophilic granulomatosis with polyangiitis, 378
for epileptic spasms in TSC, 1462
for focal mass lesions in brain, 166
for giant cell arteritis, 73, 375
for Guillain-Barré syndrome, 940
for hearing loss, 50
for immunotherapy complications, 1110–1111
for inclusion body myositis, 984
for inflammatory myelopathy, 1165
intracranial hypertension induced by, 1135
intranasal, for rhinosinusitis, 540
for IV/GM hemorrhage prevention, 1355, 1357
for Ménière disease, 598, 599
for metastatic disease, 1036, 1045
for migraine, 74
for multiple sclerosis, 722–723
for myasthenia gravis, 969–970, 970*t*, 971
for mycoplasmal (walking) pneumonia, 635

for neoplastic myelopathy, 1163
for neuromyelitis optica spectrum disorders, 731, 751, 752
neurotoxicity of, 1299
osteoporosis and fractures with, 1274–1275
for overlap myositis, 982
for paraneoplastic syndromes, 1104
for pituitary tumors, 1068
for polyarteritis nodosa, 376
for primary angiitis of CNS, 372–373
for primary CNS lymphoma, 1058, 1059
psychosis with, 1594
for radiation injury, 1107, 1342
for Ramsay Hunt syndrome, 922
for sarcoidosis, 776, 777*t*
for spinal cord injury, 447
for Susac syndrome, 395
for Takayasu vasculitis, 375
therapeutic monitoring of use, 770
for toxoplasmosis, 704, 1237
for transverse myelitis, 742
for traumatic brain injury, 434
Steroid-resistant nephrotic syndrome (SRNS), 1448, 1448*t*
Steroid-responsive encephalopathy, 760
Stevens-Johnson syndrome, antiepileptic drugs and, 583–584, 586
Stiff limb syndrome, 1005
Stiff neck (nuchal rigidity), 605, 614
Stiffness, muscle
definition of, 1004
disorders of, 1004–1007, 1004*t*. *See also specific disorders*
weakness with, 114, 115*t*
Stiff-person spectrum disorders, 759
Stiff person syndrome, 114, 1004–1006, 1004*t*
clinical manifestations of, 1005, 1006*t*
diagnosis of, 1006
electrophysiology of, 1006, 1006*f*
epidemiology of, 1005
paraneoplastic, 1101*t*, 1103, 1105
pathobiology of, 1005, 1005*f*
Stigma, related to neurologic disorders, 10, 10*b*
Stimulants
abuse/dependence, 1314, 1314*t*
for ADHD, 1431–1432
for narcolepsy (excessive sleepiness), 1189
STOP. *See* Stroke Prevention Trial in Sickle Cell Anemia
Storage dysfunction, urinary, 1264–1265
Straight-leg raise test, 43, 43*f*, 67
Stray radiofrequency interference, in MRI, 196, 196*f*
Streptococcal infection
PANDAS in, 785
Sydenham disease with, 854
Streptococcal meningitis, 604–605, 605*t*
Streptococcus bovis, 604
Streptococcus epidermidis, 618
Streptococcus pneumoniae, 604–605
Streptomycin, for end-stage Ménière disease, 600
Stress disorder
acute, 1606, 1608–1609, 1608*t*, 1612
posttraumatic. *See* Posttraumatic stress disorder (PTSD)
Stress gastric ulcer, 1264
Striatal hand, 878
Striatal toe, 802*t*, 808*f*, 878, 881
Striatonigral degeneration (SND), 894–896
Stridor, in multiple system atrophy, 109*t*
Stroke
acute ischemic. *See* Acute ischemic stroke (AIS)
alcohol and, 409, 1309
antiphospholipid antibody syndrome and, 1242–1243
anxiety in, 1610, 1612
bladder dysfunction with, 1267
CADASIL and, 398–399
cardiac procedures and, 1195–1197
cardioembolic, 303*f*, 304, 403, 407–408, 407*t*
cerebellar, 837–838
classification and subtypes of, 303–304, 303*f*
cognitive impairment in, 97
complications of, 316–317
COVID-19 and, 304, 673
critical care in, 315–317
CT of, 135–137, 138*f*, 186–187, 309, 309*f*
delirium after, 88–89
dementia with, 500–503. *See also* Vascular dementia
depression after, 411
diagnosis of, 307–311
differential diagnosis of, 133, 135*t*
drug abuse/withdrawal and, 1316
dysphagia with, 316–316, 1263
epidemiology of, 301
etiology of, 301, 303–304
first hour (acute care) after, 132–144, 307–314
aspirin administration in, 142
door-to-CT time in, 132
endovascular, 224, 224*f*
endovascular therapy in, 132, 142–143, 142*f*, 312–314
hospital disposition in, 143
initial history in, 133
initial hospital evaluation in, 307
initial management and imaging in, 132–137
initial survey and vital signs in, 133–134
intravenous access and admission labs in, 133
priorities in, 132
thrombolysis complications in, 312, 312*t*
tPA administration in, 132–133, 133*f*, 140–142, 311–312, 312*t*
giant cell arteritis and, 374–375
global disparities in, 5, 11, 11*b*
Global Stroke Services Action Plan on, 11*b*
hemorrhagic. *See* Hemorrhagic stroke
HIV-associated, 697
hydrocephalus with, 1116
hypertension in, 316
infection with, 316–317
level 1 evidence on, 317–318
marantic endocarditis and, 397–398
MRI of, 191–192, 194*f*, 196–197, 309–310, 310*f*
MR perfusion imaging in, 201
neurologic deterioration in, 316
neurologic history in, 22*t*
"other" causes of, 303*f*, 304
outcomes of, 317, 317*t*
perfusion imaging in, 310–311, 310*f*
in pregnancy, 1290–1291, 1290*t*
prehospital scales for, 307–308, 308*t*
prevention of. *See* Stroke prevention
renal disease and, 1254
risk factors for
modifiable, 401, 408–409
nonmodifiable, 401
sickle cell disease and, 1228–1231, 1524–1525
in Sneddon syndrome, 396–397, 396*f*
symptom recognition in, 307–308
symptoms and signs of, 132, 132*t*
TIAs and, 320–323
prevention, 321–322, 403, 405
risk and outcome, 322–323, 322*t*
tissue-based versus time-based approach in, 314, 314*f*
TTP-HUS and, 1239
ultrasound in, 208
undetermined cause of (cryptogenic), 303*f*, 304, 1520
varicella-zoster virus and, 682
vascular imaging in, 309*f*–310*f*, 310
Stroke, pediatric, 1515–1526
brain tumor treatment and, 1561
childhood, 1518–1524
angiogenesis disorders and, 1525
connective tissue disorders and, 1526
diagnosis of, 1520–1522
epidemiology of, 1518
genetics of, 1525–1526
management of, 1522–1523
metabolic, 1526
outcome of, 1523–1524
pathobiology of, 1518–1520
sickle cell anemia and, 1524–1525
thrombophilic disorders and, 1522, 1526
vessel wall stenosis and, 1525
diagnosis of, 1520–1521
HIV infection and, 1581, 1581*f*
level 1 evidence on, 1526
perinatal, 1362, 1515–1518
cocaine and, 1585
Stroke Belt, 5
Stroke Buckle, 5
Stroke-like episodes, pediatric, 1526
Stroke-like migraine attacks after radiation therapy (SMART), 1336, 1338*t*, 1341*f*, 1343
Stroke prevention, 401–412
anticoagulation for, 406
antiplatelet therapy for, 405–406
atrial fibrillation management for, 403, 406
blood work and other laboratory testing in, 404–405
cardiac abnormality management for, 407–408
cardiac evaluations in, 404
carotid stenosis management for, 403, 406–407
diabetes management for, 402, 408
diet for, 401–402
exercise for, 402, 409
hypercholesterolemia management for, 402–403, 408
hypertension management for, 402, 408
intracranial stenting for, 226–227
level 1 evidence on, 411
lifestyle modification for, 401–402, 408–409
modifiable risk factor management for, 401, 408–409

Stroke prevention *(Continued)*
neuroimaging in, 403–404
primary, 401, 402–403, 402*t*
primordial, 401–402
secondary, 401, 403–408, 404*f*
in sickle cell disease, 1229–1230, 1230*t*
smoking cessation for, 402, 408–409
stroke mechanism and evaluation in, 403–405, 405*f*
TIA management for, 403, 405
TIAs and, 321–322
Stroke Prevention Trial in Sickle Cell Anemia (STOP), 1229–1230, 1230*t*
Stroke rehabilitation, 410–411, 1630
Stroke unit checklist, 315, 315*t*
Strongyloides, 153, 162*t*
Strongyloidiasis, 654*t*
Stroop Color-Word Test, 274
Stroop Word Reading (SWR) test, 866
Strychnine poisoning, 1331
Stunned myocardium, neurogenic, 1195, 1195*t*, 1197–1198, 1198*f*
Stupor, 168. *See also* Coma
Sturge-Weber-Dimitri syndrome, 1462–1464
Sturge-Weber syndrome, 368, 1456, 1513, 1531
STXBP1 encephalopathy, 1506
Subacute decline, in neurologic disease, 1636
Subacute sclerosing panencephalitis (SSPE), 671–672, 675–676, 827
Subarachnoid hemorrhage (SAH), 342–352
anemia in, 347, 1227–1228
aneurysmal, 223, 342–343, 343*t*, 410
aneurysmal, complications of, 345–346
angiography in, 223, 344–345, 345*f*
arteriovenous malformations and, 351, 362
brain edema in, 346–347, 346*f*, 1130, 1130*f*
brain oxygenation in, 292
cerebral microdialysis in, 294
cerebral salt wasting with, 1257
clinical features of, 343–344
continuous EEG monitoring in, 294, 295
critical (ICU) care in, 349–350, 349*t*
CT of, 71, 135, 137*f*, 186, 344, 344*f*, 346, 346*f*, 346*t*
diagnosis of, 344–345
early brain injury in, 1130
emergency management of, 347
endovascular therapy for, 223, 342, 348, 348*f*
epidemiology of, 342
fever in, 347
fibromuscular dysplasia and, 389
fluid and electrolyte disturbances in, 347
global cerebral edema and early brain injury in, 346–347, 346*f*
headache caused by, 71–72, 343, 344, 344*t*, 523
HIV-associated, in children, 1581
Hunt and Hess grading scale for, 343, 343*t*
hydrocephalus in, 346, 1115–1116, 1116*f*
intracranial pressure in, 288
laboratory testing in, 345
level 1 evidence on, 351
lumbar puncture in, 344
misdiagnosis of, 343
moyamoya disease and, 391
neurogenic cardiac and pulmonary disturbances in, 347
nonaneurysmal causes of, 342, 342*t*
Ottawa Rule for, 344, 344*t*
outcome of, 342, 343, 350, 350*f*
in pregnancy, 1291–1292
rebleeding in, 345, 345*f*
renal disease and, 1254
reversible cerebral vasoconstriction syndrome and, 387–388
seizures in, 347
sickle cell disease and, 1230
stroke *versus*, 135*t*
stroke with, 401
stunned myocardium with, 1197–1198, 1198*f*
surgical management of, 347–348
traumatic, 426
treatment of, 347–350
triple-H therapy for, 349–350
ultrasound of, 214, 349
vascular malformations causing, 351
vasodilators for rescue therapy in, 350
vasospasm in, 214, 223, 345–346, 345*f*, 346*t*, 349–350, 349*t*
Subarachnoid heterotopias, 1377
Subclavian steal syndrome, 54, 321
Subcortical arteriosclerotic dementia. *See* Binswanger disease (BD)
Subcortical lesions, muscle weakness localized to, 111
Subcortical myoclonus, 825*t*, 826*t*, 827–828
Subdural empyema, 618–619, 619*f*
Subdural hematoma, 135*t*, 424–426
acute, 425
cerebral infarction with, 435
chronic, 226, 425, 425*f*
chronic, dementia with, 97
CT of, 424, 425*f*
evacuation of, 425–426
headache caused by, 72
pediatric, 1572, 1573*f*
surgical management of, 430
Subependymal giant cell astrocytoma, 1020*t*, 1530–1531, 1551
Subependymal heterotopias, 1377
Subfalcine herniation, 172, 174*t*, 175*f*
Subhyaloid hemorrhage, 343
Subjective experiences, quality of, 17–18
Subpial heterotopias, 1377
Substance abuse, 1313–1318. *See also specific drugs*
altered mentation in, 1316–1317
infection risk in, 1316
mood disorders with, 1602
prenatal and perinatal effects of, 1317, 1584
psychosis with, 1593
schizophrenia and, 1590
seizures in, 1316
stroke in, 1316
trauma in, 1316
Substance/medication-induced mood disorders, 1600
Substantia nigra, gait control by, 124
Substituted judgment, 1638–1639
Subtelomeric chromosomal deletion, 1411
Subungual fibromas, 1460
Succimer, 1332
Succinic semialdehyde dehydrogenase deficiency, 1390
Suction thrombectomy devices, 313
Sudanophilic leukodystrophies, 1399
Sudden hearing loss, 49–50
Sudden unexpected death in epilepsy (SUDEP), 594
Sudeck atrophy. *See* Complex regional pain syndrome (CRPS)
Sudomotor axon reflex test, 551*t*, 560
Sudomotor function, testing of, 255, 256*t*, 257–258
Suicide
bipolar disorder and, 1604
depression and, 1596, 1599, 1601, 1602, 1604
epilepsy and, 593
Huntington disease and, 866
physician-assisted, 1641
schizophrenia and, 1589
Tourette syndrome and, 787
Sulfadiazine, for toxoplasmosis, 167, 704, 1237
Sulfadoxine, for toxoplasmosis, 704
Sulfur amino acids, disorders of, 1388, 1389*t*
Sulpiride, for tic disorders, 789
Sumatriptan
for cluster headache, 74, 531
for migraine, 525–527, 526*t*
for migraine in pregnancy, 1293
SUNA headaches, 74, 531*t*, 532–533, 543
SUNCT headaches, 74, 531*t*, 532–533, 543
Sunderland nerve injury classification, 452, 452*t*
Sunitinib, for meningiomas, 1054, 1054*t*
Superficial border zone infarction, 306
Superficial fibular nerve, 931
Superior gluteal nerve
anatomy of, 931
injury of, 461
Superior sagittal sinus thrombosis, 355*t*
Super-refractory ICP, 1133
Superrefractory status epilepticus, 62
Suppression-burst pattern, in EEG, 233, 235*f*
Supranuclear palsy, 894. *See also* Progressive supranuclear palsy
Supraorbital nerve stimulation
for migraine, 527*t*, 528
for migraine prevention, 530
Suprascapular nerve
anatomy of, 927, 928*f*, 928*t*, 932
injury of, 458–459, 932
transfer of spinal accessory nerve to, 467
Supratentorial AVMs, 361
Supratentorial ependymoma, 1538, 1539*f*
Supratentorial herniation syndromes, 172–174
Supratentorial lesions, and brain death, 179, 179*f*
Supratentorial PNETs, 1534
Supratentorial tumors, pediatric, 1540, 1541*f*, 1554–1558
Sural nerve
biopsy of, 286
injury of, surgery for, 466*f*, 467*f*
Sural nerve graft, 467
Suramin, neuropathy induced by, 949
Surgical history, 19
Surgical Trial in Intracerebral Hemorrhage, 140
Survival motor neuron (*SMN*) gene, 1467, 1468*f*, 1470–1472, 1470*f*
Susac syndrome, 394–396, 715, 722
clinical features of, 394
diagnosis of, 394–395
epidemiology of, 394
level 1 evidence on, 400

management of, 395
MRI in, 394–395, 395*f*
outcome of, 395–396
pathobiology of, 394
Susceptibility artifacts, 196, 196*f*
Susceptibility-weighted imaging (SWI), 192–194, 193*t*
Sustained handgrip test, 257
Suvorexant, 1186, 1187*t*
Suzuki severity scale, for moyamoya disease, 391, 392*t*
SV2A. *See* Synaptic vesicle glycoprotein 2A
Swallowing, 1262–1263
in ALS, 908, 913, 1262–1263
assessment of, 1209
in congenital bilateral perisylvian syndrome, 1376
in Guillain-Barré syndrome, 939
in Huntington disease, 865, 867
in myasthenia gravis, 966*t*, 1263
in Parkinson disease, 878, 879*t*, 891, 1262–1263, 1267
in prion diseases, 519*t*
rehabilitative therapy for, 1632, 1633
screening protocols for, 1263
in stroke patients, 316–316, 1263
Swallow water blackouts, 1350, 1351
Sweat imprint techniques, 257–258
Sweating
in autonomic testing, 255, 257–258
in complex regional pain syndrome, 551*t*
disorders of, 1174
SWEDDs. *See* Symptomatic without evidence of dopaminergic deficits
SWI. *See* Susceptibility-weighted imaging
Swine slaughterhouse workers, neuropathy in, 942–943
Swinging flashlight test, 33–34, 33*f*
Swing phase, of gait cycle, 122–123, 122*f*
SWR. *See* Stroop Word Reading (SWR) test
Sydenham disease (SD), 106, 108, 109*t*, 854–855
Symbol Digit Modalities Test, 866
Sympathalgia. *See* Complex regional pain syndrome (CRPS)
Sympathectomy, for complex regional pain syndrome, 553–554
Sympathetic blocks
for complex regional pain syndrome, 552*t*, 553–554
in complex regional pain syndrome, 551*t*
Sympathetic function, testing of, 255–256
Sympathetic skin response, 258
Sympathetic storming, paroxysmal, 1195, 1198–1200, 1199*f*, 1199*t*, 1200*t*
Sympathomimetic toxicity, 1324–1326, 1593
Symptomatic without evidence of dopaminergic deficits (SWEDDs), 871
Symptoms. *See also specific disorders*
history of, 17–18
neurologic, in nonneurologic disease, 19
neurologic review of, 19
related, 18
severity of, 17–18
Synapse(s)
disorders (malformations) of, 1380–1381
formation of, 1381
plasticity of, 1381
sprouting *versus* unmasking, 559–560
Synaptic basal lamina-associated myasthenic syndromes, 974
Synaptic density imaging, 206
Synaptic loss, in Alzheimer disease, 479
Synaptic vesicle glycoprotein 2A (SV2A), 206
Synchronized intermittent mandatory ventilation (SIMV), 1211*t*
Syncope, 51–56
cardiac, 51, 52–53, 52*f*, 52*t*, 55, 55*t*
causes of, 51–53, 52*t*
clinical features of, 54
definition of, 51
diagnosis of, 53–55
diagnostic tests in, 55
epidemiology of, 51
focused physical examination in, 54–55
management of, 55
neurally mediated, 51–52, 52*t*
outcomes of, 55
pathobiology of, 51–53
pathophysiologic classification of, 52*f*
red flags in, 55, 55*t*
seizure *versus*, 53–54, 53*t*
spells mistaken for, 54
vasovagal, 51, 52*t*
Syndrome of inappropriate ADH secretion (SIADH), 1217, 1255–1258, 1257*t*
Synkinesis, 456
α-Synuclein
in Lewy body dementias, 494
in multiple system atrophy, 895, 895*f*
in Parkinson disease, 873–876
Synucleinopathy, 97, 873. *See also* Multiple system atrophy (MSA)
Syphilis
brain infection, 153, 161*t*
chronic meningitis in, 641*t*–643*t*, 648–649
clinical presentation of, 641*t*, 648
CSF analysis and serum diagnostics in, 642*t*, 649
diagnosis of, 649
epidemiology and pathobiology of, 648
historical perspective on, 648
HIV-associated, 705
imaging in, 641*t*
multiple sclerosis *versus*, 721
psychosis with, 1594
treatment of, 643*t*, 649
Syphilitic vasculitis, 381
Syringobulbia, 1159
Syringomyelia, 149*t*, 1159–1162
MRI of, 1159, 1162*f*
spontaneous, spinal tumor *versus*, 1096
Syrinxes, 443
Systemic lupus erythematosus (SLE)
chorea in, 855–856
CNS vasculitis in, 380
neuropathy in, 938*t*
nonbacterial thrombotic endocarditis in, 397–398

T

T1 and T2 processes, in MRI, 189–190
T1-rho, 191
T1-weighted imaging, 191, 192*f*, 193*f*, 193*t*
T2-rho, 191
T2 shine through, 192
T2-weighted imaging, 191, 192*f*, 193*f*, 193*t*
Tachyphemia, 878
Tacrolimus
for autoimmune encephalitis and meningitis, 770*t*
for dermatomyositis, 981
for GVHD prevention, 1235
for myasthenia gravis, 970*t*
for transplant patients, toxicity of, 1299–1300, 1300*f*
TACs. *See* Trigeminal autonomic cephalalgias
Tadalafil, for complex regional pain syndrome, 552*t*
Taenia solium, 654*t*, 656, 657*f*
Tafamidis, for amyloid neuropathy, 943
Takayasu vasculitis, 371*t*, 375
Tamoxifen
for meningiomas, 1054*t*
for X-linked myotubular myopathy, 1496
Tandem walk, in gait assessment, 127
Tangle dominant dementia, 97
Tapentadol, for neuropathic pain, 562*t*
Tapeworms, 653, 654*t*
Tardive akathisia, 849–852, 849*t*, 852*f*, 853*t*, 1590, 1591*t*
Tardive dyskinesia, 107, 801, 849–853, 1590
chorea with, 858
classic, 850–851
diagnosis of, 850–851
epidemiology of, 849–850
level 1 evidence on, 853
management of, 852, 852*f*, 853*t*
outcome of, 852
pathobiology of, 850
Tardive dystonia, 802*t*, 804, 809, 849–852, 849*t*, 852*f*, 853*t*, 1590
Tardive myoclonus, 849*t*, 851
Tardive pain, 849*t*, 851
Tardive tics, 849*t*, 851
Tardive tremors, 849*t*, 851, 1590
TAR DNA-binding protein 43 (TDP-43), 97, 417, 479, 486–487, 487*f*, 489, 905–906, 908*f*
Tarsal tunnel syndrome, 462, 934
Tarui disease, 1015, 1016
Taser devices, 1347–1348
Task-specific dystonia, 106, 800, 802*t*, 808, 808*f*, 809, 809*t*
Taste
COVID-19 and, 673
glossopharyngeal nerve and, 923
testing of, 262
Tau imaging, 204*t*, 206, 207*f*
Tauopathies, 97, 486
Tau protein
in Alzheimer disease, 97, 479–480, 482
in chronic traumatic encephalopathy, 417
in frontotemporal dementia, 486–487, 487*f*, 489
in mild cognitive impairment, 472–473
Taxoids, neuropathy induced by, 949
Tay-Sachs disease, 1394
TBI. *See* Traumatic brain injury
T cells
autoimmune disorders and, 756–757, 756*f*
HIV and, 692, 1580, 1580*t*
multiple sclerosis and, 711–712
myasthenia gravis and, 965
neuromyelitis optica spectrum disorders and, 747

Technetium 99m (^{99m}Tc), 203
Technetium 99m ethyl cysteinate dimer (^{99m}Tc-ECD), 204*t*
Technetium 99m-hexamethyl-propylene amine oxide (^{99m}Tc- HMPAO), 204*t*, 205–206, 483
TEE. *See* Transesophageal echocardiography, in marantic endocarditis
Telangiectasias, 368
  in ataxia-telangiectasia, 844*t*, 845, 1414*t*, 1531
  in Rendu-Osler-Weber syndrome, 368
  SAH with, 351
  in sinus pericranii, 368
  in Sturge-Weber disease, 368
Telemedicine, 13
  asynchronous approaches in, 13
  synchronous approaches in, 13
Telencephalon
  disorders (malformations) of, 1369, 1370*f*
  formation of, 1366, 1368, 1369
Telethonin defects, 1490
Telomeres, 1411
Temazepam
  for insomnia, 1187*t*
  for parasomnias, 1193
Temozolomide
  for diffuse astrocytomas, 1026
  for glioblastoma, 1028
  for gliomas, 1023*t*
  for meningiomas, 1053–1054, 1054*t*
  for metastatic disease, 1042
  for oligodendrogliomas, 1031
  for pediatric brain tumors, 1553, 1556
  for pilocytic astrocytomas, 1024
  for primary CNS lymphoma, 1059, 1060
  for recurrent astrocytoma, 1029
Temperature, body. *See also* Fever; Hyperthermia; Hypothermia
  in acute spinal cord syndromes, 149
  brain death and, 180
  and sleep, 268
  in stroke (AIS), 133
  in traumatic brain injury, 434
Temperature sensation, 40–41
Tempo, in neurologic history, 17
Temporal arteritis. *See* Giant cell arteritis (GCA)
Temporal lobe epilepsy, 573–574, 573*f*, 1593
Temporal lobe resection, for epilepsy, 589–590, 589*t*
Temporomandibular disorder (TMD), 541–542
  clinical manifestations and diagnosis of, 541–542
  epidemiology and pathobiology of, 541
  treatment and outcome of, 542
  trigeminal neuralgia *versus*, 918
Temporomandibular joint, 541, 542*f*
Temsirolimus, for primary CNS lymphoma, 1060
Tendon lengthening, for Charcot-Marie-Tooth disease, 960, 960*t*
Tendon transfer
  for Charcot-Marie-Tooth disease, 960, 960*t*
  for nerve injury, 466*t*, 468
Tenofovir disoproxil fumarate, 707*t*, 1583
Tensilon test, 966–967
Tension-type headache (TTH), 70, 523, 524*t*, 530
Teratomas
  pediatric, 1547
  pineal, 1072–1073, 1073*t*
Teriflunomide
  for multiple sclerosis, 723, 725*t*, 726
  for multiple sclerosis in pregnancy, 1292, 1292*t*
TES. *See* Traumatic encephalopathy syndrome
Testosterone deficiency, in HIV, 706
Tetanus, 636*t*, 638, 1004*t*, 1006–1007
Tetanus immunoglobulin, 638
Tetany, 1004*t*, 1006–1007, 1008, 1224, 1253
Tetrabenazine
  for chorea, 859, 866
  for dystonia, 814
  for Huntington disease, 866
  neurologic effects of, 850
  for tardive dyskinesia, 852, 852*f*, 853*t*
  for tic disorders, 789, 790*t*
Tetraplegia, 441
TFP deficiency. *See* Trifunctional protein deficiency
TGA. *See* Transient global amnesia
Thalamic hemorrhage, 334
Thalamic infarction, 307
Thalamic pain syndrome, 307
Thalamic stimulation, for essential tremor, 782
Thalamic surgery
  for essential tremor, 782
  for Parkinson disease, 889–890
Thalidomide, neurologic complications of, 949, 1110
Thallium poisoning, 936, 939, 948, 1333
Thanatophoric dysplasia, 1376
Thermal diffusion flowmetry, 293
Thermography, in complex regional pain syndrome, 551, 551*t*
Thermoregulatory sweat test, 257
The Jumping Frenchmen of Maine, 827
Thiamine. *See* Vitamin B_1
Thiazide diuretics
  for hyperkalemic periodic paralysis, 1001
  for hypokalemic periodic paralysis, 999–1000
  for Ménière disease, 598
  for nondystrophic myotonias, 1002
  for stroke prevention, 402, 408
Thioguanine, for pediatric brain tumors, 1551
Thiotepa
  for metastatic disease, 1046
  for primary CNS lymphoma, 1059, 1060
Third (oculomotor) nerve palsy, 82, 85–86
Third ventriculostomy, endoscopic, 1117, 1118–1119
30:15 ratio, 256
Thomsen disease. *See* Myotonia congenita (MC)
Thoracic disk disease, 1147, 1148, 1148*f*
Thoracic outlet syndrome (TOS), 929–930
  clinical features of, 930
  diagnosis and treatment of, 930
  disputed, 930
  pathology of, 930
  true, 930
Thoracic tumors, 1093*f*, 1095
Thoracodorsal nerve, 928, 928*f*, 928*t*
Thought process, 31–32, 31*f*
Three-dimensional conformal radiation therapy, 1544
Three-dimensional (3D) ultrasound, 211
Threshold effect, of mitochondrial DNA, 1443
Thrombectomy, mechanical, 224, 224*f*, 312–314, 313*t*, 1291, 1522
Thrombocythemia, essential, 1240
Thrombocytopenia, 1237–1240
  in alcoholics, 1309
  causes of, 1237, 1237*f*, 1238*f*
  definition of, 1237
  heparin-induced, 1239–1240, 1239*t*
  ICH in, 1237, 1237*f*
  thrombotic, 1237–1239
Thrombocytosis, 1240
Thrombolysis
  for acute stroke
    intra-arterial, 312
    in pregnancy, 1291
    tPA. *See* Tissue plasminogen activator
  bleeding associated with, 1242
  for cerebral venous thrombosis, 358–359
  ultrasound as adjunct therapy in, 215
Thrombophilia
  and cerebral venous thrombosis, 354
  and childhood stroke in, 1522, 1526
  familial, 1242
Thrombosis, cerebral venous. *See* Cerebral venous thrombosis
Thrombotic thrombocytopenic purpura (TTP), 1237–1239
Thunderclap headache, 71, 343, 387, 524*t*
Thymectomy, for myasthenia gravis, 972
Thyroid disease, 1219–1221. *See also* Hyperthyroidism; Hypothyroidism
  myopathies associated with, 992–993, 993*t*
Thyroid eye disease, 86
Thyroid function tests, 1219, 1220*t*
Thyroid ophthalmopathy, 993*t*
Thyroid-stimulating hormone (TSH), 1215, 1216*f*
  deficiency of, 1216–1217
  excess of, 1217
  in hypothyroidism, 1219–1220
Thyroid-stimulating hormone (TSH)-secreting adenoma, 1218
Thyroid storm, 1220, 1221
Thyrotoxic periodic paralysis, 993*t*
TIA. *See* Transient ischemic attack
Tiapride, for tic disorders, 789
Tibial muscular dystrophy, 1491
Tibial nerve, injury of, 460*t*, 462, 934
Tic(s), 106*t*, 784–792
  academic issues with, 787
  adult-onset, 784, 786
  behavioral treatment for, 788–789
  chronic, 784
  clinical manifestations of, 786, 786*t*
  coexisting conditions with, 784, 787
  definition of, 106
  diagnosis of, 786–787, 786*t*
  dystonia *versus*, 800, 802*t*
  dystonic, 801, 802*t*
  epidemiology of, 784
  genetics of, 785
  immune/autoimmune factors in, 785–786
  level 1 evidence on, 792
  management of, 787–791
  motor circuits in, 784–785
  neurobiology of, 784–785
  neuromodulation for, 791
  neurotransmitters in, 785
  outcome of, 791–792

pathobiology of, 784–786
pharmacotherapy for, 789–791, 790*t*–791*t*
rating scales for, 787
spectrum of severity, 106
tardive, 849*t*, 851
Tourette. *See* Tourette syndrome
treatment plan for, 787–788, 788*f*
Ticagrelor, 138, 1240
Tic douloureux, 543
Tic Impairment Score, 787
Tickborne diseases. *See also specific diseases*
Lyme disease (borreliosis), 649–650
Powassan virus, 665, 669–670
rickettsial, 624–628, 624*t*
Tickborne encephalitis virus, 666–668, 667*t*
Tick paralysis
Guillain-Barré syndrome *versus*, 940
polyneuropathy in, 936
Tic-related OCD, 1609, 1610
Tilt table studies, 256–257, 257*f*
Time-of-flight (TOF) method, 194–195
Time to echo, in MRI, 191
Timing, in neurologic history, 17
Timolol, for migraine prevention, 528, 529*t*
Tinel sign, 42–43, 42*f*, 68
Tinnitus, 48–49
causes of, 49*t*
definition of, 48
diagnosis of, 48–49
hearing loss and, 50
in Ménière disease, 597–600
neuroanatomy of, 48
treatment of, 49
Tip-of-the-tongue phenomenon, 879
Tipped magnetization, in MRI, 189
Tipranavir, 707*t*
TIPS. *See* Transjugular portosystemic shunt (TIPS) procedure
Tirasemtiv, for myasthenia gravis, 972
Tissue elastography, 211
Tissue plasminogen activator (tPA)
bleeding associated with, 1242
for cerebral venous thrombosis, 359
for ICH, 338
for spinal cord infarction, 1166
for stroke (AIS), 132, 133*f*, 140–142, 311–312
childhood, 1522
complications of, 312
contraindications to, 141–142, 141*t*, 311–312
dosage of, 142
hemorrhagic conversion with, 312, 312*t*
indications for, 140–141
post-administration blood pressure management with, 142
stroke mimics and, 142
Tizanidine
for cranial neuralgias, 544*t*
for hereditary spastic paraplegia, 1168
for neuropathic pain, 562*t*
for spasticity, 726, 727*t*
TM. *See* Transverse myelitis
TMD. *See* Temporomandibular disorder
TMS. *See* Total Motor Score; Transcranial magnetic stimulation
Tobacco use
and multiple sclerosis, 713
and Parkinson disease, 874
and stroke, 402, 408–409
Tocilizumab
for autoimmune encephalitis and meningitis, 767–770, 769*t*
for dermatomyositis, 981
for giant cell arteritis, 375
for immunotherapy complications, 1110–1111
for myasthenia gravis, 972
for neuromyelitis optica spectrum disorders, 752*t*, 753
Toddler-onset epilepsy syndromes, 1509–1510
Todd paresis, 594
TOF method. *See* Time-of-flight method
Togaviruses, 670–672
Tolcapone, for Parkinson disease, 885–886
Tolfenamic acid, for migraine, 526*t*
Tolosa-Hunt syndrome, 86
Tolvaptan, for SIADH, 1258
Tone, muscle, 116–117
Tongue weakness, 116
Tonic-clonic seizure, 1511
focal to bilateral, 570
generalized, 570
Tonic phase, 570
Tonic spasms, in multiple sclerosis, 715*t*, 716
Tonsillar herniation, 174, 174*t*, 175*f*
Top-down approach, in neurologic examination, 25–26
Topiramate, 586
adverse effects of, 584, 586
for alcoholism, 1311
for cluster headache prevention, 531*t*
for cranial neuralgias, 543, 544*t*
dosage and pharmacokinetics of, 584*t*, 586
for epilepsy, 581–585, 586
in breastfeeding patients, 1288–1289
in pregnant patients, 589, 1287–1288
teratogenicity of, 589, 1287*t*, 1288
for essential tremor, 782
for glossopharyngeal neuralgia, 924
for idiopathic intracranial hypertension, 73, 1137
for Lennox-Gastaut syndrome, 1509
for migraine prevention, 528, 529*t*
for neonatal seizures, 1361, 1361*t*
for neuropathic pain, 562*t*, 563
for nummular headache, 534
for paroxysmal hemicrania, 532
for persistent idiopathic facial pain, 547
for SUNCT/SUNA headaches, 532
teratogenic effects of, 589
for tic disorders, 789, 790*t*
for trigeminal neuralgia, 918
Top of the basilar syndromes, 307
Topotecan
for metastatic disease, 1042
for pediatric brain tumors, 1553, 1556
for primary CNS lymphoma, 1060
Torticollis, in cervical dystonia, 807, 807*f*
TOS. *See* Thoracic outlet syndrome
Total Motor Score (TMS), 866
Touch, assessment of, 40–41
Tourette syndrome, 106, 784–792
academic issues in, 787
behavioral treatment for, 788–789
clinical manifestations of, 786, 786*t*
cocaine and, 1317
coexisting conditions with, 784, 787, 1431
diagnosis of, 786–787, 786*t*
epidemiology of, 784
genetics of, 785
historical perspective on, 784
immune/autoimmune factors in, 785–786
level 1 evidence on, 792
management of, 787–791
motor circuits in, 784–785
neurobiology of, 784–785
neuromodulation for, 791
neurotransmitters in, 785
obsessive-compulsive symptoms with, 784, 787, 1609–1610, 1612
outcome of, 791–792
pathobiology of, 784–786
pharmacotherapy for, 789–791, 790*t*–791*t*
treatment plan for, 787–788, 788*f*
Toxic exposure (toxins), 636–638, 636*t*, 1319–1334. *See also specific toxins and toxicities*
anticholinergic activity in, 1322, 1327*t*
ataxia-inducing, 1320, 1322*t*
and chorea, 855*t*
clinical features of, 1320, 1321*t*–1322*t*, 1327*t*
common neurotoxidromes in, 1322–1333
diagnosis of, 1320
and dystonia, 809
epidemiology of, 1319
movement disorder-inducing, 1320, 1321*t*
neuropathies associated with, 1320, 1323*t*–1325*t*
and neuropathy, 936, 938*t*, 947–948
and Parkinson disease, 874–875
and Parkinson-plus syndromes, 899–900
pathobiology of, 1320, 1320*t*
and pediatric brain tumors, 1531
seizure-inducing, 1320, 1321*t*
smells and odors suggestive of, 1320, 1325*t*
testing for, 276
treatment for, 1320–1322, 1326*t*
tremor-inducing, 1320, 1322*t*
Toxic myelopathy, 1160*t*–1161*t*, 1167–1168
Toxic myopathies, 992, 993–996, 1320, 1325*t*
diagnosis of, 995
epidemiology of, 993–994
management of, 995
outcome of, 995
pathobiology of, 994, 995*t*, 996*f*
Toxocara, 162*t*
Toxocara canis, 654*t*, 658*t*
Toxocara cati, 654*t*, 658*t*
Toxocariasis, 658*t*
Toxoplasma gondii, 654*t*, 704
Toxoplasmosis, 153, 162*t*, 163*f*, 167, 167*t*, 613, 654*t*
hematopoietic cell transplantation and, 1236–1237
HIV-associated, 698, 704, 704*f*
imaging in, 704, 704*f*
movement disorders with, 698
transplantation-related, 1299
treatment of, 704, 1237
tPA. *See* Tissue plasminogen activator
TPPA. *See Treponema pallidum* particle agglutination (TPPA) test
Tracheostomy, 1213
Trail Making Test, 274
Tramadol, for neuropathic pain, 562*t*, 563
Trametinib, 1109
Tranexamic acid, for noncoagulopathic ICH, 336

Transcranial Doppler ultrasound, 208, 212–215
in acute liver failure monitoring, 1250
in AVM detection, 213–214
in cerebral microemboli detection, 214
in cerebral vasomotor reactivity testing, 214–215
in childhood stroke, 1520–1521
indications for, 212, 213*t*
in intracranial stenosis and occlusion, 213, 214*f*
limitations of, 215
in moyamoya disease, 392
pulsatility index in, 212, 212*f*
resistance index in, 212, 212*f*
in SAH, 349
sensitivity and specificity of, 213
in sickle cell disease, 213, 1229–1230
in sonothrombolysis, 215
in vasospasm detection in subarachnoid hemorrhage, 214, 349
Transcranial magnetic stimulation (TMS), 252–253
for complex regional pain syndrome, 554
for depression, 1596, 1602–1603
electrical stimulation *versus*, 252
in motor neuron disease/ALS, 911
for obsessive-compulsive disorder, 1612
paired-pulse, 252
for posttraumatic stress disorder, 1612
repetitive, 252, 253
signal intensity in, 252
silent period in, 253
single-pulse, 252, 253*f*, 527*t*, 528
for tic disorders, 791
Transcription, 1412, 1413*t*–1414*t*
Transcriptional factors, 1368–1369
Transcutaneous electrical nerve stimulation, for complex regional pain syndrome, 554
Transduction, in nociceptive pain, 558
Transesophageal echocardiography (TEE), in marantic endocarditis, 398
Transient circadian rhythm disorders, 1192
Transient global amnesia (TGA), 97–98, 602–603
MRI of, 603, 603*f*
treatment of, 603
Transient ischemic attack (TIA), 320–323
ABCD score in, 322, 322*t*
central retinal artery involvement in, 320
crescendo, 322–323
definition of, 320
diagnosis of, 320–321
diagnostic tests for, 321, 322*t*
embolic, 320
epidemiology of, 320
giant cell arteritis and, 374–375
imaging in, 321, 322, 322*t*
lacunar or small-artery, 320, 321
level 1 evidence on, 323
limb-shaking, 321
low-flow, 321
management of, 321–322
outcome of, 322–323
pathobiology of, 320
posterior circulation, 320,
secondary stroke prevention in, 321–322, 403, 405
sickle cell disease and, 1228
signs and symptoms of, 321
vertebrobasilar, 54
visual symptoms in, 83, 83*t*
Transient monocular blindness, 303–304
Transient visual obscurations, 83
Transient visual symptoms, 83–84, 83*t*
Transjugular portosystemic shunt (TIPS) procedure, 1246
Translation, 1412
mitochondrial, defects in, 1444–1445, 1449
Transmissible spongiform encephalopathies (TSEs), 506. *See also* Prion diseases
Transplantation. *See* Hematopoietic cell transplantation (HCT); Organ transplantation
Transtentorial herniation, 172–174, 174*t*, 175*f*, 1143
Transverse myelitis (TM), 66, 69, 145, 736–743
in anti-MOG syndromes, 732, 738, 740–741, 742*t*, 743
biomarkers of, 740–741
clinical presentation of, 738
complete, 738
CSF analysis in, 740
diagnosis of, 738
diagnostic and treatment algorithm for, 739*f*
differential diagnosis of, 736, 737*t*, 741*f*, 742*t*
disease-associated, 736–737, 736*t*
epidemiology of, 738
etiologies of, 736–737, 736*t*
idiopathic, 736–737, 736*t*
level 1 evidence on, 743
longitudinally extensive, 199, 748
management of, 742–743
MRI of, 199, 738, 740*f*, 742*t*
in multiple sclerosis, 716, 738, 743
in neuromyelitis optica spectrum disorders, 729, 738, 740, 743, 744, 748
outcome of, 743
partial, 738
pathobiology of, 738
Transverse sinus thrombosis, 355*t*, 614*f*, 615
Tranylcypromine, for depression, 1602
Trastuzumab
for metastatic breast cancer, 1043
neurologic complications of, 1109
Traumatic brain injury (TBI), 420–440
acute complications of, 434–435
airway and ventilation in, 433
analgosedation in, 434
anemia in, 1227–1228
antibiotic prophylaxis in, 434
anticoagulation in, 434, 435
arterial dissection and vascular injury in, 435
axonal-shearing, 421, 422*f*, 423*f*
blood pressure management in, 433
brain death in, 435
brain edema in, 423, 1130
brain oxygenation in, 292
brain swelling and cerebral edema in, 423
cardiopulmonary resuscitation in, 427
cerebral microdialysis in, 294
cognitive impairment in, 436–437
continuous EEG monitoring in, 294–295
contusions in, 423–424, 424*f*
cranial nerve injury in, 435
deep vein thrombosis prophylaxis in, 434
diffuse axonal, 421, 421*t*
epidemiology of, 420
fluid management in, 427, 433
gastric stress ulcer prophylaxis in, 434
Glasgow Coma Scale in, 427*t*, 428, 428*t*
hematoma in, 424–426, 424*f*. *See also specific hematomas*
high-risk group with, 430
history in, 428
hospital admission for, 429–430, 430*t*
infection in, 435
initial assessment and stabilization in, 427–429
initial neurologic assessment and stabilization in, 427–428
insulin therapy for, 434
intracerebral hemorrhage in, 423–424, 424*f*
intracranial pressure in, 288, 291, 291*t*, 430–432
level 1 evidence on, 438
low-risk group with, 429
management of, 429–434
ICU, 433–434, 433*f*
mild, 413–416, 421. *See also* Concussion
missile-related blast, 438
moderate-risk group with, 429–430
movement disorders after, 437–438
New Orleans/Charity Head Trauma/Injury Rule in, 429, 429*t*
nutrition in, 433–434
outcomes of, 435–438, 436*f*
pathobiology of, 420–426
pediatric, 438, 1572–1578
best evidence management of, 1575, 1577*t*
cognitive rest for, 1574–1575
CT indications in, 1575, 1576*f*
CT of, 1572, 1573*f*
decompressive craniectomy in, 1577
diagnosis and management of, 1574–1577
educational plan in, 1577
epidemiology of, 1572
hypothermia following, 1575
ICP management in, 1575, 1577*t*
intentionality in, 1572
level 1 evidence on, 1578
minor, 1574–1575
nonaccidental, evaluation of, 1574, 1574*t*
outcome of, 1577–1578
pathobiology of, 1572–1574, 1573*f*
primary, 1572–1573
repeat imaging in, 1576
secondary, 1573–1574, 1574*t*, 1577*t*
seizure prophylaxis in, 1575
severe, 1575–1577
plasticity and recovery in, 1630–1631
postconcussion syndrome in, 437
posttraumatic stress disorder with, 1609
prognosis (estimated mortality) in, 428, 428*t*
radiography and imaging in, 428–429, 429*t*
risk stratification in, 427, 427*t*
secondary neurologic evaluation in, 429
seizures and epilepsy after, 434, 437, 578
serial neurologic evaluation in, 433
SIBICC protocol for, 430, 431*f*
skull fractures and, 420–421, 430
steroids for, 434
subarachnoid hemorrhage in, 426
surgical intervention for, 430
temperature management in, 434
vascular injury in, 421, 422*f*
Traumatic encephalopathy, chronic. *See* Chronic traumatic encephalopathy (CTE)

Traumatic encephalopathy syndrome (TES), 417–418
behavioral/mood variant of, 417
cognitive variant of, 417
diagnostic criteria for, 418*t*
management of, 418
outcome of, 418
Traumatic microbleeds, 421, 422*f*, 423*f*
Traumatic spinal cord injury. *See* Spinal cord injury
Travel history, 22
Treatment and Education of Autistic and Related Communication-Handicapped Children, 1439
Trematodes, 653, 654*t*, 658–659
Tremors, 106–107, 106*t*. *See also specific types and causes*
action, 107, 107*f*
anxiety with, 1610
computerized analysis of, 781
definition of, 106
dystonia *versus*, 781, 782*t*, 800, 802*t*
dystonic, 106, 800, 802*t*
essential, 778–783
flow diagram for evaluating, 104*f*
focused examination of, 104
focused history on, 103–104, 103*t*
HIV-associated, 698
motor examination for, 36–37
multiple sclerosis and, 716, 726–727, 727*t*
with muscle weakness, 116
neuroanatomy of, 108
in Parkinson disease, 877, 879*t*, 881
posttraumatic, 437–438
postural, 107, 107*f*, 781
pregnancy and, 1294–1295
in progressive supranuclear palsy, 894
reemergent, 781
resting, 107, 107*f*, 877, 881, 894
tardive, 849*t*, 851, 1590
transplantation-related, 1298*t*
types of, 107, 107*f*
xenobiotic-induced, 1320, 1322*t*
Tremulousness, in alcohol withdrawal, 1305
Treponema pallidum, 648–649, 705. *See also* Syphilis
Treponema pallidum particle agglutination (TPPA) test, 649
TRESK potassium channel, 559
Trevo intrathrombus "stentriever" device, 313
Trial of intervention, 1639
Trial of Organon in Acute Stroke Treatment (TOAST), 303, 303*f*
Triamterene
for hypokalemic periodic paralysis, 1000
for Ménière disease, 598
Triazolam, for insomnia, 1187*t*
Triceps reflex, 38, 39*t*
Trichinella, 162*t*
Trichinella spiralis, 654*t*
Trichinosis, 654*t*
Trichothiodystrophy, 1413*t*
Tricyclic antidepressants. *See also specific agents*
for ADHD, 1431–1432
for anxiety disorders, 1610, 1611
for burning mouth syndrome, 547
for cataplexy, 1189
for depression, 1602
for herpes zoster neuropathy, 946
for insomnia, 1187*t*
for migraine prevention, 528, 529*t*
for neuropathic pain, 562
for new daily persistent headache, 534
for nummular headache, 534
for obsessive-compulsive disorder, 1612
for Parkinson-plus syndromes, 899
for somatic symptom disorder, 1617
for temporomandibular disorder, 542
Trifunctional protein deficiency, 1012, 1015
Trigeminal autonomic cephalalgias (TACs), 521, 523, 524*t*, 530–533, 531*t*
Trigeminal nerve (CN V)
anatomy of, 917
examination of, 34–35, 34*f*
injury (neuropathy) of, 454*t*, 455–456, 917–918
pain. *See* Trigeminal neuralgia
Trigeminal neuralgia, 539*t*, 542–545, 917–918
clinical manifestations and diagnosis of, 542–543
denervating/destructive procedures for, 543–545, 544*f*
diagnosis of, 917–918
diagnostic criteria for, 542
differential diagnosis of, 918
epidemiology and pathobiology of, 542, 917
medications for, 543, 544*t*, 918
in multiple sclerosis, 716, 727*t*
nerve blocks for, 545, 545*f*
nerve-sparing procedures for, 543
treatment and outcome of, 543–545, 918
triggers for, 543
trigger zone in, 918
Trigeminovascular system, 521, 522*f*
Triggers
for craniofacial pain, 74–75
for headaches, 70
Trihexosylceramide, 1395
Trihexyphenidyl
for dystonia, 814, 852, 853*t*, 1427
for Parkinson disease, 886–887
Trilateral retinoblastoma, 1557
Triorthocresyl phosphate, 948
Triple-H therapy, for vasospasm in SAH, 349–350
Triplex ultrasound, 208–209
Triptans
for cluster headache, 74, 531
for migraine, 524, 525–527, 526*t*
for migraine in pregnancy, 1293
for primary exertional headache, 533
Trisomy 21 (Down syndrome), 477, 1381, 1410, 1410*t*, 1419
Trochlear nerve (CN IV), 77, 78*f*
examination of, 34, 34*f*
injury of, 454*t*, 455
palsy or dysfunction of, 86
Trojan horse, virus entry via, 661
Trometanol, for ICP management, 1132
Tropheryma whipplei, 634–635
Tropical spastic paraparesis, 1007, 1164
Trousseau sign, 1008, 1224, 1253
Truncal dystonias, 809
Trypanosoma brucei, 654*t*, 655, 705
Trypanosoma cruzi, 654*t*, 655, 705
Trypanosomiasis
African, 654*t*, 655, 705
American, 654*t*, 655, 655*f*, 705, 1263, 1264
HIV-associated, 705
TSC. *See* Tuberous sclerosis complex
TSEs (transmissible spongiform encephalopathies), 506. *See also* Prion diseases
TSH. *See* Thyroid-stimulating hormone
TTH. *See* Tension-type headache
TTN-related skeletal myopathy, 1499
TTP. *See* Thrombotic thrombocytopenic purpura
Tuberculomas, 153, 161*t*, 164
Tuberculosis, 647–648
brain abscess in, 153, 161*t*, 164, 617
chronic meningitis in, 641*t*–643*t*, 647–648
clinical presentation of, 641*t*, 647
CNS vasculitis in, 381
CSF analysis and serum diagnostics in, 642*t*, 647–648
diagnosis of, 647–648
epidemiology and pathobiology of, 647
extremely drug-resistant, 648
HIV-associated, 705–706
imaging in, 641*t*, 647, 647*f*
multidrug-resistant, 648
treatment of, 643*t*, 648
Tuberous sclerosis complex (TSC), 1456, 1459–1462
brain tumor risk with, 1530–1531
course and prognosis of, 1462
cutaneous findings in, 1460–1461
diagnosis of, 1461–1462
diagnostic criteria for, 1462, 1462*t*
epidemiology of, 1459
genetics of, 1460
hamartomas in, 1460–1461, 1530–1531
historical perspective on, 1459
laboratory data in, 1461
management of, 1462
MRI in, 1461, 1461*f*
neurologic findings in, 1461
ophthalmic findings in, 1461
pathology and pathogenesis of, 1460, 1460*f*
seizures/epilepsy with, 1461, 1462, 1513
signs and symptoms of, 1460–1461
visceral and skeletal findings in, 1461
Tufted astrocyte, 893, 894*f*
Tumarkin crises, 46
Tumefactive multiple sclerosis, 154, 165*f*, 165*t*
Tumor(s). *See also specific anatomic locations and tumor types*
metastatic, 1019, 1034–1049
radiation-induced, 1050, 1336, 1338*t*
vascular, 368
Tumor necrosis factor α inhibitors, for Behçet syndrome, 379
Tumor-treating fields, for glioblastoma, 1028–1029
Turcot syndrome, 1531
Turner syndrome, 1410
Turns, in gait assessment, 127
20/20 vision, 259
Twist-drill, for traumatic brain injury, 430
Two-hit hypothesis, in dystonia, 804
Two-point discrimination, cerebral infarction and, 305
Typhus, scrub, 624, 625*t*, 628–629
Typhus group rickettsial infections, 624, 625*t*, 629

U
Ubrogepant, for migraine, 526t, 528
UFH. *See* Unfractionated heparin
UHDRS. *See* Unified Huntington's Disease Rating Scale
Uhthoff phenomenon, 715t, 716
Ulcer(s)
prophylaxis, for TBI patients, 434
stress gastric, 1264
Ulcerative colitis, 1267
Ulnar nerve, 928, 933
anatomy of, 933
injury of, 459, 933
muscles innervated by, 933, 933t
transfer to biceps, 467
Ultrasound
in brain death, 181t
in complex regional pain syndrome, 551t
in congenital myopathies, 1477
contrast-enhanced, 211
extracranial, 208–212
carotid, 208–212, 209–211f, 209t
imaging modalities of, 208–209, 208t
indications for, 211–212
multiparametric, 211
vertebral artery, 208, 211
intracranial (transcranial Doppler), 208, 212–215
in acute liver failure monitoring, 1250
in AVM detection, 213–214
in cerebral microemboli detection, 214
in cerebral vasomotor reactivity testing, 214–215
in childhood stroke, 1520–1521
indications for, 212, 213t
in intracranial stenosis and occlusion, 213, 214f
limitations of, 215
in moyamoya disease, 392
pulsatility index in, 212, 212f
resistance index in, 212, 212f
sensitivity and specificity of, 213
in sickle cell disease, 213, 1229–1230
in sonothrombolysis, 215
in vasospasm detection in subarachnoid hemorrhage, 214, 349
intravascular low-intensity, 215
of intraventricular hemorrhage, neonatal, 1356–1357, 1356f
level 1 evidence on, 215
in lumbar puncture, 277–278, 278f
in muscular dystrophy, 1477
of nerve, 250
neurovascular, 208–216
in perinatal stroke, 1516
in periventricular leukomalacia, 1363
in SAH, 349
in stroke, 310
three-dimensional (3D), 211
Uncal herniation, 172, 174t
Underwater activity, and decompression illness, 1350–1354
Undifferentiated somatoform disorder, 1615t, 1616
Unfractionated heparin (UFH)
bleeding associated with, 1242
for cerebral venous thrombosis, 358, 1523
for childhood stroke, 1522
osteoporosis and fractures with, 1274–1275
for perinatal stroke, 1517
reversal of, 139t, 336
for stroke in pregnant patients, 1291
Unified Huntington's Disease Rating Scale (UHDRS), 865, 866
Unified Parkinson Disease Rating Scale (UPDRS), 875f, 879
United Nations Children's Fund, 7
Universal heteroplasmy, 1442–1443
University of Pennsylvania Smell Identification Test, 262
Unknown epilepsy, 571, 572f
Unknown-onset seizures, 571, 571f
Unresponsive wakefulness syndrome (UWS), 168, 175–177, 177t, 436
Unspecified tic disorder, 786, 786t
UPDRS. *See* Unified Parkinson Disease Rating Scale
Upper abdominal reflexes, 39t
Upper extremity nerve injuries, 457–460
Upper motor neuron dysfunction. *See also* Amyotrophic lateral sclerosis (ALS)
disorders in, 904
single-pulse TMS in, 252
Upper motor neuron weakness, 111–112
Upper radicular syndrome, 929
Upward herniation, 174, 174t
Urea cycle disorders, 1385, 1386–1387, 1386t, 1419
Uremic encephalopathy, 1253
Uremic neuropathy, 944
Urinary bladder. *See* Bladder dysfunction
Urinary manifestations, of neurologic disease, 1264–1265, 1265f
Urinary tract infection
spinal cord injury and, 449
stroke and, 317
Utilization behavior, 306, 888
Uveitis, in Behçet syndrome, 378–379
UWS. *See* Unresponsive wakefulness syndrome

V
Vaccination
for HIV, development of, 708
in HIV patients, 701, 702, 706
for meningitis, 604
for MMR (measles-mumps-rubella), 671
in multiple sclerosis, 728
in myasthenia gravis, 973
for polio, 663, 664
for rabies, 677
for varicella-zoster, 682, 702, 946
Vacuolation
in Lewy body dementias, 492
in sporadic Creutzfeldt-Jakob disease, 508, 509f
Vagal neuralgia, 539t
Vagus nerve (CN X)
anatomy of, 924
examination of, 36
injury (neuropathy) of, 454t, 456, 924
stimulation of, 75, 527t, 528, 531, 531t, 532, 591–592
Valacyclovir, for herpesvirus prophylaxis, 679t
Valbenazine
for dystonia, 814
for tardive dyskinesia, 852, 852f, 853t
for tic disorders, 789
Valganciclovir, for CMV infection, 683, 702
Valley fever, 644. *See also* Coccidioidomycosis
Valproate/valproic acid, 586
adverse effects of, 583, 584t, 586, 1248
for bipolar disorder, 1603
for chorea, 855
for cranial neuralgias, 543, 544t
dosage and pharmacokinetics of, 584t, 586
for epilepsy, 581–585, 586
in breastfeeding patients, 1288–1289
cognitive effects on exposed infants, 1288
in pregnant patients, 589, 1287–1288
teratogenicity of, 589, 1287–1288, 1287t
hyperammonemia associated with, 1387
for Kleine-Levin syndrome, 1189
for migraine, 74
for migraine prevention, 528, 529t
for myoclonus, 829, 829t
for neuropathic pain, 563
for nummular headache, 534
for pediatric brain tumors, 1554
for seizures, 61
for traumatic brain injury, 434
Valsalva maneuver
autonomic testing with, 255–256
heart rate response to, 255
Valsalva ratio, 255–256
Vancomycin
for bacterial meningitis, 607, 607t, 609t
for brain abscess, 617, 617t
for spinal epidural abscess, 620
Vanilloid receptor 1 (TRPV1), 559
Vanishing white matter (VWM) disease, 1399, 1401–1402, 1414t
VAP. *See* Ventilator-associated pneumonia
Vaping (e-cigarettes), 402
Varenicline, for ataxia, 847
Variable-vessel vasculitis, 371t, 378–380. *See also specific types*
Variant Creutzfeldt-Jakob disease (vCJD), 507, 507t, 511t, 516–517, 518f
Variants of unknown significance (VUS), in genetic testing, 300
Varicella-zoster vaccines, 682, 702, 946
Varicella-zoster virus (VZV), 681–682
CNS vasculitis in, 381
entry mechanism of, 661
hematopoietic cell transplantation and, 1236
HIV-associated, 702
myelitis with, 1163–1164
myelopathy with, 681, 682f
neuropathy with, 938t, 946
stroke with, 682
treatment for, 662, 679t
Vascular cognitive impairment, 500
Vascular dementia, 97, 97t, 500–505
cortical syndrome in, 503
diagnosis of, 500, 503–504
differential diagnosis of, 503
epidemiology of, 500–501
gait disorder in, 129t
level 1 evidence of, 504
Lewy body dementias *versus*, 497
management of, 504, 504t
MRI of, 502f
neuropsychological testing in, 503–504
outcome of, 504
pathobiology of, 500, 501–503, 501f, 502f, 502t, 503f

subcortical syndrome in, 503
types of, 502*t*, 503*f*
Vascular malformations, 361–369. *See also specific malformations*
level 1 evidence on, 369
MRA of, 195
SAH with, 351
Vascular myelopathy, 1160*t*, 1165–1166
Vascular nidus, 361
Vascular parkinsonism, 902
Vascular tumors, 368
Vasculitic neuropathy, 938*t*, 941–942, 942*f*
Vasculitis, CNS, 370–383. *See also specific types*
associated with probable etiology, 371*t*
associated with systemic disease, 371*t*, 379–380
associated with systemic vasculitis, 374–380
classification of, 370, 371*t*, 372*f*
drug-induced, 376, 381
histopathology of, 370
infectious, 381
laboratory testing in, 371, 373*t*
miscellaneous causes and mimics of, 380–382
pediatric, 1519
therapeutic challenge of, 370
Vasculopathy, radiation-induced, 1336, 1338*t*, 1339–1341, 1342–1343
Vasodilators, for rescue therapy in SAH, 350
Vasogenic edema, 443, 1128, 1128*t*, 1133–1134
Vasopressin. *See* Antidiuretic hormone (ADH)
Vasospasm
in electrical/lightning injuries, 1348
MR perfusion imaging of, 201
in subarachnoid hemorrhage, 214, 223, 345–346, 345*f*, 346*t*
"silent" infarction with, 350
treatment of, 349–350, 349*t*
Vasovagal syncope, 51
Vatalanib, for meningiomas, 1054*t*
VDRL test. *See* Venereal Disease Research Laboratory (VDRL) test
VEE. *See* Venezuelan equine encephalitis
Vegetative state (VS), 168, 175–177, 177*t*, 436
Vein of Galen malformations, 363
Veliparib, for pediatric brain tumors, 1553
Velocardiofacial syndrome, 1410*t*, 1419
Velocity coding, 194–195, 195*f*
VEMPs. *See* Vestibular-evoked myogenic potentials
Vemurafenib
for metastatic melanoma, 1043
for pediatric astrocytoma, 1552
Venereal Disease Research Laboratory (VDRL) test, 649, 705
Venezuelan equine encephalitis (VEE), 670–671
Venlafaxine
for anxiety disorders, 1611*t*, 1612
for depression, 1602
for migraine prevention, 529*t*
for neuropathic pain, 561, 562*t*
for persistent idiopathic facial pain, 547
Venous infarction, brain edema with, 1130
Venous malformations, 351, 367
Venous thromboembolism, stroke and, 317
Ventilation-perfusion (V/Q) mismatching, 1207
Ventilator-associated pneumonia (VAP), 1211–1212
Ventilatory support. *See* Respiratory support
Ventral induction, 1369
Ventral induction disorders, 1369
Ventriculoperitoneal shunt (VPS), 1357
for normal-pressure hydrocephalus, 1122–1123
Ventriculostomy, endoscopic third, 1117, 1118–1119
Ventriculosubgaleal shunt, 1357
Verapamil
for cluster headache prevention, 531*t*, 532
for cramps, 1009
for hypnic headache, 534
for reversible cerebral vasoconstriction syndrome, 388–389
for SAH patients, 350
Verbal fluency, 274
Verbal memory, 30, 274*t*
Vertebral artery angiography, 219, 221*f*
Vertebral artery compression, 46
Vertebral artery dissection, 50, 435
Vertebral artery ultrasound, 208, 211
Vertebrobasilar territory infarction, 307
Vertebrobasilar transient ischemic attack, 54
Vertex sharp waves, in EEG, 231
Vertigo, 45–48, 45*t*, 597–601
alternobaric, 1350
causes of, 48*t*
definition of, 45
diagnosis of, 46
diagnostic testing in, 48
Dix-Hallpike maneuver in, 41–42, 41*f*
focused examination in, 46–47
focused history for, 46
hearing loss and, 50
in Ménière disease, 597–600
in multiple sclerosis, 715
neuroanatomy of, 45–46
stroke *versus*, 135*t*
treatment of, 48, 49*t*
Very long chain acyl-CoA dehydrogenase (VLCAD) deficiency, 1012, 1015, 1017
Vesicular monoamine transporter inhibitors
for chorea, 859, 866
for Huntington disease, 866
for tardive dyskinesia, 852, 852*f*, 853*t*
for tic disorders, 789, 790*t*
Vestibular-evoked myogenic potentials (VEMPs), 263
Vestibular neurectomy, for Ménière disease, 599
Vestibular neuritis, 48*t*, 597, 600–601
Vestibular rehabilitation, 48
Vestibular schwannoma. *See* Acoustic neuroma
Vestibular system, testing of, 35–36, 262–263
Vestibulocochlear nerve (CN VIII)
examination of, 35–36, 35*f*
sarcoidosis and, 774
Vibration sensation testing, 41, 41*f*
Video head impulse testing, 263
Videonystagmography, 262, 262*f*, 598
Vigabatrin
dosage and pharmacokinetics of, 584*t*
for epileptic spasms in TSC, 1462
for West syndrome, 575, 1506
Vinblastine
for pediatric brain tumors, astrocytomas, 1551
for pineal region tumors, 1076
Vincristine
adverse effects of, 1109
for diffuse astrocytomas, 1026
for gliomas, 1023*t*
neuropathy induced by, 949
for pediatric brain tumors, 1556
astrocytomas, 1551
for primary CNS lymphoma, 1059–1060
Vinorelbine, for pediatric brain tumors, 1554
Viral cytopathic change, 662
Viral encephalitis, 153–154, 161*t*, 164*f*, 661–689, 667*t*
adenovirus, 678, 678*f*
arbovirus, 665–672
arenavirus, 677–678
brain edema in, 1131
coronavirus (COVID-19), 672–673
cytomegalovirus, 683
enterovirus, 662–665
herpes simplex, 153–154, 161*t*, 164*f*, 679–680
influenza, 675
level 1 evidence on, 686–687
measles, 671–672, 675–676
neuropathology of, 662, 662*f*
rabies, 676–677
tickborne, 666–668, 667*t*
transplantation-related, 1255, 1299
treatment of, 667*t*
varicella-zoster, 681–682
Viral infections, 661–689. *See also specific infections*
diagnostics in, 661–662
hematopoietic cell transplantation and, 1236
HIV-associated, 700*t*, 701–703
invasive mechanisms of, 661
level 1 evidence on, 686–687
neuropathology of, 662, 662*f*
transplantation-related, 1255, 1299
treatment of, 662
Viral load, in HIV, 690–697, 1581
Viral meningitis, 661–689. *See also specific viral infections*
bacterial meningitis *versus*, 604, 608
benign recurrent lymphocytic, 680–681
Viral myelitis, 1163–1164
Vision
central, 78–79, 79*t*
neuroanatomy of, 77–78
peripheral, 79–80, 79*t*
Vision testing, 32–34, 78–83, 79*t*, 259–260, 259–261*f*
Visual acuity, 32, 78–79, 259
Visual distortion, 79
Visual disturbances, 77–87. *See also* Visual fields, loss in (defects)
afferent and efferent pathway, 87
afferent pathway, 84–85
in ataxia, 833, 833*t*
in Creutzfeldt-Jakob disease, 508
in diabetes mellitus, 1221
efferent pathway, 85–87
higher level dysfunction, 85
in hyperthyroidism, 1220
illicit drug use and, 1317
in multiple sclerosis, 715, 715*t*
with muscle weakness, 114, 115*t*
paraneoplastic, 1101*t*, 1103
symptom history of, 78
symptom severity in, 78
symptom type in, 78
transient symptoms in, 83–84, 83*t*
vitamin A deficiency and, 1281

Visual-evoked potentials (VEPs), 83, 238, 239, 240*f*, 260
in multiple sclerosis, 721
Visual fields
loss in (defects)
cerebral infarction and, 305, 307
common patterns and causes of, 84–85
encephalotrigeminal angiomatosis and, 1463
giant cell arteritis and, 374–375
gliomas and, 1019
ICH and, 334
intracranial hypertension and, 1136–1137
pituitary disorders and, 1215, 1216*f*
pituitary tumors and, 1065, 1065*f*
posterior reversible encephalopathy syndrome and, 384–385
thalamic infarction and, 307
TIAs and, 320
transient, 83, 83*t*
testing of, 32, 32*f*, 80, 80*f*, 260, 260*f*
Visual guidance of gait, 123–124
Visual pathways
afferent, 77, 77*f*
common patterns of disease in, 84–85
efferent, 77, 78*f*
common patterns of dysfunction, 85–87
examination of, 78–82
focal mass lesions of, 153*f*
localization in, signs and symptoms suggesting, 78, 79*t*
Visuospatial function
Alzheimer disease and, 480, 480*f*
dementia and, 99
learning disabilities and, 1430–1431
prion diseases and, 519*t*
testing of, 31
Vital capacity, 1209–1210, 1209*t*
Vitamin(s). *See also specific vitamins*
bariatric surgery and, 1277, 1283
deficiencies of, 1277–1282, 1278*t*
excess of, 1277–1282, 1278*t*
Vitamin A
deficiency of, 1281–1282
excess of, 1278*t*, 1281–1282
and intracranial hypertension, 1135, 1138, 1281–1282
Vitamin A deficiency, 1278*t*
Vitamin B_1 (thiamine)
for alcohol withdrawal, 1305*t*, 1306
for cramps, 1009
deficiency, 1278*t*, 1279–1281, 1280*f*
ataxia with, 834
bariatric surgery and, 1283
neuropathy with, 947
visual effects of, 86
for neurotoxicity, 1320
for Wernicke-Korsakoff syndrome, 1307
Vitamin B_2 (riboflavin)
for cramps, 1009
for migraine prevention, 529*t*
Vitamin B_3 (niacin) deficiency, 947, 1278*t*, 1281, 1308
Vitamin B_6 (pyridoxine)
for cramps, 1009
deficiency, 947, 1278*t*, 1281
in epilepsy, 569, 1512
excess of, 1278*t*, 1281
for neonatal seizures, 1360, 1361*t*
Vitamin B_9 (folic acid)
deficiency, 1278*t*, 1281
for medulloblastoma prevention, 1531
for neonatal seizures, 1360
for pregnant patients with epilepsy, 1288
Vitamin B_{12}
for cramps, 1009
deficiency, 1278–1279, 1278*t*
ataxia and dementia with, 97, 100
ataxia with, 834
bariatric surgery and, 1283
diagnosis of, 1278–1279, 1280*f*
neuropathy with, 936, 938*t*, 947
pathology of, 1278, 1279*f*
Vitamin C, for complex regional pain syndrome, 554
Vitamin D deficiency, 1278*t*, 1282
and multiple sclerosis, 713
and osteoporosis/fractures, 1274–1275
Vitamin E deficiency, 1282
ataxia with, 834, 835, 844*t*, 845, 847
neuropathy with, 947
Vitamin K
anticoagulation reversal with, 139*t*
for intracerebral hemorrhage, 139*t*
for pregnant patients with epilepsy, 1288
Vitamin K antagonists, for cerebral venous thrombosis, 358
Vitreous humor, 77
VLCAD deficiency. *See* Very long chain acyl-CoA dehydrogenase deficiency
VM. *See* Valsalva maneuver
Vocal tics, 106, 786, 786*t*. *See also* Tic(s)
Voiding dysfunction, urinary, 1264–1265
Volatile organic compounds, 1331–1332
Volume status, 1256–1257
von Hippel-Lindau disease, 368, 1093, 1456, 1531
Von Recklinghausen disease, 19, 937, 1089, 1456–1459
Voriconazole
for aspergillosis, 646, 1236
for blastomycosis, 646
for brain abscess, 617, 617*t*
for malignant otitis externa, 621, 621*t*
Vortioxetine, for depression, 1602
VPS. *See* Ventriculoperitoneal shunt
VR. *See* Valsalva ratio
VS. *See* Vegetative state
VUS (variants of unknown significance), in genetic testing, 300
VWM disease. *See* Vanishing white matter disease
VZV. *See* Varicella-zoster virus

W

Waardenburg syndrome, 1456
WAIS. *See* Wechsler Adult Intelligence Scale
Waldenström macroglobulinemia, 1234
Walker-Warburg syndrome, 1375, 1419, 1478–1479
Walking pneumonia, 635–636
Wallenberg syndrome, 307
Wallerian degeneration, 443
Wallgren syndrome, 677
Warfarin
for atrial fibrillation, 403, 406
as contraindication to tPA, 141
for CVT in children, 1523
for heparin-induced thrombocytopenia, 1240
intracerebral hemorrhage with, 409, 1241
reversal of, 139*t*, 336, 409, 1242
for Sneddon syndrome, 397
Warning leaks, in SAH, 343
WATCHMAN device, 409
Water hemlock, 1333
Watershed infarction, 306, 306*f*, 325, 502*f*
WBCs. *See* White blood cells
WBRT. *See* Whole brain radiation therapy
Weakness. *See* Muscle weakness
Weaning, from mechanical ventilation, 1212–1213, 1212*f*
Weber test, 35, 35*f*, 50
Wechsler Adult Intelligence Scale (WAIS), 271–275, 272*t*
Wechsler Intelligence Scale for Children, 271
WEE. *See* Western equine encephalitis
Wegener granulomatosis. *See* Granulomatosis with polyangiitis
Weight loss
in ALS, 908
in Huntington disease, 867–868
Welander distal myopathy, 1492–1493
Werdnig-Hoffmann disease, 1467–1468, 1469*t*. *See also* Spinal muscular atrophies (SMAs)
Wernicke encephalopathy, 1307
visual effects of, 86
Wernicke-Korsakoff syndrome, 1279–1281, 1280*f*, 1306–1307, 1306*t*
Wernicke syndrome, 1306–1307, 1306*t*
WES (whole-exome sequencing), 300
Western equine encephalitis (WEE), 670–671
West Haven hepatic encephalopathy scale, 1245, 1245*t*, 1247
West Nile virus (WNV), 661, 665, 667*t*, 668, 1163–1164, 1236
West syndrome, 575, 1505–1506, 1505*f*
WGS (whole genome sequencing), 19, 300
Whipple disease, 165*t*, 634–635
White blood cells (WBCs)
in cerebrospinal fluid, 278–280
disorders of, 1232–1237
White matter, MRI appearance of, 191, 193*t*
White matter disease. *See also* Demyelinating disorders; Multiple sclerosis (MS)
MRI of, 197–198, 197*f*
White matter heterotopias, 1377
WHO. *See* World Health Organization
Whole bowel irrigation, 1322
Whole brain radiation therapy (WBRT), 1037, 1041–1042, 1058, 1107–1108, 1335
Whole exome sequencing (WES), 300
Whole genome sequencing (WGS), 19, 300
Willis-Ekbom disease. *See* Restless legs syndrome (RLS)
Wilms tumor, epidemiology of, 1530
Wilson disease, 97, 881, 1282, 1392
Windows/windowing, in CT, 185–186, 186*f*
Windup, in central sensitization, 559
Winter depression, 1599

Wisconsin Card Sorting Test, 274
Withdrawal emergent syndrome, 849*t*, 850
Withdrawal syndromes
alcohol, 1304–1306, 1304*t*, 1593
drug, 1313–1318
infant, 1586, 1586*t*
psychosis in, 1305, 1306, 1593
Withdrawing medical care, 1640
Withholding medical care, 1640
Wnt signaling, in medulloblastoma, 1532–1535, 1534*f*, 1555–1556
WNV. *See* West Nile virus
Women, epilepsy management in, 588
Woodhouse-Sakati syndrome, 1393
Working memory, 29–30, 274
World Bank, 7
World Federation of Neurology, 7
World Health Organization (WHO), 7
classification of gliomas, 1021
classification of HIV infection, 690–691, 690*t*
classification of oligodendrogliomas, 1029
classification of pediatric brain tumors, 1533–1535, 1535*f*, 1539–1540, 1540*t*
collaborative partnerships and coordinated action of, 12
definition of glioma, 1019
definition of palliative care, 1637
Global Burden of Disease Study, 2
grading criteria for meningiomas, 1050, 1051*t*, 1052, 1054
International Classification of Functioning, Disability and Health, 1629
Wound botulism, 637
Woven EndoBridge (WEB) device, 223, 223*f*
Writer's cramp, 106, 802, 808, 808*f*, 809

X
Xanthomatosis, cerebrotendinous, 844*t*, 845, 847, 1397
Xenobiotics, 1319–1334. *See also specific toxins and toxicities*
anticholinergic activity of, 1322, 1327*t*
ataxia-inducing, 1320, 1322*t*
clinical features with, 1320, 1321*t*–1322*t*, 1327*t*
common neurotoxidromes from, 1322–1333
definition of, 1319
diagnosis for, 1320
epidemiology of, 1319
movement disorder-inducing, 1320, 1321*t*
myopathies associated with, 992, 993–996, 1320, 1325*t*
neurologic disorders unmasked by, 1319, 1320*t*
neuropathies associated with, 1320, 1323*t*–1325*t*
pathobiology of, 1320, 1320*t*
seizure-inducing, 1320, 1321*t*
smells and odors suggestive of, 1320, 1325*t*
treatment for, 1320–1322, 1326*t*
tremor-inducing, 1320, 1322*t*
Xerophthalmia, 1281
X-linked ataxia, 845
X-linked chorea, 856–857
X-linked lissencephaly–band heterotopia syndrome, 1374–1375, 1377
X-linked myotubular myopathy (XLMTM), 1496, 1496*f*
XP syndrome, 1413*t*

Y
Yale Global Tic Severity Scale, 787
Yeasts, 640
Yolk sac tumor, 1073
Yo-yoing, in levodopa therapy, 885

Z
Zalcitabine, 706, 707*t*, 1583
Zaleplon, 1186, 1187*t*
Zebra sign, 1143, 1144*f*
Zellweger spectrum disorder, 1376, 1405–1406, 1405*t*, 1419
Zidovudine, 706, 707*t*, 1582–1583
Zilucoplan, for myasthenia gravis, 972
Zinc toxicity, 1278*t*, 1282
Zipper artifacts, 196, 196*f*
Ziprasidone
for Huntington disease, 867
for schizophrenia, 1591*t*
side effects of, 1591*t*
for tic disorders, 789, 790*t*
Zolmitriptan
for cluster headache, 74, 531
for migraine, 525–527, 526*t*
Zolpidem, 1186, 1187*t*, 1193
Zonisamide, 586–587
adverse effects of, 587
dosage and pharmacokinetics of, 584*t*, 586–587
for epilepsy, 581–585, 586–587
in breastfeeding patients, 1288–1289
teratogenicity of, 1287*t*
for Lewy body dementias, 497–498
for myoclonus, 829*t*
Zoonotic infections, 630–634, 630*t*
Zostavax, 682
Zoster (shingles), 681–682, 702, 946
Zoster sine herpete, 681